The vermiform appendix and its diseases / by Howard A. Kelly ... and E. Hurdon ... With 399 original illustrations, some in colors, and 3 lithographic plates.

Contributors

Kelly, Howard A. 1858-1943.
Hurdon, Elizabeth.
University of Leeds. Library

Publication/Creation

Philadelphia ; London : W.B. Saunders and Company, [1905], [©1905]

Persistent URL

https://wellcomecollection.org/works/wfempgxw

Provider

Leeds University Archive

License and attribution

This material has been provided by This material has been provided by The University of Leeds Library. The original may be consulted at The University of Leeds Library. where the originals may be consulted.
Conditions of use: it is possible this item is protected by copyright and/or related rights. You are free to use this item in any way that is permitted by the copyright and related rights legislation that applies to your use. For other uses you need to obtain permission from the rights-holder(s).

wellcome collection

Wellcome Collection
183 Euston Road
London NW1 2BE UK
T +44 (0)20 7611 8722
E library@wellcomecollection.org
https://wellcomecollection.org

Unable to display this page

The University Library
Leeds



Medical and Dental
Library

STORE
WI 535
KEL

30106 004196282

Digitized by the Internet Archive
in 2015

https://archive.org/details/b21506401

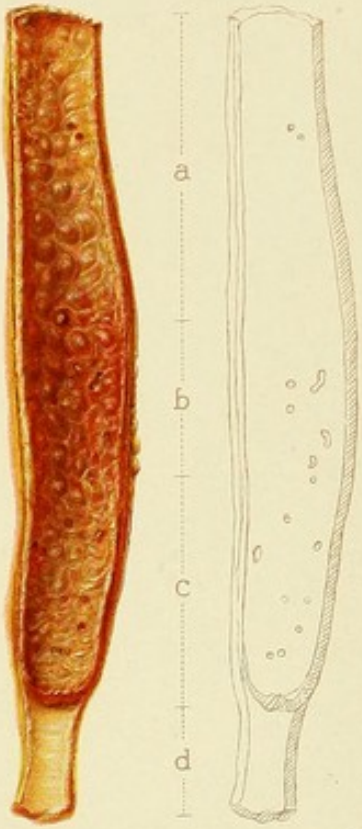

Fig. 1



Fig. 2



x 6

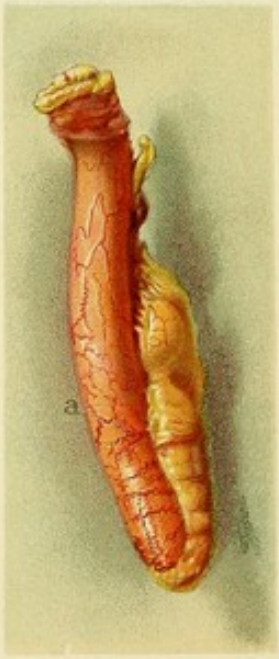

Fig. 3



Fig. 4

Brodel and Horn, fec

Ketterlinus, Lith. Phila.

DESCRIPTION OF PLATE I.

FIG. 1.—Acute appendicitis with superficial ulceration. The proximal third (a), apart from two or three pinpoint ulcers, is fairly normal. A similar condition is noticed in the distal portion of the mucosa (c). The median portion (b) is hemorrhagic and shows more extensive ulcerations. The tip (d) is obliterated. With the hand lens the ulcers are found to occupy the centre of a system of Lieberkühn's crypts, and correspond to the normal position of the lymph nodes. (W. S. Halsted.)

FIG. 2.—Chronic appendicitis. The appendix is thickened, rigid, and markedly injected. (W. S. Halsted.)

FIG. 3.—Mild acute catarrhal appendicitis. The serous covering is slightly injected. (T. S. Cullen.)

FIG. 4.—Typhoid appendix. End of second week. The appendix is swollen, erect and tense, and hyperemic. (W. S. Halsted.)

DESCRIPTION OF PLATE I.

FIG. 1.—Acute appendicitis with superficial ulceration. The proximal third (a), apart from two or three pinpoint ulcers, is fairly normal. A similar condition is noticed in the distal portion of the mucosa (c). The median portion (b) is hemorrhagic and shows more extensive ulcerations. The tip (d) is obliterated. With the hand lens the ulcers are found to occupy the centre of a system of Lieberkühn's crypts, and correspond to the normal position of the lymph nodes. (W. S. Halsted.)

FIG. 2.—Chronic appendicitis. The appendix is thickened, rigid, and markedly injected. (W. S. Halsted.)

FIG. 3.—Mild acute catarrhal appendicitis. The serous covering is slightly injected. (T. S. Cullen.)

FIG. 4.—Typhoid appendix. End of second week. The appendix is swollen, erect and tense, and hyperæmic. (W. S. Halsted.)

THE VERMIFORM APPENDIX

AND ITS DISEASES

BY

HOWARD A. KELLY, A.B., M.D.

PROFESSOR OF GYNECOLOGY IN THE JOHNS HOPKINS UNIVERSITY, BALTIMORE

AND

E. HURDON, M.D.

ASSISTANT IN GYNECOLOGY IN THE JOHNS HOPKINS UNIVERSITY, BALTIMORE

WITH 399 ORIGINAL ILLUSTRATIONS, SOME IN COLORS, AND 3 LITHOGRAPHIC PLATES

PHILADELPHIA AND LONDON

W. B. SAUNDERS AND COMPANY

1905

Copyright, 1905, by W. B. Saunders & Company.

Registered at Stationers' Hall, London, England.

Printed in America.

605787

TO

WILLIAM S. HALSTED, M.D.,

AS A MARK OF AFFECTION AND ESTEEM.

"Processus vermiformis, organon maxima ex parte secretioni inserviens non exigua dignitate æstimandus, sæpius jam mortalibus insidias struxit, quam medicorum exercitus, more consueto torpefactus, hucusque suspicabatur. Quam appendiculæ istius et physiologicam et pathologicam dignitatem perpauci solummodo media agnoscentes, organicas illius a norma aberrationes litteris mandare, pretio non indignum fore judicarunt."

F. Merling, I. D. Heidelberg, 1836.

"Der Wurmfortsatz, ein so untergeordnetes Organ, so abgegränzt in seiner Lage und seinem Bau, so unerklärt in seiner Bedeutung, vielleicht so überflüssig in seiner ganzen Existenz,—und nun die Krankheiten desselben, und noch sogar eine einzelne Krankheit mit beschränkter Ursache!"

A. Volz, I. D. Carlsruhe, 1846.

"I am firmly convinced that appendicitis is the most important acute abdominal disease of the present time, and that, excluding certain zymotic diseases, it is the cause of more deaths than any other acute abdominal lesion."

M. H. Richardson.

American Journal of the Medical Sciences, January, 1904.

PREFACE.

The present work is the outcome of an investigation undertaken some years ago when I first began to notice the condition of the appendix in every abdominal operation, an undertaking which soon grew to unexpected proportions. The literature of the subject is so extensive that I fear I may not have done full justice to the many faithful workers in the field; indeed, even as the pages are passing through the press, several valuable articles have appeared too late for recognition.

Under the conviction that surgery and pathology are best taught by demonstration I have tried to parallel the text with graphic illustrations, and in a few instances the figure with its legend stands alone. I acknowledge here my indebtedness to Mr. Horn, Mr. Brödel, Miss Huntington, and Mr. Becker for their splendid artistic work; the enthusiasm with which they have entered into various researches and prosecuted every phase of their work has greatly enhanced my own pleasure and satisfaction. The anatomical chapters were written by Mr. Brödel and illustrated, for the most part, by Miss Ruth Huntington, now Mrs. Brödel.

I will avail myself of this opportunity to say a few words relative to the illustration of medical works and the proper use of good figures.

The changes in the appearance of an organ brought about by disease are often manifested in such delicate deviations from the normal topography that it requires the hand and eye of a genuine artist, and one who is also a well-informed anatomist and careful pathologist, to represent the morbid condition accurately. The sense of vision, when unaided, often fails to grasp the significance with completeness, and in such a case the true artist will palpate the fresh specimen and then represent the combined results of sight and touch. The superficial structure alone is frequently insufficient to demonstrate the character of the specimen, and the artist must find means of exhibiting the surface relations in association with the interior. This can be done: (1) by inserting lines, (2) by cutting away portions of the surface and thus displaying the depth, (3) by magnifying the organ and drawing it as though translucent, and (4) by explanatory diagrams, cross-sections, etc.

From these considerations it is evident that an intelligent interpretation of a pathological specimen or of an anatomical or clinical demonstration through the eye and hand of a trained scientific artist must be vastly superior as a means

of instruction to the best photograph. Yet how often when we appeal to an illustration for light on a difficult text do we find a hazy, woolly, milky, or coarse drawing, which only succeeds in leaving our confusion worse confounded.

Good, true illustrations are a most valuable handmaid in medical instruction, for what the eye of the student has grasped remains, as old Horace memorably said, indelibly impressed after a fashion unequaled by the clearest verbal description. I would beg the reader, therefore, not to be satisfied with glancing hurriedly over these illustrations and their legends, returning at once to the text, but to study each figure with care.

The essential feature, its centre of interest, is generally emphasized by greater contrast in shading, by which the attention of the observer is insensibly focussed. The differences in the tone value of the peritoneum over the small and large intestine, and of the fat, adhesions, etc., are given in a manner as realistic as is possible in black and white drawings. Cysts are made translucent as in the fresh condition. The method of making our originals, whether pen and ink, half-tone, or color, has been selected with a view to the use for which the picture was designed. A simple topographical relationship is best shown by line drawing, and steps in a operation, half schematically represented, are done in pen and ink. For anatomical and pathological characteristics where delicate surface structures and plastic effects are required, we have used wash drawings adapted for half-tone reproduction.

In the microscopic pictures even the individual cells have been drawn with the utmost fidelity; in no case have they been schematized. Many of the pictures will be best appreciated if studied with a low-power hand lens.

I will here ask the reader to correct the reference on page 93 from p. 183 to p. 186.

One of the pleasantest parts of my task has been the fact that I have been constantly dependent upon the good offices of willing friends.

Dr. Caroline Latimer has been my faithful aid from the beginning, revising the English of the manuscript and caring for it and for the proof in all stages, besides assisting in various other ways too numerous to mention. Her own original labors will be found in the historical chapters, upon which she has spent months of enthusiastic effort.

Dr. Henry Christian, one of our own graduates, now of the Boston City Hospital, has contributed the chapter on autopsy findings.

Dr. William A. Ford, of the Johns Hopkins Hospital, wrote that on the bacteriology of the appendix and cecum.

My friend, Dr. Harvey Cushing, wrote the section relating to cocaine anesthesia in the chapter on preliminaries to operation.

My colleague, Dr. Halsted, from the first graciously placed the entire material of his large surgical service at my disposal. I am also glad to acknowledge my debt to Dr. J. M. T. Finney and the other members of the surgical staff;

the extent to which they have aided me is in evidence everywhere throughout the text.

My associate, Dr. Guy L. Hunner, has helped me in revising the chapters on treatment.

I am indebted to Dr. J. Erlanger for assistance in carrying out the physiological experiments described in Chap. VIII.

Many friends, notably Dr. Maurice H. Richardson, of Boston, Dr. Robert Abbé, of New York, and Dr. J. B. Murphy, of Chicago, have been most kind and patient in answering numerous and, I fear, often troublesome letters of inquiry.

I have to thank Dr. John B. Deaver, of Philadelphia, for the use of his large stock of material, as well as Dr. A. O. J. Kelly.

Dr. Henry Elsner came to my aid in the chapter on appendicitis in typhoid fever.

Every one who has had to consult many books in the preparation of a large work will realize the extent of my obligations to Dr. Robert Fletcher, and also, especially, to the late Dr. J. E. Merrill, in my necessary use of that monumental foundation of J. S. Billings, the Surgeon-General's Library.

The section on leucocytosis is not so comprehensive as I had intended, but I hope to enlarge and extend it in a subsequent edition.

In conclusion, let me thank all my friends, at home and abroad, for specimens, notes, and drawings, as well as for the genial atmosphere of cordial interest with which they have invested the subject from the beginning.

Lastly, I would call attention to the index of names. It has been one of the pleasantest features of the work to realize, as I culled these from the text, the truth of that inspired declaration of the great apostle to the Gentiles: "Others have labored, ye have entered into their labors."

HOWARD A. KELLY.

BALTIMORE, *January* 23, 1905.

CONTENTS.

CHAPTER I.

PAGE

HISTORY 1

From the First Recorded Case to the Establishment of Lesions of the Appendix as Productive of Well-defined Clinical Symptoms.

CHAPTER II.

HISTORY (Continued) 10

From the Distinct Recognition of Lesions in the Appendix to the Knowledge of Appendicitis as a Surgical Affection, 1827–1886.

CHAPTER III.

HISTORY (Continued) 31

The Surgical History of Diseases of the Vermiform Appendix, 1886–1904.

CHAPTER IV.

ANATOMY 55

Embryology of the Vermiform Appendix. Differentiation between the Appendix and the Cecum. Comparative Anatomy.

CHAPTER V.

ANATOMY (Continued) 89

Folds and Fossæ. The Reflection of the Peritoneum in the Ileocecal Region. The Inner Surface of the Ileocecal Region and its Valves.

CHAPTER VI.

ANATOMY (Continued) 118

The Position of the Appendix. The Dimensions of the Appendix. The Structure of the Appendix. The Contents of the Appendix. Obliteration of the Appendix. Retrogression.

CHAPTER VII.

ANATOMY (Continued) 155

The Arteries of the Appendix. The Veins of the Appendix. The Lymphatics of the Appendix. The Nerves of the Appendix.

CHAPTER VIII.

PHYSIOLOGY 190

CHAPTER IX.

PAGE
Natural History 195
Diseases to which the Appendix is Liable. Acute and Chronic Appendicitis. Effects of an Appendicitis upon the Appendix Itself. Effects of an Appendicitis upon the Structures in the Neighborhood. The More Remote Effects of an Appendicitis.

CHAPTER X.

The Vermiform Appendix at Autopsy 210
Acute Appendicitis. Chronic Adhesive Appendicitis. Chronic Obliterative Appendicitis. Cysts of the Appendix. Condition of Appendix in Diseases of Other Viscera.

CHAPTER XI.

Bacteriology 254

CHAPTER XII.

Pathology 263
Acute Catarrhal Appendicitis. Acute Diffuse Appendicitis. Chronic Ulcerative and Purulent Appendicitis.

CHAPTER XIII.

Pathology (Continued) 302
Peritonitis in General. Localized Peritonitis. Spreading or Generalized Peritonitis.

CHAPTER XIV.

Pathology (Continued) 328
Blood Vascular Infection. Lymphatic Infection.

CHAPTER XV.

Pathology (Continued) 335
Tuberculosis. Actinomycosis. Typhoid Fever. Amœbic Dysentery.

CHAPTER XVI.

Etiology 357
Predisposing Causes. Exciting Causes. Final Causes.

CHAPTER XVII.

Clinical History 385
Symptoms. Complications.

CHAPTER XVIII.

Diagnosis 407
Diagnosis. Differential Diagnosis.

CHAPTER XIX.

Appendicitis in Typhoid Fever 431
History. Etiology. Diagnosis. Treatment.

CHAPTER XX.

PAGE

APPENDICITIS IN THE CHILD 450
History. Etiology. Symptomatology and Diagnosis. Treatment.

CHAPTER XXI.

TYPHLITIS 485

CHAPTER XXII.

GENERAL CONSIDERATIONS REGARDING OPERATION 494
Introductory. Indications for Operation. Immediate Operation. Intermediate Operation. Late Operation. Interval Operation.

CHAPTER XXIII.

PRELIMINARIES TO OPERATION 510
Medical Treatment. Preparations for Operation. Nitrous Oxid Anesthesia. Cocaine Anesthesia.

CHAPTER XXIV.

INCISIONS 523

CHAPTER XXV.

REMOVAL OF THE APPENDIX 540
Exposure of the Appendix. Typical Operations for Removal of the Appendix. Atypical Operations for Removal of the Appendix. Meckel's Diverticulum.

CHAPTER XXVI.

ABSCESS IN THE NEIGHBORHOOD OF THE APPENDIX, OR SUPPURATIVE PERIAPPENDICITIS 603
Removal of the Appendix in Suppurative Cases. Treatment of Abscess. Treatment of Abscess in Special Cases. Pelvic Appendical Abscess.

CHAPTER XXVII.

PERITONITIS 633
Progressive Purulent Peritonitis. Diffuse Purulent Peritonitis.

CHAPTER XXVIII.

CARE OF PATIENT AFTER OPERATION AND POST-OPERATIVE SEQUELÆ 655

CHAPTER XXIX.

RELATION BETWEEN APPENDICITIS AND GYNECOLOGICAL AFFECTIONS 698
General Considerations. Diagnosis. Treatment.

CHAPTER XXX.

RELATIONS OF APPENDICITIS TO PREGNANCY, LABOR, AND THE PUERPERIUM ... 729

CHAPTER XXXI.

NEOPLASMS 737
Benign Tumors. Malignant Tumors.

CHAPTER XXXII.

PAGE
Clinical History of the Specific Infections 761
Tuberculosis. Actinomycosis. Amœbic Dysentery.

CHAPTER XXXIII.

Operative Treatment of Neoplasms and Specific Infections 772
Disease Limited to the Appendix. Disease in the Ileocecal Region.

CHAPTER XXXIV.

Hernia of the Appendix 786

CHAPTER XXXV.

Medico-legal Aspects of Appendicitis 794

LIST OF ILLUSTRATIONS.

FIG. PAGE

1. Human embryo (six weeks). Lateral and anterior views with umbilical cord cut open . . 56
2. Human embryo (seven weeks). Lateral view with umbilical cord cut open 57
3. Same embryo as in Fig. 2. Anterior view of intestinal loops within the cord 57
4. Human embryo (seven weeks). Showing coil of intestines within the opened cord and the cecum with the transient appendix 58
5. Human embryo (seven and a half weeks). Showing the receding of the cecum from the cord into the body 59
6. Human embryo (eight weeks). Showing the last stage in the receding of the intestinal coils from the cord into the body 59
7. Human embryo (eight weeks). Differentiation between the cecum and appendix 60
8. Human embryo (nine weeks). Showing the intestines entirely within the body 60
9 and 10. Human embryos (nine to ten weeks). Cecum and appendix near the median line 61
11. Human embryo (ten weeks). Cecum and appendix in the right hypochondriac region . . 61
12. Human embryo (eleven weeks). The ileocecal apparatus near the median line 61
13. Human embryo (thirteen weeks). Cecum and appendix anterior to the right kidney . . 62
14. Human embryo (three months). Cecum and appendix anterior to the right kidney . . . 63
15. Human embryo (three months). Small intestine removed, showing ileocecal apparatus anterior to the right kidney 63
16. Human embryo (three months). Transverse section through lower half of body 64
17. Human embryo (fourteen weeks). Appendix in subhepatic position 65
18. Human embryo (three to four months). Beginning descent of cecum 65
19. Human fetus (four months). Showing relative position of cecum 66
20. Same as preceding with large part of intestines removed 66
21. Human fetus (four months). Lower right-hand corner of abdominal cavity 67
22. Human fetus (four to five months). Showing body open with appendix and other organs *in situ* 68
23. Same as preceding with most of the small intestine removed 68
24. Human fetus (five months). Somewhat lateral view of the abdominal viscera *in situ* . . 69
25. Appendix region of fetus shown in preceding figure 69
26. Human fetus (six to seven months). Abdominal cavity open with ileum removed 70
27. New-born babe. Right-hand corner of abdominal cavity 71
28. Development of the ileocecal apparatus from the age of five to seven weeks 72
29. Development of the ileocecal apparatus between the ages of eight and twelve weeks . . 73
30. Development of the ileocecal apparatus between the ages of three and seven months . 74
31. Development of the appendix from the newborn to the adult stage 75
32. Primitive type of ileocolic region 80
33, 34, 35, 36, 37, and 38. Symmetrical form of cecum . . . . . 80 and 81
39, 40, 41, 42, and 43. Asymmetrical development of single cecal pouches . . . . . 81 and 82
44 to 53. Rectangular ileocolic junction . . . . . 82, 83, and 84
54 to 58. Cecal apparatus combined with structural modifications of adjacent portion of colon . . . . . 84 and 85
59. Absence of cecal pouch 85

FIG. PAGE
60. Cecal apparatus in Hyrax ... 85
61. Anterior view of ileocecal region of Ateles ... 86
62. Anterior and posterior views of ileocecal region of Mycetes fuscus ... 86
63. Anterior and posterior views of ileocecal region of Mangabey monkey ... 87
64. Anterior and posterior views of ileocecal region of Gibbon ... 87
65. Anterior and posterior views of ileocecal region of kangaroo ... 87
66. Folds and fossæ of the ileocecal region ... 90
67. Development of the vascular folds (usual form) ... 95
68. Development of the vascular folds. Anterior mesappendix ... 97
69. Anterior position of the mesappendix ... 98
70. Development of the vascular folds. Mesappendix attached to lower border of ileum ... 100
71 The eight most frequent types of peritoneal reflection of the ileocecal region ... 107
72, 73, 74, 75, 76, 77, and 78. Most striking types of intra-peritoneal and extra-peritoneal appendices ... 108 and 109
79. Valves of the ileocecal region ... 111
80. Appearance of the appendical orifice where the ceco-appendical angle measured 20 degrees ... 112
81. Appearance of the appendical orifice where the ceco-appendical angle measured 30 degrees ... 112
82. Appendical orifice in connection with a ceco-appendical angle of 42 degrees ... 113
83. Appendical orifice in connection with a ceco-appendical angle of 60 degrees ... 113
84. Ceco-appendical angle of 60 degrees ... 114
85. Ceco-appendical angle of 90 degrees ... 115
86. Exceptioual form of appendical orifice in a case where the appendico-cecal orifice measured only 12 degrees ... 116
87. Diagram showing various places on the surface of the cecum from which the appendix may take its origin ... 119
88. Fetal type of appendix ... 119
89. Persistent fetal type of cecum and appendix in an adult ... 120
90, 91, 92, and 93. Appendix arising at point (c) in Fig. 87 ... 121
94. Appendix arising from the anterior and median extremities of the cecum ... 121
95. Appendix arising from the interior portion of the cecum at point (b) in Fig. 87 ... 122
96. Point of appendical origin at (f) in Fig. 87 ... 122
97. Abnormal position of appendix and abnormal arrangement of its blood-supply ... 122
98. Point of appendical origin at (d) in Fig. 87 ... 123
99. Point of appendical origin at (e) in Fig. 87 ... 123
100. Diagrams showing the changes in the topography of the ileocecal apparatus due to distention of the colon in cases of non-adherent cecum ... 125
101. Diagrams showing the various directions in which an appendix may point ... 127
102. Normal position of the ileocecal apparatus ... 128
103. Diagram showing the positions of moderate displacement of the appendix ... 129
104. Diagram showing the excursions possible to an ileocecal apparatus with a long and movable mesentery ... 129
105. Position of cecum and large intestine affected by ileo-cecal apparatus being fixed in the position it occupied during eighth week of early embryonic life ... 130
106. Cecum fixed on left side of body ... 131
107. Cecum arrested in the subhepatic position ... 132
108. Cecum arrested in the subhepatic position and turned upward ... 133
109. Cecum in the subhepatic position and pointing laterally ... 134
110. Transposition of the abdominal viscera ... 135
111. Appendix measuring 21.5 cm. (8½ in.) in length ... 137
112. Section through normal appendix ... 140
113. Ileocecal region in a woman possessing an abnormal amount of fat ... 142
114. Longitudinal section through the distal portion of a normal appendix and its mesenteriolum ... 142

FIG. PAGE
115. Portion of the mucous membrane in a young individual showing arrangement of lymph nodes on surface ... 145
116. Surface of the mucous membrane of an appendix magnified 6.5 times ... 145
117. Portion of normal mucous membrane of an appendix magnified 150 times ... 147
118. Blood-vessels of the ileocecal region ... 157
119. A complete injection of the appendical blood-vessels in a seven months fetus ... 159
120. Reconstruction of the blood-supply of the appendix ... *facing* 160
121. Portion of mucosa injected and cleared to show the blood-vessels ... *facing* 160
122 to 138. Types of the appendical arterial circulation ... 162–166
139. Veins of the appendix and their relation to the portal and systemic circulation ... *facing* 168
140. Reconstruction of the lymphatics of appendix ... *facing* 170
141. Lymphatic circulation of the ileocecal region. Anterior view ... 175
142. Posterior view of the ileocecal region showing the main lymph trunks and their relation to the ileocolic chain of glands ... 177
143, 144, 145, and 146. Types of the appendical lymphatic circulation ... 179 and 181
147. Graphic tracing showing movements of the appendix ... 193
148. Various kinks and bends of the appendix ... 200
149. Case of appendix covered in by dense sheet of adhesions ... 201
150. Appendix passed by the rectum ... 203
151. Inflammatory residual mass at the tip of the appendix attached to the ileum at a distance from the valve ... 205
152. Senile atrophy of cecum in a man eighty-six years old ... 224
153. Thrombus in the portal vein ... 232
154. Portal infection ... 242
155. Acute suppurative interstitial hepatitis due to portal infection ... 243
156. Suppurative thrombo-phlebitis of the mesenteric veins with multiple abscess in the liver following appendicitis ... *facing* 245
157. Section from the specimen represented in Fig. 3, Plate 1 ... 264
158. Deposit of pigment in the mucosa of the appendix ... 265
159. Acute appendicitis. Hemorrhagic infiltration of mucosa ... 267
160. Acutely inflamed appendix showing greatly dilated blood-vessels ... 267
161. Acute appendicitis. Inflammation limited to the distal half of the appendix ... 267
162. Acute appendicitis. Appendix lined with necrotic material ... 269
163. Appendix almost totally gangrenous ... 269
164. Total gangrene of interior of the appendix ... 271
165. Acute appendicitis with thickened hemorrhagic mesappendix ... 271
166. Acute diffuse appendicitis ... 272
167. Higher magnification of the margin of ulcer seen in the preceding figure ... 273
168. Acute appendicitis with severe lymphangitis ... 274
169. Thrombus in a lymph sinus ... 275
170. Perforative appendicitis ... 276
171. Acute appendicitis. Showing protrusions of mucous membrane ... 277
172. Chronic appendicitis with anemic bulbous tip containing soft fecal mass ... 279
173. Chronic appendicitis. Mucous membrane forming distinct polyp ... 280
174. Chronic appendicitis. Showing changes in submucosa ... 280
175. Chronic appendicitis with complete stricture in the middle ... 280
176. Section from the preceding specimen ... 281
177. Section from the appendix shown in Fig. 2, Plate III ... 282
178. Section from the preceding case showing atypical glands and mucoid degeneration ... 283
179. Obliterative endarteritis in the mesappendix ... 284
180. Empyema of the appendix ... 286
181. Chronic suppurative appendicitis with obliterated lumen and a ruptured pus sac beyond it ... 286
182. Multiple strictures in the appendix ... 287
183. Kink and stricture produced by adhesions in a case of chronic appendicitis ... 287

FIG. PAGE
184. Cystic appendix with the proximal end protruding into the cecum 288
185. Cystic distention of the lower three-fourths of the appendix due to stricture of the canal 289
186. An appendix showing a single cyst and an obliterated withered extremity 289
187. The same appendix when removed six years later 290
188. Cystic appendix 290
189. Section from the preceding specimen of cystic appendix 291
190. Hypertrophied appendix with obliterated lumen 293
191. Atrophied appendix with obliterated lumen 293
192. Chronic appendicitis with stricture 294
193. Obliterated appendix covered in with adhesions and hidden behind the ileum 294
194. Section from specimen shown in Fig. 191 296
195. Obliteration of the lower two-thirds of the appendix 297
196. Appendix containing spherical concretions 299
197. Mucous membrane showing impression of the enterolith seen in Fig. 232 301
198. Acutely inflamed appendix with the omentum adherent to a point of threatened perforation 308
199. Appendix rolled up in the omentum 309
200. Encysted peritonitis surrounding the tip of the appendix 310
201. Encysted peritonitis of tubercular origin 311
202. Chronic appendicitis showing the appendix twisted half round upon its axis 325
203. Pocketed appendix resulting from old localized peritonitis 326
204. Tuberculosis of the appendix 337
205. Hyperplastic tuberculosis of the appendix 338
206. Section through the wall of the appendix represented in Fig. 205 ..... *facing* 338
207. Higher magnification of the superficial tubercles seen in the preceding section 339
208. Actinomycosis of the appendix 345
209. Actinomycosis of the appendix. Section through median portion of the organ 345
210. Actinomycosis of the appendix. Section through the wall of the organ at junction of the submucosa and circular muscular coats 347
211. Thrombosed vessels in the appendix in a case of typhoid fever 349
212. Typhoid ulceration of the appendix 350
213. Section from the base of the ulcer seen in Fig. 212 350
214. Higher magnification of large phagocytes 350
215. Typhoid appendix, eleventh week of the disease 351
216. Typhoid appendix. Section from Fig. 215 351
217. Amœbic dysentery. Appendix bent at right angles and held in this position by firm adhesions 353
218. Subacute appendicitis associated with the presence of two concretions 362
219. Appendix containing enteroliths resembling gall-stones 363
220. Appendix containing a calculus, probably a gall-stone 364
221. Appendix containing two small seeds 364
222. Appendix perforated by a pin 368
223. Appendix adherent to abdominal walls following discharge of pin 369
224. Appendix perforated by a four-inch shawl pin 370
225. Pin shown in Fig. 224, after removal. Head buried in a concretion 371
226. Appendix containing common pin 371
227. Bullet forming nucleus of a concretion 372
228. Appendix containing bullet 373
229. Appendix containing shot and grape-seed 373
230. Fish-fin in the appendix 374
231. Appendix containing a lumbricus 376
232. Foreign bodies and concretions in the appendix 379
233. Piezometer 411
234. Method of using the piezometer 412

FIG. PAGE
235. Funnel-shaped orifice in acute perforative appendicitis occurring in a girl three and a half years of age ... 452
236. Intestinal needle with split eye ... 515
237. Delicate, light, curved mouse-toothed forceps ... 516
238. Showing the muscular and tendinous structures involved in making the various incisions ... 525
239. Representing the principal arterial and nerve-trunks of the right abdominal wall ... 527
240. Cadaver showing location of various incisions for removal of the appendix, in right lower quadrant of abdomen ... 529
241. McBurney's incision (I) ... 530
242. McBurney's incision (II) ... 531
243. McBurney's incision (III) ... 532
244. McBurney's incision (IV) ... 533
245. Finney's incision ... 534
246. Incision in semilunar line (Battle) ... 535
247. Incision in semilunar line, opening rectus sheath ... 536
248. Incision in semilunar line. Division of strata of abdominal wall ... 537
249. Appendix concealed behind cecum and flexed on itself with its tip concealed in a retro-peritoneal pocket ... 541
250. Showing a misleading constricting band simulating the anterior tenia muscle ... 542
251. Appendix adherent across the common iliac artery ... 543
252. Embryonic displacement of appendix, which is bound down by adhesions to the pre-renal peritoneum ... 544
253. The cecum and colon lifted, showing the high retrocolic appendix kinked and wrapped in adhesions ... 545
254. Showing the appendix completely concealed by the cecum and colon ... 546
255. Showing the appendix buried in a retro-mesenteric pocket ... 547
256. Retro-mesocolic appendix with tip buried in adhesions ... 548
257. Appendix lying in a large-mouthed retrocecal pocket ... 549
258. An antero-posterior section of the preceding ... 550
259. A collective picture showing the various points of attachment of the appendix to structures in the abdomen ... 551
260. The commonest type of circulation at the appendico-cecal angle ... 552
261. Normal type of circulation in non-adherent appendix ... 552
262. The appendical and cecal circulatory systems entirely disassociated ... 553
263. Cecal vessels supplying the root of the appendix ... 553
264. Broad arterial anastomosis in the mesappendix ... 554
265. Showing method of controlling circulation when the mesappendix is bound down ... 554
266. Showing the control of the vessels in the case of an appendix adherent to the outer surface of the colon ... 555
267. Diagram after Edebohls showing the danger of burying the exposed mucous membrane of the stump ... 555
268. A simple widely used method of exsection of the appendix, I ... 556
269. II, The stump of the appendix grasped with forceps and thrust into the bowel ... 556
270. III, The circular suture tightened and tied while the forceps is withdrawn ... 557
271. IV, Final step showing the placing of the mattress sutures over the circular sutures ... 557
272. Finney's method of freeing the amputation area of all its contents and of the mucosa ... 558
273. Halsted's three-clamp method of removal, I ... 559
274. Halsted's three-clamp method, II ... 560
275. Beck's method of dealing with the stump ... 560
276. Fowler's cuff method (I) ... 561
277. Fowler's cuff method (II and III) ... 562
278. Fowler's cuff method (IV) ... 563
279. Dawbarn's method of inverting the stump ... 564
280. Edebohls' method of inverting the whole unopened appendix ... 565

FIG. PAGE
281. Edebohls' method of inversion completed ... 566
282. Deaver's method of amputating the appendix flush with the cecum ... 567
283. Downes' method of removing the appendix ... 568
284. Kelly's crushing forceps with groove for contact with cautery point for cooking the stump of the appendix ... 569
285. Kelly's method of removing the appendix (I) ... 569
286. Kelly's method (II) ... 570
287. Kelly's method completed (III) ... 570
288. Eastman's method of removing the appendix ... 571
289. Lennander's method of removing the appendix (I) ... 572
290. Lennander's method (II and III) ... 573
291. Lennander's method (IV) ... 573
292. Cystic appendix attached to the omentum ... 574
293. Enlarged inflamed appendix completely hidden by newly-formed adhesions ... 576
294. Method of stripping out the mucosa and submucosa in the case of a densely adherent appendix (I) ... 577
295. Method of stripping out the appendix (II) ... 577
296. Method of stripping out the appendix (III) ... 578
297. Method of incising the dorsum of the appendix and removing it by traction ... 579
298. Showing the inner coats of the appendix removed by stripping ... 580
299. Specimen of abnormally long appendix, of which the proximate part was removed in this way ... 580
300. Retrocolic appendix so buried in adhesions that removal in the usual manner is dangerous to the coats of the cecum ... 581
301. Method of removing retrocolic appendix (I) ... 582
302. Method of removing retrocolic appendix (II) ... 583
303. Showing such an appendix in section ... 584
304. Appendix completely concealed under adherent cecum ... 585
305. Appendix lying retro-peritoneally with its tip buried in the substance of the psoas muscle ... 586
306. Appendix densely adherent to the caput coli and ileum ... 590
307. The same as the preceding, showing the thickened tip above and the perforation near the base ... 591
308. Fistula from the appendix on to the surface of the abdomen ... 592
309. Diagram of the most primitive form of Meckel's diverticulum ... 595
310. Diagram of a more advanced form of diverticulum ... 595
311. Diagram of a still more advanced form of diverticulum ... 596
312. Usual form of Meckel's diverticulum ... 596
313. Unusually narrow Meckel's diverticulum, easily mistaken for an appendix ... 597
314. Meckel's diverticulum with several small distention diverticula at its distal portion 598
315. Large Meckel's diverticulum, 70 cm. from the valve ... 600
316. A composite picture showing the various positions in which an appendical abscess may lie ... 604
317. Location of various small abscesses in the ileocolic region ... 605
318. Appendix coiled on itself in spiral form, below and in front of the ileocecal junction. 606
319. Appendix buried under two layers of peritoneal folds forming two pockets ... 607
320. Mikulicz's natural barriers to the spread of infection ... 608
321. Abdomen showing the three major fossæ, right, left, and pelvic ... 609
322. Frozen section (sagittal) showing interior of cecum and colon with cecal opening into appendix and section of appendix and mesappendix ... 610
323. Horizontal section just above the insertion of the appendix, showing the relation of the appendix and the mesappendix to the fasciæ and muscles of the posterior abdominal wall ... 611
324. Weir's incision for enlarging the McBurney opening without dividing the muscles. . 615
325. Doughty's method for securing more room in abscess and other difficult cases ... 616

FIG. PAGE
326. Showing the wide area of exposure to the peritoneum given by Doughty's method. 616
327. Showing the complete closure of the wound by Doughty's method and the relations of the lines of sutures. 617
328. Diagram showing the method of approaching an abscess by the extra-peritoneal route 617
329. Method of approaching an abscess by the transperitoneal route. 617
330. Showing the various sites at which abscesses are more commonly found. 618
331. Unusual location of the appendix high up to the inner side of the ascending colon and covered by omentum. 621
332. Pin-point perforation at the tip of the appendix. 621
333. Method of exposing and evacuating abscess through an incision in the median or right semilunar line. 623
334. Showing the hand within the abdomen guiding and controlling the forceps in the act of opening the abscess through the lateral incision. 624
335. Appendix and cecum wrapped in omental adhesions. 625
336. Gangrenous abscess and perforation of the appendix completely enveloped and protected from the peritoneal cavity by the omentum. 626
337. Large retro-peritoneal abscess in a girl ten years old. 629
338. Tip of the appendix lost in a pool of pus filling the pelvis and walled in by adherent intestine. 630
339. Perforation near the root of the appendix in a patient dying of peritonitis. 634
340. Elsberg's operation for subphrenic abscess, showing skin incision. 639
341. Resection of ninth and tenth ribs in subphrenic abscess. 640
342. Subphrenic abscess aspirated through the diaphragm and below the pleural reflection 641
343. Fowler's method of drainage, in diffuse purulent peritonitis. 644
344. Self-retaining retractor. 646
345. Method of washing out the abdomen when full of pus by means of a long metal tube with spray attachment. 648
346. Method of using the irrigator to push forward the peritoneum in the abdominal wall when making a left lumbar incision for drainage in abdominal pyemia. 649
347. Showing direction of current from the adjacent portions of the abdominal cavity toward the various drainage openings. 650
348. Retrocecal abscess found at second operation two years after removal of the appendix 665
349. Same as preceding, showing abscess exposed behind cecum. 666
350. Intestinal obstruction following operation for appendicitis due to omental adhesions over stump of appendix. 689
351. Showing large hernia following incision in the semilunar line for appendicitis. 695
352. Operation for hernia showing rectus dovetailed between the broad abdominal muscles 696
353. Showing in detail the method of drawing rectus between muscles. 697
354. Inflamed appendix adherent to a tubo-ovarian abscess. 703
355. Obliterated appendix adherent to a chronic tubo-ovarian inflammatory mass. 704
356. Tip of appendix adherent to small dermoid cyst of left side. 706
357. Appendix densely adherent to fibroid tumor undergoing sarcomatous degeneration. 708
358. Appendix adherent to right broad ligament in a right extra-uterine pregnancy. 709
359. Detailed study of the preceding figure. 709
360. Long appendix adherent by its tip to suspensory ligament attaching uterus to anterior abdominal wall. 720
361. Extensive involvement of the appendix in a tubo-ovarian abscess of the right side. Method of removing appendix. 724
362. Method of removing an adherent appendico-tubo-ovarian mass in reverse order to that shown in preceding figure. 725
363. Tubo-ovarian abscess. Peri-appendicitis. 726
364. Distal portion of appendix adherent to the broad ligament in a case of large multilocular ovarian cyst. 727
365. Appendix adherent to uterine tube and ovary in the midst of extensive adhesions. 728
366. Appendix adherent to the pregnant rudimentary horn. 731

FIG. PAGE
367. Polypoid mass projecting from the cecal end of the appendix 738
368. Polyp in the appendix removed six weeks after an attack of appendicitis 738
369. Parasitic myoma adherent to the appendix 740
370. Fibroma of the appendix. Anterior view 741
371. Fibroma of the appendix. Posterior view 742
372. Fibroma of the appendix, section from preceding case 743
373. Carcinoma of the appendix causing acute perforative appendicitis 746
374. Primary carcinoma limited to tip of the appendix, the remainder of which is normal 747
375. Same as preceding, showing constriction proximal to growth 747
376. Carcinoma of the appendix 747
377. Section from the case shown in preceding figure 748
378. A small area from Fig. 377 749
379. Colloid carcinoma of the appendix discovered at autopsy 750
380. Section from the preceding case of colloid carcinoma 751
381. Invasion of the tip of the appendix by contiguity from a papillary carcinoma of the ovary 756
382. Sarcoma of the appendix involving the adjacent portion of the cecum 757
383. Section from the preceding case of sarcoma showing diffuse infiltration of the walls of the appendix with sarcoma cells 758
384. Higher magnification of Fig. 383 759
385. Peritoneal tuberculosis involving the appendix which has become partly twisted on its axis 762
386. Inflammatory thickening with tuberculous stricture of the ascending colon followed by perforation of the colon 766
387. Cross-section of the preceding 766
388. Tuberculosis of the cecum and appendix extending up into the colon 767
389. Carcinoma of the ileocecal valve extending into cecum and closely simulating appendicitis 777
390. Mesenteric ruffle showing the groups and disposition of the coils of the ileum 779
391. Anastomosis of a loop of the ileum into the transverse colon 780
392. McGraw's elastic ligature for lateral anastomosis 781
393. Lateral anastomosis after Halsted 782
394. Steps in Connell's operation for intestinal anastomosis by suture within the bowel .. 784
395. Appendix, with cecum, and beginning of ascending colon in a left inguinal hernia .. 788
396. Appendix, cecum, small intestine, and omentum adherent in an umbilical hernia .. 789
397. Appendix in a right inguinal hernia 790
398. Gangrenous appendix in a right femoral hernia 792
399. Case in which acute appendicitis and death followed severe muscular strain 809

LIST OF PLATES.

PLATE I ..... *Frontispiece*

Fig. 1. Acute appendicitis with superficial ulceration.
2. Chronic appendicitis.
3. Mild acute catarrhal appendicitis.
4. Typhoid appendix.

PLATE II ..... *facing page* 270

Fig. 1. Acute appendicitis. No adhesions.
2. Acute appendicitis. Distal third bent at an obtuse angle by a band of adhesions.
3. Gangrenous appendicitis.

PLATE III ..... *facing page* 282

Fig. 1. Acute appendicitis. Foci of suppuration visible.
2. Chronic appendicitis.
3. Enteroliths in the appendix.
4. Mild subacute appendicitis.

THE VERMIFORM APPENDIX AND ITS DISEASES.

CHAPTER I.

HISTORY.

FROM THE FIRST RECORDED CASE TO THE ESTABLISHMENT OF LESIONS OF THE APPENDIX AS PRODUCTIVE OF WELL-DEFINED CLINICAL SYMPTOMS.

"*Cependent, quelques observations recuilliés dans ces derniers temps prouvent que l'appendice vermiforme peut devenir, dans certains cas, le siége de maladies promptement mortelle.*"—(Mélier, Jour. gén. de méd., 1827, tom. C, p. 317.)

A knowledge of the morbid conditions affecting the vermiform appendix belongs exclusively to the nineteenth century. Occasional descriptions of disease in its structure, or of abnormalities in its size, shape, or position, are found in the autopsy records of an earlier date; but such instances were regarded simply as curiosities, and excited no particular comment beyond a passing conjecture as to a possible relationship between the lesion and the associated symptoms. Lesions of the appendix were long looked upon as secondary to disease in other parts of the intestine, and while this was the case no appreciation of their importance was possible.

It was not until the year 1824 that the vermiform appendix received recognition as an organ susceptible to disease arising primarily in its own structure; and still another sixty years elapsed before it was clearly and generally understood that many different abdominal disorders, whose obscure etiology was slowly undergoing differentiation, might be referred to a common origin in an inflamed appendix. This great point in the causation of certain inflammatory affections, so fatal in their termination, was clearly established in 1886, at a period when the whole domain of surgery was undergoing the remarkable evolution immediately following the introduction of antisepsis. The treatment of appendicitis by means of celiotomy thus assumed importance from the moment the true nature of the disease began to be understood, and the frequent opening of the abdominal cavity supplied, in its turn, opportunities for the investigation of the disease in all its stages which had heretofore been lacking.

The literature of the subject, insignificant in its beginning, increased after

the year 1886 with great rapidity, and has now assumed such proportions that it is no longer possible for a surgeon not devoting himself to its special study to keep abreast of it. In the present historical review my aim has been to emphasize the notable contributions which have marked periods of progress, rather than to offer an imposing array of names. I present here, therefore, a sifted literature, from which I trust my readers will agree that I have selected those names most worthy of being retained in the medical hall of fame—names of men possessing discrimination and keen insight; men who have reasoned on the problems presented at the bedside and at the autopsy table; men who have even, in some instances, forestalled the slow march of history by brilliant prophecy.

The first recorded case of disease of the appendix is the classical one of MESTIVIER, reported in 1759.* A man of forty-five sought relief for a tumor in the umbilical region on the right side; fluctuation could be detected, and about a pint of pus was evacuated by an incision; the wound healed readily, but the patient died shortly afterward. The account of the autopsy is that: "The cecum presented nothing extraordinary; it was covered with gangrenous patches. It was not the same with the vermiform appendix; I had scarcely opened it when we found a large pin, very rusty, and so corroded in certain places that the least touch would have broken it; a condition which proceeded, no doubt, not only from moisture, but from the acrid nature of the material enclosed in the vermiform appendix. After what I have just said, it is easy to understand (although the patient had never spoken of swallowing a pin) that the one under discussion had been concealed for a long time in the vermiform appendix of the cecum; and that it was undoubtedly this which had irritated the different coats of which the organ is composed, and had given rise to all the patient's symptoms, finally causing the death which ensued."†

In the year 1766, JOUBERT LAMOTTE, a student of medicine at the University of Angers, published a paper entitled "*Ouverture du cadavre d'une personne morte d'une tympanite.*" This patient suffered for some months before death with attacks of violent colic, the result apparently of an intestinal obstruction, since it is stated that "purgatives could not pass, and enemas returned unchanged." "The intestines," the writer goes on to say, "were so inflated that the mesentery and the mesocolon (the glands in which were completely obstructed) were as tense as the skin of a drum. The size of the large and small intestines was nearly the same, and the cecum was so large that it exactly resembled an immense bladder filled with air. Its vermiform appendix, which was a good inch ['*un bon*

* Edebohls, in his excellent "Review of the History and Literature of Appendicitis," cites this case as that of a woman in the eighth month of pregnancy; but the reference has been carefully verified, and the facts found as noted.

† See historical bibliography at the end of the third chapter (page 52) for all references contained in the first three chapters.

pouce'] in length, was wider than in its natural state. The fact appeared to me so extraordinary that I wished to ascertain what the organ could contain; I touched it, and I felt a foreign body, as hard as if it were petrified. . . . . When the cecum was reached, we found it filled with whole cherries. I say cherries, and not nuts, although their color was a dark brown. After having evacuated some fecal matter, we drew forth the hard body which I had felt through the coats of the intestine. It was the size of a large orange, and it resembled a compact potato, that is to say, one of those which are much less elongated than they are in general; its weight was four ounces, its consistency that of fine, well-worked butter, its color internally nearly that of an ordinary sponge; it seemed to be about as compact as touchwood." The writer makes no comment on the appearances he describes, and apparently he formed no opinion in regard to them. The case stands on record simply as the first account in the literature of fecal concretions in the vermiform appendix.

In 1790 the *Encyclopédie méthodique* was issued, the second volume of which contains an article on "*Tumors and Tubercles*," where an incidental allusion occurs to the condition of the appendix in a case of death resulting from disease of the lungs. "In the appendix of the cecum there was a brittle stone, the size of a small nut, which when dried was inflammable; in the centre of the layers of which the little stone was composed there was a hair." It is also remarked that the jejunum and a portion of the ileum were inflamed and blackened in certain places. In this instance not only is the presence of a foreign body noted, but the fact that a hair formed its nucleus.

JADELOT's, the next case on record, the first in the nineteenth century, was published in the year 1808. I abstract from the *Bibliothèque médicale* for 1814 a short account: A boy of thirteen died, two days after his entrance into the *Hôpital des Enfants*, of an "adynamic fever"; at the autopsy a great number of lumbricoid worms were found in various parts of the intestines, including four in the vermiform appendix.

Up to this date, 1808, the history of the vermiform appendix, which consisted of the four cases already cited, distributed over a half century, belongs exclusively to France.

In the year 1812 a case was reported in England by a London physician, PARKINSON. The patient, a boy of five, died after two days' illness characterized by vomiting, great prostration of strength, and barely perceptible pulse. The abdomen was distended and painful on pressure. The autopsy showed a general peritonitis with recent adhesions. All the viscera were healthy except the appendix, which was perforated by an ulcer the size of a crow-quill, through which its contents had escaped into the peritoneal cavity and contained a piece of hardened feces. Our author presents this case in the purely objective manner characteristic of these early reports, but it is plain that he recognized the perforation in the appendix as the

cause of death; he is therefore entitled to the credit of priority in this respect.

In 1813, a year after the appearance of Parkinson's case, another paper was published in France by a German named WEGELER. A boy of eighteen died with all the symptoms of appendicitis, including pain in the right iliac fossa accompanied by vomiting, which finally became fecal; examination showed an area of inflammation at the juncture of the ileum with the colon, while the cecum was destroyed by gangrene, having its starting-point, the writer states, in the vermiform appendix, in which organ a hard body could be felt, found on dissection to consist of several stones (*lapides*), three of them the size of peas, and the fourth as large as a pigeon's egg. The other abdominal organs were healthy. Wegeler did not believe that these stones were the original cause of disease, but he considered it probable that if the inflammatory condition had originated from other causes, the presence of irritating substances in such a situation might easily augment an otherwise trifling evil. He regarded the stones as biliary calculi,* which had undergone change from the action of the intestinal secretions; and he subjected them to chemical analysis, the results of which were as follows:

Lapidis granum 1 constabat e

Materia pingui adiposa	0.60 gm.
Phosphat. calcis	0.30 "
Materia animali	0.08 "
Ponderis diminutio erat	0.02 "
	1.00 gm.

This paper is distinctly an advance on anything previously written, for not only does the writer clearly recognize disease of the appendix as the cause of death, but he attempts to elucidate the part played by the foreign bodies, and submits a careful analysis.

Wegeler's work attracted some attention at the time of its appearance, and became the subject of discussion at a medical meeting at Paris shortly after its publication; without effect, however, so far as the stimulation of thought is concerned, for nothing more of significance appeared for yet another decade.

In the year 1824 a Frenchman, LOUYER-VILLERMAY, published an article which at once established a definite place for lesions of the appendix in the category of recognized diseases. The title of this paper, "*Observations pour servir à l'histoire des inflammations de l'appendice cecale,*" is in itself suggestive of a marked advance in knowledge, since we here find the first recog-

* This is the first of a series of statements that biliary calculi have been found in the appendix, extending down to our day, no one of which has yet been satisfactorily proved. (See pp. 298 and 363.)

nition of the fact that the appendix as a diseased organ could have an individual history. He gives an account of two cases, which I quote somewhat in detail, as they are the first clinical histories recorded at length.

Case 1.—A man of thirty-five was suddenly attacked with violent pain in the right side of the abdomen, followed by vomiting; the abdomen was extremely sensitive to pressure in the right iliac fossa. The right testicle was strongly retracted. There had been no premonitory symptoms, except a coldness of the dorsum of the right foot, present for several days before the onset of the attack. (It is curious that this particular symptom made a decided impression at the time, and is referred to by subsequent writers, who seem to have sought it constantly as a prodromic symptom of appendicitis.) Remedies, such as poultices and leeches to the right iliac fossa, were without effect, and the patient grew gradually worse until the fourth day, when he died tranquilly. At the autopsy, twenty-four hours later, the testicle was found near the abdominal ring, but sound. In the right iliac fossa there was a collection of about five ounces of a dark serous liquid with a gangrenous odor, in the midst of which the vermiform appendix was floating. This organ was about one-third longer and wider than usual, perfectly black, gangrenous, and putrefied. The evidences of gangrenous inflammation decreased from the vicinity of the appendix, disappearing entirely in the cecum, which was healthy. The folds of peritoneum around this part of the intestine, dotted here and there with small spots of gangrene, were adherent to the iliac fossa. The cellular tissue surrounding the right kidney was full of sero-purulent liquid, but the kidney itself was normal. The mucosa of the stomach was red and thickened, but that of the intestines was normal, and all the other organs of the body were healthy.

Case 2.—The patient was a man of thirty-seven, with a right inguinal hernia supported by a truss. One evening he was taken ill with nausea and severe colic, with a sense of oppression in the umbilical region, which continued without intermission until morning, when there was a short period of relief during which he was seen by a physician. The umbilical region was then slightly sensitive to touch and both hypochondriac regions were swollen. The pain soon returned, and after a few hours became localized in the right iliac fossa, being accompanied by vomiting, dysuria, and abdominal distention. Death occurred during an interval of relief following syncope, about thirty-six hours after the onset of the attack. The autopsy, held twenty-four hours after death, showed a pyramidal body in the right iliac fossa, which proved to be the appendix. It was about three inches long, and about one inch in diameter at its base; its color was a dark violet, and it was turned toward the inguinal ring, which was much dilated. Its mucous membrane was thickened and of a silvery whiteness near the cecum, but black and discolored in the rest of its extent. The cecum was healthy up to the point of attachment of the appendix. The intestines were distended by gas, though otherwise normal,

but the mucous membrane of the stomach showed signs of inflammation. The other organs were healthy.

The writer observes: "These two cases appear to us to belong to the same disease, for the incidental occurrence of an inguinal hernia in one does not make any important difference in the nature of the affection, nor even in its course, since it was completely reduced. It is, of course, possible that the appendix had originally formed part of the hernia, and had thus acquired its unusual size, but only possible, since examination of the ring and of the scrotum did not show any apparent trace of such a condition. Therefore, these two cases seem to me identical, although offering some external differences. In both, we see a man in the prime of life, with a good constitution, suddenly attacked in the midst of perfect health by an inflammation of the most acute character, with a rapidly fatal termination. In both, death was preceded by a deceitful calm suggesting amelioration, and when it occurred was free from pain." It may be noted in this connection that the occurrence of death "*sans agonie*," or, as some of the older writers express it, "*placidâ morte*," is frequently alluded to in early descriptions of appendicitis. Villermay goes on to observe that "Treatment was equally useless in both cases. The autopsies presented some differences in detail, but the fundamental lesion was the same in both; the same organ, the appendix, being affected in the same manner, and death ensuing with equal rapidity. In both cases the gangrenous process involved the whole of the appendix, but extended from it only in an accessory manner, and within very narrow limits; the entire peritoneum, the bulk of the intestines, the interior of the cecum, and all the other viscera being free from it. The inflammation of the mucous membrane of the stomach probably proceeded from sympathetic irritation produced by vomiting." In conclusion, he asks: "But how could the inflammation of an organ of such small size, and more especially of such limited importance, occasion death so rapidly, and without resulting peritonitis? We are equally in the dark as to whether disease of this organ will be always followed by results as speedy and as disastrous."

A month after the appearance of Louyer-Villermay's article, a paper was published in England by Blackadder. This communication is almost entirely occupied with the discussion of a single case, presenting unusual features. A man, forty years of age, fell suddenly to the ground in a state of collapse, without premonitory symptoms of any kind. He complained of excruciating pain in the abdomen, which was exquisitely sensitive to touch, and is described as "greatly and permanently retracted," while the respiration was purely thoracic. Death occurred in three and a half hours from the onset of the attack. A postmortem examination showed the heart much enlarged, with a clot extending nearly to the arch of the aorta. The abdominal viscera were healthy, except the vermiform appendix, which was remarkably increased in

length and thickness, resembling a firm cord to the touch; its cavity was filled by a large lumbricoid worm, with its tail projecting into the cecum. No other worms were found in the intestine, and there was no inflammation. Blackadder considered that the irritation produced by the worm caused, either directly or reflexly, a spasmodic contraction of the abdominal muscles, impeding the action of the already diseased heart. He mentions two other cases in which he had found lumbricoids or fecal concretions in the appendix at autopsies, death having occurred from causes altogether distinct from that organ.

In 1827 another Frenchman, MÉLIER, published an article so full of thought and insight that it might well have marked an historical epoch in the subject had the author possessed the courage of his convictions, and had he been able to combat Dupuytren, the greatest surgical authority of his time.

Mélier begins by noting that pathological anatomy had taught almost nothing in regard to disease of the appendix. Some recent observations, however, he says, show that disease of the organ may assume a *rôle* of the highest importance, for under certain conditions it can become the seat of a rapidly fatal disease. He then cites Louyer-Villermay's cases, and adds another from his own experience, in which a patient, when apparently on the road to recovery, after a self-administered enema had a sudden return of agonizing pain in the lower abdomen, followed by an acute peritonitis, and died eighteen hours after the onset of the second attack. At the autopsy the vermiform appendix was found gangrenous and perforated in several places. Mélier's analysis of the situation is this: "In my opinion, the fecal matter accumulated in the appendix, which then dilated little by little, becoming first inflamed, then gangrenous, and finally perforated. The earliest symptoms, appearing in the form of colic, are probably accounted for by the inflammation and distention of the appendix; its rupture occasioned the effusion, which was responsible, in turn, for the peritonitis. The perforation was determined, or at any rate hastened, by the patient's exertion in taking an enema, since it was at this moment that the intense pain began, and immediately afterward that peritonitis set in." He then cites two other cases, of lesser interest, in regard to which his own remarks are noteworthy. "This disease," he says, "is considered extremely rare; observe, however, that the five cases which form the basis of this paper have been collected in a short space of time, and that two among them were reported by the same physician; these facts entitle us to believe that if such affections have not been more frequently observed, it is because the appendix has not received sufficient attention, and because lesions situated in it have been overlooked at autopsies. In regard to diagnosis, I will say, further, that when my friend Monsieur Sévestre was called to the second of the cases, which he reported to me, he was able to state posi-

tively that the appendix was affected, so much did the symptoms resemble those in the first case, which had struck him forcibly at the time as characteristic."

Mélier then goes a step farther, and applies the knowledge gained from these acute cases to chronic forms of the same disease. A patient had a tumor in the right iliac fossa, which yielded to treatment, but returned in three years. Dupuytren saw the case in consultation, and, as fluctuation could be detected, the swelling was incised, evacuating a considerable quantity of pus. The wound remained open, continuing to discharge, and three new abscesses appeared at a little distance from the first, all of which opened spontaneously. This condition lasted more than a year, when the patient took a violent cold, followed by acute general peritonitis and death. The autopsy showed an immense abscess at the seat of the tumor, communicating with the outside by four openings. To this abscess adhered a part of the cecum, together with the vermiform appendix, the latter being closely united to the abscess walls by dense connective tissue, and opening directly into the abscess cavity. "In comparing this case," says Mélier, "with the preceding ones, I am constrained to believe that here also the appendix cæci was the original source of evil; that there had been a collection of fecal matter in its cavity, perhaps even a stercoral calculus, and that the appendix, acutely inflamed, had become adherent to the peritoneum, the adjacent cellular tissue becoming engorged, and an abscess forming in consequence of the perforation of the appendix." Could there be a clearer recognition of the causal nexus existing between disease in the appendix and chronic suppurative affections in the right iliac fossa? To Mélier undoubtedly belongs the distinction of first appreciating this causal relationship. He had not, however, unfortunately for himself, sufficient confidence in his own judgment to maintain his theory unreservedly, for he proceeds somewhat timidly: "It is possible that the tumor was first formed, and the appendix secondarily affected; indeed, it favors this view that pus was never present in the stools, nor fecal matter in the discharge from the wound." It is also interesting to find that he was sufficiently in advance of his generation to suggest surgical treatment for the condition he is discussing. His prophetic words on this point are stated in a foot-note: "If it were possible, indeed, to establish the diagnosis of these affections in a certain and positive manner, and to show that they are always entirely circumscribed, the possibility of an operation might be conceived: some day, perhaps, this result will be reached."

To Mélier, then, belongs the credit of distinguishing inflammation of the appendix from inflammatory conditions affecting other portions of the intestine with greater acuteness than any of his predecessors. He first formulated correct conclusions as to the existence of such inflammation in a chronic form; and he first recognized the causal relation between this chronic affection of the appen-

dix and suppurative tumors of the right iliac fossa. Finally, he first suggested the possibility of relief by means of operative measures. The possibility of primary disease in the appendix once established, lesions of the organ became entitled to a definite place in the category of recognized diseases, and therefore with the appearance of Mélier's article the first stage in the evolution of knowledge concerning the vermiform appendix may be considered to end.

CHAPTER II.

HISTORY.

FROM THE DISTINCT RECOGNITION OF LESIONS IN THE APPENDIX TO THE KNOWLEDGE OF APPENDICITIS AS A SURGICAL AFFECTION.

1827–1886.

"*It is the duty of every physician to be mindful that, for all practical purposes, perityphlitis, perityphilitic tumor, and perityphlitic abscess mean inflammation of the vermiform appendix.*"—(Reginald Fitz, New York Med. Jour., 1886, vol. 47, p. 508.)

We should naturally suppose that the issue in rapid succession of two papers so full of interest as those of Louyer-Villermay and of Mélier would have been followed by other immediate advances in our knowledge of disease of the appendix. Such was not the case, however, and, notwithstanding the excellence of this beginning, the further development of the subject was slow and uncertain, owing to great misdirection of effort. Abscess in the right iliac fossa at this time began to receive considerable attention, especially in France, where Mélier, as we have just seen, clearly recognized its relation to inflammation of the appendix. His views failed of acceptance, however; mainly because the most eminent surgeon of the time, Dupuytren, took a contrary position. The history of our subject, indeed, affords at this point a striking example of the difficulties encountered by originality of idea when opposed to the weight of established authority. Dupuytren stated emphatically that he believed the reason such abscesses were met with on the right side rather than the left was to be found in the natural and pathological relations of the intestine in that region. The fact that the intestinal canal ceases at this point to be freely movable, that food material here begins to assume an excremental character, and to be forced onward in opposition to the laws of gravity, together with the occurrence of stasis, favored by the smallness of the opening between the small and the large intestine, were, in his opinion, sufficient reason for the appearance of these tumors in the right iliac fossa. This opinion was formally expressed in the *Leçons chirurgicales* which appeared in 1833, but it had, no doubt, been long before impressed orally on Dupuytren's students. Two of the latter, indeed, Husson and Dance, published a paper in 1827, in which they developed Dupuytren's views with much completeness, and (as they are careful to say) with Dupuytren's approval.

Ménière, in 1828, published an article in which he also insisted on a cecal

origin for what he terms "*tumeurs phlegmoneuses*," advancing his theory that their exciting cause was an impaction of feces. In his opinion there was no connection between these tumors and the vermiform appendix, and in support of this conviction he cites the same case which Mélier had previously used to prove the relation between the two in cases of chronic suppuration of the right iliac fossa. It will be remembered that this case was one in which a fluctuating tumor existed in the fossa, and after some time the pus burrowed under the psoas muscle until it pointed externally. An incision (made by Dupuytren) brought no relief, and the patient finally died of exhaustion. At the autopsy the appendix was found full of fecal concretions, adherent to the peritoneum, and opening into the intestine. Mélier, as we have said, believed in the causal relation between the diseased appendix and the tumor, but, unfortunately for himself, he failed to insist upon it, as he considered the absence of pus in the stools, and of feces in the discharge from the external wound, inconsistent with his theory, and honestly admitted the fact. His frankness on this point gave Menière the opportunity to reject his opinion, with the remark that the originator himself did not really support it. Dupuytren also brings forward this same case in the *Leçons chirurgicales*, where he expresses himself as in agreement with Menière. More courteous than the latter, however, he adds that no doubt there is such a thing as disease of the vermiform appendix, and his former pupil, Monsieur Mélier, has written an admirable paper upon the subject; a remark evidently prompted, however, by perfunctory professional courtesy, for he declares himself emphatically opposed to the theory of any causal relation existing between right-sided iliac tumors and inflammation of the vermiform appendix. There can be no doubt that Dupuytren stood upon the brink of a great discovery, and that he entirely failed to appreciate the fact; worse still, his lack of perception absolutely hindered the progress of investigation by depreciating the influence of the man whose insight had discovered the line which further research ought to pursue. It is a pleasure, therefore, to be able after the lapse of more than three-quarters of a century, in rendering honor to whom honor is due, to accord Mélier his rightful position, foremost among pioneers in the study of diseases in the appendix.

The theory that suppurative tumors in the right iliac fossa arose from cecal disturbances of one kind or another thus became firmly established, and remained dominant for over half a century, until, in fact, it was gradually thrust aside, or rather supplanted, for it was never formally abandoned. Although Dupuytren and his followers failed to understand the real significance of disease in the appendix, they did the cause good service by stimulating investigation, and the reports of primary lesions of the appendix from now on increased year by year, until the frequency rather than the rarity of such disease became generally admitted, and correct opinions in regard to its natural history began gradually to take form.

Up to this time, that is to say, the end of the third decade of the nineteenth

century, all interest in diseases of the appendix had been confined to England and to France, but we have now reached a point when Germany, hitherto silent, began to contribute her quota of observations.

Goldbeck, in the year 1830, issued an inaugural dissertation at Worms, entitled "*Ueber eigenthümliche Geschwülste in der rechten Hüftbeingegend,*" which stimulated interest in Germany just at the moment when it began to decline in France, and for the next twenty-five years all contributions to the subject of interest or importance, with a few notable exceptions, were German. These Teutonic discussions form a distinct episode in the history of the vermiform appendix, which has not as yet been duly estimated. I will, therefore, present this historical phase of our subject at this point, deferring for the moment, for the sake of completeness, the consideration of the few important papers appearing in other countries during this quarter of a century.

The subject of Goldbeck's thesis, inflammatory tumors in the right iliac fossa, was adopted at the suggestion of his master, Puchelt, who had given close attention to these tumors, the results of which, when finally collected, appeared in the *Heidelberger klinische Annalen*, for 1832. Both Puchelt and his scholar held that these tumors were the result of collections of pus in the loose connective tissue surrounding the cecum; to this condition, therefore, which they believed to be of cecal origin, they gave the name "perityphlitis." This convenient and, may I say, euphonious term met with immediate general acceptance, and even yet continues in use in Germany and England. Differences of opinion are often found among later writers as to the real origin of this term; did it originate with Goldbeck or with his master? To settle this question it seems worth while to quote Puchelt's own words. "Ich selbst habe," he says, "einen früheren Schüler von mir, Herrn Dr. Goldbeck, veranlasst diesen Gegenstand zu bearbeiten, und es erschien die Schrift desselben als Inauguralabhandlung zu Giessen, unter dem Titel: 'Ueber eigenthümliche entzündliche Geschwülste in der rechten Hüftbeingegend.' In dieser Schrift wird bereits der Name Perityphlitis für diese Krankheit vorgeschlagen, den wir beide gemeinschaftlich gebildet hatten: ich hoffe dass er eben so sprachrichtig ist, als er der Sache entspricht." Surgery, however, has no reason to be grateful for this denomination, either to Goldbeck or to his master, as the name perityphlitis is altogether misleading, diverting attention from the real source of evil, the appendix, and clogging the wheels of progress for more than half a century by leading inquirers on the subject astray.

The excellent clinical picture of inflammation of the appendix drawn by Puchelt and Goldbeck would answer well for a description of the disease in a text-book of to-day, but so far were they from understanding the real signifi-

cance of the symptoms depicted, that Goldbeck says frankly he is at loss for an explanation of them, and that the reason these tumors do not make their appearance on the left side is one for consideration. He suggests that the position of the cecum favors the accumulation of pus on the right side, whereas on the left side the resistance offered by the surrounding peritoneum and the mesocolon forces the pus to burrow under the ilium and point toward the exterior in that direction, or else to destroy the connective tissue in the region of the rectum and form a rectal fistula.

The immediate result of Goldbeck's essay was the stimulation of others on the same subject. I find not less than twenty-four theses treating of diseases in the right iliac fossa making their appearance between the years 1830 and 1860, of which number nineteen issued from German universities. It is noteworthy that nearly all the early work contributed by Germany to the study of the appendix is embodied in dissertations, whereas in France and in Great Britain it found expression almost entirely in periodicals. In these German theses we find iliac tumors considered as primary disorders *per se*, and it is only when we interpret them in the light of knowledge lately acquired that we are able to read between the lines and discover the information contained in them as to disease of the appendix, the authors themselves being ignorant of the true significance of their work.

Merling, in 1827, published a thesis on the pathological anatomy of the appendix, in which the natural history of the diseased conditions affecting that organ is for the first time independently discussed. A considerable part of the dissertation is devoted to anatomical variations, displacements, and adhesions, but the process of inflammation is also clearly described.

The most striking characteristic of these German theses, in the light of our present knowledge, is the beautiful accuracy of their symptomatology, a quality which seems to be less appreciated to-day. The occurrence of diarrhea in the early stages of appendicitis is universally noted, together with the wandering character of the pains at first, in regard to which Puchelt says: "*Oritur ventris dolor crucians, pungens, vagus, in regione epigastrica, imprimis ventriculi et alibi . . . . ille vero dolor nychtemera nondum finito migrat ad regionem iliacam dextram, eique inhæret firmiter.*" More than one writer takes occasion to remark that the pain in inflammation of the appendix must vary with variations in the anatomical position of the organ, and one of them in particular, Genzmer, published an able dissertation in 1842, giving an admirable exposition of this point. Schmidt also, writing in 1847 upon the differential diagnosis of inflammation of the appendix, almost describes our McBurney's point, for he declares that a diagnostic sign in the disease is the increase in the severity of the pain caused by pressure in the region of the cecum, over an area scarcely the size of the thumb, or even so small that it can be covered by the tip of the finger. "*Pressu dolor augetur, ita ut ægri exclamationes vix retinere possint, in parvulo tantum regionem ileo-cæcalis loco, qui vix pollicis circuitu est, plerumque*

vero tam parvus est ut extremo digito facile tegas; quod symptoma sane non minimo ad diagnoscendum hunc momento mihi videtur." It is impossible not to feel a momentary surprise that knowledge concerning disease of the appendix should have advanced so slowly in the presence of such nice discrimination. A second thought reminds us, however, that although these early German writers described symptoms so accurately, they never ascribed them to their real source. Puchelt himself wholly failed even to suspect the causal nexus between the appendix and perityphlitis, and although occasional writers like Genzmer and Schmidt did actually recognize the existence of an acute appendicitis, it was considered as a great rarity. No one appears to have entertained the suspicion that inflammation of the appendix was the real cause of the iliac tumors with which all surgeons of that time were constantly occupied, the cecum itself and the pericecal tissue being regarded as the *fons et origo malorum.*

Albers, in 1838, published a paper on the cecum, which, contributing nothing new, yet calls for mention because of the introduction of another misleading term, namely, that of "typhlitis" for inflammation of the cecum, and because he points out that Puchelt had not discriminated between this condition and inflammation around the cecum, to which Albers restricts the name "perityphlitis."

Leaving the subject of German literature, and returning to that of other lands, I find four systematic British contributions to the history of the appendix during the fourth decade of the century—one by Copland, one by Hodgkin, one by Bright and Addison, and one by Burne. Copland's contribution is in the form of an article on the "*Cecum*" in his own *Dictionary of Practical Medicine*, the first edition of which appeared about 1832. To Copland belongs the credit of first discriminating between inflammation of the cecum, inflammation of the appendix, and inflammation of the pericecal tissue. He recognized primary disease of the appendix, but, in common with other writers of the time, believed that such disease began, as a rule, in the cecum and manifested its extension into the appendix by symptoms indicating a high degree of inflammation; indeed, he claims that inflammation of the appendix can always be distinguished by the severity of the symptoms as compared with those attending inflammation of the cecum alone. All writers of the period seem to have attached great importance to this supposed association between disease of the appendix and a high degree of pain and constitutional disturbance. Copland is, I believe, the first person to include blows and violent exertion among the exciting causes of disease in the appendix. He further considers in some detail the supposed relationship between dysentery and disease of the appendix, which he noticed during a long residence in India, without, however, citing a single case in which such an association was demonstrated, nor have I met any instance among the older writers, who persistently tabulate dysentery in the etiology of appendicitis. It seems, therefore, that the idea of an interdependence

between dysentery and disease of the appendix and cecum originated rather in a passing notion, which, once born, was nursed as the legitimate offspring of fact by one writer after another for a series of years.

Thomas Hodgkin, true follower of the great John Hunter, in his "*Lectures on the Morbid Anatomy of the Serous and Mucous Membranes,*" published in 1836, says with remarkable clearness but vexatious brevity that "the partial inflammation of the peritoneum, in the iliac fossa, is sometimes set up by disease in the appendix cæci," which may be limited, or may go on to ulceration caused by the lodgment of fecal concretions in its cavity. "Even in these cases," he continues, "nature sometimes succeeds in limiting the inflammation to a part of the right side; but it is at other times diffused over the whole of the abdomen, is accompanied by symptoms of the most serious nature, and quickly proves fatal."

Richard Bright and Thomas Addison, in the "*Elements of the Practice of Medicine,*" have left us an admirable presentation of the subject, opening up in the clearest manner the whole realm of affections of the appendix; and I wish space permitted me to quote the entire six pages of their work devoted to "*Inflammation of the Cecum and Appendix Vermiformis.*" "That portion of the intestine," they say, "which is lodged in the right iliac region is frequently the seat of inflammation. The history of the affection is often as follows: The patient has complained more or less for some time past of pain or uneasiness in the part, increased on exertion or after neglect of the bowels or excess in eating or drinking; . . . . after some unusual exposure to cold, or some long walk, or other over-exertion, he has been suddenly seized with rigors, chills, and sometimes with sickness and violent vomiting. The pain and tenderness become excessive, and extend to the neighboring parts of the abdomen. A hardness and tumefaction are soon very evident to the hand in the part first affected; this continuing, general symptoms of peritonitis often take place, and terminate fatally." The formation of abscess is noted, opening of its own accord or assisted by the lancet, securing a discharge of ill-conditioned pus soon mingled with fecal matter.

"From numerous dissections it is proved that the fecal abscess thus formed in the right iliac region arises, in a large majority of cases, from disease set up in the appendix cæci. It is found that this organ is very subject to inflammation, to ulceration, and even to gangrene; and, moreover, that it is occasionally thickened and ulcerated from tubercular deposits." "This little worm-like body is often detected in the midst of the abscess, with a perforation at its extremity, or by ulceration higher up in its parietes, a considerable portion of it, nearly or entirely separated, is found in a disorganized condition among the pus and feces which fill up the abscess. . . . . In a smaller number of instances the cecum itself is found inflamed and ulcerated, and extensively implicated in the abscess, in a way which shows that the appendix had little to do with the disease."

How clear and comprehensive are the following remarks upon "exciting causes": "It is possible that the secretions of the appendix itself may sometimes become diseased, and give rise to inflammatory action in the part; sometimes we can plainly discover that stricture, amounting even to occlusion of the cavity, has taken place, so that the extremity has been distended with its own secretions; and this may plainly give rise to inflammation; and at other times we find little oval masses of feces impacted in the canal, which have pretty obviously produced the irritation; sometimes a foreign substance, as a cherry-stone or other seed, has been detected in the appendix, but one of the most common causes is undoubtedly the formation of a peculiar concretion which is moulded to the extreme cavity of the canal, and which is composed of coats or layers of the earthy phosphates, with occasional alternate layers of animal secretion or of feculent matter."

As to diagnosis, "the situation of the abscess in the right iliac fossa will often sufficiently point out the probability of its nature"; but in some cases difficulties arise, "because, owing to the occasional burrowing of the abscess, it may become most prominent at some distant part."

In the treatment it is advised to unload the bowels by mild but effective purgatives, assisted by injections of soap and water, or gruel, or other bland liquids, so as to empty completely the large intestine. "At the same time, we must endeavor to disturb the part as little as possible"; for the contents of the intestine or of the abscess may become extravasated into the peritoneal cavity, if violence is done in our manual examination. "We must always hold in mind that, though our first object must be to allay the inflammation so as to prevent the formation of an abscess, yet much more frequently we shall be called upon to prevent an ulceration and abscess, which are inevitable, from doing essential and extensive mischief." Is not this, we may ask, an almost perfect presentation of the status of the problem to-day, over sixty years after these lucid remarks were penned? With what insight, with what perspicacity, did these great English masters of our art portray to an antecedent generation the outlines of the affection which became the malady *par excellence* of the end of the century! Had not vague speculation and a false nomenclature stepped in to alter the masterly outlines here given, who can say how different the history of appendicitis might have been!

John Burne, physician to the Westminster Hospital, contributed two papers in 1837 and 1839 to the *Medical and Chirurgical Transactions*, treating of disease in the cecum and appendix. These communications have always received much consideration, and Burne's name has, in consequence, been closely associated with the earliest literature of appendicitis. A dispassionate consideration of his work at the present time, however, shows that its value has been greatly overestimated. His undertaking, he says, is due to the fact that disease of the appendix had hitherto received no systematic consideration, showing that he was not aware of the French writers who had made such ex-

tensive contributions, nor does he seem to have been familiar with the work of his own countrymen. He refers, indeed, to no one but Menière, whose work is perhaps of the least value. He fails to discriminate between disease of the cecum and disease of the appendix, and no definite conclusions can be drawn from his cases, for even when an autopsy was made he often neglected to mention the appendix at all! He offers no valuable suggestions, he lacks every quality of the seer, and even hindered progress by introducing such a misleading term as "t u p h l o - e n t e r i t i s." I have had occasion to note already the harm done to progress by a bad nomenclature, and I am sorely tempted here to a short digression to consider the question so often asked: "What is in a name?" Everything! The whole history of medicine, age after age, has been dominated by mere names. A false name, conveying a wrong impression, once given in any new field, in the early days of investigation, opens up a path of error along which men, in their eagerness to follow, tumble over one another like sheep, and any farther real advance is rendered impossible until the steps are retraced. The unfortunate term "p e r i t y p h l i t i s" coined by Puchelt and Goldbeck ten years before had already diverted attention from the appendix, the real point at issue, and now "t u p h l o - e n t e r i t i s," in line with the extraordinary gastro-enteric pathology of the day, appeared in the field to lead inquiry still farther astray.

I find myself at a loss to discover any reasons why Burne's work has always been considered a classic in the literature of appendicitis; I believe the notice it attracted was largely accidental, and due partly to its appearance in a well-known periodical. The same reasoning accounts for the frequent reference to Grisolle's paper on "*Tumeurs Phlegmoneuses*," in the *Archives générales de médecine*, for 1837. Though Grisolle, like Burne, is often quoted with deference, a careful perusal shows that his work is almost valueless, as he sees no reason for distinguishing between tumors in the right and left iliac fossæ, nor does he exclude abscesses consequent upon the puerperal state.

Among the briefer reports in the current literature of this period is one which especially deserves the attention of our American surgeons, because it is, as far as I can ascertain, the first instance of disease of the appendix reported in the United States.

Wolcott Richards, of Cincinnati, in September, 1837, published a case of perforation of the appendix confirmed by autopsy. The patient, a man thirty-five years of age, had a distinct chill, followed by fever, but without pain in the abdomen or vomiting. For thirteen days he improved under treatment, consisting mainly of calomel and light diet, but on the fourteenth day he was found in a state of collapse, which came on twelve hours before; his attendant declared that a short time before the change occurred he had eaten imprudently of fruit. He died on the fifteenth day, without a diagnosis having been made. At the autopsy a general peritonitis was found with recent adhesions, while the pelvis was filled with fecal matter issuing from a large ragged

perforation in the vermiform appendix. Dr. Richards comments upon the strange fact that not only vomiting but abdominal pain and tenderness were absent during the entire illness; only after the final change for the worse took place was there extreme tenderness over the hypochondriac region together with slight distention.

Dr. Thaddeus Reamy, of Cincinnati, informs me that Dr. Richards was born in New London, Connecticut, in 1803, and studied medicine in the office of Dr. North, of New London, in the Yale Medical School in 1828; in this year he went to Cincinnati, where he enjoyed a large, lucrative practice for thirty years, greatly beloved both by patients and the medical profession. His death occurred in New York, in 1871, due to a sarcoma of the base of the brain.

Edward Hallowell, of Philadelphia, in May, 1838, reported a similar case. The patient, a girl of nine, in poor health for some weeks and troubled by a persistent cough, complained of pain in the right iliac fossa, and a physician, without seeing her, prescribed three compound cathartic pills, which acted violently. Dr. Hallowell, visiting her the next day, found a distinct tumor in the right iliac fossa, exquisitely tender on pressure; there was meteorism and a dark vomit, which continued until death the next day. The autopsy, attended by Drs. Warrington, Pearce, Pepper, and Hallowell, showed tuberculosis of the right lung, general peritonitis, and an appendix firmly adherent to the caput coli, with a small perforation at its base about two lines in diameter. The mesenteric glands near the appendix were enlarged and tuberculous, and there were tuberculous deposits elsewhere in the intestines. "The local peritonitis," the writer remarks, "was no doubt of long standing, its exciting cause was somewhat doubtful; the probability, however, is that in consequence of a deposit of tuberculous matter and the consequent softening, an ulceration of the coats of the appendicula was induced, but the opening being minute and the contents of the appendicula small in quantity, the inflammation was not sufficient to give rise to symptoms of an acute character, and it was not until, by the action of drastic medicines, the secretions from the mucous cryptæ of the intestines were greatly augmented, and subsequent violent efforts of the bowel induced, that the contents of the bowel found their way into the cavity of the peritoneum, giving rise to the acute symptoms we have detailed, and causing death in a few hours."

These are the only cases, with four exceptions, appearing in the United States for a period of nearly twenty years. In the following decade a case was reported, I believe for the first time, in Italy, when Carlo Vecchi, of Milan, published a paper in 1848 entitled "*Peritonitis diffuse dell' appendice vermiformi ceci.*" The writer begins by saying that he does not think he goes too far in expressing the opinion that, for Italians, the condition he describes appears as a new disease. Then, after a short and incomplete account of the literature of the subject, he cites two cases, one in his own practice, another (in a foot-note) related to him by a physician who was present at the autopsy upon Vecchi's

own patient. This second case is apparently a perforation of the appendix occurring in typhoid fever. The paper is a creditable first effort in a country where disease of the appendix had hitherto received no attention.

VOLZ, in 1846, published what is undoubtedly the most important contribution to our subject for a period of two decades. I have purposely deferred noticing this work among the German dissertations, as its importance entitles it to special consideration in its own time and place. Writing under the caption "*Die durch Kothsteine bedingte Durchbohrung des Wurmfortsatzes die häufig verkannte Ursache einer gefährlichen Peritonitis und deren Behandlung mit Opium,*" the avowed purpose of his thesis is to insist upon the benefit derived from the opium treatment in perforations of the appendix. His views on this particular point will be more appropriately considered elsewhere (see page 511); in the present connection, I am chiefly concerned with his work as a systematic contribution to the subject in its general relations. Volz, after citing three cases in which post-mortem examinations revealed the presence of fecal concretions in the appendices of patients dying from other causes, then gives a list of thirty-eight cases in which, after a fatal illness characterized by symptoms of abdominal inflammation, the vermiform appendix was found perforated by a fecal concretion, some of them occurring in his own practice. He is doubtful whether perforation of the appendix ever occurs (exclusive of cases resulting from tuberculosis and typhoid fever) from any other cause than a fecal concretion, so that he devotes his close attention to the study of these concretions, dividing them into three classes: of soft, hard, and medium (*halb-feste*) consistency. He notes the fact that concretions greatly resemble fruit stones, and therefore are often taken as such; a chemical analysis, however, proves that they are composed of organic matter and salts. Volz's account of the natural history of appendicitis is perhaps the most thoughtful and comprehensive treatment of the subject up to his time. He here points out that the condition known as "perityphlitis" is not primary, but consecutive to inflammation of the appendix vermiformis. He further distinguishes plainly between suppurative and non-suppurative forms of appendicitis, dividing the suppurative forms into two classes, one in which the pus discharges into the abdominal cavity, exciting a general peritonitis, and another in which the abscess, circumscribed by adhesions, burrows in different directions according to the efficiency of this protective barrier in limiting the extension. Volz believes that the prognosis is favorable if only the opium treatment is followed out, and he insists that constipation, the common concomitant of the disease, favors recovery and should be encouraged by every possible means.

The antiphlogistic treatment in vogue, Volz characterizes as irrational and brutal, expressing the hope that the day will come when the principle of rest for

the intestines, in cases of inflammation of the appendix, secured by means of opium, will be as clearly recognized as the same principle universally used for a broken leg when it is encased in splints, a happy parallel, which he makes all the more striking by carrying it out in some detail with both ingenuity and humor.

"*Nehmen wir einmal an, ein Arzt besässe ueber den ursächlichen Zusammenhang der Zufälle eines Beinbruchs eben so geringe Kenntniss, als ueber den der Zufälle unsrer Krankheit, welche er* lege artis *mit Calomel behandelt, und wende bei der Beurtheilung derselben das nämliche Raisonnement an, welches ihn bei der rationellen Behandlung dieser Peritonitis leitet, so werden wir erstaunen über die Heilmethode des Beinbruchs. Es wird uns absurd erscheinen bei der Fractur, was bei der Peritonitis für rationell gilt.*

"*Beinbruch.*	"*Peritonitis durch Perforation.*
"*Ein gesunder Mensch empfindet plötzlich nach einem mechanischen Eingriff (Fall) einen Schmerz im Fusse, und kann seitdem nicht mehr gehen noch stehen. Ohne die Ursache zu erkennen, urtheilt der Arzt: so lange der Mensch gehen konnte, hatte er keine Schmerzen, sobald er auf den Füssen steht und geht, werden die Schmerzen aufhören. Also: er wird mit der Peitsche aus dem Bette getrieben, und mit Gewalt auf die Füsse gestellt. Der Erfolg ist: die Schmerzen steigern sich, und der Kranke kann doch nicht gehen.*	"*Ein gesunder Mensch empfindet plötzlich nach einer mechanischen Veranlassung (körperliche Bewegung) einen Schmerz im Leibe, und hat seitdem Verstopfung. Ohne die Ursache der Krankheit zu erkennen, urtheilt der Arzt: So lange der Mensch Stuhlgang hatte, hatte er keine Schmerzen, sobald die Verstopfung beseitigt ist, werden die Schmerzen aufhören. Also: Abführmittel, Calomel. Der Erfolg ist: die Schmerzen steigern sich, und es tritt doch kein Stuhlgang ein.*

"*Denken wir uns andrerseits beide Krankheiten erkannt und behandelt, die eine mit dem chirurgischen Verband, die andere mit Opium, und nehmen wir dabei an, die nähere Beziehung des Verbandes und seine Wirksamkeit zur Fractur sei uns nur ebenso oberflächlich bekannt, wie die des Opiums zur Peritonitis, so erhalten wir folgende Parallele.*

"*Der Arzt erkennt als Ursache des Schmerzes und des Unvermögens, zu gehen, einen Beinbruch. Er wendet Mittel an, welche dieses Unvermögen noch steigern, er bindet den Fuss und den Kranken im Bette fest. Während des Gebrauchs dieses Mittels verliert sich der Schmerz, und das Vermögen, zu gehen, stellt sich nach und nach von*	"*Der Arzt erkennt als Ursache des Schmerzes und der Verstopfung eine durch Perforation eines Darms bedingte Peritonitis. Er wendet ein Mittel an, welches diese Verstopfung noch steigert, Opium. Während des Gebrauchs dieses Mittels verliert sich der Schmerz, und der Stuhlgang stellt sich von selbst wieder ein. Der Kranke verlangt auf*

selbst wieder ein. Der Kranke verlangt aus dem Bette, ohne mit der Peitsche getrieben zu werden.

den Nachtstuhl, ohne durch Calomel dazu gezwungen zu werden.

"Möge die Zeit nicht mehr allzuferne sein, in welcher es uns vergönnt ist, die Wirkungen der Arzneimittel auf die Krankheit ebenso klar einzusehen als uns jetzt die Wirkung des chirurgischen Verbands auf einen Beinbruch deutlich vor Augen liegt."

In conclusion Volz makes some sagacious and far-sighted remarks on peritonitis in general. In his opinion, almost all inflammations of the peritoneum have their origin in injuries or displacements connected with the abdominal organs, and of all organs the appendix is oftenest at fault. He maintains that the so-called idiopathic peritonitis is simply one in which our knowledge is insufficient to show us its local starting-point. Many such cases, formerly considered spontaneous, he says, have been shown at the time of writing to have a "mechanical origin," that is to say, they proved to be consequent on injury to the peritoneal surface resulting from morbid conditions in the organs which it covers, and he believes that in the future most, if not all, inflammations of the peritoneum will prove to be of this kind. Furthermore, he is convinced that a perforation is the exciting cause in the majority of cases; and if this fact is not discovered, it is because it is not looked for. His own pregnant words are as follows: *"Es ist durchaus nothwendig dass jede Section von Peritonitis mit der grössten Genauigkeit angestellt werde, dass alle mit Bauchfell ueberzogenen Organe sorgfältig untersucht und beschrieben werden, zum Beweis, dass keines, auch nicht der Wurmfortsatz, übersehen worden ist. Denn es ist mehr als wahrscheinlich, dass in mehreren mitgetheilten Fällen, welche noch als Beweise für die Häufigkeit der spontanen Peritonitis aufgeführt werden, nur desshalb eine Perforation nicht gefunden wurde, weil nach dem Wurmfortsatze gar nicht geforscht worden war."*

Rokitansky's work on pathological anatomy, appearing in 1842, contains a brief but excellent section upon the appendix, and probably represents the earliest systematic consideration of this organ from a purely pathological standpoint. Rokitansky also for the first time describes the dropsical condition known as *hydrops processus vermiformis*, or the cystic appendix. "The vermiform appendix," he says, "is thus metamorphosed into a hydropic capsule which in the course of time certainly may become the seat of inflammation resulting in ulceration and perforation."

Hancock, a London physician, in the year 1848 operated for disease of the appendix as such. Incision for the relief of a manifest tumor in the right iliac fossa had long been practised, but Hancock took the first decisive step in the direction of our modern methods when he published in the *Lancet* for 1848 the account of a case in which he operated successfully after making a diagnosis of inflammation of the appendix before any evidence of fluctuation could be made out.

During the early part of the fifth decade, between 1840 and 1850, the vermiform appendix became the theme of frequent discussions in the pathological societies in Great Britain and in the United States, resulting in the publication of a number of isolated cases.

Bamburger, the author of a series of short papers in the *Medizinische Zeitung* for 1858, is given much prominence by German writers about this time, but when his work is contrasted with that of others of the same date its value seems to have been overestimated. The author even goes back to the old theory, that the anatomical characteristics of the intestinal canal are responsible for tumors in the right iliac fossa, by causing a stercoral typhlitis with perforation, and it is evident from this fact alone how far his views were behind those of Volz, writing twelve years before.

George Lewis, of New York, in the late fifties, issued a paper in the *New York Medical Record*, deserving of our particular attention, because he has there gathered together the results of the slow evolution of our knowledge up to that date (1856), and because it constitutes the first systematic contribution to the literature of the vermiform appendix appearing in the United States of America. For insight and for clearness of exposition, Dr. Lewis's work must be classed with that of Mélier in 1827, and that of Volz in 1846, an international tripos, supported by a German, a Frenchman, and an American, and representing the most forcible and comprehensive contribution offered, up to the new epoch created by Fitz in 1886. Lewis's paper, originally read before the Society of Statistical Medicine, tabulates forty-seven cases of disease in the appendix, collected from the literature. The statistical aspect of his work attracted so much attention on the part of his reviewers, that the notion became and remained current that he offered in it little more than an able statistical contribution, and in consequence his admirable analysis of his cases has been persistently overlooked. I am happy, in giving a brief abstract of this paper, to be able both to do justice to its able writer and to give a concise presentment of the status of our knowledge at this critical period, so near the turning-point of the history of our subject.

Dr. Lewis wrote under the caption "*A statistical contribution to our knowledge of abscess and other diseases consequent upon the lodgment of foreign bodies in the vermiform appendix, with a table of forty cases.*" He declares that the obscure nature of this disease, its rapid and almost necessarily fatal termination, invest it with a peculiar interest to the physician, and render it of vital importance to the patient. He shows a clear perception of relative values when, in speaking of Grisolle's paper on "*Phlegmonous tumors in the right iliac fossa,*" he points out that this collection of seventy cases includes tumors in the left fossa as well as in the right, and confuses those dependent on the puerperal state with those resulting from disease of the appendix, pointing out that "conclusions drawn from cases so diverse in their origin and history, instead of throwing light upon any particular class, only increase the general embarrassment and leave the practitioner in doubt with regard to the whole."

Very satisfactory for such a date are his declarations regarding foreign bodies, which, entering the appendix, may remain an indefinite time without causing inconvenience. When a foreign body proves a source of irritation, it excites catarrhal inflammation of the mucous membrane, which in turn produces thickening of its coats and finally ulceration. The interruption of the circulation may produce strangulation of its terminal extremity. This in turn may be followed by discharge of the body, in which case the appendix partially or completely shrivels up, forming an opaque ligamentous cord or band. When the foreign body produces occlusion, this may be confined to the point of attack or the terminal extremity may become gangrenous, and if sloughing occurs, the contents of the cecum are discharged into the peritoneal cavity. In other cases the distention of the mucous membrane by its own secretions results in the formation of a dropsical sac. When once the perforation is complete, general peritonitis will supervene unless the discharge is circumscribed by recent adhesions, in which case the patient may live for some time (in one case recorded for four years) until the walls of the abscess suddenly give way.

The inflammatory reaction is always most intense in those parts immediately contiguous to the diseased appendix, and this may result in various complications, such as rectal and vesical tenesmus, when the appendix lies in the pelvis against the bladder, or phlebitis due to the proximity of the diseased appendix to the iliac vein. He further speaks of the formation of a sinus opening at the umbilicus, as well as of strangulation of the intestine from adhesion of the appendix.

Pain, our author says, is not invariably located at first in the immediate vicinity of the cecum; but sometimes in some other part of the body, only becoming deeply fixed in the right side as the disease progresses. Early vomiting generally arises from an overloaded stomach; later on it is a symptom of peritonitis. Diarrhea may be sometimes present at the beginning, and occasionally persists, but it is usually followed by constipation. In the ileocecal region a well-defined tumor is not always present, but inflammation always exists there in its greatest intensity, giving rise to unnatural fulness and hardness.

There are two kinds of causes, predisposing and exciting. The variations in calibre in the opening of the appendix into the cecum were accurately noted by himself, by inserting tubes of different sizes. These variations he considers a predisposing cause; the exciting cause is generally a foreign body. The effects of overloading the stomach and those of external injury are also considered.

The prognosis is extremely unfavorable, as only three out of forty-seven recorded cases recovered. The indications for treatment are identical with those in peritonitis in general, only the symptoms should here be met with more prompt and vigorous measures. When the abscess points at the surface of the abdominal parietes, the propriety of making a free incision to give exit to the pus becomes a question of importance.

In conclusion he says that neither age, sex, constitution, occupation, nor condition in life confer immunity from this disease. At least half the patients were under twenty years of age, and there is no explanation for this fact nor for the greater frequency of the disease in men.

It will be seen from this brief *résumé* that Lewis's paper is by far the most complete investigation of diseases of the appendix up to the date of its publication, and shows a thorough knowledge of the subject. In one point, however, he failed to display that perspicacity elsewhere so manifest: he did not recognize the true nature of typhlitis, perityphlitis, ileocecal abscess, cecitis, and especially "inflammation of the bowels," that vague, comprehensive, and illusory term for abdominal inflammations of all sorts, for so many years a source of satisfaction to the patient and of convenience to the physician, as well as the hiding-place for ignorance.

A perusal of contemporaneous literature of other countries reveals the fact that the true nature of disease in the appendix was at last beginning to dawn upon the medical mind. HOWARD, a distinguished clinician in Montreal, in 1858, delivered a lecture on the subject, which was afterward published, under the title "*Clinical lecture on inflammation and perforation of the appendix vermiformis,*" in the *Montreal Medical Chronicle.* After citing a case in his own practice, the writer remarks: "This is an instance of an affection which, although not very uncommon, is yet so infrequent that more than one example seldom occurs in the practice of a single individual, at least in cities the size of Montreal"! That the disease should be sufficiently known to be made the subject of a clinical lecture is in itself a sign of advance.

LEUDET, in the year 1859, issued a paper in the *Archives générale de médecine,* incited, he says, by the fact that the vermiform appendix had not as yet received systematic attention from physicians. For a period of nearly three years it had been his custom to examine the condition of the appendix at every autopsy in his own hospital service, and the results of these investigations led him to the following conclusion: "Perforation of the ileocecal appendix is in itself more common than all other perforations of any part of the intestine whatever; it at least equals in frequency all perforations of the digestive canal taken collectively." In 1824, Louyer-Villermay had concluded his essay on the same subject with the question: "But how can the inflammation of an organ of such small size and, above all, of such limited importance cause death so promptly? This we cannot explain. We are equally ignorant whether disease of the appendix would be always followed by a result as prompt and as disastrous." A comparison of these two observations shows us the progress of thirty years. And yet, if we recall the fact that Mélier had already shown in 1827 that a chronic inflammation of the vermiform appendix could exist, and in turn become the exciting cause of suppurative tumors in the right iliac fossa, the gain in the interval, considered as the fruitage of many

acute minds, seems but small; it was a real gain, however, for the knowledge attained became now diffused upon a stable basis throughout the profession. The obstacles to earlier advance along the right path were: The force of Dupuytren's authority; the misguidance of such misnomers as perityphlitis, typhlitis, and tuphlo-enteritis; and, lastly, the absence of satisfactory objective proofs that the disease of the appendix began in the appendix itself, and not in the cecum.

Dupuytren was now gone, having died in 1835; the bad nomenclature was beginning to be suspected, and the literature of the period shows a growing desire for a better classification of the diseases of the right iliac fossa. Oppolzer, in 1863, proposed the name p a r a t y p h l i t i s for inflammation of the connective tissue behind the cecum, and suggested limiting the use of p e r i t y p h l i t i s to inflammation of the peritoneal coat of the cecum and appendix, and using t y p h l i t i s for an inflammation of the bowel itself; but p a r a t y p h l i t i s was an over-refinement which never came into general use. The retarding influence due to the persistent belief that inflammation in the right iliac fossa began in the cecum, and then extended secondarily to the appendix, was the natural outcome of evidence derived exclusively from post-mortem examinations, which in those days were not held until the disease had advanced so far as to seriously involve the adjacent parts, when the observers naturally accused the larger division of the intestine of primary disease. This fatal error was finally laid in the dust only by the overwhelming proofs furnished by surgical autopsies *in vivo* held in the earlier stages of the disease, which were about to begin.

We have now reached a point in the history of the vermiform appendix when the reported cases of its diseases become too numerous to investigate *seriatim;* this increase appears to be purely literary in character and not due to the more frequent occurrence of the disease, whose true nature was, year by year, becoming better understood, and acknowledged as the hitherto unsuspected source of a variety of abdominal ailments. In quitting this period, I offer a tabular statement of the cases I have found in the hundred years between that of Mestivier in 1759 and those of Leudet in 1859; a statement which, if it is not exhaustive, is yet, I believe, the fullest hitherto published. For example, the forty-seven cases published by Lewis in 1856 were all this painstaking writer had been able to gather, while my table, covering but four years more, adds ninety-four to the list. The number would be larger still, if all cases not confirmed by necropsy were not excluded, since no other evidence could be accepted as satisfactory proof during this early period. This precautionary measure has not, however, eliminated many instances, for, unless the case ended fatally, it was rarely reported. The cases have been arranged in decades, with the different countries side by side, so that the contribution of each nation can be appreciated at a glance.

TABLE SHOWING NUMBER OF CASES OF DISEASE IN THE APPENDIX REPORTED IN DIFFERENT COUNTRIES DURING SUCCESSIVE DECADES BETWEEN 1750 AND 1860.

	1750 to 1760	1760 to 1770	1770 to 1780	1780 to 1790	1790 to 1800	1800 to 1810	1810 to 1820	1820 to 1830	1830 to 1840	1840 to 1850	1850 to 1860
France	1	1	..	..	1	1	1	7	2	9	11
England	..	..	..	..	..	..	1	2	8	8	8
Germany	..	..	..	..	..	..	..	..	12	26	11
Italy	..	..	..	..	..	..	..	..	..	2	..
United States	..	..	..	..	..	..	..	..	2	10	13
Canada	..	..	..	..	..	..	..	..	..	2	2
Total (141)	1	1	..	..	1	1	2	9	24	57	45

We find, as we should naturally expect, that after beginning with a few scattered cases, there is a steady increase in the numbers up to the year 1850, but then during the last decade (between fifty and sixty) a surprising decrease of about twenty per cent. A closer examination shows that this reduction affects Germany alone, where there is a drop from twenty-six cases to eleven, while elsewhere the number remains the same or even a little increased. This diminution corresponds to the closure of the period already alluded to, in which Germany offered more contributions than any other country to our knowledge of the appendix, and its sudden withdrawal can hardly be explained on other grounds than the diverted interests due to the well-known intestine political disturbances at that period. The decrease in France between 1830 and 1840, a decade when there are only two cases, may perhaps be explained by the fact that Grisolle's publication, the largest and most important during this period, was of so little value in stimulating research that out of seventy of his cases but two are sufficiently trustworthy to be included in my table.

From this date (1860) on, diseases of the appendix begin to become more and more a question of surgery.

Willard Parker, of New York, in 1867, published four cases of suppuration in the right iliac fossa arising from inflammation of the vermiform appendix, successfully treated by incision and evacuation of the pus. In one case he followed the example set by Hancock twenty years earlier and made his incision before fluctuation began. Parker's operation will be more fully discussed in Chapter III; it is sufficient to note here that from the date of his teaching operative treatment of appendicitis began an evolution which ended in the revolution of surgery. Most of the valuable contributions from this date on are surgical in character; a few, however, still call for notice before closing this chapter.

W. T. Bull, in 1873, published a paper on "*Perityphlitis*" in the *New York Medical Record*, it being originally an inaugural thesis which received the prize offered by the Faculty of Physicians and Surgeons of New York in 1872. This paper, which is an excellent one, was based on an analysis of sixty-seven cases;

thirty-two of these recovered; in those ending fatally the cause of death is stated in all but one. It is interesting to contrast these cases, reported at a time when the disease ran its course unhindered, with those of our own time, when it is uniformly cut short by operation. Of the thirty-two deaths, thirteen were due to exhaustion; eight to peritonitis, and six to pyemia. Of the remaining five, two deaths were from hemorrhage due to erosion of the iliac artery, one from hemorrhage caused by an incision made to let out pus, and two from empyema.

MATTERSTOCK, in 1880, published a paper on "*Perityphlitis*" in the *Handbuch der Kinderkrankheiten*. Without contributing anything new as a matter of research, Matterstock's article did good service by presenting a large number of cases gathered from literature and from hospital records. His pregnant opening words are: "By perityphlitis, we understand that form of circumscribed peritonitis with the formation of pus which develops in the right iliac fossa, generally in consequence of ulceration and perforation. We have recently begun to emancipate ourselves from the idea, which has hitherto dominated us, that the cecum was chiefly concerned in the causation of disease in the right side of the abdomen. We are now constantly obtaining a better knowledge of the nature of disease in the vermiform appendix, and the more our attention is focused on the morbid processes affecting this tiny organ, hitherto overlooked, the more frequently do we find it to be the chief if not the only cause of the rapidly fatal illness which we call perityphlitis."

This is the first clear note of a complete emancipation from the cecal theory of inflammatory disease in the right iliac fossa, and we have at last reached a point when the mask of "perityphlitis" was taken off, although such is the force of habit that the misnomer continues in use even to-day. (See accounts of King Edward's recent illness.)

WITH, a Norwegian, in 1880, contemporaneously with Matterstock, published a contribution to the subject, which does credit to both author and nation. His title is "*Peritonitis Appendicularis*," and the gist of his thought is that disease of the appendix is far more important than had been previously acknowledged. With lays stress on his personal examination of the records of three hundred autopsies, in which the condition of the appendix was noted; it was found healthy in but one hundred and ninety; in one hundred and ten it was more or less diseased. He had also seen a few cases of ulceration of the appendix followed by general peritonitis confirmed by autopsy, and his conviction was that the great variety of abdominal affections, known under such protean names, are, in reality, but disease of the vermiform appendix, which he proposes to call by the name "peritonitis appendicularis." Here we find in extreme northern soil a model contribution to our subject, leading observers back to the source of all accurate medical knowledge, the autopsy table, an excellent purely objective statement which no change of time or dogma can controvert.

SAMUEL FENWICK, in the *Lancet* for 1884, published a series of clinical lectures

relating to cases difficult of diagnosis, remarking at the outset that "there are some affections which occur so rarely that only a few fall within the observation of any practitioner," recalling the words of Howard, of Montreal, twenty-five years before. He strongly contends for a separate inflammation in the appendix, and emphasizes the necessity of giving this organ yet greater attention, for although he still believes in inflammation of the cecum, he holds that many such cases are in reality diseases of the appendix. To support this view, he relates an instance of a man seized with a so-called "typhlitis," from which he recovered, but four years later he was again taken ill, after playing a game of cricket, developed all the symptoms of appendicitis and died. There was no autopsy allowed, but Fenwick felt sure that death was due to a perforation of the appendix; and he maintains that the diagnosis between typhlitis and appendicitis must depend on the absence of tumor in disease of the appendix, together with the fact that in typhlitis the symptoms are comparatively mild.

At length, in the year 1886, an article appeared which cleared up the entire subject, and created an epoch in medical and surgical history.

Reginald Fitz, of Boston, the author of this paper, has done more than any single individual to bring about a right understanding of the morbid conditions affecting the vermiform appendix. In vain had the little shafts of light, shot out from time to time during more than half a century, sought to dissipate the darkness enveloping this subject; as long as "typhlitis" and "perityphlitis" reigned co-ordinate with the unnamed diseases of the vermiform appendix all was doubt and obscurity. Now everything was to be changed, and as a tangled skein full of knots and false clues yields at once to the hand which holds the right thread, so the perplexities, obstacles, and unfounded notions which hitherto blocked the way, disappeared as soon as Fitz supplied and enforced the acceptance of the correct fundamental fact—that the multifarious abdominal disorders hitherto variously named were all no more than forms and stages of inflammation of the appendix. Finding his subject buried under a mass of inco-ordinated facts and unstable theories, Fitz left it clarified of all obscurity and established upon a scientific basis. He declares at the outset that "even the most recent systematic writers are by no means agreed as to the exact relation of the cecum and that of the appendix to peritonitis and perityphlitis. The vital importance of the timely and appropriate treatment of the disease in question is becoming more and more apparent. Such treatment is often postponed till hopeless, even if its application is at any time entertained. . . . . The clinician obviously recognizes, as of the chiefest importance, the parts to which local treatment may be directly applied. His attention is thus conspicuously directed to the cecum, which may be evacuated, or to the perityphlitic abscess, which may be emptied. The pathologist looks for the seat and causes of the disease, and finds that in most fatal cases of typhlitis the cecum is intact, while the appendix is ulcerated and perforated. He sees that the so-called perityphlitic abscess is usually an encysted peritonitis. Further-

more, if an abscess exists in the pericecal fibrous tissue, it is in most instances caused by an inflamed appendix. Finally, if the encysted peritoneal abscess, or the abscess in the fibrous tissue behind the cecum, does communicate with the latter, such an opening is usually the result, not the cause of this attack." Fitz continues that "any attempt at explaining the various results of an inflammation of the appendix must necessarily be preceded by a statement of the peculiarities it may present with respect to structure and position, ... for variations in length, position, and patency, whether congenital or acquired, are of obvious importance in explaining many of the apparent differences in the clinical histories of typhlitis and perityphlitis." While the anatomical differences in different appendices had already been made a subject for comment by many writers, this is the first suggestion that variations in the position and structure of the appendix were the real explanation of clinical peculiarities which up to this time had been supposed to indicate two morbid conditions. These remarks are followed by an analysis of such anatomical differences, together with a description of the part played by external violence and fecal concretions. It is during this discussion that the name "*appendicitis*" appears for the first time, quite incidentally and without any formal introduction, the writer speaking of perforating inflammation of the appendix on one page, and of appendicitis on the next, and using the terms interchangeably throughout the rest of the article. Dr. Fitz speaks of the introduction of this term in a personal letter, as follows:

"The word was coined by me purely for practical purposes. I wished to call attention to inflammation of the vermiform appendix as the primary lesion, and that to which treatment was directly to be applied. Although etymologically incorrect, the term was not without analogy—of those which have been offered in its place, I much prefer epityphlitis, although at the time my paper was written I wished to discourage the prevailing view that the disease in question involved the cecum to any considerable extent. The subject is now so well understood that its nomenclature seems of minor importance. I much prefer appendicitis to Fitz's disease."

Throughout the whole article the various abdominal disorders, typhlitis, perityphlitis, paratyphlitis, and others, which had for years been separately considered and treated, are discussed, and convincingly shown to be simply varying manifestations of a morbid process originating in the appendix. "Stercoral cecitis" is still considered frequent, although perforating ulcer of the cecum is stated to be extremely rare.

Finally, when the question of treatment is brought forward, the necessity for operative measures is immediately discussed. "If," says Fitz, "after the first twenty-four hours from the onset of severe pain, the peritonitis is evidently spreading and the condition of the patient is grave, the question should be entertained of an immediate opening for exposing the appendix and determining

its condition with reference to its removal. If any good result is to arise from such treatment, it must be applied early." He then reviews in a few words the different attempts at operative procedures which had been made up to that time, and demonstrates conclusively that the date fixed by Parker for interference, namely, after the fifth day, is dangerously late; the current practice of making it later he utterly condemns..

He says: "In conclusion, the following statements seem warranted:

"The vital importance of early recognition of perforative peritonitis is unmistakable.

"Its diagnosis in most cases is comparatively easy.

"Its eventual treatment by laparotomy is generally indispensable.

"Urgent symptoms demand immediate exposure of the perforated appendix, after recovery from the shock, and its after-treatment according to surgical principles.

"If delay seems warranted, the resulting abscess, as a rule intraperitoneal, should be incised as soon as it becomes evident. This is usually on the third day after the appearance of the characteristic symptoms of the disease."

Fitz wrote two subsequent papers in 1888 and 1890, for which space permits only an honorable mention. In all his work, and especially that just considered, we are struck by the ease with which questions previously perplexed are resolved by a master hand into simplicity itself. At this date the medical profession stood in an expectant attitude, and it needed but this demonstration to force conviction and usher in an era of wholesome activity. The time was ripe, the man appeared, and surgeons, needing but the assurance of safety, gratefully accepted this transfer from the domain of internal medicine and began with alacrity to develop the operative procedures, which, in their turn supplying further opportunities for investigation, yielded more and more definite knowledge of the morbid processes affecting the right iliac fossa.

CHAPTER III.

HISTORY.

THE SURGICAL HISTORY OF DISEASES OF THE VERMIFORM APPENDIX.

1886–1904.

"*What we wish to accomplish in the treatment of appendicitis is, not to save half of our cases, nor four cases out of five, but all of them.*"—(C. McBurney, New York Med. Jour., 1889, vol. i, p. 679.)

"*There is only one logical treatment of the disease, namely, the excision of the diseased organ as soon as the diagnosis is made.*"—(A. Worcester, Ann. of Gyn. and Ped., 1892, vol. v, p. 449.)

The aggressive surgery of the vermiform appendix as practised to-day is only a development of the past twenty years. The incision and evacuation of old encysted collections of pus in the right iliac fossa, resulting from an inflammation in the appendix, was practised as far back as the beginning of the Christian era. About the year 50 B.C., ARETÆUS, in his "*Causes and Symptoms of Diseases,*" says of abdominal abscess: "But in the viscera below the diaphragm, the liver, spleen, and kidneys, the passage for the matter is by the bladder, and in women by the vagina. And I once made an incision into the abscess in the colon, on the right side near the liver, and much pus gushed out, and much also passed by the kidneys and bladder for several days." This may have been either a large pyonephrosis or a large abscess starting in the right iliac fossa. It is said that fifty years later, about 100 A.D., Soranus of Ephesus evacuated a collection of pus situated between the peritoneum and the intestines, through an incision in the region of the liver, after the method of Erasistratus.* It is manifest that these efforts were but the blind groping of the ancients, exhibiting no special insight nor calling for any unusual courage or skill.

After the year 1700, occasional records are found of the evacuation of blood and pus in the abdominal cavity. The first case in which disease of the appendix is clearly recognized among these and recorded is that of Mestivier in 1759 (see Chapter I, page 2), in a man with a suppuration in the right iliac fossa, which discharged about a pint of pus on incision; after death a pin was found in the appendix.

* "Causes and Symptoms of Acute Diseases." Bk. i, Chap. 9, p. 312. Translation by Francis Adams, LL.D.; published by the Sydenham Society, 1856.

From this date (1759) onward, tumors of the right iliac fossa received increasing attention. Their treatment by the time-honored incision at the point of fluctuation was recommended and practised by Dupuytren, but the notion of incising right iliac tumors before any fluctuation could be detected did not occur to him or his followers, and it was not until 1848 that incision at an earlier stage was attempted.

Hancock, an English surgeon, in 1848 reported such a case to the Clinical Society of London, of so much historical interest that I venture to quote it somewhat fully, and as nearly as possible *verbatim*. Hancock begins by observing that abscesses of the abdomen connected with the cecum or large intestine, attended by fluctuation, had from time to time been opened, but he was not aware of any instance in which an operation had been attempted under the circumstances about to be detailed. Other surgeons had waited for the presence of fluctuation to prove the presence of matter, but this case shows that this unequivocal sign should not always be waited for.

His patient, a married woman, thirty years of age, had had bad health following an injury to the spine, twelve years before. Since then, the bowels never moved efficiently without an enema, and she had suffered occasional attacks of pain. The present illness began at the end of her fifth pregnancy, which was characterized by incessant nausea; she was seized suddenly, while out driving, with an unusual dragging pain in her right side, obliging her to take to her bed and to use opiates. Four or five days later a premature delivery followed of a child, which lived but a few hours. The day after delivery, while turning in bed, she felt a severe pain and snapping sensation in the right groin, and from that time she suffered greatly with pain in that locality. On the third day a slight hard swelling could be distinctly traced high up in the inguinal region. When seen by Hancock on the seventh day, there was intense pain in the right iliac fossa, and tenderness over the whole abdomen with tympanites. Two days later symptoms of general peritonitis appeared. There was a cord-like swelling in the inguinal region with thickening and hardening extending out toward the ilium. Operation was then proposed, agreed to, and, the patient being under the influence of chloroform, an incision about four inches long was made from the spine of the ilium above Poupart's ligament, and as close to it as possible. Upon opening the abdomen, a quantity of turbid serum poured out, mixed with air bubbles and patches of false membrane. This discharge continued for some time very freely, and on the fifteenth day two fecal concretions were found in the wound, which had been very painful. From this date the patient improved, and ultimately recovered.

In the discussion following his report, Hancock contended that the typhoid condition into which patients with peritoneal inflammation fall did not depend upon the violence of the disease, but upon the acrid nature of the effused fluid, the removal of which he declared offered the only chance of saving life; and as

the patient in this case was so obviously sinking, and the previous treatment had been of no avail, he had proposed to make an incision from the spine of the ilium to the inner side of the internal abdominal ring, over the hardened spot, so that if it were intestine or omentum it could be freed, or if, as was thought more probable, matter had collected in the right iliac fossa, it could be let out, and the patient given a chance to recover. He urged strongly that the fecal concretions found in the wound were convincing evidence that the abscess had started in the appendix. Judging from the remarks which followed, his views made a strong impression, but the effect does not appear to have outlasted the time and place of their presentation, for nothing more is heard of the surgical treatment of such tumors, in the absence of fluctuation, for nearly twenty years.

Another case of special interest, which seems to have escaped our medical historians, appeared about two years later in a report to the Pathological Society of London for 1850–1851.

GAY presented this case under the title "*Internal strangulation between the appendix vermiformis, which had become adherent to the ileum, and a band of false membrane.*" The patient, a man of forty-two, was seized with severe pain in the right iliac region after lifting a heavy bureau, accompanied by vomiting, constipation, and signs of collapse. These symptoms continued about four days, when, with a free evacuation of the bowels, convalescence ensued. During the succeeding five years, however, he had about thirty similar attacks, lasting from one to four days, and ending in the same way in a free evacuation of the bowels. The pain always began on the left side, and then extended to the right. The last attack followed the usual course, until the fifth day, when the vomiting was clearly fecal. When seen by Gay, on the afternoon of that day, the abdomen was found hard and rather tumid, and pressure to the left of the umbilicus and along the left iliac fossa gave intense pain, while elsewhere the tenderness was comparatively slight. Around the umbilicus and over the cecum there was dulness on percussion. Gay concluded that there was an obstruction caused by some internal ring into which the bowel had slipped, without on this, as on previous occasions, being able spontaneously to free itself. Operation was determined upon, and a five-inch incision made in the linea alba, exposing distended and intensely inflamed intestines at the seat of pain, but no obstruction. But when the right iliac region was explored, about fifteen inches of flaccid, dark colored intestine was found to have passed in behind an adherent vermiform appendix. The incarcerated bowel was liberated without difficulty, and fecal matter then seen to pass on through; after which, as the obstruction was removed, the wound was closed. The patient came to, and felt relieved; he was left with strict injunctions against exertion, but in the temporary absence of his wife, at four in the morning, he rose from bed, fell to the floor, and soon after died.

An autopsy was made, and the small intestines found distended, congested, and cohering by recently exuded lymph. The strangulation was shown to

have been caused by the passage of loops of small intestine through an opening bounded by the appendix, ileum, and cecum. The appendix, which was much thickened at the tip, adhered to the ileum above the cecum, forming a complete ring, with the cecum on the right, the appendix in front, and the ileum on the left side. The small intestines below the seat of constriction and the whole of the large intestine were contracted, nearly empty, and healthy, but above the constricted portion the ileum was greatly distended, and its coats intensely inflamed, being in places quite black, or sloughing. Some distended convolutions of the small intestine overlying the cecum had yielded the dulness on percussion in the right iliac fossa. The operation was manifestly undertaken to relieve one of the sequelæ of an old appendicitis, and is, I believe, the first celiotomy in which the abdomen was opened and the diseased appendix exposed to view.

Willard Parker, of New York, took the next step in the development of the surgery of the appendix, in 1867. His name is so intimately associated with this subject in America that the method he pursued became widely known, and is still called the Willard Parker operation. It was in this year, 1867, that Parker published four cases in which he had treated abscess in the right iliac fossa, consequent on inflammation of the appendix, by incision and evacuation, one dating as far back as 1847. In the intervening years he gradually became convinced that it was not necessary, nor even desirable, to await fluctuation before making an incision, and the last case afforded him the opportunity of putting his theory to a successful test. The important object of his writing, therefore, was to declare what good results were likely to attend an early incision, and to counsel its wider adoption.

He declares that: "The matter of local treatment [of disease of the appendix] has attracted my attention for years. These questions presented themselves: Are the efforts of nature exerted in behalf of such a case, and if so, in what way? Observation indicates the reply and experience verifies its truth. Nature does labor in behalf of life in two ways: (1) by means of the wall of false membranes which she builds around the abscess; and (2) by the ulceration which gives exit to the escape of its contents. This being settled, it becomes a question whether surgery might be able to render assistance to nature in this work; and if so, at what period would assistance best come in. . . . . To be successful it is necessary that it should be made neither too early nor too late—not before adhesions are fully formed, nor, after a short period, before the maximum formation of pus has been reached, that is, the incision should be made after the fifth day and before the twelfth. . . . . If no abscess has already formed, in case one should be in process of formation, an external opening would tend to make it point in a safe direction. And even if no abscess should form, a free incision would relieve tension, thus adding to the comfort of the patient and in no way prejudicing his safety. One other question remains: Would the operation bring about a cure? Judging from the three cases reported

above, an affirmative answer seems certain; for these recovered, because, in each one, nature had provided for an external discharge of the contents of the abscess, and what nature provided in these three, an operation would provide in all cases."

The case in which these theories of Parker's were put to the test was operated upon on the ninth day, when there was an area of circumscribed tenderness in the right iliac fossa, but no definite swelling, still less fluctuation. An incision six inches long was made through the skin, commencing above and about one inch from the anterior superior spine of the ilium and running toward the symphysis. As soon as the transversalis muscle was reached, a tumor could be felt about two and a half inches wide, and on introducing an exploring needle some thick, ill-smelling pus gushed out; when the sac was freely opened, about four ounces of pus escaped. A tent was inserted, and the wound left to heal by granulation; the patient making a perfect recovery.

Dr. Daniel Stimson, Professor Parker's son-in-law, writes me: "I remember his [Dr. Parker] speaking frequently of having been impressed by an autopsy on a young girl, the daughter of an old and valued friend, whose death quite prostrated him, with the fact that he must interfere surgically, if he had another case where the diagnosis was clear and when he could operate beween the time of the walling in of the abscess by peritonitis and the breaking-down of the wall, with the subsequent diffusion of the peritoneal inflammation, this time being, according to his views, between the fifth to the seventh, and the eleventh to the fourteenth day."

Parker's paper at once provoked discussion in many quarters, and the method recommended came into use immediately. This prompt response is in marked contrast to the lack of notice of Hancock's no less able exposition, and we are here tempted to inquire why. The reason, I think, lies in the commonly observed fact that the success of any new departure in an unexplored field must depend upon two factors: the hour and the man. In Hancock's case, while the man was there, the hour had not yet struck; his insight and sagacity were equal to the opportunity, but the date was too early and the medical mind as yet immature. Parker, on the other hand, commanded every requisite to success: the child of a distinguished father, himself a man of preëminence in the medical world, a great teacher, and the foster-father of many of the best surgeons America has ever seen, he was also fortunate in that his paper was born in a happy hour. During the years that lay between Hancock's work and his own, the medical profession had been steadily acquiring the anatomical and pathological knowledge necessary for many simultaneous great advances in surgery; all things were in readiness, and a guarantee of safety alone was needed to inaugurate a new era. The year following Parker's publication this primal necessity was supplied in the principle of antisepsis, which, though discovered and published in 1863 in France, by Jules Lemaire, was also independently

discovered and introduced into surgical practice by Sir Joseph Lister in 1868, the year following the appearance of Parker's article. Then at last, with the advent of Lister, a host of new conceptions, heretofore lying dormant under the dread of working more woe than weal, were quickened into the familiar procedures by which we now, as the weeks run their course, save thousands of lives.

Had Hancock lived twenty years later, his suggestions would not, in all probability, have fallen upon sterile ground. They proved unfruitful, simply because, though technically correct, their execution involved a risk to life which circumstances could then rarely justify. Parker succeeded because antisepsis stood ready as his handmaid to step in and reduce the risk to a minimum.

Evidence of the transformation taking place in the entire surgical field becomes more and more evident after this date. Parker's first paper, just discussed, appeared in March, 1867; and in June of the same year a similar case, seen by Parker in consultation, and operated upon by his advice, with recovery, was reported by Dr. Burge.

Leonard Weber, in the year 1871, published an article on "*Abscess of the vermiform appendix*" which gives a good description of inflammation of the appendix, but the writer remarks that the symptoms are common to typhlitis and perityphlitis as well, showing no comprehension of the identity of the three conditions. In reading the literature of this period we often observe that the immediate effect of discarding the theory that disease of the appendix was but an extension of a morbid process originating in the cecum was to establish a belief in the existence of three morbid conditions in the iliac fossa, namely, inflammation of the appendix, of the cecum, and of the pericecal tissue.

W. T. Bull, in 1873, in his inaugural address on "*Perityphlitis,*" gave a list of all cases treated by incision up to that date. Strange to say, Hancock's is not included; but if this is added, the whole number of incisions (made before fluctuation) up to this date is nine.

J. W. S. Goulay, after the lapse of two years, presented another such list, including all cases up to 1875, the year in which he wrote. I cite this list as it stands in Goulay's article, except that I have prefixed to it the names of Parker and of Hancock, which in the original are mentioned in the text.

Hancock: Lancet, 1848.
Willard Parker: New York Med. Rec., 1867. (4.)
Stiegel: Schmidt's Jahrbücher. (2.)
L. Weber: New York Med. Jour., 1871.
E. Krackowizer: Schmidt's Jahrbücher.
H. B. Sands: New York Med. Jour., Aug., 1874.
Charles Kelsey: New York Med. Rec., Oct. 1 and Dec. 15, 1874. (2.)
S. B. Ward: Ibid., Nov. 2, 1874.
Samuel Whitall: Ibid., May, 1874.

Gordon Buck: Address to New York Academy of Medicine, Sept., 1874.
J. P. P. White: Ibid.
J. R. Wood: Ibid. (3.)
J. C. Hutchinson: Personal communication. (2.)
R. B. Bontecou: Trans. New York State Med. Soc., 1873. (3.)
C. A. Leale: Personal communication. (2.)
J. H. Pouley: New York Med. Rec., April 17, 1875.
J. W. S. Goulay: Trans. New York State Med. Soc., 1873.

Goulay's list includes twenty-eight cases, showing an increase of nineteen for the two years between the publication of his article and Bull's. He remarks: "These are all the cases treated by incision as above described that have come to my knowledge; but it is more than probable that since 1867, when attention was recalled to the importance of early incision, many surgeons have resorted to the operation, who have not yet given publicity to their experience. It is hoped, however, that they will soon do so, and aid in popularizing this most valuable and life-saving mode of treatment." A practical answer to this forecast is given by Noyes, who in 1882 records eighty-four cases of early incision, since Parker's in 1867. If we deduct from this number the twenty-eight cases by Goulay, we have fifty-six for the seven years between the appearance of the two articles.

It is of interest to note here the reduction of mortality from "perityphlitis" after the introduction of the Parker operation. In 1867 the death-rate was forty-seven per cent., while in 1882, when Noyes wrote, Parker's operation had been in use for fifteen years and the mortality was reduced as low as fifteen per cent.

Up to this period, that is to say, the early eighties, incision and the evacuation of pus in the absence of fluctuation was the most daring procedure any one had as yet ventured to propose; but the time was now at hand when much more radical measures were about to be adopted.

I must not omit mentioning here the names of Scandinavian and Russian surgeons of distinction in the decade 1870 and 1880, Winge, Selmer, and Holbue, of Norway, Aarestrop, of Copenhagen, and Anton Schmidt, of Moscow, who all did excellent work in elucidating the treatment of purulent peritonitis, thus contributing not a little to the advancement of surgery in general as well as to that of the appendix in particular.

Another factor furthering the progress of knowledge of diseases of the appendix, whose value we can hardly overestimate, was the constant exploration of the abdominal cavity by the gynecologists with such impunity that they may be said to have paved the way for the general surgeons who first ventured to remove the appendix.

Juilliard, a French gynecologist, in 1879 gave good grounds for hope in the treatment, even of desperate cases, by his careful record of a successful operation for a case of peritonitis in a woman of twenty-eight with an ovarian tumor. Twenty-four hours before the date fixed for its removal

she was taken ill with a peritonitis lasting for seven days, at the end of which time symptoms of strangulation appeared, when Juilliard operated. The cyst was removed, and the strangulation found due to adhesions gluing the intestines together and requiring an enlargement of the original incision to set them free. The operation was performed antiseptically, and the patient recovered. In the discussion following the report of this case, the fact was emphasized that not only was the operation done during an acute peritonitis, but it had been possible to reduce a strangulation, and make two punctures in the intestine with an aspirator, and yet, despite these acts, at that time unprecedented, the patient had made an ideal recovery. Such facts warranted the inference that the abdomen not only could, but ought to be opened more frequently; one speaker remarking, "*l'ovariotomie nous a montré qu'on peut à peu pres impunément ouvrir la cavité peritoneale.*"

Herring Burchard, of New York, in the following year, 1880, read a paper on "*Operative interference in acute perforative typhlitis*" before the New York Academy of Medicine, based upon four cases in his own practice, all ending fatally. He asks: "Is this disease necessarily fatal?" and replies to his own question: "It is surprising that some definite plan of treatment has not been, as yet, devised for an affection the anatomical lesions of which are of such a nature as not to preclude surgical interference. All hopes from the use of medicinal agents have been buried in the uniformly fatal termination of the disease, and I would, therefore, suggest that by a timely interference there is a reasonable hope of saving a certain proportion of lives." He then adverts to the numerous instances of wounded intestines which have recovered notwithstanding the large openings made, and regards it as singular that injuries of such gravity could be survived while minute perforations in the appendix proved so fatal. Burchard recommends a posterior incision in order to reach the appendix, extending transversely from a point about two inches in front of the anterior border of the longissimus dorsi muscle, forward about six inches parallel to, and just above, the crest of the ilium. Through such an opening the cecum can be readily reached, the abdominal cavity cleansed, and the edges of the perforation stitched to the wound.

Lawson Tait, that great pioneer in our art, writing a year later, in 1881, had become so convinced of the safety attending abdominal section that he challenged the surgical world in these clarion notes: "So satisfied have I been with the results in these cases, that in the next case of peritonitis to which I am called, of whatever sort it be, even puerperal, I shall advise and perform (if allowed) abdominal section, shall cleanse out the cavity and drain it; and if the operation be not deferred until the patient is moribund, I believe this treatment will prove eminently successful." Close on the heels of this prophecy followed the events foretold by the seer.

Noyes, in 1882, in the article mentioned, asks: "How shall we treat that great class of cases of perforation of the appendix vermiformis in which there

is no circumscribed collection of pus?" quotes Burchard's suggestion, and notes a similar proposal by W. A. Byrd in 1881, but concludes despondently: "I fail to find any recorded cases in which this procedure (laparotomy) has been attempted with success. However plausible and important this operation really is, the difficulty of certainty of diagnosis will stand as an almost unsurmountable obstacle to its adoption. Medicine is useless in these cases, except for the production of euthanasia, and surgery cannot even accomplish this."

It is a relief, after such despondency, to encounter the more cheerful outlook of Samuel Fenwick, who says, in 1884: "The remarkable success which has of late years attended the operation of ovariotomy encourages the belief that if our diagnosis could be made more certain some of the diseases now rebellious to medicine might be relieved by surgical treatment, for there can be no doubt that many of the operations performed prove unsuccessful, not so much from the nature of the malady, or from any special liability of the injured structures to secondary inflammation, as from the late period at which they are undertaken. I would first invite your attention to a rare disease, the occurrence of which has of late years attracted the attention of practitioners, and which often presents considerable difficulty in diagnosis, namely, inflammation of the vermiform appendix." Discussing the method in use, namely, the incision into the suppurating part and the evacuation at the most dependent portion of the swelling, he says: "Neither of these are satisfactory, for, theoretically, it would seem to be much better if we could cut down directly upon the appendix as soon as the diagnosis was tolerably certain, tie it above the seat of perforation and remove from its neighborhood any concretion or decomposing material that might be the cause of irritation."

I have emphasized these words because they represent the conclusion of the pre-celiotomy period in the history of the appendix, when simple incision and the evacuation of the pus were recognized as the proper surgical treatment. The actual removal of the appendix now became the focal point of the surgical world, and the modern era of medical surgery was about to begin.

Professor MIKULICZ, of Krakow, threw open the door which his predecessors had left ajar, in an address on "*Ueber Laparotomie bei Magen- und Darmperforation*" in 1884, to which we are greatly indebted.

"The therapeutics of the time demand," he remarks, "that perforation of the stomach and intestines should be treated by opening the abdominal cavity, suturing the perforation, and restricting the inflammation of the peritoneum by thoroughly washing out the abdominal cavity. These measures have only as yet been tried for traumatic perforation, but I am convinced that the principle should be as firmly established in every form of perforation as that of a ligature for injury to a large blood-vessel; in both cases, its accomplish-

ment is a vital necessity." In a case in his own practice the patient was taken suddenly ill with violent iliac pains accompanied by vomiting, and obstipation lasting three days. An undefined tumor was felt under anesthesia, in the right iliac fossa, and the diagnosis made of either perityphlitis or intestinal obstruction from invagination. On the fifth day the abdomen was opened by an incision in the linea alba, extending from the umbilicus to the pubis, and about a litre of purulent blood-stained fluid escaped; the intestines were adherent in many places, showing signs of intense inflammation. "I placed my hand," he says, "in the region of the cecum and the ascending colon, in the expectation of finding here the origin of the supposed intestinal obstruction in an ileocolic invagination, but I could find nothing except adhesions between loops of intestines, so that after loosening the intestines so far as they seemed to obstruct the circulation, and purifying the abdominal cavity as far as possible by means of sponges, I closed the abdomen." Immediate relief was experienced, and for a short time the patient improved, but death occurred five days after the operation. The autopsy showed a general fibrino-purulent peritonitis with extensive adhesions, and numerous encapsulated collections of pus. The inflammation was most intense in the region of the colon, and the vermiform appendix, which was flexed on itself, was perforated with numerous small openings leading directly into its lumen. Its mucous membrane was entirely destroyed. "This case," Mikulicz remarks, "is of great interest from an operative standpoint. I considered the patient's case hopeless when the abdominal cavity proved to be full of purulent exudate, and I expected him not to survive the operation more than a few hours. Therefore, when the theory of an invagination was disproved, I made no farther search for the cause of the peritonitis. To my astonishment, the patient not only did not become worse during the next day or two, but his condition improved in some small degree, no doubt on account of the favorable influence exerted by emptying the purulent exudate; and the return of the symptoms which resulted in death was doubtless due to the return of the exudate. Had I sought farther for the origin of the exudate, had I investigated the neighborhood of the cecum by sight as well as by touch, the perforation of the appendix could not have escaped me, and I should have excised it entirely, or closed the opening into the cecum by sutures. And I am convinced that the peritonitis would then have subsided, and the patient would have been saved." A similar case fell into Mikulicz's hands a few months later, and he pursued the plan he here outlined of finding the perforation and closing it by sutures, with perfect success. It happened that the perforation in this second case was not situated in the appendix, but in the small intestine. Mikulicz, therefore, although not the first to operate upon the appendix, established the propriety of such operations for non-traumatic perforations of this organ. His conclusions are: "From the foregoing experience, scanty as it is, we draw the conclusion that laparotomy should be performed for every species of non-traumatic perforation of the stomach or intestines, if it can

only be done early enough; if possible, before the advent of peritonitis. It is most important to understand the indications for it in perforation of the appendix, as well as in typhlitis and perityphlitis dependent on the latter; and it is just here that we expect our experiences in the future to set the matter in a new light. In this connection I cannot refrain from expressing my opinion that in severe cases of typhlitis and perityphlitis, even without perforation of the appendix, the therapeutic treatment hitherto employed should yield to operative. I do not mean that every case of obstipation and vomiting accompanied by swelling in the cecal region should be treated by the knife, but that where there are undeniable appearances of abscess and purulent peritonitis surgical principles should be adopted and the products of inflammation removed as early as possible. . . . . I should like to remark here also that in any peritonitis, the original cause of which is not clear, the region of the cecum should be investigated, and a possible perforation of the appendix considered. Spontaneous perforation is so extremely rare that it should never be taken for granted."

KRÖNLEIN, of Germany, in the same year, 1884, performed the operation advised by Mikulicz, for the first time.

The patient, a boy of seventeen, was suddenly attacked with violent pain in the ileocecal region, followed by vomiting, which assumed a fecal character after twenty-four hours. Seen by Krönlein on the third day, he was in a state of collapse, and an examination of the abdomen showed an area painful even on gentle pressure over Poupart's ligament on the right side. A diagnosis was made of either perforating peritonitis originating in the vermiform appendix, or of an acute occlusion of the intestine in the right iliac fossa. Operation was performed immediately in a private house and an incision was made in the linea alba from the umbilicus to the pubes; as soon as the abdominal cavity was opened, it was found full of coils of inflamed intestine covered by fibroserous exudate. The inflammation was especially intense in the ileocecal region. To cleanse the intestines, they were lifted out of the abdominal wound, and washed with a lukewarm solution of carbolic acid (2.5 per cent.), while the abdominal cavity was also washed out. The appendix was now seen freely movable in the right iliac fossa, but much infiltrated, and with a perforation the size of a pea at its middle portion; its edges were gangrenous, and fecal concretions lay loose in the perforation. A double ligature was placed at the base of the appendix, with a single ligature around the mesentery, and the appendix resected *in toto*, as well as the fetid knotted omentum, which could not be disinfected. The peritoneum was carefully cleansed, and the abdominal incision closed without drainage. The patient recovered from the condition of collapse and improved for about twenty-four hours, when the symptoms of collapse returned and death took place three days after the operation. An autopsy was not permitted.

This operation, although performed in 1884, was not published until 1886; in spite of this delay in appearance, however, it still remains the first instance of celiotomy, followed by removal of the appendix, both as to time of performance and date of publication.

CHARTER SYMONDS, an Englishman, in 1885 did what is undoubtedly the first interval operation for appendicitis, making a lateral incision, "without opening the peritoneum," and without removing the appendix. The patient, a man of twenty-three, had had repeated attacks of inflammation in the right iliac fossa during the six months preceding his admission into Guy's Hospital, and was suffering from one of these when admitted. He had a small, hard, tender lump in the right groin, and a diagnosis of inflammation of the appendix was made by Dr. Mahomed, who stated it as his belief that there was an abscess with a fecal concretion, and that the periodical occlusion of the communication with the cecum determined the recurrence of pain and the other symptoms. Dr. Mahomed advised operation when the acute symptoms should have subsided, and planned the manner of its execution. He died, however, before he could act upon his idea. Mr. Symonds, therefore, performed the operation after the attack, and relates his experience as follows: "The incision used was almost exactly similar with that used in ligating the external iliac artery. The various structures were then divided, and as it was particularly wished to avoid the peritoneum, they were at once lifted out of place, when the lump was plainly felt as a hard round body. A vertical incision was then made down on to the mass and a hard calcareous body exposed and removed. No pus at all was seen, and the cavity from which the calculus was removed seemed smooth and free from deleterious material. The lining, which was soft and purplish, was evidently mucous membrane, and the tortuous cord-like appendix could be distinctly traced, so that there seemed no doubt that it had been laid open. The opening was closed and a large drainage-tube inserted. The peritoneum was not recognized, and, presumably, not opened." The patient ultimately recovered, although troubled for some time after by a fecal fistula. Mr. Symonds's critique upon the case is as follows: "I believe I am correct in saying that this is the first case in which a concretion or calculus has been removed from the appendix vermiformis, without at the same time opening an abscess, and the credit of what value rests in the procedure must be given to my lamented friend, Dr. Mahomed, at whose suggestion the operation was undertaken, and who advocated the inguinal incision in opposition to that along the linea semilunaris proposed by myself." "I would suggest," he continues, "that some cases, at least, might be saved by earlier incision, before, I mean, fluctuation is felt. This treatment has been more especially employed by the American physicians."

The effect of Fitz's article, which appeared in 1886, the year following, has been noted, but I have reserved his views regarding operation for statement

at this juncture. Fitz points out that surgical interference should be employed at a much earlier date than was the custom. Parker recommended the fifth day as the earliest, but Fitz, in a table of sixty fatal cases, shows that thirty-four per cent. died during the first five days. "It is thus evident," he says, "that the earliest date fixed by Dr. Parker is too late to afford the possibility of relief in more than one-fourth of all the cases. Hence, if the indications for operating justify the election of a date as early as the fifth day, they still more justify the choice of the third day. The result has shown the wisdom of the former step, and the evidence here presented seems not only to warrant, but to demand the latter. It is evident that the operation to be performed is that of opening the abdominal cavity. It is therefore unnecessary to state that an act which twenty years ago might have added to the risks of the patient, may at the present time, when properly performed, be confidently expected to reduce them materially." This article, like Parker's twenty years before, appeared at the right moment, and with its clear elucidation of the relations of the appendix to various misunderstood abdominal diseases, gave a great stimulus to more aggressive methods in abdominal surgery.

It was but natural that surgeons in the United States should at once respond to such an appeal, and we actually find that most of the reports of extirpations of the appendix in the next few years came from American pens. The question of priority involved in these early cases has been the occasion of much logomachy, and I feel that I am treading on uncertain and difficult ground in approaching it; I can only declare that I have been at pains to ascertain the exact details in every case calling for individual mention.

R. J. Hall, of New York, performed the first operation on the appendix in the United States, which is the third on record, in May, 1886, and published it in the following month in the *New York Medical Journal*. The patient, a boy of seventeen, had had a reducible inguinal hernia since childhood. Two weeks before his admission to the Roosevelt Hospital he began to suffer from obstipation, and for the entire period had no passage from the bowels. Three days before admission the hernia became irreducible, and since that time he had vomited persistently and was apparently in collapse. There was constant severe pain and tenderness over the whole rather retracted abdomen, and the hernial sac was swollen, red, and intensely painful. The right scrotal and inguinal region was occupied by a pear-shaped swelling about eight inches long, about the size of two fists at its lower end; the skin over the sac was congested and semi-fluctuating, but not tense nor tympanitic. A probable diagnosis of strangulated hernia was made, and an operation performed at once; the incision, about three-fourths of an inch long, extended down to the neck of the hernial sac, which was opened, when there escaped from the peritoneal cavity a pint of fetid sero-pus. Behind the sac lay the swollen and edematous spermatic cord, while just outside the external ring on the posterior wall was found a solid, cylindrical mass covered with a greenish, diphtheritic exudate. The tunica vaginalis was moderately distended

with fluid and at the most dependent part of the scrotum was what appeared to be a normal testicle. Closer examination showed that this was the vermiform appendix, curled upon itself and so thickened near its cecal attachment as to resemble a solid tumor about the size of a testicle; near its base there was a small oval perforation. The appendix was ligated above this opening with catgut, freed from its adhesions, and removed. The stump was disinfected with a strong bichloride solution (1 : 1000), but not sutured. The original incision was then prolonged upward about three inches, and the hand with the forearm inserted, so as to explore the abdominal cavity thoroughly. The fresh adhesions were broken up, a number of large pus cavities emptied, and a large amount of sero-pus scooped out of the true pelvis. After cleansing the peritoneum a rubber drain eight inches long was inserted. The patient's condition at the end of the operation was very bad, but he began to improve at once, and made an excellent recovery. Hall remarks: "While laparotomy for suppurative peritonitis has now been successfully performed so often that single cases scarcely attract attention, the number of successful cases done for perforation is still extremely small. In a somewhat hasty search, I have been unable to find any case of perforative peritonitis due to ulceration of the vermiform appendix, successfully treated by laparotomy and resection of the appendix itself." This claim, if the qualifications are borne in mind, seems to be fully justified, for Krönlein's case, it will be remembered, did not recover, and that of Symonds was not performed for perforative peritonitis, nor did he resect the appendix. Hall's operation was undertaken for the relief of an incarcerated strangulated hernia, and the lesion of the appendix was discovered incidentally, so that while the first to succeed in extirpating a perforated appendix, it yet remains for us to discover who executed with intention the first successful operation for disease in that organ.

To Thomas G. Morton, of Philadelphia, belongs the credit of the first successful operation for the removal of the appendix, deliberately undertaken with an alternative diagnosis of disease in the organ. The date was April 27, 1887, and the report of the case is in the *Transactions of the College of Surgeons of Philadelphia* for the same year. The patient, a man of twenty-six, had been subject to repeated attacks of abdominal pain during the four years previous to the illness in question. He consulted Dr. Frank Woodbury, of Philadelphia, on April 20th, complaining of a cold. The previous day, while driving, he had had a violent attack of abdominal pain lasting some hours, by which he was still prostrated when he appeared in Dr. Woodbury's office. During the next few days he grew steadily worse, and the pain in the abdomen increased, accompanied by nausea and vomiting, while the bowels were somewhat relaxed. On examining the abdomen, a point of greatest tenderness was found midway between the umbilicus and the middle of Poupart's ligament, where a resistant mass which did not cause severe pain could be made out on pressure. A

diagnosis of probable perityphlitis was made by Dr. Woodbury and Dr. J. C. Wilson, and Dr. Morton was summoned in consultation to consider the question of operation. By his advice, this was immediately undertaken, although the patient was extremely ill. Dr. Morton made an incision directly over the swelling, and when the deep muscles were found infiltrated with pus, this was extended until it was ten inches in length. The peritoneum was opened, and a free flow of pus with a fecal odor followed. In the abscess cavity, near the appendix, was a concretion the size of a cherry-stone. The appendix itself was greatly swollen and had a perforating ulcer extending around its circumference. A silk ligature was applied close to the cecum, and another at the terminal portion of the appendix; the intervening portion, which comprised almost the whole of the organ, was then removed, together with a large piece of omentum that projected into the abscess cavity, whose walls were curetted and douched with hot water at 110° F. The peritoneal cavity was also douched until cleared of pus, and a drainage-tube carried into the lowest part of the pelvic basin. The patient began to improve at once and made a rapid recovery.

I have abstracted this account from the original publication, supplementing it with details furnished me in a personal communication by Dr. Woodbury, from whom I also learn that the patient is still living, engaged in active and successful business.

I turn here for a moment to the question of priority raised some five years later by Sir Frederick Treves. The *Philadelphia Medical News* of August 6, 1892, contained an editorial giving Morton the credit of first seeking out and removing the ulcerated appendix, and suggesting that the procedure might well be called "Morton's operation." This attracted the notice of Sir Frederick Treves, and elicited the following letter, in the issue for November 5, 1892:

"I have just read with interest a leading article in the *Medical News* for August 6 on the matter of operative treatment of the vermiform appendix. The fact that I live in a remote island, and further that a holiday of two months has taken me away from the haunts of books, must explain this tardy allusion to that paper.

"The article discusses the origin of the operation for removing the vermiform appendix, and it is stated that to Dr. Thomas G. Morton belongs the credit of first devising this procedure; the suggestion is also made that the operation should be called 'Morton's operation,' and it is asserted that Morton's operation embodies one of the most important and radical advances of modern surgery. Dr. Morton thus becomes the founder of what will, I suppose, be known as 'Appendiceal Surgery,' should the present love for ridiculous terms survive.

"I gather that Dr. Morton's first operation was performed in 1888, and was reported in the Philadelphia County Society's Transactions for that year. The nature of the transaction is not stated. Who first excised the appendix some musty and forgotten tome will no doubt reveal in course of time. . . . . In 1886 a patient with relapsing typhlitis came under my care at the London Hospital, and after due consideration, I proposed to 'deliberately seek for and remove his appendix.' I operated on him during a period of apparent health, on

February 16, 1887, and was able to correct the distortion of the appendix without removing it. He made a perfect recovery. On September 19, 1887, I brought the matter before the Royal Medical and Chirurgical Society. The paper was read in February, 1888. I advised the treatment of selected cases of relapsing typhlitis by the deliberate removal of the offending appendix during a quiescent period. The proposal was not well received. In due course, however, an exuberant reaction took place, and of late appendices have been removed with a needless and illogical recklessness which has brought this little branch of surgery into well-merited disrepute.

"Discussions on questions of priority constitute the most pitiable and petty items in the literature of medicine. The object of this letter is merely to bring up from oblivion an unpretending paper which lies buried in the annals of an ancient society.

"Believe me to remain, yours faithfully,

"FREDERICK TREVES."

As a matter of fact, neither Morton nor Treves is entitled to the distinction of first removing the appendix, since Krönlein, as I have shown, made the diagnosis and performed the operation in February, 1884, and published the account in 1886. Morton's operation was performed on April 19, 1887, and published in the Transactions of the College of Physicians and Surgeons of Philadelphia for 1887. Treves's operation, "the correction of a distortion of the appendix," was performed on February 16, 1887, but not published until the year 1888, in the Transactions of the Medico-Chirurgical Society. Any claim to priority in medicine or surgery always rests by the consent of the profession not upon date of performance, but upon date of publication. Reflection will only confirm this dictum by showing that the printed word is, after all, the only possible arbiter which can be generally appealed to and accepted when disputes arise. Moreover, in the particular case in hand, the operations done, although having the same organ in view, were essentially different—one was purely orthopedic and the other exsective; it is the difference between a plastic operation upon a limb and an amputation; therefore, in view of this fact alone, no conflicting claims as to priority can be raised.

H. B. SANDS, of New York, operated for disease of the appendix, after making a definite diagnosis, on December 30, 1887, and published the case on June 16, 1888. Sands had for some time taught the principles he here put into practice, and it was his conviction that the operation he reported was the first successful one of its kind, since Hall's case, as he truly observes, was accidental and not preconsidered; of Morton's case, apparently, he had not heard.

Sands's patient was a young man, ill for some days with pain in the lower abdomen, accompanied by vomiting in the first stages. There were exquisite tenderness over the right iliac fossa and tympanites, but no tumor. Dr. Sands made a diagnosis of acute septic peritonitis caused by a perforation of the appendix, and advised immediate operation. Dr. S. Baruch, who saw the case, was in favor of incising above Poupart's ligament, as for

perityphlitic abscess, to try to evacuate the pus without opening the peritoneum. Sands, however, confident that the patient had an acute septic peritonitis, and that opening the abdomen alone could effect a cure, preferred a vertical incision over the caput coli, giving free access to the diseased parts and allowing thorough work. At the operation, forty-eight hours after onset of the attack, a vertical incision four inches long was made, beginning at a point about half an inch above the middle of Poupart's ligament and ending about the same distance below the level of the umbilicus. This was afterward lengthened three-fourths of an inch below. The parietal and adjacent visceral peritoneum was found covered with pus and recent lymph. In the iliac fossa, a fecal concretion lay free in the peritoneum below the cecum, and a similar one had partly escaped from the opening at the base of the appendix. The margins of this opening were slightly trimmed with scissors and brought together with three silk sutures. The diseased parts were then irrigated with warm water, and syringed with half a pint of a solution of warm bichloride of mercury (1 : 1000). The upper part of the abdominal wound was closed and the lower part left open and packed with iodoform gauze. Immediate improvement followed and the patient recovered. Sands says: "I diagnosticated the case as one of acute septic peritonitis caused by perforation of the vermiform appendix, and advised an immediate resort to laparotomy," and his estimate of his accomplishment is thus briefly expressed: "I am acquainted with no case like mine in which a perforative peritonitis, due to disease of the appendix, has been diagnosticated, and treated by laparotomy with a favorable result."

Sands's article, one of the best on the subject, deserves careful consideration from the medical historian. Dr. T. W. Harvey, of Orange, New Jersey, an early student of Dr. Sands, informs me that he inculcated the surgical treatment of disease of the appendix for some time before the appearance of this paper.

We have now traced the history of our subject through the successive stages of its evolution, from the first discovery of a lesion in 1759 down to the time of Fitz in 1886, who secured recognition for its diseases as a distinct class by themselves, banishing the older misleading terms typhlitis and perityphlitis. We have furthermore witnessed the earliest efforts of the surgeon, at first timidly opening a few abscesses (the classical procedure) and then gradually growing bold enough to take the important step of making the incision before the detection of fluctuation (Hancock, Willard Parker). We then found a few surgeons, endowed with a courage born of the newly inaugurated antiseptic *régime*, venturing to open the peritoneum and to straighten out a kink (Treves), or to trim off the edges of a fistula in the appendix (Sands), and, at last, to remove the entire organ (Krönlein, Morton, Sands).

It now remains to note briefly the growing boldness of surgeons the world over, but especially in America, in opening the abdomen and removing the diseased

appendix, tracing at the same time, in brief outline, the development of the special technic of the new operation. Upon the technic, however, I shall not dwell at length, since it deals with the most modern phase of the subject and would involve repetition further on (see Chapter XXV).

Doubt dissipated, and the flood-gates once thrown open, the healing waters swept in like a torrent, carrying the beneficent influences from land to land, at first through the greater centres of learning, and then spreading more slowly out even to the remotest hamlets, until to-day we may almost say that no other surgical affection is so well understood nor so well treated as this, the bane and the opprobrium of the profession but a generation ago. In the United States, which holds a leading position in the prompt recognition of the exact nature of this one-time obscure malady, as well as in the adoption of the aggressive therapeutic *régime* necessary for its relief, we look back upon such a galaxy of names as Senn, Weir, McBurney, Worcester, Marcy, Fowler, Mynter, Richardson, and many others who deserve mention, and would receive it in a more extended work.

The farther evolution of the subject consists in the development of technic, from the crude simple ligation and amputation to the various highly specialized and often purely individual procedures now in use. One of the first steps in the advance was the sterilization of the stump of the amputated appendix, and its protection with a little cuff of peritoneum left for the purpose; then it was ligated and depressed into the cecum, while the adjacent surfaces of the cecum were drawn over it and stitched; then came the amputation flush with the cecum with the suture of the opened bowel; next the inversion of the stump, or even of the entire unopened appendix; and, lastly, we find the cautery or the cautery clamp employed to sterilize and seal the stump before burying it in the cecum.

The first step in the improvement of the technic was suggested by Treves (Med. and Chir. Trans., Lond., 1888, p. 172), as follows: "In the majority of cases it would probably be wiser to remove the appendix. If this is done, as much care must be taken to close the divided end of the tube as would be taken to close a hole in the small intestine. A mere ligature would not suffice. Two sutures would bring the mucous membrane together, and the peritoneum should be adjusted over this line of union by several points of Lembert's suture." Treves was shortly after able to put his method into practice (*Lancet*, 1889, vol. i, p. 267). "The appendix," he says, "was clamped close to the cecum, and divided about half an inch from that intestine. It should not be secured by a simple ligature. The mucous membrane was united by a number of very fine sutures, then the divided walls of the process were brought together by a second row of sutures. It is practically impossible to bring the serous coats together."

N. Senn, in the same year, recommended and employed the same improvement in technic, for the first time in the United States, where he affirms that:

"It is of the greatest practical importance to recognize the exact condition in time, and to anticipate the dangerous and only too often fatal complication by removing permanently the source of danger, which can be done at this time with comparative ease and almost perfect safety by the extirpation of the appendix." With his well-known surgical insight, he adds: "The appendix was ligated near the cecum with a silk ligature, and amputated about a quarter of an inch below the point of ligation. The lumen of the appendix was quite small, but as it was more than probable that it communicated with the cecum, I deemed it necessary to prevent the possibility of a subsequent perforation from cutting through of the ligature by covering the stump with peritoneum. The stump was disinfected, dusted with iodoform, and buried by stitching the peritoneum from each side over it by a number of stitches of the continued suture. The cecum was now returned, and the wound closed by suturing the peritoneum with catgut, while the external sutures of silk were passed down to, but not through, the peritoneum." He follows this statement with an excellent exposition of the reasons for such an accurate closure of the stump, the first definite, decided, and clearly reasoned statement upon this most important head. Then with the confidence begotten of such a perfected technic, he justly adds: "Drainage in such cases is unnecessary, and should be dispensed with."

C. McBURNEY, in 1889, deals with the same subject in an article which must ever deserve to be ranked as one of the classics in the surgical history of America. So admirable and so clear are his views as to the proper surgical treatment of appendicitis that the experience of fourteen years has not brought any radical or important changes in his methods. The value of the memoir is such that to do it justice I must quote somewhat fully. After a just tribute to the memory of Sands, whom McBurney had assisted "in a number of successful operations for the removal of the appendix at an early stage of the disease," he asks: "How many cases of localized peritonitis or perityphlitis arise from impaction of feces in the cecum? . . . . Is there a single observation brought from the dead-house or from the operating table to support this idea?" He then emphatically declares that a peritonitis localized in the neighborhood of the cecum "may with rare exceptions be attributed to an inflammation of the vermiform appendix in some one of its numerous stages. . . . . I must, therefore, prefer to use the term inflammation of the appendix or appendicitis, and give up, once and for all, the terms perityphlitis, paratyphlitis, and extraperitoneal abscess, as misleading and not valuable except in explanation of secondary pathological lesions."

McBurney then demonstrates, in full harmony with an admirable paper by Weir in the same year, that abscesses formed in the appendix around the cecum are always primarily extraperitoneal; he says: "The peritoneum may be pushed back and the abscess incised deep in the iliac fossa by a roundabout and unsurgical method, but when incised the peritoneum will be cut." Weir

had already shown this same fact in his analysis of 100 autopsies, in not one of which did the abscess originate in the extraperitoneal tissue.

In the early operations for which McBurney was entering so earnest a plea, he declares that he had "found a condition of the mucous membrane in its surroundings, varying from a mild catarrh of the mucous membrane, accompanied by infiltration and thickening of the submucous and other tissues, to the state of complete gangrene of the surrounding organs."

He further states that "the pathological condition of the appendix as compared with the symptoms in my own cases most positively show that one cannot with accuracy determine from the symptoms the extent and severity of the disease." Any advance in knowledge must be by early operations, for "by autopsies we cannot learn very much more in this direction, if we may judge by the length of time it required to learn the important fact that abscesses originating in the appendix are almost invariably intraperitoneal." He notes the varying value of the symptom pain, citing "one patient who died on the third day from violent septic peritonitis from perforation, but complained of comparatively little pain even when the iliac fossa was firmly compressed."

As to the location of the pain as a significant factor in making a diagnosis of appendicitis, the value of the "McBurney point" is now so universally known that it is most interesting to read the first statements of the author relative to this matter: "The exact locality of the greatest sensitiveness to pressure had seemed to me to be usually one of importance. Whatever may be the position of the healthy appendices found in the dead-house—and I am well aware that its position when inflamed varies greatly—I have found in all of my operations that it lay, either thickened, shortened, or adherent, very close to its point of attachment to the cecum. This, of course, must, in early stages of the disease, determine the seat of greatest pain on pressure. And I believe that in every case the seat of greatest pain, determined by the pressure of one finger, has been very exactly between an inch and a half and two inches from the anterior spinous process of the ilium on a straight line drawn from that process to the umbilicus. This may appear to be an affectation of accuracy, but, so far as my experience goes, the observation is correct."

In urging an early operation, he says: "The truth is that, in the early stage, no accurate diagnosis can be made as to whether the appendix is perforated or not, excepting in those cases where comparatively mild symptoms suddenly become much aggravated, when perforation or the rupture of an abscess may be inferred." "There is no reason to think, however, that diagnosis from symptoms alone will ever reach that perfection. . . . . I hope that I may never again go every day to visit a threatening case, waiting bashfully for the authority of a clearly defined peritonitis before I dare take action." The conclusion of the whole matter is "if it can be shown by future experience with improved methods of operation, and with more perfect antiseptic precautions, that the exploratory incision for inspection of the diseased appendix is

much more free from danger than the expectant treatment, then there could be but one answer to the question: What is the best treatment?"

In the course of this article, McBurney relates the case of a young lady who had no less than twelve attacks of perityphlitis within a year, where "the operation was done during a period of complete health, and after careful consideration, to prevent recurrence." He also adds, in the midst of a series of other cases, the description of one which he says "is, I believe, the first recorded case where an acutely inflamed appendix has been removed full of pus."

His method of removal was to tie off the appendix with silk or catgut and to cut it away; he then carefully disinfected the stump, scraping its interior, and applying a 1:1000 bichloride solution and rubbing in iodoform. In a bad case he used the fine point of a cautery to disinfect the stump. He thought it was unnecessary to sew the peritoneum over the stump, and concluded the operation by inserting a drainage-tube into the wound.

A. Worcester, of Waltham, Mass., in 1892 began a series of admirably clear presentations of our subject which must have exercised a decided influence on contemporary surgical thought.

He begins his writing with the declaration that "there is only one logical treatment of the disease, namely, the excision of the diseased organ as soon as the diagnosis is made," and he adds that he is "too timid to take the responsibility of the risk that there always is in delaying to evacuate an internal abscess, and a cake in the right iliac fossa, tender to pressure, in a patient even slightly feverish, means an abscess." When, on one occasion, an operation was delayed by the family of the patient, he declares: "In a similar case, I should not now consent to share with the family the responsibility of delay."

In conclusion, Worcester gives us the following summary expressed in the language of emphatic conviction: "(1) Appendicitis is an inflammation of a useless organ, dangerously situated. (2) At the beginning of an attack it is not possible to determine whether it will prove of the harmless or of the dangerous kind. (3) The diagnosis is easy in comparison with the task of diagnosticating the seat of any acute inflammation. (4) At the beginning of an attack, the excision of the appendix is an easy and a perfectly safe operation. (5) If so treated, all complications and all subsequent attacks are avoided. (6) In view of the results already obtained by following this treatment, no other treatment is worthy of consideration."

G. R. Fowler, in 1894, gave a clear illustrated description of the method of burying the stump of the appendix in the cecum.

Dawbarn, in 1895, described the complete inversion of the amputated appendix into the cecum.

Edebohls, in 1895, adopted the plan of inverting the entire unopened

appendix into the bowel, closing the dimpled orifice at the base in the cecum, and leaving the inverted organ to slough off and pass out by the rectum.

J. B. DEAVER, in 1897, amputated the entire unopened appendix, cutting it off flush with the cecum, and then suturing the wound as any other in the intestine.

SKENE, in 1898, introduced the crushing electro-cautery forceps.

Following PORTER, CABOT, and MARCY, of Boston, who were active in the propaganda of the new idea that had come to the surgical world, came one of its greatest exponents, MAURICE H. RICHARDSON, who in 1898 was able with G. W. Brewster to present as many as 151 cases operated upon "in the interval" between the dates August, 1894, and February, 1898, without a single death, in an article "Appendicitis; remarks based upon a personal experience of 757 cases; including 151 consecutive cases operated upon 'in the interval.'"

In Great Britain the names of DUCKWORTH, of LOCKWOOD, and of HAWKINS deserve mention, together with that of Treves, as writers who have contributed to our knowledge of the appendix in health and disease.

France claims such eminent authorities as ROUX, TALAMON, JALAGUIER, and TUFFIER.

In Germany characteristically scientific work has been done by SONNENBURG, RIEDEL, KROGIUS, and LENZMANN.

In concluding this brief enumeration, I must not omit the name of the great Scandinavian surgeon, LENNANDER, of Upsala, whose writings show the most scientific extensive comprehension of the subject in all its phases.

BIBLIOGRAPHY.

BLACKADDER: "Notices of certain accidents and diseased structures of the cecum coli, and of the vermiform appendix." Edin. Med. and Surg. Jour., 1824, vol. 22, p. 118.

BRIGHT AND ADDISON: "Elements of the Practice of Medicine." Lond., 1839, vol. 1, p. 498.

BULL: "Perityphlitis." New York Med. Jour., 1873, vol. 18, p. 240.

BURCHARD: "Operative interference in acute perforative typhlitis." New York Med. Rec., 1880, vol. 18, p. 663.

BURNE: "Upon inflammation and perforation of the cecum." Med. and Chir. Trans., Lond., 1837, vol. 20; also "Memoir on tuphlo-enteritis." Ibid., 1839, vol. 22.

COPLAND: "Cecum." Dict. of Prac. Medicine, 1834.

DAWBARN: Internat. Jour. Surg., May, 1895.

DEAVER: "Remarks upon some points in the technique of the operation for appendicitis." Ann. of Surg., 1897, vol. 27, p. 81.

DE VECCHI: "Storia di peritonite diffusa, mortale, cagionata da ulcerazione e perforamento dell' appendice vermiforme del cecco." Ann. Univ. di med., 1845, vol. 113, p. 5.

DUPUYTREN: "Des abscés de la fosse iliaque droite." Leçons chirurgicales, 1839, vol. 3, p. 516.

EDEBOHLS: "Inversion of the appendix vermiformis." Amer. Jour. of Med. Sci., June, 1895.

FENWICK: "Perforation of the appendix vermiformis." Lancet, 1884, vol. 2, pp. 987 and 1039.

FITZ: "Perforating ulcer of the vermiform appendix, with special reference to its early diagnosis and treatment." Am. Jour. Med. Sci., 1886, vol. 92, p. 32; "The relation of perforating inflammation of the vermiform appendix to perityphlitis." New York Med. Jour., 1888, vol. 47, p. 505; "Appendicitis; some of the results of the analysis of seventy-

two cases seen in the past four years." Bost. Med. and Surg. Jour., 1890, vol. 122, p. 619.

FOWLER: "Observations upon appendicitis." Ann. of Surg., 1894, vol. 19, p. 347.

GAY: "Internal strangulation between the appendix vermiformis, which had become adherent to the ilium, and a band of false membrane." Proc. Path. Soc. Lond., 1850–51.

GOLDBECK: "Ueber eigenthümliche entzündliche Geschwulste in der rechten Hüftbeingegend." I. D., Wurms, 1830.

GOULAY: "Perityphlitic abscess." Trans. Path. Soc. New York State, 1875, p. 345.

GRISOLLE: "Histoire des tumeurs phlegmoneuses des fosses iliaques." Arch. gén. de méd., 1839, tom. 4, pp. 34, 137, 293.

HALL: "Suppurative peritonitis due to ulceration and suppuration of the vermiform appendix, etc." New York Med. Jour., 1886, vol. 43, p. 662.

HALLOWELL: "Case of perforation of the appendix vermiformis; death." Am. Jour. Med. Sci., 1838, vol. 22, p. 127.

HANCOCK: "Disease of the appendix cœci cured by operation." Lancet, 1848, vol. 2, p. 380.

HODGKIN: "Lectures on the morbid anatomy of the serous and mucous membranes." Lond., 1836, p. 157.

HOWARD: "Clinical lecture on inflammation and perforation of the appendix vermiformis." Med. Chron. (Montreal), 1858, vol. 5, p. 527.

JUILLIARD: "Kyste ovarique—étranglement interne—opération—guérison." Bull. et mém. de la Soc. de chir., 1879, tom. 5, p. 627.

KRÖNLEIN: "Ueber die operative Behandlung der acuten diffusen jauchig-eitrigen Peritonitis." Arch f. klin. Chir., 1886, Bd. 33, p. 507.

LAMOTTE: "Ouverture du cadavre d'une personne morte d'une tympanite." Jour. de méd., chir., et phar., 1766, tom. 24, p. 65.

LEWIS: "A statistical contribution to our knowledge of abscess and other diseases consequent upon the lodgment of foreign bodies in the vermiform appendix, with a table of forty cases." New York Jour. of Med., 1856, Ser. 3, vol. 1, p. 328.

LEUDET: "Recherches anatomo-pathologiques et cliniques sur l'ulcération et la perforation de l'appendice iléo-cecale." Arch. gén. de méd., 1859, Sér. 5, tom. 14, pp. 129, 315.

LOUYER-VILLERMAY: "Observations pour servir à' l'histoire des inflammations de l'appendice du cecum." Arch. gén. de méd., 1824, tom. 5, p. 246.

MATTERSTOCK: "Perityphlitis." Gerhardt's Handbuch der Kinderkrankheiten, 1880, Bd. 4, p. 893.

MCBURNEY: "Experiences with early operative interference in cases of diseases of the vermiform appendix." New York Med. Jour., Dec. 21, 1889.

MÉLIER: "Mémoire et observation sur quelques maladies de l'appendice cecale." Jour. gén. de méd., 1827, tom. 100, p. 317.

MÉNIÈRE: "Mémoire sur des tumeurs phlegmoneuses occupant la fosse iliaque droite." Arch. gén. de méd., 1828, tom. 17, pp. 188 and 513.

MESTIVIER: "Observations sur une tumeur située proche la région ombilicale du côté droit, occasionée par une grosse épingle trouvée dans l'appendice vermiculaire du cecum." Jour. de méd., chir., et phar., 1759, tom. 10, p. 441.

MIKULICZ: "Ueber Laparotomie bei Magen- und Darmperforation." Samml. kl. Vorträge, 1885, No. 262.

MORTON: "Case of exploratory laparotomy, followed by appropriate remedial operation." Trans. Coll. Phys. and Surg., Phila., 1887.

NOYES: "Perityphlitis." Trans. Rhode Isl. Med. Soc., 1883, vol. 2, pt. 6, p. 495.

PARKER: "An operation for disease of the appendix vermiformis cecі." New York Med. Rec., 1867, vol. 2, p. 25.

PARKINSON: "Case of disease of the appendix vermiformis." Med. and Chir. Trans., London, 1812, vol. 3, p. 57.

RICHARDS: "A case of death from ulceration of the vermiform appendix." West. Jour. Med. and Phys. Sci., 1837, vol. 11, p. 376.

RICHARDSON AND BREWSTER: "Appendicitis, etc." Bost. Med. and Surg. Jour., July 14 and 21, 1898.

SANDS: "Account of a case in which recovery took place after laparotomy had been performed for septic peritonitis due to a perforation of the vermiform appendix." New York Med. Jour., 1888, vol. 47, p. 197.

SENN: "A plea in favor of early laparotomy for catarrhal and ulcerative appendicitis, with the report of two cases." Jour. Amer. Med. Assoc., Nov. 2, 1889.

SYMONDS: "On a case in which, at the suggestion of the late Dr. Mahomed, a calculus was removed from the vermiform appendix for the relief of recurrent typhlitis." Lancet, 1885, vol. 1, p. 895.

TREVES: "Relapsing typhlitis treated by operation." Med. and Chir. Trans., Lond., 1888, vol. 71, p. 165; Lancet, 1888, vol. 1, p. 527; and letter to editor Phila. Med. News, Nov. 5, 1892.

VOLZ: "Die durch Kothsteine bedingte Durchbohrung des Wurmfortsatzes, etc." I. D. Carlsruhe, 1846.

WEGELER: "Historia enteritiditis malignae et singularis calculosi concrementi." Jour. de méd., chir., et phar., 1813, tom. 28, p. 384.

WEBER: "Abscess of the vermiform appendix." New York Med. Jour., 1871, vol 14, p. 142.

WITH: "Peritonitis Appendicularis," etc. Nordiskt Mediciniskt Arch., Band 7. Abstract in Lond. Med. Rec., vol. 8, p. 218.

WORCESTER: "Treatment of appendicitis." Ann. of Gyn. and Pediat., May, 1892.

CHAPTER IV.

ANATOMY.

EMBRYOLOGY OF THE VERMIFORM APPENDIX. DIFFERENTIATION BETWEEN THE APPENDIX AND THE CECUM. COMPARATIVE ANATOMY.

THE EMBRYOLOGY OF THE VERMIFORM APPENDIX.

The anatomical structure as well as the topography of the vermiform appendix and the adjacent portions of the intestinal tract in the adult present so many deviations from the normal that it is difficult to arrive at an understanding of their different perplexing variations. These difficulties become reduced to a minimum, however, by a study of the embryology of the portions of intestine concerned. A brief description of the origin and development of the vermiform appendix will, therefore, be given, based on an investigation of fifty-four human embryos from the private collections of Prof. F. P. Mall and Mr. Max Brödel.

A glance at the embryological life of the appendix reveals it to be morphologically as well as structurally merely a portion of the general cecal pouch which has remained in an early stage of development.

At the end of the first month of intrauterine life the intestinal canal is in the form of a small loop protruding into the umbilical cord, and for the sake of convenience a cranial and a caudal portion or limb may be spoken of. The caudal limb lies to the left of, and usually a little higher than, the cranial (Fig. 1).

The cecum arises from the outer and somewhat posterior side of the caudal limb of the intestinal loop. It is visible during the fifth fetal week as a slight elevation or swelling, a short distance from the most anterior portion of the loop (Figs. 1 and 28). During the sixth week the intestinal loop lengthens out, the cecal protuberance having increased in size, and a very slight differentiation in calibre between the large and small intestines having become apparent (Fig. 1).

Between the sixth and seventh weeks the small intestine increases in length, forming a number of loops and contortions, which lie within the cord, to the right, partly in front of and partly below and behind the budding cecum (Figs. 2, 3, and 4). The latter is now a rounded or conical projection with a broad base, extending about 0.5 mm. from the main tube. The large intestine does not increase in length in the same proportion as the small

intestine, but remains of very nearly the same size until it begins to rotate about the small intestine.

The Transient Vermiform Appendix (Figs. 4, 5, and 28).—Between the seventh and eighth weeks a minute process is almost invariably found at the tip of the cecum. It appears at the inner or iliac side of the cecal extremity, in the form of a delicate bud or prolongation of the cecum, very much resembling a beginning appendix. It is visible to the naked eye, and has a length of from one to four or five times its breadth. The

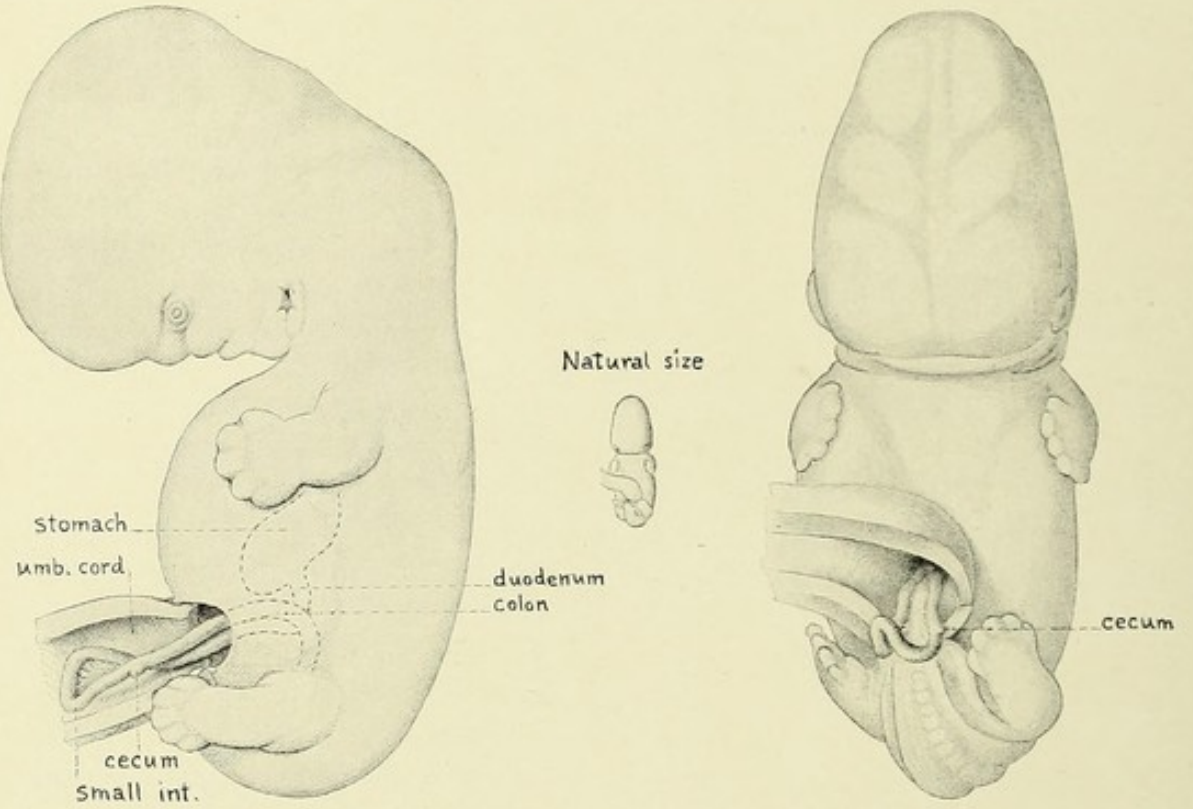

FIG. 1.—HUMAN EMBRYO. SIX WEEKS. MAG. 5½. (MALL.)

This figure represents the lateral and anterior aspects of the same embryo with the umbilical cord cut open to show the loop of intestine protruding into it. The loop is composed of two limbs: (1) the cranial, coming from the stomach, and (2) the caudal, descending toward the cloaca. At the point where they leave and enter the body, the caudal limb lies slightly above and to the left of the cranial This condition is more plainly seen in the left diagram. The small budding cecum may be seen on the lateral side of the caudal limb at about one-third the distance from its most anterior point. Its position marks the division between small and large intestines.

relation of its position and size to the position and size of the cecum sometimes presents a striking similarity to the same relations between the adult appendix and cecum, for which reason this bud might at first be regarded as the true "*Anlage*" (first indication) of the subsequent appendix. Out of ten embryos of this period (six and a half to eight weeks) the process was readily seen in eight, and serial sections of the whole ileocecal region were made of six of these. Microscopic examination proves this structure to be sometimes merely an aggregation of cells at the tip of the cecum in the form of a short

blunt process. In other cases it possesses a distinct lumen, continuous with that of the cecum and lined by the same epithelium as the rest of the intestine. This form of the cecum, with its constricted terminal portion, bears a striking resemblance to the cecum of the Mangabey monkey; in other cases the process is in the form of a cylindrical filament having no lumen, except, possibly, for a short distance at its cecal extremity. In one case, however, the lumen was



FIG. 2.—LATERAL VIEW OF HUMAN EMBRYO. SEVEN WEEKS. (MALL.)

The small intestine has increased in length, forming several convolutions which lie within the cord anterior to and below the budding cecum. The latter is now a rounded or conical projection extending about 0.5 mm. from the main tube. The caudal limb is elevated somewhat more above the cranial, suggesting the subsequent rotation of the intestine.

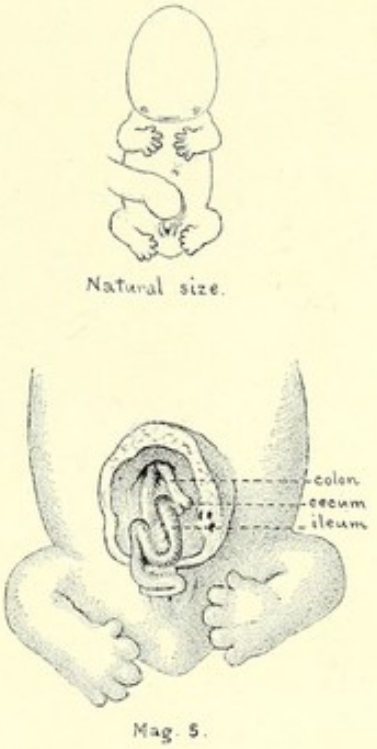

FIG. 3.—SAME EMBRYO AS FIG. 2.

Anterior view of the intestinal loops within the cord.

seen to extend fully half the length of the appendage. We have thus a form of cecum similar to that found in the gibbon. This peculiar budding process seems to be of an atrophic nature, as in slightly older embryos (seven and a half to eight weeks) it appears under the microscope as a loose and irregular chain of cells. The picture is characteristic of a structure which is about to vanish. There are no signs of its broadening out to form the future appendix, and in

all the cases examined, its calibre was so much smaller than that of the distal portion of the cecum or true appendix as to render untenable the view that it is the anlage of the future appendix. During the life of this transient appendage, the cecum, while equal in width to the intestine, increases much in length. Its growing end is round and blunt, and remains so during the entire period of its growth. The peculiar bud at its tip retains its original size, while the cecum continues to grow. At the seven and a half weeks' stage, therefore, a long cecum can be observed, on the end of which the delicate bud is still visible (Fig. 28). In subsequent stages this bud is seen to become thinner, and, finally, to disappear, while the cecum continues to grow as before, the end still maintaining its blunt shape. This disappearance of the bud seems to prove that it never becomes utilized in the promotion of the cecal growth. It is very common in embryonic life for structures to form and disappear, a large percentage of the embryonic tissue being used up in this manner.

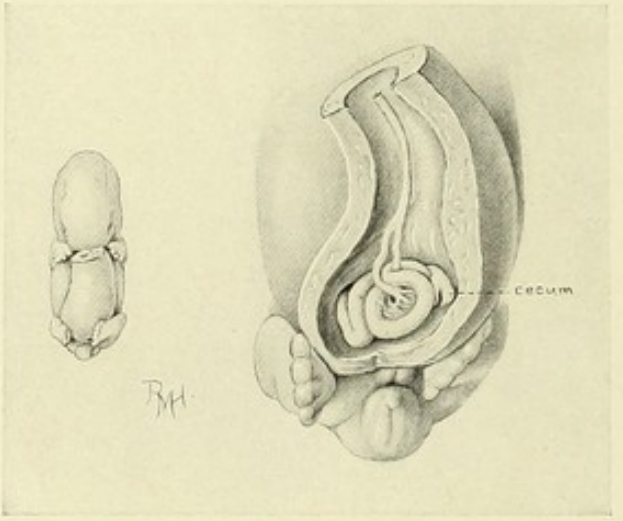

FIG. 4.—HUMAN EMBRYO. SEVEN WEEKS. (MALL, No. 28.)

At the left is seen the embryo in natural size, 20 mm. cervico-coccygeal measure. A discrepancy in size between this embryo and the one shown in the preceding figure is probably due to greater contraction in hardening. The figure at the right shows the coil of intestines lying within the opened cord and also the omphalo-mesenteric vein in its connection with the primitive intestine. At the left of the intestinal coil may be seen the cecum, at whose inner tip is now visible a tiny projection, the transient appendix.

The structure which makes its appearance at the tip of the cecum, and vanishes later on, may be a transient vermiform appendix, similar to other transient structures which are formed during embryonic life, or, as suggested above, it may represent a stage in the life-history of the human cecum, which at one time more nearly resembled that of certain monkeys; as, for example, the Mangabey monkey or the gibbon.

Between the s e v e n t h and e i g h t h weeks the cecum, with its concavity facing to the right, increases rapidly in length, and, as was said above, the formation at the tip disappears (Fig. 28). The intestines are coiled in a round mass within the umbilical cord, occupying its proximal portion. Owing to the rapid increase in length of the small intestine, there now begins a rotation of the two original portions or limbs of the loop (cranial and caudal) around each other. The caudal portion, with the attached cecum, swings a short distance around to the left, then over the cranial portion, and toward the right. In so doing, the cecum, which was previously concealed beneath the coils of small intestine, now comes to lie above them (Figs. 5 and 7).

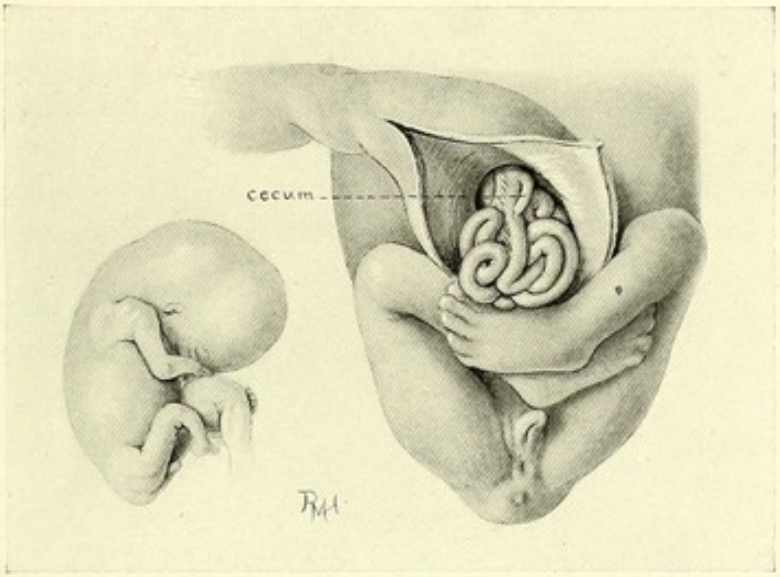

FIG. 5.—HUMAN EMBRYO. SEVEN AND A HALF WEEKS. 25 MM. CERVICO-COCCYGEAL MEASURE. (MALL, No. 89.)

The small intestine has increased rapidly in length, forming a large mass of convolutions which in greater part lie within the cord. The large intestine lies almost entirely concealed within the body, but the elongated cecum, with its minute projection at the tip, may be seen near the junction of the cord and the body, lying cranial to the rest of the intestine.

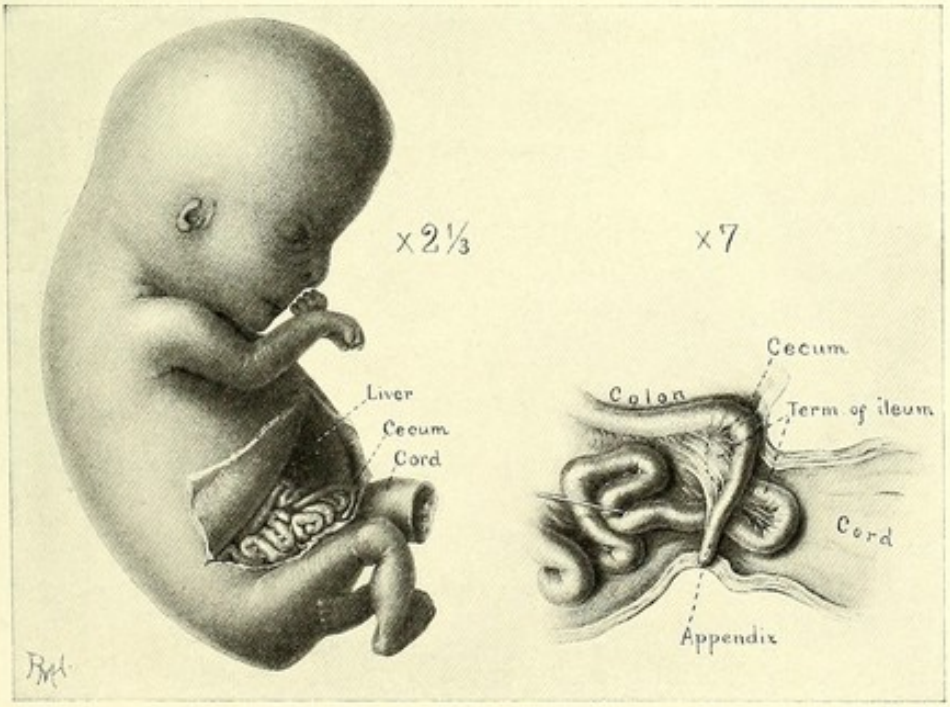

FIG. 6.—HUMAN EMBRYO. EIGHT WEEKS. 32 MM. VERTEX-COCCYGEAL MEASURE. (MALL, No. 52.)

This figure shows the last stage in the receding of the intestinal coils from the cord into the body. The ileocecal apparatus lies across the entrance, while a small loop of ileum still projects into the cord.

The differentiation between large and small intestines has now become more marked, and the cecum may show a slight bulging out at its upper extremity, which is thus differentiated from its lower or distal portion, the appendix (Fig. 7). CLADO says there is no differentiation before two and a half months; other authors say that the appendix is not a distinct organ until the sixth or seventh month. My investigations, however, demonstrate that these statements are erroneous.

A well-defined mesappendix provided with an artery may be found at this stage, but since differentiation is as yet slight, it is more properly the posterior vascular fold of the cecum, which later on, as differentiation proceeds, becomes the mesappendix. Toward the end of the seventh week the intestines begin to recede into the body, their entrance being accomplished between the eighth and

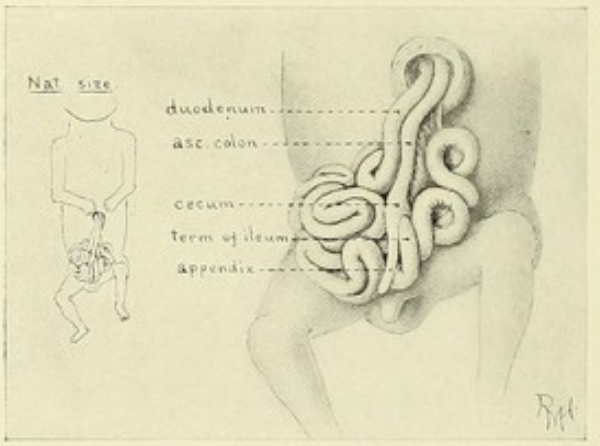

FIG. 7.—HUMAN EMBRYO. EIGHT WEEKS. (MALL, NO. 202.)

This embryo shows the intestines mainly outside the body, a circumstance probably due to imperfect development and injury. In other specimens of this age the intestines have almost completely receded into the body-cavity. (See Fig. 6.) The cecum has increased considerably in length, its proximal portion showing a slight bulging which differentiates it from the distal portion or appendix. This marks the beginning of the primary differentiation, the secondary differentiation taking place near or at the time of birth. The transient appendix at the tip of the cecum, visible during the seventh week, has now disappeared.



FIG. 8.—HUMAN EMBRYO. NINE WEEKS. ♀. (BRÖDEL, NO. 15.) NATURAL SIZE; ILEOCECAL APPARATUS ENLARGED IN SMALL DIAGRAM.

The intestines lie now entirely within the body and the growth of the ileum has forced the cecum and appendix upward in front of and just below the duodenum. The liver has been removed in order to show the proximal coils of ileum. The cecum and colon hang entirely free on their mesentery and present anteriorly the face which later becomes posterior. The appendix is bent back upon itself, and shows a slight differentiation in calibre from the cecum.

ninth weeks (Fig. 6). The cecum then lies near the umbilicus, and the entire large intestine lies wholly to the left of the median line (Fig. 7), owing to the pressure exerted by the rapidly growing coils of the small intestine. The rotation of the intestinal tube continues, and the colon, with the cecum and appendix, is pushed upward in front of the duodenum, until they lie just beneath the liver and near the middle line (Figs. 8 and 9). The variations in the position of the cecum and appendix at the age of ten weeks are shown in Figs. 10 and 11. Coils of small intestine shift to the left and take the place previously occupied by the large intestine. At two and a half months the cecum generally lies in a transverse direc-

tion on the right side of the body, just beneath the inferior border of the liver (Fig. 11). At this period of intrauterine life the iliac side of the cecum faces

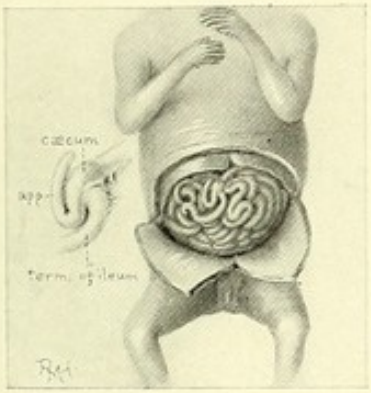

FIG. 9.—HUMAN EMBRYO. NINE TO TEN WEEKS. 5.5 CM. (MALL.)

The cecum and appendix lie near the middle line, just beneath the liver. The ileum now enters the colon from the left and from below, and the appendix is bent upon itself with its tip pointing upward. The cecal pouch tapers down to one-half its size and its distal portion may now be considered the appendix. Coils of ileum occupy the right renal region, thus preventing the cecum from entering the same.

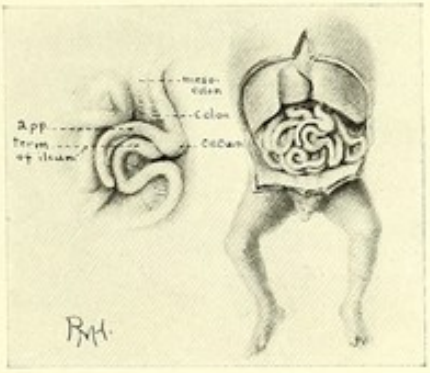

FIG. 10.—HUMAN EMBRYO. TEN WEEKS. 7.5 CM. (BRÖDEL, NO. 18.)

The cecum and appendix lie near the middle line, just beneath the liver. The differentiation between them is well marked.

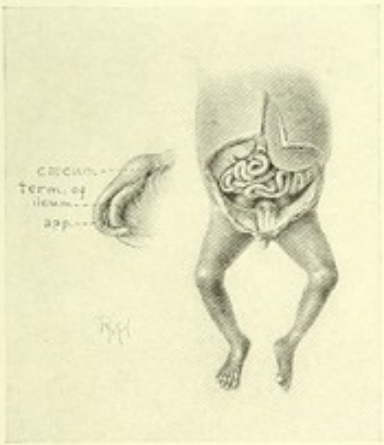

FIG. 11.—HUMAN EMBRYO. TEN WEEKS. (BRÖDEL, NO. 13.)

The cecum and appendix have moved along the edge of the liver toward the right, and lie in the right hypochondriac region. Coils of ileum intervene between them and the kidney. In the detail at the left the ileum may be seen to enter the colon from below. The face which the ileocecal apparatus presents to the front is approximately the same as in the adult.

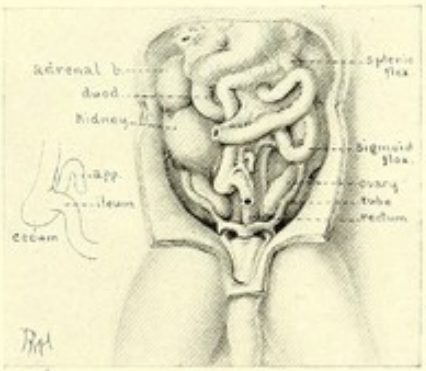

FIG. 12.—HUMAN EMBRYO. ELEVEN WEEKS. MAG. 1½. (BRÖDEL, NO. 6.)

The cecum hangs on a very free and movable mesentery, above and mesial to the ovary. The whole ileocecal apparatus assumes a position near the mid-line of the body, a rather exceptional occurrence. The appendix lies curled behind the ileocolic mesentery. The greater part of the ileum and its mesentery has been removed to show the appendix.

downward, its tip as a rule pointing to the left, the termination of the ileum running in an upward direction (Figs. 9 and 11). There is no ascending colon as yet, the tube skirting along the free border of the liver in an oblique direction,

from right to left across the duodenum, under the stomach to the splenic region, where it curves suddenly down to form the descending colon (Fig. 8).

On lifting back the anterior abdominal wall in embryos of this stage, the appendix usually lies in full view, but it may also lie coiled behind the cecum or parts of the small intestine. The large intestine still maintains the integrity of its mesentery and can be moved around freely within certain limits, there being no fusion whatever with any portion of the posterior abdominal wall. Between the age of three and four months the cecum occupies the subhepatic position, immediately anterior to the right kidney. In some instances there is already a moderate descent of the cecum noticeable, and consequently an indication of the ascending colon. The cecal pouch now points downward

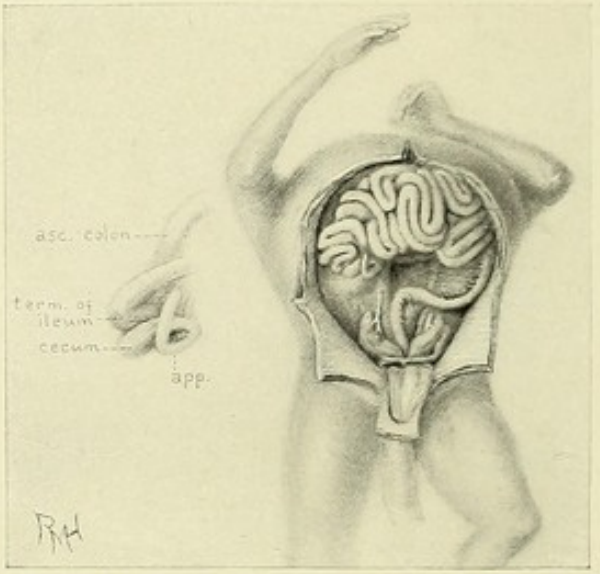

FIG. 13.—HUMAN EMBRYO. THIRTEEN WEEKS. ♀. (BRÖDEL, NO. 14.)

The body is bent somewhat backward in order to show the cecum and appendix, which lie anterior to the right kidney in the picture, probably a little lower when in their normal position. At the left is given a magnified view of the ileocecal region.

and the ileum enters from the left (Figs. 12, 13, 14, 15, 16, 17, 18, 20, and 21). The position of the appendix becomes subject to many variations. The retrocecal type, however, seems even in these early stages to be the most frequent.

Between the fourth and seventh months the cecum descends from its subhepatic position (Figs. 22, 23, 24, and 26). Sometimes the descent is not complete until the time of birth (Fig. 27). The descent is accomplished by moving somewhat to the right and passing downward anterior to the kidney, either directly in front of it, or separated from it by several coils of ileum. The cecum then approaches its ultimate position in the right iliac fossa. The revolution of the colon and cecum through an arc of 180 degrees around their own long axis produces a change in the relative position of the ileum and colon as compared with Fig. 10, the former now entering the latter not from the

right, but from the left and from below, and not from behind, but in front (Figs. 14, 15, and 17).

The fusion of the mesocolon with the posterior abdominal wall cannot take place before the small intestine has passed out of the way, which occurs, as a rule, much later. Different authors disagree as to the exact period at which this downward movement of the cecum begins. As a matter of fact, there is a great deal of variation seen in different fetuses, because in some the rate of descent is retarded by adhesions which form between the cecum and the organs passed in its descent (Figs. 20, 23, 24, and 26), while in others no obstacles present themselves (Figs. 13, 15, 17, and 18). GROHÉ states that the cecum with its appendix lies anterior to the kidney at seven months, but we have seen it advanced into this position as early as three months (Figs. 12, 13, 14, and 16). CLADO examined two infants (still-born) in which the cecum was still situated in front of the kidney. As to the time when the cecum and appendix have completed their descent, *i. e.*, when they have reached their final position in the right iliac fossa, we also find considerable variation.

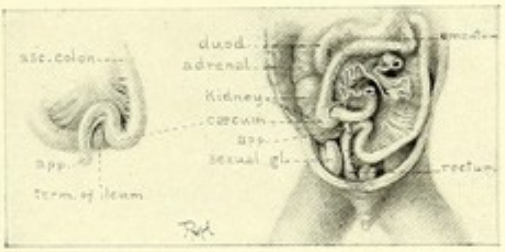

FIG. 14.—HUMAN EMBRYO. THREE MONTHS. (BRÖDEL, No. 10.)

The greater portion of the small intestine has been removed, leaving the mesenteric ruffle to indicate its position. The cecum and appendix have advanced to a position in front of the right kidney, the iliac coils in the renal region having swung over to the left, allowing this juxtaposition. The large intestine and its mesentery have not contracted any adhesions so far, and, owing to the beginning downward movement of the cecum, there is now an ascending colon proper. The appendix is almost entirely hidden behind the termination of the ileum and its mesentery, the relation of the ileum, cecum, and appendix to each other being similar to that in the adult, except for their high position. The small diagram at the left is a posterior view of the ileocecal region, somewhat magnified.

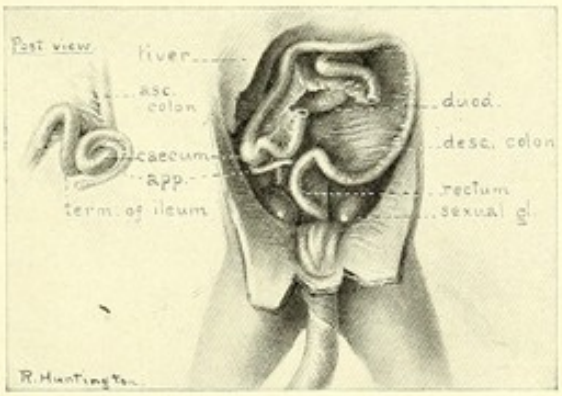

FIG. 15.—HUMAN EMBRYO. THREE MONTHS. (BRÖDEL, No. 11.)

The greater portion of the small intestine has been removed, showing the ileocecal apparatus lying anterior to the right kidney. The small diagram at the left represents the posterior aspect of the apparatus, the appendix being quite long and curled around the cecum. There are no adhesions between the colon and mesocolon and the posterior abdominal wall.

If not retarded by adhesions, the cecum may arrive in the fossa as early as the fourth month, but it is usually later than this date. Some authors say

it is not until the time of birth approaches that the cecum reaches the iliac fossa. The distance between the right lobe of the liver and the middle of the iliac fossa is relatively much shorter in the fetus than in the adult, the difference being due to the enormous size of the liver and the relative shortness of the

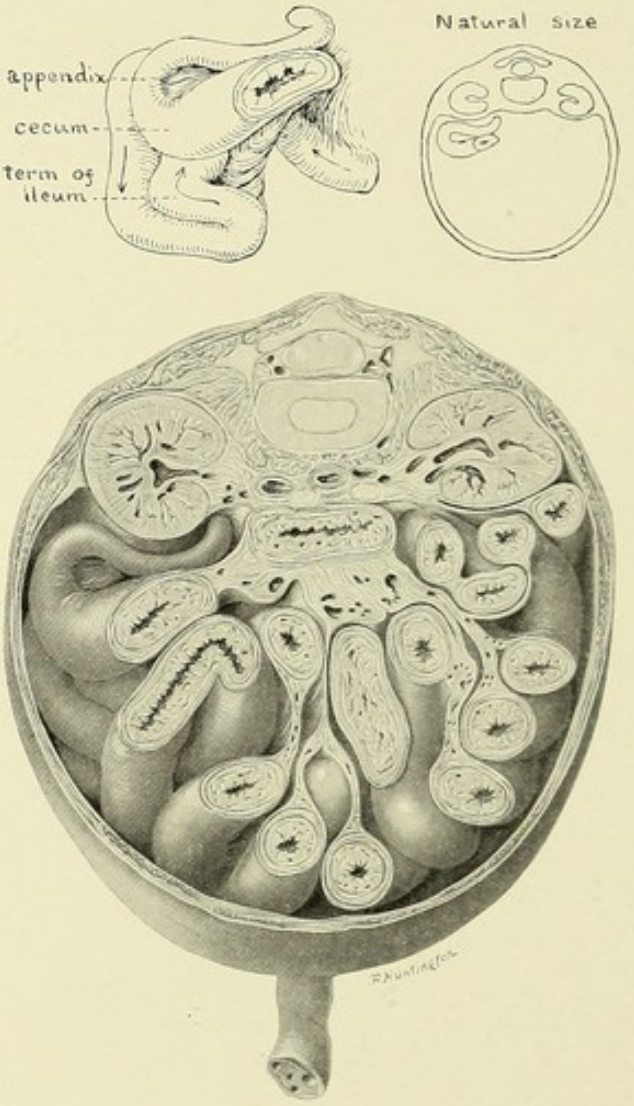

Fig. 16.—Human Embryo. Three Months. Three Times Natural Size. (Brödel, No. I.)

The figure represents a transverse section through the lower half of the body. Just beneath the left kidney, at the extreme right of the section, the descending colon with its free mesocolon may be seen; while at the left of the picture lies the ileocecal portion of the intestine, the appendix being curled up in a peritoneal pocket between the kidney and the colon with its mesentery. Above are two diagrams, the left showing the region of the appendix and course of the ileum three times magnified, while the right sketch is an outline of the section in natural size.

lumbar vertebræ in the fetus (Figs. 24, 26, and 27). Therefore, as long as the iliac fossa remains situated so close to the liver, the ascending colon must remain insignificant in length, and the cecum appear lodged, more or less, in the subhepatic position. As soon as the lumbar region grows in length, the cecum

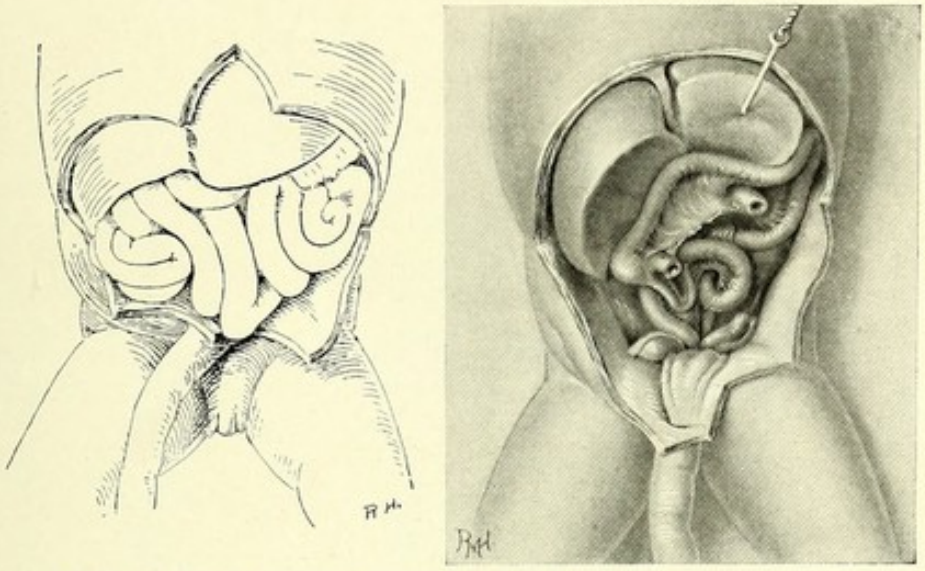

FIG. 17.—HUMAN EMBRYO. FOURTEEN WEEKS. ♀. 12 CM. (BRÖDEL, NO. 9.)

The diagram on the left shows the organs *in situ*, cecum and appendix being entirely concealed behind loops of intestine. In the right-hand picture the small intestine has been removed to show the topography of the large intestine. The cecum lies anterior to the right kidney, being bordered above by the liver. The appendix rests upon the rectum and its mesentery, the rectum and sigmoid flexure being abnormally long and curled up in a series of loops, the most distal of which reaches to the lower pole of the right kidney. The differentiation in calibre between the cecum and the appendix has become more marked, the cecum having increased in size with the rest of the body, while the appendix lags behind in development.



FIG. 18.—HUMAN EMBRYO. THREE TO FOUR MONTHS. NATURAL SIZE. (BRÖDEL, NO. 7.)

The lower half of the abdominal wall has been stretched downward somewhat to disclose the cecum and appendix. These have now descended below the edge of the liver, almost to their ultimate position in the right iliac fossa. The differentiation between cecum and appendix is marked, the latter curving, in a worm-like manner, anterior to the ileum and cecum.

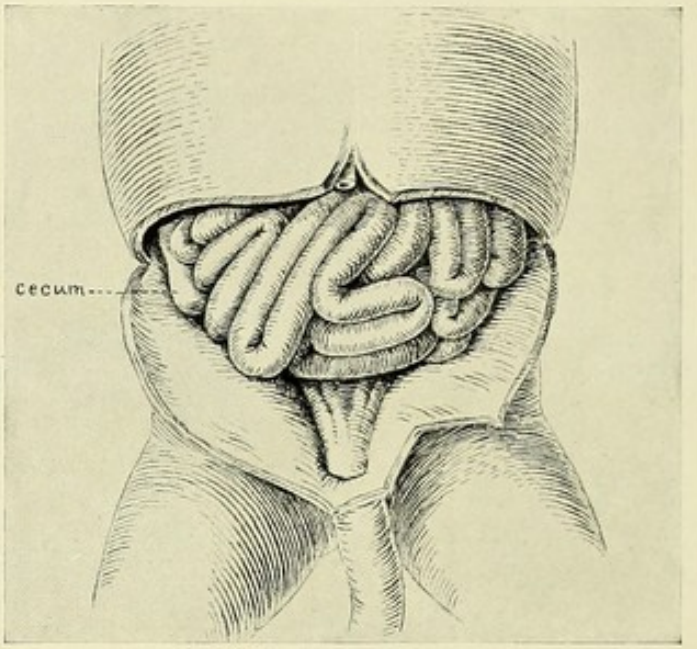

FIG. 19.—HUMAN FETUS. FOUR MONTHS. ♀. (BRÖDEL, II.)

On opening the abdominal cavity in the manner shown in this figure, the cecum is visible at the left of the picture, but the appendix remains hidden behind the folds of intestine. The next figure illustrates the same embryo with most of the ileum removed.

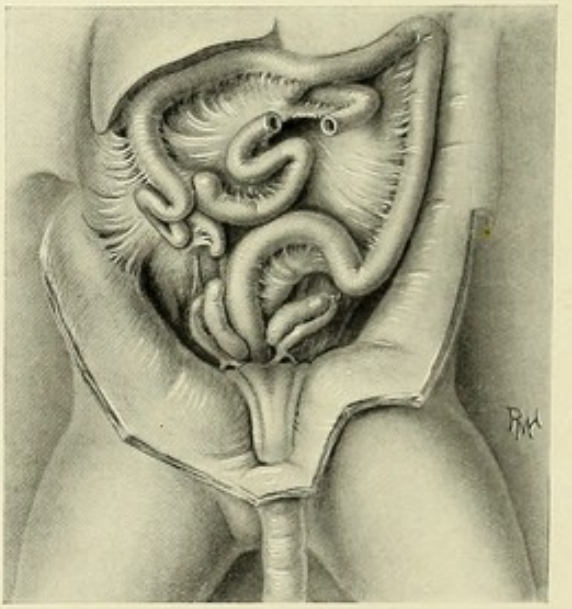

FIG. 20.—HUMAN FETUS. FOUR MONTHS.

Same as the preceding figure, a large portion of the intestine having been removed. The cecum and appendix lie anterior to the right kidney, the ascending colon, cecum, and the terminal portion of the appendix having already become firmly adherent to the posterior abdominal wall before their final descent into the right iliac fossa. For the sake of clearness the adhesions have been somewhat emphasized. The differentiation between the cecum and the appendix is not abrupt, the cecum showing no particular distention. The point where it makes its first turn upward marks the beginning of the appendix. The latter is free with the exception of its distal fourth, where the mesappendix is short and soon continuous with the peritoneum of the posterior abdominal wall. On account of the adhesions, any subsequent descent of the cecum to fill the iliac fossa would have to take place in its anterior portion, causing a retrocecal position of the appendix. The mesappendix is seen to join the posterior abdominal wall close to the ovarian vessels, a minute peritoneal fold connecting the two. This is the first stage in the formation of the appendico-ovarian ligament. It must be remembered, however, that only few fetuses show this structure.

descends with the more capacious iliac fossa, and the ascending colon increases in extent.

On the other hand, the cecum may never reach this position, if, during its descent the ileocecal apparatus, or any portion of it becomes adherent to neighboring organs, such as the kidney, the gall-bladder, or the duodenum. TREVES reports two cases of adults in which the cecum and appendix were still situated just beneath the liver, having become adherent before descent took place.

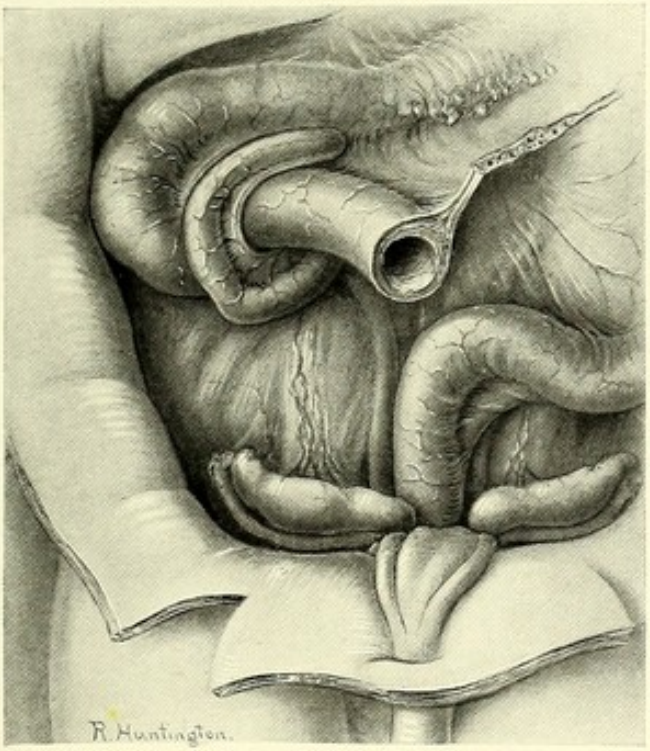

FIG. 21.—HUMAN FETUS. FOUR MONTHS. ♀. MAG. 3. (BRÖDEL, III.)

The figure represents the lower right-hand corner of the abdominal cavity, the ileum having been removed with the exception of its terminal portion. The ascending colon is very short, the cecum lying not far beneath the liver in the right hypochondriac region. The cecum shows signs of beginning sacculation, which, however, as a rule takes place much later. The proximal portion of the appendix is directed obliquely upward behind the termination of the ileum; it then bends backward upon itself, makes another turn, and curves up over the ileum, following the free edge of the ileocolic fold. Should the tip of the appendix contract adhesions in this position, the subsequent sagging down of the intestine might cause strangulation.

Concerning this descent and adhesions see section on "The Position of the Appendix," Chap. VI, p. 118.

G. S. HUNTINGTON has worked out the development of the primitive coils of intestine in their relation to the cecum and appendix. He divides the embryonic coils of the small intestine into three main groups: I, the proximal (or jejunal) set of convolutions, occupying the upper and left part of the abdominal cavity; II, the distal (or ileal) division of the small intestinal convolutions, lying to the right of, and in the earlier stages behind, the cecum; and III, the convolution connecting these two portions of the small intestine which occupy the lower part of the abdominal cavity.

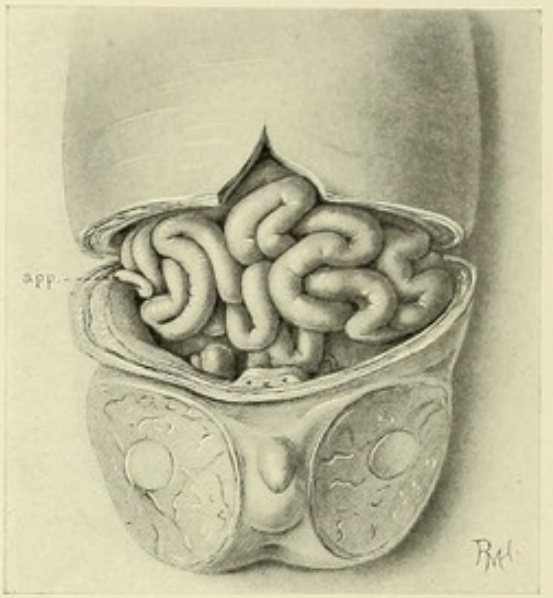

FIG. 22.—HUMAN FETUS. FOUR TO FIVE MONTHS. ♂. 19 CM. (BRÖDEL, IV.)

This figure represents the appendix and other organs *in situ*, just after opening up the body-cavity. Only the termination of the appendix is visible, and a small portion of the cecum may be seen above it.

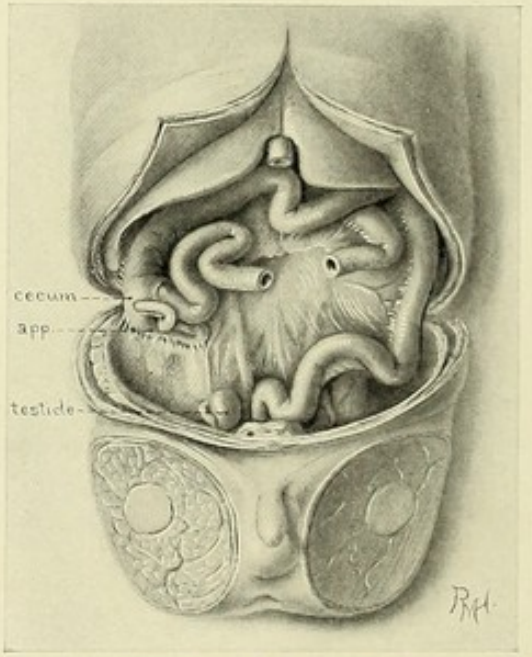

FIG. 23.—SAME AS THE PRECEDING FIGURE, MOST OF THE SMALL INTESTINE HAVING BEEN REMOVED.

The cecum lies not far beneath the edge of the liver, the ascending portion of the colon being short and of rather large calibre. For a short distance it is adherent to the lateral body-wall, and the entire cecum, as well as the proximal third of the appendix, are also bound down by adhesions to their posterior surfaces. Whether these latter adhesions are the result of a localized peritonitis, or whether they are part of the usual peritoneal adhesions, we were not able to decide. The distal two-thirds of the appendix, however, remain quite free, the tip pointing in an outward direction. Therefore, in this case the cecum and appendix have become adherent before reaching their final position in the right iliac fossa. The adult position of the appendix would have been retrocecal and partially extraperitoneal. Again, there are adhesions from the appendix to the spermatic vessels.

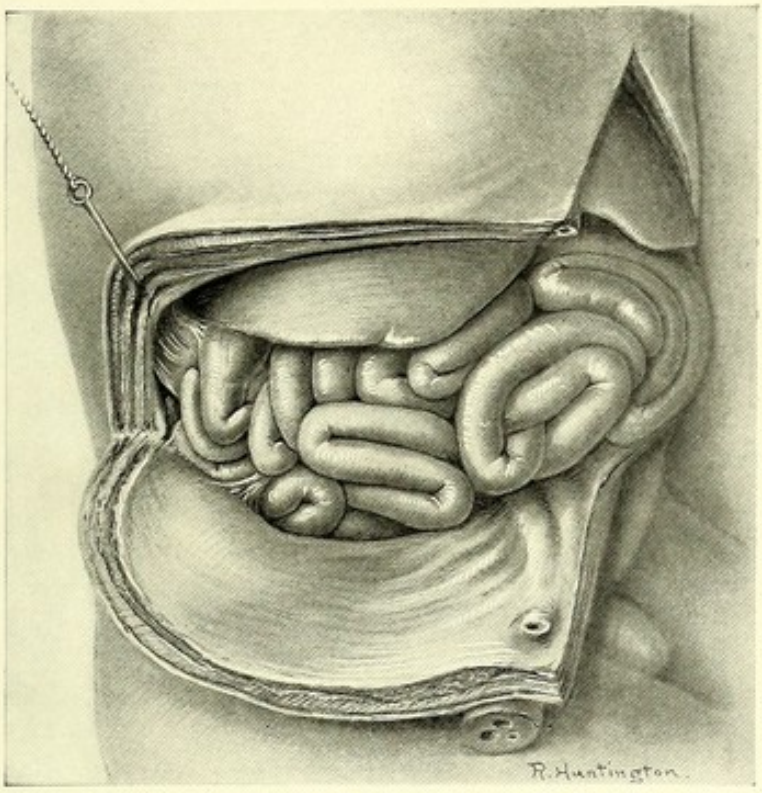

FIG. 24.—HUMAN FETUS. FIVE MONTHS. ♂. MAG. 1½. (BRÖDEL, V.)

The figure shows a somewhat lateral view of the abdominal viscera *in situ*. The cecum and appendix lie at the left of the picture just beneath the liver. The cecum presents the typical funnel-shaped appearance characteristic of the fetus, its apex being directed downward. The anterior longitudinal muscular band is faintly visible extending up and down its anterior surface. At the point where the cecum ends and the appendix begins, the latter makes a sharp turn upward and to the left; after being hidden for a short distance behind a coil of small intestine it reappears and passes upward along the external border of the cecum. Only the uppermost portion of the cecum is adherent, its remaining portion, as well as the entire appendix, being free. The ileum, however, is closely adherent for the space of a centimetre or more near its termination. (See Fig. 25.)

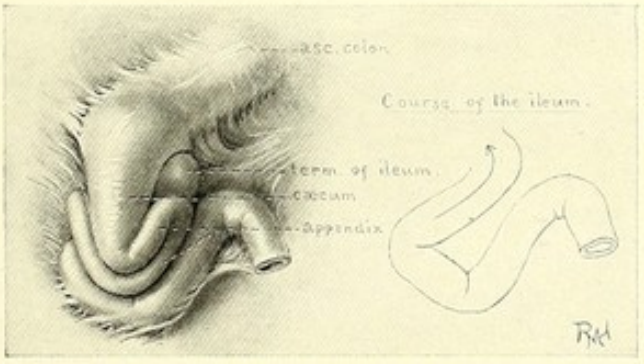

FIG. 25.—APPENDIX REGION OF FETUS SHOWN IN PRECEDING FIGURE. MAG. 1½.

The entire appendix is now visible, and the extent of the adhesions along the ascending colon, upper portion of the cecum, and along the most lateral limb of the loop of small intestine, can be more clearly seen.

It is the distal or ileal group of convolutions which affect in some measure the disposition of the cecum and appendix. At first these coils lie behind as well as to the right of the cecum, whose apex, together with the appendix, is frequently embedded among them. With the continued growth of the small intestine the cecum is pushed further upward and to the right; while at the same time the terminal ileal coils pass downward and to the left, from a retro-

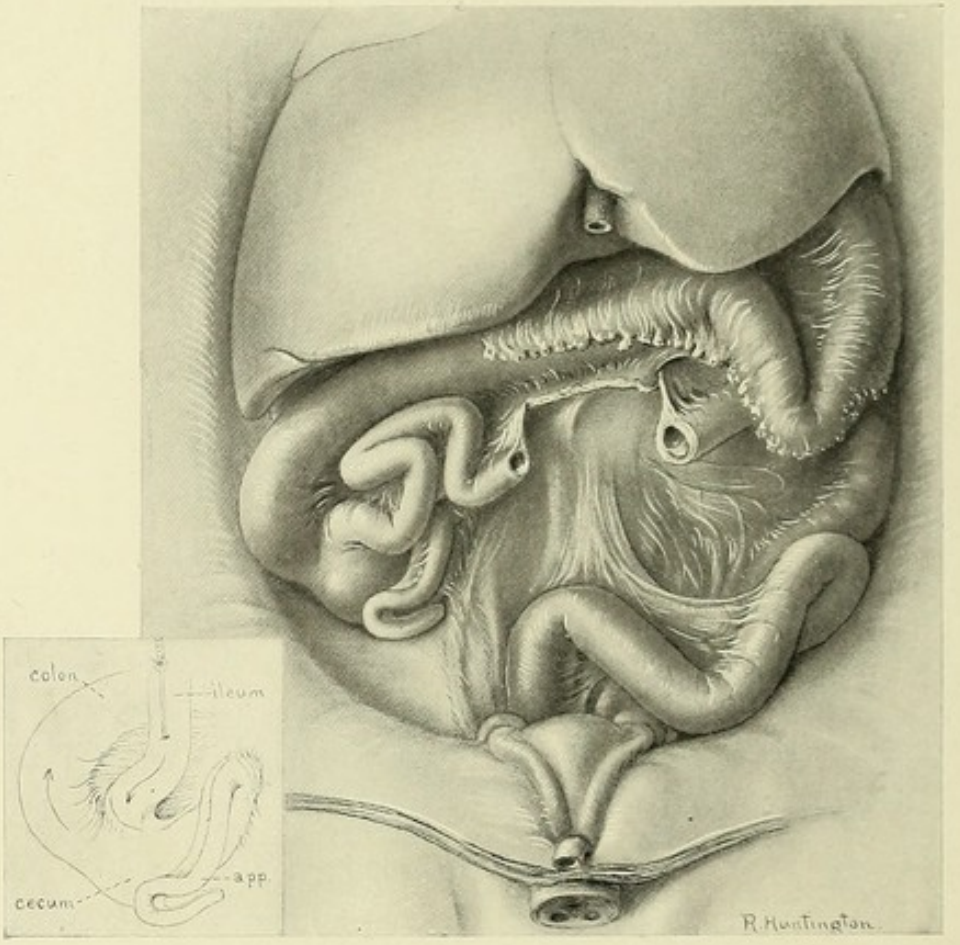

Fig. 26.—Human Fetus.—Six to Seven Months. ♂. Natural Size. (Brödel, VI.)

The ileum has been for the most part removed, exposing the large intestine, which is very much convoluted owing to the relative shortness between liver and pelvis. The transverse colon is in part covered by the growing omentum. At the left of the picture lie the cecum and appendix, which have not yet completed their descent into the right iliac fossa. The cecum and beginning portion of the colon are free from adhesions along their posterior surfaces, but the posterior fourth of the appendix is bound down by adhesions which pass from it, over the spermatic vessels, and become lost on the posterior parietal peritoneum. The remainder of the appendix is free and lies curled beneath the cecum.

cecal into a subcecal position, thus permitting a direct apposition of the cecum to the dorsal parietal (prerenal) peritoneum.

We see, therefore, that the position and form of the adult cecum and appendix depend largely upon the time during their development at which they come into contact with the posterior abdominal wall. If coils of intestine remain interposed between them during the descent of the ileocecal portion,

it may reach the right iliac fossa without having contracted any adhesions. This gives a comparatively free cecum and pendant appendix. If, however, the coils of ileum are early displaced, and the cecum and appendix come into early contact with the posterior abdominal wall, that is, at a time before or during their descent, the posterior surface of the cecum is apt to fuse at a comparatively high level with the abdominal wall, and any further descent is, as a rule, accompanied by a rotation of the cecum to the left or the median line of the body. The appendix, if not individually adherent, follows this movement. The appendico-cecal junction becomes shifted during this rotation in an upward



FIG. 27.—NEW-BORN BABE. NATURAL SIZE.

This figure shows the lower right-hand portion of the abdominal cavity, with the cecum lying in the right iliac fossa, the ileum having been drawn aside. The appendix is coiled in an S-shaped manner behind the ileum and colon, and partly concealed by them. When it again becomes visible, it lies beneath the liver in front of the right kidney, while the tip rests upon the colon. Owing to the large liver and shortness of the lumbar region, the ascending colon has not yet had a chance to develop. Both the cecum and appendix are entirely free along their whole extent. Note the beginning sacculation of the large intestine in contradistinction to the round tube of the previous stages.

and posterior direction, the appendix itself pointing in varying ways, upward, downward, outward, or toward the spleen, according to the length of its mesentery.

DIFFERENTIATION BETWEEN APPENDIX AND CECUM.

The embryology of the appendix teaches us that it is a retrogressive organ; *i. e.*, in the human being it does not maintain the degree of development it reached in the fetus. We are therefore compelled to regard the appendix as merely the distal portion of the original cecum.

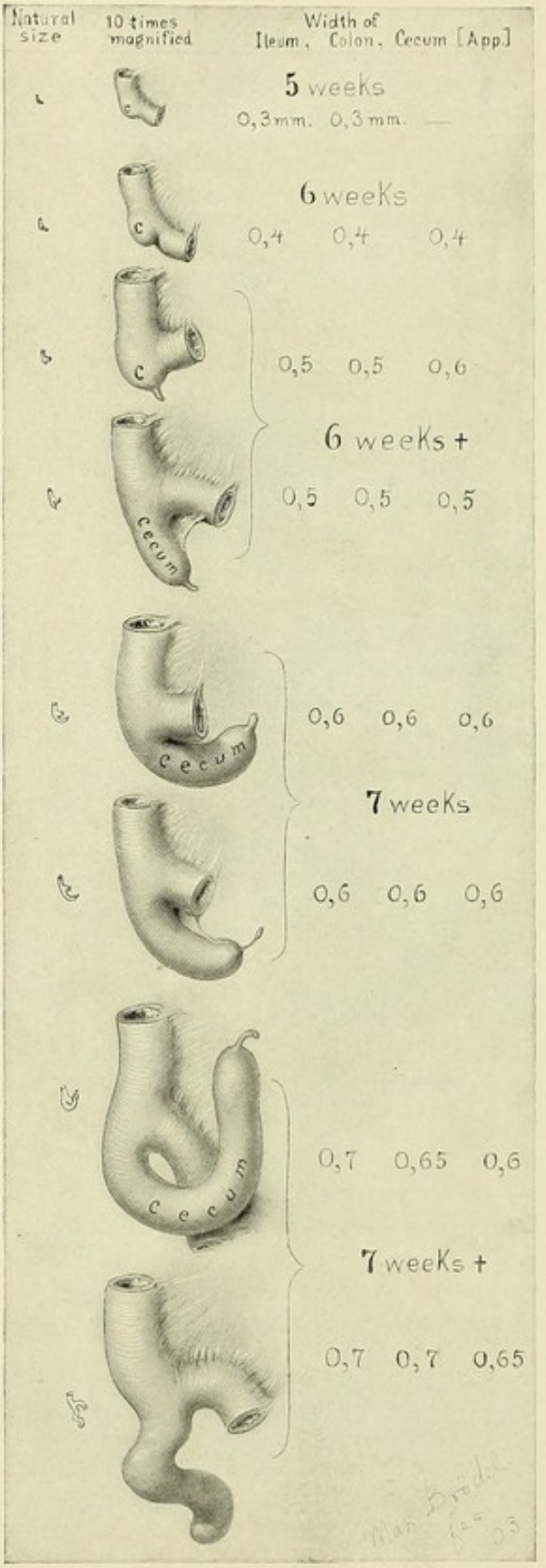

Figs. 28, 29, 30, and 31 are a complete series of ceca, beginning with the earliest indication of its formation (five weeks) and ending with the adult form, all drawn on the same scale. To the figures are added measurements of the calibres of the individual portions of the ileocolic apparatus. Up to the age of twelve weeks, enlargements of ten times natural size are given; later stages are drawn natural size.

This series demonstrates that the differentiation occurs in two distinct stages, a *primary*, beginning at about the eighth week of embryonic life, and a *secondary*, making its appearance at birth.

Beginning with the primitive form, we find that from the fifth week up to the seventh week the cecum is of the same width as the rest of the intestine. Its length increases during this period considerably, and may at seven weeks amount to from seven to eight times its thickness.

The *primary* differentiation into a larger proximal pouch

FIG. 28.—THE DEVELOPMENT OF THE APPENDIX FROM THE AGE OF FIVE TO SEVEN WEEKS.

The intestine has been drawn in the position occupied in the adult, *i. e.*, colon above, ileum approaching it from below and from the left. Note the position of the transient vermiform appendix at the tip of the cecum. The cecum grows in length, the transient appendage disappears, and the subsequent appendix is produced by a relative narrowing-down of the distal portion of the cecum. The diameters of the ileum, colon, and cecum (appendix) are given in millimetres.

and smaller distal portion begins generally after the transient process at the cecal tip has disappeared. While this differentiation varies in different embryos, like many other features of this variable organ, it generally takes place at the age of between seven and eight weeks.

At eight weeks we first begin to observe a decrease in thickness of the distal portion of the cecum as compared with the rest of the intestine. It is found to be between two-thirds and one-half the width of the colon. The

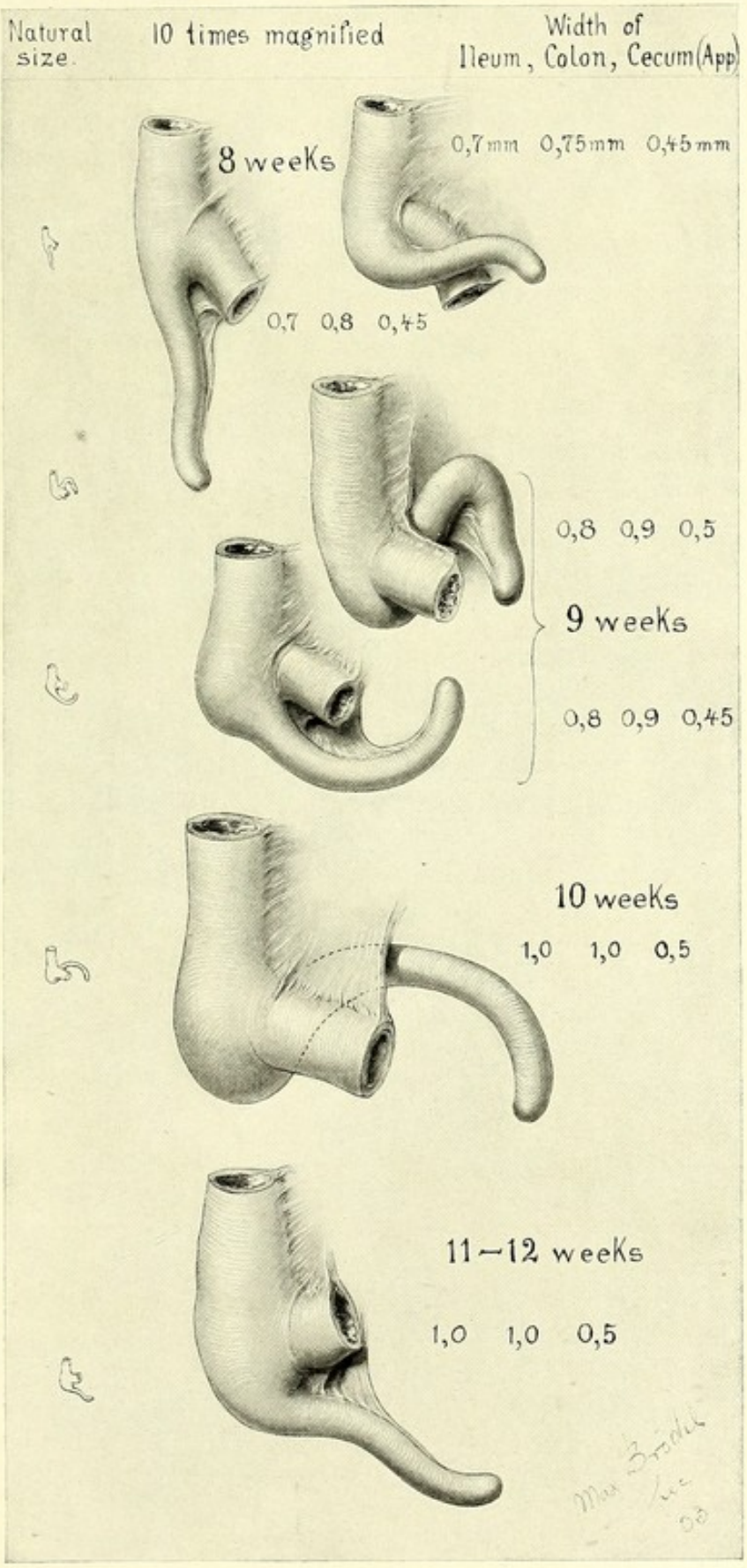

FIG. 29.—THE DEVELOPMENT OF THE APPENDIX BETWEEN THE AGES OF EIGHT AND TWELVE WEEKS.

The distal portion of the cecum is narrower than the proximal pouch, the differentiation beginning at the eight-weeks stage (primary differentiation). We have now to deal with an appendix. The variations in the position of the appendix are few, the pendant type predominating.

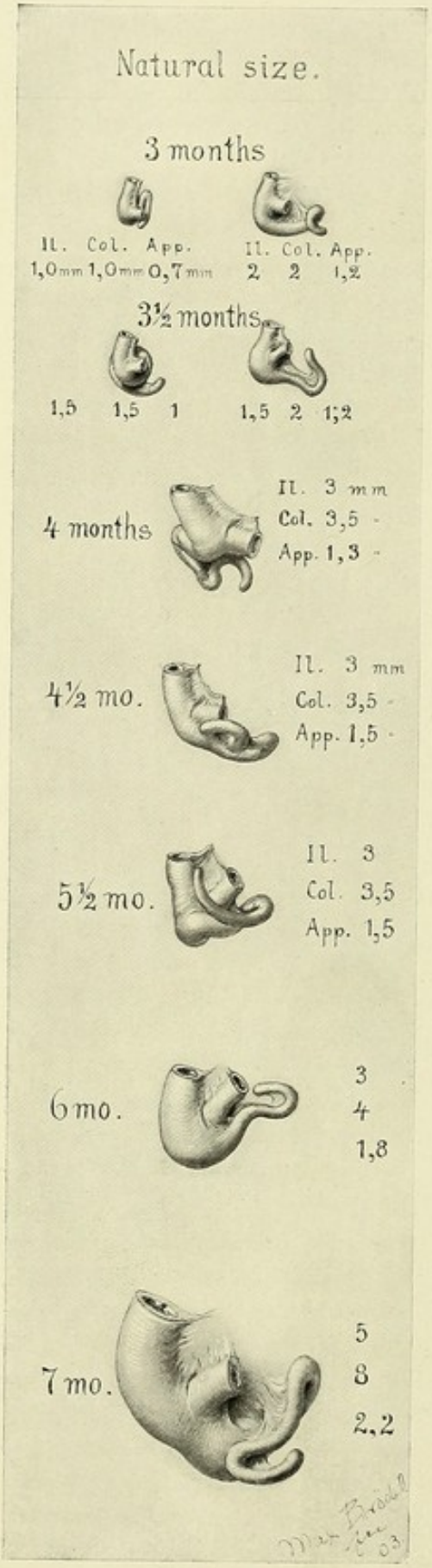

Fig. 30.

diminution in calibre may be sudden or gradual, *i. e.*, funnel-shaped. If the cecum forms an acute angle with the colon, we notice a kink at the junction between the wide and the narrow portions. This is most probably the form which develops in later life into a rounded bulging cecum with the appendix hidden behind the ileocecal junction.

From nine to twelve weeks the ileocecal apparatus grows in size without changing the relative measurements of its constituents. The narrow distal portion of the cecum is still about one-half the width of the small and large intestines, its length continuing to vary between six and eight times its thickness. The proximal portion of the cecum becomes now the focus of interest, in so far as it bulges out to form a pouch which renders it considerably larger in calibre than the ileum and the colon. This pouch may involve a portion of the colon, but is usually confined to the region of the ileocolic junction.

From the age of three months up to six months the differentiation between the cecal pouch and its narrowing distal extremity, the appendix, becomes more and more pronounced. While the ileum becomes slightly smaller

---

Fig. 30.—The Development of the Appendix between the Ages of Three and Seven Months.

From now on, the stages are represented natural size. As the appendix grows, its position becomes subject to many irregularities, most of which are traceable to mechanical influences exerted by the mesappendix and adhesions with the posterior abdominal wall.

Fig. 31.—The Development of the Appendix from the New-born to the Adult Stage.

The sacculations of the large intestine are beginning to appear, causing a still greater discrepancy between the diameters of the appendix and cecum (secondary differentiation). The third figure on this plate shows a persistence of the fetal type, *i. e.*, a funnel-shaped junction between the cecum and appendix.

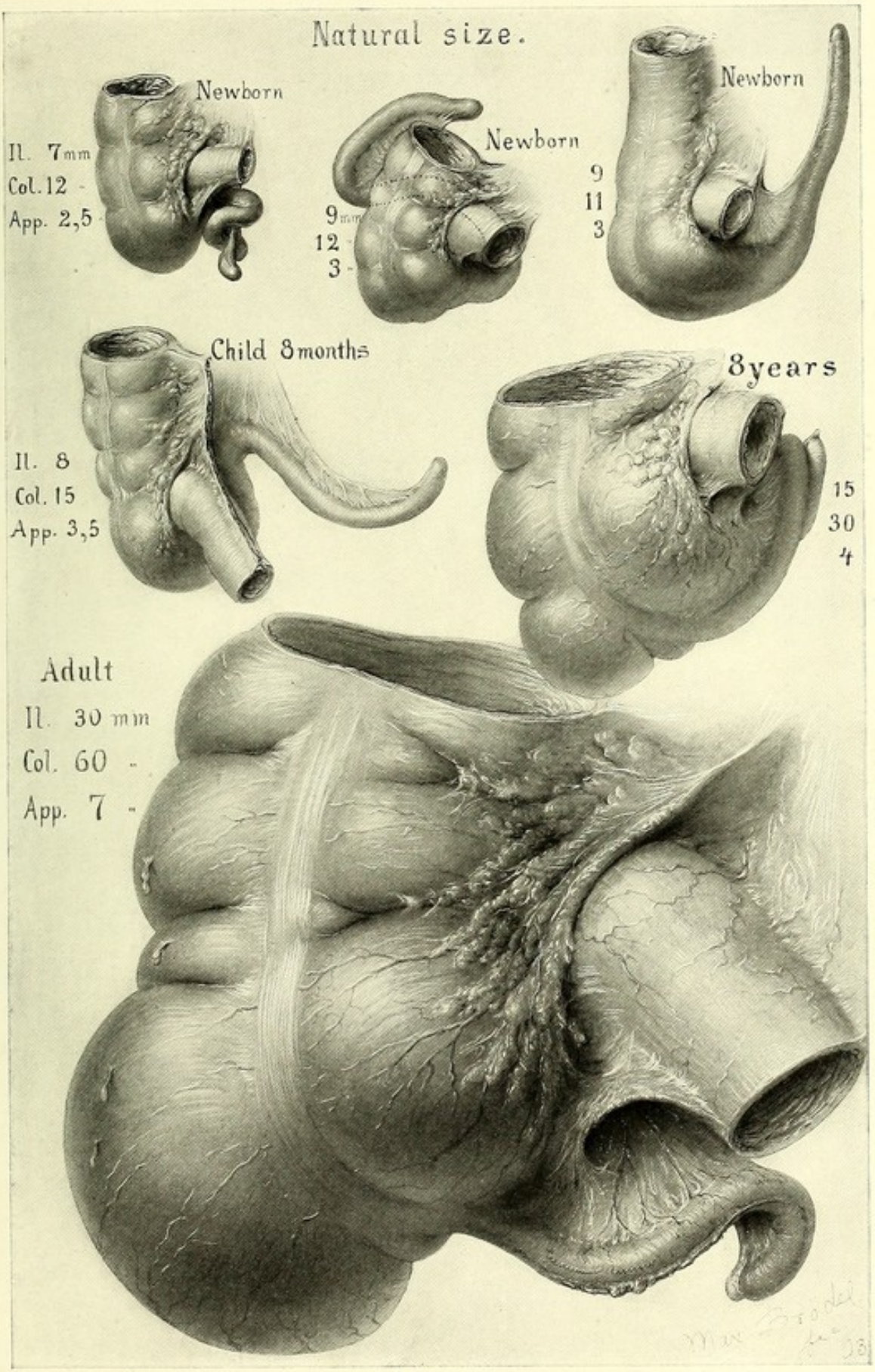
Natural size.
Newborn
Il. 7mm
Col. 12 -
App. 2,5 -
Newborn
9mm
12 -
3 -
Newborn
9
11
3
Child 8months
Il. 8
Col. 15
App. 3,5
8years
15
30
4
Adult
Il. 30 mm
Col. 60 -
App. 7 -

Fig. 31.

than the colon, the appendix decreases rapidly in thickness as compared with the colon, and at the sixth month it is only about one-third the width of the large intestine. Owing to this decrease in thickness, the length of the appendix must now necessarily appear more considerable; and we find that it varies between ten and eighteen times its width. The diagram illustrating the relation of the parts between six and seven months represents the arrangement existing, except for individual differences, up to term. The colon is somewhat larger than the ileum, perfectly cylindrical and regular, and resembles the small intestine in form. There are no pouches and no isolated longitudinal muscular bands, as in the adult large intestine. The longitudinal coat is of equal thickness all around the colon, cecum, and appendix. The latter is about one-fourth the thickness of the large intestine.

About the time of birth a *secondary* differentiation of the appendix from the cecum takes place, producing changes in the latter which give rise to the characteristic sacculation of the large intestine in general, and of the cecum especially. It is significant that this sacculation makes its first appearance just at the time when intestinal contents begin to enter through the ileocecal junction. The walls of the cecum and colon are in this manner subjected to a pressure from within which causes the longitudinal muscular coat to separate into three bundles, between which the inner coats bulge out in pouches, producing, in a sense, hernial protrusions covered by circular muscle. The transverse furrows between the pouches are due to the constricting influence of the larger vessels. There are a few thin longitudinal fibres left to cover the pouches, but the great bulk remains in the longitudinal bands. The separation of the longitudinal muscle does not involve the appendix, and so we find the three bands converging toward the root of the appendix, in order to become continuous with its longitudinal muscular coat.

We know that the peristaltic contractions of the colon in a distal direction are in certain intervals interrupted by a reversed contraction, which might be considered as the cause of the greater distention of the cecal pouch as compared with the colon (Cannon).

Between the distention of the cecum and colon in the newborn and adult there is noticeable a steady increase, and if we compare the width of the appendix with that of the cecum in the different ages concerned, we find that it amounts in the newborn to one-third to one-fourth the cecal diameter, while in the eight-months-old child it is one-fourth to one-fifth; at eight years it is one-sixth to one-seventh; and in the adult, about one-eighth.

COMPARATIVE ANATOMY.

From the standpoint of comparative anatomy the appendix vermiformis must be regarded as an undeveloped cecum. If the appendix in the human

subject were expanded to the size of the caput coli, the whole diverticulum would closely resemble the ceca of many mammalia. If, on the other hand, in a long mammalian cecum the distal portion had not developed in proportion to the rest, a cecum and appendix would then be produced which would compare with the like named parts in the human subject.

We must therefore consider the entire cecal apparatus from a comparative standpoint, in order to understand the special significance of the human vermiform appendix.

The entire alimentary canal of all vertebrates is found to respond with great readiness in its structure to variations in functional demand. The kind and quantity of the food habitually taken, and the rate of the tissue metabolism—whether rapid, as in warm-blooded animals, or slow, as in cold-blooded ones—are some of the chief factors which influence the morphology of the alimentary canal.

The changes in anatomical structure in response to physiological demand are most marked in the region of the ileocolic junction where the cecum and appendix form.

As HUNTINGTON points out, all the varieties of cecal apparatus met with in different species can be traced to one common primitive type, from which they have all developed in accordance with varying conditions of alimentation. A few principal structural types derived from this common primitive type include all the various forms of cecum. "All of the main types of ileocolic junction are found within a very limited zoölogical range, as within the confines of a single order. * * * The members of these zoölogical groups, while united by certain common anatomical characters, such as the reproductive system and dentition, differ widely in habit and in the kind and quantity of the food normally taken. These differences in the method of nutrition have impressed their influence on the structure of the alimentary canal and have led to the evolution of varying and divergent types of ileocolic junction." No reliable classification of the vertebrate groups therefore can be made from the character of the cecum and appendix.

The function of the cecal apparatus is as follows:

It increases the extent of the intestinal mucous surface for secretion and absorption, and prolongs the period during which the contents of the canal are retained for digestion and absorption. The cecal pouch acts as a reservoir in which partly digested substances, mixed with the secretion of the small intestine, are retained for a longer or shorter time in order that the process of absorption may be completed.

Among the Herbivora, *e. g.*, the Ungulates and Rodents, whose food contains a comparatively small amount of nutriment in proportion to its bulk and requires a longer time to digest, we find the most complicated and highly developed cecal apparatus; while in carnivorous animals, whose food is concentrated, easily and rapidly digested, and contains little non-nutritive material, the cecum appears as a reduced or even rudimentary organ.

Beginning with the lower orders, we find in fishes, Dipnoi, and Amphibia an undifferentiated intestinal tract; *i. e.*, no distinction between small and large intestine, and therefore no ileocecal valve. The differentiation between mid-gut and hind-gut is marked in some species by a circular constriction. In many reptiles, however, especially in Saurians, an ileocolic valve and cecum are present. The cecum is simple, is said to lack glands, and merely acts as a temporary receptacle for certain rejected foods. Among birds the cecum is found in all but a few families. It has advanced somewhat in function, for a marked change is noticed in the food on passing from the middle to the end portion of the intestine, due to the presence of two large blind pouches or ceca situated at this point.

GEGENBAUER says that these two ceca have developed from an originally single one. The ceca in different birds vary greatly in size and length. They may be in the form of short appendages, or of enormous blind pouches exceeding the main intestine in length. Their purpose is to increase the extent of the mucous surface. The longest ceca are found in vegetable-eating birds. In birds of great locomotive power, which take daily flights and make annual migrations, the increased energy in the animal and vital functions is applied also to the work of digestion, and a simpler intestinal canal, with small or no ceca, suffices for the purpose. But in those species where the process of digestion is slow, an additional complexity of the alimentary canal is required for the purpose of retaining the chyme somewhat longer in its passage. The enlarged ceca of such birds afford the requisite amount of mucous surface. The cecum acts, therefore, as a second stomach for the purpose of holding the food longer, and thus extracting from it a fuller amount of nutriment. Those birds which can obtain their food easily and in ample quantities do not require as long ceca as those which have more difficulty in this respect.

Birds which swallow stones and other foreign bodies to aid in the digestion of their food require a free passage for these through the intestinal canal, which is, therefore, generally short and of uniform diameter. In order to extract a greater quantity of chyle from the food, it is detained for a time in two large ceca which communicate with the intestines by orifices too small to admit pebbles or undigested seeds. The food mixes here with the cecal secretions, and the due proportion of nutriment is extracted.

There is a definite relationship between the length of the cecum and that of the large or end-intestine, a long end-intestine corresponding to a long cecum, and vice versa.

Almost all mammalia are provided with a cecum, a single organ which varies both in form and size. The size bears an important relation to the kind of nourishment; meat-eating or carnivorous animals possess a small and simple cecum, or none at all, while in herbivorous animals it is large and may even exceed the length of the body. Among those animals which have a mixed diet, such as many rodents, the wombat, apes, and man, a part of the cecum

undergoes a more or less marked retrogressive change, so that it remains as a thin, worm-like process attached to the otherwise well-developed cecal pouch. This condition points to a time when the appendix and cecum were of the same size, a retrogressive change having taken place, due to changed nutritive conditions. That this time does not lie very far back from man is indicated by the fact that the entire blind pouch of the fetus and new-born possesses a relatively large size to that of the adult (GROHÉ).

The arrangement of the stomach also influences the size of the cecum. In single-hoofed animals with a single stomach, the cecum is better developed than in split-hoofed animals, which chew their food twice, and which are provided with more than one stomach.

GROHÉ examined the cecal secretion of an ass and demonstrated the presence of an active digesting substance, especially for albuminous and starchy food.

The various types of the ileocolic region and of the cecum in the vertebrates are comprehensively described and pictured by HUNTINGTON. The following is a short abstract of his elaborate chapter on this subject, which is of value in demonstrating the relation of the human type to the forms found in other vertebrates. His classification has been maintained, while the pictures are partly original and partly combinations of his diagrams and photographs of specimens contained in his volume: *The Anatomy of the Human Peritoneum and Abdominal Cavity*, 1903.



FIG. 32.

Primitive Type (Fig. 32). Straight tube without distinction between small and large intestine, Cyclostomata (subclass of fishes), mudpuppy, etc.

From this fundamental type the following main groups branch out:

1. SYMMETRICAL FORM. SMALL AND LARGE INTESTINE IN DIRECT LINEAR CONTINUITY.



FIG. 33.

(Fig. 33.) 1. Annular constriction. (Ring valve.) Many amphibians, and as reduction form in arctoid group of carnivora in mammals. (Polar bear.)



FIG. 34.

(Fig. 34.) 2. Differentiation in calibre of large and small intestines (funnel-shaped). Great anteater, two-toed sloth, bull frog, pond turtle.



FIG. 35.

(Fig. 35.) 3. Same, but abrupt. Nine-banded armadillo, alligator (mississippiensis).

(Fig. 36.) 4. Two cecal pouches. American manatee, another armadillo, many carnivorous birds.



Fig. 36.

(Fig. 37.) 5. Long cecal pouches of herbivorous birds. (Long narrow neck and small orifices.) Goose, hen, owl, loon, red-breasted merganser, cassowary, ostrich, etc. Ceca in carnivorous birds are very short.



Fig. 37.

(Fig. 38.) 6. Short cecal pouches, narrow neck. Little anteater.



Fig. 38.

II. Asymmetrical Development of Single Cecal Pouch. Small and Large Intestine in Direct Linear Continuity.

(Fig. 39.) 1. Bulging out of large intestine distal to ileocolic junction and opposite mesenteric attachment. Pond turtles, three-toed sloth. (Human embryo of five weeks.)



Fig. 39.

(Fig. 40.) 2. Single lateral cecal pouch. Anaconda, Tamandua anteater. (Human embryo of six weeks.)



Fig. 40.

(Fig. 41.) 3. Prolongated pouch and reduction in calibre (resembling one of the two ceca of birds). Duck mole, spiny anteater.



Fig. 41.



FIG. 42.

(Fig. 42.) 4. Slightly curved pouch, no reduction in calibre. Capuchin-monkey.

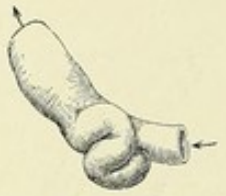

FIG. 43.

(Fig. 43.) 5. Long, more or less convoluted pouch. Dog, wolf, jackal, fox.

III. RECTANGULAR ILEOCOLIC JUNCTION; CECUM IN DIRECT LINEAR CONTINUITY WITH COLON.

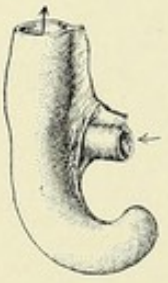

FIG. 44.

(Fig. 44.) Type form. The cecum ceases to be a lateral appendage to the intestinal canal and appears as a caudal prolongation of the colon beyond the ileocolic junction. The large majority of mammalia belong in this group. The type form is found in the opossum. (Human embryo of seven weeks.)

The following subdivisions of this type are to be made:

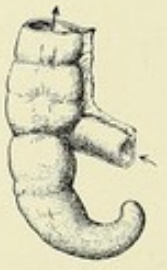

FIG. 45.

(Fig. 45.) (A) 1. Cecum long and curved, forming a hook, bending toward ileum. Pouch diminishing gradually in calibre toward distal end. Large group of new-world monkeys (spider monkey, marmoset), kangaroo. (Human embryo of nine weeks.)



FIG. 46.

(Fig. 46.) 2. Reduction of distal end of cecum to form an appendix. Anthropoid apes (orang, chimpanzee, gorilla, gibbon) and *man*.

(Fig. 47.) (B) 1. Wide cecum of varying length; without reduction of end. Lion, hyena.



FIG. 47.

(Fig. 48.) 2. Slight reduction of terminal portion. Aardwolf, harbor seal.



FIG. 48.

(Fig. 49.) 3. Increased reduction, formation of tapering appendix. Puma, red lynx, mongoose, palm-cat of India.



FIG. 49.

(Fig. 50.) 4. Gradual elimination of pouch, approaching primitive type of straight intestinal tube (annular pylorus-like valve). Great anteater, two-toed sloth, brown coatimundi, raccoon-fox.



FIG. 50.

(Fig. 51.) 5. Complete elimination of pouch; primitive type restored (no valve). Black bear, polar bear, weasel, raccoon, bat.



FIG. 51.

(Fig. 52.) (C) 1. Wide, short, cecal pouch, either blunt and globular, or slightly pointed. Chacma baboon, olive baboon, yellow baboon, bearded monkey.



FIG. 52.



FIG. 53.

(Fig. 53.) 2. Reduced distal end, forming either fairly distinct appendage or tapering distal extremity. Collared peccary, American tapir.

IV. CECAL APPARATUS COMBINED WITH STRUCTURAL MODIFICATION OF ADJACENT PORTION OF COLON.

The structures are highly developed and complex in their form, indicating that the food of the animal is bulky and difficult to digest. (Ungulates and Rodents.)



FIG. 54.

(Fig. 54.) 1. Primitive form of structural changes in colon, combined with absence of cecal pouch. Development of spiral mucous fold in lumen of colon, increasing secreting and absorbing surface, and retarding movement of intestinal contents in short and straight tube. Python, anaconda, shark, lung fish. Among mammalia, herbivorous and omnivorous animals possess mucous folds, the plicæ of the colon, which resemble this spiral fold. Carnivora have a smooth colic mucosa.



FIG. 55.

(Fig. 55.) 2. Large, capacious cecum, smooth-walled and of uniform calibre, spiral fold in colon. Rat, mouse, Bezoar-goat, nilghai.



FIG. 56.

(Fig. 56.) 3. Large, sacculated cecum, provided in its interior with spiral valve, varying in extent. Terminal portion of cecum devoid of spiral fold, tapering to form appendix, which has a great number of lymphoid follicles. Beaver, Canadian porcupine, rabbit; or much reduced in length, as in wombat.

(Fig. 57.) 4. Extensive secondary modification of parts concerned. Hare.

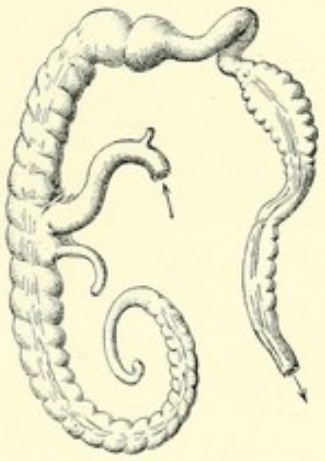

Fig. 57.

(Fig. 58.) 5. Colic modification, forming spiral coil which has the effect of retaining the food somewhat longer in the canal and is hence functionally allied to the cecal apparatus. Large cecum of uniform calibre. Horse, zebu, Japanese deer, sheep, antelope, pig.



Fig. 58.

(Fig. 59.) 6. Absence of cecal pouch, direct continuity of intestine, but formation of figure-8 twist at ileocolic junction. Long-tailed pangolin.



Fig. 59.

V. Unique Cecal Apparatus and Colon in Hyrax (Coney or Rock-rabbit).

(Fig. 60.) Typical mammalian sacculated cecum at ileocolic junction and, in addition, further down, two symmetrical, pointed lateral colic ceca of large size.



Fig. 60.

The study of the three constant pericecal folds in mammalia throws considerable light upon the development of this whole region. In those species which have a prominent cecum, a fold of peritoneum will be seen to pass to it from the ileum. (See Figs. 61–65 (b).) It comes from the margin of the ileum farthest from its mesentery and is attached to the side of the cecum nearest to the ileum. This is the true mesentery of the cecum (Treves). The fold has been derived from the peritoneal covering of the ileum by the budding out and subsequent growth of the cecum. It has nothing to do with conveying blood to it. The supply comes from the ileocolic artery, which separates into two branches, an anterior and a posterior.

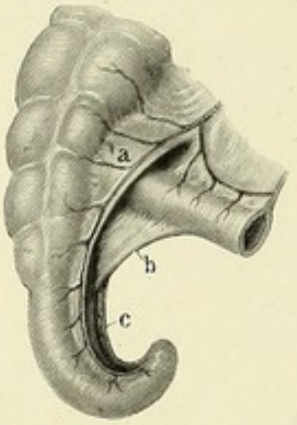

Fig. 61.—Anterior View of Ileocecal Region of Ateles (Spider Monkey).

The anterior and posterior vascular folds (a) and (c) are seen to reach the tip of the appendix, while the middle (bloodless) fold (b) remains behind in growth (after Treves).

These arteries draw the adjacent peritoneum into folds. The anterior ileocolic artery gives rise to an anterior vascular fold; the posterior ileocolic artery to a posterior vascular fold. These, as well as the intermediate fold, or true mesentery of the cecum, are constant structures, varying, however, in relative size. In Ateles, the spider monkey (see Fig. 61), the anterior and posterior vascular folds (a and c) are of about the same size, the blood-supply to the cecum being equally divided between the anterior and posterior ileocecal arteries. The intermediate fold (b) is of moderate size, distinct, free on both sides, but placed nearer the

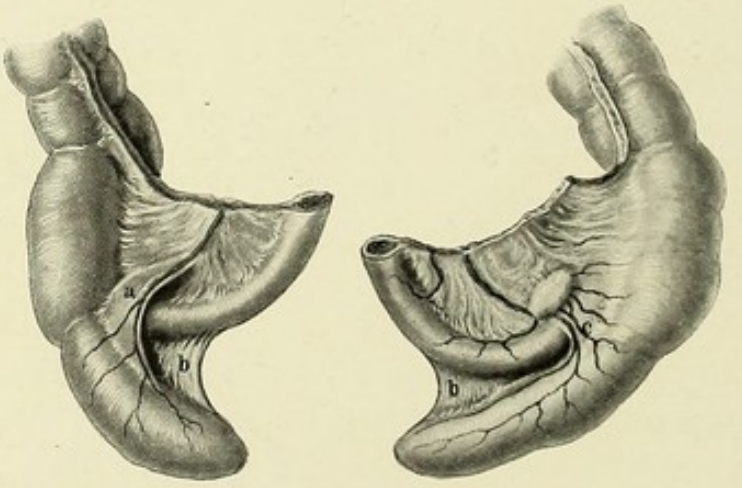

Fig. 62.—Anterior and posterior views of ileocecal region of Mycetes fuscus (monkey), showing the middle (bloodless) fold (b), and the anterior (a) and posterior (c) vascular folds, each carrying an artery to the appendix (redrawn from Treves).

posterior than the anterior vascular fold. In Mycetes and in the Mangabey monkey (Figs. 62 and 63) the anterior artery is slightly reduced in size. The

anterior vascular fold is distinct; the posterior fold is united with the intermediate non-vascular fold.

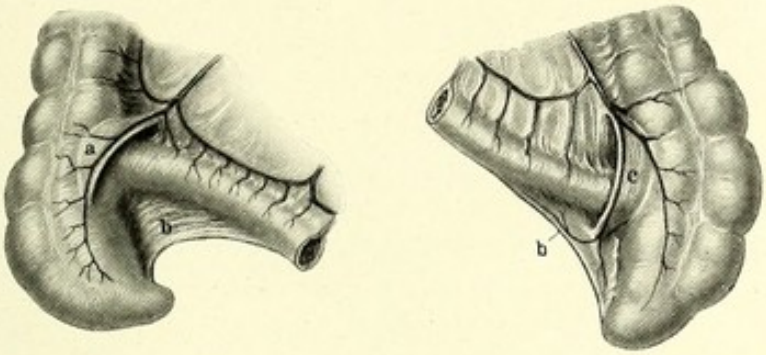

Fig. 63.—Anterior and posterior views of ileocecal region of Mangabey monkey, showing folds (a), (b), and (c) and their relation to the blood-supply (after Treves).

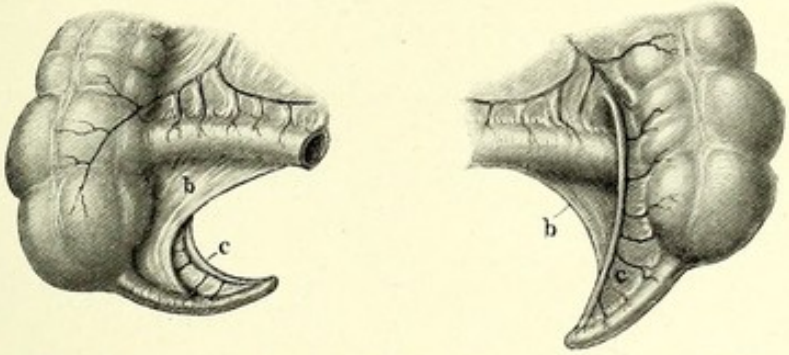

Fig. 64.—Anterior and Posterior Views of Ileocecal Region of Gibbon.

Same conditions as in previous figure, only more marked. The entire appendix is supplied by the posterior branch, which has lifted up the peritoneum, giving rise to the mesappendix (c). The middle fold (b) fuses with the mesenteriolum near the appendix. This condition resembles closely the arrangement found in man (after Treves).

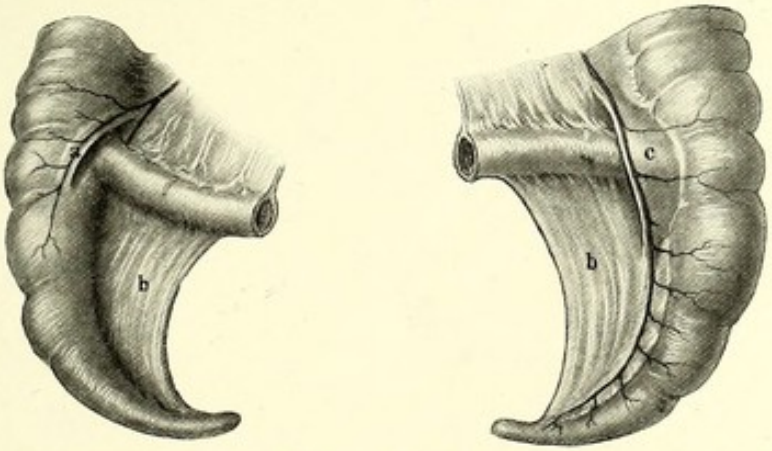

Fig. 65.—Anterior and posterior views of ileocecal region of the kangaroo, showing preponderance of posterior branch of ileocolic artery passing in posterior fold (c) over the short anterior artery passing in anterior fold (a). Middle fold (b) developed to great extent (after Treves).

In the gibbon (Fig. 64) and the kangaroo (Fig. 65) the anterior artery is still further reduced, while the posterior artery has grown out with the terminal

portion of the growing cecum, being its chief source of blood-supply, and lifting up a fold of considerable extent. In the kangaroo the posterior vascular fold (c) fuses with the intermediate fold (b), while in the gibbon the two remain distinct except at their attachment along the proximal portion of the cecum.

In the human subject we see a still further reduction of the anterior vascular fold, or the "ileocolic" fold, as it is called in man. The anterior ileocecal artery which it carries, supplies only the anterior surface of the upper portion of the cecum. The posterior ileocecal artery supplies the posterior portion of the cecum as well as the entire terminal portion, the appendix. The posterior vascular fold, or the mesentery of the appendix, has entirely supplanted the intermediate or ileocecal fold as a suspensory ligament. The latter fold fuses along its lower border with the posterior vascular fold, or mesappendix. (See "Folds and Fossæ," Chap. V, page 94.)

Thus, we have a complete series from those species where the blood-supply to either side of the cecum is symmetrical, to the condition met with in man, where the chief blood-supply comes from the posterior cecal artery, the corresponding fold becoming greatly enlarged and taking the place of the original cecal mesentery.

The reason for the preponderance of one of the cecal arteries over the other in man lies in all probability in the position which that organ assumes in its very early development in relation to the main source of blood-supply. If, as in the majority of cases, the posterior surface is nearer the arterial centre, the posterior cecal artery will have less distance to go, and can, therefore, extend further down along the cecum. It follows the growing tip, the subsequent appendix, its branches subdividing and spreading to either side, while the anterior cecal artery and its branches spread in a transverse direction to supply merely the bulging anterior surface of the cecum. (See Figs. 67, 68, and 70.)

CHAPTER V.

ANATOMY.

FOLDS AND FOSSÆ. THE REFLECTION OF THE PERITONEUM IN THE ILEOCECAL REGION. THE INNER SURFACE OF THE ILEOCECAL REGION AND ITS VALVES.

FOLDS AND FOSSÆ.

The folds and fossæ about the ileocecal region have been divided into the pericecal and the retrocecal or subcecal.

The pericecal folds lie above and to the left of the cecum and include the ileocolic and ileocecal folds and the mesappendix (see Figs. 66, a, b, and c), and are, with a very few exceptions, constant. By retrocecal or subcecal folds and fossæ we understand those situated behind and beneath the cecum. While the former are at once visible, the latter cannot be seen without lifting up the cecum.

The Ileocolic Fold.—The ileocolic fold (see Fig. 66, a) lies in the angle between the ileum and the colon. It is semilunar in shape, its free or concave margin being turned toward the ileum. It springs from the ventral or right (embryonic term) layer of the mesentery a little above the terminal portion of the ileum, passes in front of the ileocolic junction, and loses itself on the anterior surface of the cecum. The anterior ileocolic artery passes along its free or inner margin with its accompanying vein, also several lymphatic channels. Frequently it contains one or more lymphatic glands embedded between its two peritoneal layers, also a varying amount of fat. It is found early in fetal life (between the third and fourth months) and persists until old age, although occasionally diminishing relatively in size, owing to the greater growth or excessive distention of the cecum, which derives its peritoneal covering from the adjacent folds and mesentery.

The ileocolic fold bounds anteriorly a fossa of varying extent, which lies in the ileocolic angle between the fold and the mesentery of the ileum (Fig. 66, 1). It is called the ileocolic fossa, and varies in depth from a very shallow or scarcely distinguishable pocket to one deep enough to admit the thumb beyond the nail. The floor of this fossa is formed by the ileum and colon at their junction, and by their mesentery.

Berry, Lockwood and Rolleston, Kelynack, and others, agree in calling

this fold with its accompanying fossa, "ileocolic." WALDEYER, TREVES, TUFFIER, and HARTMANN give it the name, "superior ileocecal"; while JONESCO calls it the "ileocecal."

Ileocecal Fold.—The ileocecal fold, which passes, as the name indicates, from the ileum to the cecum, occupies the ileocecal angle (Fig. 66, b), and lies anterior to the mesappendix. It is of varying length, usually triangular

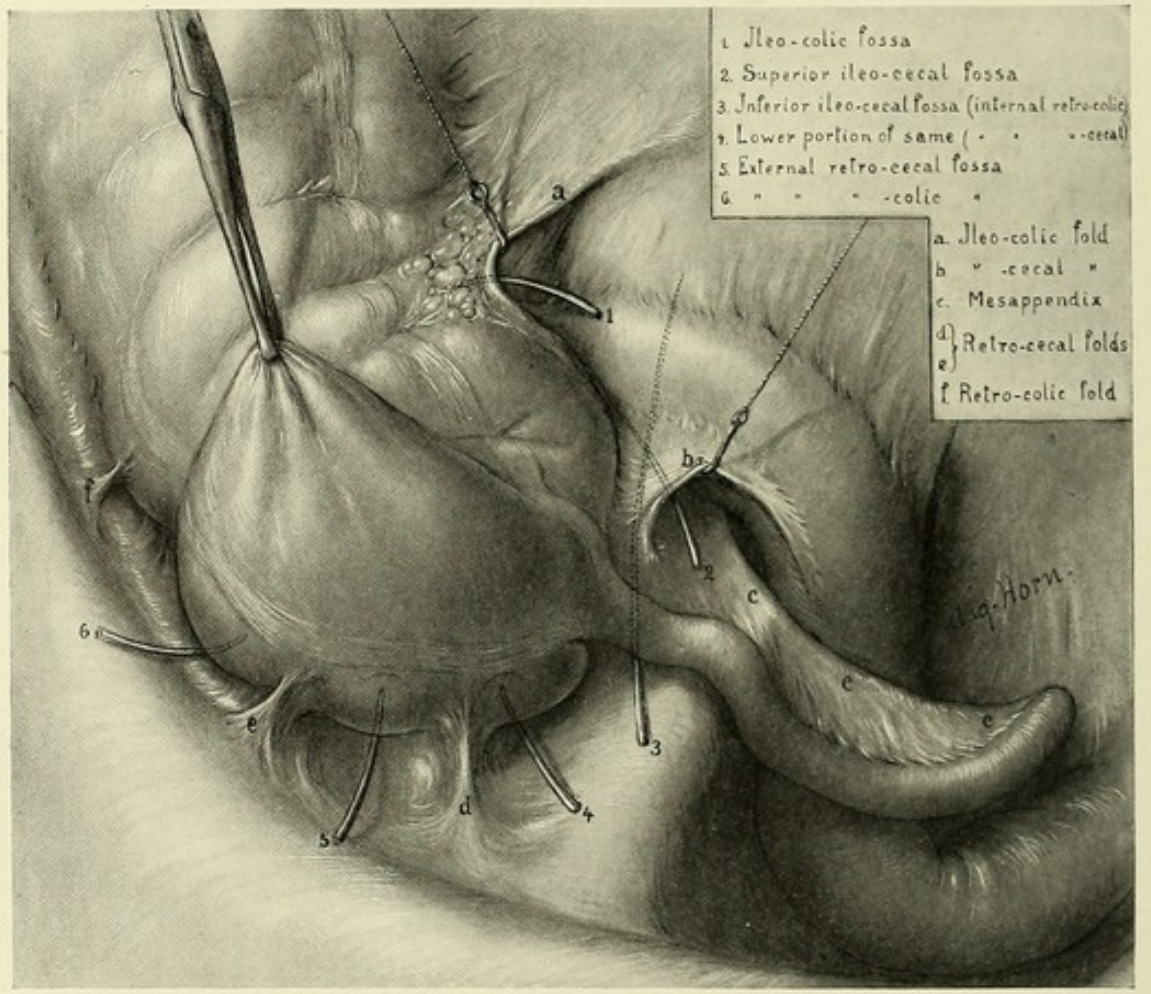

FIG. 66.—THE FOLDS AND FOSSÆ OF THE ILEOCECAL REGION.
The cecum is lifted up out of its bed in the iliac fossa, exposing the retrocecal folds and fossæ. The appendix has been drawn out of the ileocecal fossa to show the mesappendix.

but sometimes quadrilateral in outline. Its superior border is attached to the lower edge of the ileum for a distance of from 5.5 to 10 cm. Its right or external border lies along the cecum; its inferior border becomes lost on the anterior surface of the mesappendix, while the internal border is free and concave and forms the entrance to another fossa.

The fold consists of two leaves of peritoneum. The anterior leaf is con-

tinuous with the ventral peritoneal covering of the ileum, cecum, and mesappendix; the posterior leaf loses itself above on the posterior side of the ileum and below joins the cecum and mesappendix, being reflected upward to form the upper part of the anterior leaf of the mesappendix. The line of attachment of the ileocecal fold along the mesappendix forms an acute angle with the appendix, and is of variable length; seldom, however, exceeding one-half the length of the mesappendix (Fig. 66).

The ileocecal fold, unlike the ileocolic and the mesappendix, yet to be described, is not the bearer of any important arterial branch. It is supplied by a small recurrent branch from the appendical artery, and also, to a small extent, by delicate branches from the lower portion of the ileum and cecum (Figs. 118 and 122-138). The fold is therefore not "bloodless," as TREVES calls it, except in the sense that its origin was not determined by blood-vessels, as in the case of the ileocolic fold and the mesappendix. It is the original mesentery of the primitive cecum which persists in the adult, though slightly altered in its lower attachments, and fuses more or less with the mesappendix. If it develops to such an extent as to resemble in size the mesappendix, it may at an operation produce the impression of a second mesappendix (FINNEY, *personal communication*). Its comparative non-vascularity, however, will soon disclose its true character. LUSCHKA, PERIGNON, and others have determined the presence of muscle fibres in this fold, which come from the longitudinal muscular bands of the cecum. The latter continue chiefly along the appendix, forming its outer muscular coat, but a part of them have been seen to diverge and terminate in the ileocecal fold. Some muscle fibres enter it also from the inferior portion of the ileum. TOLDT has seen these fibres in a fetus of five months; BROTSCKE, in the embryo, infant, and adult.

LUSCHKA, therefore, attributes to the fold a muscular function of regulation between the ileum and cecum. He maintains that it assures the position of the parts about the ileocecal junction, and prevents, by the contraction of its muscle fibres, any obstruction to the communication between the small and large intestines which might be caused by the ileum assuming a vertical direction. It seems doubtful that such a view is correct.

The ileocecal fold frequently contains a quantity of fat, in some cases a considerable amount. It is occasionally, but very rarely, seen to take the place of the mesappendix. This occurs if in early fetal life the posterior ileocolic fold with its vessels becomes fused with the middle or ileocecal fold. We then have a broad mesappendix stretching itself between the free border of the terminal portion of the ileum and the hilum of the appendix. The appendical vessels in such cases, as a rule, run across the posterior surface of the ileum and are adherent to it. Between the ileocecal fold and the mesappendix lies the ileocecal fossa, which opens toward the left and varies in depth and size according to the size of the fold. Sometimes it is

very slight—a mere chink; at other times the fossa is deep enough to admit several fingers for a considerable distance, or even large enough to lodge a small apple.

The ileocecal fold and fossa have been described under a great variety of names. They are as follows:

1. Superior Ileocecal. Waldeyer and Tuffier.
2. Bloodless Fold. Treves.
3. Anterior Mesappendix. Clado.
4. Ileo-appendicular or Anterior Fold. Jonesco.
5. Ileocecal Omentum. Little.
6. Ileocecal Fold. Lockwood and Rolleston; Kelynack, Berry.

The Mesappendix.—Normal Arrangement.—(Fig. 66, c.)—The mesappendix, mesenteriolum, or mesentery of the appendix in a normal case has taken the place, as will be later described, of the ileocecal fold as a suspensory ligament for the appendix. The origin of its formation on the posterior side of the cecum is similar to that of the ileocolic fold on the anterior surface, a fold of peritoneum having been lifted up in each instance, owing to the presence of an artery, the anterior and posterior branches respectively of the ileocolic artery.

When normally situated, the mesappendix lies partly or entirely concealed by the ileum and its mesentery, which frequently cover also a portion of the appendix as well.

There is considerable controversy among authors on the subject as to whether the mesappendix is triangular or quadrilateral in outline. As it is quite variable in length, width, and extent of attachment, it may be either.

"The mesappendix arises above from the left (embryonic term) or under layer of the mesentery of the ileum. Its origin is along a line, situated a short distance from the intestines, and not quite parallel with the margin of the bowel" (Treves). This line forms the upper or superior margin of the mesappendix. Its right or external border is inserted along the posterior internal face of the cecum; its inferior margin corresponds to the superior or attached border of the appendix, while its left or internal border is free. The last is semilunar in outline, its concavity facing inward and upward, and it is fixed above to the mesentery, while below it is continuous over the tip of the appendix. Upon the length of this free border depends, in a great measure, the position of the appendix; if long, the appendix appears straight or slightly curved; while if too short, the appendix is drawn into a spiral or a number of varying bends (Figs. 86 and 148).

In the infant the mesappendix is thin and transparent, owing to the absence of fat. In the adult it grows somewhat thicker and more opaque and is frequently supplied with fat and epiploic appendages. Sometimes this invasion

by fat is so great that the mesappendix resembles a grape-like mass of adipose tissue (Fig. 113).

The free border of the mesappendix envelops the main appendical artery, with its accompanying vein, lymphatics, and nerve. Secondary branches pass from these to the appendix, between the two peritoneal leaves of the mesentery.

Besides vessels and fat, the mesappendix may also contain lymphatic glands along its mesenteric and cecal borders. (See Chap. VII, p. 183.)

The extent of the mesenteriolum along the appendix is also a matter of much difference of opinion.

Normally, *i. e.*, in about seventy-five per cent. of cases, the appendix is surrounded by a complete serous envelope, which adheres to it very closely and is continuous with its mesentery. In the remaining cases the appendix is situated partly or entirely extraperitoneally, *i. e.*, a portion of its surface is devoid of peritoneal covering. The mesappendix in normal cases goes all the way to the tip, or may even extend slightly beyond it, forming a knob-like projection; it, however, frequently appears to stop at some distance from the tip, extending, in some cases, according to TREVES, JONESCO, and others, only to the middle of the appendix, or to the junction of the middle and distal thirds. The artery, to the presence of which the mesappendix owes its origin, is nevertheless always to be found extending to the very tip of the appendix, though along this terminal portion of its course it may not elevate the peritoneum sufficiently to form a definite fold or mesentery. In these cases the mesappendix seems to terminate at the point where the peritoneum is no longer elevated by the artery, a distance of from 1 to 2 cm. from the tip. LAFFORGUE says this occurred in seven per cent. of his cases.

Abnormal Positions or Conditions.—About twenty-five per cent.

(*a*) The mesappendix may develop in the place of the ileocolic fold, arising from the anterior layer of the mesentery and descending in front of the ileum to the appendix, the ileocecal fold in such instances being attached to its posterior instead of its anterior surface.

(*b*) Or the mesappendix may develop from the ileocecal fold, the appendical vessels passing within it instead of originating a separate fold.

(*c*) Or the appendical artery may travel along the posterior side of the appendix near the hilum and entirely fail to lift up the mesentery into the form of a fold. This condition has been noted by LOCKWOOD and ROLLESTON, and accounts for the statement made by some authors that the mesappendix is sometimes lacking. Such an appendix resembles the type met with in the brown howler monkey of Brazil.

The absence of the mesappendix may also be brought about in the manner described under "Position of the Appendix," where the cecum by its abnormal

distention gradually forces its way between the two peritoneal leaves of the mesappendix, which separate and become appropriated to cover the cecum. This process brings the appendix vertically behind the cecum (Fig. 71, II, and Fig. 76).

Among Lockwood and Rolleston's six groups of positions of the mesappendix, we find the following of special interest.

The mesappendix may be spread on the peritoneum of the iliac fossa, and, either by coalescence or by traction of the gubernaculum, become more or less adherent to it. The posterior leaf of the mesappendix is then reflected on to the floor of the iliac fossa at a much lower level than the normal.

The mesappendix may be caught and fixed in a subcecal or retrocolic fossa (generally the internal retrocolic fossa), in which instance the appendix tip appears frequently adherent to the deepest portion of the fossa. The mesappendix may be perforated, and in the hole thus produced a loop of small intestine is apt to pass and become strangulated.

The mesappendix has been variously called meso-appendix, mesenteriolum, and "posterior meso-appendix" (Clado).

A number of peritoneal folds have been described as arising from the posterior surface of the mesappendix and connecting it with neighboring organs. Laforgue states that in five per cent. of his cases a pelvic fold united the mesappendix with the crural or inguinal arch. In about twenty per cent. of his cases he found also the appendiculo-ovarian ligament of Clado, which may establish lymphatic and vascular communication between the appendix and ovary. It passes transversely over the iliac vessels and joins the broad ligament. This structure will be more fully described on page 102.

The Origin of the Pericecal Folds.—In the foregoing pages has been given a brief description of the peritoneal folds, vascular and non-vascular, as they pass between the colon, cecum, ileum, and appendix. The nomenclature is, as we have seen, quite extensive, and the conception of different writers as to the different structures varies to a large extent. The complex relationship of these structures becomes at once very simple if we return to the earliest indications of the same in the embryo. The three folds, ileocolic, ileocecal, and mesappendix, in the primitive stage appear as shown in the first diagrams of Types I, II, and III, Figs. 67, 68, and 70. The primitive stages of Types II and III appear to be only slight variations of that of Type I, which develop, however, into very different adult forms. We see that the appendix does not exist as such, but is only visible as the cecal pouch which is connected with the terminal portion of the ileum by a peritoneal fold. This fold, the original cecal mesentery, ultimately becomes the ileocecal fold, and as the appendix is nothing but the undeveloped cecum, it might well be termed the real mesentery of the appendix. As it becomes supplanted in the adult by the posterior fold, it appears here only rudimentary.

TYPE I.

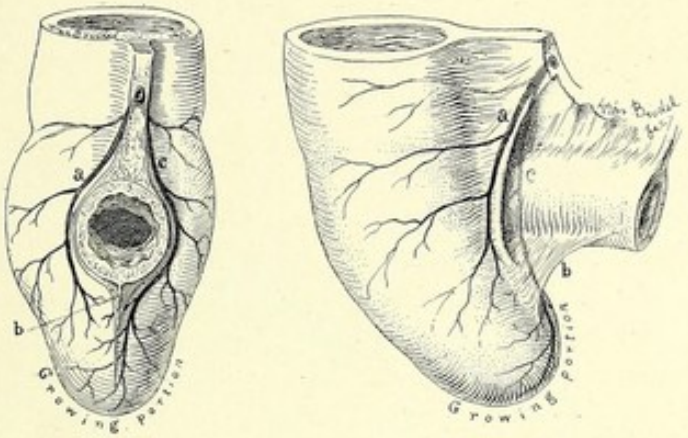

Side view. Front view.

A, Primitive Stage.

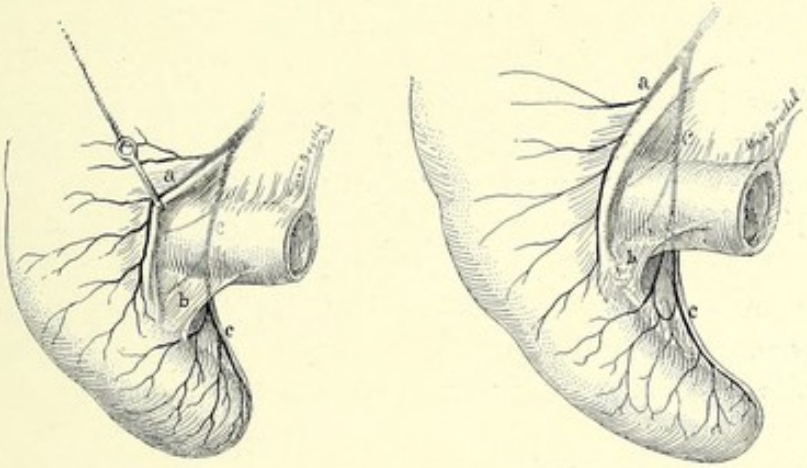

B, More Advanced Stage, Showing Growth of Posterior Vascular System c.

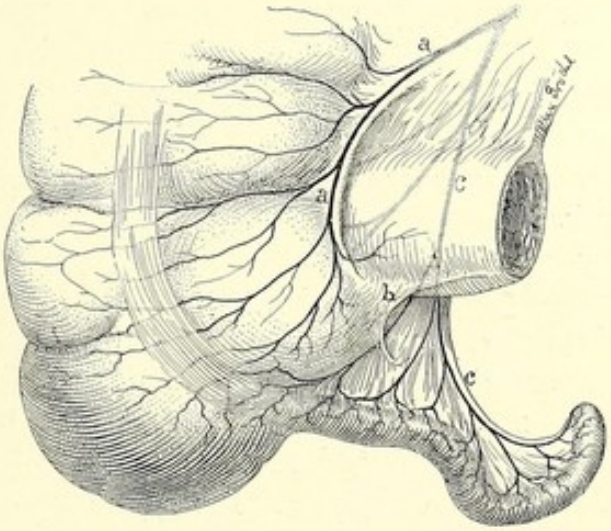

C, Adult Form.

FIG. 67.—THE DEVELOPMENT OF THE VASCULAR FOLDS. (Usual form.)

The arrangement of the anterior and posterior ileocolic folds, the latter of which becomes the mesappendix, is determined by the cecal branches of the ileocolic arteries. Each contains a vessel which causes the serous coat to be elevated, and gives rise to a definite serous fold. These two arterial branches are seen in the primitive stages of Types I, II, and III. In all they are seen to be arranged symmetrically, passing in front of, and behind the terminal portion of the ileum and giving off in their course little twigs to both sides of the cecum. Their terminal branches, however, differ in the three types to some extent. The manner of their termination in relation to the growing portion of the cecum is of the greatest importance in the ultimate formation of the three folds. If the posterior branch supplies the growing tip of the cecum, we have as a result the Type I depicted in Fig. 67, which is found in an overwhelming majority of cases. If the anterior vessel supplies the growing tip, as seen in Type II, Fig. 68, the conditions are reversed; and if the terminal branch joins the middle fold, as shown in Type III, Fig. 70, we have another variety occasionally met with in the adult. The two latter types are, however, quite rare.

From these investigations it becomes obvious that the mesappendix is nothing but one of the two cecal folds in front of and behind the termination of the ileum. Whichever vessel supplies the growing tip, develops with it, gaining in length and in complexity of terminal branches, as shown in Types I, II, and III, B and C. This development of the vessels in Type I lifts up the peritoneum of the posterior ileocecal fold and makes it dominate its anterior fellow considerably in size. It thus becomes the permanent mesentery of the terminal portion of the cecum, the original mesentery (b) remaining behind in development.

The changes from the fetal stage to the adult are easily understood by an examination of stages B and C, Fig. 67.

The mesappendix (c) is seen to come from behind the ileum; the ileocolic fold (a) with its vessel, terminates much higher up than its fellow (c). The middle fold (b) persists as the so-called "bloodless fold" (ileocecal) (b).

Except in a very few cases, the anatomy of the ileocecal region is formed according to this principle.

In Type II, Fig. 68, the mesappendix with its vessels is seen to pass in front of the termination of the ileum, the appendical artery being the terminal branch of the anterior cecal artery, while the posterior cecal artery (c) is developed to no larger extent than the anterior in the first type. The ileocecal fold (b) is seen to pass behind the mesappendix instead of in front. The first and second diagrams of Fig. 68, A and B, show that the anterior vascular system predominates over the posterior. It supplies the growing tip of the cecum and is carried and develops with it in a downward direction. This

TYPE II.

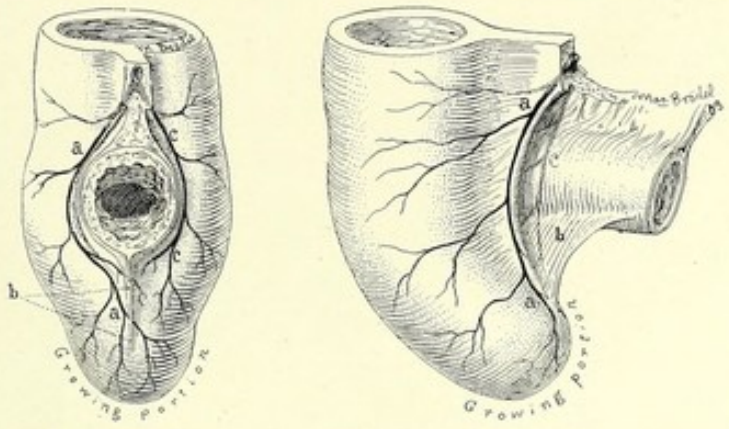

Side view. Front view.

A, Primitive Stage.

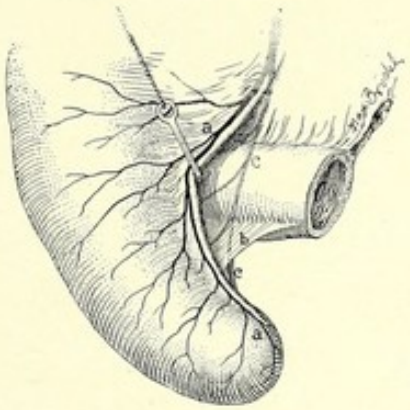

B, More Advanced Stage, Showing Growth of Anterior Vascular System a.

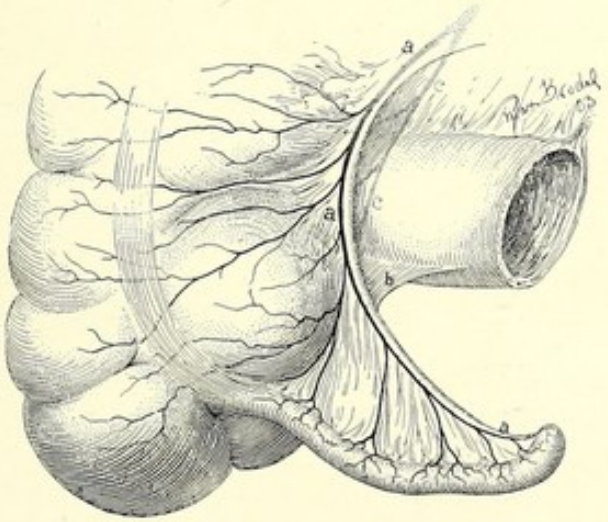

C, Adult Form.

FIG. 68.—THE DEVELOPMENT OF THE VASCULAR FOLDS. (ANTERIOR MESAPPENDIX.)

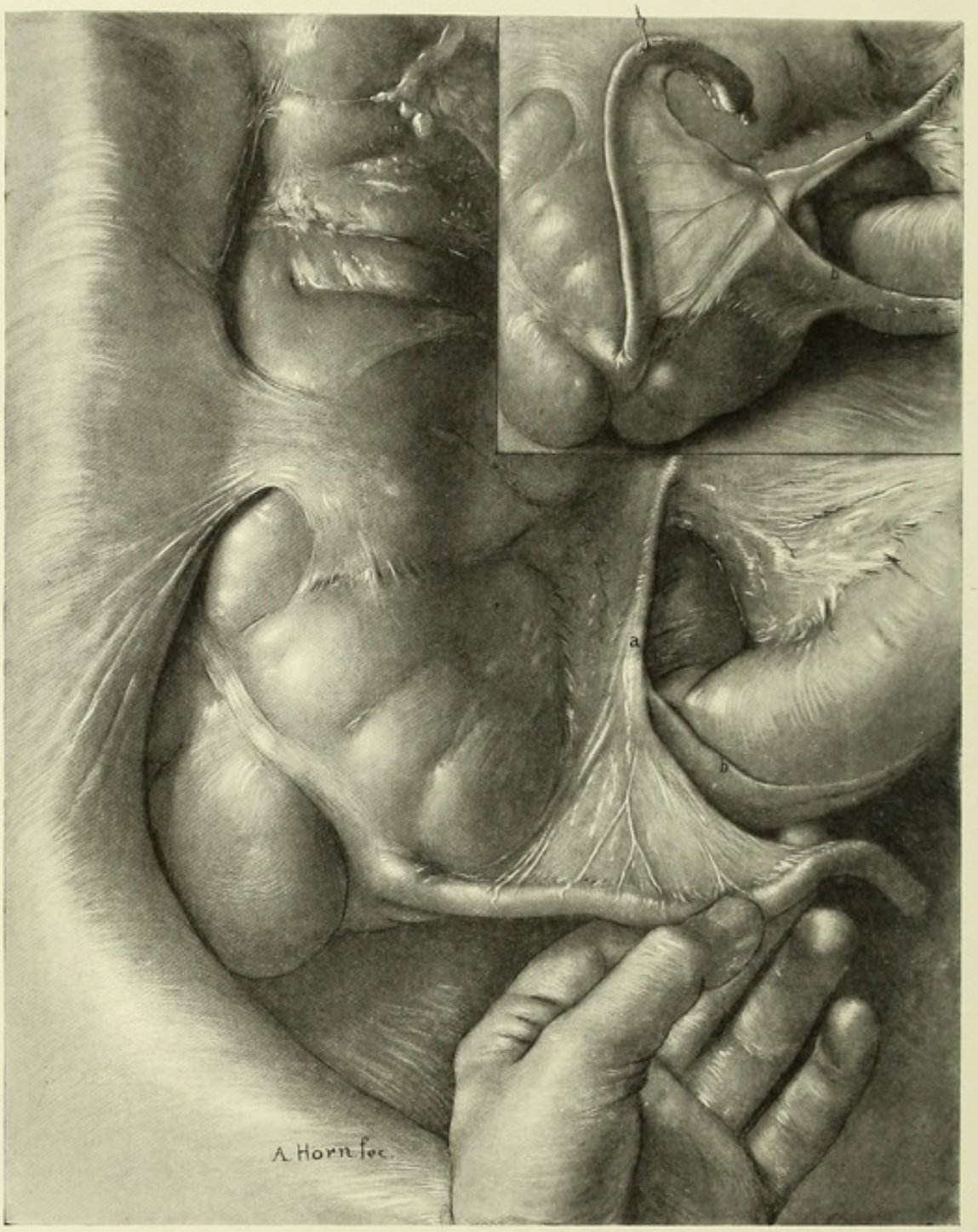

FIG. 69.—ABNORMAL POSITION OF THE MESAPPENDIX.

For development of this type, see Fig. 68. The mesappendix (a) is identical with the ileocolic fold, passing in front of the ileocolic junction. The ileocecal fold (b) is attached to the posterior surface of the mesappendix and the cecum. (See small diagram in upper right-hand corner.) An appendix of this type generally has the pendant form, hanging down in the pelvis or lodged among coils of small intestine. (Specimen from H. S. Weaver, Philadelphia.)

type is the opposite condition to that shown in Fig. 67. Fig. 69 is an actual case having this arrangement.

In Type III, Fig. 70, the ileocecal fold has become identical with the mesappendix, *i. e.*, the vessels to the appendix pass in a mesentery which arises broadly from the free border of the termination of the ileum, passing as a trapezoid leaf to the hilum of the appendix. Either the anterior artery (a) or the posterior (c) may develop into the appendical. In passing down to the growing tip, the artery passes in the mid-line, Type III, A, where it becomes identified with the original cecal mesentery, that is, the ileocecal fold, together with which it passes through its various stages of development. This form is, as was said above, quite rare.

While a combination of Types I and II, *i. e.*, a condition where both anterior and posterior cecal arteries supply the growing tip of the cecum and develop with the tip into two definite mesappendices, has to our knowledge not been observed in the human being, there are monkeys in which such an arrangement is the rule. (See Figs. 61 and 62, copied after TREVES.)

Complete lack of a vascular mesappendix, that is, a condition where neither the anterior nor the posterior arterial branches lift up a peritoneal fold, leaving the rudimentary middle fold as sole suspensory ligament for the appendix, has been observed, as before mentioned. The vessels course then in the serous layer of the appendix, along the hilum. According to TREVES, such an arrangement is met with in the ceca of certain monkeys. In man, however, we have never seen it.

Between these extreme types there are many transition forms, the most striking of which are as follows:

A long broad mesappendix, with persistent ileocecal fold, giving the impression of a double mesappendix;

A short and narrow mesappendix, the artery lifting up only an insignificant peritoneal fold, making the appendix appear as though the distal portion were without a mesentery.

The Retrocecal or Subcecal Folds and Fossæ.—Various folds and fossæ have been described as lying beneath the cecum, and therefore called subcecal or retrocecal. They depend entirely for their existence upon the coalescence or adhesion of the colon, cecum, and mesentery to the posterior abdominal wall, and are therefore secondary in origin as compared with the three folds previously described. These folds are simply elevations of the peritoneum, extending from the cecum to the abdominal parietes. They serve in a measure to hold the cecum in place, and have therefore been called the suspensory ligaments of the cecum. In some cases the cecum never becomes adherent to the posterior abdominal wall, and we therefore find no retrocecal folds or fossæ. The folds in any case exist only when the parts remain *in situ* within the body, disappearing almost entirely on removal. They may develop at any point behind the cecum, extending a varying distance

TYPE III.

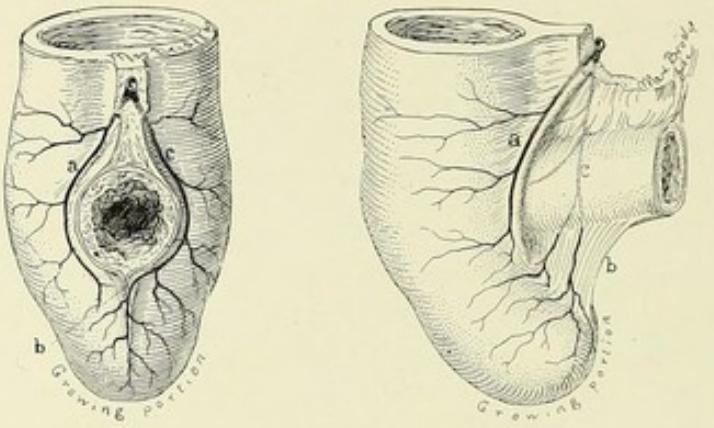

Side view. Front view.

A, Primitive Stage.

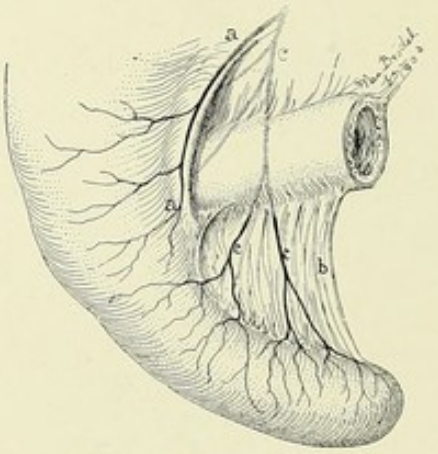

B, More Advanced Stage, Showing Union of Posterior Vascular System (c) with Middle Fold (b).

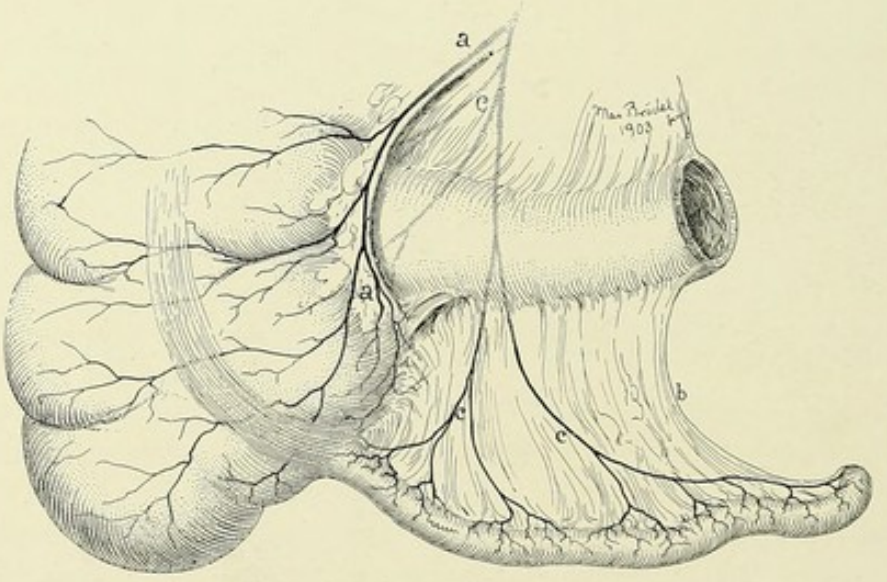

C, Adult Form.

FIG. 70.—THE DEVELOPMENT OF THE VASCULAR FOLDS. (MESAPPENDIX ATTACHED TO LOWER BORDER OF ILEUM.)

upward, back of that organ and down over the floor of the iliac fossa. On lifting up the cecum, such folds can always be produced, but there are a few which seem to be more constant and which have been described as more or less so by certain authors. Of course, any two such folds enclose a fossa which may extend to a considerable length upward, back of the cecum, and even extending as high as the colon. The appendix has frequently been found lying curled up in such a fossa, pathological conditions of the organ sometimes resulting from this position.

The number of folds and their nomenclature are considerable, and there is little unity concerning their description in the literature of the subject. We should not render the subject any clearer by quoting what different authors have said. By going back to the primitive stages and studying the development of these folds and fossæ, a much better and clearer appreciation of their topography will be obtained. Their classification will also become simplified.

The posterior surface of the cecum and colon, *i. e.*, the embryonic left side, undergoes a fusion with the parietal peritoneum during the latter months of fetal life, which may involve the posterior surface of the entire mesocolon, the colon, and part of the cecum. This would be a complete fusion. If the fusion be incomplete, a number of pockets or fossæ remain which are accessible from the general peritoneal cavity from three sides: from the left or inner side, from below, and from the right or external side. Between these fossæ folds are seen which may be variable in number and extent. The large intestine at the time of fusion represents a straight tube, to which the cecum is attached in the form of a simple round pouch. The lateral and inferior line of fusion when complete is, therefore, a comparatively unbroken one, until the cecum and colon begin to balloon out to form the characteristic compartments so pronounced in the adult. This uneven expansion lifts up the peritoneum in a series of folds which have been observed in great variation and described by many authors. If the fusion was originally incomplete, the fossæ are deep; while in cases of complete fusion the fossæ are comparatively shallow.

The most capacious and the most constant of the fossæ is the internal retrocolic (Fig. 66, 3), also called inferior ileocecal, which can only be demonstrated by lifting up the cecum, appendix, and ileum. It is then seen as a funnel-shaped pocket extending in an upward direction under the ileum and colon. From the depth of this fossa arises the posterior leaf of the mesappendix, and the entire appendix is oftentimes found curled up in this space, while its tip may point in various directions. When the intestines are in normal position it is impossible to see the appendix without lifting up the cecum and ileum so as to expose this internal retrocolic fossa.

The cecum, as a rule, is completely surrounded by peritoneum, and on lifting it upward, the folds and fossæ which become visible underneath the cecum

are found to be retrocolic and not retrocecal. There are, as a rule, two upliftings of the peritoneum (Fig. 66, d and e), between which is seen a retrocecal or, if very deep, retrocolic fossa. We repeat that both terms may be correct according to the extent of the peritoneal reflection, whether low and confined to the cecum, or whether extending high up under the colon.

If the ileocolic portion of the intestine becomes adherent comparatively high, the cecum will have to sag downward a considerable distance in order to fill the lower apex of the iliac fossa. The retrocecal pocket or pockets are then very deep and the folds exceedingly well developed. The reverse condition is found if the ileocolic region becomes adherent at a lower level. The tip of the appendix may occasionally lodge in this pocket.

On the right or external side of the colon there are also one or more folds, which are seen at varying intervals, passing from the serous coat of the ascending colon, as a rule, behind the posterior muscular band, outward to the parietal peritoneum. Traction on either or both places of attachment renders these folds more conspicuous. The pockets between the folds are, like the others, of varying depth, and it is impossible to make any statement as to their character which would be applicable to all cases. The pockets may be entirely absent, and likewise the folds, while the entire posterior surface of the colon, as well as that of the cecum, may be covered by peritoneum. The peritoneal reflection is then situated along the mesial border of the colon. The reflection may be found even more toward the median line, the colon possessing in this case a free mesentery similar to that of the small intestine. In the two latter instances the appendix is usually of the pendant type. The appendix may also be found in a retrocolic position, or in a position curving around the lateral border of the colon, with its tip pointing toward the kidney or gall-bladder, or adherent thereto. If the appendix becomes adherent to the parietal abdominal wall before the colon and mesocolon become attached, the appendix will be held in some such position while the cecum continues to descend.

The Appendiculo-ovarian Ligament.—On lifting up the appendix and cecum in the female, it is often possible to demonstrate the presence of a thin peritoneal fold passing from the mesappendix or the adjacent cecal or iliac serosa in a median direction to the infundibulo-pelvic ligament, also called the vascular pedicle of the ovary. This fold, which can be rendered more distinct by traction, is said to carry blood-vessels and lymphatics, thus establishing a connection between the vessels of the appendix and ovary, or between the portal and systemic circulation. Moreover, it is described as containing muscle-fibres.

While admitting the occasional presence of a peritoneal fold passing in a transverse direction from the iliac fossa to the ovarian vascular pedicle on a level with the division of the common iliac vessels, a fold which may be found to vary greatly in length and height, we positively deny the existence of any

considerable vascular and lymphatic communication between the ovary and the appendix by means of this peritoneal fold. The developments of the ovary and of the appendix take place a great distance apart from each other, the ovary developing on the mesio-ventral surface of the Wolffian body, one of whose vessels persists as the ovarian, while the others disappear. The ovary, together with the retrograding Wolffian body, descends into the pelvis, drawing the ovarian vessels with it, which thus become lodged in the lengthening diaphragmatic ligament of the Wolffian body. The parietal peritoneum completely covers all these structures. While these changes have taken place, the appendix has passed through its various phases of development quite independently of the ovary. It lies first within the cord, and by the time it enters the abdominal cavity in the middle line just beneath the stomach, it begins to receive its vascular supply, which it carries with it on its downward course. The blood-vessels of both the ovary and the appendix are completely formed before they become neighboring organs. The mesappendix, as well as the mesocolon, does not fuse with the parietal peritoneum until the fourth or fifth month of intrauterine life. If they do, they are generally attached high up in the iliac fossa. Any subsequent vascular connection between the two organs must therefore remain confined to the usual small amount of lymph and blood capillaries of the parietal peritoneum. The large veins traversing the fatty capsule of the kidney which drain into the renal or spermatic (ovarian) veins, do not usually reach as far down as the appendix; but even if they do, they are found on the other side of the prerenal fascia and do not communicate with the appendical vessels.

The fusion of the large intestine and mesocolon with the parietal peritoneum is subject to many individual variations. It may be more or less lacking, or, on the other hand, quite complete. The peritoneal folds established by this fusion differ, therefore, greatly in number and position in different subjects, as shown by the varying topography of the retrocecal and retrocolic folds and fossæ. The appendiculo-ovarian ligament is only one of a large number of these more or less irregularly situated peritoneal folds in the region of the iliac fossa.

That peritoneal folds may contain veins of some size is a well-known fact, and most of the folds in the ileocecal region are known to have them. These veins are rarely more than 0.5 mm. in width, and through them a small portion of the cecal and colic blood is carried toward the veins of the posterior abdominal wall, *i. e.*, into the ilio-lumbar or circumflexa-ilium profunda, and occasionally into the spermatic or ovarian veins. Such vessels establish a communication between the portal and the systemic circulation, and in cases of obstruction of the portal vein they are apt to be found much distended, as is the case with similar other collateral channels, known as the veins of Retzius.

It has been claimed that infections of the appendix are communicated to

the ovary through this ligament, and several writers have made extensive studies on the cadaver to prove this point. The various statements of the different authors, however, are not in harmony, some even denying the presence of the ligament altogether. It often seems as though they have not been referring to the same anatomical structure. DURAND terms it the ileo-ovarian ligament, and from his description it becomes evident that he has been discussing the vascular pedicle of the ovary. HASSE describes it as the infundibulo-pelvic ligament, a term which is also used by HENLE.

SCHULTZE and HASSE speak of it as terminating at the iliac vessels, while VALLIN insists that the ligament ascends into the lumbar region.

ROUGET's description is very elaborate but does not differ materially from that of the others.

CLADO makes the following statement: "In lifting the appendix it can be seen that it forms a peritoneal fold which separates from the mesappendix and continues with the superior border of the broad ligament. It is falciform; its least elevated portion rests on the iliac vessels and varies from one to two centimetres in height." He claims that it is also found in the male, although much smaller in size. In his description he mentions that by means of this ligament, lymphatic connection is established between the ovary and the appendix.

Contrary to this statement of CLADO's, all of our experiments in injecting the lymphatics of the appendix, from the periphery toward the centre, demonstrated that the lymph channels of the appendix pass inside the mesappendix toward the ileocolic group of glands, or through the cecum in the same direction ultimately to the same group. Not one single lymph channel was seen to pass in the peritoneum toward the ovary.

Descriptions of the appendiculo-ovarian ligament similar to that of CLADO have been given by LAFFORGUE, the latter, however, contesting its constancy, as he only found it seventeen times in ninety female subjects.

DURAND gives it exceptional insertions: (1) into the peritoneum, enveloping the termination of the ileum, (2) sometimes into the cecal reflection. While the ligament seems with some investigators to be an established fact, BARNSBY (1898) not only contests it, but almost denies its existence. In 127 cadavers he never found it. FERRY, also, who examined 17 cases, did not find it in a single instance. POIRIER and CUNÉO likewise emphatically state that there is no such structure as the appendiculo-ovarian ligament.

THE REFLECTION OF THE PERITONEUM.

While the anterior surface of the large intestine and its mesentery are entirely covered by peritoneum, the posterior surface becomes fused with the peritoneum of the parietal abdominal wall. This process begins about the fourth month of intrauterine life and proceeds from the centre to the periphery.

It may be extensive; and a considerable portion of the posterior surface of the large intestine may become adherent, or it may be limited to a comparatively small area, so that much of the large intestine retains its free mesentery, in which case we find capacious pockets or fossæ behind the intestine. The lines which limit the fusion mark the reflection of the peritoneum from the intestine over to the parietal abdominal wall. Viewed from behind, the portions of the intestine central to these lines are extraperitoneal surfaces, while those located peripherally are intraperitoneal.

The line of peritoneal reflection in the ileocecal and ileocolic region is, as might be supposed, subject to many variations. It may be very high (Fig. 71, I), leaving cecum, appendix, ileum, and colon free and movable, on a mesentery as long as 12 cm.; or very low, depriving the entire ileocecal apparatus of a movable mesentery (Fig. 71, VIII), and fixing it quite firmly in the iliac fossa.

Between these two extreme types, Figs. I and VIII, neither of which occurs frequently, there are many transition forms, which place the line of peritoneal reflection in different directions and at various levels. It is either longitudinal (Fig. 71, IV), transverse (II), or oblique (III), and when studied in relation with the body, TREVES finds that it lies usually between the level of the highest points of the iliac crest and that of the anterior superior iliac spines. Its relation to the muscles is as follows: if oblique or transverse, it crosses the psoas and a small portion of the iliacus; if longitudinal, it may pass along the outer or inner margin of the psoas; and a very high transverse line may correspond to the lower margin of the kidney.

Developmental and pathological distortions excepted, we find that both cecum and appendix are generally covered on all sides by peritoneum; *i. e.*, the line of peritoneal reflection passes above them, the average distance from the cecal point, according to TREVES, being 10 cm. BARDELEBEN says correctly, therefore, that the cecum is, as a rule, completely covered by peritoneum, that it is freely movable below the ileocecal junction, and that its downward movement is hindered by its attachment to the ascending colon and not by a fusion with the parietal abdominal wall. The supposition that the cecum is partly an extraperitoneal organ, and that cecal herniæ, inguinal or femoral, have no peritoneal sac, is, therefore, erroneous. In exceptional instances, however, such as are represented in Type VIII, Fig. 71, a cecal hernia may take place without formation of a complete peritoneal sac. TREVES and others deny that the cecum has a mesentery. Being on all sides surrounded by peritoneum and only attached to the colon above, there is indeed no mesocecum proper, all the cecal vessels and lymphatics passing through the ileocolic fold anteriorly, and along the cecal wall and mesappendix posteriorly. The embryonic cecal mesentery persists in the adult as the ileocecal fold, a rudimentary structure, carrying only a few insignificant vessels.

In studying the eight diagrams given in Fig. 71, a comprehensive view may

be obtained of the types of peritoneal reflection in the ileocolic region. All pictures are posterior views of the intestine. These types are not drawn with reference to the different positions the appendix may assume. Concerning the relation of the appendix to the peritoneal reflection, see Figs. 72–78.

Fig. 71. Type I. Eight per cent. An entirely free colon, cecum, and ileum, as that shown in this type, corresponds to the form found in many mammalia, but in man it is met with in only a few instances. The cecum is then apt to hang far down into the pelvis, displaying an excess of development.

Type II. Four per cent. An almost transverse line of peritoneal reflection situated some distance above the ileocecal valve. The mesappendix may or may not in such cases be utilized to cover the large intestine.

Type III. Sixteen per cent. The line is oblique and still quite high, much of the colon being free. The appendix is generally tucked away under the ileocecal junction.

Type IV. Ten per cent. The line corresponds to the median border of the colon. The entire posterior surface of the colon is covered by peritoneum, while the corresponding surface of the termination of the ileum is without peritoneal lining. The appendix hangs free below the ileocecal junction.

Type V. Eight per cent. The line of reflection has advanced over the inner half of the colon and crosses the posterior muscular band at a high level. The posterior surface of the ileum is extraperitoneal, the appendix lying free.

Type VI. Thirty per cent. This is the most frequent type, almost one-third of all cases showing such an arrangement. The next frequent types are III, IV, and VII.

Type VI. The line of reflection runs somewhat obliquely from the posterior leaf of the mesappendix, across the lower portion of the ascending colon, traversing the posterior muscular band about 8 cm. from the cecal pouch and continuing upward close to the lateral colic margin. The distance of this line from the lowest point of the cecum may vary considerably, producing transition forms with the other types. The ileum is completely covered by peritoneum and the appendix frequently lies tucked away under it.

Type VII. Sixteen per cent. The line of reflection runs along the posterior muscular band almost to the appendix; the median half of the colon and terminal portion of the ileum are extraperitoneal, the appendix either hanging down free or being adherent to the extraperitoneal surface of the cecum and colon.

Type VIII. Eight per cent. The entire posterior surface of the colon and cecum and termination of the ileum are extraperitoneal, and the line of reflection is almost identical with the outer contour of the large intestine. The appendix may again hang down free or point upward and be adherent to the posterior surface of the cecum and colon, *i. e.*, be extraperitoneal in position.

The question whether the appendix is an intraperitoneal or extraperitoneal

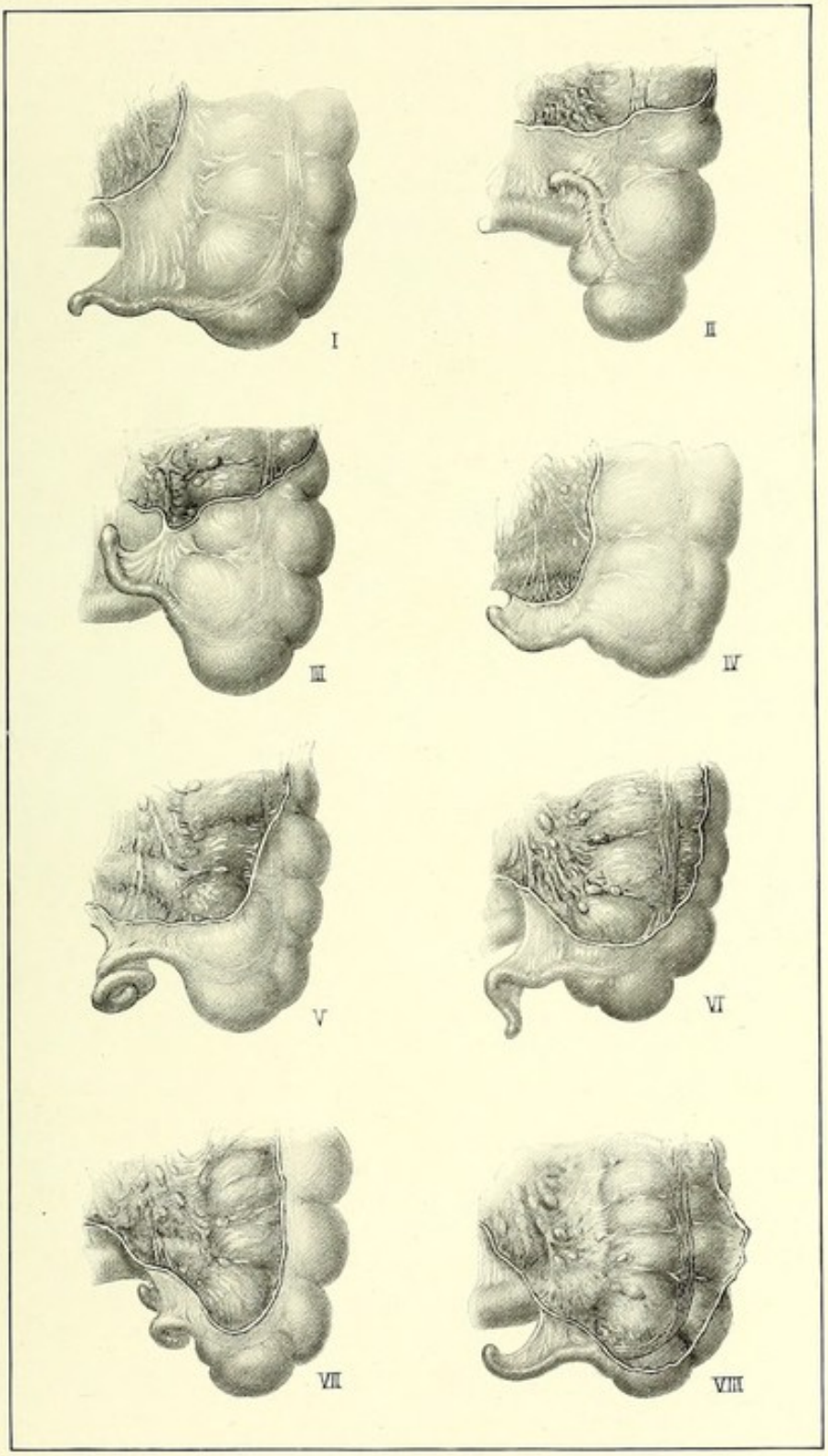

FIG 71.—THE EIGHT MOST FREQUENT TYPES OF PERITONEAL REFLECTION OF THE ILEOCECAL REGION.
The intestine is viewed from behind. The extraperitoneal surfaces are drawn darker in order to differentiate them from the smooth serous surfaces of the intraperitoneal portion.

organ is chiefly decided by the position it assumes in relation to the cecum and colon, *i. e.*, whether it be directed downward or upward. Or, in more cor-

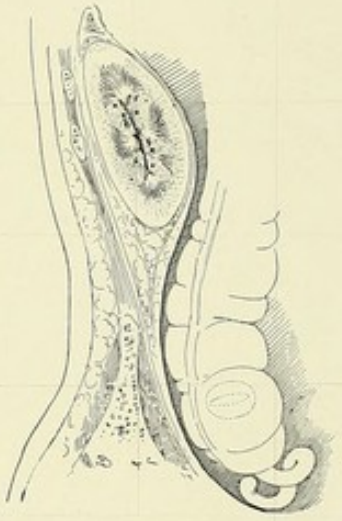

FIG. 72.—Colon, cecum, and appendix are surrounded by peritoneum.

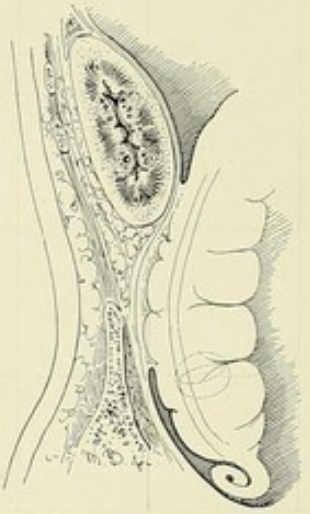

FIG. 73.—The middle portion of the ascending colon is adherent to the parietal abdominal wall; the rest of the colon, cecum, and appendix are intraperitoneal.

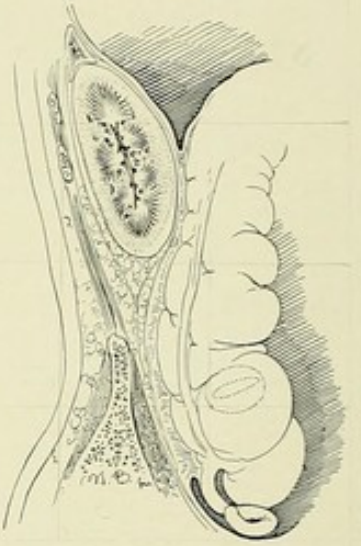

FIG. 74.—The entire ascending colon and the base of the appendix are adherent along the posterior abdominal wall, while the rest of the appendix and the cecum are intraperitoneal.

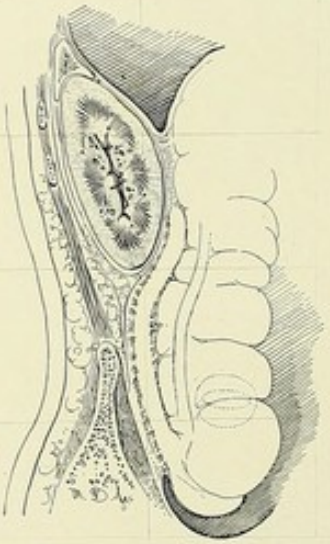

FIG. 75.—The appendix is adherent to the posterior surface of the colon as well as to the posterior abdominal wall, *i. e.*, it is of the extraperitoneal ascending type.

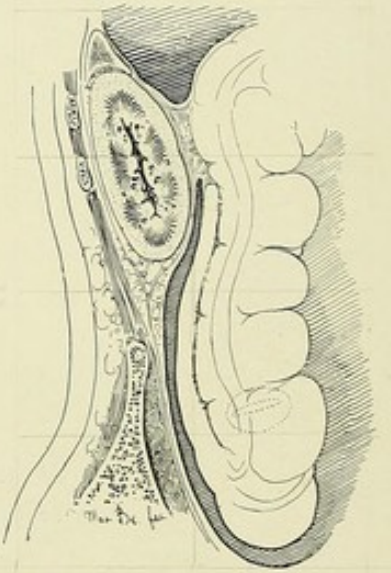

FIG. 76.—The appendix is adherent only to the posterior wall of the colon, but not to the posterior abdominal wall. On turning the colon toward the middle of the body the appendix is easily exposed to view.

rect expression: early fusion between the colon and the posterior abdominal wall is apt to produce an ascending and retroperitoneal appendix, while late

fusion brings about a pendant intraperitoneal appendix. (See "Position of Appendix," Chap. V, p. 118.)

Figs. 72 to 78 show the seven most striking types of intraperitoneal and extraperitoneal appendices, the first three figures giving the peritoneal relation of the pendant appendices, while the other four illustrate the peritoneal relations of the ascending forms.

Fig. 72. The colon is not adherent at any place and the appendix is pendant and intraperitoneal. It may, however, be drawn up on to the cecum if the latter be distended. This type is an exceptional occurrence.

Fig. 73. The colon is adherent between the kidney and the iliac crest, but

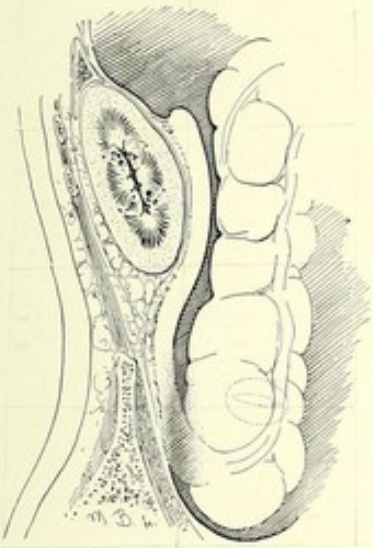

FIG. 77.—The appendix is adherent to the posterior abdominal wall, but not to the colon. Its tip may be adherent to the kidney or gall-bladder.

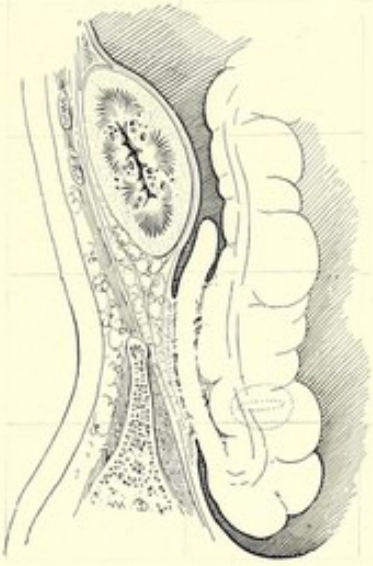

FIG. 78.—The appendix is intraperitoneal at its proximal and distal portions, while along its middle portion it is extraperitoneal, being adherent to the colon and the posterior abdominal wall.

the cecum and appendix are free and intraperitoneal. This type also is not very common.

Fig. 74. The colon, as far as the root of the appendix, is adherent. The cecum is sagging down anteriorly, giving the appendix a posterior point of origin. The appendix may be entirely covered by peritoneum or its proximal end may be extraperitoneal. This form with its variations is the most frequent.

The next four types illustrate the peritoneal relation of the ascending appendices; all four figures showing the cecum bent backward and upward, a characteristic common to this class of cases.

Fig. 75 shows the appendix intimately adherent both to the colon and to the posterior abdominal wall, *i. e.*, it is entirely extraperitoneal.

Fig. 76 gives the picture of an appendix adherent to the colon but not to the posterior parietes, the peritoneum intervening between the two.

Fig. 77 is the reversed condition, viz., the appendix adherent to the posterior abdominal wall, but not to the colon.

Fig. 78 illustrates finally an interesting condition occasionally met with. The proximal as well as the distal extremities of the appendix are intraperitoneal, while the middle portion is extraperitoneal, having fused with the colon and posterior abdominal wall.

Not infrequently an appendix is adherent in a similar manner to the under surface of the ileum and its mesentery.

THE INNER SURFACE OF THE ILEOCECAL REGION AND ITS VALVES.

The mucous membrane lining the colon and cecum is arranged in folds placed in a characteristic manner. With the intestine in a state of contraction these folds are very numerous and describe a wavy course, resembling miniature intestinal coils. Their main direction is transverse and the wavy appearance is due to the contracted circular muscle-fibres. With the intestine moderately distended, the great majority of these folds are smoothed out, leaving but a few permanent transverse folds, the so-called semilunar plicæ of the colon. Between these the pouches of the large intestine are seen to balloon out to a varying extent. The mucous folds on the inner surface of the pouches are still evident, though quite shallow, while the plicæ gain in height and stand out sharply, projecting from 3 to 8 mm. into the lumen of the intestine.

The plicæ of the colon and cecum correspond, as may be supposed, to the transverse grooves seen on the peritoneal surface, their beginning and end being marked by the three longitudinal muscular bands. As they extend from one band to another their base is attached to the inner surface of the intestine for one-third of the periphery. However, some of the larger plicæ are seen to be continuous with one another over a muscular band. This communicating portion, if present, is quite shallow. The portion of the plica projecting into the lumen has the form of a narrow crescent, the broadest part of which is at the middle between the longitudinal muscular bands. The deepest plicæ consist of reduplications of all the coats of the intestine, the musculature and serosa, however, extending only half-way into the fold. The shallower plicæ are composed only of mucosa and submucosa; the outer coats do not participate in their formation.

The plicæ are found at fairly regular intervals along the mucous surface, resembling shelves put in a round wall. Their distance from one another varies from 1.5 to 3.5 cm.; but occasionally they may be still further apart, especially in the lateral cecocolic region.

In the embryo and fetus there are no plicæ except the frenulum of the ileocolic valve, running around the median half of the large intestine and dividing the cecum from the colon. Because this is first to form, it develops to greater size than the others, which do not make their appearance until after birth,

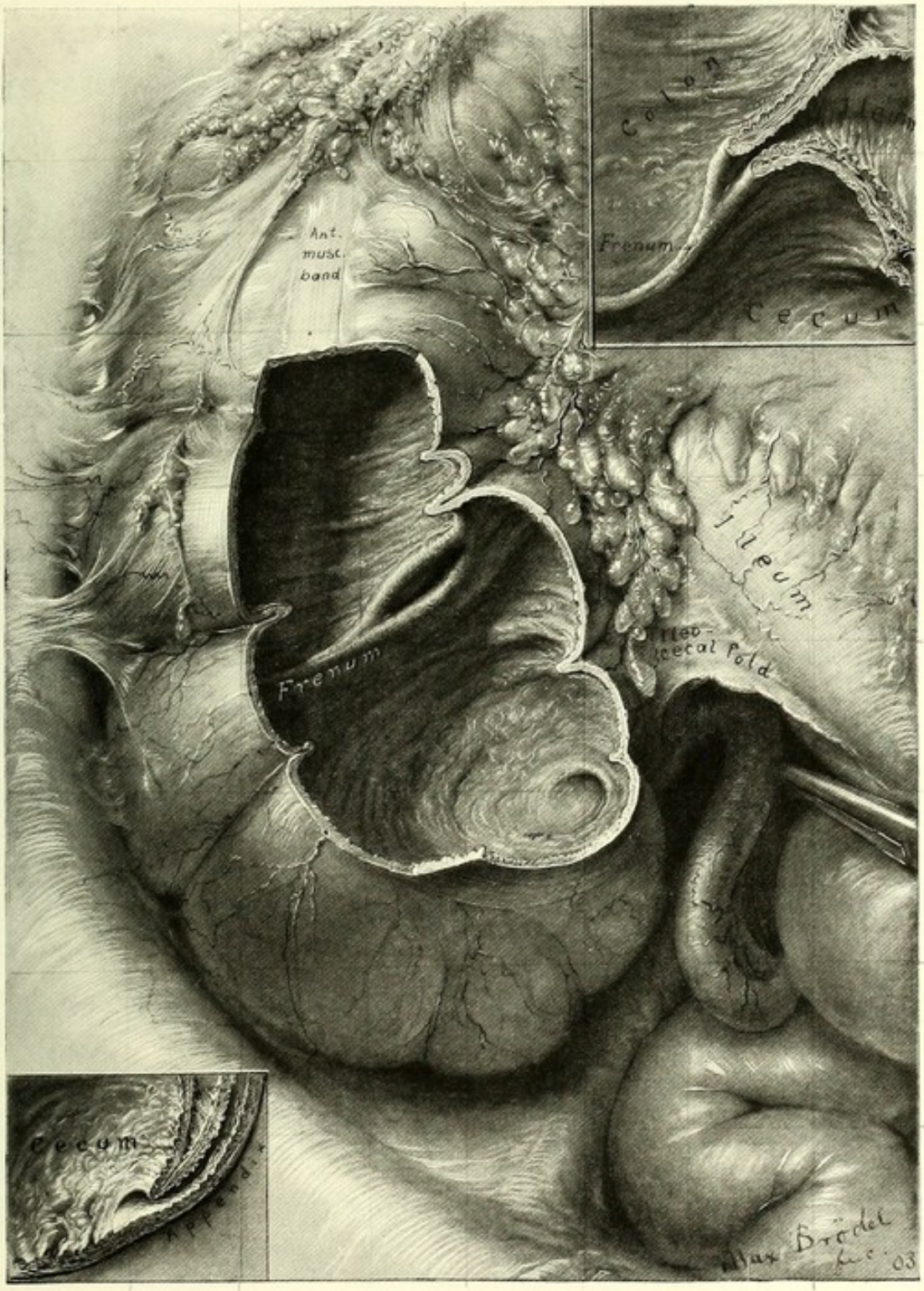

FIG. 79.—THE VALVES OF THE ILEOCECAL REGION.

A portion of the anterior wall of the large intestine has been removed in order to show the structures in the interior. The large transverse plica dividing the cecum from the colon, and called the frenulum, separates into two lips which form the ileocecal valve. The upper of these lips slightly overhangs the lower. Below the valve we see the large expanded cavity of the cecum. At the lower median portion of this lies the crescent-shaped appendico-cecal valve. The two small diagrams are sections of the two valves, the upper right-hand picture demonstrating the construction of the ileocecal valve, the lower left-hand picture that of the appendical valve.

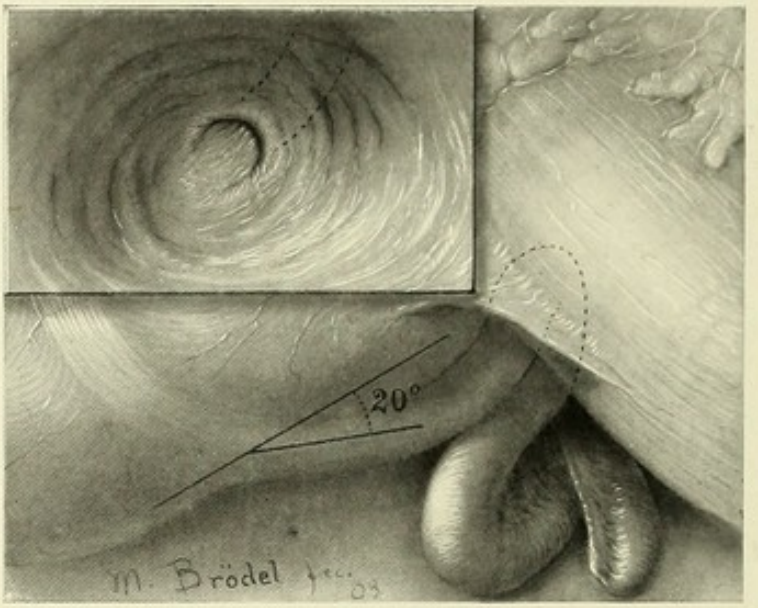

FIG. 80.—THE APPEARANCE OF THE APPENDICAL ORIFICE IN A CASE IN WHICH THE CECO-APPENDICAL ANGLE MEASURED 20 DEGREES.

The valve (Gerlach's valve) is a crescent-shaped ridge of cecal mucosa resting immediately upon the mucosa of the appendix. The mechanism is such that distention of the cecum will close the mouth of the appendix. The valve, however, will not prevent the contents of the appendix from passing back into the cecum; *i. e.*, it has the same effect as the ileocecal valve.

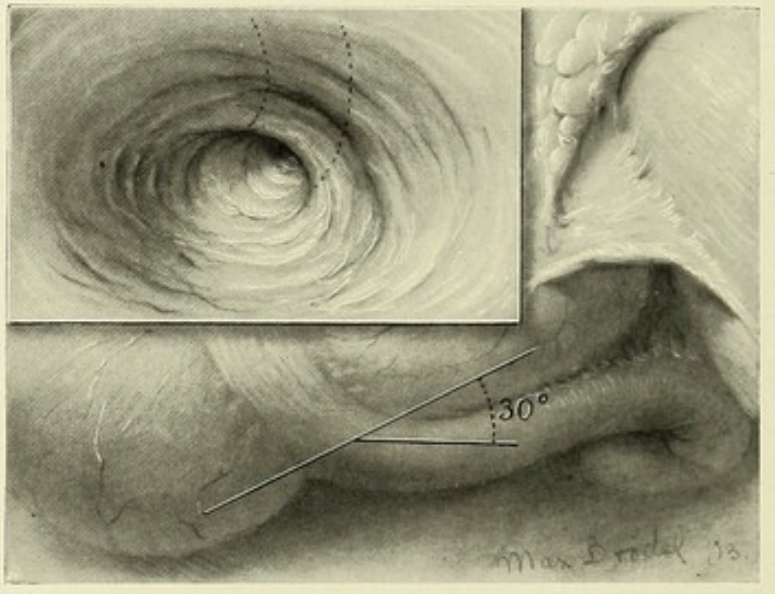

FIG. 81.—THE APPEARANCE OF THE APPENDICAL ORIFICE IN A CASE IN WHICH THE CECO-APPENDICAL ANGLE MEASURED 30 DEGREES.

The crescent-shaped mucous fold does not completely close the opening into the appendix, and further in we see, though indistinctly, a second counterfold (described by Nanninga). In distention of the cecum these folds will shut off the entrance into the appendix.

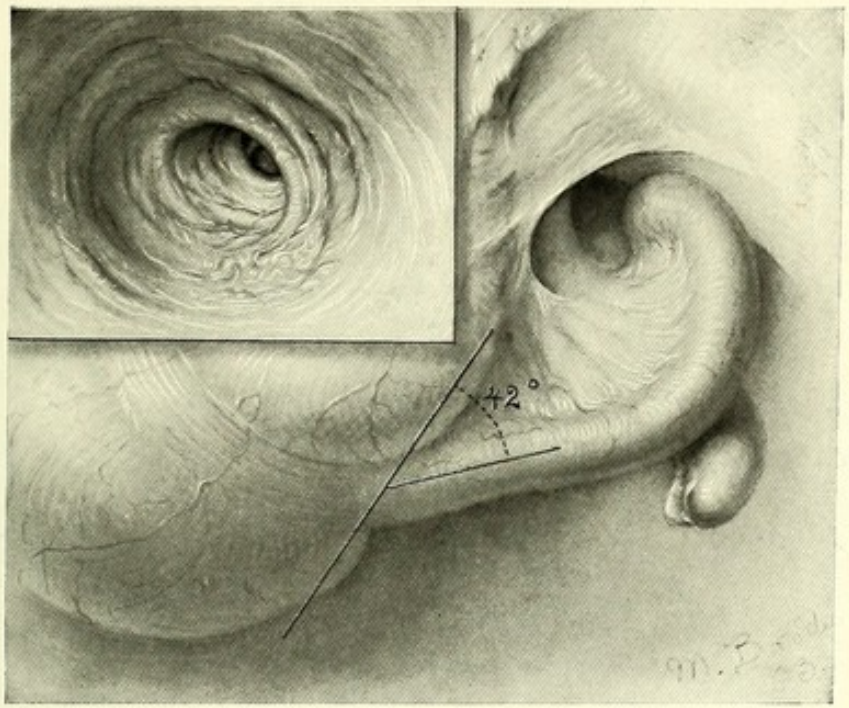

FIG. 82.—THE APPENDICAL ORIFICE IN CONNECTION WITH A CECO-APPENDICAL ANGLE OF 42 DEGREES. Both Gerlach's and Nanninga's folds are well marked but do not act as valves, as slight pressure on the cecum will cause its contents to pass into the appendix, and vice versa.

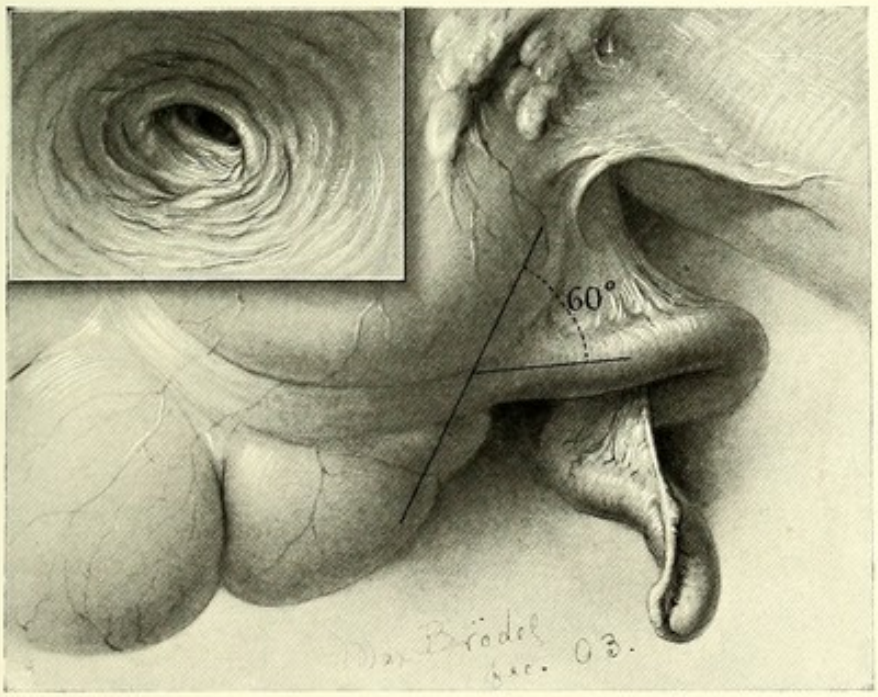

FIG. 83.—THE APPENDICAL ORIFICE IN A CASE IN WHICH THE CECO-APPENDICAL ANGLE MEASURED 60 DEGREES. Again the two mucous folds are well developed, but do not close the mouth of the appendix.

when the sacculæ of the colon begin to bulge out. The frenulum is also produced by a different process than the other plicæ, in so far as it owes its formation to a projection of the terminal portion of the ileum into the lumen of the large intestine; a beginning intussusception, though of a modified character. The ileum thus lifts up a transverse fold, which becomes a valve at this junction. This is the ileocecal valve, surrounding a narrow slit, whose direction is transverse. The valve consists of an upper and a lower lip, which join at their ends (Fig. 79). The upper lip is generally broader and overhanging the lower. Like the other transverse folds, the frenulum of the ileocecal valve is semilunar in shape, but longer, extending over more than one-half of the per-

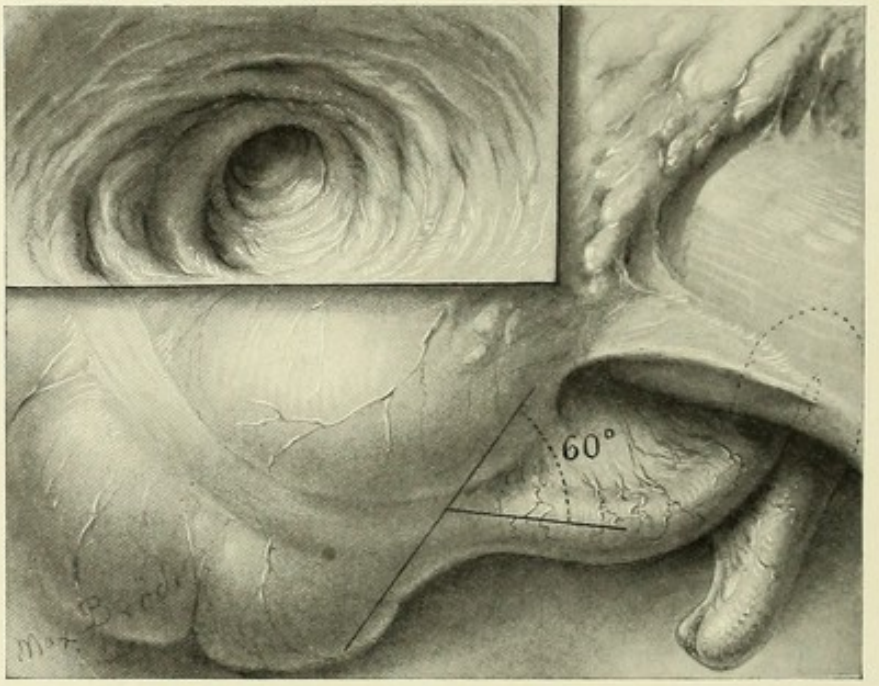

Fig. 84.—Ceco-Appendical Angle of 60 Degrees.

Wide gaping mouth of the appendix. Gerlach's and Nanninga's folds have almost disappeared and resemble the concentrically arranged mucous folds of the cecum.

iphery of the intestine. The valve is not exactly in the middle of the frenulum, but nearer its anterior portion. Seen from the peritoneal surface, the frenulum and valve correspond to the deep kink at the ileocolic junction.

The terminal portion of the ileum curves around the cecum, making a sudden turn shortly before the valve, and bringing the axis of the lumen to stand at right angles, or nearly so, to the axis of the colon ascendens. (See Fig. 79, upper diagram.)

Any pressure arising from within the cecum or colon will serve to tighten this valve, and contraction or tension of the circular muscle-fibres in the frenulum will have the same effect. Fig. 79 illustrates comprehensively the anatomical structures producing this mechanism.

The mucous surface of the cecum is also elevated at certain intervals corresponding to the depressions between the sacculæ, most of the folds being, however, quite shallow; only one or two attaining the development of the colic plicæ. Their number depends upon the length of the cecum and the degree of its fixation.

On opening the cecal pouch from above and looking toward the appendical

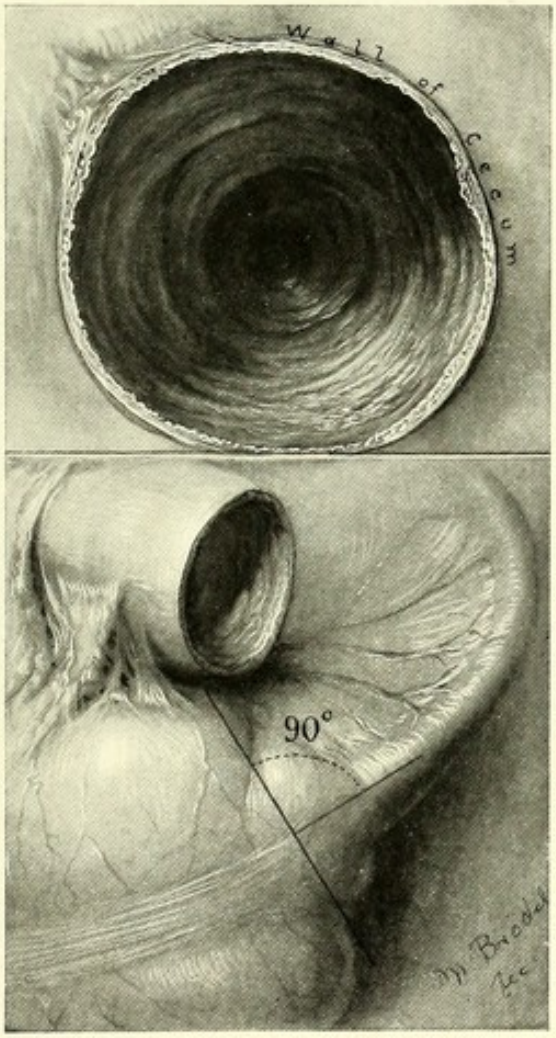

FIG. 85.—CECO-APPENDICAL ANGLE OF 90 DEGREES.

Fetal type, showing tapering ceco-appendical junction. Gerlach's and Nanninga's folds are entirely absent. There is no obstacle to the free passage of intestinal contents in either direction.

opening, the folds are seen to be grouped more or less concentrically, the shortest being around the orifice of the appendix, where they may simulate a valve (Figs. 79–86). If the cecum tapers gradually into the appendix, the folds of the funnel may appear as double or triple valvular structures.

The most frequent arrangement is shown in Fig. 80, where a semilunar fold or reduplication of mucous membrane is seen just above the appendical

orifice. This is what GERLACH * (1847) has described as the valve of the appendix.

This structure is, however, not a valve in the true sense of the word, and is clearly seen only with the appendix coming off at an acute angle from the cecum, *i. e.*, if there is a sudden kink at the appendico-cecal junction, the axis

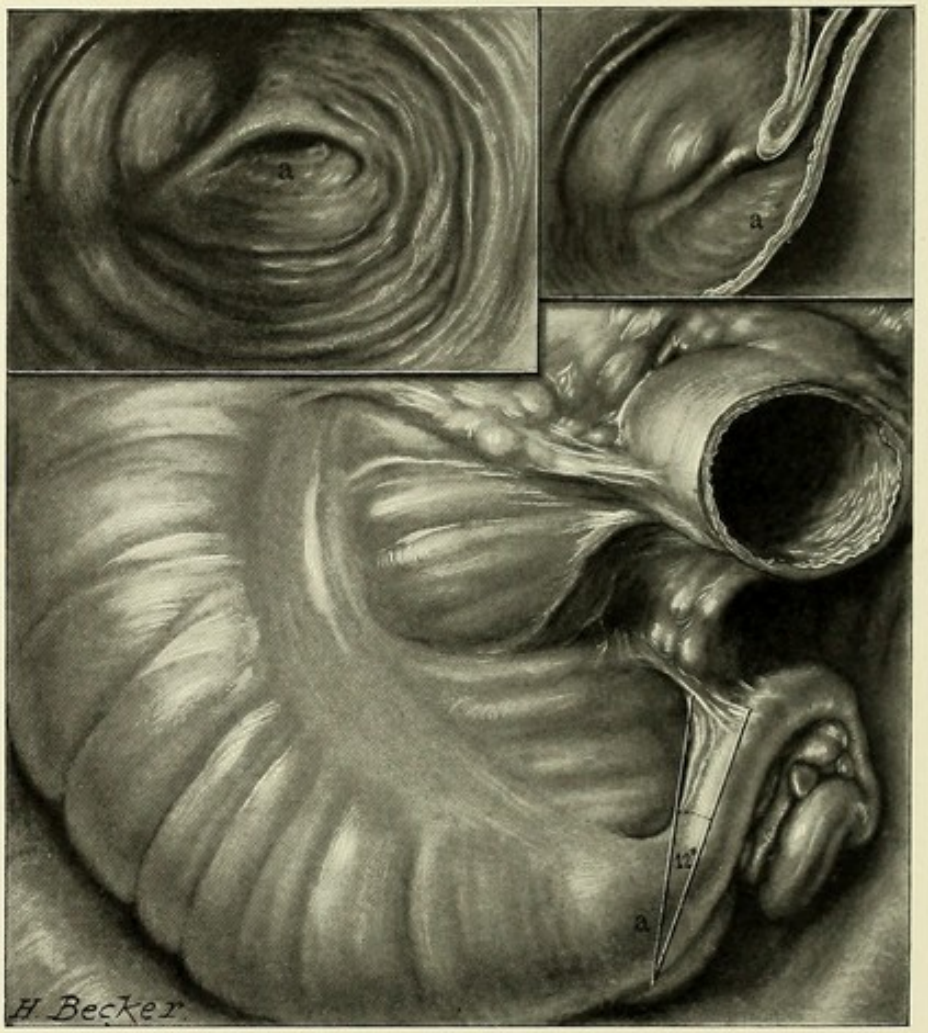

FIG. 86.—EXCEPTIONAL FORM OF APPENDICAL ORIFICE IN A CASE IN WHICH THE APPENDICO-CECAL ANGLE MEASURED ONLY 12 DEGREES.

In spite of the very acute angle the orifice was gaping, nothing preventing the passage of the contents in either direction. This condition is due to the presence of a large pouch (a) opposite the crescent-shaped fold. The pouch represents the last sacculation of the cecum, especially large in this case, and extending part of the way into the appendix.

of the appendix running at less than an angle of 45 degrees to the wall of the cecal pouch. This angle varies according to the different positions of the appendix from 10 degrees to 90 degrees. If the appendix has a short mesentery and ascends for some distance behind the ileocecal junction, as is the case in

* This valve was accurately described by Gerlach and goes by his name, but it was previously noted and clearly described by Merling, I. D. Heidelb., 1836.

the majority of instances, the smallest angles are produced (Figs. 80 and 81). A distention of the cecum will then cause the semilunar fold to lay itself over the opening of the appendix and thus act as a valve. Of course, muscular contraction plays an equally important part in the closure of the orifice.

An appendix having a wide mesentery and directed toward the iliac vessels usually forms an angle of 40 degrees to 60 degrees with the cecal surface (Figs. 82, 83, and 84). In such cases the semilunar mucous fold above the orifice is, as a rule, joined by a second and smaller fold on the opposite side and situated some distance within the appendix (NANNINGA). Both folds combined frequently do not suffice to close the orifice, and a distention of the cecum will involve the appendix.

In appendices of the tapering fetal type, the angle usually measures 90 degrees, and while there may be a succession of shallow transverse mucous folds projecting into the lumen, there is no indication of a valve (Fig. 85). The axis of the appendix is in direct linear continuity with the axis of the cecum, and if in such cases the cecum is distended, the appendix will always be distended with it.

There are exceptional cases where an acute angle may, nevertheless, be associated with a wide and open appendical orifice. One of these cases is pictured in Fig. 86. At its junction with the appendix the lateral cecal pouch forms a capacious sac (a) the presence of which makes it impossible for the semilunar appendical valve to effectively close the mouth of the appendix.

CHAPTER VI.

ANATOMY.

THE POSITION OF THE APPENDIX. THE DIMENSIONS OF THE APPENDIX. THE STRUCTURE OF THE APPENDIX. THE CONTENTS OF THE APPENDIX. OBLITERATION OF THE APPENDIX. RETROGRESSION.

POSITION OF THE APPENDIX.

Point of Origin.—The location of the point of origin depends entirely upon the topography of the cecum. According to whether the cecal pouch is directed upward or downward, outward or inward, forward or backward, or whether colon and cecum have rotated insufficiently or too much around their long axis, the point of origin of the appendix varies in position. It may be found at almost any point of the cecal pouch, as shown in Fig. 87.

There are, however, two main locations for the point of origin, viz., I, behind the cecum, and II, in front of, or at the lower region of the cecum; and it is a recognized fact that the development of either of these two positions is due to the influence of the peritoneal fusion of the mesocolon with the posterior abdominal wall, whether early in embryonic life (cecum in subhepatic position) or late (cecum in iliac position). Early fusion produces the first type; late fusion the second.

Early fusion is brought about by the ileum leaving the subhepatic region at an early date, thus permitting the cecum to lodge at once against the prerenal peritoneum; the mesocolon and inner border of the large intestine become adherent at a high level and the subsequent descent and expansion of the cecum occur mainly in its lateral and anterior portion. The distention and sagging down of the cecum in this manner causes its axis to be directed medianward and dorsally. As a result the apex, or origin of the appendix, shifts obliquely upward and backward to the left, *i. e.*, toward the middle of the body, and the appendix appears hidden behind and mesial to the cecum with its proximal portion pointing upward (Figs. 88, 89, 90, 91, 92, and 93).

Late fusion is caused by the ileum remaining in the subhepatic position between cecum and kidney during the initial stages of the cecal descent, preventing the two organs from early becoming adherent. When the ileum has finally swung around to the left and the cecum and appendix come in contact with the parietal abdominal wall, the descent has already progressed far enough to bring the cecal pouch in apposition with the iliac fossa. Peritoneal fusion

taking place at this late stage will not materially affect the subsequent form of the descending cecal pouch. There is little traction in a mesiodorsal direction, and the apex of the pouch—*i. e.*, the origin of the appendix—will remain near the lowest portion. As a result the appendix is more inclined to assume the pelvic position or lodge among coils of small intestine (Fig. 94).

The position first described—*i. e.*, behind the cecum—is that generally met with, which indicates that in the human embryo the fusion takes place usually at an early period, and therefore in the majority of cases the appendix is found to arise on the internal and more or less posterior surface of the cecum, at a distance of from 1 to 4 cm. below the ileocecal valve. This mesioposterior position of the point of origin is found in the overwhelming majority of cases.

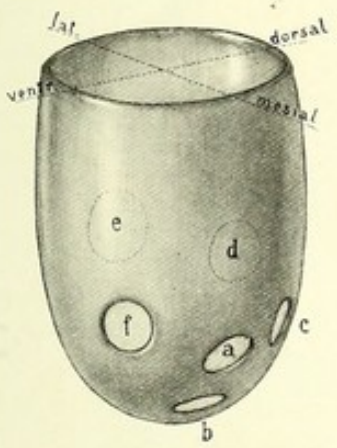

FIG. 87.—DIAGRAM SHOWING THE VARIOUS PLACES ON THE SURFACE OF THE CECUM FROM WHICH THE APPENDIX MAY TAKE ITS ORIGIN. The changes in position of the origin are brought about by the varying topography of the cecum.



FIG. 88.—The point of origin is at (*a*), Fig. 87. The specimen is from a fetus seven months old. It shows the appendix arising from the mesio-anterior portion of the cecum and pointing in an upward direction, behind the mesentery of the ileum.

The appendix is of the tapering fetal type, which sometimes persists in the adult. (See Fig. 89.)

According to TREVES, it occurs in ninety per cent. Fig. 87 (point *c*) and Figs. 90, 91, 92, 93, and 97.

Variations of this position are given in Figs. 98 and 99. If the cecum has rotated around its axis so as to render the posterior longitudinal muscular band visible, the origin of the appendix becomes shifted toward point *d*. Fig. 98 is an example of this form. If the rotation is still more pronounced, the origin of the appendix is on the lateral border, usually pretty high up (*e*), and the direction of the appendix is toward the liver (Fig. 99). The ileocolic junction shifts also in a posterior direction.

The other points of origin, *a*, *b*, and *f*, are found on the anterior face or on the lower portion of the cecum. These are the main variations of the second type, produced by late fusion. A long and free mesocolon is generally associated with this type.

Figs. 88 and 94 show the appendix arising from the mesio-anterior portion

at point *a*, Fig. 87. Fig. 88 is the typical tapering cecum of the fetus, while Fig. 89 shows the same form persisting in the adult. Fig. 95 illustrates the

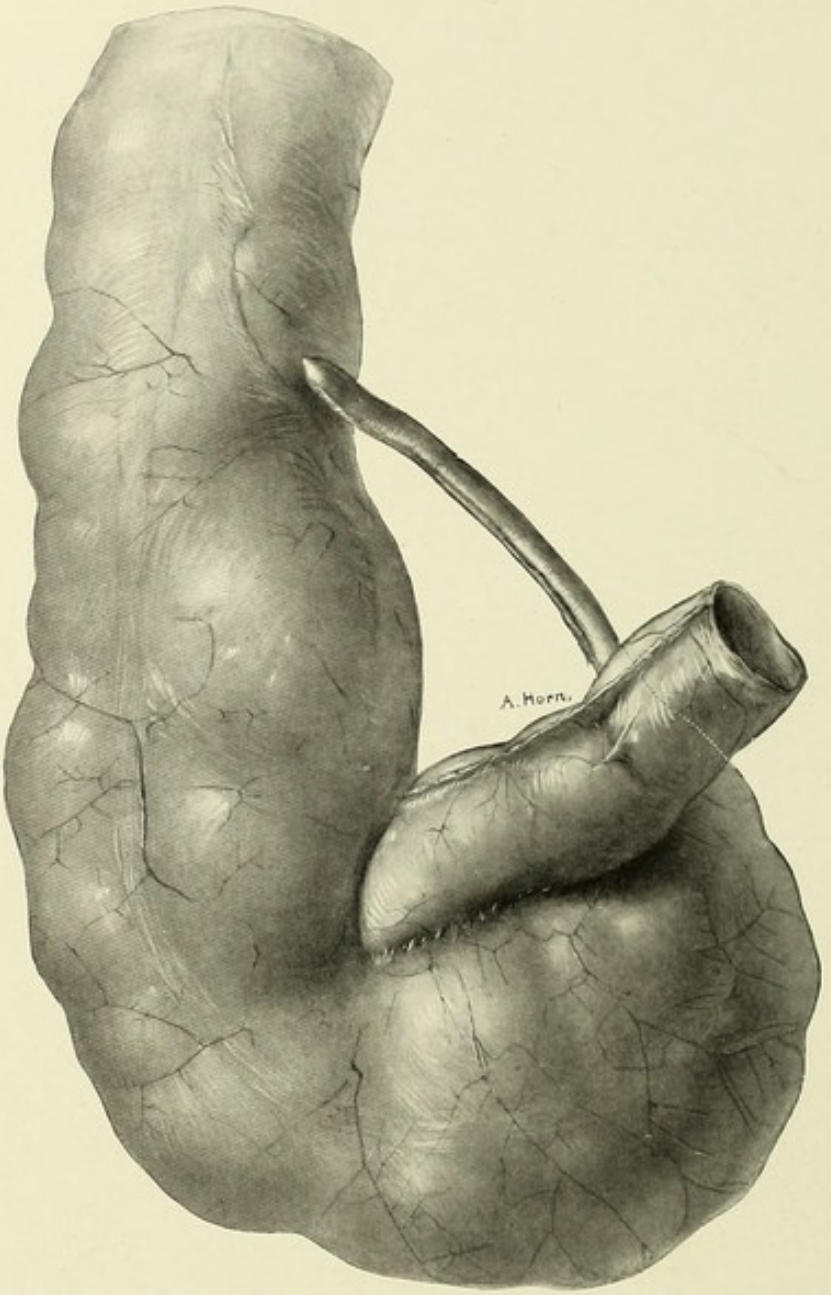

FIG. 89.—PERSISTENT FETAL TYPE OF CECUM AND APPENDIX IN AN ADULT. (SPECIMEN FROM H. S. WEAVER OF PHILADELPHIA.)

The axis of the cecum stands almost at right angles to the axis of the colon and there is a deep kink at the ileocolic junction. The cecal pouch curves upward and gradually tapers into the appendix. The latter is directed upward behind the mesocolon.

effect of a long and free mesocolon upon the form of the cecum and the point of appendical origin. The cecum does not curve over to the left, but extends straight downward in the same direction with the axis of the colon. The pouches

on both sides of the anterior muscular band are symmetrical and the appendix arises from the lowest point of the cecum. Fig. 87 (point *b*).

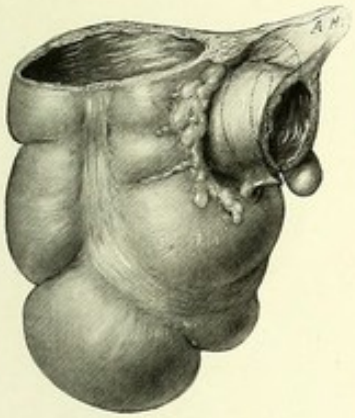

FIG. 90.—THE APPENDIX ARISES FROM THE MEDIAN PORTION OF THE CECUM AT POINT (*c*), FIG. 87.

The cecum is bent toward the ileum, and the appendix is hidden behind the terminal portion of the small intestine.

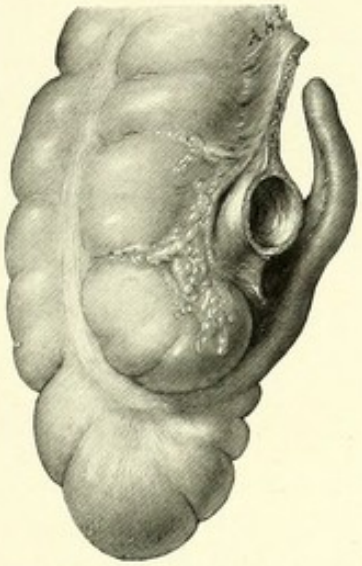

FIG. 91.—APPENDIX ARISING AT POINT (*c*), FIG. 87.

The cecum describes the same curve as shown in preceding figure and its lateral pouch has attained considerable proportions. It is often subdivided into several smaller sacculations, as shown in this picture.

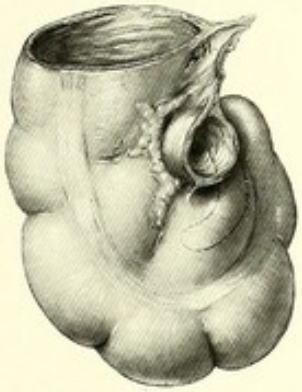

FIG. 92.—POINT OF APPENDICAL ORIGIN AT (*c*), FIG. 87.

The tapering cecum is bent inward and upward, the appendix lying curled up beneath the ileocecal junction.

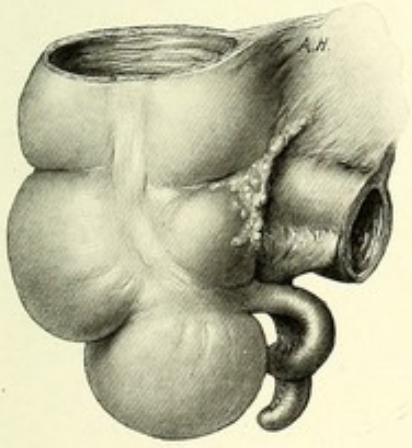

FIG. 93.—POINT OF ORIGIN AT (*c*), FIG. 87.

While the lateral cecal pouches are developed to considerable extent, the median pouch is of insignificant size. In this type the appendix arises very near the ileocecal junction. Fig. 97 shows the same position combined with abnormal arrangement of mesappendix and vessels.

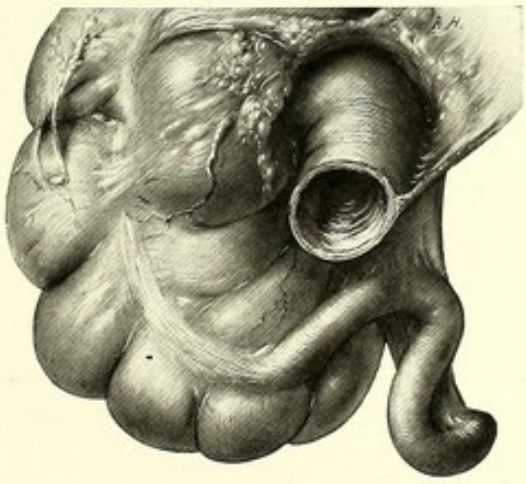

FIG. 94.—THE APPENDIX ARISES FROM THE ANTERIOR AND MEDIAN EXTREMITY OF THE CECUM. POINT (*a*), FIG. 87.

The posterior cecal pouch is visible beneath and to the left of the appendico-cecal junction.

Exceptionally the appendix appears to arise from the anterior wall of the cecum Fig. 87, (*f*). This is likewise due to a long mesocolon which allows a

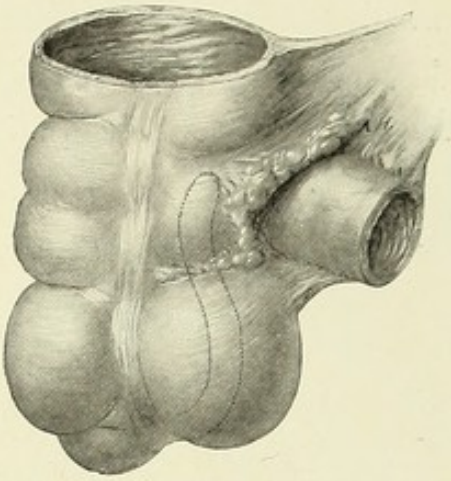

FIG. 95.—THE APPENDIX ARISES FROM THE INFERIOR PORTION OF THE CECUM AT POINT (*b*), FIG. 87.

The cecal pouches have developed equally on both sides of the anterior muscular band and there is no curve of the cecum in the direction of the ileum. The appendix may hang down or be directed upward behind the cecum, as shown in this figure. This condition is often due to distention of the cecum, causing separation of the two leaves of the mesappendix and, as a consequence, fixation of the appendix in close apposition to the cecal wall.

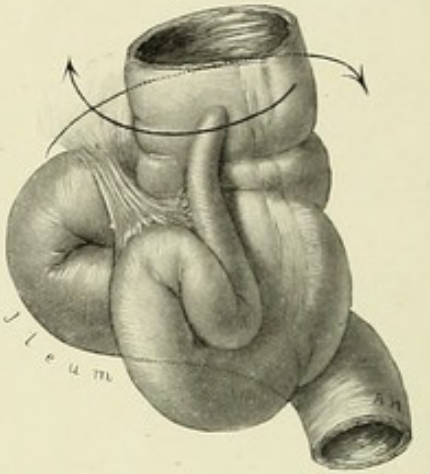

FIG. 96.—POINT OF ORIGIN AT (*f*), FIG. 87.

The ileocecal apparatus has failed to rotate around its long axis and the appendix is found arising from the anterior and lateral face of the cecum. The ileum enters the large intestine from the right instead of the left, and the appendix has retained the fetal type. The arrows indicate the manner of rotation, which would bring the parts in normal relation with the iliac fossa.



FIG. 97.—ABNORMAL POSITION OF THE APPENDIX AND ABNORMAL ARRANGEMENT OF ITS BLOOD-SUPPLY.

The point of origin is at the ileocecal junction (*c*), Fig. 87, and the mesappendix is attached to the lateral cecal pouch. The ileocecal fold is incomplete, as it is not attached to the cecum. The blood-supply of the appendix comes through the ileocolic fold and passes over the anterior surface of the cecum before entering the mesappendix. (J. M. T. Finney's case.)

degree of rotation or torsion of the whole cecum, bringing the origin of the appendix more toward the anterior side of the cecum. The ileocecal valve is in such instances found on the posterior lateral portion of the large intestine (Fig. 96).

The point of origin of the appendix on the cecum has considerable influence on pathological conditions. In connection with this we may distinguish again the two main positions above described; I, the retrocecal, and II, the prececal positions. While the latter would mean danger to the patient in case of disease of the appendix, the former would signify comparative safety.

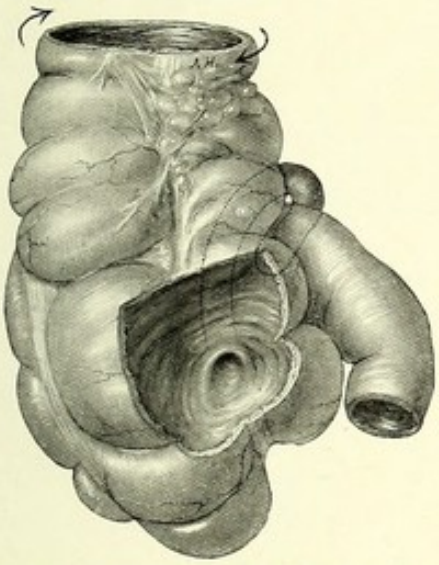

FIG. 98.—POINT OF ORIGIN AT POINT (*d*), FIG. 87.

The colon and cecum have failed to rotate around their long axis and as a consequence the posterior longitudinal muscular band is rendered visible lateral to the anterior, and the point of origin of the appendix has shifted toward the posterior surface of the cecum. The arrows indicate the rotation necessary for the reëstablishment of the normal topography of the ileocecal apparatus.

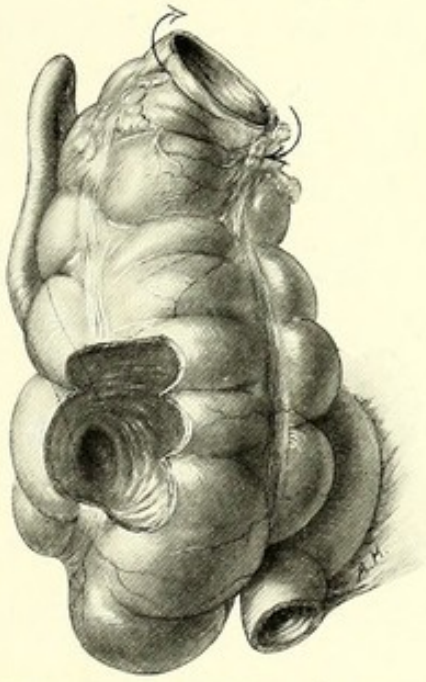

FIG. 99.—POINT OF ORIGIN AT (*e*), FIG. 87.

The ileocecal apparatus has failed to rotate as indicated by the arrows. Both muscular bands are visible from the front and the appendix is seen to arise from the outer posterior surface of the cecum. Such appendices often show the fetal tapering form and are generally directed upward.

If the point of origin is retrocecal, points *c*, *d*, and *e*, Fig. 87, it may or may not be an extraperitoneal organ, according to whether the level of the peritoneal reflection is above or below the appendix. If it is above, the appendix usually occupies a peritoneal pocket, a condition generally favorable for the prompt isolation of an abscess by means of adhesions; and if the peritoneal reflection is below, the result is an extraperitoneal appendix, a perforation of which would drain into the subperitoneal tissue of the iliac fossa, whence it might spread in several directions.

If the appendix occupies the anterior face of the cecum, *i. e.*, if it is prececal,

points *a*, *b*, and *f*, Fig. 87, it is then situated within the peritoneal cavity, into which a perforation of the appendix might open.

Position, General Considerations.—The appendix, if not hidden behind the cecum, is almost always covered by loops of small intestine lying anterior to it. When it occupies the iliac fossa, it is in close relation with the psoas muscle and occasionally with the iliacus, running either parallel to the muscle-fibres, or lying obliquely or transversely across them.

If the mesappendix is short, *i. e.*, if the posterior leaf of the peritoneum is reflected over the posterior abdominal wall at a lower level than usual, the appendix may come into closer relationship with the neighboring structures. It may be situated entirely behind the peritoneum, between the latter and the pelvic fascia and close to the psoas and iliacus muscles, or against the iliac vessels and pelvic wall. In some cases, the entire posterior leaf of the mesappendix fuses with the parietal peritoneum, and the appendical vessels repose directly on the posterior abdominal wall.

Robinson states that in cases where the appendix is found resting against the psoas muscle, there is a decided tendency to the formation of peritoneal adhesions. He claims that the powerful contractions of this muscle and perhaps of the iliacus irritate the appendix. Irritation produces adhesions, which in turn cause bends, kinks, and obstructions, thus impairing the circulation and peristalsis, and rendering the appendix incapable of emptying itself.

In cases of undescended cecum the ileum generally crosses the psoas to meet the high cecum, and Robinson claims that there are invariably peritoneal adhesions tying the ileum to the psoas. Such a case is pictured in Fig. 109. In his statistics Robinson says that the appendix was found resting on the psoas in forty-six per cent. of the male and in twenty per cent. of the female subjects he examined. Over four-fifths of such appendices showed adhesions. The reason for the preponderance of this position and condition in the male is the narrowness of the male pelvis and the greater size and strength of the psoas in the male as compared with the female, where the pelvis is capacious and the psoas less developed. Robinson gives the frequency of the pelvic position of the appendix as forty-eight per cent. in the female and thirty-seven per cent. in the male. Only one-fourth of such appendices showed adhesions. These data seem to throw some light on the question why appendicitis occurs more frequently in the male than in the female (3:1).

There is a definite relationship between the consistency of the appendix and the position it occupies. The appendix is usually quite flexible, this quality diminishing, however, with age. As a rule, it is but slightly curved, and if short, 6 cm. or less, it may appear as an almost straight tube. The same effect is obtained by rigidity of the appendix. Longer appendices, however, are frequently bent back upon themselves or drawn up by the shortness of their mesentery into various bizarre forms, a figure-8 or a spiral. If the mesappendix is sufficiently long, or if the tension acting on the appendix by its mesentery,

drawing it up into various bends and sinuosities, could be removed by gently untwisting the mesentery, the appendix would then be seen to form a fairly regular curve with its concavity turned toward the cecum; this curve carries the appendix upward behind that organ, usually continuing the curve formed by the anterior muscular band of the cecum.

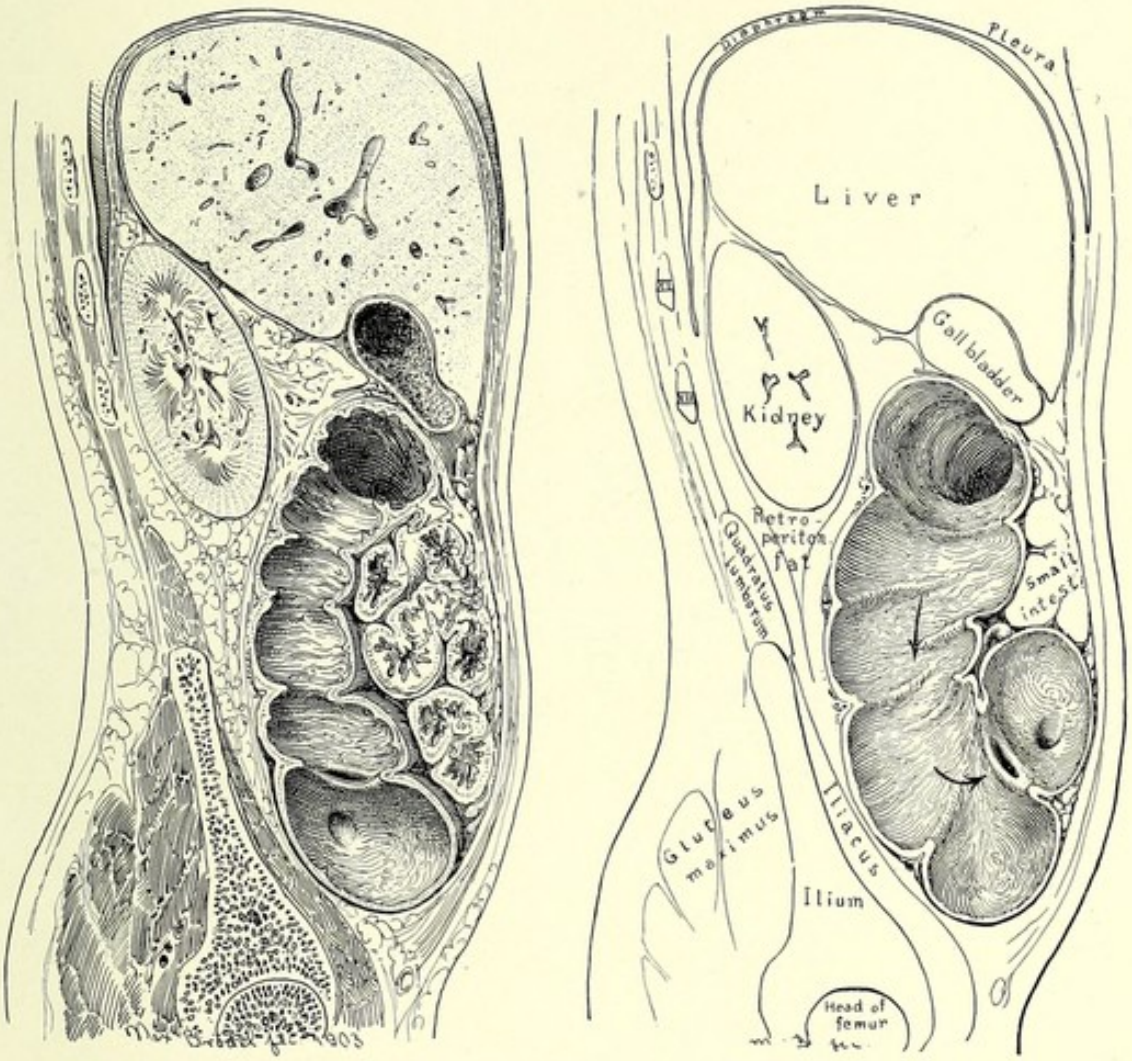

FIG. 100.—DIAGRAMS SHOWING THE CHANGES IN THE TOPOGRAPHY OF THE ILEOCECAL APPARATUS DUE TO DISTENTION OF THE COLON IN CASES OF NON-ADHERENT CECUM.

The left section shows the large intestine in normal state of distention, while the right section illustrates it in extreme state of expansion. The upper portion of the colon being anchored posteriorly by adhesions and being unable to expand in the direction of the liver, causes the lower portion with the cecum and appendix to swing in an anterior and median direction, *i. e.*, in the direction of least resistance.

A long appendix with a long mesentery may possess considerable freedom of motion, and it is probable that it assumes different positions during the day. Changes in the position of the body, whether erect or reclining, and the different degrees of distention of the adjacent intestine, may contribute to alter the topography of the ileoceco-appendical apparatus. (See Fig. 100.)

We see therefore that the direction and course which the appendix takes are regulated by its length and consistency, and by the mobility given to it by its mesentery. The tip may point in almost any direction. The relative frequency of the main directions has been given as follows:

Horizontal toward promontory, or pointing laterally	32	per cent.
Oblique, toward spleen	10	"
Ascending	34	"
Descending	24	"
	100	"

Fig. 101 pictures more in detail the various directions in which an appendix may point. These are, in order of their relative frequency

(1) Into pelvis.
(2) Along iliac vessels.
(3) To promontory of sacrum.
(4) Behind cecum.
(5) Under ileum.
(6) Lateral to cecum.
(7) Into iliac fossa.
(8) Among coils of small intestine.
(9) Mesial to cecum over ileum.

To these should be added the large number of appendices which are tucked away behind the ileocecal junction and of which no direction can be given owing to the fact that they are bent back upon themselves without assuming any distinct direction. This class is more frequent than any other (Fig. 101).

Occasionally an otherwise straight appendix is sharply bent upon itself near its extremity, forming a species of hook. Kinks or bends may, however, form at any point along the appendix, being caused by adhesions to the peritoneal lining of the abdominal cavity or abdominal organs, or from one portion of the appendix to another. (Fig. 148.)

These different bends and twists and accompanying firm adhesions may give rise to strangulation of the intestine, should the appendix become adherent to one of its loops. As, however, the kinked appendix is generally found in a retrocecal position, such occurrences are fortunately rare.

The literature on the subject of positions of the appendix is full of the most elaborate statistics; but as they make unprofitable and difficult reading, they have been largely omitted and only the average of the combined results is given.

Most Frequent Positions of the Appendix.—The normal position of the

ileocecal apparatus is in the right iliac fossa, the cecum occupying the triangular space between the iliac vessels and Poupart's ligament. The terminal portion of the ileum ascends obliquely and crosses the iliac vessels about midway between the promontory and Poupart's ligament (Fig. 102).

In the fetus the appendix is, as a rule, curled up at the posterior and inferior aspect of the cecum. While in the adult it is often found lying below or even to the right of the cecum, its most usual position is along the internal or median border of the organ, being often partially concealed behind the terminal por-

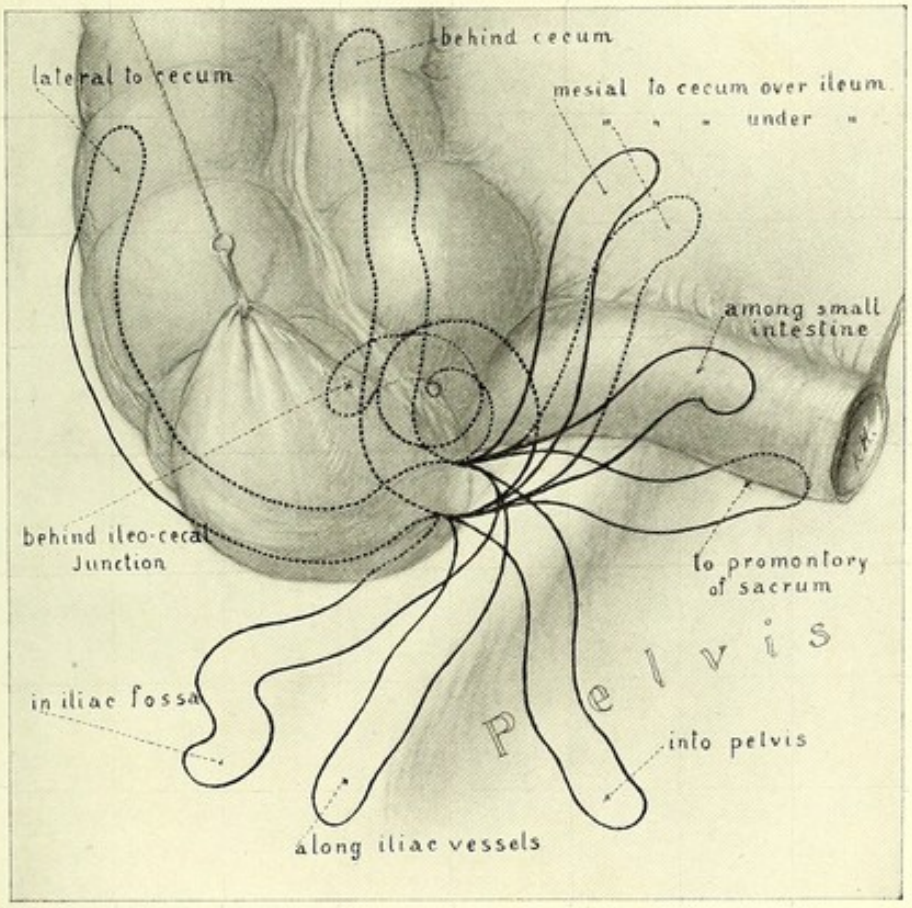

Fig. 101.—Diagram Showing the Various Directions in which an Appendix may Point.

tion of the ileum and its mesentery, to which it is not infrequently adherent. If the appendix is short, its tip will point obliquely upward in the direction of the spleen or the left hypochondriac region. If long, it may be doubled back upon itself. It is then that we find it lying on the psoas muscle parallel with its fibres, or crossing them in various directions, or also reposing on the iliac vessels. Appendices in these positions, *i. e.*, hidden behind the ileocecal junction, are found in about forty per cent. of the cases (Figs. 90, 91, 92, and 101).

The second most frequent position of the appendix is ascending vertically

behind or lateral to the cecum and ascending colon, more or less attached to the dorsal wall of the large intestine, and being either straight or curved at its extremity (Figs. 98, 99, and 101). It is found to occur in from twenty-five to thirty per cent. of the cases, and is usually associated with the absence of a well-formed mesappendix. This position may be accounted for, as TREVES explains, by the abnormal growth of the cecum, which, as it enlarges within its passive peritoneum, draws for its covering from the mesentery of the ileum and appendix. The two leaves of the mesappendix become unfolded, lessening in width. The disappearance is first noticeable near the root or proximal

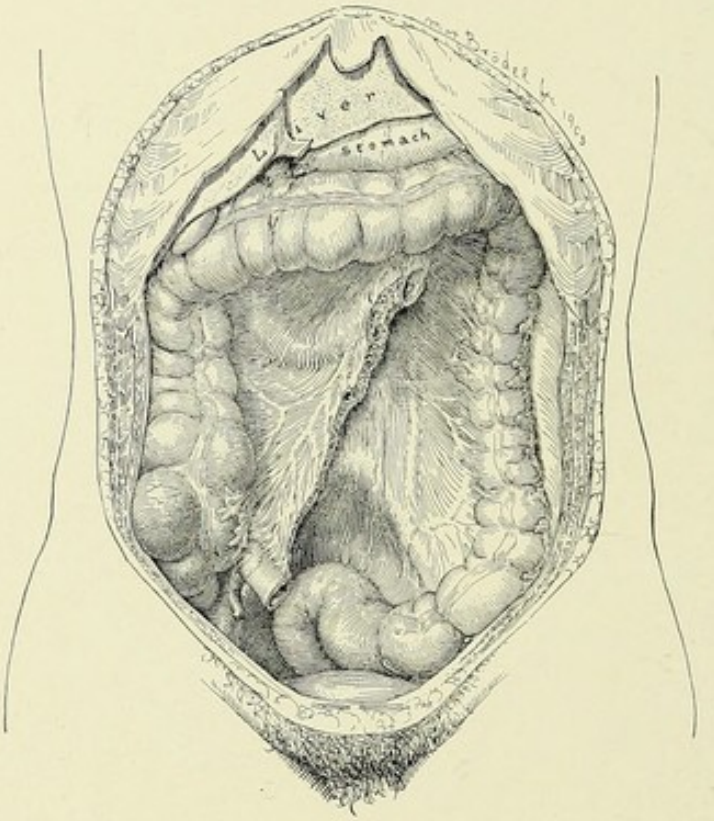

FIG. 102.—THE NORMAL POSITION OF THE ILEOCECAL APPARATUS.
The appendix is usually not visible until the cecum is lifted out of the iliac fossa.

end of the appendix, drawing this portion close to the posterior surface of the cecum. The further distention of the cecum and unfolding of the mesappendix to cover it, cause the complete disappearance of the latter and the vertical position of the appendix along the posterior surface of the cecum and colon. The bends of the appendix are generally straightened out during this process (Figs. 95 and 76). If, in addition, the colon becomes adherent to the abdominal parietes, the result is an extraperitoneal position of the appendix, which lies embedded in cellular tissue (Fig. 75). The vertical position behind the cecum may also be produced by the formation of early adhesions between

the appendix and the organs lying posterior to the cecum in its descent, the tip being held adherent in the neighborhood of the kidney, liver, or gall-bladder, and as a consequence of the cecal descent the appendix assumes a vertical position behind the colon. Later, there may be a fusion and disappearance of some of the adjacent layers of peritoneum covering the appendix and the cecum, and the two become partly or completely adherent to the posterior abdominal wall. This vertical position between the cecum and psoas muscle may subject the appendix to an abnormal degree of friction during contrac-

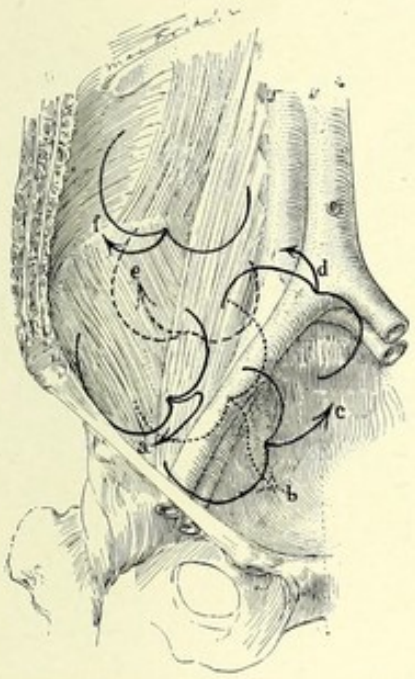

FIG. 103.—DIAGRAM SHOWING THE POSITIONS OF MODERATE DISPLACEMENT OF THE APPENDIX, VIZ., IT IS STILL FOUND IN THE RIGHT LOWER QUADRANT OF THE ABDOMINAL CAVITY.

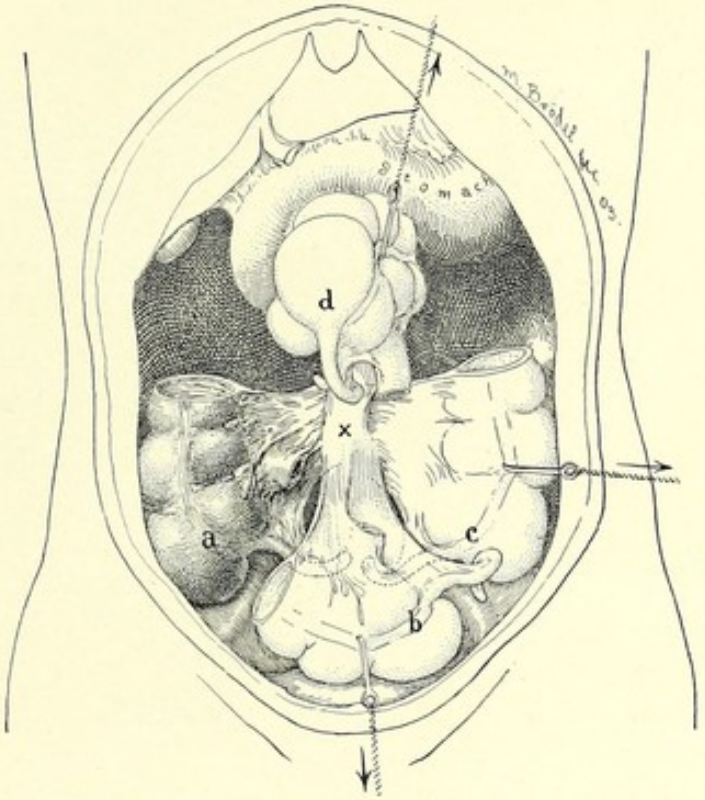

FIG. 104.—Diagram showing the excursions possible to an ileocecal apparatus with a long and movable mesentery, the fixed point being indicated by (×). The cecum and appendix in such cases may be found in any of the four positions (a), (b), (c), and (d), as well as at intermediate points. It may likewise occupy a ventral position and lodge in an umbilical hernia. (Autopsy, January 16, 1902.)

tion of the muscle, hence the more frequent occurrence of appendicitis in appendices lying in this position.

In both the first as well as the second position, the tip of the appendix, or occasionally the whole organ, may lie in a pocket or subcecal fossa, formed by folds of peritoneum. These fossæ are found in a great many cases and their position and depth are very variable. If situated in an available position, any one of them may contain the appendix. The appendix may be curled up inside such a pocket, or its tip may be kinked in the angle of the pocket

(Figs. 203, 257), in which case adhesions are generally found to be the cause, or, again, it may lie perfectly straight. A case has been cited where the tip was adherent to the under layer of the mesentery of the ileum, forming a loop in which a coil of bowel might have become strangulated.

The third most common position of the appendix is the pelvic, which occurs in about twenty-five per cent. of the cases (Figs. 93, 94, 101, and 102). This may be caused by a low position of the cecum, a long mesentery allowing it to shift toward the median line of the body or even sag into the pelvic cavity. Or the mesappendix may be of sufficient extent to permit the descent of a

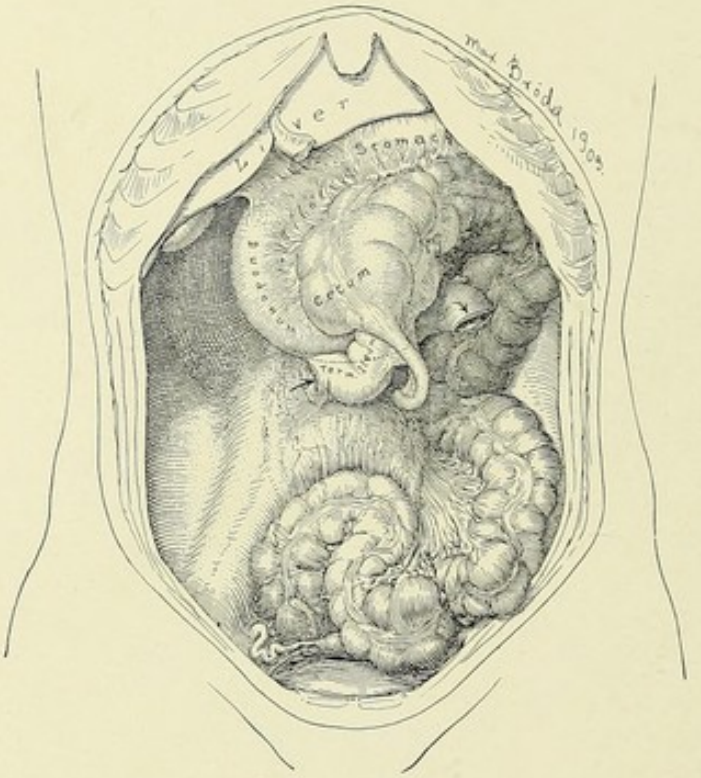

FIG. 105.—The ileocecal apparatus being fixed in a position it occupied during the eighth or ninth week of embryonic life, the position of the cecum is in the epigastric region and the large intestine shows increased tortuosity.

long appendix over the right superior strait and into the pelvic cavity. Here it may come into contact with the ovary or tube, in some cases with the uterus, rectum, or bladder. ROBINSON has found the pelvic position to be less frequent in male subjects than in female. As was pointed out before, the reason for this may be found in the fact that the male pelvis is narrower, and the psoas muscle presents a larger surface than in the female.

Abnormal Positions.—Many abnormal positions of the cecum and appendix have been observed by different authors. It has been seen in very widely different portions of the abdominal cavity; in fact, there is *no* region from liver to pelvic floor where the appendix may not be found. These abnormal

positions are due to two causes; I, an abnormally long and free mesentery, and II, arrested fetal development.

Moderate Displacement.—If the ileocecal apparatus still remains in the right lower quadrant of the abdominal cavity, we have to deal with a moderate displacement. Fig. 103 shows the main variations of cecal topography inside this area.

While (a) is the normal position,

(b) represents a shifting of the cecum over the iliac vessels and pelvic position of the appendix, due to a lengthened mesocolon;

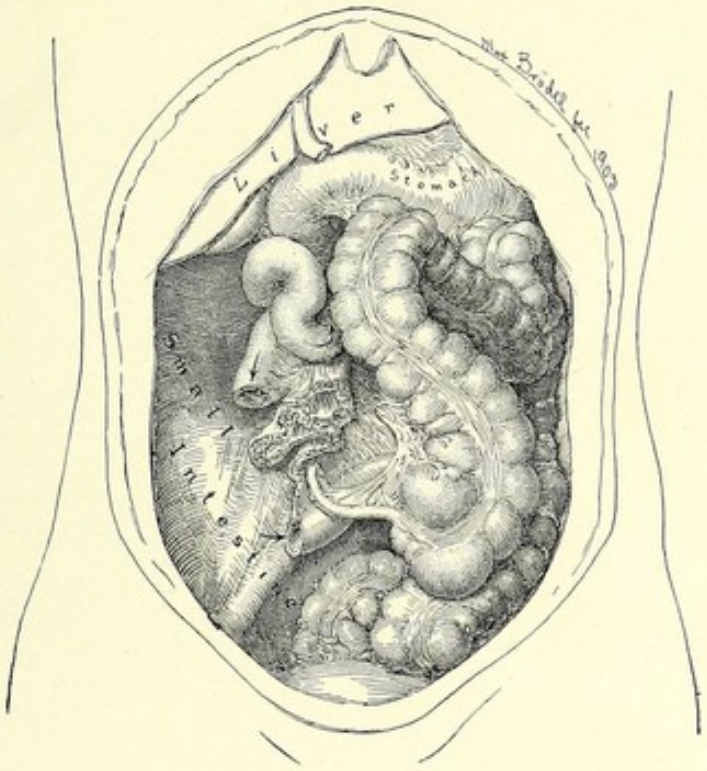

FIG. 106.—The cecum has descended from the epigastric region without swinging over to the right side. All the large intestine is coiled up in the left side while the right side is occupied solely by small intestine. Treitz's fossa duodenojejunalis does not exist, the duodenum and jejunum forming merely a number of convolutions. (After Huntington.)

(c) is the same condition still further accentuated; the sagging down of the cecum causes the appendix to point obliquely upward;

(d) shows the extreme form due to the swinging of the cecum in a median direction. The pouch points upward and the appendix lies on top of it;

(e) and (f) are examples of the moderate forms of incomplete descent of the cecum. The appendix in such instances is generally pointing in an upward direction behind the cecum.

Considerable Displacement.—Appendix and cecum outside right lower abdominal quadrant.

I. Abnormal Positions Due to a Long Mesentery.—Abnormal positions of the cecum and appendix due to a free and movable mesocolon are comparatively frequent. A long appendix with a well-developed mesappendix may extend across the median line in front of the sacrum and the ilium, the tip coming in contact with the left pelvic wall or left psoas muscle. The appendix has also been found lying anterior to the middle lumbar vertebræ, or found floating in the abdominal cavity among coils of the small intestine. Such appendices have been seen to become adherent to the anterior abdominal wall. A long mesocolon may permit a complete shifting of the large intestine

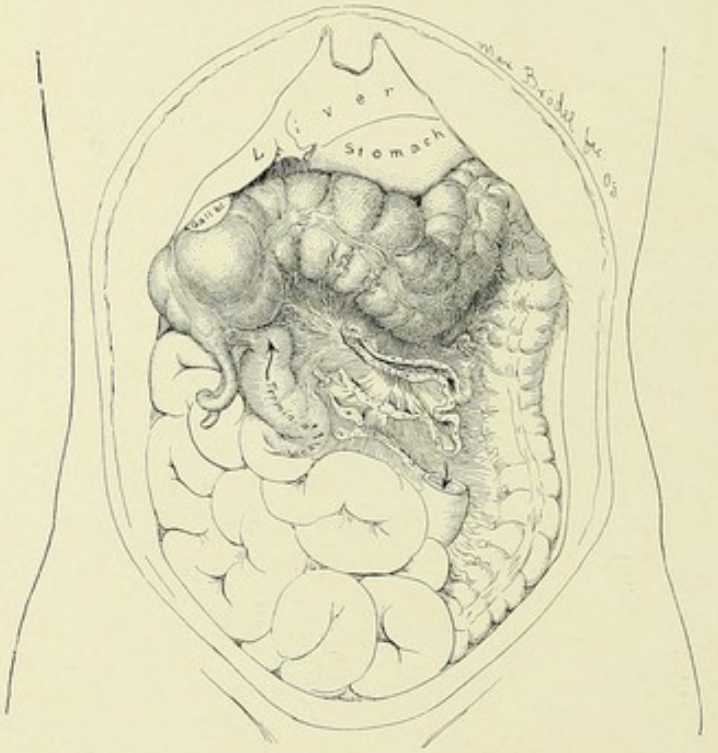

Fig. 107.—The cecum has become arrested in the subhepatic position, a place it occupies in an embryo of ten weeks. It is in close contact with the gall-bladder and the liver. The ascending colon does not exist and the transverse colon appears of exceptional length and is curved. The appendix is pendant, but may assume many different positions. The termination of the ileum runs upward, and the right iliac fossa is occupied by coils of small intestine.

to the left side of the body, the cecum and appendix forming adhesions in this region and becoming fixed (Berry). A long mesentery may also cause the entire ileocecal apparatus to slide over the iliac vessels and lodge in the pelvis, where the appendix may come in contact with or become adherent to any of the pelvic organs. Or the apex of the cecum, bearing the appendix with it, may be turned upward and toward the anterior abdominal wall, in which case it may lie in front of the transverse colon. Fig. 104 illustrates the excursions possible to such a movable ileocecal apparatus. It is evident that in such cases the appendix is apt to be located in inguinal, femoral, and umbilical herniæ.

Finally tumors of abdominal and pelvic origin have been known to change the position of the appendix.

II. Arrested Fetal Development.—During the embryonic rotation of the intestine the cecum and appendix may become fixed at any point along their course. As examples of this, the cecum has been found in the left hypochondriac region, the appendix resting on or near the spleen or below the stomach, the ascending and transverse colon being undeveloped. The large intestine is then usually coiled up in the left half of the abdominal cavity. In Fig. 105 is shown such a condition. The cecum with pendant appendix has remained in precisely the same position which it occupied between

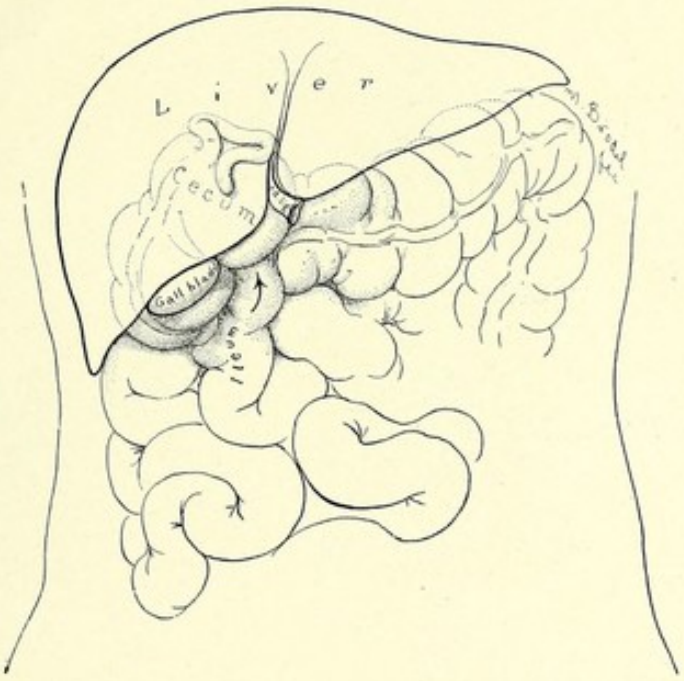

FIG. 108.—The cecum arrested in subhepatic position and turned upward, bringing the appendix in direct contact with the under surface of the liver. The terminal portion of the ileum runs in an upward direction and there are loops of small intestine between it and the kidney.

the eighth and ninth weeks of embryonic life. The cecum and appendix have also been found in an umbilical hernia, held there by adhesions due to inflammation during embryonic life (seventh to eighth week). LOCKWOOD mentions a case where all the large intestine was coiled in the left lumbar region and left iliac fossa, held there by reflection of the peritoneum, while the small intestine filled the right side of the body.

The cecum may also descend directly from the sub-stomachal position without swinging over to the right side. (See Fig. 106.) Duodenum, jejunum, and ileum fill the right half of the abdomen, while the ascending colon is situated to the left of the middle line. The usual rotation of the colon and cecum around their long axis has not occurred, and as a consequence the posterior longitudinal

muscular band is seen in front. The direction of the appendix is also reversed.

If the cecum has progressed somewhat further before it becomes adherent, it is found in the right hypochondriac region. Such a position corresponds to the cecal topography of a ten-weeks-old embryo. The appendix may then occupy various positions in relation to the liver, gall-bladder, kidney, or duodenum, to any of which organs it may become adherent. Figs. 107, 108, and 109 are examples of such abnormalities. Between the subhepatic and the normal iliac positions are several intermediary locations in which the ileocecal

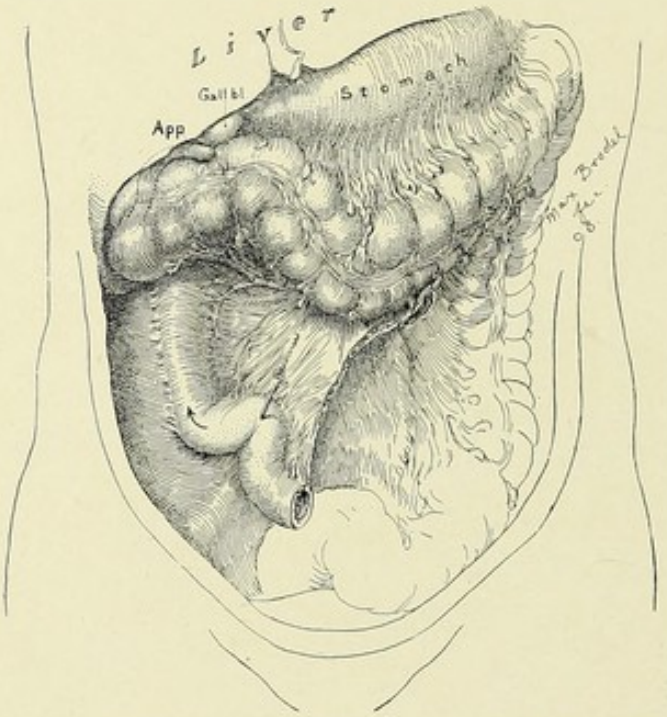

Fig. 109.—The cecum in subhepatic position and pointing laterally. The appendix arising from its posterior and lateral extremity curves upward, its tip resting between gall-bladder and colon. The terminal portion of the ileum runs straight upward just lateral to the psoas muscle and is adherent to the posterior abdominal wall for a distance of 10 cm. The ileocolic valve is situated just in front of the lower pole of the kidney. (Autopsy, 2005. ♂. Age fifty-five.)

apparatus may become permanently fixed. These have been already described as moderate displacement and pictured in Fig. 103.

According to Robinson, undescended ceca occur in three per cent. of female and seven per cent. of male subjects, the non-descent ranging between 7 and 13 cm. above the iliac fossa. The favorite lodging-place of an undescended cecum seems to be the region of the right kidney. The appendix of an undescended cecum has a tendency to preserve the fetal type.

An undescended cecum is frequently associated with an undescended testis or ovary. A band of peritoneum has been seen connecting the sexual gland with the mesentery of the ileum near its junction with the cecum.

In cases of *situs transversus* all the organs are reversed and the appendix

lies in the left iliac fossa, bearing otherwise perfectly normal relations to the reversed cecum and ileum (Fig. 110).

Misplaced and Supernumerary Appendices.—In regard to misplaced and supernumerary appendices, most of these can be accounted for on other grounds. In a number of cases appendices have been reported as arising from the ileum, at various distances from the ileocecal valve. Without wishing to criticize these statements, it seems more probable that these authors have seen and described Meckel's diverticulum, *i. e.*, the remains of the vitelline duct of the embryo. It is also possible that one of the epiploic appendages which are

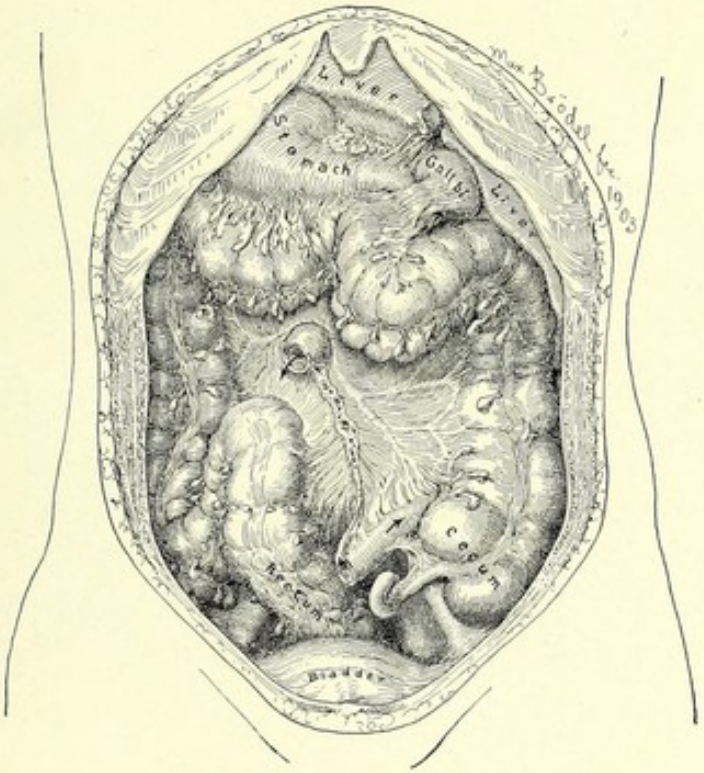

FIG. 110.—TRANSPOSITION OF THE VISCERA.

The cecum occupies the left iliac fossa and the ileum enters from the right. The appendix is of the pendant type. The arrangement of the mesappendix, its blood-supply, as well as the position of the ileocecal fold, are normal except that they are reversed. (Autopsy, 1849. ♂. January 16, 1902.)

found at intervals along the intestine may have been mistaken at times for an atrophic appendix.

DIMENSIONS OF THE APPENDIX.

The average length of the appendix has been variously estimated by different authors as from 8 to 11.5 cm., the mean of these being 9.2 cm. The most reliable observations, however, and those based upon the largest number of cases, result in a lower figure, and we agree with RIBBERT, BERRY, and others in placing it at about 8.3 cm., or between 3 and 3½ inches. Extremely short

appendices have been described from time to time by various observers—Ferguson found three which were 12 mm. long; others have noted appendices of 1 cm.; while Bryant mentions one which measured only 6 mm., and Huntington one of 5 mm. Smaller than this none have been reported. Short appendices are more frequently obliterated than those of normal or excessive length. Cases of complete absence of the appendix have been described, but it is to be doubted that such observations have always been accurate, as the appendix can be obliterated and withered to a narrow fibrous cord adherent to the wall of the cecum, and as such easily escape notice (Fig. 193). We have been able to demonstrate such a case, which had been pronounced as an instance of total absence of the appendix. Nevertheless there are a few authentic cases of complete absence of the appendix (Zuckerkandl, Bryant, and Huntington). Huntington's first case showed a rounded globular cecum with longitudinal muscular bands converging to the lowest point of the pouch. There was no scar or other evidence of operative removal or of pathological process. His second case had a cecum turned upward and to the left, terminating in a sharp point to which several lobes of epiploic fat were attached. Huntington's explanation of such forms is plausible. He assumes "that in these cases the embryonic portion of the cecal bud was developed just sufficiently to yield the required adult pouch with nothing to spare, so to speak, which could remain rudimentary in the form of an appendix."

Robinson mentions a case (female subject) where not only the appendix but also the cecum were congenitally absent.

From the minimum of 5 mm. appendices range in length up to 24 cm. (9½ inches) or more. The longest appendix on record, to our knowledge, is one presented by F. Grauer of New York to the Northwestern Med. and Surg. Soc. in 1890. It measured 12⅞ inches in length (33 cm.).

Abnormally long appendices have been found by Lenzmann (22 cm.), Luschka (23 cm.), Lafforgue (24 cm.). One of our specimens, which we owe to the courtesy of J. D. Blake, measured 24 cm. in length (Fig. 299). Another long appendix is pictured in Fig. 111.

The growth of the appendix is irregular, uncertain, and apparently not influenced by the development of the main intestinal tube. Meckel gives the length of the appendix in relation to the entire alimentary canal as follows:

In the new-born	1–71
At fifty years of age	1–115

In fetal life the length of the appendix relative to that of the rest of the intestine is greater than in the adult. The length is proportional to the age of the infant, though not in the same degree. According to Ribbert, the average length of the appendix in the new-born is 3⅔ cm. The adult body is about three times the length of the new-born, and taking the length of the

adult appendix as between 9 and 10 cm., the average given by many authors, it becomes evident that the appendix grows approximately in the same proportion as the body. The greatest length is attained between the tenth and thirtieth years, when the average reaches as high as $9\frac{3}{4}$ cm. BRYANT and other observers state that the greatest length is reached between the twentieth and fortieth years. From this time on, the appendix decreases in length, the average being $8\frac{1}{4}$ cm. at sixty years of age, a change due to retrogression.

As may be supposed, many deviations from the above-stated rules are

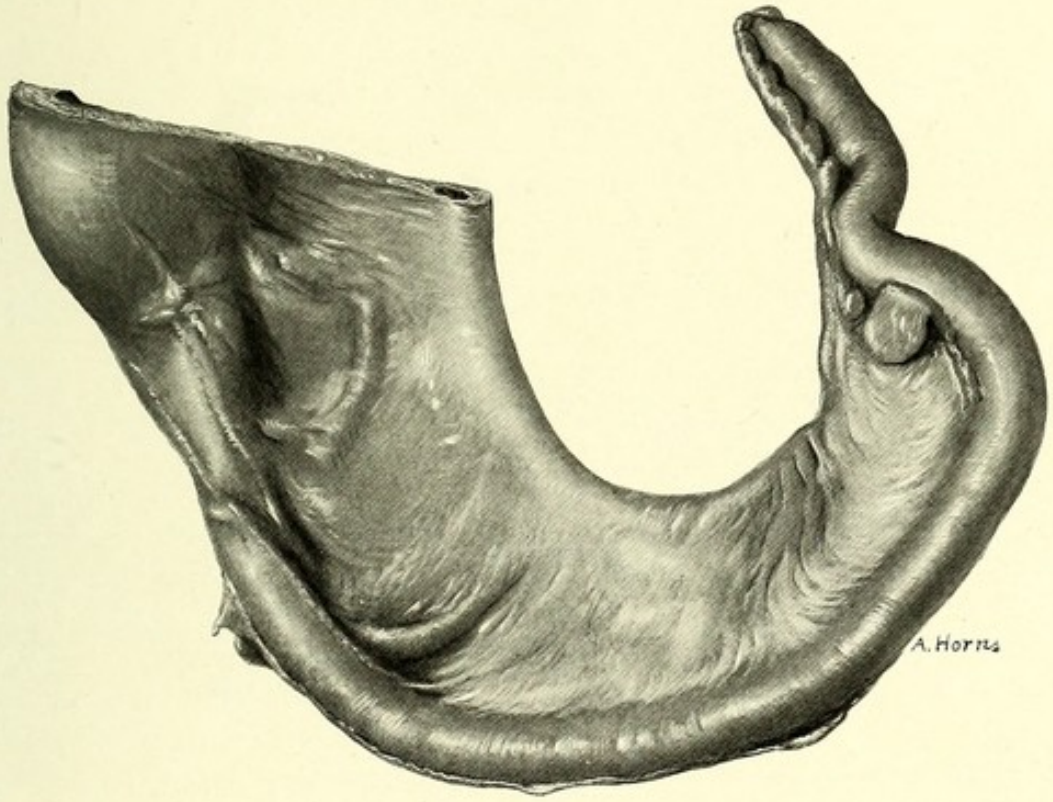

FIG. 111.—AN APPENDIX MEASURING 21.5 CM. (8½ INCHES) IN LENGTH. SPECIMEN FROM H. S. WEAVER, OF PHILADELPHIA.

Along the free border and running obliquely across the proximal third are reduplications of peritoneum containing fat. These folds are often seen, especially along the free border, and if they carry isolated clusters of fat they appear lobulated, resembling the epiploic appendages of the mesappendix. (See Fig. 113.)

found. The appendix may attain its full length much earlier in life. TREVES found an appendix of 12 cm. in a child of three years; RIBBERT one the same length in a child of five years.

While it is a general rule that the length of the appendix decreases with advance in years, nevertheless some of the longest appendices occur in old people, showing that retrogression does not always take place.

FAWCETT and BLANCHFORD found from the measurement of 350 subjects, male and female, that the average length of the male appendix is 1 cm. greater than that of the female. ROBINSON gives the difference as 6 mm.; he also

states that extremely long appendices are more apt to be from male subjects. According to Dock, the average length in negroes is greater than in whites.

There seems to be a certain relation between the length of the appendix and that of the cecum. When the appendix is long, the cecum is somewhat shortened.

The width of the appendix is much more constant and less liable to fluctuation. It is usually described as about that of a goose-quill. Ferguson gives the diameter as that of a No. 9 catheter, English scale. The average diameters of the appendix as given by various authors are as follows:

Deaver	3 to 5 mm.
Dock	5 mm.
Lafforgue	4 to 6 mm.
Bryant (40 cases)	6 mm.
Gaston	about 6 mm.
Luschka	7 mm.
Vallée (82 cases)	8 mm.

Appendices measuring 1 cm. and 1.5 cm. in width have been found. Treves describes one of a male subject, age thirty-seven years, which was 10 cm. long and 1.25 cm. broad. This width is to be considered abnormally large.

Bryant has found that the average width of the male appendix is 2.5 mm. greater than that of the female. We think that this is excessive. The relative width of the appendix to that of the large intestine changes with age. In the new-born it is about 1 to 4; in the adult it averages about 1 to 8.

The diameter of the lumen changes according to the contents of the canal, whether gaseous, liquid, or solid. It is usually of about equal size throughout, with the exception of a slight dilatation at the tip; while in those cases where the cecum has retained the fetal type, the proximal end of the appendix is funnel-shaped, and therefore possesses a greater lumen. There is, however, usually a narrowing of the lumen at the neck, caused by the usual acute angle at which the appendix arises from the cecum. The mucous membrane may elevate itself around the entrance into the lumen of the appendix in a manner very much resembling a valve.

The diameter of the lumen varies from 1 to 3 mm., the calibre not being in proportion to the length of the appendix.

There is also no constant relation between the width of the appendix and the diameter of its lumen, except that appendices of infants and young individuals have generally a wider lumen than those of older persons. The diminution is due to a considerable increase in the thickness of the submucosa as age advances.

According to Vallée, "the volume of the appendix is not constant. It usually broadens out at the cecal extremity, becoming progressively smaller

toward the tip, where it again swells out, terminating in an olive or club-shaped enlargement." These two dilatations at the two ends he considers normal. It is, however, probable that the distal club-shaped enlargement is the usual sign of beginning obliteration.

"In one case, an anomaly, the appendix presented a contraction at a point 15 mm. from the tip. The appendix was only 5 mm. thick at this point; 9 mm. thick at its origin. This shrinkage was not due to atrophy of the coats. The organ remained easily permeable and contained a serous liquid produced by the mucosa."

THE STRUCTURE OF THE APPENDIX.

In the present section the different coats constituting the appendix will be described in succession, first as to their macroscopic appearance, and then, briefly, as to the histological structure. It is impossible to give a description of the gross anatomy of the appendix suitable to all cases, as the number of variations is so great; and as regards the histology of this variable structure is concerned, there are almost as many variations as in its anatomical form.

The appendix is a worm-like appendage attached to, and continuous with the lower portion of the cecum. Like the rest of the intestine, it is enveloped in a peritoneal coat, which is continuous over its mesentery. Since the appendix develops out of the fetal cecum, it is but natural that its structure, both macroscopic and microscopic, should closely resemble that of the adjacent large intestine.

As in the cecum, the different coats beginning with the outside, are arranged as follows:

(1) Peritoneal or serous coat.
(2) Longitudinal muscular coat.
(3) Circular muscular coat.
(4) Submucosa.
(5) Mucosa.

Transverse sections through the normal vermiform appendix after hardening are usually 5 or 6 mm. in diameter. The lumen which occupies the centre may be a mere slit in the shape of the letter T or of the letter H, or irregular. Various shapes may be met with in sections through different parts of the same appendix. The thickness of the coats of the appendix varies from 1 to 2½ mm. Of this the peritoneal and muscular coats compose about one-third, the rest being submucosa and mucosa (Fig. 112).

The Peritoneum.—The serous coat with its peritoneal surface is about 0.1 mm. in thickness and is closely attached to the appendix, rendering its surface smooth and glistening. It is transparent and permits the outer muscular coat with its vessels to shine through, the color of the appendix being, there-

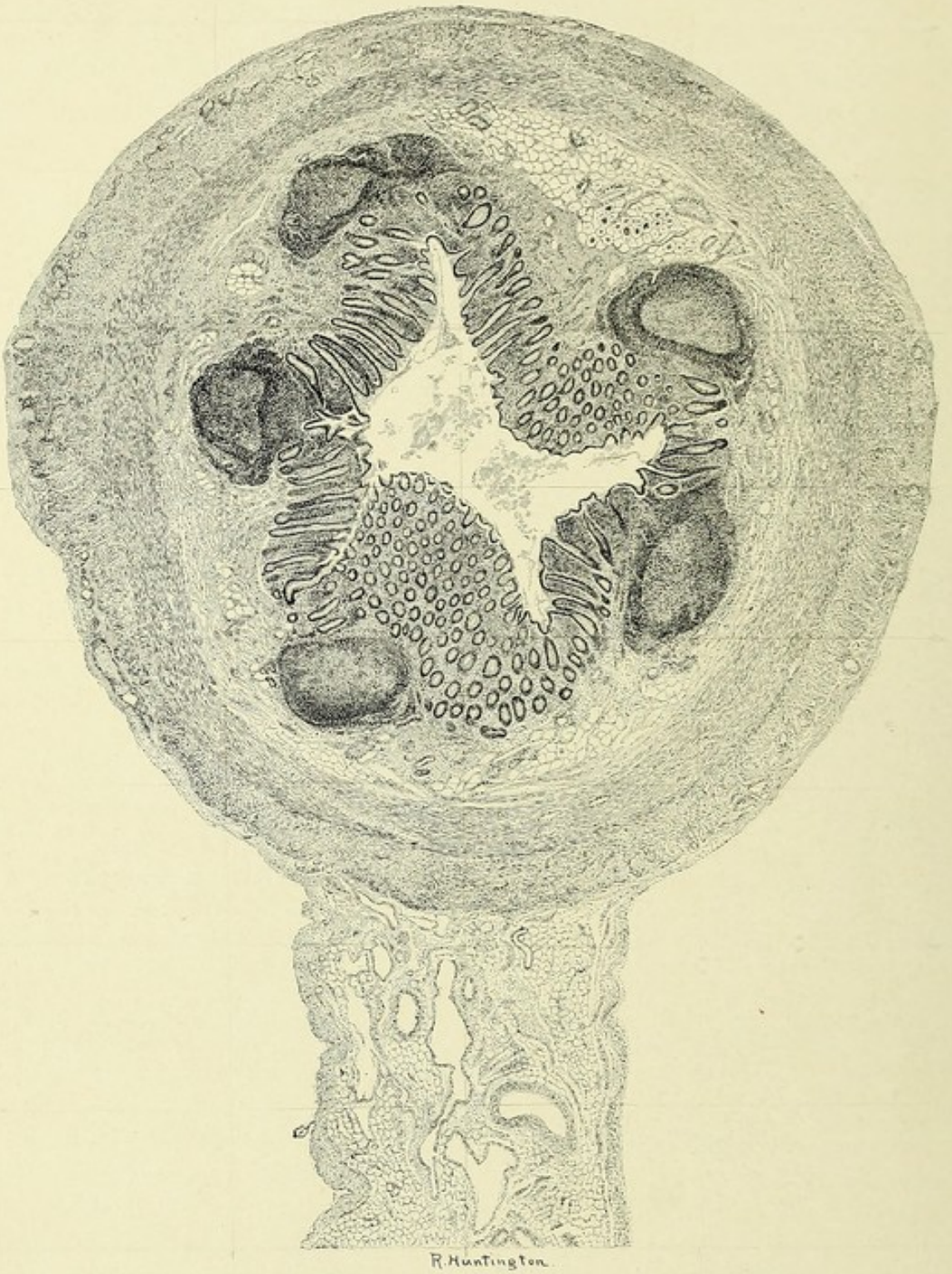

FIG. 112.—SECTION THROUGH A NORMAL APPENDIX, 25 TIMES MAGNIFIED.

The different layers from without in, are: (1) The serous coat, consisting of a simple layer of flat endothelial cells, the serous, and the subserous tissue, containing the superficial vessels; (2) the longitudinal muscular coat whose bundles are seen in cross section; (3) the circular muscular coat; (4) the submucosa, traversed by many vessels and supplied with a varying amount of fat; (5) the mucosa, consisting of a surface epithelium, dipping down into the glands of Lieberkühn, a tunica propria, situated between the glands, and a muscularis mucosæ (not distinguishable), situated between the mucosa and the submucosa. Between the crypts of Lieberkühn and the submucosa, extending partly into the latter, are seen five lymph follicles. In this particular section they do not reach the surface. Their germinal centre stains more faintly than the periphery. The lumen of the appendix contains mucus, disintegrating cells, and fecal matter. At the lower portion of the section is seen the mesappendix with its vessels. The spaces between the vessels are occupied by connective tissue containing a considerable amount of fat.

FIG. 113.—THE ILEOCECAL REGION OF A WOMAN POSSESSING AN ABNORMAL AMOUNT OF FAT.

The accumulation in the mesappendix gives rise to the formation of an unusual number of large epiploic appendages. Along the free margin of the appendix are folds or duplications of peritoneum filled with fat, some of which are pedunculated. The lumen of the appendix decreased from 2 mm. at the cecal extremity to 0.1 mm. near the tip. (Autopsy, February 6, 1902.)

FIG. 113.—THE ILEOCECAL REGION OF A WOMAN POSSESSING AN ABNORMAL AMOUNT OF FAT.

The accumulation in the mesappendix gives rise to the formation of an unusual number of large epiploic appendages. Along the free margin of the appendix are folds or duplications of peritoneum filled with fat, some of which are pedunculated. The lumen of the appendix decreased from 2 mm. at the cecal extremity to 0.1 mm. near the tip. (Autopsy, February 6, 1902.)



Fig. 113.

fore, due mainly to the deeper structures and their blood-supply and not to the surface coat, which contains comparatively few vessels. The large vessels visible on the surface of the appendix are situated below the serous coat, between it and the longitudinal muscular coat. Along the free margin of the appendix, opposite the hilum, the peritoneum is frequently lifted up in the form of a fold from one to three or more millimetres in height, and extending for a variable distance along the appendix (Fig. 111). It may be found at the proximal, as well as the distal portion of the appendix. Its width varies according to the amount of fat present between the layers of serosa, which may be very considerable in stout persons. The free border of this fold is not always continuous but often appears lobulated, in which instances the individual portions are pedunculated, resembling closely the epiploic appendages of the large intestine. The mesappendix in such cases generally shows similar masses of pedunculated fat (Fig. 113). The peritoneum of the mesappendix does not lie as firmly against the underlying structures as in the appendix, for which reason we find it forming a great number of delicate folds, more numerous at the hilum than elsewhere, lying approximately at right angles to the appendix. On tension they can be smoothed out, unless they are carriers of fat. The entire mesappendix contains a varying amount of fat grouped between the vascular loops. This is of greater thickness near the appendix. It may, however, be so small in amount that it escapes notice.

The Histological Structure of the Peritoneum (Fig. 112).—The peritoneum consists of a simple layer of flat, polygonal, endothelial cells, resting upon a delicate subperitoneal layer, which is made up of loose fibres and elastic tissue, and connects the peritoneum with the underlying structures. This subperitoneal tissue bears within its meshes a variable amount of fat and contains the superficial blood-vessels, lymphatics, and nerves.

The Longitudinal Muscular Coat (Fig. 112).—The three longitudinal muscular bands of the large intestine converge at the cecum and form the longitudinal muscular coat of the appendix. The cecum possesses a longitudinal muscle over its entire surface, but with the exception of the above-mentioned bands, it is much more sparsely developed than in the appendix. The combined width of the three muscular bands in the adult is slightly more than the circumference of the appendix. The expansion of the cecum and large intestine takes place between the three muscular bands, leaving a few longitudinal fibres to cover the pouches. The thickness of the longitudinal muscular coat of the appendix varies in different individuals from 0.2 to 0.3 mm. It is not of uniform thickness throughout the entire appendix, and in any one section it is often seen to vary considerably at different points around the circumference. Some authors state that the longitudinal muscular coat becomes thinner near the tip of the appendix, but with the exception of the muscular hiatus where the blood-vessels penetrate, we have not found it to diminish appreciably in thickness. The longitudinal coat contains a large

number of capillaries lying parallel to the fibres with short anastomosing branches running at right angles to them. The collecting vessels pass in both an outward and an inward direction (Fig. 120).

The Circular Muscular Coat (Fig. 112).—The circular muscular coats of the cecum and appendix are also continuous. The thickness of this coat is more uniform than that of the longitudinal muscular coat; and it is usually broader than the latter, measuring from 0.2 to 0.5 mm. in width. Its bundles of fibres are interlaced at the tip to form a cupola. Its blood-supply follows the direction of the fibres, the larger vessels connecting with

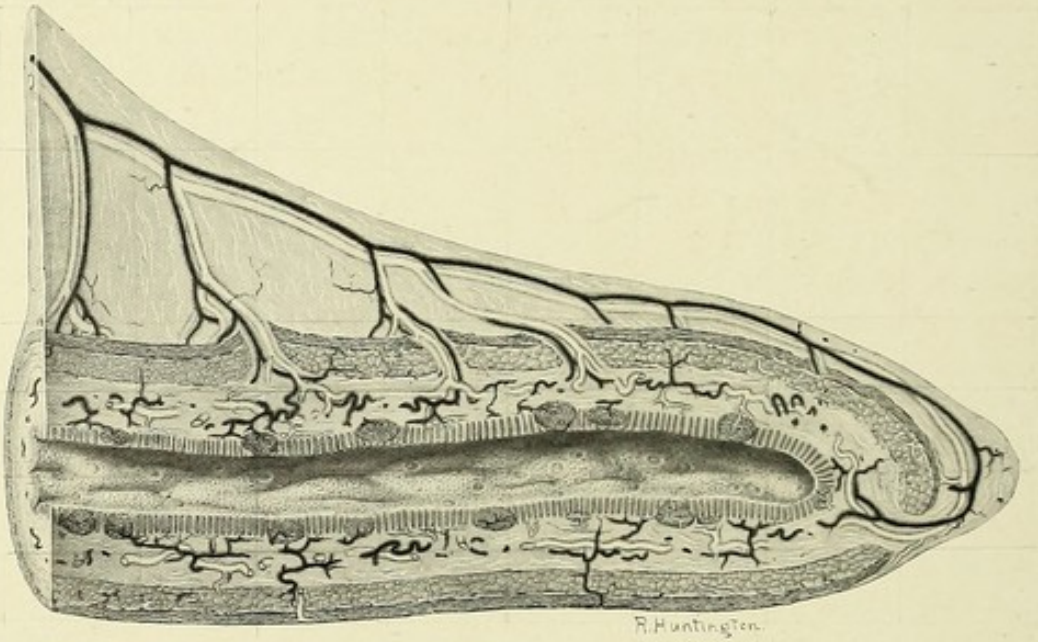

FIG. 114.—A LONGITUDINAL SECTION THROUGH THE DISTAL PORTION OF A NORMAL APPENDIX AND ITS MESENTERIOLUM, MAGNIFIED 5 TIMES.

In the centre is the mucous membrane, showing the characteristic folds and the apices of the follicles protruding from shallow depressions in the mucosa. The rest of the surface is studded with the minute orifices of the glands of Lieberkühn. Along the hilum the muscular coats are perforated at certain intervals to permit the entrance of the vessels into the submucosa. The most distal perforation or "hiatus" is at the tip, admitting the terminal branch of the appendical artery and serving as an exit for the returning vein and lymph channel. The terminal branch lies not infrequently in a little projecting peritoneal fold filled with fat, appearing like a knob on the tip of the appendix. A few strands of muscle and connective tissue, as well as lymphatics and nerves, accompany the vessels through the hiatus.

those in the submucosa and those between the muscular layers (Fig. 120). Both muscular coats are perforated at various points to permit of the entrance and exit of the nerves, blood-vessels, and lymphatics. Such a perforation is called a muscular hiatus, and they are found in varying numbers along the mesenteric border of the appendix. The last hiatus is generally found at the tip (Fig. 114) and it is considered by some writers as the cause of the weakness of the appendix at this point. The number of these perforations varies according to the number of large vascular branches at the hilum. A long appendix has therefore generally more such perforations than a short one. The vessels perforating the muscle are enveloped by a special fibrous sheet, which is strength-

ened by muscle fibres coming from the muscular coats of the appendix. In stripping the inner coats of the appendix out of their muscular envelopment these vessels are generally torn out of the submucosa, permitting the mucous membrane to protrude through the resulting perforations. Each hiatus is marked in such a specimen by a little hernia of the mucous membrane, especially if the appendix is distended (Fig. 299). If the vessels tear out of the muscular coats, they appear as delicate projections on the submucosa of the stripped out specimen (Fig. 298).

Concerning the s t r i p p i n g of the appendix out of its muscular sheath, so frequently practised in operations, a few remarks may be of value. Each coat can be separated from its adjoining layer at any point, but there are two places where such a division or stripping out is effected with greater ease than elsewhere. One of these is within the fibres of the circular muscular coat, near the periphery. The sheath which is stripped off, will then consist of the serosa, the outer muscular coat, and a few fibres of the circular coat. The second place where the stripping out is effected with ease is between the circular coat and the submucosa. As at this region there are numerous blood-vessels and lymph channels forming a rich network, the layers of the appendix are here more loosely connected. It depends largely upon the depth at which the operator starts to strip. If he begin in the circular coat, the rest of the appendix strips out within that coat. If he reaches the submucosa, the division takes place between it and the muscular layers.

The muscular layers of the intestine are composed of smooth muscle fibres. Their spindle-shaped protoplasm is of considerable length as compared with their small, elongated nucleus. A section of muscle parallel to the fibres will, therefore, show more nuclei than a section taken at right angles, where many of the fibres would be cut to either side of the nucleus (Fig. 112).

The Submucosa.—In contradistinction to the other layers of the appendix, which are of more or less constant thickness, the submucosa varies greatly in different individuals. The thinnest submucosa is 0.2 mm. in width, the thickest measures 0.8 mm. or more. While the outer surface of the submucosa is round like that of a cylinder, its inner surface follows the corrugated course of the mucous membrane. The submucosa is of a lighter color than the muscular coats, and later in life it undergoes fibrous changes, becoming harder, bluish white, and glistening. It is this layer which gains most in thickness during the process of obliteration. It may increase to two or even four times its original size. The mucous membrane disappears and is replaced by fibrous tissue which is continuous with that of the submucosa. Within the submucosa are numerous vessels, some of the largest ones of the appendix being found in this layer (Fig. 120). The spaces between the meshes of the fibrous connective tissue framework of the appendix are filled with a variable amount of fat.

Microscopically, the submucosa consists of loose, wavy strands of fibrous

and elastic tissue which forms a framework for the blood and lymph vessels and nerves. In the interspaces are fat globules. If obliteration takes place, the connective tissue increases in density, compressing the vessels, which first decrease in calibre and subsequently disappear, the process beginning with the inner layers of the submucosa and at the distal end of the appendix.

The Mucosa.—The mucosa is bound to the submucosa by the vestiges of a muscularis mucosæ. This consists of a narrow layer of non-striped muscle fibres which cannot be demonstrated by dissection. Sometimes it is not visible under the microscope. If present, it is lined on either side by a network of lymphatics belonging to the deep system (Fig. 140).

The mucosa, or the innermost layer of the appendix, in its normal state presents an irregularly folded appearance, the folds running parallel with the longitudinal axis of the appendix. On distention they become flattened out. If the appendix be cut open lengthwise and spread out, these folds are obliterated to some extent, the degree depending on the consistency of the submucosa. In the thin-walled appendix of a young person (Fig. 115) the mucosa may be flattened out to a comparatively smooth surface; while the hard thick-walled appendix of an older individual will not permit this. The mucosa will then be seen to be subdivided into many dome-like elevations separated by deep furrows (Fig. 116). In an appendix removed at operation this condition will be accentuated through contraction of the muscular coats, which would not be seen in an autopsy specimen. The mucosa *in situ* appears like a soft, thick and pulpy membrane. It is somewhat yielding and is the most fragile of all the coats. The color of the mucosa is a light brownish flesh tint, sometimes grayish, and its surface, while glistening to some extent, has a velvety appearance, due to innumerable delicate glandular openings, the glands of Lieberkühn.

These openings of the crypts of Lieberkühn are arranged with remarkable regularity around certain centres marked by slight depressions on the surface, which correspond to the apices of the lymph follicles (Fig. 116). The glandular openings describe lines radiating from these follicles and are at the same time arranged concentrically around them. Their number, as well as the distance between them, varies according to the age of the individual. There are about 25–35 to the square millimetre in the adult—this would make from 2500 to 3500 to the square centimetre. Taking the average circumference of the lumen of the appendix as about 1 cm., its length as 8.3 cm., the square contents of the entire mucous surface would amount to 8.3 sq. cm. This multiplied by the average number of glandular openings per square centimetre (3000), would result in a total number of about 25,000 glands of Lieberkühn contained in an average appendix. Their opening on the surface is not funnel-shaped, but abrupt and perfectly round, measuring 0.04 mm. in diameter. Frequently the circumference of the lumen is as great as that of the serosa, for on opening an appendix lengthwise and stretching it out on a board, the mucous surface

is seen to be almost as large as the peritoneal surface. These calculations were made from fresh material, as alcohol specimens give an erroneous impression, on account of the considerable shrinkage produced by the hardening process. The glands then appear much nearer together, a square centimetre of the mucosa of such a specimen having as many as 50 to 60 glandular openings. In a distended appendix the glands are always further apart, their opening is wider, and they are seen to dip only a short distance into the mucosa. The glands are less abundant—that is, they are farther apart at the tip than at the cecal extremity of the appendix.



FIG. 115.—A PORTION OF THE MUCOUS MEMBRANE OF A YOUNG INDIVIDUAL, SHOWING THE ARRANGEMENT OF THE LYMPH NODES ON THE SURFACE.

Their grouping is fairly regular and their exposed surface is round or oval, sometimes dumb-bell shaped. Traversing the surface of the mucosa are a number of furrows due to the folding of the membrane when *in situ*. (Natural size.)

The mucous membrane is furnished with a large number of solitary glands or follicles, which, however, are few and far between compared with the number of the glands of Lieberkühn (Figs. 115 and 116). The exact number of follicles contained in an appendix depends upon a number of circumstances, especially upon its length and calibre. LOCKWOOD gives 150 to 200 as a rough estimate of the number of follicles contained in an appendix of the usual length, 8.5 cm. I find the number varying from 25 to 50 per square centimetre, according to degree of distention, age of the individual, and location of the area examined. The entire appendix contains, therefore, between 300 and 400 follicles. As in the case of the glands, of which only the opening is seen from the surface, so in the follicles, merely the upper portion is visible, the greater part being buried beneath overhanging mucous membrane. The exposed apex is smooth, and as it does not quite reach the level of the surface, the follicle is marked on the mucous membrane as a shallow depression, the bottom of which is slightly elevated at the centre (Fig. 114). The exposed portion of the follicle is round or oval, sometimes irregularly shaped. If two are fused they resemble a dumb-bell (Fig. 116). The average measurement of the exposed portion is 0.25 to 0.20 mm. or less in diameter.



FIG. 116.—THE SURFACE OF THE MUCOUS MEMBRANE MAGNIFIED 6.5 TIMES.

The exposed portion of the follicles is visible as a dome-like elevation in a slight depression in the mucosa. Their size as well as their outline is variable, especially when two are seen to fuse. The surface of the mucosa between these nodes is studded with minute openings, the crypts or glands of Lieberkühn. Their arrangement is in rings around the lymph nodes and in rows radiating from the centre of the follicle.

On microscopic section (transverse, if not otherwise mentioned) the different structures comprising the mucous membrane come much more clearly into view. The thickness of the mucous coat in the fresh specimen varies between

0.3 and 0.7 mm., the most usual measurement being 0.45 mm. The lumen of the appendix is seen to have an irregularly corrugated or wavy outline, the follicles generally lying in the depressions or angles. The circumference, with all its depressions and folds, measures almost as much as the circumference of the peritoneal coat. In beginning obliteration, however, it measures much less. For these reasons the measurements vary from 1 mm. to 22 mm., or even more.

The number of lymphatic follicles to be counted in one section varies from 3 to 8; on an average there are about 5. Lockwood, however, found 12 in a section of the appendix of a girl aged thirteen years, 16 in a man aged thirty-five, 9 in a man aged thirty-seven, 8 in a man aged thirty-six, and 5 in a man aged sixty-eight. In any one section all the follicles are rarely cut through their centres, most of them being sectioned through their buried portion; hence the occasional appearance that the follicles do not reach the surface (Fig. 112).

The mucous membrane consists of an epithelium, a tunica propria, and the muscularis mucosæ. The epithelium dips down into a great number of simple tubular glands, the crypts of Lieberkühn, between which lies the tunica propria (Fig. 117). In an ordinary specimen from 25 to 30 tubular glands can be counted in one section; not infrequently there are 40, 50, or even 60 well-developed glands. They rarely show dichotomous branching. Sometimes they are found embedded in lymphoid tissue which is collected at certain intervals to form the follicles or lymph nodes. The epithelium which covers the surface of the mucosa and is continuous with the lining of the glands, consists of a layer of columnar cells which contain a granular protoplasm, numerous fat particles, and usually an oval nucleus and a cell membrane. Many of these cells show the common goblet form. There is also a homogeneous basal border characteristic of the intestinal epithelium. The regeneration of the epithelium taking place by mitosis in the glands of Lieberkühn, causes the cells to gradually move upward to replace the disintegrating cells on the surface, though mitosis is also known to take place in the latter. The youngest generation of epithelial cells is, therefore, as a rule found in the glands, the oldest on the surface. In obliteration of the appendix the mucous membrane disappears gradually, being shallowest in the corner of the obliterating angle. It is probable that a failure of the epithelium of the glands to regenerate, causes the mucous membrane to disappear.

The tunica propria of the mucosa fills the interspaces between the glands and consists mainly of fibrillated connective tissue and reticulum with a varying number of plasma cells and small round cells. The reticulated framework of the tunica propria is in intimate connection with the muscularis mucosæ. The mucosa is very vascular, containing numerous capillaries and a few lymphatic channels.

The Lymph Nodes (Figs. 112 and 117).—The lymph nodes develop in the tunica propria close under the epithelium, and lie with their base against the muscularis mucosæ. When they attain their full size they expand

much beyond these limits and invade the submucosa. The nodes are composed of lymphoid tissue usually containing a germinal centre. These multiplying

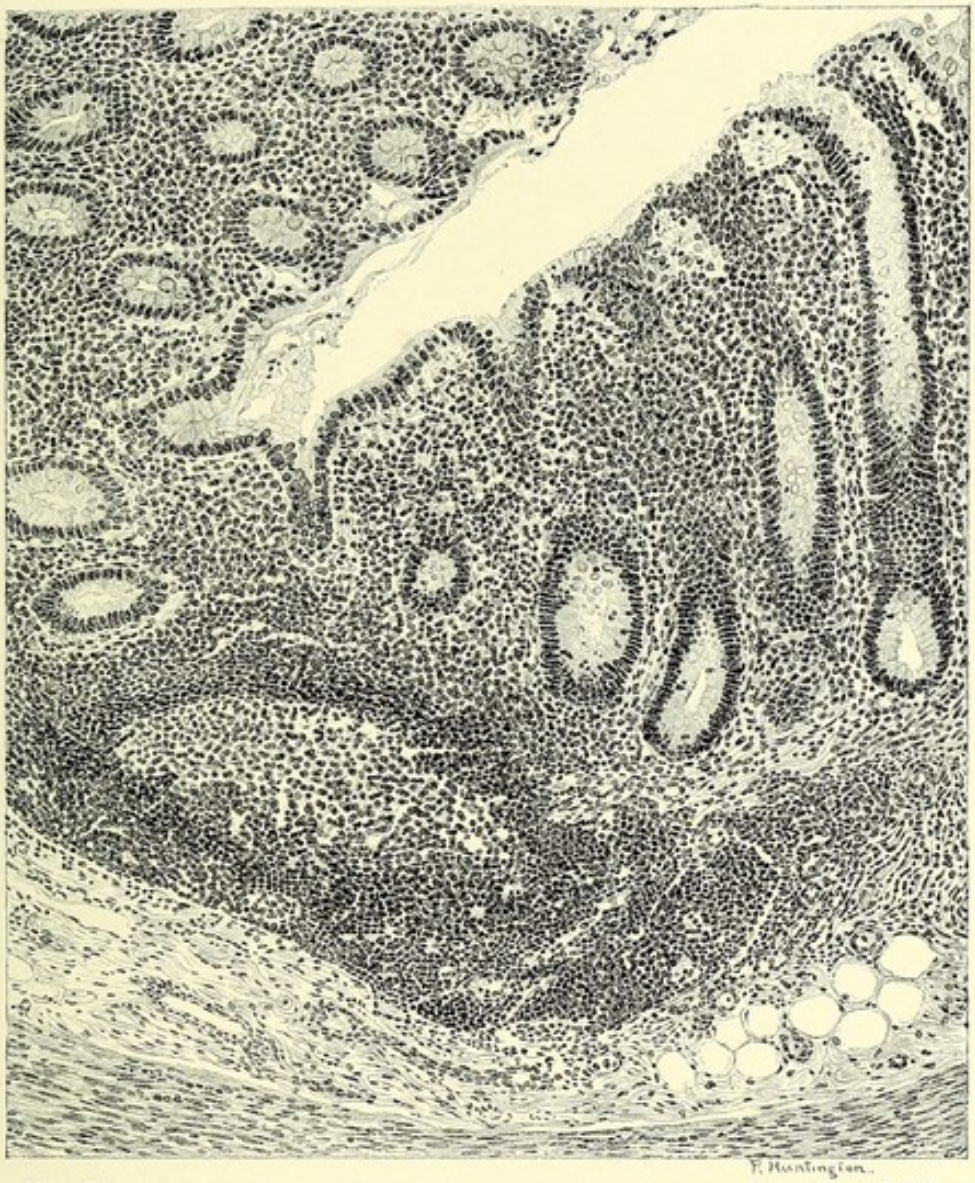

FIG. 117.—PORTION OF THE NORMAL MUCOUS MEMBRANE OF AN APPENDIX, MAGNIFIED 150 TIMES.

Above is the lumen of the appendix into which are seen to open the crypts of Lieberkühn, some of which are cut obliquely, others transversely. The epithelium of the lumen and crypts is identical and consists of a single layer of columnar cells. Between the crypts or glands of Lieberkühn is the tunica propria, consisting of connective tissue, with small round cells and a few plasma cells. The lower half of the picture is chiefly occupied by a lymph node, which above is continuous with the tunica propria. The lymph follicle has a deeply staining layer of lymphoid cells in its periphery, while the germinal centre is composed of more faintly staining cells. Below the lymph node is a small strip of submucosa with fat globules and vessels, and beneath this are a few bundles of the circular muscular coat.

lymph cells of the central portion stain more faintly than the lymphoid cells forming the periphery. The arrangement of the latter is concentric (Fig. 117).

The thickness of the mucosa varies greatly in different individuals, age being the main factor in the change. The usual thickness of a healthy mucosa

in an adult is from 0.2 to 0.3 mm. measured in alcohol specimens; in fresh specimens it is slightly thicker. The height of the follicles varies with the thickness of the mucosa. In young individuals they are round or pear-shaped, almost pyramidal, with their point projecting into the lumen; while in old age they flatten out with the mucosa. They are also much nearer together in youth, their number being greater. They have been seen to form an almost continuous ring of lymphoid tissue on cross section of the appendix of young individuals. In the adult they measure about 1 mm. or slightly less at their base, and are distinctly visible to the naked eye.

The crypts of Lieberkühn pass at right angles to the surface with the exception of those lying near the follicles, which are directed obliquely toward the surface, hugging the sides of the follicle, at the same time decreasing in length, those nearest the follicles being the shortest (Fig. 112).

CONTENTS OF THE APPENDIX.

The ordinary and normal appendix may contain fecal matter similar to that found in the adjacent large intestine, and varying in quantity according to the size of the lumen. By drawing the fingers over the surface of the appendix and pressing gently at the same time, its contents may be moved from point to point, or may even be pushed entirely back into the cecum.

On opening up the appendix its contents are seen to be of a yellowish or greenish tinge, and of a soft consistency. Not infrequently the lumen is filled with a mucous or serous liquid which is of a transparent or slightly muddy character.

Sometimes the appendix appears to be quite empty, a condition associated usually with a narrow diameter and an efficient valve. As a rule the greater the diameter of the appendix, the greater is the probability of finding fecal matter within its lumen. A straight or slightly curved appendix also is more apt to contain fecal matter than a convoluted or kinked appendix.

The cavity of the fetal appendix almost invariably contains fecal matter, which Clado says can be seen with the naked eye after the sixth month of intrauterine life. Under the microscope it has the appearance of a mass of granules and small cellular particles united by mucus. After birth the contents of the appendix are similar to those of the adult. Among 100 infant and fetal appendices, Vallée found 70 containing fecal matter (usually soft), 24 containing mucous or serous liquid, while 6 were empty. Bryant found fecal matter in 70 per cent. of his adult specimens, the others being either empty or containing foreign bodies of the usual description. These he finds to be more frequent in male than in female subjects.

The fecal matter within the appendix sometimes becomes hard and even calcareous, forming the so-called "fecal concretions." If present these are often seen and felt from the outside, their presence causing a swelling of the

appendix. They can readily be moved about within the lumen, provided they are not too large. If several of them come in contact with one another they are apt to appear faceted, in which case they may resemble gall-stones. Many cases are on record of foreign bodies which have entered the lumen of the appendix through the ceco-appendical valve; but these, together with the resulting pathological conditions, will be dealt with in another chapter. (See Chapter XVI.)

OBLITERATION OF THE APPENDIX.

While some authors, as BIERHOFF and FITZ, trace obliteration back to previous inflammatory conditions, others, as for instance, RIBBERT, consider it as a process of involution, which is a demonstration of the general retrogressive character of the organ. Each conception is, no doubt, correct if restricted to its separate process, that is to say, to pathological obliteration, or to involution. This section deals entirely with the latter, namely, obliteration due to involution advancing from the tip.

Obliteration is much more frequent than is generally supposed. In examining the appendix of a middle-aged person a probe will sometimes not pass through the lumen of the appendix. But occasionally, this obstacle may be overcome by more pressure, when the probe will penetrate through a narrow channel. If obliteration is complete, the opening of the appendix into the cecum is either not noticeable, or, if present, is indicated by a funnel-shaped depression. From without it is not always to be determined whether the lumen is obliterated or not. Generally the obliterated part is thinner than the partly obliterated portion, and much thinner than normal. There is, however, no absolute criterion. Only a great degree of lessening of calibre is a reliable test. On the other hand the obliterated portion may be thicker than the normal.

One true external test of obliteration is a club-shaped end of the appendix. This does not consist so much in thickening of the tip, as in thinning out of a neck-shaped portion just before it, an elongated oval portion differentiated from the rest of the organ being thus formed at the end. The club is generally as thick as the rest of the appendix, and may be thicker.

Extension of the Obliteration.—A transverse section of an obliterated appendix shows three distinct layers:

1. A central layer more or less rich in cells, corresponding to the mucosa, and gradually passing into:

2. A layer of connective tissue, poorer in cells, and corresponding to the submucosa.

3. A layer of muscle, and the usual serous envelopment.

The centre sometimes shows an indication of the original lumen. More careful observation shows that there may be no lumen at all, but merely a delicate zone of central tissue consisting of fibres and nuclei. It is possible to

tear this fragile substance, hence the possibility of piercing it by the use of greater pressure in testing the lumen with a probe.

The inner layer is often irregularly radiating, having a concentric arrangement of cells which follow the course of the original blood-vessels and glands. The differentiation between this layer and the second, the submucosa, is gradual. The muscle as a rule shows no change.

The manner in which obliteration takes place is best studied at the margin between normal and obliterated parts; the process is briefly as follows:

The glands become lost, and simultaneously there takes place a fusion of connective tissue between the glands. In some cases there is nothing abnormal to be noticed until the obliterated part itself is reached, the glands being preserved up to the very apex of the obliteration.

In other cases the glands in the neighborhood of the occlusion become more scarce and are seen to be less well developed; or they may be lacking altogether for some distance. On the advancing margin of the process of obliteration, and especially in the funnel or apex of the occlusion, there are none at all. In some cases there is a region 4 or 5 mm. before, or proximal to the seat of the obliteration, which is entirely lacking in glands. In one of RIBBERT's cases, ½ cm. before the obliterated portion there was found an area containing no glands, but still lined by a regular, single, well-developed layer of cylindrical epithelium with numerous *Becher Zellen*. Toward the cecum this became continuous with normal mucous membrane. As the surface epithelium was often lacking in the specimens, it was difficult to determine accurately the condition of the mucosa.

Obliteration is associated with a destruction of the glands. The fusing of the connective tissue advancing toward the cecum, forces the epithelium along with it. The follicles and glands at the tapering end of the funnel do not show any marked changes. The former are generally small, corresponding to those in normal appendices. They do not take part in the process of obliteraton as they simply disappear in the fusing connective tissue. In some isolated cases there are remains of them in the obliterated portion, appearing as small accumulations of densely packed cells, showing, rarely, a lighter centre. They are seen only in the angle or apex of the funnel, not in the obliterated portion itself. They lie centrally and are very few in number, only one or two appearing generally in a section.

Frequency.—Among the 400 cases examined by RIBBERT, 99 showed partial or total occlusion, *i. e.*, 25 per cent. In the appendices of persons over twenty years of age the percentage is about one-third, or 32 per cent.

While the obliteration in a very small number of cases, 3⅓ per cent., involved the entire appendix, partial occlusion is much more frequent. All transition forms, from the first beginning of occlusion to its completion, are met with.

In one-half the cases, the obliteration involves one-fourth of the appendix; in one-half of the remaining cases it involved one-fourth to three-fourths of

the organ; and, as was said above, only a very small percentage showed three-fourths or the whole appendix occluded. The sexes furnish about an equal number of cases.

Increase in age is shown to bring increase in obliteration:

1	to 10	years,	obliteration	found	in 4	per cent.
10	to 20	"	"	"	11	"
20	to 30	"	"	"	17	"
30	to 40	"	"	"	25	"
40	to 50	"	"	"	27	"
50	to 60	"	"	"	36	"
60	to 70	"	"	"	53	"
70	to 80	"	"	"	58	"

This table shows, therefore, that of all people over sixty years, more than one-half show obliteration.

In the new-born, obliteration was never found. The youngest child that showed it was five years, and this was not a typical case. In RIBBERT's series, a total obliteration never occurred before the thirtieth year. It is very probable that quite a number of these obliterated appendices were produced by pathological changes, for as age advances, the relative frequency of appendicitis increases in about the same ratio as that given in this table.

Relation between Length and Obliteration.—Of the longest appendices, 15 to 20 cm., all were found patent; of those 14 to 13 cm. long, one out of four had beginning obliteration; in a length of 12 to 11 cm., not one was obliterated.

The rest of the table shows that decrease of length generally brings an inclination to obliteration:

In	those	of 10	cm.	34	per cent.	was obliterated.
"	"	9	cm.	18	"	" "
"	"	8	cm.	32	"	" "
"	"	7	cm.	40	"	" "
"	"	6	cm.	30	"	" "
"	"	5	cm.	70	"	" "
"	"	4	cm.	66	"	" "
"	"	3	cm.	100	"	" "

While no absolute regularity can be made out, short appendices are, as a rule, found to be more frequently obliterated than long ones.

Causes of Obliteration.—The question whether old healed inflammatory conditions are the cause of obliteration can be determined in most cases by examining the entire serosa and mucous membrane, although there is

no doubt that even then it may sometimes be difficult to decide whether the process is not due to the other factor.

Serosa.—Adhesions of the appendix with surrounding organs are frequent and are a sign of old inflammatory conditions. Frequently a kink is found in an obliterated appendix, but since it has been found that every fourth appendix is obliterated with or without a kink, this proves nothing. Most appendices about to become occluded by involution are free of any adhesions and kinks.

Mucosa.—Signs of inflammation in the mucous membrane itself must, therefore, be sought for, but RIBBERT found none, which however does not necessarily prove that in a certain percentage of his cases they were not present at an earlier stage of the process.

The atrophy of the mucous membrane has apparently nothing to do with obliteration, because it occurs in appendices of old individuals with a wide lumen.

While RIBBERT and ZUCKERKANDL go too far in their assertion that obliteration is always caused by involution, there is undoubtedly a certain class of cases in which the pathological element may safely be excluded.

The presence of a layer of connective tissue strands, originating in the mucosa; the unchanged structure of the submucosa and muscularis; the lack of all irregularity and especially the lack of any scar-like change which might signify an old healed inflammatory process; all these are points which signify that involution is often the cause of obliteration. And, lastly, what disease would attack the end of the appendix with such regularity, beginning always at the tip and advancing toward the cecum, gradually closing up the lumen?

While pathological obliteration may occur at the tip, it is by no means confined to it, but is found frequently in other portions of the appendix. Microscopic sections will generally furnish means to distinguish such pathological obliteration from the distal obliteration due to involution.

RETROGRESSION.

The early differentiation of the appendix vermiformis from the cecum, of which it is but the continuation, its relatively greater length in the fetus and new-born as compared with the adult, together with many signs of atrophy in the organ during later life, seem to indicate that the appendix is a disappearing or retrogressive organ. In shape and outline the cecum shows considerable variation during the course of its development. Starting between the fifth and sixth weeks as a slight elevation or bulging from the left side of the caudal loop of the intestine, at seven weeks or more it is a rounded or conical projection, with a contracted portion at its apex or tip which appears like a budding appendix. This type of cecum, the s e v e n w e e k s stage, is permanently represented in anatomy by that of the Mangabey monkey. (See Fig. 63.) At e i g h t w e e k s, where the cecum is four or five times as

long as it is broad, but still scarcely differentiated from the cecum or end portion of the large intestine, we have the type of cecum represented by Ateles the Spider monkey (Fig. 61), and many other animals.

Later on, the tube increases greatly in length, but not correspondingly in thickness except in its upper portion. We now have a long, slender diverticulum, the appendix vermiformis, attached at its widened base to a rounded projection from the bowel, the cecum proper. At this stage the cecum may pass gradually into the appendix, forming the conical or typical fetal type of cecum. Something similar to this type is seen in the tapering cecum of the kangaroo (Fig. 65), and it is sometimes found persisting in the adult human body.

On examining the cecum of many of the higher animals, its shape and size are found to bear an important relation to the mode of alimentation. The herbivorous animals possess an enormous cecum, bending and curving like the human appendix, while in carnivora it is very small and simple, or may be entirely wanting. In man, apes, and many rodents, which have a mode of alimentation midway between these two, a portion of the cecum undergoes a retrogressive change, so that a thin, worm-like process is left attached to the cecal pouch. The retrogression is probably due to a change in the character of the nourishment which has taken place during the history of the species. According to Grohé, the disappearance of the last molar tooth, which comes late in life, is another indication of the change from an herbivorous to an omnivorous character in the diet of man. The relatively large size of the human cecum and appendix in the fetus and new-born indicate that this time does not lie very far back in the history of man.

It is the rudimentary character of the appendix which is responsible for much of the variation in position, shape, and size which we find in this structure.

According to Huntington the appendix is probably destined for further reduction and ultimate elimination. The appendix presents the indefinite character in regard to anatomical arrangement which belongs to such structures. The uncertain type of development due to this element expresses itself in the varieties of forms presented by the adult cecum.

While there is no doubt that the appendix has all the signs of an organ passing through the different steps of retrogression, the process being at the present time still in the initial stages, it cannot be denied that, as long as the organ is not obliterated, it is capable of performing its share of the work as a portion of the alimentary canal, though only on a comparatively small scale.

All structures of the human body which are not in constant use, soon become atrophied, a few weeks of non-use sufficing to cause the muscles to disappear. The same is the case with epithelial elements, which vanish if not called upon to functionate. The muscle, epithelial and endothelial cells are replaced by connective tissue cells, which in turn become absorbed to a certain extent. Such a process is observed, as we have learned, in about one-fourth of all ap-

pendices, and in a much larger percentage in old age. There remains, however, the overwhelming majority of appendices in children. in the middle aged, and even in very old individuals, which show no change indicating that the epithelial and muscular structures have ceased to functionate. The blood and lymph supply and the nerves are also very well developed and remain so during the greater part of life, or even throughout the whole of it. Even if the mucosa gradually undergoes atrophy as age approaches, the same is known to be the case with the cecal and colic mucosa (according to NOTHNAGEL, in 80 per cent. of the cases) or any other epithelial structures of the human body, in connection with which no one would apply the term "rudiment."

These facts indicate that the appendix retains for a considerable time the same energy as the cecum, and that its muscular coats are capable of producing an active peristalsis, perhaps of greater strength in relation to its size than is the case in any other part of the intestine.

CHAPTER VII.

ANATOMY.

THE ARTERIES OF THE APPENDIX. THE VEINS OF THE APPENDIX. THE LYMPHATICS OF THE APPENDIX. THE NERVES OF THE APPENDIX.

THE ARTERIES OF THE APPENDIX.

The vascular supply of the ileocecal region comes from the ileocolic artery, the lower division of the right colic branch, which in turn is derived from the superior mesenteric artery. There are but slight variations of the topography of the ileocolic artery, the most noteworthy of which is a separate origin from the superior mesenteric below that of the right colic branch.

The ileocolic artery passes obliquely downward in the mesentery toward the ileocolic angle, where it divides into the anterior and posterior ileocecal arteries, the appendical artery or arteries, an ascending colic branch, anastomosing with the right colic, and one or more branches to the ileum which anastomose with the adjacent loops of the *vasa intestini tenuis*, the terminal branches of the superior mesenteric. Short anastomoses are frequently found between these branches near their origin from the ileocolic artery, and as a result a somewhat complicated network arises, in consequence of which it is often difficult to determine the exact origin of the appendical and other arteries without careful dissection (Fig. 118 and Figs. 122–138).

The anterior ileocecal artery travels forward and obliquely downward over the cecum in the ileocolic fold (Fig. 118). The position of the fold is largely determined by the presence of the artery, which, together with its vein, is thus somewhat protected against extreme tension produced by abnormal distention of this portion of the intestine. The majority of the branches of the anterior ileocecal artery, from 4 to 8 in number, pass to the right over the cecum, being, as a rule, situated at the depth of the transverse depressions. They give off branches which pass out over the pouches of the cecum; while the main trunks continue outward and pass beneath the anterior muscular band. Here they break up into finer branches which anastomose with those of the posterior ileocecal artery. The anterior ileocecal artery also gives off one or more small branches to the terminal portion of the ileum. Usually there is but one such branch, which travels out on the surface of the ileum parallel with its axis and supplies its lower anterior wall, the upper portion being supplied by mesenteric branches. From this artery small branches frequently descend into the

ileocecal fold, which connects with the mesappendix, where they anastomose with branches arising from the appendix (Fig. 118).

The posterior ileocecal artery is not situated in a fold like the anterior ileocecal, and pursues a straighter and shorter course than the latter. It supplies the posterior wall of the cecum, its branches traveling in the depressions between the sacculæ like those on the anterior surface, then penetrating beneath the posterior muscular band and terminating in the lateral wall, anastomosing with branches of the anterior system. Besides the cecal branches, the posterior ileocecal artery may give off a branch passing through the mesentery to the ileum and one or more to the appendix. The lower branches of the posterior ileocecal artery frequently supply not only the median and posterior walls of the cecum, but crossing the line of attachment of the mesappendix they encroach upon the anterior surface of the cecum, anastomosing with the branches of the anterior ileocecal artery above and the artery of the appendix beneath.

The origin and number of arteries to the appendix vary considerably. (See Types I, II, III, and IV, Figs. 122–127, 128–131, 132–136, and 137–138.) In the majority of cases there is one main appendical artery which arises either from the ileocolic artery direct, or from the posterior ileocecal or one of its branches, or from a branch in the mesentery of the ileum near its origin. This appendical artery passes down behind the terminal portion of the ileum, and is enclosed between the two peritoneal leaves of the mesappendix. The formation of the latter is determined by the artery. It is usually found along the free edge of the mesappendix; in its upper portion, however, it may be some distance from it, or in cases where a large amount of fat is present in the mesappendix, its position may be still farther from the edge. In all but one of the cases examined it traveled to the very tip of the appendix, usually curving around the latter and penetrating it directly, as do the branches along the hilum or mesappendical border. (See Figs. 114 and 118.) In over one-third of the cases studied this main appendical artery supplied the entire appendix, Type I, and sometimes a little of the adjoining portion of the cecum (Type III, Fig. 132). In the remainder of the cases it supplied the distal four-fifths of the organ, while a second, or even a third appendical artery supplied the remaining proximal portion, (Type II, Figs. 128–131), and anastomosed with the cecal branches (Type III, Figs. 133–136 and Type IV, Figs. 137–138.)

The main appendical artery gives off, on an average, five secondary branches, which take a direct route to the appendix (Fig. 118). Frequently there are only three branches (Clado), yet in cases where the appendical arteries form loops, as many as ten or twelve branches are sometimes found. These branches pursue an oblique course in the mesappendix toward the hilum of the organ, and decrease in length as the mesappendix narrows down at the tip. In cases where the mesappendix appears to end some little distance from the tip, the artery may still be found just beneath the peritoneum, where it travels until it reaches the tip (Fig. 119). Some authors state that the mesappendix fre-

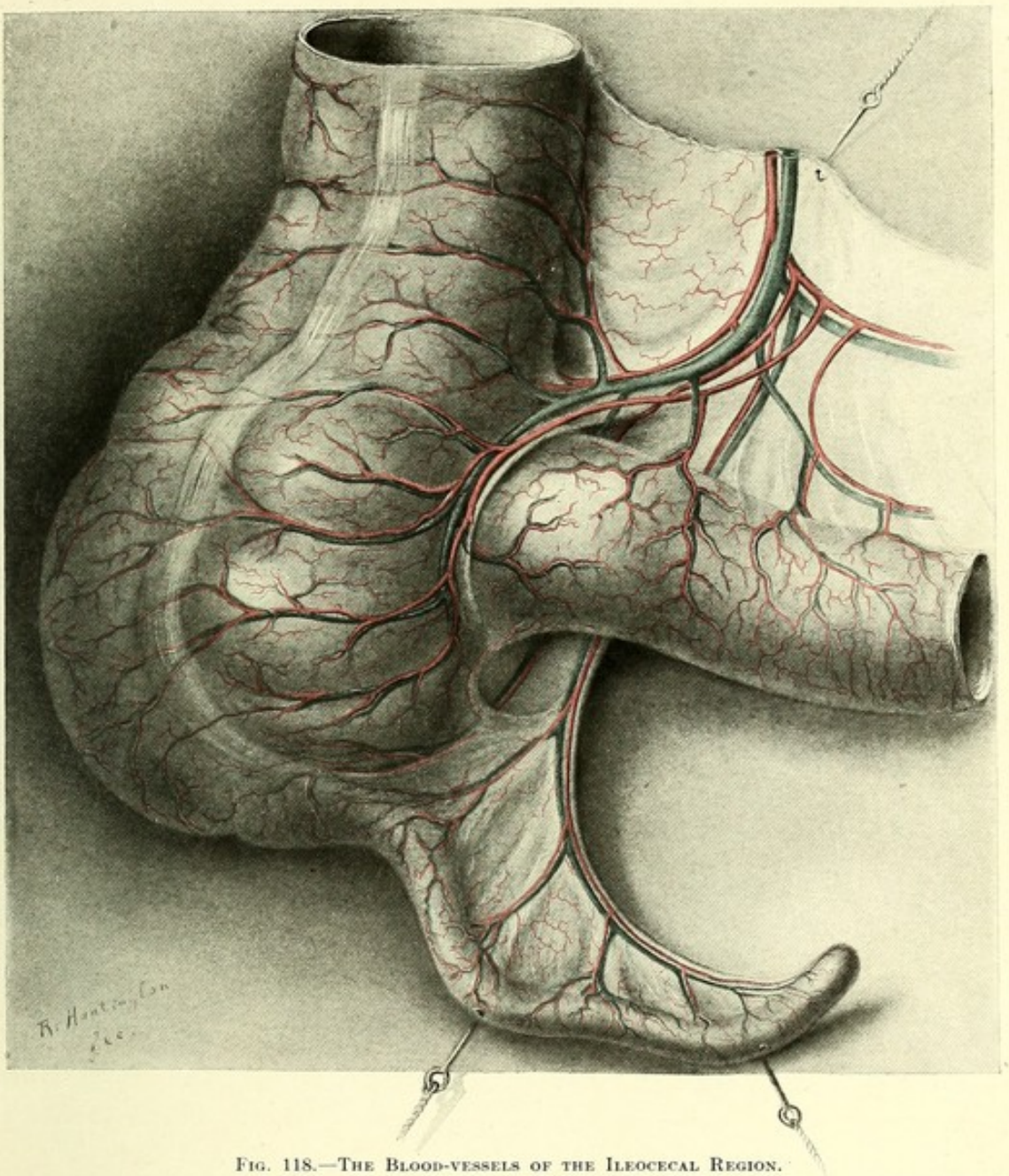

FIG. 118.—THE BLOOD-VESSELS OF THE ILEOCECAL REGION.

Arteries red, veins blue. The peritoneal covering is removed so as to show the vessels more clearly. Above and to the right are seen the cut ends of the ileocolic artery and vein. This artery gives off a branch to the ascending colon and a posterior and anterior cecal artery, the latter descending through the ileocolic fold. A short anastomosis connects the ileocolic with the mesenteric. The artery of the appendix is seen to arise from the posterior cecal artery, 2 cm. above the ileum. It passes behind the ileum in the free border of the mesappendix and gives off five branches (long appendices have 8–12, short appendices, 2–3), which traverse the mesappendix at fairly regular intervals in the direction of the hilum of the appendix, where they divide into anterior and posterior branches. The branches in the mesappendix are sometimes seen to anastomose, forming loops of varying size. The terminal branch curves around the tip. The ceco-appendical junction is supplied by a separate branch arising likewise from the posterior ileocecal trunk. This branch may or may not anastomose with the proximal appendical twig and while in some cases it supplies only the cecum, in others, as in the present case, it sends a few delicate branches into the appendix. At the place where this ceco-appendical artery crosses the ileocecal fold it is seen to give off a delicate recurrent twig to this structure. Throughout their entire course the arteries are accompanied by veins.

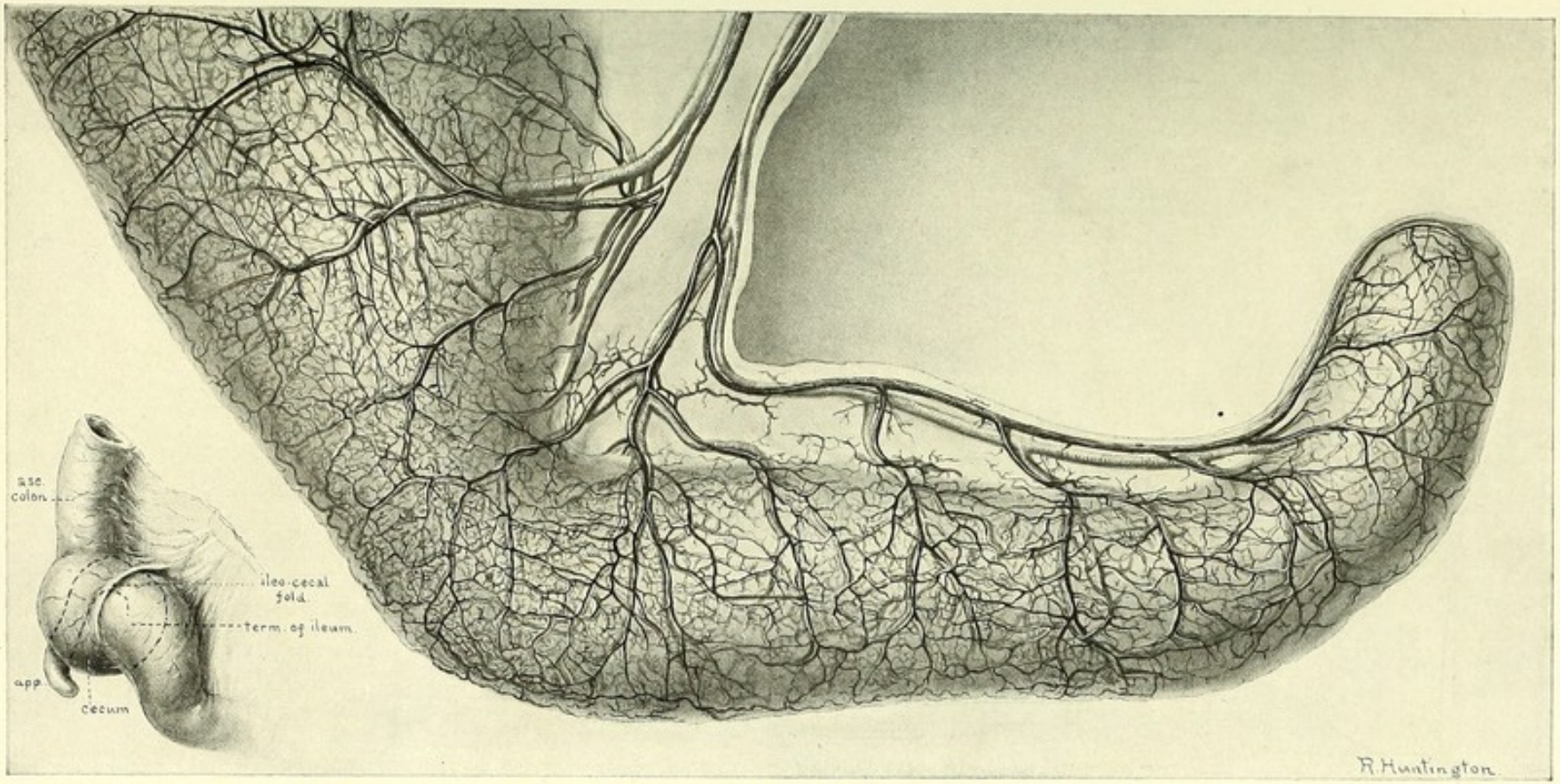

FIG. 119.—A COMPLETE INJECTION OF THE BLOOD-VESSELS OF THE APPENDIX OF A 7-MONTHS' FETUS, CLEARED IN CREOSOTE.

The vessels of all the coats are visible. To the left is a picture of the position of the appendix, drawn natural size. (Read "ileocolic" for "ileocecal" in this figure.) The arteries are of a darker color than the veins. The cecum is funnel-shaped and there is a slight bend indicating the beginning of the appendix. The blood-supply of the two organs is separate, except for a number of anastomosing vessels in the wall of the ceco-appendical junction, similar to those existing elsewhere in cecum and appendix. Most of these anastomoses are in the submucosa. The vessels along the free border show already a tendency to become tortuous, a condition very marked in the adult. The terminal branch of the artery of the appendix curves around the tip.


Mesappendix
Peritoneal coat
Mucosa
follicle
Ruth Huntington.
Circ. mus. c
Longit
Submucosa

FIG. 120.

FIG. 120.—RECONSTRUCTION OF THE BLOOD-SUPPLY OF THE APPENDIX, MAGNIFIED 16 TIMES.

The different coats of the appendix have been removed so as to show each layer and the character of its vascularization. Beginning from the left, we see the peritoneal or serous coat with its delicate vessels, and a few larger and tortuous ones. The next layer is the longitudinal muscle, the vessels of which run generally parallel with the muscle fibres. The veins in this layer anastomose very freely. The vessels of the next coat, the circular muscle, are also seen to follow the direction of the muscle fibres; they pass at right angles to the vessels in the longitudinal layer. There is free communication between the blood vessels of the two muscular coats. The submucosa has been partly removed so as to expose the large plexus of vessels contained in its interior. This is the largest plexus of the appendix, and from it all the vessels of the submucosa and mucosa are derived. Owing to the large anastomosing trunks in the submucosa it is possible to inject a comparatively large portion of the appendix through one of the subdivisions of the appendical artery in the mesenteriolum. To the right is a cross-section of the appendix, permitting a view of the corrugated or folded mucous surface with its numerous glandular openings. The apices of the follicles, which reach the mucous surface, are not represented in this section. The circulation of the mucosa is more clearly shown in Fig. 121. Along the upper margin of the mesappendix is the main artery with its accompanying vein. From it the smaller branches run obliquely down to the appendix, dividing and subdividing at varying points before they reach the hilum. Some of the smaller branches enter the outer coats, while the larger trunks pierce the muscular layer at the hilum to form the submucous plexus. The veins in the mesenteriolum anastomose much more freely than the arteries.

Fig. 120.—Diagrammatic view of the Arrangement of the Tunics.

The different coats of the appendix have been removed so as to show each layer and the character of its vascularization. Beginning from the left, we see the peritoneal or serous coat with its delicate vessels, and a few larger and tortuous ones. The next layer is the longitudinal muscle, the vessels of which run generally parallel with the muscle fibres. The veins in this layer anastomose very freely. The vessels of the next coat, the circular muscle, are also seen to follow the direction of the muscle fibres; they pass at right angles to the longitudinal layer. There is free communication between the blood vessels of the two muscular coats. The submucosa has been partly removed so as to expose the large vessels contained in its interior. This is the largest plexus of the appendix, and from it all the vessels of the submucosa and mucosa are derived. Owing to the large anastomosing trunks in the submucosa it is possible to inject a comparatively large portion of the appendix through one of the subdivisions of the appendicial artery in the mesentericolum. To the right is a cross-section of the appendix, permitting a view of the contained or folded mucous surface with its numerous glandular openings. The spices of the follicles, which reach the mucous surface, are not represented in this section. The circulation of the mucosa is more clearly shown in Fig. 121. Along the upper margin of the magnification is the artery with its accompanying vein. From it the smaller branches run obliquely down to the appendix, dividing and subdividing at varying points before they reach the lilum. Some of the smaller branches enter the outer coats, while the larger trunks pierce the muscular layer at the lilum to form the submucous plexus. The veins in the mesenteriolum anastomose much more freely than the arteries.

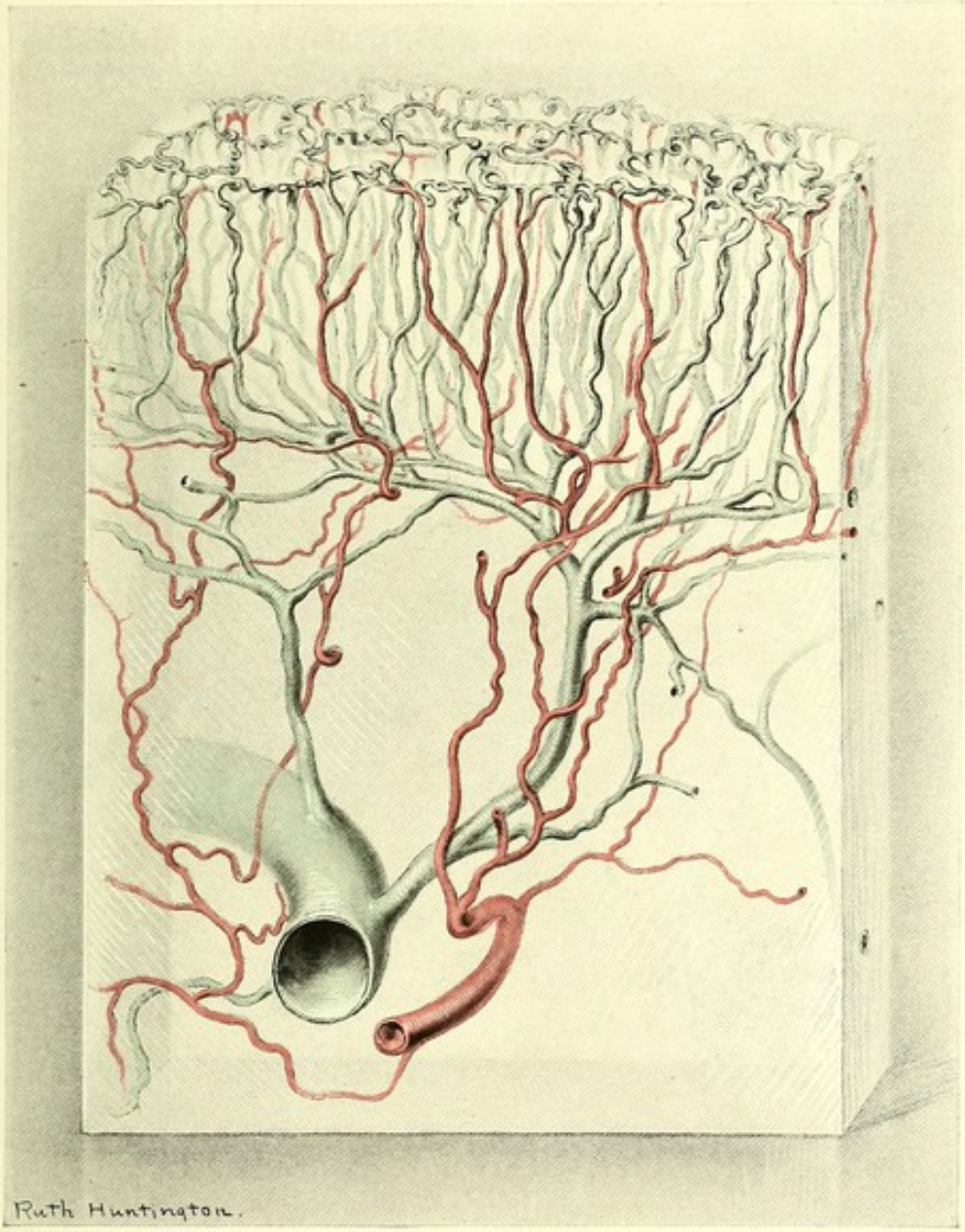

FIG. 121.—A PORTION OF THE MUCOSA, INJECTED AND CLEARED IN CREOSOTE, TO SHOW THE BLOOD-VESSELS. MAGNIFIED 80 TIMES.

Below are the vessels of the submucosa. The artery ascends, dividing until the base of the glands is reached, where a small plexus is formed, from which delicate twigs invade the tunica propria between the glands. Around the mouths of the glands there is a tortuous capillary network. (See also mucous surface of reconstruction, Fig. 120.) The descending collecting veins form a miniature forest between the glands whose roots is the venous plexus at the base of the glands This plexus drains into the submucous plexus.

quently extends only two-thirds or even one-half the length of the appendix, and that the artery, penetrating the hilum some distance from the tip, may leave the terminal portion insufficiently supplied with blood and therefore subject to disease. Our observations, however, demonstrate that this is not the case.

Having reached the hilum of the appendix each branch of the appendical artery subdivides into two or more sub-branches before penetrating the coats. The division usually takes place close to the mesenteric border or hilum, but it may occur farther up in the mesappendix (Figs. 118 and 120). These branches separate on either side of the appendix and form two main systems within the coats,—the superficial in the serous coat, and the deep in the submucosa. They contain the largest vessels and are the bases of blood-supply for the other coats (Fig. 120). Those which lie just beneath the peritoneum may be seen from the surface pursuing, sometimes, a very tortuous path and standing out prominently in cases of inflammation of the appendix. They pass around the sides of the appendix, dividing into numerous ramifications and frequently anastomosing along its free border. Most of the superficial large vessels remain immediately beneath the serous coat, and from them finer branches are sent inward which supply the muscular coats. They follow, in general, the direction of the fibres, passing longitudinally down the appendix in the outer coat and around it in the inner or circular coat. The arteries in these coats are delicate, the supply being not conspicuously great between the two coats.

The large vessels which penetrate the muscular coats at the hilum, after giving off small branches to the adjacent tissue, pass directly into the submucosa, where they form a close network about half way between the muscular and mucous coats (Fig. 120). From this network a few branches are sent outward into the muscular coats, but the majority of its branches go toward the mucous coat. Leaving the large vessels in the submucosa they ramify around the follicles and at the base of the glands, supplying each with numerous fine branches. Viewed from the mucous surface of an injected specimen, cleared in creosote, large vessels may be seen ascending vertically between the follicles, and numerous branches are seen entering the lymph-follicles from all sides and converging toward the centre of each. At the base of the glands of Lieberkühn the arteries usually spread out for some distance parallel with the fibres of the muscularis mucosa, and from this system the finer branches ascend between the glands (Fig. 121). They pursue either a straight or oblique course, branching in a fork-like manner and terminating in a capillary network around the mouths of the glands. Concerning the further course of the appendical blood see "Veins," p. 166.

The mesappendix is everywhere supplied with a network of anastomosing vessels, and near the appendix they frequently form arches between the larger trunks. The masses of fat, wherever present, are richly supplied with a network of very delicate vessels.

Through a canula inserted into one of the four or five branches of the

appendical artery, more than one-half of the appendix may be injected at once, which demonstrates connection between the areas supplied by the different branches. If one near the cecum be chosen, a circular area of the cecum around the appendical orifice, measuring from 1 to 2 cm. in diameter, may be injected as well as the appendix. This may be done in three ways,—I, through a small cecal twig or twigs coming off from the appendical branch near the ceco-

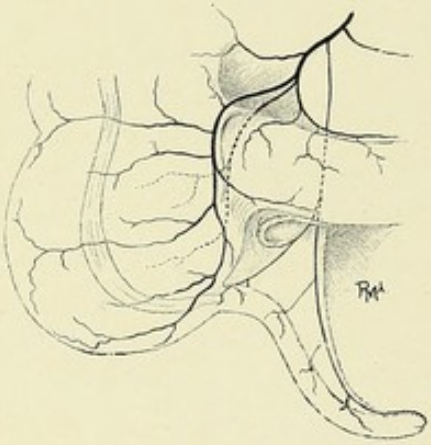

Fig. 122.—Type I, a. One Artery, Supplying only the Appendix. Origin: Ileocolic.

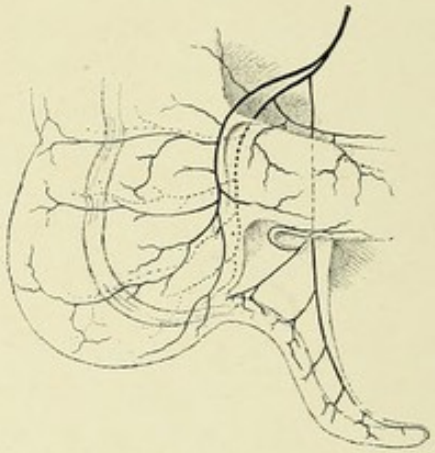

Fig. 123.—Type I, b. One Artery, Supplying only the Appendix. Origin: Posterior Ileocecal.

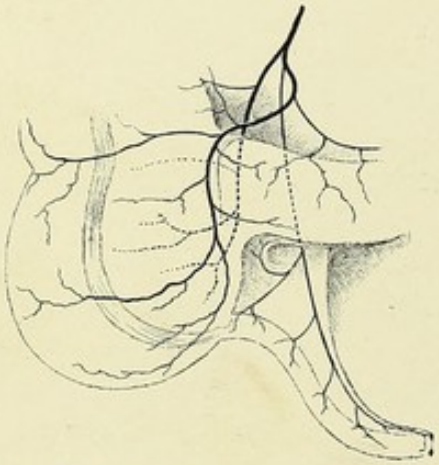

Fig. 124.—Type I, c. One Artery, Supplying only the Appendix. Origin: Anterior Ileocecal.

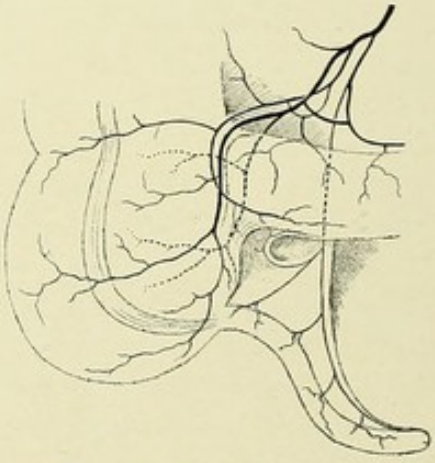

Fig. 125.—Type I, d. One Artery, Supplying only the Appendix. Origin: Mesenteric Branch of Ileocolic.

appendical angle (Figs. 132–136); II, through a broad arterial communication inside the wall of the ceco-appendical junction such as shown in Fig. 119; III, if neither the cecal twig nor an arterial anastomosis is present, the injection mass passes through the capillaries of the appendico-cecal junction and invades the adjacent cecal territory through the venous system, whose branches anastomose more freely than those of the arteries.

The appendical artery or one of its proximal branches usually gives off a

recurrent branch to the ileocecal fold, the "*artère récurrent iléale*" of JONESCO (Fig. 118 and Types I, II, III, and IV, Figs. 122–138). It travels upward along the free margin of the fold, following the curve described by the latter and giving off a number of fine branches along its course. The constant presence of this artery disproves the old belief that this fold is bloodless.

Some authors state that they have observed a vascular connection between

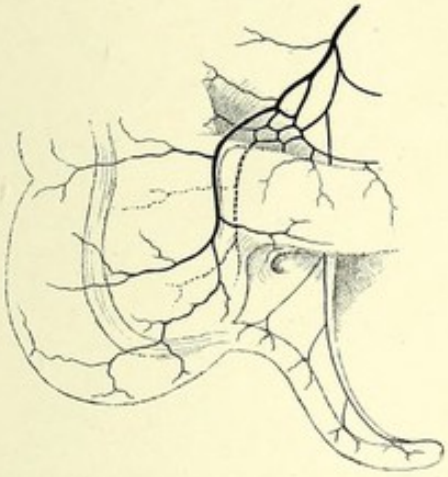

FIG. 126.—TYPE I, e. ONE ARTERY, SUPPLYING ONLY THE APPENDIX. ORIGIN: LOOP OF MESENTERIC BRANCH.

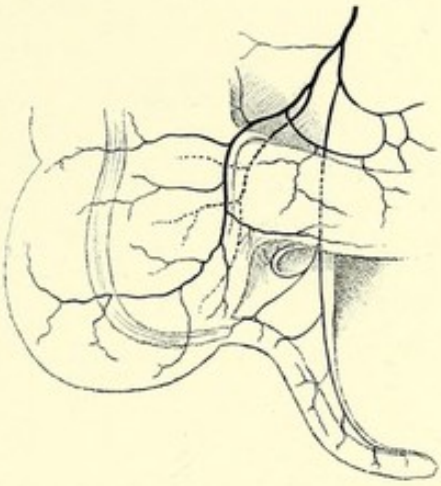

FIG. 127.—TYPE I, f. ONE ARTERY, SUPPLYING ONLY THE APPENDIX. ORIGIN: UPPER BRANCH OF MESENTERIC.

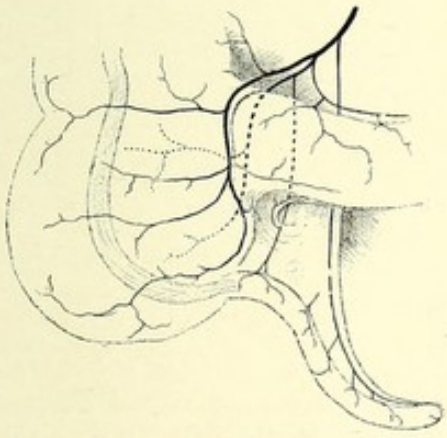

FIG. 128.—TYPE II, a. TWO ARTERIES, SUPPLYING ONLY THE APPENDIX. ORIGIN: ILEOCOLIC AND POSTERIOR ILEOCECAL.

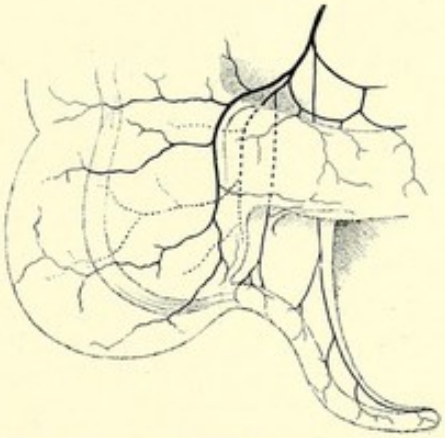

FIG. 129.—TYPE II, b. TWO ARTERIES, SUPPLYING ONLY THE APPENDIX. ORIGIN: MESENTERIC BRANCH AND POSTERIOR ILEOCECAL.

the appendix and the right ovary through the appendico-ovarian ligament. This, however, is not often found, some authors having failed to see it even among a large number of cases. It is probably merely one of the folds formed in the peritoneal reflection of the mesappendix over the posterior abdominal wall, and supplied with the usual vessels of the peritoneum, but it is not likely that the appendix itself receives in this manner any collateral arterial circula-

tion. There is, however, an occasional venous anastomosis between the appendical vein and the ovarian vein, such as are found between any neighboring organs in the human body. The fact that the circulation of both the ovary and the appendix is completely established before the two organs come into close proximity during their fetal development, is an additional disproof of the existence of an anastomosing arterial branch.

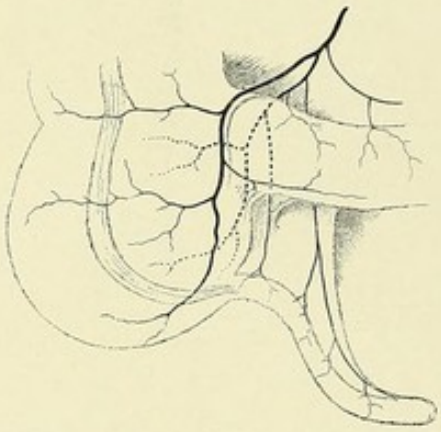

FIG. 130.—TYPE II, c. TWO ARTERIES, SUPPLYING ONLY THE APPENDIX. ORIGIN: POSTERIOR ILEOCECAL.

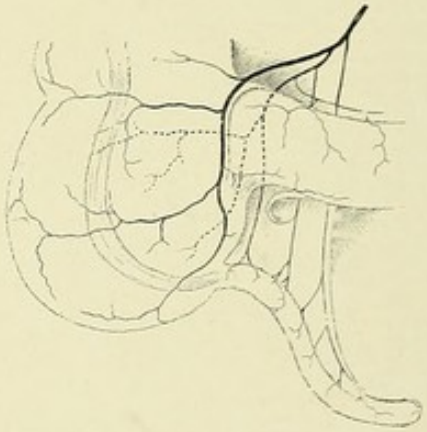

FIG. 131.—TYPE II, d. THREE ARTERIES, SUPPLYING ONLY THE APPENDIX. ORIGIN: ONE FROM ILEOCOLIC AND TWO FROM POSTERIOR ILEOCECAL.

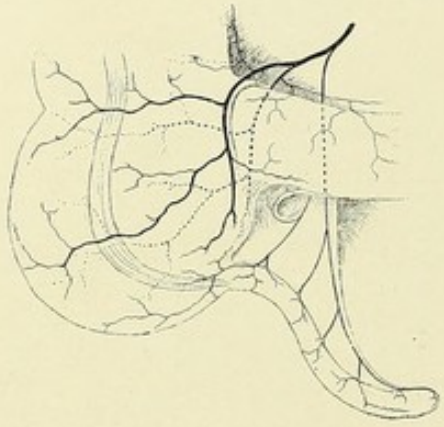

FIG. 132.—TYPE III, a. ONE ARTERY. ORIGIN: ILEOCOLIC. PROXIMAL BRANCH SUPPLIES A PORTION OF THE CECUM.

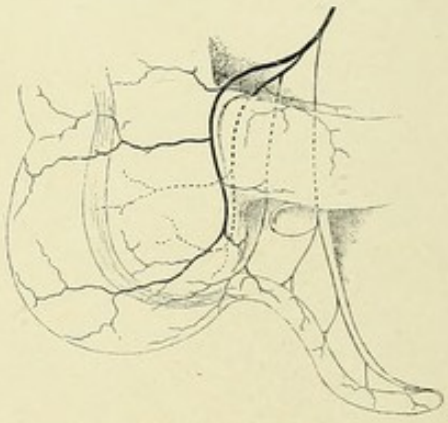

FIG. 133.—TYPE III, b. TWO ARTERIES. ORIGIN: ILEOCOLIC AND POSTERIOR ILEOCECAL. THE PROXIMAL ARTERY SUPPLIES A PORTION OF THE CECUM.

The arrangement of the main arteries of the appendix may be classed according to four types:

Type I (Figs. 122–127). A single appendical artery supplies the entire appendix, but no portion of the cecum, with the exception of minute anastomosing channels between them. The origin of this artery varies considerably, but in the majority of cases it comes from the ileocolic direct. To this type belong about one-third of the cases studied. Some of the many variations

of this type are shown in the diagrams, a study of which would be preferable to a long description.

Type II (Figs. 128–131) includes those cases where there is more than one appendical artery. The first arises as in Type I and supplies usually the distal four-fifths of the organ, while the remaining proximal portion is supplied by

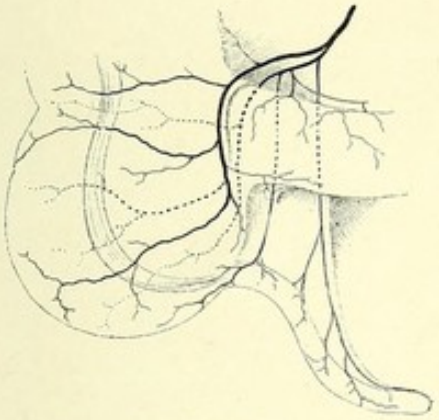

FIG. 134.—TYPE III, c. TWO ARTERIES. ORIGIN: POSTERIOR ILEOCECAL. THE PROXIMAL ARTERY SUPPLIES A PORTION OF THE CECUM.

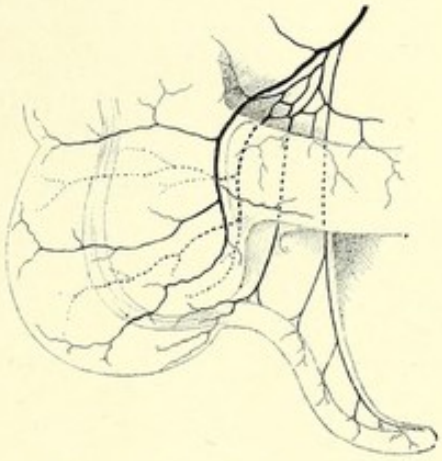

FIG. 135.—TYPE III, d. TWO ARTERIES. ORIGIN: ILEOCOLIC AND MESENTERIC LOOPS. THE PROXIMAL ARTERY SUPPLIES A PORTION OF THE CECUM.

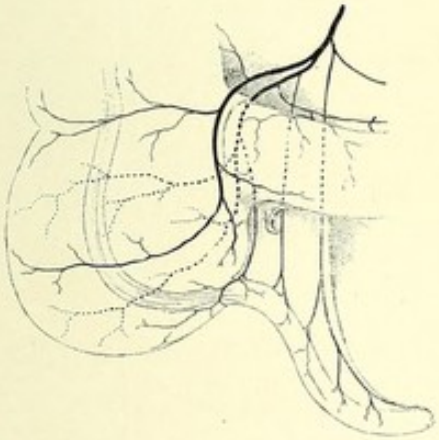

FIG. 136.—TYPE III, e. THREE ARTERIES. ORIGIN: ONE FROM MESENTERIC BRANCH OF ILEOCOLIC AND TWO FROM POSTERIOR ILEOCECAL. THE PROXIMAL ARTERY SUPPLIES A PORTION OF THE CECUM.

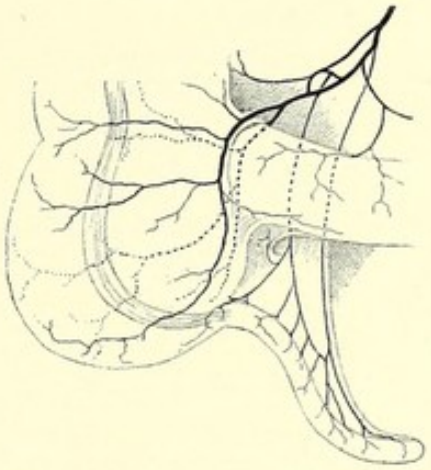

FIG. 137.—TYPE IV, a. TWO ARTERIES, FORMING A LOOP IN THE MESAPPENDIX FROM WHICH THE INDIVIDUAL BRANCHES ARISE.

a second, and occasionally a third appendical artery arising from the posterior ileocecal. It is very seldom that any communicating branches are found between the individual arteries; the proximal branch, however, often sends small twigs into the adjacent cecal wall. About one-fourth of the cases belong to this type.

Type III (Figs. 132–136) includes those cases where a single or several

appendical arteries supply both the appendix and a considerable portion of the cecum. It is quite common to find an artery arising from the posterior cecal which courses in the mesappendix, close to the cecum, and which is directed toward the appendico-cecal angle, supplying not only the proximal portion of the appendix but several square inches of the adjoining portion of the cecum. This type also includes one-fourth of the cases. An operative significance of this condition lies in the danger of cutting off the blood-supply to a portion of the cecum by ligating the proximal appendical artery.

Type IV (Figs. 137 and 138) is not often found and is distinguished by the presence of loops or arches between the main arteries, similar to those in the mesentery. It is generally associated with a very long appendix. Sometimes there is but one such arch, but two and occasionally three have been observed. From the lower or convex side of the arches arise the appendical branches proper, usually greater in number here than in the previous types.

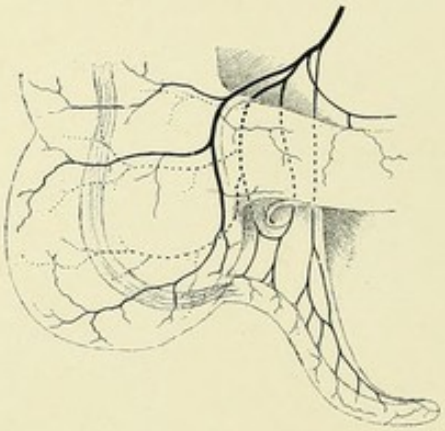

Fig. 138.—Type IV, b. Three Arteries, the Distal Artery Forming a Small Loop, while the Other Two Form a Larger Proximal Loop. The Number of Individual Branches to the Appendix is Increased.

Jonesco speaks of four branches or sets of branches coming from the main appendical artery: (1) to the posterior wall of the cecum; (2) to the cecoappendical angle; (3) to the appendix; and (4) a recurrent branch into the ileocecal fold, the "*iléo-appendiculaire*" or "*artère récurrent iléale.*" According to our researches these four branches may occur in one case, but there are a great number of instances in which the appendical artery gives rise merely to the recurrent branch into the ileocecal fold, and the cecum and cecoappendical angle are supplied by separate branches from the posterior cecal artery.

THE VEINS.

Just beneath the surface epithelium, between the glandular openings, the capillaries are seen to form a tortuous plexus (Figs. 120 and 121), which drains through short venous channels running parallel to one another and to the

glands down into the venous network of the muscularis mucosa. These branches are larger and more numerous than the arterioles of the mucosa. On their way two or three of them often unite to form a larger vessel. In the submucosa the veins converge in bundles to be gathered into a few large channels, passing in the submucosa parallel with the muscular coats. These vessels also receive the veins of the follicles and those of the submucosa proper. The latter are but few and small.

The veins of the muscular coats drain partly into the submucous plexus, partly into the superficial plexus, the majority selecting the latter course. The direction of the small venules is parallel with the muscle bundles (Fig. 120). While the small vessels of the circular coat anastomose to some extent with those of the longitudinal coat, the larger veins remain independent and do not communicate until they reach the hilum. The veins of the longitudinal coat and serosa drain either in large tortuous trunks running for a considerable distance along the surface of the appendix before turning toward the hilum, or they drain in small and short channels which pass directly toward the hilum (Fig. 120). The degree of tortuosity varies with the degree of contraction and relaxation of the muscular coats of the appendix.

The union between the different venous channels of the superficial and deep systems takes place either close to the mesappendical border or somewhat further up in the mesappendix. There are also numerous anastomoses of the larger veins, especially in the submucous plexus (Fig. 120).

Throughout their entire course inside the appendix the veins in general lie central to the arteries.

In the mesappendix the veins course close to the arteries, the latter passing, as a rule, nearer to the mesappendical border (Fig. 118). All the veins collect into one large vessel, or sometimes into two or three. If two are present, the second is found in close proximity to the cecum. The main appendical vein occasionally crosses the artery in the middle of its course, and in the vicinity of the tip we find the artery nearer the free border, while higher up the vein occupies that position; or the condition may be reversed.

In the ileocolic angle, about 3 cm. from the intestine (Figs. 118 and 139), the appendical vein joins the veins coming from the adjacent section of the intestine. As a rule, it drains first into the posterior ileocolic branch, although it may empty into any vein in the neighborhood, as, for instance, into the mesenteric vein, coming from the terminal portion of the ileum (Fig. 118), or into the anterior ileocolic branch coming up in the ileocolic fold. United, these branches form the ileocolic vein. Running upward, it joins branches coming from the ascending colon and also from the hepatic flexure. It has now become the right colic branch. This finally drains into the superior mesenteric vein just in front of and below the duodenum. The other tributaries of the superior mesenteric vein from below up are: on the left side the veins of the small intestine, on the right side above the right colic the pancreatico-

duodenal branches. Near its junction with the inferior mesenteric vein the superior mesenteric vein receives the v. gastro-epiploica dextra. The other veins of the stomach and pylorus, as well as the splenic vein, drain into the inferior mesenteric or into the portal vein just before its entrance into the liver (Fig. 139).

Under normal conditions, therefore, the blood from the appendix drains through the superior mesenteric and portal veins into the liver; *i. e.*, from the periphery toward the centre. If the centre be the seat of an obstruction, the portal system being blocked up by a pathological process, the blood seeks other channels, which are found in a certain number of preëxisting collateral branches, as a rule of small size, which establish a direct communication between the portal system and the venæ cavæ. As the entire portal system has no valves, the flow of blood is possible in any direction. It depends upon the seat of obstruction in which direction the blood will find its way. In doing so it selects the most convenient channels, which in this manner become dilated, reaching in certain instances considerable dimensions.

Such veins have been described by Retzius, Sappey, and others, and through them infections of appendical origin are supposed to be communicated from the portal system to the systemic, to enter the lungs by way of the venæ cavæ and heart.

These venous anastomoses are as follows:

1. Communication between the coronary vein of the stomach (gastric) (Fig. 139), the veins of the esophagus, and the v. azygos major, through which the blood reaches the superior vena cava and the heart. There is also often found an anastomosis between the coronary and the diaphragmatic veins, more rarely between the coronary vein of the stomach and of the gastro-epiploic with the renal vein, or of the superior mesenteric with the left renal vein. The vasa brevia passing between the splenic veins and the stomach occasionally anastomose with the left phrenic vein.

2. There is a communication between the sigmoid branch of the left colic vein through the superior, middle, and inferior hemorrhoidal veins into the hypogastric, iliac, inferior vena cava, and heart; or from the sigmoid flexure and rectum to the spermatic or ovarian veins (Retzius).

3. Communicating branches exist between the veins of the cecum, colon, appendix, and the adjacent peritoneum on the one hand, and the spermatic or ovarian on the other; or the blood drains into the ilio-lumbar vein or circumflexa ilium profunda, and through them into the inferior vena cava and heart.

Along the lateral and posterior surfaces of the cecum and the adjacent portion of the colon there are numerous small vessels, communicating with the venous plexuses of the outer coats of the intestine, which drain into the veins of the posterior abdominal wall, and as the venous network of the appendix and cecum communicate freely, the blood from the appendix is apt

FIG. 139.—THE VEINS OF THE APPENDIX AND THEIR RELATION TO THE PORTAL AND SYSTEMIC CIRCULATION.

Above the diaphragm is seen the heart, imagined transparent so as to show the azygos veins and their communication with the veins of the esophagus.

Lateral to the cecum are a number of subserous branches, which establish a communication between the veins of the ileocecal region on the one hand, and the veins in the iliac fossa, on the other; i. e., between the portal and the systemic circulation.

FIG. 139.—THE VEINS OF THE APPENDIX AND THEIR RELATION TO THE PORTAL AND SYSTEMIC CIRCULATION.

Above the diaphragm is seen the heart, imagined transparent so as to show the azygos veins and their communication with the veins of the esophagus.

Lateral to the cecum are a number of subserous branches, which establish a communication between the veins of the ileocecal region on the one hand, and the veins in the iliac fossa, on the other; *i. e.*, between the portal and the systemic circulation.

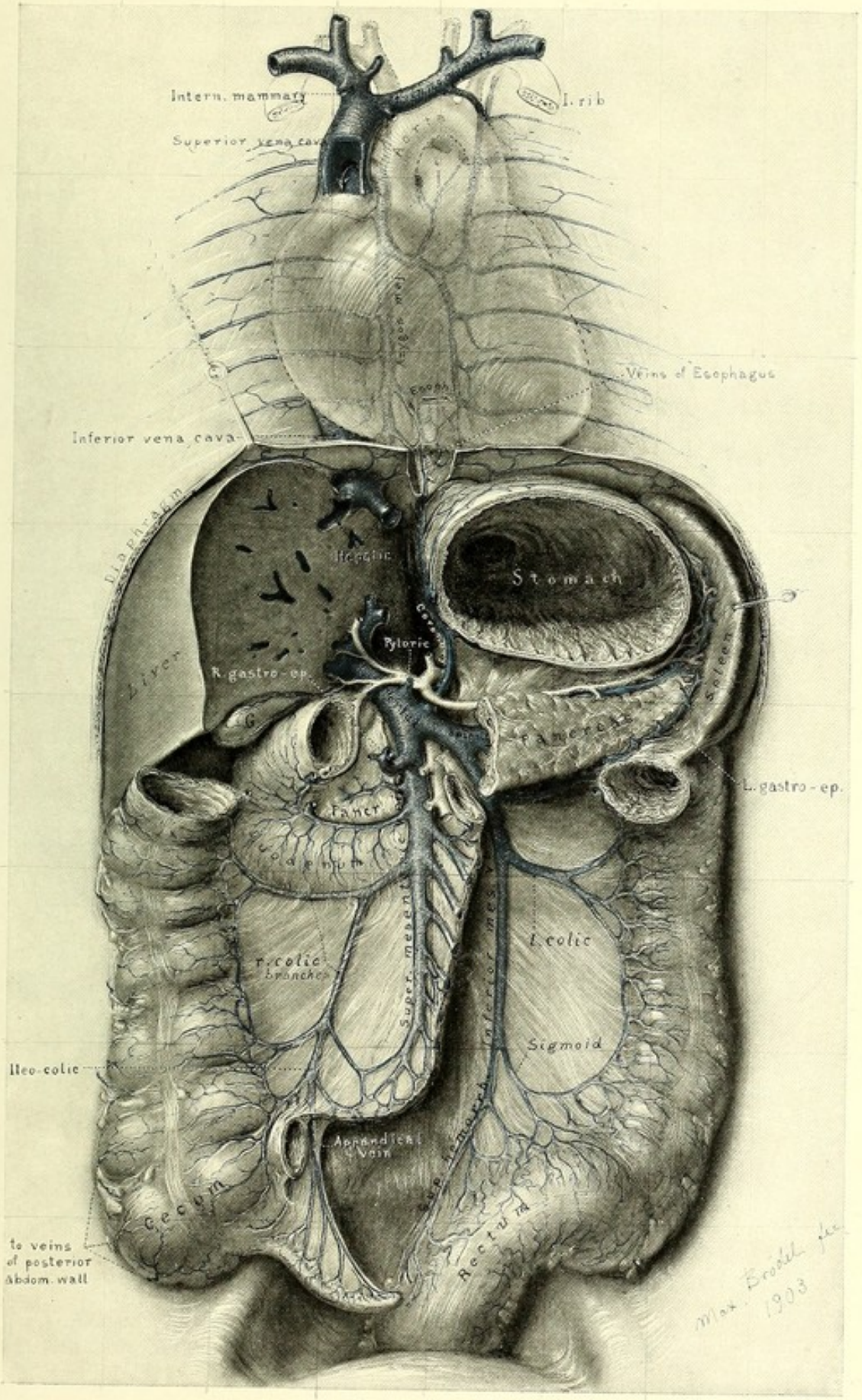
Intern. mammary
I. rib
Superior vena cava
Aorta
Azygos maj.
Veins of Esophagus
Esoph.
Inferior vena cava
Diaphragm
Hepatic
Stomach
Pyloric
Liver
R. gastro-ep.
Spleen
Pancreas
L. gastro-ep.
Pancr.
Duodenum
Super. mesent.
Inferior mes.
I. colic
r. colic branches
Sigmoid
Ileo-colic
Appendical vein
Cecum
Rectum
to veins of posterior abdom. wall
Max Brödel fec. 1903

FIG. 139.

to select these channels in cases of obstruction of the main appendical, ileocolic, superior mesenteric, or portal veins (Fig. 139).

4. There are occasional anastomosing twigs between the veins of the fixed portions of the alimentary canal; viz., duodenum (RETZIUS), hepatic flexure, and splenic flexure of the colon, as well as of those of the pancreas and the veins of the posterior abdominal wall.

5. The veins described by SAPPEY, which pass from the adjacent structures of the liver, and from the umbilical region between the folds of the suspensory ligament of the liver to drain into the portal system, belong also in this group. While the former branches anastomose above with the phrenic and the azygos veins, the latter communicate with the epigastric veins and the superficial veins of the abdominal wall, internal mammary, etc. The largest of these branches accompanies the round ligament of the liver and drains into the left branch of the portal vein. While under normal conditions the flow of blood in these vessels is toward the liver, in cases of obstruction of the portal system the direction of the flow is reversed, and as a consequence the superficial veins of the abdomen and thorax become much distended, some of the main channels attaining the size of the little finger.

Adhesions of the liver to the diaphragm are also often carriers of new vascular channels.

The veins in groups 1, 3, and 4 are most apt to become carriers of blood from the appendix in cases of obstruction of the upper portal system.

THE LYMPHATICS OF THE APPENDIX.

General Considerations.—Owing to the valvular character of the lymphatic channels, which, like the veins, do not permit a backward flow of their contents, the lymphatics must be injected from the periphery toward the centre. Infectious matter must therefore travel in a similar manner. It cannot be carried through lymph channels from one part of the appendix to another, but must pass directly into the mesappendix and thence into the first group of glands.

The superficial system may be injected by inserting the needle of a hypodermic syringe just beneath the peritoneum and introducing an aqueous solution of Prussian blue, to which a few drops of gelatin may be added to advantage to prevent granulation of the injection-mass. India ink and mercury have also been used, but the best results were obtained from the Prussian blue. Only a limited area, varying from the size of a finger nail to that of a silver dollar, or perhaps more, can be completely injected through any one such puncture. The larger vessel or vessels draining the area are always injected with it, and can be traced with ease up to their entrance into the gland. If it is impossible to obtain an injection of the delicate surface capillaries so as to render the larger channels visible also, the latter may be injected directly

by inserting the needle into the opaque, whitish-yellow channels following the blood-vessels. Tributary vessels are not injected backward from these large channels on account of the valves situated at the mouths of the smaller vessels. Within an area bordered by larger collecting channels, all the delicate surface capillaries are completely injected by one puncture, but beyond this area not a single capillary receives the injection-mass. This demonstrates the existence of valvular structures at the junction between the capillaries and the first system of collecting vessels. It demonstrates also the absence of valves in the capillaries. A focus of infection inside such an area would therefore be practically isolated from the rest of the appendix, as far as the lymph system is concerned, its only communication with the first glandular station being through its large lymphatic drainage channel. A parallel to this is found in the capillary venous network of the intestine, similar limited areas being demonstrated by injection. A dense interlacing network of capillary vessels (called "*rete mirabile*") is caused by the sudden breaking-up of larger vessels.

A large number of punctures are required to completely inject the superficial system. Some of the deeper lymphatics are often injected at the same time through channels connecting them with the superficial system. The injection may also be made from the mucous surface, but with far less success. The network at the base of the mucous glands and around the follicles may thus be demonstrated, and a few of the fine lymph canaliculi running between the glands.

After having filled all the surface capillaries of the desired region, a certain number of large lymphatic channels are filled, which represent the drainage tubes for all the lymph capillaries contained in the region. They are seen to converge in characteristic fashion, though subject to great variation, until they drain into smaller or larger glands. Small glands receive from one to two such afferent vessels, while the larger glands receive from three to six or more. As a rule, the smaller glands are situated near the periphery, the larger ones nearer the centre. The injection-mass generally stops at the glands, but the study can be made still more complete by injecting into each individual gland, inserting the needle into the peripheral portion receiving the afferent vessels and forcing the injection-mass toward the centre. It is taken up by the efferent vessels, usually less in number than the afferent, and carried to the next station of glands, situated higher up—that is, more centrally. In this manner the entire lymphatic system of the appendical and ileocecal region can be studied. Throughout their entire course the larger lymphatics, as well as the glands, are generally situated along the course of the blood-vessels. Should the injection-mass, on insertion of the injection needle, pass not only into the lymphatics, but fill the vascular system at the same time, the lymphatics are easily distinguished by their beaded structure and also by the angular character of their course.

About forty specimens, including cecum, ileum, and appendix, were in-

FIG. 140.—A RECONSTRUCTION OF THE LYMPHATIC SYSTEM OF THE APPENDIX, SHOWING THE THREE STRATA OF LYMPHATICS, MAGNIFIED 20 TIMES.

The specimen is drawn semitransparent so as to show the direction of the channels in the depth. I. The superficial system is found in the serosa. It consists of a delicate anastomosing network just beneath the peritoneum and a layer of larger beaded channels immediately beneath. II. The middle system, situated between the muscular coats and submucosa, receives comparatively few tributaries from the two coats. III. The deep system, forming a double layer at the base of the glands, receives the delicate finger-like capillaries of the mucosa and the channels coming from the lymph sinuses around the follicles. The collecting channels of the deep system drain either into the middle system or through the submucosa toward the hilum.

FIG. 140.—A RECONSTRUCTION OF THE LYMPHATIC SYSTEM OF THE APPENDIX, SHOWING THE THREE STRATA OF LYMPHATICS, MAGNIFIED 20 TIMES.

The specimen is drawn semitransparent so as to show the direction of the channels in the depth. I. The superficial system is found in the serosa. It consists of a delicate anastomosing network just beneath the peritoneum and a layer of larger beaded channels immediately beneath. II. The middle system, situated between the muscular coats and submucosa, receives comparatively few tributaries from the two coats. III. The deep system, forming a double layer at the base of the glands, receives the delicate finger-like capillaries of the mucosa and the channels coming from the lymph sinuses around the follicles. The collecting channels of the deep system drain either into the middle system or through the submucosa toward the hilum.

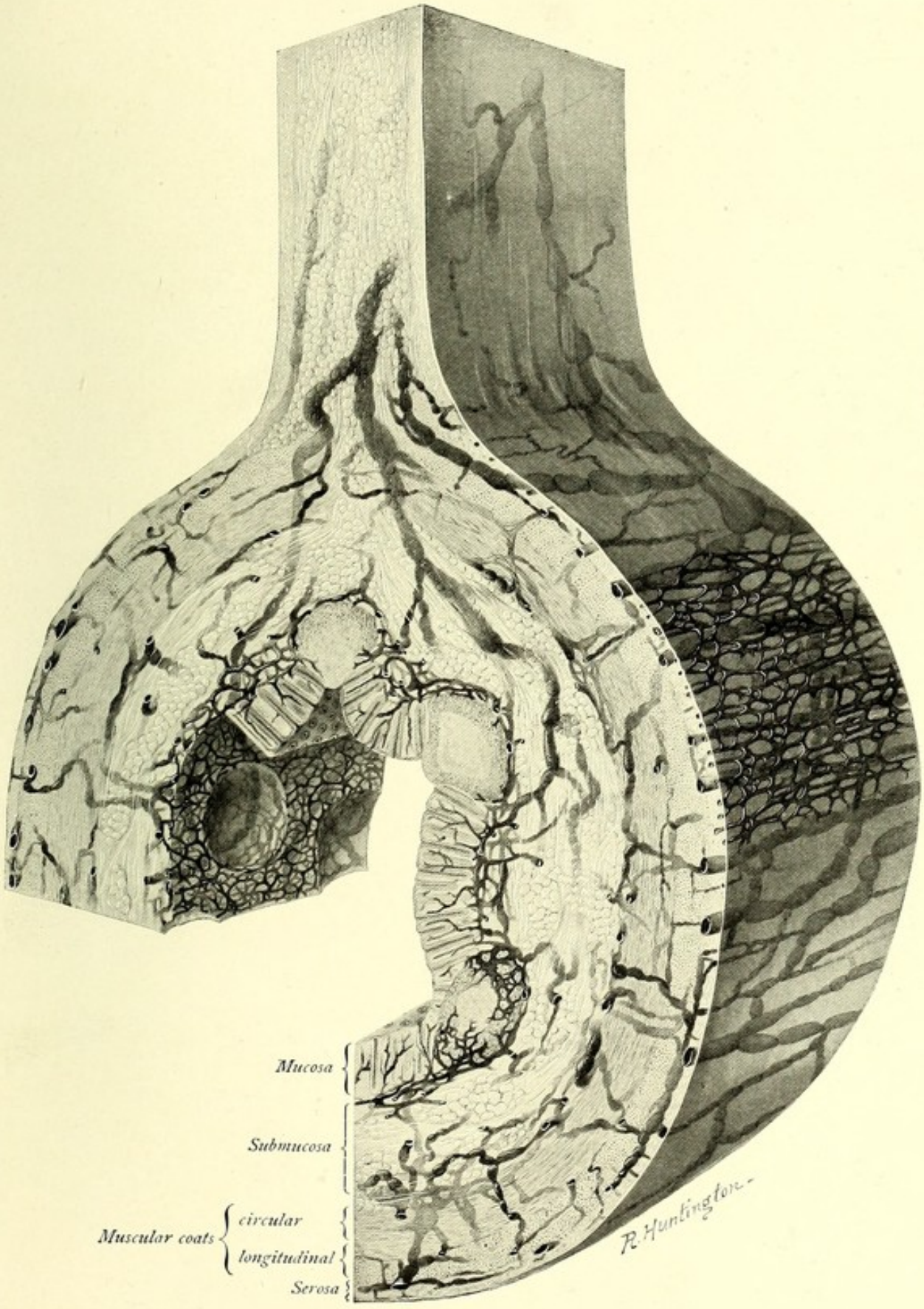
Mucosa
Submucosa
Muscular coats
circular
longitudinal
Serosa
R. Huntington

FIG. 140.

jected in this manner. In a number of them the blood-vessels were also injected —the arteries red, the veins blue, while the lymphatics were filled with lamp black, by which method specimens of singular beauty were obtained. For obvious reasons it is well to inject the blood-vessels first and the lymphatics afterward.

The Lymph Channels of the Appendix Proper.—The lymphatics of the appendix consist of capillaries and collecting channels, the greater number of the latter appearing in the mesappendix.

We shall first describe the course and distribution of the lymphatic vessels of the appendix proper, and then follow this by a description of the lymphatic channels of the adjacent region.

The lymphatics of the appendix may be divided into three more or less distinct systems which are identified with the coats of the appendix,—the superficial, the middle, and the deep. Each of these may consist of two strata of vessels, and between these three systems there are channels which afford communication. This communication must be either insignificant or inconstant, as we were not often able to inject the inner layers through a puncture of the outer, and vice versa.

The superficial system (Fig. 140) lies in the serosa and consists of two layers, or strata; first, a very delicate network of minute anastomosing channels lying just beneath the peritoneal surface. This capillary network consists of innumerable anastomosing lymph channels of 0.05 to 0.1 mm. in width, and of uneven calibre, having irregular oval or elongated interspaces, which measure between 0.2 and 0.5 mm. On cross-section they are flattened. There are no valves in this system of capillaries except at the places where they drain into the second stratum of the superficial layer, which is made up of larger collecting channels, showing the beaded structure characteristic of lymphatics. These larger collecting channels are seen in a fainter color in the depth between the network of the superficial system, and run with preference parallel to the longitudinal axis of the appendix, dividing the surface into rectangular areas. Sometimes one of these channels is seen to run along the free border or along the anterior or posterior surface of the appendix for 3 or 4 cm., or for almost its entire length (Figs. 141 and 142). Their arrangement corresponds closely to that of the lymphatics of the ileum. They leave the appendix in characteristic manner, each larger blood-vessel at the hilum being joined by two lymphatics coming from opposite directions (Fig. 141). Throughout their entire course in the mesappendix the blood-vessels are accompanied by two or more such beaded lymphatic channels which frequently anastomose around the blood-vessels. Exceptionally, such collecting lymphatic channels take an individual course in the mesappendix and are seen to cross obliquely the interspaces between the vascular loops. The collecting channels vary in width between 0.2 and 1 mm. Contrary to the arrangement of the blood-vessels, which, as a rule, have one common trunk in the mesappendix, the

lymphatics do not unite into one channel, but approach the first set of glands in from four to eight or more separate channels. Concerning these glands we shall speak after having first described the rest of the lymphatics within the appendix.

The middle system (Fig. 140) is situated in the submucosa, between that coat and the circular muscle.

An injection will not show these deeper lymphatic vessels on an inspection of the surface, as only the above-described superficial system is visible from the outside. It is not until microscopic sections have been made or the surface layer peeled off, the rest of the injected appendix being cleared in creosote or glycerin, that the middle system can be demonstrated. This system is of considerable significance in stripping out the inner portion of the appendix from its muscular envelopment. The lymphatic channels are so close together, and have such loose and delicate walls, that separation of the layers in the fresh specimen appears easier in this region than elsewhere. This question is dealt with more fully in the description of the muscular coats in the section on "Structure of the Appendix," Chap. VI, p. 139.

These two systems, the superficial system in the serosa, and the middle system lying between the muscularis and the submucosa, enclose the muscular coats, whose few lymphatics may drain to either system. The other channels seen in the submucosa, strictly speaking, belong to the third or deep system. They are large beaded trunks, dilated in places, which pass in an irregular fashion in all directions, preferably, however, toward the hilum, where they either anastomose with the other collecting systems or emerge as independent channels. These vessels may be quite distinct from the layer of lymphatics lying between the submucous and muscular coats, or the two may be combined into a single system. All the vessels of the middle system, as well as those connecting them with the superficial and deep systems, possess well-marked valves.

The deep system consists of a very complex anastomosing network, the central layer of which lies between the mucosa and the muscularis mucosæ. Into this plexus the delicate end-branches coming out of the mucosa are seen to drain. There is a second more peripheral network, the larger beaded channels of which course parallel to the central system (Fig. 140). Between the two lies the muscularis mucosæ, not well developed, however, in every instance.

Beginning at the inner surface—that is, at the glands of Lieberkühn—and following the lymphatics up to the larger collecting channels, we must first describe the delicate finger-like terminal branches which drain the mucous membrane. According to our present knowledge, they are blind channels which run more or less parallel to and between the glands of Lieberkühn. At different places between the surface and the base of the glands they are seen to unite with neighboring channels. However, they not infrequently remain single. In their course they are enveloped in a network of delicate blood capillaries.

The lymphatics of the follicles seem to be confined to their surfaces, which they are seen to envelop in a dense network. This system appears continuous, perhaps identical, with that of the base of the glands. This network, which is very well seen in Fig. 140, at the left of the picture, where the mucous membrane and follicles have been removed, is somewhat more delicate than the anastomosing capillaries of the peritoneal surface. Its meshes are less elongated, and pass without regularity in any direction. On cross-section it is seen that this network drains by means of short channels, penetrating the muscularis mucosæ, into the more peripherally located collecting system. This system has larger beaded channels, and the lymph sinuses around the follicles drain either into them, or directly into the submucous trunks. Concerning these lymph sinuses Lockwood has said the following: "Around the follicles there exists a large lymphatic sinus. This sinus surrounds the basal half of the follicle and is called 'the lymphatic sinus, or the basal lymphatic sinus, of the follicle.' In cases of appendicitis this sinus may extend farther and completely surround the follicle. At other times it is obliterated either by compression or by the accumulation in its interior of inflammatory corpuscles. These lymphatic sinuses of the follicles then empty into the lymphatics of the submucosa." As was said above, the deep system either drains downward into the middle system, or it has its own beaded collecting channels, which pass through the submucosa and converge toward the hilum where they either join the other collecting channels or pass as independent channels through the mesappendix up into the gland. Along the hilum of the appendix there are a number of points where the blood-vessels and lymph channels emerge to pass upward into the mesappendix. At these points the muscular coats are interrupted (Fig. 114), and the submucous and subperitoneal tissues become continuous with one another. Through these so-called muscular hiatuses infection is more likely to travel from the mucosa of the appendix to the mesappendix than in any other way.

The General Character of the Surface Lymphatics of the Ileocecal Region.—The general character of the lymphatics of the appendix, that is, their relation to one another and to the adjacent portion of the cecum and more remotely the ileum and colon, is of sufficient importance to warrant a somewhat detailed description.

While the lymphatic drainage of the appendix is mainly through the mesappendix into the ileocolic chain of glands, there are, as will be seen later, occasionally some small channels draining the proximal appendical portion into the cecal trunks. Along the line of peritoneal reflection of the cecum over the abdominal wall, delicate anastomosing lymph channels can be demonstrated between the lymphatics of the cecal serosa and those of the adjacent parietal peritoneum. This condition might be spoken of as a lymphatic communication, though of an insignificant character, between the appendix and cecum on the one hand, and the iliac and lumbar glands on the other. A similar communi-

cation also exists between the blood-vessels of the cecum and the systemic circulation (see section on "Veins," p. 166). The lymphatic communication between appendix and ovary, as claimed by Clado and Lafforgue, belongs probably in this class. While the direction of the surface lymphatics of the appendix is, in general, parallel to its axis, resembling the surface lymphatics of the small intestine, those of the cecum and colon appear to be arranged without such definite reference to the direction of the intestine. This peculiar arrangement of the lymphatics of the appendix has its cause, no doubt, in the fact that the longitudinal coat is more strongly developed than that of the cecum, where the longitudinal fibres are confined more or less to the longitudinal muscular bands. The larger collecting channels pass transversely around the cecum and colon, being confined more or less to the depressions. On crossing the longitudinal muscular bands the lymphatics pass beneath them. Here, as in the appendix, the lymphatics usually pass on either side of the blood-vessels. The general character of these lymphatics is best understood by studying Figs. 141 and 142.

On examination of Figs. 141 and 142 three distinct groups of channels are easily recognized:

1. The anterior cecal trunks, converging from the cecal pouches toward the ileocolic fold, where they generally pass through one or more isolated glands before reaching the ileocolic group (Fig. 141).

2. The posterior cecal trunks, converging from the posterior cecal pouches toward the ileocolic angle. They also pass through a few isolated glands (three to six) before reaching the ileocolic group (Fig. 142).

3. The appendical trunks (three to six in number), converging in the mesappendix in an upward direction. As figure 142 shows, these channels are in character similar to the posterior cecal trunks, the only difference being the fact that they usually do not pass through isolated glands on their way up to the ileocolic glandular group. The proximal lymph channel of the appendix receives one or two small tributaries passing from the ileum through the ileocecal fold (Figs. 141 and 143–146).

The Lymphatics of the Appendico-cecal Junction.—The development of the appendix out of the cecum by a process of narrowing down, or, more correctly speaking, a cessation of development of the terminal portion at a varying point from the ileocecal valve, teaches us why there is no marked line of anatomical division between the lymph system of the two organs. The same is true of their vascular systems. Thus, the proximal portion of the appendix may have its individual lymph channels passing up in the mesappendix, while the adjoining cecal region may drain upward in separate cecal channels. On the other hand, it has been found that the proximal portion of the appendix may drain into the cecal lymphatic system, and also, which seems more common, the opposite condition is noted, viz., the lower portion of the cecum draining into the lymphatic channels of the appendix (Fig. 141).

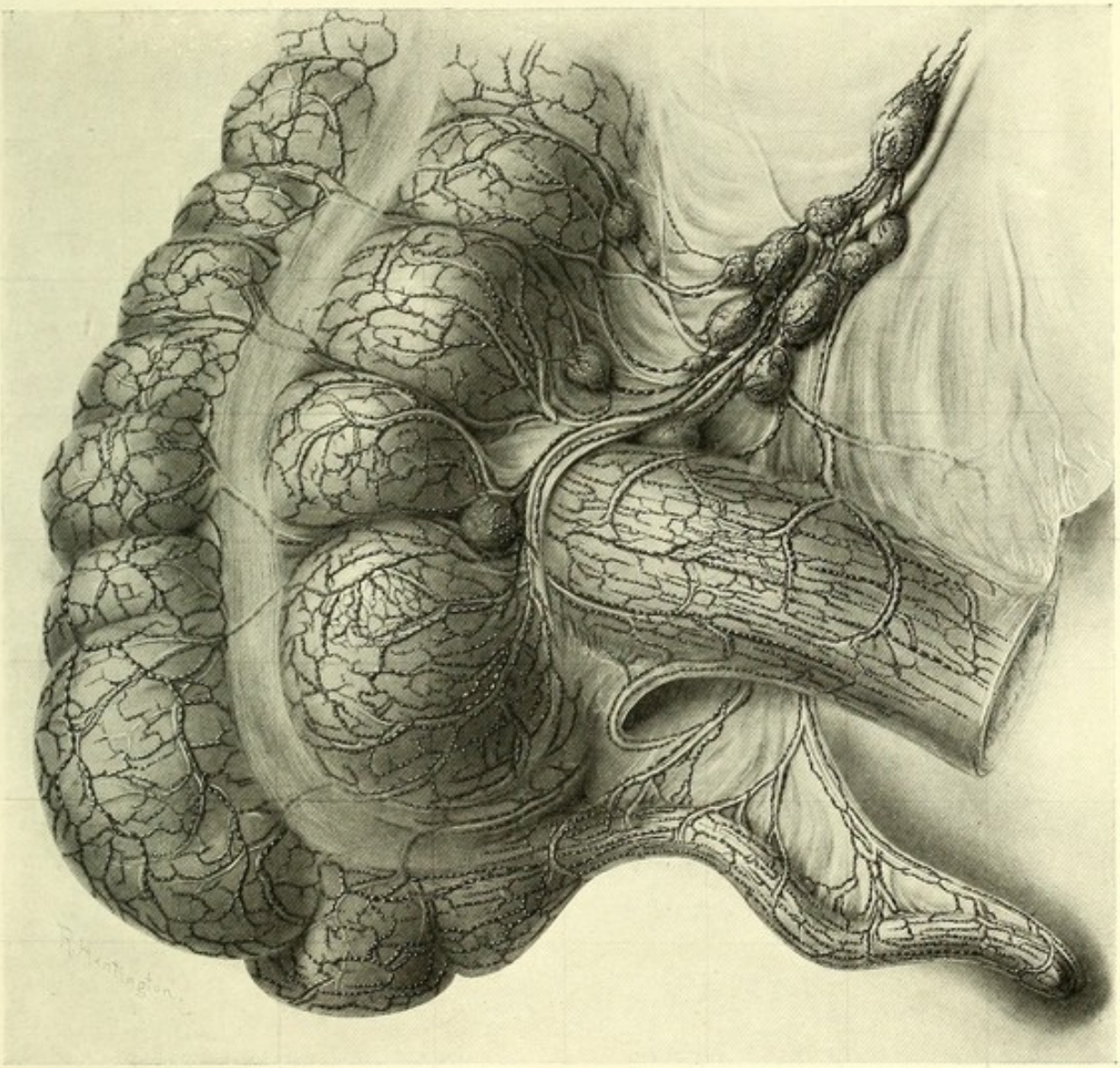

FIG. 141.—THE LYMPHATIC CIRCULATION OF THE ILEOCECAL REGION. ANTERIOR VIEW.

For the sake of clearness only the larger collecting channels are drawn. The main arteries are inserted as white channels in order to illustrate their relation to the lymphatics. The lymphatics of the appendix collect into two main channels in the mesappendix, which pass parallel to one another and to the artery. They drain into two glands situated about 3 cm. above the ileum. These glands are found in the median portion of the ileocolic chain of glands.

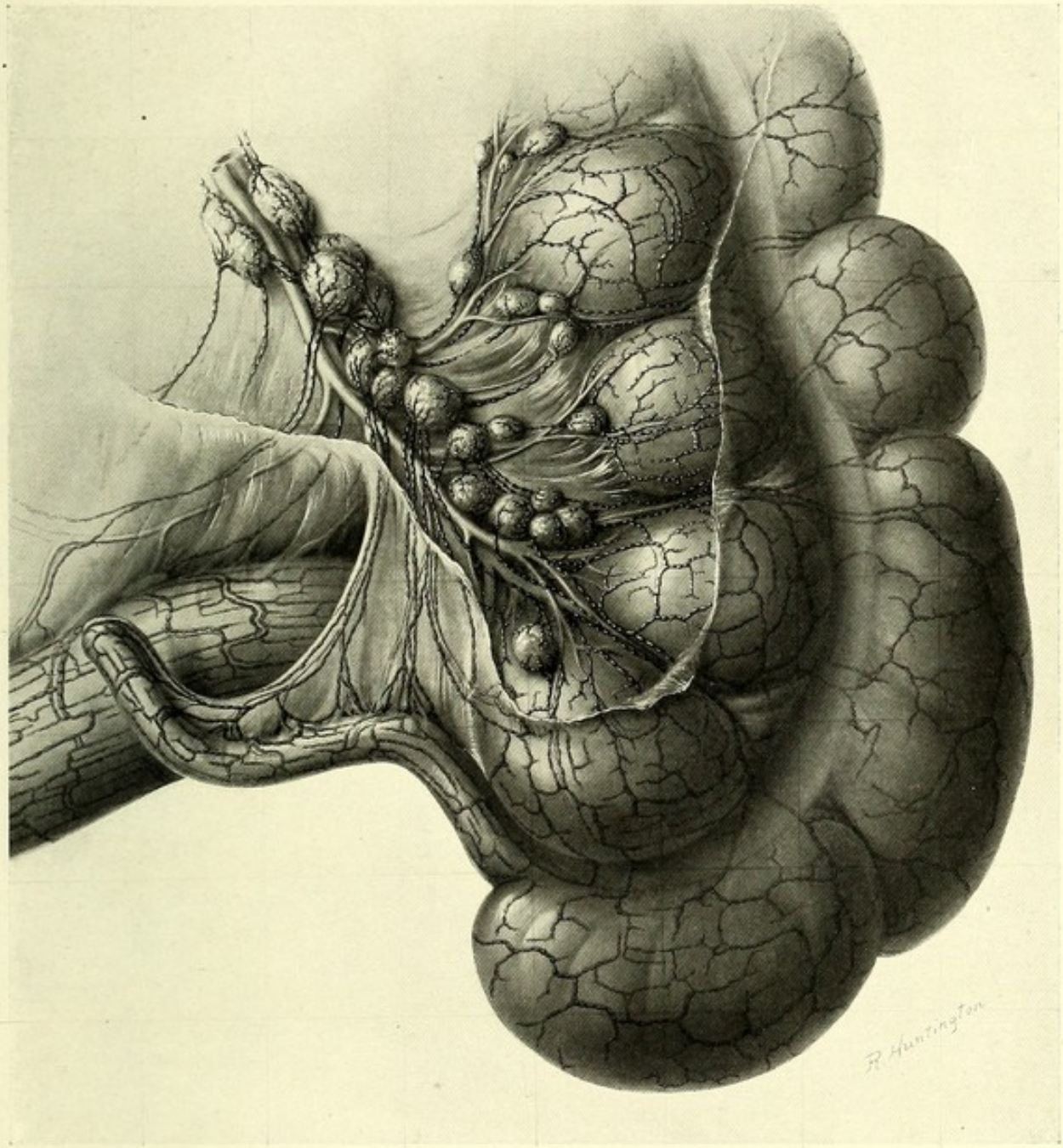

FIG. 142.—POSTERIOR VIEW OF THE ILEOCECAL REGION, SHOWING THE MAIN LYMPH-TRUNKS AND THEIR RELATION TO THE ILEOCOLIC CHAIN OF GLANDS.

The large size of the glands in this and in the previous picture is due to their distention with injection mass. The glands are confined to the extraperitoneal portion of the mesocolon and intestine, the line of peritoneal reflection having a V-shaped outline, the apex being in the ileocolic angle.

The lymphatics of the appendix in this case are more numerous than those in Fig. 141. They drain into three glands. The lowest of these three receives besides the proximal appendical channels a few trunks coming from the distal portion of the cecum. This gland might, therefore, be termed ceco-appendical. The lowest gland of the chain, situated just over the posterior cecal pouch, has been described as Clado's gland and called appendical gland, as in the state of contraction of the bowel it may become lodged in the mesappendix. However, as this injection shows, this gland, if present, receives lymph from the cecum and not from the appendix. In a very few instances it received a small tributary from the ceco-appendical angle. (See Type IV, Fig. 146, A.)

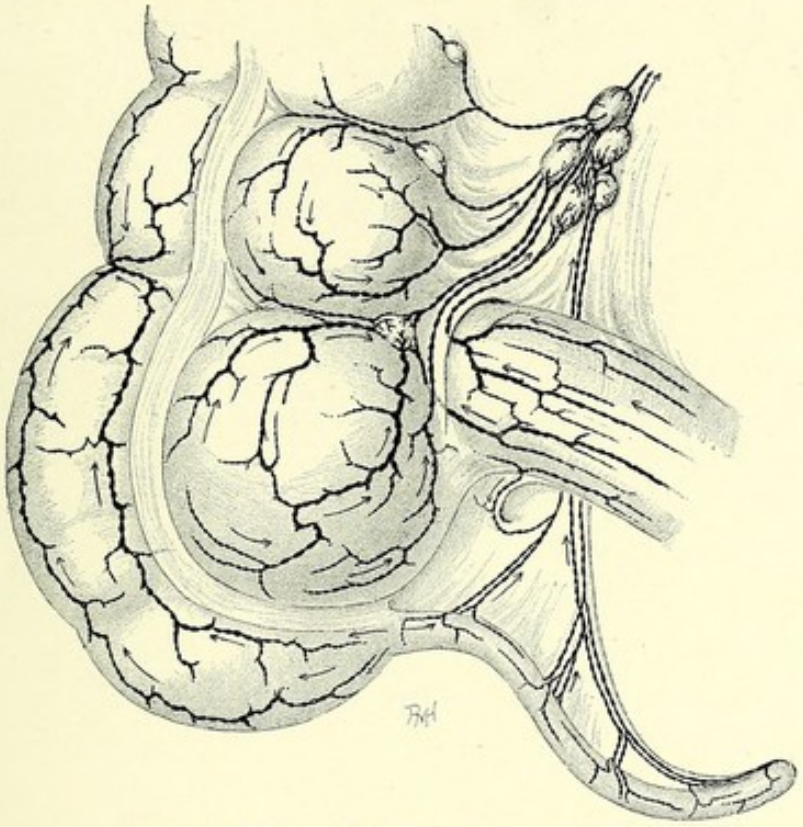

FIG. 143.—LYMPHATIC CIRCULATION. TYPE I.

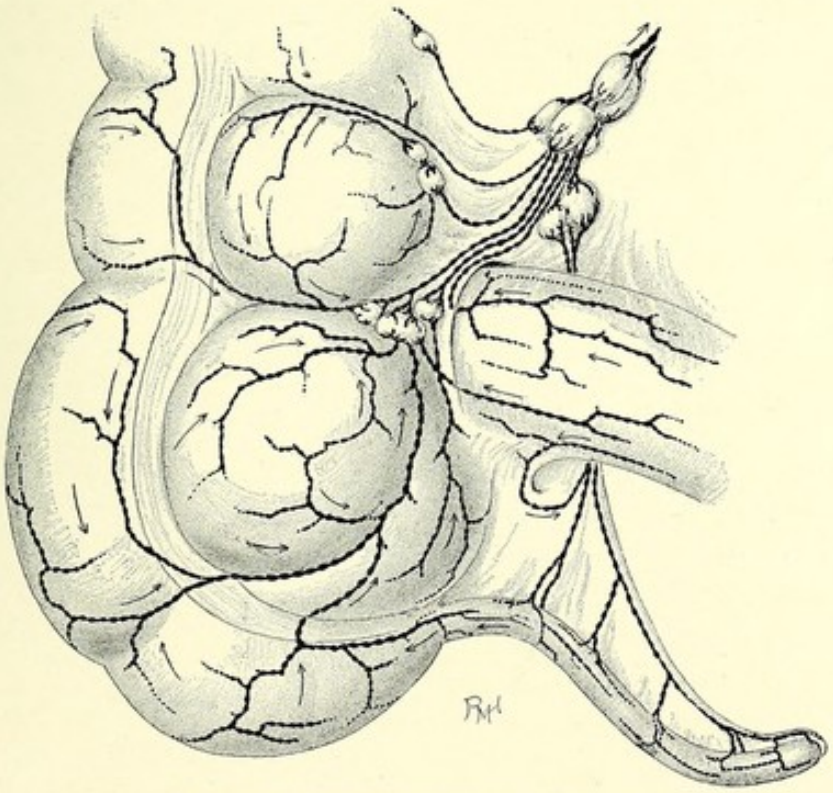

FIG. 144.—LYMPHATIC CIRCULATION. TYPE II.

Variations of the Lymphatic Circulation.—The arrangement of the lymphatic system is subject to innumerable individual changes, no two specimens ever showing the same disposition. Nevertheless, there are four types according to which practically all forms may be classified. These are pictured in Figs. 143, 144, 145, and 146. The arrows indicate the flow of the lymph.

Type I, Fig. 143.

Anterior View.—The median cecal and colic pouches drain upward and medianward by way of the ileocolic fold; traversing a few isolated glands, the lateral pouches drain toward the posterior side. The appendical collecting tubes, being only few in number, receive lymphatics from the entire appendix and a small tributary from the ileum passing through the ileocecal fold. The latter is constant in all types. The first glandular station for the appendical lymphatics is well up in the ileocolic angle. The two appendical glands are situated in the mesial portion of the glandular group.

Type II, Fig. 144.

Anterior View.—The median as well as the lateral colic and cecal pouches drain anteriorly, likewise the anterior face of the ileum. The ileocolic fold contains three small glands, toward which the collecting channels of the neighboring region converge; the efferent tubes pass from these glands upward by way of the ileocolic fold. While the proximal sixth of the appendix drains toward the cecum, the rest sends its lymphatics toward the free mesappendical border, along which the collecting tubes course. As in Type I, the first glandular station is well above the ileum; there are two small appendical glands which form the lower portion of the ileocolic group.

Type III, Fig. 145.

Anterior View.—The median cecal pouch drains partly anteriorly by way of the ileocolic fold, partly posteriorly by way of the mesappendix. The lateral pouches drain posteriorly. There are no isolated anterior colic glands. The proximal sixth of the appendix and the adjacent cecal region drain in one common trunk which runs parallel to the lowest cecal trunk, the latter receiving the ileal tributary coming through the ileocecal fold. These two channels run into a gland situated just above and behind the ileocolic junction, partly hidden in the ileocolic fossa. The rest of the appendical lymphatics are arranged in a similar manner to those in Types I and II.

Type IV, Fig. 146.

Anterior View.—The median and lateral colic and cecal pouches, excepting the lower portion, drain by way of the ileocolic fold, traversing an isolated gland ventral to the ileocolic junction. The appendical lymphatics

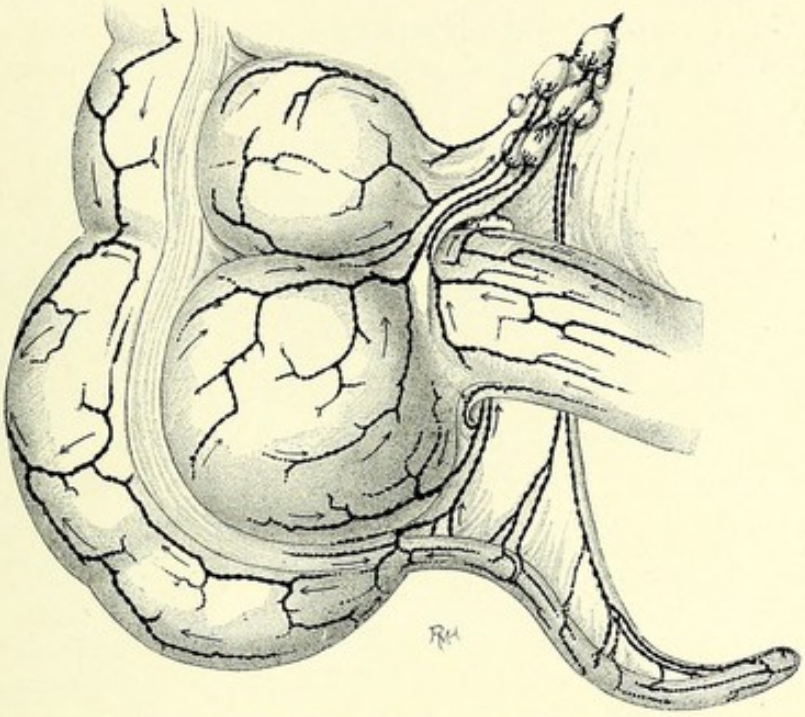

FIG. 145.—LYMPHATIC CIRCULATION. TYPE III.

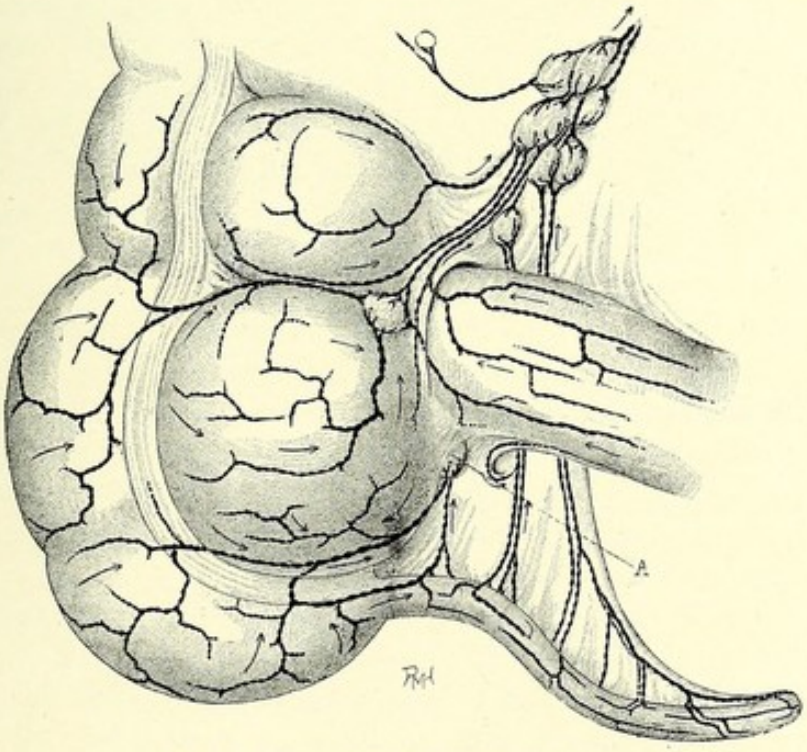

FIG. 146.—LYMPHATIC CIRCULATION. TYPE IV.

drain in three main groups, each terminating in one or two separate glands, the distal lymphatics traversing the longest distance.

The proximal appendical channel receives a tributary from the adjacent portion of the cecum and terminates in a small gland situated in the mesappendix in the inferior ileocecal angle (A). This gland, however, receives another tributary, much larger than the appendical, coming from the cecal pouch. Clado and others have called this gland appendical, owing to its position in the mesappendix; this seems an error, as it is found in only few instances, and even then its connection with the appendix is but insignificant as compared with that of the cecum. The middle group of appendical lymphatics receives the tributary passing down through the ileocecal fold. Its glandular terminus is in the mesentery just above the ileum. The distal appendical channels are the largest in size; they follow the course of the main appendical artery along the free border of the mesappendix and terminate in two glands situated in the lower median portion of the ileocolic group of lymph glands.

A study of these four figures demonstrates that the types of lymphatic circulation of the ileocolic region have the following points in common:

(a) The upper cecal and colic surfaces drain,—anteriorly, by way of the ileocolic fold, with or without glandular sub-stations in the fold; posteriorly, converging toward the ileocolic chains without gathering in a bundle like the anterior trunks. There are more posterior glandular sub-stations than anterior. The lower portion of the cecum may drain either in an anterior direction (ileocolic fold) or in a posterior direction (mesappendix).

(b) The lymphatics of the terminal portion of the ileum drain,—anteriorly, by way of the ileocolic fold; posteriorly, directly into the ileocolic glands.

(c) The ileocecal fold is the carrier of one or two small lymph channels connecting the lymph vessels of the lower border of the ileum with the mesappendical trunks.

(d) The distal five-sixths of the appendix, or the entire appendix, has its individual lymphatic drainage by way of the mesappendix. The proximal portion of the appendix rarely drains into the cecal trunks.

(e) The collecting channels, running in pairs, form one to three separate bundles, usually only one, passing along the free border of the mesappendix. If there are more than one, the others run at fairly regular intervals between the main bundle and the cecum.

(f) In the overwhelming majority of cases the first glandular station of the appendical lymphatics is in the mesentery of the ileocolic angle, from 1 to 3 cm. above the ileum. The appendical glands are rarely more than two in number and are generally situated at the lower median side of the ileocolic chain of glands.

(g) Glandular sub-stations or isolated glands in the mesappendix or in the appendico-cecal angle are rare.

The Collecting Channels in the Mesappendix.—These beaded vessels pass on either side of the blood-vessels, in an upward direction; an isolated channel may, however, occasionally seek an individual course (Fig. 141). All converge toward the appendical glands and it is the position of these which determines the length and direction of the collecting channels. Those near the cecum are shortest, the distal channels longest. Their length varies from 3 to 15 cm., the most frequent length being about 10 cm. Delicate anastomosing branches pass between the parallel trunks, thus enveloping the blood-vessels in a dense lymphatic network. Minute tributaries of mesappendical origin also empty into the collecting channels.

The Glands of the Ileocecal Region.—Like the lymph vessels themselves, the glands are also subject to great variation, both as to size and position. All cases, however, have some points in common which permit a general description.

In the ileocolic angle is a chain-like group of glands, greater in number than eleswhere in the lower portion of the mesentery. The direction of the chain is obliquely upward and inward, beginning at the region of the ileocolic junction. The individual glands are grouped around the ileocolic vessels and are either packed closely together, forming clusters around the vascular bifurcations, or are scattered somewhat more uniformly over the area marked by the ileocolic angle, in which case, however, they still remain near some blood-vessel. The larger of these glands, measuring from 8 × 10 to 12 × 16 mm., with a few exceptions are near the main vascular trunks, the smallest near the periphery. These latter will be designated and described as isolated glands.

The individual glands of the ileocolic chain are connected with one another by lymph channels, which increase in calibre as they emerge from the glands. Their farther course is along the mesenteric vessels, where they are joined by tributaries from the small intestine, large intestine, and celiac glands. They drain into the receptaculum chyli, the upper continuation of which, the thoracic duct, passes behind the aorta through the diaphragm and empties, ultimately, into the left subclavian vein.

Isolated Colic and Cecal Glands.—If present, they appear as relays placed along the course of the lymphatics (Figs. 141 and 142). They are the first to receive the lymph, though collecting channels are not infrequently seen to run past them to enter some gland situated more centrally. Isolated glands are generally small in size, measuring from 1½ × 2 to 2 × 3 mm., and situated in the depressions between the pouches of the colon. They seem to be more frequent and smaller on the posterior than on the anterior surface of the large intestine, the latter measuring from 4 × 6 to 5 × 7 mm.

On the anterior surface isolated glands are found in the ileocolic fold and along the mesenteric border of the colon (Fig. 141). The lowermost of these is met with in quite a number of instances lying ventral to the ileocecal valve and just lateral to the ileocolic fold (Figs. 143, 144, and 146; Types I, II, and IV). Occasionally, it has one or two daughter glands. This gland, or glands,

receive lymphatics from a part of, or the entire anterior surface of the cecum, never from the appendix. Below this we have found no glands on the anterior surface, although some writers claim to have seen them.

On the posterior surface isolated glands, as was said above, are more numerous, from 4 to 15 being distributed over about 10 cm. of the large intestine. The lowermost of these glands is found at varying levels. It may reach the appendico-cecal angle, but is generally found some distance above, lying close against the cecum (Figs. 142 and 146, A). This corresponds to the gland which CLADO called the "appendicular gland," and which he described as follows: "At the base of the mesappendix in the angle which separates the appendix and the cecum from the small intestine, there lies a gland, the appendicular gland. It is situated between the two layers of the mesappendix and may attain a considerable size. The gland is constant, but it is sometimes displaced and encroaches upon the terminal portion of the mesentery, when it may be considered as the last of the mesenteric glands." In the large herbivorous animals, which have a long appendix-like cecum, this gland is very well developed and receives lymphatics of the cecum independently of the mesenteric glands. However, since this gland in the human subject receives the lymphatics from the lower extremity of the posterior surface of the cecum, and only very rarely a small tributary from the proximal portion of the appendix, we think the term "appendicular" a misnomer for this gland. It is sometimes represented by a number of glands forming a little group on the posterior surface of the cecum (the ceco-appendicular group of TIXIER and VIANNEY). They are continuous with the ileocolic chain of glands and often lie entirely in the mesentery as long as the intestines are *in situ*, removal and distention of the cecum, preparatory to the injection, drawing them over onto the surface of the cecum. The other isolated glands are found scattered over the posterior surface of the colon and along the mesocolic border. They hug the blood-vessels and are situated, as a rule, in the grooves between the colic pouches (Fig. 142).

The Glands of the Appendix.—The glands of the appendix receive the lymph conveyed to them through the collecting channels of the mesappendix and communicate it to the next glands in the chain. They serve merely as an intermediary between the appendical lymphatics and the ileocolic chain of glands.

The position of the appendical glands has been described in many different ways, the literature containing the most contradictory statements.

This is not surprising, as the arrangement of the glands is so variable, hardly any two specimens ever being alike. It may, therefore, be of value to give some of the principal descriptions.

Before 1880 little was known about the lymphatic circulation of the appendix. CLADO in 1892 observed three or four channels which traveled toward a gland in the ceco-appendical angle, since known as Clado's gland. As

was said above, this gland is inconstant, and if found, receives more cecal channels than appendical.

The first fairly accurate description and statistics of the appendical glands are given by LAFFORGUE, and by TIXIER and VIANNEY.

LAFFORGUE in 1893 stated that in three-fourths of his cases there was no gland in the mesappendix, all the appendical lymphatics emptying directly into the mesenteric glands. In the other fourth he found glands within the mesappendix, viz.:

In	18.5	per cent.,	one gland.
"	3.5	"	two glands.
"	2	"	three glands.
"	3	"	four glands.

According to TIXIER and VIANNEY, in one-half of the cases there are no glands in the mesappendix, while in:

20	per cent.	there	is	1	gland.
10	"	"	are	2	glands.
8	"	"	"	3	"
4	"	"	"	4	"
2	"	"	"	5	"
2	"	"	"	6	"
2	"	"	"	7	"
2	"	"	"	8	"

TIXIER and VIANNEY have classified these mesappendical glands into three sets: I. Ileo-appendical, II. Appendical, and III. Ceco-appendical, according to whether they are behind the ileum, near the hilum of the appendix, or in the ceco-appendical angle. The latter are continuous with the ileocolic chain of glands.

AUGUY says that while the glands may be found throughout the entire extent of the mesappendix, they are more apt to be grouped at its base, *i. e.*, the region where it becomes continuous with the mesentery (thirty per cent. of his cases).

POIRIER and CUNÉO give a similar description of the glands in the mesappendix. There are three groups: I, Retro-ileal (most frequent); II, Sub-ileal; and III, Juxta-cecal (the two latter groups being present only in few instances).

While we have occasionally seen appendical glands in the retro-ileal area of the mesappendix—*i. e.*, in those few cases where the peritoneal reflection of the mesappendix was below the ileum—in the overwhelming majority of our cases the appendical glands were found some distance above the ileum in the ileocolic angle, as a rule to the left of the ileocolic vessels, near the point of origin of the appendical artery. There were generally not more than two

glands of medium size (4 to 6 mm.) forming a part of the ileocolic chain. Longer appendices may have three to five glands whose arrangement corresponds more or less to that of the origin of the appendical arteries, of which several may be present. In such cases the appendical glands form two or three groups, lying some distance apart from one another and also apart from the ileocolic chain, each receiving the lymphatics from a separate section of the appendix, the proximal portion of the appendix having the lowest, the distal the highest gland or glands. This may account for the statement of TIXIER and VIANNEY, that "the appendix, an organ of double insertion, cecal by its root proper and ileal by its mesentery, parts its lymphatic circulation into two main currents, one of them being directed toward the cecum and the mesocolic glands, the other toward the ileum and the mesenteric glands."

Glands in the Mesappendix.—As was said above, LAFFORGUE (1893) reported the occasional presence of a large number of glands in the cellular tissue of the mesappendix. AUGUY states that glands, from 1 to 8 in number, may be grouped throughout the entire extent of the mesappendix, but are generally situated along the hilum of the appendix. Three times he found a single gland in the middle portion of the mesappendix some distance from its base, and once there existed a gland very near the free border of the mesappendix in contact with the appendical artery.

Although such glands have been reported to exist in the mesappendix, we have not been able to demonstrate their presence, save for one or two stray glands of very small size, which, however, lie so near the cecum as to become dislodged upon the latter as soon as it is distended. In one specimen there were five glands half-way up the mesappendix, two of which received lymph from the appendix. As the mesappendix, however, was identical with the ileocecal fold, the posterior surface of the ileum extraperitoneal, and the entire topography of the ileocecal region presented abnormal conditions, this group had to be regarded as misplaced ileocolic glands. Glands along the hilum of the appendix are, in our experience, of very exceptional occurrence.

TIXIER and VIANNEY speak of an instance where a gland was found in the thickness of the appendico-ovarian ligament (CLADO) at the point where this peritoneal fold separates from the mesappendix. This statement has met with much opposition, and while we do not doubt the reliability of the observation, the fact that no one else has noted a gland in a similar position shows that TIXIER and VIANNEY's case was unique.

THE NERVES OF THE APPENDIX.

The blood and lymph vessels of the appendix closely resemble those of the neighboring intestines, and the nerves correspond with them in this respect.

The nerves of the appendix are derived from the superior mesenteric plexus of the sympathetic system. Coming from the lower anterior portion of the solar

plexus, and the superior mesenteric ganglion, and receiving a few fibres from the right pneumogastric nerve, the superior mesenteric nervous system accompanies the superior mesenteric vessels throughout the greater part of their course. The plexus envelops the vascular trunks, subdividing with them until the intestinal border is reached. Some few of the nerves, however, leave the vessels and run individual courses in the mesentery. Near the intestines are found frequent anastomoses of the nerves; but there is less regularity in this respect than is the case in the vascular system.

Having reached the mesenteric border of the appendix, the nerves penetrate the different coats to form two systems, an outer and an inner. The outer plexus, or plexus of Auerbach, is situated between the longitudinal and circular muscular coats. It is composed of minute sympathetic ganglia, which generally lie parallel to the muscle-fibres. These ganglia are connected with one another by delicate bundles of non-medullated fibres, among which are found a few medullated. The cords are seen to leave the ganglia by one of the several roots, dividing and re-dividing in the circular and longitudinal muscle coats. There they form a complicated network, the individual branches of which terminate at the involuntary muscle-cells of these layers. This plexus is also known as the plexus myentericus, the name expressing the function it is to perform. There are a few larger branches which do not participate in the formation of the outer plexus, but penetrate the circular muscular layer, and then enter the submucosa, where they form a second gangliated plexus, the plexus of Meissner, whose individual fibres are also apparently without medullary covering, and are much more delicate than those of the intermuscular plexus. The ganglia of this plexus are also much smaller and fewer than those of Auerbach's plexus. The two systems anastomose freely with one another.

The first set of ganglia of Meissner's plexus is situated near the muscularis mucosæ, between it and the base of the glands. A few delicate fibres are seen to pass from them into the muscularis mucosæ, the rest passing upward, and ramifying in the mucous membrane between the crypts, the end fibres being situated near or in the epithelium. According to Berkley, the nerve fibres in the muscularis mucosæ of the small intestine follow the blood vessels in twisted bundles of two or more. In some places three or four dotted lines are seen arising from the nerve bundles, and forming a spray, each line terminating in a very minute knob. In other places the dotted lines of the spray do not terminate in minute single bulbs, but join together in a spherical figure, which is apparently inclosed in a transparent capsule. Beyond the muscularis mucosæ the nerve fibres show a tendency to ascend toward the free surface. Throughout their entire course they follow, more or less closely, the direction of the connective tissue cells between which they are located.

There is a small number of ganglia in the mucosa; they are connected with one another, forming a plexus around the glands of Lieberkühn, the end

twigs terminating in a delicate knob or an elongated swelling, in the neighborhood of, or within the epithelial lining of the mucosa and glands. BERKLEY says that each epithelial cell does not possess a nerve twig of its own, the nerves only passing up to the epithelium here and there, showing that the nerve force is not conveyed to the cell by direct contact, but rather through contiguity.

The anatomical studies upon which the foregoing remarks are based are still incomplete, as only fragments of material have been available for investigation. Sections of these fragments, however, appear to indicate that the nerve supply of the appendix, like its blood and lymph supply, closely resembles that of the adjacent intestine.

BIBLIOGRAPHY.

AUGUY: "De l'adenopathie appendiculaire." Thèse de Lyon, 1901.

BARDELEBEN: "Ueber die Lage des Blinddarms beim Menschen." Virchow's Arch. f. path. Anat., 1848, Bd. 2, p. 583.

BARNSBY: "Thèse de Paris," 1898.

——— "De l'appendicite d'origine annexielle." Rev. de gynéc., 1898, tom. 2, p. 419.

BERRY: "The anatomy of the vermiform appendix." Anat. Anz., 1895, Bd. 10, p. 761.

——— "The cæcal folds and fossæ." Edinburgh, 1897.

BIERHOFF: "Beiträge zu den Krankheiten des wurmförmigen Anhanges." Verh. der phys.-med. Gesellsch. in Würzburg, 1859, Bd. 4, p. 129.

——— "Beiträge zu den Krankheiten des Wurmfortsatzes." Deutsch. Arch. f. klin. Med., 1880–81, Bd. 27, p. 248.

BRYANT: "The relations of the gross anatomy of the vermiform appendix to some features of the clinical history of appendicitis." Ann. Surg., 1893, vol. 17, p. 164.

CANNON: "The movements of the intestine studied by means of the Röntgen rays." Amer. Jour. Physiol., 1902, vol. 6, p. 251.

CLADO: "Appendice cæcal; anatomie; embryologie; anatomie comparée; bactériologie normale et pathologique." Compt. rend. Soc. de biol., Paris, 1892, 9. s., tom. 4, p. 133.

DEAVER: A treatise on appendicitis, 1900.

DOCK: "Notes on the appendix vermiformis: anatomical and clinical." Trans. Mich. Med. Soc., Detroit, 1892, vol. 16, p. 114.

DURAND: "Le ligament ilio-ovarien; contribution à l'étude du ligament large." Progrès méd., 1895, 3. s., tom. 2, p. 1.

FAWCETT and BLACHFORD: "The length of the appendix." Proc. Anat. Soc. Gr. Brit. and Ireland, 1899, p. 20. *In* Jour. Anat. and Physiol., 1900, vol. 34.

FERGUSON: "Some important points regarding the appendix vermiformis." Amer. Jour. Med. Sci., 1891, n. s., vol. 101, p. 61.

FERRY: "Thèse de Paris," 1900.

FITZ: "Perforating inflammation of the vermiform appendix." Amer. Jour. Med. Sci., 1886, N. S., vol. 92, p. 321.

——— "Appendicitis: analysis of seventy-two cases." Bost. Med. and Surg. Jour., 1890, vol. 122, p. 619.

GASTON: "The appendix vermiformis: its functions, pathological changes, and treatment." Jour. Amer. Med. Assoc., 1888, vol. 10, p. 777.

GEGENBAUER: Vergleichende Anatomie der Wirbelthiere, 1901, Bd. 2, p. 171.

GERLACH: "Zur Anatomie und Entwickelungsgeschichte des Wurmfortsatzes." Wissensch. Mitth. d. phys.-med. Soc. zu Erlangen, 1859, Bd. 1, p. 7.

——— "Tödtliche Peritonitis, als Folge einer Perforation des Wurmfortsatzes." Zeitschr. f. rat. Med., 1847, Bd. 6, p. 12.

GROHÉ: "Geschichtliche Darstellung des Wesens und der Behandlung der Typhlitis und Perityphlitis." I. D., Greifswald, 1896.

HARTMANN: "Untersuchungen an der Leiche über die Perforation des Wurmfortsatzes." Berlin. klin. Wochenschr., 1876, Bd. 13, p. 479.

HENLE: Handbuch der systematischen Anatomie des Menschen. Braunschweig, 1871–79.

HUNTINGTON: Anatomy of the human peritoneum and abdominal cavity, 1903.

——— "Cæcum and vermiform appendix." Soc. Lying-in Hospital, New York, Med. Report (1893), 1894, p. 121.

JONNESCO: Traité d'anatomie humaine. (Poirier et Charpy), 1901, tom. 4.

JONNESCO ET JUVARA: "Anatomie des ligaments de l'appendice vermiculaire et de la fossette iléo-appendiculaire." Progrès méd., Paris, 1894, 2. s., tom. 19, pp. 273, 303, 322, 353.

KELYNACK: The pathology of the vermiform appendix, 1893.

LAFFORGUE: "Recherches anatomiques sur l'appendice vermiculaire du cæcum." Intern. Monatsschr. f. Anat. u. Physiol., 1893, Bd. 10, p. 141.

——— "Des tumeurs primitives de l'appendice vermiculaire." Thèse de Lyon, 1893.

LENZMANN: Die entzündlichen Erkrankungen des Darms in der Regio ileo-cœcalis und ihre Folgen, 1901.

LITTLE: "Internal strangulation; anatomy of the vermiform appendix." Dublin Quart. Jour. Med. Sci., 1871, vol. 52, p. 237.

LOCKWOOD: "Note on the lymphatics of the vermiform appendix." Proc. Anat. Soc. Gr. Brit. and Ireland, 1899, p. 9. *In* Jour. Anat. and Physiol., 1900, vol. 34.

LOCKWOOD AND ROLLESTON: "On the fossæ round the cæcum, and the position of the vermiform appendix, with special reference to retroperitoneal hernia." Jour. Anat. and Physiol., 1892, vol. 26, p. 130.

LUSCHKA: "Ueber die peritoneale Umhüllung des Blinddarmes und über die Fossa ileo-cæcalis." Virchow's Arch. f. path. Anat., 1861, Bd. 21, p. 285.

MALL: "Ueber die Entwickelung des menschlichen Darmes und seiner Lage beim Erwachsenen." Arch. f. Anat. und Entwicklungsgesch., Suppl. Band, 1897, p. 403.

NOTHNÄGEL: Beiträge zur Physiologie und Pathologie des Darmes. Berlin, 1884.

OWEN: Comparative anatomy and physiology of vertebrates. 1866–68, 3 vols.

PIARD: "Des suppurations à distance dans l'appendicite." Arch. gén. de méd., 1896, tom. 2, pp. 290, 436, 560.

POIRIER: "Situation de l'appendice." Traité d'anatomie humaine, tom. 4.

POIRIER ET CUNÉO: Traité d'anatomie humaine. "Les lymphatiques." (Poirier et Charpy), Paris, 1902, tom. 2.

RETZIUS: "Beobachtungen über Anastomosen zwischen V. portæ und V. cava inferior, etc." Zeitschr. f. Physiol., 1835, Bd. 5, p. 105.

RIBBERT: "Beiträge zur normalen und pathologischen Anatomie des Wurmfortsatzes." Virchow's Arch. f. path. Anat., 1893, Bd. 132, p. 66.

ROBINSON: "The appendix and cecum in 128 adult postmortems, with a new theory as to the cause of appendicitis." New York Med. Rec., 1895, vol. 48, p. 757.

——— "The appendix in relation to the psoas muscle, etc." Ann. Surg., 1901, vol. 33, p. 387.

ROUGET: Jour. de physiol. de Brown-Séquard, 1858.

SAPPEY: "Mémoire sur les veines portes accessories." Jour. de l'anat., 1883, tom. 19, p. 517.

TIXIER ET VIANNAY: "Note sur les lymphatiques de l'appendice iléocæcal." Lyon méd., 1901, tom. 96, p. 471.

TOLDT: "Die Formbildung des menschlichen Blinddarmes und der Valvula coli." Sitzungsb. d. k. Akad. d. Wissensch., 1894, Bd. 103, p 41.

TREVES: "The anatomy of the intestinal canal and peritoneum in man." Brit. Med. Jour., 1885, vol. 1, p. 527.

TUFFIER: "Conformation extérieure et vaisseaux du cæcum." Bull. de la Soc. anat. de Paris, 1886, tom. 61, p. 652.

TUFFIER ET JEANNE: "Étude anatomique sur l'appendice et la région iléo-cæcale." Rev. de gynéc., 1899, tom. 3, p. 235.

VALLÉE: "Appendice chez l'enfant." Thèse de Paris, 1900.

WALDEYER: Hernia retroperitonealis nebst Bemerkungen zur Anatomie des Peritoneums. Breslau, 1868.

ZUCKERKANDL: "Ueber die Obliteration des Wurmfortsatzes beim Menschen." Anat. Hefte, 1894, Bd. 4, p. 99.

CHAPTER VIII.

PHYSIOLOGY.

Has the vermiform appendix any function? If so, what is that function, and is it of any value in the animal economy? These are questions which have interested physiologists for more than a century, and seem to be still as far from solution as ever.

Presumption is all we have as yet to guide us in answering the question: Has the vermiform appendix a function? But, while presumption from analogy and from accessory data may suggest an affirmative answer, an ultimate decision must rest upon the crucial test of demonstration. The argument from presumption, briefly stated, is as follows: We have in the appendix a distinct division of the alimentary tract, present in man, in apes, and in rodents. Its position in relation to the cecum is such as to promote the escape of its own secretions, while hindering the ingress of foreign bodies and fecal matter. Moreover, the minute anatomical structure of the appendix has characteristics especially its own, being peculiarly rich in lymphoid tissue, and so closely related to the tonsils in this respect that a near relation between the two as regards function is maintained by some observers.

The most important evidence, however, in favor of a function of economic value attached to the appendix, is the fact that, instead of atrophying before, or shortly after birth, it actually, in embryonic life, replaces a primordial appendix (see "Embryology of the Appendix," Chap. IV), and then goes on to full development, persisting throughout adult life, and even into extreme old age, partaking and sharing only in those atrophic changes of the body at large which are the index of senility.

Against these facts, on the other hand, we have the numerous experiments performed *in vivo* by surgeons, in which healthy, or relatively healthy appendices are often removed without deleterious effect.

It is necessary for us to accept for a moment the argument from analogy in favor of a function belonging to the appendix, in order to reach our second hypothetical question: What may that function be? Is it nothing more than a share in the general intestinal system; or is it of a peculiar and special character? Do the glands of the appendix merely add numerically to the total number of microscopically similar glands scattered at greater intervals through-

out other parts of the intestine; or do they secrete some, as yet not isolated chemical substance, exercising a special influence upon digestion at this point in the alimentary tract? The argument from analogy for a special function may be briefly stated thus: In the first place, the functions of a number of organs, heretofore considered functionless, as the thyroid, thymus, and suprarenal glands, have proven of such inestimable value, nay, so necessary to normal life, that the scientific physiologist will do well to reserve his judgment in regard to the appendix, and occupy an attitude of expectant observation. Again, as in the upper part of the digestive tract special secretions are poured in from such important organs as the liver and pancreas, so in the lower may we not expect, after the sudden transition from ileum to colon, to find some analogous organ or organs profoundly modifying the food under its altered conditions?

In summing up the evidence, I can only repeat that we await the final test of demonstration. Anatomy makes plain to us the structural peculiarities of the appendix, but leaves us entirely in doubt as to the existence of a function; it remains for the physiologist, or more properly the physiological chemist, to detach the appendix in some animal suited for the purpose, turn it into the surface of the body and study its secretions, for by demonstration alone, as I have said, can the question of function be finally determined.

Before leaving the subject, I think it will be of interest to give a brief account of the opinions held by different distinguished writers of an earlier date, beginning with the great LIEBERKÜHN.

J. N. LIEBERKÜHN (*De Valvula coli et usu processus vermicularis*, I. D., Lugd., Bat., 1739) says: "The surface of the vermiform appendix is full of glands secreting a fluid which mingles with the feces in the cecum, and by diluting these prevents their remaining stationary and doing harm. Glands of the same character are present in the cecum, but those of the appendix possess greater strength and usefulness. The fact that the appendix contracts at the same time as the cecum, prevents any foreign body entering its lumen."

J. VOSSE (*De intestino cæco ejusque appendice vermiformi*, I. D., Götting., 1749) says: "The uses of the vermiform appendix are as yet imperfectly understood, but when the character of its structure is considered, it will be seen that its uses are other than those of the cecum. The surface of the appendix is full of glands, which secrete a mucous, or rather a gelatinous layer. As there is naturally a tendency for feces to accumulate and harden in the cecum, there must be some provision by which they are rendered more fluid. Glands are present for this purpose in the cecum, but they are not sufficient and require aid. The function of the vermiform appendix is to provide additional secretion."

HERLIN (*Jour. de méd. chir. et. phar.*, July, 1768, p. 321) published some observations in regard to the appendix which assume that its function is mechanical.

G. von dem Busch (*De intestino cæco ejusque processu vermiformi*, I. D., Götting., 1814) emphasizes the view taken by Lieberkühn as to the secretion from glands in the appendix poured into the cecum. "If," he says, "the vermiform appendix yields a mucous secretion, and if this secretion is the same as saliva and pancreatic juice"—which he assumes as probable—"then the appendix must be considered as a second salivary or pancreatic gland, while the cecum is a second stomach."

The next contribution to the subject which I have found is that by H. Cummin, in the form of a letter (*Med. Times and Gaz.*, 1852, vol. 2, p. 498) in which he suggests that the appendix is a remnant of intra-uterine life, like the umbilical ring and the fossa ovalis. In a series of dissections of the human fetus at different stages of growth, which had extended over some years, he had always found the colon tapering into the vermiform appendix. He had also, once, in a very young subject, found the extremity of the appendix attached to the peritoneal surface of the umbilical ring. Reflecting on these facts, he says, and remembering that the umbilical vesicle and the white filament extending from it are now admitted to be the empty yolk sac and its duct, he has been led to the conclusion that the vermiform appendix is undoubtedly the anatomical termination of the vitelline duct. Anatomists who will take the trouble to make the dissections above alluded to, and to observe the gradual expansion of the appendix into the colon as well as the length of the tapering gut from the point at which the ileum enters, will, he thinks, agree with him.

I have found nothing further upon the subject, beyond passing conjectures, until the year 1888, a period when our knowledge of the appendix was entering upon its present era. H. H. Smith ("*The appendix vermiformis, its function, pathology, and treatment*," *Jour. Amer. Med. Assoc.*, 1888, vol. 10, p. 797) then writes as follows: "That the appendix exerts some influence on the action of the cecum in digestion is quite probable, as its mucous coat differs very materially from that of the cecum and colon in the arrangement of capillaries and mucous crypts, as shown by the minute injections made by Neill of Philadelphia, in 1851; whilst Gerlach states that the intervening spaces between the crypts of the appendix are so prominent as to make them look like small bridges—a marked anatomical difference. With this vascular structure, we may well suppose that the secretion of the appendix is free, and differs in some way from the cecum. Perhaps it is the source of a lactopeptone mixed with a large amount of mucus and some phosphates or some carbonate of lime, that in some way modifies the formation of feces, and by its mucous secretion facilitates their passage up the ascending colon; hence, an early symptom of appendicitis is constipation. The presence of an appendix vermiformis in certain herbivorous animals and its absence in the carnivora, would also seem to indicate that this organ has some influence on the digestion of vegetable matter. Tiedeman and Gmelin long since observed that the gastric juice of the herbivora possessed

this power, whilst that of the carnivora (that have no appendix) is not sufficiently active to destroy coarse vegetables, cereals, or hay and straw."

We proceed now to another question of physiological interest, namely: Has the appendix any proper movements? Every observer who has examined appendices with the abdomen open, and noted the length of the appendix before and after removal, must often have been struck by the fact that an appendix of some length within the body often appears much shorter when removed, and that an appendix which is flaccid *in situ naturalis*, sometimes becomes firm and even rigid when excised and laid upon the table. I have myself seen an appendix, measuring 9.5 cm. before removal, contract to a little over 4 cm. after it was removed; and VAN LENNEP

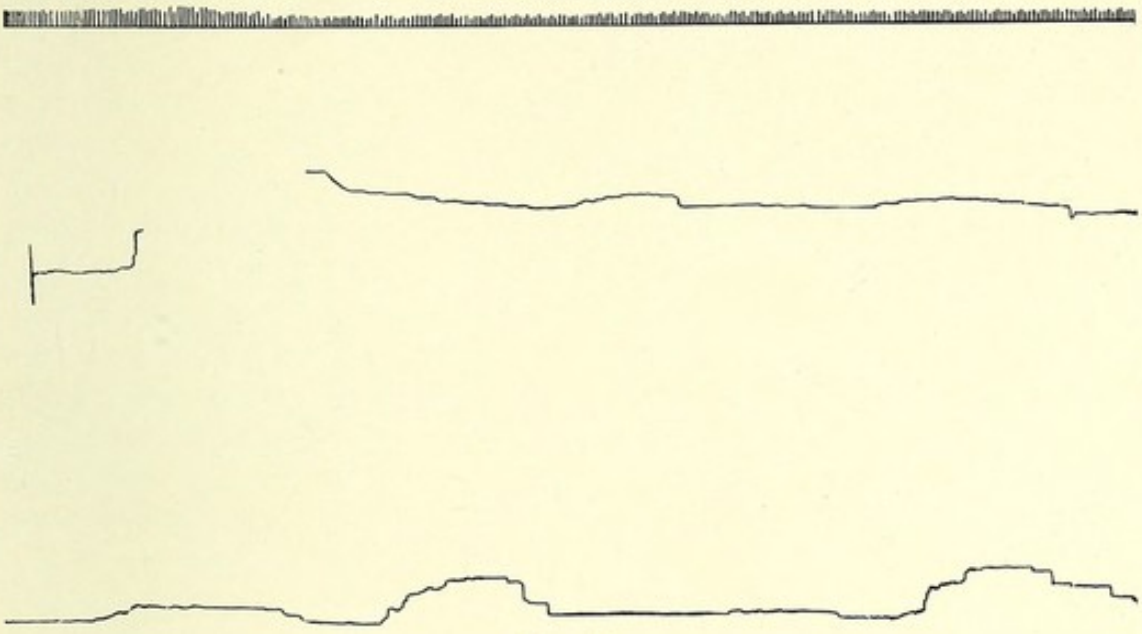

FIG. 147.

The larger curves indicate the peristaltic waves, and the secondary curves the simple muscular contractions. The respiratory movements are indicated by the undulations.

mentions a case in which the appendix appeared to be in spasmodic contraction and full of something that could not be emptied by compression, but as soon as it was removed and laid upon a plate, it spontaneously expelled a mass of soft feces (*Hahn. Med. Month.*, Jan., 1895). No definite observations recording contractions of the appendix have as yet been published; and therefore the following piece of practical work by E. HURDON is of special value, giving, as it does, a graphic representation of the contractions of the appendix in the rabbit in response to stimulation by electricity.

The apparatus used was similar to that employed by BAYLISS and STARLING (*Jour. Physiol.*, 1899, vol. 24, p. 99) in their experiments on rabbits, with a few unimportant modifications. The abdomen of a medium sized rabbit was opened under normal salt solution, at a temperature of 37.5° C.;

a longitudinal incision was then made in the wall of the cecum, on the side opposite to the attachment of the mesentery, and a balloon inserted. The appendix was next brought out of the abdominal cavity and immobilized on a small stand, after which the levers were attached to it by sutures. The point where the balloon was inserted was then fixed, so as not to interfere with the motion of the levers. Small regular contraction waves followed the insertion of the balloon, and continued to do so. Inflation of the balloon was followed by deep regular peristalsis, plainly visible and clearly recorded on the drum (see Fig. 147).

CHAPTER IX.

NATURAL HISTORY.

DISEASES TO WHICH THE APPENDIX IS LIABLE. ACUTE AND CHRONIC APPENDICITIS. EFFECTS OF AN APPENDICITIS UPON THE APPENDIX ITSELF. EFFECTS OF AN APPENDICITIS UPON THE STRUCTURES IN THE NEIGHBORHOOD. THE MORE REMOTE EFFECTS OF AN APPENDICITIS.

Under the caption "*Natural History*" I propose to give a brief outline description of appendicitis in its various phases, apart from symptomatology and uninfluenced by treatment, in the hope that by thus presenting and illustrating the different types of the disease when allowed to run its course without interference, I may be able to depict its protean forms in a fresh and vivid manner, and to demonstrate the various possibilities in any given instance. I shall, therefore, note the different developments of an appendicitis as seen by surgeons at operations *in vivo*, as well as its final forms as seen upon the autopsy table, bestowing equal attention upon each, but not discussing either with the minuteness of detail which is the province of the anatomist and the pathologist. My wish, in short, is to treat my subject as I should in a preliminary talk to a body of students, before entering upon a more complete analysis and a discussion of the details. It will be noted that some of the cases illustrating the progress of the disease are taken from the older writers, whose beautiful objective descriptions leave little to be desired, while the references to literature are simply those belonging to the cases cited, and make no pretension to constitute a complete bibliography.

I shall consider my subject, for convenience' sake, under the following heads:

1. Diseases to which the appendix is liable.
2. Acute and chronic affections of the appendix.
3. The effects of appendicitis upon the appendix itself.
4. The effects of appendicitis on the structures in the neighborhood of the appendix.
5. The more remote effects of an appendicitis.

Diseases to Which the Appendix is Liable.—The vermiform appendix constitutes a microcosm, in which all the various diseases to which its component anatomical elements are liable in other parts of the body, may occur. From the presence of epithelial elements primary adeno-carci-

noma is not infrequent. I have found upwards of forty cases so reported in the literature, and there is no doubt that a careful microscopic study of all thickened appendices after removal would show malignant disease in the organ to be more frequent than hitherto suspected. Owing to the rich supply of lymph glands the appendix is a frequent participant in the glandular changes characteristic of typhoid fever. Analysis of such cases, however, shows that a typhoid affection of the appendix is, as a rule, comparatively unimportant, except as it may give rise to an erroneous diagnosis in the early stages of the disease.

A few cases have been reported of fibro-myomata, generally of small size, affecting the muscular and connective tissue elements of the appendix. One such case, occurring in my own practice, appeared macroscopically to be, without doubt, an enormous fibroid tumor of the appendix, but a careful microscopic study of serial sections showed that the disease had developed in the contiguous connective tissues, and then in the course of its growth had enveloped and buried the appendix in its substance.

The peritoneal covering of the appendix is liable to be involved in a peritonitis arising from any source whatever. Owing to the contiguity of the appendix to the pelvic organs in women, it may be peppered over with tubercles in tubal tuberculosis. Ovarian papillomata and carcinomata when disseminated over the peritoneum involve the outer coat of the appendix as well as the adjacent organs.

The inner mucous surface of the appendix is liable to a variety of affections arising from its direct relationship to the alimentary tract. From this source, various foreign bodies cross its lumen, where, if their weight or their form favor their detention, they may become nuclei for accretions of earthy salts and layers of mucus until the lumen of the appendix is choked. An actinomycosis may arise in this manner, and, although but few cases of the affection have been reported in the United States, Isemer has published nineteen, and Spickenbaum twenty-seven; one case has occurred in the gynecological department of the Johns Hopkins Hospital.

Tuberculosis of the mucosa of the appendix is often associated with ileocecal tuberculosis; primary tuberculosis of the appendix, however, contrary to general opinion, is, as yet, a rare disease. It is generally believed that a catarrhal enteritis may produce changes in the appendix, but satisfactory demonstration of the fact, I think, is still lacking. J. H. Musser insisted strongly, some years ago, upon the relationship between appendicitis and recurring colitis in a personal communication, and G. E. Shoemaker dwells upon the same thing in an article entitled: "*The importance of chronic irritability of the colon with mucous stools as a symptom of appendicitis*" (*Ann. of Surg.*, 1898, vol. 27, p. 733).

On account of its anatomical position in the body, lying, as it does, exposed

on the hard iliac pan and protected only by the soft abdominal wall, the appendix is peculiarly liable to injury from sudden blows, prolonged pressure, etc.; from this point of view, therefore, it may become a subject of medico-legal interest. The anatomical position of the appendix is also responsible for its frequent presence in right-sided hernias. When there is an unusually long mesocecum, permitting the cecum with the appendix to travel over various parts of the abdomen, the latter may be found in a hernia on the left side, or even in one at the umbilicus. The pelvic inflammatory diseases of women, so often associated with pelvic peritonitis, also frequently involve the appendix when it lies at or below the pelvic brim; it is, naturally, in disease of the right uterine tube that this complication is usually found.

A diseased appendix may involve any of the organs which lie within its radius; it may contract adhesions with the cecum, or with a neighboring loop of ileum, into which it not infrequently opens, subsequent to the formation of an abscess. The colon is often involved by the extension of a sloughing process advancing by continuity of structure from the base of the appendix; it is involved by contiguity when a sloughing tip of the appendix opens into the colon.

In fetal life the appendix is found lying in close relation to the kidney and its pelvis, but it is not common to find any affection of the urinary tract traceable to this source in the adult. Such a case, however, is given by F. W. Mott (*Trans. Path. Soc. Lond.*, 1889, vol. 40, p. 106). A woman, operated upon for intestinal obstruction, died a few days after operation from peritonitis due to a perforated appendix. At the autopsy the appendix, which measured seven inches in length, was found to be turned up behind the cecum and mesocolon; it then crossed the second part of the duodenum, and was finally attached to the front of the right kidney by its tip.

There are a few cases on record in which the appendix has adhered to the bladder, even, in some instances, with the formation of a fistula between them. F. Kammerer furnishes me with such a case, in which the appendix was soldered to the bladder wall. The patient, a woman of forty-seven, had an abscess which was opened at the outer border of the rectus, a cupful of pus being evacuated. Two days after the operation pus was detected in the urine, and six months later the abdomen was opened, when the appendix was found firmly adherent to the wall of the bladder, at a point corresponding to an ulcerated area within. The appendix was removed, but no communication with the vesical cavity was found.

Adhesions may also occur between the appendix and the uterus. I had such a case in a negress, who suffered from strangulation soon after a confinement, and a loop of ileum was found to have slipped under the vermiform appendix, which was strongly adherent to the right side of the uterus posteriorly. J. B. Murphy

records an instance (*Jour. Amer. Med. Ass.*, 1894, March 3–24, Case 98) of a woman, twenty-four years of age, in whom the cecum was dragged over toward the uterus, and fixed by an appendix which was much elongated and adherent to the uterus, thus producing intestinal strangulation.

Thrombosis of the veins going to the appendix is frequently found in gangrene of the organ. In acute septic affections, these thrombi extend up toward the larger vessels, which may, in time, become infected or convey septic foci to the liver.

One of the most dangerous complications in an attack of appendicitis is the accompanying toxemia, which may exist with or without a definite abscess formation. It arises from the excessive formation of micro-organisms shut up in the appendix, and the absorption of their toxins into the circulation.

Dieulafoy in particular ("*Toxicité de l'appendicite*," *Presse méd.*, 1898, Nov. 2, No. 92) has drawn attention to the toxic character of an appendicitis, arising from the excessive growth of pathogenic bacteria under circumstances which serve to enhance their virulence in the highest degree; the toxins elaborated and thrown off in this state of exalted activity are absorbed by the vascular system, and act as profound poisons to the nervous system, producing the symptoms of collapse, so commonly seen and dreaded in grave cases. This element of toxemia enters into every case to some extent, and it becomes one of the chief duties of the surgeon to detect its presence and measure its severity, in order to draw from it correct inferences as to the condition of the affected organ. Dieulafoy's conclusions are: (1) that the toxicity of an appendicitis is a fact proven by clinical experience as well as laboratory experiment; (2) that the toxicity may be either light, or intense and even fatal; (3) in its commoner form it is manifested by a sub-icteric skin and urobilinuria, with albuminuria; (4) the icteric color is sometimes the sign of an extremely grave intoxication, affecting the nervous system and assuming a typhoid form.

The organisms, after escaping through the walls of the appendix, extend directly throughout the peritoneum, involving the contiguous portions of it and then successively invading other parts of the peritoneal cavity, giving rise to a general peritonitis, or to discrete abscesses among the viscera. They may, however, spread through the vascular channels, the lymphatics, or the veins, giving rise to secondary deposits which occasion abscesses in remote parts, such as the liver, spleen, pleura, lungs, pericardium, parotids, and brain.

Acute and Chronic Affections of the Appendix.—Acute affections of the appendix are inflammatory in their nature; but inflammatory affections may run a protracted course, extending over years, associated either with the walling-in of the diseased area by surrounding peritoneal adhesions, or else with changes in the interior of the organ, such as cicatrices or sharp flexures, which give rise to repeated attacks, or rather relapses of the disease.

The surrounding structures often become more or less intimately adherent to the appendix, the adhesions passing from one part of it to another, or else from the appendix to the cecum, to the pericecal folds, or to the parietal peritoneum. The appendix itself undergoes various changes of form in consequence of kinks and bends occasioned in it by these adhesions; similar bends and kinks may also result from a shortened mesappendix. (See Fig. 148.)

An appendicitis may terminate in several ways, the most favorable outcome being the entire disappearance of the disease by resolution, no vestige of it remaining. That the disease may end in this manner has been abundantly proved by surgical operations done after convalescence from an attack. Many of these cases, however, although macroscopically sound, show marked pathological changes upon careful microscopic study. Another mode of termination is complete destruction of the mucosa causing obliteration of the canal of the appendix (*appendicitis obliterans* of Senn); and this outcome may be considered a favorable one, as it obviates all liability to a subsequent attack. Repeated attacks of appendicitis may result in the appendix becoming enclosed in a bed of more or less extensive adhesions, where it lies dormant as far as any further inflammation is concerned; such appendices are frequently found at autopsies. Finally, we may have a fatal termination arising from an aggravated affection spreading beyond the appendix, involving the peritoneum or the vascular system, and ending in general sepsis, toxemia, or pulmonary embolism.

Effects of an Appendicitis upon the Appendix itself.—An appendicitis may run its course in the mucosa of the organ as a simple catarrhal affection. Catarrhal inflammation of the appendix, however, in its chronic form, is not a common disease, for when the infection advances beyond the mucosa it ceases to be catarrhal, and becomes a chronic diffuse appendicitis producing a great hypertrophy of the walls of the appendix, and not infrequently associated with ulceration, the healing of which often produces cicatrices and stenoses, more or less complete. When the appendix becomes closed by stricture, compression, or flexure, an accumulation of secretions often results, which, if the organ remains uninfected, forms a cystic appendix. Thrombosis or compression of the vessels is often followed by necrosis and gangrene.

The concretions or enteroliths so often found at operations, are caused by retained fecal material, which undergoes a process of desiccation and serves to excite the secretion of mucus with its salts in excess; their presence and their attrition often serve as an important factor in ulceration, provoking an attack of appendicitis which frequently ends in perforation or gangrene.



Single kink due to adhesion passing between mesappendix and neighboring organ.



Single kink and constriction due to narrow band of fibrous tissue passing from anterior to posterior surface of mesenteriolum.



Double kink due to adhesions passing from proximal to distal part of appendix.



Single kink on tip due to adhesion from distal to middle part of appendix.



Single kink in middle of appendix, distal half flexed upon proximal half.



Single kink in middle caused by adhesions, tip free.



Same, caused by shortened mesappendix.



Double kink due to adhesions.



Triple kink due to short mesappendix and adhesions.



Triple bend due to short mesappendix.



Same condition more pronounced.



Spiral turn due to short mesappendix.



Sudden bend due to broad adhesions to abdominal tumor.



Proximal portion adherent to psoas muscle; kink at lower angle; distal portion free and turned upward by short mesappendix.



Distal portion bent back upon itself and adherent to mesappendix and cecum; resulting twist causing mesappendix to envelop middle of appendix.



Appendix adherent to cecum, tip being free and slightly bent away from cecum.

FIG. 148.—VARIOUS BENDS AND KINKS OF THE APPENDIX.

Effects of an Appendicitis upon the Structures in the Neighborhood.—One of Nature's most interesting efforts is her attempt to limit an inflammation in the appendix to the organ itself, or its immediate neighborhood, by means of an adhesive peritonitis uniting the surrounding tissues, including the bowels, and designed to shut off the peccant organ from the abdominal cavity. The

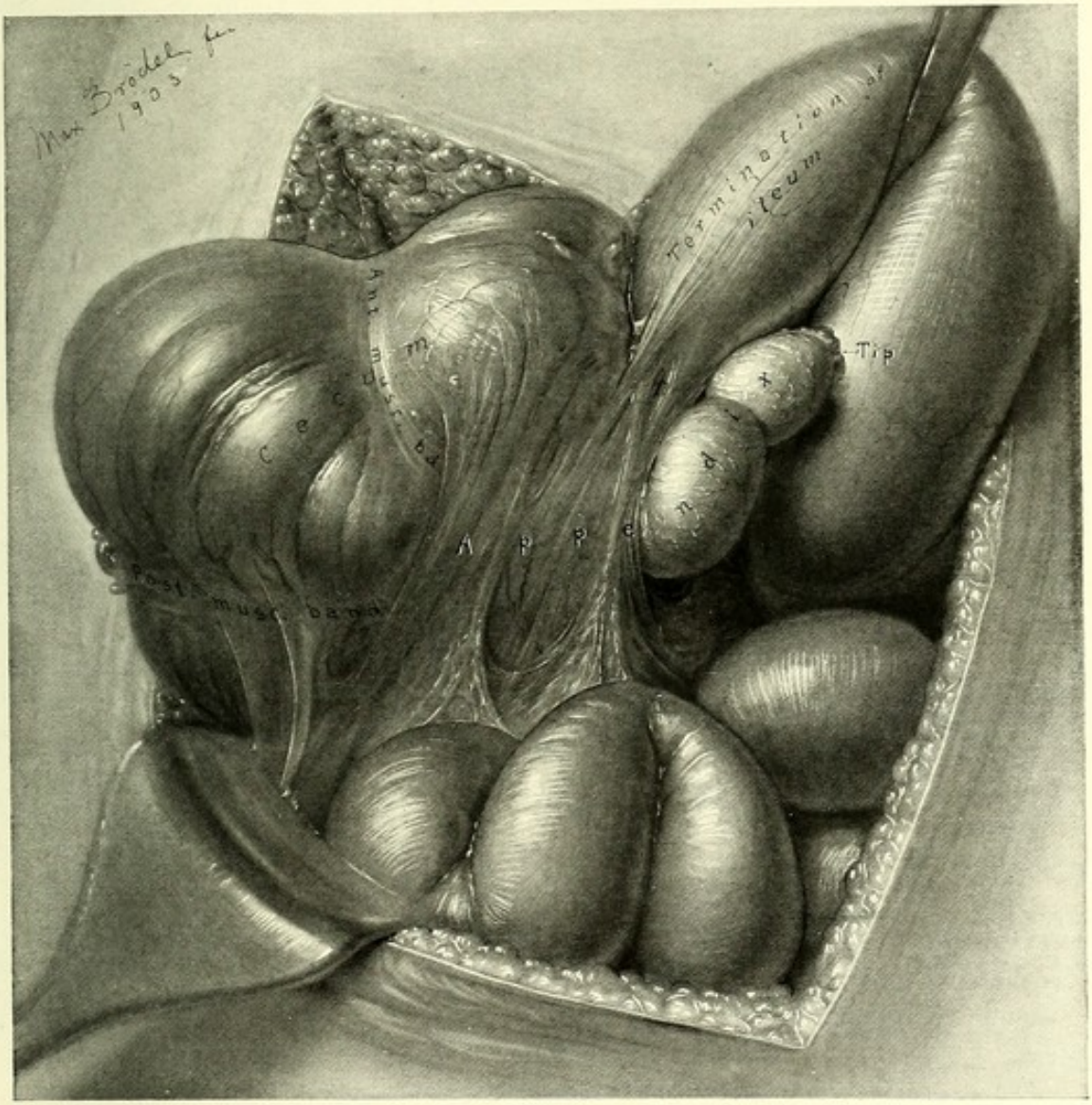

Fig. 149.—Base of Appendix Covered in by Dense Sheet of Adhesions Uniting Ileum, Cecum, and Iliac Fossa.

The exposed distal portion contains several large concretions, one as large as a date-stone. Mrs. T., op. April 24, 1901.

shutting off of the appendix may be the result of repeated attacks of inflammation, each one of which serves to agglutinate some additional portion of the peritoneum. Such a case is here shown (see Fig. 149) where the entire base of the appendix is covered in by a sheet of adhesions uniting the ileum, the cecum, and the iliac fossa, and spreading over the proximal portion of

the appendix. Unfortunately, in such a case the effect of this strong web is to compress the base of the appendix and imprison the large fecal concretion in the distal portion under tension, at the imminent risk of producing pressure necrosis, and perforation or gangrene. This circumscribed peritonitis with the associated distention of the intestines may go no further than the first stages, and with the disappearance of the disease it undergoes complete absorption. It answers a most useful purpose, however, in temporarily shutting off the purulent exudate which forms in the neighborhood of the appendix, and thus preventing its escape into the general peritoneal cavity.

It is not at all necessary that the appendix should be perforated for an abscess to form in its vicinity.

A localized abscess starting in the neighborhood of the appendix may remain *in loco*, or it may increase progressively in size and extend in various directions up or down. Again, it may become the source of numerous other abscesses formed successively in various parts of the peritoneal cavity.

The appendix may lie in the wall on one side of the abscess, or it may be found entirely detached from the cecum and floating in the abscess cavity. The detached appendix has occasionally been observed to escape from the wound, either at the time of the opening of the abscess or afterwards. Such a case is that of POOLEY (*New York Med. Rec.*, 1875, vol. 10, p. 267). The patient, a girl of seventeen, had been vaguely ill for two weeks when the symptoms became more acute and an abscess formed. On opening this about half a pint of pus was evacuated, and the next day what appeared to be the whole appendix escaped in a sloughing condition. Recovery followed.

A. WORCESTER of Waltham, Mass. (*Bost. Med. and Surg. Jour.*, Aug. 4, 1892), reports the case of a man, thirty-six years old, for whom he opened an abscess, letting out some foul pus, in the midst of which the gangrenous tip of the appendix was seen, but as the rest of the organ was firmly adherent to the abscess wall, it was not deemed prudent to attempt its removal. On the fifth day, however, the sloughing appendix escaped from the wound.

R. L. PAYNE of Norfolk furnishes me with a similar case occurring in a colored woman, twenty years old, who, after repeated attacks of appendicitis, had a tumor situated at the navel, and extending below it. When an incision was made in the median line, just beneath the umbilicus, half a pint of fetid pus escaped, and the appendix floated out. The patient recovered, but with a fistula.

DELORME presented to the Surgical Society of Paris (*Bull. et mém. de la Soc. de chir.*, 1894, p. 801) an appendix which had separated spontaneously three days after a laparotomy done for a suppurative peritonitis. The specimen, 6 cm. in length and 2 cm. in diameter, ended in a *cul de sac*, and had lost one of its walls by ulceration.

Sometimes when the abscess opens into the cecum the detached appendix escapes with the pus, travels the circuit of the lower alimentary canal, and is discharged from the rectum. Some interesting instances are on record of this curious and rare spontaneous termination.

Jackson reports such a case (*Extr. Rec. Bost. Soc. Med. Improv.*, 1862, vol. 4, p. 49) under the title "*Discharge from the bowel of the appendix cæci during convalescence from an acute attack.*" The patient, a robust farmer, twenty-four years old, had a severe attack of appendicitis with abscess, and about two weeks afterwards he passed his appendix *per rectum*. He made a good recovery.

W. L. Wallace (*Amer. Med.*, Nov. 9, 1901, p. 745) had a similar case occurring in a young man, twenty-one years old, who was taken suddenly ill on September 11th. On the tenth day, after an action of the bowels, the nurse found an appendix 3.5 in. long in the stool; it was perforated near the distal extremity and contained several concretions, one of which protruded from the perforation. (See Fig. 150.) The report closes with the remark that "the patient is probably cured of his appendicitis by a fortunate operation of nature."



Fig. 150.—Appendix Passed by the Rectum.

Flaccid, gangrenous, numerous shreds on surface, remains of outer coats. At lower extremity a perforating concretion at *a*. Specimen from W. L. Wallace, of Syracuse.

E. C. Coleman of Kosciusko, Miss., has furnished me, in a personal communication, with the case of a man, forty-eight years old, who was taken ill with a severe attack of appendicitis for which operation was advised and refused; at a later date the patient reconsidered his decision, but his condition was then so much improved that operation was deferred. On the morning of the sixth day, after taking a dose of castor oil, he had a free alvine evacuation of muco-purulent matter mixed with some blood, and at the same time felt acute pain in the right side lasting for about a minute. An hour later, on going again to stool, he felt something pass, which proved to be a fleshy tube, 5.5 in. long, closed at one end and open at the other. This proved on examination to be the vermiform appendix, with two perforations in it. The patient made an excellent recovery.

J. H. Durkee of Jacksonville, Florida, has sent me, also in a personal letter, the case of a man who refused operation in a typical attack of appendicitis. After improving sufficiently to be up, he had a recurrence of the disease, during which an enema of Epsom salts was given, resulting in an evacuation of 5 oz. pus, together with the appendix, which was about 5.5 in. long, and had two perforations, one at the tip, and another at a point about 2 in. from the base.

An abscess forming in the right iliac fossa may open at any one of a number of points. The skin surface directly over the iliac fossa is a spot where spontaneous discharge often occurs, but it may take place at a point as remote as the umbilicus. An instance of evacuation in this locality has been reported by S. H. FREIND (*Phila. Med. Jour.*, July 22, 1899), in which the patient, a girl thirteen years old, was attacked by excruciating pain in the abdomen, continuing with less severity for three weeks, at which time there was a discharge of pus from the umbilicus. At an operation, somewhat later, the opening was found to be associated with an abscess at the base of the appendix. Death followed. Freind considered that a patulous vestige of the vitello-intestinal duct had afforded access to the umbilicus from an abscess lying posterior to the appendix.

J. B. MURPHY reports a similar case (*Jour. Amer. Med. Assoc.*, 1894, March 3–24, Case 75) of a man, twenty-eight years old, who had a perforation of the appendix with a circumscribed abscess in the region of the umbilicus. Removal of the appendix and drainage were followed by recovery.

Abscess connected with the appendix discharges most frequently into the cecum, as every surgeon of experience has had occasion to observe, or it may discharge into the ileum. (See Fig. 151.) Discharge into the rectum is not so common. BAYARD HOLMES reported such a case, and exhibited the postmortem specimen of an appendix attached to the rectum into which it had opened (*Obst. Gaz.*, 1890, vol. 13, p. 418). The organ was obliterated in its middle portion and contained a concretion on the rectal side of the stricture. The right ureter was enormously dilated, apparently in consequence of obstruction by the adherent appendix lying directly across it. When the abscess opens into the bowel spontaneously there is sometimes a reflux of bowel contents into the abscess cavity. A case has even been put on record in which fecal material travelled in this way up into the right pleural cavity.

In women, the abscess may discharge by the vagina, and this is one of the most favorable avenues for rapid evacuation.

Lastly, the discharge may take place by the bladder, as in KINGDON'S case, cited also in the chapter on etiology, where a boy of seven suffered from a calculus in the bladder formed around a pin, which had migrated into the bladder from the vermiform appendix. G. R. FOWLER of Brooklyn furnishes me with the case of a man, sixty-two years of age, who had an attack of "inflammation of the bowels," during which there was a discharge of pus followed by fecal matter through the urethra. A suprapubic operation was performed and a calculus the size of an English walnut removed, when a fistulous opening between the bowel and the bladder was visible on the right side, where the cecum and bladder seemed to be involved in a mass of adhesions. The ex-

istence of an attachment between the appendix and the bladder was only presumptive and was not demonstrated.

Krogius (*Processus Vermiformis*, etc., 1901, p. 161) mentions the case of a man, forty-eight years of age, who had an enormous abscess associated with a perforated appendix pointing in the gluteal region. This was at

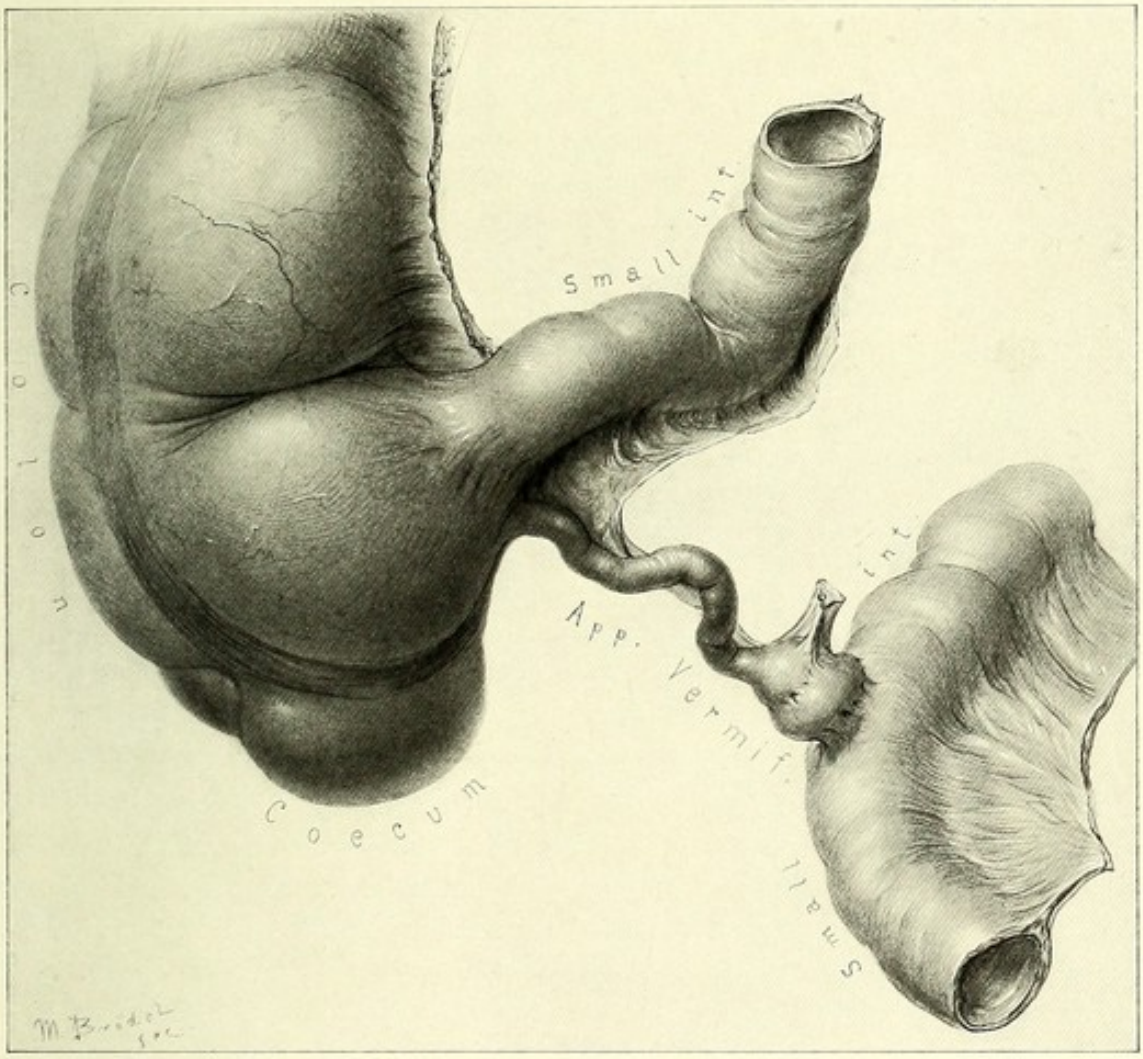

Fig. 151.—Inflammatory Residual Mass at the Tip of the Appendix Attached to the Ileum at a Distance from the Valve. This Probably Represents the Remains of an Abscess which has Emptied and Drained at this Point.

first mistaken for a hernia; but operation showed a large pus cavity over the trochanter major, and the muscles in the gluteal region were full of pus.

Lastly, an abscess may point under the crural arch, and even as low as the popliteal space.

The More Remote Effects of an Appendicitis.—The sequelæ of an appendicitis, when the disease is allowed to run its course unhindered, are not always limited, unfortunately, to the appendix itself, or to the neighboring tissues in the iliac fossa. Sometimes the sudden perforation of the appendix

takes the peritoneal cavity by surprise, before the formation of any salutary barriers in the way of protective adhesions designed to wall in the infection; in such a case as this, or in a sudden gangrene of the appendix due to vascular disturbances, the septic material is distributed throughout the peritoneal cavity, and a general, quickly fatal peritonitis is the result. The precise character and course of the peritonitis will depend on the character and virulence of the infecting organism, the amount of infection, and the rapidity of its distribution. In fulminating cases, the patient sometimes dies before the peritoneum has the opportunity to exhibit any well defined signs of reaction, such as vascular congestion, lymph, or suppuration.

Quite another picture is presented by another form of peritonitis (*progressive fibrino-purulent peritonitis* of Mikulicz) which advances by what might be called multiple foci. The focus of an infection is started in the right iliac fossa; another focus is then started at some distance from this, possibly among the intestines; a little later, a third focus develops in the left iliac fossa, or in the left flank; while possibly still another focus is found between the liver and the diaphragm, the whole process representing a typical purulent peritonitis.

Even the pleural cavity is not immune in severe cases, when the infection travels up under the crura of the diaphragm and causes pleuritis at first dry, then exudative, and finally suppurative in character. The right side is most frequently affected, but the left is not exempt.

A commoner mode of extension in empyema of the right pleura is by perforation of the diaphragm, by a suprahepatic abscess, which is a part of a progressive purulent peritonitis.

With the picture of a peritonitis, localized or progressive, goes that of an ileus due to hindrance to the movements of the bowels, or to a kinking of the bowel consequent upon adhesions, generally in the neighborhood of the ileocecal valve. The symptoms may become so prominent and so urgent as to mask the symptoms of the original disease.

Marked vascular changes are not infrequently found associated with the more aggravated forms of the disease. The appendix may, for example, be densely adherent to the iliac artery or to the iliac vein, and from such a contiguity a thrombosis of the vein extending down the leg may result. A case of adherence to the iliac artery was reported by J. B. Powell (*New Orleans Med. and Surg. Jour.*, 1854–55, vol. 11, p. 468). A negro, thirty years of age, was taken suddenly ill with intense pain in the bowels, which lasted for fifty hours, when he died. The autopsy showed a high degree of peritonitis with large collections of pus between the intestines. A perforation the size of a dime was found in the duodenum, one inch below the pylorus, with eight large intestinal worms impacted just below it; both the colon and cecum were distended with gas and with dark colored blood. The vermiform appendix, greatly enlarged, and with

its inner coats softened, was adherent to the right iliac artery. On opening the artery just below its commencement a small round perforation was found communicating with the appendix, through which clots of blood regurgitated. There was a deposit of lymph around the aperture.

Venous thrombosis is more apt to occur in suppurative cases, such, for example, as that reported by C. A. Freeman (*Canada Lancet*, 1871–72, vol. 4, p. 268). A young man, nineteen years old, had a severe pain in the right iliac fossa, in which there was a corresponding area of induration. The pain lasted for two weeks, at the end of which time about 3 oz. of pus were passed by the rectum, and immediate improvement ensued. The tumor, however, returned, and became so large that it compressed both the rectum and the bladder, causing a constant dribbling of urine and extreme difficulty in defecation, the latter function consuming about three hours, in spite of the regular use of laxatives. The abscess was excised and nearly a quart of pus evacuated, but about ten days later the patient experienced a severe throbbing in the left femoral region, followed by a rapid tumefaction of the entire limb. The pain and swelling continued to alternate for some time with discharge of pus, when, at length, a few small concretions were discharged and the patient recovered, after being bed-ridden four months.

An interesting case of the same kind is given by G. A. Browne (*St. Bartholomew's Hosp. Rep.*, 1880, vol. 16, p. 259) under the title: "*Perityphilitis complicated with thrombosis of the femoral vein.*" A man, forty years old, who had suffered for years from flatulence and indigestion was seized with a sudden pain in the right iliac fossa, which continued for nearly three weeks, when he was admitted to the hospital complaining that during the last three or four days the pain had passed down the front of the right thigh and into the calf. An ill-defined area of induration, giving a dull note on percussion, was present in the right iliac fossa. The site of the femoral vein was occupied by a tender cord filled with a thrombus, which extended into the popliteal space, and a superficial vein lying over the gastrocnemius muscle, together with the saphenous vein, were also plugged in their entire extent. The patient was able to leave the hospital, improved, in about six weeks.

Thrombosis of the mesenteric extending into the portal vein is fortunately much more rare. An early observation of this condition is that by E. Aufrecht (*Berl. klin. Wochensch.*, 1869, Bd. 6, p. 308), under the title: "*Entzündung des Processus Vermiformis; Perityphilitis, Phlebitis und Thrombose der Vena mesenterica magna; Pylephlebitis.*" A young man, nineteen years old, was suddenly attacked by abdominal pain, most marked in the epigastric region, and accompanied by chills and vomiting. His illness lasted for two weeks, during which he suffered from diarrhea, irregular chills, and pain in the ileocecal and epigastric regions extending upward into the right shoulder. A slight icterus was perceptible in the conjunctiva. Death took place on the fifteenth day. The autopsy showed that the vermiform

appendix was perforated in three places, through one of which its canal communicated with one of several abscesses situated between the ascending colon and the abdominal wall. Two more abscesses were found, one under the cecum extending into the true pelvis, and another the size of a walnut in the subcecal fossa. Into the latter opened the largest branch of the superior vein, which was the size of a crow quill and perforated at many places, from which issued a purulent fluid. Its inner wall was covered with thick, yellowish, caseous masses. The same condition existed uninterruptedly through the superior mesenteric vein into the vena porta, and at the entrance of the latter into the hilum of the liver there was a purulent mass similar to that found in the branch of the superior mesenteric vein. In the left branch of the portal vein there was a strong fibrinous exudate.

An abscess of the kidney came under my own observation in a woman upon whom I operated for J. C. McCoy, of Patterson, New Jersey. The patient had a large fibroid tumor, and quite independent of this, an appendix adherent to the ureter below the pelvic brim; in consequence of this attachment she had an accumulation of pus in the right renal pelvis, for which the kidney was removed at a later date.

A case of general sero-purulent peritonitis, with intense inflammation and swelling of the appendix, without apparent perforation or adhesion, and ending fatally, is given by A. B. Anderson of Pawnee City, Nebraska (*West. Med. Rev.*, Nov. 15, 1902).

Embolism in the lung following a thrombosis in any of the vessels communicating with the vena cava occurs when the thrombus becomes detached and, traversing the right heart, passes out into the lung to plug one of the branches of the pulmonary artery. When the embolus is a small one, the patient may complain only of a transient pain in the side, more or less severe and stitch-like in character; and doubtless many cases, being of this kind, escape observation. An embolus causing death in a case of an appendicitis whose course was uninfluenced by an operation, is shown in the following case, reported by M'Gregor (*Glasgow Med. Jour.*, Feb., 1869, p. 279). The patient, a woman, had noticed a tumor in the right iliac fossa for two months, which increased in size and became fluctuating. The fluid was about to be evacuated when sudden severe chest symptoms supervened, with dulness in the lower lobe of the right lung and absence of the respiratory murmur. The physical signs gradually extended upward, the breath and sputum became fetid, and death took place twenty-six days after admission to the hospital. The autopsy revealed a perityphlitic abscess containing pus and fluid feces, with a perforated appendix. On opening the chest the right pulmonary artery was found completely plugged with a firm fibrinous clot extending into most of the ramifications in the lower lobe, while the lung was completely gangrenous.

Embolism of the arteries of the appendix has been observed by J. M. T. Finney, in a case where the appendix was gangrenous

and the artery to it completely plugged. After operation a branch of the mesenteric artery became occluded, and later on an embolus appeared in the artery supplying one of the upper extremities. An unusual case of this kind has been reported by A. SCHEIBENZUBER of Dayton, Ohio (*Ohio Med. and Surg. Jour.*, 1877, N. S., vol. 2, p. 259) under the title: "*Case of perityphlitis, embolism of the left anterior tibial artery, gangrene, amputation, recovery.*" A woman, thirty-five years old, robust, fat, and in good health was taken ill with symptoms of "inflammation of the bowels." The physician, who saw her on the following day, found tympany and pain in the right iliac fossa, with a temperature of 102° F. and a pulse of 120. There was general prostration and some delirium. A diagnosis of perityphilitis was made, and eight days after the onset of the illness, numbness was observed in both lower extremities; ten days later several patches of a brown color, about 3 cm. in diameter, made their appearance on the right leg, but disappeared in a few days; the left leg then became discolored below the middle and was insensible to the touch, although there was a sensation of burning heat in it. Three days later still, and twenty-one days from the onset of the attack, a line of demarcation was fully developed, and it was necessary to amputate the gangrenous limb in the upper third. The arteries were unusually small, and in the anterior tibial there was an embolus, below which the leg was mummified. The wound was almost entirely healed in three weeks, although part of the flaps sloughed.

Abscess in the liver may be the result of a general infection arising from a pyemic process, in which the pyogenic organisms, in the form of minute emboli, are lodged in the liver, as they might be in the lungs, the brain, the muscles, the kidneys, or other organs. Such cases are rare, as are also those of invasion by the minuter biliary channels. The commoner mode of invasion is by the mesenteric and portal system of veins forming a pylephlebitis from which foci are distributed through the liver. A liver abscess lodged between the liver and the diaphragm does not belong in the same category as those already referred to, being in reality extra-hepatic and sub-diaphragmatic. Such abscesses belong for the most part to the group of progressive purulent peritonitides. They are among the most obscure and most dreaded of all the intra-abdominal suppurations, and usually attain considerable size before they are discovered. They may terminate by perforation of the diaphragm resulting in a suppurative pleuritis, or by perforation of a bronchus.

CHAPTER X.

THE VERMIFORM APPENDIX AT AUTOPSY.

ACUTE APPENDICITIS. CHRONIC ADHESIVE APPENDICITIS. CHRONIC OBLITERATIVE APPENDICITIS. CYSTS OF THE APPENDIX. CONDITION OF APPENDIX IN DISEASES OF OTHER VISCERA.

Introductory.—In the present state of surgery, the best opportunities for studying the gross pathologic anatomy of the vermiform appendix are in the hands of the surgeon, for it is he who sees the organ in all stages of disease, with its arterial and venous circulation still active, and with its relations to surrounding structures undisturbed by manipulation. The minute pathologic anatomy of the appendix, on the contrary, is best investigated by the pathologist. For the latter purpose the most suitable material is that supplied by the operating room, since specimens thus obtained are in the most favorable condition for the technical procedures necessary to the demonstration of the cellular structures and the changes taking place in them. It is the autopsy table, on the other hand, which furnishes the best material for studying the more general effects produced by diseased conditions of the appendix upon other organs and structures of the body, or, conversely, the effects of disease in other organs upon the appendix itself, thus furnishing a comparison with other fatal processes, or with the remote consequences traceable to lesions of the appendix. In the dead-house, only "*end processes,*" as a rule, are met with, and the preceding steps in the production of such processes can, in most cases, be only inferred. An adequate understanding of postmortem appearances, however, must depend in every case upon a knowledge of both gross and minute pathological anatomy, not only as seen by the surgeon while operating, but also as observed by the pathologist while studying the material furnished by operation.

ACUTE APPENDICITIS.

F r e q u e n c y .—The frequency of acute appendicitis as represented in the records of 4028 autopsies taken from three different sources is as follows:

The Boston City Hospital, Boston, Mass., January 1, 1896, to August 14, 1902	1890
The Johns Hopkins Hospital, Baltimore, Md., May 28, 1889, to August 13, 1902	1978
The Rhode Island Hospital, Providence, R. I., July 1, 1900, to July 1, 1902	160
	4028

Out of these 4028 autopsies, there were 86 cases, or 2.10 per cent., in which death was due, directly or indirectly, to acute inflammatory disease of the vermiform appendix. NOTHNAGEL, in 44,940 autopsies at the *Wiener allgemeines Krankenhaus*, between 1870 and 1896, found 148 cases of appendicitis, or 0.3 per cent.; while EINHORN, in 18,000 autopsies at Munich, between 1854 and 1889, found 100, or 0.5 per cent. As the figures from these two foreign sources do not differ greatly, and as they are taken from larger numbers of postmortem examinations than those of our own country, they probably represent the exact proportion of deaths from appendicitis more nearly than ours do. That our ratio is so much higher may, perhaps, be explained by the fact that our statistics cover a more recent period of time, during which interest in the subject has greatly increased, and therefore more effort is made to obtain autopsies in such cases than formerly. However, during the decade between 1891 and 1901 there have been treated in the Boston City Hospital 69,115 patients, of which number 8043 died, and of these deaths, 179, or 2.22 per cent., were due to appendicitis, a ratio agreeing very closely with those first cited.

Sex.—Out of our 86 cases, 57, or 66.2 per cent., were males, and 29, or 33.7 per cent., were females. These figures coincide with the generally accepted opinion that appendicitis is more common in men than in women; it is contrary, however, to the view expressed by EINHORN, by OCHSNER, and by others.

Age.—Our statistics in regard to age are as follows:

1 to 10 years.....	6 cases.	40 to 50 years.....	12 cases.
10 " 20 "	19 "	50 " 60 "	8 "
20 " 30 "	18 "	60 " 70 "	2 "
30 " 40 "	11 "	70 " 80 "	1 case.

It will be seen that 48 per cent. of our cases occurred in the second and third decades of life, and that here also our results agree with the commonly received opinion that inflammation of the appendix is most common in young adults.

Treatment.—Celiotomy had been performed in 57 out of our 86 cases; in 29 there had been no operation. In some of the cases in which no operation had been performed, the diagnosis was clear, but the condition of the patient did not justify operation; in others, disease in the appendix was first discovered at the autopsy, the symptoms of it having been absent, insignificant, or masked by pathologic conditions elsewhere.

Condition of Appendix.—Inasmuch as many of our cases had been the subject of operation, the material was not always that best suited for studying the lesions of the appendix. In 35 of the cases, the appendix had been completely removed, leaving only a short stump, which in some instances was entirely healed, but in others showed no evidence of healing, the ligature having disappeared and an opening into the cecum presenting, through which the intestinal contents could be squeezed. In 5 cases, only part of the appendix

had been removed. In 15, the abscess cavity, or else the general peritoneum, had been drained, without disturbing the appendix. In 29 cases there was acute gangrenous appendicitis with single or multiple perforations. In 2 of these, a gangrenous appendix had entirely sloughed away from the cecum. In 2, the remaining proximal portion of the appendix, part of which had been removed at operation, showed a perforation. Among the cases of perforation there were 2 of special interest, one being associated with typhoid ulceration of the intestine, the other with amœbic ulceration. In 7 cases there was an acute appendicitis without perforation, and in 2 there was a fibrinous exudation about the appendix, without any marked lesion of the organ itself.

PERITONEUM.

The visceral and parietal peritoneum showed an inflammatory exudation in 54 out of the 86 cases. Of these 54 cases, 38 had been operated upon, 16 had not. The character of the exudation varied greatly. In some cases, the serosa of the intestines showed nothing more than the slightest film of fibrin, with a corresponding loss of the normal sheen of serous surfaces; in others, there was an abundant exudate of yellowish, friable fibrin, gluing together adjacent intestinal loops, and forming imperfectly walled-off pockets filled with creamy pus. Between these two extremes, all forms of exudation were present, and the resulting condition varied in accordance with the proportions in which each of the component parts of the simple inflammatory exudation occurred. The cases may be divided as follows:

	Operated upon.	Not Operated upon.	Total.
Acute fibrinous peritonitis	15 cases	2 cases	17 cases
" sero-fibrinous peritonitis	7 "	1 case	8 "
" fibrino-purulent peritonitis	13 "	9 cases	22 "
" purulent peritonitis	3 "	4 "	7 "
	38 "	16 "	54 "

In 25 cases inspection of the abdominal cavity at the time of the autopsy revealed no signs of any tendency toward limitation of the inflammatory process to the immediate vicinity of the appendix, nor was there anything pointing to a previous abscess in the region of it. In 29 cases it was evident that there had, at first, been a localizing process resulting in an abscess, either completely or incompletely walled off, and that subsequently a leakage had taken place from this abscess, causing infection of the peritoneal cavity and, finally, a general peritonitis.

	Operated upon.	Not Operated upon.	Total.
General peritonitis without peri-appendical abscess	16 cases	9 cases	25 cases
General peritonitis with peri-appendical abscess	22 "	7 "	29 "
	38 "	16 "	54 "

Peri-appendical Abscess.—A walled-off cavity filled with pus, or drained and lined by fibrin or granulation tissue, was found in connection with the appendix in 47 out of the 86 cases. Of these 47 cases, leakage with general peritonitis had occurred in 29.

	Operated upon.	Not Operated upon.	Total.
Peri-appendical abscess with general peritonitis	22 cases	7 cases	29 cases
Peri-appendical abscess without general peritonitis	13 "	5 "	18 "
	35 "	12 "	47 "

The situation of the abscess, in a large proportion of cases, was, naturally, the right iliac fossa. The pelvis was next in frequency. Abscesses occurred also in other situations, but there was no great variety of them. The more common situations are tabulated here:

In right iliac fossa below cecum	27 cases
In right iliac fossa behind cecum	6 "
In right lumbar reigon	3 "
In pelvis	10 "
In mid-line just above pelvic brim	1 case
	47 cases.

The size of the abscess varied from a cavity 2.5 cm. in diameter to one filling the entire pelvic space and containing a large amount of pus. The walls of the abscess cavity were formed by the cohesion of neighboring viscera and portions of the parietes. The viscera commonly involved were the cecum, loops of small intestine, the bladder, the rectum, and in the female, the uterus and the broad ligament.

Pelvic Abscess.—The condition of the pelvis deserves some attention owing to the comparative frequency of abscess formation in this locality, and the difficulty in securing adequate drainage for pus collected in this dependent part of the abdominal cavity. In our 86 cases of acute appendicitis, 25 showed involvement of the pelvis. In some of these there was a definitely walled-off abscess, completely separated from the general peritoneal cavity; in some, again, the separation was only partial; in others, the pelvis showed merely a collection of pus in no way separated from the general cavity; while in others still, the participation of the pelvis was manifested only by a more marked deposit of fibrin. In many of the cases which had been operated upon, gauze drains had been introduced between the wound and the pelvis; and in these, there was evidence of a partial or complete drainage of a former abscess. Of these 25 cases, as has already been seen, 10 were peri-appendical abscesses. In the remaining 15 the appendix did not enter into the pelvis and in many of them it was remote from the pelvic brim. In this latter group of cases, the

surgeon, having found the appendix and treated it, is likely to overlook the pelvic condition and leave an abscess cavity undrained, to remain a source of septic absorption, or, by leakage, to produce a general peritonitis.

Subphrenic Abscess.—Since the classical publication of v. Leyden in 1880, much interest has attached to subphrenic abscesses in their various forms. They may occur in either subphrenic space; if in the right, they will be bounded above by the diaphragm, below by the liver, to the left by the suspensory ligament of the liver (*Ligamentum suspensorium hepatis*), and by the abdominal parietes; if they occupy the left subphrenic space, to these boundaries will be added below the stomach and spleen, this space not being so sharply circumscribed as the right. Between the two, the suspensory ligament of the liver forms a barrier which, as a rule, prevents the abscess from being bilateral. The ligament may, however, be eroded and the process extend from one side to the other. In exceptional instances the extension has advanced from one side to the other behind the liver, in front of the vertebral column, or, again, abscesses have originated simultaneously on both sides, so that the entire subphrenic space is occupied by purulent material, but separated by the intact suspensory ligament.

The origin of these abscesses varies greatly: those on the right side are more commonly due to a direct extension of an inflammatory process, proceeding from the liver, from appendical and peri-appendical lesions, from perforation of the duodenum, and, more rarely, from perforation of the stomach; on the left side, perforation of the stomach is the most frequent cause. Of the total number of cases, the cause, according to Nothnagel, lies oftenest, perhaps, in a round ulcer of the stomach. Other etiological factors are inflammatory conditions of the kidneys, gall bladder and ducts, echinococcus of the liver, and the extension of an inflammatory process from the thoracic wall or contents. These abscesses may contain only purulent material (*abscessus subphrenicus*) or purulent material mixed with gas (*pyopneumothorax subphrenicus* of v. Leyden). The gas comes either from perforation of some air-containing viscus, or is produced *in situ* by the bacterial flora present, either the bacillus aërogenes capsulatus (Welch) or some one of the bacillus coli communis group. This last form may occur as a complication of appendicitis, as in a case reported by Umber. These two forms are often separated, since the latter presents a distinct clinical picture, although etiologically and anatomically they are the same.

Subphrenic abscess is not frequent. Maydl collected 179 cases from literature, and Lang 173, to which he added 3 new ones. Yet, if we consider the frequency with which subphrenic abscess follows appendicitis, it would seem to be a more common affection than these figures indicate. Among 410 autopsies occurring during the past two years at the Boston City Hospital, 6 cases of subphrenic abscess, exclusive of those following appendicitis, have been found. Of these, 3 were right, and 3 were left sided. Those on the right side followed

a perforated gastric ulcer, acute suppurative cholecystitis, and typhoid fever respectively; those on the left side were the result of pyothorax, cholelithiasis with suppurative cholangitis, but no liver abscess, and acute hemorrhagic pancreatitis. In 2 of the 6 cases, the diaphragm showed gross perforation.

Of MAYDL's 179 cases of subphrenic abscess, 23 were secondary to appendicitis. LANG, out of 176 cases of right-sided subphrenic abscess, found 20 due to appendicitis. SACHS in 1895 reported 41 cases in which he included 25 of MAYDL's, although 2 of these should have been excluded, because their primary source lay in a perforation of the cecum by a foreign body. WEBER, in 1900, reported 9 cases of subphrenic abscess out of 600 cases of appendicitis operated upon by SONNENBURG; of these 600 cases, 350 had a peri-appendical abscess, so that the 9 cases of subphrenic abscess form 2.5 per cent. of the abscess cases. In a later paper, WEBER has added 5 cases from SONNENBURG's clinic. ELSBERG reports 2 cases of subphrenic abscess (upon which he operated) out of 91 cases of appendicitis, and he has collected 71 cases complicating appendicitis, making, with his own 2, a total of 73 cases. Moreover, he excluded a number of cases, because the reports were meagre or incomplete. Since the date of his article, single cases of subphrenic abscess have been reported by ROBINSON (1889), CAYLEY (1900), BLAKE (1901), GASTON (1901), DALE (1901), and others.

As WEBER found 2½ per cent. of subphrenic abscesses out of 350 cases operated on, and ELSBERG 2 cases in 91 consecutive appendicitis operations, and as we ourselves have found an inflammatory condition of the subphrenic region frequently present at autopsies, we think it a justifiable conclusion that subphrenic abscess is not a very unusual complication of appendicitis; the cases of it, however, have not, as a rule, been reported.

In our series of 86 cases of appendicitis, the subphrenic region was affected in 7, or 8.13 per cent., although not each one of these cases was a subphrenic abscess in the strict sense of the word. As these cases present a number of differences, as well as several points of interest, the autopsy protocols will be given in some detail.

I.—B. C. H. 98.247. J. H., male, age twenty-six.

Anatomical Diagnosis.—Scar of former appendix operation; acute fibrinous general peritonitis; chronic adhesive localized peritonitis; retrocecal, perisplenic, and subphrenic abscesses; right pyothorax; acute sero-fibrinous pleuritis, left side; complete atelectasis, right lung; partial atelectasis, left lung; acute bronchitis; acute purulent mediastinitis; volvulus of small intestine; thrombosis of vessels of liver. Cloudy swelling of kidneys.

In the right groin is a scar 4½ cm. in length, running parallel to Poupart's ligament, dark blue in color and slightly depressed below the surrounding skin (operation six months ago for appendicitis).

Peritoneal Cavity.—On opening the abdomen the coils of the small intestine are greatly distended, hyperemic, and covered with thin flakes of fibrin. The coils of intestine are united by easily broken, fibrinous adhesions. In the region

of the appendix and cecum are numerous firm, fibrous adhesions, in the meshes of which the appendix, with an obliterated lumen, is found. The diameter of the appendix is much decreased. Posterior to the cecum is found an abscess cavity containing a considerable amount of thick, creamy pus. The spleen is walled off from the general cavity by firm adhesions, and lies in a mass of the same thick creamy pus. This pus is very adherent to the capsule of the spleen and is only scraped off with some difficulty. The right lobe of the liver is bound to the diaphragm by recent adhesions. On separating these, there is found to be a layer of the same thick creamy pus lying between the liver and the diaphragm on the right side. Immediately over the left lobe of the liver there are fresh adhesions, but no pus. On examining the small intestine, 120 cm. above the ileocecal valve, a complete twist of the bowel is found. All of the small intestine below this point as well as the large intestine is collapsed.

Pleural Cavities.—The right pleural cavity contains 1800 cc. of thick creamy pus. The pleura is thickened, and covered with soft, yellowish, fibrin flakes. The left pleural cavity contains 800 cc. of a dark reddish fluid in which are numerous large flakes of fibrin. The fluid here is not purulent. The parietal pleura is also adherent, and shows the same appearance as the right; in addition there are numerous small hemorrhages beneath it.

Lung.—Right lung is flattened against the spinal column, and completely atelectatic. Left lung atelectatic along the back of the upper and middle lobes, but the inner and anterior portions of the lung still contain air. Bronchial glands enlarged and pigmented.

Diaphragm.—Both sides covered with an exudate of fibrin. No perforation.

Spleen.—Weight 140 gms., capsule thickened and covered with thick pus; on section, of a uniform bright red color; Malpighian bodies not prominent; pulp not increased.

Liver.—Weight 1720 gms. (see p. 228).

Cultures.—Heart's blood—Streptococcus pyogenes. Spleen—Streptococcus pyogenes, micrococcus lanceolatus, and bacillus coli communis. Kidney—Sterile. Right pleural cavity—Streptococcus pyogenes, micrococcus lanceolatus. Subphrenic abscess—Streptococcus pyogenes in almost pure culture.

Microscopic Examination.—Lung—Well marked organization is taking place along the pleural surface. The granulation tissue consists chiefly of thin-walled, widely dilated capillaries. Lung tissue more or less compressed. Blood-vessels injected. Spleen—Organization is taking place along the surface. Blood-vessels not so numerous as on pleural surface. Infiltration with lymphoid and plasma cells is greater.

II.—B. C. H. 00.115. E. A., female, age thirty-three.

Anatomical Diagnosis.—Peri-appendical, pelvic, and subphrenic abscesses; chronic localized adhesive peritonitis; acute fibrino-purulent pleuritis, right side; atelectasis, right lung; operation wounds.

In the right iliac region there is a healed scar 7 cm. long, and external to this

scar there is an incision 7 cm. long, entering the peritoneal cavity at the right side of the cecum, through which a gauze drain passes to the region of the appendix.

Peritoneal Cavity.—The surface of the general peritoneum is smooth, glistening, and dry. The region of the appendix and the end of the cecum are surrounded by slight adhesions and bloody diffluent material. The point of origin of the appendix is difficult to find, and its stump is apparently perfectly healed. The pelvis is walled off by rather strong adhesions, involving the omentum, the small intestine, the sigmoid flexure, and the apex of the bladder. On separating these adhesions the pelvis is found filled with dirty pus-like material. No direct connection between this and the condition about the appendix can be made out. Between the diaphragm and the right lobe of the liver there is a small collection of dirty pus-like material, which communicates with the exterior by means of a wound passing through the base of the right pleural cavity.

Pleural Cavities.—The left pleural cavity is normal, and also the anterior part of the right pleural cavity. The lateral and posterior parts of the right cavity, from base to apex, and the right half of the base are walled off by rather firm, fibrinous adhesions, and filled with 700 cc. of fibrino-purulent exudate. The pleural walls are here covered by thick layers of fibrin. This cavity communicates with the exterior by the incision before mentioned.

Lungs.—The left lung is pink, downy, and normal in appearance. The right lung is normal in the posterior and apical portions, but in the other parts it is covered with fibrinous exudate. Its tissue is soft and spleen-like in character, and a bit of it sinks in water.

Spleen.—Weight 100 grams. Purplish in color and somewhat reduced in consistency.

Cultures.—Heart, spleen, liver, kidneys, lungs, pleuræ, and peritoneum—Bacillus coli communis.

Microscopic Examination.—Liver—Shows marked central cirrhosis with increase of tissue around central vein, obliteration of capillaries and diffuse hemorrhage. Lung—Completely collapsed and atelectatic. Its pleural surface shows organization of a fibrinous exudation.

III.—B. C. H. 01.110. H. B., male, age thirty-five.

Anatomical Diagnosis.—Operation wounds; removal of appendix; acute fibrinous general peritonitis; mesenteric and portal pyophlebitis; multiple abscesses of liver; acute splenic tumor; parenchymatous nephritis.

The skin is generally slightly icteric, and the conjunctivæ are distinctly yellow. In the median line is an incision through the abdominal wall, 8 cm. in length, beginning 1 cm. above the umbilicus and extending to within 3 cm. of the xyphoid cartilage. In the right lower quadrant of the abdomen is an "appendix" incision 4 cm. in length. Both wounds are closed by sutures.

Peritoneal Cavity.—The peritoneal surface is lustreless. All the coils of bowel are slightly adherent by easily broken fibrinous shreds. In the cavity of the pelvis is a small amount of sero-sanguineous fluid. In the region of the appendix the stump only is found, and on pressure nothing escapes from the cecum. Bounded by the spleen, the stomach, the left side of the diaphragm, the liver, and the posterior

wall of the peritoneal cavity is an abscess, containing offensive, yellowish, semi-fluid, purulent material. Its wall is everywhere covered by a fibrinous membrane, about 1 cm. in thickness, which is readily detached. Smears from pus in the subphrenic abscess show flattened streptococci. Mesenteric lymph nodes, all somewhat enlarged.

Mesenteric and portal vein (see p. 234).

Cultures.—Heart's blood—Streptococcus pyogenes, bacillus coli communis. Liver—Streptococcus pyogenes, bacillus coli communis. Spleen—Bacillus proteus. Kidney—Bacillus coli communis. Peritoneum (beneath omentum)—sterile. Blood from vessel near portal vein—Streptococcus pyogenes, bacillus coli communis.*

IV.—B. C. H. 02.91. G. C., male, age thirty-three.

Anatomical Diagnosis.—Operation wound; appendix removed; perityphlitis; volvulus of small intestine; acute sero-fibrinous peritonitis; subphrenic abscesses; chronic tuberculosis of lung and spleen; tuberculous ulcerations of ileum; chronic interstitial nephritis.

Midway between umbilicus and anterior superior iliac spine, there is an operation wound parallel with the rectus muscle.

Peritoneal Cavity.—About 200 cc. of greenish-yellow fluid in the sub-diaphragmatic regions of both sides, smears from which show a variety of bacteria including streptococcus pyogenes. The coils of intestine are markedly meteoric. The exudate in the lower abdomen is less fluid and more fibrinous than higher up, and glues together the coils of the intestine. The sub-diaphragmatic surface of the liver shows fresh fibrin in smooth flakes which can be easily peeled away. The right lower angle of the liver shows greenish fibrin, and also an exudate which appears to have affected the liver substance itself.

2 to 3 cm. internal to the appendix incision, a portion of the wall of the cecum has become firmly adherent to the abdominal wall, and presents, on separation, a fibrous ragged surface with considerable old hemorrhage. Appendix is absent (at operation a gangrenous appendix already sloughed off had been removed); its stump is buried in a blackish mass of tissue lining the inside of the deep pocket beneath the incision.

Pleural Cavities.—Left, normal. Right, completely obliterated by old adhesions.

Gastro-intestinal Tract.—Stomach normal; duodenum irregularly and brilliantly injected over the tops of some of the *rugæ*. The small intestines are remarkably dilated, the circumference in places being 13 cm. At a point 300 cm. below the pylorus is a knot lying internal to the appendix region. This is so arranged that the lower bowel for a distance of 15 cm. curls forward, upward, and outward, to be caught in the mesentery behind and constricted to the measure of a finger. The intestine, so looped, is markedly injected, but nowhere hemorrhagic. Three Peyer's patches in the region of the cecum show old ulcers from ½ to 1 cm. in diam-

* Cultures made from heart blood and blood vessels by aspirating with a syringe and adding blood to media.

eter, oval in shape, with long axes at right angles to those of the affected patch. The borders of the ulcers are slightly raised, and injected with occasional spots of hemorrhage; the craters are pale and fairly smooth.

Liver.—Weight 1500 gms. Normal.

V.—R. I. H. 00.1. J. C., male, age fifty.

Anatomical Diagnosis.—Operation wound; acute ulcerative appendicitis; peri-appendical abscess; extension of abscess into retroperitoneal and perinephric tissues; perforation of ascending colon; acute localized peritonitis; edema of lungs.

There is an operation wound in the right groin beginning 2 cm. to the inner side of the anterior superior spine of the right iliac bone and extending upward and outward parallel to the crest of the ilium for a distance of 6 cm. The abdomen is distended.

Peritoneal Cavity.—The peritonuem is smooth, except about the seat of operation. The mesenteric lymph nodes are not enlarged; there is no fluid in peritoneal cavity. The intestines are distended by gas, with slight fibrinous adhesions to the abdominal wall around the operation wound. These adhesions are easily separated, exposing two openings; one just external, the other internal to the cecum, both extending into the retroperitoneal tissues. From them a yellowish, semi-fluid, fecal material escapes.

Appendix.—The base only is visible, arising from the posterior wall of the lower end of the cecum and extending inward along the brim of the pelvis, with the tip slightly curled upon itself. It is firmly bound down by old fibrous adhesions and measures 12 cm. in length. The proximal 6 cm. appears normal, while the distal portion is riddled with perforations, from some of which escapes a yellowish fecal fluid. The abscess about these perforations communicates with the retroperitoneal space into which the openings about the cecum lead. In the posterior wall of the cecum is an almost spherical opening, about 1½ cm. in diameter, leading into the retroperitoneal tissues as well. The retroperitoneal tissue here is softened and diffusely infiltrated with a brownish-gray, puriform material; this extends upward as a grayish-yellow exudate, in places muco-purulent, and elsewhere in masses of a tough, apparently fibrinous material. It invades the right psoas muscle, extends along the vena cava inferior, posterior to the duodenum as it crosses the spinal column, and infiltrates everywhere the perinephritic tissues of the right side, even extending between the diaphragm and the liver.

Liver.—Weight 1360 gms. It presents no abnormalities in shape. It is brownish-red, rather lax in consistence, while on section the surface is dry and the markings indistinct. From the blood-vessels, bubbles of gas escape.

Kidneys.—The left weighs 130 gms., is rather dark red in color, with consistence apparently unchanged; its capsule strips easily, leaving a smooth surface. On section, the cortex is rather pale, not diminished in thickness. The pyramids are well marked from the cortex. The right kidney is about the same size as the left. With the perinephric tissues it weighs 270 gms. The cortex is very pale, looking as though it had been boiled, all the markings appearing very indistinct. A teased specimen shows a small amount of fat in the cells of the tubules.

Right Adrenal.—Is so much involved in the perinephritic abscess as to be indistinguishable.

Bacteriology.—Streptococci are present in culture from heart's blood, peritoneum, and perinephric tissue. A chromogenic bacillus which turns the media bright red in forty-eight hours is found in cultures from lung, spleen, liver, and peritoneum. Bits of tissue from liver, lung, heart, and kidney placed in thermostat overnight, all show large numbers of bacilli with the morphological and staining properties of the bacillus aërogenes capsulatus.

VI.—J. H. H. 1581.—Female, age thirty-two.

Anatomical Diagnosis.—Operation wounds; acute gangrenous appendicitis; peri-appendical pelvic abscess; subphrenic abscess; acute fibrino-purulent general peritonitis; acute splenic tumor; cloudy swelling of myocardium, kidneys, and liver; edema and congestion of lungs; healed tubercular foci in lungs; acute sero-fibrinous pleuritis, both sides; chronic adhesive pleuritis, both sides.

Under the right edge of the rectus abdominis muscle is a recent surgical incision, 17 cm. in length, with the middle third containing a gauze drain, while the upper and lower thirds are closed and healing *per primam*. In the right flank postero-laterally is a recent surgical incision 3 cm. in length, containing drains.

Peritoneal Cavity.—Upon opening the peritoneal cavity, the intestines are found adherent to the anterior abdominal wall by firm, fibrinous adhesions, which are present everywhere, except in the region of the splenic flexure of the colon. Between the loops are numerous pockets of pus. Upon untwisting the coils of intestine, it is found that the appendix is gangrenous and has sloughed off at its attachment to the cecum. The detached portion dips over the brim of the pelvis, and is contained in a large abscess containing about half a pint of thick, grayish-yellow, foul-smelling pus. The abscess cavity occupies Douglas' *cul-de-sac*. The stump of the appendix is shut off by one of the gauze drains. The other gauze drain lies against the colon on its lateral side. A rubber drain leads into an abscess cavity between the liver, the hepatic flexure, and the lateral abdominal wall. The liver has between its right lobe and the chest wall an extensive abscess, which extends also over the lower surface of the diaphragm almost to the median line.

Gastro-intestinal Tract.—The stomach contains about a pint of dark fluid; the duodenum is clear, but at the upper end of the jejunum are several ecchymoses over the mucous membrane; otherwise the small intestine is clear. Peyer's patches over the lower portion of the ileum are somewhat swollen and red. There is an ecchymosis on the free border of the ileocecal valve. The large intestine is considerably injected, with numerous ecchymoses in the mucous membrane. The solitary follicles of the large intestine are swollen. In the cecum is a long piece of a flat worm; the remainder of the worm extends through the whole length of the small intestine, and doubles back upon itself.

Liver.—Weight 1800 gms.; dimensions $25 \times 23 \times 8$ cm. The surface is covered with a layer of fibrin adjacent to the abscess, but is otherwise normal. On section, the liver is somewhat mottled, the general color being rather a brownish-

gray, and in areas ½ cm. in diameter, of a pale, opaque, yellowish color. The connective tissue is increased in amount, the lobules plain.

VII.—J. H. H. 1865.—Male, age eleven.

Anatomical Diagnosis.—Removal of appendix; acute general fibrinous peritonitis; extensive multiple abscess formation in the peritoneum; subphrenic abscess; acute diphtheritic colitis; acute pleuritis, left side.

Peritoneal Cavity.—Upon opening the peritoneal cavity, delicate fibrinous adhesions are found everywhere between the abdominal organs and the anterior abdominal wall. There is a small abscess in the subcutaneous tissue communicating with the granulating surface of the wound by a channel at the lower end. The abdominal organs are much bound together, and an attempt to separate them ruptures the intestines. There are delicate adhesions everywhere between the intestinal coils. Just under the diaphragm on the left side, is a large abscess cavity, located outside of the stomach and partially walled off by the liver, which contains greenish-yellow pus. This cavity is lined by a rough hyperemic granulation tissue, thrown up into folds, which are almost like the valvulæ of the intestines. Pressure on the abscess causes the pus to exude from another cavity in the ileocecal region, and a probe can be passed 30 cm. along the right abdominal wall without meeting resistance. The channel can be traced with the scissors from the subphrenic abscess into the ileocecal region, where it turns toward the centre, giving rise to numerous channels passing down between the intestinal coils. Another abscess filled with fluid is found just behind the transverse colon; this cavity is continued around over the aorta, where it overlies the ascending colon. The ileocecal valve is practically in its normal position. In the walls of the abscess there are black silk sutures at the point where the cecum lies against the abscess cavity, probably at the seat of the appendix. On the left side, midway down the course of the abscess cavity, there is a fistulous communication with the ileum. The kidney lies quite free behind the abscess. The transverse colon at the splenic flexure crosses the abscess and lies behind it; the abscess is not therefore retroperitoneal. The channel follows almost exactly the course of the colon down to the region of the bladder, where it crosses over through the sinus opening on the abdominal surface. The abscess cavity on the right side extends up to the region of the liver, where it ends blindly. The pancreas is free and apparently normal. The main coils are inextricably embedded together, and there are numerous adhesions and abscesses between these coils. An attempt to separate them results in tearing the intestines. The abscesses very often lie between the adhesions of the mesentery and omental folds; they are more dense about the region of the ileocecal valve.

Lungs.—The left lung is somewhat collapsed in the lower lobe, where it is firmly adherent to the diaphragm.

Spleen.—The spleen is bound down by adhesions and its capsule is much thickened by granulation tissue. It forms the lateral wall of the large abscess described. The splenic substance is firm and slightly grayish in color. The elements of the spleen are well defined.

Gastro-intestinal Tract.—The stomach is normal, the folds of the

colon hemorrhagic, the more prominent ones having on their crests a fibrinous exudate.

Liver.—Measures 23 × 16 × 7.5 cm. It is quite densely adherent to the diaphragm. On section it is homogeneous and reddish-brown in appearance; its lobules are extremely indistinct; the gall-bladder is apparently normal.

Analysis of Cases of Subphrenic Abscess.—In 6 of these 7 cases the affection was unilateral, 4 of them being on the right side, and 2 on the left; in 1 case only was it bilateral. Subphrenic abscess following appendicitis is more frequent on the right side, indeed the cases of LANG, WEBER, ELSBERG, and UMBER were all on the right side. Strange to say, Elsberg does not seem to consider the left subphrenic region at all in treating the subject, and in his table of collected cases the site of the disease is not mentioned. If we consider the manner in which these abscesses originate when secondary to disease of the appendix, it is plain that the right-sided form is necessarily more frequent, although they can easily occur upon the left side. The localization is always influenced by the position of the appendix.

Subphrenic abscess secondary to appendicitis may occur in one of four ways:

1. As a localized abscess, forming part of a general purulent peritonitis.

2. By extension of the diseased process from the appendix to the subphrenic region by an intraperitoneal route.

3. By extension of the diseased process through an extraperitoneal route, either by way of the lymphatics, or by infiltration through the retroperitoneal tissue.

4. By way of the blood current, as part of a general embolic septic process, or as a sequence of liver abscesses—which are of embolic origin—by way of the portal vein.

When the abscess originates in either the first or the fourth ways, it can appear with equal readiness on either side; when it arises in the second manner, either side may be affected, but the right side is much more frequently so, since the ascending colon forms a natural drain or gutter in its direction; when the abscess originates in the third manner, the left side can only rarely be involved, and if it is so, a misplaced appendix will generally be found associated with it.

The greater number of subphrenic abscesses originate by extension (methods 2 and 3). Whether the route in any given case will be intra- or extraperitoneal depends on the situation of the appendix and the peri-appendical process. If the latter is retrocecal, and so retroperitoneal, the chances are that the process will take an extraperitoneal route, and reach the subphrenic region by way of the loose areolar tissue in the lumbar region. It is claimed that when the abscess is retrocecal there is greater liability to the formation of a subphrenic abscess.

When the abscess reaches the subphrenic region by the extraperitoneal route it may remain outside the peritoneum, or it may become intraperitoneal. In

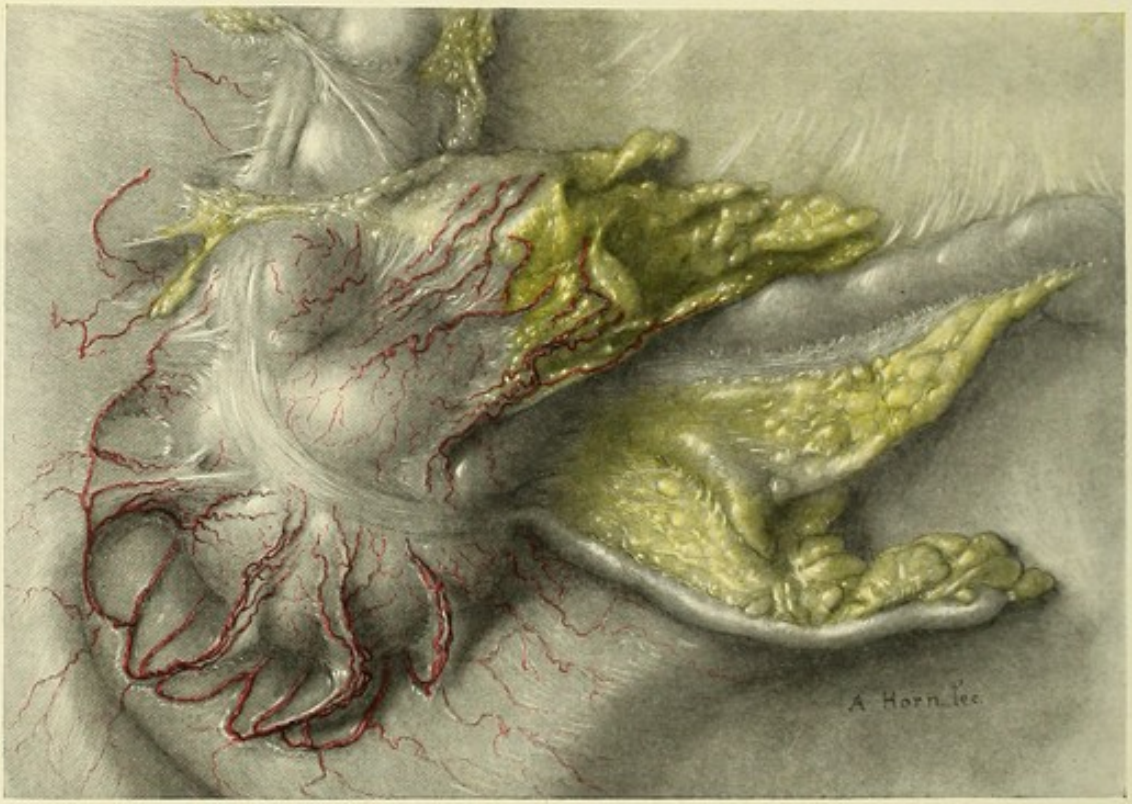

FIG. 152.—SENILE ATROPHY OF CECUM IN MAN EIGHTY-SIX YEARS OLD.

The shrinkage of the colic and cecal pouches has left, *in situ*, the lateral subserous vessels, some of which by anastomosis with the lumbar veins enter the systemic circulation (vena cava). These are the vessels first mentioned by Retzius. See also Fig. 139.

the former case it is usually small, since the peritoneum covering the diaphragm is intimately adherent to the muscle substance (HOFMANN, A. SCHMIDT, cited by ELSBERG). For the same reason it is likely to penetrate early into the space between the diaphragm and the liver. In Elsberg's cases 27 per cent. were extraperitoneal, 48 per cent. intraperitoneal, and 25 per cent. of doubtful anatomic location.

The different methods in which subphrenic abscesses may originate are well illustrated in the cases just quoted, indeed all four methods of origin are shown among the 7 cases. In case I, there was a retrocecal and right-sided subphrenic abscess, the latter arising, apparently, through the extraperitoneal route, although the case was complicated by volvulus of the small intestine, general fibrinous peritonitis, fibrinous adhesions between the left lobe of the liver and the diaphragm, and thrombosis of some of the veins in the liver. Case II also illustrates an extraperitoneal route to the right subphrenic space, but in this instance the general peritoneal cavity was clear. In case III pylephlebitis and multiple liver abscesses were present, and the subphrenic abscess was on the left. Case IV shows bilateral subphrenic collections of pus forming part of a general peritonitis. In case V, an infiltrating purulent process could be clearly traced extending upward from the region of the appendix along the retroperitoneal tissues of the right lumbar region, and finally making its appearance between the diaphragm and the liver. In case VI the course of the process is not very clearly traceable, although, as a general peritonitis and several pus pockets were present, it may have arisen as a part of the general peritonitis. Case VII shows an intraperitoneal route of extension from the appendix to the left subphrenic region.

In 4 of the 7 cases, the process had extended from the subphrenic region into the pleural cavity, though in none of them was the diaphragm perforated. In case II it had been incised by the surgeon for drainage. The pleural affection in these cases will be considered later in connection with the subject of pleurisy complicating disease of the appendix and its relationship to perihepatitis, which LAPEYRE regards as an early stage of subphrenic abscess.

PORTAL VEIN AND ITS BRANCHES.

The vermiform appendix, like other parts of the intestinal tract, is supplied with a rich network of venules which ramify in its various coats. These unite into larger and larger radicles, finally forming the appendical vein which empties into the ileocecal branch of the superior mesenteric, and in this way becomes part of the portal circulation. The region of the appendix is also supplied, but less richly, by branches from the systemic venous system, which anastomose with those from the portal venous system by means of the veins of Retzius. (See Fig. 152.) Both of these systems are of importance in connection with appendicitis, the former in relation to pyophlebitis of the superior

mesenteric and the portal veins, the latter in explaining the etiology of pulmonary embolism in some appendix cases.

In 1890 autopsies at the Boston City Hospital, thrombosis of the portal vein occurred in 15 cases, of which 10 were associated with appendicitis. These will be discussed in the next division in connection with pylephlebitis and liver abscess.

LIVER.

Associated with the acute infectious process in, or originating from, the appendix, the liver may show acute parenchymatous degeneration (the focal or central necroses described by MALLORY), acute interstitial hepatitis, acute perihepatitis, and abscesses. Acute parenchymatous degeneration was present in many of the cases. In cases studied microscopically, necroses of both types were occasionally seen. Acute interstitial hepatitis was found in 3 of the Boston City Hospital cases. Acute perihepatitis occurred in cases of general peritonitis, subphrenic abscess, or liver abscess, and is considered in connection with these. Liver abscess is described in connection with pylephlebitis.

Pylephlebitis and Liver Abscess.—Of the different complications of appendicitis few are of greater interest than pylephlebitis and liver abscess. These conditions were recognized early in the history of the disease, but for a long time they were considered very rare; later on, however, the number of such cases reported greatly increased, until they are now no longer regarded as unusual complications or sequelæ of appendicitis. BERTHELIN, reviewing the early literature of the subject, cites as the first case that of HILLAIRET in 1849, in which, at the autopsy, an abscess was found occupying the right iliac fossa and the pelvis, which contained the appendix, in part ulcerated and destroyed, while the divisions of the left branch of the portal vein were filled with pus. BUHL, in 1854, reported a case in which there were multiple liver abscesses. LOISON, however, attributes to WALLER an earlier case than either of these, in 1846.

BERTHELIN in 1895 collected 28 cases. LOISON in 1900 published one case, and says that in French literature a certain number of isolated cases of liver abscess associated with appendicitis have been reported, but that there are no statistics showing the relative frequency of the association in France. He regarded such cases as quite rare. BÄRENSPRUNG out of 7326 autopsies in Berlin between 1859 and 1873 found 108 cases of liver abscess, and of these 8 had followed affections of the cecum and the appendix. DUDLEY, in 1892, out of 28,034 patients at the Zurich clinic, between 1870 and 1891, found 12 cases of liver abscess, 2 of which had followed disease of the appendix. KOBLER, in 1901, reported 79 cases of liver abscess out of 17,204 autopsies at Vienna, occurring between 1881 and 1890, including 3 which followed "typhlitis" or "perityphlitis" and 10 of liver abscess, none of which were the result of appendicitis, out of 1307 autopsies at Sarajevo between 1894 and 1900. JACKSON, in 1899,

reported 17 cases of liver abscess, 10 of which he regarded as the result of appendicitis. Among 28 cases of liver abscess reported by HART in 1900, there were 17 of pylephlebitis, the origin of which is referred in 3 cases to the appendix. EINHORN, in 1891, found 100 cases of peritonitis following appendicitis out of 18,000 autopsies at Munich between 1854 and 1889; in these 100 there were 6 cases of pylephlebitis and liver abscess. LANGHELD, in 1890, found 4 cases of pylephlebitis and 2 of liver abscess out of 112 autopsies. FITZ, in 1886, gave 11 cases of pylephlebitis as occurring in 257 cases of perforating appendicitis. BORCHARDT in 1897 found 5 cases of pylephlebitis in 378 cases of appendicitis; and MATTERSTOCK in 1880 gave 11 of pylephlebitis and metastatic liver abscess in 146 cases. MUNRO, in 1901, reported 4 cases of portal infection following appendicitis, the diagnosis of which was confirmed at operation or at autopsy. To these, in a second paper, 1902, he added 6 cases, 5 of which are included in our series of autopsies. Single cases have been reported by KRACKOWITZER (1871), COLQUHOUN (1887), JORAND (1894), SHEEN (1896), RABÉ (1897), DIEULAFOY (1898), TROWBRIDGE (1900), DALE (1901), STOOKE (1901), and others cited elsewhere in this chapter, so that the total number of recorded cases is now a large one.

According to SONNENBURG, pylephlebitis and liver abscess as complications of appendicitis, do not occur as often as subphrenic abscess, for he observed only 5 cases of the former as compared with 15 of the latter in the large number of cases upon which he operated for appendicitis. In our series of 86 cases of appendicitis occurring in 4028 autopsies, however, we found 10 cases of pylephlebitis and liver abscess (11.62 per cent.) as compared with 7 cases of subphrenic abscess (8.13 per cent.). Strange to say, 9 of these 10 cases occurred among the 1890 Boston City Hospital autopsies, while only 1 was found in the 1978 Johns Hopkins Hospital autopsies, and none at all in the 160 belonging to the Rhode Island Hospital, though the numbers of cases of appendicitis in each group were respectively 49, 32, and 5. No satisfactory explanation for this fact has been found.

The ten cases from the Boston City Hospital were as follows:

I.—B. C. H. 97.286. G. K., male, age thirty.

Anatomical Diagnosis.—Chronic appendicitis; abscesses of mesenteric lymph nodes; suppurative pylephlebitis; multiple abscesses of liver; acute splenic tumor; chronic fibrous pleuritis.

Peritoneal Cavity.—About 200 cc. of brownish, cloudy fluid present; old adhesions of great omentum to right iliac wall; appendix and cecum bound down by old adhesions. Mesenteric lymph nodes enlarged and softened; mesentery generally thickened.

Pleural Cavities.—Left pleura adherent to lung along the spinal border. Right pleura adherent to extreme end of lower lobe.

Pericardial Cavity.—Normal.

Lungs.—Increased in density, slightly congested.

Spleen.—Weight 475 gms. Large, rather soft, capsule smooth. Malpighian corpuscles not visible; pulp much increased.

Liver.—Weight 2565 gms. On the anterior surface can be seen many small whitish patches, especially on the left lobe. On the under surface of the left lobe are areas of multiple abscesses, one about 6 × 5 cm. in diameter near the upper left border, and another near the inferior border of the same lobe. On the under surface of the right lobe are many whitish spots. Section shows abscess formation, especially in the left lobe, and dilation of the portal vein, which is filled in part with rather firm, yellowish masses, and in part with pus. On opening up the portal vein and its branches, they are found occluded by yellowish, adherent thrombi, and thick yellow pus.

Appendix.—Is bound down by old adhesions; the canal is patent and filled with pus; the mucous membrane is roughened and ragged, showing evidence of old inflammation.

Cultures.—Heart, liver, spleen, liver abscess, mesenteric lymph node, and appendix show a variety of bacilli, principally bacillus coli communis.

Microscopic Examination.—Section of the portal vein shows a thrombus principally composed of fibrin and leucocytes, irregular in shape and at one point almost surrounding an area containing numbers of red corpuscles, in which are great numbers of bacilli. Section of kidney shows acute degenerative lesions. In the spleen the follicles are small, and the pulp increased; there is no necrosis; the formation of epithelioid cells is marked; there are some plasma cells. The liver shows changes everywhere. The vessels are universally dilated and in the portal spaces there are large accumulations of cells, chiefly plasma. Around some of the larger spaces there is marked formation of connective tissue. In the capillaries there are large numbers of cells, definite polynuclear leucocytes, plasma cells and the large transitional forms. There are several abscesses in the section. In the neighborhood of the abscesses the liver cells are atrophic. The more definite abscesses show a mass of fibrin and bacteria in the centre, and around this, areas of polynuclear leucocytes with much nuclear detritus. None of these abscesses have a definite wall, but extend directly into the liver tissue.

II.—B. C. H. 98.247. J. H., male, age twenty-six.

Anatomical Diagnosis.—(See Case I.)

Liver.—Weight 1720 gms. Capsule smooth. On section the markings are rather indistinct, with a general cloudy appearance. The consistence is normal. Section made parallel to the greatest length of the organ shows in the right lobe two blood-vessels extending completely through the width of the liver, and containing a firm, dark red, adherent clot. Running off from these two main vessels are seen several smaller vessels showing the same condition. In the neighborhood of these smaller vessels there are small areas 2 to 6 mm. in diameter, of a reddish-brown color with small yellowish foci.

Gall-bladder.—Normal.

Microscopic Examination.—Liver-sections show areas of necrosis in close relation to thrombosed vessels. The peripheries of necrotic areas are infiltrated with numerous polymorpho-nuclear leucocytes.

III.—B. C. H. 00.32. M. S., male, age forty-two.

Anatomical Diagnosis.—Operation wound; chronic adhesive peritonitis right iliac fossa; peri-appendical abscess; acute sero-fibrinous general peritonitis; acute sero-fibrinous pleuritis, right; hyperplasia and acute inflammatory softening of retroperitoneal lymph nodes; acute suppurative pylephlebitis; multiple abscesses of liver; multiple abscesses of lung; thrombosis of left spermatic vein; acute purulent phlebitis of left renal vein and of hemorrhoidal and vesico-prostatic plexuses; ulceration of stomach and of rectum.

Peritoneal Cavity.—The abdomen contains 1700 cc. of slightly turbid amber fluid. There is a slight fibrinous deposit on the peritoneum in the pelvis. The cecum is adherent to the anterior abdominal wall along the line of the scar. The appendix, the cecum, and the beginning of the ileum are bound together by fibrous adhesions. Posterior to the cecum and appendix is a small abscess containing thick yellowish pus. The retroperitoneal lymph nodes are much enlarged, and several of them are completely softened. Along the spine to the left of the median line is a vessel 0.75 cm. in diameter, with thickened walls, probably the left spermatic, containing a pale red thrombus, easily removed. On section anterior to the foramen of Winslow, the portal vein is seen to be filled with yellowish pus and its walls considerably thickened. On slitting open the vein this condition is seen to extend downward a considerable distance along the attachment of the mesentery. The inferior vena cava is normal. In the transverse mesocolon, along the pyloric portion of the greater curvature of the stomach, are several small collections of thick yellowish pus, the largest 2 cm. in diameter. These are probably in veins of the portal system. The lesser peritoneal cavity appears normal. The vessels of the mesentery, on section half way between base of mesentery and small intestine, appear normal, blood flowing from the cut ends.

Pleural Cavities.—The right contains about 300 cc. of turbid, amber fluid. The left is free from fluid. The pericardial cavity is normal.

Lungs.—The left is pinkish-gray, deeply pigmented and crepitant throughout. At the apex, a few nodules are felt. On section the same color is presented. Several dry, caseous, calcified nodules are seen at the apex; also several abscesses, the largest 1.5 cm. in diameter, containing a thick, slightly greenish pus. Stained smears from these abscesses show numerous pus cells, but no bacteria; no tubercle bacilli can be found in the smears. The surrounding tissue is paler than the remainder of the lung. The bronchi are slightly injected. On slitting open the veins they appear normal. The bronchial lymph nodes are large and deeply pigmented.

The left lung presents essentially the same condition.

Spleen.—Weight 275 gms. Purplish-red in color, and of about normal consistency. On section red. Trabeculæ and lymph nodules easily seen.

Gastro-intestinal Tract.—Stomach filled with a greenish, opaque fluid, apparently containing considerable pus. Near the pyloric end are two small ulcers, the largest 1 cm. in diameter. The edges of these are elevated and slightly reddened. On slight compression a considerable amount of pus is forced out. The upper part of the small intestine contains considerable dark green, fluid material. Mucosa normal. Appendix 6 cm. long. The end is bulb-like, consisting apparently of

dense fibrous tissue. The mucosa of the colon is pale and unbroken. In the rectum are two small ulcers similar to those in stomach. Pancreas normal.

Liver.—Weight 1910 gms. Dark brownish-red. Here and there on the cut surface are groups of slightly elevated, yellow areas, the largest 0.75 cm. in diameter. On section the same color is presented. The lobular markings are distinct, and the interlobular areas are very pale. Distributed irregularly throughout the liver are numerous abscess cavities, the largest about 2 cm. in diameter, containing thick slightly greenish pus. Stained smears from these show numerous pus cells, but no bacteria. The gall-bladder is bound to the surrounding structures by rather firm adhesions. It is small, and contains thick bile.

Kidneys.—Weight 375 gms.; they are smooth and the capsules strip easily. The left kidney is pale, and the markings are indistinct. On gentle pressure pus exudes from numerous points on the cut surface, in the columns of Bertini, between the cortex and pyramids, and, to a less extent, in the cortex. Smears show numerous pus cells, but no bacteria. The pelvis is slightly injected. One of the vessels, apparently the renal vein, is filled with pus and its wall is thickened. A teased specimen of cortex shows little fatty degeneration. The right kidney on section is red, and the markings distinct. Pelvis pale.

Adrenals.—Normal.

Bladder.—Normal.

Genital System.—The testicles, the epididymes, and the seminal vesicles are normal. The prostate on section presents a few ill-defined, reddish areas. On gentle pressure, pus exudes from a number of points immediately surrounding the transverse section of the prostate, apparently a cross-section of the veins.

Aorta.—Intima perfectly smooth.

Organs of the Neck.—The esophagus and the larynx are normal. The trachea is slightly injected. The thyroid is normal. The lymph glands are much enlarged and deeply pigmented.

Brain.—Weight 1490 gms. The convolutions are visible through the dura. The pia is not adherent. The vessels at the base and the ventricles are normal.

Cultures.—Heart and Spleen—sterile. Liver—liver abscess. Portal vein—Bacillus coli communis. Abscess in transverse mesocolon—(two cultures), Staphylococcus pyogenes albus. Left kidney—Bacillus coli communis, variety produces no indol and does not coagulate milk. Lung—Staphylococcus pyogenes aureus and albus.

Microscopic Examination.—One of the sections of the kidney shows a partially organized thrombus in a branch of the renal vein near the pelvis. The thrombus contains leucocytes, fibrin and red blood corpuscles. There are granulation tissue and new blood-vessels extending into the thrombus from the wall of vein in various places.

Sections of prostate show numerous thrombi in vessels. In some of these the thrombi are composed almost exclusively of pus cells; in others, of concentric masses of fibrin and leucocytes. No organization is seen in the thrombi, and no bacteria are seen in them on microscopic examination. The heart shows very slight fibrous myocarditis. A portion of the wall of the portal vein shows an adherent thrombus composed of fibrin with beginning organization.

In the liver there are great numbers of small and large abscesses, and in some branches of the portal veins there are purulent thrombi. The abscesses represent definitely circumscribed masses of pus cells in fairly good preservation. The adjacent liver cells are compressed and elongated, and some of them clearly necrotic. In a few places there is a formation of granulation tissue in the abscess wall. The amount of necrosis varies greatly, in some places being very well marked. In the liver, at some distance from the abscesses there is very marked hyperplasia of the capillary cells with atrophy of the liver epithelium. No emboli or organisms are found. All sections of the liver seem to show about the same condition. The lung shows bronchitis, atelectasis, and well-marked abscesses. The pleura of the lung shows a massive formation of fibrin, and in this fibrin there are circumscribed collections of pus cells similar to abscesses. In some of the cells there appear to be a few short thin bacilli.

The spleen shows small necrosis with fibrin in follicles. Sections of the stomach show in one place a small opening in the mucosa which is covered with pus cells and this opening passes directly downward into an abscess cavity in the submucosa. This contains pus cells but no fibrin. No definite organisms are found. The wall of this abscess is surrounded by beautiful granulation tissue. In the rectum there are acute, deeply undermined ulcers, all of the same character.

IV.—B. C. H., U. 00.16. C. H., male, age fifty-two.

Anatomical Diagnosis.—Operation wound; chronic obliterating appendicitis; acute suppurative pylephlebitis; multiple abscesses of liver (?); chronic adhesive pleuritis, right.

In the right hypochondrium is an incision 5 cm. in length, beginning just below costal border. A gauze drain passes through this opening down to the region of the gall-bladder and the head of the pancreas.

Peritoneal Cavity.—Contains no fluid. The omentum is spread out over the intestines, its lower border being near the level of the umbilicus. The serosa of the intestines is smooth, glistening, and slightly injected. The appendix, 5 cm. long, is directed inward, its proximal half bound down posteriorly by old fibrous adhesions; the lumen of its distal half is completely obliterated. The mesenteric lymph nodes are not palpable.

Pleural Cavities.—Right lung is united to the chest wall by a few fibrous bands passing from the lateral surface of the upper lobe to the parietal pleura. Left pleural cavity free from adhesions.

Pericardium.—Normal, smooth, and glistening.

Heart.—Of normal size; myocardium, valves, and cavities normal.

Lungs.—In the lower posterior portion of the left lower lobe there is a firmer portion which, on section, is found to consist of blood. The hemorrhage occupies an area about 4 × 3 cm. When cut, the tissue here appears largely disintegrated, and replaced by soft, dark blood clots and blood-stained fluid. The branch of the pulmonary artery leading to this portion of the lung, when incised, is found to be normal. Lungs otherwise normal.

Spleen.—Small, with pale, wrinkled capsule; of soft consistence. On section it is pale red. The lymph nodules are not visible; but a little pulp can be scraped away by the knife.

Stomach and Intestines.—Normal.

Liver.—Weight 1250 gms. The lower border does not extend below the costal margin. There is a slight amount of fibrin gluing the neighboring coils of intestines together and to the adjacent portion of the liver; but there is nowhere any evidence of suppuration, and there is no fluid exudation. The common bile duct is patent. Its mucosa is normal. Its lumen is not dilated. A probe readily passes downward through the duct into the duodenum. The gall-bladder is small; its wall not thickened; it contains a small quantity of normal bile. The right border of the liver and the adjacent two-thirds of the anterior and posterior surface of the right lobe are dark reddish-brown in color. The remainder of the surface is reddish-yellow. The demarcation between the two is very sharp. The portal

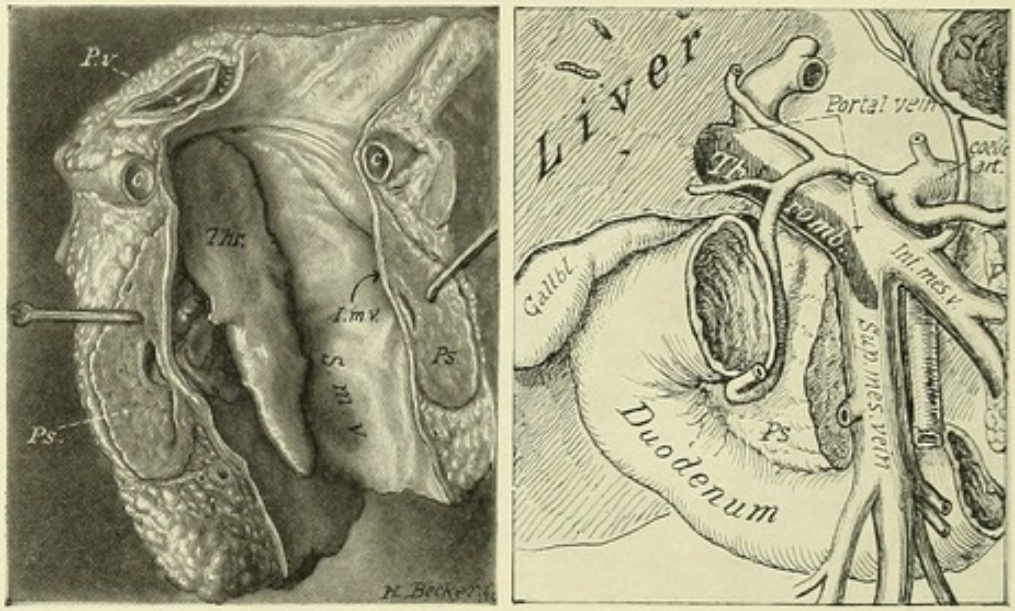

Fig. 153.—Thrombus in Portal Vein.

The left-hand figure shows the portal vein laid open and exhibiting a thrombus, *Thr.*, which extends up into the right branch, *P.v.* The left branch of the portal vein is free. *S. m. v.* and *I. m. v.* mark the superior and inferior mesenteric veins. *Ps.* is a section of the pancreas. The right-hand diagram is explanatory of the conditions found, and shows the extension of the thrombus from the root of the mesenteric vein through the portal and into the right branch.

vein is occluded by a large red thrombus firmly adherent to the vessel wall (see Fig. 153). The diameter of the portal vein at this point is about 1 cm. Traced downward toward the mesenteric roots of the portal vein, the thrombus gradually becomes smaller and passes into the superior mesenteric vein for a short distance. The lining of the lower portion of the portal vein and of the mesenteric vein appears normal. Within the liver substance, the portal vein becomes dilated to a diameter of about 1.5 cm., and is filled with a dark, grayish, puriform fluid. The liver on section is of normal consistence. The lobules can be made out with difficulty. The branches of the portal vein are filled with a rather thick pus. The walls of most of the branches can be made out, and apparently are not involved in the suppurative process. The surrounding liver tissue, the smaller bile ducts, and hepatic artery appear unchanged. Only a few branches of the portal vein are found that are not involved. These are

chiefly in the left lobe. The upper portion of thrombus already described in the portal vein near its entrance to the liver has undergone puriform softening.

Pancreas, kidneys, bladder, aorta, vena cava and hepatic veins.—Normal.

A cover-slip preparation from pus in portal vein shows a variety of bacteria, both bacilli and cocci, some staining, others decolorizing by Gram's method.

V.—B. C. H., U. 00.17. E., male, age twenty-one.

Anatomical Diagnosis.—Operation wound; acute purulent peritonitis; abscess near appendix; acute suppurative pylephlebitis; multiple abscesses of liver; acute splenitis.

In the abdominal wall, nearly parallel with Poupart's ligament, and about 8 cm. above its upper half, is an incised wound, 5 cm. long, not healed. From its upper end is a small sinus extending nearly 1 cm. into the subcutaneous tissue. There is a slight purulent discharge.

Peritoneal Cavity.—Contains about 250 cc. of yellow sero-purulent fluid, rather thin, and having a fecal odor. This fluid is present all through the cavity, but principally in the upper part. The peritoneum is dull, and in places covered with shreds of fibrinous exudation. About the spleen there are a few slight fibrous adhesions. The cecum is firmly bound to the lateral wall by fibrous adhesions. After separating these for a distance of about 3 cm. the stump of the appendix is found. It is about 5 cm. in length, and is closely surrounded by fresh fibrous adhesions. Just below this there is a small walled-off pocket containing thick yellow pus. There is no more than ½ cc. of this pus, smears from which show numerous pus cells and a few streptococci. Over the surface of the right half of the liver are numerous yellow areas, some of which are soft, and in the left lobe is an abscess cavity of considerable size. The veins about the mesentery, the cecum, and the lower end of the ileum show no signs of thrombosis. The portal vein is free from thrombus except within 2 cm. of the liver.

Heart.—Weight 250 gms.; normal. Lungs, normal.

Spleen.—Weight 180 gms. There are a few fibrous adhesions on the upper surface with some fibrin over the whole. The tissue is firm; on section it is a dark red and moist; the pulp is increased. The Malpighian corpuscles are very indistinct.

Liver.—Weight 1980 gms. It extends below the costal border for about 6 cm. The surface is covered with some shreds of fibrin, and is dark bluish-red with vessels injected. Over the whole surface are yellow areas, most of which are nearly round. They vary from 0.5 cm. to 4 cm. in diameter. About these yellow areas there is a dark, bluish-red, irregular border. In the upper posterior part of the right half, one of these yellow areas is raised over 0.5 cm. above the surface, and beneath it there is considerable fluctuation, covering a space of 5 × 7 cm. Over the rest of the right half of the liver these yellow areas are slightly raised, on an average from 2 to 3 cm. in diameter, and many of them are quite soft. Occupying a good part of the left lobe of the liver is a cavity, irregular in shape, about 15 × 12 cm. in size. In the thin upper wall of this cavity is a round opening, a little over 1 cm. in diameter. It has a yellowish, necrotic border, and through this the purulent contents of the abscess have escaped into the peritoneum. On the under surface of the liver these

abscesses are not so numerous; only one is ruptured. On transverse section through the liver not more than one-half of the liver tissue is found normal. The rest of the area is occupied by irregular abscess cavities, which are a little more numerous in the upper two-thirds. The liver tissue is dark reddish-brown; the centres of the lobules dark red. The tissue is quite moist, and near the abscess walls it has a bluish-green color. The abscesses are lined with a thin, glistening, fibrous wall. They are irregular in shape, with numerous small saccules, many of which communicate with one another. They contain a thick, light yellow, granular pus, and numerous small, hard, orange-colored particles of inspissated bile. The portal vein as it enters the liver is nearly occluded by a thrombus. This grayish-red, necrotic mass extends up on one wall of the portal vein, and after it has entered the liver about 1 cm. there is a large, gray, necrotic mass lining the opposite wall. On opening up the branches, all the veins running to the liver contain small thrombi, and a great many of the veins are found to communicate with the abscess cavities.

Gall Bladder.—Is moderately filled with greenish bile containing orange-yellow particles. The gall duct is normal. The bladder wall is not apparently thickened.

Intestines, adrenals, and kidneys.—Normal.

Cultures.—Liver abscess, liver tissue—Streptococcus pyogenes, bacillus coli communis. Spleen, kidney—Bacillus coli communis. Smears from abscess at appendix, portal vein, liver abscess, and peritoneum—many pus cells and streptococci.

VI.—B. C. H. 01.110. H. B., male, age thirty-five.

Anatomical Diagnosis (see Case III).

Mesenteric and Portal Veins.—One mesenteric lymph node is softened, and contiguous to it is a canal (mesenteric vein) communicating directly with the portal vein, with roughened, yellowish walls admitting the little finger. The contents of this canal is a sputum-like, yellowish, muco-purulent material. The portal vein, both outside and inside of the liver, is greatly dilated, and filled with the same material. The primary branch of the portal vein is 3 cm. in diameter. The splenic vein contains a red, rather friable clot. The hepatic, cystic, and common ducts are normal and pervious, as well as the gall bladder.

Liver.—Weight 1740 gms. On the inferior surface of the left lobe are two small rough holes 3 to 4 mm. in diameter, and 2 to 3 mm. deep; on pressure yellowish, muco-purulent material exudes from these openings. On section, throughout the left lobe the portal veins are dilated, and contain yellowish, sputum-like material. In the right lobe, particularly toward its superior surface and toward the right, are numerous yellowish, softened, irregular areas arranged in clusters 0.3 to 0.5 cm. in greatest diameter. On pressure, material like that found in the portal vein exudes from the surface of these areas. The intervening liver substance is brownish-red in color, and of normal consistence. The hepatic vein, as far as it can be opened, is normal. The primary branches of the portal vein are much dilated, but their walls are smooth. Smears made from contents of the portal vein show flattened streptococci.

Microscopic Examination.—Liver shows increase of connective

tissue about all portal spaces. Liver cells do not stain. At one corner of section is an area separated from the liver substance by connective tissue containing bile ducts, in which are many cells. These cells are mostly polynuclear leucocytes, many of which are degenerated, and phagocytic cells. The distribution of connective tissue suggests that the abscess is in a portal space.

VII.—B. C. H. 01.145. T. T., male, age seventeen.

Anatomical Diagnosis.—Operation wounds; localized adhesive peritonitis in right iliac fossa; pus pockets and softened lymph nodes about cecum; suppurative pylephlebitis; multiple abscesses of liver; acute splenic tumor; infarction of spleen; acute broncho-pneumonia of right lower lobe; ulcers of colon.

About in line with the outer border of the right rectus muscle, in the upper half of the abdomen, is an operation wound 7.5 cm. long, in which can be seen the protruding ends of several iodoform gauze drains. In right lower quadrant of the abdomen is an oval wound about 2 cm. in length. In the centre of this wound is an opening about 1 cm. in diameter surrounded by red granulation tissue. From this opening is a sinus extending down toward the stump of the appendix.

Peritoneal Cavity.—Contains a small amount of clear fluid. Most of the peritoneum is smooth, glistening, and free from adhesions. The mesenteric lymph nodes are enlarged, varying from 0.5 to 2 cm. in diameter, and are grayish-pink on section. About the above-mentioned appendix wound, between the abdominal wall and the lower end of the cecum, are numerous adhesions. Hidden away in these is the stump of the appendix (operation for removal about three weeks previously). Along the ascending colon, and particularly between the hepatic flexure and the neighboring parts of the abdomen, jejunum, liver, gall bladder, and stomach are numerous adhesions. These are easily broken apart, as they consist of young connective tissue and fibrin. The walls of the above-mentioned hollow viscera are also considerably thickened in this region. On tearing the cecum from its attachments, several small pockets of thick, grayish-brown pus are opened. Behind the cecum is a large lymph node, 3 cm. in its greatest diameter, which has a caseous, partly calcified centre. Another node, higher up, has a softened purulent centre. Branches of the superior mesenteric vein, running from the lower part of the ascending colon, are occluded by rather friable clots, mottled grayish-red and gray in color. These are only slightly adherent, but above in the main superior mesenteric vein, especially that portion of it behind the pancreas, the clot is pale in color and firmly adherent. The portal vein contains a grayish-brown, slightly viscid, purulent fluid. Other branches of the portal system seem to contain red clots.

Pleural and Pericardial Cavities.—Normal.

Heart.—Weight 235 gms. Myocardium of faded yellow color. Frozen section shows marked fatty degeneration of fibres. Coronary arteries normal.

Lungs.—Downy and very pale, except the lower third of the right lower lobe, which is red in color, and less voluminous as well as firmer than other parts. On section it is pale, air containing, and rather dry except at the right base, which is firm, grayish-red, and very slightly granular. The bronchi contain sticky mucopus, but are not hyperemic. The bronchial lymph nodes are normal.

Spleen.—Weight 280 gms. Is large, smooth, and dark red except at one

end over an area about 5 cm. in various diameters, which is lighter red, with a few areas of yellowish-gray. On section the tissue is dark red. The Malpighian bodies are not very distinct. Areas at the cut end are lighter in color, and there are pale areas which are softer than other parts of spleen.

Gastro-intestinal Tract.—Stomach is normal. The small intestine shows many large areas of congestion and submucous hemorrhages. The colon is hyperemic. In the region of the hepatic flexure is a deep, punched-out ulcer about 2 cm. in its greatest diameter. This has rather overhanging edges, and its base is formed by softened necrotic looking tissue suggesting a broken-down lymph node. In the connective tissue about this node (if it is one) are several stitches (at recent operation purulent lymph nodes in this region were incised and drained). About 8 cm. from this node, toward the cecum, is a second, deep, punched-out, smaller, but similar ulcer.

Pancreas.—Normal.

Liver.—Weight 1570 gms. The surface is smooth. On section, there are visible numerous small areas of bright yellow color against a brownish-gray background, at places becoming reddish. From many periportal spaces, especially in the right lobe, can be squeezed out whitish, creamy pus. Some of these abscesses are 1 cm. in diameter, but the great majority are 2 to 3. mm. Smears from this pus show leucocytes, and a smaller number of slender Gram-staining bacilli. The branches of the portal vein at the hilum of the liver contain dirty, grayish pus. Gall-bladder and ducts.—Normal. Hepatic vein.—Normal.

Kidneys, adrenals, aorta.—Normal; no cultures.

Microscopic Examination.—Heart.—Many fibres show marked vacuolation.

Liver.—There is a very extensive necrosis; the liver cells stain deeply with eosin. This staining involves almost the entire lobule, sometimes sparing the cells at the periphery, sometimes those at the centre, so that its point of origin can not be made out. Not infrequently liver nuclei are in process of indirect division. Most of such noted were at the periphery of the lobule. This indicates some attempt at repair. In the capillaries and between the liver cells and capillary wall are seen large cells of endothelial character, occasionally in mitosis. In places running in from the periphery may be seen several cells with vesicular nuclei resembling cells of bile capillaries or endothelium. These may sometimes separate and partly surround necrotic liver cells. The divisions can not be made out between the individual cells in many cases. Most of the liver cells show large fat vacuoles. In the periportal connective tissue are numerous polymorpho-nuclear leucocytes. These can be traced for only a very short distance into the liver lobule. Some of the portal veins are filled with leucocytes and fibrin threads. In the lumen of some of the bile ducts are polymorpho-nuclear leucocytes. Liver necroses, pylephlebitis, acute suppurative interstitial hepatitis.

Large Intestine.—Ulcer. At one side there is an overhanging edge of normal mucosa. The remainder of the surface is ulcerated to a varying depth, in places to the submucosa, in others to the muscularis. The base of this ulcer is in parts formed by granulation tissue, partially covered by an exudate of fibrin and leucocytes; in parts the fibrin extends down to the muscularis. At one end, in the granulation

tissue immediately beneath the fibrin, are many phagocytic endothelial cells with leucocytic inclusions. In the superficial layer are numerous intestinal forms of bacteria. No evidence of tuberculosis, typhoid or amœbæ coli.

The lymph node shows fairly normal lymphoid tissue, but in the loose areolar tissue about it there is an inflammatory process—granulation tissue in the wall of the abscess. An artery near by shows marked obliterating endarteritis. This node came from the region contiguous to the ulcer in colon. There is no evidence of tuberculosis.

VIII.—B. C. H. 10.185. D. S., male, age sixteen.

Anatomical Diagnosis.—Operation wound; chronic localized adhesive peritonitis; suppurative pylephlebitis; multiple abscesses of liver; acute splenitis; infarction of spleen; chronic adhesive perihepatitis; chronic adhesive pleuritis, right side.

In the right iliac region is an open wound with granulating edges, 6 cm. in length, parallel to, and about 5 cm. above, Poupart's ligament.

Peritoneal Cavity.—The intestines are lustreless and slightly injected in places, but there are no definite signs of peritonitis. Their adjacent surfaces are slightly adherent and easily separated, as if held together by a slight viscidity of serosa. Passing through the operation wound, the fingers enter a small walled-off cavity, the walls of which are formed by the cecum, small intestine, and parietal peritoneum. In this pocket is the stump of the appendix. The lumen is patent, and from it can be squeezed brownish fecal material. The loops of the intestine forming these walls separate with difficulty. The pelvic cavity is normal. Between the liver and diaphragm are numerous, firm, fibrous adhesions. Adhesions are also marked between the gall-bladder and colon; between the colon, the gall-bladder, and the duodenum; and between the liver and the right kidney. The gall-bladder is distended with clear, serous, bile-stained fluid. The common bile duct, the hepatic and cystic ducts are opened *in situ* and are everywhere patent. The pancreatic duct is patent as well. The liver extends 12 cm. below the tip of the ensiform cartilage in the median line. Over the anterior surface of the right lobe are numerous light yellow, irregular areas 0.5 to 1.5 cm. in diameter. The abdominal contents are removed *en masse*. The kidneys are dissected out, and the retroperitoneal tissue dissected away until the portal vein is reached. The portal vein is opened toward the liver and in the opposite direction to the mesenteric veins. The veins to the ileocecal valve, to the middle point of the small intestine, to the spleen, and to the stomach are opened to the point of juncture with each viscus. All contain a rather thick, dark, grayish-red fluid. In the upper part of the vein (toward the liver) this fluid becomes lighter in color and more distinctly purulent. The vein going to the appendix region differs in no way from the other branches. The walls of the veins are everywhere smooth and show no change. The incision toward the liver is carried into the veins going to both the right and left lobes of the liver. Both veins are filled with blood-stained pus. The hepatic vein and inferior vena cava are normal.

The ileocecal and mesenteric lymph nodes are enlarged; the largest measures $1.2 \times 0.5 \times 0.5$ cm. On section they are grayish-pink, and their consistence is normal.

The nodes in the region of the foramen of Winslow are larger, measuring 2 × 2 × 0.75 cm. They show nothing remarkable on section.

Liver.—Weight 3265 gms. (after escape of considerable pus from abscesses). The right lobe is firmly adherent to the diaphragm and the hepatic flexure of colon. The left lobe is of normal color and not adherent. The right lobe is dark green, with numerous, irregular, light yellow patches 0.5 to 1.5 cm. in diameter. On cutting through these light areas, a creamy, yellow pus exudes. On section, the right lobe is found to be honeycombed with abscesses of varying size, the largest being 3 cm. in diameter. These abscesses are most numerous in the central and anterior portions of the right lobe, and here coalesce so as almost to form a single large cavity. The extreme right of the lobe is free from them, but the normal liver markings cannot be made out. In the left lobe the suppurative process is confined to the veins, which are filled with yellowish, purulent material. The liver tissue encircling the veins is soft, and greenish in color. Smears from the abscess cavities show bacilli and cocci, the latter occurring singly, in pairs, and in short chains.

Pleural Cavities.—The left lung is free. The right lung is firmly adherent along its posterior border, and to the diaphragm.

Pericardial cavity.—Heart and lungs normal.

Spleen.—Weight 330 gms. The capsule is smooth; the surface red, with dark brown, irregular areas. On section, the tissue is grayish-red with dark brown somewhat wedge-shaped areas throughout. The Malpighian bodies are seen as grayish-white, translucent dots, surrounded by a hyperemic ring, and are ¾ to 1 mm. in diameter. The trabeculæ are indistinct; pulp apparently not increased.

The kidneys, pancreas, and genital organs.—Normal.

Cultures.—Heart's blood, lung, liver, spleen, and kidney—Streptococcus pyogenes; colon-like bacillus.

Microscopic Examination.—Liver.—Section shows many small abscess cavities, the boundaries of which are not sharply circumscribed, but which show the leucocytes infiltrating more or less deeply and irregularly into the surrounding liver epithelium. In a few of these areas the centres are broken down, and stain sharply with eosin. There are many areas of congestion, in which the red blood corpuscles extend out between the liver cells, and are not confined exclusively to the capillaries. The portal connective tissue seems to be everywhere the seat of focal collections of leucocytes, and in places the leucocytes can be seen infiltrating the space between the liver cells. The liver cells in these areas are small, irregular, granular, and stain with eosin. Foci of organisms can be seen in the necrotic material in the centres of the abscess cavities, and can also be found both within and without cells most remote from these areas. In no place in the section is a perfectly normal picture presented.

IX.—B. C. H. 01.188. E. B., female, age eleven.

Anatomical Diagnosis.—Operation wounds; localized fibrinous peritonitis, right iliac fossa; pelvic abscess; suppurative pylephlebitis; multiple abscesses of liver; acute fibrinous and chronic fibrous pleuritis, right; atelectasis of lung, right lower lobe; caseation of an ileocecal lymph node.

Beginning just below the costal margin, 5 cm. to the right and parallel to the

median line, is an open wound, 10 cm. in length, containing a gauze drain which extends down behind the liver. Also a scar, 2 cm. in length, just above, and parallel to Poupart's ligament.

Peritoneal Cavity.—The serosa appears normal. The omentum is long and devoid of fat. Its lower end is bound down to the cecum and the small intestine in the appendix region by easily separable, fibrinous adhesions. On separating these adhesions a small pocket is found containing the necrotic end of the appendix adherent to the cecum. Just behind this pocket is a small, irregular opening into the cecum, through which fecal matter can be expressed. The tissues in the neighborhood are necrotic. In the pelvis is an area 5 cm. in diameter, including the posterior portion of the uterus, the rectum, the broad ligament, and the adjacent peritoneum, covered with a thick layer of yellowish, tenacious fibrin. The mesenteric lymph nodes appear normal with the exception of one in the ileocecal region which is 2 cm. in its longest diameter, has a yellowish, irregular surface, and is caseous.

On opening the portal vein, it is found occluded by a soft, purulent, adherent thrombus extending up to the bifurcation of the branches going to the right and left lobes of the liver; while from this point to smaller branches in the liver, the vein is filled with bile-stained, purulent material, and the walls of the vessels are smooth. The same suppurative process extends throughout the upper portion of the superior mesenteric vein, and through its ileocecal branch to the appendix. Its other branches are normal. The splenic vein is normal, as are also its branches, the gastric, the pancreatic, and the inferior mesenteric veins. The biliary and pancreatic ducts are normal.

Pleural Cavities.—The right lung is bound to its parietes by fairly dense fibrous adhesions over the upper surface of the lower lobe. On freeing the lung, the diaphragmatic pleura shows an irregular area about 3 cm. in diameter, where the pleura is ulcerated and covered with bits of yellow fibrin. Surrounding this area for a distance of 3 cm. the pleura is lustreless, granular, and covered with a thin layer of fibrin. The corresponding lung surface shows a similar condition, described below. Left lung free.

Pericardial cavity.—Normal. Heart, weight 95 gms.; normal.

Lungs.—The left lung is normal. In the right, the lower lobe is atelectatic. On the inferior surface of this lobe is a ragged area 3 cm. in diameter, slightly covered with bits of yellow fibrin, between which can be seen pieces of red lung tissue. This necrotic process mainly involves the pleura, but there is a slight destruction of lung tissue. About this area for a distance of 3 cm. the pleura is lustreless, slightly granular, and covered with a thin layer of fibrin.

Spleen.—Weight 70 gms. The anterior surface is deeply notched. The capsule smooth. On section it is dark red. The Malpighian bodies are seen as irregular spheroid dots, surrounded by a slight hyperemic zone. Trabeculæ and blood-vessels distinct.

Pancreas.—Normal.

Gastro-intestinal Tract.—Throughout the cecum and for a short distance up the ileum, the mucosa is thickened, slightly granular, and injected.

Liver.—Weight 1000 gms. (after drainage of considerable pus). The surface is smooth, covered with innumerable small, gray dots against a dark red back-

ground. Over the centre of the anterior surface of the right lobe this marking is of a greenish hue. On the anterior surface of the lower part of the left lobe is an aperture, 2 cm. in length, and 1 cm. in breadth, the edges of which are ragged and covered with bits of yellow fibrin. (Operation wound for drainage.) On section, both right and left lobes are honeycombed with abscess cavities from 0.5 to 2.5 cm. in diameter, containing thick yellow pus, which exudes when they are cut. The greater confluence of these cavities is in an area a little to the left of the centre of the right lobe, involving the liver substance throughout a space as large as the hand. This appears almost as one large abscess. A similar, but slightly smaller area is seen in the lower posterior portion of the left lobe.

Between these abscess cavities, the liver substance shows a red background with numerous, minute, patent blood-vessels around it, in which there is a sharply circumscribed zone, grayish-yellow in color, making areas ½ to ¾ mm. in diameter. There are also similar areas in which no blood-vessels can be made out.

Kidneys, bladder, and genital organs.—Normal.

Cultures.—Heart's blood, liver, and kidney—Streptococcus pyogenes, and colon-like bacillus.

Microscopic Examination.—Portal Vein.—Intima of vein has disappeared and walls of the vessel are infiltrated with polymorpho-nuclear leucocytes which extend in large numbers into the lumen. Mixed with these are red blood-corpuscles, a few endothelial cells, and large cells with several nuclei. Adjacent pancreas normal.

Liver.—Congested. The liver cells are swollen, reticulated, and stain with eosin. The abscess cavity is filled with leucocytes and many granular cells, starting apparently from the periportal connective tissue. The section contains very little normal liver epithelium; everywhere are areas of cell infiltration, or degeneration and vacuolization of the liver cells, starting apparently from the centres of the lobules. The nuclei of many of the cells are fragmented, and at times numbers of these fragments are included in large pale cells. Small collections of organisms can be seen in some of the cells.

Lung.—Section of the lung shows marked infiltration of leucocytes into the lung tissue for a short distance; and the alveoli, above this, are crowded together and show some desquamation of lining epithelium. The blood-vessels are everywhere filled with red blood-corpuscles. Leucocytes crowd the periphery of the vessels.

X.—J. H. H. 1409. Female, age thirteen.

Anatomical Diagnosis.—Operation wound; acute gangrenous appendicitis; suppurative pylephlebitis; multiple abscesses of liver; infarction of kidney.

Peritoneal Cavity.—The serous surfaces are smooth. Cavity contains 500 cc. of slightly turbid, serous fluid. The appendix lies transversely across the psoas muscle and reaches from it to the sigmoid flexure, where it is adherent. The entire appendix, with the exception of the most proximal portion, is hidden from view by the ileum, near the ileocecal valve. This part of the intestine turns inward and is closely adherent over the appendix. The appendix is thus covered in on all sides by intestine or by friable adhesions. It is necrotic throughout most of its extent, and on separating the adhesions, large rents appear in its wall. The adjoin-

ing ileum shows a similar necrosis. The vein in the mesentery leading from the region of the appendix is distended with pus, and its walls are in large part necrotic. Traced upward, this vessel opens into the portal vein behind a large, partly occluding thrombus. The other branches of the portal system are normal.

Spleen.—Weight 45 gms.; it appears normal.

Kidneys.—On the right there is a small, somewhat depressed, deep pink area, with a hemorrhagic zone around it. On section this extends 1 cm. into the tissue, and is rather softer than that adjoining.

Liver.—Is very much enlarged. An operation wound leads into a cavity in the right lobe. The left lobe extends far over into the splenic region. The liver is lightly adherent to the surrounding organs. Its surface presents many fluctuating areas which are surrounded by areas of congestion. On section the whole liver, and more especially the large right lobe, are found riddled by these abscess cavities, evidently in connection with the branches of the portal vein, and probably for the most part in direct connection with them. The gall ducts are much dilated, and probably also involved in the infection. The abscess cavities vary in size from a few mm. to 3 cm. They appear to anastomose freely with one another. They are filled with thick yellow pus, streaked here and there with bile. The tissues adjoining the abscesses have the appearance of deeply congested and compressed liver substance. The walls of the abscesses are ragged and necrotic.

Gall-bladder Ducts.—Appear normal.

Cultures.—Heart's blood and hepatic abscess—Bacillus coli communis.

Analysis of Cases of Liver Abscess.—Sex.—Of these 10 cases, 8 were male, and 2 female.

Age.—Of the 10 cases, 5 were under twenty-five years of age; 3 were between twenty-five and thirty-five; 1 was forty-two; and 1, fifty-two. The earliest age was eleven years.

Condition of Appendix.—In 4 cases the appendix had been removed, and there remained only an appendix stump. In 2 cases, the appendices were gangrenous. In 2 (Nos. I and IV) the lesion was so slight as to render questionable its etiological relation to the portal process.

Condition of Liver.—The liver was enlarged in nearly all our cases, and with two exceptions, it weighed more than 1500 gms. One of these two, weighed 1000 gms., and as the age of the patient was only eleven years, it was relatively enlarged; while in the other case, a man of fifty-two, its weight was 1250 gms., and it could not be considered as a liver reduced in size. The greatest weight was 3265 gms., occurring in a patient sixteen years old. The appearance of the liver varies with the size and distribution of the abscess cavities. When these are situated in the central portions of the liver, they give a mottled appearance to its surface. Against a background of fairly normal liver tissue, brown, brownish, brownish-red, yellow, or greenish in color, the abscess usually appears as a larger or smaller area of a lighter hue, generally yellow, but sometimes greenish from staining of the contents by bile, and often surrounded by a zone

of congestion. These colors vary with the character of the contents of the abscess, and the distance at which it lies beneath the peritoneal covering of the liver. If the abscess is situated immediately beneath the serosa, the suppurative process often extends through the peritoneum, and produces a fibrinous exudation, a localized fibrinous perihepatitis. If the abscess is small, little change is produced in the contour of the liver, but larger abscesses produce distinct bulgings of the surface, which, in consequence of increased thinning of the tissue between abscesses and serosa, may penetrate and discharge their contents into the peritoneal cavity (see Case V).

The cut surface of the liver presents different appearances according to the distribution and development of the inflammatory process. The intrahepatic portal veins alone may be affected, and show, where cut, a dark red, firm, adherent clot, as in Case II, a friable, reddish-gray clot, or fluid puriform material, as in Cases IV and VII. Extension from the vein to the hepatic tissue produces abscesses varying in size from a few millimetres to many centimetres. Their contents varies from a thin fluid to a grumous mass. Their color depends on the admixture of pus cells, hepatic elements, bile, and blood. The walls may be smooth or ragged, and they are sometimes lined by granulation tissue. The abscesses are round or irregular in shape, anastomosing along the course of the venous trunks, or showing diverticula due to the parietal coalescence of adjacent cavities (see Fig. 154). In the latter case, very large abscesses may be formed, one of which, in our series, measured 15 × 12 cm.

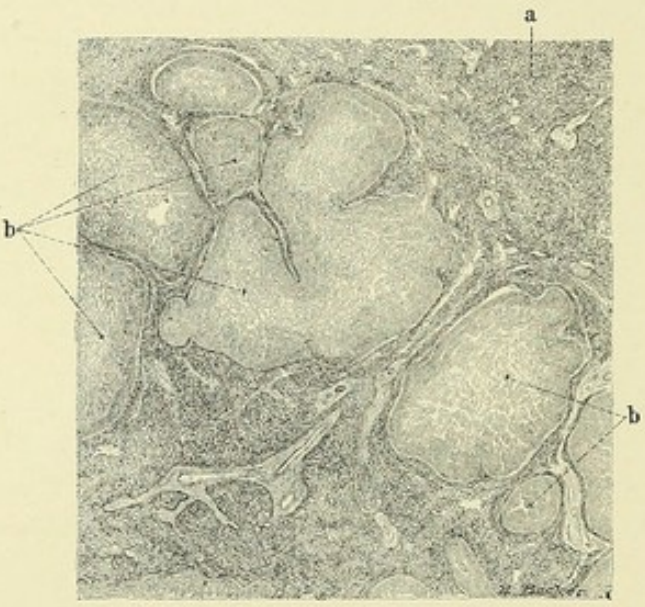

Fig. 154.—Portal Infection.

a. Multiple abscesses of the liver breaking into each other. *b*. Infiltrated liver tissue in the neighborhood of the abscesses.

The abscesses, as a rule, are multiple, and scattered throughout the liver, honeycombing its structures. All of our cases showed this condition. In spite of this uniform distribution of purulent material, however, one lobe is more frequently affected than the other. In Case I the purulent process was more marked in the left lobe, in Cases VI, VIII, IX, and X, in the right. When the liver tissue is so extensively involved, surgical intervention is hopeless, and unfortunately this is the more usual condition, certainly in the later stages of the infection. There are, however, two other types, not represented in our series of cases, which are amenable to surgical treatment, and, therefore, of especial

interest. These are (1) cases in which the abscess is single, and (2) cases in which a single large abscess is surrounded by groups of small ones, while the other parts of the liver are little, or not at all affected. Cases of the former condition have been reported by PAYNE (1870), FRÄNKEL (1891), SHOEMAKER (1893), MUNRO (1902), and others. Examples of the latter condition are given by ASHBY (1879), by CHURCH (1883), and by others.

The microscopic picture is as variable as the macroscopic. The intralobular veins are filled by thrombi or by pus, with the walls practically normal and the liver tissue showing no change; or by groups of necrotic liver cells (central or focal necroses). The interior of the veins may also appear normal, although the pathologic process has begun to invade the wall, and the peripheral connective tissue shows leucocytic infiltration. Sometimes the latter condition exists without the presence of thrombi in the veins, and there is then an acute suppurative interstitial hepatitis without pylephlebitis (see Fig. 155). When necrosis and softening begin, there are abscesses, sometimes confined to the periportal connective tissue, but more often involving the liver lobules. These abscesses may be large or small, they may be widely separated, or the section may be thickly studded with them. The abscess wall is sometimes formed of liver cells, and these may be little changed, or they may be degenerated and much compressed; sometimes the wall consists of remains of the periportal connective tissue. Reparative changes may appear in the shape of granulation tissue lining the abscess cavity (see Case II), which, if death does not ensue, eventually forms adult connective tissue. Liver cells about the abscess may be evidence of proliferation (Case VII). Degenerative changes remote from abscesses are generally prominent throughout the liver parenchyma.

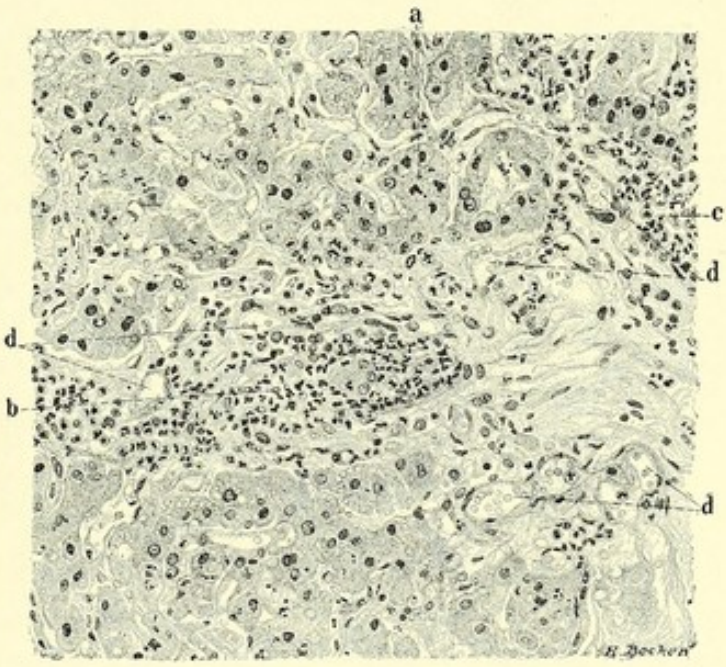

FIG. 155.—ACUTE SUPPURATIVE INTERSTITIAL HEPATITIS DUE TO PORTAL INFECTION.

a, Liver cells; *b*, marks the centre of an infiltrated portal space; *c*, leucocyte; *d*, the vessels.

E t i o l o g y.—The pathogenesis of these hepatic suppurations is of considerable interest.. How do the septic organisms reach the liver from the remotely situated appendix? According to LOISON, the path may be by the biliary, the arterial, the venous, the lymphatic, or the peritoneal route. In

addition to these there is what may be called a mixed lymphatic venous route.

The bile passages are an unusual route for the extension of the suppurative processes to the liver. PILLIET and GOSSET, however, report a case in which they claim that the abscesses occupied the bile ducts, and originated from them, affording, in their opinion, an example of suppuration of the intrahepatic bile ducts, originating in the appendix. In one of our series, Case X, the intrahepatic ducts appeared to be involved in the inflammatory process, but the portal venous system was evidently the source of the liver infection.

The hepatic artery is a route by which it is evident that infectious agents may be brought to and lodged in the liver. The infection finds its way into the general circulation from the region of the appendix, either by way of the inferior vena cava, or by the portal vein, in the latter case having passed once through the liver without lodging there. Such a condition is part of a general pyohemic process, and is accompanied by suppurative processes elsewhere in the body. None of our cases belongs to this group. In this connection, it must be remembered that general pyemic processes elsewhere may be secondary to the hepatic process, which in its turn originated in the appendix.

The portal system is by far the most important route of infection, and it is to this group that all our cases belong. By this path bacteria may be transported from the appendix to the liver, and develop in it without affecting the venous trunk. More frequently, however, septic thrombi form somewhere in the course of the vein, and we have a pylephlebitis, as in all of our cases. The septic formation may happen at any point between the appendix and the liver, after which the process extends into the liver. The various points at which such formations may occur are illustrated in our series of cases, in which the portal, superior mesenteric, and appendical veins were filled to a greater or less extent with a clot or with fluid pus, the remaining portion containing normal blood. The other branches of the portal system may remain free; or the venous trunk, in part or in whole, may be filled with puriform material as in Case VIII. The wall of the vein may show little change, or it may be so extensively involved that on microscopic examination its original structure can with difficulty be made out.

According to LOISON the lymphatics of the appendix do not communicate with the liver; but in inflammatory conditions, either by means of adhesions to the parietal peritoneum, or through a retroperitoneal abscess formation, a connection is established with the parietal lymphatics which ascend toward the diaphragm and in this way reach the liver. Cases, the etiology of which can be explained in this way, are given by KÖRTE (1892), SHOEMAKER (1893), and by PIARD (1896). For none of our cases is such an explanation necessary, but Case VIII is suggestive of what we have termed the mixed lymphatic venous route, in which the infection is carried to the lymph nodes of the ileocecal chain,


Large abscess
Large branch of portal vein, filled with debris and pus.
Dome of liver, turned up, showing grape-like clusters of abscesses
Vena cava inf.
Liver
Thrombus in left br. of portal vein.
Splenic vein, filled with pus.
Gall bladder
Inf. mes.
Group of swollen glands in hilus of liver.
Debris and pus in right br. of portal vein
Sup. mes.
Thrombus in ileo-colic vein
Congested ileo-colic glands

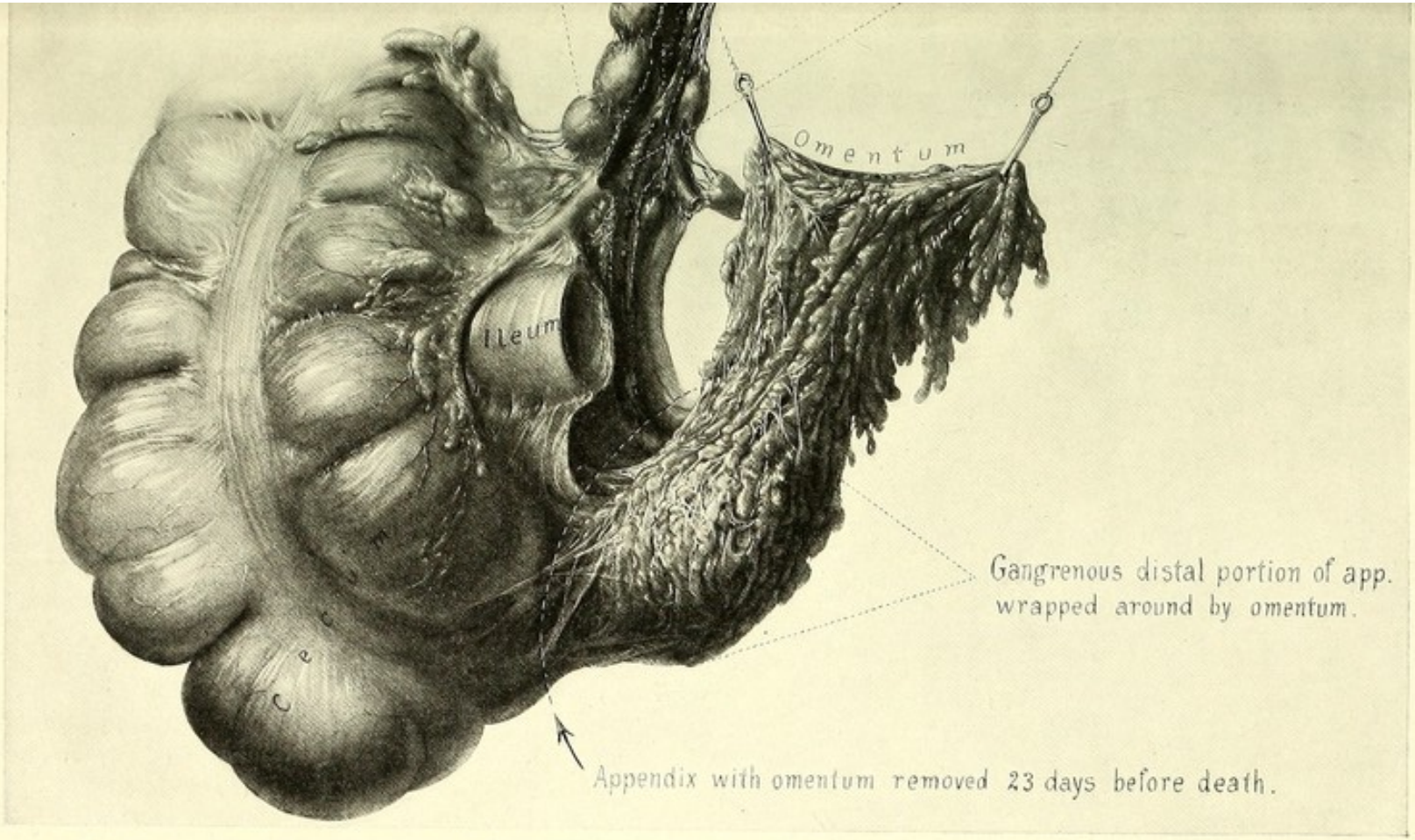

FIG. 156.—SUPPURATIVE THROMBO-PHLEBITIS OF THE MESENTERIC VEINS WITH MULTIPLE ABSCESSES IN THE LIVER; FOLLOWING APPENDICITIS.

The picture is a combination of the condition of the appendix as found at operation, and that of the veins of the portal system and liver as found at autopsy twenty-three days after operation. At the time of the operation the appendix was found lying in front of the cecum wrapped completely around by omentum; there were two kinks in the proximal end, and the distal extremity was much enlarged and gangrenous. The omentum was ligated, cut and removed with the appendix and mesenteriolum as indicated by the arrow and dotted line. On cutting through the mesappendix, a small abscess in its substance was opened. (Probably suppurative thrombo-phlebitis of a vein in the mesappendix, representing the initial stage of the subsequent extensive involvement.) The condition of the veins of the portal system and of the liver, as found at autopsy, is clearly shown in the picture and described in detail in the text. The veins of the appendix and ileocolic vein have been laid open so as to show the inflamed and partly gangrenous character of the vessel wall and the thrombus found within the lumen. The liver has been cut in transverse sections, the greater number of which have been taken out in order to demonstrate by means of the most characteristic cut surfaces the amount of destruction caused by the abscess formation. The section through the dome of the liver has been turned up, giving an unforeshortened view of the peculiar grape-like grouping of the small abscesses around the end branches of the portal vein.

and here produces hyperplasia and inflammatory softening, thus forming the starting-point of the portal infection.

Supra- or subhepatic collections of pus may form, and then extend into the liver, forming what is clinically a liver abscess. Such a case may arise by peritoneal extension of the process, and also by retroperitoneal extension. This group, however, belongs more properly to that of subphrenic or other localized abscess.

Bacteriology.—The bacteriology of liver abscess is the same as that of appendicitis. The organisms present are those of the intestinal flora, which after reaching the liver from the appendix by some one of the various routes just described, develop there, with a resulting abscess. In our cases, cultures from the contents of the portal vein within the liver or from abscess cavities showed bacillus coli communis alone in 3 cases, and combined with streptococcus pyogenes in 4. In the others no cultures were taken, but in one of them, smears made from pus in the portal vein showed a variety of bacteria, including both bacilli and cocci.

Two theories have been advanced to explain why liver abscess develops in some cases of appendicitis and not in others: (1) increased virulence of the organisms; (2) lowered resistance of the liver from some preëxisting lesion. The first theory is difficult of proof in any given case. To apply the second to our own cases is almost equally so, for in nearly all of these, the liver was so extensively involved by the process in question that but little idea of previous lesions could be entertained. In only 2 cases was there any evidence of a former cirrhosis, and in one of these it was but slightly marked.

The following additional case of liver abscess originating in the appendix has been sent me by G. Adami of McGill University, Montreal (see Fig. 156):

A. M., age fourteen, died April 24, 1901.

Anatomical Diagnosis.—Thrombosis of the ileocolic branches of the superior mesenteric vein; purulent thrombo-phlebitis of the portal and splenic veins; multiple liver abscesses.

Peritoneal Cavity.—The vessels in the great omentum are injected in the neighborhood of the wound, but there is no evidence of pus within them. The liver reaches 7 cm. below the costal margin in the right nipple line.

Liver.—Dark green areas are scattered over the surface. Near the capsule on the dome of the right lobe are two or three small abscesses. These, however, do not project, and give no indication of the suppuration within the organ. The omental veins are normal except for moderate congestion; the main, right, superior mesenteric branches, passing from the ileocecal region, are surrounded by swollen and congested lymph glands. A fine, dark, apparently adherent thrombus extends along the vein up to its junction with the superior mesenteric. There are no signs of pus here, although the walls are dark and of inflammatory appearance. The clot extends beyond the junction of the other main branches of the superior mesenteric, ending abruptly just above the point of junction of the main branches of the vein. In the

portal vein, the clot gives way to debris and to true pus, rather dirty, thin, and of a yellowish tinge. Similar matter extends the whole length of the splenic vein into the individual branches and oozes from these upon sections of the spleen. The branch of the portal vein going to the right lobe of the liver is full of pus; that going to the left is completely filled by a thrombus. Here and there in the liver substance this thrombus gives place to pus with abscess formations, which are most extensive in the upper half of the right lobe. The liver substance is disorganized, and there are groups of abscesses having a grape-like arrangement in the rest of the right lobe, with isolated groups in the left lobe. Chains of swollen glands surround the portal vein at the hilum of the liver. Smear preparations of pus from different regions give the same results in all the different regions, namely, a mixture of bacillary forms, some long and large, others slim, and others again short and in chains.

SPLEEN.

Acute appendicitis may produce an acute splenic tumor. In some cases, however, where microscopic examination shows the changes of an acute splenitis, there is not much enlargement. Abscesses and infarctions may also occur in the spleen as they do in other organs.

In our series of cases, 24 showed an acute splenic tumor. The proliferation of epithelioid cells in the Malphigian bodies, commonly found in diphtheria (Councilman, Mallory, and Pearce), were very seldom seen in those of our cases which were studied microscopically. Simple congestion and hemorrhage were much more common. The size of the spleen varied greatly; and the cases in which the weight was given, may be grouped as follows: Less than 50 gms., 1 case; 50 to 109 gms., 11 cases; 110 to 169 gms., 20 cases; 170 to 229 gms., 7 cases; 230 to 289 gms., 12 cases; 290 to 349, 8 cases; 370, and over 4 cases. The largest spleen weighed 600 gms. Infarction occurred in 2 cases in both of which pylephlebitis was present.

KIDNEYS.

The renal lesion most often associated with acute appendicitis is a degenerative nephritis. By extension from the region of the appendix, the process may involve the ureter and cause an ascending pyelonephritis. This happened in one of our cases. Furthermore, if a general pyemia should result from the suppurative process at first localized in the appendix, metastatic abscesses may be found in the kidney. Associated with an embolic process, there may be infarction of the kidney, of which we had one example, occurring in connection with acute vegetative endocarditis of the mitral and the aortic valves.

Beside these lesions, which are referable to the bacteria and toxins proceeding from the original process in the appendix, there was evidence in a number of cases of a pathogenic process in the kidney antedating that in the appendix. Of this class, there were 12 cases showing a chronic diffuse nephritis of varying

degree, beside 1 with marked acute and chronic glomerulo-nephritis. This latter case had shown the typical symptoms of nephritis for nine months, and the autopsy revealed the above lesions in a horseshoe-shaped kidney, together with an associated pelvic abscess, apparently originating in the appendix. There was one case of renal calculus, and one of amyloid kidney. In the other cases there was no chronic renal lesion.

INTESTINES.

Except for the involvement of the serosa in a general peritonitis the changes exhibited by the intestines are few. They consist of congestion, small submucous hemorrhages, and, very rarely, areas of slight diphtheritic exudation of the mucosa. In one of the cases of appendicitis, death was due to hemorrhage from an eroded vessel in a duodenal ulcer.

LUNGS.

In 18 cases the lungs were congested and edematous; 15 showed broncho-pneumonia with varying involvement of the lung; in 2 there was lobar pneumonia. The cases of broncho-pneumonia may be explained in two ways: (1) as an infection from the appendix by the vascular route; (2) as an infection by the air passages; the development of bacteria thus entering being favored by the condition of lowered resistance associated with the appendicitis. The first is a true secondary infection, the second is of the nature of a terminal infection. In 4 cases, the lungs were atelectatic. The latter condition was associated with pyothorax.

PLEURA.

The pleural cavity may show inflammatory exudation associated with appendicitis, arising in two ways: (1) by extension from a pneumonic focus or infarct in the lung; (2) by extension from the abdominal cavity by way of the lymphatics, or by erosion of the diaphragm. The latter form, which is almost always associated with subphrenic abscess, constitutes the "*appendicular pleurisy*" of some writers, and it is almost always right-sided. Some writers indeed claim that it is invariably situated on the right side, but this view cannot be accepted, for, as we have seen, subphrenic abscess following appendicitis may occur upon the left side, and may be followed by acute pleuritis on that side, as actually happened in one of our cases (see Case VII).

The appearance of the pleural cavity varies with the amount and the character of exudation present, so that all gradations between a very slight fibrinous pleuritis and an extensive pyothorax occur. In almost all the cases of pneumonia a slight pleuritis was found. In 4 cases, there was an extensive pyothorax.

HEART.

Entrance of bacteria into the general circulation may lead to an acute endocarditis. This occurred in 3 cases. All were cases of acute vegetative endocarditis, 2 of mitral, and 1 of mitral and aortic valves. Preëxisting chronic valvular lesions were seen in 3 cases; in all of which the mitral valve was affected. In 1 there was stenosis, and in 2 insufficiency. In the former the aortic valve also was reduced to a small triangular opening from interadhesion and thickening of the valve segments.

In 2 cases there was heart hypertrophy without valvular lesion, referable to general arterio-sclerosis and chronic diffuse nephritis.

BLOOD VESSELS.

Arterio-sclerosis is frequently found at autopsies, especially in patients of advanced years, but it has no etiological relation to appendicitis, although it may have influenced the course of the disease. Thrombosis and embolism may occur as a result of the inflammatory process in the appendix. Thrombosis of the portal system of veins, and septic embolism with abscess formation have already been considered.

Embolism of the pulmonary artery is not extremely rare. If the embolus is of a size sufficient to obstruct a large branch of the artery, it is rapidly fatal. If it is not so large, and blocks only smaller branches, infarction is the result, which may or may not end fatally. The latter condition results from a thrombosis of the veins, in the region of the appendix, which empty into the inferior vena cava. The thrombi, after formation, become detached and entering the larger vessels are borne to the right heart, where they may either lodge, or pass through to stop in some branch of the pulmonary artery. This complication occurs not infrequently post-operatively, often happening in cases which are running a perfectly satisfactory course, and forming one of the most unfortunate complications of the surgical treatment of appendicitis.

In our series of cases, there were 3 of pulmonary embolism. In 1 of these, the occluded branches were quite small, and hemorrhagic infarcts in the left lower lobe of the lung had been the result. The condition was associated with a chronic valvular lesion of the left side of the heart, and death was due to general peritonitis. In the other 2 cases, the main artery was occluded by a large clot, which occasioned death. In both cases, the appendix had been removed and the stumps appeared to be healing, although a small abscess was found in the neighborhood of one of them. In none of the cases was the exact source of embolus discovered, though the veins of the pelvis, of Scarpa's triangle, and of the popliteal space were examined for evidence of thrombosis.

Thrombosis or embolism of a coronary artery is less frequent. It happened only once in our 86 cases; the anterior descending branch

of the coronary artery being occluded by a thrombus in a case with acute gangrenous appendicitis, peri-appendical abscess, acute general peritonitis, arteriosclerosis, nephroliathiasis, and chronic diffuse nephritis.

CHRONIC ADHESIVE APPENDICITIS.

By this term is meant fibrous adhesions binding the appendix to neighboring structures. These adhesions may be due to a previous inflammatory process originating in the appendix, or to one extending to the appendix from adjacent structures in which it originated. The first may be considered as p r i m a r y, the second as s e c o n d a r y c h r o n i c a d h e s i v e a p p e n d i c i t i s.

F r e q u e n c y.—Adhesions about the appendix are frequently met with at autopsies, and in most of such cases there is no evidence that they have affected the health and comfort of the patient. Statistics of frequency of this condition vary greatly, but there can be no doubt that adhesions about the appendix are so common as to indicate that many people, at some time during their lives, have had an inflammatory process involving the appendix, which has not, however, caused any serious consequence.

The occurrence of fibrous adhesions about the appendix was investigated in 3770 autopsies at the Boston City and Johns Hopkins Hospitals. (Some autopsies included in those observed with reference to acute appendicitis are not utilized because very incomplete records of them are available.) Such adhesions were found in 325 cases, or 8.62 per cent. This percentage is undoubtedly too low, and it is probable that adhesions were present in some cases not mentioned. In 1632 of the protocols there was no description of the appendix; in 2138, the appendix is stated to have been normal, or a description of its condition is given. Of the latter number, 15.2 per cent. showed adhesions. The correct ratio probably lies between the two.

FERGUSON found evidence of old inflammatory adhesions in only 3½ per cent. of 200 cases examined, while WALLIS, in a collection of autopsies extending over five years, found that only 1.7 per cent. of all appendices presented evidences of disease. According to CURTIS, FINKELSTEIN found adhesions in 7 per cent., RANSOHOFF in 12 per cent., and KRAUSSOLD and TOFT in ⅓ per cent. of their autopsies. ROBINSON, in a study of 128 cases, encountered evidences of former peri-appendical peritonitis in 82, or 64 per cent. HARTLEY quotes HEKTOEN as finding adhesions 42 times in 280 cases, or 15 per cent., and MAURIN 16 times in 112, or 14.3 per cent. In "*Progressive Medicine*" for June, 1900, p. 50, it is stated that MCBURNEY in 230 autopsies found evidence of chronic inflammation in 70 per cent. BOODY studied 528 autopsies, finding adhesions about the appendix in 126, or 24 per cent. These results differ very widely, and do not justify any conclusions as to the relative frequency of chronic adhesive appendicitis.

S e x.—Of 127 of these cases, 87, or 68.5 per cent., were males and 40, or 31.5 per cent., were females. ROBINSON in 82 cases found 65 males, or 79.26 per cent., and 17, or 20.73 per cent., females. Of the 145 Boston City Hospital cases, 84 were males; 40 were females; and in 21 cases the sex was not stated.

E t i o l o g y.—Of these same 145 cases, 118 showed no evidence of any abdominal condition to which adhesions could be referred, other than a prior inflammation of the appendix, and they may, therefore, be considered as cases of p r i m a r y chronic adhesive appendicitis in the sense stated above; in 27 cases, other sources for the adhesions could be ascertained. Some of these must be regarded as cases of the s e c o n d a r y form, while in others it was not possible to determine whether the inflammation began in the appendix or in some other structure, this being especially true of cases associated with chronic salpingitis. Of these 27 cases there was chronic salpingitis in 8, and in 3 more there were pelvic adhesions with an abscess in Douglas's *cul-de-sac*. In 1 case there was hydrosalpinx and myomata of the uterus; in 3, carcinoma of the uterus with extension into other pelvic structures; in 3, disease of the gall bladder; in 1, chronic cystitis; in 3, very general adhesions without any discoverable point of origin; and in 2, tubercular peritonitis.

CHRONIC OBLITERATIVE APPENDICITIS.

Partial or complete obliteration of the appendix is frequently seen at autopsies. RIBBERT, when examining 400 appendices, found this condition in 25 per cent.; ZUCKERKANDL in 23.7 per cent. of 232 autopsies, and STEINER in 18 per cent. of 155. In the records of the 3770 autopsies examined for the occurrence of chronic adhesions about the appendix, partial or complete obliteration of the lumen of the appendix was mentioned in 111, but the examination of the lumen of the appendix was incomplete, in many cases, so that these figures have no statistical value. Of these 111 cases, 41, or 36.9 per cent., showed complete obliteration of the lumen, the appendix appearing as a whitish cord; 31 of these showed no surrounding adhesions. Of RIBBERT's cases about 3½ per cent. were completely obliterated.

CYSTS OF THE APPENDIX.

These are not very infrequent, especially when small in size. RIBBERT found 6 in 400 autopsies; BRYANT (cited by CURTIS), 1 in 124 autopsies; STEINER, 3 in 2286 autopsies; and BOODY, 1 in 528. Single cases have been reported by a number of observers. WOOD gives a case in which the cyst was 20 cm. in length and 7 cm. in diameter; he also cites 19 cases collected from literature, one of

which, that of McArthur, was situated in a hernial sac. Wölfler has also reported one case of a cyst of the appendix occurring in a hernial sac.

In 3770 autopsies at the Boston City Hospital, 16, or 0.42 per cent., cysts of this character were found, besides one which was subperitoneal and not connected with the lumen of the appendix. The latter was the size of an apricot, and contained clear yellow fluid, resembling the subserous cysts found elsewhere in the abdominal cavity. All of the former class were small, the largest measuring $2\frac{1}{2} \times 2$ cm. They were all, with one exception, formed by the dilatation of the distal end of the appendix which was situated near the middle of the organ. The contents of one was a brownish, putty-like mass of granular debris and fatty acid crystals; one showed blackish specks of extravasated blood; the wall of one was green to blackish-green in color; all the others contained colorless mucous, viscid, or gelatinous fluid.

CONDITION OF THE APPENDIX ASSOCIATED WITH DISEASE OF OTHER ABDOMINAL VISCERA.

As the tissues constituting the appendix are the same as those found in other portions of the intestinal tract, as its lumen normally communicates freely with that of the intestine, and as its serosa forms part of the general peritoneum, it is natural to infer that processes diffusely affecting any of these structures would also affect the appendix in the same manner. In general this proposition is true. However, it seems advisable to take up in slight detail some of the more frequent abdominal diseases.

Typhoid Fever.—In 119 autopsies on typhoid patients at the Johns Hopkins and Boston City Hospitals, 19 showed changes in the appendix evident enough in the gross to direct attention to that organ. The lesions in these cases were various, in general corresponding to those produced by the bacillus typhosus in other portions of the intestine. In most cases the appendix was swollen, more rigid than normal, and its subserous venules congested focally or generally. In a few cases the serosa showed a fibrinous exudation. This was present in the cases of perforative peritonitis, but was also found when there was no general peritoneal involvement. The mucosa was swollen in many of the cases, and in most of these there was ulceration. The ulceration in some was very superficial, in others deeper, with sharply defined margins. In 2 cases ulcers had perforated. In 1, almost the entire mucosa was necrotic, but no distinct ulcers were present. In most of the cases, the process closely resembled some stage of the typical typhoidal lesion of the intestine; in others the usual form of appendicitis was suggested. What part the bacillus typhosus took in the etiology of the lesion in each case, was not determined.

Tuberculosis.—Among our 3770 autopsies, tubercular lesions were noted in the appendix in 44 cases, 39 of which showed ulceration extending from the mucosa to a varying depth in the wall of the organ. Sometimes the

wall of the appendix contained caseous nodules. In a few cases ulcers had perforated and peri-appendical abscesses had formed. In 5 cases the lesion of the appendix was part of a general tubercular peritonitis. In 1 of these cases the tubercles were of the pedunculated variety.

I l e o c o l i t i s.—The structures of the appendix may participate in the pathological process belonging to the various forms of intestinal lesions included under acute and chronic ileocolitis, as well as in those of the two diseases just discussed, and we may have swelling, diphtheritic exudation, or ulceration of the mucosa. Among the cases already mentioned there is one of particular interest in which there existed extensive ulceration of the large intestine and of the appendix, diphtheritic inflammation of the small intestine, and general peritonitis from perforation of several ulcers, one of them situated in the appendix. In both the intestinal and the peritoneal contents many amœbæ coli were found.

N e o p l a s m s.—Metastasis of malignant tumors may occur in the appendix by vascular or lymphatic transportation, or by implantation. Neighboring neoplasms may involve the appendix by extension, or the appendix become attached to them by means of inflammatory products without being invaded by the tumor. Among our autopsies, in 10 cases the appendix was invaded by carcinoma, in 1 by sarcoma. In none did the much more unusual primary malignant growth occur, and there were no benign tumors.

P e l v i c D i s e a s e.—Very frequently inflammation of the tubes and ovaries extends to and involves the appendix, and, conversely, inflammation of the appendix extends to the tubes and ovaries, so that both the appendix and pelvic organs are frequently found involved in adhesions. In most cases when seen at autopsies, the inflammatory process has advanced so far that it is not possible to determine in which organ it was primary. In our cases, as already seen when considering chronic adhesive appendicitis, chronic salpingitis and appendicitis were frequently found associated.

Former Removal of the Appendix.—In 11 of the 3770 autopsies, the appendix had been removed during a previous illness, the patients had entirely recovered from this, and death was finally due to some cause in no way connected with disease of the appendix, or with the operation for it.

Appendix in Hernial Sac.—In 4 cases the appendix was found in the sac of a hernia.

BIBLIOGRAPHY.

Ashby: Lancet, 1879, vol. 2, p. 649.
Bärensprung: Arch. f. klin. Chir., 1875, Bd. 18, p. 586.
Berthelin: Thèse de Paris, 1895.
Blake: Ann. Surg., 1901, vol. 34, p. 703.
Boody: Amer. Med., 1902, vol. 4, p. 262.
Borchardt: Mitth. a. d. Grenzgeb. d. Med. u Chir., 1897, Bd. 2, p. 305.
Buhl: Zeitschr. f. ration. Med., 1854, N. F. Bd. 4, p. 348.
Caley: Lancet, 1900, vol. 1, p. 378.

CHURCH: Bost. Med. and Surg. Jour., 1883, vol. 109, p. 269.
COLQUHOUN: Lancet, 1887, vol. 2, p. 606.
COUNCILMAN, MALLORY, and PEARCE: Jour. Bost. Soc. Med. Sci., 1900-01, vol. 5, p. 139.
CURTIS: Twent. Cent. Prac. Med., N. Y., 1896, vol. 8.
DALE: Cinc. Lancet-Clinic, 1901, vol. 46, p. 451.
DIEULAFOY: Semaine méd., 1898, tom. 18, p. 449.
DUDLEY: Dtsch. Arch. f. klin. Med., 1892, Bd. 50, p. 316.
EINHORN: Münch. med. Wochenschr., 1891, Bd. 38, pp. 121, 140.
ELSBERG: Ann. Surg., 1901, vol. 34, p. 729.
FITZ: Amer. Jour. Med. Sci., 1886, vol. 92, p. 321.
FERGUSON: Amer. Jour. Med. Sci., 1891, vol. 101, p. 61.
FRÄNKEL: Berl. klin. Wochenschr., 1891, p. 1107.
GASTON: Med. Rec., 1901, vol. 59, p. 452.
HART: N. Y. Presby. Hosp. Rep., 1900, p. 157.
HARTLEY: Dennis's Syst. of Surg., 1890, vol. 4, p. 394.
HILLAIRET: Union méd., 1849, p. 248.
JACKSON: St. Paul Med. Jour., 1899, vol. 1, p. 401.
JORAND: Bull. de la Soc. anat. de Paris, 1894, tom. 59, p. 300.
KOBLER: Virch. Arch., 1901, Bd. 163, p. 134.
KÖRTE: Berl. klin. Wochenschr., 1892, p. 794.
KRACKOWITZER: N. Y. Med. Jour., 1871, vol. 13, p. 733.
LANG: "Ueber subphrenische Abscesse." I. D., Moscow.
LANGHELD: I. D. Berlin, 1890.
LAPEYRE: Rev. de chir., 1901, tom. 23, pp. 508, 646.
v. LEYDEN: Zeitschr. f. klin. Med., 1880, Bd. 1, p. 320.
LOISON: Rev. de chir., 1900, tom. 21, p. 522.
MALLORY: Jour. Med. Research, 1901, n. s., vol. 1, p. 264.
MATTERSTOCK: Gerhardt's Handbuch der Kinderkrankheiten, Bd. 4, Abth. 2, p. 893.
MAYDL: "Ueber subphrenische Abscesse," Wien, 1894.
McARTHUR: Am. Jour. Obst., 1893, vol. 28, p. 275.
MUNRO: Therap. Gaz., 1901, vol. 17, p. 71; also Bost. Med. and Surg. Jour., 1902, vol. 146, p. 81.
NOTHNAGEL: Spec. Path. u. Therapie, Wien, 1898, Bd. 17, p. 639.
OCHSNER: Handbook on Appendicitis, Chicago, 1902.
PAYNE: Trans. Path. Soc., London, 1870, vol. 21, p. 231.
PIARD: Arch. gén. de méd., 1896, tom. 6, p. 290.
PILLIET ET GOSSET: Bull. de la Soc. anat. de Paris, 1895, tom. 70, p. 641.
RABÉ: Bull. de la Soc. anat. de Paris, 1897, tom. 72, p. 468.
RIBBERT: Virch. Arch., 1893, Bd. 132, p. 66.
ROBINSON, B.: Med. Rec., 1895, vol. 48, p. 757.
ROBINSON, G. S.: Lancet, 1899, vol. 1, p. 209.
SACHS: Arch. f. klin. Chir., 1895, Bd. 50, p. 16.
SHOEMAKER: Med. News, Phila., 1893, vol. 62, p. 397.
SHEEN: Practitioner, London, 1896, vol. 56, p. 607.
STEINER: "Zur pathologischen Anatomie des Wurmfortsatzes," Basle, 1882.
STOOKE: Brit. Med. Jour., 1901, vol. 1, p. 342.
TROWBRIDGE: Phila. Med. Jour., 1900, vol. 6, p. 716.
UMBER: Mittheil. a. d. Grenzgeb. d. Med. u. Chir., 1900, Bd. 6, p. 605.
WALLER: Zeitschrift d. Gesell. d. Aerzte in Wien, 1846, Bd. 3, p. 385.
WALLIS: Hygeia, Stockholm, 1892, Bd. 54, p. 578.
WEBER: Dtsch. Zeitschr. f. Chir., 1900, Bd. 54, p. 423; IBID., 1901, Bd. 60, p. 127.
WÖLFLER: Arch. f. klin. Chir., 1877, Bd. 21, p. 432.
WOOD: Amer. Jour. Obst., 1900, vol. 41, p. 15.
ZUCKERKANDL: Anat. Hefte, Wiesbaden, 1894, Bd. 4, p. 99.

CHAPTER XI.

BACTERIOLOGY.

Chauveau in 1882 demonstrated that the injection of micro-organisms into the abdominal cavity might be followed by peritonitis, and Pawlowsky in 1887 and 1889 produced the condition by the use of virulent micrococci, while Weichselbaum in 1888 showed that peritonitis might be caused by Micrococcus pneumoniæ. The accurate investigation of peritonitis in its relation to appendicitis may be said to have begun, however, with Laruelle, who in 1889 isolated Bacillus coli from the exudate in a general peritonitis following an inflammatory process in the appendix. He was quickly followed by E. Fränkel (1890) and Predöhl (1890), both of whom examined a considerable number of cases and came to almost identical conclusions. Fränkel found Streptococcus pyogenes in the majority of the 15 cases which he examined and therefore believed that this organism played the chief rôle in the etiology of peritonitis, the other bacteria present being secondary invaders from the intestinal tract, in which view Predöhl agreed, in spite of the fact that he himself found a mixture of bacteria in his culture tubes.

A year later (1891) Fränkel examined 31 cases of peritonitis associated with appendicitis, and found Bacillus coli, Bacterium aërogenes, Micrococcus pneumoniae, and Micrococcus aureus present in addition to Streptococcus pyogenes. The cultures of Bacillus coli obtained by Fränkel proved virulent to smaller animals—a fact which convinced him that this organism played no small part in the etiology of appendicitis.

From this time forward, two distinct views have been held in regard to the bacteriology of appendicitis, each being advocated by accurate observers, and supported by careful examinations of inflamed appendices. On the one hand, a number of bacteriologists have isolated Streptococcus from the peritoneal exudate in the majority of their cases, either alone or in combination with other organisms, and, therefore, they consider that this organism, which is capable of setting up most extensive and virulent inflammations in other parts of the body, as well as pronounced and fatal infections, must also be responsible for inflammation of the appendix and resulting peritonitis. On the other hand, many investigators have utterly failed to isolate Streptococcus from the pus about the appendix, or in the general cavity of the abdomen,

finding instead Bacillus coli, or some other organism derived from the intestinal tract, and as they are unwilling to admit that they have missed Streptococcus (although it is notoriously easy to overlook) they regard other bacteria as the causative agents in appendicitis. It must be admitted, however, that their views have received considerable support from the fact that Bacillus coli, originally looked upon as non-pathogenic, can, in rare instances and in large doses, produce a fatal hemorrhagic peritonitis in rabbits.

A few of the more important investigations bearing on this question are the following: Malvoz found Bacillus coli in 6 cases of peritonitis without perforation, and Welch found it in 3 cases subject to intestinal ulceration, as well as in several cases of appendical abscess. Both Streptococci and Micrococci, however, were found with the Bacillus coli. In 1892, Jalaguier isolated Bacillus coli from the exudate in peritonitis following perforation, together with Micrococcus aureus, Bacillus subtilis, and Bacillus lacticus, but Clado, in 10 examinations found only Bacillus coli. On the other hand, Körte in 1892, after examining 19 cases, reported that he found Streptococcus and Micrococcus in the majority of them. Tavel and Lanz (1898) investigated 24 cases of appendicitis, studying carefully the different organisms encountered, and determined these to be Bacillus coli, Bacillus pyocyaneus, Bacillus fetidus liquefaciens, Diplococcus intestinalis, both major and minor, Diplococcus liquefaciens, Diplococcus pneumoniae, and Streptococcus pyogenes, besides a bacillus belonging to the diphtheritic group, and one belonging to the glanders group. They also found a number of organisms in the microscopic examinations of the exudate which could not be obtained in pure culture, organisms resembling Actinomyces, besides Bacillus tetani, some sarcina forms, and some other bacteria taken to be anaërobes, and, as they found in several cases that only Bacillus coli could be cultivated out of a mixture of different organisms seen in the pus, they concluded that its importance had been much exaggerated by previous observers. Other important investigations are those of Harbitz (1896), who in 14 cases of appendicitis found Bacillus coli, Streptococcus and Micrococcus; those of Achaud and Broca (1897), who in 20 cases found Bacillus coli alone 7 times, Bacillus coli together with Streptococcus, Pneumococcus, and Micrococcus 10 times, with only 3 cases in which Bacillus coli could not be isolated; and those of Deaver (1898), who in 200 cases found a mixture of Bacillus coli, Streptococcus, and Micrococcus usually present.

The foregoing observations apply only to the bacteria which can be cultivated by ordinary means, and which grow in the presence of oxygen. The conditions around the appendix and in the general cavity of the peritoneum, however, favor the development of pure anaërobic bacteria, that is, bacteria

growing only when oxygen is excluded, as well as those growing indifferently in the presence or absence of this substance, hence, we should expect to find a considerable number of bacteria of that character in the exudate. There is every reason to believe this is the case, but the only extensive investigation bearing out the supposition is that of VEILLON and ZUBER (1898), who in 22 cases of gangrenous and fetid inflammation of the appendix, found pure anaërobes mixed with Bacillus coli and Streptococcus in 19 cases. They determined 5 different species of anaërobes, namely Bacillus fragilis, Bacillus ramosus, Bacillus perfringens, Bacillus fusiformis, and Bacillus furcosus, which they considered responsible for the gangrenous conditions of the appendix and for the intoxication. Finally, KROGIUS (1899) investigated 40 cases of appendicitis and peritonitis, isolating Bacillus coli 35 times, Diplococcus pneumoniae 21 times, Diplococcus intestinalis 6 times, Streptococcus coli gracilis once, Streptococcus pyogenes once, Bacillus pyocyaneus twice, and Proteus vulgaris once. In 7 cases he found only Bacillus coli; in 27 cases, a mixture of two or three different species; and in only 3 cases did the cultures agree with the results found in the original examination of the exudate. He also found 2 species of anaërobes which he identified as the forms described by Veillon and Zuber as Bacillus ramosus and Bacillus perfringens.

Investigations at the Johns Hopkins Hospital bear out in general the observations of Krogius and those of Tavel and Lanz, although some difference in results naturally arises from the different means employed for the identification of the bacteria. Nearly 1000 cases of disease in the appendix were examined bacteriologically, and the results obtained from the entire series may be briefly summarized by the study of 100 cases taken quite at random from the surgical records. Thus, in 100 cases of appendicitis in which either the lumen of the appendix, the peri-appendical tissues, or the general cavity of the abdomen was examined, the Streptococcus was found in only 16 cases, while Bacillus coli was present in 86. Bacillus lactis aërogenes was obtained in 10 cases, and members of the hog cholera group in 10 cases. Bacillus pyocyaneus was found in 2 cases, Bacillus fecalis alcaligenes in 3, Proteus vulgaris in 4, and Bacillus aërogenes capsulatus of Welch in 4 cases. In the majority of the cases, several species of organisms were isolated side by side, no matter whether the lumen of the appendix only was examined, or a localized peritonitis around the appendix, or a general inflammation of the serous membranes.

This brief summary of evidence makes it plain that the results obtained by different investigators on this subject are remarkably in accord, taking into consideration, of course, that the experiments were carried on in laboratories situated in countries widely separated by distance, and by bacteriologists, each

of whom employed a technic characteristic of his own laboratory. This striking agreement is accounted for by the fact that the conditions existing in the cecum and appendix are practically uniform, not only in the normal state of the organs, but even when the appendix is attacked by disease, or affected by the sequelæ to inflammation of it. We believe that the bacteria found in inflammatory conditions of the appendix are present in the normal intestinal tract, in all cases, except those rare, and not well authenticated instances, when appendicitis develops during the course of an infectious disease, a condition under which it has been stated that inflammation in the appendix may be set up by the organisms causing the original infection.

The cecum is the point which offers the very best conditions in the entire intestinal tract for the development of bacteria. In the stomach, organisms taken from the external world find a medium too highly acid for their rapid multiplication; in the small intestine, bacteria meet with insufficient pabulum to sustain life; therefore, it is only when the ileocecal valve is reached that we find conditions allowing an abundant development of micro-organisms. Here the reaction is favorable to the growth of bacteria, and sufficient undigested food is present to supply the nutriment necessary to their increase. Not only are plates taken from this region thickly crowded with colonies, but the greatest diversity of the forms cultivated is thus obtained, even under ordinary methods of isolation. By special technic the number of different bacteria found in the ileocecal region may be greatly increased, the number of bacteria in diseased conditions of the bowel, even in normal conditions, being always much augmented. By direct continuity, the bacteria spread from the cecum to the lumen of the appendix, in which the flora is identical with that of the cecum, so far as the varieties of micro-organisms are concerned. Hence, we have the most favorable conditions for the rapid development of bacteria through to the walls of the appendix, and the initiation of an inflammatory process, the limitations of which will be largely, although not entirely, determined by the virulence of the invading micro-organisms. The following species, in our estimation, are of greatest importance in initiating and extending inflammations of the appendix.

Streptococcus pyogenes (Rosenbach, 1884). — This organism can be isolated in only the minority of cases of appendicitis; nevertheless, it must be considered as of the greatest importance etiologically in the causation of the disease. It is especially associated with all cases of very severe infection, and is the usual cause of extensive and rapidly fatal peritonitis. It is, however, an organism somewhat difficult to cultivate artificially, even when present in pure culture, and when associated with other micro-organisms it is often overgrown by bacteria, which, although more viable, are not more virulent. Its colonies, which are small and almost transparent, are easily missed in examining both agar and gelatin plates. It is, however, a normal inhabitant of the intestinal tract, especially the portion of the cecum near the appendix. The S t r e p t o-

cocci are organisms possessing great variability in virulence, some species being capable of setting up rapidly fatal infections, while others, on the contrary, limit their pathogenic action to the production of local abscesses. It is impossible to estimate the virulence of any given species without extensive animal experimentation, but its demonstration in the pus of appendicitis must be invariably regarded as of the gravest prognostic significance. Morphologically, it is apt to grow in the tissues simply as a diplococcus or as short chains, only assuming its characteristic appearance after several generations on artificial media.

Bacillus coli communis (Bacillus coli, Migula, 1900).—This organism, originally discovered by ESCHERICH in the dejecta of infants, has since been shown by numerous observers to exist normally in the intestinal tract of man, as well as to have a wide and extensive distribution in Nature. Morphologically, it appears as a small plump bacillus, slowly motile, and possessing universal flagella. It is easily cultivated on all artificial media in the laboratory, growing abundantly as a whitish-yellow deposit on surface of solid media, always acidifying and coagulating milk, and breaking up the carbohydrates with the evolution of acid and gas, but not liquefying any proteid material. Originally supposed to be lacking in any pathogenic action, it has now been shown to possess considerable virulence—its various species differing greatly in this respect. Intravenous and intraperitoneal injection of large doses will kill smaller animals, and epidemics among them have been found, in many cases, to be caused by organisms differing in no essential particular from typical cultures from the intestinal tract of man. Certain species of Bacillus coli are especially prone to set up hemorrhagic peritonitis, and its pus-producing properties have long been recognized by observers who have found it in superficial abscesses, it having been originally described in this location as Bacillus pyogenes fetidus. It occurs in the pus of general peritonitis, in abscesses around the appendix, and in its lumen; sometimes in pure cultures and sometimes mixed with other micro-organisms. It is the most common secondary invader in all cases of appendicitis and peritonitis caused by the Streptococcus or by other organisms, and it may have an exalted virulence, when associated with other bacteria. Not only can Bacillus coli be obtained from those cases in which other and more virulent bacteria are found, but in a large number of cases it is the only species which can be isolated. In these cases the microscopic examination of the exudate is confirmed by the cultural experiments, and no evidence exists to show that the Streptococcus was present and was overlooked. Moreover, the type of the disease in these cases is much milder than in those in which Streptococci are found, the inflammation being often limited to the tissues in the immediate vicinity of the appendix, the resulting peritonitis being less extensive and less severe, besides manifesting a greater tendency to the formation of localized abscesses, with the production of large quantities of pus of a peculiarly fetid character.

Bacillus pyocyaneus (Pseudomonas aëriginosa, Migula, 1900).—This organism, known for a long time as the "bacillus of blue pus," occurs in the contents of the intestinal tract in a large number of cases, in so many, indeed, that it may be looked upon as a normal constituent of the alimentary canal. Morphologically, it is a very small, actively motile bacillus, characterized by its imparting to all culture media a green color, now known to be due to the production of the pigments fluorescin and pyocyanin. It is easily cultivated in all satisfactory media, and is separated from the other fluorescent organisms by its ability to break up proteid material, such as gelatin, casein, and blood serum, causing their complete liquefaction, and also by its inability to split up carbohydrate solutions. It is possessed of considerable pathogenic properties. When introduced into the genito-urinary system it may set up extensive infections, ascending from the bladder to the ureters and kidneys, or it may invade the body through a superficial lesion of the intestinal mucosa and originate a systemic infection with fatal outcome. Experimentally, Bacillus pyocyaneus can occasion an extensive hemorrhagic and fibrino-purulent inflammation of the peritoneum, rapidly causing death when introduced into the abdominal cavity of smaller animals. There is a small number of cases in which its relation to appendicitis has been well demonstrated, but it has been reported in this connection only a few times, and at the Johns Hopkins Hospital it is found to be one of the rarer pathogenic agents encountered in this disease. It is possible that it originates inflammatory processes in the appendix, but more probably it is a secondary invader of structures already diseased.

Bacillus proteus vulgaris (Bacillus vulgaris, Migula, 1900).—Proteus forms, including several distinct species, are normally found in the intestinal tract and occasionally, though rarely, in the pus around the appendix, as well as in peritonitis. They are easily recognized on the surface of agar and gelatin by their characteristic, spreading colonies. Experimentally, these bacilli can originate extensive inflammation of the peritoneum in smaller animals, resulting in death, but their pyogenic properties in man are still problematic. They are rarely met with alone in appendicitis, being usually associated with other bacteria. It is probable that they seldom initiate the morbid process in the appendix, but, like many other intestinal bacteria, they travel through a ruptured intestinal wall in the wake of more actively pathogenic agents.

Micrococcus pyogenes (Micrococcus aureus, Migula, 1900).—The Micrococci, or as they are usually called, the Staphylococci, occur but rarely in the inflammation of the peritoneal cavity. Morphologically, they appear as collections of spherical organisms, whose tendency to assemble in groups like bunches of grapes gave them their original appellation. They are easily cultivated artificially, but they may be recognized by their characteristic appearance under the microscope. Many species are possessed of great virulence, especially the "golden yellow coccus," and when associated with

other bacteria, especially the Streptococci, they may give rise to the collections of pus often seen about an inflamed appendix. They rarely cause a general peritonitis, but when present in pure culture, they generally confine their pathogenic action to the peri-appendical tissues.

Pneumococcus (Diplococcus) (Streptococcus) (Micrococcus pneumoniae, Weichselbaum, 1888).—In our opinion this organism plays a very doubtful rôle in the etiology of appendicitis and appendical peritonitis. It has been reported as present by a number of observers, notably by Krogius, who has contributed the most extensive series of cases; but the grounds for its identification are not always of the soundest. It closely resembles Streptococcus in its cultural reactions, as well as in its colonies on agar and gelatin, but it can be positively identified only by the definite demonstration of a capsule, or by positive criteria; organisms which resemble the Pneumococcus should usually be classed as Streptococci. In an experience extending over a decade in the laboratory of the Johns Hopkins Hospital, there have been 3 cases in which Micrococcus pneumoniae was undoubtedly the cause of peritonitis, and not one of these was the result of appendicitis. The Pneumococcus, moreover, does not occur ordinarily in the contents of the cecum. Taking all these facts into consideration, its importance in the etiology of appendicitis becomes minimized. In rare instances it may reach the appendix from the lungs, being carried there by the blood stream, and in that event it may cause inflammation of the organ.

Bacillus lactis aërogenes (Bacterium aërogenes, Migula, 1902).—This organism is the capsulated bacterium normally present in the intestinal tract of all individuals. Its cultural reactions are identical with those of the Bacillus coli, with which it is usually associated. Morphologically, it is a thick, plump bacillus—non-flagellated—the growths of which on ordinary media are viscid and stringy; it is frequently found in the pus about an appendix, or in the general cavity of the abdomen, but it possesses no pathogenic properties for man, although in enormous doses it has a fatal effect on animals. When isolated in typhlitis it has no significance.

Bacillus alcaligenes (Migula, 1900).—This organism, originally described by Petrevsky, as Bacillus fecalis alcaligenes, is present in practically every individual, although in relatively small numbers. It is of importance chiefly from its great resemblance to Bacillus typhosus, from which it is distinguishable only by its failure to act upon any carbohydrates, and by its intense alkali production in litmus milk. Like Bacillus lactis aërogenes, it is of no pathogenic importance, as its cultures are quite devoid of toxic action.

Bacillus of the Hog Cholera Group.—Organisms belonging to this group, originally described as intermediate in character between Bacillus typhosus and Bacillus coli, were early recognized by Welch, Salmon, and Smith in this country, and by numerous observers abroad. The

number of species included in this group is very large, and all of them are possessed of marked pathogenic properties. Among them may be mentioned Bacillus suipestifer, or the Hog cholera bacillus, Bacillus enteritidis of GAERTNER, Bacillus Breslaviensis of GAFFKY and PAAK, Bacillus morbificans bovis of BASENAU, the various paracolon bacilli isolated in France and in America, and the "paratyphoids" obtained in Germany. Members of this group occur frequently in the normal intestinal tract, and are present in about 10 per cent. of all cases of appendicitis. Without extensive investigation, it is difficult to determine to which particular species any given organism should be assigned, and it is correspondingly difficult to estimate with any certainty the rôle which they take in appendicitis. Their pathogenic action, however, is very marked, and their importance is probably much greater than is generally supposed.

Bacillus aërogenes capsulatus (Bacterium Welchii, Migula, 1900).—This strictly anaërobic organism, originally described by WELCH and NUTTALL as the "Gas bacillus" (Bacillus aërogenes capsulatus), has since been recognized in a number of countries as having a wide distribution. It was described in Germany, by FRÄNKEL as Bacillus phlegmones emphysematosae, in England, by KLEIN as Bacillus enteritidis sporogenes; and the organism described as Bacillus perfringens by VEILLON and ZUBER is evidently the same species. The recognition of a relationship between this organism and appendicitis has already been mentioned in the consideration of Veillon and Zuber's investigations. It has been shown by Welch to have an almost universal distribution in the intestinal tract of man, as well as in that of most of the lower animals, and its constant presence in the lumen of the appendix has been demonstrated by YATES. It is, however, an organism requiring special methods of isolation in pure culture, although its morphology as a long, straight bacterium, surrounded by a capsule and retaining Gram's stain well, frequently demonstrates its presence in a mixture with other organisms. It acts as a cause of general peritonitis very rarely, and is usually considered to invade only tissues already diseased. It has, however, been found in a number of cases of appendicitis, including one associated with a severe and rapidly fatal case of general peritonitis.

BIBLIOGRAPHY

FROM KROGIUS.

ACHAUD ET BROCA: "Bactériologie de vingt cas d'appendicite suppurée." Bull. et mém. de la Soc. méd. des hôpit. de Paris, 1897, p. 442.

CHAUVEAU: "Sur la septicémie puerpérale expérimentale." Lyon méd., 1882, tom. 41, p. 272.

CLADO: "Appendice cœcal, etc." Mém. de la Soc. de biol., 1892, p. 133.

DEAVER: "Remarks upon the differential diagnosis, pathology, and treatment of appendicitis." Ann. Surg., 1898, vol. 27, p. 303.

FRÄNKEL, E.: "Zur Ätiologie der Peritonitis." Münch. med. Wochenschr., 1890, p. 23.

HARBITZ: "Om appendicitens pathologiske Anatomi og Aetiologie." Norsk Mag. for Laegevidenskaben, 1896, p. 461.

JALAGUIER: "Résultats de l'examinen bactériologique du pus d'une péritonite généralisée par perforation de l'appendice iléo-cœcal." Bull. et mém. de la Soc. de chir., 1892, tom. 18, p. 391.

KÖRTE: "Erfahrungen über die chirurgische Behandlung der allgemeinen eitrigen Bauchfellentzündung." Arch. f. klin. Chir., 1892, Bd. 44, p. 612.

KROGIUS: "Om appendiciternas bakteriologi." Finska Läkaresällskapets handlingar, 1899, p. 1198.

MALVOZ: "Le bacterium coli commune comme agent habituel des péritonites d'origine intestinale." Arch. de méd. expérim. et d'anat. path., 1891, p. 593.

PAWLOWSKY: "Beiträge zur Ätiologie und Entstehungsweise der akuten Peritonitis." Centrbl. f. Chir., 1887, p. 881.

— "Zur Lehre von der Ätiologie und den Formen der akuten Peritonitis." Virchow's Archiv, 1899, Bd. 117, p. 469.

PRÉDOHL: "Untersuchungen zur Ätiologie der Peritonitis." Münch. med. Wochenschr., 1890, p. 22.

TAVEL AND LANZ: "Ueber die Ätiologie der Peritonitis." Mittheil. a. klin. u. med. Inst. der Schweiz, 1893, I. Reihe, 1, Heft.

VEILLON ET ZUBER: "Recherches sur quelques microbes strictement anaërobies et leur rôle en pathologie." Arch. de méd. exp. et d'anat. pathol., 1898, p. 517.

WEICHSELBAUM: "Der Diplococcus Pneumoniæ als Ursache der primären akuten Peritonitis." Centralbl. f. Bakteriologie, 1888, p. 33.

WELCH: "The bacillus coli communis: the conditions of its invasion of the human body, and its pathogenic properties." Med. News, 1891, vol. 59, p. 669.

CHAPTER XII.

PATHOLOGY.

ACUTE CATARRHAL APPENDICITIS. ACUTE DIFFUSE APPENDICITIS. CHRONIC ULCERATIVE AND PURULENT APPENDICITIS.

Acute Appendicitis.

It is only by means of observations made at operations and at autopsy, accompanied by examinations of each case in detail, that we can construct a general picture representing the pathological changes taking place in inflammations of the appendix in their beginning and development, as well as the relation between the etiology of appendicitis and its pathological anatomy. In the course of a routine examination of all specimens, many important conditions are discovered, and the pathological changes underlying the causation of an attack of acute appendicitis become apparent.

The custom, which has become general during the last few years, of early operation in appendicitis, as well as of operation *à froid*, affords the opportunity essential to studying these various lesions in their inception, their development, and their final outcome. The views expressed and the conditions described in the following pages embody results obtained from a study of all the material furnished by the gynecological and surgical departments at the Johns Hopkins Hospital, as well as by its postmortems, and by a large number of interesting, and sometimes unique specimens, obtained from different parts of the country.

The material from the gynecological operating room consisted of 300 specimens, all of which were carefully examined both macroscopically and microscopically. The appendices removed in the surgical operating room, more than 600 in number, were all submitted to careful examination of the gross specimen, and the majority were sectioned and studied histologically. The specimens obtained at autopsies were examined, in most instances, only macroscopically.

A classification of the various forms of inflammation of the appendix is somewhat difficult, for there is no definite line dividing one from another. The following classification, however, dealing first with the change occurring in the appendix itself, then with the peritoneal involvement, and, finally, with the various widespread complications, seems most simple from a pathological standpoint, while at the same time it is in accordance with the clinical varieties.

Acute Appendicitis.
Subacute and chronic appendicitis.
Peritonitis.
Metastatic affections.

Acute appendicitis may be further divided into the following groups:

(*a*) Catarrhal.
(*b*) Diffuse.
(*c*) Purulent.
(*d*) Gangrenous.
(*e*) Perforative.

ACUTE CATARRHAL APPENDICITIS.

By this is meant an inflammatory process affecting only the mucous lining of the appendix throughout the attack, and not involving the deeper layers. In all cases of acute appendicitis there is probably an early stage in which the reaction is limited to the mucous membrane, but in the majority of cases this is only momentary, and so speedily gives way to a general involvement of all the coats that it cannot be considered as a well-defined era in the progress of the attack, and therefore is not of practical importance, according to our present knowledge. There is, however, a certain number of cases in which a mild infection induces definite inflammatory changes in the mucosa alone, although these are often associated with a congestion of all the blood-vessels supplying the appendix. Moreover the appendix, when it has once been the seat of a diffuse inflammation, may readily be excited to subsequent acute attacks in which the active process is sometimes limited to the mucosa. Macroscopically, in acute endo-appendicitis the appendix appears slightly thicker than normal, and owing to a more or less general edema it may be somewhat rigid. The superficial blood-vessels, both those immediately beneath the peritoneum and those between the subperitoneal fibrous layer and the muscle, are prominent and tortuous, presenting a characteristic arborescent appearance. There is not, however, the diffuse redness of inflammatory tissue, nor is there any loss of the normal sheen of the serous covering (see Fig. 3, plate I). On sectioning the

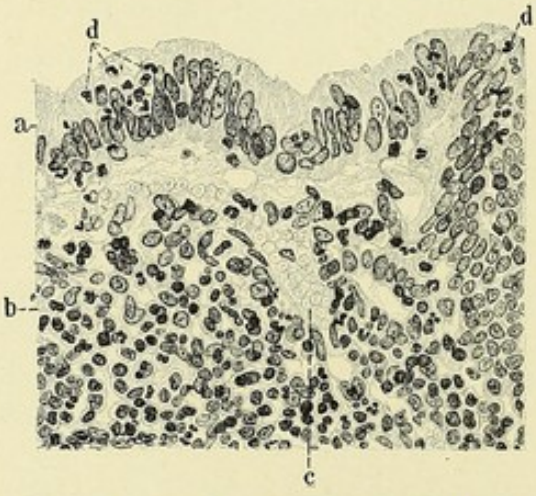

FIG. 157.—SECTION FROM THE SPECIMEN REPRESENTED IN FIG. 3, PLATE I. ACUTE CATARRHAL APPENDICITIS. MAGNIFIED 350 TIMES.

The section shows a small portion of the surface epithelium (*a*) with part of a gland on the right-hand side, and the membrana propria (*b*) containing a dilated capillary (*c*). The epithelium and membrana propria are moderately infiltrated with polymorphonuclear leucocytes (*d*).

appendix its canal is found to be patent, and, as a rule, is of uniform calibre. It contains a little muco-purulent fluid. The mucosa is edematous, diffusely injected, and granular in appearance. The tendency to a hemorrhagic infiltration of the tissue, common to all forms of appendicitis, is not wanting in the catarrhal variety. I have never seen distinct ulceration in this class of cases, and am inclined to believe that when there are ulcerations sufficiently marked to be detected with the naked eye, more or less involvement of the deeper tissues will usually be found.

Histologically, the surface epithelium, which is generally intact,

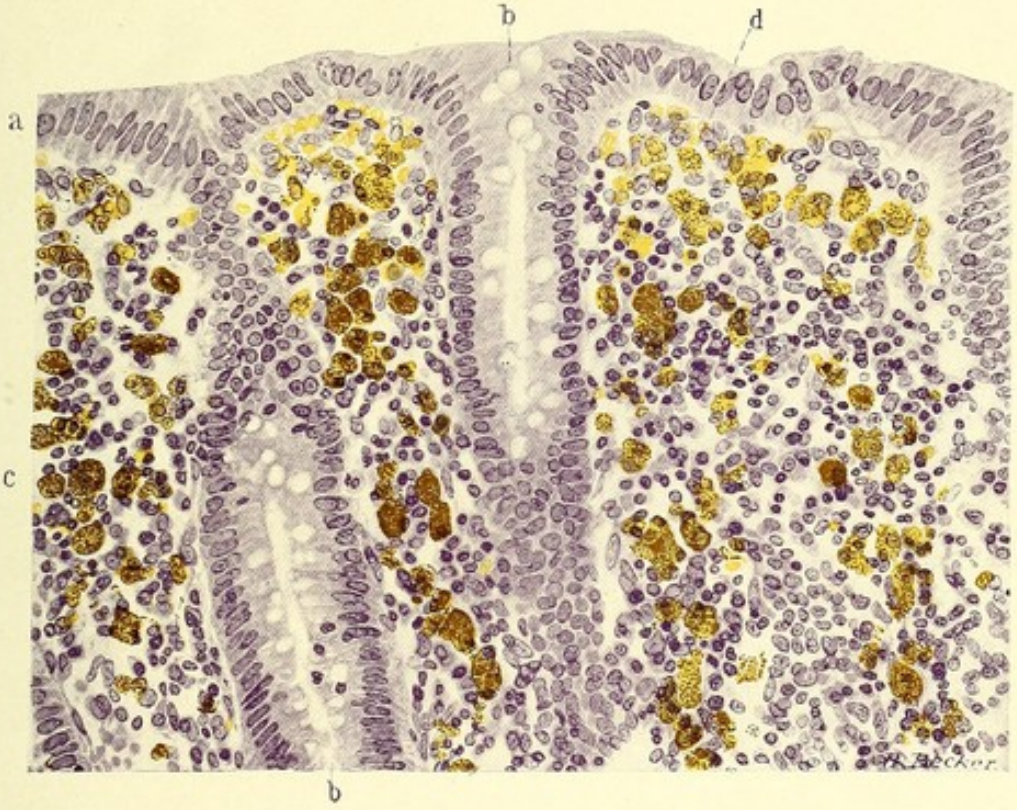

FIG. 158.—DEPOSIT OF PIGMENT IN THE MUCOSA. MAGNIFIED 400 TIMES.

a, Normal epithelium; *b*, glands; *c*, membrana propria infiltrated with a few red blood corpuscles (*d*) and containing an abundant deposit of brown granular pigment, partly contained within cells. (Gyn. Path., No. 4871.)

stains rather cloudily, and is infiltrated with leucocytes and occasional red blood cells. Slight exfoliation of the epithelium is frequently found, but the loss is soon repaired by cells derived from the surrounding epithelium, and especially from the neighboring glands. The gland epithelium, which normally multiplies chiefly by division of the cells lining the basal portion, shows great activity near the surface as well as deeper down, and from there the cells which repair the denuded surface are chiefly derived. The increased activity of the gland epithelium is also seen in the abundant mucous secretion. The stroma of the mucosa is hyperemic, edematous, and moderately infiltrated with leucocytes (Fig. 157).

The lymph nodes are swollen, the germ centres prominent, and the latter often contain a very large number of dividing nuclei. The endothelium of the capillaries and the reticular cells of the nodes are swollen, and degenerative changes are occasionally present. The submucosa, and the muscular coats of the appendix are perfectly normal, and its peritoneal covering, apart from the dilatation of its blood-vessels, is unaltered.

Simple catarrhal appendicitis may undergo complete repair, and in cases which presented clinical evidence of repeated attacks, the appendix, when removed in the interval, may appear quite normal. In other cases the presence of blood pigment in the mucous membrane is the only evidence of a former pathological process (see Fig. 158); or, again, the interglandular tissue is more fibrous than normal, and the vessel walls appear thickened.

Endo-appendicitis is a predisposing factor in the formation of enteroliths in the appendix, and a frequent cause of attacks of the more severe forms of appendicitis. The swelling of the mucosa tends to obstruct the lumen at the cecal orifice, causing more or less stasis of the secretions and whatever foreign material may be in the canal. This, as will be seen later, may be the starting-point in the formation of a concretion, and it also favors bacterial activity.

ACUTE DIFFUSE APPENDICITIS.

In the majority of cases of appendicitis which give rise to definite symptoms, the inflammatory process very early extends beyond the mucosa, and there is a general involvement of all the coats. In the gross specimen, the difference between an inflammation limited to the mucosa and the diffuse process is at once evident. In diffuse inflammation, the appendix shows a notable increase in all of its dimensions, and instead of the normal, pale, flaccid organ, of about the thickness of a goose quill, it may be twice the usual length, and is often as thick as the index finger, the tip being frequently slightly clubbed. The appendix is tense and rigid, and exceedingly hyperemic, the blood-vessels standing out in high relief (see Figs. 159 and 160). Its color is a diffuse bright red or dark mahogany, mottled with subperitoneal extravasations of blood and often presenting light yellowish, or greenish-yellow areas due to localized foci of suppuration or necrosis (Fig. 1, Plate III). These necrotic areas are usually surrounded with a deeply injected zone. The canal contains a muco-purulent, or purulent exudate, often mingled with blood. The mucosa is swollen, intensely injected, and hemorrhagic; its surface may be smooth, but is usually granular, and often shows irregular folds and furrows, or hyperemic wart-like excrescences (see Fig. 161). Frequently there are more or less extensive erosions. The ulcers may be small and punched-out in appearance (Fig. 1, Plate I), but more commonly they have ragged, irregular margins. They may be

single or multiple, and they vary from slight superficial abrasions to extensive losses of tissue comprising a large portion of the mucosa and involving the submucosa and muscular coats. External evidence of deep ulceration is often seen in slightly elevated, dark colored, granular areas on the surface. Erosions are produced in various ways: by the mechanical action of concretions and foreign bodies, by the direct action of septic material upon the surface of the mucosa, by the necrosis of an infected lymph follicle, or by the extension into the lumen of an abscess focus originating in the deeper tissues. In the speci-

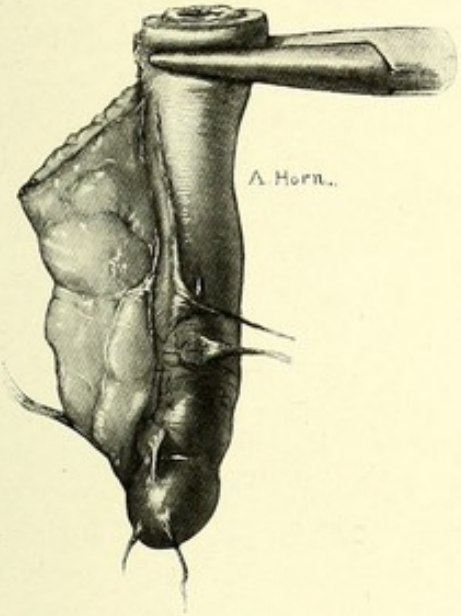

FIG. 159.—ACUTE APPENDICITIS. SEROSA DEEP MAHOGANY COLOR, DUE TO HEMORRHAGIC INFILTRATION. ADHESIONS, PRODUCING SLIGHT KINK NEAR THE TIP. (GYN. PATH., NO. 5606.)

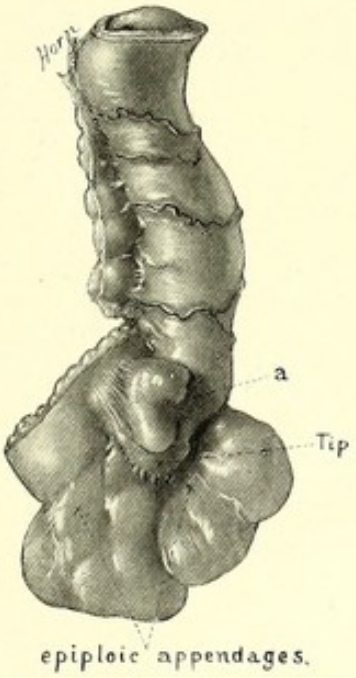

FIG. 160.—ACUTELY INFLAMED APPENDIX, SHOWING GREATLY DILATED BLOOD-VESSELS. TIP SURROUNDED WITH LIGHT ADHESIONS (*a*). (SPECIMEN FROM T. S. CULLEN.)



FIG. 161.—ACUTE APPENDICITIS. THE INFLAMMATION LIMITED TO THE DISTAL HALF OF THE APPENDIX.

The contrast between the smooth pale normal mucous membrane and the thickened, hemorrhagic, inflamed portion is very striking.

men referred to above, it appears as if the multiple punched-out ulcers had resulted from the breaking down of a large number of infected lymph follicles, each ulcer being in the centre of a system of Lieberkühn's crypts, which show the characteristic arrangement of these structures around the normal lymph nodes (see "Structure of the Appendix," Chap. VI). Unfortunately this specimen was lost after the sketch had been made, so that it could not be studied histologically.

In acute appendicitis ulcerations are almost invariably found when inspissated fecal material or concretions are present in the canal, and they correspond in position to the location of the concretion, or are distal to it. This point will

be further considered in discussing the pathogenesis of concretions and foreign bodies.

Purulent Appendicitis.—There is no sharp dividing line between purulent and non-purulent appendicitis, and at any moment a non-purulent process may become purulent. The nature of the inflammatory reaction is chiefly due to the virulence of the infection. A mild infection is commonly not suppurative, while a severe infection induces suppuration, unless the virulence of the infective material is so great that a fatal toxemia results before the tissue has had time to react. In such cases the toxic effects are so overwhelming that after the first early reaction the resistance of the organism is paralyzed. On the other hand, if there is profound degeneration of the tissues depending upon some mechanical or chemical factor, the bacterial invasion may result in gangrene of the part. In suppuration there is, first, necrosis of the tissue invaded, and, second, the reaction of the tissue producing cells which form the purulent exudate. To produce this second phenomenon a certain local reactional energy is necessary, as well as the power of resistance of the organism as a whole. It may, therefore, be said with every reason that suppuration is an evidence of the ability of the tissues to offer resistance to the invasion of the infective agent. Even where necrosis goes on and gangrene develops, the surrounding tissue still tends to react by eliminating the dead part, and suppuration ultimately appears.

One of the chief factors promoting suppuration is the existence of some anterior lesion which tends to obstruct the canal of the appendix. The acute swelling of the tissues at the outset of an attack results in complete closure of the stenosed area, and in consequence there is a damming back of the inflammatory exudate. The defective drainage, associated with the abnormal condition of the tissue, favors the development and exalts the virulence of the microorganisms, and finally induces suppuration. The increased tension as the appendix becomes more and more distended, may be sufficient to overcome the obstruction, or if the tip of the appendix has become adherent to the intestine or some other hollow viscus, a fistulous opening may form at this point. In either case drainage is re-established and may be followed by resolution. In other instances, the purulent exudate is retained within the appendix, and a large pus sac results. Besides such cases, in which the purulent process is general, there are others in which there are small localized foci of suppuration. It is not uncommon to find multiple miliary abscesses in acute inflammation of the appendix. These may originate in the lymph glands, as in a case described by FENGER, or in any of the tissues of the appendix wall. They are probably due to the direct action of the bacteria upon the tissue, and in some cases collections of bacteria have been demonstrated in the centres of these areas. These foci of suppuration are often found associated with erosions on the surface of the mucosa. In the fresh specimen they appear as minute, yellow, or greenish-yellow areas, which are in sharp contrast with the surrounding, intensely injected tissue.

A typical case is seen in Fig. 1, Plate III. The specimen was removed by T. S. CULLEN, eight days after the onset of an attack of acute appendicitis. The appendix, which is quite free from adhesions, is swollen, and deeply congested, while at two points abscess foci are seen immediately beneath the serosa, in imminent danger of rupture. A longitudinal section of the same specimen (Fig. 162) shows complete necrosis of the mucous membrane, and the two abscess foci opening into the canal. A fine perforation also extends to the mesenteric border.

Gangrenous Appendicitis.—This condition is essentially characterized by the death and putrefaction of the tissues, and is due to the action of microbes

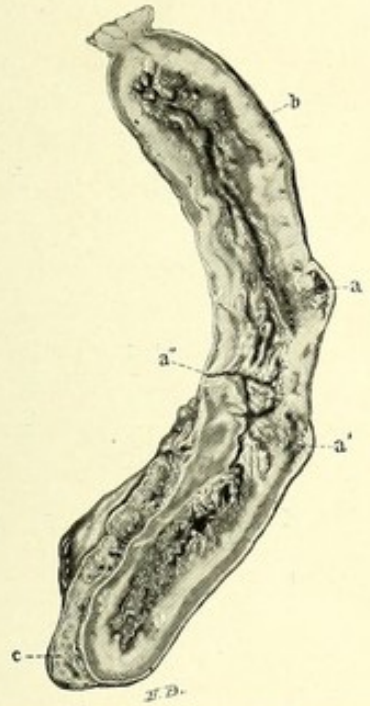

FIG. 162.—ACUTE APPENDICITIS. APPENDIX LINED WITH NECROTIC MATERIAL. MAGNIFIED 1.5 TIMES.

At a and a' are abscess foci, and at a'' a pin-hole perforation. C indicates the hypermic, edematous mesentery. There is no stricture and no concretion.



FIG. 163.—APPENDIX ALMOST TOTALLY GANGRENOUS AND SURFACE PARTLY COVERED WITH LARGE PLAQUES OF GREENISH-YELLOW LYMPH. NO EVIDENCE OF STRICTURE NOR CONCRETIONS. (SURG. PATH., NO. 3232.)

upon tissue which has been subject to some influence inducing partial or complete degeneration (see Fig. 163). Gangrene is related to suppuration by numerous transitions, the differentiation being sometimes scarcely definable. While it may be doubted if any micro-organisms can affect perfectly healthy tissue, there are some which, attacking tissue apparently normal, have the power to cause its death and subsequent putrefaction. The greater number of organisms, however, can only act upon tissue which is profoundly altered. The most important factors inducing gangrene are those which act by obstructing the circulation, and so producing a local ischemia. The interruption to the blood current

may occur in one of the small arteries which supplies only a limited portion of the appendix; or the main artery may be involved; or, in some instances, both the vein and artery, in which case the entire appendix becomes gangrenous. It is not uncommon to find the appendix represented by a dark greenish-black mass, which has separated from its cecal attachment and lies free in the abdominal cavity. The obstruction to the circulation may be caused by thromboangeitis, twists, angulations, and compression by adhesions, or by a hernial ring. Localized areas of gangrene may also be produced by the pressure of concretions. Mechanical factors may, in themselves, be sufficient to cause complete obstruction, as, for instance, when the appendix becomes strangulated by means of adhesions, etc. More commonly, however, a partial obstruction occasioned by them, is rendered complete by sudden swelling of the appendix, taking place at the outset of an acute inflammatory attack. It is only in this way that a concretion is able to produce gangrene of the portion of the wall with which it is in contact. The pressure of the concretion, added to the acute edema which accompanies the early inflammatory changes, compresses the small vessels, and produces local ischemia with subsequent gangrene.

When gangrene is the result of interference with the circulation by means of strictures, twists, or adhesions, the entire appendix, or the portion beyond the obstruction, is involved; and, as mentioned above, a similar result follows thrombosis of the main blood-vessels. Thrombo-arteritis affecting one of the branches may be followed by a localized area of necrosis, notwithstanding the rich arterial plexus in the submucosa, as it has been found that the intestinal vessels are unable to compensate circulatory obstruction of a degree readily compensated in other areas. Most frequently, the tip of the appendix is affected (see Figs. 1 and 2, Plate II), but it is not unusual to find several distinct areas of gangrene both in the proximal and the distal portions of the appendix. Such a case is shown in Fig. 3, Plate II, where the surface of the appendix is mottled bright red and green, and at no point, from the base to the tip, is the entire circumference free from gangrene. In some instances, only the proximal end becomes gangrenous, in which case the necrosis may be determined by the presence of a concretion; or, the gangrene may be of the annular variety, and probably due to thrombosis of the separate arterial branch which sometimes supplies this region. In such a case there may be a complete separation of the fairly normal appendix from its cecal attachment. In other cases, again, the outer coats may entirely slough off, leaving an intact mucous membrane. Such a case is described by Fowler. The rôle of bacteria in the production of tissue necrosis is an important one, and in cases where gangrene of the appendix is partly due to mechanical influences, the heightened virulence of the contained bacteria, in the presence of the lessened vitality of the tissue, undoubtedly promotes the destructive process. The action of bacterial poison may cause gangrene even in the absence of obstruction to the circulation, the degenerative process being then most pronounced in the interior, where the infective substance is in direct contact

DESCRIPTION OF PLATE II.

FIG. 1.—Acute appendicitis, thirty-six hours. The appendix slightly enlarged, tense and injected. At the tip a small gangrenous area surrounded by a dark colored hemorrhagic area. No adhesions. (G. P. Muller, Germ. Hosp., Phila.)

FIG. 2.—Acute appendicitis. The appendix swollen and congested. The gangrenous distal third bent at an obtuse angle by a band of adhesions. (H. A. Kelly.)

FIG. 3.—Gangrenous appendicitis, forty-eight hours. The appendix greatly enlarged, total gangrene of the distal third, and irregular areas of gangrene in proximal portion. Near the middle the canal is distended with a round, hard concretion. Masses of fibrin and a few old adhesions on the surface. (W. S. Halsted.)

DESCRIPTION OF PLATE II.

FIG. 1.—Acute appendicitis, thirty-six hours. The appendix slightly enlarged, tense and injected. At the tip a small gangrenous area surrounded by a dark colored hemorrhagic area. No adhesions. (G. P. Muller, Germ. Hosp., Phila.)

FIG. 2.—Acute appendicitis. The appendix swollen and congested. The gangrenous distal third bent at an obtuse angle by a band of adhesions. (H. A. Kelly.)

FIG. 3.—Gangrenous appendicitis, forty-eight hours. The appendix greatly enlarged, total gangrene of the distal third, and irregular areas of gangrene in proximal portion. Near the middle the canal is distended with a round, hard concretion. Masses of fibrin and a few old adhesions on the surface. (W. S. Halsted.)



Fig 1



Fig 2

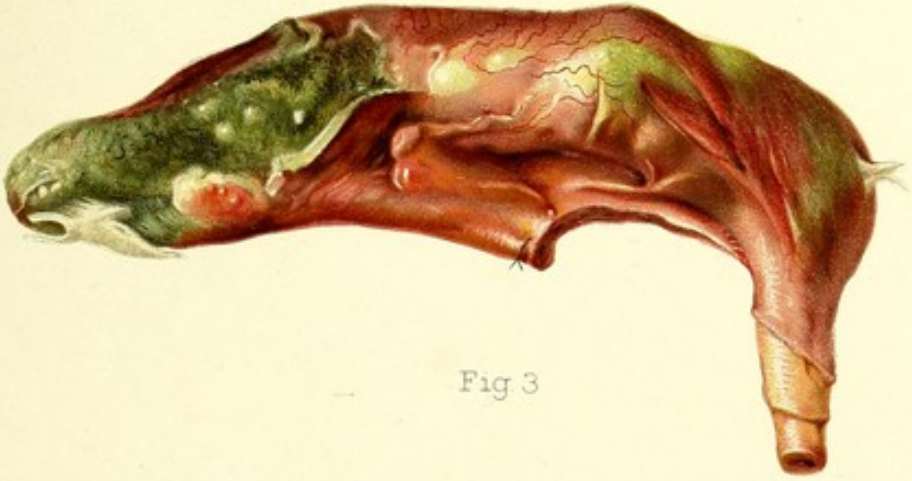

Fig 3

Horn and Becker, fec.

Ketterlinus, Lith. Phila

with the tissues. It is particularly the putrefactive organisms contained in decomposing fecal material which produce this condition. An excellent example is seen in the case illustrated in Fig. 164. Here the mucosa, as a whole, is gangrenous, but apart from the perforation at the tip the gangrenous process has not involved the deeper layers, which show an intense, purulent, inflammatory reaction.

The mesappendix in acute inflammation becomes greatly thickened, owing to the dilatation of the blood-vessels, and the infiltration of the lax areolar tissue with a serous and cellular exudate. The tissue also becomes exceedingly

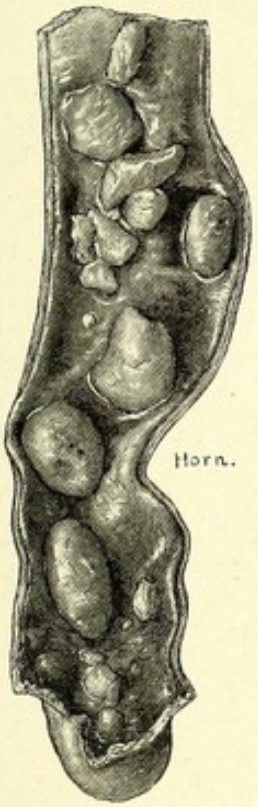

Fig. 164.—Total Gangrene of the Interior of the Appendix Associated with the Presence of Fecal Masses. (Specimen from J. M. T. Finney.)

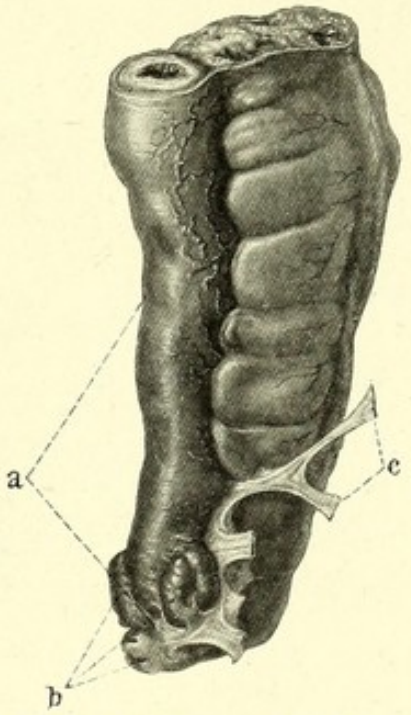

Fig. 165.—Acute Appendicitis with Thickened Hemorrhagic Mesappendix.

The distal two-thirds of the appendix (*a*) is hemorrhagic, and also the small masses of fat (*b*). Adhesions are found at *c*. (Gyn. Path., No. 6252.)

friable, so that the ligature, although placed with the utmost care, often tears directly through it. The color is usually reddish, often a dark red, from the presence of hemorrhage (see Fig. 165). In the presence of old adhesions or twists it is evident that the acute edema of the mesappendix could readily induce partial or complete occlusion of the large blood-vessels; also, in the case of advanced arterio-sclerosis of the main blood-vessel, the circulation may be greatly impeded, and even completely obstructed by the pressure of the infiltrated tissue.

Histology of Acute Diffuse Appendictis.—The whole appen-

dix shows a greater or less degree of inflammatory reaction. At the outset, there is a general congestion and edema, especially affecting the mucous, submucous, and peritoneal layers. The mucosa shows, usually, some degeneration of the surface epithelium, and, as a rule, of the gland epithelium. In some instances these changes are insignificant, consisting in a slight swelling and cloudiness of the cells; while in others a large portion of the epithelium is destroyed. This is sometimes due to effusion of blood, which, lifting up the epithelium from the underlying tissue, deprives it of its nutriment; leucocytes, chiefly polymorpho-nuclear, are found in variable numbers throughout the epithelium and in the exudate upon the surface. The glands, besides showing degenerative changes in the epithelium, are greatly compressed, and sometimes destroyed by the acute swelling of the interstitial tissue. The changes in the lymph nodes are often marked, the blood capillaries are congested, and the endothelial elements swollen and proliferating; leucocytes are present in variable numbers, and there are often large phagocytes containing cellular detritus, usually fragments of leucocytes; occasionally the centre of the follicle is degenerated, and it may even open upon the surface of the mucous membrane. The interglandular tissue, as a rule, shows the most marked changes. It is greatly congested, and permeated with a serous effusion, extravasated blood, and a more or less abundant cellular exudate. Polymorpho-nuclear cells usually predominate, but there is also an increase in the number of small round and plasma cells. In some instances, eosinophiles make up a large proportion of the infiltrating cells. Abrasions and ulcerations are usually found, under the microscope, where the inflammation is at all severe, although they may not be apparent to the naked eye. They occur most frequently in the depressions between the mucous folds, the point where the lymph nodes commonly reach the surface (Figs. 166 and 167). The surface of the erosion is covered with



Fig. 166.—Acute Diffuse Appendicitis. Magnified 40 Times.

An erosion (*a–b*) in the crevice between two folds of mucous membrane. The mucosa on either side of the ulcer is edematous and infiltrated, its surface being bathed with a purulent exudate. At the base of the mucosa there is a small abscess focus (*d*); *c* indicates a lymph follicle. (Specimen from L. M. Hektoen.)

mucus and fibrin intermingled with cellular detritus; underneath there is the usual acute granulation tissue. In the periphery of the eroded area there are often areas of canalized fibrin, and vascular changes are observable extending some distance away. Purely leucocytic, fibrinous, or hyaline thrombi, partially or completely filling the lumen of the vessel, are frequently seen, and may be found in one or more of the capillaries or small vessels in most cases of acute appendicitis, more especially in the vicinity of erosions. Thrombi, showing the characteristic arrangement of fibrin and granular material and containing a variable number of cellular elements, are also seen, particularly in the larger vessels of the subserous tissue.

Purulent thrombo-arteritis and thrombo-phlebitis occur in some cases. The vessels most frequently affected are those of the submucosa in the region of an erosion, or the comparatively large vessels coursing between the external muscular coat and the peritoneum. In exceptional instances there are acute changes, acute angeitis or thrombo-angeitis, in the large vessels contained in the mesappendix. Where total gangrene of the appendix takes place without any external constriction of the vessels, it may be assumed that in the majority of instances thrombosis of one or more of the large vessels has occurred. It is difficult, however, to demonstrate such a condition in specimens removed at operation, as, owing to the use of the cautery or the ligature, or from the effect of clamps, this portion of the specimen is usually unsatisfactory for careful study. At autopsy, however, it is not rare to find thrombosis and purulent thrombo-phlebitis involving the appendical vessels and their tributaries, and such cases have also been demonstrated at operation. The lymph channels of the appendix and its mesentery in acute inflammation are often found greatly

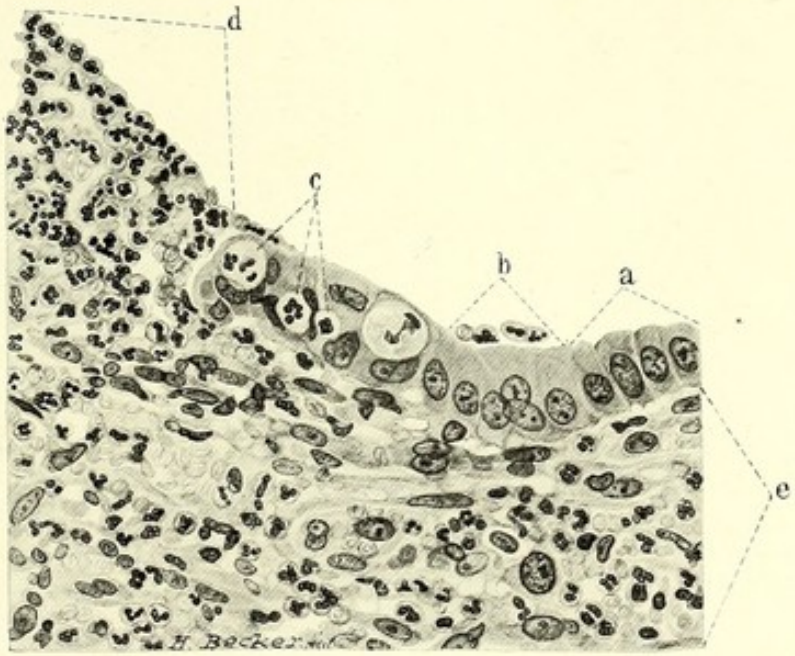

FIG. 167.—Higher magnification of the margin of the ulcer seen in the preceding figure. The epithelium at *a* is normal; at *b* the cells are swollen and cloudy, and from here to the edge of the ulcer the epithelium shows more pronounced degenerative changes and is infiltrated with leucocytes (*c*). The surface of the ulcer (*d*) consists of a mass of fibrous leucocytes and red blood cells. More deeply the tissue is composed of connective tissue, with abundant large oval and fusiform cells, dilated capillaries, and a diffuse infiltration of leucocytes and red blood cells. Magnified 400 times.

distended with lymph corpuscles, and various grades of lymphangitis may be observable.

A case of unusual interest in respect to the condition of the lymphatics has been given me by T. S. Cullen, who removed the appendix from a child eight years old on the fourth day of a rather mild attack of appendicitis. Recovery was uneventful, except for an attack of acute tonsillitis, which developed on the fourteenth day. The appendix was hyperemic and somewhat tense. There was a slight, viscid, fibrinous exudation upon the surface, but no adhesions and no evidence of peritonitis. Microscopic examination showed a diffuse acute inflammation without evident ulceration. The chief interest in the specimen centres in the acute lymphangitis. In all parts of the appendix, but especially in the serous coat and in the mesentery, the lymphatics are engorged with cells, mostly

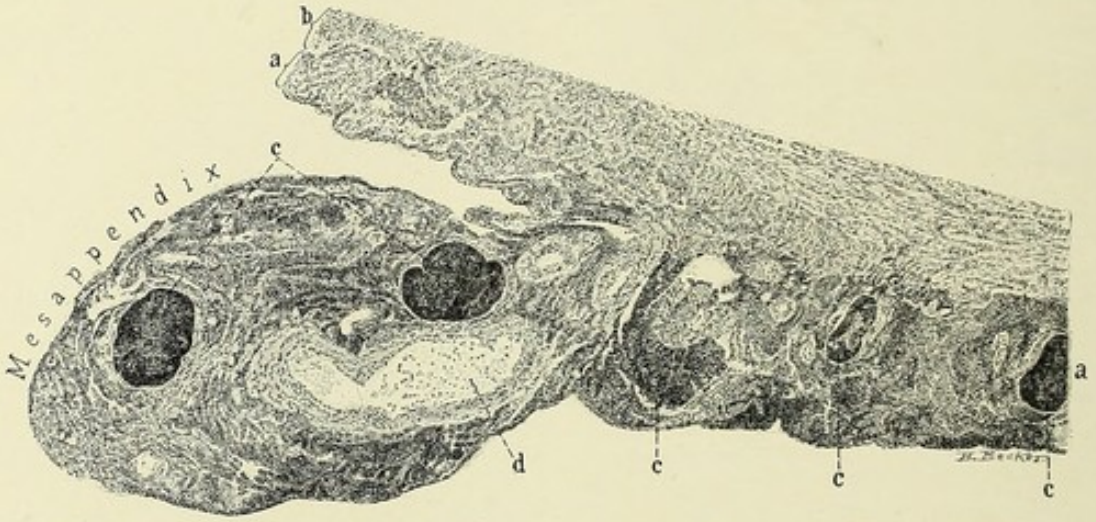

Fig. 168.—Acute Appendicitis, with Severe Lymphangitis. A Section Showing the Peritoneal Coat and Mesentery. Magnified 32 Times.

On the right-hand side of the figure the peritoneum (*a*) is thickened and densely infiltrated. On the left side the inflammatory reaction is less intense, and at *b* the edge of the external muscular coat is seen. The mesappendix is everywhere densely infiltrated and the lymphatics (*c*) in the mesentery and in the appendix wall are conspicuously distended.

lymphocytes, although abundant polymorpho-nuclear leucocytes are sometimes present, and the vessel walls are infiltrated with leucocytes (see Fig. 168). At several points organizing thrombi are found (see Fig. 169). Two or three of these occupy the large lymph sinuses in the periphery of the solitary follicles. They are formed of large, oval, endotheloid cells, an abundant intercellular substance, and leucocytes.

The submucosa in acute diffuse appendicitis usually shows a severe grade of inflammation. The blood-vessels are engorged, the tissue is highly edematous, and there is a general cellular infiltration consisting of polymorpho-nuclear, small round, and plasma cells. The connective tissue cells are swollen and actively proliferating. When ulceration occurs, the submucosa is almost invariably involved. Miliary abscesses originating in lymph nodes, as a rule,

involve this layer, and very often abscess foci develop primarily in this region.

The circular and longitudinal muscular coats share to a variable extent in the inflammatory reaction. In many instances, the only evidence of reaction is found along the course of the blood and lymph vessels in the hiatuses of the musculature. There is usually considerable leucocytic infiltration of these areas, and connective tissue proliferation. A purulent inflammation confined to the mucous and submucous layers may extend outward by way of these structures, and cause an acute peritoneal reaction, or even a perforation, without involvement of the musculature. However, as a rule, in suppurative appendicitis there is also more or less infiltration along the course of the vessels which run parallel to the muscle bundles, and in some instances rows of leucocytes separate the individual muscle fibres. The interstitial tissue of the muscular coats is edematous, and the connective tissue cells are swollen and proliferating; the muscle cells, on the other hand, show more or less marked degenerative changes.

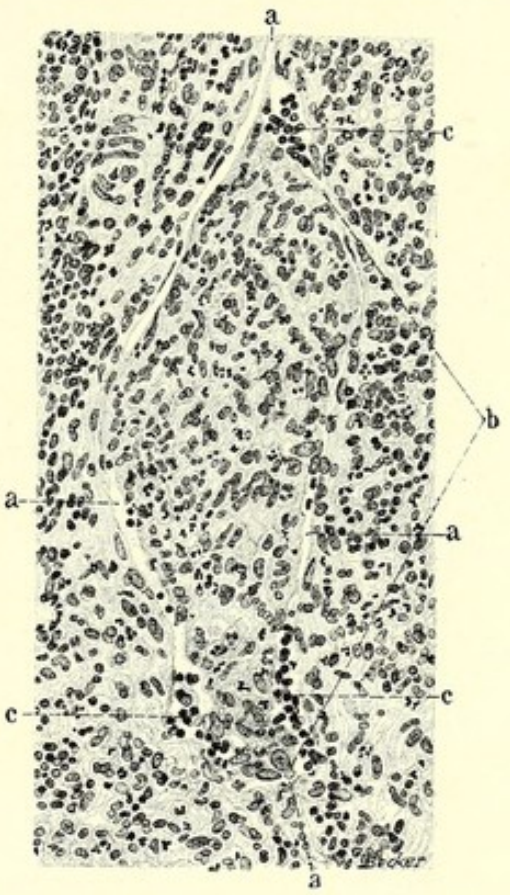

Fig. 169.—Thrombus in a Lymph Sinus. Magnified 225 Times.

a marks the lymph sinus, which contains a few lymphocytes (*c*) and is distended with the thrombus (*b*).

The peritoneum and the subperitoneal fibrous tissue undergo important changes. Often while the musculature, and even the submucosa, shows no perceptible change, a marked inflammatory reaction is found in the serous membrane. At the outset of the attack there is extreme congestion of the blood-vessels, which is almost immediately accompanied with an intense edema. Soon there is an abundant leucocytic infiltration, and a high degree of connective tissue proliferation. Vascular changes, as noted above, are frequently observable in this region. Interstitial hemorrhages usually occur and are often very extensive.

The changes in the mesappendix consist chiefly in edema and dilatation of blood-vessels. There is usually a slight leucocytic infiltration surrounding the blood-vessels and extravasations of blood are commonly met with. In some instances there is a general purulent infiltration of the adipose tissue, and necrosis of part or the whole of the mesentery is not rare. The changes in the blood-vessels and lymphatics of the mesappendix have already been described.

Perforative Appendicitis.—Perforation may take place in any variety of acute appendicitis, and in any stage of the attack. In some instances the first symptoms are due to the occurrence of perforation, while in other cases the acute attack has apparently subsided when perforation suddenly takes place. The rupture may be of pin-hole size or there may be a wide ragged aperture through which a large concretion can escape. In the appendix represented in Fig. 170, almost the entire circumference is involved in the large perforation which occupies the centre of a gangrenous area surrounded by a zone of intense hyperemia. This appendix was removed by T. S. Cullen thirty-six hours after the onset of the attack. There may also be two or more perforations. Very often, in the laboratory, unsuspected perforations are detected, which have been sealed by adhesions, most frequently by the adherent omentum. The factors concerned in the production of a rupture are various; it may follow the extension of an erosion to the peritoneal surface, the degeneration of the tissue in the vicinity of an abscess focus, or it may be the result of circumscribed or general gangrene. A tensely distended empyema often terminates in rupture of the appendix walls, and it is particularly in such cases, where a large amount of highly virulent material is emptied into the abdominal cavity that the most fatal forms of peritonitis result. Pin-hole perforations may result from the continuance of a purulent process along a muscular hiatus. An appendix apparently affected merely by a slight non-suppurative inflammation may, nevertheless, show a fine perforation corresponding to the position of an hiatus. A good example of this form of perforation is seen in Fig. 332, p. 621.



Fig. 170.—Perforative Appendicitis. (Specimen from T. S. Cullen.)

The most important cause of rupture is the necrosis of the tissue, induced by the presence of concretions, the pressure effect of which is brought into play by the swelling of the tissue in acute inflammation. The association of concretions with perforative appendicitis is so often observed that an etiological relationship cannot be questioned, and in many cases the evidence of cause and effect may be clearly demonstrated. In some instances a small rupture is found directly over the most prominent portion of the concretion (see Fig. 235), in others an impending rupture is found in a corresponding area. The direct agency of pointed and irregular foreign bodies in causing a perforation of the appendix will be considered in another section.

Where rupture follows an erosion the procedure is gradual, the various layers giving way as the degenerative process extends outward. In the case of gangrene, rupture of the different coats is probably in most instances practically

simultaneous. In some specimens the inner coats have given way, only the peritoneal covering remaining. In the appendix shown in Fig. 171, operation thirty-six hours after the onset, an extensive clean-cut perforation of all the outer layers has occurred, leaving only a pouch of mucous membrane which, although gangrenous, has not ruptured. The favorite location of the perforation is at or near the tip of the appendix, but it is not uncommon to find a perforation directly at the base, or at some intermediate point. A perforation at the base may involve the neighboring portion of the cecum and produce a wide opening through which the intestinal contents escape. The extension by continuity of the inflammatory disease of the appendix to the surrounding portion of the cecum has occasionally resulted in a perforating ulcer of the cecum. The propagation of the disease to the cecum may be owing to thrombo-phlebitis or to the direct action of bacteria upon the diseased tissues. Such cases may be wrongly interpreted as instances of primary disease of the cecum. As explained before, a perforation of the proximal end of the appendix may result in its complete separation from the cecum. It has then been found floating free in an abscess cavity, or has become attached to some other structure, receiving nutriment through newly formed vessels by means of adhesions. In a case of G. W. Crile's (*personal communication*), operated on after several attacks of appendicitis, the distal 3 cm. of the appendix was found closely adherent to the surrounding structures, 9 cm. from the normal point of attachment. The proximal end of the fragment was well rounded off, and completely closed. The lumen contained a small amount of fluid. Similar cases have been described by R. Morris, Barth and others. Acute appendicitis may undergo repair, but a complete *restitutio ad integrum* is probably exceedingly rare. As a rule, various deformities remain, such as angulations, twists, and, what are perhaps most important, irregularities in the canal, consisting of scars and strictures (see residual conditions). The vascular changes which Fowler believes to be so important I have not found to be often present, at any rate in the larger vessels. Obliterative arteritis is, however, common in the submucosa, and in some instances obliterative thrombo-arteritis is found in the large vessels of the peritoneum and muscular

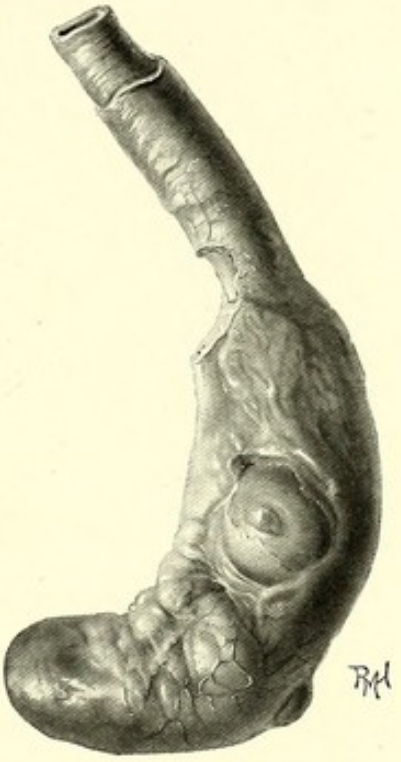

Fig. 171.—Acute Appendicitis.

The distal two-thirds distended and intensely injected. On the anterior surface a gangrenous pouch of mucous membrane, covering a concretion, protrudes through a rupture in the outer layers. A similar protrusion of mucous membrane is seen on the convex margin. There are three concretions in the appendix. (Surg. Path., No. 3173.)

hiatuses, and may even involve the main appendical vessel. This point will be further considered in connection with other residual conditions following acute and chronic affections.

Chronic Appendicitis.

In this group are included subacute and chronic inflammatory conditions of the appendix, and also that varied class of cases which I have designated r e s i d u a l a p p e n d i c i t i s, in which the essential lesions are the effects of an anterior inflammation rather than an active process.

Very often, after an attack of acute appendicitis, it may be after the first, or after several preceding attacks, changes remain which, under the continued influence of an infective agent lead to a chronic condition. But chronic appendicitis is not necessarily preceded by an acute process. It may have an insidious onset and occur independently of any acute attack. Very many cases are discovered accidentally in the course of operations undertaken for the relief of other abdominal affections in patients who have never suffered from any symptoms referable to the disease. Moreover, from the pathological findings of many specimens removed in what was supposed to be a first attack of appendicitis, it would appear that very often acute appendicitis is preceded by a primary chronic inflammation. In fact, some writers express the opinion that acute appendicitis never arises *de novo*, but is always dependent upon the deleterious effect of an anterior chronic process, excepting, of course, such cases as are the direct result of injury by foreign bodies, strangulation in a hernial ring, etc. Riedel believes that acute appendicitis has always an insidious onset, one of the most important predisposing causes being a chronic primary disease, "appendicitis granulosa." Chronic inflammation of the appendix is essentially a hypertrophic process and produces a characteristic thickening and rigidity of its walls. In rare instances the inflammatory reaction seems to be confined to the mucous membrane, but, as a rule, all the coats are similarly affected. Macroscopically the appendix is found to be thicker than normal, but may be either increased or diminished in length. It is quite common to find the appendix very thick and short, often not more than three or four centimetres long and a centimetre or more in diameter. In a case reported by Weir, the densely adherent inflamed appendix was only half an inch long, and nearly half an inch thick. There had been several sharp attacks of inflammation, and after removal of the appendix recovery was prompt and permanent. In some instances there is a moderate increase in length.

The whole organ may be uniformly thickened to the size of the little finger or larger; very often it is club-shaped, the proximal end being almost normal or even reduced in thickness, while the tip is enlarged. In other instances, the outer half or more is hypertrophied, while again there may be irregular thickenings separated by normal or constricted portions.

The mesappendix may be unaltered, but it is often thickened and indurated,

and is apt to be more or less shortened. The color of the appendix is usually reddish, and the superficial blood-vessels are very tortuous and prominent, while ecchymotic areas are not uncommon (see Fig. 2, Plate I). There are also often characteristic anemic areas, usually at the tip, significant of an obliterative process. This is well shown in Fig. 172, where the whitish knob-like tip is sharply contrasted with the brightly injected median portion.

The most striking feature in chronic appendicitis is the appearance of extreme rigidity. The appendix may project directly out from the cecum, independently of adhesions or any other external influence, the mesentery being often tightly stretched. Again, with a greatly shortened mesentery, the appendix may be sharply bent upon itself, or it may project in the form of a spiral. Fig. 148, No. IX, p. 200, presents a good example of a triple kink due to adhesions surrounding an unusually long appendix with a correspondingly short mesentery, the tissues having become rigid as a result of inflammation. The characteristic rigidity is particularly evident to the touch. Upon rolling the appendix between the fingers and compressing it, instead of the normal, easily collapsible walls, there is found a dense unyielding tube, the sides of which cannot be pressed together. Sometimes the thickened appendix may be readily palpated through the abdominal wall and rolled under the fingers. Section shows a general thickening of the tissues, but more especially of the submucous and serous membranes. The lumen, instead of assuming the stellate form of the normal appendical canal, retains a circular outline, and, except in strictured areas, remains widely open; a condition which, associated with enfeebled muscular power, favors the reception and retention of foreign material. The canal also presents various irregularities produced by the cicatrization of ulcers or hypertrophy of the walls. If the hypertrophy or constriction of the appendix walls results in complete occlusion of the canal at one point while the remainder is still patulous, or if a partial stenosis is rendered complete by means of kinks or twists, the part beyond the obstruc-

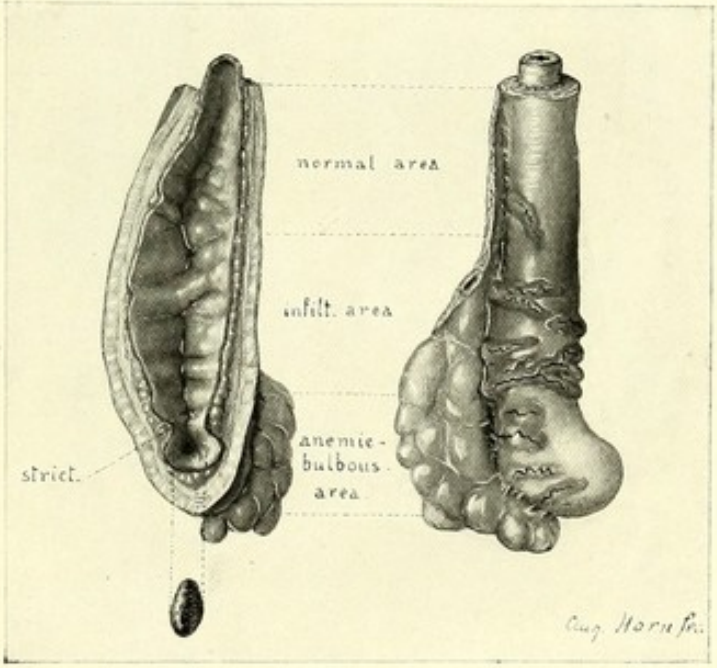

FIG. 172.—CHRONIC APPENDICITIS WITH ANEMIC BULBOUS TIP CONTAINING A SOFT FECAL MASS. (GYN. PATH., No. 5640.)

tion may become distended with a clear mucous or serous fluid, or with a turbid purulent exudate producing a hydro- or pyo-appendix. The mucosa is usually thickened, but in some instances appears to be thinner than normal and may even be indistinguishable from the underlying submucous tissue. Its surface may be smooth, sometimes having a glazed appearance, or it may be granular, or wart-like. In exceptional instances mucous polypi develop as shown in Fig. 173 (also see Chap. XXXI). The color of the mucosa is a bright red, usually mottled with petechial hemorrhages. A characteristic case of chronic appendicitis is given in Fig. 174, which shows the greatly hypertrophied, edematous walls, the circular canal at the cut end, and farther out a stricture.



Fig. 173.—Chronic Appendicitis.

The mucous membrane is thickened, rugous, and at *a* forms a distinct polyp. (Specimen from I. R. Trimble.)

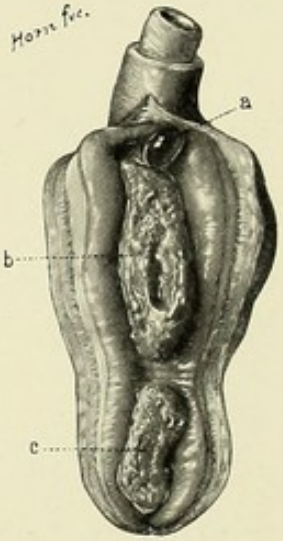

Fig. 174.—Chronic Appendicitis.

The appendical walls are thickened and edematous, the most pronounced changes appearing in the submucosa. The canal is strictured at one point and contains two soft concretions (*b* and *c*). At *a* there is a small hematoma of the mucous membrane. (Surg. Path., No. 4358.)

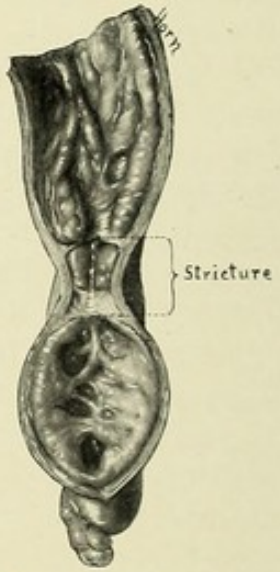

Fig. 175.—Chronic Appendicitis, with Complete Stricture in the Middle, and the Mucous Membrane Entirely Replaced by Scar Tissue. (Surg. Path., No. 4755.)

The mucous membrane is smooth and devoid of the usual folds. At one point a small hematoma is elevated above the surrounding surface. There are two soft concretions in the canal. Very frequently only a portion of the mucosa, the distal half or two-thirds, is involved in an inflammatory process, the remainder presenting the normal, pale, smooth, glistening appearance; or, again, some portion, or almost the whole mucous membrane may be replaced by chronic granulation tissue showing various stages of organization and cicatrization.

The appendix shown in Fig. 175 was removed after the fourth, and most

severe attack of inflammation. It was lightly adherent to the cecum, brightly injected, and presented a slight constriction about its middle. On section the canal was found to be completely obliterated at two points, about 5 mm. apart, the intervening space containing mucus. The whole inner surface was granular, or rugous and crossed by bands of dense scar tissue. The canal contained a little mucus. Microscopic examination revealed complete destruction of the mucous membrane, not a trace of epithelium or lymph nodes remaining. The surface in most places showed coagulative necrosis associated with a mucoid degeneration of the tissue. That the mucus was not simply a deposit upon the surface was shown by the remnants of blood-vessels and connective tissue strands which were traceable in it. The submucosa was fibrous



FIG. 176.—A SECTION FROM THE PRECEDING SPECIMEN. MAGNIFIED 40 TIMES.

On the left the surface shows extensive coagulative necrosis; on the right there is a thick layer of a mucoid substance (*a*) containing traces of fibrous tissue and vessels, a few leucocytes, and cellular detritus. *b* is the deeper portion of the submucosa; *c*, blood-vessels; and *d*, fat cells.

and edematous, likewise the muscular coats. There was a diffuse infiltration of the inner layers, chiefly with plasma cells. Here and there a deposit of yellowish, granular pigment was seen (see Fig. 176).

The most marked changes are often found in the submucosa, which appears as a thick, dense, fibrous band, sometimes forming more than half of the entire thickness of the walls of the appendix, the increase being chiefly at the expense of the mucous layer. The muscular coats may preserve their usual relation to the other tissues, or may appear thicker or thinner than normal. The peritoneum is usually thickened, and is exceedingly vascular. In some instances the different layers are indistinguishable from one another, and the whole greatly

thickened wall of the appendix appears to consist of a homogeneous, edematous fibrous tissue which is sometimes strikingly suggestive of a new growth. As the following case is unusually interesting it is given in some detail.

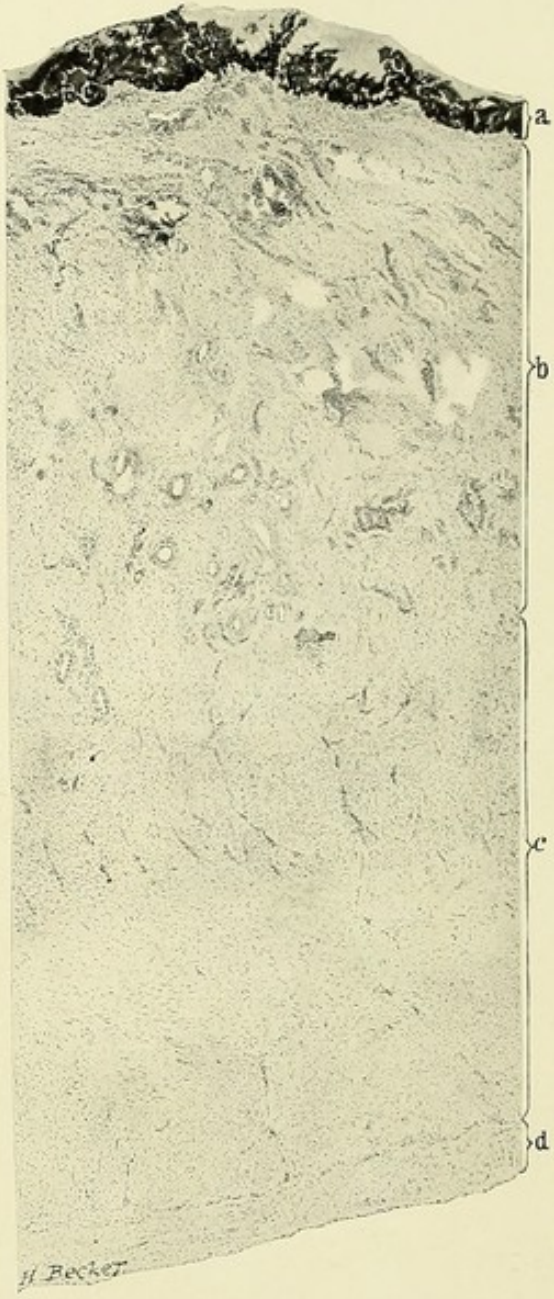

FIG. 177.—A SECTION FROM THE APPENDIX SHOWN IN FIG. 2, PLATE III. MAGNIFIED 16 TIMES.

a, Cellular detritus and calcareous material. *b*, the thick edematous submucosa; *c*, the edematous muscularis; *d*, peritoneum and subperitoneal fibrous layer. There is a general infiltration of lymphoid and plasma cells, frequently collected in clumps and along the course of the vessels. (Surg. Path., No. 4086.)

J. B., age fifty-six (J. H. H., Surg. No. 12942).—Admitted during an attack of appendicitis, with a history of numerous similar attacks extending over a period of four years. As the acute symptoms subsided, a distinct rounded mass could easily be made out in the right iliac fossa. On operation, the vermiform appendix was discovered running outward and slightly backward into the iliac fossa, where it was adherent by its tip. It was very large, extremely hard, and densely white. The picture it presented was a rather new one in appendicitis, the appendix being exceedingly edematous and infiltrated. Its mesentery was also quite thick, and the amount of induration in the cecum around the base of the appendix was so great that when sutures were inserted in the attempt to invert the stump, it proved impossible to do so effectually, and therefore drainage was thought advisable. Convalescence was normal, except for slight rises of temperature in the evening during the fourth week, which could probably be accounted for by vaccination. The appendix was about 1.5 cm. in diameter, very resistant and hard; in fact, the whole picture suggested carcinoma. On cutting it open, the bulbous tip appeared to be in a condition of degeneration which also suggested carcinoma (see Fig. 2, Plate III). The walls were everywhere thickened and exceedingly rigid, but the most pronounced changes appeared in the tip, where a dense rounded mass projected into the lumen. This, as well as the adjacent surface of the mucosa, was covered with a yellowish-white caseous material containing a large amount of calcareous

DESCRIPTION OF PLATE III.

FIG. 1.—Acute appendicitis, eight days. The appendix irregularly distended and hyperæmic. At *b* and *c* foci of suppuration are visible. (T. S. Cullen.)

FIG. 2.—Chronic appendicitis. The whole appendix is thickened, rigid and exceedingly œdematous. The tip is occupied by a dense tumor-like mass which consists of the hypertrophied œdematous submucosa covered with a whitish deposit containing calcareous material. A small papillary elevation near the tip is also covered with this whitish deposit. The remaining surface is smooth, the mucosa atrophic. (W. S. Halsted.)

FIG. 3.—Enterolith in the appendix, one distinctly facetted and resembling a gall-stone. (H. Cushing.)

FIG. 4.—Mild subacute appendicitis. Soft fecal concretions. The mucous lining of the distal portion (*a*) is swollen and hemorrhagic. (H. A. Kelly.)

DESCRIPTION OF PLATE III.

FIG. 1.—Acute appendicitis, eight days. The appendix irregularly distended and hyperemic. At *b* and *c* foci of suppuration are visible. (T. S. Cullen.)

FIG. 2.—Chronic appendicitis. The whole appendix is thickened, rigid and exceedingly edematous. The tip is occupied by a dense tumor-like mass which consists of the hypertrophied edematous submucosa covered with a whitish deposit containing calcareous material. A small papillary elevation near the tip is also covered with this whitish deposit. The remaining surface is smooth, the mucosa atrophic. (W. S. Halsted.)

FIG. 3.—Enteroliths in the appendix, one distinctly facetted and resembling a gall-stone. (H. Cushing.)

FIG. 4.—Mild subacute appendicitis. Soft fecal concretions. The mucous lining of the distal portion (*a*) is swollen and hemorrhagic. (H. A. Kelly.)

PLATE III



Fig 1



Fig 2

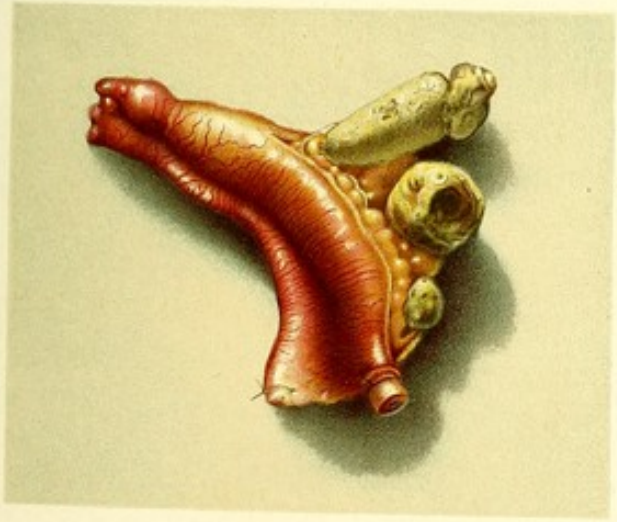

Fig 3

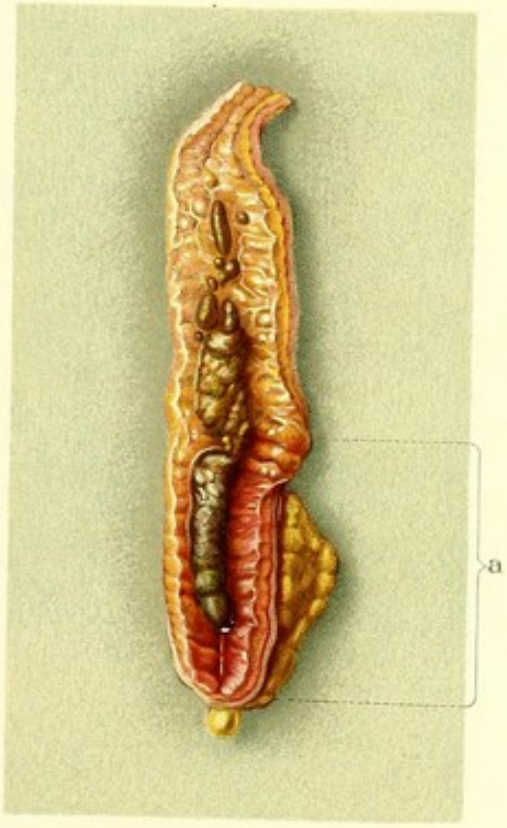

Fig 4

Brödel, Horn and Becker, fec.

Ketterlinus, Lith. Phila.

deposit. The cut surface of the tissue presented a uniform, fibrillated, edematous structure, in which there was no trace of the normal layers. Near the tip one or two slight papillary elevations were noticed. The histological examination showed that section from various regions presented a fairly uniform appearance. On the surface there was a layer of mucus, and of granular, eosin-stained material, containing cellular detritus, with a large amount of lime salts. Occasionally, a single layer of flattened epithelium was found resting directly upon the dense fibrous



Fig. 178.—Section from the Preceding Case, Showing Atypical Glands and Mucoid Degeneration. Magnified 200 Times.

a, Edematous fibrous stroma; *b*, mucus; *c*, glands.

tissue. There were no glands nor lymph follicles. The greatly thickened submucosa consisted of edematous fibrous tissue, with fairly abundant fusiform cells and numerous thick-walled blood-vessels (see Fig. 177). Small round cells, and plasma cells were fairly numerous, usually occurring in small clumps. The line of demarcation between the submucosa and circular layers was very indistinct, and, indeed, could not be determined with any certainty. The normal muscle bundles had disappeared, and the individual fibres were separated by edematous fibrous tissue, swollen

and palely stained. The peritoneal layer presented similar changes. At the angle in the sulcus between the tip and the neighboring wall, groups of proliferating glands were found (see Fig. 178). These areas were covered with a thick layer of mucus, which also filled the gland lumina and in places surrounded the base of the gland, apparently infiltrating the fibrous stroma. This mucoid degeneration has been noted in other cases of chronic inflammation. The glands were irregularly branched, their epithelium swollen, and sometimes, apparently, several layers thick. The cells were mostly degenerated. The glands exhibited no disposition to invade the deeper tissues, the appearance of invasion being due to the fact that they were in an angle and compressed by the proliferating fibrous tissue.

Histology of Chronic Diffuse Appendicitis.—The essential condition found here is a fibrous tissue transformation affecting to a greater or less degree all the layers of the appendix wall. The general fibrous change is accompanied with sclerosis, and obliterative changes in the blood-vessels. The mucous membrane is usually edematous, the interglandular tissue is vascular, more fibrous than normal, and contains an increased number of lymphoid and plasma cells. Red blood cells are often found and in many cases there is a deposit of brownish granular pigment of hematogenous origin. Hemorrhage into the tissue and beneath the epithelium may, according to RIEDEL, precipitate a sudden acute attack of inflammation, by injuring the tissue. The solitary follicles may be greatly swollen, forming a continuous zone of lymphoid tissue; or, again, they are to a great extent, or wholly, replaced by fibrous tissue. The surface epithelium is usually flattened and the glands are shallow and compressed by the infiltrated interglandular tissue. A few glands may be cystic. In some instances the only trace of the mucous membrane consists of a layer of flattened epithelium, resting directly upon a layer of dense cicatricial tissue. The submucous, muscular, and subperitoneal layers are altered to a varying degree. As a rule, the most marked fibrous tissue proliferation is found in the submucosa, which

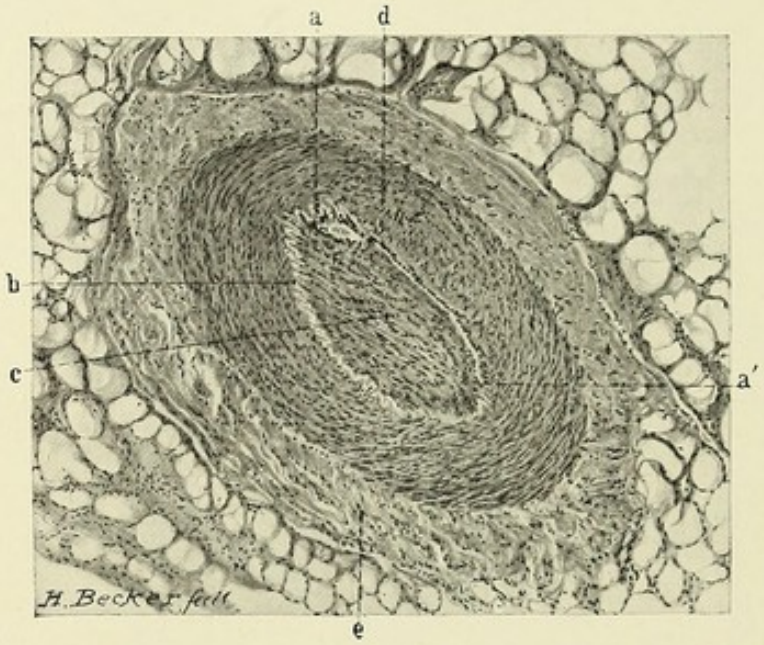

FIG. 179.—OBLITERATIVE ENDARTERITIS IN THE MESAPPENDIX. MAGNIFIED 90 TIMES.

a–a′, The vessel lumen; *b*, the external elastic layer of the intima; *c*, thickened portion of the intima; *d*, tunica media; *e*, tunica externa.

may be thickened out of all proportion to the other layers. The blood-vessels of this region have greatly thickened walls, and not infrequently are almost completely obliterated. Small round lymphoid, and plasma cells may be very abundant, the latter usually predominating. A specimen, recently sent me for examination, had been pronounced small round cell sarcoma on account of the dense masses of plasma cells found in the submucosa.

In the muscular coats the connective tissue hyperplasia occurs at the expense of the muscle fibres. The subperitoneal layer takes an active part in the general fibrous tissue increase, and usually shows sclerotic changes in the smaller blood-vessels. As a rule, the larger vessels of the peritoneal coat are fairly normal, and the main appendical vessel, with its tributaries, in the mesappendix is almost constantly so. In rare instances the vessel walls are slightly sclerotic, but advanced obliterative changes I have found in only one case (see Fig. 179), which was furnished me by STEENSLAND of Syracuse, New York.

CHRONIC ULCERATIVE AND PURULENT APPENDICITIS.

Chronic diffuse inflammation renders the appendix peculiarly susceptible to further infections, which may result in an acute reaction, or in a chronic suppurative condition. As pointed out by LENZMANN, there may be a concurrence of two factors which expose the appendix to the danger of further injury: the ready reception of foreign material from the cecum, and the more or less pronounced disability of the appendix to free itself from this material. A lurking place for fecal particles with their infective and putrefactive contents is thus created and the abundant bacterial development of the cecal region, extending by direct propagation to the appendix, is there further influenced by the condition of stasis produced by the rigidity of the tissues and the loss of muscular power. The result of these conditions is that, ultimately, the increased bacterial activity associated with the diminished resistance of the tissue, produces more or less extensive tissue necrosis and may excite an acute or subacute attack, often characterized by suppuration. Enteroliths also exercise an important influence in inducing tissue necrosis. The necrotic areas are usually in direct relation with the infective material and may be limited to the mucous membrane, or may extend deeper, sometimes involving the peritoneal coat. Sometimes also there may be circumscribed ulcers having infiltrated, irregular margins, the base being covered with necrotic material; or there may be a diffuse suppurative process. If the canal becomes obliterated at any point, a purulent exudate accumulates in the appendix, and a tensely distended pus sac results. The size of the mass depends partly upon the location of the obstruction, whether close to the cecal orifice, or at some distant point, and partly upon the nature of the infection. The slow accumulation of the purulent exudate, and the gradual distention in the case of a chronic pyo-appendix, are accompanied by a hyperplastic tissue growth in the walls of the appendix, which become greatly thick-

ened, in some instances being from 5 to 10 mm. thick. In such a case the normal constituents of the appendix walls are entirely replaced by chronic granulation tissue, rich in cellular elements. The inner surface is covered with necrotic tissue and fibrin. The mass rarely has a diameter of more than 2 to 3 cm., but it may attain enormous dimensions, as in a specimen sent me by G. MULLER (see Fig. 180).

In some instances the mass is freely movable and without adhesions, in other cases the omentum may be attached, but most frequently it is fixed by adhesions to the abdominal wall or other neighboring structures.

As in the case of acute purulent appendicitis, perforation may result from the extension of the necrosis to the peritoneal surface (see Fig. 181). But in chronic suppuration, more frequently than in acute conditions, the productive inflammatory reaction, due to the diffusion of toxins, which precedes the destructive process, has resulted in the formation of a protective barrier which limits the distribution of the infection. Moreover, whereas in acute pyo-appendix the virulence of the infective agents is exalted, in chronic suppuration the mild infection may be limited, or



FIG. 180.—EMPYEMA OF THE APPENDIX.

At the cecal end the greatly thickened walls completely occlude the canal, and the rest of the appendix is distended with pus. The whole interior is lined with ragged necrotic material. The mucous and submucous layers are almost totally destroyed, but in places are represented by islands of thickened, degenerated tissue.



FIG. 181.—CHRONIC SUPPURATIVE APPENDICITIS WITH OBLITERATED LUMEN AT *a*, AND BEYOND THIS A PUS SAC WHICH HAS RUPTURED (*b*).

The collapsed condition of the walls of this portion shows that there has been considerable distention. The mucosa here is irregular and at a point opposite the concretion (*c*) has been destroyed.

even destroyed by the reaction on the part of the tissues. Resolution may follow the rupture and drainage of the empyema into the intestine or other hollow viscus, or the fluid contents may become absorbed, and the cavity finally obliterated by granulation tissue.



Fig. 182.—Multiple Stricture in the Appendix.

RESIDUAL APPENDICITIS.

This term includes the various deformities of the appendix which may follow acute or chronic inflammation after the active disease has subsided. The results may be hypertrophy or atrophy of the appendix, stricture or obliteration of its lumen, cystic dilatation, or angulations or twists due to adhesions or cicatricial contractions in the appendix wall. These conditions have been already referred to, but are more conveniently considered as a distinct class. They are of importance not only on account of their etiological relation to recurrent acute infection, but as the usual source of the clinical conditions described by Lenzmann and by Ewald as *appendicitis larvata*. As has already been explained, acute or chronic appendicitis exceedingly rarely results in a *restitutio ad integrum*. In the mildest cases there is more or less connective tissue hyperplasia, and as a consequence a certain amount of rigidity and enfeebled muscular power persists. In the healing and repair of erosions, newly-formed connective tissue replaces the destroyed area, and like all cicatricial tissue, tends to contract, resulting in strictures, angulations, or occlusion of a portion of the canal. Abbé, who has devoted much attention to this condition and is strongly impressed with its pathogenic importance, has prepared an excellent series of specimens which show its various grades as well as the number of stenoses which may follow appendicitis. His method of distending the appendix with alcohol and thus hardening it before sectioning, has given some excellent results, but it is not applicable in all cases and is not always so useful as the examination of the fresh specimen. A typical example of multiple stenosis associated with stercoral concretions, furnished by Runyon, is given in Fig. 182. In this case one or more attacks of mild inflammation, possibly confined to the inner layers, have been productive of several areas of complete and partial stenosis, without at any time having given rise to attacks of pain or tenderness in the abdomen. The appendix was removed during the course of an operation for

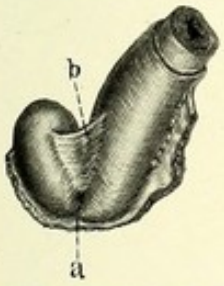

Fig. 183.—Kink and Stricture Produced by Adhesions in a Case of Chronic Appendicitis.

a, Kink, with separation of distal from proximal portion of the appendix; *b*, adhesion. The distal portion is obliterated. (Gyn. Path., No. 5218.)

myoma. General destruction of the mucosa is followed by total obliteration of the canal. If the canal is only partially stenosed, other factors, such as kinking or the compression by adhesions, may make the obstruction complete. In the appendix shown in Fig. 183, the kink produced by the dense band of adhesions has resulted in the separation of the distal from the proximal end

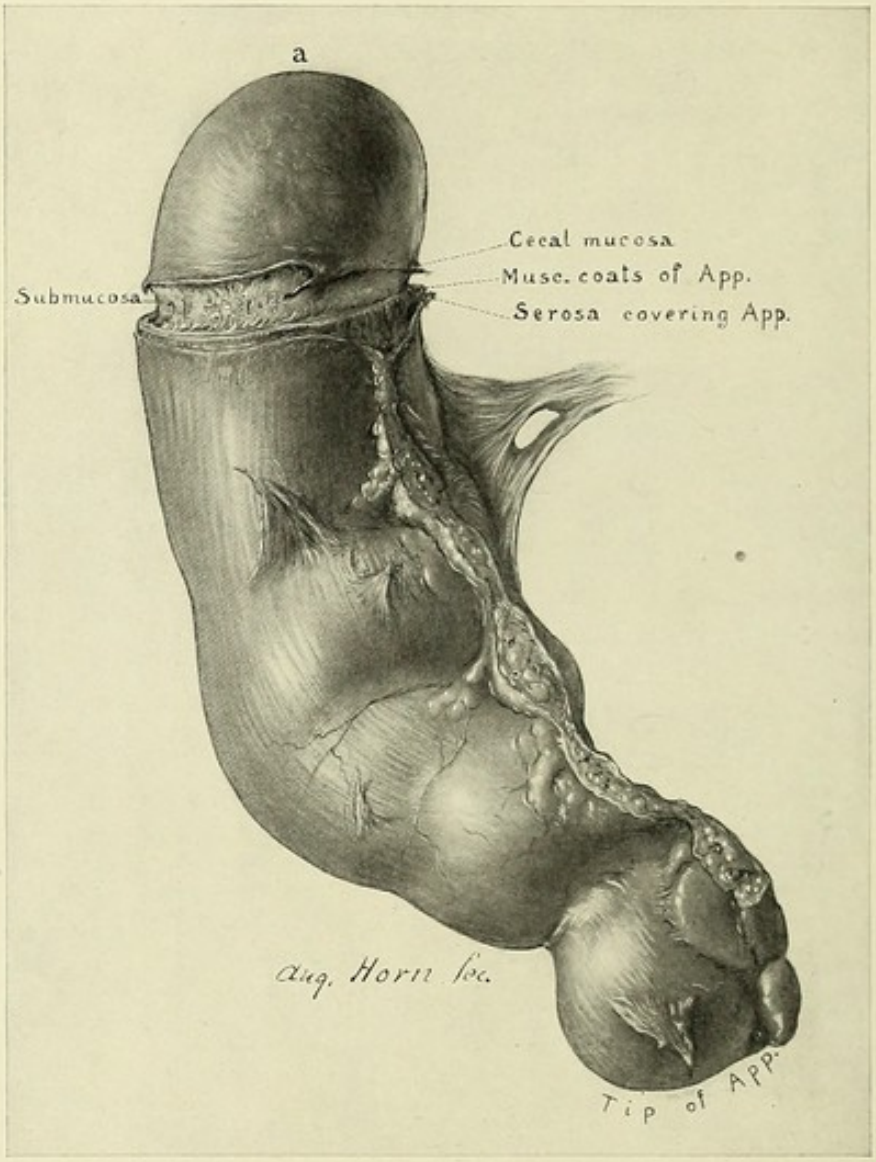

Fig. 184.—Cystic Appendix with the Proximal End (*a*) Protruding into the Cecum. Several tags of adhesions are seen on the surface of the cyst. (Sent by E. E. Montgomery from the Museum of Jefferson Medical College.)

of the appendix, the two portions being connected by the mesentery and a band of fibrous tissue.

Retention Cysts of the Appendix.—If a portion of the canal distal to the obstruction remains patent, the normal secretion, having no outlet, accumulates in it and a retention cyst is produced. The contents of the cyst is, at first, com-

posed of the normal mucous secretion of the appendical mucosa, or of a mucopurulent, sometimes sanguineous fluid; but later, probably owing to pressure atrophy of the mucosa and consequent loss of function, the mucous secretion ceases, and the fluid becomes serous or watery in character. If the occlusion has occurred close to the cecal attachment of the appendix, the cyst appears to arise directly from the cecum. In the case shown in Fig. 184 stenosis had probably taken place directly at Gerlach's valve and did not involve the canal beyond this point. The thin membrane which obstructed the canal at the valve became gradually distended by the pressure of the fluid within the appendix so that finally the cyst became partly intracecal. Other cases have been reported in which the cyst had developed almost wholly within the cecum. If the obstruction is at a more distant point the cyst appears to be pedunculated, being attached to the cecum by the normal proximal portion of the appendix (see Fig. 185). Again, only the tip may be cystic, or the middle of the appendix may be distended while the proximal and distal portions are obliterated. The canal may be occluded at two or more points, and the intervening portions may become cystic.

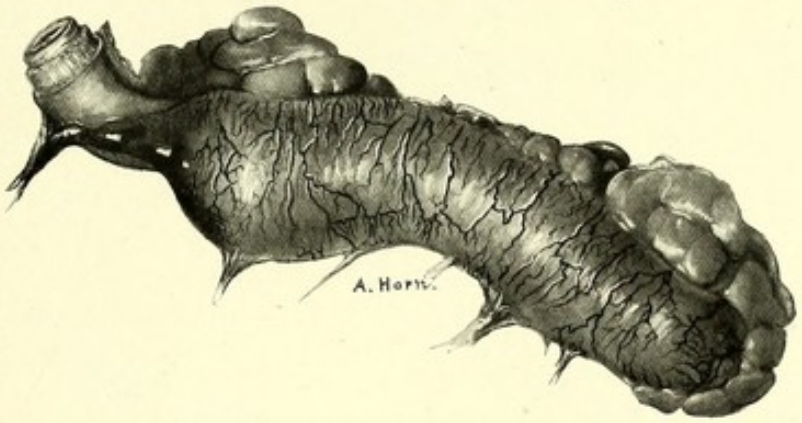

FIG. 185.—CYSTIC DISTENTION OF THE LOWER THREE-FOURTHS OF THE APPENDIX DUE TO STRICTURE OF THE CANAL.

The proximal end is pervious. The surface of the cyst covered with adhesions and markedly injected. (Gyn. Path., No. 5718.)

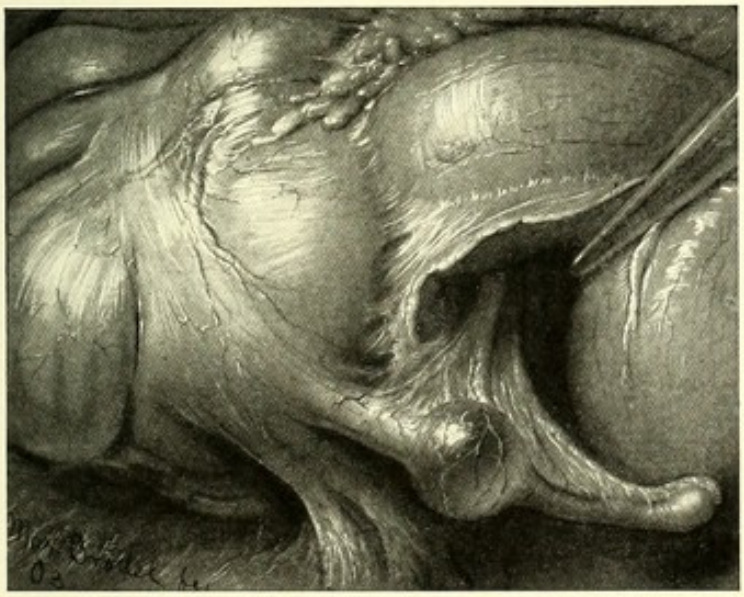

FIG. 186.—THE APPENDIX AS SEEN *in situ*, NOVEMBER, 1897, SHOWING A SINGLE CYST AND OBLITERATED, WITHERED DISTAL EXTREMITY.

An interesting case of cystic change in the appendix, affording an unusual opportunity to observe the progress of the disease, is shown in Figs. 186 and

187, which show the condition of the appendix on its removal, and the same appendix as it appeared six years previously, when, during the course of an abdominal operation it was carefully observed and sketched by the artist, but was not removed, as its condition at that time was not considered a menace to the patient's welfare. When the appendix was first observed there was a single cyst in the median portion, and beyond this point the canal was apparently obliterated. On its removal, three cyst cavities, separated by fibrous partitions, had formed, the later ones having developed in the proximal portion of the appendix. The tip had become considerably shortened. The cyst cavities are lined with a layer of flattened epithelium, which rests directly upon the muscular coat.

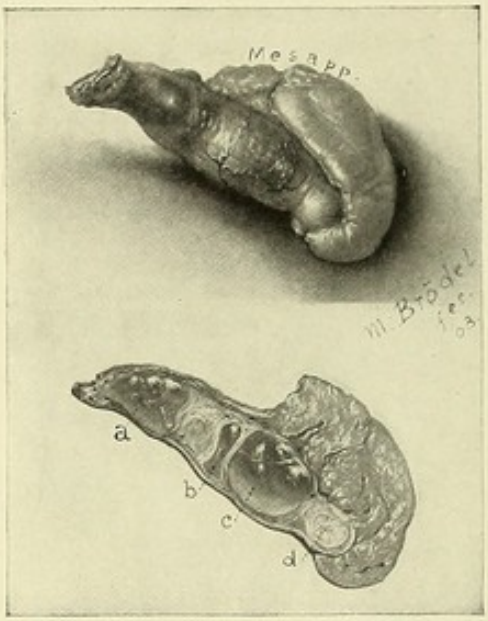

Fig. 187.—The Same Appendix (See Fig. 186), Removed October, 1903.

The obliterated distal portion has become much shortened. *c* probably represents the original cyst, and *a* and *b* are of later development. Cavities *b* and *c* communicate with each other. (Gyn. Path., No. 6996.)

In some instances secondary cysts have developed in the remains of partly occluded glands. A rare condition described by Ribbert, and by Kelynack, and which I have observed in one case, is produced when the pressure within the appendix has caused a separation of the musculature, and a protrusion beneath the peritoneum of the lining membrane with its mucous or serous contents. In Kelynack's case two distinct diverticula, which communicated with the main cavity by circular openings, extended between the layers of the mesappendix. In my case there was a single hernia-like protrusion into the mesentery. The influence of a kink or twist in producing the cystic condition may be seen in some cases in which, upon separating the mesappendix or the adhesions which produce the kink, the fluid immediately escapes into the cecum. This probably explains some cases in which a distinct mass is easily palpable, while at operation only a small appendix is found, which is, however, unusually flaccid, and has the appearance of having been distended.

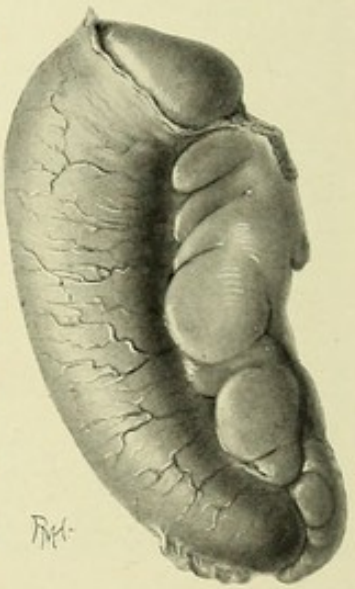

Fig. 188.—Cystic Appendix. (Gyn Path., No. 2170.)

Cysts of the appendix as a rule are cylindrical in form and vary in size from about the thickness of a lead-pencil to from one to

three centimetres in diameter. In exceptional instances very large masses develop. One described by SONNENBURG was an enormous pear-shaped cyst, 14 cm. in length, and 21 cm. in its greatest circumference. VIRCHOW described a case in which the appendix was as large as a fist. The walls of the cystic appendix are attenuated and transparent. The peritoneal surface often presents a few adhesions, but may be perfectly smooth. The inner surface is usually smooth and glistening. Figs. 188 and 185 are characteristic examples of the cystic appendix. The former is situated directly upon the cecum and has a smooth surface, while the latter is covered with adhesions and has a long pedicle.

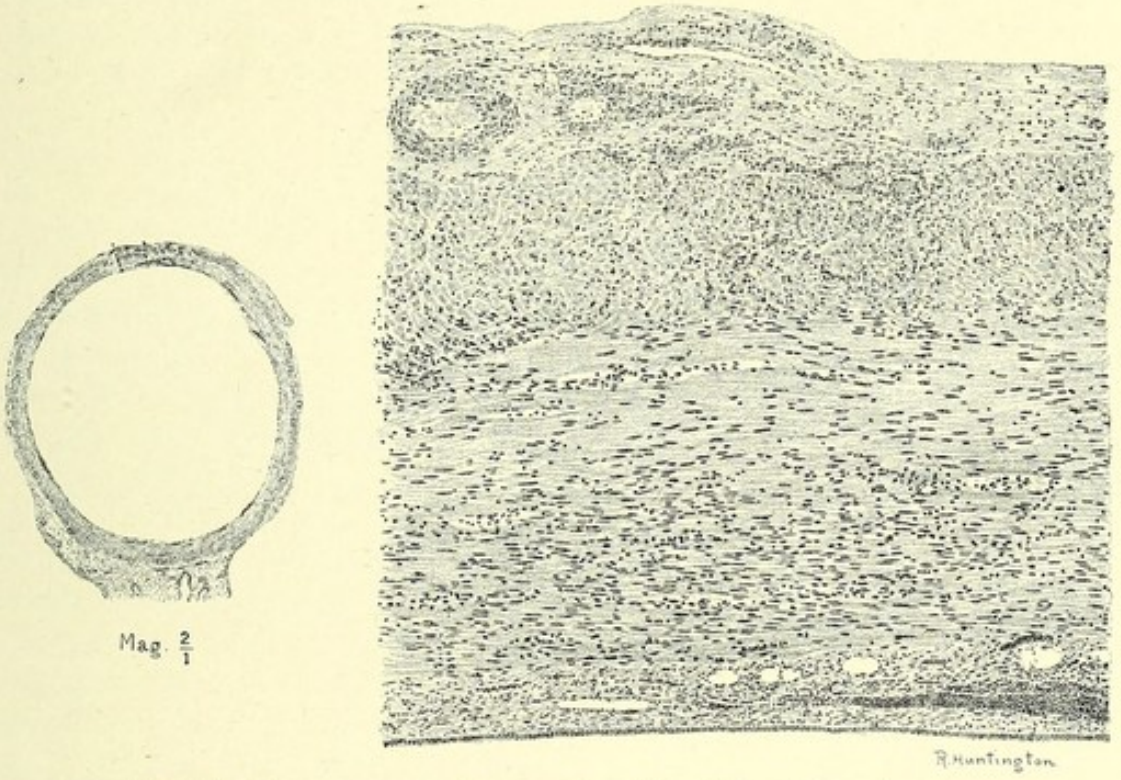

FIG. 189.—SECTION FROM THE PRECEDING CASE (FIG. 188) OF CYSTIC APPENDIX.

The small picture on the left shows the dilated lumen and thinned-out walls. The area between the two dotted lines is seen highly magnified, in the picture on the right side. The mucous membrane is represented by a layer of flattened epithelium resting upon a layer of fibrous tissue. A small flattened lymph node is seen near the edge of the picture. There is a general round cell infiltration of all the coats.

Histologically, a general connective tissue proliferation is apparent with a corresponding loss of the normal elements of the appendix walls. The whole picture is that of a mild, chronic, inflammatory reaction associated with pressure atrophy of the tissues. The mucosa, as a rule, is represented by a single layer of low columnar or cuboidal epithelium resting directly upon a layer of fibrous tissue. Glands have usually disappeared. An occasional small, flattened lymph node may be seen. In many cases the muscular coats are almost entirely replaced by fibrous tissue, but in some instances the muscle bundles are fairly well preserved. As a rule, there is a slight diffuse round cell infiltration (see Fig. 189).

Obliteration of the Appendix.—Considerable attention has been recently directed to obliterative changes in the appendix. RIBBERT, WÖLFLER, and ZUCKERKANDL, from the careful examination of a large number of cases, all arrived at the conclusion that obliterative changes in the appendix are not the result of an inflammatory process, but an involution process in a functionless organ. CRUVEILHIER, BIERHOFF, FITZ, SENN and others believe that obliterative changes have a pathological origin. TCHACALOFF, in 19 cases of partial or total obliteration, found in all, distinct evidence of a pathological process.

My investigations have dealt chiefly with specimens removed at operation, and only to a limited extent with autopsy material, as, unfortunately, the macroscopic appearance of the appendix alone was noted in the autopsy protocols, and the specimens were not preserved. For the consideration of normal involutionary processes, see Chap. VI.

In the gynecological service at the Johns Hopkins Hospital it has for some years been the rule to examine the appendix, if accessible, whenever the abdomen is opened for any reason, and if it presents any deviation from the normal, however slight, it is removed, provided always that there is no special bar to the operation. Thus, it has been the custom to remove the appendix if thicker or firmer than normal, even if the rigidity is very slight, or merely involves the tip. On this account it has been possible to examine a large number of specimens showing obliteration, and sufficient evidence has been obtained from these cases to warrant some conclusions regarding the origin of many cases of partial and complete obliteration of the appendix, although no definite conclusion can be reached regarding the relative frequency of its occurrence. The opportunity to inspect and remove the appendix occurs most frequently in the course of gynecological operations; in the general surgical department the approximately normal appendix is less frequently removed. This probably accounts for the fact that in the material from the gynecological operating room I have found 21 cases of complete obliteration of the canal of the appendix, but only two such cases among the specimens from the surgical department, although in the latter, twice the number of appendices had been removed. Partial occlusion of the canal occurred in about equal proportions in the two series of cases. In considering the etiology and pathology of obliteration of the appendix, I have chiefly studied the specimens from the gynecological department.

Out of 300 specimens, 45 were found to present some degree of obliteration, varying in extent from a small portion of the tip to the occlusion of the entire canal. Under this group I have not included cases of appendix with greatly thickened walls and narrowed but patent lumen, as these are manifestly of inflammatory origin; nor do I include simple strictures, which have clearly resulted from cicatrization of erosions.

The 45 cases comprise 21 in which the lumen is entirely obliterated, and 24 in which the lumen is partly so. In the specimens showing partial obliteration, the extent of the occluded portion varied from about 1 cm. at the tip, to a half

or three-fourths of the length of the organ. In one instance only, a few millimetres of the proximal end was provided with a central lumen. With a few exceptions the obliteration extended from the tip inward, the occluded part forming a solid cord. In one case, previously described, the proximal and distal thirds were obliterated, while the middle third was cystic. In 8 cases the proximal end was obliterated and the part beyond cystic, the occluded portions in these cases varying from a few millimetres to several centimetres; in one case only the distal third remained patent. These cases of cystic changes in the appendix have already been considered. The obliterated appendix may be thickened, firm, and cylindrical (see Fig. 190), or it may be reduced to a thin fibrous cord or flattened band (see Fig. 191). In cases of partial obliteration, also, the affected area may be either hypertrophied or atrophied. If only the tip is involved the appendix may have a clubbed appearance, or may dwindle away to a fibrous cord. When the median portion is obliterated the organ

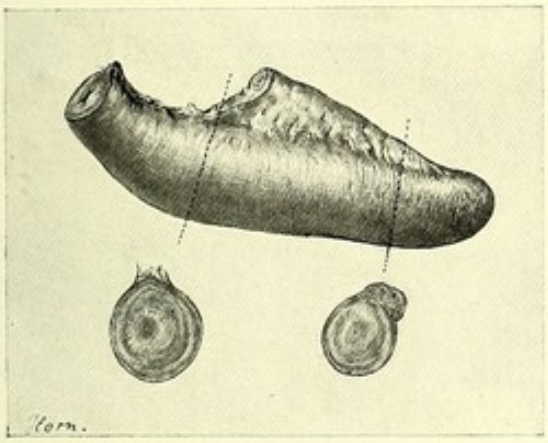

FIG. 190.—HYPERTROPHIED APPENDIX WITH OBLITERATED LUMEN. (NATURAL SIZE.)

There were a few slight adhesions in the vicinity of the appendix. (Gyn. Path., No. 3859.)



FIG. 191.—ATROPHIED APPENDIX WITH OBLITERATED LUMEN. (NATURAL SIZE.)

Fine adhesions over the middle portion. (Gyn. Path., No. 2884.)

may be divided into two distinct portions connected by a narrow fibrous cord (Fig. 192). A withered appendix, when retrocecal and extraperitoneal, or covered with adhesions, may readily be overlooked and the case regarded as an instance of absence of the appendix. Fig. 193 represents a specimen which was found in a medical museum labeled "absence of the appendix vermiformis." The appendix in this case was regarded as part of the dense adhesions which were found about the cecum, and the complete absence of any indication of an appendical orifice in the cecum supported this view. Careful inspection, however, revealed a more definite outline than in the case of the surrounding adhesions, and a section examined under the microscope showed the usual muscular layers of the appendix, the lumen having been replaced by fibrous tissue.

In all but 19 of my cases the surface of the appendix presented evidence of adhesions. The adhesions were dense in some cases, but more often they were

very delicate. The color of the appendix was always distinctly paler than normal, although occasionally the superficial blood-vessels were dilated. When the obliteration involved only a part of the appendix, it could at once be recognized by the color as compared with the rest of the organ.

Cross-sections of the obliterated appendix examined by the naked eye usually revealed two distinct layers, namely, an outer layer consisting of the musculature, and a central layer consisting of fibrous tissue. The relative proportions of these layers is quite variable. As a rule, the muscular coat is of about normal thickness, but it is sometimes greatly thickened, or it may be atrophied and scarcely distinguishable. Similarly, the central fibrous tissue may be abundant, or may have undergone considerable shrinkage. To a great

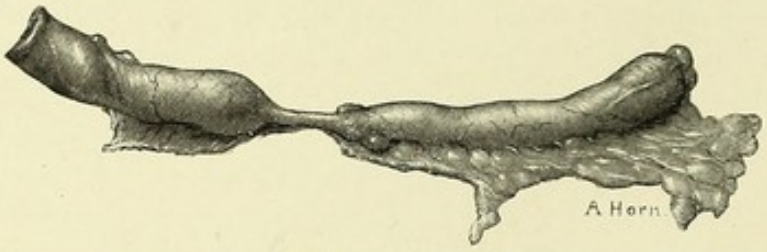

Fig. 192.—Chronic Appendicitis with Stricture.
The distal portion is completely obliterated, but the proximal end is pervious and shows an active inflammatory process. (Surg. No., 9068.)

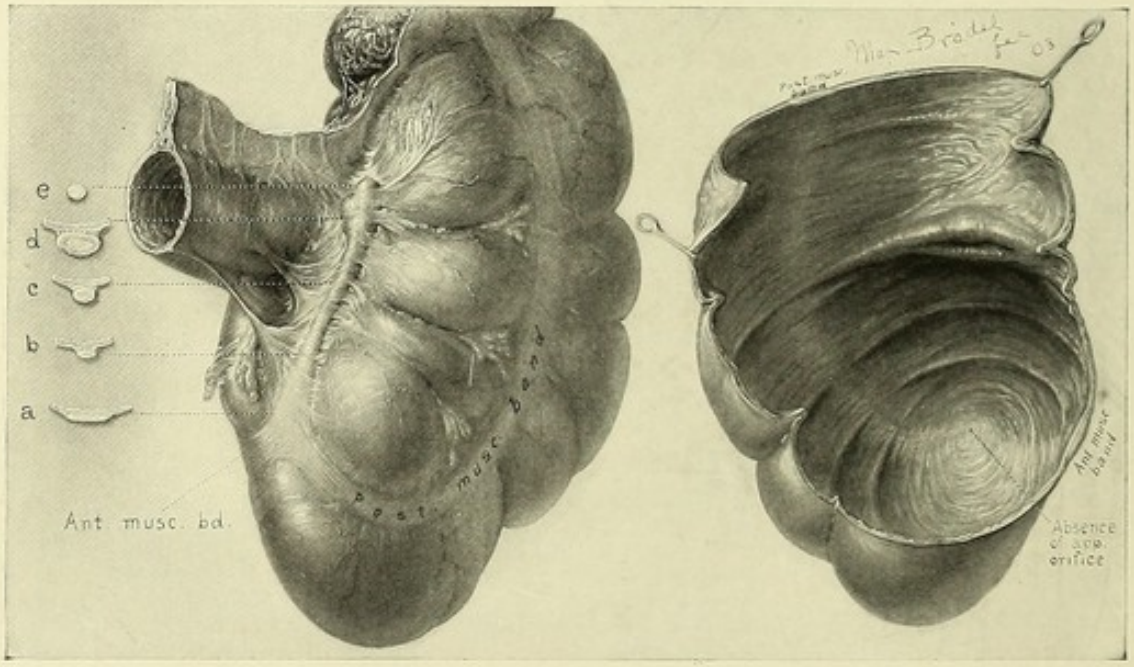

Fig. 193.—Obliterated Appendix Covered with Adhesions and Hidden Behind the Ileum.
The cecal end of the appendix (*a*) can scarcely be distinguished from the muscular bands. Advancing toward the tip it becomes more cylindrical and thicker (*b*, *c*, *d*), again diminishing in size at (*e*).
The right-hand picture shows the interior of the cecum and the normal site of the appendical orifice.

extent this variability depends upon the stage of the affection, but not entirely, as some very thick appendices show a very thin muscle layer; while in others of

the same diameter there may be a broad band of muscle; and, again, a withered appendix may have a relatively well developed muscle coat, or it may consist almost wholly of fibrous tissue.

The microscopic picture of the obliterated appendix is a varied one, the characteristic appearance depending partly upon the stage, but chiefly upon the character of the pathological process. A cross-section of a thickened, obliterated appendix may show any of the following conditions in the centre:

1. A centre of cellular fibrous tissue containing remnants of lymph follicles or glands, and sometimes both. Occasionally a microscopic triangular or irregular slit represents the former canal. This has no special cell lining, and as the tissue contracts will probably disappear. The remnants of lymph follicles and glands which are present indicate an early stage of the obliterative process, and they also will finally disappear. The submucosa is thickened, fibrous, and contains more or less fat, usually only a moderate amount, while numerous blood-vessels radiate to the centre. There is often a slight round cell infiltration of the submucosa.

2. The centre is fibrous and contains no remnants of mucosa. The tissue may be fairly cellular and contain numerous lymphoid elements, but no well-formed follicles. The surrounding tissue is usually dense, fibrous, and may contain very little, or a moderate amount of fat.

3. The centre consists of fibrous tissue, poor in connective tissue cells, and free from lymphoid elements. The surrounding tissue often contains a large amount of fat. In one of my cases the thickened obliterated appendix showed a rather thin musculature surrounding a mass of adipose tissue with a fine central strand of fibrous tissue, formed by the intersecting fibres of the framework of the adipose tissue. This appendix was also surrounded by a mass of fat.

In the majority of my sections I have found a deposit of brown granular pigment in the obliterated areas.

The muscular coats, as a rule, are of about the usual thickness. Either layer, or both, may be thicker than normal, or may be attenuated. The increase in thickness may be due to hyperplasia of muscle, but is often due to connective tissue proliferation, while the muscle itself is diminished in amount.

The peritoneal coat, where it is free from adhesions, is usually normal, but may be thickened. A high degree of sclerosis of the blood-vessels is generally visible in all the different layers, but is especially marked in the submucosa.

The withered appendix rarely shows any trace of the mucous membrane. The central fibrous tissue is dense, and its outer zone, which represents the submucosa, contains little or no fat. The muscular coats may be well preserved, but usually there is fibrous tissue proliferation at the expense of muscle tissue. Sometimes the muscle has practically disappeared. In one of my cases all that remained was a narrow band along the mesenteric border. In the section represented in Fig. 194 the muscular coats are relatively thick and well preserved. The central fibrous tissue is dense and contains a small amount of fat.

In both the hypertrophic and atrophic forms of obliteration I have usually found a complete absence of lesions affecting the nerve elements. In most cases the nerves, owing to the paucity of cells in the surrounding tissue, appear to be unusually prominent. Morris observed the implication of the nerves in cases of obliterated appendix, and in this way explained the sense of discomfort from which the patient suffered. However, in the light of the knowledge obtained from numerous recent observations and experiments, demonstrating the absence of sensory nerves in the appendix, the clinical symptoms cannot be referred directly to nerve lesions.



Fig. 194.—Section from the Specimen Shown in Fig. 191.

The centre consists of dense fibrous tissue containing a moderate amount of fat. The circular muscular coat is atrophic, the longitudinal layer well developed. The walls of the blood-vessels in the mesappendix are somewhat sclerotic. (Gyn. Path., No. 2884.)

In a partly obliterated appendix, the canal of the patent portion may be of normal size and shape and the mucous lining little, if at all altered. Very often, however, the canal is circular and the walls more or less rigid. As in diffuse chronic inflammation, the surface of the mucosa, instead of presenting the usual folds, is smooth and even; the epithelium is often a little flattened; the interglandular tissue shows some degree of fibrous change.

In some cases a gradual transition from the normal patulous condition to the completely obliterated portion may be traced. In one of my cases where the appendix was 4 cm. long and 6 mm. in diameter, the lumen was obliterated except for a few millimetres of the proximal end, the canal became narrower, the mucosa became atrophic, the glands diminished, and then disappeared, and finally the mucosa was replaced by fibrous tissue which completely occluded the canal. In other instances the transition, instead of being gradual, is abrupt. The canal may be entirely normal to a certain point, then suddenly cease. In the case shown in Fig. 192 the appendix has a lumen of normal calibre to a point where it is suddenly reduced

to a narrow impervious fibrous cord. The distal portion, although of the usual size, is also obliterated. The appendix was removed at operation after the fifth severe attack of inflammation. At the time of operation the constricted middle portion was bound down by dense adhesions.

In cases where the obliteration is limited to a small area near the centre of the appendix, the proximal end may be perfectly normal, the distal portion cystic, and the obliterated area not more than one or two millimetres in extent. Such a condition can only be explained by the adhesion of opposite sides, as a consequence of erosion.

It appears to me also that a pathological origin best explains such conditions as are found in Fig. 192. The irregularity of the median portion and the pronounced thickening in other regions can hardly be accounted for on the basis of a normal process of involution.

The majority of my specimens showed indubitable evidence of an antecedent inflammatory process, chiefly in the presence of adhesions, which were found in about 60 per cent. of the cases. The presence of pigmentary changes in some pointed to a former pathological process, while in others, again, an active inflammation still existed often in the absence of adhesions.

The examination of numerous appendices removed shortly after the subsidence of an acute inflammatory attack demonstrates most convincingly the method of procedure in the production of obliteration. These specimens still show more or less of an active inflammatory reaction, chiefly evidenced by a leucocytic infiltration. In some, pronounced hypertrophy of the walls has taken place, while the lumen is reduced to almost microscopic size; other specimens show cicatrization of erosions, producing irregular constrictions, which eventually will contract and probably cause occlusion of the canal at that point. Fig. 175 represents an appendix removed during an attack of inflammation. In this case the canal is still patent, but the entire mucosa has been replaced by fibrous tissue which is beginning to contract, and it is probable that in this case, also, complete obliteration would be the ultimate result.



FIG. 195.—OBLITERATION OF THE LOWER TWO-THIRDS OF THE APPENDIX.

The upper third distended with pus and perforated. Removed during the twenty-sixth attack.

A recent case of acute appendicitis affords a further proof of the inflammatory nature of obliteration in some cases; sections from the distal half of the specimen show the surface of the mucosa completely destroyed and the opposite sides adherent to one another by a fibrous exudate, which shows beginning

organization. Sections from the proximal end of the same specimen show here and there small areas of flattened surface epithelium, while the remaining surface consisted of granulation tissue. The walls generally are infiltrated with leucocytes. The result in this case would certainly have been, ultimately, an obliterated distal end, and an obliterated or stenosed proximal portion. Total obliteration of the canal insures perfect immunity from further attacks, but if any portion remains pervious, the disposition to repeated attacks increases with each succeeding one. The specimen shown in Fig. 195, furnished by C. Beck, was removed from a woman sixty-eight years old who had had twenty-six attacks of appendicitis, and demonstrates the danger still lurking in the diseased organ.

CONCRETIONS.

The rôle of concretions and foreign bodies in the production of inflammation of the appendix will be discussed in another section, but the nature and origin of concretions are more appropriately considered in connection with the pathology of the appendix.

It has been noted above that the normal appendix often contains fluid fecal material which readily enters from the cecum, and is as readily expressed back into it. Fecal material exhibiting various degrees of inspissation is also frequently found in the appendix, and sometimes forms rather firm cylindrical masses which conform to the shape of the canal in which they are contained. While these masses may appear somewhat dense they are quite friable and consist almost wholly of undigested food, and other foreign material, together with a small amount of mucus, and, occasionally, a few leucocytes and epithelial cells. True enteroliths are much rarer, and are found in only a small percentage of cases. These are exceedingly dense, and, unlike the softer masses, are often rounded in outline and cause a distinct bulging of the appendix walls. Apart from their pathogenesis, the chief points of interest in regard to concretions are their structure and the factors concerned in their development. In former times it was the generally accepted view that concretions lodged in the appendix were pre-formed in some other part of the intestinal canal, or in the gall-bladder, and later worked their way, or were forced into the appendix. A glance at the anatomical structure of the appendix shows that in the majority of cases it would be impossible for an enterolith, not one-quarter the size of many actually found there, to pass through such a narrow channel. The difficulty is further enhanced by the angle of attachment of the appendix, which causes almost complete closure at the site of Gerlach's valve. I would not go to the extent of some writers who deny the possibility of gall-stones or enteroliths being forced into the appendix, but I believe such accidents are extremely rare. Where the fetal type of appendix persists, foreign bodies, including gall-stones, could readily enter the wide appendico-cecal orifice. The normal reverse peristaltic contractions of the colon may possibly aid in forcing the mass

from the cecum into the appendix. The fact, however, that bodies exactly resembling gall-stones are found in appendices, in which it is manifestly certain that the calculus must have been formed *in situ*, and that these bodies, on chemical and microscopical examination have shown the presence of a nucleus of organized matter surrounded with layers of inorganic salts, makes us hesitate to accept any such cases as genuine examples of gall-stones. The presence of cholesterin does not necessarily indicate a gall-bladder origin, although large amounts of cholesterin are not often found in enteroliths. Nor does a facetted surface imply that the stone was formed in the gall-bladder, as they are occasionally seen in the appendix. A diagnosis of gall-stones in the appendix was made in the case presented in Fig. 3, Plate III, partly on account of the facetted surfaces, but chiefly because the patient had been operated on a short time previously for gall-stones in the gall-bladder. Later examination of the calculus, however, revealed a nucleus of organized matter and the usual structure of enteroliths.

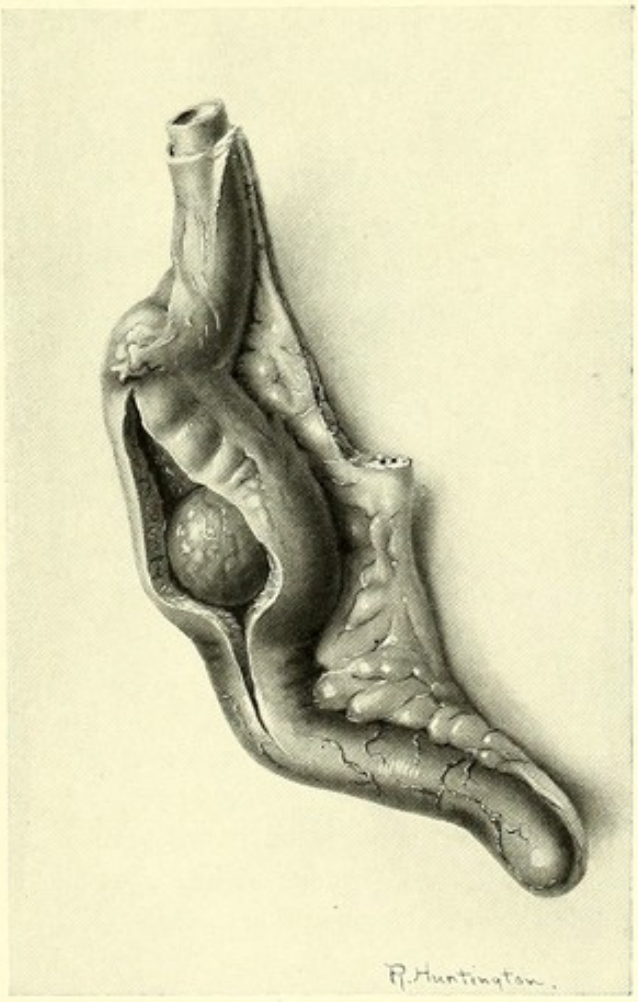

FIG. 196.—APPENDIX CONTAINING SPHERICAL CONCRETION. (SURG. NO., 3248.)

A convincing additional proof as to the formation of the appendical concretion *in situ* rather than in some other portion of the intestine, is found in the characteristic architectural arrangements of the enterolith itself, and in the relation which its chief constituents bear to the appendix walls.

Macroscopical Appearance.—The concretions, as a rule, are ovoid or spherical and have a dense, more or less smooth, polished surface (see Fig. 196). The color is a dark brown. It is common, however, to find the dark smooth surface partly covered with a grayish-white deposit of lime salts. Section through the centre shows that the interior is lighter in color and more friable than the surface. There is usually a nucleus consisting of a fragment of foreign material, and, surrounding this, concentric layers of a substance largely composed of lime salts.

Histological Examination.—The histological examination shows that the most important factor in the formation of the calculus is the mucus secreted by the glands of the mucous membrane. The mucus, which is deposited in layers around the central nucleus, becomes desiccated, and the lime salts are deposited secondarily. Frequently, fragments of epithelium, a few leucocytes and altered blood, are found in different layers. RIBBERT noted that in favorable specimens stained with Weigert's fibrin stain, the outer layer of mucus may be seen to be directly continuous with the contents of the glands of Lieberkühn. In one case, besides the two large enteroliths in the canal of the appendix, I found three smaller bodies embedded in the mucous membranes, which had evidently developed within gland lumina.

Method of Development.—Normally, the fecal particles which enter the appendix are returned to the cecum by means of the peristaltic contractions of the appendix walls. If, however, the muscular power is enfeebled in any way, or if, through the shape or size of the fecal mass, or for any other reason, as, for example, the presence of a kink or stricture, an impediment is offered to the progress of the mass toward the cecum, it is retained within the appendix and undergoes various changes. The fluid portion is gradually absorbed and the mass becomes more or less inspissated. While the drying process is taking place there is a constant factor at work, which is largely responsible for the increase in the size and density of the mass, namely, bacterial activity. The effort of the appendix to expel the foreign material is attended with more or less congestion and edema, and thus a favorable opportunity is provided for the activities of the micro-organisms contained in the mass itself. These organisms, which are often of a low degree of virulence, excite a mild catarrhal inflammatory reaction, chiefly marked by an increased secretion of mucus. There is also a slight leucocytic infiltration and some exfoliation of the surface epithelium. The congestion of the mucosa is often associated with slight interstitial hemorrhages, indicated by the deposit of pigment in the interglandular tissue, and by the presence of altered blood in the concretion.

The increased mucus secretion is the chief factor in the formation of the calculus. The mucus is deposited upon the surface of the dried fecal particle or other nucleus, and as it is deposited, becomes desiccated, and later mixed with lime salts. The influence of the continued bacterial activity in promoting a separation of calcareous material from the mucus secretion, has been demonstrated by the experiments of GALIPE (cited by Labarthe). This writer, placing some saliva in a flask, added micro-organisms which began to develop there, and soon after crystals of calcium carbonate were deposited upon the saliva. A chronic catarrhal cholecystitis associated with the presence of micro-organisms of low virulence is generally conceded to be of chief importance in the production of gall-stones, and there is sufficient evidence to show that a similar condition is an equally important factor in the formation of enteroliths in the appendix.

The concretion gradually increases in size as the layers of altered mucus and lime salts are added, while, *pari passu*, the walls of the appendix expand and usually become somewhat attenuated, until finally the glands disappear and the secretion of mucus ceases.

The spherical form of most calculi found in the appendix is supposed by some writers to be possible only when the mass has formed in a free space, and on this account the concretions are believed to enter the appendix from the cecum, but, as we have seen, a microscopic examination shows that the mucus which goes to form the calculus is derived from the glands of the mucous lining of the appendix. A particularly instructive case in this connection is seen in one of my own series. In this instance the appendix, which had given rise to no clinical signs, was removed during the course of an operation for myoma of



FIG. 197.—MUCOUS MEMBRANE, SHOWING IMPRESSION OF THE ENTEROLITH SEEN IN FIG. 232. MAGNIFIED 25 TIMES.

The mouth of a gland (*a-b*) is widely dilated by a projecting point of the concretion. (Gyn. Path., No. 2041.)

the uterus. It was free, but was excised on account of the large calculi which it contained. The appendix is 15 cm. long, its middle third is distended with a spherical concretion 12 mm. in diameter, and from here to the tip a cylindrical concretion 12 by 6 mm. fills the canal. The spherical mass has a smooth, polished surface rather closely beset with spike-like projections which are fitted into corresponding depressions in the mucosa (Fig. 197). The surface of the second mass is smooth. There are also two or three hard, smooth bodies from 1 to 2 mm. in size, which are wholly embedded in the mucous membrane.

Microscopic examination shows a normal mucous membrane excepting where the projections noted above are lodged. Here the glands are pressed apart and the surface epithelium, though intact, is flattened (see Fig. 197). Apparently these projecting points were formed in the crypts.

CHAPTER XIII.

PATHOLOGY.

PERITONITIS IN GENERAL. LOCALIZED PERITONITIS. SPREADING OR GENERALIZED PERITONITIS.

PERITONITIS IN GENERAL.

THE paramount importance of peritoneal complications of inflammatory diseases in the right iliac fossa has long been recognized, and in early times, when the cecum was regarded as the general source of the inflammatory affections of the region, the terms *perityphlitis* and *paratyphlitis* were used to designate the extension of the infection to the peritoneum and neighboring tissues. That *the appendix is the source of practically all cases of peritonitis limited to the cecal region, and is the chief source of generalized peritonitis*, is now universally acknowledged. Some well-known writers still hold that perforation of the cecum with ensuing peritonitis may result from the rupture of a deep-seated stercoral ulcer; but the majority of writers of the present day, including DEAVER, LENZMANN, and SAHLI, are inclined to doubt its occurrence, or to regard it as very exceptional. Deaver, as a result of his wide experience, remarks "that stercoral typhlitis may occur, I will not deny; that it does occur, I do not believe."

The presence of a perforation in the cecum is sometimes regarded as a proof of the occurrence of perforative stercoral typhlitis, the observers not bearing in mind the fact recognized by BURNE in 1839 that the rupture into the cecum of an abscess originating from without, is a common event. In cases where the appendix itself is but slightly altered, it is sometimes difficult to determine in which direction the rupture had taken place. As a rule, however, the cecum presents definite evidence of the external origin of the lesion, in that its outer coats show an extensive defect with necrotic margin surrounded by inflammatory tissue; the opening in the mucosa is smaller and the surrounding mucous membrane smooth and practically normal. It cannot be denied, however, that in exceptional instances a *primary non-specific typhlitis* may occur, and may give rise to an infection of the surrounding tissues and to general peritonitis. REISINGER, out of 350 cases of perityphlitis operated on at the Krankenhause in Mainz found two in which the cecum only was diseased. In one of these cases it was filled with hard fecal masses and was perforated in two places. Autopsy revealed no cause for this condition.

Carl Beck describes in detail a case originally operated upon for appendicitis, in which partial gangrene of the cecum was revealed and during the course of a laparotomy performed later, the appendix was found intact. (See Chap. XXI, p. 489.)

Sonnenburg describes a case of circumscribed inflammatory disease, primary in the cecal walls, not due to a specific infection, and apparently not associated with a stricture. This writer suggests the possibility of there having been a hernia of this portion of the bowel into a peritoneal pocket. In one instance related by Renvers, cited by Sonnenburg, a pericecal abscess followed a perforation caused by the attrition of a fecal concretion the size of a walnut, which was lodged in a pocket in the cecal wall. This case, as well as a second, in which a concretion had formed with a gall stone as a nucleus, belong rather to the relatively common class of cases in which perforation of the cecum is due to injury by a foreign body. Osler states that he has twice seen perforation of cecal ulcers. In only one (Reisinger) of the recorded cases was there any mention of fecal impaction in the cecum. The most convincing proof of the great rarity of this condition is found in the fact that at autopsy *in vivo*, and on the postmortem table, fecal stagnation in the cecum is almost never observed. That there are instances of typhlitis which go on to ulceration, and may lead to rupture with subsequent abscess formation or diffuse peritonitis, is very true, but these are practically all cases of secondary disease of the cecum due to stricture, etc., or else are cases of specific inflammatory disease, such as may affect any portion of the alimentary canal. Tuberculosis, typhoid fever, actinomycosis, and amœbic dysentery, all give rise to inflammation attended with ulceration, which may proceed to perforation, with all its unfortunate sequelæ. Tubercular infection is especially prone to become localized in the cecal region, and instances of perforation of tubercular ulcers are not rare.

Before considering the lesions of the peritoneum and contiguous tissues produced by appendicitis, a brief review of the minute anatomy and physiology of the peritoneum will aid in a clearer conception of the changes which it undergoes when endeavoring to limit or destroy any irritant to which it is subjected.

The topographical anatomy of the peritoneum, with regard to the cecal and neighboring regions, is fully demonstrated in Chap. V. For the views expressed here regarding its structure and function I am chiefly indebted to Lennander's admirable summary of the most recent investigations in this field. The surface of the peritoneum is covered with a single layer of flattened endothelial or epithelial cells. The margins of these cells adjoin one another, and are united by protoplasmic processes; thus, when the cell protoplasm is contracted, an inter-endothelial space is formed which is larger or smaller according to the degree of contraction. The protoplasmic processes at the same time undergo definite lengthening or shortening. This arrangement is well adapted to the variations requisite in the different conditions of collapse or distention of the

stomach and intestine. In the inter-endothelial spaces are the stomata vera and stomata spuria. The latter appear as larger or smaller points between the adjacent cells and are usually occupied by leucocytes which have been taken up in passing to and from the peritoneal cavity. The stomata vera are found at points where three or more cells meet, and are often lined with young endothelial cells showing active nuclear division. They may appear open or closed, apparently according to the state of contraction of the neighboring cells. They are distributed generally throughout the peritoneal cavity, but vary in number in different areas, being most abundant and largest in the centrum tendineum of the diaphragm, then in the gastro-hepatic and gastro-splenic ligaments, next in the omentum near the colon, but relatively few in the flanks. They are also numerous in the ligamenta lata and in the mesorectum. In the centrum tendineum, experiments seem to show that the stomata vera are continuous with endothelial-lined lymph channels which open directly into the lymph capillaries and are in close communication with the lymph channels of the diaphragmatic pleura.

The subserosa consists of connective tissue rich in elastic fibres, which, in some areas, contains a variable amount of fat. Under the endothelial cells of the serosa lie the lymph spaces, their ramifications surrounding the cells. The larger spaces are lined with endothelium and go directly into the lymph capillaries. The abdominal cavity is very rich in blood and lymph vessels, and these are surrounded with a network of endothelial-lined lymph spaces. Lymph capillaries are especially abundant in the central tendon of the diaphragm.

The abdominal cavity may be regarded as a large lymph sac which is connected through the lymph spaces with the arteries on the one hand, and with the veins and lymph vessels on the other. In the normal state the inflow and outflow are so regulated that while the endothelial surface is continually moist, there is a scarcely measurable amount of free fluid in the peritoneal cavity.

The great power of absorption has been clearly shown by experiments. In a dog or rabbit a collection of fluid equal to 10 per cent. of the body-weight can be absorbed in thirty minutes. In the same animals just after death 6 per cent. of the body-weight can be absorbed in the same time, but as the circulation has then ceased the absorbed fluid remains in the lymph spaces in the subserosa. The power of absorption increases to a certain degree with the increase of intraperitoneal pressure, but if the pressure becomes still greater the veins and lymph vessels are compressed and absorption diminishes. The absorption is greatest in the centrum tendineum. Fluid injected into the abdominal cavity of an animal which is in such a position that the lower part of the body is elevated and the fluid comes in contact with the diaphragm, is absorbed much more quickly than when the animal is in another position. Blood corpuscles, bacteria, etc., are also taken up from the abdominal cavity in a very short time. After an injection of Berlin blue into the abdominal cavity the colored granules are found to have passed through the abdominal cavity and lymph spaces of the diaphragm, and in a short time are found in the thoracic duct.

In the absorption from the abdominal cavity the chief factors seem to be the inter-endothelial spaces and the stomata. The absorption of colored granules appears to take place exclusively by this means, and it is probable that bacteria are taken up in the same way.

The subserous tissue is very rich in nerves, the blood-vessels especially being abundantly surrounded in their finest ramifications by sympathetic nerve plexuses.

In experiments concerning the sensibility of the abdominal cavity it has been shown that the normal serosa is not sensitive to touch nor to injury, but the diseased serosa is exceedingly so. On testing the sensibility of the peritoneum during the course of operations under local anesthesia, it has been found that the parietal peritoneum is exceedingly sensitive to pain impressions, but that the viscera, the omentum, and the mesentery do not possess pain nerves. The pain nerves in the parietal peritoneum are derived from the intercostal, lumbar, and sacral nerves, and course in the subserosa. It is very probable that painful impressions in the abdomen are largely due to traction upon the nerves in the subserosa of the abdominal parietes. It is especially noteworthy that very slight traction produces pain.

In the vast majority of all cases of appendicitis there is involvement of the peritoneum. In chronic appendicitis there are usually adhesions, indicating a former acute or chronic inflammatory process. In acute inflammation all grades of peritonitis are seen, from the mildest, in which the serosa of the appendix alone is reddened and turbid, but without appreciable exudate, to the most intense reaction, characterized by an abundant purulent exudate filling all parts of the peritoneal cavity and walled off partially, or not at all, by friable adhesions into pockets. Between these extremes all grades of the affection may exist. It cannot be considered, however, that the various forms of peritonitis merely represent different stages in the same process and that unless interrupted by operations or limited by the resistance of the organism, each individual case would proceed through all stages. On the contrary, there are some cases which run their course to a lethal termination, and show only a fibrinous deposit throughout, while in other cases there is from the outset a copious purulent exudate. As a rule, however, an early reaction accompanied with a serofibrinous exudate precedes the suppurative process.

Animal experimentation has shown that after the injection into the peritoneal cavity of a large amount of infected material of a low grade of virulence, the bacteria become absorbed and the animal lives, while the same amount of material of a high virulence causes death in from ten to twenty hours, with almost no evidence of peritoneal reaction, as the organism is overwhelmed by the rapid absorption of a large amount of toxic material. A small amount of unusual virulence causes death from toxemia with or without bacteriemia. A greater dilution of the same, in consequence of slower absorption, is more favorable. Likewise, other things being equal, a large serous or purulent exudate is

favorable. The outpouring of an abundant exudate is a distinctly conservative process, as it serves not only to dilute the infective material, but has also marked bactericidal powers. While, as stated above, the normal peritoneal fluid is bactericidal, this property is greatly enhanced by the addition of substances derived from disintegrated leucocytes, and at the same time the normal phagocytes also assist in disposing of the infection. BUCHNER (cited by Lenzmann) found that the alexins contained in the leucocytes possess a proteolytic power capable of destroying albuminous substances and bacteria.

In the slight local reaction accompanying mild attacks of appendicitis, and in more serious infections during the early peritoneal reaction characterized by a slight sero-fibrinous exudate, the peritonitis is now generally believed to be due to the diffusible toxins produced by the bacteria and is of a chemical nature. It is to this "toxic peritonitis" that a localization of an infection is due.

The varieties of peritoneal infection are differentiated according to the amount and character of the exudate, and are as follows:

Acute fibrinous peritonitis.
" sero-fibrinous peritonitis.
" fibrino-purulent peritonitis.
" purulent peritonitis.
" dry or septic peritonitis.

The various types of peritonitis appear to depend partly upon the variety of the micro-organism concerned, partly upon the amount and virulence of the infection, and partly upon the local and general resistance of the individual. By far the most important factor is the amount and virulence of the infective material.

The extension of the inflammatory reaction in appendicitis beyond the organ itself, may be conveniently considered under the following divisions:

1. Circumscribed inflammation of the peritoneum and other structures in the immediate neighborhood of the appendix; and intra- and extra-peritoneal abscesses by direct propagation, including pelvic abscesses, subphrenic abscesses, empyema of the pleural cavity, abscess in the muscles of the abdomen and back.

2. Diffuse and generalized peritonitis.

3. Extension of infection by way of the blood vascular system: thrombosis, purulent phlebitis, embolism, liver and lung abscess.

4. Lymphangitis, septicemia.

LOCALIZED PERITONITIS.

As stated above, the peritoneal investment of the appendix, which is an integral part of the organ itself, is involved in practically all cases of appendicitis, excepting instances of mild catarrhal affections. In most instances the process extends beyond this point, and involves to a greater or less degree the surround-

ing structures. When operating during the first twenty-four or thirty-six hours of an acute attack, it is common to find a slight excess of serous fluid in the right iliac fossa with a little plastic lymph deposited upon the appendix and upon the contiguous visceral or parietal peritoneum forming an easily separated adhesion, while the surrounding peritoneum is reddened and may have partly lost its normal lustre; or, even when no exudate is visible, on lifting up the appendix it may seem to be slightly adherent to the adjacent peritoneum and a somewhat viscid condition of the surface is discernible. This slight local reaction, as has been said, is not due to bacterial invasion, but is produced by the action of the diffusible toxins of the infective agent. Cultures from the affected area of peritoneum, as a rule, are sterile in these cases, and no organisms are found in coverslip preparations. In mild affections of the appendix the peritoneal reaction may not progress beyond this stage, and resolution soon follows. In other instances, however, this condition only marks the initial stage of the peritoneal involvement and is succeeded by the more intense reaction which accompanies the invasion of bacteria. When the infective material is of a low degree of virulence the reaction of the peritoneum is characterized by a more or less abundant fibrinous or sero-fibrinous exudate, forming somewhat dense, but at the outset very friable adhesions. The appendix is often entirely buried in the thick mass of friable, fibrinous material, which glues together all the adjoining structures. This inflammatory mass, including the appendix, is often very edematous, and hemorrhages from the greatly dilated blood-vessels frequently occur. In some instances the exudate is so abundant and increases so rapidly that an abscess is suspected. At an early date the invading bacteria are destroyed and beginning organization is found, which, unless some untoward accident occurs, proceeds rapidly, so that in a short time the mass becomes greatly diminished in size, and finally all that remains are the adhesions binding down the more or less thickened appendix. On examining such a specimen after removal, it is not uncommon to find that a deep-seated ulcer or area of necrosis had caused a virtual perforation of the appendix wall, but that the thick adventitious layer had acted as a barrier to the further progress of the infection. Very frequently only a small portion of the serosa of the appendix and a correspondingly limited area of the adjacent peritoneum are affected, while the rest of the appendix is practically normal. The distal end is most often involved, doubtless on account of more defective drainage, and the tendency of foreign bodies and enteroliths to lodge here, so favoring more extensive erosions and suppuration, which permit the easy penetration of the infective agents to the surface. When the first effort of nature to limit the progress of the disease is not successful, the point of greatest danger, where rupture is most imminent, fortunately tends to attach itself to a neighboring structure and thus avert the danger of a general peritoneal infection. The area of impending perforation often becomes adherent to some portion of the intestinal canal, and if drainage is established, a spontaneous cure of the attack may be obtained. It is less fortunate for the indi-

vidual when the appendix drains into some other hollow viscus, as the bladder, the ureter, the gall bladder, or the pleural cavity. One of the most striking examples of nature's ability to limit disease with the most excellent results, is seen in the often observed tendency of the omentum to gravitate to the danger point. A very small area may become attached, as in the case shown in Fig. 198, or the tip, a half, or even the entire appendix may be rolled up in the omentum (see Fig. 199). As this tissue becomes more or less infiltrated and edematous, a large oval mass the size of a fist may be formed. This is often quite movable, and on account of the density, size, and mobility of the mass, the physical signs in such a case are often suggestive of a neoplasm. When the mass is adherent abscess formation is closely simulated.

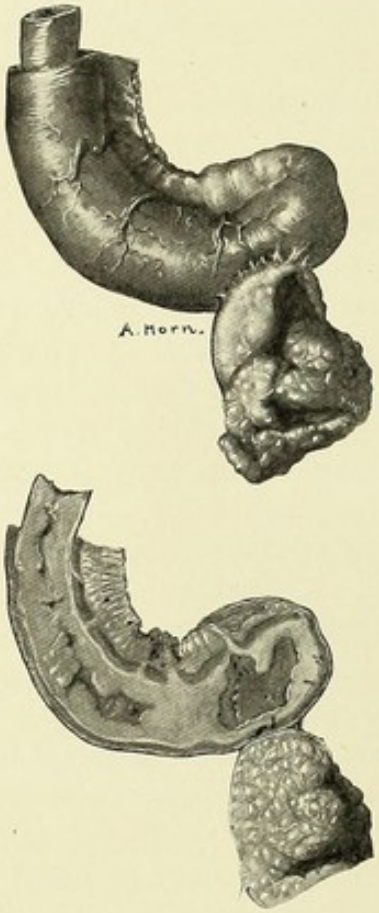

Fig. 198.—Acutely Inflamed Appendix with the Omentum Adherent to a Point of Threatened Perforation. (Specimen from T. S. Cullen.)

In examining many specimens consisting of the appendix embedded in the omentum, or with a portion of the omentum attached to it, I have found that as a rule there is a distinct defect in the wall of the appendix at one or more points, and that these areas have been sealed over by the omentum, the destroyed area being replaced by inflammatory products. In the case shown in Fig. 199 the longitudinal section of the appendix shows a sudden cessation of the normal coats at a point about 2 cm. from the tip, where for a distance of about 1 cm. the walls consist of connective tissue continuous with the fibrous stroma of the omentum. At these points it is impossible to separate the omentum without tearing the tissue, while in other parts the appendix may, as usual, be peeled quite easily out of its bed of omentum. In specimens removed during an acute attack, the omentum is found to be exceedingly hyperemic, and there is usually more or less extravasation of blood into the tissue. Purulent foci may be found here and there, and in the vicinity of the most densely adherent areas, considerable necrosis may be present. Under the microscope a general edematous and leucocytic infiltration is found.

In the peritoneal reaction which is excited by a mild irritant, an increased transudation of serous fluid accompanies the fibrinous exudate, and may be the only evidence of the peritoneal reaction. This appears chiefly as an excess of fluid collected in the dependent portions of the fossæ of the ileocecal region and in the pelvis. At other times the fibrinous exudate is permeated with

serous fluid and appears as a thick, watery, translucent membrane which is exceedingly soft and friable. Sometimes the serum is pocketed in the midst of the fibrinous exudate, and as the adhesions become organized, the surface of the appendix and the surrounding peritoneum may be studded with minute, clear, transparent blebs, varying in size from a pin-head to a split pea, while now and then cysts of considerable size are formed, in some instances inclosing

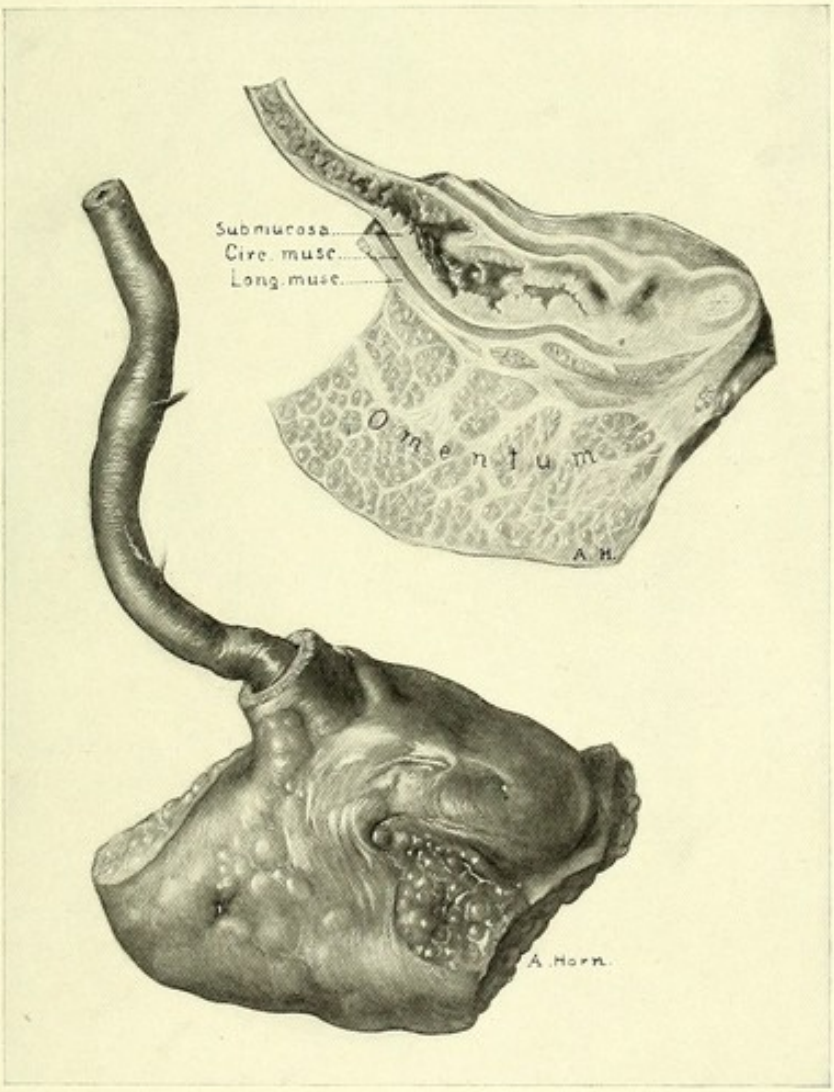

FIG. 199.—APPENDIX ROLLED UP IN OMENTUM.

The proximal portion has been stripped out between the submucous and internal muscular layers. In the sectioned specimen a defect in the appendical wall has been replaced by granulation tissue. (Surg. No., 13141.)

a part of, or even the whole appendix. Fig. 200 shows an appendix with a peritoneal cyst attached to its tip, observed at autopsy in a woman dead of an intercurrent disease. The appendix extended directly toward the vertebral column, and was adherent in its distal portion. Attached to the tip was a transparent cyst the size of an apricot, containing perfectly clear, yellow fluid. The tip of the appendix was thickened, fibrous, and obliterated, and projected

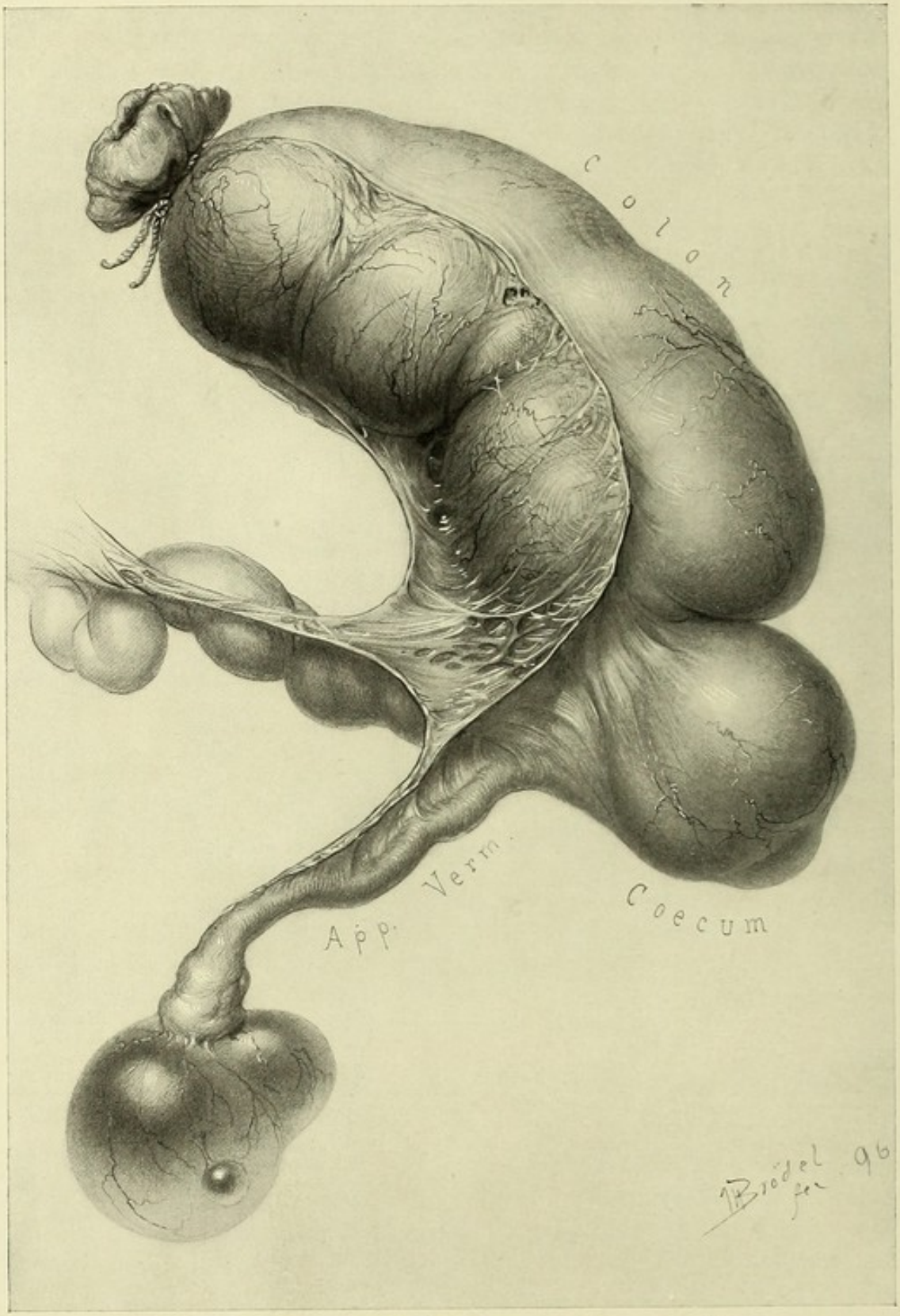

Fig. 200.—Encysted Peritonitis Surrounding the Tip of the Appendix.

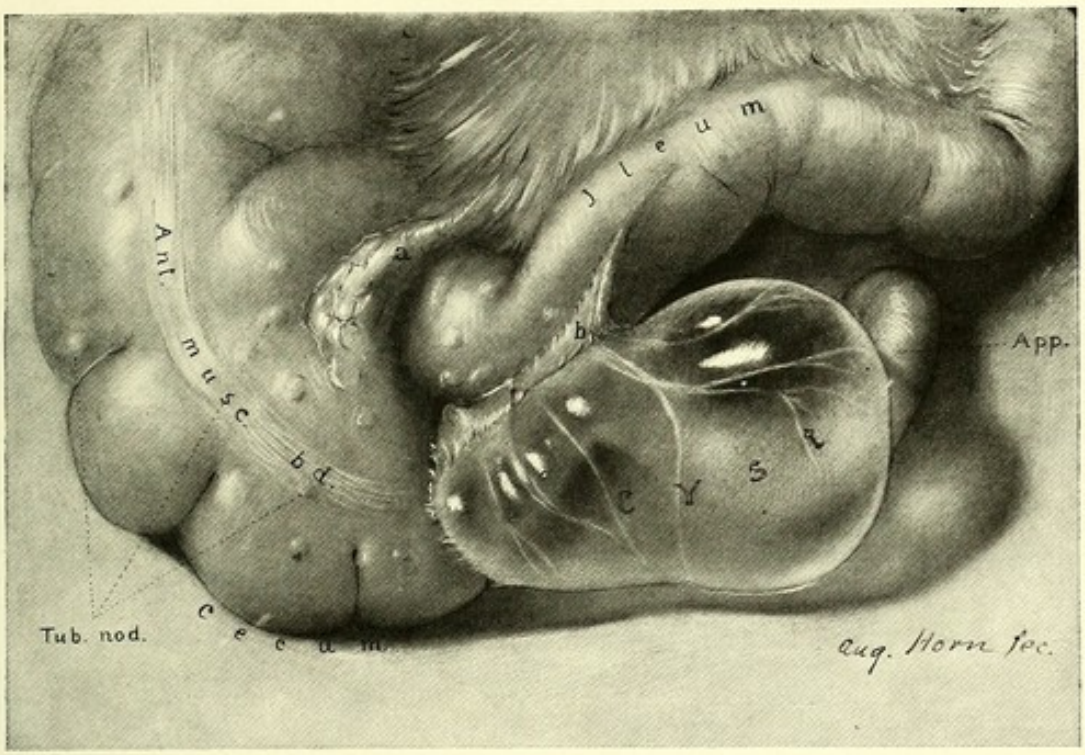

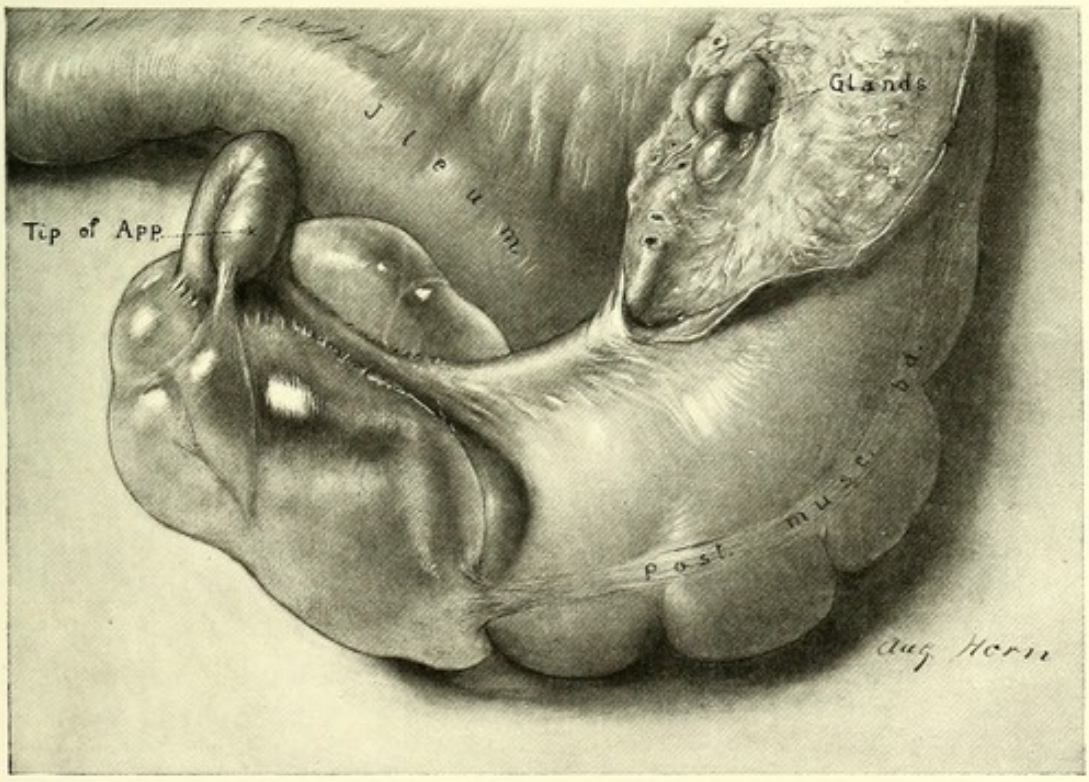

FIG. 201.—ENCYSTED PERITONITIS OF TUBERCULAR ORIGIN.
The tip of the appendix doubled upon itself and held in this position by adhesions.

a little way into the cyst. The specimen shown in Fig. 201 was also observed at autopsy. In this case the cyst which encloses the entire appendix was not due to disease of that organ, but was part of a generalized peritonitis of tubercular origin. A sero-fibrinous peritonitis, as a rule, is found only in cases of non-perforative appendicitis, but may sometimes be present in cases where there is a pin-hole perforation.

Histological Examination.—Histological examination of the peritoneal changes at the outset shows dilatation of the blood-vessels, swelling and proliferation of the endothelial cells, and edema of the subserosa, with swelling of the connective tissue cells and more or less leucocytic infiltration. On the surface there is a slight fibrinous deposit mingled with occasional leucocytes. As the infection continues there is some degeneration with exfoliation of endothelium and more abundant deposit of fibrin and leucocytes. Extravasations of blood both into the subserous tissue and upon the surface are common and may be extensive. Very soon the endothelium along the margins of the denuded areas as well as the connective tissue present evidence of rapid proliferation, newly formed blood capillaries extend into the fibrinous deposit, and the cellular infiltration, which at first consisted of polymorpho-nuclear leucocytes, contains an increasing proportion of small round, and plasma cells. Organization and cicatrization then proceed more or less rapidly. As organization becomes complete, portions of the serous surface may be enclosed by the adhesions. The endothelial lining of the enclosed area then gradually extends around the adjacent surface of the adhesions, forming an endothelial-lined sac which finally becomes distended with serous fluid and forms the transparent peritoneal cysts.

Peri-appendical Abscess.—The most frequent and most important complication of appendicitis is the occurrence of circumscribed purulent peritonitis and suppuration in the contiguous retro-peritoneal tissue. This accident may happen in the presence or absence of perforation, but is most frequently associated with perforation or with gangrene. The migration of bacteria from the lumen of the appendix, either by penetration of the appendix walls or by means of a perforation, is essential to the production of a suppurative peri-appendicitis. The chief factors concerned in encapsulating the purulent exudate and preventing its general distribution are the presence of old adhesions, or the occurrence of a plastic exudate, which precedes the suppurative process and serves to glue together the neighboring intestinal coils, thus forming a more or less perfect barrier to the further extension of the infection. The slight inflammatory reaction which produces the viscid fibrinous exudate, has already been noted as occurring in the early stage of acute appendicitis, and, excepting in some cases of very early perforation or rapid gangrene, usually precedes the penetration of micro-organisms through the walls. The pre-perforative stage of deep-seated ulcers also is marked by a local peritoneal reaction which may cause protective adhesions to form before the floor of the ulcer gives way. In

some cases the dangerous area may in this manner be effectually sealed over, but when this barrier is slight it is gradually penetrated by micro-organisms which excite a purulent reaction. Fortunately, as the suppurative process advances, the reaction on the part of the tissue which produces the purulent exudate also tends to form a limiting wall. At the outset this consists of a plastic fibrinous material of variable thickness. If the infective material is of high grade of virulence, or if a large amount of it is poured out, this barrier often gives way, but in the majority of cases it resists the first onset, increases in thickness, and undergoes speedy organization so that in a short time there is a firm dense protective wall of organizing tissue. In favorable cases, while the activity of the pyogenic organisms causes degeneration and liquefaction of the inner coats, in the peripheral layers, there is an active, productive, inflammatory process which out-balances the degenerative process in the interior.

The position of a circumscribed appendical abscess depends chiefly upon the position of the cecum, the direction and length of the appendix, and the location of a perforation, but it is influenced by gravity, and by the resistance of the surrounding structures. The wide range of the location of the abscess is graphically represented in Chap. XXVI. Naturally, the commonest site is in the right iliac region, and next in order of frequency is the pelvis. The frequent occurrence of pelvic suppuration in cases in which the appendix does not descend in this direction and has no apparent connection with the abscess, has been pointed out in Chap. X. The right iliac abscess is usually below and exterior to the cecum, but may be medianward, anterior or posterior. It is usually at some point in direct relation with the abdominal wall and is immovable. In one group of cases, however, the abscess may be more or less movable within the abdominal cavity. These develop in the midst of intestinal loops or between the two layers of the mesentery, or between the intestine and the omentum (an excellent example is shown by SONNENBURG, see Plate III), or, again, a small focus of suppuration may be embedded within the omentum, which is wrapped around the appendix. The most favorable locations as regards the general health of the patient and from the therapeutic standpoint are the pelvis and flanks. In these regions there is less danger of septic absorption, owing to the small number of stomata and the relatively poor lymphatic circulation. A large abscess in the flank, however, which extends upward, may involve the subphrenic region, where the possibility of absorption is very great. A suppurative process localized amidst coils of intestine, is especially dangerous, because of the ready absorption of septic material through the abundant lymphatic supply of this region and on account of the extensive involvement of the intestinal coils, with the added danger of toxemia from absorption of intestinal bacteria or of their products.

Surgical intervention shows the most satisfactory results when undertaken at the stage where the suppurative process is definitely localized by a firm wall of organizing tissue, and on this account many surgeons advocate delay until

this "walling off" process is well established. Unfortunately, there are several factors to be reckoned with, which materially diminish the benefits to be gained from this expectant method of treatment.

1. The abscess wall may be imperfect at one or more points and gradually give way, forming secondary abscesses which may be definitely circumscribed, or may in turn proceed to form other purulent foci, the progressive fibrino-purulent peritonitis of Mikulicz.

2. Bacteria may slowly penetrate the apparently intact wall of the abscess, and cause secondary abscesses to form which, however, do not communicate. These cases are particularly important from the therapeutic standpoint, as the operator, finding a circumscribed abscess with intact walls, may not recognize the presence of the secondary pockets and so fail to evacuate and drain them.

3. The heightened virulence and rapid accumulation of fluid may cause necrosis and rupture of the abscess into the general peritoneal cavity with an ensuing generalized peritonitis; or, without rupture of the abscess, virulent microorganisms may penetrate its walls, and induce spreading or generalized peritonitis.

4. The abscess may rupture in other unfavorable directions, as into the pleural cavity or lungs; into the gall-bladder; into some portion of the urinary tract; or it may perforate the fascia transversalis and produce a wide-spread phlegmon of the abdominal walls. It may erode the large blood-vessels, or cause septic lymphangitis or phlebitis.

5. Profound septicemia may develop.

Retro-peritoneal Abscess.—When the appendix is situated behind the cecum and is extra-peritoneal, an abscess may develop entirely without the general peritoneal cavity. Figs. 72 to 78 illustrate the arrangement of the peritoneum in these cases. Usually in such cases the posterior aspect of the cecum also is devoid of a peritoneal covering and forms part of the abscess wall. In some instances, however, the cecum may be wholly intra-peritoneal, while the appendix lies behind the peritoneal lining of the posterior abdominal wall, in which case the cecum may not be involved in the suppurative process. More rarely the appendix is covered by the peritoneum of the posterior surface of the cecum, and an abscess may develop in the posterior cecal wall, from there extending upward into the abdominal wall. In exceptional instances extra-peritoneal abscesses form, when the appendix is in the subcecal position and is provided with the usual peritoneal investment. This may occur in different ways. The infection may extend by way of the mesappendix, either by direct propagation from a purulent focus in the mesentery, with or without perforation of the appendix; or by means of the lymphatics. In other instances the appendix has been connected by adhesions to the abdominal parietes, in which case the double peritoneal layer, united by granulation or scar tissue, is penetrated by the pyogenic bacteria, and the suppurative process then continues extra-peritoneally. Finally an intra-peritoneal abscess may penetrate the abdominal fascia and become extra-peritoneal.

Abscesses developing behind the peritoneum may infiltrate the surrounding abdominal wall, or may burrow between the peritoneum and subjacent musculature in various directions. The muscles of the lumbar region are frequently involved and a huge abscess may form, pointing in the lumbo-sacral region or extending along the ileo-psoas muscle to the thigh or inguinal region. G. W. CRILE, of Cleveland, has had a case in which the abscess extended from the right iliac fossa down the inner aspect of the thigh to the popliteal space, where there was a large collection of pus. In some cases the ileo-psoas muscle becomes completely gangrenous, and the purulent process may even involve the periosteum of the lumbar vertebræ or of the iliac bones.

A glance at the anatomical relations of this part shows with what facility the infection may extend upward into the lax perirenal tissue or, advancing still further, how easily a subphrenic abscess may develop extra-peritoneally. As has been noted previously, a circumscribed peri-appendical abscess of intra-peritoneal origin may also extend to the subphrenic region. In either case perforation of the diaphragm may result in a pyothorax, or, owing to the rich anastomoses between the lymphatics of the abdominal and pleural surfaces of the diaphragm, a septic pleuritis may develop in the absence of perforation. In 4 out of the 7 cases of subphrenic abscess observed at autopsy, the process had extended to the pleural cavity, but in none was there a perforation of the diaphragm. The purulent process may extend along to the course of the large vessels beneath Poupart's ligament, and into the groin. An apparently rare condition is found in cases of retro-peritoneal pelvic abscess (see Chap. XXVI). In a case described by LENZMANN, the purulent process extended behind the peritoneum to the splenic region.

The contents of the abscess varies in amount from a few cubic centimetres to a litre or more. In a case cited by FITZ more than a gallon of pus, liquid feces, and scybalæ were removed. An apparently large abscess may consist of a thick mass of edematous, infiltrated tissue, containing only a few cubic centimetres of pus. In other instances, the abscess walls are thin and there is relatively a large amount of fluid.

The contents are usually a creamy or a yellowish purulent fluid of rather thin consistency, and having the characteristic odor of colon bacillus putrefaction. In rare instances the pus has a blue color due to the presence of bacillus pyocyaneus. Occasionally the fluid has an ichorous character. It is often distinctly feculent and of a brownish color. Particles of fecal matter are sometimes found when the area of perforation in the appendix is large. When the abscess cavity communicates with some portion of the intestinal canal, a large portion of the intestinal contents may pass directly into the abscess. An inspissated fecal mass or a concretion is found in the abscess in a considerable number of cases and it is not uncommon to find the necrotic appendix lying free in the cavity. Quite frequently there is evidence of slight hemorrhage into the cavity. EHRICH records two cases in which there were large

quantities of fluid, blood, and clots, evidently due to erosion of a large vessel, although the exact source of the hemorrhage was not ascertained. Upon opening the abscess it is not uncommon to find bubbles of gas escaping with the fluid contents. In some cases this is due to the admixture of air from the intestinal canal, and it is especially frequent when the appendix abscess is associated with perforation of the cecum. In other instances this phenomenon is due to the presence of one or more of the intestinal gas-producing microorganisms in the abscess cavity, and may exist in the absence of perforation. The bacillus aërogenes capsulatus has been found in rare cases.

Results of Circumscribed Peri-appendical Abscess.—The disastrous consequences which may follow abscess formation have been enumerated above. It is, however, unquestionably true that a spontaneous cure may terminate the attack, leaving in some instances an obliterated appendix and immunity from further attacks; in other cases, a deformed appendix, which is one of the most important factors in causing future attacks; and in other cases still, adhesions remain which are often the cause of chronic digestive disturbances and are a source of danger, in that they form constricting bands, beneath which a loop of intestine may become incarcerated.

Resolution may be brought about in two ways: namely, by rupture of the abscess in a direction which insures favorable drainage, or by gradual absorption of the inflammatory products. SAHLI believes that drainage is a much more important factor than absorption in promoting resolution. In either case, as in non-suppurative forms of peritonitis, the subsidence of the inflammation is followed by the disappearance or shrinkage of the mass.

As the abscess progressively enlarges, the increasing pressure impedes the productive inflammatory process in the periphery, and also tends to produce tissue necrosis, until finally the abscess wall gives way at the point of least resistance. This end is further hastened by the increased activity of the bacteria at the point of lessened resistance. The abscess may rupture in such a direction that more or less perfect drainage is established and a spontaneous cure may result.

Rupture through the abdominal wall, or into the intestinal canal.—The general tendency is for rupture to occur through the abdominal wall, or into some portion of the intestinal canal. The relative frequency with which the abscess opens through the abdominal wall, or into one of the body cavities, is indicated by the following statistics collected by SONNENBURG (combined by A. O. J. KELLY):

Through the abdominal wall	46
Into the cecum	40
Other portions of intestinal canal	11
Peritoneal cavity	8
Pleural cavity	6
Urinary bladder	3
Uterus	1

MÜHSAM's statistics also show that rupture occurs oftenest through the abdominal wall, and next in frequency into the intestinal canal, but give the rectum as the part of the intestine most commonly involved. The third direction in order of frequency, according to Mühsam's statistics, is through the vagina. Other writers do not regard spontaneous rupture through the vagina as a frequent occurrence.

SONNENBURG could find no reference in the literature to perforation of a peri-appendical abscess into the gall bladder, but describes a case which came under his own observation. The patient had had several perityphlitic abscesses evacuated, and then a new collection of pus, which was connected with the original cavity by a narrow channel, pushed in between the mesentery and the under surface of the liver, and opened into the gall bladder. The abscess contained dark, bile-stained pus. BREWER has reported a case in which an empyema of the gall-bladder occurred, but he does not describe a close connection between the two cavities.

Sonnenburg also describes a case in which a pyocele testiculi formed as a result of a perityphlitic abscess, probably owing to a patent processus vaginalis. Rupture through the abdominal wall usually occurs in the right flank, but is sometimes found in the back, and is not infrequent at the umbilicus. In the latter case an inflamed ductus omphalo-mesentericus is often suspected, the differential diagnosis before operation being sometimes impossible. Rupture through the abdominal wall or into the intestinal canal is most favorable for a spontaneous cure. If thorough drainage is established, the cavity is rapidly obliterated by granulation, and the opening soon closes. In a considerable proportion of cases, however, a fistula forms which may close spontaneously in a few weeks, or may persist indefinitely. In some instances an apparent cure is followed by re-opening of the sinus and increased discharge, which may again disappear, only to recur. A fistula following spontaneous rupture of a peri-appendical abscess may be simple, in which case the discharge is merely purulent; or the fistula may be fecal. The fistula may also be single or multiple. In one of Sonnenburg's cases there were several sieve-like perforations of the integument. The persistence of a simple fistula is usually due to the presence of some focus of infection, often an enterolith or foreign body, and after this comes away in the discharge, or is removed, a spontaneous cure soon follows. In some instances the failure to close spontaneously seems to depend upon the rigidity of the inflammatory walls of the sinus, which prevents approximation of its sides and delays the absorption of the pyogenic lining. A thorough curetting of the sinus in such a case usually results in speedy cure. Very often, after the spontaneous or operative opening of the abscess, a fecal fistula forms, usually communicating with the cecum either at a point corresponding to the base of the appendix, or at some other point where partial necrosis had occurred prior to the evacuation of the abscess. There is usually a single opening into the bowel, but sometimes there are several. Fecal fistulas commonly close spon-

taneously. The failure to do so, as in simple fistulas, may generally be attributed to the presence of an infective focus in the fistulous tract where drainage is defective. The eversion of the mucosa into the channel probably delays the approximation of the margins of the intestinal defect, but rarely extends far enough to prevent the final obliteration of the sinus.

The evacuation of the abscess cavity into the intestinal canal may also result in complete disappearance of the perityphlitic mass. Such cases are too common to require enumeration. There is generally the history of the presence of a large tumor associated with the usual clinical signs of intra-abdominal suppuration, then the sudden disappearance or diminution of the mass accompanied by the passage of pus *per rectum*. Fecal concretions may be discharged with the fluid portions of the abscess contents and even a part or the whole of the appendix, which has sloughed off from its attachment, may also be discharged. Fig. 150 shows a gangrenous appendix which was passed *per rectum*. In some cases there are coincident openings into the bowel and the bladder, and in a case described by SEDILLOT, vesical, intestinal, and abdominal fistulas had formed.

In some cases the evacuation of the abscess contents is only partial, and fecal concretions, foreign bodies, or collections of infective material may remain; and, again, a wide defect in the intestinal wall may form, through which the contents of the bowel pass into the abscess cavity. Not uncommonly an enterolith or foreign body which has remained in the cavity finally becomes encapsulated in a dense bed of adhesions. In one case, recently observed, a concretion was found embedded in the muscular coat of the transverse colon a short distance from the tip of the retrocecal appendix. It is probable that in this case the abscess had discharged its contents through a small opening in the intestinal wall and that the concretion had been unable to pass through.

The pouring out of feculent material from the intestinal canal into the abscess cavity is always attended with unpleasant and often disastrous consequences. The conditions present are most favorable for heightening the virulence of the contained micro-organisms and septic absorption progresses rapidly. CHRISTOFFERS reported a case in which a perityphlitic abscess ruptured into the rectum. The temporary improvement following this event was succeeded by a rapid return of the unfavorable symptoms. Autopsy showed a large cloaca containing fecal material in Douglas' *cul-de-sac*, which communicated with the rectum through two ragged openings. GRAWITZ has described a similar case of stercoral abscess.

Rupture into the Bladder.—There are numerous observations relating to infections of the bladder accompanying appendicitis and a few instances of involvement of the ureter and of the pelvis of the kidney. The toxic and infective lesions of the kidney, consisting usually of an acute parenchymatous nephritis, are common to all acute infections, and present nothing peculiar in their association with disease of the appendix. A purulent cystitis, or a

ureteritis with ascending pyelonephritis, may be produced by the direct penetration of the bladder or ureteral walls by infective micro-organisms from a surrounding inflammatory mass. In other cases the bladder wall is perforated, and the appendix or a peri-appendical abscess drains directly into the bladder. A true vesico-appendical fistula is comparatively rare, but the rupture of a pelvic abscess of appendical origin into the bladder is not uncommon. KEEN, describing an instance of the former condition in 1898, could not find a similar case in the literature, but commented upon the well-known occurrence of the latter. Out of 25 cases of perforation of the bladder collected by APPUHN, in 4 cases only was there a direct communication established between the appendix and the bladder. In many cases of appendical abscess, the suppurative process is localized well back in Douglas' *cul-de-sac* and the bladder is not affected. In other cases, however, the lateral fornices and the space of Retzius are involved, the bladder then forming part of the abscess wall. As the pressure within the abscess increases, the portion of its wall which is least resistant gradually gives way, and finally rupture occurs, sometimes into the bladder, sometimes into the rectum, or even in both directions. As a rule, an acute cystitis precedes the rupture of the bladder wall, but in a few instances the mucous membrane has remained perfectly smooth and normal even while a large abscess has been draining into the bladder. In a case described by HALLE an acute vegetative cystitis, associated with severe hematuria and the presence of a perivesical mass, led to the diagnosis of a new growth of the bladder wall. In this case two minute perforations in the midst of polypoid outgrowths in the bladder led into a hyperplastic inflammatory mass having a cavity as large as a fist, filled with clotted blood. The appendix was partly embedded in the wall of the mass. In some instances the inflammation of the bladder wall induces the formation of phosphatic calculi, and in a few cases extra-vesical calculi have formed in the inflammatory tissue.

In some instances the establishment of drainage by way of the bladder has resulted in the complete disappearance of the inflammatory mass, and is soon followed by the spontaneous closure of the vesical fistula. Again, however, drainage may not be efficient, urine may pass into the abscess cavity, and the patient finally succumbs to the effect of the prolonged suppuration, or to peritonitis. In some cases the lumen of the appendix or some portion of the intestinal canal may communicate with the abscess and a vesico-intestinal fistula is indirectly established.

True vesico-appendical fistulas, as already stated, are rare. The first essential factor in their development is that the appendix should become adherent to the bladder, which presupposes an abnormally long appendix in the pelvic position, or a high position of the bladder. To the latter factor may doubtless be attributed the fact that in four out of five cases the trouble dated from early childhood. Two of the patients were four years, one seven years, and one eight years of age when the first evidence of the trouble appeared. When adhe-

sions have formed between the organs, the further course of the process is readily understood. The usual tendency of the tip to show the most pronounced ulcerative and gangrenous lesions (p. 270) is doubtless increased when the appendix is fixed in this position, and the infective process readily spreads to the contiguous bladder wall. But the most important factor is unquestionably the influence of foreign bodies. With the exception of APPUHN's case this factor was present in all. In KEEN's case the patient, when seven years of age, was troubled with dysuria, and passed a pin *per urethram*, probably from the vermiform appendix. KINGDON's patient, a boy seven years old, for three years had had repeated attacks of dysuria, relieved on each occasion by the passage of a worm from the urethra; in this case also the bladder contained a calculus with a large pin embedded in its centre. There were two fistulous openings from the bladder into the appendix (see Chap. XVI, p. 365). In the case described by KRACKOWITZER the patient, when eight years old, passed a living worm *per urethram*, and some years after another worm and some berry seeds. In JERVALL's case the patient, between the ages of four and ten years, had four attacks of intestinal inflammation followed by vesical symptoms, and at one time vegetable matter was demonstrated in the urine. A stercoral calculus was present in the bladder. In all of these cases the true nature of the trouble was only discovered later, at operation or autopsy. In the older literature there are many highly suggestive descriptions of cases in which intestinal worms, fecal concretions, and other foreign bodies have been passed by way of the bladder, a vesico-intestinal fistula in some instances persisting. These cases, however, lacked the control of autopsy *in vivo*, or postmortem examinations.

The cases in which the perityphlitic abscess ruptures into the thoracic cavity, involving the pleural cavity, lungs, or pericardium, have been fully considered in the chapter on autopsy. The event, however, is not necessarily fatal, as there are many cases recorded in which recovery has succeeded the perforation of the diaphragm and subsequent discharge of the abscess contents through an intercostal space. H. A. MCCALLUM relates a case in which at autopsy upon an individual, who sixteen years before had suffered from peritonitis accompanied with abscess of the lung, the appendix was found on the upper surface of the liver and showed traces of an old inflammation. There were also evidences of the discharge of pus through the eighth intercostal space, and by the lung.

That resolution sometimes follows the absorption of the exudate in purulent as well as non-purulent peri-appendicitis, is evident from the clinical history and operative findings in numerous cases.

It is not uncommon to find a definite, large mass gradually diminish in the absence of any evidence pointing to a rupture into the intestine, and at operation in the interval, after the symptoms have subsided, dense adhesions are found, embedded in which there is an enterolith or foreign body, indicating that there had been a large perforation of the appendix and a strong probability that the original mass had contained a purulent focus. In many instances resolu-

tion is only partial, a chronic inflammation or a latent focus of disease remaining indefinitely. A complete cure is effected when, all organisms being destroyed, the fluid portion of the abscess contents first becomes absorbed, then the solid constituents become disintegrated and absorbed and the remaining organized portions of the abscess wall undergo cicatrization, so that, finally, the only evidence of the former mass consists in more or less numerous adhesions.

In other instances, only the fluid contents are absorbed, and the solid portions, becoming desiccated, form the centre of a dense mass of inflammatory products. Roux observed a case in which the walls of the abscess had become calcified. Micro-organisms of low virulence may also be present in a quiescent state for months or years, or, again, the contents of the abscess may be wholly absorbed with the exception of an enterolith or foreign body which escapes from the appendix and remains a source of irritation, to excite a chronic inflammatory reaction. This reaction sometimes appears to be greatly in excess of the amount required for a simple reparative process. Quite often, when operating upon a patient with a history of a tumor, a dense mass of inflammatory products is found, having as a nucleus a small focus of necrotic substance, or a foreign body; or there may even be an empty cavity lined with granulation tissue. There are numerous cases in which the excessive productive inflammatory process has led to the suspicion of the presence of a new growth (*"Appendicite à forme néo-plasique,"* Pozzi). The essentially chronic nature of the reaction, often associated with an insidious onset, is suggestive in its clinical features of a neoplasm, and the dense solid tumor found at autopsy apparently confirms the diagnosis, which, however, the pathological examination and further course of the disease entirely disprove. The following cases observed in the surgical department of the Johns Hopkins Hospital are interesting examples of this condition.

(J. H. H. Surg. No. 11,812.) Male, age thirty. Complaint, tumor and persistent pain in the right iliac fossa; progressive wasting. Insidious onset three months before admission. No fever, nausea, nor vomiting. In the right iliac region there was a slightly irregular, hard mass about 5 cm. in diameter. It was apparently fixed. At operation, dense pericecal tissue resembling carcinoma was cut through, exposing the cecum, the whole posterior wall of which was found indurated, while the glands in the neighboring mesentery were enlarged. As the growth was deemed ineradicable, a gland was removed for diagnostic purposes and the abdomen closed. Microscopic examination showed a simple adenitis, and two years later the patient was enjoying excellent health.

(J. H. H. Surg. No. 5686.) Male, age nineteen. Admitted in the second attack of appendicitis; first attack six months before, acute, with abscess. The present illness began three weeks before with slight pain, associated with rapid failure of health. No intestinal symptoms. Temperature 100° F. The abdominal walls were edematous and a slightly tender mass occupied the right iliac fossa, extending beyond the median line. On rectal examination a smooth, hard, fixed mass was

palpated. At operation the tumor was found to consist of whitish-red, dense tissue surrounding a mass of necrotic material. A diagnosis of sarcoma was made. The cavity was curetted and drainage inserted. After recovering from the operation the patient was sent home to die. Six years later he was perfectly well.

SONNENBURG cites a case of SCHEDE's, who, thinking that he was dealing with a carcinoma, found an old abscess with dense, thick walls, which still, however, contained fluid. In a case described by FENGER the hardness of the mass associated with dilatation of the subcutaneous veins strongly suggested a new growth. The removal of two stercoral concretions was followed by the disappearance of the mass. Similar cases have been described by RICHARD, FABRE, and others.

SPREADING AND GENERALIZED PERITONITIS.

By diffuse or spreading peritonitis is meant that while the entire peritoneal cavity is not involved, the inflammatory process is, nevertheless, not definitely localized, although there may be signs of an inefficient tendency to become limited, and the reaction is usually most marked in the region of the appendix. In generalized peritonitis there is no evidence of any attempt toward a limiting process, and practically the whole cavity is involved.

Diffuse or generalized peritonitis is usually regarded as one of the more remote complications of appendicitis, but, nevertheless, is apprehended with dread as an accident liable to occur without warning in any stage of the disease and in cases of apparently the mildest form as well as in those which present the most severe clinical symptoms.

It is difficult to estimate its relative frequency, as hospital statistics for obvious reasons probably give too high a proportion of cases. However, an approximate idea of the frequency with which it occurs may be obtained from the percentage of cases found at operation on cases of appendicitis, and from the number of cases of peritonitis in which the appendix was the source of the infection, compared with the number having some other origin.

In the surgical department of the Johns Hopkins Hospital, out of 600 operations on cases of appendicitis, diffuse or generalized peritonitis was present in 61 cases, or 10 per cent. There were 104 cases of diffuse peritonitis exclusive of those following gunshot wounds of the abdomen and post-operative infections. In these cases the chief sources of the infection were,—

Appendicitis	61
Typhoid perforation	15
Intestinal neoplasms	4
Amœbic dysentery	2

Other causes were acute intestinal obstruction, hernia, volvulus, gangrene following thrombosis of mesenteric vessels, acute cholecystitis, etc.

GRAWITZ found that in 560 cases of secondary purulent peritonitis the infection originated from,—

Typhoid ulceration	32 times.
Perforated appendix	24 "
Tubercular ulceration of intestine	19 "
Ulceration of stomach	16 "

BOUNESS found these causes in about the same relative proportion. RENVERS is of the opinion that 80 to 90 per cent. of all cases of peritonitis proceed from appendicitis and SONNENBURG believes that this estimate is not too high. Our statistics confirm this view.

Diffuse or generalized peritonitis in connection with appendicitis may occur in the following ways:

1. As a result of perforation or gangrene of the appendix.
2. Through rupture of a circumscribed peri-appendical abscess.
3. By means of infection by continuity from the inflamed but not perforated appendix, or from a circumscribed intra- or extra-peritoneal abscess without rupture. In infection by continuity, the pathogenic organisms penetrate the diseased but intact wall of the appendix, or the limiting membrane of the abscess.

The frequency with which generalized peritonitis follows a primarily localized peri-appendical suppuration is seen in the autopsy findings. In 29 out of 54 cases of general peritonitis there was evidence that there had been at first a localizing process which had resulted in a more or less completely walled-off abscess, and that subsequently leakage had taken place from this with a resulting generalized peritonitis. The remaining 25 cases revealed no sign of any attempt to limit the process.

Perforative appendicitis may be the means of precipitating into the abdominal cavity bacteria so virulent and in such a quantity that death occurs within a few hours, but at the autopsy examination no perceptible reaction on the part of the peritoneum is found. In these cases the rapidly fatal issue is due to acute sepsis, which may be the result of toxemia alone or of bacteriemia. These rapidly fatal infections most often follow the bursting of an acute peri-appendical abscess, or of an appendix distended with pus, the conditions in the pent-up exudate being most favorable to bacterial activities. This highly septic material is soon distributed over a large portion of the peritoneal surface and is immediately absorbed. MURPHY mentions a case in which an abscess of considerable size ruptured into the peritoneal cavity. In two hours there were symptoms of extreme shock and in twelve hours the patient was dead. In these cases the peritoneum has not had time to react before the whole organism is overwhlemed by a general toxemia. Fortunately, such cases are not common, and as a rule in fatal cases the patient lives thirty-six hours to three or four days. There is then a well-marked peritoneal reaction.

The most fatal variety of peritonitis, characterized by a very small amount

of exudate, is dry peritonitis or peritonitis septica. There is usually only a dram or two of bloody serum, and a few scattered flakes of lymph, but the serosa, wherever it has come in contact with the septic material, is an intense red and has the appearance of abrasion due to destruction of endothelium. These cases, according to MURPHY, always die, whether operated on or not.

In most instances of spreading or generalized peritonitis, resulting from either a perforative or a non-perforative appendicitis, there is an abundant fibrino-purulent exudate, the fibrinous element in some cases being greatly in excess, while at other times there is a large amount of purulent fluid and a very slight fibrinous deposit; and, again, the solid and fluid exudate may be in more or less equal proportions. A copious serous or purulent exudate has been shown to be of great value in diluting and thus delaying the absorption of the septic material, while on account of its powerful bactericidal properties it diminishes or entirely destroys the infective agents. It has frequently been noticed that pus, containing organisms of low virulence, may exist for some time in the peritoneal cavity without materially injuring the normal gloss of the serosa. MURPHY has pointed out that in cases of generalized purulent peritonitis resulting from appendicitis, in which the normal glistening appearance of the peritoneum was present at the time of operation, the patients recovered. He contrasts these cases with the invariably fatal ones of dry peritonitis in which a large portion of the peritoneum is denuded of its endothelial surface. The vast majority of all cases of diffuse peritonitis originating in the appendix may be regarded as belonging between these two extremes. In most instances the septic material is poured into the peritoneal cavity in relatively small quantities, and the tissues are able to offer more or less efficient resistance to its deleterious action. The exudate, at first sero-fibrinous, soon becomes purulent and an increasing amount of fibrin is present; the serous surfaces become injected and lose something of their normal lustre. The intestinal loops may be partly glued together by filmy, fibrinous adhesions, or may be almost wholly covered with large plaques of fibrin. Fig. 338 shows beginning diffuse peritonitis due to infection by continuity from the appendical abscess; the loops of intestine in the vicinity of the abscess being covered with large plaques of yellowish fibrin. Sometimes the entire serosa is covered with a continuous coat of fibrin. Some degeneration and exfoliation of the endothelium is gradually produced by the action of the septic material. The continued action of septic material of low or moderate virulence may ultimately produce degeneration and inflammatory reaction in the external layers of the intestinal walls, the injury to the muscle and nerve elements resulting in partial or complete intestinal paralysis and in consequence a stasis of its contents. This is soon followed by intestinal fermentation and an increase in the virulence of the contained micro-organism. As LENNANDER points out, there is then a twofold danger added to the primary infection; first, in the abdominal distention pressing the diaphragm upward

and impeding both respiration and circulation; second, and more to be dreaded, in the rapidly increasing toxicity of the intestinal bacteria and the altered condition of the walls which permits the penetration of micro-organisms. As a result of an intestinal paralysis there is therefore increased general intoxication through absorption of toxic intestinal contents and increased general infection through the passage of the intestinal bacteria into the lymph circulation and blood-vessels.

In diffuse infections, when the reactive energy of the peritoneum is preserved, a severe infection usually induces a fibrino-purulent exudate. The

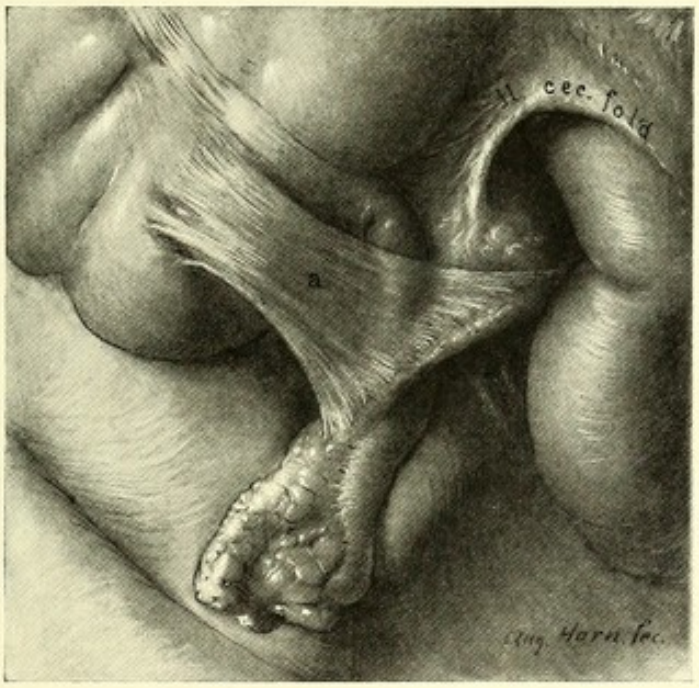

FIG. 202.—CHRONIC APPENDICITIS.
The appendix twisted one-half around its axis and held in this position by adhesions extending from the mesappendix to the cecum.

following case, in which a fatal streptococcus infection was marked by an abundant sero-fibrinous exudate, appears to be unusual.

(J. H. H. Surg. No. 14,473.) H. B., age twelve years. Admitted with a history of four days' illness, beginning with pain in the right iliac fossa and vomiting. Bowels did not move for two days. The pain continued for three days, then became less intense. On admission the rectal temperature was 101.8° F.; leucocytes, 22,000. On abdominal examination there was almost no tenderness on the left side, but slight tenderness over the whole right side, very marked in the iliac region, where a mass could be fairly well outlined. There was no muscle spasm. Upon opening the abdominal cavity the cecum presented, its surface covered with a thick coating of white, pearly, translucent fibrin, which could be stripped off in distinct layers. This same form of peritonitis extended over the vermiform appendix and surrounding tissues.

Search for the abscess was continued down into the pelvis, and the appendix found inclining in this direction, very much thickened and covered with edematous fibrin as above. The tip of the appendix was greenish; the lumen was not opened. The mass which had been felt on examination proved not to be an abscess, but the plastic

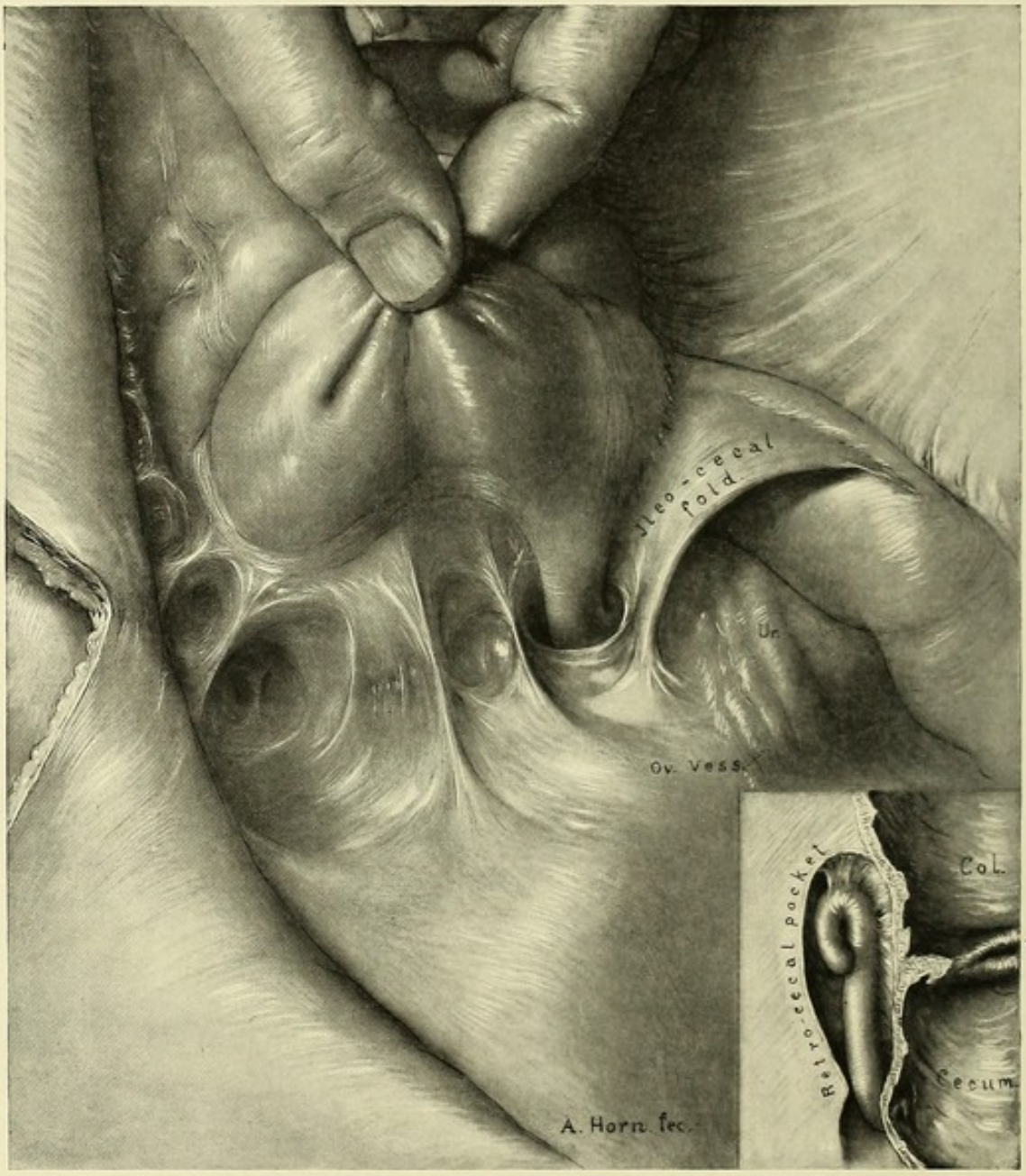

Fig. 203.—Pocketed Appendix Resulting from Old Localized Peritonitis.

peritonitis about the cecal region. The appendix was removed and drainage inserted. Death occurred the next day, the whole picture being one of rapid intoxication. At autopsy, the s t r e p t o c o c c u s was obtained from the peritoneal and pleural cavities.

Generalized peritonitis following appendicitis is fatal in a large proportion of cases, whether the patient is subjected to operation or not. That a spontaneous recovery may occur, however, is evident from the operative and autopsy findings in a number of cases. Generalized adhesions uniting the various parts of the intestine to one another and to the abdomen are unquestionable proof of the former existence of a peritonitis. When these adhesions are especially dense in the appendix region, and the appendix, which is embedded in adhesions, is partially or totally obliterated, or else presents other evidence of an old inflammation, the origin of the peritonitis is evident.

The following case, in which the patient had evidently recovered from a diffuse peritonitis due to appendicitis, is of interest in this connection and also indicates that obliteration of the appendix is often of inflammatory origin:

(J. H. H. Surgical No. 15,615.) F., age twenty-five. The patient had had a severe attack of peritonitis when nine years of age. She grew up a strong girl, but was never able to ride on horseback on account of the pain which it caused in the right lower abdomen. Four years previously she was ill for three weeks with a typical attack of appendicitis, and afterwards suffered from a constant dull pain in the right iliac region. Operation revealed several flimsy, fibrous adhesions, evidently the remains of an old, very extensive peritonitis. The appendix, which was strongly adherent, was almost obliterated, only the proximal 1 cm. possessing a lumen. The median portion was converted into a thin fibrous band, while the bulbous tip contained a stercoral concretion. Operation resulted in the complete cessation of the abdominal tenderness and pain.

In a case reported by MARKOE, a child who presented symptoms of general peritonitis on the second day of an attack of appendicitis, died within a year from another disease. Autopsy showed a perforated appendix and the intestines adherent in different places (see Chap. XXII).

The adhesions resulting from a localized or diffuse peritonitis may be velamentous in character, uniting the neighboring structures by delicate, transparent fibres, or they may be more dense, and by producing twists and angulations of the appendix form one of the chief causes of subsequent attacks (see Figs. 148 and 202). The appendix may be completely hidden by adhesions, as in Fig. 203. Sometimes adventitious pockets may be formed in the cecal region, in which the appendix may become incarcerated. In other instances the adhesions consist of fine thread-like strands or dense fibrous cords, which extend in various directions from the appendical region, and are a common source of intestinal obstruction.

CHAPTER XIV.

PATHOLOGY.

BLOOD-VASCULAR INFECTION. LYMPHATIC INFECTION.

BLOOD-VASCULAR INFECTION.

Of the remoter complications of appendicitis, those depending upon the extension of the disease by way of, and involving the blood-vessels are particularly interesting. As explained in the section on anatomy, the main blood-stream is tributary to the portal system, but in some instances, by means of small branches anastomosing a communication is established through collateral branches with the ileo-lumbar veins, and, in obstruction of the portal route, with the systemic veins. Moreover, in pathological conditions other routes may be formed, through the medium of adhesions, by which the blood from the appendical vessels may even pass directly into the general circulation.

Acute phlebitis, pyo-phlebitis, or thrombosis occurs as a complication or sequel of appendicitis, and may give rise to infarction, or to suppuration of the region supplied by the affected vessel, or through the various anastomoses with the general circulation, they may result in embolism, or in a general pyemic process.

While slowing and other irregularities of the blood flow and alterations in the vessel walls are important accessory factors in the causation of thrombosis, the chief factor in its production is unquestionably an inflammatory process due to the agency of micro-organisms. The infective agent excites an endophlebitis or endarteritis which in turn gives rise to the thrombosis. The infection of the intima may occur in one of two ways: the vessel may be involved in an inflammatory process and the organisms which are the cause of the inflammation invade the external coats, and from there, by way of the vasa vasorum or the lymphatics, gain access to the intima; or (more frequently) the bacteria enter directly from the circulating blood. Welch believes also that a form of toxic endangeitis which he describes, is of importance in the causation of thrombosis complicating infective and cachectic states. The lesion which is seen in the intima of veins, less frequently of arteries, consists of a nodular, sometimes more diffuse, accumulation of lymphoid or endothelioid cells beneath the endothelium of the vessel wall. These cells, as well as the covering endothelium, may undergo necrosis; the appearance, indeed, sometimes suggesting a primary necrosis with secondary accumulation of wandering cells and proliferation of fixed cells. It has been shown that these foci may unquestionably be the start-

ing-point of a thrombosis. Although this form of endophlebitis and endarteritis resembles that demonstrably caused by the actual presence of bacteria in the intima, bacteria are often absent even in fresh lesions, so that it is reasonable to suppose that the affection may be caused by toxins. The small vessels and capillaries in the vicinity of erosions and suppurative foci regularly show septic inflammation and frequently contain thrombi composed almost wholly of a plug of leucocytes, fibrin, or hyaline material. In the larger vessels there are thrombi of the white or red variety, or there may be a combination of the two forms. The thrombus rarely involves the entire circumference of the vessel, but more commonly is laterally adherent, so that the blood is not impeded. Later, however, complete obstruction of the vessel lumen may occur. As a rule, the thrombosis increases in the direction of the circulation, but a certain amount of growth also frequently occurs in the opposite direction (Fig. 153). A continued or propagated thrombosis extends along the course of the vessel and sometimes into communicating vessels; or a portion of the thrombus may be carried to a distant point and form the starting-point of a secondary thrombus.

The fairly recent, white thrombus appears as a compact, firm, elastic, fibrous mass, which is not easily broken up. It may show a definite trabecular structure, but often becomes granular or almost homogeneous. Histologically, the thrombus consists of lamellæ of platelets, fibrin, and leucocytes, and upon the surface a denser band of fibrin and leucocytes. The red thrombus is simply a blood clot covered with a secondary deposit of the elements which enter into the formation of the white thrombus. A mixed thrombus may be due to an intimate mixture of gray and red substance, to stratified gray and red layers, or to red propagated clots consecutive to primary white or mixed thrombi. In older thrombi the platelets and leucocytes degenerate and there is an increase and condensation of the fibrinous constituents. In red and mixed thrombi the red blood corpuscles become disintegrated, and there is later a deposit of brownish pigment.

If the infective process is arrested the thrombus undergoes speedy organization, being replaced by the products of a proliferative endangeitis. Often, however, especially if the larger veins be the seat of the trouble, the autoinfection goes on until the whole vein, or series of veins is filled with puriform fluid; or, septic embolism may form with the production of secondary thrombi with local abscesses, or with a general pyemia.

Thrombosis of the appendical vessels, as before explained, is not infrequent in both the arterial and venous branches traversing the walls of the appendix itself, but is less common in the main appendical vessels in the mesenteriolum. It is true that when total gangrene or spontaneous separation of the appendix from the cecum has occurred, the chief cause of the necrosis is an obstruction to the circulation, either from external pressure or from thrombosis; but this comparatively frequent accident is seldom associated with or followed by a con-

tinued infective thrombo-angeitis. The thrombosis which serves to close the open proximal ends of the divided vessels may be merely part of the general necrotic process, or it may be simple clotting such as occurs in non-infective as well as in infective conditions, and is rapidly replaced by organized tissue. GERSTER describes three unusually instructive cases of thrombosis of the main appendical vessels, which he has personally observed. In one case total gangrene of the appendix was associated with septic thrombosis of the vessels in the mesappendix, and later gave rise to secondary purulent thrombo-phlebitis of the portal vein with subsequent multiple liver abscesses. Operation was performed twenty-four hours after the first onset of the illness, and twelve hours after the first rigor. The appendix was found dusky, almost slate colored, and tensely distended. It was free from adhesions. The mesenteriolum was noticed to be excessively brittle, permitting the ligature to cut through it immediately, and as blood flowed neither from vein nor artery it was concluded that these vessels must be occluded. In the course of the next twenty-four hours there was considerable improvement in the patient's general condition, and the peritoneal symptoms vanished. This temporary improvement, however, was soon succeeded by the characteristic symptoms of septic pylephlebitis, and death ensued on the seventeenth day. Autopsy showed purulent phlebitis of the portal vein and multiple abscesses of the liver.

In the two other cases, one perforative purulent appendicitis, the other acute gangrenous appendicitis, the veins in the mesappendix and the adjoining caput coli were found to contain purulent thrombi. In each case, after removal of the appendix, the thrombosed vessels were incised and drained and the patients recovered.

Involvement of the mesenteric vessels in the thrombotic process usually results in a more or less extensive hemorrhagic infarction of the intestine; in some instances only a small portion, less than the area supplied by the thrombosed vessel, is infarcted; in other cases a much larger area is affected. The more acute the thrombotic process, the more liable is infarction to occur. A slowly obturating thrombus, or one secondary to portal thrombosis, in which a collateral circulation has been established, may not result in infarction; but, on the other hand, acute portal thrombosis may cause extensive intestinal infarction in the absence of any disease of the intestinal vessels. Embolism, and more rarely autochthonous thrombosis of the mesenteric arteries, is more commonly the cause of intestinal infarction than disease of the veins. The obstruction may be situated in the superior mesenteric artery or in any of its branches. As in the case of venous thrombosis, gradual closure of the artery may not be followed by infarction. The common source of an embolus is the left heart, or the aorta, but primary thrombosis of the arteries may accompany infective diseases. As a complication or sequel of appendicitis, disease of the mesenteric veins is apparently more frequent than disease of the arteries and is often associated with portal infection. Hemorrhagic infarction of the intestines in

these cases is, however, exceedingly rare. In the fairly extensive literature relating to thrombo-phlebitis and in the vast literature concerning appendicitis this condition is apparently not mentioned. Of the ten cases of purulent phlebitis and thrombo-phlebitis of the portal vein described in Chap. X, the majority showed involvement of the superior mesenteric vein or some of its branches, but none showed any evidence of infarction, with one exception, Case VII, p. 235, where the infarction was very incomplete. In this case the branches of the superior mesenteric vein running from the lower part of the ascending colon were occluded by rather friable, slightly adherent thrombi, and the main stem of the vein contained a firmly adherent thrombus. The small intestine showed many large areas of congestion and submucous hemorrhages, and the colon was hyperemic. In this connection, the following case of GIBBON'S furnished me by LONGCOPE is of unusual interest:

The patient, a colored man nineteen years old, died two and one-half days after operation for acute perforative appendicitis associated with purulent peritonitis. At the time of operation it was noted that the cecum presented a gangrenous area about the size of a twenty-five-cent piece, which did not appear to be in contact with the appendix. Autopsy showed a fresh fibrinous exudate covering the congested omentum and intestinal coils, while in the region of operation the omentum and intestines were matted together with a thick whitish-yellow, soft, friable exudate. The intestines were distended, with the exception of the cecum and the terminal portion (twelve inches) of the ileum, which were purplish in color, flaccid, and collapsed. The vessels of the mesentery leading to this portion were widely distended. The ileocolic veins contained a red and white thrombus which extended for about 5 cm. into the two branches supplying the cecum and lower portion of the ileum. In these branches the thrombus contained purulent material. About the thrombosed vessels the mesenteric glands were enlarged and softened, one being 5 cm. in size. Cutting open the infarcted area of intestine it was found to contain a thick, soft, brick-red material. The wall of the ileum was deeply congested, the mucosa was almost black and showed small areas of superficial ulceration. The cecum presented a similar appearance. The surface of the liver presented three or four dark red, slightly elevated, well outlined, infarcted areas, 1.5 to 4 cm. in diameter. The remaining surface was finely granular, and mottled red and yellow. The consistency of the liver was softened.

In a remarkable case of FINNEY'S a primary thrombo-angeitis was believed to have been the cause of the appendical disease. At the first operation the appendix was greatly swollen, almost black in color, and it was noted that the main vessels were completely occluded. At a second operation some days later there was found an extensive thrombo-phlebitis involving practically all of the mesenteric vessels.

The probable explanation of the exceptional occurrence of intestinal infarction in appendicitis is that there is not usually a completely obturating thrombus, a pyo-phlebitis being more commonly found. But, on the other hand, this

complication of appendicitis may not be so rare as it seems to be from the few cases recorded as such. In fatal cases it is sometimes mentioned that large areas of the cecum or other portions of the intestine are gangrenous, a condition which is probably the result of infarction. In the *Encyclopédie Méthodique*, 1790, tom. II, a case is described in which, associated with an inflamed appendix containing a foreign body, the liver was found enormously enlarged and softened while the jejunum and part of the ileum were gangrenous in places and generally inflamed. The wall of the completely infarcted area of intestine is thickened, edematous, of a dark red color from infiltration with blood, and covered with lustreless peritoneum. The margins of the infarct are often sharply marked, but may pass gradually into the normal tissue. The mucous membrane is necrotic, often defective, and may be covered with a diphtheritic exudate. A considerable area of the intestine may be gangrenous; the lumen contains black, tarry blood. There is bloody fluid in the peritoneal cavity and usually a fibrinous or fibro-purulent exudate covering the infarction; there may be general peritonitis. The mesentery is edematous and hemorrhagic. In less complete infarction the extravasation of blood may be limited to the mucosa or submucosa (Welch).

The most frequent complication of infective angeitis and thrombosis following appendicitis is the extension of mesenteric and portal infections to the liver, by means of a propagated thrombus, or by embolic transplantation, with consequent acute hepatitis, infarctions, or liver abscesses. This condition, as also the lesions found in the spleen and kidney, have been fully described in Chap. X.

Thrombosis of the peripheral veins, and, less frequently, the arteries, may occur as a complication of an attack of appendicitis, but much more frequently develops as a post-operative sequel. All the cases observed at the Johns Hopkins Hospital belong to the latter group and will be considered in connection with other post-operative complications. Thrombosis of the iliac and femoral vessels may be due to direct extension of the infection from a surrounding inflammatory mass, or to infection from the circulating blood, and may develop on the left as well as on the right side, the reported cases being about equally distributed between the two sides. Sometimes both sides are involved, either simultaneously or at different times. In the majority, this complication occurred during the course of a chronic appendicitis or after the subsidence of an acute attack.

Petet cites a case in which a mild chronic appendicitis was accompanied by thrombosis of the left femoral vein, and also reports another case in which the subsidence of an acute attack was followed by thrombosis of the right femoral vein with subsequent lung embolism. There are several cases recorded in which thrombo-angeitis, consecutive to appendicitis, resulted in the permanent closure of the affected vessel. In some instances, an efficient collateral circulation was established, in others the edema and the discomfort persisted indefinitely,

and in others still, the artery being involved, there was gangrene of the part supplied by the occluded vessel. SCHEIBENZUBER has described a case of perityphlitis complicated by embolism of the left anterior tibial artery with gangrene of the leg (see Chap. IX, p. 209).

BERARD relates a case in which at autopsy on an individual who had died in the third week of the attack, a perforated gangrenous appendix was found associated with complete occlusion of the left crural artery. The obliteration was due to the presence of a firm clot which presented traces of beginning disorganization.

A common sequence of thrombo-phlebitis, and probably the frequent cause of sudden death occurring during an attack of appendicitis, as the attack is subsiding, or following operation, is the occurrence of lung embolism. PETET has collected three instances from the literature, and has added five unpublished cases. Of these cases, two presented the physical signs of a small area of infarction in the lungs, but recovered. In six cases sudden death occurred, and the diagnosis was confirmed at autopsy.

LYMPHATIC INFECTION.

In inflammatory diseases of the appendix the infection may spread by way of the lymphatics and may give rise to a general septicemia, to localized lymph-adenitis, or by direct continuity may produce suppuration in the hepatic or subphrenic regions.

The extension of the infective process by way of the neighboring lymphatics into the thoracic duct, and so into the general circulation, is the usual origin of a general septicemia accompanying both suppurative and non-suppurative forms of appendicitis, and occurs either in the presence or absence of peritoneal involvement. The localized lymphatic infections have received comparatively little attention, but are of considerable importance, in that a focus of infection in the lymph glands may be the cause of a prolonged illness following the removal of the appendix. The glands may suppurate, with subsequent abscess formation in the retrocecal or retrocolic region, and as explained before (Chap. X) may be the source of subphrenic and hepatic infection. A mild chronic appendicitis as well as an acute suppurative affection may give rise to a severe lymph-adenitis. Moreover, the lymphatic infection may remain latent for months and then develop an acute process. RICARD removed the appendix during an acute attack of inflammation, marked by an appearance of sub-icterus, and the patient was discharged, apparently cured. Some time afterward he returned with the same symptoms, and his condition becoming grave, Ricard again opened the abdomen and found a chain of infected lymph glands extending from the site of the appendix toward the liver, the first two being enlarged and suppurating. Four or five glands were extirpated, and the patient made an uninterrupted recovery.

Rendu describes a case of appendicitis of obscure development, presenting symptoms of pyemia on the thirteenth day and resulting in death ten days later. The appendix was found lying in an abscess the size of an egg in the psoas muscle. The mesenteric glands corresponding to the ileocecal region were enormous, some being as large as an egg. They were red, hard, and injected; two had broken down, their centres containing putrid pus. There were several abscesses in the liver. Unfortunately the mesenteric vessels were not examined; the portal vein, however, was healthy.

In a case reported by Auguy, after two attacks of appendicitis an operation *à froid* was performed. The appendix was found slightly adherent in the retrocecal position. In the vicinity of the ileocecal angle was a group of seven or eight firm, movable, non-adherent glands. One of these, removed for bacteriological examination, furnished a characteristic culture of b a c i l l u s c o l i. The patient made an uneventful recovery.

In several other cases described by Auguy and Ferry, infected lymph glands were found in the mesenteriolum. In one case in which the appendix was only slightly enlarged and a little reddened, the mesappendix contained a suppurating gland the size of a small nut.

Slight enlargement of the glands is to be expected in all active inflammations, and on removal of the primary focus of infection will soon subside. Suppurating glands, on the other hand, will often give rise to further mischief, and in all cases they should be removed or thoroughly drained.

CHAPTER XV.

PATHOLOGY.

TUBERCULOSIS. ACTINOMYCOSIS. TYPHOID FEVER. AMŒBIC DYSENTERY.

Specific Inflammatory Diseases of the Appendix.

By specific inflammatory affections is understood that group of cases in which a more or less distinctive inflammatory process is produced in the tissue by the action of the specific micro-organisms of the disease. Probably in most instances there is not a pure infection with the specific organism, as sooner or later a secondary infection with the ordinary pyogenic bacteria is engrafted upon the primary disease, so that in many cases the characteristic lesions are not detected. The principal affections of the appendix belonging to this division are, tuberculosis, actinomycosis, typhoid fever, and amœbic dysentery.

TUBERCULOSIS.

Tuberculosis of the appendix may be primary or secondary, the latter condition being due to direct extension from the cecum, or to transplantation of the infective agent from some distant organ, usually the lungs, in which case the tubercular lesions may be disseminated throughout the entire intestinal tract, or may be limited to the appendix. In most instances the affection of the appendix is part of an ileocecal tubercular process, the disease, as a rule, probably originating in the cecum, and extending by continuity of structure to the appendix. Occasionally, however, the appendix presents the more advanced lesions, and, again, it is impossible to determine which organ contains the primary focus of infection. In rare instances the tubercular process is apparently limited to the appendix, but, on the other hand, very extensive disease of the cecum may exist without any involvement of that organ. The simple involvement of the peritoneal coat of the appendix in a general miliary tuberculosis need only be mentioned here, as it presents no special pathological features referable to the appendix, apart from the fact that adhesions may form which may lead to an attack of acute inflammation. There are two distinct types of tubercular disease of the appendix, when primary or when secondary to the ileocecal affection: the usual ulcerative or caseous variety, and the less common form, which is characterized by a massive connective tissue production, the so-called hyperplastic tuberculosis. The former is often associated with a generalized intestinal infection, whereas the latter, as a rule, is

localized in the cecal region. CORNIL and RICHELOT call attention to a third variety in which a secondary colon bacillus infection, superimposed upon the tubercular infection, results in a suppurative appendicitis, the primary tuberculosis disappearing in the midst of the purulent focus. This condition, however, although of considerable interest, is of the nature of a mixed or terminal infection, and cannot be considered a distinct form of tuberculosis.

Caseous or ulcerative tuberculosis of the appendix in many cases is not recognized upon macroscopic examination. The exterior of the appendix may present nothing to distinguish the condition from a simple chronic or subacute inflammation. The serosa is usually injected. In all the cases which have come under my observation adhesions have been present, usually very light and veil-like. In Case 2* the worm-eaten appearance of the serous surface was commented upon at the time of the operation, but the true nature of the disease was not suspected until revealed by the microscope. In SONNENBURG'S case a few gray miliary tubercles were scattered over the serosa in the vicinity of the thickened proximal portion of the appendix. The appendix is usually thicker than normal. In Sonnenburg's case the proximal end with the anterior wall of the cecum formed a dense tumor, while the distal portion, though thicker, was soft. In MOSHER'S case the appendix was long and tensely distended. In Case 3 the appendix was diminished in size, resembling a withered, obliterated organ. A careful examination of the interior may be more fruitful of results. The mucous membrane is injected and shows more or less extensive ulcerations, which have the characteristic caseous appearance of tubercular disease. The individual ulcer may be round or oval, or it may encircle the lumen of the appendix. The floor of the ulcer and the surrounding mucosa may be beset with minute grayish tubercles. In some instances almost the entire mucous membrane is caseous. In Case 3 the mucosa was replaced by partly caseous, partly fibrous tubercular products which caused complete obliteration of the canal. BIGGS presented a specimen of tuberculosis of the appendix, in which about one inch of the extremity was cut off from the remainder, and was filled with cheesy material. Where the intestinal tuberculosis is a late complication of lung tuberculosis, the process rapidly spreads, owing to the slight resistance of the organism, and ulcers are produced which show no tendency to heal. These ulcers are apt to be especially deep in the cecum and appendix, and may proceed to perforation. On the other hand, when the disease is limited to the cecum or the appendix, or is merely associated with a latent or healed focus in some other part, a reparative process may be established, with a subsequent cicatrization of the ulcerated areas, and, ultimately, the production of strictures. Annular ulcers, especially, may result in almost complete stenosis.

Histological Examination.—Histologically the characteristic lesions of tuberculosis are found. As a rule, the process is principally confined to the mucous and submucous layers, in some cases the former, in other cases

* For clinical histories of these cases, see Chap. XXXII.

the latter, showing the most pronounced changes. As a rule, a few scattered foci are found in the peritoneal layer. In Fig. 204 the maximum lesions are found in the submucosa, which is much thickened and almost wholly made up



FIG. 204.—TUBERCULOSIS OF THE APPENDIX. MAGNIFIED 40 TIMES.

A indicates a remnant of the mucosa which has disappeared in other places; *b* is the submucosa; *c*, the circular and *d* the longitudinal muscular coats. Tubercles (*e*) are chiefly found in the submucosa, but also invade the musculature. At *g* a caseous area is seen. (Specimen from I. Henrotin.)

of tubercular tissue. The mucosa is almost completely destroyed. A few small tubercular foci and areas of caseation are seen in the musculature and peritoneal layers. In Case 2 the mucous membrane was but little altered, while

the submucosa was studded with miliary and conglomerate tubercles, showing extensive areas of caseation. Usually, however, there is more or less destruction of the mucosa, and, as we have seen, it may be entirely replaced by tubercular products. Typical miliary tubercles predominate in some cases, while in others the most conspicuous feature is a diffuse fibrino-caseous process. In Case 3 typical tubercles were not seen and the centre of the appendix consisted almost wholly of epithelioid cells and caseous material. Tubercle bacilli are easily demonstrated in most cases, but are rarely numerous.

At a later stage, the invasion of secondary organisms may induce a purulent process, which obscures the tubercular lesions. In other cases there is a complete fibrous transformation of the diseased areas, and it is only on the examination of numerous sections that the tubercular origin of the process is revealed. In these conditions the regional lymph glands frequently show an active tubercular process.

Hyperplastic Tuberculosis.—Since 1891, when HARTMANN and PILLIET published the first detailed description of this form of intestinal tuberculosis, many cases have been reported, in the vast majority of which the cecal region was the seat of the disease. The appendix, as a rule, was not affected, but in some instances it was involved in the cecal tumor. I have found only one record in which the process was primary in and practically confined to the appendix. This case was described by CROWDER, to whose courtesy I am indebted for notes of the case and for the specimen pictured in Figs. 205, 206, and 207. The appendix, which was removed at operation, together with a small portion of the adjacent cecal wall, has been hardened in alcohol and consequently has undergone some shrinkage. It is 6 cm. long, and in diameter varies from 18 to 20 mm. in the thick median portion, and is 11 mm. near the cecal end. It is very firm and hard, and its surface near the middle is marked by smooth rounded elevations, consisting of infiltrated masses of subperitoneal fat. The peritoneum, with the exception of a few tags of adhesions, is smooth. The color varies from yellow to dark brown, the dark areas being due to subserous hemorrhage. Section shows greatly thickened walls and a practically obliterated lumen. The mucous membrane is 2 or 3 mm. thick and is sharply outlined from the surrounding fibrous tissue. The other

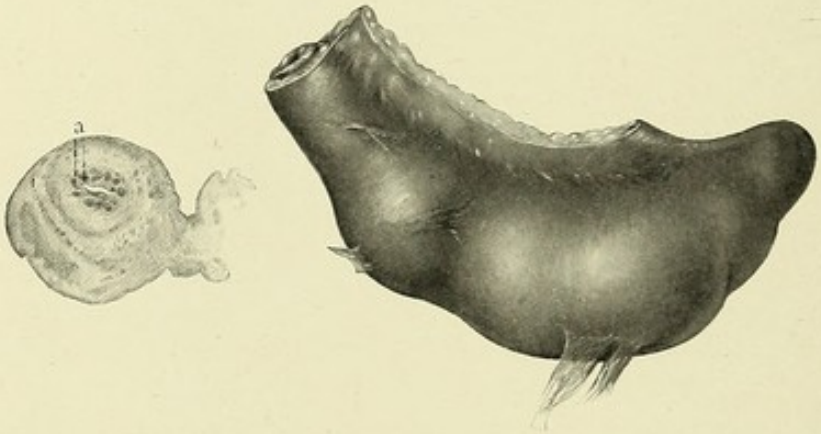

FIG. 205.—HYPERPLASTIC TUBERCULOSIS OF THE APPENDIX.
In the cross-section the tubercles (*a*) appear as deeply stained nodules.

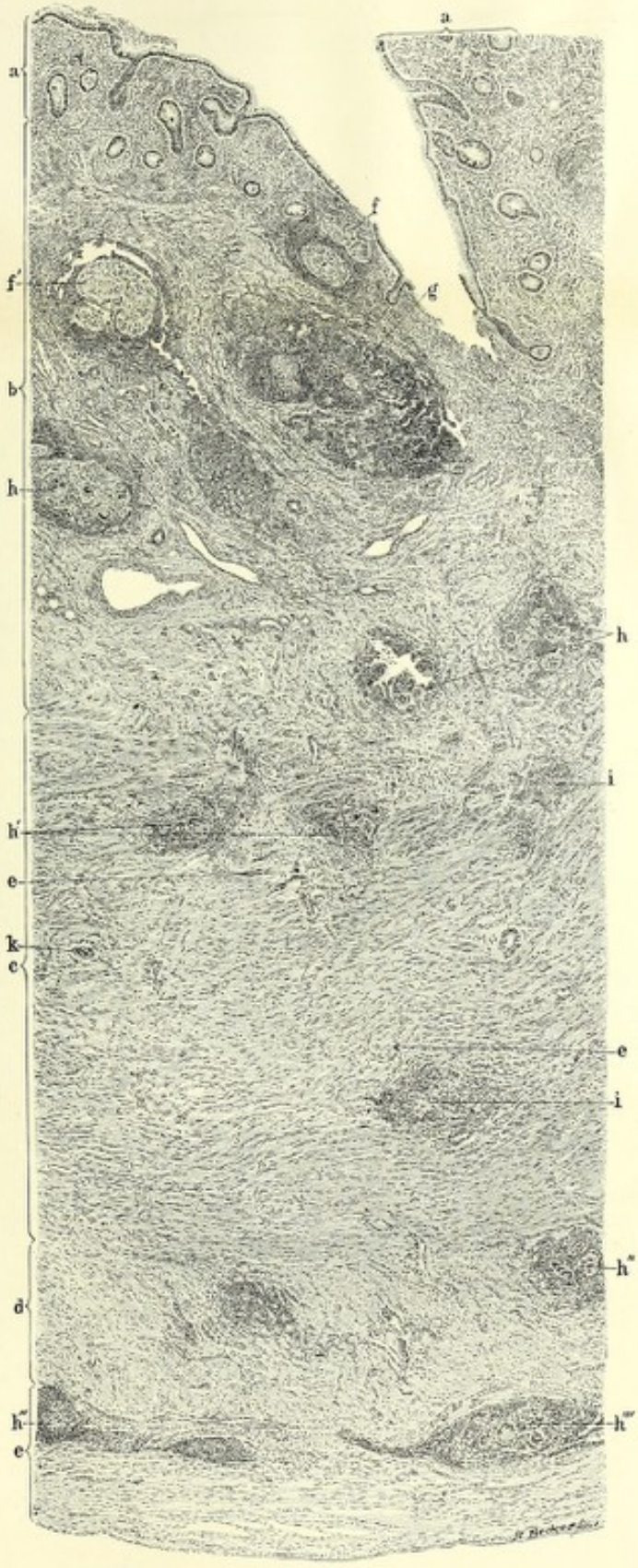

FIG. 206.—SECTION THROUGH THE WALL OF THE APPENDIX REPRESENTED IN FIG. 207. MAGNIFIED 40 TIMES.

The mucous membrane (*a*) is fairly normal, excepting at *f*, where there are two small tubercles. The submucosa (*b*) is greatly thickened and is infiltrated with tubercles (*f*), some of which contain several giant cells (*h*). The circular muscular coat (*c*) is also thickened, containing giant cell tubercles (*h'*) and free giant cells (*k*). Clumps of round cells are seen at (*i*) and mast-cells at (*l*). The longitudinal muscular coat (*d*) and the subserous fibrous layer (*e*) are infiltrated with giant cell tubercles.

coats cannot be differentiated and are represented by a dense fibrous structure of almost uniform appearance. A few yellowish foci of degeneration are seen in the subserous tissue.

Microscopic Examination.—The mucous membrane, as a whole, is well preserved, but shows an increase of cellular elements in the membrana propria, and in places is beset with a few microscopic tubercles. It is also unusually vascular. The glandular and surface epithelium show little change, the cells staining regularly and well. At one or two points where the tubercles reach the surface the epithelial cells are irregular in form and cloudily stained; some are completely necrotic. Lymph nodes are comparatively scarce. Occasionally the centre of a follicle is occupied by a clump of epithelioid cells sometimes surrounding a central giant cell. Other nodes exhibit advanced fibrous tissue changes, probably a tubercular process. The chief alteration is found in the submucosa and circular muscular coats, and here the characteristic picture of the hyperplastic tubercular process is apparent. In these layers, which are greatly thickened, the normal structure is almost wholly replaced by a cellular fibrous tissue with a more or less plentiful sprinkling of small round, and plasma cells, the latter greatly predominating. The line of demarcation between these two layers is indistinct, owing to the marked tubercular invasion of this region. In the submucosa the round cell infiltration is especially dense, and tubercular foci are also most numerous here. These consist of aggregations of round cells, which sometimes surround a central group of epithelioid cells, containing one or more giant varieties. More often, however, epithelioid cells are lacking and the tubercles consist merely of lymphoid cells, or of a group of several giant cells surrounded by small round cells. At several points

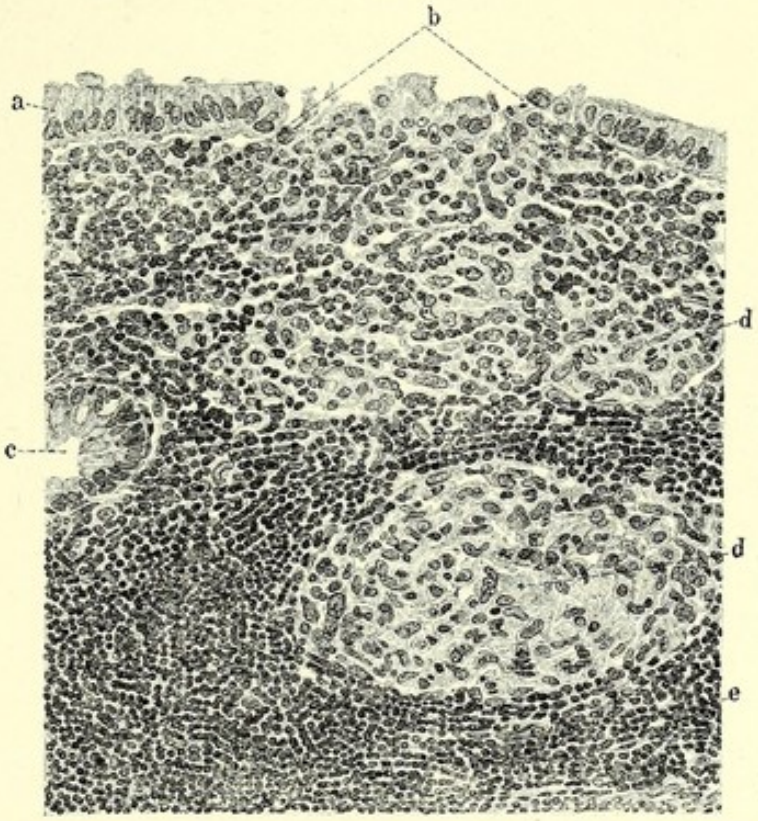

Fig. 207.—Higher Magnification of the Superficial Tubercles Seen at *f* in the Preceding Picture. Magnified 250 Times.

The epithelium (*a*) is degenerated where the tubercle reaches the surface (*b*). The tubercles consist of epitheloid cells (*d*) surrounded by a zone of dense round cell infiltration (*e*). The gland (*o*) is normal.

single giant cells are seen in the midst of the fibrous tissue. Many of these appear to be perfectly free from the surrounding tissue. Epithelioid cells are scarce throughout the specimen and typical caseation is entirely wanting. In the circular muscular coat the fibrous tissue proliferation is very abundant, separating the individual muscle fibres from one another. Toward the inner margin a few bundles are still preserved. Plasma cells and a few lymphoid elements are distributed generally throughout the tissue and at several points large *mastzellen* are seen. Focal tubercles are not so numerous as in the submucosa. The longitudinal muscular coat participates in the general thickening, but to a less degree than the other tissues. The subserous layer is thickened and infiltrated and contains many discrete tubercles. There are extensive areas of hemorrhage and some degeneration in this layer. Sections of the small portion of the cecal wall removed, show tubercular infiltration of the mucosa and submucosa, with a general round cell infiltration of the tissues. Many sections were examined for tubercle bacilli, but with negative results.

The most prominent feature of this form of intestinal tuberculosis is the immense hypertrophy of the bowel walls, the thickening being often increased by a fibro-adipose deposit in the subserous layer. The walls of the portion invaded vary from 0.5 to 3 cm. or more in thickness, one case described by TIEDENAT reaching 5 cm. On macroscopic examination it is often difficult to differentiate the tuberculous mass from a true neoplasm. As a rule, however, the mass in the case of a new growth is more sharply outlined than in tubercular disease. In the latter the thickening of the walls usually involves the whole circumference of the bowel, and, gradually diminishing, imperceptibly merges into the normal portion. Thus, although thickened and rigid, the normal contour of the intestinal tube is generally preserved. Sometimes, however, cicatricial contractions may produce various irregularities in the form of the mass, and in a case described by ROUTIER the growth was limited to the posterior cecal wall. Narrowing of the lumen of the bowel or actual stenosis is commonly found and, as a rule, is due to the gradual encroachment of the hypertrophied walls, involving the entire portion affected by the disease. Cicatrization of ulcerated areas may also produce areas of stenosis, but is less common in this form of tuberculosis than in the ordinary ulcerative variety. The characteristic polypoid masses found in the cecum and in other portions of the direct intestinal canal may aid in the formation of strictures. This condition has not been described in connection with the appendix. The cut surface of the mass presents a fairly uniform, fibrillated structure, which may bear a striking resemblance to a sarcomatous growth. Generally, however, unlike tissues invaded by a new growth, the different layers are more or less clearly defined. Yellowish foci of degeneration are occasionally seen and, as already mentioned, masses of adipose tissue are found in the outer coats. Microscopic examination reveals a picture which, though varying in many ways, is perfectly characteristic. The most conspicuous feature is the general fibrous prolifera-

tion affecting all the tissues, but most pronounced in the submucosa. There is an abundant formation of oval and spindle-shaped connective tissue cells, also much fibrillated and homogeneous intercellular substance. Distributed throughout the tissue generally, but in varying numbers and often in clumps, are numerous lymphoid and plasma cells. In the specimen examined by myself, plasma cells were greatly in excess in the diffuse infiltration, while lymphoid cells predominated in the focal tubercles. The plasma cells were mostly of the small variety, but large forms also were present. Many showed active mitosis, or contained double nuclei. The transformation of these cells into connective tissue cells could not be definitely determined. A few *mastzellen* and occasional eosinophiles were present in the submucous and circular muscular coats.

Microscopic tubercles are usually found in some places, particularly in the mucosa and submucosa, but are not numerous. They may have the typical structure, consisting of a central giant cell surrounded by epithelioid cells and an outer zone of small round cells, but more often there is merely an aggregation of lymphoid cells, or giant cells and lymphoid cells. Epithelioid cells and caseation may be entirely lacking. In some instances typical tubercles are absent, as in LARTIGAU's and PILLIET's cases. In Pilliet's case there was a general massive infiltration of embryonal cells, which at first sight was suggestive of a sarcomatous growth. While the lesions are most marked in the mucous and submucous layers, the muscular coats participate to a variable extent and the peritoneal coat frequently shows extensive lesions. The nature of the lesions is essentially that of a chronic productive inflammation associated with a tubercular process. By some writers, notably HARTMANN, PILLIET, and BENOIT, it is believed that secondary infections play an important rôle in the production of the special lesions found in this class of tubercular affections, while ITIÉ inclines to the belief that the tubercular infection is engrafted upon an antecedent inflammatory process. The chronicity of the process and its productive nature are most plausibly explained by the theory of an infection with attenuated bacteria. MALLORY, in studying the effect produced on tissues by the toxins secreted by bacteria, showed that whereas strong toxins cause degeneration or necrosis of the cells and exudation, dilute and weak toxins induce proliferation and phagocytosis. The paucity in number of the organisms usually present may have some influence upon the nature of the process, but is not in itself a sufficient explanation, for in the cases described by LARTIGAU, and by CAUSSADE and CHARRIER, tubercle bacilli were very numerous.

How the attenuation is brought about is not clearly understood. HARTMANN and PILLIET consider the action of other organisms an important factor, but, on the other hand, RAMOND and RAVAUT have demonstrated that, while in culture tubes the growth of tubercle bacilli is arrested when associated with other microbes, in the living organism, when other bacteria are present, tuberculosis develops much more rapidly. This result they believe to be due to the

impairment of the resistance of the tissues and not to the direct action of the other bacteria. CROWDER advances the reasonable view that individual resistance is probably an important factor in limiting the action and causing the attenuation of the bacillus: "The toxins of a given tubercle bacillus might be able to produce only slight irritation when growing in the tissues of one appendix, thus determining a conservative process of hyperplasia, while in another they might produce rapid necrosis." In support of this view he directs attention to the fact that in cases of hyperplastic tuberculosis of the cecum it is unusual to find any rapidly progressive or destructive lesion in other parts of the body, whereas an old healed or latent tuberculosis of the lung often exists.

ACTINOMYCOSIS.

Actinomycosis, like intestinal tuberculosis, shows a special predilection for the cecal region, but, unlike the tubercle bacillus, which in most instances primarily attacks the cecum, the actinomyces more frequently enters the vermiform appendix, and from there invades the tissues. It is generally considered that the appendix is the chief portal of entry for the infective agent in abdominal actinomycosis. While in many cases the parasite cannot be demonstrated in the appendix, the relation of the organ to the actinomycotic mass and its diseased condition permit no question as to the primary location of the infection.

The actinomyces or ray fungus is classed among the bacteria of the genus streptothrix. The colonies appear in the form of opaque, gelatinous granules, about 0.5 mm. to 2 mm. in diameter. They are usually of a sulphur or orange-yellow color, but are sometimes gray or yellowish-green. Histologically the colonies consist of several different elements. In the centre is a granular material and bodies resembling cocci or spores, while extending from the centre there is a dense network of fine filaments, from which filamentous branching threads radiate outward. These threads usually present characteristic club-like terminations, but in the human form of the disease the clubs are often inconspicuous. WEIGERT has shown that the clubs may become indistinct, or even disappear, in consequence of post-mortem changes.

Pathological Changes in the Tissues.—In the purest form of actinomycotic infection in man the reaction on the part of the tissues is merely a chronic, productive, inflammatory process, but, as in most cases the infective agent enters through a cavity which is beset with bacteria, suppuration is an almost constant accompaniment of actinomycosis. The granulation tissue is generally bathed in a scanty, thin, puriform fluid, which, owing to hemorrhages, is often of a brownish color; but according to PARTSCH, unless secondary infection with the ordinary pyogenic organisms occurs, pus is not found. ISRAEL, however, states that in man the actinomyces induces suppura-

tion, a view also held by CZERNY and HEDDAEUS. In an early state the products of the infection appear as a brawny, pseudo-fluctuant, tumor mass. The tendency of the tissue to undergo fatty degeneration and its disposition toward hemorrhages result in the formation of irregular spaces, which are lined with soft, yellow or reddish granulations and contain a sparse amount of thin fluid, in which the characteristic bodies float. Some writers claim that this material emits a characteristic odor, but PARTSCH and others consider that the odor is due to the presence of other intestinal bacteria. The disease is essentially chronic, but after a longer or shorter period it ceases to be localized and invades the neighboring structures, forming indurated, connective tissue masses accompanied with a diffuse edematous infiltration of the surrounding tissues. Softer areas are found here and there, but are not numerous. This dense scar-like connective tissue formation is characteristic of the activities of the actinomyces, and in the chronic form is never absent. It may reach such dimensions that a true tumor is simulated. The inflammatory products embed the nerves, infiltrate and separate the muscle bundles, and invade the walls of the blood-vessels. In the dense new formation, as already mentioned, there are sparsely distributed softer areas, also spaces of variable size, varying from slight chinks to cavities as large as a fist. Microscopic examination reveals a dense fibrous tissue proliferation invading and compressing the normal tissue. Here and there aggregations of small round cells, sometimes polymorpho-nuclear leucocytes, are noticed. These correspond to the softened areas observed in the gross specimen and also form the chief part of the granulations lining the cavities. As noted by MARCHAND, occasional giant cells are found. According to PARTSCH it is only in these areas of round cell infiltration that the actinomyces are found, and often it is necessary to examine several sections in order to demonstrate the cause of the disease. The demonstration of the ray fungus is, however, absolutely indispensable to a diagnosis. The intestinal mucous membrane usually presents small areas of ulceration, which are the result of the breaking-down of small nodules. The crater of the ulcer consists of the denuded muscle. The mucosa generally is deeply stained with extravasated blood, especially in the vicinity of ulcers, and as these become healed a blackish pigmented cicatrix remains. As the infection soon penetrates the intestinal walls there is a reaction on the part of the peritoneum, the intestinal coils becoming adherent to the neighboring structures and to one another. These adhesions then become infiltrated with the hyperplastic inflammatory products, the characteristic softening and cavity formation taking place later.

The disease advances in all directions, and usually penetrates the abdominal fascia, with subsequent infiltration of the parietes, which become edematous and indurated. Finally, necrosis takes place, and extending to the skin surface produces fistulous openings, several of which usually appear almost simultaneously. Cases of perforation of the bladder and rectum have also been reported, and rupture of the diaphragm is a common event. The peculiar

soft yellow or reddish granulations lining these sinuses differentiate them from simple inflammatory conditions. The infection extends mainly by direct continuity, invading all structures, but is also propagated by way of the blood-vessels and may develop at many distant points, as in other metastatic processes. Dissemination by way of the lymph circulation has never been observed. Infection of the lymph glands sometimes occurs, but is due to their direct invasion by continuity. As the morbid process advances, the older portions may become partly absorbed and in part reduced to a few thick bands of scar-like tissue. Thus, a large mass may gradually subside while an active process is advancing in other areas. In other instances, after free incision the granulation tissue gradually undergoes complete resolution. When the actinomycotic process is associated with an infection by the ordinary pyogenic organisms, suppurating foci are found here and there, and true abscesses sometimes form. The patient may ultimately succumb to the secondary infection.

In the cases originating in the appendix various conditions have been found in this organ. In only a few instances, notably the cases of HELFERICH, ILLICH, and LANGHANS, and in my own, has the specific process and parasite been observed in the appendix itself. In many cases the appendix merely shows a simple perforative inflammation. The large proportion of cases in which a fecal concretion is formed suggests the possibility that the foreign body may play an important rôle in the development of the disease, either by determining a rupture, or by causing pressure necrosis, and thus facilitating the invasion of the appendical walls. In a case described by ILLICH, a husk of corn was found with the actinomyces in the appendix; and in AMMENTORP's case a barley husk was found with the actinomyces in an abscess cavity. The appendical walls are often not invaded by the parasite, which, having lodged in the canal, escapes through a perforation, not due to its activities, and excites the characteristic reaction in the surrounding tissues. Again, there are cases in which the appendix has evidently been the seat of an old actinomycotic infection, and partial or complete repair has supervened. Such an appendix may appear thickened and rigid, its condition resembling a chronic obliterative inflammation. The interior may show a narrowed or stenosed lumen and pigmented scars representing healed ulcerations. The case which has recently come under my personal observation is a good example of this condition. In this instance the etiological relation of the almost obliterated appendix to the actinomycotic process was not clear, and the possibility of the primarily cecal origin of the disease was entertained. Histological examination, however, revealed very clearly the appendical origin of the trouble. For the clinical history of this case see Chap. XXXII, page 768. The chief points of interest in the autopsy protocol are as follows:

Anatomical Diagnosis.—Actinomycosis of the liver, spleen, and lungs; acute actinomycotic pleuritis with effusion; healed actinomycosis of the appendix and anterior abdominal wall; chronic peritonitis.

The omentum covers the small intestine, which is adherent to the anterior abdominal wall. There are a few adhesions between the uterus and sigmoid flexure to the small intestine. The liver is attached to the diaphragm by adhesions of a somewhat fibrous character. On attempting to separate the right lobe from the diaphragm an abscess cavity, 8 cm. in diameter, is broken into.

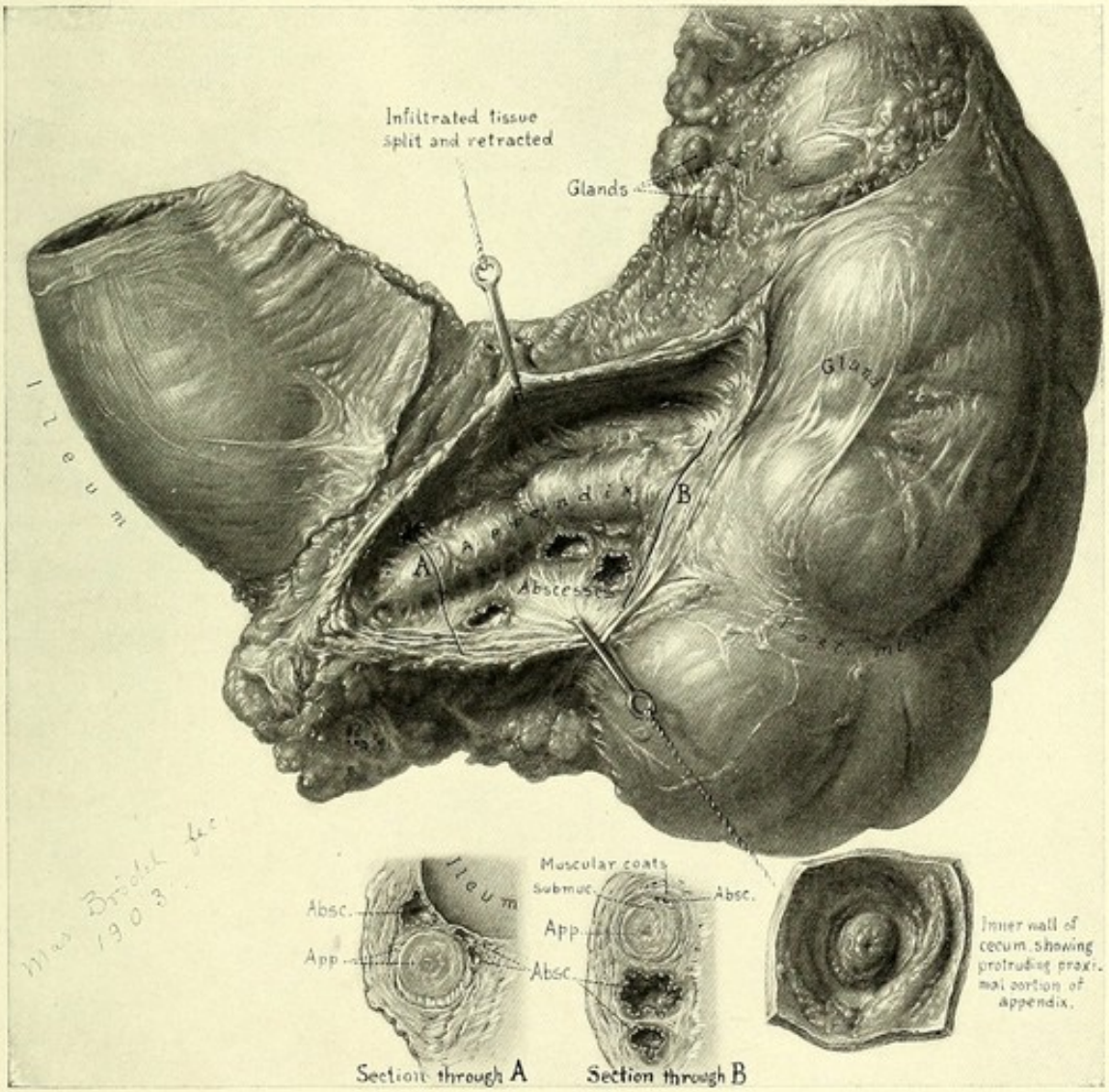

FIG. 208.—ACTINOMYCOSIS OF THE APPENDIX.

Posterior view of the ileocecal apparatus, showing the appendix enclosed in a dense mass of inflammatory tissue which is riddled with abscess foci. The appendix appears thickened and rigid and about its middle is strictured and bent at a slight angle by a band of adhesions. Sections through the distal and proximal ends show apparent obliteration of the lumen. In Section *B*, a minute abscess focus is visible in the external tunic of the appendix. (Autopsy, No. 2165.)

Intestines.—The serous surface is pale throughout. In the region of the appendix several coils are adherent to the abdominal walls, to the right round ligament, and, slightly, to the cecum. The appendix can be felt as a firm cylindrical mass lying under the ileum, where it is embedded in a mass

of dense connective tissue. In enucleating the appendix, a sieve-like abscess focus is found in the appendico-cecal angle infiltrating the inflammatory mass. The appendix is 5.5 cm. long, its walls thickened, and its lumen almost obliterated. The proximal end forms a dense knob-like protuberance into the cecum. The mucosa covering this inverted portion of the appendix and the cecal wall are both stained a dark reddish-brown. Otherwise, the intestinal mucous membrane is perfectly normal. (See Fig. 208.)



FIG. 209.—ACTINOMYCOSIS OF THE APPENDIX. MAGNIFIED 75 TIMES.

A section through the median portion of the appendix showing a granulating cavity occupying the site of the appendical canal. The cavity *a* contains shreds of mucus, round cells, a few polymorpho-nuclear leucocytes and cellular detritus. The lining of the cavity *b* is composed of typical actinomycotic granulation, the inner portion consisting almost wholly of round cells, while farther out there are abundant fusiform connective tissue cells. Giant cells are seen at *d*. The submucosa, *c*, is thickened and fibrous, and its blood-vessels highly sclerotic. *d* indicates a segment of the circular muscular coat.

Microscopical Examination. — The peri-appendical mass presents the usual hyperplastic inflammatory tissue, consisting of an abundant fibrillated or homogeneous ground substance with fairly numerous, fusiform, connective tissue cells. A few lymphoid and plasma cells are distributed throughout this tissue, occasionally forming clumps, but in the granulation tissue lining the abscesses, polymorpho-nuclear leucocytes predominate and are also present whenever the parasite is found. The appendix shows the changes characteristic of chronic obliterative inflammation. (See Fig. 209.) Its walls, particularly the submucosa, are thickened and fibrous. The canal is reduced to a hair's breadth, and is lined with atrophic mucous membrane, which contains a few shallow glands, but no lymph follicles. At one point, near the middle of

the appendix, the mucosa has been replaced by actinomycotic granulations, consisting chiefly of round cells and containing two or three giant forms. In one place there is an area of polymorpho-nuclear infiltration between the subserous and internal muscular coats, and at this point the actinomyces is found (see Fig. 210). It is also present in the peri-appendical abscess. The cecal mucosa is hemorrhagic and shows slight degenerative changes. The peritoneal surface is involved in the actinomycotic mass which also surrounds the appendix.

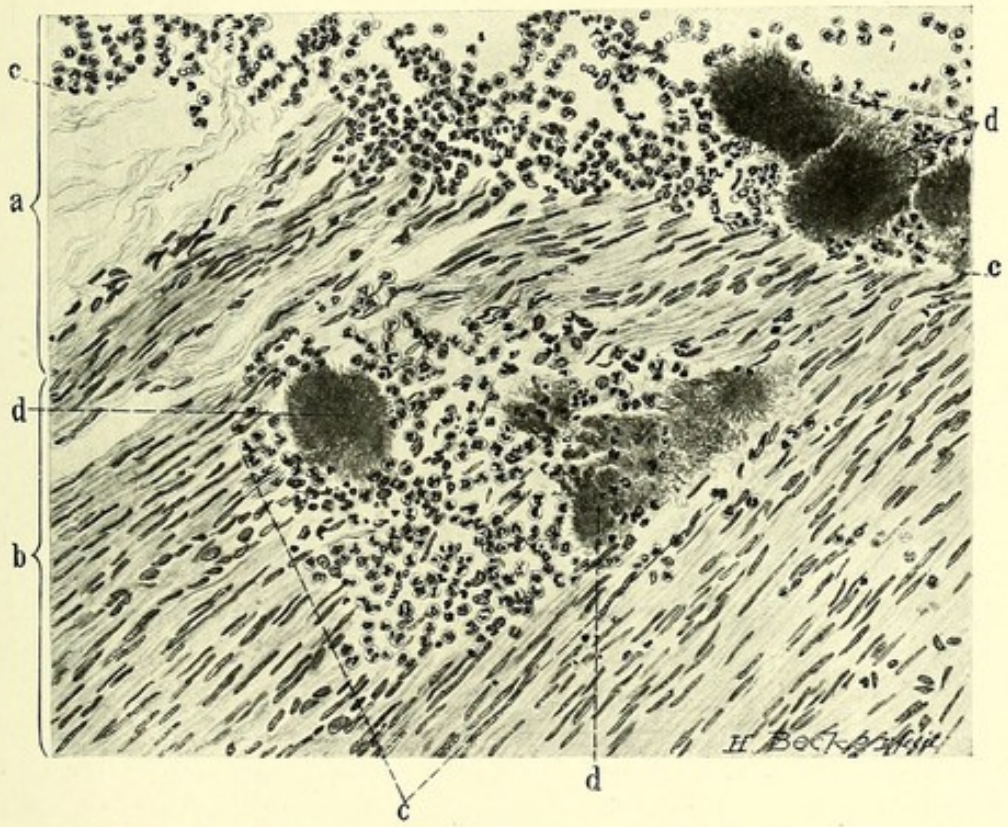

FIG. 210.—ACTINOMYCOSIS OF THE APPENDIX. ENLARGED 420 TIMES.
From a section through the wall of the appendix at the junction of the submucosa (*a*) and the circular muscular coat (*b*). (*d*) indicates parasite colonies in the midst of an abundant leucocytic infiltration (*c*).

TYPHOID FEVER.

From the standpoint of pathological anatomy the affections of the appendix arising during the course of typhoid fever may be divided into three classes of cases:

1. Those in which the appendix participates in the typhoid lesions.

2. Those in which a secondary infection with pyogenic organisms is engrafted upon the typhoid affection.

3. Those in which a simple appendicitis develops, the appendix not being involved in the typhoid infection. In these last cases, however, it is probable that the attack is often precipitated by the congestion which accompanies

the typhoid infection, although there may be no specific typhoidal lesions in the appendix.

It is generally stated that the appendix is involved in about one-third of all cases of typhoid fever, and that of the perforative cases there is a perforation of the appendix in about 5 per cent. Some statistics give a higher percentage, while others again are much lower. It is not explained, however, whether these are coincident attacks of simple appendicitis or are true typhoid lesions. O. HOPFENHAUSEN, in a series of thirty autopsies upon typhoid subjects, found some alteration of the appendix in all, the lesions ranging from a slight hyperemia to diffuse inflammation associated with ulceration. The ulceration was always superficial.

Cases in which the Appendix Participates in the Typhoid Lesions.—These cases vary greatly in the extent and severity of the lesions. In the majority of instances there is merely a slight congestion of the blood-vessels, especially in the serous and mucous coats. In other cases the whole appendix is swollen and turgid and its lumen is practically obliterated by the swollen mucosa. The appendix shown in Fig. 4, Plate I, was removed at operation on the fifteenth day of the typhoid attack. It was greatly swollen, tense, and of a uniform bright red color. On cross-section the muscular coats appeared to be distended by the greatly swollen mucous and submucous layers, which also completely filled the canal. Histological examination revealed typical typhoidal changes, without necrosis. In cases of this kind there are frequently slight extravasations of blood into the mucosa, and even into the deeper tissues. The lymph nodes may be very prominent, and they sometimes show yellow necrotic foci. In other cases, again, more or less extensive ulcerations are found, sometimes merely involving the surface of the mucosa, and sometimes extending into the submucosa and even destroying the muscular coats. The ulcers may be of pin-head size, arising from degenerated lymph nodes (as in one case of MACMONAGLE's), or they may extend superficially over the greater part of the mucous membrane. As would naturally be supposed, the most pronounced changes are found during the acute stage of the typhoid infection. HOPFENHAUSEN found the maximum lesions during the first three weeks; and later, as in the case of the rest of the intestine, the inflammation was less evident.

The characteristic typhoidal lesions found in these cases clearly differentiate them from the cases complicated with secondary infections, and from simple appendicitis. According to MALLORY, the early changes are proliferative in character and consist in a hyperplasia and hypertrophy of the reticular cells of the lymph nodes, also of the endothelial lining of the lymph spaces of all the tissues, but particularly of the membrana propria of the mucosa. The endothelium of the lymph vessels, capillaries, and veins, and to a less extent the arteries, also proliferates. These cells become epithelial in character and possess, to a marked degree, the property of phagocytosis. These large cells were also described by BILL-

ROTH, by GROHÉ, and by others. Accompanying these changes there is a proliferation of lymphoid and plasma cells and active mitosis is noticed in the glandular epithelium. In mild cases the phagocytic cells rapidly undergo fatty degeneration and disappear, the tissues soon regaining their normal condition. The degeneration of the proliferated endothelial cells in the vessel walls frequently forms the starting-point of a thrombotic process (see Fig. 211). In severe cases tissue necrosis usually supervenes, and is explained by MALLORY as due to thrombosis of the lymph vessels and veins. In consequence of the necrosis there is an inflammatory exudation which consists almost wholly of serum with very abundant fibrin. This exudation collects chiefly in the submucosa. Polymorpho-nuclear leucocytes are not numerous and are often absent in small foci; in the larger foci they are usually present in considerable numbers, especially on the surface where various intestinal bacteria are invading the necrotic tissue.

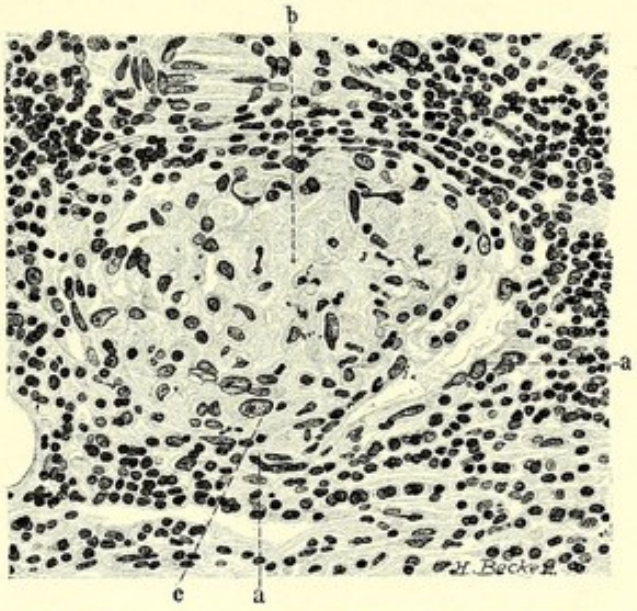

FIG. 211.—THROMBOSED VESSEL IN THE APPENDIX IN A CASE OF TYPHOID FEVER. MAGNIFIED 330 TIMES.

a, The endothelial lining of the vessel; *b*, the thrombus, containing large endothelioid cells (*c*), some of which are phagocytic. (Surg. Path., No. 3194.)

A beautiful example of typhoid ulceration of the appendix has been furnished me by H. C. CHRISTIAN, of Harvard (Figs. 212, 213, 214). With the low magnification the entire thickness of the appendix wall is seen. The muscular and subperitoneal layers are only slightly altered, but the submucosa is immensely thickened and densely infiltrated, while the mucous membrane is completely necrotic. On the surface there is a thick layer of fibrin containing leucocytes and cellular detritus, and in the underlying necrotic tissue polymorpho-nuclear leucocytes are plentiful. Beyond the necrosis the polymorpho-nuclear invasion ceases and the infiltrate is wholly made up of lymphoid and plasma cells and abundant large phagocytic cells.

Restitution may follow extensive necrosis, but, as a rule, large areas of necrosis are repaired by a connective tissue formation which is ultimately converted into scar tissue.

In one of my cases (Fig. 215), obtained at autopsy on a woman who had died in the eleventh week of the typhoid infection, the appendix, which was 11 cm. long, was slightly distended in its distal portion and somewhat injected. Its walls were not thickened. The mucous membrane, which for the most part was pale and smooth, presented several depressed injected areas represent-

ing healing ulcers, also small superficial ulcers; while the lowest portion of the canal, for a distance of about 3 cm., was filled with a tough, grayish, translucent material, which on one side was firmly attached to the appendical wall and could not be removed without tearing the tissue. On microscopic examination (Fig. 216) the muscular and submucous layers appeared normal. The deeper portion of the mucosa also was almost normal, but the superficial portion in places was necrotic. Sometimes only the epithelium was involved in the necrosis; at other times the superficial portions of the glands and membrana propria. The

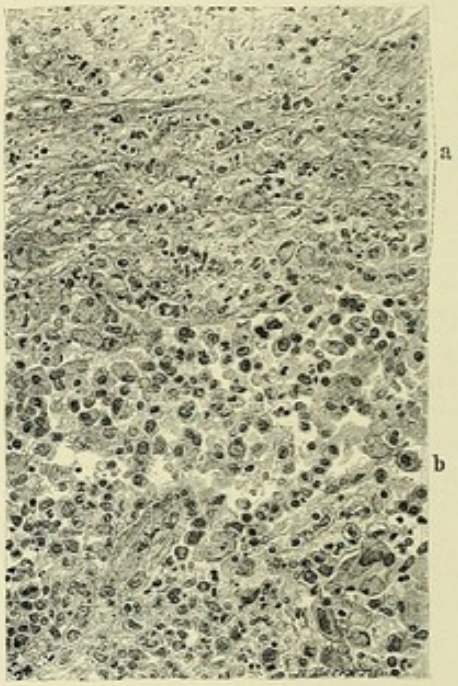

Fig. 213.—Section from Base of Ulcer Seen in Fig. 212. Magnified 300 Times.

a, Necrotic tissue; *b*, large phagocytic cells infiltrating the submucosa.

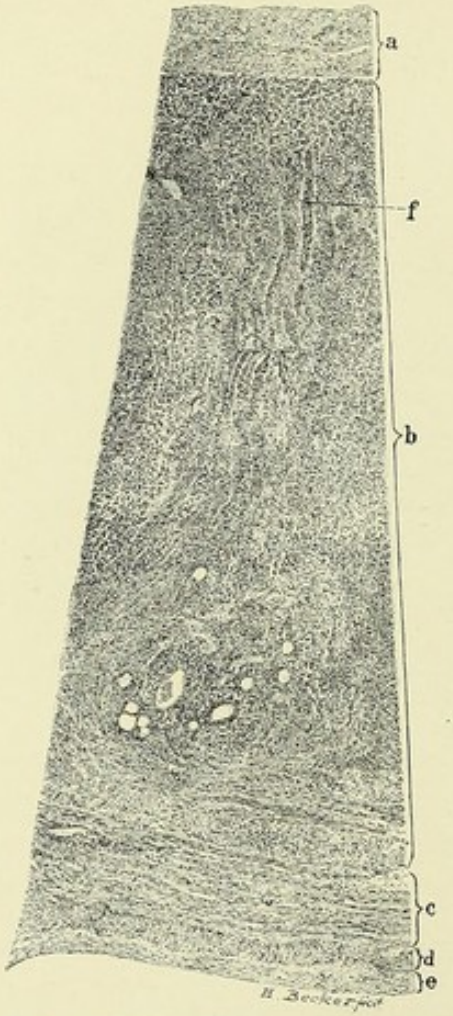

Fig. 212.—Typhoid Ulceration of the Appendix. Magnified 25 Times.

a, Fibrinous exudate; *b*, mucosa and submucosa, densely infiltrated and necrotic in the superficial portion; *f*, degenerated vessels containing leucocytes; *c*, circular muscular coat; *d*, longitudinal muscular coat; *e*, peritoneum. (Specimen from H. A. Christian.)

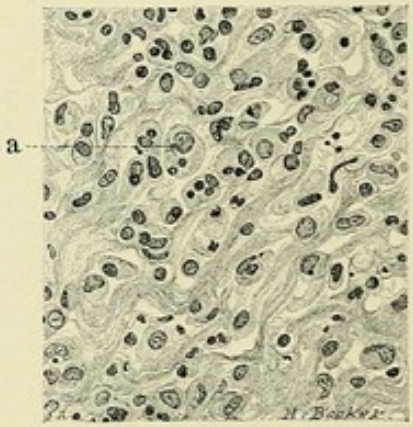

Fig. 214.—Higher Magnification (350 Times) of Large Phagocytes (*a*).

exudation covering these necrotic areas consisted of fibrin, mucus, and a few cellular elements, while a few small blood-vessels from the mucosa were traceable a short distance into it. In this case the healing process had apparently been arrested by the exceedingly low degree of vitality possessed by the patient.

Typhoid Lesions in the Appendix Complicated with Secondary Invasion of Other Bacteria.—These cases probably comprise a large proportion of those in which symptoms of an acute perforative appendicitis occurs early in the course of the typhoid infection. In the gross specimen they cannot be differentiated from the simple acute appendicitides, but microscopic examination reveals the characteristic

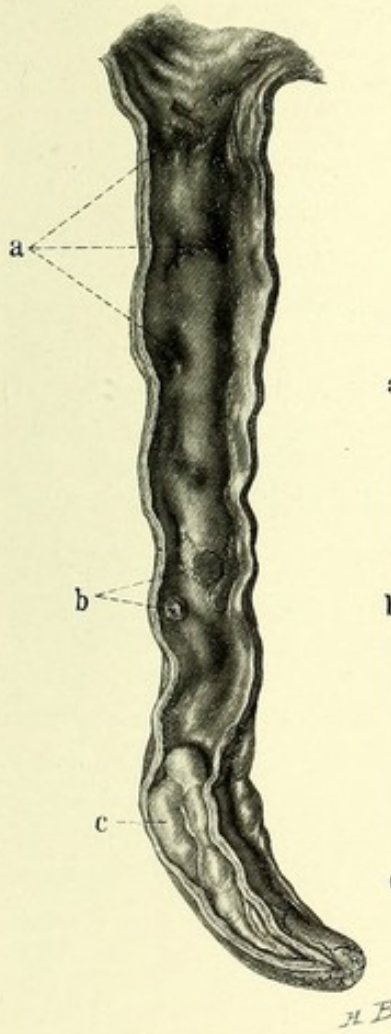

FIG. 215.—TYPHOID APPENDIX, ELEVENTH WEEK.

a, Healed ulcers; *b*, more recent superficial ulcers covered with a fibrinous exudate; *c*, mass of partially organized exudate. (Autopsy, Nov. 13, 1902.)

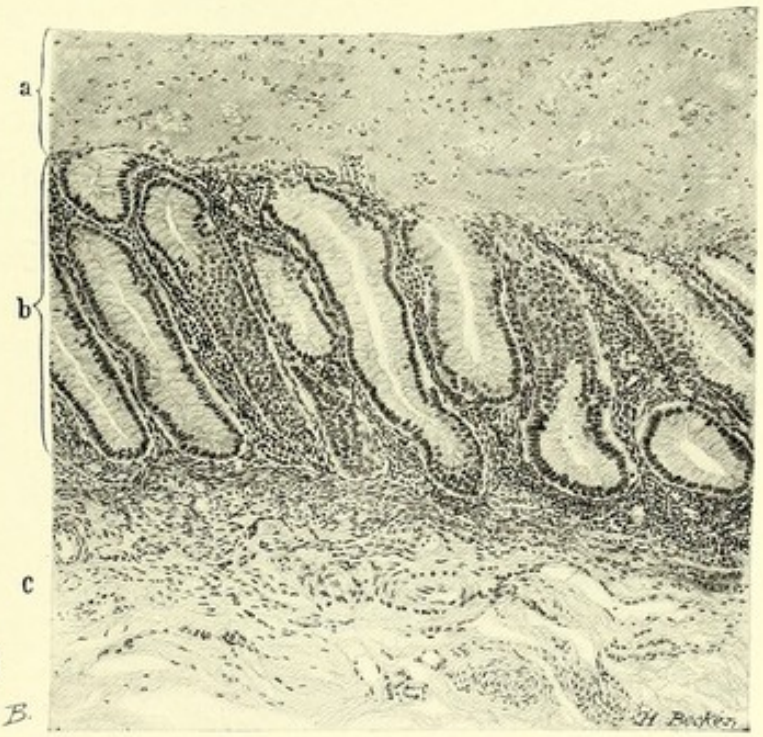

FIG. 216.—TYPHOID APPENDIX. MAGNIFIED 120 TIMES. SECTION FROM FIG. 215.

a, Fibrinous exudate covering the degenerated surface of the mucosa (*b*); *c*, normal submucosa.

typhoid lesions with the superimposed purulent inflammation. Two very interesting cases have been furnished by MACMONAGLE. Both appendices were removed at operation at the end of the second week of the typhoid infection, but while one shows a mixed infection, the other shows a simple appendicitis. The first appendix is 9 cm. long, 7 to 10 mm. in diameter, a slight constriction

dividing the thickened middle portion into two parts. The surface is deeply injected and hemorrhagic, one point showing beginning necrosis. There are adhesions about the appendix. The mucous membrane lining the proximal third is swollen but smooth; farther out it is ulcerated, the necrosis extending at one point to the peritoneal surface. Microscopical examination of the cecal portion shows that the swelling of the mucosa is produced by the presence of an abundant infiltrate, chiefly consisting of large phagocytic cells which are seen in the lymph nodes and stroma. The mucous membrane of the rest of the appendix is studded with pin-head ulcers, almost all of which are situated in the chinks between the folds, and apparently have been produced by necrosis of the lymphoid follicles. This portion of the appendix also shows a diffuse purulent inflammatory process.

Simple Appendicitis Arising During the Course of Typhoid Fever.—In the reported cases there are no data given from which to determine the frequency of this class of cases, but *à priori*, we should not expect it to be a rare event. In particular, where there are concretions, kinks, or stenoses consequent upon an old inflammation, it seems very probable that the hyperemia of the appendix accompanying the typhoid infection would have an important influence in precipitating an acute appendicitis. Histological examination of the appendix in such a case shows a simple inflammatory reaction and nothing suggestive of a typhoid infection. The second case sent by MacMonagle appears to be of this nature. The appendix is 5 cm. long, 7 mm. in diameter, with a slightly bulbous tip. The surface is injected and hemorrhagic and in places covered with a fibrinous exudate. The cecal half of the canal is distended with a concretion 1 × 0.6 cm. Beyond this the mucosa is completely necrotic. Histological examination shows complete necrosis of the mucous membrane and purulent inflammation of all the tissues, involving the portion of the appendix distal to the part containing the concretion. The mucosa of the latter area is degenerated, but the other layers, apart from being thinned out, are not affected. There is no appearance of typhoid lesions.

AMŒBIC DYSENTERY.

The Amœba coli was discovered in the stools of infants and cholera patients by Sambl and Cunningham, but Lösch first accurately described the disease in 1875. In America the Amœba was first found by Osler, in 1890. This organism belongs to the class Rhizopoda of the Protozoa. It is an actively amœboid, unicellular organism, and varies in size between 8 and 37 microns, averaging 20 microns. It consists of an inner granular portion, the endosarc; and an outer hyaline layer, the ectosarc. The nucleus, about 16 microns, is situated near the margin of the endosarc and in stained specimens a nucleolus is seen. There are often several vacuoles, and frequently foreign elements, especially red blood corpuscles, in the endosarc.

An admirable description of the lesions produced in the infected tissues is given by L. Rogers, of the Indian Medical service. These, at first, are small, pin-point elevations, reddish, with a yellowish centre. The earliest forms usually found are circular or oval ulcers, ranging from the size of a pea to an inch in length, the long axis of the ulcer running at right angles to the axis of the bowel. They appear as raised patches with well-defined thickened margins,

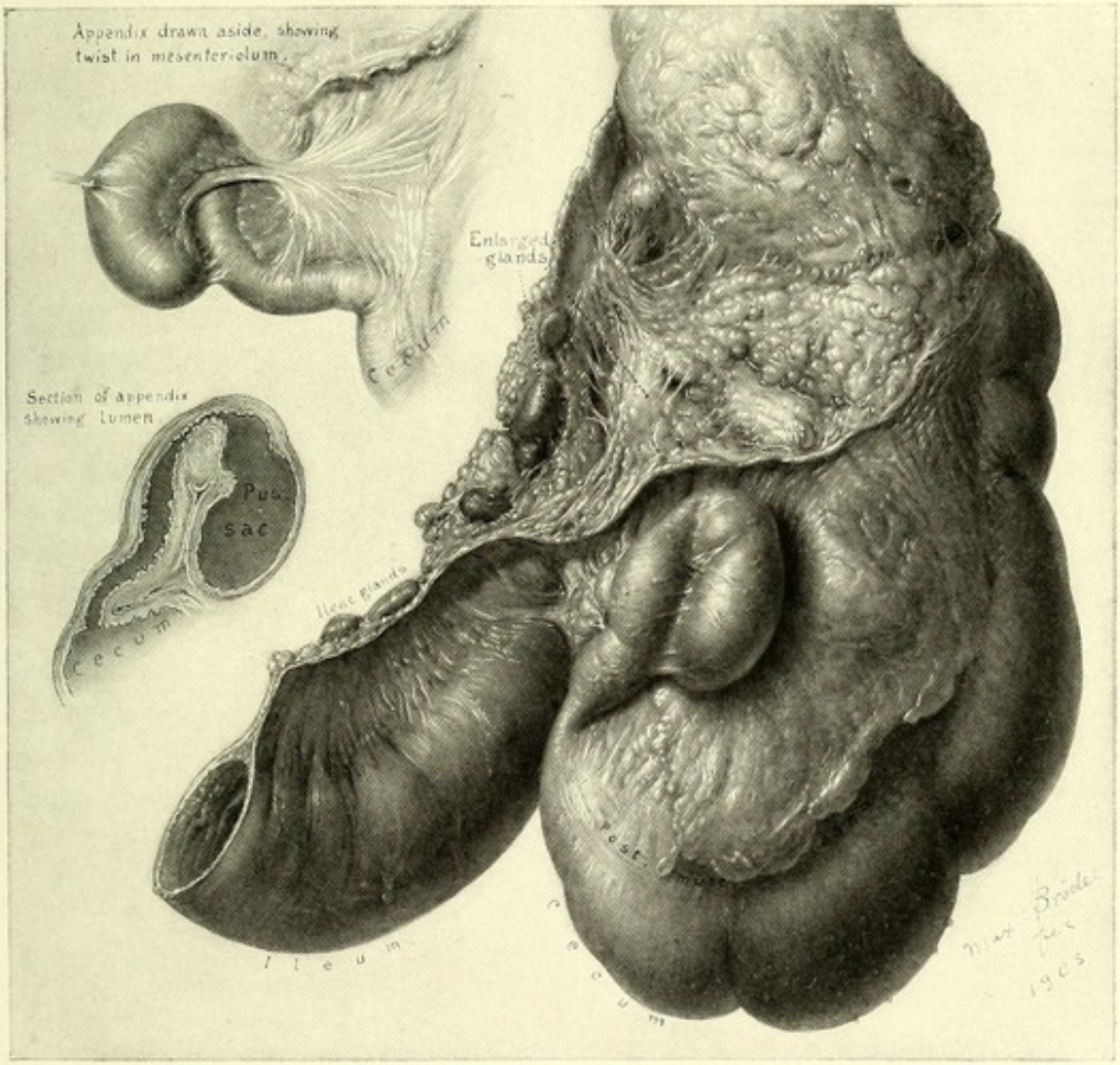

Fig. 217.—Amœbic Dysentery.

The appendix bent at an acute angle and held in this position by firm adhesions. Almost complete obstruction of the canal at the angle, and the distal portion distended with yellowish gelatinous material. (Autopsy No. 2165.)

often surrounded by a zone of congestion. The crater of the ulcer is filled with a characteristic, yellow, gelatinous material. A striking feature of the disease at this period is the healthiness of the bowel immediately beyond the ulcerated area. Later the ulcers lose their round or oval form and appear as long irregular ulcers, extending along the folds of mucosa, or as greatly thick-

ened raised patches with light yellow or tawny ragged sloughs. Occasionally black sloughs form. In very chronic cases there may be some thickening of the bowel wall. Resolution proceeds by the gradual disappearance of the gelatinous material, the base of the ulcer becomes depressed and contracted, causing a puckering of the still thickened margin, the defect is filled in by granulations, and finally a patch of scar tissue remains, which in many cases is pigmented. On microscopic examination there is found to be a notable absence of the products of purulent inflammation. According to FUTCHER, polymorphonuclear leucocytes are seldom found and never constitute purulent collections. The most striking feature is the enormous thickening of the submucous coat, while, on the other hand, the mucous layer is but little altered. There is, first, an infiltration of the submucosa, with yellow gelatinous material; a portion of the overlying mucosa then disappears, probably by a process of anemic necrosis. The gelatinous material then forms the floor of the ulcer, the infiltration of the submucosa, however, extending considerably beyond the superficial denudation.

The lesions are most marked in the upper part of the large intestine, and when the disease is slight the ulcers are usually limited to the cecum and ascending colon. The vermiform appendix is often severely affected; just as in typhoid fever, perforation of the ulcer may occur. In a case illustrated in ROGERS' article, perforation of the appendix caused fatal peritonitis. In one case, recently observed at autopsy in the Johns Hopkins Hospital (Fig. 217), the tip of the appendix was distended with the characteristic yellow, gelatinous exudate, and the mucosa of this part presented extensive areas of necrosis. The proximal half was but little altered. Histological examination of the distended portion showed a general hyperemia of the mucosa and a considerable infiltration of round cells. A few polymorpho-nuclear cells were seen in places. At one point there was complete necrosis of the mucosa, slightly involving the submucosa. The submucosa was infiltrated with abundant round cells and a few polymorpho-nuclear leucocytes. The muscular coats were only slightly infiltrated, but in the peritoneum and mesentery the infiltration was marked. Amœba are found in the exudate at the margin of the ulcer, and at one point in a distended lymph space. A second case presented similar lesions in the appendix, chiefly involving the proximal half.

BIBLIOGRAPHY.

ABBÉ: N. Y. Med. Rec., 1897, vol. 52, p. 37.
AMMENTORP: Quoted by Spickenbaum.
APPUHN: Thèse de Nancy, 1903.
AUGUY: Thèse de Lyon, 1901.
BECK: N. Y. Med. Jour., 1898, vol. 68, p. 685.
BENOIT: Thèse de Paris, 1893.
BÉRARD: Gaz. des hôp., 1840, tom. 2, p. 145.
BIERHOFF: Dtsch. Arch. f. klin. Med., 1890, Bd. 27, p. 248.
BIGGS: Proc. N. Y. Path. Soc., 1888–1889, p. 104.

Brewer: Amer. Jour. Surg., 1901, No. 33, p. 761.
Buchner: Quoted by Lenzmann.
Burne: Med. and Chir. Trans., 1839, vol. 22, p. 33.
Caussade et Charrier: Arch. gén. de méd., 1899, tom. 1, p. 410.
Christoffers: I. D. Berlin, 1887.
Coulloumme-Labarthe: Thèse de Paris, 1901.
Coquet: Thèse de Paris, 1894.
Crowder: Amer. Jour. Med. Sci., 1902.
Cruveilhier: Anat. Descrip., Bruxelles, 1837.
Czerny und Heddaeus: Beit. z. klin. Chir., No. 21, p. 513.
Deaver: Treatise on Appendicitis, 1900.
Ehrich: Beit. z. klin. Chir., 1900, Bd. 29, p. 77.
Fenger: Amer. Jour. Obstet., 1893, vol. 28, p. 161.
Ferry: Thèse de Paris, 1900.
Fitz: Amer. Jour. Med. Sci., 1886, p. 321.
Futcher: Jour. Amer. Med. Assoc., 1903, vol. 41, p. 480.
Gerster: N. Y. Med. Jour., 1892, vol. 56, p. 216.
Grawitz: Berl. klin. Wochenschr., 1889, p. 112.
Hartmann et Pilliet: Bull. de la Soc. anat. de Paris, 1891, p. 471.
Helferich: Quoted by Spickenbaum.
Hopfenhausen: Rev. méd. de la Suisse rom., 1899, vol. 19, p. 105.
Illich: Beit. z. Klin. der Aktinomykose, Wien, 1892.
Israel: Berl. klin. Wochensch., 1895, p. 377.
Itié: Thèse de Montpellier, 1898.
Jervall: Quoted by Appuhn.
Keen: Trans. Amer. Surg. Assoc., 1898, vol. 16, p. 243.
Kelynack: Pathology of the Vermiform Appendix, 1893.
Kingdon: New Eng. Quar. Jour. of Med., 1842–43.
Krackowitzer: N. Y. Med. Jour., 1871, vol. 13, p. 733.
Langhans: Schweizer Correspondenzblatt, 1888, No. 11.
Lartigau: Jour. Exp. Med., 1901, vol. 6, p. 23.
Lennander: Dtsch. Zeit. f. Chir., Bd. 63, p. 1.
Lenzmann: Die Entzündl. Erkrannk. des Darms in der Reg. ileo-cecal, etc., 1901.
Mallory: Jour. Exp. Med., 1900, vol. 5, p. 1.
Morris: Amer. Jour. Obst., 1902.
Mosher: Brooklyn Med. Jour., 1903.
Mühsam: Mit. aus d. Grenzgeb. d. Med. u. Chir., 1903, Bd. 11, p. 284.
Murphy: Med. News, 1895, vol. 66, p. 1.
Osler: Principles and Practice of Medicine, 1903.
Partsch: Samm. klin. Vort. (Chir.), 1888, p. 2833–90.
Petit: Thèse de Paris, 1902.
Ramond et Ravaut: Arch. de méd. exper. et d'anat. path., 1899, tom. 1, No. 4, p. 494.
Richelot: Union méd., Paris, 1893, No. 56, p. 17.
Reclus: Clin. chir. de la Pitié, Paris, 1894, p. 317.
Reisinger: Münch. med. Wochensch., 1903, p. 1722.
Rendu: Clinique méd., 1890, tom. 2, p. 127.
Renvers: Dtsch. med. Wochensch., 1891, p. 177.
Ribbert: "Beit. z. norm. u. path. Anat. des Wurmfortsatz," Virch. Arch., 1892, Bd. 32.
Ricard: Bull. de la Soc. de chir.
Richard: Thèse de Paris, 1903.
Riedel: Arch. f. klin. Chir., 1902, No. 66, p. 1.
Sahli: "Ueber das Wesen u. die Behandlung der Perityphlitides," Basel, 1892.
Scheibenzuber: Ohio Med. and Surg. Jour., 1877, vol. 2, p. 259.
Sedillot: Ann. chir., 1841, p. 495.
Senn: Jour. Amer. Med. Assoc., 1894, vol. 22, p. 403.
Sonnenburg: Perityphlitis, 1887, Fig. 9, p. 76.

Spickenbaum: I. D. Kiel, 1900.
Tchacaloff: Thèse de Genève, 1901.
Tèdenat: Quoted by Itié.
Virchow: Geschwülste, Bd. I, p. 250.
Weir: Med. Rec., 1903, vol. 64, p. 801.
Welch: System of Medicine, Albutt, vol. 8, p. 177.
Wölfler: Arch. f. klin. Chir., Bd. 21, p. 432.
Zuckerkandl: Anat. Hefte, Wiesbaden, 1894, Bd. 4, p. 99.

CHAPTER XVI.

ETIOLOGY.

PREDISPOSING CAUSES. EXCITING CAUSES. FINAL CAUSES.

The various factors uniting to call forth an attack of appendicitis may be considered under three headings: P r e d i s p o s i n g, e x c i t i n g, and f i n a l or e s s e n t i a l.

PREDISPOSING CAUSES.

Predisposing causes may be local or general. Among the most important are the normal anatomic and physiologic conditions. The appendix consists of a blind sac of relatively great length and small calibre, possessing a narrow orifice; it resembles the tonsil in its abundant lymphoid tissue, and, like the latter, borders upon a cavity particularly rich in bacteria. The mechanical conditions are, therefore, such as favor the stagnation of ingesta and an increase in the virulence of the contained micro-organisms, while the presence of so many follicles affords a convenient portal of entry for bacteria. It is well known that the lymphoid tissues of the body are especially prone to infective processes, and the researches of Stöhr and Ribbert show that the adenoid tissue of mucous membranes is easily accessible to infections from the surface. The analogies existing between the appendix and the tonsils, pointed out in 1876 by Watney, and later by Sahli, Southerland, Ribbert, Beck, Adrian, and others, will be referred to further in considering the relation of appendicitis to general infectious diseases. Morbid anatomic conditions, resulting from a previous acute or chronic inflammation, are of recognized importance in the development of subsequent attacks. Riedel believes that all acute attacks are preceded by a chronic inflammation. Roux remarks that the *processional de l'appendicite* finds in the adenoid tissue and in the residual cicatrices, parietal or peri-appendical, all the elements necessary to contract a new appendicitis on the occurrence of any physiologic hyperemia, the result of indigestion, or of cold, or, perhaps, accompanying menstruation. These conditions, as well as their influence in rendering the appendix susceptible to recurrent attacks of inflammation, have been fully described in Chap. XIII.

A similar *locus minoris resistentiæ* is created when the normal appendix becomes adherent to an adjacent structure, a frequent complication in pelvic inflammation, tumors, etc. I am acquainted with several instances in which an inflammatory process was apparently promoted by the attachment of the appendix to the site of a previous operation. (See Chap. XXIX.) The

influence of the floating right kidney as an etiologic factor in the development of appendicitis has been chiefly upheld by Edebohls, who would ascribe to it an important rôle in the etiology of the disease. He believes that the kidney acts as an exciting cause indirectly through disturbance of the circulation, owing to compression of the superior mesenteric vessels between the head of the pancreas and the spines of the vertebræ. C. Beck, on the other hand, believes that the kidney acts as a direct exciting cause, by pressure on the appendix itself. W. P. Manton states that in his experience movable kidney is the most frequent cause of chronic appendicitis. Other writers have observed the occasional coexistence of the two affections, but do not consider that the relation of cause and effect is always clear. C. P. Noble, in 100 operations on cases of movable kidney, did not observe the association in more than six. Out of 104 cases of movable kidney operated upon at the Johns Hopkins Hospital the appendix presented evidence of chronic inflammation in four.

Age.—Appendicitis is distinctly a disease of early life. It is not rare in children (see Chap. XX), but is most common between ten and thirty years of age. After this period there is a rapid decrease in the number of cases, although it is by no means rare even in advanced life. Fitz described a case in a man seventy-eight years of age. An analysis of the cases of acute appendicitis operated upon at the Johns Hopkins Hospital showed that 78 per cent. were under thirty years, about an equal number occurring in the second and third decades, and 5 per cent. in the first. The cases operated upon for chronic appendicitis for obvious reasons show a more advanced age. Thus, 44 per cent. occurred in the third decade and 23 per cent. in the fourth, while only 16 per cent. were under twenty years. The well-recognized susceptibility of lymphoid tissues to infections during early life is the probable explanation of the prevalence of appendicitis at this period. The more frequent dietary indiscretions and exposure to injury may have some bearing upon this point.

Sex.—The analysis of large numbers of cases demonstrates the greater liability of the male sex to appendical disease. The combined statistics of several authors give a percentage of 75 in males and 25 in females. The cases of the Munich Hospital reported by Einhorn were exceptional in presenting a larger percentage in women. In the Surgical Department of the Johns Hopkins Hospital the percentage in acute appendicitis is as 60 in the male to 40 in the female, but it is to be noticed at the same time that a number of cases were observed in the gynecological service (see Chap. XXIX). The striking difference in the two sexes is often erroneously explained by the supposed difference in the vascular supply of the organ, based on the mistaken view that in the female it receives a special branch from the ovarian artery. A really plausible explanation is found in the greater liability to exposure to injury and the greater tendency to errors in diet in the male sex. The excessive use of tobacco and the consequent digestive disturbances may also account for some cases. Byron Robinson advances the theory that the

relation of the appendix to the psoas muscle may explain the greater frequency of appendicitis in males. The psoas in them is longer, broader, and more developed generally, thus offering a greater surface for contact with the appendix. This disparity is further increased by the shape of the pelvis, which is long and narrow.

Nationality.—This is apparently an insignificant factor in the development of the disease. The great increase in the number of cases reported during the past few years is universal, and wherever the disease is carefully observed it is recognized as of common occurrence. The negro race, however, seems to be comparatively exempt from the affection. In order to obtain some information upon this point I wrote to several surgeons practising in southern cities having a large proportion of negro inhabitants. The replies were unanimous in regard to the rarity of the disease in this race. S. C. Briggs, of Nashville, Tenn., out of several hundred operations for appendicitis could recall only one upon a negro. He stated, however, that as the colored race in the South have their own physicians, they did not always come under the observation of others; nevertheless he thought that the disease was rare. H. J. Inge, of Mobile, Ala., out of 149 operations had but one in a negro, and by inquiry among other physicians found its occurrence in the race to be equally rare in their experience. G. B. Noble, of Atlanta, Ga., had never operated upon a negro for appendicitis. L. L. Hill, of Montgomery, Ala. (in the "black belt"), with a colored population of 9000, could collect the histories of only four cases that had occurred among them, and found that the physician who had been consultant for a number of years at Booker Washington's school, where there are about fourteen hundred colored students, did not remember ever to have seen a case there; at the Alabama Polytechnic Institute, however, twenty miles distant, where there are 400 boys, there was an annual average of eight cases. At the former school the diet is simple and the same for all, but at the latter the cadets live at different boarding-houses in the town. There are 800 negro prisoners at one of the Alabama coal-mines and the physician in charge states that appendicitis is unknown among them. The explanation given for this relative exemption of the negro is that their diet is simple, they take a great deal of outdoor exercise, and they are free from digestive disturbances. The statistics of the Johns Hopkins Hospital show that while the number of admissions of colored to white averages about 1 to 4, the number of cases operated upon for appendicitis is as 1 to 12.

Hereditary Influence.—Lennander (*Beit. z. klin. Med. u. Chir.*, 1895) characterizes appendicitis as a family disease, and most physicians of wide experience are impressed with the remarkable frequency of its occurrence in members of the same family. Brothers and sisters are affected more often than parent and child, although the latter association is not uncommon. A. McCosh (*Amer. Jour. Med. Sci.*, May, 1897) reports three cases in three successive generations, and Finney (*personal communi-*

cation) had five cases in one family, the father, two sons, and two daughters being affected. In one of the Johns Hopkins Hospital cases a girl, twelve years of age, was operated on for acute appendicitis while her father was still in the ward convalescing after operation, also performed during an acute attack. In several cases there was a history of one or more brothers and sisters similarly affected; in one instance two brothers of the patient had been operated upon for appendicitis in the Johns Hopkins Hospital—one four, the other two years previously. A family predisposition is explicable upon the ground of anatomic peculiarities and constitutional predisposition. It is well known that in some families there is a marked tendency toward affections of the lymphoid tissues. As a rule, the affection appears in the various members of the family at different periods, but there are a considerable number of observations referring to its development in two or more at the same time. F. W. Sears, of Albany, has furnished me with the following cases:

1. Boy, thirteen years old, operated on the morning after the onset of the second acute attack. The appendix, which was surrounded by omentum, was perforated and there was considerable pus present.

2. Four days later his sister, nine years old, who had always been well, was seized with a sharp attack of appendicitis and was operated on three days later. In this case the omentum had formed a pocket in which the perforated tip of the appendix was buried.

3. The daughter of a physician, age nineteen. Second attack of acute appendicitis. Operation the following morning. The appendix was perforated close to the cecum and there was beginning peritonitis.

4. Eight days later her sister, twenty-one years old, who had been well, was taken with an acute attack and was operated on the next morning. The appendix was perforated, but the peritoneum was protected by the adherent omentum.

These instances of coincident attacks in members of the same family suggest the presence of a general infectious origin, and will be referred to later in that connection.

EXCITING CAUSES.

Disorders of Digestion.—These have the most important influence in determining an acute attack of appendicitis. In many cases there is a history of chronic constipation and indigestion. Sometimes an acute attack comes on shortly after a hearty meal of unsuitable food. Less frequently, diarrhea, sometimes associated with symptoms of acute entero-colitis, precedes the onset of the appendical trouble. In the cases at the Johns Hopkins Hospital there was a history of constipation immediately preceding the attack in 43 per cent. In 50 per cent. the bowels were regular, but in many of these cases there was a history of indigestion, and it must always be remembered that the patient's statement that the bowels were regular is not a proof that there was no constipation. For example, in a recent case of J. C. Bloodgood's the patient asserted that her bowels were regu-

lar, but at operation the colon was found filled with scybalous masses, which were also present in the cecum. In several instances the onset of the attack was marked by more or less severe diarrhea, but this symptom was rarely present earlier and was frequently preceded by constipation. Frequently, as mentioned above, the attack may be directly traced to an undigestible meal. This was true in a considerable number of cases; in some of which the attack immediately followed the ingestion of unsuitable food, but usually occurred some hours afterward. A common history in the account of events immediately preceding the attack, is that the patient had partaken of an unusually hearty supper and a few hours later was awakened from sound sleep by agonizing colicky pain in the abdomen, accompanied by vomiting.

Menstruation.—The intimate relation existing between the menstrual periods and appendicitis has been frequently noted, not only when the appendix is situated in the pelvis, but when it is retrocecal. The probable explanation lies in the fact that the congestion of the whole splanchnic area which accompanies the lowered blood-pressure of the peripheral circulation during menstruation creates a favorable soil for the activities of the micro-organisms contained in the appendix. I have observed this association in several instances, in some of which the recurrent appendical attacks invariably occurred at the menstrual period. A good example is in the following case:

A girl, age eighteen, was admitted to the Gynecological Department of the Johns Hopkins Hospital with a history of five attacks of acute appendicitis associated with menstrual periods, the last three attacks occurring in consecutive months. While under observation in the ward at the beginning of menstruation, she was seized with pain in the right side a little above McBurney's point and extending to the lumbar region. There was marked tenderness and indefinite resistance in this area. The temperature was normal and there was no leucocytosis. The pain and tenderness steadily increased, and the next morning the temperature was 100° F., the leucocytosis 7,000; in the afternoon there was well-marked resistance in the right lumbar region, and the temperature was 100.8° F., the leucocytosis 16,000. At operation the appendix was found acutely inflamed, greatly swollen, and embedded in a mass of inflammatory exudate.

Trauma.—Trauma is a direct factor in the causation of some cases of appendicitis, more often than has been supposed. Indirect injury, such as straining in heavy lifting, is a more common cause than a direct blow. In one of our cases the attack followed immediately upon a long, hard bicycle ride; in another the patient jumped from a street-car and was immediately seized with abdominal pain so severe that he could not straighten up. In another, again, the patient had been in swimming for an hour when he was seized with a sharp, knife-like pain in the right side, which he attributed to cramp. The etiologic influence of injury has been considered in detail in discussing the medico-legal aspects of appendicitis. (See Chap. XXXIII.)

Exposure to cold occasionally bears a direct relation to the development of an

attack of appendicitis. It resembles in its action the physiologic congestions due to other causes, and is most liable to induce an acute attack in an appendix predisposed to inflammatory disease as the result of a previous attack.

Foreign Bodies and Concretions.—A few years ago the origin of appendicitis was frequently attributed to the influence of foreign bodies, the seeds of various fruits being most frequently described. Now, however, it is generally recognized that in the majority of cases appendicitis is not associated with the presence of foreign bodies or concretions; that true foreign bodies are comparatively rare; and that concretions, although present in a considerable number of cases, probably play a subsidiary rôle in the production of the disease. The frequency of foreign bodies in the appendix is indicated by the statistics of

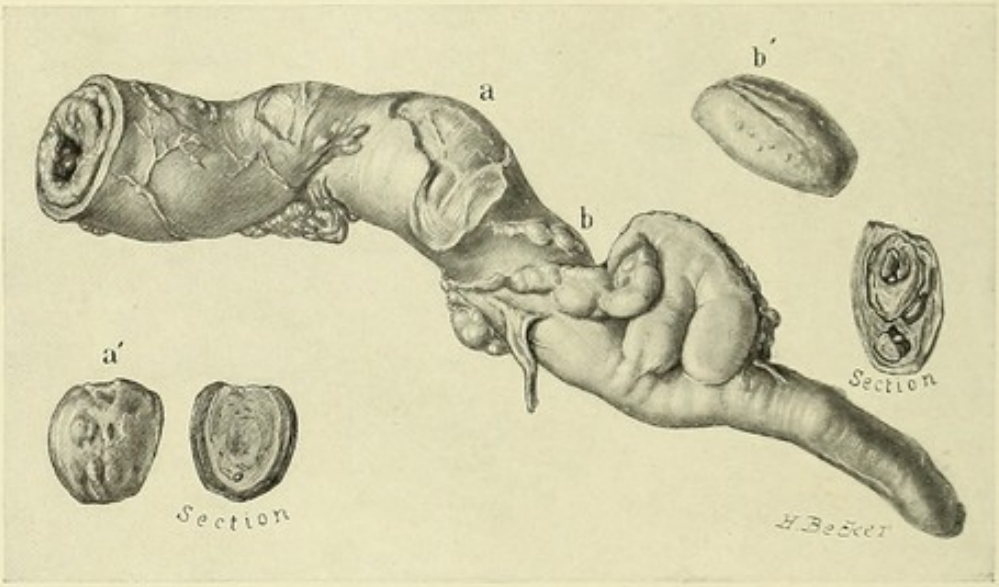

Fig. 218.—Subacute Appendicitis Associated with the Presence of Two Concretions.

The prominences a and b mark the site of the concretions (a′ and b′). The former body bears a striking resemblance to a hazelnut, while a genuine fragment of nut-shell is embedded in the latter. (Specimen from the German Hospital, Philadelphia.)

various recent observers. Thus, A. O. J. Kelly, examining 460 specimens, only once found a foreign body, which was a pin; Hawkins found none in 67 fatal cases; Bell, in about 1000 cases found five foreign bodies, a fish-bone, a core of apple, two pins, and a lumbricus; Murphy found foreign bodies in 3.5 per cent.; while Fitz, writing in 1886, noticed their presence in 12 per cent. of the perforative cases, and Matterstock, in 1880, also found them in 12 per cent. of his cases. In almost 1000 cases of appendicitis in the Johns Hopkins Hospital foreign bodies have been found in four cases, a segment of tape-worm, a mass of oxyurides in two, and a pin. Many of the seeds described in the older literature were undoubtedly merely fecal concretions, which frequently assume the appearance of a cherry or date stone and sometimes are recognized only by the most careful examination. The case shown in Fig. 218 is a good

example of the simulation of a foreign body by a concretion. In size and shape the mass exactly corresponds to a hazelnut, and indeed the drawing was made under the impression that it was such. The presence of a fragment of nut-shell in the second concretion, together with the fact that the appendix was of the fetal type and would readily permit the entrance of a comparatively large body, seemed to confirm this view, but the detection of extraneous material in the interior of the mass and its general structure showed that it was merely a concretion. Gall-stones, also, which formerly were supposed to enter the appendix frequently, are exceedingly rare; but they are often so closely simulated by enteroliths that a chemical analysis is necessary for their exclusion. The clinical evidence in some of these cases so strongly supports the gall-stone theory as to leave no doubt in the mind of the observer. A case in point, observed in the Surgical Department of the Johns Hopkins Hospital, is as follows:

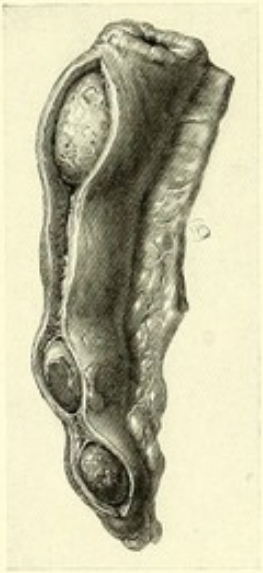

Fig. 219. — Appendix Containing Enteroliths Resembling Gall-stones. (Specimen from Rogers.)

L. F., age twenty-four. Admitted with a typical history of stone in the gall-bladder and in the common duct, and of their appearance in the stools. At operation about 100 small facetted calculi were removed from the gall-bladder. The patient was discharged well. About fourteen months later she returned complaining of sticking pain in the region of the gall-bladder, which, however, was unlike the former attacks in character. This had been of a few days' duration and was accompanied with vomiting. Operation revealed a few adhesions about the gall-bladder and the omentum closely adherent to the chronically inflamed appendix. The removed appendix (Fig. 3, Plate III) presented a stricture 1 cm. from the tip, and contained soft, tenacious fecal material which formed a mould of the whole lumen. Within it there were three hard, irregular bodies; the largest one, in the centre, was a cube about 1 cm. in diameter with facetted, slightly hollowed surfaces. It was dark brown in color, except for a superficial layer of white, corresponding to the appearance of the calculi removed from the gall-bladder at the first operation. The diagnosis was chronic appendicitis due to the presence of gall-stones. An analysis of the facetted stone made by L. Mendel, of Harvard, showed that it was a typical enterolith. The nucleus was a small particle resembling a raspberry seed; the remainder consisted chiefly of calcium phosphate with some magnesium sulphate, traces of carbonate, some fat, and amorphous material.

A similar history was given by the patient from whom the appendix shown in Fig. 219 was removed, and the operator, Dr. Rogers, naturally made a diagnosis of gall-stones in the appendix. In Fig. 220 an appendix is shown which apparently contains a genuine gall-stone. The specimen furnished by James Bell,

of Montreal, was removed from a young woman, twenty-two years old, on the second day of an acute attack. There was a history of an attack of appendicitis of nine years before. The diagnosis of gall-stones was made from the appearance of the body and from its composition, which consisted largely of cholesterin. In this case, also, the appendix had a wide orifice. In a similar case, furnished by G. W. Crile, of Cleveland, Ohio, the acutely inflamed appendix, which was short and funnel-shaped, contained a good-sized calculus, which chemical analysis showed to be a true gall-stone.



Fig. 220.—Appendix Containing a Calculus, Probably a Gall-stone.

While, however, many observations, owing to lack of careful examination, are unreliable, in some instances foreign bodies undoubtedly gain access to the appendix and directly provoke the inflammatory process. Among the objects that have been found in the appendix are pins, shot, pieces of lead, bones, hairs, bristles, various seeds, and enterozoa. The cases in the literature with especial reference to the occurrence of pins in the appendix have been carefully investigated by J. F. Mitchell (*Johns Hopkins Hospital Bull.*, 1894, p. 35), who arrives at the following conclusions: "Foreign bodies are now known to play a much smaller rôle in appendicitis than that formerly accredited to them. The appendix would seem to act especially as a trap for pointed bodies and for small heavy objects like shot or bullets. Conspicuous among pointed bodies are pins, which are the commonest and at the same time the most dangerous of all foreign bodies." Bodies of light weight, like the classical grape-seeds and cherry-stones, are exceptional. The explanation of this fact is that on account of their shape and weight, pointed and heavy bodies more readily become engaged in the appendical orifice and pass into the canal. It is a curious fact that pins rarely perforate the cecum or small intestine. It is almost impossible for the seeds of cherries, dates, oranges, etc., to enter the lumen of the appendix, except in cases where the fetal type is preserved. Small seeds, such as those of berries, are not infrequent, and I have repeatedly demonstrated their presence under the microscope (see Fig. 221), but they are of no special significance in the



Fig. 221.—Appendix Containing Two Small Seeds at Points Indicated by a.

etiology of appendicitis, as they merely form part of the fecal material commonly found in the appendix. The following cases of foreign bodies in the appendix, collected from the literature and from personal communications, bring out some interesting facts regarding the frequency of certain kinds of bodies and their pathogenicity. My list includes all the cases cited by MITCHELL in his article, and a number of additional cases as well. I have not included cases in which the right iliac abscess containing the foreign body was not demonstrated to be of appendical origin.

1. MESTIVIER. *Jour. de méd. chir. et pharm.*, etc., 1759, tom. 10, p. 441. Man, age forty-five. Abscess. Incision. Autopsy: In the appendix, a large pin encrusted and eroded so that the least force would break it. No history of having swallowed it.

2. KINGDON. *N. E. Quart. Jour. of Med.*, 1842–43, vol. 1. Boy, age seven. Difficulty in micturition and repeated passage of worms from the urethra; passage of urine from anus. Death at end of three years from exhaustion. Autopsy: Showed the appendix adherent to, and opening into the upper part of the bladder, which contained a calculus formed around a large pin, that had obviously escaped from the appendix. No history of having swallowed pin.

3. BROCA. *Bull. de la Soc. anat.*, 1849, tom. 24, p. 364. Child dead of pulmonary tuberculosis and an enormous abscess of the liver. No symptoms connected with the appendix during life. The pin had perforated the adherent portion of the appendix. There were no signs of peritonitis.

4. PARROT. *Bull. Soc. anat. de Paris*, 1855, tom. 54. Man, age twenty-four. Right iliac tumor for twelve years. Spontaneous rupture and fecal fistula. Probe encountered a hard body which was removed and found to be an ordinary pin, with point free, but otherwise encrusted with hard fecal matter. Death of general peritonitis. Patient did not remember swallowing pin. Autopsy: Showed a fistula leading into a cavity into which the vermiform appendix opened.

5. JOFFROY. *Bull. Soc. anat. de Paris*, 1869, tom. 44, p. 512. Girl, age ten. Symptoms suggested typhoid peritonitis. Acute appendicitis. Death in two months. Autopsy: Circumscribed abscess in right iliac fossa. In the appendix a pin of large size which had entered head first and penetrated the appendix wall with its point. Pin surrounded with fecal matter.

6. PAYNE. *Trans. Path. Soc. London*, 1870, vol. 31, 231. Woman, age thirty-seven. Illness of three weeks. Headache, abdominal pain and tenderness; temperature 104° F., delirium, death. Autopsy: In the appendix was a medium-sized black pin, the head and three-quarters of the shaft surrounded by a fecal concretion. The bare point of pin projected into the cecum. Appendix wall thickened, but no signs of acute inflammation. No general peritonitis. Abscesses of liver and lungs.

7. LEGG. *St. Barth. Hospital Reports*, London, 1875, vol. 11, p. 85. Girl, age six. Following scarlet fever, abscess in the groin appeared, which opened spontaneously. Patient well for a time, then began to waste away. Abscess developed in epigastrium, was opened, discharged a great deal of pus, and healed. Twelve days later, abdominal distention, vomiting, death. Autopsy: Multiple ab-

scesses among intestines. The appendix was perforated close to the cecum and contained a large pin, rusty on its head and upper third.

8. WHIPHAM. *Trans. Clin. Soc. London*, 1879, vol. 12, p. 58. Boy, age eighteen. Illness began five months before; acute recurrence seven days before death. Autopsy: Localized abscess in right iliac fossa; purulent and fecal contents; a pin 1½ inches long found free in abscess. The appendix, doubled on itself, was perforated on both sides of the fold. Appendix adherent to cecum, with perforation into it.

9. ASHBY. *Lancet*, London, 1879, vol. 2, p. 649. Girl, age eight. Four months' illness; appendicitis. Autopsy: Appendix contained a pin encrusted with phosphates and with its point sticking through appendix wall. Near this spot was a ragged ulcer adherent to surrounding parts. Large abscess of liver. No history of swallowing pin.

10. HARLEY. *Diseases of the Liver*, London, 1883, p. 846. Boy, age nineteen. Fever, rapid pulse, tenderness over the liver. Death in nine days. Autopsy: Large abscess of the liver. At the apex of the appendix a thick brass pin 1¼ inches long, head somewhat green and eroded, pointing downward, and projecting through the caudal extremity of the appendix.

11. MCBURNEY, New York, 1888. (*Personal communication.*) Boy, age ten. Right inguinal hernia contained the inflamed, thickened appendix, the bulbous distal end about 1 inch across. In this mass, the points piercing one side and the heads the other, were two black pins, lying close together. The vermiform appendix amputated and case finished as one of hernia. Recovery.

12. BAKER. *Brit. Med. Jour.*, 1889, p. 1347. Man. Swelling in right iliac fossa and symptoms of intestinal obstruction. Median incision; evacuation of fetid pus. Death six weeks later. Autopsy: Pin, with point protruding through the appendix and head buried in a mass of fecal matter.

13. SHOEMAKER. *Trans. Coll. Phys., Philadelphia*, 1892–93, vol. 14, p. 214, Man, age eighteen. Illness of twelve days. Acute appendicitis, general peritonitis, operation, death. Autopsy: General peritonitis, ruptured liver abscess. Appendix not ruptured but gangrenous and containing a common pin, head downward.

14. BELL. *Canada Med. Rec.*, Nov., 1894. Boy, age six. Acute appendicitis. following blow on abdomen two days before. Operation: on opening the appendix a pin was found lying transversely in its lumen near the tip. The head had ulcerated through the wall of the appendix and the point had nearly perforated the opposite side at this point, which was strengthened by adherent omentum. Recovery.

15. WILLARD AND LLOYD. *Trans. Path. Soc., Philadelphia*, 1894, vol. 17, p. 40. Boy, age nine. Acute appendicitis for six days. Operation: incision and drainage of abscess; death. Autopsy: general peritonitis, multiple abscess of liver. The appendix contained a large pin with its head downward and its point projecting through a perforation near its base.

16. PARK. *N. Y. Med. Rec.*, 1895, vol. 47, p. 345. Man, age thirty-two. Indefinite discomfort in right iliac fossa for five years. Acute attack for one week. Operation: removal of appendix, drainage of abscess. The appendix

contained a concretion ¾ of an inch long, and having the diameter of a lead-pencil. Embedded in it was a common pin with the point protruding. No knowledge of having swallowed the pin. Recovery.

17. McPhedren and Caven. *Canada Pract.*, 1895, vol. 20, p. 180. Man, age twenty-one. Illness of about six months. Pyemic symptoms. Autopsy: multiple liver abscesses, one connecting with abscess in right pleural cavity which communicated with bronchi. Appendix thickened and dilated, contracted in its middle, and in dilated cavity beyond containing a large common pin, bent at an obtuse angle and with its tip embedded for ⅛ of an inch in the appendix wall. Pin largely covered with calcareous matter, laid down in a regular coat.

18. Colmer. *Lancet*, London, 1895, vol. 1, p. 745. Boy, age seven and one-half years. Three days illness. Constipation, vomiting, abdominal pain. Sudden death. Autopsy: recent general peritonitis; the appendix, thickened, enlarged, and perforated, contained a fecal concretion resembling a date-stone, and enclosing a pin, whose point projected through the perforation.

19. Abbé, New York, 1895. (*Personal communication.*) Child, age five. Operation: the appendix had been perforated by a pin which had ulcerated out and was in an abscess cavity of which the sloughing appendix was the centre. The pin was considerably encrusted with salts. No history of the pin having been swallowed.

20. Kammerer. *Ann. Surg.*, 1895, vol. 22, p. 274. Boy, age seven. Illness of a week. Tumor. Operation: tumor in the omentum in which the distal half of the appendix was firmly embedded. A common pin had passed through the appendix and escaped through a perforation in the tip. The firm adhesions of the appendix to the omentum showed that this could not have been the first attack.

21. McBurney, New York, 1896. (*Personal communication.*) Man, age twenty-nine. Illness of five days, pain and tenderness in right iliac fossa. Operation: incision made over tumor under ether. 1½ ounces of pus evacuated. In the abscess cavity was a large, soft concretion with an ordinary pin as nucleus. The appendix had sloughed off near its base. Recovery.

22. Syms. *Ann. Surg.*, 1896, vol. 23, p. 624. Woman, age twenty-one. Seven years before, appendicitis with large abscess which opened spontaneously and healed. Repeated similar abscesses for six years. Finally, a large abscess was opened and drained. Second operation, for persisting sinus, showed the tip of the appendix attached to fascia under which was a cavity to which the sinus led. The appendix contained a pin, the head of which was the nucleus of a hard, fecal concretion.

23. Roberts. *Amer. Pract. and News, Louisville*, 1896, vol. 21, p. 491. Boy, age fifteen months. Illness of one day. Strangulated right inguinal hernia. Operation: contents of hernia found to be the cecum and appendix. A pin was in the appendix with point protruding through the posterior wall and into the dartos of the scrotum. Appendix removed and cecum returned. Recovery.

24. Deaver. *Treatise on Appendicitis*, 1896, p. 36. Woman, age thirty-three. Acute appendicitis for one week. Operation: appendix removed. Omentum adherent, no pus. Appendix contained a black pin which had entered point first.

25. Moriata. *N. Y. Med. Jour.*, 1896, vol. 54, p. 547. Boy, age fourteen. Acute appendicitis following a kick. Operation: Appendix found to be

swollen and perforated. An ordinary pin was found in the appendix, with its head pointing downward and its point caught in the side of the organ. Death three weeks later. Boy asserted that he had swallowed pin a year previously.

26. Daland. *Proc. Path. Soc. Phila.*, 1897. Man, adult. For some months pain in region of appendix. Acute appendicitis for ten days. Operation: appendix removed and abscess evacuated. Appendix found to contain an ordinary pin; no perforation, but evidence of chronic inflammation shown by thickened walls and adhesions. No history of having swallowed the pin.

27. Lee. *Lancet*, London, 1897, vol. 2, p. 536. Woman, age not given. Sudden seizure with violent pain in the abdomen. Death soon after. Autopsy: appendix contained a pin, the point of which had caused a perforation at the tip, communicating with an abscess in the peritoneal cavity.

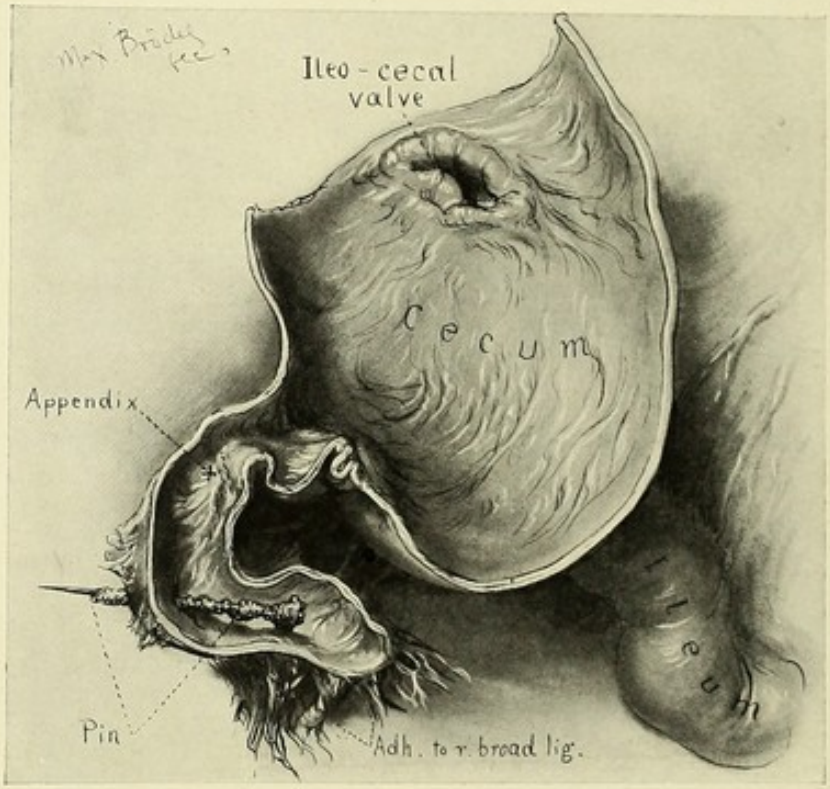

Fig. 222.—Appendix Perforated by a Pin. (Specimen from H. D. Rolleston. Case 30.)

28. Ochsner, Chicago, 1897. (*Personal communication.*) Woman, age twenty-three. For nine years attacks of pain in right iliac region, associated with tumor formation two years before. Abscess incised and drained. Persistence of fecal fistula. Operation: incision of the fistula. A pin discovered with its larger end covered by a concretion 2.5 × 1.5 cm. in size. Later operation: incision through border of right rectus exposing the cecum and the appendix which opened directly into the fistula.

29. Officer. *Intercol. Med. Jour. of Australia*, 1898, p. 229. Boy age six. Ill nine days, then signs of general peritonitis. Operation: peritoneal cavity full of pus. Irrigation, drainage. Death in thirty hours. Au-

topsy: appendix contained an ordinary pin which had ulcerated through the wall and was lying partly across the lumen.

30. Rolleston. *Trans. Path. Soc. London*, vol. 49. Girl, age seven. Stitch in right side for a year or two. Five weeks before death signs of right-sided pleurisy. Later, operation for abscess of the liver. Autopsy: appendix adherent to the right broad ligament and surrounded by recent fibrinous peritonitis. At a point where firmly adherent, a pin was found with its head inside the tube lying transversely to the long axis of the appendix. The shaft and point after passing through the wall of the appendix were surrounded by old adhesions. The whole of the pin was irregularly encrusted with calcareous matter. Abscesses of liver (See Fig. 222.)

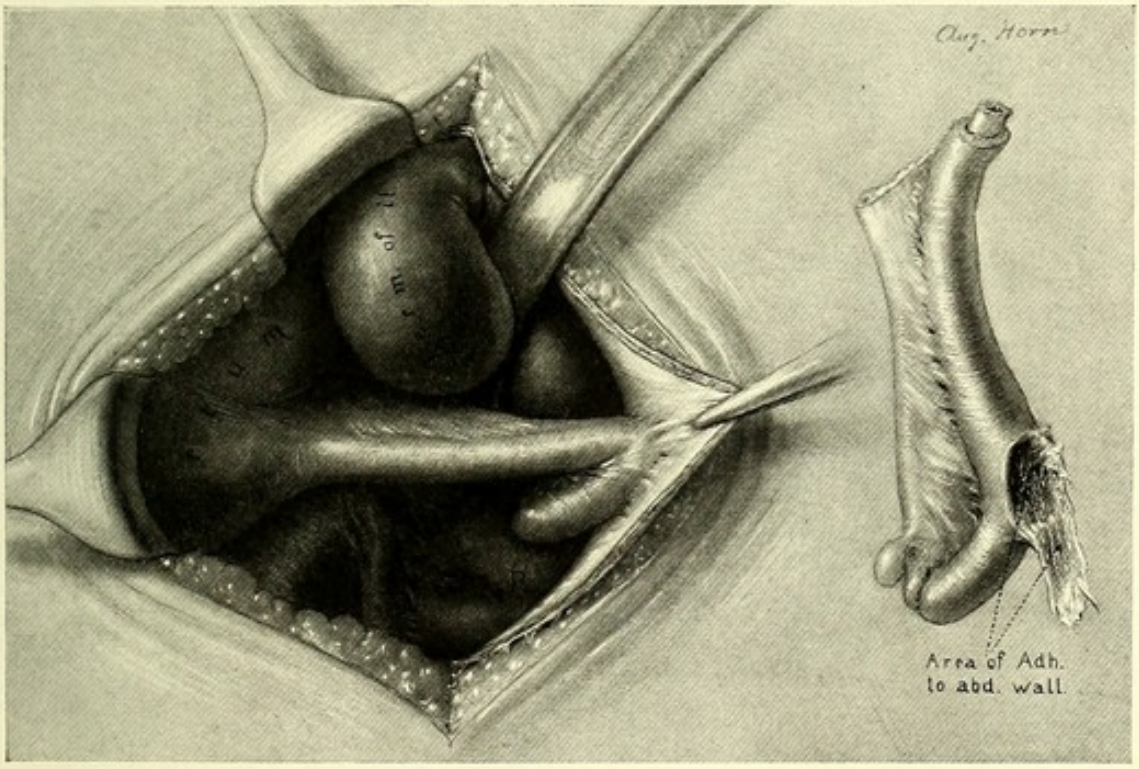

Fig. 223.—Showing Appendix Adherent to Abdominal Wall Following Discharge of Pin. (June 9, 1899, Case 35.)

31. Keen. *Trans. Amer. Surg. Assoc.*, 1898. Man, age twenty-four. When seven years old he was troubled with dysuria, and a pin found in the ureter, which he believed he had swallowed. At operation a long appendix was discovered with its tip solidly incorporated into the bladder and discharging feces into that organ.

32. Schooler, Des Moines, 1898. (*Personal communication.*) Girl, age two; Ill for several days. Localized swelling in region of appendix. Operation: incision and evacuation of pus. A pin found sticking through the wall of the appendix, the head remaining inside. Appendix removed, wound packed. Recovery. Child had swallowed a pin several months before.

33. Dawbarn. *Ann. Surg.*, Oct., 1898. Child, age twenty months. Operation: the appendix found perforated by a pin. Child's father asserted positively that the child had swallowed the pin five weeks previously. Death.

34. Harris, Philadelphia, 1899. (*Personal communication.*) Woman seen by Wm. Pepper, Sr., who made a diagnosis of peritonitis. Autopsy: a pin was found sticking through the end of the appendix.

35. Mitchell. *Johns Hopkins Bull.*, 1899, vol. 10, p. 35. Girl, age twenty. Recurrent appendicitis. Operation: incision of abscess. Patient stated that in the first attack, twelve years previously, an abscess had discharged externally

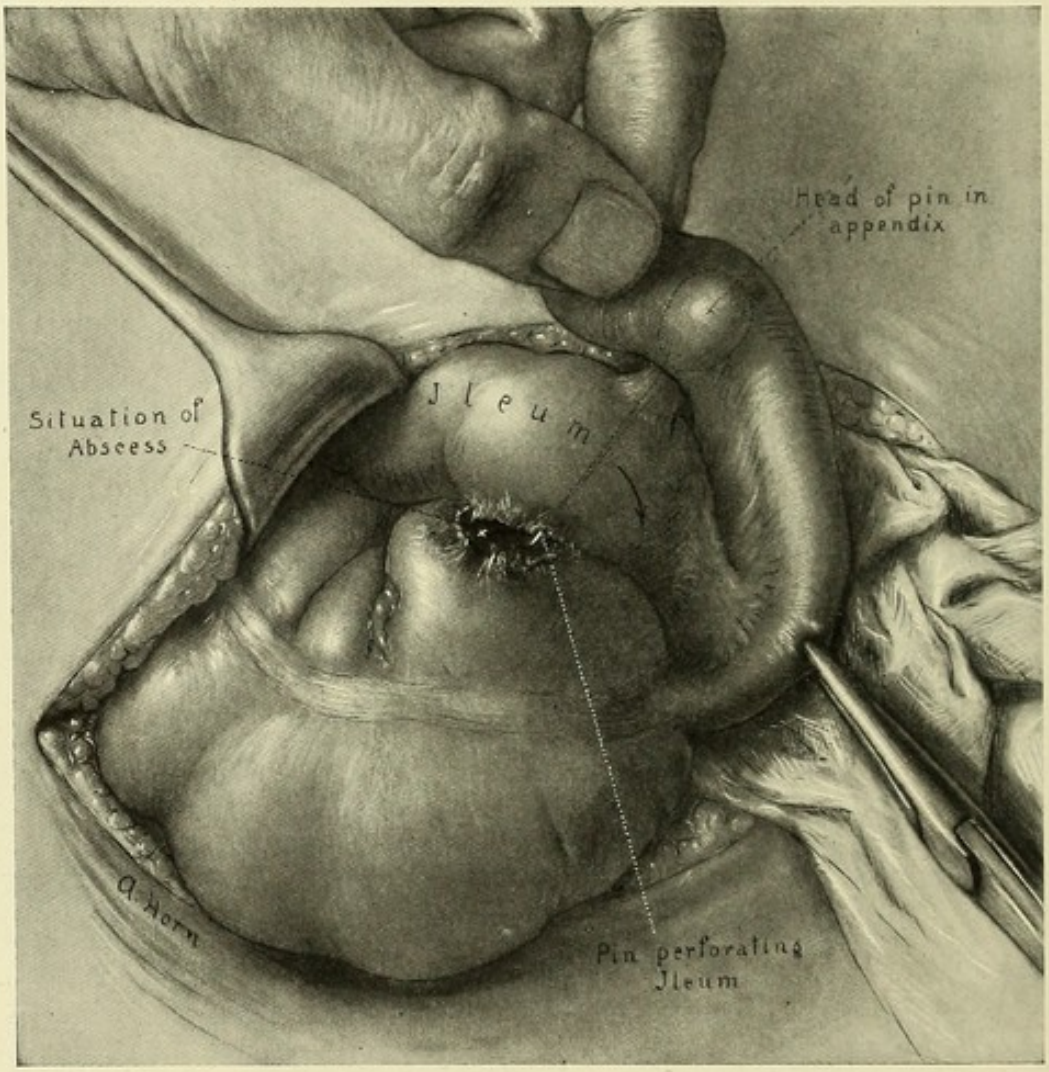

Fig. 224.—Appendix Perforated by a Four-inch Shawl-pin.
The head of the pin remains in the appendix, while the shaft transfixes the ileum and the point is surrounded by a small abscess between the ileum and cecum.

and a pin had been found in the discharge when the wound was dressed. She remembered having swallowed a pin a short time before. Second operation about a year after the first: removal of the appendix, which was found adherent to the abdominal wall. (See Fig. 223.)

36. Mitchell. *Ibid.*, p. 108. Negro boy, age seven. Recurrent appendicitis. Operation: acute attack; evacuation of abscess and removal of appendix. Pathological anastomosis of tip of appendix with ileum, through which a pin had

passed, producing a perforation in opposite wall of ileum. (See Figs. 224 and 225.) Death in less than twenty-four hours from no discoverable cause.

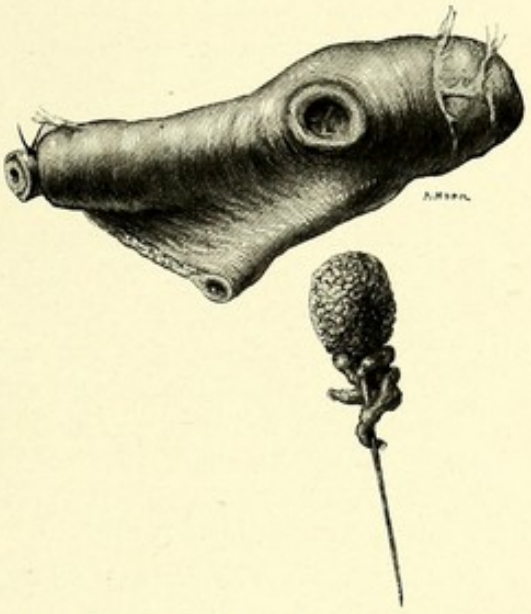

Fig. 225.—Pin Shown in Fig. 224 after Removal. Head Embedded in Concretion.

37. Brooks, New York, 1899. (*Personal communication.*) Woman, age fifty-four. Illness of a week, with headache and general pain, incontinence of urine and feces. Death. Autopsy: appendix adherent to the right ovary. Just at the centre of the appendix, where there were dense adhesions to the psoas muscle, there was a small cavity containing pus and feces. The abscess communicated with the lumen of the appendix. Lying in the proximal portion of the appendix with its head near the location of the abscess was a common pin encrusted with lime salts and fecal matter.

38. Wetherill. *West. Med. and Surg. Gaz.*, Denver, Sept., 1900. Woman, dressmaker. For fifteen years she had had pain in right iliac region with frequent severe exacerbations. Mass palpable on posterior aspect of right broad ligament. Operation: the tip of the appendix was found adherent to the right broad ligament below the ovary, the adhesions partly covering the tube and ovary. An eroded pin protruded from the tip.

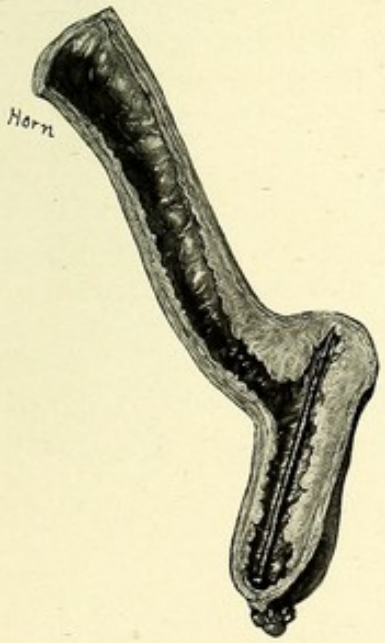

Fig. 226.—Appendix Containing a Common Pin. Removed by F. B. Lund, Boston. Case 40.

39. Walsham. *Treatment of Appendicitis*, London, 1901. Localized abscess drained, but patient subsequently developed acute peritonitis. Autopsy: a pin in the appendix had perforated the wall of the abscess and set up general peritonitis.

40. Lund, Boston, 1901. (*Personal communication.*) Boy, age twelve. Admitted on sixth day of acute appendicitis. Operation: the appendix, red, thickened, and edematous, was lying in a small pus cavity. There was pus in the pelvis and a large pocket of pus below the liver. Excision and drainage. The appendix contained a pin, lying with its head in the apex and its point in a pocket which projected from the side, looking as if muscular contraction had forced the pin against the side of the appendix. (See Fig. 226.) Stricture at base of appendix. Recovery.

41. Wright, Augusta, Ga., 1902. (*Personal communication.*) Woman, seam-

stress. For a long time severe pain in the region of the appendix. Finally severe attack caused her to see a physician. Distinct tumor felt in the right iliac region. Operation: a large mass of adhesions found, from which the appendix was enucleated. A pin was found projecting through the middle third of the appendix, with its head in the lumen. The point of the pin was thoroughly covered with adhesions, showing the effort of nature to protect the tissues. Recovery.*

42. Bell. *Montreal Med. Jour.* 1902, p. 765. Young man. Operation for sinus persisting after incision of abscess in Scarpa's triangle communicating with the open extremity of the adherent appendix, which contained a pin. The symptoms having been indefinite and subacute had not caused any suspicion of appendicitis.

43. Mayo, Rochester, Minn., 1903. (*Personal communication.*) Appendicitis with abscess. The point of a two-inch shawl-pin with glass head was found projecting from the side of the appendix, the head being buried in a mass of inflammatory deposit. Recovery.

44. Houston, Brooklyn, 1904. (*Personal communication.*) Child, girl. Appendicitis with localized abscess. The appendix was perforated and transfixed by a pin. No recollection of swallowing it.

45. Sears, Syracuse, 1904. (*Personal communication.*) Child, twenty months old (case of F. W. Zimmer, Rochester). Pin in appendix, diagnosed by *X*-ray.

46. Mudd, St. Louis, 1904. (*Personal communication.*) Male, twenty-eight years. Perforative appendicitis with localized abscess. A pin lying in the appendix.

Of the heavy bodies which gain access to the appendix, the most common by far are shot or bullets. The earliest mention of these is by Hevin (*Mém. de l'Acad. royale de chir.*, 1743, tom. 1, p. 460): "A great quantity of shot are sometimes noticed collected in the intestines, especially in the cecum and appendix, without having caused the slightest inconvenience."

1. Clark, Youngstown. (*Personal communication.*) Boy, age eight. Died of fulminating appendicitis. Autopsy: vermiform appendix contained a large, hard concretion with two bird-shot eccentrically placed. Shot showed marks of discharge.



Fig. 227.—Bullet Forming Nucleus of a Concretion. Specimen from J. Ransohoff. Case 3.

2. Holmes. *New Engl. Quart. Jour. of Med. and Surg.*, Boston, 1882–83, vol. 1, p. 257. Old man dead of pneumothorax; 122 robin shot in vermiform appendix. No symptoms referable to the appendix.

3. Ransohoff, Cincinnati. (*Personal communication.*) Young man. Recurrent appendicitis. Operation: removal of bullet surrounded by concretion. (See Fig. 227.)

4. Stone, Omaha, 1901. (*Personal communication.*) Mer-

* It would seem *à priori* probable that seamstresses and tailors, whose occupation obliges them to use constantly both pins and needles, and who are often in the habit of putting them in their mouths, would figure largely in the reported cases of such bodies in the appendix. This is not the case, however, and the above instance, with one other (No. 38), are the only ones which have come to my knowledge.

chant, age thirty-five. Acute appendicitis. Operation: the appendix contained a piece of solder, the point of which protruded through a perforation protected by omentum.

5. Mayo, Rochester, Minn., 1903. (*Personal communication.*) Sportsman. Chronic appendicitis, six years' duration. Operation: vermiform appendix contained 7 bird-shot.

6. Henrotin, Chicago, 1903. (*Personal communication.*) Girl, age eight. For two years chronic appendicitis. Operation: appendix showed chronic diffuse inflammation and contained bird-shot embedded in concretion. (Fig. 228.)

7. Beskett. *South. Calif. Pract.*, Nov., 1903, vol. 18. Merchant. Chronic appendicitis lasting one year. Vermiform appendix 4½ inches long, distended with liquid feces. Contained 4 bird-shot.

8. Warren, Boston, 1903. (*Personal communication.*) Woman. Recurrent appendicitis. Vermiform appendix contained fecal accumulation beyond a point which was obstructed by a bird-shot and a grape-seed. Recovery. (See Fig. 229.)

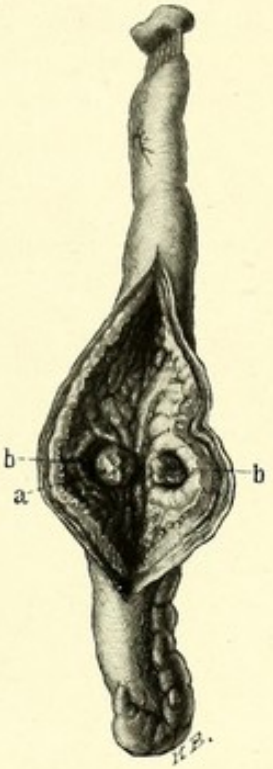

Fig. 228.—Appendix Containing a Bullet.

The presence of the bullet (a) has produced deep ulceration on the opposite side of the canal (b).

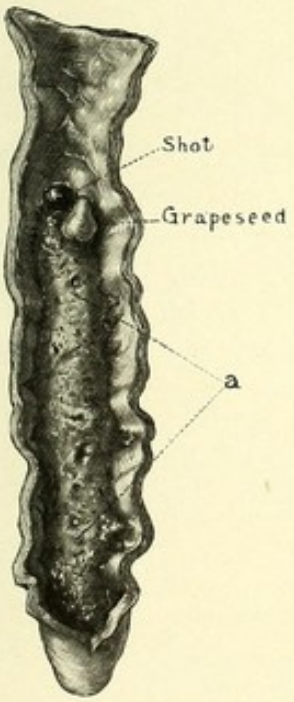

Fig. 229.—Appendix Containing Shot and Grapeseed.

The distal two-thirds of the canal is filled with fecal material (a). Removed by J. C. Warren.

Other foreign bodies found in the appendix, which have come to my knowledge, are as follows:

1. Thurnam. *Trans. Path. Soc. Lond.*, 1848–1850, vol. 1, 269. Man, age fifty-six. Patient had long worn a truss for incipient inguinal hernia, when he suddenly developed acute symptoms of abdominal disease with abscess formation. Puncture gave issue to offensive pus and bubbles of gas; two months later a piece of bone ⅝ by ½ of an inch was discharged, after which there was rapid recovery. Death occurred two months later from another disease. Autopsy: showed the thickened appendix adherent by the tip to the abdominal canal.

2. Ward. *Trans. Path. Soc. Lond.*, 1855, vol. 7, p. 97. Man. Attack of acute appendicitis ending fatally after an illness of several days. Autopsy: purulent peritonitis occasioned by perforation at the base of the appendix arising from a small worn-out bristle, apparently from a tooth-brush.

3. Murphy. *Jour. Amer. Med. Assoc.*, Chicago, 1894, vol. 23, p. 302. Woman, age thirty-four. Attack of acute appendicitis. Operation: appendix large,

swollen, and tortuous; no perforation. It contained an enterolith in which was embedded a small spicule of bone, the whole surrounded by pus. Recovery.

4. Ashton. *Med. Bull.*, Phila., 1894, vol. 16, p. 85. Woman, age forty-eight. Had had abdominal pain for three years; referred to uterus, which was curetted and cervix amputated without relief. Operation: exploratory laparotomy, in which the appendix was found adherent to the brim of the pelvis. It was removed and contained the fin of a fish, which had caused circulatory changes and ulceration through pressure. (See Fig. 230.)

5. Coleman. *N. Y. Med. Rec.*, 1895, vol. 48, p. 639. Man, age sixty-seven. Death of nephritis and pneumonia. Autopsy: in the dilated appendix was a piece of bone $\frac{5}{8}$ of an inch long and $\frac{1}{2}$ inch in its broadest part, blunt end foremost, and embedded in mucus. The thickened walls of the appendix at the site of the foreign body were evidence of its presence for a long time, but there were no other signs of inflammation and no history of disease in the appendix.

6. Mayo, Rochester, Minn., 1903. (*Personal communication.*) Patient gave a history of chronic appendicitis. Operation, performed during an acute attack: showed the appendix containing a bone resembling the leg bone of a squirrel.

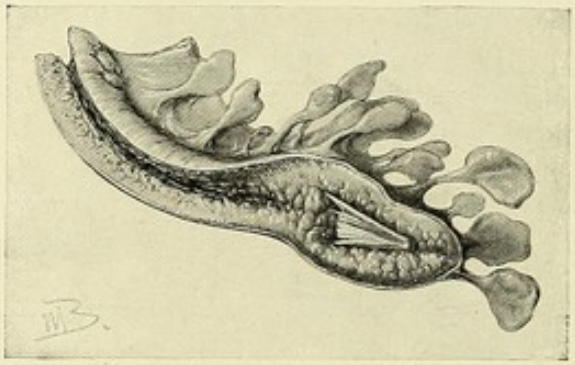

Fig. 230.—Fish-fin in the Appendix. Removed by W. E. Ashton.

7. Gardner, Baltimore, 1904. (*Personal communication.*) Woman, age thirty-six. Clinical diagnosis of pelvic inflammation following a miscarriage. Operation: the right ovary was found considerably enlarged, surrounded by dense adhesions, and firmly attached to the appendix at its upper surface. The ovary and the appendix were removed, when the appendix was found slightly enlarged; it contained several concretions, and a sliver of bone.

8. Jay, Baltimore, 1904. (*Personal communication.*) Man, age fifty-six. First attack of acute appendicitis, twenty-four hours in duration. Operation: on removal of the acutely inflamed appendix it was found to contain a piece of bone, and part of a fish-fin.

9. Goodfellow, San Francisco, 1904. (*Personal communication.*) Man, age forty-four. Recurrent appendicitis. Operation: the appendix was found deep in the pelvis, embedded in a dense mass of intestinal adhesions. It contained a fish-bone about 2 cm. long.

10. Mudd, St. Louis, 1904. (*Personal communication.*) Woman, with a history of chronic appendicitis. Operation: the appendix was surrounded by a mass of adhesions, and at its tip there was an abscess cavity. It contained a two-inch nail with the point broken off.

Recently considerable attention has been directed to the relation existing between intestinal parasites and appendicitis. It has long been

known that enterozoa are not uncommon occupants of the appendix, and in numerous cases they have escaped through a perforation of the appendix into the peritoneal cavity. Their etiologic significance in the production of appendicitis is still under discussion. DUPALLIER (*Thèse de Paris*) believes that intestinal worms cannot perforate walls so resistant, especially if these are intact; at most they may enlarge an already existing perforation by their passage, or penetrate one just ready to appear. They can, however, act as foreign bodies and determine an ulcerative appendicitis. VON MOTY (*Lancet*, 1902, vol. 2, p. 1211) attempts to make a distinction between the character of the lesions excited by the different varieties of parasites, and finds that l u m b r i c i seem to be more often associated with gangrenous appendicitis, while the o x y u r i s and t r i c h o c e p h a l u s lead to chronic inflammatory conditions. Reference to the cases cited below shows some confirmation of the view. While in many instances the association of lumbrici with perforation of the appendix may be a mere coincidence, it is readily seen that the mechanical influence of this parasite would be more deleterious to the appendix than that of the oxyuris and tape-worm, and therefore the liability to perforation and gangrene would be greater. The oxyuris is sometimes found in the normal appendix in large numbers and may cause attacks of severe spasmodic pain, simulating appendicitis. These cases have been carefully studied by ARBORÉ-RALLY (*Arch. de méd. des enfants*, December, 1900) and by METCHNIKOFF (*Jour. des praticiens*, March 23, 1901), who have urged the careful examination of the stools for the worms or ova. Again, however, these parasites are found in the acutely inflamed appendix and possibly provoked the attack. They are most frequent in children. Thus ERDMAN, in 29 cases of acute appendicitis in children, in four instances found from 6 to 30 pinworms in the appendix.

Ascaris Lumbricoides.—1. BLACKADDER. *Edin. Med. and Surg. Jour.*, 1824, vol. 22, p. 18. Man in apparent good health was seized with sudden abdominal pain and died in less than four hours. A u t o p s y: Revealed nothing abnormal except the appendix markedly increased in length and thickness and containing a large lumbricoid worm, which had forced its way in until only an inch of tail projected into the cecum. No other lumbrici were found.

2. FABER. *Gaz. méd.*, 1856. (Quoted by Crouzet, Thesis.) Case of ascarides in the appendix, in which one worm had passed through the wall of the appendix and entered a degenerated ovary.

3. DAVAINE. *Traité des entozoaires*, Paris, 1877. Case in which the ulcerated appendix had perforated and allowed the escape of 47 ascarides into the peritoneum.

4. BECQUEREL. (Quoted by Davaine.) Child. Several ascarides in the peritoneum and two caught in a perforation at the extremity of the appendix.

5. TIRIFAHY. *Presse méd.*, 1889, tom. 16, p. 89. Suppurative perityphlitis, phlegmon of abdominal wall. Incision; escape of a lumbricus.

6. C. F. BROWER, Virginia. (*Personal communication.*) Child, age twelve.

Mild attack of appendicitis. Operation thirty hours after onset; removal of appendix with portion of adherent omentum. The worm, which was still in the appendix, was divided by the scissors and half of it then withdrawn from the cecum. The appendix was gangrenous for an inch and a half of its distal end, and at one point on the verge of perforation. Recovery. (See Fig. 231.)

7. Natalé. (Cited by Metchnikoff.) Abscess in right inguinal region. On incision there was an escape of pus, together with 13 lumbrici and the gangrenous appendix.

8. Brun. (*Ibid.*) Boy, age twelve. *Operation à froid.* After removal of the appendix a small focus lined with false membrane was found, containing the remains of a lumbricus.

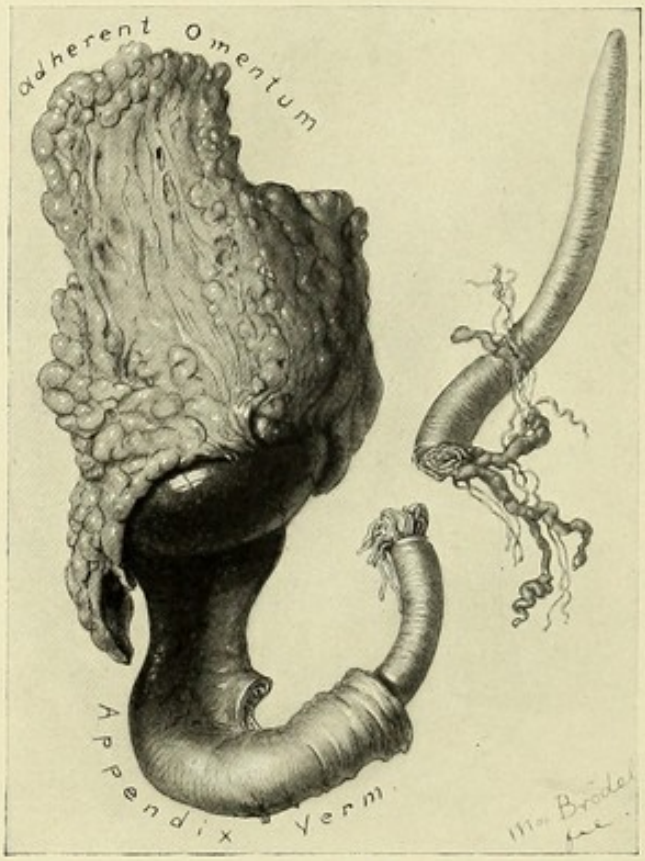

Fig. 231.—Appendix Containing a Lumbricus. Removed by C. F. Brower.

9. Bell. (*Loc. cit.*) Case in which a portion of the appendix had sloughed off and a large lumbricus lay in the localized abscess.

Oxyuris.—1. (J. H. H., Surg. No. 8150.) Girl, age twelve. Two days' illness, beginning with pain in the right side, at first intermittent and gradually increasing in severity. Constipation. Patient lay on right side, suffering intense pain, face flushed, respiration rapid, tongue dry and coated, temperature 102° F., pulse 120, leucocytes 20,000. The abdomen was hard as a board and tympanitic; tenderness in the lower right quadrant, most marked at 1½ inches to the right of McBurney's point. Operation: the peritoneal cavity was healthy; the appendix was attached by old adhesions to the colon, but retrocecal. There was no evidence of recent inflammation, but it was full of soft fecal matter and thread worms.

2. Frazier. *Univ. Med. Mag.*, 1900, vol. 13, p. 65. Girl, age two. Chronic appendicitis for four months, following an acute attack. Operation: showed the appendix full of oxyurides. Microscopic examination showed some infiltration of the mucosa and the submucosa, but no evidence of the previous attack.

3. Bryant. Meeting of Brooklyn Surg. Soc., May, 1902. Case of appendicitis due to presence of pin-worm in the appendix. Removal of appendix. Recovery. Presentation of specimen. Pin-worm *in situ*.

4. J. Hutchinson, Jr. *Lancet*, 1902, vol. 2, p. 837. Young woman. Recurrent appendicitis. Operation: the appendix was found crammed with living oxyurides; its walls were thickened, but not ulcerated.

5. Mayo, 1903. (*Personal communication.*) Girl. Attacks of pain in the region of the appendix. Operation: removal of appendix, which contained a bunch of several pin-worms. Recovery.

6. Erdman. *N. Y. Med. Jour.*, March 19, 1904. Four cases of acute appendicitis in children, in which the appendix contained from 6 pin-worms in one case to 30 in another.

7. Bloodgood, 1904. (*Personal communication.*) Girl, age nine years. (J. H. H., Surg. No. 9618.) Third attack of acute appendicitis. Slight tenderness in the right iliac fossa, muscular resistance, no definite spasm, leucocytes 17,000. Operation: no fluid nor evidence of inflammation; the appendix was free, and curled upon itself beneath the cecum, no constriction nor evidence of exudate outside of the appendix and its mesentery. Removal of the appendix, when it was found to contain a number of small pin-worms. The organ was normal, except for slight injection of the mucous membrane. Recovery.

8. A. F. Kablukoff. *Medizinskoe Obosrainie*, vol. 60, No. 14. Operation for catarrhal appendicitis. In the removed appendix were 4 living pin-worms.

Other Parasites.—There are numerous instances on record in which worms of various kinds have been found in the inflamed appendix. I cite the following cases:

Robb. *Johns Hopkins Bull.*, 1901, vol. 3, p. 23. Woman, age twenty-one. Pain in back and side and menstrual disturbance. Operation: left tube and ovary adherent to the uterus and broad ligament; escape of several drams of pus on separation of adhesions. Right tube and ovary adherent to pelvic wall and appendix adherent to the upper surface of right ovary. Four centimetres of the appendix removed and the stump seared with the Paquelin cautery. Both ovaries and tubes removed. Examination of the appendix showed it to contain a segment of tape-worm 15 × 14 mm. in size. Death in five days from streptococcus peritonitis.

Metchnikoff. *Jour. des praticiens*, March 23, 1901, No. 12. Girl. Peritonitis. Vermiform appendix contained two trichocephali, the anterior part of one of which had penetrated the depth of the mucosa and had there provoked an inflammatory reaction.

Sholler has reported a case of echinococcus of the appendix associated with echinococcus of the liver, and Birch-Hirshfeld an instance of echinococcus of the appendix alone (Deaver).

Aireton relates a case of Bilharzia disease in which the eggs of the parasite were lodged exclusively in the appendix.

Pathogenicity of Foreign Bodies and Concretions.—The direct influence of pointed bodies in producing inflammation of the appendix is evident in some of the cases cited, but it is a remarkable fact that in most in-

stances, especially in the case of pins, there was proof that the foreign body had been present for a long period before this acute process developed, in many cases lying quiescent in the appendix until encrusted with calcareous material, and, finally, determining the site of a perforation, rather than inducing the acute inflammatory attack. In BELL's two cases the acute process was directly traceable to trauma, the foreign body, in one case a pin, being merely a predisposing factor. In MORIATA's case there was a history of the pin having been swallowed a year previously to the acute attack, which was immediately induced by a kick on the abdomen.

In a case described by VÉRON (*Presse méd.*, 1902) the pin had been swallowed years before the first symptoms of appendicitis developed. The following case, already cited in brief, observed in the clinic of W. H. HALSTED, shows how a large pin can harmlessly travel the alimentary canal, until finally entrapped by the appendix, when it becomes a dangerous object (see Case 36, p. 370):

A negro boy, seven years of age, had a history of repeated attacks of abdominal pain referred to the right iliac region and accompanied by vomiting. Four days before admission he suffered from a feeling of distention, followed by cramps and vomiting. He was found lying upon his back, with his knees drawn up; the abdomen slightly distended, and the iliac region protected by his hands. Abdominal rigidity and spasm were limited to this region. The temperature was 103.2° F.; leucocytes 11,000. Operation disclosed a pathological anastomosis of the tip of the appendix with the ileum, through which a 4-inch pin had passed, producing perforation in the opposite side of the ileum, the head remaining in the appendix. The appendix was removed, both openings closed, and a gauze drain put in place. Early the following morning the child appeared to be doing well, when he suddenly became unconscious and died in a few minutes. Autopsy revealed no definite cause for death.

In the majority of instances, however, there is evidence that the foreign body excites a chronic inflammatory reaction which ultimately results in an acute process or leads to abscess formation. In one case a localized abscess was opened and drained, but death resulted from general peritonitis consequent upon the perforation of the abscess wall by a pin. A striking feature is the frequent association of abscess of the liver with the presence of a pin in the appendix. This was observed in 8 cases. In these cases, with one exception, the pin had evidently been contained in the appendix for a long time and had excited a chronic diffuse inflammation associated with a slight purulent process, a condition most favorable to the production of liver abscess.

Other sharp objects, such as pieces of bone and fish-fins, usually provoke the inflammatory attack by producing abrasions of the mucosa and thus promoting the invasion of infective microbes.

The rôle of shot, bullets, and similar bodies resembles that of concretions, which is purely passive or indirect. Such bodies may occasionally produce

abrasions of the mucous membrane, but, as a rule, they act indirectly by obstructing the lumen, or by causing pressure anemia of the appendix wall and diminishing the vitality of the tissue. These influences are often latent until brought into play by some accessory factor, usually a marked physiologic or traumatic congestion. The experiments of ROGER, BEAUSSENAT, ADRIAN, and others demonstrate that a smooth, rounded, foreign body in the healthy appendix has no influence in producing inflammatory changes and is usually soon expelled. HEVIN (*Mém. de l'Acad. royale de chir.*, 1743, tom. 1, p. 460) called attention to the fact that a great quantity of shot is sometimes found collected in the intestine, especially in the cecum and appendix, without causing the least inconvenience. In one instance (p. 372, Case 2), 122 robin shot were found in the appendix of an old man who during life had had no symptoms referable to the appendix. Concretions are seldom or never found in the healthy appendix, but it is a generally accepted opinion that the chronic inflammatory changes usually present are the cause of the formation of the concretion and not the result of its presence. Fig. 232 illustrates some of the different kinds of foreign bodies which have been found in the appendix.

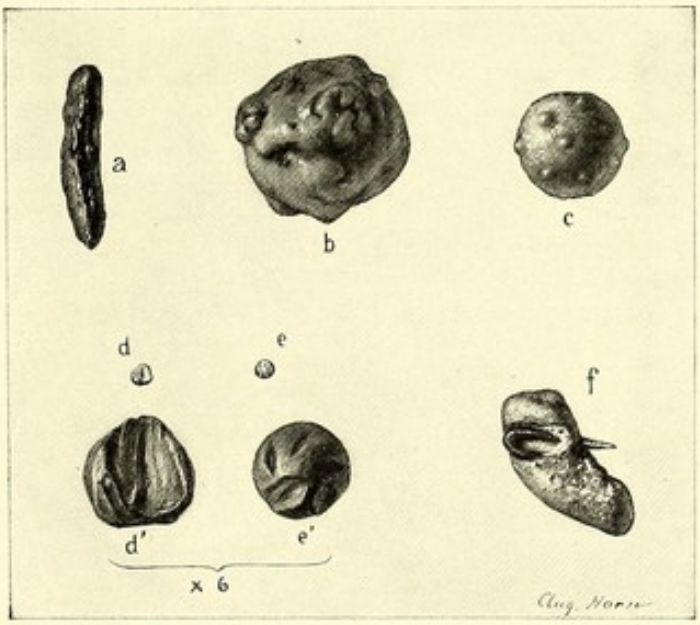

FIG. 232.—FOREIGN BODIES AND CONCRETIONS IN THE APPENDIX.

a is a fecal concretion simulating a date-stone; b, a calculus resembling a gall-stone; c, a calculus with a smooth surface beset with little projections which corresponded with crypts of Lieberkühn; d and e, shot. In the magnified pictures, d′ and e′, the marks of discharge are plainly shown. f, concretion formed around a staple.

Enterozoa have a twofold influence in the causation of appendicitis: a passive rôle, as in the case of enteroliths, and a direct effect by injuring the mucosa. The general view, as stated above, is that the parasite does not produce a perforation of the appendix, but merely profits by the rupture which results from a preformed ulcer. While, however, it is not probable that the parasites can penetrate the normal intestinal wall, it must not be forgotten, as emphasized by METCHNIKOFF, that they can produce erosions of the mucosa and inoculate it with the microbes with which they are covered. METCHNIKOFF cites a case of GIRARD'S, who found two trichocephali in the appendix, the anterior part of one being buried in the depth of the mucosa.

A point of special interest is that the lesions found in the appendix often ap-

pear to be quite inadequate to explain the severity of the symptoms, *e. g.*, violent pain, high temperature, rapid pulse, and distention, all of which may be produced by living parasites, while the appendix is almost normal in appearance.

FINAL CAUSES.

The immediate cause of appendicitis is always microbic infection. The normal appendix contains in its canal the infective agents, which, innocuous in the healthy bowel, only wait the appearance of circumstances favorable to the exercise of their activities. The experiments of ROGER (*Les Maladies Infectieuses*), of KLECKI (*Ann. de l'Instit. Pasteur*, 1899), and others have shown that it is not necessary to introduce virulent bacteria into the appendix to produce an inflammation. The aseptic ligature of the bowel, forming a closed tube, and the consequent stagnation of the contents, increase the virulence of the contained micro-organisms, and when to this is added a slightly diminished resistance of the tissues, all the conditions necessary for an inflammatory outbreak are at hand. As already explained, a virtual *vas clos* is produced in the appendix under various circumstances. Moreover, it has been demonstrated by experiments that micro-organisms which are incapable of affecting healthy tissue easily invade tissue slightly altered by traumatism. But there are also cases in which there is no evidence of obstruction nor of injury. The experiments of CHASTANET (*Thèse de Paris*, 1897) showed that appendicitis could be produced in the rabbit by making it swallow bacterial cultures. The appendix is affected to the same extent as the rest of the digestive tube, but with it, repair seems less easy. BEAUSSENAT (*Rev. de gyn. et de chir. abdom.*, 1897), by feeding rabbits with contaminated meat, produced a severe intestinal catarrh, and also found in the appendix swelling of the follicles, small abscesses in the mucous membrane, and injection of the organ. These changes were still present at a time when the other intestinal lesions had healed. He concludes from this that the vermiform appendix has a very slight tendency to a *restitutio ad integrum*. RECLUS (*Sem. méd.*, 1897, p. 237) believes that a propagated infection from the cecum is answerable for a certain number of cases of appendicitis, explaining the sequence of events by the theory of stagnation and exalted bacterial virulence. Whereas in other portions of the canal the conditions are favorable for the healing of the inflammation, in the appendix, owing to its physical peculiarities, the inflammation is rendered more intense. NICOLAYSEN (*Zeit. f. Chir.*, 1903, p. 719), as a result of his experiments and from clinical observation, comes to the conclusion that appendicitis is primarily due to the extension of an infective enteritis; DIEULAFOY (*Bull. de l' Academ. de méd.*, Paris, 1904) believes that in associated suppurative cholecystitis and appendicitis the involvement of the appendix is secondary, and is due to descending infection. He strongly insists upon the importance of inquiry for antecedent gall-stones, and of examining the gall-bladder in every case of appendicitis.

Appendicitis as a Local Expression of a General Infection.—The frequent association of appendicitis with rheumatism and other constitutional diseases, and the apparent occurrence of appendicitis in the form of small epidemics, have forcibly impressed many recent observers with the idea of the existence of an etiologic relationship between the general infections and inflammation of the appendix, some writers going to the extent of regarding all appendicitides as the local expression of a general infection; while others, again, noting chiefly its association with influenza, claim that "grip is the true cause of appendicitis." According to GOLUBOF (quoted from Adrian, *Mitt. a. d. Grenz. des Med. u. Chir.*, 1901, Bd. 7, p. 407), on the other hand, inflammation of the appendix, in the majority of cases, is an infectious disease *sui generis*,—an affection which is peculiar to the appendix to the same degree as angina follicularis to the tonsils, and dysentery to the colon. RECLUS and others, while recognizing the influence of general infections, believe that appendicitis is not a disease one and indivisible, but is produced by various causes, some more of a local, others more of a general character. In all cases the predisposing influences existing in the appendix are important.

TRIPIER and PAVIOT (*Sem. méd.*, 1899, p. 73) came to the conclusion that in appendicitis, as in the majority of intestinal lesions, a general infectious origin should be more frequently recognized. The association may be more or less remote, as the previous disease may have occasioned one or more attacks of latent appendicitis before giving place to an attack which manifests itself by the characteristic symptoms.

The etiologic relation between appendicitis and rheumatism was a matter of frequent comment by the older writers, and the theses which appeared on diseases of the right iliac fossa between the years 1840 and 1860 are full of allusion to the connection between the two. The first suggestion of it in modern times, which has come to my notice, is that of SIR JAMES GRANT (*N. Y. Med. Rec.*, 1893, vol. 11, p. 609), who described a case in a girl of twelve, whose illness began with pain in the feet, followed in two days by a typical attack of appendicitis, and who four days later presented the signs of acute rheumatism with involvement of the shoulders and elbows. Since this publication numerous similar observations have appeared, and seem to show the existence of a definite relation between the two ailments. It is important to note, as emphasized by FINNEY and HAMBURGER (*Amer. Med.*, December 14, 1901), that the articular disease may precede as well as accompany or follow the appendical inflammation. The association of tonsillitis and appendicitis has also been established by numerous observations. The frequent connection of tonsillitis and rheumatic fever is now generally conceded. The tonsillar affection may precede the joint affection or may appear simultaneously with it. In explanation of many cases of appendicitis recent observers have emphasized the analogies existing between the appendix and the tonsils. These analogies relate not only to the anatomic peculiarities of the two structures, but also to their predisposition to inflammatory affection,

especially at a youthful age. In one of FINNEY'S three cases of appendicitis associated with rheumatism there was a history of repeated attacks of rheumatism associated with tonsillitis, and finally of appendicitis associated with acute articular rheumatism and tonsillitis. In the surgical clinic of the Johns Hopkins Hospital, there were three instances, out of 91 cases of simple acute appendicitis, in which tonsillitis preceded by a few hours the onset of the appendical symptoms. The wider subject of the relation of appendicitis to the general infections was prominently brought forward by JALAGUIER, who observed the association of appendicitis with joint rheumatism and later, of appendicitis following measles, mumps, scarlet fever, typhoid fever, and chicken-pox. Animal experimentation has demonstrated that the lymphoid tissue of the appendix is the seat of predilection for the localization of infective organisms derived from the general circulation. ADRIAN succeeded in producing appendicitis by injecting suspensions of bacteria into the ear vein of the rabbit. In these experiments microscopic lesions were almost constantly demonstrable in the mucosa of the appendix before either gross or histologic changes could be detected in other portions of the intestine.

The experimental proof of the susceptibility of the appendix to become the seat of a localized process in general infections makes us more ready to accept the clinical evidence. The most frequent examples are found in the association of influenza and appendicitis. In all large epidemics it is repeatedly observed that the intestine is more or less seriously injured; indeed, as OSLER remarks, the brunt of the catarrhal affection may fall upon the gastro-intestinal mucous membrane. It should not, therefore, be a matter of surprise if, in the appendix, which is already prepared, a more severe process frequently arises. During the late epidemics of *la grippe* an increase in the number of cases of appendicitis and a frequent connection between the two diseases has been noticed by many careful observers. FINNEY (*loc. cit.*) observed an increase in the frequency of appendicitis during a recent epidemic of *la grippe* and a close relation existing between the two ailments. In at least six instances the appendical inflammation appeared during or soon after an attack of *la grippe*. SONNENBURG considers it to be an established fact that during an epidemic of *la grippe* inflammation of the appendix is much more frequent.

ABBÉ (*personal communication*) has seen some cases of appendicitis occasioned by influenza in which the affection seemed concentrated in the appendix, producing acute inflammation, with follicular ulcers and some hemorrhage. The swelling of the regional lymph glands is characteristic.

A further evidence of the relation of the appendicitis to a general infection is its frequent occurrence in epidemic form. F. FRANKE mentions three cases of appendicitis in three brothers at one time; the relation between the affection and a then prevalent epidemic of influenza could not be positively established. In other instances, although there was no direct evidence of the relation of the appendical inflammation to a specific infectious disease, the simultaneous appearance in two

or more members of the same family was very suggestive of a general infectious origin.

Leudet (*Arch. gén. de méd.*, 1859, vol. 104, pp. 137–316) describes cases of perforative appendicitis accompanying varioloid. The association of appendicitis with scarlet fever, measles, etc., has also been frequently observed. An interesting example recently communicated to me is as follows: A boy, eight years old, was taken ill with a severe attack of scarlet fever accompanied with abscess of the neck glands, and three weeks later was operated on for acute appendicitis. Turk, while attending this case, developed an erysipelatous throat, supposed to be scarlet fever, and fourteen days later had an acute attack of appendicitis associated with exudate. Blood from Turk was injected into a rabbit, and on its death, streptococci were obtained from the heart's blood.

Poljakow (*Cent. f. Chir.*, 1902, p. 206) observed a case of simultaneous appendicitis and pneumonia due to the presence of the staphylococcus. The appendicitis improved after six or seven days, leaving a finger-thick infiltration. The pneumonia ended by crisis on the ninth day.

Another argument in favor of this origin in some cases of appendicitis is the occurrence of marked constitutional disturbances preceding the appearance of local symptoms. In several of our cases one or two days' illness characterized by headache and general malaise preceded the onset of abdominal symptoms. In one case in a girl of fifteen, the illness began with pain in the chest and back, malaise, and slight cough. She slept poorly, and the next day felt too ill to get up, was feverish and had no appetite. Later in the day pain began in the right iliac fossa and a typical case of appendicitis developed. In another case there was pain in the back and head; and in still another, backache was present for one or two days before the onset of local symptoms.

These clinical observations and the *à priori* evidence derived from animal experimentation do not, however, warrant any positive deduction regarding the existence of a causal relationship between the general infection and inflammation of the appendix, and in the absence of bacteriological demonstration such deductions are open to criticism. In frequent instances the pneumococcus has been stated to be the peccant microbe, but so far as I can find, these observations all lack the demonstration of the capsule, and in the absence of this it is well known how easily this organism is confused with the streptococcus. Adrian claims to have demonstrated the influenza bacillus in a peri-appendical abscess following an attack of *la grippe*, but unfortunately no description of the morphological and cultural properties of the organism are given. Further investigation along these lines will doubtless reveal the true facts of the case. To sum up, I would say that:

1. A previous inflammation renders the appendix susceptible to further attacks.

2. The most important cause of appendicitis is digestive disturbances.

3. Acute and chronic entero-colitis may be occasionally an exciting cause.

4. Enteroliths and foreign bodies usually play a passive rôle. Pointed bodies and enterozoa may be direct exciting causes.

5. The clinical evidence is in favor of an intimate relation between appendicitis and rheumatic fever.

6. Animal experimentation and clinical demonstration make it plain that general infection is frequently the exciting cause of acute appendicitis.

7. It is not yet determined whether the general infection merely acts as an exciting factor by preparing a suitable soil for the activities of the intestinal bacteria, or whether the specific micro-organism is the direct cause of the inflammation of the appendix.

CHAPTER XVII.

CLINICAL HISTORY.

SYMPTOMS. COMPLICATIONS.

Introductory.—Any attempt at describing the symptomatology of appendicitis must be preceded by the statement that any, or even most of its characteristic symptoms, may be absent in the beginning of any given case, or even throughout its entire course; and that the clinical phenomena of the disease are not a reliable criterion of the pathological changes in progress, as symptoms of the most pronounced character accompanying certain lesions in one case may fail to appear with them in another. S. W. Gay characterizes appendicitis as the most treacherous of known diseases, insidious in its manifestations, uncertain in its career, and liable to sudden changes which, at any moment, may put the patient in a condition of extreme peril. It is a matter of common experience to find a mild attack which is apparently subsiding, develop symptoms of the gravest significance; while, in other instances, the most ominous symptoms are sometimes followed by a speedy recovery. The wider the experience of the surgeon in dealing with the protean forms of this disease, the less confidence will he have in formulating any definite conclusions regarding the interpretation of its individual symptoms, and particularly concerning their prognostic value. But, although this fact should always be borne in mind, it must be added that with few exceptions appendicitis ought always to be recognized, and we may accept with little reserve the dictum of Dieulafoy that "no one should die of appendicitis." Moreover, the association of certain symptoms and their preceding history produce a definite clinical picture in the presence of which it is justifiable to assume the existence of certain lesions; and while it is rarely safe to foretell the future course of events from the symptoms present at any single stage of the attack, it may be possible to express with some assurance an opinion regarding the outcome of the disease if immediately arrested by operation. Thus, in the majority of cases, it is possible to determine the existence of acute or chronic appendicitis, and the presence or absence of abscess formation, or of a diffuse or generalized peritonitis; but there is no symptom-complex from which we can determine the exact amount of injury under which the appendix itself is laboring, nor recognize whether perforation is impending, or a purulent periappendicitis being successfully walled in. Allowing for uncertainty due to these facts, we may divide appendicitis for clinical purposes into two classes—*acute* and *chronic;* and these may be more explicitly considered according to the presence

or absence of suppurative peri-appendicitis, of general peritonitis, or of remote metastatic infections.

SYMPTOMS OF ACUTE APPENDICITIS.

Acute appendicitis may have a sudden onset; or it may be insidious in character, being ushered in with symptoms of moderate severity which steadily grow worse; or it may possibly exhibit occasional remissions. In a number of cases a feeling of general malaise precedes the onset of the attack. The early symptoms may include pain, tenderness, rigidity, muscle spasm, nausea, vomiting, and constitutional disturbance; distention and tumor may also be present. The time at which these symptoms appear, however, is variable, and some of them may never occur at all. The most constant, most characteristic, and most important symptoms of all are pain and rigidity.

Pain.—This symptom is always present at some stage of the disease, although it is occasionally very evanescent. Sometimes suddenly, or sometimes more gradually, the patient is seized with sharp cramp-like pains in the abdomen. The attack of pain may come on as suddenly as if the patient were shot, as in a case described by J. D. Bryant, where a lieutenant, when feeling perfectly well, was seized with a sudden pain in the right inguinal region so severe that he could not move. Poncet relates a similar case in a soldier, who described the attack as "like the shot of a gun." In one case in the Johns Hopkins Hospital, a man, aged twenty, was at work when seized with abdominal pain so sudden and severe as to cause him to fall to the ground, and in another instance the patient fainted at the first attack of the pain. A sudden onset with acute abdominal pain, the patient being habitually in good health, was noticed in 43 per cent. of the cases admitted to the Johns Hopkins Hospital. Of the remaining cases, some began with slight symptoms gradually increasing in severity, but in a considerable number the onset of acute symptoms was preceded by two or three days of lassitude and headache, or slight digestive disturbance. The initial pain may from the first be located in the right lower abdomen, but is commonly referred to some other region. In about one-third of the cases at the Johns Hopkins Hospital the pain began in the right iliac fossa. In 20 per cent. there was no definite localization, the pain radiating through the whole abdomen. The second most frequent location was in the umbilical region, and in somewhat fewer cases the primary pain was in the epigastrium. In one case the attack began with pain immediately to the left of the epigastric region; again it was sometimes referred to the right hypochondrium; and in two or three instances pain in the back was the earliest symptom. In one instance the patient complained of pain in the right testicle for two days before it extended to the inguinal region. At the onset the pain is paroxysmal, cramp-like, and radiating. It is exceedingly severe, sometimes indeed agonizing, and the patient may not be able to straighten up or

stand during the paroxysms. There may be complete freedom from pain in the intervals, but, as a rule, a feeling of soreness persists. The paroxysmal character of the pain lasts from one to several hours, and in some instances continues throughout the attack; but sometimes after the first onset, there is a cessation of this pain for several hours, or even as much as a day. In some cases the pain, at first, is slight and indefinite, and then gradually increases in severity. It may begin as a vague, cramp-like sensation, or as a diffuse soreness increasing in intensity, and finally settling in the right iliac fossa. After a few hours the pain almost always becomes localized in the right lower abdomen, and, as a rule, assumes a different character, becoming less intense, but more continuous. Often, however, there are still acute exacerbations which may be brought on by movement, especially movement involving the psoas muscle. Hence the patient lies in the dorsal position, and often with the legs flexed, in order to favor the right side. The pain is also aggravated by the passage of flatus, by coughing, or by deep respirations. The site of this later pain varies according to the position of the appendix. The greatest suffering, however, is usually referred to the iliac fossa. It may be confined to a very small area, or it may be diffuse, extending into the groin, the lumbar region, or toward the median line. In the case of an ascending retrocecal appendix, the pain may centre in the right hypochondrium, or in the posterior lumbar region, sometimes radiating towards the scapula. In one case in which this particular localization of the pain was noticed, the tip of the appendix was found in close proximity to the base of the gall-bladder and a few fine adhesions surrounded the cystic duct. In a second case, the appendix was surrounded by an inflammatory exudate and a tag of omentum was adherent to the gall-bladder. At other times the chief pain is felt in the hypogastric or pelvic regions, in which case the appendix is usually found lodged in the pelvis, or else an abscess has formed there.

B l a d d e r and r e c t a l s y m p t o m s are common, and t h o r a c i c p a i n is not infrequent. The latter is sometimes due to a true pleuritis, which, according to WOLBRECHT (quoted by Sonnenburg), is a frequent accompaniment of appendicitis. In many instances, however, it is a purely reflex phenomenon, readily explained by the close anatomic connection between the abdominal wall and the pleura, through the intercostal nerves. In some cases the pain is not at any time referred to the region of the appendix, but remains more or less diffuse, or is confined to the seat of the initial pain. GAY, in relating his own case, states that in every attack the pain was definitely limited to the epigastrium. There is some discussion as to whether pain in appendicitis ever occurs without involvement of the neighboring peritoneum, and whether it is always inflammatory, or may be functional in origin. The experiments of LENNANDER (*loc. cit.*), confirmed by the clinical observations of CUSHING, MITCHELL, and others, have demonstrated the absence of sensory nerves in the viscera and visceral peritoneum, but have shown that the parietal peritoneum is exceedingly sensitive to pain impressions, the very slightest traction causing acute suffering. They have proved that the

appendix may be lifted up, may be compressed between forceps, and may even be excised, without pain; the mesentery also may be ligated without the knowledge of the patient, if due care is observed not to disturb its relations; but it has been experimentally demonstrated that if the slightest traction is brought to bear upon the appendix or mesappendix, exquisite pain is experienced. "When the ileum and ascending colon have a common free mesentery the discomfort and pain from appendicitis are felt in the pit of the stomach, or in the para-umbilical region, which is the segmental area corresponding to the point of origin of this portion of the mesentery. In healthy individuals there is no sensation during the process of digestion, and intestinal tumors may progress without pain until perforation and peritonitis occur. Strong intestinal peristalsis may only produce a sensation of rumbling, but when the parts of the intestine which have no mesentery, or those fixed to the parietes by peritoneal reduplicaation or adhesions, are over-distended, there will be tension upon the nerves in the subserosa, and each contraction will cause colicky pains." The initial colicky pain in appendicitis is partly explained by the assumption that the primary inflammatory reaction excites abnormal peristaltic contractions, but is probably due to the distention with flatus of the inflamed cecal area, and it is often relieved by the passage of flatus.

The secondary localization of the pain is due to involvement of the neighboring parietal peritoneum. The appendix is adherent to some point, or the peritoneum is inflamed, or there is a lymphangitis or lymphadenitis caused by the infective microbes or their toxic products. LENNANDER believes that possibly the toxic substances from the diseased appendix may cause pain by a direct chemical action upon the cerebrospinal nerves. This pain lessens in intensity after a few hours, and in simple cases usually ceases in from twenty-four to forty-eight. Occasionally, it is very evanescent, disappearing in two or three hours. An increase in the local infection is usually marked by the continuance of the pain, which also becomes more intense. A sudden sharp pain after a temporary subsidence often means a perforation or a beginning general infection. A sudden lull in the local symptoms, not accompanied with a corresponding improvement in the general condition ("*accalmies traîtresses*"), is an ominous symptom, and usually indicates gangrene, the rupture of a pus sac, or an unusually virulent infection. If the pain again becomes generalized, a spreading infection of the peritoneum may be suspected. General toxemia, on the other hand, is often marked by the complete cessation of all pain.

Tenderness.—Tenderness on pressure possesses a significance of such great value that the surgeon hesitates to make a diagnosis of appendicitis in its absence; nevertheless it is a symptom which must be estimated with considerable caution and with due allowance for the temperament of the individual. It is easily exaggerated by neurotic patients, but, as pointed out by M. H. RICHARDSON, exquisite tenderness is not easily feigned, and, if the patient's attention is diverted, can be accurately gauged. It is a particularly important sign, in that it

usually persists after spontaneous pain has ceased, and is present so long as an active inflammatory reaction is going on. A good example of this latter fact is afforded by the following case from the surgical clinic of the Johns Hopkins Hospital. The patient had gone to bed in his usual health, but on rising he was seized with colicky pain distributed over the whole abdomen, accompanied with nausea and a slight chill. In two hours the pain became localized in the right iliac region. At the end of seven hours after the onset the pain entirely ceased and did not return. When admitted, eleven hours after the beginning of the illness, there was a slight elevation of temperature and pulse and the abdomen, although not distended, manifested slight tenderness over the whole right lower quadrant and exquisite tenderness over McBurney's point, associated with localized rigidity and muscle spasm. There was a leucocytosis of 34,000. Operation revealed an acutely inflamed appendix, adherent by its tip and covered with flakes of fibrin. The point of greatest tenderness often corresponds exactly with McBurney's point, but frequently the most sensitive spot is a little above, or below, or to the inner or outer side of this area. It corresponds to the site of the appendix and is most marked over the diseased portion. For example, E. POND (*Med. Rec.*, 1898), in the case of a boy twelve years old, found slight rigidity of the right rectus muscle, more marked in its upper half. There was but slight pain on deep pressure in the iliac region, but in the posterior and outer part of the abdomen there was a swelling with extreme rigidity of the muscles, and at a point 2 cm. below the kidney, a spot which was "as sore as a boil." At operation the point of the gangrenous appendix was found in a position exactly corresponding to the sensitive spot. Sometimes there is tenderness on pressure in the left side of the abdomen, but this is usually accompanied with more intense pain referred to the region of the appendix. This reflex pain is often an indication of peritoneal irritation. It is not unusual to find that the pain is not felt while pressure is being brought to bear upon the abdomen, but that on removing the hand sharp pain ensues. If the appendix occupies the pelvic position, tenderness is sometimes only detected upon rectal or vaginal examination. Cutaneous hyperesthesia is regarded by BLOS (*Beit. z. klin. Chir.*, Bd. 32, p. 420) as a symptom of great importance. Where cutaneous hyperesthesia, muscular rigidity, and localized or general pain are present, peritonitis will always be found. It is sometimes exceedingly vivid, making further palpation impossible.

Rigidity.—Next to pain, rigidity is the most reliable early sign of acute inflammation of the appendix. At the outset it is general, but soon after the localization of the infection it becomes limited to the right side. General rigidity is difficult to estimate, for it is often voluntary, and is commonly found with simple intestinal colic. Unilateral rigidity, on the other hand, is readily detected, is not easily assumed, and is a definite indication of underlying mischief. Still more conspicuous is rigidity limited to a small area. The value of this symptom is thus tersely

expressed by RICHARDSON: "Rigidity with distinctly localized pain strongly suggests appendicitis, with fever it almost proves it, with tumor it fully establishes the diagnosis." While, however, of great positive value and almost constantly to be found during the first stages of an attack, it sometimes disappears early, and in the most serious conditions may be entirely wanting or so slight as to be scarcely recognizable. This is particularly true in the presence of gangrene, where local tenderness and rigidity may both fail, and also in many cases of perforative appendicitis, where rigidity is so slight and transient as to escape observation. On the other hand, there may be pronounced localized rigidity in the presence of very mild inflammatory processes. The muscular tension is sometimes so pronounced as completely to mask a tumor mass beneath. As a rule, the tension diminishes as the active inflammatory process subsides and the abdomen becomes soft. If a mass is present, its outlines are then clearly perceptible. Increasing severity of the local infection, or the beginning of a diffuse peritonitis are marked by the return and increase of the muscular tension, and in extensive peritonitis the abdomen usually becomes uniformly distended, rigid, and motionless. In some cases, however, the abdomen is soft and natural in appearance, even in the presence of generalized peritonitis.

Muscle Spasm.—This symptom is less constant than rigidity, but it is observed in the majority of cases during the early stages of the attack, and its presence is a certain sign of an inflammatory process. It is a wholly involuntary reaction on the part of the muscle, and is best detected by light palpation. The most active muscle spasm is obtained when the appendix is in close relation with the abdominal parietes, and when peritoneal infection is beginning. In early diffuse peritonitis, active muscle spasm may sometimes be found all over the abdomen.

Pain, tenderness, and rigidity are rightly called the cardinal symptoms of appendicitis, and they demand the first and most careful consideration. There are, however, other symptoms, of fairly constant occurrence, which may have a positive value. The most noteworthy of these are gastro-intestinal disturbance, elevation of temperature, and altered pulse-rate. General constitutional symptoms also are often of great significance; and, as pointed out by FEDERMANN in describing peritonitis, the general impression obtained at the first sight of the patient is to the experienced observer of the greatest importance, and often leads to a diagnosis when other signs are doubtful.

Vomiting.—This is a more or less constant and prominent early symptom of acute appendicitis. It may or may not be associated with nausea; less frequently, nausea occurs alone. There is often a single attack of vomiting at the beginning of the attack, and it may not recur. More frequently it begins some hours after the onset of the pain and occurs only once, or is repeated two or three times. It rarely continues for more than a few hours. In about 15 per

cent. of the cases admitted to the Johns Hopkins Hospital there were neither nausea nor vomiting at any time during the attack. In several instances vomiting was directly due to the administration of medicine, and in other cases, again, it occurred only after taking food. In a few instances vomiting continued at frequent intervals for one or two days, but in favorable cases it was never continuous. If the other symptoms subside, vomiting soon ceases, but with the onset of spreading or generalized peritonitis it may become persistent and uncontrollable. At first the contents of the stomach are ejected, and then bile-stained material. In unfavorable cases the material vomited may consist of dark greenish-black or brown material, but it is sometimes distinctly stercoraceous. The persistence of nausea and vomiting is always of grave significance, and an easy continuous regurgitation, in especial, is, according to RICHARDSON, a more unfavorable symptom than occasional violent retching. H i c c o u g h is comparatively rare, but it is occasionally observed in generalized peritonitis, or when a large abscess extends upwards and involves the diaphragm. It is usually an indication of the involvement of the peritoneal surface of the diaphragm, and is sometimes a prominent and distressing symptom.

Constipation.—Constipation is present in the majority of cases of appendicitis. As before noted, it is one of the most constant events preceding the onset of the attack, and it usually persists until the acute symptoms are over. When the bowels have previously been normal, or even when there has been a tendency to diarrhea, constipation usually occurs with the appearance of acute symptoms. In a considerable number of cases the initial violent intestinal contractions cause a sudden evacuation of the bowels, and in a small number, more or less severe diarrhea may continue for a day or two, being then followed by constipation; in other instances, diarrhea persists throughout the entire attack. It is exceptional to find the bowels normal during the course of the whole illness. Constipation is often very obstinate, and there may even be complete obstruction. As a rule, the bowels are moved after the first few days, but continue more or less constipated until the end of the attack. This symptom, unfortunately, is often aggravated by the large doses of opium so frequently required for the relief of the first acute symptoms. Symptoms of complete obstruction may be due to intestinal paralysis caused by the direct invasion of the intestinal walls by the infective microbes or their toxic products; or there may be true obstruction due to kinks or strangulation produced by the inflammatory exudate. The characteristic picture of i l e u s then develops: constant vomiting, becoming stercoraceous, and absolute constipation without the passage of either feces or gas. The abdomen usually becomes distended and acutely tender. With mechanical obstruction peristalsis is often at first plainly visible, but all intestinal movements cease when symptoms of peritonitis develop, whether the obstruction is due to adhesions or to primary intestinal paresis.

Hemorrhage.—H e m a t e m e s i s has been described by TREVES, by DIEULAFOY, and by MATHESON and others, and is attributed generally to a

toxic degeneration of the gastric mucous membrane with erosion of small blood-vessels. In the case reported by MATHESON (*Brit. Med. Jour.*, 1901, vol. 1, p. 1201) the hemorrhage was so severe that collapse and death occurred within a few hours. Hemorrhage from the bowels is less rare, but by no means frequent. It was noticed in four cases out of almost a thousand admitted to the Johns Hopkins Hospital. In one of these cases there was a strong suspicion of tubercular disease; in the others no cause for the hemorrhage was discovered. In one instance the hemorrhage, which was preceded by diarrhea, began four days before the patient was operated on and continued until the fifth day after. It occurred at frequent intervals, and was always accompanied by severe griping pains in the abdomen. In another case blood, without any fecal matter, was passed *per rectum* for two or three days.

Temperature.—The temperature varies extremely in different cases. It may be very high in the beginning, but subside as rapidly as it arose; or there may be a gradual rise, reaching the maximum in thirty-six or forty-eight hours; while in other cases, again, the evolution of the disease may be almost apyretic throughout, even when associated with the development of a large abscess, or in the presence of a hopeless general peritonitis. Taken by itself, the temperature is most unreliable and misleading, but in connection with other symptoms, and at certain stages of the attack, it may be of value in showing the progress of the infection. In ordinary cases the temperature is rarely high, often not going above 100° F., and seldom above 103° F. In a general way, when associated with other slight symptoms, a low temperature indicates a mild inflammatory process and a high temperature a more serious infection. But too much stress should not be laid upon this sign, as it is often deceptive. In a recent case at the Johns Hopkins Hospital, a young man walked into the hospital with a temperature of 99.4°, pulse 112; he looked bright, and complained only of slight soreness in the right side. The attack had begun after breakfast the preceding morning with pain in the epigastrium, radiating over the abdomen. After an hour or two the pain became localized in the right iliac fossa, but subsided at the end of three hours and did not return until night. He vomited once, after taking castor oil, and his bowels moved freely. There was no further vomiting and no nausea. Abdominal examination was negative, except for slight rigidity on the right side and slight pain on deep pressure over the region of the appendix. There was, however, a leucocytosis of 26,000, and, notwithstanding the low temperature and absence of marked symptoms, FINNEY decided upon immediate operation. The peritoneal cavity was found to contain free turbid fluid and the appendix was immensely swollen, distended with pus, and apparently on the point of rupture. The mucous membrane was gangrenous. Recovery was uninterrupted.

In another case the patient, a medical student, aged twenty-five years, was awakened with sharp abdominal pain, chiefly to the left of the epigastrium. The pain soon wore off and the patient went to sleep. In the morning there was

diarrhea, relieved, however, with paregoric. He vomited once in the morning and again in the evening. The next morning he felt better until after breakfast, when there was a slight return of pain, and during the day there was considerable tenderness. In the evening he walked to the hospital for advice. His temperature was then 99.2° F., his pulse 100; there was considerable tenderness in the right iliac fossa, and slight distention. Immediate operation showed the appendix distended, and covered with fibrin; there was a gangrenous patch at the base, and another, 6 cm. distant, which was perforated. The peritoneal cavity contained some cloudy fluid. Recovery.

In some instances a simple catarrhal appendicitis is accompanied with a temperature ranging from 103° to 104° F. A persistent high temperature, or a renewed elevation of it after the patient has begun to improve, is of great significance. A temperature continuously high from the outset usually indicates a severe infection, with local or metastatic extension, or with general intoxication. For example, a child at the Johns Hopkins Hospital, aged four years, was seized with violent abdominal cramp, lasting some hours, after a hearty dinner. She passed a comfortable night, however, and in the morning felt well, but her temperature was 104° F. and her pulse 160. At 10 A. M. the abdominal pain returned and grew steadily worse; the abdomen seemed slightly swollen and tender, and the temperature was 105° F. A diagnosis of entero-colitis was made and an oil enema given. During the night the bowels moved three times and she vomited once. The next morning paroxysmal pain continued, referred by the child to the epigastric region. She lay with her knees drawn up. The abdomen was swollen and tender, especially in the right ileocecal and lumbar regions; the tongue was dry and coated, the temperature 104° F., and the pulse 140, the leucocytes 32,000. Operation revealed a general septic peritonitis. The appendix showed an acute hemorrhagic inflammation with slight necrosis of the mucosa. Death occurred before the incision was closed.

On the other hand, a general peritonitis may develop with practically no elevation of temperature. For instance, a patient was admitted to the Johns Hopkins Hospital in 1891, with a history of pain beginning the preceding morning, at first localized in the right iliac region, but later becoming general, and continuing until night, when it was relieved by morphine. Nausea was almost constant and there was frequent vomiting. The bowels moved after an enema. On admission there was moderate tympanites and general tenderness, most marked in the right iliac region. Temperature 99° F., pulse 88. Frequent vomiting. The next day he was more comfortable, the abdomen not so sensitive, the nausea and vomiting diminished, and the pulse and temperature normal. He passed a comfortable night. At operation the following morning the appendix showed beginning gangrene and there was a general purulent peritonitis. Death took place on the third day.

An encapsulated abscess is usually accompanied by a continuous elevation of temperature with daily remissions, present from the outset or beginning a few

days after the initial symptoms. A persistent fever without evidence of a general infection is a fairly certain indication of the presence of a focus of suppuration. However, after the active process has subsided a very large abscess may exist with a normal temperature. In other complications, such as abscess of the liver, septic phlebitis, or pyemia, the temperature is usually high, and sometimes remittent or even intermittent and of the characteristic hectic type.

Lennander (*Beit. z. klin. Med. u. Chir.*, 1895) calls attention to the importance of observing the variations in the relation between the axillary and rectal temperatures. With early abscess formation and in spreading abdominal infection the difference is sometimes once or twice greater than normal. In very ill patients this difference is sometimes marked, and may be due to the influence of a neighboring inflammatory mass, but very often it is a sign of collapse in which there is a fall of temperature on the surface of the body and a rise in its interior.

Chills are exceptional in cases of simple diffuse inflammation, but are not rare with more severe lesions. Of the cases of acute appendicitis not associated with abscess or general peritonitis, admitted to the Johns Hopkins Hospital, 15 per cent. gave a history of chills, and in all of these, with two exceptions, the appendix was gangrenous, or perforated, or distended with pus. In the two cases showing slight lesions there were merely chilly sensations, which in one were probably accounted for by the presence of oxyurides associated with high temperature. In three cases the chill occurred at the onset of the attack; in one the patient, who had gone to bed well, was awakened with a severe chill. More frequently, the chill occurred several hours or a day or two after the onset. About 50 per cent. of the cases of diffuse or generalized peritonitis were accompanied by chills, occurring in some instances at the onset of the appendicitis, in others with the beginning of symptoms of peritonitis. A limited number of the cases associated with circumscribed abscess gave a history of chills, sometimes occurring at the onset, or again after the third or fourth day. Repeated chills occurring late in the course of the malady generally indicate a dissemination of the pyemic process.

Pulse.—The pulse is of greater importance than the temperature as an indication of the condition of the patient, and as guide to prognosis; and more especially the relation of the pulse-rate to the temperature. A very rapid pulse is always a grave symptom, and a rapid pulse out of proportion to the amount of fever usually presages a fatal termination. In the majority of cases of acute appendicitis the pulse-rate is affected early, and while an active process is going on, continues slightly accelerated, even with a normal temperature, but this is by no means a constant symptom; on the other hand, in nervous individuals and children the pulse is quickened even with simple functional disturbances. As the affection becomes localized and the active process declines, the pulse becomes normal. The development of a localized suppurative process is generally accompanied by an accelerated pulse-rate, corresponding to the rise in temperature;

but when the abscess is firmly limited and absorption diminished, the pulse and temperature are normal. With a spreading peritonitis and beginning meteorism, the pulse is rapid, full, and of high tension, the high tension depending, according to LENNANDER, upon the increased intra-abdominal tension, and the contraction of the abdominal muscles. As the infection progresses the resulting general intoxication causes paralysis of the inhibiting centre and at the same time directly affects the heart's action, consequently the pulse becomes rapid, weak, and irregular. The prognosis in such a case is exceedingly grave, and if associated with a falling temperature is practically hopeless. A slow pulse of poor quality may also indicate impending dissolution. A good pulse, on the other hand, may exist in the presence of a fatal infection, and by itself can never be relied upon as a guide to prognosis or diagnosis.

Tumor.—A mass is rarely recognizable in the early stages of acute appendicitis and is not present at any time in cases of the mildest type, nor, as a rule, in the most severe forms. The presence of a circumscribed swelling is an indication, on the one hand, of the extension of the disease beyond the appendix, and, on the other hand, of a distinct tendency toward its limitation. The inflamed appendix itself, apart from the surrounding exudate, is seldom palpable, and even when considerably swollen, the rigidity of the overlying muscle during the early acute stages effectually conceals it. As the affection subsides and rigidity diminishes, it is sometimes possible to outline the exquisitely tender, distended appendix, but very frequently it is so deeply situated that even when the abdominal walls are relaxed under an anesthetic it is not easily discovered. Often when the appendix is supposed to have been palpated, at operation it is found in a different and quite inaccessible position, the mass felt being probably contracted muscle. In some instances, however, a definitely outlined tumor is detected even at the very outset of the attack. With few exceptions this proves to be the thickened edematous omentum which has wrapped itself around the appendix, or is attached by a recent exudation to the most acutely inflamed portion of it. If seen early, this omental tumor is more or less freely movable, and appears as a cylindrical or pear-shaped mass about the size of a fist. Later, it is apt to become adherent to the surrounding structures.

An extensive fibrinous or purulent exudation is occasionally discovered shortly after the apparent onset of the attack, but in most instances these are probably cases of insidious evolution in which the first acute symptoms are in reality due to the development of the extra-appendical process. In such cases a large abscess containing a pint or more of pus may be discovered within the first twenty-four hours. Acute inflammation of the appendix persisting for more than three or four days usually results in the involvement of the surrounding tissues, and is associated with a more or less abundant exudate, which gives rise to a clearly defined tumor mass. The character of the exudation, and hence the physical peculiarities of the mass, vary considerably. In some instances the tumor may consist wholly of a massive fibrinous or sero-fibrinous exudate,

which appears as an irregular, dense, immovable thickening. In other cases there is a dense fibrinous mass, containing a small focus of pus, or, again, a large, fluctuant abscess develops, which is usually globular and prominent, forming a plainly visible swelling in the right abdomen. A purulent exudate is often accompanied by more or less edema and infiltration of the overlying integument. The inflammatory mass, as a rule, is perfectly immovable, but it may possess slight mobility, and in some instances—for example, when an abscess develops between the coils of intestine, or between the mesentery and the omentum, or between the layers of the mesentery—it may have a well-marked excursion. E. LAPLACE (*Jour. Amer. Med. Assoc.*, 1901, vol. 2, p. 949) describes a case in which a distinct tumor, the size and shape of the kidney, was movable within an area having a radius of 3 inches about the umbilicus. This mass, which was made up of omentum, ileum, colon, and mesentery, was not adherent to the surrounding peritoneum. In its midst was a foul abscess and the gangrenous perforated appendix. A small abscess, situated behind the cecum or ascending colon, may be very difficult, and often impossible to detect, although its presence is strongly indicated by a long-continued remitting temperature. Percussion may reveal the presence of a tumor, when, on account of tenderness and rigidity, palpation is unsatisfactory. The presence of a mass usually produces impairment of the normal tympany, and if superficially placed, there is absolute dulness over the most prominent portion, then relative dulness passing into the normal resonance about the margin. Some impairment of the normal sounds may be found extending a considerable distance beyond the abscess itself, being produced by the presence of an abundant plastic exudate which mats together the omentum and the neighboring intestinal coils. The percussion note, however, is not an infallible guide, for, on the one hand, excessive rigidity of the abdominal muscles may be the cause of impaired resonance; and, on the other hand, a small retrocecal abscess, or even one of considerable size, may be associated with a normal tympanitic note produced by the intervening dilated cecum or small bowel. Again, with a deeply situated posterior abscess there may be normal resonance in the anterior abdomen and dulness in the posterior lumbar region. Sometimes percussion over a large, prominent mass may elicit a tympanitic note owing to the presence of gas in its interior. This phenomenon may greatly confuse the diagnosis, as in the following example:

J. H. H. Surg. No. 11,770. Admitted with a history of one week's illness. As the patient was a Pole, a clear account of its onset could not be obtained, but it was ascertained that there had been no vomiting, and that the bowels had moved two days before admission. The tumor had been noticed for one day. The abdomen showed slight general fulness with visible peristalsis in the left lower quadrant. It was soft, and the respiratory movements free. In the right iliac region there was a large prominent tumor extending to the median line and from the

level of the umbilicus to Poupart's ligament. The mass was not especially tender and was tympanitic on percussion. No peristalsis was visible. It extended down to the right inguinal canal, and from the external ring a finger-like mass projected which was tender and hard. The right spermatic cord was thickened down to the testicle. The temperature was 103.4° F.; the pulse 120; the leucocytes 37,000. Operation was performed on the supposition that there was a strangulated hernia. An exploratory incision was first made in the inguinal region and the mass there found to be the inflamed, edematous spermatic cord. Continuing the incision through the edematous muscle and peritoneum, there was an immediate escape of a large amount of gas, followed by very foul pus. The appendix was gangrenous, perforated, and partly bound up in omentum. A fecal fistula developed six days after operation, but closed in two weeks.

Distention.—Slight meteorism at the outset is common in cases beginning with stormy symptoms, and may be due to constipation or to the formation of gas. When there is no inhibition of peristalsis, the distention only gives rise to discomfort, and as the affection becomes localized the abdomen usually assumes its natural appearance. With the beginning of spreading peritonitis the abdomen is often flat, and even scaphoid. Distention usually occurs early, however, and may be extreme, the abdomen being dome-shaped and perfectly motionless. In cases of distention due to profound infection, no sound whatever is heard on auscultation. RICHARDSON has observed that in cases of great distention there is also at times a serious interference with the portal circulation, the distended intestine being dark red or purple, and the portal radicles dark and prominent. In these cases the heavy distended coils can be felt through the abdominal wall. Portal thrombosis may give rise to a similar condition. Marked distention may also be occasionally observed in cases of profound toxemia, without any evidence of mechanical obstruction or peritonitis. Extreme distention is one of the gravest symptoms observed in appendicitis, whether due to a local infection, to mechanical obstruction, or to general intoxication. It is one of the most significant signs of a general peritonitis. On the other hand, in severe diffuse peritonitis the abdomen may be flat, hard, and board-like; or it may be soft and natural looking in hopeless cases.

Jaundice.—This symptom occurs in a comparatively small number of cases of appendicitis, but it may possess considerable significance as an index to the patient's condition. On the other hand, it is sometimes a very misleading sign, because when associated with hypochondriac pain, the appendical origin of the affection may not be recognized. Jaundice in appendicitis may be of the obstructive or non-obstructive type. The former is more common in cases of chronic inflammation, in which adhesions have surrounded the gall-bladder and its ducts. Non-obstructive jaundice is almost invariably present in cases of appendicitis accompanied with pyemic abscesses of the liver, and is also found in cases with severe toxemia. In the former, owing to the extensive disor-

ganization of the liver, the jaundice is more intense than in the latter, and is also associated with other signs of the pyemic process. The jaundice of toxemia is usually slight, being often only noticeable in the sclera. It is always an unfavorable sign.

General Appearance.—The general condition of the patient often affords valuable information as to the progress of the disease. In cases of moderate severity there is at first an expression of suffering and occasionally an appearance of slight shock, but this soon passes off and the patient lies quietly, appears comfortable, and does not look very ill. The face is usually a little flushed and slight headache is common. In more severe infection the patient may look dull and heavy and answer questions slowly; later, there is often restlessness and slight delirium. At the outset the color is good in the milder forms, but with increasing intoxication the face appears dusky and the skin is bathed with cold sweat. The sclera are sometimes slightly icteric. General peritonitis is marked from the outset by an expression of anxiety, but after recovery from the primary shock the patient for a time may appear to be improving, and look fairly comfortable and well. When peritonitis is fully developed, the appearance is very characteristic; the expression is anxious, the face pinched, the nose sharp, the eyes sunken, the skin livid, or dusky and cyanosed, and the respirations rapid, shallow, and wholly costal.

COMPLICATIONS OF ACUTE APPENDICITIS.

Suppurative Peri-appendicitis.—On account of its frequency, its immediate danger, and its many troublesome sequelæ, abscess formation is the most important complication of appendicitis. Unhappily, notwithstanding the constant effort of modern surgeons to forestall this event, it is still present in a large proportion of the cases admitted for hospital treatment, occurring in about two-thirds of the acute cases, and in nearly one-half of all. Another fact, difficult of explanation, unless it be attributable to the still too great conservatism of the family physician, is that the percentage of abscess cases admitted to the Johns Hopkins Hospital during the past three years was practically the same as during the preceding ten. The individual symptoms of suppurative peri-appendicitis have been separately discussed in connection with the symptoms of acute appendicitis, and it only remains to give a general clinical picture of this condition. The onset of an attack of appendicitis which goes on to suppuration differs in no way from an ordinary attack. It may be ushered in with violent symptoms or it may have a gradual, and sometimes very obscure, evolution. In some instances suppuration is present from the outset, in which case the initial symptoms, often unusually severe, instead of showing the usual decline at the end of thirty-six or forty-eight hours, continue unabated for a longer time. The abdomen at first is more or less distended and rigid, so that local signs of suppuration are hidden, but usually in a few days, although the general symptoms continue

severe, meteorism and rigidity diminish and a mass may be more or less easily palpated. Sometimes, while it is impossible by palpation or percussion to detect any evidence of a mass, the persistence of an area of exquisite tenderness and the continued inclination to flex the right thigh point to a hidden focus of suppuration. In other instances, suppuration develops later. The early acute attack is followed by a general amelioration of all the symptoms, and the apparent improvement of the patient, when, in a few days, a recrudescence of the fever is noticed, occasionally accompanied with a chill. The temperature keeps high, or assumes the characteristic remittent type of septic absorption. At the same time there is renewed soreness, and sometimes acute pain, in the right side, while a swelling develops more or less rapidly. In other cases, again, the initial symptoms are very misleading, being often not more than a slight soreness in the abdomen and a feeling of general malaise, the patient in the meantime going about as usual. TREVES refers to a case described by ROUX, where a man, aged forty-two, complained of some pain in the right iliac fossa, but continued his work as a carpenter for a week, the bowels acting regularly during this time. On the eighth day the pain became worse and the patient took to his bed, and on the ninth day a large perityphlitic abscess was evacuated. A similar case occurred in the practice of my associate, H. W. BUCKLER, as follows:

A boy, ten years old, suffered with frequent attacks of nausea, vomiting, and abdominal pain, relieved by purging and dieting. One day, after a heavy dinner, he complained of nausea, and later on he vomited his dinner. There was considerable colicky pain in the abdomen, but it was not localized, and the next day he was much better and the pain was relieved. On the second day he had a dose of calomel, which caused ten to fifteen small stools, and he complained of much pain in defecation and also in micturition. When seen on the third day his temperature was 100.5° F. and his pulse 90; there was no pain nor tenderness in the abdomen whatever, his only complaint being of difficulty and pain in micturition, and pain on defecation. On rectal examination a large soft mass, exquisitely tender, was found filling up the pelvis. During the following night there was rapid distention of the abdomen and the temperature rose to 102.7° F. and the pulse to 110. Operation early the next morning revealed a general peritonitis, and a large pelvic abscess containing over six ounces of pus. The appendix, which measured nine and a half inches in length, and was situated in the pelvis, was completely gangrenous and perforated at the base.

After the acute process has subsided, resolution and speedy convalescence may follow, or the abscess may remain more or less quiescent. It may be present for a long time with little constitutional effect, but, as a rule, there are the usual manifestations of chronic sepsis, namely, emaciation, progressive loss of strength, poor appetite, furred tongue, and, ultimately, complete exhaustion.

Generalized Peritonitis.—This condition is the most critical accompaniment of the early stages of acute appendicitis, and, although less frequent, is by no means a rare accident in the last stages. In some cases, symptoms

of general peritonitis are present from the onset of the attack. In other instances (the more usual course) the affection first becomes localized in the right iliac region, and symptoms of the diffuse abdominal infection develop later. Out of about 50 cases observed at the Johns Hopkins Hospital, 3 showed symptoms of peritonitis from the beginning, 20 within the first forty-eight hours, and the remainder in from two to five days. 3 cases gave a history of from nine to fourteen days' illness, but the exact date when the symptoms of peritonitis appeared was doubtful. Whether arising early or late, the onset of general peritonitic symptoms is usually very abrupt, beginning with intense radiating abdominal pain, nausea and vomiting, with a distinct chill, sometimes amounting to a severe rigor, and in a large number of cases followed by high fever. The pulse is rapid and full, the expression anxious, the face flushed, and the respirations hurried and shallow. There may be more or less profound shock, but, as a rule, the patient soon rallies. The abdomen at this stage is often flat, retracted, and board-like in its rigidity; there is general tenderness, marked cutaneous hyperesthesia, and active muscle spasm. The respiratory movements are restricted or absent. The patient lies in the dorsal decubitus, usually with both knees drawn up. As the peritonitis becomes established, the constitutional symptoms become rapidly more pronounced, the patient looks feverish and shows more or less hebetude, the tongue is dry and coated, nausea and vomiting are almost continuous, there is complete obstipation, and the respirations are very rapid and altogether costal. The abdomen is now distended and motionless, its distention being sometimes especially marked in the epigastrium. The iliac and costal grooves may be completely obliterated and the area of liver dulness greatly reduced; there may be movable dulness in either flank, and the abdomen is everywhere exquisitely tender. When the peritonitis is fully established, the patient is seen to be very ill at the first glance; he looks septic and is often very restless; the facial expression is often dull and stupid or there may be a marked *facies hippocratica;* the pulse is very rapid and irregular and the fever may be very high. In one case in the Johns Hopkins Hospital the temperature registered 109.2° F. shortly before death. Vomiting is usually continuous and is often stercoraceous. In other cases the patient is found in collapse, the skin pallid, cyanosed, and bathed in clammy sweat; the pulse irregular, rapid, and weak, the temperature low. Abdominal symptoms at this stage may be altogether lacking. In some cases, as the climax approaches, the subjective symptoms may be those of general well-being, and the patient is convinced he is improving. In the so-called fulminating forms of peritonitis, on the contrary, symptoms of collapse may be present almost from the first; the temperature may never rise above normal and it frequently becomes subnormal. Abdominal symptoms after the first acute onset may be inconspicuous. In such cases the overwhelming intoxication paralyzes the resistance of the organism from the first onset, and rapidly advances to a fatal termination. Treves men-

tions the case of a man, aged twenty-eight, who, after three weeks of "dyspepsia," during which time he was actively engaged in some outdoor work, was seized at two o'clock in the morning with definite symptoms of perityphilitis. When seen at 2 P. M. on the same day he was cold, pulseless, and dying. At 6 P. M. he was dead. Autopsy revealed perforative appendicitis. In favorable cases the severity of the symptoms gradually diminishes, the temperature falls, the pulse becomes stronger and slower, and ultimately convalescence is established.

Ileus.—The occurrence of intestinal obstruction in the course of acute appendicitis has already been described. But it may also occur as a late complication, and very commonly appears when the patient has fully recovered from all evidence of the affection; or, again, it may suddenly develop in the course of an unsuspected chronic appendicitis. It is due to the constricting bands and adhesions resulting from the former acute or chronic peritonitis, which produce a sharp angle or twist in the bowel or incarcerate a portion of intestine which has slipped under the band of adhesions. The symptoms are very characteristic: an abrupt onset with severe colicky pain, later becoming continuous and very intense; vomiting, which at first is the contents of the stomach, then bilious, and finally stercoraceous, and complete obstipation without the passage of flatus or fecal material. The abdomen becomes distended, tympanitic, and acutely tender. The constitutional symptoms are severe and symptoms of collapse soon supervene. In the beginning the temperature is normal, and may continue so. The axillary temperature may be subnormal. The pulse is rapid and weak; the tongue is dry and there is incessant thirst. Ileus as a post-operative sequela is considered elsewhere (see Chap. XXVIII).

Septicemia.—The absorption of toxins from the primary focus of disease, in other words, toxemia, is an accompaniment of the mildest as well as the most virulent forms of appendicitis, and is a part of the malady itself rather than a complication. There are, however, cases in which the microbes themselves enter the circulation, and toxins are then produced in the blood as well as absorbed from the primary seat of infection. In such cases the removal of the appendix is often attended with very disappointing results, as the general infection pursues its typical course uninfluenced by the removal of the primary seat of the disease. The symptoms of septicemia may set in within twenty-four hours or they may not appear until the third or fourth day. There is usually a chill which may recur at irregular intervals. The temperature rises gradually and remains high, or is marked by daily remissions or intermissions; the pulse is rapid and small, and there is usually great prostration. The skin becomes pale or slightly icteric, the tongue is dry and covered with a dark brown coat. There may be marked mental disquietude and restlessness, or the patient may gradually sink into a typhoid state and die in a comatose condition.

Pyemia complicating appendicitis is characterized by the formation of abscesses in various regions, due to the transportation of septic emboli from the diseased area. The clinical picture of the most important of these metastatic abscesses, that is, abscesses of the liver, will be described later in connection with suppurative pylephlebitis. Less common areas of distribution are the spleen, kidneys, and lungs. Cases have also been reported of abscesses developing in the brain and in the parotid gland. The onset of pyemia is marked by a severe chill, or rigors, with high temperature followed by profuse sweats. The chills may be repeated daily, or at irregular intervals. The fever may be slight in the intervals and there may be periods of apyrexia. There is anorexia, often with nausea and vomiting, and looseness of the bowels, the patient usually becoming greatly emaciated. The physical signs of abscess formation are readily detected in the lungs and in superficial regions, as in the parotid gland; in other cases they may escape observation. The disease may run a chronic course, lasting for months, the condition of the patient varying from time to time, but the termination is usually fatal.

Pylephlebitis, Liver Abscess, Subphrenic Abscess.—Of the remote complications of appendicitis, pylephlebitis and its accompaniment, liver abscess, is the most to be dreaded. It is usually a late phenomenon, sometimes not appearing until several weeks after the subsidence of the appendical affection, and seldom developing before the end of the first week of the attack. It may follow the most severe form of appendicitis, but is commonly found associated with the less severe, subacute cases, and often with those of insidious development, the masked cases of TREVES. There are numerous recorded examples in which the patient, who previously had complained merely of indigestion or had been a little out of sorts, suddenly presented symptoms of the acute liver affection, the appendical origin of which was not suspected. The chief points in the clinical history are: severe pain in the right hypochondrium or epigastric region, and repeated rigors, followed by high fever and profuse sweats. Icterus is present in the majority of cases and is sometimes pronounced; the liver becomes enlarged and painful and there is rapid emaciation with progressive weakness. Subphrenic abscess may give rise to a clinical picture resembling abscess of the liver. It is, however, usually associated with evidences of progressive purulent peritonitis. In addition to the general appearance of sepsis, hepatic tenderness and swelling are sometimes conspicuous features, but rigors and jaundice are not always so marked. The liver is sometimes secondarily affected, in which case the symptoms are the same as those described in connection with primary abscess of the liver. Peripheral thrombosis and embolism are occasional complications of appendicitis, but as they occur more frequently as post-operative events, they are described under that head in Chap. XXVIII.

Lung and Pleural Affections.—The most frequent thoracic complication of appendicitis is pleuritis. WOLBRECHT (*loc. cit.*) found evidence of pleural

involvement in 38 per cent. of the cases in Gerhardt's clinic, but this is undoubtedly much too high an estimate of its general frequency. There may be a simple sero-fibrinous pleurisy or an empyema. The latter is commonly a sequel of subphrenic abscess. Owing to the presence of the abdominal affection the pleural symptoms may be obscure, but they are frequently unmistakable, consisting of a sudden accession of fever, often preceded by a chill, severe lancinating pain in the side, dyspnœa, and slight cough.

Vesical and Renal Complications.—These are comparatively frequent events in the course of acute appendicitis They may be of reflex nervous origin, or they may be of an inflammatory nature, a pericystitis or cystitis resulting from the implication of the bladder wall in the inflammation of the appendix. The reflex phenomena, as a rule, are symptoms occurring at the onset of the attacks, and are more or less evanescent. They are not in themselves of serious import and soon give place to normal function. The most common early manifestations are acute retention and painful micturition. Complete retention of urine may persist from twenty-four to forty-eight hours. In one of the cases admitted to the Johns Hopkins Hospital the attack of appendicitis began with acute, colicky, abdominal pain, associated with pain in the bladder and complete retention for twenty-four hours. This was relieved by catheterization, and there was no further trouble. Reynes (*XIII Cong. intern. de méd.*, Paris, 1901) describes a case in which a typical attack of acute appendicitis was accompanied by acute retention of urine lasting for forty-eight hours. In a case described by Balzer the retention, which lasted for forty-eight hours, did not take place until the fifth day of the attack. These purely reflex phenomena do not necessarily indicate that the appendix occupies the pelvic position. In the majority of instances the bladder symptoms are not noticed until the second or third day of the attack, and are produced by the extension of the inflammatory reaction to the peritoneal covering of the bladder, or to the infection of the deeper layers. As a rule, in these cases the appendix occupies the pelvic portion and is in direct contact with the surface of the bladder. In other cases the bladder infection is due to the extension of a suppurative peri-appendicitis into the pelvis. The symptoms most commonly noticed are increased frequency and pain in micturition, tenesmus, and, less frequently, retention of urine.

The vesical irritability accompanying a simple pericystitis secondary to acute appendicitis usually diminishes with the subsidence of the active process and the definite limitation of the appendical disease. When however, adhesions form between the appendix and bladder, dysuria may be the most persistent and most prominent symptom. A good example furnished me by W. W. Keen is as follows: The patient, a medical student, aged twenty, gave a history of frequent attacks of pain in the right lower abdomen which began in the region of the appendix and extended downward and inward, causing considerable pain in the bladder and in the end of the penis. This was so

marked a feature of the attack that a skiagraph was made in order to exclude the possibility of a urethral calculus. At operation the appendix was found hanging over the brim of the pelvis and attached to something soft in front of it, presumably the bladder.

A true cystitis is a comparatively infrequent complication of appendicitis, but it is one which may have the most serious consequences. An intractable cystitis may continue or there may be a persistent fistula, or, finally, a fatal termination may be the direct consequence of these conditions. All grades of the infection occur, from a mild diffuse inflammation to a purulent infiltration of the bladder wall, with more or less extensive necrosis and perforation. The classical symptoms of acute cystitis are present, namely: painful and frequent micturition, tenesmus, and pyuria or hematuria. The involvement of the ureter or of the pelvis of the kidney in the suppurative process may produce similar symptoms. Cases have been described in which the inflammatory exudate had caused complete stricture of the ureter with a consequent development of symptoms of acute pyonephrosis. I once operated upon a woman for myoma of the uterus, and found, at the same time, an inflamed appendix densely adherent over the right ureter, which was compressed by it and completely strictured. There was also a pyonephrosis, for which nephrectomy was performed later on. Dieulafoy (*Presse méd.*, 1898, tom. 2, p. 281) in discussing the toxicity of acute appendicitis, has directed attention to the abnormalities in the composition of urine resulting from the absorption of toxic substances. The time at which these changes are observed varies according to the stage of the disease and its severity. The most important are the presence of albumen, and of increased indican and urobilin, but, as the infection progresses, all the symptoms characteristic of acute toxic nephritis develop, namely, diminished secretion of urine, the presence of casts, desquamated epithelium, leucocytes, and hematuria of renal origin or hemoglobinuria. Albumen is present, as a rule, in all acute febrile disorders, but, as pointed out by Bayet (*Thèse de Paris*, 1901), as appendicitis is at first a local affection, albumen may not be found in it at the outset. Later on, however, as the toxins become diffused it may be present in abundance. On the other hand, owing to the acute gastro-intestinal disturbances at the outset, a great increase in the amount of indican may be noticed in the first few days.

Fatal Hemorrhage.—In a few instances the erosion of a large blood-vessel occurring during the course of an appendicitis or as a post-operative complication has led to a fatal termination. Osler (*Montreal Hosp. Gaz.*, 1880) mentions an instance of fatal hemorrhage into the intestine, Matheson (*loc. cit.*) a fatal hematemesis, and Leudet (*Arch. gén. de méd.*, vol. 104, p. 140) a case of hemorrhage into the arachnoid space. The symptoms are those commonly produced by internal hemorrhage, and, as a rule, positive evidence is found in the passage of blood by the mouth or the rectum.

SYMPTOMS AND COMPLICATIONS OF CHRONIC APPENDICITIS.

Chronic appendicitis may follow an acute attack or the symptoms may be chronic from the beginning. There are three fairly distinct clinical forms of the affection, although they are not always sharply differentiated from one another: the recurrent form, which is characterized by the occurrence of repeated subacute or acute attacks with intervals of perfect freedom from any clinical evidence of the disease; the chronic relapsing form, in which the patient is never well and is subject to more or less acute exacerbations; the residual conditions, which denote the disturbances traceable to the influence of the adhesions, kinks, etc., resulting from preceding acute or chronic inflammatory attacks. The pathological conditions underlying any of these forms may be the source of the so-called latent appendicitis or *appendicitis larvata*, in which the infective process is in a quiescent state, but liable at any moment to burst forth into activity, and often terminating in acute perforative or gangrenous appendicitis. The clinical picture of chronic appendicitis is very varied, including in its mimicry almost all the chronic diseases to which the abdomen is subject. The chief symptoms are referred to disturbances of the digestive functions, but pain and tenderness may be troublesome and serious, and in consequence of the poor nutrition and the more or less constant suffering, there may be emaciation, great weakness and lack of energy, and often pronounced nervous manifestations.

The more severe recurrent and relapsing attacks are similar to the acute appendicitis already described. Constipation is one of the most constant symptoms of chronic appendicitis, and is often most obstinate. With it there are frequently more or less marked dyspeptic symptoms, especially after indulging in certain articles of food. Flatulency is especially common and sometimes seems to affect chiefly the ileocecal region. It is probably due to a condition of stasis, owing to the presence of adhesions which inhibit to some extent the normal muscular contractions (Czerny). Loss of appetite, furred tongue, and nausea are frequent accompaniments of the disturbed digestion. Diarrhea is less frequent than constipation, but is a prominent symptom in a considerable number of cases. It is, perhaps, most common in the more severe forms, in which the patient is in a state of chronic sepsis. The diarrhea may be persistent or may alternate with periods of constipation.

Pain and tenderness are characteristic symptoms in the majority of cases. The pain, as a rule, is definitely localized in the right abdomen, but, as in the acute affection, there is scarcely a spot in the whole abdomen to which it may not be referred. It is not often acute, being generally described as a dull ache, or merely a vague sense of discomfort. Occasionally, during the height of digestion, more or less severe colicky pain may be complained of, or, again, the pain may be noticed only during active exercise. I know of two cases in which the pain, which was very severe, was always referred to the rectum, and at

operation the appendix was found lodged in the pelvis and adherent by its tip to the rectum. In women dysmenorrhea is often a prominent symptom of chronic appendicitis, and in every case where dysmenorrhea follows an attack of acute appendicitis, the presence of the chronic form of the disease should be suspected.

The association of membranous colitis and chronic appendicitis is frequently observed. FINNEY has especially noted its occurrence in cases where there is a thickened, chronically inflamed appendix, densely adherent to neighboring intestines. Some writers have attributed the disease of the appendix to the influence of the chronic colitis, but the evidence as a whole is in favor of the appendical origin of the trouble, the affection of the colon being secondary. In many instances acute attacks of appendicitis have antedated the appearance of symptoms of colitis, and it is a common experience to find that the latter is entirely relieved by the removal of the appendix. LAPEYRE (*Zeit. f. Chir.*, 1903, p. 498) describes six cases in which coincident appendicitis and muco-membranous colitis were cured by the resection of the appendix.

CHAPTER XVIII.

DIAGNOSIS.

DIAGNOSIS. DIFFERENTIAL DIAGNOSIS.

DIAGNOSIS.

It is generally recognized that appendicitis is by far the most common inflammatory disease of the abdomen, especially in men under thirty and in children of both sexes. Sudden pain in the right iliac fossa with local tenderness and muscular rigidity are significant of the disease in the large majority of instances; there are, however, many cases of obscure development in which the cardinal signs of appendicitis are very inconspicuous; moreover, as pointed out by MYNTER (*Appendicitis*, 1898), few diseases present so many stages each characterized by a different set of symptoms, while, on the other hand, every one of these cardinal symptoms may be absent, or, if present, may indicate some other affection. The physician may not see the patient, in fact, he rarely does see him, during the initial stage of the attack, and by the time the disease comes under observation, the acute symptoms have subsided and the pain become localized—it may be in the right iliac fossa, but frequently at a point remote from the normal position of the appendix; again, in other instances, the pain may have ceased entirely, and there may be a lull in all the symptoms, which in one case denotes improvement and in another marks the onset of grave complications. It is not only the combination of symptoms and their appearance in a distinct order, however, which indicate the character and progress of the malady, but the impression made upon the trained mind by their combination and progress. In every case, therefore, a clear description of the onset and course of the attack should be obtained, the subjective and objective symptoms carefully weighed, and, what is often of the utmost importance, the history of the patient in regard to previous attacks of appendicitis investigated. Finally, when the diagnosis has been made in this manner by direct evidence, it should be confirmed by a general examination of the patient, in order to verify it by exclusion and thus avoid the chagrin of operating for a supposed appendicitis, and finding a case of, perhaps, thoracic disease with pronounced abdominal manifestations. The recognition of appendicitis in the majority of cases is easy, but it is often difficult, and sometimes impossible, to determine the grade of the infection and the extent of the complications; moreover, in the early stages of the disease there are no symptoms nor combination of

symptoms by which the probable course of events can be foretold with any certainty.

In the presence of the cardinal symptoms, namely, sudden, acute abdominal pain, tenderness on pressure over or near McBurney's point, and localized muscular rigidity, the diagnosis of appendicitis is justified in the majority of cases. Confirmatory symptoms, such as nausea and vomiting, constipation or diarrhea, elevation of temperature and acceleration of pulse, make the diagnosis more secure, and the presence of tumor puts it beyond doubt.

It must be remembered, however, that the position of the appendix is very variable, and it may be directed to almost any point in the abdomen, hence the local symptoms are sometimes referred to the region of the gall-bladder, to the left side of the abdomen, to the hypogastric region, or to the pelvis. H. L. Nietert (*Interstate Med. Jour.*, March, 1903) records a case in which there was an entire absence of local symptoms referable to the right iliac region, but there was dulness in the left iliac fossa. A median incision showed a transposition of the viscera and a gangrenous appendix on the left side. In a case referred to by Fowler, operative interference was delayed on account of the absence of symptoms referable to the right iliac fossa, although the clinical picture suggested an acute perforative appendicitis. At the autopsy the appendix was found lying to the left of the median line, about an inch above the level of the umbilicus and fixed in this position by a short mesocolon. Hypogastric pain with tenderness and rigidity on both sides is very characteristic of pelvic appendicitis.

During the early stages of the disease—a period when operative interference could save almost every case—it is unfortunately impossible to determine whether there is a simple inflammation which will undergo speedy resolution without surgical treatment, or if the case will proceed to the most dangerous extremities, gangrene or suppuration being already, perhaps, at hand. In general it may be said that if the attack begins with slight or moderate local symptoms and mild constitutional disturbance, it is probably an ordinary catarrhal or a diffuse inflammation, and if the symptoms do not increase in severity, but show a general improvement at the end of twenty-four to thirty-six hours, recovery will take place without further complications. A sudden onset with violent pain, high temperature, and rapid pulse, on the other hand, usually indicate a more immediately dangerous condition, and in some cases there is reason to believe that the first acute symptoms are due to beginning peritonitis, the result of perforation, gangrene, or a virulent infection. Intense agonizing pain at the onset is often due to a perforation. Collapse symptoms, whether appearing in the beginning or later in the attack, if the patient does not quickly rally, are significant of a virulent infection with general intoxication. As a rule, the patient is not seen during the earliest stages of the disease, several hours or even a day elapsing before a physician is summoned; much importance therefore attaches at this time to the following questions: Are the symptoms, both general and

local, subsiding; are they becoming more severe; or are they apparently stationary? If after twenty-four hours the patient is seen to be getting worse instead of better, complications may usually be expected. If after thirty-six to forty-eight hours there is continuous high fever and a correspondingly rapid pulse, suppuration or a general infection is strongly suggested. A rapidly increasing pulse-rate, especially when out of proportion to the degree of fever, is one of the most urgent symptoms, usually signifying gangrene, or perforation with beginning peritoneal infection, or a general septicemia. A sudden accession of local pain usually indicates a dangerous change due to the beginning of perforative peritonitis, and if the pain again becomes diffuse, especially if it is associated with shock, there is probably a sudden effusion into the general peritoneal cavity. A lull in the local symptoms, particularly in the presence of an increasing pulse-rate, is often due to gangrene or perforation of a pyo-appendix, and is soon followed by more or less quickly developing peritonitic symptoms, unless, indeed, the patient succumbs to a rapidly fatal toxemia.

Suppurative Peri-appendicitis.—This condition is recognized by the continuance or the recrudescence of high fever and rapid pulse after the second or third day, associated with pronounced local symptoms and the absence of any evidence of general peritonitis. The most positive proof of a circumscribed abscess is the presence of a tumor. It must be remembered, however, that a mass may be due to a plastic exudate, gluing together contiguous structures, or to the adherent rolled-up omentum, or it may even be simulated by rigidity of the abdominal muscles. On the other hand, a small focus of suppuration may exist without giving rise to a palpable tumor. At a later stage, when the abscess is firmly encapsulated, constitutional disturbances diminish owing to the lessened absorption, and the pulse and temperature may become normal. Fluctuation is usually not detected in the beginning of the attack, and often not at all. In the case of a pelvic abscess, however, as in one instance in my own practice, a fluctuating tumor may sometimes be detected on the second day. In the absence of distinct local signs, continuous fever may depend upon some remote metastatic infection such as pylephlebitis or liver abscess. But these complications usually occur later in the course of the disease, and, as a rule, are attended with unmistakable symptoms.

Progressive Peritonitis.—The onset of spreading peritonitis is indicated when the local pain, tenderness, and rigidity again become generalized and the pulse-rate increases. Confirmatory signs, such as chills, persistent nausea and vomiting, elevation of temperature, especially in the rectum, and an anxious expression, usually appear early, but much valuable time will be wasted, and the present deplorable failure of operative interference in this class of cases will continue, if such pronounced symptoms are waited for, because when the classical signs of a fully established peritonitis are present, the case is practically hopeless. Peritonitis occurs most commonly between the second and fifth days,

an interval which is the danger period of appendicitis. It must be remembered, however, that the first symptoms of the attack may be those of a beginning peritonitis.

Obscure and Masked Forms of Appendicitis.—There are certain cases of appendicitis which are not attended with any of the usual clinical manifestations, and the patient may pursue his usual avocation until suddenly evidences of some remote sequela develop, the appendical origin of which is not suspected. A striking example is related by TREVES, in which a middle-aged gentleman, after being a little out of sorts, was seized with pain in the hepatic region attended by a rigor and a subsequent rise of temperature. The rigors were repeated, the fever became very high, jaundice supervened, and it became evident that the patient was suffering from pylephlebitis and liver abscess. No mischief could be detected, however, in any part of the abdomen except about the liver. In fourteen days he died, when the liver was found riddled with abscesses; the appendix, which was disorganized and filled with pus, had evidently been the seat of long-standing disease. In other cases the clinical phenomena are vague and misleading, the symptoms never being referred to the right iliac region and not being acute. There is a feeling of general malaise, with loss of appetite, furred tongue, constipation or loose bowels, and a little swelling and tenderness of the abdomen. The patient may be able to walk and even to work while an appendicitis is progressing and a large abscess developing. FITZ (*Amer. Jour. Med. Sci.*, 1886, vol. 92, p. 331) mentions the case of a sailor who was at work rolling barrels of flour until the day of his admission to the hospital. He had then a prominent fluctuant tumor extending along the outer half of Poupart's ligament. The gradual evolution of the malady with slight pain, swollen and slightly tender abdomen, and the absence of localized symptoms may strongly suggest tubercular peritonitis. N. C. POWELL (*personal communication*) operated upon a man who had been ill for three years, being about one-half of the time confined to bed, with supposed tubercular peritonitis. After removal of the inflamed appendix his health was completely reestablished. Similar cases are mentioned by BROCA (*Thèse de Lyon*, 1901). In other cases, again, the patient suddenly develops collapse symptoms, or general septicemia appears without any pronounced abdominal symptoms. A history of preceding attacks of appendicitis is an important aid in the diagnosis of these obscure cases. It must also be borne in mind that many obscure cases of liver abscess, abscess of the lung or pleura, and cases of cryptogenetic septicemia are of appendical origin.

Examination of the Patient.—The characteristic posture of the patient in appendicitis immediately arrests the attention. Almost without exception he assumes the dorsal decubitus with the right leg slightly flexed, and exhibits an evident desire to avoid all movement. I once saw the case of a young girl where the only prominent symptom was the characteristic attitude. There was no spontaneous pain, and firm pressure over the region of the appendix did not

elicit any tenderness nor perceptible spasm. The temperature was 99° F., the pulse 80. There was, however, a history of acute abdominal pain on the preceding day, and when I saw her she was lying on her back with the right knee drawn up, plainly avoiding all movement whatever. In the afternoon of the same day the temperature was 99.8° F., and the pulse slightly accelerated. Operation, performed immediately, revealed a deeply situated appendix, which was swollen, turgid, almost mahogany colored, and covered with flakes of greenish lymph.

Abdominal examination must include inspection, palpation, percussion, and auscultation.

Inspection.—The abdomen in ordinary cases appears normal or it may be slightly meteorismic. It is usually symmetrical, but there is sometimes slight fulness in the right lower quadrant, possibly due to some distention of the cecum, and the right iliac groove may not be so well marked as the left. A distinct prominence indicates an encapsulated abscess. The respiratory movements are usually free in all parts; limitation of the respiratory movements in the right lower abdomen is evidence of a localized peritonitis, and absence of all abdominal movement shows a general peritoneal infection.

Palpation.—Before palpating the abdomen, the head and thorax should be somewhat elevated, the knees and thighs slightly flexed, and the patient made to relax thoroughly. He must then be put off his guard by questions, while at the same time the hand is passed over the entire abdomen, the right iliac region being avoided, and a little pressure made here and there to discover any points of tenderness, while at the same time a definite idea is obtained as to the general condition of the abdominal walls. The confidence of the patient being thus gained, the surgeon, still distracting his attention, makes a few rotary movements with slight pressure with the finger-tips over the right iliac fossa, noticing if there is any complaint of pain, and also, especially, any rigidity or spasm of the muscle; and then, without delay, before the patient has time to guard against the attack, he makes deep pressure with one or two fingers down into the head of the cecum



FIG. 233.

Piezometer used to measure the amount of pressure necessary to produce pain, as well as the force required to overcome the resistance of the muscular spasm as compared with the opposite side. The piezometer affords an objective method of demonstrating the presence of pain and resistance. The barrel contains a spring and both cylinder and rod are graduated. (One-half natural size.)

and McBurney's point, when, if there is any inflammatory trouble, the patient at once cries out and catches his hand. In doubtful cases of appendicitis the tactual sense may be supplemented and confirmed by the use of the instru-

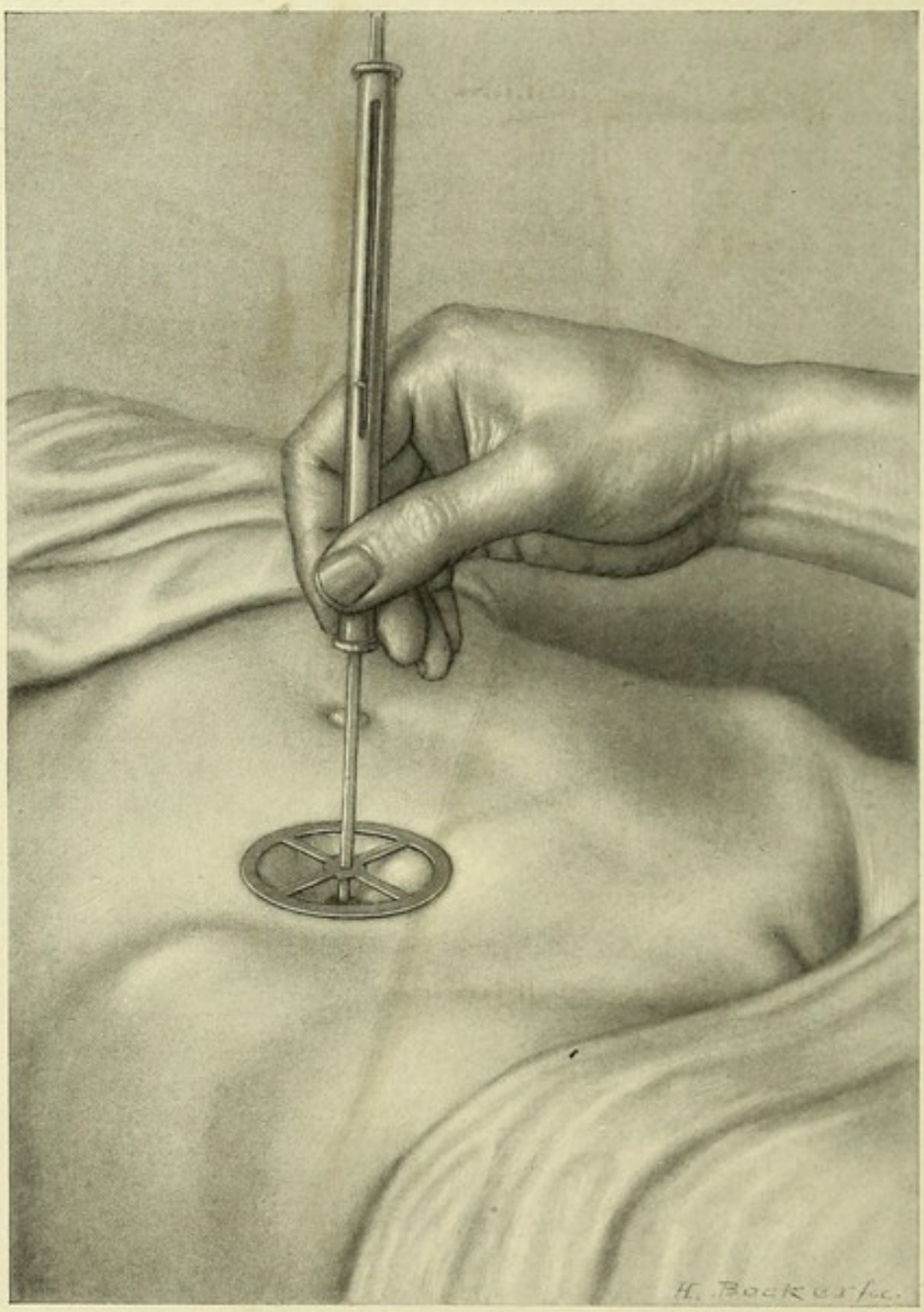

FIG. 234.

Showing the method of using the piezometer to determine the amount of pressure needed to produce pain. The sliding wheel indicates the depth of the depression produced by a given amount of pressure, and the muscle spasm is estimated when comparison is made with the corresponding point on the opposite side.

ment, piezometer, shown in Figs. 233 and 234. This may be used as an algesimeter to determine the amount of pressure necessary to elicit tenderness over the appendix, and may also be used to estimate the degree of rigidity

in the right iliac fossa by comparing the rigidity of the right and left rectus muscles. For example, with a pressure of 500, the button on the end of the rod may indent the abdominal wall so that the wheel registers 1 cm. on the right side, while at a corresponding point on the left side it registers 1.5 cm. or more. In this way the rigidity is demonstrated beyond a question and no allowance need be made for difference in tactual sense. At the same time the graduated rod indicates the amount of pressure necessary to elicit pain. (*Johns Hopkins Hospital Bulletin*, Sept., 1904.)

In acute cases, and also in patients with thick abdominal walls, it is seldom possible to palpate the appendix. Moreover, the attempt to do so is not without danger, as the distended or gangrenous appendix may easily be ruptured. In chronic appendicitis the thickened, erect appendix is plainly felt. In order to detect the appendix according to the method described by Edebohls, the examiner seeks the margin of the right rectus muscle, on the line between the navel and the anterior superior spine of the ilium. Then with light steady pressure the fingers are introduced under the margin of the rectus until the common iliac artery is distinctly perceptible. The appendix, as a rule, is felt just outside the artery, its insertion being about an inch distant from the vessel while its tip often crosses it. A perityphlitic exudate may at first be masked by the rigidity of the abdominal wall, but as the acute process subsides, it is usually easily recognized. Examination under ether will often reveal the swollen appendix or the presence of an exudate which could not otherwise be detected. This method, however, is seldom indicated except as a guide in making the incision. The examiner must always bear in mind the risk of rupturing the appendix or an encapsulated abscess, an accident which has more than once occurred.

In some obscure cases a valuable aid in examining the patient, described by B. McMonagle (*personal communication*), is the pain elicited by holding the fingers firmly over the normal site of the appendix and requiring the patient to contract the right psoas muscle by flexing the leg, held rigid at the knee, on the body. A rectal examination, and, in married women, a vaginal examination as well, should never be omitted, as it serves not only to exclude affections of the pelvic organs, but is often valuable in locating the appendix and in revealing its diseased condition. In children, particularly, the inflamed appendix may be palpated *per rectum* even when not in the iliac fossa. In adults, however, this method of examination is chiefly of use when the appendix is situated in the pelvis, when on bimanual examination, *i. e.*, with one hand on the abdomen and a finger of the other hand in the rectum, it is sometimes possible to outline the swollen, inflamed appendix or a peri-appendical exudate.

Percussion.—Normal tympany should be present throughout the abdomen, with more or less modified resonance over the region of the appendix in the presence of an omental tumor or a greatly distended appendix, or when there is an exudate. Absolute dulness, if present, is due to a very extensive

fibrinous exudate, or to an abscess; movable dulness in the flanks indicates the presence of effusion into the general peritoneal cavity.

Auscultation.—This is chiefly of use in determining whether symptoms of ileus are due to mechanical obstruction or to intestinal paralysis.

Urine.—The changes in the urine may be of some value in the diagnosis of a few obscure cases of appendicitis, especially in the differential diagnosis between appendicitis and pneumonia or typhoid fever. The early appearance of indicanuria and the relatively later appearance of albumen are the most distinctive features (see Chap. XIX).

DIFFERENTIAL DIAGNOSIS.

The frequent possibility of error in the diagnosis of appendicitis is shown by the large number of cases collected by J. M. Spillissy (*Ann. Surg.*, 1902, vol. 35, p. 758) illustrating the various lesions of the pelvis and abdomen which have been mistaken for appendicitis. The most important sources of error are in the acute visceral affections, most frequently in those which result in peritonitis. There are, as noted by Treves, "certain symptoms common to all acute disorders within the abdomen at their outset, in which a sudden and violent impression is made upon the great nerve centres. These symptoms consist of intense and sudden pain in the abdomen, of collapse in varying degree, and of a certain amount of vomiting. At the very outset such conditions as peri-typhlitis, renal and gall-stone colic, twisting of an ovarian pedicle, torsion of a movable kidney, general peritonitis, and intestinal obstruction, have been confused one with another." It is also well recognized that acute intra-thoracic affections, particularly in children, may in the beginning be characterized by abdominal symptoms so sudden and violent that the disease itself is entirely masked.

Gastro-intestinal Disease.—The gastro-intestinal diseases liable to be confused with appendicitis are acute gastritis and gastro-enteritis. Appendicitis is frequently mistaken for acute indigestion, but simple digestive disturbances are seldom mistaken for appendicitis. Intestinal colic, when chiefly affecting the appendical region, in the beginning may simulate appendicitis, but is distinguished by the entire absence of objective signs. In the severer forms of gastritis the attack may set in with a chill, fever, and vomiting. There may be constipation, but very often there is diarrhea. The abdomen may be swollen and slightly tender in the epigastric region. In the acute forms it may at first be impossible to make a definite diagnosis, but the absence of symptoms referable to the right iliac region and the general freedom from tenderness and rigidity are sufficient to put the examiner on his guard. Acute enteritis in children may set in very brusquely with vomiting, colicky pain, and high fever. The abdomen is sensitive and the

child lies with its legs drawn up. The frequency of this affection in young children and the characteristic frequent, offensive stools should prevent error. Acute enteritis accompanied with extension of the inflammation to the peritoneal surface may present a very close resemblance to appendicitis. A case related by QUENU and CAVASSE (*Bull. et. mém. de la Soc. de chir. de Paris*, 1900, tom. 26, p. 821) is that of a boy, aged seventeen, who suffered from violent abdominal pain, constant vomiting, and obstinate constipation. After two days his bowels were moved with enemata. The same evening there was slight abdominal distention, tenderness and rigidity in the right iliac fossa, slight fever, and a *hippocratic facies*. A diagnosis of appendicitis was made. Operation revealed a normal appendix, but the small intestines were congested and covered with a slight exudate, especially over the lower part of the ileum.

Stercoral typhlitis is now recognized as a rare affection. It is, however, occasionally confused with appendicitis. The diagnosis of the condition is fully described in Chap. XXI.

Foreign bodies in the intestine, especially in the cecal region, have frequently been mistaken for appendicitis. For example, in a case described by MUMFORD (*Bost. Med. and Surg. Jour.*, 1899, p. 602) a girl, aged twelve years, was suddenly seized with severe abdominal pain referred to the umbilicus, followed in a few hours by vomiting. Her bowels were moved with castor oil, but the pain increased, being especially severe in the right iliac region. On the third day the temperature was 103° F. and the pulse 112. Her abdomen was distended, rigid, and tender, especially over McBurney's point. Operation revealed a normal appendix and the cecum distended with a mass of orange pulp. The differential diagnosis in such cases can only be made by an exploratory laparotomy.

Perforation of gastro-intestinal ulcers, as well as large perforations of the appendix in which there is an extensive extravasation of septic material, are all accompanied with sudden excruciating pain, followed almost immediately with symptoms of shock. In all of these conditions the initial pain is commonly referred to the umbilical or epigastric regions, and in the absence of a history pointing to gastric or intestinal ulcer, the differential diagnosis is often impossible without an exploratory operation. In perforative appendicitis, however, there is usually a predominance of tenderness and rigidity in the right iliac region, while if the pain and other symptoms continue to be localized in the epigastrium, perforated gastric ulcer is probable. The less acute forms of gastric ulcer, where adhesions have formed, or where perforation occurs into the lesser abdominal cavity, are not apt to be confused with appendicitis. A further aid in the differential diagnosis is the greater liability of young women to the acute forms of gastric ulcer. With a preceding history of gastric disturbance, especially of hematemesis or of hemorrhage from the bowel, the diagnosis of gastric or duodenal ulcer is seldom doubtful. The possibility

of the coexistence of the two affections, as in the cases of TREVES and MATHESON, already cited, should be borne in mind. A definite diagnosis of intestinal perforations, especially when situated in the terminal portion of the ileum, the cecum, or the ascending colon, can seldom be made without an exploratory incision. In a case described by DEAVER, where a diagnosis had been made of acute appendicitis with general peritonitis, there was a perforation of the ileum about 1½ or 2 in. from its junction with the cecum. In QUINARD's case (cited by Spillissy) the cecum and appendix were normal, but there was a perforation in the ileum 30 cm. from the ileocecal junction.

Ulceration and perforation of the intestine due to the specific inflammatory affections, more especially typhoid fever and tuberculosis, are somewhat frequently confounded with appendicitis; and, on the other hand, appendicitis has sometimes been mistaken for these conditions. The clinical features of these diseases are fully considered in Chaps. XXIX and XXXII.

The relation of mucous colitis and appendicitis is interesting. As I have said elsewhere, obstipation and colitis with mucous stools are often the sign of a latent appendicitis, and are cured by the removal of the appendix. The differential diagnosis, as a rule, rests upon the history of mental strain or worry preceding the onset of the trouble and the presence of marked nervous manifestations, such as hysteria, hypochondriasis, etc. On the other hand, a history of a preceding acute or chronic appendicitis is exceedingly suggestive of the appendical source of the trouble. In any case of mucous colitis in which nervous symptoms are not a predominant feature of the disease, appendicitis should be suspected.

Tumors in the ileocecal region or in the ascending colon may be mistaken for appendical disease, particularly when symptoms of perforative peritonitis occur in a person who had not previously suffered from any distinct evidence of the disease. The exudate accompanying appendicitis, on the other hand, has also frequently been mistaken for a true neoplasm. Intestinal tumors may progress without pain, unless the parietal peritoneum is involved, and in the absence of ulceration there may be but slight digestive and constitutional disturbances. As a rule, however, there is a history of attacks of pain, the passage of blood and mucus in the stools, loss of weight and of strength. In late cases these symptoms are aggravated and there may be more or less cachexia. Symptoms of chronic obstruction are frequently observed. There may be slight fever, and leucocytosis is usually present. A tumor can generally be detected. The differentiation between the tumor in the case of a new growth, and a peri-appendical exudate is often perplexing. As a rule, a new growth is more or less freely movable, is sharply circumscribed, and develops gradually; while a perityphlitic inflammatory mass is less movable, less definitely outlined, and develops rapidly, usually with acute local and constitutional symptoms. The new growth, however, may be adherent to contiguous structures and immovable; while, on the other

hand, an inflammatory mass may possess considerable mobility. Again, the neoplasm may apparently develop suddenly in a person in good health, whereas the inflammatory exudate may be present for months or even years, as in FENGER's case, and may sometimes be accompanied by progressive emaciation and cachexia. Two years ago I operated upon the wife of a physician for what was supposed to be chronic appendicitis. She had been perfectly well, except for some trifling indigestion, until about six weeks before operation, when she suffered from a moderately severe attack of pain in the right iliac region associated with some fever, accompanied, it was said, by a leucocytosis of 12,000. She was ill for about three weeks, and after the acute symptoms had subsided she occasionally felt some slight pain in the right side, while there was a small, definitely circumscribed mass in the iliac fossa, which was not freely movable, and was not very sensitive. There was no disturbance of digestion and the bowels were normal. Operation revealed a normal appendix and a carcinoma of the cecum. The age of the patient is of some value as an aid to the diagnosis, but it must be remembered that new growths are not rare in youthful persons and that appendicitis sometimes occurs in advanced life.

LENZMANN states that the distention of the bowel with air is sometimes an aid in differential diagnosis. In the case of carcinoma, which, in the majority of cases, is an annular growth, the cecum becomes contracted when the intestine is distended by gas, but an inflammatory exudate does not, as a rule, prevent its dilation. This procedure, however, is not always trustworthy, as a new growth may be limited to the posterior surface, and would not then interfere with the cecal distention, while, on the other hand, extensive adhesions in inflammatory cases may greatly limit it. A. GERSTER (*N. Y. Med. Jour.*, Aug., 1902) had a case of relapsing appendicitis in a man, twenty years old, which presented the following points of resemblance to a neoplasm of the ileocecal region: A large rounded tumor of gradual development, movable, giving very little pain when the patient lay quietly in bed, and not accompanied with chills nor rise of temperature, the bowels being regular. The chief points in favor of the inflammatory nature of the tumor were the age of the patient, and, especially, the history of three previous attacks of appendicitis.

Ileocecal tumors of tubercular origin are distinguished from malignant growths on the one hand, and simple inflammation on the other, by their slow evolution, their characteristic contour, and, especially, by the history of antecedent tubercular trouble, or the presence of enlarged, hard glands in the cervical or other region.

Acute intestinal obstruction may be due to strangulation, volvulus, intussusception, strictures, or foreign bodies. In all of these conditions the symptoms are similar to acute appendicitis, and all have been confused with it. If the case is seen early there is, in the majority of cases, no difficulty in the differential diagnosis, the acute onset with severe abdominal pain, becoming more intense and

continuous and soon followed by vomiting of, at first, the contents of the stomach, then bile, and then fecal matter, being very characteristic. The presence of obstipation and early collapse are also most important diagnostic features. The absence of fever at the onset, and of early high leucocytosis, as well as the absence of early abdominal tenderness, distinguish it from appendicitis. Later on, when symptoms of peritonitis develop, the differential diagnosis may be impossible, unless a clear history of the onset of the attack can be obtained. Strangulation of the intestine by bands of adhesions, by a Meckel's diverticulum, by the adherent appendix, or by its incarceration in peritoneal pockets, is most commonly mistaken for appendicitis. SPILLISSY has collected 18 cases of obstruction due to trouble involving Meckel's diverticulum, in which a diagnosis of appendicitis was made. Diseases of this rudimentary structure cannot be distinguished from appendicitis before operation (see Chap. XXV).

Incarcerated internal hernia may readily be confused with appendicitis, particularly when the incarceration is not complete. As a rule, however, there are early signs of complete obstruction, while symptoms of ileus in appendicitis are not present in the beginning of general peritonitis, but follow its development. J. B. DEAVER observes that incipient hernia may simulate chronic appendicitis. Palpation of the inguinal rings will usually reveal the source of the trouble in such cases.

Intussusception may present a close resemblance to acute appendicitis. In both there may be the initial, severe, colicky pain, vomiting, and collapse. The pain may be confined to the right side and a tumor may be felt. In intussusception the pain resembles a severe colic and is often relieved by pressure; vomiting is more marked, and there is severe tenesmus with escape of blood, or of blood and mucus from the bowels. The tumor is better defined, less tender, and movable. In every case of acute colic in young children the question of intussusception should be considered and the examination directed to its possible discovery. Examples of this condition are given in Chap. XX.

Intestinal parasites may, in children, give rise to abdominal symptoms, which in their brusque onset and violent character, together with the consequent severe constitutional disturbances, closely simulate acute appendicitis. Instructive examples of this confusion, given by C. ARBORÉ-RALLY and METCHNIKOFF, are described in Chap. XX. The differential diagnosis rests chiefly upon the discovery of the ova of the parasites in the stools. It must be borne in mind, however, as is clearly shown in Chap. XX, that intestinal parasites may be associated with, and indeed may be the exciting cause of, acute appendical inflammation. The blood examination may be of great value in doubtful cases, as in helminthiasis a high grade of eosinophiles is frequently found, while in the early stages of acute appendicitis there is often a marked diminution or a total absence of these cells (SIMON, *Clinical Diagnosis*). As the infection terminates, however, the eosinophiles are relatively and actually increased (DAVID, *Thèse de Paris*, 1903).

Lead Colic.—In the absence of general symptoms of plumbism, lead colic may be mistaken for appendicitis, and vice versa. BERNARD (*Thèse de Paris,* 1901) refers to a case in which the appendix was removed on account of abdominal symptoms suggestive of appendicitis. The following year the patient suffered from an attack of an exactly similar nature, and it was then found that he was the subject of lead colic. An attack of colic in chronic lead poisoning is often preceded by gastric or intestinal symptoms, particularly constipation. The pain is over the whole abdomen and is usually paroxysmal. There is often, in addition, a dull heavy pain between the paroxysms, and there may be vomiting; attacks of pain with acute diarrhea may also occur. Acute lead poisoning may present vomiting and pain in the abdomen, with gastro-intestinal symptoms of the most intense description, accompanied by collapse which may prove rapidly fatal. In lead colic, unlike colic due to inflammatory disease, there is an absence of general or localized tenderness, in fact, the pain is usually relieved by pressure. The pulse-rate instead of being accelerated is retarded, and there is increased tension (RITZEL quoted by Osler). The blood examination is here of importance in the differential diagnosis. According to DA COSTA (*Clinical Hematology,* 1901), there is often pronounced leucocytosis, especially in cases with acutely toxic symptoms, but granular basophilia of the erythrocytes can be detected even in the earliest stage of plumbism, while in appendicitis this does not occur. Acute poisoning may simulate acute appendicitis, which at the outset presents signs of acute diffuse peritonitis accompanied by signs of collapse. In such a case the temperature, the pulse, and the leucocyte count may not present points of differentiation. As acute lead poisoning is usually the result of a large amount of poison taken accidentally or with suicidal intent, the history will usually give the clue. The most important cases are those in which there is coincident plumbism and appendicitis. A patient presenting general symptoms of lead poisoning may be seized with an attack of acute or chronic appendicitis, which is considered to be merely the usual abdominal symptoms of plumbism. The chief points in the differential diagnosis are the localization of the pain in the right iliac fossa, the presence of diffuse or localized tenderness, and rigidity of the abdominal walls. The temperature is more or less elevated and the pulse accelerated. Leucocytosis, if present, is a valuable confirmatory sign. The detection of a mass in the right iliac fossa is, of course, positive evidence that the attack is not due to plumbism.

Affections of the Peritoneum and Mesentery.—Tubercular peritonitis, both in the chronic and the acute form, may simulate appendicitis. Many cases set in acutely with fever, abdominal tenderness, and the usual symptoms of an ordinary acute peritonitis, the predominating symptoms often being referred to the right iliac region. These cases are frequently mistaken for appendicitis with localized peritonitis. In other instances the onset is exceedingly brusque, with acute abdominal symptoms and marked constitutional disturbance, simulating acute perforative appendicitis with generalized peritonitis. A case de-

scribed by ROUSSEAU (*Thèse de Paris*, 1901) is that of a child who awakened with sudden sharp pain in the abdomen, the maximum intensity of the pain being in the right flank. She vomited almost immediately, and at the same time several ascarides were passed *per rectum*. A few hours later she vomited some mucus. Twelve hours after the onset of the attack she was admitted to the hospital in a critical condition, presenting the typical *facies abdominalis*, cold extremities, rapid respiration, and extremely small pulse. The abdomen was distended, and palpation in the right flank elicited acute pain and muscular resistance. A diagnosis was made of probable peritonitis due to perforative appendicitis, and immediate operation performed. There was a small amount of serous fluid in the abdominal cavity and the serous membrane was covered with fine tubercular granulations. The child did not improve after the operation, but presented signs of increasing intoxication, and died on the sixth day. An instance of the chronic form, given by TREVES, is the case of a boy, aged thirteen, admitted to the hospital complaining of pain in the right side and occasional vomiting. He declared that the pain began suddenly some months previously, being accompanied with vomiting and a tender swelling in the cecal region, which had not entirely disappeared. An exploratory incision revealed a localized tubercular peritonitis, with evidence of extension over the general serous surfaces. The appendix appeared normal. The most characteristic features of the acute attack are the more moderate fever, the less acute abdominal tenderness, the more indefinite localization of the symptoms, the more frequent occurrence of fecal vomiting. None of these indications, however, are distinctive, and in some instances the differential diagnosis is impossible. Most important among the diagnostic points are the personal and hereditary antecedents of the patient.

General peritonitis secondary to measles has been described by R. T. MORRIS (*N. Y. Med. Jour.*, 1899, vol. 1, p. 470) as being mistaken for acute appendicitis with general peritonitis. Operation showed the peritoneum thickened and infiltrated, while the abdominal cavity was filled with viscid lymph. Recovery was retarded by an attack of meningitis accompanied by pleurisy and pericarditis.

A case of lipoma of the mesentery, twisted on its axis and producing gangrene and perforation of the ileum, which were at first mistaken for acute perforative appendicitis, has been sent me by A. C. BERNAYS of St. Louis. The patient, a girl six years old, was suddenly taken with severe colic followed by vomiting. There was an obvious tumor in the iliac fossa, but little tenderness. The child was moribund when sent to the hospital, but was operated on as a last resort—too late, however, to save her life.

A mass of gangrenous omentum, causing acute abdominal symptoms, associated with shock, in a case reported by SPILLISSY, was operated on for supposed appendicitis.

Enlarged retrocecal and retrocolic glands have frequently given rise to a diagnosis of appendicitis. The majority of these cases

have been due to tubercular disease, but in a case reported by CONDAMM and VORON (cited by Spillissy) the adenitis was of syphilitic origin. A unique case of typhoidal adenitis mistaken for appendicitis has been described by RICHARDSON (*N. Y. State Med. Jour.*, July, 1901). RUSSELL (*Mod. Med. Sci.*, Feb., 1902) reports a case of fatal vaccination infection which presented symptoms resembling acute appendicitis. The vaccination, on the right thigh, had apparently been followed by suppurative adenitis of the inguinal and iliac glands and diffuse fibro-purulent peritonitis.

Diseases of the Kidneys and Ureters.—Floating kidney has frequently been mistaken for appendicitis, and several instances have been recorded in which the true condition was only discovered at operation. In a case described by MILLER (*Med. Rec.*, 1900, p. 353) the presence of a mass in the right iliac fossa with a history of more or less constant pain extending over about a year, was very suggestive of appendical trouble. The occurrence of acute attacks ("Dietl's crises") characterized by severe abdominal pain, chills, nausea, vomiting, fever, and collapse in a patient who is not known to be suffering from floating kidney, may be very misleading. The kidney during these attacks is swollen, tender, and often less freely movable, while on account of the localized tenderness and the rigidity of the abdominal walls palpation may be difficult and unsatisfactory. The chief diagnostic features are the characteristic shape of the organ together with its mobility, and in the ordinary cases the diagnosis is rarely doubtful. By making the patient relax thoroughly, especially when lying on the left side with the right thigh flexed, the kidney can be readily grasped and made to slip back into its normal position. Sometimes also a depression in the flank corresponding to the normal site of the kidney is plainly visible.

During the acute attacks the muscular rigidity is usually more diffuse and not so marked as in appendicitis, and the tenderness is often more severe posteriorly. The condition of the urine is sometimes an aid in the differential diagnosis. During acute renal attacks an excess of uric acid is common, but high-colored, scanty urine, and the occasional presence of pus and blood may accompany either affection. Acute anuria may also occur in either, but with the subsequent voiding of a large amount of urine the renal pain is entirely relieved, while appendical symptoms are not affected. A diagnostic point of great significance is the frequent occurrence of floating kidney in neurasthenic women. A history of attacks of pain not always referred to the same region, or a history of intermittent hydronephrosis, indicate a movable kidney. Finally, in all doubful cases, examination under ether narcosis will at once reveal the presence of a floating kidney. It is, however, of great importance to remember that the two affections frequently coexist, some observers believing that a large percentage of cases of chronic appendicitis is a constant accompaniment of right floating kidney. It is therefore essential in the presence of a floating kidney to definitely exclude the presence of appendicitis.

Renal calculus may produce symptoms closely simulating acute or chronic

appendicitis. Renal colic due to the entrance of a calculus into the ureter may set in abruptly without apparent cause, or may follow a strain in lifting. It is described by OSLER as characterized by agonizing pain, which starts in the flank of the affected side, passes down the ureter, and is felt in the testicle and the inner side of the thigh. The pain may also radiate through the abdomen and chest and be very intense in the back. In severe attacks there are nausea and vomiting and the patient is collapsed. A chill may precede the outbreak, and the temperature may rise as high as 103° F. Perspiration breaks out upon the face and the pulse is feeble and quick. Micturition is frequent, and occasionally painful, while the urine, as a rule, is bloody. The attack may not last longer than an hour; in other instances it continues for a day or more, with periods of temporary relief. There is usually tenderness on the affected side. If the calculus remains in the kidney there is usually a dull pain, often referred to the back. In some cases the pain comes on in acute paroxysms. Hematuria is common, but by no means constant, and the urine may be clear for days. There may also be intermittent attacks of pyuria. The distinctive features in the differential diagnosis are the situation and direction of the pain, the retracted and painful testicle, and the changes in the urine. When the calculus is in the lower portion of the ureter, just above the pelvic brim, and the pain and tenderness centre at this point, the diagnosis is sometimes exceedingly difficult. The X-ray examination is a most valuable diagnostic aid, but may lead to erroneous conclusions, particularly when a ureteral calculus is found in the iliac fossa.

The following interesting examples of the confusion that may exist between these conditions have been sent me by Prof. D. GIORDANO of Venice, Italy:

I. A boy, age thirteen, had a history of three previous attacks of sudden acute pain in the right ilio-inguinal region, in which a diagnosis was made of muscular rheumatism. A fourth attack began with pain all over the right side and radiating to the crural region, accompanied with severe strangury and difficult, frequent, and painful micturition. A diagnosis of renal calculus was made. Dr. Giordano was then called in to examine the bladder. The vesical examination was negative and the urine normal, save for the abundance of urates. There was, however, tenderness on pressure over McBurney's point, and Dr. Giordano made a diagnosis of appendicitis with reflex strangury. At the end of a month there was almost no amelioration and micturition continued frequent and difficult. Laparotomy then performed showed the appendix, erect and trumpet-shaped, richly vascular, but free from adhesions. Its removal was followed by complete relief of the urinary difficulty.

II. The patient was a woman, twenty-seven years old, whose trouble had begun six years previously, on the eighth day after labor, with pain in the right lumbar and hypogastric regions. The pain, which was constant, was marked by acute attacks of strangury. After three years of suffering, double oöphorectomy was performed, without benefit. The pain continued and was associated with alternate constipation and diarrhea. A month before consulting Dr. Giordano the pain became more violent, and was localized in the iliac

fossa, although radiating throughout the entire abdomen. There was mucus in the stools, frequent rigidity, and occasional vomiting. The abdomen was distended, tender on pressure in the right iliac region, and acutely tender over McBurney's point. There was a small painful tumor at the base of the right broad ligament. The urine contained a large amount of indican, no albumen, and no biliary pigments. Operation revealed a long, hyperemic, claviform appendix, and the tumor noted at the base of the broad ligament, which had been taken for an inflamed lymphatic gland, proved to be a ureteral calculus 2 cm. long and 1.5 cm. in its greatest diameter.

Another case, sent me by A. J. OCHSNER of Chicago (*personal communication*), is as follows:

A man, fifty-five years old, gave a history of several acute attacks of appendicitis extending over a period of two and one-half years. In one attack there was severe pain in the region of the bladder, accompanied with frequent, painful micturition, and at this time a few clots of blood were passed in the urine. Four weeks before admission to the hospital the patient suffered from a severe attack of pain in the abdomen which became more marked in the right iliac region on the second day, but changed to the left iliac region on the third, and then extended to the left kidney. There was severe nausea, constipation, and slight fever, the whole attack lasting one week. On admission, three weeks later, the patient had a good appetite; the temperature and pulse were normal. There was slight tenderness at McBurney's point, but apart from this the abdominal examination was negative. Urinalysis was also negative. A skiagram showed two very definite shadows, considered to be calculi in the left ureter. On account of the obscure history, a median incision was made. The small intestines were found acutely congested, the appendix was adherent to the inner side of the cecum, and surrounded by omentum, which inclosed a large perforation in the vermiform appendix. There were enlarged glands in the mesappendix, and in the mesentery of the ileum to the left of the median line were two calcareous bodies.

BREWER (*Ann. Surg.*, 1901, vol. 33, p. 590) refers to three cases in which a diagnosis was made of appendicitis, but which proved to be u r e t e r a l a n d r e n a l c a l c u l i .

P y o n e p h r o s i s may closely resemble acute or chronic relapsing appendicitis. C. P. NOBLE (*personal communication*) had a case in which the patient was operated on for supposed appendicitis, but the appendix was found to be normal, and a pyelitis the source of the trouble. The patient got well of the pyelitis, while in bed recovering from the operation. The most distinctive features are the changes in the urine accompanying the acute attacks of pain, and the rigors, high fever, and sweats indicating a pyemic condition. The position of the tenderness and the distinctly outlined tumor in the kidney region usually lead to a correct diagnosis. The presence of cystitis is a confirmatory sign, of value in some cases. The fact that the renal or ureteral suppuration may be secondary to appendical disease, as in the cases described on page 204, and in

Lenzmann's and in Treves' cases, should be borne in mind. In chronic cases of persistent pain in the right side where a definite diagnosis cannot be made, I have found the following procedure of value in excluding renal disease: With the patient in the knee-chest posture a cystoscope is introduced, and through it a suitable catheter is passed into the ureter and up to the kidney. The pelvis of the kidney is then distended with sterilized water, and as soon as its normal capacity (shown by the measured resistance) is exceeded there is more or less severe pain. If this pain is similar to the pain from which the patient has suffered, there is fairly conclusive evidence that the kidney is at fault, and vice versa.

Perinephritic Abscess.—As suppurative peri-appendicitis frequently involves the perirenal tissue and is one of the common causes of perinephritic abscess, the differential diagnosis depends chiefly upon the history of the events leading up to the attack. If the onset is marked by the usual symptoms of appendicitis, the diagnosis is clear; while with a history of injury to the lumbar region or of a preëxisting kidney affection, followed by the sudden or the insidious development of the abscess, there is usually no difficulty in determining the origin of the disease. Spillissy refers to a case in which a gonorrheal ureteritis, secondary to a prostatitis, simulated acute appendicitis.

Renal tumors are rarely mistaken for appendicitis, but when the appendix ascends toward the lower pole of the kidney, an exudate may form in this region and present all the characteristics of a renal tumor. The chief features upon which the diagnosis rests are: The gradual, insidious development of the tumor, its progressive growth, the slow onset and increase of pain, its steady character, and the fact of its being located chiefly in the loin. The urinary changes are of great importance, especially the occurrence of hematuria, which is a fairly constant accompaniment of renal tumors, but is comparatively rare in appendical disease, and even if present is very seldom persistent. An example of a renal tumor mistaken for appendicitis is given by W. H. Harsha (*Ann. Surg.*, March, 1902), in which a man, forty years of age, had for some time presented the usual evidences of a large appendical abscess, which finally ruptured, producing a consequent general peritonitis. On making an incision over the site of the appendix, a solid mass was encountered, which proved to be a large tumor of the kidney containing an abscess which had ruptured into the peritoneal cavity. Microscopic examination showed that the tumor was a fibro-sarcoma.

Diseases of the Gall-bladder.—Every surgeon of wide experience has had cases in which it was exceedingly difficult, and often impossible without an exploratory section, to differentiate between appendicitis and acute or chronic diseases of the gall-bladder and its ducts. Acute cholecystitis sets in with severe paroxysmal pain, situated most commonly in the right side of the abdomen, or in the region of the liver, but frequently in the epigastrium and sometimes in the ileocecal region; "nausea, vomiting, rise of temperature and pulse, abdominal distention, rigidity, general tenderness becoming localized,

quickly follow." Intestinal obstruction is often a prominent symptom. The symptoms may not be definitely localized in inflammation of the gall-bladder; while, on the other hand, if the appendix is in a high retro-colic position, the maximum intensity of the pain and tenderness may be referred to the hypochondriac region. With a history of previous attacks of cholecystitis, or if the attack occurs during convalescence from typhoid fever, cholecystitis may be suspected.

Empyema of the gall-bladder, in addition to the symptoms of cholecystitis, presents a definite tumor in the right side, which may increase the diagnostic difficulties. OSLER records the case of a woman, admitted to the hospital with a history of very sudden onset of severe pain, three days previously, in the right side of the abdomen, and with an ill-defined tumor mass low down in the right flank. She was transferred at once to the surgical side for operation for supposed appendicitis, when the condition proved to be an acutely distended and inflamed gall-bladder, almost on the point of perforating. The tumor in appendical inflammation can usually be distinguished by the presence of a tympanitic zone between the lower border of the liver and the mass, while the distended gall-bladder disappears under the liver and the dulness over the mass merges into the liver dulness. In gall-bladder inflammation there is almost invariably a tender spot a little above and to the right of the umbilicus.

Hepatic colic, due to the entrance of gall-stones into the cystic or common duct, may present many points of resemblance to acute appendicitis. The attack sets in suddenly with agonizing pain, often associated with rigor, fever, and abdominal rigidity. The pain, as a rule, is located in the right hypochondrium and the epigastrium radiating toward the scapula, while in appendicitis the pain usually extends toward the umbilicus and downward. Tenderness under the costal margin is characteristic of inflammation of the gall-bladder and its ducts. In hepatic colic an initial rigor is more frequent, the pain is more intense, and the nausea and vomiting more continuous from the first. SONNENBURG enumerates as the most distinctive features of gall-bladder inflammation and biliary calculus: the high position of the exudate; the slight constitutional disturbance; the direction of the dulness on percussion, especially its passing into the liver dulness. Icterus may occur or may be absent in either case.

Rupture of the gall-bladder occurring suddenly without previous evidence of any disease of the gall-bladder has been mistaken for acute perforative appendicitis. Several examples of this mistake are recorded. G. M. POND (*Med. Rec.*, April, 1898, p. 585) relates the case of a man, forty-five years of age, who, while lifting a heavy weight, was seized with severe epigastric pain, and collapse. A diagnosis of appendicitis was made. The next day he had but a slight rise of temperature; his pulse was 120; his face anxious; the pain was localized over McBurney's point and the tenderness well marked. The right rectus muscle was rigid. When the abdomen was opened a quart or

more of bile gushed out, and the attack was found to be due to rupture of the enlarged, distended gall-bladder. E. G. Field of Norfolk, Va. (*personal communication*), saw a case of rupture of the common duct which closely simulated acute perforative appendicitis. A physician, aged fifty-two years, was attacked with sudden severe pain in the right side of the abdomen, extending from the region of the liver to the groin. There was great tenderness over this region and the right rectus muscle was tense. There was considerable meteorism, which gradually increased until the respirations were greatly interfered with. The temperature was subnormal, the pulse small and weak. The patient died about thirty-six hours after the onset of the attack, in great agony. Autopsy showed rupture of the common duct with beginning general peritonitis.

In considering the question of the differential diagnosis between appendicitis and diseases of the liver and gall-bladder the surgeon has not simply to determine whether he is dealing with a case of appendicitis or of hepatic or gall-bladder disease; he has also to consider that important group of cases in which affections of the organs coexist, particularly the cases in which the disease of the liver and gall-bladder is secondary to the appendical inflammation. In the preceding sections the frequency of these complications has been emphasized, and attention has been called to the fact that pylephlebitis and liver abscesses may be the result of an unsuspected subacute appendicitis. The diagnosis of the secondary condition in these cases is easy, but the primary affection is often completely masked. I have met with two or three instances in which the persistent pain in the right hypochondrium, associated with jaundice, led to a diagnosis of cholelithiasis or cholangitis, and at operation a chronic appendicitis was found, with adhesions involving the gall-bladder and compressing the ducts. Not infrequently gall-stones and cholecystitis have existed independently of the appendical disease, as in the cases cited in Chap. XVII. When the association of the two ailments is not recognized, and only one is cured at the first operation, a second operation has sometimes been necessary for the complete relief of the symptoms.

Pancreatic Disease.—In acute pancreatitis the sudden intense epigastric pain, abdominal distention, constipation, and vomiting may, at the outset, suggest appendicitis. The most important differences between the two conditions are: the more agonizing and persistent pain in pancreatitis, the tenderness on pressure over the left costal margin, and the profound prostration, which is often associated with marked cyanosis. The age of the patient, a history of alcoholism, and more particularly a history of gall-stones are important in the diagnosis. The temperature is usually normal, but the pulse accelerated. The presence of fatty stools is, of course, conclusive evidence of pancreatic disease. Suppurative pancreatitis is accompanied by fever and may closely resemble peritonitis due to a ruptured appendix. Brewer (*loc. cit.*) reports the case of a man fifty-three years old, who had presented abdominal symptoms for a year, and gave a history of peritonitis occurring seventeen years previously. He was

suddenly seized with abdominal pain accompanied with vomiting, fever, and sweats. The abdomen was distended and generally tender. At operation the only evidence of disease was the presence of small white spots covering the omentum. At autopsy the pancreas proved to contain numerous small abscesses.

Gynecological Affections.—Diseases of the pelvic organs in women form the most important class of cases liable to be mistaken for appendicitis, and vice versa. The differential diagnosis of these conditions will be fully considered in Chap. XXIX.

Intramuscular Abdominal Abscesses.—These have been mistaken for appendicitis with localized peritonitis. They are distinguished chiefly by the absence of intestinal symptoms, the position of the swelling, and sometimes its movement with the abdominal walls. Suppurative appendicitis is not uncommonly accompanied with edema and infiltration of the overlying abdominal muscles, but in such cases there are the distinctive signs of a deep-seated affection and the history of appendical inflammation. The primary affection may subside, leaving only the superficial abscess, as in a case admitted to the gynecological ward of the Johns Hopkins Hospital, where a brawny, diffuse swelling in the abdominal wall over the right iliac fossa was found to be an intramuscular abscess. This was freely opened and drained, when complete recovery followed, but later on, it was necessary to remove the adherent appendix on account of persistent pain.

Acute Psoitis.—This condition may set in with sudden severe pain and tenderness in the right iliac region, suggesting an acute appendicitis. The pain, however, extends down the thigh and to the genital organs. The thigh is flexed and rotated inward. The absence of intestinal or peritoneal symptoms, and the usual failure of acute initial symptoms, are the distinguishing points in the diagnosis; the chief difficulty in it being due to the frequent involvement of the psoas muscle in appendicitis, but in such cases other confirmatory symptoms are usually found.

Affections of the Vertebræ and of the Hip-joint.—Appendicitis developing insidiously and accompanied by gradual flexure of the thigh, or with pain in the lumbar region and an ill-defined mass, may closely simulate a lumbar abscess or a coxitis. I have not met with a case of genuine vertebral or hip-joint disease in which the question of differential diagnosis from appendicitis caused great perplexity after a thorough examination had been made. Cases of erroneous diagnosis in hip-joint disease in children have, however, been reported. The history of the patient, the gradual onset of the attack, the absence of intestinal symptoms, the location, direction, and character of the swelling, and usually the evident deformity, are indications which should render the diagnosis sufficiently clear. The subject is fully considered in Chap. XX.

Acute osteo-myelitis may, however, set in so brusquely and

with such marked abdominal symptoms that at first considerable confusion may exist as to the diagnosis. As an example the following case may be given:

A student, aged seventeen years, was admitted to the surgical department of the Johns Hopkins Hospital with a history of a week's illness, which began while travelling on the train and when he was in good health, with sudden pain in the hypogastric region so severe that he was doubled up. His bowels were constipated and micturition painful. He was nauseated on the fourth day, but there was no vomiting. The pain increased and shifted to the flanks, and when the patient was admitted was localized in the right side near the kidney region. He lay with both knees drawn up and the right thigh abducted, not being able to straighten it out on account of the pain. There was slight fulness in the hypogastric region and tenderness low down over the right Poupart's ligament. Pressure here elicited acute pain and apparently voluntary muscle spasm. The tenderness, however, seemed superficial, as if in the soft parts of the abdominal wall. There was no tenderness in the hip-joint. There was continuous fever. The next day the right thigh was distinctly swollen, indurated, and very tender, and there was also swelling over the symphysis, but the abdomen was otherwise negative. Incision into the swelling showed an abscess in the thigh containing a pint of creamy pus, extending up to Poupart's ligament, but not into the pelvis.

J. B. Deaver relates a case of gangrenous appendicitis in which, on account of the history of injury and the strongly flexed, abducted right thigh, which could not be moved without severe pain, a dislocation of the hip was suggested, although the pain did not begin until the day after the injury was received. The presence of marked abdominal distention, tenderness, and rigidity disclosed the true nature of the attack.

Hysteria and Hypochondriasis.—These conditions must be eliminated from the diagnosis in some cases of suspected appendicitis, but it is necessary to be always on guard against assuming a nervous manifestation in the presence of a true inflammation of the appendix. The distinctive features in the differential diagnosis of acute attacks are: the absence of fever and leucocytosis, and the disappearance of local tenderness and rigidity when the patient's attention is diverted. The common occurrence of digestive disturbances in neurotic individuals makes the recognition of chronic appendicitis more difficult. The palpation of the thickened appendix is sometimes possible, and this is, of course, conclusive. Le Roy Brown (*Amer. Jour. Obst.*, July, 1904) agrees with Manton of St. Louis in believing that visceral delusions in the insane are often founded upon the presence of some pathological condition. He relates a case of a woman with the delusion of evil spirits in the abdomen, from whom a large, inflamed appendix was removed. Neuralgia of the nerves of the right side of the abdomen may simulate appendicitis, but a careful examination will not fail to reveal the true nature of the ailment.

Intra-thoracic Affections.—The importance of recognizing the fact that pneumonia and pleurisy, particularly in children, may be ushered in with acute abdominal symptoms, has recently been emphasized by numerous cases, reported by BARNARD, RICHARDSON, HERRICK and others, in which the diagnosis, at first, was doubtful, and in a considerable number operation was performed for supposed appendicitis. Out of 24 cases of pneumonia with early symptoms referred to the abdomen, collected by GARREAU (*Thèse de Paris*, 1903), 5 were submitted to abdominal section for acute appendicitis. Pleurisy or basal pneumonia with involvement of the diaphragmatic pleura seems especially liable to excite acute abdominal symptoms, but a pneumonic focus limited to the right upper lobe may possibly provoke similar phenomena, and in a case where HERRICK was called upon to decide as to the advisability of operation for appendicitis, the affection was located in the left lower lobe. In this instance, however, the symptoms simulated a general peritonitis supposed to be of appendical origin, although the right iliac region was not especially involved. The attack set in brusquely with severe pain in the abdomen, fever, nausea, and vomiting. In such cases the pain may, at first, be general, and is sometimes associated with marked distention, tenderness, and rigidity. When there is a history of previous trouble in the right iliac region, as in a case described by MORRIS (*N. Y. Med. Jour.*, 1899), the clinical picture is still more confusing. The most important distinguishing features are: the sudden high temperature, which often ranges from 103° to 106° F., and is very unusual in appendicitis, together with the rapid respirations, which are often increased out of proportion to the abdominal symptoms. The tenderness and rigidity are usually less pronounced than in true abdominal inflammation. HERRICK has observed that the cutaneous hyperesthesia is often excessive, while steady, quiet, deep palpation will not increase the pain; and it has been noticed by BARNARD that the abdomen may be seen to yield slightly at the beginning of inspiration. The high leucocyte count may be a valuable confirmatory sign in doubtful cases. DA COSTA states that the leucocytosis appears early, at or soon after the initial chill, and that the average "first count" is 22,693, including cases which fail to develop an increase. In appendicitis, on the other hand, the increase is rarely so rapid. However, the main safeguard in the diagnosis, as expressed by HERRICK, is to bear in mind the possibility of a thoracic origin for the abdominal symptoms. It will then generally be found that there are some thoracic symptoms, and a careful examination of the chest will reveal some loss of motion, and, on auscultation, one or other of the characteristic signs, albeit extremely slight, will usually be detected.

Another source of error in the diagnosis under these circumstances is the occasional coexistence of appendical and thoracic disease, in which case, in the presence of an undoubted pneumonia, it may be difficult to determine whether the abdominal symptoms are merely reflex or are due to a complicating appendicitis. W. FINDER of Troy, N. Y. (*personal communication*), saw a patient

suffering from an evident pneumonia and at the same time presenting typical symptoms of appendicitis. The gangrenous appendix was removed by HOUSTON, and the patient recovered from both affections. In cases, however, where there are unmistakable symptoms of acute thoracic disease and obscure symptoms of appendicitis, the latter are almost invariably reflex in origin. There is always danger, nevertheless, of too great conservatism in doubtful cases, and, as RICHARDSON remarks: "a heavy responsibility rests upon those who advise delay when the symptoms point to a general peritonitis, even if those symptoms are not quite what they should be in typical cases. The real cases of appendicitis and of general peritonitis as compared to those of an atypical typhoid, a latent pneumonia, or some other unusual simulating lesion, are a hundred to one."

The Leucocyte Count as an Aid to Clinical Diagnosis.—In certain obscure abdominal conditions the leucocyte count may be of great assistance in diagnosis. A high leucocyte count, 20,000 or more, in a case exhibiting very mild local signs and symptoms is not infrequent, and its presence enables the surgeon to estimate the gravity of the patient's condition and authorizes him to urge the necessity for immediate operation, when without its aid both surgeon and patient might indulge in a false security. A low leucocyte count, on the other hand, must not mislead the surgeon. Our present knowledge does not furnish any definite rules for the use of the leucocyte count in diagnosis, and the following general rules should be applied only after taking into account the history, symptoms, physical signs, and all other factors usually considered in each individual case.

In acute appendicitis without complications it may be generally stated that the leucocyte count increases with the severity of the disease, an increasing leucocytosis indicating an increasing inflammation; the contrary, however, does not always hold true. A high leucocyte count in the first twenty-four hours excites great apprehension, for it is suggestive of a fulminating inflammation, with, perhaps, a gangrenous appendix. A leucocyte count above 15,000, occurring at the end of an attack, when the local symptoms have almost disappeared, generally indicates localized pus. When local abscess formation occurs in the early stages, the leucocytes, as a rule, are high, *i. e.*, above 15,000. Improvement in the clinical symptoms after the fourth day is usually accompanied by a falling leucocytosis.

If operation reveals a general peritonitis, a moderate leucocyte count gives a better prognosis than a low one, since the latter generally indicates a low grade of resistance in the patient. A very high leucocytosis, above 25,000, is a grave indication.

With a chronic abscess the count is usually low, but it often fluctuates with exacerbations of the local symptoms.

CHAPTER XIX.

APPENDICITIS IN TYPHOID FEVER.

HISTORY. ETIOLOGY. DIAGNOSIS. TREATMENT.

In typhoid fever the great and immediate source of anxiety to the watchful physician is the possibility of profound toxemia or septicemia, of hemorrhage, or of perforation. Aside from these grave complications, however, a host of lesser ills are liable to arise intercurrently. For example, on the right side of the body there lies a chain of organs, extending from the liver to the pelvis, whose links are the gall-bladder, the renal pelvis, the vermiform appendix, and the urinary bladder, any one of which is liable to become the source of an infection during the typhoid attack, long outlasting the original disease. Only one of these organs, however, the appendix, is apt to give rise to an acute disturbance in the midst of the fever. Infections of other organs, resulting in cholecystitis, pyelitis, and cystitis of the urinary bladder, manifest themselves, as a rule, at a later date, and become most prominent as sequelæ, more or less remote. Inflammation of the appendix is an intercurrent affection which is liable to assume its greatest importance at the very beginning of the fever, or else when it is at its height.

If the typhoid patient is seized with an appendicitis, it is manifestly of the utmost importance to recognize the fact promptly, and in suitable cases to interfere for its relief, in order that the vital powers, already taxed to their utmost, may not be reduced to their lowest ebb by two coincident exhaustive conditions. The decision whether or not to institute operative proceedings for an appendicitis developing in the course of typhoid fever becomes, therefore, one of the gravest responsibility. On the one hand, the surgeon has to bear in mind that an appendicitis under these conditions is woefully like a powder magazine attached to a lighted fuse, which may go out quietly, but may, on the contrary, explode the mine at any moment, unless the fire is extinguished by prompt interference at all hazards. Yet, on the other hand, if the surgeon is over-zealous in operating, and interferes merely because some of the symptoms of appendicitis are present, the event may prove that his interference was unnecessary, and he will then have to endure the chagrin of finding that he has added a useless and serious operation to the gravity of an already distressing situation. Moreover, the man who makes such a mistake cannot hope to escape the reproaches of the family, and should the patient die at any time during the course

of the disease, the natural tendency of the human mind to find relief from sorrow in anger will almost certainly bring upon him the blame for the fatal result. The responsibility of a surgeon summoned to decide for or against operation under such circumstances has been graphically described by M. H. Richardson (*Bost. Med. and. Surg. Jour.*, Jan. 9, 1903). "Operations during the course of typhoid, even those operations which in themselves are comparatively slight, have a high mortality. The surgeon must be always on his guard lest he fail to recognize typhoid fever, not only in its ordinary forms, but in its unusual and atypical aspects, and subject his patient to an operation, which, even if apparently made necessary by the clinical evidence, is entirely unjustified by the pathological findings."

History.—The condition of the vermiform appendix in typhoid fever seems first to have received attention at the hands of a Frenchman, Jadelot, in 1808 (see also Chap. I, p. 3). In describing the case of a boy of thirteen, who died of a "*fièvre adynamique*," accompanied toward the close by symptoms of ataxia, the writer says that the autopsy showed a lesion at the end of the ileum exactly like those which M. Petit, at the *Hôtel Dieu*, attributed to the fever called "*entero-mésentérique*," while the different parts of the intestine were found filled with lumbricoid worms, four of which occupied the enlarged cavity of the appendix, one of them being doubled on itself.

The next reference to the appendix in typhoid fever, if I am not mistaken, is the account of a distinct perforation described in a paper on peritonitis arising from ulceration and perforation of the appendix, by an Italian, Carlo De Vecchi, in 1848 (see also Chap. II, p. 18). The case, which is given in a footnote, was related to the writer by another physician, Robecchi, who, when making a postmortem on a sailor, dying unexpectedly on the seventh day of typhoid fever, found a perforation of the appendix near the insertion of the organ into the cecum ("*che tagliando, . . . il cadavere di un marinajo, morto quasi improvvisamente in settima giornata di febbre tifoidea, trovó un' ulcera perforata nell' appendice in vicinanza della di lei inserzione nel ceco*").

Buhl (*Zeitschr. f. rat. Med.*, 1854, N. F., Bd. 4, p. 342) gives an admirable description of three fatal cases of typhoid fever, in each of which there was an ulcerative perforation of the appendix. At the time these occurred, every fourth patient in the hospital had typhoid fever, and in the course of two and a half months, three out of five autopsies made on typhoid victims showed perforation of the appendix. One was in a woman of twenty, dying on the twenty-fourth day of the disease, who, apart from the usual lesions of typhoid, had a general purulent peritonitis, with an appendix completely amputated by a perforating ulcer just above its blind end. The second case was that of a man, also twenty years old, who began to grow worse about the fourteenth day of his illness, and died on the twentieth. The autopsy showed the usual typhoid changes, with general peritonitis, and an ulcerative perforation of the appendix near its tip. The chief difference between these two cases lay in the fact that in the

first, abscesses were found in the upper lobes of the left lung, which was otherwise anemic. One death resulted simply from the peritonitis occasioned by perforation of the appendix, while in the other case there was pyemia, apparently originating earlier than the peritonitis by which death was hastened. BUHL remarks that a pyemic process originating in the appendix may follow one of two channels: either lodging in the lungs, as in the case just described, or entering the portal system and travelling to the liver. He then describes a portal pyemia originating in the vermiform appendix, after protective adhesions had insured the patient against the dangers of a fatal peritonitis. His third case is that of a young man, nineteen years old, who died twenty-six days after the beginning of his illness. His symptoms were icterus, a liver enlarged to twice its natural size, stools colored with bile (without, however, any bile in the urine), recurring chills, and pain in the region of the liver. The autopsy showed an empyema of the appendix, which contained a fecal concretion, and had a perforated extremity associated with an abscess the size of a hazelnut, walled off from the peritoneum. A sinus led between the layers of the mesentery to the portal vein, while the adjacent veins were filled with infectious purulent debris (*jauche*). The portal branches of the liver were filled with pus and there were large parenchymatous abscesses. BUHL calls particular attention to this case on account of the rarity of suppurative pylephlebitis. Although he includes it among the three typhoid cases, he says nothing of the condition of Peyer's patches.

Three years later a case of perforation of the appendix in typhoid fever was reported in the United States by SANDS, who presented the specimen to the New York Pathological Society (*Amer. Med. Month.*, 1857, vol. 7, p. 231). The patient, a man twenty-two years old, was overcome by exhaustion and fainted while occupied in his profession as an artist. He recovered in a short time, however, sufficiently to resume his work for some hours, and ate his dinner, soon after which he was seized with severe pain in the right iliac region, with great prostration and vomiting. There was tenderness in the right iliac fossa, greatly increased by pressure, while other parts of the abdomen were free from pain. He also had headache, constipation, and great nervous prostration. The next day he was worse, and a diagnosis of a sloughing appendix was made. The pain in the abdomen became general, although it continued to be worst on the right side. Death occurred on the fourth day. At the autopsy the appendix was found fastened to the back of the cecum by adhesions. It was distended by a fecal concretion, in which were found a number of strawberry seeds and solid particles. The mucosa was the seat of sloughing ulceration, with a perforation near the extremity, permitting the escape of fecal matter, and causing the acute peritonitis of which the patient died. The solitary and agminated glands of the small intestine were diseased, "having the appearance which they often present in typhoid fever."

Frequency.—ROLLESTON (*Lancet*, May 29, 1898) says that out of 60 cases of

enteric fever examined at St. George's Hospital, the appendix was found to be altered in 14. In 5 of this number it was simply swollen, in 7 ulcerated, and in 2 perforated. Perforation had occurred in 11 per cent. out of the entire 60 (including those in the appendix). Other statistics are as follows:

	Cases of Typhoid Fever with Perforation.	Perforation Situated in the Appendix.
Heschl (reported by Wagner, *Schmidt's Jahrbuch.*, 1853, vol. 80, p. 42)	56	8
Morin (*Thèse de Paris*, 1867)	64	12
Church (*Records of St. Bartholomew's Hospital*, 1881, vol 17, p. 97)	21	3
Fitz (*Bost. Med. and Surg. Jour.*, 1891, vol. 25, p. 346)	167	5
Cushing (*Records Johns Hopkins Hospital*, 1899–1900)	20	2

ETIOLOGY.

Appendicitis may appear during typhoid fever under the following conditions:

1. The appendicitis may be purely accidental, that is to say, appendicitis and typhoid fever, both of which are common maladies, may by accident be found concurrently in the same individual; or a latent or chronic inflammation of the appendix may be roused into activity by typhoid fever.

2. An appendicitis, of a mild or of a severe type, may arise from a typhoid affection of the lymph glands or from an ulcer situated in the appendix, and may even go on to perforation.

3. Appendicitis may follow typhoid fever, appearing within such a brief time after the subsidence of the fever as to strongly suggest a causal relationship.

Appendicitis Occurring Coincidentally with Typhoid Fever, or Roused into Activity by it.—I fail to find any satisfactory instance of simple acute appendicitis occurring during the course of typhoid fever. A latent or chronic appendicitis may be roused into activity during the course of typhoid fever in several different ways, in the first of which the query which suggests suggests itself is: If the patient has a small collection of pus in the appendix will the accession of typhoid fever suffice to bring on an acute attack of appendicitis? I have found but one (doubtful) case in which this condition is recorded to have occurred, which was published by F. Bossard (*Ueber die Verschwärung und Durchbohrung des Wurmfortsatzes*, I. D. Zurich, 1869, Case 25).

If the appendix is acutely flexed, or is crossed by bands of adhesions, will the swelling incident to a typhoid affection of the glandular tissue serve to produce an attack of appendicitis? I know of no data with which to answer this question. It is, however, an important one, for the discom-

fort occasioned by any deviation from the normal in the appendix is apt to arouse the suspicion of disease in the patient's mind, and should an attack of typhoid fever occur, it may be mistaken in its initial stages for appendicitis, because both patient and physician are preoccupied with that idea. In two instances within my own knowledge, physicians who had themselves suffered for more than a year with repeated attacks of pain in the right iliac fossa, were seized with typhoid fever, accompanied in each case with acute distress in the right inguinal region, and were convinced that a severe complication requiring operation had arisen. In one case, operation disclosed the appendix surrounded by adhesions and partially obliterated, but not acutely inflamed; in the other, in which the appendix was flexed, there was nothing more than the changes so often observed in it in connection with typhoid fever; in neither case would the operation have been performed could the surgeon have known beforehand the condition of the organ. (See Cases 1 and 2, pp. 445, 446.)

If there is a foreign body within the appendix, will its action as an irritant upon the swollen mucosa serve to bring about an acute inflammation? I have found but four cases in which a foreign body is noted to have been present in typhoid appendicitis, and one of these really supervened at the end of the fourth week, when the temperature had been almost normal for two days.

In this connection I should mention that L. J. Hammond (*Jour. Amer. Med. Assoc.*, April 16, 1904) considers that an antecedent appendicitis is liable to prove a serious complication should the patient contract typhoid fever, and in proof of this statement he cites a case in which there was an extensive rupture of the ileum, at a point 1 to 12 cm. above the valve, the postmortem demonstrating that the tension caused by the adhesion of the appendix to the lateral peritoneum favored solution in the continuity of the bowel at the point of ulceration, and was responsible for the tremendous rent that took place.

True Typhoid Appendicitis.—The character of the lesions of true typhoid appendicitis has already been shown in the section on pathology (see Chap. XIII), where we have seen that the appendix may participate in all the changes to which the agminated glands are liable. The first suggestion of this possibility appears to have been in the discussion following the report of Sands' case (*loc. cit.*). After reading his paper, he inquired of the Society whether any other than an accidental relationship might be supposed to exist between the disease in the appendix and that in the intestines; and if so, which should be regarded as antecedent. The greater intensity of disease in the appendix favored the idea that it had proceeded from below upward; it might be, however, that in the present case the concretion would have remained harmless had not an additional source of irritation been furnished by the extension of disease which had begun in the small intestine. Harris said that his experience tended to confirm the latter view, he having in several instances noticed ulceration of

the follicles of the appendix, coincident with ulceration of Peyer's plates in typhoid fever.

The next expression of opinion to this effect, which I find, is that of NORMAN MOORE (*Trans. Path. Soc. Lond.*, 1883, vol. 34), who remarks: "It has sometimes been thought that ulcers in this situation were previous to, or independent of the fever, but the fact that in four cases cited there was extensive general ulceration, makes it probable that the ulceration of the vermiform appendix occasionally present in typhoid fever, has the same relation to the fever as ulceration of other parts of the large intestine."

O. HOPFENHAUSEN (*Rev. de la Suisse Rom.*, 1899, tom. 19, p., 105) has investigated the condition of the appendix in typhoid fever in thirty autopsies, and found that in every instance the appendix was affected to a greater or less extent, varying from a mere hyperemia of the mucosa to extensive ulceration.

I have myself investigated the subject by collecting from literature, from hospital records, and from personal communications, 30 cases reported in more or less detail, in which the condition of the appendix during typhoid fever was demonstrated by operation or by autopsy, in most of which there had been symptoms of appendicitis during the course of the typhoid. In 5 cases the microscope gave evidence of typhoid ulcers within the appendix; in 1 there was ulceration without perforation; in 10 perforation; in 1 appendicitis with abscess; in 4 a simple congestion with a perforation situated in the ileum; and in the remaining 7 there were adhesions, flexions, or obliterative changes. I would also call attention to H. CHRISTIAN's valuable statistics, taken from 119 autopsies in typhoid patients, in which 19 showed changes sufficient to command attention (see Chap. X, p. 25).

From all these sources we have convincing proof that true typhoid appendicitis does occur, further supported by the clinical evidence afforded by other cases which have recovered without operation. It is a matter of common observation that early in the course of typhoid fever patients often complain of marked pain in the right iliac fossa, and this is probably due, in most instances, to involvement of the appendix associated with swelling and tension, which there is every reason to believe accompanies the typhoid lesions in the intestine in all cases.

I subjoin brief abstracts of the 5 cases in which microscopic evidence of typhoid ulceration within the appendix was obtained.

1. J. B. Murphy, 1893 (*personal communication*). A woman, twenty-two years old, was ill for five days with headache and general malaise, but not confined to bed. She then began to have severe abdominal pain with great tenderness in the right iliac fossa, followed by vomiting. The temperature was 103.2° F. A diagnosis was made of appendicitis and operation immediately performed. The appendix was swollen to twice its natural size, but there was no point of threatened perforation. The ileum contained a number of Peyer's patches in process of typhoid

ulceration. Microscopic examination of the appendix showed a classical typhoid lesion. The patient went through a typical typhoid fever, and recovered.

2. *Ibid.*, 1893. A woman, age not given, was ill for two days with headache and pain in the back. At the end of that time, when she consulted a physician, her temperature was 103.5° F. It continued to rise steadily until the fourth day, when she was seized with severe abdominal pain, followed by nausea and vomiting. Twenty-four hours later there was extreme sensitiveness all over the lower abdomen, especially in the right iliac fossa, but no induration, although the area of the appendix could be outlined from the muscular resistance. A diagnosis was made of acute and infective appendicitis, and operation performed on the fifth day. The appendix was enlarged at the cecal attachment; the distal end contained muco-purulent matter; the proximal end an ulcer. The ileum showed numerous typhoid patches. Microscopic examination of the appendix showed the ulcer to be a typical typhoid one; the patient went through an ordinary attack of the disease and recovered.

3. *Ibid.*, 1894. A girl, fourteen years old, was indisposed for more than two weeks, but able to continue at work until the end of that time, when she had a severe attack of pain in the abdomen, followed by nausea and vomiting. Examination of the abdomen showed no unusual tympany, but the appendix could be outlined, and was found very sensitive. On operation, it proved non-adherent, but there was a grayish exudate on the mesenteric side of an enlarged and indurated nodule at the junction of the outer and middle third. Microscopic examination of the appendix showed that it contained a classical typhoid ulcer. The patient went through a typical typhoid fever and recovered.

4. J. H. H., Sept., 1900. Surg. No. 10940. A negro, twenty-one years old, was admitted with typhoid fever, about the seventh day of the disease. The Widal reaction was positive on the sixth day. On the ninth day there was some tenderness about the navel, and the next day at McBurney's point. On the twelfth day the pain and sensitiveness were much greater, and the leucocytes had increased from 7,700 at 8 A.M. to 8,500 at 10 P.M. On the thirteenth day, there was definite muscular spasm in the right iliac fossa, and the leucocytes had increased to 20,000; there was general rigidity on palpation, both recti being tense, and marked tenderness present over the whole area of protective spasm. On operation, the peritoneum was found inflamed, and there were two inflamed Peyer's patches in the ileum. The appendix, which lay behind the cecum, was distended, tense, and rigid, its surface vessels large and tortuous, presenting the appearance of acute inflammation. Microscopic examination showed a typical typhoid condition. The patient improved for a few hours, but died from typhoid septicemia two days after the operation.

5. B. McMonagle. *Califor. Acad. of Med.*, Feb. 25, 1901. A man, eighteen years old, began to suffer from epistaxis, headache, and malaise, and two days later he had a slight chill, with nausea and vomiting. His temperature was 101.6° F. On the thirteenth day, rose spots were observed, and on the fourteenth, the Widal reaction was positive. On the fifteenth day the patient had an attack of very severe pain in the abdomen, and the temperature, which had been about 101° F., rose to 105° F. Examination showed considerable general tenderness

in the abdomen, increased in the right iliac fossa; the muscles were tense to the point of spasm on slight pressure, and there was apparent increased dulness in the right flank. Rectal examination showed tenderness in the recto-vesical *cul-de-sac*, particularly on the right side. The spleen was enlarged, the liver dulness normal, and the leucocytes 17,000. Operation showed the appendix tensely distended in the middle and outer thirds, congested, and hemorrhagic, with an area of necrosis 6 mm. in diameter. The canal was patulous, and the mucosa of the proximal third swollen and necrotic. In the remaining portion were several deep ulcerations extending at one point to the peritoneum. Microscopic examination showed a typical typhoid ulcer at the proximal third.

Post-typhoid Appendicitis.—The fact that a true typhoid appendicitis exists naturally suggests the question: Can the debris of such infection linger in the appendix undischarged, awaiting a favorable opportunity to produce an attack of appendicitis some time after the patient has completely recovered from the typhoid? And, again, can the typhoid ulceration produce such a narrowing of the lumen of the appendix as will serve to obstruct its discharges, and so favor an attack of appendicitis at some future time?

Hopfenhausen (*loc. cit.*) has especially considered the possibility of such a causal relation between typhoid fever and appendicitis, and has collected statistics concerning it from thirteen different sources. Out of 748 cases, there were 36 in which there was a history of previous typhoid, the interval of time between the two diseases being as follows: In 5 cases, from twenty-four to forty years; in 24 cases, from ten to twenty years; in 2 cases, three years; in 1 case, two years; in 1 case, one year; and 3 cases, from two to six months. But, as she points out, although the condition of the appendix in every case resembled catarrhal appendicitis, it could not be a true catarrh, since the interval of time between the two diseases (in the majority from ten to forty years) forbids the assumption of any connection between them. The attention of clinicians, however, has not as yet been sufficiently directed to this important point, and it may yet be found that typhoid fever victims are more prone than others to appendicitis. I would suggest that a note as to infectious diseases, especially typhoid, should he carefully added to the history of every appendicitis, and further that all patients should be questioned as to any unusual pain in the right iliac fossa in the course of the typhoid. If any frequent causal relationship exist, our hospitals will probably supply the data from ex-typhoid cases discharged from the medical wards, and returning at a later date to the surgical service.

The following cases are all in which a post-typhoid appendicitis has come within my own cognizance:

J. H. H., May, 1899. Surg. No. 10940. A man, forty-eight years old, was admitted complaining of abdominal pain. In September, eight months before, he had had an attack of typhoid, with which he was in bed for three months and had two severe hemorrhages. He had also some pain in the right iliac fossa with a localized tumor slightly tender on pressure in that region. Constipation was marked during the attack and after convalescence. On entrance he was suffering from severe pain in the lower abdomen, especially on the right side, and the bowels had not moved for six days.

In the next case furnished by S. CROWELL, Dorchester, Mass., appendicitis developed at the end of the fourth week, at the period of almost complete defervescence.

A boy, seven years old, had a mild, uneventful attack of typhoid fever which completed its course favorably at the end of the fourth week. On the third day, when the morning temperature had become normal, while the evening temperature was only 99.5° F., he was attacked by abdominal pain and vomiting, with a rise of temperature to over 100° F. When seen, thirty-six hours later, the temperature was 104° F., there was pain and tenderness over the abdomen, increased over the appendix, rigidity of the muscles, and vomiting. There was no distention of the abdomen, but the patient looked ill. An immediate operation was performed, showing the appendix dark red and swollen; there was an escape of fluid from the peritoneum, with a distinct fecal odor, but there was no perforation. A small ovoid concretion was found in the appendix. The patient recovered.

I have met with two cases in which typhoid fever has followed operation for appendicitis, and I here give a brief account of each, as they seem to be extremely unusual.

C. F. NASSAU (*personal communication*, 1902). A woman of thirty-five was suffering from recurrent appendicitis for which operation was advised and refused. Seven months later she had an attack of acute appendicitis, and the appendix was removed, together with the right ovary (which was cystic) and the tube; the uterus was suspended. Two days afterward it was necessary to re-open the abdomen, on account of symptoms of obstruction, and an old fan-shaped adhesion was found, obstructing the hepatic flexure of the colon. The temperature fell to normal in six days, and then began to rise. This was ascribed to several stitch abscesses occasioned by the silkworm sutures being tied too tightly at the second operation. The patient then became suddenly delirious, with extreme abdominal distention. Typhoid fever was suspected, and also pelvic pus collection. Vaginal puncture was made, but there was no pus. On the twenty-second day after the second operation the Widal reaction was positive. The twenty-third day, there was severe hemorrhage from the bowels, and on the twenty-fourth day, death occurred from one of large size.

H. A. PULSFORD (*personal communication*, 1904). The patient, a physician, was taken suddenly ill with severe abdominal pain followed by serious symptoms necessitating immediate operation. The appendix proved to be gangrenous and perforated, there were no adhesions and a general peritonitis was beginning. It

was necessary to make an incision on the left side of the abdomen as well as on the right, and both wounds were left open with generous drainage. The patient was profoundly septic for a time, and the wounds were not entirely closed until five months after the operation. The appendix was examined only macroscopically. About three months after the operation, while the wounds were still partially open, the patient went to Old Point Comfort for a few days, and two weeks after his return he developed typhoid fever of moderate severity. There were no complications, but after recovery the patient had a perichondritis on the left side, which did not, however, proceed to suppuration. He had also a peripheral neuritis affecting the superficial nerves of the feet, producing first hyperesthesia and then anesthesia, and persisting for several months.

DIAGNOSIS.

The decision for or against an operation for appendicitis in a patient who has typhoid fever is a matter of the utmost gravity, and the preliminary question of diagnosis therefore becomes one of prime importance. When symptoms of the fever are not yet fully developed, the first question to be settled is: H a s t h e p a t i e n t a p p e n d i c i t i s , o r h a s h e t y p h o i d f e v e r ? In some cases an immediate positive answer is impossible, but where there is strong reason to suspect typhoid fever, and at the same time one or more of the characteristic symptoms of appendicitis are lacking, it is well to give the patient the benefit of the doubt and to defer decision while keeping him under close observation by both physician and surgeon. A case of appendicitis clearly demanding immediate interference ought to present the syndrome of p a i n , t e n d e r n e s s , m u s c u l a r r i g i d i t y , and f e v e r . Richardson (*Bost. Med. and Surg. Jour.*, Jan., 1902) says: "Let any of these symptoms be absent, and doubt as to the existence of an acute appendicitis arises. A peritonitis localized about the appendix is at once excluded, though it is more than likely that there is some appendicular lesion. So with pain and rigidity in the right iliac fossa, the absence of tenderness would at once rouse serious doubts as to the existence of appendicitis. Pain, rigidity, and tenderness, without fever would be the least doubtful combination, for absence of fever is sometimes conspicuous in really serious local infections of the peritoneum. When typhoid fever is suspected, one or more unusual combinations of the four symptoms just mentioned will prevail. The accurate observer cannot but be on his guard. For example, let there be pain and tenderness in the right iliac fossa,with fever, but without rigidity: The surgeon must account for the absence of rigidity before he opens the abdomen. He must inquire into a previous malaise. He must inquire most minutely into the history of the pain itself, its manner of onset, its relations with temperature and pulse, its early and late situation. He must inquire about the prevalence of typhoid in the community. Every abdominal and thoracic organ must be carefully examined. He must, furthermore, make exhaustive examinations of the blood. All this care is

imperative in the absence of a single symptom—rigidity of the abdominal muscles. Another example: Assume that in a questionable case of acute abdominal disease there has been no pain, but there is tenderness, rigidity, and fever. The absence of painful onset and of present pain at once suggests something out of the common. A temperature of 104° to 105° F., with gradually appearing tenderness and rigidity, is so unusual in appendicitis that that disease can almost certainly be ruled out, owing to the absence of pain alone. Tenderness and rigidity must be accounted for by other lesions. Indeed, it is so hard to imagine a disease in which, without pain at one time or another, there is fever, local tenderness, and rigidity, that one can almost say that the combination of these three symptoms alone—fever, tenderness, and rigidity—is an impossible one in acute abdominal disease."

The Widal reaction, which is so valuable in the diagnosis of typhoid fever, unfortunately often fails to develop before the seventh to the tenth days, and in some instances it is as late as the fourth, fifth, or sixth weeks. It should always be tried, however, as the patient may have a latent typhoid. The value of the agglutinative test is so great that it will determine the diagnosis when present. The absence of this sign in early cases, however, must not influence a decision.

The leucocyte count is a most valuable aid in making a differential diagnosis in cases where doubt rests between an acute appendicitis and a typhoid fever simply beginning its protracted course, with a temporary focusing of the symptoms in the right iliac fossa. The leucocytes in typhoid fever are always low, probably reaching their highest point, eight to ten thousand, in epidemic cases, in the first three or four days of the disease. The count never mounts up, but tends to descend rapidly. Boland has shown that the subcutaneous injection of typhoid toxins produces a decrease of the leucocytes. In such metastatic affections as pleurisy, and pneumonia due to typhoid organisms it is also the rule for the leucocyte count to remain low. In typhoid fever the mononuclear leucocytes, especially the large ones, are increased, while the rule in inflammatory disease is for the polymorpho-nuclear leucocytes to increase. But although the leucocyte count is a valuable aid to diagnosis, it may prove woefully misleading in exceptional instances, when the rule that typhoid fever inhibits leucocytosis fails to hold. In one case (see p. 446) the patient had a leucocytosis of 10,000, which rose in 3 days to 18,000; the diagnosis of appendicitis was then made and operation performed, but no serious disease was discovered. In the second (see p. 438) there was a leucocytosis of 17,000, and on operation a typhoid ulcer was found in the appendix without perforation.

Curschmann ("*Der Unterleibstyphus,*" Wien, 1898, p. 177) states that in typhoid fever a common evidence of the disturbance of the digestion of albumen is found in the presence of moderate, or even large amounts of indican in the urine. There is no particular relationship, however, between the occur-

rence of the indican and the intensity of the infection, and its presence has, therefore, no special diagnostic or prognostic value; indeed, in light cases, particularly those associated with diarrhea or obstinate constipation, the indican reaction is often more marked than in the severer forms of the disease; when a general peritonitis supervenes, or such a localized peritonitis as occurs in the limited forms of appendicitis (perityphlitis typhosa), the excretion of indican is not particularly marked.

It occasionally happens that a localized peritonitis without perforation exists around a typhoid ulcer, giving rise to sufficient adhesions and inflammatory products to form a tumor which may simulate appendicitis. On the other hand, protective and adhesive peritonitis localized in the neighborhood of the appendix occasionally follows perforation of a typhoid ulcer with tumor formation, which also simulate appendicitis. Such a case was reported by H. L. Elsner (*N. Y. Med. Jour.*, April 9, 1893), in which there was perforation of a typhoid ulcer followed by adhesive and protective peritonitis, and, finally, tumor formation, with symptoms simulating appendicitis so closely that a differential diagnosis was made with great difficulty. The patient finally died of intestinal hemorrhage, and autopsy showed that a coil of the ileum, beginning about 5 inches from the ileocecal valve, had folded itself against the bend of the colon laterally, and was firmly held there by inflammatory products. There was no evidence of escape of intestinal contents. A perforation of a typhoid ulcer 2 cm. in length was found in the portion of the ileum resting directly against the colon. So perfectly was the perforation sealed that no gas escaped during the autopsy until the ileum was lifted from its resting-place against the colon. Fitz (*Bost. Med. and Surg. Jour.*, Oct. 8, 1901, p. 365): "Most cases of recovery from symptoms of perforation of the bowel in typhoid fever are those in which an attack of appendicitis is closely simulated, while the fatal cases of perforation of the bowel in typhoid fever are, in the great majority of instances, those in which other parts of the bowel than the appendix are the seat of a perforation. Hence the prognosis of apparent perforation in typhoid fever is to be regarded as the more favorable, the more closely the symptoms and course resemble those of appendicitis."

The second diagnostic question to be answered is: If the patient has typhoid fever, has he appendicitis also? And if he has appendicitis, what is its grade? The diagnosis of appendicitis must rest upon the characteristic local symptoms of an inflamed appendix, supervening upon the already existing symptoms of typhoid fever. There is reason to suspect an involvement of the appendix in every case where severe pain, distinctly localized tenderness, and muscular rigidity exist in the region of the right iliac fossa. The earlier the stage of the disease in which these symptoms appear, however, the more should the physician be upon his guard in assuming that the complication is grave enough to demand

operation. I know of but two cases in which a perforation of the appendix has been noticed as early as the eighth day. Later in the disease, that is to say, in the latter part of the second or in the third week, the sudden supervention of severe inflammatory symptoms in the right iliac fossa raises, not so much the particular question whether there is an appendicitis or whether the appendix is perforated, as the question of an intestinal perforation in general, whether in the ileum or in the appendix. Under such circumstances the particular location of the perforation is a matter of minor importance.

There seems to be no defined set of symptoms which can be denominated pre-perforative. The physician must always, of course, give the closest attention to any unusual complaints of pain in the right iliac fossa occurring during typhoid. When a perforation occurs, there is apt to be a sudden acute pain accompanied by a fall in temperature. The sudden defervescence is also noted in hemorrhage, but without the pain. Intestinal hemorrhage occurred in four out of ten cases of perforation of the appendix several days before perforation took place, the pain coming on with the perforation. The occurrence of a hemorrhage, therefore, must put the physician on his guard, in anticipating a possible perforation. In addition to pain and fall of temperature, there are marked evidences of collapse, such as change in the facial expression, a small weak pulse, nausea, abdominal swelling, general tenderness, and signs of gas in the peritoneal cavity, with the disappearance of the liver dulness. Free fluid in the abdominal cavity must not be mistaken for an accumulation of fecal material; they can be distinguished by the fact that the fluid is easily displaced by some change in the position of the patient.

Curschmann has called attention (*loc. cit.*) to a particularly interesting group of cases, occurring more frequently than the profession are aware, in which an inflammation of the peritoneum localized in the right iliac fossa occurs during typhoid fever and which he designates peri- or para-typhlitis typhosa. The perforation of the peritoneum is extremely minute, or there may be only an excessive thinning of the intestinal wall, without rupture, to account for the surrounding peritoneal inflammation. The seat of the affection corresponds to the inflammatory tumors of the appendix. In true typhoid appendicitis the perforation also plays an important rôle. Curschmann has occasionally found deep ulcers with most minute perforations in the cecum, especially in the neighborhood of the valve, and also on the border-line between the cecum and colon, which afford an explanation of circumscribed inflammations in the right iliac fossa. This perityphlitis typhosa is sometimes found at that stage when peritonitis is most apt to develop, but rather more frequently later in the disease, or even during convalescence. He has himself observed it once on the eighteenth, and once on the twenty-first day, at a time when the patient was free from fever.

The local manifestations of such a typhoid perityphlitis are in all respects similar to other inflammatory processes in the right iliac fossa; they appear as

painful, more or less extensive, resistant, circumscribed infiltrations, which, apparently, lead to abscess formation more readily than is the case in ordinary appendicitis. In one instance there was a retro-peritoneal abscess which was successfully opened in the back. He has also noted some cases in which a period of general malaise, with irregular fever and an enlarged spleen, but without diarrhea or rose spots, was followed by a perityphlitis which at once established a correct diagnosis. In other cases, where a diagnosis of simple perityphlitis (appendicitis) had been made, the history of a febrile disturbance preceding the perityphlitis for two or three weeks aroused the suspicion of a typhoid perityphlitis, the actual existence of which was proved by the fact that the disease then ran a typical course, or else by the occurrence of a characteristic typhoid relapse.

A neglected appendicitis in which the patient falls into a "typhoid" condition from the absorption of the septic products, must be carefully distinguished from true typhoid appendicitis or perityphlitis. Curschmann recalls one case in which the development of a parotitis during the course of the disease seemed to point to typhoid fever, but the complication proved in the end to have arisen from an abscess in the right iliac fossa.

A number of cases have been reported in which typhoid fever has been mistaken, during its early stages, for an appendicitis; the reverse, namely, to mistake appendicitis for typhoid fever, is a much rarer accident. I quote, therefore, the following case:

C. R. Box and C. S. Wallace (*Lancet*, 1904, vol. 1, p. 1588). A man fifty years old was taken ill suddenly with pain in the right iliac fossa. His temperature was high (102.2° F.), his pulse 120 and intermittent, and he was mildly delirious at night. He had slight diarrhea, with pea-soup, offensive stools, and in the third week of his illness he had three large hemorrhages of bright red blood from the bowels, and a diagnosis of typhoid fever was made. There were no rose spots, and no agglutinative reaction on examination of the blood; the test was not made, however, until late in the illness. Death took place on the twenty-first day. At the autopsy an abscess was found in the right iliac fossa, but the appendix could not be recognized. There was no trace of typhoid ulceration in either large or small intestine.

TREATMENT.

In a case of suspected appendicitis with an alternative diagnosis of typhoid fever the wisest course is to wait. The best general rule is not to operate for appendicitis in the early stages of typhoid fever—say, up to about the tenth day—in the absence of exceedingly urgent symptoms; give the patient the benefit of the doubt, wait, and watch closely. The clinical history of the collected cases seems to show that, with the rarest exceptions, there is no

more occasion for operating upon a true typhoid appendix than there is for cutting down upon the ileum, and excising the affected Peyer's patches.

This rule of delay, except in extreme urgency of symptoms, accords with the established practice of some of our best operators. J. B. MURPHY of Chicago, for example, after operating upon three cases in which the symptoms of appendicitis were pronounced, and finding that the lesions in the appendix revealed by microscopic examination were those of a typical typhoid condition, refused to operate upon the next five in his practice, presenting similar symptoms, and in each instance the subsequent course of the disease justified the decision. In a personal communication he says: "It is my opinion that typhoid appendicitis should not be operated upon, unless there is a perforation. All my cases recover, those operated and not operated. At the same time, I feel that operation should not be performed, except in special cases."

There prevails in some quarters a strong tendency to operate in typhoid fever as soon as symptoms of appendicitis appear, this course of action being encouraged both by the swollen condition of the appendix as found, as well as by the favorable outcome of the operation. The surgeon in such a case congratulates himself that he has obviated a serious complication of the disease at what he considers little or no risk to the patient. This would be the case if the microscopic appearance of the typhoid appendix had the same significance as that of an ordinary inflamed appendix, but experience shows that this is not true. The inference that a swollen typhoid appendix must shortly advance to gangrene or perforation is not warranted by the well-established facts. *Per contra,* when, after a siege of pain in the right iliac fossa, the patient lapses into an ordinary typhoid, with an entire subsidence of the severe local symptoms, the observer must not hastily conclude that he was wrong in suspecting an involvement of the appendix in the first instance. The autopsy records show, as I have said, that the appendix is often much swollen, but that this condition is a frequent accompaniment of the early stages of the disease.

That operation in the early stages of typhoid fever for symptoms suggestive of appendicitis may be precipitate is shown by the results in seven of my collected cases, in which the morbid changes connected with the appendix were insufficient to justify the increased risk to the patient incurred by operation.

1. J. H. H., March, 1902. Surg. No. 13153. A physician, twenty-seven years old, had numerous severe attacks of colicky pain suggestive of appendicitis, during two years. At the end of that time he began to suffer with continued abdominal pain, most marked in the right iliac fossa, and general malaise, being confined to bed for a few days at the outset. This condition persisted for several weeks, during which time his temperature was normal, when the pain at last became localized in the right iliac fossa, convincing him that he had appendicitis and causing him to enter a hospital. The abdomen was flat and soft, and there was no

mass. At the operation, on the day of admission, the appendix was found adherent beneath the cecum, and coiled on itself; it was not inflamed, but surrounded by dense adhesions. Microscopic examination showed marked obliterative changes, converting the greater part of the organ into a fibrous cord. After the operation the temperature rose steadily to 104° F., and on the sixth day there was an intestinal hemorrhage. A few rose spots were found, and the spleen was palpable. The leucocytes, which on the fourth day were 8,000, decreased to 6,000 on the sixth. On the tenth and eleventh days the patient had several severe hemorrhages, and on the twelfth he died. There was no autopsy.

2. M. J. Lewis (*personal communication*, 1902). F. A. P., a physician, forty-one years old, had vague pains in the region of the appendix for eighteen months, which caused him some anxiety. He was taken ill with typhoid fever, and on the seventh day developed marked tympany, with pain on pressure, and over McBurney's point slight rigidity of both recti; the leucocytes were about 10,000. The Widal reaction was positive. On the fourteenth day the leucocyte count rose to 14,800, and on the fifteenth to 18,400. Operation was then done and showed the appendix free from adhesions, but flexed on a short mesappendix; the ileum was congested, dark red, and much thickened. An enlarged, inflamed Peyer's patch was seen, and the mesenteric glands were greatly swollen. The mucosa of the appendix was also much swollen, gray, translucent, and studded with punctate hemorrhages; near the cecal end was a small area like a swollen Peyer's patch. The only organism present was the b a c i l l u s c o l i . The microscope showed diffuse increase of lymphoid and epithelial cells, with small veins and capillaries packed with polymorpho-nuclear leucocytes, which in many instances seemed almost to plug the vessels. The increase of mononuclear white cells, usually seen in typhoid fever, was lacking. On the eighteenth day of the disease the leucocytes fell to 6,400, and the polymorpho-nuclear percentage was 91.6; marked tympany appeared, followed by chill. On the twentieth day, or six days after the operation, the wound had not united, the stitches were removed, and the serous coat was seen to be quite normal. The wound was closed on the twenty-fifth day. On the thirty-first day (the seventeenth after the operation) after a period of considerable distention, and a leucocyte count varying from 7,000 to 10,000, there was a sudden increase to 11,200, while the temperature fell to 97° F. The upper abdomen became greatly distended, with visible peristalsis of the transverse colon. The wound was again opened, and two fingers introduced, but no point of adhesions could be found, although the transverse colon was enormously distended. On the thirty-sixth day there was a sudden collapse of the colon, with escape of gas and feces from the open wound. Immediate operation showed a ragged necrotic opening on the under side of the transverse colon. Death occurred on the thirty-seventh day; there was no autopsy.

3. A. J. Ochsner (*personal communication*, 1904). A trained nurse, twenty-three years old, was taken ill while on duty, with excruciating pain in the abdomen. The abdominal walls were thickened, and moderately distended by gas; there was nausea, but no vomiting. The temperature was 106° F. A diagnosis of acute perforating appendicitis was made, and operation performed ten hours after the onset of the attack, when the temperature had fallen three degrees, and

the pain was still diffuse, although the tenderness was much more marked at McBurney's point. The muscular rigidity on the right side which had given the impression of an inflammatory mass in the region of the appendix disappeared under anesthesia. The patient had the appearance of extreme illness, while the day before she was the picture of health. On operation the peritoneum was found congested over all the intestines in sight, including the appendix, which was removed. Nothing abnormal was found in it, and the patient passed through a typical attack of typhoid fever, lasting five weeks, and ending in recovery.

4. E. E. MONTGOMERY (*personal communication*, 1903). A boy, eight years old, had continuous pain for two days in the right abdomen, with distention, gurgling, and rather marked tenderness, muscular resistance, and a temperature of 104° F. A diagnosis of appendicitis was made, and the operation was done on the same day. The appendix was free from inflammation, but was bent at an angle, and quite patulous. The patient then passed through an attack of typhoid fever, extending over three weeks, and ending in recovery. The diagnosis was confirmed by the Widal reaction.

5. W. J. HEARN (*personal communication*, 1904). A boy, seven years old, was brought to the Jefferson College Hospital by a competent physician with a diagnosis of appendicitis. He had marked tenderness in the right iliac fossa and a temperature of 101° F. Operation on the following day showed the ileocecal valve much injected, as well as the peritoneal coat of the appendix and the cecum. The appendix was removed, but there was no obstruction of its lumen nor a fecal concretion. A diagnosis of typhoid fever was made during the operation from the appearance of the intestines. The patient passed through an ordinary attack of typhoid fever of moderate severity, lasting four weeks.

6. J. H. H., August, 1899. A trained nurse, twenty-eight years old, was taken ill with cramps in the abdomen, diarrhea, and nausea, but no vomiting. These symptoms were followed by severe headache, loss of appetite, and fever. About a week later she had a chill, and after that severe aching pain over the whole abdomen, especially in the right iliac fossa, which continued irregularly for six days. Two weeks from the onset the leucocytes were 10,000, the next day 14,800, and the temperature 102.5° F. A diagnosis of appendicitis was made, and at the operation, two days later, the appendix was found lightly adherent, with the outer half of its peritoneal coat injected. Microscopic examination showed obliteration throughout, the centre consisting of old fibrous tissue, with slight, round cell infiltration. Three days later she developed marked typhoid symptoms, and the temperature was 102.5° F.; the Widal reaction was positive four days after operation. She went through a normal typhoid course with two relapses.

7. (See post-typhoid appendicitis case, p. 439.)

The question as to operation later in the disease depends, not so much upon the diagnosis of an appendicitis as upon the occurrence of perforation of the bowel, without respect to its anatomical site. The symptoms in order to justify operation must be of a more urgent character than would be necessary in the case of a person in perfect health suddenly affected in a similar manner, as the

greater gravity of an operation in the height of typhoid fever warrants the surgeon's assuming greater risks in waiting to make sure that an operation is inevitable. If the classical symptoms of perforation are present, the operator will, of course, proceed at once, without making any attempt to refine his diagnosis as to the exact site of the lesion. It would seem *à priori* probable that the chances of a patient with a perforation of the appendix, disposed as that organ is "in a quiet corner of the abdomen" (H. CUSHING), would be better than with a perforation of the ileum, more centrally situated. The records show, however, that of seven operations in which a perforation was found in the appendix, but one recovered.

The operation, once decided upon, should be performed with promptitude, and minutes, rather than hours, counted precious in making the preparations. If the operator is familiar with the endermic use of cocain in surgical operations, he will often do better to open the abdomen under a cocain or a cocain adrenal solution (see p. 517, Chap. XXIII), than risk the dangers of struggling, and the depressing influence of a general anesthetic.

It is best to make a free incision in the right semilunar line, and evacuate all purulent and fecal material, after which the appendix can be tied off at its base and removed. If necessary, other incisions may be made for more efficient direct drainage. In all such operations the condition of the ileum, if easily accessible, should be noted, in order to ascertain whether it is congested or exhibits diseased Peyer's patches.

The operator should always bear in mind the possibility of a perforation in the ileum as well as in the appendix, as found in one out of my 30 cases. He should also discover and turn in by sutures any Peyer's patch which seems just about to perforate.

If a perforation is found in the ileum, which is small in size, and the surrounding tissues appear healthy enough to hold the sutures, the simplest and best plan is to turn the opening into the bowel, and close it by two or three fine mattress sutures. Where there is a general peritonitis and extravasation of fecal contents, the abdomen should be washed out with a warm solution and drained. When there is excessive tympany with peritonitis, it is sometimes best to fix a loop of bowel into the wound, and open it soon after, giving free vent to the gases.

Patients under these circumstances will rarely stand much surgery, and if a more extensive operation is required to effect a closure, if the tissues around the wound are necrotic, or if there is much gaseous distention and peritoneal inflammation, the best plan of treatment is that which will save life, irrespective of the sequelæ. A method practised by R. H. FOLLIS of the Johns Hopkins Hospital, which bids fair to be of great value in the most serious cases, is that of draining the bowel by stitching the opening to the incision, and letting the fecal discharges take place outside until recovery, when the

bowel may be resected or anastomosed. This plan of treatment has also been advocated by BLAND SUTTON, and has the approval as well of E. W. GOODALL (*Lancet*, May 21, 1898, p. 1402).

After extensive operations of this character, with protracted drainage, the abdominal wall is left very thin at the site of the scar, and a hernia is almost sure to occur after the patient has been on his feet and taking active exercise for some time.

In cases of operation for typhoid perforation of the ileum, it would be of service if surgeons would always note carefully the condition of the appendix whenever it can be done with safety.

CHAPTER XX.

APPENDICITIS IN THE CHILD.

HISTORY. ETIOLOGY. SYMPTOMATOLOGY AND DIAGNOSIS. TREATMENT.

History.—The earliest recorded case of appendicitis in the child is probably that reported by PARKINSON in 1812, in a boy five years old (see Chap. I, p. 3). ILIFF, in 1832, published the case of a boy, twelve years old, who died of an abscess in the right iliac fossa, and at the autopsy the appendix was found to contain a "stone" (*Lond. Med. and Chir. Jour.*, 1832, vol. 1, p. 214). BÖHR in 1837 (*Med. Zeit. f. Heilk.*, 1837) and BURNE in 1839 (*Med. and Chir. Trans.*, 1839, vol. 13, p. 33) both reported cases in which perforations of the appendix occurred in children of ten and fourteen years old, respectively. In 1870, BETZ published a paper entitled "*Ileus in a child seven months old, resulting from perforation of the appendix and agglutination of the intestines,*" which is the first occasion on which appendicitis in the child receives separate attention, as the earlier reports all treat of appendicitis *per se*, and mention its occurrence in the child only incidentally (*Memorabil. Heilkund.*, 1870, Bd. 15, p. 118). A number of other cases are given in the very complete bibliography preceding G. K. MATTERSTOCK'S admirable treatise in GERHARDT'S *Handbuch der Kinderkrankheiten*, published at Tubingen in 1880, which forms the basis of all subsequent work in this line. In 1897 a paper of the highest merit by F. KAREWSKI appeared in the *Dtsch. medicinische Wochenschr.*, followed in 1901 by an admirable article by F. SELTER in the *Arch. f. Kinderheilk.** To these important papers, together with other scattered articles touching upon particular phases of the subject, such as that of V. GIBNEY in 1891 on the diagnosis between coxitis and appendicitis, and that of J. P. C. GRIFFITH in 1901 on the differential diagnosis between appendicitis and pneumonia in the early stages, I am indebted for many of the facts here presented. GRIFFITH'S article, in particular (*Univ. Penn. Bull.*, 1901, No. 8, p. 300), contains one of the most satisfactory cases of appendicitis in the child as yet reported, on account of the excellent clearness of the autopsy record.

A well-nourished negro boy, three months old, began to suffer from diarrhea with mucus in the stools; in twenty-four hours the fecal discharge ceased, although some blood was said to have passed, and vomiting with obstipation began. The

* An article on appendicitis in the child was read by A. MCCOSH at the meeting of the American Medical Association in Atlantic City, June 7 to 11, 1904, and appears in the *Jour. Amer. Med. Assoc.*, Sept. 24, 1904.

little patient was admitted to the Children's Hospital in a state of collapse, with a rapid weak pulse, sunken eyes, and an abdomen so distended that palpation was unsatisfactory. There were no stools and no straining. Under the impression that an intestinal obstruction might be present, large enemata were administered, but only a small quantity of mucus stained with reddish fecal matter was returned. The temperature ranged from 102° F. to 105.5° F. Death occurred five days after the onset of the illness, and the autopsy showed a general peritonitis caused by a gangrenous appendix 6 cm. long. Its proximal portion was healthy and comparatively immovable, while the distal half, which was without a mesentery, was freely movable. About the middle of the organ, separating the sound from the diseased portion, there was a constriction, characterized microscopically by a large increase of connective tissue and the abrupt disappearance of the mucosa, presenting evidence of a chronic inflammation, associated with the presence of newly organized blood-vessels. A little beyond the constriction, and at the beginning of the gangrenous area, the appendix was crossed by a band of lymph, evidently of recent formation and not tightly adherent to it, which stretched from the mesentery of the ileum to the peritoneal coat of the bowel. The end of the appendix was blackish in color, and within it there was tremendous congestion, extravasation of blood, and a complete degeneration of the epithelial cells with a granular detritus remaining to show the former localization of the tubules. It seems probable that this condition was caused by a kinking of the appendix occasioned by the shortness of its mesentery and by the fixation of its proximal half, associated with the free movability of its distal end. No concretions nor other foreign bodies were present.

Anatomy.—In the chapter on anatomy it was shown that the appendix develops by a process of narrowing down of the embryonic cecal pouch; and the section on "Differentiation" exhibits a series on appendices of all sizes up to the adult stage (Chap. IV, Figs. 28, 29, 30, 31). While primary differentiation between the cecum and the appendix takes place at the eight weeks stage (intrauterine), the secondary differentiation occurs at birth. It manifests itself in a dilatation of the proximal pouch, giving rise to the formation of cecal sacculations. The appendix, owing to this cecal enlargement, now appears relatively narrow, and lies coiled up in the iliac fossa beneath the cecum, while, as the lumbar region is relatively shorter in the child, the cecum lies at a comparatively higher level. Moreover, the iliac fossa is less capacious in the infant than in the adult, so that the entire ileocecal apparatus appears at a somewhat higher level than McBurney's point.

The permanent position of the appendix in relation to the ileocecal apparatus is determined previous to birth, the only subsequent change being a slight sagging out of the anterior pouch or pouches of the cecum to fill the growing iliac fossa. This explains the more retrocecal position of the appendix in the adult as compared with the child. The usual fusion of the mesocolon and the attachment of the mesappendix to the posterior wall take place long before birth, and at this time the position, direction, amount of fixation, and degree

of mobility of the appendix have all been determined and undergo no further change. Abnormal positions of the entire ileocecal region due to arrested development are not infrequent in children, but as these malformations persist into adult life, and are not a special characteristic of the infantile type, they cannot be specially considered here.

As for the appendix itself, the differences between the infantile type and the adult form lie in the relative size of the appendix, the thickness of the coats, and the form of the ceco-appendical junction. Compared with the adult form, the infantile appendix is slightly larger in relation to the size of the body, and considerably larger, if it is considered in relation to the entire alimentary canal (see Chaps. IV and V, sections on "Differentiation" and "Dimensions"). The coats of the infantile appendix are much more delicate in proportion, especially the submucous coat; the ceco-appendical junction is occasionally funnel-shaped, especially if the cecum and the appendix are in direct linear continuity. It is stated that the funnel-shaped entrance facilitates the entrance of foreign bodies, but it is probable that it renders expulsion equally easy (see Fig. 235). The valves of the infantile appendix, if present, do not seem to close the mouth of the organ as readily as do those of the adult. The reason for this lies in the relatively greater lumen and smoother mucosa of the infantile appendix, as compared with the narrower lumen and corrugated mucosa at the appendico-cecal junction in the adult.



FIG. 235.—FUNNEL-SHAPED ORIFICE (a) IN A CASE OF ACUTE PERFORATING APPENDICITIS IN A GIRL THREE AND ONE-HALF YEARS OF AGE. (From the Surgical Department, Johns Hopkins Hospital, Oct. 31, 1903.)

Note the large opening in the gangrenous appendix choked by a fecal concretion (J. M. T. Finney).

Age.—Determination of the earliest age at which appendicitis has been known to occur in the child has been a matter of frequent investigation, as well as the relative frequency of its occurrence in the child as compared with the adult. Among the most valuable contributions to this phase of the subject are a thesis by Miss GORDON (*L'appendicite chez l' enfant, Thèse de Paris*, 1896); an article by P. SELTER, already mentioned (*Die Perityphlitis des Kindes, Arch. Kinderheilk.*, 1901, Bd. 31, p. 59); and another by T. H. MANLEY (*Jour. Amer. Med. Assoc.*, June, 1901). Miss GORDON shows that for a period of twelve years antedating 1883, 26 cases of appendicitis were found among nearly 50,000 sick children, while during a period of three years between 1893 and 1896, 80 cases were collected, although the number of children was decidedly smaller. SELTER, reckoning from Matterstock's statistics, and allowing at the same time for the relative frequency of children and young adults in the hospital wards, found that appendicitis was seven times more frequent before the age of fifteen than it was from fifteen to thirty. He makes the

same computation from Sonnenburg's statistics. MANLEY shows that appendicitis is extremely rare under the age of five, but that it increases in frequency after that age, occurring nearly as often between the ages of ten and fifteen as later in life.

GRIFFITH, in his admirable essay already mentioned, treating of appendicitis in children of two years old and under, gives fifteen cases within that limit. The earliest case at the time he wrote was six weeks; since then, however, a case has been reported by A. GLONIGER of Lebanon, Pa., in which a male child was delivered in a normal labor by J. HARRIS of Jonestown, who was about to ligate the cord when he noticed an enlargement at its base, in which, upon viewing it by transmitted light, a coil of intestine could be distinctly seen. Twelve hours later the case was seen by Gloniger, who found the tumor increased in size; and as other means of relief proved ineffectual, he operated the next morning under ether anesthesia, when the baby was only forty-one hours old. The sac was opened throughout its entire length, and the greater part of the small intestine, with the cecum, and the transverse colon were found within it. The appendix, which was about an inch in length, stood up straight and stiff, and showed unmistakable signs of inflammation. The intestines were firmly adherent to the sac and were liberated with difficulty. Upon enlarging the umbilical ring, the relief from strangulation was at once apparent by the restoration of the normal color. The appendix, which had no mesentery, was excised, and the wound thus made closed with a suture of fine catgut. The hernial sac was cut away, and the peritoneum closed with catgut. The umbilical vessels were then ligated and some troublesome oozing from the skin was controlled by coapting the skin surfaces by means of Thiery's clamps. The child made an excellent recovery.

ETIOLOGY.

The causes operating to produce appendicitis in a child are much the same as those acting in adults. The reason why infancy and early childhood are comparatively exempt lies in the fact that the hard fecal concretions so often met with in appendicitis take some time to form, and are, therefore, rarely found during the first years of life; an additional reason is that an infant spends most of its life lying down; and, furthermore, trauma, which is the most frequent exciting cause in older children (see Chap. XVI), is practically absent during infancy.

The great liability of the male sex to disease of the appendix is as conspicuous in childhood as in later life. According to MANLEY'S statistics, the proportion of boys to girls is as two-thirds; according to other observers, it is as follows:

	MALES.	FEMALES.
Jalaguier	112	70
Matterstock	21	51
Jacob	21	8

Errors in diet are frequently noted in the histories of children, especially in the recurrent form. The relationship between appendicitis and infectious diseases has been fully dwelt upon (see Chap. XVI). It must always be remembered that in children the acute exanthemata may be ushered in by misleading symptoms of appendicitis.

Foreign bodies and concretions are met with in children from five years old and upward about as frequently as in adults; it is a matter of surprise, however, to find a foreign body present in a little child, and even in an infant but a few weeks old. In BETZ's case already mentioned, a child seven months old had a perforated appendix covered with a diphtheritic exudate, inside which were three fecal concretions as large as hempseeds, yellowish-white in color, easily broken, and showing the usual concentric arrangement. In another case originally reported by Demme, and cited by FENGER in the *Cyclopedia for Children's Diseases*, a child of seven weeks, fed entirely upon porridge since it was a week old, was taken ill at the beginning of its seventh week with high fever, tympanites, and tenderness in the cecal region, followed by peritonitis and death. The autopsy revealed a diffuse peritonitis, and an appendix dilated and filled with firm concretions, which the microscope showed were nothing more than conglomerate masses of undigested porridge; there was no perforation of the appendix.

There is undoubtedly an etiologic relation between intestinal worms and some forms of appendicitis. METCHNIKOFF (*Semaine méd.*, 1901, No. 11) and GENSER (*Wien. med. Wochenschr.*, 1901, No. 9) have called attention to the frequency with which a s c a r i d e s have been found under varying conditions. I have myself given several such instances, accompanied by illustrations (see Chap. XVI). In one of these, a woman, operated upon in my clinic, a segment of a tapeworm was found.

In several instances children with symptoms of appendicitis have been entirely relieved by s a n t o n i n. ARBORÉ-RALLY (*Arch. de méd. des enfants*, 1900) relates such a case in a boy, ten years old, suffering with excessive constipation; two surgeons made a diagnosis of general peritonitis, but on account of his bad general condition did not operate. On the fifth day of his illness he vomited a living a s c a r i s; three days later, after the administration of santonin, a second worm 25 cm. long was passed, and after large evacuations he recovered. METCHNIKOFF cites three cases showing distinct symptoms of appendicitis in which the patients, one of them a child twelve years old, were relieved by anthelmintic treatment, without operation. In each instance the eggs of both a s c a r i s and t r i c h o c e p h a l u s were found in the stools. He justly lays stress upon the necessity for a microscopic examination of the stools for ova in all cases in which there is any room for suspicion, a measure especially important in children, in whom a slight intra-abdominal source of irritation may provoke violent symptoms with fever. The rôle of the worms may be to produce an erosion of the mucosa, and so open the way for the invasion of bacteria; it may be that an inoculation takes place with the act of

exciting the lesions. The trichocephalus found in the cecum produces lesions by its habit of boring inward and imbedding the anterior end of the body beneath the mucosa.

STILL (*Brit. Med. Jour.*, April 15, 1899) looks upon the oxyuris vermicularis (pin-worm) as the cause of catarrhal troubles in the appendix. MOTY (*Semaine méd.*, 1901, Nos. 11–14) found oxyuris in three out of five cases recently under his care. He insists that an immediate examination of the appendix after removal is necessary to discover the worms. A case of this kind which occurred in the practice of my colleague, J. C. BLOODGOOD, has been already cited (see Chap. XVI, p. 377).

The activity of children in running about and playing especially exposes them to trauma, in the blows, falls, and violent exertion which are the familiar, hourly events of childhood. The effort, for example, of skipping rope backward many times in succession has been reported as causing a rapidly fatal appendicitis with perforation of the appendix, which contained a concretion.

Several observers have commented upon a supposed connection between appendicitis and the uric acid diathesis in children. SUTHERLAND in an article on this subject (*Brit. Med. Jour.*, 1892, vol. 1, p. 856) bases his theory on the anatomic similarity between the appendix and the tonsils, which are so often affected in gout, both organs being largely composed of adenoid tissue, a theory first brought forward by BLAND-SUTTON, who also lays stress upon the pathologic resemblance between simple and suppurative appendicitis and the analogous condition of the tonsils.

SYMPTOMATOLOGY AND DIAGNOSIS.

The differences which appear in appendicitis in the child and the adult assume the utmost importance upon the clinical side. There is a general consensus of opinion that the symptoms in childhood are often extremely vague, and lack the pointed precision of the adult form, which so frequently forces the diagnosis even upon the lay mind.

The abdomen of a little child is but a miniature of the adult in the relative approximation of all the organs, and in the close contiguity of those in the pelvis and in the upper abdomen. *Pari passu* with age and the assumption of the adult form, the organs are separated by a wider interval, their differentiation being thus facilitated. With the earlier age, and the approximation of the boundary lines of the abdomen, we have also incapacity for fixed attention while describing subjective conditions; lack of appreciation as to the value of questions and vagueness of expression in answering them; together with impatience under examination, especially when painful. As it is often impossible to elicit a clear statement as to the exact seat of pain, the surgeon must depend greatly upon palpation, watching the

face of the child at the same time, while the attention is diverted during the process. In examining an ill-trained child, or one under the age of ten years, the services of a specialist skilled in children's diseases are of the utmost value, as he, from force of habit and long experience, will better understand the child nature and more readily elicit a response; he is also better fitted to estimate the value of symptoms under circumstances which would only confuse an ordinary observer. While there are these disadvantages, there is, fortunately, the counter-advantage that an anesthetic (chloroform) is easily administered in children, affording a good opportunity to examine the iliac region through the thin relaxed abdominal wall.

An examination by the rectum should never be neglected, since the adult finger reaches higher in the infantile pelvis than in that of the adult, so that the suspected area is more easily touched. KAREWSKI and SELTER have shown that in almost every case in which the disease has advanced beyond the appendix, the extension takes place along the right pelvic wall, where the inflammatory masses can be easily felt. In 28 cases of appendicitis in children given by Selter, 6 had a general peritonitis and 11 a circumscribed abscess; out of the 11 cases of abscess, suppuration in all but one extended down into the right lesser pelvis, and in 2 of these 10, the abscess had traveled across the rectum and formed a mass on the left side, above Poupart's ligament. In one instance it was noted that the abscess lay on the left side and had no connection with the cecum, but at the operation, when an incision was made in the left groin, a tubular abscess channel the width of two thumbs was found extending down into, and across the pelvis, in front of the rectum, and up over the right pelvic wall.

CARRON DE LA CARRIÈRE has put on record 4 cases of recurrent appendicitis in children, manifested by vomiting alone, abdominal symptoms and fever being entirely lacking. FRUITNIGHT believes that there is often "in children a prodromal stage, lasting weeks or even months, before conclusive signs are developed by which a diagnosis can be arrived at." (*Arch. Pediat.*, 1891, vol. 8, p. 937.) Among the premonitory symptoms, he mentions interference with walking and standing, with tingling in the right leg.

MARÉCHAL (*XIII Cong. Intern. méd. et chir.*, Paris, 1900, p. 644) reports the case of a little girl, eight years old, who had an acute appendicitis characterized by entire absence of fever, a quiet pulse, and no vomiting. There was no tenderness at McBurney's point, neither was there resistance, fluctuation, nor infiltration. The patient complained vaguely of pain in the right side of the abdomen, which, however, was not aggravated on palpation; her expression was slightly distressed, but she was not prostrated. At the end of four days the pain was more marked, there was some diarrhea, the countenance was pinched and she appeared prostrated; at the same time a slight sense of resistance over the abdomen became perceptible, with a little dulness on percussion. A diagnosis of appendicitis was made, and operation performed four days after the patient came under obser-

vation; the appendix was a little violaceous in color, but not perforated, although its extremity was bathed in pus, which also filled the pelvis. In spite of evacuation, drainage, and removal of the appendix, death took place in twelve hours.

No examination of a child with a suspected appendicitis is complete which does not include an investigation of the thoracic viscera; often the first sign of a pneumonia or pleurisy or even of a bronchitis (RICHARDSON) is a right iliac pain, liable to be mistaken for an appendicitis. The least sign of disturbance in another organ in a doubtful case should command the examiner's attention, and such a clue, if followed up, will in some instances lead to a correct solution of a puzzling problem. It is absolutely necessary that the medical attendant should approach the bedside with calm undisturbed judgment, forewarned and on his guard against the public attitude of expectation, which is ready at once to count every obscure abdominal pain the sign of an appendicitis and the forerunner of an operation.

KAREWSKI has laid special stress upon the fact that most cases of appendicitis in children are preceded by many attacks of gastro-intestinal disorder, with more or less pain and diarrhea, or constipation, together with nausea and vomiting. As these attacks often occur in association with an overloaded stomach, attention is almost sure to be directed to the digestion in the early days of illness. Where a child has repeated attacks of colic and intestinal disturbance, especially if any tenderness is found on the right side of the abdomen, appendicitis should be suspected until the contrary is proved. A common preliminary sign is the desire to empty the bladder frequently, associated with pain in doing so. Appendicitis in a child is easily mistaken for a digestive disturbance, from the mild and transient character of the initial symptoms, the discomforts, the abdominal pains, and the constipation. In treating constipation in a child there should always be positive assurance that there is no appendicitis behind it; in doubtful cases it would be far wiser to treat constipation with opium than with castor oil. In all cases where the diagnosis is not clear, it is wiser to put the child to bed and watch for a few days, than to risk the accidents of an extension while the child is going to school or romping with other children. SELTER, in 11,000 cases of children's affections, observed 27 of appendicitis, including some very mild cases. He insists that many cases are lost through a false diagnosis of digestive disturbance such as colic or intestinal catarrh, and cites his personal experience as an example. Up to the age of fourteen, he suffered year after year from attacks of pain in the ileocecal region, with nausea, quickened pulse, anxiety, and sweatings, associated alternately with diarrhea or constipation. The diagnosis at the time was "intestinal catarrh" or "typhlitis stercoralis." After he was fourteen he had no more attacks. He insists that in the intestinal catarrh associated with colicky pains, of both nursing chil-

dren and those of riper years, an unusual tenderness in the region of the cecum is often revealed by examination, and his conclusion is to the effect that "*colica appendicularis*" is common in children.

The tendency to a larvate form of appendicitis in children, together with the obscurity which may attend it, is well shown by two cases in young girls, patients of E. A. CUSHING of Cleveland, Ohio.

In one the child, going regularly to school, attended as usual on the morning of the day on which Cushing first saw her. She had had no pain, nor evident fever, had not been at any time confined to bed, and there was no history of previous attacks of colic. The services of a physician were sought simply because she looked white, felt languid, and had no appetite. There was no reason for suspecting any particular organ, but as a routine matter an examination of the entire body was made, when a well-defined mass was discovered in the right iliac fossa. DUDLEY ALLEN operated the next morning, opening an abscess, and removing an appendix which was on the point of perforation. In the second case, a girl seven years old was seen on the second day of an attack of what was supposed by her watchful mother to be indigestion, because of epigastric pain, nausea, and constipation. Her temperature was 100° F., her pulse 80, and her expression bright. Operation on the same day, by Allen, disclosed an abscess and an appendix near perforation.

While making his abdominal examination the surgeon must bear in mind that the adhesions in a child may be extremely delicate, and more than ordinary care must be exercised in order to avoid any risk of rupturing them. H. GAGE (*Bost. Med. and Surg. Jour.*, May 24, 1894) mentions a case in which the adhesions around a localized abscess in a child were ruptured during sleep, and another in a young adult, where rupture took place during an effort at stool. In both instances the disappearance of symptoms was accompanied by collapse, a rapidly progressing general peritonitis, and death. A movable kidney ought not to be mistaken for a diseased appendix from the very fact of its mobility. A congenitally misplaced kidney, however, lying in the right iliac fossa, might easily be so mistaken, if the simple discovery of a mass were taken as decisive.

It must always be remembered that in children, the early symptoms of appendicitis are apt to be those associated with motion. A. WORCESTER of Waltham, Mass. (*Bost. Med. and Surg. Jour.*, Aug. 4, 1892), relates a case in which a boy, ten years of age, with an indefinite history of three weeks' illness presenting undefined symptoms, was sent at the end of that time to consult a physician; he entered the office with a marked stoop, and a limp so pronounced that he could not stand upright. A diagnosis of appendicitis was made, and on operation a good-sized abscess of the "larvate" form was discovered. Another case of the same kind occurred in the practice of R. D. FREEMAN of South Orange, N. J. While calling professionally upon another member of the family, he noticed a little girl, eleven years old, limping as she played tennis in the yard close by, and standing in a position similar to that of hip disease.

On inquiry it was found that she had complained for a few days of indefinite pains in the lower part of the abdomen, and on calling her into the house and examining her, a tender fluctuating mass was found in the right iliac region; the right leg was flexed and adducted, there was muscular rigidity over the lower abdomen, and considerable pain on pressure over and around the mass; the rectal temperature was 103° F. and the pulse 90. She had had no considerable pain at any time, and no chill. At the operation, performed at midnight of the same day, a large abscess surrounding the appendix was evacuated and the remains of a sloughing appendix removed.

In several instances it has happened that a pleural empyema has been discovered and operated upon, while the primary cause, a suppurating appendix, has not been discovered until the postmortem. It behooves the operator, therefore, in every case of empyema, particularly in right-sided affections, and above all when the pus is ill-smelling, to bear in mind this possibility, and to make such examinations of the right iliac fossa (rectal above all!) as shall decide this question.

Without doubt, says KAREWSKI, many of the puzzling cases of a puffed-out umbilicus and abscess at this point, followed by fistula, are due to lesions of the appendix. In a few instances the diagnosis has declared itself in the appearance of a small fecal calculus at the umbilicus.

Appendicitis in the child may be mistaken for: Acute indigestion; typhoid fever; ileus; pneumonia or pleurisy; tubercular peritonitis; intussusception; hip disease; hernia; ovarian disease.

Acute Indigestion.—We have here, it may be, the history of an indiscretion in diet, vomiting, and pain, the latter probably generalized in character without any special localized tenderness in the iliac fossa. There is fever in both cases, but that of the indigestion is more sthenic in character, and there is no progressive increase in the leucocytes as counted from hour to hour; in indigestion the attack is sudden in its onset, with intense pain from the first, associated with much restlessness, and the symptoms disappear quickly with a thorough evacuation of the bowels and a restricted diet.

Typhoid Fever.—This disease is slower in its prodromata than appendicitis, creeping up day by day to its crisis while appendicitis develops much more quickly and with more definitely localized symptoms. I know of no case as yet in which an appendicitis has apparently arisen in the course of typhoid fever in a child to confuse the medical attendant. The profounder and more striking signs of appendicitis will usually prevent any confusion. The Widal reaction becomes the important diagnostic criterion in the later stages.

Ileus.—Appendicitis in its earlier stages may be mistaken for ileus, beginning, as the latter often does, with obstinate constipation, vomiting, and other evidence of a profound systemic disturbance, without fever, and with a good pulse. In such cases the closest attention must be paid to the local

manifestations, and the counting of leucocytes should never be omitted. The worst possible treatment of an appendicitis is the use of enemata to overcome a suspected ileus. KAREWSKI has twice seen cases of diffuse appendicitis which had been treated for five or six days with high injections, and in one instance the castor oil thrown into the rectum was found floating in the peritoneal cavity.

Pneumonia and Pleurisy.—Experienced clinicians have repeatedly noted, especially in children, cases of intrathoracic disease, pneumonia and pleurisy, in which at the outset the pain has been chiefly abdominal. Such being the fact, we cannot be too much on our guard, when called to a patient manifestly very ill, with abdominal pain, an elevated temperature, fixation of the diaphragm, constipation, drawn-up knees, and perhaps a swollen abdomen, against too hastily assuming the existence of an appendicitis and the necessity for immediate operation.

I cannot better illustrate these difficulties than by citing a case published by H. L. BARNARD (*Lancet*, Aug. 2, 1903), who is indebted for it to the rare frankness of F. S. EVE, the operating surgeon.

The patient, a girl seventeen years old, had attended the outdoor clinic at the London Hospital during some months for gastric ulcer with marked anemia. She had once before had an attack similar to the one about to be described. One morning, in 1899, she started for work, as usual, and on her way was seized in the street with violent epigastric pain and vomiting. She was brought to the hospital at once in a state of collapse, her pulse being 120 and thready, while her temperature was 104.5° F. Her abdomen was rigid, motionless, distended, and very tender, these signs being most marked in the epigastric region. She was admitted to the surgical wards as a case of perforated gastric ulcer, and within two hours her abdomen was opened. The anterior and posterior surfaces of the stomach were explored as well as the greater and lesser curvatures, but no trace of gastric ulcer was found, nor was there any peritonitis. Unfortunately ether was the anesthetic given, and her cough became so violent that a coil of intestine and some omentum escaped between the stitches, requiring to be washed and returned, after which the abdomen was again sewed up. On the second day after admission it became clear that she had right basal pneumonia, but her temperature had fallen to 101° F. On the third day it rose again to 104° F., signs of consolidation appeared at the left base, and she died on the fifth day from the commencement of the attack. At the postmortem examination double basal pneumonia and right diaphragmatic pleurisy were found, while in the stomach was a shallow ulcer the size of a sixpenny piece, which was not near perforation. There was no peritonitis.

J. P. C. GRIFFITH, in an article entitled "*Pneumonia and pleurisy in early life simulating appendicitis*" (*Jour. Amer. Med. Assoc.*, Aug. 29, 1902), presents the dangers of an error in diagnosis in a most convincing manner, and I quote one clear case from this source.

"K. S., male, seven years old, admitted to the Children's Hospital Novem-

ber 2, 1899, under the care of H. R. Wharton. He had had at various times more or less abdominal pain, which was never severe until three weeks previously, when he had a typical attack of appendicitis, as regarded by the physicians in charge of him. The symptoms at the time consisted of severe pain and tenderness in the right side of the abdomen, especially at McBurney's point, fever, constipation, and restlessness. He recovered partially, but the tenderness is said to have remained. On October 30th, three days before admission, he had had a recurrence of pain, and again on November 1st. There had been no vomiting at any time. Fever was said to have persisted since the attack three weeks before. On admission the temperature was 103° F., the respiration varying from 32 to 80, and the pulse from 132 to 196. The abdomen was distended, tender, and somewhat rigid. These symptoms were especially marked on the right side. There was also bronchial respiration over the entire lower lobe of the left lung. The attending physician had in person taken the child to the hospital in order to have an operation for appendicitis performed. On refusal by the surgeon to do this, he became very angry, disputed the diagnosis of pneumonia, said he had brought the child for the sake of operation solely, and would remove him if it was not performed, and used other language more forceful than polite. He was requested to go to the ward to examine the patient himself again. This he did—and then, apologized. By the evening of the same day the temperature had fallen to 99.2° F. No further abdominal symptoms were recorded, and the pneumonic consolidation rapidly disappeared."

Out of 8 cases given by GRIFFITH, it is noticeable that, while severe abdominal pain, tenderness, and distention, were prominent in all, cough was so slight as to attract the attention of only the most watchful eye. A little girl, eight years old, had such intense abdominal pain and tenderness that the resident physician feared arsenic poisoning. Another child, four years old, had obstinate abdominal pain, tenderness in the right iliac fossa, and distention, so that the physician who first saw the case made the diagnosis of appendicitis, but the child was admitted to the medical wards, because operation was forbidden by the parents. When first seen by Dr. Griffith, "except for a few coarse râles, nothing could be detected on examining the lungs in front. Owing to the great distress of the child, and because the diagnosis of appendicitis seemed so positive, the posterior part of the chest was not examined on this date. On the next day pneumonic consolidation of the left lung was easily found. The abdominal symptoms remained unchanged." On the following day all the abdominal symptoms had disappeared, and the crisis occurred two days later.

J. L. MORSE of Boston has given us a picture of such cases, so complete and clear that nothing is wanting (*Ann. Gyn. and Ped.*, 1900, vol. 13, p. 143), and he warns us that "the abdomen has been twice opened in children by well-known Boston surgeons for appendicitis, when the trouble was lobar pneumonia." His first case presents a typical picture of the shifting character of the signs of pneumonia, from the first abdominal symptoms to the final unmistakable thoracic one.

The little patient, who was seven years old, and in perfect health, was struck in the abdomen, during recess at school, by one of his playmates. Shortly afterwards he became faint and nauseated, and was sent home by his teacher. He continued to vomit for twenty-four hours, and on the day following the injury he complained of headache, nausea, and pain in the abdomen, the bowels not having moved. There had been no cough nor sore throat, and the temperature and pulse were but moderately elevated, with no special disturbance of respiration. There was a little abdominal tenderness and slight distention, but a routine examination of the lungs proved negative. On the second day the bowels continued closed, in spite of calomel and salts; there was considerable abdominal distention and increased tenderness, more marked in the right iliac fossa, where there was slight dulness; but no tumor. The temperature was now high, and the pulse and respiration rapid, but, although there was a constant hacking and evidently painful cough, examination of the lungs was again negative, so that the trouble, which seemed abdominal, was considered as probably appendicitis, and as the increased respiration and cough appeared secondary to the abdominal disturbance, but little attention was paid to them. More salts were ordered and the abdomen was poulticed! During the third night there were four movements of the bowels, after which the abdominal distention diminished, and there was very little tenderness, but the cough became more troublesome, and the child complained of pain in the right lower chest and the umbilicus, the respiration being now 65 and painful. An examination of the lungs now showed marked dulness, with bronchial respirations and a few high-pitched râles over the right lower lobe. The diagnosis of lobar pneumonia with reflex abdominal symptoms was then made. The next day the abdominal distention was nearly gone, and during the succeeding twenty-four hours even the slight tenderness disappeared.

Morse remarks that "cases of pneumonia in children beginning with symptoms pointing to the abdomen, while not common, are nevertheless not very unusual. The predominance of the abdominal symptoms may, however, lead to serious errors in diagnosis. . . . . These cases are probably most often overlooked because the possibility of their occurrence is not borne in mind and the examination of the chest is neglected. As is shown by the cases detailed above, however, the physical signs of pneumonia may not be recognizable for several days. Yet even in the absence of physical signs the combination of symptoms is usually such as to justify a probable diagnosis of pneumonia. An acute onset with high temperature is always suggestive of pneumonia. If in addition to the acute onset and high temperature the rapidity of the respiration is increased out of proportion to that of the pulse, the combination is almost pathognomonic of pneumonia. This is true even in the absence of cough. Too much importance can hardly be attached to this combination of temperature, pulse, and respiration in diagnosis, and many errors may be avoided by keeping it constantly in mind. When it is present, vomiting, abdominal pain, constipation, and even distention and tenderness, may usually be regarded as symptoms of secondary importance, probably reflex in origin."

It is evident from a consideration of these, as well as of other important cases, that, as RICHARDSON says, "in acute right-sided diseases of the thorax, the symptoms of appendicitis may be so easily simulated that a surgeon may be completely deceived."

The differential diagnosis must depend upon attention to the following factors, commonly present in intrathoracic disease: (1) A sudden rise of temperature, and persistent high temperature, without, as a rule, corresponding increase in the pulse-rate. (2) Full and sthenic character of the pulse. (3) Disappearance of the fixation of the abdominal muscles with each respiration. (4) Superficial character of the tenderness, which is probably due to a neuritis affecting one of the lower intercostal nerves, and disappears under firm pressure with the whole hand. (5) Rapidity of the respiration, which should always excite attention, and call for closer attention to the chest.

In addition, great caution should be displayed in regard to the following points: Close attention should be given to any cough. Examination for thoracic disease should be made in every case of suspected appendicitis in a child. In cases of reasonable doubt it is better to wait, and watch for more definite local symptoms, either in the chest or in the abdomen, before assuming the responsibility of operating. Fewer lives, I think, will be sacrificed by such a policy than by a hasty interference instituted because there is a possibility of disease in the appendix.

Tubercular Peritonitis.—In the absence of any other known focus of tuberculosis, an attack of acute tuberculosis accompanied by pain, together with some swelling and resistance localized in the right iliac fossa and associated with marked fever, may present insuperable diagnostic difficulties until the disease has progressed into the chronic stage.

KAREWSKI has reported an interesting case of tubercular peritonitis originating in the appendix.

A child, two years old, had an abdominal tumor situated below the navel and extending both to the right and to the left, the swelling having formed first upon the right side. The child came from tuberculous parents, and had had swollen glands from its infancy; it was emaciated, very tympanitic, and had been ill for a long time. There was diarrhea alternating with constipation, and attacks of ileus. An incision revealed cheesy pus, and a vermiform appendix perforated at its extremity, where there was a small abscess. The child died in twenty days, and at the autopsy the cecum was found covered with tuberculous ulcerations, extending into the appendix. There was no tuberculosis in any other part of the intestinal tract and the general peritoneal cavity was walled off.

In a second case a boy, five years old, had had an attack of appendicitis a year before coming under observation, a little hard lump remaining in the neighborhood of the appendix. After several months he began to limp, and to keep the right leg constantly flexed. Hip-joint disease was suspected, and on this account he was brought to the surgeon, who found a contracture of the ileopsoas muscle,

due to the remains of the perityphlitic exudate. An operation was refused. The tubercular character of the disease seemed probable on account of an old bony focus below the knee-joint. A large tumor soon began to form in the right lower abdomen, with free ascites. At a subsequent operation a cheesy abscess was found surrounding the extremely hardened and thickened appendix.

M. H. RICHARDSON, speaking from his own experience, says: "A tumor at the ileocecal valve was in one case supposed to be appendicular. It proved to be an acute tuberculosis of the mesenteric glands of the mesocolon. A dissection carried thoroughly as far as the receptaculum chyli was permanently curative." (*Bost. Med. and Surg. Jour.*, July 14, 1898.)

MANLEY in speaking of such cases says: "It is quite impossible to affirm whether or not the appendix is involved. Under these circumstances, I have often seen an operation undertaken for appendicitis reveal no lesion of the organ" (*loc. cit.*).

In making a differential diagnosis between tubercular appendicitis and appendicitis arising from other causes, it must be borne in mind that tubercular appendicitis tends to run a protracted course, and the patient seems more tolerant of an accumulation in the iliac fossa than he would be with abscess due to any other cause. There is often an ileopsoas contraction accompanied by a tendency to limp, and emaciation increases as the disease progresses. The history of the parents, and also of the locality and the house in which the patient lives, are of importance; the early history of the child itself must also be investigated, especially as to the former presence of enlarged glands, or of cheesy troubles in or near the joints. Finally, whenever a case of appendicitis runs an obscure course, tuberculosis should be suspected.

Intussusception.—Intussusception of the vermiform appendix is a rare affection, limited, as a rule, to childhood; I have found but one case occurring in an adult, and that was in a woman forty years of age. I have collected and analyzed 19 cases of this condition in children, and I find that the average age is four years and eight months, the oldest in my list being nine years and the youngest thirteen months. In regard to sex, there were 11 males and 7 females, the sex in one not being stated.

These cases of intussusception may be divided into three groups:

1. Those in which the vermiform appendix is simply carried along with the intussusceptum in an incidental manner; that is to say, in which the appendix is compelled to travel with the intussuscepted colon simply because it is organically connected with it.

2. Those in which the base of the appendix itself forms the apex of the intussusceptum; that is to say, cases in which the intussusceptum starts at this point of the colon.

3. Those in which there is an inversion of the appendix, partial or complete, with or without inversion of the cecum, colon, or ileum.

The clinical picture of such an ailment is that of a chronic affection characterized by abdominal pain, sudden severe attacks of colic, doubling the child over, and a diarrhea with blood and mucus in the stools. After such an attack, the child may show improvement, play, and go to school, until there is a recurrence. There is usually, however, a gradual loss of health and some emaciation. I have found but one case in which the temperature was elevated; and the pulse is not quickened in the intervals. An extraordinary case in which pain was the one symptom is that of McKidd (*Edin. Med. Jour.*, 1859, vol. 11, p. 763):

1. A boy, seven years old, suffered for several weeks with abdominal pain localized about one inch below the umbilicus; at the end of this time the pain became so excruciating that it was necessary to keep the child under the influence of chloroform on account of the distress occasioned to the neighbors by his constant screaming. There was no tenderness or swelling in the abdomen, nor any symptoms besides the pain at any time. The bowels were somewhat constipated, but responded to purgatives, and the stools were normal in appearance. At the autopsy a hard mass was found in the cecal region which was at first thought to be impacted feces, but on opening the colon it proved to be the invaginated appendix, projecting into the lumen of the intestine, its base being just over the valve, so as to "act as a barrier to the proper exercise of its function and obstruct the passage of excrementitious matters from the ileum." There was, properly speaking, no caput ceci, and what trace of it seemed to exist was invaginated with the appendix, which was spiral in form, acutely inflamed, and gangrenous in parts.

In examining the abdomen there is no marked tympany or localized tenderness. A peculiar, elongate tumor, sometimes sausage-shaped, occasionally more or less globular, is found, most frequently in the left flank, but sometimes in the region of the transverse colon, or in the neighborhood of the umbilicus. In several instances a second swelling has been noted. Such a tumor, when carefully examined, and its position and dimensions noted, is apt at a later examination to appear different in size and position. It is often extremely movable upon manipulation, owing to a long mesocecum. A case in which two intussusceptions were found in the same patient is given by W. H. Waterhouse (*Trans. Path. Soc. Lond.*, 1898, vol. 49):

2. A little girl, four years old, was sent to the Victoria Hospital for Children, with a diagnosis of intussusception. Five days before, the child had been examined under chloroform, and a tumor found in the right side of the abdomen, which subsequently disappeared. When admitted to the hospital, the tumor reappeared, accompanied by pain and vomiting in an aggravated form. On attempting to reduce the tumor by enemata, the second enema returned blood-stained. Operation was then performed, and an intussusception found, four feet above the ileocecal valve, which was easily reduced; but as it was lying transversely, it was obviously not the tumor previously felt on the right side. A second intussusception of the ileocecal variety was then discovered and reduced with difficulty bit by bit;

when this was effected, however, it was plain that the cecum contained a firm globular body about one inch in diameter, while only one-half of the vermiform appendix was visible externally. On investigation the globular body proved to be directly continuous with the mass in the cecum. While attempting to reduce the inverted appendix the tumid wall of the cecum gave way and the partially gangrenous appendix was seen in the interior. The cecum was then excised, and the ileum and ascending colon anastomosed by means of a Murphy's button. The child never recovered from the collapse, and died in about thirty hours. The excised parts showed the invaginated portion of the appendix on the inner side of the cecum as a globular mass, three-fourths of an inch long, and one-eighth of an inch in circumference at the widest part; with a somewhat constricted neck, one and three-fourths inches in circumference. The portion of the appendix outside the cecum was five-eighths of an inch long. Neither by traction from without nor by pressure from within could the intussusception be reduced.

If the intussusception is extensive, the bowel may be seen protruding at the anal orifice. A rectal examination should never be omitted, as the soft polyp-like mass may be found just within the anus, or within reach of the finger. It greatly facilitates the examination in these little patients, to give enough chloroform to produce complete relaxation.

A remarkable instance, similar to that of McKidd just cited, in which no tumor could be detected, was a little patient of T. A. McGraw (*Brit. Med. Jour.*, 1897, vol. 2, p. 956):

3. A little boy, two years old, had an attack of cholera morbus in which the stools were occasionally streaked with blood. After apparently complete recovery, he began to have attacks of excruciating pain in the abdomen, which yielded only to large doses of opium, and these were followed by slight amounts of blood and mucus in the stools. As the intervals between these attacks decreased in length, he lost flesh and strength, until his condition became so bad that an abdominal section was advised to discover their cause. During the paroxysms of pain, the abdominal muscles would contract and become hard and tense, but there was no fixation in the intervals, nor could any tumor be felt in the iliac fossæ nor in the rectum; the child referred the pain to the epigastrium. The temperature was normal until the day before the operation, when it was 100° F. Intussusception was considered out of the question, because there was no obstruction and scarcely any disturbance of digestion, and a chronic appendicitis was excluded on account of the normal temperature and absence of tenderness in the iliac fossa. The most plausible theory was that of omental hernia, either in the median line above the navel, or within the abdomen through some pathological aperture. A median incision was made above the umbilicus, when the transverse colon presented itself, intensely inflamed, and coated with lymph. On pulling this out, it proved that the ascending colon had a mesentery of such enormous length that it could be drawn, together with the cecum, through the incision above the navel. The whole of the large intestine was greatly inflamed. The cecum, which was of the fetal variety, was unusually long; its end, with the appendix, was invagi-

nated inside the bowel, and could be felt through its walls. The intussusception involved the cecum and the appendix only. The invaginated structures were excised just at the point where infolding occurred, the opening closed, and the whole covered by catgut sutures. The child made a rapid recovery, retarded only by a stitch abscess.

The etiology will vary with the starting-point of the inversion. A predisposing factor is a long mesocecum. Any inflammatory process in the head of the cecum causing a localized thickening of its walls, or an inflammatory condition around the orifice of the appendix, causing it to pout out into the lumen of the cecum, would offer a convenient grip for the circular muscles of the bowel to catch and exercise propulsive force in the direction of the current. A tumor at or near the base of the appendix, if there was a loose mesocecum, would seem to offer a most favorable opportunity for the inversion of the cecum with the appendix, but no case of this kind has yet been reported.

It is not so difficult to understand how an inflammatory process involving the proximal process of the appendix might cause, at first a swelling, and then a pouting of its mucosa into the cecum, when the swollen edematous tissue with its strangulated veins would serve to draw the remainder of the mucosa onward, step by step, until the entire organ was inverted.

In the following case, given by K. MONTSERRAT, the writer says positively that the point of origin was at the base of the appendix (*Liverpool Med. and Chir. Jour.*, 1901, vol. 21, p. 68):

4. A boy, four years old, was admitted to the Children's Infirmary with paroxysmal pain in the right side of the abdomen, which had persisted for a month, lasting a day or two at a time, and then disappearing for an interval of varying duration. A mass could be plainly felt extending across the abdomen from the right loin to the splenic region, freely movable, and not tender. The bowels were somewhat relaxed, and two days after admission, the administration of an enema was followed by stools containing mucus and blood. The swelling could be reduced towards the right, but did not disappear entirely; it varied in size from day to day. On operation, an incision was made at the outer border of the right rectus and on a level with the umbilicus, and it was then seen that there was an intussusception of the cecum into the colon, carrying with it the ileocecal valve and the terminal portion of the ileum. This was easily reduced down to the last knuckle, which consisted of the vermiform appendix and a part of the cecal wall, the base of the appendix being invaginated into the cecum, until only about one-eighth of an inch of its tip was visible. There were no adhesions, but the peritoneal surface of the appendix and the cecum were so hard and indurated that it was with difficulty the invagination could be turned out by using both thumbs in making steady pressure on the mass in the cecum. The appendix was then amputated at the base; the child made an uneventful recovery.

When the appendix becomes more or less inverted into the cecum, it may then act as a polypoid tumor within the bowel and give rise to further invagination.

The following case, given by CONNOR, is one in which a blow on the abdomen is supposed to have given rise to the invagination (*Lancet*, 1903, vol. 2, p. 600):

5. A boy, nine years old, was admitted into St. Bartholomew's Hospital with abdominal pain, stating that about a month previously he had received a blow on the abdomen, after which he vomited and was ill in bed for four days. On getting up, he was much constipated, and the abdominal pain continued at intervals. On admission, he seemed to be in good general condition, his temperature was 99.2° F., both knees were drawn up, and the abdomen was rigid, the right rectus especially standing out. There was no abdominal dulness, but some tenderness and an ill-defined resistance in the right iliac fossa. A rectal examination was negative. The case was supposed to be one of subacute appendicitis or of tuberculous disease. He improved under treatment, and was discharged in two weeks, quite well except for some thickening in the right iliac fossa. For a week he did well, when he was seized with abdominal pain, followed by vomiting, and was again brought to the hospital. On examination, the abdomen was found slightly rigid, and an oval swelling was apparent just above the umbilicus, moving with respiration; this was firm, tender, and freely movable towards the right iliac fossa. He passed two drachms of bright red blood from the bowels. On operation, an intussusception was found at the level of the umbilicus, the apex of which could be felt as a smooth hard mass within. The bulk of the intussusception consisted of the ileum, and was easily reduced until the cecum was reached, when it was found that the hard mass felt within was inside the cecum, its base being marked by a dimple on the internal aspect of the cecum and surrounded by adhesions. This proved to be a completely inverted appendix, with its mesentery drawn into the dimpled area. All attempts at reduction were futile and the appendix was removed in one mass with the caput cæci, and the opening closed by sutures. No mention is made of drainage.

The title of this paper is "*Intussusception of the vermiform appendix,*" but from the description of the case and the accompanying diagram, it appeared to me to be one of complete *inversion* of the appendix. On referring the matter to Connor, he writes me as follows: "The appendix was completely intussuscepted in the true sense of the word. By this I mean that the appendix was completely thrust into the cecum, 'inverted' on itself like the finger of a glove; thus, when excised, the relative positions of the peritoneal and mucous coats were reversed. The contiguous part of the cecum was slightly pulled in, forming a dimpling at the basal attachment of the appendix. This evidently was the first step, and was followed by a large intussusception, with the tip of the inverted appendix as the summit of the intussusceptum; the cecum and ileum being in turn drawn into the ascending and transverse colon. The diagram in my article exactly reproduces the condition found, when all but the appendix itself was reduced. The part excised is now in the St. Bartholomew's Museum."

HAESLER (*Archiv f. klin. Chir.*, 1902, Bd. 36, p. 817, Case 9) cites a case which shows several stages of invagination quite clearly:

6. A boy, nine years old, was attacked with pain in the abdomen, which yielded at once to cold applications. A week later he had another attack, accompanied by vomiting, after which the attacks became more and more frequent, until in four and a half months, when he was admitted to the hospital, he was confined to bed most of the time and was much emaciated from constant vomiting. About four weeks before this date his mother noticed a swelling on the left side of the abdomen, which increased in size during the attacks of pain, and she stated that for about six months his stools had contained large pieces of mucus. Examination showed a roundish abdominal swelling the size of a child's fist in the left hypochondrium, freely movable, and only painful when compressed. During eleven days spent in the hospital, he had several attacks of pain extending towards the bladder, and large lumps of mucus appeared in the stools. A diagnosis of intussusception was made, and on operation the tumor was found in the right hypochondrium; it was easily lifted out of the peritoneal cavity by reason of the extremely long mesentery, when it was seen that the cecum, together with the appendix, was chronically inflamed, and invaginated with the lower ileum into the ascending colon. All attempts at reduction were futile, and the invaginated parts were, therefore, resected, the colon being divided three finger-breadths beyond the tumor. An iodoform gauze drain was inserted. A good recovery followed. The specimen showed various stages of invagination, and it could be plainly seen that the primary one was that of the cecum and appendix. The invaginated appendix lay free in the lumen, and its base was gangrenous at the point of reflection.

In one of my collected cases a probable appendicitis is cited as the supposed cause of the intussusception, but it is certain that if the appendix had been previously inflamed, its walls thickened, or bound down, an inversion could not occur.

If the colon enters the intussuscipiens, the appendix of course goes with it. The invagination of the appendix with the colon may then be inferred in all such cases. The inversion of the appendix, more or less complete, may be suspected when the invagination is reduced down to a small hard tumor in the right iliac fossa. On the other hand, an appendicitis in a child has been mistaken for an intussusception. GRIFFITH gives two such cases in his series of 15 occurring in children of two years and under.

The question of carcinoma in the differential diagnosis is raised by the following case, the only one reported of intussusception in an adult. The operation was done with the expectation of finding a malignant affection, and even when the abdomen was opened, it was not possible at first to get a clear idea of the nature of the disease:

7. (HAESLER, *loc. cit.*, Case 9.) A woman, forty-two years old, who had always had good health, fell from an electric car, receiving a blow on the head, after which she was ill in bed for some time, suffering from sleeplessness and severe vomiting. One night she had a sudden severe pain near the navel, extending toward the right iliac fossa. No resistance was perceptible at first, but after three weeks she noticed a knot in her abdomen which was freely movable and increased in size.

The attacks of pain continued at intervals for six weeks, when she entered the hospital. Examination then showed a smooth tumor in the right iliac fossa, the size of a large fist; her bowels moved only after medicine, and she was suffering from meteorism, nausea, and vomiting. Her general condition was so bad and she was so much emaciated that a provisional diagnosis was made of carcinoma of the ascending colon. On operation the cecum and the vermiform appendix could not be found. After separating adhesions so thick as to resemble a solid tumor, the intestine was resected from 10 cm. above the ileum to the hepatic flexure of the colon. The patient recovered and was in good health three years after the operation. Examination of the resected portion of the intestine showed the ileum passing directly into the colon, the cecum and the appendix being apparently lacking. On cutting into the bowel, the valve and the invaginated appendix could be seen projecting into its lumen. The appendix was the most prominent portion, so that it seemed not unlikely that it was the starting-point of the difficulty. Its lumen contained a small amount of fecal material.

Treatment of Intussusception.—It occasionally happens that nature herself will effect a cure by a spontaneous amputation of the appendix. An excellent illustration of this is shown in a case reported by J. McFarland (*Proc. Path. Soc. Phila.*, 1902, vol. 4, p. 163):

8. A little girl, eight years old, was treated for an abdominal trouble supposed to be intussusception. The symptoms relieved themselves spontaneously, and during convalescence a mass of tissue was passed *per rectum*, after which she made a rapid and uneventful recovery. The discharged mass consisted of two separate fragments, one of which, about 5 cm. in length and 3 cm. in breadth resembled the cecum; the second fragment consisted of a flat piece of intestine, the size of a half-dollar, from which a tube was given off, about 10 cm. long, "which," the writer says, "was certainly the vermiform appendix." The naked-eye diagnosis was confirmed by microscopic examination.

The following plans of treatment may be employed, preferably in the order given:

Palliative, by means of manipulation, massage, enemata, etc.

Celiotomy and reduction, by manipulation, with removal of the appendix.

Celiotomy and reduction, by opening the cecum, and effecting reduction by counter-pressure from within, followed by removal of the appendix.

Amputation of the appendix and of the adjacent chronically inflamed cecum.

Amputation of the entire cecum.

Amputation of the cecum and ileum.

Amputation of cecum, ileum, and colon, as far as involved.

The first attempts at treatment will naturally be palliative and directed toward ileocolic intussusception in general. Warm enemata of flaxseed tea may be given, with the pelvis elevated, and an attempt may be made under chloroform to reduce the tumor. The patient should then be well bandaged and kept on a restricted diet.

Where there remains a persistent tumor, however small, the intussusception is sure to recur, and the only proper plan of treatment is that of operation, by some one of the methods mentioned above. Several cases in my list appeared to do well for a time under palliative treatment, but a recurrence always soon took place, making it necessary to have recourse to surgery. It may be laid down as a rule, therefore, if there is a residual mass, operate. The danger in waiting is that of the obstruction to the circulation, with the peritonitis, and the sloughing which may take place, as in a case of W. S. COLMAN (*Trans. Clin. Soc. Lond.*, 1898, vol. 31, p. 227):

9. A boy, eight years old, was admitted to the Hospital for Sick Children, with a history of paroxysmal pains in the lower abdomen and vomiting, for fifteen weeks past. The bowels were open and the stools normal. Examination showed a full and somewhat resistant abdomen, with a definite movable swelling in the left flank, between the costal margin and the iliac crest, which appeared to vary in size even during the examination. An hour later, after an attack of pain, the swelling was found considerably altered in size and consistence, having almost reached the middle line and become much harder; in the course of several days it became elongate and firmer. Three weeks after admission the patient had a severe attack of pain with violent vomiting. Two distinct tumors could then be made out: (1) A firm, sausage-shaped mass in the position of the transverse colon, and (2) a firm, round mass in the left lumbar region. The next day the conditions had again changed, and the sausage-shaped swelling could no longer be felt. On operation, the tumor in the left hypochondrium was easily recognized as an intussusception in the transverse colon and splenic flexure. Reduction was easy up to the last two inches of the bowel, when it became difficult, and during manipulation the vermiform appendix was suddenly extruded, distal end first. When reduction was completed, an ulcer the size of a threepenny piece was found close to the juncture of the appendix with the cecum, extending through all the coats of the bowel. The ulcer was excised and the opening closed. I presume that the appendix was removed with the ulcer at its base, but the writer does not say so. No drain was used. The child did well at first, but two days after the operation became worse, there being much tenderness and resistance in the region of the cecum. The wound was then re-opened at its lower end, pus found, and a drainage-tube inserted, but the child died during the same night.

The incision may be made over the tumor, or in doubtful cases in the median line, near the umbilicus. The appearances may then, at first sight, be puzzling, as in the following case of P. S. HALDANE (which also illustrates one of the phases of invagination) (*Scot. Med. and Chir. Jour.*, 1903, vol. 12, p. 333):

10. A little girl, three years old, was brought to the Carlisle Infirmary suffering from abdominal discomfort and constipation. There was no history of previous attacks of a similar character, although the patient had always required frequent aperients to keep the bowels open. On examination, a rounded, elastic swelling was found near the splenic flexure. The child was then removed from the hospital,

but when brought back a fortnight later, an oblong cystic tumor, resembling a cystic kidney, was felt in the left hypochondriac region, reaching down to the umbilicus. This tumor disappeared after the administration of chloroform, but another smaller swelling of the same kind was then found at the hepatic flexure of the colon. There was no pain on examination and no vomiting. The following night, after the administration of an enema, there was a severe attack of pain in the abdomen, with accompanying tenderness and rigidity of its walls; the patient had several stools consisting of some mucus streaked with blood. Examination showed the same swelling about and around the umbilicus. A diagnosis of intussusception was now made, and on operation the cecum was found distended, its surface friable, and at the lower and posterior part there was a small projection, which proved to be the vermiform appendix, invaginated from root to tip, the root forming the apex of the intussusception. This was reduced with difficulty, the invaginated part proving much swollen and deeply congested, while the part at the edges of the cecum was constricted and showed a tendency to gangrene. The appendix was removed and the stump treated in the usual way. It is not stated whether the patient recovered.

Here the appendix was simply invaginated from root to tip and enclosed in the sheath of the cecum. If we would divide these invaginations in which the appendix forms the apex of the contained bowel into groups, we might classify them as follows:

1. Those in which there is a partial invagination.

2. Those in which there is a complete invagination of the whole organ, as in the case last cited.

3. Those in which there is an invagination of the appendix with the cecum, advancing a varying distance into the colon.

The simplest operative procedure, and that most suitable when the appendix alone is the peccant organ, is celiotomy and reduction by manipulation. The intussuscepted bowel is inverted, squeezing it gently from above, while exercising traction from below, so as to bring the entire appendix into view, when it may be amputated and removed. HALDANE's case, just cited, is a good illustration of this method, and I give another example in a case reported by H. G. HOGARTH (*Brit. Med. Jour.*, 1893, vol. 1, p. 850):

11. A little girl, six years old, was admitted to the Children's Hospital in Nottingham with a diagnosis of intussusception. Six weeks before she had been attacked by diarrhea lasting a week, and when this was stopped, abdominal pain came on, recurring every ten minutes day and night up to admission. For two weeks the pain had been accompanied by vomiting, but the bowels had been normal. There was considerable emaciation and a subnormal temperature. Examination of the abdomen showed tenderness on palpation, especially in the left flank; a tumor could be felt in the line of the transverse colon, which passed down the left flank and ended in a rounded extremity. It could not be determined with certainty whether the horizontal and the vertical portions of the tumor were continuous. The splenic dulness was separated from the tumor by a resonant area; the loin

dulness was continuous with a dull note over the tumor. Diagnosis was uncertain between tubercular peritonitis of the plastic variety and intussusception. Operation showed a large intussusception of the ileocecal kind, ending half-way down the descending colon; this was easily reduced until the end was reached, when the appendix was found invaginated into the cecum. An attempt at reduction was made by pushing the appendix out from the inside through the wall of the cecum, without opening the latter, but it was found impossible to reduce it completely, as a small portion of the base was densely adherent. The appendix was therefore removed and the wound stitched up. The child made an uninterrupted recovery.

If the bowel just above the cecum is soft and pliable, it may be invaginated into the cecum, and used in this way to make counter-pressure on the appendix, while attempting its re-inversion. Unfortunately, the thickening of the surrounding parts is frequently such that the method of reduction by manipulation often cannot be accomplished without great risk of rupturing the cecum, a thing which has actually happened in one of the cases already cited (No. 2).

The method of opening the cecum and reducing the appendix by pressure from within is well illustrated by the following case, published by G. A. Wright and K. Renshaw (*Brit. Med. Jour.*, 1897, vol. 1, p. 1470):

12. A boy, two and a half years old, was admitted to the Hospital for Children with a history of diarrhea alternating with constipation for twelve months previously. For some months a slight protrusion of the anus had been noticed. When first seen, he had an attack of colic in which both legs were drawn up, and there was increased resistance to the right side of the umbilicus, but no tumor. The temperature was normal, the bowels constipated. After an attack of colic and vomiting lasting for two days, a distinct tumor could be made out above and to the right of the umbilicus and below the liver. The child continued in this state for ten days, the tumor meanwhile moving downward and to the right, and was then sent to the hospital, where a diagnosis of intussusception was made. Gurgling could sometimes be heard over the seat of the tumor, and there was a little mucus in the stools, but no blood. Under chloroform, a definite tumor could be made out in the course of the transverse colon, most distinct in the left hypochondrium, manipulation of which without an anesthetic caused pain. The child's condition grew worse for a month, when an operation was performed. The mesenteric glands were at once noted as enlarged, hardened, and apparently tuberculous, but no tubercles were seen on the peritoneum. A hard, movable tumor was found which slipped about in the abdomen from the right iliac region to the left side of the abdomen, though only with difficulty. It was brought up out of the wound, when it was found to consist of the cecum, much thickened, with inflammatory infiltration, and the adjacent small intestine. The appendix was firmly tied down by its apex between the cecum and the ileum, thickened, flexed, and covered with lymph; its root was found invaginated into the cecum. "The condition was as if the base of the appendix had been pushed into the cecum, carrying part of the

cecal wall with it, and forming a depression about the size of the first joint of an adult index-finger, from which the appendix sprung like the stalk of a mushroom." All attempts to reduce the invagination from without having failed, a slit was made in the cecum in the course of a longitudinal muscular band, and the finger passed into the bowel; by this means the invagination was partly reduced, but the depression was still not wholly obliterated. As the lumen of the bowel was not materially encroached upon, the opening in the cecum was closed and the appendix then removed. Its cavity was completely obliterated at the root. It is not stated whether a drain was inserted.

In cases where the inverted appendix is the only portion of the intussusception which cannot be reduced, it is best, after opening the cecum, to amputate the appendix, a plan pursued successfully by PITTS in the following case (*Lancet*, 1897, vol. 1, p. 1602):

13. A little girl, two and a half years old, was admitted to St. Thomas's Hospital, her mother stating that three and a half months before she had been turning head over heels, immediately after eating her dinner, when she suddenly complained of pain in her abdomen. She continued to have similar attacks of pain of short duration for several days, the abdomen becoming hard and rigid while they lasted. The bowels were relaxed and the stools contained mucus and blood. Two weeks before she entered the hospital a protrusion of intestine, four inches long, was seen at the anus by the physician who attended her, and a tumor could be felt in the abdomen by palpation. The rectal protrusion was replaced, after which the child was inverted and the abdomen kneaded, during which process the tumor disappeared with a gurgling sound. A few days after this, however, she became worse, and on examination a sausage-shaped, freely movable tumor, which changed its position from time to time, was found in the position of the transverse colon. On operation, a median incision was made just below the umbilicus and an intussusception at once discovered, which was easily reduced, but after complete reduction it was noticed that the vermiform appendix was not visible, its normal position being occupied by a dimple. An elongated swelling could be felt through the cecal wall, resembling the thickened appendix, and when an incision was made into the cecum a "chronically inflamed and completely inverted appendix was found." As all attempts at further reduction failed, the appendix was cut away *in toto* within the bowel, and its base sutured. In addition, the peritoneal coat was drawn over the little orifice, the incised bowel was sutured, and the abdomen closed—presumably without a drain. The child made an excellent recovery. The writer remarks that the inverted appendix was probably the primary step in the invagination.

When the appendix is completely inverted, it seems hardly necessary to make the colic incision, as was done here. If the mesappendix can be tied off, it ought then be sufficient to ligate and divide its vessels and sew up the little pit at the inverted base, as is done by EDEBOHLS in his ordinary operation for removal of the appendix by inversion, after which the appendix sloughs off

within the bowel and passes out by the rectum. Such a plan has the advantage of avoiding the very serious risk of exposing the wound to the often foul cecal accumulations, as occurred in a case reported by A. R. KNIGHT (*New Zealand Med. Jour.*, 1890–91, vol. 4, p. 106):

14. A child, thirteen months old, sex not stated, was taken ill with vomiting and great pain in the abdomen, together with diarrhea in which the stools contained some blood. Examination of the abdomen showed only an indistinct dulness, but on the following day a tumor was found in the position of the left colon, extending from the margin of the ribs to the hips. Intussusception was then suspected, and an attempt was made to reduce the tumor by high enemata, with partial success. The general condition improved, but as the tumor persisted, an operation was performed on the third day. A hard tumor situated above the umbilicus was brought into view, but all attempts at reduction failed. The appendix could be seen projecting from the invagination. The bowel was then laid open, and the valve exposed to view, when it was found in a putrid condition. The mortified portion was resected, but the child's condition was so bad that this could not be satisfactorily accomplished, and death took place within an hour after the completion of the operation.

In cases of old intussusceptions, in which the appendix, together with a portion of the cecum, is either invaginated or inverted, the chronic inflammatory alterations, which are characterized by great thickening, rigidity, and edema of all the tissues involved, as well as by numerous adhesions, are often so marked that any persistent or forcible attempts at reduction become fraught with the utmost risk of serious injury to the bowel, or even its complete rupture. The rule may, therefore, be laid down that g e n t l e e f f o r t s o n l y a r e w a r r a n t e d i n a t t e m p t i n g t o e f f e c t a r e d u c t i o n. In chronic irreducible intussusceptions a more radical plan of treatment must be adopted. Excision of the appendix with the adjacent portion of the cecum should be the rule here, as illustrated in the case of MCGRAW, already cited (No. 3), in which he cut through the cecum at the neck of the intussusception, just where the infolding occurred, removing the invaginated portion, and leaving behind at least an inch or more of the cecal wall extending from the cut edge to the ileocecal orifice. This opening he united by a double row of catgut sutures, and covered the wound with the omentum.

Amputation of the entire cecum with the appendix has been successfully practised by D. ACKERMANN (*Beitr. f. klin. Chir.*, 1902, vol. 37, p. 580):

15. A delicate little girl, four years old, had a fall from a chair upon her side, after which she was subject to attacks of abdominal pain resembling colic, which lasted from a few hours to a day, and were accompanied by vomiting of slimy greenish material. These attacks at first occurred at intervals of a day or two, and then came daily. The bowels were generally regular, but there was occasionally diarrhea or constipation, and blood was often found in the stools. At the end of six months, when the child was admitted to the hospital, the attacks of pain and

vomiting were constant, and the general condition was bad. In the left flank was a round tumor, elastic to pressure, and the size of a goose's egg, while above it lay numerous hard lumps, varying in size from a hazelnut to a walnut; the rectum was empty, but the tumor could be felt between the finger in the rectum and one outside. A diagnosis was made of chronic intussusception. On operation, the tumor which had been felt from the exterior, proved to be the cecum and colon invaginated into the sigmoid flexure, while the vermiform appendix could be distinctly felt as a round thick cord through the intussuscipiens. Reduction was effected as far as the valve, but as it was impossible to reduce the remaining invagination on account of adhesions, this portion was resected, and the patient made a good recovery. Examination of the resected portion showed the appendix invaginated into the cecum, and so closely attached that a reduction was impossible, the whole mass forming a hard rigid tumor, going over into gangrene.

The plan of resecting the entire cecum with a portion of the ileum as well, has been successfully employed by D. B. Lees (*Lancet*, 1898, vol. 1, p. 1400):

16. A boy, four and a half years old, was admitted to St. Mary's Hospital on account of an intussusception, which was relieved by irrigation so completely that he was discharged in two days. He had repeated returns of the same affection, which was as often relieved by the same measures, until about four months later, when the tumor could no longer be entirely reduced, and his condition became serious. On operation, it was found that the parts concerned were the lower end of the ileum and the cecum, and as reduction could not be accomplished, these were excised, the ileum being divided two or three inches above the ileocecal valve and the colon some inches beyond the cecum. The ends of the intestine were approximated by Lembert's sutures; nothing is said of drainage. The patient made a good recovery. Examination of the excised specimen showed that the posterior wall of the cecum, carrying with it the appendix, had been invaginated into the ascending colon; and the ileocecal valve had been dragged upon, carrying with it about one inch of the ileum.

In cases where the diseased process has progressed so far as to involve the colon as well as the ileum, it becomes necessary to employ the last method on our list: amputation of the cecum, with both ileum and colon as far as they are involved. The following case, reported by G. J. Westermann, is the only one I have met with in which such extensive measures were necessary (*Weekblad van det Neederlandsch Tijdschrift von Geneskunde*, No. 24; see also abstract in *Beitr. f. klin. Chir.*, 1903, vol. 37, p. 585):

17. A little girl, six years old, had a chronic intussusception, and on operation the greater part of the ascending colon (15 cm.), the cecum, and a long piece of ileum (20 cm.) were removed. The vermiform appendix, which was 6 cm. long, and the thickness of an index-finger, was found inverted (*umgestülpt*) into the cecum.

In all cases the amputation should be done in the healthy tissues of the bowel, above the inflamed thickened portion. The resected and sutured bowel ought

then to be brought down to the wound, and an iodoform gauze drain inserted. This is better, I think, than covering the bowel with omentum. If the operation demands haste, one of Murphy's buttons is the best expedient.

The following cases complete my collection:

18. CHAFFEY (*Lancet*, 1888, vol. 2, p. 17). A boy, three years old, was admitted to the Hospital for Sick Children, Brighton, with a history of vomiting, and the passage of mucus and blood from the bowels for ten days. On examining the abdomen, an elongated sausage-shaped tumor could be outlined in the region of the transverse colon, which was not tender to the touch but descended at each respiration. The next day the child was semi-collapsed, and examination under chloroform showed that the tumor was less defined, but a distinct swelling could be made out in the right hypochondrium. For twelve days the patient grew weaker, the tumor appearing and disappearing, blood and mucus being occasionally present in the stools, when he died of exhaustion. The autopsy showed the omentum drawn over to the right side, and fixed to the parts in the vicinity of the cecum by old adhesions; the position of the cecum was occupied by a round tumor, about three inches long, composed of the cecum invaginated on itself along the ileocecal valve, with bands of old adhesions holding the parts together. The distal end of the appendix could not be found, though it was diligently sought for; the proximal end had become inverted so as to form a little polypoid projection about one inch long in the cavity of the cecum, close to the ileocecal valve. The apex of the polypoid protuberance presented a well-marked ostium leading into a tubular cavity about half an inch long.

19. ENDERLEN (*Münch. med. Wochenschr.*, July 17, 1900, p. 1021, abstract *Beitr. f. klin. Chir.*, 1903, vol. 37, p. 587). A boy, two and a half years old, was seized with severe colicky pain over the umbilicus, accompanied by stools in which blood and mucus were mixed with normal fecal movements. When admitted to a hospital at the end of five months, he had a sharply defined tumor lying transversely in the epigastric region, which gradually developed in the direction of the transverse colon, until it finally lay across the upper half of Poupart's ligament on the left side, and at the end of about five weeks it could be felt in the rectum. At the tip of the prolapsus there was a knob-shaped projection, with a short narrow lumen, from the base of which the lumen of the intestine could be reached. The child died about seven months after the first symptoms made their appearance, with all the symptoms of acute perforative peritonitis. At the autopsy, the beginning of the invagination was found near the middle of the transverse colon, from which it extended down to the anal region, a distance of about 35 cm. Its outer coat had several deep fissures, through which two short secondary invaginations had formed. The tumor was sharply flexed at its entrance into the true pelvis, and at the flexion there were two perforations. The starting-point of the invagination was at the ileocecal opening, and not, as appeared in life, at the knob formed by the partly inverted appendix (*der teilweise umgestülpte*); the ileocecal invagination had traversed the whole colon in the space of seven months.

20. W. H. BISHOP (*Chironian*, 1903, vol. 20, p. 81). A boy, five years old, was admitted to the Flower Hospital with great pain in the abdomen, vomiting, and a

rapid pulse. On inspection, a mass was observed protruding from the anus, which on one side had an elongated sausage-shaped excrescence resembling an inverted appendix. On palpation a tumor was found on the left side of the abdomen, over the upper part of the descending colon. The mass protruding from the anus was replaced, but immediately returned. An anesthetic was then given and the excrescence amputated close to the bowel. The intussusception was then again replaced and the lower bowel inflated with oxygen through a rectal tube, with the child in an inverted position. The mass then disappeared from the rectum. The vomiting and abdominal pain soon returned and the mass on the left side was again prominent. Laparotomy was then done, but it was not possible to deliver any portion of the intussusception, nor to drag out the invaginated portion by traction on the upper section. Inflation of the rectum was again practised, and by grasping the rectum and sigmoid flexure and keeping up a kneading squeezing motion from below upward, the tumor was moved upward as far as the ileocecal region, where it disappeared. It was now seen that in place of the appendix, there appeared its stump i n v e r t e d, with the ligature, of course, within the lumen of the bowel, and constricting all the coats of the intestine. Uninterrupted recovery.

Hip Disease.—H. V. GIBNEY, in 1881, first called attention to the d a n g e r o f m i s t a k i n g c h r o n i c a p p e n d i c i t i s f o r h i p d i s e a s e, and the article he then published under the title "*Perityphlitis in children, illustrating points in the differential diagnosis of hip disease*" (*Amer. Jour. Med. Sci.*, 1881, N. S., vol. 81, p. 119), still remains the best contribution to this branch of the subject, although it has been made a matter of comment by more than one writer. It will be a sufficient warning to the unwary to state that an error in diagnosis between these two conditions has been committed by surgeons of excellent reputation, and therefore coxitis must always be considered as a possibility in uncertain cases.

In GIBNEY's original article he cites 6 cases occurring within his personal experience.

One of the six (the fourth), a boy six years old, was carried into the office of the Massachusetts General Hospital, because he was unable to walk, and gave the following history: He had been in perfect health and sound of limb until three weeks before, when he had a fall. During the following night he began to have pain in the right hip; the next day he could scarcely walk; and four or five days later, when seen by a surgeon of distinction, he was pronounced suffering from hip disease, a weight and pulley being applied as appropriate treatment! During the next three weeks the patient suffered much pain in the right knee and groin, severe enough to require anodynes at night. His rectal temperature on admission to the hospital was 101° F.; he was much emaciated; his tongue was heavily coated; and he was unable to stand without bearing his whole weight upon the left limb, while keeping the left semiflexed at the hip, with the knee rotated inward; walking was entirely out of the question. Sitting on the side of the bed, he voluntarily crossed the right leg over the left knee; lying prone, nothing abnormal was seen,

except a deviation of the lumbar spine to the left; lying on the back, he voluntarily flexed the thigh on the pelvis completely. He could both abduct and adduct the limb, but he could not extend it beyond 90 degrees without pain, and, if passive extension was tried, he resisted and cried. Rotation could be easily made if carefully executed; pressure over the trochanter in the line of the neck as well as concussion gave no pain. There was no infiltration about the trochanter, nor below Poupart's ligament. The abdominal walls were a little retracted, and there was no tenderness nor infiltration in either ileocostal space nor in the left fossa, but in the right, tumefaction could be distinctly felt within a triangular area, bounded above by a line extending from top of the crest of the ilium to the median line, just below the navel. There was dulness and excessive tenderness, but no well-defined tumor. A diagnosis of perityphlitis was made, and the case treated by rest in bed, laxatives, vesication, and poultices or hot fomentations. Under these measures the symptoms gradually subsided, and in less than four weeks after the child entered the hospital, he was completely cured. The functions of the hip were perfect, and when seen again, three months later, he was as well as ever.

GIBNEY's remaining cases, while not so striking as this one, demonstrate plainly that such an error in diagnosis is easily made during childhood. Another case of the same kind is given by H. MYNTER (*Appendicitis*, 1897):

A girl, thirteen years old, was taken ill with severe pain in the ileocecal region. A physician made a diagnosis of appendicitis, and the patient recovered rapidly under medical treatment. For six months she continued well, but then complained of severe pain in her right hip and became quite lame. She saw a physician, who told her she had hip-joint disease, on account of which she entered a hospital for treatment. Upon examination, a hard, swollen appendix was felt, extending from McBurney's point in an upward direction. It was intensely tender on pressure, producing pain in the right hip, although both hip-joints were normal. On operation, the appendix was found to be six inches long, lying flat on the outside of the cecum, and completely bound down by old adhesions. It was stiffened and thickened; the mucous membrane was enormously thickened and softened, with here and there intense local congestion, amounting at one spot to necrosis. The appendix was removed, and the patient made a good recovery.

Such an error in diagnosis as these cases illustrate, will be avoided by the physician who sits down carefully at the bedside and spends a little time in palpating and compressing the hips, in palpating the lower abdomen, and in slightly rotating and extending the leg, the attention of the child being at the same time diverted. In any case of lingering doubt, an examination should be made under an anesthetic, and the patient watched from day to day.

Hernia.—Of 56 cases of hernia of the appendix analyzed by RIVET, 13, or 23 per cent., occurred under the age of thirteen. It is naturally more frequent in males than in females, occurring in the proportion of nearly 70 per cent. in the former to 30 in the latter, including all ages, while the inguinal form is much the commonest (J. H. JOPSON, *Proc. Path. Soc. Phila.*, 1900). These hernias may

be divided into two classes: congenital and acquired, congenital hernia being understood as a congenital predisposition which manifests itself, if not at birth, at least soon afterward. It would, perhaps, be more literally correct to use the term "infantile" to designate a hernia occurring in the earliest years of life, and "acquired" for the forms developing later.

G. A. PIERSOL, in a clear, thoughtful article on "*Early infantile hernia of the vermiform appendix*" (*Univ. Penn. Med. Bull.*, Oct., 1901), says:

"The favorable conditions offered by the vaginal process before birth for the engagement of the neighboring parts of the intestine are universally recognized. That such involvement does not more frequently occur is probably due, as stated by Schmidt, to the preponderance of head presentations, the absence of respiratory movements, the inactivity of the abdominal muscles, and the meagre peristalsis of the fetal intestines. Additional evidence of the influence of gravity is shown by the fact that although 14 per cent. of all inguinal hernias occur during the first year, they usually do not appear until after the third month, or not until the infant is carried in an upright position."

The causes of the descent of the vermiform appendix into the hernial sac (inguinal canal) are: (1) an anatomical attachment connecting the appendix closely with the cord called the *plica vascularis*, analogous to Clado's ligament in the female, extending from the cecum and appendix to the infundibular pelvic ligament and the ovary; or (2) to adhesions of the appendix to the migratory peritoneum adjacent to the cord; or (3) to an open inguinal ring with a preternaturally long appendix; or, (4), what amounts to the same thing, a cecum with a long mesentery.

In a case described by PIERSOL, of a negro infant about three months old, the cecum, which was of the typical infantile form, occupied a position considerably lower than usual in the right iliac fossa. The entire length of the appendix lay in a hernial sac, extending a little more than half-way to the bottom of the scrotum. The appendix was 84 mm. in length, or nearly two and a half times longer than the average length at birth, which, as determined by RIBBERT, is 34.1 mm. There was a circumscribed attachment of this appendix to the wall of the sac, as well as a marked thickening of the latter, from which Piersol concluded that the adhesion of the appendix was the result of an early inflammatory process, and not of persistent fetal attachment.

The diagnosis of a hernia of the appendix is possible when the worm-like organ can be palpated within the sac, especially when, after palpation, upon inversion of the child, it slips out of the sac. It is more easily felt when inflamed, thickened, and rigid. A diagnosis will be made more frequently if the displacement is always suspected and felt for.

The sequelæ of such a misplacement may be those of an appendix normally placed, with the added liability to inflammation from trauma, kinking, adhesions, the accumulation of foreign material, or strangulation at the neck of the sac. An appendix in a hernial sac may become irreducible in consequence

of inflammation and adhesions contracted with the surrounding part; or suppuration may be set up in the neighborhood, forming an abscess, opening externally and creating a fecal fistula; or, finally, general peritonitis may result.

The operation for this condition may be relatively simple, and it can be performed on the surface of the body, much like an appendicitis operation, so long as it is done early, and the disease remains limited to the extraperitoneal pouch. Neglected cases, however, may be associated with a general peritoneal infection with all its attendant risks.

Ovarian Disease.—Several instances have been reported of a mistake in diagnosis between appendicitis and ovarian disease in the child. PORTER, in 1892, reported the case of a little girl eleven years old, in which the mistake arose from the twisting of the pedicle belonging to a small ovarian cyst. The little patient had had three previous attacks of pain in the region of the right iliac fossa, all of which had come on rather suddenly and disappeared as quickly; one after a warm rectal enema, the others spontaneously. She had never menstruated, nor did she seem to be near puberty. When seen, forty-eight hours after the beginning of the attack, there was a slight elevation of temperature with pain and exquisite tenderness in the right iliac fossa, and a sensitive tumor just above Poupart's ligament. The tenderness and tumor seemed to be rather too far down for the appendix, and the diagnosis of appendicitis was made with some hesitation, disease of the uterine adnexa being considered and excluded. At the operation a vertical incision through the right rectus revealed a right ovarian cyst the size of a small egg, its pedicle being slightly twisted by three complete turns, and showing beginning gangrene. A similar case of twisting of the pedicle is mentioned by FITZ, and VON FABER has reported a case of "*Steatoma of the ovary*" with perforation of the appendix, in a child three and a half years old. Here the symptoms were colicky pain in the abdomen with marked enlargement, and a worm-like swelling in the right iliac fossa. The abdominal enlargement increased until the child could not stand, and was accompanied by edema of the right foot. Death took place at the end of six months from the beginning of the illness, and at the autopsy the right ovary was found converted into a "steatoma, weighing sixteen and a half pounds, more than half of the body-weight. In the middle of the tumor was a cavity containing serum, and a bluish substance, in size and appearance resembling a pregnant uterus. In the vermiform appendix was a pinworm, which had bored through the tip of the appendix to the tumor." (*Med. Cor.-Bl. d. württemb. ärztl. Verhandlstultg.*, 1885, Bd. 25, p. 221.)

Actinomycosis.—KAREWSKI (*Dtsch. med. Wochen.*, 1897, Bd. 33, p. 321) records the following case:

A child had an appendicitis with considerable exudate, but slight general disturbance. On recovery he was sent to the country, when he began to show much peculiarity of gait, in the form of persistent flexion at the hip-joint, which was attributed to weakness. Soon after his return to the city he became ill again, with

more general symptoms of an indefinite description, and nothing characteristic of appendicitis. At last a swelling developed in the right inguinal region, eventually occupying the right lower abdomen, where there was a board-like infiltration, arising from an abscess which had broken on the outer side of the thigh, after passing the fossa vasorum, and under Poupart's ligament. There was no fever and no pain; some resistance could be felt through the rectum. When an incision was made, the golden-yellow granulations characteristic of actinomycosis were found. The abscess was traced as far back as the brim of the pelvis, and behind the peritoneum; Poupart's ligament was divided, after which the incision was carried over to the bladder and the region of the appendix exposed. The author says that it was clear there was an affection of the appendix, because, after a few days, and with the diminution of the swelling, a tit-like process of the intestine was visible in the wound, from which fecal matter escaped. After some deceptive improvement, an extension of the process between the liver and the bladder was discovered. The case had not terminated when reported.

TREATMENT.

The treatment of an attack of appendicitis in a child should begin when the disease is in its earliest stages, or even when it is merely suspected. If the child has an attack of acute gastro-intestinal disturbance with vomiting and some pain in the right iliac fossa; or if there is a mild incipient attack of catarrhal appendicitis, it must be kept quiet in bed, on restricted liquid diet, with enough opium to set the bowels at rest, and with an ice-bag applied over the appendix. It is of the utmost importance in these prodromal stages to avoid such active treatment as purgation and enemata, which are calculated to do so much harm in an appendicitis.

A patient detained in bed, while the diagnosis is uncertain, should be closely watched by physician and nurse, and careful note of the symptoms kept from hour to hour. If the physician judges that an operation may be needed, he should have all his plans made in advance to act with the utmost promptitude when the decision is reached.

Every case of frank appendicitis in a child should be operated upon, if seen in the early stages of the disease. If seen at a later date, that is to say, from the third or fourth day on, it is best not to operate, if there are decided signs of improvement, as shown by lessened temperature, slower pulse, and such amelioration in the general condition as is evident to a practised eye, but, above all, by a regression in the local symptoms, particularly in the absorption of the exudate.

So many cases of appendicitis in children end in a general peritonitis, and so many (SELTER estimates about one-half) end in the formation of an abscess, that it should be a rule to give prompt surgical relief as soon as a clear diagnosis is made. So eminent a pediatrist as ROACH (*Pediatrics*, 1896, p. 888) has declared that "inflammation of the appendix cæci is essentially a surgical disease, and is one which under all circumstances should be placed immediately

in the hands of those who are skilled in abdominal surgery. From my observation of this disease I am so strongly impressed with this fact that I consider an extended description of it in medical lectures, and by physicians, out of place."

SELTER, however, recommends that in every case, even with severe symptoms, a course of expectant treatment should be tried for one or two days, and then, if there is no improvement; if the swelling, which is being watched by rectal examinations, is found increasing in size; and if the peritoneal pockets are filling out, he declares there is no time to lose. I feel sure, however, that this is too great conservatism, and will often prove fatal in a long series of cases. If the diagnosis is clear, and if a good surgeon can be had, it is better to operate a few times too often than to regret having occasionally postponed doing so. The rule may, therefore, be laid down, that operation should always be performed: when the symptoms are progressive; when there is increase in fever, in pulse-rate, and in the exudate; when vomiting persists; and when tympany is present. If operation has been postponed on account of general improvement, and the exudate, which is being closely watched by careful palpation above as well as through the rectum, does not diminish after five or six days, it is better to operate than to risk septic infection from a concealed focus of suppuration.

If a child has had a number of attacks, the interval operation is to be preferred, on account of its safety; skilled operators estimating the risk of operation at this date as 0 per cent.

When a child has survived an attack of appendicitis, and a mass or a cord remains in the iliac fossa, there is less danger in operating and removing the appendix than in risking a sudden general peritonitis from the rupture of a small abscess left behind in this way.

When an abscess has formed, the incision should be made over the most prominent part, at any point between the median line and the anterior superior spine. The incision should always be a large one, and an extensive transverse incision, such as KAREWSKI has made use of in some instances, may sometimes be required. Two incisions, one on the right and one on the left side, are necessary more often in children than in adults; several instances have occurred in children where death was due to an abscess on the left side which had been overlooked. An incision on the left side alone should never be considered sufficient. As a rule, it is best to do as little as possible beyond thoroughly opening and evacuating the abscess and removing the pus. If the abdominal cavity is opened by accident, the utmost care must be taken to prevent the entry of pus, and the opening should at once be plugged with gauze. BROCA has in many cases successfully adopted the plan of opening the abscess and clearing up the suppuration, and then at a later date performing a secondary operation to remove the appendix. It is best to avoid extensive resection above the omentum in large abscess cases. Karewski has often

brought out the necrotic or deeply infected omentum, and left it lying on the surface, where, if it is properly protected and rendered harmless, it may slough off and granulate, or it can be drawn back again into the abdominal cavity.

In every operation it is well to stimulate the patient throughout with small doses of brandy in warm enemata, or small doses of strychnine, from $\frac{1}{60}$ to $\frac{1}{100}$ of a grain hypodermically, given two or three times, and, above all, to keep up the vitality by avoiding exposure of the surface of the body, by operating in a warm room, and by keeping the little patient warm on a blanket with hot-water bags beneath. The preparations for the operation should be so carefully made that the moment the child is ready, the operator will be able to begin and advance to a conclusion without delays. The delicate tissues of the abdomen must be handled with extreme care, and adhesions clearly distinguished from bowel before cutting.

If the child is very restless after the operation, and cannot be readily restrained by the nurse, a Bradford frame affords an excellent means of restraining it in a relatively immobile posture for the first few days, while the infected area is being walled off from the peritoneal cavity at large.

Even desperate cases of general peritonitis should be given a chance. There is absolutely no hope, under such circumstances, without an operation, and there is always a possibility of recovery with one. Karewski relates a case in which he positively refused to operate, because the child, which was brought to him with a profuse peritonitis, was moribund and pulseless, but the mother begged so piteously for some action that he opened the abdomen in the median line, cleansing it as well as he could, and tamponing the wound without sewing. The child recovered. Other cases of recovery under the most desperate and apparently hopeless conditions are reported. Extensive incision under a cocaine solution is a method which might be favorably employed in cases such as these.

CHAPTER XXI.

TYPHLITIS.

There is, perhaps, no subject in the whole realm of medicine in regard to which the views of the profession have undergone such a complete revolution as that of inflammatory affections of the right iliac fossa. The medical historian traces the evolution of knowledge concerning them from decade to decade, through the past century, with ever-increasing interest, and notes with surprise how often keen and well-trained observers, in possession of facts which should have afforded a right understanding of the nature of these affections, have yet failed to draw the simple conclusion so abundantly warranted by the premises. The records of the subject closely resemble the mortifying history of the search for the cause of malaria, in which a few facts patent to everybody contained the solution of the problem. Where, to-day, are the affections known as typhlitis, cecitis, stercoral typhlitis, tuphlo-enteritis, and their ilk? All these names, so well known of old, have vanished, and in their stead appendicitis appears.

The typhlon, or cecum, was the organ persistently accused in all right iliac inflammatory diseases for over half a century, whence the still too frequent misnomer "perityphlitis." The first step toward a clear understanding of the truth was the establishment of two sets of diseases in clinical nosology; one being the acute and perforative forms of inflammation, which were attributed to the appendix, the other the slow-forming, indolent swellings, laid to the account of the cecum. Aggressive surgery next made it plain that the appendix was the cause of the latter affections as well as of the former, and, finally, to-day, the question is seriously raised whether the cecum is ever the seat of primary inflammatory lesions, aside from those occasioned by such specific infection as tuberculosis, cancer, typhoid fever, and lues.

By typhlitis is understood a localized inflammatory affection of the cecum, beginning in the mucosa and going on, it may be, to ulceration and perforation. A typhlitis secondary to an appendicitis is not rare, and it may also exist as a part of a dysenteric inflammation of the colic tract. Primary typhlitis, however, is among the rarest of diseases, although as has been pointed out, an inflammation of the appendix, resulting in perforating ulcer of the cecum through continuity of tissue, may be wrongly interpreted as primary disease of the cecum. (Chap. XII, p. 277.) The long

cherished opinion that the cecum was liable to an inflammatory affection peculiar to itself and possessing certain characteristic signs must be definitely abandoned. Never again will the cecum be reinstated in its former nosological importance. Affections of the cecum, as NOTHNAGEL says, are identical with those of other portions of the intestinal tract, and if in some instances an inflammation, an ulcer, and a perforation are found in it, it is not because there exists a special predilection for this locality; their occurrence there is merely accidental, and the peculiarities of the case are those imposed by the anatomic relations of the bowel. STRÜMPELL (*Lehrb.*, 1899) declared that "typhlitis had never been demonstrated anatomically."

In the hope of setting this old but important question at rest, I will adduce such facts as have come to my notice in the literature of the subject.

In the first place, there are three possible conditions to be borne in mind in investigating the relations of inflammatory diseases of the cecum to those of the appendix:

1. An ulceration of the appendix may involve the cecum either by continuity or by contiguity.

2. An ulcer in the appendix may exist at the same time as an ulcer in the cecum, one being entirely separate from the other.

3. Inflammation or ulceration may exist in the cecum alone.

An inflammation of the cecum associated with a sloughing appendix and advancing to ulceration and gangrene, is by no means uncommon in neglected cases of appendicitis, or in the fulminating form; so common, indeed, is this direct extension of the disease from the base of the appendix by continuity that it is not worth while to collect cases to prove what forms a part of the experience of every active operator. This group of cases, however, is well worth a separate, careful anatomico-pathologic study.

The involvement of the cecum, by extension of the sloughing process from some point in the appendix beyond its base to the contiguous cecum, is only found in cases where the appendix is anatomically disposed close to the side of, or behind the cecum, being often plastered down to it by old inflammation. Instances of this condition are not rare, and I cite one given by MISS GORDON ("*L'Appendicite chez l'enfant*," *Thèse de Paris*, 1893).

A boy, eight years old, had characteristic symptoms of appendicitis, and, on operation, a localized abscess was opened, letting out fetid sero-pus. He died with a creptitant edema of the right thoracic wall, extending up to the shoulder-blade. At the autopsy there was no peritonitis, but a perforation of the cecum as large as a one franc piece was found on its posterior external surface, in contact with gangrenous tissues at the extremity of the appendix, whose remaining portion adhered to the cecum. The abdominal muscles were infiltrated with pus and gas bubbles.

Another interesting case of this kind, reported by FENGER, is given elsewhere. (See Chap. XXV, p. 590.)

The practical importance of recognizing this group of cases in which infection proceeds by contiguity, lies in the fact that it may be possible for the surgeon to prevent such an occurrence as a post-operative perforation of the cecum by using extreme care in detaching an adherent appendix from the colon, as well as by suturing carefully the torn muscular coat of the cecum. In many instances it is better to strip the mucosa out of the external muscular coats of the appendix rather than to attempt to detach the entire organ. (See Chap. XXV, p. 576.)

Ulcer of the appendix coincident with ulcer of the cecum is a rare occurrence, in which the colic affection is probably secondary to that of the appendix, except when it is due to typhoid fever. MISS GORDON (*loc. cit.*) cites a case in which there was an ulcerative affection in the appendix, complicated by an ulcer in the cecum, the two being anatomically separated.

A child, eight years old, was taken ill with all the classical symptoms of appendicitis, and a hard mass on the right side could be felt through the rectum. After four days' delay the peritoneal cavity was opened, and found healthy, but on pulling away the attached omentum, pus escaped from a perforation in the mesentery at the ileocecal angle. The appendix, which was 8 cm. in length, was found divided 3 cm. from its base, while posterior to, and to the outside of it, near its insertion, there was a perforation of the cecum. In spite of drainage, the little patient died in two days of general peritonitis.

The third of the possible contingencies, namely, the possibility of inflammation or ulceration of the cecum in the absence of any disease of the appendix, constitutes the real crux of the question. Were we to draw our statistics in regard to it from the older records, the condition would not appear so infrequent; ulceration of the head of the cecum with perforation was then often noted, but in these statements the appendix is either not mentioned at all, or it is significantly stated that it was involved in the sphacelation; our present knowledge enables us to read plainly between the lines, that in every one of these instances there must have been a gangrenous process originating in the appendix and extending by continuity into the adjacent cecal wall. MATTERSTOCK (*Handb. d. Kinderkr.*, 1880, Bd. 4, Abth. 2, p. 903) says that out of 49 cases of "perityphlitis," one or more perforations of the appendix were found in 37, and in this number he cites 4 cases taken from literature dating from 1853 to 1880, in which it is stated that the cecum was perforated, but in none of them is the condition of the appendix mentioned. No case can be accepted as one of primary disease of the cecum in which it is not also definitely stated that the appendix was examined and found healthy.

RENVERS, of the Moabit Hospital (quoted by Sonnenburg), says that, leaving

out of consideration the more frequent carcinomatous and actinomycotic tumors, as well as tubercular and typhoid ulcers, ulceration may occur on the posterior wall of the cecum in association with fecal accumulations. Twice he has himself seen pressure necrosis of this kind; once, due to a coprolith the size of a pigeon's egg, held fast in a cecal pocket, and once, caused by a fecal concretion, which formed in the cecum about a gall-stone the size of a walnut. It may, perhaps, be asserted without fear of contradiction that ulceration of the cecum never occurs simply as the result of fecal stasis in the cecum.

Out of 600 operations (*autopsies in vivo*) on patients with symptoms of "typhlitis," SONNENBURG found but a single instance in which the disease was primary in the cecum, and that was an inflammatory affection of the mucosa (*Perityphlitis*, Leipzig, 1800, p. 10).

An instance of simple, localized, primary typhlitis is given in JORDAN's case (*Archiv f. klin. Chir.*, Bd. 1, p. 534), in which there was an exact microscopic examination of the cecal wall during or soon after the attack, in addition to the necessary definite statement as to the normal condition of the appendix.

A girl, ten years old, was taken ill with typhlitis (*Blinddarmentzündung*), with fever and pain; in a short time a growing exudate, a hand's breadth in size, and painful on pressure, appeared in the cecal wall. The exudate could also be felt through the rectum. The abdomen was not distended or sensitive, the inflammation was localized, and there were no symptoms of any serious general prostration. Although there was some diminution in the induration, and the general condition was good, obstipation continued, and there were pains in the cecal region when the bowels moved. The diagnosis was made of an acute appendicitis in the stage of diminution, with perhaps an appendix containing pus and imbedded in lymph, and six weeks after the onset an operation was performed. An incision was made above Poupart's ligament, and the cecum discovered in the midst of inflammatory adhesions of the small intestines. After separating the adhesions, the vermiform appendix was found free, with smooth intact surface. It was removed and proved normal, except for a fecal concretion the size of a pea. After freeing the cecum, a brawny area of infiltration corresponding to the intestinal adhesions on the anterior wall, and the size of a two-mark (fifty-cent) piece, 0.5 cm. thick, was found and excised. The healthy edges of the wound were then united with silk sutures. The resected area lay below the level of the ileum, and about 0.5 cm. to the outside of the base of the resected appendix. The abdomen was closed with drainage, and a rapid recovery ensued. The piece of cecal wall removed was 3 by 2 cm. in size, and on its mucous surface there was a superficial ulcer 2.5 cm. in length and 0.5 cm. in maximum breadth; the surrounding mucosa was swollen. Microscopic examination showed no evidences of tuberculosis, but an extensive small-celled infiltration, most marked in the mucosa and submucosa. In the infiltration zone, staphylococci were seen. The case, therefore, presented a simple, primary, acute typhlitis without perforation, which in its clinical course as well as in its anatomic details corresponds to the classical picture of a stercoral typhlitis.

Other cases are as follows:

1. L. S. McMurtry (*Jour. Amer. Med. Assoc.*, 1888, vol. 2, p. 9). A young man had suffered from colic for several months, and in the last attack he had intense pain in the right iliac fossa and in the head of the penis. His general condition improved under sedative treatment, but at the end of a week there was increased soreness over the iliac region, and five days later a slight induration could be detected there, with dulness on percussion. This induration increased until it formed an oblong sausage-shaped tumor. On the sixteenth day a hemorrhage from the bowels occurred, with hiccough, tympanites, and vomiting, when a diagnosis of cecal inflammation was made. Symptoms of collapse supervened, and an immediate operation was advised, under the impression that there must be a perforation of the vermiform appendix. An incision three inches long, made over the tumor, revealed a limited peritonitis, and a normal appendix. On the anterior and external surface of the cecum two gangrenous perforations were found, one about 2 cm. and the other 1 cm. in diameter. The edges of these perforations were trimmed with scissors and the openings closed with silk sutures. The abdominal cavity was then carefully cleansed and the wound dressed; immediate improvement ushered in complete recovery.

2. J. B. Murphy (*Jour. Amer. Med. Assoc.*, March, 1894, Case 125). A man, twenty-four years old, had suffered for ten weeks with severe pain uniformly distributed over the abdomen, accompanied by tumefaction, tympanites, and pain in micturition. The temperature reached 101° F. and the pulse 104. There was diarrhea during the entire illness, with bloody stools during the last five days. An exploratory laparotomy was made, when half a pint of pus escaped, together with a piece of necrotic tissue three inches long. The cavity looked like that of a diphtheritic abscess. The patient's condition grew worse, and he died within twenty-four hours, when an autopsy showed that the incision had passed directly into the cecum, and the appendix was not affected in any way; the mucous membrane of the colon was gangrenous and detached from the submucosa.

3. J. D. Rushmore (*Ann. Surg.*, 1894, vol. 19, p. 577). A man, age not given, had three or four attacks of pain in the region of the appendix with fever, lasting a week or ten days each time, and recurring at intervals of a few months. In the last fatal attack the patient was up and about the day before dysenteric symptoms supervened. The autopsy showed an enormous collection of pus, which had burrowed down under the rectum, giving rise to the tenesmus and bloody discharges. The abscess had perforated the head of the colon, apparently from without inward, reversing the picture of a perforating typhoid ulcer, the opening through the peritoneal coat being much larger than that in the mucous coat. The appendix was to all appearance healthy, but it was not subjected to a microscopic examination.

4. M. F. Porter (*Med. News*, 1895, vol. 67, p. 299). No history could be obtained. A man, who was thought to have appendicitis, refused operation and died a few days later. The autopsy showed a healthy appendix, while the upper part of the cecum and seven or eight inches of the ascending colon were gangrenous.

5. C. Beck (*New York Med. Jour.*, July, 1898, Case 9). A man, aged forty, began to have intense pain in the umbilical region and in the right iliac fossa, accompanied with nausea and vomiting. He was up and about, however, for ten

days, when he was admitted to the hospital in a septic condition, with a small pulse, high temperature, tumefaction, and corresponding dulness in the right iliac fossa. Operation revealed partial gangrene of the cecum, but the appendix was not found. The illness continued, and repeated abscesses formed in the intestinal loops around the cecum. An ectropion of the bowel as large as the palm of the hand appeared, but closed again when a small abscess under the liver was opened. Three weeks after the first operation, enteroplasty was performed. On separating the adhesions in the intestines, a perfectly intact appendix with a healthy mucosa was found. It may be assumed, therefore, that the gangrenous process was at first confined to the wall of the cecum.

6. F. A. Southam (*Brit. Med. Jour.*, 1898, vol. 2, p. 1130). A man, aged twenty-nine, was admitted to the hospital with symptoms of an acute appendicitis of four days' duration. There was distinct fulness above the outer part of Poupart's ligament, tenderness on pressure, and slight dulness on percussion, with rigidity of the abdominal muscles on the same side, and some tympanites. The temperature was only 99.4° F. On the ninth day the temperature was normal, the patient was up and appeared to be doing well, when vomiting set in, which shortly became fecal. An exploratory laparotomy was done on the eleventh day, and an incision made over the region of the appendix, letting out a small quantity of pus, which contained a fecal concretion formed about a pin, the head and point of which protruded. The localized abscess was then washed out with a boric acid solution, and a drainage-tube inserted, after which the patient recovered, except that a fecal fistula remained. About two months after leaving the hospital he was re-admitted, as the fistula showed no signs of closing; at the second operation the wound was enlarged and found to open directly into the cecum, which was adherent to the abdominal walls; the opening, about 2 cm. in diameter, was in the anterior wall of the bowel, about 3 cm. from the insertion of the appendix, which was healthy and free from adhesions. The protruding cecal mucosa was reduced and the opening closed after liberating the margin, when recovery followed.

7. Southam (*ibid.*). A boy of nineteen was admitted to the hospital with a fecal fistula in the right groin, about 1 inch above the centre of Poupart's ligament. He had had an abscess in this situation about six months before, with the usual symptoms of a "perityphlitis"; this was followed by a fistulous opening. After an ineffectual attempt to close it by scraping, the opening was enlarged, and the fistula traced to its connection with the bowel, which was found on the anterior wall of the cecum, close to its junction with the ileum. The appendix was quite healthy. It was impossible to free the margin of the opening sufficiently to permit a plastic operation, therefore an ileo-colostomy was performed, and a drainage-tube inserted into the wound, after which the patient made a good recovery.

8. Southam (*ibid.*). A man, sixty-seven years old, was admitted to the hospital with symptoms of incomplete obstruction, beginning seven weeks before. He had considerable abdominal distention, but nothing was perceptible to palpation. Four days after admission he was suddenly seized with a severe chill, and the temperature, previously normal, rose to 103° F. He recovered from the rigor, but the same evening complained of great pain in the right iliac fossa, went into

collapse, and died in two hours. The autopsy revealed a peritoneal cavity containing pus and fluid feces, most abundant in the neighborhood of the right iliac fossa. The upper part of the rectum, the colon, the cecum, and the small intestine for some distance, were distended with masses of hardened feces. Behind the cecum were a number of old adhesions bounding an irregular abscess cavity containing pus mixed with fecal matter, and communicating with the general peritoneal cavity. On opening the cecum, a superficial ulcer, about 3 cm. in diameter, involving only the mucous membrane, was found on the posterior wall, and at the centre of the ulcer there was a small perforation about the size of a pea, opening into the abscess. The appendix and other parts of the intestines, small and large, were healthy.

9. Sonnenburg (*Perityphlitis*, 1900, p. 13). A seamstress, twenty-two years old, had gradually increasing and finally violent pain in the right lower abdomen, without vomiting or fever; she had never had a previous attack, but had recently suffered from constipation. The abdomen was sensitive at all points, especially in the pit of the stomach and in the right iliac fossa, where there was a definite, diffused area of resistance without any defined boundaries. There was moderate dulness and no tympany. On opening the abdomen the peritoneum was found thickened and attached to a portion of the cecum, the rest of which was normal; the appendix was free, movable, and normal. The diseased portion of the cecum, which was larger than a dollar (*über fünfmarkstück gross*) and sharply defined from the surrounding healthy tissue, was excised. The adjacent portion of the bowel was found lined with normal mucosa. The wound was closed, a drainage-tube inserted, and the patient recovered. Microscopic examination of the excised tissue showed a uniform cellular infiltration of all the coats, but no carcinoma, syphilis, or tuberculosis. Sonnenburg could think of no cause for such a peculiar localized affection other than that this portion of the bowel must have been incarcerated in one of the neighboring retro-peritoneal pockets, bringing about such characteristic changes as are commonly noted in a chronically inflamed hernia of the intestinal wall.

10. Gordon (*loc. cit.*). A little girl, eleven years old, had a lumbar traumatism, falling on a piece of furniture and at once complaining of pain, which soon passed away. Five days later she had violent pain in the right side of the abdomen without vomiting, but with a little fever, and constipation. There was no definable mass. An iliac incision evacuated about a wineglassful of fetid pus, but she died of general peritonitis, when at the autopsy a fecal calculus about the size of a date-seed, was found below and to the outside of the cecum. Miss Gordon states that the appendix was not perforated, but that there was a perforation of the cecum to the inner side of the appendix from 2 to 3 mm. in diameter.

11. Von Eiselsberg (*Archiv f. klin. Chir.*, 1898, Bd. 56, p. 309). The patient suffered from violent attacks of abdominal pain with exacerbations of fever. On opening the abdomen the small intestines were found extensively adherent among themselves in the neighborhood of the cecum, while the cecum itself was united with the right ovary into a rigid, densely adherent tumor. The appendix was easily removed, but it was inpossible to extirpate the cecum, largely on account of the risk to the ureter. The case was then treated by dividing the cecum at the lower level of the cecal valve and closing the distal portion of the bowel by

continuous sutures in two rows. The lower part of the bowel and the entire cecum were closed down to a small fistulous orifice, which was left open for an iodoform drain. At first there was a free purulent secretion from the excluded cecum, without, of course, any fecal material. After three weeks the discharge had greatly diminished, so that the patient was able to leave the hospital thirty days after the operation, free from pain. The cecal tumor could not, at that time, be felt. Five months later she returned, complaining that numerous ligatures were coming through the fistula. An anesthetic was then given and the entire area curetted, after which she recovered entirely.

12. Meusser (*Mitt. a. d. Grenzgeb. d. Med. u. Chir.*, 1897, Bd. 2, p. 397). The patient, a girl seventeen years old, had had a "typhlitis" in her ninth year, lasting five weeks. In her sixteenth year she had another attack with high fever, tympany, great sensitiveness in the region of the cecum, and vesical disturbance, lasting three weeks. Fourteen days before she entered the clinic she had a third attack. The ileocecal region was then very sensitive to pressure. At the operation adhesions of the cecum to the anterior and lateral abdominal walls were found, as well as adhesions of the omentum to the colon and gall-bladder. The appendix was thin, 9 cm. in length, and hung down into the true pelvis; it appeared normal, except for a few fecal fragments. The adhesions of the intestines were loosened, but the appendix was not removed.

The following additional case is of interest, although it cannot, I think, be admitted to the category of primary cecal affections, as daily experience shows that the appendix can recover perfectly after a violent attack of inflammation. The evidence would be stronger if the appendix had been removed and examined microscopically for remains of an old attack, more apt to be found on its mucous surface.

Schlafke (*Münch. med. Wochenschr.*, 1895, Bd. 42, pp. 22, 753). A young man had had an attack of colicky pain a half-year before he was first seen. Celiotomy was performed, and on the under surface of the cecum a number of delicate cord-like adhesions were found, which connected it on the outer side and below to the parietal peritoneum. The appendix, which lay to the outside of the cecum, was very long, movable, and showed no abnormal conditions; it was not removed, therefore, although the adhesions of the cecum were loosened.

From these cases it is evident that a localized inflammatory disease of the cecum, when it occurs, is usually mistaken for disease of the appendix. I believe, however, that a presumptive diagnosis could be made in some cases, if the onset of the attack were carefully observed, if the local physical signs were minutely noted from day to day, and, above all, if sufficient importance were attached to the condition of the bowels. It will be seen by consulting the scanty information afforded in these records, that diarrhea, dysentery, and hemorrhage were prominent features in several of the cases. There is no differential sign by which we

can distinguish a case in which a pin perforates the cecum, from one in which it perforates the vermiform appendix. A foreign body, such as a large coprolith, might be felt by careful palpation, if the abdominal walls were thin; foreign bodies might also be revealed by the X-ray skiagraph.

Celiotomy, in accordance with the indications given in the section on treatment (see Chap. XXV), is the proper treatment, whether the disease is confined to the cecum or includes the appendix. An abscess should be opened and drained; at a later date the bowel can be exposed and liberated, and the fistulous orifice excised and closed. If it fortunately happens, as in the McMURTRY case, that it is possible to expose the openings in the bowel in such a way that they can be treated and sutured at once, this is manifestly the best plan, saving a tedious convalescence. Care must be taken, in such a case, to cut well out into the sound tissues of the bowel beyond all suspicion of disease, looking out for gangrene and undermining of the mucosa. The best treatment of ulcerated areas, threatening to break through the external coat of the intestine, would probably be by infolding the bowel at those points, using one or two layers of sutures. A loose drain should always be left in place for several days, in case the sutures do not hold. In JORDAN'S case the ulcer was resected with success.

CHAPTER XXII.

GENERAL CONSIDERATIONS REGARDING OPERATION.

INTRODUCTORY. INDICATIONS FOR OPERATION. IMMEDIATE OPERATION. INTERMEDIATE OPERATION. LATE OPERATION. INTERVAL OPERATION.

INTRODUCTORY.

Relations Between Physician and Surgeon.—Although appendicitis is now generally reckoned a surgical affection, and a familiarity with its symptoms has now become so common that the patient himself will often send at once for a surgeon, the disease is still in most instances first seen by the medical man, summoned under the impression that the attack is one of simple colic, due perhaps to indigestion. The relations between the physician and the surgeon become, therefore, a matter of importance, for while it is generally conceded that as soon as an appendicitis is found to be actively progressive a surgeon ought to be called, it is not always understood that he is not summoned merely because his knowledge of anatomy enables him to find and remove the diseased organ, but rather because of his greater diagnostic skill in surgical affections, and his more extensive knowledge of their natural history, which cause him to realize more fully the dangers attending each step in the progress of the disease; he is better able, therefore, to decide upon the best time to operate, since the family physician has not always a keen appreciation of those conditions in which a grave prognosis would at once be given by an experienced surgeon. Too often, however, in spite of the multiplied experiences of the last fifteen years, does the surgeon still have reason to lament the fact that patients who have been first in the hands of his medical *confrère* are recommended to seek the aid of surgery only when the conviction is overwhelming that an operation is imperative, and at a date too late for him to act with any reasonable assurance of success. My attention has been specially directed by J. E. Stokes to the fact that this happy-go-lucky procrastination is notably the habit in remote rural and mountainous districts, where a consultation is often sought only *in extremis*. But even in our large cities and hospitals, in communities where both the medical periodicals and the constant discussions of our societies conspire to teach men better, the surgeon often has just reason for complaint that he is not given a better chance to demonstrate the safety of operative procedures under suitable conditions. The duty of a physician is aptly expressed in W. W. Keen's aphorism, "The first indication in appendicitis is to call in a

surgeon"; it is the office of the surgeon to determine upon the necessity for an operation, and for this reason he should be asked, at the very outset, to see the case in consultation with the physician.

After the surgeon has been summoned, the question may arise: What is his duty when operation is advised by him and refused by the patient or his relatives? In a case of well-defined appendicitis with persistent symptoms of a severe type, the proper and dignified course is to retire from the case; but if the surgeon does this, he should carefully state that it is because he is unwilling to stand by, able to relieve and yet helplessly watching the patient who is taking such desperate chances. He ought, as he withdraws, to make it plain that it is always within the limits of possibility, even if it is highly improbable, that a desperate case may recover without operation. If he abandons the case with the unqualified statement that the patient will surely die without operation, and recovery, as has often happened, takes place, nothing will hurt his reputation so greatly, and, what is of far greater importance, other sufferers, also urgently in need of surgical aid, will be encouraged to take their chances without it, under the impression that his art is mere guesswork. No blame, however, for lack of dignity, but rather praise, should be given to the professional man who, although his urgent advice is not taken, nevertheless, from a sense of duty, and with the assurance that he has not in any degree lost the confidence of the family, continues to watch over the helpless sufferer as he battles for life, with faithful, tender care, exhausting every palliative resource, even to the fatal end.

On the other hand, the surgeon called in late to save a desperate case, ought never, for a moment, to consider his own reputation and the probable fatal outcome, but should a ways be ready to give the patient, who is usually the innocent victim of circumstances, the slender chance held out by an operation. He should feel that, under these circumstances, he is rendering a valuable service, if he saves but one life in fifty, when death is certain without his intervention.

Removal of the Normal Appendix and the Incidental Removal of the Appendix.—Before discussing the special indications for operation, it is, I think, worth while to consider certain circumstances in general, under which removal of the appendix may be necessary or advisable.

1. Routine removal of the normal appendix as a prophylactic measure.

2. Removal of the normal, or the adherent appendix, whenever the opportunity is afforded incidentally to do so with safety.

Should the normal appendix be removed as a prophylactic measure? Under the caption "normal prophylactic appendectomy" the question has actually been debated "whether the appendix should be removed in children as a matter of routine, in order to insure them against appendicitis." This question was answered, and seriously discussed by 88 American surgeons (*St. Louis Med. Rev.*, March 17, 1900). It is sufficient to declare that the proposition was regarded almost unanimously as "absurd,"

"unjustifiable," "unsurgical," or "without excuse." The mere entertainment of such a suggestion is evidence of a state of public hysteria, induced by the often sudden and alarming onset of the disease, as well as by the increasing frequency of operations for its relief; but, more than all, perhaps, is it the fruit of constant discussion and fomentation of the subject by the laity, and by the daily press; all of which factors combine to bring about a state of panic-stricken uncertainty when each man feels that he may be the next victim. Should appendicitis become still more frequent than at present, this question may again be propounded, when the following data have been secured: first, the actual *pro mille* risk to each individual that he will have the disease; second, the proportion of fatal and non-fatal cases, when the disease is let alone; third, the *pro mille* risk from the operation itself.

Should the normal, or the adherent appendix, be removed whenever the opportunity is incidentally afforded by a celiotomy undertaken for other affections? In urgent and desperate cases of abdominal surgery it is clear that no additional operation is justifiable. The question whether the appendix, normal or adherent, should be removed in simple and uncomplicated cases is one attended with so much interest that I have been at some pains to ascertain the sentiment of the profession in America in regard to it. Fuller data will be found elsewhere (see Chap. XXIX); I here note simply that 44 surgeons consulted were against removing the appendix under the conditions stated, while 26 were in favor of doing so. To the second question, namely, the propriety of removing the adherent appendix, 66 surgeons replied in the affirmative, while 7 gave a negative answer. My own opinion agrees with the majority in both instances, and my reasons are given as cited elsewhere.

INDICATIONS FOR OPERATION.

The operator in appendicitis must always be on his guard lest he open the abdomen only to find there is no disease at all, or, perhaps, a morbid condition entirely unconnected with the appendix, such as intestinal obstruction, an ileus, a movable kidney, a gall-bladder filled with stones, a pyo-salpinx, an ovarian tumor, or an extra-uterine pregnancy. An error in diagnosis is not so serious when there exists a surgical affection in itself demanding operation, for the harm then done is limited to the additional incision needed to reach the unsuspected disease, but it is a very different matter when the malady turns out to be nothing more than simple colic with indigestion, or else a case of "peritonism" (Guebler). I shall never forget one of my first patients, a young woman who had been under my care for a gonorrheal salpingitis, for which I had done a radical operation. She called me a long distance from home, one Sunday morning, for intense lower abdominal pains, and I distinctly felt

an exquisitely sensitive, nodular mass, behind the uterus. I opened the abdomen with the hope of removing the focus of infection and nipping an acute peritonitis in the bud, but, to my chagrin, discovered only a rectum full of beans, eaten at a late supper and imperfectly masticated.

The group of positive symptoms which the surgeon must keep before him as indications for operation are:

Pain about the umbilicus, or in the right iliac fossa.
Muscle spasm over the affected area.
Tenderness, evident on palpation.
Localized swelling.
Nausea or vomiting.
Constipation.
Elevation of temperature.
Increased pulse-rate.
Increasing leucocytosis.
Ileus.

In a typical case all these symptoms may be present, but the surgeon will often be called upon to decide for or against an operation when several of them are absent; for example, if there is muscle spasm and local tenderness with marked and increasing leucocytosis, or, as Robert Abbé puts it, "when there is tenderness and muscle spasm with a fairly active onset," an operation is imperative, although other signs are absent. A well-developed local tenderness with muscle spasm, and a pulse increasing in rapidity may be the sole symptom in some of the worst forms of appendicitis during the early stages.

Pain.—Pain may be situated in any part of the abdomen during the initial period of the disease; at first it shows a striking predilection for the umbilical region, but a little later it settles down to the affected area in the right iliac fossa. After the pain has once become localized in the iliac region, an increase in its intensity or an enlargement of its boundaries points either to the occurrence of suppuration, or to an extension of the disease into new territory. A sudden cessation of pain may be due to the rupture of an abscess into the bowel, or, in the case of an extensive infection, this may be the first ominous sign of collapse from an overwhelming toxemia. M. H. Richardson (*Trans. Amer. Surg. Assoc.*, 1899) says, "If pain is severe, and increasing in severity after the early hours, operation is demanded by this symptom alone."

Tenderness.—Tenderness on pressure together with pain are the symptoms simulated by neurotic patients with an appendicito-phobia, or "appendicitis on the brain" (Osler). The surgeon must be ever on the watch to detect these often involuntary malingerers (*sit venia verbo*). As a rule, it is easy to throw them off their guard by engaging them in earnest conversation while examining the painful area, or by using the other hand simultaneously upon some other part of the body and thus confusing the attention. It is a good prac-

tice to begin the examination by palpating other parts of the abdomen, especially the left iliac fossa, and so securing a basis of comparison. When tenderness is really present, it constitutes a valuable sign indicative of an underlying inflammatory process, often corresponding to the area outlined. It is well to test the tenderness by first making gentle, graduated pressure with all four fingers, and then outlining the area more precisely with one or two. Tenderness confined to a small area may indicate an inflammation limited to the immediate neighborhood of the appendix or an intra-appendical affection, according to the stage of the disease. Van Lennep reports a case which illustrates very well the importance of tenderness as a single symptom (*Hahn. Med. Month.*, Jan., 1895):

A man, forty-four years old, was taken ill with appendicitis presenting very mild symptoms. These increased for about twelve hours, and then gradually lessened for about five days. There was then a moderate increase, followed by a diminution of every sign except tenderness. On account of this symptom, his physician summoned surgical aid. At the time of operation, which was late the same night, every symptom was practically gone, except the tenderness, which was exquisite. An incision showed an entirely unprotected abscess, while the appendix was injected and gangrenous in several spots and surrounded by a quantity of sero-pus.

Rigidity.—Rigidity, local, in the early stages of the disease, becomes general in a diffuse peritonitis; it is one of the remarkable efforts of nature to put the parts at rest and thus limit the spread of an infection. When present, it constitutes a most valuable sign, perhaps, indeed, the one sign which comes nearest to being pathognomonic. When associated with localized pain, fever, and a rising leucocytosis, the diagnosis is sufficiently clear to demand operation. Both rigidity and tenderness, however, are absent in some of the worst cases. The decision to employ active measures must then depend upon pain, fever, and increasing leucocytosis, after the possibility of intrathoracic disease has been carefully excluded. Richardson says: "As an indication of spreading infection, tenderness ranks with pain and rigidity. If these symptoms increase in extent, the infection is spreading, when, it is needless to say, immediate intervention is required."

Temperature.—Rise of temperature is a most variable sign in appendicitis; it is usually elevated, although rarely high, and occasionally it is almost normal throughout the attack. Fever, in combination with other signs, constitutes a valuable asset in the diagnostic complex, but in some of the worst cases, requiring immediate operation, the temperature is normal. We may have fever without infection in hysteria, and (in children) with a trifling indigestion. With these exceptions the presence of a persistent fever is generally associated with, and a pretty good index of the activity of the inflammatory process. When, therefore, fever is present together with the necessary

local signs, the operator may proceed with a comfortable assurance that the lesions under consideration demand surgical interference.

Pulse.—A good full pulse gives a better prognosis in operation than a pulse running up to 120 to 140, and small in volume. If a pulse which has been but little accelerated begins to go up steadily in the presence of other signs of disease, a speedy operation is indicated.

Tumor.—This is the result of adherent intestines, of exudate, or, perhaps, of an abscess with rigidity of the overlying abdominal wall. Sometimes the tumor cannot well be felt because of this rigidity, and an anesthetic is necessary to relieve the muscle spasm, and enable the surgeon to outline the mass below. Unless all the symptoms are decidedly improving, the presence of a tumor is an indication for operation. If it is stationary or enlarging, or if there are signs of pus, an operation ought to be done at once.

Vomiting.—Most attacks of appendicitis begin with vomiting, but if it is persistent, and, above all, if it is associated with constipation, distention, and other local signs of appendicitis, operation is urgent. Later on, a constant vomiting and retching form the most marked signs of a general peritonitis, where immediate operation is the only hope.

Leucocytosis.—As an aid to diagnosis and an indication for operation the value of the blood-count depends upon the stage at which the leucocytes are counted. Early in the disease, a rising leucocytosis is an indication for immediate operation; later on, when abscess formation has begun, no reliance can be placed upon the leucocyte count. At this stage there may even be a decrease. The variation of opinion at present found among physicians as to the importance of leucocytosis as a guide to operation arises from the fact that the count is made by them at different periods. Those who make a count early in the disease find in it a reliable guide and praise it highly; while those who postpone it until the later stages, derive little or no assistance from it, and consequently deprecate its usefulness.

Ileus.—Of all indications for operation during the attack, ileus, unless of the most transitory character, is, as LENNANDER says, one of the most urgent. It may arise from the violence of the attack, or it may be occasioned by the peritonitis. An ileus appearing at the onset may disappear after the administration of a little opium; when persistent, it usually arises from a fixation of one or more loops of bowel, compressed or kinked in such a manner as to hinder the passage of gas or feces. The patient vomits constantly, throwing off, at first, the contents of the stomach, and afterward fecal matter. After the lower bowel is emptied, no more feces pass, unless the obstruction is only partial. In many cases these symptoms supervene gradually, and the obstruction does not become complete for some days. The abdomen swells, at first on one side, or in the median line, and the patient is tormented with paroxysmal pain associated with periodical, and often visible contractions of the proximal portion of the ileum. Under these circumstances, operation is urgently in-

dicated, before the persistent distressing symptoms have depleted the vitality. Prompt action is all the more necessary because the operation, in many instances, proves to be one of unusual severity.

Promptitude in Operation.—As soon as operation is definitely decided upon, each minute of delay is valuable time lost, since in every case of appendicitis there is a moment when relief, possible before, arrives too late; and as this critical period draws momentarily nearer, prompt measures must be taken to anticipate its advent. It is not always the medical man who is responsible for injurious delay in operation, for we find, to our surprise, frequent reports of cases seen by eminent and experienced surgeons, who have countenanced a delay of days, or even weeks, in the face of the most pronounced symptoms of the disease, such as extreme pain (quieted by opium), continued elevation of temperature, muscular spasm, and well-defined mass in the right iliac fossa. It is distressing to hear of the golden moments wasted in continued efforts to dissipate these symptoms by purgative drugs. It would be invidious to select illustrative instances, here and there, from medical literature; it is enough to sound a warning, which should be reiterated until it is effectually dinned into the ears of each rising generation: Our trust is sacred, and whenever we assume the responsibility of life in a dangerous case, we ought to act with the same energy and promptitude in bringing relief and in forestalling danger as we should wish, were we ourselves the patients. I do not desire here to criticize the attitude of those members of the profession who are under the conviction that it is better to wait until the affected area is well walled off from the peritoneal cavity, but I do wish to protest against dawdling when the necessity for operation is clearly recognized. A surgeon watching a case with progressive symptoms day after day, ought to experience a positive sense of humiliation when he tardily opens an abscess and lets out pus. I have before me the case of a poor fellow, twenty days in the hands of a surgeon, who finally naïvely remarked that "operation now became imperative, and three pints of pus were evacuated"!

Every surgeon who expects to be called on to operate for appendicitis should keep his instruments and other paraphernalia in readiness to be transported to the patient at a moment's notice, so that no time may be lost in sterilizing, in collecting necessary articles, or in packing. A nurse with experience in such cases and surgical assistants ought always to be available. The question of personal convenience ought not to be considered, and the night should be regarded as the day. Two distressing experiences due to delay are frankly related by Tuffier (*Rev. de chir.*, 1895, p. 705) as a warning to the man who lets convenience, comfort, or engagements delay an operation. In one, a patient with an acute appendicitis refused operation; later in the day the pain increased, and when seen next morning by Tuffier, he was found with a peritonitis characterized by a dissociation between pulse and temperature; the operation was then

planned for five o'clock in the afternoon, but when the hour arrived, the patient was dead. The second case was that of a child who had been ill for three days. The next day was fixed for the operation, but at the appointed time the child was moribund.

Another source of fatal delay may be the desire of the patient, or the relatives, to await the arrival of members of the family from a distance. If the surgeon is convinced that an operation is imperative, he must not sacrifice the advantages of time to sentiment, but must assume the added responsibility of urging, and even insisting upon instant action. The evils of procrastination are well shown in a case reported by CARMALT (*Amer. Jour. Med. Sci.*, Jan., 1894):

> The patient, a college student, was under the immediate care of another physician; the initial constitutional symptoms were severe, but the local evidences of appendicitis were not marked. His home was at a distance, and word was received that his father was hastening on, accompanied by his own surgeon. From a natural wish not to seem precipitate, the operation was postponed until such serious symptoms arose that further delay was out of the question; it was then done without the father's presence. Unfortunately the eighteen hours' delay had carried the patient beyond the safe period, and a general septic peritonitis had arisen from the rupture of a thin-walled abscess, associated with a gangrenous appendix containing a fecal concretion.

A common idea, prevalent even among the medical profession, is that the patient is too weak to stand operation in an acute stage; the notion also prevails in some quarters that hot weather drains the strength, and therefore is a contraindication to active measures. These factors, although undoubtedly deleterious, need not hinder prompt operation in urgent cases.

It may be positively stated that no case of appendicitis where an operation was necessary was ever operated upon too soon, and when the decision to operate is made, no consideration, however plausible, should be admitted as a reason for unnecessary delay.

Operations for appendicitis classified according to the stage of the disease at which they are performed are four in number, namely, early operation, performed at the very outset; intermediate operation, performed from the second to the fifth days; late operation, performed after sufficient time has elapsed for the formation of an abscess; and interval operation, performed between the attacks.

Early Operation.—By early operation we mean one in which the progress of the disease is arrested by surgery before the occurrence of various untoward complications, such as peritonitis, septicemia, pylephlebitis, etc. The cases which die in the hands of a good surgeon are those with complications, death being due to exhaustion, sepsis, injury to the bowel,

extensive adhesive peritonitis, abscesses formed elsewhere in the peritoneum, above the liver, or in the pleura. These complications arise in the course of the disease and are not present at the outset. An operation done in the initial stages encounters none of these risks and is as safe, or almost as safe, as an interval operation. To put the matter a little differently, it is clear that in every appendicitis, no matter how desperate, there existed at one time, early in the history, a stage in which it could be treated without risk to life, and no surgeon ever yet saw a bad case in which he did not regret his inability to operate under conditions antecedent by some weeks, days, or even hours.

The opinion of American surgeons from the first has been that early operation is the only safe plan, and many of the best French surgeons now take the same position. The attitude of most of the Germans, on the other hand, is more conservative and strongly in favor of delay, a point of view in which the English surgeons, to a large extent, agree. The diversity of opinion between American and German surgeons as to what constitutes "an early operation" is nowhere more apparent than in BORNHAUPT's able paper entitled "*Zur Frühoperation der Appendicitis*" (*Langenbeck's Arch. f. klin. Chir.*, 1903, Bd. 70, p. 300), in which v. BERGMANN's cases are discussed. He says, in speaking of early operations in Germany: "We divide the cases into two categories. To the first group belong 102, in which there was an encapsulated abscess; to the second group we assign those in which a general peritonitis was found." He adds, farther on, "of an early operation in the restricted sense of the word we cannot speak, as the earliest was after fifty-seven hours."

The ideal time for operation in acute appendicitis is within the first few hours, and not later than the first twenty-four, when the organ can be readily detached from the surrounding structures, and before the formation of an exudation or of an abscess with adhesions among the bowels. If a patient with a frank, well-defined appendicitis is seen at the very outset of the attack, he has a better chance, if a good surgeon is available, by immediate operation than by waiting. If, however, the surgical skill at command is not all that could be desired, he will do better to take the chances of a spontaneous cure, or to wait for the formation of a localized abscess, which can be opened and drained later on.

Another argument for immediate operation is the fact that the disease has already seated itself in the appendix and made definite progress—who can say how far?—before giving rise to the first recognizable symptom. Also, as W. H. DOUGHTY of Augusta, Ga., insists, acute cases almost always carry with them the signs of antecedent disease, so that we are dealing either with a recurrence or with the culmination of a pathologic process, which, in most cases has only just reached the point of involving the peritoneum, through which it makes itself known.

It must always be remembered that in the present condition of our knowledge it is impossible to estimate how rapid the progress of an appendicitis

will be. In one case of FINNEY's, a hospital nurse was seized with her first attack of pain shortly after coming on duty in the morning, and the operation, performed within three hours of the apparent onset, showed the appendix gangrenous on one side and ready to perforate. In another case of the same surgeon's, the patient, a young physician, operated upon within six hours of the initial complaint, was found to have a spreading peritonitis, and there was every reason to believe that the very first pain he felt was occasioned by the perforation; both cases recovered.

The advantages of early operation may be summed up as follows:

It is safest, because it can never be foreseen which cases will go on to suppuration and which will not; moreover, fatal complications may arise at any moment, absolutely without warning.

The operation is more easily done, for there are no fresh adhesions, or, if there are, they are not dense; there is often no extra-appendical pus, and the appendix is more easily reached than it can be at a later stage through adherent, matted intestines.

The patient is spared days of suffering, for the attack, being cut short, is reduced to a brief surgical illness with rapid recovery, instead of a protracted convalescence of weeks or months. The patient is also saved the pain which inevitably attends the changing of the gauze dressings necessary when drainage is employed.

The liability to recurrent attacks is obviated, and this is not always the case in later operations, for the longer the delay, the less the likelihood that the surgeon will find and remove the appendix. It must always be remembered that recovery from the attack does not always mean recovery from the disease. Recovery from the attack may take place under conservative treatment; recovery from the disease, as a rule, is certain only when the appendix has been removed.

An early operation obviates the risk of hernia, which is so common in suppurative cases.

INTERMEDIATE OPERATION.

When the patient is first seen on, say, the second to the fifth day of a frank appendicitis, the question of operation becomes more complex. At this period the surgeon has to consider the difficulties and dangers of breaking up adhesions, together with the associated risk of distributing a localized infection, and some operators regard these as so great that they prefer to wait until a later period, in the hope that the disease will either abate and be absorbed, or else that a well-defined abscess may be evacuated without danger, the case being watched meantime from hour to hour. There is no class of cases which present such difficulty to the conscientious surgeon as these, which we may, for convenience of discussion, divide into three classes:

1. Cases which are manifestly getting worse, as evidenced by continued local pain, swelling, tenderness, muscle spasm, and increasing elevation of temperature, with quickened pulse. These symptoms, together with the facial expression, make up a *tout ensemble* which the experienced eye quickly recognizes. My colleague, W. S. Halsted, tersely says, "if a case is on the rise, operate; if it is on the fall, you may wait; if a case is falling but not fast enough, one is prone to operate to relieve anxiety." I think that all surgeons will agree with the first part of this statement.

2. Cases in which the patient, although not growing worse, is not distinctly improving, and there are sufficient signs of activity to suggest the possibility of latent trouble, should be operated upon at once. Most surgeons, I think, will agree to this.

3. Cases which are undoubtedly on the mend, as shown by improvement in the general condition of the patient, the occurrence of free evacuations from the bowels, and decreasing tympany, together with lessening of muscle spasm over the affected area, lowering of temperature and pulse-rate, and a decrease in the leucocyte count. It is of the utmost importance to remember in such cases that the most marked signs of improvement may be entirely illusory, and the surgeon must be on his guard against misinterpreting that commonly observed, but dangerous lull in the symptoms, that so often precedes another outbreak of pus or the occurrence of general peritonitis. There is a large group of cases in which, as Jacobson says, "there may be a mitigation of all, and a complete disappearance of most of the symptoms, and yet, during the period of their subsidence, the diseased process has gone on steadily." A good illustration of such a case is given by Cordier (*Jour. Amer. Med. Assoc.*, Feb. 22, 1896):

A girl of sixteen was seized with intense pain in the right iliac fossa, followed by shock, from which, however, she rallied; later the pain spread over the entire abdomen, but subsided in eighteen hours. When seen by the surgeon, her pulse was 90, and her temperature 100.9° F.; she complained of a sense of distention, but no pain. She was bright and cheerful, and insisted on getting out of bed to have her picture taken, so that she was standing upright not half an hour before the operation. This was performed two days after the first symptoms made their appearance, and showed a diffuse septic peritonitis, while the intestines were as lifeless as a rubber hose. Death took place shortly after.

It will be seen that the really difficult cases in the intermediate class belong in this division, and any satisfactory conclusion in regard to them can be reached only by a process of elimination. If the patient is in the country, and the surgeon is obliged to return to town, it is safer to operate than to leave him under circumstances where he cannot command the surgeon's services should he suddenly require them. If the patient is so situated that he can obtain surgical

aid at once in case of necessity, it is safe to wait, supposing he is kept under hourly observation, and provided the discretion of the physician and the intelligence of the patient can be depended upon, especially if the attack is not a first one. But if the physician's judgment or the patient's intelligence is below par, it is safer to operate than to take the chances involved in waiting under such conditions.

Again, if the patient is in a hospital, it is safe to wait and watch, when it would not be so in a private house, because he is under incessant skilled observation and a surgeon can be secured, if he is needed, without delay. Even these conditions, however, cannot guarantee safety, as shown by the fact that in two or three cases at the Johns Hopkins Hospital perforation occurred under the eyes of skilled professional attendants, and operation revealed a spreading peritonitis. If the physician has no surgical experience, and a good surgeon cannot be had, the patient will stand a better chance without operation, or at least by holding off until a well-defined abscess has formed. The same rule holds good for a surgeon with but little experience, although with improved manual dexterity, a better knowledge of the disease, of the methods of handling infected tissues so as not to spread the infection, and, above all, of drainage, the same man will find that he can give the patient a better chance of recovery by removing the *fons et origo mali* than by leaving it to nature, that is to say, to blind chance. Urgent personal reasons for delay may be admitted in cases of the kind under discussion, where they would be excluded in others. It may be added that, as FINNEY says, the surgeon himself is never so unhappy as when he is watching an appendicitis which has not been operated upon.

Some of our best surgeons are of opinion, however, that operation is indicated under all circumstances. ABBÉ, while dwelling upon the necessity for formulating two sets of rules, one for the surgeon and another for the attending physician, says that "when the diagnosis is made is the time to operate, for there is no case of appendicitis which can be trusted, no matter how simple the symptoms seem to be, and even in the absence of fever, quickened pulse, difficult respiration, or leucocytosis." RICHARDSON also finds himself more and more inclined to operate at any stage of the disease, no matter when it is detected. Finally, I wish to emphasize the statement that no hard-and-fast rule should be laid down as regards operation in this class of cases. Just as it has wrought much harm to hold "the interval" as the ideal time for removal of the appendix, thus inducing men to try to tide over an acute attack in order to reach this desirable period, so in like manner does the prevailing idea as to a so-called "twenty-four hour period" often work detrimentally by conveying the impression that no serious lesion or extension of the disease can take place within the first twenty-four hours, when there is abundant evidence to the contrary. If we must fix a date, it would be better to establish a two-hour rule, and call two hours the safe period, the preparations to operate being hastened in the meantime. Each case must be a law unto itself, and it is as dangerous to gener-

alize here as it would be in plastic surgery to fit a particular pattern to every case; moreover, a rule which is good for an experienced surgeon is dangerous for one with little or no experience. As a matter of fact, most surgeons, even the best, are guided in their conduct toward any individual case by their personal experience in the immediate past, thus demonstrating their fallibility of judgment and lack of precision in a matter where the reverse is of so much importance.

LATE OPERATION.

A late operation, as has been said, is one performed after the formation of a well-defined abscess shut off by adhesions; or else undertaken for a spreading peritonitis. Although the operation for an abscess (suppurative periappendicitis) is often a simple and a safe procedure, it is never the procedure of election on the part of a good surgeon, on account of the risks of peritonitis incurred in the delay. FINNEY says: "The presence of pus in an appendicitis case is *prima facie* evidence of a mistake on the part of somebody, the patient, the physician, or the surgeon. If, however, a skilled surgeon is not available in the early stage of the disease, the patient will run less risk from delay, and the subsequent incision of an abscess, than from a clumsy operation."

INTERVAL OPERATION.

It is most important to have a clear understanding as to what is meant by the term "interval operation." Many lives have been risked, and not a few lost, through a misunderstanding and a misuse of this expression. E. M. POND, of Rutland, Vt., expresses this point in a clear and practical way while speaking of his own *clientèle* in a personal communication: "One of the worst features that I have to contend with is the idea that many have regarding interval operations; the symptoms of the disease appear to them so mild that they take the chances of recovery. You might be surprised if you knew the number of deaths due to delay on this account in this section of country. I am positive that the teachings of those who advocate interval operations account for many deaths from appendicitis. I mean by this that the majority of general practitioners are unable to discriminate between those cases that should have an immediate operation and those that might be delayed, consequently they remind you that 'B. ——— waits for the interval.'"

The term interval operation is, strictly speaking, a misnomer, as the second attack, or that which is to follow the period of quiescence, is always a hypothetical one. The interval operation depends for its *raison d'être* upon the reasonableness of the presumption that a patient who has had one

or more well-defined attacks of appendicitis will, in all likelihood, suffer from a repetition; it should be clearly understood that in using the expression "interval operation" there is no implied argument that a patient suffering from an appendicitis should risk his life by deliberately waiting until the attack is past to have his appendix removed "in the interval." The interval operation is not for the acute sufferer, but for him who has passed through one or more attacks, and for this reason decides to submit to the operation while enjoying apparent health, rather than incur the risk of another, possibly fatal attack. The cogent reason for performing an operation in the interval of quiescence lies in the fact that the risk to life incurred by operating in the course of an attack of appendicitis is vastly greater than the risk incurred in doing so after all the symptoms have subsided. During this period of complete defervescence the risk is almost, some operators claim quite, *nil*. LENNANDER operated on 271 cases without a death. The French surgeons have appropriately distinguished between operations performed during the height of the disease, often marked by febrile disturbances, which they call operations *à chaud*, and those performed after the attack has subsided, to which they apply the suitable term operations *à froid*, a term for which there is no English equivalent. The true purpose of the interval operation is well expressed by the phrase "prophylactic appendectomy" (VIGNARD).

An interval operation, therefore, is one in which the operation is undertaken after the subsidence of the general and local symptoms. The patient is free from fever, his functions are normal, he has recovered his appetite, and feels able to resume his usual occupations, there is little or no pain, the abdomen is no longer distended, there is no spasm of the muscle, tenderness is not marked, and there is no mass. And yet (I would emphasize this fact) these signs of a *restitutio ad integrum*, both general and local, satisfactory as they may seem to be, do not define with sufficient precision the proper time for an interval operation. It is most important not to operate until at least several weeks have elapsed since the acute, severe attack has subsided. Surgeons who operate too early in the interval have in numerous instances opened up small concealed pockets of pus, full of organisms still retaining an enhanced virulence, by which they have inoculated the peritoneum and destroyed their patients, in spite of abundant drainage. This error is most apt to occur where there is a little residual abscess at the end of an appendix hanging down into the pelvis. It is better to keep the patient under observation, and to wait from four to six weeks, or longer. We must distinguish clinically between an interval operation in an apparent subsidence of all symptoms, with no tangible evidence of lingering disease, and an operation undertaken for the sequelæ of an appendicitis, when a residual abscess can be plainly felt. This distinction will often rest upon the accidental

position of a chronically inflamed appendix, which in one case is easily accessible, and in another lies out of reach in the pelvis.

DESPERATE CASES.

The question must sometimes arise as to the surgeon's duty in those cases which he first sees *in extremis*. Under these conditions the sole consideration with the operator should be the possibility of saving life, and the experience of the best surgeons shows conclusively that this question must always be answered in the affirmative, unless the patient is actually moribund. There is no surgeon of large experience who has not seen desperate, and apparently hopeless cases occasionally recover. The situation may be regarded in this way: A vessel is wrecked and a lot of poor wretches are thrown into the sea. The chance of saving them seems desperate from the shore, but a few determined men put out, and each of them manages to bring in one or two alive. The men ashore excuse their inactivity and their refusal to go, on the ground that they saw clearly they could not save all. Under circumstances where death is certain, every life saved is pure gain, and if but one in twenty, one in fifty, if you will, can be rescued, the effort to accomplish this end is obligatory. An interesting case illustrating this point is given by Van Lennep (*Hahn. Med. Month.*, Jan., 1895).

A child of twelve was sent to him after a long illness, with supposed tubercular peritonitis. The abdominal distention was so great, and the child so nearly dead, that the operation was begun almost without anesthesia. On opening the abdomen, pus poured out as from a geyser, and it was estimated that fully two gallons of it were evacuated. The abscess was bounded by the floor of the pelvis, the abdominal walls, the spine, and the diaphragm; up under the latter the intestines were squeezed into an inconceivably small space. The patient made a surprising, though tedious recovery.

McCosh and Hawkes (*Amer. Jour. Med. Sci.*, May, 1897) give an analysis of 69 cases of appendicitis treated surgically at the Presbyterian Hospital, New York, between January, 1895, and 1897, the results of which are of considerable interest in this connection. The patients, generally speaking, were brought to the hospital in a desperate condition. "As a rule," the writers remark, "the ambulance was summoned as a last resort, after medical treatment had been employed for days and even weeks; indeed, several of the patients were sent to the hospital by their friends simply for purposes of euthanasia." The average duration of the acute cases was nine days, the shortest being twenty-four hours, and the longest seven weeks. In spite of these untoward conditions the statistics were as follows:

Out of 51 cases operated upon before the development of general peritonitis, there were 50 recoveries and only 1 death. Out of 11 cases in which septic

peritonitis developed prior to admission, 9 were operated upon and 2 were not; out of the 9 cases operated upon, there were 6 deaths and 3 recoveries.

The writers especially call attention to the fact that during the second of the two years covered by their report, it had become noticeable that patients were sent to the hospital at an earlier stage of the disease than formerly, and they express the hope that this fact signified a realization of the importance of early operation, not only on the part of physicians, but by the general public. It is evident that in such cases as these the patient has everything to gain by operation and nothing to lose, so that every case saved is clear profit. The only contraindication to operation is the certainty of approaching death, expressed by a small weak pulse, anxious expression, dusky skin, and a composite of signs and symptoms quickly read by the experienced surgeon, but not easily described.

CHAPTER XXIII.

PRELIMINARIES TO OPERATION.

MEDICAL TREATMENT. PREPARATIONS FOR OPERATION. NITROUS OXID ANESTHESIA. COCAINE ANESTHESIA.

MEDICAL TREATMENT.

Before proceeding to consider the question of operation, it seems suitable to say a few words upon the medical treatment of appendicitis; that is to say, to consider briefly what remedies it is advisable to apply in any case until the services of a surgeon can be secured, as well as the best measures of relief in cases which do not require operation.

The first step, which is of prime importance in the treatment, is to put the patient to bed, and keep him quiet in the dorsal position; the next is a rigorous regulation of diet, medication, and treatment in general, all of which is best carried out by a trained nurse, acting under careful surveillance from hour to hour, until all danger is past. If the patient is constantly watched by a nurse, and the surgeon makes his visit, at first, from two to four times a day, any increase in the symptoms denoting an undue extension of the disease will at once be noted, and the surgeon will be in readiness to abandon the medical treatment without a moment's delay, in order to attack the disease by the more direct measures of surgery.

Of equal, if not greater importance to general rest of the body at large, is local rest of the alimentary tract, and the first care, after putting the patient to bed, must be the absolute withdrawal of food; a step taken for two reasons, first, to secure that freedom from peristalsis which is only found in an empty intestinal tract, and, second, to unload the bowel of such materials as might in case of rupture escape into the peritoneum. In cases where the stomach contains remnants of food, A. J. Ochsner (*Appendicitis*, 1902) recommends gastric lavage, by first spraying the pharynx with a 4 per cent. solution of cocaine, and then introducing a stomach-tube and irrigating with a normal salt solution. This form of treatment is also endorsed by Jonnesco (*Rev. de chir.*, 1903, No. 6). As long as there is vomiting the patient has but little desire for food, and thirst may be satisfied with little sips of iced water, a little cold tea in coffee-spoonful measures, or hot water to rinse the mouth. Sometimes minute quantities of champagne are helpful.

Ice should be applied locally over the right iliac fossa in a rubber bag, spread out thin so as to cover a wide area, and not heavy enough to produce discomfort by its weight. The bag should be separated from the skin by a layer of flannel, and the ice often renewed. D. H. WILLIAMS uses menthol dissolved in alcohol locally for the relief of pain. Thin poultices sprinkled with tincture of opium may also be used over the entire abdomen.

The treatment of the bowels constitutes the crux of the subject to-day. Some surgeons are still loud in their praises of the advantages accruing from free purgation, especially with saline cathartics. The opinion of most, however, is largely in favor of keeping the bowels entirely at rest by the use of opium or morphine, in order to check peristalsis, a method strongly advocated by some of the earliest writers on appendicitis.

The first mention of the subject is by two English physicians, GRAVES and STOKES (*Dubl. Hosp. Rep.*, 1830), who advocated the treatment of intestinal perforation and resulting peritonitis by means of opium in large doses, urging its use on the ground that it favors the organization of protective false membrane, and supports the vital powers at a time when they are at their lowest ebb. They state, with creditable frankness, that the antiphlogistic treatment, then universally employed in such cases, had resulted fatally in all of the seven which they report, while they are convinced that one of these, which was improving under opium, might have been saved, had not the treatment been discontinued in favor of blood-letting and purgatives. Two years later one of these writers, STOKES, published a second paper on the same subject, in which he was able to report two cases of recovery under the treatment recommended. In 1837, a Frenchman, PETREQUIN, again brought forward the opium treatment with special reference to perforation situated in the vermiform appendix and the resulting peritonitis, using in its favor the arguments of GRAVES and STOKES, whom he quotes (*Gaz. méd. de Paris*, 1837, p. 368). He gives in detail one case of appendicitis in which the diagnosis was made and the treatment with opium begun after perforation had occurred. The opium was then continued for seven days, 184 grains being given in that time, inducing complete narcosis. The patient made an excellent recovery.

Nearly ten years later a German, ADOLPH VOLZ, published an inaugural dissertation (see Chap. II, p. 18) in which he argues most earnestly in favor of the use of opium in perforation of the appendix, and accompanies his arguments with substantial proofs of its efficacy. He first cites 38 cases of perforation of the appendix treated with blood-letting and purgatives, all of which ended fatally, the diagnosis being confirmed in every case by the autopsy. He then gives 14 cases in which the characteristic symptoms of appendicitis were present, accompanied by peritonitis, usually circumscribed, but sometimes general. All of these recovered under the administration of opium in doses of one grain every half-hour, continued until the pain was distinctly

relieved, when the dose was gradually reduced. One of these cases died seven months later of tuberculosis of the lungs, and an autopsy which was then held showed no signs of tubercles in the intestines, but made it evident that the appendix had at some time been the seat of a morbid process, for there was evidence of a pus pocket at its blind extremity and a number of strong fibrous adhesions were present which could only have resulted from a peritonitis of a very high grade. Volz claims that these cases should be sufficient to establish the opium treatment, and he expresses a hope that the day will come when the principle of rest for the intestines in inflammation of the appendix by means of opium will be as clearly recognized as the same principle for a broken leg by means of splints (see Chap. II, p. 20). The antiphlogistic treatment he characterizes as imprudent and irrational.

Notwithstanding this convincing evidence, however, and the able reasoning which accompanied it, the opium treatment never came into general use in any country, although from time to time it has been individually advocated. In the report of one of the early meetings of the Pathological Society of New York (*Amer. Med. Month.*, 1858, vol. 10, p. 359) there is a discussion in which it seems to have met with favor in several quarters, and Markoe, in particular, described a case in which he had successfully treated a perforation of the appendix with large doses of opium, and the death of the patient within a year from other causes had afforded the opportunity for an autopsy, which confirmed the previous diagnosis, and showed that the process of repair after perforation had actually taken place (see Chap. XIII, p. 327).

It is a good plan to begin the administration of opium by giving the patient just enough to relieve pain and afford a little ease, either in the form of morphine hypodermically, or in small doses of opium ($\frac{1}{4}$ to $\frac{1}{2}$ a grain) by the mouth. The principle of its use is to "splint" the bowels, and by checking peristalsis to favor the formation of adhesions which wall off the affected area and prevent a general peritonitis. It should be kept up for several days, until all the symptoms have subsided, and a general improvement is noted. The form of its administration may be varied by using the aqueous extract or the tincture in small starch enemata.

After complete subsidence of the symptoms the bowels may be unloaded by small oil enemata, given at intervals of several hours, or by calomel or castor oil given by the mouth. The use of strong salines for the purpose of emptying the bowels in these cases has so often been associated with disastrous results that it is probably wiser to abandon them altogether. A large enema is also extremely dangerous; cases have been reported in which a considerable portion of one has been subsequently discovered by the surgeon lying among the intestines in the abdominal cavity. The surgeon will sometimes find it of advantage to introduce a well-oiled finger into the rectum, and then, if he finds impacted feces, to soften them and empty the bowel by throwing in a few ounces of sweet oil.

When using opium, it must be constantly borne in mind that large doses

have the disadvantage of obscuring the clinical picture, and concealing the real condition of the patient. It relieves the pain and sensitiveness only in an artificial way, and the meteorism which it causes obscures palpation. Only enough opium should be given to produce quiescence, the pupils being watched, and the urine kept under observation in order to be sure that it is not too much diminished in quantity; the sensorium also must not be too much obtunded. With improvement, both local and general, small quantities of food may be given by the mouth, beginning with albumen and water, a little cold coffee, or tea. Small nutrient enemata may be given even in the midst of the attack, and continued until convalescence.

PREPARATIONS FOR OPERATION.

The operative treatment of appendicitis is daily becoming more and more frequent as its results appear more and more satisfactory. In order to ascertain what proportion operations for the removal of the appendix bear to other surgical operations in our large hospitals, I have collected statistics on the subject from the following reports, and I present them here in tabular form. It will be seen that, although there is considerable variation among them, the proportion of appendix operations to others is large in every case.

RATIO BETWEEN OPERATIONS ON THE APPENDIX AND GENERAL SURGICAL OPERATIONS IN HOSPITALS

Hospital	Period Covered by Report	Total Number of Surgical Operations	Operations on Appendix	Ratio
Roosevelt Hospital, New York.	January 1, 1902, to December 31, 1902	1319	179	1 in 7 +
St. Luke's Hospital, New York.	October 1, 1901, to September 30, 1902	1383	167	1 in 8 +
University of Pennsylvania Hospital, Philadelphia.	Year ending December 31, 1901	972	46	1 in 21 +
German Hospital, Philadelphia.	Year 1902	1210	437	1 in 3 —
Massachusetts General Hospital, Boston.	January 1, 1902, to December 31, 1902	3266	389	1 in 8 +
Boston City Hospital.	February 1, 1902, to January 31, 1903	1928	171	1 in 11 +
Mercy Hospital, Chicago.	October 1, 1900, to October 1, 1901	741	148	1 in 5
Johns Hopkins Hospital, Baltimore.	February 1, 1900, to January 31, 1901	1697	106	1 in 16

Preparation of the Patient.—The preparation of the patient is often largely in the hands of the medical man who has first seen the case, and the wise physician having in view the possible necessity of an incision in the abdominal wall, will avoid using any blistering application, such as cantharides or iodine, which is liable to be followed by suppuration, for it introduces a grave risk, namely, the danger of infecting the abdominal cavity. Immediately preceding operation, while the active preparations are under way, a small dose of morphine, $\frac{1}{4}$ or $\frac{1}{8}$ of a grain, with $\frac{1}{100}$ of a grain of atropine, is often of value in quieting the nervous system, and preparing the patient to look forward with equanimity to the surgical procedure. If the bowels are loaded, a small enema may be cautiously given. All food should be withheld.

Cleansing the Field of Operation.—The field of operation should be cleansed by scrubbing the skin well with warm water and soap, applied with a piece of gauze over the entire right abdomen; following this, a little alcohol or ether may be used to remove fat, and a solution of bichloride 1: 1000 to further sterilize. The most important feature is the soap and water. If an abscess is suspected, great care must be exercised not to rub too vigorously for fear of bursting it. If there is a suppurating area, following a blister or a mustard plaster, in the line of the incision, it is best to sterilize it with a strong solution of permanganate of potash, followed by one of saturated oxalic acid, each of them being applied only for a few seconds, and the surface then scraped.

Posture.—The best posture for the patient is the dorsal one, with the right leg slightly flexed. The Trendelenburg posture is a disadvantage here. Sometimes it is of material assistance in exposing the cecum and appendix to elevate the right side so that the small intestines will gravitate toward the left and out of the way.

Preparation in a Private House.—Operations for appendicitis must always be done with frequency in private houses, owing to the fact that in a large proportion of cases by the time the surgeon arrives the condition of the patient is such as to demand immediate operation, and to forbid removal to a distant hospital. There is no valid reason why, with due precaution and a satisfactory artificial light at hand, the surgeon should not do as good work in the patient's house as in a hospital. In an interval operation the incision is small, and when closed, sealed, and covered by dressings is no more liable to infection than a similar wound in a hospital. If an abscess has to be drained, it can be done equally well in either place. Some surgeons even find the statistics of their private work better than those of the hospital. In a private house there is, moreover, the advantage of a well-chosen trained nurse, working in a spirit of fidelity to both surgeon and patient, a thing not always found in a hospital, where the sense of personal responsibility on the part of the attendants is often dulled. The disadvantages of a private house are that, as a rule,

serious complications are not so well provided for, and the surgeon loses much more time in visiting his patients.

A well-lighted room should be chosen for operation, if possible near the bath-room. Abundance of hot water must be available, and if there is sufficient time, the room should be cleaned, the floor scrubbed, and afterward a drugget laid upon it and sprinkled. The room must be bared of all unnecessary articles of furniture, such as upholstered chairs, pictures, and mantel ornaments. A single bed must be provided, standing at a height of 26 to 28 inches, including the mattress; an ordinary bed can be made to serve the purpose by placing it on blocks. This will save both surgeons and attendants much awkwardness in the subsequent care of the wound and the bowels, as well as in bathing and turning the patient. Several small tables, about 3 × 2 feet, should be brought in for the instruments and dressings, and a bench or some chairs provided for the basins of water and solutions. The operating table, which should be a portable folding table like that of Edebohls, must be sent in by the surgeon himself. A gas stove, and an Arnold or a Beckmann sterilizer are necessary for the dressings, towels, and sheets. The surgical instruments should be sterilized at home, and packed ready to use on taking them out of the kit.

The instruments and other articles needed in operating at a private house are: Operating table; water and solution basins; scalpels; dissecting forceps (2); artery forceps (12); retractors; ligature and suture materials; scissors; needles, including fine intestinal needles; needle-holders; gauze for packing, and sponges, carefully counted; iodoform gauze strips for drainage; hypodermic syringe; chloroform, ether, nitrous oxid gas, cocaine, and suprarenal extract; apparatus for saline infusion; towels (about two dozen); culture-tube and platinum loop; a bottle of formalin (10 per cent.), or of alcohol, for the appendix.

Only a few of these instruments require any special description. The most convenient retractors are those with blunt teeth, made in a curve. The needle-holder is the Reiner, with the beak made small in order to hold the needles without breaking them. For intestinal suturing I use the delicate, round, French needles with the split eye, and fine black silk (see Fig. 236). The delicate forceps are of the kind which I use in intestinal, ureteral, and vesical work (see Fig. 237). On grasping the tissues with them, but slight injury is done, and at the same time they are adapted to catch up the tissue at any point and hold it for the passage of the finest needles. The mosquito forceps, which I have adopted from the surgical staff of the Johns Hopkins Hospital, are convenient for grasping small vessels in delicate tissues in the peritoneum, or about the base of the appendix. I have modified them for the purpose



FIG. 236.—INTESTINAL NEEDLE WITH SPLIT EYE.

The needle commonly used is often finer still, only three-fourths the size here figured.

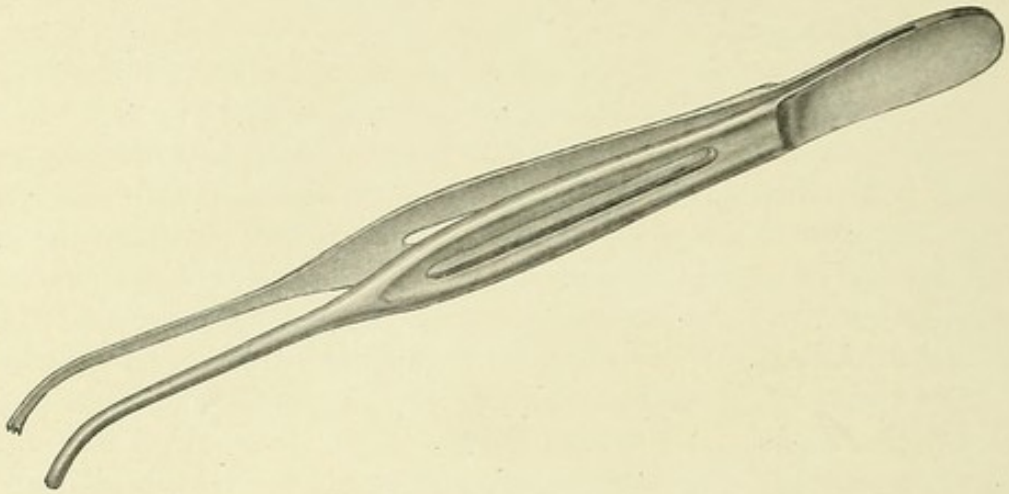

Fig. 237.—Delicate Light Curved Mouse-tooth Forceps for Picking up the Bowel and Holding it while the Sutures are Passed. (Two-thirds natural size.)

of grasping and retaining tissues by adding a broad point and several teeth.

ANESTHESIA.

It is unnecessary to devote time and space here to the discussion of the familiar anesthetics, chloroform and ether. Ether is to be preferred, as a rule, on account of its greater safety, but chloroform is the better of the two for children and for old people, as well as when there is a tendency to bronchitis, or in the presence of nephritis.

Nitrous Oxid Gas.—During the past decade sundry efforts have been made to render the process of anesthetization less unpleasant to the patient, and less tedious to the operator. The one method which has proved itself satisfactory is the combined nitrous oxid and ether method, in which nitrous oxid gas is used to induce unconsciousness and followed by the administration of ether. Chloroform cannot be used under these conditions, as it is dangerous to follow the depressing effects of the partial asphyxiation of nitrous oxid gas by such a cardiac depressant.

The rapidity of the nitrous oxid method is of advantage to the patient, the surgeon, and the anesthetizer; since the time required for loss of consciousness with the gas is only from one, to two and a half minutes, and the time necessary to secure complete anesthesia from one to five minutes. The patient is also relieved from the unpleasant sensations induced by the administration of ether, and in most cases suffers much less from disagreeable after-effects, especially nausea and vomiting. A further minor benefit is the smaller quantity of ether required, the amount necessary to maintain unconsciousness after anesthesia has been induced by the gas having been estimated at

50 to 70 grams in an operation lasting twenty minutes, up to 300 grams in one lasting three hours and forty minutes.

The only difficulties in the use of the method are an occasional cyanosis during the administration of the gas, and an increased secretion of mucus. A slight degree of cyanosis is inevitable in most cases, but if the anesthetizer is experienced and skilful, any marked symptoms of asphyxia are present in but a small number of instances. An increased secretion of mucus is rare, and is always much less than after the administration of ether alone. The nausea also is undoubtedly less, and, as a rule, is absent altogether. Too much stress cannot be laid upon the fact that in the use of nitrous oxid gas the anesthetizer should be thoroughly familiar with the method, as upon this its success largely depends; most of the instances of failure or of unpleasant results having been due to lack of experience, or to want of skill. It is occasionally, but rarely, impossible to secure complete anesthesia with nitrous oxid gas, owing either to extreme nervousness on the part of the patient or to his being habituated to the use of stimulants.

I first used this method in my private hospital in 1900, and I have since found it most satisfactory in many hundreds of anesthesias. A brief account of the results attending its use during the first eight months of my experience has been published by my associate, T. R. Brown ("*On new methods of anesthesia,*" *Phila. Med. Jour.*, Nov. 3, 1900).

Nitrous oxid gas has also been employed with good results as the sole anesthetic in prolonged operations, such as those for removal of the appendix, where disease of the kidneys renders anesthesia by ether or chloroform dangerous to life. I have tried it in several cases of appendicitis when other anesthetics were contraindicated for this reason, with excellent results. Let me cite one such case in illustration.

Mrs. A. (*San.* No., 13243, March, 1902.) Operation for chronic appendicitis. Nitrous oxid gas was chosen as an anesthetic because of chronic nephritis and a persistent albuminuria of thirteen years' standing, without casts. The patient was under the anesthetic for one hour and six minutes, during all of which time she was completely unconscious. Her pulse before anesthesia was 100, and afterward 80. There was no nausea after the operation, and although a little was complained of at the end of twenty-four hours, it was very slight, and she suffered less than the usual amount of pain. She made an uninterrupted recovery, the only point presenting anything unusual being that she slept almost continuously for the first week. The secretion of urine was not diminished.

My experience in this and other cases has convinced me that nitrous oxid gas can be employed as the only anesthetic during long operations with perfect safety, and I strongly recommend its use when the existing conditions contraindicate the use of ether or chloroform.

Cocaine.—It frequently happens that an operation for appendicitis is advis-

able or necessary when the administration of any general anesthetic is contraindicated by the existence of morbid processes, such, for instance, as chronic pulmonary or cardiac lesions. Under these circumstances the use of a local anesthetic, such as cocaine, becomes most valuable. An illustrative case is here given:

A young man, twenty-one years old, developed a primary tuberculosis of the larynx at the end of his college career. The opportunity was offered him of recruiting in a remote camp in the Carolina mountains. Under the advice of a specialist he was desirous of taking advantage of this opportunity, but as he had had several attacks of appendicitis during the preceding year, the last of considerable severity, he was afraid of being removed from the possibility of surgical aid for such a length of time. As the removal of the appendix seemed justified by the circumstances, and as the condition of his larynx contraindicated the inhalation of either ether or chloroform, the appendix, which proved to be adherent, strictured, and filled by a concretion, was removed under local cocaine anesthesia. In ten days he was able to leave the hospital for his proposed outing.

The operation on this particular patient was performed in the spring of 1899, by HARVEY CUSHING, and, so far as I am aware, it was the first in which the appendix was removed under local anesthesia.

Diseases of the blood-vessels, of the myocardium, or of the respiratory tract, a marked anemia, a suspected renal insufficiency, an infectious disease, either in itself the cause of the local process, or merely a concomitant illness, and many other conditions as well, might be cited as involving considerable risk in administering the usual anesthetic. The dangers arising from them apply, of course, not only to the operation for removal of the appendix, but to any operative procedures called for during their progress. During typhoid fever, for example, it is well known that the administration of ether or chloroform may have most serious consequences, and only since the introduction and general use of local anesthesia in these cases, has the high mortality rate following operations for perforation and for cholecystitis, as well as for an associated appendicitis, been considerably lowered. On several occasions, cases of suspected typhoid perforation, from the clinic of my colleague, W. OSLER, have been explored under a local anesthesia, and an acutely inflamed appendix found to have occasioned the symptoms. The removal of the appendix in these cases was not followed by any fatalities.

There are three different methods of using a local anesthetic for operative purposes, but only one of them is widely applicable to the operation in question:

I. Segmental anesthesia, produced by lumbar subarachnoid injection of the drug, which thus acts symmetrically on the posterior nerve roots of the two sides up to a variable segmental level.

II. Regional anesthesia, in which a certain territory is rendered anesthetic by injection of a solution of the drug directly into the per-

ipheral sensory nerve trunks, at a distance more or less remote from the operative field.

III. Local anesthesia proper, in which the tissues are infiltrated and divided as encountered in the incision.

The first two of these methods depend for their efficacy upon the physiologic principle of "blocking" sensory impulses, which is a consequence of the local action of the drug.

Segmental anesthesia has unfortunately many drawbacks. In the first place, it is necessary that a solution of sufficient concentration, namely, 1 to 2 per cent., be introduced into the subarachnoid space, and toxic symptoms are almost invariably seen after this, with fall of blood-pressure and serious symptoms of shock. The reasons which contraindicate a general anesthetic in critical cases prohibit spinal anesthetization as well. Although it may not be injudicious to employ this method in selected instances, there has been a very natural reaction against the indiscriminate use of Beir's procedure in the generality of cases.

Regional anesthesia, so satisfactory in certain operations, such as herniotomy, or operations on the neck or extremities, is, unfortunately, hardly applicable to removal of the appendix, when the operative incision lies in a territory overlapped by the lateral and anterior cutaneous branches of two or three of the lower dorsal nerves, each one of which would consequently have to be separately anesthetized under the borders of their respective ribs before an analgesic cutaneous field could be assured.

Operations for removal of the appendix are, therefore, restricted to the infiltration method, or local anesthesia proper, and the principles of technic belonging to it will be briefly discussed.

Major operations under local anesthesia are, generally speaking, considerably more difficult than those performed in the usual manner. In the first place, it is distracting to the operator to have a conscious patient, and exhausting to be called upon, during a procedure which is necessarily more prolonged than would otherwise be the case, not only to operate, but to assume the responsibilities of sustaining the patient's *morale*. This latter duty should partially devolve upon an assistant, especially detailed to play the part of a "moral anesthetist," who, by occupying the patient's attention, by encouragement, and by attention to his occasional wants, can do much to relieve the surgeon, although the successful accomplishment of the operation, especially in a nervous patient, depends largely upon the moral influence of the operator himself. It is needless to say that the sight of the operating room, the noise of instruments, or anything else which might shock the sensibilities of the patient is to be studiously avoided.

The method of operating must necessarily be quite different from that commonly followed. Painstaking and tedious dissection, with absolute hemostasis must of course be observed, since the tissues must be kept dry and free

from blood-staining, in order that nerves and blood-vessels unexpectedly encountered need not be divided and clamped in a bloody angle of the incision. The tissues must be handled with the greatest circumspection and the usual rough methods of retraction and of sponging are prohibited. Familiarity with the neural anatomy of the region is essential, a subject to which far too little attention is paid in ordinary methods of operating. The accidental division or clamping of a single uncocainized nerve trunk, unexpectedly met with in the parietal incision, may promptly and completely exhaust whatever inhibition the patient possesses long before the peritoneal cavity has been opened. Nerve trunks of any size must be separately anesthetized, as the infiltration hardly suffices to benumb them, and difficulties are apt to arise because vessels and nerves are likely to accompany one another. Moreover, blood-vessels of any size are, in themselves, apt to give pain when crushed with forceps.

A minimal solution of cocaine, or one of its equivalents, should be used. Eucaine B, for example, is highly recommended by many persons as being less toxic, and more resistant to sterilization. As a matter of fact, however, such weak solutions are required for infiltration purposes that toxic effects should never be seen, and the drug withstands high temperatures sufficiently well to waive the latter objection. The solutions most commonly employed are those advocated by Schleich (*Schmerzlose Operationen. Vierte Auflage*, Berlin, 1899), in which the cocaine is combined with small percentages of morphine and sodium chloride. Three such combinations are given by him, varying only in the percentage of cocaine, his No. 2 being as applicable to the general run of cases as any other preparation: Cocaine mur., 0.1; Morph. mur., 0.02; Natr. chlor., 0.2; Aq. destil. ad 100.0.

Weaker solutions than this 1 : 1000 formula may be satisfactorily employed, even up to a 0.01 per cent. solution; as a matter of fact, an isotonic saline solution, when infiltrated so as to produce a local edema, has a decidedly deadening influence upon pain transmission.

It has recently been recommended to add a small amount of adrenalin to the cocaine solution (a few drops to a 1 : 1000 solution) in order to check local venous oozing, which is sometimes very troublesome.

Necessarily there is always a certain amount of pain inflicted in operating under local anesthesia, although this becomes relatively insignificant under the management of those experienced in its use. Ordinarily no adjuvant to the drug is called for beyond the influence of moral suggestion, already emphasized. Should such aids be indicated, however, it is well, before the operation, to administer hypodermically a small dose of morphin ($\frac{1}{8}$ grain) and to hold a chloroform mask in readiness to tide the patient over a difficult moment in the operation, such as may be produced by the introduction of gauze for purposes of "walling off," or by the manipulations required to free a tightly adherent appendix. It is astonishing how few whiffs of chloroform, not even enough

for a "primary anesthesia," will suffice to accomplish this purpose, and indeed a few inhalations of spirits of ammonia dropped on the mask may be no less efficacious. The performance has in consequence been often referred to as the combined "morphine-cocaine-chloroform" method of anesthesia.

There are certain steps in the operative procedure itself where especial precautions must be taken. To make the skin incision, in the first place, is a simple matter, provided there has been a linear wheal of local edema produced by the infiltration. There should be no unpleasant subjective sensation experienced after the first single insertion of the needle, which should be made to follow the spreading edema in the line of proposed incision. An ordinary hypodermic syringe or two will suffice for the injection, although many persons prefer a syringe with a larger barrel, as it obviates the necessity for exchanging or refilling the smaller instrument. The skin incision may be made immediately after the completion of the subcuticular infiltration; the anesthesia endures long enough to insure the possibility of a painless closure at the end of the operation, provided a subcuticular running suture is used instead of the through-and-through suture, which would penetrate normal skin outside of the edematized strip, and so be painful.

The most difficult part of the operation is the parietal incision through panniculus, muscle, and serosa. Care is necessary in going through the fat, since stray filaments of the cutaneous nerves may be met with, and, owing to the impracticability of edematizing the tissue, such fibres must be individually dealt with. The aponeurosis and muscle belly of the external oblique can usually be opened painlessly in the direction of the muscle bundles, because the chief nerve trunks lie at a lower level, namely, between the transversalis and internal oblique muscles. The incision of election, furthermore, lies more or less parallel with the direction of these main, buried trunks, and, as a rule, midway between the twelfth thoracic and first lumbar nerves, so that the incision may be carried directly down to the serosa without exposing them. Whenever the incision is longer, or more vertical than usual, the operator should watch for these nerves, and should the McBurney incision be used, and the fibres of the internal oblique be separated in a line perpendicular to the more superficial opening, both nerves will almost invariably be encountered. The necessity for a clean and bloodless field can thus be appreciated. Should the division of these nerves be deemed essential, one or two drops of a 1 per cent. solution of cocaine may be injected into the trunk, as far dorsally as possible; the peripheral portion, thus rendered anesthetic, is then divided where necessary.

The parietal layer of the peritoneum, curiously enough, contains sensory fibres, and may need cocainization, although a simple incision through it, provided it is uninflamed, does not usually give much discomfort. Dragging or pulling of the peritoneum, however, with retractors or with gauze is painful, and must be avoided as much as possible.

The abdomen being opened, the viscera may be handled at will. Observations under local anesthesia on the peritoneal surface have shown that the visceral serosa is completely devoid of sensory nerves of any sort. LENNANDER has especially called attention to this point in his "*Beobachtungen über die Sensibilität in der Bauchhöhle*" (*Mitth. a. d. Grenzg. d. Med. u. Chir.*, 1902).

The appendix, for example, may be crushed, ligated, or amputated without the patient's being aware of the slightest sensation. The same may be said of any portion of the gastro-intestinal tract, and resections and anastomoses are common enough under local anesthesia. One reservation, however, must be made, namely, that any manipulation which causes sufficient tension upon the mesenteric attachment of the viscera will produce pain on account of the stretching of the adjoining parietal serosa. This pain is ordinarily of a reflex, sickening character, and is referred to the area of distribution of the corresponding spinal segments. Thus, in my experience, tension on the mesappendix occasioned by lifting the organ into the wound previous to amputation may cause the characteristic epigastric pain of appendical colic (see HEAD'S *Referred Pain of Visceral Disease*). In consequence of this, should the appendix in an interval operation be tightly adherent to the parietal serosa, or should the latter, in an acute case, be inflamed and hypersensitive, a few whiffs of chloroform may be necessary before liberation of the organ can be satisfactorily effected.

Closure of the wound, as a rule, offers no difficulties, provided the skin edges are approximated by a subcuticular suture not passing beyond the area of original edematization, which remains insensitive for an hour or two.

CHAPTER XXIV.

INCISIONS.

It may be laid down as a general rule that the appendix can be reached in all cases where a liberal incision is made anywhere in the right lower quadrant of the abdomen; that is to say, in the space included within the triangle indicated by a line drawn (*a*) from the umbilicus to the symphysis, (*b*) from the symphysis along Poupart's ligament to the anterior superior iliac spine, (*c*) from the umbilicus around to a point on the crest of the ilium midway between the anterior and posterior superior spines (see Fig. 238, p. 525). No one form of incision is best in all cases, for its location must be adapted to the condition of the abdominal wall and to the stage and peculiarities of the disease. If the abdominal wall is rigid and thick, it is easier to reach the appendix when the incision is made directly over it; if the wall is lax, however, an incision made anywhere in the lower quadrant of the abdomen, or even in the median line, can be retracted so as to bring the appendix into the opening. Whenever the local signs, such as swelling, tenderness, redness, and edema, are pronounced, they should determine the site of the incision. In cases in which swelling is pronounced, the incision should be over its most prominent part, rather to the outside, especially if there is a sausage-shaped mass or plastron. When there is no swelling, but localized tenderness in the right iliac fossa, the incision should be made at some point between the right rectus muscle and Poupart's ligament. If the pains persistently follow one particular direction, as upward toward the liver, or backward toward the kidney, the operator will do well to bear this in mind, and make his incision as much as possible over the course of pain, since the appendix will probably be found in this situation. If the pain is situated in the back, the appendix may lie behind the cecum, or to its outer side, and it is best to make the incision posteriorly, and work up behind the cecum. The location of the important nerve trunks encountered in making the various incisions is shown in Fig. 239 (p. 527).

The conditions necessitating operation must also influence the choice of incision. From this standpoint operations for removal of the appendix may be classified under three heads:

1. The exposure and removal of the appendix for disease confined to the organ itself. In this case the incision is usually made at some point over or near the right iliac fossa.

2. The incidental examination and removal of the appendix during an operation undertaken for morbid conditions elsewhere, such as gall-stones, floating kidney, inguinal hernia, or disease of the pelvic organs. The question then is how to utilize an incision made for another purpose, in order to remove the appendix at the same time.

3. The removal of the appendix during operations rendered necessary by disease of another organ, which disease, there is reason to suspect, is secondary to inflammation of the appendix. In such cases the complication may be situated at some distance from the appendix, and the choice of incision must then be governed by the necessity of relieving both conditions, if possible.

A number of different incisions have been employed by surgeons of ability and experience, and I think it well to give here a brief description of some of these with a few words on the special field of usefulness in each case.

Median Incision.—(See Fig. 240, a a.) This was the form of incision employed in all the earliest celiotomies for removal of the appendix. So soon, however, as the operation promised to become at all general, the utility of an incision in the median line began to be questioned, and as early as 1888 there was a general consensus of opinion in favor of abandoning it for some form of lateral incision, either vertical or oblique (*Trans. Amer. Surg. Assoc.*, 1888, vol. 6, p. 413). The advantages of the median incision are that no nerves or important blood-vessels are encountered, and the closure of the wound is easily effected; it also permits, in women, an easy inspection of, and operation upon, all the pelvic viscera. Its disadvantage is its distance from the iliac fossa, which often necessitates undue traction to bring the appendix into view, a serious drawback when the appendix is adherent or the mesocolon short. In cases where the abdominal walls have been stretched by a pelvic tumor or by repeated pregnancies, the right side of the incision is easily drawn over and the right iliac fossa fully exposed, but when the abdominal walls are rigid and thick, as in a nullipara or in a man, the median incision offers a bad route. It is never now deliberately used for the purpose in an uncomplicated appendicitis. It may, however, be employed with advantage for the inspection and removal of the appendix in all cases where chronic appendicitis complicates some graver affection, as, for example, an ovarian tumor, a fibroid uterus, or tubal and ovarian disease on the right side. The peculiarity of the median incision when used under these conditions is that it must be a long one, and should, as a rule, extend not less than two-thirds or three-fourths of the way up to the umbilicus, in order to allow the right border of the incision to be drawn sufficiently far over to the right iliac fossa to bring the appendix within easy reach.

Vertical Incision.—Incision 5 to 8 cm. in length, along the outer border of the right rectus muscle. The advantages of this incision are that, as the deep tissues are purely tendinous, the hemorrhage is slight, and the closure of the wound easy and satisfactory. Its disadvantages are that often it is not

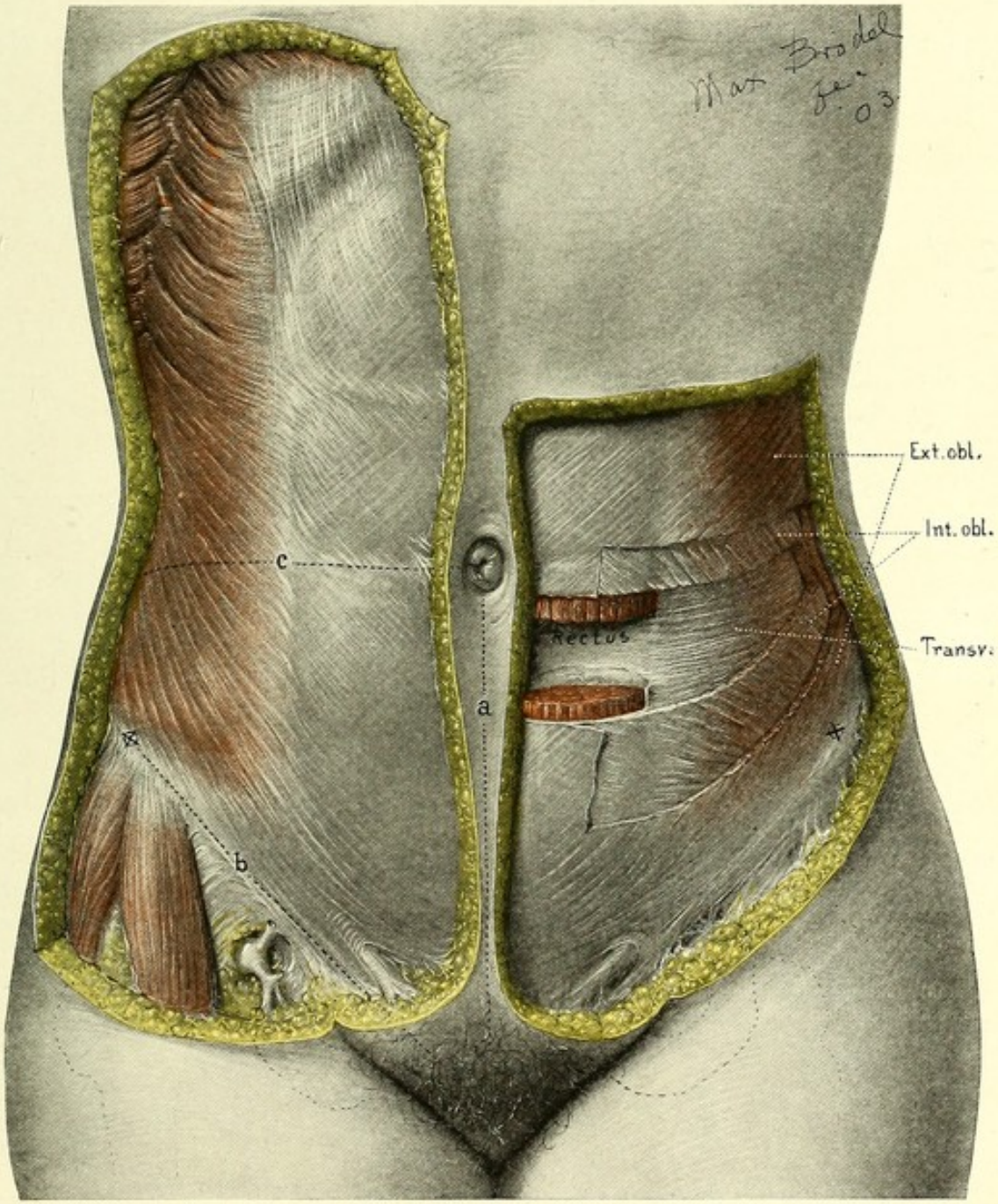

FIG. 238.—SHOWING THE MUSCULAR AND TENDINOUS STRUCTURES INVOLVED IN MAKING THE VARIOUS INCISIONS.

On the right side the panniculus is removed, exposing the intact superficial muscle, the external oblique, and the rectus in its sheath. On the left the various muscular structures are seen in their mutual relations in several layers.

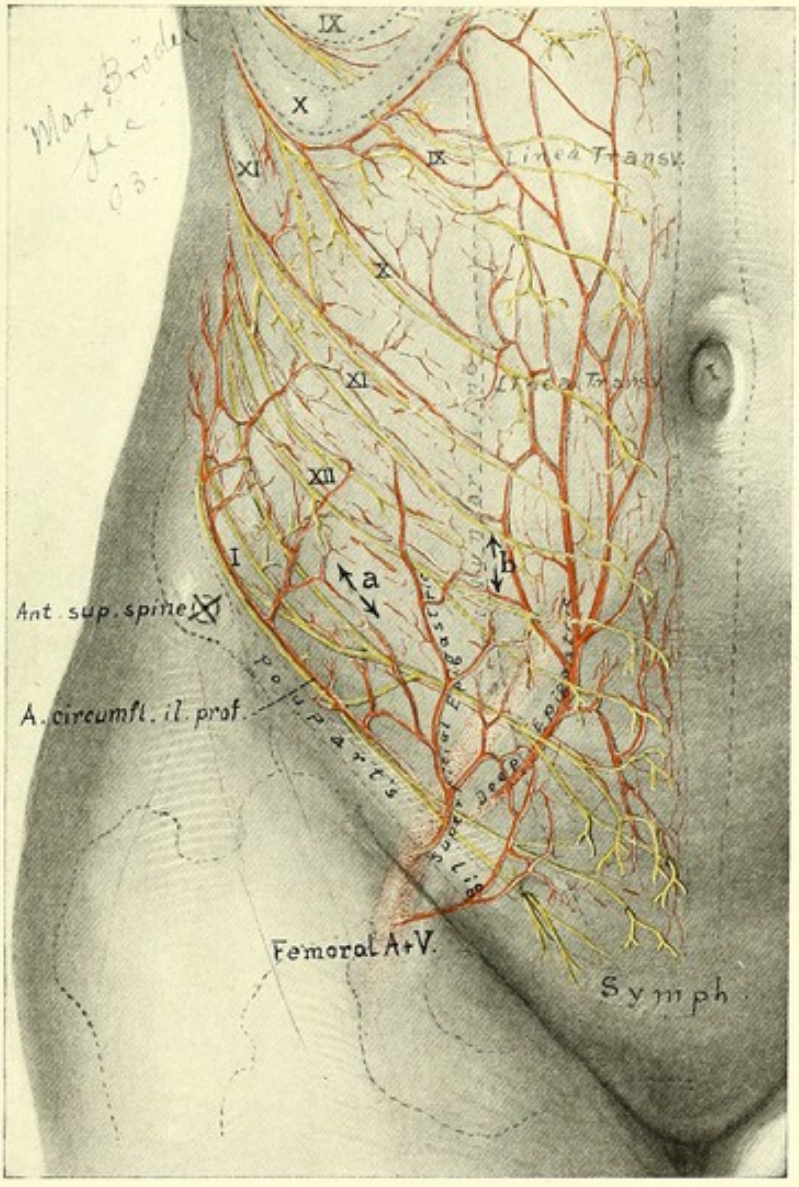

FIG. 239.—REPRESENTING THE PRINCIPAL ARTERIAL AND NERVE-TRUNKS OF THE RIGHT ABDOMINAL WALL.

The larger trunks running obliquely, in the direction of the ribs extended, are found between the internal oblique and transversalis muscles. The smaller branches given off by these pass out toward the skin or deeper into the transversalis. The deep epigastric and the deep circumflex iliac arteries pass in under the surface of the abdominal wall. The arrows at *a* and *b* indicate the position of McBurney's and Battle's incisions respectively. It is of great importance to avoid dividing any of these major nerve trunks in making the incision; this is best effected by blunt dissection.

directly over the site of the appendix, and therefore the operator in many cases works awkwardly. Moreover, drainage is sometimes difficult. The vertical incision was that employed by MORTON, by SANDS, and by other of the earliest operators in this country. It was introduced into Germany by SCHÜLLER

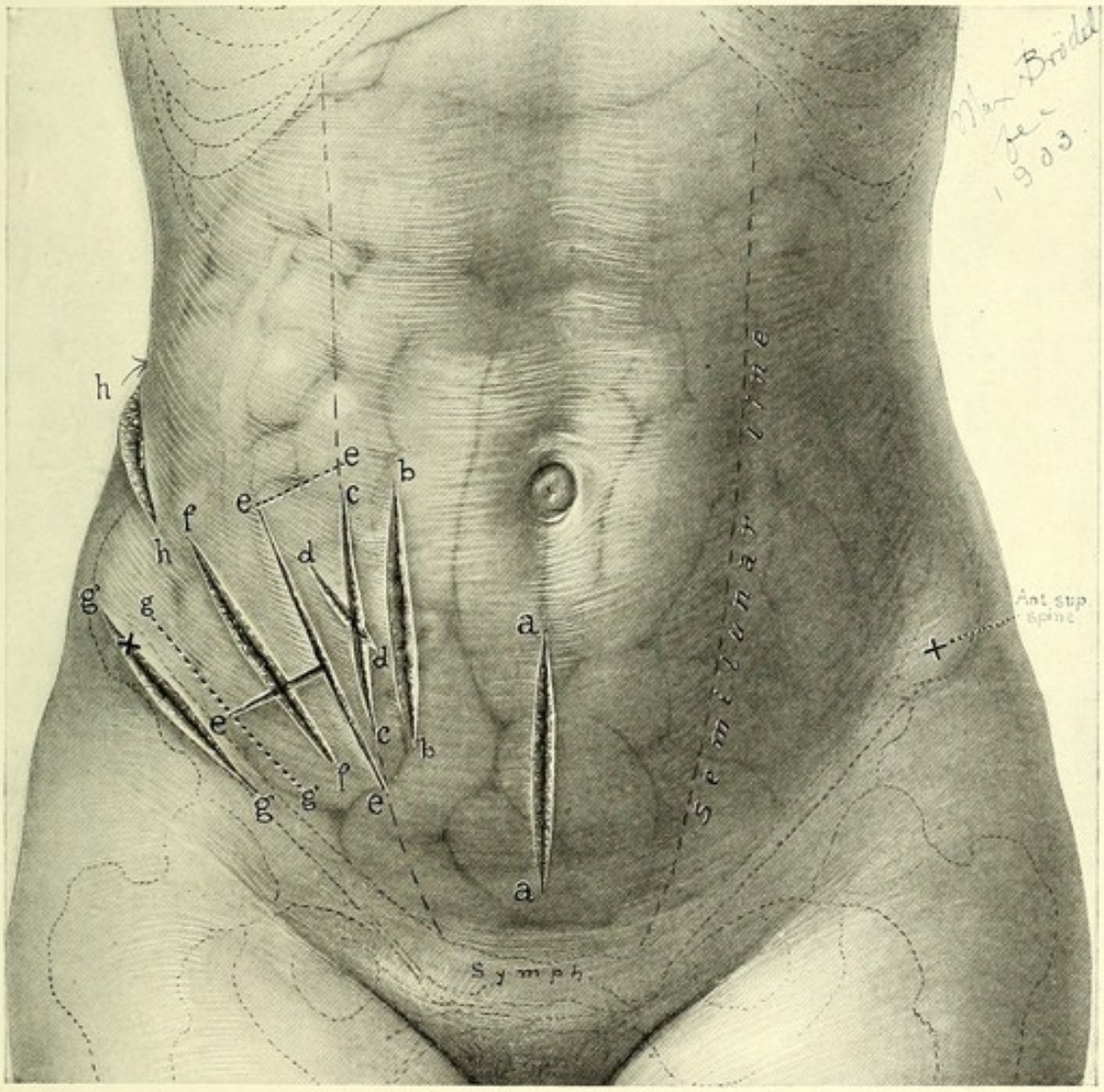

FIG. 240.—CADAVER SHOWING THE LOCATION OF THE VARIOUS INCISIONS, FOR THE REMOVAL OF THE APPENDIX IN THE RIGHT LOWER QUADRANT OF THE ABDOMEN.

The body wall is represented as semitransparent in order to show the position of the underlying viscera. a, Median incision; b, Battle's incision; c, Lennander and Schüller (vertical incision); d, Morris; e, Fowler's oblique incision with extensions; f, McBurney; g, Sonnenburg, solid line—skin incision, dotted line—deep incision along Poupart's ligament; h, Edebohls' incision for both kidney and appendix.

(*Arch. f. klin. Chir.*, Berlin, 1889, p. 845), and is called by KROGIUS "Schüller's incision. (See Fig. 240, b b.)

Sonnenburg.—(See Fig. 240, g g.) (*Perityphlitis*, 1900, p. 324.) The incision is made close to the ileum, down to Poupart's ligament. It is seldom necessary to divide the epigastric artery. The layers divided are: The skin,

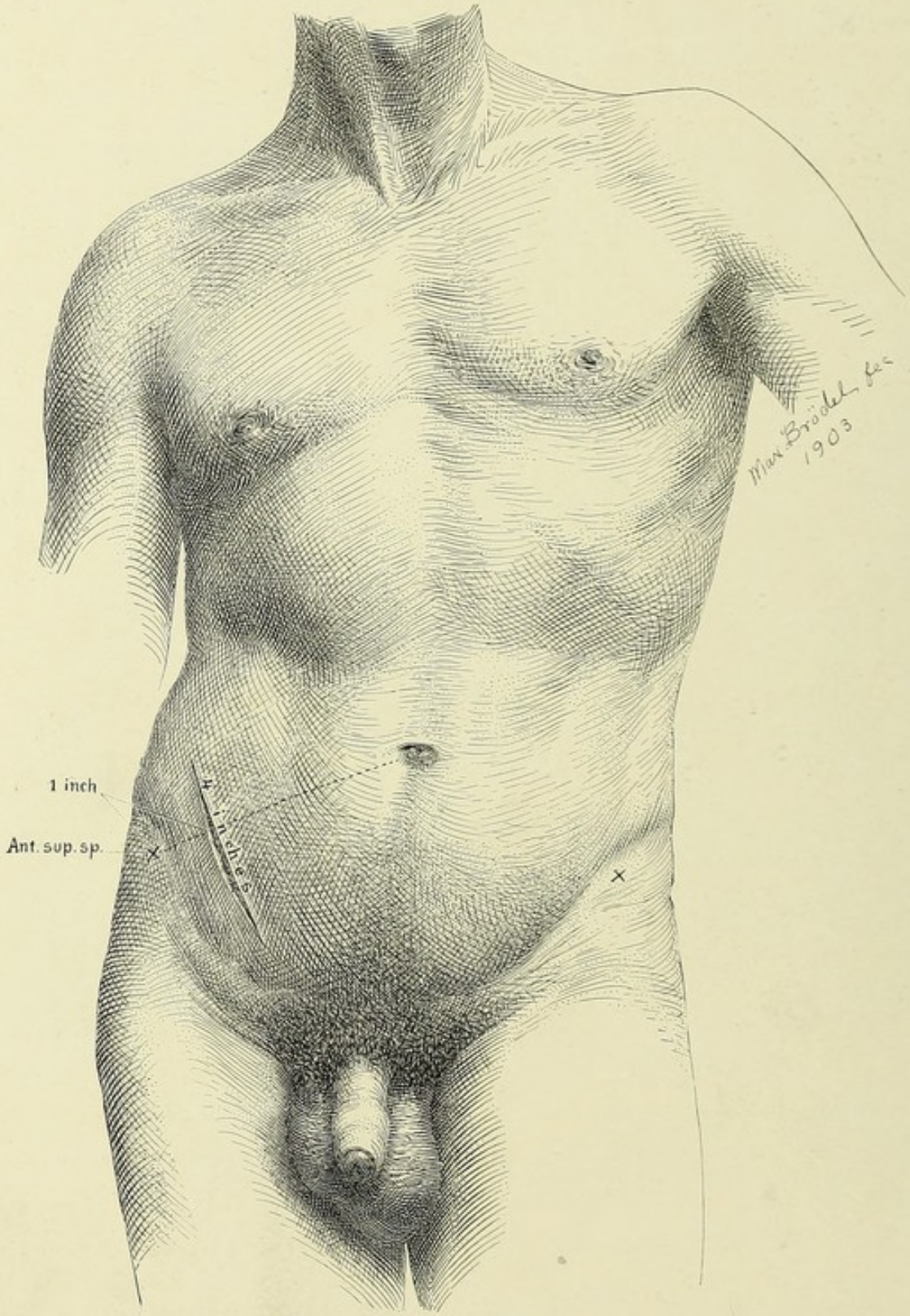

FIG. 241.—McBURNEY'S INCISION (I) IN THE SKIN. (See p. 533.)

the superficial fascia, the external oblique muscle, the internal oblique muscle, the transverse muscle, the transverse fascia, and, finally, the peritoneum. A branch of the circumflex artery must usually be tied off, and also a large vein which runs outward in the direction of the incision.

G. R. Fowler.—(Oblique Incision, *Treatise on Appendicitis*, 1894, p. 156.)

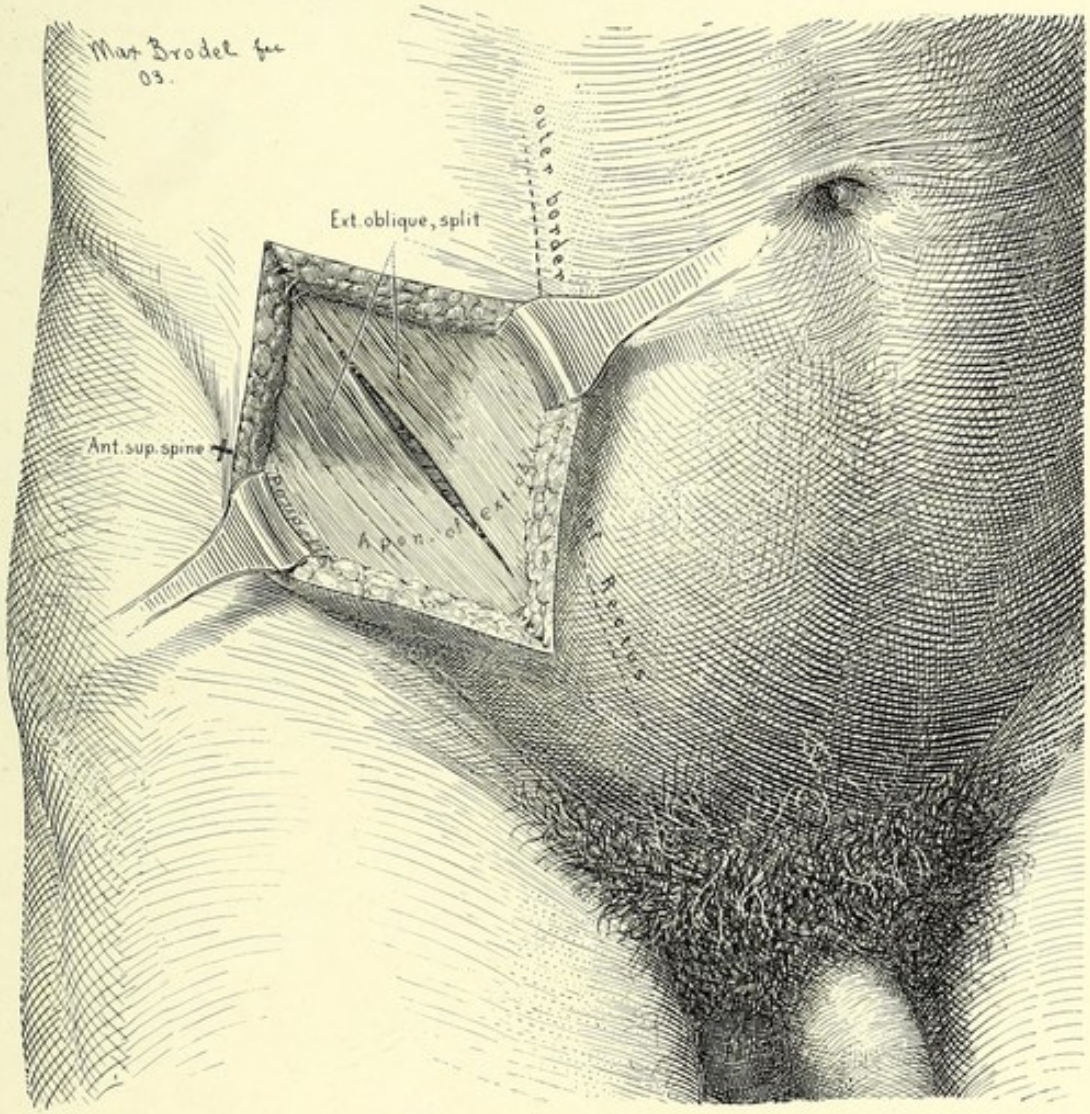

FIG. 242.—MCBURNEY'S INCISION (II).

Skin retracted, exposing the external oblique muscle and its aponeurosis; the muscular fibres are only found in the upper half of the exposed area. The division is made in the line indicated by the separation of the fibres in the figure. (See p. 533.)

(See Fig. 240, e e, p. 529.) Incision two to three inches long, the middle of which intersects at right angles an imaginary line drawn from the right, anterior, superior iliac spine to the umbilicus. The direction of the incision, therefore, is not quite parallel to Poupart's ligament, though it is frequently spoken of as being so. The structures divided are, the skin, the superficial fascia, the external and internal oblique and the transversalis muscles, the transversalis fascia,

and the peritoneum. It has the advantage of giving ready access to the appendix, and of being easily extended upward or downward; it is frequently followed by hernia, however, in cases requiring drainage.

Roux.—(*Rev. méd. de la Suisse Rom.*, 1890, tom. 4, p. 325.) The oblique incision was introduced into France by Roux, with a slight variation in method by which the peritoneum, when it is reached, is incised only in the superior external part of the wound just over the cecum, and not enlarged unless it is necessary to do so.

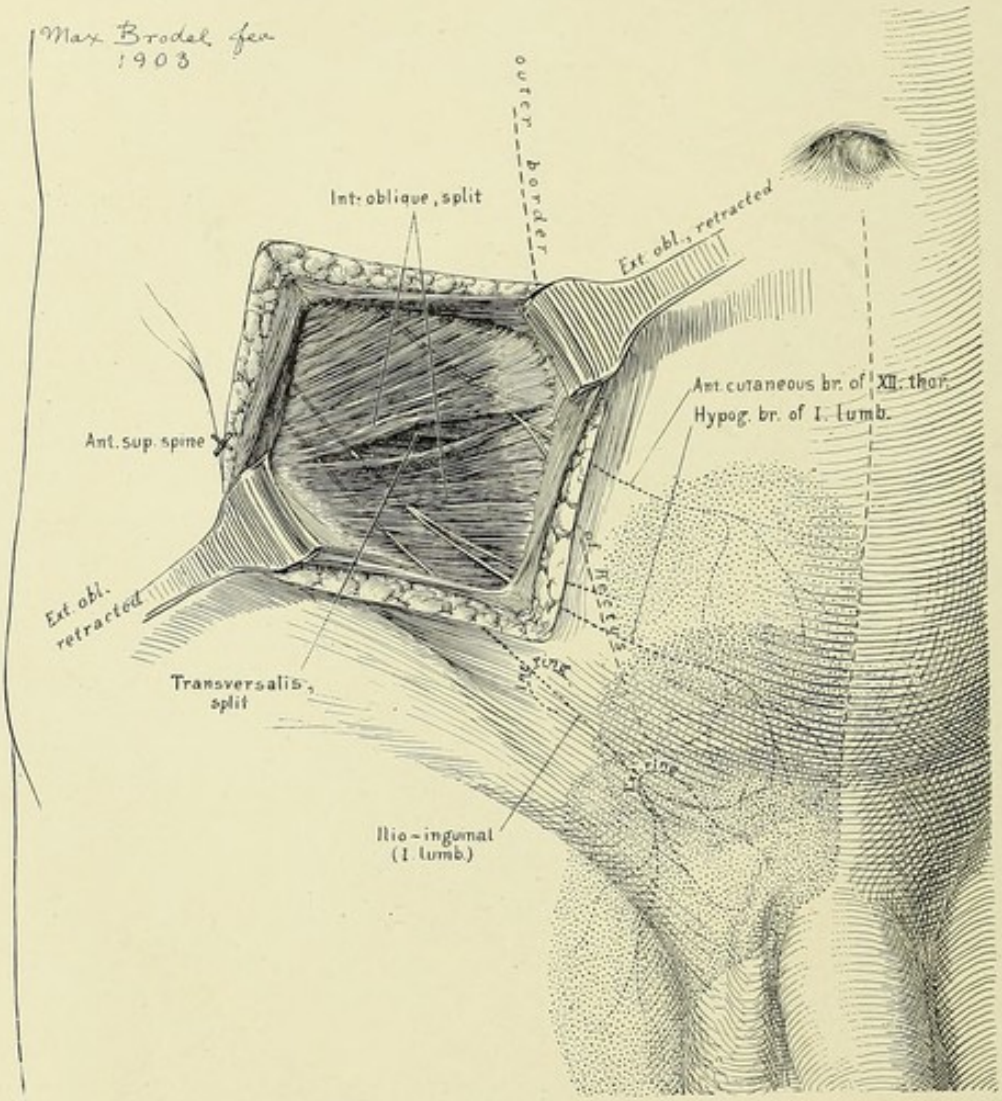

FIG. 243.—MCBURNEY'S INCISION (III).

Showing the skin with the external oblique muscle retracted, and exposing the internal oblique, which is also slightly drawn apart in the direction of the incision about to be made, exposing the transversalis muscle below. The fibres are divided where they are longest. The important point at this stage of the operation is to avoid injury to the nerve trunks readily found crossing the upper and lower portions of the field. An injury to the muscular or cutaneous branches of the twelfth nerve is followed by muscular paralysis or by an anesthetic area over the zone indicated. Injury to the ilio-hypogastric nerve, seen just above the ilio-inguinal, produces similar disturbances in the lower zones of the rectus and the skin. The arrangement shown is that most commonly found.

C. McBurney.—("Gridiron.") (*Ann. Surg.*, July, 1894, p. 38.) (See Fig. 240, f f.) Incision about four inches long, crossing at right angles an imaginary line drawn from the right anterior iliac spine to the umbilicus, the upper third of the incision lying above the line. (See Fig. 241, p. 530.) The section of the external oblique muscle must correspond with that of its aponeurosis, no fibres being cut across. (See Fig. 242.) The edges of the external oblique are then pulled apart by retractors in order to expose the internal oblique, whose fibres,

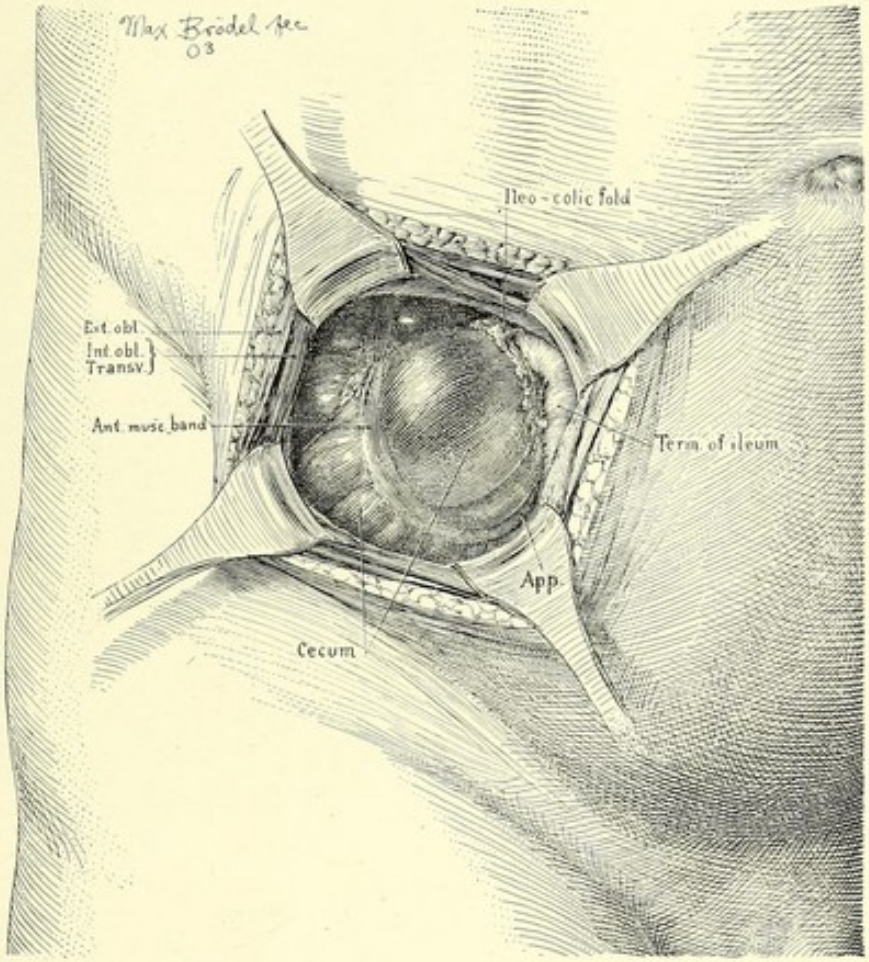

FIG. 244.—McBURNEY'S INCISION (IV).

Showing the excellent exposure of the cecum and structures adjacent to the appendix. The size and position of the opening can be materially altered to meet changing conditions, such as an abnormally placed appendix, by traction in one or another direction.

as well as those of the underlying transversalis muscle, are now separated with a blunt instrument in a direction parallel to their course, which is nearly at right angles to the incision previously made in the external oblique. (See Fig. 243.) Not more than an occasional muscle fibre need be cut. The edges of the opening are then separated by blunt retractors, thus exposing the transversalis fascia, which is divided in the same line as the muscle. Finally, the section of the peritoneum is made. The perfect exposure secured in this way

is shown in Fig. 244. After the appendix is removed, the wound in the peritoneum is closed by suture; the fibres of the transversalis and of the internal oblique fall together as soon as the retractors are withdrawn, and their closure is made complete by a couple of fine catgut stitches. The wound in the external oblique is sewed with catgut from end to end. This method was devised for the purpose of obviating the occurrence of hernia, a common sequela after vertical or oblique incisions. The abdominal wall owes its strength largely to the gridiron-like arrangement of its muscular and tendinous fibres, and as in this operation these fibres are not cut, but separated, their normal arrangement is not disturbed, and the strength of the wall after the operation

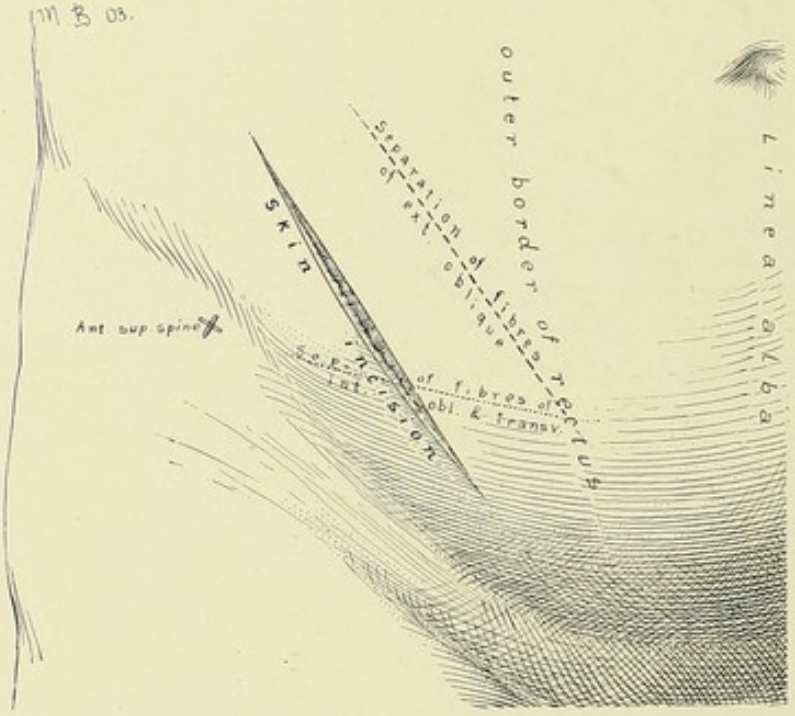

Fig. 245.—Finney's Incision.

Showing marked disassociation of skin and muscle incisions for the purpose of protecting the deep wound. The deep incisions are those which are displaced.

is finished is almost as complete as if no operation had been done. This method possesses the additional advantage of causing no bleeding except from the incision in the skin, and little or no post-operative pain, since no nerves nor muscle fibres need be divided. Finney's modification of the McBurney incision is shown in Fig. 245.

Incision in the Semilunar Line.—(Battle, *Brit. Med. Jour.*, 1895, vol. 2, p. 1360.) This is a vertical incision of variable length in the right iliac region, following the direction of the linea semilunaris. (See Fig. 246, a.) The middle of the incision corresponds to the point where, in the opinion of the surgeon, the appendix will be found. The skin and the subcutaneous tissue are incised, and the aponeurosis of the external oblique is

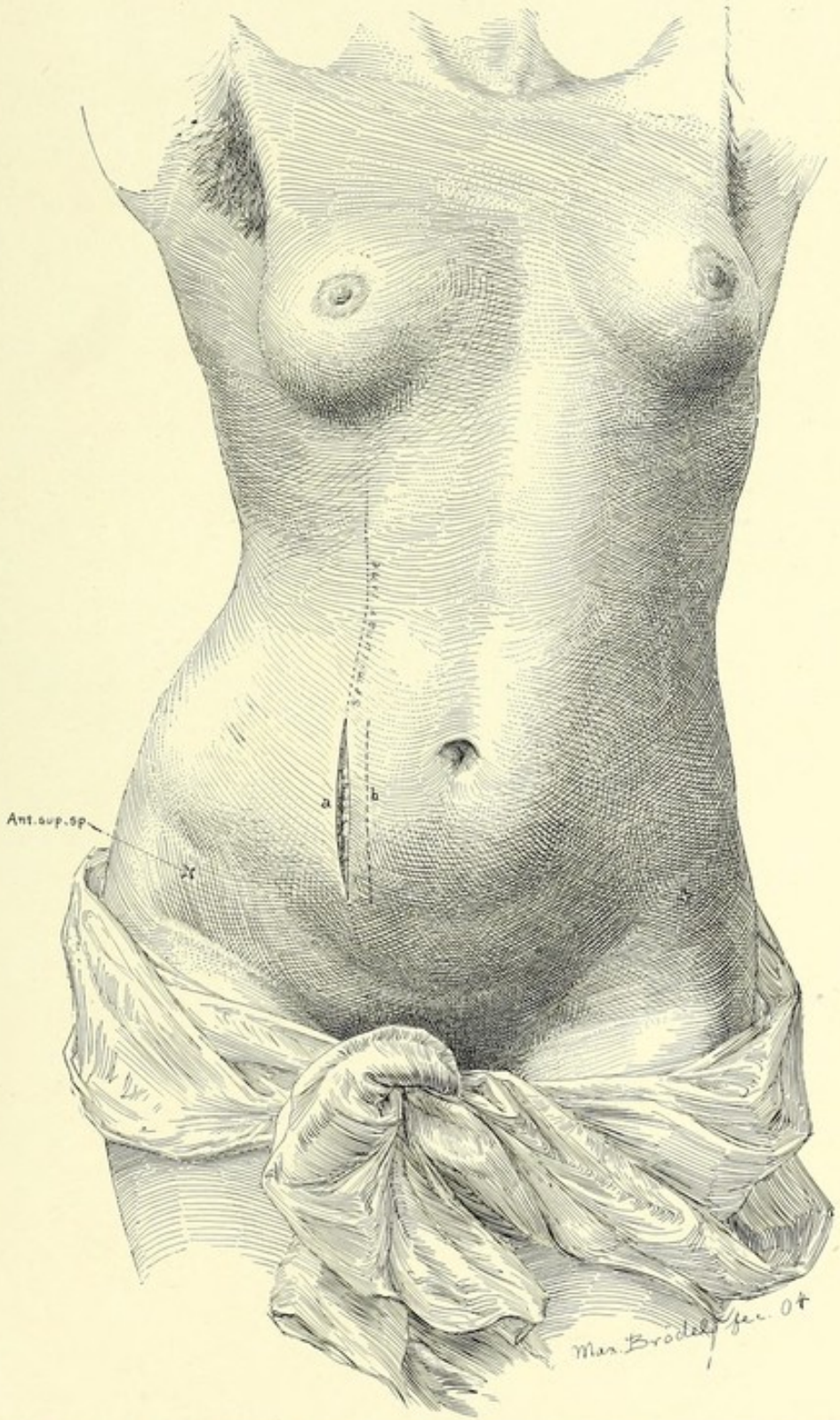

FIG. 246.—Incision in the semilunar line (a) practised by Battle, Kammerer, Jalaguier. Lennander makes his skin incision, and also that which divides the anterior lamella of the rectus sheath, 0.5 to 2 cm. median to the lateral border of the rectus (b).

exposed as it spreads over the rectus muscle. The outer part of the sheath of the right rectus is then incised, and the muscle, having been separated from the sheath with the forefinger, is drawn toward the median line. (See Fig. 247.) On retracting the muscle the deep epigastric artery is seen lying on its posterior sheath, but this is easily avoided. The thin posterior sheath of the rectus, the subperitoneal tissue, and the peritoneum are all divided to the

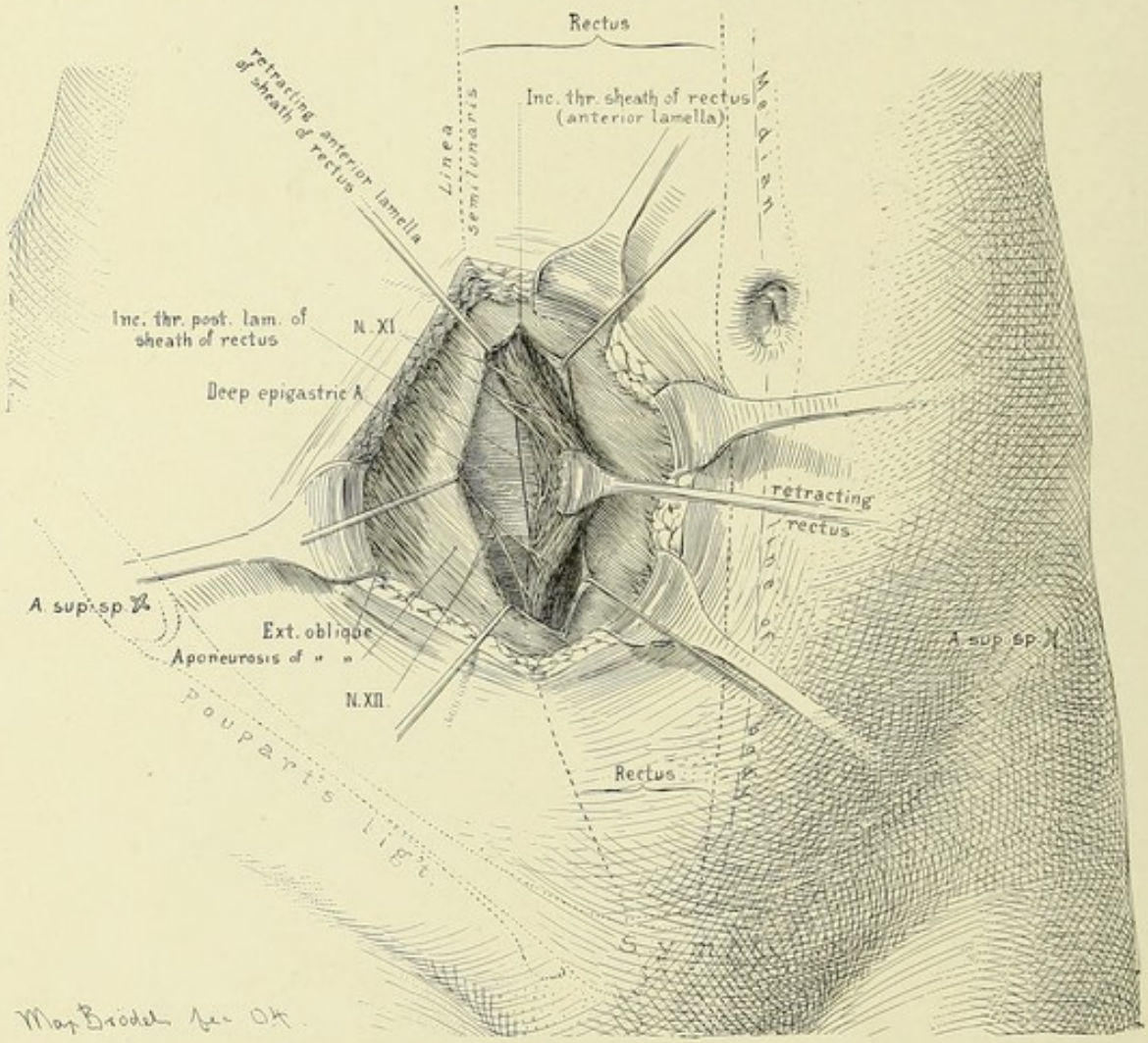

Fig. 247.—Incision in Semilunar Line Opening the Rectus Sheath and Exposing the Deep Epigastric Vessels under the Retracted Rectus Muscle.

Note carefully the nerves exposed and implicated. The subsequent incision through the posterior sheath of the rectus is indicated by the vertical line.

full extent of the incision. After removal of the appendix, the wound is closed by interrupted silk sutures in three layers from behind forward. The posterior part of the sheath and the structures behind the muscle are brought together in one line of sutures, after which the rectus muscle is allowed to return to its normal position. (See Fig. 248.) The anterior part of the sheath, with its external oblique aponeurosis, is next sutured, and finally the subcutaneous

tissue and the skin. This method has the same advantage as that of McBURNEY, namely, the avoidance of hernia as a post-operative sequela. It has also the same disadvantage of requiring a slightly longer time than the simpler operations.*

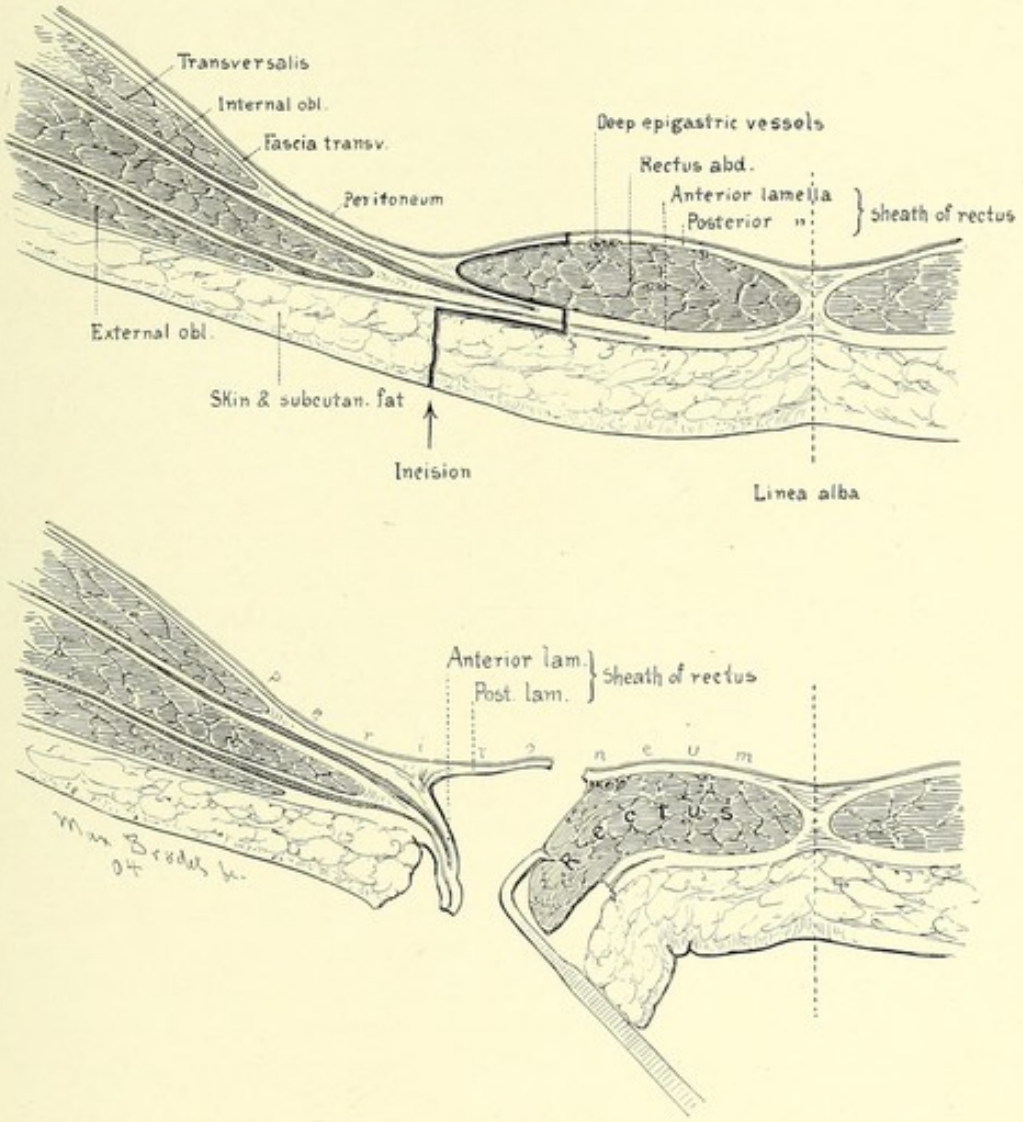

FIG. 248.—SHOWING THE DIVISION OF THE STRATA OF THE ABDOMINAL WALL IN THE INCISION OVER THE SEMILUNAR LINE.

The upper figure shows the direction taken in the incision, while the lower shows the tissues divided and retracted.

This incision has also been independently advocated by KAMMERER (*Ann. Surg.*, 1897, vol. 26, p. 225); JALAGUIER (*Presse méd.*, 1897, tom. 5, p. 53); and LENNANDER (*Centralbl. f. Chir.*, 1898, vol. 25, p. 90).

*Battle's original publication in 1895 was very brief, scarcely more than a note, and possibly for this reason was almost entirely overlooked. After the appearance of other claims he published a second paper describing his method at greater length (*Brit. Med. Jour.*, 1897, vol. 1, p. 965).

R. T. Morris.—(Short Incision.) (*Med. News*, April 7, 1894.) (See Fig. 240, d d, p. 529.) Incision 1½ inches long exactly over the site of the appendix in a line following the direction of the external oblique fibres. The distal end of the incision terminates at the right margin of the right rectus muscle. After cutting the skin the muscles and fascia are separated by blunt dissection. The transversalis fascia and the peritoneum are then picked up on a hook, and a guy-line made of a strong thread of catgut is passed through them. A forceps is then snapped on the loose end in order to keep the guy-line out of the way, and left there until the wound is closed. After the removal of the appendix the retracted margins of the divided transversalis and the internal oblique aponeurosis, as well as the peritoneum, are brought up into sight by traction on the guy-line. They are then closed with one suture of catgut; the guy-line is cut away, and the external oblique with its aponeurosis is closed with one or two uninterrupted sutures. While the skin is being closed it is kept on the stretch, and care is taken not to include any fat in the suture. The advantage of so short an incision is that it reduces the length of convalescence, the patient being in bed only one and a half weeks, and that it leaves an almost imperceptible scar; but it is unavailable where there is pus or when complications are present. The right tube and ovary and the posterior surface of the uterus are all that can be explored through this incision. The disadvantages and dangers of it lie in the fact that unexpected conditions are very often encountered, and the peritoneum as well as the wound are seriously contaminated before the operator is aware of the fact.

G. M. Edebohls.—(Lumbar.) (*Amer. Jour. Obst.*, 1895, p. 165.) (See Fig. 240, h h.) This incision is employed only when the appendix is removed during an operation undertaken for suspension of the kidney. The incision is the same as for a suspensory operation, but it is extended farther down across the loin in the direction of the anterior abdominal wall, so as to bring the anterior portion of the incision into relation with the peritoneal cavity and the ascending colon. The peritoneum is then opened to the outside of the ascending colon. This method is never indicated except as an accompaniment to right nephropexy.

My own custom is to use McBurney's incision when no pus is present, as is the case in most interval operations, and Battle's (semilunar) incision when an abscess must be evacuated, and there is necessity for extensive packing with gauze. In exceptional cases, when there exists a mass of peculiar form or location and the diagnosis is uncertain, I sometimes find it advantageous to make two incisions. The first, which is purely for exploration, corresponds to Battle's incision. After finding the exact location of the mass and its relations to the peritoneum, a second incision is made over the mass or somewhat laterally to it, while one hand is inserted through the exploratory wound for guidance. Before the infected area is entered the first incision is closed.

Closure of the Incision.—After a perfectly aseptic operation the inci-

sion should be closed by means of cumol catgut or fine silk, the tissues being united layer by layer in an order the reverse of that in which the incision was made. The peritoneum should be closed by a continuous catgut suture. The transversalis muscle is rarely sufficiently developed to call for a special suture. After this the internal oblique is united, preferably by interrupted sutures. The external oblique then follows, its aponeurosis being united by interrupted sutures. Lastly, the skin wound is closed by a continuous subcuticular suture of catgut, silkworm-gut, or silver wire. In all doubtful cases it is best to close the wound only in part, leaving an opening for drainage. The dictum of A. WORCESTER, of Waltham, Mass., uttered on this subject over twelve years ago, is the opinion of all experienced surgeons to-day: "Many a patient has been sacrificed after an otherwise good operation by the close suturing of the abdominal wound" (*Bost. Med. and Surg. Jour.*, Aug. 4, 1892). C. P. NOBLE lays great stress upon the overlapping of the tissues as an important factor in the subsequent strength of the abdominal wall (*Amer. Jour. Obst.*, 1897, No. 4).

CHAPTER XXV.

REMOVAL OF THE APPENDIX.

EXPOSURE OF THE APPENDIX. TYPICAL OPERATIONS FOR REMOVAL OF THE APPENDIX. ATYPICAL OPERATIONS FOR REMOVAL OF THE APPENDIX. MECKEL'S DIVERTICULUM.

EXPOSURE OF THE APPENDIX.

The first care of the surgeon after opening the abdominal cavity should be to explore the area surrounding the cecum, in order to note the presence of swelling or induration, as well as of intestinal or omental adhesions. The following local conditions may give rise to an error in diagnosis:

A tumor of the right ovary.
Inflammation of the right ovary or tube.
Extrauterine pregnancy.
Worms in the intestinal canal.
A Meckel's diverticulum.
A stone in the right ureter.
A movable right kidney.
Intestinal and omental adhesions.
Stones in the biliary tract.

An error is most likely to occur in cases of right-sided pain in women, and here the first step should always be to examine the condition of the tube and ovary on the right side. A movable kidney is frequently mistaken for an appendicitis, and when there is no visible affection of the appendix the kidney should be grasped and the extent of its mobility tested by gentle traction. The gall-bladder will in some instances be found to contain stones the removal of which will clear up the diagnosis. Intestinal and omental adhesions should always be sought out and separated if present. The right ureter can be inspected on the pelvic brim just to the inside of the ovarian vessels; if there is a stone at this point, it can readily be seen, and if it is lower down, the ureter will, as a rule, be found dilated. Round worms are sometimes felt through the wall of the small intestine, which can be killed by squeezing or needling, after which the dead worm will be found in the stool. A Meckel's diverticulum should be looked for along the free border of the ileum, beginning at the valve and examining the bowel for a distance of three feet

or more. The symptoms of an inflamed or perforated Meckel's diverticulum are often precisely the same as those arising from an appendix similarly affected. In all cases in which the abdomen is opened *for appendicitis* the appendix

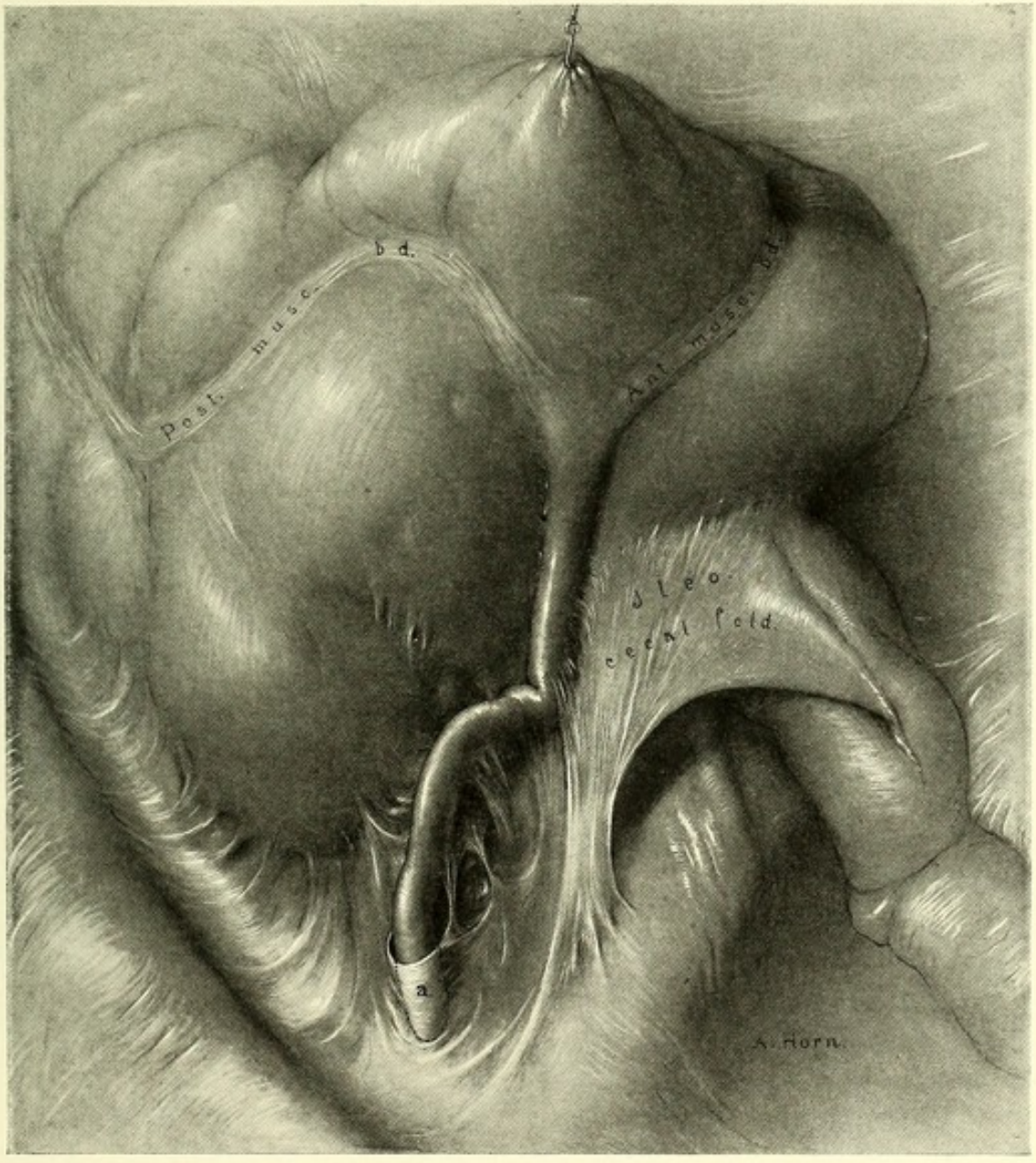

FIG. 249.—THE APPENDIX CONCEALED BEHIND THE CECUM AND FLEXED UPON ITSELF HAS ITS TIP CONCEALED IN A RETRO-PERITONEAL POCKET.

The ileocecal fold terminates in the parietal peritoneum over the psoas muscle. Autopsy January 24, 1902. (Natural size.)

must be removed when it can be found, whether it appears normal or not, for strictures and minute ulcerations of the mucosa may be present which produce no alteration of the peritoneal surface recognizable to the naked eye.

In a favorable case the appendix may slip out of the incision at once; if it does not do this, it must be sought for by feeling with the thumb and forefinger, the tenia muscle serving as a guide (see Fig. 249). Sometimes, however, a band passes from the tenia across the cecum, which tends to mislead the operator very seriously in looking for the appendix, should it lie behind the cecum and beneath the ileum, as shown in Fig. 250. Search should always be directed to the iliac fossa below the cecum; then to the pelvic cavity, where the appendix may sometimes be found hanging over the brim of the pelvis, or even along it (see Fig. 251); then to the inner side of the cecum in the angle between the cecum and the ileum;

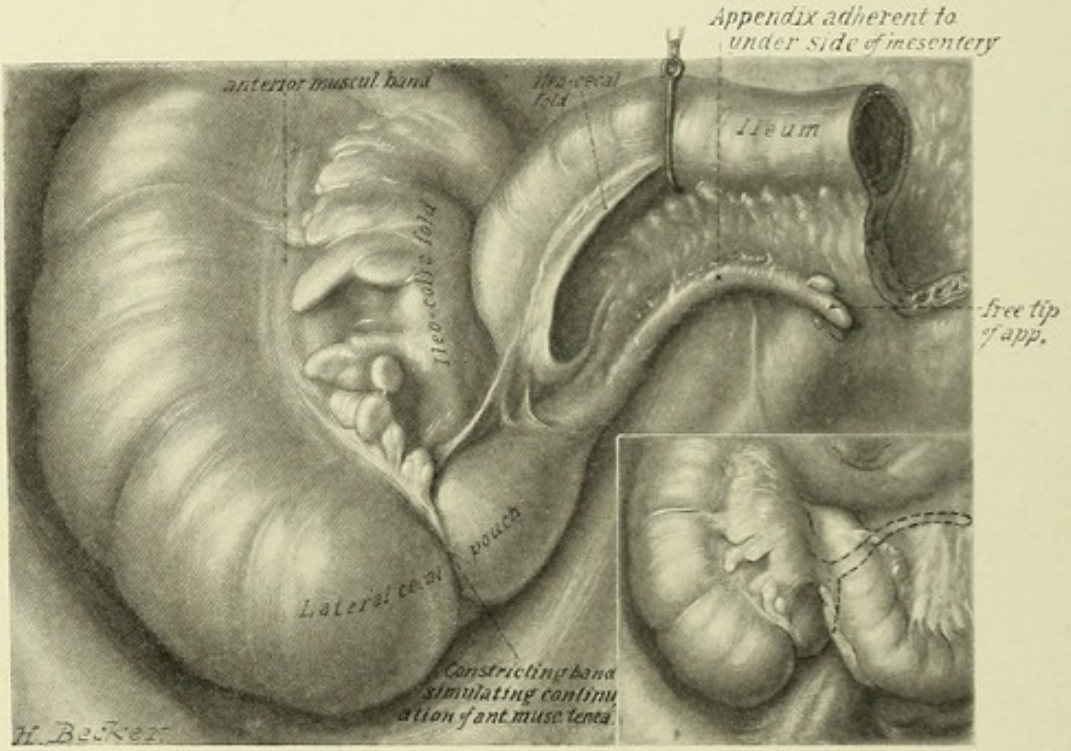

Fig. 250.—Shows a Misleading Constricting Band, Simulating the Anterior Muscular Tenia, well Shown in the Right-hand Lower Figure.

By following this band, the surgeon will be misled into searching for a retrocecal appendix, when the organ lies as seen. M. C., æt. twenty-four. Autopsy February 1, 1903. (Two-thirds natural size.)

then to the outer side of the cecum (see Fig. 252); and, finally, to the posterior part of the cecum. If the appendix occupies the retrocecal position, as it does in a large number of cases (see Figs. 253 and 254), it is discovered, after the exclusion of other positions, by lifting up the cecum with the tenia muscles in view, and inspecting the point at which the appendix disappears behind the bowel. If the appendix is of the retrocecal, extraperitoneal type, it is then exposed to view by incising the cecum on its outer side, and detaching the bowel from the iliac fossa until the whole posterior surface of the cecum lies bared. An extreme case of this type is shown in Fig. 255, in which the appendix could only be brought to view by an extensive dissection, begun on the outer surface of the cecum and

colon and carried inward. Another unusual case, in which the appendix, although intraperitoneal, lay completely to the inner side of the cecum and colon, is shown

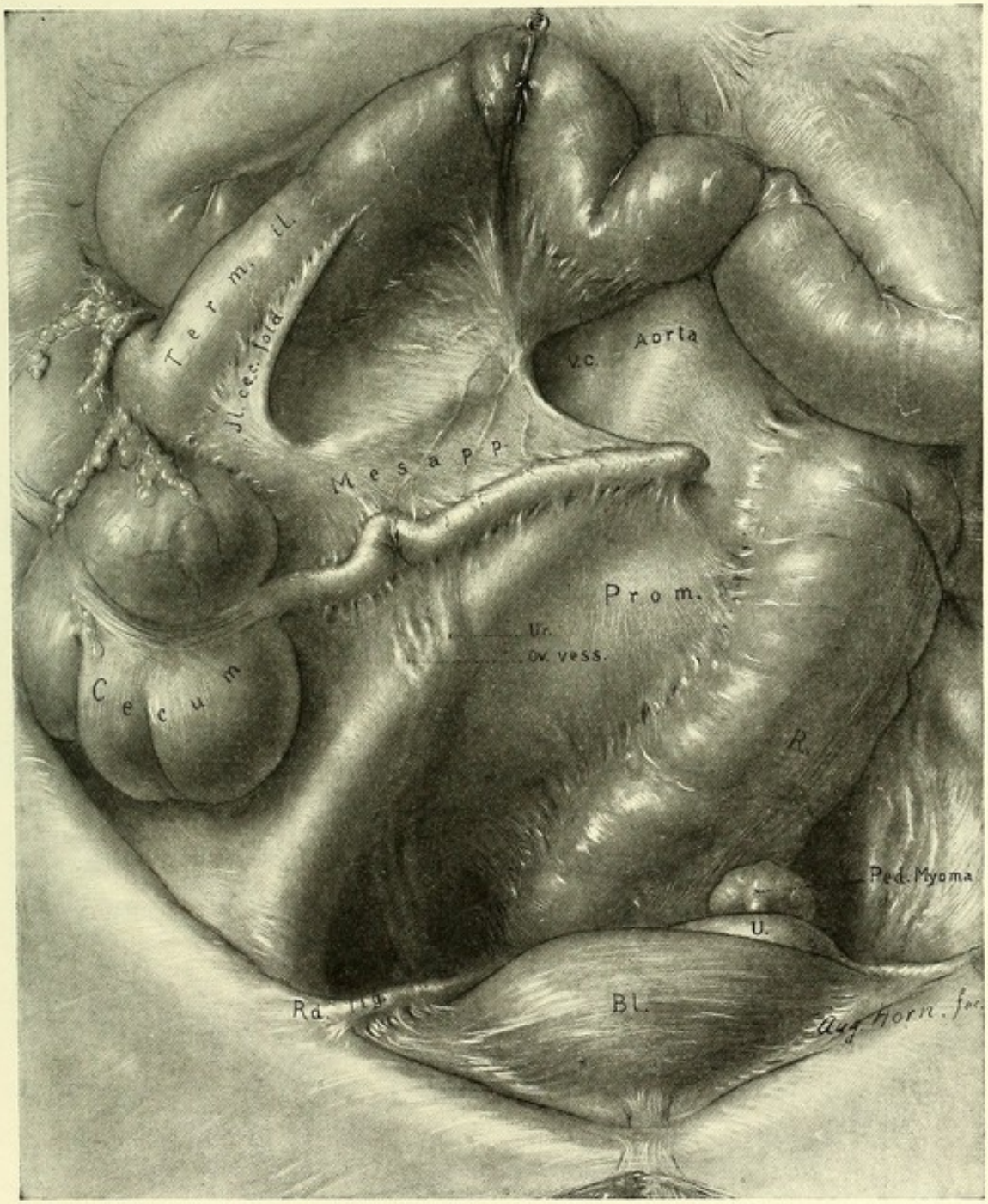

FIG. 251.—APPENDIX ADHERENT ACROSS THE COMMON ILIAC ARTERY ABOVE THE PROMONTORY OF THE SACRUM. Note also the relation of the appendix to the ureter and to the ovarian vessels. P. W., col., æt. seventy-five. Autopsy March 13, 1899.

in Fig. 256 (see p. 548). An interesting group of cases is formed by appendices trapped within peritoneal recesses and pockets, as shown in Figs. 257 and 258 (see pp. 549, 550). Search for the appendix must

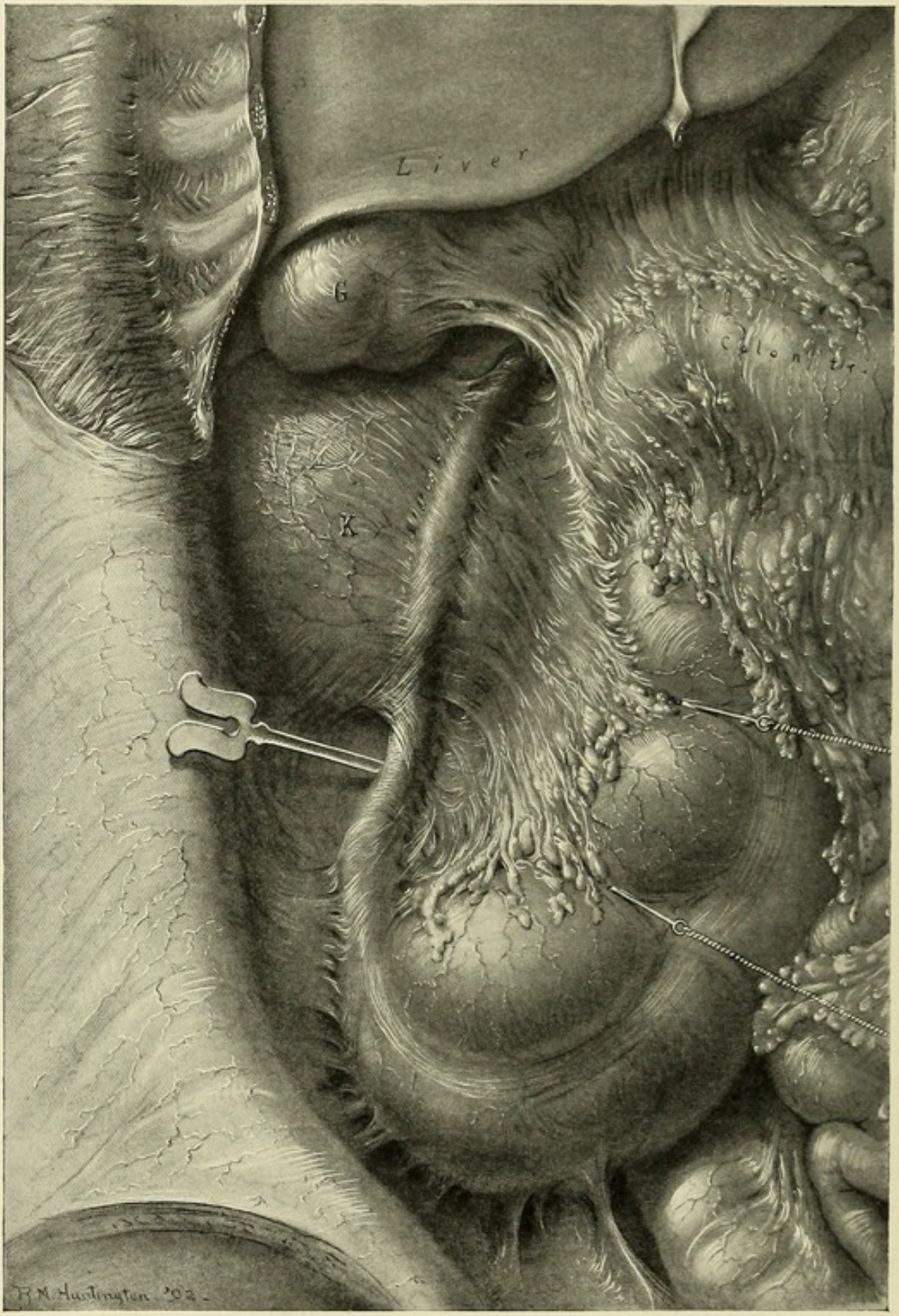

FIG. 252.—EMBRYONIC DISPLACEMENT OF THE APPENDIX, WHICH IS BURIED IN ADHESIONS UNITING THE COLIC FLEXURE TO THE GALL-BLADDER, AND IS BOUND DOWN TO PRE-RENAL PERITONEUM.

This picture is invaluable in explaining the occasional association of appendicitis with cholecystitis and pyelitis. Autopsy December 2, 1901. J. G. col. æt. fifty-five. Carcinoma of stomach, metastases. (Three-fourths natural size.)

always be carried on with the utmost caution, and the operator should be ever on his guard, since the incautious lifting of a loop of bowel or the

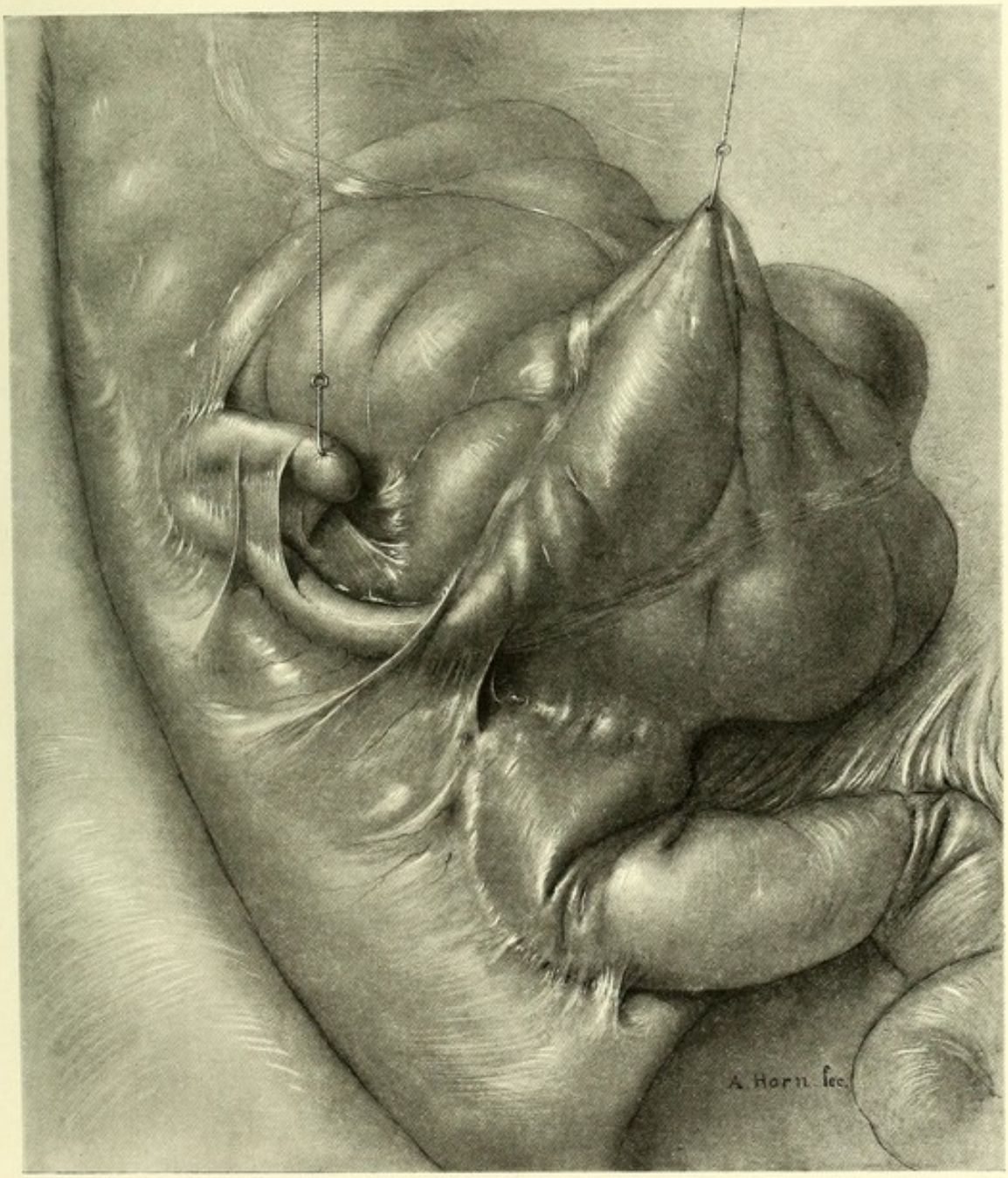

FIG. 253.—THE CECUM AND COLON LIFTED, SHOWING THE ADHESIONS OF THE TERMINAL ILEUM AND THE HIGH RETRO-COLIC APPENDIX, KINKED AND WRAPPED IN VEILS OF ADHESIONS.

This case shows well the difficulties which may sometimes be experienced in finding the appendix. Autopsy January 23, 1902. (Natural size.)

separation of some trifling adhesion may prove sufficient to let loose the contents of an abscess, hitherto scarcely restrained by an insufficient barrier. In order that the operator may carry clearly in mind the various sites in which

the appendix may be found, as well as the different attachments, as he opens the abdomen to find and remove it, a graphic presentation of these varying positions is given in Fig. 259 (see p. 551).

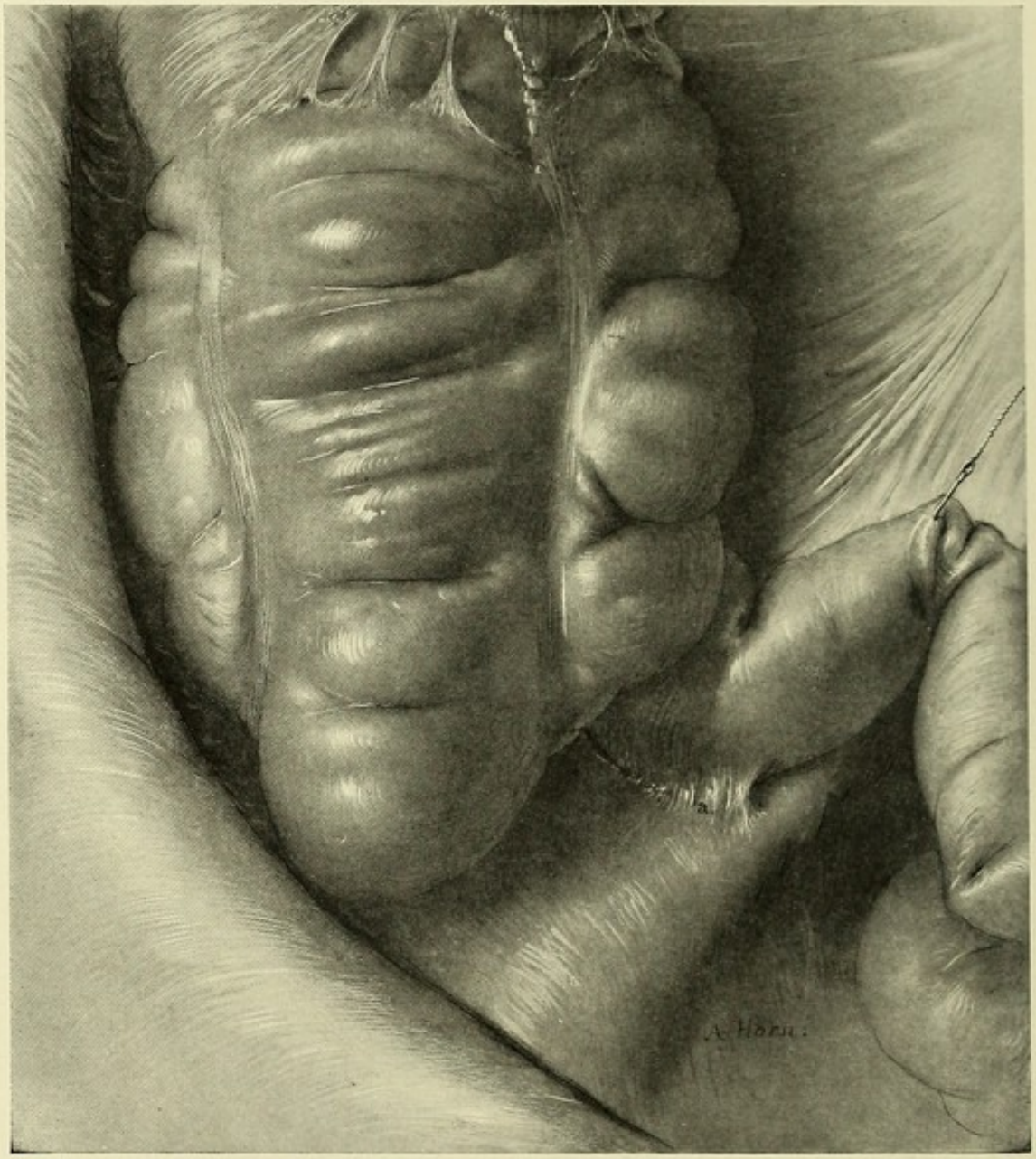

FIG. 254.—SHOWS THE APPENDIX COMPLETELY CONCEALED FROM VIEW BY THE CECUM AND COLON. There is a moderate degree of rotation of the cecum, which renders the posterior muscular band visible. This may be due to the adhesions of the ileum to the psoas muscle seen at (a). (Natural size.)

Operations for the removal of the appendix may be divided into two classes:

1. Typical—In which the infection is localized in the appendix and can be readily isolated from surrounding structures.

2. Atypical—(*a*) In which the appendix is densely adherent to some other

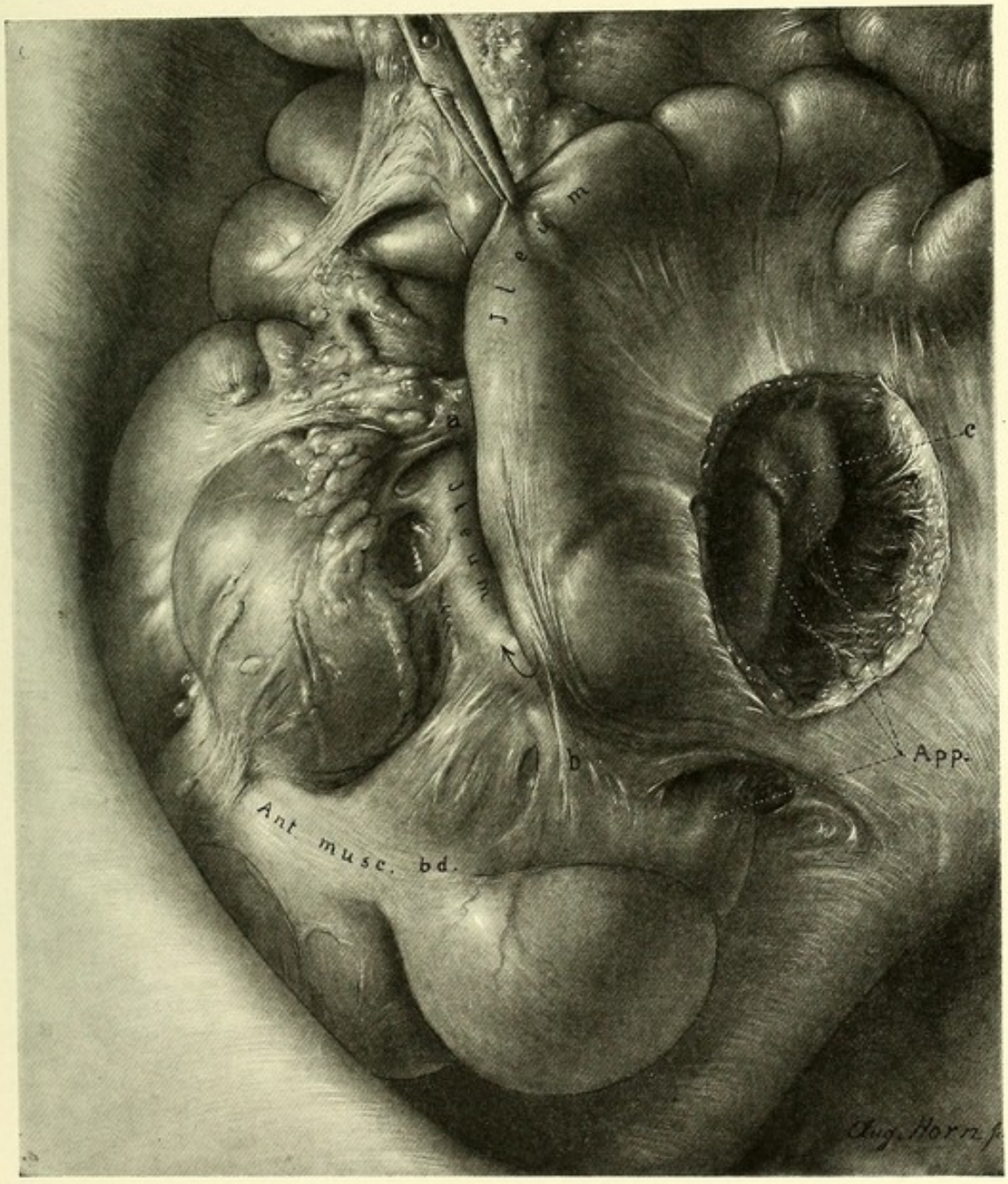

FIG. 255.—SHOWING THE APPENDIX BURIED IN ONE OF THESE RETRO-MESENTERIC POCKETS.

The orifice of the pocket, in this case, was completely occluded by adhesions, and the pocket, within, was completely obliterated by adhesions to the appendix on all sides. The peritoneal coat of the appendix was not distinguishable. The ileocecal valve lies at (a) under the ileocolic fold. The ileocecal fold is at (b). In order to expose the appendix the ileum has been lifted up to the right, and an opening made in its mesentery. C. C., col., æt. twenty-six. Autopsy December 15, 1902. (Natural size.)

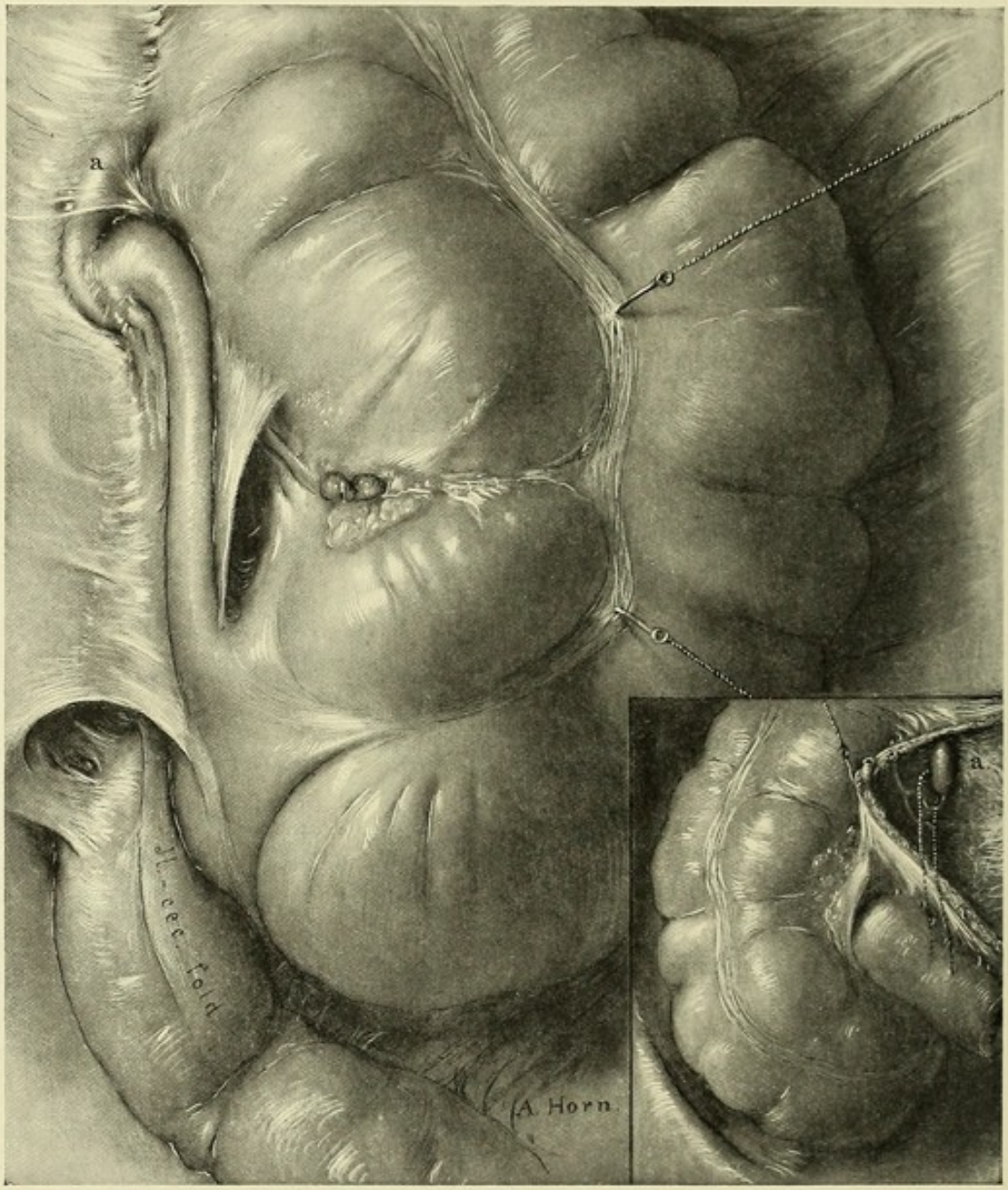

FIG. 256.—THE NORMAL POSITION IS SHOWN IN RIGHT-HAND LOWER FIGURE.

The tip of the appendix lies at point a, while the dotted lines mark the position of the remainder of the organ. The large figure shows the colon drawn aside so as to expose the retro-mesocolic appendix. The importance of this case in explaining deep-seated concealed abscesses cannot be overestimated. Autopsy January 28, 1892. (Natural size.)

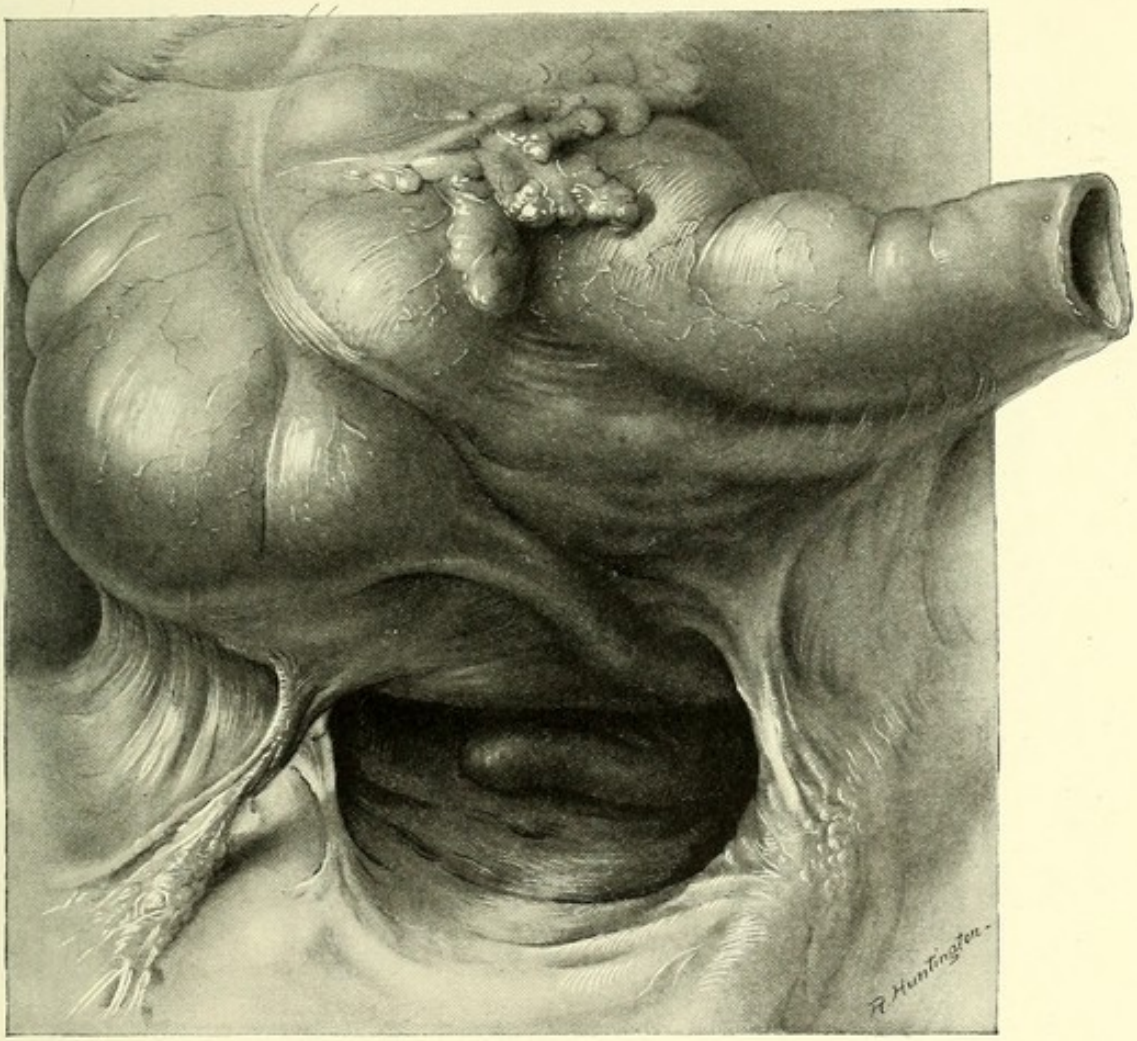

FIG. 257.—THE APPENDIX HERE LIES IN A LARGE-MOUTHED RETROCECAL POCKET.

In this case the border of the omentum was adherent on the outer side of the sac, and is indicated by the little remaining mass. The significance of this position of the appendix in relation to abscess is evident. Note the well-developed appendico-ovarian ligament pathologically produced. (Natural size.)

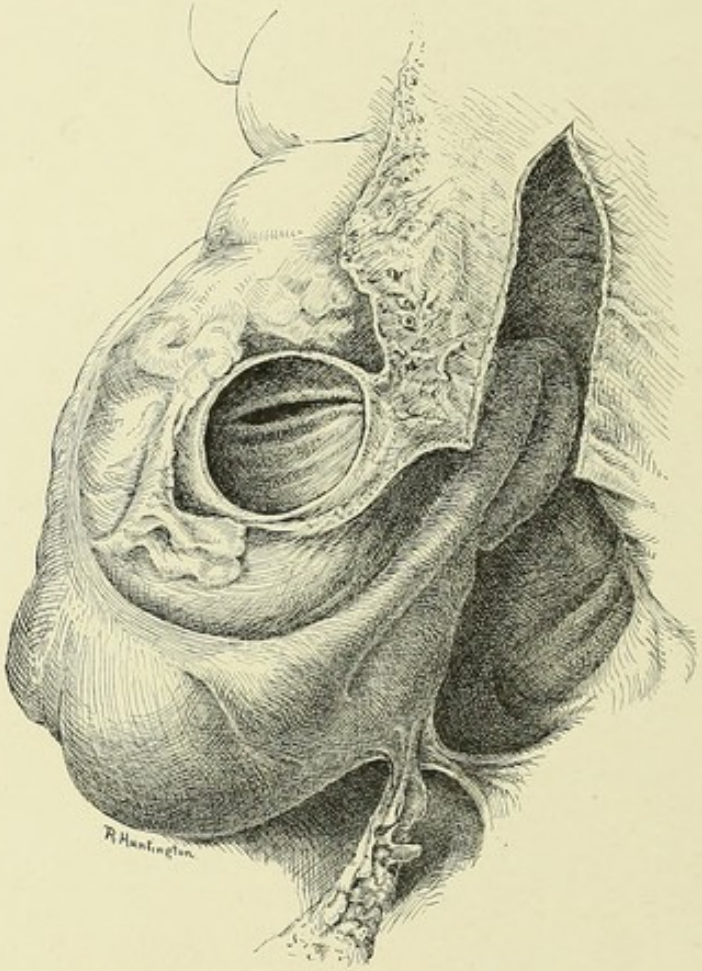

FIG. 258.—AN ANTERO-POSTERIOR SECTION OF THE PRECEDING.

Shows the extreme depth of the pocket and its narrowing above, as it extends high up under the mesocolon. The ileum has been detached and the ileocecal valve is shown.

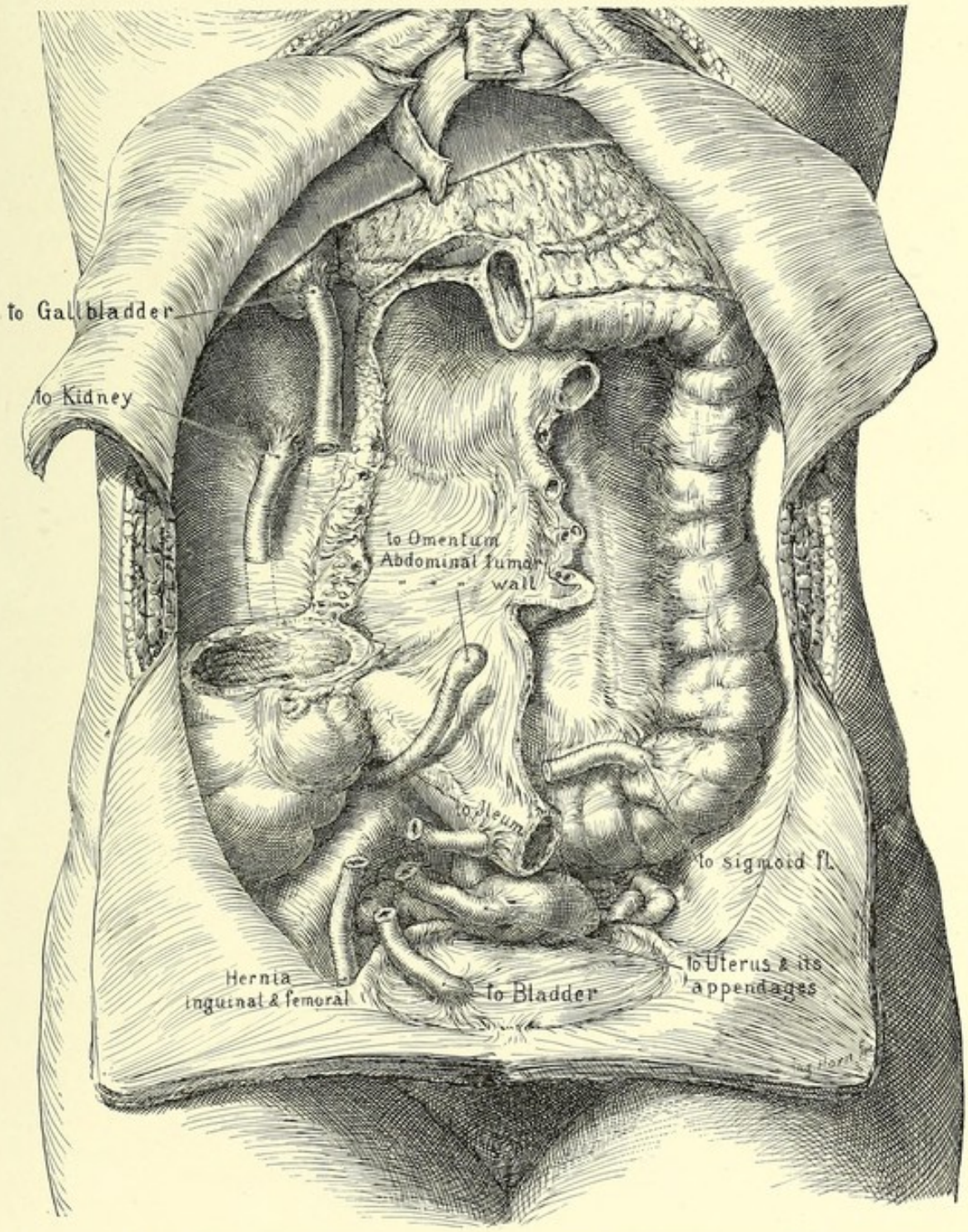

FIG. 259.—A COLLECTIVE PICTURE SHOWING THE VARIOUS POINTS OF ATTACHMENT OF THE VERMIFORM APPENDIX TO GALL-BLADDER, KIDNEY, ABDOMINAL WALL, ILEUM, UTERUS AND ADNEXA, SIGMOID FLEXURE, BLADDER, AND A HERNIAL SAC.

structure. (*b*) In which the appendix lies behind the cecum. (*c*) In which the disease of the bowel is not limited to the appendix, but involves the adjacent part of the cecum as well.

TYPICAL OPERATIONS FOR REMOVAL OF THE APPENDIX.

The one feature common to all operations for removal of the appendix is the ligation of the mesappendix so as to control the vessels. This ligation

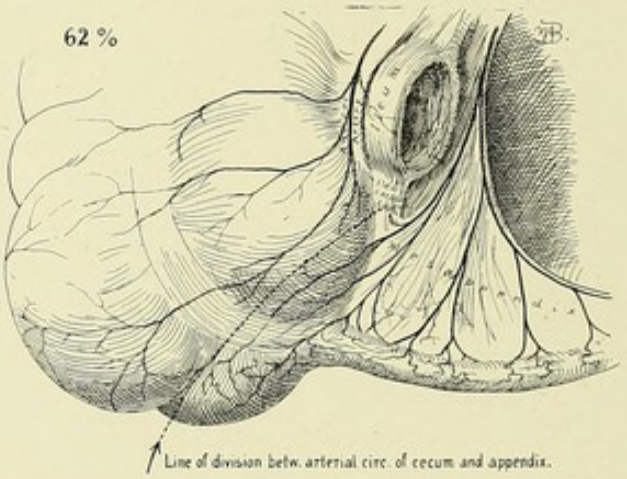

FIG. 260.—THE COMMONEST TYPE OF CIRCULATION AT THE APPENDICO-CECAL ANGLE.
Follow the dotted line which indicates the division between the cecal and appendical vessels in this and the following diagrams. The dotted line represents the maximum area (62 per cent.).

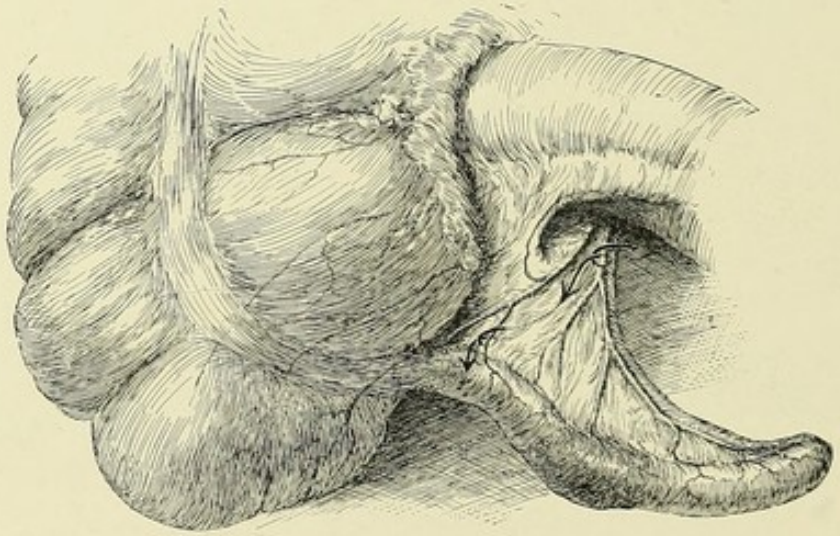

FIG. 261.—NORMAL TYPE, NON-ADHERENT APPENDIX.
The circulation is best controlled by locating the vessels in the mesappendix, and then ligating only the main trunks which supply the appendix, sparing any important branch going to the cecum, as shown in the diagram.

begins on the free border, so as to control the vessels of the mesentery and is continued onward as far as the ceco-appendical angle, a little

on to the surface of the appendix. It is important for the surgeon to familiarize himself with the varying conditions in the vascularization of the appendix and the adjacent cecum, in order that the ligatures may be applied so as to control the hemorrhage, and at the same time avoid cutting off the circulation of any portion of the cecum. The line of division between the arterial supply of the cecum and of the appendix in 62 per cent. of the cases is found well out on to the cecum (see Fig. 260). It is manifest

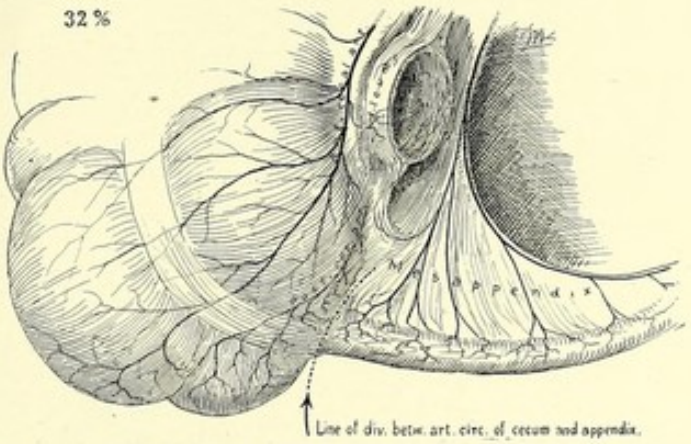

Fig. 262.—The Appendical and Cecal Systems are here Entirely Disassociated (32 per cent.).

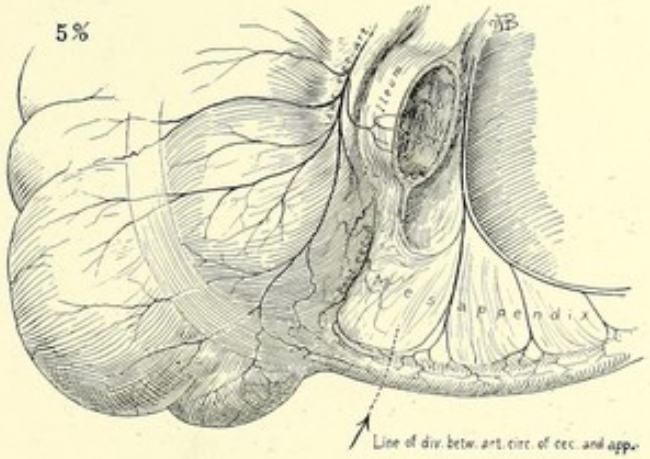

Fig. 263.—The Cecal Vessels here Supply the Root of the Appendix (5 per cent.).

that, for this reason, it is of advantage not to tie all the appendical vessels at too high a point. Fig. 261 shows the best methods of ligating in such a case, sparing the last cecal artery, and thus insuring a maximum nutrition to the parts during the healing process. In 32 per cent. of the cases the circulation is neatly divided at the base of the appendix (Fig. 262), and here the ligature may be applied high enough to give perfect control of all the vessels. Again, in 5 per cent. of the cases we have a condition in which the cecal artery supplies the proximal portion of the appendix (Fig. 263). It is in such cases that we must be on our guard against

bleeding after amputation, and especially for the occasional case (see Fig. 264) in which there is a broad arterial anastomosis between the cecal and the appendical vessels in the little mesentery.

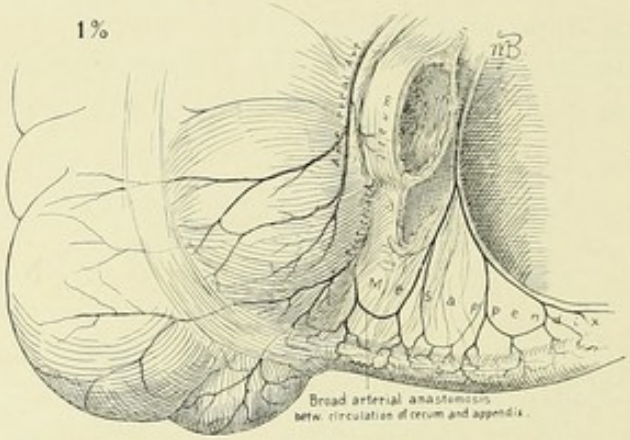

Fig. 264.—Broad Arterial Anastomosis in the Mesappendix (1 per cent.).

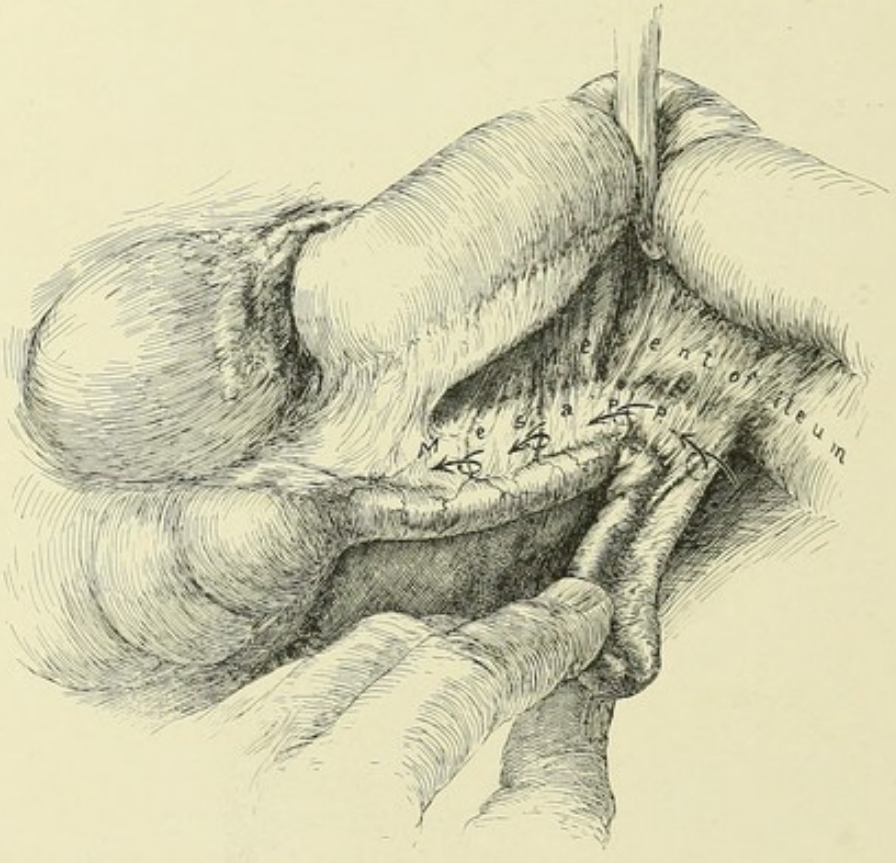

Fig. 265.—Showing the Method of Controlling the Circulation when the Mesappendix is Bound Down. The ligatures must here control the individual vessels close to the appendix.

It sometimes happens that the mesappendix is so short that the main trunks cannot be exposed above; in such cases it will be necessary to tie the vessels singly (a procedure some surgeons elect by preference) close to the

appendix, as shown in Fig. 265. When the appendix lies to the outer side of the cecum, and the mesenteriolum is closely attached, as shown in Fig. 266, it is always safer to control the terminal vessels close to the appendix, proceeding, as a rule, from tip to base.

In dealing with the stump of the appendix it is important to avoid two things,

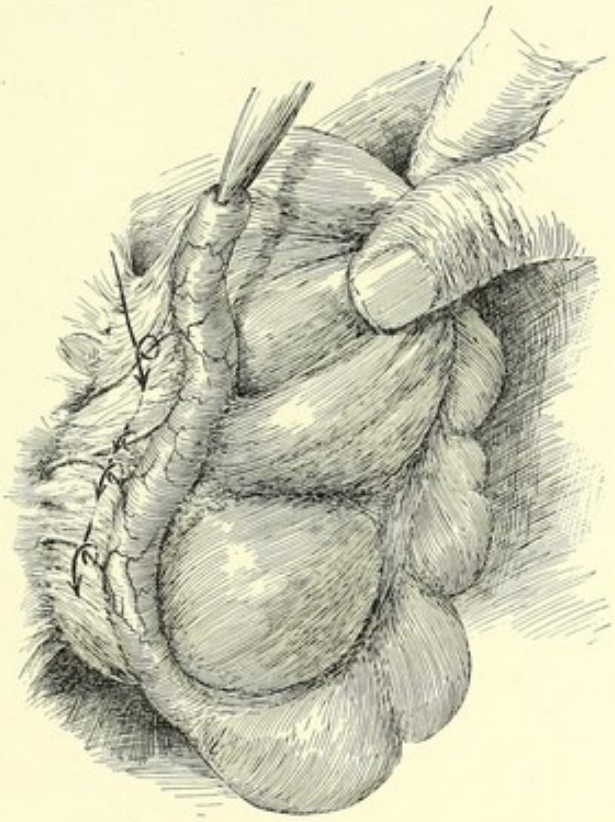

FIG. 266.—SHOWING THE CONTROL OF THE VESSELS IN THE CASE OF AN APPENDIX ADHERENT TO THE OUTER SURFACE OF THE COLON.

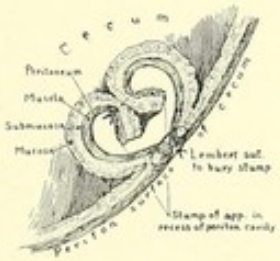

FIG. 267.

A diagram, after Edebohls, to show the danger of burying the exposed mucous membrane of the stump bottled up in a recess of the peritoneal cavity.

first, the simple ligation and amputation, leaving the mucous membrane exposed, whether sterilized or not; second, a method which has been frequently practised (see Fig. 267), namely, that of ligating, amputating, and burying the little stump by means of sero-serous sutures. This

proceeding has in more than one instance, been the source of serious post-operative sequelæ.

The earliest methods of treating the appendix are now obsolete, and no one

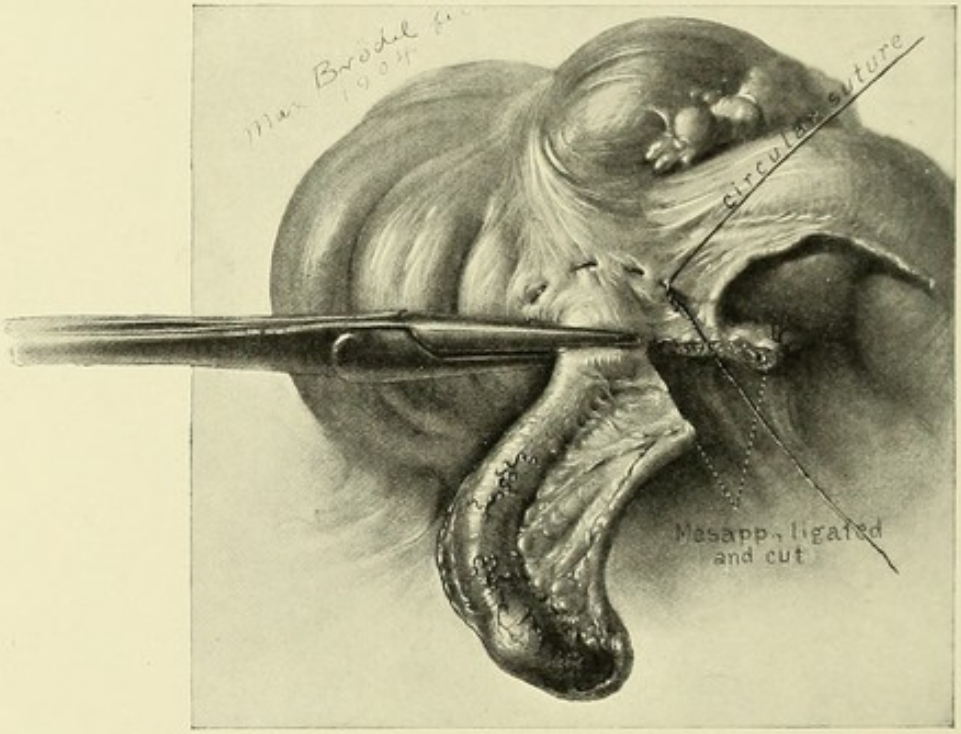

FIG. 268.—I, A SIMPLE, WIDELY-USED METHOD OF EXSECTION OF THE APPENDIX. The mesentery is tied off, a circular suture placed, and the appendix clamped. (See p. 558.)

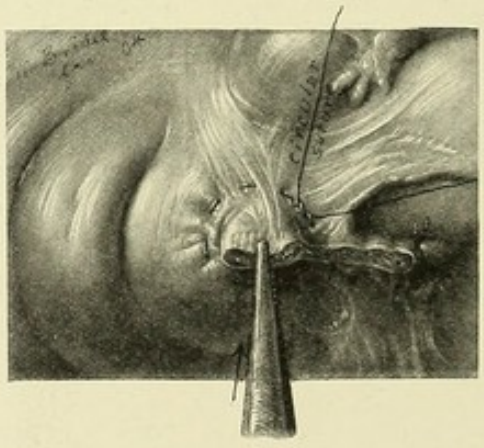

FIG. 269.—II, THE STUMP OF THE APPENDIX IS THEN GRASPED WITH FORCEPS AND THRUST INTO THE BOWEL. (See p. 558.)

to-day would think of trimming off and closing the rough edges of a perforation, as in 1887, or even of simple ligation and excision without sterilization, as in 1888.

A number of improved methods for removal of the appendix in simple uncom-

plicated cases are now in use. These typical operations, however different in detail, may be classified into the following groups:

1. Ligation, excision, and sterilization with projection of stump.

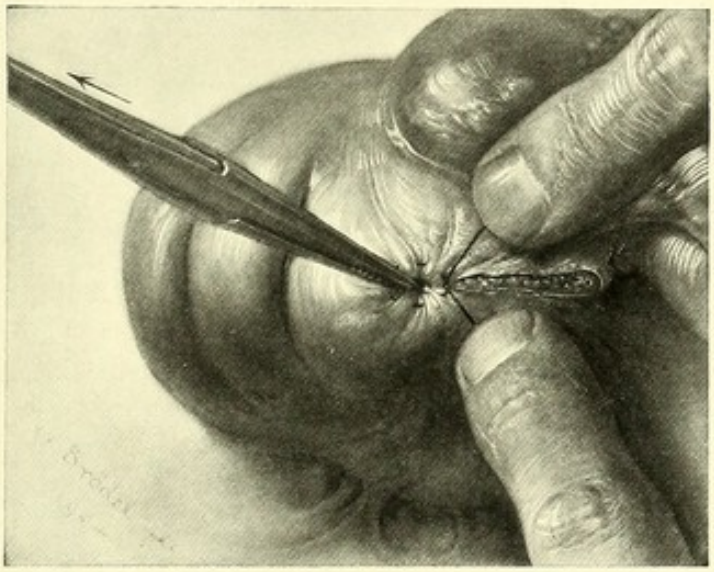

FIG. 270.—III, AT THE SAME TIME THE CIRCULAR SUTURE IS TIGHTENED AND TIED, AFTER WHICH THE FORCEPS IS WITHDRAWN. (See p. 558.)

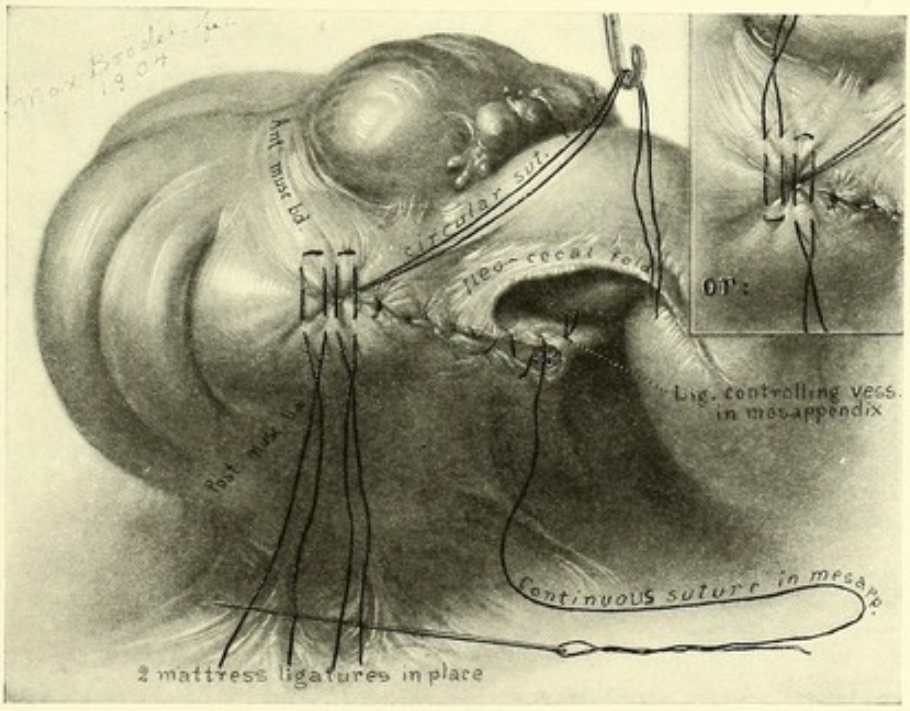

FIG. 271.—IV, FINAL STEP SHOWING THE PLACING OF THE MATTRESS SUTURES OVER THE CIRCULAR SUTURE. (See p. 559.)

2. Ligation, excision, and sterilization, with depression of stump.
3. Inversion of stump.
4. Inversion of the entire unopened appendix.

5. Amputation flush with the cecum.

6. Amputation by means of the cautery.

A simple, satisfactory method of removing the appendix is that represented in Figs. 268 to 271 (see pp. 556, 557). In these figures the mesappendix is tied off down to the angle. A circular suture of silk or chromicized

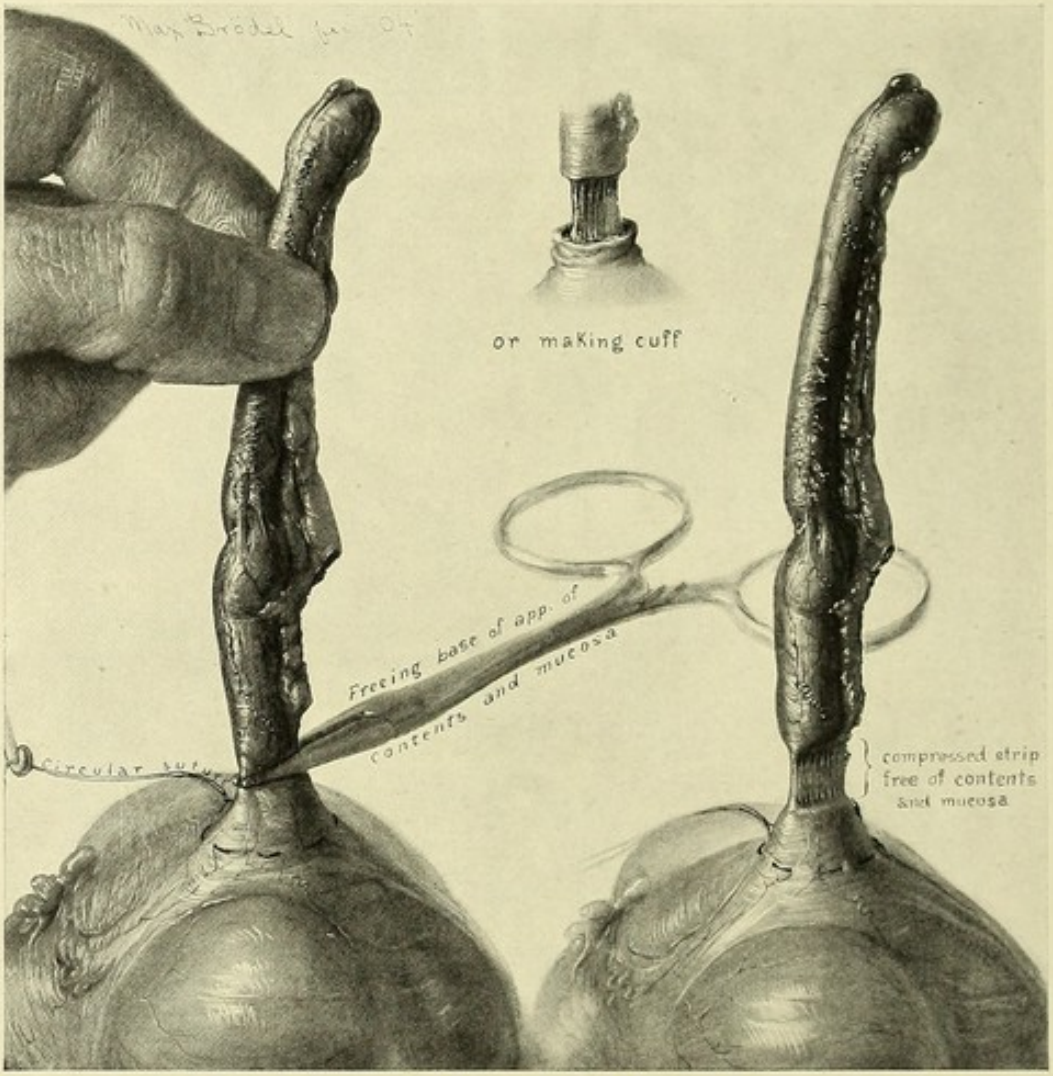

FIG. 272.—SHOWS THE METHOD OF FREEING THE AMPUTATION AREA OF ALL ITS CONTENTS AND THE MUCOSA, AS USED BY FINNEY.

The appendix is clamped and the forceps then worked up and down, producing the thin strip of tissue seen in the right-hand figure. This may be ligated, the appendix amputated, and the stump inverted under the circular ligature. A modification of this plan is to turn back a cuff before clamping.

catgut is then laid in the cecum near the base of the appendix, transfixing the mesentery if necessary. The appendix is then grasped with forceps and amputated, about 1 cm. from the cecum. The cautery may be used in making the amputation. If the knife is used, the end of the stump should be sterilized with carbolic acid. The stump is then grasped with a pair of forceps (see Fig. 269) and pushed into the cecum as the circular suture is tied (Fig. 270). The

wound area is then buried under two or three mattress sutures and the mesenteriolum covered in by a continuous fine silk suture (Fig. 271).

In order to render the appendix perfectly pliable at the point of amputation, FINNEY uses the plan of crushing it near the base with a pair of forceps, and then working the forceps up and down so as to free the interior of the appendix of its mucosa. This plan produces a narrow strip of tissue

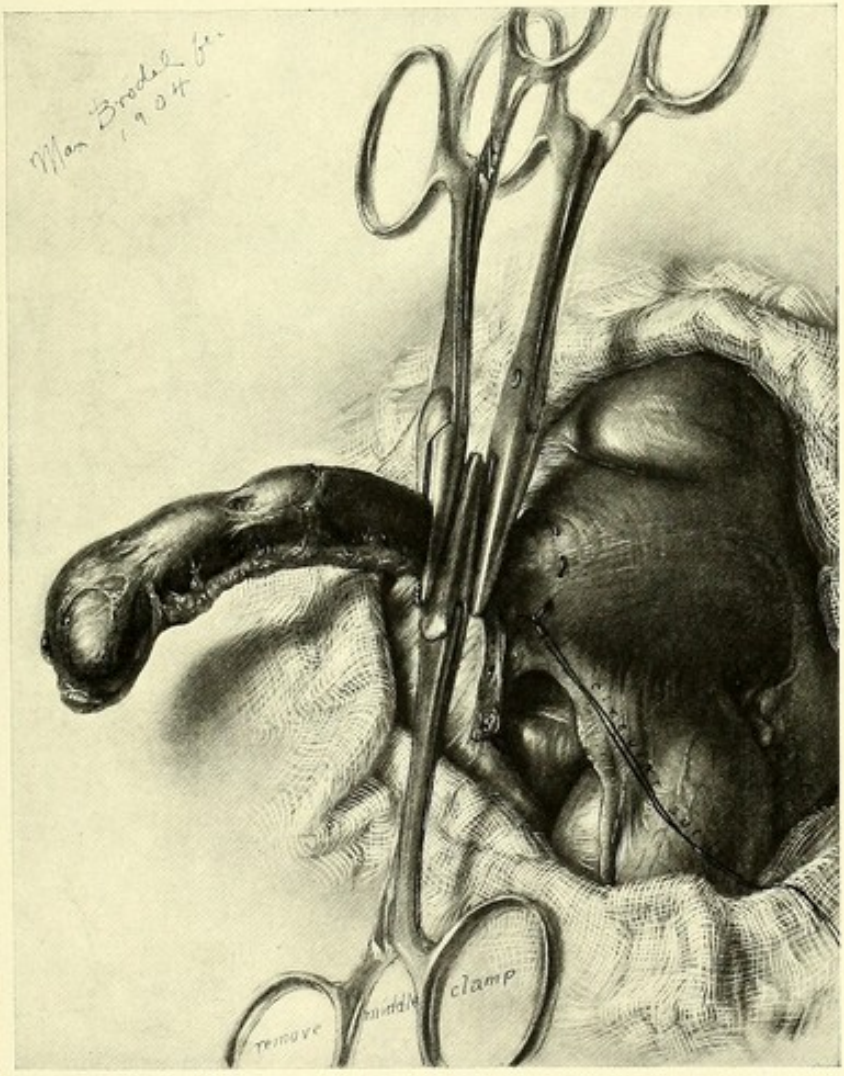

FIG. 273.—HALSTED'S THREE CLAMP METHOD OF REMOVAL. FIRST STEP.
The circular suture is placed as shown; the three clamps are then applied, the middle one first.

which may be ligated (Fig. 272) and inverted into the cecum while a circular suture is tied.

Another method, constantly used in the surgical department of the Johns Hopkins Hospital, is that of the three clamps; applied as shown in Figs. 273 and 274; first the middle clamp, then the one above, and then the one below. Upon removing the middle clamp, a narrow strip of compressed tissue is exposed for amputation with knife or cautery.

Other methods as used by different surgeons are as follows:

C. Beck (*N. Y. Med. Jour.*, Dec. 10, 1898). After squeezing the contents

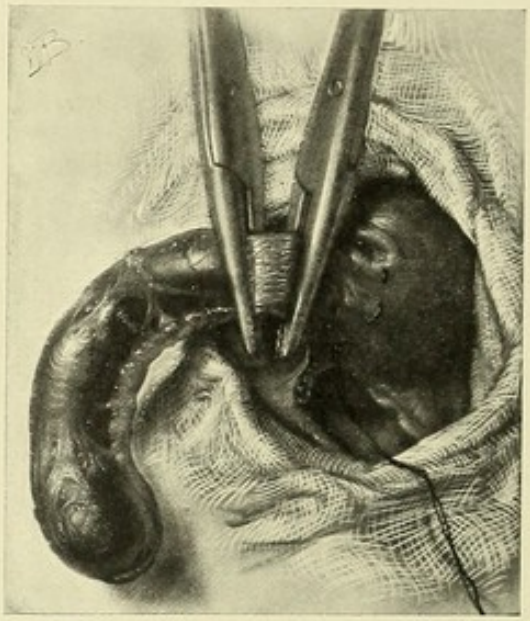

FIG. 274.—HALSTED'S THREE CLAMP METHOD, SECOND STEP.

The middle clamp is removed, the ribbon burned through with the cautery, and the stump inverted. The knife may be used in place of the cautery, taking care to sterilize the end of the stump with carbolic acid.

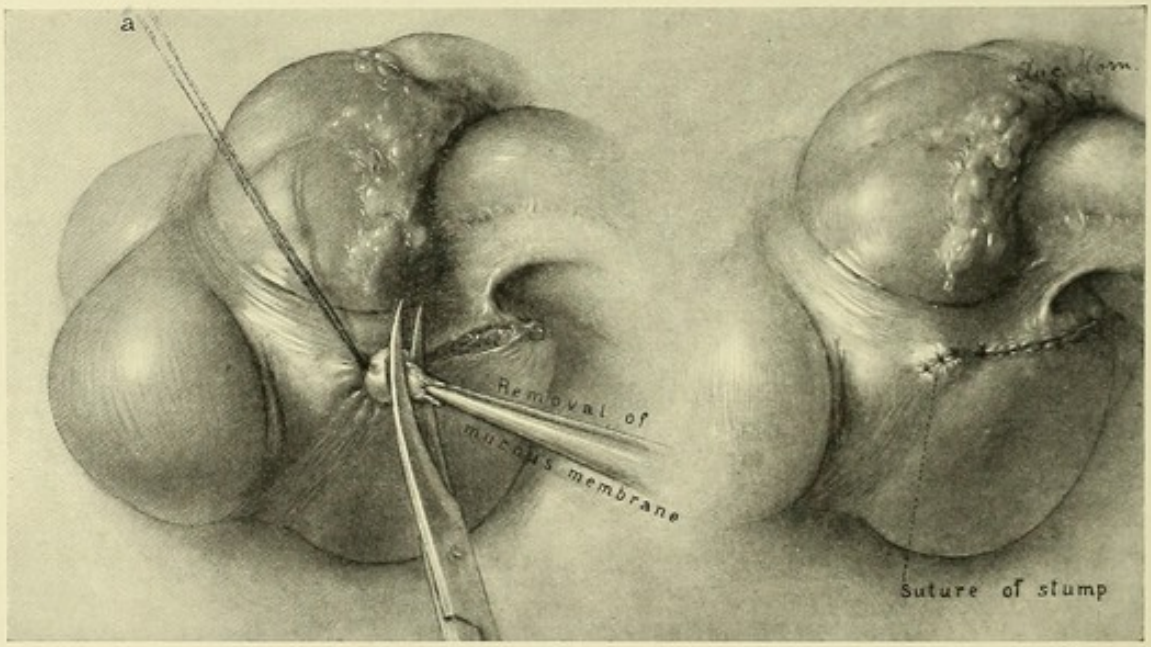

FIG. 275.—BECK'S METHOD OF DEALING WITH THE STUMP.

Catgut ligatures thrown around the liberated base of the appendix and the mucous membrane excised as shown. The musculo-serous flap is then united by three Lembert sutures.

of the appendix into the cecum, a catgut ligature is tied round the base of the organ, and a similar ligature is applied half a centimetre below the first. The appendix is then amputated with scissors, close above the lower ligature; the exit

of any fecal matter being prevented by the previous squeezing and tying. The protruding mucous membrane of the appendix is first disinfected with a strong solution of bichloride of mercury, then seized with an artery forceps, pulled out as far as possible, and cleanly cut off with the scissors, the remnant being dusted with iodoform powder (Fig. 275). A muscular serous flap is thus left, which can easily be united with Lembert sutures. Dusting the little wound margins, which are to be united, with iodoform is to be carefully avoided.

Riedel (*Berl. klin. Wochen.*, 1899, p. 749; also, *Centralbl. f. Chir.*, 1903, Bd.

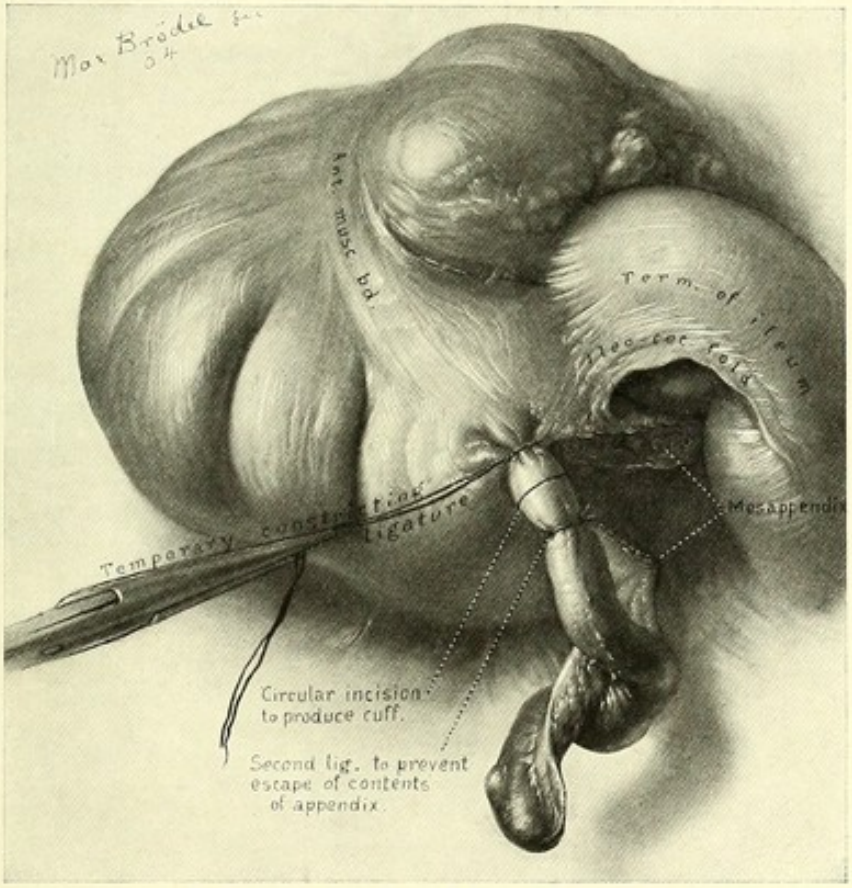

FIG. 276.—FOWLER'S CUFF METHOD. FIRST STEP.

Mesappendix divided; a temporary ligature at the base and a ligature beyond to close the appendix. A circular incision between the ligatures dividing only the outer coats. (See p. 562.)

30, p. 1339). The mesenteriolum of the appendix is tied off down to the cecum. The cecum is then freed of all fatty tissues around the base of the appendix, which is ligated with catgut close to the cecum, and again with silk 1 cm. from the catgut ligature. The appendix is divided and removed between the ligatures. The accessible mucosa of the stump is now cut away with scissors curved on the flat, after which the serosa and the muscularis are united with three interrupted silk sutures. The catgut ligature is now cut and removed. Close to the three silk sutures, five other silk sutures are passed through the serosa and muscularis of the cecum, in such a manner as to turn in the little stump and approxi-

mate the serous surfaces over an area a good centimetre in breadth. Sometimes Riedel applies a third row of six or seven catgut sutures, which turn in the appendix stump still further.

G. R. Fowler (Circular Flap Method) (*Treatise on Appendicitis*, 1894, p. 162). A temporary ligature is thrown around the base of the appendix close to the cecum, and twisted until it constricts the organ sufficiently to prevent the escape of fecal matter. A second ligature is applied about half an inch from the first, and tied. A circular incision, including the serous coat and the subserous connective tissue, is now made in the space between the two ligatures (Fig. 276). A cuff-shaped flap formed of these structures is turned back

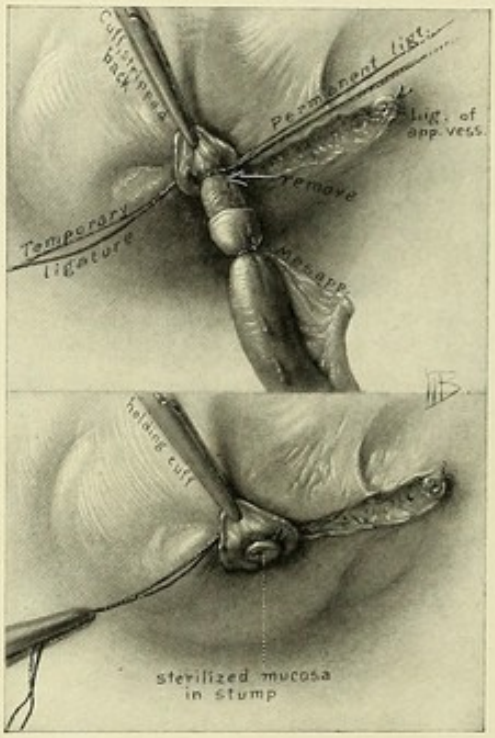

Fig. 277.—Fowler's Method, Second and Third Steps.

Upper figure, the cuff stripped back, a ligature applied at the base, and the appendix removed close to ligature at arrow. Lower figure, short stump sterilized.

toward the temporary ligature, and another ligature of fine ordinary catgut (which has not been hardened) is placed around the wall of the appendix at the bottom of the reflected cuff of serosa and within it. This ligature is tied tightly, and cut off close to the knot (Fig. 277). The appendix is now amputated, and the mucous membrane of the stump touched with the thermocautery or with fuming nitric acid. The cuff-shaped flap is next placed over the face of the stump, which is then grasped by a pair of dissecting forceps and crowded against the wall of the cecum in such a manner as to form a furrow or depression in it (Fig. 278). The edges of the cecum are sutured over the stump of the appendix by means of a double row of Lembert

sutures, so disposed that the stump is buried out of sight. In two or three days the ligature about the wall of the appendix gives way, but in the meanwhile the sutured edges of the furrow have become strongly adherent, so that there is no danger of escape of the contents of the intestines.

R. H. M. Dawbarn (*Internat. Jour. Surg.*, May, 1895). The appendix is surrounded by a purse-string suture, three-fourths of an inch from its base, and the first half of a surgeon's knot is made ready, but not tightened. The appendix

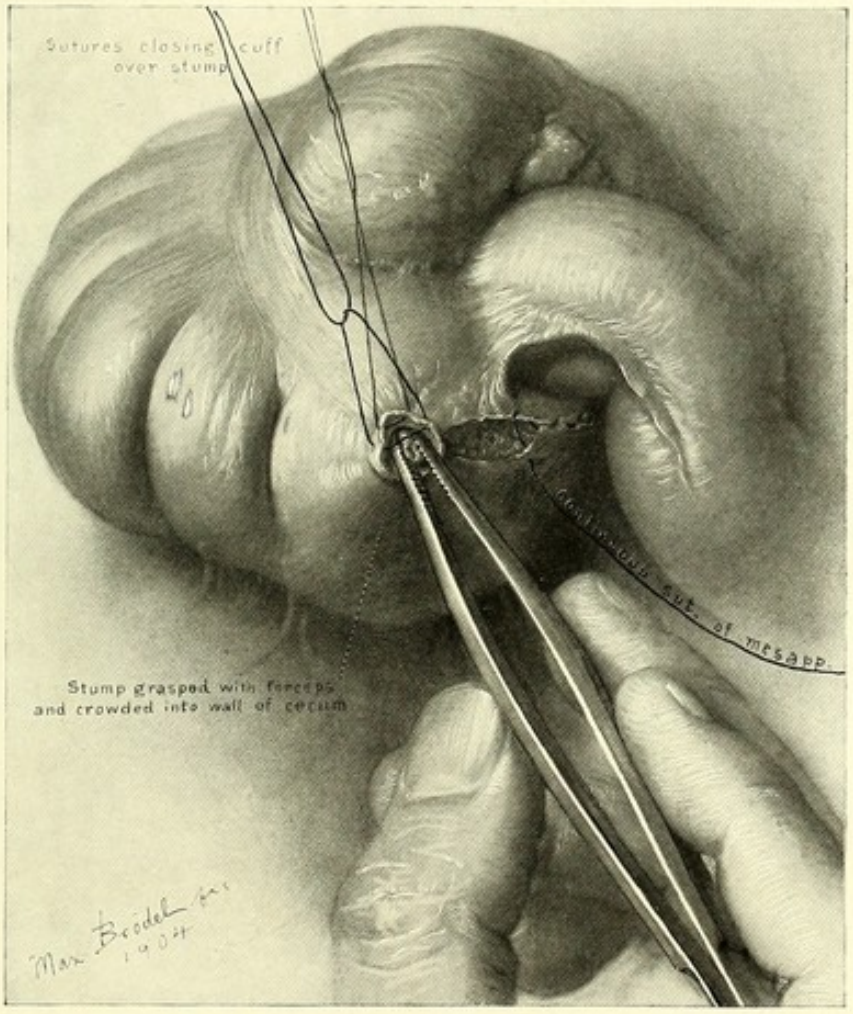

FIG. 278.—FOWLER'S METHOD, FOURTH STEP.
Closure of cuff over stump.

is then divided, leaving a stump of variable length, but never shorter than half an inch. A pair of forceps with closed blades is introduced through the stump into the cecum, the blades opened, and the calibre of the stump stretched so as to overcome any stricture (Fig. 279). The extreme free end of the stump is then seized by a similar pair of mouse-toothed forceps and the stump invaginated like a glove finger. When this proceeding is accomplished, the forceps and the appendix are one-half an inch inside the cecum. The purse-string is

now tightened, and while this is being done, the forceps are withdrawn. This method, which is very rapid, has the further advantage of doing away with the evil of approximating infected surfaces, since it brings two peritoneal surfaces into contact.

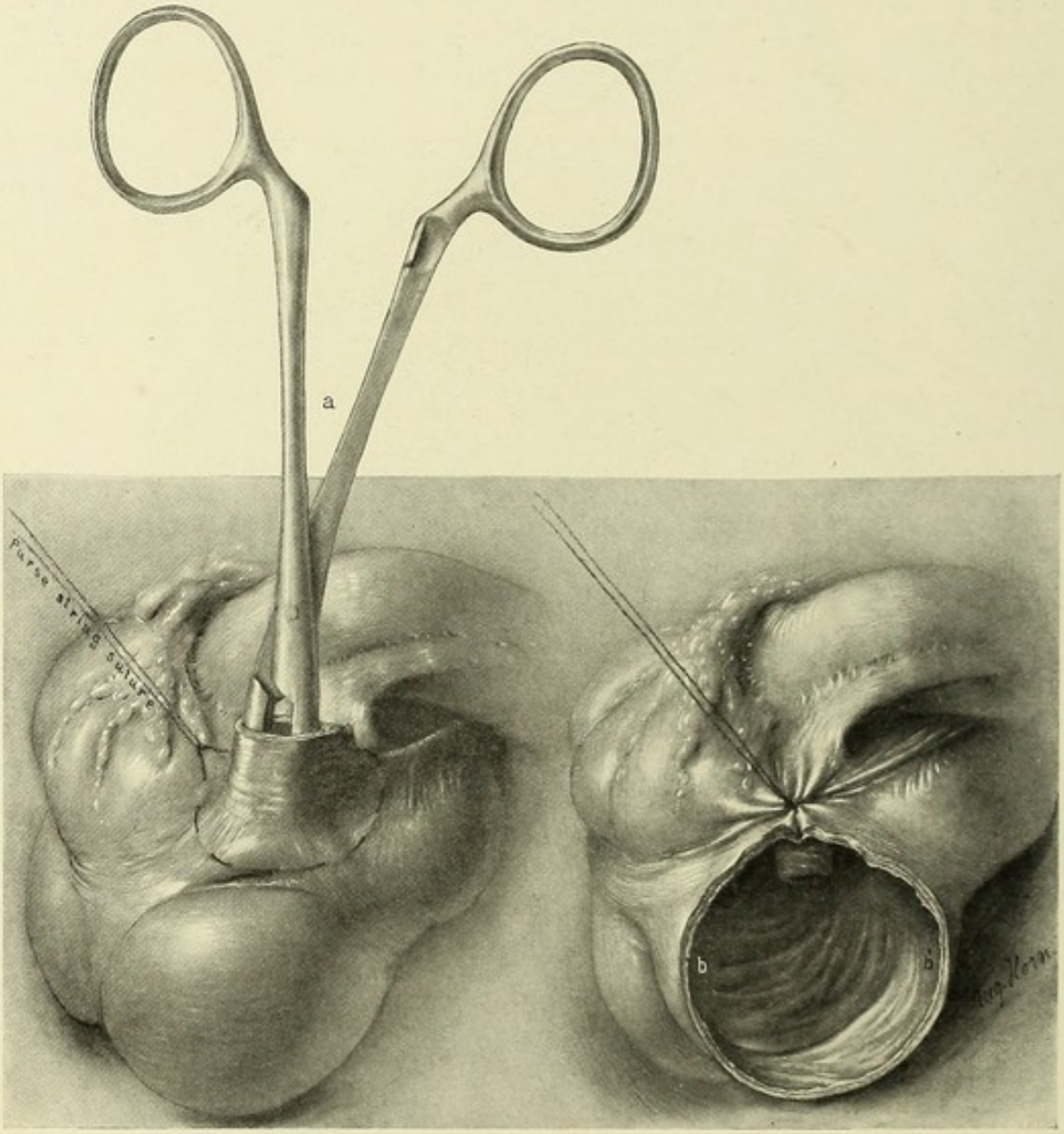

Fig. 279.—Dawbarn's Method.

A purse-string ligature is applied around the appendix ¾ of an inch from the base. The appendix is then amputated, and the stump stretched with a pair of forceps (a) as shown. This facilitates the inversion, which is effected by clasping the cut edges with a pair of delicate forceps and turning the stump into the cecum, as shown in the right-hand figure. b, b', is a window cut in the cecum to show the inverted appendix.

M. W. Herman (*Centralbl. f. Chir.*, 1901, Bd. 28, p. 1026), under the title "*Zur Technic der Skolikoidektomie,*" cites a case in which an abscess developed in the little dead space between the end of the amputated and ligated appendix and the sero-serous sutures which buried it in the cecal wall. The

details of the autopsy, unfortunately, are not given. On account of this experience the plan was adopted in RYDYGIER's clinic of inverting the stump of the appendix, amputated a few millimetres above its base, into the cecum, and closing the opening by two rows of sero-muscular sutures; an operation not dissimilar to DAWBARN's.

G. M. Edebohls (*Amer. Jour. Med. Sci.*, June, 1895). The appendix is separated from its mesenteriolum, and cleanly freed from all surrounding tissues down to its cecal origin. A strand of fine silk or chromicized catgut is next passed through the peritoneal investment of the caput coli, as close as possible to the point

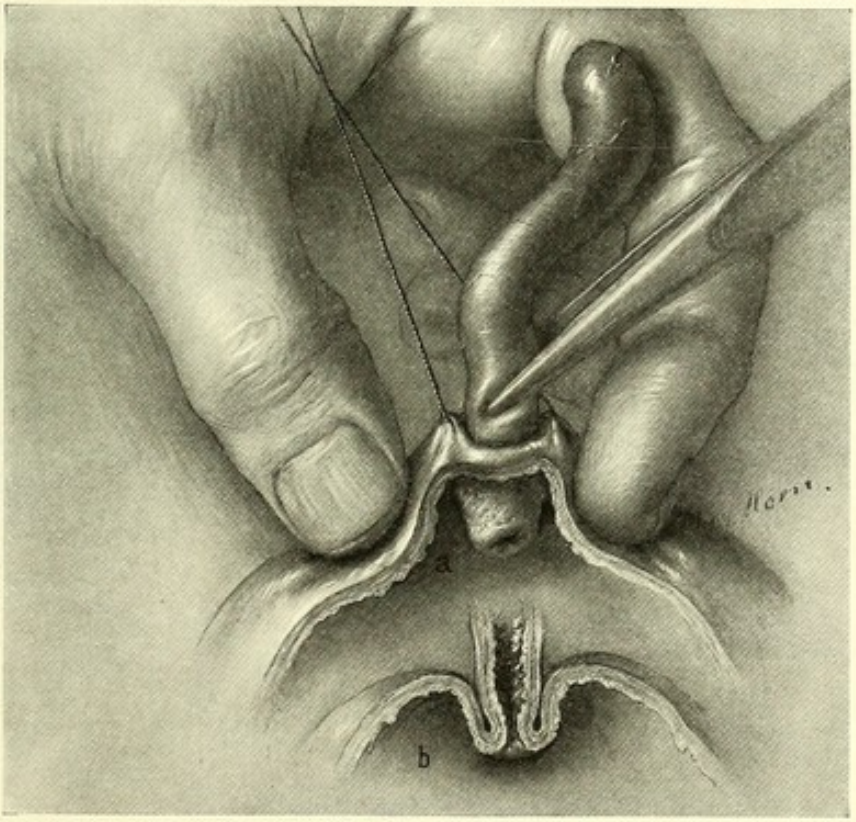

FIG. 280.—EDEBOHLS' METHOD OF INVERTING THE APPENDIX.
A strand of chromicized catgut is inserted as shown and used in the inversion of the appendix, which is gradually effected with fingers and forceps as shown (a). b shows the same in cross-section.

of origin of the appendix, either above or below. The assistant then gently grasps the caput coli with the index finger and the thumb of one hand just above the appendix, and with those of the other hand just below it (Fig. 280). This brings the opening through which the appendix is to be inverted between the fingers of the two hands. The operator then seizes the appendix near its base with thumb forceps, and inverts its proximal part. The portion inverted is held in place by a finger of the other hand, or by a second forceps, while the first forceps grasps another portion of the appendix and pushes it in after the first, this process being repeated until at last the tip of the appendix is pushed inside

of the peritoneal mouth. The operator grasps the lips of the opening through which the appendix has disappeared with the thumb and forefinger of one hand. With the fingers of the other hand he feels for and seizes the now half inverted appendix through the coats of the caput coli, and by appropriate manipulation directed from the origin toward the free end, the semi-inversion is soon converted into a complete one (Fig. 281). The exact moment when inversion is accomplished is readily recognized by the fingers. The peritoneal orifice is closed by continued sutures. This method has the advantage of keeping the abdominal cavity free from foreign material by doing away with the necessity for opening the appendix and suturing it.

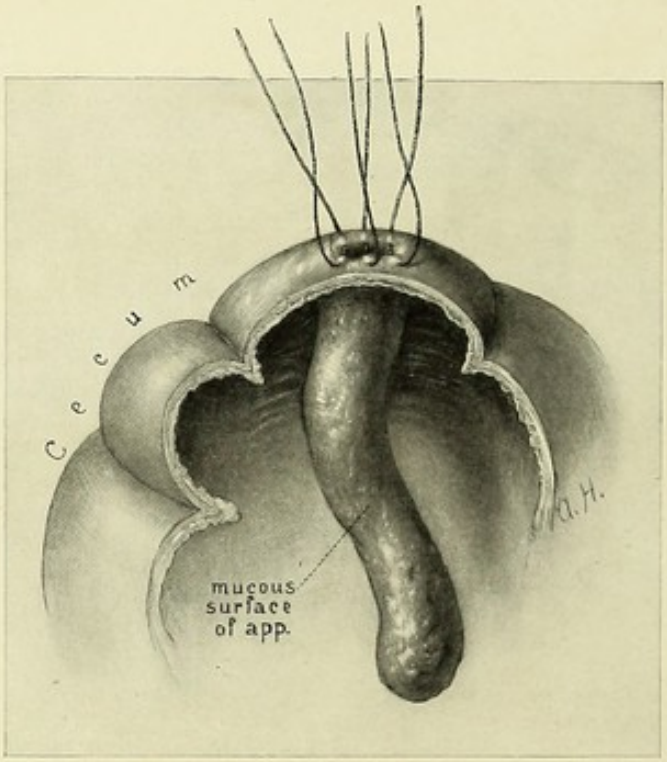

Fig. 281.—Edebohls' Method, the Inversion Completed.
Edebohls closes the inversion by a running Lembert or a purse-string suture.

R. T. Morris (*Lectures on Appendicitis*, 1896, p. 59). The muscular and serous coats of the appendix are divided in a circle close to the cecum, leaving the mucous coat untouched. This inner coat is then ligated with a strand of fine eye silk, and the appendix amputated. The peritoneal surfaces of the stump are scarified, after which it is depressed and buried by bringing the walls of the cecum together over it with three or four Lembert sutures.

J. B. Deaver (*Ann. Surg.*, 1898, vol. 27, p. 79). After the appendix is in the grasp of the thumb and finger, the cecum is replaced within the abdominal cavity. The appendix is then amputated flush with the cecum, and the opening in the latter closed with Lembert sutures (Fig. 282). This method

is also recommended by A. ZELLER (*Centralbl. f. Chir.*, 1902, Bd. 30, p. 121), as obviating all risk of infection from the stump.

A. J. C. Skene (*N. Y. Med. Jour.*, March 5, 1898). The description of this method as it was first performed is as follows: The forceps was applied upon the mesappendix close to its mesenteric attachment. A current which heated the forceps to 180° F. was then induced for half a minute. Upon removing the forceps the tissues were found not to be charred, but dried, having the appearance of white horny matter. The desiccated area was then bisected with scissors.

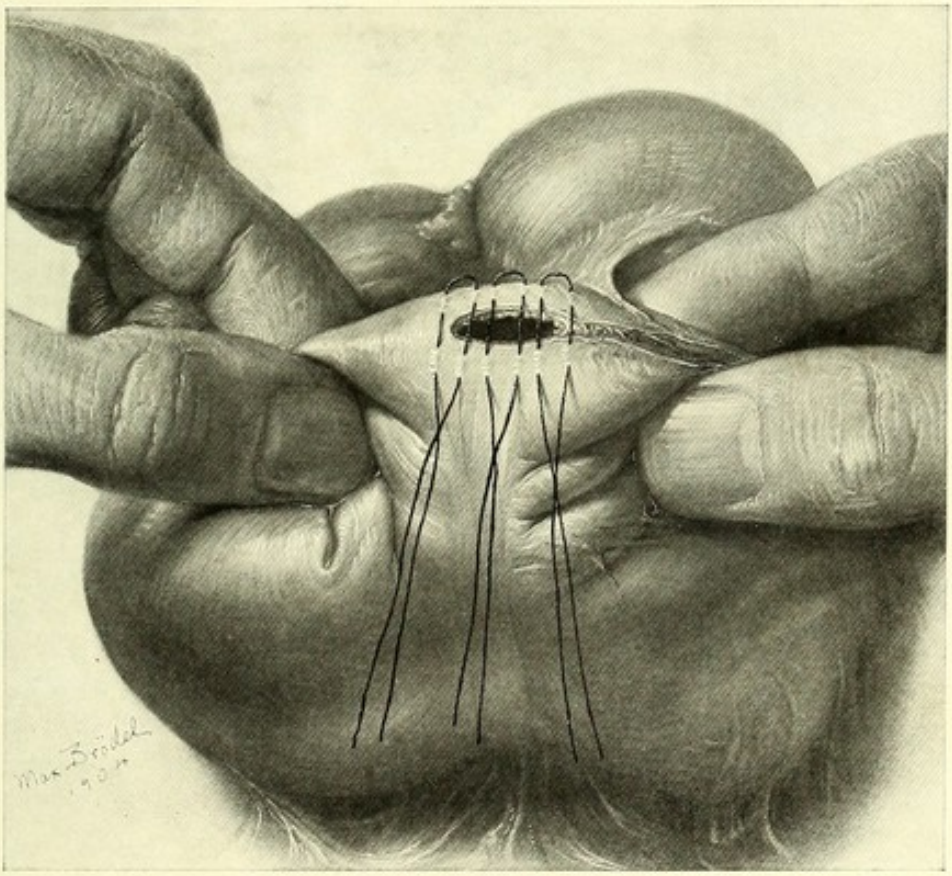

FIG. 282.—DEAVER'S METHOD OF AMPUTATING THE APPENDIX FLUSH WITH THE CECUM AND CLOSING WITH MATTRESS OR LEMBERT SUTURES.

A second seizure was then made, this time upon the appendix itself, close to the caput coli, after which the same current was induced and continued for ninety seconds. The forceps was then removed, and the tissue divided in the line of the desiccated area, away from the caput. The same result as before was apparent, namely, no charred tissue, no bleeding, and, more important than all, no escape of the contents of the appendix. The tissues had been simply dried out. Just at this point a rather violent attack of retching came upon the patient, which continued for nearly a minute, without inducing any change whatever in the stump. Even the severe pressure and strain thus occasioned failed to force

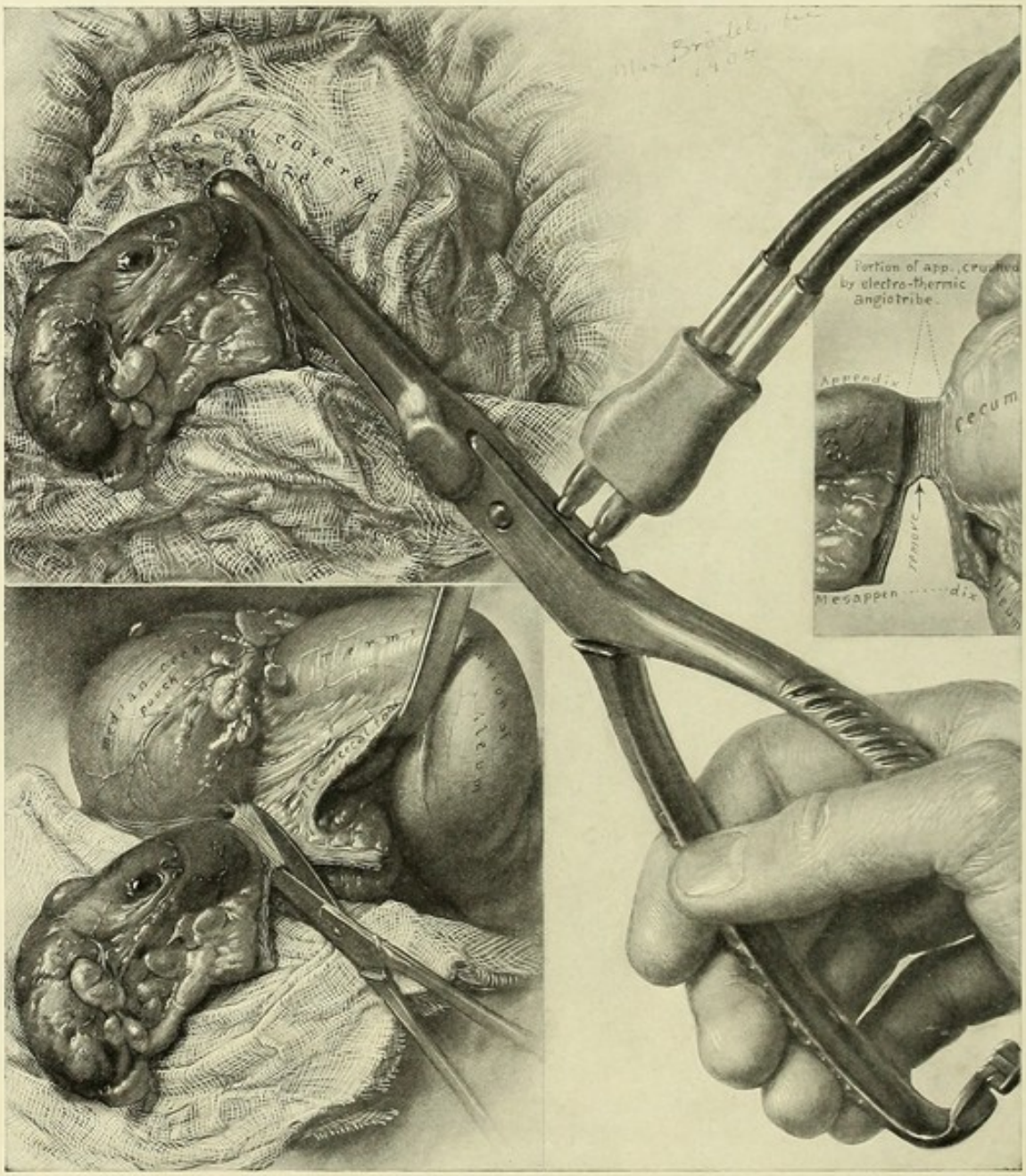

FIG. 283.—DOWNES' METHOD.

The base of the appendix is converted into a flat translucent cord by Downes' electrothermic angiotribe. The right-hand figure shows the appearance of the tissues, the mesappendix divided and the appendix about to be amputated in the direction of the arrow, as shown by the left-hand lower figure. (See p. 572.)

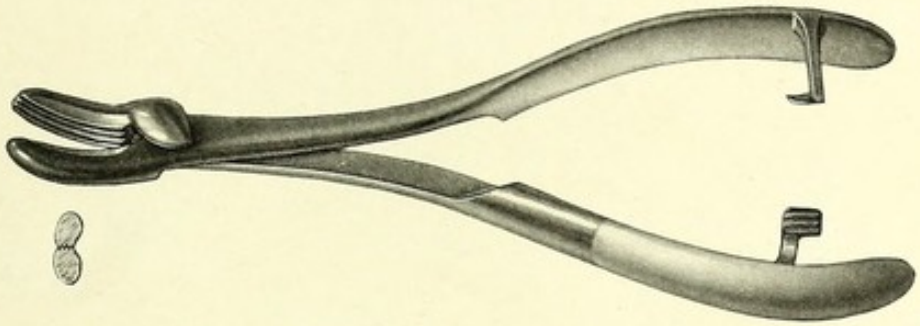

FIG. 284.—H. A. KELLY. CRUSHING FORCEPS, HALF NATURAL SIZE, WITH GROOVE FOR CONTACT WITH CAUTERY POINT FOR COOKING THE STUMP AND CONVERTING IT INTO A TRANSLUCENT BAND.

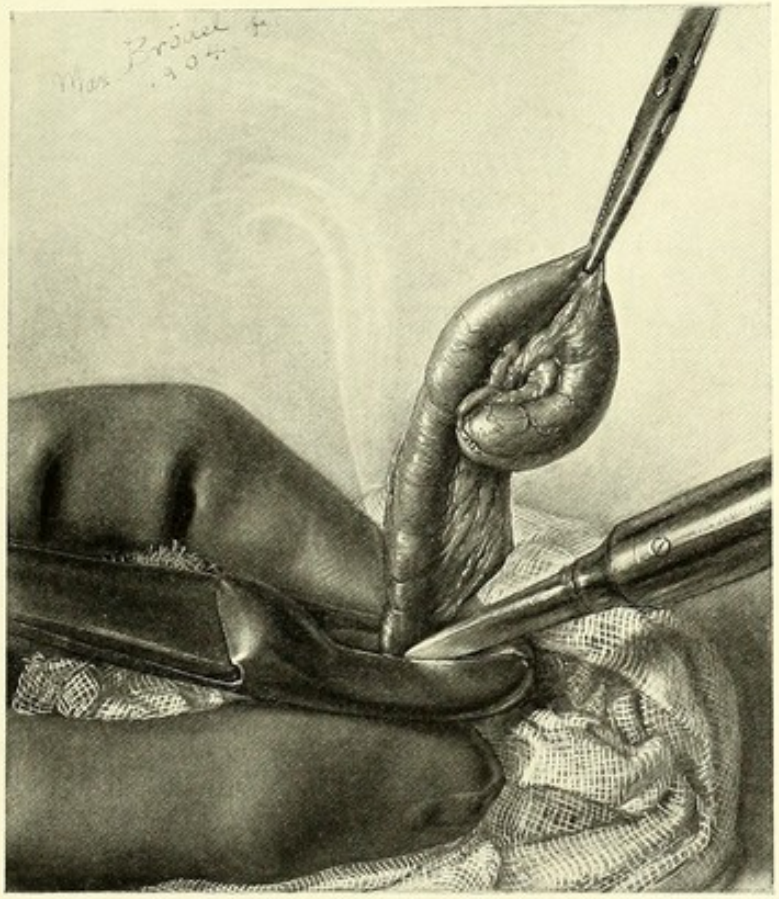

FIG. 285.—H. A. KELLY'S METHOD. I. THE MESAPPENDIX IS LIGATED AND DIVIDED. A CIRCULAR SUTURE OR MATTRESS SUTURES ARE THEN PLACED READY TO TURN IN THE STUMP. THE APPENDIX IS THEN CRUSHED NEAR ITS BASE WITH POWERFUL GROOVED FORCEPS AND HELD AWAY FROM THE CECUM BY THE WET GAUZE. IT IS THEN SLOWLY AMPUTATED WITH THE CAUTERY. (See p. 572.)

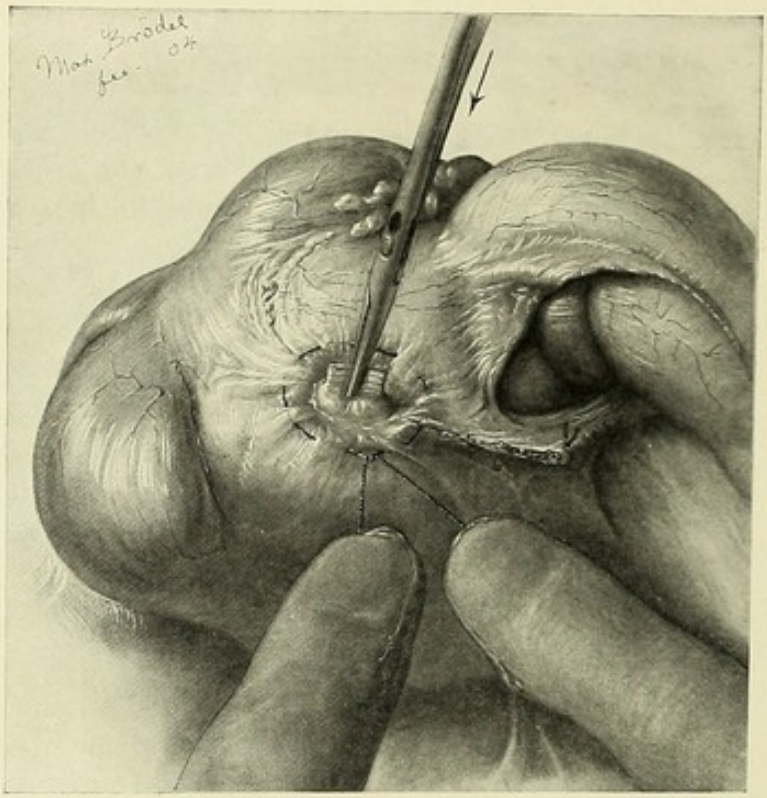

FIG. 286.—KELLY'S METHOD. II. THE LITTLE TRANSLUCENT STUMP IS THEN SIMPLY INVAGINATED INTO THE CECUM BY THE CIRCULAR SUTURE. (See p. 572.)

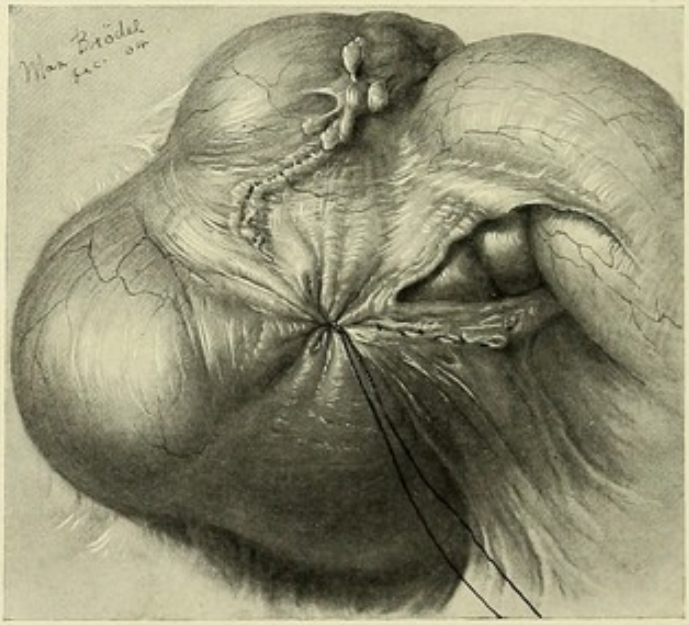

FIG. 287.—KELLY'S METHOD. III. THE OPERATION COMPLETED. (See p. 572.)

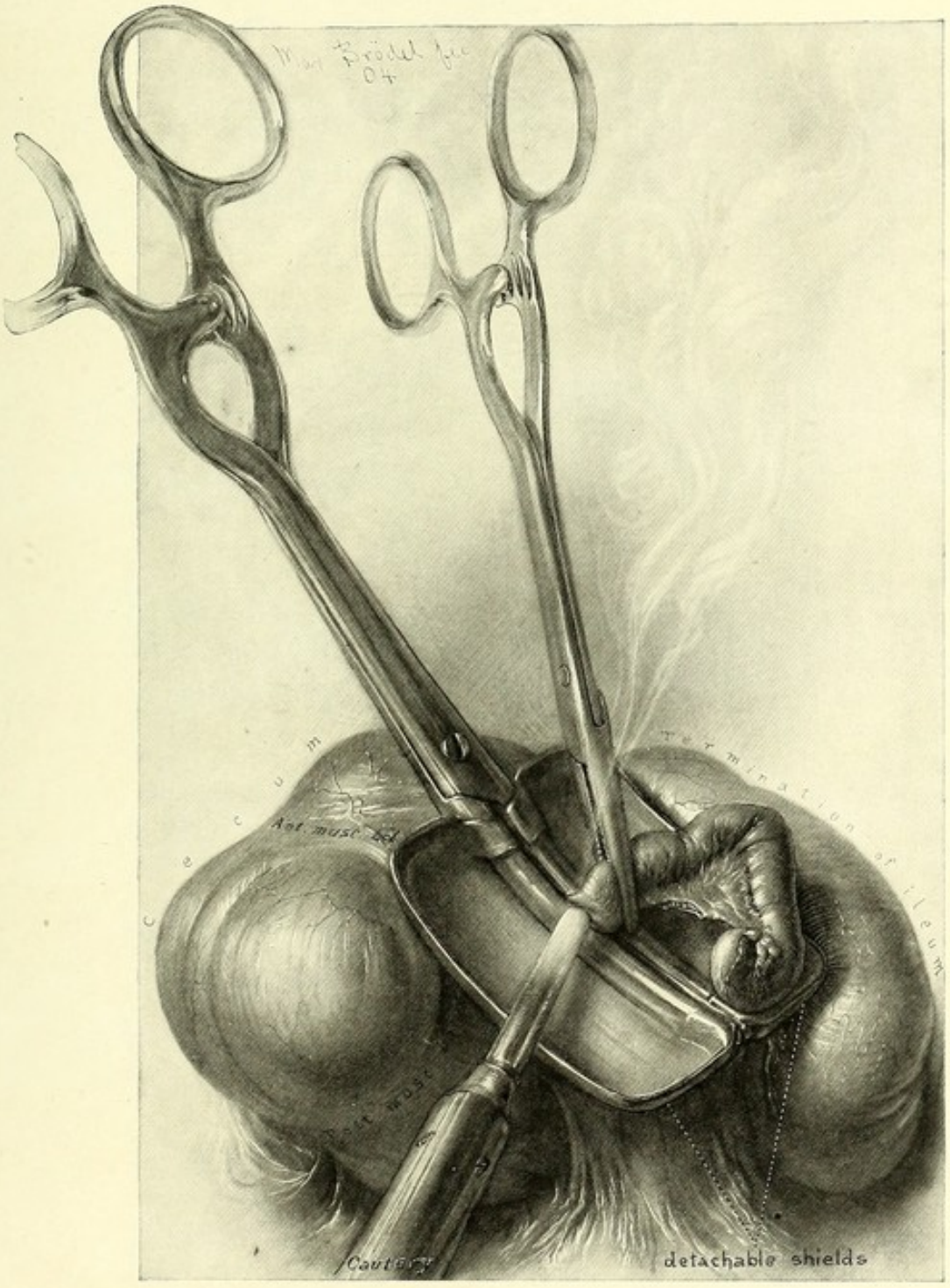

FIG. 288.—EASTMAN'S METHOD.

Showing the appendix grasped at its base by a pair of forceps armed with detachable shields which serve to protect the adjacent bowel and catch any secretions. (See p. 572.)

a drop of blood or serum into the compressed area. The wound was closed without the necessity of introducing any foreign body in the shape of suture material into the abdominal cavity. The patient made an uninterrupted recovery. The method just described has only become generally available since the invention of A. J. Downes' admirable electrothermic crushing forceps, which are shown in the illustration with full description in the legend (see Fig. 283, p. 568).

H. A. Kelly. My own method is that of crushing the base of the appendix with a pair of powerful forceps (see Fig. 284), and then slowly amputating it with the Paquelin cautery at a bright red heat, taking from thirty to forty-five

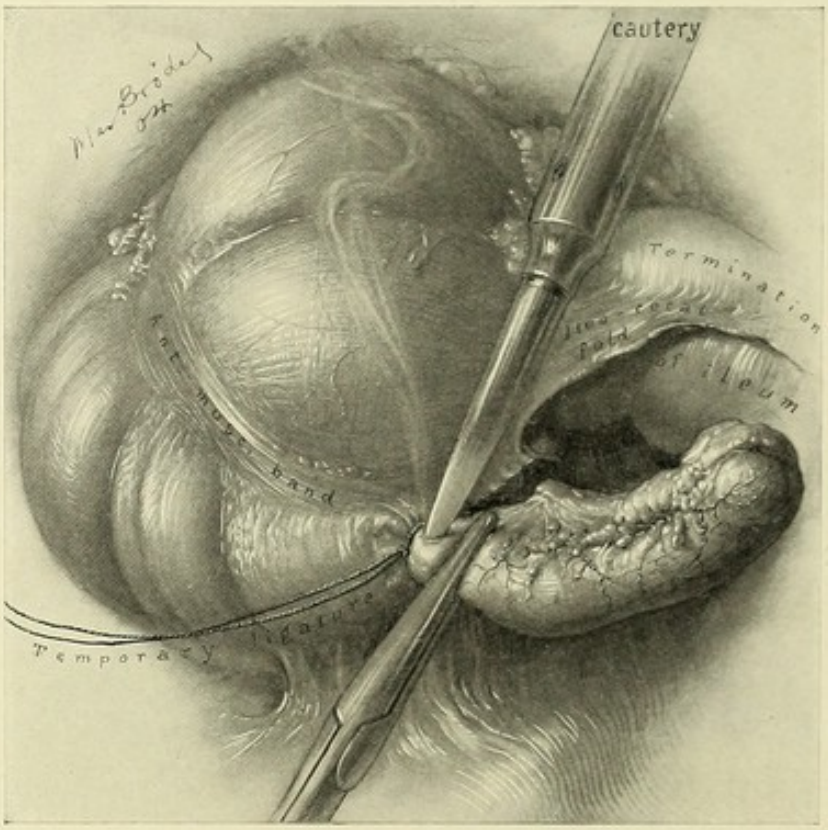

Fig. 289.—Lennander's Method, First Step.

The mesappendix is cut and a temporary ligature applied at the base of the appendix, which is then clamped distally and amputated with the cautery. (See p. 575.)

seconds in the process. The distal end of the appendix should be clamped to prevent the escape of its contents (Fig. 285). By keeping the cautery in close contact with the forceps, which is beveled for this purpose, the latter is converted into a heating iron, and thoroughly cooks the little stump, firmly sealing it, and converting it into a translucent ribbon of tissue, after which it is invaginated into the cecum (Fig. 286), and the circular suture drawn up covering the wound area (Fig. 287). It is safer to add a row of sero-serous mattress sutures over this.

J. R. Eastman (*Jour. Amer. Med. Assoc.*, Oct. 11, 1902). Eastman uses

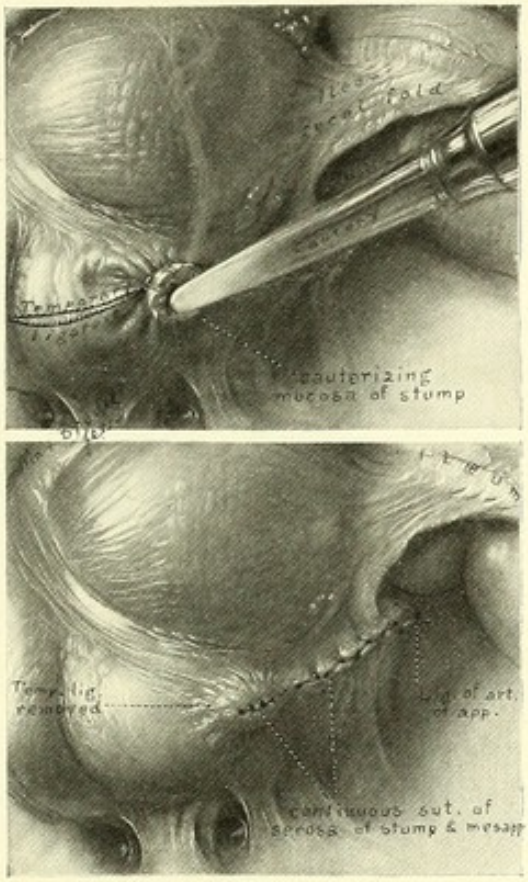

FIG. 290.—LENNANDER'S METHOD, SECOND AND THIRD STEPS.

The mucosa of the stump is sterilized with the cautery, as shown in the upper figure, after which the outer coats are carefully approximated by suture, and the temporary ligature is then removed. (See p. 575.)

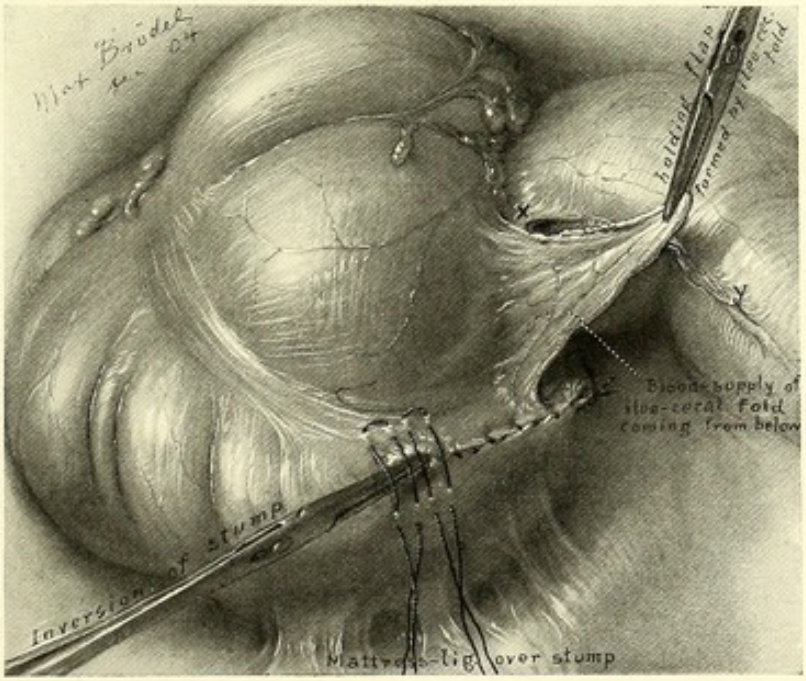

FIG. 291.—LENNANDER'S METHOD, FOURTH STEP.

The inversion of the stump by mattress sutures. If the closure is unsatisfactory, the ileocecal fold is resected above and drawn over the wound area. Its vascularization comes from below and is not interfered with.

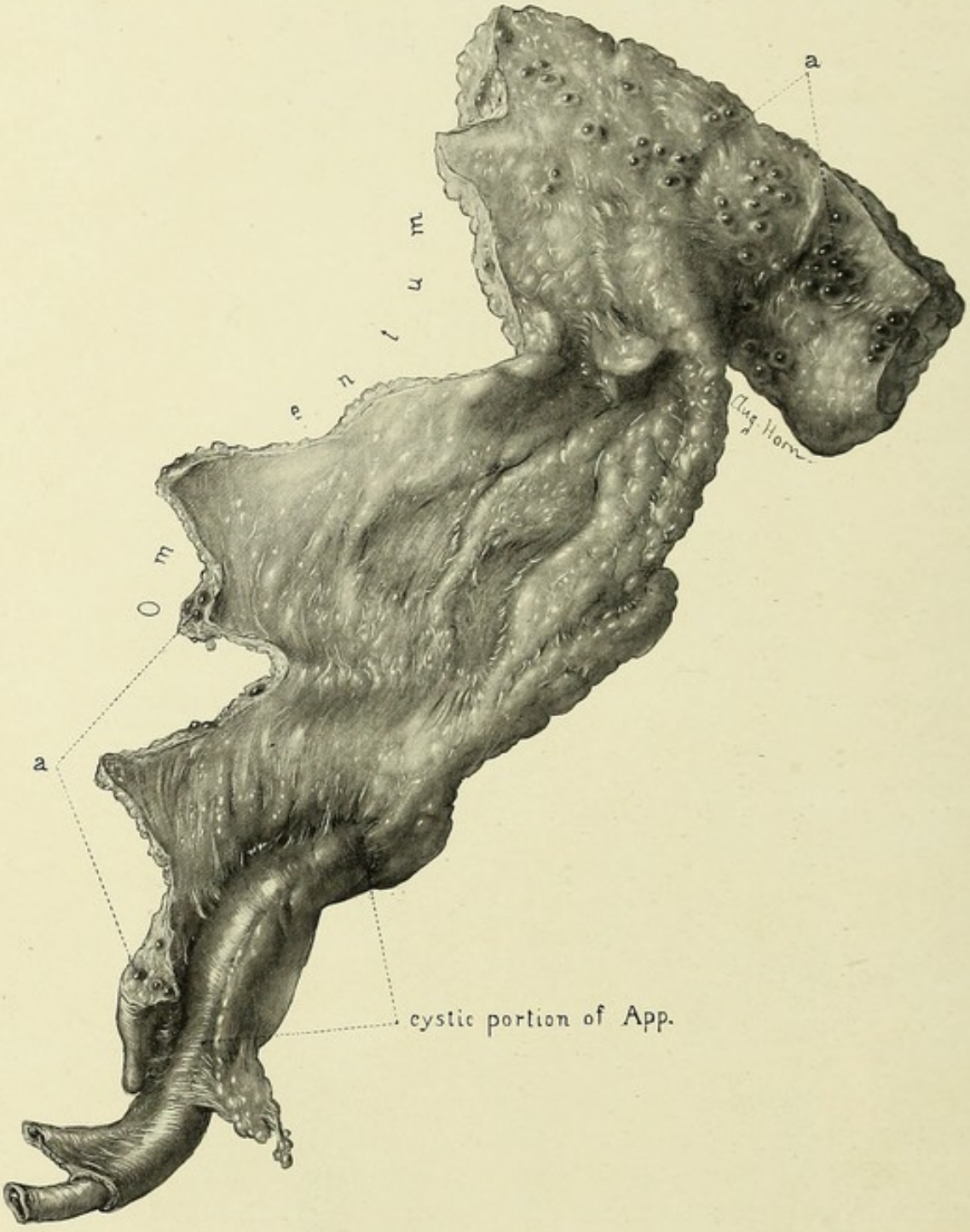

FIG. 292.—CULLEN'S CASE.

Cystic appendix attached to omentum; the latter is thickened and contains numerous colloid areas, also seen on cross-section, a, a. Removal of appendix, double ovariotomy. L. M., æt. fifty-seven. Church Home, May 25, 1903. (Natural size.)

a pair of artery forceps, armed with detachable shields, for the purpose of facilitating the amputation of the appendix with the cautery. The shields are light and slip on and off the blades of the forceps with ease (Fig. 288, p. 571).

Lennander (*Rev. de gynéc. et de chir. abdom.*, Sept.-Oct., 1900). In this method the cautery is used in the following manner. All adhesions are freed as far as possible and the appendix ligated close to the cecum with a temporary ligature. It is then clamped a little beyond this ligature with forceps (Fig. 289, p. 572), and amputated with a cautery. The projecting mucosa is thoroughly sterilized (Fig. 290), and the sero-muscular edges of the stump are brought together with a continuous suture of silk. After this the little stump is inverted and buried by one or two rows of mattress sutures (Fig. 291). An important point is the occasional use of the ileocecal fold to cover in the same area.

ATYPICAL OPERATIONS FOR REMOVAL OF THE APPENDIX.

Adhesions.—In a case of appendicitis complicated by adhesions it is of the utmost importance to avoid injury to the coats of the adherent intestines. One of the simplest complications is that of omental adhesions, in which the diseased part of the appendix is not infrequently found enveloped in the free border of the omentum, which acts as a protecting barrier, effectively limiting the spread of the disease. In all such instances the safest plan is to remove the omentum, with the appendix, by excising as large a piece as may be necessary, and then amputating the appendix as it lies undisturbed in its omental blanket (see Fig. 292). In the case shown here an unusual amount of the omentum was removed on account of numerous cysts in its substance.

One of the simplest forms of adhesions, which is also one representing a conservative effort on the part of nature to shut off the peccant organ, is the formation of a net of adhesions uniting the ileum to the cecum, and pocketing the diseased appendix below (see Fig. 293). In the removal of such an appendix it is only necessary to pack off on all sides with great care, and then to cut through the tent wall, and to liberate and excise the organ.

When the diseased appendix is densely adherent in its distal portion it is a good plan to expose its base, and then detach it in such a manner as to free the appendix from the cecum. The distal freed portion is then wrapped in a piece of gauze for protection, while the opening into the bowel is closed by whatever method the operator prefers. After this has been done, the adherent end of the appendix can be dissected out of its bed with far greater facility than was possible when both extremities were anchored, the one to the cecum and the other by the adhesions; the precaution of surrounding the matted mass on all sides with gauze, before handling it, and so risking the rupture of an abscess, must never be omitted. This plan is especially suited to the gynecologic field.

When the whole appendix lies imbedded in strong

old adhesions, and can be removed only by digging it out of its bed, there is considerable risk of tearing the adjacent structures, or of exciting hemorrhage by rupturing one of the numerous small vessels, which, being situated in the midst of the matted tissues, are difficult to control. In all such cases it is a good plan to detach the base of the appendix as just described (or as shown in Figs. 294 and 295), and then, catching the freed end with a pair of artery forceps, to lift it up and circumcize the organ just below the forceps by cutting through the peritoneal and on to the muscular coats. A longitudinal incision,

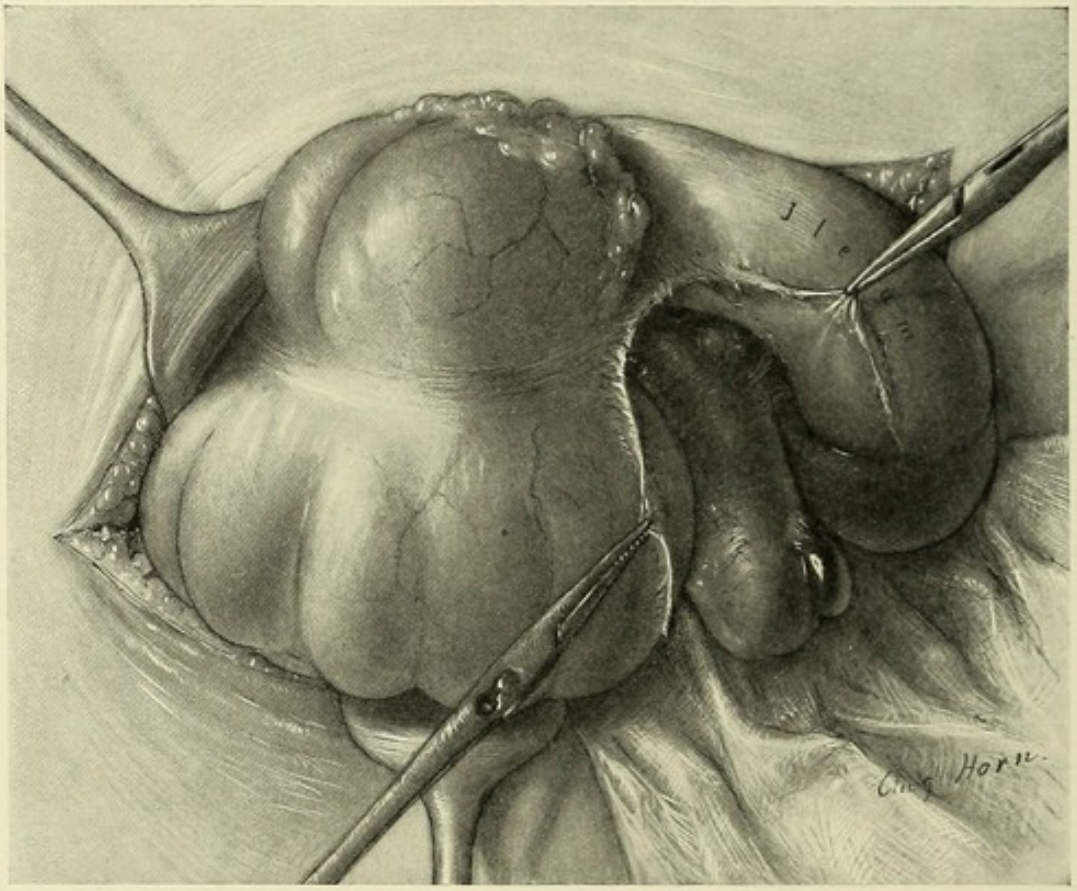

Fig. 293.—Showing the Enlarged Inflamed Appendix 5.5 cm. long, 1.5 cm. thick, Completely Hidden away by Newly formed Adhesions Uniting the Ileum to the Base of the Cecum in the Ileocecal Angle, thus forming a Tent Completely Shutting in the Disease.

Recurrent appendicitis. B., æt. thirty-two, Feb. 15, 1902. Recovery.

including only these coats, is then carried down to the dorsum of the appendix as far as it is visible, after which the appendix can be stripped out of its bed (see Figs. 296 and 297) by traction in the direction of the tip, or it can sometimes be delivered by a straight pull. If it begins to break, it must be grasped afresh with the forceps, lower down, and the stripping process resumed. In this way the entire mucosa with a portion of the circular muscular coat is left behind (Figs. 298 and 299). There is often no bleeding at all, and even if there is, it is more easily controlled than when the appendix has been dissected out. This

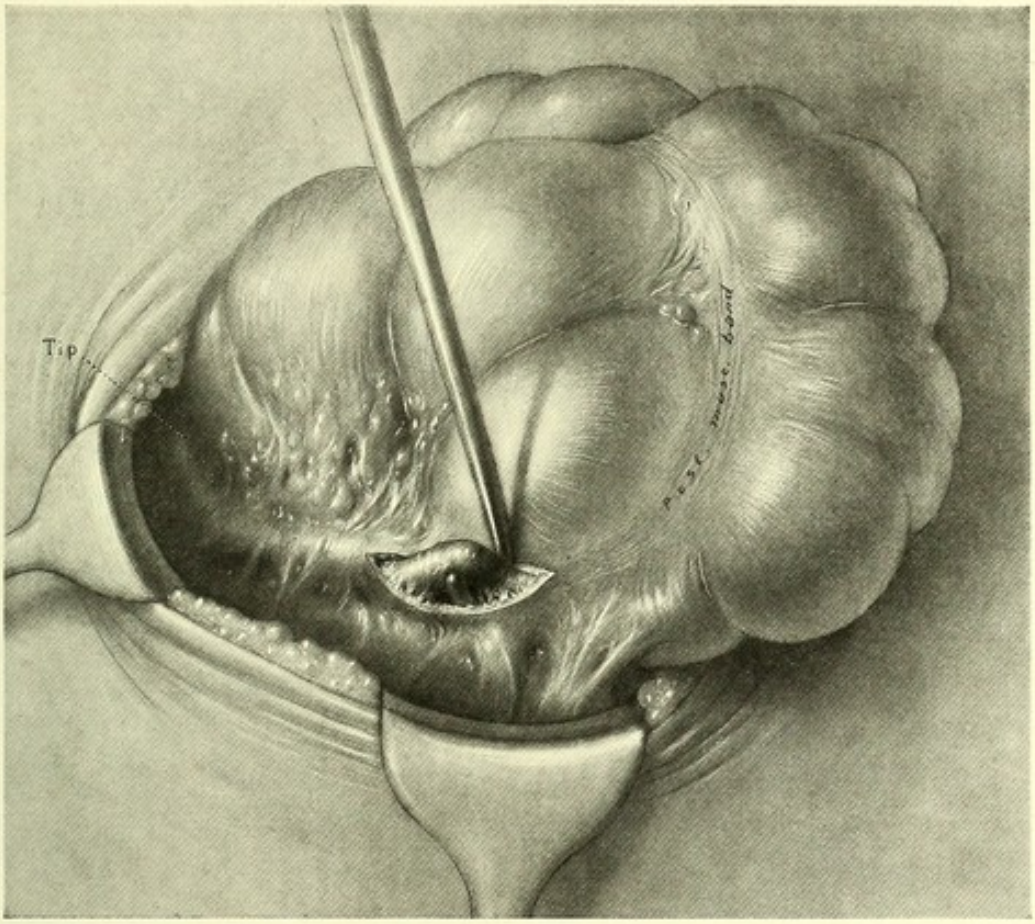

FIG. 294.—H. A. KELLY. I. SHOWING THE METHOD OF STRIPPING OUT THE MUCOSA AND SUBMUCOSA IN THE CASE OF A Ddensely ADHERENT APPENDIX.

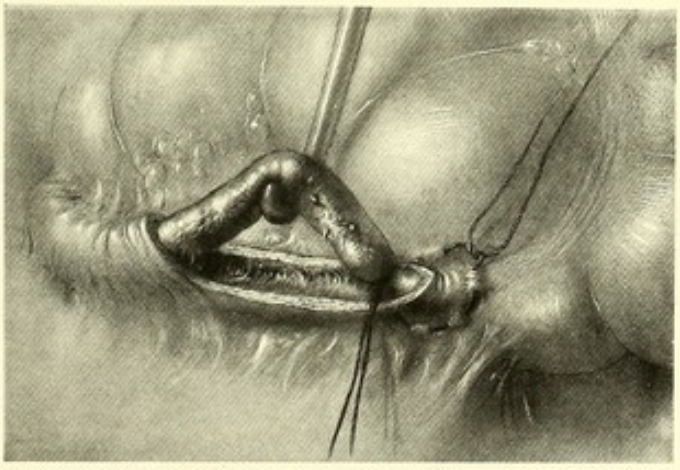

FIG. 295.—H. A. KELLY. THE INCISION IS CONTINUED A SHORT DISTANCE DOWN THE APPENDIX, WHICH IS FURTHER LIFTED OUT OF ITS SEROSA AND MUSCULAR COATS, AS SHOWN.

is a dangerous method if the appendix contains pus in its distal portion. WALSHAM (*Treatise on Appendicitis*, 1901, p. 25) advises that when the appendix is so adherent to important structures that the whole of it cannot be removed, it should be divided near its cecal attachment, the proximal end closed in the

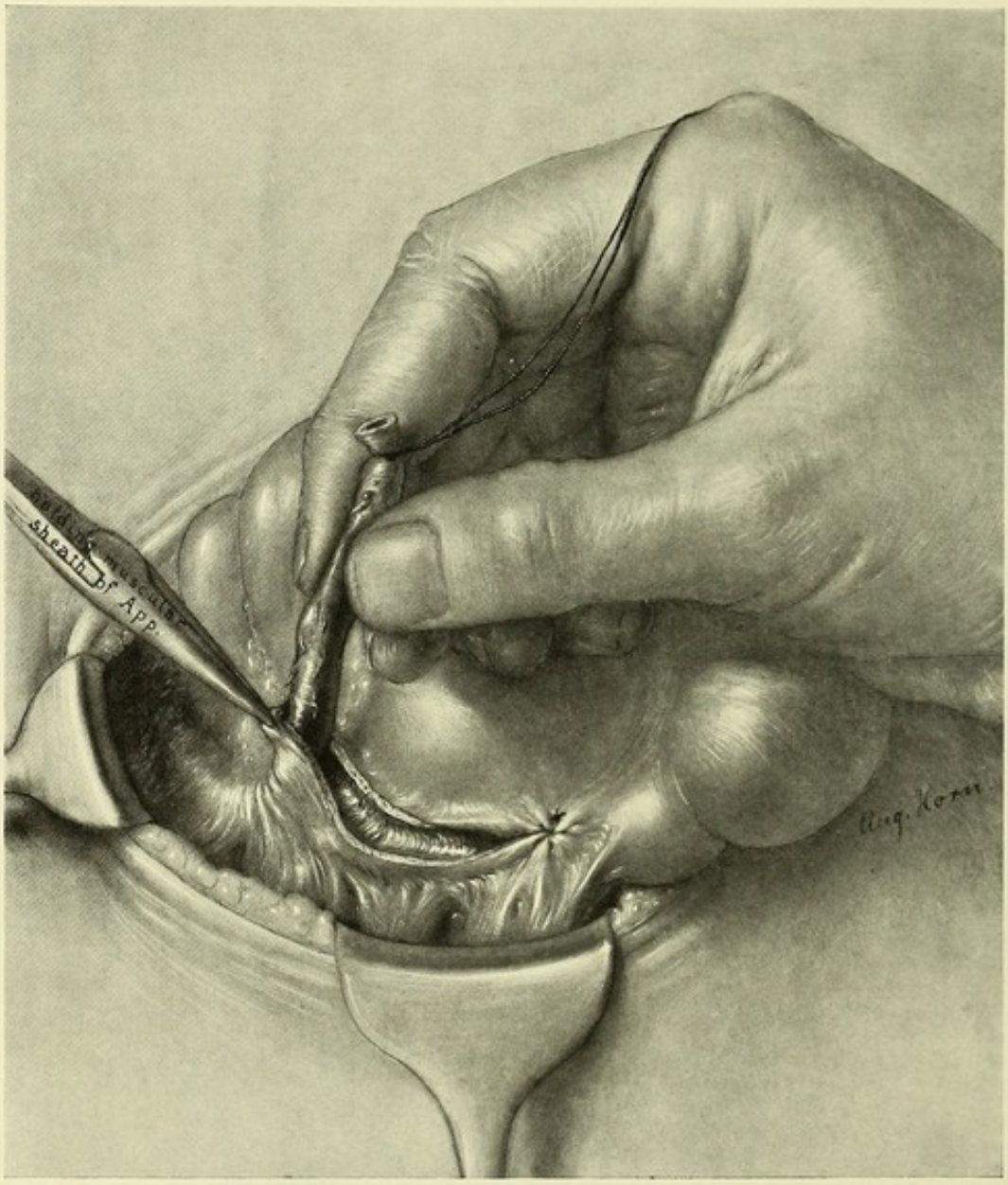

FIG. 296.—H. A. KELLY. THE REMAINDER OF THE APPENDIX MAY THEN OFTEN BE WITHDRAWN BY SIMPLE TRACTION.

usual manner, and as much of the organ removed as safety will permit, either by dissection or by shelling out from the peritoneal cavity.

In cases where the end of the appendix enters a small abscess cavity and is surrounded by adherent intestines which cannot be stripped off with safety, I employ the following method: After freeing

the base of the appendix from the cecum, I trace the appendix upward until it enters the abscess cavity, as, for example, under the ascending colon, where the separation of adhesions cannot be effected without injuring the coats of the bowel. I then pack off the field of operation from the surrounding peritoneum on all sides, and after dividing the appendix at its base with a pair of forceps, proceed to split it open all the way to the tip, using the blade of a pair of open scissors or a grooved director as a guide. It is thus possible to penetrate the abscess cavity, to open and to cleanse it, without doing any damage to the colon. In one case of this kind, I followed the cleansing of the cavity by drainage, and the patient made an uninterrupted recovery. Whenever possible in these or similar cases (see Figs. 300, 301, 302, and 303), the mucosa and submucosa of

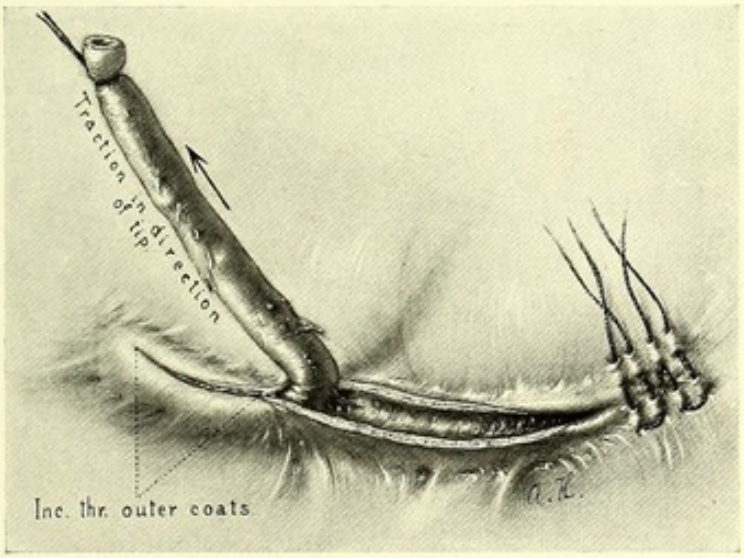

FIG. 297.—H. A. KELLY. WHEN THE APPENDIX DOES NOT ESCAPE READILY ITS DORSUM MAY BE INCISED DOWN TO THE TIP, WHEN BY TRACTION, AS SHOWN, THE INNER COATS ARE REMOVED FROM THEIR MUSCULAR BED. (See p. 576.)

the appendix should be removed by dissection or by scraping. Drainage should always be used.

When the appendix is lost in a mass of adhesions surrounding the head of the cecum, and careful efforts to release and expose it are unavailing, the best plan, especially if the operator becomes uncertain as to his landmarks, is to approach the mass in an entirely new direction, namely, from above and behind the cecum, as recommended by W. H. CARMALT (*Yale Med. Jour.*, Jan., 1896). His case was one where an abscess had discharged into the bowel two years previously, and had been followed, apparently, by complete recovery. "The cecum," he says, "presented itself directly under the incision, its longitudinal bands being easily recognizable. Tracing these down towards the head in search of the appendix, the cecum was found quite distorted in position, the head firmly fixed and lost in a mass of adhesions attached to the abdominal



Fig. 298.—Mixter's Case, Showing the Inner Coats of the Appendix, Including Mucosa, Submucosa, and a Few Fibres of the Circularis, Removed in this Way.

The little tails hanging from the appendix are vessels torn from the outer coats. (Natural size.) (See p. 576.)

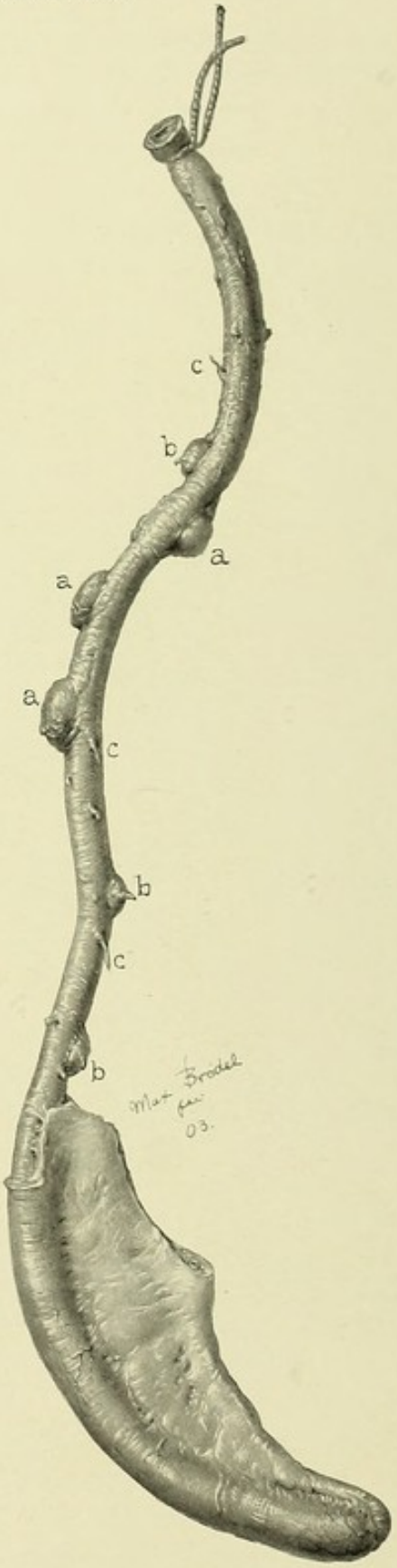

Fig. 299.—Blake's Specimen of Long Appendix (24 cm.), of which the Proximate Portion has been Stripped out of its Muscular Bed in this Way.

a, a, a, are hernial protrusions of the mucosa through muscular hiatus; b, b, b, are similar hernias with vascular tits; c, c, c, are vascular tits as shown in preceding figure. (See p. 576.)

Fig. 299.

wall directly over the psoas muscle. By careful separation of these adhesions their area was reduced from a couple of inches, more or less, in diameter, to about three-fourths of an inch, at which point they were found so dense that it would have been impossible to separate them further without great danger of tearing a hole in the intestines, and as yet no trace of the appendix was discoverable. I therefore decided to approach the mass from above and behind the

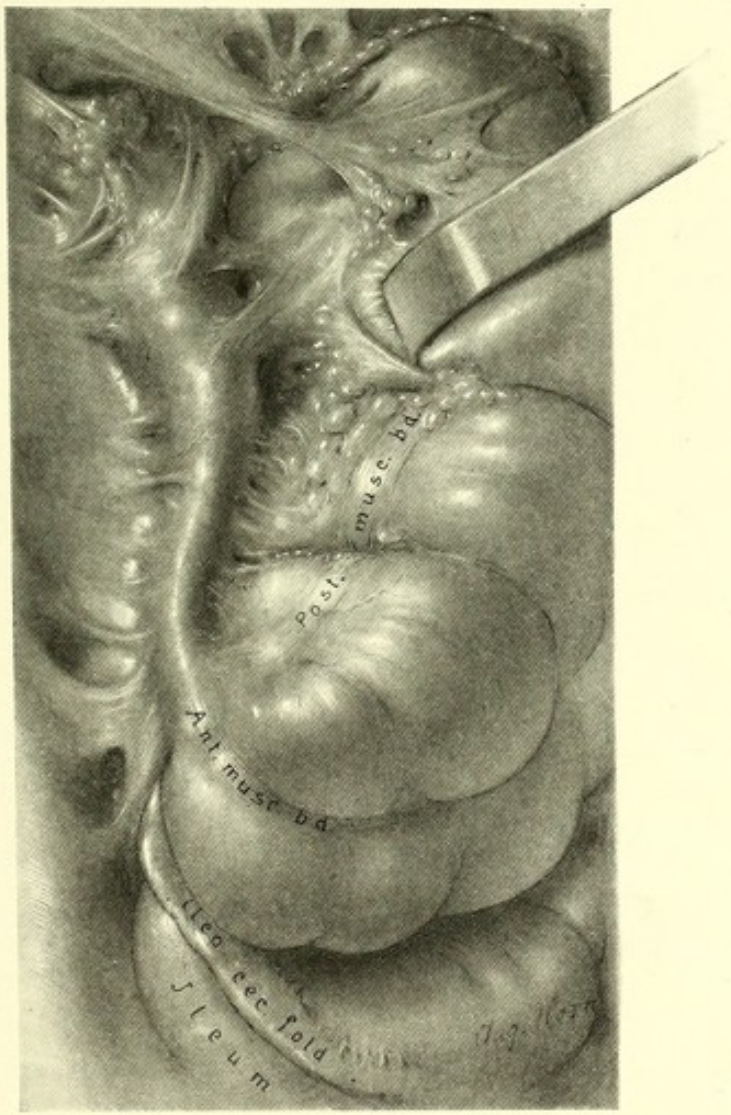

FIG. 300.—I. SHOWING A RETROCOLIC APPENDIX SO BURIED IN A BED OF ADHESIONS THAT REMOVAL IN THE USUAL MANNER IS FRAUGHT WITH DANGER TO THE COATS OF THE CECUM. (See p. 579.)

cecum, and was obliged to enlarge the abdominal incision an inch, so that it was about four inches long. The appendix, which was quite buried in the mass, was greatly enlarged, being fully five times the normal diameter; it was sharply bent upon itself, forming alternating contractions and dilatations, and bound together to both intestine and abdominal wall. With some difficulty it was isolated for about two-thirds of its distal extremity, but the proximal third was

lost in the mass of adhesions already described as binding down the cecum so strongly to the abdominal wall. This was now dissected off from the wall so that the head of the cecum was free. The appendix was cut off close to the mass after tying it firmly with catgut. The stump was thoroughly cauterized with pure carbolic acid, the thick wad of adhesions now attached to the cecum was pared to one-half or less of its thickness, and the surface cauterized in the same way. The abdominal wound was then closed. The patient made a good recovery, although she was under the anesthetic somewhat over three hours."

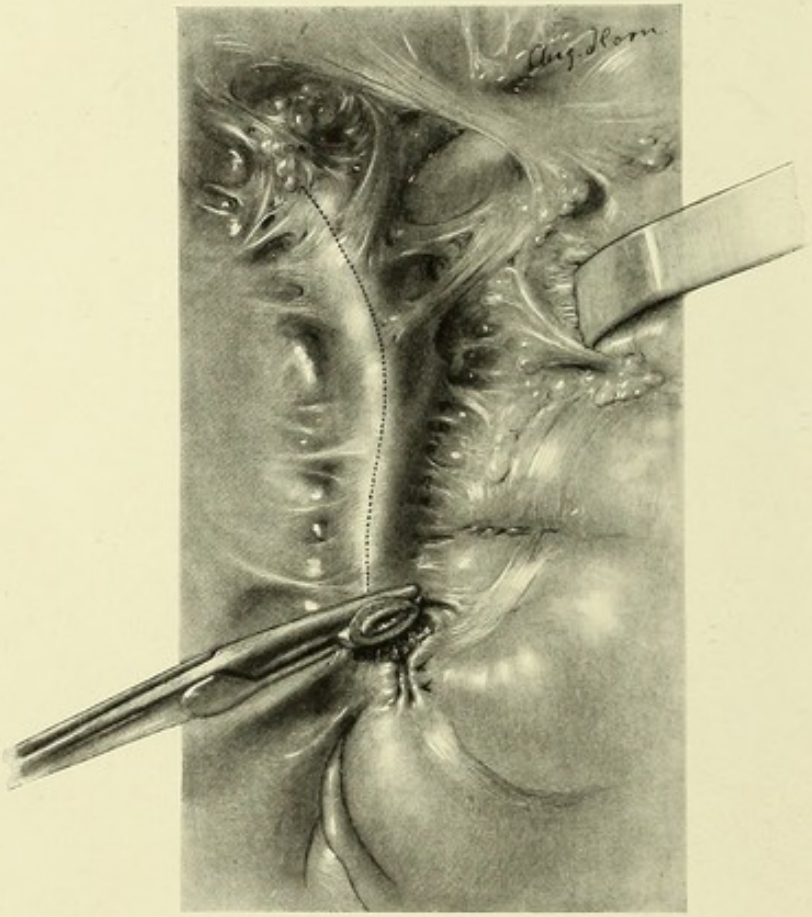

FIG. 301.—H. H. A. KELLY'S METHOD OF DEALING WITH SUCH AN APPENDIX BY DETACHING THE BASE FIRST OF ALL AND CLOSING THE CECUM. IF IT IS THEN IMPOSSIBLE TO FREE ANY PORTION OF THE ORGAN FROM ITS ADHESIONS WITHOUT GREAT RISK TO THE COATS OF THE COLON, IT MAY BE SPLIT OPEN, AS SHOWN IN DOTTED LINE. (See p. 579.)

Fig. 304 represents a buried retrocecal appendix operated upon by FOLLIS, who was able first to locate the firm organ by palpation through the cecum, and then to expose it in its retro-peritoneal position from the cecal end by an incision through the peritoneum, as shown in the lower figure.

A remarkable and, I think, unique case is that of FINNEY, shown in Fig. 305, in which a retrocolic appendix was not only situated behind the peritoneum, but actually lay with its tip plunged into the substance of the psoas muscle.

When the appendix is held down by a short mesentery, or when the mesentery is absent, especially in cases where the appendix extends high up behind the cecum, it is best to detach it at the root, and then extirpate it by pushing the colon gently to the median line, rather than by dragging on the appendix itself and thus risking rupture of its vessels. A case of this kind in which the appendix was tightly adherent to the cecum occurred in the practice of DELANO KIRCHER, and was excised by him without ligatures.

When the omentum is attached firmly to one part of

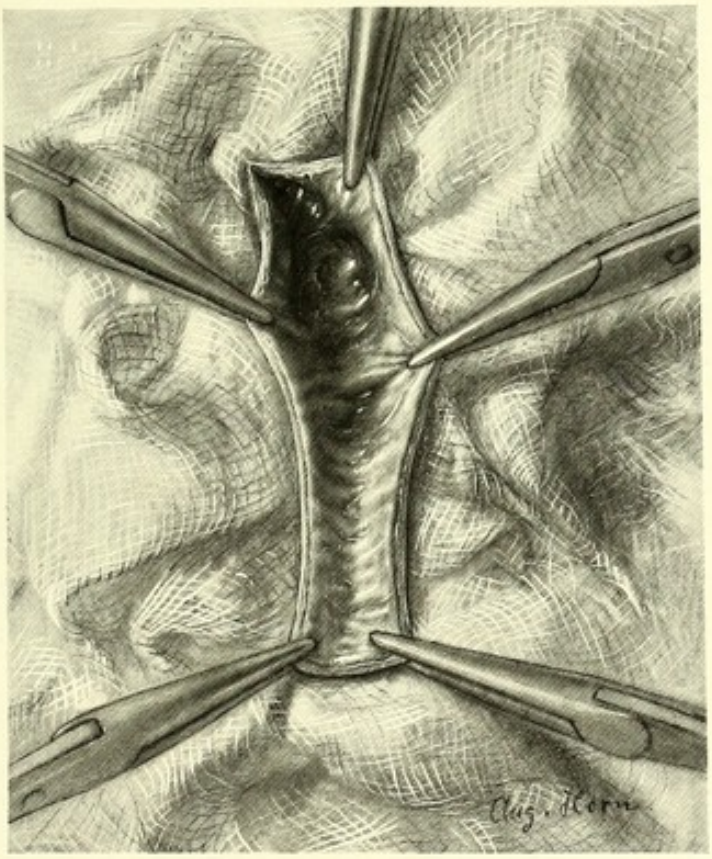

FIG. 302.—H. A. KELLY'S METHOD. AFTER ISOLATING THE APPENDIX WITH GAUZE, ITS EXPOSED MUCOUS SURFACE AND ANY ABSCESS NEAR THE TIP ARE CAREFULLY CLEANSED AND THOROUGHLY CAUTERIZED. (See p. 579.)

the appendix, the safest plan is to tie the omentum and separate it, so that the part attached to the appendix is removed with that organ. This is particularly necessary because the omentum, when attached in this manner, sometimes encapsulates a small abscess, or contains the point of perforation. When on opening the abdomen, the omentum is found adherent in the iliac fossa or about the head of the cecum, it should be detached with the utmost care a little at a time and under the closest inspection. When the omentum is adherent to the appendix or wrapped around it, it is safe to presume that there has been a perforation of the appendix, and that the omentum envelops an abscess,

which is ready to distribute its contents over the peritoneum the moment the barrier is removed. There are two forms of omental adhesions to the appendix, namely, a knuckle adhesion or an adhesion of the free border directly against the inflamed organ; and an enveloping of the appendix in the border of omentum, which is wrapped around the extremity of the appendix. The omentum often under these circumstances saves the life of the patient, by grasping the appendix with its infectious materials, in such a manner as to prevent

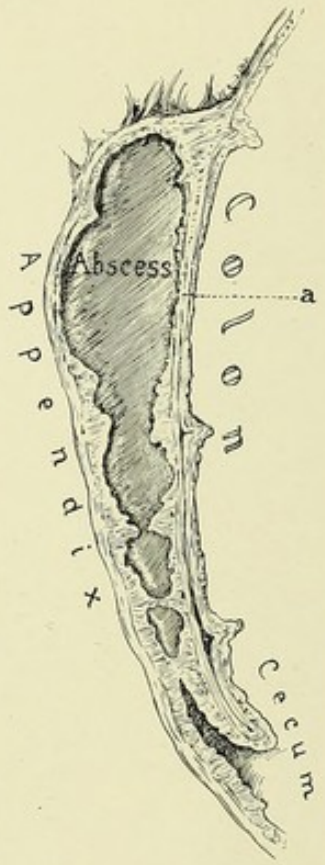

FIG. 303.—SHOWS SUCH AN ADHERENT APPENDIX IN SECTION, WHOSE WALLS ARE FUSED WITH THE CECUM AND COLON.

The object of the incision, cauterization, and drainage is to leave the coats of the appendix as a protecting barrier to the colic wall (a). As much of the mucosa and inner wall should be dissected as possible. (See p. 579.)

extravasation, especially when the disease is situated in the outer portion of a free appendix.

When the appendix is so concealed that it cannot readily be identified, it is important to utilize the various landmarks and to investigate the cecum minutely on all sides in order to find its base, if possible, or at least some other portion. If this is not done, and the operator simply attempts to enucleate a mass somewhere in the region of the appendix, he may be betrayed into such an unfortunate mistake as was made by N. P. DANDRIDGE (*Ann. Surg.*, 1903, vol. 38, p. 367), which he has reported with commendable frankness in order

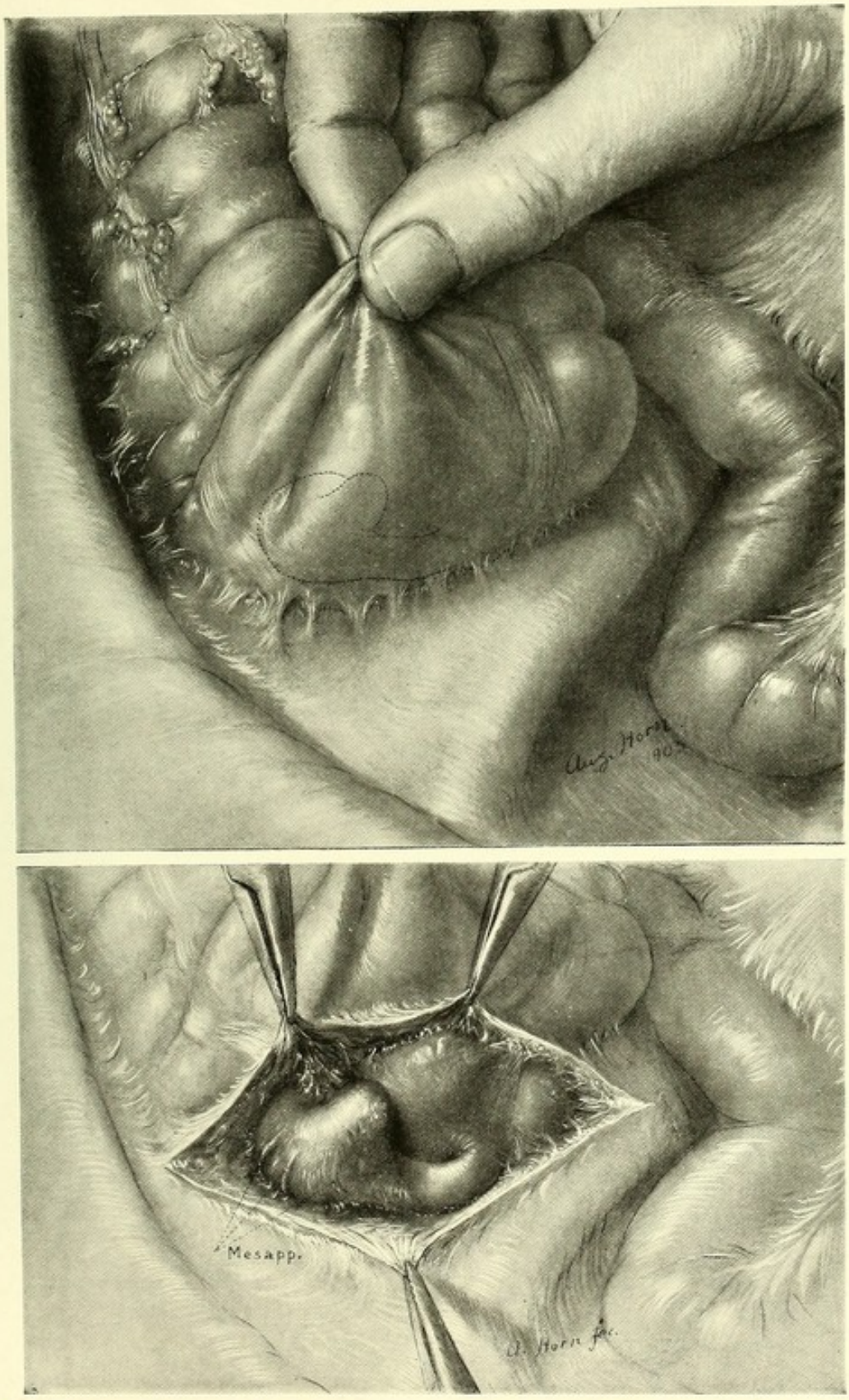

FIG. 304.—FOLLIS' CASE SHOWING THE APPENDIX COMPLETELY CONCEALED UNDER ADHERENT CECUM, AS IS SEEN IN OUTLINE IN UPPER FIGURE.

Palpation revealed the site of the appendix, which was very hard, owing to a concretion in its tip. The lower figure shows the adherent appendix as exposed by a transverse incision through the peritoneum. Note the manner in which the vessels of the mesappendix are disposed. G. A., æt. twenty-nine. Chronic recurrent appendicitis. Operation April 9, 1903. Recovery. (See p. 582.)

that others may profit by his experience. In this case, which was that of a man twenty-six years old, an incision was made at the outer margin of the rectus, and, as the appendix could not be found, a mass lying beneath the peritoneum,

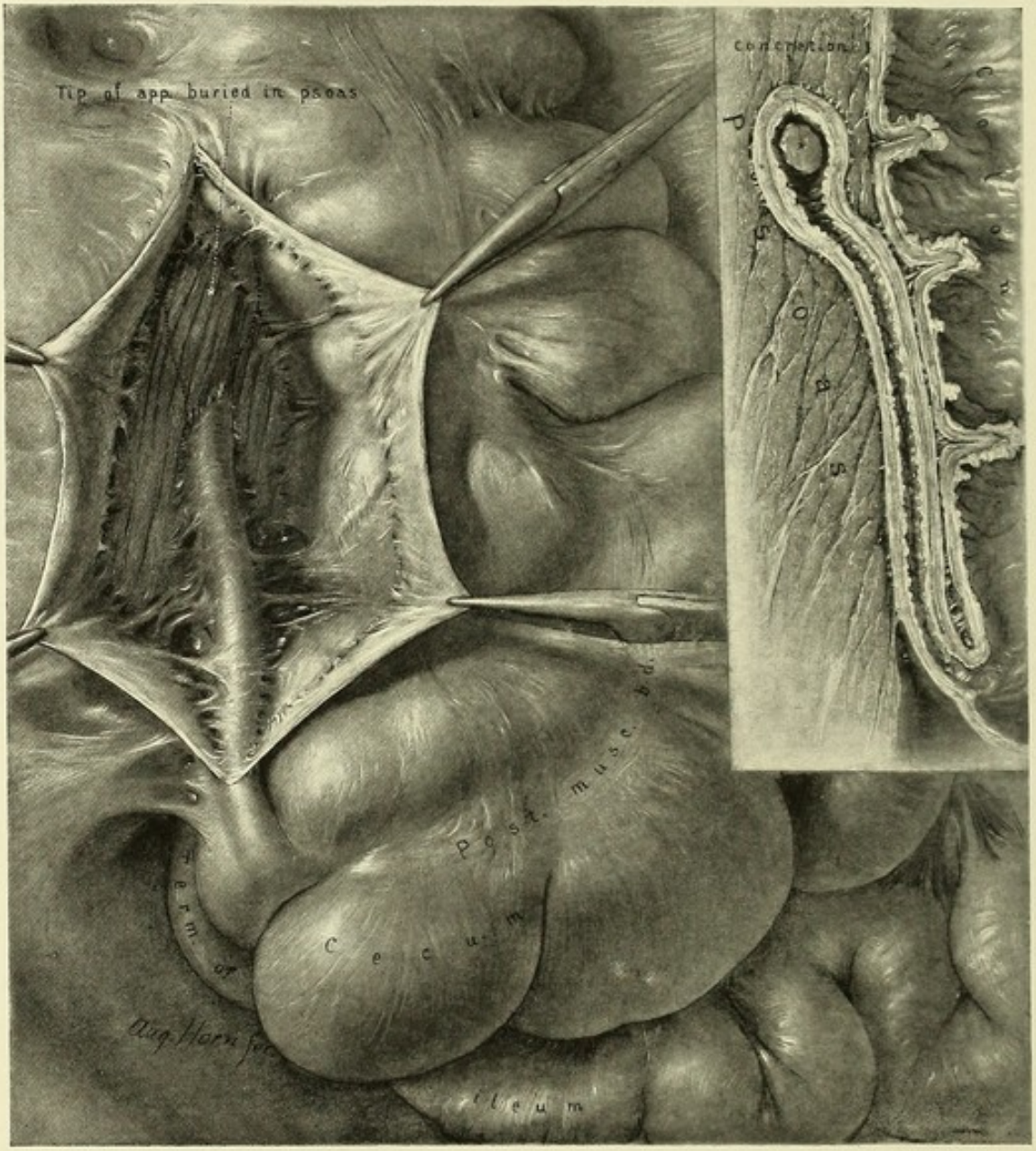

FIG. 305.—FINNEY'S CASE IN WHICH THE APPENDIX LAY RETRO-PERITONEALLY AND THE TIP, OF THE SIZE OF AN ALMOND, CONTAINING A CONCRETION, LAY BURIED IN THE SUBSTANCE OF THE PSOAS MUSCLE, AS SHOWN IN THE RIGHT-HAND FIGURE. U. P. I., April 18, 1899. (See p. 582.)

to the inner side of the colon and above the ileocecal valve, was thought to be an exudation around it. This exudate was freed with the finger, and a pulsating vessel of some size, which passed through it, was ligated. On removal, the parts proved to be a mass of enlarged glands about the size of a hen's egg, which the

microscope showed were not tuberculous. The thickened and club-shaped appendix was found behind the cecum and removed. The wound, which was completely closed, broke down after the eighth day, fecal matter escaped, and afterward about 15 inches of small intestine and cecum sloughed away. This injury was repaired after four intestinal operations.

Retrocecal Appendicitis.—The fact that a retrocecal position of the appendix demands special consideration, and may mislead the operator who is not upon his guard, was first noticed, to the best of my knowledge, by C. B. NANCREDE, of Ann Arbor, Michigan (*Med. News*, 1888, vol. 52, p. 570). Recent investigations show that the retrocecal position occurs more frequently than was formerly supposed. MONKS and BLAKE found that the appendix was behind the cecum in over 17 per cent. of all cases (*Reports Bost. City Hosp.*, 1903); BYRON ROBINSON found it so situated in 20 per cent. in men and in 35 per cent. in women (*Ann. Surg.*, 1901, vol. 33, p. 407); while statistics from the Johns Hopkins Hospital give the retrocecal position as present in 20 to 30 per cent. of all cases (Chap. VI, p. 127).

It often becomes necessary, therefore, to treat cases of appendictis in which the appendix must be sought for behind the cecum. Several instances of this kind which have recently come under my observation induced me to hope that it would be possible to find in retrocecal appendicitis such a characteristic syndrome of symptoms as would clearly define this interesting and important group of cases at the bedside. If we could, with a fair degree of certainty, predicate in a large percentage of cases that the appendix and the abscess were to be found in a retrocecal position, such knowledge would be of material aid to the surgeon in guiding his exploration. If, for example, he knew that the appendix lay behind the cecum, he would often seek to conduct the operation extra-peritoneally, lifting up the peritoneum, much as is done in tying the common iliac artery; and he would, in many instances, make his external incision at a point higher up, above the crest of the ilium; and with the colon once exposed he would with greater precision seek for the appendix, which has not infrequently been abandoned and recorded as "not found" in cases belonging to this very group.

My investigation of this point has covered the histories of 90 patients in whom the appendix occupied the retrocecal position; 40 of which were gathered from general medical literature, and 50 from the records of the Johns Hopkins Hospital, all of the latter, with two exceptions occurring in my own clinic, being from the service of my colleague, Prof. W. S. HALSTED.

In order to determine any special characteristics which might mark this group the following points were determined: (1) The seat of pain; (2) the seat of swelling, and its form; (3) adduction of the right thigh; (4) the presence of blood and mucus in the stools.

The pain was located in the right iliac fossa in 65 of the 90 cases. In 6 of the 40 cases collected from literature it was present in the right loin, but it was not noted as so found in any of the others.

The seat of the swelling whenever stated, was in the right iliac fossa, and in both my own cases, as well as in some others, it is noted as extending backward toward the loin. It is frequently noted that the swelling was ill defined.

Adduction of the thigh is only noted in a few cases, and the same is to be said of blood and mucus in the stools, which appear as a note in the history but 5 times in all.

In 60 out of the 90 cases, previous attacks are noted to have occurred.

It is manifest that no special group of symptoms can be constructed from these facts. I believe, however, that there is a tendency on the part of the abscess to extend upward, behind the cecum, and out toward the iliac brim, forming an elongated swelling high up. In cases where this occurs we may reasonably expect that the appendix will be found behind the cecum, and make a corresponding incision in the loin, working back toward the retrocecal region in the endeavor to expose the affected area.

The matter has not, as yet, been borne specially in mind by surgeons, and I venture to hope that closer attention will reveal some differential points of value, which may enable us to subdivide this difficult subject and thus simplify the treatment of at least one group of obscure cases. I present here brief histories of the two cases occurring in my own practice.

1. Miss A. B. (J. H. H., Gyn. No. 8060, age seventeen.) The patient gave a history of five previous attacks of appendicitis, and stated that she had not been free from suffering since the third, at which time the pain became localized in the right iliac fossa. There was decided resistance in the region of the caput ceci on palpation, and the indurated area was cylindrical, extending upward along the outer border of the rectus muscle to the umbilical level. The resistant body, which could not be displaced, was palpable between the fingers and the pelvic brim. The mass in the cecal region was thought to be fecal, since pressure caused gurgling. An incision in the line of the external oblique muscle, rather high up and away from the anterior superior spine, revealed a mass posterior to the cecum and ascending colon, which proved to be a sac with thick necrotic walls, containing the appendix in its centre. Extirpation was followed by recovery.

2. Mrs. E. N. (J. H. H., Gyn. No. 9009, age thirty-nine.) The patient gave a history of two previous attacks, the first of them a year previously. The second one began with severe pain in the abdomen, at first diffuse, and then localized in the right iliac fossa. There was slight general fulness on the right side of the abdomen, and distention of the superficial veins, with some tenderness. On palpation, an elongated, circumscribed mass, 11 cm. in length and 3 cm. in breadth, could be made out, filling the upper portion of the right iliac fossa. An incision made parallel to Poupart's ligament disclosed an abscess containing 2 ounces of "laudable" pus. By pressure over the abdominal wall the cecum was delivered with its abscess walls, and by tracing its longitudinal bands, the base of the appendix was located, behind it. The tip of the cecum, which was gangrenous, opened into the abscess. The appendix was removed, and the patient made a good recovery.

There is a well-defined group of cases, where the appendix lies back of the cecum and the ascending colon, in which a small pus cavity forms somewhere near the tip of the appendix and continues to cause exacerbations in the symptoms from time to time. The appendix is always embedded in a mass of inflammatory tissue and plastered into the walls of the cecum so firmly that it is impossible to separate it without injury to the larger bowel. The abscess may be an old one, with thickened, inspissated pus, or it may contain a few cubic centimetres of pure pus, and sometimes a concretion is found lying outside the appendix.

Whenever the induration or area of fluctuation extends upward and backward toward the loin, having an elongate, ovoid, or a sausage shape, it is better to make the incision correspondingly over the iliac brim, and even to extend it around the side somewhat posteriorly. After cutting through the skin, in a direction from above obliquely downward, the oblique muscles are best separated by a blunt dissection in the direction of their fibres; the transversalis is pierced with the blunt end of an artery forceps, and the abscess cavity opened. If it is desirable to secure more room for drainage, the muscle fibres of the internal oblique may then be carefully incised, avoiding the injury of any nerve trunk. The advantage of an incision in this locality lies manifestly in its dependent position for drainage, when the patient lies recumbent or turned somewhat to the right side. If the abscess is a long or a large one, a counter-opening may be made below, over the iliac fossa, so as to facilitate the cleansing by through-and-through irrigation.

Disease in the Neighborhood of the Appendix.—The surgeon should never be contented to discover and remove a diseased appendix only; he ought also always to explore the parts within reach in order to discover any evidence of further disease. First, he should investigate the condition of the cecum, for sometimes there is an evident involvement of that portion of its base surrounding the insertion of the appendix, and occasionally isolated ulcers may be found at some point in the caput coli, when they should be excised.

Figs. 306 and 307 illustrate the method of excision to be used when the disease is located in the neighborhood of the appendix or surrounds the cecal orifice of the appendix, as in a case reported by C. Fenger (*Amer. Jour. Obst.*, 1893, p. 194).

The patient was a man of thirty-two. He had had two typical attacks of appendicitis, the second of which was followed, a month later, by an abscess which was incised, leaving a fistula in the right lumbar region which was still open when he consulted Fenger, a year later. The patient's whole right side was then occupied by a board-like swelling, covered with dilated veins in the lumbar region, while below the twelfth rib there was a fistulous opening. This large abscess was opened by an incision leading from Petit's triangle, downward and forward toward the

crest of the ilium, cutting through skin, oblique muscles, and a layer of hard, white, connective tissue, a half an inch thick. From this cavity there opened a sinus which was found to run down into the iliac fossa, and extend from there downward to four inches below Poupart's ligament, along the line of the femoral vessels. In an upward direction the sinus extended under the ribs and the liver, as well as backward four inches toward the vertebral column. These cavities were curetted and the granulation lining removed. During irrigation of the upper cavity an unusually large fecal stone, an inch and a quarter long and a quarter of an inch wide, was washed out. Two drainage-tubes were passed in opposite directions, and the cavity filled with iodoform gauze. A month later a second fecal stone was washed out, and in another month the cavity had closed.

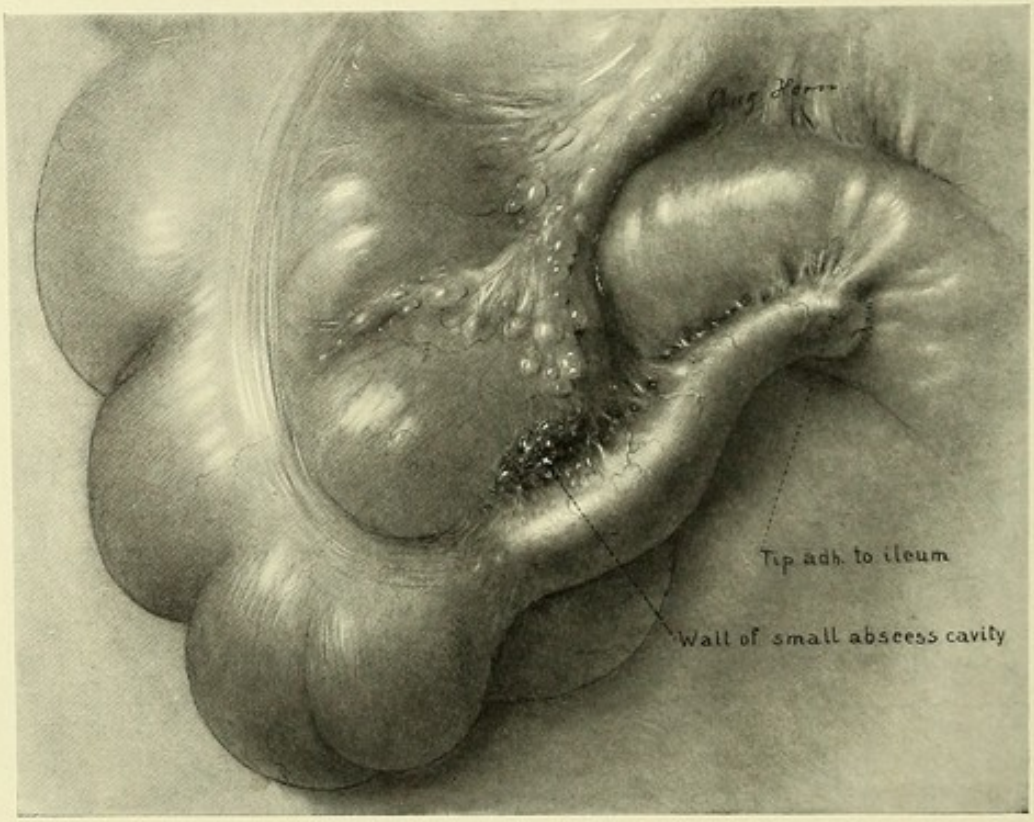

Fig. 306.—Christian Fenger's Case of Appendix Densely Adherent to Caput Coli and Ileum.

Another group of cases in which the large bowel is more or less involved is that of a tuberculous process involving the cecum (ileocecal tumor) in its early stages; and in such instances, if the attention of the operator is directed to the diseased appendix alone, he may amputate this, and then have the annoyance of seeing a permanent fecal fistula remain, while the disease in the iliac fossa advances. Richardson (*N. Y. Med. Jour.*, July, 1901), in speaking of cases where he has been called on to operate for permanent fistula following operation for appendicitis, says: "In several of these patients it was necessary to resect a large portion of the cecum, for the tubercular pro-

cess had invaded all the layers, and had caused extensive ulceration of the mucous membrane."

Fistula.—Fistula occurs in connection with disease of the appendix under one of two conditions, namely:

1. As a sequela to appendicitis. These cases will be considered in Chap. XXIX.

2. As a complication of chronic appendicitis. In these cases the treatment

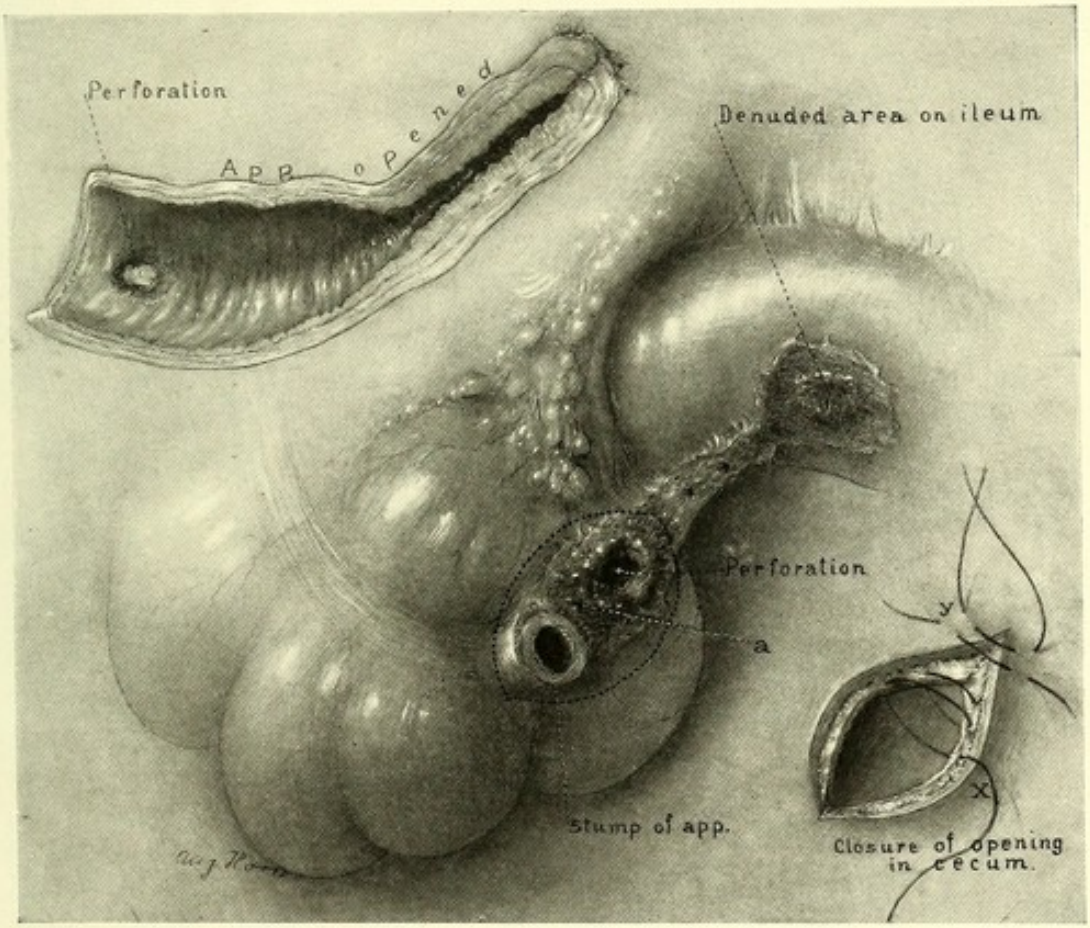

FIG. 307.—FENGER'S CASE SHOWING ABOVE THE THICKENED TIP AND THE PERFORATION NEAR THE BASE.

The middle figure shows the perforation and the area of tissue excised, including both perforation and base of the appendix. The opening was closed by a continuous suture in the mucosa (x), a row of Lembert sutures (y) including serosa and muscularis, and over this a serous suture burying the whole.

is concerned with the removal of the appendix as well as with the cure of the fistula, and they will, therefore, be considered here.

In operations where there is an indurated, suppurating area, with a fistulous opening on to the exterior, the important question is how far to carry the operation. In other words: shall an effort be made to remove the fistulous tract and the appendix together; or shall the treatment, at first, consist simply in a free incision with curettage, and the establishment of direct and thorough drainage?

The excision of the entire area with the appendix as shown in Fig. 308 is the ideal procedure, but it is not always safe. It is best adapted to those cases in which the fistulous tract is well defined and contracted, leading directly into the diseased appendix. A good illustration of this class of cases is the following:

Miss K. (San., Feb., 1902.) Following an operation for suspension of the right kidney the patient had an attack of inflammation and swelling on the right side, extending mostly above, but also somewhat below, and toward the anterior superior spine of the ilium. An incision was made by her physician, in the scar of the renal suspensory operation, and about 500 cc. of pus discharged; a counter-opening was also made below the anterior superior spine, and a drain passed from one opening to the other. Soon after the drain was removed, the fistulous openings closed and the abscess reformed, to prevent which the openings were then kept open with coarse thread. It was at last suspected that the appendix was keeping up the trouble, and sixteen months after the original operation, I made an

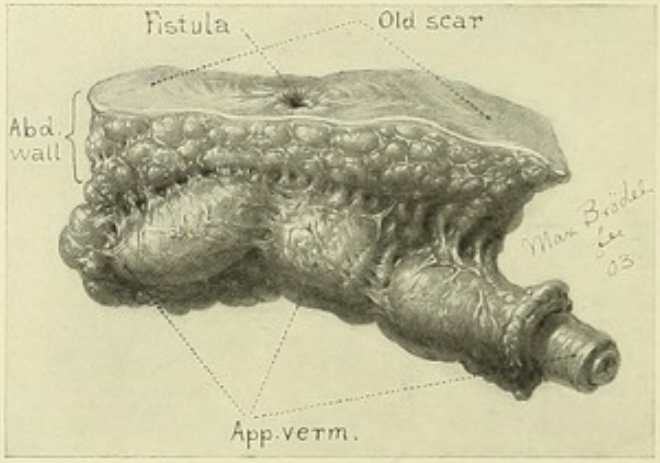

Fig. 308.—Case of Van Cott's. Fistula from an Appendix onto Surface of Abdomen. The operation consisted in excising scar with fistula in appendix *en masse*.

incision 13 cm. long extending from one fistulous opening to the other, and encircling both. All the muscles in the abdominal wall were cut through, the retro-peritoneal tracts connecting the two orifices were dissected out, and numerous bleeding vessels in the dense muscular tissue were clamped; at a point about one-third of the way above the fistulous orifice a fistulous diverticulum was found running down toward the external iliac vessels, which proved to be the appendix wrapped in masses of cicatricial tissue and lying completely extra-peritoneally, behind the cecum. It was removed by drawing it out, and at the same time drawing back the tissues until its base was reached, after which this was approached from the under side of the cecum by rotating the inner side of the latter upward and outward. The base of the appendix was then clamped with fine forceps close to the cecum, the appendix cut away at once, and mattress sutures applied over the forceps, as close as possible to the root of the appendix. One of the sutures, which was of fine black silk, was drawn up ready to be tied, and while this was being done the forceps was released and withdrawn. Several mattress sutures completely

closed the wound. The first row of sutures were covered in by others. There was no escape of bowel contents nor soiling of the wound at any time. Some granulation tissue was cut out from the lower part of the wound in the iliac fossa; above, there was an opening in the peritoneum, about 6 cm. in length, through which the normal omentum and part of the colon were prolapsed. The protruding parts were cleansed with salt solution and returned, and the peritoneal opening carefully closed. The wound was then secured with two layers of catgut sutures, one set in the internal oblique muscle, which had been cut directly across its fibres, the other in the external oblique, which had been simply pulled apart in the line of its fibres. An iodoform gauze drain was left in each angle of the wound on account of the unavoidable contamination with the contents of the fistula. The patient made a good recovery.

The important points in this operation are:

1. The occurrence of two persistent fistulæ.
2. The lateness of the operation after the original attack.
3. The location of the appendix in connection with the position of the abscess, by which the distinct clinical character of this form of retro-peritoneal appendicitis is demonstrated.
4. The character of the operation, which demanded a much longer wound than usual, and one much higher up.
5. The method of separating the external oblique fibres, and of cutting the internal fibres.
6. The removal of the appendix by pulling it out of its bed, while stripping it of its adhesions on all sides.
7. The amputation and removal of the appendix by exposing its base from above and behind the cecum, instead of exposing it by the trans-peritoneal route.

The following case illustrates the use of both methods successively:

Miss C. (J. H. H., April, 1898, age twenty.) When six or seven years old, the patient had an attack of pain in the right side followed by an abscess which developed sufficiently to be opened in forty-eight hours. Some days after it was opened, a pin was found in the dressing, and the whole trouble attributed to that. She had no further attacks until sixteen years old, but after that time she had several, the last one occurring a week before her admission to the hospital. In this illness she had pain and swelling in the right iliac fossa, with constipation, and some pain and frequency in micturition; there were no chills, but probably fever; no nausea nor vomiting. On operation an abscess cavity was found between the skin and the fascia of the external muscles. There was an opening, about 1 cm. long, and 2 cm. broad, situated about 3 cm. above Poupart's ligament. This opening was lengthened parallel to the ligament both above and below. At the bottom of the cavity the fascia of the external oblique muscle was found covered with necrotic material. No opening could be found connecting this with any other cavity below. The walls of the cavity were scraped, the wound

was partially closed and the cavity packed. The patient recovered, and about a year later, in June, 1899, an interval operation was done for removal of the appendix. On opening the abdominal cavity the appendix was found adherent by its tip to the abdominal wall. It was removed, the muscle being excised, and the patient made an uninterrupted recovery (see Chap. XVI, p. 370, Fig. 223).

Obliteration of the Lumen of the Appendix.—Bryant has reported a case (*Jour. Amer. Med. Assoc.*, Nov. 3, 1894) in which there was a mass below the cecum extending toward the cavity of the pelvis. The extreme end of the appendix was free for about half an inch, while the rest was buried in exudate and could not be found. During manipulation the end of the appendix was torn off, and a probe was then passed in until it met with an obstruction due to stricture. An incision was then made up to the stricture, a grooved director was introduced up to the cecum, and the rest of the appendix was thus located. It was dilated beyond the stricture and found to contain much offensive pus. The appendix was tied off and removed, after which the wound was drained with iodoform gauze. Lautard, of Nice, on opening an abscess containing one and a half litres of pus, found the appendix gangrenous at its free extremity, and so densely adherent to the cecum for the rest of its extent that it could not be detached without great risk of rupturing the bowel. The ragged edges of the wound in the appendix were trimmed off smoothly and the opening was then united by four catgut sutures to the inner angle of the abdominal wound, and protected by a narrow iodoform gauze drain. The large abscess cavity was stuffed with gauze. In two weeks the canal of the appendix was wholly obliterated and in three weeks the entire area was cicatrized.

MECKEL'S DIVERTICULUM.

Diverticula of the intestine are to be divided into two classes, false and true.

The false or distention diverticula are found anywhere in the alimentary canal, at the mesenteric border, at the sides, or at the free border. They are round and globular, with a somewhat contracted base, and their size varies from that of a pea to an apple, or they may be even larger. The individual coats of the intestine are not all continuous over these false diverticula, for on dissection the fibres of the muscular coats are found to be either much thinned out, or pushed aside altogether. These diverticula are therefore hernial protrusions of the inner coats through the muscle, and there may be a great number of them on the intestine of any one individual.

The true diverticulum, or Meckel's *diverticulum ilei*, represents the most frequent anomaly of the alimentary canal, occurring, according to various statistics, in from 0.5 to 2 per cent. of all bodies. It is found within a definite area of the ileum, *i. e.*, at a distance of 30 to 290 cm. from the ileocecal valve, the most frequent measurement in the adult being 100 cm., in the newborn child

about 30 cm. The diverticulum may, however, in rare instances be found outside the classic region, either high up (jejunum, duodenum) or far down (cecum, colon), according to whether the upper or lower limb of the primitive intestinal loop has undergone excessive development. It is always single and all the coats of the intestine participate in its formation. Its shape is cylindrical, or conical, or it may balloon at the extremity.

Embryology of Meckel's Diverticulum.—In the very young embryo the short and straight intestinal tube is still in open communication with the yolk-sac, which is situated directly in front of it. As the structures forming the body wall grow from the sides toward the front, they gradually narrow down the

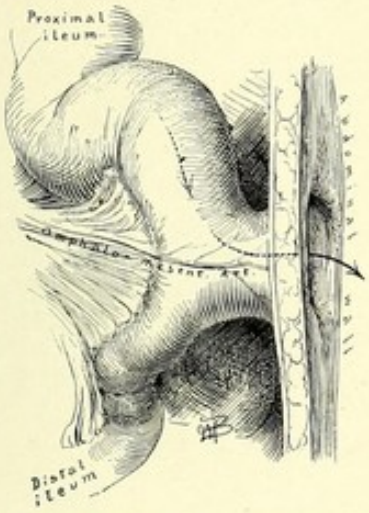

FIG. 309.—TYPE I. DIAGRAM OF THE MOST PRIMITIVE FORM OF MECKEL'S DIVERTICULUM, RESEMBLING THE ORIGINAL VITELLINE DUCT.

It appears as a short canal which connects the ileum with a ventral fissure, the extent of which may be considerable. The distal ileum is insufficiently developed, the anus being either constricted or occluded, and the intestinal contents pass through the fissure. The canal is accompanied by the remains of the omphalo-mesenteric vessels.

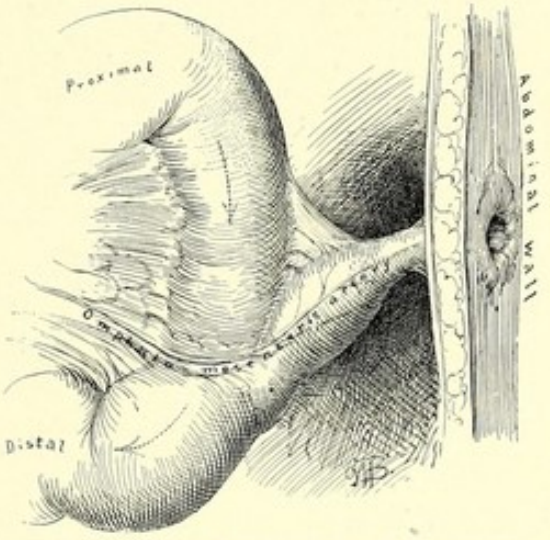

FIG. 310.—TYPE II. DIAGRAM OF A MORE ADVANCED FORM OF THE DIVERTICULUM.

The fissure persists, but is narrower, the canal longer and more slender, and, owing to an intact anal orifice, the intestinal contents pass in the usual manner. The omphalo-mesenteric vessels accompany the canal.

communicating portion between the intestinal tube and yolk-sac until it is but a narrow channel. This is the vitello-intestinal or omphalo-mesenteric duct, which normally becomes obliterated and absorbed as soon as the body wall of the embryo is closed. If it fails to disappear, it may persist in the adult as Meckel's diverticulum, of which we distinguish four different types. These represent, with tolerable exactness, the stages of embryological changes through which this peculiar structure has to pass.

Type I.—If the arrest in development has taken place before the closure of the opening of the gut in the yolk-sac has occurred, we find a broad fissure at the umbilicus, through which fecal matter is discharged. Associated with

this condition is generally found another anomaly, dating back to the same embryonic stage, namely, constricted or occluded anus (see Fig. 309).

Type II.—This is a somewhat more advanced condition, in which the fissure is smaller, the canal longer, and owing to an intact anal orifice, the intestinal contents pass in the usual manner. This type may be produced, if at the time of birth, a diverticulum still extended part of the way into the cord and became tied off with it, an ulcerative process developing in the diverticulum and leading to the formation of an umbilical fecal fistula (see Fig. 310).

Type III.—This is a still further advanced stage. The ventral fissure

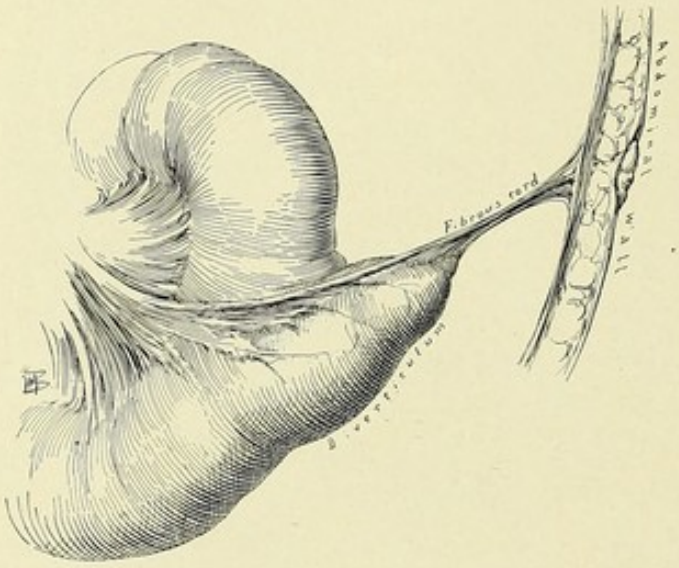

FIG. 311.—TYPE III. DIAGRAM OF A STILL FURTHER ADVANCED FORM OF DIVERTICULUM.

The ventral fissure is closed and the distal portion of the canal has become transformed into a fibrous cord, which may or may not contain remains of the omphalo-mesenteric vessels. The proximal portion has retained its lumen and appears as a sac attached to the free border of the ileum.

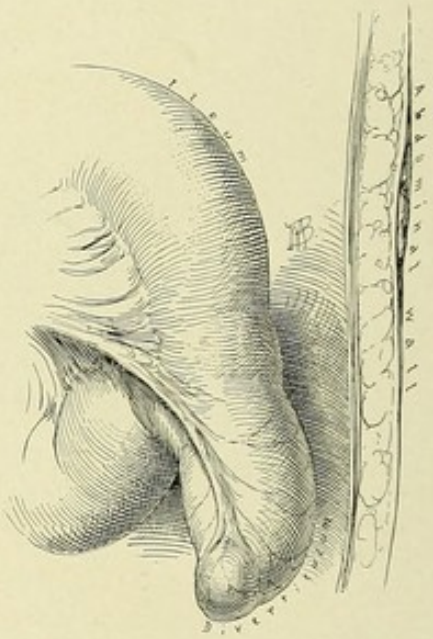

FIG. 312.—TYPE IV.—THE USUAL FORM OF MECKEL'S DIVERTICULUM.

The proximal portion of the original vitelline duct persists, but having become closed at its end and detached from the umbilical region, it appears as a pouch hanging free from the convex border of the ileum. The omphalo-mesenteric vessels run up to its tip.

is now closed; the vitelline duct persists only in its proximal or ileal portion, forming a diverticulum of various length, while its distal or umbilical portion has become obliterated and transformed into a fibrous cord, which acts as a suspensory ligament for the diverticulum (see Fig. 311).

Type IV.—This is the form most frequently met with, and is that which is most apt to resemble a vermiform appendix. Here the ventral or umbilical portion of the duct has become absorbed and the ileal portion or diverticulum projects from the free border of the ileum (see Fig. 312).

The length of Meckel's diverticulum varies from 1 to 20 cm., 2.5 cm. being the most frequent measurement.

The w i d t h may be that of the ileum; more often, however, it is slightly less; it is occasionally very narrow, resembling a vermiform appendix (Fig. 313). Again, many cases have been noted in which a diverticulum was found two or three times as wide as the adjacent ileum.

The diverticulum is generally a t t a c h e d to the free margin of the ileum, *i. e.*, opposite the mesenteric border, in which case, however, its axis frequently points toward either one side or the other. It may, however, also come off at the sides or even near the mesentery. ORTH (*Lehrb. d. speciellen Path. Anat.*, Bd. 1, p. 764) states that it may even be found extending between the leaves of the ileal mesentery; but it seems more likely that he has referred to a false or distention diverticulum. If attached to the free border the passage from one to the other is, as a rule, uninterrupted by any valvular structure. Not infrequently, however, the diverticulum is found leaning toward the ileum in a distal direction (Fig. 314). The resulting acute angle between ileum and diverticulum gives rise to the formation of a semilunar valvular fold at the junction, similar in character to the semilunar fold at the ceco-appendical

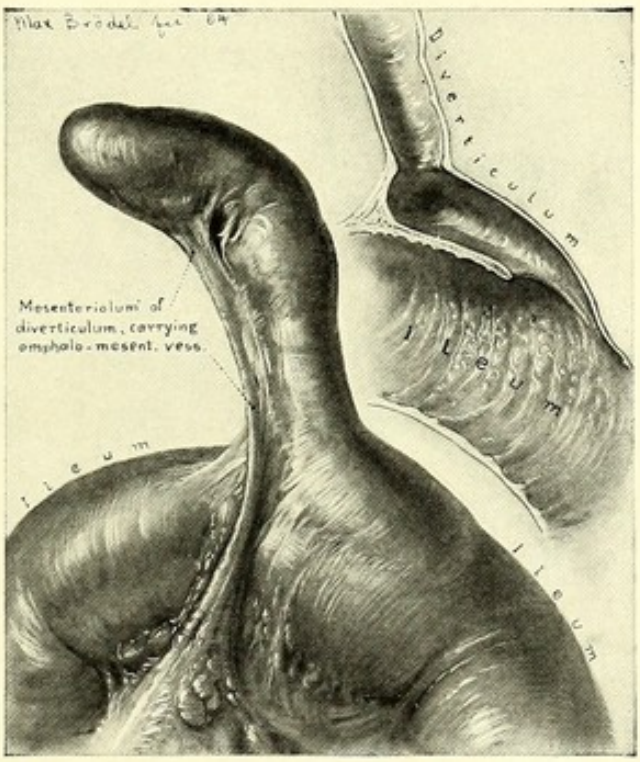

FIG. 313.—AN UNUSUALLY NARROW MECKEL'S DIVERTICULUM, WHICH MIGHT EASILY BE MISTAKEN FOR AN APPENDIX.

The resemblance is still more marked if viewed upside down. Careful examination of its mode of attachment and recognition of the fact that it arises from the ileum, will at once determine the true character of the structure. For a distance of 2 cm. the diverticulum is adherent to the ileum, and the resulting acute angle between the two gives rise to the existence of a semilunar valvular fold at the junction, which, however, does not suffice to prevent free communication between ileum and diverticulum. The diverticulum has a well-developed mesenteriolum arising from the mesentery, in which pass the omphalo-mesenteric vessels supplying the organ. Specimen from the pathological collection of the Johns Hopkins Hospital, 506. (Natural size.)

junction. The diverticulum may be closely adherent to the ileum for a variable distance, in which case the semilunar fold is still more pronounced (Fig. 313). MECKEL (*"Ueber die Divertikel am Darmkanal," Arch. f. d. Physiol.*, Halle, 1809, Bd. 9, p. 421) thought that this narrowing and the presence of the valve signified a tendency on the part of the ileum to effect a normal closure at this point. If the fold projects from both the distal and the proximal margin of the orifice, this assumption is not without ground, and there are even instances where the opening was completely occluded (ORTH,

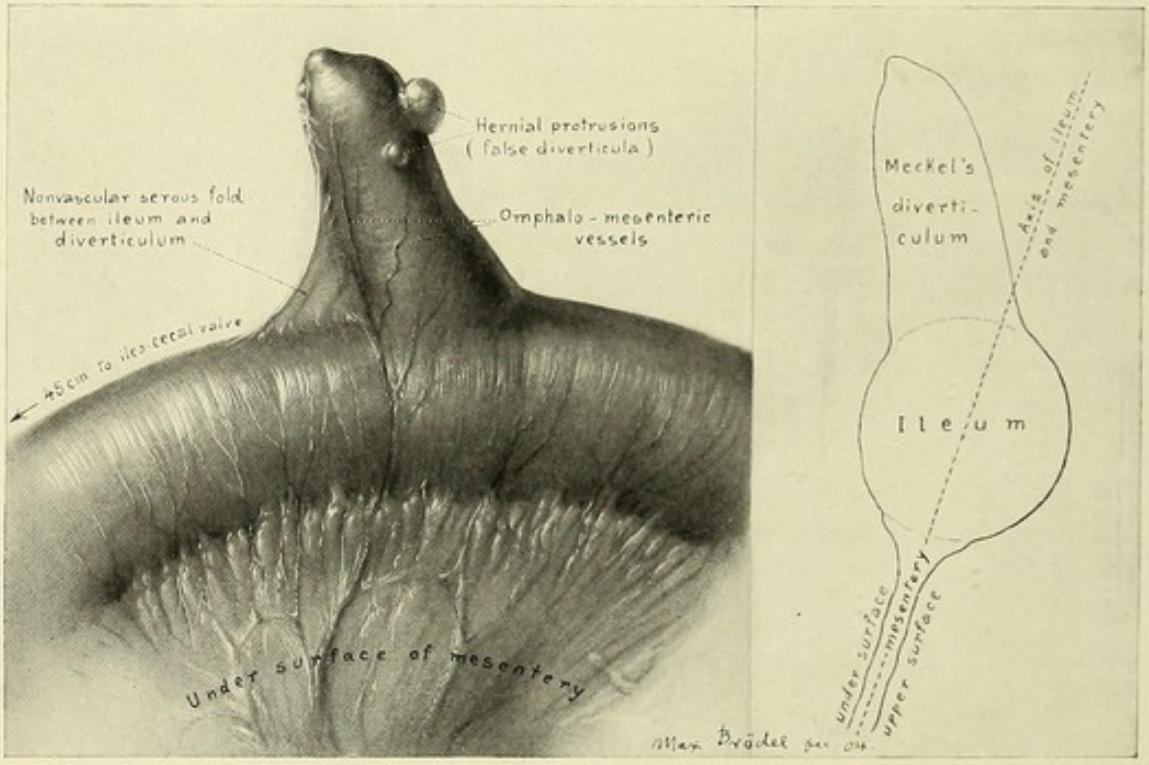

FIG. 314.—A MECKEL'S DIVERTICULUM ILEI WITH SEVERAL SMALL DISTENTION DIVERTICULA AT ITS DISTAL PORTION.

The diverticulum is situated at a point 45 cm. from the ileocecal valve and attached to the free border of the ileum, pointing, however, slightly toward the under surface of the intestine. The omphalo-mesenteric vessels exist only on the under side (the embryonic left side), whence they send their branches around the structure. A triangular, transparent, non-vascular, serous fold runs in the distal acute angle between ileum and diverticulum. Observed June 6, 1904. (Natural size.)

loc. cit.). If seen only on the side toward which the diverticulum leans, it should be regarded as of merely mechanical origin.

The tip of the diverticulum is a subject of interest, in so far as the muscular coats are here apt to leave gaps through which the inner coats may protrude. These hernial formations vary from the size of a pea to that of a walnut. They are identical in character with the above-described distention diverticula found at any point of the alimentary canal. We thus have a true Meckel's diverticulum with false diverticula at its cupola (Fig. 314). MECKEL (*loc. cit.*) has described this peculiarity and advanced the opinion that in the development of the diver-

ticulum the same energy is not expended as in the development of the intestine. The entire process should disappear, and it is not surprising that for this reason the remaining portion, on account of less firm texture, should frequently show traces of insufficient development, more pronounced in the last and weakest spot—the tip.

The muscular layers of the diverticulum are similar to those of the ileum; viz., an inner circular and an outer longitudinal. The latter, however, is very delicate in some specimens, and may, in places, be wanting. The mucosa is also identical in character with that of the ileum, and OSLER (*Ann. Anat. and Surg.*, 1881, vol. 4, p. 202) mentions a case in which a Peyer's patch was found in a diverticulum.

The blood supply is of sufficient interest to merit a brief description. The diverticulum is supplied by the remains of the vitelline or omphalo-mesenteric vessels. These belong to the first circulation of the embryo, and through them the blood of the vascular area inclosing the yolk-sac is carried into the two primitive aortas of the embryo. Veins accompany these arteries, which are at first multiple, but when the intestinal canal is formed they are reduced to two, one passing on either side of the intestinal tube. When the intestine bends away from the now single aorta, to form its first loop, the primitive mesentery makes its appearance and the omphalo-mesenteric arteries unite to form one single vessel, which arises from the aorta and passes inside the newly formed mesentery to the most ventral portion, where it divides into two branches which pass right and left around the intestine and then into what remains of the vitelline duct and yolk-sac. The omphalo-mesenteric artery changes in later stages into the main trunk of the superior mesenteric artery, and the portion of the intestine in the adult toward which this artery points is the region where the vitelline duct has been, and where we have to look for a Meckel's diverticulum.

Even if the diverticulum disappears, the omphalo-mesenteric artery may persist and run in a connective-tissue strand up to the umbilicus. This was the case in a man, fifty-four years of age, mentioned by HUNTINGTON (*Anatomy of the Peritoneum and Abdomen*, 1903). The strand containing the omphalo-mesenteric artery may arise from the ileum or from the mesentery, and its presence among the intestines is undoubtedly an element of danger. According to ORTH (*loc. cit.*), this fibrous band may exist between the ileum and umbilicus without the presence of a diverticulum, or a diverticulum may be found adherent, with or without a band, not to the umbilicus, but to another portion of the parietal or visceral peritoneum; and finally a band may arise from the umbilicus and be attached, not to the intestine, but elsewhere.

The diverticulum may be supplied by two persistent branches of the omphalo-mesenteric artery, or there may be only one, the other having become atrophied. From the material at my disposal, it appears that the right (embryonic term)

or upper branch is more apt to atrophy. In Fig. 314 the diverticulum is supplied by the left branch (embryonic term), *i. e.*, the one running around the under surface of the ileum. It courses along the side of the diverticulum toward the tip, and gives off branches to right and left.

In case there are two omphalo-mesenteric arteries (Fig. 315) they ascend one on either side, but not exactly opposite one another. The branches given off form broad anastomoses with those coming from the other side. When viewed from the side, we see three or four superimposed vascular arches passing

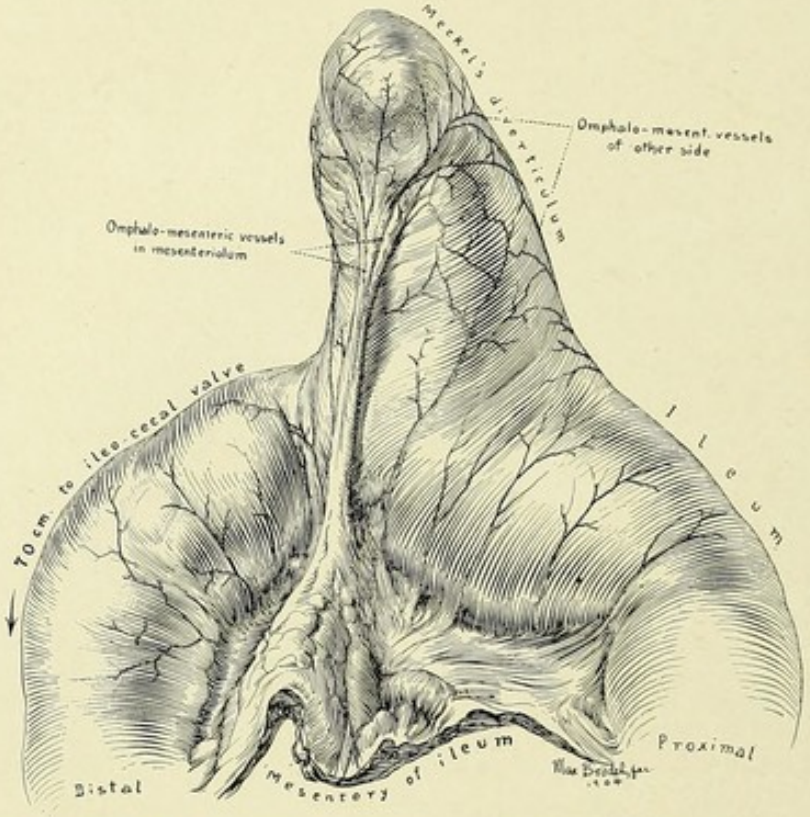

FIG. 315.—A LARGE MECKEL'S DIVERTICULUM 70 CM. FROM THE VALVE.

It is supplied by two omphalo-mesenteric arteries, one of which has given rise to the formation of a mesenteriolum on the under surface (embryonic left), while the other passes in close contact with the ileum and diverticulum along the upper surface (embryonic right). Broad anastomosing branches pass between the two. Autopsy, March 17, 1899. (Two-thirds natural size.)

in intervals of 1 to 2 cm. from the right to the left omphalo-mesenteric vessel. They become shorter as they approach the tip. All arteries are accompanied by veins.

An important feature of the vascularization is the occasional presence of a m e s e n t e r i o l u m which contains the omphalo-mesenteric vessels. While in some instances in which the diverticulum is short and attached to a portion of the ileum equally far away from the mesenteric border, the vessels hug the ileum closely without lifting up any serous fold; in other instances, in which the diverticulum is long, or in which it arises more from the upper or lower side

of the ileum, the vessels are very apt to lift up a serous fold of various size. which may contain a considerable amount of fat and resemble in every way the mesenteriolum of the appendix. It extends from the mesentery near the ileal border up to the tip of the diverticulum, but may also be shorter. Sometimes it forms a little fatty protuberance at the tip. It is evident that the development of such a structure is purely mechanical, resulting from the oblique position of a contracting and expanding tube in which the vessels were subjected to tension and lifted up a triangular peritoneal reduplication. Excessive distention of such a specimen shows clearly that tension of the vessels produced the mesenteriolum (Fig. 315). If there are two omphalo-mesenteric arteries, only one lifts up a mesenteriolum, *i. e.*, the one on the concave surface, while the other courses along the convex side of the ileum and diverticulum, accompanied by a varying amount of fat.

A diverticulum may also possess a non-vascular serous fold, which passes in the acute angle between the ileum and diverticulum. It is triangular in form and closely resembles the ileocecal fold (Fig. 314, p. 598).

It is worthy of note that Meckel's diverticulum is frequently associated with other anomalies; such as, harelip, cleft palate, insufficient development of the bones of the skull, spina bifida, congenital deficiency of septum of the heart, ventral fissure, double uterus, horseshoe kidney, double bladder, exstrophy of bladder, atresia of anus, club-foot, supernumerary digits, transposition of the viscera, double and triple monsters.

Another interesting feature is that a Meckel's diverticulum has been found in several children of the same parents, JAEGER (*Dtsch. Arch. f. Physiol.*, Halle, 1817, Bd. 3, p. 539) reporting two cases of infants with this anomaly, and RIEFKOHL (*Berl. kl. Wochenschr.*, 1874, Bd. 11, p. 249) three, one of the three, however, being doubtful.

Pathology.—The presence of a diverticulum may give rise to a number of pathological conditions. The fibrous band passing from the tip of the sac to the abdominal wall or to any part of the viscera may form a ring in which the bowel can become strangulated. The existence of a valvular structure at the junction between the ileum and the diverticulum may cause a retention of the secretion of the mucous membrane of the diverticulum and give rise to the formation of a cystic dilatation, a so-called entero-cystoma.

Foreign bodies, such as cherry-stones, peas, orange pips (OSLER, *loc. cit.*), may enter a diverticulum and bring about inflammation and ulceration; while fecal concretions have not to my knowledge been reported.

Typhoid ulceration in a Peyer's patch situated in a diverticulum, with perforation, has been observed by GALTON (*Trans. Path. Soc. Lond.*, vol. 23).

A diverticulum may enter an inguinal hernia and become adherent with subsequent inflammation and perforation.

Finally, it may, on becoming inflamed, simulate in all respects an attack of appendicitis.

Symptoms.—The symptoms of a diverticulitis are in all respects similar to those of an appendicitis, except that the pain may be situated somewhat higher up than is usual in inflammation of the appendix, as was noticed in two cases, by FINNEY. A good illustration of such a case has been furnished me by C. OVIATT, of Oshkosh, Wis., in a personal communication.

The patient, who was a man thirty-six years old, had had three well-defined attacks of appendicitis within a year. The last attack differed from the others in the fact that there were two distinct foci of pain and tenderness, one slightly below McBurney's point, the other about 12 cm. above it, nearly on a line with the umbilicus and at the outer border of the rectus muscle. He was admitted to the hospital when recovering from the third attack. At this time the upper focus was more sensitive to touch than the lower. The ordinary incision along the border of the rectus was made, and an appendix which contained a good-sized fecal stone removed. Upon extending the wound to the upper focus of pain, a mass of adhesions was encountered, which, when freed, showed a Meckel's diverticulum 8 cm. in length, and about two-thirds the size of the ileum. It had evidently been but recently in a state of active inflammation similar to that in the appendix. The diverticulum was removed close to the ileum, and the wound closed with the Czerny-Lembert sutures; the abdominal wound was closed without drainage. The patient made a good recovery.

Treatment.—The operation for diverticulitis consists in the detachment and isolation of the diverticulum, extreme care being taken not to rupture its tender coats. The mesentery, if present, is ligated, and the diverticulum also is ligated near the ileum, the bowel wall being kept well elevated, and pinched together to prevent any escape of its contents. The wound is then closed with mattress sutures, which are again turned in with sero-serous sutures. If a large diverticulum is caught in a hernia and strangulated, it may be necessary to resect the bowel in part, or even across its entire lumen.

CHAPTER XXVI.

ABSCESS IN THE NEIGHBORHOOD OF THE APPENDIX, OR SUPPURATIVE PERI-APPENDICITIS.

REMOVAL OF THE APPENDIX IN SUPPURATIVE CASES. TREATMENT OF ABSCESS. TREATMENT OF ABSCESS IN SPECIAL CASES. PELVIC APPENDICAL ABSCESS.

The term *suppurative peri-appendicitis*, introduced by TERRIER, includes all cases in which the suppuration is localized in the neighborhood of the appendix, or, in other words, in which there is an *iliac*, *lumbar*, *pelvic*, *inter-intestinal*, *sub-umbilical*, or *retrocecal abscess*.

The location of an abscess directly connected with the appendix varies according to: the position and the length of the appendix; the situation of the infected area, whether in the middle, the base, or the tip; the presence of abnormalities in the position of the cecum, or of the appendix. An appendix of average length, for example, may lie in the iliac fossa, or it may hang over the pelvic brim into the pelvis, or it may lie under the ileum, or behind or in front of the cecum to the inside (Fig. 318, p. 606) or outside, or, finally, it may lie underneath the cecum (Figs. 316 and 317, pp. 604 and 605).

In some cases the presence of a pocket or a peritoneal diverticulum will determine the location of an abscess and limit its extent, as in Fig. 203 (see p. 326), where an acute process in the tip might be shut off by an agglutination of the peritoneal surface at the mouth of the pocket. In some extraordinary instances the appendix may be completely concealed under one or more layers of peritoneal folds with more or less valve-like openings (see Fig. 319, p. 607), in which case great anatomic advantages exist for the limitation of a spread of infection.

MIKULICZ has drawn especial attention to the natural barriers in the abdomen (see Fig. 320, p. 608), which tend to limit, and also to determine the direction of the spread of any infectious materials. The abdomen, as he has shown, may be divided into a supra-omental and an infra-omental space; the supra-omental space being subdivided into a subphrenic and an infra-hepatic. The diaphragmatic area is again subdivided into right and left areas by the hepatic ligament. The space below the transverse colon and the omentum is subdivided by the mesentery of the ileum, which follows a generally oblique direction from above on the left, down into the right iliac fossa. The pelvic cavity constitutes the most important subdivision of the lower area. It will at

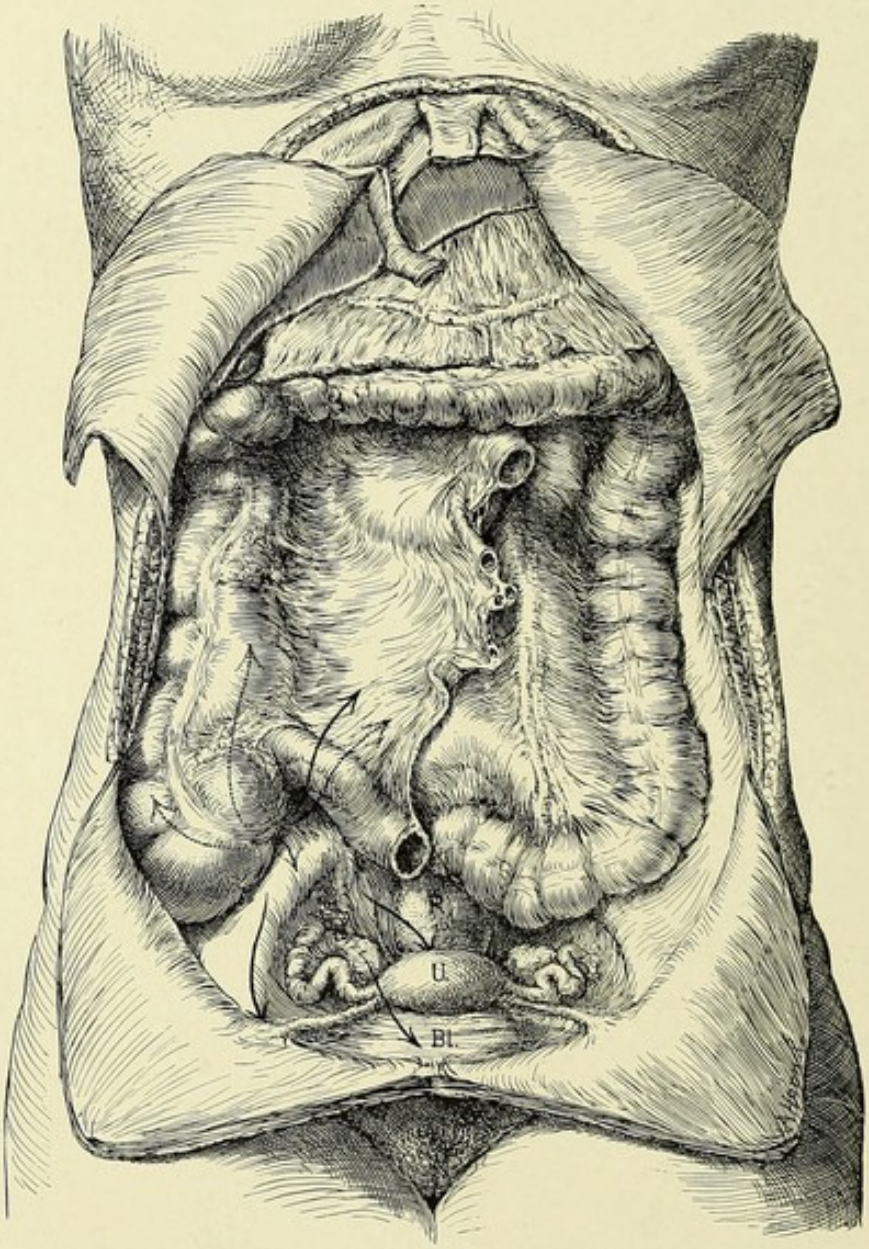

FIG. 316.—A COMPOSITE PICTURE SHOWING THE VARIOUS POSITIONS IN WHICH AN ABSCESS MAY BE FOUND, IN THE PELVIS, BEHIND OR IN FRONT OF THE ILEUM, OR BEHIND THE COLON OR THE CECUM. (See p. 603.)

The location of the abscess, as a rule, is determined by the position of the appendix.

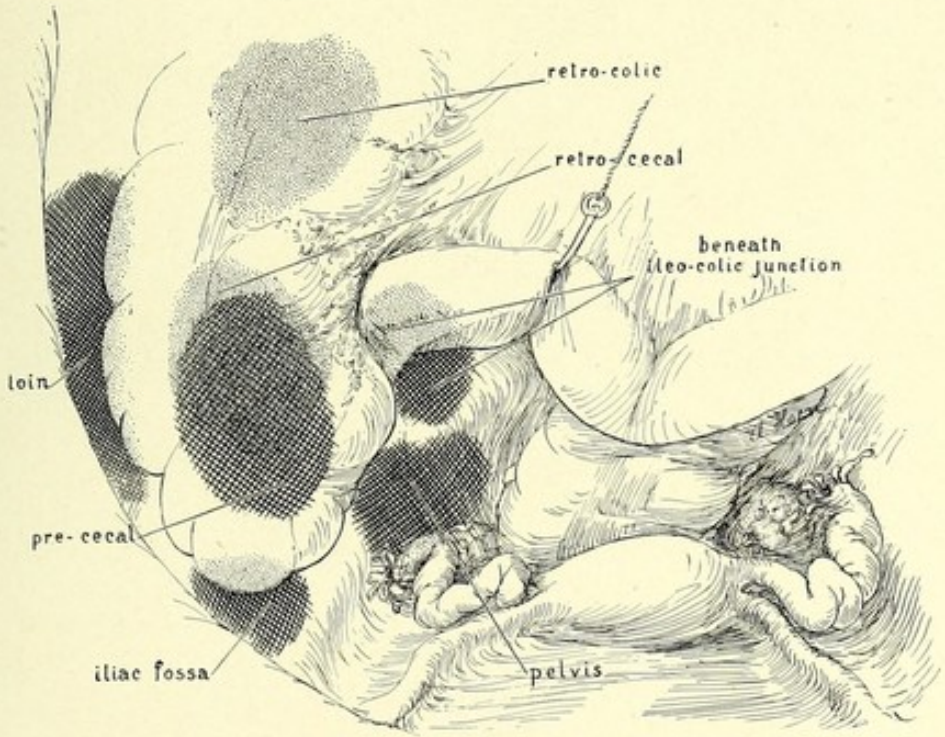

FIG. 317.—THE LOCATION OF VARIOUS SMALL ABSCESSES IN THE ILEOCOLIC REGION. (See p. 603.)

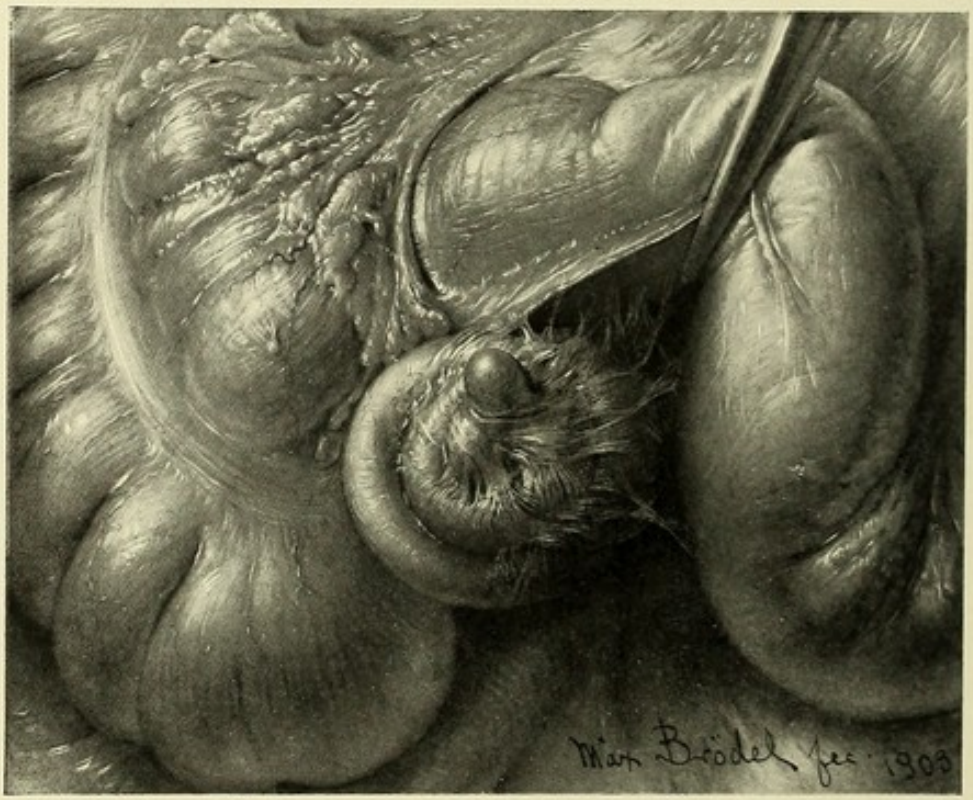

FIG. 318.—SHOWING AN APPENDIX COILED ON ITSELF IN SPIRAL FORM BELOW AND IN FRONT OF THE ILEOCECAL JUNCTION.

The ileum is shown lifted up, so as to expose the proximal portion of the appendix. The appendix was bound down by numerous adhesions, passing in every direction, immobilizing the individual coils of the organ. The tip, however, was free and pointed directly forward. The whole organ was intensely inflamed, so much so as to make it impossible to recognize the different coils until the adhesions had been partially severed and removed. The extraordinary spiral form of the appendix resembles, in a remarkable manner, a rattlesnake coiled and ready to spring.

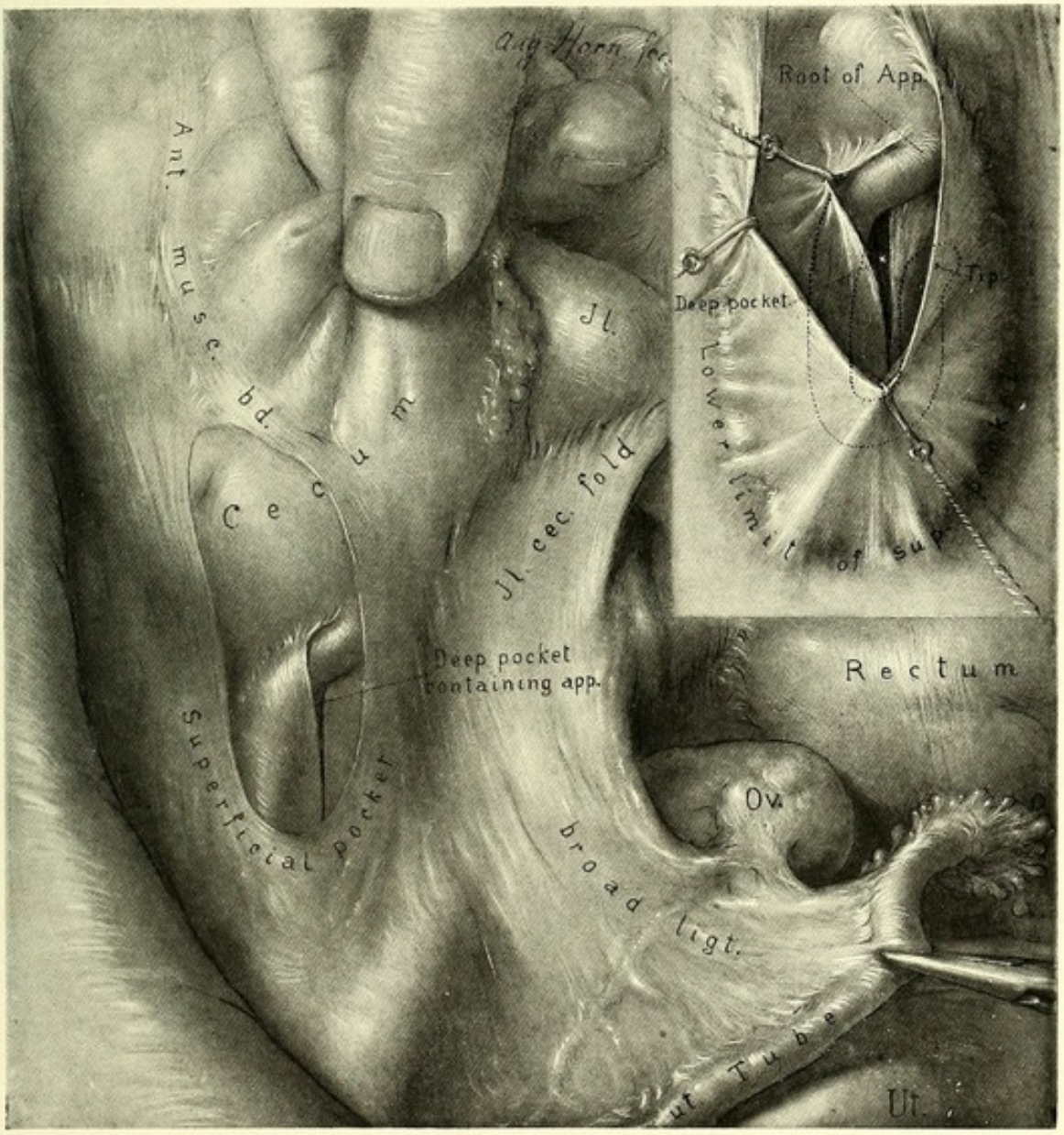

FIG. 319.—W. W. RUSSELL'S CASE SHOWING THE APPENDIX BURIED UNDER TWO LAYERS OF PERITONEAL FOLDS FORMING TWO POCKETS. (See p. 603.)

The appendix lay flexed on itself in the innermost pocket, as shown in the upper right-hand figure. Gyn. clinic. October 8, 1903. Note that the ileocecal fold is continuous with the broad ligament.

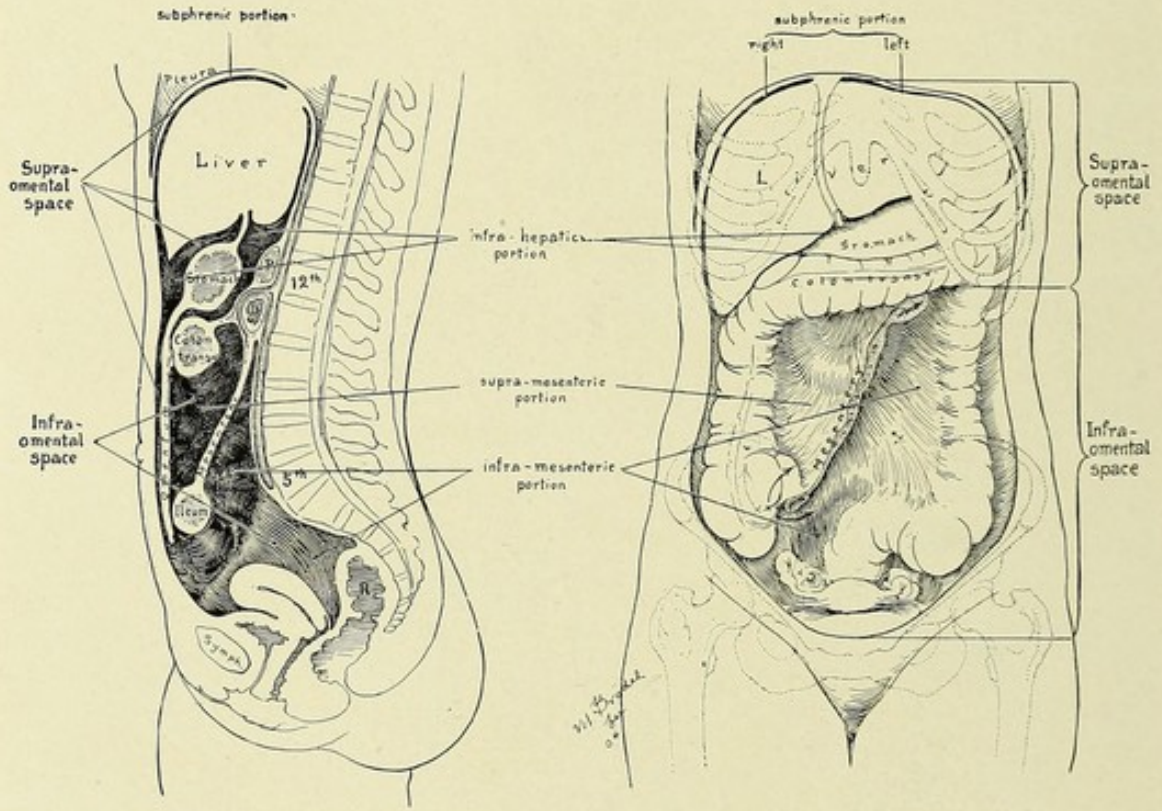

FIG. 320.—MIKULICZ'S BARRIERS TO THE SPREAD OF INFECTION, AIDING IN THE LOCALIZATION OF INFLAMMATORY PRODUCTS. (See p. 603.)

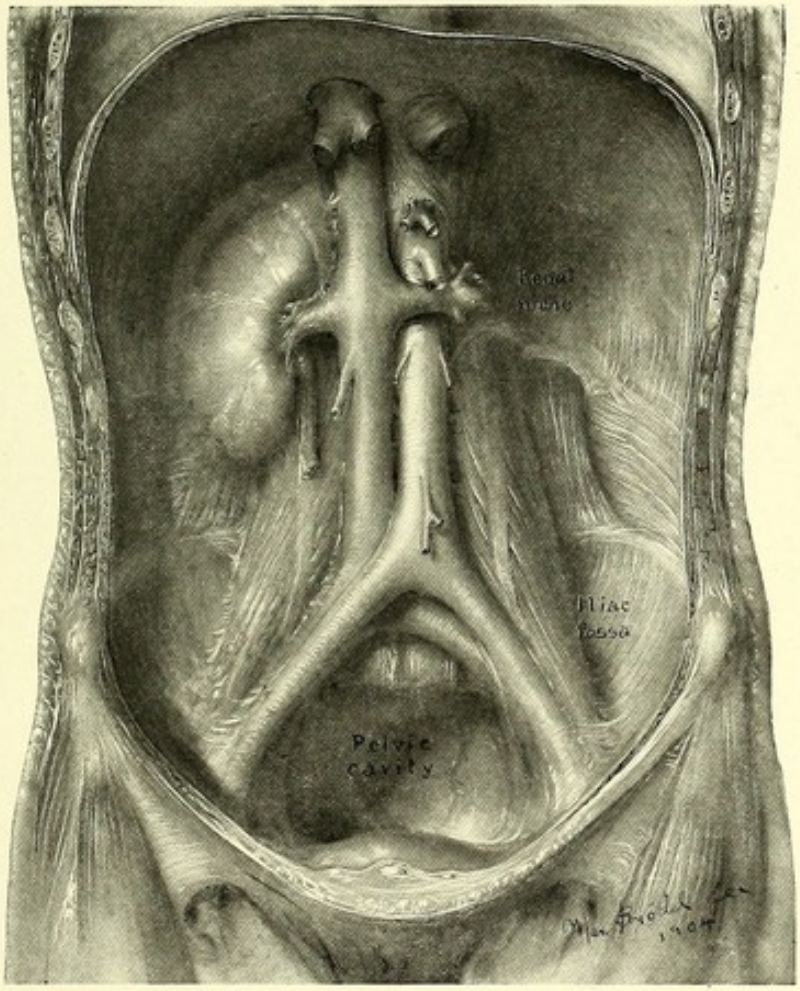

FIG. 321.—ABDOMEN SHOWING THREE MAJOR FOSSÆ, RIGHT AND LEFT ABDOMINAL, AND PELVIC.
The abdominal fossæ are subdivided into renal and iliac. In these fossæ fluids are prone to accumulate with the patient in recumbent position. (See p. 601.)

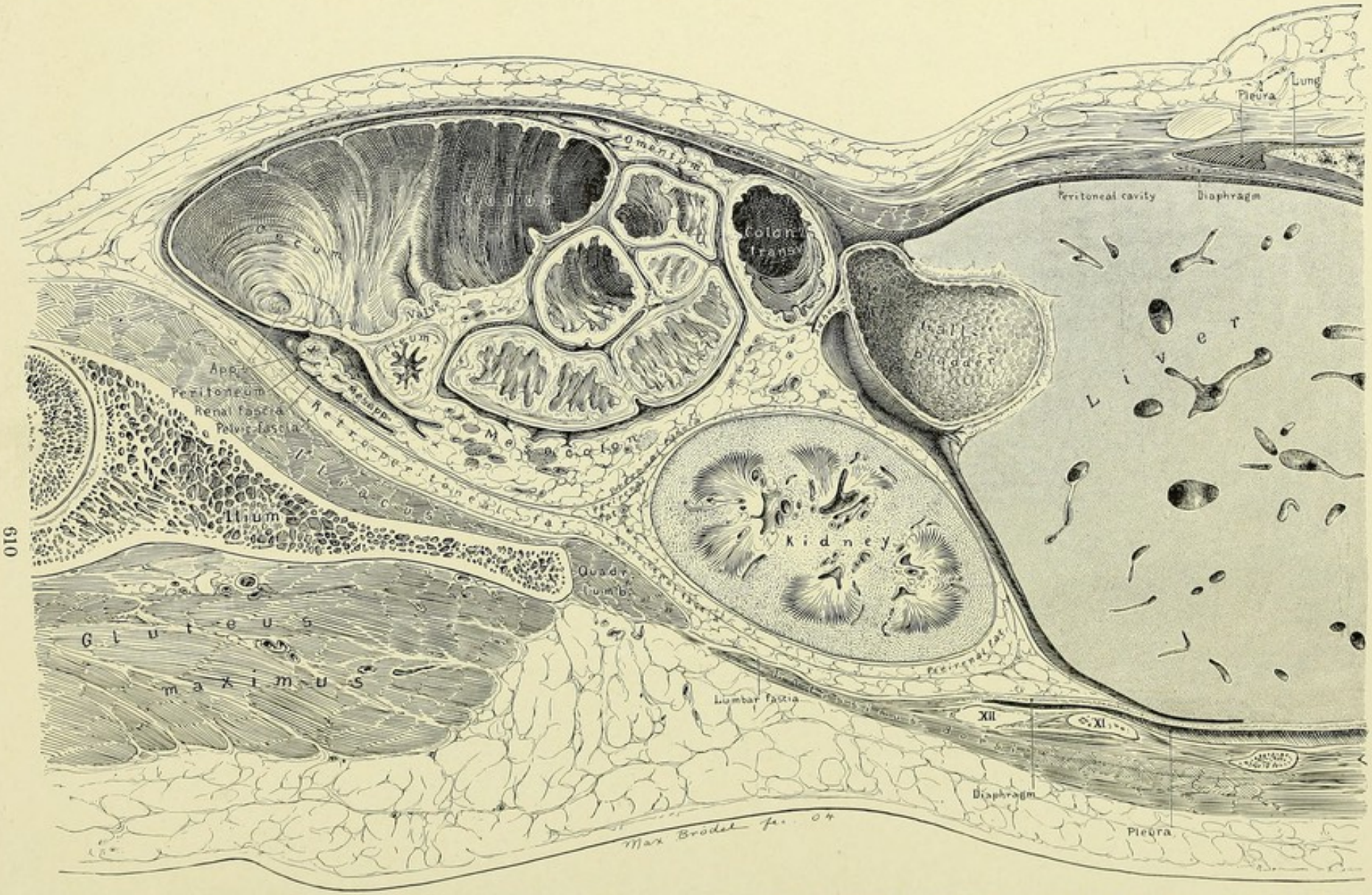

FIG. 322.—FROZEN SECTION (SAGITTAL) THROUGH THE MIDDLE OF POUPART'S LIGAMENT IN THE RIGHT MAMMARY LINE, SHOWING INTERIOR OF CECUM AND COLON WITH CECAL OPENING INTO APPENDIX AND SECTION OF APPENDIX AND MESAPPENDIX. (See p. 612.)

The picture shows well the position of the appendix upon an inclined plane formed by the posterior abdominal wall in the recumbent position. Fluid accumulating about the appendix, as may be seen from this section, following gravity, may take one of two courses: either pass in front of the renal fascia and so over and around the kidney to the under surface of the liver, where an infra-hepatic abscess may be formed; or, on the other hand, the fluid may perforate the renal fascia and follow the course of the retro-peritoneal fat behind the kidney up to the diaphragm, where it may penetrate the pleura through a weak space in the fibres of the diaphragm. The peri-renal tissues may be invaded in either of these directions. Gall-bladder cystic.

once be seen that an abscess starting below the mesentery will be prone to enter the pelvis and extend into the opposite iliac fossa, while an abscess on the outer side of the colon may readily extend upward into the region of the liver.

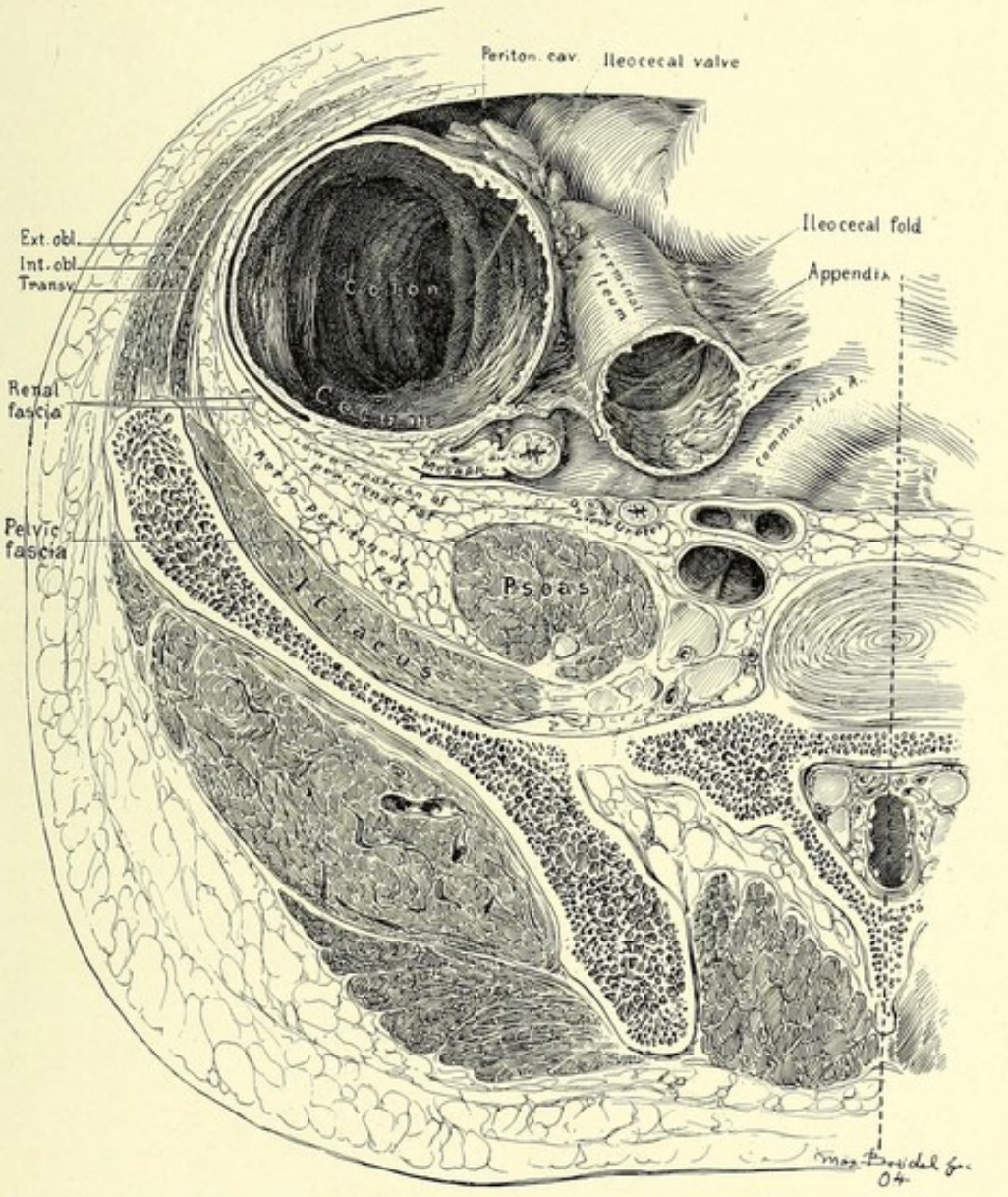

FIG. 323.—HORIZONTAL SECTION JUST ABOVE THE INSERTION OF THE APPENDIX, SHOWING THE RELATIONS OF THE APPENDIX AND THE TISSUES OF THE MESAPPENDIX TO THE FASCIÆ AND MUSCLES OF THE POSTERIOR ABDOMINAL WALL.

This figure also demonstrates the method of approaching an abscess about the appendix by an extra-peritoneal route. The section is made in a fat person, and therefore shows the individual layers of the fascia more widely separated than usual.

If we remove the intestines and study the configuration of the posterior abdominal wall, we find the various depressions shown in Fig. 321 (see p. 609), constituting niches in the body in which pus is apt to collect, forming well-

defined abscesses. There are, in general, three of these niches, the deep pelvic, and the right and left abdominal respectively, the latter of which may be subdivided again into iliac below and renal above.

The natural tendency of pus to gravitate upward as the patient lies recumbent will be best understood by consulting Fig. 322, where it is manifest that the posterior abdominal wall is disposed on an inclined plane at an angle of about 30 degrees. The upper course of the infection is facilitated not only by gravity, but by the natural drainage of the lymphatics in this direction.

Fig. 323 shows the natural tendency of an abscess to pour into the pelvis or to extend up under the layers of the mesileum, when the appendix is disposed as represented in the section. It is also evident from this figure that an infection perforating the posterior layers of the fascia is not only in a position to invade the upper region, as shown in Fig. 322, but to work downward under Poupart's ligament into the thigh.

REMOVAL OF THE APPENDIX IN SUPPURATIVE CASES.

One of the most important questions connected with suppurative periappendicitis (appendical abscess) is the treatment of the appendix itself. In most cases, especially where there is a large abscess, and the patient is exhausted by the disease, the best plan is simply to lay open the abdominal wall freely so as to drain off the pus, and to pay no attention to the appendix whatever. Treated in this way, the appendix is sometimes discharged as a slough when the dressings are changed, or as the wound is washed out. Or, if the appendix is not seen at any time, it may be so greatly obliterated by the disease, and so thoroughly incorporated in the scar tissue of the contracting abscess cavity that it causes no future harm. When the appendix is clearly exposed, or when it lies at some point where it can be reached without risk of opening the peritoneal cavity,—as, for example, along the posterior wall of the fossa, or behind or to the outside of the cecum or colon,—the surgeon may then cautiously expose the appendix from end to end, amputate and remove it. Not infrequently, however, in such cases, the sutures at the base, closing in the opening into the cecum, refuse to hold, and the result is a discharge of fecal matter onto the dressings, lasting for a few days or weeks, and finally disappearing spontaneously; a fecal fistula often follows the simple incision of an abscess, and closes without further trouble, after a short interval.

The alternative plan is that of hunting for the appendix in the abscess cavity or in its walls, even breaking up the adhesions which form the walls of the cavity in the determination to discover and remove the cause of the trouble. While there can be no objection to pulling out a loosened appendix when it appears sloughing and gangrenous, in common with other sloughing tissues, the practice, once so widely recommended by surgeons, more to be admired for their courage than their discretion, of "always removing the appendix," is to-day pretty

generally condemned, although a few excellent members of the profession still continue it.

It is encouraging to feel assured that when an appendix has gone so far as to produce an abscess in its neighborhood, it is itself, in most instances, so completely disorganized as to occasion no further trouble. The advantage of the simple incision with drainage is well shown by BARLING (*Lancet*, Feb. 22, 1903), who, in a series of 74 abscess cases, removed the appendix in only 25. The remaining 49 cases, where the appendix was left undisturbed were kept under observation, and in only one was there a recurrence of the disease; this one was then operated upon successfully. It is safe to assert that had the surgeon insisted upon finding and removing the appendix in the 49 cases, he would have lost a large percentage of them. I must add here, however, that there have been two fatal cases in the Johns Hopkins Hospital from a recurrence of the abscess after simple incision. The balance-sheet, however, may be said to be overwhelmingly in favor of drainage without extirpation, where the latter course presents any serious difficulty, or exposes the patient to the dangers of opening the free peritoneum.

JAFFÉ (*Berl. klin. Wochenschr.*, Dec. 14, 1903, p. 1148), out of 100 cases which were opened and drained, saw only 5 in which it was necessary to remove the appendix at a later date. The obliteration and destruction of the appendix which goes on concurrently with the formation of an abscess is, in his opinion, a strong argument for deferring operation in those cases where the inflammatory process is manifestly shut off from the peritoneal cavity, as evidenced by the wall of adhesion surrounding it on all sides as well as posteriorly, a wall "as sharply defined as the margin of the liver." He draws attention to the comparative advantages of the intermediate operation, pointing out that, if the operation is done before the suppuration of the entire exudate ("*Falls der Kern des perityphlitischen Exudats noch nicht eitrig eingeschmolzen ist*"), the operator is under the necessity of finding the appendix in the midst of adherent intestines and scattered deposits of pus, fibrin, and exudate, as there is under such conditions no assurance that the peccant organ will be so involved in the cicatrix during the healing process as to become harmless for the future.

NEUMANN (*Langenb. Archiv f. klin. Chir.*, 1901, Bd. 62, Hft. 3) advocates the plan of a secondary operation for removal of the appendix, after the draining of the abscess, claiming for it the following advantages:

1. The duration of the original operation, which occurs at a time when the patient is more or less exhausted, and when every effort should be used to sustain vitality, is much shortened.

2. It prevents an already existing peritonitis from spreading, and avoids exciting a fresh peritonitis by exposing closed peritoneal surfaces.

3. The appendix can be removed at the secondary operation close to the cecum, while the patient is in good condition and the absorbing power of the peritoneum possesses its normal activity.

4. Adhesions are easily freed and the formation of fresh ones avoided.
5. The risk of ventral hernia is greatly lessened.

When the appendix exceeds the normal length, and the diseased area is situated in the tip, the location of the abscess may be more or less distant from the usual site of an appendix. The same unusual location is found when the position of the appendix is abnormal from congenital displacement of the caput coli, especially when the latter is high up behind the liver; or when a previous attack of inflammation, resulting in contraction, causes upward displacement of the cecum.

TREATMENT OF ABSCESS.

Evacuation.—The best place to open an abscess is at the site indicated by nature through swelling and tenderness. A free incision should be made over the location of the pus and rather to the outside, near Poupart's ligament, or the spine or crest of the ilium, and in the direction of the external oblique muscle. Edema of tissues under the skin, or beneath the muscles is an indication of pus near at hand, a little deeper in. It is a good plan to pull the muscles widely apart without cutting them, and then to open the abscess by a blunt dissection; if it is large enough to need a freer avenue of drainage, an incision can be made, both up and down, through the entire thickness of the abdominal walls. Fig. 324 shows Weir's method of securing a large opening through which an abscess or other complication may be dealt with without embarrassment (*Trans. Congrès internat. de méd.*, Paris, 1900, p. 801). Doughty's method (*personal communication*) of securing a larger avenue of approach and a better opening for free drainage is seen in Figs. 325, 326, and 327.

It is sometimes very difficult to recognize the peritoneum if it is adherent, and the surgeon should then use a fine needle or the point of a knife to enter the abscess, introducing a pair of artery forceps with closed blades as soon as the pus appears, and spreading the blades apart after they are inserted; the forceps is then withdrawn and the fingers inserted, in order to keep the hole widely open, and give the pus free exit. If there is any suspicion of the peritoneum, it is best to work carefully backward on the outer side toward the flank in order to open the abscess without disturbing the peritoneum (see Fig. 328, p. 617). If the unopened peritoneum is found freely movable over the mass, the surgeon has a choice between several plans of procedure. First, the peritoneum may be gently pushed toward the median line, until the mass is reached extra-peritoneally, as just described. Second, the mass is reached extra-peritoneally in a similar manner, after it has first been thoroughly explored through an incision opening into the peritoneal cavity; this opening ought to be closed before breaking into the abscess from the lateral extra-peritoneal route; such an opening clears up the diagnosis as to the extent of the trouble and points out the safe

way for the evacuation. Third, the abscess may be emptied trans-peritoneally (see Fig. 329, p. 617). This last method gives visual command of the field, and better control of all possible conditions and complications that may arise, and for many cases with abscesses awkwardly disposed toward the interior of the abdomen, it is the plan to be preferred. It is contraindicated for very weak patients,

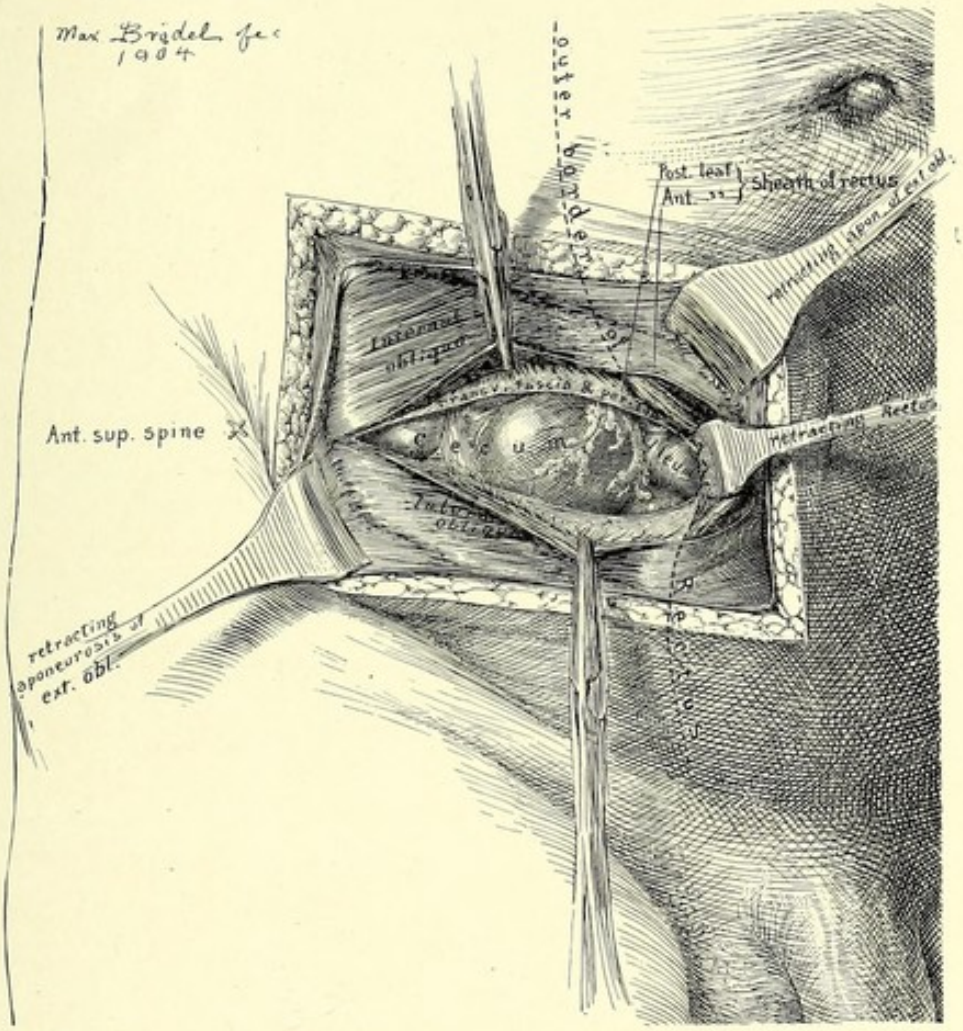

FIG. 324.—WEIR'S INCISION FOR THE PURPOSE OF ENLARGING THE MCBURNEY OPENING WITHOUT DIVIDING THE MUSCLES.

The skin incision and the separation of the external oblique fibres are made obliquely downward across the semilunar line. The rectus, with the epigastric vessels, is thus exposed and can be retracted. The internal oblique transversalis and posterior lamella of rectus sheath with the peritoneum are then divided, giving abundant room, as shown, for dealing with complication. The figure does not represent the maximum space which can be secured by drawing the transversalis fascia strongly up and down.

whose vitality is better conserved by a simple extra-peritoneal evacuation of the pus. For such a trans-peritoneal treatment a long vertical incision is made, either near the rectus or through its fibrous sheath, so as to deliberately expose the mass on the median aspect. The swelling is then carefully outlined by sight and touch, and then an efficient, protective barrier is formed about the

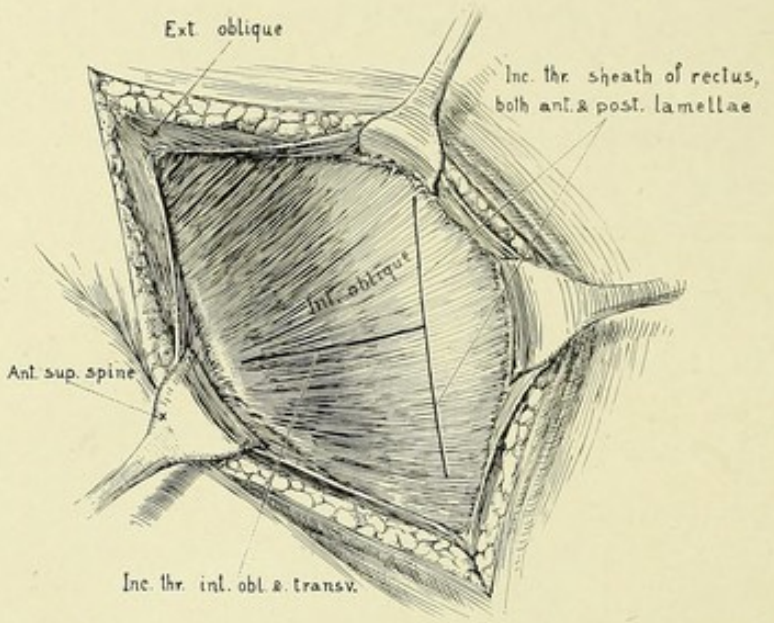

FIG. 325.—DOUGHTY'S METHOD FOR SECURING MORE ROOM IN ABSCESS AND OTHER DIFFICULT CASES.

The incision is made in the skin in an oblique direction. The external oblique fibres are then separated, and afterwards those of the internal oblique and transversalis. This opening is enlarged with scissors until the edge of the rectus is exposed. The layers of the sheaths of the rectus are then cut up and down, as indicated.

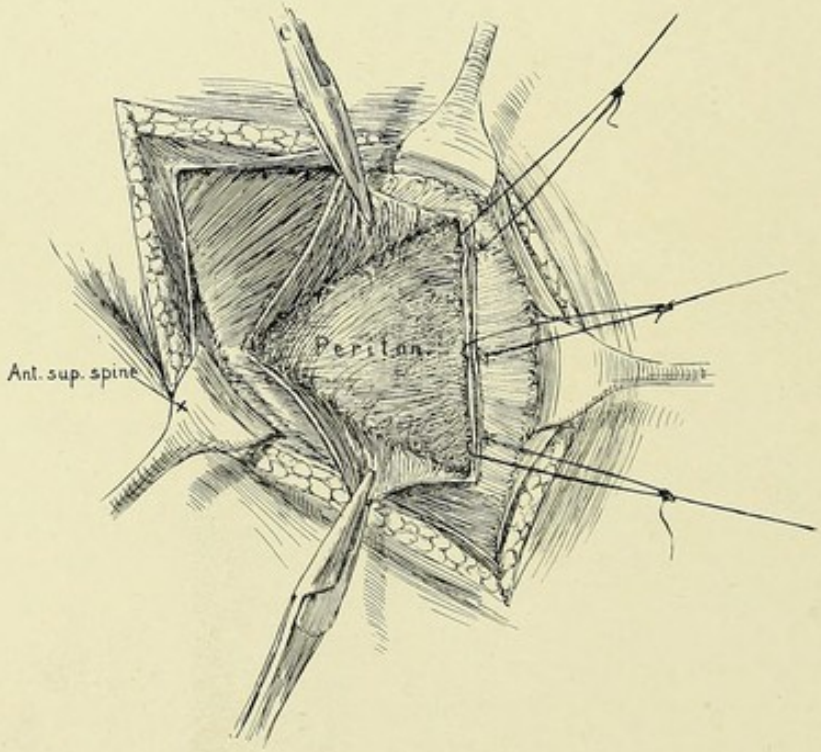

FIG. 326.—THE TRIANGULAR FLAPS THUS FORMED ARE DRAWN UP AND DOWN, GIVING A WIDE AREA OF EXPOSURE TO THE PERITONEUM.

If the wound is to remain open for packing, the several structures are identified by loops of silk.

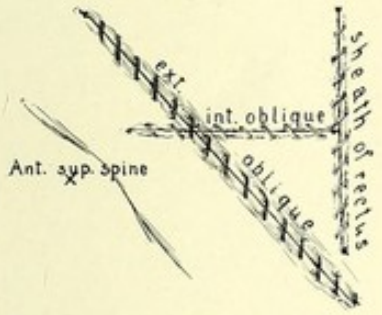

Fig. 327.—Doughty's Method Shows the Complete Closure of the Wound and the Relations of the Lines of Suturing.

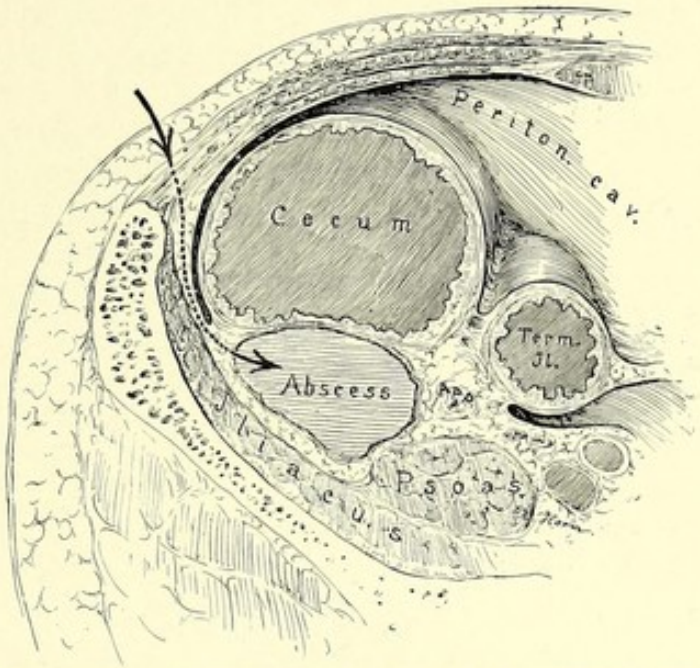

Fig. 328.—Diagram Showing the Method of Approaching the Abscess by the Extra-peritoneal Route. (See p. 614.)

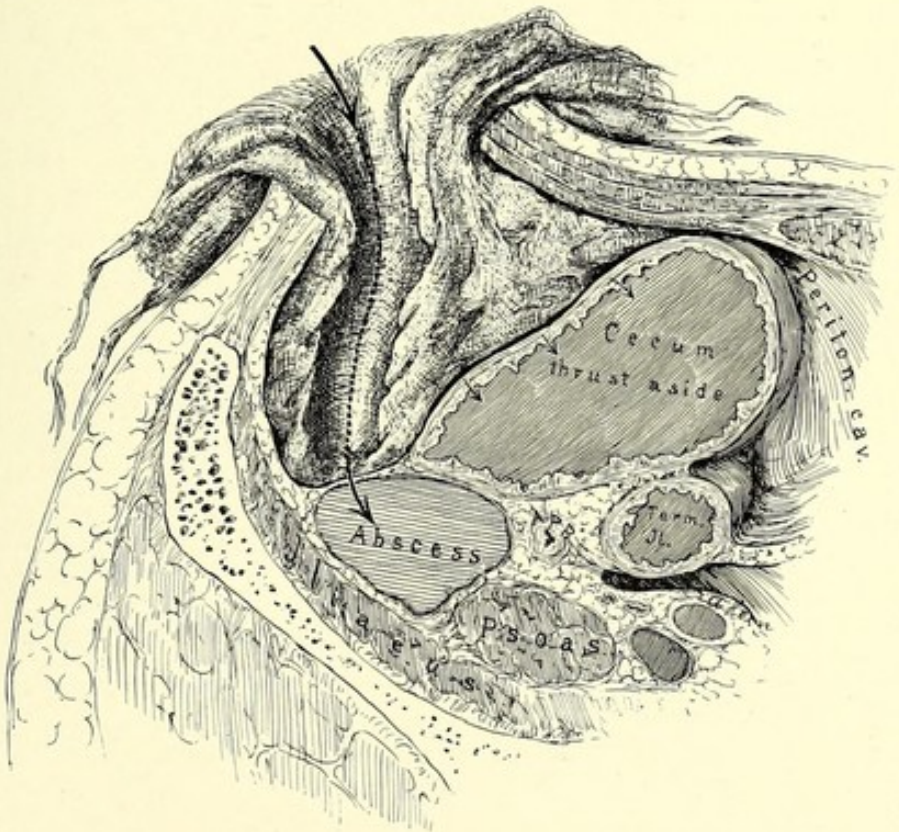

Fig. 329.—Shows the Transperitoneal Method, Packing off the Uncontaminated Peritoneum on all Sides in Order to Approach, Evacuate, Clean out, and Drain the Abscess by this Route.

mass, by means of pads of folded gauze, which holds back every loop of the healthy bowel, and protects the abdominal cavity above, toward the middle

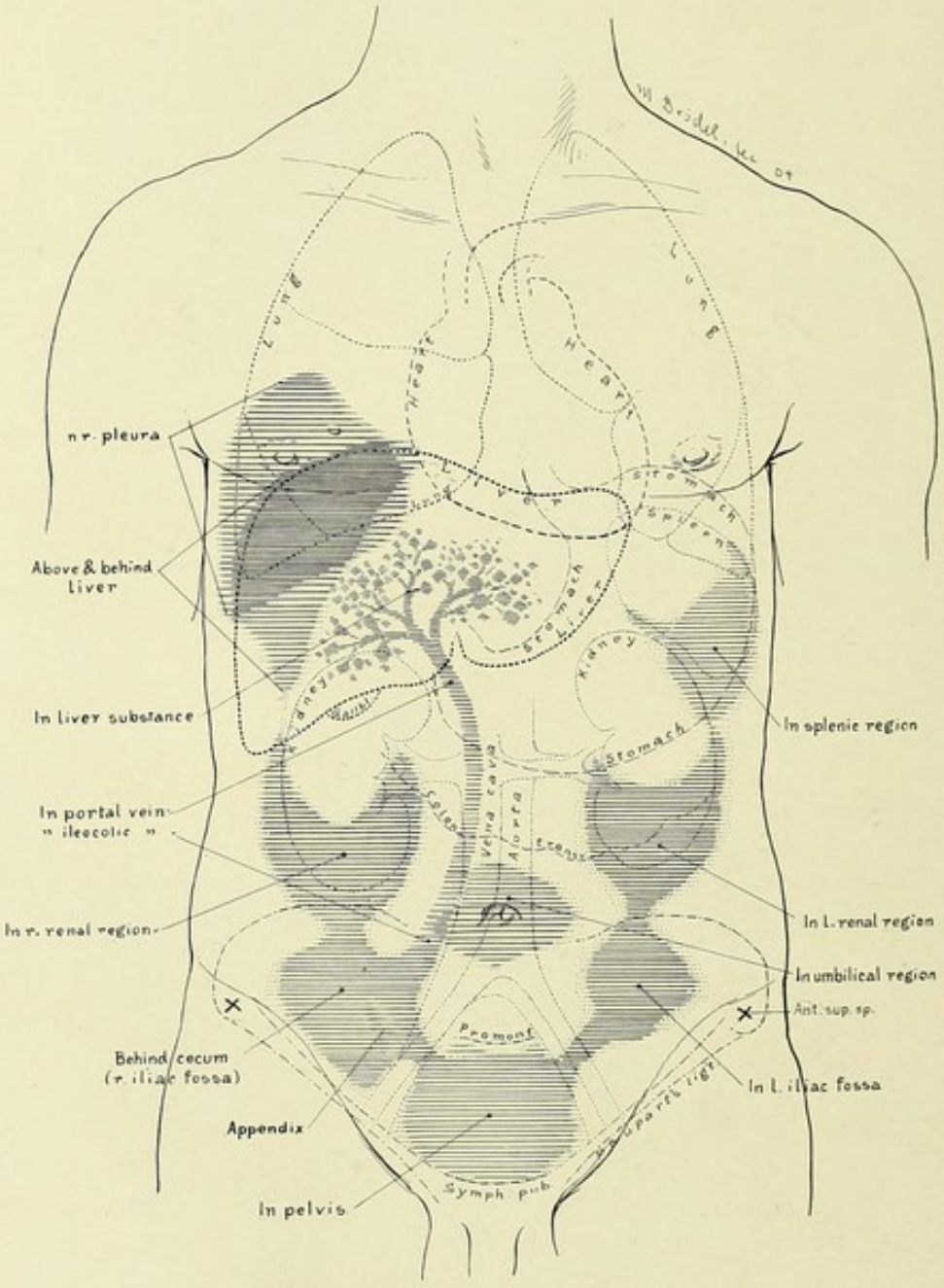

FIG. 330.—SHOWING THE VARIOUS SITES AT WHICH ABSCESSES ARE MORE COMMONLY FOUND.

The appendix is seen below on the right in the centre of a chain of abscesses which extend upward on the right into renal region, supra-hepatic and right pleural, or into the liver by portal vein. The extension up the left side is usually effected by traversing the pelvis, the left iliac fossa, and the left renal fossa. Occasionally the abscess is found located among the intestines in the neighborhood of the umbilicus, and, rarely, in the splenic region.

line, and in the true pelvis. Before opening the abscess a few large strips of dry iodoform gauze may be loosely laid about the point of evacuation. The

cecum is carefully raised, and as the pus appears it is taken up with small sponges. The iodoform strips may be removed and replaced as rapidly as they are soiled. When all the pus and fibrin that the gauze sponges will remove have been taken up, the appendix is dealt with as best suits the case. After its exposure, a large abscess is often best treated by aspiration, to take off the tension and the excess of pus; it may then be opened and cleaned, the appendix being removed, if it is accessible. Other foci of pus should then be carefully evacuated in the same way.

If a second mass is found in the lumbar region or in the pelvis, it may be best to make a separate incision or a counter-opening at the nearest point on the abdominal wall. In women, vaginal puncture and free drainage are often most useful, and in men a similar puncture through the rectum is occasionally of great service.

After evacuating all pus and thoroughly opening and cleansing the cavities with dry gauze, the infected areas should be loosely packed with washed-out iodoform gauze (SÄNGER). The protective gauze pad may then be withdrawn, and the wound closed with a wide opening for the exit of the iodoform gauze. After emptying the right iliac abscess, the surgeon must carefully palpate the adjacent accessible regions, within the limits of safety, in order to discover any communicating or secondary abscesses, which may be found at any of the points shown in Fig. 330. He should also bear these regions in mind throughout the convalescence.

Cleansing the Abscess Cavity.—Too much stress cannot be laid upon the necessity for care and dexterity at this stage. WALSHAM (*Treatise on Appendicitis*, 1901, p. 22) cites a good example of the harm which may result from any but the gentlest manipulation. A boy, aged seventeen, was admitted to hospital with acute appendicitis, on the seventh day of the disease. An incision, about one and a half inches long, was made just above the outer part of Poupart's ligament, and a localized abscess containing two ounces of pus was opened. A finger was then introduced to explore the abscess, and the latter was washed out. The temperature and pulse both rose gradually after the operation, the patient became very restless and died on the second day. The postmortem, which showed that the appendix was ulcerated and contained a concretion, also showed that a hole had been accidentally made through the adhesions into that part of the peritoneal cavity which had been previously healthy, and that through this hole, pus and lotion had been injected into the general peritoneum, thus setting up septic peritonitis! After the abscess is evacuated and wiped dry, it is often advantageous, especially if the cavity is a small one, to sterilize it as thoroughly as possible. This may be done by means of a strong antiseptic solution applied for a brief space of time and wiped off. For a small abscess pure carbolic acid is most efficient, applied on a little pledget of cotton, care being taken that no excess of acid is allowed to run over the adjacent tissues; if this is followed by an application of pure alcohol, no harm ought to result

from its escharotic tendency; great caution, however, must be used, in the proximity of the iliac vessels, or in applying it on the bowel. This form of treatment is best suited to small indurated cavities containing a little pus, which are attached to the cecum, lie behind it, or are lodged in the true pelvis. Large abscesses I swab out with a solution of mercuric chloride (1 : 1000), or a solution of formalin followed by plain water. Fetid abscesses may be cleansed with peroxide of hydrogen.

Drainage.—An abscess cavity should never be disinfected and closed without drainage. When there has been much pus, a large opening ought to be left for free drainage; but before the drain is inserted, the relations of the abscess must be studied, and pressure made upon it in various directions, in order to ascertain that there is not some other cavity communicating with the primary one. If there is, it should be explored to its bottom, and, if it extends into any other dependent position, such as the right renal region, or the floor of the pelvis, a counter-opening should be made there also. The pelvis, in particular, should be carefully explored, to discover a possible hour-glass abscess, that is to say, an abscess of the iliac fossa communicating with the pelvis, often by a narrow and almost imperceptible orifice or channel, which is one of the most dangerous of all forms of secondary abscesses. Douglas' *cul-de-sac* should always be explored, when there are no adhesions to contraindicate it, by the introduction of gauze on a probe.

The essential points to be remembered in drainage are these:

The drain is only a drain to a limited extent and for a short time; it acts chiefly as a protective pack.

It is essential that the whole septic area should be drained.

The drain must be loose in order that it may absorb rapidly. It must never be firmly packed.

The drain must have exit through a large orifice.

Whenever possible, the drain must be to an orifice in a dependent position.

The drain must be watched, and as soon as it ceases to discharge it must be loosened or wholly withdrawn.

In a small abscess it is sometimes best to leave the drain in for a week. Fatal infection has occurred from removing it too soon and thus breaking up protective adhesions.

One of the most dangerous forms of abscess is that in which there is a small accumulation of pus, it may be not more than a few drops, walled off about the tip of the appendix. Such cases are oftenest found at the tip of an appendix dipping into the pelvis; Fig. 331 represents one of these abscesses high up in the neighborhood of the hepatic flexure. The danger lies in the fact that the operator is tempted either to cleanse the cavity and close it entirely, or to attempt to get along with insufficient drainage by a long and circuitous route. It is imperative that operators should confer upon these minute abscesses all the dignity of the larger form, treating them with the most extreme care to

avoid any contamination of the peritoneum, sterilizing the cavity with painstaking care, introducing an abundant gauze drain, which should be left in for five or six days, and, lastly, draining onto the surface by the most direct avenue, even if it is necessary to make an additional incision, or to enlarge the incision already made. Fig. 332 shows the cause of the minute abscess, namely, a pin-point perforation of the tip of the appendix.

The best material for drainage is washed-out iodoform gauze, used in strips two or three inches wide and about twenty inches long, and in two or three thicknesses. Before introducing the drain, all sound bowel should be lifted up *en masse* to one side, and held off from the abdominal parietes; then, with the abscess cavity freely exposed, it is loosely filled with strips of gauze. If

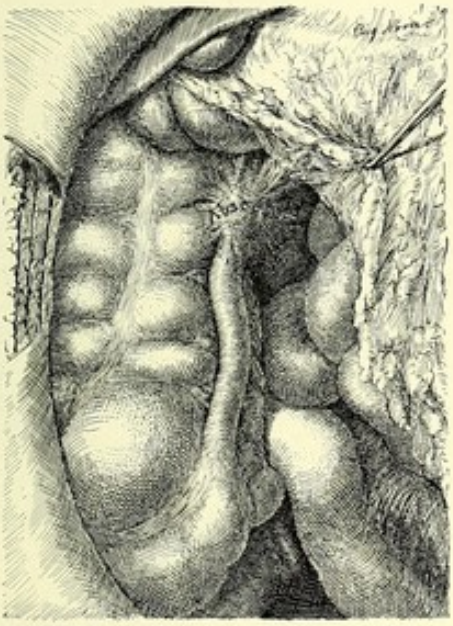

Fig. 331.—Downes' Case Showing the Unusual Location of the Abscess high up to the Inner Side of the Ascending Colon, Covered by the Omentum. Recovery.



Fig. 332.—Downes' Case of Pin-point Perforation. a, of the Tip of the Appendix; b, Ragged Area of Adhesions Walling off Abscess. (Natural size.)

the abscess is in the pelvis, it should be loosely stuffed on all sides, in such a manner that the sound bowel rests upon the gauze. Great care must be exercised in introducing the gauze, for many cases have been lost from a kink in the bowel after operation resulting in an obstruction. According to Halsted, a small drain may be more effective in causing the kink than a large one. The packing should always keep the intestines away from the drainage area as one solid organ, and the gauze must not be left among the coils. For this purpose "the cigarette drains" used by Morris and by Warren (see p. 653) are very satisfactory.

The size of the drain must depend upon the nature of the infection. During operation a smear should be taken, and if nothing is found except the colon bacillus there is no reason for special caution; if, however,

the streptococcus or staphylococcus is present, there must be a wide drain with everything left open. The drain may remain untouched from five to seven days, or longer, provided the patient is improving. As long as there is a free flow from the wound, it need not be disturbed. It should not be removed on account of an elevation of temperature during the first day or two, when the patient is otherwise doing well, as this is usual.

In removing the gauze, it is well to use traction forceps in order that it may be drawn out steadily and slowly. If there is much pain in doing this, nitrous oxid gas may be administered. The second tampon should be much smaller than the first, in order to favor the collapse of the abscess cavity. The external skin opening of the drain must always be kept freely open, and the gauze should never be allowed to plug the orifice and bottle up the secretions. If necessary, a hot saline poultice may be used to soften the gauze and facilitate its removal.

TREATMENT OF ABSCESS IN SPECIAL CASES.

In some unusual cases I have adopted the plan of opening the abdomen in the median, right, semilunar line, and then, when the abscess is located, and found accessible by an extra-peritoneal route, I have made a second incision in the skin, close to the crural arch (Fig. 333), or to the spine of the ilium, and worked up beneath the peritoneum until the abscess was reached and evacuated, one hand acting through the second incision, and being guided by the other hand and the eye acting through the first (Fig. 334). After evacuation of the abscess, every adjacent part must be examined by bimanual palpation with the hand inside to discover any remaining foci of pus. The clean abdominal wound must then be closed by an assistant who has not been contaminated, or, if it is done by the operator himself, he must first change his glove; the lateral incision is left open for drainage.

The most favorable of all abscesses are those encapsulated in the omentum (see Figs. 335 and 336, pp. 625 and 626), and in some such cases it is possible to excise the whole abscess cavity enclosed in the omentum, and close the wound without drainage. Van Hook, on opening the peritoneum in a case protected by the omentum, found a layer of it lying between the tumor and the abdominal wall. He stitched the omentum to the parietal peritoneum, and the next day he opened the pus cavity. The patient made a good recovery.

Abscess Connected with a Gangrenous Appendix.—Terrier, who has insisted with great emphasis (*Rev. de chir.*, Jan., 1900) upon the importance of certain anaërobic bacilli as a causative factor in some of the worst forms of appendicitis, especially the gangrenous, points out that the suppurative processes due to these bacilli can be recognized by their extreme fetidity, and that they rapidly produce the gravest lesions. The temperature in a case of this kind is apt to be low, while the pulse runs up, it may be as high as 140, and the case presents all the appearance of a rapid and grave intoxication.

Terrier anticipates that the study of this new class of organisms in their relation to appendicitis will disclose a near connection between clinical forms of appendicitis and the bacterial agents at work in their causation. He also believes that the local phenomena in such cases as he describes will eventually be shown to depend upon the specific infection rather than upon special anatomic considerations (*"Recherches sur quelques microbes strictement anerobic et leur rôle dans pathologie," Arch. de méd. expér.*, July, 1898, p. 517). The under-

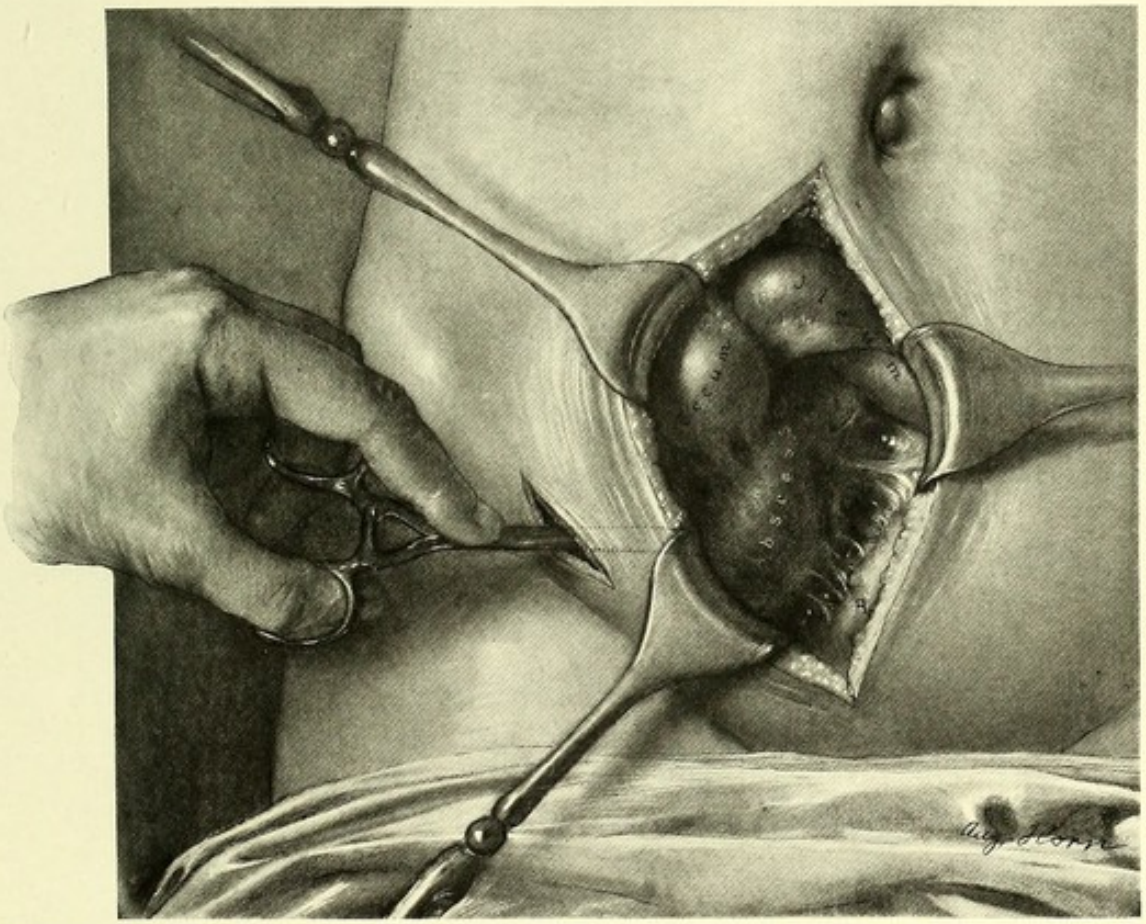

FIG. 333.—SHOWS THE METHOD OF EXPOSING AN ABSCESS BY AN INCISION IN THE RIGHT SEMILUNAR OR MEDIAN LINE AND THEN OPENING AND EVACUATING IT EXTRA-PERITONEALLY BY A SECOND SMALLER INCISION IN THE RIGHT LOIN.

standing of the anaërobic nature of some of the worst infections leads to one deduction of great practical importance, namely, the necessity in such cases for opening the wound largely and using peroxide of hydrogen in dressing all infected parts. In one of the cases cited by Terrier, where there was a fetid suppuration and sloughing of the whole appendix due to anaërobic infection, a gangrenous phlegmon was found in the abdominal wall, and the patient's life was only saved by extensive incisions in the tissues, begun at the earliest possible moment and repeated several times in the effort to combat the rapidly

invading gaseous gangrene. The necrosed cartilages of several ribs had to be resected in treating the last focus of suppuration. Peroxide of hydrogen was repeatedly and extensively used in association with the aggressive surgical treatment.

Another dangerous, but fortunately rare form of abscess, is that occurring

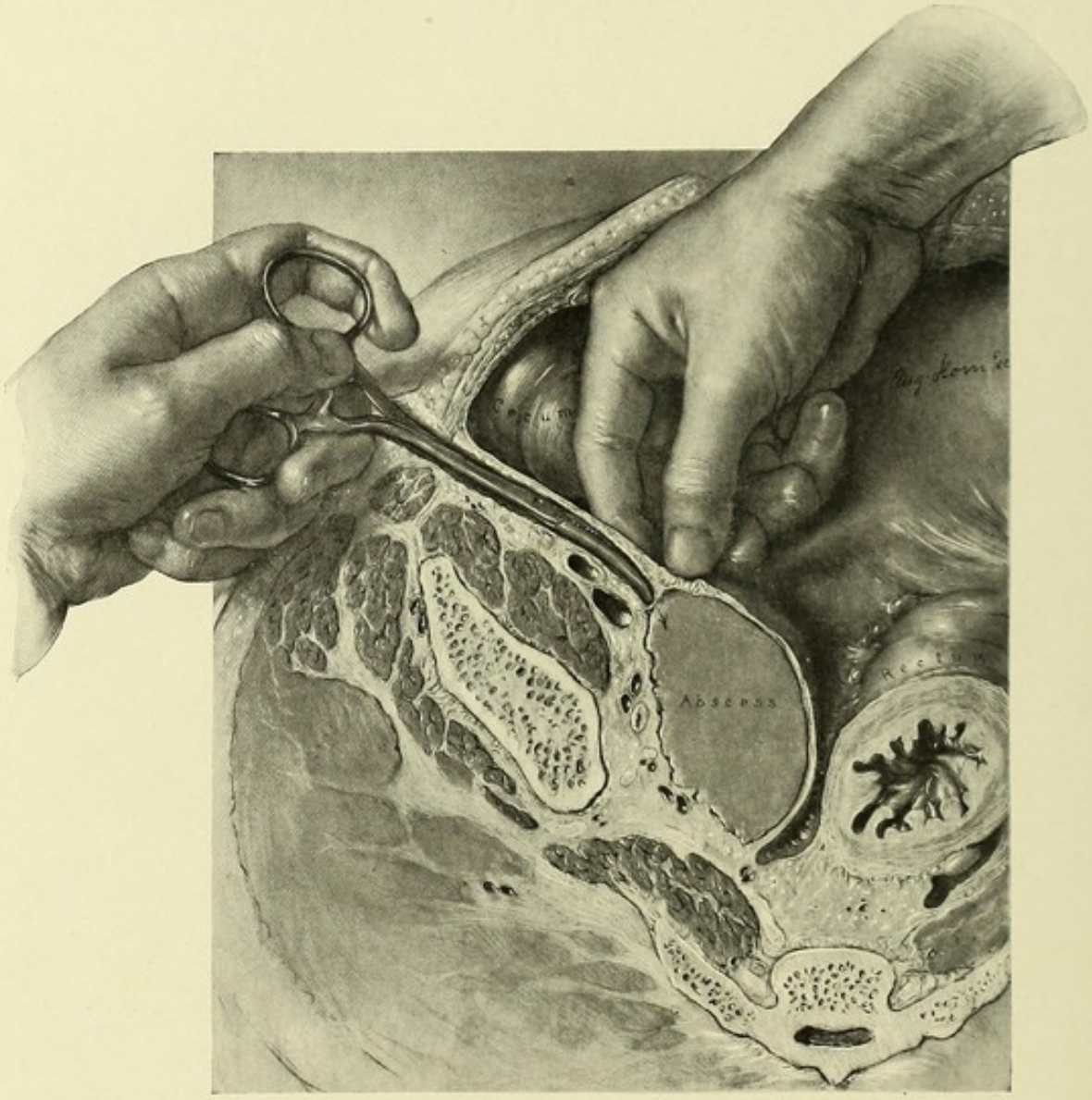

Fig. 334.—Shows the Hand within the Abdomen Guiding and Controlling the Forceps in the Act of Opening and Evacuating the Abscess through the Lateral Incision.

between the layers of the mesentery of the small intestine. An interesting case of the kind is reported by J. C. Bloodgood (*Jour. Med. Sci.*, 1903) in which the appropriate treatment is incidentally demonstrated.

The patient, a little girl, eight years old, was taken ill with severe abdominal pain referred to the umbilical region, without nausea and vomiting. The tem-

perature was 101° F.; the pulse 110; the respiration 24 to 30 and chiefly thoracic. The abdomen was slightly distended; both recti were rigid; there was muscle spasm in both iliac fossæ, slightly more marked in the right. In the umbilical and upper

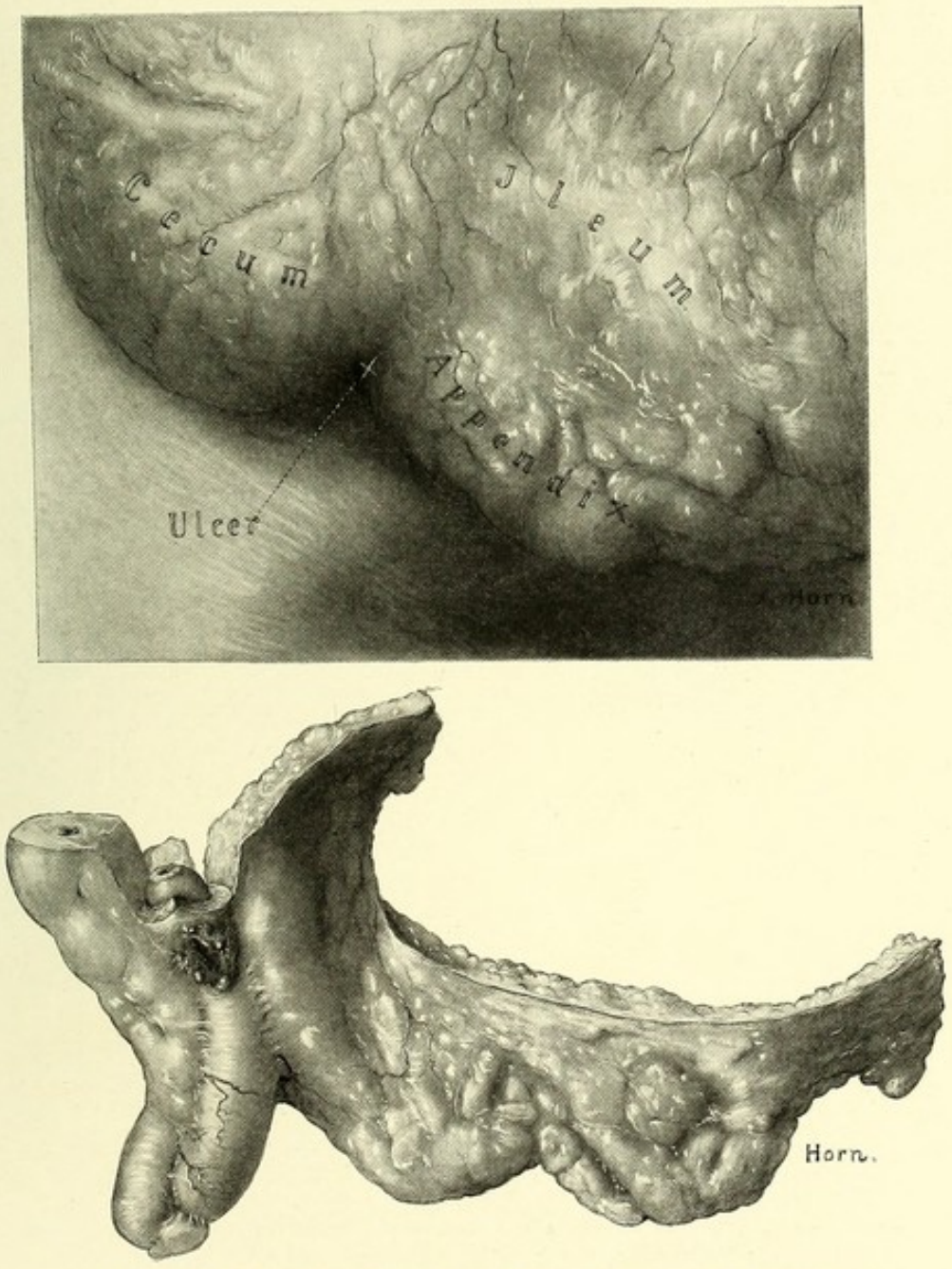

FIG. 335.—APPENDIX AND CECUM ARE WRAPPED IN OMENTAL ADHESIONS.
The lower figure shows the perforated appendix removed with the attached omentum. A., San. No. 1314. March, 1902. Recovery. (Natural size.) (See p. 622.)

hypogastric regions the percussion note was a little duller, and here the pain and tenderness were most acute. There were no symptoms of obstruction. Under anesthesia a tumor the size of two fists could be felt in the middle zone of the ab-

domen. On section of the abdomen, a mass was found beginning at the cecum and extending to the third lumbar vertebra, between the folds of mesentery. There was sufficient exudate in the mesocolon at the junction of the cecum, ileum and appendix to obliterate the appendix. There was no exudate in the mesocolon behind the cecum. A large abscess cavity was found between the folds of the mesentery extending toward the vertebral column. The intestines were pushed

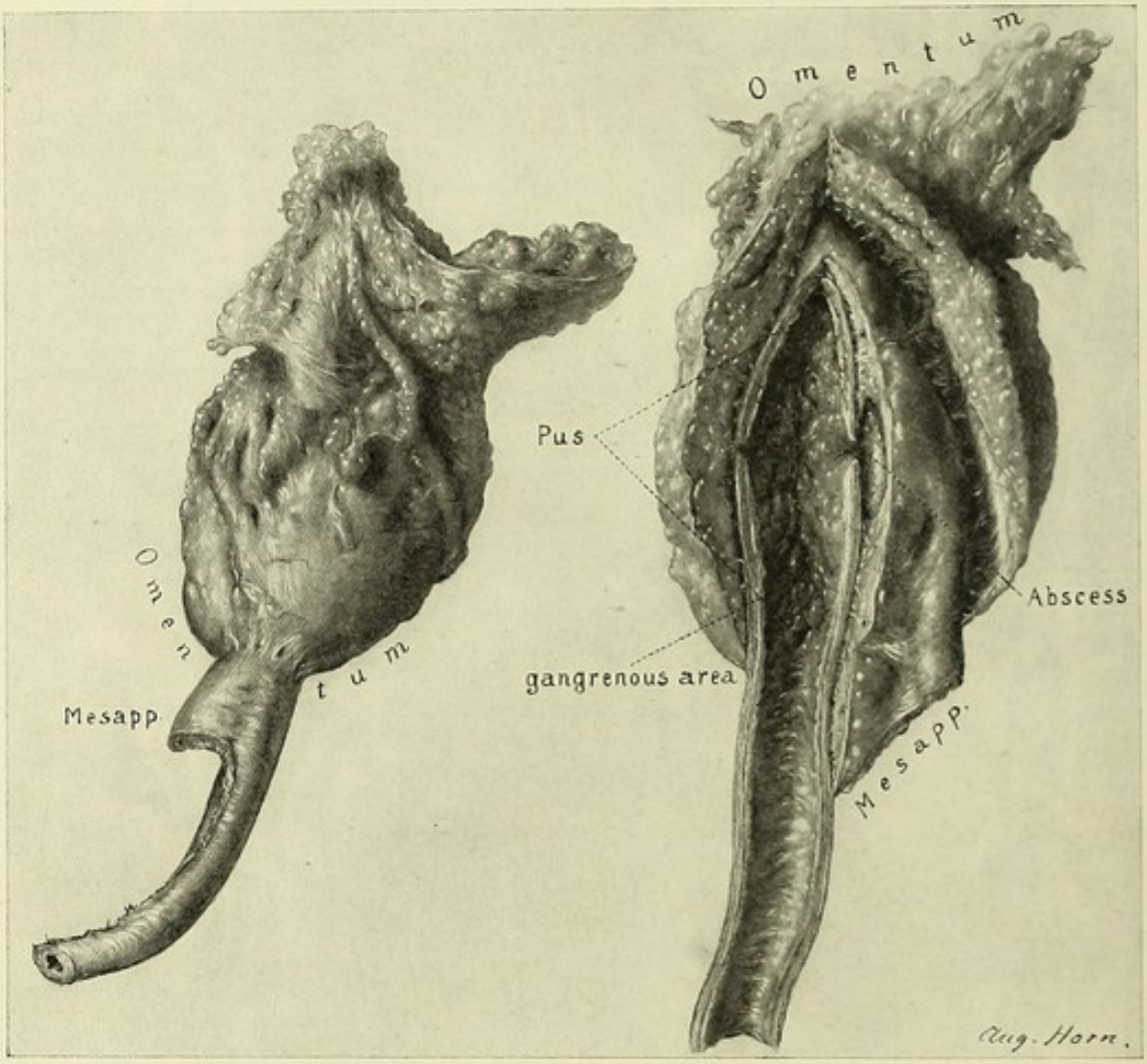

FIG. 336.—FOLLIS' CASE. GANGRENE, ABSCESS, AND PERFORATION OF THE APPENDIX AS SEEN IN THE RIGHT-HAND FIGURE, COMPLETELY ENVELOPED AND PROTECTED FROM PERITONEAL CAVITY BY OMENTUM AS SHOWN IN LEFT-HAND FIGURE.

The omentum formed a tight constricting neck around the appendix beyond the disease. R., boy thirteen years. Nov. 23, 1903. Recovery. (Natural size.) (See p. 622.)

aside, the peritoneal cavity walled off with gauze, and the abscess drained. Obstruction developed, however, from the firm packing of the gauze, and in a second operation an unsuccessful attempt was made to drain through a second incision to the outer side of the cecum. In removing some of the primary packing of the abscess cavity, several round worms were extracted. A loop of presenting small intestine was then opened, and after gas and thin fecal matter had been evacuated, a fecal

fistula was established. It was finally found possible to establish a permanent intestinal anastomosis, and the patient eventually recovered completely, although there were a number of very distressing symptoms, in particular those of starvation, owing to the high opening in the small intestine, while associated with these, there was marked mental disturbance, during which the child had to be restrained by a strait-jacket.

PELVIC APPENDICAL ABSCESS.

ARCHIBALD (*Montreal Med. Jour.*, 1890, p. 81), in 22 cases of abscess originating in the appendix, found 7 situated in the pelvis. ROTTER (*Dtsch. med. Woch.*, 1890, No. 39), out of 132 abscesses starting in the appendix, found 40 which were pelvic, and of these 40 cases, there were 27 in which the appendix itself was located in the pelvis. In 21 cases out of the 40, the pus was situated in the pelvis alone, while in the remaining 19, the pelvic abscess was associated with an extension into other regions. Out of the 21 cases in which the abscess was confined to the pelvis, there were 7 in which it was concealed in the true pelvis, and not perceptible to abdominal examination, but in 14 cases it could be felt through the abdominal walls. In the 19 cases of pelvic abscess with extension, the right iliac fossa was the seat of the second abscess 14 times, and in every instance the iliac abscess was isolated from the pelvic. In 3 cases the extension of suppuration was into the left iliac fossa. Out of 24 pelvic abscesses collected by BÉRARD and PATEL, the suppurative process was confined to the pelvis in 11 cases: in 7 there was an avenue of communication between the iliac and pelvic abscesses; in 4 the pelvic suppuration was secondary to iliac abscess; and in 2 there was a pelvic abscess with bilateral iliac diverticula. Bérard and Patel divide these pelvic abscesses into two classes: the p e r i - a p p e n d i c a l, in which there is a direct connection with the abscess surrounding the appendix; and the p a r a - a p p e n d i c a l, in which the appendix is situated above the pelvic brim, and has no apparent direct communication with the abscess.

Sometimes there are two abscesses, one surrounding the appendix on the iliac fossa, and another filling the pelvis; these may be entirely distinct from each other, or they may communicate more or less freely over the brim of the pelvis under the adherent coils of intestines. A. C. BERNAYS, of St. Louis, has employed a method which throws light on the mode of origin of pelvic abscesses. In an incipient peritoneal infection without pus, he always introduces a long glass pipette as far as the floor of the pelvis and catches the secretion from there, in which he almost invariably finds abundant bacterial flora, which develop on suitable media.

BROCA (*Bull. méd.*, June 29, 1901, p. 589) distinguishes two sorts of abscesses under the title s u p e r i o r and i n f e r i o r p e l v i c. S u p e r i o r p e l v i c a b s c e s s e s start near the superior strait, in which situation they may be quite out of reach in an examination through the

abdomen, or by the rectum. Later on, as they develop, they become iliac, or again pelvic, or at once both iliac and pelvic. Inferior pelvic abscesses cannot be detected by an examination from above, but they are perceptible to the rectal touch, as they generally lie in close association with the anterior wall of the rectum. In rare instances the sigmoid flexure lies between such a collection of pus and the rectal wall. These pelvic abscesses are walled off from the general peritoneal cavity by a layer of adhesions uniting the small intestines one to another.

Sometimes after the disappearance of an acute appendicitis, rectal palpation reveals a line of infiltration against the pelvic wall, and possibly a very tender spot in the wall of the bowel. The patient may also complain of severe pain on straining in the evacuation of the bowels. These signs point to an appendix hanging over the brim into the pelvis, and attached to the rectum.

Symptoms.—The special symptoms of pelvic abscess are radiation of the pain down the right leg, McBurney's point being generally painless, as the pus is located lower down; but most characteristic of all, are the signs of pelvic peritonitis, consisting of vesical and rectal disturbances. The vesical disturbance sometimes amounts to little more than frequent or painful micturition. In other cases there is decided tenesmus, noted soon after the beginning of the attack. Retention of the urine has also been observed in some instances. Rectal tenesmus is a frequent sign, beginning generally on the second day and lasting for a short period. In some cases there is a discharge of mucus by the rectum. In two instances a diagnosis of nephritic colic has been made on account of the pain radiating down the inguinal region and into the testicle ("*De l'appendicite pelvienne,*" Chevalier, Paris, 1900). In another instance anuria coexisting with tenesmus and hypogastric swelling gave rise to a diagnosis of retention of urine. An important means of recognizing the involvement of the appendix is through the radiation of the pain toward the umbilicus, when pressure is made over the position of the diseased appendix.

Treatment.—The recognition of pelvic abscess is essential to its proper treatment and is, therefore, of great importance. One of the most important avenues for opening, evacuating, and draining an abscess in the region of the appendix is through the rectum. The rectal passage is a particularly satisfactory method in men, in young women, and in children, and is especially suitable in all cases of large pelvic abscess filling the pelvis, as well as in all those in which an abscess actually points in the bowel. In advanced cases rectal evacuation has the advantage of causing little shock to the patient, while at the same time it offers the greatest of all desiderata, namely, an opening at the bottom of the area to be drained; whenever it is possible, by making an opening posterior to the cervix uteri or into the rectum, to secure drainage in a dependent position, the abscess will be better drained than when the opening is made above, through the abdominal wall.

In a married woman, especially in a multipara, the retro-uterine peritoneal pouch affords a most convenient avenue for drainage by the v a g i n a , which is at the same time free from any objection on the score of contamination from fecal discharges. When the abscess can be felt through the posterior *cul-de-sac,* this should in all instances be opened. The operation is done by retracting the posterior vaginal wall so as to expose the vault; the cervix is then caught and drawn forward, while the vaginal vault just behind the cervix is laid open from side to side with scissors or knife. As soon as the bulging peritoneum is reached, it is opened widely and then stretched to a maximum from side to side by hooking in the right and left index-fingers. This gives

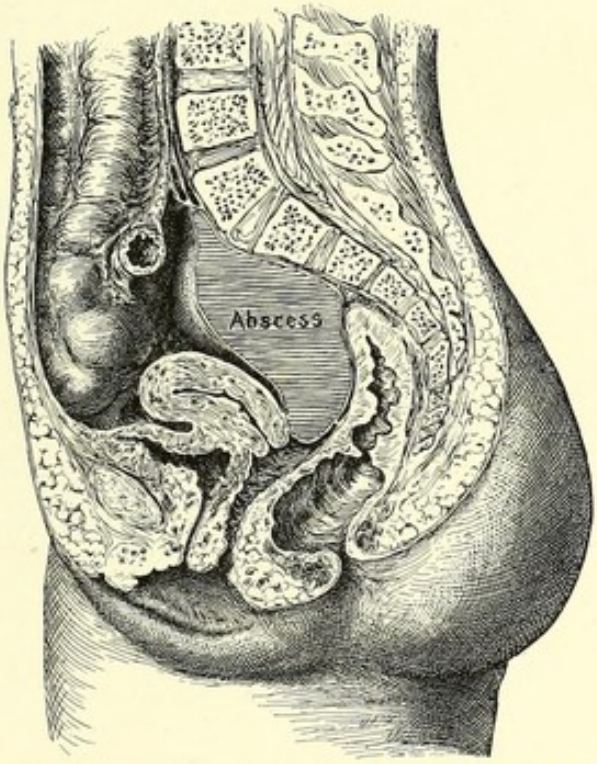

FIG. 337.—Gallant's case. Large retro-peritoneal abscess in a girl ten years old extending from the region of the appendix behind the pelvic peritoneum and pointing back of the cervix uteri, where it bulges into the vagina. Vaginal drainage impossible on account of age of patient. Drainage above. Recovery.

free exit to all the discharges, and the cavity may be carefully washed out, a rubber tube being inserted with a loose pack of iodoform gauze. In a child either the rectum or the superior strait must be utilized (see Fig. 337).

When the abscess is located entirely in the pelvis, the indication is to find the point of least resistance through the inferior strait, and to make an opening there. To evacuate a collection of pus by separating the agglutinated intestine through the superior strait is exceedingly dangerous. QUÉNU's method, in two steps, is also not to be recommended, if the collection can be reached from below. The first step in his procedure is to open the peritoneal cavity, locate the abscess,

and introduce the tampon down to it, so as to establish an avenue for the escape of the pus. The next step is to open the abscess at a later date.

It sometimes happens that an operator is surprised upon opening the abdomen to discover, as in CULLEN's case (Fig. 338), a large accumulation of pus in the pelvis, the exact position and size of which are only known after sufficient adhesions have been separated to release the pus and make it imperative to proceed. In such cases, although the point of election for the opening would have been by the vagina in a woman, or by the rectum in a man, the operator,

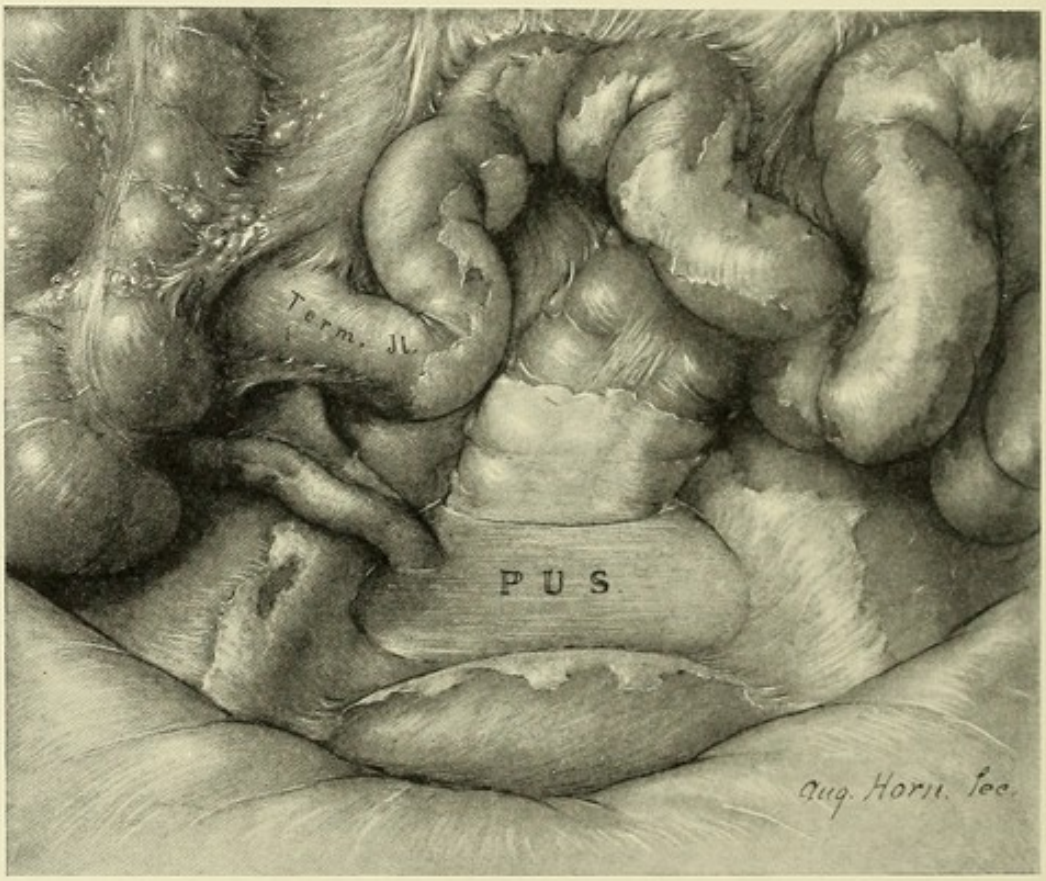

FIG. 338.—CULLEN'S CASE. THE TIP OF THE APPENDIX IS LOST IN A POOL OF PUS FILLING THE PELVIS AND WALLED IN BY ADHERENT SMALL INTESTINE EVERYWHERE COVERED BY LYMPH.

The intestine has been lifted up and the adhesion separated so as to show the abscess. Church Home. Removal of appendix, drainage. W. P., male, æt. twenty-seven. June 26, 1902.

having advanced so far as to open the abscess from above, is obliged to proceed with the evacuation in this direction. The closest attention must be given to protecting the surrounding peritoneum, while the entire pus cavity is emptied and dried out, a liberal drainage orifice filled with loose gauze being provided, which also fills the infected pelvis.

The para-sacral method was clearly defined by JABOULAY in 1892 (*Rev. de chir.*, 1892), but it is the very last to be recommended, unless, as in the case of BÉRARD and PATEL, the collection of pus finds

its way back to the sacro-iliac notch and tends to open spontaneously at that point.

The perineal method, devised by MAUCLAIRE in 1895 (*Soc. Anat.*, 1897, p. 868), has been utilized by DELANGLADE, who has written an article upon it, entitled "*De l'incision prérectale des abscès pelvienne appendiculaire*" (*Soc. de chir.*, Paris, 1900, pp. 600 et 857). E. M. SUTTON, LAGOUTTE, and especially ROTTER have also used the perineal method, the latter eleven times.

SUTTON (*Jour. Amer Med. Assoc.*, 1898, vol. 30, p. 1438) reports the case of a locomotive fireman, thirty-five years old, in whom a pelvic abscess was watched into the second week, when, on account of symptoms of obstruction, such as vomiting and distention, it was evacuated through the rectum by puncturing the anterior wall high up, with a small trocar, upon which 22 ounces of pus escaped. After some amelioration, severe septic symptoms followed, and the abscess was found to have refilled. It was then opened and drained through the peritoneum by making a horseshoe incision in front of the anus, and carrying the dissection carefully upward between the urethra and the rectum; the external sphincter fibres were divided, where they interlace with the bulbo-cavernosus; the deep fascia also was divided, the levator ani separated, and the prostate, when reached, was pushed forward as the dissection was carried up to the peritoneal *cul-de-sac*. On reaching this point, the abscess cavity was opened, and nearly a quart of foul pus mixed with liquid feces escaped, after which a drainage-tube was inserted. The temperature and pulse dropped to normal, the bowels moved six hours after the operation, and the intense suffering was immediately relieved. The drainage-tube was removed on the twelfth day, and the patient was able to be out of the house in the third week.

The method of opening and draining the abscess by the rectum is as follows: The rectum is emptied and washed out, and when the patient is well under an anesthetic, the anterior wall is exposed by means of a Sims speculum, or by long narrow retractors. The incision is then made near the median line and in front, where the vessels are least voluminous, or at a point which has been determined by the finger as the most prominent or the most yielding portion of the inflammatory mass. The operator should have previously determined by careful bimanual examination, with one finger in the rectum, the exact location and the size of the abscess. The dilatation of the anus is effected by the traction instrument used to expose the field of operation. In case of doubt as to the presence of pus an aspirating syringe may be used, passing the needle obliquely through the wall of the bowel.

BÉRARD and PATEL advise a transverse incision, crossing the median line, made with curved scissors under the control of the left index finger; the coats of the bowel are then cut through successively, and in an oblique direction, proceeding upward. As soon as the abscess is opened, the orifice is enlarged by introducing the scissors and then separating the blades; after the

abscess has been explored by means of the finger, it can be completely evacuated by pressure made softly from above. The cavity should then be gently washed out until the fluid returns clear.

Drainage ought never to be omitted, and it is best carried out by means of rubber tubes a centimetre in diameter. A mushroom tube of this size is readily retained, while the outer end of it, lying on the exterior, conducts the discharges on to a gauze pad. Through such a tube the cavity can be washed out from time to time under gentle pressure.

R. Peterson (*Amer. Jour. Gyn. and Obst.*, 1900, vol. 16, p. 240) opened an abscess containing over a gallon of foul pus, which pointed just within the anus. On the sixth day afterward the patient walked home, a distance of about a mile and a half, and made a rapid recovery.

In order to avoid a reflux of stercoral materials into the abscess Jaboulay recommends the following method, which he has occasionally practised: The coats of each lateral wall of the rectum are brought together behind the drain, and fixed temporarily at the anus in such a manner as to form a double canal, one opening being in front for drainage, and one behind for the escape of fecal matter and gas.

CHAPTER XXVII.

PERITONITIS.

PROGRESSIVE PURULENT PERITONITIS. DIFFUSE PURULENT PERITONITIS.

PROGRESSIVE PURULENT PERITONITIS.

When infection spreads beyond the bounds of the original focus of the disease in the appendix (see Fig. 339), it may be limited, as we have just seen, to the neighborhood of the diseased organ, by a wall of adhesions agglutinating the adjacent intestines and the general peritoneum. If, for any reason, however, such as the suddenness of the outbreak finding the peritoneum unprotected or unable to defend itself on account of the virulence of the organisms, the infection is poured out over a larger area of the peritoneal cavity, the resulting peritonitis either becomes diffuse, and even general and universal as it enlarges its boundaries; or, on the contrary, it becomes encapsulated here and there between the viscera, forming so many separate foci of suppuration, by which the disease advances, establishing new foci, from point to point.

A peritonitis arising in this way, whether *focal* or *diffuse*, possesses all the characteristics of the original disease in the right iliac fossa, resembling the lesser areas of infection in every point except in the extent of surface involved. The profound shock and the depressing effect upon the patient which characterize this form of the affection are due simply to the large area involved, associated with the absorption of toxins and pathogenic bacteria. In the more extensive peritonides we observe such variations in the character of the inflammatory changes as are indicated by the terms *serous*, *fibrinous*, *purulent*, *putrid*, or *hemorrhagic*. One or more of these forms may predominate in any given case, or even in different areas of disease in the same case.

One of the most distinctly characterized forms of peritonitis is the *disseminated focal*, described by Mikulicz under the term *progressive fibrino-purulent* (*Langenb. Arch.*, 1899, Bd. 39), in which the disease, running an acute or a subacute course, advances by means of the peritoneum to an adjacent area, where it forms a fresh fibrino-purulent deposit, at first shut off by adhesions from the remaining intact peritoneum; it next infects a fresh area through the escape of pus between the adherent coils of intestine, and starts up another focus of deposit, walled off in its turn,

only to again advance to some other point in the neighborhood, and thus continue its progress.

Secondary abscesses of this description are met with behind the cecum, in the pelvis, in the right renal region above the



Fig. 339.—Showing Perforation near the Root of the Appendix in a Patient Dying of Peritonitis. J. H. H. M. S., æt. sixty. Aug., Sept., 1903. Surg. Path. No. 2181. The kink is probably responsible for the location of the perforation.

liver, in the right pleura, in the left iliac fossa, in the left renal region, and among the coils of the intestines. Jaffé speaks of cases in which he found secondary abscesses above and to the inside of the spleen. A surgeon must bear in mind all these seats

of predilection in every case in which the opening of an abscess in the neighborhood of the appendix is not followed by immediate improvement. Only by the closest attention to all parts of the abdominal cavity and to the pleura, can he exclude the presence of one or more of these foci of secondary infection, or suspect and watch some particular area, prepared to open and drain the abscess as soon as it is formed. The effect of a concealed, unopened abscess upon the general condition of the patient is so marked as to be evident even to the untutored eyes of the family, anxiously watching for signs of improvement. The course of the affection is more protracted than that of a diffuse peritonitis, and there is not the same evidence of profound intoxication. The fever is usually high, the pulse is quickened, there may be chills, and there is certainly restlessness, abdominal discomfort, tympany, and often pain in the affected region. At this juncture a careful palpation of the abdomen, made by little quick movements of deep pressure with the finger-tips as they play the gamut of the muscular fibres, will often localize the affected area in the right or left lumbar region. The affected areas are markedly sensitive, and as the fluid accumulates, resistance increases, while the area of dulness is enlarged; all this is best revealed by light percussion. The pelvis must be investigated by rectal examination in order to discover any unusual tenderness, boggy condition, bulging or infiltration of its walls. The liver should be investigated by auscultation and percussion, in order to detect any friction sounds indicatng a peri-hepatitis or any enlargement of the area of dulness, such as would be produced by an abscess. Any icteroid tinge must receive the closest attention. A bulging of the ribs may indicate an empyema.

Not only one, but two, or even more secondary abscesses may form, necessitating several operations. An instance of this kind occurred in the practice of W. S. Halsted, myself, and J. M. T. Finney, each of us operating successively on the same patient.

A nurse, twenty-five years old, had a first attack of acute appendicitis with typical symptoms, for which Halsted operated, and found the appendix beginning to be gangrenous, and partially separated from the cecum. There was a small post-cecal abscess and the pelvis contained a cloudy fluid. She did well until the fourth day, when she complained of dull pain all through the abdomen and down the right leg. The temperature, which had been nearly normal, rose again, while the abdomen became distended and very tender in the supra-pubic region. On the fifth day I made a vaginal opening behind the cervix uteri, evacuating about 200 cc. of foul-smelling dark pus. After this there was an immediate improvement, but on the tenth day from the original operation the patient complained once more of pain and chilliness, the temperature again rose, and there was slight nausea. A localized area of moderate tenderness was found in the left flank, but there was no distinct tumor or fluctuation. Two days later, that is to say, on the twelfth day after the original operation, Finney made an incision in the upper left inguinal region, evacuating about 400 cc. of pus. The opening into the vagina was enlarged,

a communication established between the other two openings, and rubber drains inserted. The patient steadily improved, and eventually made a perfect recovery, there being no sign of hernia after several years.

Another series of sequences is shown in a case operated upon by Professor PONCET, the patient entering his clinic in March, 1892, with "alarming symptoms of appendicitis." This patient was operated upon successively at several days' interval for (1) a peri-appendical abscess in the right iliac fossa, (2) an abscess above the liver, and, finally, (3) a purulent pleurisy (E. SALLET, "*Des abscès peri-hepatique*," *Thèse de Lyon*, 1894).

Subphrenic Abscess.—One of the most important of these secondary abscesses is that in which the purulent deposit is situated above the liver and below the diaphragm, in other words, a subphrenic abscess (see Chap. X, p. 214). This form of abscess has been well described by ELSBERG, who justly remarks that its importance as a complication is not sufficiently recognized. He has collected 73 cases in all, 2 of which occurred in his own practice. His treatment of the subject is so satisfactory that I cannot do better than quote his words (*Ann. Surg.*, 1901, vol. 34, p. 729):

"Subphrenic abscess processes secondary to disease of the vermiform appendix may occur in one of three ways:

"1. As a localization in the right or left subphrenic region of a general systemic infection,—the infectious agents being carried to the subphrenic region by the blood current. Here the process is secondary to a generalized infection and hence is not considered in this paper.

"2. As a localized abscess formation in the right or left subphrenic region, a part of a general purulent peritonitis with foci of suppuration in various parts of the abdominal cavity. This variety is infrequent, as the patients generally die before encapsulation of the abscess can occur.

"3. As a local process by direct extension, or through the lymph channels from disease in or around the vermiform appendix. This is the most frequent variety and the one with which this paper is concerned.

"According to Fränkel, inflammatory processes in the region of the liver may lie entirely within the peritoneal cavity, or entirely outside of it. The intra-peritoneal variety is usually the result of the direct extension of the inflammation from below. In the extra-peritoneal variety the process advances by the retro-peritoneal route, behind the ascending colon and kidney. The abscess generally lies behind and above the kidney, and, unless it is very large, causes little or no downward displacement of the liver. In the 73 cases collected, the abscess was extra-peritoneal in 20 cases (27 per cent.), intra-peritoneal in 35 (48 per cent.), and the anatomic location was doubtful in 18 cases (25 per cent.).

"In the large majority of patients the subphrenic affection is secondary to a suppurative inflammation in or around the appendix. Of the 73 cases

under discussion, there was an abscess in or around the appendix in 50 cases (68 per cent.): in the other 16 no details were given. When the subphrenic inflammatory condition is caused by direct extension from below, its position varies with the location of the diseased appendix. Of the 73 cases the appendix lay behind the cecum of the ascending colon in 17 patients (23 per cent.), in front of or below the cecum or the colon in 12 patients (16 per cent.), and details were wanting in 44 patients (61 per cent.). In about 15 per cent. of the patients the abscess contained gas. Perforation of the diaphragm occurred in 25 per cent. of the cases.

"The symptoms of subphrenic inflammation may come on days, or weeks, or months after the disease of the appendix or the operative measures instituted therefor. Several modes of onset are characteristic.

"(*a*) A few days after the acute symptoms of appendicitis have been relieved, and the temperature has fallen to normal, the patients complain of pain in the lower part of the right chest, the temperature begins to rise, the area of liver dulness is somewhat enlarged, there are friction sounds over the hepatic region, and tenderness in one or two intercostal spaces. There may be slight or well-marked jaundice. Within a few days the pain over the liver becomes less, while the signs of fluid become evident.

"(*b*) Before the acute signs of appendicitis have entirely subsided, although the local symptoms are much improved, the daily temperature begins to take on a remittent type, and the patient begins to lose flesh and strength rapidly. These patients look very ill from the beginning. They do not complain of much pain, although they may have tenderness in the lumbar region; the most marked symptom is the rapid loss of flesh and strength. No further physical signs may be discoverable until the bulging of the abscess in the lumbar region is found.

"(*c*) After having recovered from the attack of appendicitis in a satisfactory manner, some of the patients never regain their former health. Without any change in the temperature, respiration, or pulse, the patient complains of continual slight pain in the right chest. The pain persists for weeks or months, although physical examination and aspiration of the right chest result negatively. These patients never look very ill. After a varying length of time, the presence of fluid under the diaphragm, and perhaps also in the pleural cavity, is discovered by means of physical examination and the exploring needle.

"When the subphrenic abscess contains gas, the diagnosis is generally more easy, because of the obliteration of the liver dulness by full tympanitic resonance and because of the presence of succussion sounds. When it does not contain gas, the question may arise whether one has not to deal with an effusion into the right chest. Most of the errors in diagnosis that have been made, have been along this line. Three conditions are possible: there may be an effusion into the pleural cavity, or there may be both a subphrenic and a pleural effusion, or there may be a subphrenic effusion alone. The differential diagnosis must

rest on the fact that when there is a well-marked effusion under the diaphragm there are usually no thoracic symptoms; the upper level of the dulness is a straight line or is convex upward; there is little change in the line of dulness with a change in the position of the patient. While in a pleural effusion the respiratory murmur is much diminished or absent below the level of the fluid, in subphrenic effusions the murmur can generally be heard plainly below the level of the fluid. Depression of the liver is frequent in subphrenic abscesses; it is rare in pleurisy, unless the effusion is a very large one. The heart is never appreciably pushed to the right, nor are the intercostal spaces bulged out in effusions under the diaphragm. If pus is withdrawn by aspiration through one of the lower intercostal spaces, and clear fluid by aspiration higher up, the diagnosis of an association between the two conditions is almost assured. When perforation of the diaphragm occurs, it is characterized by the sudden appearance of symptoms of invasion of the pleural cavity,—cough, rapid respiration, expectoration, and, frequently, rapid collapse.

"The differential diagnosis between subphrenic abscess and abscess of the liver is often very difficult, and sometimes impossible before operation. Abscess of the liver is, however, much more rare after appendicitis than is subphrenic abscess. Pain in the right shoulder-blade is rare in subphrenic cases and frequent in abscess of the liver. Paralysis of the diaphragm, and hence diminution or absence of respiratory movements of the liver, occurs far more often in subphrenic affections. Chills and profuse sweats are more frequent in abscess of the liver. The final and positive diagnosis must be made with the aspirating needle, the puncture being made in the seventh to the tenth intercostal space in the axillary line, unless there are signs of pointing in front or in the lumbar region. The fluid obtained by aspiration should be always examined for liver abscess. The characteristic pus of liver abscess is of a light chocolate color with little or no odor. Foul odor of the pus will generally mean subphrenic abscess and not liver abscess, although the possibility of an hepatic abscess which has ruptured into the subphrenic region must be remembered.

"Of the 73 cases collected, the total mortality was 40 per cent."

The method of treatment recommended by Elsberg is as follows: "About two inches of the ninth and tenth ribs are resected in the usual manner (Fig. 340), somewhere between the scapular and the anterior axillary lines, according as the exploring needle has located the pus more anteriorly or posteriorly. The two ribs can easily be resected through one incision, made in the intercostal space between them (Fig. 341). After the ribs have been resected, the diaphragm, with the liver showing below it, will appear in the lowermost portion of the wound, and the pleural reflection will be seen in the upper part. If there is suspicion that the pleural cavity contains pus, aspiration of the pleura should first be done. If pus is obtained, the cavity should be opened and drained at once. If aspiration of the pleura is deemed unnecessary or inexpedient (as is generally the case), the upper part of the wound should be carefully

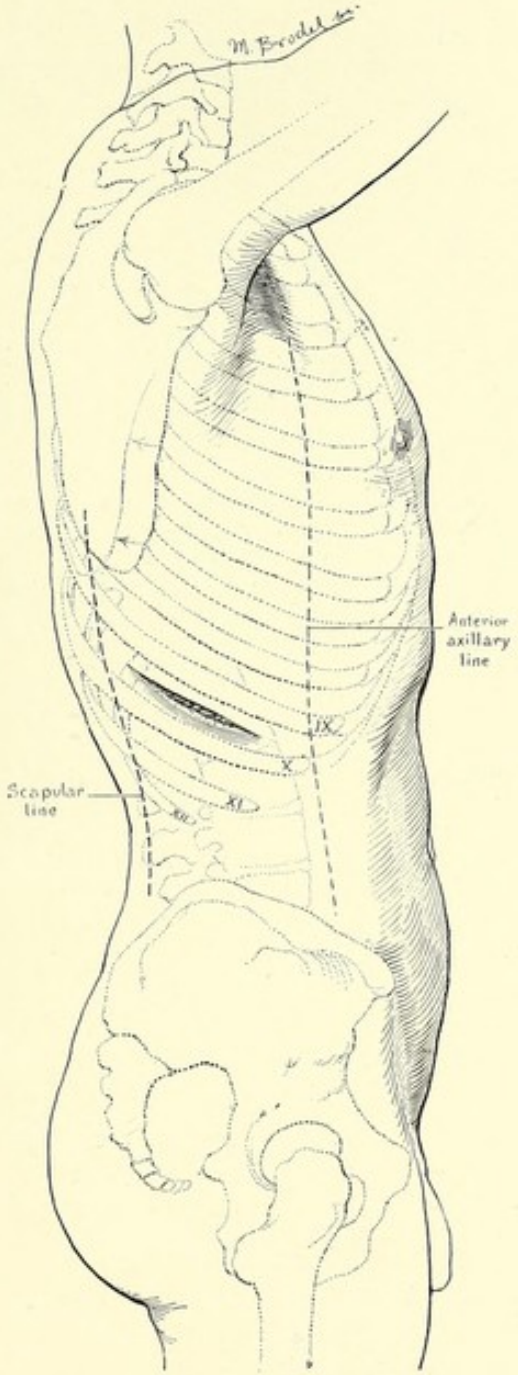

FIG. 340.—ELSBERG'S OPERATION FOR SUBPHRENIC ABSCESS, SHOWING THE SKIN INCISION, TWO INCHES IN LENGTH, MIDWAY BETWEEN THE ANTERIOR AXILLARY AND SCAPULAR LINES BETWEEN THE NINTH AND TENTH RIBS.

protected with gauze, and the aspirating needle then made to perforate the diaphragm below the reflection of the pleura (Fig. 342). If the needle enters the abscess cavity, it should be allowed to remain in place and be used as a director. A small incision of the diaphragm alongside of the needle, the dilatation of the small opening with the dressing forceps, and the drainage of the abscess cavity with tubes, according to general principles, are all that is required. The

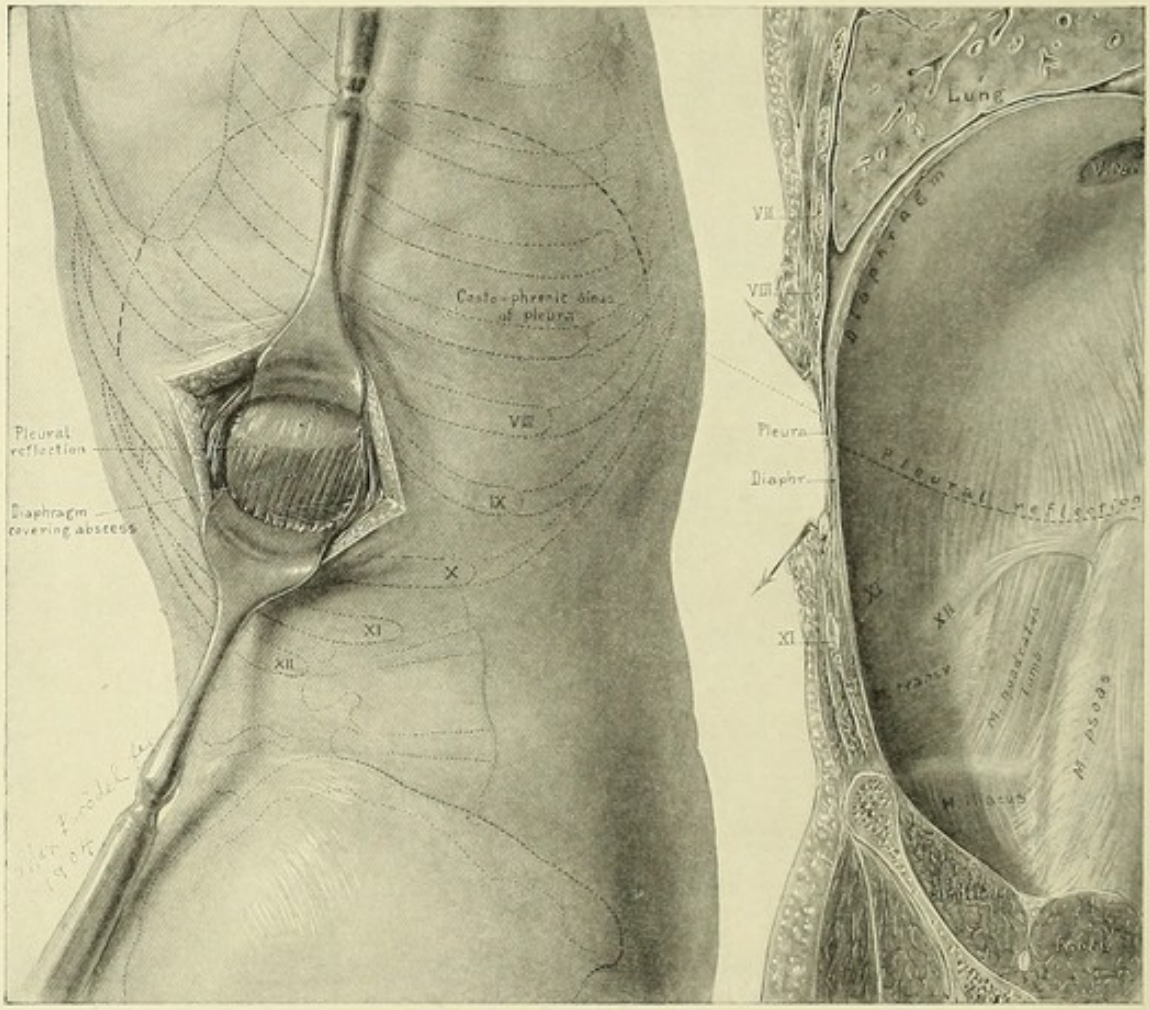

FIG. 341.—RESECTION OF ABOUT TWO INCHES OF NINTH AND TENTH RIBS.

The pleural reflection is seen below the costo-phrenic sinus of the pleura. Below this lies the diaphragm covering the abscess. The figure to the right shows a coronal section of the body revealing the pleural reflection with the costo-phrenic sinus above and with the diaphragm below.

abscess cavity may, however, be situated so near the median line, high up under the dome of the diaphragm, that it can only be reached by the transpleural route. The pleural cavity can then be opened without further delay through the upper part of the wound. In some cases the costo-phrenic sinus has been entirely obliterated by adhesive inflammation, so that the pleura can be incised without opening the pleural cavity proper. If this is the case, great care must be taken not to tear the adhesions, as they are often very weak and easily sep-

arated. If the pleural cavity must, nevertheless, be opened, it should be done as rapidly as possible. By means of upward pressure against the liver, it is often possible to so closely approximate the diaphragmatic to the costal pleura

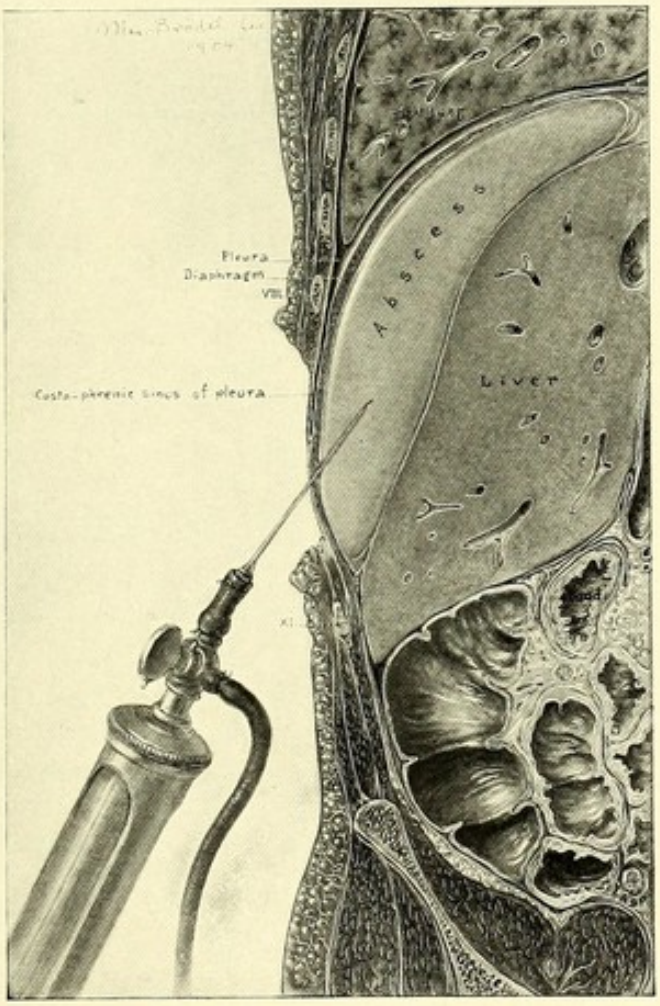

FIG. 342.—ASPIRATING THE ABSCESS THROUGH THE DIAPHRAGM AND BELOW THE PLEURAL REFLECTION. The operation may be transpleural if necessary, when there is fluid in the pleura as well. The aspirator indicates the position of the abscess, which is then evacuated and drained through a free incision.

that little, if any, air can enter the pleural cavity when the opening is made. Sometimes it is impossible to unite the two pleural layers by suture, and all that can be done is to wall off the cavity carefully with antiseptic gauze."

DIFFUSE PURULENT PERITONITIS.

A diffuse peritonitis is one in which the exact limits cannot be determined *in vivo*. The entire area accessible to the eye is more or less involved, the infectious material being distributed over a large extent, and tending, unless checked, to a rapid involvement of the entire peritoneum. The statement that a peritonitis is "general" or "universal" can hardly be made without

such a painstaking investigation of every portion of the abdomen as is unjustifiable in the course of an operation. A diffuse peritonitis of this kind is so called, in contrast to the circumscribed peritonitis limited to the right iliac fossa, and the disseminated focal peritonitis involving particular areas and shut off from the rest of the cavity by limiting adhesions. A large abscess occupying the entire lower abdomen, and sometimes containing quarts of pus (which is oftenest found in children), is, nevertheless, circumscribed in character. A diffuse peritonitis, on the other hand, may go on to the formation of an abscess filling the entire abdomen and resulting in abdominal empyema. There is a strong temptation to speak of a case as one of "general peritonitis" when the intestines of the lower abdomen, as far as seen, are found inflamed and covered with deposits of pus in both flanks as well as in the pelvis. Von Burckhardt proposes to use the term "progressive" in place of the vague expression "diffuse."

A general, or perhaps more correctly, a total peritonitis, is one in which the entire abdominal cavity is involved, including the structures above the omentum and the colon, especially in the diaphragmatic regions, as well as those below. The most acute form of diffuse peritonitis is appropriately termed peritoneal sepsis (Witzel, "*Diffuse eitrige Peritonitis und peritoneale Sepsis,*" *Dtsch. med. Woch.*, 1888, No. 40); it being one in which the patient dies with an acute intoxication so soon after the onset of the disease that little or no reactive signs are found in the peritoneum. There is only a slight injection, perhaps a little loss of lustre, and a little fibrin, some bloody serous exudate, and, most important of all, no adhesions setting up a barrier for the limitation of the disease.

A diffuse purulent peritonitis is occasioned by an infection of lesser intensity existing for a longer time; where nature has been able, more or less successfully, to combat the infection, pus is found widely distributed, particularly in dependent regions; the intestines are everywhere deeply injected, and in place of the normal lustrous coat a shaggy surface is seen covered with little bits of fibrin, often with a capillary vascularization, which float out under water, the coils of intestines are mutually adherent, and there is an abundant fibrinous and fibrino-purulent deposit.

Diagnosis.—The diagnosis of a diffuse peritonitis is made by giving close attention to the general character of the abdominal pain and the marked tenderness on pressure. The abdomen is, as a rule, tympanitic, the tympany being a conservative effort on the part of nature to limit the spread of the infection. Once in a while, however, an extensive peritonitis is found in a scaphoid abdomen. The fever is often marked, though sometimes quite wanting. The pulse is small and shows an increased rapidity, often going up to 120, 140, and even higher, although where the infection is not so severe in character,

the pulse-rate may remain nearly normal. One of the most important signs is the persistent, distressing nausea and vomiting which generally characterize the affection from first to last, although they sometimes cease toward the end, the cessation producing an illusory impression of improvement. A further most important sign, which is associated with the cessation of peristalsis, is the cessation of fecal movement and the passage of gas. The distended abdomen is fixed, and the respiration becomes superior thoracic in type. There is often a dry, typhoid tongue, and later on a mild or marked delirium. As the infection spreads the system becomes dried out for want of water and the excretion of urine is much diminished. There is sometimes an accumulation of ascitic fluid. One of the most marked signs in advanced cases is the facial expression, which is distressed and anxious, the patient having a collapsed look, with hollow eyes and a dusky skin, the expression alone being often sufficient to indicate the nature of the malady to an experienced eye. V. H. WILLIAMS graphically says of one of his cases: "He had that gray, hard, sallow, anxious look of sepsis, which means much to the eye of the surgeon" (*Trans. Amer. Surg.*, 1893, p. 261).

The first step in the differential diagnosis is to distinguish between these cases of diffuse peritonitis and cases of a circumscribed abscess still limited to the neighborhood of the appendix, in which the local inflammation has called forth a marked reactive disturbance of the entire peritoneum. In a localized peritonitis there may be fever, quickened pulse, vomiting, and a general tympany of the abdomen, associated with more or less general discomfort. A careful examination, however, will usually show that the tenderness is pretty well localized, and that there is a well-defined mass shut off in the iliac fossa. Furthermore, the effect on the general condition of the patient is not that of the profound depression associated with the more extensive disease. It is in just these cases, however, in which a local affection is passing into a general one, that the most serious mistakes are made, and, where there is doubt, it is better to operate than to wait for the extension of the disease.

The differential diagnosis between intestinal obstruction and peritonitis accompanied with tympany, nausea, and pain, is sometimes even more difficult. In intestinal obstruction, however, fever, at first, is lacking, there is no such widespread sensitiveness to pain as in peritonitis, and the distention is limited to the loops of intestine which lie near to the obstruction. These loops can often be seen and felt as they contract, and roll their gaseous contents under the fingers in the effort to force a passage through the barrier, the pain being associated with the attacks of peristalsis. Moreover, in intestinal obstruction there is no increasing leucocytosis. In either case relief is to be sought in operative measures.

Prognosis.—The prognosis in cases of diffuse peritonitis depends upon the character of the infection, as well as upon its extent. Where it has spread very rapidly, and there is a profound depression, as in cases of peritoneal

sepsis, there is scarcely any hope, whatever may be done. In all cases the prognosis is serious, but in those which tend to run a protracted course with decided local reaction against the infection, there is a chance with operation and none without it. The reaction of the leucocytes should be studied, the blood should be examined, and cultures taken, to ascertain if there is any marked septicemia. As soon as pus is reached in the course of the operation, it should be examined microscopically; if streptococci are found the prognosis is far more serious than in a more extensive colon bacillus infection even though the disease is limited in its area. Cultures should also be made for examination throughout convalescence.

Treatment in General.—Where it is not possible to operate immediately, the first step in the treatment of a diffuse peritonitis is to put the patient as

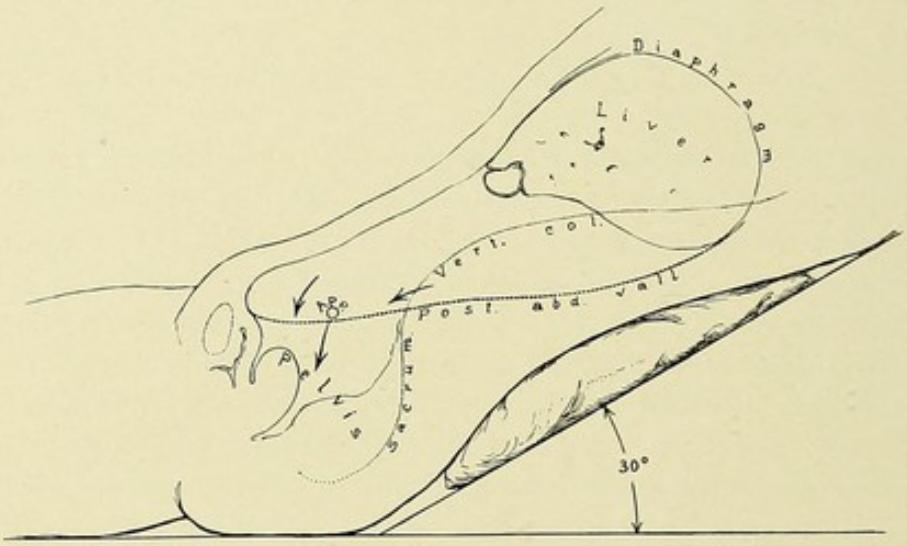

Fig. 343.—Fowler's Method of Drainage.
The thorax is elevated to cause the fluids to gravitate into the pelvis instead of upward toward the diaphragm.

nearly as possible in a condition of absolute repose. He should lie on his back with his head on a low pillow, and his knees drawn up and supported by a round cushion, so perfectly at rest that he appears as if fused with the bed. Any movement for the purpose of giving necessary attention, such as the use of the bed pan, bathing, alcohol rubbing, etc., should only be made with the utmost care. The bowels are best kept at rest ("in splints") by the administration of opium in small quantities; this relieves the pain and checks peristalsis, thus favoring the formation of adhesions and limiting the spread of infection. If the bowels are much distended, morphine, as Körte says, is better than opium.

A decided elevation of the head of the bed is advisable (see Fig. 343), if not disagreeable to the patient, as it may limit the spread of the infection upward into the most unfavorable part of the abdomen, and determine its gravitation toward the pelvis, where it can be better drained. The patient

will be more comfortable if the bedclothes are kept off the body, but if the abdominal walls are thin, hot poultices, which dilate the capillaries and thus facilitate the elimination of the infectious products, may give comfort and also be of service in limiting the infection. Ice poultices, if better borne, may check the growth of the bacteria.

Where there is much vomiting, the washing out of the stomach, which for many years has been tried and found of the utmost service by KUSSMAUL and others, often affords the greatest relief. It should be done with a soft rubber tube, and even though attended with considerable discomfort to the patient, should not be neglected. As a general rule, it is best to give no food or drink, using the rectum as an avenue of alimentation by injecting about 100 cc. of albumen water or pancreatized milk at intervals of six hours. It also relieves thirst, besides improving the pulse and general condition of the patient, to give from 100 to 1000 cc. of a normal salt solution twice a day, as recommended by LENNANDER, and widely practised by American surgeons for some years past. Sometimes it is necessary to accede to the urgent entreaties of the patient and give a little cracked ice or a teaspoonful of hot or cold water, or, as KÖRTE advises, a carbonated water. If water is given by the mouth, the occasion may be utilized by administering a little albumen with it. If an operation is to take place within an hour or two, and the bowels are loaded, a warm saline enema may be given in order to evacuate the rectum.

Surgical Treatment.—It is important in surgical treatment to observe the following rules:

1. To make the operation as brief as possible, consistent with thorough technic.

2. To watch the patient closely, and keep up the vitality during the operation.

3. To remove all septic products as quickly and as completely as possible.

4. To extirpate or to wall off the original focus of the infection, the appendix.

5. To provide abundant avenues for the escape of any further septic material which may accumulate.

6. To relieve excessive tympany.

If the pulse is small, the heart weak, and the patient collapsed, it is well to begin the operation by injecting from 500 to 1000 cc. of normal salt solution as the patient goes on the table, the injection continuing during the operation. Hypodermics of strychnine help to keep up the strength and to tide the patient over the shock of the operation. They may be begun with one-thirtieth of a grain, and continued with one-sixtieth, every two hours, until a good reaction is established, and then be kept up at intervals of every three or four hours for several days, unless there are signs of the physiologic action of the drug.

As a preventative against shock, all unnecessary exposure of the body must be avoided, the patient should be kept wrapped in blankets while on the operating table, and hot flasks covered with flannel should be placed under the arm-

pits, at the sides of the chest, and by the legs. Whenever hot bottles are used either on the operating table or in the bed, they should be closely watched to avoid a burn.

All preparations must be made before the anesthetic is given; it is best to begin the anesthesia with nitrous oxide gas followed with ether.

The Incision.—If the abdomen is small and the walls flaccid, it is a good plan to make a liberal incision in the right semilunar line. Where the affection is advanced, and all parts of the abdomen seem uniformly involved, an incision in the linea alba from the umbilicus to the symphysis affords a still

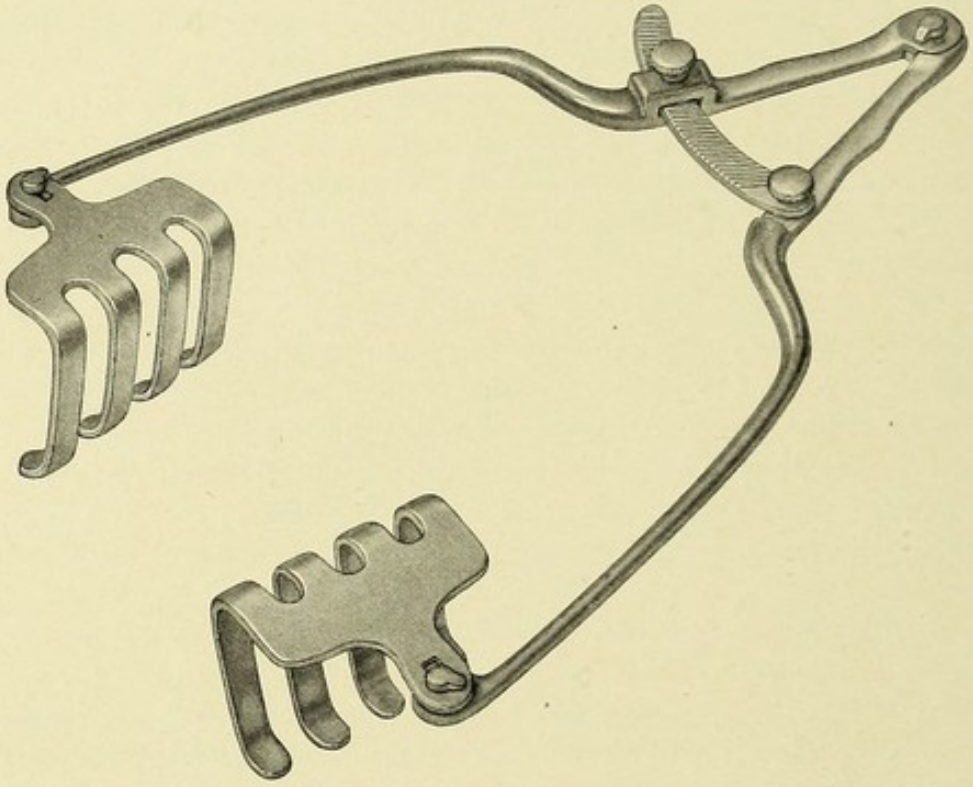

Fig. 344.—Self-retaining Retractor.

Saves an assistant by holding the abdominal walls widely apart while the abdominal cavity is being cleansed in general peritonitis. (One-half natural size.)

better opportunity for examining all parts of the abdomen, for cleansing the peritoneum, and for making counter-openings for drainage. Good broad retractors are of service in exposing one part of the abdomen after another. The practitioner who has not the advantages of a hospital clinic and well-trained assistants, will often find a self-retaining retractor (Fig. 344), which gives a maximum exposure of the abdomen through the wound, of great service while he is mopping out or irrigating the abdomen.

J. Israel (*Verhandl. d. dtsch. Gesell. f. Chir.*, 26th Congress, Berlin, 1897, p. 15) says that as it is impossible to empty a generally infected abdomen completely of its purulent exudate, he has been in the habit for some years, in order to

limit the harm done by the remaining infectious masses, of making an extensive transverse incision of the abdominal wall (*Kreuzschnitt*) in such a manner as to do away with intra-abdominal pressure, and in this way hinder the absorption of fluid. He does this by making the aforesaid transverse incision, dividing both recti, and then, after thoroughly drying out all accumulations of purulent material, leaving the abdomen open. In order to prevent any prolapse of the intestines the deficiency in the abdominal wall is replaced by an extensive iodoform gauze apron, the corners of which are thrust under the edges of the wall. This treatment insures free drainage from the abdomen, yet the intestines do not escape, and the large wound begins to contract surprisingly soon. Israel has secured much better results from it in bad cases of general peritonitis, than those he formerly obtained.

Lifting out the Intestines.—With the great irregularities and the numerous recesses of the abdominal cavities in mind, it is a strong temptation to the surgeon, in his desire to get rid of all the infection, to lift out the intestines and to expose and cleanse them, as well as the emptied abdomen. This plan has been faithfully tested by some of our best surgeons, notably FINNEY (*Johns Hopkins Hospital Bull.*, 1897, vol. 8, pp. 141 and 143) in a series of experiments upon dogs, which showed a remarkable number of recoveries under this treatment. He therefore advocated the removal of the intestines, which were wrapped in warm towels; the peritoneal cavity was then thoroughly washed out with hot salt solution, and dried with strips of gauze, after which the intestines were cleaned, loop by loop, under a continuous irrigation with salt solution, and finally returned to the abdominal cavity and the incision closed, a small opening being left for drainage. MCCOSH (*Ann. Surg.*, 1897, vol. 26, pp. 179 and 687) also recommends removal of the intestines, associating this in suitable cases with incision of the ileum to evacuate gas and feces, and with the injection of magnesium sulphate into the intestine, followed by closure of the intestines and then of the abdomen. Experience, however, has demonstrated that it is better to refrain from taking out the intestines on account of the profound shock which rapidly supervenes.

Irrigation.—It is still a moot point whether or not it is best to irrigate the peritoneum. When it is easily inspected, and accumulations of septic materials are seen in all parts, irrigation may be carried out with a hot normal salt solution at a temperature between 105° and 110° F., using such an instrument as that shown in Fig. 345. The fluid is allowed to accumulate in considerable amount, first in one part and then in another, and then, the edges of the incision being raised, to escape with a rush, bringing away quantities of septic material. After washing out in this way, the abdominal wall may be pushed forward, first in the right, and then in the left flank, and rapidly incised, for the insertion of a large rubber drainage-tube in the position for natural drainage (Fig. 346). The various positions for drainage are shown in the composite picture, Fig. 347, which also indicates the areas

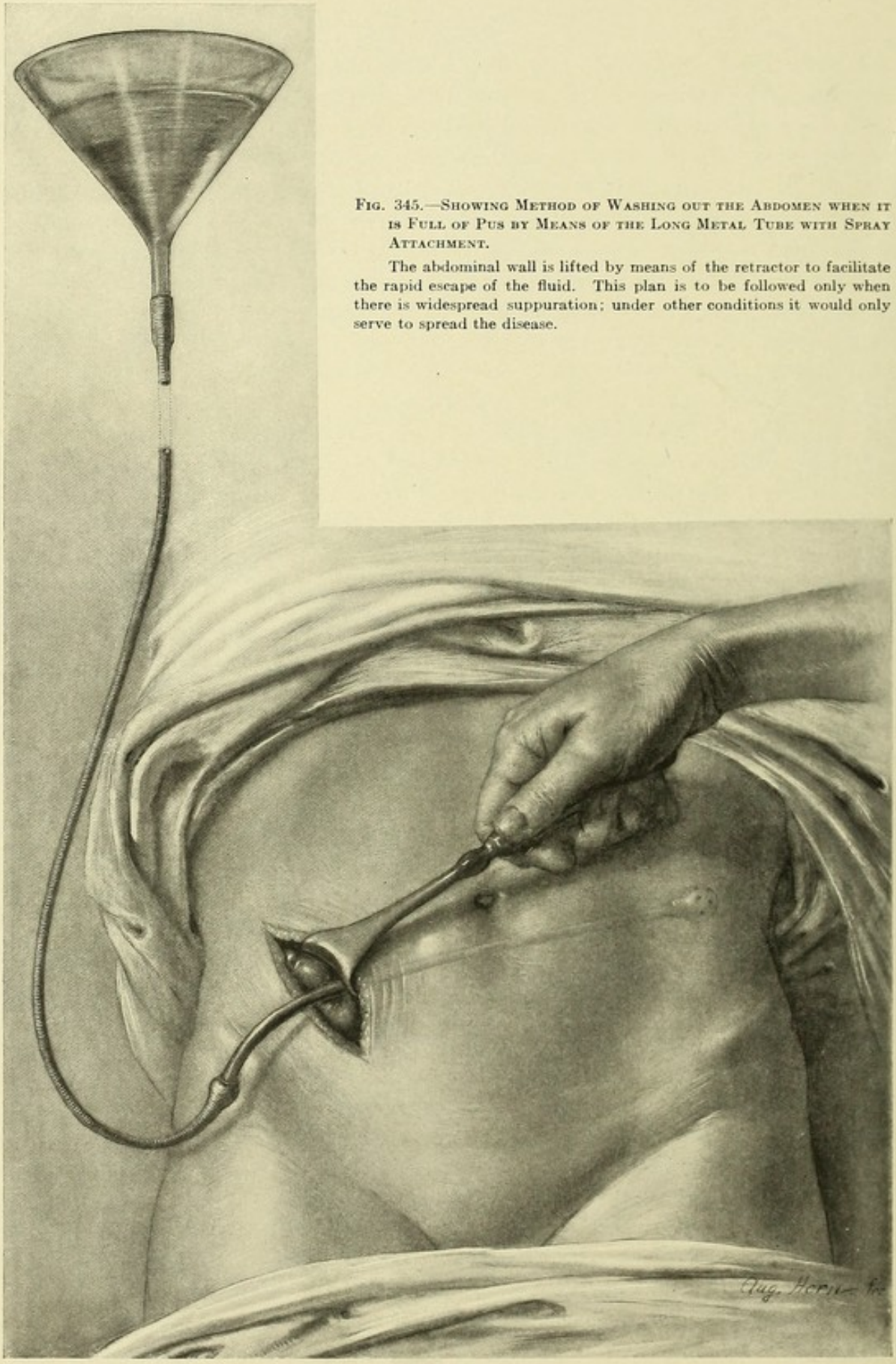

FIG. 345.—SHOWING METHOD OF WASHING OUT THE ABDOMEN WHEN IT IS FULL OF PUS BY MEANS OF THE LONG METAL TUBE WITH SPRAY ATTACHMENT.

The abdominal wall is lifted by means of the retractor to facilitate the rapid escape of the fluid. This plan is to be followed only when there is widespread suppuration; under other conditions it would only serve to spread the disease.

controlled by the drains. It is best not to use any strongly medicated solutions in washing out the peritoneum, such as corrosive sublimate, advised by LÜCKE (*Dtsch. Zeitschr. f. Chir.*, 1887, Bd. 26) and MORTON (*Jour. Amer. Med. Assoc.*, 1888, vol. 10, p. 75), or salicylic acid, as recommended by STEINHAL (*Verhandl. d. dtsch. Gesellsch. f. Chir.*, 1888, Bd. 2, p. 243).

The appendix, *the fons et origo mali*, should be clamped off and removed whenever it is possible. If the tissues about the organ are gangrenous, and there is little hope of the sutures holding, the entire area surrounding the head of the cecum must be walled off from the rest of the abdominal cavity, and

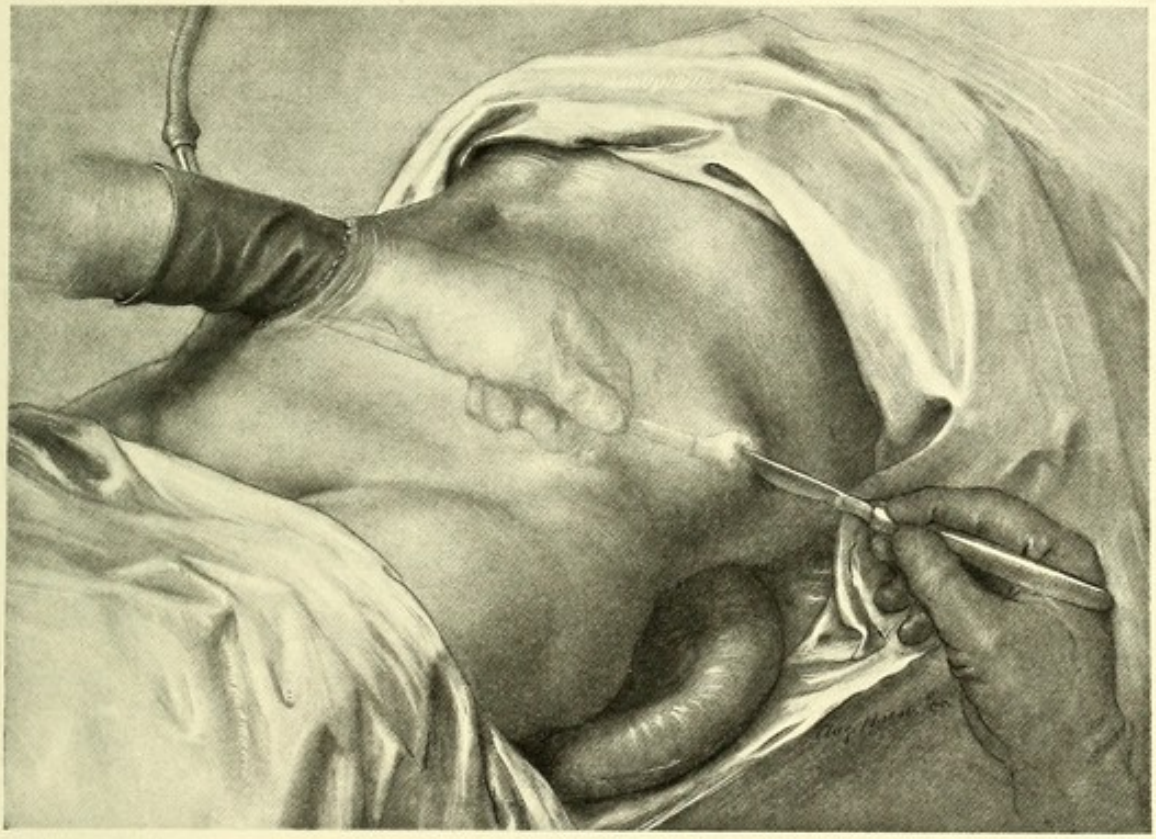

FIG. 346.—METHOD OF USING THE IRRIGATOR TO PUSH FORWARD THE PERITONEUM IN THE ABDOMINAL WALL IN MAKING A LEFT LUMBAR INCISION FOR DRAINAGE IN CASE OF ABDOMINAL PYEMIA.

drained separately through a liberal incision made at the nearest point in the abdominal wall.

Some successful and interesting efforts have been made to save life by continuous irrigation of the abdominal cavity; for example, E. LAPLACE (*Phila. Med. Jour.*, Oct. 14, 1899) reports "*A case of acute general peritonitis treated by continuous irrigation with normal salt solution.*"

The patient had a disseminated fibrino-purulent peritonitis with a gangrenous omentum. After a thorough cleansing, lasting for forty-five minutes, Laplace, who had never seen so grave a case recover, adopted the following plan: the glass

nozzle of the irrigator, still attached to its rubber tube, was introduced as far as Douglas' *cul-de-sac*, and the tube fixed to the abdominal wall by means of a suture at the lower end of the incision. An ordinary glass tube with rubber tubing attached was inserted at a point 3 inches above this. The rest of the incision, above the second tube was closed, while the wound between the first and second tubes was

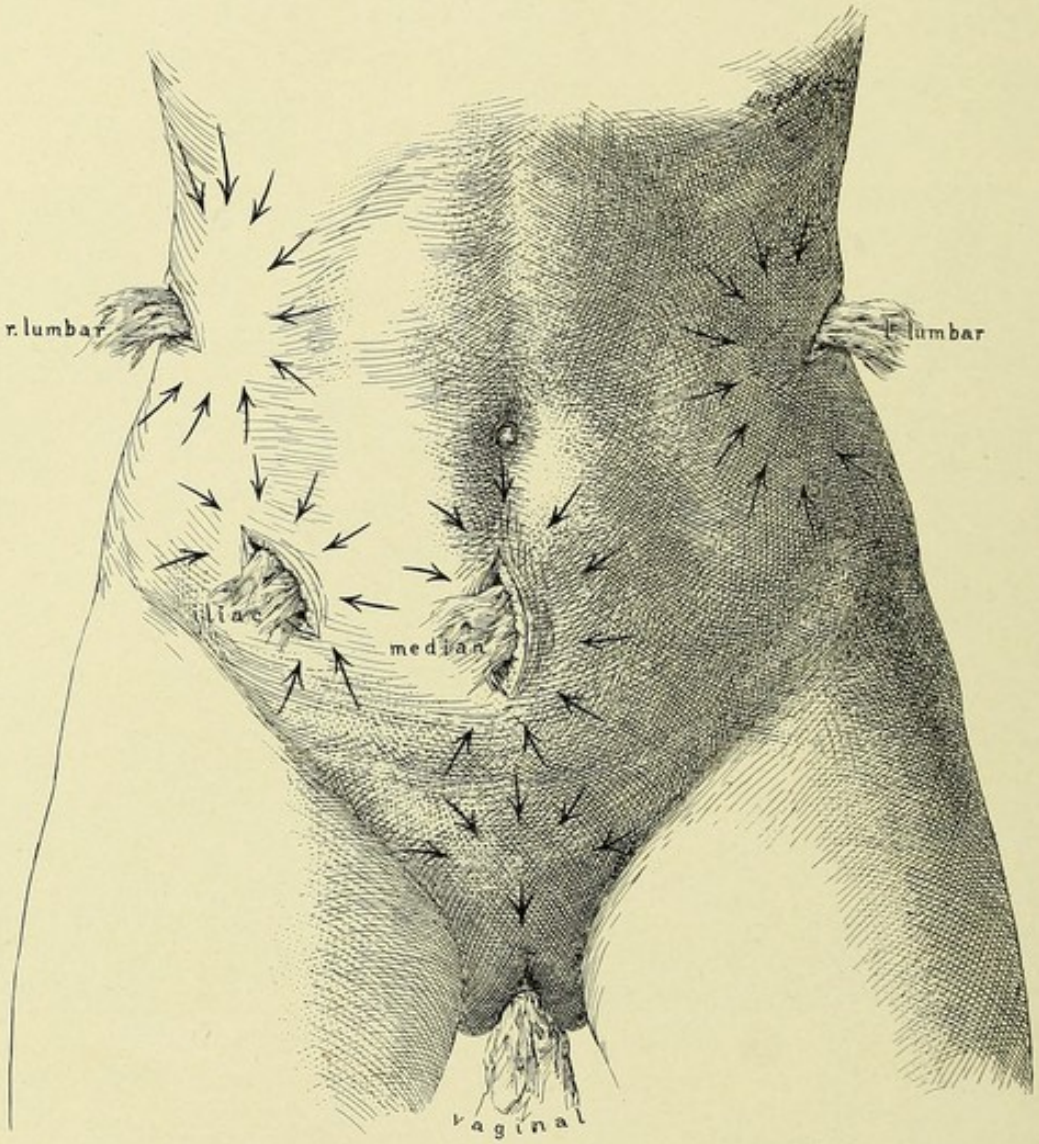

Fig. 347.—Showing Direction of Current from the Adjacent Portions of the Abdominal Cavity toward the Drainage Openings in the Right Iliac Fossa, in the Right and Left Lumbar Regions, in the Median Line, and through the Vagina. It is only in Exceptional Cases that more than one Opening is made. (See p. 648.)

packed. A small gauze dressing was loosely laid on the wound and held in place by adhesive plaster. The patient was then placed on a Kelly drainage pad, communicating with a bucket under the bed. An irrigator was attached to the first tube and a warm normal salt solution was allowed to flow continuously through the abdominal cavity, draining through the second tube and out through the wound on to the pad, and thence into the bucket. This irrigation was kept up continu-

ously, day and night, for seventy-two hours from the time of operation, at the rate of 10 pints every fifteen minutes, making a total flow of 360 gallons of normal salt solution through the abdomen in that time. One-fortieth of a grain of strychnine sulphate was given every three hours. At the end of the seventy-two hours, when the irrigation was discontinued, the patient's condition was good, the temperature 99° F., and the pulse-rate 70.

A year later VAN LENNEP reported a similar case (*Hahn. Med. Month.*, Feb., 1900), the treatment in it having been suggested by the report of LAPLACE.

The patient, a man of twenty-four, had had several attacks of appendicitis, and operation was performed at the end of twenty-two hours from the beginning of the last one, his condition being then very bad. The pelvis and abdomen contained pints, if not quarts, of thin, offensive, sero-purulent fluid. The appendix was removed and a glass ovariotomy tube, inverted, and with the perforated end covered by rubber drainage tubing, was inserted through the lower angle of the wound into the bottom of the pelvis. Another bent glass tube, "right end up," was placed under the liver and connected with a rubber tube leading into a tub beside the bed. The intermediate peritoneal layers were closely sutured and the closure tested by liberal irrigation before the patient was removed from the operating table. The remainder of the wound was left open. Continuous irrigation was kept up for about twelve hours, nearly 20 gallons of sterilized normal salt solution being passed into and out of the peritoneal cavity during that time. It was then deemed advisable to stop on account of dyspnea and rapid respiration. Recovery followed.

Another form of treatment which calls for mention in connection with that of continuous irrigation, is that of injection of alcohol directly into the abdominal cavity, successfully practised by Z. E. EVANS, of Travers City, Mich. (*Ann. Gyn. and Ped.*, 1893, p. 744).

The patient, a physician, thirty-three years old, had had five previous attacks of appendicitis. When operation was performed, his temperature was over 103° F., his pulse 140, and the abdomen distended to its utmost capacity. The abdominal cavity was opened by a five-inch incision. It was found ruptured, and its contents distributed freely over the general peritoneal cavity. The appendix was gangrenous, detached, and floating in feces. In spite of the extremely low and unpromising condition of the patient, Evans took time to wash out the abdominal cavity with warm water, and, to use his own words, "with one hand in the abdomen, I paddled the water around among the various coils of the intestines, washing them absolutely clean." The abdominal cavity was then filled with warm water, and about three yards of gauze were introduced deep down into the pelvic cavity and spread about among the intestines. A suture was passed at each angle of the wound, and "the patient placed in bed, more dead than alive." The next day, as his pulse and temperature were still up, and his mouth and skin dry, the drainage gauze was removed and the abdomen again filled with warm water with immediate good effect, made apparent in a sleep lasting five hours. On the third day he began

to cough and to bring up a "thick pus-like substance mixed with blood"; at the same time he complained of a fixed pain in the right side. The base of the right lung was found to be pneumonic, and as the stomach was rebellious and the sphincters relaxed, Evans then threw a stimulant into the abdominal cavity, injecting by means of a Davidson syringe, 3 ounces of pure alcohol diluted with 2 quarts of warm water. Following this treatment, the pulse dropped from 140 to 107, and the temperature, which was over 103°, to about 100° F. About eighteen hours later the same process of stimulation was repeated, and five hours after it the pulse was 92, the temperature 99° F., the respiration 22, the skin moist, the stomach quiet, and the sphincters contracted so that urine or feces were no longer passed in bed. At the end of five weeks from the day of operation the patient had so far recovered that he was able to go to his office and attend to his professional duties. In a personal communication Dr. Evans states that he was in good health in February, 1902.

Delbet ("*Recherches expérimentales sur le lavage du péritoine,*" *Ann. de gynec.*, 1889, tom. 32, p. 165) has shown that after irrigation for ten minutes, the absorptive powers of the peritoneum are so reduced that it is possible to follow the irrigation with a poisonous solution without harm to the animal.

Wiping out the Intestines.—The majority of surgeons to-day prefer to attack an extensive peritonitis by what may be called, in contrast with the method just described, the dry plan of treatment; that is to say, the abdomen is opened, the areas of accumulation of septic material, when there are such, are exposed, and this material wiped off as far as possible with gauze or sponges. The advantage of this plan is that there is no danger of carrying septic materials into corners where they have not been before, and lodging them there. No one, perhaps, is more emphatically opposed to irrigation than Reichel, who has expressed himself in the oft-cited dictum that "*die Spülerei der Peritonealhöhle eine Spielerei ist.*"

Under the dry plan of treatment a bunch of gauze or a marine sponge is grasped in a long holder and carried down to the bottom of the pelvis, which is then repeatedly sponged out until clean. A fresh sponge is carried over into the right and left renal regions; the mesenteric folds are inspected, and the upper and the under surfaces of the liver. A general agglutination of the intestines *in situ* is not a bad sign and ought not to be disturbed. In introducing the sponge first into one quarter and then into another, it should be carried up close to the abdominal wall. After drying out the disease without spending much time in picking off plates of lymph, the abdomen is closed, drains being inserted extending either from the median incision down into the fossa and into the pelvis, or through fresh openings into the sides, and, in women, into the vagina. This line of treatment accords with the recommendation made by Tietze in 1889 (*Die chir. Behandl. der akut. Periton.*).

Drainage.—After opening the abdomen, cleansing it of poisonous secretions, and, if possible, removing the focus of trouble, the appendix, the next step is to provide against further accumulation and absorption of septic mate-

rial by an efficient plan of drainage. If the patient seems to be almost *in extremis*, and there is a large accumulation in the abdomen to be opened, the surgeon may not be able to do more than make an incision under cocaine, let out as much pus as will escape spontaneously, and insert a large rubber drainage-tube. In less serious cases a gauze drain, whether washed-out iodoform gauze or plain sterilized gauze, acts well for a few hours or a day, but after that time it ceases to affect any area greater than that directly in contact with the gauze itself. The meshes of the gauze then become plugged, and if left *in situ*, it is apt to choke the opening in the abdomen, and bottle up the secretions, rather than promote their escape. To avoid this ill effect it is well, in some cases, after the first day, to begin to pull the gauze out, and so keep it moving day by day until the whole is removed. The "cigarette drain" used by MORRIS, of New York, and WARREN, of Boston, answers this purpose excellently; it is made up of sterilized gauze, rolled in rubber tissue, and can be made of any calibre, is soft and flexible, and does not, like the unprotected gauze, stick to the tissues within, giving great pain with its removal.

Rubber tubing from 6 to 8 inches long and $\frac{1}{3}$ to $\frac{1}{2}$ inch in diameter, introduced and surrounded by gauze, also affords an efficient drain which is not liable to become plugged. If the removal of a drain is painful, a little nitrous oxide gas will overcome the difficulty.

F. BODE (*Centralbl. f. Chir.*, 1900, Bd. 27, p. 33) describes "*A new method of treatment of the peritoneum and drainage in diffuse peritonitis*" as follows: An extensive incision is made with the pelvis elevated, and the peritoneal cavity eviscerated, as far as possible, under a continuous irrigation of a warm saline solution. The separate coils of intestine outside of the abdomen are then wrapped up in compresses wet with salt solution and irrigated afresh, from time to time, to prevent any chilling. BODE says that under this treatment, patients with a small rapid pulse, so far from collapsing, began to improve on account of the relief of tension and the removal of toxic materials. The point of perforation now being found and treated, and the abdominal cavity disembarrassed of its contents, the abdomen is washed out with 30 to 40 litres of salt solution, especial attention being given to the upper surfaces of the liver and the neighborhood of the spleen, as well as to the pelvis. The peritoneum is then carefully and gently cleaned with compresses, the coils of intestines are also cleansed, and returned under saline irrigation into the abdomen. At this juncture a bunch of the small intestines from about the middle of the abdomen is grasped and lifted up, bringing the mesentery into view. The mesentery is then perforated near its root, at a point free from vessels, and a thick and correspondingly long drainage-tube with openings in its walls, is passed through the mesentery and out of the right and left walls of the abdomen over the colon. Besides this principal drainage-tube, another is introduced from each of the lateral wounds, with a fourth from the median incision extending to the deepest part of the pelvis. Further drainage-tubes are introduced, if necessary, to the neighborhood of

the liver, stomach, and spleen, after which the incision is closed with through-and-through sutures. By pouring in fresh salt solution as the wound is being closed, a not inconsiderable quantity of fluid is left behind in the abdomen. The patient is put to bed with the head elevated to favor the downward flow of any pus, which is then washed out through the drainage-tubes by running in salt solution, 1000 to 1500 cc. twice or three times daily. Under such treatment considerable pus escapes, peristalsis begins, gas passes, and the bowels move.

Treatment of the Distended Intestines.—If the intestines are so distended that they can only be returned to the abdominal cavity with difficulty, and if there exists a large accumulation of fluid within the ileum, McCosh's plan of bringing the loops of the intestine outside, incising, emptying, and then closing and returning the bowel may sometimes be tried with advantage. Where the intestines are paralyzed an enterostomy has saved life in numerous instances. This is best executed by keeping the wound open and leaving one of the distended loops, as near as possible to the cecum, exposed in the wound, simply covering it with a pad of iodoform gauze. In order to mark the exact spot for the opening, two fine black silk sutures may be inserted about 2 cm. apart into the outer coats of the bowel, and left hanging out of the wound. Then after six or seven hours, or more, the dressings are removed, the sutures picked up and held apart, and a small opening about 1 cm. in length is made into the lumen of the bowel, affording exit for gases and fecal material. The attention of the profession has been called to this mode of treatment by W. W. Van Arsdale in a paper entitled "*The treatment of the intestinal paralysis of peritonitis by enterostomy*" (*Ann. Surg.*, 1889, vol. 29, p. 1).

CHAPTER XXVIII.

CARE OF PATIENT AFTER OPERATION AND POST-OPERATIVE SEQUELÆ.

CARE OF PATIENT AFTER OPERATION.

All is not finished with the completion of the operation. Success or failure still largely depends upon the intelligent, watchful after-care of the surgeon and the nurse; proper attention to many seemingly trivial, yet important details during the first two or three weeks following operation will often do much to shorten the period of true convalescence.

The surgeon must always bear in mind that there are two factors in every convalescence, namely, the recovery from the wound and the disease, and the recovery of the nervous system from the exhaustion caused by the illness and the shock of the operation. From the patient's standpoint, his convalescence is divided into two periods: a first, in which he is confined to bed; and a second, in which he is up and looking forward to complete recovery of his strength and the entire removal of the discomforts left by the operation. During the whole period of convalescence the physiologic economy of the man is actively engaged in striking a fresh balance with his resources, in order that he may once more enter upon the duties of life with renewed vigor.

It is a fond superstition of the laity, often, I am sorry to say encouraged by physicians, that the convalescent period is shortened by hustling the patient out of bed a few days after the operation; while, on the contrary, it is often lengthened by such treatment. I have seen patients, untimely thrust from the hospital, and reported as "up in eight days," who, weeks afterward, were still feeling miserable, and unable to work. It is possible, of course, to get a patient out of bed in eight days, and they may do well in spite of this treatment, but it is not to their best interests, and it does not really shorten the convalescent period, which truly ends only when they are able to resume their normal activities with zest.

I also mention, only to condemn, the practice pursued by some surgeons of performing the operation, and then leaving the patient entirely in the hands of a medical man without experience in surgical work. When the case is remotely situated in the country, this may be unavoidable, or a choice of evils, but even under these circumstances, a trained assistant should either remain behind or make some subsequents visits. It is never justifiable to operate and then abandon the patient, as a compliment to the family physician, who is anxious to

enhance his services in the eyes of the relatives. The man who does this is treating his surgery in the light of a trade.

The post-operative period requiring the greatest watchfulness and care, extends, in the average case, over the first five or six days, during the first two or three of which the patient is getting over the shock of the operation and the nausea caused by the anesthetic; a day or two longer is required to re-establish the much desired regular activity of the bowels.

The signs of a normal convalescence following a surgical operation which is the termination of a protracted illness, are to the anxious bystanders what the rest of a quiet harbor is to the storm-driven mariner. With extreme satisfaction does the surgeon announce to the anxious family the hourly improvement, manifested by the falling temperature, the full, steady, quiet pulse, the decreasing abdominal tenderness and softening of the abdominal walls, the diminution of pain, and the passage of flatus. As improvement progresses, the patient recovers a sound healthy color, his interest in his surroundings quickens, annoying thirst is replaced by a sound, healthy hunger, and the balm of sweet refreshing sleep during the night extends its blessing over the waking period.

If convalescence proceeds uninterruptedly after this manner, the patient may rise from bed in two weeks, but he is wiser if he consents to stay there for three; then for a few days, if the weather permits, he should be wheeled in a rolling chair into the fresh air; a little later still he takes a few steps, and so, in five or six weeks he dispenses with nurses and doctors and is able once more to care for himself.

If the wound is a small one, and especially if the muscular fibres have not been much cut, it is not necessary that the patient should wear an abdominal bandage, which is at best but an awkward contrivance for giving support over the iliac fossa. Where the wound is extensive, however, and above all where there has been drainage, a snug, supporting bandage should be worn for six months or longer.

Nursing.—It is of the utmost importance that the nurse should be personally acceptable to the patient as well as one well trained in abdominal surgery. In a simple, uncomplicated case of appendicitis one nurse may suffice, but if the patient is critically ill, two, or even three will be required.

Immediately after the operation the patient should be placed in a warm bed, carefully prepared. The room must be darkened, the air kept fresh and sweet at a temperature of about 63° F. Absolute quiet must be maintained, and members of the family should, as a rule, be excluded for several days. The first person admitted should be that near relative whose presence is pleasant and comforting to the patient, the rule being imposed that "silence is golden." The surgeon must constantly bear in mind that he has under his care a wound which is healing and a nervous system which is recovering its balance after a severe shock; the latter is longer in recup-

erating than the former, and nothing so much delays this part of the convalescence as excessive visiting. No outside visitors should be admitted for several weeks.

Posture.—The best posture for the patient is on the back with the knees slightly flexed, but he should be turned occasionally on the right side to rest the tired muscles. The moving must always be done by the nurse.

Sedatives.—Severe pain must be relieved by hypodermics of morphine, say one-eighth of a grain repeated in twenty minutes if neccessary, during the first twenty-four to forty-eight hours whenever the pain becomes unbearable. In the case of a child it is best to give one thirty-second to one-eighteenth of a grain every twenty minutes until the pain is relieved. In ordinary cases no morphine should be given after the first forty-eight hours, as its continued use retards recovery; and it may be laid down as a good general rule that the less morphine given, the more satisfactory is the convalescence. In some cases a grain of the aqueous extract of opium in a suppository works better than the morphine, exerting a more direct local influence.

Diet.—All nourishment should be suspended after the operation until the stomach is settled. The first food given should be egg albumen, prepared by beating the whites of four eggs to a froth, and allowing it to stand in a cool place for an hour or more, when the liquid (about 50 cc.) can be drained off, leaving the frothy part behind. It is best to give a teaspoonful at a time mixed in two or three tablespoonfuls of cold water with a little sugar and five or ten drops of lemon juice. It may also be given in ginger ale, in orange juice, or in sherry wine. About the third or fourth day soft food may be given, and after the first week a stronger diet may be gradually resumed. As a rule, attendants are over-anxious to feed patients, who can often stand absolute starvation for four or five days very well. Where the stomach has been much disturbed previous to operation, J. F. Mitchell has found it of great service to wash it out on the operating table, using abundance of warm water, and continuing until the washings return clear. In cases which suffer from persistent nausea after the operation, with no other ill symptoms, one or two good washings often bring great relief.

Care of the Wound.—Protection from exposure, and rest are the two important factors in the care of the wound. Protection is best secured by the dressings, held in place by a suitable bandage applied at the conclusion of the operation, in such a way as to cover the right iliac fossa, the groin, the upper right thigh, and the lumbar region. If the bandage is snugly applied, the parts are immobilized, and the formation of a loose sliding plane between the dressings and the body is avoided. An infected wound may easily arise from dressings loosely applied or which have worked loose in the convalescence; in such a case every movement of the body, every deep respiration, tends to suck in the air beneath the bed-clothes and to bring gross particles into contact with the incision. To avoid this, the dressings and the bandages must be

properly placed, secured if necessary by adhesive straps, and watched as well, to make sure that they are not loose or slipping upward. To insure rest, the patient must lie in perfect repose during the first days of convalescence, above all avoiding any use of the right leg. All movements must be of a passive nature, effected by the skilled hands of the nurse or of the medical attendant. If all goes well, as shown by pulse, temperature chart, and general condition, the wound should not be disturbed for from seven to nine days, when all the dressings may be removed with care, and the parts contiguous to the wound cleansed with alcohol and water, or soap liniment, and some fresh lighter dressings applied. If there is a subcuticular wire or catgut suture, it may be drawn out at this time. A few days later all dressings may be removed, and the wound simply covered with a pad of gauze to protect the tender tissues from violence.

If for any reason the patient does badly, the pulse and temperature go up, the general condition cause any anxiety, or if there is much persistent pain, the wound should always be examined. If it is found sensitive, red, and puffy or swollen at any part, it should be opened at once under a little cocaine, and then, if pus is found, poulticed. It is a mistake to try to let out the pus through a small orifice under these circumstances; the focus of infection, whether just under the skin or lower down, must be regarded as the apex of a pyramid whose base is at the skin surface. It is always unfortunate when the infection extends down into the iliac fossa to the seat of the operation on the bowel, but if the condition is recognized promptly, and effectively treated by thorough exposure and drainage, the misfortune is limited, after all, to a delayed convalescence, and the risk of a hernia at a later date. Even when the bowel breaks down, and a fecal fistula is established, it is, as a rule, but temporary, and exhibits a remarkable tendency to rapid spontaneous closure within a few weeks.

Care of the Bowels.—The movement of the bowels gives as much cause for anxiety as any single feature in the average convalescence. When the surgeon has mastered the complications, the appendix has been removed, and the wound well closed, no anxiety need be felt as to the administration of the necessary purgative for moving the bowels. If it is a matter of importance, as it is in some cases of appendicitis, that they should move soon, the plan pursued by J. M. T. Finney may be adopted, and about six ounces of a saturated solution of Epsom salts run into the stomach at the conclusion of the operation. The saline given in this way is rarely vomited, and a satisfactory evacuation may be secured as early as eight hours later. In severe cases one or two drops of croton oil may be administered in this way. If purgation is not urgent, a substantial dose of calomel may be given on the second day, followed by an enema in from eight to twelve hours, or broken doses of calomel may be given, say a sixth of a grain every hour, followed by an enema in about eight hours. A teaspoonful of liquorice powder of the German Pharmacopœia answers very

well with some patients. BURRELL uses a saline cathartic whenever there is a rise in temperature, a quickened pulse, and a glazed tongue. He gives a saturated solution of salts in tablespoonful-doses, taken in soda water from a siphon, and very cold. This may be repeated from hour to hour. After giving sufficient purgatives and using an enema, it is well to wait for six to eight hours and give nature a chance to act, if the case is doing well in other respects. The bowels will then often move spontaneously and satisfactorily without further stimulus. The doctor and nurse must be careful not to let their good judgment fail them through an over-anxiety to hasten the movement; too many or too severe purgatives may leave behind a troublesome diarrhea.

Urine.—A free flow of normal urine is one of the reassuring signs during convalescence. The urine should be kept, measured, and examined in all cases; if albumen or casts have been found in the urine before operation, it will naturally be watched with greater care during convalescence and the gradual disappearance of these pathologic elements hailed with satisfaction. Kidneys which have been injured by a septic storm are best cared for by promoting a free flow of bland urine, and this is accomplished in most cases by giving a hypodermocleisis of 600 to 1000 cc. of normal salt solution, administered on the operating table, and repeated once or twice in each twenty-four hours for several days.

Severe and Fatal Cases.—The surgeon must always feel that a patient who has strength enough to pull through an operation and live for two or three days afterward, ought to recover, unless some unforeseen and unavoidable sequelæ, such as a metastatic abscess, pneumonia, or embolism, should occur. It sometimes happens, however, that a case which would otherwise recover, fails to do so from some defect in technic, not necessarily due to a fault on the part of the surgeon, but arising rather from our still imperfect knowledge as to the best method of drainage, the propriety of draining at all, or some other vital point. The conditions which should occasion anxiety are as follows:

Persistent pain, usually associated with elevation of temperature, is a sign of suppuration in the wound or beneath it, and the local condition should be investigated at once. A quick pulse and persistent nausea, growing worse rather than better, point toward septic peritonitis. A distended abdomen accompanied by vomiting is an indication for the evacuation of the intestinal tract. If auscultation reveals gurgling it is reassuring evidence in cases of paresis of intestinal activity, showing that the intestines are capable of performing their normal functions.

Psychic disturbances, such as great restlessness, persistent painful wakefulness, or too eager assurance of recovery, are often associated with profound septic troubles.

Where not the signs of a graver trouble, they should be combated with mild sedatives, such as bromides, trional, heroin, etc.

POST-OPERATIVE SEQUELÆ.

Introductory.—It is an unfortunate fact that the conclusion of an operation does not invariably terminate all anxiety as to the patient's recovery. Oftentimes the operation, especially if it has been difficult, is followed by a more or less stormy convalescence, interrupted, it may be, by sequelæ which seriously threaten life itself.

Many of these disturbances are common to all major surgical procedures in which an anesthetic has been used, such, for example, as nausea and vomiting, hiccough, extreme nervousness, excessive pain, sleeplessness, and mania. Other sequelæ are those more peculiarly associated with lower abdominal operations, especially such as involve infected areas, *e. g.*, peritonitis, abscesses forming in or underneath the wound, ileus, phlebitis, pneumonia of embolic origin, or septic pleurisy.

The character of the post-operative sequelæ is apt to vary according as the case has been simple or difficult, and for this reason it is possible to anticipate certain evils according to the nature of the preceding illness; for example, after a simple removal of the appendix, only such disturbances are apt to arise as affect the earliest period of convalescence, *e. g.*, tympany from atony of the bowel, or pain arising from a simple traumatic peritonitis. After a more serious operation, in which, for instance, an abscess has been opened or the peritoneum has been soiled, the anxiety of the medical attendant during the first few days of convalescence is concentrated upon those symptoms which point toward a fresh accumulation of pus, to a spreading peritonitis, or an intestinal obstruction. The best guarantee against the onset of serious symptoms during the convalescent period is the correct performance of every step of the operation, and the recollection of having done this is a source of great comfort to the operator. Careful work and painstaking attention to detail are the best prophylactics against accidents during convalescence, and many of the most serious post-operative sequelæ may be obviated by these means. Moreover, the peculiar difficulties of an operation often throw light upon the possible sequelæ and suggest means of obviating them. If, after closing the stump, it is well embedded in the cecum, it will not then contract adhesions with the bowel or omentum. By avoiding undue handling of the intestines and the adjacent peritoneum the delicate epithelium is spared abrasions, and traumatic peritonitis with adhesions will, to a large extent, be avoided. In using a retractor, great care must be taken not to bruise the iliac vein; as this precaution insures against one prolific cause of phlebitis. By thorough cleansing of abscess

cavities and the freest possible drainage, the necessity of opening them again at a later date will often be obviated. Secondary operations will also be avoided, if the surgeon is careful at the time of the first operation to locate other abscesses in the pelvis, among the intestines, or in the flanks, and to drain them in their most dependent portions. An extension of peritonitis by the extravasation of feces a few days after the operation will be avoided if torn and sutured intestinal areas are brought out, with less hesitation than is usual, and left exposed to view in the open abdominal wound. When an operation is undertaken for an ileus, the surgeon will often be spared the mortification of repeating it, if he examines carefully all the adjacent coils of intestine to make sure that he has not overlooked any important adhesions. Hernia is best avoided by operating early, before the advent of such symptoms and complications as necessitate drainage of the wound, that is to say, by a very early operation, or by one in the interval.

If we look at these sequelæ according to their relation in time to the original operation, we may conveniently divide them into early, intermediate, and late.

Early sequelæ are those associated with the anesthetic, the nervous condition incident to the operation, and the continuation of those disturbances which are projected forward into the time of convalescence from the pre-operative stage, such as the extension of a peritonitis.

Intermediate sequelæ are those which begin a few days to a few weeks after the operation, and are caused by the evolution of an abscess, by an ileus, the formation of a phlebitis, or the lodgment of an embolus.

Late sequelæ, which may arise months or years after the original operation, are hernia in the scar, and intestinal obstruction.

Homer Gage reports that out of 228 cases operated upon for appendicitis whose subsequent history he was able to trace (in many of which the abscess was simply drained), 42 made complaints of one sort or another on inquiry. Out of 54 cases there was a recurrence in 10 per cent. In a number of instances, however, the replies indicated that the complaints were of long standing, and not post-operative. Thirteen complained of more of less discomfort in the region of the scar; of soreness caused by exercise; of pain on the approach of a storm; of a weakness noticeable most of the time. Every operator is familiar with the complaint of persistent pain in the neighborhood of the wound, and the assertion that the discomfort is the same as it was before the appendix was removed. Some of these discomforts are caused by the large, tender scar; some, undoubtedly, are due to the injury of nerve fibres during the operation; others to a localized peritonitis and adhesions about the head of the cecum. One of Gage's cases was a young school-teacher, whose appendix had been removed in the interval, and who experienced such severe pain in the region of the scar, with

tenderness over the upper end, that she had to give up her work and go to bed. On re-opening the abdomen an adhesion of the omentum was found, about half an inch square. This was liberated, and the relief was immediate and complete, all pain and tenderness disappeared, and she was able to resume her occupation. In another case a woman, thirty-five years old, complained of great soreness and tenderness in the region of the scar, which was excised and freed with equal success; some omental adhesions also were freed.

Sometimes the pain in the iliac fossa simulates the old attacks of appendicitis, but this, for the most part, wanes steadily, and disappears after some months or a year. In one case, however, occurring at the Johns Hopkins Hospital, a man had such definite attacks following operation that it was at last thought the appendix could not have been removed. On a second operation, however, there proved to be nothing at the site of the organ but adhesions.

One of the most troublesome sequela is an area of anesthesia over the lower abdomen at some point between the scar, the median line, and the symphysis. This is due to the injury done by division of the sensory nerve fibres, and is best avoided by a careful dissection with blunt separation of the tissues, the nerve trunks thus being spared. The division of the nerves entering the rectus muscle across the semilunar line is often responsible for a marked atrophy of the muscle and a thinning of the abdominal wall. This serious accident is also easily avoided by duly respecting the nerves, when the tissues are divided in opening the abdomen (LENNANDER).

Hemorrhage.—A post-operative hemorrhage may take place from some vessel large enough to cause a serious loss of blood, which may have been perfectly controlled during the operation by the crushing power of the clamp. A warning example of this contingency is frankly furnished by R. L. PAYNE, of Norfolk, Virginia, who, when operating upon a child, divided and clamped the epigastric artery while making the abdominal incision, and in the anxiety and hurry attendant upon a difficult operation, no ligature was applied, as there was no bleeding when the clamp was removed. The wound had to be drained, and when the hemorrhage occurred, although there was every opportunity for the nurse to call the surgeon, she did not do so, until the patient had bled to death, when all the dressings and the bed were found saturated with blood.

SIR DYCE DUCKWORTH (*Med. and Surg. Trans.*, 1889, vol. 72, p. 433) operated upon a boy of sixteen, for the removal of an appendix which was gangrenous for two-thirds of its length. The patient did well for eight days, when he began to have pain in the region of the wound, for which half a grain of the extract of opium was administered. As the pain continued to increase, the dressings were removed and a large blood-clot was found; this was removed, but the source of the hemorrhage could not be discovered. The drainage-tube in use was then replaced by a plug of iodoform and lint, and the wound tightly ban-

daged. In the afternoon the wound was dressed, and a quantity of dark, clotted, and grumous blood removed; recovery followed.

WALCH (Havre), under the title "*Hemorrhagie intestinale grave à la suite d'une operation d'appendicite à froid*" (*Bull et mém. de la Soc. de chir. de Paris*, tom. 27, p. 374), cites a case in which he resected the appendix in a man forty years old, three months after an attack of appendicitis. He placed a ligature around the base of the appendix, but did not cover the stump with the serosa. Three days later the temperature rose, and the man developed an undoubted right-sided pleurisy. Six days after the operation he became suddenly worse, and suffered from tenesmus, followed by the sudden discharge of an enormous quantity of blood from the rectum; in addition to three litres discharged in this way, he vomited about 300 to 400 cc. of blood mixed with the contents of the stomach. WALCH believed that the bleeding proceeded from the site of the operation, on account of the manifestly arterial tint of the blood, and he considered that the hemorrhage arose from the slipping of a ligature. The patient recovered with no more serious disturbance than the great fright.

In order to avoid a secondary hemorrhage of this nature it is best to tie all large vessels as soon as they are divided, especially those in the deeper layers of the wound, and in the peritoneum. It is also well to sterilize all sloughing areas over the iliac vessels by cautiously applying a little pure carbolic acid, at once neutralized by alcohol. Any serious hemorrhage ought to be controlled temporarily by the compression of the internal iliac artery, or even the abdominal aorta, until the arrival of the surgeon, when the whole wound must be opened up and cleansed, the bleeding points being exposed and ligated. Hemorrhage from the little vessel in the wall of the appendix or from the cecum can be obviated by the ligation of the artery of the mesenteriolum down in the angle near the colon, by crushing the stump, or by cauterizing it.

Suppuration of the Abdominal Wound.—In removal of the appendix, as well as in other abdominal operations where there is an antecedent infection, there is a liability to suppuration of the abdominal incision, which may seriously disturb convalescence, although grave fears for the safety of the patient do not arise until the nature of the trouble becomes evident. This disturbance usually manifests itself in four or five days or, perhaps, a week after the operation, when the patient, who has been doing well, or who has had at most a slight and inexplicable rise of temperature for a few days, begins to complain of a pain, often definitely localized, the temperature goes up to 102° F. or even higher, and there is sometimes a pronounced chill. The aspect of the wound, hitherto favorable, now takes on the appearance characteristic of a localized infection with suppuration. In all cases with such a history, attention should first be directed to the condition of the wound. The dressings should at once be removed and the incision carefully inspected; if it is infected, the edges will be reddish and pouting from puffing of the skin at some definite point, or else all along the wound; or, induration, slight swelling, or tenderness may be discovered at some point on

palpation. In such a case the diagnosis is clear, and a little gas should be administered as soon as possible, after which the edges of the incision are drawn apart and the infected area laid widely open, cleansed, drained, and then allowed to heal by granulation.

Gas Formation.—H. L. BURRELL (*Bost. Med. and Surg. Jour.*, May 2, 1894) reports three instances of this condition, in which, on the tenth or twelfth day after removal of the appendix, and after the temperature had become normal, its sudden and continuous rise, accompanied by chills, obliged him to open the wound. On separating the intestines, the escape of a large quantity of gas took place, causing a bystander on one occasion to remark that there must be a perforation of the bowel. No opening was found, however, and in every case the temperature fell to normal as soon as the wound was packed, the patient making a complete recovery. In the absence of other reports of a similar post-operative sequela, it must be concluded that some special local cause temporarily associated with the operator had been at work in these cases.

Gangrene of the Wound.—In badly infected cases, contamination of the wound at the time of the operation may result in gangrene, affecting the exposed muscles, the fat, and the skin; it is manifested by redness, infiltration, fever, local pain, odor, and the appearance of sloughs. The proper management of such a condition consists in the freest possible exposure of the entire affected area, and its daily treatment by cutting away the dead tissues, cleansing with peroxide of hydrogen, and disinfecting the area with a poultice of Labarraque's solution (sodium carbonate 10, chlorinated lime 8, water to 100; made up with flaxseed meal or corrosive sublimate 1 : 1000). Instead of this, or alternating with it, a charcoal poultice may be applied.

Abscess.—Sometimes, but fortunately in rare instances, a small localized suppuration will take place in or about the head of the cecum, which, becoming encapsulated by adhesions and an adherent omentum, remains indefinitely *in situ*, giving rise to pain and local discomfort, which are apt, sooner or later, to necessitate a secondary incision. A suppuration within the peritoneal cavity may also be lodged in some other part of the peritoneum, as, for example, in the right lumbar region, in the pelvis, or among the intestines. Suppurations at a distance from the wound, although discovered at some date subsequent to the operation, are not properly to be classed among the sequelæ dependent upon the operation itself. We shall, therefore, consider only the local suppurations in contiguity with the wound.

Sometimes an infection starting in the neighborhood of the amputated appendix or under the cecum develops slowly and becomes completely walled in, giving rise to symptoms of infection and local discomfort, more or less resembling the original attack of appendicitis. Such a case occurred in the practice of T. S. CULLEN (*New York Med. Jour.*, 1902, p. 1111. See Figs. 348 and 349).

A boy, fourteen years old, had a severe fall, followed some days later by an acute

appendicitis. The appendix was removed and an abscess drained, but a week later there was an elevation of temperature, and on taking out some of the stitches nearly half a pint of pus was discharged. In eight weeks the patient was about again, and for two years remained fairly well; at the end of that time a boy fell across him, causing a return of the pain in the right iliac fossa. Shortly after this accident he fell out of a boat, and was again seized with pain, after which he was confined to bed, and his temperature ranged from 102° to 104° F. When seen, ten days after

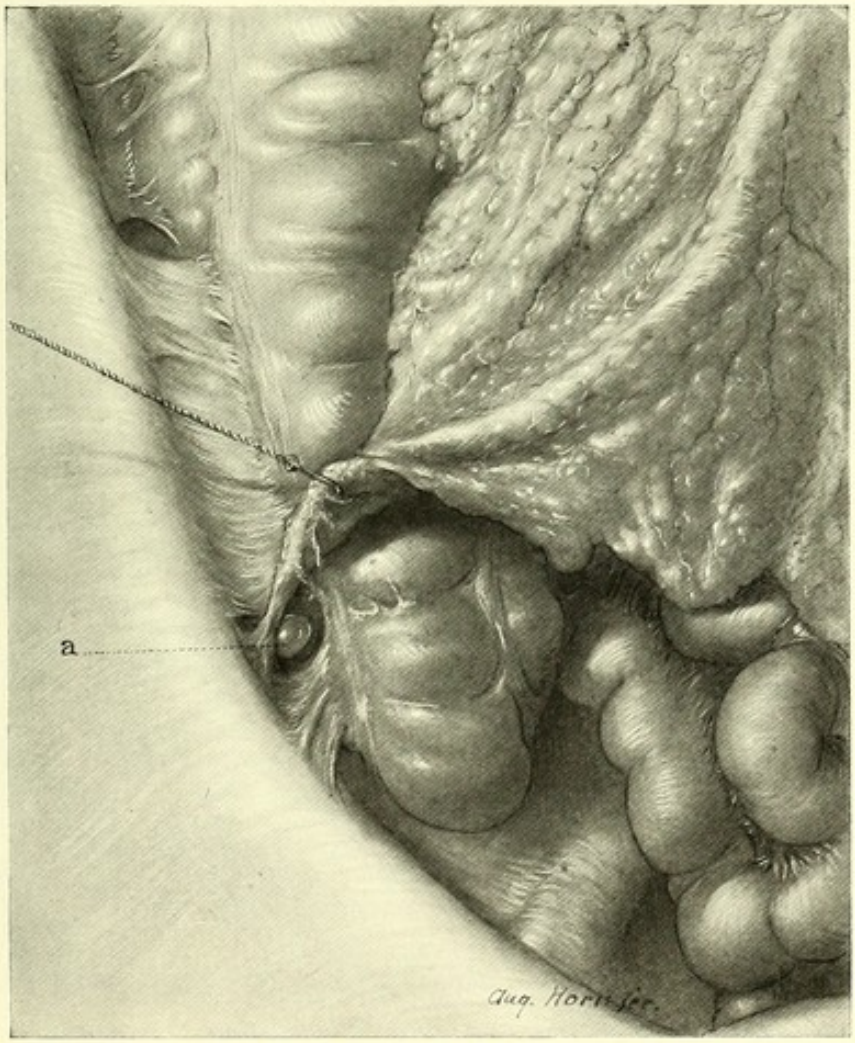

FIG. 348.—CULLEN'S CASE. THE APPENDIX HAD BEEN REMOVED TWO YEARS BEFORE.
At the second operation the omentum was found adherent over the outside of the cecum, and behind this lay the small abscess (a).

this last attack, an area of induration could be recognized on deep palpation just to the outer side of the scar. At the operation, on the next day, the scar was dissected out, and the convex lower end of the cecum exposed. The stump of the appendix was found in perfect condition and free from adhesions, but at a point about two inches above it, the cecum with a small portion of the omentum, was attached to the abdominal wall by a few adhesions. On gently pushing back the omental adhesions from the cecum and the lateral abdominal wall, a drop of pus made its appear-

ance. This region was at once carefully walled off from the surrounding intestine by a gauze pack, and a pocket containing fully 100 cc. of thick, creamy, yellow, offensive pus was then evacuated. The abscess cavity, which lay between the lower surface of the cecum and the parietal peritoneum, was loosely packed with iodoform gauze, while the intestines were shut off in the same way. The temperature soon dropped to normal, and recovery was uneventful, the wound closing in about four weeks. The origin of this abscess was probably a minute pus pocket behind the cecum, overlooked

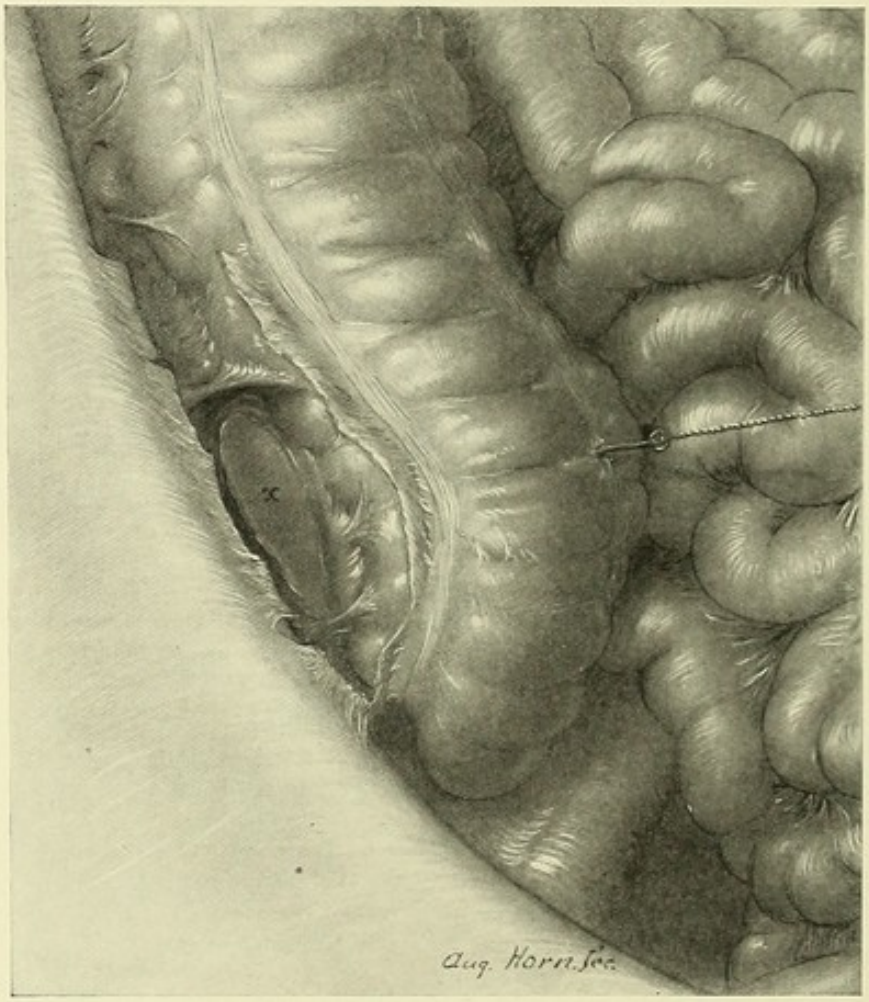

FIG. 349.—SAME AS PRECEDING, SHOWING ABSCESS (x) EXPOSED BEHIND CECUM.

at the original operation; the tissues had been able to take care of so small a purulent focus until repeated injuries ruptured the walls and aided its further extension.

In a case of my own, the removal of a very adherent appendix, in which there was no trace of infection, associated with an extensive and difficult enucleation of adherent pelvic viscera, was followed by the development of a localized infection behind the cecum. The abscess was promptly opened, when it discharged about 30 cc. of a milky, watery fluid. There was no general peritoneal infection, but the patient died subsequently from obstruction, due to general

adhesions among the small intestines, which had been associated with inflamed pelvic viscera.

Epididymitis.—A. WORCESTER, of Waltham, Mass. (*Boston Med. and Surg. Jour.*, Aug. 4, 1898), gives a case of epididymitis in a boy ten years of age, which supervened after the opening of an abscess in the right iliac fossa and in which several ounces of thick pus escaped and a sloughing mass was found which resembled the appendix.

Cancer in the Wound.—RICHARDSON and BREWSTER cite a case of cancerous infiltration of the whole ileocecal region, occurring a few months after the removal of a chronically inflamed appendix at the Massachusetts General Hospital (*Bost. Med. and Surg. Jour.*, July, 1898). It is probable that a small cancerous appendix had here given rise to an early perforation with extension of the disease beyond the organ removed, and that its true nature was overlooked. Such a case has been discovered in the pathological laboratory of the Johns Hopkins Hospital by E. HURDON.

Pyelitis.—I have seen one instance of infection of the right kidney as a sequela to an operation upon an inflamed appendix, and this was the case of a physician whose appendix was removed at another clinic in June, 1900. His bladder and upper urinary tract were apparently infected by the attendant who catheterized him, and a persistent pyelitis followed. This was not relieved until I did a nephrotomy and drained the kidney on the fifth of July, 1900, an operation which was followed in a few weeks by a complete and permanent recovery. WILLY MEYER (*Med. Rec.*, Feb. 29, 1896) reports the case of a young woman who, "after complaining of pain in the right groin for eight days, developed symptoms of a most acute peritonitis." At operation, the appendix showed an acute catarrhal inflammation, but no gangrene or perforation, as had been fully expected; neither was there a fecal concretion nor any adhesions, but the neighboring peritoneum was highly hyperemic and the true pelvis contained sero-purulent fluid. The wound was left widely open for drainage, and the patient hovered between life and death for five days with symptoms of acute sepsis. On the twentieth day after the operation, when her temperature and pulse for the first time were normal, fever set in with pain in the left renal region, and the urine, which up to this time had been slightly turbid, suddenly became clear. A diagnosis was made of obstruction of the ureter by pus and clotted blood, due to an abscess of one of the pyramids of the kidney. The difficulty was suddenly relieved by the reappearance in the urine of a heavy, bloody, purulent deposit. Three weeks later the urine was normal, and the patient recovered.

Cystitis.—Inflammation of the bladder, due to neglect in allowing overdistention, or to defective catheterization, or often in spite of every precaution, is a frequent sequela to operations of all sorts, including appendicitis. Cystitis would be discovered more often than it is, if cultures were habitually taken whenever the patient makes the least complaint of dysuria, but, as it is, the lesser grades

of disturbance of the urinary system are rarely observed, owing to the general neglect of this practice. In my private hospital it is my invariable custom to draw a little urine when the patient is brought on the operating table, and make cultures from it. In this way the presence of infection is often demonstrated before operation. Dysuria, and perhaps cystitis, will be noted much less frequently in the convalescence, if the practice is generally followed of administering a saline enema in all simple cases, while the patient is still upon the operating table. Some surgeons prefer, instead of this, to give urotropin beforehand in five or ten grain doses three times a day.

Auto-infection (Acetonemia).—G. E. BREWER has reported a fatal acetonemia following an operation for acute appendicitis (*Ann. Surg.*, Oct., 1902). Acetonemia is a form of auto-intoxication characterized by a well-marked sweetish odor of the breath, by delirium, and by a rapidly fatal coma. The odor, which is sometimes faint and scarcely appreciable, and in other cases strong enough to fill the room, is that of acetone, and is compared by some persons to a pippin apple, and by others to chloroform. Acetonuria was at first recognized only in fatal cases of diabetes, but has now been shown to occur in infectious fevers, in general sepsis, in intestinal fermentation, and in putrefactions, etc. Acetonemia constitutes a form of acid intoxication, or "acidosis," which results in a marked diminution in the alkalinity of the blood, diminishing its power of absorbing carbon dioxide from the tissues, so that the clinical signs are due to a carbonic acid poisoning as well as to the acetonemia.

In BREWER'S case the patient, a school-boy twelve years of age, had a perforated, gangrenous appendix, surrounded by a small abscess cavity containing but a few cubic centimetres of foul-smelling pus. The appendix was removed, the cavity disinfected, and two cigarette drains inserted; the duration of the anesthesia was only about twenty minutes. On the third day, the temperature was normal, the pulse seventy-six, and the patient was cheerful, free from pain, and hungry. The bowels moved well and much gas was expelled. The urine, which was normal before operation, showed afterward a slight trace of albumen, with finely granular and hyaline casts; there was no sugar. The third night after the operation the patient slept quietly until shortly after midnight, when he awoke with a piercing shriek, in agonizing terror. This condition continued at intervals, with profound sleep intervening, until death occurred, a little over twenty-four hours later. The temperature was not elevated, nor was the pulse quickened, the abdomen was soft, there was no distention, and the excretion of urine was free. When Brewer wakened him, he "uttered an agonizing cry and looked the picture of abject terror. His eyes wandered from one person to another without the slightest sign of recognition. He continued to scream with such vehemence that his cries were heard all over the building. All efforts to soothe him were unavailing; his terror was painful to witness, and the whole picture suggested unspeakable fright, with the most acute mental suffering. These paroxysms would last from a few seconds to two or three minutes, and would be succeeded by a comparatively long interval of rest, during which he

would apparently be sleeping quietly." In a short time a peculiar, sweetish, ethereal odor of the breath was noticed, and acetonemia suspected. Examination of the blood and urine showed the presence of large quantities of acetone and diacetic acid in both. He died the following morning in coma.

The treatment employed was the rational one of the abstraction of 400 cc. of blood followed by the infusion of 1000 cc. of normal salt solution, containing about 15 gm. of pure bicarbonate of sodium, in addition to purgatives by the mouth and saline irrigation by the rectum. BREWER gives the following test for acetone: Place about 20 cc. of the urine in a small glass retort, heat over an alcohol flame, and condense the vapor in a test-tube; then add a small amount of potassium hydrate to render reaction alkaline, after which add four or five drops of Gram's solution of iodopotassic iodide, and heat gently. If acetone is present, a strong iodoform odor will be perceived, and yellow crystals will form in the tube.

Nervous Sequelæ.—The nervous sequelæ following an operation for appendicitis do not differ in any way from those attending other grave operations. They vary in character and are more or less intense, according to the temperament of the individual and the gravity of the disease. Profound nervous disturbances are apt to arise after previous exhaustion from a protracted illness, or where there has been undue excitement at the prospect of surgical interference; and when the shock of a grave operation is added to these factors, we need seek no further to discover adequate cause for nervous sequelæ. Something can be done in the way of prophylaxis to obviate these most distressing conditions, by calming the patient beforehand, gaining his confidence in his physician and surgeon, and avoiding detailed and picturesque descriptions of the necessary surgical procedures in his presence. Whenever possible, the anesthetic should be gently and quietly given, with the full consent of the patient, and should be administered in his own bed or in a room adjoining the operating room, entirely undisturbed by the bustling preparations for the operation. It is better to defer the proceedings than to begin the anesthesia under compulsion and against struggles. I would also insist on the importance of making the anesthesia as brief as possible in cases where the patient shows marked signs of nervousness. Much can also be done in the way of prophylaxis during the early convalescence by relieving pain and securing some hours of refreshing sleep during the twenty-four by the administration of hyoscyamus (one-fiftieth of a grain) or even a little morphine hypodermically.

Mental disturbances have been reported, varying in degree from a slight transient confusion to violent mania, as in a case reported by G. G. COTTAM (*St. Louis Med. Rev.*, Sept. 15, 1894). The patient, a farmer's wife, thirty-seven years old, had an appendix removed, which was incarcerated by bands of organized lymph, and on account of the extensive handling of the tissues a gauze drain was left in. On the third day, after moderate elevation of temperature and

increase of pulse, "acute maniacal delirium with high temperature abruptly followed, the patient making frantic attempts to bite, scratch, kick, and otherwise injure those who tried to restrain her." Death shortly closed the scene. W. H. DOUGHTY, of Augusta, Ga., related to me the case of a delicate girl about sixteen years of age, who had been hard worked at school, was nervous, worried, and cried easily. At the operation for an acute appendicitis the appendix was found swollen, but not perforated, with a few drops of pus on its outside. The wound was drained, and the patient did perfectly well for three days, having no fever, when suddenly at two o'clock in the night, sixty hours after the operation, she awoke screaming, and in a violent mania, which continued until her death forty-eight hours later. Her pulse rose to 160 and her temperature to 105° F.; she bit her mother on the cheek, and fought and scratched all who came in contact with her. No peritonitis was found at the postmortem and the area of the wound was perfectly walled off by the gauze. The symptoms of these two cases are exceedingly suggestive of an acetonemia, as observed by BREWER, and it is plain that all our cases of mental disturbance and mania following operation must be subjected to a more systematic investigation from this standpoint.

A dry cough or a hiccough, trifling ailments in themselves, may cause extreme distress when associated with a recent wound, on account of the uncontrollable contractions of the abdominal muscles. Minute doses of morphine may be necessary here to bring relief. The superficial use of the actual cautery over the epigastrium will often stop the hiccough, and a mustard plaster over the chest will sometimes relieve the cough. In a bad case it is a good plan to give inhalations of the compound tincture of benzoin, prepared by pouring a pint of boiling water on a drachm of the drug; the vapor from this is then inhaled through a funnel-shaped tube; tincture of opium may be added to it.

Bronchial Catarrh.—A bronchial catarrh is best avoided by operating in a warm room, and by keeping the patient warm during the preliminary preparations, as well as during the operation. As little anesthetic as possible should be given, especially if ether is used. When the condition occurs, the envelopment of the chest in an extensive mustard plaster has been found an effective agent in relief.

Pleuritis.—A pleuritis is usually a sequela to the graver forms of appendicitis, such as the perforative and the gangrenous. It may vary in degree from a light transient form, recognized only by the pain and a slight friction sound, to an extensive exudate filling the right chest and compressing the lung, which ultimately becomes purulent and emits a foul fecal odor due to the colon bacillus. The severer forms of pleuritis are often associated with other suppurative foci within the abdomen. Pleuritis of this description has been particularly studied by L. LAPEYRE (*Rev. de chir.*, 1901, tom. 23), who, following DIEULAFOY, recognizes two absolutely distinct forms of pleurisy, one the result of pyemic infection in which the infecting organisms enter the circulation by the vein, and form embolic infarcts which reach the pleura, as they reach the lungs, the muscles,

the kidneys, and the brain. This variety is very rare, and has no clinical or therapeutic interest. The second form, which is distinctively an appendical pleurisy, is simply an abscess of the pleura resulting from the focus of infection, the appendix. The pyemic form occurs with equal frequency on either side, but the appendical form is always found in the right pleura. LAPEYRE insists that appendical pleurisy is always preceded or accompanied by a focus of suppuration under the diaphragm (subphrenic abscess) of which it is but the terminus. He lays great stress upon this fact, and holds that the theory of a propagation of the pleurisy from a septic focus at a distance by means of a suppurative lymphangitis, as described by PIARD and DIEULAFOY, must now, in view of many clinical facts, be given up ("*elle . . . ruine la théorie de la pleurisie à distance par lymphangite pleuro-pariétale*").

The symptoms of a right-sided pleurisy are: fever, quickened pulse, rapid respiration, and, often, pronounced sweats, with sticking or stabbing pain in the lower thorax, or at a point near the shoulder-blade; there are friction sounds in the early stages, and later on, dulness on percussion, extending gradually upward, even as high as the fourth interspace; the liver is frequently pushed down, there is tenderness on pressure over the thorax, and sometimes edema of the chest walls. A hollow needle may be used to make the diagnosis certain. It is important in all such cases to bear in mind the likelihood of suppuration within the abdomen, sometimes in the neighborhood of the ascending colon, sometimes under the liver, and almost always above the liver and below the diaphragm. The intra-abdominal focus of infection is sometimes so completely masked by the extensive pleuritic effusion that the surgeon may wholly fail to recognize the source of a purulent pleurisy until he has opened and evacuated it. It has happened in a number of instances, especially in children, that an appendicitis has been recognized for the first time after opening the chest to evacuate the pleura.

Treatment.—The best prophylactic treatment consists in the free drainage of the retrocolic abscess, or in the early recognition and drainage of a subdiaphragmatic abscess. In the event of the formation of a pyemia of the pleura, the surgeon should take prompt steps to secure good drainage. If the accumulation is a small one, an opening may be made in the intercostal space in front of the posterior axillary fold, between the seventh and eighth, or the eighth and ninth ribs, a little external to the angle of the scapula. The incision should be about two inches long, just above the rib. When the pleura is opened, it should be thoroughly washed out, wiped as far as accessible, and then drained.

In cases in which the collection in the pleura is serous in nature, entire relief may follow a simple aspiration. Where there is a considerable collection of pus, the better plan is to resort at once to the resection of a rib: this proceeding gives abundant room to explore, to cleanse, and to drain the infected space. As the resection is done under the periosteum, the intercostal vessels and nerves are not injured, and the integrity of the rib is restored after the necessity for

drainage is done away with. An incision is made over the ninth rib, rather posteriorly, in order to secure good drainage, as the patient lies in bed. The costal periosteum is then divided, elevated, and peeled back from the bone on all sides, the groove at the posterior inferior surface being included. After completing the periosteal detachment, the denuded bone is removed with bone pliers or a small chain saw. When the pleura are exposed, a hypodermic syringe may be used to locate the pus, which is then drained off slowly through a small opening, so as to avoid syncope. The empty cavity should now be washed thoroughly clean of pus and lymph, great care being taken not to use undue pressure in irrigating. The next step is to introduce a good-sized rubber drainage-tube, which is kept from slipping out by sewing it to the skin with a couple of silk sutures. The wound is then swathed in handfuls of loose gauze handkerchiefs, kept in place by straps and a bandage. As the cavity closes and the discharge grows less, the condition of the patient improves. If the drainage is not satisfactory, a counter-opening may be made at a more dependent point, between the two ribs, by carrying an instrument into the original opening and using it to push the pleura forward while the operator cuts down on its point. A rubber drainage tube may then be inserted from one opening to the other. This secondary operation can be done under cocain anesthesia.

Lung Complications.—The subject of lung complications following operations for appendicitis is one of peculiar interest to the pathologist as well as to the clinician, and to the surgeon. Interest in it began with the studies of the phenomena leading to the formation of a thrombus in intravascular coagulation; phenomena closely associated with the names of VIRCHOW, who attributed the greatest importance in the process to the retardation of the blood-current, and of BRÜCKE, who drew especial attention to the alterations taking place in the walls of the vessels; the interest being further sustained by the studies of COHNHEIM and of EBERTH-SCHIMMELBUSCH on the organization of the thrombus. From thrombus to embolus is a natural sequence. GERHARDT showed the character of the hemorrhagic infarct in a paper entitled "*Der hämorragische Infarkt*" (*Volkmann's Samml. kl. Vortr. f. inn. Med.*, No. 31). GUSSENBAUER demonstrated that the pneumonias so often observed after the release of an incarcerated hernia were always embolic in origin. It has only recently been shown, however, that the pneumonias, and also many of the pleurisies, following abdominal operations of all kinds are due to thrombosis and embolism. For a complete exposition of the subject see WELCH's article in *Allbutt's System of Medicine*. A valuable article has also been written by A. OPPENHEIM, utilizing SONNENBURG's material, entitled "*Lungenembolien nach chirurgischen Eingriffen mit besonderer Berücksichtigung der nach Operationen am Processus Vermiformis beobachteten*" (*Berl. klin. Woch.*, Feb. 3, 1902, p. 94).

Frequency.—In a study of 1000 cases of appendicitis, SONNENBURG found lung complications in 5 per cent. (*Archiv f. klin. Chir.*, 1902, Bd. 68, p. 468). All of these cases were in the public hospital at Moabit, and in this group

thrombosis and embolism were observed 17 times, while in 260 cases occurring in SONNENBURG's private hospital the same complications occurred 19 times. According to him, the discrepancy between the two sets of figures is due to the difference in the class of patients treated in the two hospitals.

Etiology.—A pulmonary embolus following an operation on the vermiform appendix is a sequela to a thrombus previously formed in the pelvic or femoral veins. Small emboli may form in the vessels of Retzius which traverse the outer surface of the cecum and enter the lumbar veins; it is also possible for an embolus to pass into the heart by the portal anastomosis with the cava. For practical purposes, however, the sole source of pulmonary emboli lies in the tributaries of the common iliac veins. The pathologic chain, whose last link is the pulmonary arterial branches of the lung, consists of the following individual links: an appendicitis, an operation, the formation of a thrombus in the adjacent veins, the detachment of the thrombus, its journey through the iliac veins and upward through the vena cava into the right heart, its transit through the auricle and ventricle into one of the pulmonary arteries out into the lung, where it lodges as an embolus which gives rise to a hemorrhagic pulmonary infarct. Cases of embolism without operation are almost, if not quite, unknown.

Symptoms.—The attack comes on in one to four weeks after the operation, and it may come on when the patient is first up and about, being especially apt to occur during some act of exertion, especially straining at stool. The patient feels a severe pain in the pelvis due to the detachment of the thrombus, or in the back or shoulder from the lodgment of the embolus. The pulmonary pain then increases in intensity, and there is evidence of air hunger, the patient becoming cyanotic or lead-colored, while the respiration is embarrassed and rapid. There is great mental distress and apprehension with profuse sweating and sometimes vomiting, the heart becomes feeble and irregular in action, and the pulse is small and quickened to as much as 140 a minute, or, it may be, disappears altogether. As a rule, there is slight elevation of temperature, but the fever is not usually high and never runs the course of an ordinary pneumonia. There is pain in breathing and a slight pleuritic exudate may be noted. After a day or two, when the infarct has formed, there is characteristic bloody sputum, a few cubic centimetres at a time. The thorax is sometimes excessively sensitive, even to the stethoscope, which reveals râles and an absence of the regular respiratory sounds.

Diagnosis.—A pulmonary embolism may be mistaken for a pleurisy on account of the intense stabbing pain in the chest, associated with embarrassed respiration, and a moderate elevation of the temperature. There can be no doubt, as shown by G. B. MILLER (*Amer. Med.*, 1902, vol. 4, p. 173), that most of the so-called pleurisies which follow ab-

dominal operations are due to emboli of medium size. The diagnosis of an embolus, however, can be made by noting the cardiac embarrassment, the quickened respiration and pulse, with slightly increased dulness on percussion, and, later, signs of hepatization. The fever, as stated, is slight, and never pneumonic in type. The characteristic bloody sputum from the infarct appears in twenty-four hours. Slight attacks are often recognized by their tendency to repetition. There is no doubt that if close attention is paid to all complaints referred to the thorax, the diagnosis of embolism will be made much more often in the future.

Treatment.—Much may undoubtedly be done in the way of prophylaxis by avoiding all injury to the pelvic veins in the course of the operation on the appendix. If an adherent appendix crosses the iliac vein, it will often be better to strip the inner coats of the appendix out of the outer coats, so as to avoid injuring the vein. Especial care must be taken to avoid the formation of the parent thrombus; if, however, a thrombus is known to have formed, all active exertion or straining, especially at stool, must be sedulously avoided. After the embolic attack the patient must be kept as nearly as possible in absolute rest, if necessary with the head and shoulders elevated. Small hypodermic doses of morphine repeated at intervals do much to compose the mind and quiet the action of the heart. As pointed out long since by Gerhardt, digitalis is dangerous and should never be given. The responsibility of the physician is heightened when the patient has had one attack; he must then guard with the utmost care against the slightest exertion, insisting upon complete quiet and absolute rest until the infarcts are absorbed and all thrombi organized or absorbed. Oxygen should be administered to supplement the need created by the diminished area of aeration; dry cups applied over the pleura are valuable to relieve pain. The pulmonary infarct tends to heal rapidly, and needs no other treatment than the avoidance of infection by the respiratory channel; to this end care should be taken to avoid raising any dust in the room, and on windy days to prevent its entrance from the outside. As a rule, general improvement takes place, and the patient passes in a few days or weeks to complete recovery, but it is always possible that death may close the distressing scene.

Intestinal Fistula.—A fecal fistula is one of the commonest sequelæ to an operation for appendicitis, especially when the disease has advanced to suppuration or gangrene. Fowler observed 6 cases in 169 operations on appendicitis (*Ann. Surg.*, May 18, 1894); Van Lennep gives 6 in 118 operations. M. F. Porter noted 8 instances of fistula persisting for four months or longer after incision and drainage, out of 187 operations (*Amer. Jour. Med. Sci.*, Dec., 1893). E. Mühsam (*Mitt. a. d. Grenzgeb. der Med. u. Chir.*, 1903, Bd. 11, 284) notes 78 cases of fistula occurring in Sonnenburg's practice in a series of 441 operations for appendicitis, while in a further study of 815 cases, immediately following those just cited, there were only 54 fistulas, showing a difference of 6.6 per cent. in contrast to 16.3; an improvement of almost 10

per cent., attributable in part to increasing experience and greater skill on the part of the surgeon, and in part to better judgment among physicians, who recognize the appendicitis earlier than formerly, and send their patients more promptly for operation. It should be noted that three of these fistulas, one of which was vesical, were not post-operative.

The fistulas which originate spontaneously through the discharge of an abscess on to the skin surface have been already discussed (Chap. XXV, p. 592), and I desire to speak here only of those which occur as sequelæ to operation. Fistulas of this kind vary from those which are extremely minute, secreting not more than a drop or two *per diem* of a purulent and watery fluid, to those with a freer secretion of thin fecal matter and bubbling gases; or, it may be, the entire alvine evacuation, short-circuiting the cecum, escapes by this route.

The external opening of the orifice may be single or multiple; or, occasionally, it may be cribriform. After traversing the abdominal wall the fistula may open into the appendix directly, or into the colon at the base of the appendix, or into the colon or cecum at some point above the base, or, in rare instances, into the ileum. Blind fistulas are rarely seen. SONNENBURG mentions a fistula (not post-operative) in which a communication had formed between the cecum and a pocket containing fecal concretions. In this case the appendix had sloughed off, and left a perforation opening into the bowel at the base of the appendix, while the surrounding reactive peritonitis had been able to build up a wall of adhesions dense enough to shut off the peritoneal cavity, as well as any other route by which the infectious material might be discharged. Such blind fistulas are occasionally met with as a disagreeable surprise in interval operations.

Our surgeons ought to distinguish carefully between a fistula and a slow-healing sinus in which there is no communication with the bowel at the base. A sinus is nothing but a pocket, kept from healing by some foreign body, as a ligature or a concretion, or by the devitalized nature of its walls, while a fistula must be a through-and-through communication between the intestinal tract and the surface of the body. I do not speak here of fistulas between the adherent vermiform appendix and the adjacent cecum or the ileum, nor of fistulas opening into the vagina or the bladder.

E t i o l o g y.—A fistula rarely follows an ideal operation in which the amputation of the appendix has been made in sound tissues and followed by a satisfactory suturing of the opening. The causes of fistula are most commonly to be found in the conditions imposed upon the operator by the nature of the disease; for example, they occur oftenest when it has been possible only to incise an abscess, leaving behind, from necessity, the perforated, sloughing, or gangrenous appendix. The simplest forms of fistula, in which there is no fecal discharge, are apt to occur when the perforation takes place either at the tip of the appendix, or somewhere in its course, beyond the base. A fistulous tract is sometimes kept open by a foreign body, such as a fecal concretion, which has escaped from the appendix, and lies in the iliac fossa; or by a silk ligature,

hurriedly applied to the base of the appendix in an abscess case. In a case of PORTER's (*Amer. Jour. Obstet.*, 1902, p. 688) an abscess had been incised and drained, leaving a sinus, and whenever it closed, the patient, a little boy, had a fresh attack of pain only relieved by its spontaneous reopening. On opening the abdomen a large fecal concretion was found in an appendix entirely detached from the bowel. In several of SONNENBURG's cases the fistula was due to tubercular disease of the appendix; in two out of five there was a lung affection as well. This possibility should always be borne in mind when a fistula, secreting a thin fluid, remains persistently open without apparent cause. A careful physical examination of the chest, as well as of the secretions of the fistula, may illuminate the diagnosis.

A fistula is particularly apt to follow an excision of one of those old inflamed appendices found lying behind or to the outside of the cecum, and so densely adherent that any attempt to dig the organ out of its bed is almost sure to be accompanied by the rupture of the outer coats of the bowel; such an occurrence, possibly not recognized at the time, may be followed by the sloughing of the remaining thin septum, and the escape of the contents of the bowel. It is evident that the occurrence of such an untoward sequela, interrupting recovery and retarding convalescence, is always due to imperfect technic; that is to say, to a technic which, while it may have been necessarily imperfect under the conditions imposed upon the surgeon, would yet have been better, perhaps even ideal, had the patient been seen before the existence of the complications. In a bad case, however, where the operation is done upon an *indicatio vitalis*, the surgeon may be well content if he saves life, whatever disagreeable concomitants go with the purchase.

T r e a t m e n t.—Prophylaxis is, perhaps, the most important element in the treatment of fistula, because so much can be done to avoid a result so annoying to the surgeon, and a source of great mental disquietude to the patient. *Pari passu* as appendicitis is recognized and operated upon in the earliest stages of the disease, that is to say, before the formation of an abscess, is fistula unlikely to occur. As long as abscess cases, especially neglected ones, continue to be incised and drained, just so long will fistulas continue to soil the dressings. KOCHER's plan of making a separate incision a few days after opening and draining the abscess, in order to discover and remove the appendix, will lessen the frequency of fistulas in the suppurating cases. A fistula will never arise in a simple case if fine silk sutures are used for the bowel, while catgut is employed only in tying off the little mesentery. When the appendix is simply ligated and amputated in an abscess, formalin or chromicized catgut ought to be used. Surgeons will reduce their percentage of fistulas if they take great care to excise well into the sound tissues, and then to sew up the bowel opening with mattress sutures, using fine silk and a fine needle, and burying the wound under one or two layers of sero-serous sutures. I have never seen the fine silk sutures give rise to any after-disturbance.

A serious form of fistula, namely, that arising from the rupture of the outer coat of the cecum or ascending colon in the enucleation of a densely adherent appendix, will be avoided by following the plan of first detaching the appendix from the bowel at its base, then incising the peritoneal and longitudinal muscular coat along its dorsum, and finally stripping the appendix out of its bed inside its circular coat and with its mucosa, leaving the bowel untouched (see Chap. XXV, p. 576). If this is done, a fistula will rarely ever be seen after an interval operation.

In the case of a post-operative fistula of doubtful etiology it is well to explore it with a little crochet hook, and if there is a ligature at the bottom to draw it out. It is well also to keep all abscess cavities widely open, and wash them out vigorously so as to remove any foreign body. Where the cecal wall about the base of the appendix seems likely to break down, it is a good plan to draw the omentum down over the affected area and suture it there at the base of the appendix (SONNENBURG).

MÜHSAM (*Mitt. a. d. Grenzgeb. der Med. u. Chir.*, 1900, Bd. 5, p. 111) conveniently divides fistulas, from a clinical standpoint, into those in which the discharges are purulent, and those in which there is leakage of fecal matter. Of 35 cases in which the discharge was merely serous or purulent, 60 per cent. recovered spontaneously, or markedly improved while 10 were operated upon. Out of 49 cases with fecal discharges, 38 (about 62 per cent.) either healed spontaneously or were decidedly improved, 8 recovered after operation, and 12 died, 3 of the deaths being among the patients operated upon. The causes of death in the 12 cases where it occurred were: three times, tuberculosis; once (probably), post-operative hemorrhage; six times, peritonitis, recognized in part at the time of the operation; once, ileus; once, progressive weakness.

Fistula (even in aggravated cases) tends to spontaneous recovery in such a remarkable way, even, it may be, after weeks and months, that the expectant plan of treatment should always be the first thought of the surgeon. G. W. PERKINS had a case where for two weeks all the feces were discharged by the wound, but in the fourth month a complete recovery had taken place. T. W. HARVEY, of Orange, N. J., had a curious case in which a fistula closed after a few days, and then opened again to give exit to a large round-worm, after which it closed definitively. On the other hand, a case of GAGE's ran seven years and then recovered.

After an operation in which there is reason to anticipate a fistula, it is best to avoid a tight pack in suturing the wound. MÜHSAM praises the Mikulicz tamponade, which consists in an apron of gauze inserted at the bottom of the wound, while inside of this protective covering is laid the drain proper. By leaving the apron in place, the drainage may be changed without injury to the tissues. It is, further, a matter of urgent importance to avoid interfering with the delicate granulations which form and tend so rapidly to blockade any preternatural openings; by such means alone can nature cure the ill; if these are repeatedly broken down through a meddlesome and mistaken

zeal, a fistula may even be created where none would otherwise have occurred. The first complete change of the dressings may take place after five days or a week, as in other abdominal suppurative conditions; the outer layers of gauze which soak up the secretions on the skin surface being removed constantly in the meantime.

The patient in danger of acquiring a fistula ought to receive only a minimal amount of food, and live as much as possible on albumen water. The bowels, if quiet, should be opened by a rectal enema consisting of a few ounces of oil, after five or six days. As long as the fistula is discharging, the wound should be kept widely open, more widely at the top than at the bottom, and the surface frequently cleansed by the attendant applying fresh gauze in the form of loose fluffy napkins. The surrounding skin should be protected from the irritating discharges by a stiff paste of oxide of zinc or an ointment of salicylate of zinc. MÜHSAM recommends a poultice made with acetate of aluminium.

In bad cases of fistula, h y d r o p a t h y affords a treatment of the utmost value, during their early stages of granulation. By this method the wound is kept continually bathed by the circumambient water and thus kept clean; the closure goes on with surprising rapidity, and greatly to the satisfaction of the patient. If the patient can stand it, he does best kept in this bath for the entire day, with shoulders and chest well wrapped and protected; a weaker patient may remain one to two hours at a time, each morning and evening. After removal from the bath, a vigorous rub, a warming drink, and a comfortable bed induce an enviable state of *bien-être*. In my private hospital I have such a bath arrangement installed in a room adjacent to a bath-room, where the supply and discharge pipes for the attachment of the tub when needed, are conducted along the floor under the wash-board; in the bath-room there is a large gas heater with a thermostat which acts upon the coils of cold-water pipes by which the water is discharged at a constant temperature of, say, 102° F. in a slow stream into the bath-tub, if possible directly over the wound; the outflow going on, of course, at the same rate. By this means a continuous temperature is easily maintained and the wound has the advantage of a constantly changing water dressing, while the patient has the comfortable assurance of perfect cleanliness.

The closure of a fistula by operation may vary all the way from a procedure which is comparatively easy (in skilful hands) to one of the utmost difficulty. If there is more than one opening on the skin surface, it is best to do a preliminary operation by slitting up the skin so as to establish a single orifice which leads directly to the fistulous tract, in this way getting rid of the undermined infected area. Such cases which seem most difficult at first sight may prove comparatively easy in the end. If the skin is much excoriated an effort should be made to heal it by protecting it with a stiff bland salve and keeping it clean. G. W. PERKINS in order to get rid of an infected skin area in the way of an abdominal incision, made a preliminary operation conducting the discharges out of the way into the right lumbar region. The bowels should be well evacuated and

the stomach emptied before the operation. If the fistula simply leads down to an appendix which is only slightly adherent, the operation presents but little more difficulty and danger than the ordinary interval operation. HALSTED deals with the fistulous orifice by surrounding it with a purse-string suture, which is then tied, closing the opening; the suture is left long enough to serve as a tractor, making tense the sinus, and so marking it out, while the operator carries his dissection inward toward the objective point, the intestinal opening. Another plan is to stuff into the sinus a narrow strip of iodoform gauze which serves to plug the opening, the operator then depending upon the rigid canal as his guide.

In a simple fistula the operator may excise the adjacent abdominal scar tissue, including the fistulous orifice, and so carry the dissection inward to the bowel; at the same time it is kept as close to the fistulous tract as possible until the bowel is reached. The intestinal end of the fistula is then excised in the sound tissues of the bowel, and sewed up with fine silk mattress sutures taking in all layers down to the mucosa, a continuous sero-serous suture being applied above these for security. The parietal wound is then closed, down to an opening the size of a little finger, which is left with a small drain for a few days for security.

In difficult cases, if the fistulous tract is a long one walled in by adherent intestines and cecum, it is not safe to try the simple plan of excision, for there is great risk of injuring the adjacent bowel by working in the dark in this manner. Under these circumstances it is best to carry the skin incision completely around the old scar, including the fistulous orifice, and to enter the abdominal cavity at a distance above and below the fistulous area. This gives a chance to study carefully the extent of the involvement of the adjacent intestines, which can then be dissected free, together with the omentum; after this the fistulous area is gradually isolated from end to end by working backward with a blunt dissection needle. The bowel is then lifted out onto the skin surface, the fistula is excised, and the opening closed by suture.

The extent of a difficult operation for post-operative fistula will be realized by consulting the description of W. W. KEEN in the *Medical News*, December 10, 1892.

An unusual instance of a permanent fecal fistula of the small intestine following the opening of an abscess, which was treated with great surgical skill, is that of G. W. PERKINS, of Ogden, Utah (*Ann. Surg.*, 1896, vol. 24, p. 726).

The patient, a boy of sixteen, had an attack of "inflammation of the bowels." An incision through the right semilunar line was followed by the escape of several ounces of offensive pus mingled with feces; the appendix was not seen. Recovery was rapid, but at the end of a week a small fistulous opening, seen at the operation, had enlarged to one-half an inch in diameter, and all the feces passed through it. The patient became in a short time much emaciated and debilitated, and nine months later he appeared in the doctor's office anemic, icteroid, and very feeble, walking with pain and difficulty and bending over to the right. Near the centre of

the cicatrix of the operation wound was an opening, easily admitting the index finger into the bowel in either direction, from which protruded a ring of intestinal mucous membrane. Just outside this opening was a smaller one admitting a probe 4 to 6 inches upward and backward to the right lumbar region, and downward and backward toward the true pelvis. Over the right pubic bone there was a fluctuating swelling which ruptured and discharged pus. Charcoal given by the mouth appeared at the fistula in ten minutes. In order to get rid of the infection of the abdominal wall, before opening it, PERKINS made a free lumbar incision, scraped the wound, and inserted a large, long, rubber drainage-tube. In a month the local condition had so much improved that he was able to operate, when an elliptical piece of the abdominal wall with the fistulous opening for its centre was excised, opening the peritoneal cavity. After freeing this segment, it was lifted out, bringing with it, attached to its under surface, the coil of small intestine in which the fistula lay. The fistula itself was then excised and closed with 15 to 20 interrupted silk sutures, leaving a wound from 2.5 to 3 inches long, and narrowing the lumen of the bowel about one-third. After a slightly disturbed convalescence the boy made a perfect recovery, and two years later was the picture of robust health.

SONNENBURG, in a case of fistula of the small intestine in the neighborhood of the cecum, attempted to relieve the difficulty by resecting the affected part of the ileum and joining the ends by means of a Murphy button. The patient, however, unfortunately died from the progressive peritonitis which had begun at the time of the operation. The fistula in this case was noticed three days after the operation, when fecal matter was found in the dressings, and three days later still the patient died.

When, owing to the density of the adhesions, the extensive cicatrices, or the immobility of the bowel, fistulas cannot be closed, several plans of treatment come up for consideration. The whole mass may be resected, as in cancer, actinomycosis, or ileocecal tuberculosis, and the sound end of the ileum above the disease, joined to the sound end of the ascending colon, beyond the disease. In cases in which the disease cannot be extirpated, the ileum may be anastomosed into the ascending or transverse colon, and this may be done as a simple anastomosis, or the entire diseased area may be excluded from the continuity of the intestinal area by amputation and closure by suture of both ileum and colon. The "ventilated opening" which v. BARACZ has shown to be necessary for the excluded bowel (*Archiv f. klin. Chir.*, Bd. 58) may be provided by the fistula.

v. EISELSBERG (*Archiv f. klin. Chir.*, 1898, Bd. 56, p. 22), under the title "*Ueber die Behandlung von Kothfisteln und Stricturen des Darmkanales mittelst der totalen Darmausschaltung,*" reports a case where the incision of a perityphlitic abscess resulted in the formation of an *anus preternaturalis cecalis.* A celiotomy was done to heal this condition, but on account of the extensive adhesions of the cecum, as well as of the coils of the small intestine themselves, neither resection nor total exclusion of the bowel could be done; total exclusion was impossible, as the operator could not determine which was the distal end,

and which the proximal portion of the ileum. Under these circumstances he did a lateral ileo-colostomy (Fig. 350, p. 689). By this means the *anus preternaturalis* was converted into a fecal fistula. Inasmuch as this continued to discharge freely, a second operation was performed seven weeks after the first, when the diseased portion of the bowel was divided from the remaining sound tissue, and the ends sewed up sausage fashion, four lumina, two cecal and two iliac, being closed in this way. This operation was followed by a perfect recovery. The whole illness lasted about eight months. In a favorable case an end-to-end anastomosis of the ileum into the ascending colon might be done.

Urinary Fistula.—A urinary fistula is, fortunately, of rare occurrence after an operation for appendicitis. A case of this kind, which was, in all probability, a wound of the ureter, is reported by C. A. Powers (*Med. News*, 1899, vol. 75, p. 427).

A young man, eighteen years old, had an acute attack of appendicitis with fever, and a tender mass the size of a thumb was discernible at the outer border of the right rectus muscle. At the operation an incision was made in the right semilunar line. The mass proved to be an inflamed omentum and the small intestines were matted together by old adhesions. The inflamed appendix was found, and dug out of its bed with much difficulty, the finger being used as a hook to pull up its tip from the depths of the pelvis; as the finger brought it into view, between the loops of small intestines, a gush of straw-colored fluid appeared and continued to well up throughout the operation, although it was a protracted one. This fluid was found to contain urea. The appendix, which was 4 inches long, was friable, and gangrenous at three points. The source from which the urine escaped could not be found; when fluid was injected into the bladder the same amount was returned. An incision was then made just above the symphysis for the purpose of examining the bladder, but when this was done no lesion could be found. The wound was closed with two glass drains and an iodoform gauze pack. Immediately following the operation there was a profuse discharge of urine through the wound, while about 20 ounces of urine were passed daily by the urethra. On the fifth day the urinary fistula was completely closed, and in six weeks was firmly healed.

Mühsam reports the case of a vesical fistula in a man twenty-eight years old, who in the course of a third relapse in appendicitis acquired a perforation into the bladder. This was followed by the discharge of large amounts of pus in the urine which also contained gas and had a foul odor. The appendix was released from its adhesions, and removed with the utmost difficulty, but the point of perforation could not be found; cystitis continued, but after two months the patient appeared to be well again, until, later on, the urine became turbid again, proved to contain plant cells and undigested fibres, and showed a connection between the cecum, which had been shelled out close to the bladder, and the bladder itself. About a year after the first operation a median incision was made, when the last loop of the ileum ascending to the cecum was found

intimately adherent to the bladder by adhesions which could not be separated without great danger to both bowel and bladder. An anastomosis was then made between the ileum and the upper part of the cecum, in the hope of diverting the fecal current from the fistula. The patient improved remarkably, the urine became clearer, and he seemed to be quite well except for the fact that the Murphy button, used in making the anastomosis, failed to pass out. The X-ray showed the button lying over the right sacral iliac symphysis, where, however, it seemed to create no disturbance.

Skin Affections.—I have found but one instance in literature in which appendicitis was followed by d e r m a t i t i s.

A girl, five years of age, was seized with vomiting and violent abdominal pain, not localized, and without any meteorism, but accompanied by a general sensitiveness; in the lower abdomen there was an area of dulness. After a free stool the child was relieved, but a few hours later she began to complain again of violent pain. The temperature rose, the pulse quickened, and the general condition grew worse, with a recurrence of vomiting, moderate tympany, and some dulness in the right iliac fossa, without a tumor, however, nor any localized pain. At the operation pus was found in the free abdominal cavity, and a minute opening appeared in the tip of the appendix, which was somewhat thickened. The appendix was removed, the wound closed with several silk sutures, and drainage established. A fecal concretion as large as a bean was found in the appendix, surrounded by a gangrenous area of mucosa associated with the perforation. Recovery was interrupted on the sixth day by an acute dermatitis with fever as high as 40° C., and a troublesome, violent itching followed by desquamation. It was not a case of scarlatina, as there were no throat symptoms. On the sixteenth day after operation there was an elevation of temperature, and two days later a discharge with a fecal odor. On the twenty-third day a pointed object was found in the wound, which when drawn out proved to be a female ascaris 30 cm. in length. On giving santonin and calomel, a male and a female ascaris were passed *per anum*. The wound healed up to a minute fistula.

Acute Yellow Atrophy of the Liver.—A case of this condition occurring as a sequela to removal of the appendix under chloroform anesthesia is reported by M. Ballin (*Ann. Surg.*, 1903, vol. 37, p. 362).

The patient, a brassworker, twenty years of age, had three typical attacks of appendicitis. He was operated on in the third, when the appendix, which was adherent, friable, and covered with a fibrino-purulent exudate, was removed. The stump was touched with carbolic acid, but inversion and overstitching were impossible, as the thread cut through the infiltrated tissue. The abdomen was closed without drainage, the operation, which was done under ether narcosis, having lasted but twenty-five minutes. Two days later, when the temperature and pulse were normal, there was slight jaundice of skin and conjunctivæ, some vomiting, and restlessness. Two days after this, again, the jaundice was increased, the vomiting greenish, and there was delirium. The next day there was noisy delirium with increased jaundice, and vomiting of black fluid, with intervals of deep coma. These

symptoms all increased, the stools and urine became involuntary, and the patient had to be held in bed by two men, and finally tied there. The jaundice went on to a deep brown color, when venesection and intravenous saline infusions were used. The urine, six days after operation, showed albumen, casts, bile, and crystals of leucin and tyrosin. From this time on there was a gradual improvement, and, ultimately, complete recovery.

BAYARD HOLMES reports two similar cases, occurring in young women ("*Four Clinical Notes on Appendicitis*," Chicago, 1904, p. 17), in which the symptoms preceding death were, he says, "comparable only to acute yellow atrophy."

Ileus.—An ileus is an obstruction of some portion of the lower alimentary tract interfering with the passage of the intestinal contents. The term ileus, now commonly used by surgeons to denote an anatomic condition, more properly refers to the severe, twisting, colicky pain, which is the characteristic sign of the affection.

Etiology.—The obstruction which produces an ileus may arise from a number of causes, such as a volvulus, or twisting of the bowel, following an injury; adhesions between loops of bowel and strictures within the lower abdomen; the slipping of a loop of bowel underneath a peritoneal band, resulting from an old peritonitis; the incarceration of a loop of bowel under other adherent loops, or under an adherent omentum, or an attached or twisted appendix. Ileus occurring as a complication of appendicitis is oftenest due to sharp flexures caused by the numerous adhesions at the terminal portions of the ileum, arising in the course of nature's efforts to shut off an infected area. When the ileus follows an operation for appendicitis, at a date more or less remote, it is apt to arise from the constriction of bands of adhesions cutting across the small intestine.

Among all the various causes of ileus, one of the most important is paralysis of the bowel from a gaseous distention. This distention may be so marked and the symptoms of obstruction associated with it so pronounced that the original disease in the appendix is entirely masked. The obstruction in an ileus may be immediate and complete; as a rule, however, it comes on gradually, only becoming complete after a few hours, or, it may be, several days. Where the obstruction is only partial, the signs of an ileus may be intermittent in character, occurring only when the upper bowel becomes overloaded. The result of an obstruction is the accumulation of fluids and gases in the upper proximal portion of the bowel, while the lower, distal portion is empty and contracted. It is of the utmost importance to bear this fact in mind when endeavoring to locate the obstruction, in order to avoid hunting aimlessly among the bowels under circumstances when time is too precious a commodity to be wasted.

E. v. Wahl (*Centralbl. f. Chir.*, March 2, 1889) calls attention to the inexactitude of surgeons in failing to determine the precise seat of an ileus before operation, as well as to the want of satisfactory clinical descriptions of the portion of the bowel involved. He insists that an "anatomical diagnosis of the seat, nature, and character of the occlusion must first be established before the knife is taken in hand." In the first place, it is necessary, according to him, to be more exact in mapping out on the abdomen the area of meteorism, and not to be satisfied with the general vague statement that meteorism is present. He asserts emphatically that the obstructed loop itself is preëminently the seat of meteorism, and that this symptom is caused by hindrance to the circulation and by the decomposition of the contents of the intestine with the formation of gases. Finally, he enunciates the dictum that "in certain forms of occlusion of the intestine—strangulation or volvulus—a certain part of the intestinal canal within the abdomen undergoes an abnormal fixation and gaseous distention, which under inspection is manifest by the asymmetrical form of the abdomen, and is recognized by careful palpation through the distinct increase in resistance."

Kader, following v. Wahl (*Centralbl. f. Chir.*, 1891, No. 26, p. 106), states that the meteorism is due to an increased circumference of the intestine, occasioned by the following factors:

1. Increased thickness of the intestinal walls.
2. Accumulation of fluid within the bowel.
3. Development of gases within the affected loops.

And, as the result of experiments on dogs, he declares that meteorism in all forms of intestinal occlusion is a consequence of two complementary factors, which are (1) circulatory disturbances in the venous system; and (2) stagnation and decomposition of the contents of the bowel.

In ileus following operation on the vermiform appendix, the obstruction is almost invariably situated in the neighborhood of the ileocecal valve, that is to say, in the last group of the small intestines located in the right lower abdomen. In searching for an obstruction, therefore, we are able to neglect the proximal groups of the ileum and jejunum, and devote attention at once to the omentum and the last group which occupies the pelvis and the right iliac fossa. I would especially call attention to the fact that the terminal portion of the bowel in this group is usually found lying on the pelvic floor, from which it ascends to terminate at the ileocecal valve, its mesentery growing shorter and shorter until at the valve it almost disappears.

A. T. Cabot, in speaking of chronic obstructions of the bowel with recurring symptoms of ileus, draws attention to the partial twists and kinks found when the terminal ileum lies over the head of the cecum, and walls in an inflamed appendix to the left and in front. If the bowels are in good order, they are able to pass their contents comfortably through such a

partially obstructed coil; when, however, they are overloaded, peristalsis is checked and all the symptoms of an acute stoppage ensue.

It is of the utmost importance to recognize the fact that an ileus is not due simply to the existence *per se*, of adhesions between the various coils of intestines, however numerous these may be. The entire intestinal tract may be bound together by webs of adhesions, or the whole peritoneum may actually disappear, without producing an obstruction. An obstruction arises when a loop of bowel is caught and held in a lower position than that which it naturally occupies in the abdomen, as, for example, when one of the loops normally lying well above the pelvis grows fast to a pelvic wound. If a small area of the bowel is held fast in this way, a sharp kink occurs and a knuckle adhesion, which is much like a finger flexed sharply upon itself, is formed. Another way in which an ileus occurs is by the formation of adhesions between two loops of bowel, which then contract and bind the intestine in one fixed position. Again, after adhesions have formed between two different loops of intestine, another loop may slip in underneath the adhesion, as under a bridge.

One of the commonest causes of late post-operative obstructions is the gradual rolling up of a thin layer of adhesions into a strong band, by the contractions and tuggings of the intestines. All band adhesions are formed in this way. The more recent the adhesion (if it is not omental), the more apt is it to involve broad surfaces, and on this account the difficulties in dealing with it are increased.

Symptoms.—The clinical signs of ileus are: vomiting, at first bilious and from the upper intestinal tract, then ill-smelling, and, finally, fecal; colicky pain coming on at the same time and usually beginning at one spot in the right lower abdomen, after which it becomes general and is associated with vermicular contractions of the bowel, easily felt, and often visible. These symptoms are accompanied by gurgling sounds due to the movements of flatus in the coils of intestine. A marked localized tympany soon develops and the passage of flatus and feces *per anum* ceases entirely. The temperature is slightly if at all affected, and the pulse is at first quickened only during the tormina. In the post-operative form of ileus the development of these symptoms is often gradual, and the first indication is an increasing difficulty in moving the bowels.

The cardinal symptoms of ileus are: Obstipation; intermittent abdominal pain; vomiting, becoming fecal in character; gaseous distention, often localized.

Diagnosis.—A diagnosis of ileus is easily made in the presence of the symptoms just mentioned. One of the most characteristic signs is the formation of a hard tumor, due to the contractions of the intestine just above the obstruction, and easily detected by laying the hand upon the abdomen. The vermicular movements of the bowel and the displacement of the gases as they rumble from loop to loop are also often easily felt. The leucocyte count is of little value, because it may show a marked rise early, and then a drop.

T r e a t m e n t .—The amount of progress made in the treatment of obstruction during the short space of sixteen years is evident on the perusal of such an article as ROSWELL PARK's brief but lucid paper entitled "*Laparotomy or Enterostomy*" (*N. Y. Med. Rec.*, March 3, 1888). It is hard to realize that shortly before this date the treatment of ileus belonged exclusively to the domain of internal medicine. The emancipation heralded by PARK and his contemporaries began with the introduction of surgical measures in the opening of the obstructed bowel onto the skin surface; and then advanced to the making of larger incisions, in order to inspect the affected area, and, if possible, relieve, the cause without doing an enterostomy. KÜMMELL as early as 1887 advocated an exploratory incision extending from sternum to symphysis (*Centrbl. f. Chir.*, 1887, No. 45, p. 836). SCHEDE (*Arch. f. klin. Chir.*, No. 36, p. 635) insisted that "the fate of those suffering from an ileus depends entirely upon an early diagnosis. There is, perhaps, no other acute disease in which the patient's ability for resisting shock so rapidly vanishes."

A plan of treatment introduced by MADELUNG (*Arch. f. klin. Chir.*, Bd. 36, p. 283) was to begin with a small incision in the abdominal wall, through which he made such investigations as were possible into the condition of the immediate adjacent intestine. He then pulled up a loop of distended gut, and held it out of the wound by two strong silk threads passed under it and through its mesentery. The patient was then turned on his side, the knuckle of intestine and the wound protected by iodoform gauze, after which the gut was deliberately incised, so that all its contents could escape, the outflow being encouraged by the insertion of a soft catheter. In order to do this effectually it was necessary to wait for fifteen minutes or so, during which time the anesthetic was sometimes intermitted. The wound in the intestine was then carefully closed by sutures, and after thoroughly cleansing the parts, the original abdominal opening was enlarged. If an obstruction was found, it was treated as seemed best, but if nothing was discovered, the intestinal loop first opened, was found again by means of the silk threads left *in situ*, and sewed into the abdominal wound, after which it was reopened at the point where first incised, an artificial anus being thus formed (see PARK, *loc. cit.*).

The best treatment of ileus, as of other post-operative complications, is by prevention, effected by taking care during the operation to remove, as far as possible, all existing difficulties, and to avoid causing any injury which is liable to result in obstruction. This is accomplished by a minimal exposure and handling of the intestines; by keeping exposed peritoneal surfaces moist with a warm saline solution; by hunting out and relieving all adhesions which can possibly be found; by covering in any raw or bleeding surfaces with intact peritoneum; and by draining septic areas in such a manner as to prevent the extension of the infection. If the bowel is badly injured and requires extensive suturing, especially in operations which must, of necessity, be done in haste, the dangers of a fatal peritonitis, or of an ileus, may sometimes be obviated by

bringing the injured loops of intestine into the wound and leaving them exposed there. Should this part of the bowel break down later, the discharge takes place onto the surface and no harm is done, as the resulting fistula may be closed at a later date. It is best to avoid the use of long strips of gauze for the purpose of draining between the intestines, as a slight displacement of the coils of the bowel serves to produce a kink or an obstruction.

When an obstruction occurs after a gauze pack has been introduced into the wound, the first thought of the surgeon should always be that the stoppage is due to the pressure of the gauze, or to the entanglement of a loop of the intestine by strips of it. The first effort to relieve the cause should be to remove the pack, and perhaps readjust or straighten out any coil of intestine which is obviously kinked. Every surgeon of experience has had occasion, more than once, to relieve cases in this way, which at first sight seemed alarming. It is a good rule to give an anesthetic and do this little operation thoroughly, as it may obviate the necessity for a far more serious operation later on. A bad case can also sometimes be relieved by opening the distended bowel in the wound with the cautery point, thus establishing a fistula. Cases which have seemed almost moribund from obstruction and gaseous distention have been repeatedly saved by making an artificial vent in this manner.

In cases in which the bowels are becoming more and more difficult to move, or in those where an obstruction has certainly developed though the vomiting and pain are not yet pronounced, if the patient's condition is good, the surgeon may try for a short time to effect a movement by giving enemata, such as a litre of water containing glycerine and two teaspoonfuls of turpentine, or glycerine and oil; he may also try the administration of calomel, or even castor oil, by the mouth. It is best not to give any nourishment at all. The passage of gas is encouraging, as it is often the premonitory sign of a fecal movement, but if this does not shortly occur, especially if the symptoms continue unabated or begin to grow worse, it is better to interfere promptly, rather than continue to make efforts to force a passage, which exhaust the patient's strength. In few diseased conditions is time so important; a patient who appears to have been doing well while purgatives are being poured into him and the physician is anxiously watching at his bedside, will often suddenly show signs of collapse, and within an hour or two it becomes evident that a more radical plan of treatment has been delayed too long. It is better to make a few mistakes, and to open the abdomen occasionally without necessity, than to delay systematically in all cases and then, when operation is performed as a last resort, to lose every case operated upon.

I would, therefore, advise operating promptly, as soon as the patient fails to respond, provided the classical signs of obstruction are present.

When there is fecal vomiting the stomach should be thoroughly washed out before operation. If this cannot be accomplished, it is better to do the opera-

tion under cocaine than to risk drowning the patient in his own vomit as he goes under the anesthetic. Where time is so important, all preparations should have been made beforehand. The abdomen must be cleansed while the anesthetic is being given, and the operator stand ready to begin the operation the moment the patient is ready. It is best to give the anesthetic on the operating table. The cardinal rules of operation in ileus are as follows:

1. The operation must be done as promptly as possible, when the diagnosis is once clearly made.

2. It must be as brief as it can be consistently with thorough work.

3. As little anesthetic as possible should be given, but the relaxation must, nevertheless, be complete. Local anesthesia (Schleich's solution) is best in bad cases where there has been much fecal vomiting (see Chap. XXIII).

4. The bowels should be handled as little as possible.

5. It is especially important to avoid pulling upon the bowels.

6. Evisceration should be avoided as far as possible, the proximal distended coils in the abdominal cavity being left *in situ*, and the search directed beyond them (distally), near the ileocecal valve, for the obstruction.

7. It is better to empty any escaping over-distended bowels than to attempt to force them back with great difficulty.

8. If the obstruction is not entirely overcome, as shown by the distended bowel beginning to unload itself at once into the lower intestine, a distended loop must be brought up into the wound and left there, to be opened a little later.

9. If there is any doubt as to the complete relief of the obstruction, a loop of bowel must be brought up into the wound, in readiness for enterostomy.

10. The use of saline infusions with a little adrenalin (15 to 20 cc. of 1 : 1000 solution of adrenalin in 800 to 1000 cc. of normal salt solution) is of value in keeping up the heart action.

11. Every possible effort must be made to keep up the body-temperature and to avoid chilling the patient from exposure of the viscera.

The operator who opens the abdomen to relieve an ileus must in each case do one of three things: he can (*a*) overcome the obstruction by dividing adhesions or loosening attached coils of intestine; if unable to overcome the obstruction, he can (*b*) short-circuit the bowel across the obstructed area by an anastomosis of the ileum into the colon; or he can (*c*) bring a loop of the bowel above the obstruction onto the surface for an enterostomy later on. If the last method is used, it is well to mark the point for incision by inserting black silk threads in the outer coats of the bowel and leaving them hanging out of the wound. When the operator is uncertain as to whether he has completely overcome the obstruction, he can employ a combination of these methods by leaving the wound open and bringing a loop of bowel into it, ready to be incised if the symptoms persist.

Where the original operation has been a comparatively simple one, the operator may expect to find nothing more than the simple adhesion of a knuckle

of intestine, or of the free border of the omentum, under which the ileum has slipped, to the head of the cecum, the latter forming a large gurgling tumor yielding signs of an incomplete obstruction. I saw such a case in consultation with B. C. HIRST, in which the patient suffered severe paroxysms of

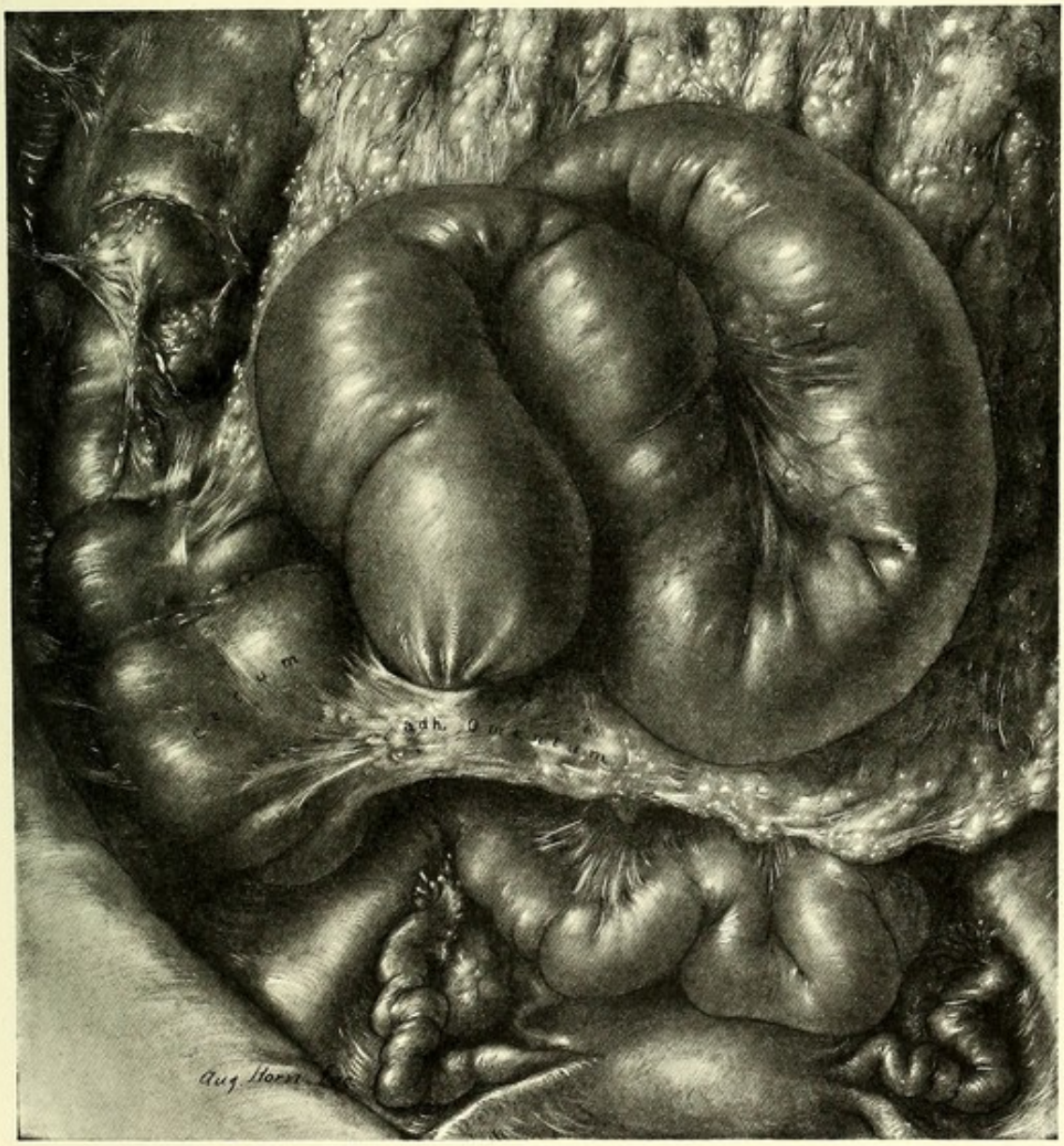

FIG. 350.—HIRST'S CASE. INTESTINAL OBSTRUCTION FOLLOWING OPERATION FOR APPENDICITIS DUE TO OMENTAL ADHESION OVER STUMP OF THE APPENDIX. January 18, 1903.

pain at variable and sometimes considerable intervals, associated with swelling to the right of the umbilicus and an extremely tender abdomen. The obstruction, however, was manifestly partial, as there was no fecal vomiting, and the passage of the intestinal contents was obviously only impeded. At the operation the edge of the omentum was found adherent in such a manner as to form a strong

band attached at the seat of the appendix operation. A large, deeply reddened loop of ileum had slipped under this band and then dropped down in front of the omentum so as to form an incomplete strangulation. Fig. 350 shows the condition as found at the operation. In such a case the old incision may be cautiously reopened, after which the bowel is released by freeing and suturing the loop, or by dividing the omentum. In the case of a relative of mine, a boy of fourteen, I made a little opening parallel to and to the inside of the first incision, after which I freed a single knuckle of the ileum and evacuated a serous accumulation. Recovery followed.

If a loop of bowel is evidently gangrenous and in need of resection, while at the same time the patient's condition will not permit any extension of the operation, the difficulty may be met, and life, in many instances saved, by the simple expedient of bringing out the gangrenous loop onto the surface of the body, together with a sufficient amount of the adjacent, apparently healthy bowel to provide for a possible extension of the gangrene. The diseased bowel is opened and left, carefully wrapped in dressings, isolated from the wound. At a later date, when the sloughing process is completed, the ends of the bowel may be anastomosed without using a general anesthetic.

When there has been an abscess, or when the adhesions have been extensive at the original operation, it is best to open the abdomen by a long incision medianwards from the original one, and not more than one or two inches distant from it. The viscera must first be carefully inspected, in order to determine whether the obstruction is situated at a particular point or is caused by general adhesions. The distended portion of the intestine must next be noted, as well as the presence of any collapsed bowel on the proximal side of the ileocecal valve, which, if present, must be traced up to the limit between the two, after which the operator may proceed to deal with the disease according to the findings, which are likely to be one of the following conditions:

1. A band, or bands of lymph stretching over the pelvis and the intestines.
2. A twist in the bowel, or, in other words, a volvulus.
3. Omental adhesions with a loop of bowel caught under the free edge.
4. A loop of bowel, or several loops, adherent at the site of the operation, at the abdominal incision, to an abscess wall, or, it may be, in the pelvic cavity.
5. Angulation of the ileum, produced by the adhesions binding together distant loops.
6. Angulation of the ileum over the cecum.
7. General adhesions among the bowels in which a particular line of demarcation, defining the obstructed area, is scarcely discoverable.

Great care must be taken not to overlook bands of adhesions, especially if they are a little distance from the field of operation, when it is very easy to do so. I had a case of this kind recently, in which an obstruction followed an operation for appendicitis, and the bowels were so matted together that a fecal fistula had been formed to give relief. I opened the abdomen widely in the

old scar, dissected out and sewed up two fistulas, one in the cecum and one under the ileum, and then found the obstruction lying at the splenic flexure of the colon. The proximal portion of the large bowel was so enormously distended that it resembled a large stomach, and appeared to fill the abdomen. After dividing numerous adhesions around the head of the cecum, and under a long scar in the median line, I found some strong bands of adhesions passing from the pelvis upward in the direction of the obstruction. These I caught under my fingers, and divided them with scissors, being guided in doing so by touch alone, on account of the distance from the wound. The tumors which had been formed by the colic mass disappeared when the patient recovered. Later a tumor was found at the splenic flexure, necessitating an anastomosis of the ileum into the descending colon.

When a mass of adhesions is to be dealt with, it is best to handle it as a whole, first locating the sound areas above and below, and then, if possible, bringing the mass outside and surrounding it on all sides with wet saline gauze. The loops, which stretch like bridges across other loops, are best detached by pulling them apart with pledgets of wet gauze, a light being held at the same time on their other side. In this way, as the adhesions are pulled apart a little at a time, it is possible to cut between the loops without injuring the coats of the bowel or of the blood-vessels. This method of inspecting adhesions so as to differentiate between them and the viscera, and at the same time discover the presence of blood-vessels, I have called d i a p h a n o s c o p y, in order to emphasize it as a practical procedure. It is well not to refine too much in dividing all the adhesions between areas of the bowel which are naturally separated by only a few centimetres.

The worst cases of adhesions are those on the pelvic floor. The treatment of these requires abundant room and light, and can only be accomplished after displacing the other bowels. After isolating the affected loops of bowel in the manner just described, it is best, if circumstances will permit, to elevate the pelvis, and then, while making a little gentle traction upon the bowel, to snip the adhesions very slowly and deliberately with scissors. If the coats of the bowels are injured, one or two fine mattress sutures must be put in at once. In a case where the general adhesions are badly matted, it is best to be satisfied with bringing out a distended loop of the intestine to be incised soon after the operation; a few weeks later the fistula may be closed.

When the adhesions are too extensive to be dealt with, or when there is imminent risk of rupturing the intestines in separating them, a lateral anastomosis of the distended ileum into the cecum may be made, as in the following case treated by J. M. T. FINNEY:

In 1896 the patient, then a boy of fourteen, developed an appendicitis for which W. S. HALSTED operated, removing a gangrenous appendix 9 inches long. There was a large abscess with a proteus infection in Douglas' *cul-de-sac,* and a general plastic

peritonitis had spread over the bowels. An area of gangrene in the cecum about 3 cm. in diameter was packed and left; following this treatment he had a fecal fistula lasting six months, which finally closed spontaneously. He made a good recovery, and in a few years he developed from a small boy to a large man over six feet tall and weighing 175 pounds. Six years after the operation he had a sudden acute attack of intestinal pain with immediate fecal vomiting. In forty-eight hours there was a complete obstruction, no more feces nor gas being passed; there was, however, very little distention. He seemed utterly collapsed, with a pulse of 160 and a temperature of 101° F. Operation was performed forty-eight hours after the onset of the attack, and adhesions were then found so extensive that two and a half hours were spent in freeing them, during which the bowel was torn and sutured in four places. As he seemed to be in collapse, a loop of intestine near the cecum was brought out of the wound and the operation concluded. On opening this loop it proved to be distal to the obstruction, and no relief was obtained. Twenty-four hours later the abdomen was reopened, and on incising an enormously distended, black loop of bowel a large amount of gas and fecal accumulations were evacuated. The patient was much shocked, but a rapid improvement followed; six weeks later the abdomen was again opened and the fistula thus formed closed, but it proved utterly impossible to reach the obstruction, which lay like a large mass in the pelvis. A lateral anastomosis of the ileum into the cecum was then made, which was followed by an immediate improvement and an undisturbed convalescence. The patient is now able to go about without pain, vomiting, or fever, and his evacuations take place normally.

Coley reports a case (*Ann. Surg.*, 1900, vol. 22, p. 451) of a boy operated upon in April, 1896, for an acute appendicitis from which he made an uneventful recovery. In August of the same year he developed symptoms of acute intestinal obstruction, and on opening the abdomen three and a half feet of intestine were found strangulated, which it was necessary to resect. The procedure was followed by a fistula, the boy's general health failed, and he became greatly emaciated. At a second operation, in November, 1899, an incision 2 inches long was made to the left of the sinus, the adhesions were separated, and the ends of the gut resected, after which they were approximated with a Murphy button. The wound was drained for a week. The boy's health improved rapidly and he gained 23 pounds in six weeks.

Hernia.—Hernia following an operation for appendicitis is due to a separation of the firm aponeurotic and muscular structures which constitute the natural support of the abdominal viscera. Such a diastasis is followed by an eversion of the thinned out cicatricial tissue so as to form an extra-peritoneal diverticulum or pouch which is occupied by the omentum or the intestines. A hernia of this kind may occur at one or several places in the tract of the wound, and generally makes its appearance after an interval of a few months to one or two years after the operation.

Etiology.—As regards the frequency of hernia following operations upon the appendix: Homer Gage found 19 hernias in 228 cases operated upon for appendicitis, the subsequent history of which he investigated. This is less than

19 per cent., and all made their appearance in cases which had been drained; 17 appeared in the first, and 2 in the second year after operation. The greater number occurred during the first six months.

Post-operative hernias are more apt to occur where the tissues have lost their tone, or in flabby neurasthenic patients. There is, of course, a greater liability to hernia when a long abdominal incision has been made, but the prevailing impression that a tiny incision, from an inch and a half to two inches in length, is a guarantee against the occurrence of hernia is not borne out by the facts. I have myself seen a case in which a minute incision about 5 cm. long at the outer border of the rectus muscle suppurated, and a year later, when I operated upon the patient, a well-built muscular young man, there was an omental hernia at this point. One of the most serious objections to long incisions, especially when made parallel to the border of the rectus muscle, is the fact that it is still the common practice to divide the tissues without any effort to save the nerve trunks which supply the rectus. When these nerves are thus ruthlessly cut, an atrophy of the muscle follows, and even if a hernia does not take place, there may be a distinct weakness and bulging of the abdominal wall over the atrophied area. A careless closure of the abdominal wall, associated with neglect in bringing the layers together in their proper order, or carelessness in placing the sutures at too great intervals, also predisposes to hernia, which is more apt to occur in patients who are slender at the time of the operation, but grow stout soon afterward and lead a life of active exertion. The commonest of all causes, however, is the necessity for leaving the wound open for drainage in abscess cases. A wound of this description closes slowly, and when it finally does so, the cicatrized margins are held together by a veil of scar tissue that yields readily to any pressure from within, such as is brought to bear upon it whenever the abdominal walls contract upon the contained viscera. If through some fault in technic, or some accidental contamination, a healthy wound is infected after closure, breaks down, and finally closes only after suppuration, the final result is the same as in cases which have been drained, and a hernia is likely to result.

Prophylaxis, which is the best safeguard against hernia, lies in the use of a small incision whenever it can be employed with equal safety, and in the separation of the muscular layers without cutting them (McBurney, see Chap. XXIII, p. 533). I cannot too earnestly advise against the unnecessary division of the important nerve trunks, the analogues of the intercostal nerve trunks above, which supply the abdominal muscles. It is one of the chief advantages of interval operations that it is never necessary to use drainage after them, and that the diseased appendix can be removed through so small an opening that liability to the formation of a hernia is minimized. In drainage cases something may be done to reduce the liability to hernia by establishing such free drainage for the first few days that the abscess quickly empties itself and begins to contract. The external wound may then be rapidly closed, and to this end provisional interrupted sutures of silver wire are laid during the operation as

though the layers of wound were to be closed entirely and at once; they are then drawn aside and left loose until the drainage is almost completed, when the wound may be rapidly closed down to a small orifice which at last fills in with a plug of cicatricial tissue. When the abscess extends down into the pelvis, drainage by the vagina or by the rectum is preferable, both on account of its greater efficiency in a dependent position and the fact that any risk of hernia is obviated. Drainage cases should be kept in bed until the wound is firmly closed; the physician will then at least save himself the blame which is sure to be laid upon him if he hurries the patient out of bed, and a hernia subsequently forms. Whenever there is any reason to fear the formation of a hernia, the patient should wear a snug-fitting bandage.

In spite of the utmost precautions a certain percentage of hernias are inevitable as long as surgeons are forced to operate in the suppurating stages of appendicitis. It must be remembered that in all such cases the operation is essentially a life-saving operation procedure, and the risk of a hernia must be accepted as a trivial consideration in comparison with the danger from which the patient is rescued. It is best to forewarn him in such a case, either just before or soon after the operation, and advise him to accept cheerfully an inconvenience which is so easily remedied by subsequent operation.

T r e a t m e n t .—The proper treatment of a hernia is the excision of the scar together with the hernial sac, followed by the careful approximation of sound tissues in their natural order and relations, from the peritoneum to the skin surface.

It is important to remember that while the hernial orifice feels like a sharply defined ring as large as the end of the finger, that is to say, an inch or more in diameter, this ring is surrounded by thinned out areas of scar tissue, which often involve the entire length of the original wound, and are sometimes cribriform. In order to effect a radical cure of the rupture, this whole area must be dissected out. A ventral hernia can never be cured by simply exposing and suturing the sharp margins of the neck of the sac. Let me reiterate and emphasize the fact that the operation for hernia must not only include the actual, manifest, hernial sac with its orifice, but the entire weakened area in which the hernia is situated, and in which it is progressively extending its boundaries from month to month.

The operator proceeds by excising the scar and baring the tendinous muscular tissues, which are healthy and well vascularized; the various anatomic structures must then be sought out and recognized individually, after which they are laid bare so that they can be brought broadly together. As a suture material it is best to use fine silk or silver wire, at intervals of from 2 to 2.5 cm., so as to splint the tissues together in their proper order; catgut may be employed between these sutures to secure accurate approximation. After such an operation the patient should remain in bed not less than three weeks, and go about with caution for many weeks longer.

When the hernia is at the border of the right rectus muscle, its cure is more difficult, as the lateral oblique muscles must be united to the vertical rectus instead of being approximated to homonymous tissues, as in hernias situated more laterally. A. B. JOHNSON gives a clear description of the procedure to be

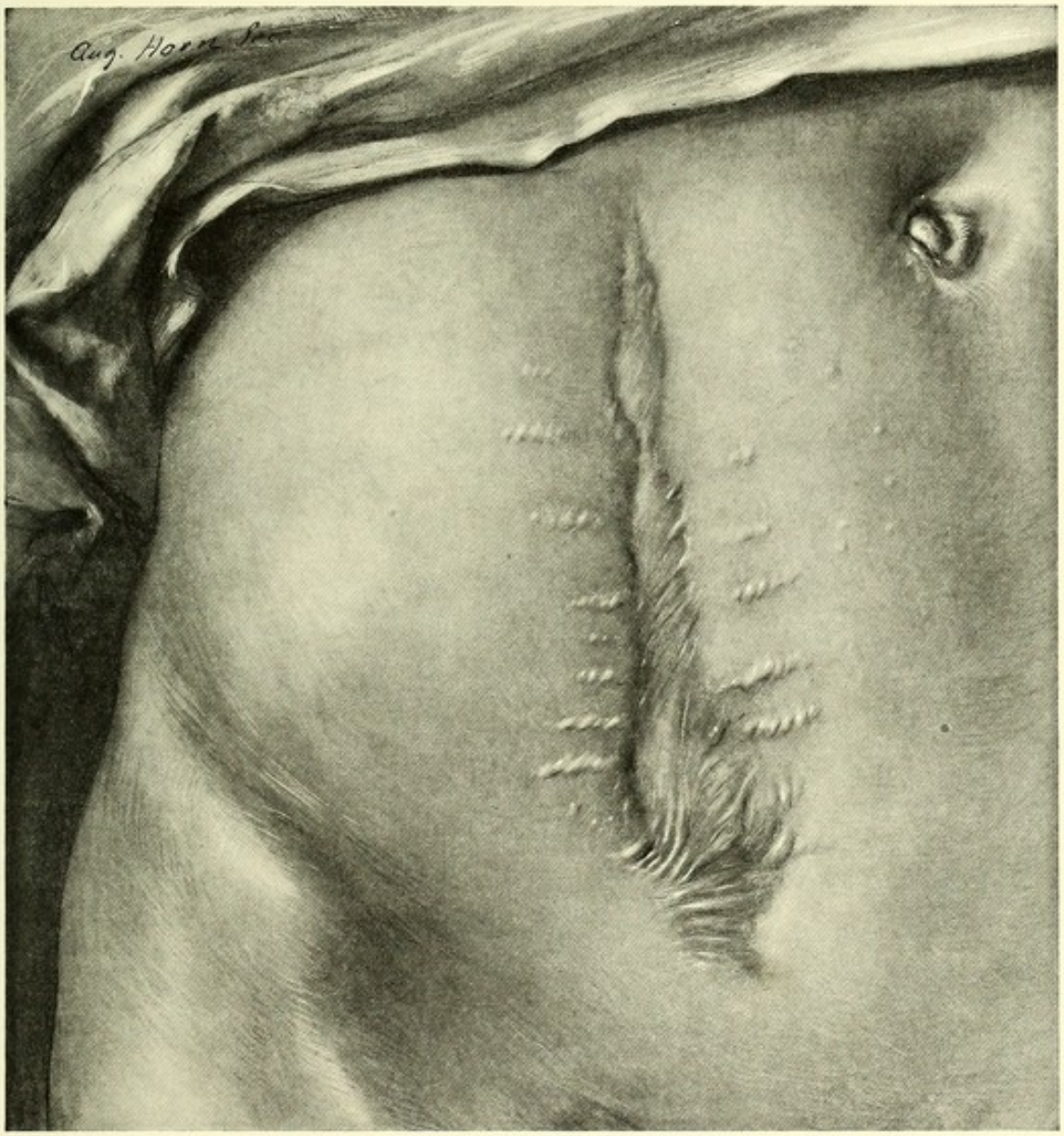

FIG. 351.—SHOWING LARGE HERNIA FOLLOWING INCISION IN THE SEMILUNAR LINE FOR APPENDICITIS; FIRST OPERATION ELSEWHERE, OPERATION FOR HERNIA AND FLOATING KIDNEY IN GYNECOLOGICAL CLINIC.
J. H. H. J. R., æt. thirty. January 24, 1903. Recovery.

pursued for hernia in the semilunar line (*Ann. Surg.*, 1899, vol. 29, p. 625). The patient, a woman, forty years of age, had been operated upon at the Roosevelt Hospital for an appendicitis with abscess, and three years later she was re-admitted with a hernial protrusion measuring 3 by 4 inches, situated at the right border of the rectus muscle. After excision of the scar and of the

peritoneal sac, the outer margin of the hernial ring, consisting of the aponeurosis of the external oblique and tendinous portion of the internal oblique and the transversalis, was split; the external oblique was then dissected away from its underlying structures for a distance of 2 inches over a vertical

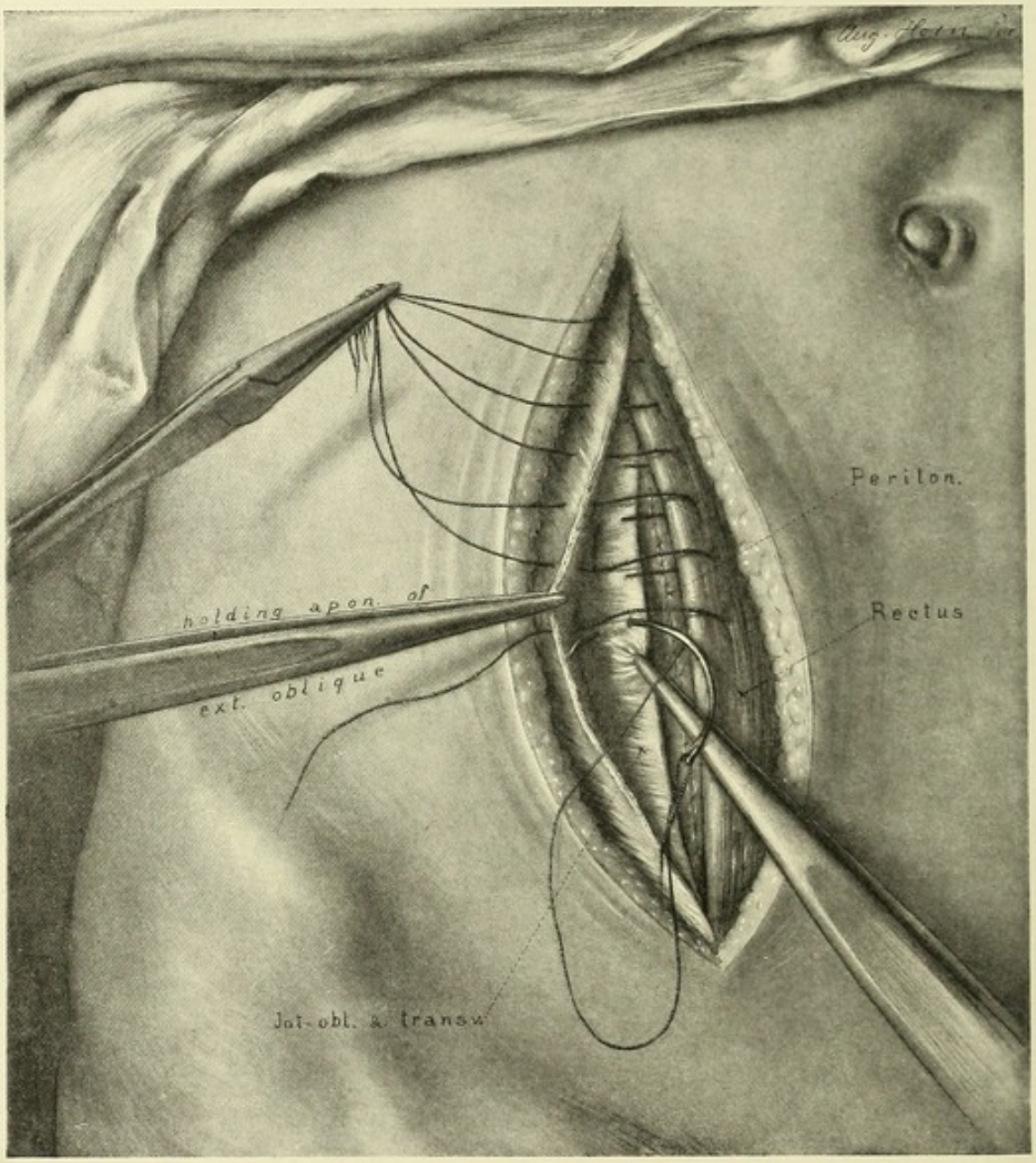

FIG. 352.—SHOWING OPERATION FOR HERNIA DOVETAILING RECTUS BETWEEN THE BROAD ABDOMINAL MUSCLES.

area 4 inches in length. Upon the inner side of the hernial opening the sheath of the rectus was laid open for a distance of 4½ inches. The internal oblique and the transversalis were then attached to the posterior layer of the rectus sheath by catgut sutures, while the body of the rectus muscle was dragged

from its sheath and attached by mattress sutures to the under surface of the aponeurosis of the external oblique, so as to cover completely the site of the hernial protrusion. The free margin of the aponeurosis of the external oblique was then sutured onto the anterior surface of the rectus sheath, and, lastly, the skin wound was closed. Five months later there was no evidence of weakness in the region of the scar. The method of closure was not unlike that used in one of our own cases, which is here figured.

Fig. 351 shows the characteristic appearance of a large hernia in the right semilunar line; the drawing represents the flaccid scar filled in with thin skin.

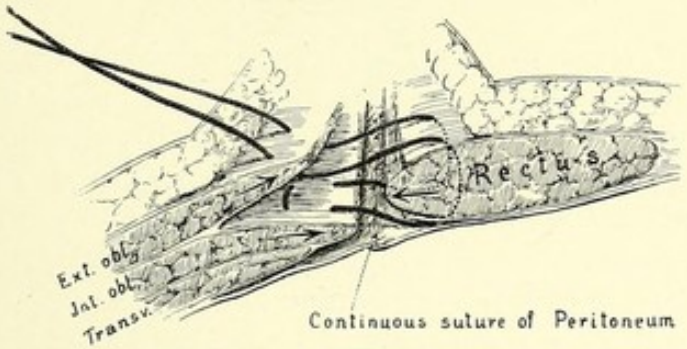

Fig. 353.—Showing in Detail Method of Drawing Rectus between Muscles.

The larger opening in the diastasis is characteristically in the lower part of the wound. The incision, which had been made in another clinic, had evidently been closed by through-and-through sutures with drainage below. The method of closure is shown in Figs. 352 and 353. After dissecting out the scar tissue, the margin of the rectus muscle is exposed, clean and clear, throughout the entire length of the wound. The lateral muscles are likewise laid bare. The next step is to split the lateral muscles, separating the external oblique with its stronger fascia from the internal oblique and the transversalis below. The sutures are shown in full view in Fig. 352, while Fig. 353 exhibits the method of passing a single suture in profile.

CHAPTER XXIX.

RELATION BETWEEN APPENDICITIS AND GYNECOLOGICAL AFFECTIONS.

GENERAL CONSIDERATIONS.

Pozzi, in 1890, and also Terillon, in 1890, emphasized the importance of the relationship between appendicitis and diseases of the pelvic organs in women, but it is only within the past five or six years that a general appreciation of this relationship has been manifested. Previous to this time, and even to a great extent to-day, the relative immunity of women to inflammation of the appendix has been chiefly dwelt upon, the exemption being partly attributed to the supposed accessory blood-supply from the ovarian vessels. Some writers, on the other hand, recognizing the coincident infection of the appendix and pelvic organs, believe that the infection has been conveyed from the one to the other through a pre-existing lymphatic connection between the appendix and the right ovary. It is now, however, generally conceded that the vascularization of the appendix is similar in the two sexes, and that an additional blood-supply from the ovarian or spermatic vessels, while occasionally observed, is very inconstant. It is also well recognized that diseases of the pelvic organs in women are often the chief factor in exciting an appendical attack, and, what is of still greater significance, that appendicitis is often the direct cause of tubal and ovarian disease, the secondary infection in either case being due to contiguity and not to continuity of structure. The confusion of diagnosis which frequently occurs between the two is of great importance, for patients suffering from chronic appendicitis are sometimes subjected to prolonged treatment for supposed pelvic disease, while, on the other hand, a case of acute salpingitis may be operated on for appendicitis. I would especially emphasize the fact, mentioned elsewhere (see Chap. XVI), that dysmenorrhea is in many cases wholly due to the presence of a chronically inflamed appendix. It is partly due to mistaken diagnoses as well as to the failure to recognize the appendical origin of some cases of salpingo-ovaritis that appendicitis is found to be so much less frequent in women than in men. In Chap. XVI it is noted that of the cases of uncomplicated acute appendicitis admitted to the surgical department of the Johns Hopkins Hospital, about 40 per cent. were women and 60 per cent. men; but if we add the cases admitted to the gynecological clinic, usually with a diagnosis of pelvic disease, practically the same proportion obtains for the two sexes; while the cases of chronic

appendicitis are in the ratio of 4 in females to 5 in males. I have not included in these statistics the cases of acute and chronic appendicitis which were associated with gynecological affections, but if these cases are added, out of a total of over 900 cases of appendical disease admitted to the Hospital, the number occurring in women is slightly greater than in men. It would appear, however, that the most severe forms, especially cases complicated with general peritonitis, are more common in the latter, occurring in the Johns Hopkins Hospital in the ratio of 2 to 5.

The relationship between disease of the vermiform appendix and disease of the pelvic organs in women may be either accidental or causal; and the most obvious classification of disease of the appendix from this point of view is the following:

1. Cases in which the disease of the appendix is primary, and the pelvic affection is secondary, that is to say, consequent on the lesion of the appendix.

2. Cases in which the gynecological affection, whether it is tubal, uterine, or ovarian, is primary, and the disease of the appendix is secondary.

3. Cases in which the disease of the pelvic organs and the disease of the appendix are independent of each other.

In cases falling under the third class, namely, those in which disease of the appendix and disease of the pelvic organs exist independently, and their association is purely fortuitous, the affection of the appendix is, as a rule, an old one. The appendix will be found attached to adjacent structures, or, as I have often seen it, in the course of gynecological operations, completely atrophied and even reduced to a fine cord, in some instances no more than a filament. On the other hand, unsuspected disease of the uterus, tubes, or ovaries, associated with the remains of an old pelvic peritonitis, may be of long standing and only discovered unexpectedly during the course of an operation for acute appendicitis. It is not always an easy matter, in inflammatory cases, to decide whether disease of the appendix and the right tube and ovary are independent or associated, for extensive inflammatory affections proceeding from the vermiform appendix or from the uterine tube may spread from one organ to the other and then subside, leaving traces behind in the form of adhesions, enveloping both organs. In these circumstances reliance must be placed on the history of the case, which should always be carefully investigated.

In my clinic at the Johns Hopkins Hospital I have had occasion to remove the appendix in 240 cases, in the majority for combined gynecological and appendical disease. Prior to 1895, appendical adhesions observed during the course of a gynecological operation were often released and the appendix left *in situ*, but it is now my invariable custom to remove the appendix in these cases, unless the condition of the patient absolutely interdicts the slight additional strain. An analysis of the cases in which the appendix was removed is as follows:

Acute or chronic appendicitis not associated with gynecological affections	96 cases
Appendicitis associated with inflammation of the pelvic organs	64 "
Appendicitis associated with retroflexion of the uterus (sometimes adherent)	11 "
Appendicitis complicating ectopic gestation	7 "
Appendicitis associated with tuberculosis of the tubes and with secondary tubercular invasion of the appendix	4 "
Appendicitis associated with tuberculosis of the tubes, with simple adhesions of the appendix	3 "
Primary tuberculosis of the appendix	1 case
Appendix adherent to ovarian cysts	19 cases
Appendix adherent to ovarian myomata	15 "
Appendix adherent to malignant ovarian tumors, with secondary invasion of the appendix	2 "
Appendix adherent to malignant tumors, with simple adhesions of the appendix	1 case
Primary malignant disease of the appendix	1 "

In the remaining 16 cases the appendix was removed either as a prophylactic measure, or (in three instances) on account of obscure pain in the right abdomen, without apparent disease.

Appendicitis Associated with Secondary Pelvic Inflammatory Diseases.—Pelvic inflammation, the result of direct propagation from a right iliac abscess, is a common event, and is apparently more frequent in women than in men, probably owing to the greater number of cases in which the appendix occupies the pelvic position in women. As I have previously insisted, however, a pelvic abscess may form with an appendix high up in the iliac fossa. The great significance of this accident in women is that the uterus and its adnexa, particularly on the right side, may become implicated in the suppurative process with a resulting permanent impairment of their functions. Pus tubes and ovarian abscesses are not infrequent sequelæ of suppurative appendicitis, and in less severe cases the pelvic organs remain bound up in adhesions which are a frequent cause of persistent pelvic pain, severe dysmenorrhea, and sterility. A good example of the late effects of a suppurative peri-appendicitis (Krüger, *Zeit. f. Chir.*, 1897, Bd. 45) was the case of a woman, thirty-two years old, who was admitted with a pelvic disease, the result of several attacks of appendicitis. The appendix was removed and the abscess drained, the result being that the patient was cured of the appendical trouble, but left with the uterus fixed in retroposition, while the tubes and ovaries, especially the right one, were fixed deep in the pelvis.

Barnsby (*Thèse de Lyon*, 1898) relates the case of a woman, aged twenty-five years, who gave no history of previous pelvic trouble, but had suffered from

three attacks of appendicitis, the second and third terminating in the discharge of pus *per rectum*. Operation revealed a perforated appendix opening into an old inflammatory focus. There was an old abscess in Douglas' *cul-de-sac*, communicating with the rectum; double salpingitis, most pronounced on the right side; and the left ovary was adherent and sclero-cystic. The appendix and right tube were removed and it was then found necessary to extirpate the uterus to insure drainage.

One of my cases (Johns Hopkins Hospital; Gyn. No. 6502) was as follows:

The patient, who had had five normal childbirths, gave no history of pelvic disease. While in perfect health she was suddenly seized with severe abdominal pain, nausea and vomiting, and slight fever. The next day a lump appeared in the right side. She was in bed one month, and afterward suffered from pain in the right side which caused her to limp. Five months later there was a sudden exacerbation of the pain, attributed by the patient to the onset of the menstrual period; it soon subsided, but fearing to precipitate another attack, she remained in bed until entering the hospital five weeks later. At operation the pelvis was found entirely walled off from the abdominal cavity and there was evidence of recent peritonitis involving the adjacent intestinal loops. Neither uterus nor tubes were visible. The appendix was visible only at its base, the tip extending into the plastic lymph walling off the pelvis. On bimanual examination *per vaginam* and through the opened abdominal cavity the uterus could be felt, but no mass suggesting the condition seen above. The adherent bowel was freed and the general peritoneal cavity packed off with gauze. The pelvic adhesions were carefully separated, the uterus being first freed. When the appendix was freed, pus was seen oozing from it. It was brought out and removed. The right tube and ovary were then inspected; the latter was found to be normal, but the tube was swollen and engorged and its mesentery much thickened; it was, therefore, removed. As no streptococci were found in the exudate, the cavity was thoroughly cleansed with salt solution and the abdomen closed without drainage. Convalescence was absolutely smooth. Examination before discharge showed a natural abdomen; there was no resistance in the right pelvis, but on the left side slight bands of adhesions and an indefinite sense of resistance. I would now drain such a case.

ZWEIFEL especially directs attention to cases of appendicitis with a purulent exudate, which, sinking into the pelvis, involves the tubes, and by sealing the abdominal ostia produces sterility. DÜHRSSEN, SHOEMAKER, SHOBER, and others believe that the perimetric adhesions due to appendicitis are a frequent cause of uterine displacements. In five out of the eleven cases in which I found appendical disease associated with retroflexion, the uterus was bound down by light adhesions which could not be accounted for by pelvic infection, and the uterine tubes were quite healthy. In these cases it was probable that an old appendicitis had been the cause of the perimetritis.

Unilateral disease of the adnexa is more commonly produced by appendicitis than bilateral affections. In exceptional instances, where a long appen-

dix descends into and across the pelvis, the left tube and ovary are implicated. As a rule, however, the right adnexa are attacked, the left remaining perfectly healthy. In many of these cases the appendical origin of the infection is clear, both from the clinical history of the trouble and from the appearance of the organs at operation.

T. H. Hawkins (*Med. Rec.*, May 6, 1899) describes two cases, observed in young girls, in which there was no history of pelvic trouble, and which presented a typical clinical picture of acute appendicitis; operation showed the inflamed appendix caught up in the fimbriated end of the right tube, and a secondary acute purulent inflammation of the tube.

A very interesting case is related by R. Morison (*Lancet*, 1901, vol. 1, p. 533).

A young woman, aged twenty-seven years, was admitted to the Royal Infirmary, Newcastle, with a history of five days' illness, beginning with sudden pain in the epigastrium, accompanied by vomiting. Two days later the pain settled in the right iliac region. The pain and vomiting continued, and on the third and fourth days there was dysuria. On admission, the patient looked flushed; her temperature was 100.8° F.; her pulse 120. The whole abdomen was slightly distended, tender, and rigid, and the note over the whole lower abdomen was dull. Rectal examination was negative. Ten days later there was an escape of fetid pus from the cervix uteri. At operation, about the end of the third week of illness, the pouch of Douglas was found to be practically converted into a large abscess which extended upward into the left iliac fossa. A fecal concretion was found in the abscess, and on drawing the cecum forward the whole appendix was seen to have sloughed off, leaving an opening into the cecum the size of a sixpenny piece. The right side of the abscess had been drained by the Fallopian tube, which was thickened, but pervious, and contained fetid pus in the lumen. The opening into the cecum was sutured, the right tube removed, and a large drain inserted. Recovery was complicated by the development of a vaginal fecal fistula, but the patient was discharged well at the end of six weeks. Examination a year later showed no adhesions or other abnormality in the pelvis.

The importance of recognizing the presence of pelvic complications is seen in the following case. The patient, an unmarried woman, forty years old, was admitted with acute appendicitis. At operation there was no abscess and no pus nor fluid in the general cavity. A mass felt in the pelvis, supposed to be an enlarged right ovary, was not disturbed. There was slight pain and distention after operation, which on the third day began to increase somewhat, and the general condition was rather alarming; face flushed, pulse 130, temperature 100° F., respirations difficult. The wound was reopened and a large pelvic abscess was opened and drained. The mass which was felt at the first operation was also explored and found to be a tubo-ovarian abscess. Death occurred the following day.

In many instances it is difficult to determine the origin of the infection. The fact that the pelvic disease is limited to the right side is suggestive confirma-

tory evidence of the appendical origin, but the chief reliance must be placed on the history and on the condition found at operation.

Appendicitis Secondary to Pelvic Inflammation.—In the majority of instances in which there are coexisting affections of the pelvic organs and the appendix the primary infection is in the pelvis. As a rule, the appendix is merely adherent by its distal portion, but more or less extensive pathological changes in its walls are frequently found. The appendix in women, as we have said, frequently occupies the pelvic position and is in contact with the upper portion of the right broad ligament. In such a case a peri-salpingitis readily involves the peritoneal surface of the appendix. Moreover, in puerperal infection and in gonorrheal salpingitis, when the large tube is higher than usual, the appendix may be involved even when situated above the pelvis. In a case described by BARNSBY (*loc. cit.*) the large, firm, turgid appendix was densely adherent to the posterior surface of an enormous tubo-ovarian abscess which extended almost to the umbilicus. Usually, as I have said, the appendix is attached to the tubo-ovarian mass merely by more or less firm adhesions; sometimes by a delicate strand of tissue extending from the tip of the appendix to the pelvic mass, the appendix itself showing practically no gross changes. But careful examination of such appendices shows that comparatively few are perfectly healthy, a mild catarrhal inflammation being most often met with. More severe lesions, however, are not unusual, an unsuspected acute diffuse inflammation being found in some instances at operation; but more often a chronic inflammation or various residual conditions, viz., strictures, obliteration, or cystic distention, are present.

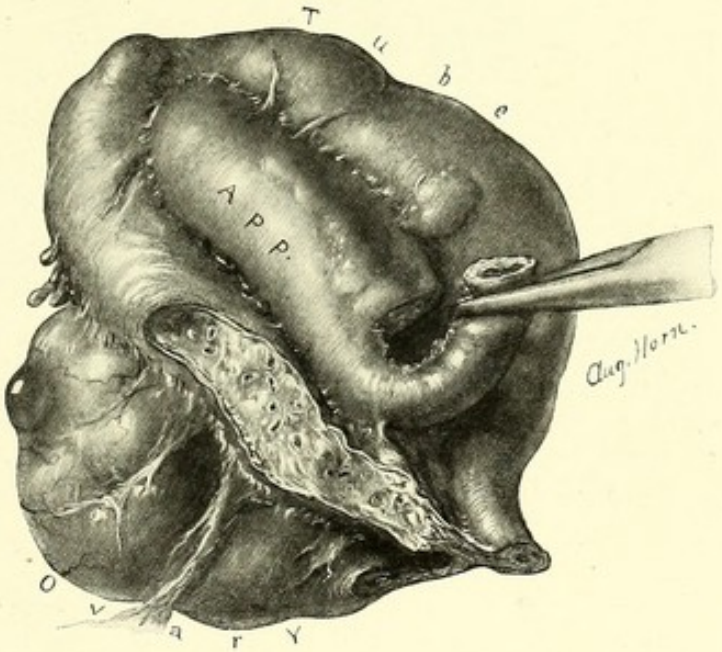

FIG. 354.—H. A. KELLY. INFLAMED APPENDIX ADHERENT TO A TUBO-OVARIAN ABSCESS. (Gyn. Path. No. 5622.)

In the case represented in Fig. 354 the patient had had the left ovary removed two years before for inflammation, dating from her second confinement nine years previously. The pain, however, continued in both sides of the abdomen, but was more intense in the right side. Operation revealed a large inflammatory tubo-ovarian mass in the right side, with the thickened, chronically inflamed appendix densely adherent over its surface. In another case (Gyn. No. 9560)

the patient had suffered for fifteen years (since her last pregnancy) from leucorrhea and neuralgic pains in her thighs and legs, and from constipation. There was no history of appendicitis. At operation an old inflammatory condition of the pelvic organs was found. The right tube was irregularly distended with clear fluid, its surface was covered with dense adhesions, and showed many sub-peritoneal cysts. The appendix was densely adherent to the uterine tube by its mesentery, which also contained a small peritoneal cyst (see Fig. 355).

In one of my cases (Gyn. No. 3650) a left pyosalpinx was removed, but as

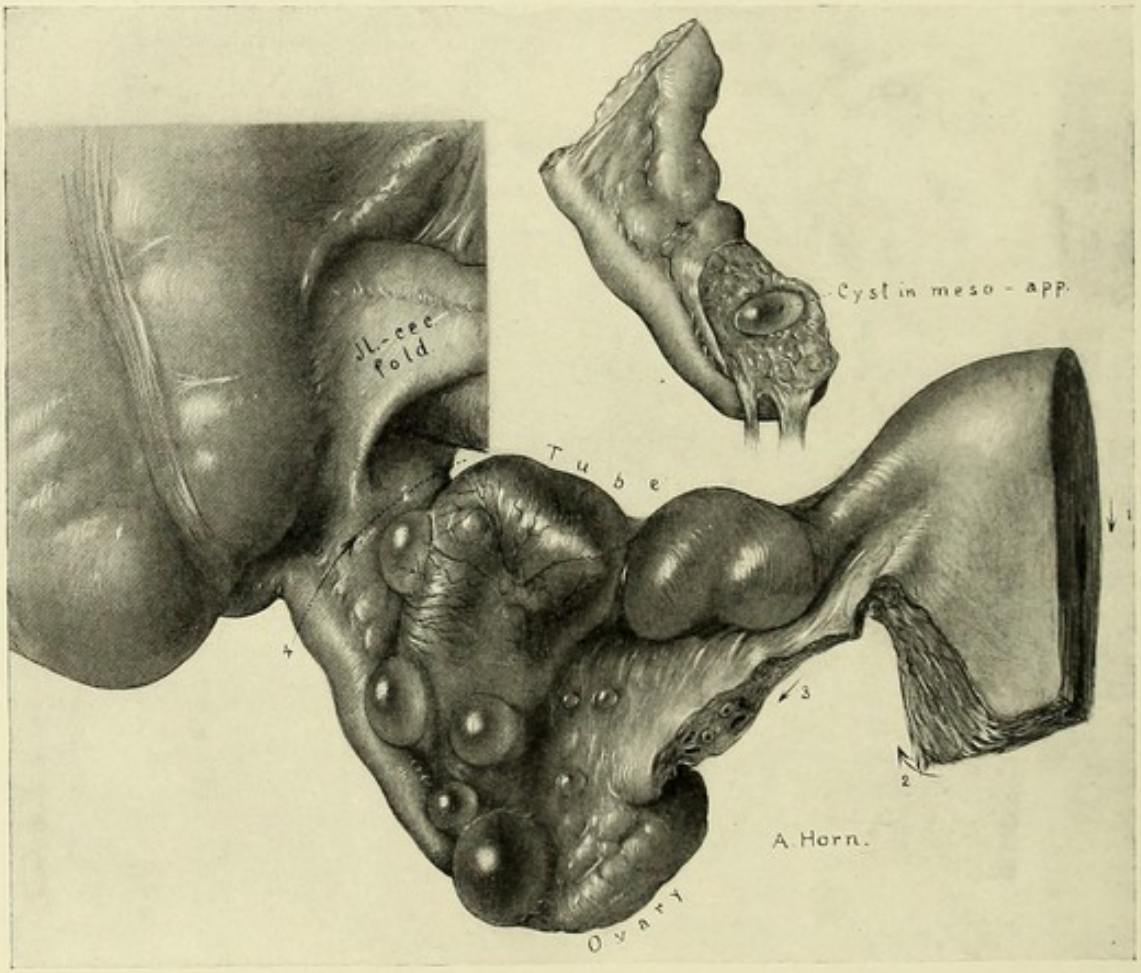

Fig. 355.—H. A. Kelly. Obliterated Appendix Adherent to a Chronic Tubo-ovarian Inflammatory Mass. (Gyn. Path. No. 5742.)

the right tube was free and only slightly reddened, it was left *in situ*. The patient was discharged apparently well. A few days later, however, she returned with a mass on the right side. Operation showed the tube distended with pus, and the reddened, fluctuant appendix adherent to it. Removal of the tube and appendix resulted in complete cure.

The causal relation of the pelvic disease to the appendical inflammation may be direct or indirect. In the first, the appendix in the beginning becomes involved in the pelvic exudate, the adhesions thus formed become organized, and

then, lymph and blood-vascular connections being established between the appendix and the tube, the infection is easily transmitted. It seems probable, however, that usually the pelvic disease, by fixing the appendix in adhesions, limits its movements, and by inducing stasis, acts as a predisposing factor in the development of the appendicitis. The bacteriologic proof of the mode of infection is generally unsatisfactory, as an old pelvic inflammatory focus is often secondarily invaded by the bacillus coli, and streptococci are present in most acute appendicitides. In a case in my clinic reported by H. Robb (*Johns Hopkins Hospital Bull.*, 1892), in which there was a history of pelvic disease, and at operation double pus tubes were found with the inflamed appendix adherent to the one on the right side, the fact that a pure culture of streptococcus was obtained from both the tube and the appendix suggests the direct infection of the appendix from the tube.

The history of the onset and course of the disease is the most important point in determining its o iginal focus. It is frequently possible to obtain a clear history of puerperal or gonorrheal infection accounting for the pelvic disease, and in these cases, as a rule, clinical evidence of the appendical complication is conspicuously absent.

Tuberculosis of the pelvic organs not infrequently involves the appendix in the peritoneal adhesions which usually accompany this condition, and in a number of these cases the appendical walls are invaded by the tubercular process, even where there is no evidence of other extension of the disease. Out of 7 cases, examined by myself, in which the appendix was adherent to the tubercular tube, in 4 the appendix was slightly infiltrated with tubercles. A circumscribed tubercular peritonitis was present in only one of these instances. These cases are more fully considered in Chap. XXXII.

Tumors of the uterus and ovaries, complicated by disease of the appendix. Cases in which the appendix is adherent to cysts of the right ovary are frequently observed, and occasionally it is found attached to a left ovarian cyst (see Fig. 356). Out of about 300 operations for cystoma in the Johns Hopkins Hospital, the appendix was found adherent to tumors of the right side in 16 cases, and to those of the left side in 3. In some instances the appendix is merely secondarily involved in the general adhesions which so frequently surround pelvic tumors and are the residue of an old widespread peritoneal reaction. Dermoids, and cysts with torsion of the pedicle are particularly liable to give rise to general adhesions, and it is in such cases that the appendix is most often involved. In our series the cyst had become twisted on its axis in one-fourth of the cases, and in these the appendical adhesions were unusually dense and extensive. In other instances the appendix is adherent to the otherwise smooth surface of the cyst, or to the broad ligament. The cause of the formation of such adhesions is not always clear. It is probable, however, that the direct mechanical influence of the tumor, by disturbing the relations of the appendix, by interfering with its circu-

lation, or by direct pressure, has indirectly excited a mild diffuse inflammation of the appendix with extension to the peritoneum. It is readily seen how such an effect would be produced when the appendix occupies the pelvic position and is subject to direct pressure of the tumor. In some cases the tip only is adherent; in others the entire appendix, including its mesentery, is plastered to the surface of the tumor. The organ itself may be practically normal, but, as a rule, its walls are thickened and rigid, while kinks, twists, strictures, and other results of an inflammatory process are commonly found. In two instances

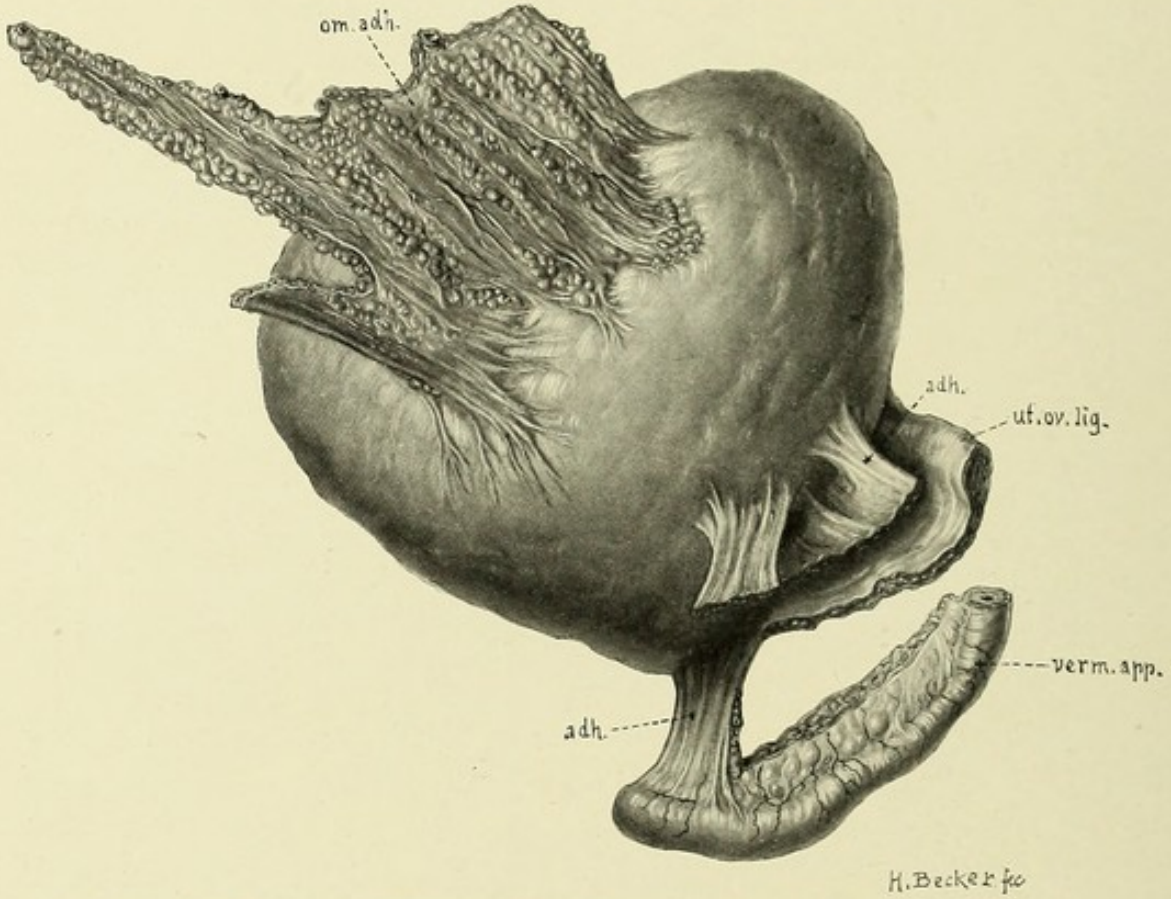

FIG. 356.—H. A. KELLY. TIP OF THE APPENDIX ADHERENT TO SMALL DERMOID CYST OF LEFT SIDE. Note also omental adhesions above. Appendicitis, cholecystitis. S., age fifty-four, Feb. 6, 1899. Recovery.

of ovarian cysts I found the appendix stenosed near its base, and the remainder converted into a large transparent cyst. Acute appendicitis may develop and cause secondary infection of the cyst wall. In 3 cases described by X. O. WERDER (*Jour. Amer. Med. Assoc.*, Jan. 1, 1898) acute appendicitis complicating ovarian cysts gave rise to symptoms simulating torsion of the pedicle. In all the cyst wall was congested and apparently involved in a secondary infection from the appendix; in one, the sac was dark and exceedingly friable. WIKERSHAUSER (cited by Pollak, *Centrbl. f. d. Grenzb. d. Med. u. Chir.*, Bd. 7, p. 161) reports a case of large suppurating ovarian cyst with firmly adherent appendix, and was of opinion that the infection had extended from

the appendix to the tumor. In one of the Johns Hopkins Hospital cases the appendix, together with the cecum, was attached by its entire length to a suppurating cyst of the left ovary.

Parovarian cysts are equally disposed to be complicated by appendical adhesions, or by acute or chronic appendicitis. In a case described by KRÜGER (*loc. cit.*, Case 12) the patient, a girl nineteen years old, gave a history of recurrent attacks of appendicitis extending over a period of two years. When admitted, during the third severe attack, there was tenderness in both hypogastric regions, with dulness and marked resistance. In the left side fluctuation was detected. At operation a right parovarian cyst, with its pedicle twisted two and a half times, was found lying in the left abdomen. The appendix, which was 12 to 13 cm. long, deep red, and injected, descended into the pelvis, where it was adherent by its tip. In the case of malignant ovarian tumors the appendix may become adherent and be secondarily invaded by the new-growth. These cases, as well as the occurrence of metastatic growths in the appendix secondary to ovarian tumors, will be considered in Chap. XXXI.

Uterine myomata are less frequently complicated by disease of the appendix than ovarian cysts. In some 500 myomectomies the appendix was adherent in about 3 per cent. As in ovarian tumors, the appendix usually presents evidence of chronic inflammatory changes. In one case (Johns Hopkins Hospital, Gyn. No. 5302) the patient, a woman forty-six years old, was suddenly seized ten days before admission, while enjoying good health, with pain in the right lower abdomen, associated with dysuria and constipation. At operation the large myomatous uterus was found densely adherent to the pelvic floor, the sigmoid flexure, the rectum, and the colon, while the appendix was entirely embedded in a tubo-ovarian abscess on the right side. In another case DOLÉRIS (Pollak) removed a suppurating myoma *per vaginam*, death occurring a week later, when the postmortem showed a perforated gangrenous appendix lying in the centre of an abscess, encapsulated amidst coils of intestine. Fig. 357 shows the appendix adherent to a large uterine myoma which exhibited sarcomatous changes.

Ectopic gestation is complicated with appendicitis in a considerable number of cases. Personally, I recall seven instances, forming about 10 per cent. of the cases of extrauterine pregnancy observed in my clinic, in which the appendix was adherent to the sac, or was acutely inflamed. A good example of the simple adhesion of the appendix to a tubal pregnancy is shown in Fig. 358. In this case the patient had an old, inflammatory, pelvic disease binding down both tubes and ovaries, and grafted on this, an extrauterine pregnancy, with adhesions as shown. A very difficult enucleation was done by bisection (see Fig. 359). The patient died shortly afterward, seemingly of collapse. The great danger in these cases lies in the infection of the products of conception by the appendicitis. KRÜGER describes the case of a woman, aged thirty, with a history of acute appendicitis beginning four weeks previous to admission. Men-

struation was regular; her temperature was 99.1° F.; her pulse 120. Incision in the right flank exposed the abdominal cavity filled with large clots. The

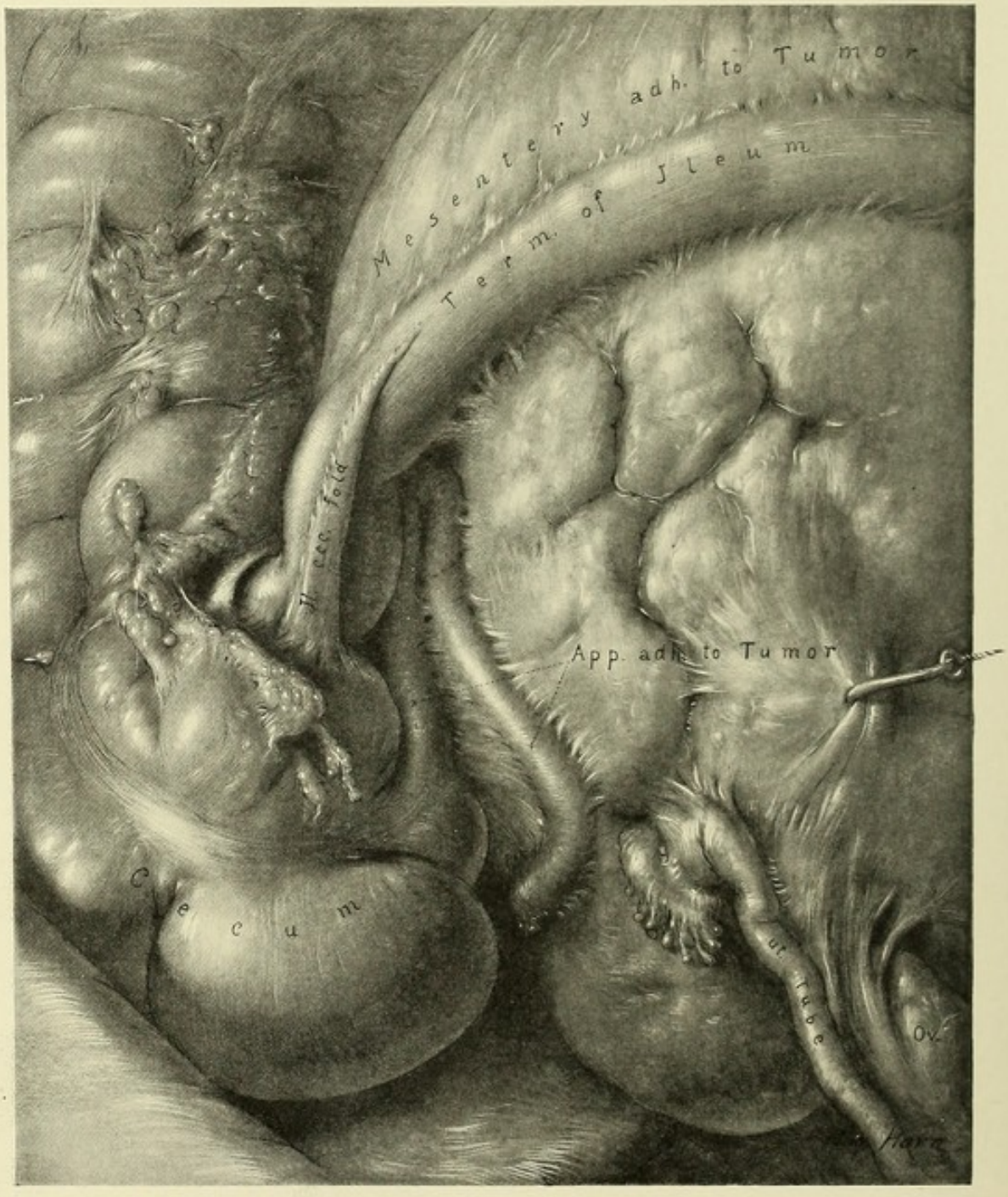

FIG. 357.—H. A. KELLY. APPENDIX DENSELY ADHERENT TO FIBROID TUMOR, UNDERGOING SARCOMATOUS DEGENERATION.

Note the displacement of the ileum and the adhesions of the uterine tube and ovary. Appendix 13 cm. long, and contained many small concretions. E. M., age fifty-six. Death without operation. Autopsy, April 24, 1898. (Path. No. 1085.) (Natural size.)

thickened, reddened appendix was firmly bound to the gestation sac, and it was evident that infection of the contents of the hematocele had occurred. Enucle-

ation of the sac and the appendix was followed by smooth recovery. A very interesting case is related by SUMMA (*St. Louis Cour. of Med.*, 1900, p. 434), in which, after the appendix had been extirpated at an operation for acute perforative appendicitis, a severe hemorrhage suddenly welled up from the depth of the pelvis. Investigation of the cause of this accident revealed a fresh rupture of an ectopic pregnancy on the left side, a one month's fetus being found.

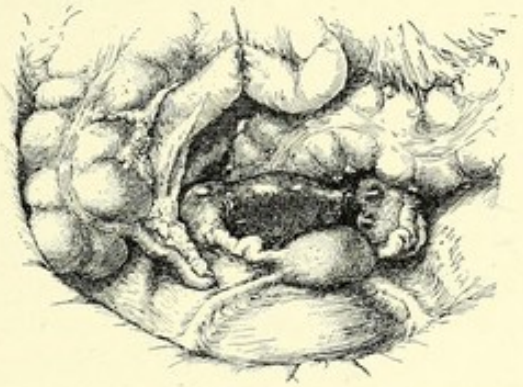

FIG. 358.—APPENDIX ADHERENT TO RIGHT BROAD LIGAMENT IN A RIGHT EXTRAUTERINE PREGNANCY. (M. A. Runyon. Orange, N. J., Feb. 14, 1903.)

In a case observed in the Johns Hopkins Hospital (Gyn. No. 4576) the patient, aged thirty-eight years, entered with a history of having fainted one week before, while hanging up clothes, having since had continuous hemorrhage. As the patient was subject to attacks of syncope, this attack did not alarm her, and was ascribed to the heat. There was pain about the umbilicus and in the inguinal regions, especially the right. Temperature 100° F.; pulse 100. Operation

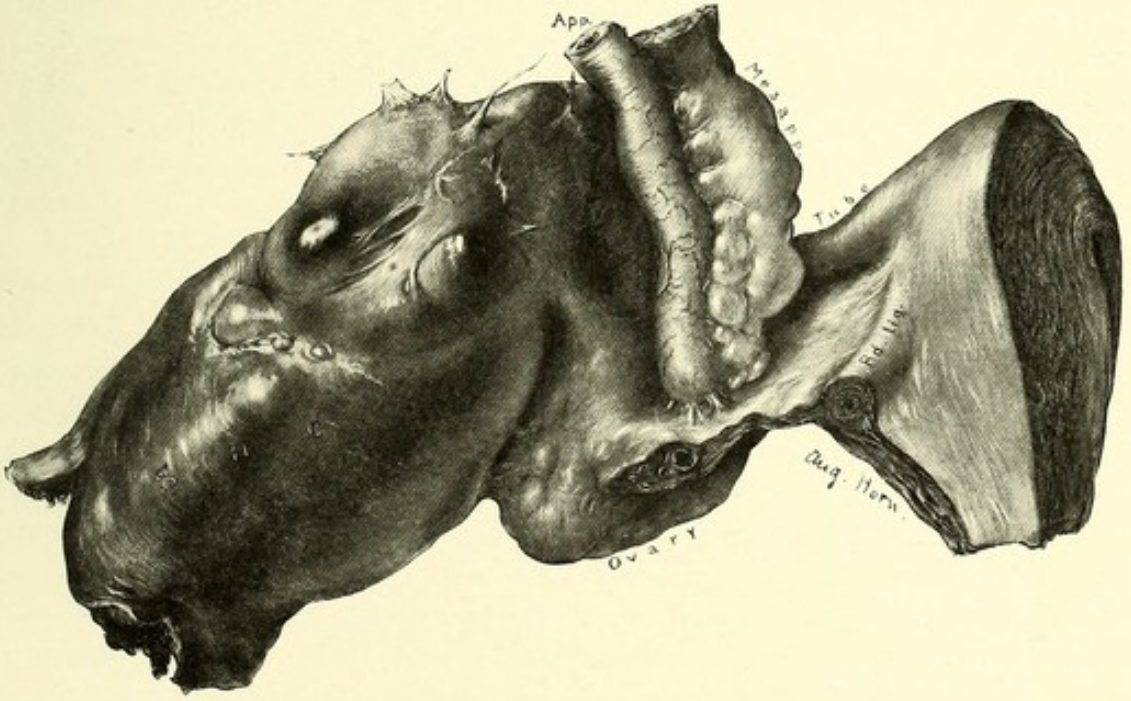

FIG. 359.—DETAILED STUDY OF THE PRECEDING SHOWING THE RIGHT HALF OF THE BISECTED UTERUS, THE AMPULLA OF THE UTERINE TUBE DISTENDED WITH CLOTS, AND THE APPENDIX ADHERENT IN THE ANGLE BETWEEN THE AMPULLA AND THE ISTHMUS. (Natural size.)

showed a recently ruptured, right tubal pregnancy, and an acutely inflamed appendix.

Independent Affections of the Appendix and the Pelvic Organs.—The

possibility of the coexistence of pelvic and appendical disease should always be borne in mind, especially in cases which are being treated for pelvic disease. The cure of the pelvic affection in such instances has disappointing results, and the patient continues to suffer from much of the discomfort and pain for which she was treated, relief being finally obtained only upon removal of the appendix. A good example is the case of a patient who came under my care suffering from general pelvic discomfort and painful menstruation. I made a median incision and found the uterus retroflexed, and the ovaries adherent. The adhesions were freed and the uterus suspended. The patient was little, if at all, improved by my treatment. Some months later she was operated on by J. B. Deaver of Philadelphia, who removed the chronically inflamed appendix, with the complete relief of all her previous symptoms. Wiggin (*N. Y. Med. Jour.*, 1894) operated upon a woman for double pyosalpinx and general pelvic peritonitis resulting from puerperal infection. The appendix was not examined, as the intestinal adhesions were light and easily separated. At the end of the third day after operation, the patient suddenly presented the typical symptoms of acute appendicitis, and at operation the following day a large quantity of fetid pus was evacuated while the adherent, perforated appendix was removed. The author believed that the appendix was diseased at the time of the previous operation and that the trauma during the operative manipulations had excited the acute attack. Delagénière (*Congrés de chir.*, 1897) relates the case of a woman who had had the right ovary, which was sclerocystic, removed, and the uterus suspended, on account of pain in the abdomen coincident with the menstrual periods which dated from a childbirth five years before. Six weeks later she was attacked with symptoms of appendictis, and shortly afterward had a second attack. Operation revealed an adherent and chronically ulcerated appendix, associated with the presence of concretions. In a case at the Johns Hopkins Hospital the patient gave a history of severe pain in the abdomen and back, beginning shortly after her marriage, two months previously, and accompanied by leucorrhea and painful menstruation. One week before admission she began to suffer from cramp-like pains in the abdomen extending down the thighs, accompanied with painful defecation and dysuria. At operation, double pyosalpinx was found, and the appendix, which was free and in the right iliac fossa, was acutely inflamed, hard and rigid. Quite often, after the removal of uterine or ovarian tumors, which are not complicated by adhesions, investigation of the cecal region will reveal the presence of independent appendical disease. Thus, in one case after removing a non-adherent ovarian cyst, I found the appendix converted into a translucent, cucumber-shaped cyst. In a case of myoma, the appendix was found completely filled and distended by two large concretions; in another case of myoma the appendix was obliterated and enveloped in adhesions. In cases of ectopic gestation the association of an independent appendicitis has been frequently observed, as in the case of Summa, mentioned above.

DIAGNOSIS.

The greatest interest in regard to the relationship existing between disease of the pelvic organs and appendicitis centres in the diagnosis. The questions to be determined are: Is the case one of pelvic disease; is it one of appendicitis; or is it one of coincident appendical and pelvic disease? In many instances the differential diagnosis is of interest chiefly from its bearing upon the technic of the operation, as in any case surgical intervention is imperative, but in other cases it is of the utmost importance that a correct diagnosis should be made; as, for example, if we are dealing with a case of early acute salpingitis, palliative treatment may be indicated; whereas, if it is a case of acute appendicitis, conservative treatment may result in the death of the patient.

Inflammatory diseases of the right uterine adnexa are most frequently confounded with appendicitis. With an accurate history of the onset of the malady and a careful physical examination, mistakes should seldom occur, since both diseases present such characteristic differences. In the history of the development of acute pelvic infection it will usually be found that there has been a yellowish vaginal discharge, often associated with burning micturition, for a longer or shorter period before the acute symptoms appeared; whereas in appendicitis a history of previous attacks of pain in the right side, or of digestive disturbances is often given. Abdominal pain associated with nausea and vomiting may appear as suddenly in disease of the adnexa as in appendicitis, and there may be local pain on pressure over the right lower abdomen; but the local pain and tenderness are usually situated more deeply in the pelvis and right inguinal regions, the most intense pain being elicited on deep palpation in the region of Poupart's ligament. On vaginal examination exquisite tenderness is felt on one or the other side of the uterus. If the tenderness is equal on both sides or if it is most marked on the left side, perimetritis is suggested. It is, however, in just those cases where the appendix occupies the pelvic position, even extending to the left side, and in which the pain and tenderness are referred to a point deep down in the pelvis or inguinal region, that confusion is apt to exist. One of the most characteristic differences in the early stage of the attack is found in the character of the pain, which at the onset of appendicitis is usually paroxysmal, while in pelvic inflammation it is more steady and less intense. Fever, accelerated pulse, and leucocytosis offer no points of differentiation. Chills are more common in appendical inflammation, but are very inconstant. The relation of the attack to the menstrual periods is often the cause of error, which sometimes leads to a fatal delay in surgical intervention. The two following cases illustrate this point.

C. K. Lemon. (*Personal communication.*) The patient was seized with an acute attack of appendicitis associated with suppression of the menstrual flow, on the

second day of the period. The presence of pain in the lower abdomen, slight fever, and constipation led to a diagnosis of acute congestion of the uterus, and the patient was treated with laxatives and hot applications. When seen by a consultant on the fourth day, there was great distention, high temperature, and complete obstipation, soon followed by incessant vomiting, which became stercoraceous. Death occurred on the sixth day. An important clue in the early diagnosis in this case was the history of several previous attacks of pain in the lower abdomen, the first of which antedated the beginning of the catamenia.

G. I. McKelway. (*Med. and Surg. Rep.*, 1892, p. 603.) A young unmarried woman suffered from excruciating pain in the right ovarian region at every menstrual period and constant tenderness on pressure. She became pale and weak and was unable to work. A vaginal examination showed a retroverted uterus, bound down by adhesions, and an exceedingly sensitive, adherent mass the size of a walnut, to the right of the uterus. Abdominal section showed an adherent uterus, a normal tube and ovary on the left side, and an appendix greatly enlarged and tense, which was adherent to the right tube and ovary, occasioning the sensitive mass palpated in the examination. The tube and ovary, which apart from the appendical adhesions, were healthy, were freed and left *in situ*, and the uterus was freed. The appendix was removed and the patient made a perfect recovery, with the uterus in its normal position and no lateral mass.

The development of pelvic inflammation in a young girl or an unmarried woman of good character should always arouse the suspicion of primary appendical disease, even when the bimanual examination shows definite disease of the adnexa on one or both sides, as in many cases it will be found that the tubo-ovarian disease is due to a secondary infection from the appendix.

In the early stage of either affection a tumor cannot usually be detected; later, a more or less well-defined resistance posterior or lateral to the uterus may signify a pelvic inflammation or pelvic appendicitis. In the latter, the resistance is usually situated higher, extending from the posterior border of the right broad ligament toward the iliac fossa, and the broad ligament itself is free. In pelvic disease the tumor is deep in the pelvis, and it is often possible to palpate the thickened uterine end of the tube and to trace it out to the mass. An interesting case related by Barnsby (*loc. cit.*) is as follows:

An unmarried woman, twenty-five years old, was suddenly seized, when in perfect health, with severe abdominal pain, vomiting, constipation, and fever. The abdomen was generally sensitive, but especially so in the right iliac fossa, although no tumefaction was present. On the sixth day, menstruation appeared and the symptoms subsided, but a dull pain persisted in the right side, and on this account a vaginal examination was made three weeks later. The uterus was found fixed and painful, the lateral fornices being indurated and filled with a mass of exudate. On the right side the mass seemed glued to the uterus. The iliac fossa was tender but free. Following the examination menstruation reappeared. The general condition of the patient then improved. During the next two years similar attacks occurred, and at the end of that time she entered the hospital. On

bimanual examination a large mass was found, situated toward the lower part of the crural arch, apparently descending from the iliac fossa to the right cul-de-sac, and seemingly independent of the uterus. On account of the intact hymen, the resemblance of the anterior attacks to appendicitis, the absence of connection between the mass and the uterus, and the normal left adnexa, a diagnosis of appendicitis was made. The day after the examination, however, an acute exacerbation occurred, and a second examination showed the mass adherent to the uterus and completely filling the right fornix. The diagnosis was then changed to inflammation of the right adnexa. Operation revealed a voluminous appendix, with thickened walls which contained three calculi. It was adherent by its tip to the right side of the uterus. Removal of the appendix resulted in perfect cure.

In other cases a large pyosalpinx may extend up into the iliac fossa and closely simulate an appendical abscess. A case observed at the Johns Hopkins Hospital in which the clinical history and physical signs were very confusing, is the following:

J. H. H., Gyn. No. 5750. A woman, twenty-two years old, was admitted with a history of pain in the right iliac fossa, beginning immediately after a normal delivery six weeks before, from which she soon recovered and was able to attend to her usual duties. Three weeks later she was suddenly seized with severe pain in the right abdomen and at the same time a swelling was discovered. The pain and swelling steadily increased, and although going about, the patient felt ill and weak. On admission, the right leg was slightly flexed and there was a hard tumor mass in the right iliac fossa, having a well-defined, sharp margin toward the median line of the abdomen and extending down to the upper part of the pelvis. The temperature was 100° F.; the pulse 100. A vaginal puncture was first attempted, but the mass was too high to be reached easily. An incision was then made in the right linea semilunaris opening over the mass, which was found to consist of several small pus cavities with exceedingly dense walls, which appeared to contain the right tube extending up from the cornu of the uterus toward the right iliac region and the umbilicus. The intestines were adherent to the mass, as well as the omentum on the inner side. The right ovary and the left appendages were free and normal. The cavity was drained, and the patient made an uninterrupted recovery.

Acute pelvic inflammation accompanied with spreading or generalized peritonitis in the absence of a clear history, cannot usually be differentiated from appendicitis. In two cases admitted to the Johns Hopkins Hospital a diagnosis of appendicitis with diffuse peritonitis was made, but at operation a generalized peritonitis originating from acute gonorrheal salpingitis was found.

J. H. H., Surg. No, 7760. A girl, eighteen years old, was admitted with a history of acute abdominal pain beginning suddenly five days before, and accompanied with nausea, vomiting, hiccough, and constipation. The pain was localized from the first in the right side. On admission the abdomen was not distended; there

was no tenderness nor muscle spasm on the left side; on the right there was marked tenderness, most pronounced at a point 3 cm. from the umbilicus, on the line to the right anterior superior spine of the ilium. There was slight muscle spasm over this area; temperature 100° F.; pulse 100; leucocytes 34,000. Bimanual examination caused pain in the above area, and there was no induration in the vaginal vault. The hymen was absent, and there was a history of vaginitis for six months. Operation revealed a general fibrino-purulent peritonitis and double gonorrheal salpingitis. The tubes were removed and the abdomen closed with a small drain. Prompt recovery followed.

J. H. H., Surg. No. 7719. A single woman, aged twenty-five years, admitted exposure to infection for five years and during the past year had suffered from slight *ardor urinæ*. She entered with a history of acute abdominal pain for three days, most intense in the left side and epigastrium. The pain was constant but subject to acute exacerbations. The bowels were constipated and micturition was painful. The patient looked flushed, the tongue was coated, and the abdomen somewhat full in the umbilical region. Tenderness was most marked in the left flank, in the epigastric, and in both hypogastric regions. Vaginal examination was negative. The temperature was 102° F.; the pulse 110; the leucocytes 19,000. Operation showed a general plastic fibrinous peritonitis, the appendix being involved to the same extent as the rest of the bowel; the tubes were not thickened, but acutely inflamed, and contained pus. The g o n o c o c c u s was obtained from the peritoneal exudate in both cases.

In both of these cases, notwithstanding the definite history of venereal exposure, the prominence of the abdominal symptoms and the absence of pelvic symptoms occasioned a wrong diagnosis.

In another case diffuse peritonitis resulting from a ruptured right pyosalpinx was mistaken for acute appendicitis. Siegel (cited by Pollak) found a ruptured ovarian abscess at operation upon a case in which a diagnosis of perforative appendicitis had been made. Fenwick (*Lancet*, 1897) reports a case of ruptured pyosalpinx mistaken for appendicitis. A pelvic abscess whether originating from the generative organs or from the appendix, presents no distinctive features, and in either case there may be a complete absence of abdominal pain and tenderness. The history of preceding vulvo-vaginitis or of puerperal infection on the one hand, or of attacks of right iliac pain on the other, are most important guides to a diagnosis.

A. E. Gallant (*Amer. Med.*, 1903, No. 1, 836) describes two very interesting cases in children, one ten years old, the other thirteen, in which a retroperitoneal appendical abscess burrowed down in the recto-vaginal septum and formed a bulging tumor at the outlet. A diagnosis of pelvic disease was made and laparotomy performed, but in each case the pelvic organs and peritoneum were absolutely healthy. Mundé (*Med. News*, 1897, p. 621) describes a similar case; a well-defined elastic swelling in the median line of the abdomen was taken for an ovarian cyst. A median incision showed the uterus and appendages normal and the swelling retroperitoneal. The incision was closed and a vaginal examina-

tion, neglected before, revealed a tense protrusion of the posterior wall. On opening this, a large quantity of fetid pus escaped, and a probe introduced into the abscess cavity passed readily up to the crest of the right ilium.

Confusion in the diagnosis between appendicitis and ovarian cyst, with torsion of the pedicle is very common. NIOT (*Thèse de Paris*, 1901) cites 11 instances of dermoid cysts with twisted pedicle, mistaken for appendicitis. In 2 out of 5 cases of cyst with twisted pedicle observed by FOWLER, the patient was sent into the hospital with a diagnosis of appendicitis. As a guide to the differential diagnosis a previous knowledge of the existence of the tumor is of the greatest importance. It happens, however, that acute torsion is most common in the case of cysts of medium size, which had not previously produced any visible swelling, the subjective symptoms being absent or else very slight. The frequent association of constipation with pelvic tumors leads rather in the wrong direction in considering the diagnosis. The sudden onset of severe pain, often accompanied with nausea and vomiting, may closely simulate acute appendicitis. The chief distinguishing features of torsion of an ovarian pedicle are the character of the pain, which is more continuous and diffuse, unlike the colicky initial pain of appendicitis, with its later localization in the right iliac fossa. At a later stage when peritonitis supervenes, the subjective symptoms are very similar. Palpation is the most valuable means of differentiation. It is sometimes possible at the very outset to distinguish the rounded, well-defined, elastic ovarian tumor, while in appendicitis a mass is rarely observed in the early stages, and, if it is, has not the sharp contour of the cyst. Fluctuation in the case of dermoids and some multilocular cysts is often indefinite, and never to be depended upon. In many cases, however, the distention and extreme sensitiveness of the abdomen render palpation very unsatisfactory, and the cyst may be completely masked by the rigid abdominal walls. Percussion may then be serviceable in outlining the tumor. As the early acute reaction subsides, the tumor is sometimes readily palpable; whereas in appendicitis, not complicated with diffuse peritonitis, the abdomen becomes natural-looking and soft, with the exception of the appendical region. In either case, however, peritonitis may complicate the situation. In this event a differential diagnosis is sometimes impossible, but, in general, it may be noted that the peritonitis accompanying ovarian cyst is of a milder type, and is not associated with the severe constitutional symptoms of peritonitis originating from appendicitis. Moreover, the abdominal tenderness is usually less pronounced. Examination *per vaginam* and *per rectum* will sometimes give valuable information regarding the malady, and it may in this way be possible not only to outline the cyst, but also to recognize the twisted pedicle, which is felt extending from the side of the uterus up to the abdominal mass. If the tumor is entirely intra-abdominal, the uterus may be displaced upward. As in either condition operative interference is imperative, the differential diagnosis is not of great importance except as a guide to the incision; and, as a rule, when the patient is anesthetized the

tumor is easily recognized if a careful bimanual examination is made. It is advisable in making the rectal examination immediately before operation to protect the hands with rubber gloves.

The diagnosis between ruptured tubal pregnancy and appendicitis is seldom difficult, if an accurate account of the events leading up to the attack can be obtained, as well as a clear description of its onset. The history of irregular menstruation, especially the statement that a period has been delayed for a week or more, with a subsequent slight, irregular flow, is very suggestive of tubal pregnancy. The onset of the attack with sudden agonizing pain, followed almost immediately by fainting and marked pallor, is pathognomonic. Chills, vomiting, and sudden evacuation of the bowels, may occur at the onset of ruptured tubal pregnancy or with acute perforative appendicitis. Tenderness and muscle spasm on palpation over the right iliac region may be observed in a right tubal pregnancy; usually, however, the local signs are situated deeper in the pelvis. On bimanual examination the enlarged tube is usually easily palpated. Finally, it may be said that the most important point in arriving at a correct diagnosis is the recognition of the fact that confusion may exist.

Diagnosis of Coexisting Affections.—An important question to be determined in some cases in which the presence of the gynecological affection is well recognized, is whether there is a complicating appendicitis. The fact that the appendix is frequently involved in pelvic adhesions is now too well known to require especial emphasis, and at the present time it is improbable that such accidents could occur as were reported by Tait and Wiggin, in which, during the course of an operation upon the pelvic organs, the appendix, which was involved in the universal dense adhesions, was severed without the knowledge of the operator, the fact being only discovered on the postmortem table. It must be remembered, however, that independent affections, acute or chronic, may coexist, and that one may be masked by the predominant symptoms of the other. This is of especial importance in the case of acute appendicitis developing during the course of an acute pelvic inflammation. The greater severity of the abdominal and general constitutional symptoms, the paroxysmal pain, and the localization at or near McBurney's point, should suggest this complication. In doubtful cases an exploratory section entails less risk than delaying the operation until the diagnosis is clear. Moreover, when pelvic inflammatory disease is attended with increasing abdominal pain, tenderness, and rigidity, operative interference is usually indicated. An abdominal section is preferable to the vaginal route in all cases where there is a possibility of error. Acute appendicitis occurring in a patient who is known to be the subject of an ovarian cyst would naturally suggest a torsion of the pedicle, as in three cases recorded by Werder (*loc. cit.*). Fortunately the differential diagnosis in such a case is not of great importance, as early operation is indicated in either case, and the condition is then easily recognized. The coexistence of appendicitis

and extrauterine pregnancy is usually easily recognized if a careful history of the case is obtained and a thorough abdominal and bimanual examination made. Both affections present such a characteristic clinical history that even when associated, mistakes should not often occur. The greatest danger lies in the fact that when an acute appendicitis exists at the same time as an unruptured tubal pregnancy which has not given rise to any pronounced symptoms, the operator may not be aware of its presence. In one case of a young unmarried woman, giving a definite history of recurrent appendicitis, there was also a history of irregular menstrual flow for about three weeks, and on vaginal examination the tube seemed to be thickened. After removing the chronically inflamed appendix I also removed an early, unruptured, tubal pregnancy.

TREATMENT.

Examination of the Appendix whenever the Abdomen is Opened.—The frequency with which disease of the appendix is associated with disease of the pelvic organs affords a sufficient reason for examination of the appendix whenever the abdomen is opened for any reason whatever. I have elsewhere emphasized the duty incumbent upon every surgeon of utilizing the opportunity afforded by abdominal section to examine the appendix whenever it can be done without additional risk.* For the last eight years I have made it my invariable practice not only to examine the appendix, but to note its condition as regards length, soundness, and freedom from adhesions, including these data among others which the anesthetizer is expected to fill in upon a printed slip.

Removal of the Appendix as a Prophylactic Measure.—The first question which arises at this point is whether the normal appendix should be removed as a prophylactic measure whenever the opportunity to do so is afforded by abdominal section. During the time this book has been in preparation I have discussed the question with various friends, and I find that the greatest diversity of opinion exists among them in regard to it, some of them urging the radical plan of removal in every case, and others condemning such a practice as meddlesome and unsurgical. The variance of opinion among men of equal ability and experience was indeed so striking that I believed it would be both of use and of interest to investigate and make known the views of a number of professional men upon the subject. I wrote, therefore, to 80 well-known surgeons in different parts of the United States, asking for their opinions and requesting permission to publish them. The method of interrogation which I used was to send each individual a return postal card with the following question: W h e n t h e a b d o m e n i s o p e n e d f o r o t h e r c a u s e s , a n d t h e p e r f e c t l y n o r m a l a p p e n d i x i s e a s i l y a c c e s s i b l e , i s i t y o u r r u l e t o r e m o v e i t ?

* "The exploration of the abdomen as an adjunct to every celiotomy." *Med. News*, Dec. 16, 1899.

To 80 applications I received 74 replies, which have been published elsewhere in some detail (*Jour. Amer. Med. Assoc.*, Oct. 25, 1902). It is evident from them that no uniformity of opinion exists among medical men as to the conditions under which the appendix should or should not be removed. One surgeon of ability and experience, for instance, replies: "Yes, always"; while another, whose opinion is no less entitled to consideration, answers: "No, it is unsurgical." The categorical form of my inquiry, of course, made it impossible for surgeons to qualify their answers, as some of them, apparently, wished to do. In classifying the replies, I have treated answers such as "Usually, but not always," or "If the patient's condition permits," as unqualified, since I asked only for the rule, not the exception; and I assume in my question that no serious contraindication is present. A few answers, however, were received which could not be classified unreservedly as either affirmative or negative.

Exclusive of these, there were 70 replies, 44 of which were against removing the normal appendix, and 26 in favor of doing so.

Assuming these results to represent a general consensus of opinion throughout the United States, they show a decided majority (44 to 26) against the removal of the normal appendix, simply because the opportunity to do so is present. My own opinion coincides entirely with this view. I never remove the appendix in the course of an operation for other causes, when it proves on inspection to be entirely normal; and my reasons for this position are as follows:

1. The removal of the appendix involves a slight additional risk, owing to the fact that no matter how good the patient's condition may be at the time of the removal there is no guarantee that it will remain so until the end of the operation; and should a condition of shock ensue, the additional five minutes thus consumed will lessen the patient's chances of recovery.

2. We are not as yet in a position to estimate the importance of removing the normal appendix as a prophylactic measure, for statistics have not yet made it evident what is the exact risk of an attack of appendicitis to each individual in the community.

3. The fact that the appendix has no known function does not prove that it is a functionless organ, although we are in the habit of calling it so; and it is within the bounds of possibility that an increase in our knowledge concerning it may in the future demonstrate some reason for its preservation. It is only a few years since the ovaries were considered to have no use or purpose besides that of reproduction, and their extirpation, apart from interference with their primary function, was a matter of no importance. Now, however, when their relation to the process of internal secretion is beginning to be understood, we find ourselves responsible for their preservation for entirely other reasons.

Removal of the Adherent Appendix.—I availed myself of the opportunity afforded by the above inquiry to ascertain also the opinion generally held as to the advisability of removing the vermiform appendix when it is adherent, or, in other words, when it deviates in the slightest degree possible

from normal. I appended a second question to the following effect: When the appendix is even slightly adherent to neighboring structures, peritoneum, ovarian, or fibroid tumors, do you then remove it? To this query I received 7 answers so qualified that they could not be classified. Out of the remaining 67 answers, 60 were in favor of removing the appendix under the conditions specified, and 7 were against it. It will be seen that the majority in favor of removing the appendix under the conditions is very large, so large as to constitute almost unanimity of opinion. For myself, I believe it to be an excellent general rule to remove the appendix whenever it is adherent to another organ, because it is prone to bleed, and if returned to the abdomen, may very readily contract adhesions which are the occasion of an attack of appendicitis. I also think it a good special rule to remove any appendix which hangs free from the end of the cecum, as well as one which is long enough to reach the field of an adjacent operation, because such appendices are specially liable to become adherent. I do not, however, remove a short appendix, nor one which is curled up on either side of the cecum, and I would carefully avoid pulling out an appendix which lies above the horizontal line traversing the lower end of the cecum. In this connection I should also like to recall and to endorse the opinion of R. Abbé, namely, that the perfectly normal appendix never contains fecal concretions, therefore, whenever, an apparently healthy appendix is felt to contain these, there is sufficient reason for its removal.

In any case also where the patient specially requests that the appendix be removed, I think the surgeon should comply. The risk of the operation, properly done, is extremely small, and it is sometimes a great relief to a patient's mind to know that it has been removed, especially if there have been other cases of appendicitis among his family and friends.

Removal of the Appendix when Operations are Performed in its Neighborhood that might give rise to Post-operative Adhesions.—In the case of men there is practically no risk that disease will arise in the appendix from altered conditions due to operations in its immediate neighborhood, but in women there is a possibility, although a remote one, that the appendix may become adherent to the fresh scar resulting from operations on the uterus or the right ovary. In my *Operative Gynecology*, published in 1895 (vol. 2, p. 523), I said: "The vermiform appendix may become involved in post-operative adhesions attaching it to the pedicle left in the pelvis, and causing severe pain in the right iliac fossa, with attacks simulating appendicitis. I operated on a patient of this kind, whose right ovary had been removed three years before by H. Robb; I removed an inflamed left ovary and the uterus together with the appendix, which hung over into the pelvis and was firmly adherent at its end to the pedicle on the right side." Two other cases of this kind have come to my own personal knowledge, and I have collected six more reported in periodicals, or sent me in personal communications. I cite all these here categorically,

in order to emphasize the necessity of guarding against a rare but possible contingency.

1. San. No. 673, Jan. 24, 1899. Miss P., twenty-five years old. Both ovaries had been removed one year previously on account of painful menstruation, without relief. On opening the abdomen, I found parts of both ovaries remaining, and the vermiform appendix was adherent to the remaining tubal and ovarian tissue on the right side. The appendix was removed as well as the diseased tissues, and these

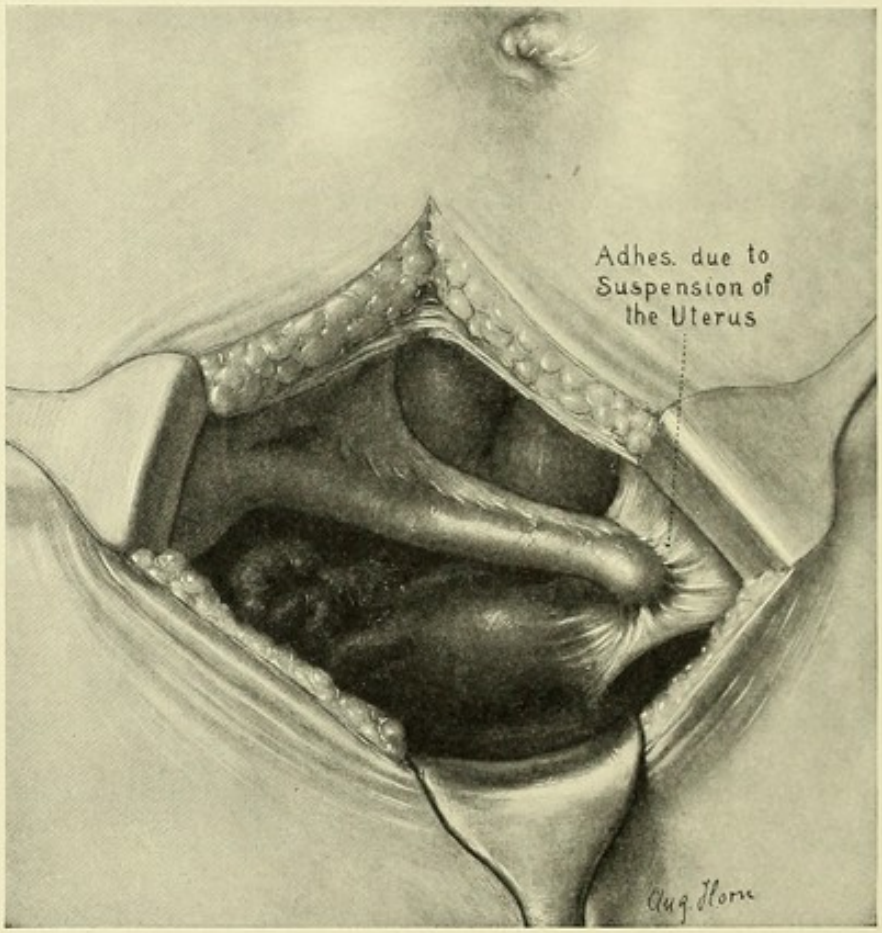

FIG. 360.—FINNEY'S CASE OF LONG APPENDIX ADHERENT BY ITS TIP TO SUSPENSORY LIGAMENT ATTACHING UTERUS TO ANTERIOR ABDOMINAL WALL.

Case of myomectomy and suspension by author; subsequent operation by Finney for the appendical complication. M. O. G., age forty-two. Jan., 1902. Recovery.

measures were followed by a good recovery. There had been no symptoms of appendicitis in the interval between the two operations.

2. J. H. H., Gyn. No. 7566, Feb., 1900. Miss F., forty years old, had suffered from pelvic pain and irregular menstruation for fourteen years. Ten years previously a conservative operation had been done by T. A. EMMET, after which she was somewhat improved. On operation I found the uterus in retro-position, with a pedunculate myoma, three times its size, attached to the fundus. The suspensory ligament from the former operation had stretched to about 10 cm. in length, but both tubes and ovaries were free from disease. The appendix was free and

normal, and measured 8 cm. in length. The myoma was excised and its stump sutured with catgut. Two small subperitoneal myomata were also excised, and the suspensory ligament was shortened. The abdominal wound was closed in the usual manner with catgut. Uninterrupted recovery followed. In January, 1902, however, the patient was readmitted to the hospital, just after a third attack of appendicitis, the first of which occurred in Egypt six months after the gynecological operation described. At a second operation, performed by J. M. T. FINNEY, the appendix was found with some difficulty, its tip being firmly adherent to the scar in the body of the uterus (see Fig. 360). The uterus was normal, but the right tube and ovary were bound down by adhesions. The appendix was removed, and the small granular spot to which it had adhered, touched with pure carbolic acid, and turned in with several mattress sutures. An uninterrupted recovery followed.

3. H. MCGUIRE (*Trans. Med. Soc. Va.*, 1895). A married woman, twenty-four years old, had had her uterine tubes and ovaries, which were extensively diseased, removed by McGuire two years before. Eighteen months after this operation the patient had her first attack of appendicitis, which was followed by several other severe attacks. On opening the abdomen, the appendix was found attached to the stump of the right ovary, sharply bent upon itself, and flexed. It was easily separated and brought forward for inspection, when it was found congested and swollen. After removal, it proved to contain several hard fecal masses. The patient made an excellent recovery.

4. *Ibid.* A married woman, forty-five years old, had had both ovaries removed two years and a half before. Two years after the operation she had her first attack of appendicitis, after which other attacks recurred at intervals of a few weeks, increasing in severity. At the time of the second operation, there was great pain, fever, and swelling of the whole flank, but no mass. On opening the abdomen the appendix was found greatly elongated, swollen, and congested; it was firmly adherent to the stump of the right ovary, from which it was peeled loose with some difficulty and removed. The mucous membrane showed ulcerative changes and there was a muco-purulent secretion. Recovery.

5. J. PRICE, 1903. (*Personal communication.*) In this case hysterectomy had been performed by the suprapubic method. A few years later the patient returned with symptoms suggesting adhesions. On opening the abdomen, the appendix, which was thickened and diseased, was found strongly adherent to the stump of the uterus.

6. MAYO ROBSON, 1903. (*Personal communication.*) The patient, a middle-aged woman, had had an abdominal hysterectomy performed by a well-known surgeon twenty years before on account of severe pain in the right side. At the operation the surgeon had noticed some adhesions, but the appendix was not suspected, and was not sought for. The patient made a good recovery from the operation, but never completely lost the pain on the right side of the abdomen, which became more troublesome in later years. When seen by Robson, she presented all the symptoms of chronic appendicitis, for which he operated. The appendix was found surrounded by firm adhesions, and fixed to the pedicle on the right side of the uterine stump. The distal end of the appendix was obliterated, but the proximal end was inflamed, and evidently causing trouble. The appendix was removed, after which the patient made a good recovery and was much relieved.

7 and 8. G. R. Fowler. (*Brooklyn Med. Jour.*, April, 1897.) The resemblance between these two cases in their histories and sequelæ is so great that they are combined by Fowler for the sake of brevity. The patients were both young women, suffering from pyosalpinx, who were operated upon by double oöphorectomy and salpingectomy at the Methodist Hospital. In both, the difficulties of removal of the adnexa were such as to leave more or less exposed, raw serous surfaces, and in both, gauze tamponing and drainage were necessary. Both left the hospital relieved, to return within six months complaining of symptoms referable to the region of the appendix. On re-opening the abdomen, the appendix was discovered, in both cases, bound by adhesions to the stump at the site of the amputated right tube and ovary. The appendix and its mesentery in each case had been subjected to considerable tension, and upon examination showed indubitable evidences of chronic inflammation from vascular disturbances.

In speaking of these cases Fowler remarks: "This experience opens up a new field of inquiry as to the causes of painful stump and abdominal symptoms sometimes observed to follow operations upon the adnexa. Ever since the occurrence of these two cases, I have made it a rule to perform typical excision of the appendix when the latter is intraperitoneally situated, in every case in which the abdomen is opened for any operative structures within the reach of this mischievous and useless organ."

Judging from the evidence just collected, it seems likely that adherence of the appendix to the scar of a previous operation stands in etiologic relation to a post-operative appendicitis much more frequently than has hitherto been supposed. Further data on the subject, therefore, are to be desired. These can only be obtained by operators for appendicitis, whether they are gynecologists or general surgeons, publishing all cases in which the appendix is found adherent to a scar at the site of a previous operation. The value of such statistics will, of course, be much enhanced if it can be shown by reference to a previous record that the appendix was normal at the time of the first operation, as was possible in Case 5; we have here also an additional reason for not neglecting the opportunity to examine the appendix whenever an occasion is afforded by abdominal section, as well as its removal when preternaturally long, or lying within reach of a denuded surface in the peritoneum.

In order to avoid just such accidents as the adhesion of the appendix or of any other intact structure to the raw surface in the pedicle, Condamin of Lyons, following the distinguished Laroyenne, has urged the careful covering in of all raw surfaces created by surgical operations in the peritoneal cavity. He dignifies this important principle by the name of "*peritonisation*" (*Lyon méd.*, 1894, p. 567). McGuire, in the article referred to (*loc. cit.*), makes the important suggestion that whenever the right ovary is removed, the raw stump should be protected by covering it with peritoneum and burying it out of sight. H. Kreutzman of San Francisco, in discussing the treatment of the pedicle in ovariotomy and salpingo-oöphorectomy, recommends freeing a serous cuff from the

vessels before ligating them, and after the ligation, delicately sewing together the serous surfaces so as to cover the stump completely (*Amer. Jour. Obst.*, 1896, p. 830). The same plan has also been advocated by WATKINS of Chicago. The necessity of protective measures is shown by the cases just cited, in which the adherence of the appendix to a raw surface after the removal of the right ovary was the exciting cause of an attack of appendicitis.

Incisions for Removal of the Appendix.—The median incision is best in cases where the abdominal walls have been greatly stretched by a pelvic tumor, or by repeated pregnancies, for then the right side of the incision is easily drawn over, and the right iliac fossa fully and easily explored (see Chap. XXIV, Fig. 240). If the incision is not more than two and a half inches in length, it is difficult to reach the appendix, but this is easily accomplished through an incision three and a half to four inches long, extending not less than three-quarters or two-thirds of the way up to the umbilicus. The incision having been made, the right side is forcibly retracted toward the cecum, which, at the same time, is drawn toward the opening. If the cecum has a short mesentery, and the abdominal walls are rigid, it may be necessary to make another separate incision over the appendix in order to remove it. This is easily done by introducing the four fingers of the left hand into the abdomen and pushing up the abdominal wall, at the same time cutting down on muscles which can then be pulled apart after McBurney's method (see Chap. XXIV, p. 533). The peritoneum is then opened, the appendix picked up by the hand inside the abdomen and pushed through the second small incision. To operate in this manner successfully it is always necessary to have the patient on a level table, as Trendelenburg's position causes the appendix to gravitate up toward the diaphragm, and it cannot be brought down without dangerous traction.

Semilunar Incision.—In cases where coincidence of appendicitis and pelvic disease is suspected before operation, or where the diagnosis is doubtful between right-sided pelvic inflammation or extrauterine pregnancy and appendicitis, the best incision is in the semilunar line, directly over the right side of the pelvis and close to the root of the appendix.

Lateral Incision.—If, after opening the abdomen in the median line for pelvic disease, an abscess is found in association with the appendix, it is best to open the sac extra-peritoneally, using the median incision as a guide. The steps in the operation are as follows: The operator, if right-handed, steps to the left of the patient, and introduces four fingers of the left hand into the abdomen in such a manner as to grasp the abdominal wall between the thumb and fingers, the tips of the fingers resting upon the point of contact of the abscess with the abdominal wall. The incision is then rapidly made to the outside of this point through the skin and muscles and then cautiously prolonged into the abscess; if there is any uncertainty as to its exact location, the blunt end of a pair of artery forceps may be pushed into the tissues, after incising the muscles, without danger, care being always taken to avoid opening the peritoneal cavity

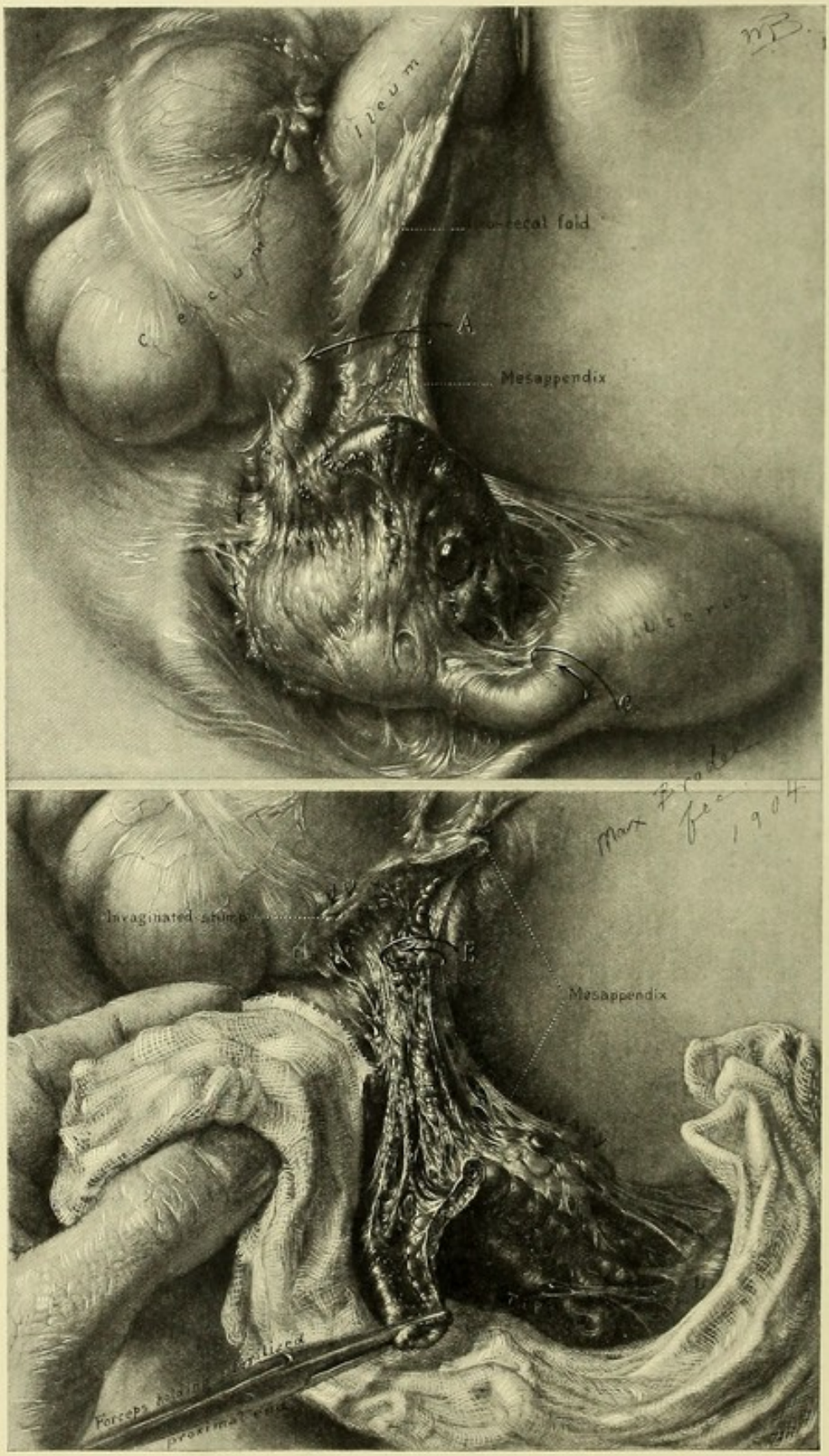

FIG. 361.—THE UPPER FIGURE SHOWS EXTENSIVE INVOLVEMENT OF APPENDIX IN TUBO-OVARIAN ABSCESS OF THE RIGHT SIDE. WIDESPREAD ADHESIONS TO UTERUS AND PELVIC WALLS. THE METHOD OF REMOVAL IS SHOWN IN UPPER AND LOWER FIGURES.

A, the meso-appendix is tied off and the appendix detached at its base and grasped as shown in lower figure, when the ovarian vessels are exposed and tied at B. Lastly as appendix, uterine tube, and ovary are lifted out of their bed of adhesions, the tube is exsected from the uterine cornu and the vessels controlled at C.

by the fingers inside the abdomen, all contamination being thus limited to the hand used outside. After opening, evacuating, and drying out the abscess, and putting in the drain, the gloves can be changed, and the closure of the median incision proceeded with. If any intra-pelvic operation has to be performed, it had best be done before opening the abscess in the appendix.

Removal of the Appendix.—If there is no suppuration, it is a matter of indifference whether the appendix or the pelvic disease is first treated, but, generally speaking, it is best to do the pelvic work first, and that on the appendix last, so as to close the opening into the cecum at once. If there is suppuration

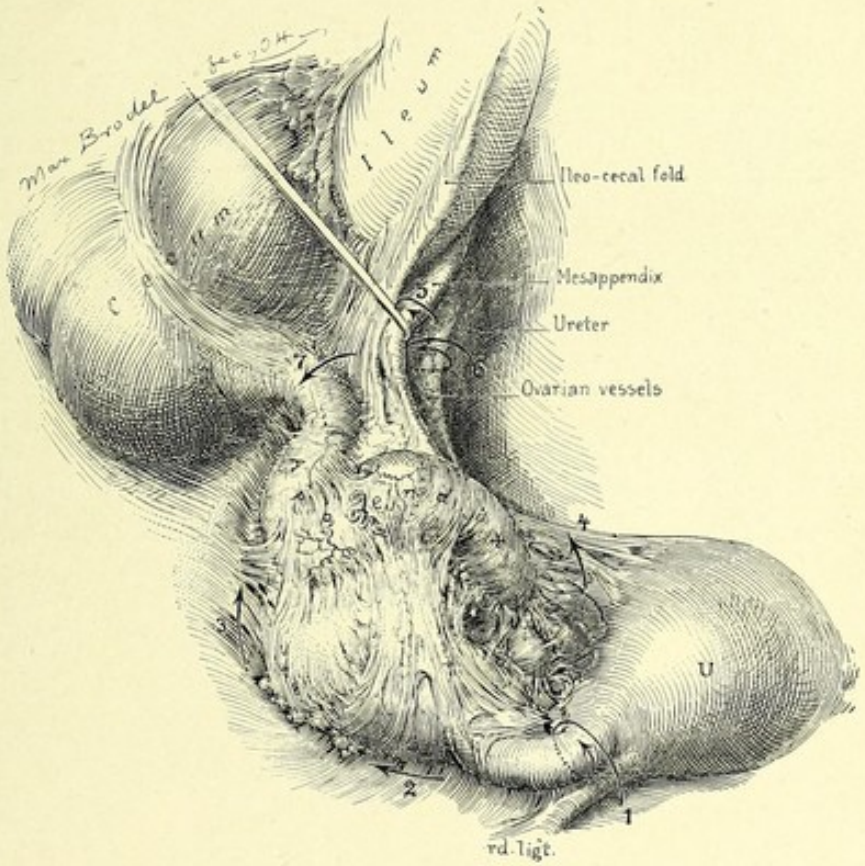

FIG. 362.—SHOWS THE METHOD OF REMOVING AN ADHERENT APPENDICO-TUBO-OVARIAN MASS IN REVERSE ORDER, FOLLOWING THE ARROWS, 1 TO 7.

in either the pelvis or the appendix, the clean operation should be done first. If both are infected, it is best to do the easier first, taking out the appendix at once by preference, as this must be removed, while the suppuration in the pelvis can be quickly drained by the vaginal vault.

When the Appendix is Adherent to the Ovary and Tube.—After widespread pelvic peritonitis, it may be without the presence of infective organisms, the ovaries are often adherent and attached to the pelvic walls, while the sigmoid flexure, together with the appendix, is bound down or covered in by adhesions. If the adhesion is a light one, it

may be simply detached, and the pelvic organs treated separately to the appendix, as their condition may require. If the adhesion is firm and intimate, one of two plans may be followed.

1. The base of the appendix is clamped first and the appendix severed;



Fig. 363.—H. A. Kelly. Tubo-ovarian Abscess. Peri-appendicitis.

Appendix adherent from root to tip, the distal portion following the dotted line lies upon the pelvic floor under tubo-ovarian abscess. Douglas' pouch is obliterated. E. L., colored, age eighteen. Autopsy, June 12, 1899.

the ovarian vessels are then exposed and tied; and, lastly, the tube is exsected from the uterine cornu and the vessels controlled (see Fig. 361).

2. The tube or the tubo-ovarian mass is first detached, beginning at the uterine cornu, and enucleation conducted in a direction the reverse of that just described according to the direction indicated by the arrows in the figure, the base of the appendix being finally clamped and severed (see Fig. 362).

When the Uterine Tube and the Ovary Coalesce with the Appendix to form

an Abscess on the Pelvic Floor (see Fig. 363).—Under these circumstances extreme caution is necessary in order not to distribute the contents of the abscess over the peritoneal cavity. In the case of a large abscess with a patient in bad condition, I prefer to make simply a vaginal incision, and secure good drainage, leaving the appendix to be removed, if possible, at a later date. If the abscess is small and situated down in the pelvis, all the surrounding parts of the peritoneum must be walled off with gauze and completely protected from contamination upon the escape of the pus. The appendix should then be detached from

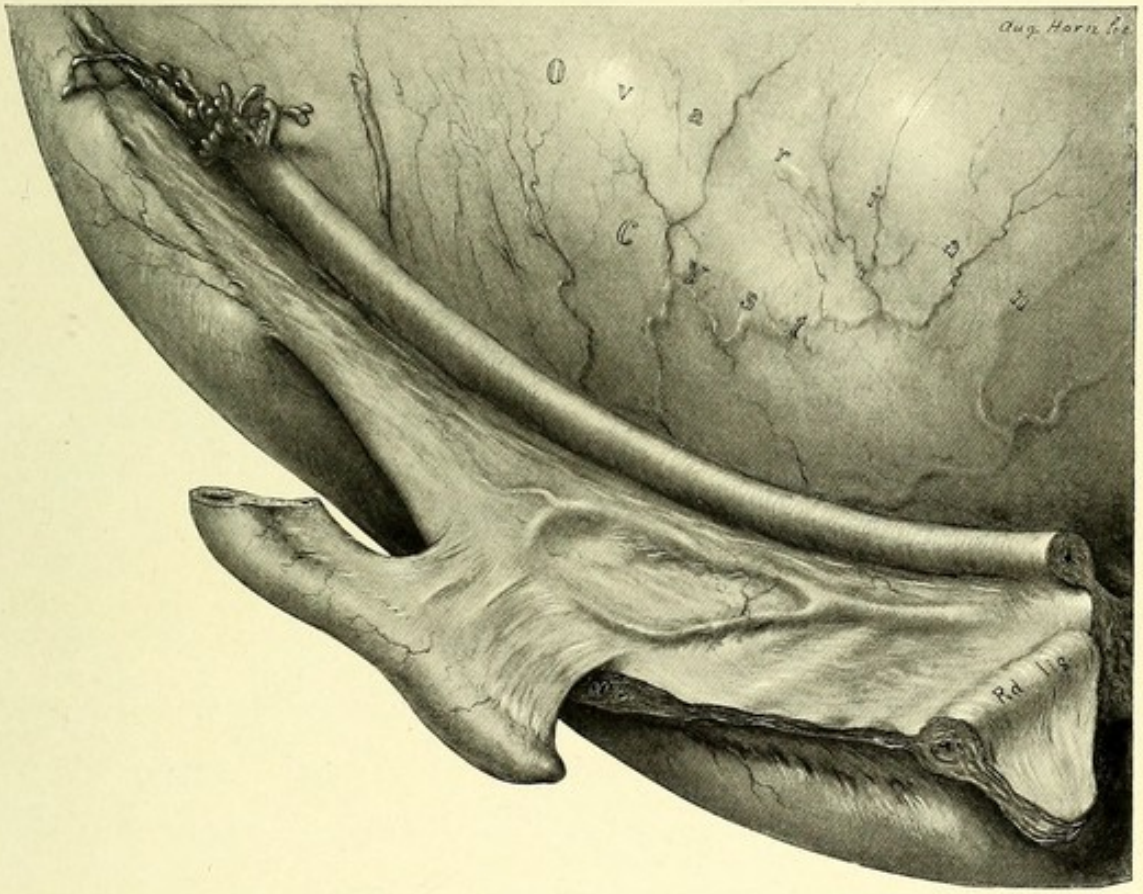

Fig. 364.—H. A. Kelly. The Distal Portion of the Appendix Adherent to the Broad Ligament in Case of Large Multilocular Ovarian Cyst. H. F., age forty-eight. June 4, 1902. Recovery. (Natural size.)

the cecum, and its mesentery, together with the ovarian vessels, tied off. The uterine vessels should also be tied at the uterine cornu. As much of the pus as possible should be removed with an aspirator. Then the surgeon must make a cautious effort to peel out the whole mass, carefully working his fingers down underneath it in the posterior pelvis. Gauze or sponges should be freely used to take up any escaping fluid. If when the mass comes away it leaves any portion of its infected wall clinging to the pelvic wall or floor, the latter should be scraped with a knife-blade or a curette, and then freely touched with pure carbolic acid, followed by alcohol, after which the whole area should be covered with a

loose handful of washed-out iodoform gauze, draining either at the abdominal wound, or through a large opening at the back of the cervix into the vagina.

When the Appendix is Strongly Adherent to a Tumor of the Uterus or Ovary (see Fig. 364).—Under these circumstances the best plan of enucleation is to detach the appendix from

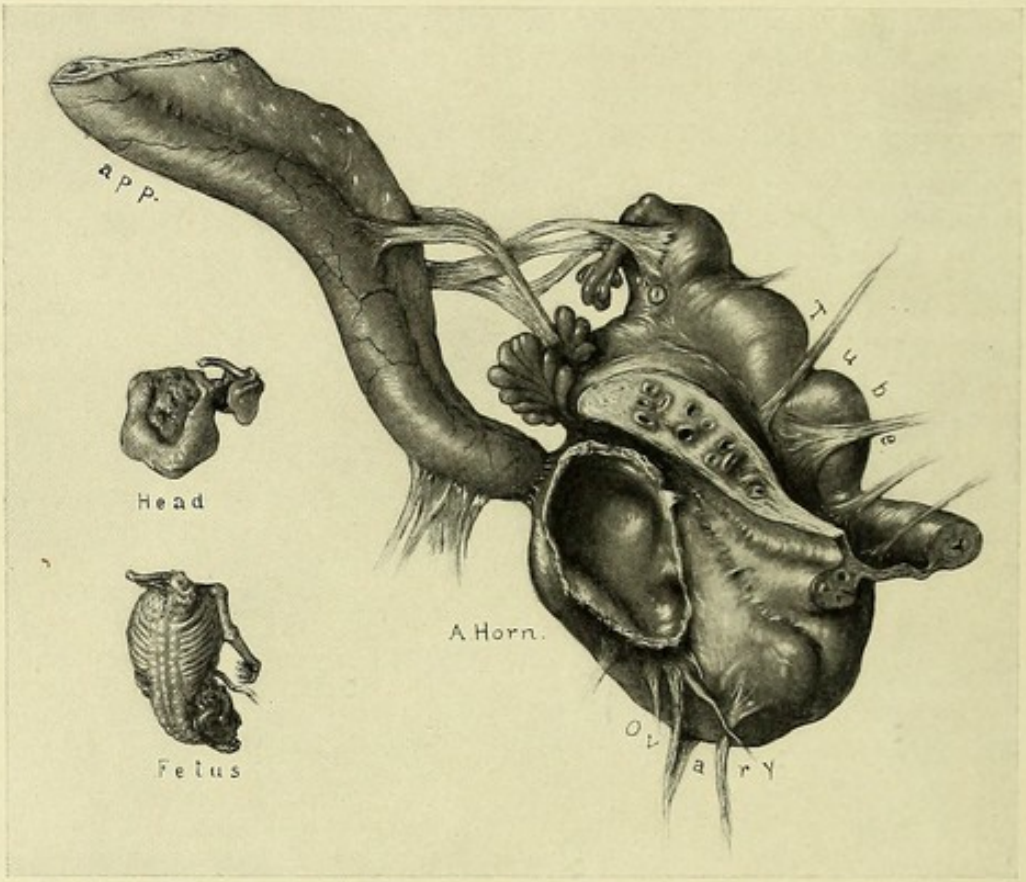

Fig. 365.—H. A. Kelly. Appendix Adherent to Uterine Tube and Ovary in the Midst of Extensive Adhesions.

The fetus shown on left was found buried apparently in substance of ovary. A. W., age thirty. May 31, 1902. Recovery. (Natural size.)

the cecum, and close the opening at once if possible. The tumor should then be removed with the appendix attached to it.

When Appendicitis is Complicated with Extra-uterine Pregnancy.—This condition offers no difficulties not dealt with in the preceding sections. The appendix should be removed either with the mass or separately, as the occasion requires (see Fig. 365).

CHAPTER XXX.

RELATIONS OF APPENDICITIS TO PREGNANCY, LABOR, AND THE PUERPERIUM.

GENERAL CONSIDERATIONS.

The relation of appendicitis to pregnancy, labor, and the puerperium demands especial consideration for several important reasons. The extreme gravity of the complications which may arise, involving the welfare of both mother and child, as well as the diagnostic difficulties, and the risk to the child involved in operation, combine to render this one of the most difficult questions for the obstetrician and for the surgeon. Although there are fairly numerous references in the literature to the occurrence of appendicitis during pregnancy, the cases are still too few to warrant any positive conclusions regarding the relative frequency of the complication; and as, unfortunately, only severe cases, in general, are reported, it is impossible to form a definite opinion concerning the prognosis, as regards either the mother or the child. In the early literature only a few isolated cases appeared. A case described by STUMPF in 1836, as one of rupture of the cecum in a pregnant woman, was probably an early instance of perforative appendicitis; but the first case clearly recognized as such, and made the occasion of operation, was that of HANCOCK (*Lancet*, 1848, vol. 2, p. 381), who opened a perityphlitic abscess on the tenth day after a premature delivery. The patient stated that she had observed a swelling in the right side of the abdomen before her pregnancy, but previous to her confinement it had not caused her any uneasiness. Upon opening the abscess a quantity of turbid serum with shreds of fibrin and false membrane passed out. The patient improved immediately, but the wound did not heal, becoming inflamed and painful, until at the end of a fortnight two fecal concretions escaped, after which recovery soon followed (see Chap. III, p. 48). ABRAHAMS (*Amer. Jour. Obst.*, 1897, vol. 35) collected and analyzed 15 cases, which were all which had been reported at that time.

It is to be expected that appendicitis should frequently develop during pregnancy, because the early child-bearing age corresponds with the time when the disease is most frequent. The apparent rarity of the coexistence of the two conditions is probably to be explained by failure to recognize the mild forms of appendicitis, the symptoms doubtless being often attributed to disturbances due to the pregnancy; many of the more severe cases are mistaken for puerperal sepsis. It is not, however, necessary to assume a direct etiologic relationship to account for the occurrence of appendic-

itis during pregnancy, and probably in the majority of cases the coincidence is purely accidental. Fränkel (*Samml. klin. Vort.*, 1898, No. 229, p. 1335), opposing the view of Hlawacek (*Monat. f. Geb. u. Gyn.*, Bd. 6, p. 327) and others, who hold that pregnancy is an important factor in the causation of appendicitis, considers that the appendix is subject to no different conditions in pregnancy than at other times. "An organ so variable in its size, its form and position, and normally so freely movable, can easily become adapted to the varying condition of pressure in the abdomen." It is probable, however, that in some instances pregnancy and labor have an indirect influence in exciting the inflammatory attack, especially when the appendix is already prepared by preëxisting disease. The obstinate constipation which is so common during the later months of pregnancy may readily provoke an active process in a latent appendicitis, while the excessive engorgement of the pelvic and hemorrhoidal veins very possibly affects the circulation in the appendix. Le Gendre (*Rev. prat. d'obst. et de paed.*, 1897, No. 10, p. 200) refers to a case of Tuffier's in which three successive pregnancies were accompanied with appendical attacks. Resection of the appendix, which contained a concretion, resulted in cure. Le Gendre also calls attention to the fact that during pregnancy, as well as in the non-pregnant state, the menstrual molimen may cause relapses in a chronic appendicitis. He relates the case of a young woman who had suffered from repeated attacks of appendicitis, and in her first two pregnancies the appendical attacks, which had always been mild, occurred in greatly aggravated form. An attack during the second month of the second pregnancy was accompanied by symptoms of peritonitis. The illness gradually subsided, but two days after the date for the menstrual period, an acute exacerbation took place. Recovery again followed, but it was decided to operate eight days before the time for the next period. The appendix, which was perforated at its base, was resected, together with a mass of inflammatory exudate and an enlarged gland. A smooth recovery followed, and the pregnancy continued its normal course.

When the appendix, as a result of antecedent inflammatory attacks, has become adherent to the uterus, or to the ovary, tube, or broad ligament (see Fig. 366), the alteration in the anatomic relations and the traction upon the appendix consequent upon the pregnancy involve more or less danger. The strong contractions of parturition and the sudden diminution in the size of the uterus when it has become empty, have a more harmful effect than the gradual growth of the uterus during pregnancy. The most dangerous complication is met with when the uterus forms part of the wall of a peri-appendical abscess. With the expulsion of the fetus and sudden contraction of the uterus, rupture of the abscess, according to König, is almost inevitable. A good example of the danger of this complication is described by Muret (*Zeit. f. Gyn.*, No. 94, p. 1359), where in the fifth or sixth month of pregnancy, a typical appendicitis developed, but soon subsided with a disappearance of all symptoms. The

pregnancy went on to term, and a normal delivery followed, but two days later the patient died from perforative peritonitis. Autopsy showed that the contraction of the uterus had caused rupture of an abscess.

Mayo Robson (*personal communication*, 1903) has operated on two cases of suppurative appendicitis, developing almost immediately after accouchment. The first case was one of suppurative peritonitis arising from an appendix which perforated the day after delivery. Operation was performed on the third day, the appendix being removed, the pelvis and abdomen cleaned of pus, and lavage of the peritoneum performed. The patient completely recovered. In the second

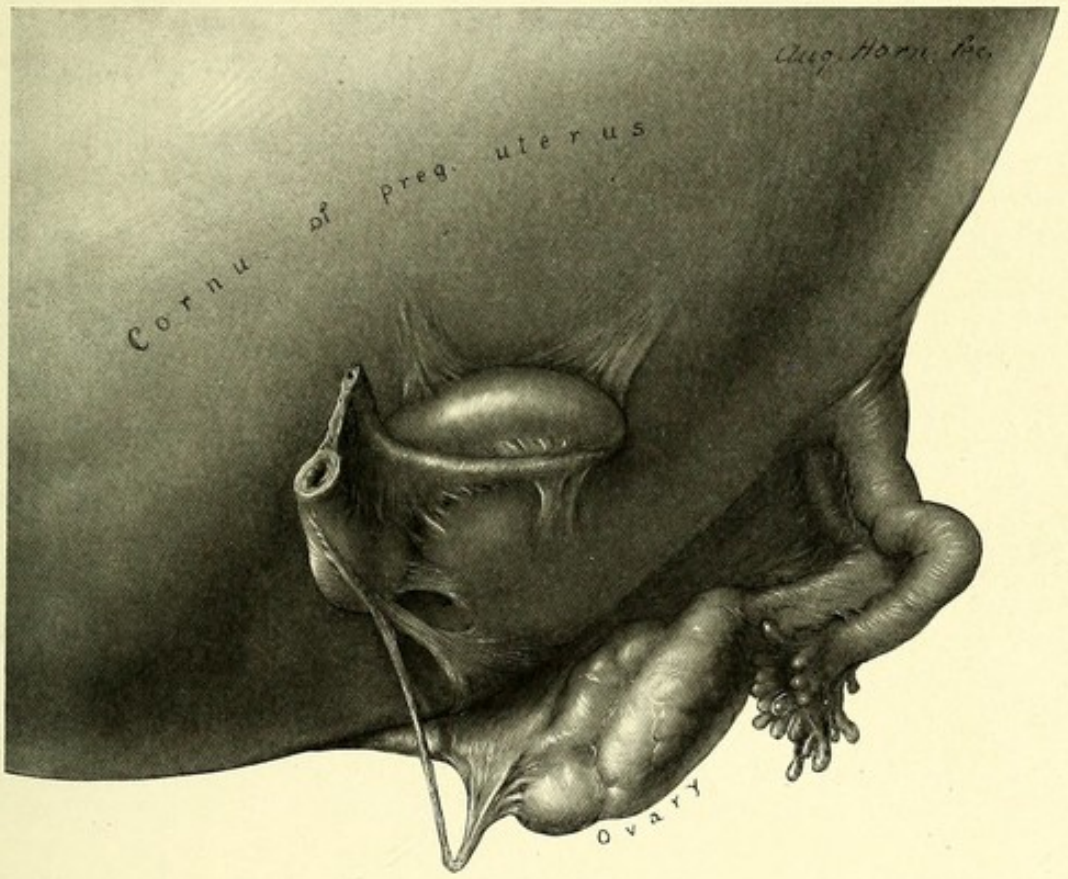

Fig. 366.—H. A. Kelly. Appendix Adherent to the Pregnant Rudimentary Uterine Horn. Seen from Behind. (Gyn. No. 5802, May, 1902.)

case, acute appendicitis, ending in abscess formation, developed a few days after confinement. At operation, performed ten days after delivery, it was found that the appendix, which was perforated and necrotic, had become fixed to the open end of the right tube, down which the pus was creeping. The tube and appendix were removed together and the patient made a good recovery.

The Effect of Appendicitis upon Pregnancy.—No statistical proof can be obtained from the limited number of observations reported regarding the relative frequency with which the death of the child results when pregnancy is complicated by appendicitis, yet all writers are agreed as to the extremely

grave prognosis for it in severe cases. In mild attacks the normal course of the pregnancy is not disturbed. Boije (Pollak, *loc. cit.*, Chap. XXIX) cites 18 cases from Engström's clinic, mostly of a mild type, in all of which the pregnancy proceeded normally. In other cases, even where a severe inflammation is cut short by operation, the pregnancy often proceeds normally. D. Lewis (*Med. Recorder*, Chicago, 1901, p. 369) has successfully operated on five occasions during early pregnancy. In one instance a large abscess was incised and drained in the fourth month of pregnancy; and the labor proceeded without incident. C. Strickler (Gloniger, *Amer. Med.*, Jan. 10, 1903) operated, in the fifth month of pregnancy, for acute appendicitis with obstruction due to adhesions. Recovery was uneventful, and a living child was born at term. T. K. Holmes (*Amer. Jour. Surg. and Gyn.*, St. Louis, Feb., 1903) reported the case of a woman four months pregnant, operated on for gangrenous appendicitis with general peritonitis. Recovery followed, and the pregnancy proceeded to term, when a healthy child was delivered. Similar cases have been reported by Penrose, McCosh and Hawkes, and many others. Generally, however, in severe cases abortion ensues. In some instances the fetus dies *in utero* from general toxemia or septicemia, and is then expelled. Cases have been described in which the infection of the fetus and placenta was demonstrated bacteriologically. In Krönig's case (*loc. cit.*, Chap. XXIX) a recently dead fetus was delivered spontaneously five days after incision of a peri-appendical abscess. The bacillus coli communis was found in pure culture in the organs of the fetus, in the placenta, and in the large uterine veins. In most instances uterine contractions are primarily excited, and a living child is delivered, which, however, often soon dies on account of non-viability or from infection. The uterine contractions may be provoked by direct inflammatory irritation or through general constitutional disturbance, especially high fever. In many cases premature delivery occurs early in the appendical attack, and in such a case a healthy child may be born, but when delivery occurs after the patient has become profoundly septic or when infection of the uterus has taken place, the prognosis for the child's life is less favorable.

With the act of parturition, whether it occurs at full term or prematurely, a dangerous complication is added. In the first place, as already explained, there are the almost inevitable rupture of adhesions and the probability of general distribution of the infection; and in the second place, there is the danger of infection of the uterus with the virulent appendical organisms, constituting a true puerperal infection.

Oppenheimer (quoted from Pollak) relates the case of a woman who, in the seventh month of her pregnancy, presented symptoms of peritonitis. On the third day a living child was born. Three days later, a large mass resembling a tumor of the kidney had developed, while necrotic masses were removed from the uterus. The patient died without operation, and the postmortem showed peritonitis resulting from perforative appendicitis and secondary infection of

the placental site. A case of unusual interest described by A. MANTÉ (*Arch. gén. de méd.*, 1903, No. 25, p. 1547) is as follows:

The patient, two days after delivery of a living child at term, began to have fever and fetid lochia. On admission, on the ninth day, her abdomen was distended and she was evidently septic. Curettage and intrauterine lavage were followed by a general improvement, but very soon the temperature again became elevated, the pulse small and rapid, and there were chills. A vaginal hysterectomy was then performed, and the uterus was found large and edematous, but it only contained some fibrinous clots, the inner surface being a pale pink color. The patient died four days later, and at the autopsy the pelvis was found covered with greenish-white fetid pus, and the appendix, the tip of which was gangrenous and perforated, hung down into the pelvis and was in contact with the broad ligament. It was, however, absolutely free, and was doubtless the primary focus of the infection. The bacteria found in the appendix were the same as those obtained from the uterus.

While abortion is often followed by a rapidly fatal termination, this unfavorable result is not necessarily occasioned by the miscarriage, which, as pointed out by FRÄNKEL, is only one step in the development of the disease, and the severe general or local infection which induces the abortion also causes the death of the mother. KÖNIG believes that the presence of exceptionally dense adhesions between the intestines and pelvic organs may interfere with the normal growth of the uterus and so predispose to abortion. In one case observed by this writer the patient had been the subject of several miscarriages, and at operation the adhesions found between the appendix, the intestinal coils, and the uterus were so dense that they could be severed only with the knife. These adhesions may also interfere to some extent with the normal involution of the uterus. In CRUTCHER'S case (cited by Abraham), after abortion complicating gangrenous appendicitis, it was necessary to curette and pack the uterus, which at autopsy was found to be normal except for the appendical adhesion. In MUNDE'S and THOMASON'S cases (*ibid.*) manual removal of the placenta was necessary.

DIAGNOSIS.

The diagnosis of appendicitis complicating pregnancy may be exceedingly difficult. A typical attack, beginning with sudden, severe, abdominal pain, soon becoming localized in the right side and associated with localized tenderness, muscular rigidity, and constitutional disturbances, is generally recognized without difficulty; but if the pain and tenderness are not definitely localized, and the constitutional symptoms are slight, the pains, especially in a primipara, may be mistaken for a threatened miscarriage; and even if the pain is accompanied with vomiting, this is of little value in the diagnosis, because it may also accompany labor pains. Still greater confusion is found when the actual parturition is complicated with appendicitis. as the symptoms of the latter may be

completely masked by the former or may be attributed to it. In a case related by HLAWACEK the patient had a chill a few hours after the onset of labor-like pains, and it was difficult to determine whether the chill was caused by labor or if there was an appendicitis. Palpation and percussion are often unsatisfactory in the later months of pregnancy on account of the distention of the abdomen by the pregnant uterus. It is, however, sometimes possible to detect an area of localized rigidity, and a tumor, very rarely the thickened appendix, may be clearly defined as separate from the uterus. FRÄNKEL suggests, as an aid in differentiating a peri-appendical exudate from the uterus, that the patient be placed on her left side, when the uterus sinks in that direction, and the inflammatory mass is more easily palpated. The presence of a severe infection is readily recognized by the characteristic constitutional disturbances, and its source may usually be determined if a careful description of the onset of the attack is obtained, and especially if there is found to be a history of antecedent appendicitis. Great difficulty in arriving at a diagnosis is also experienced when the appendicitis develops a few days after delivery, in which case the symptoms may simulate puerperal infection, or, indeed, may be accompanied with a secondary infection of the uterus, as in the case of MANTÉ, already cited.

In the early months of pregnancy the differential diagnosis between uterine pregnancy complicated with appendicitis and ruptured ectopic gestation may be very perplexing. The distinguishing features have already been described in Chap. XXIX. The differential diagnosis of appendicitis from other conditions accompanying pregnancy, especially pyelitis and other renal diseases, is based upon the same characteristic features as it is in the non-pregnant state (see Chap. XVIII).

TREATMENT.

The operative treatment of appendicitis in pregnancy and in the puerperium is a matter of great importance, as, owing to the constant changes in the anatomic relations of the viscera, the severer forms of the disease, in which an abscess is evolved, are less liable to be checked or limited in their extent. Furthermore, the danger always involves two lives, and the happiness of an entire family.

For these reasons, and because of the well-recognized clinical severity of any attack of appendicitis associated with suppuration during pregnancy, prompt interference is demanded as soon as a diagnosis is clearly made. The operator, in urging upon the patient a prompt recourse to surgical treatment, however, must be guarded in his statements, for numerous cases are recorded in which the patient has refused the operation, and yet has recovered, gone on to term, and been delivered of a living child. HERRGOTT has said, that for women in the child-bearing period of life the operation for a recurring appendicitis is more than usually urgent, on account of the dangers they incur should an attack take place during a pregnancy. In these cases, therefore, the interval operation is

in a special sense prophylactic, saving both mother and child, a risk which has often been reckoned as having a mortality as high as 50 per cent.

The earlier in the course of pregnancy the operation is done, and the earlier in the course of the disease, the better for the patient. In these cases the usually conservative surgeons of Germany take, as a rule, the same radical stand which is taken by their American and French colleagues. FRÄNKEL, for instance, says that "in case of a relapse in a pregnancy, the operation is to be recommended even while the clinical symptoms are of a mild nature, especially in the earlier months of the pregnancy."

In performing the operation it is best to use a McBurney's incision, enlarging it, if necessary, by dividing the aponeurotic and the muscular fibres in order to secure the freest possible drainage when there is suppuration. It is important to handle the tissues as little as possible in the course of the operation, and, above all, to avoid exposure and all manipulations of, or traction upon, the uterus. The intestines should be well packed off, and the whole procedure should be conducted under the assumption that any infection is far more likely to spread throughout the peritoneum than under ordinary circumstances.

If the operation is a timely one, and has been conducted with gentleness and without trauma, undue prolongation, or shock, the pregnancy may advance to term without interruption. If a widespread peritonitis is found associated with pregnancy, the hopes for the patient's life are but small. In such cases the most liberal drainage should be used; if tympany is excessive, a small intestinal fistula should be made, and the pregnancy terminated by emptying the uterus *per vaginam*. It is of the utmost importance that the pelvis should also be perfectly drained, preferably in an upward direction on account of the risk of infecting the uterus.

In the case of an active appendicitis occurring at the end of pregnancy the pregnancy may be terminated by an *accouchement forcé*, as recommended and practised by MARX, to save the life of the child, and the abdomen then opened in order to treat the appendicitis. The risk of the two operations, however, associated with the likelihood of distributing an infection by the contractions and changing volume of the uterus, is so great that this plan should be adopted only in exceptional cases. When there is reason to believe that pus is present or that an abscess has formed, it is wiser to open and drain simply and let the uterus alone. Such cases can go on undisturbed to term, with apparently less risk than if the uterus is emptied at once in order to anticipate the slow abortion which often occurs, but upon this point further data are wanting.

While appendicitis occurring in the course of pregnancy is dangerous, it is still more dangerous, and prompt interference is even more urgent, in appendicitis arising in the early puerperium. In some instances these cases owe their origin to the recent violent changes in the anatomic relations of the lower abdominal viscera, which break up adhesions, and where the uterus has formed part of the protecting wall of an abscess, rupture the sac, and distribute its contents

through the peritoneum. This last group of cases is well-nigh hopeless; nevertheless a prompt operation should be performed, and liberal drainage instituted. If the appendicitis comes on during labor, it is best to terminate labor first, and then make sure of the diagnosis and operate on the appendicitis (LABHARDT).

CHAPTER XXXI.

NEOPLASMS.

BENIGN TUMORS. MALIGNANT TUMORS.

Introductory.—The number of cases recorded of primary tumors in the vermiform appendix is small, but during the past few years, since the operative treatment of right iliac disease and careful, routine, laboratory examination of the removed organ have become general, it has been found that they are by no means so rare as was formerly supposed. The few instances described in the older literature were supposed to belong to the carcinomata, but owing to the lack of microscopic examinations and the meagre description of the gross appearance, there is just doubt in many of these cases as to the true nature of the growth. Since 1898 a considerable number of cases of malignant neoplasms limited to the appendix have been carefully described, while secondary involvement of the organ is comparatively common. Benign tumors, however, are still (it would appear) extremely rare. This may be partly owing to the fact that on account of their small size and clinical insignificance they have not been considered worthy of special attention. The tumors originating in the appendix may be classified as follows:

Benign Tumors: { Polyp. Myoma. Fibroma. Myxoma. Lipoma.

Malignant Tumors: { Carcinoma. Sarcoma.

In addition to these it may be mentioned that LAFFORGUE (*Thèse de Paris*) mentions two instances of lymph-adenomata of the appendix; and in a case of Hodgkin's disease, furnished me by L. HEKTOEN of Chicago, the appendix was enormously enlarged, forming a sausage-shaped tumor 12 by 2.5 cm. Its walls were uniformly thickened, the canal almost obliterated, and the neighboring portion of the cecum contained a large lymphomatous mass which projected into the bowel. Microscopic examination revealed the usual hyperplasia of lymphoid elements.

BENIGN TUMORS.

Polypi.—Unlike other portions of the intestinal tract, the appendix is but rarely the seat of these formations, and so far as I can discover no cases have

been mentioned in the literature. I have observed four instances, one of which occurred in my own practice. In subacute inflammation the mucous membrane lining the appendix is often thrown up into polyp-like folds, which may be so exuberant as to form a distinct tumor, causing considerable distention of the canal, and at first sight even suggesting a new-growth. Inspection of the sectioned surface, however, shows that the outgrowths are composed of submucosa and mucosa, and differ from true tumors in that the tissues preserve their normal relations to one another. Histologically, there is merely a more or less severe inflammatory process, characterized by a marked increase

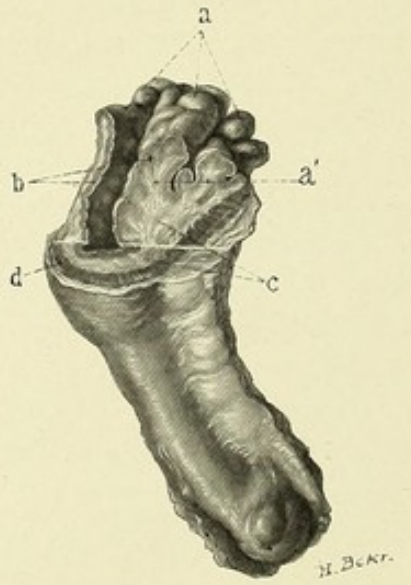

Fig. 367.—H. A. Kelly. Polypoid Mass (a) Projecting from the Cecal End of the Appendix. (Gyn. No. 7272.)

a', Cut surface of polyp; b, mucosa; c, submucosa; d, musculature.

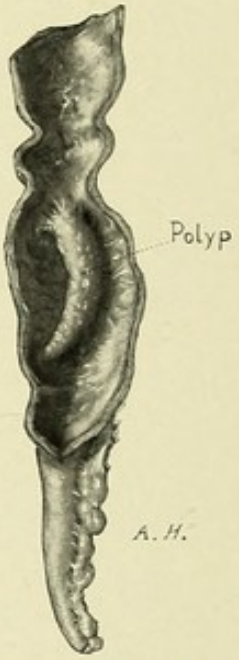

Fig. 368.—Oviatt's Case of Polyp in the Appendix, Removed Six Weeks after an Attack of Appendicitis.

in the number and size of the blood-vessels, associated with hyperplasia of stroma cells and leucocytic infiltration. A good example of this condition is illustrated in Fig. 367.

J. H. H., Gyn. No. 7272. The patient, a woman thirty-two years old, was operated on for pelvic inflammatory disease. There was a tubo-ovarian abscess on the left side, and on the right, the appendix was adherent to the inflamed tube and ovary. There was no history of appendicitis, the patient's only complaint being of a profuse vaginal discharge. The appendix was short, with its somewhat bulbous extremity buried in adhesions. Its base was densely attached to an area of thickened cecum extending about 2 cm. on all sides. The bowel was extensively opened by amputation of the appendix with the entire thickened area of cecum. Projecting from the orifice of the appendix was the curious polypoid mass shown in the figure. The microscope showed merely a subacute inflammation.

Single sessile, or pedunculated polypi are also the product of an inflammatory process. They may be composed entirely of mucous membrane, but more often they have a stem consisting of the submucosa. In the specimens that I have seen, the glands of Lieberkühn, the stroma, and the lymph nodes were well preserved and, excepting for slight congestion of the blood-vessels and leucocytic infiltration, the tissue was normal. The specimen shown in Fig. 368 was removed at operation by C. W. Oviatt of Oshkosh, Wis. The patient, a boy of twelve, had suffered from a severe attack of appendicitis six weeks previously, and at the time of his admission to a hospital a tender mass was detected in the region of the appendix. On opening the abdomen a perforation was found near the base of the appendix and a moderate-sized fecal concretion lay free in an abscess cavity. The middle portion of the appendix was abruptly distended, and upon being opened after removal, proved to contain a small pedunculated tumor. Under the microscope this was found to consist of the normal elements of the mucous membrane. The specimen shown in Chap. XII, Fig. 173, was removed at operation, by I. R. Trimble, for acute appendicitis, and shows practically the same structure. A similar specimen was sent to J. C. Bloodgood by Carson of St. Louis.

Myxoma.—The only instance of myxoma in the vermiform appendix that I find recorded is a case shown by Churton to the Medical and Surgical Society of Leeds (H. Aboulker, *Thèse de Paris*, 1899). The patient, a young woman, twenty-two years old, admitted with a history of two attacks of appendicitis, complained of being unable to work on account of constant pain in the cecal region. The appendix was removed by Mayo Robson. It presented a thickened extremity, and on being opened showed a sessile, transparent tumor, the size of a small haricot-bean, obstructing the lumen to within 3 cm. of the tip, which was slightly distended with mucus. There were no adhesions nor other sign of peri-appendicitis. An instance has also come under my own observation in which the tumor was attached to the peritoneal surface of the appendix. The patient was a young colored girl, upon whom an exploratory laparotomy was performed for the purpose of discovering the cause of severe abdominal pains of which she complained. Nothing was found except a few adhesions between the liver and the anterior abdominal wall and, attached to the middle of the appendix, which was hypertrophied and obliterated, but free, was a small, firm, transparent nodule, 1.5 by 1 by 0.8 cm. in size, which, on microscopic examination, proved to be a pure myoxma.

Myoma and Fibroma.—Three cases of myoma of the appendix have been recorded, two by A. O. J. Kelly and one by Hayem. In the two cases described by Kelly the tumors were small, about 5 mm. in diameter, and were situated in the muscular coat. They were designated fibro-myomata. In one case (Kelly) there was a considerable amount of calcareous deposit. In all three cases there was an associated chronic inflammation of the appendix, characterized by hypertrophy of its walls and arteriosclerosis. The case of probable parasitic

myoma shown in Fig. 369 was removed from a woman who was operated on for uterine myoma. The iliac tumor, which had no anatomic connection with the uterine growth, was situated behind a peritoneal fold and received its blood-supply by branches from the superior mesenteric vessels. A similar case is described by SONNENBURG, but in this instance the appendix was not found.

Fibroma limited to the appendix has not been reported, but in this connection a remarkable tumor of the kind, which chiefly involved the appendix

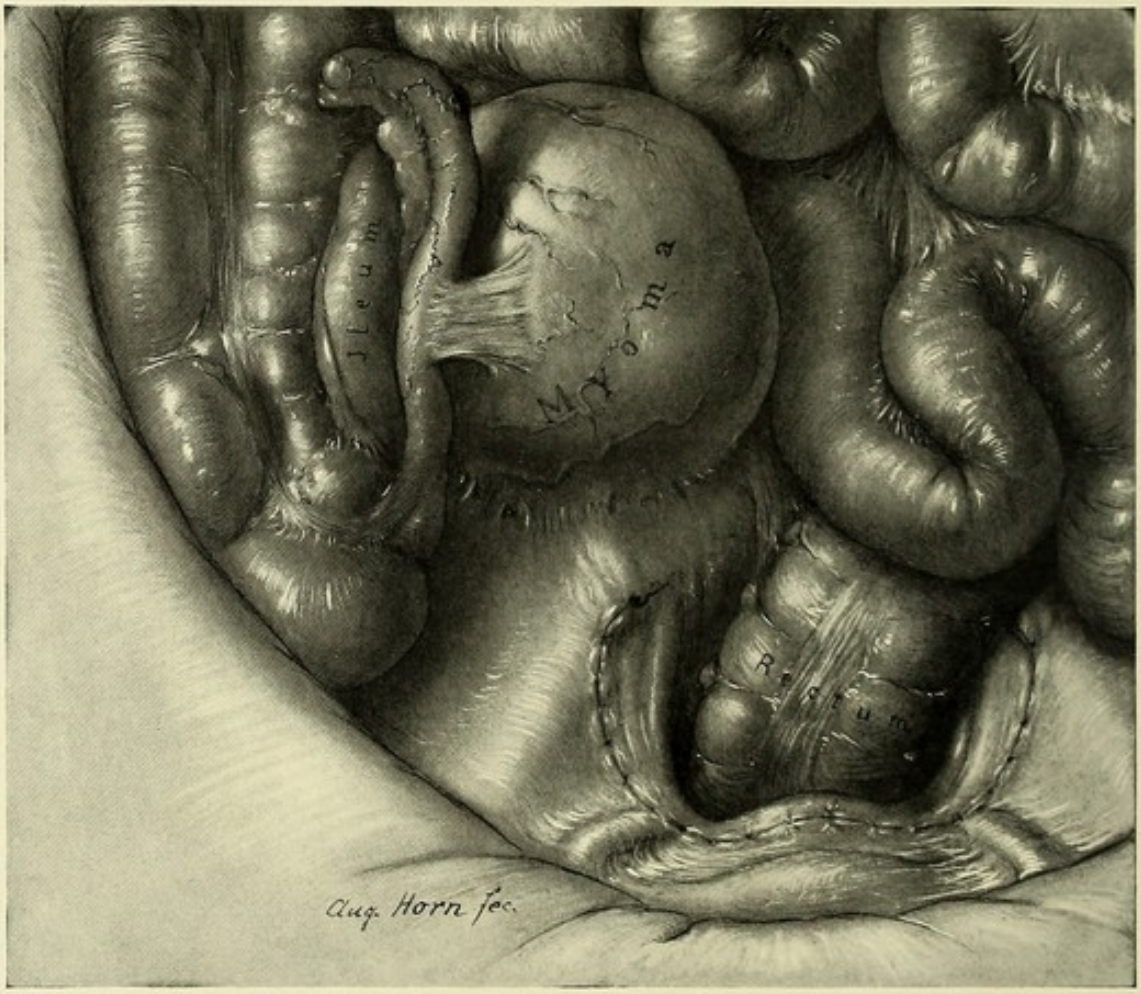

FIG. 369.—T. S. CULLEN'S CASE OF PARASITIC MYOMA ADHERENT TO THE APPENDIX. (Path. No. 5754.)

and had evidently originated in the mesentery of the appendico-cecal region, was observed in the gynecological department of the Johns Hopkins Hospital. The history of the case is briefly as follows:

M. P., colored, aged thirty-three, was admitted complaining of an abdominal tumor, noticed for the first time six weeks before. At that time the tumor was about the size of a large duck-egg and was situated low down on the left side. It increased rapidly, and two months before admission she was told by her physician that the tumor was the size of two fists. There was no pain, and the patient stated

that if she had not felt the hard mass, she would not have been conscious of its presence. Defecation was normal; her appetite and digestion good; micturition was somewhat frequent. On examination the lower abdomen was found to be occupied by a large tumor somewhat more prominent on the left side. There was considerable bulging in both flanks, but especially in the right. The tumor was slightly movable from left to right, more movable upward and downward. The mass extended up to and was lost under the right costal margin. Pelvic examination

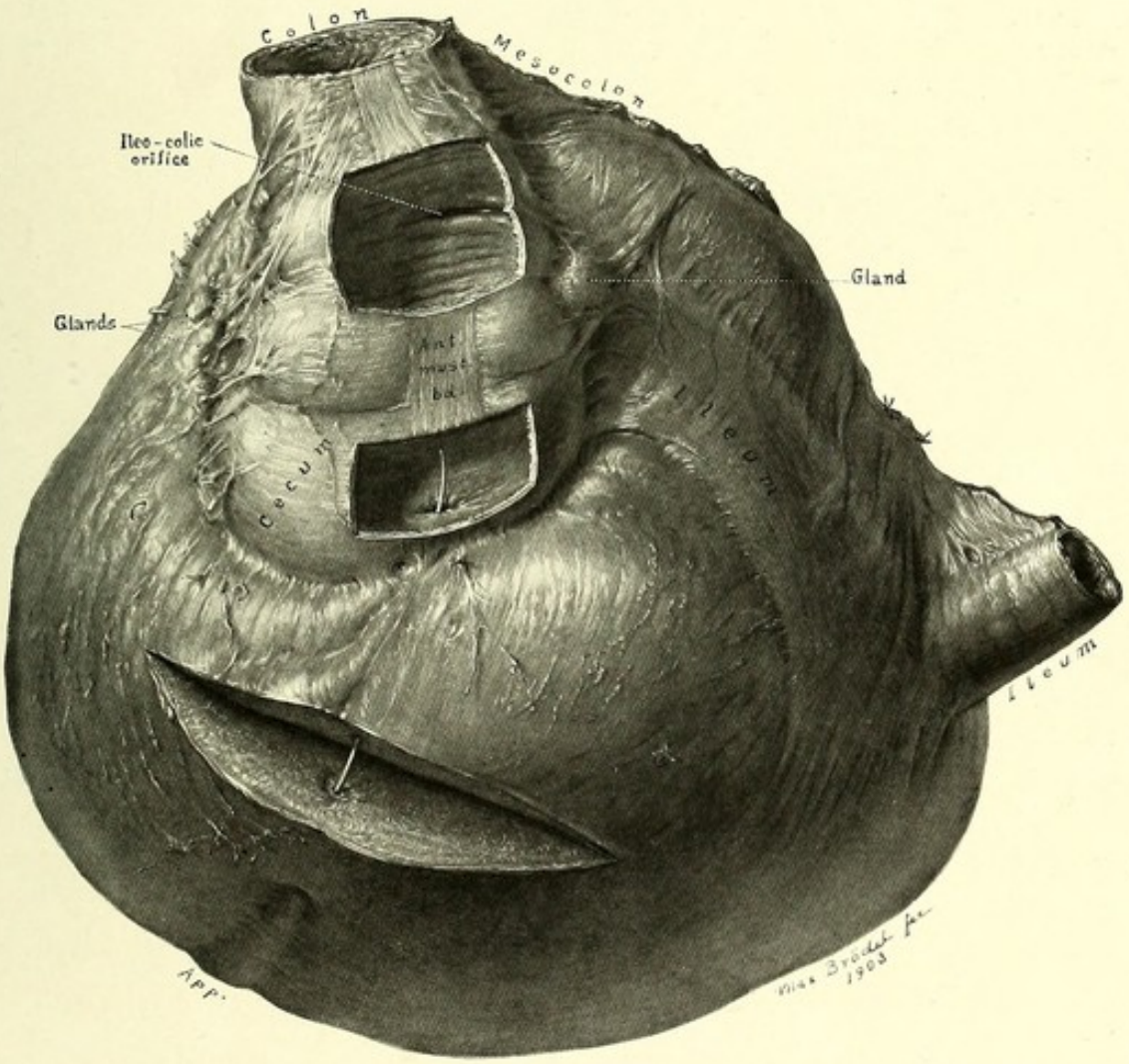

Fig. 370.—H. A. Kelly. Fibroma of the Appendix and Appendico-cecal Angle. Anterior Aspect of Tumor. (M. P., age thirty-three. Jan. 22, 1900.)

showed that the uterus was small and pushed into retroposition by the hard tumor which extended down into the true pelvis. The diagnosis was tumor of the right ovary. On operation, a median incision exposed the tumor lying between the layers of the mesentery and behind the peritoneum of the iliac fossa, with the ileum lying like a flat cord on its upper surface, to the length of 10 cm., the cecum and the ascending colon being spread over it to the same extent. The appendix, which was 18 cm. long, disappeared entirely for 9 cm. of its length into the substance of the

tumor, its distal half being free. The enlarged, congested ovarian vessels coursed down over the surface (see Figs. 370 and 371). A free incision was made through the peritoneum on the convex surface of the tumor, in the hope of enucleation and of avoiding a resection of the bowel, but the hemorrhage was so free that this plan had to be abandoned. The mesenteric vessels were then tied off and the bowel ligated at two points, one above and one below the tumor. The ovarian vessels

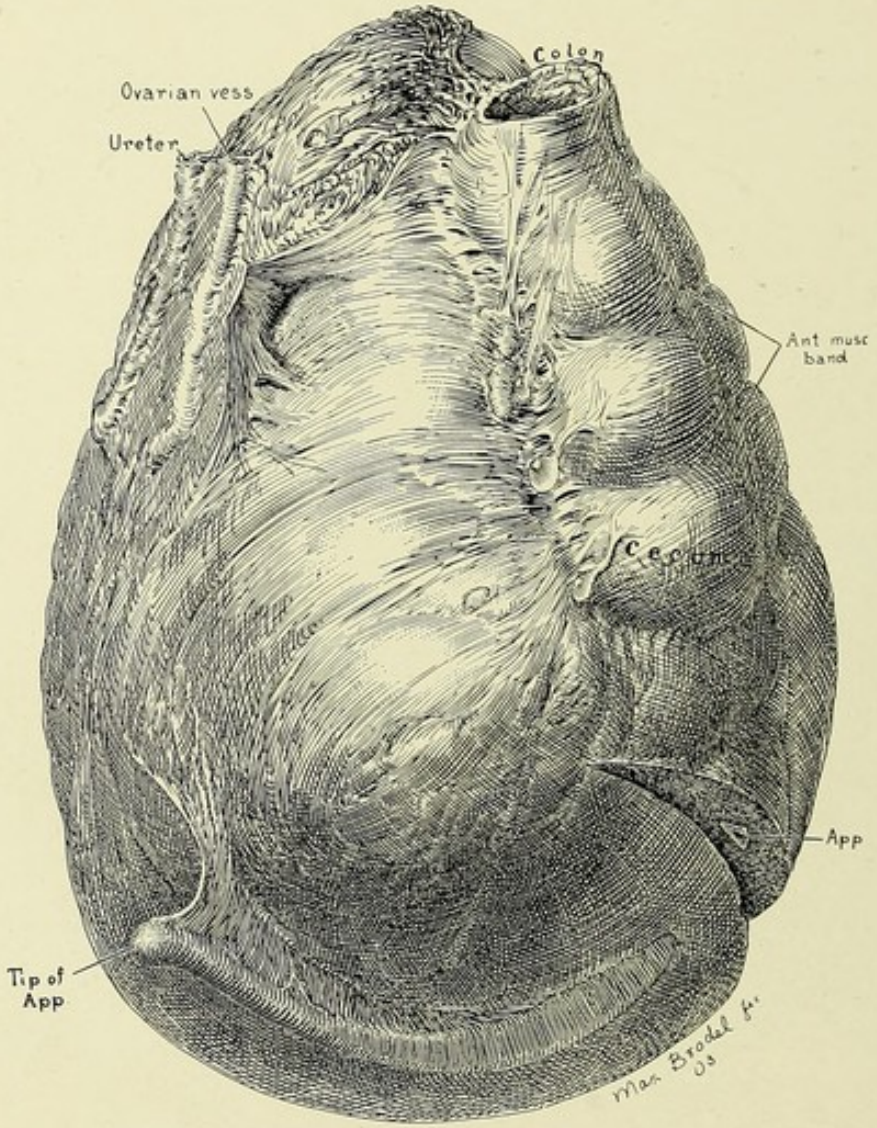

FIG. 371.—FIBROMA. POSTERIOR ASPECT.

were then ligated at the point where they were attached to the under surface of the tumor, a hydroureter being laid bare where it entered the tumor, and resected to the extent of 5 cm. of its length. The bowel was united by an end-to-end anastomosis of the ileum into the cecum, and the ureter was similarly united. The latter procedure was difficult on account of the distended condition of the proximal end, and the tension arising from the removal of 5 cm. of its length. Drains were placed leading down to the site of each of the anastomoses. Conva-

lescence was interrupted by the development of a ureteral fistula on the second day, but this gradually closed and the patient was discharged, well, at the end of seven weeks. Histologic examination showed that the tumor was a typical fibroma, of generally uniform appearance but edematous in places, and slightly infiltrated with plasma and lymphoid cells. The vascularity was moderate. The most interesting portion of the tumor was that where parts of the intestine were involved. The cecum and ileum were flattened from before backward; the mucosa, while showing the signs of pressure, was practically normal; the muscular coats of the anterior wall were normal, but the longitudinal layer of the posterior wall had to a great extent been replaced by tumor cells. The appendix



FIG. 372.—FIBROMA OF THE APPENDIX. SECTION FROM THE PRECEDING CASE, MAGNIFIED EIGHT TIMES, SHOWING THE APPENDIX EMBEDDED IN THE TUMOR.

The canal of the appendix is seen to be pervious, and the mucous and submucous layers practically normal. The muscular coats in this section are fairly well preserved except on the side corresponding to the mesenteric attachment.

had a patent lumen throughout, and the mucosa was well preserved, but where the organ was most deeply embedded in the tumor, the muscular coats had been almost entirely replaced by connective-tissue fibres (see Fig. 372).

MALIGNANT TUMORS.

Carcinoma.—The older writers were of opinion that all neoplasms of the appendix were secondary, and it was not until MERLING in 1838 (*Jour. de l'expér.*, 1838) described a case of primary carcinoma that it began to be referred to in literature. The second case was reported by PRUS in 1865 (Crozet, *Thèse de Paris*), and two years later ROKITANSKY described 4 cases of colloid tumor of the appendix (*Med. Jahrb.*, 1867, Bd. 3, p. 3). Ten years ago the total number of cases re-

ported was 12, and only one of these was described histologically. The cases of MAYDL (*Ueber Darmkrebs*, 1883), of LEICHTENSTERN (ZIEMSSEN, *Handbuch*, 1876), and of LEMAN were mentioned in autopsy statistics without further comment; in other cases the description left some doubt as to the nature of the disease in some instances, and in some, again, as to the organ in which the growth originated. The majority of the early cases described cannot, therefore, be accepted as genuine instances of primary carcinoma of the appendix.

During the past ten years, as stated above, the number of cases reported has been greatly augmented, and, in most instances, the tumors have been carefully described. A. W. ELTING in 1903 reported 40 cases of carcinoma of the appendix collected from literature to the New York State Medical Society, 24 of which were undoubtedly primary (*Trans. N. Y. Med. Soc.*, 1903, p. 324). Since then three cases have been reported by MOSCHOWITZ (*Ann. Surg.*, 1893, vol. 37, p. 891); one by NORRIS (*Univer. Penn. Med. Bull.*, Nov., 1903, p. 334); one by WEIR (*N. Y. Med. Rec.*, May, 1903); and one by BURNAM (*Johns Hopkins Bull.*, 1904, p. 136). There are now on record 49 cases of carcinoma of the appendix, including 2 designated endothelioma. Thirty cases are described microscopically, and appear to have been undoubted instances of primary tumor of the appendix, and it is possible that some of the less carefully described should really be included in this category. There are also 5 instances of primary sarcoma of the appendix. Four cases of malignant disease of the appendix, hitherto unpublished, may be added to this number, namely, 3 of carcinoma and one of sarcoma, all of which were discovered at operation, undertaken for the relief of chronic appendicitis. Brief histories of these cases of carcinoma are as follows:

1. THORNDIKE. *Boston City Hospital.* Woman, thirty years old, with a history of recurrent appendicitis extending over a period of seven years. One week before admission the pain became very severe and continuous. On examination, tenderness was elicited on deep palpation over the right iliac fossa, and a small, cord-like structure was felt close to the ilium. In a few days the pain and tenderness had practically disappeared, but the patient desired operation to prevent further trouble. The appendix was found very much thickened, the distal portion cystic, and the base much indurated; it was removed, a V-shaped portion of the cecum being taken out with its base. The wound in the cecum was closed without drainage. The patient made an uninterrupted recovery. Histologic examination showed that the proximal indurated portion of the appendix was the seat of a carcinoma which had infiltrated all the coats out to the peritoneum. The growth was characterized by the formation of small alveoli lined with columnar cells, which often entirely filled the lumen.

2. MONKS. *Boston City Hospital.* A woman, twenty-four years old, was admitted with a history of two days' illness beginning with pain in the epigastrium which soon settled in the lower abdomen, chiefly on the right side. There was no vomiting and the bowels moved daily with enemata. Her family history was good. She had had no previous attacks of the kind, but had been troubled

more or less with indigestion. She had had "grip" five years before. On admission the patient appeared nervous, but not apparently in much pain. Her general condition was good. The abdomen was natural-looking and soft; palpation elicited moderate tenderness to the left and below the umbilicus, and very slight muscular spasm over these areas. The patient was kept under observation for several days and presented no new symptoms, although the pain continued. Operation showed that there was no free fluid in the abdominal cavity and the serosa was normal in appearance. The appendix was found lying in the iliac fossa near the head of the cecum and twisted upon itself. The tip was bulbous and was enveloped in a mass of chronic inflammatory exudate, from which it was separated with comparative ease. The appendix was extirpated and the abdomen closed, with the exception of a very small drain, removed two days after operation, and the provisional sutures, which were tied. The wound united by first intention and the patient made an uneventful recovery.

Pathologic report: Gross: Appendix opened lengthwise, 5 cm. long, mesentery adherent with some fat. Surface reddened. Mucous membrane grayish and gelatinous. Yellowish nodule 0.6 cm. in diameter, 1.5 cm. from distal end. Microscopic: Slight infiltration of muscularis with lymphoid cells. At site of tumor the mucosa is entirely replaced by a mass composed of connective tissue surrounding collections of epithelial cells. Anatomic Diagnosis: Adeno-carcinoma. Slight chronic appendicitis.

3. J. H. H., Surg. No. 9037. A colored man, aged nineteen, was admitted with a history of recurring abdominal cramps, but never any characteristic appendical attacks. Bowels regular, appetite good. The family history was negative. Ten days before admission he was seized with general abdominal pains, but continued to go about until the eighth day, when the pain became more severe, diarrhea set in, and he vomited once. There was no abdominal distention nor general tenderness. In the right half of the abdomen the abdominal muscles were slightly rigid, and in the iliac fossa there was a distinct oblong mass. This was extremely painful, and light palpation over the tumor elicited active muscle spasm. His temperature was 101.8° F.; his pulse 110; the leucocytes 16,000. Operation showed the tumor mass to consist chiefly of a thickened, adherent omentum which walled off a small abscess, containing fetid pus, from the general peritoneal cavity. The appendix was densely adherent to the wall of the abscess. It was removed with difficulty, the last 2 cm. being freed only by stripping off the outer coat. The abdomen was closed with a small drain. Recovery was uneventful. The appendix was 8 cm. long and markedly thickened (see Fig. 273). It was partly surrounded with adherent omentum, and a perforation opened into the adherent mass. About 2 cm. of the median portion of the appendix was much more dense than other portions, and on section this area was found to be the seat of a new-growth, which had obliterated the lumen and penetrated to the peritoneal layer. A small perforation was found at the junction of the tumor with the distal portion of the appendix. The cut surface of the tumor was sharply differentiated from the surrounding tissue, and consisted of dense, whitish, partly granular, partly fibrillated, tissue. The mucous surface was necrotic. Histologic examination showed that the tumor was made up of small alveoli closely packed with small polymorphous cells having a scanty protoplasm and sharply stained nuclei. All the coats were

seen to be invaded, but on account of the poor preservation of the specimen, the relation of the growth to the mucosa could not be studied.

Pathology.—As regards location of the tumor, its growth is indicated in 24 cases. Of these, 8, or one-third, were situated at the tip of the appendix, and 5 others were within 4 to 5 cm. of the tip. In ROLLESTON's

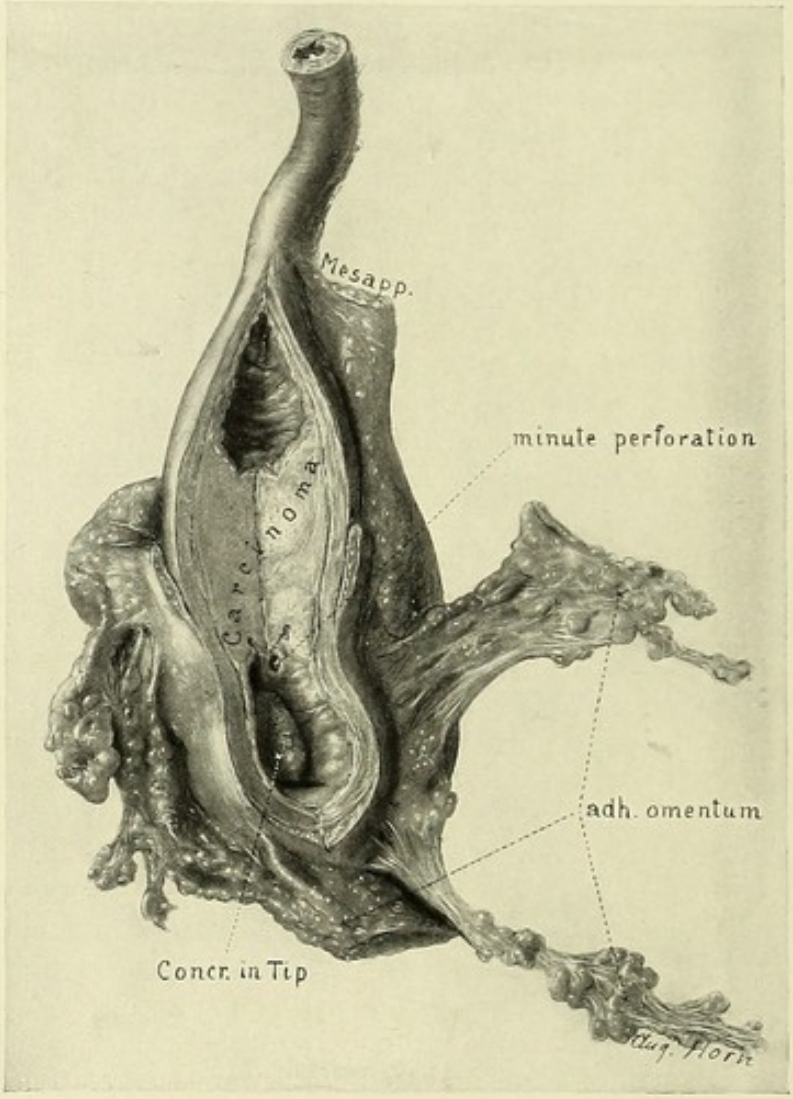

FIG. 373.—W. S. HALSTED'S CASE OF CARCINOMA OF THE APPENDIX CAUSING ACUTE PERFORATIVE APPENDICITIS. (Surg. Path. No. 2599.)

case (*Lancet*, 1900, vol. 2) the tumor is described as being near the tip. In 5 instances the growth was situated at or near the cecal attachment of the appendix, and in the remaining 5 cases at intermediate points. It is noteworthy that in more than half the cases the growth was located at or near the distal extremity, and in only 5 instances was it found near the cecal end. Two characteristic examples of carcinoma limited to the tip, sent me by C. MCBURNEY, are shown in Figs. 374 and 375. Attention has been directed to the fact that in some in-

stances of carcinoma of the cecum involving the appendix, the original focus may have been in the latter. In a case reported by DRAPER (*Bost. Med. and Surg. Jour.*, 1899, vol. 38, p. 180), in one of REYLING'S, and in one of ELTING'S cases, it cannot be definitely determined whether the growth originated in the appendix or in the cecum. In a case of carcinoma of the cecum involving the appendix, observed in Prof. HALSTED'S clinic, the possibility of an appendical origin was considered.

Gross Appearance.—The size of the tumor is noted in 18 cases. Of these, 15 varied from 5 to 12 mm. In GLAZEBROOK'S case, described as



FIG. 374.—MCBURNEY'S CASE OF PRIMARY CARCINOMA LIMITED TO THE TIP OF THE APPENDIX, THE REMAINDER OF WHICH IS NORMAL.



FIG. 375.—MCBURNEY'S CASE OF PRIMARY CARCINOMA OF THE TIP OF THE APPENDIX.

There is a slight constriction proximal to the growth and the mucosa is somewhat swollen and hyperemic. (Museum, N. Y., No. 2020.)

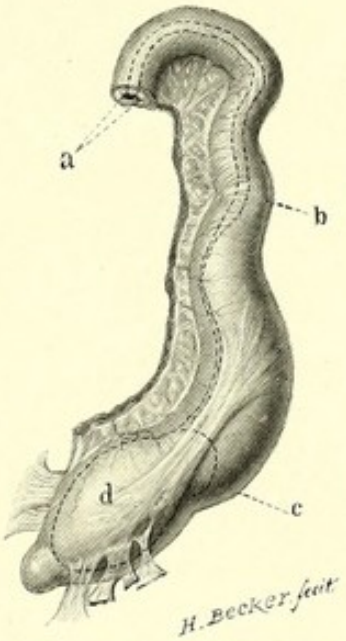

FIG. 376.—H. A. KELLY. CARCINOMA OF THE APPENDIX.

The proximal end of the appendix (*a*) is normal; from *b* to *c* there is a distinct thickening; and beyond this area the lumen is dilated (*d*). (Spec. No. 2854.)

epithelioma, the tumor was the size of a pigeon's egg (*Virg. Med. Month.*, 1895, vol. 23, p. 186), in BEGER'S the size of a walnut (*Berl. klin. Wochenschr.*, 1882, vol. 19, p. 616); while in a case reported by HARTE and WILSON (*Med. News*, 1902) the growth was diffuse, and with the naked eye could not be distinguished from chronic obliterative appendicitis. As a rule, the tumor appeared as a firm, white nodule, fairly definitely circumscribed. Such a growth upon superficial examination may readily be mistaken for a simple fibroma, but careful inspection reveals a less coarsely fibrillated structure and the presence of homogeneous, yellowish-gray areas studding the fibrous tissue. Furthermore, while the tumor appears to

be generally circumscribed, it cannot be shelled out, and in places, the margin gradually merges into the surrounding tissue. In the case of Harte and Wilson cited above, there was no distinct tumor, but a general invasion of almost the entire appendix was visible under the microscope. In ROLLESTON's case the mass presented a caseous appearance and tuberculosis was suspected.

Histologic Examination.—Only a few of the cases of carcin-

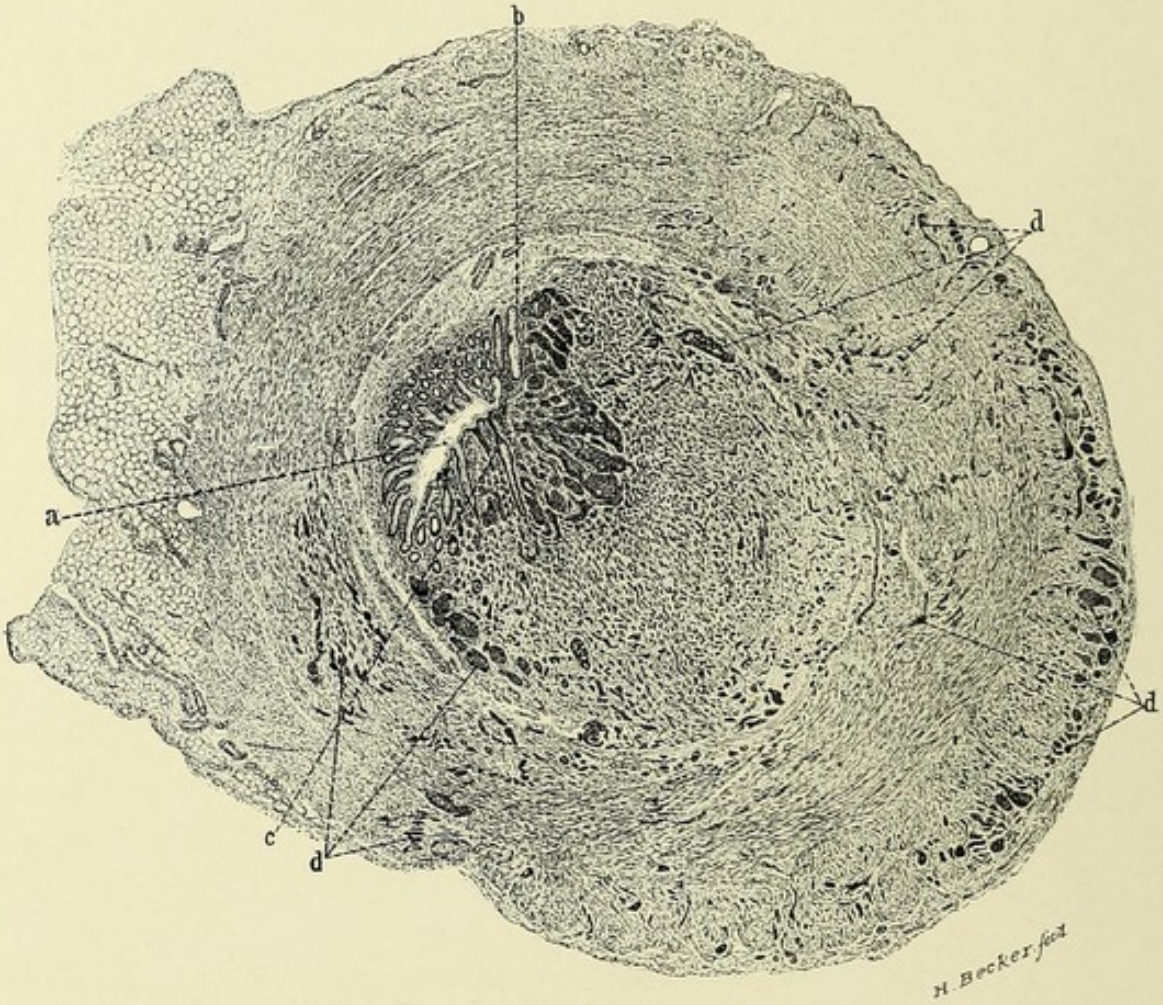

FIG. 377.—SECTION FROM THE PRECEDING CASE OF CARCINOMA OF THE APPENDIX.
The lumen (*a*) is almost obliterated by the encroachment of the tumor, which has apparently originated in the mucosa at the point between *b* and *c*. Cell nests (*d*) have penetrated all the layers.

oma of the appendix conform to the usual type of glandular intestinal carcinomata. In the cases reported by BEGER the tumor is described as consisting of proliferating Lieberkühn's glands (*Arch. f. Chir.*, Bd. 18, p. 306), and in KOLACZEK's (*Arch. f. klin. Chir.*, 1875, Bd. 18, p. 366) a distinct glandular structure was apparent. The majority of cases belong to a less usual type, consisting of round, oval, or irregular alveoli filled with small polymorphous cells, having a scanty protoplasm and sharply stained vesicular nuclei. Mitotic figures are seldom abundant

and may be scarce. In but few places is there any evidence of a glandular formation. Generally, however, where the growth is traced to its origin in the mucous membrane, a lumen may be detected in one or two of the alveoli, and it is usually possible to trace a direct histogenetic relationship between the tumor and the crypts of Lieberkühn. The tumors show a distinct local invasive tendency penetrating the submucous and muscular coats with but few exceptions. In the case reported by NORRIS (*Univ. of Penn. Med. Bull.*, 1903, p. 334) the cell nests extended into the mesappendix. Out of 11 cases which I have had the opportunity to study under the microscope, including a case reported by myself in the *Johns Hopkins Hospital Bull.*, 1900 (see Figs. 376, 377, and 378), 9 were of

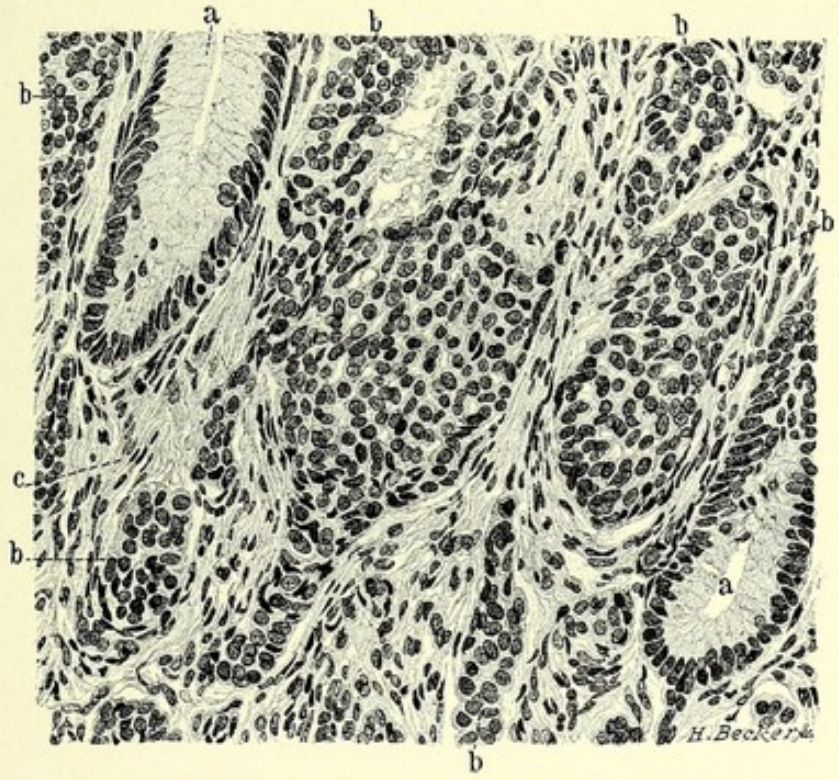

FIG. 378.—A SMALL AREA FROM FIG. 377. ENLARGED 350 TIMES.
Normal crypts of Lieberkühn are seen at *a*, and nests of tumor cells at *b*; *c* indicates the stroma.

this variety, one a distinctly glandular type, and one a colloid carcinoma. These tumors in their histologic and their gross appearance are very similar to a group of multiple carcinomata of the small intestine found by C. BUNTING and to be reported hereafter (*Johns Hopkins Hospital Bull.*). From a study of one case observed and the few recorded in the literature, this writer arrives at the conclusion that such tumors have a generally benign tendency, and bear a striking resemblance to the basal-cell carcinomata of the skin, described by KROMPECHER. Unlike the tumors observed in the appendix, these tumors of the ileum were all found in persons of advanced years. A less benign tendency is noticeable in the appendical tumors, notwithstanding the fact that many were discovered

accidentally at operation or at autopsy. In 3 instances there was extensive invasion of the surrounding structures. In 5 or 6, perforation of the appendix with consequent peritonitis had occurred, the rupture showing a definite relation to the new-growth. In other instances there was fairly definite evidence that

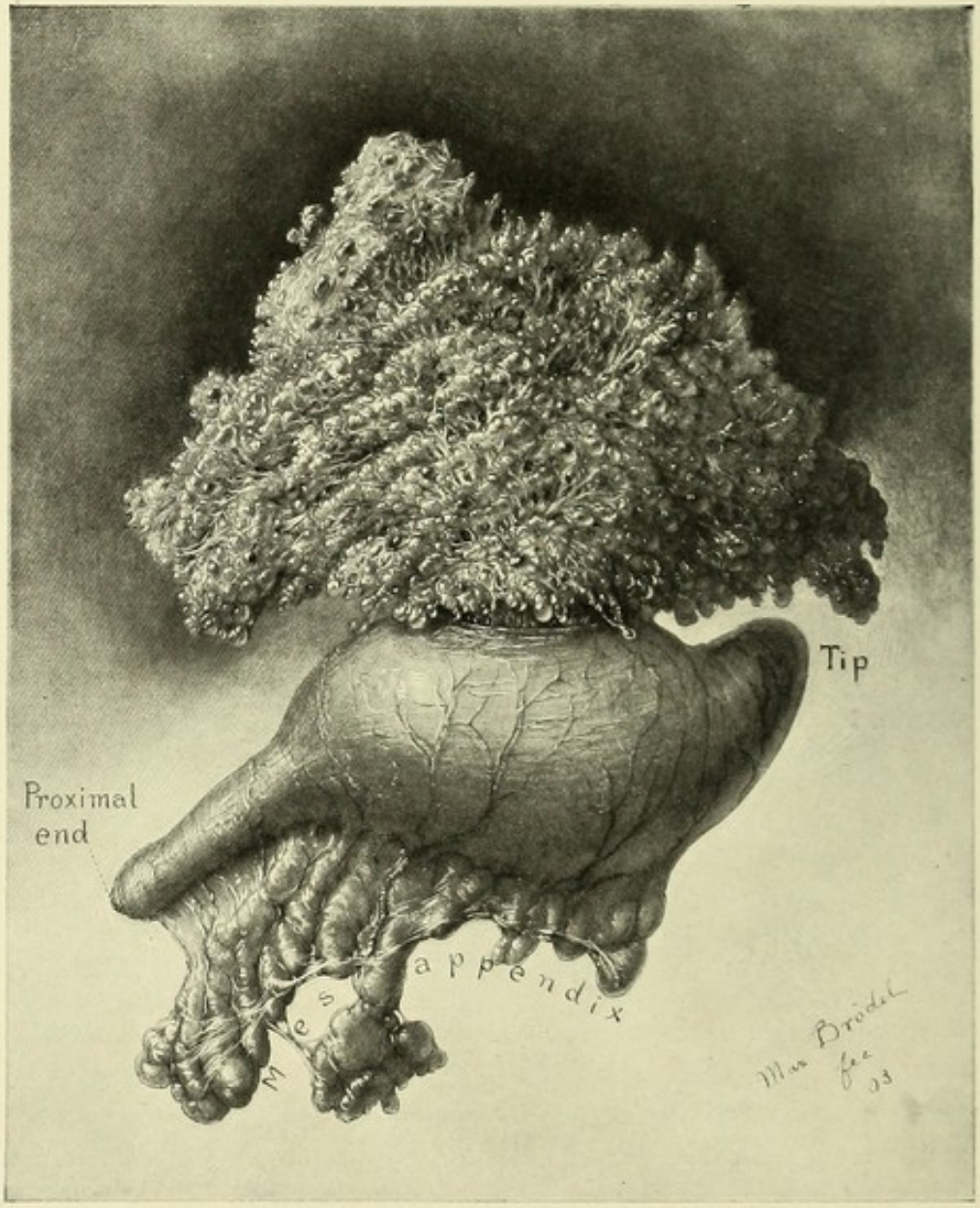

Fig. 379.—Colloid Carcinoma of the Appendix, Discovered at Autopsy. (From A. Elting, Albany, N. Y.)

a carcinoma of the cecum was secondary to the appendical growth. De Ruyter (*Arch. f. klin. Chir.*, Bd. 69, p. 281) relates a case in which at autopsy a carcinoma was found to have developed in the stump of the appendix, which had been removed six years previously. Involvement of the regional lymph glands occurs apparently late in the disease, and was observed in only 2 cases.

Colloid carcinoma is found in a somewhat larger percentage of the cases of carcinoma of the appendix than obtains for the intestine as a whole. Of a total of 43 cases recorded, 7, or 26 per cent., were of this nature. Of these cases 4, described by ROKITANSKY, were not examined histologically, and possibly

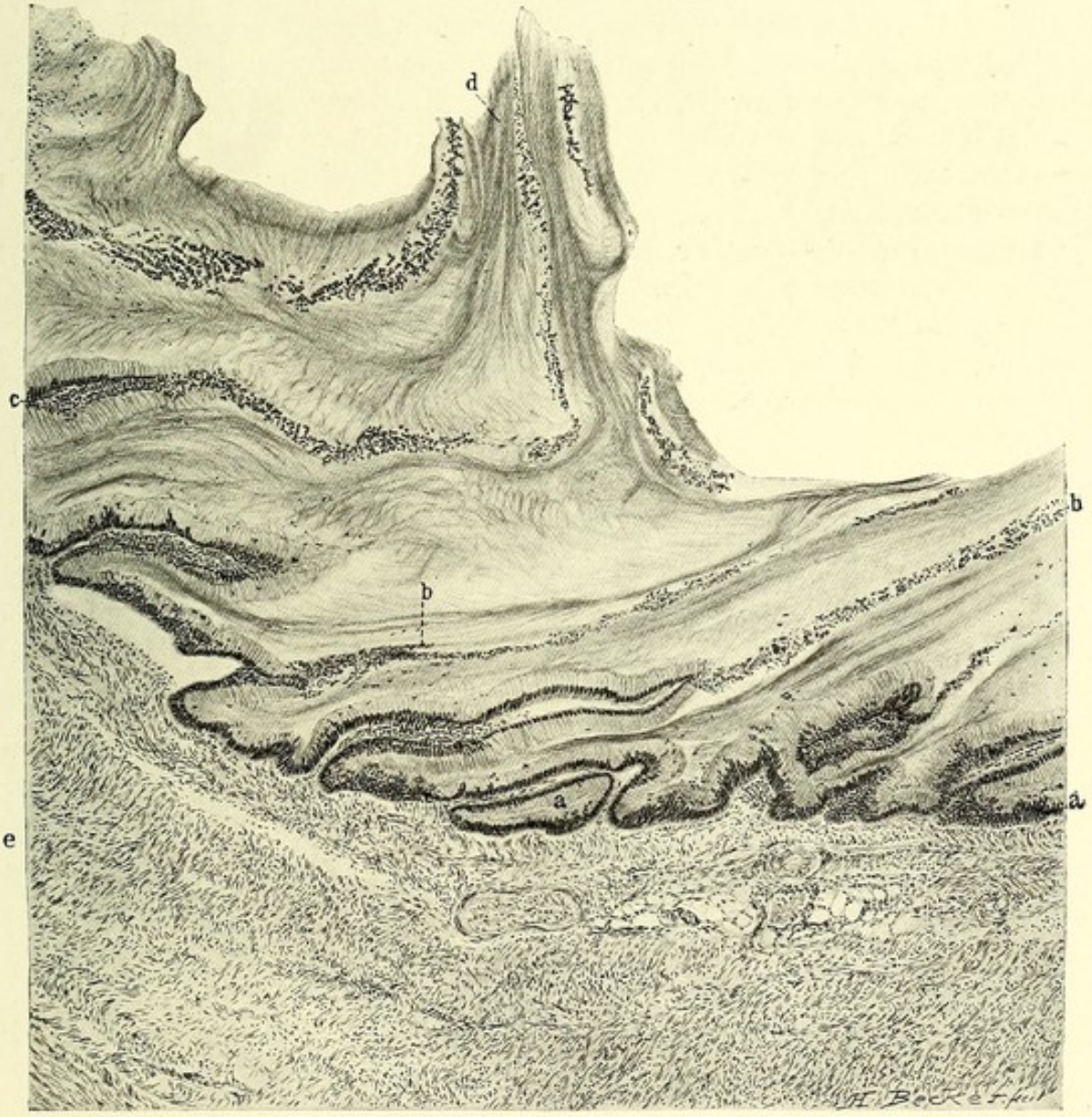

FIG. 380.—SECTION FROM PRECEDING CASE OF COLLOID CARCINOMA.
a, Gland lined with cylindrical epithelium; *b*, epithelial cells, colloid degeneration; *c*, beginning degeneration of the cells; *d*, colloid material; *e*, submucosa.

some of them were instances of simple cystic distention. With the exception of one of ELTING's cases, these growths were all discovered at autopsy (see Figs. 379 and 380).

Etiology.—The frequent occurrence of chronic obliterative appendicitis in association with the carcinoma, and the definite relation which the new-growth

sometimes bears to stenosed areas, afford strong presumption of an etiologic relationship. In cases described by LETULLE and WEINBURG, and by HARTE and WILSON, as well as in one of ELTING's cases, there was distinct evidence of chronic obliterating inflammation. In 2 cases described by Letulle and Weinburg the tumor was situated at a point of stenosis, the result of several attacks of appendicitis. It has been frequently pointed out that malignant growths are especially prone to develop in atrophying or vestigial structures. The appendix, therefore, would seem to afford a particularly favorable site for them.

Mechanical irritation appears to play an unimportant rôle in the development of tumors in the appendix. Considering the frequent occurrence of carcinoma following stones in the gall-bladder and bile-ducts, it is somewhat surprising how few cases occur similarly in the appendix. This may, perhaps, be explained by the fact that hard concretions, such as are formed in the gall-bladder and its ducts, and are liable to injure the tissues, are less common in the appendix, most of the so-called concretions consisting of inspissated fecal material, being of rather soft consistency. Enteroliths and hard bodies, owing to the structure of the appendix and the abundant bacterial life, often determine a perforative appendicitis; therefore the appendix is not subjected to the long-continued mechanical irritation which obtains in the case of calculi in the gall-bladder. In 3 cases, 2 reported by HARTE and WILSON and one by myself, concretions were found, but they showed no demonstrable relation to the growth. In Case 3, p. 745, a concretion was present in the canal immediately beyond the portion involved in the tumor.

A g e .—The age at which malignant tumors of the appendix develop is especially noteworthy. Of the cases, conclusively shown to be instances of primary carcinoma, the ages are given in 25 instances. Four of these were under twenty years of age, 11 between the ages of twenty and thirty. The youngest patient was a girl twelve years of age, operated on by JALAGUIER for recurrent appendicitis. In this case the tumor was situated at the point where stenosis had resulted from the chronic inflammation. In one of ELTING's cases the tumor was found at autopsy in a man eighty-one years old, and one of ROKITANSKY's in a man eighty-two years old. These were both instances of colloid cancer. Of the cases reported above, the ages were respectively twenty-four, thirty, and nineteen years. In the cases of sarcoma the patients were thirty-nine, twenty-nine, and six years of age. The correspondence between the age at which new-growths so often occur and the age at which appendicitis is most common, suggests an etiologic relationship between the two. From an etiologic standpoint it may also be noted that, at an early age, the tip of the appendix is often undergoing a process of normal involution without evidence of inflammation, and in several of the recorded cases the tumor was situated in the tip, while the remainder of the appendix was normal, showing no trace of an inflammatory process.

Clinical History.—The clinical symptoms in practically all cases of carcinoma

of the appendix which come to operation are the symptoms of chronic appendicitis, or of perforative appendicitis without previous evidence of appendical disease. Of the cases described at autopsy, death in some instances was due to general peritonitis following rupture of the carcinomatous appendix, no symptoms of appendical disease having existed previous to the fatal attack; in others the fatal termination was the result of the extensive invasion of neighboring structures by the growth; and in other cases the patient had presented no evidence of disease of the appendix during life, death being due to some intercurrent affection. In one case reported by ELTING, in JESSOP'S case, in NORRIS'S, and in my own the condition of the appendix was discovered during the course of an operation for disease of the pelvic organs. There had been no symptoms pointing to disease of the appendix in these cases. The clinical history of appendical tumors, therefore, is not pathognomonic. In the majority of cases the history was that of appendicitis of the chronic, relapsing variety. Pain was the most constant feature, although some patients were free from it during the entire course of the disease. When present, the pain was usually produced by certain movements, or by active exercise, and was rarely acute. In some instances the clinical picture resembled that of recurrent acute appendicitis, the patient feeling perfectly well in the intervals between the attacks. As a rule, digestion was normal and the bowels regular; some patients, however, suffered from such disturbances of digestion as usually accompany chronic appendicitis. Alternating diarrhea and constipation, melena, or other signs indicating a new-growth of the direct intestinal canal were never observed.

As the disease progresses peri-appendical abscess is a common sequela, and in one case in which the abscess was opened a sinus persisted which communicated with the lumen of the appendix, and finally became lined with the new-growth. In this case, although the right iliac disease was present for three years, there was no disturbance of digestion. The iliopsoas muscle may be invaded and the ilium eroded, as in a case described by Kolaczek. Extension to the cecum probably occurs in a considerable number of cases. In ELTING'S case the complete destruction of the distal portion of the appendix, and the intimate relation of the remaining part to the growth, show, fairly conclusively, that the carcinoma was primary in the appendix, but the possibilty that it had originated in the cecum cannot be denied. When the cecum has become implicated, the appendical lesion is masked by the symptoms arising from the involvement of the direct intestinal canal; viz., disturbed digestion, alternating diarrhea and constipation, melena, and obstruction. The tumor may give rise to an attack of acute appendicitis resulting in perforation and general peritonitis. Perforation of a carcinomatous appendix may also occur without previous warning of the presence of an abnormal condition. WRIGHT described an autopsy upon a case of purulent peritonitis of obscure origin. There were a few adhesions about the appendix, but no definite evidence of perforation. As a routine procedure, sections of the appendix were made, and on microscopic examination a small

carcinoma of the head of the appendix was found, and just at the junction of the tumor with the bowel there was a minute perforation which was the starting-point of the infection. The growth apparently was limited to the appendix. A similar history is found in case 3, p. 745. As I have already indicated, it is undoubtedly because carcinoma of the appendix has a tendency to give rise to perforation or gangrenous inflammation while in its very early stages, that so few cases are discovered.

Diagnosis and Differential Diagnosis.—With one or two exceptions the recorded cases of tumors of the vermiform appendix were discovered at operation or on the postmortem table, and owing to the similitude of the clinical picture to that of chronic appendicitis, it is impossible with our present methods of examination to make a diagnosis, clinically at least, in the early stages of the growth. The discovery of a mass in the right iliac region, presenting the characteristics of a new-growth, and not accompanied by the signs and symptoms usually occasioned by a tumor involving the direct intestinal canal, is strongly presumptive of a tumor originating in the appendix. In the presence of a tumor mass the differentiation between a new-growth and inflammatory conditions is often difficult. In some cases the clinical history is of value. A sudden onset, associated with high temperature, leucocytosis, and other acute symptoms, indicates inflammatory disease. The sudden development of a tumor mass where none previously had existed also points to an inflammatory origin. As a rule, a new-growth is more definitely circumscribed, not so firmly fixed, and is less sensitive on palpation. In BEGER's case a correct diagnosis was made before operation, being based upon the fact that the growth which lined the abdominal fistula showed the typical structure of intestinal carcinoma, that it originated in the region of the appendix, and that there were no symptoms referable to disease of the direct intestinal canal.

Tuberculosis of the hyperplastic form may readily be mistaken for a new-growth. The more cylindrical, less nodular shape of the tubercular tumor, associated with the presence of other tubercular foci, are the most distinctive features. Bacilli would probably not be found in the stools, or at any rate but rarely, while the disease is limited to the appendix. The tuberculin test may possibly aid in the differential diagnosis. Fortunately, in all these conditions an operation is indicated; even after the abdomen is opened the true nature of the disease is not always recognized, and often the new-growth when small is overlooked, or is considered to be simply an obliterating appendicitis. This is of little moment when, as is often the case, the growth occupies the tip of the appendix; but when it is situated near the cecal end it is of vital importance.

While the usual mistake is that of considering a new-growth to be a simple inflammatory condition, the converse may also occur, and in some instances a chronic inflammatory condition, accompanied by excessive tissue production,

has given the impression of a malignant neoplasm. The following case is a striking example of the diagnostic difficulties in such cases.

J. H. H., Gyn. No. 8751. Negress, age twenty-four. Admitted with a history of pelvic pain, dating from a childbirth two years previously. The pain was dragging in character, increased on exertion and relieved by recumbent position. There was a feeling of obstruction on defecation and at times considerable pain; there was also slight bladder irritation. All symptoms had been much worse during the past five or six months. She was well nourished, her tongue clear, temperature and pulse normal. Examination showed the pelvic organs normal except for the retroposed uterus. In the ileocecal region there was a mass the size of a hen's egg, slightly irregular in outline, of rather firm consistency. The mass could be moved upward away from the pelvic brim, but could also be brought well down into the pelvis on the right side. On opening the abdomen the mass in the ileocecal region was found to involve the head of the cecum; it was about the size of a hen's egg and hard. The appendix was not seen. As the mass strongly suggested a new-growth, extirpation of the entire affected area was decided upon, and was accordingly done, after which an end-to-end anastomosis was made. Examination of the removed structure showed a retrocecal appendix, surrounded by a mass of dense inflammatory tissue.

Similar cases are described by SONNENBURG, FENGER, GERSTER and others, and have been cited in Chap. XV.

The finding of a distinct tumor in the appendix should always be regarded with suspicion, because innocent tumors are rare; whereas carcinoma is relatively common. While it is often impossible to determine the true nature of the growth when it is *in situ*, it can usually be recognized in the gross specimen by examining the cut surface and noting the relation of the tumor to the appendical walls. In doubtful cases, especially if a wide resection of the bowel is necessary, frozen sections should be examined at once during the operation.

Prognosis.—The time which has elapsed since the majority of the cases of carcinoma have been operated on, is too short to permit of a positive statement regarding the prognosis. Up to 1900, only 3 cases had been discovered at operation, BEGER'S in 1882, STIMSON'S in 1896, and WEIR'S, reported in 1903. In the first of these, extensive invasion of surrounding structures had taken place at the time of operation. I have not been able to obtain the later history of Stimson's case. Weir's patient remained well during the three years he was under observation. Since 1900, 20 cases have been operated on. All recovered from the operation, and so far as I can learn, with the exception of ROLLESTON'S case, none have shown evidence of recurrence. Some months after operation Rolleston's patient was in poor health and the possibility of a recurrence of the growth was suspected. MCBURNEY, in May, 1903, wrote me that his patient (operated on eighteen months before) was in good health. THORNDIKE'S patient two years after operation gave no evidence of return

of the growth. The case which I reported in 1900 shows no evidence of recurrence at the present time. MONK's case, two years later, was operated on for pelvic inflammation, and at that time there was no evidence of recurrence. BURNAM's case, operated on one year ago, is now in good health. HALSTED's patient (case 3) was living five years after operation.

Secondary carcinoma of the appendix is not uncommon, occurring most frequently by direct invasion, apparently more often by contiguity than by continuity of structure, and occasionally by means of metastases. In a considerable number of cecal tumors the appendix is involved; it is quite

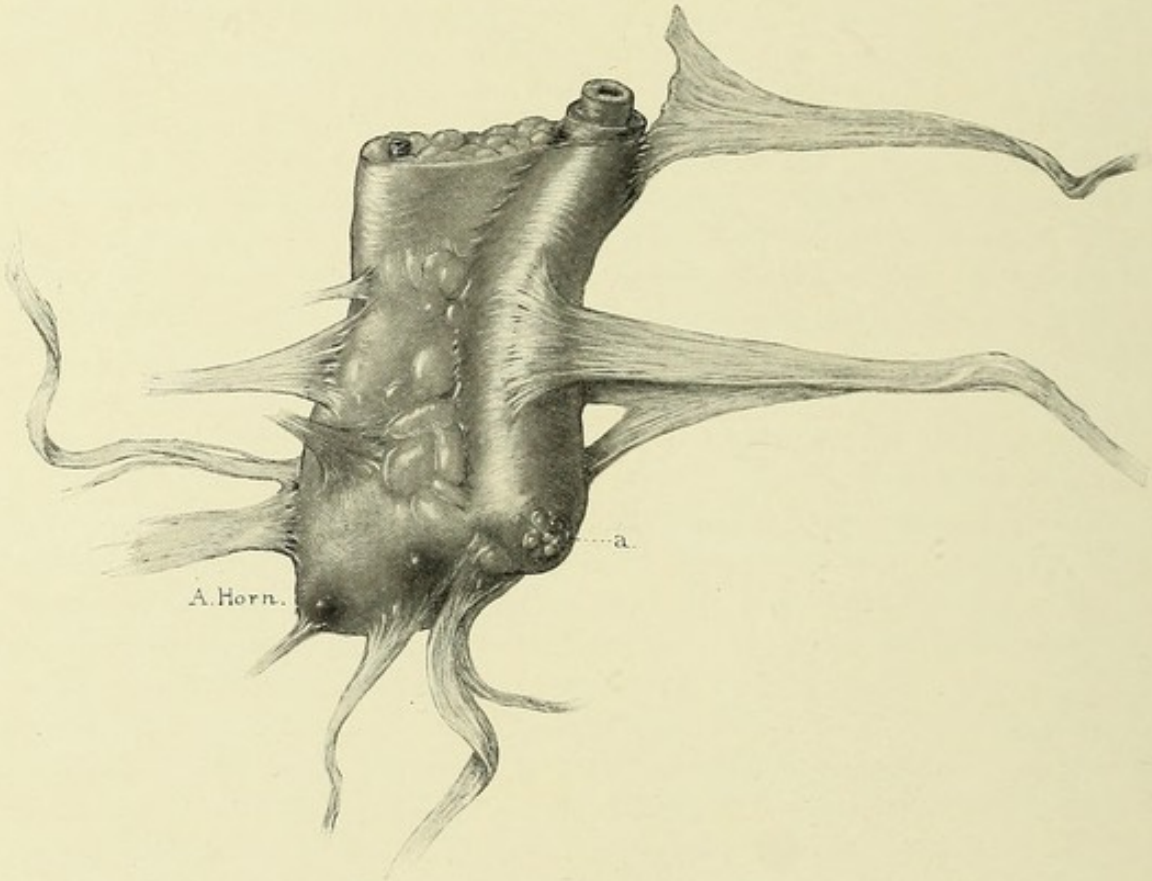

FIG. 381.—H. A. KELLY. INVASION OF THE TIP OF THE APPENDIX BY CONTIGUITY FROM A PAPILLARY CARCINOMA OF THE OVARY. *a*, PAPILLARY CARCINOMA. (Gyn. Path. No. 5607.)

frequently invaded by tumors to which it has become adherent; and, naturally, it is involved in cases of general abdominal carcinosis. Out of 3 cases of malignant ovarian tumors to which the appendix had become adherent (observed in the gynecological service of the Johns Hopkins Hospital), in 2 the growth had invaded the appendical walls (see Fig. 381), and in another case a non-adherent carcinoma of the ovary had given rise to metastasis in the appendix. In these cases, as a rule, the growth had penetrated the peritoneal and muscular coats of the appendix, but had not involved the mucous membrane. In a case reported by WHIPHAM, a small carcinomatous tumor, situated in the mucous and

submucous layers of the appendix, and associated with carcinoma of the ovary accompanied by general metastases, was regarded as primary, on account of the location, but it was probably a metastatic growth from the ovarian tumor.

Sarcoma.—Sarcoma of the intestine in general is rare, and NOTHNAGEL, in his enumeration of the distribution of the collected cases, did not note its occurrence in the vermiform appendix. LAMERS (I. D. Giessen, 1902) mentions two

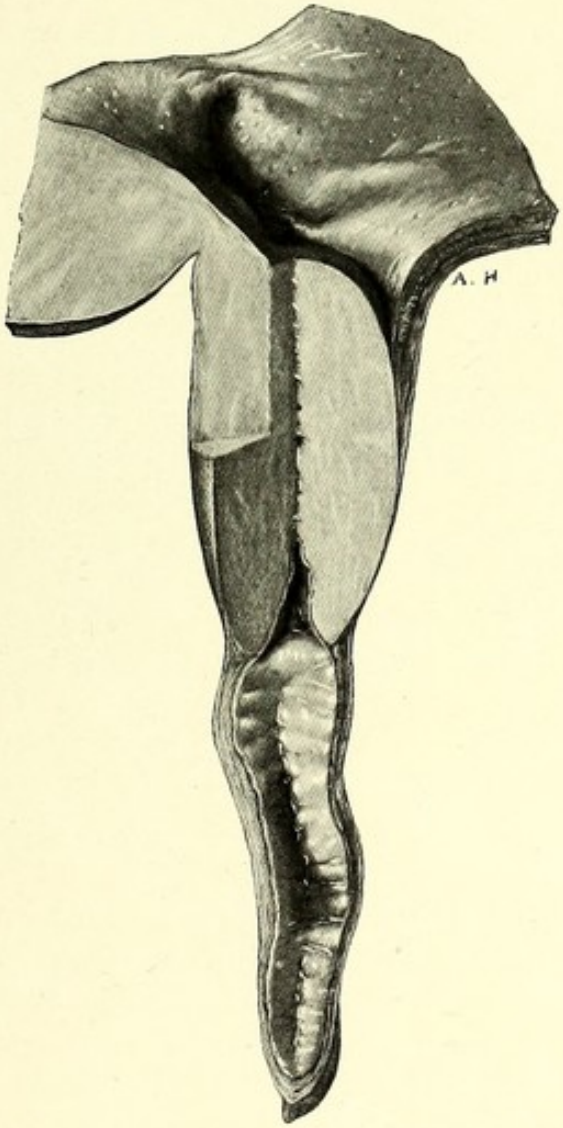

FIG. 382.—BERNAYS' CASE OF SARCOMA OF THE APPENDIX INVOLVING THE ADJACENT PORTION OF THE CECUM.
(See p. 760.)

cases in the cecum and one in the appendix. He also describes a new case of cecal sarcoma in a boy six years old. From time to time cases of sarcoma of the appendix have been reported, but in the majority of these the description is very unsatisfactory. SONNENBURG merely mentions the fact that he has seen a case; GILFORD describes a case in which the sarcomatous tissue had formed around a concretion, but there is some question as to whether he was not dealing

with a hyperplastic inflammatory process. Undoubted examples of sarcoma originating in the appendix are described by P. PATERSON and by J. C. WARREN, and a third case has been furnished me by A. C. BERNAYS of St. Louis. On account of the rarity of sarcoma of the intestine and of the especial interest attached to these cases of sarcoma of the appendix, a brief account of each of these is given.

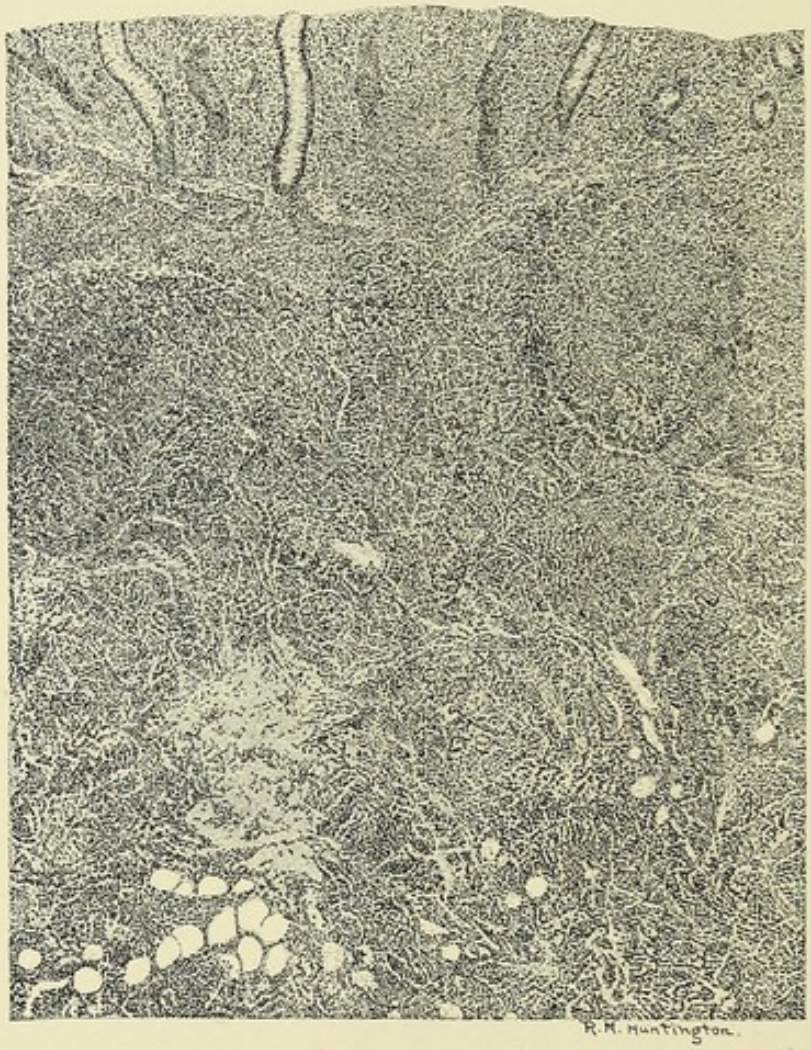

FIG. 383.—SECTION FROM THE PRECEDING CASE, SHOWING THE DIFFUSE INFILTRATION OF THE WALLS OF THE APPENDIX WITH THE SARCOMA CELLS. (See p. 760.)

The crypts of Lieberkühn are preserved in places, but the stroma of the mucosa, the submucosa, and the muscular coats are wholly replaced by the new-growth.

1. J. C. WARREN. (*Bost. Med. and Surg. Jour.*, 1898, vol. 138, p. 177.) A boy, six years old, entered the hospital with a history of a month's illness occasioned by what was supposed to be a chronic appendicitis characterized by intermittent pain in the appendical region and slight fever. On admission there was a small tumor at McBurney's point. He was kept under observation for ten days, during which the subjective symptoms subsided, but the tumor remained. Operation showed a new-growth in the ileocecal angle, instead of a suppurative inflammation,

the surrounding parts being more or less glued together. The mass proved to consist of the greatly enlarged appendix, which was the size of a thumb in diameter, and of enlarged glands, going back to the root of the mesentery. A piece excised for examination showed round-cell sarcoma. The cecum, with part of the ileum and corresponding part of the mesentery, was then excised and the intestine anastomosed with a Murphy button. Complete recovery followed, and a personal communication in 1902, four years after operation, stated that the boy was enjoying excellent health, with no evidence of recurrence.

2. P. Paterson. (*Practitioner*, 1903, p. 55.) A man, thirty-nine years old, gave a history of uneasiness in the right iliac fossa for three months, with occasional attacks of sharp pain, lasting for several days. His bowels were constipated during the acute attacks, but otherwise normal; he had never had any vomiting. When first seen, the patient was suffering from an acute attack, characterized by severe pain in the right iliac fossa, nausea, and anorexia. His temperature was 100.8° F.;

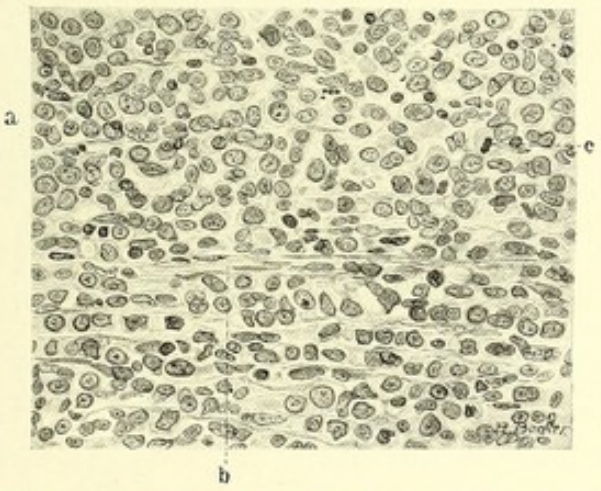

Fig. 384.—Higher Magnification of Fig. 383. Sarcoma of the Appendix. (× 290.)
The section shows closely packed, round cells (a), having large vesicular nuclei which vary somewhat in size and staining properties; c indicates nuclear division; delicate blood capillaries (b) traverse the field.

his pulse 100. Palpation revealed a distinct, tender mass in the right iliac fossa. On operation the appendix was found much thickened, firm, and bound down by adhesions posteriorly, while the omentum was attached to its apex. The cecum was also thickened for a radius of about one-fourth of an inch around the attachment of the appendix. The appendix, together with the thickened part of the cecum, was removed, and the opening closed. The patient never rallied from the operation and died six hours later. Postmortem examination failed to show any trace of tumor formation elsewhere, and the part of the cecum that remained *in situ* appeared healthy. The appendix was 16.5 cm. long and 10 cm. in its greatest circumference. The growth had apparently begun near the apex of the appendix and extended toward the cecum, which was only slightly infiltrated. Histologic examination showed a round-cell sarcoma infiltrating all the coats with the exception of the peritoneum.

3. A. C. Bernays, 1902. (*Personal communication.*) A woman, twenty-nine

years old, with a good family history, and both parents living, had been in good health up to one year before her illness. She then began to have periodical attacks of pain in the right side of the abdomen, and was referred to Bernays with a diagnosis of appendicitis. A hard tumor could then be plainly felt. Operation was deferred for a few days, because, although the hard tumor was what might have been expected after an acute attack of appendicitis, the temperature was normal. On opening the abdomen, the appendix was found free in the peritoneal cavity; it was 10 cm. long, and apparently normal in its distal half, but in its proximal portion it was greatly enlarged and firm to the touch, the infiltration involving the adjacent wall of the cecum for a short distance on one side (see Fig. 382). A complete excision of the cecum was made, and the patient made an excellent recovery. Histologic examination showed a typical round-cell sarcoma infiltrating all the layers of the appendix (see Figs. 383 and 384). The cells, which were fairly regular in size and in their staining properties, showed very active nuclear division. The distal portion of the appendix was normal. I have not had an opportunity to examine the wall of the cecum beyond the growth. A note just received from Bernays states that now, September, 1904, two years after the operation, a tumor is again present in the abdomen, which is probably a recurrent growth.

CHAPTER XXXII.

CLINICAL HISTORY OF THE SPECIFIC INFECTIONS.

TUBERCULOSIS. ACTINOMYCOSIS. AMŒBIC DYSENTERY.

TUBERCULOSIS.

Intestinal tuberculosis is mostly secondary, occurring in the last stages of lung tuberculosis. In such cases the resistance of the organism is so slight that the lesions become widely distributed over the intestine, and ulcers showing no tendency to heal are produced, which frequently advance to perforation with consequent fatal peritonitis. In a considerable proportion of these cases the perforation occurs in the appendix. Intestinal tuberculosis is of especial importance when localized in the ileocecal region. In such cases the disease is usually primary, or if secondary has a comparatively insignificant focus in some other organ, usually the lung. The organism still having the strength to limit the tubercular process, the lesions show a tendency to healing with cicatrization of the ulcers, or to infiltration and connective-tissue proliferation (LENZMANN).

It has long been known that the ileocecal region is the favorite site for the localization of intestinal tuberculosis, whether secondary or primary, and since HARTMANN and PILLIET in 1890 called attention to the occurrence of the tumor-like tuberculous lesions in the intestine, this form of the disease has been found to be almost constantly confined to the ileocecal region. Infection of the appendix commonly occurs by direct continuity from the cecum, or as a local manifestation of a general infection; an infection of the bowel secondary to pulmonary tuberculosis, however, may be entirely localized in the appendix. FENWICK and DODWELL (*Lancet*, 1894, vol. 2, p. 133) found that in 17 cases occurring among 2000 autopsies on persons dying of tuberculosis, the intestinal ulceration was limited to the appendix. Furthermore, the appendix is often invaded through direct contact with a tubercular tube or ovary. Thus, out of 7 instances in which I have found the appendix adherent to the diseased pelvic organs, in 4 the tubercular process had invaded the wall of the appendix. In one, the appendix was involved in a general peritoneal tuberculosis, secondary to the tubal disease (see Fig. 385). Primary tuberculosis of the appendix is apparently very rare. It is difficult to judge of its exact frequency, because in the absence of postmortem demonstration, the presence of other foci cannot be positively excluded; while, on the other hand, many cases undoubtedly pass unrecognized, owing to their resemblance, both clinically and macroscopically, to ordinary acute or subacute appendicitis.

A few cases, however, have been described in which the evidence strongly pointed to a primary affection of the appendix, and was confirmed by the complete restoration of the patient's health after the appendix had been removed. The only definite examples which I have been able to find are the cases of the usual ulcerative form described by SONNENBURG, and by MCCOSH and HAWKES, and a case of hyperplastic tuberculosis described by CROWDER. MOSHER describes a case in which at operation the tubercular infection seemed limited to the appendix, but three years later the patient died of pulmonary tuberculosis. An additional case has been sent me by F. HENROTIN of Chicago, and two others have come under my own observation, one in my private hospital, and the other in the practice of my associate, T. S. CULLEN. The nature of the lesions in these cases was wholly unsuspected, until it was discovered in the course of the routine laboratory examination of the specimen. A third case, operated on for acute appendicitis, was found on microscopic examination to present advanced tubercular lesions, but on account of some thickening in the walls of the cecum observed during the operation, as well as owing to the presence of hardened cervical glands, it seemed probable that the lesion of the appendix was secondary. The clinical notes of the cases are as follows:*

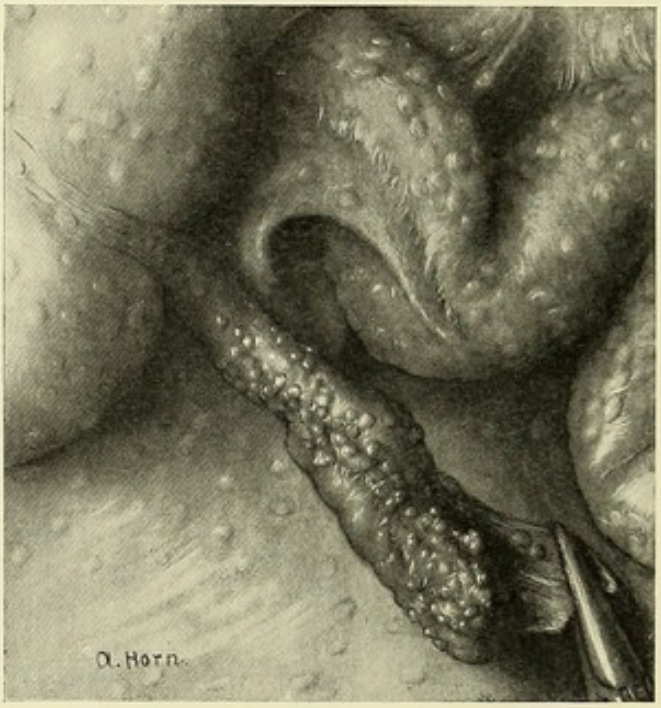

FIG. 385.—PERITONEAL TUBERCULOSIS INVOLVING THE APPENDIX, WHICH HAS BECOME PARTLY TWISTED ON ITS AXIS. (Mrs. P., April 12, 1902.)

1. F. HENROTIN. (*Personal communication.*) A woman, twenty-one years old, was admitted to a hospital with a history of severe pain accompanied by vomiting, occurring at each menstrual period. The first attack occurred eighteen months before she was seen, but there was no recurrence until six months later, since which time it had accompanied every period. The attacks began with pain, very severe on the right side and slight on the left. Vomiting followed in a few hours. The spontaneous pain ceased when menstruation ended, but tenderness in the right side was almost constantly present. The bowels were fairly regular, but the patient suffered from indigestion, and had become considerably thinner than usual. At operation the appendix was found elongated, thickened, and adherent to the iliac

* For pathological description see Chap. XV.

fossa at its apex by web-like adhesions; there were also a few adhesions near its base. It was removed by the usual cuff operation, and a portion of the right ovary, which was cystic, was also removed. The result was primary union, with entire recovery from the previous symptoms, and no evidence of tubercular disease (Fig. 204).

2. T. S. Cullen. The patient, an unmarried woman, twenty-three years old, whose family and personal history were unimportant, had complained for about a year of dull pain in the right lower abdomen. There had been, however, no acute attacks. Apart from the local condition, the physical examination was negative; the temperature was normal. At operation the appendix was found to be brightly injected, and its surface presented a pock-marked appearance; it was, however, free from adhesions. There was no other evidence of abdominal disease. The patient made an uneventful recovery and was relieved of her symptoms. Histologic examination showed extensive tubercular invasion of the mucosa and submucosa, with slight involvement of the muscularis.

3. S. Q., San. No. 1309, Feb., 1902. Thirty-two years old, married. Marked family history of tuberculosis. The patient had had pleurisy when twenty years old, also "inflammation of the bowels" followed by diarrhea lasting for two years, and cystitis. Two months before coming under my care myomectomy had been performed, but the bladder symptoms and bearing-down pain in the pelvis, from which she suffered, continued. There were no signs of appendical disease and no physical evidence of tuberculosis. Operation showed extensive pelvic disease with adhesions involving the uterus, tubes, and ovaries, as well as the appendix, which was atrophied and adherent behind the colon. It was 3.5 cm. long and 4 mm. in diameter, covered with adhesions, and its canal was totally obliterated. There was nothing in its gross appearance to suggest tuberculosis, but under the microscope it was found that the mucosa and submucosa were entirely replaced by typical tubercular tissue. Tubercle bacilli were found, but with difficulty. Six months later the patient wrote that except for the continued bladder irritability, she was in excellent health and was gaining in weight.

4. Sonnenburg. (*Perityphlitis*, 1900, p. 68.) The patient was a single woman who gave a history of recurrent appendicitis extending over a period of three years. There was an indefinite resistance in the right iliac fossa, which was slightly tender on deep palpation. There was no evidence of any tubercular affection of the lungs or other organs, and no family history of tuberculosis.

5. McCosh and Hawkes. (*Amer. Jour. Med. Sci.*, 1902.) The only statement made in regard to this case is that the symptoms from which the patient suffered were evidently due to pyosalpinx and to appendicitis. The inflammation of the appendix was found on microscopic examination to be tubercular, the pyosalpinx non-tubercular.

6. Crowder, Chicago. (*Personal communication.*) A man forty-seven years old, whose father had died of tuberculosis, gave a history of griping pain in the abdomen beginning several months before he was seen. The pain had been of only a few minutes' duration until the last few weeks, when it increased in frequency and in severity, and after about ten days it was accompanied by nausea and once by vomiting. There was pain and tenderness in the right iliac fossa. On admission to the hospital there was a tender swelling in the region of the appendix, extending down

to Poupart's ligament. The next afternoon the temperature was 100° F., but thereafter it remained normal. Eight days later all spontaneous pain had disappeared, the swelling was much reduced in size, and pressure gave only an indistinct sense of tenderness. At operation, performed a week later by C. FENGER, the enlarged appendix, including a portion of the cecal wall which was moderately thickened, was removed. There was no evidence of peritoneal tuberculosis. Healing took place without complications. Two weeks after operation the patient developed an acute orchitis, on the right side, which gradually subsided, but on account of some induration persisting, an incision was made three months later; no evidence of tuberculosis, however, was discovered. When seen eighteen months later, the patient reported perfect health and showed no signs of local recurrence or any evidence of tuberculosis in any other part of the body (Figs. 205, 206, and 207).

An analysis of these few cases shows that apart from the family history of tuberculous disease in two, and the indefinite history of antecedent tubercular foci in one, there were no signs nor symptoms by which the affection could be distinguished from simple chronic, or subacute appendicitis. The irregular diarrhea, or alternating constipation and diarrhea, often found with tuberculosis of the direct intestinal canal, was not observed, nor was there ever any blood in the stools. With the exception of Case 1, the general health of the patient was not affected. The detection of the specific organism in the stools would be a valuable aid in the diagnosis, but, while the disease is limited to the appendix, it is not apt to be present. The tuberculin test would be only of negative value, as it is impossible to exclude other foci. Moreover, its use is scarcely justifiable, since operation is advisable in any case. These cases of localized tuberculosis, as I have said before, are essentially chronic, and have a tendency to undergo fibrous transformation; it is apparently but seldom in an early stage that they are the source of a more general infection. As a rule, adhesions are present, which in the event of a perforation would tend to limit the infection to the right iliac region. Involvement of the regional lymph glands, however, is frequent, and the invasion of the ileocecal region is, finally, extremely extensive.

When tuberculosis of the appendix has involved the neighboring portion of the cecum, or when it merely accompanies a primary cecal or general intestinal affection, the symptoms are masked by those of a more pronounced character produced by the latter disease. In the ordinary, widely disseminated, ulcerative tuberculosis of the bowel, which occurs in the late stages of a large proportion of all cases of lung tuberculosis, the gastro-intestinal symptoms are general, and are characterized chiefly by anorexia, by more or less constant diarrhea, abdominal pain, irregular pyrexia, and frequently by the passage of mucus and blood in the stools. When the affection is localized in the right iliac fossa, acute symptoms are seldom observed, and the disease may advance so insidiously that the first evidence of its presence is the occurrence of sudden acute intestinal obstruction, or of perforation.

In a recent case of T. S. Cullen's, the patient, who was a strong-looking Irish woman, twenty-four years old, gave a history of abdominal cramps occurring two or three times a month for about a year, in addition to which she was somewhat

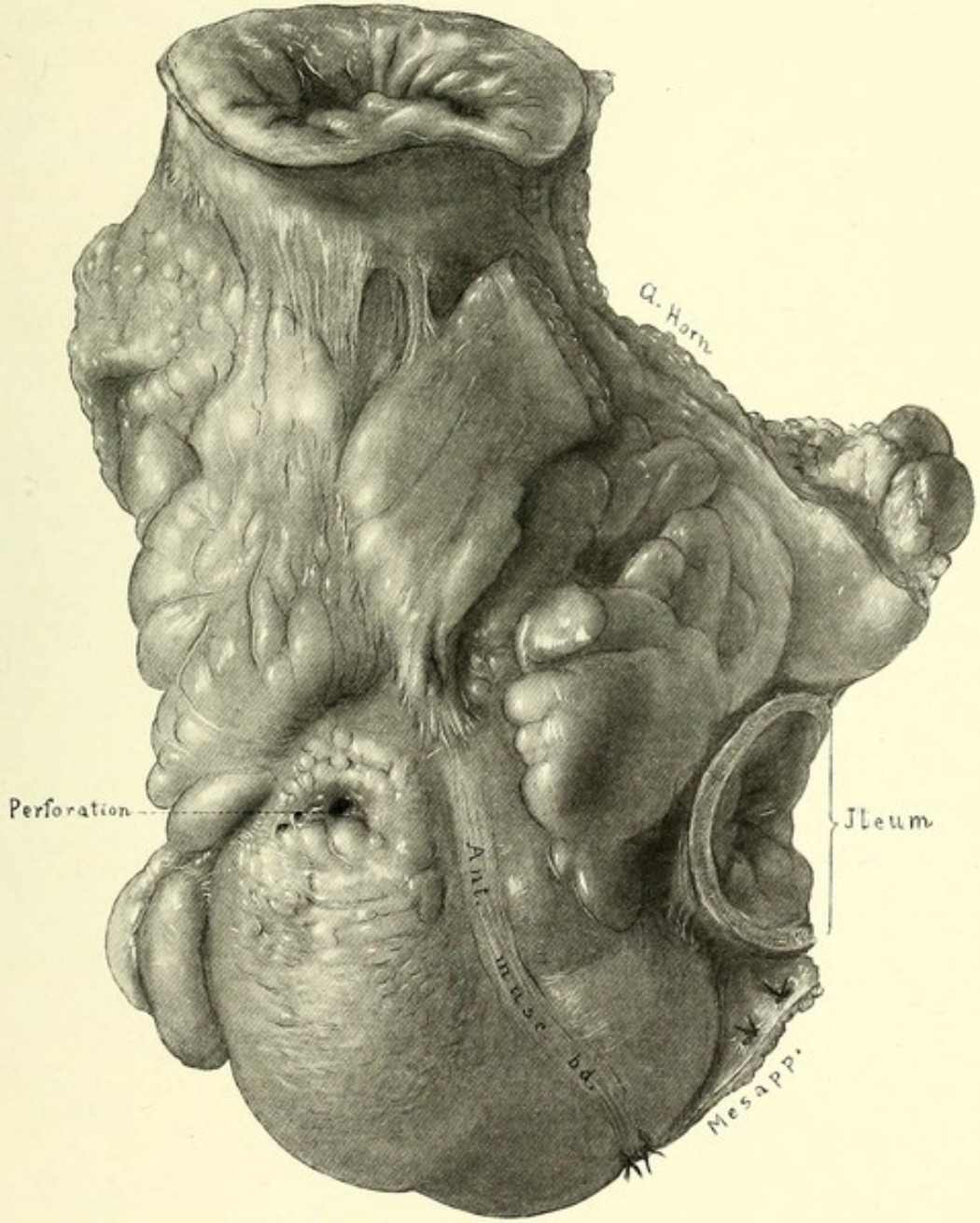

Fig. 386.—T. S. Cullen's Case of Inflammatory Thickening with Tuberculous Stricture of the Ascending Colon Followed by Perforation of the Colon just Above the Cecum.
Tuberculous lymph glands present at ileocecal angle. Resection and end-to-end anastomosis. Recovery. (Natural size.)

constipated. For about a week before admission to the hospital she had intermittent pains in the right abdomen, and the night before operation she was taken with a severe pain, followed by a movement of the bowels. The following morn-

ing she was able to attend to her usual duties, but in the evening was again seized with acute pain in the region of the appendix. When seen about two hours later, there was marked rigidity of the muscles over the appendix region, with slight fever, pulse full and regular. Examination of the blood showed a total absence of eosinophiles, which was the chief indication for an early operation, performed

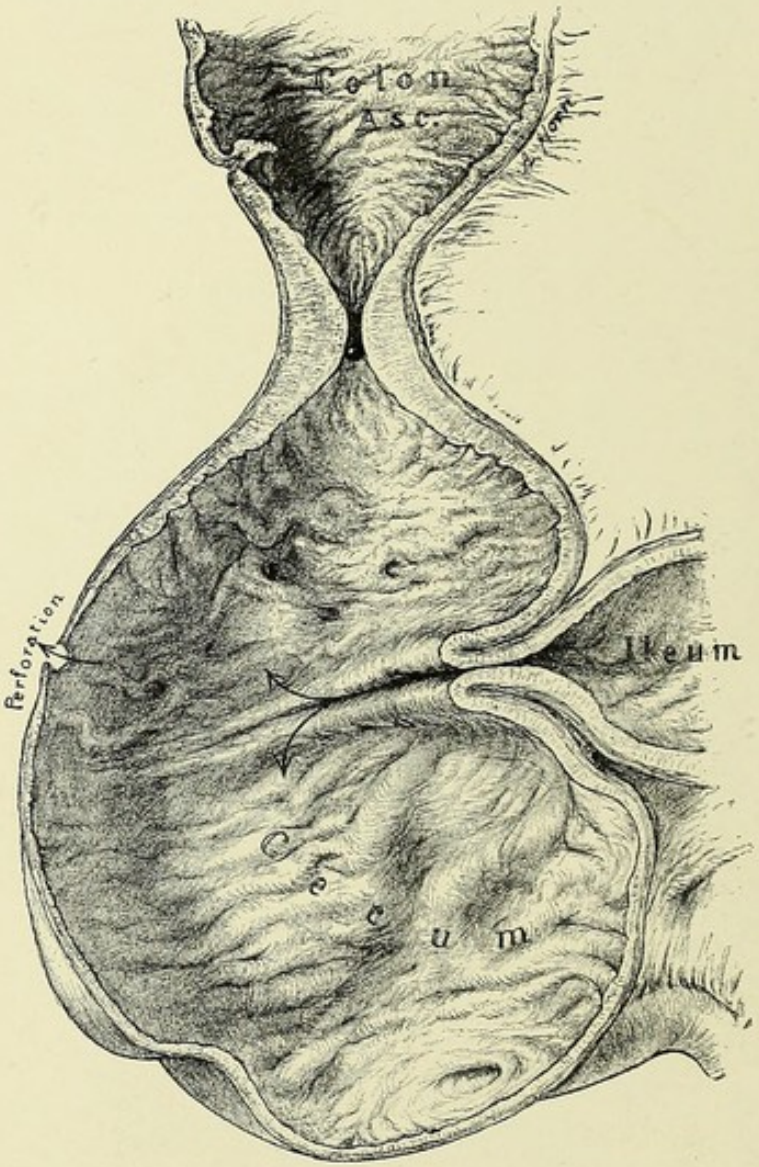

Fig. 387.—Cross-section of the Preceding.

Showing the great thickening of the bowel at the point of stricture, and its funnel-shaped orifice completely occluded by a shot. The point of perforation is seen on the left.

four hours later. There was then found a perforation of the cecum, consequent upon an almost complete stenosis, due to the cicatrization of an old annular tubercular ulcer (see Figs. 386 and 387).

The onset of the ileocecal affection is usually indefinite, the earliest symptoms, as a rule, consisting of dyspepsia, anorexia, nausea, irregular diarrhea,

and slight fever. When stenoses have formed, symptoms of chronic obstruction are common. Colicky pains in the abdomen and more or less flatulency, most marked in the cecal region, constipation alternating with diarrhea, and sometimes vomiting, are then prominent symptoms. The stools may show nothing characteristic; sometimes there is a great deal of mucus, and occasionally blood.

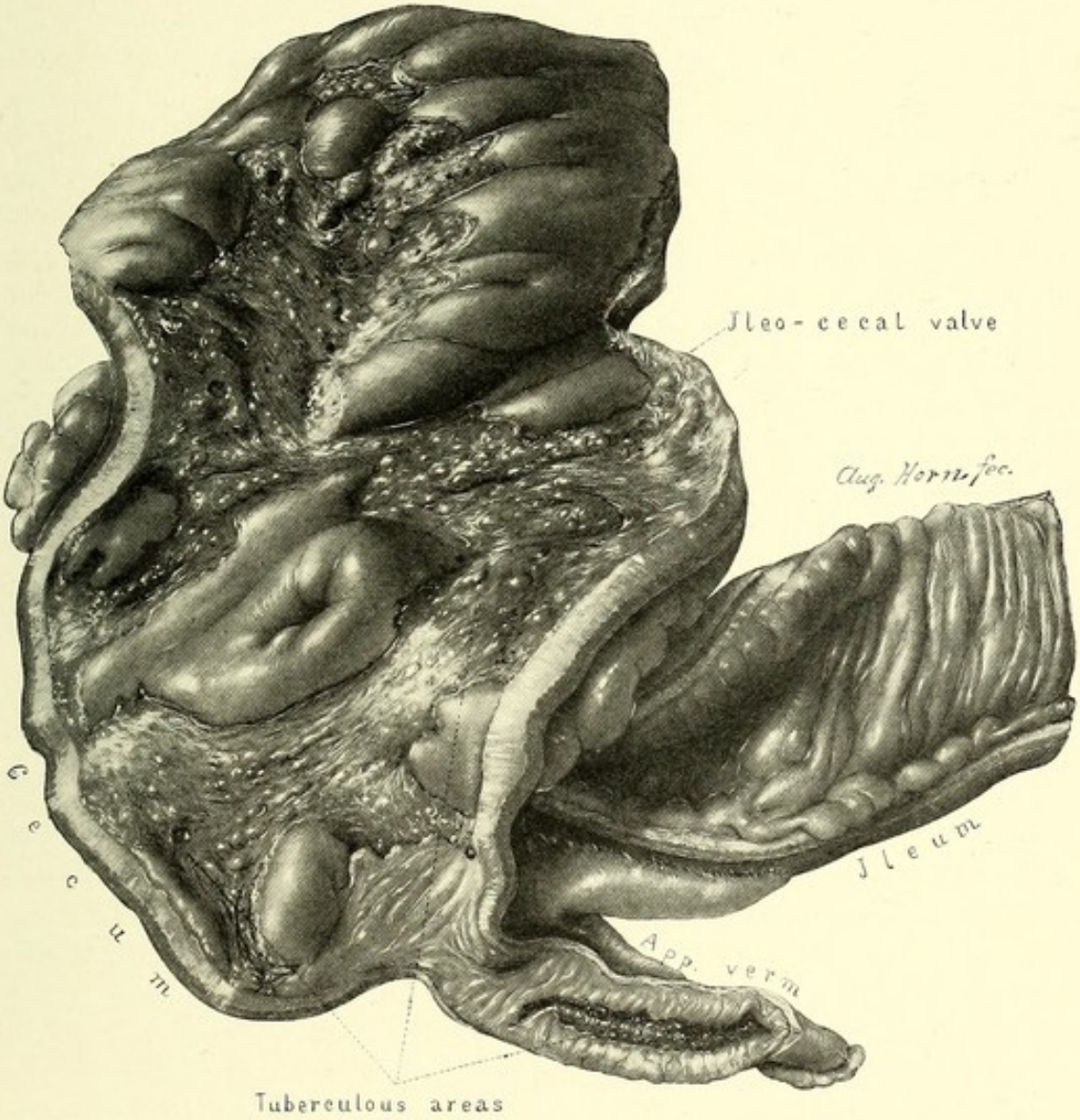

FIG. 388.—FINNEY'S CASE OF TUBERCULOSIS OF CECUM AND APPENDIX EXTENDING UP INTO COLON. Resection and anastomosis, March 25, 1903. L. J., female, age twenty-six. (Natural size.)

In the case shown in Fig. 388 (Surg. No. 14506) there was a history of frequent stools, with severe attacks of gastric pain and distention, slight elevation of temperature, and emaciation extending over a period of three years. There was a marked family history of tuberculosis. The stools contained much mucus, but no blood, and search for tubercle bacilli was negative. The abdomen felt

somewhat boggy, but there was no especial tenderness. The temperature was 99.5° F.; the leucocyte count was 5600.

The hyperplastic form of tuberculosis develops very insidiously. Colicky abdominal pain, at first occurring at long intervals, but becoming progressively more acute and more frequent, is the most constant symptom. The later symptoms are usually those of gradually advancing obstruction, accompanied with evening pyrexia, emaciation, and loss of strength. In some cases recurrent acute attacks, closely simulating recurrent appendicitis, are the most prominent features in the clinical history. As a rule, however, the patient does not entirely recover in the intervals. The most conspicuous physical sign is the presence of a tumor in the right iliac fossa. This may be so prominent as to be noticeable on mere inspection. It is more or less cylindrical, somewhat nodular, and as a rule possesses slight or no mobility. It is somewhat tender, but rarely acutely so. The disease may closely simulate a new-growth of the cecal region, or a peri-appendical exudate. The age incidence of the disease corresponds with that of carcinoma. The most distinctive features in the diagnosis are the gradual development and the character of the tumor, which is more sharply outlined and less tender than a perityphlitic mass, while it is less nodular than a carcinoma and more nearly preserves the normal contour of the bowel. The shape may strikingly resemble that of a sarcoma. The latter condition, however, is too rare to complicate the diagnosis frequently. The detection of tubercle bacilli in the stools is of positive value, pointing directly to intestinal tuberculosis, because, as mentioned above, this localized tubercular process is seldom complicated with active tuberculosis elsewhere, so that the possibility of other sources for the organisms need not be considered.

ACTINOMYCOSIS.

Actinomycosis hominis has only recently come to be regarded as anything more than a pathologic curiosity. MURPHY in 1885 reported the first case in America, but since then over 100 cases have been reported in this country by W. S. ERVING (*Johns Hopkins Hospital Bull.*, 1902), while ILLICH (*Beit. z. klin. Akt.*, Wien, 1892) collected 421 cases from the literature. In about 20 per cent. of these cases the disease was localized in the abdomen, and in the majority, the infection atrium was the vermiform appendix. Four cases of actinomycosis affecting the right side of the abdomen have been observed in the Johns Hopkins Hospital, 3 in the surgical department and 1 in my own clinic. The clinical histories of these cases were so strikingly similar that only one case will be cited as an example.

J. H. H., Gyn. No. 6961. A negress, twenty-eight years old, had spent most of her life on a farm. Five months before admission, while in good health and having had no symptoms of intestinal trouble, she was suddenly seized with intense

colicky pain in the right lower abdomen. The pain continued several weeks, and at the end of the first week a swelling the size of a hen's egg was noticed in the region of the appendix. This swelling gradually spread throughout the entire lower abdomen. About a week before admission a small sinus appeared in the vicinity of the umbilicus discharging puriform material. The mass was hard and board-like and the abdominal walls densely infiltrated. The temperature was remittent, ranging from 99° to 100° F., with a leucocytosis of 12,000. An incision in the median line opened into a large necrotic cavity in the abdominal wall. The tissue removed showed actinomycotic infiltration. There was no attempt at healing, although the temperature fell to normal. About four weeks later, extensive lateral incisions were made and the potassium iodide treatment, begun a few days before, was continued. Marked improvement was then observed, the induration almost disappeared, and the incisions healed rapidly; but a few weeks afterward pain made its appearance in the right thoracic region, accompanied with fever. Two weeks later there was a severe chill, followed by a rise of temperature to 106° F.; the leucocytes at the time were 5800. There was tenderness over the liver and increase in its area of dulness. A few days before death, three months from the time of admission, definite signs of lung involvement appeared (see Fig. 208).

Etiology.—The disease is probably contracted from grain, or from infected animals. It is most commonly found in farmers, cattlemen, and those concerned with the management of live stock or grain. In some instances there is a definite history of caring for infected animals, and in several of the reported cases a grain of wheat or barley has been found in the midst of the actinomycotic mass. Men seem to be more frequently attacked than women, the proportion being about 3 to 1. The difference may be plausibly explained by the fact that men are more frequently employed about animals, and in handling grain, and more often have the habit of putting grains or straw into the mouth. Any age may be affected, but the disease is most frequent about middle life. It may run a very slow course or may develop rapidly. In one instance it continued only four weeks, in another thirteen years (Erving), but, as a rule, the course is chronic, the parts affected early showing a tendency to heal, while new foci are developing elsewhere. In the abdominal cases the clinical history at the outset resembles appendicitis. The onset is often acute, and is characterized by the occurrence of sharp, cramp-like abdominal pains, which continue more or less constantly for a few days or weeks, then subsiding and perhaps not recurring for two or three months. Generally, however, after the acute attack has subsided, more or less soreness persists and a tender swelling is noticed in the appendical region. In a case related by L. Thédenot (*N. Y. Med. Rec.*, 1900) the patient, a young man, aged eighteen, who had been a groom, gave a history of a sudden attack of violent and continuous pain in the right iliac fossa. He improved, and operation was advised. On admission there was no pain, but great lassitude and anorexia. The appendix, which was apparently slightly inflamed and swollen, was removed and a

gauze drain left in. The wound healed slowly and a very hard mass formed in contact with the appendix stump, which appeared to increase. Examination of scrapings showed the ray fungus, which had not been found in the appendix. In the 4 cases observed in the Johns Hopkins Hospital the onset was marked by sudden, severe colicky pains, occurring without warning while the patient was in good health, and not accompanied with nausea, vomiting, or other gastro-intestinal symptoms. The temperature is usually but slightly elevated in the early stages, but, owing to the liability of mixed infection supervening in the abdominal cases, a septic temperature accompanied with chills frequently develops. The leucocytes vary greatly, in some cases being almost normal, in others numbering 28,000 to 36,000. As the disease advances the most characteristic sign is the progressive increase in the mass and the brawny infiltration of the tissues. The rigid, board-like abdominal walls are not found in any other condition. Practically the whole abdomen may be involved, the older foci, as I have said, retrogressing while others form. The infection gradually extends to the surface, when sinuses, often multiple, appear and discharge a reddish-yellow puriform material, which is often extremely offensive. The characteristic sulphur granules are then usually seen. In rare instances the disease spreads superficially and remains localized in the intestinal mucous membrane. Two cases only (Canali and Chiari) have been described (O. Daske, *I. D.* Griefswald, 1902). Hofmeister (*Beit. f. klin. Chir.*, 1900, Bd. 26, p. 344) describes two unusual cases in which, without extension to the neighboring structures, there was great thickening of the walls of the appendix and cecum, which might have been confused with neoplasm, especially sarcoma, or with hyperplastic tuberculosis. In such a case the nature of the disease is recognized by the appearance of the characteristic granules in the stools. The final event in the course of the disease is the occurrence of metastases, with the development of nodules in the lungs, heart, brain, liver, and other organs.

AMŒBIC DYSENTERY.

Amœbic dysentery is of interest in connection with diseases of the vermiform appendix, on account of the comparatively frequent occurrence of perforation of this organ as a fatal complication of the disease. Rogers, who has observed a large number of cases in India, finds that the appendix is often severely affected and is especially liable to become perforated. As a rule, symptoms referable to the appendical involvement cannot be distinguished from the symptoms produced by the lesions in the cecum and colon. The distinctive features of the disease are the "irregular diarrhea, marked by exacerbations and intermissions, and progressive loss of strength and flesh." The stools are often bloody or mucoid at the outset, but later their chief characteristic is their fluidity. The detection of the amœba in the stools is the only positive evidence of the nature of the disease. In the event of a perforation the characteristic symptoms of perforative

peritonitis develop, and when the patient has been known to be the victim of the amœbic affection, the onset of peritonitis and its cause are readily recognized. In somewhat rare instances where acute symptoms are absent the nature of the dysentery is not recognized, and in such a case the sudden development of symptoms of perforative appendicitis may be referred to a simple appendicitis. As prompt surgical intervention is indicated in either case, this is of less importance, and at operation the characteristic lesions are usually easily recognized.

CHAPTER XXXIII.

OPERATIVE TREATMENT OF NEOPLASMS AND SPECIFIC INFECTIONS.

DISEASE LIMITED TO THE APPENDIX. DISEASE IN THE ILEOCECAL REGION.

OPERATION FOR DISEASE LIMITED TO THE APPENDIX.

Tumors.—The operation for removal of a polyp, a myoma, or a carcinoma of the appendix differs in no important respect, as a rule, from the extirpation of the appendix for other causes.

Polyps of the appendix, so far as they have yet been observed, appear to be little, soft tumors, which may not be discovered before the removal of the organ, or if they attract attention earlier, are simply noted as enlargements of its lumen.

Myomata, on the other hand, in the three cases reported, were little nodules, not unlikely to be mistaken for chronic inflammatory thickening; they might also be mistaken for carcinoma.

The carcinomata (adeno- and colloid) are the only other tumors limited to the appendix. The adeno-carcinomata, which have never yet been diagnosed before operation, appear, as a rule, as little circumscribed nodules, usually associated with peri-appendicitis, and in several instances with perforation. Bearing in mind the marked characteristics of this affection, and the fact that it occurs with a frequency hitherto unsuspected, as shown by the number of collected cases (see Chap. XXXI), operators will, no doubt, be more alert in future concerning it, and more ready to suspect the nature of the disease with which they have to deal, even before it is established by microscopic examination. An incision through the nodule while the patient is on the operating table, will often give unmistakable evidence to a practised eye. The treatment is a wide excision extending well into the mesenteriolum, and a painstaking investigation for glandular metastases. Where the disease has extended beyond the appendix into the neighboring cecum, a resection of the appendix, together with a wide resection of the cecum, is the proper course. This method must also be pursued in those cases, carefully noted, in which the disease has localized itself near the base of the appendix. In two instances in which the glandular metastases were so far advanced that an operation was out of the question, there was no cecal involvement whatever.

I know of but one case of colloid carcinoma of the appendix which

has been the subject of operation, and this was ELTING's. Elting's other case (Chap. XXXI, Figs. 379 and 380) was one in which it will be seen from the reproductions that the mass could easily have been extirpated, as it was perfectly localized in the appendix.

The only cases of sarcoma of the appendix which have been operated upon, so far as I know, are those of J. C. WARREN, P. PATERSON, and A. C. BERNAYS (see Chap. XXXI, p. 758 to p. 760). In each of these the appendix was enlarged and thickened and the disease extended a short distance upward into the cecum. In operation upon one of them the excision was made just beyond the growth, while in the other two the entire cecum was extirpated.

Tuberculosis.—A simple tubercular process limited to the appendix may assume an obliterative form like that of a uterine salpingitis, or it may appear as an acute appendicitis, with ulceration of the mucosa and surrounding adhesions. Such cases need no special comment from a surgical standpoint, as they differ in no way from other appendicitides to the naked eye, and the nature of the process is discoverable only after a microscopic study of the part removed. In CROWDER's case of hyperplastic tuberculosis (*"appendicitis tuberculosa hyperplastica"*) not only was the diameter of the organ much enlarged, but the disease extended up into the neighboring cecum as well. The removal of the disease was effected by an excision including the cecum, a procedure which requires no special description.

OPERATIONS FOR ILEOCECAL TUMORS.

The fact that tumors in the ileocecal region are frequently confused with appendicitis convinces me that their surgical treatment ought to be, at least, briefly described here.

Extensive operations upon the ileocecal region with resection of the cecum, of a part of the ileum, or of the ascending colon, or of both, are still more recent in their origin than operations for appendicitis.

The first case reported was that of H. KRAUSSOLD, in April, 1889 (*Volkm. Samml. klin. Vortr.*, No. 191; and *Centrbl. f. Chir.*, 1881, p. 186); it was performed for carcinoma attributed to a blow from a stone, received six years previously. The patient was a man, sixty-two years old, who had suffered for thirteen months from two fistulas with extensive fecal discharge. The cancerous disease involved the vermiform appendix, the cecum, and the ileocecal valve, all of which were excised, the head of the ileum being united to the end of the colon by Lembert sutures. The patient unfortunately died of collapse in two and a half hours; at autopsy the bowel was found tightly closed; there was involvement of one mesenteric gland, and a small metastasis was found in the liver.

The first successful operation was done by MAYDL, in 1882 (*Wien. med. Presse*, 1883, p. 438). R. SUCHIER, in 1889, reported what I believe to be the

first successful operation for tubercular stricture of the ileocecal region (*Berl. klin. Woch.*, 1889, p. 617), treating it by excision and an end-to-end anastomosis, and resecting about 20 cm. of the cecum and colon, the valve not being in the excised portion.

W. S. McGill, in an admirable monograph, the first in the English language upon this subject (*Ann. Surg.*, 1894, vol. 20, p. 642), says that Czerny, in 1884, resected the ileocecal valve for invagination on finding the valve cancerous.

Wassilief in 1886 did a resection to cure an artificial anus established for an acute invagination; and Czerny again resected in 1892, this time for tuberculosis.

In 1894, when McGill's article was published, he was able to collect 104 operations, undertaken for various causes on tumors in the ileocecal region, up to that date, and there presented. The subject has also been ably discussed by Kocher (*Dtsch. Zeit. f. Chir.*, 1891); Czerny (*Beit. z. klin. Chir.*, 1890, Bd. 6); König (*Arch. f. klin. Chir.*, 1890, Bd. 40); Sachs (*Arch. f. klin. Chir.*, 1892, Bd. 143, p. 123); Körte (*Dtsch. Zeit. f. Chir.*, 1895, Bd. 40); Hofmeister (*Beit. z. klin. Chir.*, 1896, Bd. 17, p. 577); and Conrath, in a monograph over 100 pages in length on "*Chronic local cecal tuberculosis*" (*Beit. z. klin. Chir.*, 1898, Bd. 21, p. 1).

Methods of Operation.—The first efforts of the surgeon should be directed to the discovery of the exact nature of the disease, as the operation will necessarily be more or less extensive, according as he has to deal with a mass of a simple inflammatory or tubercular nature, or with a carcinomatous or sarcomatous growth. He must, therefore, bear carefully in mind all the data furnished by the history, since these often suggest a probable diagnosis in advance of the inspection of the parts *in situ*. A history of a pulmonary tuberculosis, or a tubercular process elsewhere, makes ileocecal tuberculosis probable; moreover, in such cases the patient is sometimes cachectic for a long period, and is more apt to have suffered from stricture and obstruction. Carcinoma also, however, may run an indolent course, and any marked cachexia may be wanting until the later stages of the disease. Bloody stools are more apt to be associated with carcinoma.

A long oblique incision, either transmuscular or in the semilunar line, should be made in order to expose the whole diseased area and give abundant room for the subsequent extirpation. The disease will be studied to better advantage if the incision is made somewhat toward the median line. As a preliminary measure, the mass is then inspected and its size, its extent up and down the bowel, and its amount of fixation noted; the possibility of an enucleation can then be roughly determined. The operator next turns his attention to the rest of the abdominal cavity in order to secure the valuable data furnished by metastases, which may at once determine the nature of an affection which is puzzling even after the abdomen is opened. This investigation assumes the more importance from the fact that Durande, Billroth, and Hartmann and

PILLIET (*Soc. anat. de Paris*, July and Dec., 1891), as well as SALZER (*Langenb. Arch.*, Bd. 43), have shown that it is often impossible to distinguish a tuberculous process from one cancerous in nature while it is still situated in the body; it may also be impossible even when the resected bowel is removed from the body and held in the hand. Recalling this fact, the surgeon will treat every uncertain case as though it were a carcinoma, giving the patient the benefit of the doubt. When the abdomen is open, and before any steps are taken to pack off the intestines as a protection from any subsequent manipulations, the nature of the affection may sometimes, as I have said, be at once determined by inspecting the metastases. A tubercular process may be disseminated all over the abdomen, or it may be discernible only in the form of characteristic little granules situated at the focus of the disease, in the neighborhood of the ileocecal valve. Again, in tuberculosis the omentum may be infiltrated with tubercles; and multiple strictures of the bowel, if present, speak for tubercular disease. As COHN has shown (I. D. Freiburg, 1902), skin fistula as a complication is more frequent in tuberculosis than in malignant disease; 24 out of 48 tuberculous tumors in his investigation having been complicated by fistula, while MATALAKOWSKI's statistics showed only 2 complicating fistulas out of 17 carcinomatous tumors, and of these 2, only one was spontaneous. The smaller number of fistulas in carcinoma may to some extent be accounted for, however, by the fact that malignant disease is apt to destroy life before it has progressed so far.

The hyperplastic form of tuberculosis is that which most often gives rise to errors in diagnosis under circumstances so favorable as those just described. One of the most characteristic signs of tuberculosis as a disease is the presence of caseous glands in the mesentery. The surgeon must also examine the omentum, for this may be converted into a carcinomatous roll extending transversely across the abdomen in the umbilical region, and so dense that it can be felt even before the incision is made; this condition, when it exists, affords a grave prognosis. Carcinomatous nodules, if not present on the peritoneum, may be found lodged in the deepest part of the pelvis. Another point in diagnosis is that the density of the carcinomatous nodules situated over the vertebral column, differs from that of nodules caused by the tubercular process. The pylorus, the liver, and the spleen should also be inspected or palpated for any malignant masses. In some instances an inflammatory process of unusual character arising from an appendicitis has transformed the bowel into a mass so rigid that it has been mistaken for malignancy and extirpated. Such an accident happened to one of my associates, who, not doubting the malignant nature of the disease, and, therefore, the urgent necessity of an extirpation, amputated the cecum with the appendix and anastomosed the ileum into the colon end-to-end. With this possibility in mind, the operator should not allow the simplest inflammations to pass unsuspected, where the conditions admit of any doubt at all; in an urgent

case he may even make a small incision into the neighboring healthy bowel and introduce his finger, in order to investigate sufficiently to put the question at rest.

An actinomycotic process is recognized by the characertistic yellow granules and by its tendency to extend in every direction into all contiguous tissues, without respect to natural anatomic barriers. Actinomycosis advances by continuity and contiguity alike, and this is true of no other affection.

The real nature of the disease having been determined by this direct method of autopsy *in vivo*, the next question which arises is: Shall the operation proceed farther than the simple exploratory incision? The answer depends upon two factors: first, the vital status of the patient, that is, whether he is much exhausted or not; second, the stage to which the disease has advanced and its complications. As regards the patient, it may be said at once that the present tendency is to exaggerate lack of vitality and power of resistance. It is astonishing how much a weak patient will often stand, if the operation is skilfully performed, without much exposure, chilling, and handling of the intestines, and, above all, if the adjacent parts are so protected, both during the operation and subsequently by drainage, that a peritonitis will not tread right upon the heels of an exhausting operation. Much here depends upon the skill and experience of the operator, and every man who deliberately undertakes a delicate and difficult task of this kind ought, at least, to have previously performed a number of successful resections upon dogs. Such an occasion is neither the time nor the place for maiden experience!

As regards the stage and extent of disease, there can be no doubt that a radical operation should be carried out when there is a reasonable hope of a successful issue, immediate and remote. If a carcinoma is so far advanced in its invasion of other parts that a speedy recurrence of the symptoms is to be looked for, it will not be wise to extirpate the primary focus in the cecum, and a better plan is to do an entero-anastomosis, short-circuiting the affected area.

In tuberculosis and in actinomycosis the outlook in attacking a great mass of diseased tissue is more cheerful, since it is well known that in these conditions perfect and permanent relief may follow a successful anastomosis after enucleation. Fig. 388 (Chap. XXXII, p. 767) shows an extensive tuberculous area in the appendix, the cecum, and the ascending colon, extirpated by Finney, while Figs. 386 and 387 (Chap. XXXII, pp. 765, 766) represent an older form of the disease in which the patient suffered from the resulting stricture. This, as shown in Fig. 387, was reduced to the calibre of a small shot, and, marvellous to relate, a grain of shot had actually entered, and engaged itself in the minute orifice so as to occlude it completely! The stenosed bowel had found an outlet for the alvine contents in the perforation shown in both pictures.

The different appearance of a carcinoma is well shown in Fig. 389, which

represents a case of my own, that closely simulated an appendicitis in the presence of febrile crises with localized pain and tenderness. The only suspicious circumstance was the indolent nature of the rather hard mass. The appearance peculiar to carcinoma is shown in the cross-section *a*.

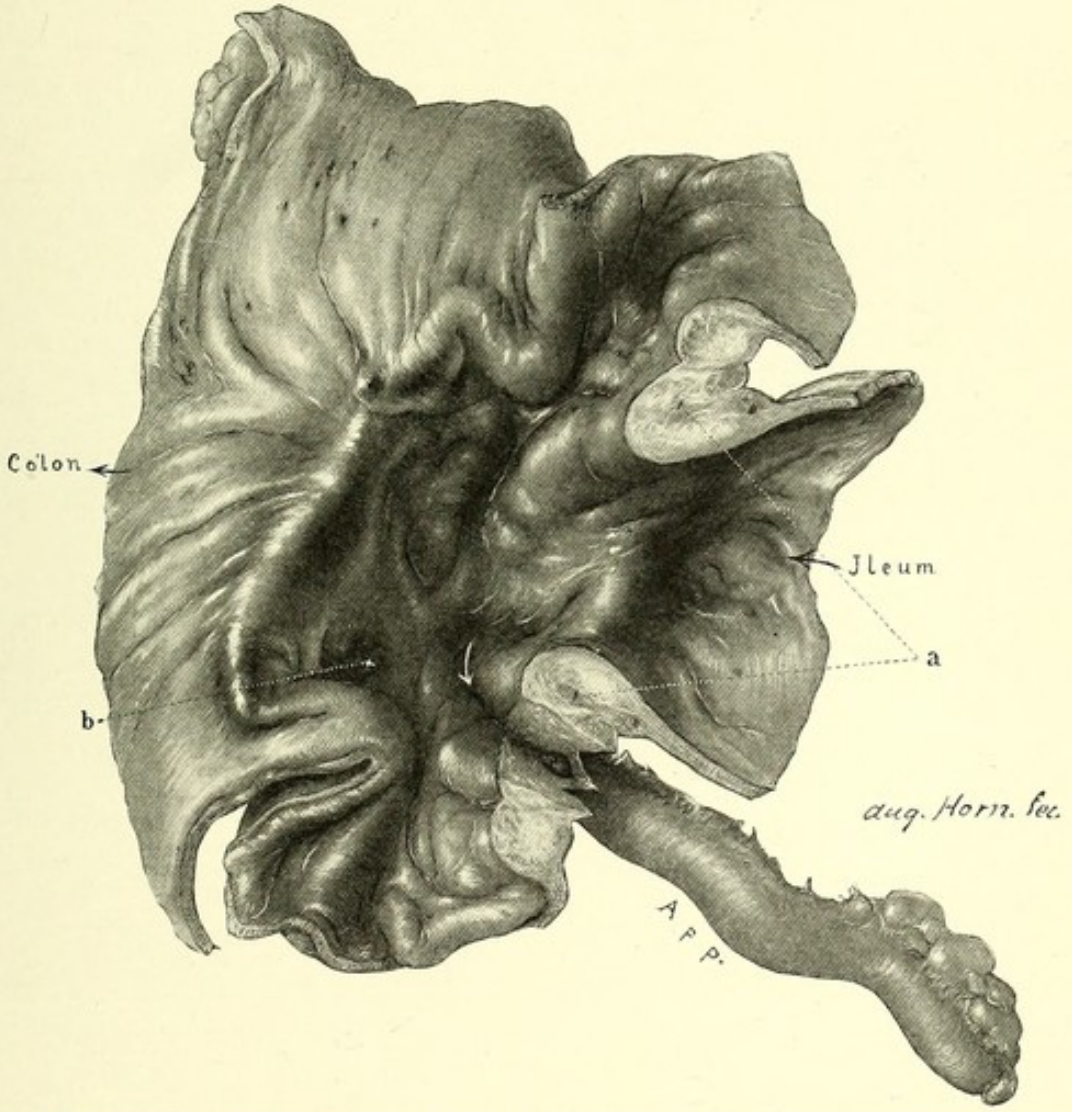

FIG. 389.—CARCINOMA OF THE ILEOCECAL VALVE (a) EXTENDING INTO THE CECUM (b) CLOSELY SIMULATING APPENDICITIS.

The ridge indicated the limits of the disease. Operation, H. A. Kelly, A. McC., San., Feb. 3, 1903; resection and end-to-end anastomosis. Death from recurrence sixteen months later. (Natural size.)

The alternative operations in any given case are:

1. A simple exploratory incision, associated, it may be, with the drainage of an abscess in carcinoma or in actinomycosis; any further attempt to operate upon the bowel being abandoned, on account of the patient's condition or the advanced character of the disease.

2. Simple entero-enterostomy, by means of a lateral anas-

tomosis of a loop of ileum above the disease to the colon below it, thus short-circuiting the diseased area.

3. Complete exclusion of the diseased area, effected by amputating the bowel above it, and closing the end, or the ends leading into and out of the affected portion, at the same time anastomosing the healthy bowel from above, to a point below the disease.

4. Extirpation of the diseased appendix and cecum, with so much of the ileum and the ascending colon as may be necessary, followed by the anastomosis of the ileum with the colon.

If, after the extirpation of the diseased portion of the bowel, the patient's condition is such that it is impossible to proceed with the operation of anastomosis, the ends of the bowel, distal and proximal, may be brought out onto the surface, so as to establish an *anus preternaturalis*. This should be closed by completing the anastomosis at a later date, which, of course, simply makes two steps of the fourth alternative, and is only to be adopted on account of urgent necessity.

The second alternative, a simple entero-enterostomy, short-circuiting but incompletely excluding the diseased area, is most valuable in cases of advanced disease, where removal is out of the question, or where the patient has suffered so long from obstruction that his condition will only admit of the most essential, life-saving operation. An entero-enterostomy by means of lateral anastomosis of a loop of the bowel, to the ascending or transverse colon, is the quickest and the simplest method, as well as that which affords most security of overcoming the difficulties, and giving prompt relief from the most urgent symptoms. In 10 cases out of CONRATH's list a simple ileo-colostomy was done: in one, on account of the extent of adhesions; in two, on account of disseminated tuberculosis and the weakness of the patient; in one, because an abscess was present as well as adhesions; in one, to avoid shock from prolonged operation, a cholecystectomy having preceded the cecal operation; in one, on account of a fresh tubercular disease in the chest; and in one, on account of chronic Bright's disease and general weakness. In 4 closely noted cases the tumor was observed to grow smaller after the exclusion of the diseased area, the difficulties disappearing; and in 7 the patients were reported either as well, or steadily improving. In one case (KÖRTE) in which resection of the diseased area was not made on account of the extensive adhesions, the ileum was joined to the colon just beyond the disease by a lateral anastomosis. Ten months later the operator was able to extirpate the now movable tumor, amputating the ileum above the anastomosis and implanting it anew into the transverse colon. Recovery followed. CONRATH concludes that the late results of a simple entero-anastomosis for tubercular cecal tumor are to be reckoned, from every standpoint, among the very best.

In performing an entero-enterostomy, the first point of importance is to unite the nearest free loop of the ileum to the colon just beyond the diseased area,

in order to short-circuit the disease effectively, and yet not throw out of function any more of the bowel than is necessary. In selecting a loop of the ileum for anastomosis into the colon, the surgeon must always bear in mind the definite disposition of the small intestinal coils in the abdomen, which, not unlike the convolutions of the brain, are subject to minor variations, but in their general grouping are always the same. This fact will be best understood by consulting Fig. 390, showing the mesenteric ruffle, which, of course, corresponds precisely



FIG. 390.—THE MESENTERIC RUFFLE SHOWING THE GROUPS AND DISPOSITION OF THE COILS OF THE ILEUM.

A and B occupy the left and right, splenic and hepatic flexures of the colon respectively, and should always be avoided in any colic anastomotic operations. E lies in the small pelvis and is thus easily distinguished; more care must be taken in distinguishing C and D.

to the arrangement of the intestinal coils that have been removed to facilitate the demonstration. The groups may be conveniently lettered and designated from duodenum to cecum, as Group A, Group B, Group C, Group D, and Group E, the capital letter marking the centre of its group, which is limited by the small letters preceding and following. The surgeon will at once perceive that if he were to pick up a loop of intestine under the left colic flexure from Group A, he would short-circuit almost the entire intestinal canal, and starvation of

his patient would inevitably result. The mistake he is most likely to make is to take a loop in B, and attach it to the ascending or the transverse colon, thus committing the serious error of throwing Groups C, D, and E out of function. The anastomosis should be made in E, which must be picked up and drawn over to the colon; or it must, at any rate, not be higher than D, in case E is too much involved in adhesions, as shown in Fig. 391, taken from an actual case of VON EISELSBERG. The bowel, thus brought up, should lie in easy apposition, without folds, flexures, twists, or undue traction. The methods of making the

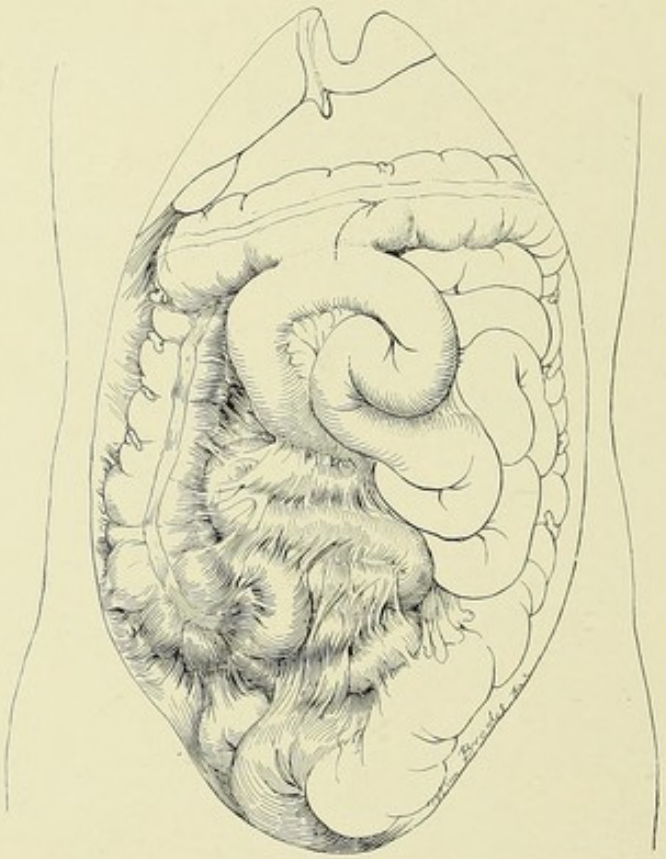

FIG. 391.—ANASTOMOSIS OF A LOOP OF THE ILEUM INTO THE TRANSVERSE COLON, AFTER A CASE OF VON EISELSBERG (*Arch. f. klin. Chir.*, Bd. 56, p. 303).

The last group and the ascending colon were not available here on account of the extensive adhesions.

anastomosis are the same as those employed for lateral anastomosis, shown in Figs. 392 and 393. Previous to the anastomosis the diseased area has been extirpated and the ends closed.

Complete exclusion, the third alternative, includes, according to WÖLFLER (*Verhandl. d. dtsch. Gesell. f. Chir.*, 1889), unilateral as well as bilateral occlusion of the diseased portion. If a unilateral occlusion is done, the ileum is amputated above the disease and the proximal end anastomosed into the colon by an end-to-side or a side-to-side anastomosis, while the distal end, leading into the diseased portion, is closed by suture. A complete bilateral exclusion is effected

when the diseased bowel is cut free from the healthy ileum above and the colon below, yet is not removed. Experience and experiment have shown that the sequestrated portion must have an exit, and this may be provided in bad cases, by a fistula (as in 3 out of 8 cases in CONRATH's collection), or by bringing one or both cut ends onto the surface. In one case (FUNKE, *Prag. med. Wochen.*, 1895, p. 342) an end-to-end anastomosis was made of ileum into colon, while both ends of the diseased bowel, were closed, the preëxisting

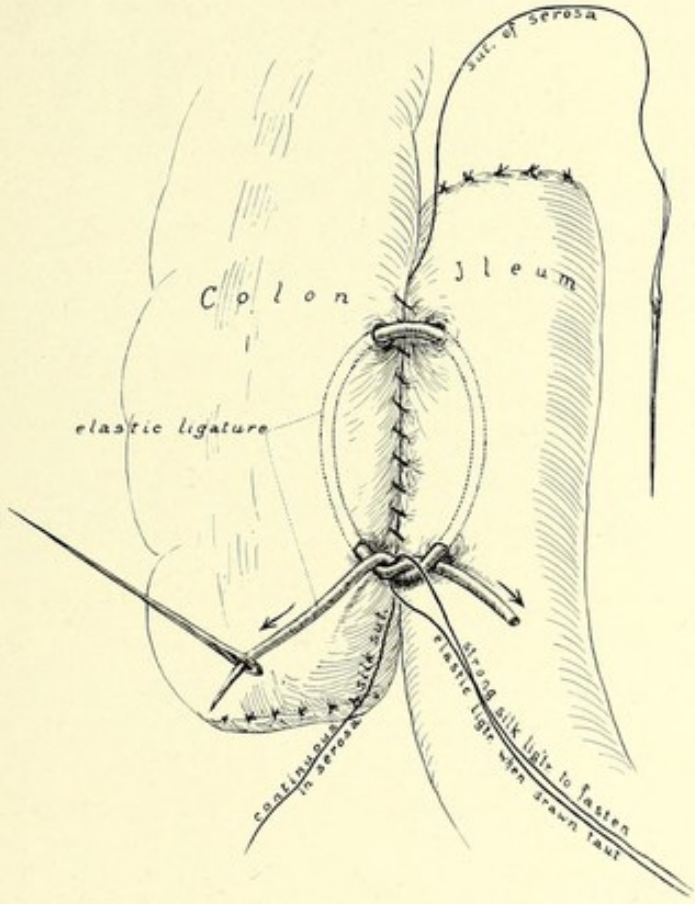

FIG. 392.—MCGRAW'S ELASTIC LIGATURE FOR LATERAL INTESTINAL ANASTOMOSIS.

A continuous silk suture is first applied. Above this the elastic ligature passes through all the coats of the bowel as shown. This is tied so tight that it speedily cuts its way through the bowel, establishing the anastomosis. The continuous suture is then carried over the elastic ligature, completely covering it in. A strong silk ligature is used to secure the knot in the elastic ligature as shown.

fistula also being denuded and closed; but on the third day it was necessary to cut the fistula sutures, on account of some fever and discomfort, a measure resulting in the escape of a slimy, fecal fluid, followed by immediate improvement. The occasion for pursuing this plan of complete exclusion in 7 of the 8 cases cited was: in one, multiple stenoses, which would have involved too extensive a resection of the bowel; in 5, the immobility of the tumor and the danger of opening paratyphlitic abscesses; and in one, the wretched

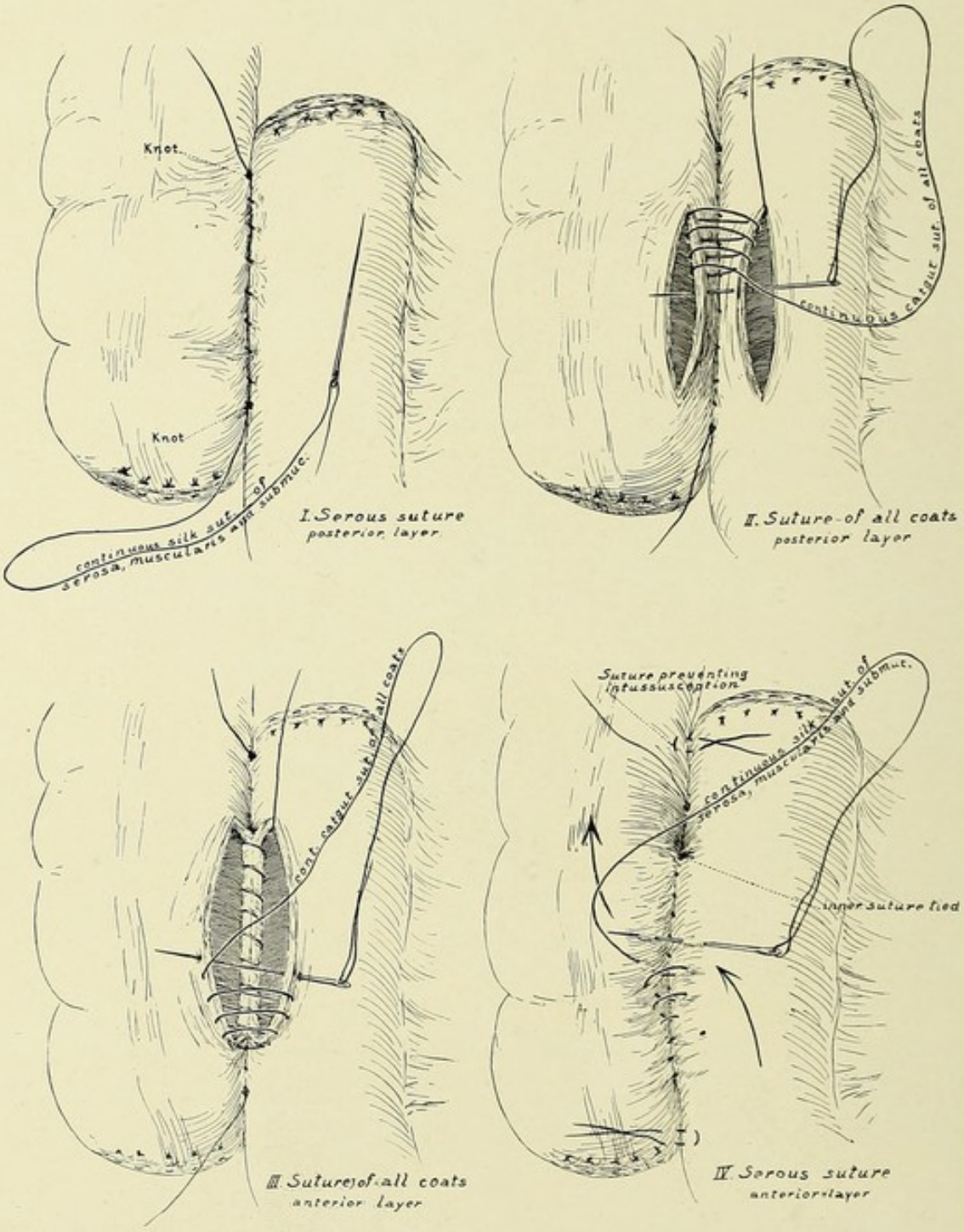

FIG. 393.—LATERAL ANASTOMOSIS AFTER HALSTED.

The ends of the bowel have been inverted by continuous or mattress sutures and the lateral approximation is made (I, left upper figure). Recently Cushing, Roux, and others, instead of the interrupted sutures used by Halsted, have employed continuous sutures which insure greater rapidity; puckering can be avoided if knots are tied at intervals. Then the bowel is incised and its margins united by suturing through all its coats, as shown in II and III. Lastly, the continuous suture first applied is continued so as to cover in the anastomotic opening completely, as shown in IV. Cushing has demonstrated to his class that if the blind pouches are left free, they may become intussuscepted and thus close the opening. To prevent this contingency, he sutures the pouches to the side of the intestine, as shown in the figure.

general condition of the patient. The better plan of procedure is to bring outside and leave open both ends of the excluded area; and if the patient is weak and the extirpation of the disease promises to be too extensive, the best plan of all appears to be the simple intestinal anastomosis (short-circuiting), followed at a later date by the removal of the diseased portion, for complete exclusion has hardly yet won for itself a recognized place in the intestinal surgery of this area.

We now come to the fourth alternative, namely, the complete removal of the disease associated with the immediate suturing of the healthy bowel above it to the healthy colon below it. Out of 81 cases collected by CONRATH, this method of treatment was adopted in 48, 8 of whom died from the operation, while one remained unimproved on account of the re-opening of a fistula. The great sources of danger from this operation are: insufficient closure in the line of suturing, resulting in infection and death from peritonitis due to contamination of the peritoneum with abscesses, or with the foul contents of the bowel. The patient may also die of collapse, if the operation is unduly prolonged. In one of the fatal cases of tuberculosis the ureter was cut through, and a nephrectomy was performed. The following methods of operation were adopted in CONRATH'S 48 cases of extirpation: In 40 the cecum was extirpated and the ends of the bowel united with a circular suture; in 3 the bowel was united by lateral apposition of ileum to colon; in 3 a lateral implantation of the end of the ileum into the side of the colon was employed; in 2 the Murphy button was used; in one the ends of the bowel were brought together over a carrot cylinder.

The mortality for resection in cecal tuberculosis (16.7 per cent.) is 37 per cent. better than in resections of the bowel for carcinoma, and 25 per cent. better than in the results of ileocecal resections in general; and CONRATH points out that since 1898, when WÖLFLER collected his statistics, an improvement of 10 per cent. has taken place. The fate of 30 cases, which Conrath was able to follow up after the operation for tuberculosis, shows that within six months one died of hemorrhage from the rectum, one of hemoptysis, one of a local recurrence of the disease, one of tuberculosis of the lungs, and one of a relapse and the accompanying marasmus. One patient died of tuberculous lungs within a year after operation; another within two years; another in three; and still another in three and a half, of tuberculosis of lungs, intestine, and peritoneum. Out of 30 cases, only 16 remained in good health, one to seven years after operation.

In ileocecal tuberculosis it is important not only to excise the disease, but to remove any intimately adherent and suspicious areas of the neighboring small intestine as well. The method of end-to-end anastomosis is as follows: After packing off the rest of the abdomen with the utmost care, in order to avoid any contamination and the fatal peritonitis which is almost sure to follow such a misfortune, the affected area is freed on all sides, if fistulous with a portion

of the abdominal wall attached, or with some of the densely adherent parietal peritoneum. The tumor mass is then brought outside and laid on compresses, while the assistant controls the bowel, well above the disease, with his fingers,

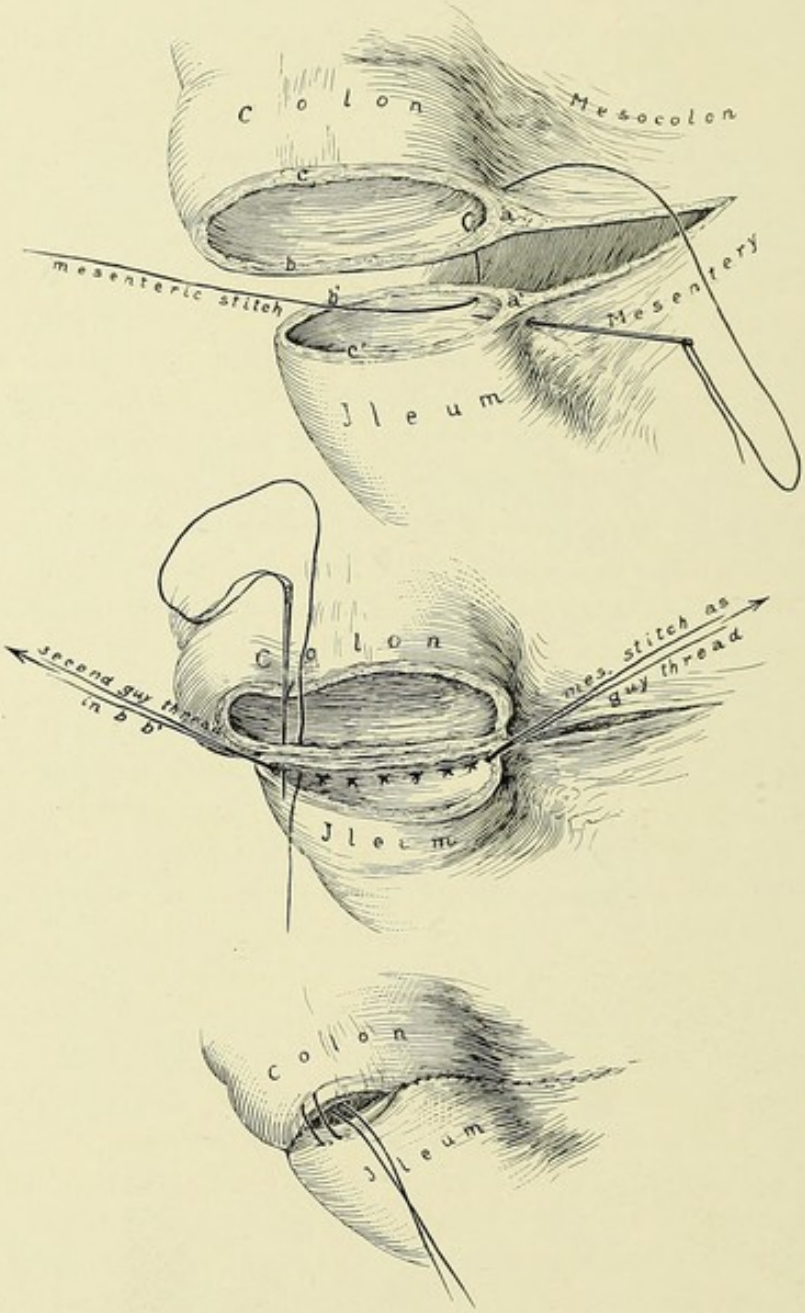

FIG. 394.—STEPS IN CONNELL'S OPERATION FOR INTESTINAL ANASTOMOSIS BY SUTURE WITHIN THE BOWEL AND TRANSFIXION OF ALL THE COATS, INCLUDING THE MUCOSA.

or with a rubber band transfixing the mesentery. A clamp is applied close to the diseased portion and the small intestine is divided between the two. The diseased portion is then lifted up, exposing the mesenteric vessels going to it. The mesentery is next cut in the form of a V; including the entire diseased area.

Care must be taken not to divide or ligate any of the vessels supplying the bowel beyond the affected areas. As the mass is lifted, the colon is exposed, clamped next to the disease, and controlled by simple compression, without any controlling force beyond this, and divided between the two, thus completely severing the diseased portion, which is then removed. The exposed mucosa is carefully cleansed, and the end-to-end anastomosis is then made, by one of several plans. In event of haste Murphy's button, which has found such wide acceptance, may be used; otherwise a deliberate suture which secures careful union by two or more rows of fine silk sutures is always preferable. For this purpose I would recommend following one of two plans. HALSTED'S method of using inflatable rubber bags, which serve to equalize any inequality in the lumina which may exist, is simple and satisfactory. The bowel ends are basted together, as it were, by three or four sutures; the collapsed bag is then inserted between them and inflated. The accurate apposition of the ends by two layers of mattress sutures, first sero-muscular, and then sero-serous, is now easily effected. The sero-serous, which is protective, may be made continuous to save time. Especial care must be taken to bring the mesenteric border into snug apposition, as this is the weakest feature of the operation.

Another most satisfactory plan of suture is that employed by CONNELL of Chicago. Fine silk sutures are used, and all the suturing is done on the inside of the bowel, as shown in the illustrations (see Fig. 394). The mesenteric stitch, applied as shown at *a a* in the upper figure, secures snug apposition at this point, and it is left of sufficient length to act with a second stitch applied at *b b*, about one-third of the way around the lumen, to hold the bowel taut and the edges together, while mattress sutures are applied through all the coats, as shown in the middle figure. Another gut suture at *c c* (upper figure) serves, together with those at *a a* and *b b*, to facilitate the application of the remaining sutures, all of which enter, emerge, and are tied on the mucous surface. The author himself takes pains to apply even the very last suture on the inside, but this is unnecessary. The last two or three sutures may be placed through the serous and muscular coats on the outside. A continuous suture, outside of the row just described, serves to support it and gives an additional security. A lateral anastomosis may be effected, after closure of the amputated ends, by MCGRAW'S method (*Jour. Amer. Med. Assoc.*, May 16, 1891), as shown and described in Fig. 392 (p. 781), where the anastomosis is secured after the operation by the cutting of a tight elastic ligature through all the coats of the bowel. A more deliberate plan, of lateral anastomosis, is shown in Fig. 393 (p. 782), where the opening from bowel to bowel is united on all sides by a continuous silk suture including all its coats, and protected by a sero-serous suture, surrounded on all sides as described in the legend.

CHAPTER XXXIV.

HERNIA OF THE APPENDIX.

The free mobility and uncertain length of the cecum, and the variations in its position due to developmental anomalies (see Chap. VI), are such that the appendix may be found in any region of the abdomen and in close relations with the various abdominal rings, in which it may, finally, become engaged. As a matter of fact, this little organ has been discovered in the inguinal and femoral canals on either the right or left side, and also within the umbilicus, within the obturator foramen, and in the various retrocolic and retrocecal fossæ. The appendix may be found in a hernial sac, either as its sole content, or in combination with other portions of the bowel, or with the omentum. The earliest observation of a hernia of the appendix is probably that of Morgagni in 1751 (Jopson, *Univ. Med. Mag.*, 1900). Another was soon after reported by Soemmering, and then one by Morse, who in 1802 (Graziani, *Thèse de Montpellier*, 1900) mentioned a case of crural hernia containing the appendix. In the collection belonging to the Hunterian Museum in London there is a specimen, accompanied with a history of a right inguinal hernia, which had proceeded to abscess formation and was finally opened, discharging feculent pus, a good recovery following. At autopsy, thirty years later, the cecum was found adherent to the internal ring by the area corresponding to the site of the appendix; the latter, however, had entirely disappeared. Only isolated examples of appendical hernia are to be found in the literature up to the time when the radical cure of rupture became customary, but it is now known that the appendix is present in from 1 to 2 per cent. of all hernias. Of 101 cases analyzed by Prüss (I. D., Halle-Wittenberg, 1902), 21 per cent. occurred in children of two years and under; the relative number of cases then diminished until the fifth decade, when a sudden marked increase was again noticed. The cases collected by Rivet (quoted from Jopson) also showed that the affection is more common in young children and in advanced life than in early adult and middle age. Men are affected more often than women, the proportion, according to Rivet, being 70 per cent. in the former to 30 per cent. in the latter; while Prüss gives 78 and 22 per cent. There is, however, a great preponderance of the femoral variety in females. The inguinal form constitutes from 70 to 80 per cent. of all cases, the femoral 20 to 30 per cent., while only 2 or 3 cases of umbilical and one of obturator hernia have been reported. In Eccles' report of the cases at St. Bar-

tholomew's Hospital there were 13 femoral and 16 inguinal hernias of the appendix.

The hernia may be congenital or acquired. I have found only two cases (SANDEFORT'S and LETTAU'S) in which the hernia was observed at birth, but if by congenital hernia is understood a congenital predisposition, namely, a patent funicular process, many of the cases fall under this head, a large proportion occurring, as I have said, in infants. SANDEFORT'S case (quoted from Graziani, *loc. cit.*) was that of an infant born with a scrotal hernia which did not receive any attention until three months later, when a bandage with pressure was applied under the impression that reduction was complete. Soon symptoms of strangulation developed and death followed. An autopsy showed that the hernia was formed by the cecum, the termination of the ileum, and the vermiform appendix, the latter being adherent to the testicle and to the bottom of the sac, and on account of the hardening of the appendix it was judged that the adhesion had taken place during fetal life. LETTAU'S case (*Dtsch. Zeit. f. Chir.*, 1903, Bd. 70, No. 2, p. 84) was an example of the umbilical form and was mistaken for a patent Meckel's diverticulum. At operation the appendix was found to be the only content of the sac. Congenital hernia of the appendix is generally ascribed to the formation in the fetus of adhesions between the appendix and the peritoneum covering the testis and gubernaculum. ROKITANSKY, VIRCHOW, ORTH, and others claim that the peritoneum in the fetus is frequently the seat of a chronic or acute inflammatory process, and that the resulting adhesions are often the cause of anomalous positions of the abdominal organs. With few exceptions, in the cases observed in children, the appendix is adherent.

The principal causes of the acquired form are, unusual mobility and length of the cecum and appendix, and, what amounts to the same thing, the descent of the colon in general enteroptosis. The causes usually in action in the causation of hernia in general, contribute to produce appendical hernia as well. It is probable, as pointed out by PRÜSS, that, in many cases, the cecum or some other portion of the bowel enters the sac with the appendix, but while the former returns to the abdomen, the latter, on account of its length and small diameter, or because of adhesions, remains in the sac. The presence of adhesions between the appendix and omentum may result in the former being forced into a hernia at the same time as the latter. In a case of J. M. T. FINNEY (*personal communication*) the sac contained a large incarcerated omental hernia, while the appendix was found in the outer posterior portion of the canal, but was entirely extraperitoneal, its inner surface only being covered with a reflection of the sac. The factors concerned in producing left-sided hernias are, congenital anomalies in the position of the cecum and appendix; as, for instance, when the cecum occupies the left iliac fossa owing to failure of development of the transverse colon, or in cases of *situs transversus*. Again, a long cecum and appendix, especially when associated with descent of the colon, may extend

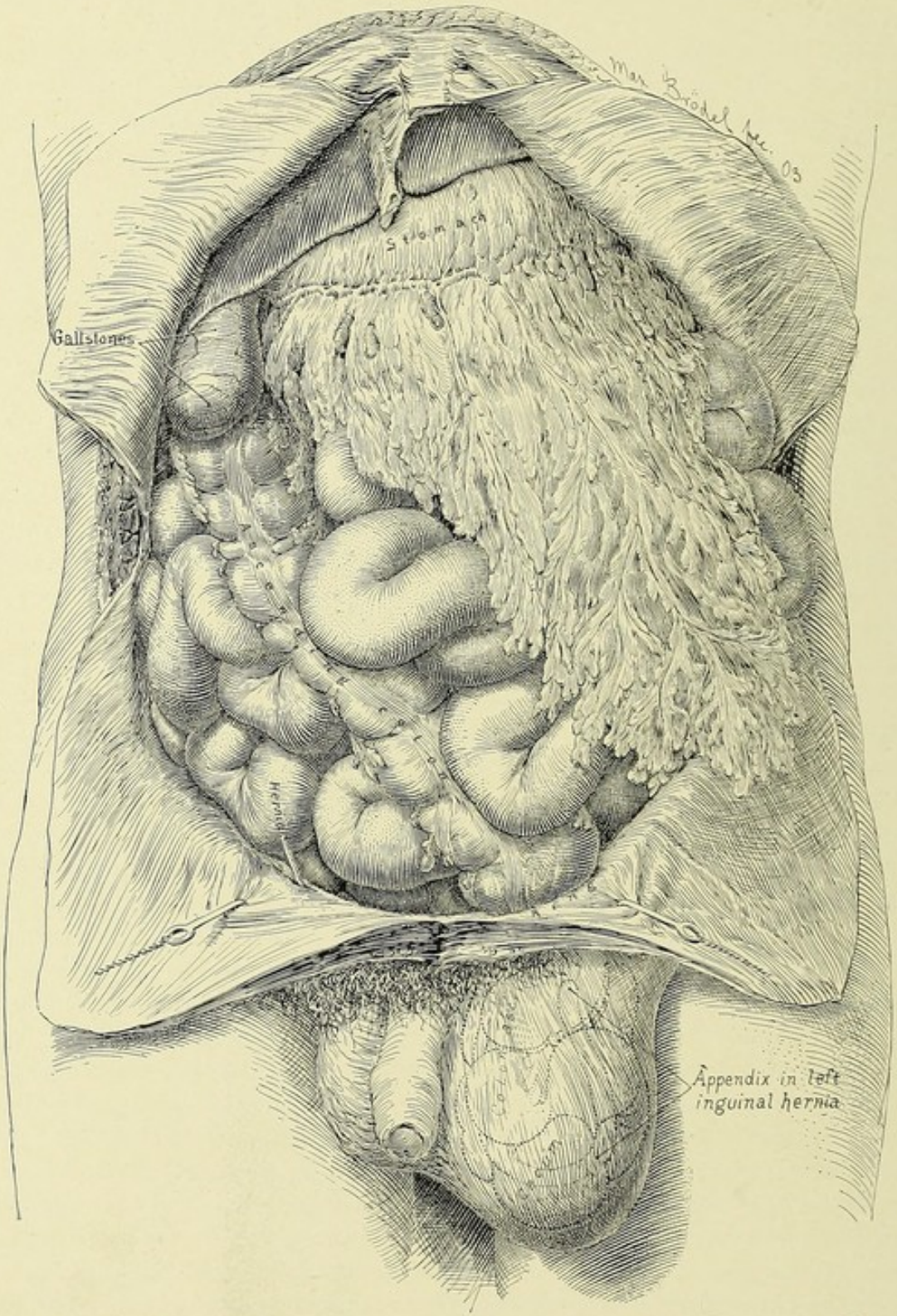

FIG. 395.—APPENDIX, WITH THE CECUM AND BEGINNING OF ASCENDING COLON IN A LEFT INGUINAL HERNIA.
J. H. H., July 12, 1903. Autopsy No. 2136; age eighty-one.

across from the right to the left side. Deformities, such as scoliosis and kyphosis may, as FOERSTER claims (*Univ. of Pa. Med. Mag.*, 1901), be etiologic factors in producing left appendical hernias. A large iliac hernia on the left side in old individuals with lax abdominal walls may draw the cecum and appendix into the sac. This was evidently the mechanism of the case shown in Fig. 395, which was observed in an old man of eighty-one years who had entered the Johns Hopkins Hospital suffering from general arteriosclerosis, and having

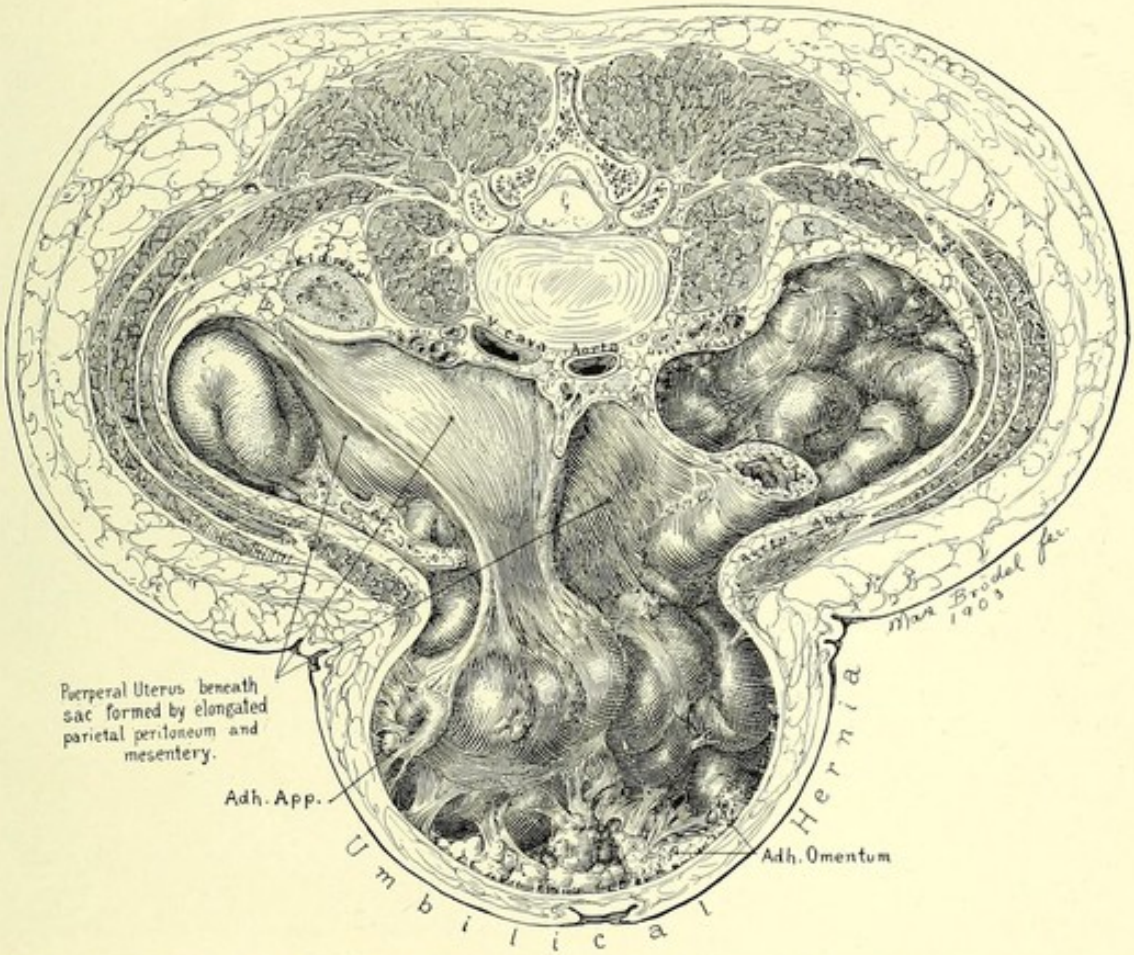

FIG. 396.—THE APPENDIX, CECUM, COLON, SMALL INTESTINE, AND OMENTUM, ADHERENT IN UMBILICAL HERNIA.

a cardiac aneurysm. The abdominal walls were greatly relaxed and there was an easily reducible inguinal hernia on both sides, the left being much the larger.

The appendix rarely forms the contents of an umbilical hernia, two instances only, so far as I know, having been reported, namely, that of LETTAU, already mentioned, and a case related by JEANNIEL (cited by Prüss). I have met with one example of this form of hernia (see Fig. 396), observed at autopsy on a woman aged twenty-five, who had died of acute miliary tuberculosis during the puerperium. BARY (I. D. Greifswald) recorded a fatal case in which the appendix was adherent in the obturator foramen.

The complications which may arise are irreducibility, strangulation, and inflammation. The irreducibility of the appendix is usually the result of the adhesions which are commonly present, but, as JOPSON remarks, the fact that the easily reducible hernias are often not operated upon makes it impossible to estimate the frequency of its occurrence. Kinking of the appendix may prevent its return to the abdomen, and also cystic distention, as in the cases described by WÖLFLER (*Arch. f. klin. Chir.*, Bd. 21, p. 432) and VAN HOOK (*Med. and Surg. Rep.*, 1896). Strangulation and inflammation can-

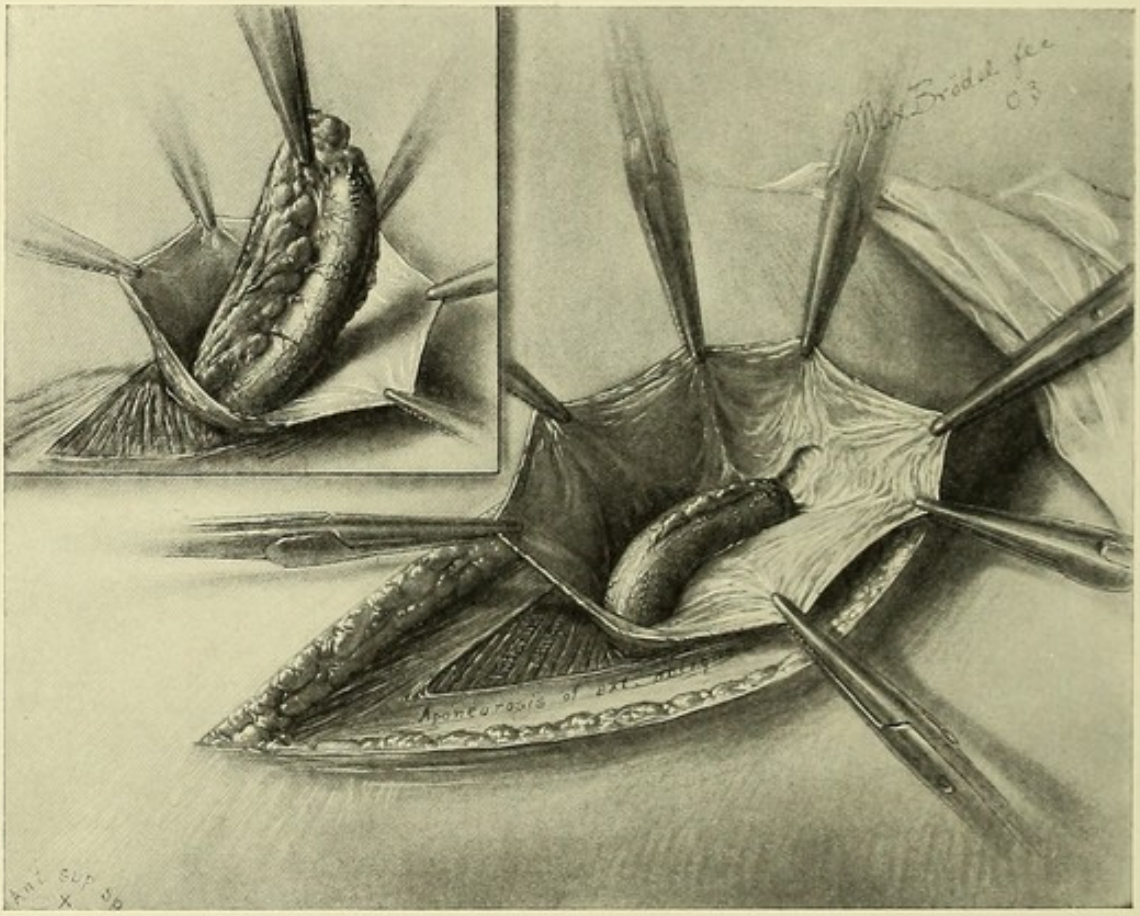

FIG. 397.—THE APPENDIX IN A RIGHT INGUINAL HERNIA.
The appendix was thickened and rigid, but free from adhesions. Man, age sixty-seven.

not always be differentiated before operation, and as strangulation induces inflammation, and vice versa, it is often difficult, even at operation, to determine which was of primary occurrence. Chronic or acute inflammation may, however, develop without evidence of strangulation. It is produced by the usual causes of appendicitis, especially trauma, and gives rise to the characteristic symptoms of the affection.

The case of right inguinal hernia represented in Fig. 397 was that of a sailor aged sixty-seven, who had first noticed the swelling in the groin shortly after a severe

strain in lifting. The hernia was easily reduced and kept in place with a truss, but the patient desired a radical cure on account of the pain experienced when walking without the support. The sac, which was of considerable size, was found empty except for the tip of the thickened, indurated, but not adherent appendix.

In another case occurring in the practice of my associate, G. L. HUNNER, acute gangrenous appendicitis in a right femoral hernia developed without producing any symptoms of strangulation. The patient, a woman aged sixty-nine, gave a history of attacks of abdominal pain sometimes located about the umbilicus, at other times across the lower abdomen. Her bowels were habitually constipated. Three days before admission to the hospital she began to suffer from rather severe pain in the lower right abdomen and for the first time noticed a swelling in this region. There was slight fever, but no nausea nor vomiting. The abdomen was soft and natural-looking, except for the swelling in the right lower quadrant, where a somewhat tender mass extended a few centimetres above Poupart's ligament and into the groin. The skin over the mass was infiltrated and indurated as well as slightly reddened. Operation showed that the entire appendix, with a small portion of the cecum, was gangrenous, the distal half forming the contents of a femoral hernia (see Fig. 398).

Acute perforative appendicitis in a hernial sac has frequently been described and in several instances has been associated with the presence of foreign bodies, and has sometimes followed traumatism. Several cases have been described in which the cecum and proximal portion of the appendix were contained in the sac, while the tip of the appendix passed back into the abdominal cavity. In such cases the tip may become gangrenous or perforated, while the part in the hernia is only slightly inflamed. Symptoms of complete obstruction probably reflex in origin may develop in cases of strangulated appendical hernia. As a rule, the obstruction is found to be less complete than when other portions of the bowel are involved.

The diagnosis of appendical hernia from other forms is seldom possible. It may easily be mistaken for an omental or a Richter's hernia. Sometimes when the appendix occupies the sac alone it can be felt as a cord-like structure. COLEY (*Ann. Surg.*, 1895, vol. 21, p. 385) succeeded in making a correct diagnosis in two instances, in one of which it was based upon the fact that after reducing the hernia, a small and evidently adherent portion remained. In the other case, the hernia, which was small, was easily reduced, but traction upon the testis caused it to return, thus demonstrating the presence of adhesions.

TREATMENT.

Operations for the relief of hernia in the appendix are of two kinds, namely, of election or of necessity. An operation of election is one performed when there is nothing in the circumstances to make it urgent and it is a matter of choice with the patient, who desires to get rid of his hernia, and decision with the surgeon, whose services are to accomplish this end. An operation of neces-

sity is one urgently demanded on account of strangulation, or the supervention of an inflammatory condition in the sac.

When the sac is opened, the operator may find its contents to consist of the

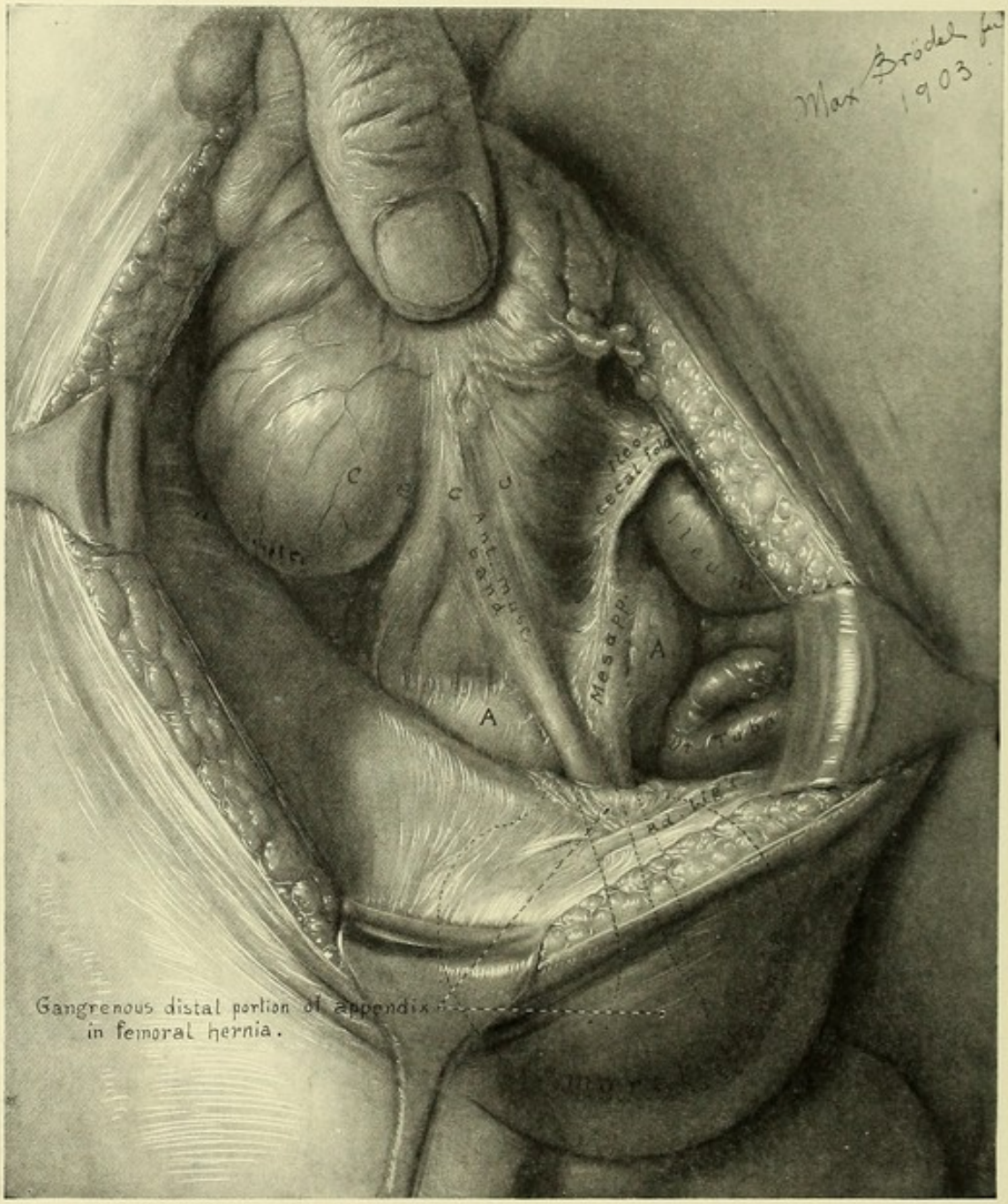

FIG. 398.—HUNNER'S CASE. GANGRENOUS APPENDIX IN A RIGHT FEMORAL HERNIA. THE OVERLYING TISSUES INFILTRATED AND ACUTELY INFLAMED. Woman, age sixty-nine.

appendix alone, or of the appendix and cecum together, associated, it may be, with more or less of the adjacent bowel. If the appendix and the associated bowel are perfectly normal and free from adhesions, and if there have been no

previous suspicious attacks of pain and tenderness in the sac, they may be returned to the abdominal cavity. In my judgment, however, it is better, as a general rule, under such favorable conditions for exposure and manipulation, to remove the appendix by ligating its mesentery, and then amputating the organ, turning it into the cecum and suturing the orifice, according to one of the plans described in Chap. XXV; after which the hernial sac is closed *secundum artem*. In grave cases, where there is suppuration in the sac, it must be drained, and here, as well as in the cases where there is gangrene in the appendix, resulting from strangulation (see Fig. 398), the utmost care must be observed in handling the diseased tissues in order to avoid inoculating the peritoneal cavity. If the diseased portion is found to extend up into the peritoneal cavity, the operator must, at all hazards, discover the upper limits of the infection and resect the bowel in its healthy portion. Moreover, he must do this with the least possible manipulation and traction upon the parts, preferably by enlarging the abdominal opening in the direction of the canal, while protecting the healthy regions and keeping the disease well isolated by abundant gauze compresses. When the infection extends still further up into the abdomen, an even wider incision must be made, if necessary in the form of an inverted T in order to provide abundant drainage after removal of the disease. In such cases the cure of the hernia becomes a matter of secondary consideration, to be taken up after recovery.

CHAPTER XXXV.

MEDICO-LEGAL ASPECTS OF APPENDICITIS.

The existence of a legal status in certain cases of appendicitis is not, as might be expected, a matter of only recent recognition. As far back as 1837 PETREQUIN, in his well-known article on the value of opium in perforation of the intestines, and of the vermiform appendix in particular (see Chap. XXIII, p. 511), commented on the legal aspects of such cases as follows: "Are not intestinal lesions of this kind (spontaneous perforation) really a branch of legal medicine? Monsieur Alphonse Devergie says that the study of spontaneous perforations is of special interest to the medical lawyer; the collection of symptoms to which they give rise and the pathologic alterations which follow in their train being capable of simulating poisoning and occasioning symptoms which attack individual reputations." LARRET-LAMALIGNIE, writing in 1862, also emphasizes the resemblance between the symptoms of arsenic poisoning and those of perforation of the appendix. A medical man studying history, and reading between the lines, must often feel a conviction that many of the suspected poisonings so common a few centuries ago were, in reality, only cases of acute and fulminating intestinal affections, and not infrequently of appendicitis and peritonitis; indeed, literary investigation along these lines offers a field of interesting conjecture to any student of history gifted with the necessary insight. A case of fulminating appendicitis is not so likely, to-day, to be mistaken for one of acute poisoning in any well-organized community, for the universal suspicion of the poisoner as well as of the evil eye is now a thing of the past; moreover, the symptoms of appendicitis are at present so well understood that it is immediately suspected not only by the medical attendant, but often by the patient himself or his friends. Still it is possible that such an error might arise and demand investigation, although the risk to-day is rather in the opposite direction, namely, that a veritable poisoning will be labelled appendicitis, and so escape recognition.

A new field of inquiry, however, has appeared since PETREQUIN's time, arising from a long-standing conviction that a causal relationship exists between appendicitis and trauma, and may be a matter of considerable importance.

The naturally protected position of the appendix, lying as it does against the posterior abdominal walls and covered by intestines, would seem at first sight to negative the possibility of any injury from a direct trauma, unless of the severest character. There is abundant evidence, however, to the contrary, and the medico-legal complications which may arise in cases of appendicitis

occasioned by such common, and apparently trivial injuries as a blow, a kick, a contusion, or even a violent strain are numerous and interesting. From this standpoint appendicitis becomes of importance to life insurance corporations where there are limitation clauses in the policies, as well as in benefit associations where insurance is guaranteed for bodily injury but excluded in spontaneous internal disease, or when, on the contrary, the patient is insured against ordinary ailments, but not against accident.

It has already been noted (see Chap. XVI) that the number of cases in which appendicitis is associated with injury or violence is much greater than is generally credited, and it follows that the desire to establish the connection between appendicitis and trauma should receive greater attention in the future. It is a curious fact that patients are prone to account for tumors, notably of the breast or in the abdomen, by a fall, a bruise, or a strain; but in acute abdominal affections, beginning with colic, the attention is turned at the outset in an entirely different direction, and an indiscretion in diet or an exposure to cold is the first thought in seeking an explanation of the malady. In this field, therefore, the surgeon will do well not to depend upon the spontaneous suggestion of the patient as to injury or violent exertion preceding the attack of appendicitis; he must, in each instance, seek to elucidate an immediate provoking cause by careful, well-directed questioning. If, however, the case has any possible medico-legal bearing, the medical attendant must be guarded in his inquiries so as not to suggest or insinuate that a trauma is the directly responsible agent in producing the malady.

My personal interest in trauma as a cause of appendicitis was first aroused by an incident occurring some twenty years ago, and I believe I cannot better illustrate the change of attitude undergone by the profession relative to the subject during this period than by briefly citing the facts and instituting a comparison between the case and a similar one recently brought to my notice.

During my residence at the Episcopal Hospital in Philadelphia, in the year 1882–1883, a boy of about ten years old, was brought into the children's ward suffering from an attack of peritonitis with much pain and fever; his abdomen was tumid, and he was evidently very ill. He stated that he had been struck in the abdomen by another boy, and the illness had followed promptly upon the injury. The boy who inflicted it was being held by the police until the upshot of the case should be known. The little patient died, and the autopsy revealed a perforation of the appendix by a coprolith, with a consequent suppurative peritonitis. At this date, three or four years before Fitz's article had laid the foundations of knowledge, our understanding of such cases was still most imperfect, and at the inquest I asserted with a clear conscience that there was no demonstrable connection between the lesion in the appendix (the manifest cause of death) and the blow which had preceded it; it seemed to be a clear case of *post hoc* and not *propter hoc*, and the boy in custody was, therefore, at once released. Had I been called upon to testify some years later under the same conditions, my opinion would have been more guardedly expressed.

The second case, which I wish to contrast with this one, occurred in Baltimore twenty years later, and was reported in one of the daily papers (*Baltimore Daily Sun*, July 28 and 29, 1902). A boy, twelve years old, died at St. Joseph's Hospital, after an operation for appendicitis, immediately following a blow upon the abdomen, struck by a companion, during a quarrel. The assailant was arrested on the charge of assault, and then released, but on the death of the patient he was re-arrested to await the verdict of the coroner's jury. The city physician, N. G. KEIRLE, testified that "the autopsy showed inflammation of the appendix which had given rise to appendicitis. The appendicitis could have been occasioned by a blow." There was no foreign body in the appendix. The verdict of the coroner's jury was: "We find that death was caused by appendicitis and peritonitis, but we are unable to say in what manner said appendicitis was caused." The prisoner was, therefore, released. It will be seen that in the twenty years between my first experience and this case, professional opinion had so far advanced that the possibility of a traumatic origin for the appendicitis was readily admitted, although not considered sufficiently established to justify an unfavorable verdict. It is but natural that only the most positive proof should influence a jury to find the defendant guilty under such circumstances.

W. B. SMALL, of Lewiston, Maine, writing upon the relation of trauma to appendicitis (*N. Y. Med. Rec.*, 1898, vol. 54, 364), says: "I believe the true cause of the greater percentage of appendicitis in young men is found in the more frequent exposure to accidental injuries and strains, and to the strong contractions of the abdominal muscles necessary in their work. . . . . This explanation brings the subject into prominence from a medico-legal point of view. Some cases show plainly the direct results of external violence, and I believe accident insurance companies or corporations, and individuals responsible for the occurrence of accidents, are as plainly liable as for a broken limb." This opinion accords with my own. SMALL, six years ago, was able to collect 15 cases of appendicitis occasioned by trauma, from the literature and from individual reports; now, six years later, I find 50 with but little effort. I present these as illustrative without comment, in the form of brief abstracts, with the original reference in every instance.

1. GOLDBECK. I. D. Wurms, 1830. A boy, ten years old, fell from the top of a hay-wagon, and eight days later began to have pain in the right iliac fossa, with the usual symptoms of appendicitis, increasing in severity until death. At the autopsy the appendix was found gangrenous and perforated; its tip contained a fecal concretion.

2. G. SOUTHAM. *Lancet*, 1840, vol. 2, p. 565. A man, twenty years old, a weaver by trade, received a severe blow from his beam, which swung round and struck him in the abdomen. Slight pain, generally distributed over the abdomen, began shortly after the injury was received, and persisted for six months, although it was not severe enough to prevent the patient's working for some time; at the end of half a year, however, it increased in severity and became localized in the right

iliac fossa. A year after the accident, when the patient was admitted to the hospital, he had a swelling in the right groin, which burst and discharged externally at the navel. Death occurred sixteen months after the receipt of the injury; the autopsy showed an appendix bent upwards, and adherent to the anterior abdominal wall at a point within an inch of the umbilicus, with which it was connected by a short fistulous tract. The appendix was thickened and dilated, with the shell of a large hazelnut impacted in it.

3. HARTSHORNE. *Trans. Coll. Phys. Phila.*, 1853, p. 86. A girl, fourteen years old, became exhausted by skipping rope backwards forty times in succession, making a revolution of the rope for herself each time. Immediately after she felt a tearing pain in the bowels, accompanied by nausea and faintness, but these symptoms soon passed away. Eight or ten days later, however, she was seized with the same symptoms while at school, and when seen by HARTSHORNE on the fifth day of her illness she was *in extremis*. The autopsy showed a perforation of the appendix with a fecal concretion just above the opening, and still within the appendix.

4. O. WARD. *Trans. Path. Soc. Lond.*, 1856, vol. 13, p. 210. A boy, thirteen years old, was kicked on the right side of the abdomen. Symptoms of appendicitis showed themselves within a week, and a physician was summoned. Death took place on the eighth day, and the autopsy showed a perforated appendix containing a fecal concretion.

5. G. T. ELLIOT. *Amer. Med. Month.*, 1858, vol. 10, p. 359. A boy, eleven years old, received a blow on the abdomen from a playmate severe enough to render him breathless for a moment. Soon afterwards he ate his dinner, and at once began to have pain in the abdomen. A physician was called twenty-four hours later, and the patient died on the twenty-fourth day after the injury was received. At the autopsy the appendix was found perforated, and bound to the cecum by adhesions. There is no mention of a concretion.

6. L. DOWN. *Trans. Path. Soc. Lond.*, 1867, p. 97. A man, thirty years old, had had one attack of pain in the right iliac fossa with vomiting. A year later, after dancing at a party, he was again seized with pain in the abdomen, which was soon relieved, and a physician, sent for on the fourth day, found him apparently recovering. On the ninth day, however, after a sudden movement in bed, the pain returned with symptoms of collapse, and he died the same evening. The autopsy showed an appendix bound down to the omentum by adhesions; it was perforated, and contained two small fecal masses.

8. R. H. PARKER. *Brit. Med. Jour.*, 1872, vol. 2, p. 526. A boy, seven years old, was struck on the abdomen by some iron railings. Shortly afterwards he was attacked by nausea and vomiting, and the next day by pain in the abdomen with tenderness on pressure. On the third day he was taken to a hospital, and died on the sixth. At the autopsy the appendix was found perforated, and near to it, in the right iliac fossa, lay a fecal concretion.

9. C. D. HOMANS. *Bost. Med. and Surg. Jour.*, 1873, vol. 88, p. 45. A girl, seven years old, fell for a distance of eight or ten feet. The day afterwards she began to have severe pain in the abdomen, most marked on the right side, and a physician was sent for, who pronounced her to have appendicitis; on the fifth day she died.

The autopsy showed that the appendix was perforated and contained a fecal concretion.

12. W. M. Campbell. *Med. and Chir. Reporter, Liverpool*, 1885, vol. 10, p. 26. A boy, nine years old, received a severe blow on the abdomen, and a week afterwards he was seized with paroxysms of abdominal pain. A physician was called as soon as the pain began, but the child died on the fourth day. At the autopsy the appendix was found much dilated, and adherent to the umbilicus. No mention is made of perforation, or of a concretion.

11. T. G. Morton. *Jour. Amer. Med. Assoc.*, June 16, 1891. A young girl, age not given, had a severe fall on the buttocks, immediately followed by nausea and vomiting, lasting for hours. These symptoms passed off after a time, but returned occasionally, after fatigue, during eighteen months; she then had an attack of pain in the right iliac fossa followed by others of the same kind. Four years after the injury she had a violent attack of such pain, accompanied by symptoms of a high degree of inflammation, and on operation the appendix was found perforated and firmly adherent to the cecum. Search was made for a foreign body, but none was found.

12. Ibid. *Trans. Coll. Phys. Phila.*, 1890. A boy, eleven years old, subject for two or three years to attacks of "colic" in the right iliac fossa, was struck in the right side of the abdomen with the handle of a spade, while at play. This injury was followed immediately by intense pain, but he was not confined to bed until the next day. An operation, performed on the fifth day, showed the appendix perforated and glued to the cecum; there was a small fecal concretion in the perforation.

13. N. Bridge. *Med. News*, May 24, 1890. A boy, fourteen years old, previously strong and active, was out hunting all day, and became excessively fatigued. On his return he felt badly, and on the third day had diarrhea, with pain and tenderness in the cecal region. A physician was sent for on the fifth day, but, until the eighth, the symptoms continued mild; there was then a violent attack of pain with vomiting, and death ensued soon after. At autopsy the appendix was found perforated. There is no note of a fecal concretion.

14. H. O. Marcy. *Bost. Med. and Surg. Jour.*, 1891, vol. 124, p. 524. A man, twenty-nine years old, was exposed to a severe strain while operating on the cadaver, and felt something give way; immediately afterwards he had an attack of appendicitis. About six months later he had a second attack, followed by others to the number of eight during the next six months. On operation, in the quiescent period after the ninth attack, the appendix was found shorter and wider than usual. It did not contain a concretion, and was not adherent, but there were numerous adhesions running from the head of the cecum.

15. Perret. *Lyon méd.*, 1892, tom. 70, p. 279. A girl, seven years old, had a fall on the right side, followed by severe pain in the right iliac fossa. From this she recovered, but a second attack occurred in two months, and a year later she was seized with pain in the right groin, with other symptoms of appendicitis. At operation the appendix was found red, swollen, and perforated. There is no mention of a concretion.

16. T. W. Kelynack. *Pathology of Appendicitis*, 1893, p. 99. A boy, fifteen

years old, was forcibly seized, hung up by the legs, head downward, over a man's back, and violently shaken. A short time afterward symptoms of appendicitis appeared, mild at first but increasing in severity until the end of a week, when he was seen by a physician and sent to a hospital. The abdomen was opened and washed out, but the patient died in a few hours. At the autopsy the appendix proved larger than normal, was acutely flexed on itself, gangrenous, and perforated; it contained nodules of hardened feces.

17. G. R. Fowler. *Appendicitis*, 1894, p. 127. A man, age not given, felt severe pain in the right iliac fossa while lifting a heavy cake of ice. The pain continued, but was not severe enough to confine the patient to bed. On operation the appendix was found gangrenous and perforated; it contained a fecal concretion.

18. H. P. Hawkins. *Diseases of the Vermiform Appendix*, 1895, p. 96. A boy, sixteen years old, was lifting some heavy baggage when he felt a severe pain in the right side of the abdomen, followed by the usual symptoms of appendicitis. These decreased, and for a time he improved, but in the third week of his illness he had a severe recurrence, and was sent to a hospital, where he died. At the autopsy it was found that the tip of the appendix had sloughed off; there is no mention of a fecal concretion.

19. Gordon. *Thèse de Paris*, 1896. A girl, six years old, was kicked in the upper right side of the abdomen. About twelve hours after the injury she was attacked by vomiting, accompanied by black stools, and was then taken to a hospital, where, on the fourth day, severe abdominal pain began with other symptoms of appendicitis, shortly followed by death. The autopsy showed a perforated appendix; there is no mention of a fecal concretion.

20. Ibid. A girl, nine years old, was struck on the abdomen by one of her companions with the fist. The day after the injury the patient began to have pain in the right iliac fossa, and was taken to the hospital three days later, where she soon afterwards died. At the autopsy the appendix was found perforated at its free extremity, with a small concretion situated near the perforation.

21. Ibid. A boy, nine years old, was playing with a companion, who jumped suddenly on his back and upset him. A violent pain in the right iliac fossa felt at the time of injury soon disappeared, but returned a few hours later, with all the symptoms of appendicitis. He was then taken to a hospital, where, on operation, the appendix was found bent upon itself, and adherent by its tip to the omentum. It was not perforated, nor is there any mention of a concretion.

22. D. C. Moriata. *N. Y. Med. Jour.*, 1896, p. 546. A boy, fourteen years old, was kicked in the abdomen by a playmate, and a few days later he developed symptoms of appendicitis, when a physician was summoned. On operation the appendix was found swollen and perforated; it contained a common pin, which the child stated he had swallowed about a year before. The case ended fatally.

23. Delorme. *Bull. et mém. de la Soc. de chir. de Paris*, 1897, tom. 22, p. 543. A man, age not given, was kicked by a horse in the region of the umbilicus, and immediately became ill with appendicitis, from which he died on the third day. The autopsy revealed a perforated appendix with a concretion lying in the perforation.

24. H. Mynter. *Appendicitis*, 1897, p. 225. A youth, nineteen years old, in

previous good health, received a blow in the abdomen, not instantly followed by bad effects. A few hours later, however, he began to have pain in the right iliac fossa, soon followed by other symptoms of appendicitis. A physician was sent for the next day, and at operation, on the third day from the injury, the appendix was found perforated; it contained two fecal concretions, in the middle of one of which was a foreign body.

25. W. B. Small. *N. Y. Med. Rec.*, 1898, vol. 54, p. 364. A boy, nine years old, spent some time in pushing a heavy dump-cart with its tongue resting against his abdomen. Within twenty-four hours he was taken ill with appendicitis, and a physician was sent for. On operation the appendix was found to have sloughed away; there is no mention of a concretion.

26. Ibid. (*from* F. L. Dixon). A man, thirty years old, jumped from a small island to the mainland, and in the act he felt a pain in the right iliac fossa, so sharp as to force him to lie down at once. The pain lasted several days, and then disappeared. Three or four similar attacks preceded his final illness, in which he received no medical aid until near the end. On operation, numerous old adhesions were found, but no concretion is mentioned; he died a few hours later.

27. Ibid. (*from* F. L. Dixon). A man, twenty-seven years old, fell through a trap-door, for a distance of seven or eight feet, into a cellar. He complained at once of injury in the right side, but did not feel ill enough to send for a physician until the end of two weeks. On operation the appendix was found gangrenous, and it contained two enteroliths.

28. E. M. Pond. *N. Y. Med. Rec.*, April 23, 1898. A boy, twelve years old, received a blow on the abdomen, whose exact character is not stated. For two weeks afterwards he had some digestive symptoms and pain in the right iliac fossa; at the end of that time, while at a circus, he was suddenly taken ill with severe abdominal pain and vomiting, and two days later he was seen by a physician. A diagnosis of appendicitis was made, and on operation the appendix proved perforated; it contained a fecal concretion.

29. A. P. Gould. *Lancet*, 1898, vol. 1, p. 10. A man, twenty-four years old, who had always been robust, took an unusually long bicycle ride, after which he felt sick. Thirty-six hours later he began to suffer with pain in the right iliac fossa; and on the fourth day after the ride a physician was sent for. On operation for appendicitis the appendix was found perforated in four places, and it contained three fecal concretions.

30. M. Neumann. *Langen. Arch. f. klin. Chir.*, 1900, vol. 62, p. 408. A boy, ten years old, in previous good health, ran against the tongue of a wagon, striking his abdomen with such force against it that he fell to the ground. The pain shortly afterwards increased so much that he was forced to go to bed, after which it spread through the whole abdomen, and was accompanied by vomiting, until, on the third day, he was taken to a hospital. Examination showed a distended abdomen, quickened breathing, a rectal temperature of 38.5° C., and dulness on the right side. Puncture let out a gray, stinking fluid; and a posterior incision, made on the fifth day, opened a foul abscess and exposed a thickened, gangrenous appendix. Death occurred on the seventh day, of fibrinous peritonitis, and at the autopsy a concretion was found in a necrotic appendix.

31. IBID. A boy, seven years old, was kicked twice in the abdomen by another boy, immediately after which he suffered great pain and went to bed. During the night he vomited, and next day was much worse. On the second day he entered a hospital, where examination showed a distended abdomen and pain, most severe on the right side. At operation, on the third day, a peritonitis was found, caused by a red, thickened, perforated appendix, the mucous lining of which was gangrenous over a zone 1.5 cm. in breadth, while, corresponding to the perforation, there was a grayish-yellow, firm, oval calculus as large as an orange-seed. Death took place two days later.

32. IBID. A boy, fourteen years old, received a blow on the abdomen, the source of which is not stated, and developed symptoms of peritonitis on the same day, although he was not seen by a physician until the fourth. At operation the appendix was found perforated, and it contained a fecal concretion.

33. IBID. A boy, nine years old, in previous good health, was jumping in some athletic exercises, when he suddenly felt a severe pain in the right side of the abdomen. The day afterwards he was obliged to return from school on account of severe pain, which increased for two days, and on the third he entered a hospital. On operation the appendix was found perforated and it contained a small concretion.

34. IBID. A man, twenty-nine years old, whose health had always been good, was lifting a heavy weight when he suddenly felt a severe pain in the abdomen, which steadily increased. A physician was sent for next day, and the patient taken to a hospital the day afterwards. On operation the appendix was found perforated and a concretion was lying in the perforation. Three more concretions were found at the autopsy.

35. IBID. A man twenty years old, whose health had always been good, although he had once spent a few days in a hospital on account of bruises due to a kick from a horse, began to have pain in the right iliac fossa shortly after lifting a heavy sack. The next day he was better, but shortly afterwards the pain became severe. On the ninth day after the injury he was admitted to a hospital, where an operation showed that nothing was left of the appendix except a thickened stump, 1.5 cm. long; a concretion the size of a hazelnut was lying in the abdominal cavity.

36. IBID. A man, thirty-two years old, in previous good health except for rheumatism, was thrown down by a large hog and trampled upon over the abdomen. Immediately after the injury he was taken to a hospital. On operation, the appendix proved to be perforated, and a concretion lay just outside the perforation.

37. IBID. A boy, twelve years old, in previous good health, received a blow on the abdomen, and shortly afterwards began to have pain in the right iliac fossa, which confined him to bed and required opium for its relief. On the tenth day he entered the hospital, where, on operation, the appendix could not be discovered, but, when the dressings were changed, a fecal concretion was found in the wound.

38. IBID. A man, forty-one years old, whose health had always been good, took a long ride on his bicycle, and five hours afterwards began to have pain in the right iliac fossa. On the third day after the pain began, he entered a hospital, with all the symptoms of a diffuse peritonitis. On operation, the appendix was found perforated, and it contained a fecal concretion.

39. Ibid. A man, twenty-six years old, whose health had always been good, was lifting a heavy weight when he suddenly felt a severe pain in the right iliac fossa, followed immediately by other symptoms of appendicitis. He was seen at once by a physician and sent to a hospital on the third day after the pain began. On operation, the appendix was found just about to perforate; it contained a fecal concretion.

40. Ibid. A boy, sixteen years old, in previous good health, was seized with severe pain in the abdomen while lifting a heavy sack of potatoes. The morning after the injury he was taken very ill with symptoms of appendicitis, which continued to grow worse, until the fifth day, when he was admitted to the hospital *in extremis*. At the autopsy the appendix was found perforated; it contained a concretion the size of a cherry-stone.

41. A. J. Ochsner. *Month. Jour. Med. and Surg.*, Louisville, Feb., 1900. A girl, age not stated, received a blow on the abdomen from a heavy board which swung round rapidly and struck her. Immediately after the injury she began to have pain, which persisted for two years, when she had an attack of acute appendicitis. On operation, the appendix was found inflamed, but not perforated; no mention is made of a concretion.

42. Du Barry. *Thèse de Paris*, 1901. A child, ten years old, fell, striking the abdomen against the handle-bar of a bicycle. Immediately after the accident, general abdominal pain began, which became localized within two days, and shortly afterwards subsided; it returned, however, eight months later. A physician was sent for on the ninth day of the second attack. On operation, the appendix was found inflamed, but not perforated; there is no mention of a concretion.

43. E. W. Sharp. *Brit. Med. Jour.*, 1902, p. 1519. A man, nineteen years old, in previous good health, was working in a coal-mine, where he sustained a severe crush, involving the abdomen, between two coal-wagons. At the time of the accident there was not much suffering, but about a month later the patient complained of pain and tenderness in the right iliac fossa, which confined him to bed for a short time. Five months later he had another attack, and at the end of three weeks he entered a hospital *in extremis*. Autopsy showed an ileus with a subacute inflammation of the appendix (see p. 805).

44. C. B. Lockwood. *Appendicitis, its Pathology and Surgery*, 1901, p. 93. A man, twenty-two years old, was seized with abdominal pain after dancing, followed by other symptoms of appendicitis, which became steadily worse. A physician was sent for on the second day, and on operation the appendix was found perforated; it contained a fecal concretion.

45. T. S. Cullen. *N. Y. Med. Jour.*, 1902, vol. 76, p. 1111. A boy, fourteen years old, had a severe fall, followed by pain in the right iliac region, lasting eight weeks. Some time after recovery he went on a fishing excursion, where he was exposed to much cold and fatigue, and the next day he had severe pain over the appendix. This continued for ten days, when operation showed the appendix inflamed, but not perforated; there is no mention of a fecal concretion. (See Figs. 348 and 349, pp. 665 and 666.)

46. B. McMonagle. *Personal communication*, 1902. A man, twenty-two years old, had been rowing for exercise, immediately after which he felt pain in the right

iliac fossa, accompanied by severe bladder symptoms, and sent at once for a physician. He recovered from this attack, but a year later he had another in which an abscess was opened, without, however, restoring him to health. At a second operation the appendix was found inflamed and adherent to the bladder; there is no mention of a concretion.

47. A. E. MALLOCH. *Personal communication*, 1902. A young man, age not given, was lifting a heavy cheese from a shelf, while standing upon a step-ladder, and as the ladder shifted to one side, he suddenly strained violently to keep himself from falling. Pain in the side began immediately, and kept him in bed, more or less, for three days. On the tenth day he was seized with symptoms of perforation and died on the eleventh. The postmortem showed a ruptured abscess sac, containing a hard, pencil-like piece of feces, a sharp, bristle-like substance, and the sphacelated appendix (see fuller account, p. 808).

48. J. H. H., Surg. No. 14451. A man, twenty years old, was run over when he was twelve years of age, by a wagon, which passed over the lower part of the abdomen. He had, ever since, had occasional attacks of "colic," with a tendency to swelling in the abdomen. Just before he was seen he had a severe attack, brought on by excessive fatigue. He was operated upon in the quiescent period after this illness. The appendix was subacutely inflamed, and adherent to the under side of the cecum. There is no mention of a concretion.

49. J. H. H., Surg. No. 12477. A man, forty-four years of age, was lifting a heavy fertilizer when he felt a sharp pain in the side of the abdomen, which was relieved for the time, but returned next day accompanied by symptoms of appendicitis. He entered the hospital five days after the injury, and on operation the appendix was found sloughed off from its base; it contained a concretion in its tip.

50. J. H. H., Surg. No. 1591. A man, twenty-four years old, experienced a sudden pain in the right iliac fossa, while playing foot-ball, so severe as to oblige him to go home to bed, where he was ill for two weeks. About eight years later he had a second attack, after which they occurred repeatedly. He was operated on in the quiescent period after the last attack, and the appendix was found bent upon itself at a sharp angle. There is no mention of a concretion.

I have analyzed this series of cases, keeping in view the following points: Age; Sex; Previous health; Nature, locality, and severity of the injury; Evidence of external violence; Length of time elapsing between the injury and the first symptoms of appendicitis; Severity of illness; Evidence of any previous morbid condition of the appendix; and I present here my analysis in tabular form.

ANALYSIS OF 50 CASES OF APPENDICITIS ASSOCIATED WITH TRAUMA, AND, PRESUMPTIVELY, OF TRAUMATIC ORIGIN.

Sex.

Male	41	cases
Female	8	"
Not mentioned	1	case (child)

Age.

5 to 9 years old, inclusive	11	cases
10 to 14 " " "	13	"
15 " 19 " " "	5	"
20 " 29 " " "	11	"
30 " 39 " " "	3	"
40 " 49 " " "	2	"
Not mentioned	5	"

Previous Health.

Noted as good	13	cases
Previous attacks	2	"
Not mentioned	35	"

Nature and Locality of Injury.

Blows	24	cases
Falls	6	"
Exertion	20	"

Evidences of External Violence, such as Contusion or Laceration.

Not noted in any instance.

Length of Time After Injury Before Definite Symptoms of Appendicitis Appeared.

Immediately	24	cases
Few hours	13	"
One to two days	5	"
Two to three days	2	"
One week	1	case
One to two weeks	1	"
Two weeks	1	"
One month	1	"
Two years	1	"
Not mentioned	1	"

Severity of Illness.

Severe at outset	26	cases
Mild " "	12	"
Severe symptoms followed by interval and recurrence	12	"

Evidences of Previous Morbid Conditions in the Appendix.

Foreign body in appendix	30	cases
Adhesions	7	"
Flexion	1	case
Size abnormal	1	"
Cystic	1	"
Not noted	10	cases

Age and Sex.—A large proportion of these traumatic cases (29 in 50) occurred between the ages of five and twenty, as we would naturally expect, owing to the greater liability of the young to such mild accidents as blows and falls, and to the more exposed condition of the appendix in childhood, where it is covered only by the tender, thin abdominal walls. The fact that there are 41 males to 8 females (the sex in one case is not stated) accords well with the marked difference in the sexes in their habits of life.

Previous Health.—In most of the cases I have collected, the previous health is not noted, except where it is stated as good. In this respect the results of my analysis have not substantiated my expectations, for I had anticipated finding that a trauma would often prove to be the exciting cause of a recurrent attack of appendicitis. In only two cases in my collection, however, is there any record of a preceding attack. Further investigation would, perhaps, bring other cases to light.

Evidences of External Violence.—My statistics do not furnish a single record of any marks of violence on the surface of the body, such as contusions, abrasions, or effusion of blood and discoloration of the skin. I believe, however, that here too the fact has not been considered of sufficient consequence to note, and that more careful examinations in the future, and more detailed reports will show that, in many cases, the blow left some mark on the surface, if only a slight one.

Nature and Locality of the Injury.—The character of the injury is of three kinds: b l o w s , f a l l s , or m u s c u l a r e x e r t i o n . The b l o w s are either kicks, or violent impacts with the fist, given in the course of quarrels. Case 19, in which a little girl, six years old, was kicked in the abdomen by a boy, is a typical example of this class. Case 43 is of somewhat different character, being a contusion of the deep viscera by forcible impact due to a crushing force rather than a blow. A youth of nineteen, working in a coal-mine, was caught and squeezed in the abdomen between two coal-wagons; symptoms of appendicitis appeared a month later, followed by obstruction, and after repeatedly improving and then relapsing, the patient died at the end of six months. The autopsy showed a constriction of the end of the ileum, from a fibrous band about two and a half inches long, passing from the end of the appendix to the mesentery. There were signs of subacute inflammation above the appendix, at the distal end of which was a cyst. It will be noted that in all cases the injuries were inflicted by blunt instruments, and therefore liable to injure the parts for a distance around the appendix as well as the organ itself. In such cases the important question to be determined is whether there is an increased vulnerability of the appendix, owing to previous disease or to the presence of a foreign body in the form of a concretion.

The traumata coming under the head of f a l l s are of two kinds: those in which the patient in falling strikes himself violently against the region of the appendix, in which case the injury is, of course, due both to a blow and

a fall; and those in which there is no violent impact in the neighborhood of the appendix, but the shock *per se*, or the sudden translation of the viscera, followed by instant arrest, results in the tearing of some attachment, or of adhesions. Case 11, in which appendicitis followed a fall upon the buttocks, is a good illustration of this class. The numerous cases which follow on violent or prolonged exertion are also, perhaps, examples of trauma in a somewhat different sense, and I here enumerate the various sorts of strain and fatigue noted in my collected cases in order to show the variety of forms under which this particular kind of trauma may occur. Skipping rope backwards forty times, making a revolution of the rope each time; dancing (two cases); violent shaking of the body with the head downward; long hunting, over-exertion and fatigue; lifting heavy weights (2 cases); unusually long bicycle ride (2 cases); jumping (2 cases); rowing; playing foot-ball; severe strain while operating.

The trauma in these cases cannot depend upon any blow or impact upon the appendix, for it is inconceivable that the soft, surrounding structures should be capable of inflicting such injury. We are, then, limited to the inference that the exertion has been the direct cause of the injury by rupture of adhesions; or, as in the case of the boy hung up by the heels, of rupture of the anatomic attachments of the appendix; or that a foreign body lying in the appendix has shifted its position so as to bring on an attack.

Length of Time Elapsing Between Receipt of Injury and Development of Appendicitis.—In the large majority of cases pain was complained of immediately or else within a few hours. It is noticeable that whenever an interval of weeks or months elapsed between the accident and the well-defined symptoms of appendicitis, there were more or less well-marked symptoms of continuous digestive disturbance, or, on the other hand, there was a history of repeated attacks following the injury and before the patient came under observation for appendicitis.

Severity of Illness.—Somewhat more than half the cases were severe at the outset and continued so without intermission; in about 25 per cent. the initial attack was followed by an interval of relief, while in the remainder the symptoms were mild in the beginning and gradually increased in severity.

Evidences of Previous Morbid Conditions in the Appendix.—The question whether the appendix was normal at the time of the injury which resulted in appendicitis is of considerable importance, for, if the appendix was diseased and therefore liable to an outbreak of inflammation under slight provocation, the status of the defendant in a lawsuit is manifestly altered by the fact. I am indebted to Mr. H. M. BRUNE for the following extract bearing upon the subject from the *American and English Encyclopedia of Law* (second edition, vol. 7, article "*Contributory Negligence*").

Aggravation of Injury by Plaintiff's Negligence.—While the negligence of the injured person contributing proximately to his injury

will bar his recovery of damages, it is held that when he is guilty of no negligence contributing to the injury, negligence upon his part after the injury, by which it is aggravated, will not prevent him from recovering damages for so much of the injury as the original wrong-doer caused by his negligence. In such cases it seems that the damages may be apportioned or allowance made by the jury for that portion of the injury due to the plaintiff's fault.

Injury Enhanced by Disease.—1. Defendant's negligence causing or aggravating disease. In cases where the defendant's negligence caused a disease, developed a latent tendency to disease, aggravated a prior disease, or led in immediate sequence to disease, the defendant must respond in damage for such part of the diseased condition as his negligence caused. And if there can be no apportionment, or if it cannot be said that the disease would have existed apart from the injury inflicted by the defendant, then the defendant is responsible for the diseased condition.

2. Diseased condition independent of injury—Defendant's knowledge.—But when the diseased condition exists independently of the injury, and does not flow from it as a natural consequence following in direct sequence, the defendant's liability is only for such consequences as, independently of the diseased condition, were directly and immediately caused by his negligence. Yet if he knew of the diseased condition, and could have foreseen that it would aggravate an injury inflicted by his negligence, he is liable for the entire consequences that flow from the combination of his negligence with the existing diseased condition.

In 40 out of my 50 collected cases the appendix deviated in some way or other from normal, and 30 out of the 40 abnormal appendices were noted as containing concretions; in 7 of the remaining 10, which were without a concretion, there was evidence of old adhesions; of the last 3, 1 was flexed on itself; 1 was cystic; and 1 was unusually short and wide. No case has as yet appeared in which it has been shown that an injury *ab externo* has produced an appendicitis in a previously normal appendix, the presence of a foreign body being taken as indicative of disease, since it is the consensus of the educated medical profession that an appendix containing a fecal concretion is abnormal, although it is true that such an appendix may remain quiescent for an indefinite period. We may, therefore, conclude from the reported cases that a patient who is carrying a concretion in his appendix is far more liable to an attack of appendicitis from a blow of sufficient force when suitably directed than he would be were the appendix in all respects normal. In such a case there can be no allegation of negligence on the part of the plaintiff in bringing about or aggravating his condition, since he must have been entirely ignorant of it until it was revealed by the surgeon's knife. On the other hand, it cannot be said that the disease would have existed apart from the injury inflicted by the defendant, who becomes, therefore, liable for the lighting up of the disease into activity, and is responsible under the clause "developed a latent tendency to disease, aggravated a prior disease, or led in immediate sequence to disease," as above quoted.

In order to determine the degree of responsibility of the defendant it will be

necessary to ascertain how much violence was used, and to associate this factor with the previous condition of the appendix, as seen at operation or postmortem, according to the statement made by the physician. In view of the grave consequences to the defendant involved in an action for damages, the physician who examines the appendix and neighboring structures in such a case ought to note carefully the presence or absence of any old adhesions (evidences of previous attacks), of peritonitis, of rupture, of perforation, or of acute strangulation of the appendix. The appendix itself should be most carefully preserved, and preferably in formalin or in Kaiserling fluid, in order to demonstrate any ulcers of the mucous surface, any old scars, or strictures. If the appendix shows signs of old disease, if it contains a large concretion, or if the patient had had previous attacks and it can be shown that but slight force was used, and that without intent of injury, the status of the defendant will be different from what it would be in a case of disease, or one in which much violence was used.

The question of trauma as it affects the liability of life insurance companies becomes somewhat different, since the injury giving rise to appendicitis in these cases is due to exertion on the part of the patient himself, rather than to force in the hands of another. In the absence of a specific exception in the policy, the company ought to own its liability for appendicitis, as for any other internal disease. The only instance in which such a company could escape liability would be where it could show that the plaintiff had knowledge of previous attacks or weakness, which he concealed, or failed to state in applying for his insurance, and which information, under the terms of his policy, he was bound to furnish.

In the case of accident insurance, the company should be held liable when the appendicitis sets in directly after a blow or a strain.

Medico-legal Complications.—As an instance of legal complications relating to an appendicitis, I cite the following case (No. 47), for which I am indebted to A. E. Malloch, of Ontario, Canada:

A young man was attempting to lift a heavy cheese down from a shelf, while standing on a step-ladder, and the added weight causing the ladder to shift its position, forced him to exert himself, and occasioned a violent strain of the abdominal muscles; he remarked at once to those present that he had strained himself seriously. He began to have pain in his side almost immediately, severe enough to keep him in bed, more or less, for three days, after which he improved. On the tenth day, however, he was seized with symptoms of collapse, and died the day afterward. The postmortem examination made by Malloch "showed general purulent peritonitis with a ruptured abscess sac, containing a hard, sloughing appendix" (see Fig. 399). The patient, having taken out an accident policy in the Commercial Traveller's Insurance Company, the family presented a claim, which the company refused to pay, because there was no external lesion discoverable. On receiving a letter, however, signed by Dr. Mullin, the physician in charge, as well as by Drs. Malloch and Olmstead, who attended in consultation, testifying as follows, they paid the claim: "The deceased immediately after lifting the weight stated that

he had been hurt, and subsequently repeated this to all whom he saw. As symptoms which were located in the region of the appendix followed immediately, we have no doubt that the appendix was injured at the time, and that this must be considered of the nature of an accident."



Fig. 399.—Case of A. E. Malloch, Hamilton, Ont., in which Acute Appendicitis and Death followed Severe Muscular Strain.

In concluding the subject of trauma, I would emphasize the following points:

Evidence is lacking to show that trauma has caused appendicitis in a previously sound appendix.

An appendix containing a fecal concretion or other foreign body is not sound, and in such a case a severe muscular strain or blow upon the right side of the abdomen may produce a lesion of the mucous or muscular coats sufficient to

favor the invasion of pathogenic organisms, giving rise to an attack of appendicitis in nowise differing from the common forms of the disease.

If the patient strains, or makes active use of the abdominal muscles at the time of the receipt of the blow, these factors may act conjointly in causing the attack.

The more violent the blow or the greater the strain, the greater is the likelihood of an injury to the appendix.

A blow acts more efficiently upon a person with a shallow or a scaphoid abdomen where the walls are thin, than upon one who is stout or strongly built.

The blow acts as the immediate cause in producing the attack, which, while it might have occurred soon without such intervention, might also not have occurred for some years; the mediate cause is usually a foreign body.

Whenever a physician is called to a case the history of which is suggestive of traumatic origin, he will do well to make careful notes at the time, quoting as far as possible the patient's own language and expressions relating to the following facts:

1. The nature of the injury, whether a blow, a fall, or a strain.
2. The agent producing the injury.
3. The exact point and manner of impact, and whether the patient was engaged in active exertion or straining himself at the time the injury was received.
4. The expressions used by the patient at time and the the nature of his immediate complaints.
5. The length of time elapsing between the injury and the call for medical aid.
6. Any external evidence of violence (to be noted most carefully).
7. If an interval of some weeks has elapsed, an inquiry into the condition of the patient during this period should be made, it being stated whether he was able to resume his ordinary occupations, and with or without distress.
8. If death ensues or an operation is performed, it is of the highest importance to record the exact condition of the peritoneum and the viscera underlying the injured area, a minute and careful statement regarding the presence or absence of fecal concretions being always recorded.

The following case, in which a concealed trauma and infection were suspected, is of great medico-legal interest. It was reported by H. M. Biggs to the New York Pathological Society as an instance of suspected criminal abortion which proved to be appendicitis.

The patient, an unmarried servant, was suddenly seized with severe pain during a menstrual period. The attending physician discovered a general peritonitis, and associating this fact with the occurrence of an excessive menstrual flow, and "some evidence of a circumstantial character," concluded that the case was one of criminal abortion, and so reported it to the Board of Health. The woman died, and the autopsy revealed a general peritonitis resulting from a perforation of the appendix about one and a half inches from its base; a small, hard mass of fecal matter was found in the peritoneal cavity.

I hope that enough has been said to convince my professional colleagues that appendicitis must always be regarded as an affection for which an active human agency can be responsible, and that testimony to that effect must be given, when the facts warrant it, with assurance, whether it be for or against an individual or an association.

It is the duty of every physician, in taking the history of all cases of appendicitis, to inquire carefully into antecedent blows, falls, or unusual exertion, and to listen with attention to any suggestion made by the patient which points in that direction. He must also bear in mind that the injury need not, necessarily, be of recent date, although some symptoms, it may be of a vague character, will probably be recalled as immediately following it.

INDEX OF NAMES.

Aarestrop, 37.
Abbé, 367, 382, 719.
Abrahams, 729.
Achaud, 255.
Ackermann, 475.
Adami, 245.
Adrian, 357, 379, 383.
Aireton, 377.
Albers, 14.
Allen, 458.
Ammentorp, 344.
Anderson, 208.
Appuhn, 319, 320.
Arboré-Rally, 375, 454.
Archibald, 627.
Aretæus, 31.
Ashby, 243, 366.
Ashton, 374.
Aufrecht, 207.
Auguy, 334.

Baker, 366.
Ballin, 682.
Balzer, 403.
Bardeleben, 105.
Barnard, 429, 460.
Barnsby, 104, 700, 703, 712.
Barth, 277.
Baruch, 46.
Bary, 789.
Battle, 529, 534, 535, 537, 538.
Bayet, 404.
Bayliss, 193.
Beaussenat, 379, 380.
Beck, 298, 303, 357, 358, 489, 560, 561.
Becquerel, 375.
Beyer, 747, 748, 754, 755.
Bell, 362, 363, 366, 372, 376, 378.
Benoit, 341.
Bérard, 333, 627, 630, 631.
Berkley, 187, 188.
Bernard, 419.
Bernays, 420, 627, 757, 758, 759, 773.
Berry, 89, 92, 132, 135.
Berthelin, 226.
Beskett, 373.
Betz, 450, 454.
Bierhoff, 149, 292.
Biggs, 36, 810.
Bishop, 477.
Blackadder, 6, 375.
Blake, J. A., 215.
Blake, J. B., 587.
Blake, J. D., 136, 137, 580.
Bloodgood, 360, 377, 455, 624, 739.
Blos, 389.
Bode, 653.
Böhr, 450.
Boije, 732.
Boland, 441.
Boody, 249, 250.
Borchardt, 227.
Bornhaupt, 502.
Bossard, 434.
Bouness, 323.
Box, 444.
Brewer, 423, 426, 668, 670.
Brewster, 52.
Bridge, 798.
Briggs, 359.
Bright, 14, 15.
Broca, A., 255, 410, 627.
Broca, P., 365.
Brödel, 55.
Brooks, 371.
Brotske, 91.
Brower, 375, 376.
Brown, L., 428.
Brown, T. R., 517.
Browne, 207.
Brücke, 672.
Brun, 376.
Brune, 806.
Bryant, 136, 137, 138, 148, 250, 376, 386, 594.
Buchner, 306.
Buckler, 399.
Buhl, 226, 432.

Bull, 26, 36.
Bunting, 749.
Burchard, 38.
Burge, 36.
Burnam, 744, 756.
Burne, 16, 17, 302, 420.
Burrell, 664.
Byrd, 39.

Cabot, 52, 684.
Campbell, 798.
Canali, 770.
Cannon, 77.
Carmalt, 501, 579.
Carson, 739.
Caussade, 341.
Caven, 367.
Cayley, 215.
Chaffey, 477.
Charrier, 341.
Chastenat, 380.
Chauveau, 254.
Chevalier, 628.
Chiari, 770.
Christian, 349, 436.
Christoffers, 318.
Church, 243.
Churton, 739.
Clado, 60, 63, 92, 94, 98, 104, 148, 184, 255.
Clark, 372.
Cohn, 775.
Cohnheim, 672.
Coleman, 203, 374.
Coley, 692, 791.
Colman, 471.
Colmer, 367.
Colquehoun, 227.
Condamin, 421, 722.
Connell, 784, 785.
Connor, 468.
Conrath, 774, 778, 781, 783.
Copland, 14.
Cordier, 504.
Cornil, 336.
Cottam, 669.
Councilman, 246.
Crile, 277, 315, 364.
Crowder, 338, 342, 762, 763, 773.
Crowell, 439.
Crozet, 743.
Crutcher, 733.
Cruveilhier, 292.
Cullen, 267, 269, 274, 276, 308, 574, 630, 664, 665, 740, 762, 763, 802.
Cummin, 192.
Cunéo, 104, 185.
Cunningham, 352.
Curschmann, 441, 443, 444.
Curtis, 249.
Cushing, E., 458.
Cushing, H., 387, 448, 518.
Czerny, 343, 405, 774.

Da Costa, 419, 429
Daland, 368.
Dale, 215, 227.
Dance, 10.
Dandridge, 584.
Daske, 770.
Davaine, 375.
David, 418.
Dawbarn, 51, 369, 563, 564.
Deaver, 52, 138, 255, 302, 367, 416, 428, 566, 567.
De la Carrière, 456.
Delagénière, 710.
Delanglade, 631.
Delbet, 652.
Delorme, 202, 799.
Demme, 454.
De Ruyter, 750.
De Vecchi, 18, 432.
Dieulafoy, 198, 227, 380, 385, 391, 404, 670, 671.
Dock, 138.
Dodwell, 761.
Doughty, 502, 614, 616, 617, 670.
Down, 615.
Downes, 568, 572.
Draper, 747.
Du Barry, 802.
Duckworth, 52, 662.
Dudley, 226.
Dührssen, 375.
Dupallier, 375.
Dupuytren, 10, 11, 25.
Durand, 104.
Durande, 774.
Durkee, 203.

Eastman, 571, 572.
Eberth-Schimmelbusch, 672.
Eccles, 786.
Edebohls, 2, 51, 358, 474, 529, 538, 565, 566.
Ehrich, 315.
Einhorn, 211, 227, 358.
Elliot, 797.
Elsberg, 215, 222, 225, 636, 638, 639.
Elsner, 442.
Elting, 744, 747, 750, 751, 752, 753, 773.

Emmet, 720.
Enderlen, 477.
Erdman, 375, 377.
Erving, 768, 769.
Escherich, 258.
Evans, 651, 652.
Eve, 460.
Ewald, 287.

Faber, 375.
Fabre, 322.
Fawcett, 137.
Federmann, 390.
Fenger, 268, 322, 417, 454, 455, 487, 589, 590, 591, 755, 764.
Fenwick, 27, 28, 39, 714, 761.
Ferguson, 136, 138, 249.
Ferry, 104, 334.
Field, 426.
Finder, 429.
Finkelstein, 249.
Finney, 91, 122, 208, 271, 331, 359, 381, 382, 392, 406, 452, 503, 505, 506, 534, 558, 559, 561, 582, 586, 602, 635, 647, 658, 697, 720, 721, 767, 776, 787.
Fitz, 28, 29, 30, 42, 43, 47, 149, 227, 292, 315, 358, 362, 410, 442, 481, 795.
Foerster, 789.
Follis, 448, 582, 585, 626.
Fowler, 48, 51, 204, 270, 277, 408, 529, 531, 561, 562, 563, 644, 674, 715, 722, 799.
Franke, 382.
Fränkel, 243, 254, 261, 730, 732, 733, 734, 735.
Frazier, 376.
Freeman, C. A., 207.
Freeman, R. D., 458.
Freind, 204.
Fruitnight, 456.
Funke, 781.
Futcher, 354.

Gaertner, 261.
Gaffky, 261.
Gage, 438, 661, 677, 692.
Galipe, 300.
Gallant, 629, 714.
Galton, 601.
Gardner, 374.
Garreau, 429.
Gaston, 38, 215.
Gay, 33, 385, 387.
Gegenbauer, 79.
Genser, 454.
Genzmer, 13, 14, 454.
Gerhardt, 672, 674.
Gerlach, 116.
Gerster, 330, 417, 755.
Gibbon, 331.
Gibney, 450, 478, 479.
Gilford, 757.
Giordano, 422, 423.
Girard, 379.
Glazebrook, 747.
Gloniger, 453, 732.
Goldbeck, 12, 13, 17, 796.
Golubof, 381.
Goodall, 449.
Goodfellow, 374.
Gordon, 452, 486, 487, 491, 799.
Gosset, 244.
Goulay, 36, 37.
Gould, 800.
Grant, 381.
Grauer, 136.
Graves, 511.
Grawitz, 318, 323.
Graziani, 786, 787.
Griffith, 450, 453, 460, 461, 469.
Grisolle, 17.
Grohé, 63, 80, 153, 349.
Guebler, 496.
Gussenbauer, 672.

Haesler, 468, 469.
Haldane, 471, 472.
Hall, 43, 44.
Halle, 319.
Hallowell, 18.
Halsted, 378, 504, 559, 560, 587, 621, 635, 679, 691, 746, 747, 756, 782, 785.
Hamburger, 381.
Hammond, 435.
Hancock, 21, 32, 33, 35, 47, 729.
Harbitz, 255.
Harley, 366.
Harris, 370, 453.
Harsha, 424.
Hart, 227.
Harte, 747, 748, 752.
Hartley, 249.
Hartmann, 90, 95, 338, 341, 761, 774.
Hartshorne, 797.
Harvey, 47, 677.
Hasse, 104.
Hawkes, 508, 732, 762, 763.
Hawkins, 52, 362, 702, 799.
Hayem, 739.
Head, 522.
Hearn, 447.

Heddaus, 343.
Hektoen, 249, 272, 737.
Helferich, 344.
Henle, 104.
Henrotin, 373, 762.
Herlin, 191.
Herman, 564.
Herrgott, 734.
Herrick, 429.
Hevin, 372, 379.
Hill, 359.
Hillairet, 226.
Hirst, 689.
Hlawacek, 730, 734.
Hodgkin, 14, 15.
Hofmann, 225.
Hofmeister, 770, 774.
Hogarth, 472.
Holbue, 37.
Holmes, B., 204, 683.
Holmes, C. C., 372.
Holmes, T. K., 732.
Homans, 797.
Hopfenhauser, 346, 436, 438.
Houston, 372, 430.
Howard, 24, 28.
Hunner, 791, 792.
Huntington, 67, 78, 80, 131, 136, 153, 599.
Husson, 10.
Hutchinson, 377.

Iliff, 450.
Illich, 344, 768.
Inge, 359.
Isemar, 196.
Israel, 342, 646.
Itié, 341.

Jaboulay, 630, 632.
Jackson, 203, 226.
Jacobson, 504.
Jadelot, 3, 432.
Jaeger, 601.
Jaffé, 613, 634.
Jalaguier, 52, 255, 382, 535, 537, 752.
Jay, 374.
Jeanniel, 789.
Jervall, 320.
Jessop, 753.
Joffroy, 365.
Johnson, 695.
Jonesco, 90, 92, 93, 95, 97, 166.
Jonnesco, 510.
Jopson, 479, 786, 790.
Jorand, 227.
Jordan, 488, 493.
Juilliard, 37, 38.

Kablukoff, 377.
Kader, 684.
Kammerer, 197, 367, 535, 537.
Karewski, 450, 456, 457, 459, 460, 463, 481, 483, 484.
Keen, 319, 320, 369, 403, 494, 679.
Keirle, 796.
Kelly, A. O. J., 316, 362, 739.
Kelynack, 89, 92, 94, 96, 290, 798.
Kingdon, 204, 320, 365.
Kircher, 583.
Klecki, 380.
Klein, 261.
Knight, 475.
Kobler, 226.
Kocher, 774.
Kolaczer, 748, 753.
König, 730, 733, 774.
Körte, 244, 255, 644, 774, 778.
Krackowitzer, 227, 320.
Kraussold, 249, 773.
Kreutzmann, 722.
Krogius, 52, 205, 256, 260, 529.
Krompecher, 749.
Krönig, 732.
Krönlein, 41, 42, 46, 47.
Kruger, 700, 707, 722.
Kücher, 583.
Kümmell, 686.
Kussmaul, 645.

Labhardt, 735, 736.
Lafforgue, 93, 94, 104, 136, 138, 174, 185, 186, 737.
Lagoutte, 631.
Lamers, 757.
Lamotte, 2.
Lang, 214, 215, 222.
Langhans, 344.
Langheld, 227.
Lanz, 255, 256.
Lapeyre, 225, 406, 670, 671.
Laplace, 396, 649, 651.
Laroyenne, 722.
Larret-Lamalignie, 794.
Lartigau, 341.
Laruelle, 254.
Lautard, 594.
Lee, 368.
Lees, 476.

Le Gendre, 730.
Legg, 365, 565.
Leichtenstern, 744.
Lemaire, 37.
Leman, 744.
Lemon, 711.
Lennander, 52, 303, 324, 359, 387, 388, 394, 395, 499, 507, 522, 529, 535, 537, 572, 573, 575, 644, 645, 662.
Lenzmann, 52, 136, 285, 287, 302, 306, 315, 417, 424, 461.
Lettau, 787, 789.
Letulle, 752.
Leudet, 24, 25, 383, 404.
Lewis, D., 732.
Lewis, G., 22, 24, 25.
Lewis, M. J., 446.
Lieberkühn, 191.
Lister, 36.
Little, 92, 96.
Lloyd, 366.
Lockwood, 52, 80, 92, 93, 94, 96, 98, 145, 146, 173, 802.
Loison, 226, 243, 244.
Longcope, 331.
Lösch, 352.
Louyer-Villermay, 4, 6, 10, 24.
Lücke, 649.
Lund, 371.
Luschka, 91, 95, 136, 138.

MacMonagle, 348, 351, 352, 413, 437, 802.
Madelung, 686.
Mahomed, 42.
Mall, 55.
Malloch, 802, 808, 809.
Mallory, 226, 246, 341, 348, 349.
Malvoz, 255.
Manley, 452, 453, 464.
Manté, 733, 734.
Manton, 358, 428.
Marchand, 343.
Marcy, 48, 52, 798.
Maréchal, 756.
Markoe, 327, 512.
Marx, 735.
Matalakowski, 775.
Matterstock, 27, 227, 362, 450, 487.
Mattheson, 391, 392, 416.
Mauclaire, 631.
Maurin, 249.
Maydl, 214, 215, 744, 773.
Mayo, 372, 373, 374, 377.
McArthur, 251.
McBurney, 13, 29, 31, 48, 49, 50, 51, 249, 366, 367, 529, 530, 531, 532, 533, 534, 537, 538, 693, 746, 747, 755.
McCallum, 320.
McCosh, 359, 450, 508, 647, 654, 732, 762, 763, 764.
McCoy, 208.
McFarland, 470.
McGill, 774.
McGraw, 466, 475, 781, 785.
McGuire, 721, 722.
McKelway, 712.
McKidd, 465, 466.
McMurtry, 489, 493.
McPhedren, 367.
Meckel, 598.
Mélier, 1, 7, 8, 9, 10, 11, 24.
Mendel, 363.
Ménière, 10.
Merling, *motto*, 13, 116, 743.
Mestivier, 2, 25, 31, 365.
Metchnikoff, 375, 377, 379, 418, 454.
Meusser, 492.
Meyer, 667.
M'Gregor, 208.
Mikulicz, 39, 40, 41, 603, 608, 633.
Miller, 421, 673.
Mitchell, 364, 365, 370, 387, 657, 687.
Mixter, 589.
Monk, 756.
Monks, 587, 744.
Montgomery, 288, 447, 467.
Montserrat, 467.
Moore, 436.
Morgagni, 786.
Moriata, 367, 378, 799.
Morison, 702.
Morris, 277, 296, 420, 429, 529, 537, 538, 566, 621, 649, 653, 752.
Morse, 461, 462, 786.
Morton, 44, 45, 46, 47, 529, 798.
Moschowitz, 744.
Mosher, 336, 762.
Mott, 197.
Moty, 455.
Mudd, 372, 374.
Mühsam, 317, 674, 677, 678, 681.
Muller, 286.
Mullin, 806, 808.
Mumford, 415.
Mundé, 714, 733.
Munro, 227, 243.
Muret, 730.
Murphy, 197, 204, 323, 324, 362, 373, 436, 445, 489, 768.
Musser, 196.
Mynter, 48, 407, 479, 799.

Nancrede, 587.
Nanninga, 116.
Nassau, 439.
Natalé, 376.
Neumann, 613, 800.
Nicolayson, 380.
Nietert, 408.
Niot, 715.
Noble, C. P., 358, 423, 538, 539.
Noble, G. B., 359.
Norris, 744, 749, 753.
Nothnagel, 154, 211, 214, 486, 756.
Noyes, 37, 38.
Nuttall, 261.

Ochsner, 211, 368, 386, 423, 446, 510, 802.
Officer, 368.
Olmstead, 808.
Oppenheim, 672.
Oppenheimer, 732.
Oppolzer, 25.
Orth, 597, 598, 599, 787.
Osler, 303, 352, 382, 404, 419, 422, 497, 518, 599, 601.
Oviatt, 602, 738, 739.

Paak, 261.
Park, 366, 686.
Parker, R. H., 797.
Parker, W., 26, 34, 37, 43, 47.
Parkinson, 34, 450.
Parrot, 365.
Partsch, 342, 343.
Patel, 627, 630, 631.
Paviot, 381.
Pawlowsky, 254.
Payne, 202, 243, 365, 662.
Pearce, 18, 246.
Penrose, 732.
Pepper, 18.
Perignon, 91, 95.
Perkins, 677, 678, 679.
Perret, 798.
Petel, 332, 333.
Peterson, P., 758, 759, 773.
Peterson, R., 632.
Petrequin, 511, 794.
Petrevsky, 260.
Piard, 244, 671.
Piersol, 480.
Pilliet, 244, 338, 341, 761, 775.
Pitts, 474.
Poirier, 104, 185.
Poljakow, 383.
Poncet, 386, 636.
Pond, 388, 425, 506, 800.
Pooley, 202.
Porter, C. B., 52, 481.
Porter, M. F., 489, 674, 676.
Powell, J. B., 206.
Powell, N. C., 410.
Powers, 681.
Pozzi, 321, 698.
Predöhl, 254.
Price, 721.
Prüss, 743, 786, 787, 789.
Puchelt, 12, 14, 17.
Pulsford, 439.

Quénu, 415, 629.
Quinard, 416.

Rabé, 227.
Ramond, 341.
Ransohoff, 249, 372.
Ravaut, 341.
Reamy, 18.
Reclus, 380, 381.
Reichel, 652.
Reisinger, 302.
Rendu, 334.
Renshaw, 473.
Renvers, 303, 323, 487.
Retzius, 168, 169.
Reyling, 747.
Reynes, 403.
Ribbert, 135, 136, 137, 149, 150, 152, 250, 290, 292, 357, 480.
Ricard, 333.
Richard, 322.
Richards, 17, 18.
Richardson, *motto*, 48, 52, 388, 390, 391, 397, 421, 429, 430, 432, 440, 457, 463, 464, 497, 498, 505, 590, 667.
Richelot, 336.
Riedel, 52, 284, 357, 561.
Riefkohl, 601.
Ritzel, 419.
Rivet, 479, 786.
Roach, 482.
Robb, 377, 705, 719.
Roberts, 367.
Robinson, 124, 130, 134, 136, 137, 215, 249, 250, 358, 587.
Robson, 721, 731, 739.
Roger, 379, 380.
Rogers, 363.
Rogers, L., 353, 354, 770.

Rokitansky, 21, 743, 751, 752, 787.
Rolleston, 89, 92, 93, 369, 433, 746, 748, 755.
Rotter, 627, 631.
Rouget, 104.
Rousseau, 420.
Routier, 340.
Roux, 52, 321, 357, 399, 582.
Runyon, 287, 709.
Rushmore, 489.
Russell, 421, 607.
Rydygier, 565.

Sachs, 215, 774.
Sahli, 302, 316, 357.
Sallet, 636.
Salmon, 260.
Salzer, 775.
Sambl, 353.
Sandefort, 787.
Sands, 46, 47, 433, 435, 529.
Sänger, 619.
Sappey, 168, 169.
Schede, 322, 686.
Scheibenzuber, 209, 333.
Schlafke, 492.
Schleich, 250.
Schmidt, A., 37.
Schmidt, J. C., 13, 14, 225.
Schooler, 369.
Schüller, 529.
Schultze, 104.
Sears, 360, 372.
Sedillot, 318.
Selmer, 37.
Selter, 450, 452, 456, 457, 482, 483.
Senn, 48, 49, 292.
Sharp, 802.
Sheen, 227.
Shober, 701.
Shoemaker, 196, 243, 244, 366, 701.
Sholler, 377.
Siegel, 714.
Simon, 418.
Skene, 52, 567.
Small, 796, 800.
Smith, 192, 260.
Sonnenburg, 52, 215, 227, 291, 303, 313, 316, 317, 322, 323, 336, 382, 488, 490, 491, 529, 672, 673, 675, 676, 680, 740, 755, 757, 762, 763.
Soranus, 31.
Southam, F. A., 490.
Southam, G., 796.
Southerland, 357.
Spickenbaum, 196.
Spillissy, 414, 418, 420, 421, 424.
Starling, 193.
Steensland, 285.
Steiner, 250.
Steinhal, 649.
Still, 455.
Stimson, 35, 755.
Stöhr, 357.
Stokes, J. E., 494.
Stokes, R. J., 357, 511.
Stone, 372.
Stooke, 227.
Strickler, C., 732.
Strümpell, 486.
Stumpf, 729.
Suchier, 773.
Summa, 709, 710.
Sutherland, 455.
Sutton, B., 449, 455.
Sutton, E. M., 631.
Symonds, 42.
Syms, 367.

Tait, 38, 716.
Talamon, 52.
Tavel, 255, 256.
Tchacaloff, 292.
Terillon, 698.
Terrier, 603, 622, 623.
Thédenot, 769.
Thomason, 733.
Thorndike, 744, 755.
Thurnam, 373.
Tietze, 652.
Tirifahy, 375.
Tixier, 184, 185, 186.
Toft, 249.
Toldt, 91, 95.
Treves, 45, 46, 47, 48, 49, 52, 86, 90, 91, 92, 93, 99, 105, 106, 119, 128, 137, 138, 391, 400, 402, 410, 414, 416, 420, 424.
Trimble, 280, 739
Tripier, 381.
Trowbridge, 227.
Tuffier, 52, 90, 92, 95, 500, 730.
Turk, 383.

Umber, 214, 222.

Vallée, 138, 148.
Vallin, 104.
Van Arsdale, 654.
Van Cott, 592.

Van Hook, 622, 790.
Van Lennep, 193, 498, 508, 651, 674.
Veillon, 256, 261.
Véron, 378.
Vianney, 184, 185, 186.
Vigniard, 507.
Virchow, 291, 672, 787.
Volz, *motto*, 19, 21, 511.
Von Baracz, 680.
Von Bergman, 502.
Von dem Busch, 192.
Von Eiselsberg, 491, 680, 780.
Von Faber, 481.
Von Leyden, 214.
Von Moty, 375, 455.
Von Wahl, 684.
Voron, 428.
Vosse, 191.

Walch, 663.
Waldeyer, 90, 92, 94, 96.
Wallace, C. S., 444.
Wallace, W. L., 203.
Waller, 226.
Wallis, 249.
Walsham, 371, 578, 619.
Ward, N., 373.
Ward, O., 797.
Warren, 373, 621, 653, 758, 773.
Warrington, 18.
Wassalief, 774.
Waterhouse, 465.
Watkins, 723.
Watney, 357.
Weaver, 90, 98, 120, 137.
Weber, 36, 215, 222.
Wegeler, 4.
Weichselbaum, 254, 744.
Weigert, 342.
Weinburg, 752.
Weir, 48, 49, 278, 614, 615, 744, 755.
Welch, 255, 260, 261, 328, 332, 672.
Werder, 706, 716.
Westermann, 476.
Wetherill, 371.
Whipham, 366, 756.
Wickershauer, 706.
Wigan, 710.
Wiggans, 716.
Willard, 366.
Williams, D., 511.
Williams, V. H., 643.
Wilson, 747, 752, 748.
Winge, 37.
With, 27.
Witzel, 642.
Wolbrecht, 387.
Wölfler, 251, 292, 780, 783, 790.
Wood, 250.
Woodbury, 44, 45.
Worcester, 31, 48, 51, 202, 458, 539, 667.
Wright, G. A., 473, 753.
Wright, T. R., 371.

Yates, 261.

Zeller, 567.
Zuber, 256, 261.
Zuckerkandl, 136, 152, 250, 292.
Zweifel, 701.

INDEX.

Abdominal cavity; irrigation of, in general purulent peritonitis, 647–652; power of absorption in, 304–306; sensibility of, 305, 321, 322.

Abdominal fossæ, 611, 612.

Abnormal positions of the appendix; due to arrested development, 133–135; due to displacement, 130–132; due to length of mesentery, 132, 133.

Abortion, criminal, mistaken for appendicitis, 809, 810.

Abscess of kidney in appendicitis; natural history of, 208; post-operative sequela, 667.

Abscess of liver in appendicitis; at autopsy, 226–246; complication, 402; natural history of, 209.

Abscess, peri-appendical; at autopsy, 213; between layers of mesentery, 313, 624–627; encapsulated in omentum, 622; gangrenous, 622–624; pathology of, 312–314; resolution of, 316; results of, 316–322; treatment of, 313, 614–622; treatment of, in special cases, 622–627.

Abscess, peri-appendical, rupture of; into abdominal wall, 316, 317; into bladder, 204, 318–320; into cecum, 204; into gall-bladder, 317; into gluteal region, 205; into intestinal tract, 317; into popliteal space, 205; into rectum, 204; at umbilicus, 204; into vagina, 204, 317; under crural arch, 205.

Abscess, pelvic peri-appendical; at autopsy, 213, 214; frequency of, 627; para-sacral method of opening, 630; perineal method of opening, 631; symptoms of, 628; treatment of, 628–632; varieties of, 627.

Abscess, perinephritic, 424.

Abscess, retro-peritoneal, 314–316.

Abscess, subphrenic, in appendicitis; at autopsy, 214–225; complication, 402; etiology of, 636, 637; symptoms of, 637, 638; treatment of, 638–641.

Acetonemia as a post-operative sequela, 668, 669.

Actinomycosis, appearance of at operation, 776; clinical history of, 768, 769; in child, 481, 482; etiology of, 669, 670; frequency of, 196; pathology of, 342–347.

Adhesions; between appendix and site of previous operation, 719–723; delicacy of, in child, 458; treatment of, in removal of appendix, 575–587.

Amœbic dysentery, clinical history of, 770, 771; pathology of, 352–354.

Anastomosis of intestines, 777–785.

Anatomical bibliography, 188, 189.

Anatomy of appendix in child, 451, 452.

Anesthesia, 516–522.

Anus preternaturalis, 680.

Appendices; abnormally long, 136; misplaced, 135; supernumerary, 135.

Appendicitis, acute catarrhal; natural history of, 199; pathology of, 264–266.

Appendicitis, acute; complications of, 398–404; diagnosis of, 407–414; differential diagnosis of, 414–430; exciting causes of, 360–380; final causes of, 380–384; first recorded case of, 2; frequency of, 210, 211; medical treatment of, 510–513; natural history of acute and chronic, 198, 199; origin of name, 29; pathological classification, 263, 264; predisposing causes of, 357–360; symptoms of, 386–398.

Appendicitis, acute diffuse; histology of, 266; pathology of, 268.

Appendicitis, chronic adhesive, 249, 250.

Appendicitis, chronic diffuse; complications of, 405, 406; histology of, 284, 285; forms of, 405; pathology of, 278–285; rigidity of appendix in, 279; symptoms of, 405, 406.

Appendicitis, chronic obliterative, 250.

Appendicitis, gangrenous, 269–271.

Appendicitis larvata, 405, 458, 459.

Appendicitis, perforative, 276–278.

Appendicitis, purulent, 268, 269.

Appendicitis, residual, 278, 287, 288.

Appendicitis, traumatic, 795–803.

Appendicitis, ulcerative, 285–287.

Appendico-cecal junction, lymphatics of, 174.

Appendiculo-ovarian ligament, 102–104.

Appendix; arteries in, 155–166; coats of, 139–

146; contents of, 148, 149; dimensions of, 135–139: distortions of, 124, 125, 126, 199; embryology of, 55–71; exposure of, in operation on, 540–546; function of, 190–193; glands of, 144–146, 184–186; lymphatics of, 169–173, 333, 334; lymph nodes in, 146–148; movements of, 193, 194; nerves of, 186–188; position of, 118–135; retrogression of, 152–154; structure of, 139–148; transient, 56–58; veins of, 166–169.
Arteries, appendical; arrangement of, 164–166; embolism of, 208, 209; method of injecting, 161; origin and number of, 156–161.
Artĕries of mesappendix, 161.
Arterio-sclerosis, 248.
Auto-infection as a post-operative sequela, 668, 669.
Autopsy records, bibliography of, 252, 253.

Bacteria in appendix; conditions favorable for development of, 256, 257; species of, present, 257–260.
Bacteriological bibliography, 261, 262.
Bibliography, anatomical, 188, 189; autopsy, 252, 253; bacteriological, 261, 262; historical, 52, 53; pathological, 354–356.
Bladder; adhesion of, to appendix, 197, 204, 205, 318–320; symptoms in appendicitis, 387.
Blood-vascular infection, 328–333.
Bone, pieces of, in appendix, 373, 374.
Bowels; care of, after operation, 658, 659; treatment of, in acute appendicitis, 511–513.
Bradford frame, use of, in appendicitis in child, 484.
Bristle, piece of, in appendix, 373.

Carcinoma of the appendix; clinical history of, 743–757; operation for, 772, 773.
Carcinoma, differential diagnosis between, and appendicitis, 417, 469, 470.
Causes of appendicitis; exciting, 360–380; final, 380–384; predisposing, 357–360.
Cecal apparatus, function of, 78–80.
Cecal glands, isolated, 183, 184.
Cecum; appendical abscess discharging into, 204; resection of, 475–477; types of, 80–85.
Cecum, primary ulceration of, 302, 303; cases of, 488–492; diagnosis of, 492, 493; operation for, 493.
Cecum, varieties of ulceration in, 486, 487.
Child, appendicitis in; age for, 451; delicacy of adhesions in, 458; diagnosis of, 459–482; examination by rectum in, 456; examination of thoracic viscera in, 457; gastro-intestinal disturbance in, 457, 458; history of, 450, 451; symptoms of, 455–459; treatment of, 482–484; vomiting as sole symptom of, 456, 457.
Chills, symptom of appendicitis, 394.
Cigarette drains, 621, 653.
Clado's gland, 184.
Coats of the appendix, 139–148.
Colic glands, isolated, 183, 184.
Complications of acute appendicitis, general peritonitis, 399–401; hemorrhage, 404; ileus, 401; liver abscess, 402; lung affections, 402, 403; pleural affections, 402, 403; pyemia, 402; pylephlebitis, 402; septicemia, 401; subphrenic abscess, 402; suppurative peri-appendicitis, 398, 399; vesical and renal affections, 403, 404.
Complications of chronic appendicitis, 405, 406.
Concretions, fecal; appearance of, 148, 149; cause of appendicitis, 362–365; cause of appendicitis in child, 404; method of development of, 199, 300, 301; pathology of, 298–301.
Connell's method of intestinal anastomosis, 785.
Constipation; symptom of, acute appendicitis, 391; of chronic appendicitis, 405.
Contents of appendix, 148.
Cutaneous hyperesthesia in appendicitis, 389.
Cystitis in appendicitis; post-operative sequela, 667, 668; symptom, 403, 404.
Cysts, appendical, 250–251, 288–292.

Diagnosis of appendicitis, 407–414; in child, 459–482.
Diet after operation, 657.
Differential diagnosis between appendicitis and; actinomycosis, 481, 482; carcinoma, 417; coxitis, 427, 428, 478, 479; foreign bodies in intestine, 415; gall-bladder affections, 414, 415; gastro-intestinal affections, 414–418; gynecological affections, 427; hypochondriasis and hysteria, 428; hernia, 418, 480, 481; ileocecal tumor, 416, 417; intestinal obstruction, 417, 418; intestinal parasites, 418; intramuscular abdominal abscess, 427; intussusception, 418, 464–478; kidney affections, 421–424; mesentery, affections of, 419, 420; ovarian disease, 481, 715, 716; pancreatic disease, 426, 427; pelvic inflammation, 711–717; perinephritic abscess, 424; peritoneal affections, 419–421; pneumonia and pleurisy in child, 460–

463; psoitis, acute, 427; pyonephrosis, 423, 424; renal tumor, 424; tubercular peritonitis, 463–481; typhoid fever, 459; vertebral disease, 427.
Differentiation between appendix and cecum in embryonic life, 72–77.
Digestive disorders as a cause of appendicitis, 360, 361.
Dimensions of appendix, 135–139.
Diseases to which appendix is liable, natural history of, 195–198.
Displacements of appendix, 131–133.
Distention of abdomen, as symptom of appendicitis, 397.
Distortions of appendix, 124, 125, 126, 199.
Diverticula, false, 594.
Diverticulitis, 602.
Diverticulum, Meckel's; arteries of, 599; attachment of, 597, 598; embryology of, 595, 596; mesenteriolum of, 600, 601; size of, 596, 597; types of, 596.
Drainage; in appendical abscess, 620–622; in diffuse purulent peritonitis, 652–654; in pelvic abscess, 632.
Drainage, best material for, 621.
Drains, cigarette, 621, 653.
Dysmenorrhea in chronic appendicitis, 406, 698.

Ectopic gestation. See *Extra-uterine pregnancy.*
Effects of an appendicitis upon the appendix itself, natural history of, 199, 200.
Effects of an appendicitis upon neighboring structures, natural history of, 201–204.
Embolism; of appendical arteries, 208, 209; of coronary arteries, 248, 249; of pulmonary artery, 208, 248; of tibial artery, 208, 333.
Embryology of the appendix, 55–71.
Empyema; of the gall-bladder, 425; of the pleura, 459.
Endocarditis, 248.
Entero-enterostomy, 778–780.
Enteroliths. See *Concretions.*
Enterostomy, 654.
Epididymitis as a post-operative sequela, 667.
Etiology of appendicitis; age in, 358, 452, 453; digestive disorders in, 360, 361, 454; foreign bodies and concretions in, 362–374, 379, 380, 454; floating kidney in, 358; heredity in, 359, 360; infectious diseases in, 381–383; intestinal parasites in, 374–377; menstruation in, 361; microbic infection in, 380; nationality in, 359; sex in, 358, 359; trauma in. See *Traumatic appendicitis.*
Examination of appendix whenever the abdomen is opened, 717.
Examination of patient in appendicitis, 410–414, 455–459.
Exposure of appendix, method of, 540–546.
Extra-uterine pregnancy; diagnosis between, and appendicitis, 734, operation for appendicitis in, 728.

Fibroma of appendix, 740–743.
Fibro-myomata of appendix, 196, 739.
First recorded case of appendicitis, 2.
Fish-fin in appendix, 374.
Fistula, intestinal, 317, 318, 674–681; urinary, 318–320, 681, 682.
Floating kidney a cause of appendicitis, 358.
Folds; ileocecal, 90–92; ileocolic, 89, 90; pericecal, 86–88; retrocecal, 99–102.
Forceps, Eastman's 572, 575; mosquito, 515.
Foreign bodies in appendix; cases of, 365–374; etiologic relation of, to appendicitis, 362–365; pathogenesis of, in appendicitis, 377–380.
France; early history of appendicitis in, 2–11; first reported case of appendicitis in, 2.

Gall-bladder, disease of, mistaken for appendicitis, 424–426.
Gall-stones (supposed) in the appendix, 363, 364.
Gangrenous appendicitis, 269–271.
Gas-formation as a post-operative sequela, 664.
Gastric lavage in treatment of appendicitis, 510.
Gastro-intestinal disease mistaken for appendicitis, 414–418.
Gastro-intestinal symptoms in appendicitis, 457.
General appearance in appendicitis, 398.
Germany, early history of appendicitis in, 12–14.

Heart, condition of, in appendicitis at autopsy, 248.
Hemorrhage in appendicitis: complication, 404; post-operative sequela, 662, 663; symptom, 391, 392.
Heredity in the etiology of appendicitis, 359, 360.
Hernia of appendix; acquired, 787–789; congenital, 787; diagnosis of, 791; frequency of, 252, 786, 787; treatment of, 791–793.
Hernia of appendix, in child, 479–481.

Hernia, intestinal; mistaken for appendicitis, 418; post-operative sequela, 692–697.
History of appendicitis in; England, 14–17; France, 2–11; Germany, 12–14, 19–21; United States, 17–18, 22–24, 28–30.
History of appendicitis, surgical, 31–52.
Hypochondriasis mistaken for appendicitis, 428.
Hysteria mistaken for appendicitis, 428.

Ice in treatment of appendicitis, 511.
Ileocecal artery, 155, 156.
Ileocecal fold, 90–92.
Ileocecal region; lymphatics of, 173, 174; inner surface of, 110–117.
Ileocecal tumor; mistaken for appendicitis, 416, 417; operation for, 770–785.
Ileocolic artery, 155.
Ileocolic fold, 89, 90.
Ileus, in appendicitis; complication, 401; indication for operation, 499, 500; post-operative sequela, 683–692.
Ileus mistaken for appendicitis, 499, 500.
Iliac artery, hemorrhage from adhesion of, to appendix, 206, 207.
Incision in appendicitis; closure of, 538, 539; double, 483, 538; general rules for, 523; lateral, 723–725; median, 524, 531, 723; oblique, 531, 532; semilunar, 534–537, 723; vertical, 524, 527.
Incision in appendicitis; methods for, Battle's, 534–537; Edebohls's, 538; Finney's modification of McBurney's, 534; Fowler's, 531, 532; McBurney's, 533, 534, 735; Morris's, 538; Roux's, 532; Sonnenburg's, 529, 531.
Incision for ileocecal tumor, 774.
Incision in diffuse purulent peritonitis, 646, 647.
Indican, presence of, in urine, 404, 441, 442.
Indications for operation in appendicitis, 496–500.
Indigestion, acute, mistaken for appendicitis, 459.
Infarction, intestinal, in appendicitis, 331, 332.
Infection, peritoneal, varieties of, 306.
Inferior pelvic abscess, 627, 628.
Intermediate operation for appendicitis, 503–506.
Interval operation for appendicitis; definition of, 506; first performed, 42, 43; safety of, 507; time for, 507, 508.
Intestinal anastomosis, methods of, 778–785.
Intestinal fistula; pathology of, 317–318; as a post-operative sequela, 674–681.
Intestinal parasites, 374–377, 454, 455.
Intestines, condition of, at autopsy in acute appendicitis, 247; lifting out of abdominal cavity, 647; irrigation of, 647–649; wiping off, 652.
Intramuscular abdominal abscess, mistaken for appendicitis, 427.
Intra-thoracic affections, mistaken for appendicitis, 429, 430, 460–463.
Intussusception, 464–475; mistaken for appendicitis, 418.
Intussusception of appendix, mistaken for carcinoma, 469, 470.
Inversion of appendix, 464, 468, 474, 475.
Irrigation of peritoneum, 647–652.

Jaundice, symptom of appendicitis, 379, 398.

Kidney, abscess of, in appendicitis; history of, 208; post-operative sequela, 667.
Kidney, condition of, in acute appendicitis at autopsy, 246, 247.
Kidney, disease of; complication of appendicitis, 403, 404; mistaken for appendicitis, 421–424.
Kidney, floating, mistaken for appendicitis, 421–424.

Lameness as a symptom of appendicitis in child, 458, 459.
Larvate form of appendicitis, 458.
Late operation for appendicitis, 506.
Lateral incision, 524, 531.
Lead colic, mistaken for appendicitis, 419.
Length of appendix, 135–138.
Leucocyte count; in diagnosis of appendicitis, 430; in diagnosis between appendicitis and typhoid fever, 441; as indication for operation, 499.
Lipoma of mesentery, 420.
Liver abscess in appendicitis; at autopsy, 226, 227; as complication, 402.
Liver, acute yellow atrophy of, 628, 683.
Local anesthesia, 519–522.
Lungs, condition of, in appendicitis at autopsy, 247.
Lungs, disease of, in appendicitis; complication, 402, 403; post-operative sequela, 672–674.
Lymph nodes in appendix, 146–148.
Lymphatic infection of appendix, 333–334.
Lymphatics of appendico-cecal junction, 174.
Lymphatics of appendix, 169–173.
Lymphatics of ileocecal region, 173, 174.

McGraw's method of intestinal anastomosis, 781–785.
Meckel's diverticulum; attachment of, 597; blood-supply of, 599–601; embryology of, 595, 596; pathology of, 601, 602; size of, 596, 597; structure of, 599.
Median incision, 524, 531, 723.
Medical treatment of appendicitis, 510–513.
Medico-legal complications in appendicitis, 197, 704–706, 806–811.
Menstruation, disturbance of, a symptom of appendicitis, 361.
Mesappendix; arteries of, 161; glands in, 186; length of, affecting position of appendix, 125, 126, 132; ligation of, 552–555; lymphatics of, 183; veins of, 167.
Mikulicz's natural barriers of infection, 603.
Misplaced appendices, 135.
Movements of appendix, 193, 194.
Muscle spasm in appendicitis; indication for operation, 497; symptom, 390.
Myoma of appendix, 707, 739, 740, 772.
Myxoma of appendix, 739.

Nail in appendix, 374.
Nationality in etiology of appendicitis, 359.
Natural history of; acute and chronic affections of the appendix, diseases to which appendix is liable, 195–198; effect of an appendicitis on the appendix itself, 199, 200; effect of an appendicitis on neighboring structures, 201–205; more remote effects of an appendicitis, 205–209.
Needle-holders, 515.
Neoplasms of appendix; at autopsy, 252; benign, 737–743; malignant, 743–751.
Nerves of appendix, 186–188.
Nervous manifestations as post-operative sequelæ, 669, 670.
Nitrous-oxid anesthesia, 516–517.

Obliteration of appendix, 149–152, 199, 292–298, 594.
Obscure and masked forms of appendicitis, 410.
Omentum, adhesion of; to appendix, 583–584; gangrene in, mistaken for appendicitis, 420; protection of appendix by, 308.
Operation in appendicitis; care of patient after, 655–660; cleansing the field of, 514; early, 501–503; foreign views on, 502; ideal time for, 502; in desperate cases, 484, 508, 509; indications for, 496–500; instruments for, 515, 516; intermediate, 503–506; interval, 506–508; late, 506; promptitude in, 500, 501; severe symptoms following, 659, 660.
Operation for ileocecal tumor, 772–785.
Opium in the treatment of appendicitis, 19–21, 511–513.
Origin of name appendicitis, 29.
Ovarian cyst, torsion of, mistaken for appendicitis, 481, 715, 716.
Ovarian tumors complicating appendicitis, 705–707.

Pain in appendicitis; indication for operation, 497; in scar, 661; symptom, 386–388, 405.
Pancreatic disease, mistaken for appendicitis, 426, 427.
Patient, care of; after operation, 655–660; preparation of, for operation, 514.
Pathological bibliography, 354–356.
Pelvic appendical abscess. See *Abscess, appendical.*
Pelvic disease; as cause of appendicitis, 703–709; coincident independently with appendicitis, 709, 710; secondary to appendicitis, 700–703; treatment of, when associated with appendicitis, 717–728.
Pelvic disease; diagnosis between, and appendicitis, 711–715; in appendicitis at autopsy, 252.
Pelvic position of appendix, 130.
Peri-appendical abscess, 213, 627.
Peri-appendicitis; mistaken for appendicitis, 409; suppurative, complication of appendicitis, 398, 399. See *Abscess, peri-appendical.*
Pericecal folds, 86–88.
Perinephritic abscess mistaken for appendicitis, 424.
Peritoneum, affections of, as complications of appendicitis, 419–421.
Peritoneum; condition of, at autopsy in acute appendicitis, 212; irrigation of, 647–652; reflection of, 104–110; structure and function of, 303–306.
Peritonitis, diffuse purulent; definition of, 641, 642; diagnosis of, 642, 643; prognosis of, 643, 644; treatment of, 644–654.
Peritonitis, disseminated focal, 206, 633–636.
Peritonitis, dry, 324.
Peritonitis, general; complication of appendicitis, 399–401; pathology of, 322–327.
Peritonitis in general, 302–306.
Peritonitis, localized, 306–312.
Peritonitis, progressive, fibrino-purulent, 206, 633–636.
Peritonitis septica, 324.
Perityphlitis typhosa, 442, 443, 444.

Phlebitis in appendicitis, at autopsy, 226; pathology of, 328–333.
Piezometer, 412. 413.
Pins in appendix, 365–372.
Pin-worms in appendix, 375–377.
Pleura, condition of, in acute appendicitis at autopsy, 247.
Pleuritis; complication of acute appendicitis, 402, 403, 460–463; post-operative sequela, 670–672.
Point of origin of appendix, 118–124.
Polypi of appendix, 280, 737–739, 772.
Position of appendix, 118–135.
Post-operative sequelæ; abscess, 667; acetonemia, 668, 669; acute yellow atrophy of liver, 682, 683; bronchial catarrh, 670; cancer of wound, 667; cystitis, 667, 668; epididymitis, 667; gangrene of wound, 664; gas formation, 664; hemorrhage, 662, 663; hernia, 692–697; ileus, 683–692; intestinal fistula, 674–681; nervous manifestations, 669, 670; lung complications, 672–764; pain in scar, 661, 662; pleurisy, 670–672; pulmonary embolism, 672–674; pyelitis, 667; skin affections, 682; suppuration of abdominal wound, 663, 664; urinary fistula, 681, 682.
Post-typhoid appendicitis, 38, 439.
Posture of patient after operation, 514.
Prececal position of appendix, 123.
Pregnancy, appendicitis during; diagnosis of, 733, 734; effect of, 731–733; treatment of, 734–736.
Pregnancy, diagnosis between, and appendicitis, 733, 734.
Preparations for operation, 513–516.
Psoitis, acute, as complication of appendicitis, 427.
Pulse, symptom of appendicitis, 394, 395, 499; indication for operation, 499.
Pyelitis in appendicitis; complication, 402; post-operative sequela, 667.
Pyemia, 402.
Pylephlebitis in appendicitis; at autopsy, 226, 227; complication, 402.
Pyonephrosis mistaken for appendicitis, 423, 424.

Rectal symptoms in appendicitis, 387, 628.
Rectum; discharge of appendix from, 203; drainage by, 628; examination by, 413, 456, 628.
Relations between physician and surgeon, 494, 495.
Remote effects of an appendicitis, natural history of, 205–209.
Removal of appendix; in absence of mesentery, 583; in extra-uterine pregnancy, 728; in pelvic disease, 725–728; by stripping out, 576; in suppurative cases, 612–617.
Removal of appendix; evolution of technic in, 48–52; first, 41, 42; first successful, 44, 45; incidental, 495; prophylactic, 717–719.
Removal of appendix, when adherent; to cecum, 579, 581, 582; to omentum, 583, 584; to ovary, 725, 726; to tumor of uterus or ovary, 728.
Removal of appendix, methods for; Beck's, 560, 561; Dawbarn's, 563, 564; Deaver's, 566, 567; Edebohls's, 565, 566; Fowler's, 562, 563; Halsted's, 559; Kelly's, 572; Lennander's, 575; Morris's, 566; Riedel's, 561, 562; Skene's, 567.
Removal of appendix, operations for; atypical, 575–594; typical, 552–575.
Renal complications in appendicitis, 403, 404.
Renal disease mistaken for appendicitis, 421–424.
Residual appendicitis, 278, 287, 288.
Retrocecal appendicitis, 587–589.
Retrocecal folds and fossæ, 99–102.
Retrocecal glands, enlargement of, 420, 421.
Retrocecal position of appendix, 123, 127–130.
Retrocolic glands, enlargement of, 420, 421.
Retrogression of appendix, 152–154.
Retro-peritoneal abscess, 314.
Rigidity, abdominal; indication for operation, 498; symptom of appendicitis, 389–390.
Rigidity of appendix in chronic appendicitis, 279.

Sarcoma of appendix; clinical history of, 757–760; operation for, 773.
Sedatives, use of, after operation, 657.
Septicemia as a complication of appendicitis, 401.
Severe and fatal symptoms after operation, 659, 660.
Sex in the etiology of appendicitis, 358, 359, 453.
Shot in the appendix, 372, 373.
Skin affections as a post-operative sequela, 682.
Spleen, condition of, in appendicitis at autopsy, 246.
Spontaneous amputation of appendix, 470.
Structure of appendix, 139–148.
Subphrenic abscess in appendicitis, 214–225; complication, 402; etiology of, 636, 637; symptoms of, 637, 638; treatment of, 638–641.

Suppuration of abdominal wound, 663, 664.
Symptoms of acute appendicitis; chills, 394; constipation, 391; distention of abdomen, 397; general appearance, 398; hemorrhage, 391, 392; jaundice, 397, 398; muscle spasm, 390; pain, 386–388; pulse, 394, 395; rigidity of abdomen, 389, 390; tenderness, 388, 389; vomiting, 390, 391.
Symptoms of appendicitis in child, 455–459.
Symptoms of chronic appendicitis, 405, 406.

Temperature, elevation of, in appendicitis; indication for operation, 498, 499; symptom, 392–394.
Terminations of appendicitis, 199.
Thrombosis, of appendical vessels, 198, 329, 330; of iliac and femoral vessels, 332, 333; of mesenteric vessels, 330, 331.
Toxicity of appendicitis, 198, 276–278.
Transient appendix, 56–58.
Trauma in etiology of appendicitis, 361, 362, 455, 794–796, 805–806.
Traumatic appendicitis; analysis of, 804–806; cases of, 776–803; history of, 794–796; medico-legal complications of, 806–810.
Tuberculosis of appendix; at autopsy, 251; clinical history of, 761–768; pathology of, 336–342.
Tuberculosis of peritoneum; affecting appendix by contiguity, 196, 705; mistaken for appendicitis in child, 463–481.
Tumor in appendicitis; indication for operation, 499; symptom, 395.
Tumors of appendix. See *Neoplasms.*
Typhlitis. See *Cecum, primary ulceration of.*
Typhoid fever, appendicitis in; diagnosis of, 442–444; etiology, 434, 435; frequency of, 433, 434; history of, 432, 433; operation for, 444–449.
Typhoid fever, condition of appendix in, at autopsy, 251.
Typhoid fever, diagnosis between, and appendicitis, 440–443, 444, 459.
Typhoid fever followed by appendicitis, 438, 439.
Typhoid fever following appendicitis, 439, 440.
Typhoid lesions in appendix, 348–352, 435–438.

Umbilical hernia, appendix contained in, 789.
Umbilicus, appendical abscess discharging at, 204.
United States; development of appendical surgery in, 47–52; early history of appendicitis in, 17–19, 22–24; first case of appendicitis in, 17.
Ureters, disease of, mistaken for appendicitis, 421–423.
Uric acid diathesis in etiology of appendicitis in child, 455.
Urinary fistula in appendicitis; pathology of, 318–320; post-operative sequela, 681, 682.
Urinary tract, disease of, in appendicitis, natural history of, 197.
Urine, examination of, after operation, 659.

Vagina; appendical abscess discharging into, 204; drainage by, in pelvic abscess, 629; examination by, in appendicitis, 413.
Veins of appendix, 166–169.
Vertebral disease mistaken for appendicitis, 427.
Vesical complications of appendicitis, 403, 404.
Vomiting in appendicitis; indication for operation, 499; symptom, 390, 391; sole symptom in child, 456.
Vomiting, symptom of diffuse purulent appendicitis, 643.

Widal reaction in diagnosis between appendicitis and typhoid fever, 441.
Width of appendix, 138, 139.
Willard Parker operation, 34–36.
Wound, abdominal: cancer of, 667; care of, after operation, 657, 658; closure of, 538, 539; discharge of appendix at, 202; gangrene of, 664; suppuration of, 663, 664.