

## **The ophthalmoscope : a manual for students / by Gustavus Hartridge.**

### **Contributors**

Hartridge, Gustavus, 1849-1923.  
University of Leeds. Library

### **Publication/Creation**

London : J. & A. Churchill, 1907.

### **Persistent URL**

<https://wellcomecollection.org/works/d6mgvtv56>

### **Provider**

Leeds University Archive


### **License and attribution**

This material has been provided by This material has been provided by The University of Leeds Library. The original may be consulted at The University of Leeds Library. where the originals may be consulted.

Conditions of use: it is possible this item is protected by copyright and/or related rights. You are free to use this item in any way that is permitted by the copyright and related rights legislation that applies to your use. For other uses you need to obtain permission from the rights-holder(s).



Wellcome Collection  
183 Euston Road  
London NW1 2BE UK  
T +44 (0)20 7611 8722  
E [library@wellcomecollection.org](mailto:library@wellcomecollection.org)  
<https://wellcomecollection.org>



assessed for retention 2002

**STORE**

WWS

143

HAR

Histology, Store (Salvage)

Path. Ophthalmic instruments

H 10.16



3 0106 01349 9834

SCH  
UNIVERSITY OF LEEDS.

72 I



THE OPHTHALMOSCOPE

*By the same Author.*

THE REFRACTION OF THE EYE.

Fourteenth Edition, with 109 illustrations, crown 8vo, 5s. net.

THE  
OPHTHALMOSCOPE

*A MANUAL FOR STUDENTS*

BY

GUSTAVUS HARTRIDGE, F.R.C.S.

SURGEON TO THE ROYAL WESTMINSTER OPHTHALMIC HOSPITAL; OPHTHALMIC  
SURGEON AND LECTURER ON OPHTHALMIC SURGERY TO THE WESTMINSTER  
HOSPITAL; CONSULTING OPHTHALMIC SURGEON TO ST. BARTHOLOMEW'S  
HOSPITAL, CHATHAM, AND TO ST. GEORGE'S DISPENSARY,  
HANOVER SQUARE, ETC.

WITH SIXTY-EIGHT ILLUSTRATIONS AND FOUR PLATES

FIFTH EDITION




LONDON

J. & A. CHURCHILL

7, GREAT MARLBOROUGH STREET

1907



PRINTED BY ADLARD AND SON, LONDON AND DORKING

## PREFACE TO FIFTH EDITION

---

IN preparing a fifth edition of 'The Ophthalmoscope' for the press, every page has been carefully revised, and a few additions made which will, I trust, enhance the value of the book as a guide to ophthalmoscopic work.

G. H.

12, WIMPOLE STREET, W.;  
*April, 1907.*



## P R E F A C E

---

THE subject of this volume is one that has made great progress during the last few years, not only in the mechanism of the instrument, but also in the methods of using it to the best advantage. In the present day the ophthalmoscope is almost as necessary to the physician as it is to the ophthalmic surgeon, since many serious general diseases may first be detected by changes taking place in the fundus, frequently without any subjective symptoms ; thus the importance and usefulness of the instrument is greatly extended.

In introducing this small work to the profession, I do so in the hope that it may be found useful not only to the ophthalmic students who, in London and other large medical schools, have the advantage of practical demonstrations on the subject, but also to the large class of practitioners whose opportunities of seeing cases are few and far between, and who may desire to learn the use of the ophthalmoscope when practical instruction is out of their reach.

While hoping that the description given will be found sufficiently clear and elementary to enable the most inexperienced to understand it, I trust that even the advanced student may find some help and instruction.

The arrangement of the book is simple and systematic, and an endeavour has been made to keep it small, so that it may be conveniently carried in the pocket for reference in the out-patient room ; and this, perhaps, constitutes one of its chief advantages. The work is profusely illustrated with woodcuts—a matter of some importance, as it is almost impossible to make the subject clear without them, especially to those of my readers who may not have access to an instructor ; illustrations, although in many instances conveying only a somewhat imperfect idea, certainly impress the subject on the student's mind. A slight knowledge of optics is essential, and therefore the first chapter from my work on the ' Refraction of the Eye ' is reproduced, and several of the woodcuts from that book are doing duty again.

G. H.

65, GREEN STREET, PARK LANE, W. ;

*August, 1891.*

# CONTENTS

---

## CHAPTER I

	PAGE
OPTICAL PRINCIPLES INVOLVED IN THE USE OF THE OPHTHALMOSCOPE . . . . .	1

## CHAPTER II

THE OPHTHALMOSCOPE . . . . .	21
------------------------------	----

## CHAPTER III

METHODS OF EXAMINATION . . . . .	32
----------------------------------	----

## CHAPTER IV

THE APPEARANCES OF THE NORMAL FUNDUS . . . . .	74
--	----

## CHAPTER V

THE CORNEA, ANTERIOR CHAMBER, IRIS, AND LENS . . . . .	85
--	----

## CHAPTER VI

THE VITREOUS . . . . .	92
------------------------	----

## CHAPTER VII

THE CHOROID . . . . .	98
-----------------------	----

## CHAPTER VIII

THE RETINA . . . . .	109
----------------------	-----

## CHAPTER IX

THE OPTIC NERVE . . . . .	130
APPENDIX . . . . .	145

## LIST OF ILLUSTRATIONS

---

No.	PAGE
1. Reflection by a plane surface . . . . .	2
2. Virtual image formed by a plane mirror . . . . .	3
3. Reflection by a concave surface . . . . .	4
4. Ditto ditto . . . . .	5
5. Reflection by a convex surface . . . . .	6
6. Refraction by a plane surface . . . . .	7
7. Refraction by a prism . . . . .	8
8. Ditto ditto . . . . .	8
9. Refraction by a spherical surface . . . . .	9
10. Ditto ditto . . . . .	10
11. Formation of a convex lens . . . . .	11
12. Different forms of lenses . . . . .	12
13. Refraction of secondary axes by a biconvex lens . . . . .	12
14. Refraction of parallel rays by a convex lens . . . . .	13
15. Ditto ditto . . . . .	14
16. Properties of a biconvex lens . . . . .	14
17. Ditto ditto . . . . .	15
18. Properties of a biconcave lens . . . . .	16
19. Refraction of parallel rays by a concave lens . . . . .	16
20. Formation of an inverted image . . . . .	17
21. Real inverted image formed by a convex lens . . . . .	18
22. Virtual image formed by a convex lens . . . . .	19
23. Virtual image formed by a concave lens . . . . .	19
24. Light entering the eye and returning by the same path . . . . .	21
25. Light returning from hypermetropic eye . . . . .	22
26. Light returning from myopic eye . . . . .	23
27. Helmholtz's first ophthalmoscope . . . . .	24
28. The ophthalmoscope . . . . .	25

No.	PAGE
29. Morton's refracting ophthalmoscope . . . . .	29
30. Concave mirror . . . . .	31
31. Frost's artificial eye . . . . .	34
32. The oblique illumination . . . . .	36
33. Oblique illumination with magnifying glass . . . . .	37
34. Rays coming from emmetropic eye . . . . .	38
35. Rays coming from hypermetropic eye . . . . .	39
36. Rays coming from myopic eye . . . . .	39
37. Position for the indirect examination . . . . .	42
38. Formation of image in indirect examination . . . . .	43
39. Indirect examination in emmetropia . . . . .	46
40. Indirect examination in hypermetropia . . . . .	46
41. Indirect examination in myopia . . . . .	47
42. Size of the image in emmetropia . . . . .	47
43. Size of the image in hypermetropia . . . . .	48
44. Ditto ditto . . . . .	48
45. Diagram showing the real size of the disc and the size of the images in the indirect and direct methods . . . . .	50
46. Position for the direct examination . . . . .	54
47. Formation of image in direct examination . . . . .	55
48. Size of image on retina in emmetropia . . . . .	57
49. Determination of size of image by coin . . . . .	58
50. Method of estimating enlargement . . . . .	60
51. Direct examination in emmetropia . . . . .	62
52. Direct examination in hypermetropia . . . . .	63
53. Direct examination in myopia . . . . .	63
54. Lamp for retinoscopy . . . . .	67
55. Lamp for retinoscopy . . . . .	67
56. Plane mirror in retinoscopy . . . . .	69
57. Shadows in retinoscopy . . . . .	70
58. Oblique shadows . . . . .	70
59. Method of recording the chief meridians . . . . .	73
60. Retinoscopy with the concave mirror . . . . .	75
61. Diagram of the normal disc and nerve . . . . .	82
62. Position of opacities . . . . .	90
63. Movements of vitreous opacities . . . . .	95
64. Physiological cup . . . . .	134
65. Atrophic cup . . . . .	135

# LIST OF ILLUSTRATIONS

xiii

No.	PAGE
66. Glaucoma cup . . . . .	136
67. Parallax . . . . .	137
68. Papillitis . . . . .	139

Coloured Plates (between pages 76 and 77):

I.—Fig. 1. Fundus of a child of medium complexion.  
Left eye. Direct.

Fig. 2. Albino. Right eye. Indirect.

II.—Fig. 1. Dark fundus. Left eye. Direct.


Fig. 2. Choroid tigré. Right eye. Indirect.

III.—Fig. 1. Choroiditis in the exudative stage

Fig. 2. Disseminated choroiditis .	} opposite page 103.
Fig. 3. Senile choroidal change .	
Fig. 4. Coloboma of the choroid .	

IV.—Fig. 1. Retinitis pigmentosa .

Fig. 2. Thrombosis of central vein .	} opposite page 116.
Fig. 3. Atrophy of the optic disc .	
Fig. 4. Albuminuric retinitis .	



# THE OPHTHALMOSCOPE

---

## CHAPTER I

### OPTICAL PRINCIPLES INVOLVED IN THE USE OF THE OPHTHALMOSCOPE.

LIGHT is propagated from a luminous point in every plane and in all directions in straight lines; these lines of direction are called *rays*. Rays travel with the same rapidity so long as they remain in the same medium.

The denser the medium the less rapidly does the ray of light pass through it.

Rays of light diverge, and the amount of divergence is proportionate to the distance of the point from which they come; the nearer the source of the rays the more they diverge.

When rays proceed from a distant point such as the sun, it is impossible to show that they are not parallel, and in dealing with rays which enter the eye, it will be sufficiently accurate to assume them to be parallel when they proceed from a point at a greater distance than 6 mètres.

A ray of light meeting with a body may be *absorbed*; *reflected*; or if it is able to pass through this body, it may be *refracted*.

## Reflection

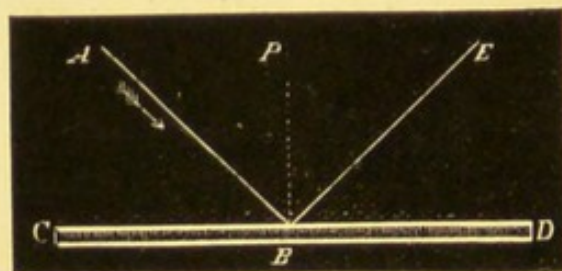
### *Reflection by a Plane Surface*

Reflection takes place from any polished surface, and according to two laws:

1st. The angle of reflection is equal to the angle of incidence.

2nd. The reflected and incident rays are both in the same plane, which is perpendicular to the reflecting surface.

FIG. 1.



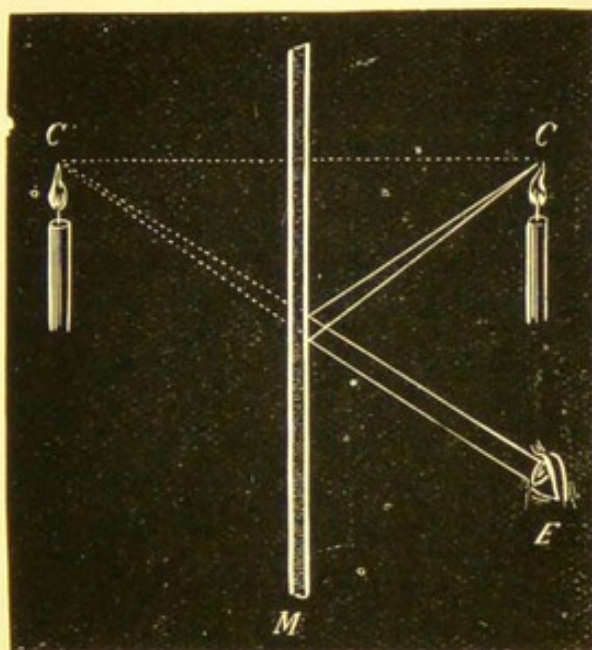
Thus, if  $AB$  be the ray incident at  $B$ , on the mirror  $CD$ , and  $BE$  the ray reflected, the perpendicular  $PB$  will divide the angle  $ABE$  into two equal parts; the angle  $ABP$  is equal to the angle  $PBE$ ; and  $AB$ ,  $PB$ , and  $EB$  lie in the same plane.

When reflection takes place from a plane surface, the image is projected backwards to a distance behind the mirror, equal to the distance of the object in front of it, the image being of the same size as the object.

Thus in Fig. 2 the image of the candle  $c$  is formed behind the mirror  $M$ , at  $c'$ , a distance behind the

mirror equal to the distance of the candle in front of it, and an observer's eye placed at  $E$  would receive the rays from  $c$  as if they came from  $c'$ .

FIG. 2.



$M$ . The mirror.  $c$ . The candle.  $c'$ . The virtual image of the candle.  
 $E$ . The eye of the observer receiving rays from mirror.

The image of the candle so formed by a plane mirror is called a *virtual image*.

### *Reflection by a Concave Surface*

A concave surface may be looked upon as made up of a number of planes inclined to each other.

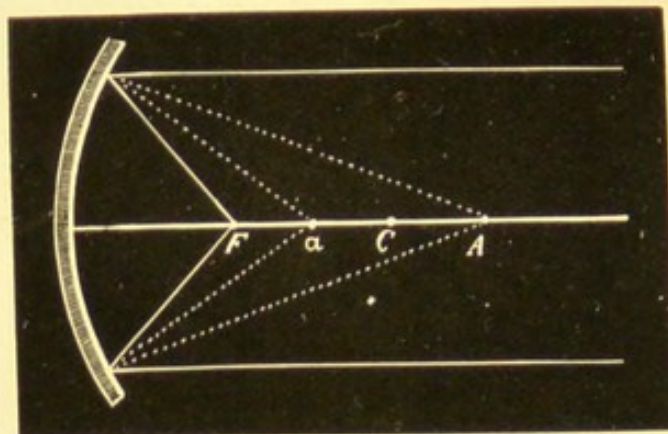
Parallel rays falling on a concave mirror are reflected as convergent rays, which meet on the axis at a point ( $F$ , Fig. 3) called the *principal focus*, about equally distant from the mirror and its centre  $c$ . The distance of the principal focus from the mirror is called the focal length of the mirror.

If the luminous point be situated at  $F$ , then the diverging rays would be reflected as parallel to each other and to the axis.

If the point is at the centre of the concavity of the mirror ( $C$ ), the rays return along the same lines, so that the point is its own image.

If the point be at  $A$  the focus will be at  $a$ , and it

FIG. 3.



will be obvious that if the point be moved to  $a$ , its focus will be at  $A$ ; these two points, therefore,  $A$  and  $a$ , bear a reciprocal relation to each other, and are called *conjugate foci*.

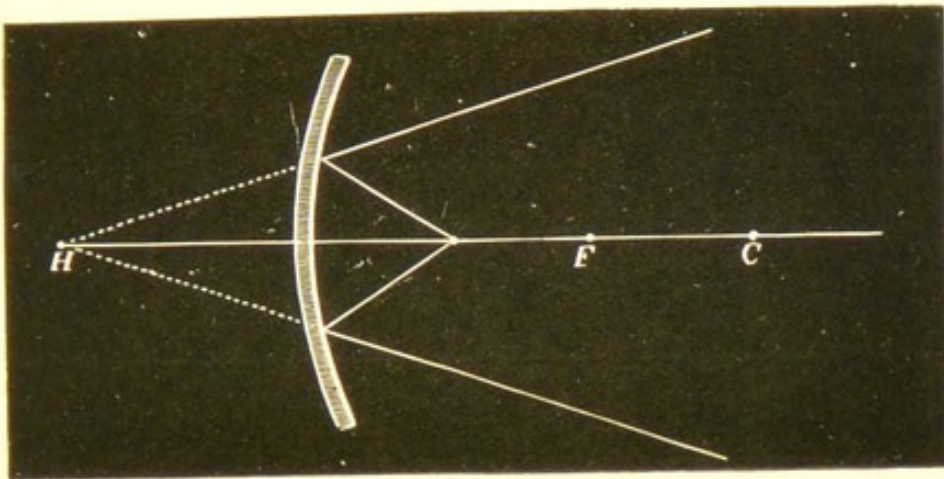
If the luminous point is beyond the centre, its conjugate focus is between the principal focus and the centre.

If the luminous point is between the principal focus and the centre, then its conjugate is beyond the centre; so that the nearer the luminous point approaches the principal focus, the greater is the distance at which the reflected rays meet.

If the point be nearer the mirror than ( $F$ ) the principal focus, the rays will be reflected as divergent,

and will therefore never meet; if, however, we continue these diverging rays backwards, they will unite at a point ( $H$ ) behind the mirror; this point is called

FIG. 4.



the *virtual focus*, and an observer situated in the path of reflected rays will receive them as if they came from this point.

Thus it follows that—

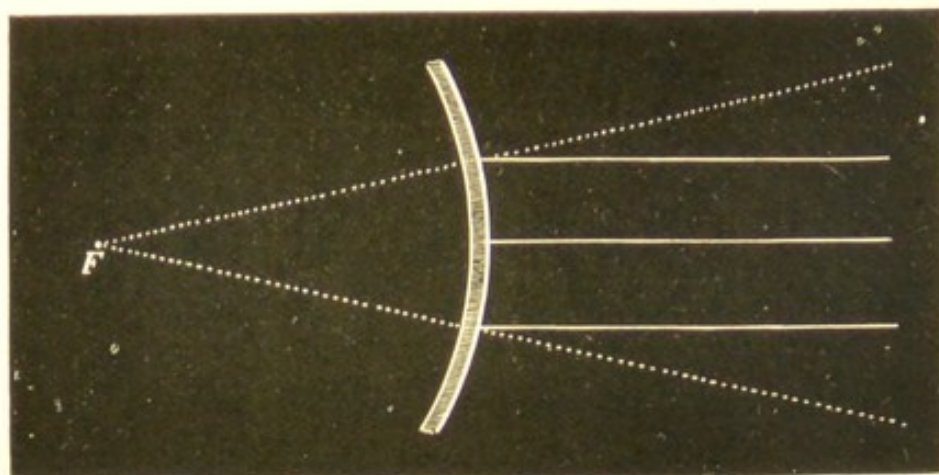
Concave mirrors produce two kinds of images or none at all, according to the distance of the object, as may be seen by looking at oneself in a concave mirror. If the mirror be placed nearer than its principal focus, then one sees an enlarged erect virtual image, which increases slightly in size as the mirror is made to recede; this image becomes confused and disappears as the principal focus of the mirror is reached; on moving the mirror still further away (that is, beyond its focus) one obtains an enlarged inverted image, which diminishes as the mirror is still further withdrawn.

*Reflection by a Convex Surface*

Parallel rays falling on such a surface become divergent, hence never meet; but if the diverging rays thus formed are carried backwards by lines, then an imaginary image is formed which is called *negative*, and at a point called the *principal focus* (F).

Foci of convex mirrors are virtual; and the image, whatever the position of the object, is always virtual, erect, and smaller than the object.

FIG. 5.



The radius of the mirror is double the principal focus.

**Refraction***Refraction by a Plane Surface*

A ray of light passing through a transparent medium into another of a different density is refracted, unless the ray fall perpendicular to the surface separating the two media, when it continues its course without undergoing any refraction (Fig. 6, H K).

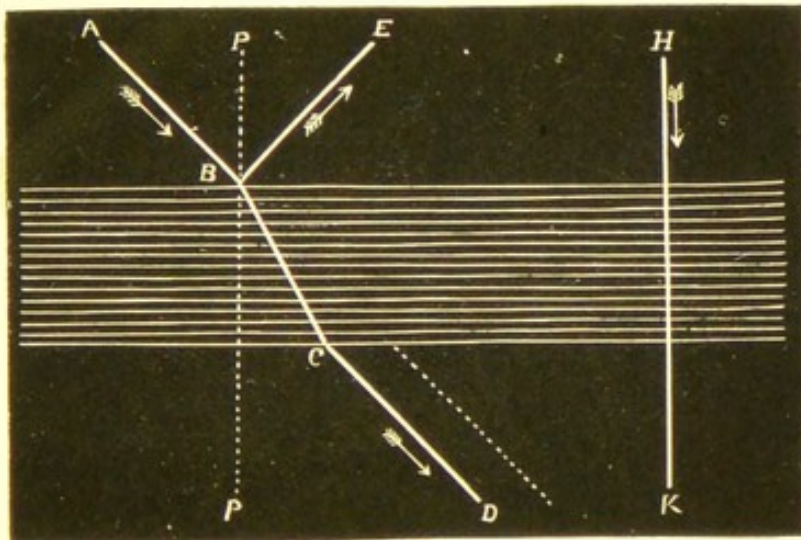
A ray is called *incident* before passing into the second medium, *emergent* after it has penetrated it.

A ray passing from a rarer to a denser medium is refracted towards the perpendicular; as shown in Fig. 6, the ray A B is refracted at B, towards the perpendicular P P.

In passing from the denser to the rarer medium the ray is refracted from the perpendicular, B D is refracted at C from P P (Fig. 6).

Reflection accompanies refraction, the ray dividing itself at the point of incidence into a refracted portion (B C) and a reflected portion (B E).

FIG. 6.



The amount of refraction is the same for any medium at the same obliquity, and is called the index of refraction; air is taken as the standard, and is called 1; the index of refraction of water is 1.3, that of glass 1.5. The diamond has almost the highest refractive power of any transparent substance, and has an index

of refraction of 2.4. The cornea has an index of refraction of 1.3 and the lens 1.4.

The refractive power of a transparent substance is not always in proportion to its density.

If the sides of the medium are parallel, then all rays except those perpendicular to the surface which pass through without altering their course, are refracted twice, as at *B* and *C* (Fig. 6), and continue in the same direction after passing through the medium as they had before entering it.

If the two sides of the refracting medium are not parallel, as in a prism, the rays cannot be perpendicular to more than one surface at a time.

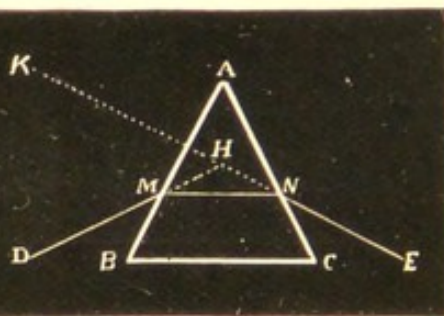
Therefore every ray falling on a prism must undergo refraction, and the deviation is always towards the base of the prism.

The relative direction of the rays is unaltered (Fig. 7).

FIG. 7.



FIG. 8.



If *DM* (Fig. 8) be a ray falling on a prism (*ABC*) at *M*, it is bent towards the base of the prism, assuming the direction *MN*; on emergence it is again bent at *N*; an observer placed at *E* would receive the ray as if it came from *K*; the angle *KHD*, formed by the two lines

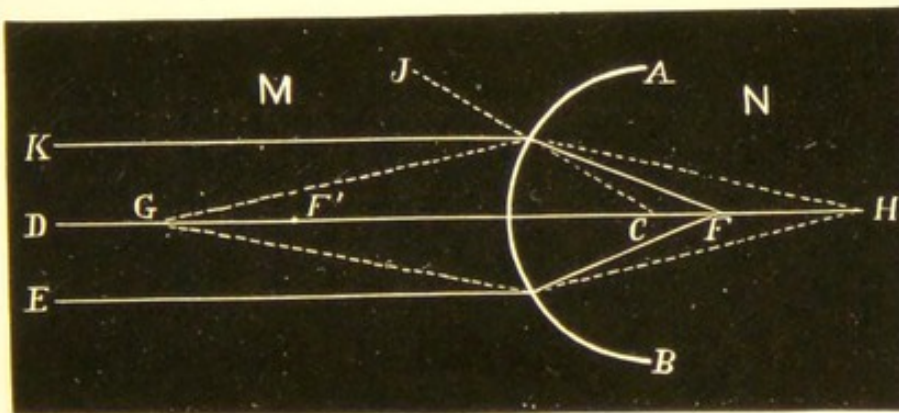
at  $H$ , is called the *angle of deviation*, and is about half the size of the *principal angle* formed at  $A$  by the two sides of the prism.

### *Refraction by a Spherical Surface*

Parallel rays passing through such a surface, separating media of different densities, do not continue parallel, but are refracted, so that they meet at a point called the principal focus.

If parallel rays,  $K, D, E$ , fall on  $AB$ , a spherical surface separating the media  $M$  and  $N$ , of which  $N$  is the denser; ray  $D$ , which strikes the surface of  $AB$  at right angles, passes through without refraction, and is called the *principal axis*; ray  $K$  will strike the surface at an

FIG. 9.



angle, and will therefore be refracted towards the perpendicular  $CJ$ , meeting the ray  $D$  at  $F$ ; ray  $E$  will be refracted in the same way, likewise all rays parallel in medium  $M$ . The point  $F$  where these rays meet is the *principal focus*, and the distance between the principal focus and the curved surface is spoken of as the *principal focal distance*.

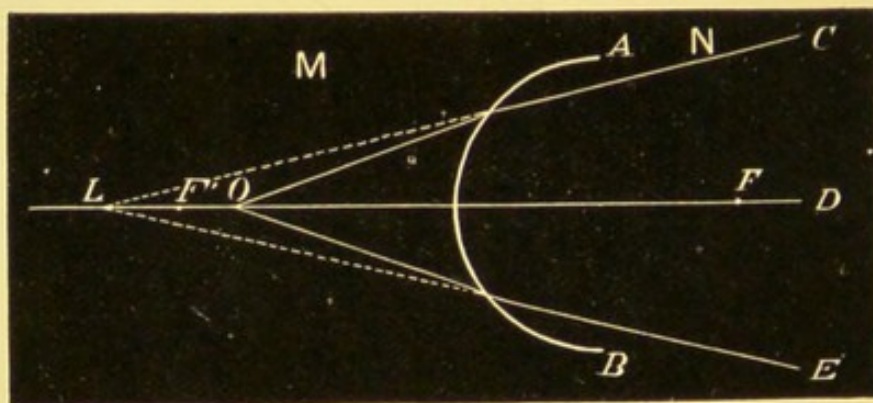
Rays proceeding from  $F$  will be parallel in  $M$  after passing through the refracting surface. Rays parallel in medium  $N$  will focus at  $F'$ , which is called the *anterior focus*.

Had the rays in medium  $M$  been more or less divergent, they would focus on the principal axis at a greater distance than the principal focus, say at  $H$ , and conversely rays coming from  $H$  would focus at  $G$ ; these two points are then *conjugate foci*.

When the divergent rays focus at a point on the axis twice the distance of the principal focus, then its conjugate will be at an equal distance on the other side of the curved surface.

If rays proceed from a point  $o$ , nearer the surface than its principal focus, they will still be divergent after passing through  $A B$ , though less so than before,

FIG. 10.



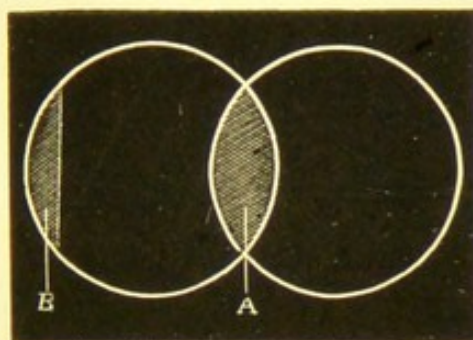
and will therefore never meet; by continuing these rays backwards they will meet at  $L$ , so that the conjugate focus of  $o$  will be at  $L$ , on the same side as the focus; and the conjugate focus will in this case be spoken of as *negative*.

*Refraction by Lenses*

Refraction by lenses is somewhat more complicated.

A lens is an optical contrivance usually made of glass, and consists of a refracting medium with two

FIG. 11.



opposite surfaces, one or both of which may be segments of a sphere; they are therefore called spherical lenses, of which there are six varieties:


1. Plano-convex, the segments of one sphere (Fig. 11 B).
2. Biconvex, segments of two spheres (Fig. 11, A).
3. Converging concavo-convex, also called a converging meniscus.
4. Plano-concave.
5. Biconcave.
6. Diverging concavo-convex, called also a diverging meniscus.

Lenses may be looked upon as made up of a number of prisms with different refracting angles—convex lenses, of prisms placed with their bases together; concave lenses, of prisms with their edges together.

A ray passing from a less refracting medium (as air) through a lens, is deviated towards the thickest part, therefore the first three lenses, which are

thickest at the centre, are called *converging*; and the others, which are thickest at the borders, *diverging*.

FIG. 12.

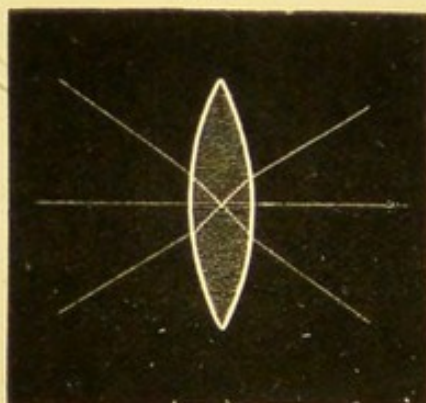


A line passing through the centre of the lens (called the *optical centre*) at right angles to the surfaces of the lens is termed the *principal axis*, and any ray passing through that axis is not refracted.

All other rays undergo more or less refraction.

Rays passing through the optical centre of a lens, but not through the principal axis, suffer slight deviation, but emerge in the same direction as they entered; the deviation in thin lenses is so slight that they are usually assumed to pass through in a straight line; these are called *secondary axes* (Fig. 13).

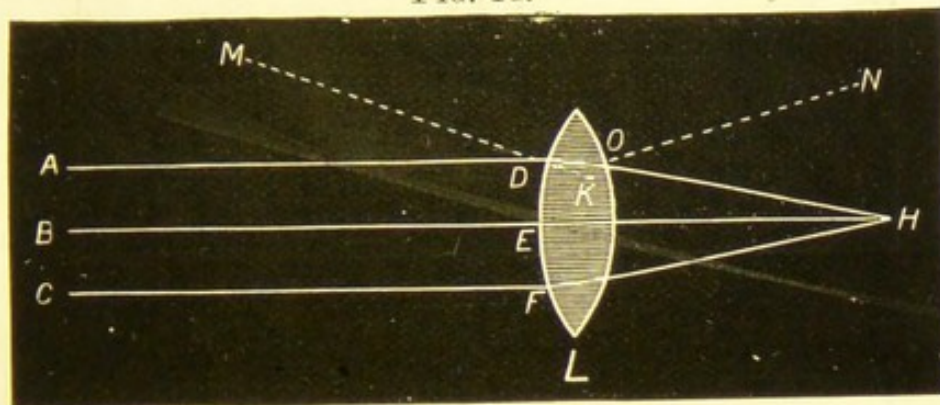
FIG. 13.



Lenses with secondary axes undergoing slight deviation.

Parallel rays falling on a biconvex lens are rendered convergent; thus in Fig. 14 the rays A, B, C, strike the surface of the lens (L) at the points D, E, F; the centre

FIG. 14.

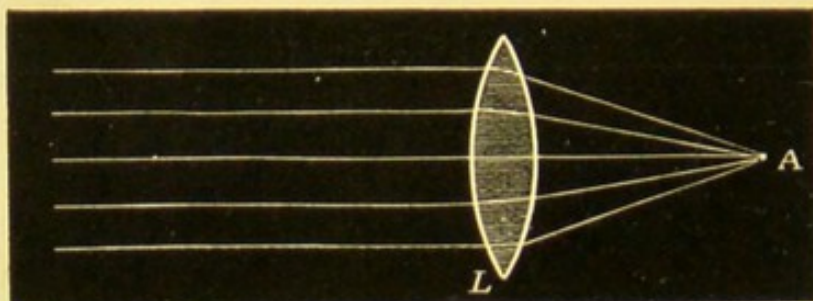


ray (B) falls on the lens at E perpendicular to its surface, and therefore passes through in a straight line; it also emerges from the lens at right angles to its opposite surface, and so continues its course without deviation; but the ray A strikes the surface of the lens obliquely at D, and as the ray is passing from one medium (air) to another (glass) which is of greater density, it is bent towards the perpendicular of the surface of the lens, shown by the dotted line M K; the ray after deviation passes through the lens, striking its opposite surface obliquely at O, and as it leaves the lens, enters the rarer medium (air), being deflected from the perpendicular N O; it is now directed to H, where it meets the central ray B H; ray C, after undergoing similar refractions, meets the other rays at H, and so also all parallel rays falling on the biconvex lens (L).

Parallel rays, therefore, passing through a convex lens (L, Fig. 15) are brought to a focus at a certain fixed point (A) beyond the lens; this point is called

the *principal focus*, and the distance of this focus from the lens is called the focal length of the lens.

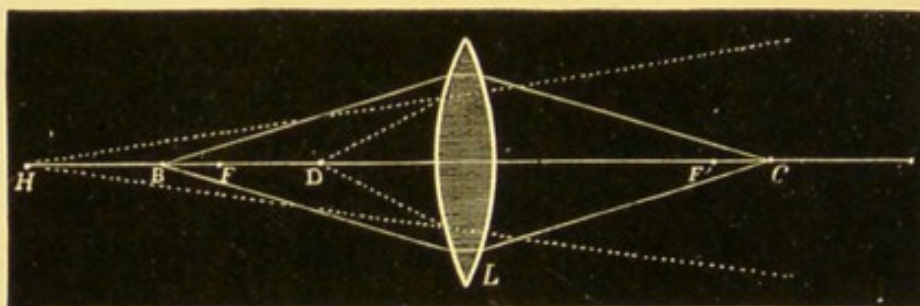
FIG. 15.



Rays from a luminous point placed at the principal focus (A) emerge as parallel after passing through the lens.

Divergent rays from a point (B) outside the principal focus (F, Fig. 16) meet at a distance beyond (F') the

FIG. 16.



principal focus on the other side of the lens (L), and if the distance of the luminous point (B) is equal to twice the focal length of the lens, the rays will focus at a point (C) the same distance on the opposite side of the lens, rays coming from C would also focus at B; they are therefore called conjugate foci, for we can indifferently replace the image (C) by the object (B) and the object (B) by the image (C).

If the luminous point (D) be between the lens and

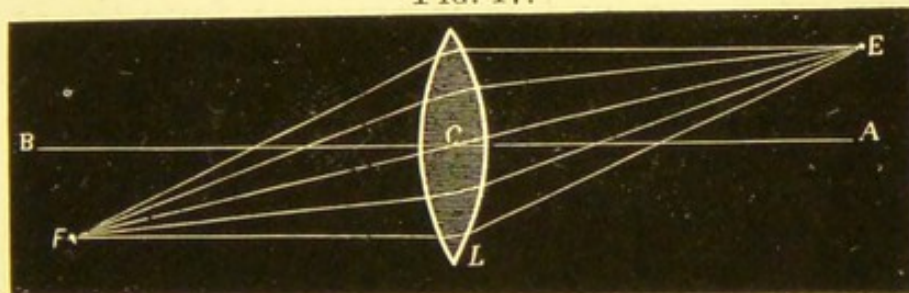
the principal focus ( $F$ ), then the rays will issue from the lens divergent, though less so than before entering; and if we prolong them backwards they will meet at a point ( $H$ ) further from the lens than the point  $D$ ;  $H$  will therefore be the virtual focus of  $D$ , and the conjugate focus of  $D$  may be spoken of as *negative*.

Biconvex lenses have therefore two principal foci,  $F$  and  $F'$ , one on either side, at an equal distance from the centre.

In ordinary lenses, and those in which the radii of the two surfaces are nearly equal, the principal focus closely coincides with the centre of curvature.

We have assumed the luminous point to be situated on the principal axis; supposing, however, it to be one side of it as at  $E$  (Fig. 17), then the line ( $E F$ ) passing through the optical centre ( $C$ ) of the lens ( $L$ ) is a

FIG. 17.



secondary axis, and the focus of the point  $E$  will be found somewhere on this line, say at  $F$ , so that what has been said respecting the focus of a luminous point on the principal axis ( $A B$ ) is equally true for points on a secondary axis, provided always that the inclination of this secondary axis is not too great, when the focus would become imperfect from much spherical aberration.

In biconcave lenses the foci are always virtual, whatever the distance of the object.

Rays of light parallel to the axis diverge after refraction, and if their direction be continued backward, they will meet at a point termed the principal focus (Fig. 18, F).

FIG. 18.


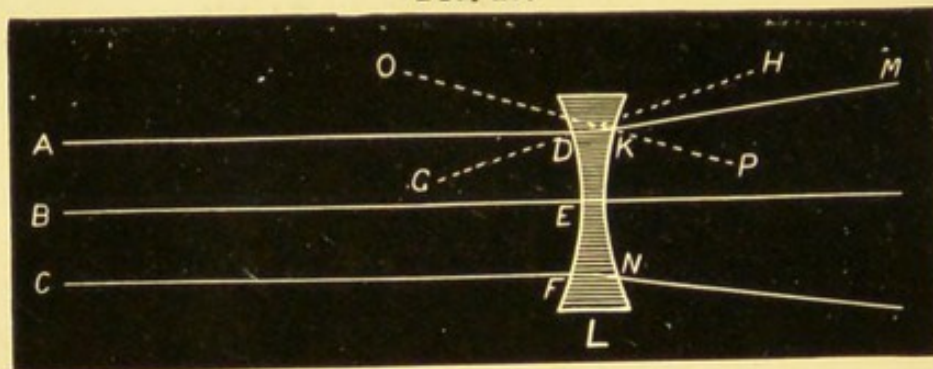


Fig. 19 shows the refraction of parallel rays by a biconcave lens (L); the centre ray B strikes the lens at E perpendicular to its surface, passing through without refraction, and as it emerges from the oppo-

FIG. 19.




site side of the lens perpendicular to its surface, it continues in a straight line; the ray A strikes the lens obliquely at D and is refracted towards the perpendicular, shown by the dotted line G H; the ray after deviation passes through the lens to K, where

on entering the medium of less density obliquely, it is refracted from the perpendicular  $OP$ , in the direction  $KM$ ; the same takes place with ray  $c$ , at  $F$  and  $N$ , so also with all intermediate parallel rays.

**Formation of Images.**—To illustrate the formation of images the following simple experiment may be carried out. Place on one side of a screen having a small perforation, a candle, and on the other side a sheet of white cardboard at some distance from the screen, to receive the image formed; rays diverge from the candle in all directions, most of those falling on the screen are intercepted by it, but some few rays pass through the perforation and form an image of the candle on the cardboard, the image being inverted because the rays cross each other at the orifice; it can further be shown that when the candle

FIG. 20.



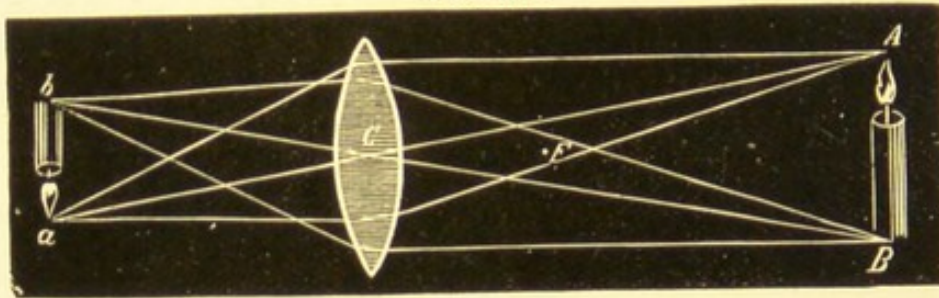
and cardboard are equally distant from the perforated screen, the candle flame and its image will be of the same size. If the cardboard be moved further from the perforation the image is enlarged, if it be moved nearer it is diminished; if we make a dozen more perforations in the screen, a dozen more images will be formed on the cardboard, if a hundred, then

a hundred; but if the apertures come so close together that the images overlap, then instead of so many distinct images we get a general illumination of the cardboard.

The image of an object is the collection of the foci of its several points; the images formed by lenses are, as in the case of the foci, real or virtual. Images formed, therefore, by convex lenses, may be real or virtual.

In Fig. 21, let  $A B$  be a candle situated at an infinite distance; from the extremities of  $A B$  draw

FIG. 21.



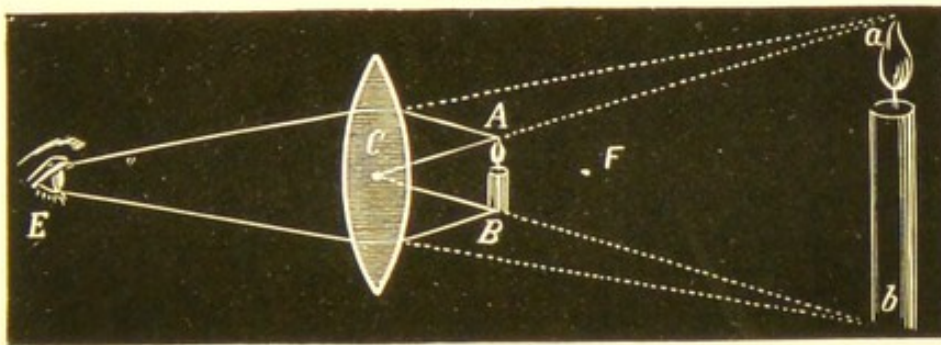
Real inverted image formed by convex lens.

two lines passing through the optical centre ( $c$ ) of a biconvex lens, the image of  $A$  will be formed somewhere on this line  $A c a$  (termed a secondary axis), say at  $a$ ; the image of  $B$  will be formed on the line  $B c b$ , say at  $b$ ; therefore  $b a$  is a small inverted image of the candle  $A B$ , formed at the principal focus of the convex lens. Had the candle been placed at twice the focal distance of the lens, then its image would be formed at the same point on the opposite side of the lens, of the same size as the object, and inverted.

If the candle be at the principal focus ( $F$ ), then the image is at an infinite distance, the rays after refraction being parallel.

If, however, the candle ( $AB$ ) be nearer the lens than the focus, then the rays which diverge from the candle will, after passing through the convex lens, be still divergent, so that no image is formed; an eye placed at  $E$  would receive the rays from  $AB$  as if they

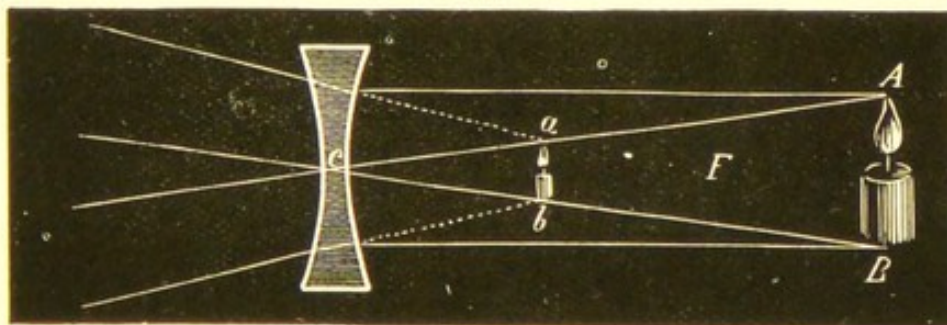
FIG. 22.



Virtual image formed by convex lens.

came from  $ab$ ;  $ab$  is therefore a virtual image of  $AB$ , erect and larger than the object, and formed on the same side of the lens as the object.

FIG. 23.



Virtual image formed by concave lens.

Images formed by biconcave lenses are always virtual, erect, and smaller than the object; let  $AB$  be

a candle, and  $F$  the principal focus of a biconcave lens; draw from  $A B$  two lines through  $C$ , the optical centre of the lens, and lines also from  $A$  and  $B$  parallel to the axis; after passing through the lens they diverge and have the appearance of coming from  $a b$ , which is therefore the virtual image of  $A B$ .


A real image can be projected on to a screen, but a virtual one can only be seen by looking through the lens.

## CHAPTER II

## THE OPHTHALMOSCOPE

WHEN an eye is looked at, the pupil appears black although the media are perfectly transparent ; this is because the rays entering the eye return to the point from which they emanate, and therefore, unless the observing eye can be placed in the path of returning rays, none of them will pass through the observer's pupil, and so no illumination will be seen.

FIG. 24.




In Fig. 24 rays will be seen entering the eye from candle A, and since the refractive system of the eye is exactly adjusted for the candle flame, the rays returning from the eye will traverse the same path as those entering it ; if the eye be not adapted for the candle flame, then the rays will return towards the source of light.

In the albino, as in the white rabbit, the pupil may appear illuminated; this is due to the transparency of the iris, so that the returning rays cover a larger area than is the case when passing through an ordinary pupil, then some of the outer rays may pass through the observer's pupil, if his eye be placed nearly in the line of light from which the observed eye receives its rays: that this is the correct explanation can easily be proved by covering up the part corresponding to the iris by an opaque diaphragm, when the pupil will at once appear black, as in the normal eye. In hypermetropia and myopia with a dilated pupil, one frequently gets a slight fundus illumination. This is illustrated in the following figures.

In hypermetropia, Fig. 25, the returning rays,

FIG. 25.




instead of being parallel as in emmetropia, diverge somewhat, so that the observing eye placed at B would receive some of the returning rays.

In myopia, Fig. 26, the returning rays converge, cross, and diverge, so that the eye placed at B would receive some illumination.

The ophthalmoscope is a contrivance which enables the observing eye to be placed in the path of the re-

turning rays, and consists of a reflector with a hole in the centre.

FIG. 26.



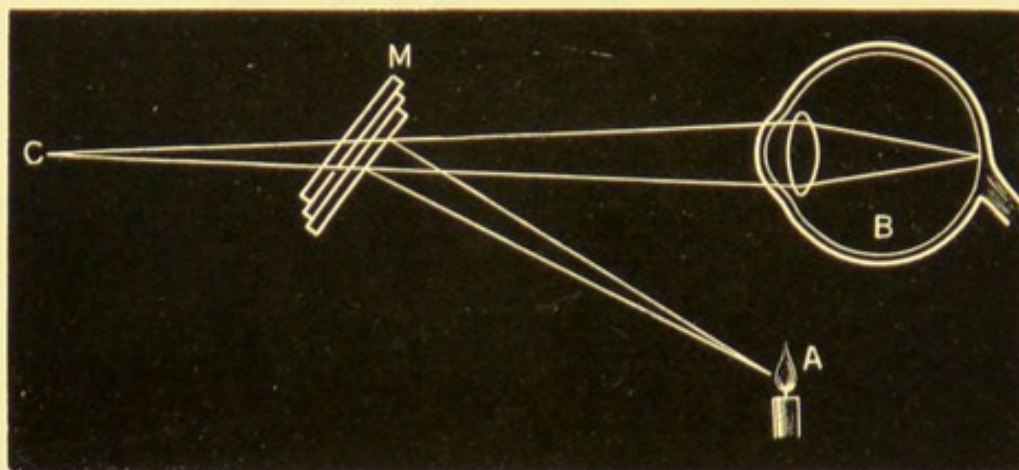
Although the invention of the ophthalmoscope is of recent date, it had long been known that the eye was illuminated by rays entering the globe, and it was thought that these rays were entirely absorbed by the pigment contained in the retina and choroid, but it was afterwards pointed out that some parts, such as the disc, must even then reflect some light, and that the apparent blackness of the pupil must be due to the optical law "*that rays of light leaving the eye, return towards the source of illumination,*" so that unless the eye of the observer can be placed in the path of the returning rays, no illumination can be obtained. Brücke was very nearly solving the problem by placing a tube through the flame of a candle, which enabled him, on looking through it, to catch some of the returning rays of light; but it remained for Helmholtz to overcome the difficulty by producing his first ophthalmoscope.

Helmholtz's ophthalmoscope, which he introduced in 1851, was composed of three pieces of plane glass. Fig. 27.

Rays reflected from a light A, are projected into

the eye B, by the mirror M, the light returning from the observed eye by the same path will fall on the glass M, a part is reflected to A, and a part passes

FIG. 27.



through the glass towards C; an observing eye placed behind the mirror will, therefore, receive some of the returning rays.

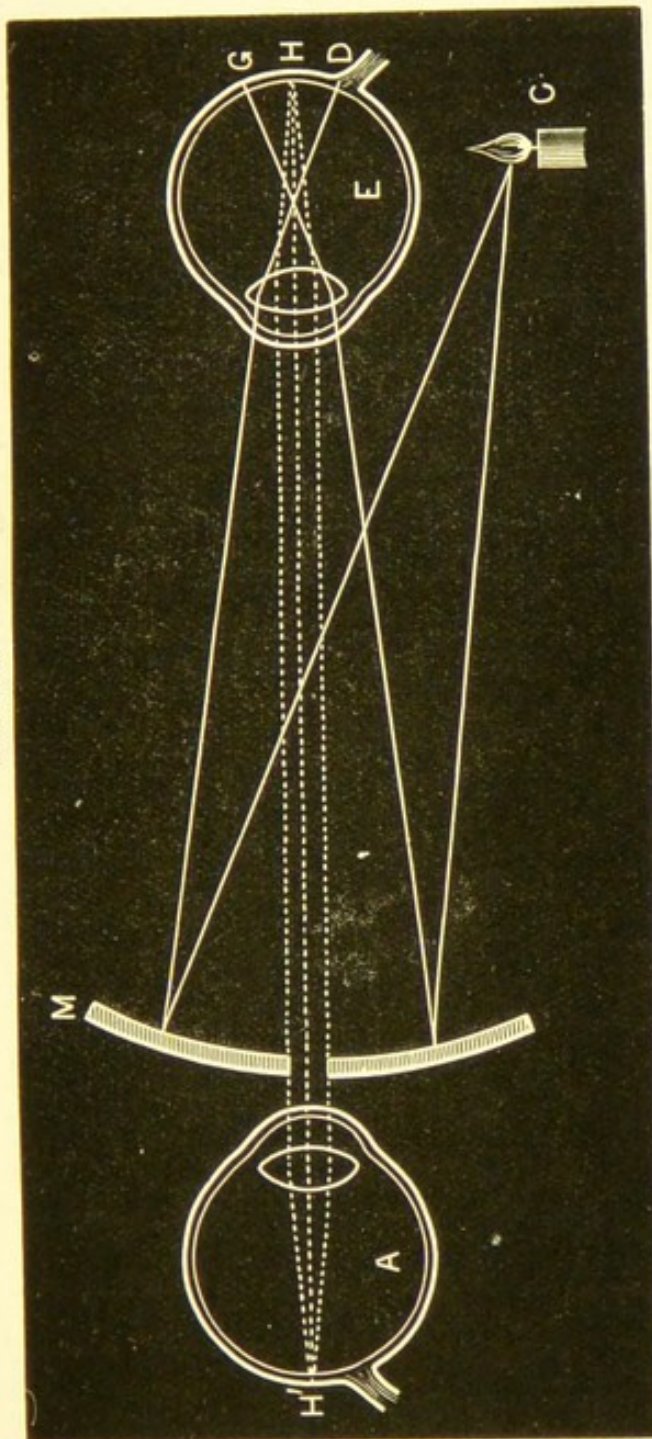
Ophthalmoscopes have undergone numerous modifications, and the instrument with which we now work consists of a silvered concave glass mirror, with a central perforation.

In Fig. 28, divergent rays from a candle C, falling on the mirror M, are rendered convergent, and when reflected into the eye E, cross in the vitreous and light up the fundus between the points G and D; if point H of this illumined area be taken, the rays will (in the emmetropic eye) issue parallel, and passing through the sight-hole of the mirror, will enter the observing eye A, forming on the retina at H' an image of H.

The amount of fundus illumination obtained will

necessarily depend upon the source and intensity of the light, the concavity of the mirror used, the dis-

FIG. 28.



tance from the eye at which the examination is made, and the size of the pupil in the observed eye.

Modern ophthalmoscopes are fitted with a series of lenses, which can be revolved in front of the sight-hole; these are known as refracting ophthalmoscopes. Many good ones have been devised, varying but slightly in some or other minor particulars.

The essential points of a thoroughly complete ophthalmoscope are, that it should be supplied with three mirrors,—a small concave, a large concave, and a plane one; together with a fairly complete set of lenses, which can be brought in front of the sight-hole of the instrument as occasion requires.

(1) The small concave mirror is for the direct examination; it should have a focus of about 7.5 cm., so that light reflected from it will enter the eye as convergent rays. The sight-hole should not be larger than  $2\frac{1}{2}$  mm., because only that part of the mirror which immediately surrounds the aperture is available in the direct examination, and should the sight-hole be larger than the pupil, then no fundus illumination will be obtained. The small mirror may be conveniently tilted about  $25^\circ$ ; this allows the ophthalmoscope to be held perfectly straight while the light is reflected into the observed eye, enabling one to look through the lens which may be behind the sight-hole at right angles to its surface. With the old-fashioned mirror the ophthalmoscope itself had to be tilted towards the light, and with it, of course, the lenses, so that they were looked through obliquely, and thus the strength of the lens was increased and some astigmatism produced; hence the estimation of the refraction by the

direct method was liable to be inaccurate. The disadvantage of some tilted mirrors is the distance that intervenes between the two sides of the sight-hole, technically called "tunnelling"; this tunnelling somewhat diminishes the size of the field seen, but, what is more important, prevents the eye of the examiner from approaching sufficiently near that of the person examined; and it may be stated as an axiom, that *the nearer the observing eye can approach the observed, the more accurate will be the estimation of the refraction.*

(2) The large concave mirror is for the indirect method of examination; it should have a focal length of 25 cm., so that rays from a light situated 25 cm. from the mirror will be reflected parallel; when the light is further off than 25 cm. then the rays will be slightly convergent; this mirror may possess an aperture of 3 or  $3\frac{1}{2}$  mm.

(3) The plane mirror is useful for retinoscopy, for the examination of the vitreous, and for high myopia; with this mirror rays of light coming from a lamp at a finite distance, will be reflected into the eye as divergent rays.

The ophthalmoscope should be supplied with a set of lenses, which can in turn be brought behind the sight-hole by means of a finger-wheel; this wheel should be so made and placed, that it may be rotated easily while the instrument is in position without losing sight of the fundus. The lenses may be somewhat as follows: a convex series + .5 D., + 1 D., increasing by one diopetre up to + 10 D.; and a

concave series  $- \cdot 5$  D.,  $- 1$  D., increasing by one dioptré up to  $- 12$  D., and then by two dioptries up to  $- 20$  D. Sometimes a higher glass may be required; these may be supplied on a separate disc; the lenses in this disc may, by combination with the other lenses, form a very large series.

The lenses should not be less than 6 mm. in diameter, otherwise they are difficult to centre properly, and cannot be easily cleaned—a point of some importance; they may occasionally be used for the subjective test of estimating the visual acuteness, should the box of trial lenses not be at hand.

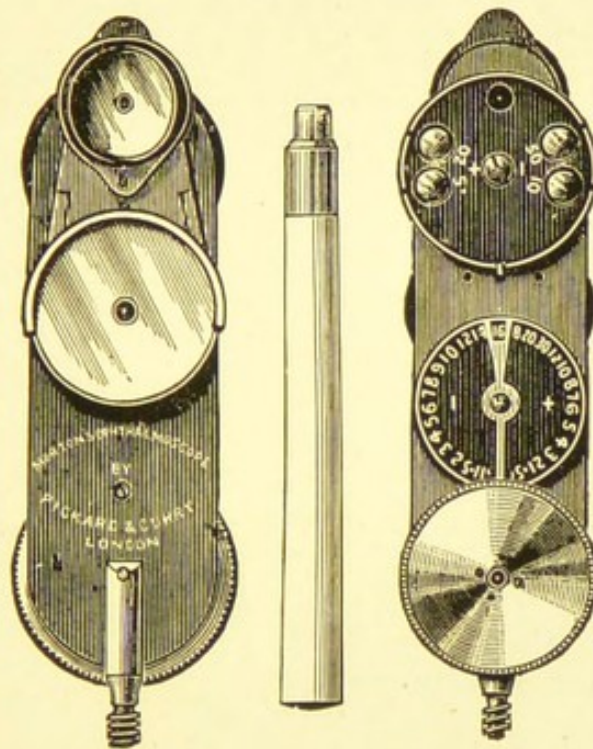
It will be sufficient here to describe and to figure one of the ophthalmoscopes in general use, though numerous other good instruments will be found in this country and abroad.

Morton's ophthalmoscope, shown in Fig. 29, is a modification of an instrument introduced by Mr. Couper; it contains a series of twenty-nine lenses in metal rings, and one metal ring without a glass; these run round a continuous channel, and are so arranged that each can be brought successively in front of the sight-hole by means of a driving wheel.

When no lens is required, then the empty ring occupies the sight-hole; these lenses touch each other sideways, but are not fixed in any way; on the spindle that carries the driving wheel is another wheel with teeth, which propel the lenses round the instrument; a spring and notch attached to the driving wheel centres each lens as it arrives at the

sight-hole. The strength of the glass before the sight-hole is recorded by an index wheel, which, being geared to the driving wheel, keeps pace with it, and therefore with the lens series. The minus glasses are contained in white rings, and are indicated by white numbers; the convex glasses are in red rings and have red numbers.

FIG. 29.



This series of lenses is usually sufficient for most ordinary purposes, but occasionally other lenses are required, and are provided on a special disc. Sometimes a strong convex glass is required for the examination of the cornea or lens; at other times a strong concave lens is necessary for a case of high myopia. This separate disc, therefore, has a  $+ 20$  D. and a  $- 50$  D. so placed that they can be instantly

put in front of, or removed away from the sight-hole, without rotating the whole series of lenses. On this same disc are also a  $+ 5$  D. and a  $- 10$  D.: the former of these enables one to estimate to within half a dioptré in special cases; and the latter, by use in conjunction with other concave lenses contained in the series, gives us from  $- 1$  D. to  $- 20$  D., with intervals of one dioptré, and  $- 20$  D. to  $- 30$  D., with intervals of two dioptries. This disc is well shown in the illustration. The instrument is supplied with three mirrors; a large concave one of 25 cm. focus, and a small tilted one of 7.5 cm. focus; these are fixed by a pivot, so that either can be turned in front of the sight-hole as occasion requires: the large concave mirror can be replaced, when necessary, by a plane one.

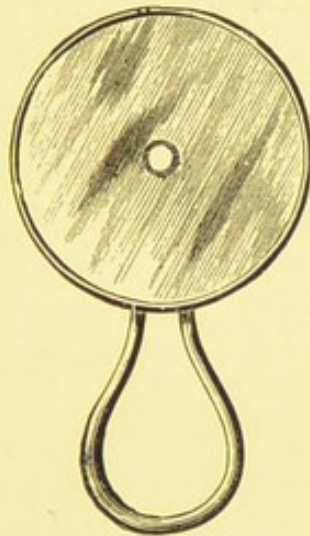
The movement in this ophthalmoscope is a great improvement over the method formerly employed, of placing the lenses in a revolving wheel. The credit of this ingenious invention is due to Mr. Couper, who was much assisted by Mr. Paxton, of the firm of Curry and Paxton.

M. Parent, of Paris, has recently brought out a very beautiful instrument, combining the advantages of all the recent ophthalmoscopes, and fitted with a series of cylindrical lenses in addition to the ordinary spherical series. M. Parent strongly advocates the use of cylindrical lenses for the estimation of the refraction in cases of astigmatism by the direct method.

Lang's ophthalmoscope is also used a good deal in this country, and is a very convenient instrument.

A useful concave mirror to carry in the waistcoat pocket is shown in Fig. 30. Another convenient form is the double mirror, one concave, of 25 cm. focus, and the other plane; one slides over the other, so that they mutually protect each other and require no case.

FIG. 30.



The student also requires a large biconvex lens (+ 13 D.), which is necessary for focal illumination and the indirect method of examination.

A magnifying glass made by cementing together one crown glass lens with two flint glass lenses, and having a focus of 1.5 cm., is of great assistance in examining the cornea, iris, and lens.

Demonstrating ophthalmoscopes are also made, but need not be described.

## CHAPTER III

## METHODS OF EXAMINATION

THE incandescent focal lamp of sixteen-candle power, and the ordinary gas Argand burner, are both suitable lights for ophthalmoscope work ; they should be arranged on a bracket which is capable of up and down as well as lateral movement, while the arm of the bracket should be sufficiently long to allow the light to be placed on either side of the patient without his having to move. When these lights are not to be obtained, an ordinary oil lamp may be used. The patient should be seated on a chair, while the observer may conveniently use a music stool, the height of which can be altered as occasion requires ; some observers prefer to stand when making an examination. A dark room is also an advantage.

In many cases it is necessary to dilate the pupil with a mydriatic ; one that acts quickly and fully, and the effect of which soon passes off, is to be preferred.

The most convenient combinations are—

℞ Homatropinæ Hydrobromatis, gr. iv.  
Cocainæ Hydrochloratis, gr. x.  
Acidi Salicylici, gr. j.  
Aquæ Destillatæ, ʒj.  
Ft. guttæ.

℞ Euphthalmine Hydrochloratis, gr. v.  
Acidi Salicylici, gr. j.  
Aquæ Destillatæ, ℥j.  
Ft. guttæ.

A drop of either of these solutions will produce full dilatation in a short time, and the effects pass off in two or three hours. Of course in many cases no mydriatic is required, but when a thorough examination is necessary it is a great advantage to examine the eye through a well-dilated pupil; this is especially the case when some changes have been detected in the fundus, and further information is desired by a more searching examination, carried out under the most favourable conditions.


But the student should learn not to rely too much upon these minor aids, but accustom himself to examine the fundus in various positions and under different surroundings, with or without a mydriatic.

It is recommended that every opportunity be taken to make repeated ophthalmoscopic examinations, and where a large number of patients is not to be met with, Frost's artificial eye (Fig. 31) will be of great service in enabling the student to acquire the necessary associated movements, as well as to understand and appreciate many points of importance with regard to the size and formation of the images in the various conditions of refraction.

The first thing for a beginner to do is to familiarise himself with the variations of the normal fundus. Very great differences are met with; as numerous almost as the various shades of hair found in the human race.

Besides, even in those cases where the visual acuteness is normal, and no symptoms indicative of disease are present, gross changes may be found, or congenital peculiarities may exist which ought not to be missed.

FIG. 31.



Generally, young ophthalmologists disdain to look at a normal fundus, caring only for pathological conditions; it would be much better for every one to look at a certain number of normal fundi before passing on to the various diseases. Usually the reverse

is the method of procedure; abnormal cases are looked at first, varied only very occasionally by a normal case.

In undertaking an ophthalmoscopic examination, it should be conducted quietly and without hurry; a number of students standing round anxious to look at the same case is not conducive to a thorough examination. A regular routine is absolutely necessary; accuracy and confidence are thereby attained.

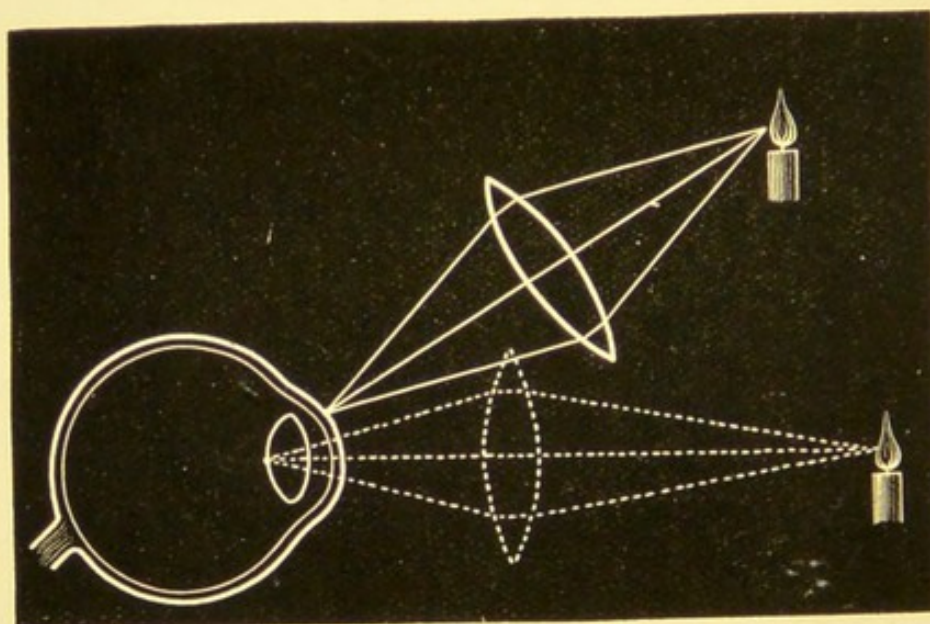
First, examine the cornea, iris, and lens by *focal illumination*; then the large concave mirror is used *at a distance* of about two thirds of a metre, and this may give an indication of the refraction of the eye, and allow the condition of the vitreous to be ascertained; then follows the *indirect method* or the *examination of the inverted image*, which enables that part of the fundus which is within reach of the ophthalmoscope to be readily scanned; the examination is completed by the *direct method* or the *examination of the upright image*, which gives a much larger image and allows minute changes, not visible by the indirect method, to be detected, while at the same time it allows of an estimate of the refraction being made.

When any change has been detected in the cornea, iris, or lens, this may conveniently be examined with the oblique mirror, having a + 20 D. behind the sight-hole of the ophthalmoscope, and approaching close to the patient as with the direct method; when the iris and lens are examined in this way, a somewhat weaker glass may be used, + 16 D.

### Focal Illumination

The patient being seated opposite a good artificial light, the observer takes up the large biconvex lens of 13 D. between the thumb and forefinger of one hand, and concentrates the light obliquely on the cornea, iris, and crystalline lens successively. By this means opacities and irregularities of the cornea, affections of the iris, opacities of the lens, and even disease involving the anterior part of the vitreous may be detected. To examine every part of the lens and the vitreous, it is absolutely necessary that the pupil be dilated with a mydriatic. Then, tumours of the ciliary region, vitreous opacities, sparkling synchysis, and even detached retina, may be seen.

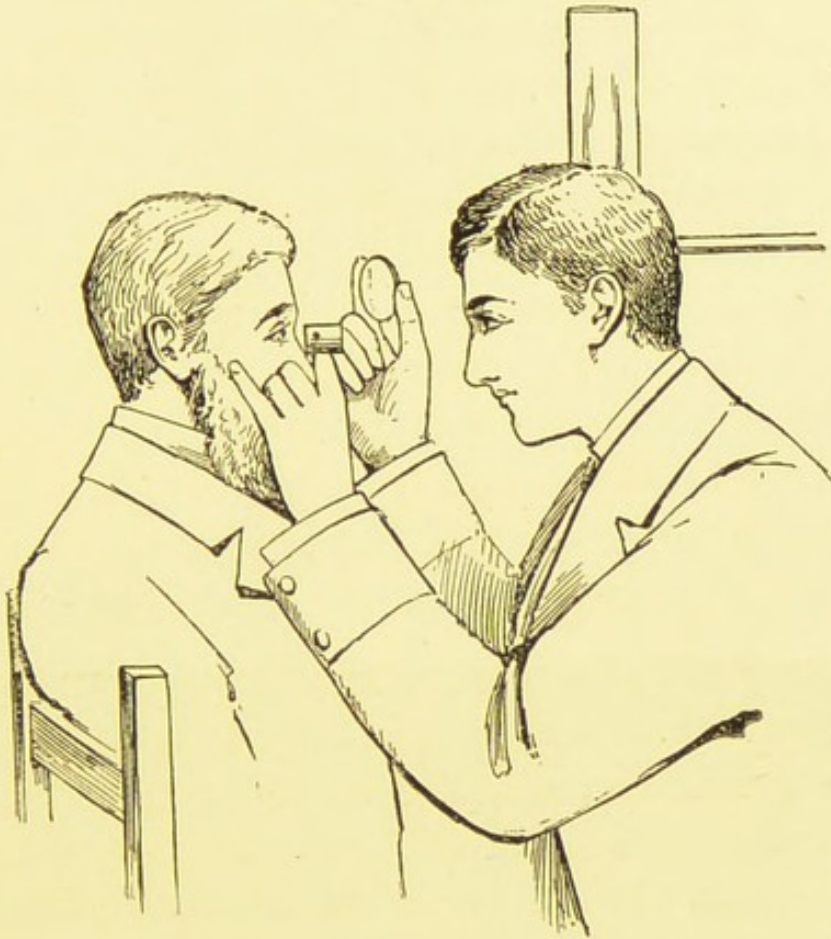
FIG. 32.



By varying the position of the light and of the eye under examination, every part can be thoroughly in-

spected. When the deeper parts of the lens and the vitreous are examined, the light must be thrown into the eye at right angles to the cornea, as shown in Fig. 32.

FIG. 33.



One great advantage of focal illumination is that everything is seen of its real colour and in its true position.


This examination may with advantage be supplemented by using a second lens before the eye as a magnifying glass, or, still better, the small achromatic glass made for that purpose and referred to on p. 31. (Fig. 33.)

### The Large Concave Mirror at a Distance

The light should now be placed on one side of the patient, on a level with the head and slightly behind, so that no direct light falls on his face; the observer, sitting opposite, places before his eye the *large concave mirror*, and at a *distance* of about two thirds of a metre reflects the light into the eye he wishes to examine; usually a red reflex is obtained, but no details will be visible because rays are received only from one point of the fundus: should any of the vessels or a part of the disc be seen, then we shall know that the eye under examination is ametropic, and the observer is receiving rays from two points.

Because in emmetropia (Fig. 34), the rays which come from the two extremities of the disc (A B) emerge as two sets of

FIG. 34.

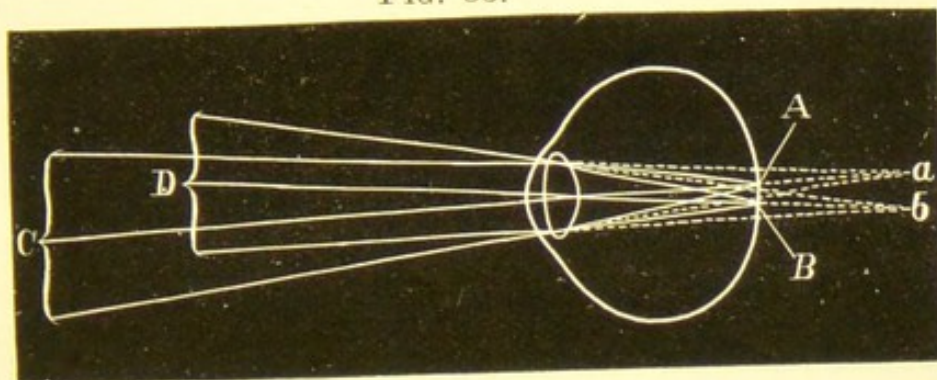


parallel rays in the same direction as the rays A C, B D, which, having passed through the nodal point, undergo no refraction. These two sets of rays soon diverge, leaving a space between them, so that an observer, unless he be quite close to the observed eye, is unable to receive rays from more than one point; therefore at a distance from the eye the observer sees only a diffused and blurred image.

In hypermetropia (Fig. 35) the rays from the two points (A B) emerge from the eye in two sets of diverging rays, in the same

direction as the rays A C, B D, which undergo no refraction. These diverging rays have the appearance of coming from two points (*a b*) behind the eye, where an erect imaginary image is formed (*a b*).

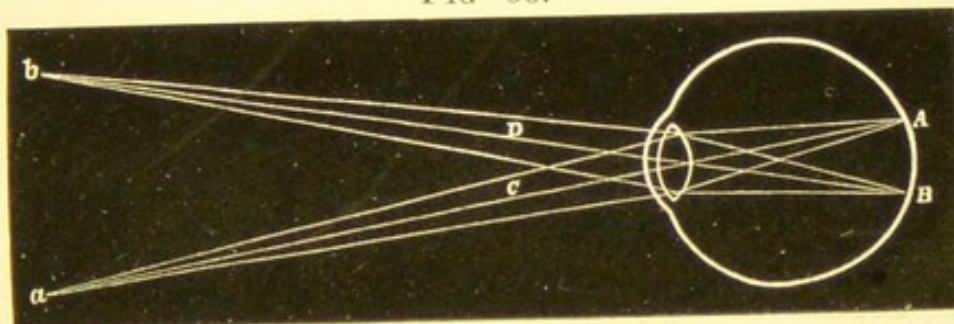
FIG. 35.



Here the observer at a distance sees a clear, erect image, which is formed behind the eye.

In myopia (Fig. 36), the rays from the two points (A B) emerge

FIG. 36.



as two converging sets of rays, which meet at *a b* on their secondary axes, thus forming an inverted image in front of the eye. This image can be distinctly seen by the observer if he be at a sufficient distance from the point, and accommodating for the particular spot at which the aerial image is formed. The higher the myopia the nearer to the eye will this image be formed.

From the above observations it will be understood that if the observer now move his head from side to side, and the vessels of the disc are seen to move in the same direction, the case would be one of hypermetropia, the image formed being an erect one.

Had the vessels moved in the opposite direction to the observer's head the case would be one of myopia, the image being an inverted one formed in the air in front of the eye.

If the vessels of one meridian only are visible, then we have a case of astigmatism, hypermetropic if moving in the same, and myopic if moving in the opposite direction to the observer's head, that meridian being ametropic which is at right angles to the vessels seen.

In mixed astigmatism the vessels of one meridian move against the observer's movements, and those of the other meridian with them; this is difficult to see.

Should no fundus reflex be obtained when the light is thus properly reflected into the eye, the case may be one of hæmorrhage into the vitreous, or other serious lesion; but the reflex may be good, and yet it may appear irregular by the presence of black spots here or there; in this case probably some opacity exists in the cornea, lens, or vitreous, which interferes with the returning rays of light, and so appears black, whatever the real colour of the opacity may be; and if nothing was seen by careful inspection with focal illumination, the opacity is in all probability situated in the vitreous; this is certainly the case if the opacity is *floating*. The movements of these floating opacities will be more conspicuous if the patient be directed to first look upwards, then downwards, and finally straight in front of him; the rate of movement will be a guide as to the consistency of the vitreous.

Sometimes the vitreous opacities may be so thin that some of the returning light may pass through them; they will then appear more or less white or

pink; occasionally light may be reflected from the surface of the opacity, and then it will appear white and more or less glistening; this is the case when chlolesterine or tyrosin crystals are present.

### The Indirect Method

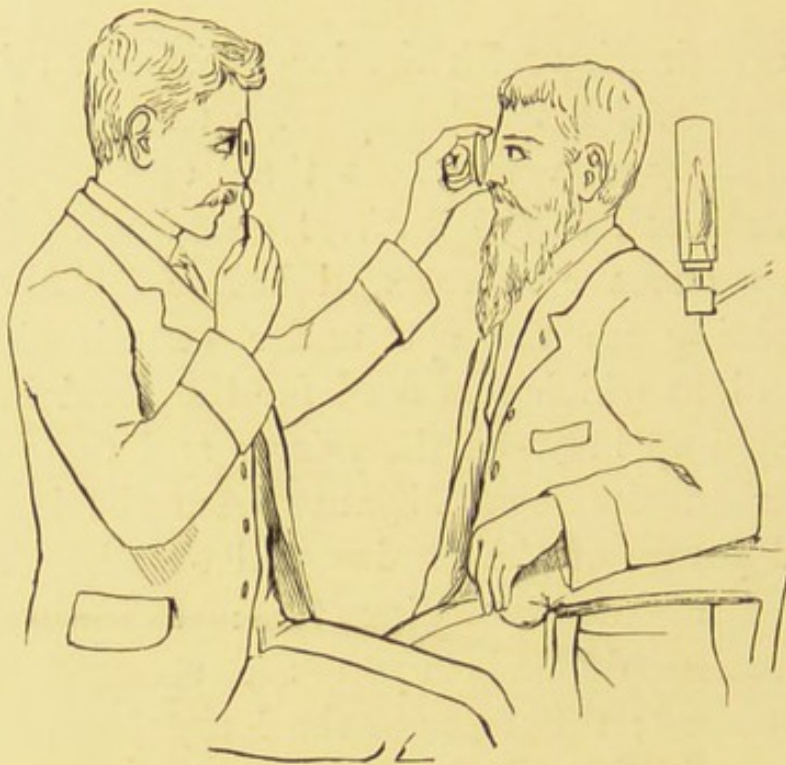The examination with the large concave mirror at a distance, which has taken some time to describe, occupies only a very short time, and we pass on without a break to the *indirect examination*. With the large concave mirror still before the observer's eye, lighting up the eye under examination, the biconvex lens which was used for the focal illumination is held up between the mirror and the patient's eye at about its focal distance from the latter; an inverted image of the fundus will thus be obtained, magnified about five diameters: the amount of magnification depends upon the strength of the objective used; the stronger the lens, the less is the image magnified, and therefore the greater the field that comes into view. The size of the field that can be seen at once will depend upon the strength and size of the object-glass: thus, with a dilated pupil and a lens of + 13 D., having a diameter of about 5 cm., the size of the field will be about 8 mm., or four times as large a field as will be seen by the direct method.

The image formed by the lens will in the case of emmetropia be at the focus of the convex glass, between it and the observing eye, so that the learner

has to remember to accommodate for the image at this distance.

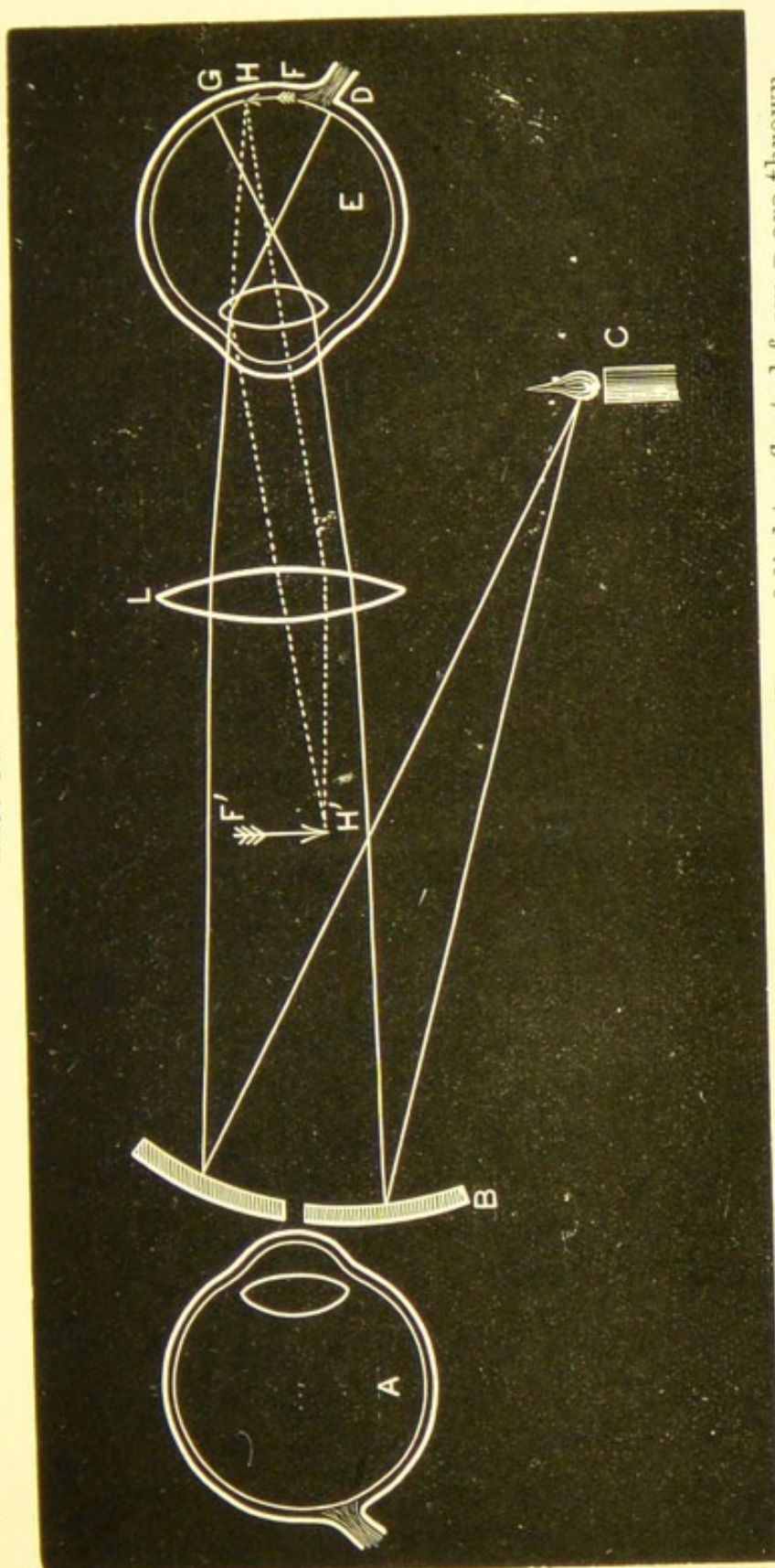
It is convenient to use the mirror before the right eye with the right hand when examining the patient's right eye, and before the left eye with the left hand

FIG. 37.



when examining the patient's left eye; then the objective will be held between the finger and thumb of the opposite hand. This may be steadied if necessary by resting the little finger against the forehead. By adopting this procedure the hand holding the objective is not over the patient's face. Some observers, however, always use the same eye for the indirect examination; thus if the right be the one preferred, the observer will always hold the ophthalmoscope in his right hand, using the objective with

FIG. 38.



This figure is intended to show the indirect method. Rays of light reflected from B are thrown through the lens L into the emmetropic eye E, lighting up that portion between G and D. Rays returning from H will pass out of the eye parallel, and falling on the objective L will be brought to a focus at  $F'$ ; so also will rays from F be brought to a focus at F', so that the lens L will give an enlarged inverted image of H F at F' H', which will be situated in the air at the focus of the convex lens L, and will be visible to the observing eye A. The rays are only drawn from the one point, H, so as not to confuse the diagram. The distance between the aerial image thus formed and the observing eye is too short; this is done to make the figure a convenient size.

the left: this is simply a matter of individual convenience. The eye of the observer not in use may with advantage be kept open.

Although not necessary it is a good plan to use a + 4 D. behind the ophthalmoscope; one thus obtains a somewhat larger image, which can be seen without accommodating, at the focus of the biconvex lens used. Thus when examining the fundus of an emmetrope, the aerial inverted image will be formed at the focus of the objective, which in the case of a + 13 D. lens will be a little less than 8 cm., the observer (with a + 4 D. behind his mirror) situated at 25 cm. from this image will see it clearly and well defined at this distance without any accommodation: the advantage of this plan is that the observer sits nearer the patient than when the examination is made without the + 4 D., and does not have to stretch his arm out so far when holding up the objective.

The first part to which attention should be directed is *the disc*. If one is examining the right eye, the patient should be told to look towards one's right ear, or, what is perhaps better, at the upheld little finger of the right hand which is holding the mirror; the fundus reflex being obtained, it will be noticed to be somewhat whiter when coming from the optic disc; the large convex glass is held between the thumb and finger of the left hand, about 3 or 4 cm. directly in front of the observed eye; this will form an inverted image of the disc, which should be clearly seen by the observer. The beginner will find some difficulty at first in performing these asso-

ciated movements of lighting up the fundus with the mirror, and keeping the light steadily on the eye while the objective is held in the other hand and moved about backwards and forwards, and from side to side.

The next part to examine is the *periphery*; this must be gone over systematically by directing the patient to look up, then down, then to the right, and finally to the left. By this means the posterior hemisphere of the eyeball may be thoroughly inspected, especially when the pupil has been dilated with a mydriatic.

A still more peripheral part of the fundus can be seen by using an objective glass which is composed of two elements, a biconvex lens and a prism; such a glass is called a prismosphere.

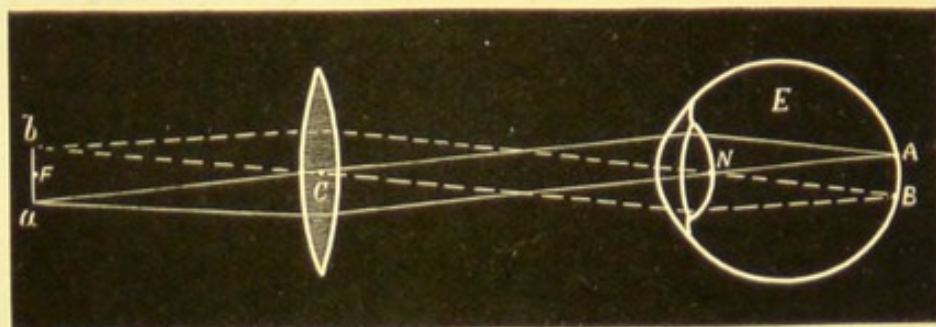
Finally the *macula* region demands attention. This part is difficult to see, as the pupil contracts vigorously when the light is directed on this, the most sensitive part of the fundus; besides, the corneal reflex comes directly in the line of vision. The patient should be told to look at the sight-hole of the mirror, or slightly to one side of it; then, with a little manœuvring with the mirror and lens, and a certain amount of practice, a fairly good view of this part may be obtained.

The reflections formed by the cornea and by the objective are always somewhat troublesome to the beginner; by tilting the lens slightly these images will be thrown out of the line of vision.

**Variations in the Size of the Image in Ametropia.**—The condition of the refraction of the eye under examination

will cause some variation in the size of the images obtained ; thus in emmetropia, rays coming from A, Fig. 39, emerge from the eye parallel, and are focussed by the biconvex lens at  $a$ , and rays coming from B are focussed at  $b$  ; so also with rays coming

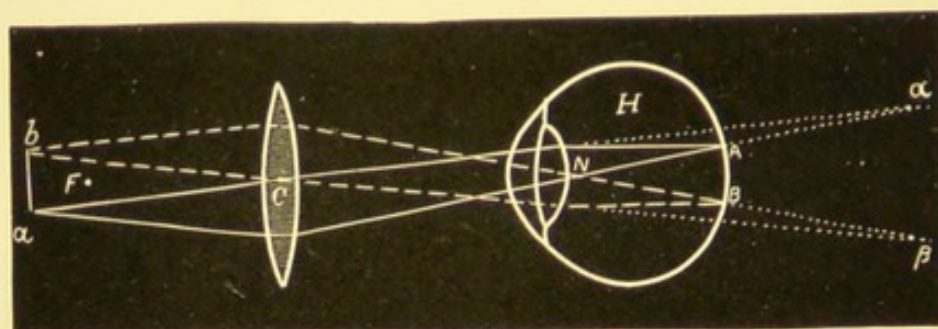
FIG. 39.



from every part of A B, forming an inverted image of A B at  $ba$ , situated in the air at the principal focus of the biconvex lens.

In hypermetropia (Fig. 40) the rays from A emerge divergent, so also, of course, those from B ; if these rays are continued

FIG. 40.

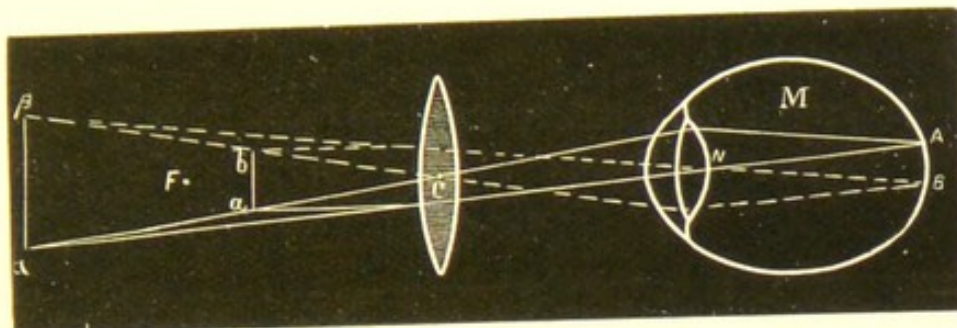


backward, they will meet behind the eye, and there form an enlarged upright image ( $a\beta$ ) of A B ; it is of this imaginary projected image that we obtain, by the help of the biconvex lens, a final inverted image ( $ba$ ), situated in front of the lens beyond its principal focus.

In myopia (Fig. 41) the rays from A and B emerge from the

eye convergent, forming an inverted aerial image in front of the eye at  $\beta a$ , its punctum remotum. It is of this image we obtain,

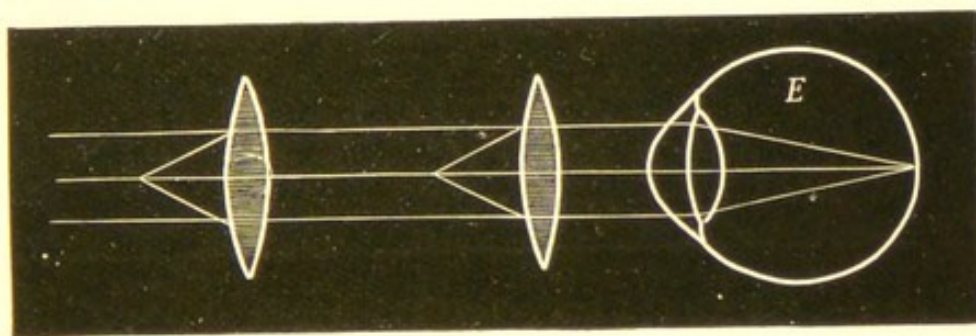
FIG. 41.



with a biconvex lens placed between it and the eye, a final image ( $b a$ ) situated within the focus of the biconvex lens.

The inverted image of the disc, produced by a convex lens at a certain fixed distance from the cornea, is larger in hypermetropia, and smaller in myopia, than in emmetropia. The lens should next be held close to the patient's eye, and then gradually withdrawn, while the aerial image of the disc is steadily kept in view; if any increase or decrease take place in the size of this image, we shall know that the eye is ametropic.

FIG. 42.



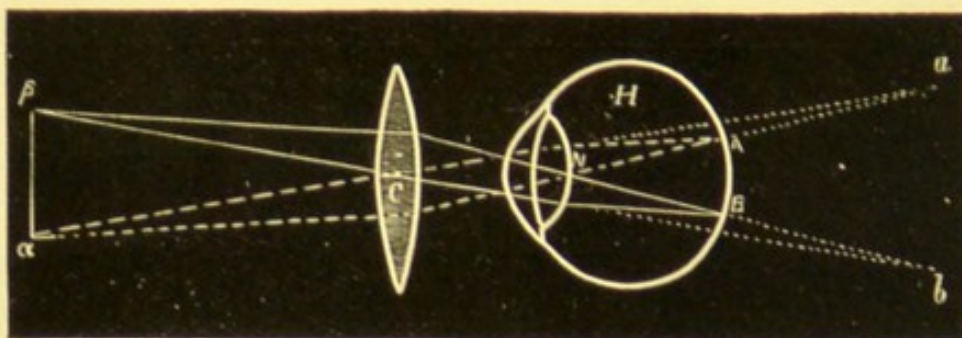
E. Emmetropic eye. Rays issuing parallel, image formed at the principal focus of the lens, no matter at what distance the lens is from the eye.

If no change take place in the size of the image on thus withdrawing the objective the case is one of emmetropia, because rays issue from such an eye parallel, and the image

formed by the object-glass will always be situated at its principal focus, no matter at what distance the glass is from the observed eye (Fig. 42). As the distance of the image from the object-lens is always the same, the size of the image will also be the same.

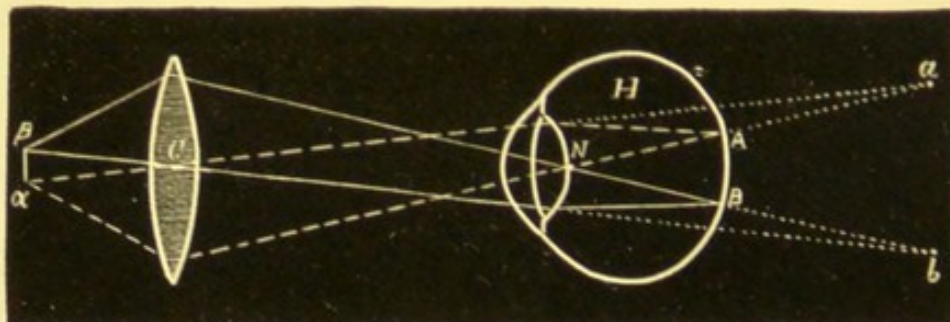
If diminution take place in the size of the image the case is one of hypermetropia, and the greater the diminution the higher is the hypermetropia.

FIG. 43.



Lens at 4 cm. from the cornea.

FIG. 44.



Lens at 12 cm. from the cornea.

H. Hypermetropic eye.  $C$ . The centre of the lens.  $A B$ . Image on the retina.  $a b$ . Projected image.  $\beta \alpha$ . The final image formed by the objective.

This change in size may be explained by remembering that in hypermetropia the image of the disc formed by the object-glass is situated beyond its principal focus, owing to the rays issuing from the eye being divergent; the relative size of the

final image  $\beta a$  to the object  $a b$  will therefore vary directly as the length  $c a$ , and inversely as the length  $c a$ ; so that on withdrawing the lens  $c$  from the observed eye,  $c a$  diminishes and  $c a$  increases; therefore the ratio of  $a b$  to  $a \beta$  diminishes, *i. e.* the size of the image diminishes. The two diagrams 43 and 44 show images formed by the object-glass when held at 4 cm. and at 12 cm. from the cornea, the latter image being the smaller.

If the image become larger on withdrawing the object-glass, the case is one of myopia; the greater the increase of the image, the higher the myopia.

This increase in the size of the image can also be explained with the help of mathematics, remembering that, in myopia, an inverted image is formed in front of the eye (Fig. 36), and it is of this we obtain a final image, with a convex glass placed between the eye and the inverted image, which we must regard as the object, the object and its image being both on the same side of the lens.

In astigmatism the disc, instead of appearing round, is frequently oval. If the image of the disc decrease in size in one meridian, while the other remains stationary as the objective is withdrawn, it is a case of simple hypermetropic astigmatism. If the whole disc decrease in size, one meridian diminishing more than the other, it is compound hypermetropic astigmatism, that meridian being more hypermetropic which diminishes more.

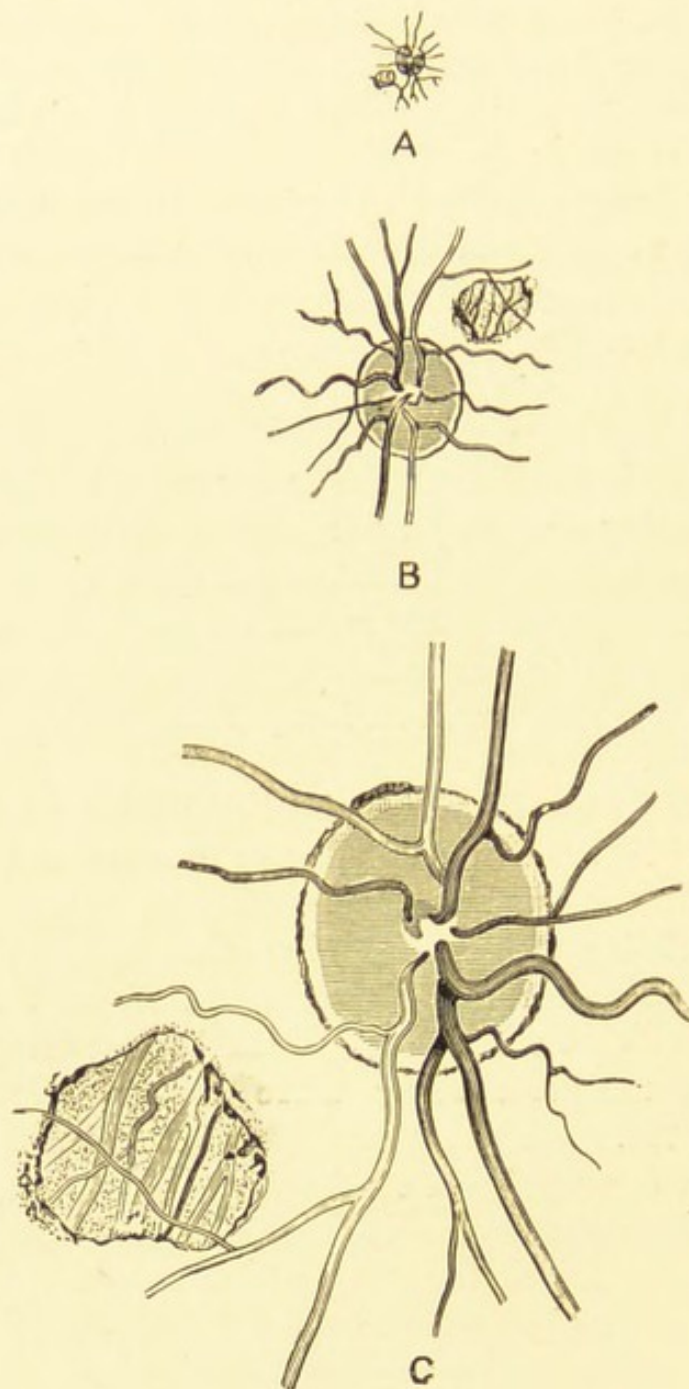
Increase in one meridian of the disc, the other remaining stationary, indicates simple myopic astigmatism.

Increase in the size of the disc, but one meridian increasing more than the other, indicates compound myopic astigmatism, that meridian being more myopic which increases most.

If one meridian increase while the other decrease the case is one of mixed astigmatism.

It must be remembered that by the indirect method everything is inverted; thus the apparent position of the macula is to the inner side, when of course its

FIG. 45.



The above figure is intended to represent, by means of A, the real size of the optic disc ; by means of B, the size of the image formed by the indirect method ; and by C, the size of the image formed by the direct method. It also shows in the case B the effect of the inversion ; this effect is rendered more apparent by the patch of choroiditis shown in the figure.

real position is outside, the apparent upper edge of the disc is the lower, and so on. Fig. 45 B represents this inversion.

**Magnification of the image seen by the indirect method.**

—To estimate the degree of enlargement obtained by the inverted image we must recall to our minds the fact, that the image we see in this method of examination is a real image formed in the air by the union of the rays coming from the eye and passing through the convex lens. This image can be received upon a screen and measured exactly; therefore to estimate the degree of enlargement, we have only to measure the size of the inverted image of the disc and compare it with the size of the disc itself.

We are at once met by the difficulty that the size of the disc varies in different individuals, so that we do not know its exact size in any particular case.

If the biconvex lens with which we obtain the inverted image be placed at such a distance from the eye that its focus coincides with the nodal point of the observed eye, a point situated in the emmetropic eye 15 mm. in front of the retina; then the enlargement may be expressed by the simple formula—

$$X = \frac{f}{n}$$

of which  $X$  equals the amount of enlargement of the image;  $f$  equals the focal distance of the lens used to produce the inverted image; while  $n$  is

the distance between the nodal point and the retina.

Suppose, for example, we wish to know the amount of enlargement of the image in the case of an emmetrope with a glass of 13 D. Then  $f$  equals the focal distance of the lens 13 D., which is 77 mm.; and  $n$  equals 15 mm., that is the distance between the nodal point and the retina; we shall then have for our formula—

$$X = \frac{77}{15} = 5 \text{ times.}$$

Therefore the enlargement will be five times, and if on measuring the image thus obtained we find it to be 7.5 mm., then we shall know that the real size of the disc was 1.5 mm.

In hypermetropia we must find the amount of shortening of the eyeball (3 D. = 1 mm.), and deduct this from the 15 mm. which is the distance between the nodal point and the retina, and then proceed as before.

In myopia the increase in length of the eyeball must be added on to the 15 mm.

To carry out this experiment practically a demonstrating ophthalmoscope such as Beale's is necessary, provided with a screen marked out in millimetre squares on which the image is received. With Frost's artificial eye the experiment can be easily demonstrated.

**The large lens used as a condenser and magnifier.**  
—The indirect examination being completed, before

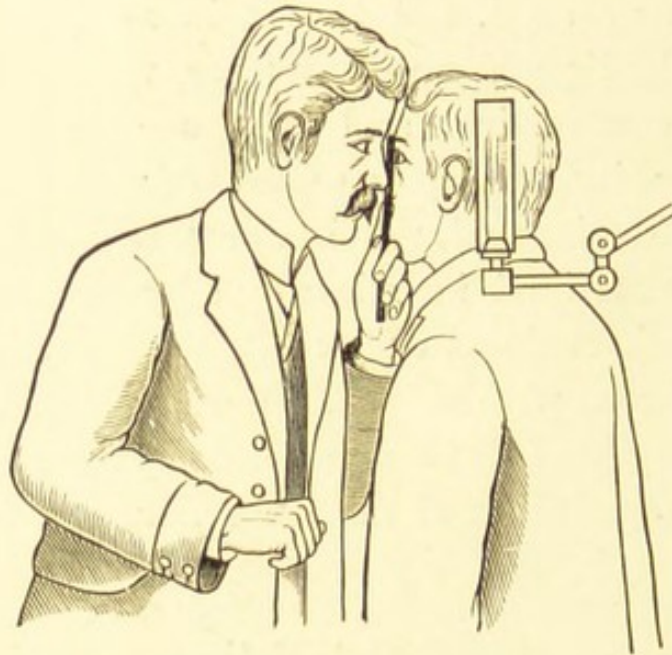
laying down the mirror and lens a further method of examination may be briefly mentioned. The observer approaching to a short distance from the patient (about 15 or 20 cm.), reflects the light into the eye by means of the mirror, and having illuminated the eye he then interposes the convex lens, which is now used, not to obtain an image, but to condense the light from the mirror, while at the same time the cornea, iris, and lens are seen under its magnifying influence; opacities of the cornea, injuries or affections of the iris or lens are often conveniently examined in this way; by slightly moving the lens backwards and forwards the light is focussed on the different planes. This method of examination, though very useful in many cases, must never be used to the exclusion of the *focal illumination*.

### The Direct Method

The direct method of examination is next employed. This method has the advantage of enabling us to see the parts in their true position, and gives us an image magnified some 16 to 18 diameters, though, of course, a much smaller part of the fundus is seen at once. The amount of fundus which will be visible depends chiefly upon the size of the pupil, but partly also upon the size of the light used; with a pupil of 4 mm. and a large gas flame, one gets a field little bigger than 2 mm.; although only this small part can be seen at once, yet by varying the position of the head and ophthalmoscope one is able to look over a

considerable part of the posterior hemisphere of the eye. A strong prism placed behind the ophthalmoscope will allow a still more peripheral part of the fundus to be seen.

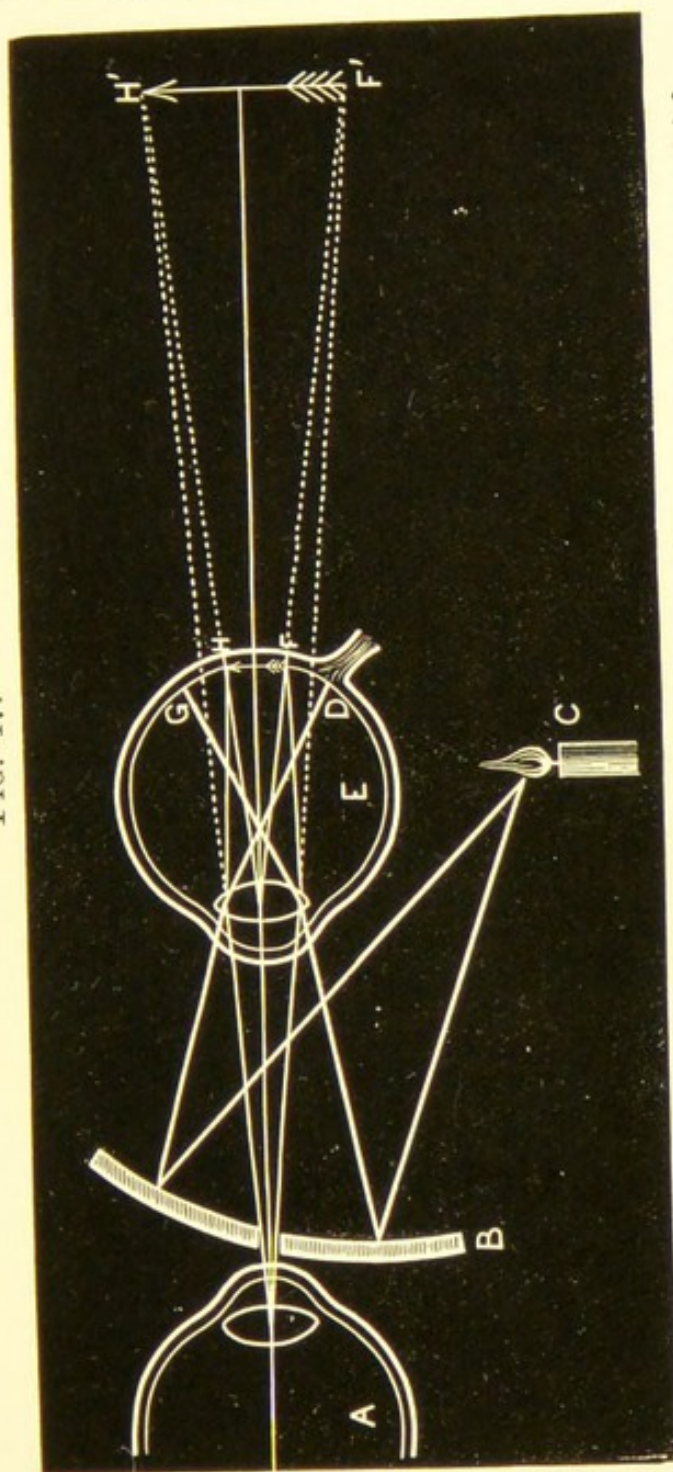
FIG. 46.



For the direct examination the tilted short focussed mirror is used; it may be quite small, as only those rays reflected from the part immediately around the sight-hole enter the pupil,—this is especially the case when the pupil is small; the sight-hole should not be larger than about  $2\frac{1}{2}$  mm., for if the sight-hole be larger than the pupil, then no rays may enter the eye, and we shall fail to get any illumination. The observer first corrects any ametropia that he may have, either by having the proper correction in a suitable clip behind the sight-hole of his ophthalmoscope, or he may deduct his own ametropia from the glass

which corrects the refraction of the patient and himself in the manner to be presently described; he

FIG. 47.



In Fig. 47, A is the observing eye, B the observed, C the candle from which divergent rays fall on the mirror B, and being reflected into the eye light up the area between G and D; rays from the point H and F pass through the sight-hole of the mirror and enter the observing eye A, forming on A's retina an image of H F. By continuing these rays backwards an enlarged upright image of H F will be formed behind the eye at H' F'.

then sits or stands as he may prefer on the same side as the eye he is about to examine, so that the observer

uses his right eye for the patient's right and his left for the patient's left.

The light is placed on the side to be examined a little behind and on a level with the patient's ear; the examinee's head may with advantage be inclined slightly towards the observer, while the observer inclines his own head slightly in the reverse direction; *i. e.* in examining the right eye the patient inclines his head slightly to the right, while the observer inclines his slightly to his own right, so that the two eyes may come very close together, the brows even may touch, while the respiratory orifices of patient and observer are away from each other.

The patient is directed to look straight in front of him, and take as little notice as possible of the surgeon, who resting the edge of the ophthalmoscope against his brow, reflects the light into the eye, and approaching close to the patient, first looks for the disc; then scans the periphery by directing the patient to look in different directions; and finally examines the macula region.

The great difficulty which the beginner finds with this method is to keep his accommodation passive; usually some practice is required before this can be managed, so that a concave glass has to be used behind the sight-hole of the mirror ( $-3$  or  $4$  D.) before a clear view of the fundus can be obtained. By using a weaker concave glass each time, the accommodation will be gradually relaxed. Should the disc, when first seen, appear quite clear and distinct, one must not at once assume that the patient is emme-

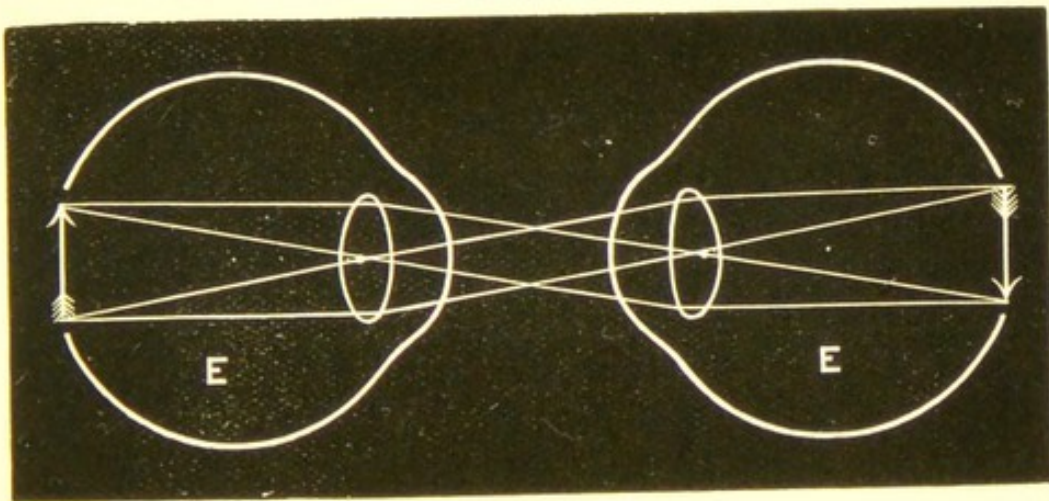
tropic, but only on finding that the weakest convex glass behind the ophthalmoscope impairs the clearness of the image. Another difficulty the beginner has, is to disregard the corneal reflex, which is most troublesome when the macula region is inspected.

**Magnification of the image seen by the direct method.**

—The estimation of the amount of enlargement by means of the direct method of examination is more difficult and less exact than with the indirect method.

The size of the image of the disc of an emmetrope formed on the retina of the emmetropic observer will be exactly the same size as the disc itself. This is clearly shown in Fig. 48.

FIG. 48.



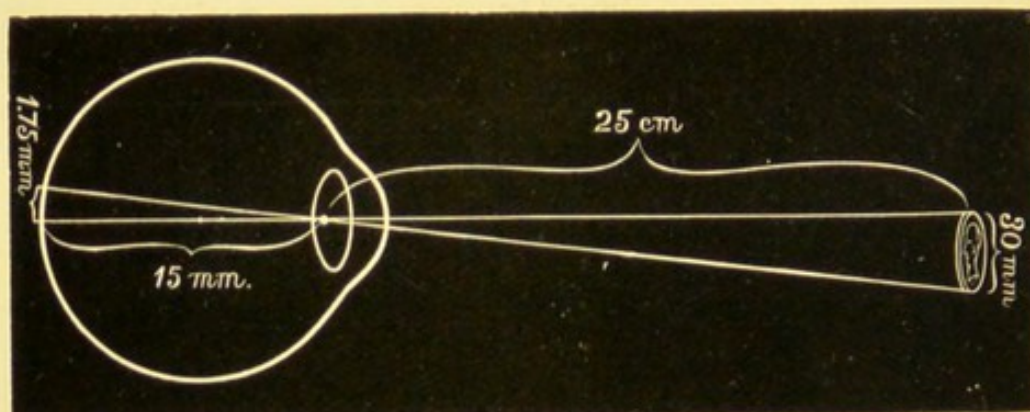
The image is therefore of considerable size, and covers a good many retinal elements; and to find out the magnification, we have only to consider some external object which, placed at a certain distance from the eye, forms a retinal image of the same size, viz. 1.75 mm.; half-a-crown held 25 cm. from the eye will produce a retinal image of about this size.

If we divide the distance at which the coin is placed (25 cm.) by the distance from the retina to the nodal point, 15 mm., we shall arrive at the amount of enlargement:

$$\frac{25 \text{ cm.}}{15 \text{ mm.}} = \frac{250 \text{ mm.}}{15 \text{ mm.}} = 17.$$

The diameter of our coin should therefore be 17 times larger than its retinal image; we know the size of the retinal image is 1.75 mm., therefore the diameter of the half-crown should be about 30 mm.; on measuring it this will be found to be the case.

FIG. 49.



It is obvious that the disc or any part of the fundus will appear more magnified, the greater the distance to which its image is projected.

Hence the ophthalmoscopic image of the same disc does not always appear of the same size to different observers, owing to the varying distance to which the image is mentally projected by them. To still further elucidate the subject, the following explanation may be of service.

Every student is familiar with the plan sometimes

adopted in the case of the microscope ; when making a drawing of a specimen, the observer looks with one eye—we will assume the left—down the tube of the microscope, while with the right he looks by the side of the tube on to a piece of drawing-paper placed on a level with the stage of the instrument. The specimen, seen by the left eye, is projected upon the paper with the right, and can there be drawn ; or if it is wished to estimate the magnifying power of the microscope, a scale divided into hundredths of a millimetre is placed under the eye piece, while beside it on the stage, or on the same level, is placed a scale divided into millimetres, so that the image seen in this case with the left eye is projected on to the scale placed at the side of the instrument ; thus the two scales are superimposed, and a comparison can be made ; if the squares on the two scales exactly cover each other, then we should know that the microscope magnified one hundred times.

This experiment will also enable anyone to understand what is intended by the expression “ projecting a retinal image.”

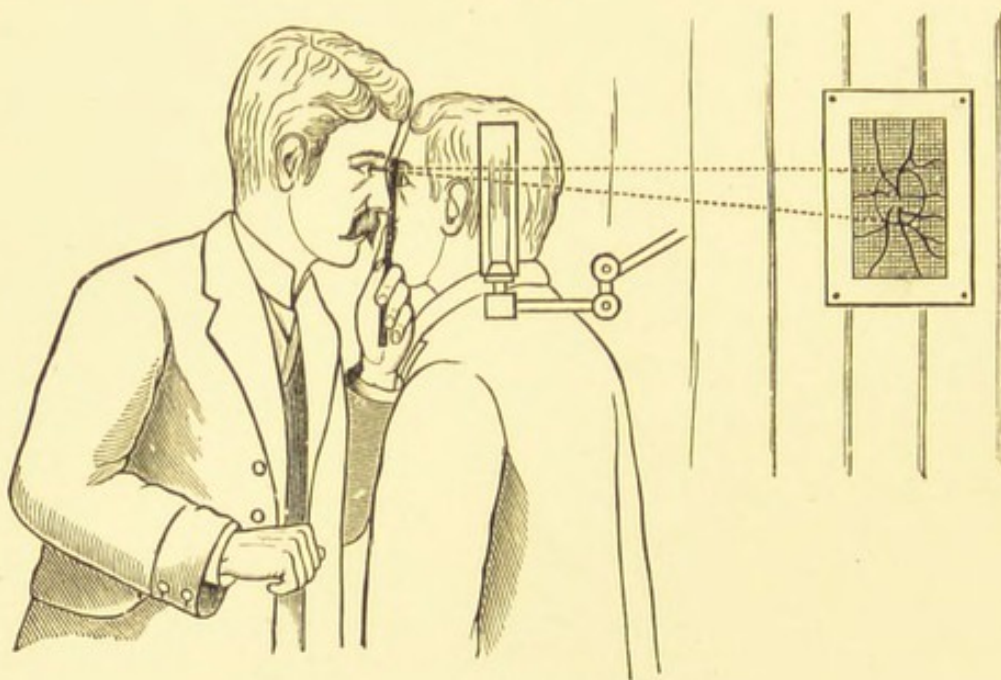
A somewhat similar plan is adopted with the ophthalmoscope, but it must be slightly modified, since the conditions are different.

For with the ophthalmoscope, using the direct method, we approach so near to the observed eye that it would be impossible to see it at the same distance with the eye alone ; it is just the same as looking through a strong convex lens. For this reason it is obvious that we must place the standard scale at a

greater distance from the eye, and since the apparent size of the image is larger in proportion to the distance to which it is projected, it is necessary to fix some distance at which the measuring scale shall be placed so as to render this method of any value; 33 centimetres has been decided upon, a distance at which we ordinarily look at near objects.

Therefore, to estimate the amount of enlargement by the direct method of examination, we look with one eye through the ophthalmoscope at the disc of the observed eye, while with the other we look at

FIG. 50.



a sheet of paper on which is ruled a millimetre scale placed 33 cm. away; with a little practice the student will be able to project upon this scale the image of the disc which he sees with the other eye, and, by counting the number of squares on the scale

that is covered by the image, the amount of enlargement can be estimated.

We encounter here the same difficulty that was referred to on page 51, that the size of the disc may vary in different individuals.

If the observer be emmetropic, then it is necessary for him to put on  $-3$  D. behind his ophthalmoscope, so that he may accomodate 3 D. with each eye; he would then see clearly the disc of the eye under observation, while the other eye will be adapted for the distance at which the scale is placed, 33 cm.; were this proceeding not adopted, the eyes would have to accommodate in unequal degrees in order that both the disc and the scale may be seen clearly.

Another plan of estimating the enlargement by the direct method is to place behind the sight-hole of the ophthalmoscope a plain mirror from which a good deal of the silvering has been scratched away, to receive an image of the scale which is placed behind the observer's head and a little to one side, and thus the image of the disc and the scale will be superimposed, and the two will be seen by the one eye. This plan is useful when the observer's eyes are not of equal value.

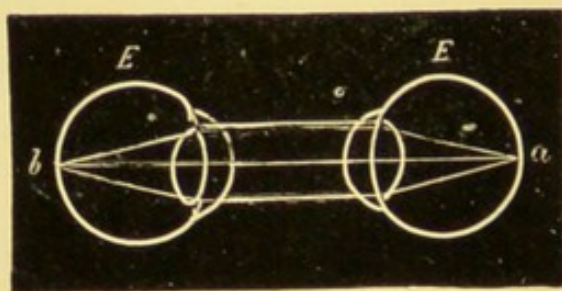
Both the *indirect* and *direct* examinations should always be employed; each method has its own special advantages; thus the *indirect* method gives us a large field and allows us quickly to scan over the whole of the posterior part of the fundus, while the patient's refraction need not be corrected, and the observer may disregard his own ametropia provided he can adapt his

eye for the distance at which the aërial image will be formed.

The *direct* method gives a smaller field but greatly magnified, so that minute changes which are not visible by the indirect method can be detected ; it also gives us more accurate information of any lesion with regard to its level, etc. ; being an upright image everything is seen in its proper position, whereas with the indirect method the image is inverted ; and finally with the direct, the refraction of the observer and observed must be corrected.

**The estimation of the refraction by the direct method.**—To estimate the refraction of the patient by the direct method, it is necessary that the patient's accommodation should be relaxed ; this will generally be the case when the examination is made in a dark room, or atropine may be used ; then if the observer's own accommodation be suspended, and the image of the disc appear quite clear and distinct, the case is one of emmetropia ; because rays coming from an emmetropic eye (Fig 51, E) issue parallel, and the observing eye

FIG. 51.



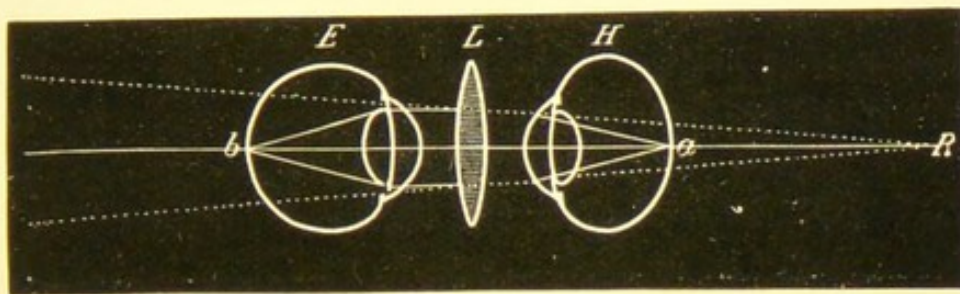
receiving these rays will, if emmetropic with its accommodation suspended, be adapted for parallel rays, so that a clear image of *a* in the observed eye will be formed at *b* on the retina of the observing eye.

Supposing the image does not appear clear and distinct

without an effort of the accommodation, then we turn on convex glasses behind the sight-hole of the ophthalmoscope.

The *strongest* positive glass with which we are able to get a perfectly clear image is a measure of the hypermetropia, because rays coming from *a* (Fig. 52) in the hypermetropic eye (*H*) issue in a divergent direction, as though coming from *R*,

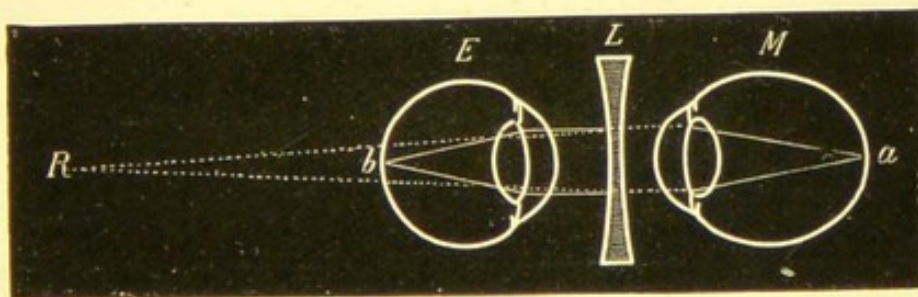
FIG. 52.



the punctum remotum behind the eye. The convex lens (*L*) renders them parallel, and they then focus at *b*, on the retina of the observing emmetropic eye (*E*).

If, however, the image of the disc appear indistinct, and the convex glass, instead of rendering the image clear, have the opposite effect, we must turn the wheel of the ophthalmoscope in the other direction, and so bring forward the concave glasses. The *weakest* with which we can see the details of the fundus clearly is a measure of the myopia, because any stronger glass merely brings into play the accommodation of the observer.

FIG. 53.



Rays from *a* (Fig. 53) leave the myopic eye (*M*) so convergent, that they would meet at (*R*) the punctum remotum. The con-

cave lens (L) renders them parallel before falling on the relaxed eye (E) of the observer.

If the ophthalmoscope is not held very close to the eye, we must deduct from the focal distance of the lens the distance between the cornea and the instrument in hypermetropia, adding them together in myopia.

If astigmatism exist the proceeding is more difficult, because one wishes to find out not only the refraction of the two chief meridians, but also the axis of these meridians. To discover the meridian of greatest refraction, and to estimate it by the direct method, we keep in view the disc, then if the case be one of hypermetropic or mixed astigmatism, we find the strongest convex lens through which one of the vessels still remains distinct (vessels going in other directions will be indistinct); this lens will be the measure of the refraction of that chief meridian which is at right angles to the vessel. To estimate the other chief meridian we select a vessel whose course is at right angles to that first chosen; the strongest convex glass through which this vessel is seen distinctly will give us the measure we require.

Had the case been one of myopic astigmatism, then the weakest concave glass with which any vessel is first clearly defined will indicate the strength of one meridian; to estimate the other meridian we must as before select a vessel which is at right angles to that first clearly seen, then the weakest concave lens which allows us to see it well defined will indicate the refraction of the other chief meridian. The estimate is more easy to make when the chief meridians are vertical and horizontal; but unfortunately many cases occur in which they are more or less oblique, and it is not always easy to find a vessel whose course exactly coincides with these oblique meridians.

The essential point to remember in estimating astigmatism by this method is, that the glass with which the vessel in one direction is clearly seen, is the measure of the refraction of that meridian which is at right angles to the vessel; the student needs only to recall to his mind the principles of the perception of a line by an astigmatic eye to understand this.

The subject may possibly be made clear by quoting a few examples; we will take a case in which the vertical vessels and lateral sides of the disc appear distinct without any lens, and which the weakest convex glass renders indistinct, then the horizontal meridian, *i. e.* the meridian at right angles to the vessels clearly seen, is emmetropic; and suppose, also, that the horizontal vessels with the upper and lower borders of the discs require a convex or concave glass to render them clear and distinct, then the vertical meridian is hypermetropic or myopic, and the case is one of simple hypermetropic or myopic astigmatism.

If both the vertical and horizontal vessels can be seen through a convex glass, but a stronger one is required for the vertical than for the horizontal, then the case is one of compound hypermetropic astigmatism, the horizontal meridian being the more hypermetropic.

If both meridians had required concave glasses, but of different strengths, then the case would be one of compound myopic astigmatism.

If the vertical vessels and the lateral sides of the disc can be seen clearly defined through a convex glass, while the horizontal vessels require a concave glass to render them distinct, the case is one of mixed astigmatism, the horizontal meridian being hypermetropic, the vertical meridian myopic.

The estimation of the refraction by the direct method is exceedingly valuable, but requires great practice. In cases of hypermetropia and low myopia one is able to estimate the amount of error within half a dioptré, and in cases of astigmatism where the chief meridians are horizontal and vertical, one can come very near the exact correction, and without subjecting the patient to the inconvenience of having his accommodation paralysed with atropine.

The comparison of the direct and indirect methods of examination is also very useful in astigmatism. If, for instance, the disc is elongated horizontally in the erect, and oval vertically in the inverted image, we know that the curvature of the cornea is greater in the horizontal than in the vertical meridian.

The ametropic observer must always remember, when using

the direct method for the estimation of errors of refraction, that he must correct his own defect, either by wearing spectacles, or by having a suitable glass in a clip behind his ophthalmoscope; he is then in the position of an emmetrope: but, if he prefer it, he may subtract the amount of his own hypermetropia or myopia from the glass with which he sees clearly the patient's disc. Thus, if the observer have 2 D. of hypermetropia and require + 3 D. to see the fundus clearly,  $(+ 3 \text{ D.}) - (+ 2 \text{ D.}) = + 1 \text{ D.}$ , the patient would have 1 D. of hypermetropia. Had he required - 2 D. then  $(- 2 \text{ D.}) - (+ 2 \text{ D.}) = (- 4 \text{ D.})$  the observed would have 4 D. of myopia.

The same with the myopic observer; if his myopia amount to 3 D., then he will require - 3 D. to see clearly the emmetropic fundus; if he sees well without a glass, then the eye under examination has 3 D. of hypermetropia; if he require a + 2 D., then the hypermetropia will be 5 D., and so on.

### Retinoscopy.

RETINOSCOPY will conclude our systematic ophthalmoscopic examination; this test becomes especially necessary when the vision has been found defective and nothing abnormal has been detected to account for it.


The electric focal lamp of sixteen candle power or the ordinary Argand gas light are either suitable for retinoscopy.

The light is usually placed over the patient's head and slightly behind, so as to leave the eyes in shade.

Some observers prefer a bright, screened light coming from a diaphragm opening of 5 to 10 mm. placed 3 cm. from the mirror: the illumination is brighter the nearer the light is to the mirror.

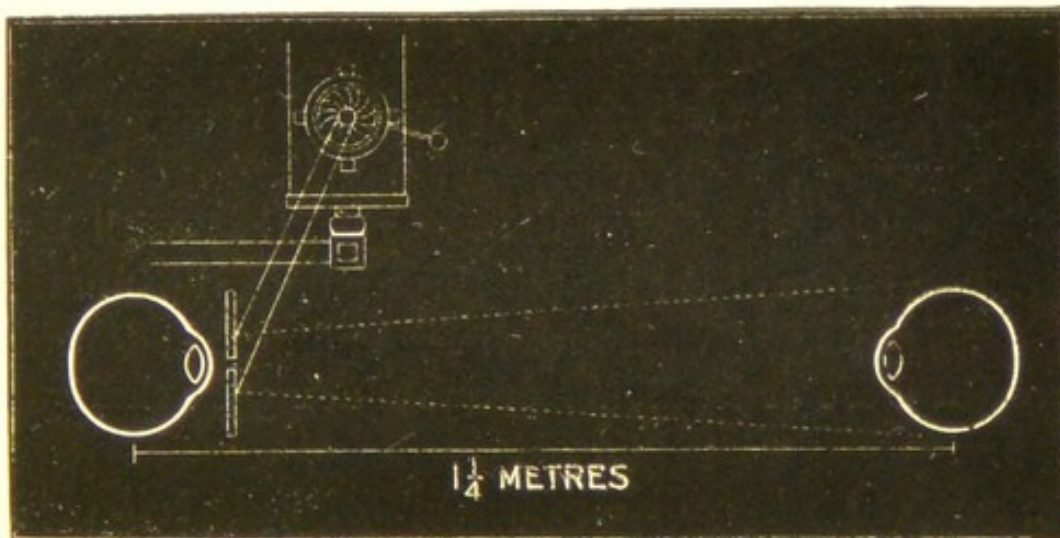
The patient having his pupils dilated and being seated in the dark room, the observer takes up his

FIG. 54.



position one and a quarter metres away or further, and reflects the light into the eye with a plane mirror; a fundus illumination is now obtained which

FIG. 55.



will be bright if the patient is emmetropic, less so if he be ametropic; the greater the ametropia, the less bright will the fundus reflex be.

It is usually necessary for the patient to be under a mydriatic, as it renders the examination easier and allows the refraction at the macula to be estimated: whereas when a mydriatic is not used the pupil contracts so vigorously when light is thrown on the macula that we have to be satisfied with the refraction at the optic disc, which may occasionally vary considerably from that at the macula.

Therefore, when the patient is under a mydriatic, he should look directly at the sight-hole of the mirror; when not under a mydriatic he must look a little inwards, so that the light is reflected along the optic axis.

The observer having obtained with the mirror the ordinary fundus illumination, if the mirror be now rotated slightly from side to side on its vertical axis, he may see a shadow come out from behind the pupil moving horizontally across the illuminated part. The edge of this shadow may be linear or slightly crescentic, it may be vertical or oblique, and it may move with or against the movement of the mirror.

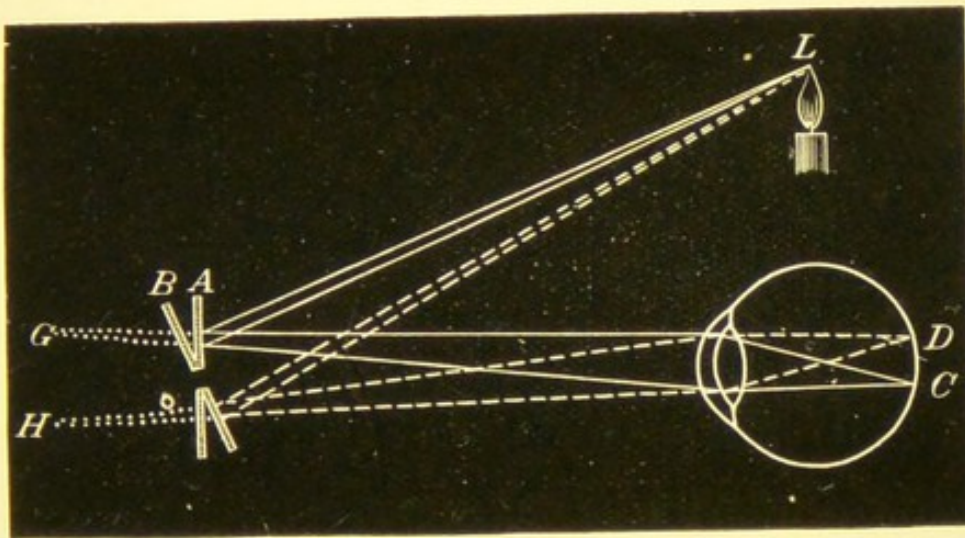
The explanation of retinoscopy is that with the mirror an image of the lamp is thrown upon the fundus, and this image with its surrounding shadow is brought more or less to a focus producing the shadows we see.

Therefore when diverging rays of light fall on a plane mirror they are reflected as divergent rays, as if coming from a point behind the mirror forming a virtual image; the diverging rays passing through the pupil of the eye under observation are brought

more or less to a focus according to the refractive condition of the eye; on rotating the mirror in one direction the retinal image will move in the same direction.

The following diagram (Fig. 56) may help to make this clear.

FIG. 56.



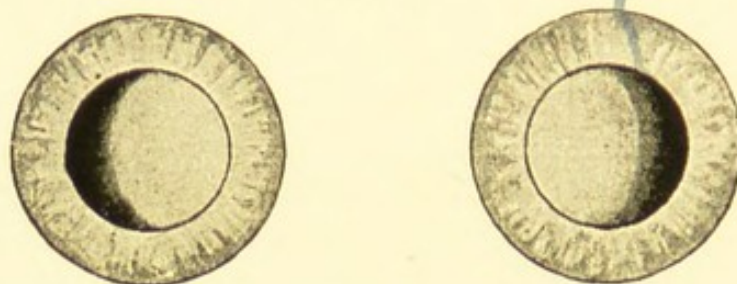
Rays of light from *L* fall on the plane mirror *A*, and are reflected as divergent rays into the eye, as if coming from point *G* behind the mirror; these rays focus on the retina at *C*. On tilting the mirror into position *B*, the rays from *L* diverge from the mirror (as if coming from *H*) and focus at *D*; therefore the real movement of the light on the retina is with the mirror. But as these movements are seen through the refracting system of the eye the apparent movements may differ from the real ones.

In hypermetropia the image seen by the observer is an upright one, and therefore moves with the

mirror. In myopia it is an inverted one, and therefore moves against the movement of the mirror.

Thus assuming the shadow's edge to be vertical, if it move with the mirror the case is one of hyperme-

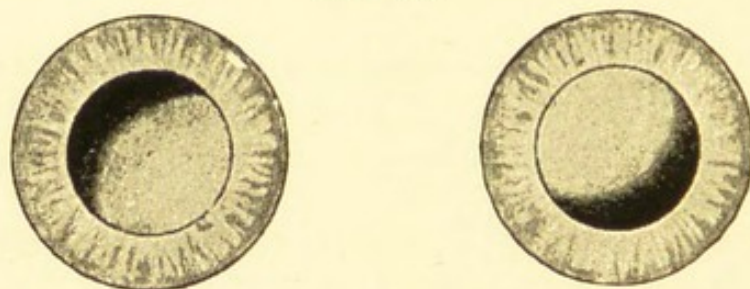
FIG. 57.



tropia; but if it move against or in the opposite direction to the movement of the mirror, the case is one of myopia. If the shadow's edge is oblique, then we know at once that astigmatism is present.

The movements of the shadow tell us the form of ametropia we have to deal with. The extent of the

FIG. 58.



movements on rotation of the mirror, the clearness of the image and the brightness of its edge, enable us to judge approximately the amount of ametropia to be corrected.

A few examples will assist in making this description clear.

Having placed in position a pair of trial frames, we com-

mence by throwing the light into the right eye and watching the fundus illumination; now rotate the mirror on its vertical axis to the right; if a vertical shadow come across the pupil from the patient's right, *i. e.* in the same direction as the movement of the mirror, or what is the same thing, if the shadow move in the same direction as the circle of light on the patient's face, the case is one of hypermetropia. Should the edge of the image appear well defined and move quickly, in addition to a bright fundus reflex, we infer that the hypermetropia is of low degree.

Place a weak convex glass, say + 1 D. before the eye we are about to correct. If the image still move with the mirror, place in the frame + 1.5 D., then + 2 D., and so on, until we find the point at which no distinct shadow can be seen. Supposing this to be + 2 D. and that on trying + 2.5 D. the image move against the mirror, + 2 D. is assumed to be the correcting-glass.

Had we obtained a reverse shadow, we should then try concave glasses, proceeding exactly as before, putting up stronger and stronger glasses, until we are unable to make out the movements of the image. This is assumed to be the correcting-glass.

When the myopia is of high degree, and a strong concave glass has to be used for its correction, the light reflected from the mirror is so spread out by the concave glass, that fewer rays pass into the eye, and therefore the illumination is not so good as in other states of refraction.

In astigmatism the two chief meridians will be different; we judge if one shadow be more distinct or quicker in its movements than the other, though we are not always able to say at once that astigmatism exists. We therefore proceed to correct one meridian. If the shadow move with the mirror in all meridians, we first take the vertical, and put up in front of the patient, in a spectacle-frame, convex spherical glasses, until we find the glass which neutralises the shadow; we put this down as the correcting-glass for the vertical meridian, and let us

suppose that glass to be  $+ 2$  D. We next take notice of the horizontal meridian, and if  $+ 2$  D. is also the glass required we know the case is one of simple hypermetropia. But supposing  $+ 4$  D. is necessary, we indicate it conveniently thus :

$$\begin{array}{c} + 2 \text{ D.} \\ | \\ \text{---} + 4 \text{ D.} \end{array}$$

The case is one of compound hypermetropic astigmatism, and will require for its correction  $+ 2$  D. sphere combined with  $+ 2$  D. cylinder axis vertical.

Take another case—that in which the vertical meridian requires  $- 2$  D., and the horizontal  $+ 2$  D. Here we have a case of mixed astigmatism which can be corrected by a  $+ 2$  D. sphere combined with  $- 4$  D. cylinder axis horizontal.

Supposing the axis of the shadow to be oblique, we know at once that astigmatism exists, and we proceed to correct each meridian separately, moving the mirror at right angles to the edge of the shadow, not horizontally and vertically. We judge of the amount of obliquity by the eye, and can frequently tell within a few degrees. If the vertical meridian be  $20^\circ$  out, and require for its correction  $- 2$  D., and the axis at right angles to this (which will be therefore at  $110^\circ$ ) require  $- 3$  D., we express it as in Fig. 59, and correct it with sphere  $- 2$  D. combined with cylinder  $- 1$  D. axis  $20^\circ$ , the case being one of compound myopic astigmatism.

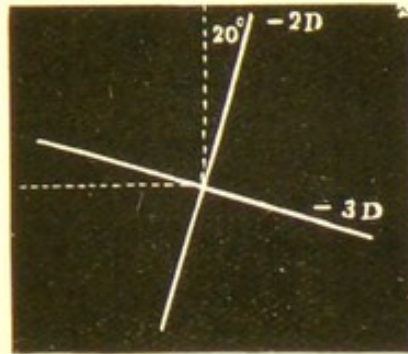
Often one is able to put up the cylinder in the spectacle-frame with the exact degree of obliquity.

Having found the glasses which correct the two meridians, we put up the combination in a spectacle trial frame, and if we now get only a slightly reversed shadow in every direction, the glasses are assumed to be the right ones, and we proceed to confirm it by trying the patient at the distant test type, making any slight alterations that may be required.

The student must remember that the glass which neutralises the shadow in retinoscopy is not an exact estimate of the

refraction, because he does not sit at infinity but about 120 cm. from the eye under examination, so that when no shadow is

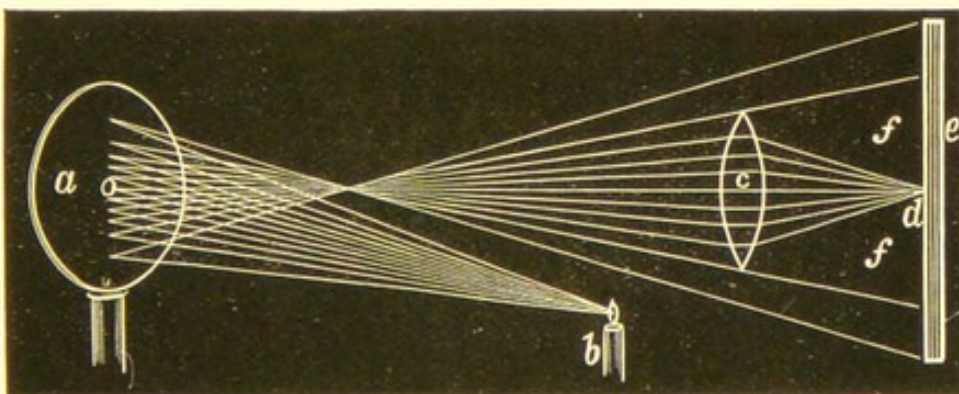
FIG. 59.



obtained he is sitting practically at the patient's far point: for this reason, therefore, the hypermetropia is slightly over-corrected (+ 1 D.) and the myopia is under-estimated ( $-1$  D.), so that in hypermetropia 1 D. must be deducted, and in myopia 1 D. added to the correction-glass when confirming the result with test types.

A few observers still prefer the use of a concave mirror in retinoscopy; the movements then obtained

FIG. 60.



are the reverse of those already described, the shadows moving against the movements of the concave mirror in hypermetropia and with them in myopia, the image having suffered an additional inversion.

## CHAPTER IV

## THE APPEARANCES OF THE NORMAL FUNDUS

It is essential that the learner should become familiar with the different varieties of the normal fundus before passing on to the various pathological conditions. The beginner may think this a very easy matter, but he will soon discover that it is far from being so ; for instance, in cases of slight indistinctness of the margin of the disc, it may sometimes be exceedingly difficult for even the most experienced and skilful ophthalmoscopist to know exactly when this slight blurring has passed the border line of health and become pathological.

As the complexion and the colour of the hair varies greatly in the human race, it is not to be wondered at that the colour and appearance of the back of the eye, which depend in great measure on the amount of pigment contained in the tissues, should also show great variations. Plates I and II are intended to illustrate some of the types of the normal fundus and when we consider that no distinct line separates these different varieties, but that one type passes imperceptibly into another, it will be realised what great differences may be met with.

These variations depend in great measure upon the amount of pigment contained in the hexagonal cells of the epithelial layer of the retina, and upon the stellate pigment present in the tissue of the choroid.

The pigmentation varies greatly in different people; as a rule the lighter the complexion the less pigment is found in the retina and choroid; the albino may be taken as the specimen at one end of the scale, in which the least pigment is found, while the negro represents the other end of the scale, in which there is the greatest amount of pigment. Plate I, fig. 2, represents the right fundus of an albino, as seen by the indirect examination: Plate II, fig. 1, the left eye of a very dark English child, seen by the direct method.

The ordinary red fundus reflex is due to the highly vascular choroid, modified more or less according to the amount of pigment present; the colour and amount of light used will also have much influence on it; and some variations will be found in different parts of the same eye; thus the macula region is somewhat darker than the rest of the fundus, shading off gradually into the colour of the other parts. The periphery is usually lighter and may possibly show some of the details of the deeper parts of the choroid; the colour immediately round the disc may also be somewhat lighter than the general tint of the fundus.

**The retina.**—The retina is a membrane of considerable thickness, being .4 mm. at its posterior and thickest part; this is four times as thick as the

choroid. At the macula, its thinnest part, the retina is only  $\cdot 1$  mm. thick.

The retina anterior to its epithelial layer is transparent; this is necessarily the case, since it is so constructed, that rays of light entering the eye have to pass through the superficial layers to reach the layer of rods and cones on which images must be formed.

In dark complexioned persons a sort of shimmer or bloom may be sometimes detected, especially in the region of the macula; occasionally a striated appearance is visible at the upper and lower margins of the disc, spreading a considerable way over the retina. This is due to the nerve-fibres being slightly visible over the part where they are thickest, and is best seen in young hypermetropic children. The case from which Fig. 1, Plate II, was drawn, afforded a good example of this striation. But, speaking generally, the retina, except for its large vessels, is transparent, so that in most medium or dark complexioned people one looks with the ophthalmoscope through the retina on to the retinal epithelium, which, if fairly pigmented, allows the red of the choroid to shine through, but effectually hides any of the vessels or details, so that one gets a uniform red reflex, often having a slightly granular appearance when viewed by the direct method, due to the pigment contained in the epithelial layer; this is, perhaps, the commonest type of the normal fundus, and is shown in Fig. 1, Plate I. When the epithelial layer contains but little pigment or pigment of a light colour, as in fair people, then we can see through this layer more or

7 7 76

## PLATE I.

FIG. 1.—Fundus of a child aged 10 years; of medium complexion, light brown hair, grey irides, fair skin. Erect image. Left eye.

The disc is not so sharply defined as in many cases; there is slight pigmentation of the outer edge of the disc, which indicates the edge of the choroidal ring, and may be looked upon as physiological. There is no physiological cup.

FIG. 2.—Fundus of an albino aged 24; white hair, eyebrows, and eyelashes; irides light grey and translucent. Inverted image. Right eye.

The absence of pigment is here well shown; each vessel of the deep layer of the choroid can be seen. The disc appears darker than normal, in contrast with the lightness of the rest of the fundus. The light-coloured interspaces between the choroidal vessels are due to the white of the sclerotic. On the outer side of the disc is a slight crescent, caused by the choroidal opening being rather larger than the sclerotic ring, so that a small portion of the sclerotic is here exposed.

Plate I.

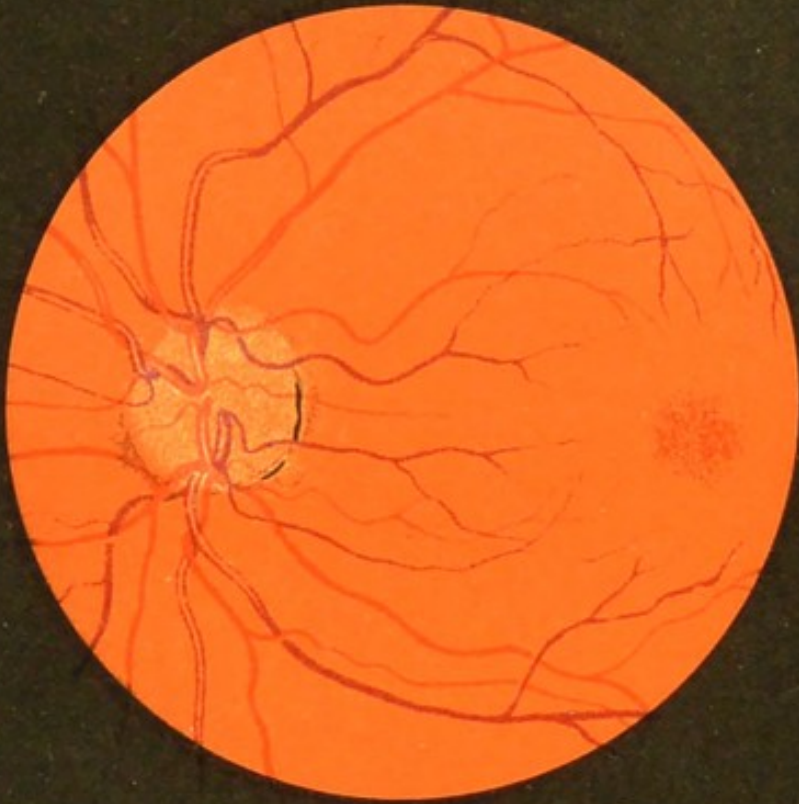


Fig. 1.

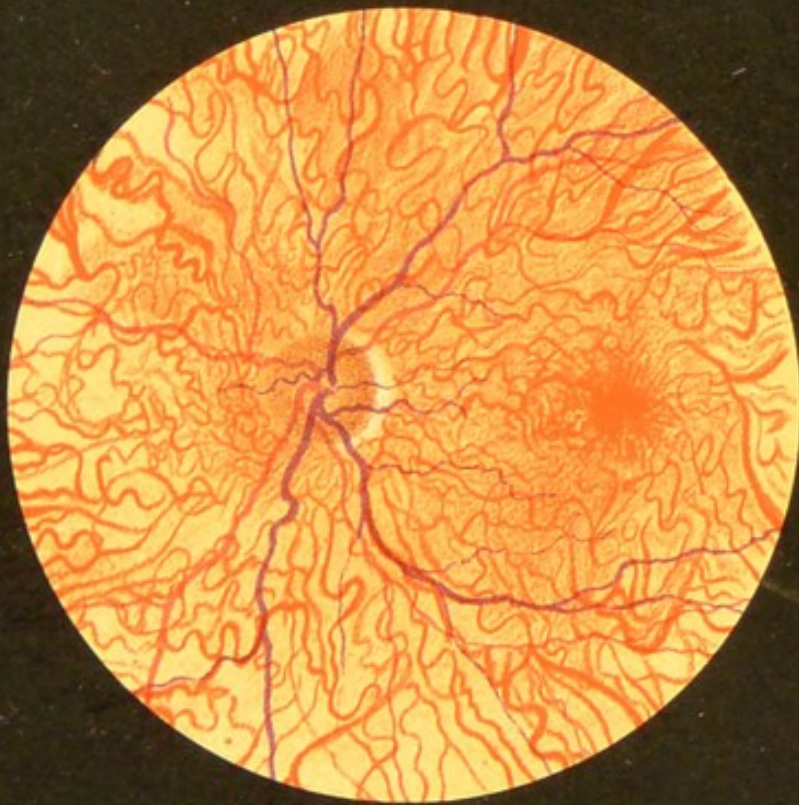

Fig. 2.





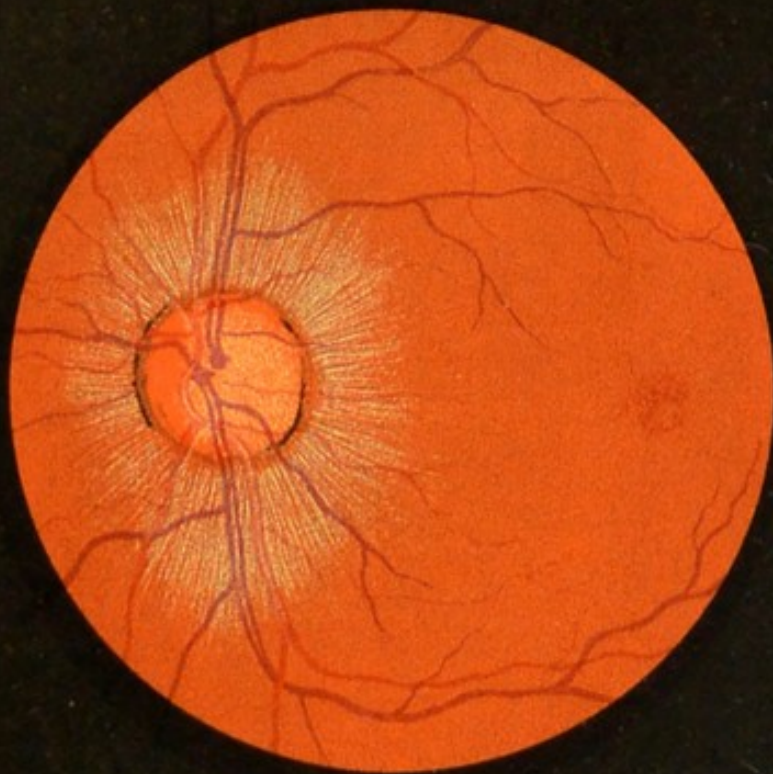


Fig. 1.

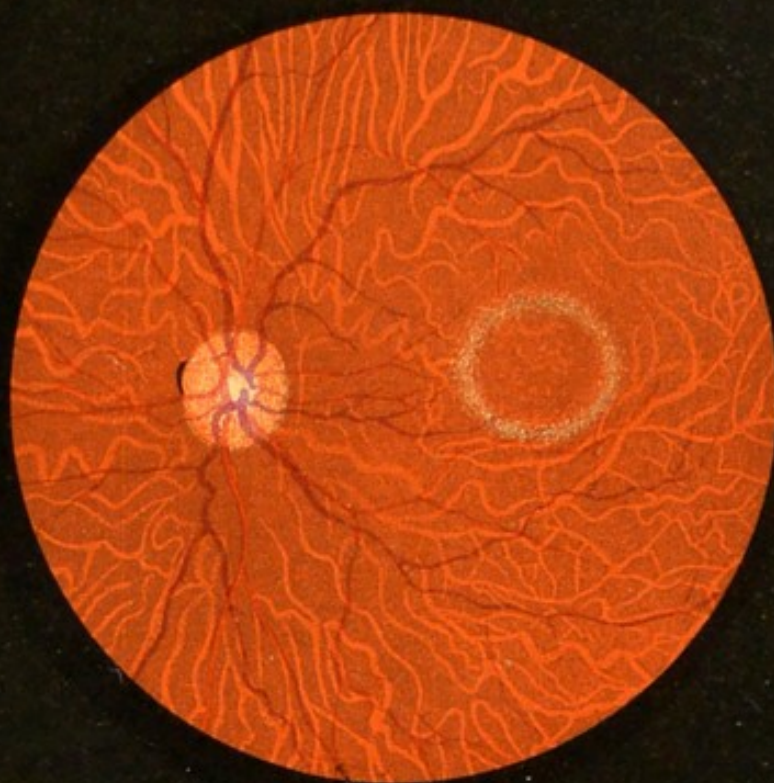


Fig. 2.

## PLATE II.

FIG. 1.—Fundus of a very dark child aged 10; skin dark, hair black, eyebrows and eyelashes black; irides dark brown. Erect image. Left eye.

The striation around the disc is unusually distinct. The stippling of the lamina cribrosa can be seen in the centre of the disc.

FIG. 2.—Right fundus of a child aged 10 years; hair dark brown, eyebrows brown, eyelashes black; irides dark brown. Inverted image.

The tissue of the choroid contains a large quantity of very dark pigment, which causes the interspaces between the choroidal vessels to appear very dark—much darker than the vessels themselves. The pigment in the epithelial layer of the retina must be of a lighter colour than usual, to allow one to see through it on to the deeper layers of the choroid. There is a well-marked physiological cup present. The halo around the macula is due to reflection.



less of the details of the choroid; the capillaries of the chorio-capillaris are too small to be seen, but the large choroidal vessels may be fairly distinct, having between them small islands of tissue, which may be lighter than the vessels themselves in very fair individuals, where very little pigment is present in the connective tissue of the choroid (a very striking example of this condition is seen in the albino, Fig. 2, Plate I) ; or the interspaces may be darker than the vessels, when a good deal of pigment is present, Fig. 2, Plate II: these interspaces are small, triangular or irregular in shape about the disc; more elongated in the periphery. The details in the choroid are often best seen in the periphery, sometimes only there.

Thus we may distinguish three chief types:

1. The fundus having a slightly granular appearance, with no choroidal details visible. Met with chiefly in people of dark complexions, Fig. 1, Plate I, and Fig. 1, Plate II.

2. The fundus in which the large choroidal vessels are seen with lighter coloured interspaces; light complexioned people, Fig. 2, Plate I.

3. The fundus, in which the large choroidal vessels appear with dark coloured interspaces; this is sometimes known under the name of "choroid tigré," and is found in people with medium complexions. Fig. 2, Plate II, is intended to represent this condition.

Though these are the three chief types of the normal fundus, it will be understood that one variety

gradually merges into the next, so that every possible variation may be met with.

In old persons the epithelial layer may become deprived of its pigment, and so allow the deeper parts of the choroid to come into view.

It must be remembered that the arteries and veins of the choroid cannot be distinguished from each other by the ophthalmoscope.

**The macula lutea**, which is the part of most distinct vision, is free from any visible vessels, nevertheless it is exceedingly vascular, the capillary meshes being much closer together than in any other part, except at the fovea centralis, where they are absent. The macula is situated about 2 mm. on the temporal side of the disc and 1 mm. lower; it is directly in the line of vision, and is slightly larger than the disc, being in shape an ill-defined oval with its long diameter horizontal; the colour is darker than the rest of the fundus, and shades off gradually into the general orange red colour. Its centre is marked by a depressed, whitish pink spot, the *fovea centralis*. The macula is sometimes surrounded by halo, which is due to reflection from the sloping edge of the depression; this halo is often seen in dark children with the indirect method, and is shown in Plate II, fig. 2. It requires much practice before this region can be satisfactorily examined and usually a mydriatic must be employed. The macula never appears yellow with the ophthalmoscope.

Sometimes a good deal of reflex takes place from other parts of the retina, and is spoken of as a

“watered silk” appearance ; this reflection takes place from the superficial part of the retina, and shows a tendency to run along and over the vessels, shifting with every movement of the mirror ; it is best seen in dark hypermetropic children, and is rare after the age of twenty. The exact cause of this retinal reflex is not known, but it has been suggested that it may be due to minute parallel striations of the cells of the ganglion layer of the retina.

**The optic disc or papilla** is the intra-ocular end of the optic nerve, and consists of nerve-fibres which spread out to form the retina, together with a certain amount of connective tissue, and the central artery and vein of the retina. The disc is situated a little to the nasal side of the posterior pole of the eye ; it is a little raised, and is usually circular or slightly oval in shape, with its long axis nearly vertical ; its real size is about 1.75 mm. ; sometimes one side is slightly flattened. The anatomically oval disc must not be confounded with the oval, due to astigmatism ; the diagnosis between the two can easily be made ; when using the indirect method the anatomically oval disc will not alter its shape as the objective is gradually withdrawn, while the astigmatic oval will undergo considerable change in its shape as the convex glass is moved away from the eye.

The colour of the disc varies much from the rest of the fundus, being considerably lighter ; it varies at different periods of life, being rather paler in old people. The colour of the disc is due to the combined effect of the nerve-fibres, the blood-vessels,

and the connective tissue, the result being a pinkish rose tint; considerable variations of colour are found in different parts of the disc; thus the pinkish colour is often most pronounced on the nasal side, while the whitest part of the disc is often its centre and towards the temporal side; in most cases the nerve-fibres separate immediately after perforating the lamina cribrosa, leaving a conical depression, the "*physiological cup*." This cup may vary much in size and shape, but always has the one characteristic, that it never involves the whole disc, as is the case with the glaucoma cup. The physiological is usually a deep shelving cup, while that due to glaucoma is overhanging. When the physiological cup is large and deep, its nasal side may be steep or even excavated, but the temporal side has almost invariably a gradual slope, which may extend in this direction to the margin of the disc. Frequently a stippling is seen at the bottom of a deep cup; this is due to the details and perforations of the lamina cribrosa being visible. Fig. 63 represents a deep physiological cup, and should be compared with the figures illustrating the other two varieties of cupping, Figs. 64 and 65.

The disc has usually a well-defined margin with some traces of pigment; this is known as the *choroidal ring*, and is well shown in Fig. 61; though spoken of as an opening, it is not so in the true sense of the word, since fibres pass into the nerve on all sides, and cases occasionally occur in which the choroidal tissue can be traced for some distance on to the face of the nerve; the edge of the choroidal opening is

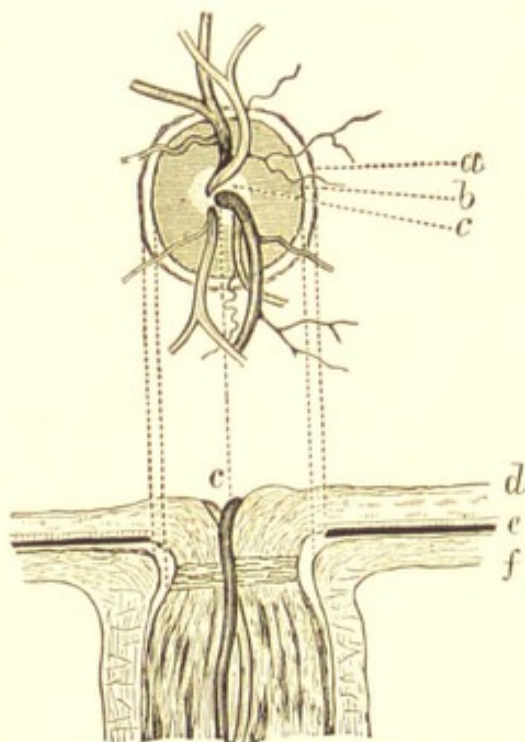
often slightly larger than the corresponding opening in the sclerotic, and when this is so, a small rim of this coat may be visible just within the choroidal ring; this is called the *sclerotic or connective-tissue ring* (b). The sclerotic ring is often partially hidden by the slight expansion of the optic nerve, after passing through the lamina cribrosa, though usually a trace of it can be seen on the outer side: so that we have from within outwards: (1) a white central depression, the *physiological cup*; (2) surrounded by a zone of pinkish colour, most marked usually on the nasal side: this zone is composed chiefly of nerve-fibres and their capillaries; (3) outside this is a well-defined white margin, the *sclerotic ring*; and finally, (4) the slightly pigmented margin of the *choroidal ring*. Great variations will be met with in different subjects; the discs on the two sides should always be compared. The colour of the different parts of the disc can be best appreciated by the direct examination, and by using only a moderate illumination. The edges of the disc should be clearly defined; sometimes the upper and lower margins are less distinct than the sides; this may be due to the nerve-fibres being thickest over these parts; this condition is most frequently met with in cases of hypermetropia, being then due to an excess of connective tissue about the disc and around the vessels.

Fig. 61 is a diagrammatical representation of the optic disc; the choroidal and sclerotic rings are seldom seen in the complete form here represented, but it is necessary the student should be acquainted

with them and know how they are formed; (a) choroidal ring, (b) sclerotic ring, (c) physiological cup. (d) The retina, (e) the choroid, (f) the sclerotic, (c) the central vessels.

The central artery and vein of the retina are seen issuing from near the centre of the disc, usually a

FIG. 61.



little to the nasal side, the artery being on the nasal, the vein on the temporal side; they divide into branches which spread out on the nerve-fibre layer of the retina; when seen in a microscopical section, the vessels project above the surface of this membrane.

The retinal vessels are exceedingly small, although, with the direct method, they give one the idea of being of fair size; the main divisions of the retinal artery may be about  $\cdot 4$  mm. in diameter, while the smallest visible vessels will be about  $\cdot 06$  mm.; the

capillaries being considerably smaller than this, are necessarily invisible.

The arteries may be distinguished from the veins (*a*) by their colour, (*b*) by their size, and (*c*) by their general appearance. The vessels are really transparent oval tubes, so that it would be more correct to speak of the blood column contained in them.

The arteries are bright red in colour, about one third smaller than the corresponding veins; they cross over the veins, and have a marked white central streak. There is some difference of opinion as to the cause of this light streak; the probable explanation is that it is due to reflection from the column of blood, though some observers think it is due to the refraction of the rays of light passing through the vessels and reflected back.

The veins are darker in colour, larger, and pass under the arteries, the central white streak is less marked and less regular than in the arteries; frequently pulsation may be seen in the veins, or can be easily produced by very slight pressure on the eyeball.

The main central artery often divides just before emerging from the disc into two branches, a superior and inferior; these again divide into temporal and nasal branches, other branches are given off dichotomously; sometimes the main artery divides on the disc itself. As one would expect, the distribution varies much in different persons, though there is frequently great similarity in the circulation of the two eyes. A separate artery is often found on the outer

side of the disc curving outwards on to the retina, and fulfilling the functions of a retinal artery ; this is usually a branch of one of the posterior ciliary arteries, and is known as a *cilio-retinal* vessel.

## CHAPTER V

## CORNEA—ANTERIOR CHAMBER—IRIS—LENS

I HAVE no intention of entering into a discussion on the various diseases which affect the different structures of the eye, but it may be well to refer briefly to the methods recommended for the examination of each part in a systematic manner, while at the same time the ophthalmoscopic appearances indicative of disease of the various tissues of the eyeball may be shortly described.

**The cornea.**—The cornea is the most important external part of the eye, and its prominent position renders it especially liable to accident: the chief pathological conditions from which this tissue may suffer usually produce some alteration in its curvature or some loss of transparency; these changes are almost invariably accompanied with a diminution of vision, together with other symptoms.

*Focal illumination* is of the greatest value in the examination of the cornea—with it, everything will be seen in its true position and of its proper colour; foreign bodies such as chips of metal, particles of coal, etc., frequently become embedded in this tissue and

may easily escape detection when small, unless great care is exercised; nebulæ, irregularities, ulcers of various kinds—opaque, transparent, shallow, deep, etc.—are very frequently met with. The curvature of the cornea may be much altered, as in conical cornea; this can best be seen in profile. Vessels may be found on the corneal surface as in pannus or phlyctenular keratitis, or in the tissue of the cornea itself as in interstitial keratitis (in this condition it is not possible to distinguish the separate vessels, which are often closely grouped together, forming what is known as a “salmon patch”).

Keratitis punctata may also be detected by focal illumination; it consists of small particles of lymph deposited on the posterior part of the cornea; these small dots increase somewhat in size by proliferation of the epithelium; frequently the spots are arranged in the shape of a pyramid, with the apex to the centre of the cornea and the base downwards. The focal illumination may be supplemented with advantage by the high magnifying glass (Fig. 33).

This examination having been extended to the anterior chamber, iris, and lens, the *large concave mirror* is next taken up, and light reflected into the eye from a distance of half a mètre; corneal opacities will now appear as black spots in the red of the fundus, due to the interruption of the returning rays of light from the back of the eyeball. In conical cornea a central illumination will be seen with the mirror, surrounded by a dark, circular shadow, corresponding to the base of the cone. On moving a little further

back, so as to use retinoscopy, the shadow will be found to have a circular movement.

Finally the corneal examination may be completed by using the direct method, having behind the sight-hole of the ophthalmoscope + 20 D. and approaching close to the patient. By this means the various opacities may be seen in detail. Sometimes a number of fine arborescent lines may be detected; these are the transparent remains of vessels which are left as permanent evidence of previous keratitis.

**Aqueous chamber and iris.**—In some cases with the oblique illumination the contents of the aqueous chamber may be seen to be muddy; this is due to inflammatory material poured out in iritis or cyclitis; here the apparent colour of the iris may be altered, or the contents of the aqueous chamber being quite transparent, the surface of the iris may be seen to be dull, discoloured, and indistinct, the result of inflammatory exudation into its tissue; sometimes the exudation forms a distinct gumma. Blood may be found in the lower part of the anterior chamber and is spoken of as *hyphæma*; it is usually due to a blow or iritis; a collection of leucocytes may also take place, forming *hypopyon*, the cause of which may be iritis or a spreading corneal ulcer. When perforation of the cornea has taken place, adhesions between the cornea and iris may form (*anterior synechiæ*). Points of adhesion between the iris and lens may be detected (*posterior synechiæ*). Sometimes one or two fibres may be seen crossing the anterior chamber from one point of the iris to another; these fibres arise not from the extreme

pupillary edge, but from the junction of the radiating and circular fibres ; these fibres are the remains of the pupillary membrane which existed during intra-uterine life. Perforation of the iris from a penetrating wound may be readily detected with the oblique illumination, and with the mirror the red reflex will be seen through the opening ; in these cases the lens is usually wounded and soon becomes opaque ; the iris may have become more or less detached from its ciliary border (*iridodialysis*), as the result of a violent blow. Atrophy of the iris and growths of the iris or ciliary body may also be conveniently examined by these means ; finally, the iris may be examined with the ophthalmoscope, having a + 16 D. behind the sight-hole. Foreign bodies may occasionally be detected in the anterior chamber, and now and then a cilium is carried into this chamber by a perforating body, and may form the starting-point of a cyst of the iris.

**The lens.**—To examine the lens thoroughly, the pupil must first be dilated with a mydriatic (p. 32). The examination should be commenced with the focal illumination ; and here a word of warning is necessary—do not be too hasty to assume that the lens is becoming opaque. This mistake is very liable to be made by the inexperienced, especially when light from a window is concentrated on the eye with the biconvex lens. The reason of this apparent opacity is, that as age advances, the lens becomes harder, so that a good deal of reflection takes place from the anterior surface of the lens, and gives somewhat the appearance of diffuse opacity.

With the oblique illumination opacities of the lens appear in their true colour ; spots of pigment may be detected on the anterior capsule, and are evidence of previous iritis ; the iris has been adherent to the lens at these points, and when the synechia was torn away by a mydriatic the pigment was left attached to the lens ; pigment in this position may increase by proliferation.

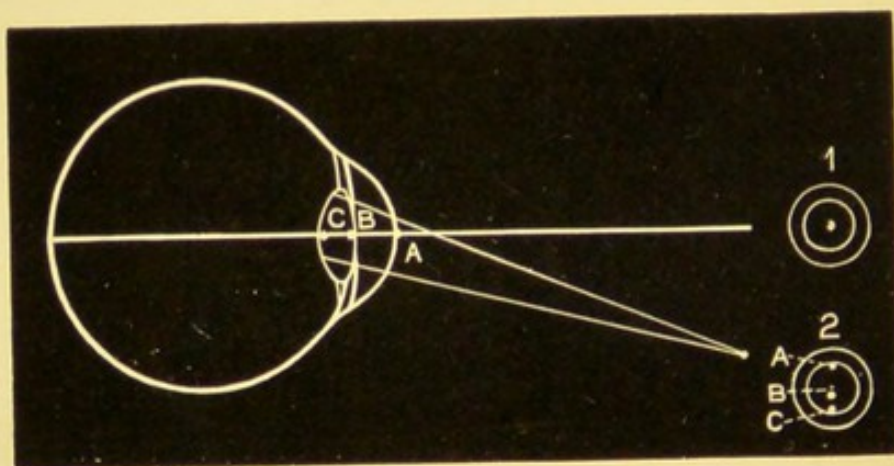
Anterior polar and pyramidal cataract may easily be detected ; the latter variety is usually due to the cornea having been in contact with the lens owing to perforation having taken place during an attack of infantile purulent ophthalmia, a nebula may often be seen in the cornea at the point where perforation took place ; anterior polar cataract may occasionally be connected with the remains of the pupillary membrane. Cortical, central, and posterior polar opacities may also be seen, but when examining the latter the light must be directed into the eye almost at right angles to the cornea. Posterior polar cataract is frequently congenital, and may be connected with the remains of the hyaloid artery ; at other times it may be secondary to disease of the fundus, such as retinitis pigmentosa, etc. Lamellar is a variety of cataract which is usually congenital, and consists of a layer of opaque lens substance included between a clear nucleus and cortex. This can be well examined by focal illumination through a well dilated pupil.

The examination by focal illumination being completed, the concave mirror is next taken up, and affords us valuable information as to the amount

of opacity present; the opacities in this method of examination show up as black spots, patches, or striæ, against the ordinary red of the fundus, the returning rays of light being interrupted by the opaque portions of the lens. In lamellar cataract the opacity will appear denser at the margin of the opaque portion than it does in the centre. Finally the lens may be inspected with the direct method, having a + 16 D. behind the sight-hole of the instrument.

Sometimes it is difficult by focal illumination to make out the exact position of a fixed opacity in the anterior part of the eyeball; we may then employ the concave mirror and notice the displacement which the opacity makes with regard to the pupil when we move our head slowly from one side to the other. Thus

FIG. 62.



supposing, as in Fig. 62, we have three opacities all situated on the optic axis, A an opacity on the cornea, B one on the anterior surface of the lens, and C one at the posterior pole, then it is clear that the observer looking along the optic axis will see these spots exactly

in the centre of the pupil, as at 1. If the observer now move his eye from 1 to 2, the position of the points with relation to the pupil will have changed ; opacity A will have moved towards the upper margin of the pupil, opacity B will still be in the centre, while opacity C will be nearer the lower edge of the pupil.

Therefore we may state the following rule, that if we look into the eye from directly in front, and the opacity remains stationary when we move our head to one side (the patient's eye being fixed), then we know the opacity must be in the same plane as the iris, probably the anterior surface of the lens ; had it been on the cornea, then it would appear to move in the opposite direction to the movement of the head ; had it been at the posterior pole, then it would appear to move in the same direction as the observer's head. The quicker the movement that takes place, the further is the opacity from the plane of the iris.

## CHAPTER VI

## THE VITREOUS

THE two chief indications of disease of the vitreous are *loss of transparency* and *diminished consistency*. The focal illumination is sometimes useful in detecting disease in the anterior part of the vitreous, but to use this method to the best advantage it is necessary to dilate the pupil and to place the light in front of the patient, so that the rays may be concentrated on the part we wish to examine, almost at right angles to the cornea (Fig. 32). In this way blood, large vitreous opacities, or even the crystals of cholesterine in sparkling synchysis may be detected when near the posterior surface of the lens; a growth or a detached retina projecting a long way forward may occasionally be seen. This method of examination has the distinct advantage of allowing things to be seen in their proper colour and in their true position; but, as a rule, much fuller information will be gained by the concave mirror, though the examination of the cornea and lens by the focal illumination should always extend to the vitreous before taking up the mirror.

If no fundus reflex is obtained with the concave mirror at a distance, when the light is properly directed into the eye under observation, then the case is probably one of profuse hæmorrhage into the vitreous, presupposing, of course, that the cornea, aqueous, and lens are transparent.

Vitreous opacities when of fair size are readily seen with the large concave mirror; the patient should be directed to look quickly upwards, then downwards, and finally straight in front of him; this movement will stir up any opacities which may have gravitated to the lower part of the vitreous chamber. When the opacities are very fine and difficult to see, a plane mirror and a subdued light may be an advantage.

Usually these opacities are floating, moving with every movement of the eye, and continuing to do so after the eye has come to rest; but sometimes the opacities may be fixed. They vary much in shape, size, and position, sometimes being exceedingly small like dust, and may require some trouble to detect them; at other times they are large and membranous, or in shreds, or resembling the wings of insects. Their rate of movement will give us some idea of the consistency of the vitreous: when they move very quickly the vitreous must be abnormally fluid; should the opacity float very slowly across the field, then its consistency may not be diminished.

These opacities may be—(1) Inflammatory exudation from one of the surrounding vascular structures, as the choroid, or ciliary body. (2) Hæmorrhage from the retina, choroid, or ciliary body. (3) Coagu-

lation of the albuminous elements of the vitreous itself.

When the opacities are very fine, they may simply cause a slight blurring of the details of the fundus, while the disc may appear very red, and the case may then be easily mistaken for papillitis. These very fine opacities should be looked for with the direct method of examination having a + 8 D. behind the sight-hole; they can best be seen against the lighter coloured background of the disc, and a plane mirror is an advantage. Fine opacities are generally due to the migration of cells accompanying the exudation of inflammatory material of a serous character from some part of the adjacent uveal tract.

To thoroughly examine every part of the vitreous the observer must vary his distance from the patient as well as the strength of the lens behind the ophthalmoscope; the stronger the lens required the more forward will the vitreous opacity be. When hæmorrhage takes place into the vitreous, or the exudation is rich in fibrin, the opacities are liable to be large and membranous, and may, if very numerous, prevent any details of the fundus from being seen.

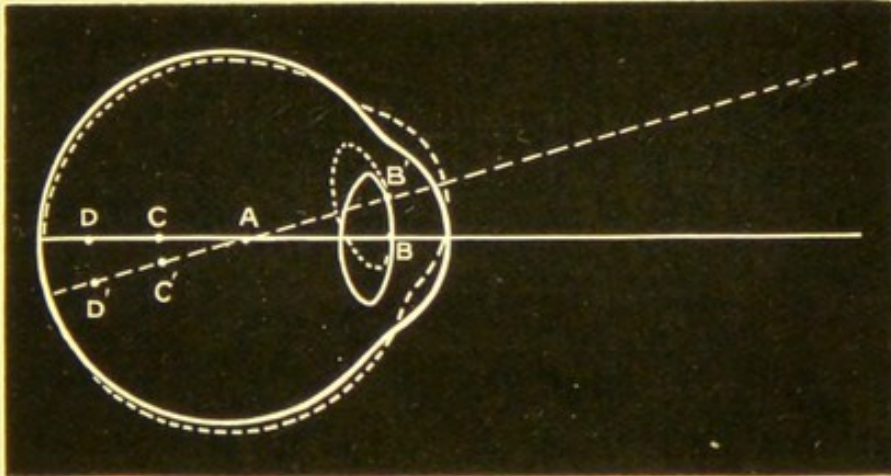
Opacities usually appear as black spots, whatever their real colour may be, owing to the interruption to the returning light, unless they happen to be partially transparent, when they will appear grey. Should they reflect light from their surface, as do crystals of cholesterine and tyrosin, then they may sparkle like particles of gold-leaf. A beautiful illustration of this condition may be occasionally seen, and goes by

the name of *sparkling synchysis* ; it is a degenerative process, usually accompanied by great fluidity of the vitreous.

In making a diagnosis of opacities in the vitreous, corneal and lenticular affections should first be excluded by focal illumination ; the position of any opacity may be judged of partly by its direction and amount of movement, and partly also by the convex glass through which it can best be seen.

To estimate the depth of any fixed opacity, we illuminate the eye by the concave mirror at a distance ; then, if the patient be directed to look upward, it will be obvious that any opacity situated in front of the point round which the eye turns (A, Fig. 63), will also move upward, while if the opacity be behind this point,

FIG. 63.



it will move downward ; and the farther the opacity is from the point of rotation, the greater will its movement be, and therefore the deeper will be the position of the body. A glance at the above drawing will make this clear. A is the centre of rotation of the

eye, B is an opacity on the anterior surface of the lens, which on movement of the eye upwards will move with it to B'; C and D are vitreous opacities, which, being situated behind A, will move in the opposite direction to the eye, so that on turning the eye upwards C will move to C', and D to D'; since D is deeper than C, D will have made a greater change in its position than C.

The real movement, therefore, which fixed opacities in the media make, is with the eye when the opacities are in front of the centre of rotation, and in the reverse direction when behind this centre. Some practice is required to enable one to correctly interpret what is seen, because with an undilated pupil when a point some distance behind the iris but in front of the centre of rotation is watched while the eyeball is moved in different directions, this point may have the appearance of going against the movement of the eyeball though really with it; this is owing to the greater displacement of the iris, as explained on page 90.

Foreign bodies, such as chips of metal, may sometimes be seen in the vitreous more or less covered with lymph according to the time which has elapsed since the accident. Now and then a few air-bubbles are carried in with the foreign body, which the observer might easily mistake for the foreign body itself unless aware of this possibility; air-bubbles are round, reflect light from their centres, and have dark margins, whereas the reflex from a foreign body is chiefly from its edges.

In the case of a perforating wound, a streak of opacity may be seen extending through the vitreous along the line taken by the penetrating substance. I have seen cases where after a puncture of this kind the vitreous has remained clear for several days, then gradually an opaque line has formed, becoming more marked each day, leading eventually to shrinking of the vitreous. Here some bacilli must have been introduced by the perforating body, and finding the vitreous a suitable medium, have undergone proliferation and growth (stab culture).

Occasionally some remains of the hyaloid artery may be seen floating about in the vitreous, one end being attached to the disc, while the other end may or may not be connected with the posterior surface of the lens.

A rare condition is one in which new vessels may be formed in the vitreous as a result of inflammation or large vitreous hæmorrhage; these vessels are more or less supported by connective tissue, and when met with are usually found in cases with a history of syphilis; *retinitis proliferans* is the name given to this condition.

## CHAPTER VII

## THE CHOROID

THE important part taken by the choroid in the ophthalmoscopic picture of the fundus has already been fully described in Chapter IV. Variations from the normal produced by disease of this structure are frequently met with, and produce very various and striking ophthalmoscopic appearances.

These alterations may display themselves as—

1. Changes in colour, pigmentation and level, due to inflammatory exudation.
2. Atrophic patches and scars, the permanent results of previous mischief.
3. Hæmorrhages from one of the choroidal vessels.

Hyperæmia of the choroid, though probably frequently present, is not recognisable with the ophthalmoscope.

The choroid, owing to its great vascularity, is especially prone to inflammation; the term *choroiditis* must be accepted in its widest sense, to include not only those cases in which the inflammation is in actual progress, but others in which all inflammatory symptoms have long subsided, and of which we have permanent evidence in the shape of atrophic patches, and spots variously pigmented, as well as those cases

which from the very first, present more of the characters of an atrophy than an inflammation, as in senile and myopic choroiditis.

Choroiditis may be divided into—

*Plastic.*

*Suppurative.*

**Plastic choroiditis** commences as an exudation into the substance of the choroid. The exudations are cellular in character; they are generally numerous, with a tendency to occur in patches or spots scattered over the fundus. They can be seen with the ophthalmoscope as pink-yellowish coloured spots, slightly raised, with soft-looking edges and some haze or œdema of the retina. These spots are beneath the retinal vessels, and may appear in every possible shape, but most frequently tend to the circular.

In some cases when the deeper part of the choroid is primarily affected, and where no disturbance of the retinal hexagonal epithelium has taken place, nothing may be detected with the ophthalmoscope except a slight haze and lifting up of the retina; but sooner or later the epithelial layer becomes involved, and undergoes atrophy, the pigment is set free, proliferates, and travels forward into the retina, accumulating there into spots having all the characteristics of retinal pigmentation, very like retinitis pigmentosa, which will be referred to on page 115. When the retinal epithelium is thus involved in the inflammatory process, the condition may be spoken of as *Choroido-retinitis*.

When the inflammatory symptoms are marked,

vitreous opacities are usually present, and will more or less veil the appearances of the choroidal mischief: in some acute cases no details of the fundus can be made out owing to the number and density of the vitreous opacities, and it may only be after these have partially cleared up that the patches of choroiditis come into view. So that in all cases of choroiditis, vitreous opacities must be carefully looked for with the direct method and a + 8 D. glass behind the sight-hole of the ophthalmoscope, as described on page 94.

As the inflammatory symptoms diminish, the exudation undergoes absorption together with destruction of the affected portions of the choroid, so that ultimately a white patch or scar remains, surrounded or dotted over more or less with pigment, and frequently involving the retina in the cicatrix. The pigment in many of these cases has two sources: first and chiefly, the pigment cells contained in the tissue of the choroid; second, the pigment which has escaped from the epithelium. The white patches are the bare sclerotic, and may be described as patches of choroidal atrophy. The time occupied from the commencement of the exudative stage of choroiditis to that of complete atrophy of the patches may extend over many months, or even years; and when it is remembered that the disease gives no external sign of its presence, and produces no subjective symptoms so long as the retina and vitreous are not implicated, and then makes itself known to the patient, only by the impairment of vision which results, it will not be

surprising that the mischief may have been in progress a long time before it is detected, so that the ophthalmoscopic appearance may vary very greatly according to the stage and extent of the disease. Any part of the choroid may be the seat of inflammation; sometimes the periphery is chiefly affected, while in others the region of the macula is alone involved.

One of the difficulties that beset the beginner is to decide whether a patch of exudation is in the retina or choroid. When a patch of exudation is seen surrounding or covering up one of the retinal vessels, then it is certainly in the anterior part of the retina: as a rule retinal exudations are whiter in colour than choroidal, and have very soft-looking edges, with little or no pigmentation. Experience alone can teach us to arrive at a correct conclusion; in some cases it is difficult for the most expert observer to assert positively the exact situation of a given patch.

In the case of patches of pigment or hæmorrhage the diagnosis is not so difficult; retinal pigmentation and hæmorrhages usually have distinct retinal characteristics, which will be referred to on page 115.

**Purulent choroiditis** is due to septic emboli in the choroidal vessels, and may sometimes be detected by focal illumination; as the purulent exudation makes its way forward from the back of the fundus violent inflammatory symptoms set in, the eye becomes tense, and the cornea hazy, so that little can be seen.

In young children this condition may run a very chronic course, when the appearances might be mistaken for glioma (see p. 128).

The clinical varieties of choroiditis usually recognised by the ophthalmoscope are—

*Disseminated choroiditis,*

*Central choroiditis,*


*Myopic choroiditis,*

*Senile choroiditis,*

though many cases present mixed characters.

**Disseminated choroiditis** (Plate III, figs. 1 and 2) is perhaps the most common variety of the disease, and commences as a number of small spots or circular patches of exudation which are scattered over the fundus, chiefly in the periphery; as the inflammatory exudation becomes absorbed, the tissue of the choroid becomes atrophied and destroyed, leaving circular patches of bare sclerotic, surrounded more or less by pigment. These spots of choroidal atrophy frequently have a sharply defined and punched-out appearance, with pigment surrounding them like a collar: in some cases no white patches are seen, but spots of pigment surrounded by a lighter margin; at other times the patches may run together, forming one large patch.

Usually both eyes are affected, though frequently the mischief is further advanced in one eye than in the other. Syphilis, either acquired or inherited, is almost invariably the cause of this form of choroiditis; the only distinction that can be made with the ophthalmoscope is, that usually there is a greater amount of pigment present in the inherited form of the disease. Vitreous opacities are frequently met with during the exudative stage, and are then generally of a fine dust-



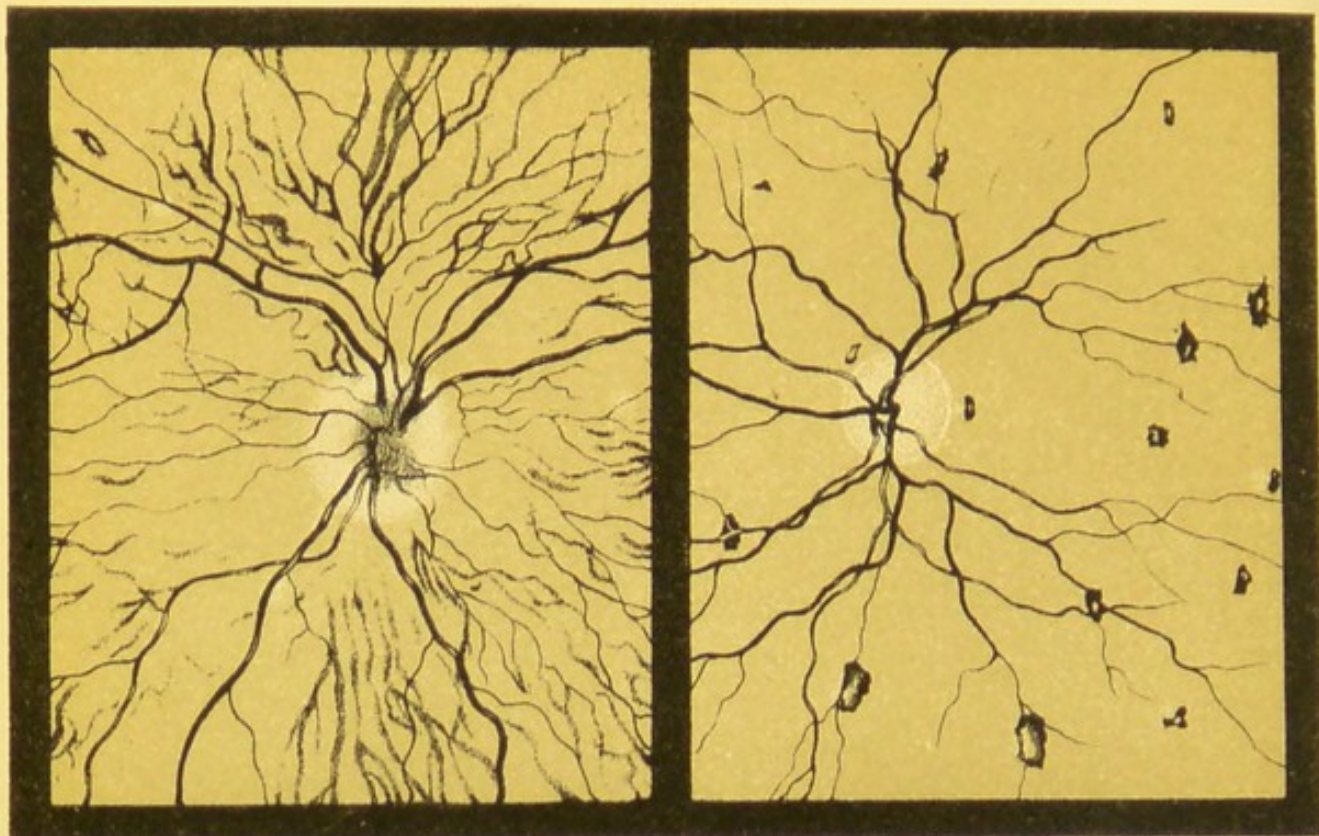


Fig. 1.

Fig. 2.

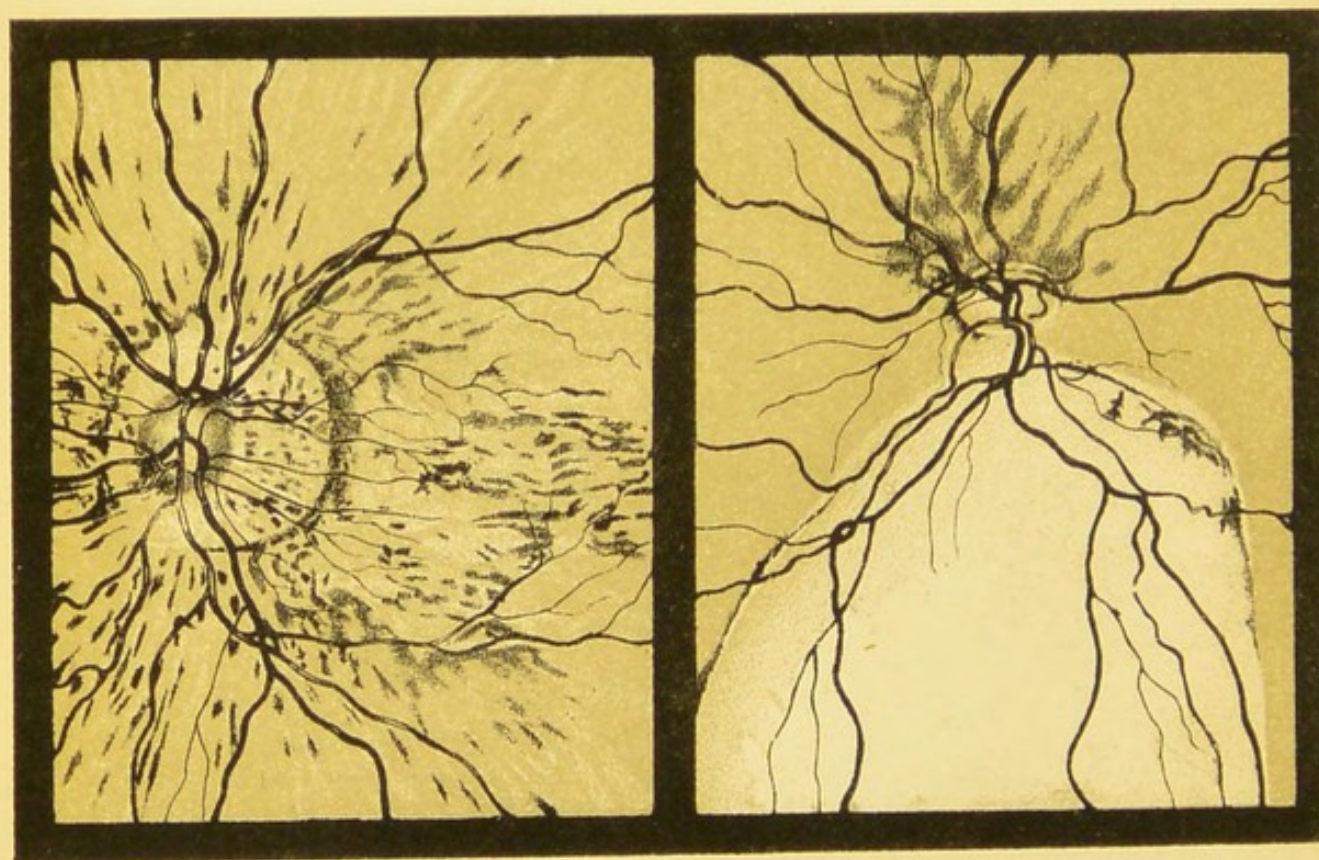


Fig. 3

Fig. 4

### PLATE III.

FIG. 1.—Choroiditis in the exudative stage. Some of the patches are of fair size, others are very small; no pigmentation had taken place when the drawing was made, though it occurred some months later; the vitreous was full of fine opacities, which rendered the disc margins very indistinct. The patient was a man of about 30 years of age, with a very definite history of syphilis. Both eyes were affected.

FIG. 2.—Disseminated choroiditis in a child of 12, with the facial characteristics and notched upper incisor teeth of inherited syphilis.

FIG. 3.—Senile changes in an old man: there has been absorption of the epithelial layer of the retina, with great thinning of the superficial layers of the choroid; these changes allow the deeper vessels of the choroid to be seen in detail. The vessels of this layer have undergone considerable sclerosis.

FIG. 4.—Coloboma of the choroid. The disc is very oval horizontally; the retina vessels pass over the coloboma without interruption.



like character, slightly blurring the general details of the fundus.

The degree of impairment of vision depends chiefly upon the situation of the patches and the resulting scotomata; when the mischief is confined to the periphery, central vision may be but little affected.

**Central choroiditis.**—In central choroiditis the mischief is chiefly limited to the yellow-spot region. There are several varieties of the disease; in some the changes are of a gross character, while in others they are so extremely fine that they can only be seen by the direct method of examination, and may even then be easily overlooked unless the greatest care is exercised.

In a few cases the appearances are such as would suggest that an inflammatory exudation had taken place at the macula, that it had afterwards become absorbed, and with it most of the choroidal tissue in which it was situated, leaving a considerable interval between the retina (which in these cases may be rendered visible by the pigment on its surface) and the sclerotic; the retina may or may not be perforated. The ophthalmoscopic evidence of this interval is supplied by the parallax produced, and by the different lens necessary to focus first the retina and then the sclerotic.

Patients with central choroiditis often complain that objects appear distorted (*metamorphopsia*); this is due to displacement and separation of the cones. Central vision is usually very defective, and when the retina is much implicated a positive scotoma results.

**Myopic choroiditis.**—Choroiditis is exceedingly common in high myopia; besides the congestion and thinning of the choroid, which take place with the formation of a large crescent and posterior staphyloma, mischief is apt to begin in independent centres, frequently in or about the macula, and the case is often complicated with choroidal hæmorrhages; the patient usually complains of great impairment of vision, together with metamorphopsia and general discomfort of the eyes.

**Senile choroiditis** (Plate III, fig. 3) occurs in several varieties; in one kind the changes are chiefly confined to the superficial layers of the choroid, with atrophy of the epithelial layer of the retina, affecting the parts immediately around the disc or extending over the greater part of the fundus. Seen by the ophthalmoscope the choroidal vessels are unusually distinct, with thickening of their sheaths; some of the epithelial pigment which has been set free may travel forward into the retina; the disease is usually symmetrical in the two eyes; vision is much reduced, and is generally worse at night. In another variety of senile choroiditis a central patch of an irregular or circular form takes place at the macula of each eye, producing a scotoma; this variety of the disease shows but little tendency to spread, so that although central vision is lost, absolute blindness is not to be feared.

A third form of senile central choroiditis is that in which a number of very small whitish-yellow spots may be seen at the macula, with but little or no dis-

turbance of pigment; they can be detected only by the direct method of examination. These spots evidently invade the retina, so that central vision is defective.

**Atrophy of the choroid.**—One frequently meets with cases in high myopia, and also in old people as a senile change, in which the chorio-capillaris together with the epithelial layer of the retina have undergone almost complete atrophy, producing a very distinctive ophthalmoscopic picture, allowing the vessels of the deep layer of the choroid to come very clearly into view. These cases somewhat resemble those normal light-coloured fundi of which the albino is so striking an example. In the senile condition of atrophy of the choroid the walls of the large vessels are usually thickened. In many of these cases the retina would seem to be included in the atrophic changes leading to deterioration of vision.

**Choroidal hæmorrhages** are not so frequent as retinal; they are usually large, somewhat irregular, and of a diffused character; the retinal vessels will be seen passing over them; they are never flame-shaped, as is the case with hæmorrhages taking place in the nerve-fibre layer of the retina. The most frequent cause is a blow on the eyeball, but they are also met with in high myopia. These choroidal hæmorrhages frequently leave behind them pigmented scars which are not to be distinguished from those left by choroiditis.

**The myopic crescent** is commonly formed in medium and high degrees of myopia, and is due to the choroid

being dragged away from the margin of the disc together with a certain amount of choroidal atrophy; the crescent is always found on the temporal side of the disc; sometimes it completely surrounds the disc, but even then its greatest breadth is usually at the outer side. In high myopia, where a large posterior staphyloma is present, a good deal of thinning of the choroid may take place, the retinal epithelium may be more or less atrophied, and in addition to all this some horizontal markings may be seen midway between the disc and yellow spot; these are probably slight tears in the superficial part of the choroid and pigment layer of the retina. The myopic crescent is again referred to on page 142.

**Rupture of the choroid** occasionally takes place as the result of a severe blow on the eye; the rupture is usually curved, with the concavity towards the disc. When the case is seen early, the details of the rupture are usually hidden by the hæmorrhage that has taken place; later, a white curved scar will be seen having pigmented edges. The degree of impairment of vision of course depends upon the situation of the rupture; when near the macula it may be very great.

**Tubercle of the choroid** may occur either in the miliary form or as a large tubercular mass; though not very frequently met with, it probably often exists undetected in cases of tuberculosis. The disease appears in small white or yellowish-white spots, somewhat raised; sometimes several spots become confluent, forming a mass as large as, or larger than, the disc.

**Coloboma of the choroid** (Plate III, fig. 4) is a con-

genital condition occasionally met with, and, unless the student is aware of its existence, he will be sure to confound it with some serious pathological condition.

Coloboma of the choroid is due to imperfect closure of the foetal ocular cleft ; it always occurs downwards, and may be associated with a similar defect of the iris, lens, or ciliary body. The coloboma may vary much in size, being usually very white with variations in the colour at different parts, owing to irregularities of the sclerotic ; sometimes there is considerable bulging outwards of the part. The retinal vessels may be seen coursing across the white area ; when the coloboma extends up to the edge of the disc, the latter is usually misshapen, being more or less of a horizontal oval.

**Colloid disease of the choroid.**—Occasionally small transparent bodies may be found growing from some part of the choroid, especially in eyes that have been affected with choroiditis ; these bodies may occur as minute separate spots or arranged in a group ; each spot grows from the lamina vitrea, at first pushing forward the retinal epithelium, which gradually undergoes atrophy, and finally allows the most prominent part of the growth to pass through ; in this case some pigment may be found surrounding the base of the small transparent growth.

**Sarcoma of the choroid** may be met with either pigmented or unpigmented, and may belong to any of the varieties—round-celled, spindle-celled, or mixed. When seen in an early stage of the disease, it may be

difficult to distinguish from a simple detachment of the retina (p. 117).

In the **albino** there is a congenital absence of pigment both in the retinal epithelium and in the tissue of the choroid, as well as in the iris. This condition is shown in Plate I, fig. 2.

## CHAPTER VIII

## THE RETINA

WHEN it is remembered that the retina in front of the pigment layer is transparent, it will be understood that the appearances produced by disease of this part may be much modified by the condition of the choroid, etc. Affections of the retina may give rise to—

1. A loss of transparency.
2. Swelling of the retinal tissue.
3. Inflammatory exudation into the retina.
4. Hæmorrhages of various kinds.
5. Changes in pigmentation.
6. Differences in level of different parts, due to detachment or new growth.
7. Changes in the retinal vessels.

(1) **Loss of transparency** is most commonly the result of retinitis, and may vary from the slightest haze which is found in the early stage of inflammation, and which can only be detected with difficulty by the direct examination and by using a very subdued light, to dense white patches which may conceal everything behind them.

(2) **Swelling of the retinal tissues** is generally most marked near the disc, being due partly to increased fulness of the capillaries with hypertrophy of the connective-tissue elements, together with swelling of the nerve-fibres. The most obvious ophthalmoscopic signs of this swelling of the retina are, that the striations of the nerve-fibres are more distinct than normal, while the vessels are more tortuous, the tortuosity showing itself not only in a lateral but also in an antero-posterior plane; this is proved by the change of colour where the vessel bends backwards, and signifies great irregularity of the retinal surface.

(3) **Inflammatory exudation** into the retina may be serous, fibrinous, or purulent in character. Retinitis may affect the whole retina or be limited to one part.

The clinical varieties commonly met with are—

**Albuminuric retinitis,**  
**Diabetic retinitis,**  
**Syphilitic retinitis,**  
**Leucocythæmic retinitis,**  
**Septic retinitis ;**

but cases are sometimes seen in which the cause is obscure, and these are called *idiopathic*.

Retinitis produces no subjective sign of its presence beyond impaired vision. The ophthalmoscopic symptoms are loss of transparency, hæmorrhages, white patches, increased fulness and tortuosity of the veins, with swelling of the retinal tissue.

The white patches are usually irregular in shape, with softish-looking edges, and occur most frequently around the macula or between it and the disc. These

patches consist partly of inflammatory exudation in various stages of fatty degeneration, together with thickening and degeneration of the nerve-fibres: they may lie in front of and partly hide the retinal vessels; when this is the case we know that the anterior part of the retina must be involved in the morbid process. Sometimes the patches are behind the vessels, which may then be slightly lifted up by them.

*Albuminuric retinitis* is the commonest variety of retinitis, and presents the most characteristic appearances; the white patches often occur in the form of a star, radiating from the macula like the spokes of a wheel, the whole forming a circle or portion of a circle, and having a white, lustrous appearance; in most cases numerous retinal hæmorrhages are present and there is marked arterio-sclerosis. Both eyes are usually affected, and the condition is often accompanied with papillitis.

The kidney disease which most commonly gives rise to this form of retinitis is that known by the name of granular kidney, the mischief being invariably in an advanced stage; although it must be borne in mind that occasionally the retinitis precedes the presence of albumen in the urine by some months: though the radial artery will usually feel rigid with increased arterial tension. Tumours of the brain sometimes produce exactly the same ophthalmoscopic appearance as the retinitis due to kidney disease.

*Diabetic retinitis* presents very much the same ophthalmoscopic signs, though there are usually more hæmorrhages and the patches appear less white and

are more scattered, having little tendency to form the stellate arrangement so characteristic of the albuminuric variety. This form of retinitis may be complicated with vitreous opacities.

*Syphilitic retinitis* may occur with or without choroiditis; when the retina is alone affected the most marked ophthalmoscopic sign is a diffused haze over the whole retina, which diminishes the bright red fundus reflex.

*Leucocythæmic retinitis* is characterised by the great tortuosity and size of the retinal vessels as well as by the light yellow colour of the fundus reflex.

*Septic retinitis* may occur in pyæmia as a result of septic emboli, the retinitis becoming purulent and extending to the other tissues of the eye, ending in general panophthalmitis.

(4) **Hæmorrhages** in the retina come most frequently from the capillaries, but they may take place from the veins or the arteries, and are usually symptomatic of some general disease. Retinal hæmorrhages may be caused either by increased pressure within the vessels, by degeneration of the coats of the vessels, by changes in the blood itself, or by trauma; they may be met with in retinitis, papillitis, embolism of the central artery, thrombosis of one of the veins, anæmia, pressure on any part of the optic nerve between the disc and the point where the vessels pierce the nerve-sheath, cardiac disease, glaucoma, or any of the numerous accidents to which the eye is liable. The shape and extent of the hæmorrhages depend in great measure upon the part of the retina

in which they occur; the most common are those taking place in the nerve-fibre layer, when the hæmorrhages are "flame-shaped," with well-marked lateral edges and feathery ends. These hæmorrhages most commonly take place from the capillaries and have a linear shape, radiating from the disc; they are usually small and numerous, and occur near and follow the course of the vessels, especially the veins, though it is rare to find any visible rupture; sometimes they partially cover up one of the vessels. The next most frequent position for retinal hæmorrhages is the inner nuclear layer. When taking place into the deeper parts of the retina they may occur as small spots or irregular-shaped circles, and are usually capillary in character. If the bleeding take place from a large vessel and is profuse, some may escape into the vitreous, or being effused backwards may separate the retina from its epithelial layer, and so produce a detachment of the retina.

Retinitis with a large number of hæmorrhages is sometimes spoken of as *hæmorrhagic retinitis*.

Large hæmorrhages are occasionally seen in the macula region, and are called *sub-hyaloid*, because they occur between the retina and the hyaloid membrane. They are usually circular in shape, several times as large as the disc, and are accompanied with great loss of vision for the time being. When the extravasated blood forms only a very thin layer over the retina, the patient may see everything of a red colour. These hæmorrhages, which are at first circular, soon become decolourised above, partly no

doubt by gravitation of the blood-corpuscles, and partly also by absorption, so that when the case is seen later it may have taken the form of a half-circle or crescent with its convexity downwards, the upper part of the circle being of a light colour and the lower part dark red, separated by a well-defined line of demarcation. Vision in these cases is usually completely restored.

Recent retinal hæmorrhages are of a bright red colour; they may retain this colour for a long time and then become of a dirty, reddish-brown tint, ultimately turning black; or the colouring matter may be absorbed, leaving white or yellow patches, which gradually undergo degeneration: ultimately they may leave no trace behind, or there may be irregular spots left to mark their previous position. These spots may be white or light coloured, showing more or less of the structure of the choroid, with some pigment about their margins. Sometimes the spots are very small, consisting merely of pigment, which may be either the remains of the colouring matter of the blood, or pigment set free from the hexagonal epithelial cells. It is not always possible to make a diagnosis between inflammatory and hæmorrhagic scars in the retina and choroid.

The only conditions which might be mistaken for a hæmorrhage of the retina are—(i) The cherry-coloured spot which occurs at the macula in cases of embolism of the central artery. (ii) A red spot at the macula met with in traumatic cases, and is probably produced by a tear in the retina at this part.

(iii) The somewhat similar appearance produced in a detached retina in the macula region, the retina being detached all round but remaining adherent at the macula itself; this is a rare condition. (iv) Minute new vessels which have formed in a retinal exudation. All these may more or less simulate a retinal hæmorrhage, and it is necessary the student should be on his guard.

(5) **Changes in pigmentation** may be due to any inflammatory or atrophic change taking place in the retinal epithelium.

*Retinitis pigmentosa* (Plate IV, fig. 1) is the disease in which these changes are most frequently seen. It consists of hypertrophy with gradual shrinking of the connective tissue contained in the different layers of the retina, together with atrophy of the nerve elements and the migration of the pigment set free from the epithelial layer, which travels forward into the anterior part of the retina, and there undergoes proliferation. This pigment shows a great tendency to coalesce into spots with radiating processes, very much like bone-corpuscles as seen under the microscope. As the radiating processes from one spot join with those of adjacent spots, a fine network is produced, somewhat resembling black lace. In some cases the pigment will be found accumulating along the sheath of one of the retinal vessels. These pigment changes are usually most marked in the periphery, often occupying a zone midway between the margin of the disc and the equator; no satisfactory explanation has been

given of this peculiar arrangement taken up by the pigment.

While these changes are going on, the walls of the vessels are becoming thicker at the expense of their internal capacity, and this diminution of the blood-stream is frequently the first ophthalmoscopic sign of the disease. The diameter of the vessels continues to decrease, while the retina undergoes a gradual sclerosis until ultimately the different layers become unrecognisable, the rods and cones being quite destroyed. Early in the disease the disc becomes pale, assuming gradually a waxy opaque look; both eyes are always affected.

The chief symptoms which accompany this disease are, great torpor of the retina, with decreasing vision, concentric contraction of the visual fields, night-blindness, etc. Frequently posterior polar cataract accompanies retinitis pigmentosa, and may be due to pigment travelling forward from the retina along the central lymph channel to the back of the lens, where it adheres and proliferates.

Retinitis pigmentosa may be congenital, or it may occur in early life. Some varieties of specific choroido-retinitis present much the same ophthalmoscopic appearances.

Exposure to a strong light, as looking at an eclipse of the sun, or an electric light, may produce pigmentary disturbance at the macula.

It is most important to distinguish *retinal* from *choroidal* pigmentation.

*Retinal pigmentation*.—The pigment is lace-like or has the appearance of bone corpuscles.



## PLATE IV.

FIG. 1.—Retinitis pigmentosa. In this case a great deal of pigment has migrated into the superficial layers of the retina. The vessels are very fine, and the disc waxy-looking.

FIG. 2.—Thrombosis of the central vein. Probably in this case the main vein is only partially obstructed; one vein appears to carry no blood; numerous hæmorrhages are present, some of which are becoming decolourised.

FIG. 3.—Atrophy of the optic disc. The vessels are attenuated, the disc is very white. There is a large sclerotic ring, which is probably congenital. The choroidal vessels are to be seen with dark-coloured interspaces.

FIG. 4.—Albuminuric retinitis. Numerous hæmorrhages, both flame-shaped and punctate in character, are present; the white patches of degeneration are very bright in the region of the macula. The vessels are characteristic of the disease, the veins being full and tortuous, the tortuosities being both lateral and antero-posterior. Where the lower temporal artery crosses the vein it conceals it for a short distance on both sides; this indicates thickening and opacity of the arterial coats.

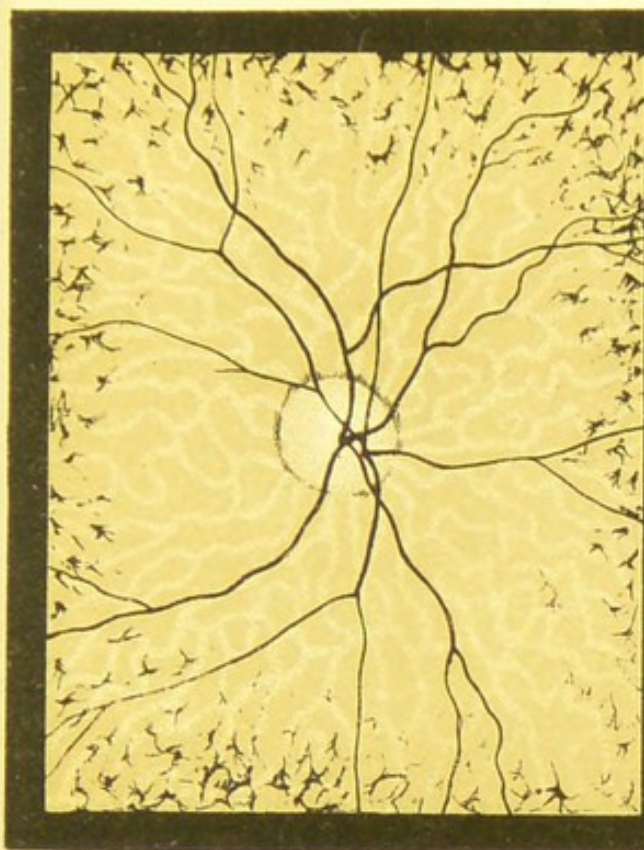


Fig. 1

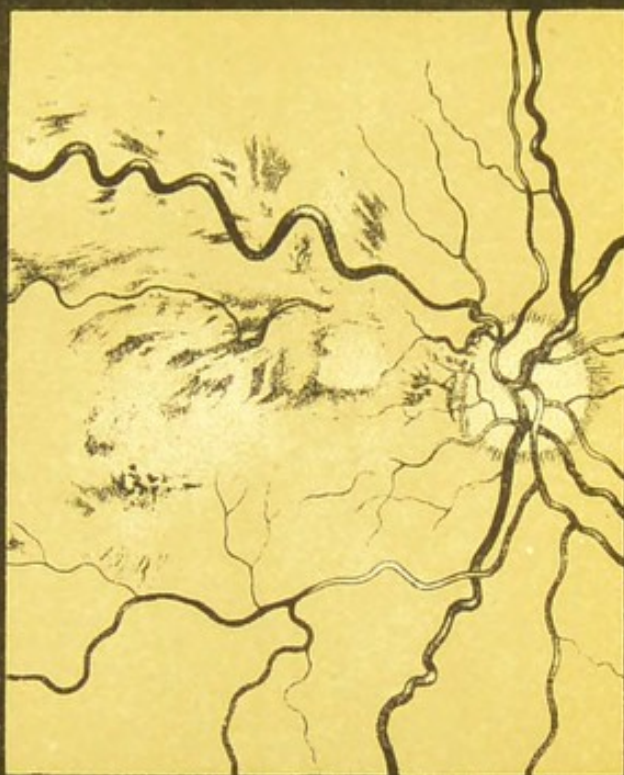


Fig 2.

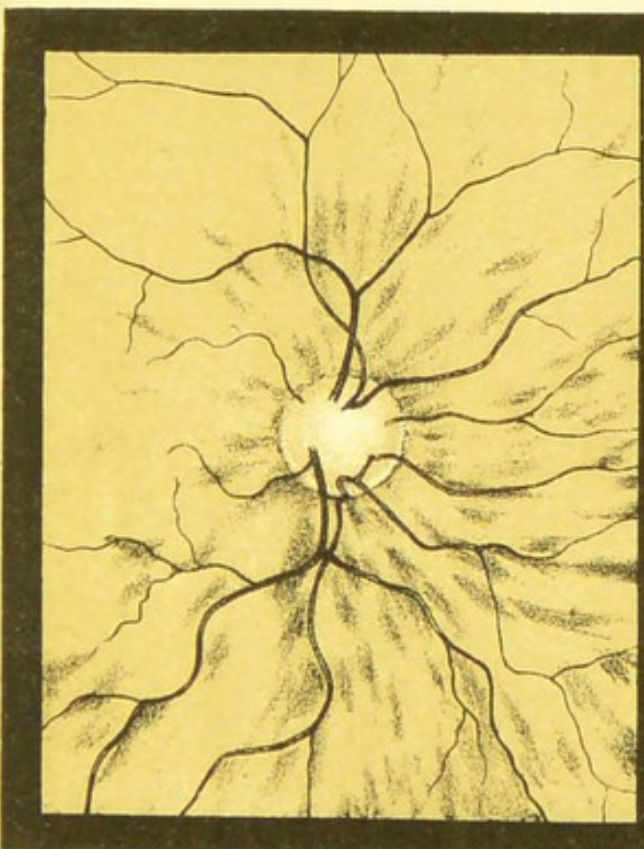

Fig 3.

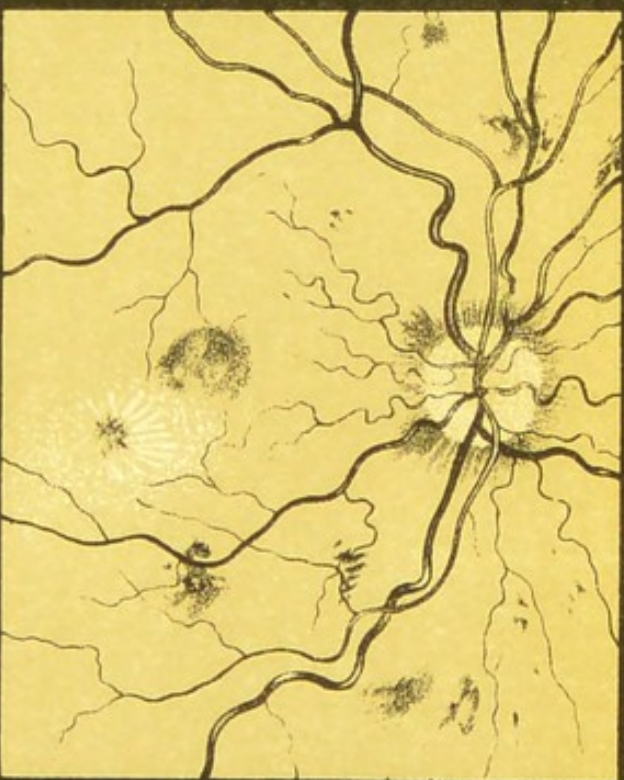


Fig 4.



The pigment shows a tendency to get into the sheaths of the retinal vessels and into the anterior layers of the retina. No white patches of choroidal atrophy.

*Choroidal pigmentation.*—The pigment occurs in large irregular masses, often surrounding patches of choroidal atrophy. The pigment is always below the retinal vessels and usually in the deep layers of the choroid.

(6) **Differences in level of various parts of the retina.**  
—It is essential that the student should learn to recognise these differences, since detachments of the retina are very common. When such detachments are large and the retina opaque, they can hardly escape detection; but when the portion of retina detached is small and retains its transparency, the diagnosis is by no means so easy. In making a systematic examination, a detachment may now and then be seen with focal illumination, when the displaced portion of the retina is very large and lies a long way forward. Usually, however, this is not the case, and having detected nothing with the focal illumination, one passes on to the concave mirror held at a distance from the eye, the patient being directed to look first up, then down, and finally straight in front of him; thus one is enabled to make a thorough examination of the vitreous. Should the reflex from one part of the fundus appear much lighter than the rest we may suspect a detachment, especially if the reflex of the part alters while the eye is kept in one position, as it may do when the retina changes its position so that

the light is reflected differently. Not only is there an alteration in the reflex of the part, especially when the detachment is opaque, but a portion of the details may come into view, while nothing can be seen of the rest of the fundus; this is because the detached portion is very hypermetropic, so that an upright image of that part will be seen. The detached portion may, if opaque, appear in white undulating folds, on which some of the vessels may be clearly seen; on movement of the eye it may float about. When, however, the retina retains its transparency, the ordinary fundus reflex from the choroid will be seen, and the diagnosis will rest upon the position of the vessels on the detached transparent retina. When a retinal vessel on a transparent detachment thus comes into view it has a characteristic appearance; it shows up very clearly, appears smaller than normal, undulates when the eye is moved, and is more tortuous than usual. Besides all this it has a much darker look than normally, while the central light reflex on it will have disappeared. The darker appearance is due to the light reflected from the choroid being somewhat obstructed by the vessel, so that it is seen partly by reflected and partly by transmitted light; this appearance is quite characteristic, and should at once set one on the right track. Then, on putting up the objective for the indirect method, the detached retina or the vessels on it will appear different from the rest of the fundus; and on moving the lens slightly from side to side while the image is kept in view, the detached portion will look to slide over the other

part, and thus a "parallax" will be produced (p. 137).

The direct examination gives us much fuller information; when the detachment is thus looked at, the vessels have a foreshortened and wavy appearance; the detachment and the vessels on it will also be found to be very hypermetropic—that is, supposing the details of the disc are seen clearly without a convex glass behind the ophthalmoscope, and that the weakest convex glass blurs these details: the detached portion of the retina, or if it be transparent, then the vessels on it, may be seen with a strong convex glass; the more forward the retina, the higher the glass through which it can be seen. If the strongest glass be thus found out, we may estimate the distance between the detachment and the sclera; for 3 D. equals 1 mm., so that if the vessel in question could be seen with a convex 12 D., while the disc was emmetropic, then we should know that this distance was 4 mm. Detachments are, however, most frequently met with in myopes, so that a concave glass would be necessary to see the details of the disc; and yet perhaps the detachment may be clearly seen with a convex glass; the difference between the weakest concave glass with which the disc can be clearly seen and the highest convex glass with which the particular vessel can be seen, will give us the measurement we require.

In many cases a part of the detachment is transparent while a part has become opaque; sometimes a rent can be detected, so that the fluid in front and

behind the detachment being in direct communication, the retina can float about with every movement of the eye. The edges of the torn retina will be found turned in towards the vitreous.

When the detachment takes place in the macular region, the retina usually remains adherent to the macula itself, thus producing an ophthalmoscopic appearance somewhat like the cherry-red spot of embolism; this red spot might also be mistaken for a hæmorrhage by an inexperienced observer.

The character of fluid behind the detachment cannot often be diagnosed; it is most frequently serum of a light straw colour, but it may be blood: a more important point, however, to arrive at is—is the detachment due to fluid or is it due to a new growth? Other points not resting on the ophthalmoscope must be called to our aid to enable an accurate opinion to be formed. Thus the history of the case, the position of the detachment, and the tension of the eyeball may help us to arrive at a correct conclusion. In simple detachment the tension is liable to be diminished, while in that due to a growth the tension is usually above the normal at some period of its growth. As a rule the surface of a growth is more prominent, sometimes a hæmorrhage being visible upon it. No undulation of the detachment will be detected on moving the eye, and if the case be watched for some weeks it may be noticed if any increase is taking place. Detachments are most frequent in myopic eyes, but a new growth may occur in any eye, whatever its refraction. Detachments are frequently accompanied by vitreous

opacities, which may interfere more or less with the ophthalmoscopic picture. Posterior cortical cataract is another complication that may arise from detached retina.

(7) **Changes in the retinal vessels.**

- (a) They may be increased or diminished in size.
- (b) They may be unusually tortuous.
- (c) Pulsation may be present in the veins or arteries.
- (d) There may be alterations in the central light streak on the vessels.
- (e) The coats of the vessels may be thickened and their transparency diminished.

(a) *Changes in the size of the retinal vessels* may present numerous varieties, and are not always easily detected on account of the great individual differences that are met with; but a careful comparison of the vessels in the two eyes, together with the relative size of the arteries and veins, may assist one in arriving at a correct conclusion; the veins are as a rule about one third larger than the arteries.

The comparison of the relative size of the veins and arteries may be somewhat complicated if their distribution does not correspond; for instance, two veins may accompany one artery, or *vice versâ*.

Increase in the size of the arteries is not common, and when it does occur is usually due to some affection of the coats of the artery which has impaired its tone and contractility; it is seldom seen as a result of retinitis or papillitis, as might be expected. Increase

in the size of the arteries is most marked in retinitis due to leucocythæmia.

Decrease in the size of the arteries is much more common, and is often very marked in optic atrophy, retinitis pigmentosa, or any other disease causing atrophy of the retina; it is also a frequent result of the retrogressive changes following papillitis and retinitis; other causes are, increase in the intra-ocular tension, embolism, thrombosis, and anæmia.

Increase in the size of the veins is frequently met with, and it is usually due to inflammation of the retina involving the walls of the vessel, or to some disease producing general venous congestion, or to direct pressure on the venous trunk as it leaves the eye; the increase in the size of the vein is generally accompanied by an increase in its length which shows itself by greater tortuosity than normal; all the veins may be thus affected or only one, or even only a part of one.

Decrease in the size of the veins is much less common than increase, and may be due to atrophy of the retina or optic disc, embolism, thrombosis, or any degenerative process taking place in the vein itself. When the veins seem slightly enlarged, especially if the disc is redder than usual, the case may be one of *hyperæmia*.

In *anæmia* the arteries are slightly diminished, and the disc and general fundus pale, owing to the blood being of a lighter colour than normal from a deficiency in the number of red blood-corpuscles.

In albuminuric retinitis the coats of the arteries are always thickened and their calibre diminished.

Occasionally small aneurisms are found on some of the arteries.

In atrophy of the papilla or retina the vessels will be found diminished in size, and when this atrophy is the result of inflammation a white line may frequently be traced a good way along the sides of the larger arteries. This white line is due to sclerosis of the middle coat of the artery, or to an increase of the connective-tissue elements of the arterial sheath, which not being transparent can be easily seen by the direct method. In rare cases not only may the sides of the vessels be visible, but the front part also, so that no blood-stream can be detected, the vessels appearing as white-looking cords. The same condition may occasionally be seen in the choroidal vessels. When the retinal vessels are very much diminished in size they may appear as small threads, stretching but a short distance over the fundus.

But the most obvious change produced in the size of the vessels is that due to *embolism* of the central artery; and since this artery has no anastomoses, the retinal circulation can never be thoroughly re-established. The cause of embolism is usually a plug of lymph detached from one of the cardiac valves, plugging the main central artery; there is sudden and almost total loss of sight without pain or giddiness; and if the case be seen early the ophthalmoscopic appearances are very characteristic. The embolus is not generally visible, but there is great pallor of the disc; the arteries are much diminished, the veins slightly dilated, but decreasing in size towards the

disc ; sometimes the blood-stream is broken up into segments, retinal hæmorrhages are usually present, and a white hazy, opaque appearance surrounds the macula, the centre of which is occupied by a bright red spot (cherry-coloured spot). This opaque appearance is due to œdema of the nerve-fibre layer. The retina of the fovea centralis is very thin, and contains but little connective tissue, so that no œdema takes place here, therefore the red of the choroid shows through ; this colour is much intensified by the white appearance around, and possibly also by congestion of the choroid ; so that really the cherry-coloured spot is produced chiefly as the result of contrast. Should the embolus be too small to plug the central artery, then it may block up one of the main branches, and the ophthalmoscopic picture will vary accordingly. Later, the disc becomes atrophic, the œdema subsides, and therefore the red spot disappears, while the arteries will always remain very small. A similar condition may be produced by a hæmorrhage into the optic nerve sheath.

*Thrombosis* of the central vein produces somewhat analogous appearances, but the arteries are larger, the veins much fuller, while retinal hæmorrhages are more numerous and larger.

(b) *The vessels may be unusually tortuous*, which is expressed by their increased length ; these tortuosities when present are usually lateral. The condition may be met with in cases where a nævus of the skin of the lids or brow exists, or it may be one of the permanent remains of an attack of neuro-retinitis ; it

is also occasionally found as a congenital condition, and then usually in eyes that are highly hypermetropic. The tortuosity of vessels on a portion of detached retina has already been referred to, and may then be in an antero-posterior plane, *i. e.* at right angles to the surfaces of the retina, as well as lateral.

(c) *Pulsation of the arteries and veins.*—Arterial pulsation is almost always a pathological condition, and is due either to increased tension or to heart disease; it is most commonly seen in cases of glaucoma, and is then an important diagnostic sign; when due to heart disease it is usually the result of aortic regurgitation, the pulsation extending a considerable distance along the artery, sometimes even to the smaller vessels, while in glaucoma the pulsation is usually confined to the disc. Arterial pulsation occurs in glaucoma either spontaneously, or may easily be produced by slight pressure on the eye; and since the tension of a glaucomatous eye is liable to vary at different times, so will the pulsation be more apparent sometimes than at others; it is usually not present in all the arteries at once, and is best seen on the disc. It consists of a very sudden dilatation, which is synchronous with the cardiac systole, and is followed by a gradual emptying, the rapidity of arterial pulsation is a great contrast to the steady pulsation which takes place in the veins.

No pulsation exists in the normal eye, partly because the arteries here are so small that the pulse-wave has become very feeble, and partly because the intra-ocular tension exactly balances the tension on the in-

side of the vessels, and therefore the blood passes on in an almost continuous stream. In glaucoma the intra-ocular tension is greater than that in the vessels, so that the blood is able to flow along the retinal arteries only during the systole of the heart; when the pressure is lowered during the diastole, the arteries are occluded by the intra-ocular pressure.

Venous pulsation is usually physiological, but it may occur with an increase of the intra-ocular tension. This pulsation can best be seen on the disc, sometimes at the point where the main vein is formed by the junction of the upper and lower retinal veins. It consists of a gradual emptying and refilling of the vessel, and is possibly due to the slight increase of the intra-ocular tension which occurs with each contraction of the left ventricle, this increase being transmitted through the vitreous to the veins, causing them to empty. The veins, however, quickly refill as the tension is lowered.

(d) *Alterations in the light streak of the retinal vessels.*—It must be remembered that the retinal vessels on section are oval, the perpendicular diameter being less than the horizontal; the fuller the vessels the more they tend to the circular. This condition influences considerably the breadth of the light reflex; the flatter the vessels the broader the reflex. The colour of the blood in the vessels also makes some difference; the lighter the colour, the better marked is the central streak.

The light reflex is better marked and more regular in the case of the arteries than the veins, and can be

traced further upon the former than upon the latter. In œdema of the retina the reflex is much diminished, while in detached retina it is usually absent.

(e) *The walls of the vessels may be thickened.* The arteries are most frequently affected (*arteriosclerosis*) as a result of inflammation or degeneration. Inflammation may produce a thickening of the vessel-wall without any loss of transparency and so cause a diminution in the carrying capacity of the vessel, or the thickening may be of an opaque character; inflammation may affect the outer part of the vessel and its sheath causing an increase in the connective-tissue elements, with a corresponding increase in the outside diameter of the artery, while its calibre may be diminished; or the muscular coat of the vessel may be considerably thickened. The ophthalmoscopic signs of these conditions are, an apparent interruption in the blood-stream of a vein where the thickened artery crosses it; increase in the light streak of the arteries, as well as a white line along the sides of the vessels; in extreme cases the vessels may appear as white opaque cords.

This condition of thickening of the sheath and outer part of the vessel is known as perivasculitis; when the condition exists only in the arteries it may be spoken of as periarteritis.

**Retinitis circinata** is that condition which is occasionally met with in which there is a dense exudation arranged in the form of a large circle around the macula, with pigmentary disturbance in the macula region itself.

**Commotio retinæ.**—Sometimes after a severe contusion of the eyeball some part of the retina may assume a white clouded appearance, which may be accompanied by impaired vision, ciliary redness, and photophobia. These symptoms usually pass off in thirty-six hours. The condition is probably one of œdema of the retina.

**Retinitis proliferans** is the name given to that condition in which new vessels grow out into the vitreous supported by connective tissue. Bands may be seen stretching from one part of the fundus to another. Some observers think that these cases commence as large vitreous hæmorrhages.

**Glioma of the retina** is a very malignant disease, commencing usually in the neuroglia of one of the granular layers of the retina. It is most common in infants, but may occur up to the age of ten or twelve years. Sometimes both eyes are affected. This condition is best examined by focal illumination, when the growth will be seen of a pink-whitish colour, smooth or lobulated, and frequently with blood-vessels on its surface.

Glioma may be mistaken for inflammatory exudation in the vitreous, a condition sometimes called *pseudo-glioma*; the distinguishing points are, that in *pseudo-glioma* the colour is usually yellow or straw-coloured, the surface is flat, posterior synechiæ frequently exist, while the iris itself is pushed forwards in the centre and retracted in its ciliary portion; the tension is usually subnormal; whereas in glioma the whole of the iris is pushed forward, and the tension

may be increased during some part of its growth, and is never subnormal so long as the coats of the eye have not given way ; no posterior synechiæ exist, and the growth is of a pinkish colour and vascular.

Among ophthalmoscopic curiosities may be mentioned a very striking appearance ; the whole macula region may be found dotted over with light-coloured spots of various sizes, a condition which always exists in both eyes, and has been described under the name of *guttate choroiditis*, though it is probably not choroiditis at all but a physiological condition due to the pigment in some of the hexagonal epithelial cells being of a lighter colour than it is in the rest of the fundus, and may be somewhat analogous to freckles on the face ; but as no case has yet come within range of the microscope, the exact situation and cause of these spots is doubtful.

The vision in such cases is usually good, some having been watched for years without undergoing any change.

Now and then a row of spots may be seen, somewhat like a number of small air-bubbles. These are probably small transparent growths from the lamina vitrea.

A few very bright refracting spots are occasionally met with, usually near the vessels. Their pathology is unknown. Cases in which they are present often suffer from asthenopia.

Besides the conditions already mentioned, cysts of the retina, rupture of the retina without a corresponding rupture of the choroid, and congenital retinal pigmentation may occasionally be met with.

## CHAPTER IX

## THE OPTIC NERVE

THE only part of the optic nerve to be seen with the ophthalmoscope is the disc. Changes taking place in the nerve may or may not cause alterations in the disc. It is necessary to remember that the optic nerve passes through the rigid sclerotic opening, which is somewhat funnel-shaped, the narrowest part being in front; the nerve fits it closely, so that when any swelling takes place in this part, the sclerotic opening acts as a ligature, and may cause serious changes in the nerve-fibres as well as considerable obstruction to the retinal circulation. These changes may be made apparent by swelling, etc., of the optic disc.

The central artery and vein are for the nutrition of the retina, and have nothing to do with the nutrition of the disc itself. Since no anastomoses take place between these vessels and those of the surrounding structures the retinal circulation is terminal.

Abnormal conditions of the disc may cause—

1. Alterations in colour and transparency.
2. Alterations in surface level.
3. Changes in the margins of the disc.

1. **Alterations in colour.**—Great variations are met with in the colour of the discs in different subjects, so that it is extremely difficult in many cases to decide when any increase of the normal colour has taken place; sometimes, no doubt, the illumination necessary for the examination may cause temporary flushing of the disc, hence too much reliance must not be placed on this fact alone. A comparison of the colour of the discs on the two sides may help one to arrive at a correct conclusion. Undoubtedly *hyperæmia* does frequently exist, and will cause an increase in the normal pink colour, this increase of colour being due to fulness of the capillaries. When the hyperæmia is marked in character, it is usually accompanied by some increase in size of the retinal veins, with possibly some slight softening of the margin of the disc; this change will be best detected by the direct examination.

Both eyes are usually affected. This condition of hyperæmia may remain for a long time and then gradually subside, or it may go on to inflammation, and will be referred to later under the head of papillitis; or it may pass on to the opposite condition, atrophy of the optic disc.

*Anæmia* may cause the discs to look paler than usual; whilst at the same time the retinal vessels may be badly filled. In pernicious anæmia the red of the choroid may be diminished, while the retinal veins may be almost as light-coloured as the arteries. As age advances the disc becomes paler, so that a pale disc, which, when seen in an old person, may be normal,

may in a young individual indicate a condition bordering on atrophy.

Atrophy of the optic nerve may be divided into—

**Primary.**

**Secondary.**

**Consecutive.**

**Primary atrophy** is that condition which is not preceded by any inflammatory action ; though it must be remembered that since failing vision is almost the only symptom of atrophy, the disease may have been in progress for a long time before being detected, and any inflammatory action which may have preceded the degenerative processes may have vanished, leaving no indication behind. Primary atrophy may exist as a purely local disease, but is most commonly met with in association with locomotor ataxy and disseminated sclerosis.

**Secondary atrophy** is the term used by most authors to signify an atrophy due to some injury or disease of the nerve or retina ; common causes are pressure on any part of the nerve, embolism of the central artery of the retina, retinitis pigmentosa, choroido-retinitis, syphilitic retinitis, etc.

**Consecutive or post-neuritic atrophy** is due to the gradual destruction of the nerve fibres of the optic nerve following upon inflammation of the papilla.

In *atrophy* the disc is usually very white, or in some cases grey, but the ophthalmoscopic appearances will vary considerably with the stage of the disease and its cause. The whiteness of the disc is due to degeneration of the nerve-fibres, together with the capillaries

which supply them. If a case of primary atrophy is seen when fairly advanced, with the *indirect* method the disc will appear intensely white, with well-marked margin; the latter being rendered very distinct by the shrinking of the nerve-fibres, which exposes the sclerotic ring. With the *direct* method the white may be less marked; in fact, it may be of a bluish-white colour or grey, the stippling produced by the perforations of the lamina cribrosa being usually very distinct. As the optic nerve shrinks no decrease takes place in the size of the disc, but a depression of its surface is gradually produced, forming what is known as the *atrophic cup*. This cup is always shallow, while the vessels can be seen to slope gradually down to the bottom of the disc. When the atrophy is of a consecutive character, as in cases of papillitis, the atrophy may be spoken of as post-papillitic. The ophthalmoscopic signs indicating this condition are, badly defined disc-margin, vessels somewhat tortuous and diminished in size, with a white line extending along some of them; little or no cupping is present, while some remains of organised material may be seen about the disc, or covering some of the vessels. With the direct method the disc has often a strikingly opaque appearance.

Atrophy of the optic nerve may commence in any part of its course between the optic chiasma and the eye, extending in either direction from the point first attacked.

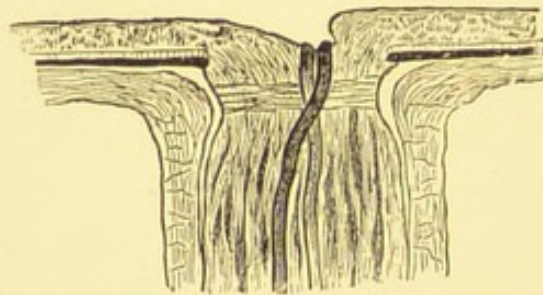
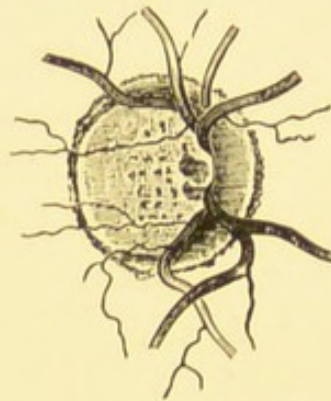
Atrophy following retinitis pigmentosa produces a

waxy-looking disc, while the vessels are often very small.

Very great differences in sight will be found in optic atrophy; some may have very white discs and yet retain fair vision, while others have extremely bad vision and yet the discs may not be very white. Sometimes the margins of the disc are a safe guide to the cause of the atrophy, while at other times this is not the case.

2. **Alterations in surface level.**—Although the disc is spoken of as the papilla, it is really but very slightly

FIG. 64.



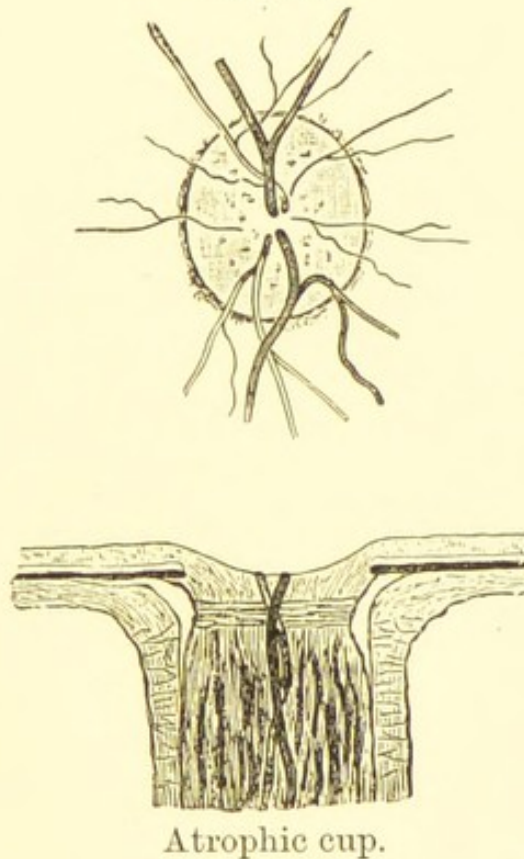
Physiological cup.

raised above the general level of the fundus. The disc may be depressed so as to form a cup, of which there are three kinds: (1) *the physiological cup*; (2) *the*

*atrophic cup*; (3) *the glaucoma cup*. The disc may be raised as in *papillitis*.

The *physiological cup* is a congenital condition, and was mentioned on p. 81. This cup is cone-shaped, and is formed by the separation of the nerve-fibres which spread out to form the retina, its chief and important characteristic being that it does not involve the whole disc. The cup is usually the whitest part of the disc, because it contains few nerve-fibres, and is therefore less vascular; it occupies more or less the centre, and when deep, allows the details of the lamina cribrosa to be seen.

FIG. 65.



Atrophic cup.

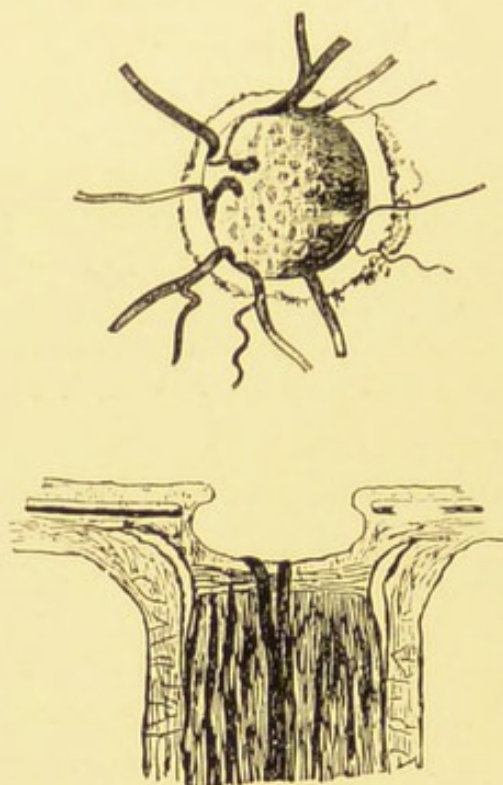
The illustration of a physiological cup (Fig. 64) was drawn from life; it is an exceptionally large one,

reaching almost to the edge of the disc on the temporal side, and being excavated on the nasal side, which is unusual; the stippling of the lamina cribrosa is well seen.

The *atrophic cup* involves nearly the whole disc, but is shallow, and formed by a very gradual slope from the disc margins. The vessels can be traced down the cup without any interruption. This form of cup is common in cases of primary atrophy.

The *glaucoma cup* is produced by an increase of the intra-ocular pressure driving the nerve backwards,

FIG. 66.



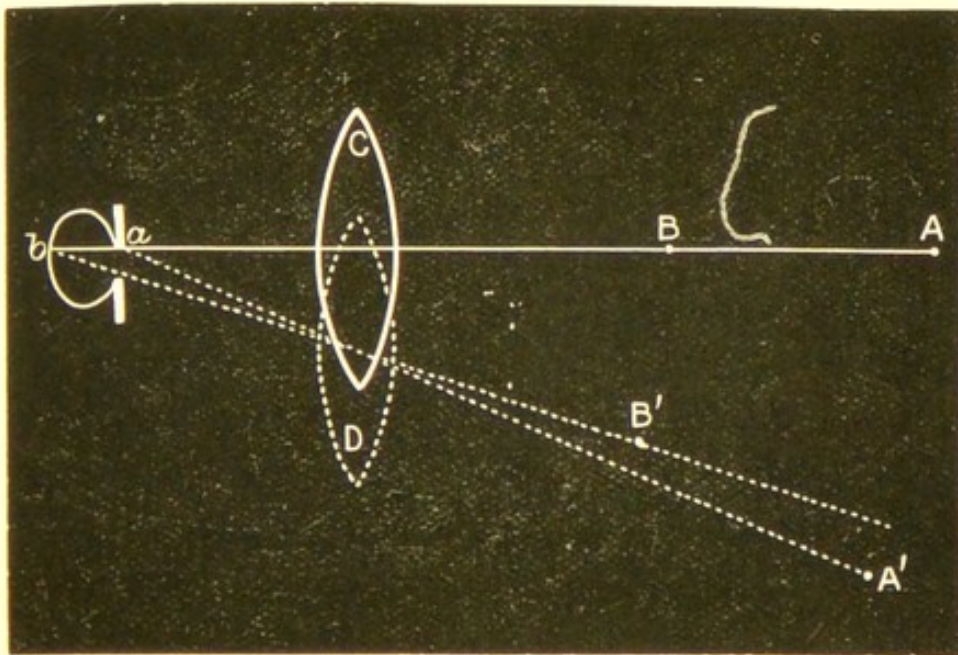
Glaucoma cup.

and displacing the lamina cribrosa. The optic nerve entrance is the weakest part of the coats of the eye-

ball, and is therefore the part which gives way first to increased intra-ocular pressure. The essential characteristics of this cup are, that it involves the whole disc, is more or less excavated, and the vessels are pushed over to the nasal side of the disc. When these characteristics are well marked it is impossible to mistake them; but in others when the cup is only forming, it is very easy to mistake it for one of the two preceding varieties. Besides, in some cases the two conditions may co-exist; thus a case of glaucoma occurring in an eye with a well-marked physiological cup may be some time before it develops the characteristics belonging to the glaucoma cup.

With the indirect examination one will see, on

FIG. 67.



moving the objective slightly from side to side, a well-marked *parallax*, *i. e.* the margin of the disc will appear to slide over the bottom of the cup. This is

due to the image of the margin of the disc making a greater movement than the image of the bottom of the cup. Thus, in Fig. 67, let *a* represent the edge of a glaucoma cup, and *b* the lower part of the same; the image of *a* will be formed at A, and *b* at B. On moving the lens *c* to *D*, B will move to B' and A to A'; therefore the image A, which represents the margin of the edge of the cup, will have made a greater movement than B, which is the image of the bottom of the cup. With *the direct* method a parallax may also be seen. We may estimate the depth of the cup by the direct method, if we remember that 3 D. = 1 mm.; first find the glass through which the edge of the disc is seen clearly, and then the glass through which the bottom of the disc is seen well defined; for example, if the edge of the disc is seen clearly with a +2 D., whilst the lowest part of the cup requires -4 D., we should know that the cup was 2 mm. deep.

This deep excavated cup is found most marked in cases of chronic glaucoma.

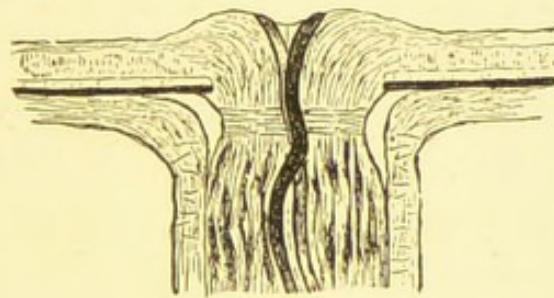
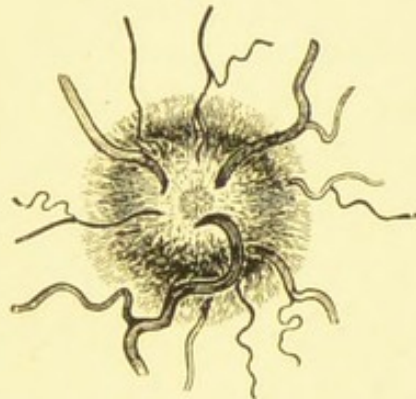
With the ophthalmoscope the vessels of the retina will appear to stop at the edge of the disc as they twist under the overhanging edge; they will be seen again at the bottom of the disc, only more or less out of focus. Other characteristics of the glaucoma cup are, that the vessels are pushed towards the nasal side, and frequently pulsation can be detected in the arteries. This pulsation will be found referred to on p. 125.

*Neuritis.*—Inflammation may attack any part of

the nerve between the optic chiasma and the eye, and may, according to its location, be designated as *papillitis* (choked disc) when the disc is chiefly involved; *papillo-retinitis* when the retina is also implicated; *neuritis* when the nerve itself is inflamed, and may then be either ascending or descending; *retro-bulbar neuritis* when the disease is behind the eye, affecting chiefly the central fibres of the nerve.

A well-marked case of papillitis produces the most characteristic ophthalmoscopic appearances, the disc being swollen and raised, somewhat like the

FIG. 68.



Papillitis.

end of a champagne cork. In a simple case of neuritis the appearances are less marked. Neuritis

may exist alone or in conjunction with retinitis, and may be caused by pressure on any part of the optic nerve; by brain mischief; or by some general disease such as albuminuria, diabetes, syphilis, rheumatism, influenza, etc.

No distinct line of demarcation exists between hyperæmia and inflammation of the disc, the one passing imperceptibly into the other. When the edge of the disc has become slightly indistinct, accompanied by distinct swelling, papillitis may be said to have commenced. Papillitis may exist in varying degrees; it is usually manifested by increased redness, with swelling of the optic nerve, which fills up the physiological cup, and gradually raises up the centre of the disc, sometimes to an enormous extent. The swollen disc overlaps its edges, so that the margins are very ill-defined or quite lost, while the colour of the disc may be increased, being much the same as the surrounding choroid. The disc margins have a striated or woolly appearance, due partly to opacity and swelling of the nerve-fibres, and partly to exudation of inflammatory material. The arteries may be diminished in size, and at places hidden from view by exudation; the veins are dilated and tortuous, the bendings taking place not only in a lateral direction, but often in an antero-posterior plane, especially when the swelling is very great. A few hæmorrhages may be seen near the disc, radiating from it in the direction of the nerve-fibres. This condition may be well seen by the indirect method, but the indistinctness of the disc margins

and the difference in level of the swollen disc can best be appreciated by the direct method. The amount of swelling may be estimated if we remember that every + 3 D. means an increase in level of 1 mm. As the swelling diminishes shrinkage takes place, and the condition is liable to pass on to atrophy.

Retro-bulbar neuritis is a variety of inflammation affecting the orbital part of the optic nerve; it exists in two forms. The acute variety usually affects one eye only, and is due to pressure on some part of the optic nerve between the chiasma and the globe, such as periostitis involving the optic foramen, hæmorrhage, or effusion into the nerve-sheath.

There is sudden loss of vision with pain in and around the orbit increased by movements of the eye or pressure on the globe; the disc looks pale and opaque with blurred edges, while the retina is often slightly hazy and the light streak on the retinal vessels diminished. If the pressure is not too long continued complete recovery may take place; in some a central scotoma is left, while in a few cases the optic nerve becomes atrophic.

The chronic form of retro-bulbar neuritis is usually produced by some poison, most commonly tobacco; it almost invariably affects both eyes, involving chiefly the central fibres of the nerve, so that the ophthalmoscopic signs are but slight. Sometimes the discs are congested in the first stage, afterwards becoming rather pale on the temporal sides; there is usually a central colour scotoma present in both eyes.

3. Changes in the margin of the disc have already

been referred to under the diseases papillitis and post-papillitic atrophy. In the first condition the margin of the disc is often completely lost, as is shown in Fig. 68; in slight cases or in an early stage of the inflammation, the edge of the disc can still be made out, but it has a woolly striated appearance, more marked at some parts than at others. In post-papillitic atrophy the margin of the disc is usually somewhat irregular, with disturbance and heaping up of displaced pigment.

The most common cause of change in the margin of the disc is, however, that produced by myopia, a crescent being formed on the outer edge. Myopia is nearly always due to an increase in the antero-posterior diameter of the eyeball. This increase in length is usually produced by a stretching of the tissues at the back of the eye; the sclerotic bulges at the point of least resistance, *i. e.* on the outer side of the optic nerve, between it and the macula, while the choroid, instead of stretching with it, becomes dragged away from the disc margin, exposing a crescent-shaped portion of the sclerotic. In slight cases a mere increase of the sclerotic ring will become visible on the outer side of the disc; while in high degrees of myopia the crescent may attain an enormous size, completely surrounding the disc and extending a long way towards the macula, the broadest part of the myopic crescent being invariably outwards. This myopic crescent is occasionally seen in cases of emmetropia, and even in hypermetropia; here probably the eye was originally hypermetropic, and

is on the high road to myopia, but the crescent becomes formed before it has arrived at this condition. Sometimes it is not quite easy to distinguish the line of demarcation between the disc and the crescent; frequently some traces of pigment are to be seen on the outer edge of the crescent.

**Congenital crescent** was first accurately described by Fuchs under the name of coloboma of the nerve-sheath. It is not a very uncommon defect, and consists of a pale coloured crescent, with the broad part downwards; in some cases there is difficulty in making out any division between the disc and the crescent. The congenital crescent is a part of the disc itself and not the exposed sclerotic, as in the case of the myopic crescent. The disc is darker in colour than usual, horizontally oval and sometimes misshapen; frequently the crescent is staphylomatous; the eyes in which it is present have usually more or less astigmatism, with a visual acuteness below the normal.

**Opaque nerve-fibres** is a congenital condition sometimes met with. As a rule, when the nerve-fibres penetrate the lamina cribrosa they become divested of their medulla, passing on as transparent fibres; occasionally some of them retain their sheaths for a time after passing into the eye, or, having lost them at the optic nerve entrance, quickly regain them for a short distance. The patches of opaque nerve-fibres may be met with in various shapes and sizes; perhaps the commonest form seen is that in which a tuft is present above and below the disc, extending from

near its margin upwards and downwards for some distance on to the retina. Sometimes isolated patches are seen a short way from the disc. They are always white and opaque-looking, somewhat flame-shaped with well-defined lateral margins and feathery ends, shading off gradually into the normal retina. The opacity occupies the anterior part of the retina, and may even hide the retinal vessels more or less completely. When the patches are large, and extend a long way over the retina, they bend out towards the macula. Opaque nerve-fibres may exist in one or both eyes, and when once seen are not likely to be mistaken for a pathological condition; their dense white appearance, elongated shape, and feathery ends are quite characteristic. It may be mentioned that in the rabbit opaque nerve-fibres are the normal condition; here they are arranged in two tufts extending in a horizontal direction on both sides of the disc. Opaque nerve-fibres should be examined both by the indirect and the direct methods.

**Connective tissue on the disc.**—Some part of the disc or its vessels is occasionally more or less obscured by a small shred, band, or irregular mass of connective tissue; sometimes resembling a very small piece of cotton wool, just faintly blurring the vessels beneath it, at other times forming a very opaque white patch concealing a good portion of the disc and vessels. The condition is usually a congenital one, being the remnant of the foetal hyaloid artery; when not congenital it may be the organised remains of inflammatory exudation poured out in papillitis.

## APPENDIX.

---

I WILL now conclude this small volume by shortly recapitulating the plan of examination recommended; which if carried out in the systematic manner suggested, should prevent any serious lesion escaping detection.

1. With the oblique illumination inspect the cornea, lens, iris, and the anterior part of the vitreous. Notice if any opacity or irregularity of the cornea is present, and if its curvature appear normal. The aqueous should be quite transparent; the iris movable and free from adhesions. Adhesions may exist either between the iris and the cornea as a result of perforation, or between the iris and lens as a result of iritis. The lens should be perfectly transparent; sometimes it will be found dislocated, either congenitally or the result of an accident. Pigment may be noticed on the anterior capsule; this has been torn from the posterior surface of the iris, and is evidence of previous inflammation of this tissue. Opacities may be detected in any part of the lens; when at the posterior pole the opacity appears to be further back than might be expected. The anterior part of the vitreous may contain blood, which may thus be detected; or a growth; or a very prominent detached retina may come into view. This examination may be supplemented by a strong magnifying glass, or the cornea may be further examined with a

+ 20 D. behind the ophthalmoscope, the observer approaching close to the patient.

2. Next take up the large concave mirror, and reflect the light into the eye from a distance. Opacities of the cornea and lens will then appear as black spots on a red ground. The cornea and lens being transparent, notice if any vitreous opacities are visible; these are usually floating, and can best be set in motion by directing the patient to look quickly up, then down, and finally straight in front of him. Should any vitreous opacities be detected, they may be further examined with a plane mirror and a + 8 D. behind the ophthalmoscope. Nothing being detected in the vitreous, notice if the disc or any part of the fundus come into view. Should a vessel be seen, note if it appear to move with the observer's head, in this case it will be hypermetropic; if it move against the movement of the observer's head then it will be myopic. Should a detachment of the retina exist, then, of course, this part will be very hypermetropic, and will answer the tests for that condition. If the detachment be transparent, then a vessel may be seen on the detached portion of retina; the vessel will appear darker than usual, more tortuous, have a foreshortened appearance, and move with the undulations of the detached retina.

3. Nothing being detected by the mirror alone, the large biconvex lens should be held up in front of the eye we are examining, while the light is still reflected by the large concave mirror: thus one obtains an inverted image of the fundus. Notice first the

shape, size, and edges of the disc, whether well defined or blurred, whether cupped or otherwise. Distinguish the arteries from the veins, and note if they be full, tortuous, or if pulsation is present; whether clearly defined, or covered up in parts, and whether a line can be traced along the edge of any of the arteries; then examine the periphery by directing the patient first to look up, then down, and finally to either side. Attention must next be directed to the macula region.

4. Examine the eye by the direct method, first the disc, then the periphery, and finally the macula region, compare the result by this plan and the indirect method. Estimate the refraction at the disc. When any patches of pigment, exudation, or hæmorrhages are found, we must decide whether they are retinal or choroidal.

5. Finally notice the refraction of the patient by retinoscopy.

When the observer has time, a sketch may be made of the disc. Nothing improves the powers of observation so much, or leads to such accuracy, as making a drawing of what is really seen; every detail must then necessarily receive considerable attention.

---

#### A TABLE OF THE ENLARGEMENT OF THE OPHTHALMOSCOPIC IMAGE.

	Inverted image with + 13 D.	Upright image.	Proportion.
Emmetropia ... ..	5.2 ...	20 ...	1 to 4
Hypermetropia (axial) of 12 D.	7 ...	18.4 ...	1 to 2.6
Myopia (axial) of 12 D.	4.3 ...	30 ...	1 to 7



# INDEX

---

## A

Albino, 22, 77, 108  
 Albuminuric retinitis, 111  
 Anæmia of discs, 131  
 Angle of deviation, 9  
     principal, 9  
 Anterior chamber, 85  
 Appearances of normal fundus, 74  
 Appendix, 145  
 Aqueous chamber, 85  
 Arterial pulsation, 125  
 Artery, central, 83  
     embolism of, 123  
     hyaloid, 89, 97  
 Artificial eye, Frost's, 34  
 Atrophic cup, 136  
 Atrophy of discs, 132  
     of retina, 115  
     of the choroid, 105  
 Axes, secondary, 12  
 Axis, principal, 9

## B

Biconcave lens, 11  
 Biconvex lenses, 11

## C

Cataract, 89  
 Central artery and vein, 82

Chamber, anterior, 85  
 Cherry-coloured spot, 124  
 Cholesterine, 94  
 Choroid, 98  
     colloid disease of, 107  
     coloboma of, 106  
     rupture of, 106  
     sarcoma of, 107  
     tubercle of, 106  
 Choroidal hæmorrhage, 105  
     pigmentation, 117  
     ring, 81  
 Choroiditis, 99  
     central, 103  
     disseminated, 102  
     guttate, 129  
     myopic, 104  
     plastic, 99  
     purulent, 101  
     senile, 105  
     suppurative, 101  
 Choroido-retinitis, 99  
 Cilio-retinal vessel, 84  
 Colloid disease of choroid, 107  
 Coloboma of choroid, 106  
 Commotio retinae, 128  
 Concave lens, 11  
     mirror, 26, 27

Concave mirror at a distance, 38  
 Congenital crescent, 143  
 Conical cornea, 86  
 Connective tissue on disc, 144  
 Consecutive optic atrophy, 132  
 Convex lens, 11  
 Cornea, 85  
 Corneal opacities, 86  
 Couper's ophthalmoscope, 28  
 Crescent, congenital, 143  
     myopic, 105, 142  
 Cribrosa, lamina, 80, 135  
 Cup, atrophic, 135  
     glaucoma, 136  
     physiological, 80, 135

## D

Detachment of retina, 117  
 Deviation, angle of, 9  
 Diabetic retinitis, 111  
 Direct examination, 53  
     positions for, 54  
 Disc, optic, 79  
     anæmia of, 131  
     atrophy of, 132  
     hyperæmia of, 131  
     image of, 41  
     inflammation of, 138  
     size of, 79  
 Disseminated choroiditis, 102

## E

Embolism of central artery, 123  
 Emergent ray, 7  
 Estimation of refraction by retin-  
     oscopy, 66  
     by the direct, 62  
 Euphthalmine, 33

Examination, methods of, 32  
     direct, 53  
 Examination, focal illumination,  
     36  
     indirect, 41

## F

Floating opacities, 40, 93  
 Focal illumination, 36  
 Focus, anterior, 10  
     conjugate, 4, 10  
     negative, 10, 15  
     principal, 6, 14  
     virtual, 5  
 Formation of images, 17  
 Fovea centralis, 78, 124  
 Frost's artificial eye, 34  
 Fuchs, 143

## G

Glass, index of refraction of, 7  
     magnifying, 31  
 Glaucoma cup, 136  
 Glioma of the retina, 128  
 Guttate choroiditis, 129

## H

Hæmorrhage, choroidal, 105  
     into nerve-sheath, 124  
     into vitreous, 93  
     macular, 113  
     retinal, 112  
     subhyaloid, 113  
 Hæmorrhagic retinitis, 113  
 Helmholtz, 23  
 Homatropine, 32  
 Hyaloid artery, 89, 97  
 Hyperæmia of choroid, 98

Hyperæmia of disc, 131  
 of retina, 122  
 Hyphæma, 87  
 Hypopyon, 87

## I

Illumination, focal, 36  
 Images, formation of, 17  
     real, 20  
     virtual, 18  
 Incident ray, 7  
 Index of refraction, 7  
     of cornea, 8  
     of glass, 7  
 Indirect examination, 41  
 Inflammation of the choroid, 99  
     disc, 138  
     retina, 110  
 Inverted image, 18, 41  
 Iridodialysis, 88  
 Iris, 88

## K

Keratitis, 86  
     punctata, 86

## L

Lamellar cataract, 89  
 Lamina cribrosa, 80, 135  
     vitrea, 107  
 Lens, 88  
 Lenses, 11  
     biconcave, 11  
     biconvex, 11  
     converging, 11  
     diverging, 11  
 Leucocythæmic retinitis, 110  
 Lutea macula, 78

## M

Macula lutea, 78  
 Macular hæmorrhage, 113  
 Magnification by the direct  
     method, 57  
     by the indirect method, 51  
 Magnifying glass, 31  
 Methods of examination, 32  
 Mirror, concave, 26, 38  
     for retinoscopy, 31, 67  
     plane, 26, 67  
     tilted, 26  
 Morton's ophthalmoscope, 28  
 Mydriatics, 32  
 Myopia, 105  
 Myopic choroiditis, 104  
     crescent, 105, 142

## N

Nerve, optic, 79, 130  
 Nerve-fibres, opaque, 143  
 Neuritis (see Papillitis), 138  
     retro-bulbar, 141  
 New vessels in vitreous, 97  
 Normal fundus, appearances of, 74  
     varieties of, 75

## O

Objective lens, 31  
 Oblique illumination, 36  
 Opacities, corneal, 86  
     floating, 40, 93  
     vitreous, 93  
 Opaque nerve-fibres, 143  
 Ophthalmoscope, 21  
     demonstrating, 31  
     Morton's, 28  
 Optic disc, 79

Optic nerve, 79, 130  
Optics, 1

## P

Papillitis, 139  
Parallax, 119, 137  
Physiological cup, 80, 135  
Pigmentation, changes in, 115  
Pigmentosa, retinitis, 115  
Plane mirror, 26, 67  
Positions for direct, 54  
    for indirect, 42  
Primary atrophy, 133  
Principal angle, 8  
    axis, 9  
    focal distance, 9  
    focus, 6, 14  
Prisms, 8  
Pseudo-glioma, 128  
Pulsation, arterial, 125  
    venous, 126  
Punctata, keratitis, 86  
Purulent choroiditis, 101

## R

Rays, 1  
Real image, 20  
Reflection, 2  
    by a concave surface, 3  
    by a convex surface, 6  
    by a plane surface, 2  
Refraction, 6  
    by a plane surface, 7  
    by a prism, 8  
    by a spherical surface, 9  
    by lenses, 11  
    estimation of, 62, 66  
    index of, 7

Retina, 76, 109  
    detachment of, 117  
    glioma of, 128  
Retinal hæmorrhages, 112  
    pigmentation, 115, 116  
    vessels, 121  
Retinitis, 111  
    albuminurica, 110  
    diabetic, 110  
    leucocythæmic, 110  
    pigmentosa, 115  
    proliferans, 128  
    septic, 110  
    syphilitic, 110  
Retinoscopy, 66  
Ring, choroidal, 81  
    sclerotic, 81  
Rupture of choroid, 106

## S

Sarcoma of choroid, 107  
Sclerotic ring, 81  
Secondary axes, 12  
    optic atrophy, 132  
Senile choroiditis, 105  
Septic retinitis, 110  
Shadows in retinoscopy, 68  
Sparkling synchysis, 95  
Subhyaloid hæmorrhage, 113  
Suppurative choroiditis, 101

## T

Thrombosis of central vein, 124  
Tilted mirror, 26  
Tubercle of choroid, 106  
Tyrosin, 94

## V

- Variations in the size of image,  
45
- Varieties of the normal fundus,  
74
- Venous pulsation, 126
- Vein, central, 82  
thrombosis of, 124
- Vessels, central, 82  
cilio-retinal, 84
- Vessels, retinal, 82, 121
- Virtual focus, 5  
image, 18
- Vitreous, 92  
air-bubbles in, 96  
hæmorrhage into, 93  
new vessels in, 97  
opacities, 93, 100



