

**A system of oral surgery : being a treatise on the diseases and surgery of the mouth, jaws, face, teeth, and associate parts / by James E. Garretson.**

**Contributors**

Garretson, James Edmund, 1828-1895.

**Publication/Creation**

Philadelphia ; London : J.B Lippincott, 1884.

**Persistent URL**

<https://wellcomecollection.org/works/arwagfyf>

**License and attribution**

This work has been identified as being free of known restrictions under copyright law, including all related and neighbouring rights and is being made available under the Creative Commons, Public Domain Mark.

You can copy, modify, distribute and perform the work, even for commercial purposes, without asking permission.



Wellcome Collection  
183 Euston Road  
London NW1 2BE UK  
T +44 (0)20 7611 8722  
E [library@wellcomecollection.org](mailto:library@wellcomecollection.org)  
<https://wellcomecollection.org>









22101029141





Digitized by the Internet Archive  
in 2015

*Edward I. Oliver*  
*Philadelp*  
*4 Sept. 18*

A SYSTEM  
OF  
ORAL SURGERY:  
BEING  
A TREATISE ON THE  
DISEASES AND SURGERY  
OF THE  
MOUTH, JAWS, FACE, TEETH,  
AND  
ASSOCIATE PARTS.

BY

JAMES E. GARRETSON, M.D., D.D.S.,

Dean of the Philadelphia Dental College; Surgeon in Charge of the Hospital of Oral Surgery; Member of the Philadelphia County Medical Society; Member of the Philadelphia Pathological Society; Honorary Member of the Delaware County Medical Society; Honorary Member of many Dental Societies; Late Oral Surgeon to the University of Pennsylvania; Late Lecturer on Anatomy and Surgery in the Philadelphia School of Anatomy, etc., etc.

*Illustrated with Numerous Steel Plates and Wood-Cuts.*

---

FOURTH EDITION, THOROUGHLY REVISED, WITH ADDITIONS.

---

PHILADELPHIA:  
J. B. LIPPINCOTT & CO.  
LONDON: 16 SOUTHAMPTON STREET, STRAND.  
1884.

Copyright, 1881, by J. B. LIPPINCOTT & Co.

Copyright, 1884, by J. B. LIPPINCOTT & Co.

WELLCOME INSTITUTE LIBRARY	
Coll.	weiMOmec
Call	
No.	WU100
	1884
	G23 s
Acc.	339403



## PREFACE TO THE FOURTH EDITION.

---

IN presenting the fourth edition of this work to a professional public, the author desires to acknowledge the encouragement and stimulation derived from the continued generous reception and the constantly increasing sale.

The present book is enlarged by addition of several chapters on subjects not heretofore embraced. Exertion has been increased to condense and simplify. Illustrations to the extent of seventy-five new cuts have been added. Every part of the volume has been rearranged, rewritten, or complemented.

The fact that this "system" has come into common use by dental colleges makes desirable unexceptionable fulness in the direction of things considered by the specialty. Effort has been made to have no principle absent. Irrelevant matter is not present to perplex.

The teachings and demonstrations being prepared specially for the guidance of students and practitioners of oral surgery, the author offers them as a result of thirty years of practice. Time has been taken for experimentation, for consideration, and for execution. The responsibility has been continuously in mind. The writer has done all he finds himself able to do.

The author is under special obligation to Prof. D. Hayes Agnew and Dr. James W. White for the free use of costly diagrams, and to the publishers for the courteous attention and care shown while his work was passing through the press.

J. E. G.

1537 CHESTNUT STREET, November 10, 1883.





# CONTENTS.

## CHAPTER I.

### SURGICAL ANATOMY OF THE HEAD.

	PAGE
Introductory—The Skull—Superior Maxilla—Inferior Maxilla—Palate Bone—Vomer—Ethmoid Bone—Sphenoid Bone—Nasal Bone—Malar Bone—Lachrymal Bone—Hyoid Bone—Section of Skull—Base of Skull .	25

## CHAPTER II.

### THE MOUTH.

The Mouth—Muscles of Face—Arteries of Face—Carotid Arteries—Deep Arteries of Facial Region—Veins of Face—Nerves of Face—Sectional Expression of Mouth—Muscles of Tongue—Surface Anatomy of Tongue—Papillæ of Tongue—Mucous Membrane—Anatomy of Salivary Glands—Temporo-Maxillary Articulation . . . . .	50
---	----

## CHAPTER III.

### FIFTH PAIR OF NERVES.

Common View of Distribution—Trifacial Division and Ganglia—Ganglion of Casserio—Ophthalmic Nerve—Superior Maxillary Nerve—Inferior Maxillary Nerve—Physiological Function of Nerve . . . . .	69
--	----

## CHAPTER IV.

### ANATOMY OF THE TEETH.

A Tooth a Body <i>sui generis</i> —Resemblance to Ivory—Dental Pulp—Dentine—Enamel—Cementum—Microscopic Anatomy of Fang of Tooth, exhibiting Dentine and Cement—Enamel Columns—Interglobular Spaces—Relation of the Teeth with Jaw—Peculiarities of Individual Teeth—Names and Surfaces of Teeth . . . . .	83
--	----

## CHAPTER V.

### DENTITION.

Development of Teeth—Dental Germs—Primitive Dental Groove—Dental Papilla—Hyaloid Structure—Developing Germs—Tunica Propria—Haltus of Tooth-Sac—Calcification—Formation of Enamel—Illustration in Dental Germ Development—Relations of First and Second Dentitions—Positions of Tooth-Germs—Articulation . . . . .	93
---	----

## CHAPTER VI.

## ASSOCIATIVE LESIONS OF FIRST DENTITION.

	PAGE
Dental Irritation—Localized Stomatitis—Lancing Children's Teeth—Hemorrhage—Angina Simplex—Chronic Angina—Irritative Fever—Diarrhœa of Dentition—Spasms—Eruptions—Cutaneous Hyperæmia—Papulæ—Exanthemata—Bullæ—Pustulæ—Vesiculæ—Tubercula—Maculæ . . . . .	100

## CHAPTER VII.

## ANOMALIES OF SECOND DENTITION AND THEIR SURGICAL RELATIONS.

Teeth Erupting External or Internal to the Arch—Teeth denied Space in the Arch—Encysted Germs—Supernumerary Teeth—Third Dentitions—Periodontal and Periosteal Associations—Germs with Heterogeneous Development—Illustrations . . . . .	124
---	-----

## CHAPTER VIII.

## THE TEETH AND THEIR DISEASES.

Caries—Health in the Dental Organism—Causes Provocative of Caries—Scrofulosis—Rickets—Shapes of the Teeth—Nutritional Circumstances—Relation of Organs with each other—Self-Cleansing Features—Constitutional Relations—Character of Agents in Contact with the Teeth—Mucous Deposits—Acid Secretions—Parasites—Electro-Chemical Relations—Medicines and Articles of Food—Accidental Influences . . . . .	135
---	-----

## CHAPTER IX.

## SURGICAL CONSIDERATION OF DENTAL CARIES.

Phenomenal Expressions of Caries—Principles of Treatment—Neutralization of Adverse Oral Fluids and the Induction of a state of General Health in the Mouth—Medical Treatment of the Teeth—Characteristics of Saliva—Teeth of Sanguine and Allied Temperaments—Teeth having a Blue Shade—Chalky Teeth—Pearly Teeth—Soft Dentine—Zinc Chloride—Filing as a Prophylactic and Curative Agent—Vitrification—Inclined Surfaces—Illustrations in Filing . . . . .	177
--	-----

## CHAPTER X.

## DENTAL THERAPEUSIS.

Inertness of Gold as a Filling Material—Therapeutical Plugs—Recalcification of Teeth—Oxychloride of Zinc—Gutta-Percha—Copper Dust—Oxide of Tin—Electrical Disturbances—Parasitocides . . . . .	187
--	-----

## CHAPTER XI.

## THE ORAL FLUIDS.

Saliva—Composition of; Characteristics of—Mucous Oral Detritus—Analyses of Oral Fluids—Saliva unduly Alkaline—Healthy Saliva—Parotid Secretion—Submaxillary Secretion—Accessory Parotid Secretion—Saliva
--



	PAGE
and Food Bolus—Saliva unduly Acid—To make Analyses of Saliva— Abnormal Saliva—Accidental Substances found in Saliva—Carbolic Acid and Saliva—Magitot's Experiments with Acids and Teeth—Sordes—Excess of Ptyaline—The Acids of Fruits in Relation with Soft Teeth . . . . .	190

## CHAPTER XII.

## ODONTALGIA.

Causes of Toothache—Sensitive Dentine—Exposure of Pulp—Disease of Periodontum—Pus and Gas in the Pulp-Cavity—Granules of Osteo-Den- tine in a Pulp—Sympathetic Toothache—Recession and Absorption of Gum and Alveolus . . . . .	198
--	-----

## CHAPTER XIII.

## PERIODONTITIS.

Synonymes—Acute Periodontitis—Chronic Periodontitis—Case of Ringed Root—Treatment of Periodontitis . . . . .	219
---	-----

## CHAPTER XIV.

## ALVEOLO-DENTAL ABSCESS.

History and Meaning of—Local Features of—Prophylaxis of—Association with Antrum—Illustration of—Anomalous Cases of—Rheumatism and Gout, Associates of . . . . .	225
---	-----

## CHAPTER XV.

## THE PULP-CHAMBER AND CANALS.

Death of Pulp—Removal of, from Cavity—Nerve Extractors—Preparing Cavity for Filling—Test Plugs—Filling over Exposed Pulp—Devitalized Dentine—Pulp Cappings—Materials used for . . . . .	239
---	-----

## CHAPTER XVI.

## DISCOLORED TEETH.

Causes of—Treatment of Pulp-Chamber—Bleaching—Whitening—Blood Coloring . . . . .	248
---	-----

## CHAPTER XVII.

## REPLANTATION AND TRANSPLANTATION OF TEETH.

Hunter's Experiments—Replantation—Mistakes in Extraction—Treatment in Replantation—Transplantation: Danger of Disease from; Lack of Correspondence between Tooth and Socket; Brutes' Teeth and Human Jaws; Illustrations from Practice; Danger from Tetanus—Illustration in Fixation . . . . .	251
--	-----

## CHAPTER XVIII.

## SALIVARY CALCULUS.

Analysis of Saliva—Analysis of Calculus—Common Positions of Tartar—	PAGE
Anomalies—Illustration—Treatment of Calculus . . . . .	258

## CHAPTER XIX.

## DENUDATION OF DENTINE.

Obscurity of Cause—Prophylaxis—Treatment of the Condition—Abrasion	
of Cutting Faces of Teeth—Treatment of . . . . .	266

## CHAPTER XX.

## OPERATIVE DENTISTRY.

## INSTRUMENTS USED IN PREPARATION OF CAVITIES.

Typical Dentures—Expression of Cavities—Excavators—Drills—Dental En-	
gines—Chisels—Files—Corundum Disks—Drop Tubes—Chip-Blower—	
Water-Syringes—Exposing Existence of Cavities . . . . .	268

## CHAPTER XXI.

## OPERATIVE DENTISTRY.

## EXCAVATION AND PREPARATION OF CAVITIES FOR FILLING.

Cavities—Simple Crown—On Posterior Face of Incisors—On Anterior Face	
of Incisors—In the midst of Imperfect Enamel—On Approximal Surfaces	
—Complications in Cavity Relations . . . . .	282

## CHAPTER XXII.

## OPERATIVE DENTISTRY.

## RELATIONS OF MOISTURE.

Relation of Moisture to Filling—Napkins—Compressors—Saliva-Pump—	
Rubber Dam—Hot Air—Clamps—Medicinal Means . . . . .	293

## CHAPTER XXIII.

## OPERATIVE DENTISTRY.

## MATERIALS USED IN FILLING TEETH.

Amalgam: Submarine; Usual; Contour; Front Tooth; Instruments for	
Working; Illustrations in Practice; Chemistry of—Gutta-Percha: Vari-	
ous Preparations of; Compatibility with Tooth Bone; Brittleness and	
Porosity in Specimens; Stickiness as a Characteristic; Combinations with	
—Hill's Stopping—Instruments for Working Gutta-Percha—Manner of	
Use—The Oxychlorides: Recipe for; Characteristics of; Different Uses of	
—Zinc Phosphates: Various Preparations of—Tin—Plastic Tin—Tin Foil	
—Gold: Soft; Cohesive; Varieties as to Preparation; Sheets; Mats;	
Pellets; Cylinders; Blocks; Ribbons; Twists . . . . .	303



## CHAPTER XXIV.

## OPERATIVE DENTISTRY.

## FILLING TEETH.

PAGE

Filling with Non-Cohesive Gold: Use of Cylinders; Employment of Mats; Ribbons and Twists in Filling; Foil Carrier; Pluggers used with Non- Cohesive Gold; Studies in use of Non-Cohesive Gold; Matrices; The Loop; Jack's—Cohesive Gold: Requirements for Working; Light and Heavy Foils; Annealing—Pluggers: Atkinson's; Butler's; Smith's; Abbot's—Practitioners' Requirements in way of Instruments—Students' Instrument Case—Plugging Mallets—Illustrations in Practice—Contour Operations—Electric Mallets—Automatic Mallets—Finishing Plugs— Files—Burs—Burnishers—Porte Polishers—Wood and Corundum Points —Operating-Chairs—Office Conveniences . . . . .	320
--	-----

## CHAPTER XXV.

## OPERATIVE DENTISTRY.

## ARTIFICIAL CROWNS.

Repair of Teeth by Substitution—Cap Crowns—Talbot's Operation—Bing's Partial Crown—Simple Pivoting—Instruments used for—Dennet's Plan of Pivoting—Bonwill's—Marshall Webb's—M. H. Cryer's—Flagg's— Crown Grafting—Ferruling—Porcelain Facing—Rambo's Operation— Plastic Facing—Dental Catalogues . . . . .	350
--	-----

## CHAPTER XXVI.

## OPERATIVE DENTISTRY.

## IRREGULARITIES OF THE TEETH—ORTHODONTIA.

Irregular Relation of Teeth to Arch—Temperament and Dyscrasia in Patient —Age as related with Correction—Character of Alveolar Process—Com- plexity signifying lack of Skill—Illustrative Cases in Orthodontia— White's Correcting Apparatus—Coffin's System—Transverse Bars—Rub- ber Loop—Traction by Ligatures—Capping Teeth—Jaw Ramus at vary- ing Ages—Occipito-Mental Sling—Catalan's Inclined Plane—Use of Wedges—Redman's Rubber Cap—Double Jack-Screws—Slit Plates—Far- rar's Positive System . . . . .	366
--	-----

## CHAPTER XXVII.

## OPERATIVE DENTISTRY.

## EXTRACTION OF TEETH.

Indications for Extraction—Illustration of Classes of Teeth—Extraction of Teeth of the First Class—Of Second Class—Of Third Class—Of Fourth Class—Of Fifth Class—Of Sixth Class—Instruments used for Extraction: Forceps; Elevators; Scissors; Screws—Deformed or Anomalous Teeth.	384
---	-----

## CHAPTER XXVIII.

## OPERATIVE DENTISTRY.

## GENERAL REMARKS ON EXTRACTION.

	PAGE
Relation of Teeth with Jaws—Alveolus and Alveoli—Three-Rooted Teeth—Two-Rooted Teeth—Single-Rooted Teeth—Alveolo-Dental Membrane—Fractures of Alveolar Process—Laceration of Gum—Hemorrhage—Luxation of Jaw—Use of Local Anæsthetics . . . . .	407

## CHAPTER XXIX.

## PROSTHETIC DENTISTRY.

Mechanical Dentistry—Preparation of Mouth—Taking Impressions—Materials used for: Wax; Plaster of Paris; Gutta-Percha; Modelling Compound—Trays used—The Model—The Denture—Partial Denture—Articulation—Arrangement of Teeth to Plate—Articulating Instruments—Studies in Grinding and Setting of Teeth—Oral Æsthetics . . . . .	415
---	-----

## CHAPTER XXX.

## PROSTHETIC DENTISTRY.

## THE MATERIALS VULCANITE AND CELLULOID.

Vulcanite: Composition of; Definition of Vulcanizing; Dental Plates as an Example; Apparatus used in Vulcanizing; Kinds of Vulcanite; Effects upon Mucous Face of Mouth—Celluloid: Composition of; Characteristics of; Use of in Dentistry; Instruments and Apparatus used in Celluloid Work—Continuous Gum—Repairing Breaks—Illustrations in Practice . . . . .	431
--	-----

## CHAPTER XXXI.

## PROSTHETIC DENTISTRY.

## OBTURATORS.

Definition of Term—Palatine Defects—Impressions of Breaks—Making Casts—Defects in Hard Palate—Defects in Velum—Artificial Nose—Stearn's, Kingsley's, Suersen's, Booth's, and Baker's Vela—Masks . . . . .	442
---	-----

## CHAPTER XXXII.

## THE GUMS AND THEIR DISEASES.

Anatomy of—Ulitis—Accumulations of Tartar—Parulus—The Mercurial Impression—Scurvy—Syphilis—Dead or Loose Teeth—Crowded Dental Arch—Use of Improper Dentifrices and Brushes—Improperly inserted Artificial Teeth—Malignant Impressions—Anomalous Conditions—The Lead Line—Proliferating Gingivitis of Pregnant Women—Gum inflamed by Vulcanite—Congenital Union of Gums—Stomatitis and Pharyngitis Leucæmica—Osteo-Gingivitis Gangrænosa Neonatorum—Accidental Gingivitis—Gangrene of Gums—Oidium Albicans—Calcified Dentinal Tubules . . . . .	475
--	-----



## CHAPTER XXXIII.

## THE APHTHÆ.

	PAGE
Definition of Term—Variety in Character of Patches—Typical Case—Canker—Thrush—Follicular Inflammation—Cancrum Oris—Gangræna Oris—Oidium Albicans—Parasitic Fungi—Views of Different Writers . . . . .	495

## CHAPTER XXXIV.

## WOUNDS OF THE MOUTH AND ASSOCIATE PARTS.

Distinctions in Wounds—Complications—Indications—Foreign Particles—Hemorrhage—Torsion—Acupressure—Knotted Bandage—Astringents—Shock—Idiosyncrasies—Anodynes—Virus—Healing Wounds—Complicated Wounds—Burns and Scalds—Skin-Grafting—Illustrations from Practice . . . . .	512
--	-----

## CHAPTER XXXV.

## THE TONSIL GLANDS.

Anatomy of Glands—Illustrative Section—Angina Tonsillaris—Treatment of Herpes of Gland—Hypertrophy—Illustration—Treatment of Hypertrophy by London Paste—Tonsillotomes—Specific Disease of Tonsils—Medicinal Agents—Cystic Disease—Strumous Abscess—The Trachea—Tracheotomy—Laryngotomy . . . . .	534
---	-----

## CHAPTER XXXVI.

## THE TONGUE AND ITS DISEASES.

The Tongue as an Index to Disease—Meanings associated with Changes in Form, Color, and Appearance—Localization of Diseased Action—Injuries—Specific Conditions—Scirrhomia—Epithelioma—Tobacco Tongue—White Tongue—Tubercle—Cystoma—Acute Glossitis—Illustrations—Lingual Neuralgia—Effusions—Erysipelas—Bites of Insects—Erectile and Fatty Tumors—Metastatic Disease—Hypertrophy—Atrophy—Papilloma—Venous and Cartilaginous Tumors—Immobile Tongue—Operations practised upon the Tongue—Strangulation—Écraseur—Operations: Regnoli's, Syme's, Nunneley's, Paget's—Tongue-Tie—Swallowing the Tongue—Operations for Tongue-Tie—Speech after removal of Tongue . . . . .	549
--	-----

## CHAPTER XXXVII.

## THE UVULA AND ITS DISEASES.

Surgical Anatomy of Uvula—Enlargement of Organ—Neoplasms—Fatty Growths of—Operation for Excision of—Serosus Effusions in—Fibromata and Cysts of—Restrictions as to Ablation of—Hemorrhage after Ablation of . . . . .	587
---	-----

## CHAPTER XXXVIII.

## DISEASES OF THE FLOOR OF THE MOUTH.

Anatomy of Part—Ranula: Varieties of; Treatment of—Lipoma—Enlargement of Sublingual Gland—Encysted Calculi—Cystomata—Epitheliomata—Venous Aneurism . . . . .	PAGE 590
--	-------------

## CHAPTER XXXIX.

## HYGROMATA OF THE NECK.

Bursæ of Front of Neck—Ranula—Illustration in Complicated Ranula—Fistula in Association with Hygromata—Illustration of Deep-Seated Ranula . . . . .	597
---	-----

## CHAPTER XL.

## DISEASES OF THE PHARYNX.

Anatomy of Pharynx—Illustrations of Acute Pharyngitis—Pharyngitis Sicca—Effusions—Post-Pharyngeal Abscess—Specific Conditions—Tubercles—Wounds—Stricture—Imperforate Pharynx—Neoplasms—Polypi—Uvula—Œsophagus Forceps—Bristle Probangs—Foreign Bodies in Pharynx and Œsophagus—Œsophageal Bougies—Naso-Pharyngoscopy—Electric Illuminator—Trouvè's Polyscope—Margetson's Lamp—Study of Posterior Nares . . . . .	602
--	-----

## CHAPTER XLI.

## PALATINE DEFECTS, AND THEIR TREATMENT BY OPERATION.

Cleft Palate—Fissure of Hard Parts—Pressure in the Treatment of Cleft Palate—Uranoplasty—Staphyloraphy—Preparation of Patients for Operation—Surgical Anatomy of Soft Palate—Muscles of Soft Palate—Stages of Staphyloraphy—Roux's Operation—Warren's Operation—Fergusson's Operation—Author's Operation—Illustration of Operation—Curved Needles—Holes in the Palate—Screw Levers . . . . .	618
--	-----

## CHAPTER XLII.

## THE NOSE AND ITS DISEASES.

Anatomy of Internal Nose—Anatomical Illustrations—Simple Nasal Catarrh—Hemorrhage—Ulcers—Polypi—Strumous Abscess—Ozæna—Neoplasm—Belloc's Canula—Kolbe's Powder Insufflator—Areling-Hodge Polyp-trite—Gooch's Canula—Torsion Forceps—Polypus Forceps—Frog-Face—Nasal Speculum—Anterior Rhinoscopy—Hypertrophy of Nasal Mucous Membrane—Deviation of Septum—Syphilitic Coryza—Gonorrhœa of Nares—Tobold's Illuminating Apparatus—Chancre of Nose—Imperforate Nostril—Foreign Bodies in Associate Sinuses—Tumors of External Nose—Fractures—Fracture Splints—Loss of Substance—Studies in Rhinoplasty—Illustrations in Nose Surgery—Adams's Septum Forceps—Screw Plates for holding Forceps straight—Nasal Douche—Naso-Pharyngeal Syringe .	631
--	-----



## CHAPTER XLIII.

## DISEASES OF THE FACE.

	PAGE
Immediate Diseases—Mediate Diseases—Callositas—Cornu Cutaneum— Lichen Pilaris—Vitiligo—Nævus Pigmentosus—Lentigo—Chloasma— Nævus Pilosus—Scleroderma—Dermatolysis—Unilateral Atrophy—Ele- phantiasis—Morphœa—Frambœsia—Verruca—Ichthyosis—Seborrhœa— Miliun—Molluscum Sebaceum—Sebaceous Tumors—Hyperidrosis— Chromidrosis—Anidrosis—Sudamina—Keloid—Molluscum Fibrosum— Xanthoma—Rhino-Scleroma—Nævus Vasculosus—Arterial Tumor—Ve- nous Tumor—Illustrations of Nævi—Capillary Nævi—Maculæ—Port- Wine Stain—Strangulations of Nævi—Compression of Nævi—Injections in Nævi—Seton in Nævi—Electrolysis in Nævi—Scrofuloderma—Syphilo- derma—Parasites—Tinea Sycosis—Tinea Circinata—Horn growing from Nose and Face—Laminæ of Horn . . . . .	667

## CHAPTER XLIV.

## LUPUS.

Lupus Erythematosus—Lupus Vulgaris—Illustrations . . . . .	698
--	-----

## CHAPTER XLV.

## EPITHELIOMA.

Definition of Term—Benign Epithelioma—Cancerous Epithelioma—Illus- trations of Disease—Treatment of by Medicinal Means—Treatment of by Plastic Operations—Illustrations in Plastic Surgery—Illustration in Microscopy . . . . .	697
--	-----

## CHAPTER XLVI.

## OPERATIONS UPON THE LIPS AND CHEEK.

Hare-Lip—Definition of—Time of Life suited to Operation for—Condition of Patient—Mode of Operating—V-paring—Atlee's Suture—McLeon But- ton—Malgaigne's Operation—Levis's—Studies in Simple Hare-Lip— Studies in Complicated Hare-Lip—Illustrations—Figure-of-8 Suture . . . . .	711
--	-----

## CHAPTER XLVII.

## OPERATIONS UPON THE LIPS AND CHEEK.

Study of Plate VI.—Dieffenbach's Operation—Mouth-Stretching—Cheilo- plasty—Study of Plate VII.—Restoration of Lip: Chopart's Operation, Horn's, Dupuytren's, Serres's, Roux's, Morgan's, Blasius's, Dieffenbach's, Liston's, Mütter's, Author's, Leidillot's—Treatment of Burns . . . . .	726
--	-----

## CHAPTER XLVIII.

## VASCULAR SYSTEM OF EXTERNAL AND DEEP FACIAL REGIONS.

Arteries of the Face—Arrestation of Hemorrhage—Ligation of Facial Artery—Surgical Anatomy of Face—Ligation of Temporal Artery; of
--

	PAGE
Occipital Artery; of Lingual Artery: Lines of Incision for—Surgical Anatomy of Lingual Artery—Ligation of External Carotid Artery; of Primitive Carotid Artery—Surgical Triangles of the Neck . . .	741

## CHAPTER XLIX.

### THE ANTRUM OF HIGHMORE AND ITS DISEASES.

Character of Troubles associated with—Indolent Tumor of—Distention with Softening of Walls—Periodontal Abscess of—Dropsy of—Furuncular Epidemics affecting—Scorbutus in Association with—The Mercurial Diathesis—Syphilis in Association with . . . . .	747
--	-----

## CHAPTER L.

### SALIVARY FISTULÆ.

Definition of—Causes of—Illustration of—Common Manner of Treating— Horner's Operation for—Agnew's Operation for—The Author's Operation for—Fistule of the Parotid Gland Proper—Foreign Bodies in Salivary Ducts—Dribbling . . . . .	760
--	-----

## CHAPTER LI.

### CARIES OF THE MAXILLÆ.

Expressions of the Condition—Virchow's Views concerning—Treatment of Acute Stage—The Use of the Surgical Engine in—The Employment of Sulphuric Acid—Miller's Views of Treatment—Pollock's Experiments with Sulphuric Acid—Illustrative Cases . . . . .	764
---	-----

## CHAPTER LII.

### NECROSIS.

Definition of Term—History of Disease—Dental Necrosis—Alveolar Necrosis —From lack of Room for Eruption of Wisdom-Tooth—Syphilitic Necrosis —Mercurial Necrosis—Necrosis from Injuries—Exanthematous Necrosis —Phosphorus-Necrosis—Illustrations of Sequestra . . . . .	774
--	-----

## CHAPTER LIII.

### DISLOCATION OF THE INFERIOR MAXILLA.

Forms of Displacement—Diagnosis of—Exciting Causes of—Predisposing Causes of—Conditions of—Parts in Luxation—Subluxations—Associa- tions with Fracture—Congenital Luxation—Treatment of Luxation— Use of Anæsthetics in . . . . .	797
--	-----

## CHAPTER LIV.

### FRACTURES OF THE MAXILLARY BONES.

Division into Classes—Weak Points of Jaw—Causes of Fracture—Symp- toms of—Illustrative Cases—Treatment of—Barton's Bandage—Paste- board Splint—Gibson's Bandage—Author's Bandage—Bean's Interdental Splint—Sudduth's Mento-Dental Splint—Non-Union in Fractures—Gun- shot Injuries—Interdental Splints . . . . .	802
--	-----



## CHAPTER LV.

## EXSECTIONS OF THE MAXILLARY BONES.

History of Operation—Ligation of Carotid Artery—Manner of Exposure— Instruments used in Excision of—Illustrative Cases—Surgical Engine and Appliances . . . . .	PAGE 816
---	-------------

## CHAPTER LVI.

## ANCHYLOSIS OF THE JAW.

Definition of Term—Arthritic Inflammation—Complicated Arthritis—Acute Synovitis—Rheumatoid Arthritis—Treatment of Arthritic Trismus—Tet- anus: Symptoms of; Treatment of—Trismus Nascentium—Trismus Den- tium—Excision of Operculum—Instrument used for—Illustrative Cases— Trismus Traumaticus . . . . .	830
---	-----

## CHAPTER LVII.

## NEURALGIA.

Definition of Term—Not a Disease—Temperament a Predisposition—Ob- scurity of Causes—Predisposing Causes—Local Causes—Reactions of Vas- cular Perversion on Nervous System—Derangements in Respiration— Depressants in the Vital Economy—Sedative Poisons—Irrrespirable Gases —Anstie's View of Nerve Pain—Illustrations in Neuralgia—Uterus and Teeth—Treatment of—Recipes used in . . . . .	855
---	-----

## CHAPTER LVIII.

## NERVE LESIONS PROPER AND THEIR TREATMENT BY OPERATION.

Inferior Maxillary Nerve exposed; Garretson's Operation for Exsection of —Surgical Engine—Exsection of Nasal Branch of Superior Maxillary Nerve—Carnochan's Operation for Exposure of Second Branch of Fifth Nerve—Langenbeck's Operation for Exsection of Maxillary Nerve—Pan- coast's Operation for Exposure of Second and Third Branches of Trifacial —Garretson's Operation for Exposure of Second and Third Branches of Trifacial—Garretson's Operation for Exposure of Foramen Rotundum . . . . .	871
---	-----

## CHAPTER LIX.

## NERVE LESIONS PROPER AND THEIR TREATMENT BY STRETCHING.

Meaning of Operation—Exposure of Special Nerves—Of Infraorbital—Of Inferior Maxillary—Of Auricularis Magnus—Of Occipital—Of Lingual— Of Supra-orbital . . . . .	880
---	-----

## CHAPTER LX.

## CLASSIFICATION OF TUMORS.

Definition of Term—Division of Tumors into Two Classes—Local and Sys- temic Tumors—Homologous and Neoplastic Growths—Clinical Illustra- tion in Diagnosis—Examples of Cases—Relationship of Tumors—Simple Inflammatory Tumors—Hypertrophic Tumors—Tumors resulting from Interference with Function—Histological Distinctions—Examples of Forms—Synonymes . . . . .	884
---	-----



## CHAPTER LXI.

## THE EPULIDES.

	PAGE
Definition of Term—Pulp-Fungoid Tumor—Odonto-Periosteal Growth— —Ulitic Tumor—Epulo-Erectile Growth—Treatment of Erectile Epulides —Epulides not self-explaining—Illustrations of Epulic Growths—Treat- ment by Use of London and Vienna Pastes; by Hypodermic Medicaments; by the Seton; by Heated Needles; Electrolysis; Piecemeal Removal; of the Serres-fines; of Astringents; of Bone-Section . . . . .	892

## CHAPTER LXII.

## EXOSTOSES AND SUBACUTE INFLAMMATORY TUMORS.

Derivation of the Term Ostosis—Definition of Term—Exostosis and Enos- tosis, Varieties of—Ossific Diathesis—Non-Specific Exostosis—Alveolar Exostosis—Exostosis Dentium—Diagnosis of Dental Exostosis—Warty Teeth—Odontomata—Venereal, Scorbutic, and Tubercular Exostoses— Scrofulous and Scorbutic Tumors—Simple Inflammatory Tumefaction of Maxilla—Hyperostosis: Illustrative Cases of—Osseous Tumor of Right Superior Maxilla: Microscopical Analysis of . . . . .	904
---	-----

## CHAPTER LXIII.

## SELF-EXPLAINING CYSTIC TUMORS.

Simple Cysts: Diagnostic Signs of; Treatment of—Odontocoele and the Oral Cystomata—Osteo-Enchondromatous Cysts—Situation of Odontomata— Illustrations of—Unique Case of—Analysis of Teeth—Enamel—Dentine —Cementum—Dental Pulp—Periodontal Membrane—Recapitulation of M. Forget's Case—Data for Diagnosis of Dentigerous Tumors—Cystiform Antra—Giraldes on Multiple Cysts of Antrum—Secondary Cyst of An- trum—Meningocoele—Hydatid Cysts . . . . .	915
--	-----

## CHAPTER LXIV.

## NON-EXPLAINABLE TUMORS.

Neoplasms—Kinds of Tumors—Appreciable Systemic Tumors—Apprecia- tion of Cancer through Exclusion—Diagnosis from Stand-point of Treat- ment—Placing of Tumors Clinically—Histological Definition of Tumors —Classification—Fibrous Tumors—Microscopic Appearance of Fibroma— The Myomata of Virchow—Sarcoma—The Myeloid of Paget—The Fibro- plastic of Lebert—Epitome of the Fibromata—Cysto-Sarcoma—Cysto-Sar- coma Phyllodes of Müller—Cartilaginous, or Enchondromatous, Tumors —Osteo-fibrous Tumors of the Sinus Maxillare—Softening of Tumors— Suppuration of Tumors—Histoid Mixed Tumors—Illustration of Sarcoma —Scirrhus: Illustration of; Microscopic View of Cells of—Encephaloma: Malignancy of; Illustrations of; Microscopic Views of; Microscopic Ap- pearance of . . . . .	937
--	-----



## CHAPTER LXV.

## ANÆSTHESIA.

	PAGE
Definition of Term—Agents Used. SULPHURIC ETHER.—Dr. Jackson's Formula for—Essentials for the Proper Exhibition of Ether—Author's Inhaling Instrument—Relation of with the Action of Alcoholic Beverages—Dead-Drunkenness—French Academicians' Experiments with Ether—Action of the Agent on Nerve Centres—Good and Bad Ether—Manner of Administering in Hospital of Oral Surgery—Concerning Dose Required—Judgment as to Effects—Sick Stomach—Prolonging the Impression—Relation of Atmosphere with Ether Exhibition—Idiosyncrasies. CHLOROFORM.—Formula for Preparing—Appearance, Taste, and Smell of—Test of Purity—Weight—Chlorine and Hydrochloric Acid Formed in the Decomposition of—Test for Hydrochloric Acid—Test for Sulphuric Acid—Degradation by Admixture with Alcohol—Test for Action on the Heart—Use of Agent in Oral Surgery—Average Quantity Required to Produce Anæsthesia—Relation of Agent with Temperature—Danger in Use of—Stimulants Conjoined with—Position of Patient—Ether in Combination with Chloroform—Air and Chloroform—Relation of Temperament with Induction of Insensibility—Treacherousness of Agent—Relation of Agent with Age—With Strength and Debility—With Hysteria—With the Menstrual Period—With Pregnancy—With Disease of the Lungs—With Disease of the Circulatory Apparatus—With Surgical Operations—With Cerebral Diseases—With Insanity—Treatment of Chloroform Narcosis. NITROUS OXIDE GAS.—Discovery of—Introduction of as a Pain Obtunding Agent—Sir Humphry Davy—Dr. Horace Wells—Preparation of the Gas—Apparatus Used for—Nitrate of Ammonia—Test of Purity—Heat Required for Making Gas—Washing—Collecting—Dispensing. LIQUEFIED NITROUS OXIDE.—Accidents in Use of Gas—Action of Nitrous Oxide Gas. ETHYL BROMIDE.—A New Anæsthetic—Color, Odor, and Taste of Agent—Miscibility with Ether and Water—Action of the Agent—Experiments of Dr. Laurence Turnbull—Time Required for the Production of Anæsthesia—Sick Stomach—Hysterical Excitement—Prostration—Wolff's Formula for Making Ethyl Bromide. BONWILL'S METHOD OF RAPID BREATHING.—Usefulness of in Quickly Performed Operations—Relation of with other Anæsthetic Agents—Danger Associated with Use of Means. MEDICINES USED BY HYPODERMATIC INJECTION.—Mixed Narcosis—Morphia and Chloroformization—Semi-consciousness and Anæsthesia—Sulphate of Morphia and Sulphate of Atropia—Chloroform Used Subcutaneously—Ether Used Hypodermatically . . . . .	956

## CHAPTER LXVI.

## INFLAMMATION.

Definition of—Perversion of Circulation—Analysis of the Condition—Irritation always the Cause of—Excess of Blood in Parts—Illustration by Rabbit's Ear—By Wings of Bat—By Enlarged Capillaries—Phenomenal Meaning of Inflammation—Simple Vascular Excitement—Congestion—Stagnation—Suppuration—Taking Cold—Local Treatment of Inflamma-
---

	PAGE
tion—Derivation — Cupping—Venesection — Leeching—Blistering—General Treatment of—Diaphoretics—Cathartics—Diuretics—Narcotics—Scrofulous Inflammation — Chronic Inflammation—Redness — Heat—Pain—Swelling—Functional Disorder—Repair—Lymph—Cell Segmentation	980

## CHAPTER LXVII.

### ON DIAGNOSIS.

Definition of Term—Ease the Normal Condition—Dis expressive, of the Reverse of Ease—Disease a Generic Term—Manner of Pursuing Diagnoses—The Process of <i>Exclusion</i> —Illustrative Suggestion	999
--	-----



# LIST OF ILLUSTRATIONS.

FIG.	PAGE	FIG.	PAGE
1. View of skull . . . . .	27	41. Dental pulp magnified . . . . .	84
2. Superior maxillary bone . . . . .	29	42. Nerves of dental pulp . . . . .	84
3. Superior maxillary bone . . . . .	29	43. Tubuli of dentine and enamel . . . . .	84
4. Inferior maxillary bone . . . . .	34	44. Vertical section of canine tooth . . . . .	85
5. Inferior maxillary bone . . . . .	36	45. Enamel columns magnified . . . . .	85
6. Section of face . . . . .	37	46. Section of enamel magnified . . . . .	85
7. Palate bone . . . . .	37	47. Interglobular spaces . . . . .	86
8. Palate bone . . . . .	37	48. Vertical section of molar tooth . . . . .	86
9. Vomer . . . . .	39	49. Transverse section of molar tooth . . . . .	86
10. Articular relations of vomer . . . . .	39	50. Deciduous teeth . . . . .	87
11. Turbinate bones . . . . .	40	51. Teeth of upper jaw . . . . .	88
12. Ethmoid bone . . . . .	42	52. Teeth of lower jaw . . . . .	88
13. Sphenoid bone . . . . .	43	53. Lateral view of teeth . . . . .	91
14. Sphenoid bone . . . . .	43	54. Illustrations in dentition . . . . .	95
15. Nasal bone . . . . .	46	55. Illustrations in dentition . . . . .	98
16. Malar bone . . . . .	47	56. Illustrations in gum lancing . . . . .	103
17. Lachrymal bone . . . . .	48	57. Illustrations in gum lancing . . . . .	103
18. Hyoid bone . . . . .	48	58. Illustrations in gum lancing . . . . .	103
19. Section of cranium . . . . .	49	59. Illustrations in gum lancing . . . . .	103
20. View of right half of base of skull . . . . .	49	60. Illustrations in gum lancing . . . . .	108
21. Muscles of the face . . . . .	51	61. Fused teeth . . . . .	131
22. Arteries of the face . . . . .	52	62. Warty teeth . . . . .	131
23. The common carotid artery . . . . .	53	63. Odontoma . . . . .	131
24. Internal maxillary artery . . . . .	54	64. Microscopic diagram . . . . .	132
25. Veins of face . . . . .	56	65. Intramaxillary bone . . . . .	132
26. Nerves of face . . . . .	57	66. Tumor of lower jaw . . . . .	132
27. Sectional view of the nose, mouth, and pharynx . . . . .	59	67. Osseous cyst in jaw . . . . .	133
28. Side view of muscles of tongue . . . . .	60	68. Intramaxillary osseous tumor . . . . .	133
29. Upper surface of the tongue . . . . .	62	69. Microscopic diagram . . . . .	133
30. Papillæ of the tongue . . . . .	63	70. Dental arch . . . . .	158
31. Papillæ of the tongue . . . . .	63	71. Dental arch . . . . .	159
32. Vertical section of temporo-maxil- lary articulation . . . . .	67	72. Calcified tooth . . . . .	178
33. Vertical section of temporo-maxil- lary articulation . . . . .	67	73. Filled tooth . . . . .	183
34. Fifth pair of nerves . . . . .	69	74. Illustrations in filing . . . . .	185
35. Division in ganglia of fifth nerve . . . . .	70	75. Illustrations in filing . . . . .	185
36. Superior maxillary nerve . . . . .	74	76. Illustrations in filing . . . . .	186
37. Inferior maxillary nerve . . . . .	75	77. Illustrations in filing . . . . .	186
38. Ophthalmic ganglion . . . . .	78	78. Separating disks . . . . .	186
39. Spheno-palatine ganglion . . . . .	78	79. Illustrations in filing . . . . .	186
40. Vertical section of cuspid tooth . . . . .	83	80. Bur instruments . . . . .	201
		81. Section of tooth . . . . .	213
		82. Section of tooth . . . . .	213
		83. Section of tooth . . . . .	214



FIG.	PAGE	FIG.	PAGE
84. Nodular dentine . . . . .	215	132. Cavities on buccal face of molars .	283
85. Nodular dentine . . . . .	215	133. Cavities on buccal face of molars .	284
86. Ringed tooth . . . . .	222	134. Carious denture . . . . .	284
87. Metal cap . . . . .	223	135. Carious incisors . . . . .	285
88. Sac of dental abscess . . . . .	225	136. Irregular incisors . . . . .	286
89. Opening of dental abscess . . . . .	227	137. Jarvis's separators . . . . .	287
90. Imprisoned tooth . . . . .	234	138. Approximal cavities . . . . .	288
91. Imprisoned tooth . . . . .	235	139. Inferior anterior teeth . . . . .	288
92. Imprisoned tooth . . . . .	236	140. Excavators . . . . .	289
93. Imprisoned tooth . . . . .	236	141. Flagg's tongue-holder . . . . .	294
94. Imprisoned tooth . . . . .	236	142. Morrison's compressor . . . . .	294
95. Imprisoned tooth . . . . .	237	143. Saliva-pump . . . . .	295
96. Nerve extractors . . . . .	240	144. McQuillen's extension-finger .	295
97. Nerve extractors . . . . .	240	145. Rich's duct-compressor . . . . .	296
98. Nerve-canal pluggers . . . . .	243	146. Taft's thimble . . . . .	296
99. Pulp caps . . . . .	246	147. Depressed rubber dam . . . . .	297
100. Fixation of replanted tooth . . . . .	252	148. Rubber dam mirror . . . . .	297
101. Instruments for removing tartar from teeth . . . . .	265	149. Rubber dam punchings . . . . .	297
102. Denudation of teeth . . . . .	266	150. Rubber dam applier . . . . .	298
103. Denudation of teeth . . . . .	266	151. Rubber dam clamps . . . . .	298
104. Superior dental arch . . . . .	268	152. Rubber dam clamps . . . . .	298
105. Superior dental arch . . . . .	269	153. Rubber dam clamps . . . . .	299
106. Hoe excavators and modifications .	269	154. Rubber dam clamps . . . . .	299
107. Hatchet excavators and modifica- tions . . . . .	270	155. Rubber dam clamps . . . . .	299
108. Rose drills and spear drills . . . . .	270	156. Rubber dam forceps . . . . .	299
109. Merry's drill . . . . .	271	157. Rubber dam weight . . . . .	300
110. Bur thimble . . . . .	271	158. Rubber dam holder . . . . .	300
111. The White dental engine . . . . .	272	159. Gum-forcing instruments . . . . .	300
112. The Bonwill instrument . . . . .	272	160. Rubber dam applied . . . . .	301
113. Hand-piece of dental engine . . . . .	273	161. Hot-air syringe . . . . .	302
114. Obtuse attachment of dental en- gine . . . . .	273	162. Amalgam cups . . . . .	309
115. Some forms of chisels used in den- tistry . . . . .	275	163. File flat . . . . .	309
116. Jack's double-end enamel chisels .	275	164. Amalgam pluggers . . . . .	309
117. Gauges and paraboloid chisels . . . . .	276	165. Smith's plastic fillers . . . . .	315
118. Separating files . . . . .	276	166. Cylinders . . . . .	219
119. Plug-finishing files . . . . .	277	167. Mats and blocks of gold . . . . .	320
120. Files for separating molar teeth .	278	168. Introduction of cylinders . . . . .	320
121. Forbes's file carrier . . . . .	278	169. Introduction of mats . . . . .	320
122. Miller's file carrier . . . . .	279	170. The wedge principle . . . . .	320
123. Knife-edge saws . . . . .	279	171. Foil-carrier . . . . .	321
124. Side view of corundum disks . . . . .	279	172. Redman's pluggers . . . . .	322
125. Disks of corundum . . . . .	279	173. Loop matrices . . . . .	324
126. Herrick's fountain drip-point . . . . .	280	174. Jack's matrix . . . . .	325
127. Water-syringe . . . . .	280	175. Jack's matrix . . . . .	325
128. Cavities on grinding face of molars	282	176. Jack's matrix . . . . .	325
129. Cavities on posterior face of inci- sors . . . . .	283	177. Jack's matrix . . . . .	325
130. Cavities at neck (anterior face) of incisors . . . . .	283	178. Jack's matrix . . . . .	325
131. Cavities among imperfect enamel .	283	179. The Atkinson pluggers . . . . .	328
		180. Burnishers . . . . .	329
		181. Butler's pluggers . . . . .	329
		182. Smith's pluggers . . . . .	330
		183. Abbott's pluggers . . . . .	331
		184. Plugging mallets . . . . .	333
		185. Tooth cavity . . . . .	335



FIG.	PAGE	FIG.	PAGE
186. Teeth prepared for contouring . . . . .	337	240. Irregular teeth . . . . .	374
187. Teeth contoured and prepared . . . . .	337	241. Correcting apparatus . . . . .	374
188. Teeth contoured . . . . .	338	242. Corrected denture . . . . .	374
189. Dental illustrations . . . . .	338	243. Metal tooth-cap . . . . .	375
190. Dental illustrations . . . . .	338	244. Protrusion of lower jaw . . . . .	375
191. Illustrations in contour work . . . . .	338	245. Maxillary angles . . . . .	375
192. Illustrations in contour work . . . . .	338	246. Occipito-mental sling . . . . .	376
193. Illustrations in contour work . . . . .	338	247. Corrected denture . . . . .	377
194. Illustrations in contour work . . . . .	339	248. Correcting plate . . . . .	377
195. Illustrations in contour work . . . . .	339	249. Wedged denture . . . . .	378
196. Dental illustration . . . . .	339	250. Double screw . . . . .	378
197. Dental illustration . . . . .	339	251. Protruding jaw . . . . .	379
198. Contour operation . . . . .	339	252. Jack-screw plate . . . . .	379
199. Hand mallet . . . . .	340	253. Correcting plate . . . . .	379
200. Electro-magnetic mallet . . . . .	340	254. Farrar's correcting apparatus . . . . .	380
201. Buckingham mallet . . . . .	341	255. Farrar's correcting apparatus . . . . .	380
202. Finishing files . . . . .	342	256. Farrar's correcting apparatus . . . . .	381
203. Bur and wheel files . . . . .	343	257. Farrar's correcting apparatus . . . . .	381
204. Set of burnishers . . . . .	343	258. Farrar's correcting apparatus . . . . .	381
205. Porte polishers . . . . .	344	259. Farrar's correcting apparatus . . . . .	382
206. Corundum points . . . . .	345	260. Farrar's correcting apparatus . . . . .	382
207. Finishing stones . . . . .	345	261. Farrar's correcting apparatus . . . . .	382
208. Polishing wheel . . . . .	346	262. Farrar's correcting apparatus . . . . .	383
209. Wood polishing-points . . . . .	346	263. Farrar's correcting apparatus . . . . .	383
210. White's head-rest . . . . .	348	264. Permanent teeth of upper jaw . . . . .	385
211. Artificial tooth crowns . . . . .	351	265. Permanent teeth of lower jaw . . . . .	385
212. The Talbot tooth crown . . . . .	351	266. Upper incisor forceps . . . . .	386
213. The Bing gold crown . . . . .	351	267. Upper lateral incisor forceps . . . . .	386
214. Pivot tooth . . . . .	352	268. Lower incisor, hawk-bill forceps . . . . .	386
215. Excising forceps . . . . .	353	269. Lower incisor and bicuspid forceps . . . . .	387
216. Excising saw . . . . .	353	270. Hawk-bill forceps . . . . .	387
217. Pivot files . . . . .	354	271. Upper and lower root forceps . . . . .	388
218. Hand-lathe . . . . .	355	272. Lower root forceps . . . . .	388
219. Foot-lathe . . . . .	356	273. Upper and lower bicuspid forceps . . . . .	388
220. Pivot teeth . . . . .	359	274. Universal lower forceps . . . . .	388
221. Pivot teeth . . . . .	359	275. Half-curve lower forceps . . . . .	389
222. Pivot teeth . . . . .	359	276. Upper bicuspid and canine forceps . . . . .	389
223. Pivot teeth . . . . .	360	277. Upper bicuspid and incisor forceps . . . . .	390
224. Pivot teeth . . . . .	360	278. Lower bicuspid and canine forceps . . . . .	390
225. Forked screw-driver . . . . .	360	279. Lower bicuspid and canine forceps . . . . .	391
226. Amalgam crowns . . . . .	360	280. Upper bicuspid and canine forceps . . . . .	391
227. Pivot teeth . . . . .	361	281. Upper molar forceps . . . . .	391
228. Pivot teeth . . . . .	362	282. Upper molar forceps . . . . .	392
229. Porcelain facing . . . . .	363	283. Upper molar forceps . . . . .	392
230. Porcelain facing . . . . .	363	284. Upper molar forceps . . . . .	393
231. Porcelain facing . . . . .	364	285. Cow-horn forceps . . . . .	393
232. Irregular denture . . . . .	368	286. Cow-horn forceps . . . . .	394
233. Irregular denture . . . . .	368	287. Lower molar forceps . . . . .	394
234. White's correcting plate . . . . .	370	288. Lower cow-horn forceps . . . . .	395
235. Westcott's appliance . . . . .	370	289. Lower cow-horn forceps . . . . .	395
236. Irregular teeth . . . . .	372	290. Lower cow-horn forceps . . . . .	395
237. Correcting plates . . . . .	372	291. Wolverton's lower molar forceps . . . . .	396
238. Irregular tooth . . . . .	373	292. Hutchinson's lower molar for- ceps . . . . .	396
239. Irregular teeth . . . . .	373		



FIG.	PAGE	FIG.	PAGE
293. Forceps for wisdom-teeth . . . . .	397	346. Studies in obturators . . . . .	451
294. Physick's forceps . . . . .	397	347. Studies in obturators . . . . .	452
295. Elevators used in extracting teeth . . . . .	398	348. Studies in obturators . . . . .	452
296. Lower dentes sapientiæ forceps . . . . .	399	349. Studies in obturators . . . . .	454
297. Jones's forceps . . . . .	399	350. Studies in obturators . . . . .	454
298. Perrine's forceps . . . . .	399	351. Face without nose . . . . .	456
299. Lower molar forceps . . . . .	400	352. Internal view of superior arch . . . . .	457
300. Upper molar forceps . . . . .	400	353. Nose with attachments . . . . .	459
301. Relation of fractured roots to alveo- lar line . . . . .	401	354. Attachment of nose . . . . .	459
302. Stellwagen's incising forceps . . . . .	401	355. Artificial nose . . . . .	460
303. Stellwagen's incising forceps . . . . .	401	356. Face without nose or lip . . . . .	461
304. Dental screw . . . . .	402	357. Lip operation . . . . .	461
305. Dubs's screw forceps . . . . .	403	358. A surgico-mechanical correction . . . . .	461
306. Hullihen's screw forceps . . . . .	403	359. Artificial nose . . . . .	462
307. Straight tooth forceps . . . . .	404	360. Artificial palate . . . . .	463
308. Half-curve tooth forceps . . . . .	404	361. Artificial palate . . . . .	463
309. Full-curve tooth forceps . . . . .	404	362. Palatine defect . . . . .	464
310. Bayonet forceps . . . . .	404	363. Obturator . . . . .	465
311. Long beak forceps . . . . .	404	364. Obturator and velum . . . . .	465
312. Molar root forceps . . . . .	405	365. Obturator and velum . . . . .	466
313. Anomalous teeth . . . . .	405	366. Kingsley's velum . . . . .	466
314. Anomalous teeth . . . . .	405	367. Kingsley's velum . . . . .	466
315. Anomalous teeth . . . . .	405	368. Kingsley's velum . . . . .	467
316. Spray apparatus . . . . .	412	369. Kingsley's velum . . . . .	467
317. Spray apparatus . . . . .	413	370. Baker's velum . . . . .	469
318. Impression trays . . . . .	416	371. Baker's velum . . . . .	470
319. Impression trays . . . . .	416	372. Transverse section of obturator . . . . .	470
320. Impression trays . . . . .	417	373. Transverse section of obturator . . . . .	471
321. Teeth articulation . . . . .	425	374. View of gums inflamed by vulcanite plate . . . . .	484
322. Articulator . . . . .	427	375. General hypertrophy . . . . .	486
323. Arches in articular relation . . . . .	427	376. Chronic ulitis with recession . . . . .	486
324. Study in denture . . . . .	428	377. Knotted bandage . . . . .	513
325. Study in denture . . . . .	428	378. Cicatrix of neck . . . . .	532
326. Study in denture . . . . .	428	379. Tonsil glands . . . . .	535
327. Study in denture . . . . .	428	380. Hypertrophied tonsil . . . . .	538
328. Study in denture . . . . .	429	381. Tonsil laid open . . . . .	539
329. Study in denture . . . . .	429	382. Physick's tonsillotome . . . . .	541
330. Study in denture . . . . .	429	383. Kolbe's tonsillotome . . . . .	541
331. Study in denture . . . . .	430	384. View of the air-tubes . . . . .	545
332. Teeth used with vulcanite . . . . .	431	385. Microscopic view of cancer-cells . . . . .	559
333. Moulding flask . . . . .	432	386. Cystic tumor of tongue . . . . .	562
334. Moulding flask . . . . .	432	387. Illustration in strangulation . . . . .	579
335. Vulcanizer . . . . .	434	388. Strangulating ligature . . . . .	579
336. Boiler and lamp of vulcanizer . . . . .	434	389. Chassaignac's écraseur . . . . .	580
337. New mode heater . . . . .	436	390. Ligature extemporanée . . . . .	580
338. Sectional view of new mode heater . . . . .	437	391. Ablation of tongue by écraseur . . . . .	581
339. Case ready for gum . . . . .	439	392. Ablation of tongue by écraseur . . . . .	581
340. Celluloid blank rim . . . . .	440	393. Regnoli's operation for removal of tongue . . . . .	582
341. Metal plate with celluloid gum . . . . .	441	394. Syme's operation for removal of tongue . . . . .	582
342. Studies in obturators . . . . .	448	395. Nunneley's operation for removal of tongue . . . . .	583
343. Studies in obturators . . . . .	448		
344. Studies in obturators . . . . .	450		
345. Studies in obturators . . . . .	450		



FIG.	PAGE	FIG.	PAGE
396. Paget's operation for removal of tongue . . . . .	583	444. Dermatology . . . . .	670
397. Division of lingual frænum . . . . .	586	445. Sebaceous tumor . . . . .	676
398. Amputation of uvula . . . . .	588	446. Keloid of neck . . . . .	678
399. Uvula scissors . . . . .	588	447. Arterial nævus . . . . .	682
400. Superficial ranula . . . . .	594	448. Venous nævus . . . . .	682
401. Hygroma of the neck . . . . .	597	449. Venous varix . . . . .	682
402. Deep-seated ranula . . . . .	601	450. Nævus of lip . . . . .	683
403. Side view of pharynx and its muscles . . . . .	602	451. Transfixing ligatures . . . . .	685
404. Posterior view of muscles of pharynx . . . . .	602	452. Transfixing ligatures . . . . .	685
405. Bond's œsophagus forceps . . . . .	608	453. Illustration of parasitic growth, oïdium albicans . . . . .	690
406. Bristle probang . . . . .	609	454. Horns growing on nose and face . . . . .	692
407. Bristle probang . . . . .	609	455. Section of horn . . . . .	692
408. Œsophagus bougie . . . . .	610	456. Lupus erythematosus . . . . .	693
409. Electric illuminator . . . . .	611	457. Lupus vulgaris . . . . .	694
410. Rhinoscopic view of posterior nares . . . . .	612	458. Epithelioma of lip . . . . .	700
411. Uranoplasty . . . . .	617	459. Epithelioma of lip . . . . .	700
412. Staphyloraphy . . . . .	625	460. Epithelioma of jaw . . . . .	701
413. Curved needles . . . . .	625	461. Epithelioma of lip and chin . . . . .	702
414. Palate instruments . . . . .	628	462. Epithelioma of eyelid . . . . .	705
415. Kolbe's screw lever . . . . .	629	463. Flap operations . . . . .	706
416. Goodwillie's screw lever . . . . .	629	464. Flap operation . . . . .	707
417. View of nasal septum . . . . .	631	465. Flap operation . . . . .	707
418. Lateral view of nose . . . . .	632	466. Microscopic view of epithelial cancer . . . . .	707
419. Belloc's canula . . . . .	635	467. Hare-lip . . . . .	713
420. Kolbe's powder insufflator . . . . .	640	468. Hainsby's compressor . . . . .	715
421. The Areling-Hodge polyptrite . . . . .	640	469. Study in hare-lip . . . . .	718
422. Gooch's canula . . . . .	640	470. Study in hare-lip . . . . .	718
423. Torsion forceps . . . . .	641	471. Study in hare-lip . . . . .	719
424. Polypus forceps . . . . .	641	472. Study in hare-lip . . . . .	723
425. Frog-face . . . . .	642	473. Study in hare-lip . . . . .	723
426. Polypus related with turbinated bone . . . . .	642	474. Study in hare-lip . . . . .	723
427. Removal of polypi with forceps and the canula and loop . . . . .	642	475. Study in hare-lip . . . . .	724
428. Frankel's nasal speculum . . . . .	655	476. Study in hare-lip . . . . .	724
429. Tobold's illuminating apparatus . . . . .	655	477. Study in hare-lip . . . . .	724
430. Study in rhinoplasty . . . . .	660	478. Figure-of-8 tie . . . . .	725
431. Study in rhinoplasty . . . . .	660	479. Mouth-stretcher . . . . .	727
432. Study in rhinoplasty . . . . .	660	480. Study in lip operation . . . . .	733
433. Study in rhinoplasty . . . . .	660	481. Study in lip operation . . . . .	733
434. Study in rhinoplasty . . . . .	661	482. Study in lip operation . . . . .	733
435. Study in rhinoplasty . . . . .	661	483. Study in lip operation . . . . .	733
436. Belloc's canula applied . . . . .	662	484. Study in lip operation . . . . .	733
437. Removal of polypi . . . . .	662	485. Study in lip operation . . . . .	734
438. Adam's forceps for straightening nasal septum . . . . .	662	486. Study in lip operation . . . . .	735
439. Adam's screw plates . . . . .	662	487. Study in lip operation . . . . .	736
440. Study in rhinoplasty . . . . .	664	488. Study in lip operation . . . . .	736
441. Study in rhinoplasty . . . . .	665	489. Study in lip operation . . . . .	736
442. Use of nasal douche . . . . .	666	490. Study in lip operation . . . . .	736
443. Naso-pharyngeal syringe . . . . .	666	491. Study in lip operation . . . . .	737
		492. Study in lip operation . . . . .	737
		493. Study in lip operation . . . . .	737
		494. Study in lip operation . . . . .	737
		495. Surgical anatomy of face . . . . .	742




FIG.	PAGE	FIG.	PAGE
496. Ligation of arteries . . . .	743	544. Neuroma of nasal bone . . .	874
497. Surgical anatomy of neck . . .	744	545. Exsection of nasal bone . . .	875
498. Surgical anatomy of anterior cer- vical triangles . . . . .	746	546. Pancoast's operation for exsection of the trifacial nerve . . . . .	876
499. Salivary fistule . . . . .	760	547. Author's operation for exsection of superior maxillary nerve at base of skull . . . . .	878
500. Illustration in treatment of sali- vary fistule . . . . .	761	548. Exposure of infra-orbital nerve .	881
501. Tent for treatment of salivary fistule	762	549. Auricularis magnus nerve exposed	882
502. Tent for treatment of salivary fistule	762	550. Line of incision for exposing au- ricular and occipital nerves .	882
503. Diagram of tooth nutrition . . .	778	551. Exposure of occipital nerve and artery . . . . .	882
504. Necrosis of skull . . . . .	782	552. Exposure of supra-orbital nerve .	883
505. Sequestrum after measles . . . .	787	553. Dental fungoid tumors . . . .	893
506. Phosphor-necrosis . . . . .	791	554. Odonto-periosteal growth . . . .	894
507. Appearance of patient in phosphor- necrosis . . . . .	795	555. Ulitic tumor . . . . .	894
508. Dislocation of jaw . . . . .	797	556. Epulic tumor . . . . .	898
509. Reduction of dislocated jaw . . .	800	557. Epulic tumor . . . . .	898
510. Vertico-mental sling . . . . .	800	558a. Epulic tumor . . . . .	898
511. Jaw fracture . . . . .	802	558b. Epulic tumor . . . . .	898
512. Jaw fracture . . . . .	802	559. Epulic tumors . . . . .	899
513. Compound fracture of jaw . . . .	805	560. Epulic tumors . . . . .	899
514. Compound fracture of jaw . . . .	805	561. Resections of bone . . . . .	901
515. Barton's bandage . . . . .	806	562. Odontoma . . . . .	906
516. Gibson's bandage . . . . .	807	563. Odontoma . . . . .	906
517. Author's bandage . . . . .	808	564. Microscopic section . . . . .	906
518. Bean's interdental splint . . . .	809	565. Hyperostosis . . . . .	909
519. Bean's splint applied . . . . .	809	566. Osseous tumor . . . . .	911
520. Sudduth's mento-dental splint . .	810	567. Hyperostosis of tuberosity of max- illa . . . . .	912
521. Interdental splint . . . . .	814	568. Microscopic section . . . . .	913
522. Dental splint . . . . .	814	569. Cystic tumor . . . . .	917
523. Interdental splint . . . . .	814	570. Cystic tumor uncovered . . . .	917
524. Excision of upper maxilla . . . .	819	571. Odontocoele . . . . .	918
525. Lion forceps . . . . .	821	572. Odontoma . . . . .	921
526. Cutting bone forceps . . . . .	822	573. Microscopic section . . . . .	922
527. Mouth-stretcher applied . . . . .	824	574. Hypertrophied periodontium . .	922
528. Mouth-stretcher . . . . .	824	575. Odontoma . . . . .	923
529. Exsection of lower jaw . . . . .	826	576. Odontoma . . . . .	925
530. Exsection of lower jaw . . . . .	826	577. Odontoma . . . . .	925
531. Exsection of lower jaw . . . . .	827	578. Microscopic section . . . . .	926
532. Exsection of lower jaw . . . . .	827	579. Antral cyst . . . . .	934
533. Exsection of lower jaw . . . . .	827	580. Secondary cyst of antrum . . .	935
534. Surgical engine and appliances . .	829	581. Meningocoele . . . . .	936
535. Operculum excising forceps . . . .	847	582. Fibrous tumor . . . . .	938
536. Kolbe's jaw dilator . . . . .	851	583. Microscopic section of fibroma .	939
537. Wedge of Scultetus . . . . .	852	584. Microscopic section of fibro-recur- ring tumor . . . . .	940
538. Modified wedge of Scultetus . . .	852	585. Sarcomatous tumor . . . . .	941
539. Cicatricial expander . . . . .	852	586. Microscopic section of sarcoma .	942
540. Expander applied . . . . .	853	587. Osteo-sarcomatous tumor . . . .	948
541. View of inferior maxillary nerve .	871	588. Cysto-sarcoma . . . . .	948
542. Garretson's operation for exposure of inferior maxillary nerve . . . . .	872	589. Scirrhus nodules . . . . .	949
543. Garretson's operation for exposure of maxillary nerve at base of skull . . . . .	874		

FIG.	PAGE	FIG.	PAGE
590. Hard cancer-cells . . . . .	950	604. Nitrous oxide gas apparatus . . .	974
591. Microscopic appearance of scirrhomatoma . . . . .	950	605. Mouth-piece for use of gas . . .	976
592. Encephaloid tumor . . . . .	951	606. Holder for liquid nitrous oxide . .	976
593. Encephaloid tumor . . . . .	951	607. Illustration in inflammation . . .	981
594. Encephaloid tumor . . . . .	952	608. Illustration in inflammation . . .	981
595. Encephaloid disease of face . . .	953	609. Illustration in inflammation . . .	982
596. Microscopic appearance of encephaloid cancer . . . . .	953	610. Illustration in inflammation . . .	982
597. Medullary cancer-cells . . . . .	954	611. Illustration in inflammation . . .	983
598. Medullary cancer-cells . . . . .	954	612. Anatomy of bend of arm . . . . .	987
599. Medullary cancer-cells . . . . .	954	613. Thumb lancet . . . . .	987
600. Medullary cancer-cells . . . . .	954	614. Spring lancet . . . . .	989
601. Medullary cancer-cells . . . . .	954	615. Position of blood-corpuscles in inflammation . . . . .	996
602. Medullary cancer-cells . . . . .	954	616. Nutritional pabulum exuding through the walls of vessels . . . . .	998
603. Ether inhaler . . . . .	957		

## PLATES.

I. A view of operations performed on the trachea . . . . .	facing 548
II. Operations on the tongue . . . . .	" 578
III. The operation of staphyloraphy . . . . .	" 630
IV. Operations in rhinoplasty . . . . .	" 659
V. Rhinoplastic and cheiloplastic operations . . . . .	" 662
VI. Hare-lip and atresia oris . . . . .	" 711
VII. Plastic surgery of lips . . . . .	" 730
VIII. Resection of maxillæ . . . . .	" 822
IX. Appearance and position of some of the tumors seen about the neck . . . . .	" 955





# DISEASES

OF THE

## MOUTH, JAWS, FACE, TEETH,

AND

## ASSOCIATE PARTS.

---

### CHAPTER I.

#### SURGICAL ANATOMY OF THE HEAD.

ORAL surgery, viewed as a specialty in medicine, claims to treat of the various lesions associated directly and indirectly with the mouth, jaws, face, teeth, and associate parts.

Studies in special medicine are properly preceded by education in medicine at large, particularly as such education considers the relation and application of principles to practice. The present work assumes, in the treatment of its subjects, that certain required preliminary study has been accomplished; otherwise, that general text-books are at hand for convenient reference; it accepts, however, that plainness and simplicity in description are high attributes in any written page, and that to combine elements and practice is in the present volume markedly a desideratum.

Of foundational matter, assumed to be elementary, knowledge of anatomy asserts itself as of primary importance. Another direction refers to physiology. Still another relates with pathology. These subjects understood, or otherwise contemporaneously studied with the topics of the volume in hand, full comprehension of the details herein treated is arrived at easily.

Special parts require to be specially considered in order that special practice be directed with that absolute expression of intelligence which is the presumed virtue of specialism. Recognizing such necessity, and reminding the student that oral surgery deals with the head, the work is commenced by directing attention to what is known as the "surgical" anatomy of the region.

In presenting pictures, here shown, of parts associated with the specialty, the suggestion is to be urged that a skull, and disarticulated bones, be pro-



cured, and that these be kept in fit relation with the study-chair. It is important, too, that a specialist dissect extensively with close regard to minutiae. It is necessary that he establish clearly in his mind the correlative relations of localities and phenomena.

A human head consists of a cranial and a facial portion; it is divisible also into soft and hard parts. The cranial portion is the superior and posterior aspects; it accommodates and protects the brain. The facial portion is the inferior anterior division; it supports, and as well relates, the organs of expression.

The hard framework of a head is called the skull; it is made up of twenty-two different bones. Of these bones eight pertain to the cranial, fourteen to the face portion. The names of the bones are as follows: Belonging to the cranium—sphenoid, ethmoid, frontal, occipital, two parietal, two temporal. Belonging to the face—inferior maxilla, two superior maxillæ, two nasal, two malar, two inferior turbinated, two lachrymal, two palate, and a vomer. The teeth, and the six bones associated with the auditory apparatus, are not commonly numbered.

The bones of the head are related with each other by means of sutures; these are known as articulations, and vary somewhat in character. Articulations find names in the relating bones, as, for example, temporo-maxillary, maxillo-malar, inter-maxillary, naso-frontal, etc.; that is to say, the lower jaw,—maxilla,—to make an example, relates with the temporal bone; hence the name of articular association, temporo-maxillary, maxillo-temporal; either being, of course, right and expressive. As character of articulation is concerned, the naming is directed to the peculiarity. The temporo-maxillary joint admits of a gliding movement, its peculiarity being the relation of two free surfaces, one convex, the other concave; it belongs to diarthrodial, or movable joints; its special feature of gliding places it in the subdivision Arthrodia. The relation of the parietal with the frontal bone is by indentations interlocking with each other,—*sutura*, a seam; peculiarity puts it in a special subdivision called Limbosa, meaning that the edges are bevelled and that there are dentated processes. Gomphosis is a term signifying the relation of a conical process with a socket; teeth in the articulation of their roots with the alveoli of the jaw-bones come under this signification. Harmonia refers to the apposition of rough contiguous surfaces; the two upper jaw-bones as they come together at the median line of the face furnish illustration. Schindylesis distinguishes articulations where the thinned or bevelled edge of one bone is received into a fissure existing in another; the relation of rostrum of sphenoid with free edge of vomer is illustrative. Dentata signifies teeth-like surfaces; the parietal bones fit into each other as the cutting faces of two saws might do; hence *sutura dentata*. (See *General Anatomy*.)

Fig. 1 represents the lateral region of a skull; this is seen to form, almost accurately, an oblong square. A modification on such a square, however, is

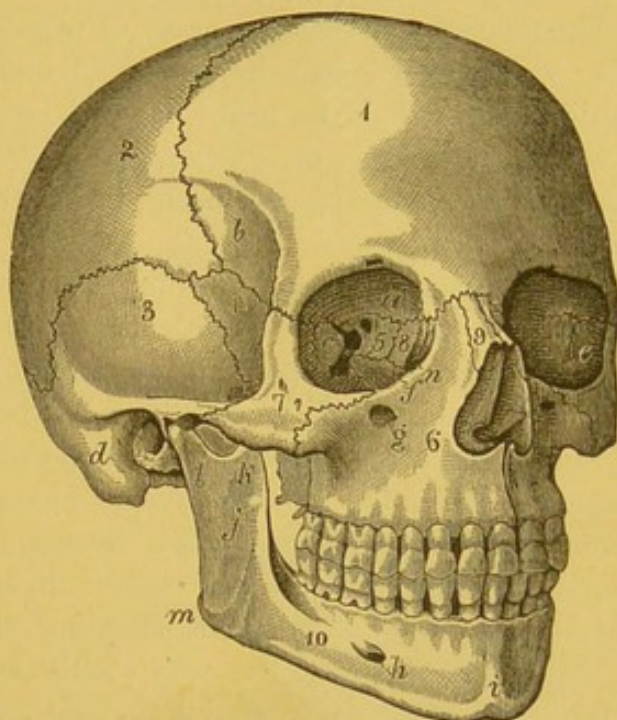


found to exist in childhood, where the ramus of the inferior maxillary bone is at a more obtuse angle with the body; also in the case of an adult with prominent os frontis; in either of these cases this aspect is triangular. Bounded circumferentially by the supraorbital ridge of the frontal bone, the nasal process of the superior maxillary, and by the malar bone, we find a pyramidal cavity, the orbit, for the accommodation of the organ of sight. Examining this cavity attentively, no less than seven pieces are observed entering into its composition, some of which pieces, in their relations, closely affect proceedings in oral sur-

gery. It is seen, for example, that a large portion of the floor of the cavity is made up by a process, the orbital (*f*), which is a part of the superior maxilla; glancing at a disarticulated bone, Fig. 2 (4), it is remarked that this process constitutes as well the roof of the antral sinus; it is also noticed to be a very thin plate, and capable of being easily elevated or depressed, according as pressure may be brought upon it from below or above; constituting a source of support to the eye, it will be accepted that, where possible, it is to be left undisturbed in operations demanding extensive interference with the bone of which it is a part. At the inner inferior aspect of the cavity a groove, Fig. 1 (8), is observed, the lachrymal, being the entrance to a canal, the ductus ad nasum, as it is called, which canal

carries the tears from the orbit to the nose. The outer wall of this duct is made up by the inner face of the nasal process, Fig. 3 (5), another portion of the superior maxillary bone. Diseases of the sinus not infrequently react on the eye; this to such extent that blindness of several months' standing has been cured by so simple a proceeding as the extraction of a diseased tooth-root which had affected the antrum to its engorgement. Closure of the tear canal, Fig. 3 (8), is almost certain to occur if the nasal process become

FIG. 1.—LATERAL—AND FRONT—REGION OF THE SKULL.



THE SKULL SEEN PARTLY IN FRONT, AND ON THE RIGHT SIDE. 1, frontal bone; 2, parietal bone; 3, temporal bone, its squamous portion; 4, sphenoid bone, temporal surface of its great wing; 5, ethmoid bone, its orbital surface; 6, superior maxillary bone; 7, malar bone; 8, lachrymal bone; 9, nasal bone; 10, inferior maxillary bone. *a*, orbital plate of the frontal bone; *b*, temporal surface; *c*, orbital surface of the great wing of the sphenoid bone; *d*, mastoid portion of the temporal bone; *e*, orbital surface of the malar bone; *f*, orbital plate of the superior maxillary bone; *g*, infraorbital foramen; *h*, mental foramen; *i*, symphysis; *j*, ramus; *k*, coronoid process; *l*, neck supporting the condyle; *m*, angle; *n*, lachrymo-nasal duct.



inflamed. Such inflammation is frequently met with as the result of an odontoccele.\*

Immediately below the inferior boundary of the orbit a foramen is seen, the infraorbital, Fig. 1 (*g*), for transmission of the infraorbital branch of the fifth nerve. Passing a bristle through this foramen, it is found to emerge in the groove marked on the floor of the orbit,—the infraorbital groove. This groove and this canal are both in the maxillary bone, and, alike with the ductus ad nasum, are influenced by its diseases.

The canine fossa, seen back of and above the canine tooth, has, as its floor, a thin plate of bone, which plate is the external face of the antrum, and through which, if it be found necessary, the cavity is easily to be entered.

The tuberosity of the bone, occupied in part by the wisdom-tooth, is a point of surgical interest,—it being not at all uncommon to have necrosis of this portion, the result of an ostitis, induced and kept up by an imprisoned dens sapientiæ. Standing, as it is seen to do, tubercle-like, it is plainly evident that neither deformity nor harm would result from its separation as a sequestrum.

The alveolar processes (see stippled portion, Fig. 6) are remarked to constitute quite a large part of both the superior and inferior maxillæ. These processes, vascular and spongy, accommodative of the roots of the teeth and being subject to all irritations residing in their presence, are, without doubt, more liable to take on pathological action than any other portion of the ossa corporæ. From the alveolo-dental periosteum spring epulic outgrowths of various signification. Sarcomatous degeneration finds here a favorite seat: simple and compound cysts are familiar; degenerative ostitis is not uncommon, while abscess is found in almost every mouth. The mental foramen, Fig. 1 (*h*), seen upon the inferior maxilla, a little anterior to the middle of the body, is the outlet of a canal traversing the centre of the bone, a canal conducting, beneath the teeth, the dental artery and nerve. The size, general character, and inlet of this canal are to be thoroughly studied, as not infrequently injuries to the artery require that it be plugged, either as foramina are concerned which exist beneath each tooth, or as the channel proper is interfered with in operations for removal of tumors or sequestra.

Neuralgia of some of the peripheries of the inferior dental nerve makes necessary, occasionally, its section within the canal. To get at this nerve, requires either that some tooth be extracted, and the section be made from the base of the socket, or otherwise that entrance is had from the outside. The easiest mode of performing such operation is to be observed, as relation is had to location, and to character of the bone.

The association of the teeth with their spongy processes, Fig. 6, is a matter which is to receive close attention, the operation for the extraction of these organs being an every-day matter. These processes, if examined in a number

---

\* Odontoccele. An encysted tooth.



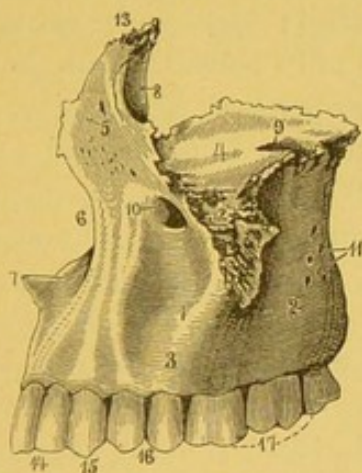
of bones, will be found to vary greatly in character: in some being of such loose structure that the teeth are capable of easiest separation; in other instances being so firm and unyielding that it is quite an impossibility to make such extraction without more or less fracture.

The number and shape of the roots of the teeth are to be fully examined. A knowledge of their relations and curves contributes much to ease in their removal. Indeed, no one but the experienced can appreciate how much easier it is to extract teeth with than without the advantages of such knowledge. (See chapter on *Extraction*.)

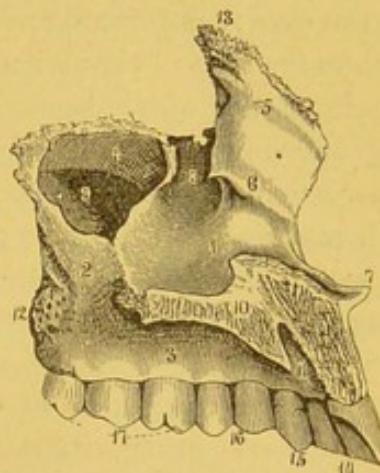
The nasal bones, resting upon the nasal processes of the maxillæ, forming in the conjunction the nasal arch, are to be examined in their relation to each other and to neighboring pieces. Articulating above with the perpendicular plate of the ethmoid, it has not infrequently happened that the depression of this arch from a blow received upon it has carried the crista galli into the substance of the brain, and thus produced fatal consequences. The nasal bones are frequently the seat of syphilitic degeneration. Their destruction allows the falling in of the arch, thus yielding the flattening of the bridge occasionally observed,—one of the most repulsive of deformities.

The incisive fossa, observed between the anterior nasal spine, Fig. 2 (7),

FIGS. 2, 3.—SUPERIOR MAXILLARY BONE.



SUPERIOR MAXILLARY BONE OF THE LEFT SIDE, outer view. 1, body; 2, tuberosity; 3, alveolar border; 4, orbital plate; 5, nasal process; 6, nasal notch; 7, nasal spine; 8, lacrimal groove; 9, entrance of the infraorbital canal; 10, infraorbital foramen; 11, orifices of the posterior dental canals; 12, malar process; 13, articulation for the internal angular process of the frontal bone; 14, incisor teeth; 15, canine tooth; 16, premolar teeth; 17, large molar teeth.



SUPERIOR MAXILLARY BONE OF THE LEFT SIDE, inner view. 1, nasal surface of the body; 2, surface for the palate bone; 3, alveolar border; 4, orbital plate; 5, nasal process; 6, ridge for the articulation of the turbinated bone; 7, nasal spine; 8, groove contributing to form the lachrymo-nasal duct; 9, maxillary sinus; 10, palate plate, its articulating border for the right maxillary bone; 11, incisive foramen continuous with the naso-palatine canals; 12, tuberosity; 13, articular extremity for the internal angular process of the frontal bone; 14, incisor teeth; 15, canine tooth; 16, premolar teeth; 17, large molar teeth.

and central incisor teeth, frequently yields its floor to the ravages of necrosis or caries. There would seem to be just here less vital resistance than in other



parts of the bone, as necrosis of a tooth is almost necessarily associated with disease of the superficial surface of its alveolus. This plate is, however, quite thin, and its loss seldom seems of consequence.

The position of the groove for the passage of the facial artery, seen on the inferior maxilla, is to be noticed, as location and distance from the angle of the jaw are concerned,—the control of hemorrhage about the lips and cheeks being here secured through simple pressure on the vessel as it passes over the base. Here, too, is the place of election for ligation. The number (10) marked on the line designates the position of the notch.

With such observation of the surgical features of the general facial osseous region, we pass to a close study of the parts referred to, which study is to be made by examining the bones in their separate capacities.

#### SUPERIOR MAXILLARY BONE.

The superior maxilla consists of a series of processes, so grouped as to form, or rather to enclose, a cavity so large that the apparently solid body is seen to be simply a shell. This cavity of the shell is called the maxillary sinus, or the antrum of Highmore, Fig. 3 (9). It is a very irregular cavity, differing, indeed, in shape in almost every bone; generally, however, being found as a single cave, but not infrequently divided into two or more parts by septi of bone vertically placed. How far, in the mean of cases, the cave runs forward and how far backward; what, in the mean, is its relation to the roots of the various teeth; which of its boundaries are the thinnest; are matters which, because of their very practical signification, prove worthy of being attentively studied, the information being derived only by an observation of many bones. Abscesses of the roots of teeth frequently void themselves into this cavity; we are to understand how and why, anatomically, such accidents occur. Engorgements of the cavity, puruloid or dropsical, bulge outward some part or other of the circumferential walls, throwing, perhaps, the eye upon the cheek, projecting the canine fossa, or making a tumor on the palatal aspect of the mouth; we are to appreciate why such bulging, from a common cause, is found so variously situated, and why the accumulations exist.

If such a section be made of the superior maxillary bone as exposes the antral cavity, we find that in many cases, not indeed in all, its floor is studded with little hills. Break into one of these, and it is found to be a very thin crust, concealing the root of some tooth. In infrequent cases, a root or roots is found projecting into the cavity entirely uncovered, save with the membrane which had existence in the living part. Such a view explains satisfactorily the discharge of dental abscess within this sinus.

The processes which, in their conjunction, make up the bone, are four in number: the alveolar, Fig. 2 (3), the palate, Fig. 3 (2), the nasal, Fig. 2 (5), and the malar, Fig. 2 (12).

The alveolar process, wedged in between the malar and palate, constitutes



the bulk of the bone. Looked at from below, this process is found excavated into cavities, or pits, corresponding with the character and number of the roots of the teeth; these pits are termed alveoli, and, in the recent bone, are lined with periosteal tissue, which tissue is simply periodontal membrane; a bond of union between teeth and jaw. (See *Extraction of Teeth*.) In some bones, the structure making up this process is exceedingly loose and spongy; in others it is condensed, and cortical-like. After the loss of the teeth, it is removed through absorption; hence the approximation, in old people, of chin and nose. Fractures of this process, the result of falls, blows, or attempts at tooth extraction, are quite common. (See *Fractures of Jaw*.)

The tuberosity of the bone is to be esteemed as the posterior extremity of the alveolar process, being, indeed, not infrequently excavated for the accommodation of the wisdom-tooth. This tubercle, as implied in its name, is simply a bulb of bone; it is quite vascular, and its relation to the posterior tooth subjects it to sources of irritation which not infrequently results in its inflammation, death, and exfoliation.

The malar process, seen projecting from the middle of the maxilla, is a rough, serrated facet for articulation with the malar, or cheek, bone. This process, in front, is somewhat concave; behind it has similar curvature, and forms part of a fossa known as the zygomatic. The chief point of surgical interest connected with it lies in the character of the suture which unites the maxillary with the malar bone, this being the place of separation in removal of the maxillary.

The nasal process, Fig. 2 (5), well represented in the drawing, but infinitely easier of study and understanding from observation of the bone itself, is seen standing above the orbital surface. Rising from the anterior facial aspect, this process continues upward and somewhat backward, until it ends in a rough facet, which articulates the maxillary with the frontal and ethmoid bones, and assists in closing in the anterior ethmoidal cells. Lined in the recent state with mucous membrane, which membrane is continued into the cells of the ethmoidal and frontal bones, a moment's reflection recognizes the meaning of that sense of fulness so common about the anterior base of the cranium, when congestion exists in the nasal canals. Externally, the face of the process is concave, thus assisting in carrying out the natural curve of the lateral aspect of the nose; numerous foramina are also observed on this face, for the passage of vessels. The tendo oculi has its attachment on this surface, while near, on the same plane, is a line giving origin to the levator labii superioris alæque nasi and orbicularis palpebrarum muscles. Anteriorly, the border of the process is thin, and is serrated for articulation with the nasal bone. Posteriorly, it is thick, and hollowed into a groove for lodgment of the lachrymal sac and duct. When in position, in the articulated skull, this groove is converted into a canal by annexation with the lachrymal bone. The canal, traced downward, is found to have somewhat of an hour-glass shape, being considerably contracted in the centre, and finally terminating at the inferior



meatus in a bell-shaped opening. A little tubercle, the lachrymal, Fig. 1 (*n*), is seen where the anterior lip of the groove joins the orbital surface; this is a guide, directing the bistoury of the surgeon into the canal, when operations for its stricture are demanded.

The orbital surface of the bone, seen in Fig. 1 in its articulative position, is here observed separate; falling at an almost direct right angle from the facial aspect of the bone, it is remarked by such relation to form a large part of the floor of the orbital cavity; while looked at from the cave of Highmore, it is seen to form as well the roof of that vault. When broken, or held against the light, it is found to be almost a scale in thinness. The infra-orbital ridge is simply the rim made by the bending downward of this orbital surface. Running along the free edge three distinct articular faces are to be seen: the outer, for the palate bone, the two inner for the orbital, or plane plate, of the ethmoid and lachrymal bones. Below the rim, or infraorbital border, is seen the orbital foramen, Fig. 2 (10). Passing a bristle into this opening, we find it directed to the groove on the orbital face, the infraorbital. Thrusting the bristle now from the groove toward the foramen, we learn it may take some other track, and not appear at the opening. Searching for an explanation, we find the groove, soon after entering the ridge, dividing into two canals, one of which passes to the face, as observed; the other enters the antrum, and transmits across that cavity the nerves and vessels designed for the nutrition of the anterior teeth.

The osseous boundary of the nose is seen to advantage in this drawing. It is a complete curve, and gives attachment by its continuous crest, or edge, to the cartilaginous wings.

The zygomatic surface, seen back of the malar process, enters into the formation of the fossa of that name. This surface is, to a degree, convex, and more or less rough. Dotting its face a number of foramina are observed; these are entrances to canals, posterior dental they are called, and they transmit vessels to certain teeth; to all situated back of the canines. At the lower part of this surface, that is, to the nasal aspect of the tuberosity, a groove is seen, destined to be converted into a canal through an articulation with the palate bone; posterior dental groove is its name, Fig. 2 (11). This groove, or canal, transmits vessels to the palatal face of the bone, and is seen to terminate on the under side of the tuberosity.

The muscles of expression, to which the outer surface of the bone gives origin, are numerous. From the second bicuspid tooth back to the tuberosity, is a rough line for the trumpeter's, or buccinator (a similar line existing on the inferior maxilla). Above this first line, and below the malar process, certain fibres of the masseter are attached. Above the canine fossa is the origin of the levator anguli oris; while without this, toward the concavity of the nose, is the line for the compressor naris. In the incisive, or myrtiform, fossa is seen the origin of the depressor ala nasi.

Turning now toward us the inner face of the bone, we remark the fourth



process, the palate. This process starts out from the middle of the bone, and divides it into two unequal parts. Like the orbital plate, it is related at right angles with the body, and, when the maxilla is articulated, the plate is seen to separate the nose from the mouth, constituting the floor of the first cavity and the roof of the second. Posteriorly, it is quite thin, and articulates with a process of the palate bone. Running forward, it grows thicker and heavier, and ends in the anterior nasal spine. Viewed on its nasal surface it is slightly concave. Externally, it becomes merged into the body of the bone; internally or mesially, it rises into a ridge, which ridge is the one side of a groove receiving into articulation the vomer. A bristle passed through an opening in the thick part of the process shows the position of a canal, the anterior palatal, transmitting vessels of that name, which vessels find entrance into the oral cavity through the incisive foramen seen just back of the centre tooth. Fig. 3 (11). A nerve, the naso-palatine, having considerable surgical significance, enters the mouth at the orifice of this canal; it is not, however, transmitted by it, but has a canal of its own existing in the intermaxillary suture. The three marked points of surgical interest in this process are—first, the fact of its forming the boundary between the mouth and nose; a break in its continuity, and which, unfortunately, is not an infrequent accident, throwing these two cavities into one; second, the nature and the relation of suture—harmonial, it is called—with the palatine process of the palate bone, this being the line of separation in ablation; third, the position of entrance of the naso-palatine nerve, paralysis of the parts supplied by this nerve being a frequent result of ill-applied pieces of dental apparatus. To these three might be added a fourth; the position of the artery occupying the posterior palatine canal, an artery which is sometimes of considerable size, and which might easily be cut by the slip of a lancet applied to the gum of a wisdom-tooth, or in the act of dividing the tendon of the flexor palati where it curves around the hamular process.

The other features observable on this aspect of the bone are without special surgical interest. Above the inferior meatus, which is the space between the floor of the nares and the inferior turbinated bone, Fig. 11 (21), is seen a crest for the attachment of that scroll. Still higher, on the nasal process, are the crests for union with the superior and middle scrolls (see also Fig. 11). The middle meatus (20), into which the antrum opens, is observed to be quite a large space, particularly when compared with the superior meatus (19), which is the slit lying between the upper and middle crests. The opening of the antrum, seen in the back part of the middle meatus, Fig. 3, is portrayed of a natural size,—that is, natural to the disarticulated bone. In Fig. 11 (26) it is shown as in articulation. It is to be known, however, that in the articulated skull this opening is intruded on by various bones, which intrusion reduces the opening to an outlet not larger than an ordinary probe. The bones closing in this cavity are the ethmoid, palate, and inferior turbinated. (See descriptions of these bones.)



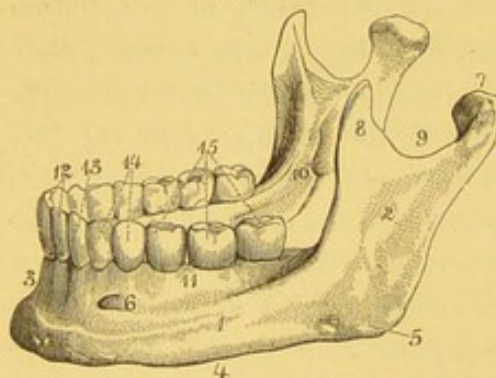
A superior maxillary bone articulates with nine others: by its nasal crest with the frontal, ethmoid, lachrymal, and nasal; by its malar process with the malar; at the intermaxillary suture with the opposite maxilla; by its palate process with the palate and vomer, and by the lower of its lateral crests with the inferior turbinated bone.

Nine muscles have their origin from this bone: the orbicularis palpebrarum, the inferior oblique of orbit, the elevator of superior lip and wing of nose, the proper elevator of lip, the angular elevator, the compressor naris, the depressor of the ala, the masseter, and the buccinator.

#### INFERIOR MAXILLARY BONE.

The inferior maxilla, Fig. 4, the largest and strongest bone of the face, consists of a body (1), horseshoe in shape, and of two rami (2), joined to the body at right angles. The body, which is the anterior portion, is surmounted by a process of more or less spongy bone, excavated for the reception of the teeth; this is the alveolar process. The basement portion of the body, or that part beneath the alveolar process, is made up of a dense structure, and

FIG. 4.—INFERIOR MAXILLARY BONE.



1, body; 2, ramus; 3, symphysis; 4, base; 5, angle; 6, mental foramen; 7, condyle; 8, coronoid process; 9, semilunar notch; 10, inferior dental foramen, the entrance of the corresponding canal; 11, alveolar border; 12, incisor teeth; 13, canine tooth; 14, premolars; 15, large molars.

is so hard and resisting as to be able to withstand very considerable blows. The rami, curved and angular at the base, terminate above in two processes: the condyloid (7), for articulation with the glenoid cavity in the temporal bone, and the coronoid (8), for the attachment of the temporal muscle. The angle of relation of the perpendicular to the horizontal portion of the bone varies with age. In early infancy it is very obtuse; indeed, the two portions are nearly on the same plane. In adult life a right-angled relation is obtained, and this changes again to the obtuse as age advances, and the teeth are lost. Taking advantage of a knowledge of these

changes, the surgeon is enabled to correct, in young life, the great deformity of an unduly projecting lower jaw.

Looking at the external face of the body, attention is first attracted by a prominent foramen situated beneath the bicuspid teeth. This foramen is called the mental (6), from it pass out, to be distributed to the lip and gum, the inferior dental artery and inferior dental nerve (see Fig. 6); the situation of the foramen represents the line of relation between the hard and spongy portions of the bone. It is at this opening that section of the nerve is occasionally made for severe and resisting labial neuralgia. A bristle passed into this foramen, and inclined backward, is directed along a canal at the base of



the teeth, and emerges at a second foramen, the dental, situated on the inner face of the ramus. Passed forward, it enters a smaller canal, which continues under the central teeth, carrying to these organs branches of the nerve and artery. An oblique line—the external oblique, as it is called (Fig. 1 is just below it)—fairly divides the surface of the body into two triangles. This line is for the attachment of muscles, and accommodates, in part, the buccinator, the depressor anguli oris, and the depressor labii inferioris. In old persons, after falling of the teeth, and absorption of the alveolar process, the line is found to run almost along the upper surface. All that portion of the bone which is above the ridge belongs to the facial region proper; all below it, to the cervical region. The centre vertical line, called the symphysis (3), represents the separation, or division, existing in the young bone, union of the two halves not occurring until about the end of the first year. The levator menti muscle has its origin from a fossa at the side of this line. The mental process, the tubercle at the base of the symphysis, is only a thickening, for the greater strength of the part. Viewed from above downward, the body of the lower jaw is concave; from behind forward it is convex.

The external face of the ramus, or perpendicular portion, of the bone, exhibits a quadrilateral aspect, broken above by a notch, the semilunar (9), which separates the two projecting processes. The anterior of these processes (8), the coronoid, is a thin, flattened, triangular eminence, giving attachment to the masseter and temporal muscles. The posterior eminence, the condyloid process (7), is an oval projection, convex and smooth, with its face covered with articular cartilage, and having its greatest width from side to side. This process articulates the bone with the temporal, and is occasionally the seat of fracture and luxation.

The internal face of the bone presents the same general view as the external.

A ridge, the mylo-hyoid, divides the body by its obliquity into two parts. To this ridge is attached, or rather from it has origin, a muscle bearing the same name. This muscle, with its fellow of the opposite side, forms the floor of the mouth, the two joining at the median line, so that looking at the line one sees exactly how much of the bone is within and how much without the oral cavity. Just below the line, about midway of the body of the bone, is seen a fossa or depression, the submaxillary, for the accommodation of the gland of this name. The mesial line, or symphysis, presents on either side two tubercles, called the genial tubercles, to which are attached the genio-hyoglossi and the genio-hyoideus muscles. Outside of these tubercles, on either side, are two fossæ for the lodgment of the sublingual glands; these fossæ are called by the name of the glands. It will be observed that as these fossæ lie above the ridge, the lingual glands must be within the mouth, while the submaxillary fossæ being below it, those glands are without the cavity. One most important feature to remark is the relation of the anterior border of the vertical portion of the bone to the molar teeth. It not infrequently hap-



pens that this border so nearly approximates the second molar that there is no room for the eruption of the third; formidable inflammations sometimes result from such a cause, the crown of the tooth being held down under the ramus.

A marked feature of difference between the internal and external face of the ramus is the existence in the former of a large foramen, the posterior dental, for transmission into the canal alluded to, as passing beneath the teeth, of the inferior maxillary vessels and nerve (see Fig. 5). A groove, the mylohyoid, transmits to the muscle of the ridge an artery, which comes from the inferior maxillary just as it is about to enter its canal. Attached to the border and internal face of the coronoid process is the tendinous expansion of the temporal muscle, while to the face of the condyloid process is attached the pterygoideus externus, the internal pterygoid being related to the angle. The semilunar depression, or notch, separating the two condyles, is crossed by the masseteric artery and nerve, while in its immediate proximity are the internal carotid and internal maxillary arteries.

Fig. 5 affords a view of the inner face of this bone, as reference is had to the mylohyoid ridge, or line. All that portion of the jaw which is above

this line, marked "Facial," is within the mouth, consequently is mucous lined; the part below, marked "Cervical," is without the oral cavity, therefore non-mucous.

FIG. 5.

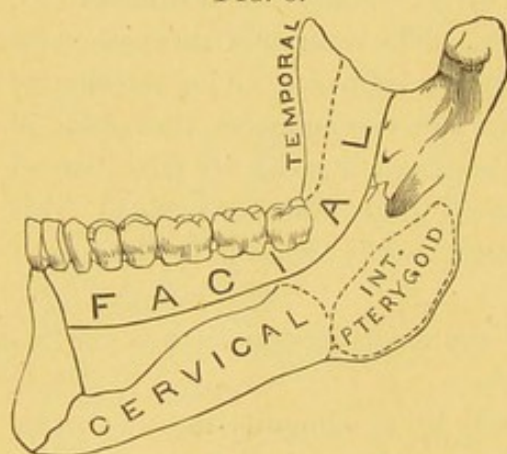


Fig. 6 shows the maxillary region uncovered, the outer or cortical plate both of superior and inferior jaws being removed. In the drawing is to be appreciated the relation of the spongy or alveolar processes, to body of the bones; also the relation of the roots of teeth to this process and to each other.

In the lower jaw is exhibited the position of the dental canal occupied by its vessels, a square of plate being left to show the anterior mental foramen, and the manner of escape from the canal of its vessels. The stippled part is the alveolar process; the unstippled, bone proper. Alveolar process is to be accepted as related to the teeth rather than to the bone; it disappears on loss of the dental organs.

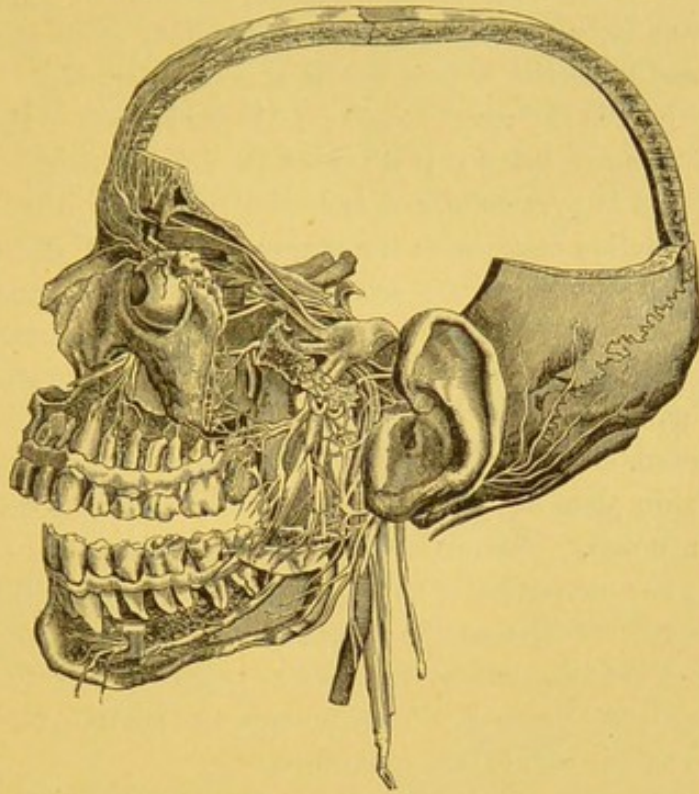
#### THE PALATE BONE.

The palate bone, when in position, forms the back part of the hard palate, a portion of the floor and side of a naris, and a part of the orbital cavity. It also enters into the formation of three fossæ: the zygomatic, the sphenoidal maxillary, and pterygoid. Like the inferior maxilla, the bone consists of two portions: one horizontal, the other at right angles with it, or vertical. The horizontal portion is irregularly quadrilateral, presenting two surfaces and



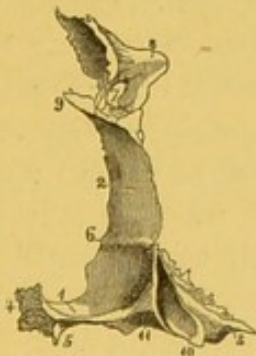four borders: the upper of the two surfaces is concave, and forms the back part of the floor of a naris; the lower, or under surface is also concave, and

FIG. 6.

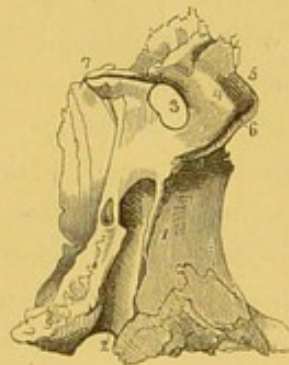


forms the back of the hard palate. The suture of connection with the maxillary bone is always plainly seen; it is called palato-maxillary suture.

FIGS. 7, 8.—PALATE BONE.



POSTERIOR VIEW OF THE RIGHT PALATE BONE. 1, palate plate; 2, nasal plate; 3, pyramidal process; 4, articular border for the left palate bone; 5, palate spine; 6, ridge for junction with the turbinated bone; 7, speno-palatine notch, between 8, the orbital, and 9, the sphenoidal process; 10, groove for the internal pterygoid process of the sphenoid bone; 11, position of the posterior palatine foramen.



EXTERIOR VIEW OF THE RIGHT PALATE BONE. 1, rough surface articulating with the superior maxillary bone, and diminishing the aperture of the maxillary sinus; 2, posterior palatine canal, completed by the tuberosity of the superior maxillary bone; 3, speno-palatine notch; 4, 5, 6, orbital process; 4, surface directed toward the ptergo-maxillary fossa; 5, orbital surface; 6, maxillary border; 7, sphenoidal process; 8, pyramidal process.

In glancing at a disarticulated palate bone, holding its posterior face in



profile, it is seen very markedly to resemble the letter L. Studying it from such position in detail, we remark, first, the spine, situated at the base of the interpalatal suture, and which gives attachment to one of the *motores uvulae* muscles; passing toward the vertical portion, the concave character of both nasal and palatine faces is observed, the former much more marked than the latter. This nasal concavity is seen to end at a crest, or ridge, on the vertical portion. This ridge is the most posterior articular surface of the inferior turbinated bone; the space below it is a part of the inferior meatus. The base of the vertical portion is pyramidal, and ends in a tuberosity called the pterygoid process, its articulation being with the pterygoid plates of the sphenoid. At the back part of this process are seen three grooves; the middle one, wide and smooth, forms part of the pterygoid fossa, and gives attachment to the internal pterygoid muscle; the two lateral are rough and uneven, and articulate with the anterior border of each pterygoid plate.

Passing upward, a prominent feature is the sphenoid process. This is a comparatively thin plate, made up of an articular and non-articular surface, a groove and a notch. The articular surface associates the plate with the sphenoid bone; the non-articular enters into the composition of the zygomatic fossa. The groove contributes to the formation of the pterygo-palatine canal; and the notch, closed in above by the orbital process, forms the greater part of the speno-palatine foramen. This process also contributes, by one of its surfaces, to the lateral wall of the nasal fossa.

The orbital process, resting on the sphenoidal, is composed of five plates, or surfaces, and includes a cavity. Of these processes, three are articular, two, free surfaces. The articular are the maxillary, the sphenoidal, and the ethmoidal, associating the process with the bones named. The free surfaces are the orbital, forming a small part of the orbital cavity, and the zygomatic, entering into the composition of the zygomatic fossa.

Looking on the inner face of the bone, we remark, first, the articular process. This process, or surface, associates the bone with its fellow of the opposite side; above, it forms, with its neighboring piece, a ridge receiving the vomer. The body of this face seems made up of two great concavities, with a separating ridge. This ridge articulates the inferior turbinated bone; the concavity above is part of the middle meatus; that below, part of the inferior meatus; the ridge or crest is called the inferior turbinated crest. A second crest, situated at the upper boundary of the middle meatus, articulates the lower scroll of the ethmoid, or the middle turbinated bone. This is called the superior turbinated crest. Just below it is seen the now perfected notch in the sphenoidal process, the speno-palatine foramen, for the transmission of the vessels and nerve of that name. Above the superior crest is seen the posterior part of the superior meatus, a horizontal groove, bounded above by the lower border of the ethmoidal face of the orbital process.

The orbital process, seen from this side, presents three surfaces: the maxillary in front, the orbital above, and the ethmoidal internally.



The lateral surfaces of the bone are almost entirely articular. That looking forward associates in its full length with the superior maxillary bone; that looking backward, with the sphenoid, through its pterygoid processes. This very full articulation with these two bones leads the anatomist to speak of the palate bone as being wedged between, and supported by them.

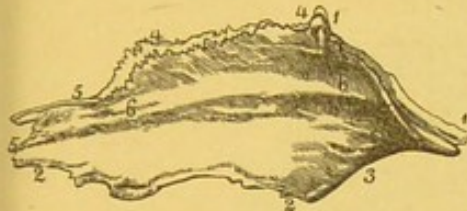The articulations of the palate bone are with seven others: the superior maxillary, the inferior and superior turbinated, the vomer, the sphenoid, the ethmoid, and its fellow of the opposite side.

The muscles attached to it are the tensor palati, the motores uvulæ, and the internal and external pterygoid.

### THE VOMER.

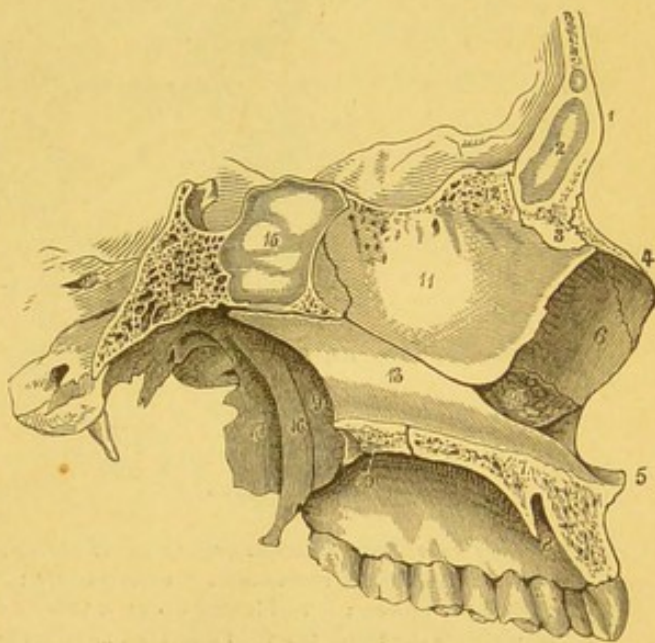
The vomer, ploughshare-shaped, constitutes a portion of the septum of the nose. It articulates below with the interpalatine suture of the superior

FIG. 9.—THE VOMER.



VIEW OF LEFT SIDE. 1, 1, broad groove receiving the rostrum of the sphenoid bone; 2, 2, inferior border articulating with the palate plates of the superior maxillary and palate bones; 3, posterior border, the dividing line of the posterior nares; 4, 4, groove border receiving a narrow slip of cartilage, situated between the vomer and the nasal plate of the ethmoid bone; 5, 5, border for the cartilaginous septum of the nose; 6, 6, nasal surface.

FIG. 10.—ARTICULAR RELATIONS OF VOMER.



VERTICAL SECTION OF THE FACE, exhibiting the osseous nasal septum. 1, frontal bone; 2, frontal sinus; 3, nasal spine of the frontal bone; 4, nasal bone; 5, nasal spine of the superior maxillary bone; 6, nasal process of the same bone; 7, border of the palate plate of the same; 8, incisive foramen; 9, left posterior naris; 10, palate plate of the palate bone; 11, nasal plate of the ethmoid bone; 12, ethmoidal crest; 13, vomer; 14, left turbinated bone; 15, sphenoidal sinus; 16, internal pterygoid process; 17, external pterygoid process.

maxillæ and palate bones; above, with the perpendicular plate of the ethmoid; by its base with the laminae and rostrum of the sphenoid bone; in front it associates with the triangular cartilage. Posteriorly it separates the nares. The naso-palatine groove, seen running from the base, forward and downward, toward the triangular cartilage, transmits the naso-palatine nerve to the interpalatine canal.

Occasionally it is the case that the vomer is found markedly bent to one side or the other, and this to such an extent as completely to obliterate one of the nares, requiring an operation for relief. The vomer is also subject to



syphilitic attacks, and frequently breaks down, allowing the arch of the nose to fall in.

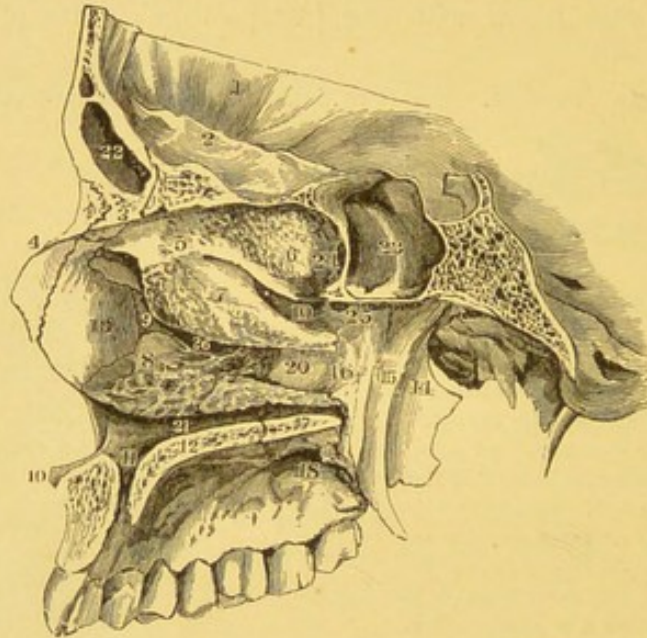
The articulation is seen to be with six bones: the two superior maxillary, the two palate, the sphenoid, and the ethmoid; also with the cartilaginous septum; this last not shown in the view, but occupying the position of the triangular break.

#### TURBINATED BONES.

Running across the lateral face of each nasal cavity are three scrolls, known as the turbinated bones. Of these scrolls, the two upper are simply processes, or portions of the ethmoid bone; the lower is a distinct piece; it is called the inferior turbinated bone.

Observing the relations of these scrolls, it is remarked that each curves over

FIG. 11.—POSITION AND RELATIONS OF TURBINATED BONES.



VIEW OF THE OUTER WALL OF THE RIGHT NASAL FOSSA. 1, frontal bone; 2, its orbital plate; 3, its nasal spine; 4, nasal bone; 5, ethmoid bone; 6, its upper turbinated process; 7, its lower turbinated process; 8, turbinated bone; 9, process of the lachrymal bone, within the position of which is the lachrymo-nasal duct; 10, nasal spine of the superior maxillary bone; 11, nasopalatine canal; 12, palate plate of the superior maxillary bone; 13, nasal process of the latter; 14, external pterygoid process; 15, internal pterygoid process; 16, nasal plate of the palate bone; 17, its palate plate; 18, posterior palatine foramen; 19, superior meatus of the nose; 20, middle meatus; 21, inferior meatus; 22, frontal sinus; 23, sphenoidal sinus; 24, its communication with the upper back part of the nose; 25, sphenopalatine foramen; 26, orifice of the maxillary sinus.

a portion of the sides of a naris. A space thus enclosed is called a meatus. The lower, or inferior of these cavities is bounded below by the floor of the nose; above by an inferior turbinated bone. An opening seen about its middle is the outlet of a lachrymal canal. The middle meatus is the space bounded below by the upper surface of an inferior scroll; above by the lower surface of a middle scroll. A foramen seen in this meatus is the outlet of the antrum. The superior meatus is the slit seen between two upper scrolls.



The distinct, or inferior turbinated bone, is a thin, spongy scroll; it has a base of attachment the whole length of the lower crest seen on the nasal surfaces of the maxillary and palate bones; the opposite, or inferior edge, is free, and lies in the middle of the inferior meatus. Viewed from its inner surface, the bone presents a most irregular appearance, being perforated with numerous apertures, sulci, and grooves, for the accommodation of arteries and veins. Two processes, the lachrymal and the ethmoid, are seen to break the regularity of the upper convexity. The anterior—the lachrymal—articulates with the inferior angle of the lachrymal bone, and with the nasal crest of the maxillary bone, thus assisting in forming the lachrymal canal. The posterior—the ethmoidal—articulates with the descending unciform process of the ethmoid bone.

Turning here the bone, we see a third process, or division as it were, made in the ethmoidal. This process is called the maxillary. It curves downward within the inferior meatus, assisting in filling up the antral orifice, and in its attachment, steadies the bone firmly on the side of the naris. Externally, the general appearance of the bone is concave; internally, or looking toward the septum narium, it is convex. If the external surface were convex, and the processes absent, the bone might very well be likened in shape to the Indian stone arrow-head.

The turbinated bone is very subject to specific inflammation, which inflammation, if not judiciously combated, is apt to end in its death.

The bone articulates with four others: the ethmoid, the lachrymal, the maxillary, and the palate. No muscles are attached to it.

#### THE ETHMOID BONE.

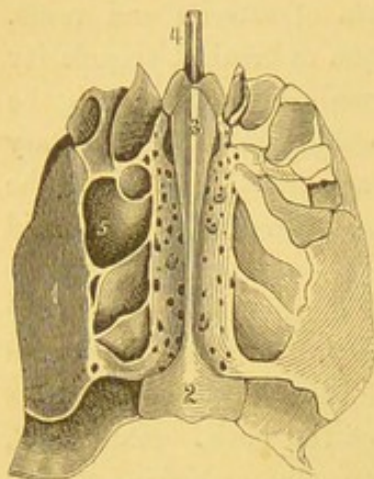
A horizontal cribriform plate of bone, with a crest along its middle; a perpendicular plate dropping down from the centre of this first piece; two little oblong square boxes, hung on either side of the perpendicular plate, leaving the space of a narrow slit between the boxes on either side and the plate, and we have the complete idea of an ethmoid bone. Looking at the piece from above, we remark, first, the crest—*crista galli* it is called—giving attachment to the *falx cerebri*. On either side of this crest is seen a depression perforated with a number of foramina. These depressions lodge the olfactory bulbs, and the foramina transmit to the nose the olfactory filaments, the three sets having corresponding foramina. A slit seen at the side of the *crista galli* transmits the nasal branch of the ophthalmic nerve. Looked at anteriorly, the crest is seen to terminate in two little horns, or wings; these articulate with depressions in the *os frontis*, and occasionally in a manner so imperfect as to leave an opening, or foramen. When existing, this foramen accommodates a nasal vein, which passes upward, to terminate in the longitudinal sinus; the rupture of this vein, discharging the sinus, has saved many a life in congestive attacks of the brain.

The perpendicular plate, exhibited by the removal of one of the lateral



masses, is simply a thin layer of bone. This, descending in the middle line of the nose, assists the vomer in separating that cavity into two lateral halves. In front, it is received into the groove

FIG. 12.—ETHMOID BONE.  
—GENERAL VIEW.



1, orbital surface of the lateral mass; 2, posterior extremity of the cribriform plate, which unites the lateral masses, and is depressed and perforated with numerous foramina on each side of the ethmoidal crest; 3, the two oblique processes in advance of the latter are the ethmoidal wings; 4, anterior extremity of the nasal plate; 5, the ethmoidal sinuses.

between the two nasal bones; below, it looks downward and forward, and receives the triangular cartilage; back of this it articulates with the vomer, and still farther back with the sphenoid.

On each side of the plate are seen numerous grooves leading from the foramina in the horizontal or cribriform plate; these are channels receiving and shielding the inner olfactory filaments.

The boxes, or lateral masses, are very loose and areolar-like; they constitute a series of cells. Disarticulated, many of these cells appear broken. When associated with the ethmoidal fissure of the frontal bone, with the sphenoidal scrolls, with the orbital processes of the palate bones, and with the nasal processes of the maxillary and palate bones, the cells are found to be complete. The relation of these cells, more or less directly with the common nares, and the fact that they are all lined by mucous membrane continued from these fossæ, explain the sense of congestion and fulness known as "cold in the head."

The outer surface, or face of the boxes, looks very much in color like the common clarified quill, is semi-translucent, is square in shape, and very smooth. Referring to the view of the skull (Fig. 1), this surface will be seen entering into the composition of the orbital cavity.

The portion of the ethmoid which receives and articulates the process passing upward from the inferior turbinated bone is a hook-like projection from the under surface of these lateral masses. It is called the unciform process, and assists in narrowing the orifice of the antrum and supporting the masses.

The internal surface of each lateral mass approaches the perpendicular plate. At the upper part is the narrow fissure, bounded by a scroll-like process on the surface, known as the superior meatus. The scroll has received the name superior turbinated bone. Below this first scroll, on the same surface, is a second. This second scroll is called middle turbinated bone, and the space below it, between it and the inferior turbinated bone, is the middle meatus.

In looking at the ethmoid bone in position, it is seen to be wedged in between the nasal, frontal, lachrymal, and maxillary bones in front, and the



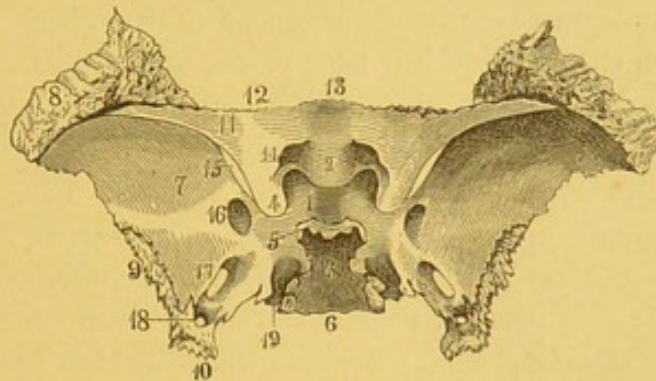
sphenoid behind; below it is supported by the turbinated, vomer, and palate bones. Maxillary diseases find easy road to the base of the cranium through the nasal communication with the ethmoidal cells.

### THE SPHENOID BONE.

The sphenoid bone, named from its wedge-like relations to other bones of the cranium, has been frequently and not inaptly compared in appearance to a "bat" with extended wings and unflexed legs.

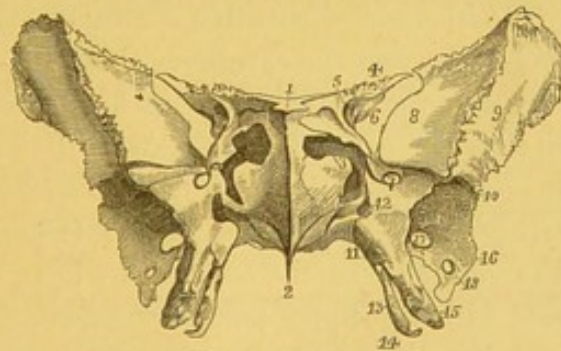
In looking at the disarticulated bone, we first observe a central portion, or body; this body is irregularly square, and marked on all its surfaces with fea-

FIG. 13.—SPHENOID BONE.—UPPER VIEW.



1, pituitary fossa; 2, olivary process; 3, declivity; 4, anterior clinoid process; 5, posterior clinoid process; 6, posterior border of the body; 7, cerebral surface of the great wing; 8, articular surface for the frontal bone; 9, articular border for the temporal bone; 10, spinous process; 11, small wing; 12, border articulating with the orbital plate of the frontal bone; 13, border joining the ethmoid bone; 14, optic foramen; 15, sphenoidal foramen; 16, rotund foramen; 17, oval foramen; 18, spinous foramen; 19, groove for the internal carotid artery.

FIG. 14.—SPHENOID BONE.—FRONT VIEW.



1, 2, sphenoidal crest and rostrum for joining the nasal plate of the ethmoid bone and the vomer; 3, entrance of the sphenoidal sinuses; 4, small wing; 5, optic foramen piercing its base; 6, sphenoidal foramen; 7, rotund foramen; 8, orbital surface of the great wing; 9, temporal surface of the same; 10, ridge separating the temporal and spheno-maxillary fossæ; 11, position of the pterygo-palatine canal; 12, pterygoid canal; 13, internal pterygoid process, ending in a hook; 14, 15, external pterygoid process; 16, spinous process; 17, oval foramen; 18, spinous foramen.

tures which one at once infers to be possessed of anatomical significance. Extending laterally on either side from the body are two great wings; these wings are made double by a lacerated foramen, and instead of being spoken of and described as a single pair, are mostly viewed as two pairs,—the larger



portion being called the greater, the smaller the lesser wings. The legs, falling from the base of the cranium, are found separated by a notch into two portions,—this separation being much more marked behind than in front: they have received the name of pterygoid processes.

Beginning a study of the body from its superior, or cranial surface, attention is first naturally attracted to a saddle-like depression occupying a large portion of the face. This depression lodges a little body attached to the floor of the third ventricle, the pituitary body; hence it is called by many authors the pituitary depression, or fossa; and from its resemblance to the Turkish saddle it is as frequently named the sella turcica. A number of little pits seen on the floor are foramina transmitting vessels of nutrition. On either side are two processes; these correspond to two others, terminating the plate of bone which represents the back of the saddle. The four have been compared to the posts of a bedstead, and are called clinoid processes. Passing forward, an olive-shaped eminence is next noticed,—the olivary process; and directly in front of this, a groove, or oblong fossa. This groove has resting in it the commissure of the optic nerve, and hence is called the optic groove. Passing directly forward, we find the surface terminate in a spine, or projecting point; this point articulates the surface with the ethmoidal bone, and is called the ethmoidal spine; between this spine and the optic groove is a slight eminence falling off on either side into a line of depression; these lines lodge the olfactory nerves. Two foramina, seen on this surface at either terminus of the optic groove, are called optic foramina; they transmit to the orbital cavities the optic nerves and ophthalmic arteries. From the back of the saddle the surface is seen to slope gradually downward; this concave plane lodges the medulla oblongata, and terminates at a line of union with the occipital bone. On either side is situated a tortuous depression, in which lie the internal carotid artery and the cavernous sinus.

Turning now to the anterior surface, there is first observed a rostrum, or beak, for articulation with the perpendicular plate of the ethmoid. On either side of this beak are seen scrolls of bone, or rather lamellæ,—the sphenoidal turbinated bones, as they are called. These lamellæ imperfectly close sinuses which hollow out the substance of the body, and which, in articulation, are found to communicate with the upper part of the nose, and frequently with the ethmoidal cells; being lined with the mucous membrane of the nares, and subjected consequently to the sympathies of continuity.

The inferior surface presents, first, the rostrum or beak; continued from the anterior face this spine is received into a groove, or fissure, in the vomer. On either side are laminæ of bone, which pass to the pterygoid processes; these plates, or laminæ, are called vaginal processes. Close to the pterygoid process is seen a groove, which the sphenoidal process of the palate bone converts into a canal; this groove transmits the pterygo-palatine vessels and pharyngeal nerve.

The posterior surface exhibits simply a quadrilateral sawed surface, union



existing with the occipital at this point, which has required the saw for its separation. Because of such union it is common with many writers to consider the sphenoid and occipital as one piece, and to refer to them as the spheno-occipital bone.

The wings, claiming attention next, are called the greater and lesser, the separation existing at the lacerated foramen. The greater wings extend laterally, and assist largely in forming the floor of the fossæ which receive the middle lobes of the brain. Looked at from the encranial aspect, the sight is first attracted to six foramina,—three on either side. The first of these is a round hole, and is called the foramen rotundum; it transmits from the brain to the superior maxillary bone the second branch of the fifth nerve. The second hole is oval in shape; hence called foramen ovale: it transmits the third, or inferior maxillary branch of the fifth. The third, the foramen spinosum, transmits the middle meningeal artery. A fourth foramen is occasionally found in the great wing,—the vesalli. When existing it is occupied by a small vein. The general floor of these wings is concave, and is marked with elevations and depressions for the accommodation of neighboring convolutions.

Turning the bone, these wings are seen to be made up of three surfaces: the encranial face, as just described; an external surface, occupying, when in articulation, a place in the base of the skull; and an orbital surface.

The external surface is irregularly convex, and is separated into two portions by a ridge called the pterygoid. The superior of these two faces is seen entering into the composition of the temporal fossa for lodgment of the temporal muscle. The inferior face lies beneath the zygoma, and forms part of the fossa of this name, giving attachment to the external pterygoid muscle. Running from the postero-lateral angle of the surface is seen a prolonged spine: to this are attached the laxator tympani muscle and the internal lateral ligament of the lower jaw.

The orbital face of the wing assists in forming the outer boundary of the orbit; it is quadrilateral in form, smooth, and concave. Below, it has a somewhat rounded border, and enters into the formation of the spheno-maxillary fissure; internally, it assists in defining the sphenoidal fissure. At the lower edge of the inner border is a delicate spine, giving origin to one head of the external rectus muscle. The foramina seen on this face are called orbital foramina: they transmit small arteries.

The lesser wings, frequently described as the processes of Ingrassias, are seen on the encranial surface, extending outward, overlying at their apices the great wings. These wings are triangular in shape, having their bases associated with the body of the bone. In articulation they complete the posterior boundary of the anterior fossæ of the cranium, and are lodged in the fissure of Sylvius. The fissure, or slit, which separates them from the great wings, is called the lacerated foramen. It transmits the first, or ophthalmic branch of the fifth nerve, the third, fourth, and sixth nerves, and the ophthalmic vein. The lesser wings are connected with the body by two footstalks, en-



closing within them and assisting in forming the optic foramina. A process seen jutting backward from the foramen is called the anterior clinoid process; to it is attached the common tendon of the recti muscles.

The legs, or pterygoid processes, seen falling from the point of union of the great wings with the body, consist of two plates, separated behind by a deep notch, but united almost fully in front. The external plate is broad and curved; it forms part of the zygomatic fossa: to it is attached the external pterygoid muscle. The internal face forms part of the pterygoid fossa, and gives origin to the internal pterygoid. The internal plate is possessed of particular interest; it ends in a tubercle, or hook-like process, which is felt in the mouth just back of the maxillary tuberosity,—the hamular process; around it turns the tendon of the tensor palati muscle,—a tendon to be divided in the Fergusson operation for cleft palate. The base of this internal plate forms a fossa, the scaphoid, from which originates the tensor muscle just alluded to. The outer surface of the plate forms the pterygoid fossa; the inner assists in marking the outer posterior boundary of the nares.

The base of the pterygoid process is quite broad, and in front gives support to Meckel's ganglion. The vidian canal passes through it.

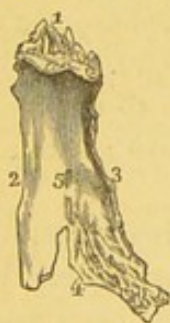The sphenoid articulates with all the bones of the cranium, with the two malar, the vomer, and the two palate bones of the face.

The muscles to which it gives origin are the temporal, external and internal pterygoid, tensor palati, laxator tympani, levator palpebræ, the recti of the eye, and superior oblique of eye.

#### THE NASAL BONE.

The figure exhibits the faces of a left nasal bone articulating with its fellow, which is its counterpart. The two occupy the quadrilateral space existing between the two maxillary bones and the frontal, and form the prominence known as the nasal bridge. That

FIG. 15.  
NASAL BONE.



ANTERIOR VIEW OF  
THE LEFT NASAL BONE.  
1, frontal border; 2,  
nasal border; 3, max-  
illary border; 4, lower  
border; 5, nasal fora-  
men.

these bones vary considerably in shape would be inferred from variations in the shape of the bridge so frequently seen. Looked at from above downward, each bone is observed to be concave, while viewed from side to side it is convex; several light grooves are commonly noticed on the surface for the accommodation of vessels; the foramen seen about the centre transmits a small vein.

The inner surface reverses relations with the outer,—being convex from above below, concave from side to side. Its only feature of interest is a groove for the lodgment of the nasal nerve.

The borders of the bone are three articular and one free. The superior, serrated and somewhat narrow, fits in the frontal notch, forming the fronto-nasal articulation. The lateral border is bevelled, at the expense, above, of the internal plate, below,



of the external, and fits with corresponding bevellings of the nasal processes of the maxillary bone. Internally, or mesially, the bone articulates with its fellow of the opposite side, being prolonged below into a crest, which forms a part of the nasal septum, and articulates with the nasal spine of the frontal above, and the ethmoidal perpendicular plate below. The lower border is free, at least so far as any bony articulation is concerned; it gives attachment by a thin, sharp edge to the lateral cartilage of the nose. A notch, seen at the centre of this border, transmits the nerve occupying the groove on the inner surface.

#### THE MALAR BONE.

The malar, or cheek bones, are to be likened to two bony pads laid on either lateral aspect of the face for the purpose of influencing a general convexity. Each bone is irregularly quadrilateral, supported above by articulation with the frontal, sphenoid, and superior maxillary bones; in front by the malar process of the maxillary; posteriorly by the zygomatic process of the temporal.

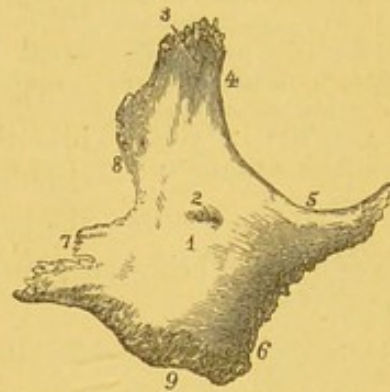
The bone presents two surfaces, four processes, and four borders. The external surface, convex and smooth, presents little of interest; the foramen, seen upon this face, is sometimes replaced by two or more; they are simply the orifices of canals, transmitting unimportant vessels. The surface, in relationship, is mostly covered by the orbicularis palpebrarum muscle, while the zygomatici have origin from the lower and inner aspect.

The internal face is concave, and assists in forming, above, the temporal fossa, below, the zygomatic. It yields partial origin to both the temporal and masseter muscles.

Of the four processes, the orbital is the most important; turning at right angles with the external face of the body, it assists in forming a portion of the outer wall of the orbit and orbital ridge. The frontal is thick and serrated, and articulates with the external angular process of the frontal bone. The maxillary is rough, and triangular in shape, and attaches the bone in front. The zygomatic is sharp and flat, and forms part of the yoke overlying the ridge separating the zygomatic from the temporal fossa.

The four borders are the orbital, the maxillary, zygomatic, and temporal. These borders correspond with the relations named, but have no interest apart from the processes.

FIG. 16.—MALAR BONE.



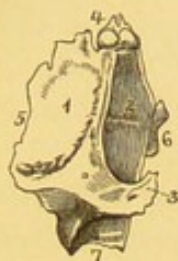OUTER VIEW OF THE RIGHT MALAR BONE. 1, external or facial surface; 2, malar foramen; 3, frontal process; 4, 5, orbital border; 6, maxillary border; 7, zygomatic process; 8, temporal border; 9, inferior border.



## THE LACHRYMAL BONE.

Looking at the diagram, or, much better, at an articulated skull, the lachrymal bone is seen to occupy a position of some prominence in the composition of the orbit.

FIG. 17.—LACHRYMAL BONE.



(EXTERNAL VIEW OF THE RIGHT LACHRYMAL BONE. 1, orbital surface; 2, lachrymal fossa; 3, small process bounding the latter inferiorly; 4, frontal border; 5, ethmoidal border; 6, maxillary border; 7, process articulating with the turbinated bone.

A ridge on its anterior surface divides the bone into two parts: one part, called its orbital face (bounded above by the orbital plane of the horizontal plate of the frontal bone; laterally, by the os planum of the ethmoid; below, by the orbital surface of the maxillary bone), enters into the composition of the orbital cavity. The face, to the inner side of the ridge, is smooth and concave, and articulates with the nasal process of the maxillary bone, internally, and with the lachrymal process of the turbinated below; these three bones in their union form the ductus ad nasum, or lachrymal canal, transmitting the tears to the inferior meatus.

The bone, by its internal, or nasal surface, enters into the composition of the middle meatus, and assists in closing in the anterior ethmoidal cells. Like the external surface, it is divided into two faces, the

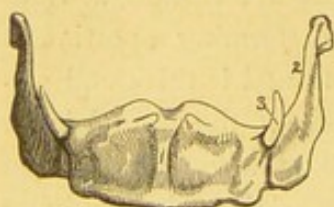line of division being a depression corresponding with the ridge on the opposite surface.

Only one muscle has its attachment to this bone,—the tensor tarsi.

## THE HYOID BONE.

The os hyoides is the bone situated on the anterior part of the neck between the chin and sternum. In shape it somewhat resembles an ordinary horseshoe, being held in place entirely by a series of antagonizing muscles, of which it gives attachment to some ten pairs. A glance at the bone naturally divides it into a body and four cornuæ, or horns; the greater pair of these cornuæ

FIG. 18.—HYOID BONE.



1, body; 2, greater horn; 3, lesser horn.

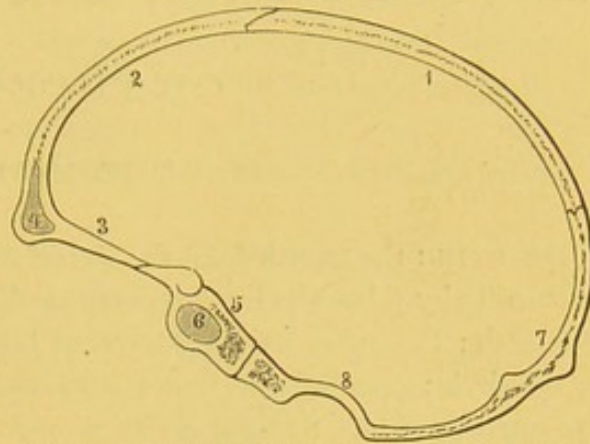
extend widely over the lateral aspect of the neck, giving attachment, on each side, to the hyoglossus, middle constrictor of the pharynx, and thyro-hyoid muscles, and by a bulb constituting the extremity, to the thyro-hyoid ligament; they also serve as a guide to the surgeon in seeking the position of the lingualis artery. The lesser cornuæ are simply two conical eminences, more or less prominent on different specimens; starting

out at the point of junction of the great horns with the body, these look upward toward the chin, and serve to afford attachment to the stylo-hyoid ligaments.



The body of the bone is irregularly quadrilateral in shape, convex in front, concave behind. A crucial ridge, the intermuscular, divides the front face into four fossæ. This surface is devoted exclusively to the attachment of muscles; above, to the genio-hyoid and the genio-hyoglossus; below, to the stylo-hyoid, mylo-hyoid, and digastricus. The posterior surface is smooth and concave, and occupies a position just in front of the epiglottis, being separated from it above by some cellular tissue and a membrane called, because of its relationship, the thyro-hyoid.

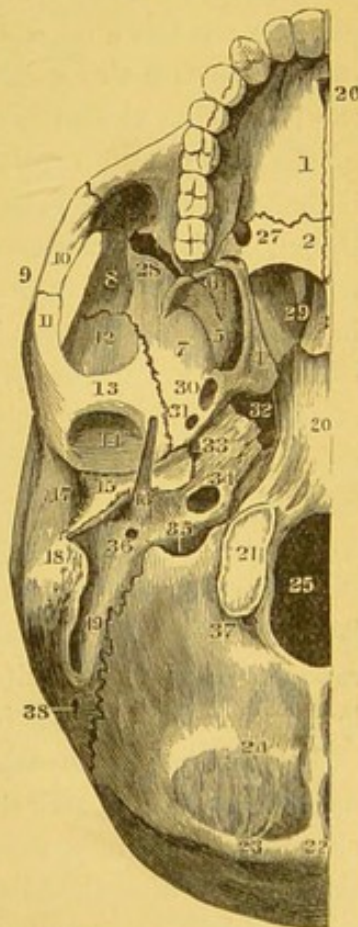
FIG. 19.



ANTERO-POSTERIOR SECTION OF THE CRANIUM, exhibiting the mode by which the connection of the different bones contributes to preserve its integrity. 1, parietal bone; 2, frontal bone; 3, its orbital plate; 4, frontal sinus; 5, body of sphenoid bone; 6, sphenoidal sinus; 7, occipital bone; 8, marginal ridge of the occipital foramen.

FIG. 20.

VIEW OF THE RIGHT HALF OF THE BASE OF THE SKULL. 1, palate plate of the superior maxillary bone; 2, palate plate of the palate bone; 3, vomer; 4, internal pterygoid process; 5, external pterygoid process; 6, pyramidal process of the palate bone; 7, under surface of the great wing of the sphenoid bone; 8, its temporal surface; 9, zygomatic arch; 10, zygomatic process of the malar bone; 11, zygomatic process of the temporal bone; 12, squamous portion of the temporal bone; 13, glenoid tubercle; 14, glenoid cavity; 15, vaginal process, its outer border constituting the auditory process; 16, styloid process; 17, external auditory meatus; 18, mastoid process; 19, digastric groove; 20, basilar process of the occipital bone co-ossified with the body of the sphenoid bone; 21, condyle; 22, occipital protuberance; 23, superior, and 24, inferior semicircular ridges; 25, occipital foramen; 26, incisive foramen; 27, posterior palatine foramen; 28, spheno-maxillary foramen; 29, posterior naris; 30, oval foramen; 31, spinous foramen; 32, lacerated foramen; 33, Eustachian tube; 34, carotid canal; 35, jugular foramen; 36, stylo-mastoid foramen; 37, 38, foramina for veins.





## CHAPTER II.

### THE MOUTH.

STUDYING the mouth from the living subject, we remark, first, an entrance of two fleshy folds, the lips; separating these, we are met by a second portal, the teeth; the space existing between these two entrances is called the hall, or vestibule; opening this inner gateway, by depressing the lower jaw, we are introduced into the oral cavity proper.

The mouth is the commencement of the alimentary canal. It has as offices, the reception of food, gustation, mastication, insalivation, and expression in sound; consequently must possess organs and agencies pertinent to these ends.

Looking into the cavity, it is observed to be an oval archway, bounded posteriorly by a veil, or curtain. This curtain falls obliquely into the pharynx; it has a central pendulum, and terminates laterally in curves. We can see beneath this veil, or between it and the base, and thereby recognize the part being viewed as simply the commencement of a canal. Every part of the cavity is seen to be covered by a common membrane, which membrane is found to associate externally on the lips with the skin; internally with the throat,—this is mucous membrane; examination reveals it to be continuous from the lips to the outlet of the rectum. The teeth, thirty-two in number in the adult, are placed in two harmonizing, or articulating arches, and are, in shape and character, correspondent with omnivorous habits. Thus certain of their number, the incisors, are so arranged as to cut, or incise. Certain others, the cuspidati, or canines, are spear-shaped; these tear, or lacerate. Still others, the bicuspidati and molars, have broad and roughened surfaces; they act the part of grinders. The tongue, a muscular body, rests within the lower dental arch; it evidently is fitted and suited to preside over the labor of the teeth, to receive or reject articles to be comminuted, to place and retain articles in a position to be masticated, and, when ready to be swallowed, to roll up masses into a bolus, and pass this into the pharynx.

The roof of the mouth, beginning with the palatal faces of the teeth, is made up of hard and soft tissues. The hard portion is the flesh-colored alveolar and palate processes of the superior maxillary bones and the palate processes of the palate bones. The soft part dissection reveals to be a simple attached basement tissue covered with the common membrane.

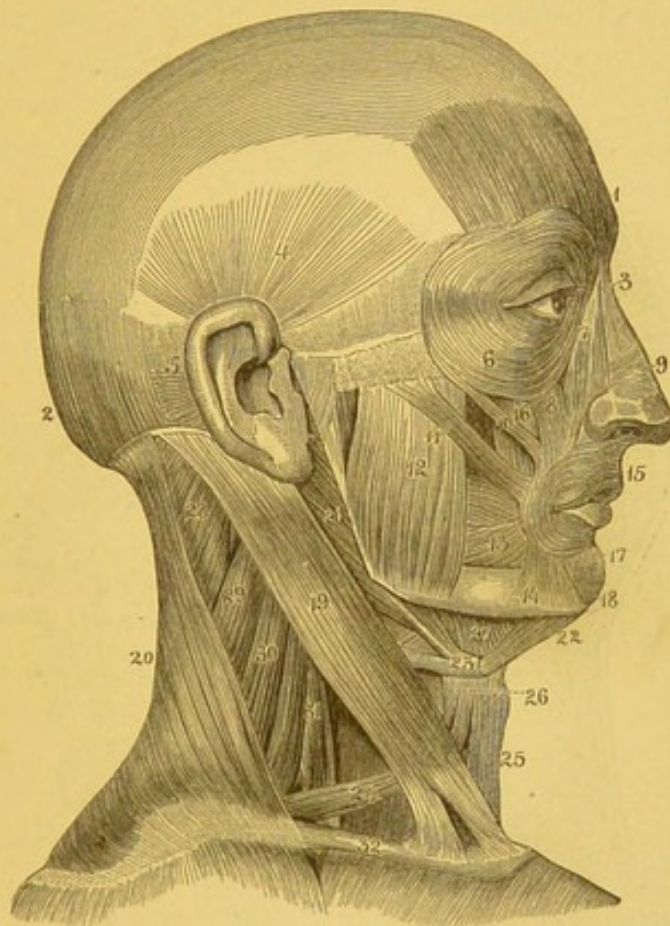
The uvula, the central pendulous termination of the soft palate, consists of two symmetrical muscles enclosed in a common envelope of mucous mem-



brane. The office of this body is to act as an agent excitve of the act of deglutition. It draws the veil against the upper wall of the pharynx, thus closing the posterior nares during the process of swallowing. In the production of loud declamation and in the guttural forms of language, it is supposed to modify speech by lessening the pharyngo-nasal passage when it acts as an elevator; this elevating force being most exhibited in the highest ranges of the singing voice, and least in the lower keys.

Looking for a short period into the mouth, it is observed that jets of fluid

FIG. 21.—MUSCLES OF THE FACE.



MUSCLES OF THE HEAD AND NECK. 1, 2, occipito-frontal muscle; 1, its frontal belly; 2, its occipital belly; 3, nasal pyramidal muscle; 4, superior, and 5, posterior auricular muscles; 6, palpebral orbicular muscle; 7, labio-nasal elevator; 8, elevator of the upper lip; 9, nasal compressor; 10, 11, zygomatic muscles; 12, masseter muscle; 13, buccinator; 14, depressor of the oral angle; 15, oral orbicular muscle; 16, elevator of the oral angle; 17, 18, depressor of the lower lip; 19, sterno-mastoid muscle; 20, trapezius; 21, posterior belly of the digastric and the stylo-hyoid muscle; 22, anterior belly of the former; 23, loop of fibrous tissue attaching the tendon of the digastric muscle to the hyoid bone; 24, omohyoid muscle; 25, sterno-hyoid; 26, sterno-thyroid, seen to the outer side and behind the anterior belly of the omohyoid; 27, mylo-hyoid; 28, splenius; 29, elevator of the scapular angle; 30, 31, middle and anterior scalene muscles; 32, clavicle.

are occasionally sent up from the anterior floor just back of the lower central teeth. We also see drops constantly issuing from an orifice situated on the cheek by the side of the superior second molar tooth. This fluid is the salivary secretion, and comes from glands situated in the immediate neighbor-

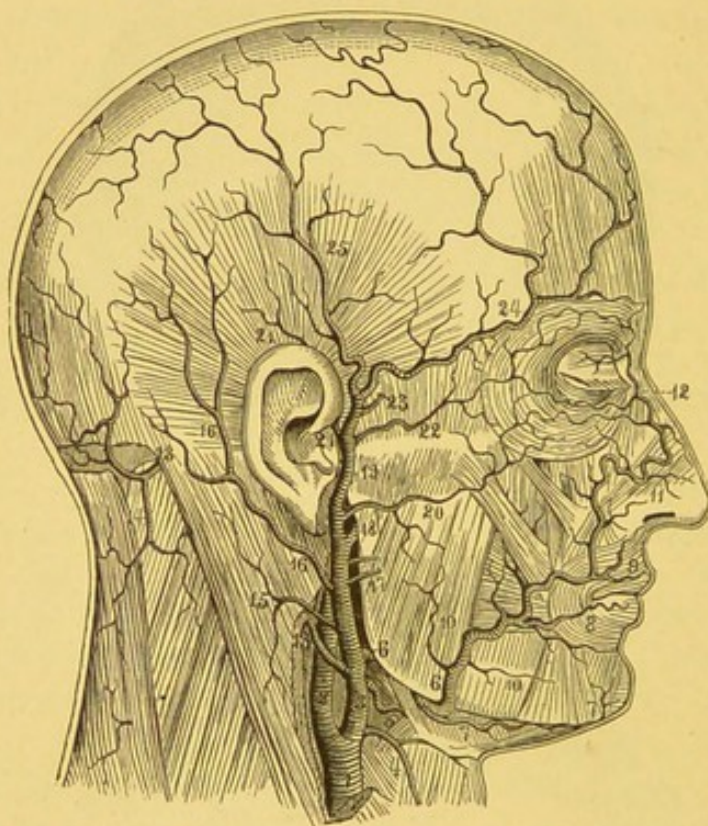


hood. Besides this salivary fluid, pearly drops are seen, more or less plainly, over the surface of the common mucous membrane. This is mucus, and is the product of the follicles, crypts, or glands of the common membrane.

The mouth, then, we are to say, is made up of, and invites a study of, the lips, cheeks, gums, teeth, mucous membrane, tongue, hard and soft palate, and salivary glands; and if we accept, as indeed surgically we must, that the cavity begins with the lips and ends at the posterior wall of the pharynx, then we include in the study all the relations which exist between inlet and outlet.

Lips and cheeks are alike in their composition, and are truly part and parcel of each other. First, in the dissection, we have a layer of skin on

FIG. 22.—ARTERIES OF THE FACE.



THE EXTERNAL CAROTID ARTERY AND ITS BRANCHES. 1, right common carotid; 2, internal carotid; 3, external carotid; 4, superior thyroid; 5, lingual; 6, facial; 7, submental; 8, inferior coronary; 9, superior coronary; 10, muscular branches; 11, lateral nasal artery; 12, angular artery; 13, occipital artery; 14, descending cervical; 15, muscular branch; 16, posterior auricular artery; 17, parotid branches; 18, internal maxillary; 19, temporal; 20, transverse facial; 21, anterior auricular; 22, supraorbital; 23, middle temporal; 24, anterior temporal; 25, posterior temporal artery.

the outside and a layer of mucous membrane on the inside. Removing the skin, which here is thin as compared with that upon other parts of the body, we expose a layer of cellular fascia, in which is more or less fatty tissue. This, superficial fascia, as it is called, differs from other fasciæ of the same signification, in not being distinct, or laminated. It is intimately connected with the skin, and closely associated with the muscles. Removing this, a

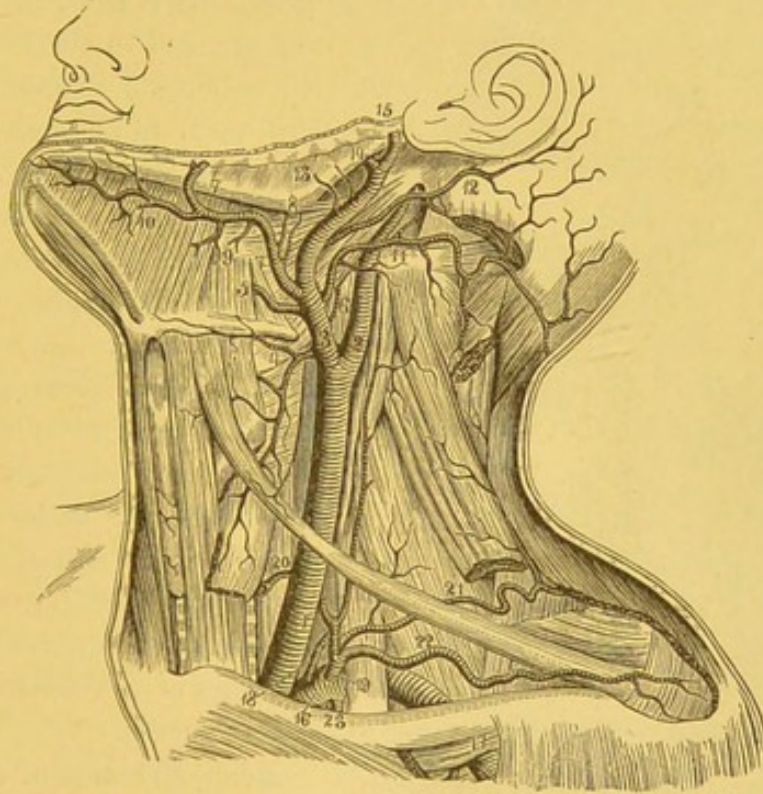


complex grouping of muscles is exposed,—the muscles of expression. (For names of these, refer to description under Fig. 21.)

The view (Fig. 21) expresses so fully the position and signification of these muscles that it scarcely seems necessary to enter on any description of them. The orbicular, or sphincter of the lips, may, however, be specially noted, as its influence is concerned in retracting wounds of the part. In studying the muscles of the face, it will be observed that they naturally arrange themselves into groups. Thus we have a group that are elevators, another that are depressors. Then groups that pertain to particular regions, as the nasal, superior maxillary, inferior maxillary, intermaxillary, etc. Surgically, however, information pertaining to the muscles is sufficiently elicited in comprehending their general plan and arrangement.

Situated upon, and running among these muscles, we have the arteries of the face. These are all branches of the external division of the common

FIG. 23.—THE COMMON CAROTID, WITH ITS DIVISIONS.



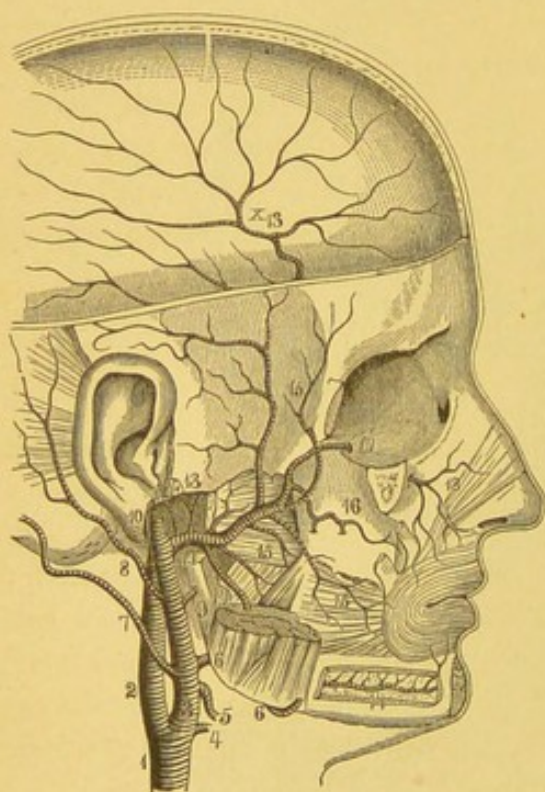
LEFT COMMON CAROTID DIVIDING INTO THE EXTERNAL AND INTERNAL CAROTID ARTERIES. 1, common carotid artery; 2, internal carotid; 3, external carotid; 4, superior thyroid; 5, lingual; 6, pharyngeal artery; 7, facial; 8, inferior palatine and tonsillar arteries; 9, submaxillary; 10, submental; 11, occipital; 12, posterior auricular; 13, parotid branches; 14, internal maxillary; 15, temporal artery; 16, subclavian artery; 17, axillary; 18, vertebral artery; 19, thyroid axis; 20, inferior thyroid giving off the ascending cervical; 21, transverse cervical; 22, suprascapular; 23, internal mammary artery.

carotid, and will be found, in a dissection, distributed exactly as seen in the view. The facial, the third branch of the carotid externus, is observed to cross over the lower jaw just in front of the masseter muscle; and, in the



subject, is seen to emerge from or beneath the submaxillary gland, generally passing through its substance. Its branches are ten in number; four are offshoots from its cervical portion; six are facial. The facial branches are: first, the inferior labial—which passes forward under the depressor anguli oris, and supplies the lower part of the lip, anastomosing with all the subjacent vessels; with the submental, inferior coronary, and inferior dental arteries. The coronaries—the second and third of the branches of the facial—penetrate the substance of the underlying muscles, and pass around the lips immediately beneath the mucous membrane; their pulsation is to be felt very plainly; in many persons these vessels are of such large size as to render hemorrhage from them a matter of trouble to control. The lateralis nasi, the fourth of the branches, ascends along the side of the nose, supplying the

FIG. 24.



INTERNAL MAXILLARY ARTERY. 1, right common carotid; 2, internal carotid; 3, external carotid; 4, superior thyroid; 5, lingual; 6, facial; 7, occipital; 8, posterior auricular; 9, parotid branch; 10, temporal artery; 11, internal maxillary; 12, tympanic; 13, the great and small meningeal arteries from a common branch; 14, inferior dental artery; 15, muscular branches; 16, superior maxillary, or alveolar, artery giving off the posterior dental arteries; 17, 18, infra-orbital artery.

ing behind the neck of the lower jaw, and running horizontally forward between the pterygoid muscles; its relation with the neck of the jaw is a point of special interest and of importance to remember. The artery, almost

alæ and dorsum. The fifth, the angular artery, passes between the inner canthus and nasal bridge; it gives off sub-branches to the orbicularis muscle, to the lachrymal sac, and to the integument of the suborbital region, and finally loses itself in an anastomosis with the ophthalmic artery. A point in the diagram to observe is, that the inferior and all the mesial line of the face is supplied by branches of a common trunk, and that this trunk is compressible on the lower jaw just in front of the masseter muscle, facial hemorrhage being thus perfectly under control by compression. Observation is also to be extended to the internal anastomosis that exists between the branches of the facial and neighboring vessels.

**Deep Arteries of Facial Region.**—The deep circulation relates with the internal maxillary artery. This is a terminal branch, or division, of the external carotid, which division occurs in the substance of the parotid gland; the vessel pass-



immediately on its origin from the carotid, gives off the inferior maxillary vessel (14), which, entering the posterior dental foramen, supplies all the lower teeth. Passing inward, it terminates in two branches; one of these, the infraorbital (17), enters the orbit at the speno-maxillary fissure, passes into the infraorbital canal, emerges from the foramen externus of this canal, lying here beneath the levator labii superioris muscle, and breaks up into vessels which supply the lachrymal sac and inner angle of the orbit; while in the canal branches are given off which descend through foramina in the bone to the anterior teeth and to the mucous membrane of the antrum. The other terminal branch, the alveolar, the origin of which lies in the speno-maxillary fossa, passes along the maxillary tuberosity, breaking into branches, which supply the molar and bicuspid teeth, the mucous membrane of the antrum, and the gums. Besides the three named, the internal maxillary gives off eleven other branches; 12, tympanic; this supplies the tympanum: it enters the bone at the Glasserian fissure; 13, great and small meningeal: the first passes into the cranial cavity through the foramen spinosum, the second through the oval foramen; both supply the dura mater; the latter sends a branch to Casserio's ganglion; 15, muscular branches, known as "deep temporal," "pterygoid," "masseteric," "buccinator." The other branches—not distinguished in the diagram—are descending palatine, pterygo-palatine, speno-palatine, and vidian. (See *Anatomy*.)

#### THE VEINS OF THE FACE.

The veins of the face are seen to correspond closely with the arterial distribution. Surgically, these vessels are of little import, as it is seldom that wounds of any of them are sufficiently consequential to demand special attention; the blood is passed by them into one or another of the two jugulars, being not by any means constant in the selection. Between all, however, the most thorough anastomosis always exists, thus rendering it really of little consequence what may be the direct downward course of the current. The veins of the antero-exterior head are the facial, the temporal, the internal maxillary, and the temporo-maxillary.

The facial (5), commencing at the inner angle of the orbit, is formed by the confluence of vessels from the supraorbital, palpebral, nasal, and angular regions. It commences its course downward and outward, passing beneath the zygomatic muscles, taking the superior and inferior lip veins, the buccal, and the masseteric; passes to the base of the jaw, receiving just below it the circulation from the submental, the inferior palatine, the sub-maxillary, and the ranine localities, and, finally, with a great branch, received from the temporo-maxillary vein, loses itself in the deep jugular.

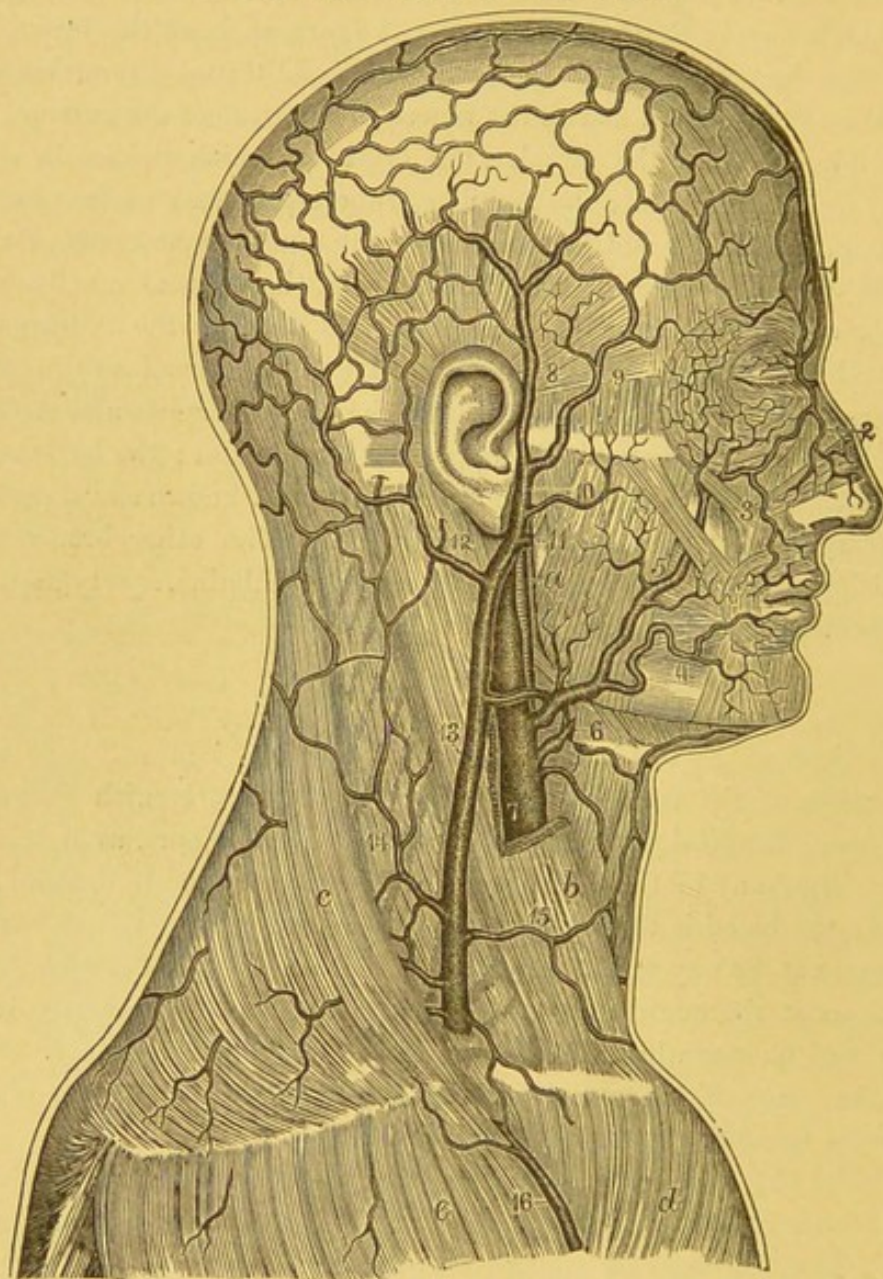
The temporal commences by a plexus upon the side of the head and vertex, passes downward in front of the ear, receives the transverse facial, posterior auricular, occipital, and deep maxillary veins, enters the substance of the



parotid gland, and, finally, being enlarged by these various branches, becomes the external jugular.

The internal, or deep maxillary, is, in its origin, a series of veins collecting the blood from the parts supplied by the internal maxillary artery and ad-

FIG. 25.—VEINS OF THE FACE.



VEINS OF THE HEAD AND NECK. 1, frontal vein; 2, nasal vein; 3, 4, labial veins; 5, facial vein; 6, lingual vein; 8, internal jugular vein; 8, 9, posterior and anterior temporal veins; 10, transverse facial vein; 11, internal maxillary vein; 12, posterior auricular vein; 13, external jugular vein; 14, posterior, 15, anterior jugular veins. *a*, external carotid artery; *b*, sternomastoid muscle; *c*, trapezius; *d*, pectoral muscles; *e*, deltoid muscle.

jacent parts. These various veins, the middle meningeal, deep temporal, pterygoid, masseteric, buccal, and inferior dental, forming the common trunk, empty into the temporal.

The temporo-maxillary is simply the name given to that part of the tem-

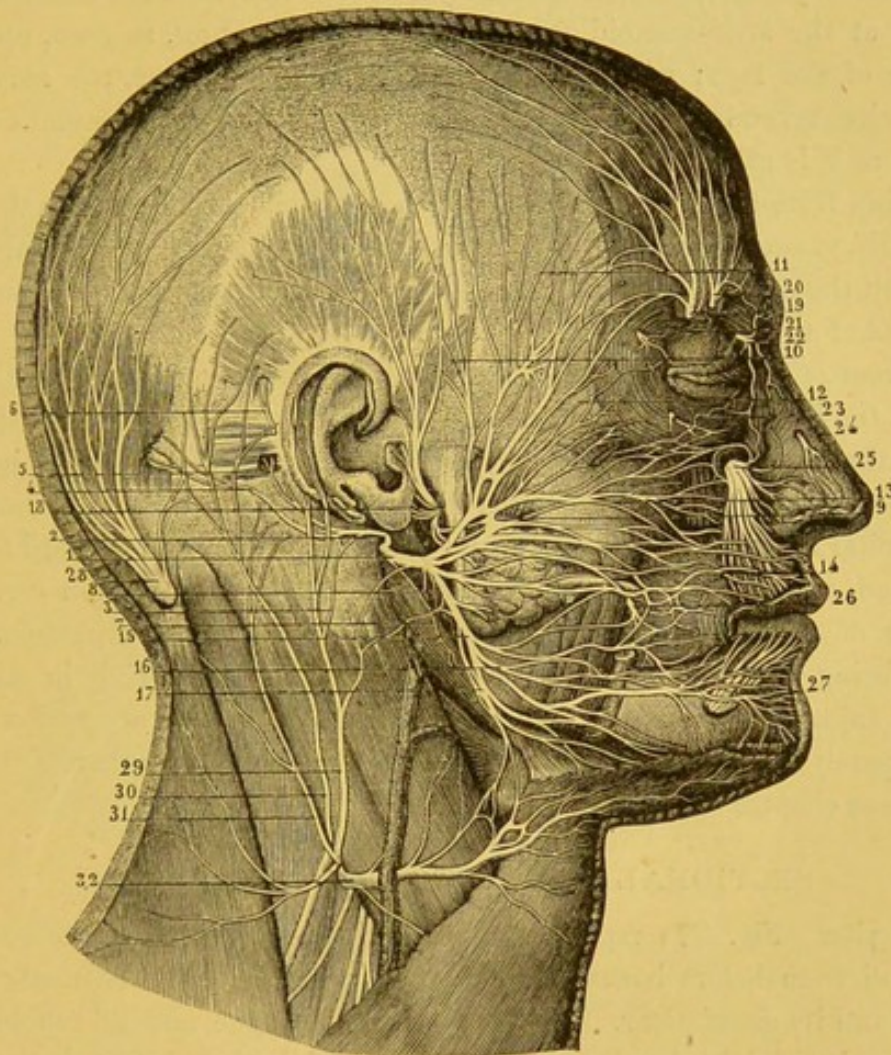


poral vein below the point of entrance of the maxillary—either name is used with equal propriety. (For an elaborate dissection of the veins of the face, see chapter on *Face Operations*.)

### THE NERVES OF THE FACE.

The nerves of the face belong to two classes, sensor and motor. The

FIG. 26.—NERVES OF THE FACE.



1, trunk of the nerve emerging at the stylo-mastoid foramen; 2, its deep auricular branch; 3, anastomosis of the latter with the great auricular nerve of the cervical plexus; 4, 5, 6, branches to the contiguous muscles; 7, 8, branches of the facial to the digastric and stylo-hyoid muscles; 9, temporo-facial division of the nerve; 10, branch to the temple, anastomosing with the auriculo-temporal nerve; 11, temporal branches; 12, zygomatic branches; 13, infraorbital branches; 14, 15, cervico-facial division of the facial nerve; 14, buccal branches; 16, inferior maxillary branches; 17, cervical branches; 18, auriculo-temporal nerve; 19, 20, terminal branches of the frontal nerve; 21, terminal branch of the lachrymal nerve; 22, external nasal nerve; 23, branch of the temporo-malar nerve; 24, terminal branch of the internal nasal nerve; 25, infraorbital nerves; 26, anastomosis between the buccal branch of the inferior maxillary nerve and the buccal branches of the facial nerve; 27, terminal branches of the inferior dental nerve; 28, great occipital nerve; 29, 31, branches of the great auricular nerve; 30, small occipital nerve; 32, superficial cervical nerve, anastomosing with the facial nerve.

first is known as the fifth, or trifacial nerve, the second as the facial nerve. The first pertains to sensation, the second exclusively to motion.



The view (Fig. 26) exhibits beautifully the distribution of the branches of the facial nerve. The main trunk, seen emerging just below the lobe of the ear, in front of the anterior border of the sterno-cleido-mastoideus, is the *portio dura*, or hard portion of the seventh nerve, the motor nerve acting on the muscles of expression. It arises from the medulla oblongata, passes outward over the crus cerebelli, and enters the auditory meatus with the soft, or auditory, portion. Passing to the bottom of this meatus, it enters the Fallopian aqueduct, follows the serpentine course of that canal until it arrives at the stylo-mastoid foramen, whence it emerges, as seen, upon the outside of the face; while, however, in the temporal bone, the nerve connects with several others, and forms a ganglion, the *intumescencia gangli-formis*, as it is called.

Issuing from the stylo-mastoid foramen, the facial associates with the pneumogastric, glosso-pharyngeal, auricularis magnus, and auriculo-temporal nerves, and with the carotid plexus. Passing to the face, it unites with the three divisions of the fifth nerve.

In front of the ear the nerve is seen to divide into two primary divisions, or trunks, the temporo-facial and cervico-facial. The first, the larger of the two, passes through the parotid gland, crosses the neck of the lower jaw, and divides into three sets of branches, distributed to the temporal, malar, and infraorbital regions. The cervico-facial passes downward and forward through the gland, and divides into buccal, supra- and inframaxillary branches. The manner of distribution and anastomosis is shown in the dissection. The facial, being a motor nerve, has its apportionment exclusively in muscular tissue: injury to this nerve exhibits its results in altered expression of the face; paralysis follows its destruction. (For full description of trifacial nerve, see chapter on *Fifth Pair of Nerves*.)

#### SECTIONAL EXPRESSION OF THE MOUTH.

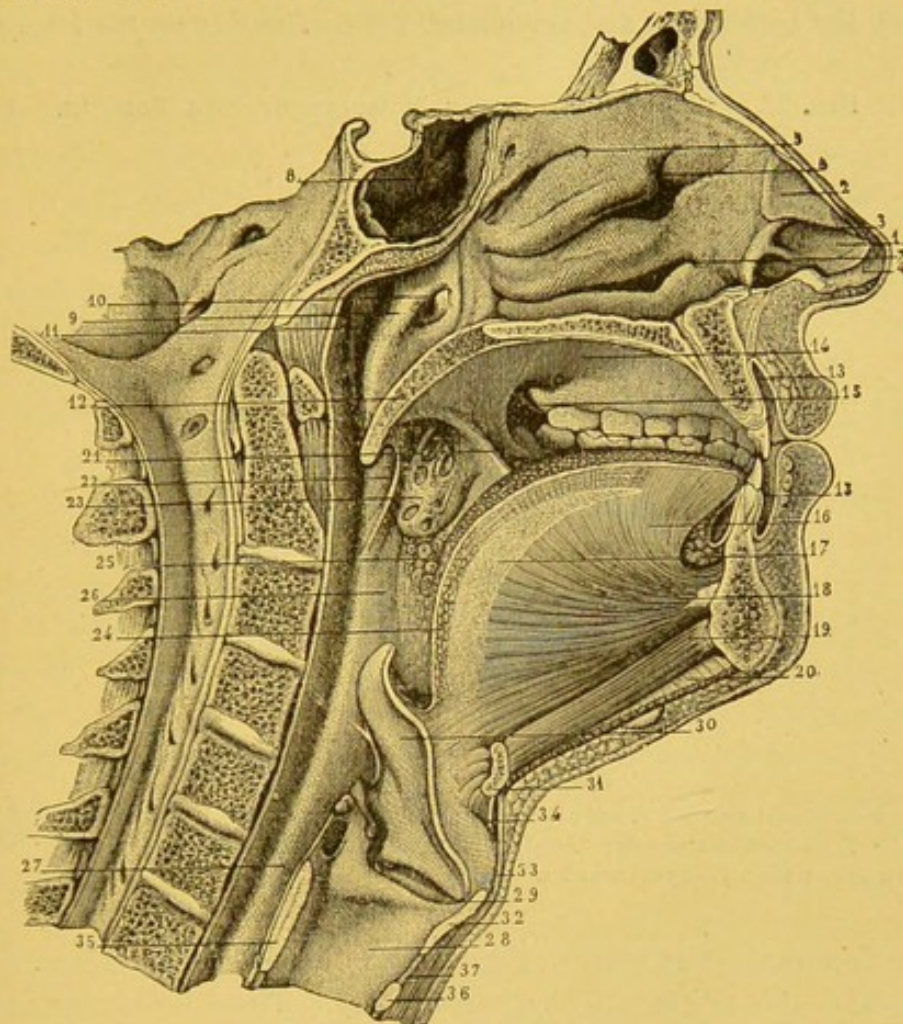
The view (Fig. 27) represents a section directly through the centre of the skull from before backward, and exhibits perfectly the character of the mouth and its associations. Below is seen the tongue and its relations; in front, to the genial tubercles; behind, to the epiglottis. A fossa between the root of this organ and the epiglottis, one on each side of a common centre, the *frænum epiglottidis*, is particularly worthy of note, as it is a not infrequent receptacle for fish-bones and other foreign bodies, which give sometimes much trouble in their removal. The free surface of the tongue is seen to be convex, while the section reveals its common body to be triangular; the apex looks forward.

The roof of the mouth, seen above, is remarked to be a quite thin plane, forming as well the floor of the nares. Its relation to the oral cavity is concave, but differs widely in various persons, being in some almost flat, in others very deep. The anterior portion, bony, will be recognized as being formed by the palatine processes of the maxillary and palate bones. The



posterior part, soft, veil-like, and movable, is the velum, terminating in the uvula in the centre, just above and in front of the tip of the epiglottis. Laterally are two pillars, or half arches, called respectively the anterior and

FIG. 27.—SECTIONAL VIEW OF THE NOSE, MOUTH, AND PHARYNX.



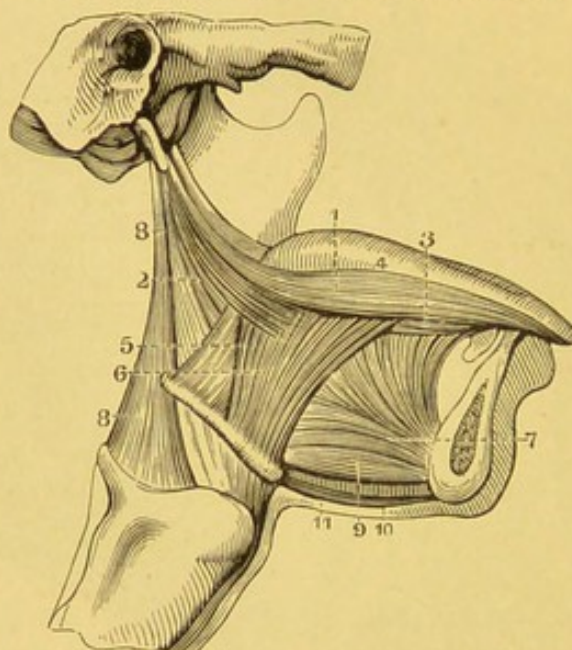
VERTICAL SECTION OF THE FACE AND NECK, THROUGH THE MEDIAN LINE ANTERO-POSTERIORLY, EXPOSING TO VIEW THE NOSE, MOUTH, PHARYNX, AND LARYNX. 1, oval cartilage of the left nostril; 2, triangular cartilage; 3, line of separation between the two; 4, prolongation of the oval cartilage along the column of the nose; 5, superior meatus of the nose; 6, middle meatus; 7, inferior meatus; 8, sphenoidal sinus; 9, posterior part of the left nasal cavity, communicating with the pharynx; 10, orifice of the Eustachian tube; 11, upper extremity of the pharynx; 12, soft palate, ending below in the uvula; 13, interval of the mouth between the lips and jaws; 14, roof of the mouth, or hard palate; 15, communication of the cavity of the mouth with the interval between the jaws and the cheek; 16, tongue; 17, fibrous partition in the median line of the latter; 18, genio-glossal muscle; 19, genio-hyoid muscle; 20, mylo-hyoid muscle; 21, anterior half arch of the palate; 22, posterior half arch of the palate; 23, tonsil; 24, 25, floor of the fauces; 26, 27, pharynx; 28, cavity of the larynx; 29, ventricle of the larynx; 30, epiglottis; 31, hyoid bone; 32, 33, thyroid cartilage; 34, thyro-hyoid membrane; 35, 36, cricoid cartilage; 37, vocal membrane.

posterior pillars. The first of these—the one seen in the view as associating itself with the tongue—is formed by a projection of the palato-glossus muscle; the second, or posterior, is likewise the projection of a muscle, the palato-pharyngeus, passing from the veil to the pharynx. The fossa existing



between these pillars lodges the tonsil gland. The hard portion of the oral roof, or nasal floor, is frequently the seat of necrosis; it will be remarked that only a very small loss of substance is required to associate the two cavities. The oro-pharyngeal space, the space between the two arches, is bounded, above, by the margin of the palate, below, by the base of the tongue, laterally, by the half arches and amygdalæ. (See *Diseases of the Pharynx*.)

FIG. 28.—SIDE VIEW OF THE MUSCLES OF THE TONGUE.



1, 2, stylo-glossal muscle; 3, lingual muscle; 4, upper part of the tongue; 5, 6, hyoglossal muscle; 7, genio-glossal muscle; 8, stylo-pharyngeal muscle; 9, genio-hyoid muscle; 10, 11, median line of the mylo-hyoid muscles.

**THE TONSILS.**—The tonsils (Figs. 27, 29) are glandular organs, situated one on either side of the oro-pharyngeal space. These bodies are made up of many lobules, having many sulci lined by involutions of the common mucous membrane. They are not infrequently the seat of such hypertrophy as to make necessary their amputation, while in their sulci is apt to be lodged débris, which, in its retention and decomposition, becomes one of the sources of an unpleasant breath. Externally these bodies are in very close relation with the internal carotid arteries, a point necessary to be kept in remembrance in performing operations on them. (See *Tonsil Glands*.)

The relationship of a bolus of food with the pharynx, and with its direction, over the chink of the glottis into the œsophagus, by the epiglottis, are clearly exhibited by the drawing.

**THE TONGUE.**—Dissection of the tongue reveals it to be a somewhat complex body, although made up in the great mass of its bulk by muscular substance. Attached to the inferior maxillary bone in front, and to the hyoid behind, it yet moves with the greatest freedom and latitude in either direction, affording the idea that if it be muscular substance, it must be free



muscle set upon fixed muscle, and this is practically the case, as is understood by studying a dissection.

The muscular structure of the tongue is made up of five distinct pairs and certain non-attached fasciculi. The body, as its surface is concerned, is seen with a base looking backward into the pharynx, and a tip, which represents the apex of a pyramid. Beginning the study of the organ with its relations to the hyoid bone, we observe, first, that from that bone arises a muscle, the hyoglossus, which, passing almost directly upward, enters, with the stylo-glossus, the root of the body, and expands itself laterally and forward. Passing toward the centre of the bone, we remark a second muscle, the genio-hyoglossus, which, having apparent origin from the genial tubercles, radiates downward and upward, attaching one of its wings to the os hyoides, the other spreading out to assist in the formation of the tongue. The stylo-glossus, the third muscle, arises from the styloid process of the temporal bone, passes downward and forward, and occupies, or makes up, either lateral aspect from the tip to the bone. The fourth, the lingualis, seen between the stylo-glossus and genio-hyoglossus, passes from the tip to the base, having, indeed, some few of its fibres continued to the os hyoides. The fifth, the palato-glossus, is the muscle of the anterior half arch; it assists in forming the base and side. The unattached fibres are certain longitudinal and transverse bands running through the substance of the organ. The tongue, as an organ of nutrition, is adapted most happily, through its muscular character, to preside over the act of mastication, and, this process completed, to transfer the comminuted mass back into the grasp of the pharyngeal constrictors. Its ability and variety of action are comprehended by a moment's observation of the dissection.

Fig. 29, exhibiting the enlarged upper surface of the organ, discovers it covered with mucous membrane, dotted here and there with more or less regularly located papillæ, of varying size and character.

The mucous membrane envelops the tongue wherever the body has free surface. Above, it is dense, and affords support to the papillæ; below, it is exceedingly delicate, and is traceable through the ducts of the submaxillary and sublingual glands.

The papillæ, seen upon the dorsum, are cone-shaped projections of homogeneous tissue, holding arteries, veins, and nerves in plexiform arrangement; they are located in three separate sets, each having distinctive features.

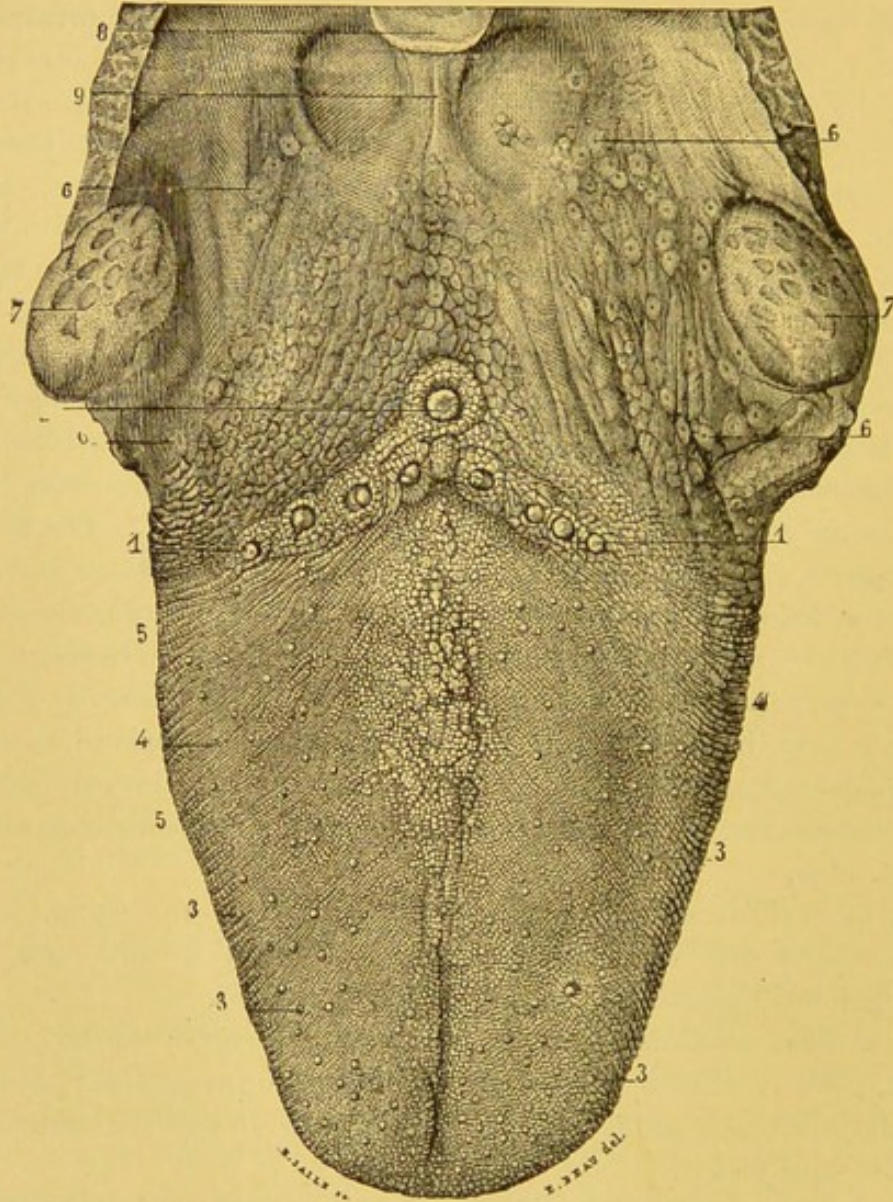
The most posterior are the largest, and occupy a position which very much resembles the letter V; they may be likened to inverted cones, the apices resting in cup-shaped depressions of the mucous membrane, hence surrounded each by a valley. They are variously named, the maximæ or circumvallatæ. Of this class there are some fifteen. The elevated margins of the fossa surrounding these papillæ are studded with secondary papillæ. The structure of the bodies is accurately exhibited in the magnified drawing.

The papillæ fungiformes, or mediæ, are scattered somewhat irregularly over



the sides and apex of the organ; they are exceedingly vascular, and closely covered with secondary papillæ; are broad and rounded on their free surfaces, narrow and pointed at their attachment to the tongue; their middle size and

FIG. 29.—UPPER SURFACE OF THE TONGUE.



1, 2, V-like row of the circumvallate papillæ; 3, capitate papillæ; 4, 5, conical papillæ; 6, 6, floor of the fauces, with numerous simple follicular glands; 7, tonsils; 8, summit of the epiglottis; 9, the middle glosso-epiglottic frænum, with depressions on each side bounded externally by the lateral fræna.

red color easily distinguish them. The magnified fungiform papillæ are seen in the drawing.

The smallest, or filiform, papillæ follow somewhat in their arrangement the order of the maximæ, being interspersed among the fungiformes. They are very minute, and covered so deeply with epithelium as to appear quite white; they are enveloped with secondary papillæ, as exhibited in the figure.

In the tongue, besides these papillæ, numerous mucous glands are found;



these bodies, scattered over the whole surface, secrete the ordinary mucus; they differ in no respect from mucous glands wherever situated. In the valleys surrounding the maximæ papillæ they are found in larger number than in any other portion of the organ.

A transverse section exhibits the tongue as composed of symmetrical halves, separated from each other by a fibrous septum, each half consisting, as seen,

FIGS. 30, 31.—PAPILLÆ OF TONGUE.

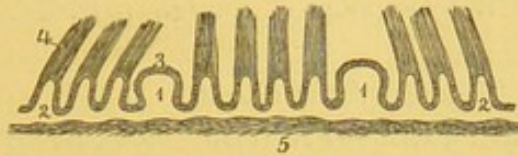
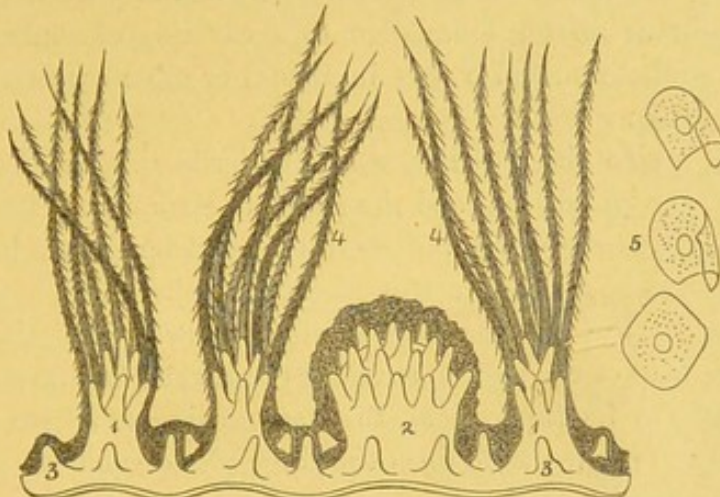


DIAGRAM OF THE PAPILLÆ OF THE TONGUE, moderately magnified. 1, capitate papillæ; 2, conical papillæ; 3, epithelium; 4, the same structure forming bunches of hair-like processes; 5, connective tissue.



PAPILLÆ OF THE TONGUE, highly magnified. 1, conical papillæ; 2, capitate papillæ; 3, simple papillæ, occupying the intervals of the compound papillæ; 4, epithelium ascending from the conical papillæ in hair-like processes; 5, isolated epithelial scales from the latter.

of muscular structure supplied with vessels and nerves, and having, in most cases, much interposed fat.

The tongue, being an organ of both special and common sense, is furnished with nerves of like signification. Thus the papillæ, at the apex and sides, are supplied with gustatory filaments from the third branch of the fifth nerve; the great papillæ and base of the organ, from filaments of the glossopharyngeal; the muscular structure, by the hypoglossal.

The arteries of the tongue are the lingual, branches of the facial, and ascending pharyngeal. The one of most signification is the first. This vessel, in its continuation known as the ranine, anastomoses with its fellow, just above the frænum, on the under surface of the organ, and is liable to be opened in the operation for tongue-tie; it is the second branch from the external carotid; it pursues a course parallel, for a short distance, with the



great horn of the hyoid bone lying between it and the hypoglossal nerve. Wounds of the tongue occasionally make the artery at this point the seat of ligation. (See *Ligation of Arteries*.)

The epiglottis, seen by depressing the dorsum, forms, practically, the base of the tongue; it is supported in the centre by a bridle, the frænum epiglottidis, and at either side by two duplications of the lingual mucous membrane, the glosso-epiglottic ligaments, or folds, as they are called; these boundaries form two lateral depressions, or fossæ, fossæ linguales, noticed as being so frequently the seat of the lodgment of foreign particles. (See *Diseases of the Tongue*.)

THE GUMS.—See *Diseases of the Gums*.

THE MUCOUS MEMBRANE.—Practically considered, the oral mucous membrane is to be viewed as commencing at the lips and terminating at the anus, so much is it in sympathy part with part. Anatomically, it is to be described as consisting of a plane of homogeneous tissue, underlaid by a vascular supply, the vessels being supported by and in cellular tissue. This basement membrane affords foundation to a covering of squamæ, or scales, known as the epithelium, and covers in tissues or organs which have offices of a recrementitial nature.

The tissues, beside the vascular, which underlie the mucous membrane, are the nerves, the lymphatics, and the papillary structure. The epithelium, the covering layer, is singularly various in its character, being in some parts columnar, in others squamous, in still others ciliated.

Commencing at the alveolar margin of the lower jaw, this membrane passes over the floor of the mouth, envelops the tongue on all its free surface, forming beneath, by its duplications, the frænum linguæ; from the back of the organ it is so reflected as to form the three glosso-epiglottic fræna; from this it lines the pharynx and larynx, and is then continued over the digestive and respiratory tracks, lining, in the latter, the very terminal vesicles.

The mucous cysts, or follicles, so plentifully scattered over the oral mucous surface, have, as their office, the secretion of a limpid fluid, which is commonly to be seen standing over the membrane as drops of cold sweat are observed on the forehead in typhoid conditions, the two, indeed, looking very similar. The constituents of mucus are, water, the peculiar organic principle called mucosin, and alkaline salts. Mucous glands are variously named, according to their location, as glandulæ labiales, buccales, etc.

Columnar epithelium consists of rod-like particles, crowded closely together, and bulged near the centre by a nucleus; this variety is found in the air-passages, on the intestinal villi, in the bile duct, and elsewhere. The scaly is found in the alimentary tract, as low as the stomach. The glandular seems to be a constituent of all the glands, being made up of particles bulky and globular. Ciliated epithelium is the columnar variety clothed with secondary particles.



## THE SALIVARY GLANDS.

The salivary glands are of the conglomerate order, and are very well represented by an ordinary bunch of grapes. There is, first, a great number of lobules, each lobule being a miniature gland; from these come ducts, or channels of outlet, representing the grape-stems; these are all associated with a common branch or duct, which is the channel of outlet into the mouth.

**PAROTID.**—The parotid, the largest of the salivary glands, is situated in the hollow between the external ear and ramus of the inferior maxillary bone. Its weight varies considerably in different individuals, the mean being in the neighborhood of an ounce. The boundary of the gland above, is the zygoma; below, a line carried directly across from the angle of the jaw to the sterno-mastoid muscle. Dissected from its bed, the organ is found quite deeply seated; it extends above into the glenoid fossa of the os temporis, and below rests upon the styloid process and muscles, extending forward to the space between the two pterygoid muscles. It is exceedingly vascular, having embedded in it the external carotid artery, which here divides into the temporal, internal maxillary, transverse facial, and posterior auricular. The temporo-maxillary vein also traverses the structure, while the deep jugular and the internal carotid artery lie very close to its inner surface; it is also pierced by the facial and great auricular nerves. Externally, the gland is smooth, and has its lobes protected by a covering, very similar in appearance to the pia mater of the brain. Upon this covering lie two lymphatic bodies, the enlargement of which is often mistaken for disease of the gland itself. Covering the body are the parotid fascia, a reflection of the common deep fascia of the neck, the platysma myoides, fascia superficialis, and skin. The gland empties its secretion into the mouth through a duct known as that of Steno. This duct passes across the face between the superficial fascia and muscles, perforating the buccinator opposite the second molar of the upper jaw: a line, designating its position, and which is most important to be remembered, is drawn from the lobe of the ear to the middle of the upper lip. The duct is composed of firm and resisting tissue, is about the diameter of a crow-quill, and is some two inches in length; it consists of three coats,—an external, or fibro-muscular, an internal, or mucous, lined with ciliated epithelial scales, and a middle, or cellular coat. A glandular body, the associated parotid, is found related with Steno's duct; its location is just outside the perforation of the buccinator muscle by that tube. A tumor associated with the glandular bodies overlying the parotido-masseteric fascia is movable, one situated beneath the fascia is fixed. Tumefaction of the parotid itself shows at the angle of the jaw, otherwise inward toward the throat.

**SUBMAXILLARY.**—The submaxillary, the second in size of the salivary glands, is situated beneath the lower jaw in the superior cervical, or submaxillary triangle. The gland is somewhat of the size and shape of an almond-hull, and has a weight of two or three drachms; it is completely enclosed



in a triangular envelope, made by two leaves of the deep fascia attached below to the digastric tendon. Directly upon the gland, and within the envelope, are two lymphatic bodies, which are quite liable to take on inflammatory enlargement; these glands I believe to be pretty constant, as I have examined many subjects for them, and mostly with the common result of finding them. The so-called extirpation of the submaxillary gland is, most generally, the removal of one of these bodies enlarged through inflammatory action; these ganglia may be surgically viewed as being strictly non-vascular, a ligature being seldom needed in operations upon them. The gland, itself, on the contrary, is very vascular, the facial artery passing frequently directly through its substance, or so closely connected with the lower surface as to compel the division of it, or some of its large branches, before the body can be raised from its bed; the lingualis also sends branches to it. The veins correspond with the arteries. The gland is closely in relation with the parotid, behind, and the lingual, in front, being separated from the first by the stylo-maxillary ligament, and from the latter by the mylo-hyoid muscle. The duct by which the gland conveys its secretion to the mouth is some two inches in length; it passes between the mylo-hyoid and genio-hyoid muscles, and opens by the side of the *frænum linguæ*. It is the most common seat of ranula. It is called Wharton's duct.

**SUBLINGUAL.**—The sublingual is the smallest of the three glands; it rests directly beneath the mucous membrane, being between it and the mylo-hyoid muscle; its weight is about one drachm. The exact position of the gland, as it lies at the lateral aspect of the *frænum linguæ*, can be seen by raising the tip of the tongue; its bulk will be noticed by elevating the mucous membrane, upon which its excretory ducts, some twenty in number, open; these ducts are named Rivini, and are to be distinguished from one or more, called the Bartholin, opening into or near Wharton's duct. The lingual gland, when diseased, may frequently be removed with very little hemorrhage. The author has extirpated it without using a single ligature.

#### TEMPORO-MAXILLARY ARTICULATION.

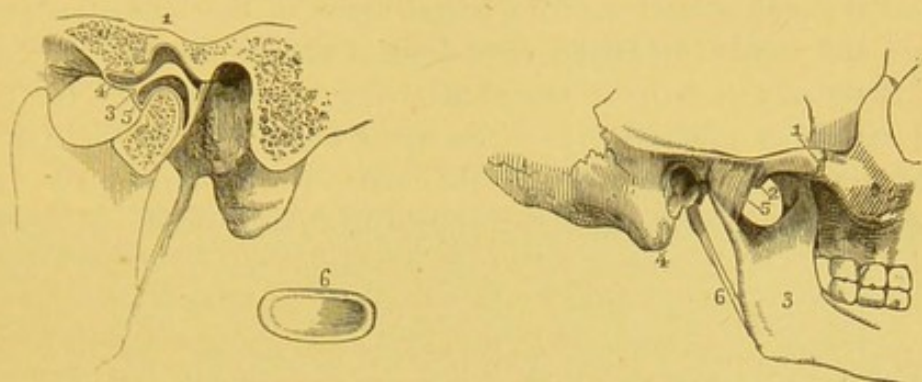
The inferior maxillary bone articulates with the anterior portion of the glenoid cavity of the temporal, forming what is known as an arthrodial, or gliding joint. The direct composition of this joint consists of the convex condyloid head of the maxillary bone, the concave surface of the glenoid fossa, interarticular fibro-cartilage, a double synovial membrane, and a loose capsular ligament. (See engraving.)

The double character of the glenoid fossa, with its fissure of division, its articulating eminence in front, and the cartilage-covered condyle of the maxillary bone, is best understood by looking at the bones. The view represents the parts in position and in physiological relation. Above is seen the glenoid cavity; below, the condyle of the inferior maxilla; between, the interarticular fibro-cartilage, with a synovial, or lubricating, membrane lining each aspect



of the joint; the back part of a common capsular ligament is also exhibited, which, if completed, would be seen enveloping the whole joint.

FIGS. 32, 33.—VERTICAL SECTION OF TEMPORO-MAXILLARY ARTICULATION.



VERTICAL SECTION OF THE ARTICULATION OF THE LOWER JAW. 1, is placed above the glenoid cavity; 2, glenoid cavity; 3, interarticular cartilage dividing the joint into two cavities, 4 and 5; 6, an interarticular cartilage separated from a joint, to exhibit its form.

EXTERNAL VIEW OF THE TEMPORO-MAXILLARY ARTICULATION. 1, zygoma; 2, glenoid tubercle; 3, ramus of the inferior maxillary bone; 4, mastoid process; 5, external lateral ligament; 6, stylo-maxillary ligament, a process of the cervical fascia.

Back of the section is that portion of the cavity which lodges the upper part of the parotid gland.

The capsular ligament is an exceedingly loose sac, very much, indeed, like the capsule of the humero-scapular articulation; it is attached above to the circumference of the glenoid cavity, and in front to the articular root of the zygoma; below, it clasps the neck of the bone just beneath the head.

The interarticular fibro-cartilage is an ovoid plate placed between the two bones. It is supported in its position by a more or less perfect circumferential attachment to the common capsule, the external lateral ligament, and to the tendon of the external pterygoid muscle: below, its face is concave, corresponding with the convexity of the condyle; above, it is concave in front, convex behind, corresponding with the glenoid cavity proper, and the *eminentia articularis*. In composition the circumference is markedly fibrous, shading off to a cartilaginous centre frequently quite soft and sometimes perforated.

The synovial membranes, placed, as seen in the view, one above, the other below the interarticular fibro-cartilage, are the ordinary lubricating membranes of closed cavities; they may very well be likened to two simple bags, with parietal attached faces. These bags secrete the synovia, a fluid which looks not unlike the white of an egg, but which is much more oily and resistive in its nature.

From the spinous process, seen on the great wing of the sphenoid bone, a ligament, the internal lateral, descends to be attached to the inner face of



the ramus. Behind, from the styloid process of the os temporis, a second, the stylo-maxillary, passes to be inserted just above the angle.

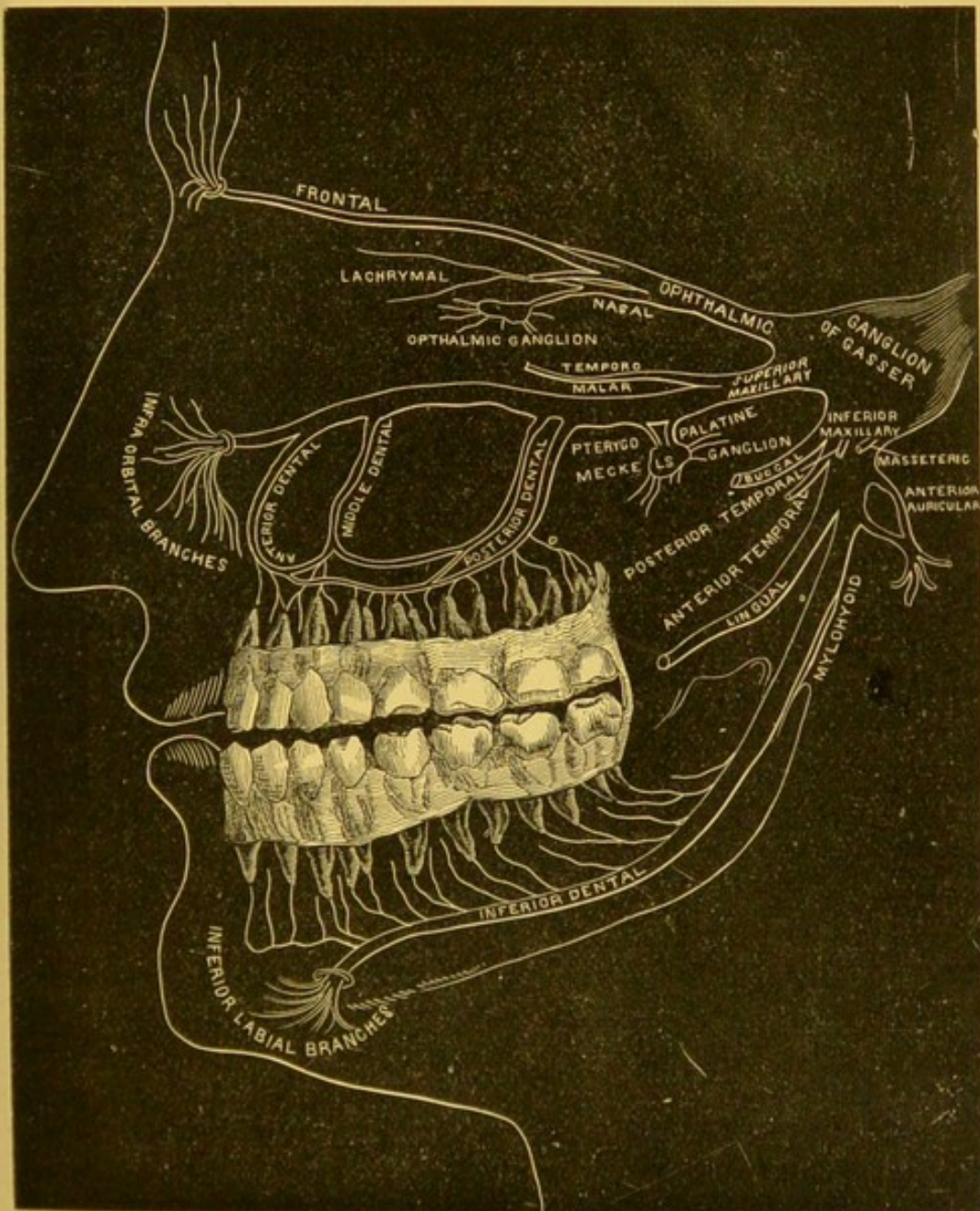
The external lateral ligament is a short, somewhat triangular-shaped band of fibrous tissue, having origin from the zygoma; passing obliquely downward and backward, and inserted about the neck of the condyle. Just below the head it lies in contact with the lateral aspect of the interarticular fibro-cartilage and assists in forming, or at least in thickening, the common capsule. Externally, it is quite superficial, being covered only by the integuments, except in instances where the upper border of the parotid gland spreads over it. The importance of the character of this articulation renders necessary its careful study by direct dissection.



## CHAPTER III.

### FIFTH PAIR OF NERVES.

FIG. 34.—OUTLINE DRAWING EXHIBITING AT A COMMON VIEW THE DISTRIBUTION OF THE FIFTH PAIR OF NERVES.



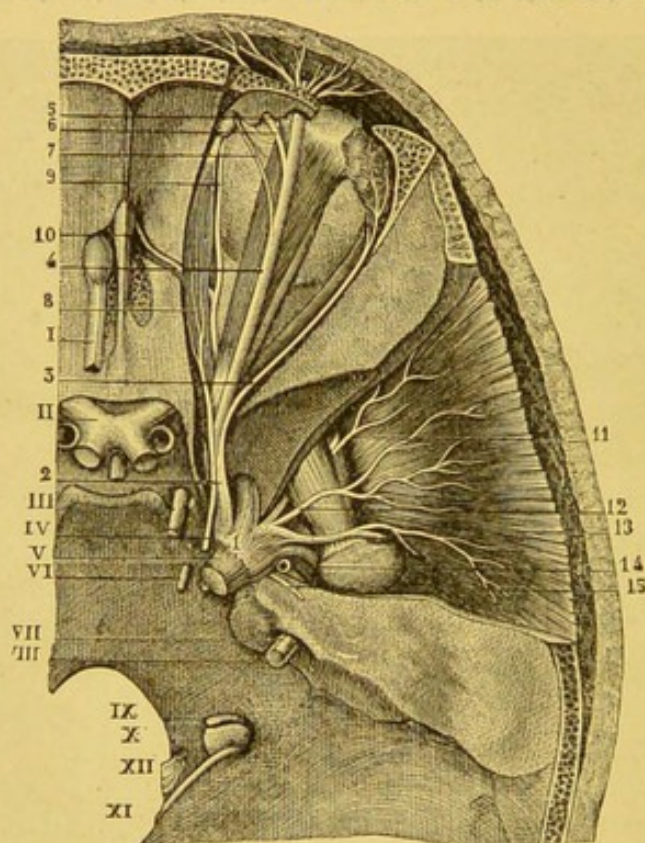
THE Fifth is an encephalic nerve,—that is, it comes off from that portion of the cerebro-spinal centre lying within the cranium. It is called the fifth,



because this is its order of emergence; also trifacial, because it divides into three portions, which portions, in their divisions and subdivisions, are distributed respectively to the superior, middle, and inferior portions of the facial region; also, "trigeminus," a name derived from *tri*, three, *geminus*, twin, or double, signifying literally three double, triple, referring to its threefold division. The fifth is the nerve with which oral surgery has most to do.

The fifth, trifacial, or trigeminus, is first discovered as a number of filaments, of which there are two distinct sets, coming off from the sides of the

FIG. 35.—TRIFACIAL DIVISION AND GANGLION.



TRIFACIAL NERVE, the upper part of the orbit and temporal fossa removed. 1, semilunar ganglion; 2, ophthalmic nerve; 3, lacrimal nerve; 4, frontal nerve; 5, 6, its two principal branches; 7, a branch passing from the orbital above the pulley of the superior oblique muscle; 8, nasal nerve; 9, its external nasal branch; 10, course of the internal nasal nerve from the orbit into the cranium and nose; 11, 12, 13, temporal branches of the inferior maxillary nerve; 14, commencement of the auriculo-temporal nerve; 15, greater petrosal nerve. I, olfactory nerve; II, optic nerves; III, oculo-motor nerve; IV, pathetic nerve to the superior oblique muscle of the eye; V, trifacial nerve; its small root visible beneath the cut end of the large root, which forms the semilunar ganglion dividing into the ophthalmic, superior, and inferior maxillary nerves; VI, abducent nerve; VII, facial, included in a groove of the auditory nerve, VIII, both entering the auditory meatus; IX, glosso-pharyngeal, X, pneumogastric, and XI, accessory nerves emerging at the jugular foramen; XII, hypoglossal nerve.

pons Varolii; this is called the superficial origin of the nerve. The deep, or true origin, is to be traced into the substance of the pons as far as the lateral tract of the medulla oblongata. These filaments of origin are called the roots of the nerve, and, being twofold, afford the likeness which exists between this particular encephalic nerve and those of the spinal cord.



The fifth nerve is peculiar in being both compound and special: that is to say, it supplies parts with filaments of sensation, with filaments of motion, and through one of its branches, the "gustatory," with filaments which pertain to the sense of taste. It is the great sensitive nerve of the head and face; the nerve of motion to the muscles of mastication; a nerve of special sense to the anterior part of the tongue. (See *Function of Nerve*.)

Immediately on the emergence of the roots from the points of their superficial origin, they pass through a slit-like opening in the dura mater at the apex of the petrous portion of the temporal bone. Here the larger root, called the sensor, enters a ganglion, lying in a fossa on the anterior face of this triangular apex, the Casserian, or semilunar.

The ganglion of Casserio is a small reddish-gray semilunar knot enveloping apparently the great, or posterior, root of the fifth nerve as it passes over the temporal apex; its size is about equal to that of an ordinary buckshot, although, from its flattened and crescentic form, the measurement from tip to tip of its horns would surpass somewhat the diameter of such a shot. The convex face of the ganglion looks forward.

On emerging from this ganglion, the posterior root is found divided into three cords,—the three primary divisions of the sensitive portion. The first of these cords constitutes what is called the ophthalmic nerve, or the ophthalmic portion, or division, of the fifth nerve. The second cord is the superior maxillary nerve, or superior maxillary division of the fifth. The third is the inferior maxillary nerve.

The first of these nerves has its distribution over the orbito-frontal region.

The second is distributed over the superior maxillary region.

The third associates with the lesser, or motor root, which root first connects with it at the base of the skull, and finds its office in the inferior maxillary region.

#### OPHTHALMIC NERVE.

This division of the fifth passes from the Casserian ganglion along the outer wall of the cavernous sinus, and enters the orbit through the sphenoidal fissure; before entering this, however, it breaks up into three branches. These branches supply the eyeball, the lachrymal gland, the mucous lining of the nose, and the muscles and the integument of the forehead; they are named frontal, lachrymal, nasal. The ophthalmic is the smallest of the three divisions of the fifth; it is a flattened band not more than an inch in length, receiving, before breaking up into its terminal branches, filaments from the carotid plexus of the sympathetic, and giving off itself two or more filaments, which, with a branch from the fourth nerve, pass between the layers of the tentorium.

The *Frontal Branch* is the largest of the divisions of the ophthalmic, and is commonly regarded as the continuation of the nerve. In the orbit it lies above the levator palpebræ muscle, between it and the periosteum;



dividing about midway of the cavity into two branches,—supratrochlear and supraorbital.

The supratrochlear branch passes inward to the pulley of the superior oblique muscle, giving off here descending filaments which anastomose with similar trochlear filaments from the nasal nerve. A second or terminal branch passes from the orbit between the superior oblique and supraorbital foramen, ascends behind the corrugator supercilii and occipito-frontalis muscles, to both of which it distributes filaments, and is finally lost in the integument of the forehead.

The supraorbital branch, or division, of the frontal runs forward until it reaches the supraorbital foramen, when it passes out upon the forehead. In this situation it gives off a number of filaments to the upper eyelid, called palpebral. In its distribution over the forehead, it sends branches to the orbicularis palpebrarum, occipito-frontalis, and corrugator supercilii muscles, anastomosing in the first-named muscle with filaments of the facial nerve. Other two sets of terminal filaments supply: the first, the periosteum covering the frontal and parietal bones; the second, the integument, as far back as the occiput.

The *Lachrymal*.—This is the smallest of the three divisions of the ophthalmic. It is almost always accompanied by filaments from the fourth nerve. In the eye cavity it connects itself with the orbital branch of the second, or superior maxillary division of the fifth nerve. Its distribution is to the lachrymal gland, the conjunctiva, and the integument of the upper eyelid, in which last situation it joins with filaments of the facial nerve.

The *Nasal*.—This division is intermediate in size between the frontal and lachrymal. Entering the cavity of the orbit between the two heads of the external rectus, it passes directly across the optic nerve to the anterior of the ethmoidal foramina; through this foramen it passes into the cavity of the cranium, where it traverses the shallow groove on the front of the cribriform plate of the ethmoidal bone, until arriving at the nasal slit it passes directly downward into the nose, terminating in two branches. Of these two branches, the external descends on the inner surface of the nasal bone, supplying the mucous membrane of its neighborhood; leaving the cavity at the juncture of the bone with the lateral cartilage, it passes, on the external part of the nose, to supply the integument of the lips, and join with the facial nerve. The second branch, the internal, supplies the mucous membrane about the front of the septum.

In the orbital cavity three branches are given off by the nasal,—the ganglionic, ciliary, and infratrochlear.

The ganglionic is a slender cord, about half an inch in length, which is the sensor filament to the orbital, or ophthalmic, ganglion. (See *Ganglia*.)

The ciliary separates into branchlets, called long ciliary, to distinguish them from certain shorter branches, called also ciliary, given off from the ophthalmic ganglion. These branches are two or three in number; in asso-



ciation with the short ciliary they pierce the posterior face of the sclerotic, and, passing between this coat and the choroid, are distributed to the ciliary muscle and iris.

The infratrochlear branch is given off just as the main portion passes into the ethmoid foramen, joining, beneath the pulley of the superior oblique muscle, with a filament of the supratrochlear nerve; this branch continues to the inner angle of the orbit, where it is distributed to the orbicular muscle, the integument of the eyelid, and side of the nose, to the conjunctiva caruncula lachrymalis and lachrymal sac.

*Recapitulation.*—The ophthalmic, or first, division of the fifth nerve supplies the tentorium, lachrymal gland, caruncula lachrymalis, lachrymal sac, ciliary muscle and iris, muscles of eyelid and forehead, integument of forehead and nose, mucous membrane of eye and nose, and pericranium of frontal and parietal regions.

#### SUPERIOR MAXILLARY NERVE.

This nerve, or division, arises, as a flattened band, from the middle of the Casserian ganglion. It passes forward over the greater wing of the sphenoid bone, until, reaching the foramen rotundum, it leaves the cranium, and presents itself in the spheno-maxillary fossa; from this fossa it passes to the orbital cavity, through the spheno-maxillary fissure, where, being lodged in the infraorbital canal, it continues forward to the points of its ultimate distribution.

BRANCHES OF DISTRIBUTION.—1. *In the Spheno-maxillary Fossa.* Three,—the orbital, the ganglionic, the posterior dental.

The orbital enters, with the main branch of the nerve, the orbital cavity, and divides into two branches, temporal and malar. The temporal branch passes from the orbit through a foramen in the malar bone, and enters the temporal fossa; it here perforates the temporal muscle and fascia, and is distributed to the integument covering the side of the head, and associates, with the facial nerve, also with an ascending branch, auriculo-temporal, of the inferior maxillary. The malar branch leaves the orbit also through a foramen in the malar bone, perforates the orbicularis palpebrarum muscle, and joins with a branch of the facial.

The ganglionic divides into two branches, which drop directly down into the spheno-palatine, or Meckel's, ganglion; hence they are commonly known as the spheno-palatine branches.

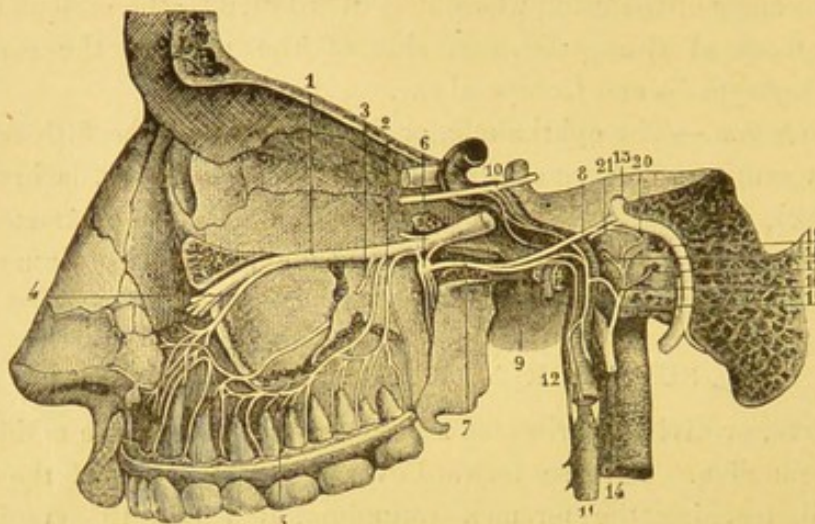
The posterior dental arises from the trunk just as it enters the orbit; it immediately breaks up into an anterior and a posterior portion. The first supplies the gums and buccinator muscle; the second pierces the tuberosity of the maxillary bone, and, after forming a minute plexus above the alveolus, distributes filaments to each of the posterior teeth; its termination is lost in a union with the anterior dental nerve.

2. *In the Infraorbital Canal.*—One, the anterior dental. This branch



is given off about midway of the canal. It enters a second canal existing on the anterior face of the maxillary sinus, and curving backward, associates itself, as above alluded to, with the posterior dental; from the curve are given off filaments to the anterior teeth,—incisors, canines, and bicuspidati.

FIG. 36.—SUPERIOR MAXILLARY NERVE.



THE EXTERNAL WALL OF THE LEFT ORBIT AND OF THE SUPERIOR MAXILLARY BONE REMOVED. 1, superior maxillary nerve in its course through the infraorbital canal; 2, 3, posterior dental nerves; 4, anterior dental nerve; 5, anastomosis between the dental nerves; 6, sphenopalatine ganglion; the branch from the superior maxillary nerve above is the commencement of the temporo-malar nerve; 7, pterygoid nerve; 8, greater petrosal nerve joining the facial nerve; 9, deep petrosal nerve joining the carotid plexus of the sympathetic; 10, abducent nerve with its communicating branches of the latter plexus; 11, superior cervical ganglion; 12, ascending branches to the carotid plexus; 13, facial nerve; 14, glossopharyngeal nerve; 15, the tympanic nerve; 16, branch to the carotid plexus; 17, 18, 19, branches to the round and oval windows and Eustachian tube; 20, branch to the smaller petrosal nerve, 21.

3. *On the Face.*—Three,—palpebral, nasal, labial. These are the terminal filaments, the division occurring as the nerve issues from the infraorbital foramen. The palpebral filaments ascend to supply the orbicularis palpebrarum muscle and the integument and conjunctiva of the lower eyelid; at the outer angle of the orbit they associate with the malar branch of the orbital and filaments of the facial nerve. The nasal filaments pass across the nose, supplying the muscles and integument of this region; they usually join at the tip with the nasal branch of the ophthalmic. The labial filaments pass downward beneath the levator labii superioris, and are distributed to the muscles and integument of the upper lip, to the mucous membrane of the mouth, and to the labial glands. The intricate plexus situated in the canine fossa is formed of filaments from the facial nerve associating with twigs of the trimaxillary division.

*Recapitulation.*—The superior maxillary nerve, or second division of the fifth, supplies the integument on the side of the head, Meckel's ganglion with its sensor filaments, the upper teeth, the antrum, orbicularis palpebrarum muscle, integument and conjunctiva of lower eyelid, muscle and integument

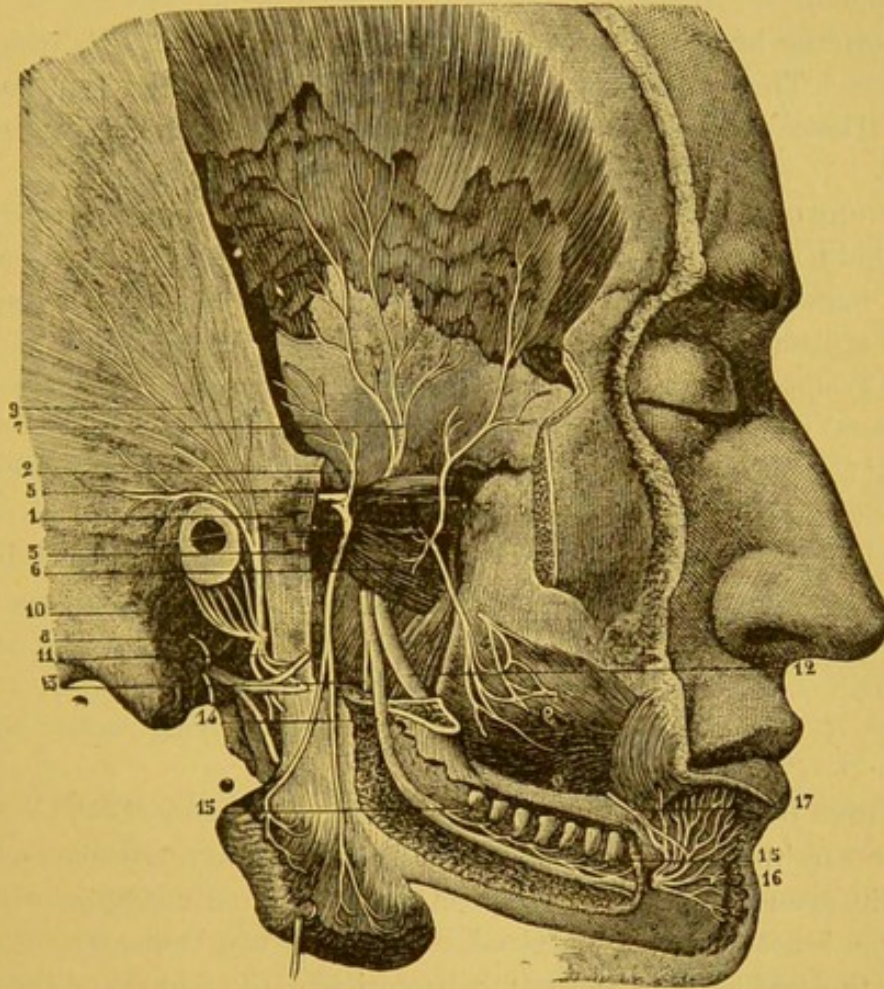


of nose, muscles, integument, and mucous membrane of superior lip, and labial glands.

### INFERIOR MAXILLARY NERVE.

This nerve, or division, is the largest of the three, and constitutes, justly speaking, the only portion of the fifth nerve compound in character. The sensor portion is the third of the cords emerging from the Casserian ganglion :

FIG. 37.—INFERIOR MAXILLARY NERVE.



DISTRIBUTION OF THE INFERIOR MAXILLARY NERVE. 1, muscular branch to the masseter muscle; 2, 5, 7, branches to the temporal muscle; 3, branch to the buccinator, anastomosing with one from the facial at 4; 6, external pterygoid muscle; 8, auriculo-temporal nerve; 9, branches to the temple; 10, branches to the ear; 11, its anastomosis with the facial; 12, lingual nerve; 13, branch to the mylo-hyoid muscle from the inferior dental nerve, 14; 15, branches to the teeth; 16, terminal branches to the lower lip and chin.

the motor portion is that lesser root alluded to as coming off from the pons Varolii; the sensor cord falls quickly into the oval foramen of the sphenoid bone, through which it passes from the cranium. The motor cord, which has passed forward beneath the Casserian ganglion, unites with the sensor just as it emerges from this foramen. Here then is made, by this union, a single cord, the perfected, or compound inferior maxillary nerve,—a nerve made up of filaments of motion and filaments of sensation. At the point



of juncture of these two cords is found a little ganglion, the otic. (See *Ganglia*.)

Immediately beneath the base of the skull, this compound inferior maxillary nerve divides into two branches,—anterior and posterior. Into the anterior branch pass most of the motor filaments.

The anterior branch breaks up into five divisions, and is distributed to the muscles of mastication. These divisions, or branches, receive names from the parts supplied by them; they are the masseteric, buccal, deep temporal, and pterygoid.

The posterior branch is the larger of the two divisions: it subdivides into three parts. These supply the inferior teeth, tongue, and auriculo-temporal region. Hence the branches are named inferior dental, lingual, and auriculo-temporal.

**DIVISIONS OF ANTERIOR BRANCH.**—*Masseteric*.—This branch runs across the sigmoid notch of the inferior maxillary bone, enters the substance of the masseter muscle, and is distributed in it. In crossing the notch it occasionally gives off a filament to the articulation.

*Deep Temporal Branches*.—These are two in number. They pass under the temporal muscle, and supply its deep surface.

*Buccal*.—This branch pierces the external pterygoid muscle, passes beneath the coronoid process of the jaw, pierces the fibres of the temporal muscle, and, reaching the buccinator, divides upon it into a superior and inferior branch. The superior supplies the upper part of the muscle and the integument; the inferior, the lower part of the muscle and its lining mucous membrane.

*Pterygoid Branches*.—Two in number,—one supplying each pterygoid muscle.

**DIVISIONS OF POSTERIOR BRANCH.**—*Auriculo-Temporal*.—This branch passes out to the inner side of the temporo-maxillary articulation, turns upward in company with the temporal artery, and, on emerging with this vessel from beneath the parotid gland, divides into two branches. The posterior of the two supplies the *attrahens auriculæ*, the pinna, and the neighboring integument. The anterior passes upward with the terminal branches of the artery, and is distributed to the temporal integument. Branches of communication exist between the auriculo-temporal nerve, the facial, and the otic ganglion. The articulation, the parotid gland, and the external auditory meatus receive nerve endowment from the auriculo-temporal.

*Lingual, or Gustatory*.—This branch is a nerve of special sense, presiding in part over the function of taste; its terminal filaments, as might be inferred, are distributed extensively to the papillæ and mucous membrane of the tongue. Of the three sets of papillæ, the filiform and fungiform, or those situated on the anterior two-thirds of the organ, receive the principal supply, the posterior, or great papillæ, being endowed from the glosso-pharyngeal. On this account it was deduced that the gustatory presided over taste only as



the anterior two-thirds of the tongue was concerned; and this inference has been abundantly borne out by vivisection. (See Todd and Bowman's Physiology, pages 385 to 390.) In the dissection, the gustatory branch is seen coming off just opposite the sigmoid notch. In company with the inferior dental nerve, or branch, it passes down along the inner side of the ramus, until, leaving the dental somewhat above the posterior dental foramen, it crosses obliquely to the side of the tongue, along which it pursues its way to its points of final termination, anastomosing at the tip of the organ with filaments of the hypoglossal. In its course it lies first beneath the external pterygoid muscle, crosses the internal pterygoid, rests upon the superior constrictor of the pharynx, and passes over Wharton's duct, where it reaches the apex of the tongue. In its course, branches of communication are given off to the submaxillary ganglion and the hypoglossal nerve.

*Inferior Dental Nerve, or Branch.*—This is the largest of the three divisions of the inferior maxillary nerve. Between its point of origin and entrance into the dental canal, it gives off a branch, the mylo-hyoid, distributed to the mylo-hyoid and anterior belly of the digastric muscles. The main portion, after entering the posterior foramen of the dental canal, pursues its way beneath the teeth, giving, in its course, filaments to all these organs, terminating finally in a branch, the mental, which passes from the canal at the mental foramen, and has its distribution in the muscular and cutaneous substance of the inferior lip.

*Recapitulation.*—The inferior maxillary nerve, or third division of the fifth, supplies the muscles of mastication, the auriculo-temporal region, the anterior two-thirds of the tongue, the mylo-hyoid and digastric muscles, the inferior teeth, and the muscles and skin of the lower lip.

#### GANGLIA OF THE FIFTH PAIR OF NERVES.

Associated with the fifth nerve are six ganglia: they are called Casserian; ophthalmic, lenticular, or ciliary; Meckel's, or spheno-palatine; naso-palatine, or ganglion of Cloquet; otic; submaxillary.

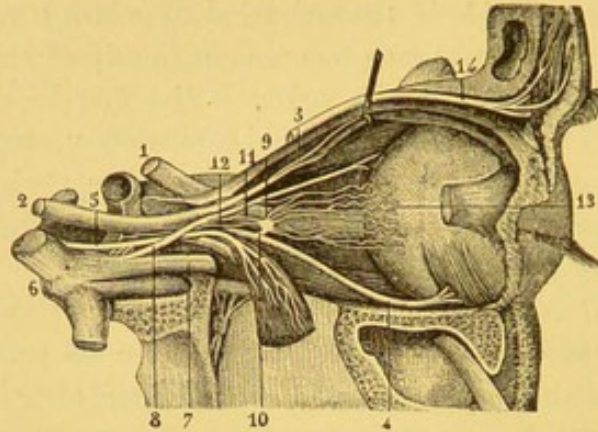
*Ganglion of Casserio.*—This ganglion, called as frequently the semilunar, from its shape, is found lying in a slight depression on the anterior face, near the apex of the petrous portion of the temporal bone. It receives the posterior or sensor cord of the fifth nerve, and transmits it divided into three parts. The ganglion receives filaments from the carotid plexus of the sympathetic, and gives off filaments to the tentorium cerebelli, and to the dura mater of the middle fossa of the cranium.

*Ophthalmic, Lenticular, or Ciliary Ganglion.*—This ganglion, as implied in its name, is found in the cavity of the orbit. It is a small, quadrangular, flattened body, not larger, generally, than the ordinary pin-head. It is situated between the external rectus muscle and optic nerve, well enveloped in the mass of fat found occupying this portion of the cavity. Its branches of communication are derived, the first, or sensor, from the nasal; the second, or



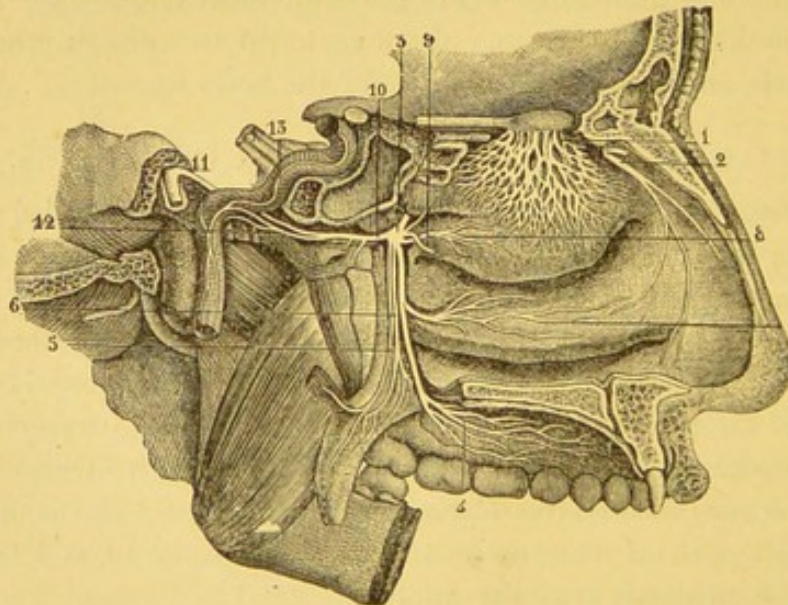
motor, from the third nerve; the third, or sympathetic, from the cavernous plexus. Its branches of distribution are the short ciliary nerves. These nerves, ten or twelve in number, arise from the anterior face of the ganglion, being

FIG. 38.—OPHTHALMIC GANGLION—THE OUTER PART OF THE RIGHT ORBIT REMOVED.



1, optic nerve; 2, oculo-motor nerve; 3, branch to the superior straight and oblique muscles; 4, branch to the inferior oblique muscle; 5, abducent nerve to the external straight muscle; 6, trifacial nerve, its ganglion and three principal branches; 7, ophthalmic nerve; 8, nasal nerve; 9, ophthalmic ganglion; 10, its communicating branch with the oculo-motor nerve; 11, do. with the ophthalmic nerve; 12, do. with the carotid plexus of the sympathetic; 13, the ciliary nerves; 14, frontal nerve.

FIG. 39.—VIEW OF THE SPHENO-PALATINE GANGLION AND OF THE OUTER WALL OF THE LEFT NASAL CAVITY, AND THE OLFACTORY NERVE.



1, olfactory nerve; 2, nasal branch of the ophthalmic nerve; 3, sphenopalatine ganglion; 4, 5, 6, palatine nerves; 7, branch to the nose; 8, nasal nerve to the outer wall of the nose; 9, do. to the inner wall; 10, pterygoid nerve; 11, facial nerve; 12, deep petrosal nerve joining the carotid plexus; 13, the other branch of the pterygoid is the larger petrosal nerve, which joins the facial.

connected, as two sets of filaments, with the superior and inferior angles. The two sets pass forward, one being above, the other below the optic nerve,



until, reaching the sclerotic coat of the eye, they penetrate this organ, and are distributed to the ciliary muscle and iris.

*Meckel's Ganglion—Spheno-Palatine.*—This is the largest and most extensively connected of the cranial ganglia. Its position is in the spheno-maxillary fossa, immediately in front of the vidian foramen. In shape it is triangular, and in color reddish-gray. Its branches of communication are derived, the first, or sensor, from the superior maxillary nerve, which, as has been seen, gives to it two filaments while crossing the fossa. The second, or motor, is derived from the facial nerve, or rather from the intumescencia gangliiformis of that nerve. This branch is known as the great petrosal nerve; it emerges from the Fallopian canal through the hiatus Fallopii, passes along the groove leading from this foramen, until, reaching the foramen lacerum basis cranii, it pierces the cartilaginous substance, filling up this osseous break, and entering the vidian canal, associated with the carotid nerve, passes forward, under the name of vidian, to the ganglion. The third, or sympathetic, is derived from the carotid plexus through the vidian.

The branches of distribution from this ganglion are numerous; they supply a portion of the orbital periosteum, the nares, the hard and soft palates, the half arches, the tonsil, the pharynx, etc.

The ascending branches, two or three in number, enter the orbit through the spheno-maxillary fissure; they supply the periosteum.

The descending, called palatine branches, are three in number; the anterior of these, or large palatine nerve, descends through the posterior palatine canal, passes along the groove on the hard palate, and is distributed to the gums, the mucous membrane, and palatine glands, anastomosing back of the incisor teeth with the naso-palatine nerve; while in the palatine canal, filaments are given off which pass to the middle and inferior turbinated bones.

The middle branch, called external palatine nerve, descends through the same canal as the preceding: it distributes its filaments to the soft palate, to the uvula, and the tonsil.

The posterior, called small palatine nerve, descends through the accessory palatine canal, and emerges back of the posterior palatine foramen. It is distributed to the levator palati muscle, to the soft palate, tonsil, and uvula.

Coming off from the internal surface are two sets of branches; these are called superior nasal and naso-palatine.

The superior nasal, four or five in number, enter the nasal fossa by the spheno-palatine foramen; they supply the mucous membrane of the superior portion of the fossa.

The naso-palatine enters the fossa with the other nasal nerves, runs across the roof of the nose, until, reaching the septum, it descends between the periosteum and mucous membrane to the anterior palatine foramen; passing through this canal, it unites with its fellow of the opposite side, and distributes its filaments to the mucous membrane about the incisive fossa.



*Naso-Palatine Ganglion, or Ganglion of Cloquet.*—This is simply the small swelling situated in the incisive fossa, the result apparently of the union of the naso-palatine nerves. The very name of ganglion is denied it by most writers.

*Otic Ganglion.*—This is an oval flattened body, of small size, lying on the sensor portion of the inferior maxillary nerve, immediately beneath the oval foramen. Its branches of communication are: by sensor filaments, with the auriculo-temporal nerve, by motor with the inferior maxillary nerve, and with the sympathetic by the plexus surrounding the middle meningeal artery. Branches of communication also exist with the glosso-pharyngeal, and through the medium of the lesser petrosal with the facial nerve.

The branches of distribution are two in number: one to the tensor tympani, and one to the tensor palati muscles.

*Submaxillary Ganglion.*—This is a small-sized circular body situated upon the submaxillary gland. It is connected, through communicating branches, with the gustatory nerve, sensor; with the facial through the medium of the chorda tympani, motor; and with the sympathetic by filaments from the plexus of the nervi molles.

The branches of distribution are five or six in number; these arise from the lower part of the ganglion, and supply the duct of the gland and mucous membrane of the floor of the mouth.

Relations of the ganglia, the Casserian excepted, will be understood as being mediate. Ganglia have as office intensification or modification of expression. The many associated with the fifth pair explain its complexity of relation.

#### FUNCTION OF THE FIFTH NERVE.

The resemblance of the fifth to spinal nerves is now regarded by most writers as complete.

The origin of the nerve is by two roots, the smaller being motor, the larger sensor. The origin is after this manner, or otherwise the motor division, joining the inferior maxillary division of the sensor branches just external to the ganglion of Casserio, is to be esteemed as a pure spinal nerve. The judgment and studies of the author accept this motor branch as a spinal root of the common nerve.

The nerve breaks up, in the Casserian ganglion, as understood, into three branches. The first and second of these receive no filaments from the lesser root, and are, therefore, purely sensor. The third is compound by reason of relation with the anterior division of the spinal cord through such lesser root.

The distribution of the first and second branches is to skin of forehead; to the lids, balls, and conjunctivæ of eyes; to the temples, the ears, and sides of cheeks; to the nose, outside and inside; to the upper lip and its appendages; to the pulps and alveolo-dental periosteal of teeth; to the dura mater. The distribution of the third division is to the muscles of mastication



by its motor filaments; to the chin, the lower lip, the mucous membrane of mouth and tongue; to the pulps of inferior teeth, etc., by its sensory filaments.

In addition to the double function of a compound nerve, evidence worthy of acceptance connects the lingual branch of the third division with the special sense of taste, although it is to be noted that such office is attributed by equally good authority exclusively to filaments of the glosso-pharyngeal and chorda tympanic.\* The intimate inosculation existing between the filaments of the nerves named, serves without doubt to profoundly complicate inferences. The writer, with all deference, retains the old view, namely: that gustatory office belongs to all these nerves; the fifth doing its office in relation with the anterior two-thirds of the tongue.

It is in point here to refer to the fact that confusion exists as to the use of the terms taste and smell; the two being not so easy to keep separate. Taste, critically defined, relates to sensation arising out of the touch upon the tongue, anterior pillars of fauces and palate, of acid, saline, bitter, and sweet substances. Smell applies to sensations produced in the nerves when intangible, but not less real, substances come in contact with filaments of the olfactory nerve: necessarily as well with filaments of the trifacial.

The fifth nerve presides markedly over both salivary and oro-nasal mucous secretions. Excitement of its filaments increases these secretions; section being made of them, flow is diminished.† In this connection, if in no other, the nerve may justly be associated with both taste and smell, seeing that necessity exists for the intermediate agency of moisture, that such special functions exist at all.

Inferences of office are to be derived from study of parts in a state of disease. Pathological perversion of the fifth nerve shows the most marked separation of the two expressions of motility and sensibility according to the tract affected. Sensation and motion are alike destroyed only when disease of the nerve is general.

In such state of general involvement it is common to find the eyeball without sensibility; the muscles of mastication waste and become flabby; tongue and mouth grow so unconscious of the presence of food that morsels remain in the cavity until decomposed; the nostrils oftentimes afford no response to applications of the most pungent character.

The fifth is to be accepted as a nerve of wide excito-motor capacity; it stimulates the facial in all its offices; water dashed over parts supplied by it excites the respiratory tract. It too often produces distant neuralgia as the result of an aching tooth.

---

\* See a Text-Book on Physiology, by M. Foster, M.A., M.D., F.R.S., New York, 1881. Pp. 586-88. See also Principles of Human Physiology, by William Carpenter, M.D., etc., etc. Henry C. Lea, Philadelphia, 1876. Pp. 620-55.

† See Outlines of Physiology, by John Marshall, F.R.S., with additions by Francis Gurney Smith, M.D., p. 264. Henry C. Lea, Philadelphia, 1868.



The wide relation of this nerve is nowhere so markedly illustrated as during the dentitional period; convulsions, skin eruptions, diarrhœas, indeed tetanus passing to a fatal termination, are all found in the category of its associations.

RÉSUMÉ.—The fifth nerve affords sensibility to the face and associate parts. It is the nerve of motion to the muscles of mastication. It has to do with taste and smell. Indirectly it is a prominent excito-motor apparatus.



## CHAPTER IV.

### ANATOMY OF THE TEETH.

THE direct and associative lesions of the teeth being so many and so common, study of oral diseases commences naturally with these organs. Here too begins the study of dentistry proper.

A tooth is a body *sui generis*; it resembles ivory, but is not that substance; it is allied with bone, but is not osseous.

Dissection of a tooth recognizes the presence of five constituents; these are:

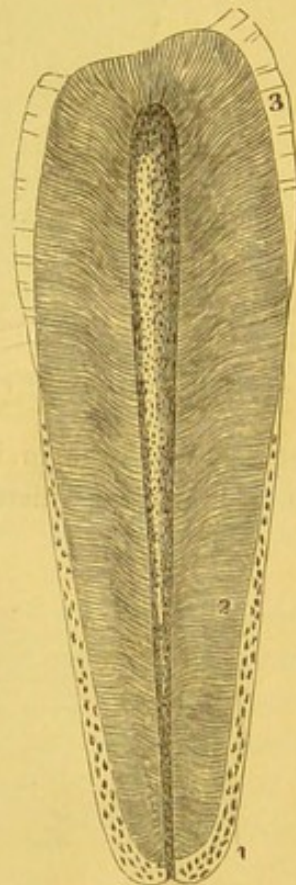
1. Pulp.
2. Dentine.
3. Enamel.
4. Cementum, or Crusta Petrosa.
5. Periodontemum.

Fig. 40 shows the vertical section of a cuspid tooth. 1, cementum; 2, dentine; 3, enamel. The pulp is seen occupying the central cavity. The dotted envelope of the root represents the position of the cementum. The periodontemum is a fascia attached to the cementum.

**Pulp.**—The pulp, exhibited here several times enlarged (Figs. 40, 41, 42), is a mass of delicate connective tissue, in which ramify the radicles of blood-vessels and nerve-filaments. It has no enveloping membrane proper, as will be understood in the study of odontogeny; it is the contracted original papilla, or tooth germ. Through the vessels of this body the internal structure of a tooth is nourished; in its death the organ loses its translucency, becoming discolored and opaque,—being, indeed, devitalized, except as nourishment is received from the periodontemum. The pulp of a tooth is so highly endowed with nerve matter that the slightest touch suffices to provoke exquisite pain.

**Dentine.**—The dentine, or dentinal portion of a tooth, is marked 2 in the diagram (Fig. 40). This substance is called, also, the ivory. While histological dispute exists as to the real constitution of the structure, a full surgical signification is found in accepting it as a fibro-calcareous stroma,

FIG. 40.



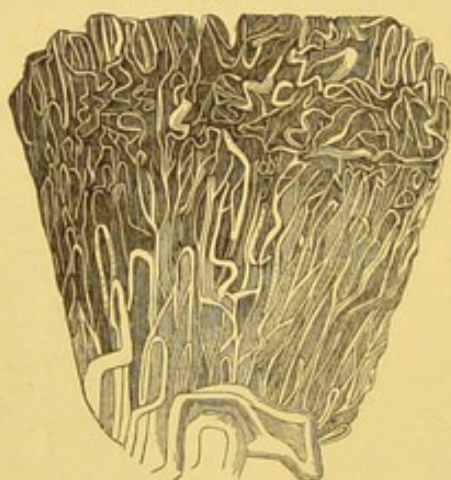
Vertical section of a cuspid tooth.



tubular in character. The tubuli, commencing at the enamel membrane, the original tunica propria (see *Dentition*), approach the pulp, opening into the cavity by capillary mouths, and thus receive the halitus which is their nutrition. The tubuli of dentine are in some instances almost straight, at other times curvilinear. In the neighborhood of the enamel they are dichotomous and trichotomous. Figs. 43 and 44 show these varieties of tubes. Fig. 49 shows the tubes in transverse section. The diameter of a dentinal tubule is about the  $\frac{1}{35000}$  of an inch. (For mode of formation of dentine, see *Dentition*.)

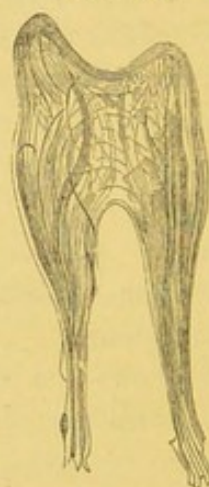**Enamel.**—No. 3, Fig. 40, exhibits the position and relation of the enamel as a cap to the crown portion of a tooth. This structure is almost

FIG. 41.



Dental pulp, magnified.

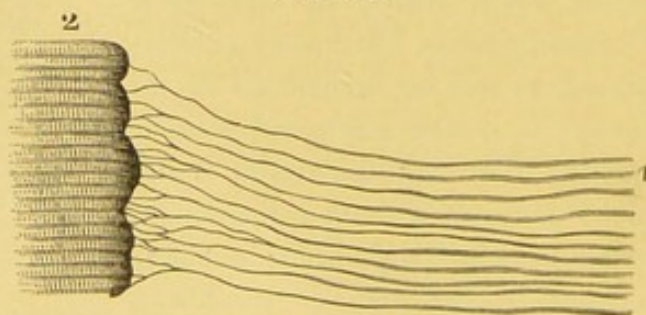
FIG. 42.



Nerves of dental pulp.

entirely inorganic in its composition, containing but about two per cent. of animal, or living, matter; it is hard, flinty, brittle, and decreases in thickness

FIG. 43.




1, tubuli of dentine; 2, enamel.

as it passes from the cutting face to the neck of the tooth. In arrangement, enamel is made up of a series of hexagonal fibres, having a double direction, by which each is strengthened by its fellow as it is crossed and recrossed, one set undulating outward, another crosswise. The nutrition of enamel is received through the tunica propria. (See *Dentition*.)



**Cementum, or Crusta Petrosa.**—Fig. 40 (1) exhibits the relation of the cement as a sheathing to the fang. This structure so closely resembles bone

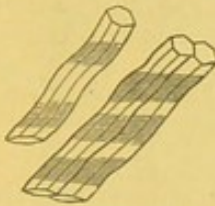
FIG. 44.



VERTICAL SECTION OF THE FANG OF A CANINE TOOTH, exhibiting the structure of the dentine and cement. 1, inner extremities of the dentinal tubules; 2, outer extremities of the tubules, terminating in interspaces at the boundary of the dentine; 3, cement; 4, lacunæ like those of bone. Highly magnified.

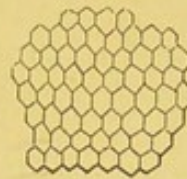
proper as to be liable to the diseases of that substance; it possesses all its chemical elements. A thick cementum contains well-marked Haversian

FIG. 45.



THREE ENAMEL COLUMNS, highly magnified; exhibiting the six-sided prismatic and waving character.

FIG. 46.



SECTION OF ENAMEL, highly magnified at right angles to the course of its columns; exhibiting the six-sided character of the latter.

canals and Purkinjean corpuscles, or lakelets; vessels from the periodontium are occasionally traced into its substance. (See manner of its formation in chapter on *Dentition*.)

**Periodontium.**—This is the analogue of the periosteum of the common osseous structures. It is a composition of fibro-cellular tissue, serving the double purpose of attaching the teeth to their alveoli and supporting the external vessels of nutrition. Originally it was simple mucous membrane forming the covering of the rudimentary jaw cartilage. At the neck of a tooth it is found dense and resisting; toward the apex it attenuates to softness and delicacy.

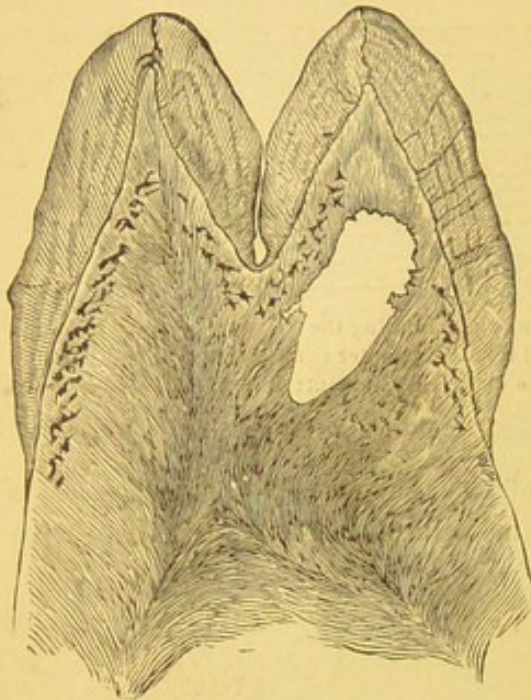
**Interglobular Spaces.**—Fig. 47 exhibits what are termed interglobular spaces, as seen in the dentine of certain teeth: these spaces possess much surgical interest, as it is to be presumed they represent an imperfect development, and thus explain the rapid breaking down of many teeth. In an excellent paper on this subject, by Dr. J. H. McQuillen,\* that gentleman

\* Dental Cosmos, vol. viii. p. 113.



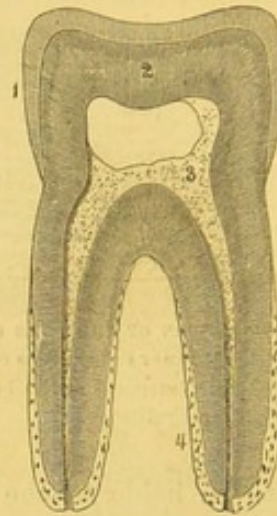
wisely remarks that it is well to direct attention to the fact that the existence of the spaces in teeth which have completed their growth must be regarded

FIG. 47.



Interglobular spaces.

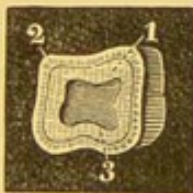FIG. 48.



VERTICAL SECTION OF A MOLAR TOOTH, moderately magnified. 1, enamel, the lines of which indicate the arrangement of its columns; 2, dentine, the lines indicating the course of its tubules; 3, thin lamina of the dentine forming the wall of the pulp-cavity, the dots indicating the orifices of the dentinal tubules; 4, cement.

as an *abnormal condition*, predisposing such teeth to decay, and that when, either by mechanical action, as by a fall or blow, or by the penetration of

FIG. 49.



TRANSVERSE SECTION OF A MOLAR TOOTH OF THE NATURAL SIZE. (The cut is made through the body of the tooth.) 1, dentine; 2, enamel; 3, cavity.

external caries, such spaces are reached, the *disease here would run riot*; hence the importance of care on the part of patients and operators to have the most minute cavities filled; for though reached only through a microscopical opening, the result would be the same, while, if protected from the action of external influence or the *exciting causes of decay*, this *predisposition* might remain dormant for a lifetime. Reference is here to be made to these spaces, as they furnish habitations to parasites. The cavities not infrequently communicate with one another, and are in turn communicated with by breaks in the enamel. It is not uncommon to find them occupied by micrococci. (See *Parasites*.)

Figs. 48 and 49 represent sections of molar teeth; they will assist in comprehension of the organs. It is very necessary to have accurate ideas concerning the relations of a pulp-cavity to the external parts of a tooth. Such understanding, to be of practical use, is to be gained only through examination of many teeth. What are called the cornuæ, or horns, of pulps (extensions), are to be closely observed.

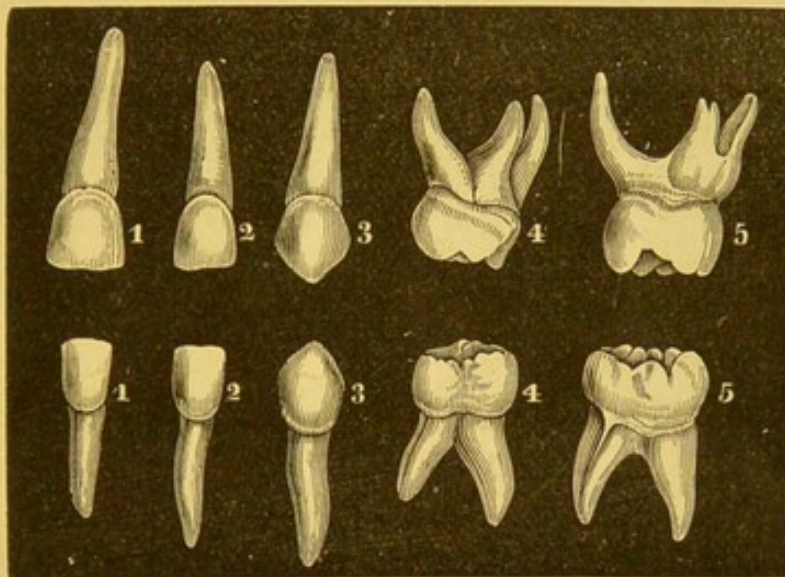
**Relation of the Teeth with the Jaw.**—The teeth associate with the jaw



through the intervention of a peculiar cellular bone described as the alveolar processes. (See Fig. 6.) This structure, as there seen, is hollowed into pits corresponding with the shape of the roots accommodated by them. In some persons it is very spongy, in others it closely resembles in density the cortical portion of bone; in proportion to this density teeth are found loosely or firmly fixed. It is a matter of experience that in proportion as this process is solid, teeth are found resistive of disease.

Fifty-two teeth belong to the human species. These are divided into two sets. The first pertain to infancy; the second associate with adult life.

FIG. 50.—DECIDUOUS TEETH OF THE LEFT SIDE—(After T. Bell.)



DECIDUOUS TEETH OF THE LEFT SIDE OF THE JAWS. 1 and 2, incisors; 3, cuspidati; 4 and 5, molars.

The first set, termed milk, deciduous, or temporary, consist of twenty teeth—ten in either jaw: four central incisors, four lateral incisors, four cuspidati, and eight molars; the form and general characteristics are illustrated in Fig. 50. The second or permanent set are thirty-two in number—sixteen in either jaw: four central incisors, four lateral incisors, four cuspidati, eight bicuspidati, eight molars, and four dentes sapientiæ. The derivations of these terms are as follows: incisores, from the Latin verb *incido*, to cut; cuspidati, from *cuspis*, a point; bicuspidati, from *bi*, two, and *cuspis*, point, having two points; molares, from *mola*, a mill; dentes sapientiæ, teeth of wisdom, so called from being developed in mature life.

INCISORS.—Nos. 1 and 2 of Fig. 51 represent the incisor teeth of the upper jaw, and Nos. 1 and 2 of Fig. 52, the incisor teeth of the lower jaw: two centrals and two laterals. *Labial* aspect of crown is like frustrum of pyramid, or shovel-shaped, and slightly convex. *Lingual* surface, same shape, but slightly smaller, and concave.

*Laterally* they are triangular, widest at neck, and represent the labial and



lingual surfaces gradually approaching one another until they unite to form the cutting edge.

When first erupted, the cutting edges of these teeth terminate in three points, which points rapidly wear away in mastication.

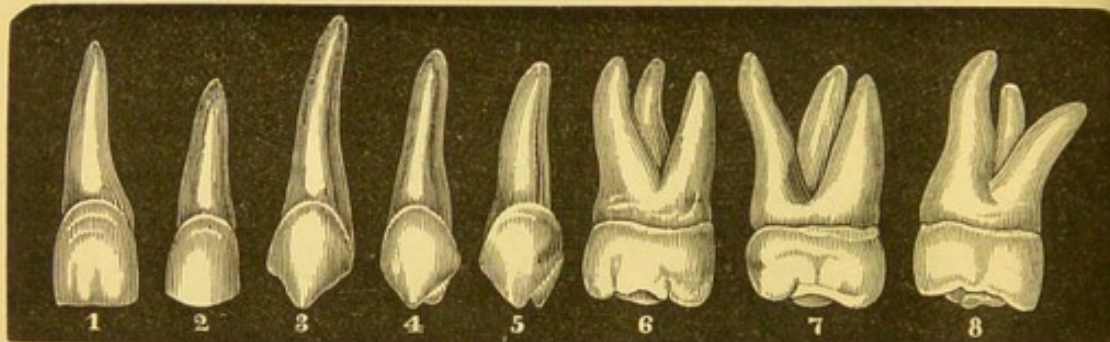
*Enamel* extends to greatest distance toward root on labial and lingual surfaces, and terminates at neck in a curve, with convexity directed toward gum. On mesial and distal surfaces enamel does not extend up so high, and again terminates in curve line, but in this case with convexity toward cutting edge.

In other words, outline of enamel corresponds to outline of festoon of gum.

All of these teeth have single conical roots.

*Superior Centrals* (Fig. 51, 1).—Larger than laterals; about one-third wider, and usually a little longer. Their greater width at cutting edges than

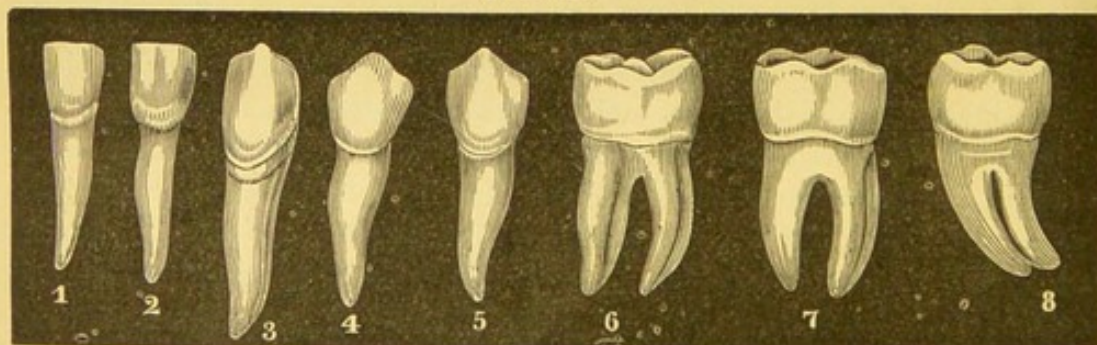
FIG. 51.



Permanent teeth of superior jaw.

at neck leaves spaces between themselves and fellows at latter point. Median side straighter and longer than distal; consequently a more acute angle at median corner than at distal. Lingual surface, which is concave, often ter-

FIG. 52.



Permanent teeth of inferior jaw.

minates near gum in a ridge, or prominence, called the *basal ridge*, or *cingulum*; this is most frequently found and is most pronounced in laterals; it is a favorite spot for caries.

*Superior Laterals* (Fig. 51, 2).—In every way smaller than centrals, but quite similar in general outline. Greater disproportion between width of cutting edge and neck than in centrals. Distal angle of crown more rounded than



same angle of central. Median surface slightly concave, and distal more convex than in central. Basal pit more strongly marked, and hence more ready to decay.

*Lower Central Incisors* (Fig. 52, 1).—Very much narrower than superior centrals; not much more than half the width at cutting edges. From before backward are very deep at neck; hence fangs are much flattened from side to side. Termination and outline of enamel at neck is similar to superior incisors, but there is neither basal ridge nor pit.

*Lower Laterals*.—Unlike the superior laterals, these are larger than their adjoining centrals in every respect, but especially in length of root. Distal angle of cutting edge is not rounded off as in laterals of opposite jaw.

*Cuspidati*.—*Eye-, Stomach-Teeth* (Figs. 51, 52, 3).—Are thicker and stronger teeth than the incisors. Crowns are distinctly conical, with a slight bulging near middle of tooth; consequently they are (unlike the incisors) convex on lingual as well as on labial surface. Crown terminates in a blunt point, and the root is much longer than that of any of the other oral teeth. Slight ridge runs from cutting edge to neck on labial surface, dividing it into two unequal portions, of which the distal is the longer. This enables us to tell the side of the jaw to which it belongs. On lingual surface a slight median ridge runs from cusp to neck, sometimes terminating in a slight prominence or cingulum. Outline of enamel on lateral surfaces is more distinctly angular than in incisors, with angle pointing toward cusp. Section at neck shows root to be a rounded triangle in outline. Synonyme, eye-teeth.

*Inferior Cuspidati*.—*Singular, Cuspidatus, Cuspis* (Fig. 52, 3).—Less pronounced in form than upper. Point more blunted, fang shorter, and lingual surface more distinctly convex. Synonyme, stomach-teeth.

*Bicuspidati*.—*Singular, Bicuspidatus, Bicuspis* (Figs. 51, 52, 4, 5).—Eight in number, two on each side of upper and lower jaws.

*Superior Bicuspidati* (Fig. 51, 4, 5).—Crown, as seen on grinding surface, is a rounded quadrilateral. Buccal side is larger than palatine, which latter is more distinctly circular than former. The mesial and distal sides are nearly plane surfaces, though slightly rounding toward the palatine side. They have two cusps, the external being larger and broader than the internal. A deep transverse fissure separates the cusps, and slight elevations border the anterior and posterior edges of the grinding surface. First bicuspis usually has its root bifurcated for about half its terminal length, and if not bifurcated, is deeply grooved.

*Second Bicuspidatus*.—*Superior*.—Differs from first in having cusps more nearly of a size, and in having an unbifurcated root. Root is, however, constricted in the middle, in the direction of its length. Like the canine, both bicuspidati have distal slope of cusp greater than medial.

*Inferior Bicuspidati* (Fig. 52, 4, 5).—Are smaller than the upper, and differ considerably in shape. The buccal surface is much more convex, and dips strongly inward at the masticating surface. In the first bicuspis the lingual cusp



is so much shorter than the buccal as often to seem but rudimentary. Another distinguishing feature of first bicuspid is the joining of both cusps by a ridge of enamel instead of being separated by a fissure, as is the case with all the other bicuspidi. Roots of lower bicuspidati are rounder and less constricted than the upper,—more decidedly oval in outline. The second bicuspid is squarer and larger in all its dimensions than the first, with a higher inner cusp than its fellow. This inner cusp is often divided by a fissure.

*Molares—Molars; Singular, Molar.*—Largest and strongest teeth. Have quadrilateral crowns, surmounted by several cusps and implanted by means of two or three roots. Twelve in number, named respectively First, Second, Third. The last commonly called “wisdom-teeth,” *dentes sapientiæ*.

*Superior Molars.*—Crowns are rhomboidal in sectional outline. Buccal and lingual surfaces (more particularly the latter) are convex, while the proximal surfaces are flattened. The angles connecting these sides are rounded; the mesio-palatine and the disto-buccal more markedly than the other two. The crown is surmounted by four cusps,—two buccal and two lingual,—which cusps are separated by fissures running between them. One main fissure extends from the anterior to the posterior margin in an irregular line, while from this there branch off two others. One of these starts from the anterior part of the main fissure and runs obliquely backward and outward between the two buccal cusps, terminating on the buccal surface. The other branches off from the main fissure near its posterior terminus and runs obliquely forward and inward between the lingual cusps, and terminates on the lingual surface near the gum. Of the four cusps, the mesio-palatine is the largest. After it, in point of size, come respectively the mesio-buccal, the disto-buccal, and the disto-palatine. The crowns of the first and second molars differ but little from one another, but in the latter the two lingual cusps are sometimes united into one larger one, thus giving the lingual surface a more distinctly semi-circular outline. When they are not so blended, the fissure dividing the lingual cusps will be found to be less pronounced in second than in first molar. The roots of these teeth are three in number,—two buccal and one palatine. Of the two buccal, the anterior is the larger, and stands out more prominently toward the cheek. Both are compressed laterally. The palatine fang is much larger than either of the others. It is round, long, and curved obliquely upward toward its fellows. Usually the three roots are separate and divergent. The enamel terminates in a nearly even line around the neck of the tooth.

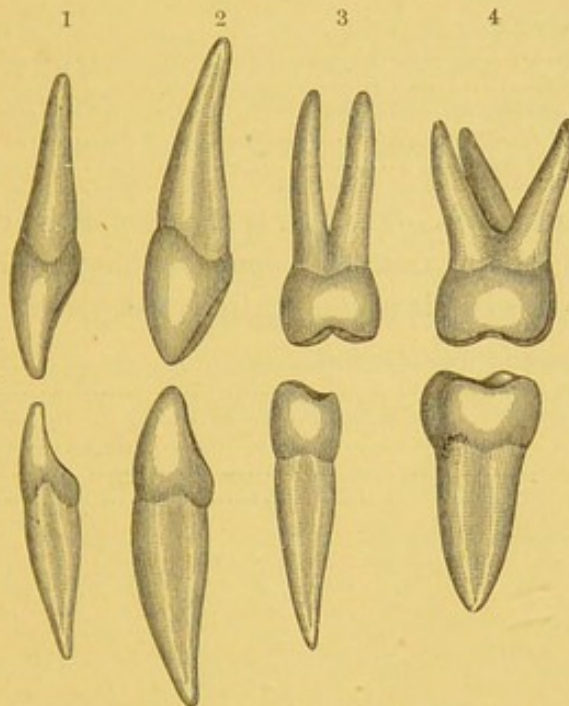
*Inferior Molars.*—First molar the largest. Has five cusps,—three on buccal and two on palatine surface,—visually separated by fissures. Of the three buccal cusps, the anterior is the largest and the posterior the smallest. The second molar has but four cusps, separated by a crucial fissure. One arm of this fissure generally extends to and over the buccal surface between the cusps, and terminates near the gum in a small depression, where caries is apt soon to show itself. These teeth have usually but two roots, situated anteriorly and pos-



teriorly. They are flattened and grooved, and the anterior is the broader and longer of the two. They are usually divergent and curved slightly backward. The roots of the second inferior molar differ from those of the first principally in their lying closer together and in their greater backward curvature.

*Third Molars—Dentes Sapientiæ, Wisdom-Teeth.*—In the upper jaw these teeth closely resemble the second molars. The two palatine cusps are

FIG. 53.



LATERAL VIEW OF THE UPPER AND LOWER PERMANENT TEETH. 1, first incisors; 2, canines; 3, first premolars; 4, middle molars.

always blended into one, and the three roots are usually confluent, forming an abrupt tapering cone. The crown is the smallest of the three molars. Often it is abnormally small, almost rudimentary in character. In the lower jaw these teeth are considerably larger than the corresponding ones above, and are also usually larger than the superior second molars. They are very little, if any, smaller than the first lower molars, and greatly resemble these in crown, having five cusps similarly situated. They are usually two-rooted, but the roots are often confluent and curve strongly back toward angle of jaw.

*Recapitulation of Names.*—The names of the teeth, expressed in the singular number, are, incisor, cuspidatus, bicuspidatus, molar, dens sapientiæ.

A tooth is divided into three parts; a crown, root or fang, and neck. The crown of a tooth is the exposed part; the fang, the part which associates it with the jaw; the neck is the intermediate part. In the language of dentistry the surfaces of the teeth are known as mesial, distal, labial, buccal, palatal, lingual, articulating, cutting.



## ANALYSIS OF DENTINE.—

Phosphate of lime.....	62.
Fluorate of lime.....	2.
Carbonate of lime.....	5.5
Phosphate of magnesia.....	1.
Soda and muriate of soda.....	1.5
Gelatin and water.....	28.

Attention is to be directed to the variable density of the teeth; consequently any individual analysis can only be an approximate.

## ANALYSIS OF ENAMEL.—

Phosphate of lime.....	85.3
Fluorate of lime.....	4.
Carbonate of lime.....	7.
Phosphate of magnesia.....	1.5
Soda and muriate of soda.....	1.
Animal matter and water.....	2.

ANALYSIS OF CEMENTUM.—The near approach of cementum to bone affords large proportions of organic matter,—twenty to thirty parts to the one hundred. A quantitative analysis of a given specimen yielded as follows:

Phosphate of lime and fluoride of calcium.....	58.73
Carbonate of lime.....	7.22
Phosphate of magnesia.....	0.99
Salts.....	0.82
Cartilage.....	31.31
Fat.....	0.93



## CHAPTER V.

### DENTITION.

By dentition is meant the development of teeth. Teeth, together with the alveolar process, develop upon the bone proper of the jaws.

In the earliest days of foetal existence the jaws are planes of cartilage. These planes are overlaid by mucous membrane. Between the cartilage and the membrane the papillæ known as dental germs are first met with.

The period at which dental germs are earliest seen is about the sixth week of intra-uterine life. At this period, a little sooner or later, such germs are to be exposed by lifting the mucous covering from the basement cartilage. At all subsequent periods previous to eruption section through the overlying parts exhibits their presence.

The alveolar process, with its many pits, is simply an osseo-spongy tissue, serving as a common envelope to the growing tooth-germs. In its origin it constitutes the primitive dental groove. This groove is never, however, a ditch, or depression, except as such an idea is conveyed by the pits and depth of an adult jaw. Neither are alveolar process and body of bone one except as regard is had to relationship. Alveolar process is a provision associated with teeth; as dental germs develop so does it; when the teeth are lost so also does it disappear. Alveolar tissue grows around papillæ; the dental pits signify obstruction. The papillæ are not first met with in a groove.

A dental germ is made up of a congeries of granular nuclei dispersed irregularly through a firm homogeneous blastema. It is not enclosed in a cell-wall, or membrane of its own; it is a hyaloid structure.

A developing germ carries with it the overlying mucous membrane; the membrane hugging it closely. This covering, or envelope, constitutes a tunic; it is to be denominated coat first, or tunica propria. The relationship of this covering to a papilla is precisely that of parietal peritoneum to a knuckle of intestine in incarcerated or strangulated hernia. The shape of this coat is that of the papilla it encapsules.

While, after the manner described, a tunic has been secured by the tooth-germ, it is recognized that the common mucous membrane has in no wise altered its relation to surrounding parts; it abuts closely all the circumference of a papilla; it is contracted, like an elastic substance, about its base; it associates from this base with adjoining parts.

Corresponding with the growth of a papilla is that of its alveolar envelope.



As such envelope is of submucous nature, being an organization arising out of cells existing between the mucous membrane and plate of jaw, among which cells the germ lies, it is to be recognized that as this increases about the germ it necessarily carries around it a second coat, or tunica; tunica reflexa it is not unwarrantable to call it. This now is the dental relation: a germ, originally microscopic, has enlarged until it stands in shape and size the representative of a tooth; this germ is enveloped in a double sac; it is overgrown on all its circumference by tissue which later is to express itself as alveolar process and gum.

At this period the dental pulp, as the papilla is now to be called, having attained the size of the tooth-crown it represents, commences the formation of dentine. Before the attainment to full size by the papilla, there existed between it and its sac proper a halitus. This halitus, now that the congeries of cytoblasts or nucleated granules have obtained their full growth and secretive power, is replaced by a more highly endowed production; the work of matured cells. This secretion constitutes the future dentine. Calcification is progressive with secretion.

As this deposit deepens within the mucous envelope, so the pulp contracts until, finally, it stops at that certain point which maintains within the tooth a canal, or cavity, and a vascular and nervous pulp to occupy it,—this pulp being the contracted original papilla. The vessels of this papilla are analogous to those of the ordinary papillæ of touch.

Why this secretion, in its organization, should assume the position of the elongated tubular cells which pertain to the structure of dentine, is not here to be discussed, and it is quite enough for our purpose to say that it is a law of form perhaps not to be fully comprehended, apprehension of which would, at any rate, have but little clinical signification.

The formation of dentine completed, the covering of it with enamel begins; or rather this deposit is, to a degree, coincident with the dentinal formation. Secreted by the same pulp which forms the dentine, the same secretion, some portion finds its way into and through the primary sac. As it passes through this sac, to be moulded against the second, it is modified by the epithelial surface, which constitutes the outer face of the tunica propria; this sac, as it is understood, being a mucous membrane. Between the enamel, thus formed, and the dentine, exists the primary sac; simply the modified mucous membrane, which we first saw as overlying the papilla. The sac of mucous membrane—tunica propria as it has been termed—continues to exist between these two hard bodies, and receives and modifies, for the support of the enamel, the liquor sanguinis found in the dentinal tubules and intertubular structure. This tunica propria is the enamel membrane. It is from this that we receive impressions of pain when it becomes exposed by a break in the continuity of enamel.

In the process of tooth development, particularly at that stage when the hard structures are being formed, a grade of vascularity is present in the ex-



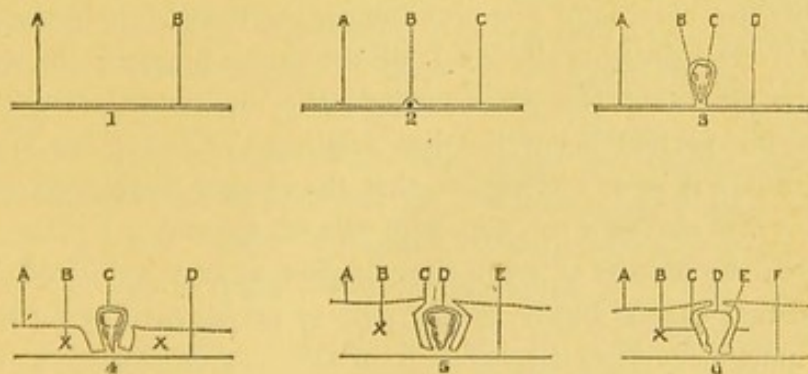
ternal sac which seems quite to have deceived microscopic observers, as these persist in viewing such congested and thickened membrane as the agent which deposits enamel, whereas, in reality, it serves here simply as a mould, and has its permanent office and meaning in the periodontum, which membrane a moment of reflection will show to be the persistent remainder of the tunic after the crown portion has been lost in eruption of the tooth. Enamel is analogous with epithelium. The only place where dentinal secretion comes into relation with, and under the influence of, epithelial correlation, is where it passes through the tunica propria into the moulding interspace existing between this and the tunica reflexa. A tooth at large is not a dermoid structure; the enamel of a tooth is dermoid to the extent and expression that its characteristic is received from, and is impressed by, a mucous membrane as just described.

The growth of a root of a tooth, as its dentine is concerned, has precisely the history of the body. Such growth is associated with pyramidal elongation of the pulp, which, pushing upward the crown, extends upon itself the enamel membrane and tunica reflexa. This elongation, with a greater vascularity and vitality assumed by it as approach is made to the basement vessels, modifies again the result obtained by the exudate passing through it from the dentinal pulp, the result being an approach to true bone in the production of cementum. Analogy is found in nails and epiderm structures of similar significance and origin.

Periodontum, as suggested, is the modified external sac, lost, of course, above the neck, as the tooth has emerged through it.

This is a very simple and easily understood explanation of tooth growth. The observations leading to the conclusions have been somewhat extensive, and the phenomena are certainly endorsed by general anatomical analogy. Let them be objected to, however, as, perhaps, they will be by the physiologist, they are irrefutable as all surgical relations with the teeth are concerned.

FIG. 54.



ILLUSTRATIONS.—The tooth selected is an inferior central incisor. Subfig. 1 shows two lines; A represents mucous membrane overlying B, a plane of cartilage.



Subfig. 2 shows, A, mucous membrane; C, basement cartilage; B illustrates the mucous membrane as it begins to be raised as an envelope—*tunica propria*—for the tooth-germ seen below it.

Subfig. 3 is diagrammatic of the mucous envelope—*tunica propria*—as it invests the developed germ, no reference being made in the drawing to the developing alveolar walls.

Subfig. 4 is diagrammatic of the idea of the manner of envelopment of germ by the second tunic,—*tunica reflexa*. It is understood that  $\times \times$  (B) is the growing alveolar walls, and that as this develops between the base bone and the covering of mucous membrane, it necessarily lifts the latter, but that in lifting it the *tunica propria* is not disturbed; hence a second tunic, having as its eventual office the meaning of a *periodontum*,—*i.e.*, a bond of relationship between tooth and alveolus. The cut is to be understood as being purely diagrammatic. A, mucous membrane; B, alveolar process; C, *tunica propria*; D, base of jaw.

Subfig. 5, also diagrammatic, is designed to afford idea of a *tunica reflexa* about completed. The relations of the parts in this cut need alone, in order to be exactly as in nature, that the two *tunicæ* be in relation with each other, separated only by an intervening *halitus*, and that similar relations exist between *tunica propria* and pulp. A, mucous membrane overlying gum-tissue, which tissue in its turn overlies  $\times$  (B) alveolar process; C, developing *tunica reflexa*, being part of the original plane of mucous membrane seen in Subfig. 1, and which here has been made to envelop the tooth-germ and its original tunic by reason of the developing alveolus of the germ represented and of the other germs; D, *tunica propria*, got by the germ, as shown in Figs. 2, 3, and 4; E, base of jaw.

Subfig. 6 shows similar relations as in 5, except that here the tooth-germ is withdrawn from its envelope, and the parts stand exposed, as would be shown by a transverse section. A, original mucous plane; B  $\times$ , alveolar process; C, *tunica reflexa*, which tunic is eventually to constitute the *periodontum*; the portion above, or that portion which relates with the tooth-crown being lost because of the organ emerging through it in the act known as cutting;\* D represents the inside of the *tunica propria*; the whole tunic, as shown, is persistent, the portion above the line constituting the enamel membrane, the portion below the line relating the *cementum* and *dentum*. From this tunic it is, as understood, that the enamel receives its whole nourishment; it acts also as a part-feeder of the *cementum*.

Accepting the process of tooth development as here exhibited, it becomes understood that enamel has no special pulp as propounded by the histologists. It is also understood that it calcifies from the outside inward, and not from

---

\* The so-called *ligamentum dentes* is simply the thickened ring of the *tunica reflexa*, resultant of the remnant of the crown portion of this coat; part is absorbed, part contracts towards the root portion.



the inside outward. It is as well seen that it is a vital tissue nourished exactly as are other parts.

The description illustrates as well the manner and matter of periodontal formation. It exhibits that a correct naming of that tissue would designate it alveolo-dental or alveolo-odontal membrane.

Also it is made plain that the enamel membrane is not strictly dependent on the common pulp for its nutrition. It has another source of supply, namely, that received through the cemental portion of the tunica propria coming in its turn from the osseous-like circulation of the cementum derived from the periodontum,—i.e., the persistent root portion of the tunica reflexa,—from the alveolo-dental membrane, and that gotten from vessels which come to it from apical vessels.

We pass here to a more directly clinical consideration of the subject; to the relation of the first and second dentitions.

The first of the papillæ of the deciduous teeth to make their appearance pertain to the anterior molars; after these are the germs of the canines and incisors; last, the posterior molars. About the fourth month these papillæ are all in their saccular envelopes, while forming behind the lids of the sacs are little crescentic depressions, called cavities of reserve, lined with mucous membrane, and containing the germs, or papillæ, of the second set of teeth,—one to each deciduous germ. The first molar of the permanent set is markedly related to the deciduous, by having a common origin from and on the primitive dental plane. From sacs, secondary to the capsule of this tooth, spring the reserve cavities of the second and third molars of the second set.

The eruption of the temporary set, although more or less irregular, ensues, as a rule, in the following order and time,—the lower teeth erupting first: Central incisors about the seventh month, lateral incisors about the eighth month, anterior molars about the thirteenth month, canines about the sixteenth month, and the posterior molars about the twenty-fourth month. The age intervening between the first and the last eruption is considered the critical period in infantile existence. (See chapter on *Associative Lesions of First Dentition*.)

The calcification of permanent teeth commences, just before birth, with the anterior molars, proceeding forward, but terminating with the premolars at about the third year. This description does not, however, include the posterior molars, which are really the last to dentify.

The position of the permanent papillæ, which at first are situated between the sacs of the deciduous and the gum, gradually recedes behind, falling deeper and deeper, at least relatively so, as the milk set elongate; until, on the completion of growth in the deciduous, the germs of the permanent set are found in the common alveoli at the apices of these cavities, occupying, indeed, almost the position and physiological relations of the original papillæ.



At this period, whenever it may be, and it varies of course with different individuals, a process of antagonism commences. It is intended that the new may advance and increase, that the old shall decline and diminish. The relative position of the two bodies is as follows: extending to the apices of the alveoli, and receiving at these apices the principal vessels of nutrition, are the perfected roots of the first teeth. Crowding down into these alveoli, with nutritious vessels of their own, possessed with the high vitality of growing bodies, are the pulps of the second teeth. As these pulps enlarge, so is there a corresponding absorption in the alveoli containing them, until, finally, through such process of absorption they have fallen directly beneath the roots of the first set. Of course a pressure has been equally exerted upon these roots, and as a result, the nutrient vessels passing into the pulp-cavities, through the foramina at the apices, have been gradually obliterated.

But do the pulps of the milk-teeth die? Not at all; or at least not necessarily. The neighboring vascularity is very great, the requirements of the organs very small; a sufficient supply is received from the circulation in the dentine, as well as from the periodontum, which, to the last, continues to close in the enlarging foramina. This, however, does occur: the absorbent, or destructive, system has been given the mastery, little by little, day by day, month by month, the roots of the first teeth disappear, while the crowns of the second advance, and occupy the space gained, until at length, as is witnessed every day, the milk-teeth drop out of their cavities, minus roots, while the crowns of the permanent ones are seen in their places.

If here we take up a thrown-off tooth, we find that the pulp-chamber, or what remains of it, instead of having an almost complete bony envelope, as is the case in the perfect organ, has communicated more and more largely, for

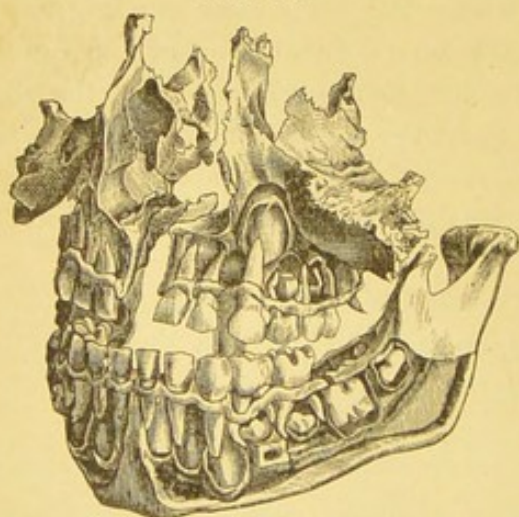
a varying period, with the soft parts, guarding us, in such knowledge, against a treatment in aching milk-teeth, at certain periods, which would be most applicable at others.

To judge of the condition of the foramina of the first teeth, the practitioner is to compare them with periods of eruption of the second, recognizing that the enlargement, or absorption, corresponds with such advance in the permanent.

The first teeth of the second set erupt entirely back of the temporary, and in no way interfere with them.

These are the anterior, or first molars, they appear commonly at about the sixth year, seldom earlier, not infrequently from one to several months later; the sixth year, however, is the rule. The

FIG. 55.



First and second dentition, upper and lower maxillæ.



second teeth to appear are the central incisors, the lower a little in advance of the upper—about the seventh year ; the third, the lateral incisors, at the eighth year ; the fourth, the anterior premolars, at the ninth year ; the fifth, the posterior premolars, at the tenth year ; the sixth, the canines, or cuspidati, at the eleventh year ; the seventh, the second molars, at the twelfth year ; and the last, the third molars, or wisdom-teeth, at a period varying from the seventeenth to the twenty-fifth year—most commonly, however, about the eighteenth year.

The teeth, in their eruption, arrange themselves after a physiological regularity in arches which have enlarged for their accommodation through a process of elongatory and interstitial growth ; if development and functional harmony have not been interfered with, the fully-grown organs are found occupying in regular relations the two jaws, yielding perfect occlusion and articulation. (See *Associative Lesions*.)

**Articulation.**—In examining the articulated skull, it is seen that the six upper front teeth close over and in front of those of the inferior jaw, while the external tubercles of the bicuspidati and molars of the lower jaw lodge in the sulci between the external and internal tubercles of those of the upper jaw ; thus, in the articulation, placing the tubercles of the upper teeth external to the outer tubercles of the lower. The central incisor of the upper jaw, because of its greater width, closes not only over the inferior central, but overrides the lateral. The superior lateral overrides the cuspis ; the cuspis its fellow and the first premolar. The premolars override their fellows and the anterior third of the first molar. The first molar opposes the anterior third of the second molar and the posterior two-thirds of the first. The second molar antagonizes the posterior two-thirds of the second molar, and the anterior third of the wisdom-tooth. The wisdom-tooth of the upper jaw, being smaller than that of the lower, finds a required antagonism in the portion of its fellow left unoccupied by the second molar. Thus it is seen that no two teeth exclusively oppose each other,—an admirable provision, which not only guards as much as seems possible against loss of the organs from lack of articular relation, but secures the fullest results in the trituration of food. (For a splendid diagram showing articular relations of the teeth, see chapter on *Prosthetic Dentistry*. See also Fig. 1.)



## CHAPTER VI.

### ASSOCIATIVE LESIONS OF FIRST DENTITION.

THE calculations of Dr. Arbuthnot that, at the period of dentition, one child in every ten has its life destroyed through the associative and influenced lesions of the age, may, perhaps, not be strictly in accordance with statistics at large; but the mortality is so alarmingly great that, to the general practitioner, no subject offers in its study more important and vital interests. Professor Camper is authority for the statement that out of 5989 infants admitted into foundling-hospitals, only 884 were found alive at the end of the fifth year.

In the first place, it is to be remarked that the process of dentition, while a physiological one, is yet, like that of utero-gestation, one of continuous irritation. Of the meaning of this word irritation, every surgeon and every physician has in his mind quite enough reminiscences. Irritation, then, is the matter of consideration in all of these associative lesions; if happily, in such cases, we could exactly appreciate and exactly control such irritations, N we should of course abort, or resolve, the results.

It is not, however, by any means to be esteemed that all infantile diseases are influenced by, or indeed even remotely associated with, dentition: mistakes of such nature are quite too frequently made, and infants are tortured, and in many cases have the existing disease aggravated, by the lancing and cutting which follow. It is very true that irritation from this cause has not always an associated external local manifestation; but such manifestation is much more frequently found present than absent,—at any rate, it is always to have its full share in the making up of a diagnosis. It will of course be taken for granted that dental irritation is influenced to a most marked extent, all other things being equal, by the slowness or rapidity of the evolution of the teeth. Thus, such equality existing, we would not anticipate from the eruption of a single tooth the trouble of five or six, and such a difference in evolution is so common that it may be said of some children that they cut their teeth in mass, while with others it is a process of the greatest regularity and harmony. Again, the physical condition and age of the child are matters not without significance. A delicate infant suffers more, as a general thing, than a robust one; while premature dentitions are attended with more danger than late ones. In taking into consideration the influences of this process, we are not to forget either the varying degrees of susceptibility manifested in different individuals, as thus we are led to appreciate the fact that judgment is



not to be founded alone on the extent or degree of local manifestation. Some children are preternaturally susceptible to stimuli, and these are not at all necessarily of the weak and feeble class; others, on the contrary, are so obtuse, even from earliest age, as to be very little influenced by any ordinary or common cause of irritation.

To the experienced physician, the appreciation of associated or abstract dental irritation should not be a matter of difficulty. He sees, and he does, what is to be done,—what only can be done; if the treatment fail, the fault resides not in the practice. In the first place, to understand dental irritation, one must be familiar with dental evolution; this, of course, is the understanding of the physiology of the subject. We know the varying periods of eruption, and we are thus at once led very directly in our researches. If we find a source of offence, as manifested by a tumid, congested gum, we have only to pass a lancet down to the confined tooth, and, having done this, we are to expect and hope for relief from any trouble which has been engendered by the just liberated organ. If we look into the mouth, and see no manifestations of offence, it is generally the case that dentition has nothing to do with a trouble which may have influenced the search,—not always, however, for it has been inferred that dentition may be a source of reflected trouble, while itself presenting no local signs. Still, such cases are very rare, and when existing, depend on great rapidity in evolution; either as a single tooth is concerned, or the simultaneous development of many. Several teeth, rapidly advancing at the same time, could very well be appreciated as a source of constitutional offence, not only as diverting in such direction an excess of the vital force, but also in local irritations induced in neighboring structures, and which might not at all be evident by any external signs. In these latter cases the physician can do nothing but increase, by indicated means, the ability of the system to endure the irritation; such means being more frequently found in tonics than in sedatives. In the weak, strict attention is to be given to diet, to exercise, and to cleanliness. The character of the clothing is also of much consequence. If the milk of the mother be not properly nutritious, other means are to be taken to nourish the child.

In cases where there seems simply an excess of irritability, such susceptibility is to be lowered by the withdrawal of everything capable of fostering it; this will pertain to the lodgment of the child, to its food, drink, clothing, exercise, etc., matters which should at once strike an observant practitioner.

Disturbance provoked in the alimentary canal, and fever induced through the process of teething, when existing conjointly with acute disease, of whatever character, necessarily aggravate such disease, and increase by just that much the attending discomfort or danger; hence the recognized increased mortality in the exanthemata occurring at this period.

The diseases, if they may be so called, directly associated with and dependent on abnormal dentition, and having, therefore, necessarily their cure more or less intimately associated with the correction of the primary lesions, are,—



1. Localized Stomatitis.
2. Irritative Fever.
3. Diarrhœa.
4. Spasms.
5. Eruptions upon Skin, especially of Scalp and Face.

1. **Localized Stomatitis.**—The first indication in this condition, dependent on advancing tooth eruption, consists, most likely, in a sense of titillation or itching,—as, before any local sign is visible, the child is found disposed to rub the parts with anything coming into its hands, seeming most comfortable when biting upon hard substances. Slavering is also associated with this stage. After a time, tumefaction of the gums is observed, and this inflammatory action circumscribes or extends itself on the same principle as the vaccine areola,—that is, as influenced by constitutional or local circumstances. If several teeth be attempting eruption at the same time, and these situated at opposite sides of the cavity, then the probability is that the inflammation will be a diffused one. If, on the contrary, the irritation be confined to a single tooth, and there be in the habits of the child no particular inflammatory tendency, then it may reasonably be anticipated that the area of congestion will be very circumscribed. The shape and extent of face in the erupting tooth do not seem to have as much to do with the amount of irritation as one would naturally infer to be the case. The author has certainly seen quite as much trouble from an erupting incisor as in the case of a four-cusped molar. Bad and degenerating inflammations are always associated with constitutional conditions. Thus, in scrofulous children it is sometimes the case that a semi-gangrenous ulceration is the result of cutting a tooth which it is quite troublesome enough to manage; while in children of a mercurio-syphilitic cachexia such a condition will be even aggravated, the gums and continuity of mucous membrane looking as if it was impossible to keep the parts from breaking down into general ulceration. When tumefaction of the gum is dependent on tooth eruption, and the child is of healthy condition, a certain evidence is found in the glistening character of the swelling: the part immediately over the tooth or teeth looking stretched and feverish. This tense look is nearly always present, and may, under all circumstances, be esteemed an indication demanding the use of the lancet.\* In unhealthy conditions this glistening is not commonly present, its absence being dependent on the flaccid relaxed condition of the gum-tissue. Here, as implied, the congestion is of more diffused character; the part and associate parts are turgid and soft-looking. You esteem, in looking into the mouth, that scarification would be of service, but that it is demanded for a sense of general relief, rather than for a strictly acute local condition. Lancing, in the first of these cases, if properly performed, yields

---

\* Application of the tincture of belladonna to a gum thus congested is a source of much relief. A full saturation of the bromide of potassium is also an agent of more or less comfort. The first is to be used with care, the last is harmless.



an almost instantaneously good result ; in the second, such relief is gradual, and most likely inconsiderable. In the first, it is all-sufficient to the cure ; in the second, the constitutional indications are soon felt to be of much more consequence than any local requirements.

To lance the gums of a child, the surgeon seats himself directly in front of the nurse, the height of the knees of the two parties corresponding. Let the nurse now take the child on her lap, supporting its whole body, excepting the shoulders and head, which are to rest upon the knees of the operator. In this position the nurse controls perfectly the legs and arms of the infant, while the surgeon has complete command of its head, and can examine and operate upon its mouth at his convenience. The face of the child should look toward the window, or, if night be the time of operation, artificial light is to be employed.

A tooth is to be lanced in consideration of its shape. Thus, if it be any of the anterior four teeth, either of the upper or lower jaw, a single incision made sufficiently deep to feel the lancet strike upon the enamel is all that is required. This incision is to be made on the line of the cutting edge of the teeth. With the posterior teeth, the cuspidati being included among these, the crucial form of incision is demanded : such form will alone relieve the advancing cusp or cusps, and afford the result desired.

The accompanying diagrams, after Dr. J. W. White, admirably and fully illustrate the subject. Fig. 56 shows the single cusp of an eye-tooth making its way through the gum : Fig. 57 exhibits the proper manner of freeing such a tooth : Fig. 58 shows a gum made turgid by an advancing molar : Fig. 59 exhibits the first expression in eruption of this tooth : Fig. 60 illustrates a form of crucial incision required for the liberation of

FIG. 56.

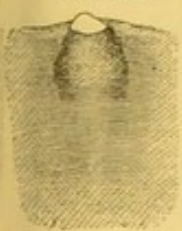

FIG. 57.

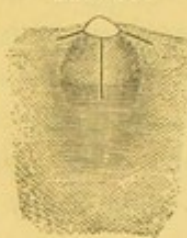

FIG. 58.

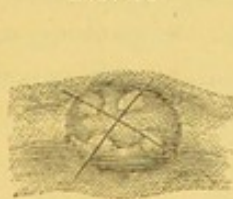
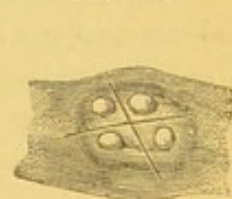


FIG. 59.

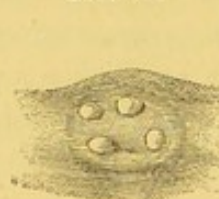

FIG. 60.



the circumferential and central portions of the organ. Observation of the diagrams affords illustration that gum-tissue may require lancing quite as much after as before a partial appearance of an advancing tooth.

Concerning hemorrhage, it is not a common experience that any special danger is to be apprehended ; a practitioner certainly seldom hesitates to lance the gums of a child on this score, and seldom meets with a case that gives any particular trouble. With ordinary patients, the loss of a little blood is rather to be desired than otherwise ; while if a hemorrhagic diathesis exist, the local application of tannic acid or of bayberry-powder will generally be found all-sufficient for control of the bleeding. A little cobweb,



as found in the cellar, wet with borax-water, and then dipped in bayberry-powder, will in ninety cases out of the hundred control the hemorrhage when laid over the incision,—the application to be secured by passing over it, if necessary, one layer of a delicate roller. Pressure made by a finger and continued for some little time is a reliable means.

A constitutional medicament, of good effect in these cases, is found in the *Erigeron Canadense*,—one drop of the tincture to be given in a little water, each minute, until the bleeding ceases, or until twenty or thirty are taken. Opium and lead act very happily in combination. The dose of each must of course be small. A very good formula is as follows:

R.—Pulveris opii, gr.  $\frac{1}{4}$ ;  
Plumbi acetatis, gr. j;  
Aquæ rosæ,  $\mathfrak{z}$ ij.

Sig. Tablespoonful to be taken each half hour, p. r. n.

Another plan is to stuff the cut with a pledget of cotton which has been saturated with phenate of soda. Still another consists in taking a stitch in the parts, drawing the lips of the wound tightly together.

Touching a bleeding gum with Monsel's solutions, or with nitrate of silver, is dangerous practice. The only alarming cases of hemorrhage ever seen by the author have been the results of these applications. It is true that such effects may rest rather with the operator than with the agents; but it is seldom that one seems to succeed in using these means with sufficient cleverness and localization. They are certainly much more apt to do a great deal of harm than any reliable good; secondary hemorrhages are common to them, and, when ensuing, are always of a character much more difficult to manage than the primary trouble.

Another matter in this connection particularly worthy of note, is the influence on the hemorrhage through the sucking propensity of infants. This is to be obviated by passing a roll of rubber or other convenient material across the mouth, and so confining it that, while it shall not fret the little patient, it will destroy the ability to make a vacuum. This manipulation is very simple and easy of accomplishment. The ordinary soft india-rubber ring may be cut in the middle; tie a piece of string or tape to each end, pass the rubber across the mouth, and fix the tapes on the back of the neck; an hour or two will be found quite sufficient to retain the apparatus in the mouth.

Cases of localized stomatitis, having association with the strumous, scorbutic, or syphilitic cachexia, require a treatment external to the cause exciting it; the child must be built up. Such an inflammation, passing quickly into an adynamic type, demands for its cure stimulation rather than depression. To express the requirements more explicitly, a local treatment is to be quieting, and perhaps refrigerating, while tonics, combined with the mineral acids, are demanded constitutionally.



A child eight years of age, of marked scrofulous condition, tissues relaxed, abdomen pendent, was presented at one of the author's clinics, suffering with trouble in the oral cavity. Making an examination, the mucous membrane of the palate aspect of the superior jaw was found angry and uncomfortable-looking, no tension at any point, but the whole membrane turgid, and yet flaccid-looking. In searching for the cause of trouble, the age of the patient directed a first attention to the position of the first bicuspid teeth, the lateral incisors being erupted and in position. Exploration with the lancet—the deciduous molars had been removed long before—revealed these teeth on either side, with the second bicuspids of the right side nearly ready to erupt. The ordinary crucial incisions were then made. In the case of a healthy child, this treatment would have been all-sufficient; with such a child as this, however, not so. Relief to some extent is certainly to be obtained from the incision; but the congestion will continue, and, not unlikely, will grow worse, the parts seeming to lack the energy necessary to self restoration. In this particular case, here noted merely as a type, the mouth was ordered to be washed three times each day with dilute brandy and aromatic sulphuric acid. Internally lemonade was given every two hours, five drops of brandy being added to each wineglassful. Aromatic sulphuric acid acts very happily in these and similar cases, or nitro-muriatic acid may be administered in from two- to five-drop doses, three or four times a day. Iron, combined with an acid, as in the *Ferri Chloridi Tinctura*, is a most admirable medicine, given in from five- to eight-drop doses, three times a day. It is found also not infrequently necessary in these cases to bring the acid, in a more concentrated form, directly to bear upon some obstinate point of ulceration; this is done very readily by means of a pine stick or brush. Dip the tip into the acid used, and employ concentrated or dilute according to the requirements of a case. The acid nitrate of mercury so applied is found sometimes to act very happily. Deliquesced chloride of zinc may also be used. The zinc, followed by a brush of the officinal tincture of iodine, will sometimes induce granulation as if by magic; or tincture of iodine combined with creasote can be employed with good hope of success.

In syphilitic stomatitis, a specific treatment is to be conjoined with the supporting. A combination that may be directed with very satisfactory effect is as follows:

R.—Hydrargyri chloridi corrosivi, gr. j;  
Potassii iodidi, ℥j;  
Syrupi ferri pyrophosphatis, ℥iv. M.

Sig. From a quarter to half a teaspoonful, according to age, three times a day.

It not infrequently happens, however, that a treatment which may have preceded ours has been too free in the exhibition of mercurials; here this medicine is no longer to be used, but, conjoined with the supporting treatment, we are to employ the chlorate of potash:



R.—Potassii chloratis,  $\bar{z}$ ss;  
Aquæ,  $\bar{z}$ viiij. M.

S. Teaspoonful, internally, four or six times a day, and the mouth to be washed with the same, ad libitum.

An admirable local application in the syphilitic sore mouth and throat is made by adding to a six-ounce infusion of white oak bark two drachms of aromatic sulphuric acid and six grains of nitrate of silver.

In all adynamic conditions of childhood, it is assumed a common experience that no better treatment is to be found than lies in the observance of general hygienic laws. Food is to be nourishing, and not given to repletion. Fresh air and exercise are necessities. The child should sleep by itself, or, what, as it is concerned, is even better, it may sleep with some young person of more robust and healthy condition. The daily use of a salt-sheet bath, the water being tepid or cold, according to the ability of the patient to bear, is an invaluable adjunct to restoration. Throw the wet sheet quickly about the person of the child, and rub until a fine glowing reaction sets in. In the use of this means, however, close attention is to be given to daily result. If reaction be not secured, but, on the contrary, the child grow cold, and the cutaneous capillaries contract unduly, then such bath is to be discontinued; or if cold water has been used, it is to be modified, even perhaps to absolute warmth. A good plan to adopt with this bath, is to commence with milk-warm water and advance by gradations to cold.

All the functions of a child of scrofulous or syphilitic condition are to be carefully watched. If the bowels be habitually costive, as is frequently the case, olive oil of good quality may be administered q. s. This oil not only obviates such a condition, but acts as a most desirable article of nutrition. If given alone, a teaspoonful or dessertspoonful, each day, administered at any convenient period, will generally be found sufficient,—and, indeed, in many cases, too laxative. If the child be of an age to take the oil mixed with other food, much attention to the quantity employed will not be found of special consequence. A mineral water of great service in costiveness is prepared as follows: Take of magnesia sulphas one and one-half ounces; of aromatic sulphuric acid two drachms; of sulphate of iron sixteen grains; of water seven ounces. This is used by putting a teaspoonful during the day into the water drank by the child. In cases where the kidneys fail to eliminate with sufficient rapidity, small doses of sweet spirits of nitre are to be exhibited. Buchu, where there is undue irritability of the urinary apparatus, is found to apply very happily. A prescription affording good results is as follows:

Take of buchu one ounce; add one and one-half pints of hot water, and simmer down to one pint; when cold, strain, and give in teaspoonful doses, four or six times a day, as may seem indicated.

Attention is to be directed to the state of the skin. This tissue should feel soft, not relaxed; moist, and reasonably oily; it is to be kept clean, but



not washed too frequently with soap. Whisky or brandy, where stimulation seems indicated, may be added to the water with which a child is bathed; but a healthy skin is to be made rather from within outwardly than from without inwardly,—that is to say, a skin which does not properly perform its offices, indicates, as a general thing, some derangement ulterior to itself, so that the local attention implied is never to be esteemed but as adjunct treatment.

**Angina.**—Angina simplex, simple inflammation of the fauces, is not infrequently dependent on irritations existing or having origin in the oral cavity. Here the trouble is one of continuity of structure, and its relief is found, of course, in cure of the exciting cause. Angina simplex is generally first made evident in difficulty of swallowing. Examination reveals the throat red and congested, the degree being influenced by the condition of the patient. Sometimes this congestion is so great as to make the act of deglutition an impossibility; even fluids taken into the throat are ejected through the nostrils. The uvula occasionally is enlarged to an extent, as the result of effusion into its cellular structure, which seriously endangers the respiration of the patient, compelling, indeed, in many cases, the amputation of the organ. In some instances degenerating aphthous patches (*angina aphthosa*) appear upon various parts of the mucous membrane; these denote that the inflammation is adynamic in its type, and are always a matter of concern, just, indeed, as a phagedenic chancre is a cause for more alarm than a simple sore, implying a degenerative tendency and absence of vital force. An aphthous ulcer is a patch of varying signification. It is the form of ulceration and exudation so frequently seen in weakly, broken-down women. Angina simplex, when dependent on any oral trouble, may be expected to retire on removal of the immediate cause. This, however, is not always the case, as is witnessed in the adynamic types, or in children of very full or sanguine temperament. In these cases, a treatment is to be pursued as implied in the indications. If the continuance of such inflammation depend on a surcharged condition of the vessels, general or local depletion is demanded. Three or four Swedish leeches, or twice as many American, may be put upon the upper part of the throat; the number to be graduated to the strength of the patient and the urgency of the case. A treatment preliminary to this, and one which in his own practice is always employed by the writer when the case is not especially urgent, consists in reducing the volume of blood by the administration either of diaphoretics or of the saline cathartics. Epsom salts, a teaspoonful in a wineglass of water, will carry much fluid from the blood of a young child; or the spirits of Mindererus—covering the patient warmly until diaphoresis is produced—given in teaspoonful doses, every ten minutes, is found sometimes very quickly to break up such inflammations. As a gargle, to be used half a dozen times a day, useful in every kind and condition of sore throat met with, *phénol sodique* is to be recommended in the proportion of a tablespoonful to an ordinary goblet of water.



Hot pediluvia are not to be neglected; the feet and legs of the little patient, kept in hot water for the space of a quarter of an hour, will, in very many cases, be all-sufficient for a cure. A less speedy but frequently successful way of treating angina, consists in diverting, as it were, the seat of irritation; for example, administering nitre, that it may be directed to the kidneys, or tartar emetic, that it may be thrown upon the skin.

R.—Spiritus ammoniæ aromatici,  
Spiritus ætheris nitrosi, āā  $\tilde{\text{ss}}$ . M.

S. Give from five drops to a teaspoonful, according to age, every three or four hours.

The ammonia in the above prescription drives the congesting blood forward, while the nitre directs it toward the kidneys.

An emetic will not infrequently break up a sthenic sore throat. In the case of children, syrup of ipecacuanha answers a good purpose. This may be given in doses varying from a half to a full teaspoonful, according to age, every ten or fifteen minutes, until the desired result of emesis be obtained.

If, conjoined with the local inflammation, we have sympathizing by the system at large, as manifested in fever, febrifuges are to be employed. The following combination is found happily adapted to such indications:

R.—Liquoris potassii citratis,  $\tilde{\text{ij}}$ ;  
Spiritus ætheris nitrosi,  $\tilde{\text{ss}}$ ;  
Pulveris antimonii et potassii tartratis,  
Morphiæ acetatis, āā gr. j. M.

Of this mixture the dose for an adult is a dessertspoonful every two hours; to an infant one year of age, from five to eight drops may be given, being diminished or increased according to effect. Overdoses produce sick stomach.

*Diet.*—This should be light, as in all sthenic inflammations. The child is to be limited to the breast; or if age or circumstances do not permit this, gum-water, or other light and unstimulating food is to be employed,—that is to say, is to be employed while the grade of the inflammation is running upward. Ice-cream is an admirable food, particularly when eaten slowly and continuously. By continuously, however, is not meant that great quantities are to be taken, but that a reasonable portion be made to last as long as possible. Eaten in this way, the article is refrigerant, not only to the inflamed part over which it necessarily passes, but to the system at large, lowering the heat of the whole body, and thus quieting the disturbed circulation.

*Alcohol.*—Of all means known to the author for refrigeration in general febrile conditions, none equal the use of alcohol rubbed over the body, particularly over spine and stomach. The means is specific.

**CHRONIC ANGINA.**—Inflammation of the throat, running into a chronic condition, in children, may perhaps always be accepted as depending on some constitutional predisposition. In these cases the glandular bodies seem to be markedly the seat of trouble. Granulations are commonly prominent over



the mucous membrane, this tissue being covered with a mucoid or muco-purulent secretion. Ulcers are very common, and not infrequently are of such degenerative tendency as to threaten the continuity of parts. A disagreeable association, connected nearly always with a neglected angina, is chronic enlargement of the tonsil glands; the patient is constantly kept coughing and hawking. Operation is compelled in these cases, as every slight cold so swells up the bodies as to render respiration almost as difficult as in asthma. The author has just now under treatment a little girl, in whom, from this cause, these glands are so enlarged that respiration during sleep is accomplished only by an effort that it is absolutely painful to listen to. Of course the case is curable by excision or by the cauterant; but to this neither parent nor child can be brought to submit.

The sense of tickling and rawness in the throat, in chronic angina, is another source of discomfort. This is induced, not infrequently, through the dryness of the membrane, and again, as the result of the irritating nature of the secretions, or it may be dependent on ulceration. From whatever cause arising, nothing is found better adapted to its temporary relief than gum arabic or the jujube troches held in the mouth and allowed slowly to dissolve. A gargle compounded as follows may be used ad libitum:

R.—Tincturæ iodinii compositæ, gtt. xl;  
Acidi carbolici fluidi, gtt. vj;  
Glycerinæ, ℥j;  
Aquæ, ℥viij. M.

Brushing the part with the tincture of belladonna, or with a saturated solution of the bromide of potassium, is sometimes found to abort severity in these cases speedily. Difficulty in hearing is another frequent association of chronic angina,—the explanation being found in the inflammatory thickening of the Eustachian tube. Pain in the act of swallowing is the result of a lymph exudate in the submucous cellular tissue. This it is which gives the irregular thickening so observable about the posterior wall of the pharynx.

Chronic angina, if not dependent on any specific constitutional condition, is most rationally treated by stimulation, local or general, or both, as seems to be indicated. The ordinary domestic remedy of a red-pepper gargle, if judiciously used, not infrequently produces a speedy cure. Unhappily, however, domestic medication is apt to be carried to excess, and thus add to, in place of subverting, a disease.

If a true uncomplicating chronic angina be present in a child,—and it will not do to deny that such cases exist,—let the patient first be treated with a lotion compounded as follows:

R.—Tincturæ capsici compositæ, ℥ss;  
Aquæ, ℥viij. M.

If a few applications of this gargle effect no change, let nitrate of silver be added, in proportion of one-half a grain to the ounce. If even this result not



in the desired change, then it will be well to esteem that general medication is indicated. First we set about correcting any functional disturbances that may be present, and follow such correction with tonics. Muriated tincture of iron is an admirable medicine, where the system seems to require building up; quinine, in the majority of cases, is to be given in addition, with happy effect.

R.—Tincturæ ferri chloridi, ℥iij;  
Quinæ sulphatis, gr. x. M.

S. To be taken in from three- to ten-drop doses, according to age, three times a day.

Where treatment as just suggested, fails, alterative medicaments of the various classes are used,—alum-water, tincture of iodine, weak dilutions of creasote, acid nitrate of mercury, chloride of zinc, solutions of lead, etc. Constitutional vices are to receive a proper share of attention. It is to be assumed that in children affected with chronic angina the cause is always found to exist in such direction. Scrofula is by far the most common of these vices. A scrofulous child is liable to almost any description of physical degeneration. Now, scrofulous degeneration is rather a difficult thing to describe, the conditions being so diversified and varied. A child descended from consumptive parents is degenerate,—it is not amiss to say, is scrofulous. A scrofulous child has not necessarily always a special distinctive type as in general signification is hereafter described. Such a one, for example, may have white, delicate skin, tumid abdomen, non-compact pouting lip, and a languid, listless gait. It may have every belonging of the most marked lymphatic temperament; or, on the other hand, a scrofulous patient may look as if possessed of all the characteristics of a vigorous constitution. One does not know what better to do, in cases of this kind, than make a general observation of antecedent and present conditions and treat accordingly. Syphilis, it has been inferred by some writers, lies closely, or it may be in the distance, as the root of such conditions; but if this should be the case, a treatment anti-syphilitic is not necessarily implied. That peculiar vice may have lost itself in a general degenerative condition, just as an injury, which has of itself gotten well, may yet be the cause of broken health and physical adversity,—just, indeed, as phthisis may succeed syphilis, long since inferred to have been cured. In all such cases we can only hope, in the correction of ill conditions recognized as existing, to find the good required. We may philosophize and reason, but if nothing functionally wrong be perceived, we must have recourse to a somewhat empirical treatment, building, as we say, the patient up. In other words, there are no specific means of cure; therefore we resort to such general tonics as experience has demonstrated to be useful. Cod-liver oil, cream, mixture of spermaceti and milk, preparations of iron, infusions or tinctures of the bitter barks, as the Peruvian, serpentaria, gentian, etc., are medicines to be employed in these cases.

2. **Irritative Fever.**—Fever from the irritation of teething is a direction of infantile trouble very frequently demanding the attention of the physician.



It may not be amiss, for the benefit of the student, to recall that by irritative fever is meant fever the result of something that produces overexcitement. This, it is true, would also be a definition of inflammatory fever, the two conditions being, as we understand, really one and the same, except in degree. Now, the irritative fever of dentition is, as a rule, a rapid fever,—that is, it appears and disappears quickly; the lancing of a gum causing it very frequently to vanish almost instantly; not always, however, for it can readily be understood that such a disturbance of functional conditions could be excited as to make a return to an equilibrium less probable than the production of some organic lesion.

All febrile conditions in children of a sthenic type are attended with much restlessness; but the fever of dentition is markedly so accompanied. Muscular excitability is a prominent association; sleep is broken; thirst is very great; appetite is impaired and irregular, the child taking the breast rather for the relief obtained from the moisture of the milk than from desire for food; the pulse is not infrequently driven to an incredible rapidity; the face is flushed and burning; the eyes are congested and protruded. Convulsions, and not infrequently death, mark the climax.

The disturbance effected in the system is found in proportion to the local irritation, and to the age, constitution, and general condition of the patient. The marked mobility existing in the nervous structure of infants renders the brain peculiarly susceptible; it is therefore a most common association to find the feverish infant flighty, perhaps entirely out of its head; while if febrile disturbance, consequent upon dentition, supervene when other diseases are in progress, such diseases will be commonly much intensified.

The diagnosis of dental irritative fever is not always easy, this simply because the fever is irritative, and not invariably inflammatory,—that is to say, the local disturbance is confined to the *vis vitæ*, and does not involve, to a perceptible extent, the local vascular system. We look into the mouth, but see no swelling of the gums, no evidences of inflammation; yet the trouble is there, and it may be that it is only by incision that the fever is to be controlled. Diagnosis must therefore necessarily not infrequently be of a differential character. To aid us in this, we not only consider the absence of other causes of irritation, but we have marked assistance in a knowledge of the varying periods of tooth eruption, and of the causes advancing or retarding such evolution.

Where dental evolution is inferred to be the cause of a febrile manifestation, and incisions do not seem to be demanded, we are to resort to ordinary general treatment. Lemonade, prepared with crushed ice, is a most grateful and refrigerating febrifuge; the neutral mixture, freshly made, by simply adding the carbonate or bicarbonate of potassa to lemon-juice, is another excellent medicine. This addition may be made to a full saturation. A refrigerating mixture, as follows, may be prescribed, and administered *pro re nata* in teaspoonful doses:



R.—Liquoris potassii citratis, ℥iij;  
 Potassii bromidi, ℥j;  
 Aquæ, ℥j.

Much relief is commonly given by sponging the skin when it is very hot, using water and alcohol, or water and cologne, or water and vinegar. Bathing the wrists in alcohol is another source of great comfort. Bromide of potassium is an admirable preparation to administer in febrile conditions. To children it may be given, dissolved in ice-cold water, in doses of two grains or more to the tablespoonful. Tartar emetic, added to these doses in the proportion of the fortieth of a grain to each, assists the quieting influence. Where the pulse is much excited, and an infant is of sthenic condition, tincture of veratrum viride may also be added, one drop to each dose; in the use of this last agent, however, the effect as its action on the circulation is concerned is to be watched with care. Emetics are highly valued by some. Cathartics may also be used to good purpose; sulphate or carbonate of magnesia being employed, as preferred.

When, in defiance of treatment, a fever of irritation continues, efforts are to be directed to effects that may be produced outside of the ordinary functional disturbances. The extension of inflammation by continuity, where, for example, severe and unyielding inflammation, resulting from dentition, exists, may produce pharyngitis, parotitis, bronchitis, pneumonitis, gastritis, or it may excite to take on morbid action the brain, the heart, the liver, or, indeed, any organ of the body. When such sequelæ occur, we are to treat the parts involved, as in any common inflammation, just, indeed, as we have been treating the unyielding fever, except that we feel the necessity to make such treatment more vigorous; it may be that under such circumstances we will find the local or general abstraction of blood an absolute necessity.

In these cases it is not to be forgotten, however, by the practitioner, that, conjoined with the original cause of inflammation, some other might exist; thus, a malarial influence may have been lying in abeyance, and needed but the depression, the result of the dental trouble, to allow of its asserting itself; or it may be that some half-corrected tendency to congestion is, by the excitation, entirely undone. Such associations are to be considered if treatment is to be successful. This excitation of morbid action is well demonstrated in the association, with dentition, of diarrhœa and the cutaneous eruptions; while the treatment, wherever the secondary irritation shall exhibit itself, is recognized to have a common character.

3. **Diarrhœa.**—The alimentary mucous membrane being continuous from the mouth to the anus, it will be at once recognized that a localized inflammation could render the whole tract irritable. It is thus that diarrhœa, or, indeed, more commonly all the symptoms of cholera infantum, associate with difficult tooth eruption, and it is thus that to cure a diarrhœa or an attack of cholera infantum we have so frequently only to cut down upon certain con-



finer teeth or a tooth. I am led, however, to infer that it is quite too common a practice, during the time of dentition, to ascribe to this process not only every diarrhoea, but the numberless other functional irregularities which happen to occur at the period. Diarrhoea, or this combined with vomiting, has many causes apart from the influences of tooth eruption.

The stomach of an infant may be likened to an enlarged portion of a common tube; not only this, but it is a vertical, or almost vertical, tube; hence a child overfed needs only to be inverted to have the milk run from the orifice of the tube.

Again, the mucous membrane of the intestines of an infant is tender and susceptible; excess of food, or food not easy of digestion, irritates this membrane, and, by the relationship of tissue, excites to action the middle coat of the tube, yielding discharge or diarrhoea. Crapulous diarrhoea may thus be somewhat continuous, for the reason that, unassisted, the contractions fail to relieve the canal of the source of offence, and thus their continued efforts keep up the continued discharges. Worms irritating the canal are the frequent cause of diarrhoea. In hot weather we generally have an increase in diarrhoea cases; and not only is the irritation thus induced not limited to the intestinal tract proper, but the liver as markedly sympathizes; hence the frequency in these months of cholera infantum, the excess of bile being thrown both ways. Enteritis, from follicular ulceration in typhoid conditions, may induce and keep up a diarrhoea in a child as it does in an adult. *Tabes mesenterica* is a cause of diarrhoea in the scrofulous infant. Syphilis may ulcerate and irritate the intestinal tract, just as we so frequently see such irritation in the mouth. These allusions are sufficient to remind us that diarrhoea is not a disease, but only a symptom, and that, whether occurring in the dentitional or any other period, it may have, as its provocative, a great variety of sources, or lesions. When a diarrhoea depends on a dental origin it is perhaps always a condition of vascular perversion, and is entirely direct in its nature; the erupting tooth or teeth inflame the mucous membrane of the mouth, and, by the continuity of tissue, the irritability expends itself over the intestinal portion of the structure. It is well to remember that in diarrhoea of this character there is much or little mucin, according to the state of the inflammation, and much casting off of epithelial scales; but there is, of course, nothing diagnostic in such phenomena, because of their not being peculiar to a particular form, or character, of inflammation. We are to look at the mouth and at the throat; if there be a local condition of irritation and inflammation, and if the vascular derangement extend as far as we can follow it, we have reasonable grounds for inferring that in the teeth resides the origin of the trouble, particularly if, having examined the system at large, we fail to discover other lesions. The author does not desire to be understood as asserting that it is only in this way we have dental diarrhoea, for he well knows there is another way, and that is through the second of the legs of Bichat's tripod. He very well knows that there is an influenced inner-



vation, and that, if the bowels of an infant be weaker than its lungs or its brain, such deranged innervation will there expand itself. He has seen the diarrhœa of such deranged innervation relieved almost instantly by an incision into a tooth-cyst, and yet there was no redness, no swelling, nor any other evidence of local excitability. These cases are, however, rare, and have their analogues in reflex spinal irritations. The diagnosis must necessarily be somewhat differential in character; yet, where a case is at all obscure and the circumstances urgent, it is commendable practice to make incisions over the positions of teeth whose periods of eruption correspond most nearly with the time of operation.

It is well, however, and indeed necessary, to remember that a mucous membrane may be inflamed, in varying localities, without having intermediate sanguineous disturbance. Thus a stomatitis and an enteritis might be present at the same moment; the one depending on local dental disturbance, the other upon a cause or causes of entirely dissimilar nature. Now, in a case of this kind, having associative diarrhœa, it will plainly enough be seen that any treatment directed to the stomatitis would not (except as a similarity in practice might pertain to both troubles) affect the enteritis. To recognize these cases, antecedent conditions are to be inquired into. Colds or atmospheric vicissitudes will, most frequently perhaps, be found explanatory of the disturbances. The cutaneous circulation, as a result of some injudicious exposure, has been depressed, perhaps, and thus the enteritis has been forced upon a part having the least ability to resist an inrolling wave. In some infants, restless and nervous in their natures, a predisposition to enteric irritation seems inborn; the slightest disturbance reacting in this way; it may not be that diarrhœa is the result, but the trouble exhibits itself in some evident way.

The milk of a nurse is occasionally the source of a diarrhœa. Infusoria and crystalline substances are found frequently, on examination, in such milk. Here a cure is to be obtained only by change of diet,—good cow's milk, diluted or pure, according to the age of the infant, being the best substitute. Other causes of diarrhœa, to be considered in connection with a supposed but doubtful dental source, are debility, hepatic derangements, interfering with the venous circulation, an increased peristaltic action through mental emotions, as anger or fright, a rheumatic or scrofulous diathesis, malarial influence, etc.

Diarrhœa from dental irritation, if inflammatory by continuity of relationship in the membrane, generally demands the lancet alone for its cure; the operator is to free the advancing tooth or teeth. If, however, on the removal of such cause, the effect does not subside, the invoked and persistent irritability is to be treated on such principles as commend themselves. Sweet oil and paregoric, administered internally, are oftentimes found to act very happily. To each teaspoonful of the oil add from five to twenty drops of the opiate, according to the age of the little patient. Heating applications to the abdomen are very useful; for example, a sinapism made as follows:



Flour,  $\mathfrak{Z}_{ss}$ ;  
Mustard,  $\mathfrak{Z}_{j}$ ;  
Ginger,  $\mathfrak{Z}_{ij}$ ;  
Black pepper,  $\mathfrak{Z}_{ss}$ .

Mix these together with a little vinegar, and retain against the skin until the part is well reddened. It is not at all necessary to blister the surface.

Another, and perhaps a more comfortable, mode of treatment, is to give small doses of Dover's powder, or, what is to be preferred, the liquor potassii citratis, in conjunction with minute doses of tartar emetic.

R.—Spiritus ætheris nitrosi,  $\mathfrak{Z}_{ss}$ ;  
Liquoris potassii citratis,  $\mathfrak{Z}_{ij}$ ;  
Antimonii et potassii tartratis, gr.  $\frac{1}{2}$ . M.  
Give in ten- to fifteen-drop doses each two hours.

This combination serves to direct the irritability to the surface, and, by a relief thus afforded the affected part, not infrequently yields a cure.

If the inflammation have anything of a sluggish or passive character, the spirit of Mindererus will act happily. Half-teaspoonful doses each two or three hours may be given.

Diarrhœa from dental irritation, not inflammatory in character, is to be treated in consideration of its nervous relation; and just here is the condition in which the bromide of potassium acts most satisfactorily. This salt may be given in five-grain doses, dissolved in water; or, if the practitioner do not like to commence, in the infant, with such a dose, he may try if less will answer his purpose, and increase pro re nata. Less than five grains, however, is not found to do much good, unless, indeed, the child be very young. Spirit of Mindererus, sweet spirit of nitre, and the camphorated tincture of opium also act satisfactorily in these cases. These may be given in such proportions as seem indicated. An ordinary prescription would be about as follows:

R.—Spiritus Mindereri,  $\mathfrak{Z}_{ij}$ ;  
Spiritus ætheris nitrosi,  $\mathfrak{Z}_{ss}$ ;  
Tincturæ opii camphoratæ,  $\mathfrak{Z}_{ij}$ . M.  
S. About twenty-five drops each two hours.

The following combination is a valuable one, when other sources of irritation, not perhaps thoroughly appreciated, exist in conjunction with the dental trouble:

R.—Hydrargyri chloridi mitis, gr. ij;  
Pulveris opii,  
Pulveris ipecacuanhæ,  $\bar{a}\bar{a}$  gr. j;  
Magnesiæ carbonatis, gr. xij.

Divide into eight powders, and administer one after each operation, if profuse; otherwise, each two, three, or four hours, according to judgment.

4. **Spasms.**—To appreciate the cause and condition of spasms and convulsions in early childhood, whether influenced or not by the excitements of den-



tition, one has but to consider the restless mobility of the cerebro-spinal system at such age. If, at an early period of life, the gray matter of the spinal cord be examined, we are struck with its development when compared with the similar substance in the cerebral portion of the encephalic mass. To express ourselves differently, the ganglion of excito-motor or reflex action we find to be much in excess in its development, and not only so, but sensitive and susceptible, as its offices are concerned, to the last degree,—a result most likely of the necessity for the motion of growth and development existing in the members of a child; such a system may be compared to a tensely-strung instrument, responding to the slightest touch.

The difference between a regular and irregular motion is the difference between an ability or disability of the cerebellar gray matter to perform its functions of co-ordination; the difference between a co-ordinated and an irregular motion is the difference of spasm; and if we carry this to the disability of the cerebral mass to influence, it is the difference of convulsion.

Spasm, then, may be defined as irritation, direct or indirect, of the spinal cord or of its terminal outshoots, or nerves. This foundation-principle appreciated, a further consideration of the subject is not at all difficult. Very true it is, that there may be causes of disturbance not to be discovered; but the results, and the meaning of these, are not thereby rendered obscure: it is only the cure that is to be delayed or denied.

We are prepared, now, to recognize in what way dental evolution is a cause of spasm: it is precisely as it is a cause of diarrhoea, as it is a cause of fever; but the reflected irritation in the latter case expends itself on the muscular rather than on the mucous or vascular system. The cure, or the mode of cure, suggests itself: first, we are to remove the condition of irritation; second, if the parts do not quickly soothe and quiet themselves, we are to help. To meet a first indication we simply lance the gums. It is not thought that in these cases we are to be influenced entirely by local manifestations of congestion: we are to cut freely down upon teeth whose periods of eruption suggest them as being the source of offence. Take a pledget of cotton, and, saturating it with a solution of atropiæ sulphas, one grain to the ounce of water, thrust it, by means of some delicate instrument, into the cut you have made. This is quite equal, at least as such a case is concerned, to the more common subcutaneous injection, and tends to quiet the disturbed nerve filaments. Or the bromide of potassium, as before suggested, may be used; or, drying the gum with a napkin, the smallest possible quantity of the extract of belladonna may be rubbed over the part, or a point of nitrate of silver may be employed. If yet the spasms persist, some general effect on the nervous system at large is to be secured. Tinctures of valerian and gentian in equal parts, given in ten-drop doses, repeated *pro re nata*, will sometimes act most satisfactorily. If this should not answer, the bromide of potassium, internally, may be employed. Tincture of belladonna is, in the author's experience, one of the best remedies for spasm. The bromide of potassium, cantharides,



and camphor, as recommended by Dr. Chambers in epilepsy, constitute an admirable combination :

R.—Potassii bromidi, gr. iij;  
Tincturæ cantharidis, gtt. iij;  
Misturæ camphoræ, gtt. x. M.  
Sig. Repeat this in a little water, p. r. n.

If, after proper trial of the above,—say a few hours,—the irritability fails to be subdued, the inference will be that our diagnosis has been a mistake, and that dentition has not been wholly, at least, in fault.

At this point we see the necessity of glancing at other causes of irritation which may exist. Many children incline to nervous disturbance from anæmia; this we know to be a quite common cause of such derangement. An anæmic condition might not of itself, in a special case, induce spasm, but assisted by conjunction with a second irritant, the two together could excite to the condition; and one removed, the other might yet very well resist a curative agent. A glance here shows us why the sedative has not effected a cure; let us add iron to our prescription, and a very few more days will give a different result. Perhaps the condition of a child is just the reverse; instead of being anæmic, it is plethoric. Give to this child repeated doses of some suitable saline mixture, and conjoin with bromide of potassium quarter-grain doses of calomel; or, if you do not wish thus to medicate, diet closely for a few days,—give nothing but the breast, and this only in the daytime; or, if the period be that of second dentition, deprive it of all but vegetable food, with water for drink; a cure will most likely follow such treatment. Lack of good, fresh, pure air; unwholesome food; deficient or improper clothing; sleeping with debilitated persons; the milk of the nurse; articles of food not easy of digestion; hepatic derangements; worms in the alimentary canal; influences passed from mother to infant; and numberless similar conditions, are exciting and predisposing causes of spasm and convulsions; all demand, in every case, their share of consideration, if we are to be successful in treatment.

Spasm resulting from the congestion of nerve centres, however induced, is not infrequently tonic in its character; the child may lose all consciousness; it passes into the state that we call convulsion. In these cases results must be obtained immediately; we must relieve the overburdened part. How? By derivation. Try first a hot foot-bath; let it be as hot as the skin will bear. Inclose the steam of the water so that it shall envelop all of the child but its head; compel the taking, if possible, of teaspoonful doses of the spiritus Mindereri. The steam, or the steam and mixture in conjunction, will soon compel profuse perspiration, and thus secure a double derivation. Such treatment will, most likely, relieve the congested part. If it should not answer the intention, then a vein may be opened, or leeches may be applied. The opening of a vein in such cases the author has had no occasion to resort to, but it is good practice, and is recommended by the best writers.



Hot pediluvia, and derivation by perspiration, will be found reliable. If, after consciousness is restored, the pulse continue rapid, with fulness, give one-drop doses of the tincture of veratrum viride, or relax the system generally by doses of tincture of lobelia or the syrup of ipecacuanha. Ten drops of either of these medicines, repeated as indicated, will very well answer the purpose. Keep the child now cool, and guard against every source of discomfort.

An instructive and suggestive case where epilepsy had its irritant in dental irritation is described in the *Medical Record* by Dr. Nathaniel Field. The paper states that a small boy, about five years of age, while apparently in good health, was suddenly attacked with an epileptic fit, from which he soon recovered. The parents were much surprised at the occurrence, and were unable to account for it. About two weeks afterward he had another strong convulsion, lasting several minutes: but it passed off without any constitutional disturbance. No cause for the attack was discovered by the relator or other practitioners. In a day or two the fits returned, and were repeated at short intervals for about ten days, during which time it is asserted that he must have had a thousand. Every resource in the power of Dr. Field was exhausted, and three eminent medical professors examined the child from the crown of his head to the soles of his feet, but no local irritation was discovered. After carefully watching the commencement of the paroxysms, Dr. F. observed that the muscles of the left side of the face invariably began to twitch on the recurrence of a fit. After a convulsion had passed off, and while the child was in a state of unconsciousness, he raised the upper lip, and found the corona of the second canine tooth, instead of having caused by a just relation the absorption of the root of the deciduous tooth, had passed behind it, and had forced it through the alveolus and gum into the lip. The gum was now slit vertically and the old tooth removed. In less than an hour the convulsions began to subside, and before the day was over they had entirely gone, and never again appeared.

Passive congestions are sometimes a cause of infantile spasms; these are not difficult to distinguish from the acute, or active, conditions, the languor and sluggishness markedly contrasting with the turgidity and fulness. Again, they are distinguished from the active state in their results, these being not immediate, but mediate. Passive congestions depend on some obstruction in the circulatory apparatus, and are, perhaps, more frequently associated with the chylopoietic than with any other system. Stagnations may also occur as a result of some interference with the respiratory office, or they may be the result of the action of some directly sedative poison. Wherever and however they exist, they are to be removed, if possible, by meeting and combating the cause, which, of course, is the philosophy of cure.

In cases of pure irritation, as Dr. George Wood happily puts it, besides removing the cause, it is proper to diminish the nervous susceptibility and to control the cerebral irritation by diffusing the excitement over the whole system. To meet the first indication, narcotics may be employed; and none



is more efficacious than opium, which, to diminish its stimulant influence, may be combined in some instances with ipecacuanha. Hyoscyamus, lactucarium, or conium may be substituted, if on any account thought preferable. But before resorting to these remedies, the practitioner must be very sure of his grounds. He must be quite convinced that it is nervous irritation, and not active congestion of the brain, that he has to encounter. The second indication, above alluded to, is to be fulfilled by antispasmodics, administered by the mouth, the rectum, or the skin, and by the use of tonics, of which the metallics are deemed most efficient. Of these the oxide of zinc has perhaps enjoyed most reputation, though the chalybeates should be preferred in anæmic cases. Should the digestion be impaired, and the system at large feeble, the simple bitters or quinia might be preferable to the metallic tonics. These remedies may often be combined in the same prescription. Thus, opium or hyoscyamus, asafetida, and either oxide of zinc, carbonate of iron, sulphate of quinia, or extract of gentian or quassia, may very properly go together. The cold or shower-bath, cautiously used, may also serve to strengthen the nervous system. Fresh air and nutritious diet of easy digestion are important. Any derangement in the hepatic secretions should be carefully observed, and treated with minute doses of calomel, blue pill, or mercury with chalk. When the disease depends on intestinal spasm, great advantage will often accrue from the use of laudanum, with asafetida or spirits of ammonia by the mouth, the injection of musk into the rectum, the application of a mustard cataplasm, or blister over the abdomen; and if, as often happens, the bowels are distended with flatus, from the introduction of a catheter into the colon, and drawing off the air by means of a syringe. Should the disappearance of an eruption have preceded the convulsions, efforts should be made to restore it by friction with croton oil or other active irritant. In urgent cases a blister might be produced, by means of a strong solution of ammonia, on the surface previously affected.

In frequently recurring convulsions, resisting other measures, and threatening life, the practitioner would be justified in resorting to the inhalation of chloroform, which will often quickly quiet the spasms, and, if reapplied with each return, may obviate the danger until the tendency is past. It has the advantage, moreover, over other narcotics, of not congesting the cerebral centres, though the danger of fatal prostration from its use must not be forgotten.\*

Even when asphyxia or apparent death may have resulted from the convulsions, hope is not to be abandoned; but efforts made by artificial respiration to restore the functions of the lungs, and consequently that of the heart.

Finally, on this subject, attention is to be directed to the connection between the troubles we are considering and the predispositions of hereditary nature, so often found in association. When these deteriorative conditions exist, it is a necessity for success in treatment that they be considered and combated.

---

\* It is found safer to combine with it a portion of sulphuric ether.



5. **Eruptions.**—That the skin of childhood should be the subject of irritative changes is certainly only what is to be expected, and that variations in condition do most frequently occur is as true as that they are thus expected.

Certain general considerations of the subject give us the key-note. Thus, in the beginning, a momentary thought directed to the great change which must result in the passage from intra- to extra-uterine life, would naturally lead to the anticipation of a cutaneous hyperæmic condition at once to be developed. In intra-uterine life we not only have the delicate and susceptible skin lubricated with the soft, bland smegma, but pressure on any and every part is jealously guarded against by the surrounding amniotic fluid. A single minute, frequently, and the most irritative changes occur: the waters pass away, the uterus crowds and presses upon every part of the child, while the outside world, still less considerate, receives it on its birth, its atmosphere stimulating and irritating, its rough points jaggling and abrading, while unnecessary and too frequently ill-advised appliances and applications add to the common discomfort.

Cutaneous hyperæmia—erythema, as it is generally called—is a child's primary skin trouble. Such an erythema is certainly nothing more nor less than the variegated blush of an overstimulated circulation. Perhaps if the smegma were left undisturbed for a few hours, just as nature puts it over the body, or until the skin had become somewhat accustomed to its new atmosphere, such hyperæmia would be avoided; but as such excitability seems to do no immediate harm to the child, neither nurse nor mother are likely to be found satisfied with such an arrangement. But does this hyperæmia do no harm? Does it not provoke an excitability in the skin which would be better absent? Certainly children are most susceptible to cutaneous impressions, as witnessed not only in colds so easily taken, but by the variety of local manifestations, to the relief of which the practitioner is so frequently called. Dental irritations pertain to these troubles only as they act as excitants to the existing predisposition, or as they keep up an excitability which overmasters the corrective force natural to the *vis vitæ*.

Hyperæmia running into an excess is inflammation. Inflammation of the skin finds a primary expression in the term Dermatitis. A dermatitis has secondary signification, as it presents peculiarities which lead us to look for reasons for such expressions. Thus, one inflammation in the skin is a simple sthenic increased vascularity, having the phenomena of redness, heat, pain, and swelling. A second is not regular and honest in its expressions, but throws out claw-like expansions, and looks dusky and threatening, throwing to the surface, here and there, blebs of serum. We distinguish this second from the first by the subterm erysipelas, or erysipelatous inflammation. Then we have an inflammation which presents the peculiarity of studding the face of the skin with pustules, and this derangement we distinguish by the term pustulæ or pustular inflammation. Another form covers the inflamed surface with vesicles; another throws out groups of nodules,—



popular; another circumscribes its redness to patches,—rashes; another presents raised or elevated wheals,—urticaria, etc. All have alike the primary signification of a perverted circulation, but differ in presenting distinctive phenomena, these marking differences in local or constitutional circumstances.

That dental irritation develops or creates the distinctive features in a skin disease is sheer nonsense. All that such irritation can have to do with the matter is that it exhausts the system, just as any pain exhausts and tires, and reduces, as remarked, the ability of the vital force to guard or protect itself against an enemy or enemies in waiting at the threshold. It does not make the enemy, it only lets him in by weakening the bars.

That a skin disease is thus introduced, and continued in an ability to resist applied medication, would seem to be true beyond the shadow of a doubt; and it is for such a reason that the consideration of dental irritation, in connection with infantile skin diseases, is important; and yet this study, as the evolution of the teeth is concerned, differs in no wise from its study in relation to stomatitis, diarrhoea, or spasm, as certainly any intelligent mind must at once appreciate.

Skin diseases belong to one of eight orders:

1. Pimples.
2. Scales.
3. Rashes.
4. Bullæ.
5. Pustules.
6. Vesicles.
7. Tubercles.
8. Spots.

1. **Pimples—Papulæ.**—Small and pointed elevations of the cuticle, with an inflamed base—very seldom containing fluid, seldom suppurating, and commonly resolving as scurf.

Three primary divisions of papules are made: strophulus, lichen, and prurigo.

*Secondary divisions.*—Strophulus intertinctus.

S. albidus, S. confertus, S. volaticus, S. candidus.

Lichen simplex, L. pilaris, L. circumscriptus.

L. agrius, L. lividus, L. tropicus.

Prurigo mitis, P. formicans, P. senilis.

P. pudendi muliebris.

2. **Scales—Scaly Diseases—Squamæ.**—Scales or laminæ form upon the skin. Scales are of various forms,—in some cases, as in pityriasis, resembling a scurf; in other cases, as in ichthyosis, being broad and flattened, and bearing likeness to fish-scales. To mark the various prominent differences, four varieties are enumerated: Psoriasis, Lepra, Pityriasis, Ichthyosis.



*Subdivisions.*—*Lepra vulgaris*, *L. alphoides*, *L. nigricans*.

*Psoriasis guttata*, *P. diffusa*, *P. gyrata*.

*P. inveterata*.

*Pityriasis capitis*, *P. rubra*, *P. versicolor*, *P. nigra*.

*Ichthyosis simplex*, *I. cornea*.

3. **Rashes—Exanthemata.**—Irregular, variously figured patches, appearing on various parts of the body, leaving interstices of a natural color, and terminating in exfoliations of the cuticle. The designation is generally limited to efflorescences originating in fevers, as for example measles and scarlet fever.

Bateman, however, includes, and perhaps more philosophically, *Erythema*, *Urticaria*, and *Purpura* in the division.

The first division is, then, according to Bateman, *Rubeola*, *Scarlatina*, *Urticaria*, *Purpura*, *Erythema*.

*Subdivisions.*—*Rubeola vulgaris*, *Scarlatina simplex*.

*S. anginosa*, *S. maligna*, *Urticaria febrilis*, *U. evanida*.

*U. persistans*, *U. conferta*, *U. subcutanea*.

*U. tuberosa*, *Purpura simplex*, *P. hæmorrhagica*.

*P. urticans*, *P. senilis*, *P. contagiosa*, *Erythema læve*.

*E. papulatum*, *E. tuberculatum*, *E. nodosum*.

4. **Bullæ.**—A condition in which effusion occurs on the true skin, separating the cuticle in the form of blebs or blisters. An effusion developed by a blister comes justly in its consideration under this head, for it is surely not less a bleb because a blister has produced it. The difference between such a bleb and one resultant from an erysipelalous inflammation is that one has strictly a traumatic signification, while the second is a specific offence. Blebs or bullæ have three primary classifications: *Erysipelas*, *Pemphigus*, *Pompholyx*.

The subdivisions are into *Erysipelas phlegmonodes*, *E. œdematodes*, *E. gangrænosum*, *E. erraticum*, *Pompholyx benignus*, *P. dinuturus*, *P. solitarius*.

5. **Pustules—Pustulæ.**—An inflammation of the skin, resulting in the formation of purulent matter, which accommodates itself by throwing up little circumscribed tumors. Whether one or many of these pustules rise on a common inflamed base depends on the fundamental or exciting cause; and because the conditions which produce pustular inflammation vary, so have we various names by which to distinguish and appreciate these causes. Five primary pustular inflammations exist: *Impetigo*, *Porrigio*, *Ecthyma*, *Variola*, *Scabies*.

The subdivisions are numerous, depending on peculiarity of features. *Impetigo figurata*, *I. sparsa*, *I. erysipelatodes*, *I. scabida*, *I. rodens*, *Porrigio larvalis*, *P. furfurans*, *P. lupinosa*, *P. scutulata*, *P. decalvans*, *P. favosa*, *Ecthyma vulgare*, *E. luridum*, *E. cacheticum*, *Variola*, *Scabies papuliformis*, *S. lymphatica*, *S. purulenta*, *S. cachectica*.

6. **Vesiculæ—Vesicles.**—Vesicles differ from pustules in containing lymph—they look like little water pimples, although it is very frequently the



case that the contained lymph is quite opaque; the end of a vesicle is by scurf or scab. There are seven primary varieties: Varicella, Vaccinia, Herpes, Rupia, Miliaria, Eczema, Aphtha.

The subdivisions are Varicella lenticulus, V. conoidæ, V. globate, Herpes phlyctænodes, H. zoster, H. circinatus, H. labialis, H. præputialis, H. iris, Rupia simplex, R. prominens, R. escharotica, Eczema solare, E. impetiginodes, E. rubrum, Aphtha lactantium, A. adultorum, A. anginosa.

7. **Tubercula—Tubercles.**—These are small, hard, circumscribed tumors—they may be fixed in a state of integrity, or they may be degenerative. There are eight kinds of these tumors—or, to express it differently, there are eight distinctive differences: Phyma, Verruca, Molluscum, Vitiligo, Acne, Sycosis, Lupus, Elephantiasis, Framboesia.

Among these, subdivisions seem only necessary with acne and sycosis. Thus, there are three peculiarities in acne, which are marked by the terms Simplex, Indurata, Rosacea. In sycosis, Sycosis menti, and S. capillitii, designating the location of the tubercles.

8. **Macula—Spot—Mother-Mark—Freckles, or Ephelis—Nævus.**

These eight classifications, after Bateman, with his subdivisions, make out of skin diseases all that concerns a present consideration of them. It is for the student to comprehend the primary divisions, as their pathological differences are concerned; the radii, or subdivisions, will be found to take care of themselves. Without an understanding of the general subject one could scarcely expect to appreciate any accidental or positive dental relations. The subdivisions will be remarked, on examination, to be simply as family surnames distinguishing one child from another; it is true, of course, that there are peculiarities of character, just as each child is peculiar, and by such peculiarities are these modifications on the primary condition named. Now, it is not by any means common to associate all these conditions with dental irritations; yet it is certainly true that any one of them may have such association: therefore, if the student would understand one he must understand all. (See *The Face and its Diseases*.)



## CHAPTER VII.

### ANOMALIES OF SECOND DENTITION AND THEIR SURGICAL RELATIONS.

UNDERSTANDING and appreciating the characteristics and relations of a normal dentition, we are prepared to pass to the consideration of abnormal, or pathological, conditions. Such conditions may be justly grouped under the head of anomalies.

Anomalies in second dentition are classifiable under seven heads :

- 1st. Teeth common to the age, but erupting external or internal to the arch.
- 2d. Teeth denied space in the arch, because of natural or surgical interference with the process of maxillary enlargement.
- 3d. Germs developing in positions where their product must remain encysted.
- 4th. The production of supernumerary teeth.
- 5th. Third dentitions.
- 6th. Teeth the periodontium of whose fangs associate with the periosteum of the maxillary sinus.
- 7th. Germs with heterogeneous development.

These seven conditions, then, because they differ from a just, or normal, dental evolution, we call anomalies.

ANOMALY FIRST.—A tooth external or internal to the alveolar arch not infrequently gives origin to an ulcer or locates epithelioma. Yet close as is this primary to the secondary lesion, and evident as such relationship would seem to be, the writer has known ulcers of the tongue, lips, and cheeks treated for months—of course, without success—where it has never seemed to strike the practitioner that a tooth could have any association with the disease; indeed, in one case, where the patient was remotely connected with himself, death was the result of cancer located in the cheek from this very anomaly. Many cases of like character are familiar to the experiences of every surgeon.

*Note.*—Even where there is excess of room, the permanent teeth not infrequently erupt irregularly; indeed, this applies so directly to the inferior incisors, that it may almost be said to be the rule rather than the exception. Unless, however, specially indicated, it is the best practice to leave such teeth to nature; they will almost always be found to come right of themselves. Such eruptions are to be classed with the anomalies only as derangement is marked and permanent.



ANOMALY SECOND.—*Teeth denied space in the arch.* This anomaly has perhaps the largest associative pathological connection.

It is to be remarked that this lesion, if we may term it such, is more frequently the fault of the surgeon than of nature. If, for one moment, we refer to the physiological relations existing between the first and second dentures, we may find that it is within our power to prevent the many ills that follow so frequently in this train, and this simply by doing little, or, more commonly, nothing.

The deciduous dental arch is filled, as we are all aware, completely by its ten teeth. The second, or permanent, set is to comprise in number sixteen, and each tooth certainly quite as large again as its predecessor. This increase in number and size of the teeth, it is evident, must be provided for in an enlargement of the alveolar arch. This provision is always attempted by nature in the process described by the physiologist as the elongatory.

This process of maxillary enlargement is to be illustrated by considering the ten milk-teeth as so many wedges placed in a springy arch. This arch it is designed to lengthen by additions to either end. If, now, these wedges should be removed before others were ready to take their place, it is evident that the elongation, being made at the ends, would, to a greater or less extent, be counterbalanced by the springing together of the parts at the sites of the removed wedges. The process of maxillary, or rather alveolar, absorption, is truly represented by this retraction of an arch. In proportion to the number of deciduous teeth removed prematurely, will be the curtailment in size of the arch; at least of its alveolar face.

Let us, then, look at the results of such abridgment,—approximal caries of the teeth, periodontal troubles, trismus, odontocoele, necrosis, the violent inflammations attendant on the development of the *dentes sapientiæ*, etc.

*Note.*—If there be a pathological Pandora's box, it is certainly the lesion of an overcrowded maxillary arch.

The condition of overcrowding is made evident to a practitioner the moment he looks into the mouth of his patient: the teeth are jammed into the most uncomfortable-looking positions; the deformity, however, mostly existing in the front of the mouth,—either the central incisors override, or the laterals are thrown back, or otherwise the cuspidati take a tusk position, standing out prominently from the arch, the bicuspidati occupying too anterior a location, approximating, indeed, not infrequently with the lateral incisors.

*Treatment.*—To abort the ill consequences of such a contracted arch, extract at as early a period as possible the first bicuspidatus of either side. This very simple operation will frequently not only secure against secondary lesions, but will occasionally correct the most annoying deformities. Let it be remembered, however, by the practitioner who prefers prophylactic to operative surgery, that on his treatment of the deciduous mouth depends, in a measure, the health and comfort of the adult.

If the question be asked, What is to be done with the deciduous aching



tooth? it is to be answered by saying that the cavity exposing the pulp should have been filled on appearance of the decay. This is a matter which no parent can afford ever to neglect. In the armamentum of the oral surgeon are plastic materials, easy and painless of introduction, which are to be depended on to accomplish the services required of them.

Equal parts of chloroform and tincture of aconite, applied to an aching nerve on a delicate pellet of cotton, will sometimes instantaneously relieve this form of toothache. Another admirable application, used in the same way, is the atropiæ sulphas, dissolved in water, in the proportion of one grain to the ounce. Still another, a means in universal use, is creasote. Other remedies are found in oil of cloves, in Goulard's extract, tincture of iodine, bismuthi subnitras in saturation, chloral hydrate, and tincture of ergot.

An exposed pulp in the deciduous tooth is, however, so constantly subject to irritation, that every indication calls for its destruction. The necessity is unfortunate, but the demands are persistent, and the removal of the part seems the lesser of two evils between which the practitioner is compelled to choose. The application of arsenic, however, to such an exposed pulp has come to strike the experienced as questionable, and, as it is not a necessity, it will be found best perhaps to restrict the use of this agent to the permanent teeth. A deciduous pulp is to be destroyed by touching it a few times with a fully saturated tincture of iodine, or with either of the Monsel's solutions of iron. (See chapter on *Odontalgia*.) Arsenical applications are, however, frequently employed, but unless a practitioner be conversant with the physiological change that occurs in the fangs of these teeth, he had better not risk this means; if, however, he feel prepared to employ such an escharotic, he can use no better formula than the following:

R.—Acidi arseniosi,  
Morphiæ acetatis, ãã gr. x;  
Creasoti, q. s. to make a thick paste.

This is a paste quite universally employed for destroying the pulps of adult teeth. To apply it to a milk-tooth, take a piece not larger than a pin's head, and, dropping it lightly into the cavity, cover loosely with cotton; the part is to be washed out with warm water after four or five hours; it is not well to leave such a preparation in a deciduous tooth over five hours; if absorption of the fang had advanced to any extent, even one might be too long. Employ it fearlessly in the adult mouth, only remembering that you deal with arsenic; but with the child too much caution is not to be exercised.

The central incisors of the deciduous set of teeth should (a normal life continuing) last until the seventh year; the laterals until the eighth; the first deciduous molar until the ninth year; the second until the tenth; the deciduous cuspis until the eleventh; and let it be remembered that the most posterior molar teeth that are in the mouth at the sixth year are the first permanent molars, and that these teeth get their place in the jaw without displacing any of the deciduous.



For an account of some of these secondary lesions, together with treatment, see future pages.

**ANOMALY THIRD.**—This anomaly is remarked by examination of the classes of teeth erupted. Teeth all erupt in pairs, so that one is not likely to be deceived. The anomaly is not infrequently the result of interference with the development of the germ of the permanent through non-absorption of the root or roots of the deciduous teeth.

*Example.*—A deciduous central incisor erupts—as a rule—about the seventh month, and is succeeded by the permanent at the seventh year. Now the physiological relation existing between the two teeth is as follows. At the time when the deciduous has attained its full development the germ of the permanent is at its apex. (See Fig. 55.) Retrograde metamorphosis now commences in the fang of the deciduous, while, in an inverse ratio, the development of the permanent advances. It sometimes happens, however, that no process is set up for the taking away of the deciduous fangs, and, as a consequence, the crowns of the permanent are compelled to make places for themselves; this they generally do by emerging posterior to the deciduous; but, as can readily be imagined, odontocoele, or encystment, is not infrequently a result.

*Note.*—Sometimes, long after the period at which second dentition is usually completed, the incisors, as would seem to be natural, are to be remarked, each occupying its respective alveolus. Yet here we may have odontocoele. One of the teeth that we see belongs to the milk set. This anomaly could, however, deceive only the very superficial observer, the difference in the classes of teeth being sufficiently marked.

Because of this non-absorption of deciduous fangs, arrest in the development of the permanent occasionally is met with. It is really quite a nice point in practice to give advice in such cases; if extraction of the deciduous tooth be advised, and no other come to replace it, the practitioner will be sure to get a good deal more censure than he could possibly deem himself deserving. There are a number of conditions to take into consideration in such a case, the most prominent of which is the existence or non-existence of the anomaly in a hereditary point of view. The author is acquainted with a family where continued integrity on the part of certain front deciduous teeth, conjoined with the non-appearance of the permanent, has been a striking peculiarity as far back as the ancestors can be remembered. Ability to advise, in such cases, can only be gained by careful study of the laws of dentition and idiosyncrasies.

*Surgical Relations.*—In an examination of any obscure tumor of the maxillary bones, examine the dental arch; if a deciduous tooth occupy the place of a permanent, or the permanent be lacking, not having been extracted, the existence of odontocoele is reasonably to be inferred.

**ANOMALY FOURTH.**—*Supernumerary Teeth.*—These teeth differ from all others in being doubly fully conoidal; this as a rule. It is, however, to be



remembered that exceptions are met with. Harris mentions having seen teeth of this kind so resembling normal organs as "to make it impossible to distinguish which should be called the supernumerary;" few observers, however, have met with such decided exceptions.

An encysted condition of these bodies obscures very much a recognition of their existence. In diagnosing diseases of the mouth, we are to bear in mind that there are such odontocles. The study of the evolution of these teeth is very interesting, but, of course, concerns the physiological rather than the surgical writer. The place where they are met with is the roof of the mouth.

*Surgical Relations.*—With the exception of the relation of supernumerary teeth to tumors, we have only to deal with them as they so strangely present themselves in the mouth. An example in this direction of practice may be given. A patient presents himself and tells you that there is a piece of bone working out through his mouth; and, truly, an examination will seem to verify his assertion. But there is one point which, if observed, will save the practitioner from being misled. Necrosis is always preceded by, and is associated with, tumidity of the gum. The eruption of a supernumerary tooth is very gradual, and, so far as the writer's experience goes, is never associated with inflammation. To extract such teeth, wait until they have emerged to the base of the cone; or, if such waiting do not seem desirable, carefully force sharp-bladed forceps through the bone until the nibs grasp this base, then with a rotary motion they are easily to be pulled away. Their alveoli need no attention.

ANOMALY FIFTH.—*Third Dentitions.*—We are not to be understood as referring here to that extra development sometimes occurring in young adult life, and yet the mention of the existence of such an anomaly is, perhaps, desirable. Thus, Columbus reports that one of his children had three rows of teeth. Valerius Maximus and Pliny relate similar facts. A son of Mithridates is said to have had two, and Hercules three. The author has seldom seen this anomaly, and inclines to think that its existence, in these modern times, is not coextensive with the ancient period. He certainly has had quite five hundred persons tell him that such and such tooth or teeth were the third of the class, but examination, in almost every individual case, has satisfied him of a mistake; this anomaly has, however, surgically, little or no signification.

Third dentitions, as here referred to, are those which are associated with advanced age. The student will recognize their physiology when they are classified with second sight, etc. The lesions of this anomaly are what might be termed associative,—that is, we are occasionally so deceived by them as to be led falsely to interpret engorgements, congestions, etc.

A single case will illustrate the anomaly. An individual, aged sixty-five, applied to Dr. Chapin Harris, suffering with pain in the gums and jaw. No local lesion was discoverable. A tentative treatment was resorted to. The apparent disease went on, entirely uninfluenced by the experimental medication, until at last it attained an intensity positively excruciating. In twenty-



one day the mystery was explained by the eruption of a third set of teeth. The report of another case is, at the time of this writing, appearing on the pages of various journals describing a new and full dentition in the person of a gentleman eighty years of age.

ANOMALY SIXTH.—*Association of the odonto-periosteum with the membrane of the antrum of Highmore.*

It will be remembered that the easiest entrance to the maxillary sinus is through the palatine foramen either of the second or the first molar tooth. It is, indeed, a very common thing to find the roots of these teeth perforating the cavity. Remembering this association of parts, it will be seen that many conditions, which may have been deemed obscure, are thus made very plain. Dr. Harris, who seemed a close observer in diseases of the mouth, went so far as to say that two cases, mentioned by Bell and Bordenave, were the only authenticated exceptions where abscess had formed in this cavity at any other point than that at which it had been penetrated by the root of a tooth.

A case mentioned in Braithwaite, from the practice of a Mr. Louis Oxley, of London, illustrates most happily the relations of this lesion. A young woman, of rather strumous habit, complained of a dull, aching pain under the orbit. The pain lasted from three to four months, attended by a gradual elevation of the orbital surface of the maxilla. The eye above this surface became at length so affected as entirely to lose its functions. At this stage of the case she was directed to use leeches and blisters behind the ears, and to employ drastic purges. After three months' blindness, the patient first perceived a discharge, from the right nasal fossa, of a thick, purulent fluid. This discharge had existed, he says, eighteen months, when he first saw the case. An examination of the mouth at once revealed the cause of so much misery; the removal of three roots, in a state of periodontitis, was the simple means by which two most important organs regained their proper functions.

The nasal opening of the maxillary sinus, it is known, is, in a healthy condition, almost closed by the duplicature of membrane lining the turbinated and neighboring bones; congestion of this membrane not infrequently closes the outlet entirely. Thus secretions accumulate, giving alarming and threatening disfigurements to the face. The weakest points in the osseous boundaries of this cavity are, the floor of the orbit, the hard palate, the tuberosity of the bone, and the canine fossa. Any accumulation would necessarily be apt to vent itself at one of these four points, unless atresia of the duplicated membrane alluded to should occur, and which is not commonly the case.

*Note.*—The author's experience regarding acute abscess of the antrum is, that in the great majority of cases the pus seeks to vent itself through the floor of the cavity. After the inflammatory action has passed to the suppurative stage, a swelling will be noticed in the roof of the mouth at the side of the mesial line, corresponding to the diseased sinus: this is the abscess pointing, and, if left to itself, is sure to make an ugly opening. Such a result will be found particularly undesirable if there be any specific virus



lingering in the system. But, wherever this abscess should tend to point, it is of course desirable to abort it.

If the assertion of Harris be true, concerning the almost invariable dental origin of the trouble (and certainly experience confirms him), we turn naturally to the alveolar arch, seeking there the source of offence and defence. For a single moment, then, let attention be directed to a few dental lesions of a most practical character, without the ability to recognize which, the practitioner will assuredly find himself at sea.

Because, when turning to the dental arch, we find it entirely clear of teeth, and healthy-looking, we are not hastily to conclude that the primary lesion lies in some other direction. We are to remember that fangs of teeth are not infrequently broken off in an attempted extraction, and that when so broken, particularly if very deep in the socket, practitioners are not unapt to leave the pieces. Now, it is easy to understand that a fang so situated may be the source of extensive disease, and yet the gum over it be without break in its continuity, and perfectly healthy-looking. The relation, in such a case, of the fang, is with the antrum,—it need necessarily have no external sinus. Here an explorative incision along the gum down to the bone is to be made. If, happily, we come to a cavity, we will have hit on the origin of the trouble; if nothing be found, we have made but a simple incised wound, which left to itself heals in a few hours.

Again, because the part may have its complement of teeth, and each tooth seem perfectly healthy, we are not to turn hastily away. There may be in one of these teeth a dead pulp. To satisfy ourselves on this point, we take up a delicate steel instrument, and strike with it each tooth separately, directing the patient to note any difference in the sensations; if he start when a particular tooth is struck, we have found the primary lesion. But still again the lesion may be here, and yet the patient not express the anticipated pain. A hand-mirror is now taken, and, placing the patient full in the sunlight, rays are to be reflected over the teeth, by placing the glass back of them. If in the arch there be a dead tooth, an opacity not belonging to its neighbors will show itself; this is the offence; remove it.

If a tooth have a plug of metal in it, take the filling out: the cavity will, not unlikely, be found to communicate with the pulp-chamber.

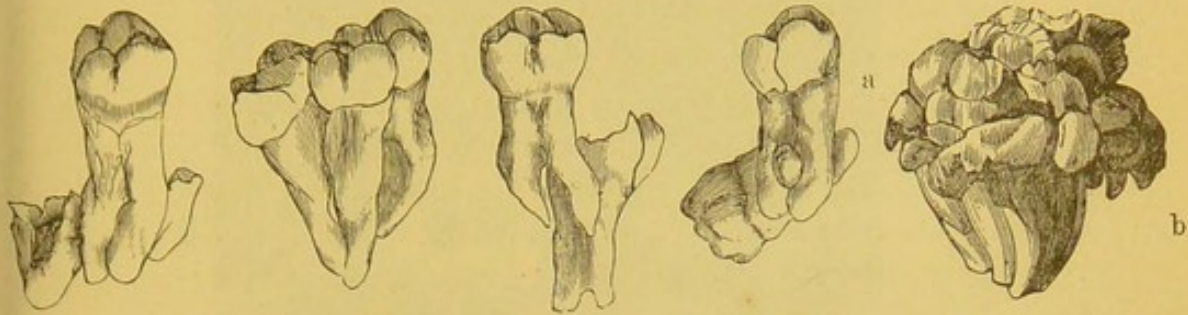
ANOMALY SEVENTH.—*Germis of heterogeneous development*.—It occasionally happens that the dental germ, instead of arranging its parts according to the ordinary manner, assumes the most fantastic and heterogeneous complexion, giving, indeed, such heterologousness of appearance that nothing but the microscope can at times discover its true character. Out of this condition arise tumors, caries, necrosis, and other derangements. Fig. 61 shows the most simple expression of heterogeneous development. The fusing of teeth after the manner here exhibited is so common as to be very familiar. Every variety has been met with from time to time. No confusion exists, however, as recognition of tooth character is concerned.



Fig. 62 is a marked departure from simple fusion. At the point *b* ordinary tooth roots are recognizable. At the summit of the mass, *a*, the appearance is cauliflower-like.

FIG. 61.

FIG. 62.



Figs. 63 and 64 are other illustrations of heterogeneous development.

FIG. 63.

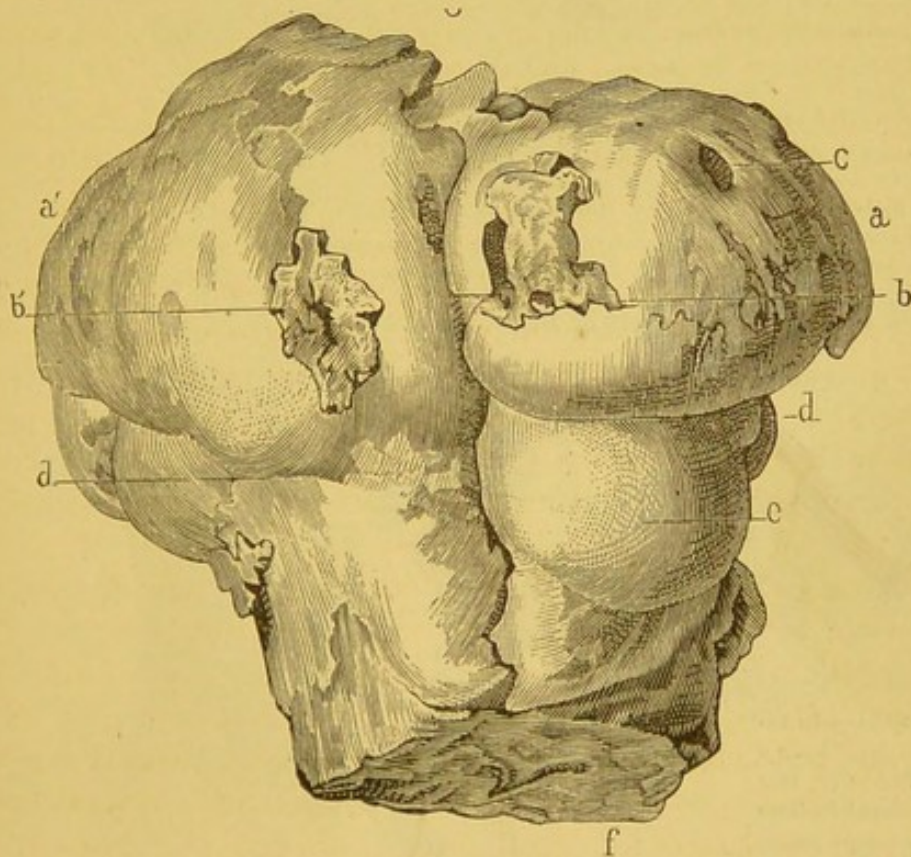


Fig. 63.—*a*, *a*, second grinding tooth of a horse, natural size, with considerable development of the roots, transformed into two spheroidal swellings. *b*, *b*, portions of the maxillary bone sheathed in the tumor, and broken in its extraction. *c*, orifice conducting to the interior of an intradental cavity. *d*, *d*, circular groove corresponding to the alveolar arch, and forming a sort of strangulation between the tuberosity *a* and the swelling *e*, which is underneath. *f*, inferior surface of the crown of the tooth.



FIG. 64.

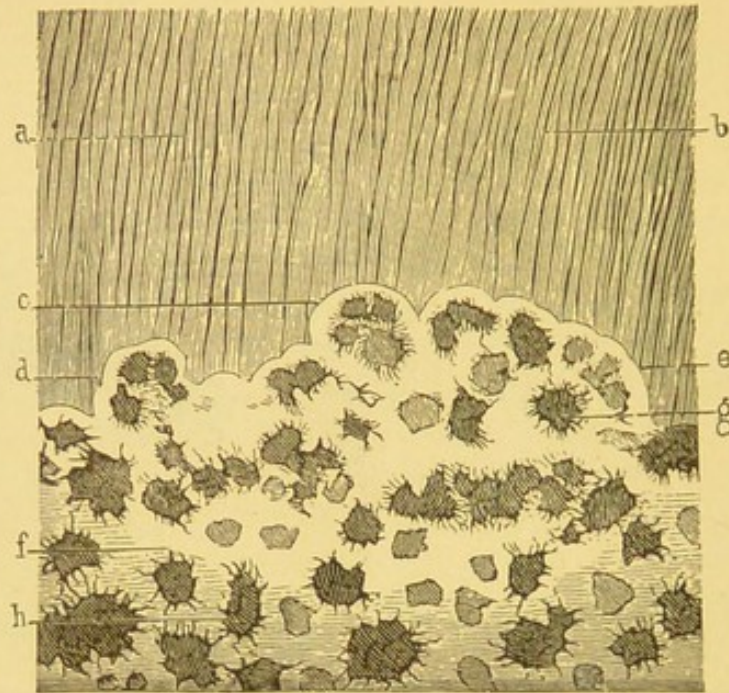


Fig. 64.—Microscopic examination of the tumor (300 diameters).—Represents part of a thin section of the tumor shown in Fig. 63. The tumor was formed jointly by a hypertrophy of the dental ivory and a hypertrophy or exostosis of the cement, the greatest part being formed of the substance of the cement. *a, b*, represents the ivory in its canaliculi—not ramified in this section—and terminating near the union of the ivory and enamel. *c, d, e*, exhibits the mammillated arrangement seen in the cement at certain points of the surface of union with the ivory or dentine. This arrangement, often very elegant under the microscope, is also met with in the normal teeth. *g, h*, osteoplasts, or characteristic cavities of the cement. They are especially remarkable for their size in all the preparations taken from this piece. *f*, proper substance of the cement, or bone, in which the characteristic cavities are excavated. It is here, as always, homogeneous; little transparent, except when it is reduced to very thin laminae.

Figs. 65 and 66 afford further illustration.

FIG. 65.

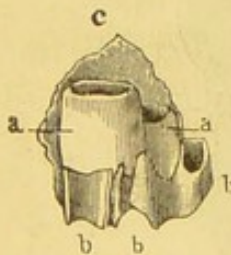


FIG. 65.—Intra-maxillary bone bearing the two permanent incisors (*a, a*) superposed, and exhibiting an anomalous development. The alveoli of the same infantile teeth are partly destroyed; this section formed the deposit.

FIG. 66.

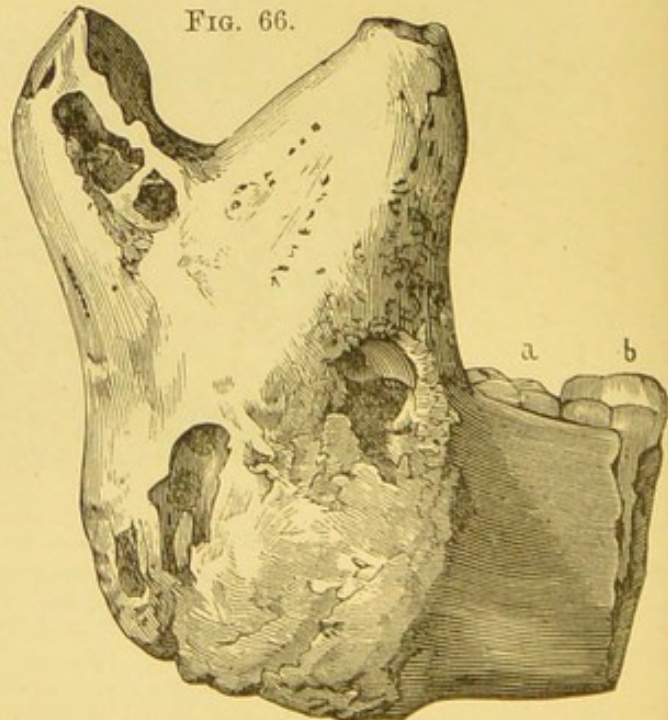


FIG. 66.—Tumor of the ramus of the inferior maxillary bone, affected with mollities ossium. At the surface are many openings of encysted abscesses; and the last molar, the crown of which extends slightly beyond the alveolar edges, and is developed in the thick part of the base of the coronoid apophysis.



Figs. 67, 68, and 69, after Forget, furnish still other examples.

FIG. 67.

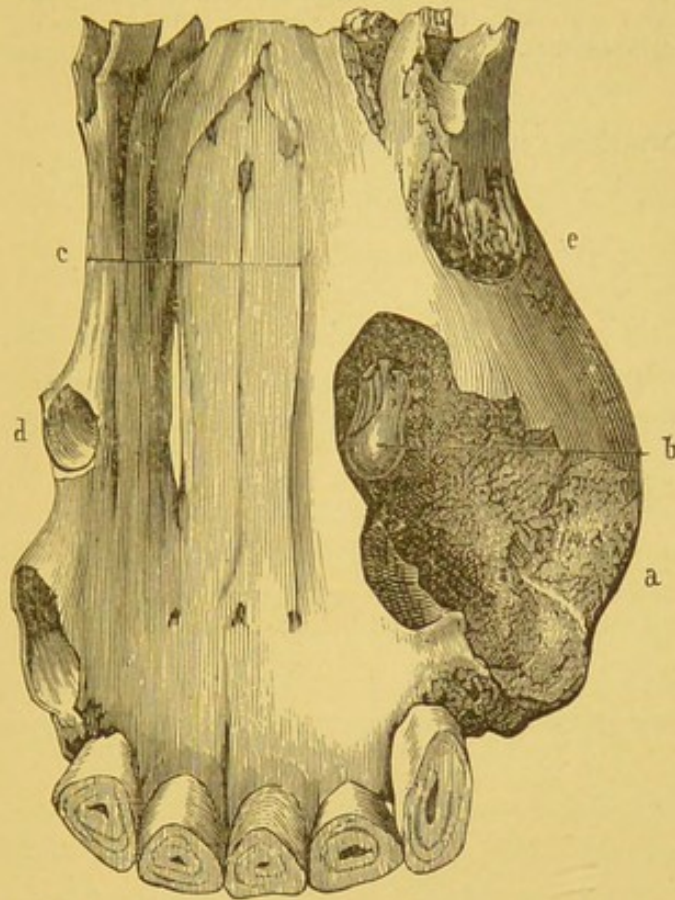


FIG. 68.

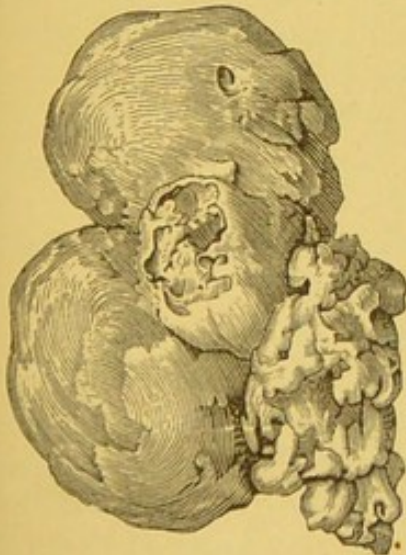

FIG. 69.

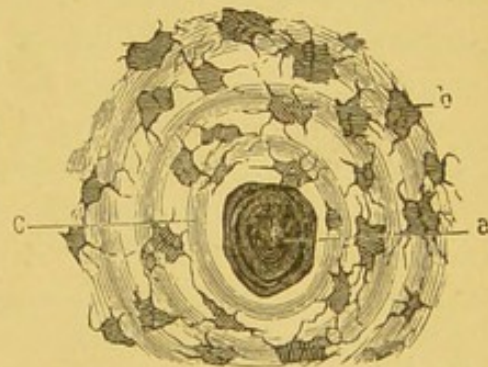


FIG. 67.—Upper jaw of a horse; view of half of the palatine face. *a*, osseous cyst developed in the interior and right side of the jaw; it includes the tumor represented in Fig. 68. *b*, right canine, thrust backward and inward toward the mediopalatine line. *d*, alveolus of the left canine tooth. *e*, osseous perforation, conducting to the interior of the cyst.

FIG. 68.—Intermaxillary osseous tumor (natural size); it was contained in the cyst represented in Fig. 67.

FIG. 69 (300 diameters).—Represents a part of the section of the tumor shown in Fig. 68. This tumor appears to be formed entirely of the cement or osseous substance surrounding the



dental root. It is an exostosis of the dental cement. *a*, vascular canaliculi of the osseous substance of the tumor (Havers' glands). The tumor is traversed by these as in the normal osseous substance,—only they are more rare, more scattered, and more irregularly distributed. *b*, osteoplasts disposed circularly, or nearly so, in a concentric manner around the Haversian canal, but less exact and evident than in the normal condition. *c*, the osseous substance, properly so called, in which the osteoplasts, or characteristic cavities of the osseous tissue, are excavated.

For further illustration, see *Odontomata*.



## CHAPTER VIII.

### THE TEETH AND THEIR DISEASES.

#### CARIES.

CARIES of the teeth being a disease so destructive to comfort and to health, and withal so common as to possess its illustration in almost every human mouth, makes the subject felt as one claiming earnest investigation and attention.

Caries of a tooth, most simply expressed, is corrosion of its substance: the disease may occur on any part of the surface of the crown or even on the root, but as a rule is found to originate on parts possessed of the least self-cleansing characteristics. Thus, it is most common to the sulci on the grinding faces of the molars and bicuspidati, to the posterior depressions met with so frequently in the superior incisor teeth, and to approximal faces of the teeth generally.

Caries is a disease of chemico-vital relation, and is unfortunately most markedly of congenital association and predisposition: indeed, so true is this latter, that it is to be prognosed that the offspring of parents afflicted in this way will be in like manner affected, and that, on the other hand, the children of parents possessing good teeth will be in like manner favored. So constant is an analogy in the teeth of parents and child, that in most instances it extends to the very shape and arrangement of the organs, deformity insuring deformity, regularity regularity. One parent alone may influence for good or for evil.

Hereditary dental caries finds its explanation in likeness of condition, this being of local or constitutional signification, or more commonly a conjoining of these; such teeth being not only imperfect in development in one or more directions,—in shape, in deficiency of enamel-covering, in non-calcification as exhibited in the existence of interglobular spaces, in position, in tubular circulation, in nerve endowment,—but in an equal number of cases in lack of physiological harmony, either in surrounding secretions or in the offices of nutrition: any or all of these may be the conditions, as indeed, resultant from them are all cases of caries.

Health in the dental organism depends:

1. On circumstances associated with the original formation.
2. On the shape of the teeth, their relation to each other, and their self-cleansing features.
3. On constitutional conditions.



4. On character of agents in contact with the teeth.
5. On the absence of mechanical destructives, as salivary calculus, the bands of artificial dentures, etc.
6. On accidental influences.

CONDITION 1. *On circumstances associated with the original formation.*

To appreciate the reasons explaining the inability on the part of certain dentures to fulfil the intentions of their creation, we are compelled to consider, not infrequently, influences and associations apparently far remote from them. That the student may be made familiar with the principles involved, without which, indeed, he might not otherwise than mechanically treat carious teeth, it is proposed to invite his attention to that study and understanding of the subject which practice will demonstrate as the exhibition of it in a clinical fulness.

It is to be assumed, as a premise, that like begets like; therefore may unhealthy parents not fail to impress upon their offspring that which is of their own constitution. Of these impressions, some are readily appreciable; others are obscure. As examples, we may refer to cachexiæ, evident enough in their individuality as exhibited over the general system; again, to a transmission which illustrates itself alone in the direction of the teeth, the individual at large being otherwise healthy. These two type conditions exhibit themselves to every observer.

Of the cachexiæ pertaining markedly to the matter of our investigation, we have three,—scrofulosis, rickets, syphilis; cachexiæ so widely associated with asthenic conditions, so adverse to the healthy performance of the nutritional functions, that without an understanding of their expressions one might not hope to antidote their multitudinous sequelæ. Because, therefore, of the marked importance of the cachexiæ, viewed in hereditary association, the student is invited to complete, by reference to the proper works, the epitome here presented.

DISTINCTIVE FEATURES IN TYPICAL CASES OF EACH CONDITION.

*Scrofulosis.*—Temperament lymphatic; abdomen tumid; complexion flat and pasty; lips and alæ tumid; saliva stringy; breath insipid and offensive; mucous membrane markedly deficient in circulating activity, and much disposed to degenerative inflammatory action; lymphatics enlarged and prominent, especially those of the cervical and mesenteric regions, with great disposition to suppuration; bones very loose and spongy in their areolar tissue, often fatty, breaking down on slight provocation into caries and necrosis; teeth, alike with the bones, deficient in inorganic material, loose in the character of the intertubular structure, more or less deficient in the integrity of the enamel cap; the animal matter very susceptible to the irritating influences



of the unduly alkaline oral fluid; the pulp pabulum cacoplastic to an extent which almost completely stagnates the tubular circulation, thus antagonizing nutrition; conditions of dental health adverse without and within.

*Rickets.*—Physical force deficient; habits sluggish; mentality small, with precocity; large head, more commonly broad than long; abdomen prominent and heavy; leanness; general debility, with indigestion; puffiness of the extremities; skin muddy; thinning of cranial bones, together with a plastic thickening of other flat bones and enlargement of the extremities of the long bones; tendency to aplastic infiltrations of the viscera; the teeth late in erupting, slightly attached to their alveoli, non-resistive of external offences, easily acted on by chemical agents, apt by slight causes to be pushed from their sockets.

*Syphilis and Mercurio-Syphilis.*—Stagnant complexion; leanness; atony of the skin and muscles; susceptibility to skin affections; poor and scanty hair; interstitial keratitis, with interlaminal corneal lymph effusions; stomatitis; tendency to iritis; the teeth more or less notched on their cutting edges, with pittings of the enamel; mucous membrane passively congested and easily breaking down into ulcers, which ulcers have pasty bottoms; seroplastic effusions into the submucous Schneiderian tissue, interfering with respiration, inducing in the patient constant snivelling; eruptions on the skin of a coppery-red color; periosteal indurations, with subperiosteal aplastic exudates; suppuration of organs, as the liver, thymus, testes; caries and necrosis of bones, particularly the turbinated and the maxillæ, and of the teeth.

SCROFULOSIS—SCROFULA—LYMPHANGITIS.—This is a constitutional condition having its recognition in the cacoplastic conditions common to it and begotten of it, the manifestations of malnutrition being most frequently met with in the skin, mucous membrane, hip- and knee-joints, and in the lymphatic glands, which latter, in their suppuration, present most markedly the feature of a cheesy degeneration. These malconditions arise out of lymphangitis, disturbing in turn tissue metamorphosis.

Scrofula is commonly an inherited cachexia, but may, through depressing circumstances, be engrafted into any constitution. Bad and ill-nourishing or insufficient food, continued exposure to impure air, intemperance, excessive venery, mental anxiety, the effects of severe courses of medication, secondary effects of poisons,—these and similar causes may induce the cachexia.

A marked scrofulous hereditary transmission has its expression in the type case given, but from this it is to be esteemed as shading into the greatest variety of aspect. Two primal expressions are clearly to be recognized. These are the fair and the dark; to be again subdivided into the fine and the coarse. The fine is the disease as existing and exhibiting itself in the sanguine temperament; the coarse is the typical case, as exhibited in the slug-



gish lymphatic. It is well just here for the reader studying this disease from the stand-point of dental caries to exclude the fair variety, and to place it under the head of Tuberculosis,—a distinction in the conditions which one most practically recognizes as relation with the health of the teeth and general digestive apparatus is concerned; the typical form being markedly provocative of dental disease; the fair variety exhibiting its manifestations in the viscera, and most particularly by deposits in the lungs, leaving the teeth quite exempt from any impression. Hence in persons affected with phthisis it is not uncommon to find the most beautiful and perfect dentures. It is to be remembered, however, we are writing of predispositions, and not of manifestations from active or recent conditions; of impressions made on the teeth during the stage of formation and development, and not of impressions made by the acquired disease on teeth whose period of growth might have been associated with such vigorous and health-yielding life that the result is not to be easily overcome.

Scrofulosis of the lymphatic type expresses that condition of a system in which morbid action results on the slightest provocation. Every part seems lax and incapable of self-sustenance. The slightest injury produces inflammatory action, yet of a grade requiring for its control stimulation rather than depression. In a word, it is a condition in which the vitalizing principle has no proper proportionable correspondence with the matter of the body. Hence the characteristic sluggishness,—the body is only half living, and was so born,—the parents, before it, lacking that fulness of force necessary to the vitalization of the offspring. No single tissue has been harmoniously constructed, the production being to an extent an abortion.

Perhaps the student will possess himself of a clearer conception of scrofulosis if we deny to it the name of a disease, and associate it alone with the idea of cachexia; and this, if we exclude from the relation tuberculosis, with its peculiar deposit, one inflicts no violence in doing. It is thus, from clinical observation, the writer has been led to consider it, and such understanding seems best to conduce to antagonizing its relations. We view the house as one ill built and of poor materials, and do what we can to remedy the deficiency. It is a condition in which attempts at specific treatment have no signification: there is no special condition to combat.

In conjoining the axioms that "excitement must terminate in exhaustion," and that "from nothing nothing comes," we may undeniably find the precedents and conditions of scrofulosis. In an animal body are so much matter and so much vitality. As the *vis vitæ* may be abstracted from one part to minister to the excitation of other parts, so necessarily must both come to suffer; the first from an over-stimulation which begets hypertrophic degenerations, morbid plastic formations capable of organization, thus compelling alteration in physiological expression; the second, from exhaustion through the absence of its correlating force, thus denying the changes necessary to the fulfilment of functional life,—breeding, of necessity, debility.



Over-stimulation, with its consequent exhaustion, finds examples in the intemperate, the venal, and the gluttonous. Children begotten of these in the days of their exhaustion, are apt to be possessed of evidences of the vices.

Exhaustion, on the other hand, is found a primary condition, being a result of exposure to influences debilitating in themselves; as, for example, to poisons, deprivation of proper food, insufficiency of clothing, to lack of cleanliness, being ill housed, unhealthy employment, continuous subjection to mental disquietude or oppression, excessive secretions and discharges, deprivation of light and sunshine, etc. We are to assume that the disease we study is not a *materia peccans* in the blood, but, as Billroth expresses it, "a debility of the organization." Dr. C. J. B. Williams, while admitting no distinction between scrofulosis and tuberculosis, yet describes the condition as "a degradation of the nutritive material from which old textures are renewed and new ones formed, in that in its origin it differs from the normal plasma or coagulable lymph, not in kind, but in degree of vitality and capacity of organization."

What cacoplastic lymph is, we appreciate. What tubercle is, we do not know; the highest authorities, in such direction, are still at issue concerning not only its origin, but even its nature, and whether, therefore, tubercle is or is not an expression of struma, we are, in our present connection, not concerned to discuss.\* Protoplasm, lymph, is the basal nutritive agent; plasma is not self-creating or of itself, but a product of vital force acting on materials taken for the nourishment of the body. That organs be normal, protoplasm must be healthy. The diseased protoplasm of degraded parents—more particularly, perhaps, that of the mother—may not afford that nourishment which is the proper life of a child; on the contrary, it associates its own degradation with all with which it may come in association.

Following such line of view, it will be recognized that we may not have any marked distinction between scrofulosis and the hereditary manifestations of syphilis, of the mercurial vice, or of other parental adynamic transmissions; and, therapeutically viewed, this premise we believe to be the proper one,—the principle of treatment being found the same,—this being tonic medication, and having no specificity to which it is to be directed. If, however, special organs be specially affected, this would of necessity direct to them particular attention, and the treatment, as the part affected is concerned, would, in local requirements, differ,—as, for example, whether we might have to combat caries of the bone or caries of the teeth; the constitutional treatment may, however, only be the same, and from such aspect,

---

\* Since originally publishing the above assertion concerning tubercle the author has pursued a course of investigation which makes him quite willing to here commit himself to the conviction that lymphatic stasis will eventually be recognized and admitted as the source of phthisis tuberculosis. Koch's bacillus is to a tuberculous lung exactly what the micrococcus is to a carious tooth, or what *oidium albicans* is to an aphthous ulcer. (See these subjects.)



what would be the cure of the one would necessarily tend to the same result in the other. Unfortunately, however, as the teeth are concerned, from the low grade of their vitality, and, consequently, the inactivity in their molecular changes, counter-impressions are long in being made; therefore, in the constitutional caries of these organs, too much attention cannot be given to the local relations. The fluids of the mouth are, if adverse, to be neutralized to the required non-antagonism. Cleanliness is to be particularly insisted on, and all cavities are to be filled or filed away, as may seem indicated.

**RACHITIS—INNUTRIO OSSIIUM.**—A constitutional disease, having its predisposition in hereditary transmission: characterized by non-solidification of the growing layers of bone, by the formation of medullary cavities in the older or more mature bones, thus rendering the bony laminæ thin and brittle (Virchow), and by excess in the formation of phosphoric and lactic acids, with great excess of the earthy phosphates.

It is not to be maintained that rickets is a constitutional disease, save in the sense of predisposition. Neither is it to be affirmed that it possesses a constancy of expression which allows of a common formulary for a description of its diagnostic signs; on the contrary, the expressions vary from the most simple manifestations of a disturbed nutrition to a specific alteration in the bones, which renders them, from lack of inorganic constituents, incapable of performing their functions. Indeed, it is probable that degrees of rickets may quite frequently present themselves and yet be overlooked. While, as suggested by Hillier, the secondary diseases, such as bronchitis, collapse of the lungs, atrophy, measles, whooping-cough, or convulsions, are recognized, the primary disease, which renders these secondary conditions fatal, is quite ignored.

As rachitis is congenital, or as it associates itself with the dentitional periods, so are manifested the effects of the condition upon the health of the teeth,—these organs being delayed in their development, disposed to caries, and not infrequently of such loose relation to their sockets from aplastic softening of the peridental tissue as to be displaced by slight force: the periodontum, and also the pulp, may be affirmed to present evidences of the common amyloid degeneration as seen in the viscera, particularly in the liver and spleen. The delay in the cutting of the teeth is simply delay in development, the albuminoid pulp lacking organic force to secrete dentinal tissue; while, as is to be inferred, that which is made is of such imperfect organization, so mottled with uncalcified spots,—interglobular spaces,—as to be rendered quite incapable of resisting that excess of lactic acid found in the secretions coming in contact with it.

*History.*—Rachitis is a disease having perhaps in all cases the association of hereditary predisposition, yet, like scrofulosis, existing in such variety of aspects and in such states of modification as to make it not easy of recognition through any constant signs. These modifications are of a twofold



nature. First, the character of the hereditary impression. Second, the associative surroundings and conditions of the patient. Sir William Jenner, whose lectures on the subject are worthy of all respect and attention, speaks of this disease as "without question the most common, the most important, and, in its effects, the most fatal of all that exclusively affect children." Hillier (Meigs and Pepper) presents a table showing the proportion borne by the number of cases of this disease to the total number of out-patients treated at the Hospital for Sick Children, London, from which calculation exhibits that of 128,656 children treated during thirteen years (1854-66) not less than 8419, or 6.5 per cent., were rachitic; and in some years the proportion of such patients rose as high as 9 per cent. In London hospitals and in the other great hospitals gathering in the poverty and degradation of any large city, such percentage does not strike us as at all a matter for surprise. It must be recognized, however, as is to be inferred from home observation, that such statistics designate the disease as included in its diversified phases.

The cachectic state preceding the osseous manifestations of rickets is not generally to be noticed at birth, but develops commonly during the process of the first dentition, seldom appearing at a later period than during the time of the active stages of the second. The incubation precedes, however, the manifestations of the cachexia, residing, as we incline to believe, in an original molecular impression: at least it is only thus that we find explanation of the organic impressions found in the structure of the deciduous dentine and enamel.

The relation of rickets with scrofulosis is found in the pre-association of the two conditions. Thus, "Whatever tends to produce debility and anæmia in a mother, as too frequent pregnancies or prolonged lactation, renders it probable that her next-born children will be rickety." Jenner states "that it is very common for the first, or the two or three first-born children, to be free from any signs of rickets, and yet for every subsequent child to be rickety;" which he explains by the fact "that among the poor the parents are generally worse fed, worse clothed, and worse lodged the larger the number of their children; and among the rich and poor alike, the larger the number of children, the more has the constitutional strength of the mother been taxed, and the more likely is she to have lost in general power."

Predisposition in a child may be overbalanced by its prophylaxis. Thus, children of wealthy parents, even where the antecedents are very unfavorable, may escape the evident expressions of rickets as the result of hygienic antagonisms, just as adverse conditions are found to prove exciting causes to its development. It is indeed because the most characteristic expressions of this disease—namely, affections of the skeleton—are so influenced by outward circumstances, that eminent observers have in some instances come to deny its existence among the better classes; though this differs much from the statement of Jenner, who asserts that he has very often met with it among the children of the very wealthy. We think, however, that it is to be made



a cardinal point that the disease is not necessarily to exhibit its osseous complication to have existence, and that its prodroma are as much the condition (*in abstracto*) as is the observable softening itself.

The relation of rickets with hereditary syphilitic disease is affirmed by Vogel, who professes to base the deduction from wide clinical inquiry. Such relation is, however, denied by Sir William Jenner, the denial being founded mainly on the following facts: "The parent who infects his offspring (with syphilis) has usually contracted the syphilis before marriage, and the children first begotten after infection are those who suffer (from inherited syphilis); while, as a rule, it is only the younger children of a family that suffer from rickets." Sir William Jenner is also doubtful as to the health of the father affecting the child, but throws the weight of his influence in that scale which attributes the disease to insufficient nutrition; thus suggesting the inference of the direction in which lies its prophylaxis, and as well indorsing, without intention, the oneness of cachexia. Mr. Lonsdale expresses himself as having invariably found "that in all rickety children the parents have had little or no milk for their supply, and have been obliged to feed them either partially or wholly with food other than their own milk. The mothers observe that the children never grew properly from the first, and it is mainly the improper nature of the supplementary food given by hand which impairs the health of the child." The rearing of the children of the poor in London is thus described by Sir William Jenner:

For the first two or three days after birth their tender stomachs are deranged by brown sugar and butter, castor oil and dill-water, gruel and starch-water. As soon as the mother's milk flows, they are, when awake, kept constantly at the breast; and well for them if they are not again and again castor-oiled and dill-watered, and even treated with mercurials. After the first month, bread and water sweetened with brown sugar is given several times a day, and during the night the child is, when not too soundly asleep, constantly at the breast. As soon as the little ill-used creature can sit erect on its mother's arm, it has, at parents' meal-time, "a little of what we have,"—meat, potatoes, red herring, fried liver, bacon, pork, and even cheese and beer daily, and cakes, raw fruit, and trash of the most unwholesome quality as special treats, or as provocatives to eat, when its stomach rejects its ordinary diet. Then, instead of being weaned when from ten to twelve months old, the child is kept at the breast when the milk is worse than useless, to the injury of the mother's health, and to the damage of its after brothers and sisters, in the hope that thus keeping it at the breast may retard the next pregnancy. (Holmes)

According to M. Guérin, there will commonly be in rickets a period of at least six months before the practitioner may feel assured of the exact character of the case, or fairly distinguish it from other diseases to which the prodroma are common.

The incubative stage is characterized by irritations of a gastro-intestinal



character. The stools are irregular, being sometimes scanty, but more commonly profuse, marked by absence of bile, not infrequently being of leaden color and most offensive in odor. Sometimes, however, and this more particularly in the beginning, the discharges are greenish, of a serous or watery consistence, with a smell which has been compared to that of rotten meat. The child is found to run down as from a chronic diarrhoea.

A marked symptom soon supervening, and one which is not infrequently the first that suggests to the practitioner the peculiar nature of the disease, is profuse perspiration of the head. These perspirations weaken the child very rapidly, and, when in progress, the evidences of congestion are to be observed in all the neighboring vessels,—veins and arteries.

Associated with this sweating, and more or less synchronous with it, is a general soreness of the body, the little patient in many cases lying motionless for hours, rather than endure the discomfort of moving. Such soreness has always more or less connected with it a desire on the part of the child to be cool, even in winter; such patients seeming most comfortable when lying entirely uncovered,—a fact sufficiently demonstrated in hospital wards.

The deformities of the head in rickets are thus distinguished by Sir William Jenner:\*

1. By thickening of the bones. This is usually most perceptible just outside the sutures, the situation of these being indicated by deep furrows.

2. By the length of time the anterior fontanelle remains open. In the healthy child, it closes completely before the expiration of the second year. In the rickety child, it is often open at that period.

3. By the relative length of the antero-posterior diameter of the head.

4. By the height, squareness, and projection of the forehead. The first two of these peculiarities of the rickety head are the result of the affection of the bones; the last two are chiefly due to disease of the cerebrum.

The succeeding conditions are those which associate themselves with bone disease.

The process of dentition (Holmes) is invariably arrested or delayed; and if the teeth be formed, they soon decay, or they early fall from their sockets, the incisors frequently being lost before the second molars of the first set have made their way through the gums. So important is the knowledge to be derived from the progress of dentition, that Sir William Jenner lays down the following rule of practice:

If a child pass over the ninth month without teeth, you should carefully inquire for the cause. It may be that an acute illness has retarded dentition. It may be (and this is infinitely the most common cause of late dentition) that the child is rickety. Fail not, then, when called to a child in whom the teeth are late in appearing, to look if it be rickety, for if you do fail to look for rickets, you will most likely attribute to the irritation of teething symp-

---

\* Medical Times and Gazette, 1860. See also Holmes's System of Surgery, vol. i.



toms which are the consequences of the rickety diathesis,—the late dentition in rickets being in itself merely a symptom of the general disorder. The rickety deformities may be very trifling, and yet the teeth considerably retarded in their development.

The inorganic constituents of bone—the earthy phosphates—are sometimes found in great excess in the urine, a case being recorded by Mr. Solly where such excess was fourfold. It is perhaps, however, as frequently the case that the deficiency in lime-salts results from non-ingress of these materials, without change in the egress; while a hypothesis founded on the observations of Marchand attributes the absence of the phosphates to their dissolution by lactic acid. This is effected, as inferred, by the lactic acid changing the carbonate and phosphate of lime into the soluble lactate, which in this state is capable of being taken up and carried from the system; or, when not removed in this way, it might be possible for the organic basis of bone to be dissolved by the inflammatory neoplasia with a breaking down of the chalky substance, whose molecules might either be dissolved or carried away.

In rachitis, according to Virchow, the bones are histologically formed, except that the bone-cartilage has no chalky salts,—or, at least, little in proportion to their requirements. Billroth directs attention to the effect of the dyscrasia upon dentition. The treatment he regards as of that general nature which pertains to the building up of the health of the patient. As food, it may not be well to use too freely of bread, potatoes, mush, or flatulent vegetables, but the child is to partake freely of meat, eggs, milk, and all nitrogenous diet. Billroth, in discussing the use of preparations of lime, expresses a doubt as to any benefit that may arise from their employment, deeming it not impossible that rachitis is a disease of digestion in which such preparations may not be absorbed,—which view is indeed a common one among American physicians.

A rachitic child should be daily bathed in salt water, lukewarm or cold, as seems most suitable; the dress is to be adapted to the season; and daily exercise, active or passive, is to be taken in the sunlight and open air. The use of cod-liver oil has the recommendation universally both of European and American practitioners. Vogel asserts that rickets is to be cured by the use of cod-liver oil alone. Rickety children tolerate the oil well, and are usually found to become fond of it. Iron and the vegetable tonics are almost always found useful; while beer or wine in limited quantities, graduated to the age and condition of the patient, is sometimes found to meet the indications most admirably.

**SYPHILIS.**—Viewing the relations of this disease with the health of the teeth, we necessarily embrace, or, indeed, perhaps more fully treat of, the association of the mercurial poison than that of syphilis itself, inasmuch as the two are found so constantly combined that it may be esteemed a matter of some doubt if the single relation is ever met with in the hereditary aspect. I use



the term in the fullest sense of heredity, not embracing the cases in which a foetus receives inoculation in passing over an unhealed vaginal chancre, or where the father, having incipient secondary manifestations, extends such to the impregnating sperm.

That the syphilitic poison impresses of itself the growing teeth is made evident by the very frequent imperfect development of these organs found in association with the disease. Allusion is made to the notching, the pitting, and the small size,—conditions which may fairly be presumed not to have special relation with the second of the poisons, inasmuch as this renders its expression in that general molecular depression which is seen in the lowered vitality of the parts at large, and which has been considered under the head of scrofulosis.

The pittings in the enamel of the teeth, and the irregularities of the cutting faces, represent expressions believed generally to be found only in connection with hereditary syphilis, and which it seems proven may be transmitted to the third generation. These deformities are seen most generally in the second set alone; the first are liable to early decay, but not so much to the malformations. The impressions are confined commonly to the anterior six teeth, and vary from the most marked examples to scarcely perceptible irregularities of the cutting edges, or an occasional depression seen here and there upon the anterior face, or it may be the posterior,—most frequently, however, upon the anterior alone. Observation is found to greatly vary concerning the existence of any constancy in phenomenal expressions of the teeth in this relation.\*

---

\* That the notchings found on teeth are not strictly associated with the vice of syphilis will clearly enough discover itself to an observer who takes the trouble to investigate. In one instance three children were exhibited at a clinic of the Oral Hospital dispensary service all having badly notched teeth, traceable unmistakably to attacks of measles occurring during the dentitional period.

The alterations of teeth here considered are atrophic in nature, and are recognized as of different origin by close observers. Hutchison's syphilitic teeth pertain chiefly to pitted central incisors, the pits, breaks or sulci, disfiguring the cutting edge or closely adjoining parts. This observer has established a relation between these atrophies and chronic inflammation of the cornea.

Atrophic change is most common to the six-year molars, and is here least traceable to any specific cause; the defect showing in general imperfection of the enamel and irregularity of faces, particularly the grinding surface. Color too is abnormal, yellow points and streaks intermingling with white of varying shade. The cusps of these teeth are too often found of foreign expression, resembling at times portions of a hard variety of yellow sandstone. That such atrophic condition relates itself with the bicuspidati is practically known to every practising dentist, these teeth being recognized proverbially as least resistive of aggression.

Forms of atrophy related with the oral teeth are known as cup-shaped, sulciform, pitted, notched, and grooved.

Cup-shaped atrophy is commonly met with in the labial faces of the incisors, although it is not peculiar to these; generally a number of pits exist, the bottoms of which may or may not be enamel-covered: carious evolution finds here most frequent start-points; the teeth are never of natural translucency, the color varying from a dead yellow to a dirty white.

Sulciform atrophy is simply a variety of the cup-shaped; it consists in furrows, one or



The diagnostic signs and conditions of acquired syphilis, it is to be taken for granted, are known to the reader. With these we have nothing to do, inasmuch as the influences here considered are those impressed in utero.

The assumption will be borne out that it is only in earliest infancy that syphilis expresses itself with that distinctness which, outside of a history, renders its diagnosis reliable; and, further, that parents afflicted with the advanced tertiary stage of the disease do not transmit the disease with diagnostic individuality, but rather that in the term *scrofulosis* lies its expression, that the condition of the syphilides is the state in which the transmission retains specificity,—the tertiary stage expressing the exhaustion of the disease in the molecular degeneration induced of it,—and that when transmitted in such secondary stage, its continuous course in the child is apt to be the same as that in the parent.

As a syphilitic impression has been made on the *fœtus*, with the condition of the parent or parents most closely allied to the first of the secondary manifestations, so will the child exhibit rashes, or the graver expressions of inflammation of mucous surfaces. Thus, without perhaps proper attention to such data, it has become common to write of the confounding of the secondary with tertiary manifestations,—a confusion that does, however, without doubt, occasionally exist, owing to the general slighter resistive force of particular infants, just, indeed, as the same confounding of conditions is not infrequently met with in the adult.

The expressions of the transmission of uncomplicated syphilis show themselves commonly by the third week; although instances enough occur where the child is born with such evidences; or the little patient may live for a year without any sign of the disease exhibiting itself,—seldom longer, however.

Hereditary syphilis differs of course from the acquired in having no primary stage. As the author's observations are concerned, the most common manifestation of the condition is found in that morbid congestive state of the Schneiderian mucous membrane, which, as in a common cold, yields what the parents call snuffles, being universally attributed to the child's having a cold. Unfortunately, however, such colds do not tend to self-cure, but in very many instances, perhaps in a majority, produce changes in the nasal relations which result in a flatness of the bridge of the organ, bearing the sign throughout life, and which is justly to be esteemed as markedly diagnostic of the hereditary association.

---

more running across the faces of teeth, commonly central and lateral incisors, occasionally the cuspidati. The separation of these sulci, of which there are often three, more commonly two, infrequently four, is by means of what looks like a ridge of pathological enamel. Instances occur where the sulci pursue a wavy course, or one that is oblique or vertical.

The pitted, notched, and grooved varieties described by authors will be recognized as nothing different from expressions of forms described above.

Objection is repeated to the fixing of heredity in syphilis out of the signs of the teeth. Any condition interfering with evolution at the dentitional period affords alike with syphilis acceptable explanation.



A child afflicted with this disease may, without doubt, be born plump and apparently vigorous; but such vigor proves evanescent. After a few days, or weeks, or, it may be, months, it begins to emaciate, the skin wrinkles from absorption of the underlying fat, the face shows discolorations, and a peculiar expression of premature age comes on: this expression of age is so marked and persistent that it will be found to characterize every child, young or old, afflicted with transmitted syphilis. The writer has this moment in memory the faces of a number of little girls who are in the habit of occasionally presenting themselves at his clinic, and, although the eldest is not over thirteen, they have, all, the demure expression of years quite in advance of them. Yet such expression, it is to be remarked, seems influenced by the stage of their affection, those afflicted with bone-troubles being usually older-looking (in proportion to their years) than others presenting alone the skin-manifestations.

The appearance of pemphigus soon after birth, associated with the ordinary early symptoms, is deemed by experienced observers very diagnostic. Interstitial keratitis with inter-laminar lymph-effusions is associated alone with the hereditary form of syphilis,—iritis being an expression of the acquired form. In hereditary syphilis the manifestations are symmetrical; in the acquired form they are rarely so. The manifestations of the hereditary form run one into the other; those of the acquired tend to remain distinct.

From consideration of hereditary vices we pass to that aspect of the subject which treats of the relation of developing teeth with nutritional instrumentalities.

In viewing, from a systemic stand-point, the composition of the teeth, we have primarily to remark that the component parts are formed from and preserved by the chemico-vital relationship existing between blood and parts to be nourished. We recognize, and know, that in the fluid which we denominate blood resides the element of nutrition, and that as this material is well or ill adapted to meet the requirements of the different tissues, so are these tissues found to be in varying states of health. We infer that blood, rich in the elements of tooth-structure, is capable of yielding good teeth, provided the process of assimilation resides to a proper extent in the part to be built up and nourished; so that the study of caries, from the constitutional stand-point, consists in looking at the condition of the blood and the amount of vital force residing in the teeth themselves.

A tooth in its composition is made up of cementum, dentine, enamel, and pulp substance. Excluding the pulp substance, we find, with some variation, the relative proportions of organic and inorganic matter to be as follows:

	Cementum.	Dentine.	Enamel.
Organic matter.....	29.27	28.70	3.59
Inorganic matter.....	70.73	71.30	96.41



The character of this inorganic material we find, by a more complete analysis, to be as follows: phosphate of lime, fluorate of lime, carbonate of lime, phosphate of magnesia, salts.

The composition of healthy blood yields the following analysis:

Water.....	780.15
Fibrin .....	2.10
Albumen.....	65.09
Coloring matter.....	133.00
Crystallizable fat.....	2.43
Fluid fat.....	1.31
Extractive matter.....	1.79
Albumen, in combination with soda.....	1.26
Chlorides of sodium and potassium; carbonates, phosphates, and sulphates of potash and soda.....	8.37
Carbonates of lime and magnesia; phosphates of lime, magnesia, and iron; peroxide of iron.....	4.50
	<hr/> 1000.00

In a healthy and normal condition of the human system we find always the existence of a relationship between the requirements and material of supply which should, and which does, afford proper tissue; where, then, such conditions exist, the teeth, *cæteris paribus*, are perfectly formed, and, as constitutional relations are concerned, are healthily preserved.

In the study of the pathological conditions of these organs, we are to discover, if possible, wherein the harmony of demand and supply is or has been interfered with; and that we may look at the subject from the most comprehensive stand-point, we must study not only hereditary complications which may exist, but are to understand as well the direct relations of the developing organs. This brings us to the subject of nutrition proper; a matter which refers the student to his works on Physiology.\*

---

\* Prophylaxis is assuredly preferable to cure. It is the intention of this foot-note to call attention to nutrients and conditions out of which healthful dental organisms arise, and in which they preserve their resistive power.

Alluding to American women and their early decay, James Paul, M.D., in the best paper on the subject ever met with by the author, laments the fact that even the progeny of other continents coming to this show expressions of degradation, as the teeth are concerned, even in the very first generation.

Admitting the too evident fact of the degradation as comparison is held with European and other races, the subject of cause presents itself with a relevancy not admitting of being passed over.

The refusal of Europeans to drink of iced water is a matter familiar to the writer from personal observation, and not less common is knowledge of the inference drawn by that people that if Americans indulged less in iced refreshments their teeth would be proportionably better. That dental caries has not its existence, however, in cracking of enamel arising out of violent alterations in temperature needs but very little observation to decide. Caries, may, and assuredly does, show itself in sulci and fissures, but it is so frequently met with under the reverse circumstances as to declare the former not a necessity to its appearance. That alternations of extremes in cold and heat are after other manner in-



CONDITION 2. *On the shape of the teeth, their relation with each other, and their self-cleansing features.*—On examining the two arches, Figs. 70

jurious to the health of teeth is as truly and plainly evident as that the general health is thereby affected.

Dental deterioration is accepted in these pages as being more commonly associated with constitutional weakness than with any of the various local causes, and the agreement of the writer with Dr. Paul is absolute as to this weakness having its existence in a deficiency of the inorganic or earthy constituents being taken into the system, most particularly in early life. Accepting such conclusion, the oral surgeon, as well as the general physician, necessarily agree that correction of the condition rests with such understanding of subjects involved as permits of reconciliation between demand and supply.

Referring to the analyses, given in the text, of teeth and blood, Dr. Paul directs attention to the very great proportion of certain earths that enter into the structure of the teeth and the bones of man, the chief being the phosphate of lime; that in proportion as the definite earths are properly distributed so is the health both of bones and teeth.

To be distributed a material must not only exist, but it must be in a channel of distribution. The teeth require lime. The channel by which such requirement is supplied is the blood. It is necessary that the blood possess a proper quota of lime, that vessels of relation with the teeth exist, and that the teeth are able to appropriate to the full satisfaction of a want.

It is seen, as will be recognized, that if we take away from the blood the proportion of water, amounting to 780 parts, and the coloring matter, amounting to 133, we have left scarcely 90 parts of organic and earthy matter, the salts and earths forming upwards of a 10th,—the salts being in proportion to the earths as 4 to 1. It is here the subject opens from the stand-point of the derivations by the blood of the elements needed by the teeth.

Having then shown the constituent portions of the bones and teeth to be in the blood, the next consideration is, whence are these constituent portions derived?

Out of deference for the industrious compiler and worker, and with a view of keeping the memory of a man in the minds of people his investigations benefit, Dr. Paul's analyses and conclusions are here appended precisely as they were presented in a paper read before the Medical Society of Mercer, N. J.

Before entering on this subject further, wrote the lamented author, let us for a moment take a broader and more comprehensive view of what must be most interesting to mothers, and of great consequence to the well-being of the infant generation, in a short time, in a very few years, to become in their turn the mothers and fathers of another generation.

The question then presents itself, what is the nourishment or food best adapted and necessary to the wants of an infant, that the foundation may be laid for a strong frame and vigorous constitution? For here, we must recollect, is the starting-point in by far the majority of instances. We know that in some cases disease is hereditary,—that the offspring unfortunately inherits from the parents constitutional defects; but we also know that more misery, suffering, and constitutional derangement are entailed on children by want of care and improper food in the first years of life, by which their hopes of health are blasted, and they are doomed to struggle through a weary life, to be hurried at last into a premature grave.

Now, that the frame—that is, the bones, muscles, and other portions—of the infant may be fully developed, it is necessary that it should be supplied with nourishment containing all the constituents required for this important undertaking. And this nourishment, by the all-wise ordering of Providence, is contained in the milk secreted from the mother's bosom.

The infant is entirely dependent on the nourishment derived from its mother, and nature has wisely ordained that the secretion from the mother is its very best food; for we find in



and 71, the observer will instantly be struck with the decided difference presented. In the first is represented a denture which, mechanically speaking,

the composition of milk—that is, healthy milk, derived from healthy blood—all those ingredients we have hitherto traced as requisite in the formation of the bones and teeth, and not only these, but every constituent required for the life and growth of the individual; milk containing the albuminous, saccharine, oleaginous, saline, and earthy compounds requisite and necessary for the health, strength, and development of the infant child.

An analysis of cow's milk gives the following proportions of the various constituents; that of human milk is not so elaborate, but contains the average of observations taken at fourteen different times from the same individual, by Simon.

## COW'S MILK, BY M. HAIDLEN.

Water.....	873.00	Phosphate of iron.....	.07
Butter.....	30.00	Chloride of potassium.....	1.44
Casein.....	48.20	Chloride of sodium.....	.24
Milk sugar.....	43.90	Soda in connection with casein.....	.42
Phosphate of lime.....	2.31		
Phosphate of magnesia.....	.42		1000.

## WOMAN'S MILK, BY SIMON.

Water.....	883.6	Fixed salts.....	2.3
Butter.....	25.3		
Casein.....	34.3		1000.
Milk, sugar, and extractive matter.....	48.2		

	Maximum of 14 observations.	Minimum of 14 observations.
Butter.....	54.0	8.0
Casein.....	45.2	10.0
Sugar and extractive matter.....	62.4	39.2
Salts.....	2.7	1.6

Now, although these amounts will no doubt vary, under every variety of circumstances, according to the *health, exercise, passions, and food* of the mother, yet they show that healthy milk contains all the requisites for the nourishment of the infant; but then it must be *healthy* milk, secreted from healthy blood, and that blood must derive these ingredients from the *food* consumed.

Cow's milk differs from that of woman in the proportions of some of the constituents: it abounds more in butter, but particularly in casein, or cheese; and, on the other hand, human milk abounds more in the saccharine principle, or sugar of milk. Now, this points out a circumstance from which great benefit may be derived. It is of very frequent occurrence that infants are deprived of the natural nourishment of the mother, and diverse opinions are given relative to the food of infants by persons who really know very little about the matter; one recommends a milk diet, another that the infant must be fed on starch and sugar.

Now, to enable the infant to receive a nourishment in every respect similar to the mother, the knowledge of the various proportions which we obtain by chemical analysis enables us to rectify and produce milk very analogous to human milk from that of the cow, by diluting it with water in the proportion of about half as much again; that is, to a pint of milk should be added half a pint of water that has been boiled, which will reduce the cheese principle to the proper proportion; add a small portion of cream to restore the proportion of butter, and then add sugar until the whole is distinctly sweetened, and we have a compound in every respect similar to the milk from the human breast.

To understand the subject of nutrition, let us remember that food should, or must, embody two great principles: one to nourish, the other to give heat to the body. And food, when consumed, is applied to one or the other of these purposes. Now, in the process of digestion, the constituents of the food are separated, and arranged in three classes:

1st. All that portion derived from animal food, eggs, the curd of milk, the gluten or adhesive portion of wheat and other grain, and whatever in animal or vegetable food can be rendered into *albumen*—of which the best example that can be offered in illustration is



may be pronounced physiological, every tooth having a harmonious relation with its fellow, and each individual tooth being perfect in itself.

the *white of egg*, which is in reality nearly pure albumen—and the principle is therefore called *albuminous*.

2d. All that portion of the food derived from vegetables, starch, sugar, etc., that can be converted into *sugar* in the process of digestion. This principle is therefore called *saccharine*.

3d. All the fat, butter, oil, etc., which, when deprived of the other substances, is left in the state of *oil*, and therefore called *oleaginous*.

Now, of these three the *albuminous* is the *nutrient*, and the *saccharine* and *oleaginous* are the *calorific*, or heat-giving; and chemical analysis shows that they vary in composition.

	ALBUMINOUS.		OLEAGINOUS.	
	Eggs.	Wheat.	Mutton fat.	
Carbon.....	55.000	55.01	78.996	
Hydrogen.....	7.073	7.23	11.700	
Nitrogen.....	15.920	15.92		
Oxygen.....			9.304	
Sulphur.....	22.007	21.84		
Phosphorus.....				

	SACCHARINE.			
	Starch, arrow-root.	Sugar from starch.	Sugar of milk.	Cane sugar.
Carbon.....	44.40	37.29	40.00	42.301
Hydrogen.....	6.18	6.84	6.61	6.384
Oxygen.....	49.42	55.87	52.93	51.315

It will be observed that the albuminous or nutrient differs from the saccharine and oleaginous, in containing nitrogen, and sulphur and phosphorus, with carbon, hydrogen, and oxygen, while the latter contains only carbon, hydrogen, and oxygen,—nitrogen being required in those compounds which give strength and formation to the frame.

Now, the albuminous or nutritive, being that portion which affords nourishment to the body, contains those constituents required in the first place for the formation and giving strength to the different portions of the body, and, when fully developed, of repairing the general waste continually going on in the system, whether from the usual wear and tear, fractured bones, or the ravages of disease. And the saccharine and oleaginous—the calorific or heat-making—to keep up a continual supply of fuel, as it were, that the body may be kept of a regular and proper temperature; for all are no doubt aware that there is a continual supply of carbon, or, in more simple language, of charcoal, required to keep up the natural temperature of the body; and what is not required for immediate use is stored away in the form of fat, to be called into action as occasion requires.

We have seen in the analysis of milk that that fluid contains butter, cheese, and sugar; consequently we can understand how an infant can thrive so well upon it,—the cheese or casein\* of the milk containing the nitrogenized or nutrient principle, which, together with the earths and salts contained in the milk, goes to form the bones, muscles, and the different tissues of the body,—the sugar, which, we have seen by the analysis, contains a large quantity of carbon in its composition, going to keep up the temperature of the infant, while the butter, in the nature of fat, is stored away in a healthy infant, filling up every vacant interstice, causing a roundness and plumpness, the pride and joy of the happy parent.

Now, let us mark the difference of the babe that has been denied a milk diet, and is doomed by ignorance to be fed on starch and sugar. We will recollect that these two sub-

	Analysis of casein from fresh milk.	Albuminous substances found in whey after coagulation with an acid.
* Carbon.....	54.825	54.96
Hydrogen.....	7.153	7.15
Nitrogen.....	15.628	15.89
Oxygen.....		21.73
Sulphur.....	22.394	0.36



In the second of the diagrams the artist has exhibited imperfections which, in truthfulness to nature, have been extended to every individual tooth, even

stances are composed of carbon, hydrogen, and oxygen only. By a process of digestion which I need not here enter into, such food is converted into sugar, the carbon of which becomes the fuel by which the temperature of the body is kept up; there being no principle in the food to give albumen, there is nothing taken into the stomach upon which the gastric fluid can expend its solvent powers; the infant is, therefore, much troubled with acid eructations, and the stomach becomes weak and irritable. The want of the nutritive constituent of the food, and the earths and salts, etc., necessary and essential for the formation of the bones and teeth, show a lamentable deficiency in the child's development; and there being no fatty matter to be laid up, the body is emaciated, the countenance is ghastly, the flesh and integuments hang soft and flabby over the bones; no absolute disease can be detected; the child is ravenous and hungry, and the unfortunate babe descends to the tomb a spectre and an object of the most pitiful description. This is no fancy sketch, but one too often met with in the ordinary walks of professional life. And why is it so? Simply because the composition of the human frame, the component parts of our food requisite to produce that frame, and the process of digestion and nutrition, are so little understood.

We now advance from infancy to childhood; and this is a period when the greatest attention is required in supplying nutriment to aid nature in the great work of developing the body. The child is now deprived of the maternal secretion, and dependent on food prepared for its use by the hand of man,—perhaps living in a city, and deprived of pure and wholesome milk from the cow. And we know there is a vast disproportion in the quality of milk when the cow is country-fed on the natural productions of the farm, and when city-fed on slops and grain, the refuse of the brewery.

It is at this age that the great proportion of bony substances is deposited; those of the extremities are lengthened, become more compact and stronger, and the substance of the teeth is deposited in the cells of gelatinous tissue. How necessary is it, then, that this subject should receive the utmost attention of parents! It has hitherto been too much the custom to leave all this, as belonging entirely to nature, as a thing we had nothing to do with. We have been too much in the habit of considering that nature furnished her own materials, and man had nothing to do with her operation. The potter cannot fashion the bowl without the clay, neither can bone be formed without earth: nature must be supplied with the material, which, although offered in the most incongruous forms, she has the power of decomposing, selecting from, and supplying for the various purposes required: one portion, as we have already stated, to act as fuel in keeping up the temperature; another portion she selects to add to the flesh, the muscle, skin, and different tissues; and the earths which are held in solution she carries away by vessels adapted for that purpose, and deposits them atom by atom, until they are so compressed, so strongly compacted together, as to become what we call *solid bone*,—and all this so wonderfully wrought that, as we have seen, small tubes are left in the hard, stony formations both of the bones and of the teeth, that nourishment may be supplied them, holding in solution the material of which they are composed, that the natural waste and decay may be replaced and injuries repaired.

It is to this nutrition, and to the earthy matter of which the bones and teeth are composed, a deficiency of which is attended with results so deplorable, that I particularly wish to call attention.

To what can we attribute the calamity which too often befalls the young? I allude to distorted spines, where the bones composing the spine, instead of forming a column, allowing the body to be erect and dignified, are zigzag in their course, causing one shoulder to bulge out, and the opposite side to bend or double upon itself. This deformity has been long understood to arise from a deficiency of *lime* in the composition of the bones of the vertebrae, allowing them to fall, press upon, and injure each other, destroying the beauty of the fabric and the health and comfort of the individual.

Now let us take a glance at the inhabitants of two countries, natives of which are no strangers on this continent. I take them as examples, because the food of the *common*



to the crowding and wedging of them which are so frequently remarked. Examining the molar teeth, the grinding faces are seen more or less pitted.

people of those countries is well known to be of the most common kind. I allude to natives of Scotland and Ireland,—the principal food of one being *oatmeal*, and of the other *potatoes*. We have heard a great deal of the famishing poor of those countries, and particularly of the latter, of the misery and wretchedness seen in every hovel; and there cannot be a doubt that famine walked through the land when the blight and rot despoiled them of their potato crop, on which for so long a period they depended as the great article of food. Now, allowing all this,—allowing, in the *best seasons*, the chief article of subsistence has been potatoes for breakfast, dinner, and supper;—glad indeed many of them to get a little animal food once a week to dinner, or even far more seldom,—I now ask, what number, in the thousands of emigrants from that country who yearly arrive at our ports, are there that show a constitution weak, fragile, and wanting in physical strength? Many, no doubt, arrive worn down by disease and suffering, and in the last stage of debility; but let them recover from that state, and the robust frame and healthy constitution will be again developed; the bones are strong, the teeth undecayed, and the muscular energy only wanting opportunity to display itself;—in fact, when we wish to denote strength in woman, we use the familiar phrase “strong as an Irishwoman,” and all this from being reared on *potatoes*.\* But then, if we examine the analysis of the potatoes, we shall find contained in 100 parts of dry potatoes,—

Carbon.....	41.1	Nitrogen }	48.1
Hydrogen.....	5.8	Oxygen }	
		Ashes.....	5.0

Here we see that potatoes not only contain the nutrient but the earthy constituents.

But we have a stronger and more healthy race yet, from Scotland and the north of Ireland, who are generally descendants of the Scotch, and continue, in a great measure, the same means in rearing the young. Now, a principal—I will not say *the* principal—food of the youth of Scotland, high and low, rich and poor, except in the larger cities, among those who class themselves as more refined and more civilized, but who number few in proportion, consists, for breakfast, at least, of oatmeal,—that is, porridge and milk; and milk, potatoes, and wheaten, oaten, or pease bread, or *bannocks*, at other times of the day. Animal food among the poor is a rarity, a meat dinner on Sunday *only* being common. Even among the youth of the better class, butcher’s meat, or animal food, is by no means a principal article of subsistence. And I would particularly remark that *Scotch oatmeal* (the oatmeal generally used throughout Scotland) is coarse, and contains much of the bran which invests the oat,—containing, as it does, a large proportion of the earthy constituents required for the production of bone. Analysis of 100 parts of dried oats gives—

Carbon.....	5.07	Nitrogen.....	2.2
Hydrogen.....	6.4	Ashes.....	4.0
Oxygen.....	36.7		

I may here casually remark, that the advantage to be derived from this wholesome food has not escaped the observation of her majesty Queen Victoria, who appears in the multiplicity of her public duties not to lose sight of the equally sacred duties of a mother; and we hear of her son, the heir to the crown of Great Britain, being as fond of his oatmeal porridge as the meanest peasant child in Scotland.

\* According to a memorial presented to the French minister, on the proportions of nutriment of the means of living, by Dr. Glaser, we find potatoes taking no mean rank.

#### NUTRITIVE ELEMENTS.

100 lbs. wheat bread contains 30 lbs.	
“ flesh	21 lbs.
“ fresh beans	80 lbs. }
“ peas	83 lbs. } casein and starch.
“ lentils	94 lbs. }
“ potatoes	25 lbs., albumen, starch and sugar.
“ carrots	14 lbs. }
“ beets	8 lbs. } albumen with sugar.



These sulci are generally found uncovered at some point by enamel, an imperfection so common as to render them less resistive than their fellows; hence

I rather doubt if parents generally have given to this subject the attention to which it is entitled. I trust, however, that those who have followed me thus far, may be impressed with its importance. We cannot shut our eyes to the complaint which so generally prevails of decayed teeth; and a moment's reflection will call to mind the number of the young and beautiful who are prematurely hurried to the tomb, ere yet the bud has expanded into the full-developed flower. Nay, comparing the two countries, the statistics of life and death communicate to us also the important fact, that while the greatest mortality shows itself in England in infancy and childhood, on this side the Atlantic it is found at a more mature age.

Neither has the tendency of the physical organization of woman on this continent to degenerate escaped the observation of one of our greatest medical philosophers in this country, who regards this retrogression as a national calamity, and impresses upon his students the importance of the subject, and the propriety of their attention in attempting to arrest it; and he particularly specifies the great object to be gained in the use of bran-bread made from unbolted flour. On this head I shall have more to say hereafter.

With these observations, let us now direct our attention to what can be offered in remedy of this evil.

We have already stated that in no country in the world are children more beautiful or more lovely,—healthy in complexion, quick, smart, and intelligent,—active, sprightly, and playful in their disposition. Now, in the period from infancy until the child becomes mature,—let us, at all events, say until thirteen or fourteen years, and even to a more advanced age,—there is a continued growth,—a continual deposition of organic and inorganic or earthy particles, which are required for the formation of bone, teeth, flesh, and every part of the human body. I have shown that the essential ingredients for these several formations are all found in the milk of the mother; consequently, as long as the infant is deriving nourishment from the mother, she ought to partake of good, wholesome, nourishing food, that the blood, deriving these principles from the food, may be able to supply them in turn to the milk from which it is secreted. So long, then, as the child is thus nourished, so long is it safe, and the rudiment or foundation of a robust frame is laid. And if we are to expect, in future life, the stalwart frame of man, or the enduring, firmly-knit, compact, and healthy physical constitution in woman, the organic and inorganic or earthy compounds of which that frame is composed must not be denied. Nature must be supplied, or nature will fail.

It is not for me to dictate to any parent what shall be the food of his child: it is enough that I point out for their information what may be required to give what in common language is called "bone and sinew" to their offspring. It is necessary, then, that the food of children shall contain:

1st. Aliment having the *calorific* or heat-sustaining principle. And this is contained in quite sufficient quantity in the usual food,—in milk, wheaten bread, potatoes, arrow-root, Indian corn (as mush, hominy, or corn-bread), in most vegetable matter, and in sugar.

2d. Aliment containing the *nutrient* principle. And this is contained in animal food,—the lean of beast, bird, and fish,—in milk, eggs, wheat, rye, potatoes, beans, etc.

And 3d. Aliment containing the inorganic or earthy constituents,—on which depends strength of frame, and from which are formed the bones and teeth of the individual. And these are contained in milk, eggs, animal food, and particularly in wheat, rye, oats, potatoes, etc.\*

\* On this subject, the author extracts the following from Carpenter's Physiology, p. 488: "These substances are contained, more or less abundantly, in most articles generally used as food; and where they are deficient, the animal suffers in consequence, if they are not supplied in any other way. Thus, common salt exists, in no inconsiderable quantity, in the flesh and fluids of animals, in milk and in eggs;



caries is most frequent in this class. Particularly is this the case with the *dentes sapientiæ*, an operculum of gum being too often found an added cause

Of the inorganic constituents contained in wheat (and the same may be said of the other *cereal* grains) I have already alluded to the benefit to be derived from using bread made of unbolted flour. On this subject allow me to refer to the difference of flour having much of the bran remaining, and superfine flour, or that in general use throughout this country, and on which Prof. Johnston has made the following curious but practical observations. Examining wheat and flour, as to the amount of the nutrient or muscular matter, the fat-forming principle, and the bone and saline material, contained in grain in different states, he found—

	Muscular matter.	Fat principle.	Bone and salt.
In 1000 lbs. of whole grain...	156 lbs.	25 lbs.	170 lbs.
" " fine flour.....	130 "	20 "	60 "
" " bran.....	.....	60 "	700 "

Taking the three substances together, according to Prof. Johnston, of a thousand pounds, the three substances contain of the ingredients mentioned,—

	Whole grain.	Fine flour.
Of muscular matter.....	156 lbs.	130 lbs.
Of bone material.....	170 "	60 "
Of fat.....	28 "	20 "
	354 lbs.	210 lbs.

Accordingly, the whole grain is one-half more nutritious than fine flour.\* It also shows the very great proportion of *bone material*—that is, *earthy constituents*—contained in the bran; no less than 700 out of a thousand parts, or a *little more than two-thirds* of the whole. Now, by reference to the same work, we find, in a communication from a Mr. Bentz, the difference in weight of a barrel of flour without the bran, and when only the outer coating of the wheat is taken off. He says, "The weight of the bran or outer coating would, therefore, in the common superfine flour, constitute the *offal*, weighing only 5½ lbs. to the barrel of flour, while the ordinary weight of offal is from 65 to 70 lbs. to each barrel of flour; showing a gain of from 59½ to 65 lbs. of wheat in every barrel of flour." Now, if we estimate the earthy constituents to be two-thirds of the offal or bran, we must consider that there is an actual loss of these important constituents, which might be reserved, in every barrel of flour, of 40 lbs.

Again, if we estimate (according to the average of the consumption of flour to the amount of population, as one barrel to each individual) that every child shall consume annually only half a barrel of flour, then we find that by the use of the superfine flour, as commonly used in families, the child is deprived yearly of twenty pounds of those earthy substances which are required to form the bones and the teeth. When we speak of a child consuming half a barrel of flour annually, it appears a large quantity; but when we reduce the same

it is not so abundant, however, in plants; and the deficiency is usually supplied to herbivorous animals by some other means. *Phosphorus* exists also in the yolk and white of the egg, and in milk; and it abounds not only in many animal substances used as food, but also (in the state of phosphate of lime or bone-earth) in the seeds of many plants, especially the *grasses*. In smaller quantities, it is found in the ashes of almost every plant. *Sulphur* is derived alike from vegetable and animal substances. It exists in flesh, eggs, and milk; also in the azotized compounds of plants; and (in the form of sulphate of lime) in most of the river- and spring-water that we drink. *Iron* is found in the yolk of egg and in milk, as well as in animal flesh; it also exists in small quantities in most vegetable substances used as food by man,—such as potatoes, cabbage, peas, cucumbers, mustard, etc. *Lime* is one of the most universally diffused of all mineral bodies; for there are few animal or vegetable substances in which it does not exist. It is most commonly taken in, among the higher animals, combined with phosphoric acid: in this state it exists largely in the seeds of most grasses, and especially in wheat-flour. If it were not for their deficiency of *lime*, some of the leguminous seeds (peas) would be more nutritious than wheaten flour; the proportion of azotized matter they contain being greater. A considerable quantity of lime exists, in the state of carbonate and sulphate, in all hard water."

\* Patent Office Report, 1847, p. 116.



of offence. To write any exact description of the irregularities of the faces of the molar teeth would be impossible, owing to the diversified aspects pre-

to a daily allowance, we find that it is little more 4 oz. or  $4\frac{1}{2}$  oz.; and every parent must know that this would be a very small amount to limit children to. Yet we see how large a quantity of the bony material would be added if unbolted flour was used instead of the present superfine flour. I may here add that the oatmeal used in Scotland, already referred to, contains the bran or inorganic constituents, while the oatmeal used in England is deprived of it. Now, this is a great loss of the most valuable constituents in only one of the principal articles of the food of children; and if we allude to another article, which is largely used on this continent,—I mean Indian corn (and I may also add the fat of meat, both of which, children, if allowed, will partake of very freely),—we shall find that both of these abound more in the calorific or heat-sustaining principle, and for the deposition of fat, than the nutrient, and that they are quite deficient in the earthy material of *lime*,—that material on which so much depends the proper structure of the teeth. Analysis of Indian corn shows the following composition,—as taken from Mr. Salisbury's prize essay read at the New York Agricultural Society for 1849:

Whole kernel:		Ash of the kernel, constituting about two per cent.:	
Starch.....	50.64	Carbolic acid.....	a trace.
Sugar and extractive.....	7.46	Silicic acid.....	1.450
Sugar.....	1.50	Sulphuric acid.....	0.206
Fibre.....	6.28	Phosphoric acid.....	50.955
Matter separated from fibre.....	0.05	Phosphate of iron.....	4.355
Albumen.....	8.64	Lime.....	0.150
Casein.....	1.70	Magnesia.....	16.530
Gluten.....	4.56	Potash.....	8.286
Oil.....	4.00	Soda.....	10.908
Dextrine or gum.....	4.84	Chloride of soda.....	0.249
Water.....	10.22	Organic acid.....	3.400
	99.89		97.000

This is a most elaborate analysis,—far more minute than any analysis we have had of any of the articles of food,—in fact, more minute than satisfactory; for the analysis of the whole kernel does not exhibit any amount of inorganic constituent; and when the whole is converted into ashes, we find that the *lime* only amounts to the *one-sixth of one part* in a hundred. Now, on inquiry, I find, on the authority of a very intelligent miller of this city, that in grinding corn the bran or thin skin of the grain is detained in forming it into corn-meal; consequently, it is deprived of even that portion more particularly containing the earthy constituents. This gentleman, in conversation, mentioned an important fact relative to this deficiency of lime in corn. To the best of my recollection, he observed, "This stands to reason; for, ten years ago, all the lower part of Jersey grew excellent corn, but would not grow wheat; but since the introduction of *lime* as a manure they have raised considerable wheat crops." Now, the fact is, it is not the habit or food of this plant, even had *lime* been in the earth; and magnesia and the saline manures are recommended to the agriculturist as best suited for its proper development.

It is generally looked upon as invidious, and one is more likely to incur odium than to receive credit for saying one word against a food which stands so high in public estimation and is so universally used over this continent. Yet it must not for one moment be supposed that I condemn the use of Indian corn in its various forms of mush, hominy, bread, or pudding as an article of diet; far from it. But, containing, as it does, a large proportion of starch and fatty matter, rather a small proportion of the nutrient principle, and quite a deficiency of the inorganic or earthy constituents, I consider it as valuable, as a light diet, for heat-sustaining purposes only, and therefore a desirable adjunct to *other food* containing more nutriment and a due proportion of the earthy constituents.

As an example or illustration of the want of the nutrient principle in corn or corn-meal, I may here allude to the effects I have seen in the West Indies, where, in a dearth of the ordinary provisions on which prisoners were fed, corn-meal was substituted; corn-meal and salted herrings, fish, etc., constituting their food. Now, the effect was that all the prisoners lost their natural strength; at the same time they became fat and bloated, inclining to



senting themselves. Sometimes such sulci are double, crossing each other at right angles. Frequently a single depression will separate the face into two

dropsy. And this was not the effect of incarceration; for the prisoners were engaged in road-making, trimming fences, etc.,—consequently, in a healthy and exhilarating employment.

In reference to our domesticated animals, it may be asked, Why is corn so useful as an article of food to animals generally,—horses, hogs, sheep, etc.? I have already shown that the overplus of the calorific food, after what may be required for sustaining the temperature, is stored away in the form of fat. Now, if we instance the horse, corn is generally, if not always, given as an adjunct to his more usual food,—hay. And we find by an analysis that grass or hay contains not only the nutrient principle, but the inorganic constituents required in the formation of bone, etc.

One hundred parts of dry hay contain—

Carbon.....	45.8	Ashes†.....	9.0
Hydrogen.....	5.0		
Oxygen.....	38.7		100.
Nitrogen*.....	1.5		

Thus, the hay gives to the animal strength in bone and muscle, while the corn supplies additional heat-sustaining properties, and lays by, in the form of fat, the overplus as a reserve. The harder the horse is worked, the more corn he can bear; the great proportion of the carbon being carried off by the lungs, and the hydrogen and oxygen, as water, in exhalation and perspiration. But if the same quantity is given to a horse at rest, it overloads him with fat, which in his case accumulates more internally, or around the internal organs, and will, in course of time, induce disease; while in the pig, under similar circumstances, the fat is laid on externally, if I may so speak, giving the rich fat pork of our markets. And here I would again remark that no farmer would consider it necessary or essential to give corn to a young colt or horse, until required to work; nay, so careful is nature in appropriating just so much and no more of any constituent that may be required, that the food of the young horse should be more nutritious than heat-sustaining, and that there shall be no superfluity to store away fat, we find by analysis that the milk of the mare has little or no butter—in fact, only traces of it—in its composition.‡ What a lesson in the animal economy is here given, and what a practical illustration of the requirements of the young of that and other animals!

Again, it may be contended that among the beautiful children we see on every hand, there is no want of those who are fat and hearty. It is not *fat* we want; it is bone and muscle, with so much fat only as shall give firmness to the flesh and plumpness to the figure. Fat, although it enters intimately into union with the other component parts of bone and muscle, cannot be transformed either into the inorganic constituents of bone or teeth, or into muscular fibre. These must be contained in the food consumed, in the first place, and thence transferred to the blood.

How necessary, then, how important it is, if we expect to give strength and vigor to the constitution, that the food, in the first years of infancy and childhood, when the formative process is going on, should receive some further attention than has hitherto been given to it! and if our youth,—if our young females have hitherto been deprived of the necessary constituents for the full development of every portion of the body,—can we wonder that a woman should be the delicate and fragile being she is, or that by the decay which assails the teeth in early life she should be deprived of an ornament of so much value? If this

\* Fifteen pounds of such hay, containing oz. 3.095 of nitrogen.

† These ashes having a good proportion of lime.

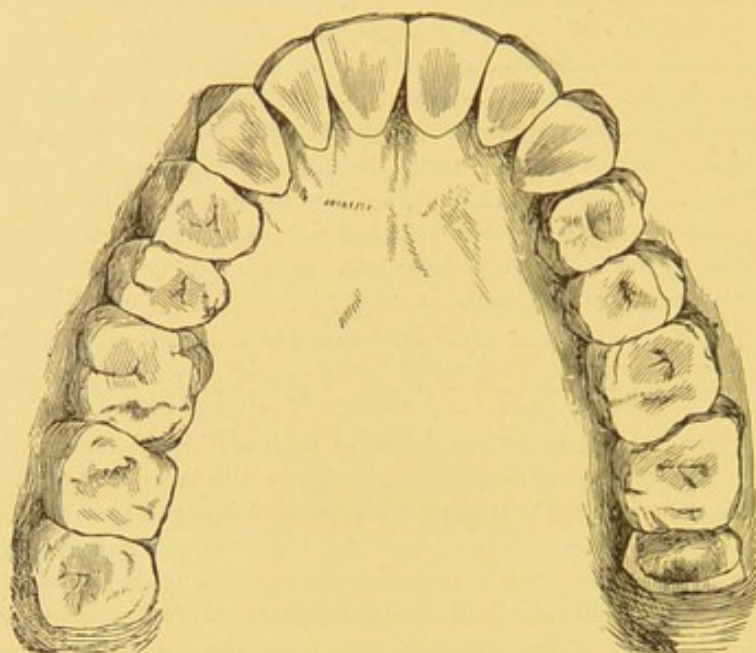
‡ Analysis of mare's milk:

Water.....	896.3
Butter.....	traces.
Casein.....	16.2
Sugar of milk, extractive matters, and fixed salts.....	87.5
	1000.



principal cusps, and, running over the side, will terminate in a pit. Still again a single deep sulcus will occupy the very centre of the grinding face,

FIG. 70.—SUPERIOR DENTAL ARCH.



the four cusps being more or less associated and ranged round it, ring fashion. In still other cases, a multitude of pits will cover the surface. On a single face as many as fifteen have been counted.

The bicuspidati, for a similar reason, are markedly subject to be attacked. These teeth not only decay from their cutting face, but, because of a peculiar flatness characteristic of their approximal planes, are more frequently affected upon the sides than even upon the grinding surface.

The next in the order of liability are the incisors of the upper jaw. Observation of the diagram exhibits a flatness on the palatine face of these

---

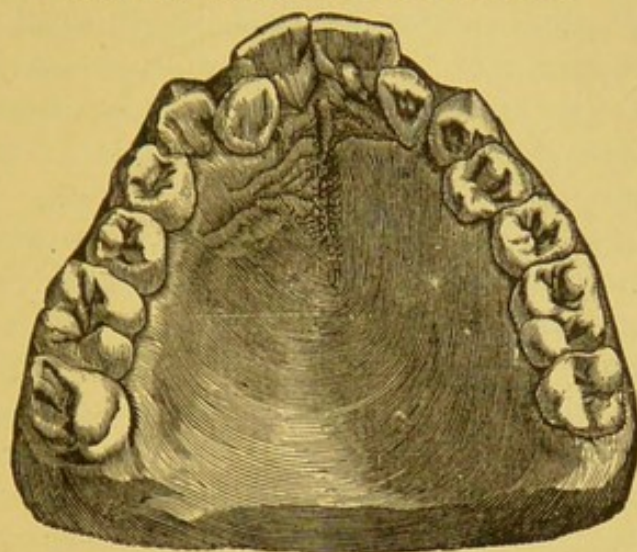
state of things can be altered,—if the physical constitution of woman in America can be saved from further degeneracy,—a purpose may be effected of consequence even in a national point of view; for it is to the healthy and vigorous constitution of woman that we must look for a race of hardy, vigorous, and enterprising freemen.

In conclusion, I would briefly state that this is a matter in which professional aid can avail little; it lies at the door and must be the work of parents generally. It is for them to understand the great value to be attached to the food on which their children subsist,—that it shall be wholesome and nutritious, and abounding in the earthy compounds so absolutely necessary to their proper development. If the chief articles of food have hitherto consisted of compounds made of superfine flour, corn-meal, and the fat of meat, let there be substituted in their stead bran-bread, milk, eggs, the lean of meat, and potatoes; let more attention be given to the nutrient quality of the food; let there be no deficiency of those articles containing the earthy material, that the bones and teeth shall not be deficient in those constituents so necessary in their composition and structure; and I should be inclined to hope that the evils which now exist will be lessened, and the physical organization of succeeding generations be equal to that of any nation upon earth.



teeth, which in many instances falls into a positive sulcus. These pits it is impossible to keep clean: hence an antagonism which results in caries.

FIG. 71.—SUPERIOR DENTAL ARCH.



The surface most liable to suffer from caries is the approximal. This in many instances finds explanation in the constant abrasion here going on as the result of motion produced by the act of mastication, the enamel being literally worn or cracked away. In other instances, a species of pocket-like flatness is found near the necks, in which is lodged and retained the débris of diet. In still other instances, the dentine becomes deprived of its protecting enamel as the result of lateral pressure, such pressure being increased with the development of each new tooth; this applies most particularly when the relation of approximal contact is a limited one and not diffused over the face of the tooth at large.

The inferior incisors and cuspidati are the teeth least disposed to decay. An explanation of such exception seems found in the shape of the organs and in their being fully surrounded by an antiseptic saliva.

The wisdom-teeth, universally viewed as being most predisposed to caries, derive such tendency from a twofold direction. Developing at a period when the formative force is losing vigor, these teeth are commonly deficient in the amount of that inorganic material which constitutes what might be called the mechanical resistance of the dental organs: in structure they are found, comparatively speaking, loose, while their general resistive power is low; they might, indeed, be likened to the osteophytes which form after bone operations, and which represent so imperfectly the tissue replaced, being found unable to resist antagonisms not at all injurious to properly-formed tissue. Again, as a local signification is concerned, these teeth, making their appearance at a period when all the others are formed, find so little room in the arch as to render the process of eruption difficult, slow, and in some cases impossible: hence not only is a chronic morbidity engendered, but the face of the tooth is



in many instances so long overlaid by an unabsorbed operculum (see diagram) that a perfect pocket exists, constantly filled by ingesta.

CONDITION 3. *Constitutional relations.*—This is the purely medical aspect of the question: it considers the varying alterations in the individual as manifested in the changes of dental health,—whether such relation resides in altered nutrition of the organs or in the production of adverse associated expressions. An example is furnished in the condition of utero-gestation, a second in dyspepsia, a third in the anæmic diseases.

The common proverb, “for every child, a tooth,” has passed into general acceptance: statistics demonstrate that women lose their teeth in a twofold proportion to men, and that child-bearing women lose them in a threefold proportion to single women. Teeth which, up to a period of pregnancy, never required attention, will, in some individuals, be attacked by a malignancy of carious action that quickly destroys a whole denture; such caries having the twofold signification of a perverted nutrition and antagonistic local action.

An all-important question here presenting itself is the cure. To esteem this as residing in plugs of gold, and to so practice, is to find one's self resting upon a staff of reed. The matter, primarily, is solely one of nutrition; not that necessarily phosphate of lime or other special material is demanded; the patient may have of such agents quite enough, both for teeth and fœtus; but the presence of agents of nutrition is not nutrition. Repair in living tissues resides in that function, as expressed by the physiologist, “by which nutritive matter, already elaborated by the various organic actions, loses its own nature and assumes that of the different living tissues, to repair their losses and support their strength.” Here lies the indication: it is, to correct the morning sickness which compels the stomach to refuse its food; to keep cleansed an alimentary canal which, because of perverted secretions, is denied the office of its lacteals, the whole economy thereby, Tantalus-like, being starved, even with plenty around; it is to antagonize the perversions of appetite, which, refusing proper pabulum, craves substances injurious to the health at large; it is to control nervous irregularities. To express the requirements in one sentence, it is to secure, and to preserve to the system, that assimilative force through which it may be enabled to add to its ordinary functional work the new labor demanded.

Dyspepsia and anæmia, as causes of dental caries, have the same general constitutional signification as found in the condition just referred to. To enter into a discussion of these relations would, as is seen, carry us necessarily over the grounds of general medicine,—a domain with which it has been taken for granted the reader is familiar.

CONDITION 4. *Character of agents in contact with the teeth.*—The idea, as commonly held, that caries of the teeth depends exclusively on the existence of free acids in the oral cavity, is, to the mind and experience of the



writer, a proposition which needs but little observation to limit to very circumscribed boundaries. If any one hundred mouths be taken, having in them carious teeth, and the ordinary test of litmus-paper be made, four-fifths of them will be found neutral, if not alkaline. Alkalinity we would infer, then, to be a more common association of caries than acids; and of the truth of such position experiment will show that there can be little doubt. It is, however, a fact that the presence of any alkali may result in the formation of an eroding acid in a depression, or sulcus, and it does this precisely as the same effect results in decaying woody fibre,—namely, by enabling substances to absorb oxygen which do not in themselves possess such power, or possess it to a very limited extent. Thus, perhaps in every mouth in which the fluids are alkaline, carbonic acid will be found in the débris of decaying teeth. (See *Oral Fluids*.)\*

*Mucous Deposits.*—Every one who has occasion to make observations in the mouth has met most frequently with that condition of the mucoid secretion in which this fluid is glairy and tenacious, alkaline to the test, and not infrequently offensive in odor,—a condition universally associated, when a habit, with dental caries, and, indeed, with general dyscrasia. Teeth in such a mouth are universally covered with a film, and this so persistent that the ordinary use of the brush fails to disperse it, while the common dentifrices have alone the signification of a temporary good.

Teeth so diseased find relief alone in acids, not only locally employed, but internally administered. A system secreting such mucus may be said to labor under the dyscrasia of super-alkaline poisoning, the agent having its point of exhibition most markedly in the mouth. It is really the condition of oral typh fever,—a typhoid condition expressing itself in this particular secretion, precisely as in other instances accident might have directed it to

---

\* "No acids or soluble lime-salts are in the innermost decayed mass; hence no acetic, tartaric, or lactic acid has dissolved much of the lime-salts, because the acetates, lactates, etc., would not be found washed out completely from the decayed mass, but a small amount would still remain, which, being soluble, would be easily shown by oxalate of ammonia acid."

"One large decay sliced up into several parts, and the slices analyzed, showed as follows:

"First slice—Outermost, very gelatinous, soft layer.

"Water, 58 per cent.; organic, 26 per cent.; lime-salts, 16 per cent.

"Or, omitting the water: Organic, 61 per cent.; inorganic, 39 per cent.

"Second slice—Middle, water not determined, because no longer reliable. (The specimen had become a little dry.)

"Organic, 55.8 per cent.; inorganic, lime-salts, 44.2 per cent.

"Third slice—Innermost, white, friable mass just close to the healthy dentine; scraped out with a soft iron wire, and very crumbling.

"Organic, 32.1 per cent.; lime-salts, 67.9 per cent.

"This decay which was analyzed in these slices shows, therefore, from the outside, a uniform advancement to the normal composition of the tooth. It shows that the lime-salts are removed, but not in any way which the acid theory demands. . . . The tooth is disorganized, the soft, friable white decay is no longer organized, though chemically differing only slightly from the tooth-substance."—*Experiments by Prof. Charles Mayer, A.M.*



the degeneration of the glands of Peyer or of the liver. A poison is in the blood, and by means of the circulation is diffused throughout every part of the system; that it expends its force most markedly on certain parts is not unlike the expression of disease in general. If the blood of a patient laboring under this typh condition be examined under a microscope, it will be found that the normally-shaped red disks are diminished in number as compared with what are known to the pathologist as "the melanosed" corpuscles; that is to say, as expressed by Chambers, "the dying or dead disks, shrivelled and small, of a dark color, with black specks in them, and with gimped edges."

But what is this typh poison? it may be asked. Unfortunately, the nature and scope of the present volume limit an answer to the simple elements of one of the most interesting questions in medicine. By typh poison is meant the existence in the blood of a super-alkalinity, which tends to dissolve the blood-corpuscles and to defeat the ends of tissue-metamorphosis. This poison, according to its quantum, depresses to death, as seen too often in cases of typhoid fever, or it may expend itself in a simple deranged vitality, as witnessed in the stringy mucus now under consideration. How this poison enters the system, necessarily provokes much discussion. That one of its inroads, however, is by the stomach, is not to be doubted, seeing that in epidemic typhoid fever an emetic at the beginning of an attack seldom fails to lessen the force and extent of the impression, such emetic seeming to act mechanically by emptying the stomach, thus preventing all the poison which had been received into that viscus from being taken up; while still again it is observed that during the prevalence of such epidemics, those who smoke and chew tobacco, and thus eject their saliva, are least apt to be attacked.

That, however, the typh poison may be generated from within, is scarcely to be doubted. In such chronic cases as associate with dental caries, this is the direction, no doubt, of the production; and yet the condition may reside in a subacidity, the alkalinity being what might in proper health be normal, but which is in excess from the deficiency of a neutralizing acid. Unable, however, to devote a greater space to the consideration of a question well worthy a chapter in itself, we leave the subject with this hasty glance, extracting the deduction that the prophylaxis of caries in this direction is found in the free use of acids. If to the mind of any one this may need confirmation, let a deduction be drawn from any two cases of ordinary typhoid fever,—one being treated with alkaline medicines, the other with acids. In seven cases out of ten, the patients treated exclusively with the first will die; seven out of ten treated with acids will recover.\*

As a systemic medicament, let, therefore, the following be prescribed:

---

\* This assertion is founded on observations made in daily attendance on quite a number of patients during an epidemic lasting nine months.



R.—Acidi hydrochlorici diluti, gtt. x;  
 Syrupi, ℥ss;  
 Aquæ, ℥j. M.

S.—To be repeated from one to three times a day, as may seem required; or it might be that even five drops of the acid would be found sufficient for the requirements. In cases of typhoid fever, the author has administered as many as twenty-five drops to the dose, repeated every three hours for two weeks.

Conjoined with the acid it will be found serviceable to employ the quiniæ sulphas,—a grain pill once or twice a day, according to the length of time it is proposed to continue the medicine. A very good plan is to direct thirty pills:

R.—Quiniæ sulphatis, gr. xxx;  
 Extracti gentianæ, ℥j. M.

To be divided into pills No. xxx; one or more to be taken each day.

As a mouth-wash, the following combination will be found applicable:

R.—Tincturæ capsici compositæ, ℥ij;  
 Aquæ Coloniæ, ℥ij;  
 Spiritus vini, ℥ij;  
 Tincturæ quillai, ℥iss;  
 Tincturæ gentianæ compositæ, ℥j;  
 Acidi acetici diluti, ℥ss;  
 Acidi carbolicæ fluidi, ℥ij. M.

S.—To be used by saturating a tooth-brush which has been first dipped into water.

Where much offensiveness in odor is associated with this inspissated mucus, it may be necessary to use a gargle of the permanganate of potassa or of the aqua chlorinata. For the former, a very good proportion would be as follows:

R.—Potassii permanganatis, gr. xv;  
 Aquæ, ℥vii. M.  
 S.—Use as required.

Still another most excellent preparation for such disinfection is the phenol sodique; indeed, by many, preference is given to this article above most others. It is used diluted with water in such proportions as seem demanded to meet the indication of the special cases prescribed for,—ordinarily one part to twenty parts of water.

*Acid Secretions.*—That the common oral fluids are occasionally found of an acidity sufficiently strong to be injurious to the limy structure of the teeth is not, of course, to be denied. When such state exists, it is easily to be demonstrated by furnishing the patient with a few strips of litmus-paper, which are to be wet with the fluids of the mouth at varying periods of the twenty-four hours. In the morning, immediately upon rising and before taking fluids, is the test perhaps of most signification. If such test reddens the paper for a series of mornings, an antacid indication would seem to be



fairly established, and local prescriptions, something in combination like the following, may be directed :

R.—Aquæ calcis, ℥iv;  
Tincturæ cinchonæ,  
Tincturæ pyrethri, āā ℥j;  
Tincturæ quillai, ℥ij;  
Potassii chloratis, ℥j;  
Aquæ chlorinatae, ℥ij;  
Spiritus vini, ℥j;  
Tincturæ gaultheriæ, q. s. M.

S.—To be used with the tooth-brush.

Or,

R.—Potassii chloratis, ℥ss;  
Aquæ, ℥iij;  
Tincturæ capsici compositæ, ℥ij;  
Aquæ Coloniae, ℥j;  
Tincturæ quillai, ℥iiss;  
Olei limonis, *vel* verbenæ, *vel*  
gaultheriæ, q. s. M.

S.—To be used with the brush.

If it prove more convenient to employ powders, something like the following will be found to answer the required purpose :

R.—Cretæ præparatæ,  
Iridis Florentinæ pulveris, āā ℥ss;  
Ossis sepiæ pulveris, ℥ij;  
Olei limonis, q. s. M.

Or,

R.—Cinchonæ rubræ pulveris, ℥ij;  
Capsici pulveris, gr. x;  
Potassii chloratis pulveris, ℥j;  
Pulveris aromatici, ℥ij;  
Saponis castiliensis pulveris, ℥j;  
Magnesiæ carbonatis, ℥ss;  
Iridis Florentinæ pulveris, ℥j. M.

Or,

R.—Cretæ præparatæ,  
Iridis Florentinæ pulveris,  
Ossis sepiæ pulveris, āā ℥ss;  
Sacch. alb. pul.,  
Carbo lig. pul.,  
Pul. aromat., āā ℥i.

Conjoined with the local antacids, attention is likewise demanded to the functional, or it may be organic, conditions producing the acids. Different derangements of the general health will exhibit different acids. Thus, in one mouth will be found the uric, in another the lactic, in still another the nitrous, etc. These productions have their constitutional meaning and indi-



cations. As examples in such directions of practice, the presence of uric acid in the mouth, as in the urine, is apt to be found associated with deficiency in respiratory action and with circulatory sluggishness. Lactic acid in the saliva almost certainly indicates the condition of diabetes, although diabetes does not necessarily yield lactic acid to the saliva. Formic and acetic acids found continuously in certain mouths have been made quickly to disappear through treatment directed to an existing leukæmia.

*Parasites.*—The parasitic theory of dental caries holds good only as fungi, animal or vegetable, are added causes of deterioration. Lodged in a cavity of a tooth of soft structure, these no doubt act the part of destructive agents, by insinuating themselves into the tubular and intertubular spaces, interfering with and counterbalancing the resistive efforts of dentinal consolidation, and serving as sponge-like bodies, to hold in contact with the parts agents alike injurious with themselves, lowering also the resistive vitality through an appropriation of nutritional pabulum. The matter of parasitic relation with dental caries, properly summed up by Dr. Miller, is appended as a foot-note.\*

To destroy these fungi, few agents are found more reliable than what is known as the dental carbolic acid soap. This soap should be used twice a day, and particularly is not to be neglected on retiring for the night. Powders also serve an excellent purpose, removing the offence mechanically. Acid washes, as suggested, may also be prescribed. Dr. Aitkin, of Edinburgh, recommends the production in the mouth of sulphurous acid through a solution of the sodæ sulphis:

R.—Sodæ sulphitis, ʒj;  
Aquæ, fʒj.

In proportion as the secretions are acid, the salt is decomposed, the sulphurous acid being set free. This disengaged acid will, it is affirmed, destroy the parasites in twenty-four hours.

In the case of a family of children where parasitic offence was associated most markedly with putrescent caries, a change quite wonderful in its char-

---

\* "2. Decalcification of the enamel signifies total destruction of that tissue; of the dentine there remains after decalcification a tough, spongy mass, which becomes subject to the invasion of enormous numbers of fungi (leptothrix-threads, bacilli, micrococci, etc.).

3. The leptothrix-threads are found, with rare exceptions, only upon the surface, or in the superficial layers of the softened dentine, and appear to take but a small part in the invasion. The bacilli, on the other hand, penetrate far into the dentine, even into the finest branches of the canaliculi. Micrococci penetrate farthest.

4. In the separate tubules is frequently to be seen a gradual change from leptothrix-threads to long bacilli, from long to short bacilli, and from the latter to micrococci.

5. The fungi produce anatomical and pathological changes in the deeper layers, stop up the canaliculi, and necessarily lead sooner or later to death of the dentinal fibrils. The outer layers of dentine, thereby deprived of nourishment, die and fall a prey to putrefactive agents.

6. The invasion of the fungi is always preceded by the extraction of the lime-salts.

7. The fungi have not the power either to penetrate or to decalcify sound dentine, so that the infection of a perfectly sound tooth by a carious one seems to be excluded."



acter was produced by alternations of acid and alkaline washes. Either of these, by itself, failed utterly in any satisfactory result. The writer was led to infer, therefore, that two orders of fungi harmoniously existed,—the one impressible by acids, the other by alkalies; and the result of the treatment certainly seemed to verify the conclusion. The fluids of all the mouths were neutral. The *Protococcus dentales*, very minute organisms, are referred to by microscopists as being most frequently found in carious dentine, although it is not at all uncommon to meet in profusion the spirilla, amœbæ, monads, etc.

The following examinations, made by Dr. Joseph G. Richardson (author of the "Handbook of Medical Microscopy") on the first five patients coming into the office of the author after completion of the required arrangements, will be read with interest:

SPECIMEN I.—Patient, young lady. Mouth remarkably healthy-looking; gums hard; had lost no teeth; cavities very few in number; oral fluids neutral; teeth clean; no tartar or other collections, specimen examined being a particle of carious dentine. Examination with a one-twenty-fifth-inch objective, giving with the No. 1 eye-piece a power of about twelve hundred diameters, showing multitudes of bacteria and short leptothrix filaments, all, however, quite motionless.

SPECIMEN II.—Old lady. Teeth breaking down in every direction; diffused collection of pasty débris; gums soft and unhealthy-looking; epithelial cancer involving left half of lower lip, and passing around the commissure to upper lip; patient very deficient in vital force. Specimen examined being débris from the side of an inferior cuspis, against which rested the disease. Exhibited long bundles of leptothrix filaments, consisting of from five to fifty mycelial threads, each about one-ten-thousandth of an inch in diameter, and sometimes attaining the enormous length of one-tenth of an inch. These fibrous-looking bundles were interlaced and imbedded in a large amount of granular stroma, apparently composed in great measure of bacteria and bacteridia, as many of the former could be seen in very active movement around the margins and in the interstices of the masses.

SPECIMEN III.—Patient, young lady. Mouth in the highest degree healthy-looking; had lost no teeth; very few cavities, and these all filled beautifully and perfectly with gold; fluids neutral; no tartar. Specimen examined was a mere particle of débris found between the inferior central incisors. This showed great numbers of comparatively short leptothrix filaments, among whose interstices floated, in molecular (Brunonian) movement, multitudes of bacteridia and nearly motionless bacteria. A few of these minute organisms manifested voluntary action, which continued in certain instances for at least thirty-six hours after removal from their parent mouth and immersion into the three-quarter per cent. salt solution.

SPECIMEN IV.—Boy with hare-lip. Oral fluids alkaline, stringy, and tenacious. Specimen examined was carious dentine from a lower molar. It



showed immense numbers of bacteria, short leptothrix filaments, chains of spores, and occasionally a specimen of spirillum. These fungi were especially abundant around the margins of dentine scraped from the cavity; and, as they were not accompanied by salivary leucocytes, it is probable that they did not proceed from the saliva, but had developed within the tooth.

SPECIMEN V.—A molar tooth with a large cavity in its side was extracted from the mouth of fifth patient, a scrofulous lady, with most unpromising teeth, and, after being split open, was subjected to examination. A branch of the cavity, extending into one of the fangs, was filled with a soft spongy mass, which, under the microscope, was seen to be composed of long interlacing filaments of leptothrix buccalis, such as were found in Specimen II., and to be swarming with bacteria.

A portion of the cavity at the edge of the split surface was scraped clean, and thin sections of the still firm but diseased dentine were made with a strong sharp knife. These fragments, when examined with a power of twelve hundred, were seen to be associated with many bacteria and filaments of leptothrix, the latter of which *seemed* in several instances to occupy the dentinal tubules and to project from their fractured extremities. Although being then, of course, without movement, it was difficult to say with absolute certainty that the structureless fibre-like bodies were actually portions of the vegetable growth.

*Electro-chemical Relations.*—Every observer must have remarked how much more common caries is to moist than to dry mouths, and how much more frequent is the failure of an approximal plug at the base-wall of a tooth than elsewhere about its circumference. These conditions have been discussed by Mr. Kencely Bridgman, L.D.S., in a paper on the electro-chemical action of metallic substances upon the teeth, with an exhibition of experimental research which commends his views to respectful consideration.

While investigating, says this observer, the action of voltaic electricity upon organic compounds, it was observed that all defects of metallic fillings in the teeth could be represented by results obtained out of the mouth. That decay might be, and probably was, a chemical action, every one was quite ready to admit; but how it could be electro-chemical did not appear to be in the slightest degree comprehended. The immediate effects of chemical action could easily be recognized as such; but the previous electric condition giving rise to this chemical action required a somewhat intimate acquaintance with the laws of physical forces to render its presence appreciable; and, consequently, the only valuable portion of the theory has hitherto been left in abeyance.

A basal experiment upon which the deductions of Mr. Bridgman are founded is as follows:

A rod of absolutely pure zinc, three and a quarter inches long, after being thoroughly amalgamated with fresh distilled mercury and drained, and weighing four hundred and eighty-seven grains, was placed half its length in cold



dilute sulphuric acid, and the other half exposed to the atmosphere, in the same position as the ordinary plates of a battery. In a very short time bubbles of hydrogen made their appearance over the whole surface exposed to the acid, and after forty-eight hours the metal was found to have lost upwards of ten grains in weight. This loss, however, was by far the least important part of the results obtained. The immersed portion of the metal had not been acted upon uniformly over its whole surface; but the action had been greatest at the surface of the liquid. At the same time the exposed portion had become covered with patches of crystalline sulphate of zinc, high and dry upon the projecting portion of the metal. Therefore, not only had chemical action been exerted between the metal and the acid and the water decomposed, but there was the additional evidence that the metal itself had become polarized.

Associated with this first is the experiment by Faraday, copper being used instead of the amalgamated zinc, the color of the crystals and the coloring of the acid affording more conspicuous evidence of the results produced.

A piece of stout copper wire being placed similarly in acid, the latter very soon gave signs, by the coloring it received, of the copper commencing to undergo solution; and, after having been suffered to remain undisturbed for twenty days, it presented the appearance above the acid of a bushy rod, the portion exposed to the atmosphere becoming coated with a layer of minute and beautiful crystals of sulphate of copper, extending from near the top to within three-sixteenths of an inch of the liquid. At this intermediate portion a greater amount of chemical action had been induced, corroding the wire about half-way through and forming a neck tapering upwards.

That the action which arises between the metal and the acid is due to polarization is evidenced by the following proceeding: "A similar piece of copper wire, wholly submerged in the acid, so as to entirely exclude any portion of the metal from coming in contact with the air, has remained for many months without imparting the slightest tinge of color to the liquid; but on suffering the fluid to evaporate, so as to bring the upper end of the metal near to its surface, the instant the slightest portion becomes exposed to the atmosphere chemical action immediately commences." There is thus, where no sufficient normal affinity exists between the metal and the liquid to effect the decomposition of water, a power imparted, by the metal being polarized by the atmosphere, which renders it then capable of accomplishing it.

The atmosphere, says Mr. Bridgman, in its normal state being electro-positive, renders, by a well-known law of induction, bodies opposed to it electro-negative. The exposed end of the copper is, therefore, thus rendered electro-negative, and the acid, by the same rule, being electro-negative also, the immersed end of the metal becomes electro-positive. It is an established rule that bodies to be electro-decomposed must first be rendered electro-positive; and it is also a part of the same rule that bodies receiving an addition of matter must first be made electro-negative. Hence the exposed end of the



metal has become negative and received the crystallization, while the immersed portion, being positive, has been acted upon accordingly.

The appearance, however, of the crystallization upon what was at first the dry end of the metal requires particular attention. It is one of the special effects of electrolytic action that fluids pass to, and accumulate at, the negative pole. Obeying this law, the acid immediately begins to ascend and spread itself over the surface of the unimmersed end of the metal. But now we have another special provision, which demands the most careful and attentive consideration, as it constitutes the first step in the resulting chemical action.

One metal placed in two dissimilar fluids, as the air and the acids, acquires the same condition that two dissimilar metals, or one metal non-homogeneous, assume when exposed to the air: each has become polarized, and rendered amenable to chemical action. Water, being a compound of gases chemically combined, can have its gases uncombined only by equal degree of force being antagonistic to them; and consequently the decomposition of water must be preceded by some other arrangement. Now, the atmosphere being only a mixture of gases, or gases merely in a state of mechanical admixture, which admits of their being readily separated on the slightest interference, supplies the initiatory steps by which decomposition can be effected.

The first immediate effect upon a polarized metal is to drive the oxygen of the atmosphere to the positive end. Its combination with the metal, in oxidating or rusting it, is a chemical action determined by the electro-polar condition; and it has been established by Faraday and others that this chemical union is invariably accompanied by a development of electricity, which in its turn can be made to produce electro-chemical results of an equal degree in another direction.

The greater amount of action taking place at the neck of the copper wire will now be readily comprehended. The oxygen of the atmosphere has been driven toward the positive end of the metal; but its progress has been arrested by the acid surrounding it. The thin fibres, however, rising from its surface, being soon saturated with the oxygen, and presenting the latter in its most favorable form for acting upon the metal, facilitate its oxidation, and consequently accelerate its solution, and render the ascending acid saturated and ready for at once becoming a crystalline deposit, while little or no solution has been effected in the acid below.

It must be kept in mind that an electric state is not a fixity, but is relative, and depending upon attendant circumstances. Thus, if the copper wire had been subsequently inverted, the immersed end, which is now positive, would then have been rendered negative, and *vice versa*; or had the acid at any time been filled up to the top of the tube, the exposed portion only, however small that might be, would have remained negative, the surface of the liquid determining the line of demarkation between them.

Let us now apply these facts to the mouth. The external epithelial layer



of the gum is constantly throwing off its worn-out cells, and by this wasting process it determines its electro-positive state, while the crown of the tooth, as a continuation of the epidermal layer, partakes of the like condition. Were the teeth wholly and constantly submerged, and protected from the air, it is probable that, like the copper wire beneath the acid, they too might remain intact. But as the air is constantly passing into the mouth, or even through it in the act of breathing, they are thus, having one end exposed to the air and the other to the fluid moistening the gum, subject to the same polarizing influence as the metals.

The negative portion of the polarized tooth being represented by the portion of the wire exposed to the atmosphere, it will be at once comprehended why tartar accumulates upon certain parts only of the teeth, and how it is enabled to creep over the surface and adhere with tenacity.

In the case of the partly-submerged wire it has been shown that the principal amount of electro-chemical action takes place near the surface of the fluid, this point determining the line of demarkation. Hence in the mouth this line may be taken as the existing free edge of the gums. The moisture accumulating here, in the event of any electro-chemical action taking place, it would necessarily be immediately above that line, and consequently the substance of the tooth directly above the gum would be attacked. We see this actually taking place in the peculiar decays so common at the exterior or anterior basal area of the molars, and also on the same part of the upper incisors.

In the interstitial divisions, the moisture accumulates between the teeth by capillary attraction, and in connection with this we have approximal decay as one of the commonest forms occurring. The oxygen is attracted to the part, and produces the acid so invariably present, while by electrolysis, the lime is abstracted and removed to another part, or carried away in solution. By such electrolysis, Mr. Bridgman thinks, every other phase and phenomenon of decay is to be traced and explained.

Viewing the matter strictly from the stand-point of a chemist, our author has overlooked vital resistive force. We trust we have, however, completed this lacking portion of his subject, and thus afforded him a required support in the chemico-vital aspect of his subject in which his foundation seems wanting.

We may here follow Mr. Bridgman in his consideration of filling-materials.

In a prize essay, he says, I have shown that an amalgam filling in the side of a tooth having one edge near the gum generates acid at the latter point. This is due to polarization. A body of metal having its two ends or opposite sides exposed, under different circumstances, becomes polar, and in proportion as there is any substance to be acted upon by oxygen, so is the amount of chemical action regulated. Thus, a metallic plug in an approximal cavity, or in the external basal area of the molars, will have the cervical edge continually wet, while the upper part may be comparatively dry; and hence will



be assumed the two conditions as represented by the intermediate and exposed portion of the wire. It has often been lamented that, however carefully and well these fillings may have been done, there is the ever-recurring annoyance of finding, in a few years at the most, and not infrequently in a few months, that the sides of the plugs and baso-caval surface have become defective; showing that, although all the defects may have been removed in the first instance, the cause has been retained.

With the entire range of metals and metallic compounds, it may be taken as a fact that from gold to copper and zinc it is only a question of degree, for the one cause affects them all more or less. In respect to this, gold is unquestionably the best by very far, as being one of the least oxidizable; but even with this, certain precautions are essential to success. The one indispensable condition is *that there shall be no lodgment for moisture at any point of its circumference*. The edge of the plug must be made as perfect as possible, and no fissures communicating with it are to be suffered to remain; for, if all be not right, electro-chemical action will be certain to recommence.

With amalgams, such precautions are, if possible, even more important; but with these there are other points requiring attention. The composition of amalgams is a subject which has never yet been systematically investigated, and those now in use differ considerably in character.

Zinc and copper, and their various alloys, with tin and silver, etc., form the hardest amalgams; while gold, silver, palladium, and platinum form only imperfect amalgams, which never acquire sufficient hardness to resist friction. In the latter, too, the mercury readily oxidizes and produces discoloration, while some of the former pass very quickly from oxidation to the acidifying stage, and thus soon reproduce the electro-chemical destruction of the dentine.

There is another and more serious objection still to be urged against some of the more modern preparations. Amalgams hardening under a state of polarization assume, in some cases, a peculiar surface-crystallization, but almost invariably possess coarser crystals.

I have exhibited, says Mr. Bridgman, two pieces of zinc which had been amalgamated and suffered to harden,—one under polarization, the other without it. With the polarized surface the metal had acquired a considerable amount of crystallization of a peculiar character, projecting above the level of its surface, together with a somewhat coarsely crystalline texture without; while that which had been allowed to harden without being polarized was much finer in texture, although distinctly crystalline. Two pieces of amalgam, treated in a similar manner, showed the same corresponding results. In addition, both the polarized metals exhibited more discoloration than the unpolarized ones, and all showed that amount of roughness inconsistent with a perfect filling.

Having thus traced the defects of metallic fillings, Mr. Bridgman proceeds to consider whether the objections are insuperable.

There are two proceedings indicated, he remarks, as being desirable.



The one is to prevent polarization; the other, to prevent the effects of polarization being reflected upon the dentine. The former is not by any means difficult, but it requires a thorough knowledge of the laws under which it takes place to adopt the provisions under all the different circumstances required. Insulation, however, is one of the means to be secured. This, too, is the end to be sought in protecting the dentine. Either gutta-percha, waxed tissue-paper, or allotropic sulphur—but, above all, the so-called os-stopping—forms an admirable lining for a cavity, where little success could be hoped for from an unprotected amalgam. It also compensates for the want of fineness in the texture of the metal.

There is another point in connection with the electro-chemical action of metals upon the teeth discussed in the paper under consideration. Wherever a gold band comes in contact with the exposed dentine of a tooth, injury is commonly seen to ensue, and decay supervenes if the touched part be near the gum. This is assumed to be fully explained in the experiment with the copper wire. The gold, says the observer, may touch any part represented by the blue sulphate, but at the intermediate portion—that is, that portion of the tooth just above the margin of the gum—it is fatal.

Criticism on the deductions of the experiments is anticipated in a recognition of the fact that their author considers special cases alone, and does not lay down a general rule. That the condition of many mouths is fairly exposed seems entirely beyond doubt; and it must be admitted that Mr. Bridgman has given a very satisfactory expression to the chemical aspect of the subject of dental caries. (See chapter on *Denudation*.)

Since attention was first called by the English experimentalist to the electro-chemical relations as a cause of dental caries, the American has taken hold of the matter with an earnestness that fills the dental journals with communications on the subject.

*Medicines and Articles of Food.*—That medicines, even the nitro-muriatic acid so frequently prescribed as an hepatic alterative, and the muriated tincture of iron used by almost every practitioner as a tonic, are not such sources of offence to the dental organs as is generally inferred, the author has come to be reasonably well satisfied. Prescribing both combinations with much frequency in his clinic as well as in private practice, he founds this conclusion on an extent of observation that would seem to render it entirely reliable. Not that the careless employment of such medicines is at all to be excused; but the inference is meant to be conveyed that caries associated with the periods of such prescriptions has explanation in the conditions prescribed for, rather than in the medicines prescribed.

Acids are not best given through glass tubes, but, being sufficiently diluted, the draught, if such care be thought necessary, may be thrown into the back part of the mouth, and swallowed in a single muscular act, after which the teeth may be rinsed with water rendered slightly alkaline by the addition of a few drops of liquor ammoniæ. The system, however, which demands an



acid medication will seldom find its dental organs injured by the reception of a share. Chalk, in place of the ammonia water, is suggested by Dr. J. D. White, he asserting that in this article acid medicaments find their quickest and most reliable neutralization.

Mercury, as a medicine, has no direct effect on the teeth,—its action having an intermediate signification; neither have any of the potash preparations as ordinarily administered.

Sugar, as usually employed, is not to be considered an agent deleterious to the teeth; locally it can only act through its conversion into acetous acid. A too free use of the agent, however, by debilitating the digestive functions, indirectly affects the teeth in common with all other parts, by diminishing the resistive force,—in other words, through malnutrition.

Vinegar, lemon-juice, the malic acid of apples, the tartaric of grapes, will all of them, in varying extent, decompose tooth-structure through affinity for the lime. When, however, their action is thus injurious, the fact is easily recognizable by the patient in the loss of that polish noticeable on touching the organs with the tip of the tongue; or in the presence of the feeling familiar to every person, of "the teeth being on edge."

It is not, however, to be affirmed or maintained that any of these articles, when brought in contact with the teeth under the circumstances of mastication, with their speedy dilution by the oral fluids—always proportioned to requirements—are sources of disease to the parts. Prudence in the use of such things is, nevertheless, to be recommended to every person having teeth of loose structure,—soft, chalky teeth. (See *Oral Fluids*.)

Of the dried fruits, raisins may, it seems to the author, be with most reason denied; they do without doubt rapidly corrode the teeth, and are most tenacious in their lodgment. That it is necessary to proscribe their use, except in the case of children, is, however, at least debatable.

The spiritus nitri dulcis,—a compound of the nitrate and carbonate of potassa, sulphuric acid, and alcohol,—freely used in the United States as a febrifuge, particularly with children, is credited with being a frequent cause of dental caries; the diluted state in which the medicine is always administered may lead this inference to be received *cum grano salis*.

CONDITION 5. *The absence of mechanical destructives*, as salivary calculi, the bands of artificial denture, etc. (See chapters on *Salivary Calculus* and *Dentures*.)

CONDITION 6. *Accidental influences*.—Under the sixth head reference is first to be made to what may be termed the gymnastics of the teeth. These organs, like all others of the body, require to be used, and, when denied the exercise of their function, deterioration universally follows. Illustration of this is markedly exhibited in slop-fed cows, the teeth refused their accustomed task quickly becoming carious and loosened; also in the case of persons using



alone one particular side of the dental arch,—the unused organs being soon enveloped in tartarized débris, and the gums becoming turgid and debased. This debasement is shown also in those who live on food which demands but little trituration.

The practice indulged in by many persons of breaking the harder shell nuts with the teeth is most reprehensible, cracking and splitting the enamel, and thus exposing the more susceptible underlying dentine,—or, even where such accidents do not occur, exciting through shock a species of chronic inflammation which lowers the resistive force of the organs.

Dental operations, as justly remarked by Dr. J. Taft in his work on "Operative Dentistry," performed at an improper time and in an improper manner, the vitality of the teeth being thus impaired, or a diseased condition being established, are to be esteemed as exciting causes of caries. Often from injudicious use of the file extensive deterioration of the dentine supervenes, which is sometimes followed by death of the tooth and by disease of contiguous parts. Another cause enumerated in that volume is sudden transition from one extreme of temperature to another.

Cleanliness is an essential to a healthy denture. Teeth should be cleansed after every meal; to this end a tooth-pick—always to be made of wood—is passed through the interspaces, and the mouth afterwards rinsed with water, or water to which has been added a few drops of alcohol or cologne. As a dentifrice, to be used when required,—which will, most likely, be once each day at least,—the following combination may be employed :

R.—Ossis sepiae pulveris,  $\mathfrak{Z}_{ss}$ ;  
 Cretæ præparata,  $\mathfrak{Z}_{ij}$ ;  
 Coralli albi pulveris,  $\mathfrak{Z}_{ss}$ ;  
 Iridis Florentinae pulveris,  $\mathfrak{Z}_{j}$ ;  
 Carbonis ligni pulveris,  $\mathfrak{Z}_{j}$ ;  
 Lapidis pumicei pulveris,  $\mathfrak{Z}_{ij}$ ;  
 Olei limonis, q. s.

In a mouth self-cleansing, however, where there is little tendency to the accumulation and retention of débris, it would not, of course, be found necessary to have such excess of cutting ingredients. A modification of the prescription might therefore be made :

R.—Cretæ præparatæ,  $\mathfrak{Z}_{ij}$ ;  
 Ossis sepiae pulveris,  $\mathfrak{Z}_{ss}$ ;  
 Iridis Florentinae pulveris,  $\mathfrak{Z}_{j}$ ;  
 Cinchonæ rubræ pulveris,  $\mathfrak{Z}_{j}$ ;  
 Saponis albi pulveris,  $\mathfrak{Z}_{ij}$ . M.

In the treatment of any case of dental caries which may present itself, the careful practitioner first endeavors to satisfy himself of the causes, constitutional and local, influencing the diseased condition. Of the constitutional causes, all, as must be inferred, affect the integrity of the teeth which are deterio-



relative to the system at large. Unhappily for the dental organism, primary unhealthy impressions made upon the teeth, while in their formative, or pulpy, state, are apt to influence more or less their character for life, just as certain of the exanthemata,—variola, for instance,—occurring at this period, are so apt to impress permanent pittings upon the enamel.

Unhealthy parents, as has been suggested, cannot possibly beget healthy offspring. Here is a great primary antagonism. The teeth, however, are living and, consequently, changing bodies: particularly is this true, physiologically, of young teeth. Constitutional treatment may thus do service even as every molecule of tooth-structure is concerned. Such treatment would of course be longer in receiving apparent response, as must be evident on considering the relative low vitality of these organs, than treatment directed to the production of an impression on the soft parts, or on common bone; yet, because a tooth is an organized body, because it has innervation and circulation, such treatment, to a greater or less extent, must have its influence.

A first indication calls, therefore, for the consideration of causes interfering with the proper vitality of any denture coming under observation. Whether deteriorated hereditarily or otherwise, duty to the patient demands such consideration of the case.

We will suppose a trouble to be hereditary. Here, if we can find in a patient the observable existence or continuance of habits of functional irregularity, or of animal habits common to the parent and which are to be esteemed of deteriorating import, our first attention is to be directed to a correction. The parent may have been specifically diseased, let us suppose, by his parent, and thus the bad teeth of both father and child lie in a venereal molecular impression. Here a predisposing cause would have come from and would be still residing in the transmitted condition. Granting, then, that such molecules, still living, are impressible, would not judgment direct a primary treatment to the production of an impression in such direction? The writer has treated many a child, for skin and other disease, where the affliction was a true hereditary venereal transmission, and he never thought of directing medication otherwise than in recognition of such a transmission; and satisfied, as every medical man must be, that the circulatory fluid permeates tooth-structure, he treats venereally deteriorated teeth on a common principle, and has found in the result that measure of success which has justified the conclusions. In other words, he has prolonged the life and health of such organs, just as are prolonged the life and health of the patient upon whose molecules is impressed the fiat of the tubercles of phthisis. Such a treatment consists, however, not necessarily in administering specific or supposed specific remedies, but in viewing the system as laboring under depressing influences, either of a general or special local signification. This fact it is most important to recognize.

A child, as we have studied, may have its molecules deteriorated by a transmitted mercurial impression, or a parent may have been an inebriate, and



thus have debased his child in himself. The results of an excessive venery may have been transmitted. A mother, from lack of nourishing material, may have degenerated her offspring. These causes of transmitted ills, the appreciable ones, are many: all must recognize them.

Improper diet to the developing child, as has been suggested, is plainly enough a cause of bad teeth. The state of health of such a developing child has its influence; indeed, so marked is this, that by an observation of teeth belonging to the various periods of life, one can easily trace constitutional variations; for just as at different periods the functions of organic life were healthily or unhealthily performed, so we find the disturbances written in the character of teeth belonging to the period. More expressive even than this is the fact that the deciduous teeth mark, in the progress of their development, the health of the mother.

That the teeth, in their formative state, partake of the healthy or unhealthy condition of the system at large, all observers admit. But here, unfortunately, the matter has been left, most practitioners acting on the premise that such impressions are never to be altered. At such a conclusion it is impossible not to express surprise. Who, in his own person or in the persons of friends, has not remarked the varying conditions of the health of the teeth? Up to the age of sixteen the writer was a martyr to toothache; yet about that period a change occurred, since which time he has had no trouble. Is it suggested that the teeth may have been filled? True, they have been; but certain of the fillings came out years ago, and have never been replaced, yet the teeth are quite as good as those in which the operations remain.

Similar instances exist in profusion, and yet the lesson seems unheeded. There is a constitutional treatment for the carious tooth, as there is for the carious maxilla, and from a common stand-point are the diseases of both to be viewed. It is not, of course, every case of a carious bone that demands systemic treatment, neither is it so with the teeth; the source of offence in the one, as in the other, may be strictly local in character; but ill success must ever attend that practitioner who has not the inclination to look for meaning of a lesion outside of things strictly local in signification.

*Résumé.*—Integrity of the teeth depends on two general conditions: inherent vital resistive power, and the absence of irritating influences. A tooth may, in its vital relations, be just strong enough to resist external forces brought to bear against it, if in its construction there be no mechanical imperfection. It may, even with imperfections, be able to resist temporary injurious impressions. The vitality of a tooth can be elevated as the vitality of a lung is increased. The study of the vitality of a tooth, and the study of its adverse influences, is the study of vitality and the expression of irritation anywhere. The treatment of dental caries is both medicinal and operative.



## CHAPTER IX.

### SURGICAL CONSIDERATION OF DENTAL CARIES.

CARIES of a tooth differs surgically from caries of bone proper in the fact of a too common inability to repair by any effort of nature the injury done through the destructive influences of the disease. Not but what such repair is attempted, and indeed oftentimes successfully accomplished, as witnessed in tubular consolidation, where power sufficient exists to perfect the attempt, —seen in the process generally spoken of as vitrification or eburnification, a mode of natural cure and resistance which no mechanical operation, however successfully performed, can equal. This process of secondary calcification, or eburnification, exhibits fully the circulatory relations associated with dental caries, for not otherwise than as such expression is it possible to explain the phenomena: it is, in every particular, a modified repetition of the ordinary lymph exudation and circumvallation seen in abscess, either of bone or soft parts.

A tooth attacked in any part by caries expresses the stages and steps of the inflammatory process, inasmuch as at the first attack of the disturbing agent immediate alteration occurs in the circulation or nutrition of the part, the tubules being filled up and solidified, or such attempt inaugurated, by deposit of adventitious matter. Disease being thus resisted and retarded, it conquers only when stronger than the vital force which combats it.

Such phenomena express to an observing mind the principles of the treatment of dental caries, *i.e.* to relieve the part from the agent of offence, and to strengthen the resistive ability.

Passing from the first of these principles, which has been considered on preceding pages with perhaps quite sufficient fulness, we proceed to the discussion of the second.

A tooth attacked at a given point by irritating agencies will, step by step, break and give way before the irritant; or, otherwise, will resist and antagonize. Resistance implies assistance, which assistance may be either of nature, of art, or of both. Whatever shall tend so to consolidate or protect the parietes of a cavity as to render the parts impervious and insusceptible to external agents, will save the tooth. Such result is aimed to be secured through the removal of dead and dying dentine from a cavity, and provocation to tubular consolidation through the introduction of an agent exciting to the vascular system of the tooth; the chloride of zinc being among the best of such agents, and most conveniently employed in the preparation known as oxychloride. (See

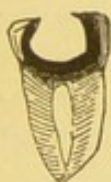


*Dental Therapeutics.*) Zinc so introduced into a tooth will not infrequently be found followed by such inflammatory consolidation that parietes from being soft and of loose structure are seen to become solid and dense to an extent that makes them entirely self-protecting; they have become glass-like in hardness: this occurs, however, only where the vital force is able to respond to the excitation. The practitioner, aware of this fact, directs a medication to the assistance of an asthenic system laboring under advancing dental caries, precisely as, under similiar circumstances, he endeavors to assist nature in the arrest of caries of bone. In the one case as in the other, thus only may he expect to get a cure. Such principle of treatment is so in accordance with the exhibitions of nature's expression, that no medically educated experience may doubt the indications.

The cure of caries by filing finds its explanation precisely as expressed in the employment of the zinc. The file cutting away the weak point, and exciting, through the exposure of the dentine, vascular response, structural consolidation results, and thus external or offending agents are shut out, precisely on the same principle as a ball may become encysted in a bone and remain for years innocuous.

Gold or other ordinary agents employed in filling act to an extent in the same way: these, however, being commonly non-irritating, or non-exciting, are not apt to be found associated with the same extent of

FIG. 72.



change; in all reasonably vital teeth, however, are to be seen such attempts at resistance. A filling of metal represents, and, to a degree, stands in place of, tubular or structural consolidation.

Fig. 72 represents a section of carious tooth from life, exhibiting structural consolidation as shown in the black boundaries of the cavity. In this particular case, although the hole—being in a lower molar—was large enough to contain a pea, caries was held completely in abeyance, and had been so for years. The parietes of the part were as hard as flint.

In the local treatment of dental caries, three indications exist:

1. Neutralization of adverse oral fluids and the induction of a state of general health in the mouth.
2. Medical treatment of the tooth.
3. Mechanical treatment of the cavity.

1. The normal condition of the oral fluids is neutral. A healthy saliva, in which practically is included the secretion of the mucous glands, as well as that brought into the mouth by the ducti salivarii, is an inodorous, tasteless, slightly viscid fluid, bland, unirritating, subject to changes as influenced by physiological impressions, affording at times an alkaline reaction, again being temporarily acid, sometimes sweet, and often, under the impressions of dry bodies, mucilaginous to a marked extent, owing this last characteristic to



excess of mucus, a substance almost analogous to vegetable mucilage, having as a chief constituent an albuminoid compound, with the office of preserving the membranes moist and in a condition fitted to the performance of their functions.\*

\* Messrs. Griffith and Henfrey, the able editors of the "Micrographic Dictionary," state, when speaking of the oral cavity: "The mucous liquid of the mouth contains, in addition to detached epithelial cells, very transparent corpuscles about 1-2000 to 1-1500" in diameter, consisting of a delicate cell-wall, a nucleus, with a number of minute moving molecules. We have figured these among the TEST OBJECTS. (Plate I., Fig. 5.) They are called mucous or salivary corpuscles. Kölliker regards them as a form of exudation corpuscles; and this view is probably correct, for they may occur in the secretion of any mucous surface and have no special connection with the salivary glands; we have found them in myriads in the urine."

Dr. Joseph G. Richardson, of this city, Professor of Pathological Anatomy in the University of Pennsylvania, claims, however, to be the first to demonstrate their true nature and origin, viz., that they are simply "migrating" white blood-corpuscles, which have become distended by the endosmosis of a fluid less dense than the liquor sanguinis. He remarks, "From my experiments as detailed in the same article, page 253, and briefly described on page 157 of this chapter, I conclude that 'tracing now the white blood-corpuscle from its condition of irregular outline and amoebaform movement, as observed in serum and in heavy urine, when the circumambient fluid approaches the density of 1028, through its rounded form, with slightly more distinct nuclei, in the liquor puris and in urine of lower specific gravity, we find that immersed in a rarer liquid approximating to the mean density of the saliva (1005), it has an accurately spherical outline, is more than twice the magnitude, and contains a number of minute actively-moving molecules, thus exactly resembling in all sensible characters the true salivary corpuscles; and it therefore seems reasonably certain that the blood, under the appointed nervous influence, congesting the buccal mucous membrane and associated glands, moves slowly enough through their capillaries to allow some of its white globules to penetrate the walls of the vessels, as they do those of the frog's mesentery in Cohnheim's experiment (*Virchow's Archiv*, Band xl. S. 38 et seq.), which, under the influence of the rarer saliva expanding them and setting free to move their contained molecules, constitute the bodies so long known to histologists as the corpuscles of the salivary fluid.'" (*Vide Handbook of Medical Microscopy*, p. 165.) The demonstration by Dr. Richardson is as follows: "Placing a drop of blood from the tip of my finger," says Dr. R., "upon a growing slide" (see *Pennsylvania Hospital Reports*, 1869), "I covered it with a thin glass and placed it upon the stage of the microscope. After finding a white blood-corpuscle showing well-marked granules, I raised the objective and arranged a fine filament of thread from the reservoir filled with fresh water to the upper edge of the cover, and a fragment of wet paper to the lower, according to the usual method for securing a constant current beneath the thin glass. On depressing the body of the instrument and bringing the corpuscle again into view, I found it still adhering to the surface of the cover, notwithstanding the torrent of red globules hurrying over the field; and as these became paler and less distinct by reason of the diminished density of the serum, the white cell first gradually expanded and displayed its delicate wall with two rounded nuclei, then, after acquiring the magnitude of about  $\frac{1}{1700}$ th of an inch, it exhibited the rapid and incessant movement of its contained molecules, and, finally, when its diameter reached about the  $\frac{1}{1400}$ th of an inch, it burst suddenly, discharging a portion of its contents, whose outbreak resembled that of a swarm of bees from a hive, and some particles of which, actively revolving as they went, swam off to the confines of the field. On repeating the observation and allowing some aniline solution to flow in with the water after the first few moments, the nuclei were strongly stained and beautifully distinct, although the movements of the molecules promptly ceased,—in this respect, as in all the others, showing a precise identity with the reactions afforded by the pus and the salivary corpuscles, as above



Analysis of the fluids bathing the teeth is to precede operations upon these organs. As acidity or alkalinity is concerned, such analysis is most easily made—demanding but a few days—by furnishing the patient with two strips of test-paper,—litmus, as it is called; paper colored with the dye of the plant *Lichen roccella*,—one piece being blue, as found in the shops; the other made red by subjecting it to the action of a weak acid, or for this latter purpose turmeric paper may be used. Having these pieces of test-paper, the patient is to wet them with salivary fluid, slip after slip, at varying periods of the twenty-four hours, particularly in the morning immediately on rising and before taking anything into the mouth. If persistently the result be acid or alkaline, as evidenced by the blue slips being turned red if the first condition exists, or the red slips of litmus being changed to blue, or the yellow of the turmeric to brown, if the action be alkaline, then is primarily indicated the necessity for antagonizing agents as suggested in the prescriptions presented a few pages back.

When sordes are found enveloping the teeth, or where the mucus is glairy, the condition manifested by such secretions is to find correction before any reasonable hope is to be indulged of saving the denture or of making mechanical operations which may have in them any special import of good. (See *Mucoid Saliva*.)

The restoration to a state of health of gums, turgid and congested from any cause, is to precede dental operations. Of such causes of ulitic troubles there are many. These will be found discussed in the chapter on Diseases of the Gums. In a word, attention to local or systemic indications is to precede, or have association with, as judgment may determine, the operative requirements of existing cavities of decay.

The physical history of a tooth to be treated demands consideration. Teeth so vary in character as to suggest their division into four classes.

I. *Teeth of the Sanguine and Allied Temperaments with Similar Hereditary Association*.—These teeth are white, shading into a cream tinge which deepens as it approaches the gum and as age advances: the organs are uniform in dimensions and arrangement, are dense, and have a periodontium of the most resisting character,—the associated alveolar process being condensed to a corticle-like extent; their relation with the jaw is so unyielding as not infrequently to suggest union of the parts. Such teeth, as justly remarked by Harris, indicate, “if not perfect health, at least a state which bordered very closely on it at the time of their dentinification, and the possession by

---

described. It should be noted that a certain variable proportion of the white cells of the blood thus treated exhibited no moving molecules, and apparently consisted solely of nucleus and cell-wall.”

Since the above was in type, this doctrine seems to have been corroborated by further experiments of Dr. Richardson, in which salivary globules were again reduced to the size of the white cells of the blood, and their amœboid movements restored, under the influence of a three-quarter per cent. solution of common salt. (*Vide* paper on the Structure of the White Blood-Corpuscles, Transactions of American Medical Association.)



their proprietors of stomachs always willing to digest whatever the teeth are ready to masticate."

II. *Teeth having a Blue Shade*.—These, without doubt, are much more common to females than to males. Constitutionally they indicate the lymphatic temperament. They are commonly super-sensitive, having a softness yet tenacity of structure that expresses disproportionate excess in animal matter; observation seems to indorse the conviction that such teeth are associated more or less in a hereditary history with struma. Certain it is, that to preserve them constant watchfulness is necessary, both as a systemic and a local aspect are concerned.

III. *Chalky Teeth*.—Teeth of this class are not infrequently to be met with having so little mechanical resistance as to suggest their relation with plaster of Paris. As such teeth have in themselves no resistive force, an only hope of prolonging their existence lies in the antagonizing of agents injurious to them. Thus arises a necessity for that care on the part of a person so afflicted, which is to keep him informed continuously of the state of the oral fluids, or if such care be not consistent with the character of the individual, then are antacid agents to be kept in constant use.

IV. *Pearly Teeth*—*Teeth frequently found allied with the Tuberculous Predisposition*.—Teeth of this class are commonly of great symmetry, being in harmony with the delicate conformation of the individual, and akin with the organization which has produced them. The inherent force of such organs is much in proportion with that of the common body. A treatment which tends to preserve them is that which increases the physical integrity of the individual at large. The author is not aware of a tendency to any peculiar local disease in them. The fluids of such mouths are commonly neutral.

Teeth of the first and fourth classes seldom have indications of any required direct preparatory treatment. Teeth of the third class may only have immediate adverse associations antagonized. Teeth of the second class, however,—and these constitute four-fifths of all diseased teeth,—are benefited by direct local medication to a degree that is oftentimes found to be their salvation. (See chapter on *Dental Therapeutics*.)

A soft moist dentine indicates non-resistance on the part of the immediate vital force (residing in the organ) to the advancing disease. There is here little or no antagonizing structural consolidation. Can this be remedied? Without doubt, in perhaps the majority of cases; such remedy residing in stimulation of the dental pulp, and in affording to it a power of response. To secure such response implies combination with the local of general stimulation. As the first is concerned, it has been implied that no agent surpasses the aqueous solution of chloride of zinc as used combined with osteo-dentine.

A soft, non-resisting tooth, in which such a temporary plug has been used, will not infrequently in the course of a few months be found so hard that an ordinary excavator shall scarcely be able to make an impression on the dentine; indeed, in many cases, so thorough has been the calcification that no



other treatment is found necessary; the caries has been cured, the dentine vitrified.\*

In the employment, however, of such stimulation, it is to be inferred that the nicest exercise of judgment is demanded. Quite as many teeth are destroyed by chloride of zinc fillings as are saved; perhaps the preponderance is to the first side; but this is the fault of a practice which overstimulates, provoking inflammation and suppuration where gentle excitation to a hyper-nutrition is alone demanded. A good rule to adopt is to feel one's way, recognizing always that the extent of local stimulation is to be commensurate with the ability of the pulp to respond; the object aimed at being to re-excite the formative capacity of the pulp, and thus oppose advancing disease by securing a calciferous barrier.

Secondary indications to be met preparatory to filling a carious tooth exist in a necessity for the destruction of any fungi that may be found in the cavity, the immediate antagonism of the carbonic or other acids, or any alkali temporarily present, and the saturation of the part with an antiseptic,—warm alcohol being about the best preparation that may be used for the last purpose. By saturation is meant that the dentine be bathed in this fluid after the preparation of the part and immediately before the introduction of the filling. A person undergoing the process of having teeth filled should freely use as a rinse alcohol and water, combined in the proportion of one part of the first to four of the second. Or, where the refrigerating influences of the spirit are found irritating to the cavity, it may be replaced by the permanganate of potassa, one grain to the ounce of water. Creasote is also justly lauded as an application to be made to the walls of a cavity just before the introduction of the filling. If the odor of this medicament be objectionable, it may be replaced with a weak solution of chloride of zinc.

*Separation as a prophylactic and curative agent.*

Having in a chapter on operative dentistry referred to the use of the file from the mechanical stand-point, we have here to consider the instrument as a prophylactic and curative means.

In the process of preparing approximal cavities for filling, it is seen that in very many cases—indeed, in a majority—the dentine of teeth has been exposed, and that afterward no steps have been taken for its protection. This absence of care arises out of the experience that such dentine left to itself does not tend to decay, but that when the operation of filling has been accomplished with judgment and the proper delicacy, the tooth seems in quite as resistive a condition as before being denuded.

Acting on the premises of such experience, it is to be commended not only

---

\* Vitrification, vitrified. The use of a term signifying glass—glass-like—would in such a case seem quite as permissible as its application to one of the humors of the eye, the condition being one of glass-like hardness and smoothness. Eburnification, or conversion into a substance resembling ivory, is another term used to express the same condition.

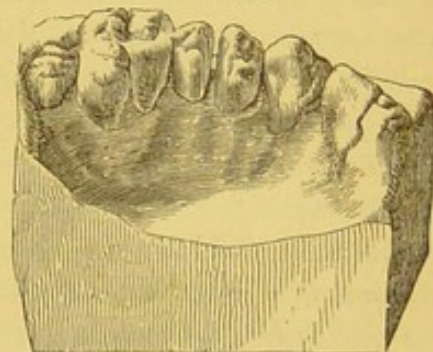


that conditions of incipient caries be filed away, but also that in irregular dentures the irregularities which invite disease be treated—in prophylaxis—in like manner. Of all the various operations performed upon the teeth, none, certainly, demands more experience than the one now being considered; or if experience is to be replaced, it may only be by a judgment which possesses the fullest recognition of the requirements.

It is to be borne in mind as a cardinal principle that, in prophylaxis, dentine is never to be uncovered except the surface exposed can be made self-cleansing; hence it is at once seen that certain positions of decay preclude this treatment; cavities, for example, occupying sulci upon the grinding faces of teeth.

A second principle, which is to possess its weight with the operator, lies in the premise that separation is not to be practised upon teeth the conformation and relation of which deny continuance of the position in which the operation leaves them. This second might be considered but an iteration of the first premise if it were not so well known that filed teeth, unless wedged, tend to change position. Hence the judicious use of a file or disk considers not only a present, but a future. In Fig. 73 an illustration is given of what is meant. Observing the bicuspid and approx-

FIG. 73.



imating teeth in this diagram, it is seen that between the first and the second bicuspids the file has been passed directly through to the gum, the space being the same behind as in front, and at the necks as at the cutting edges; this is, as seen, a free and open space. Referring now to the molar-bicuspid relation, it is shown that these teeth, which have been filed in a precisely similar manner, have fallen together, and so fallen as clearly to exhibit the impossibility of keeping them cleansed unless by a care that very few persons are found to give to the organs. Teeth so filed are cut only to their injury, unless, indeed, it may be that, by the act of cutting, such response is excited from the pulp as to eventuate in a resistive consolidation of the structure,—a result that it would scarcely be wise to anticipate, being certainly possible, but scarcely probable.

Eburnification, or vitrification, the process by which exposed and irritated dentine becomes self-protective, has been described on a preceding page. An operator, before resting anticipations of the cure of superficial caries on the file, is to appreciate well the responsive efforts with which the manipulations are likely to meet.

Teeth of soft character are perhaps never found so tolerant of the file as are those of more solid structure, and when cut not infrequently give way as by a process of invisible ulceration, just, indeed, as caries in bone, while so commonly cured through the relief afforded from operative means, will be



seen at times and under adverse systemic influences to have had the little force which existed in them destroyed by the operation. This is the case with teeth where the pulp life, instead of reacting, succumbs to the irritation.

Appreciating these conditions influencing the use of the file, our study may lead to an observation of examples illustrative in the direction.

As a first of such examples, attention is to be directed to surfaces of contact between teeth of the two dentures. A permanent tooth manifesting expressions of approximal change and being adjoined by a tooth of the first set, which tooth exhibits itself in the relation to be a cause of offence, may, if such first tooth be not too sensitive, find relief by filing directed exclusively to the latter organ. The use of the file is here and there oftentimes made available as the approximal relations of the six-year molar and second deciduous are concerned, or as are related the temporary cuspis and a permanent bicuspid, or, still again, as the permanent superior incisores centrales and milk laterales are seen to be sources of mutual injury. Milk-teeth, it is to be recognized, may not, however, always be filed with impunity: in very irritable temperaments spasms might very readily be found to result from such an operation.

Referring now to the six superior anterior teeth of the permanent set, it is to be recognized that caries attacking the approximal surfaces is not an infrequent condition, being excited, in part at least, as has been suggested, not only by the lodgment of detritus, but by a motion attendant on the masticatory act, which motion abrades or cracks the enamel of these surfaces.

To discover incipient disease of the approximal faces of teeth in the very earliest stage is a matter of no difficulty, a waxed thread passed into the interspaces exhibiting roughness of the surface, or a sharp excavator demonstrating the existence of a process of softening. Teeth so conditioned, if reasonably hard and of such shape as to permit of self-sustaining separation, may be cut with the prospect of a permanent cure. If, on the contrary, the structure be soft, and if the relation be such that continued separation is not to be secured, then it must of necessity prove the better practice to depend, at a period somewhat later, on separation by means of wedges and the clearing out and filling of a cavity that may ensue. In the interim, however, the disease is to be held markedly in abeyance by means of waxed floss silk passed frequently, by polishing with soft powders used as for dressing fillings, and by attention to every condition which may be recognized as an agent of offence.

In filing or disking away incipient caries, inclined surfaces are always to be the aim. Such surfaces secured and maintained, the parts from necessity are made self-cleansing; the act of mastication itself is made a cleansing one. Especially is this so where the denuded surface has been burnished and polished with that care which is as indispensable as the plane itself.

To prevent separated teeth from falling together, it is requisite to secure at some position surfaces of abutment; such surfaces, when possible, are to be maintained at the necks of the teeth. An abutting surface is, however,



in itself an ill,—but it is the smallest part of a common ill combated. When the absence of abutment of the teeth at the neck does not allow of the sustaining points being here secured, it may be proper first to press the organs asunder by means of a wedge of wood as directed in the chapter on filling, and, having thus the enamel in front intact, cut, by means of a safe-edged separating file of convex face, a V-space the base of which looks into the oral cavity. The wedge removed, and the teeth coming together, it is plainly seen that only the enamel-covered edges left in front may impinge.

The objection to the employment of a file, prevalent among the community, has arisen from the fact of the instrument being used with so little judgment: perversions, both pathological and artistic, rather than good results being witnessed as too frequently the result of its employment: hence in reasonable data has this prejudice had its origin. Such ill, however, resides no more in the instrument of itself than does discord in the keys of a piano, and nothing is required but an intelligent touch to disabuse the minds of people of such prejudice.

That sensibility of dentine and irritation of the dental pulp are frequently witnessed in connection with filed teeth is a fact too common to be denied. Indeed, many sets of teeth have been rendered permanently useless from such results: but here error in judgment has influenced the operation. Another objection urged against separating has been thought to lie in chronic ulitis engendered by the pressure of ingesta. Teeth treated as exhibited in diagram, Fig. 73, could but result in such conditions; but the fault here, as in the example above, lies with the operator.

Fig. 74 represents four incisor teeth carious on the meso-approximal faces from which the disease has been cut. The diagram shows two ways of filing. *Q* is a space made directly between the teeth, affecting alike the front and back faces. *D* is done by means of a disk, a diamond reamer, or a pyramid of corundum, and concerns the palatal face alone. *C* is a form of separation sometimes found advisable: it removes the centre, leaving impinging points both at neck and cutting edge. In the filing *Q* the impinging point is observed at the base of the teeth.

FIG. 74.

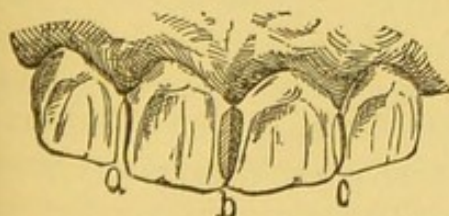

FIG. 75.

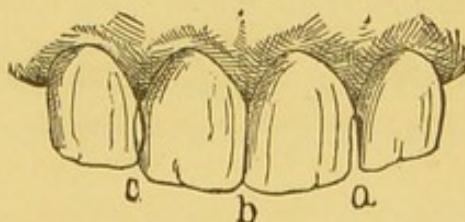


Fig. 75 shows the front faces of the same teeth figured in Fig. 74. It will be observed that, as the centrals are concerned, the front face remains untouched.

Bicuspid and molar teeth related as shown in Fig. 76, the impinging



points situated as exhibited by the cross-lines, are to find self-cleansing surfaces after the manner displayed in the succeeding cut (Fig. 77). To so alter the faces of these teeth, a disk of half inch diameter is used (see Fig. 78). Fig. 79, after T. T. Chupein, D.D.S., shows several teeth, molars and

FIG. 76.

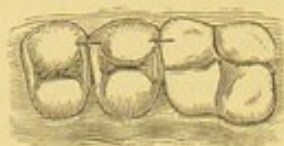

FIG. 77.

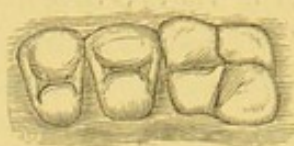
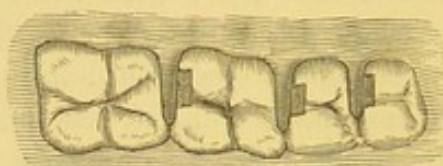
FIG. 78.



FIG. 79.



bicuspidati, which are filed in the treatment of approximal caries after a manner that is not too highly to be commended. When engaged in dental practice it was ever the habit of the author to place approximal faces in relation as here shown. It is the only proper way to prepare such teeth for the reception of plugs, as will surely be made evident to every practitioner by experience. The original relation of these cavities to each other is appreciated by a glance at the diagram.

A diamond reamer devised and presented to the profession by William G. A. Bonwill, D.D.S., has a large circle of admirers. This instrument does its work with thoroughness and rapidity. The pros and cons of separation claim large attention at the hands of the experienced. This book is to be understood as indorsing or condemning the practice according to the circumstances of its performance.



## CHAPTER X.

### DENTAL THERAPEUSIS.

A CARIOUS tooth is to be saved through the character rather than by the quality of a plug. The expression of gold is one of compatibility with dentine; that only. It is a substance wholly without therapeutic meaning, save as such meaning lies in an ability to protect an exposed weak surface against external agents of offence. Teeth made up of solid, resisting stroma are well treated if invariably filled with gold. Preference assuredly is to be given this metal in instance of every individual case, *cæteris paribus*, where a plug is to show. It is also to be given where elegance and purity of expression come at all into consideration. In a word, it is desired to have markedly understood that the teachings of this volume favor the employment of gold as a tooth-filling material whenever and wherever not contra-indicated. It is as well desired to have plainly expressed the view that fully one-half the operative dentistry of the day differs in no respect from a jeweller's work.

To be able to fill a tooth solidly and beautifully with gold, especially as contouring is concerned, is to have achieved a very creditable accomplishment; it is not, however, to have learned anything scientific. What is done is not half so difficult as things being accomplished every day by workmen who think nothing at all of what they do.

Operative dentistry is not special surgery: it is art, not science. In this respect Oral Surgery is of little relation with dentistry; that art being viewed as a profession whole in itself.

Whoever would treat and fill a carious tooth in relation with the laws of surgery is to treat and fill it in relation with indications. A filling of gold is an inert filling; it does nothing but stop a hole. Removal of a thoroughly well-made plug of gold, which has remained in relation with a cavity intact for many years, is not apt to exhibit change in the parietes of the cavity; the part remains as when brought in relation with the metal.

Other materials brought in contact with the parietes of a cavity in a vital tooth are found on removal to show changes; these have stopped holes, they have as well worked therapeutically.

A first consideration, as reference is had to selection of a tooth-filling material, may be instanced as referring to thermal conductivity. With some, with a great many teeth, such conductivity means nothing; with others, a great many others, it means inflammation of a pulp.

Gold is the most marked among the tooth-filling materials as a conductor. Where irritation is contra-indicated the metal is not judiciously to be used



except in combinations. Where a cavity is large or a pulp nearly exposed non-conducting substances are to underlie plugs made of gold; otherwise plugs are to be made of other materials.

Teeth are found where gold is unsuitable because of its density; a soft tooth filled with cohesive gold, the mallet having been used, is oftentimes felt by the patient as possessed of a stuffed feeling; the discomfort being so great as to compel removal of the mass.

The opposite of gold, conductivity being considered, is gutta-percha. Judgment plays the one against the other.

Soft teeth are most surely to be saved by a prophylaxis that considers a re-excitation of the calcific power lying in the dental pulp. Agents used with this intent, named in the order of the excitant quality possessed, are chloride of zinc, copper, tin.

To recalcify a tooth means to harden it. To harden the parietes of a cavity of decay means to render the tooth resistive of external influences. Calcification arises out of judicious stimulation of a pulp; over-stimulation changes excitation to degeneration: defeats and perverts, consequently, the result of an intention.

To judiciously use oxychloride as a filling material is to possess measurement of the wants of the tooth to be filled. A majority of teeth can be recalcified. What, however, proves the equitable stimulation of one is over-stimulation to another. It is not to be denied that chloride of zinc has destroyed more pulps than it has calcified teeth. No rule resides in the measurement of its use; proper employment of the agent lies in deductions arising out of experience.

In over-excitabile teeth gutta-percha takes the place of the zinc chloride; or, in instances, the floor of a cavity may be covered with the gum or with a layer of oxide of zinc, and the oxychloride placed upon this. Where gutta-percha is used the red variety is to be preferred.

Where gutta-percha is selected as a material for a foundation it is not infrequently to have advantageously incorporated with it fine filings of copper; or, otherwise, dust of the metal may be spread over the floor of the cavity and the gum used to hold it in place. Tin filings and sheet-tin apply admirably in the same direction.

Oxide of tin, found in connection with all tin plugs, is a reliable medication as the calcific process is concerned. Teeth from which the finest made gold plugs fall away by reason of secondary decay are restored to integrity through the use of tin. As a rule, all children's first teeth, and all soft teeth, are filled safely where tin is the agent employed. In many cases the removal of gold plugs and the refilling of the teeth with tin foil results in the preservation of a denture. After recalcification the tin may be replaced with gold.

The progress of secondary calcification is to be measured by the occasional removal of a therapeutical plug. If it be found in such examination that



the process is not advancing with sufficient sureness or rapidity, opportunity is afforded to remedy the default in the application.

Electrical disturbance is to have consideration. Viewing the matter apart from unsettled theories, it is undeniably the fact that a plug made of gold or of amalgam, more particularly of the former, quickly becomes imperfect at a point where metal, gum, and tooth associate. Where, in filling such teeth, dryness was secured, the explanation of the deterioration is to be assumed as lying apart from original defect in manipulation. Such teeth are saved by making a neck plug of gutta-percha or of tin.

Amalgams made with cadmium as a component, when used in a tooth, induce a condition of the pulp analogous to albuminoid degeneration. On the contrary, admixture being made with copper the result is so peculiarly tonic that subsequent years will not unlikely show the pulp contracted to a thread, this arising out of the physiological effort, made by the organ, at calcification.

A concluding reference is to be directed to the use of agents acting as parasitocides. No tooth is prepared for any, save an oxychloride, plug until a fungus-destroying application has been made to the cavity to be filled. Teeth of loose structure most particularly are infected with parasites. These parasites are to be eradicated, for it is these which conduce much to leakiness, which leakiness, in its turn, has related with it the meaning of tooth or plug decomposition. Such decomposition being resultant of a battery made by the juxtaposition of two solids and a fluid.

As a parasiticide creasote conspicuously recommends itself. It is to be used with every plugging material save those containing zinc chloride, this last being an agent of the same import. A cavity thoroughly saturated with creasote is rendered clear of all fungi.



## CHAPTER XI.

### THE ORAL FLUIDS.

THE principal fluid found in the oral cavity is the saliva. Other fluids are those coming into it from without, those regurgitated into it from below, and the secretions from mucous and associated glands. The oral fluids have to do with dental caries.

What is known as saliva is a commingled fluid secreted by three sets of glandular bodies,—namely, the parotid, the submaxillary, and the sublingual glands,—while another association of the fluid, as it is met with in the mouth, consists of a substance known as mucus, which is furnished, in varying quantity, by follicular glands lodged in the oral and pharyngeal mucous membrane. To see this latter, wipe the roof of the mouth, when it shows itself as dewdrop-like particles standing over the surface. Other admixtures of the fluid consists of particles of articles of food, cast-off epithelial scales, animal and vegetable parasites; these latter commonly in great variety.

The type of a salivary gland is seen in a bunch of grapes; the tube of outlet corresponds with the branch, the individual canals with the stem of the fruit, the secreting cells with the fruit itself. The development of a gland begins with the canal, this sending off bud-like processes which find accommodation in a cellular blastema; cells, canals, and blastema comprise the bulk of an organ.

Analysis of true saliva is more or less an unsatisfactory proceeding, owing to the difficulty of securing unmixed specimens. In 1000 parts ordinary analysis yields in the neighborhood of 990 of water and 10 of solid matter. A formula made by Dr. Wright gives the solid matter at 11.90, as follows: ptyaline, 1.80; mucus (and epithelium), 2.60; fatty matter, .50; albumen (with soda), 1.70; sulpho-cyanide of potassium, .90; alkaline and earthy salts, 3.20; loss, 1.20. Variation of from 7 to 12 is suggested by Carpenter as allowable within the health range. The quantity secreted daily by the healthy average man he approximates at 18 ounces.

Saliva is normal or abnormal; the first state relates with health, the second with pathological conditions; to appreciate the latter requires understanding of the former.

*Parotid Secretion.*—The secretion of this gland has a specific gravity of about 1.006; it is without viscosity, according to late writers, and contains in solution carbonate of lime, together with traces of chloride of potash, bicarbonate of soda, and sulpho-cyanide of potassium. Magitot gives 95 to



98 parts of water to the 100 against 2 to 5 parts of the solid substances named.

The parotids secrete alternately, and from the fact of their excessive development in ruminant animals are to be esteemed the lubricants of the oral cave. Meal or dry bread put into the mouth excite these glands to vigorous action. This fluid seems to be variously acid, alkaline, or neutral as times and circumstances relate with it; it may be inferred to be the second of these when the carbonate of lime deposits against the molar teeth in form of tartar. Innervation lies with the 5th and 7th nerves, explanation existing in this of the profuse salivation found so commonly associated with oral operations. Influence of mind on glandular secretion finds a striking example in the parotid, violent emotion suspending elimination; the Indian method of discovering a criminal by means of rice held in the mouth is familiar.

**SUBMAXILLARY SECRETION.**—The secretion of this gland is markedly in relation with the process of insalivation, as witnessed by the excitation of its action when sapid substances are tasted and its almost total suppression during periods of fasting. Experiments made by Claude Bernard show the excito-motor to lie with the gustatory and chorda tympani nerves. The fluid of this gland while very clear is yet very tenacious. Excess of ptyaline affords a coagulable appearance under the influence of cold. Animals making use of the viscid principle, as example is furnished in the ant-eater, have submaxillary glands of large proportion. The secretion, according to analyses made by Bidder, contains 3, in 100 parts, of organic, and about 5, in 100 parts, of inorganic matter. No sulpho-cyanide of potash is found.

*Sublingual Secretion.*—This differs but in degree from the secretion of the submaxillary gland. A viscosity characterizing it is owing to the presence of ptyaline, which is proportionably greater than in the other.

*Accessory Parotid.*—This is an associate gland related with the duct of Steno; its secretion is thought generally to correspond with that of the immediately preceding, and with that of the submaxillary.

Claude Bernard performed the following experiment, which affords clinical demonstration of the difference alluded to as existing in the composition of the secretion from the different glands. First he effected an entrance through external incision into the œsophagus of a horse, extracting the food bolus as it descended from the mouth; weighing this, he found that it had increased in weight elevenfold as a result of the saliva it had absorbed. A succeeding step was to tie Wharton's duct, with the result of finding that it required forty-one minutes to masticate what before had taken but nine; while the mass, when withdrawn from the œsophagus, was coated with a glutinous mucoid fluid, the interior being dry and friable; the increase of weight was only about three and a half.

Healthy saliva is a slightly opalescent fluid, somewhat glairy, commonly alkaline; the meaning of it in the animal economy is both excrementitious



and recrementitial. Whether, however, the latter office pertains alone to deglutition, or to this and to digestion as reference is had to starchy matter, does not yet seem definitely to be settled. Perhaps physiology will eventually decide that the parotid secretion pertains to the first office, the syrupy product of the submaxillary and the ptyaline of the sublingual to the second. Carpenter expresses the conviction that the most important action of saliva relates to preparing food for chemical influences to which it is later to be subjected.

The organic matter found in the parotid secretion is coagulable by heat, by nitric acid, and by the sulphate of magnesia. In the case of the submaxillary it is not so coagulable. The secretion of the sublingual is so viscous that it is with difficulty its density can be ascertained by the areometer; it is not clouded by exposure to air, contrary to that of the other salivas. Healthy saliva is characterized by the presence of a limited number of corpuscles. (See foot-note in chapter on *Dental Caries*.)

*Abnormal Saliva.\**—Attention is required to be given the oral secretions

---

\* In Magitot's instructive and interesting work treating of dental caries reference is made to laboratory experiments on human teeth with the sugars, lactic acid, butyric acid, malic acid, cider, carbonic acid, albumen and albuminoids, alum, oxalic acid, and the acid oxalates, acetic acid, tartaric acid, and acid tartrates, chloride of sodium and tannin. The experimenter directs attention to the fact that the teeth selected were from adults, and that they were perfectly sound, with the exception of a few taken intentionally showing a beginning more or less advanced of caries. In one group the teeth were absolutely free in the liquids; in the second they were completely coated with sealing-wax, having a single perforation over the enamel with a view of strictly localizing action of the liquid. These experiments are easily to be repeated by anybody; little, however, is gained from them as judgment is to be made up concerning vital teeth.

*Experiment 1.*—Solution in water of cane sugar, 1 to 3. Teeth placed and allowed to remain two years. Result: Teeth softened, blackened, enamel chalky, friable, and detached at several points, roots gelatinous. Certain of the teeth protected, except at single point, with coating of wax, showed at exposure alterations identical with the preceding.

2. Same solution, with addition of a fragment of animal matter for the purpose of making fermentation more active. Result: Teeth so changed as to be unrecognizable.

3. Same solution, with addition of a few drops of creasote, with view of retarding fermentation. Result: Teeth showed roots softened and brown without intense blackness of former experiment.

4. A one-third solution of glucose placed in same condition, with addition of creasote. After two years, liquid had not changed in appearance. No alteration showed in the exposed teeth.

5. Cold saturated aqueous solution of sugar and milk. After two years, fluid remained clear; no mouldiness or deposit; reaction perfectly neutral; no alteration in teeth.

6. One-third solution in distilled water of cane sugar filtered, and raised to the boiling-point, was placed in a flask and hermetically sealed in the flame, and left to itself for two years. A group of sound human teeth, weighed with the greatest care, had been previously introduced into the boiling liquid, and when weighed, after being washed and dried, proved to have undergone no loss nor any appreciable change.

7. A solution of glucose under identical conditions gave the same negative results as to action on teeth.

*Lactic Acid.*—1 gramme of acid to 1 litre of water (1 part to 1000). No change in teeth after two years of exposure.



during the continuance of general acute affections. Under the influence of pathologic conditions of this kind, pyrexia, eruptive fevers, inflammatory

2. Lactic acid 1 part, water 100 parts. Teeth exposed to this solution became gelatinous and reduced in volume; enamel chalky, friable, and changed to a brown color.

*Butyric Acid.*—Solution, 1 part to 1000 of water. Enamel of exposed teeth green, white, chalky, opaque, and brittle. Roots were made penetrable by an excavator.

2. Solution of 1 part to 100. Enamel removable without the least effort. General color yellowish. Roots softened throughout their extent and made flexible or gelatinous.

*Citric Acid.*—Solution, 1 part to 1000 (1 gramme to 1 litre of water). Teeth exposed two years; were found enveloped in mammillated, whitish growths, composed of citrate of lime; deprived of enamel; roots softened; no special coloration.

2. Solution, 1 part to 100. Teeth left exposed found completely deprived of enamel, the whole being converted into citrate of lime and deposited in bottom of glass. The teeth, thus reduced to their ivory and cement, had undergone no other apparent change, neither loss of substance; taken between the fingers they were found flexible, spongy, and gelatinous.

*Malic Acid.*—Solution, 1 part to 1000. Teeth exposed presented a complete opacity of the whole enamel layer, which was friable and chalky, but not removed from its position, nor detached from the surface of the dentine.

2. Solution, 1 part to 100. Teeth presented same alteration in character with the preceding, but with an intensity proportioned to strength of liquid.

*Cider.*—Common Normandy cider used, acid malic. Injurious effect on teeth deduced from preceding experiments.

*Carbonic Acid.*—Seltzer water used. 1 volume water to 5 of gas. Result: At the end of a week thin plates of ivory were found softened and flexible. Sound human teeth had undergone marked alteration in their substance, and a loss of weight to the amount of about a tenth; dentine of root could be pierced with a sharp instrument; enamel had become friable and chalky.

2. A second experiment submitted preparations to a solution of carbonic acid exposed to the air,—that is, to equal volumes of gas and water. Result: Nil.

*Albumen and Albuminoids.*—Solution composed of one litre of water to the white of two eggs well shaken in the liquid. Experiment lasted two years. Result: Teeth left freely exposed found to have undergone general and uniform softening; roots translucent; enamel friable and opaque. One tooth, protected with wax, except at a very resisting point of enamel, was found to show but slight alteration, this resembling the beginning of caries. Another tooth, exposed upon free edge deprived of enamel, showed softening of more pronounced character, which had resulted in formation of a cavity in the form of a deep cleft, with every characteristic of caries.

*Alum.*—Solution, 10 grammes of alum in a litre of water. Experiment continued two years. Reaction clearly acid. Teeth left free in the solution not at all affected as to their roots. Enamel deprived of its glossy look, having become opaque; its disorganization was so complete as to offer the appearance and brittleness of chalk.

*Bi-oxalate of Potassa.*—Solution of 1 part to 1000 of water. Result: Nil.

2. Solution, 1 part to 100. Result: Enamel of teeth found opaque, friable, and easily reducible to powder. No change in cementum nor in dentine.

*Acetic Acid.*—Solution of crystallizable acetic acid, 1 gramme to 1 litre of water (1 part to 1000). Experiment two years. Result: Nil.

2. Solution identical with above, creasote being added. Result: Nil.

3. Solution of 1 part to 100 (water 200 grammes, acetic acid 2 grammes). Experiment two years. Result: Teeth freely exposed exhibited, as the roots were involved, the alterations of softness, flexibility, yellow color; the roots being thinned lengthwise until of little greater circumference than common pins. Enamel undisturbed offered the curious appearance of crowns supported by pivots or pegs.



diseases, phlegmasiæ of glandular tissue, marsh fever, etc., Magitot most practically and appreciatingly calls attention to the fact that there are produced by reflex action upon the mouth, immediate phenomena which are the suppression, more or less complete, of the salivary liquids, while at the same time the mucus is increased yet not less deteriorated. Glairy alkaline muco-saliva is a common associate of amygdalitis, acute or chronic, and is not infrequently met with in general pharyngitis. A condition of this kind is assuredly adverse to the health of the dental organism, as the tenacious fluid not only bathes continuously the necks of the teeth, but invites and retains the débris of ingesta; to keep such a mouth cleansed is next to an impossibility. *Sordes*, a good name to apply to the incrustations about the teeth, is, undeniably, a softener of enamel; removal of the incrustations, where of long existence, showing the parts of a dirty yellow, and altered as extent of cohesive force is concerned. Magitot attributes the dental change to the acid formed in the fermentation.

Excess of ptyaline, combined as it always is with perversion in follicular activity, furnishes the agent for cheesy deposits; at the same time that

*Tartaric Acid*.—Solution, 1 part to 1000 (tartaric acid 1 gramme, water 1 litre). Result: Nil.

2. Solution, 1 part to 100 (tartaric acid 2 grammes, water 200 grammes). Result: The teeth freely exposed showed no change on their crowns; the enamel was simply covered with a layer of crystals, but remained absolutely intact. The roots, without being generally softened, had yet undergone a real alteration in their substance; dentine had retained its color and translucency.

3. Cream of tartar 1 gramme, water 200 grammes. Result: Nil. Magitot suggests that the peculiar action of the tartrates is to be regarded as a solution of the phosphates. As for the acid tartrates contained in wine, and especially in many kinds of fruits, it is to be esteemed as analogous to that of tartaric acid.

*Chloride of Sodium*.—Solution, 1 part in 100 of water, with the addition of three drops of creasote. Experiment covering two years. Result: Teeth freely exposed underwent no alteration of their substance, except that they took on a darker color generally, which was intense at the roots.

*Tannin*.—Solution, 1 part in 1000 (tannin of commerce 1 gramme, water 1 litre). Result: Nil.

2. Solution, 1 part in 100 (tannin 2 grammes, water 200 grammes). Result: No effect on enamel; kept its polish, but was covered with a light deposit of a greenish coloring matter. Cementum showed marked softening; was easily penetrated by excavator; assumed a light brown color.

In a résumé, M. Magitot classifies as follows:

1. Agents which act uniformly upon all the dental tissues; such are: the sugars by their products of fermentation; the lactic, butyric, citric, and malic acids; cider, carbonic acid, the products of putrefaction of albumen and albuminoid substances.

2. Those which disorganize the enamel specially and exclusively, with formation of salts of lime, soluble especially in the acid liquors: alum, oxalic acid, and the acid oxalates.

3. Those which act specially and exclusively on the dentine and cementum, with formation of salts of lime, soluble especially in the acid liquors: acetic acid, tartaric acid, and the acid tartrates, tannin.

4. The substances wholly without action on the teeth, as chloride of sodium, and generally all other substances which may be met with in the buccal cavity soluble in water and the saliva with neutral or alkaline reaction.



which has affected the integrity of the secreting bodies has involved as well the health of the teeth. Caries, here, is simply a result of what may be called stasis in resistive force; if there were more acid, there would be more health; a condition well expressed in typhoid fever, where progressive deterioration in every direction finds its only check in the free use of agents which offset the super-alkalinity out of which the disease arises. (See Condition 4, chapter on *Caries*.)

Salivary secretions, unhealthy in themselves by reason of a constitutional expression, are characterized by offensiveness of odor; to smear such saliva over a cold body, a common writing-slate being particularly adapted to the purpose, is to possess one's self quickly of perception of an offence residing in the organic constituents. Such saliva is not wisely swallowed into the stomach without being disinfected.

Saliva deteriorated by admixture with local sources of offence, as with the pus of abscess and ulcers, the detritus of decaying teeth, the chippings of tartar, the sordes of mercurial, typhoid, or scorbutic deposits, is to find correction by treatment directed to the offending cause.

Saliva unduly alkaline is accompanied by excess in secretion; unduly acid, it is expressive of dyspeptic complications. Excess in salivary secretion is almost certain to be related with moist and decaying teeth; limited secretion prognoses long life to the dental organism. A weak acid state of the oral fluids is infinitely preferable to a condition strongly alkaline,—the dental association being alone considered.

Saliva unduly acid acts destructively on the lime-salts, of which the inorganic portion of a tooth is composed. Remedy lies in correction of the condition from the constitutional stand-point and in the prescribing of antacid washes. Acids sometimes found in the mouth, in association with saliva, are the acetic, carbonic, hydrochloric, nitric, sulphuric, malic, oxalic, lactic, citric, tartaric.

Unduly alkaline saliva being expressive of sub-acidity of the blood, counter-medicaments are indicated. In this connection the author knows of no better treatment than is found in dilute hydrochloric acid prescribed in conjunction with sulphate of quinia and strychnia:

R.—Quinæ sulphatis, ʒi;  
Strychniæ sulphatis, gr. ss.

M. and make into pills No. 30, using for the purpose extract of gentian. Of these pills one is to be taken three times a day.

The acid is to be prescribed in fifteen-drop doses, repeated three times a day; the time of taking being intermediate to that of the first medicine. The fungi in such mouths find destruction by evolving sulphurous acid after a manner suggested a few pages back; or, a bearable dilution of chloride of zinc may be used as a wash: this last will destroy cryptogamia almost immediately. By treatment as just suggested the author has been instrumental in saving many a denture.



The test for alkalinity consists of nothing more than the use of slips of turmeric paper employed at varying periods in the twenty-four hours: alkaline fluids turn this paper yellow. The conditions of alkaline oral fluids seem to depend on an excess of the phosphates of lime and soda. An ammoniacal smell in the saliva is indicative of danger to the system at large. In an alkaline diathesis the demand is for an excess of animal over vegetable food; this indication is not to be neglected.

Acid conditions of the oral secretions find a simple test in the use of litmus paper; this paper, which is blue, being turned red by contact with an acid. To secure therapeutical analysis of acid saliva, nothing more is required than that a given specimen be measured by its effect on lime-salts. To an indefinite quantity of the secretion is added a measured and weighed proportion of the salt; either phosphate, carbonate, or fluoride of lime being used. The saliva being evaporated after a given time, a sufficiently just estimate is to be made of its influence on the teeth; the resistance residing in vitality being taken into the account.

Analyses of acids are made according to the ordinary provings of chemistry, which see. Sulphuric acid is to be presumed present where carious holes in teeth show a black surface. To directly test for this acid a solution of barium chloride is added to the saliva; if the acid be present a white precipitate deposits. This precipitate is not to be mistaken by reason of being insoluble either in acids or alkalies.

Nitric acid is peculiarly objectionable to tooth structure; its presence in saliva is to be exposed by boiling with the suspected fluid some copper filings; red fumes being given off if the acid is present, and the liquid acquiring a blue color. Another test is to dip a piece of litmus paper in a weak solution of potash; after this in the saliva; if nitric acid be present the paper burns with deflagration. This last, however, is not so reliable a test as the former.

Hydrochloric acid, objectionable in the mouth only when in excess, finds a simply applied test in nitrate of silver. To an indifferent quantity of the saliva a solution of the nitrate, sixty grains to the ounce of water, is added; if the acid be present its presence is shown by a white precipitate. This precipitate, which is a chloride of silver, is insoluble in nitric acid, but very soluble in caustic ammonia; it soon turns dark if left exposed to the atmosphere.

Lactic acid is an associate of gout, rheumatism, malarial fever, diabetes, and of general gastro-enteric derangements. A person with decaying teeth laboring under any one of these conditions is to have the oral fluids tested for the objectionable agent. The treatment is, of course, to be directed to the systemic vice.

Accidental substances found in the saliva are uric acid, urea, urates, bile, milk, cholesterine, and albumen. The presence of these is never disassociated from disturbance in the related organs or systems: treatment is to find direction accordingly. (See works on Practice of Medicine.)



In prescribing for salivary conditions it is necessary that a practitioner distinguish between local and systemic productions: thus, for example, it is not difficult to understand that in a strongly alkaline mouth, with much soft caries present in the teeth, each cavity shall show an active corroding agent in the presence of sulphuric acid; this acid being evolved through the action of some existing agent on the albuminoid expression in which such soft teeth are rich.

Carbonic acid serves as another illustration. This acid may be found existing in the fluids of the mouth to an extent markedly injurious to the teeth. Eight ounces troy is the medium quantity of carbon expired by a healthy man in the course of twenty-four hours. Indefinite is the amount that may be converted by the oral moisture into a corroding acid by the amount of oxygen therein intimately related with it. People inhabiting warm climates have better teeth than the residents of cold regions. The proportion of carbonic acid expired by the first is quite one-half less than of the other. Teeth decay in many instances very much faster in winter than in summer weather. Between  $86^{\circ}$  and  $106^{\circ}$  the carbonic acid set free in man is one-half less than when the thermometer marks the freezing-point.

Age, sex, development of body, state of health or disease influence carbonic exhalations. These relations are to be considered in connection with dental caries manifesting itself under the different conditions.

The acid of fruits acts injuriously on very soft teeth alone; where acids are freely used in this form frequent rinsings of the mouth with pure or medicated water will not be amiss.



## CHAPTER XII.

### THE TEETH AND THEIR DISEASES.

#### ODONTALGIA.

UNDER this common head are to be studied the various pains in the teeth, however induced. The term comes from the two Greek roots, *odons*, a tooth, and *algos*, pain,—odontalgia, toothache, or pain in a tooth.

The causes of toothache are to be classed under the following heads:

1. Sensitive dentine.
2. Direct or indirect exposure of the pulp to sources of irritation.
3. A diseased state of the periodontium.
4. Confinement of pus and gas in a pulp-cavity.
5. Granules of osteo-dentine in a pulp.
6. Sympathy.
7. Recession and absorption of the gum and alveolus.

1. *Sensitive Dentine*.—Some teeth, immediately on the breaking down of the enamel and the consequent exposure of the dentine, become exceedingly sensitive; in other words, exhibit themselves as peculiarly susceptible to the influences of irritating agents. This impressibility is attempted to be explained by the most dissimilar hypotheses, few subjects connected with the teeth having elicited more discussion and controversy.\*

---

\* An observation of the pulps of certain teeth which have been exposed to irritation in cavities unopened as well as open will exhibit the existence of fungoid excrescences. Only very lately it has happened the author to open several teeth which had been partly destroyed by caries, the pulp-chamber, however, being intact; in two of these cases a magnifying-glass of very ordinary power exhibited thread-like excrescences of most minute and fibrilla-like appearance, passing in clusters from the surface of that portion of the body of the pulp adjoining the cavity of decay. These excrescences were in each instance of a pearly-white color, and might well have been likened to bundles of the delicate cobweb. It is suggested to the attention of the microscopist that it is possible that such excrescences passing into the tubular structure have been mistaken for nerve-fibrillæ. Without qualification, however, the author believes that exception may be taken to the doctrine that nerves pass from the pulp into the tubuli. It scarcely seems to need the microscope to demonstrate the correctness of such an opinion. That fibrillæ, however, may be found in teeth of loose structure, being intertubular, may readily be received as a fact, but their origin is to be sought in the enamel membrane and not in the pulp. One explanation at least of sensitive dentine would seem to be found in the relation of the dentinal circulation to the pulp through the medium of the halitus of the chamber; this finds (at times) demonstration in the marked relief so commonly gained through absorp-



In teeth thus sensitive, the operation of excavation is occasionally found so painful as to be quite unbearable, and is only to be accomplished through the employment of means that lessens such sensibility. Even sweets taken into the mouth, or cold or hot drinks, or acids, the latter particularly, will occasionally provoke pain in such teeth. Instances quite numerous exist where such dentinal sensibility is continuous, the pain being of a dull annoying character existing quite independent of foreign agents of offence. In these latter cases the exciting cause must be looked for in some irritative condition existing in the oral fluids: these may be too acid or too alkaline. Tests, however, are here easily made with the aid of litmus or turmeric paper. Specific remedies, accordingly, may have immediate employment.

As direct applications to teeth sensitive from the nature of their organization, medicinal obtunders in great variety are suggested. Of these perhaps the most permanently effective is arsenic: this application, however, possesses an objection in ill results almost certain to accrue to the dental pulp which renders the use of it entirely inadmissible; it is, nevertheless, very frequently employed.

Chloride of zinc is a favorite preparation, and where used immediately preparatory to excavating will be found commonly to answer most satisfactorily. In the employment of this agent, as in that of arsenic, care is to be exercised that such impression be not produced as shall unduly irritate the pulp. The application of the chloride of zinc is variously made. A common mode is to take a deliquesced preparation, dropping it, when it may conveniently be done, from the point of an instrument into the cavity, which cavity has been previously dried; the parts being protected from any inroad of moisture by means of napkin or dam. Another mode consists in employing a pellet of cotton saturated with the zinc. Still another manner, and the one to be preferred, consists in using the crystals direct, a few of these being placed in a cavity and allowed to liquefy. This last plan is to be commended above the others.

The almost immediate result of an application of zinc to a sensitive cavity is the production of quick, sharp pain; this, however, commonly disappears in from one to two minutes, when, the sensibility being found obtunded by the action of the agent upon the superficies of the cavity, excavation may painlessly proceed to that extent of depth to which the salt has acted. Re-applications are to be made as found necessary, although it is to be recognized that the fewer one can get along with the better for the subsequent health of the tooth.

Chloride of zinc in full strength obtunds immediately the part to which it is applied; diluted, it simply irritates and worries, increasing the very sensi-

---

tion from the cavity of all moisture, and the preservation of such dryness during the process of cutting. That entire dryness in a dental carious cavity is among the best antidotes to sensibility has come to have such common practical recognition that a large class of the most experienced operators rely exclusively upon it.



bility it is intended to destroy. Where the pain attendant on an application of the zinc is objectionable to the patient, it is to be in great part antagonized by a preliminary employment of the extract of belladonna.

Agents having no ulterior ill influence, and which frequently render all required service, are found in such preparations as creasote, chloroform, an ethereal solution of the terchloride of gold, aconite, oil of cloves, London paste, nitrate of silver, glycerole of thymol used warm, etc. It is sometimes found that by sealing up in a cavity for one or two hours portions of sulphate of morphia, excavation may be accomplished with entire absence of pain. Cauterizing the cavity with a point of the nitrate of silver frequently answers the same end. A similar mode of treatment, the actual instead of a potential cauterant being used, is a suggestion by Dr. Stellwagen: this operator using a live coal secured by igniting the point of a hickory stick. A mixture of equal parts of tincture of aconite and a saturated solution of iodine is highly recommended as an excellent cauterant and obtunder. Still other obtunders are chloride of calcium, carbonate of potassium, and ethylate of sodium. A combination highly commended by Dr. Flagg is prepared by mixing up fifteen grains of carbonate of potash with an ounce of glycerine; it is applied by means of a pointed stick or on a delicate pellet of cotton-wool. Another, a favorite application with many, is found in rubbing up together equal proportions of sulphate of morphia and gum camphor. The value of any or all of these agents is not, however, to be overestimated, as a very little experience will be sure to make evident that what is found to answer satisfactorily in one case is seen to be of little effect in another.

A means of overcoming the difficulty which is perhaps more reliable than the employment of obtunding agents, consists in using very sharp excavators and by rapid motion making deep cuts, which sweep the circumference of a cavity.\* In acid mouths, where the carious mass is mostly made up of semi-

---

\* In a paper read before the Pennsylvania Odontological Society by Dr. Guilford, attention is called to the important fact that burs, used with the engine, are obtunders or producers of pain, according to their sharpness or dulness. The author alludes to the three forms manufactured,—the hand-cut, the stoned, and the machine-made; commending warmly the second, criticising severely the others. A dull bur he condemns as one that should never be used, and certainly the evolution of heat out of such an instrument in rapid motion might not be overlooked by the most careless. Recut burs are also exhibited as necessarily imperfect, for while a workman can sharpen them after a fashion, he cannot equalize the height of the teeth, some of which have been broken or been worn more than others. In order to enable his class at the Philadelphia Dental College to observe and distinguish critically, Dr. Guilford has arranged an appliance and fitted it to the microscope in such a way as to bring a bur head into the field of vision, and there revolve it so that every point may be seen in a magnified form, as shown in the diagram.

In examining the stoned bur (Fig. 1), the polished sides of the teeth and the clear and keen cutting-edges are to be noticed. Even the bottom of the furrows between the teeth is smooth and polished, enabling the bur thereby in the very best manner to clear itself in the act of cutting. This latter point is one not to be under-estimated, for when a bur is in a condition to favor the retention of the débris in the furrows, these soon fill up, and thus

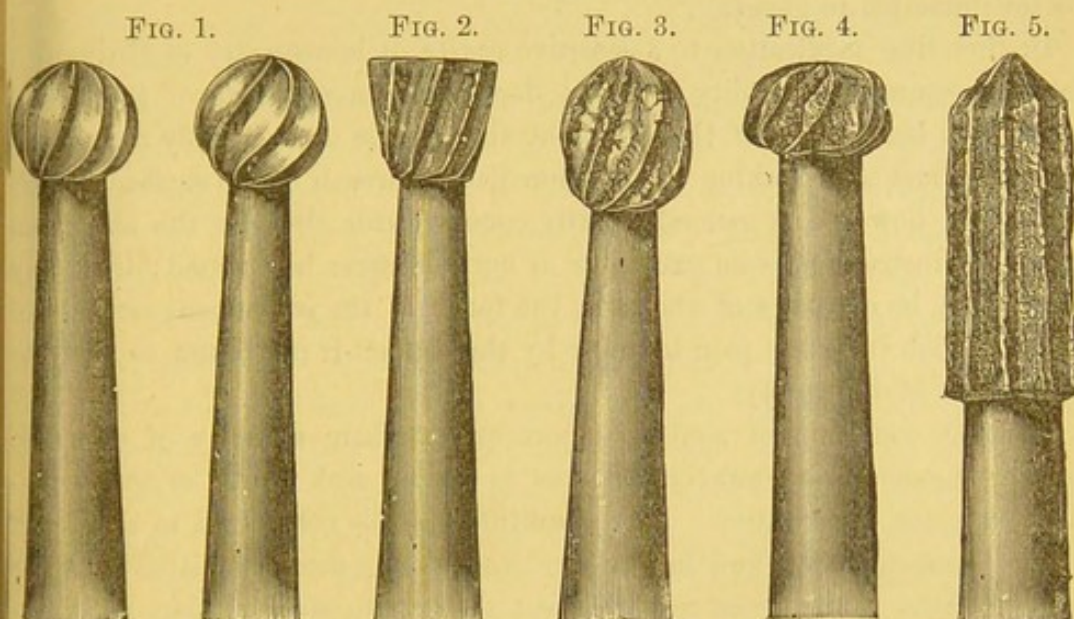


Revitalized animal matter, such treatment commonly proves so satisfactory that on the removal of a superficial horny layer all sensibility is found to

practically lessen the depth of the cutting-edges. The general appearance of the head of the stoned bur shows the care, skill, and labor necessary to its production.

In direct contrast to this most perfect of cutting-tools, notice the ordinary bur (Fig. 2). When this instrument is well made, the teeth will be of uniform height and shape, and it will be as perfect as the file can make it before tempering; but in the latter process, by the

FIG. 80.



oxidizing of the metal, its entire surface is covered with scales, making it rough and irregular, where, before tempering, it was comparatively smooth. No doubt the file-marks, fine as they are, favor the retention of this scale upon the surface of the metal. It is perceived that not only are the furrows rough from this scale, but the cutting-edges are also made dull and uneven by it. It is easy to decide as to the relative value of the two instruments.

In the recut bur (Fig. 3), similarity is remarked to the new plain bur (Fig. 2) so far as roughness from scale is concerned. Its teeth, however, are of unequal length, caused by some of them having been previously broken and their being filed to an edge in their present shape. This fact makes it one degree worse than the ordinary bur as a pain-producer.

Attention is called to the worn bur (Fig. 4). Some of its teeth are broken, while others are worn down so as to more closely resemble a burnisher than a cutting-tool. These worn and smooth edges, together with the irregularity of the teeth, make it an instrument that, by heating and thumping the tooth, would cause more pain and do less work than any other. It denounces itself as worthless.

In the machine-cut bur (Fig. 5), in addition to the scale, a general roughness, not only of the cutting-edge, but of every part of the furrow, is to be noticed. All its surfaces present the appearance of having been coarsely draw-filed. This is no doubt due to the rough face of the tool used in cutting them. It is also noticeable that pieces have been chipped or broken out of some of the cutting-edges. This is probably due to the hard temper of the bur and the lack of delicacy of the tool cutting it. Of the specimens shown in the diagram all are entirely new and have never been used, except, of course, the worn bur and the recut one; the latter has not been used since coming from the instrument-maker's hands.

From examination of the diagram it is readily seen what qualities a bur should possess, in order to commend itself to favor as a minister to a patient's comfort. In the first place,



have disappeared. The success of this manner of treatment does not, however, apply so happily in alkaline mouths or in the case of very hard teeth. Indeed, it may be said that with dense teeth zinc is the only agent yet known which invites any special reliance. Perfect dryness is to be associated with the cutting. Dry heat, or the chloride of calcium applies.

Sensibility of dentine is also at times found to be dependent not on a strictly localized nor on a general hyperæsthesia, but, on the existence of true inflammation. Here the indication suggests precisely the treatment required for inflammation in general.

In directing medication to a sensitive cavity, it is necessary to distinguish between common sensibility and that depending on exposure of the dental pulp; note being made of the fact that the cornuæ of this body are not infrequently met with making a very immediate approach to the surface. Such distinction, however, is generally easily enough made through the aid of an exploring instrument,—an excavator or nerve-plugger being used; if at any point there be exposure of the pulp, the touch of the instrument cannot fail to distinguish it, as the pain induced by the contact is not found to apply to other parts of the cavity.

Another condition of similar import exists where a cavity of decay so nearly approaches the pulp-chamber as to render each stroke of the instrument an agent of irritation. This condition is to be recognized in the depth of the common cavity, and in the tenderness being most associated with the deepest part. These cases require great delicacy in manipulation, as an inadvertent cut would most likely plunge into the substance of the pulp.

Etherization, as a means to enable an operator to excavate a sensitive tooth, is not infrequently nor objectionably resorted to, it certainly effectually answers the purpose, and where a patient is easily affected, as is occasionally found to be the case, a few inhalations inducing insensibility, there is no

---

it is to be made of the best steel, and so treated as to give it the best qualities possible. Next, it is to be most carefully made, with keen, even, and regular cutting-edges, and perfectly smooth furrows. It is to be well tempered and must be perfectly true. The tool-holder or hand-piece in which it is carried must also necessarily run perfectly true.

In selecting burs an operator should use a magnifying-glass, in order the better to examine the various points. Having succeeded in getting the proper quality and kind of burs, they are to be employed properly. For the excavating of living dentine a new and sharp bur is always to be used, lifting it frequently from the surface operated upon to prevent heating. The best results are generally obtained by running the bur rapidly. The tool is to be watched that it does not become clogged; an accident is less liable to occur, however, in a dry cavity than in a wet one.

Another matter, hardly less important than sharpness in the bur, relates with the hand-piece that carries it. If this tool be not true, as pointed out by Dr. Guilford, the bur, in its revolution, will not describe a perfect circle, but, rather, an ellipse, by travelling in an eccentric way. The result of this would be that the head, in its motion, instead of touching the dentine all the while, as it should, would alternately touch and leave it, thus giving a series of raps or blows, productive of very decided pain. The operator might not be conscious of these blows, but the patient would be, although, not unlikely, there might be ignorance as to the cause.



objection to its employment. Anæsthesia need not, of course, be carried to any profound extent.

The administration in hyper-sensitive cases of morphia subcutaneously is a practice that an annoyed practitioner need not hesitate to adopt. To an adult from an eighth to a quarter of a grain may be given half an hour before commencing the excavation. Bromide of potassium answers also at times a reasonably reliable purpose; twenty-five grains may be administered, by mouth, in a wine-glass of water. Syrup of lactucarium is another agent not without virtue; it is to be prescribed in tablespoonful doses. All of these means affect the local by diminishing the general sensibility.

Viewing sensitive dentine as a cause of odontalgia, the operator finds his most satisfactory means of cure in the introduction of a filling into the cavity. Another means resorted to, as a temporary treatment, is the excavation and polishing of the surface. Still others, the cauterization, as above suggested, with the solid nitrate of silver, or the use of the various other agents mentioned. A method where the parts are very sensitive consists in introducing into an unexcavated cavity a filling of oxychloride of zinc. The filling is allowed to remain three or four weeks, or even longer. This practice the writer commends as one of the most desirable and reliable that is to be pursued. The sensitive grooves so often met with across the neck portion of the face of the teeth are frequently to be most happily obtunded by an occasional repetition of polishing the surface by means of a burnisher. Such means, just here, is greatly to be preferred to the use of zinc.

2. *Direct or Indirect Exposure of the Pulp to Sources of Irritation.*—Reference to the anatomy and relations of the dental pulp exhibits it as a body composed of the most delicate connective tissue, in which ramify nerves, arteries, and veins. This body is lodged in a bony cavity, sufficient only in size for its comfortable accommodation, and for the halitus, or fluid, which surrounds it. Any undue congestion will therefore at once be perceived to result in a pressure, which, from the presence of nerve-matter, must cause acute suffering. This appreciated, the pains resulting from an inflamed pulp must be admitted to be alike in general character.

A pulp need not, as suggested in connection with applications employed to obtund sensitive dentine, be fairly exposed to be the subject of irritation.

Cases not infrequently occur where the plate, or floor, of a cavity is so thin, and so altered in structure, that it yields or bends. In these instances the agencies of mastication may and do readily enough force the plate down upon the pulp. As a consequence of such pressure we have irritation, and, it may be, inflammation.

Irritation of a pulp is much more apt, however, to be associated with exposure of the organ. Here everything entering the cavity is a source of offence, and the lesion is always plainly enough discoverable; foreign particles coming in contact with such an exposed pulp give instant and perhaps exces-



sive pain. This pain may quickly subside, or it may continue for hours or days; in the latter case, inflammation will be found to have established itself.

A free and open break into a pulp-cavity is attended with much less pain in inflammation of the organ than is the more limited exposure. In the first case, the swelling pulp has plenty of room, and consequently less pressure is exerted on the nerve-filaments. In the second, the protruding, congested organ quickly becomes strangulated, and thus pain of an acute and severe character results.

The treatment of an exposed pulp is of a twofold character,—palliative and radical. The first consists in the employment of soothing and quieting applications, and is employed principally for the relief of children. The second implies the destruction of the part; this being generally effected through the instrumentality of escharotic applications. To quiet an irritated pulp, attention is to be directed first to the removal of every source of offence. If the fluids of the mouth be irritative, the character of the condition must be sought for and corrected. If foreign particles have found their way into a cavity of decay, they are to be carefully syringed away with warm water. Such attention may be all that is needed. If not, and the excitability continue, recourse is to be had to soothing applications: the tincture of hamamelis applied warm, or the oil of cloves, or creasote much diluted, or chloroform, aconite, and laudanum, in equal parts, will sometimes act very happily; particularly in such cases as depend on excitation unattended with inflammation. Where evidence of congestion, or vascular excitement of any grade, exists, lead-water and laudanum frequently acts like magic.\* Persulphate of iron and tincture of iodine are found sometimes to serve very happily in similar conditions, constringing the vessels, and thus breaking up, or aborting, as it were, the congestion. In the odontalgia of first dentition, it is well that parents be provided with some order of general prescription. A very good one is as follows: the obtunder to be applied by saturating a small piece of cotton and laying it loosely in the cavity:

R.—Creasoti, gtt. vj;  
Tincturæ iodinii, ℥j;  
Liquoris plumbi subacetatis, ℥j;  
Chloroformi,  
Tincturæ opii, āā ℥ss. M.

Such a prescription is suggested on the principle of Dewees' carminative, and is found apt to meet, in some one of its ingredients, the single or various indications that may be present.

In severe inflammation of a pulp, it may be necessary to conjoin with the directly local the more indirect means of medication: blisters upon the nape

---

\* R.—Plumbi acetatis, gr. v;  
Tinct. opii, ℥ss;  
Aquæ, ℥j. M.



of the neck frequently result in speedy relief; hot pediluvia; saline cathartic medicines, as the sulphate or carbonate of magnesia; diaphoretics, as the spirits of Mindererus, or Dover's powder; or diuretics, as the nitre preparations. An inflammation of the dental pulp, if not too far advanced, will almost invariably be broken up by the administration of from five to forty grains of bromide of potassium, the application of a mustard poultice to the back of the neck, and a hot foot-bath continued from twenty minutes to half an hour.

The atropiæ sulphas is also to be relied on as a valuable agent in soothing, or obtunding, the pain of an irritated pulp. If severe inflammation have not supervened, and if the trouble be taken to syringe from the cavity any agent of offence, the instances will be found few indeed where it will not afford almost immediate relief.

R.—Atropiæ sulphatis, gr. i;  
Aquæ destillatæ, ℥j. M.

To be marked "poison" for safety, and to be applied precisely as the immediately preceding combination.

A cause of odontalgia from an irritated pulp frequently exists in the case of plugged teeth, from proximity to this organ of the material used in the filling. In these instances a constant irritation is kept up by thermal impressions induced by the presence of the metal. If inflammation supervene, the pain, because of the perfectly enclosed condition of the pulp, becomes of an acute throbbing and unbearable character; relief is generally obtained by the removal of the filling; or, if that should not succeed, the pulp may be treated as shortly to be described. Where several teeth are in a state of irritation from such a cause, and confusion as to distinct location is thereby induced (as is not infrequently witnessed), the affected teeth can be made clearly to designate themselves by holding cold water in the mouth; or, what is even better, by touching each particular filling with some cold steel instrument. The increase in sensation will commonly be thus made very marked. An operator may frequently cure such teeth by removing the plug, and before reinserting it introducing between the filling and floor of the cavity some non-conducting substance,—a piece of ordinary quill, a particle of asbestos, a layer of gutta-percha, a portion of the Hill stopping, or a cap of platinum. Oxychloride of zine prepared very dry is an admirable article to employ.

Still another source of irritation to the dental pulp is found in wearing down of the teeth. This is particularly observed in persons who use tobacco freely, or in such as have the upper and lower teeth directly articulating. Happily, however, in the generality of such cases, nature antagonizes the external influence by depositing, in quantities as needed, secondary dentine within the pulp-cavity, at the same time contracting this organ, so that, in proportion as a tooth wears away on its cutting face, the pulp recedes, and casts out, for its protection, this secondary material. It is a beautiful and wonderful process of offence and defence, and commands admiration.



In some cases, however, and these not a few, this reparative or protective power does not seem to exist; where this happens, the pulp, of course, soon becomes the subject of irritation. The writer has seen some of the severest cases of odontalgia result from such a cause. The only cure is found in the destruction of the pulp. To apply arsenical paste under such circumstances (see radical treatment of pulp), there being no cavity of decay, it will be sufficient to lay it in the cup-shaped depression commonly existing on the cutting faces of such teeth (the result of the more rapid wearing of the inner dental structure than of the outer enamel wall), keeping it in place with a covering of wax. When possible, however, it is much better, and more speedy practice, carefully to drill an opening into the pulp-cavity, and with a delicate needle pick the arsenic directly into the organ. The death of the pulp secured, the part is to be removed from its cavity by means of a barbed broach, and its place supplied later with gold or other material. Another mode of devitalizing the pulp of such a tooth will be found described in connection with the setting of pivot-teeth (which see).

Improper union of metals in the filling of a tooth is another not infrequent source of irritation to the dental pulp. Tin foil is sometimes placed in the bottom of a cavity, and the operation finished with gold. In many instances (depending not unlikely on lack of solidity in the overlying plug, thus admitting moisture) this combination produces a galvanic action, which, if not corrected, will quickly enough destroy a pulp.

Still another source of irritation is the employment, in cavities more or less in proximity to the pulp, of the preparation later described as oxychloride, or tooth bone; the chloride of zinc used in excess in the compound will not infrequently, within a very few hours after its application, produce an inflammation in the parts almost, if not entirely, uncontrollable. Few preparations require to be used with more judgment.

A tooth so irritated is to have the filling removed, and perhaps it will always be found the best practice to finish the death of the pulp as speedily as possible. As a reverse to this, it is to be recognized that the use of this material, as has been explained, will sometimes be provocative of just sufficient irritation to excite the secretion of secondary dentine, thus proving the best practice that could have been pursued. Experience is to direct the practice.

A pulp may give every evidence of being in an irritated condition where the osseous integrity of the tooth is perfect, or seemingly so. Here the cause may be still strictly local, on the other hand it may be constitutional. Blows received by a tooth often result in such irritation. Atmospheric changes sometimes account for the condition. Pieces of ice brought and retained in contact with teeth of loose structure are the frequent source of such trouble. Cracks in the enamel, induced from whatever cause, and permitting the impression of external influences upon the dentine, is another explanation. In a constitutional direction, rheumatism is, perhaps, the most frequent source;



after this, gout. Reflex or radiated irritability is a frequent manifestation. This is, perhaps, most observable in the hysterical female. In these cases no special practice may be directed. It is only necessary to discover the cause of offence, wherever and however situated, and, if possible, remove it. In the odontalgia of gout, dependence is to be placed on the exhibition of colchicum; twenty drops of the *vinum colchici radidis*, three or four times a day, according to the urgency of the symptoms, may be given. In rheumatism, there is, perhaps, no better combination than the following: administration, in the plethoric to be preceded by free purging with a saline cathartic:

R.—Potassii iodidi,  $\mathfrak{z}_{ss}$ ;  
 Tincturæ colchici radidis,  $\mathfrak{z}_{ss}$ ;  
 Extracti belladonnæ, gr.  $\mathfrak{v}\mathfrak{j}$ ;  
 Tincturæ guaiaci compositæ,  
 Aquæ cinnamomi,  $\mathfrak{āā} \mathfrak{z}\mathfrak{v}\mathfrak{j}$ . M.

Sig.—To the adult give a tablespoonful three times a day in a little water; if it act too freely on the bowels, add opium q. s.

Functional derangements of the stomach as the origin of reflex, or radiated, odontalgia, are to be considered. Any one who has ever observed the relationship existing between the pneumogastric and the third nerve, as manifesting functional stomachic derangement in the enlargement of the pupil of the eye, will be at no loss to associate the fifth and the ninth nerve. Pure neuralgia, as the term has common signification, is a very rare affection; an aching nerve will generally be found to have some lesion outside of a so-estimated idiopathic condition, and the lesion can generally be discovered by closely looking after it.

Passing now to a consideration of the same conditions as reference is had to a tooth required to be filled, we will be impressed with the intelligence and observation which have enveloped the subject with the light of a large common and reliable experience.

We consider first the condition of a tooth with the pulp-chamber nearly exposed,—a very thin lamina of dentine existing between the two cavities. A pulp in this state and relation has, as the result of its subjection to irritating influences, one of three sequelæ. It may maintain, just as it normally exists, its integrity unaffected by the association: second, it may accept just that extent of stimulation which re-excites the formative capacity, increasing the distance between it and external relations by a secretion consolidating the overlying dentinal structure, and not unlikely attaching a secondary deposit between itself and the original boundary of its cavity: third, it may succumb to the irritation.

Of the probable result in all such cases, a reasonable experience enables the observing practitioner to form a fairly reliable estimate. To maintain that all pulps in such relation are to be saved is to maintain a very foolish



fallacy. A dental pulp is a part of the general organic life with which it is related, and will be seen to have residing in it the impressions of the system at large. Thus, a first observation necessarily considers the state of health in the individual who may be the patient. As is found equilibrium in excitability, with normal nutritional functions, or otherwise degenerative tendencies, so will it prove the experience that attempts to save dental pulps are responded to or defied.

Founding the practice to be pursued in each particular case on an experience which shall come of observation, if indeed it be not already possessed by him whose judgment acts from the foundation of a knowledge of the principles governing all such matters, the practitioner determines either on destroying a pulp and removing it, or on attempt to preserve it. This latter conclusion is always to have the benefit of any doubt which may exist in the mind of the operator, as it is never to be overlooked that a destroyed pulp signifies necessarily a tooth with a diminished vitality, which diminution makes it a body more or less foreign to the parts with which it is in association.

The destruction of a pulp decided on, the operation is to be accomplished as follows: Should irritability and pain be present, these are, if convenient and possible, to be first subdued by means as suggested on a previous page. Quiet secured, and anæsthesia existing by reason of the presence of the morphia, the operator uses, of what is known as nerve paste, a portion corresponding with the requirements of his case; a piece larger than the ordinary pin-head being seldom needed. This paste is dropped gently into the deepest part of the cavity and overlaid with a pellet of cotton, which cotton is made protective against external influences by means of a solution of gum sandarac, which is dropped upon it from the point of an instrument, otherwise the pellet may be slightly touched to the solution previous to being put in place. A very little experience will demonstrate that it is undesirable to have the cotton too fully saturated,—an objection sure to exist if care be not taken to avoid it. Formulæ for nerve paste are variously given, but the author has found every reason to be satisfied with one here suggested:

R.—Acidi arseniosi,  
Morphiæ acetatis, ʒʒ gr. x;  
Creasoti, q. s.

Sig.—A thick paste to be made; rubbing to be continued an hour.

The length of time that arsenic is to be allowed to remain in a tooth is found to depend on the structure of the organ and the amount of paste used. A proper measure would be just that quantity necessary to accomplish the destruction of the pulp, and which in such destruction would find itself antagonized. As such quantity might not, however, have accurate measurement, it is found desirable to consider rather the structure of a tooth. When this is very solid and close, there exists little objection to allowing the preparation to take care of itself. Where, however, the structure is loose, organic



matter being in excess,—a condition made satisfactorily evident by a few cuts with an excavator,—the effect of an application is to be watched with a judgment which, perhaps, comes only of observation. A period which approximates a rule as to the time arsenic is to be left in the adult tooth, is fifteen hours; although nothing is more common than to allow it to remain for twenty-four. The danger in excess of time lies in the passage of the agent through the foramen and tubuli, affecting thus the periodontum.

That the action of an arsenical destructive on a pulp in a tooth of loose structure shall be as direct and speedy as possible, it is desirable practice—where the touch is sufficiently delicate to accomplish it painlessly—freely to expose the organ before making the application. Such exposure effected, the paste may be at once pricked, by means of a very sharp-pointed broach, into the part. By such an operation a pulp is to be destroyed almost without pain, particularly if morphia be previously used as an obtunder, and may be removed from its cavity within a period of time not exceeding fifteen minutes.

Recognition of the death of a pulp is found in the absence of a previously-existing sensibility, as made manifest by the touch of the exploring instrument.

3. *A Diseased State of the Periodontum.* (See *Periodontitis* and *Alveolar Abscess.*)

4. *Confinement of Pus and Gas in the Pulp-Cavity.*—When the dental pulp dies, decomposition is likely to follow. As the result of such lesion we have two sequences: either the decomposed matter is gradually absorbed into the dentinal tubuli, and thus disposed of, as made evident in the marked opacity of the tooth, or it becomes a source of great irritation and offence to the surrounding healthy structures, periodontitis being provoked, the evolution of gas forcing the matter unduly into, and in many cases entirely through, the foramen. If inflammation of the alveolo-dental membrane do not result, then the trouble induced becomes of the ordinary neuralgic character, the living nerve-filament at the foramen, still more or less associated with its continuation ramifying in the dead pulp, taking on inflammation, and thus irritability not only of these special filaments results, but the whole tri-facial tract is apt to sympathize. Some of the most severe and unbearable neuralgias situated about the various parts of the head, have been quickly cured by discovering and treating the cause in a confined dead pulp. A case just now recalled furnishes an example. The patient, a professional man, had been completely lost to self-control, or reason, for a period of three days, from the effect of neuralgic pain running between the orbit and dura mater of the anterior portion of the cranial cavity. In this case not the slightest complaint was made of any of the teeth. Examining the mouth in search for a cause, discovery was made of a half-carious and evidently



dead lower bicuspid tooth, but with no connection between the cavity of decay and that of the pulp. With a spear-shaped drill communication was effected, and in a single instant the patient expressed himself as cured. Relieved of the pain, he fell into a sound sleep, which continued some fifteen hours; the next morning he went about his duties as usual.

Any portion of the head, throat, or associate parts supplied by the fifth nerve, or, indeed, by its related nerves, may be the seat of reflex trouble from a dead pulp. Thus we have odonto-gastralgia, odonto-cephalgia, odonto-cardialgia, etc.; even sciatica has been cured by the extraction of a diseased tooth.

A common practice in all such cases is to remove the tooth, or otherwise, if it be desirable to save the organ, drill an opening into the pulp-cavity. The relief experienced is generally instantaneous.

A tooth containing a dead pulp is distinguished by a loss of translucency when compared with its fellows, or in an opacity, exhibited by reflecting upon it, by means of a hand-mirror, the rays of the sun.

A case illustrative of practice in this direction finds example in a patient under the care of the author at the moment of writing this paragraph. Mrs. H., a lady of delicate organization, suffered for a whole week with severe pain situated in the alveolar region overlying the superior incisor teeth,—the teeth, however, seeming not at all implicated. In the beginning of the second week of the attack the lady first presented herself, directing attention to an elongation of the right central tooth, but which elongation according to the statement of the mother, had always existed. Examination of the mouth exhibited not the slightest discoloration or inflammation about the gums. The lateral incisor, however, was recognized to be slightly loose,—this and the continuous pain being the only expressions of a pathological condition. Diagnosing the existence of a dead pulp in this tooth, the chamber was entered by a means of a spear drill applied to the palatal face. On opening the cavity at least a teaspoonful of pus escaped into the mouth. A treatment pursued, which has so nearly eventuated in a cure that the patient will be dismissed on her next visit, is as follows: The quantity of pus demonstrating the existence of a reservoir outside the tooth, an incision was made through the gum at the apex of the root, thus exposing the bone; to this bone was next applied the point of a strong bistoury, which being pressed forward was felt to pass through a shell and enter a cavity; out of this cavity issued a second volume of pus. Examination of the cyst exhibited it as capable of accommodating all the fluid that had escaped, while, furthermore, absorption was seen to be progressing towards the right naris, into which, without doubt, sooner or later, the abscess would have discharged itself. The cavity, after being washed out, was injected with the ordinary officinal tincture of iodine, a tent of cotton being inserted to keep the opening in the soft parts patulous. On the third day the pulp-canal of the tooth was filled with gold to its apex, great care being taken that no portion of the metal should be thrust through



the foramen, which foramen, without doubt, was enlarged. Up to the present hour—two weeks having passed—the cyst has been daily injected with the iodine solution, and has been daily growing smaller, until now it is about obliterated.

The inflammation in this particular case was decidedly of a cold, or chronic character. Had it been acute, the tooth would have been found too painful to fill with so short a period intervening between the time of attack and operation. One sinus, however, is always enough in an alveolar abscess; if this exist in the gum there can be no objection to filling the tooth as soon as the sensibility of the organ admits of the operation being performed.

The splitting of teeth from expansion of gas confined in a pulp-cavity seems a matter of record too authentic to be doubted. A case having peculiar interest in such direction, published by Dr. J. H. McQuillen, is to be found on the pages of the *Dental Cosmos*, vol. xiii.

5. *Granules of Osteo-dentine in the Pulp.*—In rare cases there is found to exist an irritability of the dental pulp which exhausts itself in the formation of isolated granules of semi-bonelike character, which granules obtain lodgment in some portion of the organ, and become, in turn, a source of great offence to the parts, resulting indeed frequently in an odontalgia than which there are few severer forms. To diagnose this condition is an exceedingly difficult matter. The manner of doing it is by exclusion. The teeth in these cases present every appearance of the highest health: no discoloration, no soreness on pressure, commonly no local pain; this last manifestation being situated in some distant part, as the ear, the eye, the scalp, etc. Whether, however, the pain be localized or diffused, it is always expressed by the patient as being of a nature entirely unbearable; it is generally more or less paroxysmal in character, thus being mistaken for idiopathic neuralgia, and frequently so treated. A case illustrative just comes to mind. During a late session of the University of Pennsylvania, a student in the medical department suffered from neuralgia so severely as to have entirely incapacitated him for study for a period of some three weeks. During that time he had tried all the ordinary remedies which had suggested themselves, without finding the slightest relief. The pain varied between the tuberosity of the superior maxilla and the ear. The teeth, about the part, were entirely sound and healthy-looking; there was apparently no local lesion; while, on the other hand, the physique of the gentleman was not at all of the neuralgic type. The writer was at sea with the case, until, after a day or two, there came to his mind an instance of innodular calcification of the dental pulp once seen, where the patient had suffered in about a like manner. Now, while not prepared positively to affirm that here was a second case of calcification, permission was requested and obtained to pass an exploratory drill into the pulp-cavity of the wisdom-tooth. The result was the finding of the pulp filled with granules,—granules of secondary dentine, as they are techni-



cally termed. The extraction of the tooth was followed by immediate cessation of all pain, and the patient was able to go direct from the operation to lectures.

A marked case, where the lesion gives direct local manifestation, the pain being seated directly in the affected tooth, exists in the person of a professional friend. The gentleman may be said to be affected with a diathesis in this direction. More beautiful teeth than he possesses, or, rather, did possess, are seldom seen; and yet, one by one, they take on this condition, exciting such maddening pain that, regardless of everything, he flies to extraction for relief. In this way, within the past few years, he has lost all those of the upper jaw.

The treatment for this form of odontalgia consists in drilling into the body of the affected tooth, and securing thus a cavity of retention, applying the arsenious paste as has been directed. There are, however, cases in which, under these circumstances, it seems impossible to effect the destruction of the pulp. Here nothing is to be done but extract the tooth or teeth.

The subject of the changes which may take place in the dental pulp, being the result either of age or other circumstances, commands, necessarily, the attention of the surgeon. Much as physiologists differ with regard to the precise method of dentinification, says Mr. R. T. Hulme, M.R.C.S., in an admirable paper on the Calcification of the Dental Pulp, yet all are agreed that it takes place through the agency of the pulp, and that, commencing on the apex and external surface of the formative organ, it then proceeds inward until the tooth acquires its prescribed form and size, and the dentine has attained its normal thickness.\* When this is accomplished, the formation of the tooth is completed, and the same arrest of growth takes place as occurs in every part of the body at the adult period of life. If the person enjoy good health, and the tooth remain free from injury or disease, the organ may continue for some time without any appreciable alteration, in either the hard tissues which enter into its formation, or in the pulp itself. Sooner or later, however, as years go on, a change takes place in the character of the nutritive process throughout the body. The proportion which the fluids bore to the solids in early or middle life is diminished, nutrition is accomplished more slowly, and the composition of the various tissues undergoes a marked alteration. There is a general induration of the parts, and a tendency to the deposition of ossific matter; ligament is converted into cartilage, cartilage into bone, the coats of the blood-vessels are often impregnated with calcareous matter, and the cartilage of the ribs becomes ossified. If we turn our attention to the teeth, or, more correctly speaking, to the dental pulps, we shall find that they also are liable to a similar alteration of structure. When a section is made through an old tooth, apart from the changes which are to be

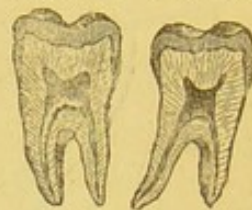---

\* Dentinification is not, as deemed by Mr. Hulme, calcification of the pulp itself, the process occurs in a secretion by the pulp. (See *Dentition*.)



noticed in the color and transparency of certain portions of the original dentine, the pulp-cavity will be seen to have been greatly encroached upon, and the entire mass of the tooth increased in thickness. The extent to which this filling-up of the pulp-cavity can take place is shown in the accompanying drawings. Fig. 81 represents a section of a fully-developed molar in early life, when the tooth has attained its normal amount of growth; while Fig. 82 represents a similar section of a molar tooth taken from an elderly person, and in which the pulp-cavity has become diminished to the extent of fully one-half its original dimensions. This change in the cavity of the tooth can only have taken place through the agency of the pulp, which, after a period of repose, must have returned to its original function of calcification, and have added fresh layers of dentine to the inner surface of the tooth.

FIG. 81. FIG. 82.



The teeth, as suggested by Wedl, are distinguished at different ages by a diminution of the pulp-cavity, an increase of thickness in the *cementum*, and a lessening of that of the enamel, and of the transparency of the three dental substances; by the edges and angles becoming blunted, and the surface assuming a yellow tinge, etc. These distinctions are most striking in the teeth of old men. In the *pulps* of teeth in this condition will be noticed a considerable diminution in the quantity of blood, the color of that tissue often passing into a brownish yellow, from the quantity of pigment deposited in it. Earthy salts, assuming the outward form of the botryoidal corpuscles met with in the pineal gland, occur on the inner surface of the pulp-cavity and of the dental canal, and also deposited in groups in the substance of the pulp. An increased number of layers of *cementum* will be observed, though these are often concealed by the opaque, brownish-yellow color of the inter-corpuscular substance. In thin sections, the *dentine*, sometimes throughout, sometimes only in isolated spots, appears less transparent than natural, and the dentinal tubes become less distinct, and occasionally disappear in the dark-gray or brownish-yellow substance. These partial opacities of the dentine are manifested, even to the naked eye, by a speckled appearance. The enamel presents dark, reddish-brown spots, and, as well as the dentine, appears to have lost some of its elasticity, and to have become more brittle.

Teeth subjected to sources of local irritation are frequently—indeed, it is rather to be said, are commonly—found responsive in the way of self-attempting deposits. This subject is discussed in connection with filling and filing teeth (which see). In Fig. 83, after Mr. Hulme, is exhibited a tooth which, as may be seen, has been worn into a groove at the neck; in the pulp-cavity, antagonizing the groove, is seen a deposit of secondary dentine.

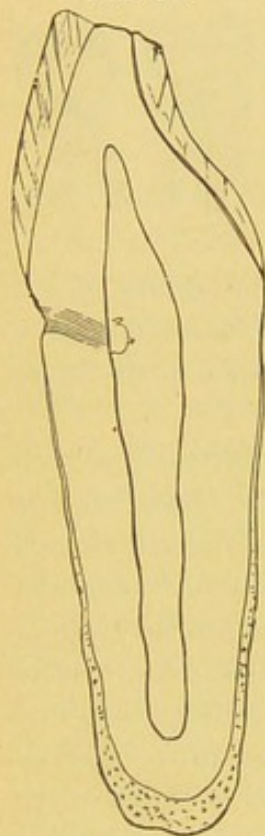
The re-formative efforts of the dental pulp differ from conditions as shown in the diagrams to the complete conversion of its substance into a species of dentine, so that it is often found, on cutting open a tooth long subjected



to irritating influences, that the cavity commonly existing is occupied by solid matter.

A form of secondary dentine occasionally met with is shown in Fig. 84.

FIG. 83.



This diagram represents a specimen described by Mr. S. J. Salter, and by him presented to the attention of the Pathological Society of London. In this case, as is seen, the mass is attached to the chamber-wall of the tooth.

The tooth, as mentioned in Mr. Hulme's paper, was a central incisor which had been extracted from a woman on account of severe neuralgic pains, obviously connected with one of the central incisors of the upper jaw. The pain was described as of a gnawing character, abiding, but not constantly severe; frequently amounting to a mere consciousness of the presence of the tooth, and at other times sharp and darting. In the former condition it was confined to the region of the tooth; in the latter, it flashed up the side of the face, and through all the branches of the superior maxillary division of the fifth nerve of that side. Sudden pressure or a tap upon the tooth, or a marked change of temperature, produced a considerable augmentation of pain. The tooth itself was sound, to all external appearance; it was somewhat elongated beyond its fellow, and was very slightly loose. The gum surrounding it was red at the edge, and a little swollen. When the tooth was removed, no exostosis was discovered on it; and, with the exception of some small patches of half-organized lymph, it appeared quite healthy.

Upon making a vertical section of the organ from side to side, a small pear-like excrescence of dentine was found growing from the side of the pulp-cavity, so as to encroach much upon it, and occupying for a short space more than half its diameter. It was of an oval form, its long axis corresponding to that of the tooth; in color less opaque, and yellower than the neighboring tissue.

The structure was of that irregular character which has been previously described as occurring in secondary dentine, which has arisen from the wearing away of some part of the tooth's surface. The removal of the tooth was accompanied with a violent paroxysm of neuralgic agony, but was followed by a total cessation of pain, and the cure was permanent.

Masses of dentine—nodular dentine, as it has been named by Mr. Salter—occupying positions in the substance of the pulp, are to be met with as among the causes of odonto-neuralgia, as alluded to on a former page. These nodules may be single or multiple; the author has in his possession specimens in which at least a dozen are to be found in the same pulp. These



nodules differ markedly in form. Dr. J. F. Flagg, whose curiosity has prompted him to the preservation of a large number of specimens, makes an

FIG. 84.

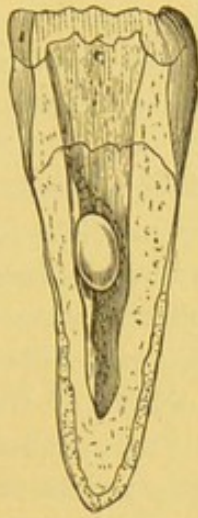
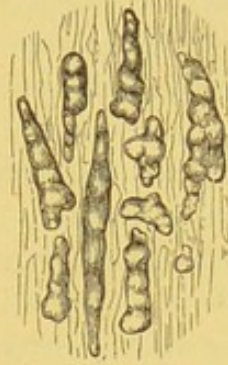


FIG. 85.



interesting classification. The author has to add a suggestion as to the frequency of their deposit where the syphilitic vice is present.

Taking advantage of a cut at command (Fig. 85), a specimen is shown from the collection of Mr. Hulme, and which is thus described by that gentleman :

*Examination of the Tooth.*—The decay extended to the pulp-cavity, and the median third of the crown was more or less affected by caries. The tooth was then broken open and the pulp examined. It was of a pinkish color, and somewhat more vascular than usual. On endeavoring to withdraw the pulp from the cavity, at the part which was directly under the carious portion there was found a solid lump of osseous matter as large as a canary-seed, and something less than a grain in weight; it was not adherent to any part of the inner wall of the tooth. On examining the remainder of the pulp beneath the microscope after the addition of a solution of caustic soda, it was seen to be thickly crowded with rounded masses of dentine, but more opaque and of a different character to the dentine globules of Czermac. The drawing represents the appearance presented by this portion of the pulp.

No form of odonto-neuralgia is more severe and persistent than this arising out of pulp calcification. In this direction it has happened the author to see among his clinic patients quite a number of cases. The diagnosis is perhaps always, as has been suggested, difficult, and at times only satisfactorily to be settled by the extraction of teeth presenting more or less evidence of complication. The condition is more frequent than generally supposed, and is to have consideration in all cases of obscure neuralgia. A multitude of illustrative cases could be quoted. (See *Neuralgia*.)

6. *Sympathy.*—Sympathetic toothache is most frequently found associated



with teeth having a common period of eruption. Thus, if attention be called to an aching bicuspid, and examination discovers the tooth to be in healthy condition, we will commonly find the primary lesion in either of the three fellow-teeth. If it be the first or third molar, or any particular tooth, that seems to be aching, the real seat of pain may be found in an associate organ. This is the first and most common relation of sympathy. Other and indirect causes exist in various directions, the most constant of such associations being, first, with the ear, second, with the uterus.

That odonto-otalgia, cephalalgia, gastralgia,—indeed, any reflex or radiated pain having origin in the teeth, but expressing its manifestation in distant organs, and *vice versa*,—may exist, is at once to be appreciated in a recollection of anatomical associations; instances abundant are on record illustrative of such relationship. Thus, as an example, allusion is to be made to a suggestive case reported by J. L. Suesserott, M.D., of Chambersburg. The patient, Mr. J. G., an old man seventy years of age, applied to me, says Dr. S., with the hope of being relieved of an intensely painful tic douloureux through the extraction of two or three fragments of roots of the superior incisor teeth, all the other teeth and roots of the upper jaw having been long before removed.

The suffering of the patient at the time of this first visit is described as of extreme character, a breath of air, the slamming of a door, or even an allusion to his disease, being sufficient to produce violent paroxysms. The irritation, although reflected, as it afterward proved to be, appeared confined principally to the superior and middle branches of the par trigeminum of the left side. The suffering had been so intense and long-continued that there was considerable swelling and tenderness upon pressure along the course of all the ramifications of the fifth pair.

Feeling the case, continues the description, to be a desperate one, although not suspecting the *causa morbi*, I determined on an active and energetic course of treatment. Directing my efforts to the removal of the existing irritation, and I might also say inflammation, I established an issue on the back of the neck, which, together with blisters to his temples, produced a considerable amount of counter-irritation. The external use of aconitine, and the internal administration of the citrate of iron and quinine in full doses, produced a marked alleviation; but just at the time when hope was the brightest, another severe paroxysm would fill us with disappointment, and almost compel us to declare that there is no virtue in medicine.

A period of two weeks having been uselessly expended, together with no small amount of medicine and patience, the patient, as I was dressing his issue, happened to remark that "*his stomach was not in fault, for that he could digest without discomfort pieces of meat as large as he could swallow.*" Those who have anxiously watched over an interesting and difficult case can enter into my feelings of congratulation, for like Archimedes, I felt I might exclaim, Eureka! Remembering the old maxim, *tolle causam, cessat effectus*,



I directed my efforts to the improvement of the patient's manner of mastication and to the directing of a proper character of food, with the result of a speedy cure of his trouble.

As an example of reflection in an opposite direction, a case may be cited from an interesting paper read by Julius Chesebrough, D.D.S., before the American Dental Association.

I have met, says this gentleman, a case wherein a fine-formed young woman suffered for a year after the birth of her child with pain in her teeth, alternately with that of the uterus. This case was one that had perplexed the physician in charge, and was presented to the medical society for advice. Being called on, and a statement of the case made to me, I at once suggested that the uterine derangement was a reflection from the teeth, and that these organs were morbid ones. There was some doubt expressed as to this being a correct diagnosis of the case, for the patient had no toothache before her labor, and the pain in her mouth was since that event. Suggesting that examination be made of the teeth, a visit was paid, with the result of finding decay in the four posterior molars. Three of these were extracted without giving much pain, but while extracting the fourth—the left superior—it seemed as if the woman was contracting within herself, and suffered intensely from uterine disturbance. After half an hour, however, she was entirely free from pain.

A case even more directly the opposite of the first example is mentioned in this same paper, in which a patient suffering from continual pain in the stomach was cured only upon the accidental treatment of a carious tooth,—the pain ceasing immediately upon the application of arsenical paste to an exposed pulp. A second time the same patient is reported as presenting himself,—the pain, which was of similar character and location as in the first instance, finding again immediate cure in the treatment of a second diseased tooth. In neither instance was discomfort referred to the mouth.

Of odontalgic associations with the various viscera, cases in variety could be cited, while pains outside the splanchnic cavities, as in the hip-joint, etc., have found relief not infrequently only in an attention directed to the teeth. In the chapter on neuralgia the reader will find the subject abundantly illustrated.

To understand the matter of radiation, or reflection, of pain, consideration is to be given to the anatomical associations of the nervous structure. This considers the cerebro-spinal and ganglionic systems, and refers the reader to his text-books on anatomy and physiology.

7. *Recession and Absorption of the Gum and Alveolus.*—When, for any reason, the gum falls below the enamel cap, the periodontum and cementum become exposed to various sources of irritation. The odontalgia thus provoked is seldom, however, acute or severe in its character, but only dull and annoying. The practice in these cases is generally most unsatisfactory, resulting, sooner or later, in a necessity for extraction. If the recession be associ-



ated with acute conditions or with the presence of agents of offence, treatment directed to meet the indications may result very well; but commonly such recession is slow and chronic, and admits of no remedy. Medicaments to neutralize or correct irritative conditions in the oral fluid are sometimes demanded, and answer a very good end. Of such neutralizing agents, acids or antacids are employed, according to the indications yielded by the test-papers; generally lime-water in the one direction, and very dilute citric acid in the other.

A treatment for absorption of the alveolus consists in scraping the absorbing bone, precisely as is done in osseous caries. This is to be accomplished without difficulty by introducing between the neck of the tooth and gum the common lathe-shaped excavator, which, upon reaching the alveolus, is made to cut away the surface surrounding the tooth. Dr. Riggs, of Hartford, recommends instruments especially prepared for the purpose, but any kind which is capable of meeting the indication answers the purpose of the suggestion. Such an operation has, in theory, much to commend it; in practice, however, the benefit accruing is not by any means all that is to be desired. To receive good results from freshening the alveolar edges one is to do the operation only where indicated,—a selection which it requires much experience to make. To freshen the bone, as a majority of the cases is concerned, is to expedite the falling of the teeth.

A character of recession of the gums from about the necks of the teeth, or, to express it better, a condition in which the teeth are raised in their sockets, and where a cure is impossible, is found as the result of a growing density in the structure, in which the equilibrium of circulation between these organs and surrounding parts becomes so deranged that they are as foreign bodies, and the recession really implies a filling up of the alveoli by an osseous deposit with the object, on nature's part, of their removal. In these cases the teeth will seldom be seen affected by caries, being dense to an extent which is cognizable to the naked eye.

Recession arising from the employment of non-soluble dentifrices is frequently to be met with. Such condition is recognized from the history of the case, from the presence of particles of the substance of offence, and from the disease seeming to implicate the gum alone. Such cases have their cure in withdrawal from use of the injurious agent, in the free syringing of the part with a medicated water,—stimulation being required,—and in effecting the contraction of the turgid gums by free bleeding secured through occasional scarification.



## CHAPTER XIII.

### THE TEETH AND THEIR DISEASES.

#### PERIODONTITIS.

THE importance of the disease known as Periodontitis commands for its consideration, in a work on Oral Surgery, a special chapter.

Periodontitis, peridentitis, pericementitis, dental periostitis, as the condition is variously designated, implies inflammation of the membrane associating the root of a tooth with its alveolus. (See *Peridontium*.)

Periodontitis, like inflammation in general, may exist either in a condition of activity or chronicity.

The active form is most frequently found as an expression of direct local irritation; the chronic, as a result of systemic influences.

Acute, or active, periodontitis, if not resolved, or aborted, has a history which associates it with parulis. The inflammation commences commonly with a dull, heavy gnawing in the parts affected: this is the signification of simple vascular excitement. As the grade of the trouble advances, pain increases with it. The tooth seems to the touch of the patient to project beyond its fellows, and really does so. Occlusion of the jaws gives pain, which pain so grows in severity that the whole attention of the patient becomes directed eventually to the avoidance of contact. Finally, when not arrested, the action goes on to a suppurative condition,—the state of abscess; and the pus, discharging through a sinus which it creates for the convenience,—generally opening upon the gum opposite the diseased point,—establishes the condition of parulis.

Chronic periodontitis—subacute, as it might with as much propriety be termed—has a history markedly distinguishing it from the sthenic form: its causes are manifold. Mercurial ulitis is perhaps the most frequent. Scorbutus is a common cause; being abundantly expressed in every neighborhood where much pork is eaten to the exclusion of a mixed diet. Many cases have origin from the exanthems: of such causes scarlatina seems the most provocative; rubeola follows this in frequency. The phosphoric impression, as seen in connection with the workmen of match-factories, is a cause familiar to most surgeons. Neuralgic associations certainly beget irritability in the periodontal tissue, and, in cacoplastic states of the blood, may degenerate the nutritional changes. Rheumatism and gout, as toxical conditions, are frequently found from clinical experimentation to be the irritants supporting a



resisting periodontitis. Uterine reflections, those particularly from the menstrual relation, are other causes. Age is a common cause,—old people losing their teeth by a degenerative condition of this membrane, which allows the organs to drop out; or the same result is found frequently to coincide with tubular consolidation of the fangs, the excess of nutritional work thrown thus on the periodontium exhausting finally the capability of the membrane. Tartar is a common and frequent cause of periodontitis.

Chronic periodontitis—existing as a primary form—differs diagnostically from the acute condition in the absence of a sthenic expression. The tooth or teeth affected grow sore, tender, and elongated, but the progress is so slow as not to make the offence of sufficient import to the comfort of the patient to invite any vigorous antagonism, the expression commonly being that associated with the chronicity so frequently succeeding the acute form; the parts are recognized to be in the state of disease, but the condition is sufficiently bearable to be endured.

The acute and chronic forms of periodontitis find constantly a combined relation. Thus, the constitutional offences are found capable of provoking the active condition, while local offences, as instanced in salivary calculus, conjoin not infrequently with the chronic state.

Chronic periodontitis, except as associated with the acute form of the disease, is not found to tend to parulis, but when degenerating to the formation of pus, has the discharge about the neck of the diseased tooth or teeth.

The importance and frequency of periodontitis rendering the condition one most necessary to be thoroughly understood, advantage may be taken of the present and succeeding chapters to direct attention to the subject in a required detail.

First and most commonly, it will be seen that the acute form of the condition depends on preliminary disease in the dental pulp, that organ, being in a state of profound inflammation, affecting the periodontium by its continuity of relationship, or otherwise being dead, proving the source of offence by its post-mortem changes and influences. In any and every case of acute periodontitis which presents itself, whether exhibiting the first expression of a scarcely noticeable uneasiness, or the tooth being so elongated and tender as to render the slightest touch unbearable, attention is to be directed to the condition of the pulp-cavity. If this, as is frequently the case, be found open, and the pulp dead or absent, then it is at once—no evidence of other vice, either constitutional or local, being seen—to be inferred that the trouble is that of a sthenic, free inflammation, demanding for its relief common anti-phlogistic medication.

Where a pulp-cavity is found closed, the tooth being undecayed, or otherwise having in it a filling, a first indication directs an opening into the chamber, no hesitation being necessary, as in perhaps all instances where a tooth has become thus tender to the touch, the pulp, if not actually dead, will be found in such a state of congestion that its destruction has been in-



sured. If, however, it be desired to attempt an abortion both of the pulpitis and periodontitis, the plan suggested of uncovering the organ will be the wisest that is to be pursued, as thus depletion is to be practised with the most immediate effect, and medicaments find direct application. Instances, however, present—and these are much the most numerous—where the periodontitis depends on a preliminary operation in which the pulp of the tooth has been purposely destroyed and removed, its place being occupied by metal as in what we are to study as a root-filling. Here it is not unlikely the trouble depends simply on an excess of work thrown upon the periodontium from the abstraction of the pulp life; or it may be that the tooth is unable to endure the thermal changes resulting from the presence of the filling material; or perhaps some particle of the pulp was not removed, which, disintegrating and decomposing into its gaseous elements, has provoked the inflammation through pressure upon the parts about the foramen; or, still again, it may be that a slight twist of the cotton or gold, or whatever may have been used to fill the root, has been forced through the foramen. The consideration of a condition of this nature calls always for the exercise of individual judgment aside from ordinary rules. If a pulp-cavity has been well and scientifically treated, it would scarcely seem necessary or desirable to undo what had been done; as having been properly done, with all collaterals considered, it is not to be esteemed that undoing and doing over would improve matters. We would therefore naturally consider the periodontitis as the lesion, and consider this alone. If, on the contrary, there be doubt as to the perfectness of the operation,—if there be reason to infer that any portion of the pulp remains in the cavity, or that a twist of the filling has passed the foramen,—then a first indication lies in such direction.

Accumulation of tartar provoking periodontitis would not be difficult to distinguish, and the indication for its removal would be self-suggesting.

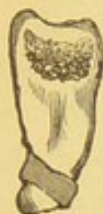False occlusion, another cause of periodontitis, calls alone for its appreciation to an observation which considers the common articulation. A tooth which, from any reason, strikes prematurely, is certain to succumb to the irritation if the offence be continued for any length of time. In such relation, the condition of newly-placed fillings is to be considered. A plug is never to afford the feeling of special contact. When a filled tooth becomes sensitive in its periodontium, attention is first wisely directed to its articular relations; should the metal be unduly prominent, it will, most likely, be at once remarked through an indentation seen upon its face. Should such indentation not exist, the surface may be rubbed over with a little pulverized pumice-stone, so as to deaden it: the contact of the opposing tooth, if now it unduly touch, will distinguish itself by a polish produced.

Teeth unduly occluding from false articulation are to find remedy in the file or disk, which is to cut away from the unaffected organs (or, if seemingly necessary, from the one which has expressed the irritation) such portion as shall remedy the defect.



Still another cause of periodontal inflammation, not infrequently met with, exists in accidents arising out of the use of escharotics, which, having been applied to a cavity for the destruction of the dental pulp, have escaped and fallen around the neck of the tooth. A similar result has ensued

FIG. 86. from application of caustics to the gum for the arrestation of mucous oozing, or of hemorrhage. Still again has such inflammation been provoked by ligatures used with the rubber dam, or by forgotten rings of rubber tubing or thread. In Fig. 86 is exhibited a ringed tooth, where the cause of a defying abscess was discovered only after extraction. The relation of ring and tooth here shown is just as when removed from the mouth.



Still another cause of periodontitis, one happily likely to be of very limited duration, is found in the process of wedging. All teeth are made more or less sore through this manipulation, and the soreness expresses inflammation. Such wedging, however, employed in the mouths of old persons, or with those of bad constitution, may well result in the necessity for a medication, aside from the removal of the cause exciting the trouble.

Taking it for granted that any and all existing sources of irritation have been removed, an acute periodontal inflammation, taken in time, may in nine out of twelve cases be aborted as follows. Pass a lancet several times through the gum down to the alveolus; let the patient hold water in the mouth, so as to prevent the formation of clot, and provoke free bleeding; as soon as the vessels and capillaries have disgorged themselves, paint the parts with tincture of iodine. The philosophy of this treatment is sufficiently evident not to need explanation.

A routine plan followed commonly with satisfactory results in incipient periodontitis is as follows:

Place the feet of the patient in hot water. Apply just in front of the ear a fly-blister the size of a silver dime piece, and upon the nape of the neck a second, the size of a silver dollar. Administer internally twenty-five grains of the bromide of potassium, having combined with it five drops of the tincture of veratrum viride,—this combination to be repeated in four hours, if relief be not sooner obtained. Lance the gums freely with a very sharp lancet, and afterwards keep cotton applied saturated with tincture hamamelis, or this medicine combined with lead-water. This treatment, if all local cause of offence has been removed, will seldom fail in securing a satisfactory result. It is found well to retain the feet in the hot water until a patient grows faint or breaks out into a perspiration. In the plethoric, in addition to the above course, half an ounce of the sulphate of magnesia may be given in a gobletful of water.

In the employment of arterial sedatives in periodontitis, as in an inflammation of any other part, regard is always to be had to the condition of the pulse, such medicaments being alone indicated in the sthenic conditions, and



acting here with an efficiency and influence sometimes quite magical. Of such sedatives few seem possessed of the virtue of *veratrum viride*. I am well satisfied that it is in very many cases all that is needed in the treatment. Hydrate of chloral is another of this class of agents highly commending itself. That it, however, possesses sedative qualities dangerous in extent is scarcely to be doubted. To commence its exhibition in doses of not over seven grains is to err on the safe side.

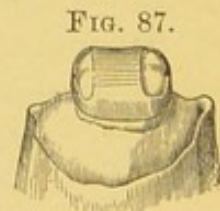
As adjuncts, leeches are occasionally employed with great benefit. If the inflammation be associated with the lower maxilla, these may be applied below the jaw; or, if objection be not made by the patient, they may be used directly to the gum. Great care is required that they do not escape and get down the throat. Salt water kills them.

A very simple plan of treating incipient periodontitis, one which will frequently be followed by immediate relief, consists in making a minute blister upon the gum overlying the affected root, through an application of a saturated solution of iodine. Lead-water and laudanum, as used so commonly in general surgical practice, is found a valuable refrigerant lotion to an inflamed periodontium. It is applied on a pledget of cotton placed between the gum and cheek. A satisfactory combination is as follows:

R.—Plumbi acetatis,  $\mathfrak{zss}$ ;  
Tincturæ opii,  $\mathfrak{zss}$ ;  
Aquæ,  $\mathfrak{zvi}$ . M.

Another and a most admirable plan of treating incipient periodontitis consists in the application of dry cups to the side of the face; this plan can scarcely be too highly commended.

To protect the affected tooth from contact with its neighbors, resort is to be had to a cap placed over adjoining organs. To this end, gutta-percha is commonly employed, being easy and instantaneous of application, requiring alone that a piece of the material about an inch square be softened in a flame and moulded over the parts, a mouthful of cold water hardening it into the required resistance. An instrument, however, more delicate, is found in a cap of silver, as devised by the late Dr. J. H. McQuillen. (See Fig. 87.) Such a cap is quickly made by the mechanical dentist, he requiring alone an impression of the tooth or teeth proposed to be covered, and which is secured in a moment by means of a small lump of softened beeswax.



Metal cap.

An acute periodontitis resisting the various means here suggested, the attack increasing in severity, the surgeon finds himself compelled to abandon antiphlogistics, the indication being to advance the condition to the suppurative point as quickly as possible. To this end, heating and exciting medicaments are required; warm water is to be held in the



mouth, or a weak dilution of the tincture of capsicum may be employed; about twenty-five drops to an ordinary-sized goblet of warm water will be found sufficiently stimulating. The domestic application of a roasted split fig to the gum increases the heat of the parts and invites suppuration to the surface to which it is used. Pursuing a natural course, the periodontitis ends in the formation of pus and the establishment of alveolo-dental abscess.



## CHAPTER XIV.

### THE TEETH AND THEIR DISEASES.

#### ALVEOLO-DENTAL ABSCESS.

PERIODONTITIS, or inflammation of the alveolo-dental membrane (considered in the previous chapter), when not resolved, has as its other termination, as there suggested, alveolo-dental abscess. To this condition, as a distinct one, attention is now to be directed.

Alveolar, or alveolo-dental, abscess has, of course, the history of an inflammation and suppuration anywhere in the body, having nothing peculiar to its history, except as special features associate with the anatomical characteristics and influences of the parts involved. It is a condition in which a tooth, diseased to the suppurative point in its enveloping membrane, or periodontum, is discharging, through some convenient orifice of exit, pus secreted by or formed in such membrane.

The local features of alveolar abscess are to be described in a very few words. At the apex or somewhere about the root of the affected tooth, a degenerative thickening of the membrane occurs,—pyogenic membrane, as it was termed. (Fig. 88.) This, a diseased condition of the part, becomes shreddy and stringy, failing to organize the lymph constantly exuded or effused by it. The degeneration of this lymph is pus. As such membrane grows thicker and softer, and such pus accumulates, it becomes evident that space and vent are made necessities; thus absorption, through the pressure, is effected, and the matter, sooner or later, influenced in the direction it takes by the vulnerability of the surrounding osseous parietes, finds egress, giving generally that peculiar fistule in the gum, known as parulis, or gum-boil. The morbid process exhibited in an inflamed root-membrane consists in the accompaniment of the hyperæmia by a hyperplastic state of the tissue-cells, these cells increasing not only in number but in size. In this change it is that we find the explanation of the shreddy periodontum seen more or less markedly upon all abscessed roots.

A recognizable hyperæmia is not, however, a necessity for the excessive proliferation of connective-tissue cells; hence it is that epulic tumors frequently have origin in such hyperplasticity of the odonto-alveolar periosteum where expressions of vascular change have never been observed.

The formation and confinement of pus in a cavity so obstinately closed as

FIG. 88.



Shreddy sac of tooth abscess as met with in dental parulis.



the alveolus of a tooth must necessarily inflict the severest suffering, and such pain is so constant an attendant of the condition, and is of such almost unbearable character, that any means calculated to abort or limit its persistence is to be hailed as a boon; it is to be taken for granted, judging from observation, that this is the severest form of odontalgia. The condition of throbbing pain, however, is confined to the period intervening between the accession of the acute inflammatory attack and escape of the pus; the period, properly speaking, of periodontitis,—a period lasting from two days to ten. Abscess fully formed, pain decreases to soreness. The treatment of the perfected alveolar abscess is very simple, at least as the indications are concerned; it consists simply in breaking up of the cyst and sac, and the excitation of an action sufficiently vigorous in character to fill with granulations, of organizable force, the fistule. Indications met, a practitioner can do nothing more.

The appreciation of the prophylaxis of alveolar abscess considers a treatment of the acute periodontal trouble, of which the suppuration is seen to be only a result. This was considered in the previous chapter, leaving here little to add, except that if such means as were there recommended fail in securing resolution, more formidable, if thought desirable, are to be brought into requisition.\*

As periodontitis is so frequently found abortable by scarifying the gums freely and deeply, and, after the congested vessels have relieved themselves, constricting the parts by applications of strong tincture of iodine, so parulis can very frequently be anticipated by the following trifling operation: With a sharp scalpel make a slight cut through the soft parts at the apex of the affected tooth. Next take up a spear-pointed drill and pierce the outer plate of the bone, thus entering the cavity in which the sac is being developed. Break up the sac, and, by means of a delicate tent, keep the wound patulous for a few days. Judgment is demanded, however, as to the time when such puncture is to be made; it is to anticipate the moment at which pressure from accumulation of pus commences. Done previously to this, more harm than good results.

Fig. 89 furnishes a correct idea of the cyst to be entered. A is a perforating bit used with the engine; B is an ordinary steel probe.

Exception is to be taken to the common practice of ordering warm fomentations to the face in incipient abscess; such practice is objectionable, resulting not infrequently in scars which much deform a patient. If the practitioner should not desire to adopt the operative suggestion offered, let him order a roasted fig or raisin directly to the affected part; either of these will do equally well the work of the poultice. Leeches, general blood-letting, vigorous antiphlogistic medication, any and every means that promises resolution, should come between the periodontitis and the abscess.

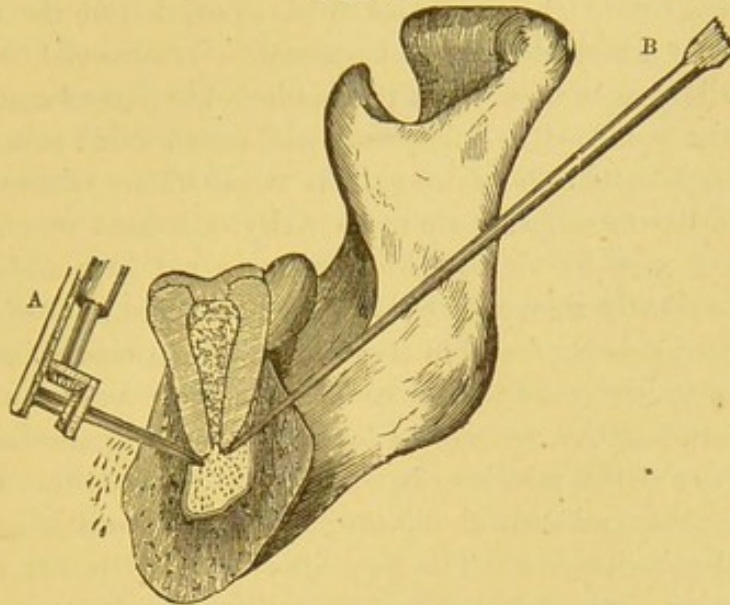
---

\* More formidable would apply to the free use of diaphoretics, diuretics, cathartics and venesection.



The anomalies of alveolar abscess, if such a term be applicable to conditions not at all infrequent, may perhaps be best studied through the medium of

FIG. 89.



examples. A few are selected from the practice of the author and that of others. If, happily, they serve to throw light on any obscure case at present perplexing some inexperienced practitioner, the trouble of collecting them will be repaid.

A few years ago the author saw, in consultation with a Dr. B. of this city, Mrs. —, who had been afflicted with a running ulcer at the apex of the chin for four years. During this period the lady had been under the care of some five or six different practitioners, and had twice been operated upon for supposed disease of the bone.

Suggesting that the origin and cause of this fistule might be found in some diseased tooth, assurance was given that these organs had been most carefully examined, and that there was not an unhealthy one in the mouth.

A superficial exploration seemed to verify the truth of the assurance. Not satisfied, however, by such examination, experiment was commenced by striking with a steel instrument each tooth separately; the patient thought that in the left inferior lateral incisor she experienced a sensation differing from that felt in the others.

Placing her now in the full sunlight, rays were reflected over the teeth by means of a hand-mirror; this test demonstrated that the incisor alluded to had lost its pulp,—it showed a slight opacity.

Now convinced that the disease was dental abscess, it was predicated on the demonstration that an opening made into the affected tooth would discover the death of its pulp; this was done, and the part found as anticipated. The offending organ was extracted, some necessary local attention given the sinus, and the patient was well in a week.

Comment on this case scarcely seems necessary; and yet it may not be



amiss to suggest the explanation of the deceptively healthy appearance of the dead tooth.

When the pulp of a tooth dies, discoloration of the enamel is a common result, this discoloration being caused from absorption of the dead matter by the tubuli of which dentine is made up. Occasionally, however, the opacity is so slight as to be scarcely perceptible, this depending on the dense character of the tooth,—not infrequently the tubuli being so occluded as to destroy their capillarity: the dead pulp is not therefore taken up. A very vascular tooth, having a dead pulp in its cavity, will soon be turned almost black. A tooth in which the death of the pulp has been sudden discolors always more markedly than where it has been preceded by a chronic inflammation, explanation being found in the absence of that renewal of the process of calcification which in the chronic condition is apt to occlude the tubuli.

A dead tooth, however, can always be distinguished by the tests given.

The pathology of this case is to be summed up very briefly. The death of the pulp provoked periodontal difficulty. The inflammation, uncombated, resulted in alveolar abscess. The pus, after inducing by its presence the absorption of the bone, dissected its way under the soft parts down to the apex of the chin, where it discharged itself,—the abscess passed into the chronic stage; the annoying and formidable fistulous ulcer was of course, because of its character, rendered incapable of being healed by any directly local treatment, or that not addressed to the true seat of the trouble.

In another consultation the writer saw a Miss B., a young lady, nineteen years of age. In this patient, a fistule in the very centre of her hard palate had existed for some two years, giving rise to great uneasiness (as it had refused to yield to much treatment), a cancerous cachexia existing in the family. The denture in this mouth was also so complete as not to have attracted observation, every tooth being perfect, with the exception of a single molar, which had a small filling of gold on its grinding face. The filling in this tooth was removed, and the pulp found dead. Extraction was resorted to, and in three or four days all discharge had ceased. On the sixth day the patient was dismissed cured.

It is not at all uncommon to find the sinus of an alveolar abscess venting itself somewhere on the cheek. This is too frequently the result of inviting the matter to the surface by the warm applications made to the side of the face. When pus thus seeks the surface it is to be vented from the inside should such procedure be prudent. Experience exhibits, however, that little objection exists to an opening on the outside. Scar is not apt to result if nature's manner of cure be anticipated by use of the bistoury. Care must be taken not to wound the facial artery or the duct of Steno.

A case having likeness with the examples just quoted is recorded by Prof. Harrison Allen: A young man in whom the roots of a lower wisdom-tooth had been prematurely filled, was attacked with acute periodontitis, ostitis, and maxillary periostitis. This was sufficiently severe to excite inflammation in



the loose connective tissue between the mylo-hyoid muscle and the jaw. An abscess followed here, and the pus gravitated to form a collection about the hyoid bone, and from that point passed upward upon the face in the line of the facial artery. The abscess in addition pressed directly upward against the floor of the mouth, and caused unilateral glossitis, from the mechanical effects of which upon the organs of respiration the patient died. The duration of the extra-maxillary complication was but four days.

Abscesses, associated with the wisdom-teeth, sometimes pass in the direction of the parotid region; in these cases it is not uncommon to find the orifice of the fistule as low down as the clavicle, the unyielding character of the parotid fascia—a continuation, as it will be remembered, of the deep cervical—compelling this lengthened dissection.

A form of alveolar abscess, which may lead to false diagnostic premises, exists in cases where, from a relation of a diseased fang with the maxillary sinus, the discharge empties itself into that cavity, to be in turn voided into the naris. (See *Diseases of Antrum*.)

Another, and very curious, result of alveolar abscess is the formation of osseous cysts on the side of the jaw; the pus, instead of inducing the ordinary absorption, is provided for by the expansion of the outer plate of the bone. These cysts give little or no sense of fluctuation or crackling on pressure. There is no appearance of surrounding inflammation; the soft parts covering them do not differ in any respect from the adjoining tissue. Such cysts or tumors generally associate with teeth in which the pulps have been destroyed and the fangs filled with metal; they form sometimes very rapidly,—that is, when compared with solid tumors, for which they may be mistaken. The author has treated them where the cyst has enlarged to the size of a half hickory-nut in a few weeks. This rapid growth is particularly diagnostic. The easiest treatment of such cyst is, of course, the extraction of the offending tooth; but cure is to be obtained by opening them transversely and stuffing the cavity with lint saturated with tincture of iodine, or other stimulant; the cyst is thus obliterated, and the sac at the end of the fang destroyed, through the healthy reaction which the treatment excites. These cysts are not to be confounded with the sub-periosteal exudates frequently found overlying the site of diseased roots. Diagnosis lies in the use of an exploring needle.

Mr. Smith, in illustrating a lecture on alveolar abscess, notices the following cases:

A few years ago, he says, a middle-aged man asked his opinion about a fistulous sore which opened on the middle of his whisker of the right cheek. Mr. Smith introduced a probe, and finding that it came in contact with the fang of the last molar tooth of the upper jaw, persuaded the patient to allow him to extract it, on the promise that he should be well in a few days. On the tenth day the gentleman wrote, by post, to say that the discharge ceased the day the tooth was extracted, and that at the time of writing he was perfectly well.



He relates also the case of a young woman who came under his charge at the infirmary, with a fistulous sore in the fore part of the throat, within an inch of the sternum. It had been discharging upwards of a year. On probing it, the instrument could be passed in the direction of the molar of the lower jaw on the left side. On inquiry, the patient said that eighteen months before she had a tooth drawn, but the fangs had been left in the jaw. Afterwards an abscess formed, which descended lower and lower until it burst midway between the sternum and pomum Adami. Mr. Smith extracted the stump, the sinus still discharged for a week, then it got well without other treatment.

Mr. Smith alludes also to a case where a horse had been condemned to the knacker's yard, as being afflicted with the glanders, having a foul, offensive discharge of purulent matter from the nostrils, and being in the last stage of emaciation. A veterinary surgeon, finding that it could not masticate its food, examined the mouth, and detecting a carious tooth in the upper jaw, extracted it. The discharge ceased; the horse soon began to thrive, and got well. A cat belonging to the author has furnished a similar experience.

Mr. Fleischman (*British Medical Journal*) relates the following example: Miss Rose S., a little girl, aged five years, had been troubled about three months with a constant, though not profuse, discharge of slightly-purulent mucus from the right nostril; it appeared to be the sequel of a cold. The mucous membrane, so far as it could be examined, was healthy, and there were no indications of any morbid growth. She was ordered a strong injection of gallic acid, and took, concurrently, small doses of the sesquichloride of iron. The only advantage she derived was that the discharge lost its purulent character; in amount it remained about the same, though the treatment was long persevered in and other local astringents tried. I suspected, says Mr. Fleischman, there must be some undiscovered local irritation. Not being able, on careful examination, to find anything wrong in the nasal passages, I looked to the condition of the teeth, and finding the right upper canine carious, removed it. The discharge was much lessened on the next day, and in the course of one or two more disappeared altogether. Mr. Fleischman, although he does not seem to see that his case is simply one of alveolar abscess, but offers it as a good illustration of reflected irritation, truly remarks that it teaches us that the *fons et origo mali* is not always just where we might expect to find it.

The author has had, in his own practice, a number of cases where the pus of an alveolar abscess discharged itself into the naris; but the disease, in every case met with where the sinus passed in such direction, was associated with central incisor teeth. It is, however, to be inferred that other of the teeth might relate fistules, with the posterior aspect of the nares, dripping their discharge behind the veil of the soft palate. A number of such cases are on record.

Abscesses of this nature are not infrequently associated with the eruption



of the wisdom-teeth. The arch being too small to accommodate the advancing organ, it becomes, as a matter of necessity, an agent of irritation; inflammations of the most severe nature are thus oftentimes provoked, inducing, too commonly, trismus and abscess. (See *Trismus Dentium*.) Abscesses from this cause generally discharge about the neck of the tooth; they may, however, void themselves in other situations, as, for example, upon the face or neck. A case illustrative comes this moment to mind:—Dr. D., a medical gentleman, suffered for some time with heavy, dull pain in the right half of his lower jaw, attributed to two of his teeth, much decayed, which teeth, however, had been treated and plugged. Inflammation of a severe character finally developed, and, in defiance of all treatment, ran on to abscess, which abscess discharged upon the neck. The pus voided, relief, of course, was obtained. The sinus, however, continued to discharge, and at the time of consultation, the ulcer had become a source of much annoyance as well as deformity. This case had been examined by various friends of the gentleman, and, while all pronounced it alveolar abscess, all associated it with the treated teeth. The removal of a developing dens sapientæ, a single cusp alone of which presented, caused the fistule to heal in a single week.

A complication sometimes met with in abscess discharging upon the cheek, and of which it is most important that note be taken, consists in a relation of the sinus with the duct of Steno. Within the past few years the writer has met with several cases of this nature, and by the operation required for salivary fistula has been enabled readily to cure them after the failure of every device not entertaining an appreciation of such condition. It is to be impressed that such fistulæ deceive in the very limited salivary discharge, this fluid being easily overlooked in its relation with the pus; experience leads to the inference that the opening into the duct is not infrequently of the most diminutive calibre. Where such a case is recent, it is proper to attempt a cure through the granulative process, trusting by such means to cover in the break of the duct. To accomplish this, no better means is to be employed than daily touching the parts with tincture of iodine or with crystals of the chloride of zinc, it being of course understood that the dental relation of the disease has been previously cured. If such treatment fail, and this will be found most likely, then an operation becomes necessary. (See *Salivary Fistule*.)

Dental abscess not infrequently exists where the discharge is exclusively through the foramen of the tooth; that orifice being enlarged. The gums in these cases may be unaffected, affording no signs of disease, the evidence of the lesion being perhaps alone in a peculiarly disagreeable taste experienced by the patient. To cure these discharges, it may be all sufficient to throw the required injection through the canal of the tooth; but, should this fail, the method of entering the cyst through the alveolus is to be tried. To so enter such a cyst, a very delicate trephine is employed, or, what commonly answers every purpose, a spear-shaped drill may be passed through the outer



plate. Incising the gum over the apex, the drill is simply to be rotated into the cyst; precaution, however, is to be taken that none of the bony particles be allowed to remain, adding their quota of offence. This is guarded against by the free use of a syringe.

An alveolar discharge, which may be termed false abscess, is met with frequently in association with alveoli into which salivary calculus is intruding. In these cases no difficulty is experienced in the diagnosis; the discharge is seen about the necks of the affected teeth, the gum is more or less puffy, and the irritating deposit evident enough. To cure cases of this kind, it is alone necessary to scale or cut away the offending agent, and, after making a few incisions through the congested and debased gum, stimulate the parts by such applications as seem indicated. Few medicaments are more reliable in this direction than the dilute aromatic sulphuric acid, or this combined in equal proportions with the tincture of capsicum. It is found, however, not infrequently the case that the deposit has so destroyed the sockets of the teeth that no cure is possible outside of extraction. (See *Salivary Calculus*.)

Chronic alveolar abscess, resisting local treatment, is to be viewed commonly as of constitutional association. In persons who are laboring under the effects of a mercurial poisoning, the cases are found most resistive; indeed, in many instances, it is felt to be useless to make any attempt to save the affected teeth, the organs being absolutely thrust from their sockets and falling into the mouth. Where not too loose, however, the gums are to be incised every few days in a vertical direction, and attempts made to resolve the turgidity and puffiness by paintings of the tincture of iodine and capsicum, alternated with washes of chlorate of potash and cologne.

R.—Potassii chloratis, ℥ss;  
 Aquæ Colonæ, ℥j;  
 Aquæ, ℥vij. M.  
 Sig.—Use many times daily.

Internally the chlorate of potash may be employed in doses of fifteen grains, repeated three times daily.

R.—Potassii chloratis, ℥iij;  
 Aquæ, ℥viiij. M.  
 Sig.—Tablespoonful as a dose.

Another prescription is as follows:

R.—Tincturæ myrrhæ et capsicii compositæ, ℥j.  
 Sig.—To be used in the proportion of 5 drops to ℥j of water.

The rheumatic diathesis is to be recognized as at least a predisposing cause of alveolar abscess, and one which at times forces itself on attention in treatment of the condition. As this toxical influence is recognized as having affinity with periosteal tissue, so there is no reason to doubt that occasionally it is the resistive agent in the cure of such conditions. A similar view will



also be found to hold good of the malarial poison, and, indeed, it very well may be, of all the other toxical expressions. Not that it is to be affirmed that such poisons have necessarily, in all instances, a direct relation, but that, being depressent to the system at large, they antagonize that reparative influence, without which parts may not restore themselves; precisely, if an illustration be needed, as a venereal ulcer, however proper and vigorous the local treatment, may refuse to be made well until systemic influences are considered and antagonized.

Gout is another constitutional predisposition to chronicity in alveolar abscess, just as it is a frequent excitant to pulpitis. An abscess which refuses to respond to any direct medication yields, with such predisposition, to a few doses of colchicum. Defying abscesses of this nature are oftentimes found to give way to the alterative influence of a week at the seashore, or a trip to the mountains.

In chronic abscess the discharge must necessarily continue so long as the periodontium remains in its pathological state. It is therefore always necessary in association with any systemic treatment which it may be desirable to adopt, to break up the local lesion. To accomplish this, no better means is to be employed than tearing the sac to pieces by means of a delicate, temperless excavator passed through the sinus. After such breaking up, the part is to be syringed daily with an aqueous or vinous dilution of the ordinary officinal tincture of iodine,—about half and half being a good proportion. Another most excellent agent is found in the chloride of zinc. Of this salt, a solution of three grains to the ounce of water may be employed, a tent of cotton being saturated and carried into the cyst, or, charging with a few drops the ordinary hypodermic syringe, the fluid may be thrown into the cavity. Other local medicaments are found in nitrate of silver, sulphate of copper, tincture of capsicum, permanganate of potash, in the passage of the electro-galvanic current, in carbolic acid, in creasote, in alcohol, *et hoc genus omne*. The indication lies in the direction of stimulation.

Where an abscess discharges itself exclusively through the pulp-canal, the very best plan of treatment is to make a counter-opening in the gum and proceed as directed for the abortion of the acute state of the disease, using, besides this means, injections and tents until all discharge ceases; or, if objection exist to this, threads of silk saturated with the medicament selected may be carried into the canal. Another and better mode than the use of the threads is, however, to introduce into the canal a plug of gutta-percha, in which a hole is to be made of a size just sufficient to receive the nozzle of a delicate syringe. Thus directed and controlled, injections may be forced through the foramen. Any treatment, however, except that by the counter-opening, is seldom found satisfactory.

A tooth having such discharge through its canal, and thus incapable of bearing a filling, may have such filling retained without response by making the counter-outlet through the alveolar wall. Such a treatment is frequently



adopted with much satisfaction, affording success in saving the tooth where, without the puncture through the gum and bone, the cavity would not have endured the plug for half an hour.

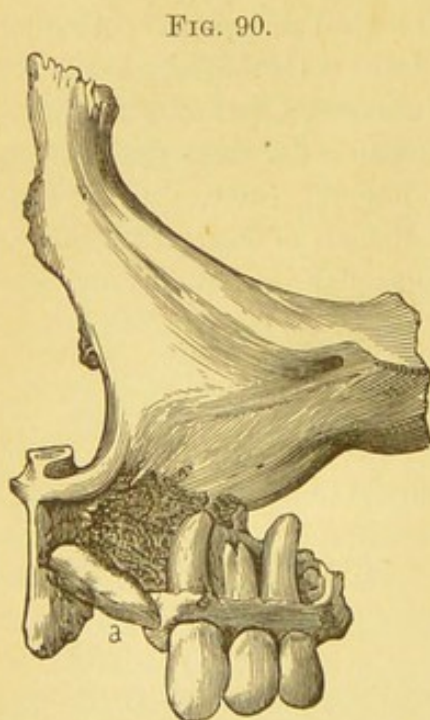
An explanation of chronic alveolar abscess where no medication can possibly avail is found sometimes in a twist of gold which has been thrust through the foramen in the act of filling a root. The writer has several times met with this cause, although never appreciating it until exhibited by the extracted tooth.

An alveolar abscess connected with the teeth of scrofulous children will not infrequently result in necrosis of the surrounding process. A case of this kind, coming quite lately under notice, resulted in the loss of quite half of the right superior maxilla; while a second case, occurring in a mercurialized man, destroyed the whole bone.

A chronic alveolar abscess is not infrequently found resistive to treatment as the result of the mechanical cause of a malarticulation, which keeps the affected tooth continuously worried. This is an offence for which we are always to examine, as it is readily induced by changes which may have occurred from the inflammatory associations. Any single tooth, however healthy, striking in its articulation before its fellows, will become thereby diseased. This is often enough witnessed where, in filling teeth, the metal

has not been sufficiently dressed down, and is thus unduly impinged upon; such teeth becoming sore to the touch, even to the result, when the cause is not appreciated and removed, of fretting the part into abscess.

Abscess, associated with temporary teeth, is always to be looked on with concern, irritability and excitability of the young jaw being so great that any addition to the excitation of the dentitional period is found commonly to prove more than the force of the parts can antagonize,—thus resulting not infrequently in extensive disorganizations. Should the disease in the temporary tooth have association with any of the exanthems, the immediate removal of the organ is made a necessity. Indeed, these infantile abscesses, however associated, are never to be allowed to run on, but, if not speedily re-



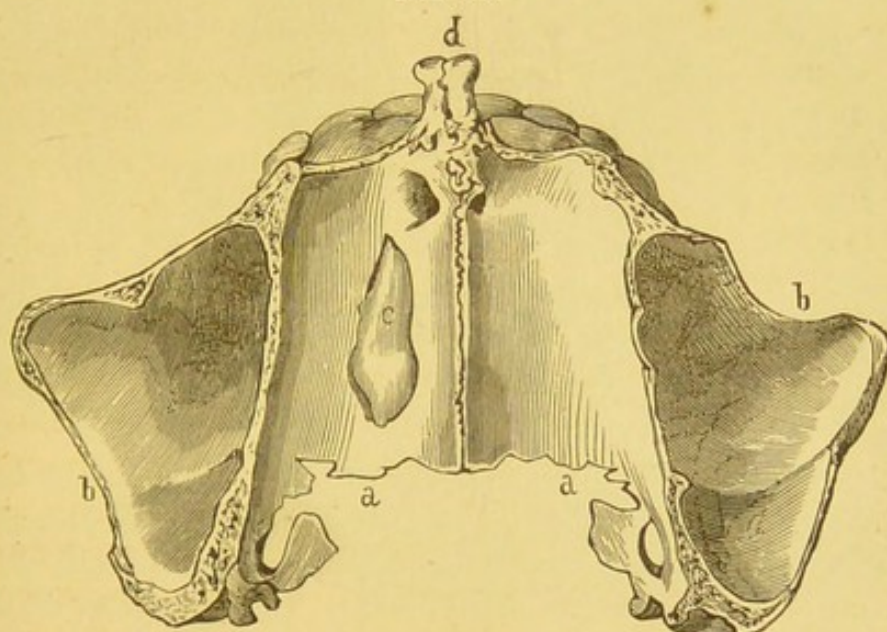
sponsive to medication, should be cured by extraction of the offending tooth or teeth.

Alveolar abscesses arising out of imprisoned teeth are occasionally associated with much obscurity in the diagnosis. In this direction the consulting experience of the author has brought to his acquaintance many curious illus-



trations. Figs. 90 to 94 furnish examples of imprisoned teeth. Fig. 90 shows a condition of abscess not infrequent; not only does the seat of degeneration relate to the malplaced tooth, but, being long uncombated, it has enlarged its boundaries to such extent as to destroy the buccal plate and alveoli of three neighboring teeth. In a case like this extraction of all the teeth involved is only in anticipation of a result sure to be achieved by nature. It is, indeed, not infrequently the case that health is to be recovered in the parts alone through a process of scraping the bone. Fig. 91 shows a cuspid tooth lying in the palatal process, a malposition threatening abscess at all times. Fig. 92 exhibits a cuspis in process of self-liberation through means of abscess. Fig. 93 displays an eye-tooth freeing itself after a similar manner.

FIG. 91.



Imprisoned teeth, related as above, are commonly to be located by means of a bistoury passed through the soft parts and bone, as required. Cases enough exist, however, where a sinus of discharge issues from a lesion of distant situation; here dependence is to be placed on a steel probe, one that is sharp-pointed and that can be bent to suit.

The history of a case of alveolo-dental abscess very lately under the care of the author is as follows. The patient, a gentleman of leisure, remarked a soreness that commenced in the neighborhood of the left naris. The discomfort increasing, he applied to his dentist, under an impression that the trouble was connected with the root of an incisor tooth. This organ being faultless and no other cause offering itself, the case was allowed to take its course. Two weeks later inflammatory disturbance had progressed to the extent of abscess. A week later still the gentleman was in bed with a vascular disturbance which involved the whole side of his face; the discharge reasonably profuse without abatement of discomfort. This condition existed for a month, when fungoid proliferations projected abundantly from the now widely extended mouth of



the sinus, giving rise to a fear of malignancy. The trouble was cured by the discovery and removal of an imprisoned tooth lying upon the nasal floor.

FIG. 93.

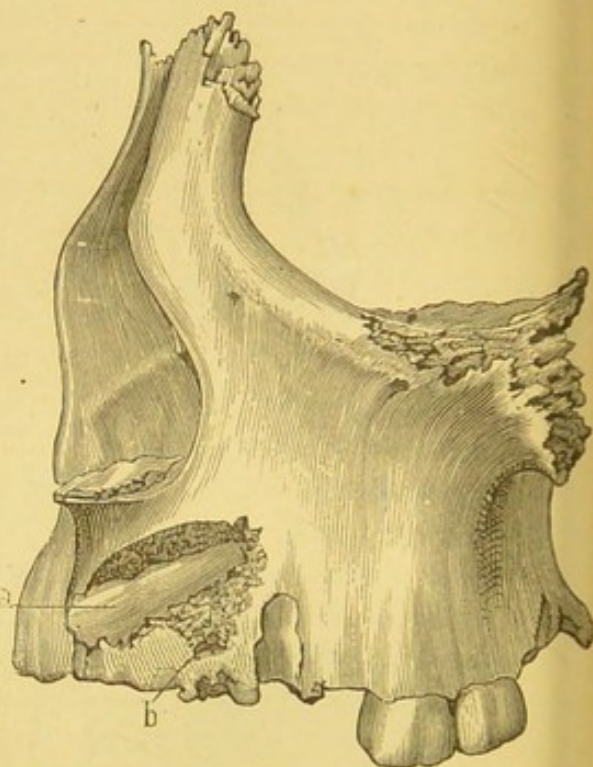
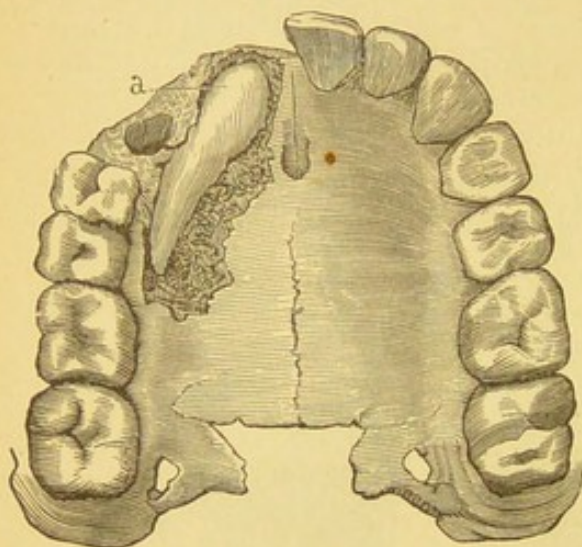


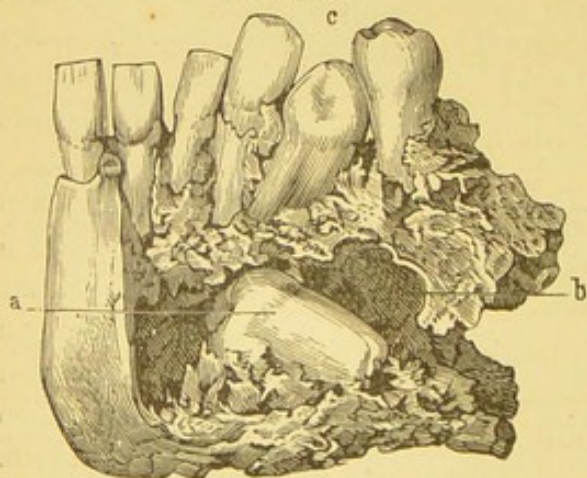
FIG. 92.



Another history is as follows. A lady consulted concerning a discharge from the alveolar ridge, which had continued two years. Neither pain nor soreness attended. Examination revealed the presence of osseous caries, but no evidence of any dental origin of the trouble. On operation for the removal

of the diseased bone the antrum was reached; from this cavity there dropped an eye-tooth.

FIG. 94.



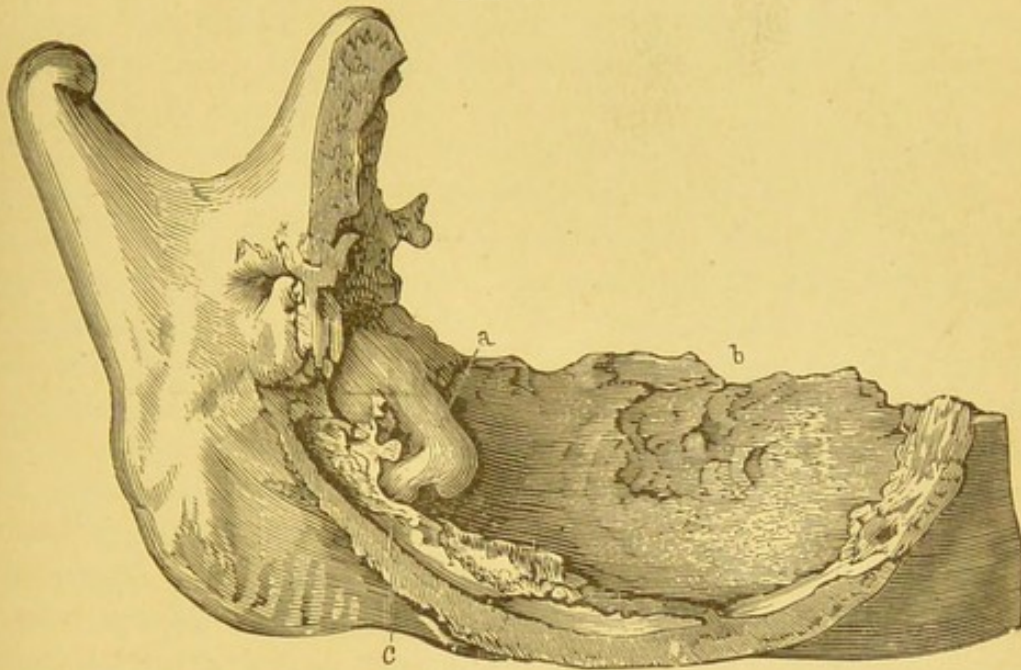
Still another case is as follows. A young lawyer was afflicted with a swelling of the lower jaw, which long had given both himself and his physician much anxiety. Later on inflammation resulted in abscess. Fig. 94 shows what was discovered in the process of search after a diagnosis: *a*, molar tooth; *b*, cyst.

Another illustration still is well exhibited by Fig. 95. The patient, a gentleman connected with the naval service, had labored for a period of two years under much concern as to the meaning of a growing discomfort situated at the angle of his jaws. This



culminated finally in abscess, for which many examiners failed to discover a cause. A probe passed along the sinus met with an obstruction that felt like healthy bone; nothing resembling the touch of enamel was to be appreciated. The case was under treatment two weeks before it was recognized that the trouble lay in a tooth developed upside-down. A cure was finally secured by chipping away the process at the point *a* and working to the situation *c* twist after twist of cotton, the swelling of which finally lifted the organ from its bed. The sinus led to the extreme tip of the root, this being the only part that was uncovered. The cut, although designed for other purpose, shows the position and relation of the tooth accurately.

FIG. 95.



As a principle involved in the treatment of abscess, it is required simply that the practitioner recognize pus as protoplasmic degeneration: matter breaking down because of an inability to organize itself into self-supporting tissue. Whatever shall afford or add needed force must prove the cure of the degeneration. To this end all deteriorative local causes of offence are to be removed. If a tooth contain a dead pulp, such pulp is to be extirpated; if it unduly strike its neighbor, such false occlusion is to be remedied; if irritation be kept up by subjection of the membrane to foreign agents of offence, as a habit of biting improper articles, cracking nuts, untying knots, cutting threads, subjection of the parts to rapid and great alternations of heat and cold, as in the use of ices and hot drinks, these and any other causes of offence are to have consideration.

General indications are to restore healthy innervation, circulation, secretion, and excretion, by such medication, hygienic or otherwise, as shall tend to allay irritation, increase plasticity through tonicity, and restore normal action. To such an end, besides the local medication which may be required, resort,



as indicated, may be compelled to the employment of specifics, nervines, alteratives, astringents, and antiseptics. In one sentence, we are to recognize and appreciate the indications, local and general, and to meet them. When this has been done, and yet a cure is not secured, the only remaining question is between the extraction of the affected tooth or teeth, and the risk of such consequences as osseous caries or necrosis.



## CHAPTER XV.

### THE TEETH AND THEIR DISEASES.

#### THE PULP-CHAMBER AND CANALS.

AT this point is properly to be studied the treatment of teeth containing dead pulps; the relation of the condition with periodontitis and with alveolo-dental abscess being fresh in mind from comprehension of the two immediately preceding chapters.

The pulp of a tooth dead, and the intention being to save the organ, appreciation is to be had of the means tending to such end. The performance is one of full surgical import, demanding both skill and physiological understanding. It is, indeed, within the memory of the present generation when a dead pulp was synonymous with the loss of a tooth. Now, however, it has come, happily, to be recognized that such attendant loss is the exception,—observation eliciting the fact that the almost universally associated destructive sequelæ depend on the presence of the putrid mass in the cavity rather than on the fact of death of the pulp. Death of a pulp is recognized in loss of translucency by the tooth containing it.

With such understanding, the first step in the treatment of the pulp-chamber and canal is found to consist in the thorough cleansing of them from substance which has become foreign.

To remove a dead pulp, the operator commences by creating an opening into the chamber, or in enlarging to convenient size one that may already exist;\* this accomplished, it is not infrequently the case that the part may be caught and lifted away with a pair of delicate finger-forceps. A more common mode of procedure, however, consists in the employment of a barbed broach; this instrument being passed into the canal, and, when rotated, catching and twisting into its teeth the organ, its withdrawal brings with it necessarily the structure. Fig. 96 represents such a broach, a variety of blades being shown adapted to a common handle.

In attempting to remove a pulp entirely dead, it is occasionally found that considerable pain attends the operation. This pain is seen to arise out of the manipulations. A broach thrust directly upon a dead pulp will carry necessarily the impression to the living structure still in relation with it at

---

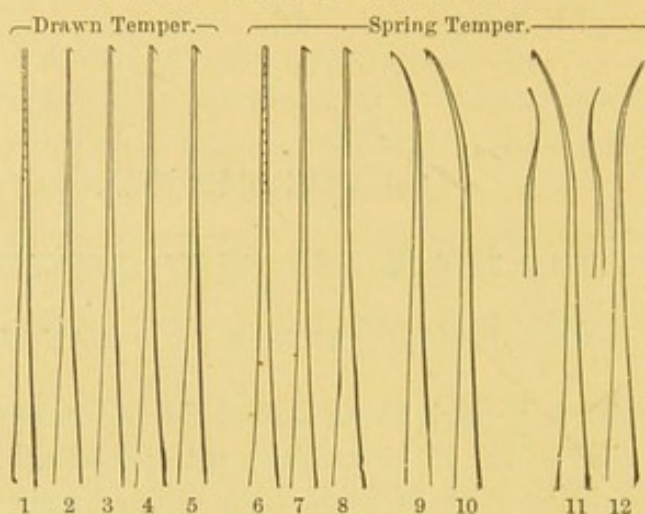
\* While the present chapter finds proper place in relation with the studies which here immediately precede it, the student will be advantaged if he defer its reading until he has familiarized himself with the more ordinary performances of operative dentistry.



FIG. 96.

Nerve  
Extractor,  
with  
holder.

FIG. 97.—NERVE EXTRACTORS.



the foramen of the canal. A proper plan is to enlarge the opening to such extent as allows the introduction of the instrument between the wall of the canal and the organ. Delicately insinuated in this manner, the rotation being commenced only when the instrument has reached the bottom of the canal, a pulp may commonly be removed without even discomfort.

In teeth having more than one root, it is generally found necessary first to extract the pulp of the chamber proper. This is to be effected through the use of a common excavator, simply cutting it away; the continuations occupying the canals, are next withdrawn by the use of the broach, as described.

An indication following immediately the removal of a dead pulp consists in such sealing of the emptied chamber and canals as shall prevent occupancy by foreign matter, whether from within or without. This embraces the process of preparation and filling,—a subject to which attention may now be directed.

Taking as a first example a tooth from which, after the arsenical application, the devitalized pulp has been removed, the operator is to consider that the surface of separation at the foramen of the tooth cures itself either by the process of immediate cicatrization, or by granulative effort. Could assurance be entertained of the first result, then no better practice might be pursued than the immediate introduction of a permanent filling. As this may not, however, be the case, what is termed a test stopping is to be used. Disinfecting thoroughly the canal, or canals, as the tooth may be single or of several roots, using for such purpose plain water thrown forcibly into the cavities by means of a tooth-syringe, the test is to be made by preparing a most delicate twist of cotton, which in length may double that of the tooth. This twist, being moistened in a very weak dilution of creasote, in phenate of soda, oil of cloves, or in glycerine,



and then thoroughly dried by a free use of bibulous paper or by other means, it is taken up with the point of a delicate root-plugger, and, being carried as deeply into the cavity as possible, fold after fold is to be forced upon it until the space is solidly packed. The canal thus plugged, the chamber proper of the pulp and the common cavity of decay are to be filled either with white wax, with gutta-percha, or, what is found to answer most satisfactorily, a tuft of cotton which has been partly saturated with gum sandarac.

A manner of filling canals temporarily, which will be felt to commend itself, consists in employing the ordinary cotton wrapping twine of the grocer. A canal being cleansed, the thread, holding the antiseptic, is carried into the cavity, and packed precisely in the same way as the twist; an end being allowed to extend to the orifice of the common crown cavity, that thus the packing may be easily removed.

The length of time that a test filling is to be retained varies with almost every case. As a direction which may serve for a principle, it is to be remarked that when, after a single day, a closed cavity remains comfortable,—the patient affected by no consciousness of the presence of the tooth,—and when, on the withdrawal of the test, complete cleanliness is to be recognized in the absence of offensive odor, such a pulp-cavity is to be esteemed in condition to receive the permanent filling. Very often, however, it is found to happen that a test filling is so poorly endured that its presence for a single half-hour will develop symptoms of periodontal irritability, the tooth becoming sore to the touch and sensitive to all impressions. Here we have nothing to do but remove the test and resort to required applications. Quiet restored, the cavity is to be loosely filled with cotton, or it may be left open, and allowed to rest until the irritability has subsided, when, a few days, or a week, having elapsed, the test filling is to be again tried.

In cases where in single-rooted teeth irritability is continuous, it is implied that a suppurating surface exists on the external face of the root, and that the discharge, or oozing, finds its vent through the canal. In these cases, while the operator may, if he please, try stimulating injections forced through the foramen, trusting thus to find himself able to break up the morbid action, a plan which is practised with much more satisfaction consists in the immediate permanent filling of the canal with gold, and the making of a counter-opening through the alveolus, such opening being kept patulous by the use of a tent of cotton. No better plan of treating a suppurating periodontum is to be adopted than using injections through a counter-opening as thus made.

In the case of multi-rooted teeth resisting the test filling, trial is to be made until the particular fang diseased is discovered. Such information is quickly elicited by treating each canal separately.

The treatment of an irritable root here offers itself for consideration. First, the cause of the irritability is to be appreciated. A common one exists in the unhealed condition of parts about the apical foramen. To jam against such a sore part cotton wet with creasote, carbolic acid, and perhaps rolled as



well in iodoform, tannic acid, chalk, or other powdered substance, is to certainly increase the trouble it is the intention to avoid; doing too much is the fault. A well part does not need to be cured. An unhealed part, if progressing favorably, wants simply to be let alone; the requirement of such a condition is protection, not medication. In place of filling such root or roots, as directed, place as closely in contact with the sore part as possible particles of common zinc ointment; nothing is to be found that is more protective than this. A few days and the wound more than likely will be found cicatrized.

A second common cause lies with irritability of periodontal membrane, existing by reason of excess of nutritional work thrown on it. Here time alone can do good; nothing is to be done but wait; every extraneous source of irritation is to be avoided.

A third cause lies with decomposing debris occupying the dentinal tubules, a source of trouble common enough to teeth of loose structure. Here the indication points in the direction of antiseptics. Free, and oft-repeated washings with water forcibly thrown into the canal by means of a syringe is means to the end. Filling a canal with calcined magnesia, repeating the performance daily, is an admirable proceeding. Another means is found in a mixture of iodoform, yellow cinchona bark, and chalk powders; one part of the first, two of the second, and three of the third; this, like the former, is used as a daily dressing until absolute cleanliness is secured. Still another medicament seen to be of value exists in a combination of zinc sulphas with bismuthi subnitras, the proportions being 3ss of the former to 3j of the latter; this is used precisely as the others. Creasote, carbolic acid, phénol sodique, permanganate of potash in solution, Watson's chlorinated water, iodoform rubbed up with glycerine, with oil of eucalyptus, or, best of all, with cacao butter, are alike agents used as disinfectants, and may be employed.

A canal thoroughly cleansed and an irritable one made quiet, a common practice repeats the test plug, and in this direction there is to be found nothing better than the cotton string or twist prepared and introduced dry as directed.

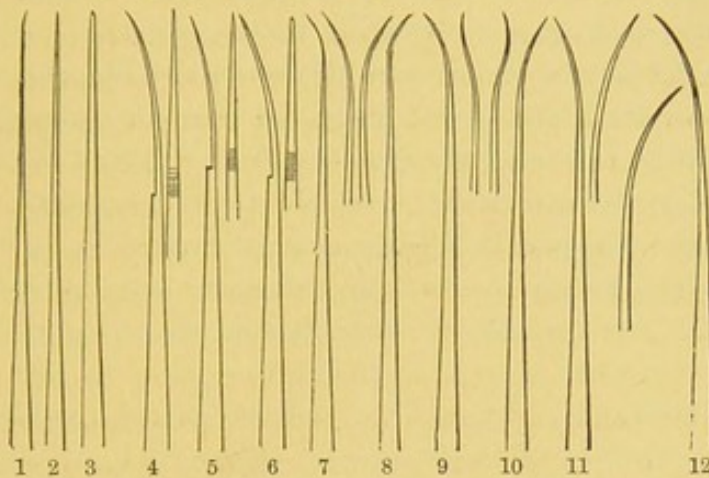
Assured permanency of quiet existing in a pulpless tooth, the filling of the root-canal is to follow, and is accomplished as follows. Take a sheet of gold (say, for illustration, No. 5); cut it into four strips. Take one of these strips, and, folding it once upon itself, run it into a spiral upon a broach or a common pin. Take now this spiral, and carry it by means of a foil-carrier into the canal; if it have been solidly rolled, it may be forced at once quite to the apex of the cavity. Following the carrier with a root-plugger (Fig. 98), the spiral is condensed by forcing turn into turn, spy-glass fashion. Of the remaining pieces of foil, cylinders are to be made of such varying sizes as seem required for the operation.

Another method of using gold in root-filling consists in taking a strip of heavy foil (say No. 20), and, cutting off a delicate thread, carrying it by a point to the apex of the canal. The plugger, fixing thus the initial extremity,



is to be slightly withdrawn, and the thread, portion by portion, crimped upon itself until the canal is full.

FIG. 98.—NERVE-CANAL PLUGGERS.



Still another manner of treating a canal, being that one which is most frequently practised, consists in filling first the apex of the canal with a twist of cotton which has been impregnated with creasote or oil of cloves. Upon this cotton gold is packed. To introduce the cotton, a twist is made, the initial extremity of which is to be of great tenuity. This initial end, or as near it as may be possible, is caught by the end of the root-plugger, and, being carried to the apex of the canal, the remainder of the twist is crimped upon it. Operators of repute are found whose commendation of the cotton plugs extends to the employment of the material for permanently filling the whole canal. Such free use, however, of so loose a material is not to be indorsed except for teeth of most solid structure. Gold is, without doubt, the very best material to be used in the direction, sealing as it does the cavity with an imperviousness which is the highest requirement of all such cases. A common fault with canal-fillings of gold is that the operator fails in carrying the metal to the apex of the cavity, thus permitting the existence of a receptacle in which accidental deposits at once become foreign. A canal solidly full to the very foramen, any exudate which may occur must be associated necessarily with absorbent vessels which adjoin, no road of ingress into the tooth-canal being open.

A source of disease equally to be guarded against exists in the accident of forcing a root-filling into and beyond a foramen. This may occur only where the openings are enlarged, either because of natural condition or from absorption. Such an accident the practitioner is to guard against by informing himself as to the condition of the apex through exploration by a broach. If the part be normal, the sense of touch will discover a closed cavity; if abnormal, the instrument is felt impinging upon soft parts. The latter condition existing, the filling is influenced in the depth to which it is to be carried, by a measurement secured by the broach.



In the use of so delicate an instrument as a broach, great care is to be exercised that the steel does not become jammed in the canal,—perhaps, as has been the case, in the foramen,—and, breaking, leave a cause of offence which may result, not alone in the loss of the tooth, but which, in more than a single instance, has caused loss of life from tetanus. Should such accident occur, every effort is to be made to remove the fragment; the desired result being generally attained by catching the piece in a wisp of dry cotton revolved about it by means of a second broach. Where a broach has been caught and broken in the foramen, it may be found necessary to enlarge the opening by means of a spear drill,—a practice the necessity for which will be found unfortunate, as almost invariably does it result in necrosis of the root so treated. The magnet is another means of getting rid of a broken piece.

The conducting facility of gold being well recognized, the value of a non-conducting substance placed between a plug in the canal and one which is to occupy the crown, is appreciated. Teeth not so treated are subject to a source of continuous irritation to which many succumb; a chronic inflammation, resulting in necrosis, being not infrequently the result of varying thermal impressions. Founded on such experience, the practice is pursued of filling the pulp-chamber proper—that is, the cavity out of which the canals run—with such preparations as the oxychloride of zinc, gutta-percha, Hill's stopping, etc. Lead is sometimes used: preference resides with the oxychloride of zinc. (See chapter on *Filling Teeth*.)

The canal and the pulp-chamber of a tooth filled, observation demonstrates the desirability of a few days' rest to the organ before performing the crown operation; the cavity to be temporarily filled with a sandarac and creasoted cotton plug.

**Filling over Exposed Pulp.**—So common has the practice become of attempting the performance of the filling of complicated cavities and, at the same time, the saving of pulps, that in the operation dental writers, in their multitudinous suggestions, are too frequently found forgetful of general principles which underlie necessarily all such character of manipulations.

On a former page, mention was made of three sequelæ associated with exposure of the pulp. These three conditions are as naturally conjoined with the relation as is the immediate union of a wound with plastic blood, or non-union with the cacoplastic. Whether or not, therefore, it be worth while to attempt the saving of an exposed pulp, is found to depend exclusively and strictly on the common condition of the individual.

That the vitality of an exposed pulp may be preserved, and a tooth so affected be successfully treated and filled, is a fact attested by every-day record; but that such success is associated more closely with physiological relations than with mechanical skill requires only experience to become to every observer a self-evident fact.

Assuming the existence of such conditions as justify the attempt to save an



implicated pulp, attention is to be invited to methods of practice found by demonstration to be most applicable.

Taking, as a first illustration, a case where the pulp should be scarcely uncovered, but be found overlaid by a layer of devitalized dentine, it has become the quite common practice to trust such layer to the offices of nature, allowing it to remain, rather than expose the pulp-chamber, trusting that through some means the foreign body may be taken care of,\*—a desired result which frequently occurs, as case after case on record satisfactorily exhibits. In placing a filling, however, over such diseased dentine, it is desirable first to put the tissue in a state of neutrality; that is, tests are to be made for acid or alkaline conditions, and, if either state be found, it is to be antagonized; fungi, an almost constant inhabitant of such devitalized dentine, are to be destroyed: in short, if vitality is not to be restored, causes of change and disintegration are to be removed.

A plate of living dentine, be it ever so thin in the centre, but having circumferential relations sufficient for the maintenance of its vitality, is to be viewed as in a condition which, properly assisted, will tend to grow better rather than worse.

A plate of dentine, on the contrary, with very limited parietal relations, will be found much more disposed to degenerate than to maintain or increase its resistive force.

Cavities of decay opening into the pulp-chamber are treated in a variety of ways. Of the means adopted, the various modes employed may be studied with advantage; it being a common experience that the unsatisfactory and unreliable character of any or all of them tempts the practitioner to try each in its turn.

A means at the present time enjoying large favor is the employment, as a capping, of the preparation described, in the chapter on tooth-filling material, as the oxychloride of zinc. It has, however, become a too common habit to treat of this substance as a specific in the direction, and with such false impression it is every day used by many with a recklessness which has no excuse. That oxychloride of zinc is an admirable agent in the direction, when employed with judicious care, is not to be denied; no substance introduced into a tooth seems to exert greater influence in the excitation of that action which produces secondary dentine, but injudiciously employed, no compound more quickly provokes antagonistic inflammatory action.

In using oxychloride, it certainly is not to be understood that it may be plastered over an exposed pulp *ad libitum*; on the contrary, if it is to be used with prospect of satisfactory result, every consideration must be had to the delicate and susceptible nature of the organ treated. Oxychloride of zinc placed directly upon an exposed nerve can only have good results by an acci-

\* A layer of devitalized dentine may be liquefied and absorbed, or it may become encysted; that is to say, between it and the pulp there may be deposited a layer of secondary dentine.



dent which should just level the break in the continuity of the roof of the cavity, and which should have alone that most happy vascular response which tends to the formation of secondary dentine. These results, however, are precisely what are claimed as the rule by the supporters of the practice; the proof or disproof of the claim the student will, without doubt, incline at some time or other to make for himself.

Oxychloride is recommended in this volume as a capping; indeed, the experience of the author would lead him to esteem it as the most valuable of the agents employed,—and thus far does he fully agree with its enthusiastic admirers; but whether it is to be used with an excess of the chloride, or with this powerful excitant neutralized as much as possible by the inert oxide, depends entirely on the character of the tooth treated. Again, the preparation is not to be brought, in its plastic state, into direct contact with the pulp, but always is it the safer practice to have an interposed plate. As the material of such a plate, oiled paper may be used, or what is still better, caps of platinum as prepared and sold at the dental depots. Fig. 99 shows such caps.

Again, in the use of the agent it is the best plan to feel one's way; success

FIG. 99.



will not infrequently be secured by letting the application, as first made, be so thin a film as may alone prove self-supporting. Upon such film, if no response be made, a second is to be placed, and upon this second a third; the cavity

being finally filled complete, and thus allowed to remain until, from continued or accruing comfort, there is reason to infer that the pulp has entirely accommodated itself to the new condition of things.

Perhaps always is it the result that pain, more or less severe, is experienced by a patient upon the introduction of zinc chloride; particularly is this found to be the case where the mixture has been prepared watery, or where a local anæsthetic or a cap has not preceded the application. When such pain continues longer than a few minutes, it is found the safer practice to remove for the time being the filling, or otherwise it is necessary to call off the persistent irritability through means of counter-irritants applied to distant parts; also to diminish circulatory force by the exhibition internally of *veratrum viride*. By such means it is not infrequently the case that quiet may be restored and the desired protective conditions secured. In the case of a pulp-chamber fairly exposed the process of capping particularly commends itself.

A simple mode of capping an exposed pulp consists in taking a piece of clarified quill, and, after cutting and scraping it into a required shape and thinness, lay it over the break, the circumference being supported by the surrounding hard parts. While held in place with a delicate instrument, it is to be fixed by a plug of oxychloride placed upon it, this material being afterward removed in part for the accommodation of the permanent filling.

Still another manner of accomplishing the proposed protection is found in the use of a layer of oiled silk, or of vellum. These are most suitable as non-



conducting qualities are considered, but are objectionable as permanency is concerned.

Other preparations used for capping are lead, tin, asbestos, and the Hill stopping. A plan which many think to be commended by results consists in inclosing asbestos between layers of gold foil, arching metal thus stiffened over the exposed pulp.

Dr. Allport, of Chicago, a skilful dentist, has proposed—and professes to have practised with a success entirely satisfactory—the following delicate operation: Exposing fully the pulp, he takes out of the body of the organ a V-shaped piece, bringing afterward the lips together, and so retaining the apposition as to secure an immediate union. The necessity for such an operation, however, may only occasionally apply.

In the case of a pulp exposed, with the orifice of the exposing cavity jagged, sharp, and irregular, necessity exists for such enlargement and dressing of the same as shall insure the organ—enlarging from time to time, because of functional office—from irritation and strangulation. To accomplish such dressing, it is desirable to constrict the pulp by such means as are found best to answer the end. Tannin in a menstruum of glycerine is a favorite in the direction. Alum-water is an excellent application; tincture of nut-galls is another. The prick of a very sharp instrument, resulting as it does in depletion, is an admirable procedure.

A very effective plan consists in conjoining with the local means hot foot-baths, calling the excess of blood away from the head; also the administration of medicines which tend to diminish the propulsive force of the heart,—the tincture of *veratrum viride* being perhaps the best of such agents.

An orifice, as described, being enlarged and dressed, capping completes the operation.



## CHAPTER XVI.

### DISCOLORED TEETH.

A TOOTH of loose structure quickly becomes dark, and in instances, almost black, on the death of its pulp. This opacity possesses a twofold explanation: First, death of pulp implies diminution in vital relations; out of this arises loss in translucency. Second, a dead pulp decomposes more or less quickly, becoming, in its liquefied expression, absorbed into the tubules.

To restore translucency in a dead tooth is impossible; the organ can be whitened, never vitalized.

When a tooth-pulp has died experience directs as a proper course to pursue that it be at once removed from its cavity, and that its place be occupied by a plug of gold, solidly impacted; such plug extending to the extreme end of the canal.

A tooth already discolored, the pulp-canal is to be freely opened, and any remaining contents removed by means of a broach. Succeeding this is the syringe. Repeated washings are to be employed. The fluid used may be dilute chlorine water.

A pulp-canal enlarged, cleansed, and the tubules saturated with chlorine water, a napkin or the dam is to be placed about the tooth, and a process of intra-tubular drying inaugurated. To effect this drying, pellet after pellet of bibulous paper is to be introduced until, as such means express it, all moisture has disappeared. Next the canal is to be packed with carbonate of magnesia. Thoroughly removing this, after a few minutes have passed, the hot-air syringe being used to blow it away, the extreme apex of the canal is plugged solidly and permanently with gold. By this plugging the bleaching process, if that be the mode of whitening adopted, is not at a later time interfered with by reason of secondary discoloration.

**Bleaching.**—Immediately on completion of the apex plug, and while the part is still enveloped in dam or napkin, a wisp of absorptive cotton is made to entangle as much as possible of common chloride of lime, which wisp is carried into the pulp-canal: the orifice being sealed instantly. In the use of this material advantage is taken of the antiseptic virtue of the chlorine, but most particularly is it the object to suck out from the tubules of the tooth the putrescent moisture attracted by the affinity existing between itself and the preparation. Taking into consideration the caustic quality of the application, judgment is required to be exercised as to the length of time it is to be left in a tooth. Where the dentine is loose in structure and full of moisture,



the unsealing of the cavity after one or two minutes will show the cotton to be wet. Here it has been in quite long enough, perhaps too long. If, on the contrary, the cotton be found dry, the lime has not yet done its work, and the application is to be continued or renewed.

One or two employments of the lime having been made, a succeeding step considers its complete removal. This is generally accomplished by the clinging of the moisture to the cotton; not so fully, however, is this a result as to be entirely trustworthy; it is found desirable to use freely a syringe.

The cavity again made as dry as possible by means of Japanese bibulous paper, it is packed, either with a fine article of English prepared chalk, or with the carbonate of magnesia. This completes the operation for the day; the orifice being hermetically sealed.

Zinc in place of lime is preferred by many. Having the cavity plugged at the apex, and under dam or napkin as before, pack into the canal as many of the crystals of the chloride of that salt as it will hold. When full, seal quickly the outlet, and retain for from five minutes to half an hour. The application may be repeated daily until color is restored. In the interim the tooth is to be kept filled with chalk or magnesia as before directed.

A manner of bleaching, having in it little risk or danger, consists in free syringing with dilute chlorine water, and the use of chalk continued for some few days, the preparation being renewed each twenty-four hours. A week having passed, an oxychloride plug, made by union of the aqueous solution of zinc chloride with a perfectly white preparation of oxide of zinc, the chloride being in excess, is introduced into the cavity, and protected until about two-thirds set. This imperfectness permits of an easy removal, which removal is to be succeeded by renewals of the plug. Repetition results in whiteness.

Another bleacher is the familiar salt, chlorate of potash: this is to be used without much regard to evil results.

Labarraque's solution, an aqueous chlorine preparation, permits of reasonable freedom in its employment; it is conveniently applied on a wisp of cotton and the orifice of the cavity is to be sealed while it is in a tooth. Renewal of the application is to find directions in indications.

Immediate bleaching is secured by fitting a delicate canula tightly into the orifice of a tooth-canal, and forcing a stream of chlorine gas into the tubules.

In the use of chlorine preparations the facts are to be constantly in mind that the agent employed is a decomposer of organic substance; that it is of such chemical characteristic advantage is taken to get the hydrogen of organic combinations, consequently, in the case considered, the discolored element; that acting primarily on the most exposed material, which, in the instance of a discolored tooth, is the pulp-substance filling the tubuli, this is primarily removed or destroyed; that a secondary action must be on the animal portion of the dentine; that necessarily secondary action is destructive to the integrity of a tooth, rendering it brittle and crumbling.



**Whitening.**—Integrity of relation being disturbed by the use of chlorine preparations, the peculiar and marked harm arising out of their employment where caries has undermined the enamel of a tooth is evident enough. Taking as an example a front tooth where decay, running in from an approximal face, has decomposed much of the underlying substance, the injudiciousness of the use of chlorine needs not to be discussed. Whitening in this and similar cases is to be effected by removal of the discolored dentine and the replacing of it by oxychloride of a shade to suit. Here injurious result is to be obviated by complete neutralization of the chloride by the oxide of zinc; such neutralization rendering the filling entirely inert from a chemical standpoint. Free chlorine being no longer existent in it, the plug is one that has in it the meaning alone of color.

A manner of whitening employed with fair satisfaction in particular cases consists in underlaying a plug of gold by a sheet of plaster of Paris. Another manner employs a mat of white paper, which, being put in place, is immediately overlaid by a second made of gold. Still another manner is to take a scale of porcelain and mould it as a support to the wall to be whitened; plaster of zinc chloride being used as the plastic. Another manner still shows a brushing of zinc or lead paint through the discolored face, the paint being covered by zinc phosphate or other plastic material. Preference is to be given to the zinc chloride plastic.

**Hæmatin.**—Immediate discoloration of a tooth sometimes arises out of a pulpitis so severe as to rupture the red corpuscles of the blood, permitting thus escape of the hæmatin and its speedy absorption by the dentinal tubules. A tooth so disturbed is the subject of such discomfort to a patient that the practitioner is apt to be brought very quickly in contact with it. Treatment consists in opening at once into the pulp-cavity and by means of warm water thoroughly cleansing it. So almost certainly is the death of such a pulp assured that it will commonly be found the best practice to quiet by use of obtunders and afterward apply the arsenical paste; or, if the organ have been freely exposed, its destruction is to be instantaneously assured by means of London paste, a small portion of which, if laid directly in contact with it, kills the part in a moment. Subsequent treatment is as directed in previous cases. Hæmatic discoloration, having the expression of purpura, may take place slowly; the condition is very uncommon.

Discoloration being dependent on absorption of a liquefied dead pulp, or constituents of a pulp, it follows that inter- and intra-dentinal calcification are antagonistic to discoloration; hence, shadings of vascular excitement, existing to an extent promotive of calcareous expression in the dental pulp exudate, are prophylactic of absorption. Teeth naturally dense darken slowly or little at all.

It is not amiss to add in conclusion of the subject that experience leads to much stronger dependence being placed on processes of whitening than of bleaching.



## CHAPTER XVII.

### REPLANTATION AND TRANSPLANTATION OF TEETH.

By replantation is meant the return of a tooth to its socket after extraction.

By transplantation is meant the transference of a tooth from its original to some other locality.

The initiative of these operations lies in experiments performed by John Hunter, in which that famous anatomist transferred teeth taken from the human mouth to slits made in the combs of cocks. These transferred teeth were found not only to become fixed and tolerated in their new position, but subsequent examination of the relation showed that teeth and combs were attached after a manner similar to that which exists between teeth and their natural alveoli.

**Replantation.**—The frequency with which this operation has now been performed and the success attending it in the hands of a capable practitioner justify the placing of it in the category of operations to be recognized and commended.

It is to be assumed as a start-point that any healthy tooth can be lifted from a healthy socket and returned within reasonable time with an almost absolute certainty of reunion. Per contra, it is to be deduced that in proportion as parts are unhealthy probabilities of reunion are lessened.

**MISTAKES IN EXTRACTION.**—A wrong tooth being accidentally removed, the parts being healthy, it is to be returned to its socket immediately on the cessation of bleeding; this cessation to be expedited by means of cold water held in the mouth. To retain the organ in place silk or thread ligatures will most likely be required.

Teeth that have been extracted many hours are found capable of re-fastening. **EXAMPLE:** Some fifteen or eighteen years back a young gentleman applied to the author about six o'clock of an evening with a view to having an impression taken for the purpose of replacing with an artificial substitute a central incisor that had been extracted very early in the morning of the same day. Inquiry elicited that the tooth had been removed by mistake. Replantation being proposed, the organ was found, after some search, in one of the pockets of the patient, being mixed up with keys, pieces of money, a knife, and the varied et ceteras of that receptacle, not to exclude the mention of a fair amount of dust. A first step was to throw the tooth into warm water, to which was added about ten per cent. of tinctura iodinii. A second



was to remove the plasma, with which the socket was filled, and to touch the circumference with the iodine tincture. A third consisted in replacing the tooth in its alveolus and in binding it firmly as possible in place by means of silk ligatures. A fourth implied the combating of an active inflammation which showed itself by the next morning, and of a chronic form into which the first degenerated, the latter continuing its discharge of pus, in defiance both of local and constitutional stimulation, for a period of over two weeks. **RESULT:** The patient was last seen some twelve years after his accident; the tooth was then about as firmly implanted as its fellows. Very trifling change in color was present.\*

Extraction and replantation of teeth for the cure of dental abscess is now claiming attention. It is to be appreciated that a tooth is endowed with a twofold source of nutrition: namely, pulp and periodontum; that vitality is preserved commonly where the first of these has ceased its office; that necrosis certainly ensues where both are dead. With such understanding it is recognized that a necrosed tooth is fit only for the first operation, not for the second.


A tooth in a state of abscess is a tooth lacking pulp vitality; it is an organ chronically inflamed in its periodontal structure. Chronic inflammation of a periodontum implies disease of part, perhaps of all, that membrane. A tooth so diseased is found on extraction to have what is known as a pus-bag attached to its root. The cure of abscess implies removal of this pus-bag. In the chapter on alveolar abscess what is to be accepted as the most rational mode of treating that condition is to be found fully considered.

In making up a prognosis as cure, by extraction and replantation, of an abscessed tooth is concerned, an important factor to be taken into considera-

---

\* A plan of retention suggested by Dr. Herbst is not less ingenious than suggestive; the accompanying cut shows it. First, a piece of rubber-dam material, oblong square in shape, with four holes punched in it. Second, this piece applied as exhibited; the lateral incisor is the replanted tooth.

FIG. 100.



Another manner of holding takes an oblong strip of red base-plate gutta-percha that shall be of a form and size, when cut into shape, to reach and cover several neighboring teeth on either side of the one replanted. Softening this gum by use of warm water, it is laid over the arch and moulded back and front. Next, and while it is still soft, the teeth of the opposing jaw are closed against and slightly into it. Articulation being maintained, the splint is hardened by means of cold water thrown about it from a syringe. Finally, a strip bandage is applied with a view of preventing movement.

In the use of means of retention delicacy of arrangement is a necessity. Added to this a mouth-wash, to be used several times a day, and which has seemed to the author never to be lacking in desirable effect, is made by mixing a teaspoonful of the *tinctura capsici et myrrhæ* with a goblet of water.



tion is the extent to which periodontal denudation has progressed. The periodontum is to be recognized as the life, the only source of supply to the tooth; if there be no periodontum then the replanted organ occupies a relation with its alveolus differing in the single respect from that which would be held by a plug of ivory or wood that it is a something that once was in physiological harmony. The author is not prepared to deny that such harmony is of favorable import; it is not to be objected to, however, that the history of dead parts, or sequestra, exhibit them as things offensive to nature and which are thrown off. It is a just deduction that a necrosed tooth is not suited for replantation.

A tooth, in the mouth of a healthy person, having alone the extreme end of the fang in a state of abscess, the remainder of the periodontum being in health, is in favorable condition for treatment by extraction and replantation. The process is as follows:

1. The tooth is to be removed with all delicacy and care, thrown at once into warm water which has been previously medicated with tincture of iodine, the socket, in the mean time, being stuffed with cotton or lint alike medicated.

2. The pus-bag is to be removed from the root. If the underlying cementum be vital in appearance it is left undisturbed; if it be dead, as shown by blackness or by evidence of absorption, it is to be cut away with as little disturbance to adjacent parts as possible.

3. A third step considers treatment of the pulp-cavity. In a tooth where the apex of the root has been retained, the cavity is opened from the crown, and after being thoroughly washed out and profoundly disinfected it is filled solidly to the extreme end of the canal with gold. This being done it is ready for replantation. A root with a necrosed apex demands different treatment. The periodontum is to be dissected back to an extent which shall insure the covering of the tip of the fang by it when the diseased part has been removed. Next, the pulp-canal is to be exposed from the apex portion of the tooth and filled with gold as in the first instance; great care to be taken in the finishing and polishing of the part lying about the extremity. The filling accomplished, the periodontum is made to cover the gold; a delicate catgut ligature being used if necessary.

4. The bony cavity in which is accommodated the sac of a dental abscess being covered by an adventitious membrane, a fourth step considers the destruction of that membrane. To accomplish this, after the best surgical manner, the operator employs a delicate spear drill, passing it through the alveolus into the cyst, tearing the parts away. Another, and commonly a necessary, plan of treating such cyst and membrane is to make an opening through the alveolar wall, proceeding with the drill as before. The membrane torn away a twist of cotton saturated with iodine is to be introduced, thus furnishing a drain which serves to void any excess of exudation, or it may be, pus.

5. Relation of tooth and cavity is renewed by simply pushing the first into its socket and confining it in place by tying to neighboring teeth. At this



stage in the operation it is that both danger and trouble are to be, not unlikely, encountered; danger from nervous relations which may, and has, resulted in tetanus; trouble from vascular perversion which over and again has made necessary the re-removal of the tooth, and which, unless skilfully looked after, may very possibly lose for a patient his jaw-bone.

When a tooth is removed from its socket an immediate sequence is the filling up of the alveolus with lymph, which lymph, as a rule, progresses to speedy organization. When, on the contrary, any body, be it foreign or only semi-foreign, is put into the cavity, such lymph does not advance to organization, but, on the contrary, degenerates to pus. Pus in a closed cavity means irritation, associated with much pain. The pathology of such a trouble is not involved by obscurity.

A replanted tooth closes an outlet; one of two things surely follows. It may be, and often is, the case, that a cyst fills with a character of lymph so plastic and coagulable in disposition that organization is effected without the formation of a single drop of pus. This is analogous to the healing of a wound by what is known as "first intention." It is not impossible that degeneration of so limited extent occurs that liquefaction is coincidently followed by absorption; this in like manner is fortunate and conduces to immediate cure. A rule, however, allied with the practice here considered is, that pus forms in the alveolar cavity, finding vent for itself by pushing the replanted tooth from its socket. To obviate or overcome this trouble two means present themselves: one considers an opening through the alveolar plate, as suggested, a second implies a drain-tube preserved in the canal while that cavity was being filled.

To create a drain in the bone nothing more is necessary than to pass a spear-pointed drill through gum and alveolar plate; keeping this opening patulous by means of a cotton twist as heretofore suggested. Than such manner of caring for the necessities of a cyst none other more philosophical is to be adopted.

Drain-tubes used in teeth need little description: they consist of channels of gold passing from apex to crown; being firmly built into the root-canal by means of cohesive gold.

A practice to be mentioned, one highly commended by respectable authority, consists in replacing with gold the removed apex of a tooth to be replanted, the contour to be a fac-simile as to length and circumference of the original part. To do this one of two plans is to be adopted: The part may be built out, as before suggested, cohesive gold being used, or, adopting the manner of capping crowns, a similar gold cap may be applied to a root, the delicately-thinned edges being worked up to a slight distance beneath the periodontum. To hold such cap firmly in place it is to be attached to the drain-tube, or, if it be proposed to use the bone as a vent, the cap may have its fixedness secured by a pin soldered upon its cap-face, which pin shall pass into the canal, being there retained by the root plug.



**Transplantation.**—This refers to the use of the teeth of humans or brutes. The most simple illustration of transplantation considers the removal of a tooth from the mouth of one person and its immediate transference to that of another. This, *cæteris paribus*, differs little from replantation, and is a practice which assuredly will become widely practised as operators become confident and society grows æsthetic.

The conditions necessary to success in this immediate expression of transplantation pertain to selection of teeth and to the health relations of the two individuals concerned in the transfer. Sale and price enter too into the consideration. One person disposes of charms to another. A surgeon takes the place of a broker.

As an illustration, a defective central incisor may be instanced. One person has such a defective tooth, the renewal of which he or she is very willing to pay for. A second person has a perfect organ which will be gladly parted with for a price. Two matters only remain: Is the tooth on sale of a form perfectly in accord with the requirements? Is it free from objectionable associations?

A transfer being decided on, the parties meet the surgeon, who extracts first the defective tooth, and, when all bleeding has ceased, lifts the second from its socket, which, after immersion for a few minutes in a weak solution of carbolic acid, he plants in the new alveolus made for its reception. Subsequent attention required relates to fixation by means of ligatures and to the combating of vascular perversion provoked.

It may very well happen, however, that in attempt to introduce the tooth into its new socket there is found lack of correspondence. This proves a sad complication, and lessens, in proportion to its demands, the chances of a successful result. The operator making himself acquainted with the unduly impinging relations has nothing to do but at once give up the case or otherwise proceed to trim the root to suit. Where it is possible to effect it, this trimming is always to be done after the enveloping membrane has been lifted from the part to be removed.

Transplantation of brutes' teeth into human sockets is professed to have been accomplished with satisfactory results. The author has had no experience in the direction. The principle of procedure would differ, however, in no respect from that now understood. Able to accomplish the one, an operator would have no hesitation in passing to the other.

Quoting from cases reported in the literature of the subject, it would seem to make little difference whether a root correspond or not with an alveolus. Thus, in one cited by M. Pietkiewietz, that surgeon claims to have extracted an anomalously related lower lateral incisor and to have successfully planted it in the alveolus of a lateral incisor removed from the upper jaw. In this case the circumference of the root planted did not at all correspond, it is said, with the cavity in which it was placed, being very much smaller, while at the same time it was so out of proportion in length that a piece



had to be cut off. Notwithstanding all this difference a perfect success is reported.

Dr. David, a pupil with M. Pietkiewietz of M. Magitot, reports sixty-two cases, fifty-seven of which are claimed to have been successful. In these cases are found included varying ages in patients and all the variety of single and multi-rooted teeth. Reasons for the operations are named as follows: 1. For the adjustment of anomalies of direction. 2. The treatment of caries where situation did not admit of the pulp being reached in order to destroy it, and the practising *in situ* of a satisfactory filling. 3. The treatment of that form of alveolo-dental abscess in which this affection is limited to the summit of the root. 4. Getting at a cavity on another tooth not otherwise to be reached.

A singularity in this matter of tooth-planting relates to the length of time that an organ can be out of the mouth and yet preserve vitality, as manifested by later attachment to an alveolus into which it may be transferred. A case illustrative is reported in the *Dental Cosmos*, where a practitioner having removed a sound eye-tooth from the mouth of a lady in preparation for an artificial denture, planted it four weeks later in the mouth of a gentleman who had applied to him with the view of having a crown pivoted upon the root of a similar class tooth. In place of pivoting, the root was extracted by means of a screw-instrument, and the lady's tooth inserted in the gentleman's jaw. "I opened," says the operator, "into the canal and pulp-chamber from the apex of the root, cutting off first from it the eighth of an inch, it being that much too long; reduced the size somewhat in the centre, it being a trifle larger than the root extracted, filled and placed it in position." Such a success is claimed for this particular case that it is asserted that dentists were unable to distinguish the foreign from the natural organs.

An advantage lying certainly with root-canals filled after extraction of the teeth is the perfection with which the operation is to be accomplished. It is undeniably the case that canals treated after the ordinary manner are almost sure to be unoccupied about the extremity, thus affording a receptacle for decomposing fluid, which proves one of the severest sources of irritation to which a tooth can be subjected. Howsoever manipulated, a pulpless tooth-canal is put in its best condition when solidly and completely filled with gold. If necessary to avoid thermal changes, such root-filling is to be separated, as before suggested, from that required in the crown through interposition of a layer of gutta-percha or oxychloride.

A tooth replanted in restitution—that is, put back into a socket from which it has been removed—may be expected to become reasonably fast in the course of a week. If, in place of a cure that is continuous and progressive, degenerative changes supervene, stimulation is to be resorted to. Cure here may be delayed for weeks.

A tooth transplanted by transposition—that is, removed from one alveolus to another—will seldom unite with any degree of firmness before end of the



second week. It will be found that such teeth seldom or never perfectly harmonize with their new relation. A cold taken, vascular perversion quickly distinguishes them.

Danger from tetanus is never for a single moment to be absent from the mind of an operator who attempts either replantation or transplantation. Nervous irritability is to meet with instant combat; if it succumb not quickly, the offending tooth is wisely taken from the socket. Tincture of belladonna administered in doses of ten to fifteen drops each three or four hours is found the best remedy. Poisonous effects showing from the use of the medicine, an antidote is found in opium.



## CHAPTER XVIII.

### DISEASES OF THE TEETH.

#### SALIVARY CALCULUS.

SALIVARY CALCULUS, or tartar, as it is commonly called, is that limelike material so often seen collected upon the necks of the teeth. Observation elicits the fact that the primary seat of deposit is about the posterior or lingual faces of the inferior incisors and the buccal aspect of the superior molars. As in these situations exist the outlets of the salivary secretions, an inference is that from these secretions comes, in part at least, the deposit.

Analysis of Saliva.	Analysis of Salivary Calculus.
Water.	Carbonate of lime.
Ptyalin.	Phosphate of lime.
Fat.	Fat.
Chloride of sodium.	Mucus.
Chloride of potassium.	Accidental matter.
Phosphate of lime.	
Sulpho-cyanide of potassium.	

When the salivary secretions are sluggish, the inorganic material, not being held in solution until fairly ejected into the mouth, becomes deposited about the roughened and inviting surfaces of immediately neighboring teeth. A nucleus once formed, aggregation goes on, until serious secondary lesions are apt to result.

The first and most marked effect of salivary calculus is upon the teeth themselves; beginning about one face, it soon involves the whole organ, and, if undisturbed, envelops, sooner or later, in an imperfect sheath, the whole denture. A mouth so filled with tartar is not only disgusting, but necessarily in an unhealthy condition. Salivary calculus soon destroys the integrity of the teeth. It does this by its effects on the secretory crypts about their necks and by compelling a gradual diminution in the periosteal supply; that membrane receding little by little as the foreign body encroaches on it. As a result of such abstraction of nutrition, the tooth soon dies, and is exfoliated like any other sequestrum; tooth after tooth necrosing, and each month or year one or more dropping from its socket.

Not infrequently there may be seen standing, isolated and alone, on some portion of the dental arch,—most frequently, however, either on the anterior portion of the inferior arch, or the posterior portion of the superior,—a yel-



lowish-looking tumor, which might not inaptly be compared to a shellbark covered with inspissated mucus. Sometimes this tumor will be found quite firm in its position, seeming, indeed, as if it might have sprung from the socket of some long-ago-extracted tooth; at other times you will be able to move it quite freely, as if it had a fleshy peduncle. These tumors give to the mouth a most disagreeable appearance, are oftentimes insufferably offensive, and so detrimental to health that five or six grains of their substance, given to a small animal, will not infrequently cause its death. The composition of such collections consists of phosphate and carbonate of lime, epithelial scales, inspissated mucus, and the various detritus of a cavity devoted to mastication. The nucleus of the growth is of course a tooth. The manner of formation is too evident to need description. The author has removed these calculi, where the nucleus had become so encysted, from crown to apex, that no trace of it was to be discovered without dividing the mass. Where, however, the encystment has advanced to this extent, the tumor is about ready to drop from the mouth. A calculus of this kind has been met with where the six lower front teeth were encysted, making as strange a looking tumor as could be well imagined.

Similar calculi develop, as may be inferred, in other parts of the mouth. Thus, just within the orifice of the duct of Steno they are occasionally found; the tumor, in such a case, bulging out from the cheek against the second molar tooth of the upper jaw. The formation of such a tumor in this situation does not necessarily imply the closure of the orifice of the duct; it forms when the gland is sluggish. The secretion not being in sufficient abundance to hold the lime of the saliva in solution until it is ejected from the duct, that substance falls upon the floor of the duct, and, lodging, makes the calculus.

An instance is recalled where a mass of this calcareous matter, fully the size of the largest almond, seemed to be growing from all that portion of the sublingual region anterior to the gland of that name; one-half the tumor looked as if it might be below the level of the floor of the mouth, the mucous membrane enveloping the mass with a ragged and an ulcerated fringe, the condition presenting a strange and threatening look; there was no apparent direct association between the tumor and the neighboring teeth, and it was as firmly fixed as though it might be a growth springing from neighboring bone. Yet this was a salivary calculus and nothing else, the only question being as to its cause and fixedness.

Looking about the mouth, it was perceived that the patient had certain artificial teeth on the left side of the arch; these teeth were all coated with tartar, and so associated thereby with the natural teeth as to be only distinguishable by that difference in the translucency so immediately noticeable by any one experienced in such direction. Knowing well that it is a plan with many dentists to secure such teeth by passing a strong gold wire across the mouth, and which wire not infrequently buries itself within the mucous mem-



brane, thereby occasionally becoming concealed, it was inferred that this would be found the nucleus of the calculus, and accordingly examination was so directed. This was commenced by cutting away the mass from about the artificial teeth, and, as anticipated, a band was revealed; next was sought the concealed attachment of the opposite side, and this being discovered and exposed, the two ends were forced from the teeth which they clasped, and thus the artificial teeth, wire, and calculus were lifted from the mouth in a body.

The site of the calculus, as may be inferred, presented a cup-shaped ulcerated depression, and was quite angry-looking.

The only after-treatment consisted in the use of an astringent wash. The ulceration healed kindly in a very few days.

It is to be suggested that the existence of such calculi is not an infrequent cause of dyspeptic and other alimentary troubles. The writer has in mind the memory of a case of dyspeptic consumption very illustrative.

In her mouth, the patient, a lady, had but a single tooth, and this for years had been so imbedded in salivary calculus as much more to resemble a half-rotted shellbark than a tooth,—her breath was made insufferable by it. The offensive mass was removed, and the recovery of the patient was really magical in its rapidity.

Such calculi are to be removed in any convenient manner: they may be pulled away, broken in pieces, or, when loose, may be cut from the gum; the operation being entirely a mechanical one, and of course very simple.

Calculi situated in the salivary ducts are to be removed, either by enlarging the orifices and crushing the stones, or by cutting down upon them at the most convenient point. When so cut upon, the wound does not commonly require any after-attention.

The existence of salivary concretions in the ducts, particularly the Whartonian, is not at all infrequent; indeed, they are occasionally to be met with in the substance of the glands themselves. A specimen, extracted from the submaxillary gland, had its diagnosis in a continuous issue of pus from the tubal outlet. A second instance is on record where the glands of either side were found stuffed with calculi. When situated in the ducts, the sense of touch, exhibiting the hardness and irregularity of the body, will not infrequently afford recognition of the condition. Where, however, the enveloping tissues have become infiltrated and thickened, a diagnosis by such means is rendered obscure, and is perhaps to be secured only by passing into the tumor the blade of a delicate bistoury, or the point of an exploring needle.

In the case of a calculus in the substance of the submaxillary gland, met with by the author, a happy cure was effected by working the stone to a presentation upon the floor of the mouth, the purpose being accomplished by depressing the chin upon the neck and thrusting the gland from without upward. Knowledge of the exact position thus secured, a single cut, passing through the mucous membrane and mylo-hyoideus muscle into the substance of the gland, reached the body, which, with some little trouble, was secured



in the grasp of the forceps and removed. In size this calculus was about the circumference of a hazel-nut. The wound made healed completely after a week, and the patient had no future trouble. It is a feature to be added that in this case the facial artery had been obliterated as a result of the long-continued pressure.

An interesting and most suggestive case in this direction has the following record:

Mrs. B., a lady, sixty-nine years of age, residing in West Philadelphia, applied to the author, being directed by some unknown professional friend, concerning a tumor of the mouth, from an inflamed condition of which she was at the time enduring much suffering.

Ocular inspection revealed the following condition: a tumor, very scirrhus-like, hard, lobulated, and angry-looking, occupied all that portion of the floor of the mouth to the right of the mesial line; general inflammation of the whole oral cavity, to such extent as to make mastication too painful to be practised, and to render deglutition very difficult. All the teeth in the neighborhood loose, and occupying irregular positions,—the result evidently of a hyperplastic condition of the alveolo-dental membranes. The superficial cervical glands, especially those of the submaxillary region, sympathizing to a considerable extent; while the submaxillary gland itself was so enlarged as to render it sufficiently prominent to be easily mapped out.

The patient seeming unable to talk of anything except her present great pain, which she described as cutting, tearing, burning, the case was dismissed for the day, after prescribing for the immediate discomfort,—namely, the ordering of leeches, aperients combined with Dover's powder, astringent local applications, etc.

Two days after, the patient was again seen. The general inflammation was resolving very rapidly, while the mental equilibrium was quite restored.

This disease had been pronounced cancer by several gentlemen, and advice given that no application of any kind be made; that the patient should not even permit the tumor to be handled for any further examination. Under such impression as to its character, the lady had given up all hope of permanent relief.

The history of the case is as follows:

Eighteen years before, while engaged in milking an intractable cow, a kick was received under the chin, so severe in character as to compel a confinement to bed for over two weeks. This trouble gotten through, the parts soon recovered their natural tone, and seemed as well as ever.

A little more than nine months had passed, however, when the patient was made conscious of occasional slight inflammatory attacks about the region of the sublingual gland. These attacks continued to grow in frequency and extent, terminating, to use her own language, "by a something which looked like a whitish worm, coming from somewheres, into her mouth." This worm, she said, "was always the assurance of immediate relief."



The trouble continued to recur for over a year, when a tumor began to develop in the parts. The inflammatory attacks now decreased in number, but increased in severity,—the patient noticing that after each inflammation the size of the original tumor was augmented.

The case ran on after this manner for a period of several years. It was remarked, however, nearly ten years back, that the tumor had ceased to enlarge from the inflammatory attacks, having at that time gained the size of a pullet's egg, and neither increasing nor decreasing up to the time of examination. Reference is made, of course, to the tumor in a quiescent state, for each succeeding inflammation swelled all the parts, tumor included, temporarily, more than the one which had preceded it.

The patient's general health was quite good; there was no constitutional evidence to be perceived of a cachexia.

Now, while the history of this tumor, in its local features, was in many points the history of cancer, yet, considering the affection of the gland duct, which, as indicated by the story of the worm, evidently had association with the tumor; considering the inflammatory attacks to which the parts had been so frequently subjected, and which had resolved harmlessly; considering the length of time the tumor had existed, without passing or tending to pass to the ulcerative stage, it seemed necessarily decided that the tumor was of local signification, certainly not a cancer.

What then was it? The trouble commenced evidently as inspissated ranula. A conviction, founded on the history, was, that it was still a ranula. Not ranula, as derivatively we understand the meaning of that word, but ranula, as pathologically the term has association with the salivary ducts. What the contents of such cyst, if cyst there was, might be, the writer did not feel prepared absolutely to decide.

Acting on the strength of this conclusion, it was suggested to the patient that a bistoury be exploratively passed through the parts. This, however, met with a most decided negative,—the refusal not being, perhaps, at all strange, considering the assurance that Mrs. B. had so often received, that any attempt to operate would be her death-warrant.

Failing in several other attempts at persuasion, the case was later dismissed.

About a month after, prompted by curiosity, Mrs. B. was visited. There was now not the slightest evidence of inflammation about the parts. The tumor was about the size of a pullet's egg, hard almost as stone, and distinctly divisible into three lobes. The patient stated that, with the exception of an occasional sharp pain, she felt at the time little or no inconvenience.

At this visit, more than ever satisfied in a diagnosis, an exploration was re-urged, but was refused as before.

On a Saturday morning was called to see the patient. She was suffering from another of the inflammatory attacks; the most severe yet experienced.

Examination discovered the tumor swollen to such an extent as to throw the tongue over into the left cheek. Mastication had been impossible for three



or four days, while the ability to swallow was being very rapidly lost; yet, with all this inflammation, there seemed no tendency to the formation of abscess.

Placing the old lady in an arm-chair, before the window, the mouth was got under control, and, before she was aware of the intention, a bistoury was passed directly through the body of the tumor; the knife grated over a hard substance.

After a time spent in making peace, greatly assisted by the assurance given of the discovery which was to result in her immediate cure, the foreign body was dissected away. This, as anticipated, proved to be a salivary calculus. The specimen was presented to the pathological museum of the Philadelphia Hospital, and is, perhaps, one of the largest, if not the largest of such calculi, on record.

The pathology of such a lesion is at once appreciated: the formation of the calculus in this region was merely secondary to the occlusion of the mouth of a gland duct.

Dr. J. J. Woodward, the eminent microscopist, who made an analysis of a portion of the calculus, informed the writer that he found it composed almost exclusively of the phosphate of lime, only a very small trace of the carbonate being perceptible.

Saw Mrs. B., for the last time, one month later. All induration had so completely disappeared that it would have been difficult for any one who had not seen the case to say which side of the mouth the tumor had been removed from; not the slightest expression of disease being visible.

A case of calculus, interesting from its rarity, has been presented to the attention of the French Academy of Sciences, in which a concretion was removed from a sublingual duct of an infant but three weeks old. The history of the case is thus given. On the —, a poor woman called upon Dr. Burdel, complaining that the child could not take the breast, which she attributed to its being tongue-tied. Upon examination, Dr. Burdel did not discover any string or ligament of undue shortness, but found the sublingual gland so excessively developed as to raise the tongue considerably from the cavity in which it lies. He soon discovered, by touching the tumor with his little finger, that it must contain a hard substance. A slight pressure brought to light the extremity of a calculus, ending in a fine point, and, after some unsuccessful attempts, he succeeded in extracting it without an incision. The calculus is described as somewhat of an egg-shape, but ending, as already stated, in a fine point. Its size was that of a grain of wheat, its color yellow, its surface granulous, wrinkled, and formed of a number of minute cones or paps, cemented together at their bases. This is an instance of a salivary calculus formed before the birth, when the saliva, according to Dr. Cloquet, is but little charged with salts. An analysis of the concretion exhibited it as being composed almost exclusively of tribasic phosphate of lime and a small fraction of nitrogenous organic matter, which must have been mucus from the salivary duct.



As seen upon the teeth, tartar varies markedly in color and consistence, being sometimes so hard and closely adherent as to seem almost a part of the organs. In other instances it is found soft, and of such flaky nature that the slightest effort suffices to break it away in bulk. A character of tartar is found allied with the mucoid, or typh condition, being of pasty consistence, having, perhaps, a truer expression of its signification in the term *sordes*, being composed of detritus, combined with inspissated mucus.

In color, tartar varies from a dirty white to black, the shade depending on the temperament of the individual, yet being necessarily much influenced by personal habits. In the sanguineo-bilious, tendency to the deposit of flaky brown tartar is very marked. This deposit is the truest expression of salivary calculus, being composed almost exclusively of the constituents of the saliva.

United with all tartar are fungi. Here, as truly suggested by Herr Schrott, do the infusoria find convenient habitation, remaining the longest time, attaining their highest age, dying, and leaving their limy remnants to interlace with epithelial scales, parasites, remains of food, slime, and secretions of saliva, forming in this manner the tartar of the teeth.

That all tartar is not salivary calculus is made evident enough by minute examination. The deposit about the teeth of the scorbutic is in great part from the mucous glands situated in the mucous membrane enveloping the necks of the organs. Again, in mouths abounding in parasites, microscopic analysis shows plainly enough the analogy with the coral reef. Hence it is that analyses of this supposed common material are found so markedly and decidedly to differ.

The treatment of the ordinary collections of tartar about the teeth is very simple, and is to be made very effectual. Various cutting and scraping instruments, very well understood by glancing at the engravings, Fig. 101, are used in the process of removal. The operation consists simply in scraping away the mass (scaling, it is termed), being careful not to scratch the enamel, and afterward thoroughly polishing the teeth,—using for the purpose, first, pulverized pumice, afterward the ordinary burnishing instruments.\*

To prevent re-collection, cleanliness is a first requirement: the use of acid washes, carbolic acid soap, or dentifrices, is to be directed, as may seem to the judgment of the practitioner indicated, and the action of the glands is to be increased, by the use either of local or constitutional sialagogues. Or, if in any individual case the advisability of such prescriptions seem debatable, then pumice-stone, finely pulverized, may be used with a good stiff brush; or, what will be found a still better plan, the patient may, every few days, standing before a mirror, use the grit on a piece of soft pine or orange stick.

Salivary calculus, lodged about the teeth, has been thought to produce

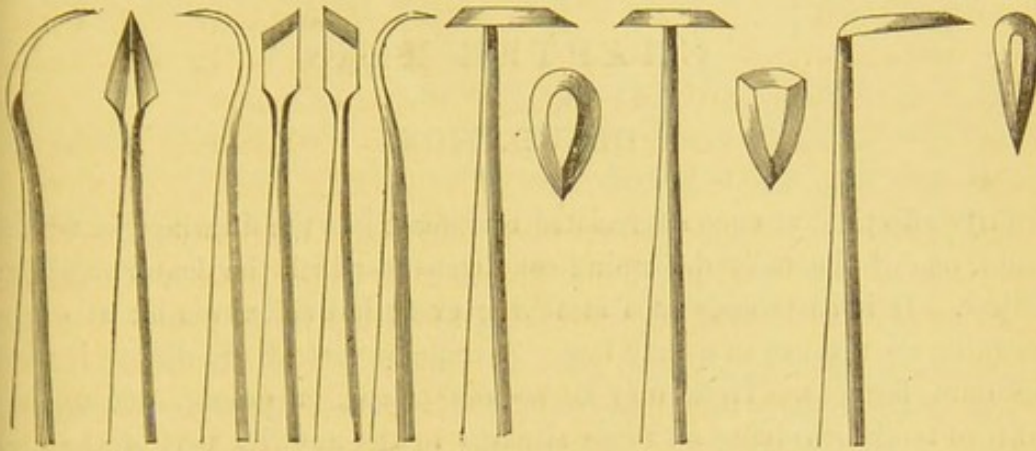
---

\* A set of instruments devised by Dr. Riggs, of Hartford, Conn., has a wide use in the treatment of calculus collections.



caries and necrosis of the alveolar processes. The author does not, however, remember in his own practice ever to have seen such a result. As the

FIG. 101.—INSTRUMENTS EMPLOYED IN REMOVING TARTAR FROM TEETH.



teeth drop out, the calculus falls away with them, and thus its power for evil ends. A spongy and scorbutic character of gum-tissue, and consequent hemorrhage, are, however, very common associations; but the practitioner at once sees that the cure is in his own hands.

The use of acids, highly commended by some as a conclusion to the operation of scaling, is by no means an objectionable practice. Not only does an acid, judiciously applied, cleanse the teeth thoroughly, but it also destroys infusoria which are themselves, as we have seen, tartar; and it serves as a stimulus to the deteriorated and generally spongy neighboring soft parts. Of acids which may be used for this purpose, none have advantage over the aromatic sulphuric, this being employed pure or diluted, according to the nature of the teeth to which it is applied, and the work proposed to be done with it. Acid is most conveniently used from the end of a pine stick, the detritus left by the scaler being softened and dissolved by it. Ulterior ill effects are neutralized by frequent rinsing with ammoniated water. The objection that an acid will dissolve the lime-salts of the teeth, as well as the offence against which it is directed, has as little weight as that a scaler will cut enamel, or that calomel will salivate.




## CHAPTER XIX.

### DENUATION.

THIS affection, at once appreciated by referring to the drawings, is, without doubt, one of the most deforming conditions to which the dental organs are subject. It is sometimes seen attacking every individual tooth; at others, confining its ravages to a very few. A common seat of the disease is where the gum festoons. Here may be seen a sulcus, or groove, passing from tooth to tooth, involving all those situated in the anterior part of the arch. Another form of the condition involves the cutting edges alone; while in still other cases the depressions are situated promiscuously over every portion of the teeth.

The disease, commencing as a slight gutter, or break, in the enamel, progresses with a varying degree of rapidity, sometimes moving with such slow

FIGS. 102, 103.—DENUATION.



pace as scarcely to be observed from year to year; in other instances, and these, unfortunately, much the most frequent, making constant attention necessary to the preservation of the organs. Occasionally the process begins at a number of points, and these, enlarging, finally coalesce, to the destruction not infrequently of all the anterior enamel wall.

Concerning the cause or causes inducing this condition, much diversity of opinion exists. The present conviction of the author is that the true explanation is just now, for the first time, enunciated in the electro-chemical experiments made by Mr. Kencely Bridgman (see *Dental Caries*), and that in this direction will be found to lie not alone the cause, but the prophylaxis. As all that may be said on this subject is expressed in the experiments themselves, the careful attention of the reader is directed to them. True it would seem to be that back of the immediately-acting cause must lie a predisposition: here would seem to be the result of impressions made on the enamel at the period of its formation, and which deficiency the nutritive functions have failed to correct. It might, indeed, very well be that such enamel is entirely deficient in vital resistance, and thus subject to be acted on as any inorganic structure; being by electrolytic action simply dissolved. To



combat such a condition, electrolysis must be negated. If the assumptions from the experiments of Mr. Bridgman, here made, and which seem to the author so rational, be accepted, the treatment of denudation is the antagonism of electro-chemical action; this perhaps alone, as devitalized enamel might not be aided by vital defence.

Treatment of denudation has heretofore been confined exclusively to combating by operative means the ravages inflicted, such means consisting in reaming out and filling with metal the cavities, as one after another may threaten from its extent and depth.

#### ABRASION OF CUTTING FACES.

Abrasion of the cutting face of the teeth from mechanical causes is a very common affection, and a very unfortunate one. The articulation of the two dentures has much to do with the production of such a condition; indeed, everything, if we except an abnormal softness of enamel as found in certain teeth. Teeth that articulate scissor-fashion, the one set over or in front of the other, seldom suffer from this trouble. It is most markedly an affliction of direct articulation.

Persons having jaws thus articulated find their teeth year by year wearing shorter; and were it not that, as this abrasion goes on, nature offsets the waste by internal repairs, throwing out layer after layer of secondary dentine, the dental pulps would be quickly enough exposed.

The character of food used, while perhaps it would never yield this condition, yet, the predisposition in the articulation existing, without doubt assists in the destruction. Thus, it is remarked that sailors, eating constantly of hard bread, and chewers of tobacco, are most subject to abrasion. This is strictly true, however, only as it applies to such as have the peculiarity of articulation, and with such the progress of abrasion is commonly very rapid.

A means of relief to this condition which, while fairly successful, is associated with more or less discomfort, consists in the adaptation to the posterior teeth of caps of metal. These caps take the strain of mastication, and thus protect the teeth. Another mode, but which is apt to excite inflammation, consists in cutting out cavities from the abrading faces of the teeth, and supplying the place of the removed dentine with plugs of gold. This latter plan has many advocates, and is highly commended by practitioners of experience and judgment.



## CHAPTER XX.

### OPERATIVE DENTISTRY.

#### INSTRUMENTS USED IN PREPARATION OF CAVITIES.

WE are here introduced to a department of Oral Surgery familiar under the name of dental art, a department which considers the mechanical treatment of carious cavities and other physical defects found in relation with the teeth.

Fig. 104 is re-introduced as illustrative of a perfect denture; to find a set of teeth so complete in construction and relation is an experience of exceeding rarity. Teeth so arranged and free from irregularities seldom decay.

FIG. 104.—SUPERIOR DENTAL ARCH.

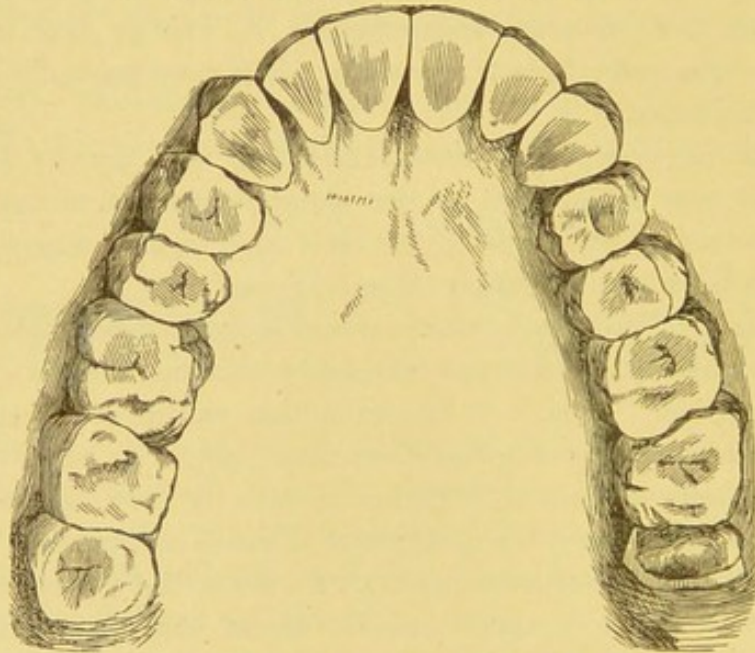


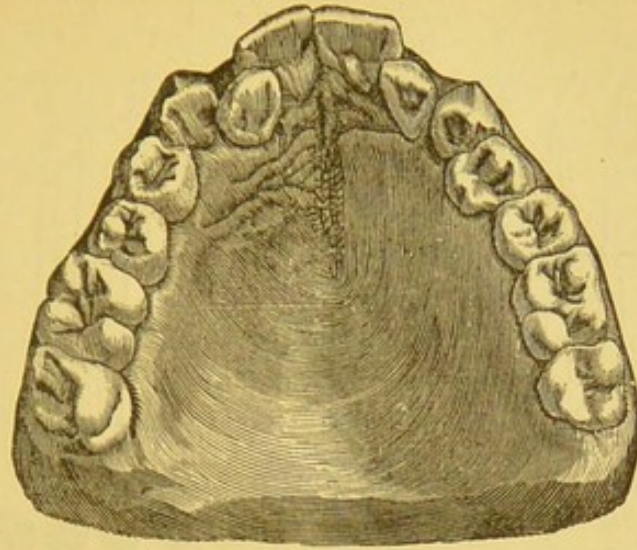
Fig. 105 represents the typical American mouth; the imperfection of face of the organs illustrated, combined with overcrowding of the arch and deficiency in the inorganic constituents of the dentine and enamel, render such teeth the easy prey to disease.

Cavities found in teeth are of every variety as regards size, shape, and location; dental art exposes, cleanses, and fills, with metal or other material, these cavities. Understanding of the instruments used, manner of preparing cavities, processes of making fillings, together with associative treatment required in the conduct of cases, implies comprehension of operative dentistry.

The subject opens with a view of means employed for the exposure and excavating of cavities; these means appropriate various instruments known as excavators, drills, the dental engine, chisels, files, saws, disks, chip-blower, and water-syringe.

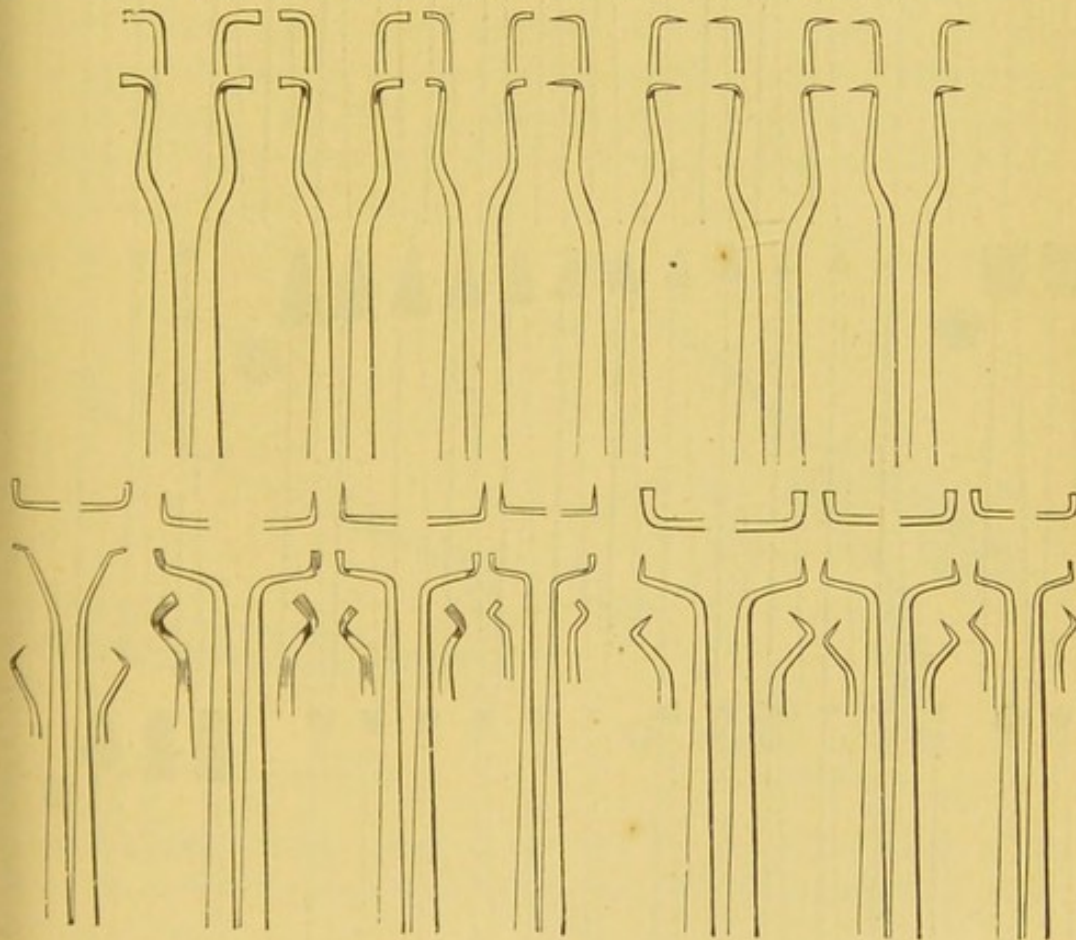


FIG. 105.—SUPERIOR DENTAL ARCH.



**Excavators.**—An excavator is an instrument designed to excavate, or clean out, a cavity. Excavators, while variously modified, are founded on two

FIG. 106.—HOE EXCAVATORS AND MODIFICATIONS.



elementary styles: one, hoe-like in shape, cuts as it is drawn toward the operator, the other represented by the relation of the edge of the ordinary hatchet to its shaft or handle, cuts with lateral motion.



FIG. 107.—HATCHET EXCAVATORS AND MODIFICATIONS.

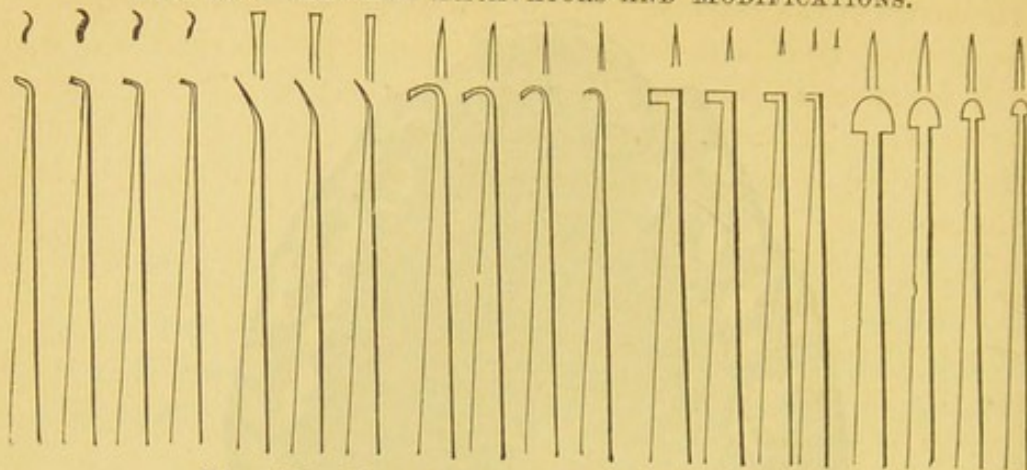



FIG. 108.—ROSE DRILLS AND SPEAR DRILLS.

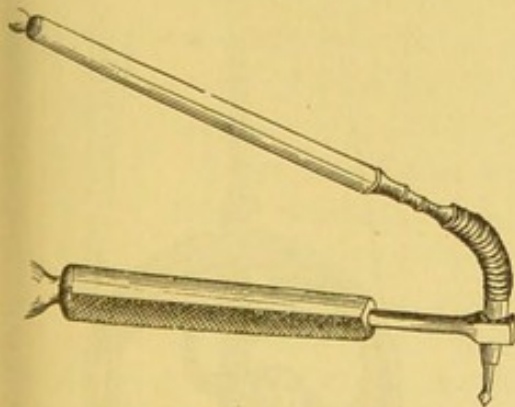




Examination of the diagrams gives a general idea of these instruments. Unless, however, made of the finest steel, and shaped and tempered with the nicest appreciation and care, it is impossible to execute with them the requirements demanded. Excavators fit for the hand of an operator should be able to endure the test of an unturned edge when used to cut a cavity in a piece of ordinary ivory.

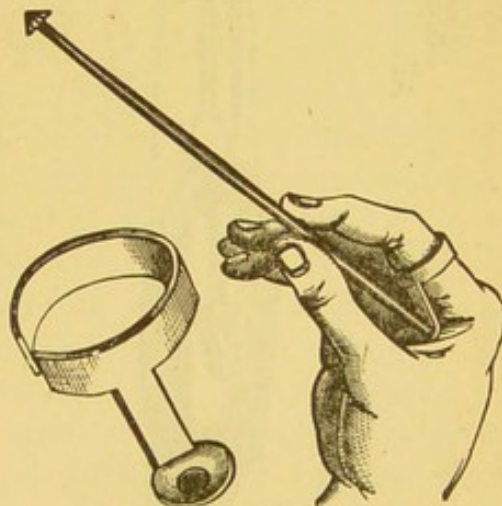
**Drills—*Rose and Spear.***—These express modifications of the excavator. When properly tempered they cut with rapidity, and while clearing a cavity tend to give convenient shape for the retention of the filling; the spear-drill is used also for the purpose of securing what are called retaining-points for plugs,—a matter to have consideration in connection with particular cavities. Drills, like excavators, are made with handle and point in one piece, or are fitted to separate handles, which handles may be made of steel, ebony, pearl, or more expensive material, to please the taste; the single piece is, however, commonly preferred, as being the most convenient form. To use this instrument it is only necessary to rotate it between the thumb and finger, or, where pressure is found desirable, the palm of the hand is spared by receiving the butt of the drill in a socketed ring or thimble. Drills are also used associated with handles, which allow of application at any angle desired. Of such stocks there are quite a variety, the most simple of which is perhaps that known as Merry's. Fig. 109 exhibits this drill as ready for use. Fig. 110 represents the bur thimble: this consists of an open ring for the middle or

FIG. 109.



Merry's Drill, ivory handle.

FIG. 110.



Bur Thimble.

index finger, with a socket attached, in which the end of the handle of the drill rests: it saves the hand, while at the same time the instrument is rotated with more ease.

**Dental Engine.**—A manner of using both excavator and drill now almost universal, being a great saver of both time and trouble, consists in the adaptation of these instruments to, and the employment of what is known as, the dental engine. This machine, capable of producing several thousand



FIG. 111.—THE WHITE DENTAL ENGINE.

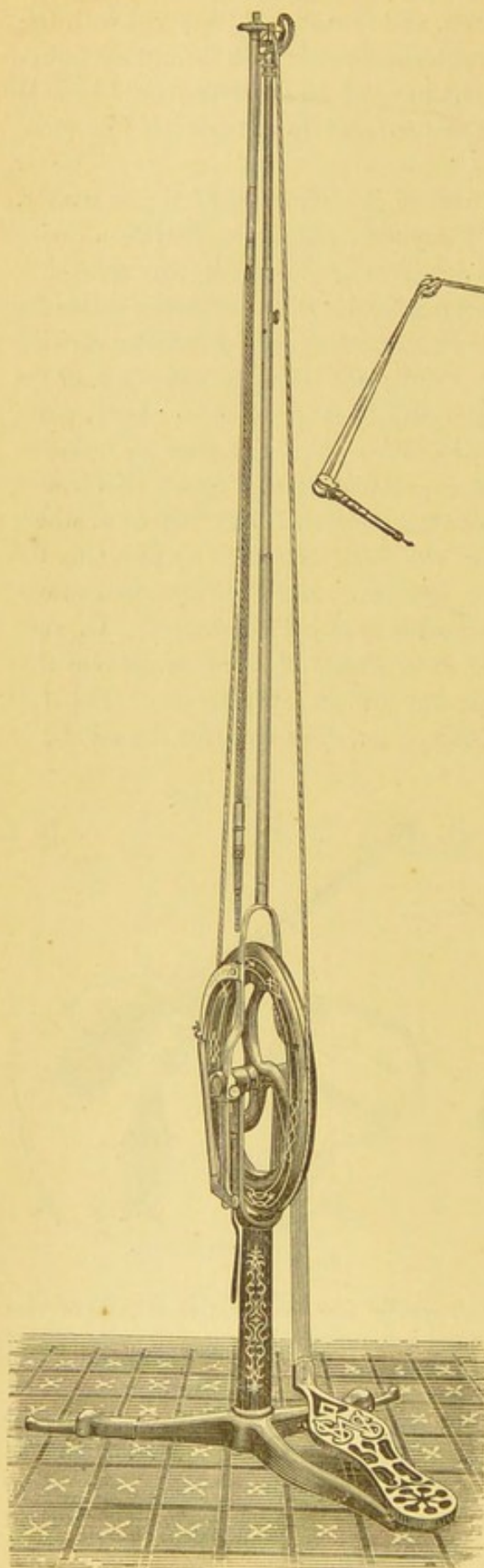
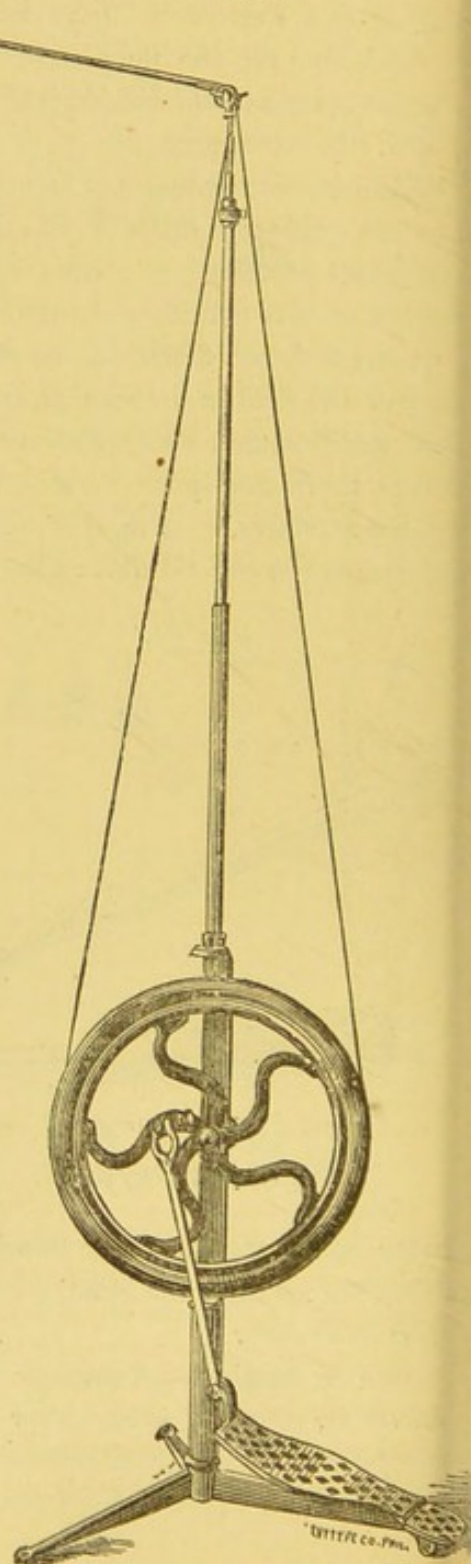


FIG. 112.—THE BONWILL INSTRUMENT.



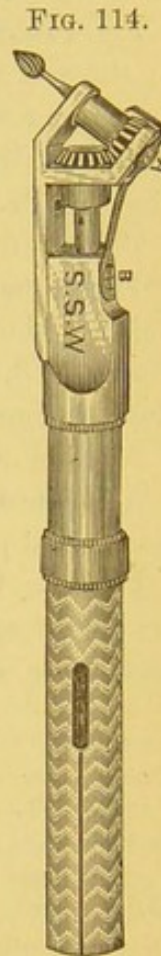



revolutions of a mandrel in a minute, carrying at the same time a bit with such steadiness that motion is not observable, enables an operator to accom-

plish his end with a certainty and precision to be appreciated only by him who is familiar with the work; it is a great saver of time and trouble.

Of these engines there are two general forms: one, known as White's, has its individuality in a flexible shaft; the other, Bonwill's instrument, is constructed after the type of a human arm. Several modifications on the two principles are in the market, each laying claim to peculiar and special virtues.

A capability to act in any direction is given the hand-pieces of these engines by means of attachments. Fig. 113 represents a straight hand-piece; the action of it will be recognized by the mechanic. G, spindle, or bit-holder; D, sleeve-bearing, to which the front and rear portion of the casing are attached; H, adjustable collar, by which any end-wise movement of the collar is taken up. The rose drill, seen in place, is fixed or loosened through means of the slot at its terminal end. The relation of this drill to the hand-piece is that occupied by the very great variety of instruments used in connection with the engine. Fig. 114 exhibits an attachment acting at an obtuse angle. A dental engine is to be looked on in the light of a duplicate hand possessed of an ability to work rapidly; it is not an instrument necessary to the accomplishment of dental operations.\*



**Chisels.**—Chisels used in dentistry are of great variety in form. Although not employed with a former freedom, their purpose being superseded in part by disks, they are yet found valuable adjuncts to every operating-case. All cavities in the approximal faces of teeth require for their proper exposure the employment of chisels or of something representing them. As the various

\* While Fig. 113 illustrates perfectly the action and meaning of a hand-piece, the attention of a student is to be directed to the existence of quite a variety as to forms and pretension; the latest is known as the cone journal hand-piece. Dental catalogues, obtainable by application to the dental depots, keep one informed of the improvements, real and so called. Advantages claimed for the cone instrument are,—

*First.* It has an absolutely SECURE and TRUE bur-fastening. When locked, the bur and spindle become like one STRAIGHT and SOLID piece.

*Second.* The working parts are readily exposed for oiling, cleaning, or inspection, without disturbing the adjustment of the bearings of the spindle.

*Third.* The bit can be changed while the engine is in motion, the spindle running as



forms possessed by the cutting faces of these instruments have evolved out of experience, so a very little use of them suffices to show an operator which are to be selected to meet a purpose.

Fig. 115 shows styles and forms of chisels in ordinary use. A modification on these is known as Jack's double-end enamel-cutters. Six instruments constitute a set of these last, such set being designed to furnish all the forms needed for freely cutting the enamel in separating teeth. Fig. 116 exhibits these chisels.

Other varieties of the same instrument are designed for opening fissures, making retaining-points, and also for enamel-cutting wherever applicable. Fig. 117 shows chisels of this kind designed by Dr. Forbes and Dr. Jack. Nos. 1, 2, 3, 7, 8, and 9 are known as gouges. Nos. 4, 5, 6, 10, 11, and 12 illustrate paraboloid chisels.

A chisel of late device, the invention of Dr. E. P. Brown, is three-edged; it is designed for opening fissures, trimming down walls of enamel, dressing the cervical parts of cavities, and to assist in removing calcareous deposits.

**Files.\***—Fig. 118 represents a simple straight file, which is to be viewed as the base from which all others digress. A file of such form will at once be accepted as well adapted to separating approximating surfaces; as, for example,

---

free with the lock released as when the bur is clamped,—a very desirable feature, especially when a motor is used.

*Fourth.* The facility with which one bit is substituted for another without changing the position of the hand-piece in the hand.

Hand-pieces require continuous attention in order that they work properly. Rust is a difficulty. Blood or water when allowed to remain upon the bit quickly rusts it into solid attachment with the holder. Oil is a necessity. A hand-piece is to be taken apart at the end of each day's operations, and after being wiped thoroughly clean is to be lubricated with sewing-machine oil. Where a bit is found rusted, an easy plan to remove the incrustation is to rub with oil and lay by for a few days, after which a scouring of quicklime restores the original brightness. Mercurial ointment is recommended as a protection against rust; to be used by coating instruments with a thin film.

Absolute dryness is to be esteemed an essential in the preservation of instruments, no other care compensating for lack in this.

A matter to be borne in mind in the use of all surgical tools is danger in carrying disease. As a guard in this direction disinfection is never wisely omitted. Such guard is found in the free use of very dilute carbolic acid. In the Hospital of Oral Surgery phénol sodique is used.

\* Files require to be kept very clean, not only as disinfection is concerned, but in order that they cut properly. At the conclusion of an operation it is well to throw such as have been used into a vessel containing soap-water, and after allowing them to remain for a few minutes to thoroughly cleanse by means of an ordinary nail-brush.

Files are instruments which particularly demand fine tempering. Many makes or individual lots are, in this respect, absolutely worthless, either bending or breaking at the moment of application. Of the two faults the former is the worse.

A perfectly tempered file will accomplish an amount of work that is quite surprising; and when met with is to be treasured as a something that is not easily to be replaced.

Considering the many makes of these instruments offered for sale and carrying large recommendation, it is to be suggested as a judicious plan that samples of the different kinds be tried with a view of the student possessing himself of the desired practical information. Manufacturers, with an idea to economy in the purchases, put up the straight files of different numbers in a common package.



FIG. 115.—SOME FORMS OF CHISELS USED IN DENTISTRY.

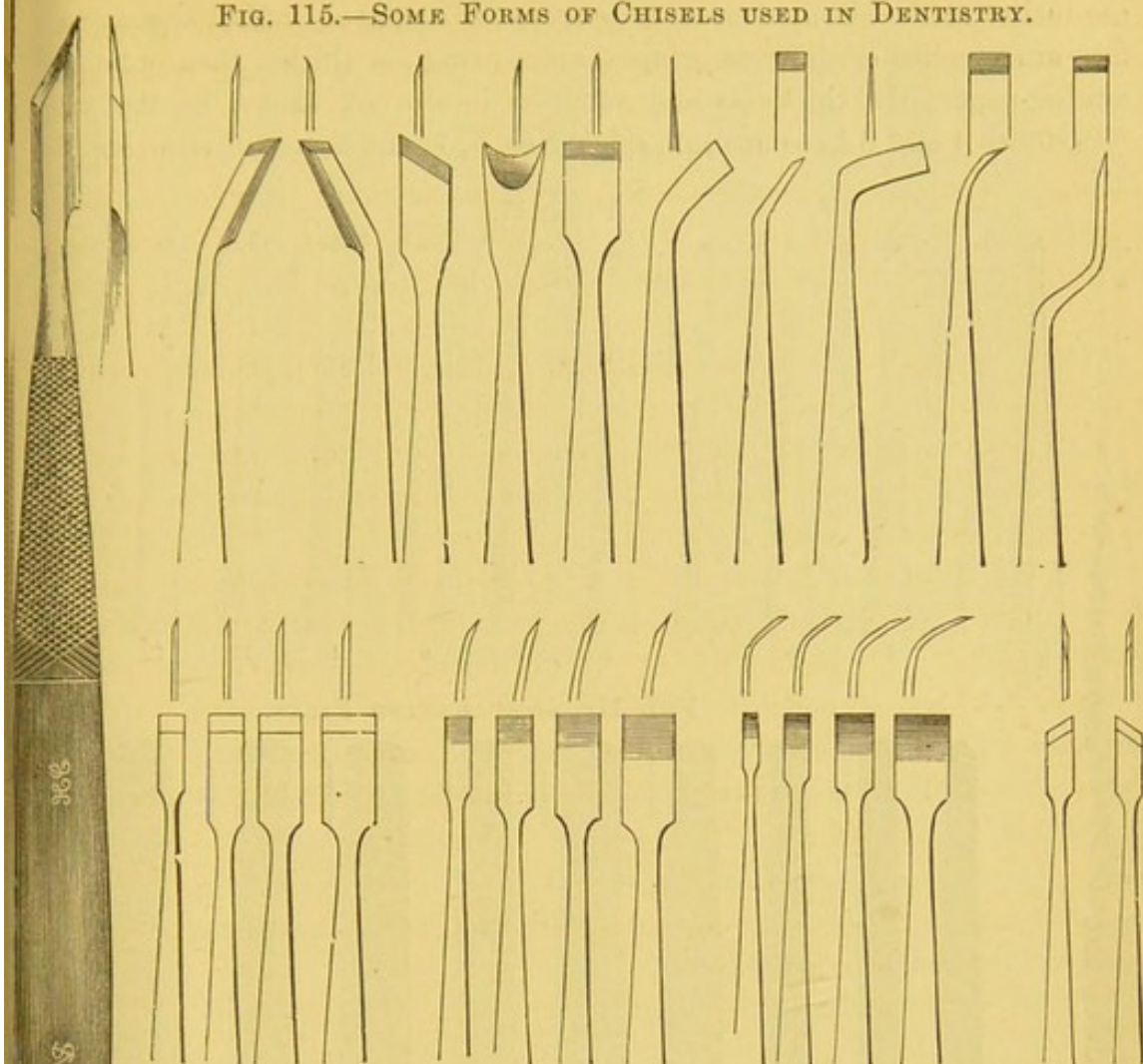
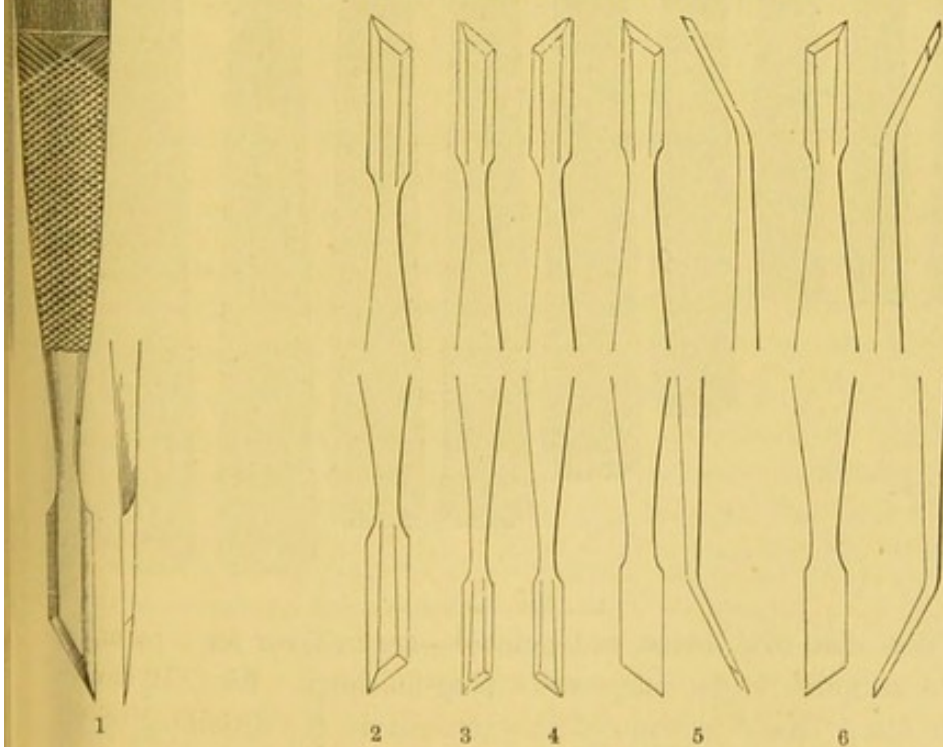


FIG. 116.—JACK'S DOUBLE-END ENAMEL CHISELS.





the incisor teeth. Simple or, as they are more commonly called, separating, files are supplied of different gauges, some being not thicker than ordinary writing-paper; the thickness and variation in size are shown by the cut. Nos. 00 to 4 and 6 have one safe side; Nos. 5, 7, and 8 are cut all over.

FIG. 117.

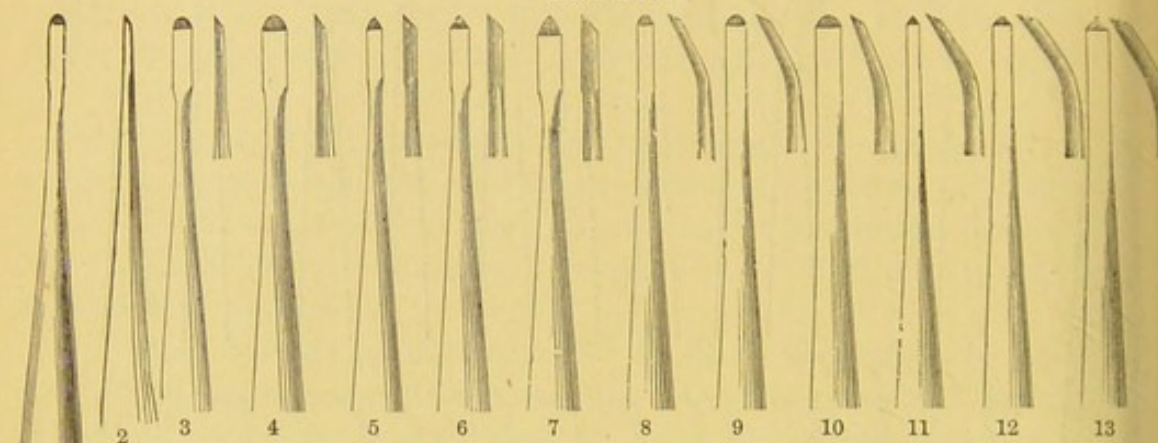
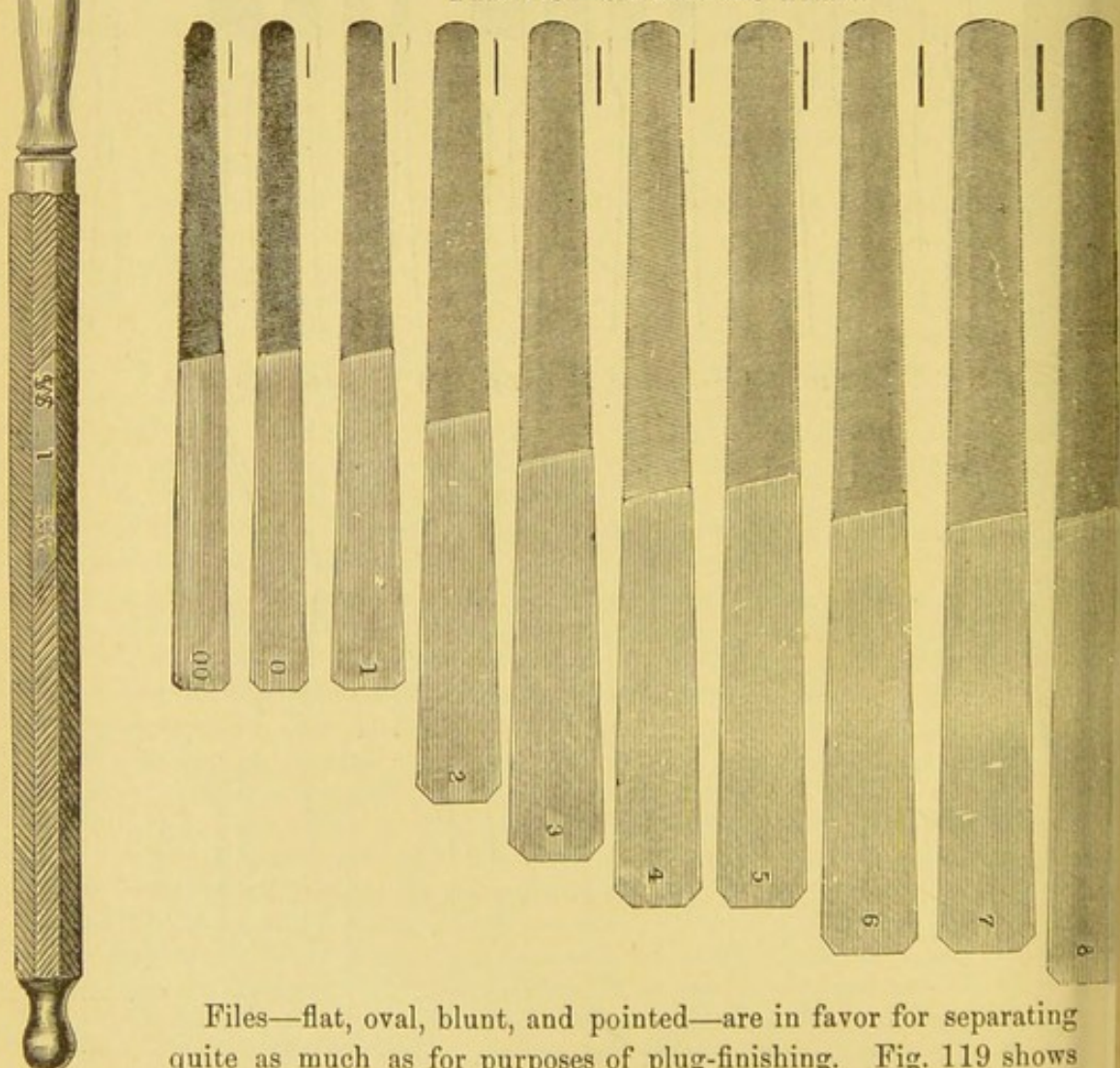


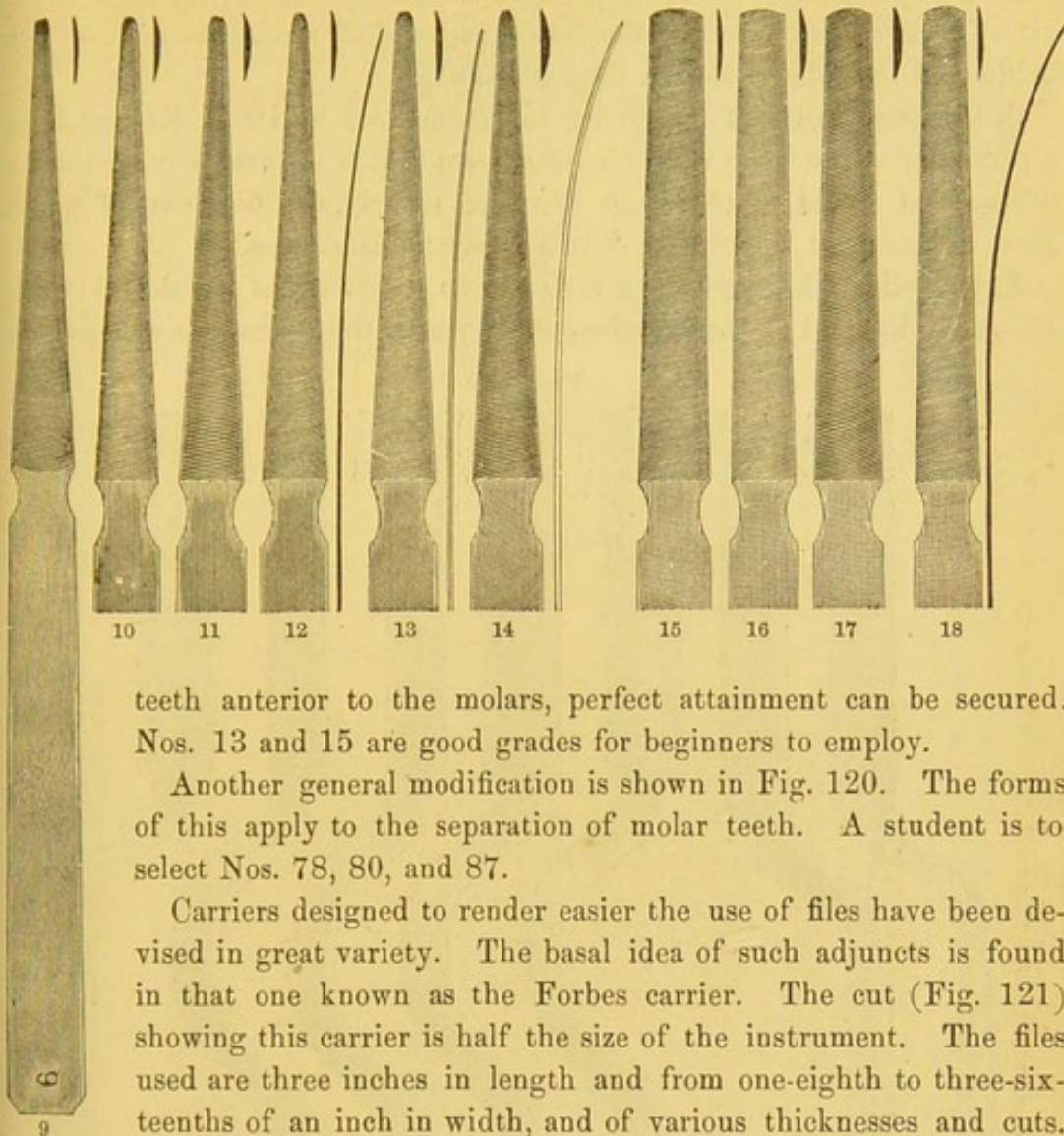
FIG. 118.—SEPARATING FILES.



Files—flat, oval, blunt, and pointed—are in favor for separating quite as much as for purposes of plug-finishing. Fig. 119 shows such files. Made to succeed the straight in the disjoining of all



FIG. 119.



teeth anterior to the molars, perfect attainment can be secured. Nos. 13 and 15 are good grades for beginners to employ.

Another general modification is shown in Fig. 120. The forms of this apply to the separation of molar teeth. A student is to select Nos. 78, 80, and 87.

Carriers designed to render easier the use of files have been devised in great variety. The basal idea of such adjuncts is found in that one known as the Forbes carrier. The cut (Fig. 121) showing this carrier is half the size of the instrument. The files used are three inches in length and from one-eighth to three-sixteenths of an inch in width, and of various thicknesses and cuts.

The shaft of the carrier extends through the handle, and can be adjusted at any point by a thumb-screw at the end. Files of shorter lengths can be used and held firmly.

Fig. 122 shows a carrier designed by Dr. W. G. Miller, which is in much favor with operators. This appliance, with the different frames and heads shown, will hold and carry files and saws in any position desired for operations on the teeth. Frame No. 1 is jointed, so that the head can be passed on to the top of it and carry the file at any slope, as seen in No. 3. No. 1 head is also notched, so that, when in a direct line, the top of file drops in the notch, as seen in No. 2, which greatly adds to its rigidity in place. No. 2 frame carries the file or saw rigidly in a straight line, and also at an angle; besides which, its shape at one end allows the head to pass to the place shown in No. 3 and hold the frame at any slant desired.

This carrier, with its three heads, as shown, admits of changing direction and slant very quickly. With either the No. 1 or No. 2 it is complete for use. The No. 3 is desirable for holding files to cross-cut and separate;

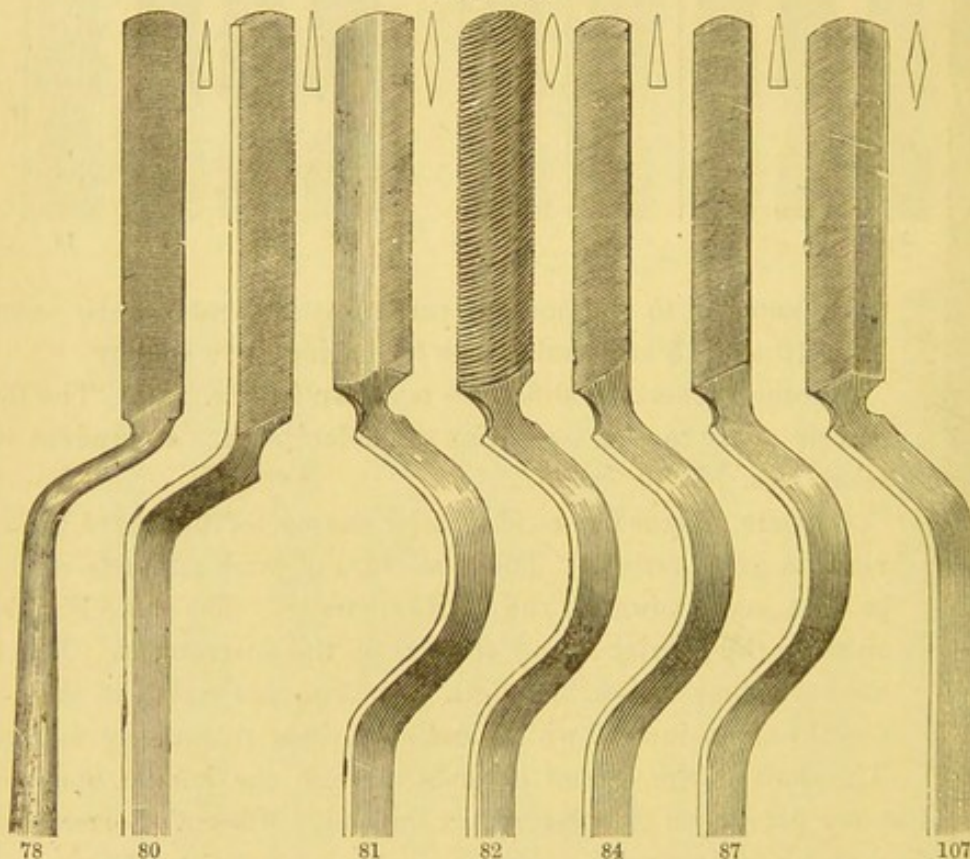


rigidity is gained by the bow-spring form of frame. A friction-block in the cavity of the head, between the frame and end of screw, insures very firm holding of the frames, so that they will not slip.

A still later design of file-carrier is one devised by Dr. J. Edward Line; a particular virtue lying with this instrument is that it enables an operator to utilize what would otherwise go to waste, namely, the best part of broken files. The carrier is met with figured in dental catalogues.

**Saws.**—Saws for separating teeth are an outgrowth of the dental engine. Delicately handled by the experienced, they meet the indications with a degree

FIG. 120.



of perfectness which, so far as molar teeth are concerned, make them favorites with all. These saws are circular in form.

**Corundum Disks.**—Disks made of corundum, used with the engine, are in general use as a means of separating teeth. Fig. 124 represents a side

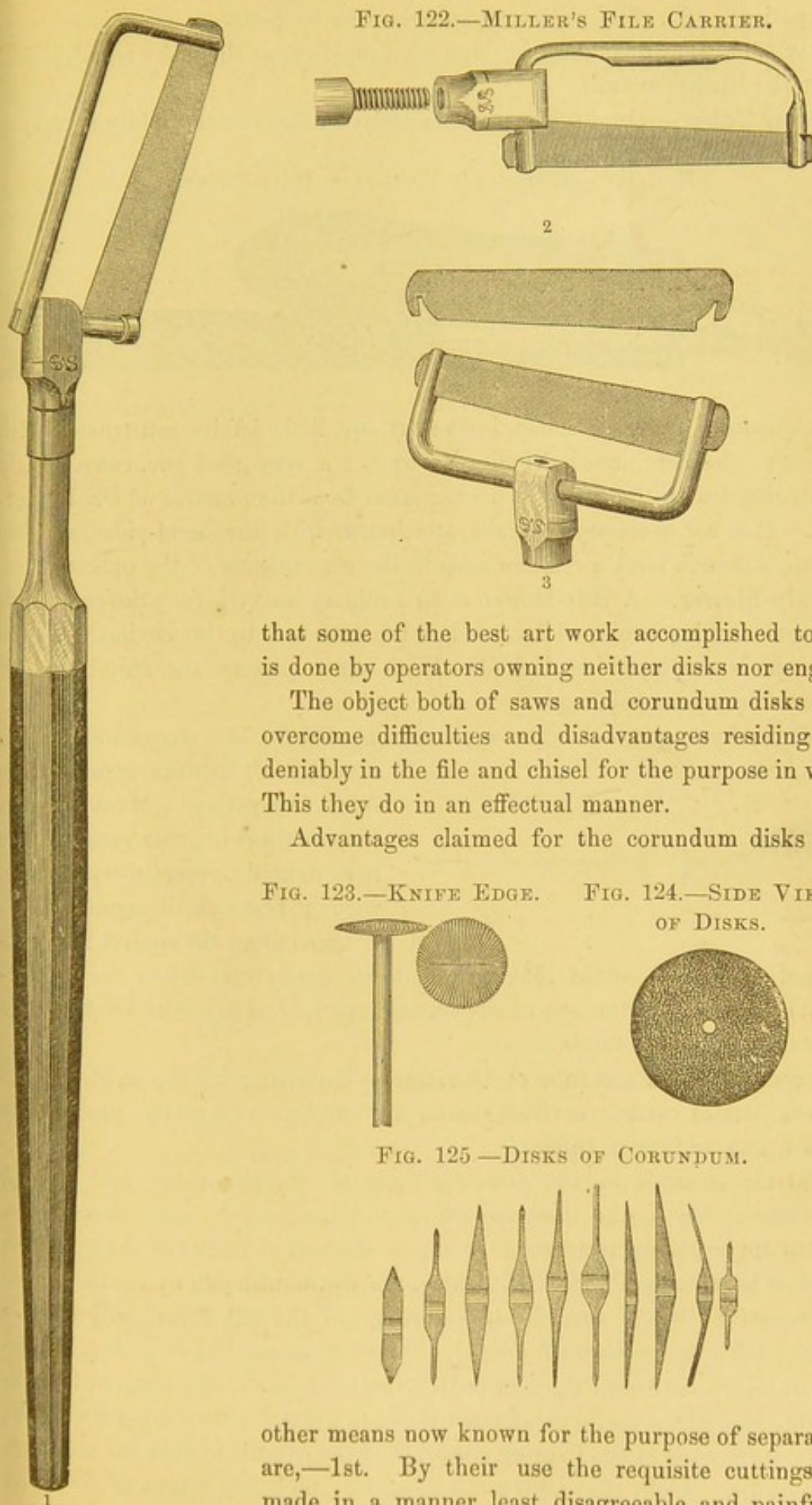
FIG. 121.—FORBES'S FILE CARRIER.



view of the instrument. To apply a disk of this brittle material requires a delicacy of manipulative tact to be gained alone out of experience. One unfamiliar with its use breaks the piece almost at the moment of application. Students are to master chisel and file before passing to disk and engine; the latter are luxuries, not necessities, in practice. It is not to be overlooked



FIG. 122.—MILLER'S FILE CARRIER.



that some of the best art work accomplished to-day is done by operators owning neither disks nor engine.

The object both of saws and corundum disks is to overcome difficulties and disadvantages residing undeniably in the file and chisel for the purpose in view. This they do in an effectual manner.

Advantages claimed for the corundum disks over

FIG. 123.—KNIFE EDGE.

FIG. 124.—SIDE VIEW OF DISKS.

FIG. 125.—DISKS OF CORUNDUM.

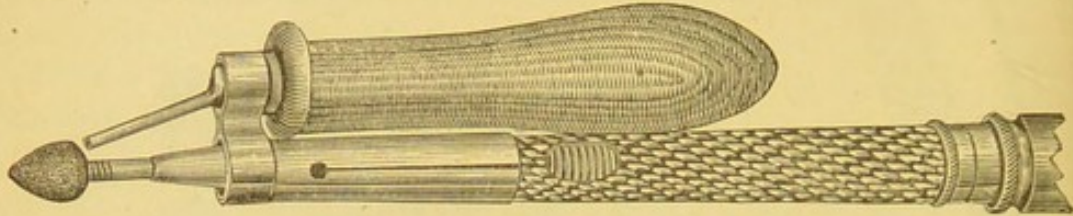
other means now known for the purpose of separating are,—1st. By their use the requisite cuttings are made in a manner least disagreeable and painful to



the patient. 2d. The separated surfaces can be polished quickly and perfectly. 3d. The disjoining is done with rapidity, as the disks readily grind away the hardest enamel.

**Drop Tubes.**—Drop tubes are a necessity in the use of rapidly revolving

FIG. 126.—HERRICK'S FOUNTAIN DRIP-POINT.

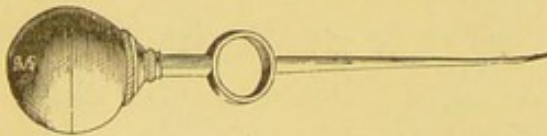

instruments. These, as shown in the cut, are little affairs constructed with a view to the continuous dripping of water; a very good one, conveniently manipulated with the finger, is a suggestion from the practice of Dr. F. Herrick. It is not necessary to make attachment with the hand-piece, as here shown, although such a relation adds to the convenience of the operator.

**Chip-Blower.**—A chip-blower is an ordinary air-syringe. Several kinds are made. They are used by hand or are attached to the engine. Hot or cold air is employed as desired. With most persons the chip-blower is replaced by a water-syringe.

**Water-Syringes.**—A water-syringe is needed for the purpose of freeing a cavity of detritus accumulating from excavation. Manufacturers prepare these in great variety. One here figured answers every purpose, without being at all expensive.

FIG. 127.—WATER-SYRINGE.



Concluding the subject here considered, it is to be added that a student acts wisely who defers the employment of a dental engine and its apparatus until he has educated his fingers to accomplish ends by simple means.

**Exposing the Existence of Cavities.**—To distinguish the existence and peculiarities of carious cavities, dental art employs excavators, probes, silk thread, and wedges of rubber.

Cavities situated in the grinding faces of the bicuspidati and molares are discoverable to the most superficial examination, it being alone necessary to apply a sharp instrument to expose the soft character of the structure. Cavities between teeth, if at all sizable, are distinguishable by insinuation of an excavator: where superficial, the passage of the silk thread will discover enamel deficiency. Rubber wedges, or the instrument known as Jarvis's separator, placed between suspected teeth dispart the organs and admit of free exposure. A probe is useful as reference is had to a search after pin-point cavities; the instrument is to be of spring temper, and the point is to have the acuteness of a needle. Light is at all times a requisite; no better means of obtaining



this is to be found than lies in the use of the ophthalmoscopic mirror of Anagnostakis; this glass not only reflecting powerfully but extensively magnifying.\*

The employment of cold water is found valuable in exposing the existence of a cavity, and as well in furnishing idea as to proximity of pulp; it is used by being thrown from a syringe over the suspected locality. The existence of cavities is to be inferred, *cæteris paribus*, where sweets or acids, hot or cold articles of diet, are found to disturb the comfort of the teeth.

---

\* For dental purposes this glass is reduced to a circumference of six inches, with a focal point of two inches. For concentration of light-rays, and for magnifying power, this mirror shows itself everything to be desired or that is required in the direction; human incisor teeth are made to approximate those of the horse in size.



## CHAPTER XXI.

### OPERATIVE DENTISTRY.

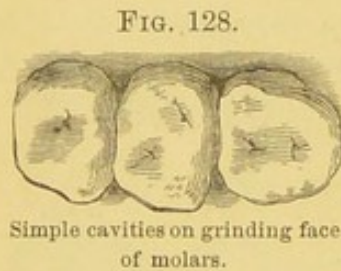
#### EXCAVATION, OR PREPARATION, OF CAVITY FOR FILLING.

HAVING considered the kinds of instruments used in the process of preparing a cavity for its plug, or filling, we pass to the subject itself.

First we treat of simple cavities,—*i.e.* holes more or less round, situated in the grinding faces of molar teeth. Fig. 128 shows such cavities.

Caries, as seen in the cut, varies as to the extent and character of the hole. In teeth of solid structure the orifice commonly represents the extent of circumferential involvement. On the contrary, where

tooth structure is loose and disposed to degeneration, a small orifice is not infrequently found leading to extensive underlying disorganization. To prepare such cavities for filling, an operator may use either excavator or drill; the most simple means, certainly the most expeditious, is found in the drill. Selecting a size suited to the opening,



the operation consists simply in reaming out the hole, the single precaution being observed of having the common diameter of the cavity as large as the outlet; to have it a trifle larger is even better, as thus a filling is retained with greatest security.

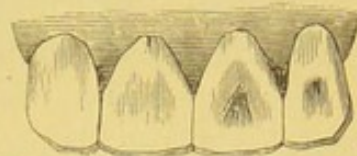In cases where, after breaking through the entrance, a large cavity is seen to exist, drill after drill of increasing sizes is to be employed, thus making it correspond with the cavity being made within. Or, in such cases as present a resisting enamel, the orifice is to be most conveniently enlarged through the use of a chisel. Selecting such chisel of suitable size, the operator, little by little, chips away the operculum until the circumference of the diseased dentine is exposed; this accomplished, it remains only to refer to the drill or the excavator. In using a rose drill precaution is taken to avoid evolution of discomforting heat ensuing from rapidity of rotation, which is done by careful drilling, or otherwise through the frequent dipping of the instrument in cold water, or still else by the use of a drop tube.

Fig. 129 represents cavities of a kind frequently found on the posterior face of incisor teeth. Such cavities correspond closely in their mode of preparation with those just described. A peculiarity occasionally observed



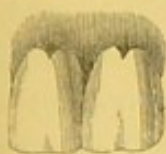exists in the tendency of a delicate line of disease to start from the bottom of the common cavity, making its way directly toward the pulp-chamber. Where such line is found, it is neither necessary nor desirable to associate it with the first cavity otherwise than by a reaming correspondent with its own diameter: should it be found to increase greatly in sensibility as it approaches the pulp, experience has demonstrated that it is the best plan to allow a portion of the diseased dentine to remain; harm is not apt to ensue from its presence if it be disinfected and put in a state of neutrality. Rose drills are commonly used, to the exclusion of other instruments, in the preparation of these cavities, although the occasional convenience of the excavator is not to be denied. Great care is to be exercised in these cases, as, indeed, in all others, to have the orifice of the cavity sharply defined in its circumference; if it is strictly round so much the better, as thus the material used in filling can be made the more easily to associate harmoniously with it, such union being an absolute essential to the integrity of a plug.

FIG. 129.



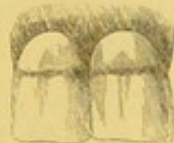Cavities on posterior face of incisors.

FIG. 130.



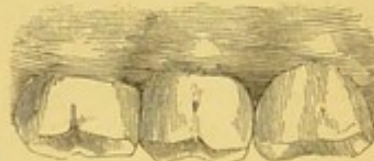Cavities at neck—anterior face—of incisors.

FIG. 131.



Cavities found in the midst of imperfect enamel.

FIG. 132.



Cavities on buccal face of molars.

Fig. 130 represents what is to be described as the third class of cavities; these being very frequently met with in the position shown in the cut. A more common location, however, is on the buccal face of the molar teeth in a sulcus about midway of the face. (Fig. 132.)

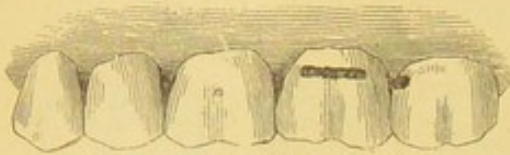When a cavity is situated as seen in the drawing (Fig. 130), part of it being overlaid by the gum, it is found most convenient to remove a portion of the carious dentine by the use of an excavator, and to stuff the hole thus secured with a cotton filling, which cotton is to be allowed to project to some little extent; this filling, as it absorbs moisture and swells, naturally throws the gum from off the roof of the cavity, thus allowing the completion of the excavation as described in previous cases. The cotton is to remain in a cavity over-night.

Fig. 131 represents a condition of imperfect enamel, in which frequently is found a number of pits: if examination, made with a sharp excavator, show the bottom of such pits to be enamel-covered, they need not be filled; if, however, the point of the instrument is found to stick, or wedge, then it is best to ream out with a spear or rose drill and plug: not to treat such cavities is to allow caries to destroy the teeth. Unless of themselves running into each



other, these cavities are not to be associated; situated on the buccal faces of the molars, such holes are to be reamed out with the rose drill. A complica-

FIG. 133.



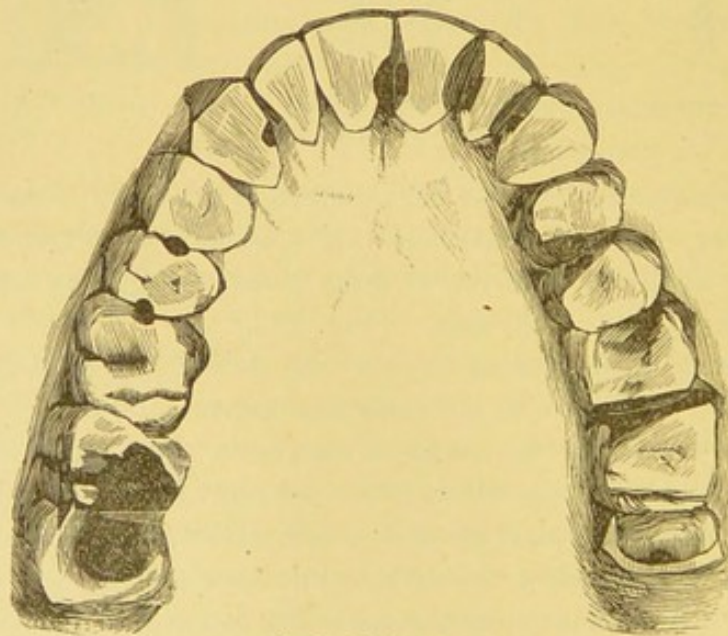
Cavities on buccal face of molars.

tion frequently found to exist is where, starting from such a point, it may be in an abrasion near the neck of the tooth, the disease extends laterally, scooping out, as it were, a cavity (Fig. 133): here the excavator is found most convenient, while the em-

ployment of the chisel to uncover the caries is most likely made necessary. In excavating cavities of this aspect, it is common to make a slight undercut immediately beneath the enamel, this being necessary for the support of the filling.

From cavities situated as described, we pass to the consideration of others so related as to demand for their exposure not only the exercise of considerable ingenuity, but also such clinical data as shall show what extent of chiseling, filing, or pressure is permissible; not alone as the endurance of the teeth is concerned, but as reference is had to appearance and where possible, to self-cleansing surfaces.

FIG. 134.



Carious denture.

The denture seen in Fig. 134 is a type of many. On the left hand are shown teeth as involved by the caries when a patient presents himself. On the opposite side are represented the same cavities when made ready to receive the fillings. The second and third molars of left side, however, are utilized to exhibit cavities prepared for what are known as contour plugs.

Approximal cavities are to be exposed by V-shaped filing. This is the



common rule, yet having exceptions, as hereafter to be explained. A central incisor tooth, decayed upon a surface concealed by its neighbor, the relation of the teeth being as exhibited in the diagram, the operation of exposure is commenced by passing a delicate separating file between the two teeth, a shoulder being left at the neck, which is to prevent the future falling together of the cut faces. Space for the play of the file being thus secured, the first instrument is replaced by a second, this latter being curved in its blade (Fig. 119, Nos. 10 to 14), and having a single cutting surface, which is slightly convex.

Using a convex file, it is plainly seen that it is only necessary to incline the free face against the tooth not to be cut, that an inclined plane looking inward shall be made upon the affected one. When the decay is common to both teeth, double filing is seen to make a V-cut with the base backward. Looking at the central incisor on the right of the diagram, the cavity (shown on the right incisor) is found placed on an inclined plane, all its parietes being exposed and easy to get at. This desirable exposure has been the result of the filing. The tooth, while widely separated from its fellow behind, affording plenty of room for operating, shows in front but the space made by the passage of the delicate straight file. This mode of separating applies to the six anterior teeth.

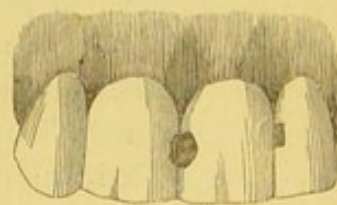After making the primary cut, with a separating file, between the teeth from the front, it is a habit with many operators to rely for the back separation principally on the chisel. If handled delicately, there is perhaps little doubt that this instrument is found less disagreeable to patients, and, when used very sharp and of proper curvature, it assuredly will satisfactorily accomplish the work: the file, however, is commonly employed to finish the separation, affording, as it does, a smoother surface than that left by the chisel.

An approximal cavity, without complications, thus exposed (see central, lateral, and cuspid teeth in diagram), nothing remains but to treat it as the simple cavities before described,—that is, cut away the carious dentine, and form the hole of a shape to retain the filling. Such excavating is generally done with hoe and hatchet instruments, the head of the patient being thrown backward. The rose and spear drills, however, at times are found convenient of use, particularly where, the cavity being of a saucer-shape, requires what are called retaining-points.

*Complications.*—The cavities just described are those of such limited size as to have made little alteration in the front or back faces of the teeth. From the consideration of such we pass to a class represented in Fig. 135, where, as seen, the labial face is markedly affected.

In examining these teeth, let the student draw a transverse line midway between the cavities and the gum. From this first line let him drop vertically others which shall just include the carious breaks on the faces of the teeth.

FIG. 135.



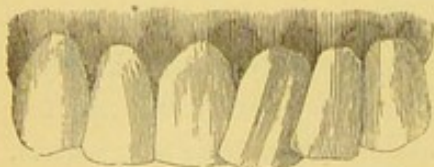

Where the cavities are no more extensive than exhibited in the diagram, it is found that the file, removing all between his lines, will yield no deformity, but afford, on the contrary, a space possessed of healthy look and not unbecoming singularity. As a next step, let the convex-faced file be used, cutting wider the space posteriorly, so as to allow the cavity to be seen only from that surface. He has thus his cavities in the same position and relation as exist in the cases previously described.

A second complication on such order of cavities is where the affected teeth are so related with each other and to the arch, and the holes of so extensive a character, as to make any alteration in the outlook impossible. Cases of this kind are found where caries has extended its ravages over half the anterior face of a tooth, or where a tooth has such position in the arch that what should be the approximal surface is found looking almost directly forward, the tooth being twisted, as it were. Conditions of such expression are commonly treated by excavating in any manner found convenient, the original contour of the tooth being restored by the filling; otherwise such teeth may be filed in front until resisting parietes to the cavities are found, and then treated precisely as in the case of the posterior V. Outlooks having the base of the V presenting forward are of course objectionable, but many teeth so treated—the fillings being of gold and highly finished—are far from unsightly. (See *Contouring*.)

Another class of complications exists in teeth related as in Fig. 136, the central incisors being the organs considered.

FIG. 136.



In cases of this kind it is scarcely probable, by reason of the overriding, that either file, chisel, or disk will be found admissible; it is plainly seen that no expedient will apply to prevent the cut surfaces falling again together. In exposing the cavities in

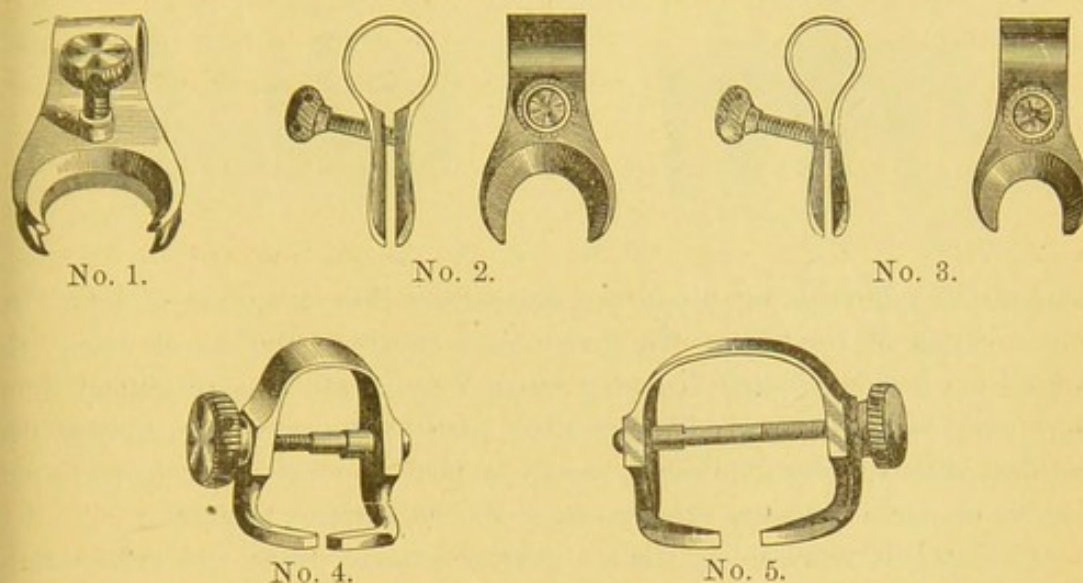
these cases,—if found, as is usual, on the covered surface,—the means employed is that of pressure, either a wedge of some soft wood or a section of tough rubber tubing being employed.\* Of the two means, the immediate wedging by wood is found to produce least pain, a wedge of the proper size being driven delicately between the teeth until sufficient room to work at the cavity has been secured. Where the india-rubber is used, it is common to exert the pressure gradually, pieces of increasing size being introduced day after day until the desired separation is obtained. Objection to this latter means of separating teeth lies in a soreness provoked, the subsequent operation of

\* An instrument lately introduced with a view to disparting is known as "Jarvis's Separator." Two forms are shown by the cuts; of the first there are three sizes, Nos. 1, 2, and 3, No. 1 being the largest. Nos. 4 and 5 show forms of compound signification; these are deemed particularly applicable to the incisor teeth, and are freely used for the assistance rendered by them in the application of the rubber dam. The employment of such instruments is to be commended only to experienced practitioners.



filling being at times rendered so painful as to be nearly if not quite unbearable. In using a wedge of wood, the separating, excavating, and filling

FIG. 137.—JARVIS'S SEPARATORS.



are to be done at the same sitting. To introduce such a wedge, orange or pine being employed, it is found most convenient to cut it on the end of a stick of some length, nicking deeply at the base of the wedge. It is thus easily thrust by the hand between the teeth, or allows of the convenient application of the required blows from a mallet. When got into place, the wedge is cut or broken off at the nick.

Referring again to the diagram, Fig. 136, another modification is found in the relation of the lateral incisor of the right side to the central. As in the case of the central with its fellow, this is seen also to override, but it differs from the first in possessing an impinging surface, continuing from cutting edge to neck. Teeth so related are to be separated, first, by a wedge introduced at the neck; and, second, space thus secured is to be increased by the file, the cutting, however, to be so directed as to leave at the neck an unfilled portion which shall prevent the parts falling again together after the removal of the wedge. To excavate and fill a cavity in such a situation would seem to be a very difficult matter, and, indeed, will be found so, unless the operator forces for himself sufficient space, and which in all instances is to be effected, wedges of wood or india-rubber and the file or disk being used as found necessary. It is to be accepted as a rule that file or disk is used where after-changes are not to bring cut surfaces in contact.

Still another modification is exhibited in Fig. 138. Here the soft parts are found somewhat receded, the necks of the teeth being exposed. In the approximal surface of each tooth near the gum is a cavity of decay. To get at such a cavity, the space made by nature in the V-spaces seen in the diagram may be all-sufficient. If this should not be the case, then the wedge is employed, being driven midway between the cavity and the cutting



edge. Such cavities being excavated and filled, the teeth are allowed to fall together. It must be seen that the misfortune of fillings so placed lies in

FIG. 138.

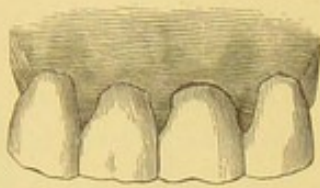
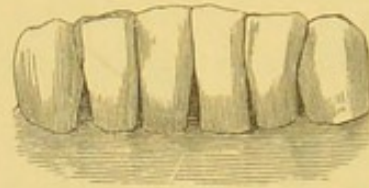
FIG. 139.



absence of self-cleansing properties, compelling thus continual care for the preservation of the teeth. To obviate such objection, the use of reamer or chisel has been advocated, scooping out a V-space which is to extend from the neck to the cutting edge; treating such teeth, indeed, precisely as described with the uncomplicated cases,—a plan undoubtedly to be preferred where no lateral pressure exists to force the cut surfaces together.

In Fig. 139, representing the six inferior anterior teeth, the same condition is exhibited as shown in previous cut. The plan of treatment is, of course, the same.

Other modifications connected with the anterior teeth are not infrequently encountered, but with the general ideas here given the ingenious student will find in his own skill, after a little experience, all the directions required.

In deciding on a mode of separating teeth, a practitioner finds constant demand for the exercise of judgment. It is to be laid down as a rule that never more than two teeth are to be undergoing the process in the same mouth at the same time. When rubber is used, it is also to be accepted as proper practice that plenty of time be allowed for the operation, from two to five days being the average required; that when soreness arises no increase in the thickness of the rubber is to be made until the pain has subsided. Further, it is to be accepted that young teeth endure displacement better than old ones; indeed, it seems to be a common conclusion that separation of the teeth in persons over forty years of age is to be made with safety by means of file or disk alone.

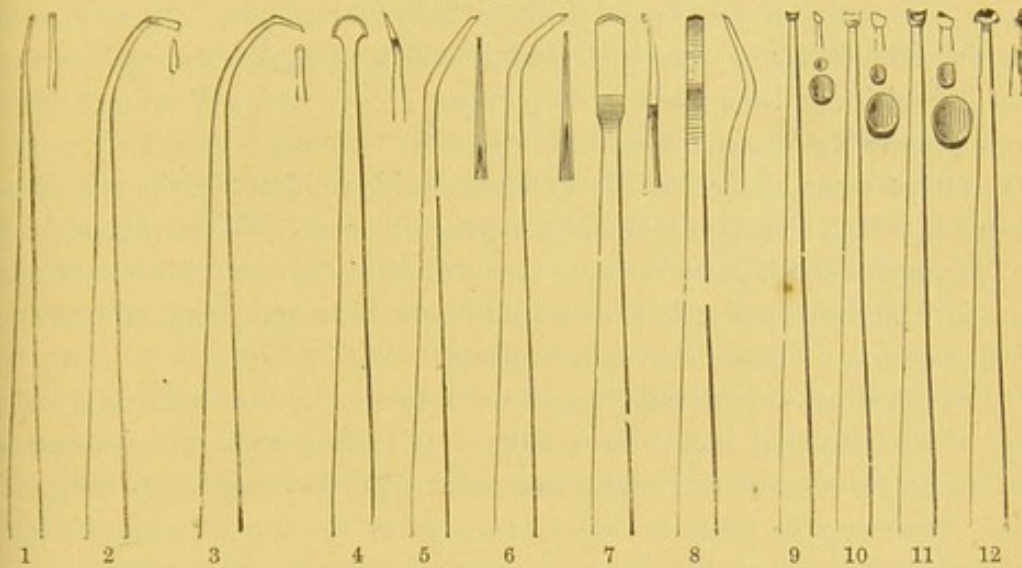
A modification of excavators, exhibited in Fig. 140, will be found invaluable for excavating; indeed, than the forms 1, 2, 3, 5, and 6 none better are to be bought; they cannot be too highly commended, being recognized to apply to almost every form and position of cavity.

We pass now to bicuspid teeth. Fig. 134 exhibits approximal decay of these organs involving both of the left side. Teeth presenting lateral cavities extending to the grinding face, as here seen, are invariably found scooped out, the carious part being overhung by unsupported enamel. To fully uncover such cavities, no instrument applies better than the chisel; the operator simply cuts away the operculum, directing, where possible, the greatest breadth of the cut inward; such manner of exposure is expressed upon



the opposite side of the diagram, where, as is seen, the cavities are fully opened upon the sides of inclined planes, while the anterior faces of the teeth

FIG. 140.



are not at all disturbed, the cavities being put into a position and aspect in which they may be esteemed as simple and without complication.

*Complications in Cavity Relations.*—A first complication is to be described as an approximal cavity associated with a second occupying a sulcus on the grinding face of a tooth. Here a plan pursued by many consists in exposing the first cavity, as just directed, and this accomplished, preparing the second precisely as any simple crown hole. If the two be entirely separate, healthy dentine lying between, each is to be treated as a distinct cavity; if, on the contrary, there be found the slightest association, the two are joined by cutting out the septum which relates them.

A second complication is found in the existence of that extent of decay which has so weakened the front or back wall of a tooth as to make the removal of the wall necessary. Such condition is unfortunate, as it renders the operation of filling more difficult,—except, indeed, to the experienced, who are able to adopt the plan of making a contour filling,—that is, building up with metal the part lost. To prepare such a tooth for its plug, the operator finds himself compelled to cut wherever the disease leads. This he does, using the chisel,—chipping away the weak parts little by little, desisting only when evidences of disease are passed. Commonly, teeth so decayed are found with pulps exposed; if this prove not the case in any particular instance, the question of how the required filling is to be retained becomes of all consideration in the cutting of the cavity, the answer mostly existing in the formation of retaining points. Retaining points are slots cut out of the dentine, acting as places of anchorage; fillings in such teeth being made—when gold is used—of that form of the metal known as cohesive; it being understood that gold so prepared can, with all facility, be attached piece to piece until any desired form is built up. (See *Cohesive Gold*.)



Another complication, met with occasionally, consists in cavities meeting in the middle from either approximal surface. Such cavities are treated by cutting away the overlying grinding surface, thus making a common hole, which hole occupies, perhaps, the whole body of the tooth. Thus exposed, this common cavity is excavated and cleansed precisely as though it were, what indeed it has been made, a deep crown decay. (See *Matrices*.) Such a cavity necessitates contour work.

The most common form of decay found in bicuspid teeth, the approximal excepted, is that situated in the sulcus between cusps. Where this is simple, it is prepared for filling by reaming it out at either extremity with a delicate spear drill, and connecting the two drill-holes by the employment of excavator, chisel, rose bur, or other convenient means.

A modification on this single groove is frequently met with in a middle point of division that is entirely healthy. If such septum be of reasonable size, it may be allowed to remain, and each cavity be reamed out separately. When, however, the slightest doubt exists as to the integrity of this intermediate portion, it is the safer plan to remove it, thus making the two cavities one.

We refer now again to diagram, Fig. 134, and observe the relation of the approximal faces of the first and second molars as seen on the left side. These teeth, while presenting at the angles a healthy aspect, are yet found to have cavities midway of this face, which cavities, as thus situated, have only been discovered by the insinuated point of a delicate excavator, or, what is more likely, the passage of a silk thread. Referring now to the opposite side, the cavities are found prepared. The exposure has been accomplished by the use either of chisel, disk, or files. The cavities, before unseen, now exhibited upon the sides of the inclined planes, are recognized to have surfaces that allow fillings placed in them to be self-cleansing.

Passing to the grinding faces of these same teeth, cavities of decay are seen running out over the lateral walls. The excavation of these is accomplished simply in following the sulci wherever they lead, bearing in mind that said excavation is to be of such character as provides for the retention of the filling; that is, that at all aspects the cavity is to have a wall slightly concave. Sometimes, when much depth has been attained by that portion of the decay situated in the crown, and perhaps as well that upon the side,—the connecting sulcus being of slight signification,—it is good practice to scoop out this intervening portion, without regard to the shape of the walls, and to carry the gold, arch-like, into and over it from one plug to the other.

Referring now to the approximal faces of the second and third molars, left side, attempt has been made by the artist to represent cavities in these teeth prepared for contour fillings,—a plan of excavating all approximal cavities of any extent in the bicuspidati and molars growing rapidly in general favor, and certainly contributive to an ability to make beautiful operations. First,



it is seen that a separating file or disk, slightly V-shaped, has been passed between the teeth. Next, the cavities have been excavated, being cut directly down from the crown surface, and have been so shaped that in putting in the metal the operator finds himself able to work directly from this crown surface. These teeth are so prepared that when filled the operation restores fully the portion lost.

The excavation of teeth—molars or others—for contour plugging is to find direction in experience. It is to be recognized that the idea and intention are to repeat in metal what has decayed or been cut away. In proportion as the part removed has been extensive, so is it to be recognized that proportionate difficulty will exist in securing fixedness for the plug. Contour fillings, save in exceptional cases, are to possess reasonably inclined surfaces; a filling which represents the surface of an inclined plane has been amply demonstrated by experience to be the best kind.

In excavating cavities of any class, certain general rules are to be observed and practised :

1. A cavity is to have such exposure as affords room to introduce the filling properly.

2. Walls are to be made as perpendicular as a case admits of, and the margin of a cavity is to be at right angles with the surrounding surface.

3. The orifice of a cavity is to be without fissures or irregularities wherever these may be avoided ; it must have firm decided margins, and must be supported solidly by underlying dentine. Roughness or brittleness in the edges of a cavity is most objectionable.

4. In excavating a tooth, regard is to be had to the proximity of the pulp. This organ is not unnecessarily or carelessly to be exposed, nor to be too closely approached ; for if the first, the case is immediately changed from simple to complicated ; if the latter, the pulp is apt eventually to become chronically inflamed, and to die as a result of the thermal irritation arising from the presence of the filling. It is not permissible to file or chisel or disk a tooth too freely, except where regard is had to density. A tooth of loose texture not infrequently has an irritation of the dentine and pulp provoked by the removal of even a slight portion of its enamel ; on the contrary, one of dense structure is commonly to be cut with considerable impunity.

5. In cavities having radii running from a common centre, which radii may not with propriety, on account of their extent, be included in a single round hole, care is to be observed that the extremities be rounded ; never being allowed to retain their natural sharpness or fissure-like aspect.

In the process of excavating teeth, a practitioner finds it necessary to employ freely the water-syringe for washing away the débris. A mouth-mirror, used for casting additional rays of light, or for showing more conveniently the cavity at which one is working, is found of much service.



Tact yields the largest measure of success in the process of preparing cavities. Rules, while well as a means for general direction, are always wisely laid aside by him who finds in his own ingenuity better means for accomplishing ends. A student gains much advantage in studying, and in cutting, teeth out of the mouth, and such practice is not to be over-sufficiently commended to a learner.



## CHAPTER XXII.

### OPERATIVE DENTISTRY.

#### RELATIONS OF MOISTURE.

No tooth is filled perfectly that has not been operated upon under absolute exclusion of moisture.

A tooth is protected against the salivary flow, and against moisture from the breath, through various means now to be considered.

1. **Napkin.**—Answering in all ordinary cases we have the napkin. A dental napkin is an oblong square of linen, varying in size to suit the idea of the operator; dimensions found convenient are: length, twelve inches; breadth, three. In applying this napkin to the upper denture, it is folded upon itself in part obliquely, until one end is brought to a point. Beginning with this point, the linen is laid delicately and smoothly between the gum and cheek, being carried backward or forward according as the initial end may have been placed, until turned into the mouth at a convenient distance from the organ to be operated upon, it is made thus to envelop it, being supported on either side of the arch by the fingers of the operator's left hand.

Applied to a lower denture, the napkin is first folded upon itself into a ribbon shape of an inch in width; second, the initial extremity is back-folded until a pad is made which corresponds in length to its width; that is, being an inch each way. This pad is to be laid upon the floor of the mouth directly back of the incisor teeth, thus covering the orifices of the ducts of both the submaxillary and sublingual glands, which orifices it is the design to compress; from this point it is carried around the arch into the vestibule as required.

To hold the floor pad firmly in place, as is demanded, various plans are adopted. A common one, where the tooth to be filled is upon the right side of the jaw, is for the operator himself to fix it by the thumb of the left hand while the index finger is extended over the part occupying the vestibule. Where the tooth to be shielded is upon the left side, the index finger of the right hand of the patient is employed, the three remaining fingers being flexed out of the way beneath the chin.


As encroachment of the saliva constitutes about the most troublesome offence in dental operations, ingenuity has been extensively exercised for its control. Fig. 141 represents a tongue-holder devised by Dr. J. Foster Flagg.

It will be found that the use of this instrument insures additional facility



to the operator, and maintains the tongue in position with comfort to the patient, causing no fatigue nor unpleasant sensation, even removing desire to resist constraint. To apply it a fold of napkin, or a small piece of muslin,

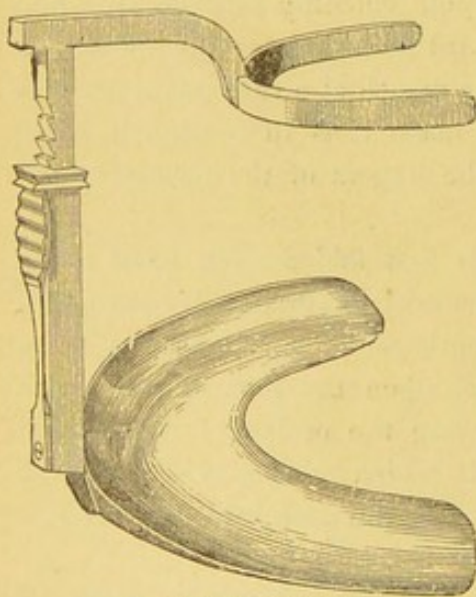
FIG. 141.



is placed under the tongue, and then covering that organ by back-folding the napkin, or by placing another small piece of the cloth upon it, the holder is put in position nearest the side where it is proposed to operate, and the patient is requested to retain it in place, using his *right* hand if the cavity be on the *left* side, and the *left* hand if the cavity be on the *right* side. The elbow is to rest upon the arm of the operating-chair.

Another instrument, a modification of an ingenious invention by Dr. Hawes, bears the name of Morrison's Compressor. (See Fig. 142.)

FIG. 142.



Morrison's Compressor.

The diagram fully illustrates its working. The napkin being put in place beneath the tongue, is held by the bars of the curve, the cup receiving the chin, the ratchet-work approximating and holding the two parts in the required relation. A later instrument of this same character is one designed by P. T. Smith, D.D.S., the variation consisting in the sliding of the bar which supports the compress, and in an ability to change the position of the chin-rest. A still later device is a porcelain compressor, the invention of Dr. Osborn, which highly commends itself. (See dental catalogues.)

Fig. 143 represents a saliva-pump and tongue-holder combined, the invention of

Dr. Dibble. The object of this instrument is to facilitate the operation of filling teeth of the lower jaw by keeping the mouth free from saliva, and as a means of holding the tongue away from the parts; also as a means of supporting the upper jaw, thus assisting the muscles which keep the mouth open; the application is readily understood in studying the illustration. The instrument is composed of coin silver and hard rubber, the former heavily plated with gold. A designates the plate which keeps the tongue away from the teeth; B, the arm which supports the jaw; C, the silver tube and base which fit over the jaw; D, the opening where the saliva enters the tube; E,

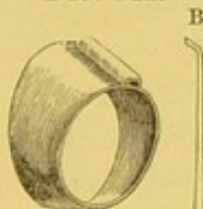


the chamber that receives the saliva: a vacuum is made in the saliva chamber by the pressure of the bulb I, thereby causing the saliva to flow into the opening D; H, the opening where the saliva is discharged; G, the exhaust-valve. There are two mouth-pieces, one for the right side and one for the left side of the mouth. The instrument is readily cleaned internally by drawing soap and water through it. It must not be laid down on its side after using until emptied of saliva.

An automatic saliva ejector, known as Fisk's, is an elegant and convenient piece of apparatus in this same direction.

An instrument serving happily as an adjunct to the managing of a napkin by reason of facility furnished for holding in place pellets of spunk, bibulous paper, etc., is an extension-finger devised by the late Dr. J. H. McQuillen. This consists of a silver shield (see Fig. 144), to be worn upon the index finger, with a socket on

FIG. 144.

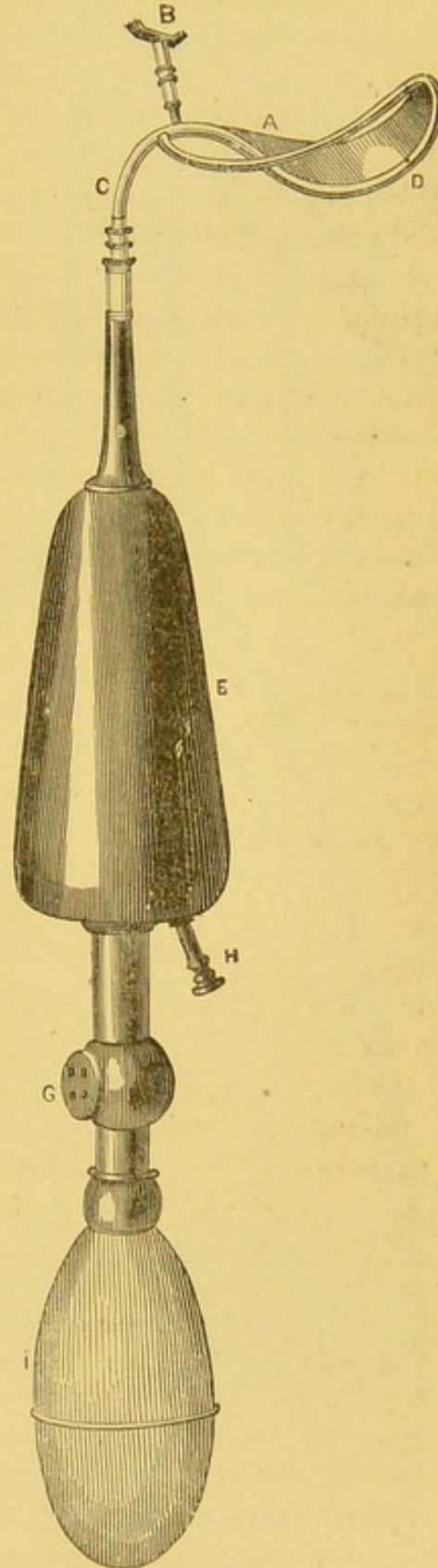


McQuillen's Extension-Finger.

the under surface, in which a steel finger, B, fits. A number of these fingers, or bits, bent at different angles, accompany the shield, being adapted to meet various requirements.

A second form of instrument having similar signification with that just described, is known as Taft's Thimble and Extension. (See Fig. 146.) This thimble is to be used upon the index or middle finger of the left hand. It is also employed to aid in fixing the napkin, paper, spunk, or whatever may be used to prevent the encroachment of saliva. The point of this instrument, like the first, can be

FIG. 143.

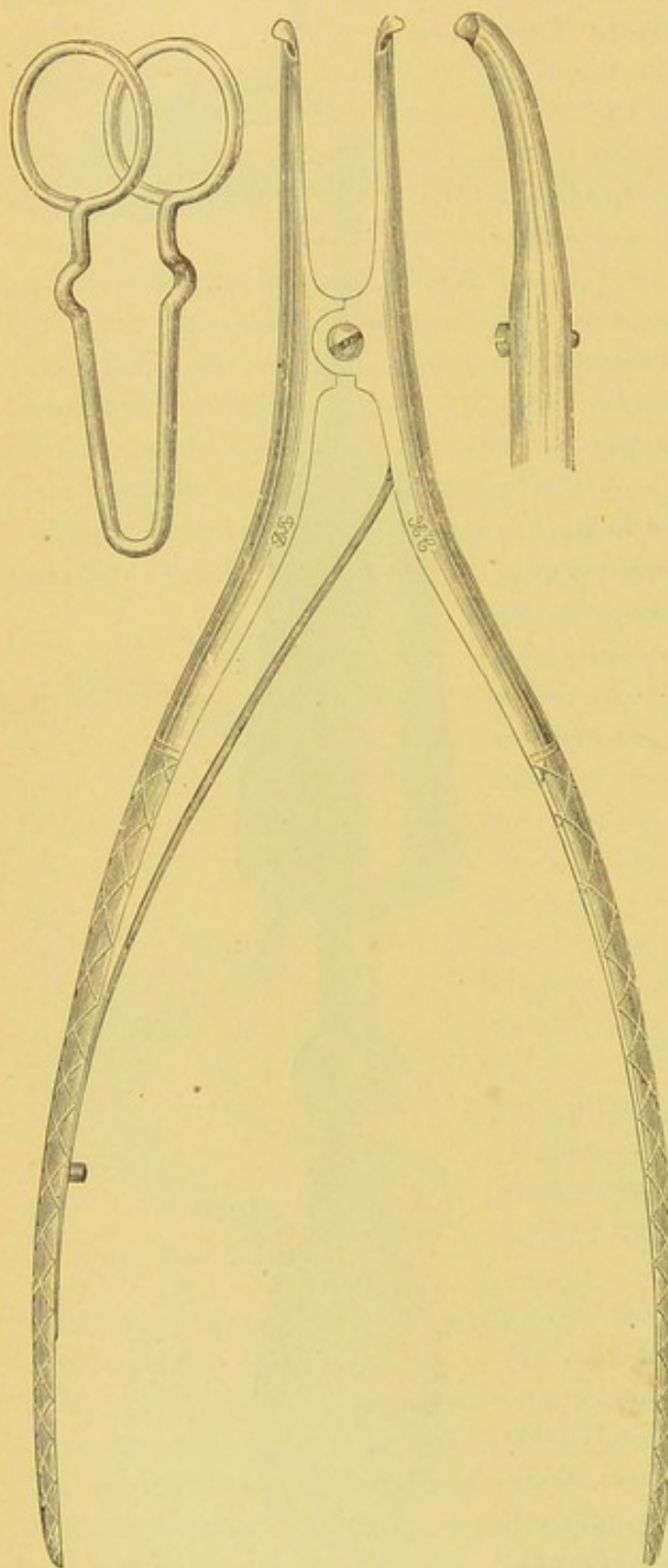


Saliva-Pump.



extended into parts of the mouth where a finger, either on account of its diameter, or for want of length, cannot very well go. It is likewise found a

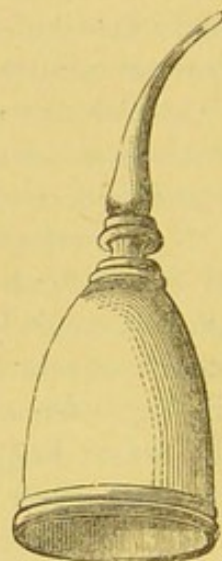
FIG. 145.—RICH'S DUCT-COMPRESSOR.



convenience with which to reach over and draw the napkin firmly against the lingual side of the teeth.

A form of compressor for the Stenonian duct, the in-

FIG. 146.



Taft's Thimble.

vention of Dr. Rich, of New York, is represented in Fig. 145. This forceps and spring assume to accomplish the closure of the duct more perfectly than any other appliance. The spring, used with a pad of bibulous paper, or with a napkin, prevents all flow of saliva, while the tip is free to yield to every motion; whereas with a wad of napkin in the cheek, the lip is tight, while very little motion frees the duct, allowing the saliva to flow.

When in use, the recurved ends of the forceps fit in the recess of the spring, closure of the handles of which expand it. Having placed the pad in



position, exactly opposite the second upper molar, release the grasp upon the handles, the spring will close and the forceps be detached at once. An outer pad may be slipped under the spring afterwards, if desirable.

An operative plan of controlling the parotid secretions has been suggested, and perhaps to some extent practised, consisting in placing a temporary ligature about the ducts. This is certainly to be opposed as an unsurgical proceeding, and one which might most readily eventuate in stricture.

**Rubber Dam.**—Of the various appliances, aside from the napkin, designed for the control of the salivary secretion, not one has met with so universal an approval as what is known as the coffer-dam of Barnum. This means consists in the use of a simple sheet of thin rubber, prepared and sold for the purpose, into which one or more minute holes are punched for the passage of certain teeth associated with a proposed operation. When properly applied, even a lower tooth may be protected from the saliva for a period of four or five hours, should such time be a requirement.

In using the dam, the operator starts with the principle that a delicate round hole is to be made in a sheet of rubber; this is to be enlarged by passing the tooth through it. The rubber contracting tightly grasps the organ, putting it in a water-tight dam.

Applying this dam of Dr. Barnum to an isolated tooth, an inexperienced operator would be led to conclude that nothing in its way was left to be desired; passing, however, to a case of complicated relation, he would err as far on the other side in inferring it to be without value.

**Application of Rubber Dam.**—A sheet of rubber may be made to inclose one tooth, or several at the same time. We consider first, relation with a single tooth; this tooth being supposed to stand alone.

The operator cuts a piece of dam material into a size and shape adapted to the want, into the centre of which he punches a small hole. He isolates his tooth by forcing it through this hole. This simple procedure constitutes the performance.

FIG. 147.—DEPRESSED RUBBER DAM.

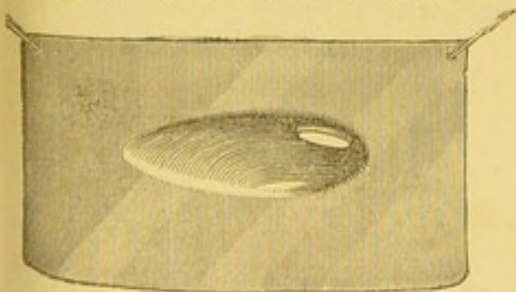



FIG. 148.



FIG. 149.



In connection with a form of dam, known as depressed (Fig. 147 shows it), allusion is to be made to the use of a mirror for lighting purposes. Such a mirror is shown in Fig. 148. It is fixed in a required position by punching for it a hole in the rubber precisely as for a tooth. It is seldom used.

Where ordinary sheet-rubber is employed for making a dam, it will require,

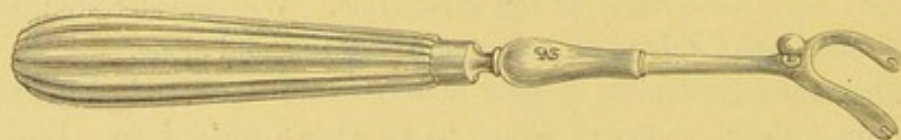


even when placed on an isolated tooth, to be fixed after a manner that shall prevent its slipping off. To such end a strand of common waxed silk is tied about the tooth above the sheet. A second suggestion is practised and taught by Clinical Professor Dorr. This operator first incloses the neck of the tooth to be operated upon by a waxed ligature, the ends of which he brings through the perforation in the rubber. This ligature serves not only to direct the dam into place, but being finally tied above fixes it firmly.

Where a tooth to be placed in dam has immediate neighbors on either side, not less than three teeth require to be included in the sheet. Here the rubber is to be adjusted in the mouth, and by means of a soft pencil the position of each tooth is marked; the sheet is then removed and the perforations made. The cut, Fig. 149, shows holes adapted in size for, 1, cuspidatus; 2, bicuspidatus; 3, molar. Perforations are made by means of a punch or by a heated blunt steel probe.

The difficulty experienced in applying and keeping the rubber sheet in place as complicated locations are concerned has called out much inventive tact,—first as to application, second as to retention. For placing a sheet about the teeth no instrument can equal human fingers, or that which is their nearest representative. Education of fingers, then, stands as the highest expression of tact. The principles of the application being understood, the student is to familiarize himself with the work through practice. An instrument, duplicating fingers, applicable particularly to forcing the rubber between back teeth, is shown by Fig. 150.

FIG. 150.—RUBBER DAM APPLIER.



**Clamps.**—Clamps to hold the rubber in place take the place of ligatures with many operators: these are little circles of metal made with the quality of a spring; slipped about a tooth they close tightly, and thus fix the sheet. Clamps are of many varieties to correspond with varying indications. Fig. 151 affords an idea of the instrument.

FIG. 151.

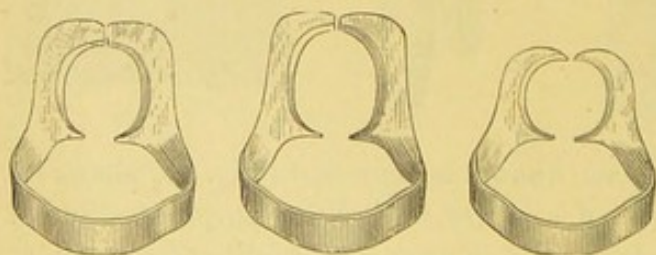
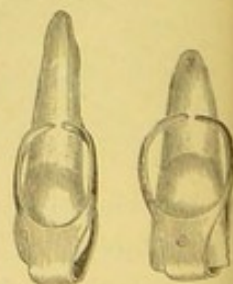


FIG. 152.

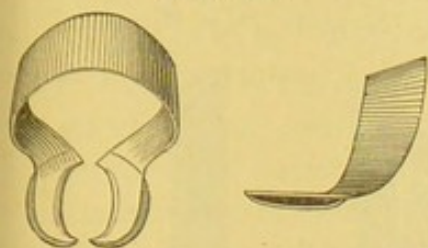


A form of clamp intended for incisor and bicuspid teeth is illustrated in Fig. 152.



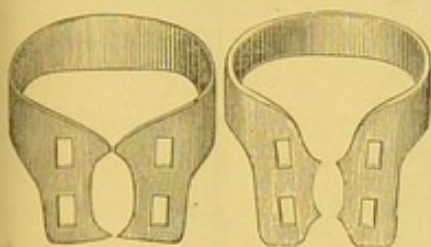
Another form is a design by Dr. Hickman, Fig. 153. Still

FIG. 153.



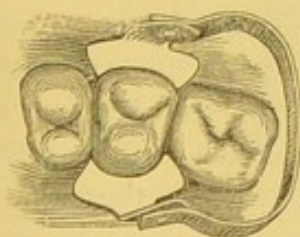
another is known as Elliot's, Fig. 154.

FIG. 154.



A clamp, Buckman's pattern, is shown applied, the rubber being in place, at the base of the three teeth shown, Fig. 155.

FIG. 155.



Clamps are put on by aid of forceps, as explained in the demonstration afforded by Fig. 156.

The sheet in place, as teeth are concerned, a matter to consider relates to that portion of the rubber outside the mouth. To keep this dependent, weights are attached by means of springs to the inferior free borders.

FIG. 156.

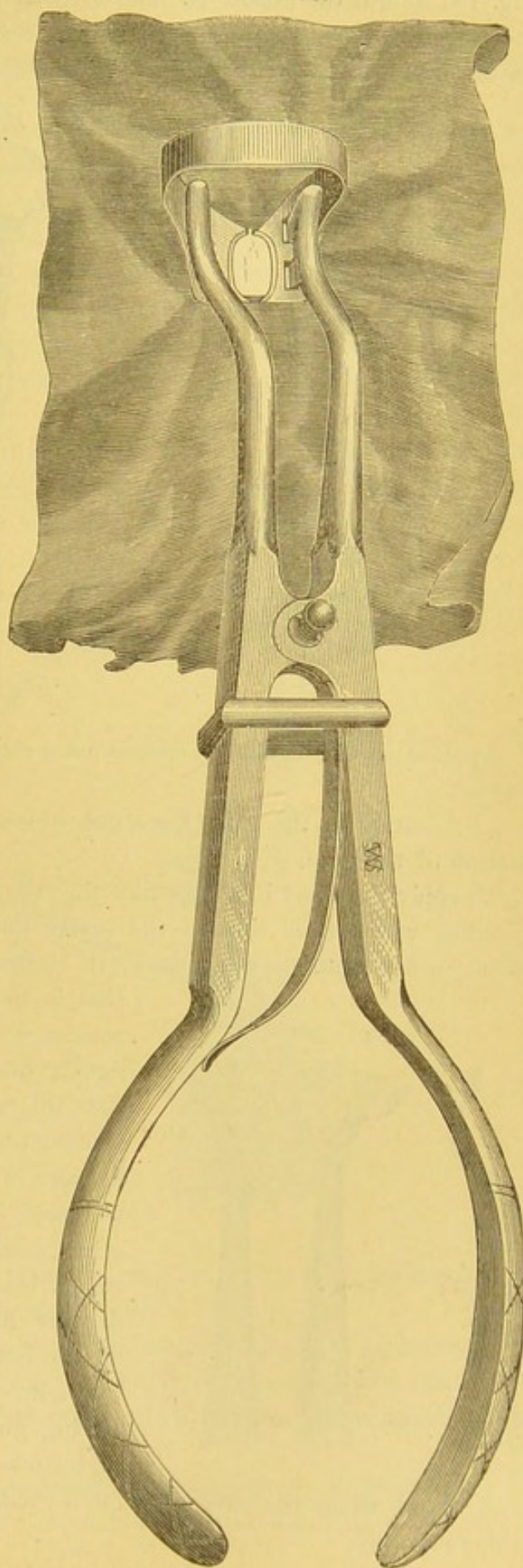




Fig. 157 affords the idea. To hold it from the lips, springs are caught to the upper borders, these springs being related by a band of elastic braid passed around the head. This will be understood by reference to Fig. 158.

FIG. 157.

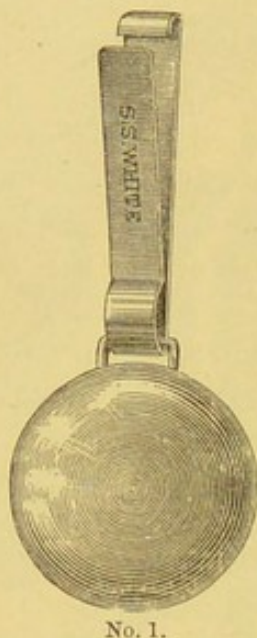
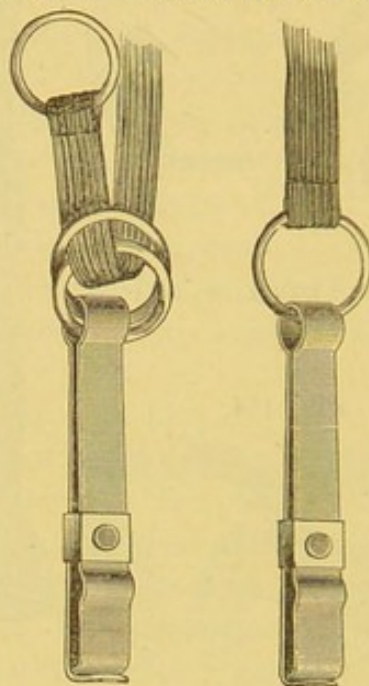


FIG. 158.—RUBBER DAM HOLDER.

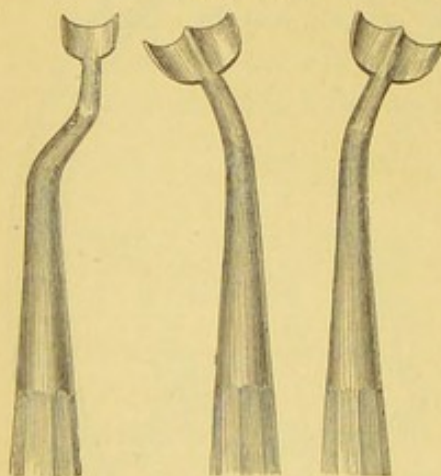


Application of the dam to special cases claims attention before leaving the subject:

1. A cavity in the side of a tooth where the cervical wall is below the margin of the gum.

To apply the sheet in a case like this the operator has recourse to cotton packing, which shall convert the cavity into one of uncomplicated character; a few hours or a few days will suffice to accomplish this. A second

FIG. 159.



plan is to ligate deftly into the required position a tuft of compressed sponge; if so tightly tied as to render slipping impossible this will surely expose the neck. Still another plan is to throw about the tooth a ligature of loosely-twisted silk, this is to be forced gradually about the neck of the organ until full exposure is secured; the rubber being made to cover this, a second ligature forces the sheet upon the first. To the last a weight is suspended holding the dam in place. A valuable aid in forcing gum tissue from about the neck of teeth is shown in Fig. 159.

2. Teeth where the gum overlying a cavity is hard and immovable. Cut the gum away.



3. Partly-developed teeth. The dam does not apply. Fill such teeth temporarily.

4. Approximal cavities, the necks being beneath the gum. Wedge away the gum by means of soft pine.

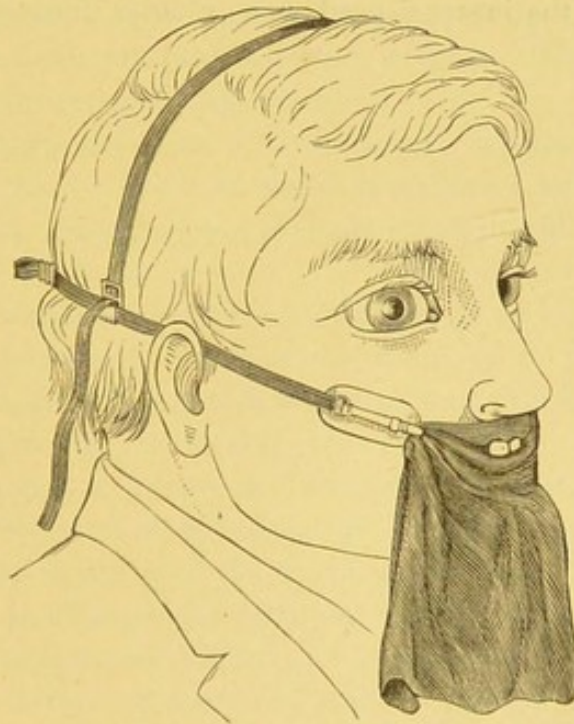5. Conical teeth. Force the rubber below the base of the double cones.

6. Cases where the rubber can be applied by the individual operator only at the expense of great pain to patient. Use other means.

Mechanically viewed, the coffer-dam is perfect; surgically considered, no means employed in dental art is more abused. Where an application compels much forcing and bruising of the gum-tissue, appliances of different character will always justly take its place. Expressed in other words, where the rubber is not to be applied without doing an injury to the parts it is best to do without its aid.

The subject is concluded by a suggestion that in proportion to skill clamps are rejected; ligatures answering every purpose of retention, and being preferable both because of inflicting less pain and less injury. Facility in using

FIG. 160.—RUBBER DAM APPLIED.



the rubber dam is to be found alone in practice. Fig. 160 affords idea of a dam as applied to certain of the front teeth.

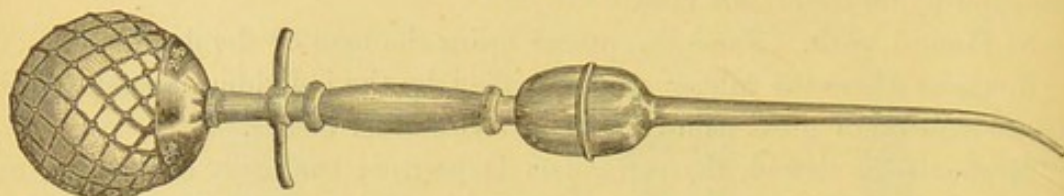
**Direct Drying of Cavity.**—A cavity before prepared to receive the plug is to have a direct drying. To this end what is known as bibulous paper is commonly used; other agents are pellets of old and fine linen, spunk, absorptive cotton, etc.

A manner of drying much employed is the application of direct heat; such application is made by means of an air-syringe, the metal bulb of which has



been held for a moment in a flame. Fig. 161, showing such instrument, will afford at a glance an idea of the manner of its working.

FIG. 161.



In filling a cavity in the approximal face of a tooth, the napkin being used, it is necessary to consider the oozing from parts immediately surrounding the neck. To control this some operators depend on pads of absorbing paper kept close to the parts, others use a wedge of soft pine, forcing it firmly against the gum, others throw a ligature of loose silk or a twist of cotton about the neck, working it out of the way of the cavity to be filled. Another mode yet, one however, requiring care, lies in the use of cauterants, the agents used being nitrate of silver, a saturated solution of iodine, or, best of all, chloride of zinc. The mechanical means suggested are to have preference, certainly by the inexperienced, as no ulterior ill consequences are to be apprehended.



## CHAPTER XXIII.

### OPERATIVE DENTISTRY.

#### MATERIALS USED IN FILLING TEETH.

A CAVITY properly prepared, a succeeding step is the selection of a material with which to fill it. At our present view we treat of such material simply as it is found possessed of qualifications to meet mechanical requirements.

Teeth are filled with a variety of agents; prominent among these are gold, tin, amalgam, oxychlorides, zinc phosphates, gutta-percha.

Not to depart from the intention of considering the simplest and by degrees passing to the complex, the plastics claim a first consideration.

By a plastic is meant a material of putty-like consistency, which is put in its soft state into a tooth, and which quickly hardens. The last four articles named in a preceding paragraph are plastics.

**Amalgam.**—This is the oldest of the plastics; it consists of hard metals in union with a solvent. The hard metals composing a tooth amalgam, commonly silver and tin, are melted together and afterwards filed up; the solvent is mercury.

Amalgam is furnished the market by a number of makers; the price is so low that few practitioners care to take the trouble of preparing it for themselves. It is recommended, however, that a student familiarize himself with the processes and principles of making.

A standard amalgam is known as Townsend's formula; this preparation stands as the representative of all amalgams; to appreciate this combination is to understand the meaning of the modifications of it. All amalgams are simple, important, or unimportant variations on this common formula.

Townsend's amalgam, more properly to be called an alloy, is made as follows: take of pure silver four ounces, of pure tin five ounces. Place the first cut into small pieces in a crucible quarter filled with borax, and when melted add the tin, and stir with a pipe-stem. Next pour the molten combination into an ingot, and when cooled, rasp into grains and bottle for use. A common coke or coal fire is sufficient to secure the fusion.

Many manufacturers of amalgam claim many virtues each for his particular preparation. The virtue of a tooth amalgam consists in absence of change, either of shrinkage or expansion, and of the ability to maintain a clean, white surface and sharp edge. Amalgams obtaining a use more or less wide are known as Arrington's, the Standard Alloy, Lawrence's, Weston's, Holmes's,



Caulk's, Oliver's, and Johnson & Lund's. Weston's cement, or amalgam, is prepared in three varieties,—hard, medium, soft. The Standard Alloy surpasses, perhaps, all other where sharpness and solidity of edge are required. Weston's soft is admirably suited for use in children's first teeth, being easy of removal. Besides the usual combination of silver and tin, various other metals are finding their way into the amalgam plastic. Oliver's claims precedence because of gold and platinum contained in it. Sharpness of edge is claimed for the Standard Alloy by reason of the presence of gold entering into its composition. Copper as an element in amalgam plastic yields hardness as well as a curative virtue; objection is blackness of surface apt to be begotten of it. Cadmium secures a putty-like mass, which seems to be the perfection of a working amalgam; objection is its injurious effect on tooth-bone, and the dirty yellow of a sulphide quickly forming on plugs made of it.

To afford idea as to additions made to the Townsend formula two analyses are presented:

1.		2.	
Silver.....	47.50	Silver.....	38.50
Tin.....	47.50	Tin.....	59.40
Copper.....	5.00	Platinum.....	40
Gold, a trace.....	$\frac{1}{100}$ of a grain	Gold.....	60
		Cadmium.....	1.06

It is common for practitioners at large to depend on a single amalgam; some selecting one kind, some another. Accomplished workers in the direction use a variety; five are noted by Dr. J. F. Flagg: one, submarine; two, usual; three, contouring; four, front tooth; five, facing. Submarine amalgam has a formula as follows: silver 60 parts, tin 35 parts, copper 5 parts. Amalgam denominated "Usual" is prepared by mixing one part of submarine with two parts of contour. "Contour" amalgam is, approximately, silver 58 parts, tin 37 parts, gold 5 parts. "Front-tooth" amalgam is a mix of one part "contour" with two parts "facing." "Facing" amalgam is, approximately, tin 50 parts, silver 30 parts, gold 6 parts, zinc 4 parts.

The article called submarine is, in the experience of the writer, quite preservative of tooth substance; objection to promiscuous use of it lies in a tendency to discoloration, both as plug mass and tooth are concerned. The use of this particular combination is to be recommended in the case of posterior soft teeth, and in instances where operations are not to be made without relation with the saliva. An English preparation of this class, known as Sullivan's Copper Amalgam, carries in its virtues marked self-commendation.

The alloy termed "Usual" is used for ordinary operations; front teeth excepted, this amalgam is esteemed to work with nice plasticity, to shrink but little, to hold good edge, and to discolor but triflingly.

"Contour" amalgam finds, perhaps, its best expression in what is known as the "Standard Alloy"; this compound possesses the addition of copper, works with admirable plasticity, holds its white color exceedingly well, has



great edge strength, and is quick setting. Its use is to build up broken teeth.

"Front-tooth" amalgam is deemed by many as possessing advantages over Standard Alloy as a means of preserving incisor teeth where non-interference with whiteness is particularly indicated, and where difficulty exists in the way of using linings of oxychloride of zinc. This alloy is slow in setting, and lacks in edge strength.

"Facing" amalgam is most resistive of all the alloys to discoloration; its use is in situations exposed to sight. An incisor tooth having its labial wall wanting has been built up by means of this preparation so satisfactorily as not to invite objectionable attention.\*

Studying the composition of an amalgam, the writer inclines to afford peculiar conspicuousness to the presence of tin, and favors the conviction that in proportion to the extent of use of this metal in a filling of the alloy class it is found most preservative of teeth. Copper added to tin favors still further conservation, and if it be true that additions of gold to such compound antagonizes tendency to discoloration, then amalgams are to be preferred that hold the articles named in proper measure.

Silver is necessary to hardness in an amalgam, and it is true that without such influence tin would lack solidity when in combination with mercury; it does not follow, however, that silver is the virtue of an amalgam.

Zinc as an ingredient in an alloy promises more than results yet obtained from its use; it will be found, therapeutically considered, to apply in the case of all soft teeth where decomposition exists in vital rather than in chemical cause.

Copper, besides being curative or alterative, is accepted as a result of wide experimentation, to diminish shrinkage in an amalgam mass; on this latter score alone its presence is invaluable.

The presence of gold in an alloy has not impressed the writer as being of particular consequence one way or another; it is credited by Dr. Flagg, than whom there is no higher authority on the subject of amalgams, with increasing the rapidity in setting, imparting fine-grained plasticity, controlling maintenance of color, and securing desirable edge strength. Experiments made by Dr. C. S. Tomes would seem to establish the fact of a control of shrinkage by the metal. Other experiments exhibit gold as a retarder of setting.

\* CHASE'S NEW AMALGAM AND MANNER OF PREPARATION.—Melt forty pennyweights of pure silver; add to this thirty pennyweights pure tin; stir, then add five pennyweights of antimony and five pennyweights of pure tears of zinc. When mixed, add thirty pennyweights of tin again; stir, and throw on the surface of the "melt" one half-ounce of bees-wax to burn off; and while burning pour the "melt" into the cup of a vulcanizing flask to cool. Cut it up with very coarse file. Remove every particle of iron with a horseshoe magnet. This amalgam must be washed in alcohol while mixing with mercury. Squeeze it in dry buckskin. This amalgam is whiter for washing, and takes less mercury. Squeezing injures some amalgams; it does not hurt this. The amalgam pellets must be dry when placed in the cavity. This amalgam remains very white in the mouth. If all the tin is melted at once the antimony and zinc do not melt. If the antimony and zinc are put in the melted silver before the tin then the antimony and zinc burn up or oxidize.



The metal platinum occupies a position not dissimilar to gold ; just what it does or what it does not do seems rather undefined in the minds of alloy-workers ; a view is projected that the virtue both of this metal and gold lies in some catalysis of action arising out of a relation with the other components of an amalgam mass ; that is, if alloys are really found to be better because of such presence.

Cadmium is directed to be experimented with most cautiously ; the opinion seems almost universal that the ingredient is hurtful to the health of tooth-bone ; crevicing at edges, softening and breaking up of the plug mass, are faults arising out of its presence. Teeth filled with amalgams containing special freedom of cadmium quickly become of a dirty yellow color, while at the same time the dentine rapidly softens by reason of decalcification.

Plugging alloy combinations, however composed, have a common manner of preparation for office use ; this preparation consisting in breaking up an ingot into grains or into shavings, which is done by means of rasp or lathe ; grain-shape is the preferable form. Alloys possessing an excess of tin are best used in form of very coarse grains. Alloys containing excess of silver, or having as an ingredient copper, gold, or platinum, are best cut with fine files. Non-clogging of a fine file while cutting is being done is given as one of the tests of a good alloy. After being cut into grains an alloy is to be carefully sifted and magnet picked ; the magnet to be passed and repassed until no more of the file particles are to be gathered. Thus prepared, and being bottled, it is suggested, as a matter of particular importance, that the material be laid aside for a period of three or four months with a view to what is termed aging. It is inferred of an alloy that mixes readily with a small relative proportion of mercury, when freshly cut, that it " will shrink notably, set slowly, bulge markedly, and have little or no edge strength."

Mercury, the solvent of alloys, is procurable in the proper purity at the shop of any chemist ; the only need is that it be free from mixture with other metals, a virtue that suggests the inadvisability of using the same portion with other than one mix. The proper quantity of quicksilver to employ with the different alloys is just that weight which is found to melt the mass into an apparently homogeneous ball. When too much mercury is allowed to remain with a plug, the mass refuses to harden ; too little favors easy disintegration of a filling. Making the least quantity do by using heated instruments in the packing is not to be accepted as a desirable practice.

**The Plug Mass.**—An alloy when in solution with mercury is converted into an amalgam ; here only is the latter term applicable, although out of deference to common habit the words are used in the chapter interchangeably.

To make an amalgam mass take a portion of an alloy, enough to correspond with the size of the cavity to be filled, place the grains in a mortar, add a small quantity of mercury, rub the two together by means of a pestle for a few moments, and the solid grains will be found to have disappeared. Add now to the mass secured a few drops of deliquesced chloride of zinc, and rub



the whole together, using this last time a finger. As a result, the bottom of the vessel will be colored a dirty black, while the amalgam, robbed of its impurities, presents itself as a fluid ball of frost-white silver. The next step is to take the ball, and, enveloping it in buckskin, cotton cloth, or linen stuff, press out, with forceps, the excess of mercury; the result is now a semi-solid material, which is the preparation to be used in the cavity of the tooth.

The employment of the chloride of zinc as a purifying agent is not a necessity in the preparation of a plug mass, and may be omitted if the salt be not conveniently at hand; it is, however, a manner of treating the button deserving of high recommendation: a plug mass that has been frosted or washed with pure zinc will remain white much longer than if unwashed. This mode of cleansing amalgam was introduced many years back by the author, and seems to have passed into quite common use. After wiping away the black sediment—no water is to be used—the mass is to be absolutely dried by means of bibulous or other moisture-absorbing paper; such drying is to be insisted on, as it conduces markedly to the tenacity of the plug, through an influence on the process of crystallization.

None of the agents employed in the operation of filling teeth has elicited so much discussion, pro and con, as amalgam. That it affects injuriously the general health, as affirmed by many, is not perhaps to be accepted as true; assuredly the writer is not able to recall any decided case of such result. No material is in more common use; thousands of teeth are filled with it every day, and it is not to be denied that cases enough offer where such a filling seems the only one that is practicable. It is claimed that if a tooth be properly prepared, and the material be carefully introduced, an amalgam filling will last quite as long as one of gold. Assuredly in a multitude of instances it will preserve a tooth very much longer.

The employment of amalgam seems necessitated in many cases in which gold cannot be used because of therapeutic reasons, and where tooth-bone or the gutta-percha preparations are not able to bear the demands of the act of mastication or the action of chemical antagonists. In the teeth of soldiers, where the convenience of the service, lack of manipulative skill on the part of the surgeon with gold or tin, or the habits of most of the patients, would render the use of foils scarcely admissible, amalgam certainly recommends itself.

An explanation, in part, of a bad repute in which\* amalgam is held by many is to be found in poor manipulation. Being easy of preparation and of introduction into cavities, the use of the article has begotten great carelessness in its employment. A carious cavity in which amalgam is used is to receive not less attention in the way of perfect cleansing than where gold is proposed to be employed; quite as good reasons obtain for the perfect drying of it.

Another matter is the manner of introducing amalgam fillings. Experiments have clearly shown that it is not enough to smear the mass into a hole: it is to be packed in. Expert operators use a tap-blow, working piece upon



piece in a manner not unlike that employed in consolidating cohesive gold. Without such care an amalgam plug leaks everywhere and is necessarily worthless.\*

Returning to the subject of the plug mass, attention is to be directed to a marked improvement on the manner of making a mix introduced with the "Standard Alloy"; this consisting of relation through weight. In preparing this amalgam a proportion found to result in absolute harmony lies in five parts of alloy to six of mercury; the union of the two being complete, the mass desirably plastic, and no mercury to be pressed out. To save the trouble of weighing the proportions in each plug mass the exact relative weights are found to be obtained when the alloy is put in a scale which is weighed down by the plate of the opposite side by as much quicksilver as gives a declension of 45 degrees. Absolute harmony of measure between an alloy and its mercurial solvent is to be accepted as representing absolute antagonism; the mercury is rendered inert. Alloys demand the solvent according to grade: Townsend's will antagonize and be antagonized by 36 per cent.; Lawrence's consumes 41 per cent., Johnson & Lund's 39½ per cent.; Arrington's takes 36 per cent. The solvent, as seen, is demanded in proportion as the metals used in the alloy are of high melting grade under ordinary heat. Particular stress is desired to be laid on this matter of measure for measure; it is worthy of being worked out in the instance of every lot of alloy made or purchased. Where an alloy is regular in its proportions, and the age is known, the trouble of weighing individual specimens is spared.

An alloy amalgamated, the mass is taken from the mortar and gently kneaded into smoothness by a finger of one hand in the palm of the other; this apparently simple performance requires delicacy of touch, otherwise the practitioner in place of securing a button of putty-like softness will find himself possessed of nothing but a portion of dust. A button of amalgam is to be kept warm and pliable until ready for use by being held between the ring finger and palm of left hand. It is good practice to varnish the bottom of a cavity before introduction of a plug. (See chapter on *Therapeutics* for other suggestions.)

**Instruments for Working Amalgams.**—Special instruments add to convenience in working amalgams. Cup tools (Fig. 162) are deemed a convenience by many in carrying the paste to the cavity. Another means which equally secures against dropping the mass into the mouth is found in the use of a file cut flat. (Fig. 163.) Amalgam demanding to be packed, instruments corresponding somewhat with those used in working cohesive gold are required; the faces are to be serrated, but the cuts must be very dull. A set here shown (Fig. 164), highly commends itself.

\* A young practitioner cannot do better than inform himself of the relative solidity and porosity of the amalgam plugs he makes than by packing different specimens of the material in glass tubes and pouring over the same aniline alcohol: leakage will be found the rule.



Another, most valuable, is the device of Dr. D. D. Smith.

No. 1.—For filling undercuts generally.

Nos. 2 and 3.—For crown and buccal cavities in upper and lower molars.


Nos. 4 and 5.—V-shaped fissure pluggers for filling anterior and posterior V-shaped fissures in molars and bicuspidati.

Nos. 6 and 7.—Right and left V-shaped fissure pluggers for right and left V-shaped cavities in molars and bicuspidati.

FIG. 162.—AMALGAM CUPS.



FIG. 163.—FILE FLAT.

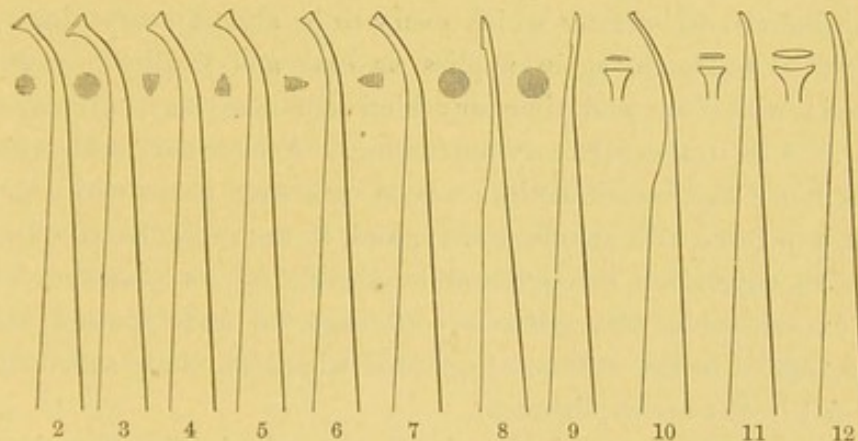


Nos. 8 and 9.—Adapted for working in anterior and posterior approximal cavities, and specially useful in removing excess of amalgam when finishing.

No. 10.—For commencing a filling in the cervical portion of an approximal cavity.

Nos. 11 and 12.—Burnishers, applicable to a great variety of cases.

FIG. 164.—AMALGAM PLUGGERS.



**Illustration in Amalgam Practice.**—We take as an illustration in making an amalgam plug an irregular cavity, dipping in part beneath the gum; situate upon the side of an inferior molar. Rubber dam or napkin in place, the plastic mass, kept pliable by being held in the warmth of the palm, as directed, is taken up by cup or file flat, preferably the latter, and, being carried to the bottom of the cavity, is condensed by tap-blows, particle after particle being added until the hole is full. To finish, a match-stick bevelled to a feather



edge removes the excess, and a little later, according to time of setting of the amalgam, a reapplication of the stick affords a clean, white, smooth surface not at all unsightly. This manner of finishing applies strictly with the Standard Alloy. With other amalgams advantage is sometimes gained by polishing and burnishing precisely as is done in making a gold plug. The observing will remark in the case absolute necessity for a preliminary treatment which shall fully and fairly expose the base of the cavity, a matter that necessarily compels the use of cotton plugs preliminarily continued for hours or it may be days.

A second illustration may consider a cavity upon the grinding face of a deciduous molar. To operate for children is at all times a tedious process. The demands are for easy and rapid execution. The cavity cleansed, engine or hand drill being used, the amalgam, a soft variety being selected, is packed precisely as in the previous case, except, indeed, as frequently enough happens, the restlessness of the child prevents. Under such circumstances instruments known as the "Arrington set" accomplish the work speedily.

The use of amalgam obtains at the present day so largely that it has become not less common to use the article with the anterior than with the posterior teeth. Here most decidedly is it to be esteemed that circumstances control indications. Undeniably is it the case that oral teeth are met with afflicted with such seat and character of decay that question narrows itself at once to extraction or to filling with an alloy. An incisor or cuspid tooth, for example, broken to the point of disfigurement, and of a frailness denying sufficient promise from the use of gold, and being of root character denying thoughts of pivoting, finds a contouring advantage from the use of amalgam of an indicated character which seems to be almost everything that could be desired. Amalgam, again, applies as ease and facility in working are concerned; with care and time any kind of a case may be entered upon with assurance as to a satisfactory outcoming. A bicuspid tooth with but a trifle of its inner wall remaining intact is to be started below with submarine alloy, built into form with standard alloy, and, if desirable, faced with a zinc amalgam, the operation being found invaluable by its possessor. Certainly, as the experience of the writer is concerned, he finds himself able to refer to cases treated in the manner suggested where not only satisfaction but pride was felt in the accomplishment.

Large cavities in teeth, associated with a limit of dollars in pocket, finds great good in the direction of alloys; a plug of amalgam is to be preferred on every score to a plate tooth.

Amalgam is to be accorded its advantage, as relation is held with dental workers at large; few can fill teeth perfectly with gold; a judicious use of amalgam is to be accomplished by almost any one who will take time to try.

Objections to the use of amalgam relate most markedly, if not exclusively, to immediate local effects. As a rule all the preparations discolor; some more, some less. Teeth in which the material is used lose their translucency,



darken, and sometimes blacken. A second fault relates with porosity of surface; this being influenced markedly by the character of alloy employed, but it is so common as to compel recognition. Relation with galvanic electricity is another objection; where an amalgam-filled tooth has a gold band placed about it, galvanic action immediately results; a condition adverse to the health of tooth-bone and markedly irritative to the pulp. As here the irritation of the pulp is concerned, the effect is obviated by removing the plug and interposing between it and the bottom of the cavity a layer of oxychloride of zinc introduced dry as possible, or else using a portion of gutta-percha. Other means applied to the same end are found in varnishes, slips of adhesive plaster, layers of quill scraped very thin, oiled silk, etc. To antagonize effects on the tooth-bone is a less easy matter. Here it is recommended that the polish of the gold be removed by subjecting it to the action of a flame, and that, if the face of the plug be bright, it be smeared with a coating of an amalgam that tends to rapid and persistent blackening. Wrapping a spring with silk thread is a means,—a dirty one, however. Still another is found in mercury-coating the inside of the clasp,—that is, touching it with a film of the metal. A method that is to be tried with a certain extent of good effect consists in the free use of alkaline mouth-washes.

Putrescency of pulp, so frequently found in conjunction with amalgam fillings, is to find explanation most commonly in a chronic inflammation, which has resulted in death of the organ, the cause being extent of decay and size of plug mass rather than character of material; the same explanation applies to conditions of periostitis, ulitis, ostitis, caries, and necrosis of bone as found in connection with amalgam.

Temporary salivation (not of systemic meaning) is in rare instances attributed to the presence of amalgam in the teeth; such ptyalism is found quite as frequently associated with newly-placed gold or other plugs; it is very common as a sequel to surgical performances done on the jaws.

Bad taste in the mouth is another of the implied objections to amalgam; it is worthy of consideration here whether lack of cleanliness rather than influences of the alloy is not the root of an explanation. Amalgam fillings in approximal relation are not infrequently so indifferently placed as to form receptacles for the accumulation of débris; the writer has met with many such cases.

Systemic complications in relation with amalgams are unknown to the author; it is not impossible that idiosyncrasy exists in the direction, but assuredly the cases must be rare where observation extending over thirty years has failed in showing a single instance.

*The place for, and the use of, amalgam, is to be decided by the judgment of an operator, and in proportion as such judgment is good or bad so is a patient served or abused.* Amalgam is unsightly when compared with gold, consequently as an æsthetical aspect of the question is concerned, it is not suited to exposed situations. Solid and highly burnished plugs of gold be-



speak cleanliness and an idea of purity never associated with an alloy, hence gold-filled teeth are of healthier appearance than are the amalgam-filled. Impression of refinement and of delicacy as conveyed by teeth golden strikes all; amalgam lacks in affording social classification; it impresses disagreeably. We place our individual opinion in a single line by saying that gold, when not contraindicated, is the material with which human teeth are always to be filled. Saying this, we are to be understood as recognizing the existence of conditions constantly being met with where gold is flatly unable, however well worked, to preserve teeth.\*

**Gutta-percha.**—Like amalgams, various preparations of gutta-percha are

---

\* CHEMISTRY OF AMALGAMS.—To some extent most metals are capable of combining with each other in definite proportions. Their chemical affinity is for the most part very feeble and easily disturbed. The more unlike metals, the more stable their compounds.

Amalgams, as understood, are alloys containing mercury. Combinations of mercury with other metals result in a liquid or varying solid, according to the proportions. Heat decomposes all amalgams. In ordinary use iron and platinum are the only metals which can be brought in contact with mercury without being corroded by it; however, quicksilver adheres to platinum. It is found that if a little amalgam of sodium be added to metallic mercury, it gives to it the power of adhering much more readily to other metals; even it will adhere to iron.

By experiment it has been found that the following definite proportions can be obtained:

Amalgam of Iron, FeHg.	
“ “ Silver, AgHg.	
“ “ Lead, PbHg.	
“ “ Zinc, ZnHg.	
“ “ Copper, CuHg.	
“ “ Platinum, PtHg <sub>2</sub> .	

There is a native amalgam of silver found associated with mercurial and silver ores, AgHg<sub>2</sub>, in dodecahedral crystals. Beautiful crystals of amalgam of silver, having the composition Ag<sub>2</sub>Hg<sub>3</sub>, are to be obtained by dissolving 400 grains of nitrate of silver in 40 measured ounces of water, adding 160 minims of concentrated nitric acid and 1840 grains of mercury; after a few days crystals of from two to three inches in length will be deposited.

As an illustration of proportions in amalgam one or two formulæ may be cited: 1. To promote the action of electric machines, mercury 6 parts, zinc 1 part, tin 1 part. 2. For the silvering of glass, mercury 1 part, tin 4 parts.

Mercury combines very readily with bismuth. Heat a mixture of 497 parts of bismuth, 310 of lead, 177 of tin, 100 of mercury. This makes an amalgam solid at ordinary temperature, melts at 171.5° F., and solidifies at 140°. This is often used in injecting delicate anatomical preparations.

Whenever mercury is combined with potassium and sodium there is always a disengagement of heat; the resulting amalgams have a pasty consistence, and decompose water.

Tin, lead, and mercury, when heated together and left to cool slowly, yield a solid crystalline amalgam of definite constitution.

Gold unites peculiarly with mercury; even a large quantity of gold does not affect its fluidity. Where mercury is saturated with gold the result is a mass of waxy consistence.

When 1 part of gold is dissolved in 1000 of mercury, the combination being pressed through chamois leather and the residue treated with dilute nitric acid at a moderate heat, there is obtained a solid amalgam, AuHg, in shining, four-sided prisms which retain lustre in the air.

There is also a ternary combination of hydrogen, mercury, and nitrogen.



used in dental art for the purpose of stopping carious teeth. Two varieties are white and red; of these there are sub-varieties, having their distinctive features either in the temperature at which they become plastic or by reason of admixture with other substances.

Compatibility with tooth-bone is markedly characteristic of gutta-percha. The article assuredly has an advantage over the metals in that it is purely a non-conductor of thermal changes. While gutta-percha is in a tooth cavity there is no interference with nature's process of recalcification, even if there is little excitation of the act. Were it not because of an inability to resist the wear of mastication, no plug would surpass one made of gutta-percha as a tooth preserver.

Gutta-percha is resistive in proportion as it is tough and of high softening point. In proportion as it is resistive, it is adapted to the office of a tooth-plugging material.

Brittleness in gutta-percha expresses porosity, the cause being an over-admixture of foreign inorganic substances, such as oxide of zinc, siliceous, quicklime, etc.; on this account, if on no other, a brittle preparation is to be refused. Great attention is being paid at the present time to the manufacture of the material. To secure the best quality, one is to apply to a reputable maker, or, what is still better, test each purchase for himself by means of a spirit-lamp and water-box. Stickiness in a specimen, when hot, is one of its greatest virtues.\*

---

\* **TEST OF QUALITY.**—Dental preparations of gutta-percha are reasonably to be divided into grades, these grades referring to degrees of solidity. The form of preparation most in use is procured from the depots under the name of base plate; of this there is much that is very good for the purpose of filling teeth and plenty that is not so good. Base plate, lacking admixture with other substances, is valuable in proportion to its possession of a high softening power; this refers more especially to preparations made particularly for plugging purposes. Plasticity of gutta-percha, and of its dental combinations, is secured at a temperature varying from 112° Fah. to 235°. Easy plasticity is attained at the expense of durability; it expresses over-softness. Resistance to softening implies over-combination with inorganic substances, which is quite as inimical to satisfactory results as is over-softness. The best gutta-percha for filling teeth lies in a quality that approaches 180° and is unmixed with other material.

The grade of a gutta-percha is measured, as the unmixed variety is concerned, by using a flat boiler, or any convenient means representing one, and after laying the specimen to be tested upon it, heat the water by use of a spirit-lamp; a thermometer bulb related to the water of the cup or boiler shows the extent of heat. Plasticity obtained below 150° is not acceptable for surface plugs, but is found useful in filling canals. Plasticity standing at 180° allows of the making of a plug which, while not as resisting as the mixed gutta-perchas of higher grade, is eminently conducive to tooth preservation.

Dry testing, a manner that has to be used with the mixed varieties, the grade of which is above the boiling-point of water, is to be esteemed as injurious to the specimen; hence a conclusion that grades of gutta-percha requiring to be softened by means of hot plates are not apt to prove serviceable. It is not, however, to be understood that the material may not be softened after this latter method without injury, but it seems to be a quite common experience that it is likely to get burned or otherwise deteriorated.

To dry test gutta-percha, take a specimen and lay it upon a metal, or preferably, a por-



Combinations with gutta-percha are illustrated in a very familiar tooth-plugging material, known as Hill's stopping. In this agent the gutta-percha has worked into it definite proportions of quicklime, feldspar, or other inorganic material. As an agent for filling children's teeth it is in much favor. It is also used freely in frail adult teeth.

Gutta-percha, alone or in combination, recommends itself in that multitude of cases where patients are undergoing what might be called a season of dental metamorphoses. These seasons are familiar to every observing practitioner of the dental art. A set of teeth, good for previous years, suddenly, and without observable change in the constitution, take on decay. To fill such teeth with expensive material is to incur great cost to the patient, with a certainty as well to the operator that what is done will prove of little avail; that it will require quickly to be done over. Such failure certainly comes to the dentist who fails to appreciate that his operations are directed alone to effect, not to cause. The inexpensiveness, the easy manner of introduction, and the quickness with which gutta-percha is to be removed from teeth and replaced, render the material one of pre-eminence for selection in such cases.

Red gutta-percha has seemed to the writer to possess virtue as a tooth conservator not enjoyed by the white. The latter, however, is commonly selected to be used with front teeth for the reason that it calls less attention to the defect. To prepare the first, it is desirable to heat and soften it by means of hot water. Any convenient means to this end may be adopted, it being understood that the material is not to come in immediate relation with the moisture. A metal cup filled with water, the cover serving as a plate to hold the plastic, a ring and stand to support this cup, a spirit-lamp for purpose of heat, constitute an admirable apparatus. White gutta-percha is made ready for the tooth by exposing it, upon a plate of tin, silver, or mica, to the action of a flame acting on it from beneath. (See foot-note.)

**Instruments.**—Special instruments are required for a proper use of gutta-percha. Of many different patterns, preference would not unjustly be given the D. D. Smith set. (Fig. 165.) These instruments are employed by the deviser for all kinds of plastics; they are here commended particularly in connection with the material under consideration. Nos. 1, 2, and 3 have smooth heads. Nos. 4 to 9 are dully serrated. No. 6 is for distal cavities in molars and bicuspidati. Nos. 10 and 11 are spatulæ for carrying and inserting the material, and used also as burnishers. No. 12 finds its exclusive use for mesial and distal cavities. No. 13 is a cutting instrument for trimming excess of plug from cervical margins.

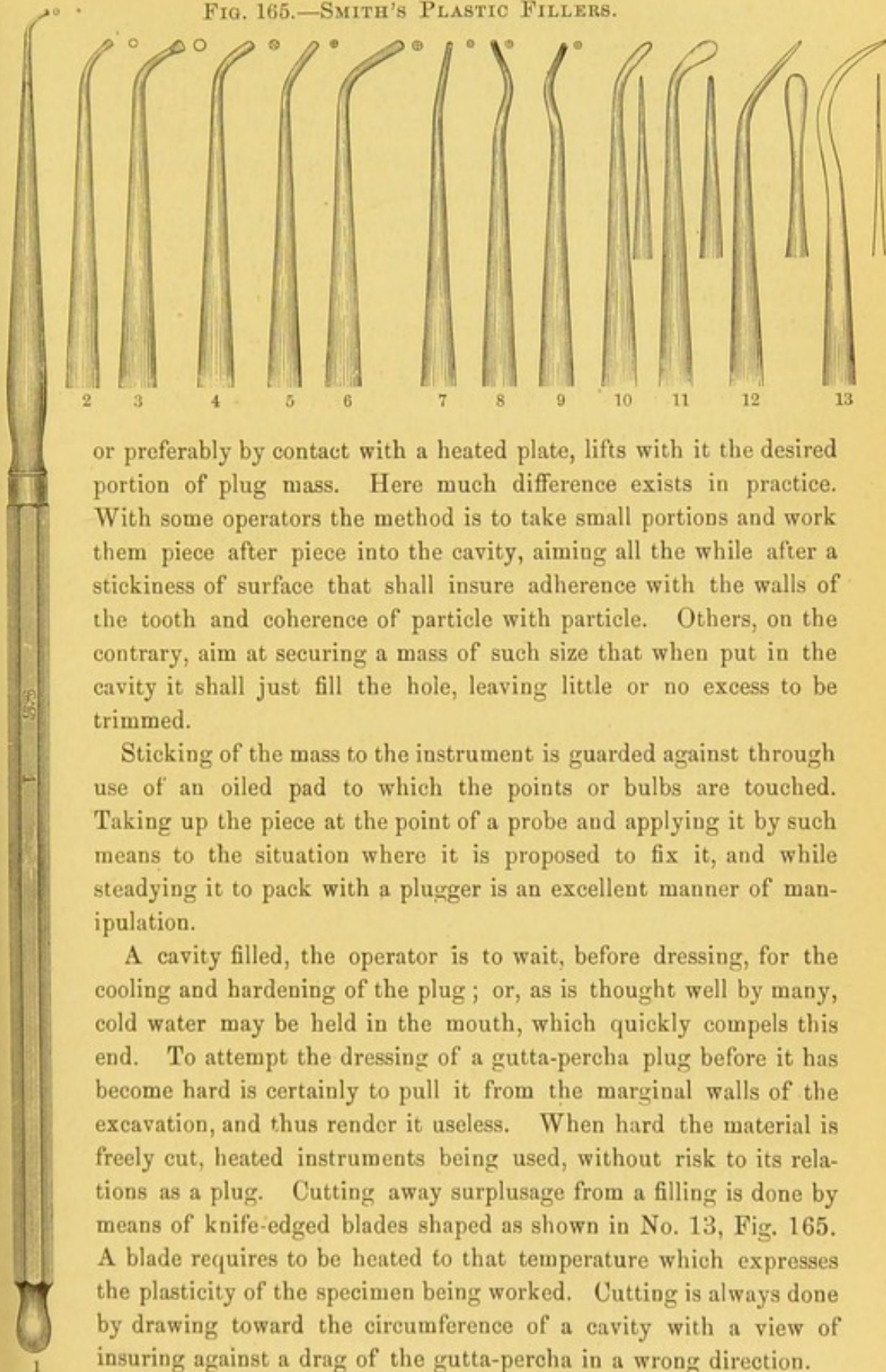
**Introduction of Material.**—A cavity made ready, the operator takes up the selected instrument, and gently warming it by means of his spirit lamp,

---

celain plate, apply now the flame of a spirit-lamp from the under surface, and bring the heat up in the most gradual manner. The proper place for the relation of flame with plate is the farthest possible point away from the plastic. To apply heat immediately beneath a specimen is almost certainly to bubble or burn it.



FIG. 165.—SMITH'S PLASTIC FILLERS.



or preferably by contact with a heated plate, lifts with it the desired portion of plug mass. Here much difference exists in practice. With some operators the method is to take small portions and work them piece after piece into the cavity, aiming all the while after a stickiness of surface that shall insure adherence with the walls of the tooth and coherence of particle with particle. Others, on the contrary, aim at securing a mass of such size that when put in the cavity it shall just fill the hole, leaving little or no excess to be trimmed.

Sticking of the mass to the instrument is guarded against through use of an oiled pad to which the points or bulbs are touched. Taking up the piece at the point of a probe and applying it by such means to the situation where it is proposed to fix it, and while steadying it to pack with a plugger is an excellent manner of manipulation.

A cavity filled, the operator is to wait, before dressing, for the cooling and hardening of the plug; or, as is thought well by many, cold water may be held in the mouth, which quickly compels this end. To attempt the dressing of a gutta-percha plug before it has become hard is certainly to pull it from the marginal walls of the excavation, and thus render it useless. When hard the material is freely cut, heated instruments being used, without risk to its relations as a plug. Cutting away surplusage from a filling is done by means of knife-edged blades shaped as shown in No. 13, Fig. 165. A blade requires to be heated to that temperature which expresses the plasticity of the specimen being worked. Cutting is always done by drawing toward the circumference of a cavity with a view of insuring against a drag of the gutta-percha in a wrong direction.

Gutta-percha is supplied by manufacturers for tooth-filling purposes in the various forms of squares, blocks, pellets, and disks.

**The Oxychlorides.**—The oxychloride is a plastic made by mixing dry



oxide of zinc into a watery solution of chloride of zinc. As met with in the dental depots it consists of a powder and fluid, occupying different bottles.

Of this plastic the variety offered is greater even than that of the amalgams. A single formula affords not only an idea of the composition of all, but, as well, a recipe which secures a preparation equal perhaps to any.

*Recipe.*—For the powder, simple French oxide of zinc.

For the fluid, aquæ, ℥vi; zinci chloridi, ℥j. After mixing water and zinc chloride the solution is to stand uncorked twenty-four hours.

An oxychloride plug, when prepared as above, is absolutely white, or so nearly colorless as not to accord with many teeth in which it may be desired to use it. Shade to-suit is secured by addition to the powder of scraped slate, or preferably, in the judgment of others, by ochre. Another element, used in many preparations with a view of increasing hardness of surface, is borax. Still others are feldspar, flint, silex, titanium, alumina.

Taking oxychloride of any formula, that is, taking from a bottle which contains dry oxide of zinc and from another holding a watery solution of chloride of zinc, the preparation of a mass for tooth-plugging purposes is nothing more complex than making a mixture of powder and fluid upon a glass slab, using for the purpose a knife-blade or an ivory or a platina spatula; the consistence is to be that of fresh putty.

For use in frail and poor teeth oxychloride has much to commend it. It will support a weak tooth and harden a soft one. It will whiten one that is dark and purify one that is foul. There is a multitude of cases in which no filling material but this will save a tooth. It is a therapeutical filling; it does very much more than stop a hole. Not understood or properly managed, it becomes quickly an agent of evil.

Viewed mechanically, an oxychloride filling is made very much the same as one of amalgam. It is not, however, necessary to tap-blow it. Preparing the paste, which, for therapeutic reasons, is to be mixed thick or thin, the operator lifts upon an instrument a portion corresponding in size with about a fourth of the cavity to be filled; this he introduces, obtunding the pain which almost instantly follows, and at the same time forcing the material into all the irregularities of the hole by means of a pledget of bibulous paper used as a ball in the grasp of a pair of finger forceps. This use of bibulous paper with the first portion is never to be omitted by a student, otherwise the price paid for his neglect may be the loss of the tooth upon which he operates; the paper takes up any excess of the chloride; which is a powerful irritant.

Of the different filling materials used in dental art, none requires more absolute freedom from moisture, both at time of making a plug and the setting of it, than an oxychloride. It is seldom, however, that the trouble of coffer-damming a tooth is required. The material being easy and quick of introduction, a napkin, aided by a free use of bibulous paper, is all that is commonly found necessary.

A plug in place, setting is to be expedited by pressure with an absorptive pad.



Once solidified, perfect protection against the fluids of the mouth is secured by dropping upon the filling from the point of an excavator a solution of gutta-percha made by dissolving that gum in chloroform. A skin of gutta-percha thus secured remains intact for a period varying from several hours to several days.

A secondary mechanical use is found for the oxychlorides in employing them as a foundation for metal fillings. A great cavity partly filled with this paste is of better promise than where metal alone is used; this applies in every instance where such combination does not interfere with the ability to anchor metals solidly. Still another good service is rendered by this material as a facer of amalgam plugs in anterior teeth. Another use is as a capper of nearly exposed pulps. Cements of this class are prepared particularly for this purpose; they set quickly and may be used so creamy as to be poured into a cavity. One such preparation, known as "Foundation Cement," hardens sufficiently in from two to five minutes to allow of packing gold or other filling material upon it.

Oxychloride fillings are not to be esteemed as of permanent signification. Two years is quite as long as any exposed plug of this class may be expected to last. They continue longest in mouths that are acid. The manner of their disappearance is by crumbling and wearing.

An oxychloride filling when thoroughly dry will take a polish by being burnished gently with heated talc; unfortunately, such polish quickly disappears, consequently is of no service.

Oxychloride is invaluable as a means of strengthening the weak walls of dental cavities. An incisor or other tooth, for example, having the dentine almost completely decayed away from the circumferential enamel walls is fortified satisfactorily by a lining of oxychloride, and is then to be filled with gold without danger of fracture. As a hardener of chalky teeth its value is well known; soft and septic organs are always to have a filling of gold preceded by one of oxychloride. Caries rarely progresses in presence of immediate contact of the part with oxychloride. (See chapter on *Filling Teeth*.)

**Zinc Phosphates.**—The zinc phosphates closely resemble the oxychlorides in common appearance and manner of working.

A phosphate-of-zinc filling is made by mixing glacial phosphoric acid and basic oxide of zinc in proportions affording a mass of putty-like consistency. The common time of setting is two minutes.

Difference in the quality of this stopping is assumed to be influenced more by the quality of the materials named than by admixtures with other agents, many samples, both of acid and base, being so imperfectly made as to be worthless for purposes of cement. The trouble and uncertainty of preparing the syrup renders purchase, rather than attempt at making, desirable.

Phosphoric acid being less an irritant than chloride of zinc, fillings made with it are less dangerous, necessarily, as well less therapeutic, than those made of the oxychlorides. A claim for superiority on the part of a phosphate-of-zinc plug lies in the direction of hardness.



Forms of phosphate filling material in the market which have attained to most prominence are Flagg's, Peirce's, Fletcher's, Weston's, Poulson's.

It is to be mentioned that there are in the depots forms of cement which claim to be something besides either of these just named. One, Guillois's preparation, is known to the commercial world in the form of imitation coral, sleeve-buttons, shirt-studs, etc. Another, Weston's Insoluble, has prominent claims put forth with it. Both preparations possess worthy indorsement.

Still other articles of the kind are the "Cement Plombe" and the "White Enamel Stopping" of Oehlecker. The former finds many to recommend it; the latter has an advancing reputation. Directions for manner of use accompany the preparations.

From the employment of oxide of zinc as a base manufacturers of zinc phosphates are passing to the employment of the nitrate; this latter is found to secure a greatly increased stableness in the compound.

The syrup used in kneading the powder of fillings of this class is to be fresh and of specific character; when old it is over-thick or otherwise rendered useless by being found separated into fluid and sediment.

Zinc phosphate is wisely to be dismissed with a suggestion that the material, as at present understood, is commonly found to prove disappointing.

**Tin.**—Tin is furnished in form of foil. In color this foil is like the metal as met with in commerce. As a filling material quality is in accord with purity. When freed from alloys, tin furnishes the dentist with an agent which serves a wide purpose,—much less wide, however, than previous to the introduction of gutta-percha and the chloride plastics. As the use of metals is concerned, tin is undeniably, in case of soft teeth, eminently superior to gold as a preservative. It is easy of introduction into a cavity, and, as compared with the nobler metal, pre-eminently easy of a required consolidation.

Tin is prepared in sheets of various numbers, these numbers giving the thickness of the leaf. From Nos. 4 to 10 are commonly used; higher numbers are 14, 18, 20, the latter being the highest.

For use in children's first teeth, particularly the molars, tin foil is an admirable article; certainly in every way preferable as irritative qualities are concerned, the metal being peculiarly in accord with tooth-substance.

Tin foil is used precisely as gold foil; forms of it are in the market, both soft and cohesive. (See *Gold*.)

**Plastic Tin.**—Plastic tin is a preparation of the metal which is used by amalgamating with mercury, employing for the purpose 48 parts of the latter to 100 of the former. It is not to be washed nor squeezed. Neither is alcohol to be used, but it is to find its cleansing through the aid of zinc precisely as directed in the case of amalgam. This preparation makes a solid cohesive plug, and one that is decidedly therapeutical; it is claimed that it has only one-fourth the conducting power of gold, and that on a scale of 100 it stands 40 degrees nearer to tooth-substance than the latter metal.

Another preparation of tin is known as stannous gold. This material



comes prepared in the form of heavy, coarse sheets. It is used precisely as cohesive foil, and works with a plasticity not much inferior to amalgam.

All preparations the base of which is tin deserve consideration at the hands of the operating dentist.

**Gold.**—We come now to gold, a material which is to be accepted as holding the position *par excellence* as a material for filling teeth,—certainly a material which yields the most artistic and beautiful results, in such respects outranking all preparations used in operative dentistry.

Gold is prepared for the hands of the dentist at the present time in such variety as to form, and with such view as to fitness, as indications are concerned, that in reality the operator finds much of his work anticipated.

A division of gold is into soft and cohesive; the first has a kid-like character and is worked by a process of wedging; the second is sticky: plugs are made of it through a process of cold welding.

Varieties of gold are sheets, mats, pellets, cylinders, blocks, ribbons, twists. These are forms fitting the material for the table of the operator; they are prepared both from the soft and plastic gold. A preparation looking not unlike golden sponge and known as Watt's crystal gold is popular; the working of it differs nothing, however, from that of the kinds now to be described.

**Sheets.**—A sheet is gold in the form of leaf: it comes to the dentist in books marked variously from Nos. 4 to 240. Number designates the weight of a leaf. High numbers express heavy foils; they are comparatively infrequently used. Low numbers distinguish the preparations most easily worked. From Nos. 4 to 8 are commonly selected. Leaf gold is soft, or non-cohesive, cohesive, and semi-cohesive.

**Mats.**—A mat consists of a square made by folding leaf gold into a strip, and afterwards cutting it into sections.

**Pellets.**—A pellet is made by compressing a mat into ball form.

**Cylinders.**—A cylinder is a form of gold secured by rolling a strip about a broach or common pin.


**Blocks.**—A block differs from a mat only as thickness is concerned; it is made in the same way.

**Ribbons.**—A ribbon is leaf gold folded upon itself until a desired width is obtained.

**Twists.**—A twist is a ribbon coiled upon itself.

All these forms are furnished by manufacturers. Fig. 166 represents cylin-

FIG. 166.—CYLINDERS.



ders prepared of various lengths and diameter. Those known as Peck's are loosely wrapped, and can be used, if desired, as pellets. Fig. 167 shows forms for mats and blocks.

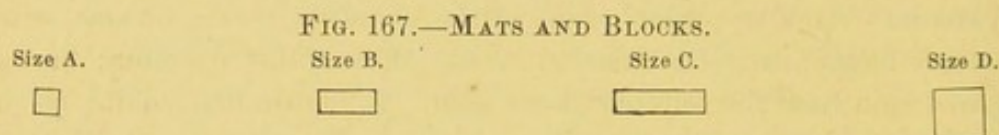


## CHAPTER XXIV.

### OPERATIVE DENTISTRY.

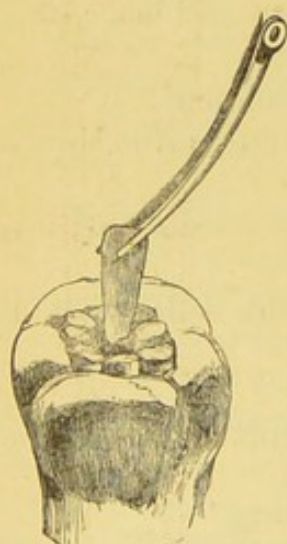
#### FILLING TEETH.

**Filling Teeth with Gold—Non-Cohesive.**—Referring to individual cavities, which shall serve as studies to direct the ingenious hand, attention is first given to such simple forms as are represented by round holes,—cavities



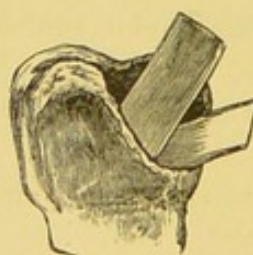
alluded to as being common to the crowns and sides of the molar teeth and to the posterior faces of the incisors. To fill cavities of this class, the cylinder naturally suggests itself. Selecting one of a size that will reach the bottom and extend beyond the margin, it is, after being placed, to be laterally expanded by a wedge-plugger carried through its centre, or otherwise is condensed in mass

FIG. 168



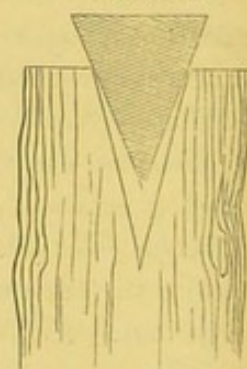
Cylinders and mats in the act of being introduced into a crown cavity.

FIG. 169.



Mat in place.

FIG. 170.



The principle of wedging.

against the wall of the cavity. The space thus secured is to be filled by a second cylinder of convenient size, the wedging to be repeated, and the introduction of cylinder after cylinder to follow, until no more can be introduced. (See Fig. 168.)



Mats are found, in the beginning of an operation, to conveniently replace the cylinder where crown cavities are large and of more or less irregular form; as in Fig. 169. These are used precisely as the latter, being carried into position by means of the foil-carrier, and condensed carefully and accurately against the immediately neighboring wall. Other mats, following the first, are to be arranged around the cavity, thus making as it were a gold tube into which cylinder after cylinder, as before directed, is wedged, or, one plate may be condensed against its fellow until in this way the cavity is full. Wedging throws apart laterally, thus insuring marginal solidity to a plug; it is the master principle of making perfect operations. Soft gold is commonly used. The idea of wedging is fully illustrated in wood-splitting, Fig. 170.

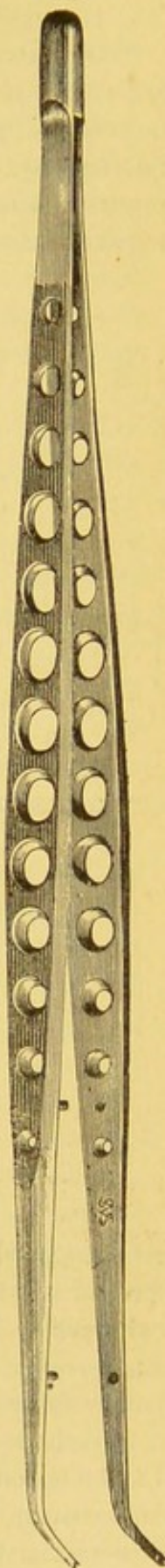
Filling a cavity with the ribbon is now an almost obsolete practice, although highly extolled by many; it is associated with much more trouble than is the use either of cylinder or mat. To manipulate gold so prepared, the operator, after carrying the initial extremity to the bottom of a cavity and fixing it by any convenient means,—generally by holding it with an instrument held in the left hand, or confiding the task to an assistant,—folds upon this first, layer after layer, making the bend at such distance above the orifice of the cavity as considers the condensation to which, later, the metal is to be subjected, and which, if properly done, is to afford a solid surface that shall not be sunk below the margin when the necessary filling and polishing shall have been completed.

Twists, or ropes, are used precisely as the ribbon, fold after fold being bent and carried into a cavity until no more will be received. It is more common to confine the use of the rope to small cavities, such as are found on the approximal faces of anterior teeth, although operators are met with who employ gold in this form exclusively.

A modification on the use of ribbon and rope, as just described, consists in wedging the centre during the progress of the filling. The operator first gets his cavity loosely filled; then, leaving the rope as related with the last fold, he wedges the gold against the parietes. The secondary cavity thus made is then filled by turning the rope into it precisely as in the first instance, the lateral pressure securing solidity.

Another study, which will serve as the demonstration of a second class of fillings made of non-cohesive gold, relates to cavities in anterior teeth, approximal faces. As the filling

FIG. 171.



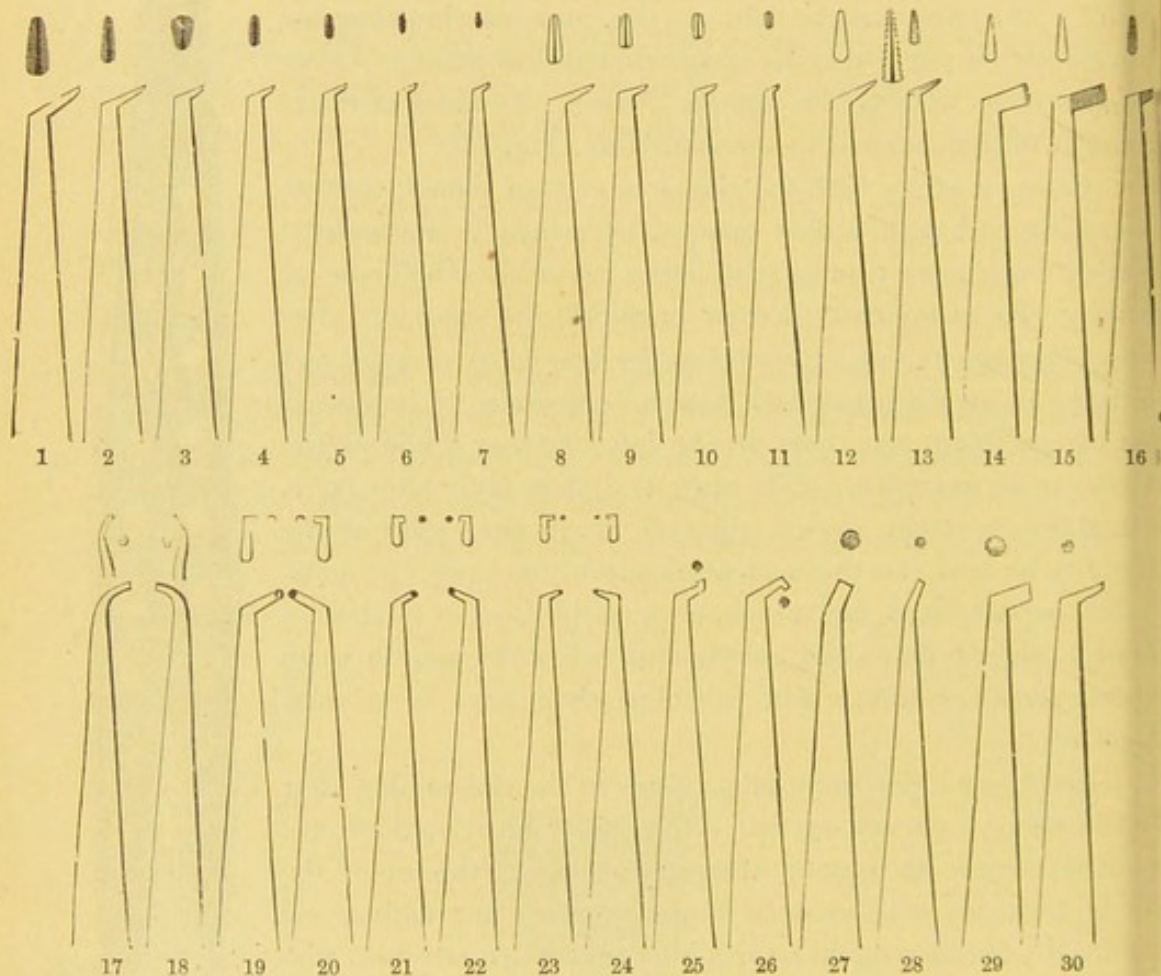
Foil-Carrier



of all such cavities is on a common principle, we will take the superior incisor, Fig. 134, right side, as seen prepared.

To fill this tooth,—being made ready as understood,—the operator takes a leaf of gold, preparing with it, besides a rope, a number of mats. The mats he arranges upon his tray or table, having various sizes in such convenient rotation that, without search, he is able to pick up each as required. The rope is to be cut into small pieces. The material thus made ready, the next requirements are the necessary instruments. Fig. 172 exhibits a set of plug-

FIG. 172.



gers, designed by Dr. W. G. Redman. Possessing these instruments, an operator will find himself able to readily introduce and pack cylinders, mats, and ropes in the various cavities to which they are found adapted. These cuts represent thirty of the most approved points. They can be procured with handles to suit. A half-inch ivory or ebony handle is recommended. Nos. 1 to 7 (serrated-foot instruments) are lateral condensers for all cavities. Nos. 8 to 11 (smooth-foot instruments) are used in the same cavities and in the same manner, but not until the cavities are nearly full. Nos. 12 to 24 are all approximal condensers. No. 25 is for anterior approximal cavities, molars, and bicusps. No. 26 is for posterior approximal cavities, molars, and



bicuspid. Nos. 27 and 28 are for crown cavities, upper molars, and bicuspids. Nos. 29 and 30 are for crown cavities, lower molars, and bicuspids.

To fill the tooth selected, the operator takes up with his foil-carrier a mat of gold of a size suited to an easy introduction into the cavity. This mat it is designed to place firmly against the neck-surface. To so direct and place it, any of the instruments, Nos. 7, 11, 27, or 28, may be employed. The first piece in position, a second is to follow, being introduced in like manner and consolidated against the first. Sometimes, particularly where the labial wall of a cavity is delicate, it is best to lay the second mat against such wall, obtaining thus increased security against fracture. Mat after mat is now added until the cavity is full; or, if preferred, the cut rope may be used, piece after piece being carried and wedged into place.

Another plan of using mats in cavities of this character consists in first lining the circumference with them and afterward wedging the cut rope into the centre.

Still another plan that is found at times convenient consists in placing one mat against the neck-wall, and a second in that portion of the cavity nearest the cutting edge of the tooth, wedging next the cut rope, or other mats, between these.

Another plan still is found in using a twist or rope of gold, as directed in the case of crown cavities, turning into the cavity layer after layer, until no more can be introduced. This formerly was the almost universal practice, being now, however, almost as universally replaced by cohesive foil, a manner of working gold shortly to be described.

In operating on a cavity of such position as has just been considered, the head of the patient is to be thrown back, the mouth looking upward. The operator stands at the right side of the chair, while the fingers of the left hand support the tooth and adjacent parts.

Passing to still another study, we consider anterior approximal surfaces of the bicuspidati and molars. Referring to the diagram, Fig. 134, it is seen that such cavities, when properly exposed, are converted into a very simple form. To fill them it is only necessary to employ the mechanical means given. Commonly the operator commences with a mat which he fixes against the cervical wall, laying one after another of these over this first one, until the cavity is full. Where the cylinder is employed, the manner of introduction and consolidation is precisely the same. In large cavities of this position it is found an excellent plan first to bound the cervical and lateral walls with mats, and afterwards wedge cylinders or mats within this golden cavity.

Posterior approximal faces are commonly much more difficult to fill than anterior. Such difficulty, however, is found markedly influenced by the preparation of the cavity and the state of the boundaries of the mouth to be operated in. A deep narrow arch with the oral orifice small and tense, and strong buccal muscular tissue, and with the patient unable or unwilling to assist by keeping the mouth open, will worry the most skilful and experienced.



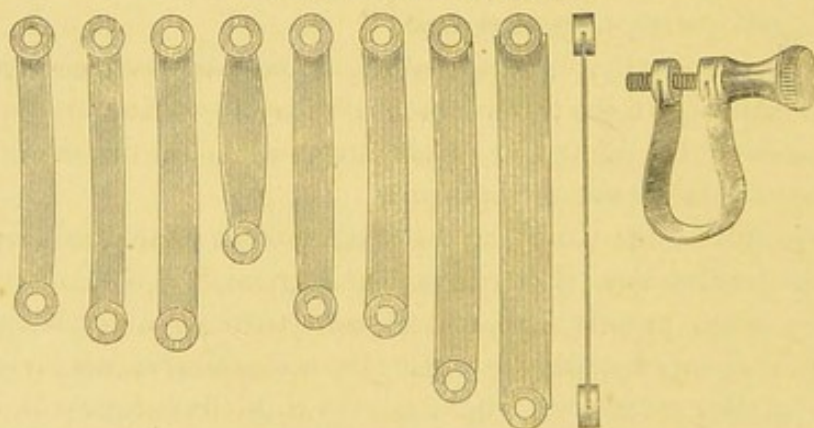
On the contrary, in the wide mouth of free and lax orifice, little more trouble is experienced than in the case of anterior faces. Such cavities are filled with the non-cohesive gold precisely as are the anterior.

The use of matrices in the construction of a temporary wall for the conversion of approximal cavities into simple holes has long been a favorite means employed by many persons. A very easy and always convenient way of making a matrix, and one which the author has employed in hundreds of cases with satisfactory success, consists in breaking off a section of an ordinary separating file having a free or uncut surface, and slipping it between the two teeth, wedging it in place. This, as must be seen, is not by any means a complete wall, but it will be found to answer an excellent end, needing, indeed, to be seconded only by a reasonably skilful touch to fulfil sufficiently the indications. Such a matrix is most conveniently used if the temper be first removed.

Another mode of making a matrix applicable to an approximal inclined plane consists in taking a delicate strip of silver, and after cutting and filing so that it shall half cover the cavity, being bulged, however, just over it, wedging it by means of splints of boxwood into place; this manipulation forms, as is seen, a limited last wall, but such wall is quite sufficient to answer the ends.

A matrix known as the "Loop" is a late device and one of much promise;

FIG. 173.—LOOP MATRICES.



a set of these consists of eight thin flexible steel bars and a milled thumb-screw. The bars have heads on each end, with eyes, in one of which a thread is cut to fit the thumb-screw. To use them, select the proper size for the case in hand, pass the head with the smooth hole over the thumb-screw, bend the screwed head around and screw to place on the tooth.

A character of matrix invented by Louis Jack, D.D.S., has attained deserved popularity; reference to Figs. 174 and 175 will afford idea of its construction. When cavities are of such extent as to very much complicate the process of introducing and fixing gold, these matrices, from what might be termed their permanent and full character, will be found not only to spare



the operator much fatigue, but to assist materially in giving form and solidity to a plug.

Fig. 174 shows that surface of a matrix which is placed next the cavity ; it will be observed to correspond with the part to be restored. This face is file-cut or coarsely draw-filed. Fig. 175 shows reverse face, which is in most cases plane and smooth, excepting at the section *c*, which is file-cut. It is

FIG. 174.



FIG. 175.

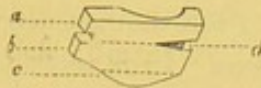


FIG. 176.



often, according to the experience of the inventor, desirable to have this side in two surfaces ; one, section *a*, parallel with the plane parts of the face, and from this point inclining to a thin edge. A very desirable form is to have section *c* bent backward to follow the incline of the proximate tooth beneath the gum ; *b d*, show square cuts made to accord with the pincer-ends shown in Fig. 176.

To apply a matrix, it is necessary first to secure space either through pressure, or preferably by means of file or disk. As well is it necessary to the performance of a preservative operation that before wedging a matrix in position the edges of a cavity, as well as the cavity itself, be so prepared that no obstruction exist to an easy reaching of every part.

Employing the Jack matrix, selection is to be made of one corresponding in curve, size, and thickness with the requirements of a particular case under treatment. For small cavities it is recommended by the inventor that the drying be first done, the napkins or dam applied, and a hard rope of bibulous paper pressed against the gum, followed by the matrix. Fig. 177 represents the appearance of the parts at this stage, except the wedges, which are not shown. When the cavity is now examined, it will be found to present an open mouth, formed by its curved lower edge of enamel and by the boundary of the matrix, through which funnel-shaped opening every part of the space is easily seen and directly touched. The case is now ready for the reception of gold.

FIG. 177.

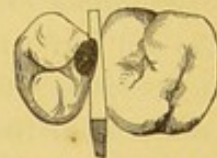


Fig. 178 represents a transverse section of two cases at a point immediately above the grinding surface, which exhibits the outline of the form of the cavity and finished surface of the gold.

Referring again to the diagram, Fig. 134, attention is directed to the filling of the very irregular crown cavities represented, two of which are shown running, upon the first molar, into the lateral walls. In filling such cavities, the operation is to be accomplished without much difficulty by introducing first into either extremity (which has been prepared as described) cylinders or mats of gold, and, after securing the fixedness of these,

FIG. 178.





packing subsequent mats or twist-pellets one after the other, until the line of association is full. It is, however, in instances of this kind that the use of the cohesive gold is felt to be almost a necessity. Working gold so prepared and understood, one would scarcely be likely to depend on the mode just described. (See *Cohesive Gold*.)

A last study that seems necessary to be made in connection with the exclusive use of the non-cohesive gold is to be directed to the cavity seen in the crown face of the wisdom-tooth, Fig. 134, right side. This cavity has a complex relation, only, however, from the fact that it is seen to be half covered by an operculum of gum-tissue. In filling such a cavity (or, indeed, rather would it pertain to the preparation of the cavity), it is found necessary to uncover the parts; to accomplish this, a tuft of cotton or sponge is to be thrust between the tooth and operculum, which tuft, in the process of swelling, will sometimes remedy the trouble by pushing the gum beyond the posterior wall of the tooth, around which it may have gathered. If the operator be not successful in this performance he is to cut the part away, using scissors or a bistoury.

**Cohesive Gold.**—Two leaves or portions of that preparation of gold known as cohesive, when pressed together with a moderate degree of force, will cohere so strictly as not to permit of subsequent separation.

To fill a tooth with cohesive foil, absolute dryness is essential to even a comparative success. To make ready such gold for use, if not bought sufficiently prepared, it is desirable that the operator first wash his fingers with alcohol: this cleans and dries them thoroughly. The foil is now to be cut according to the number used, being folded loosely into twists or cut into strips. Confining one's self to what is known as No. 5,—that is, a leaf of this number of grains in weight,—the manner of procedure is first to fold the full leaf ribbon-fashion, making the folds very loose, and about an inch in breadth; afterward lightly twist it upon itself. In making the twist, it would seem that nothing is more necessary than that the bright crisp and polish of the foil be not broken, while to avoid so breaking it requires only the exercise of a very little care. The twists are to be cut into pellets.

Heavier foils—those ranging from 20 to 120—are commonly used cut into little oblong squares, a delicate strip being first taken from a leaf and this strip subdivided into pieces of a size suited to the cavity to be filled. These heavy numbers are, however, confined mostly to use on the surface of a filling the bulk of which has been made by the lighter foils, or otherwise are employed for filling the root-canals,—which see.

Cohesive gold exposed to the atmosphere or to association with phosphorus or sulphuretted-hydrogen gas, loses always more or less of its quality. To restore lost cohesiveness, it is the practice to anneal the leaf, doing this either by laying it upon a heated plate or by passing it through the flame of a spirit-lamp. The amount of heat to which foil is to be subjected is found to vary considerably. A satisfactory test of cohesiveness is found in touch;



a plan is to pass the twist through the flame, and then touch to it a finger: if it stick, it is to be considered sufficiently annealed; if it do not stick, greater heat is required. A practice with many is to heat every twist to a cherry red at the moment of introducing it into the cavity; and while such a rule may be found generally applicable, many lots of foil are met with which the treatment assuredly ruins. A rule to be observed in every case is not to burn the gold and not to heat it to an extent which destroys its softness. A foil that is not made cohesive by a heat which varies from that which shall simply dry it to that which exhibits the cherry red can never be made so by any such means; it is faulty.

It is not, however, to be understood that cohesive foil always requires annealing at the hands of the operator. Many makes are so perfect in this respect, as received from the makers, that it is only necessary to keep the books in a strictly dry place, and inclosed, when not being used, in the envelopes which accompany them.

Placing foil in the rays of the sun transmitted through glass, as an ordinary window, is a reasonably satisfactory way of annealing. In cool weather concentrated sunshine answers every purpose where the gold is good.

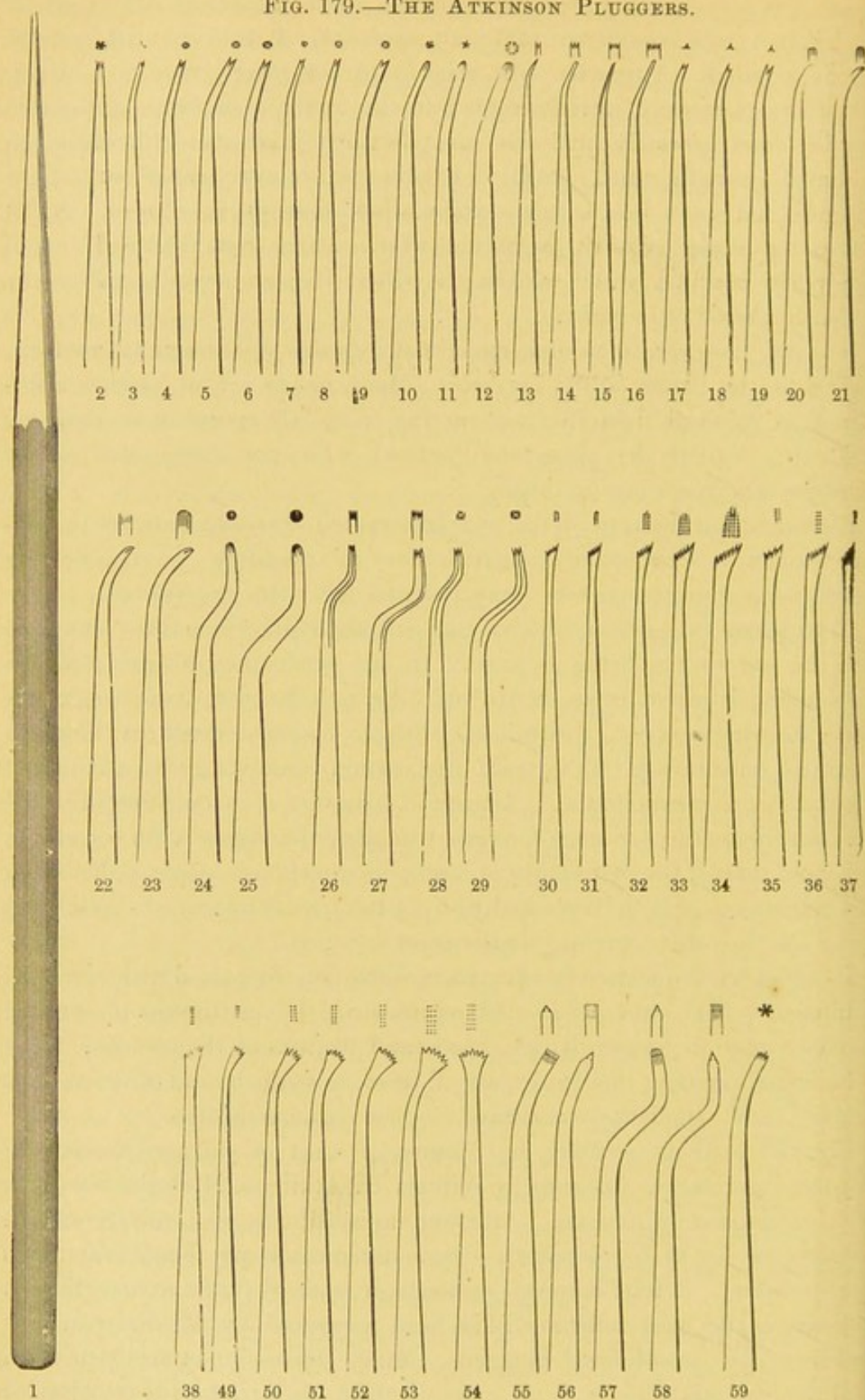
Instruments with which cohesive gold is worked differ from those employed with the soft foil in being serrated. In the production of such tools the most accomplished skill has exerted itself, both in the way of devising forms and in securing temper. Instruments when too deeply serrated cut the gold; when too smooth they fail to assist the natural cohesiveness by addition of the quality of interdigitation. Attention, however, is to be directed to the fact that there are operators of repute who deny the necessity for serrations, and even, indeed, the desirability of using instruments so prepared, believing that cohesive gold is to be worked with better results by smooth-faced pluggers. At the other extreme, needle-points are used.

To afford the student every advantage which is to be gained without actual manipulative trial, cuts are inserted representing the instruments of serrated character most in esteem by the experienced dentists of the country. It is to be found, perhaps, that in the use of these, as with the use of the various kinds of gold, familiarity constitutes the best recommendation.

Fig. 179 exhibits perfectly the features of a set of pluggers, comprising fifty-nine instruments, designed by William H. Atkinson, M.D., of New York City, and known by his name. Although intended to be used with the mallet,—a process yet to be described,—these instruments are found adapted to hand-pressure. Lately, however, as has been reported to the writer, this set, long among the most celebrated, has been renounced by the designer, in a preference for smooth-faced pluggers. Much reputation attaches to them with the best practitioners; a too great depth in the serrations is an objection that has been urged. A set of these instruments, consisting of twenty-four pieces, selected from the full complement, is found to answer the purposes of most operators.



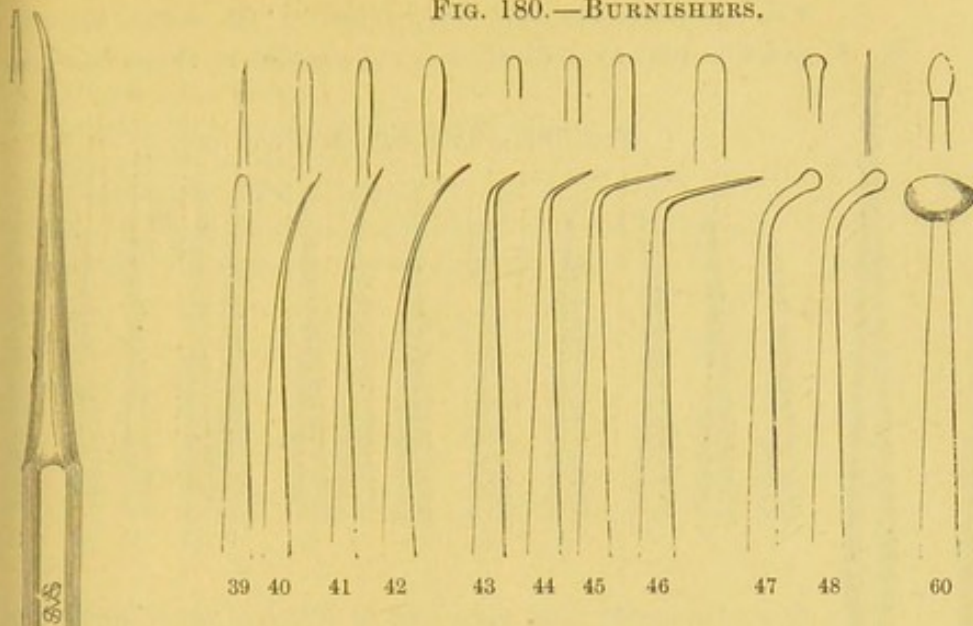
FIG. 179.—THE ATKINSON PLUGGERS.



Accompanying the pluggers is a set of burnishers of designs corresponding with requirements. Fig. 180 exhibits these burnishers.

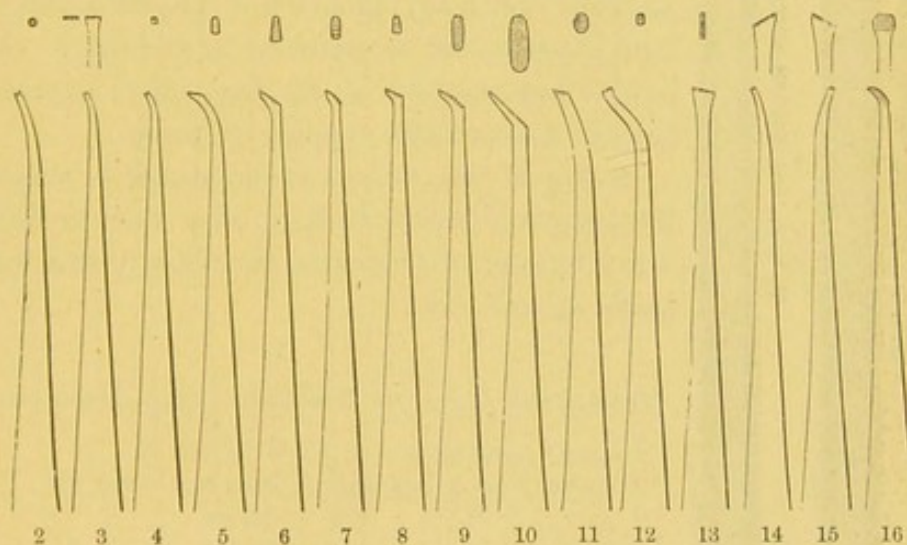


FIG. 180.—BURNISHERS.



A system of pluggers, composed of sixteen pieces, designed by C. R. Butler, M.D., is represented in Fig. 181. These are in great favor

FIG. 181.—THE BUTLER PATTERN.



with a wide circle of operators. The serrations, as seen in the cuts, are very fine.

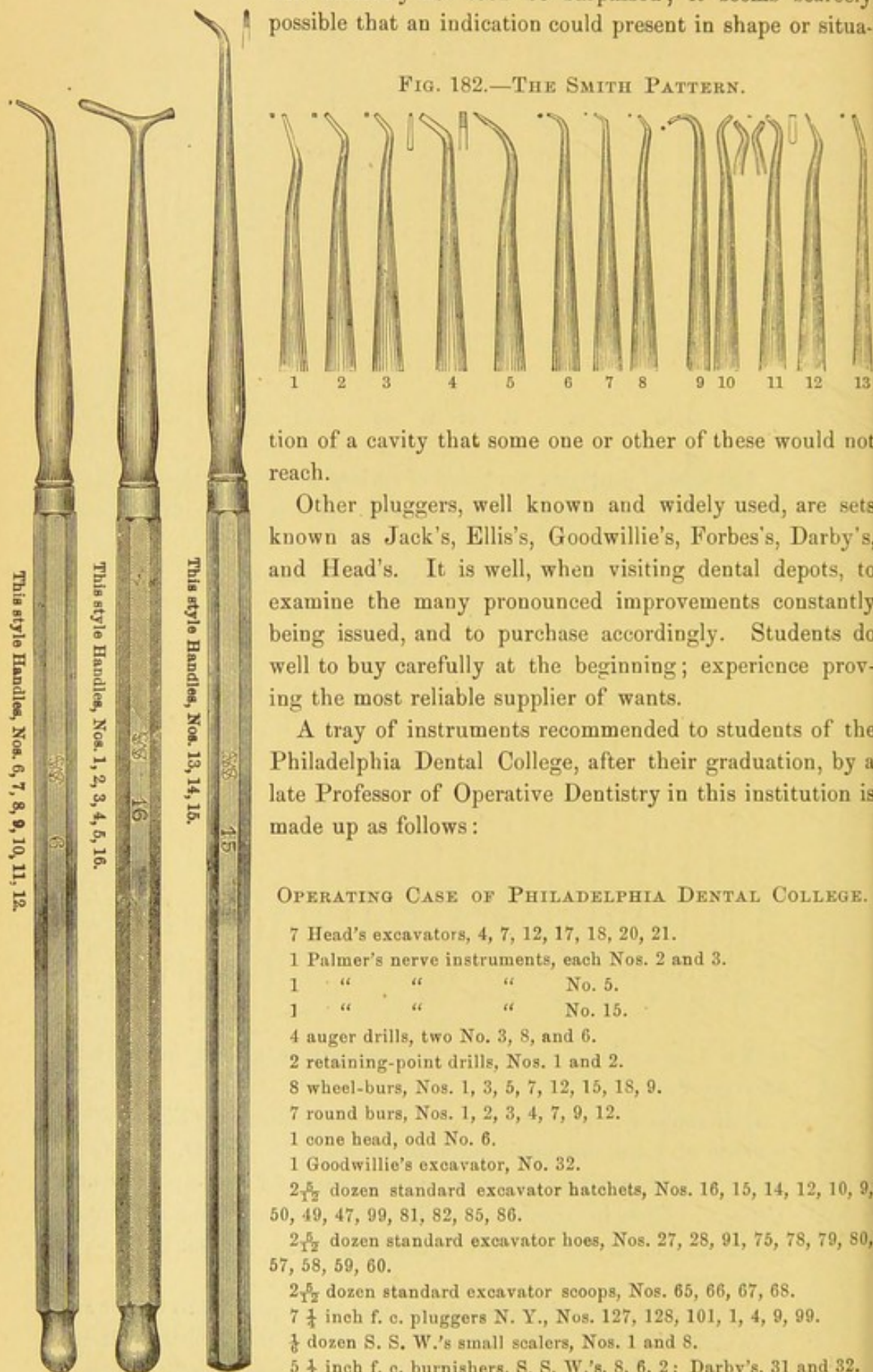
Still another form—"a student's set," as it is called (Fig. 182)—consists of selections and modifications made by Dr. D. D. Smith, and which are used by many of the class in the Philadelphia Dental College. These instruments are alike adapted to malleting and hand-plugging, and for use with soft or cohesive gold. The set has a wide reputation.

Another set, and which is the last that space permits to be shown, is exhibited in Fig. 183. These are known as the Abbott pattern. Like the others, these have many admirers; the forms of the points



will certainly not soon be surpassed; it seems scarcely possible that an indication could present in shape or situa-

FIG. 182.—THE SMITH PATTERN.



tion of a cavity that some one or other of these would not reach.

Other pluggers, well known and widely used, are sets known as Jack's, Ellis's, Goodwillie's, Forbes's, Darby's, and Head's. It is well, when visiting dental depots, to examine the many pronounced improvements constantly being issued, and to purchase accordingly. Students do well to buy carefully at the beginning; experience proving the most reliable supplier of wants.

A tray of instruments recommended to students of the Philadelphia Dental College, after their graduation, by a late Professor of Operative Dentistry in this institution is made up as follows:

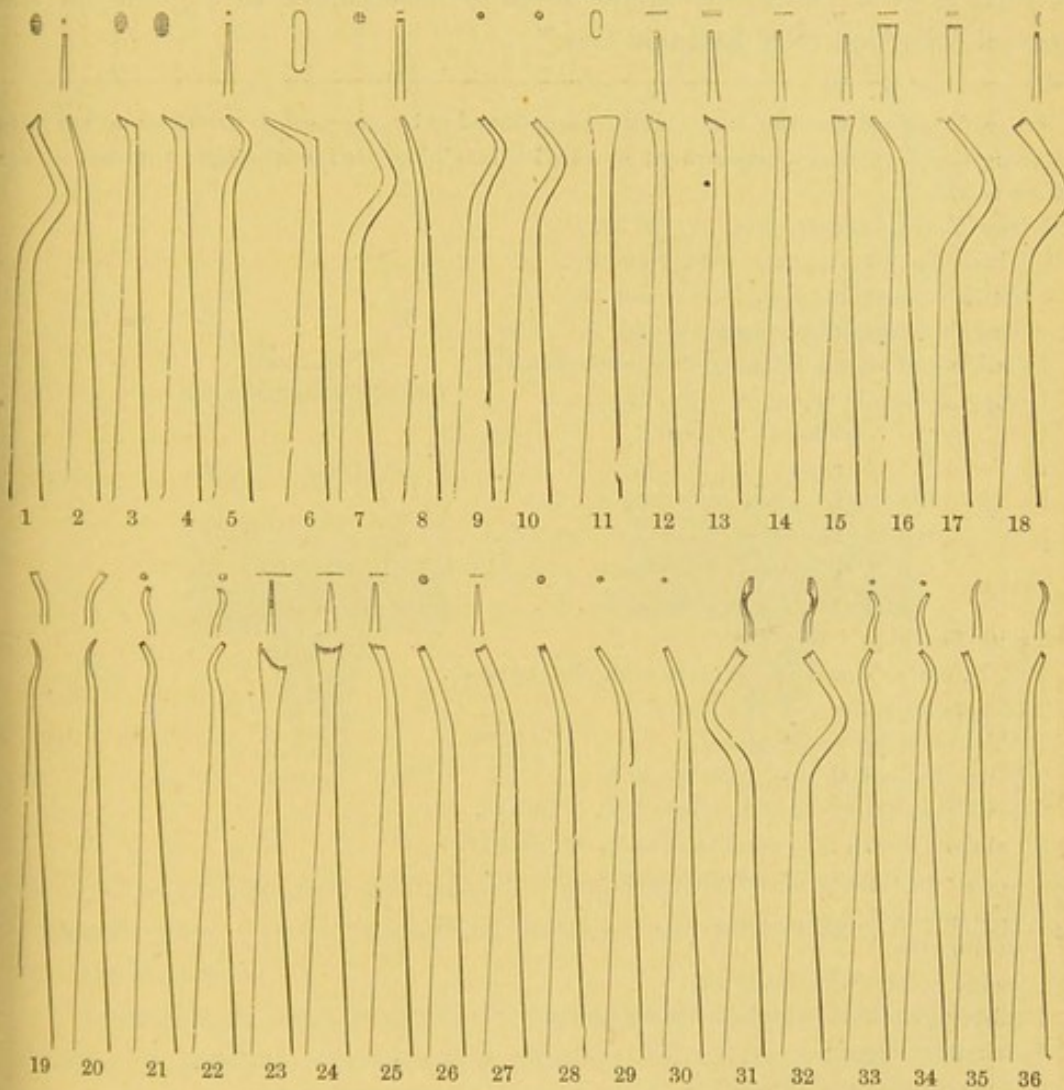
#### OPERATING CASE OF PHILADELPHIA DENTAL COLLEGE.

- 7 Head's excavators, 4, 7, 12, 17, 18, 20, 21.
- 1 Palmer's nerve instruments, each Nos. 2 and 3.
- 1 " " " No. 5.
- 1 " " " No. 15.
- 4 auger drills, two No. 3, 8, and 6.
- 2 retaining-point drills, Nos. 1 and 2.
- 8 wheel-burs, Nos. 1, 3, 5, 7, 12, 15, 18, 9.
- 7 round burs, Nos. 1, 2, 3, 4, 7, 9, 12.
- 1 cone head, odd No. 6.
- 1 Goodwillie's excavator, No. 32.
- 2  $\frac{5}{12}$  dozen standard excavator hatchets, Nos. 16, 15, 14, 12, 10, 9, 50, 49, 47, 99, 81, 82, 85, 86.
- 2  $\frac{5}{12}$  dozen standard excavator hoes, Nos. 27, 28, 91, 75, 78, 79, 80, 57, 58, 59, 60.
- 2  $\frac{5}{12}$  dozen standard excavator scoops, Nos. 65, 66, 67, 68.
- 7  $\frac{1}{4}$  inch f. c. pluggers N. Y., Nos. 127, 128, 101, 1, 4, 9, 99.
- $\frac{1}{2}$  dozen S. S. W.'s small scalers, Nos. 1 and 8.
- 5  $\frac{1}{4}$  inch f. c. burnishers, S. S. W.'s, 8, 6, 2; Darby's, 31 and 32.



- 4  $\frac{1}{4}$  inch f. c. pluggers: Ellis's, 10, 11, 12, and Darby's, No. 3.
- 1 universal porte polisher.
- 1 box corundum points.
- 1 long handle wood magnifying mouth-mirror.
- 1 Cogswell rubber dam holder.
- 1  $\frac{1}{4}$  inch f. c. rubber dam punch.
- 1 glass syringe, silver-plated mountings, with one curved pipe.
- 1  $\frac{1}{4}$  inch f. c. plugger, bayonet-shaped, no number.

FIG. 183.—THE ABBOTT PATTERN.



- 2  $\frac{1}{4}$  inch f. c. scalers, R. L. Stellwagen's pattern.
- 1  $\frac{3}{8}$  inch bayonet-shape condenser.
- 1 octagon handle plain steel small scaler, No. 5.
- 1 set of six Jack's chisels, single-bladed, heavy handle.
- 1 lead mallet in gas-pipe, nickel-plated.
- $\frac{1}{2}$  dozen five-sided drills, three faced.
- 1 set of ten mallet-pluggers. Nos. 1, 3, 4, 5, 6, 7, 8, 9, of the set of mallet-pluggers for sponge gold, No. 2 of Ellis's pluggers, and Atkinson's No. 32.
- $\frac{1}{2}$  dozen Froid's separating files, Nos. 00 and 8, cut three sides.
- 8 Murphy's files, Nos. 12, 20, 14, 33, 40, 41, 42, 19.
- 3 " " Nos. 54, 99, 100.
- 2 " " Nos. 81, R. and L.



- 2 Scotch stones.
- 1 box each pumice and polishing putty.
- $\frac{1}{4}$  dozen square handle probes, one foil-carrier and plugger combined.
- 1 abscess lancet.
- 1 student's large morocco case.
- 3 trays and instruments fitted.

A set of instruments as designated above is to be recognized as full and complete for the purposes of filling teeth; they are to be purchased at once, or what is even better, the catalogue is to be accepted as a guide for the gradual collection of a desirable case.\*

---

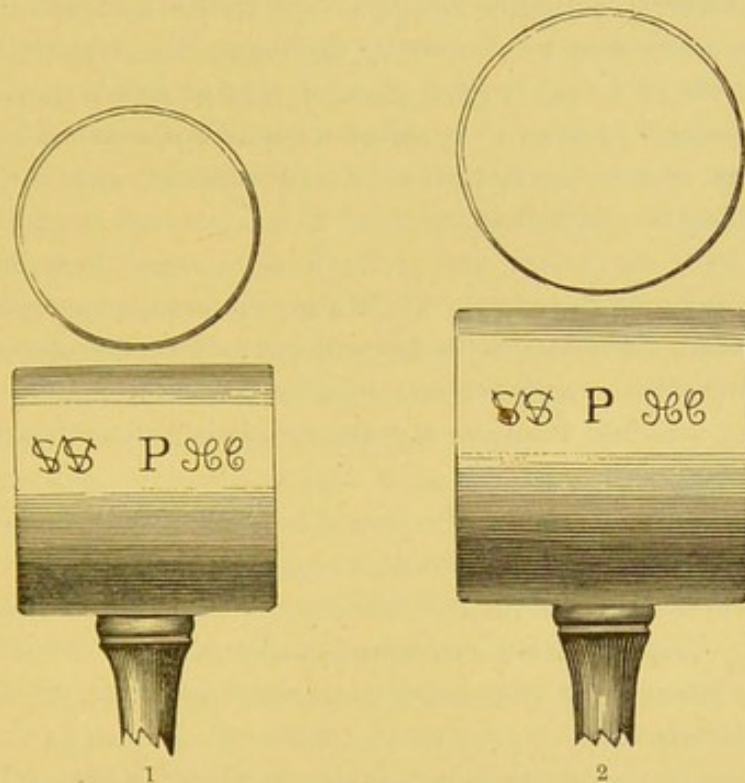
\* The following are the instruments recommended by the clinical professor to students entering the dispensary department of the Philadelphia Dental College; the cost of the whole is \$27.31.

- 4 New York pluggers, Nos. 22, 23, 37, 50.
- 2  $\frac{1}{4}$  inch file-cut pluggers, Nos. 9 and 28.
- 3 Smith's pluggers, Nos. 14, 15, and 16.
- 4 Flagg's filling instruments, Nos. 1, 5, 7, and 12.
- 1 double-end amalgam plugger (nickel-plated).
- 1 octagon-handle wheel bur, No. 5.
- 1 " round " No. 7.
- 1 " cone " No. 8.
- 1 " inverted cone bur, No. 2.
- 1 " retaining-point drill (round).
- 8 " excavators, Nos. 5, 6, 7, 9, 28, 74, 141, 142.
- 1 " Head's excavator, No. 11.
- 2 plug-finishing burs, Nos. 2 and 7.
- 1 D. D. Smith's approximal trimmer, No. 1 (blue).
- 2 Chappell's scalers, Nos. 1 and 3.
- 1 Abbott's small scaler, No. 2.
- 2  $\frac{1}{4}$  inch file-cut chisels, Nos. 2 and 8.
- 2 Arrington's nerve instruments, Nos. 2 and 13.
- 3 Palmer's nerve instruments, Nos. 1, 15, and 20.
- 1 rubber syringe (with silver pipe).
- 1 chip syringe.
- 1 steel mallet.
- 1 wedge cutter (nickel-plated).
- 1 rubber dam holder (with buffalo guard).
- 1 Arkansas stone.
- 1 ebony-handle mouth-mirror.
- 1 ebony-handle gum lancet, No. 1.
- 1 pair college pliers.
- 1 pair foil scissors.
- 1 dozen nerve broaches (assorted).
- 1 bundle orange-wood.
- 1 ounce spunk.
- $\frac{1}{2}$  quire Japanese bibulous paper.
- 1 skein gilling twine.
- 1 dozen emery strips.
- $\frac{1}{2}$  dozen separating files.
- 1 mortar and pestle.
- 1 bottle sandarac varnish (with brush).
- 1 " nerve paste.



Fillings of cohesive gold are made either by hand-pressure or by the use of a mallet. Where the latter means is employed, experience certainly demonstrates the necessity for shallower serrations in the instruments. Mallet filling consists simply in condensing the gold by repeated taps from a hammer made of wood, lead, tin, or steel, applied to the head of the plugger. To employ a hand mallet, an assistant is commonly deemed necessary, although not by any means an indispensable adjunct, the operator being quite able to

FIG. 184.—PLUGGING MALLETS.



manipulate both plugger and mallet. Fig. 184 represents the size of mallets ordinarily used. No. 1 is made of metal,—lead, preferably; No. 2 is made of lignum-vitæ.

Provided with some selection of the serrated pluggers, the operation of fixing and packing cohesive gold, whether foil or crystal, may very well be practised to its appreciation by employing the perfectly clean surface of a metal dollar, either silver or gold being used.

First, that a hold be secured, the operator washes the coin thoroughly with sulphuric ether, and follows this by making a series of deep cross-scratches over a portion of the surface selected for the attachment of the foil. Taking up now with the serrated point a pellet of gold which has been prepared, it is laid upon the scratches, and by a very few manipulative touches is solidly attached to the coin. The building up of a cone to any desired height is simply a repetition of these attachments. Appreciating through such practice the principle upon which a plug of cohesive gold is to be constructed, the



experience is to be quickly enlarged by passing to the filling of simple crown cavities in teeth.

To fill a simple crown cavity with cohesive gold, the operator (after adoption of such means as insures to the end of the operation against the inroad of saliva) takes up a piece of metal of such size as being packed solidly in the bottom of the cavity shall give it fixedness; upon this first, piece after piece is to be attached, precisely as in the case of the coin. If the mallet be used, each second or third layer is to be condensed by its aid, although it is a habit with many operators to mallet every pellet,—a plan only permissible where the shallowest serrations are used, such frequent blows, where the instruments are at all deeply cut, quickly destroying the integrity of the plug.

Another mode of fixing the first piece of gold in such a cavity is to make at some convenient spot what is called a retaining-point: this is simply a slight undercut or slot: the first piece being worked into this slot, the remainder of the filling is attached to it.

A much more convenient, and certainly more expeditious, way of filling such a cavity is found in wedging into it the gold prepared as cylinders, mats, or the cut twist. When no more can possibly be thus introduced, the metal is to be hand-packed or malleted into solidity, foil, worked after the cohesive manner, being attached wherever a place invites addition, thus building up the required face.

As another study in the use of cohesive foil, reference may be had to the cavities seen upon the grinding faces of molar teeth, Fig. 134, running over into the lateral surface. With the cavity prepared as described, the operator commences by fixing in either extremity a pellet of gold. This being solidly malleted into place, pellet after pellet is attached upon it, until the irregular, sulcus-like place is filled.

We pass now to the approximal cavities—exhibited in the same figure—in the anterior teeth. Taking, as an example, the incisor tooth: the operation is commenced with a pellet of gold carefully and delicately worked into an undercut, the remainder of the plug, as before directed, is attached to this. A plan, however, which is exceedingly easy and convenient as to execution consists in first laying a mat, precisely as suggested in the use of uncohesive foil, against the neck-wall of the cavity; this is to be of such size that when consolidated into place its relation with the boundaries of the cavity makes it self-supporting. Against and into this wall of gold the cohesive pellets are worked with such serrated instruments as are found most conveniently to apply.

A third plan of filling such cavities consists in rolling into balls three suitable-sized twists of cohesive foil. Taking up the first ball, it is carried to the neck-wall and there partially condensed. The second ball is now placed in that part of the cavity which adjoins the cutting edge; the third ball is wedged between the first and the second, and the mass is condensed by the serrated pluggers against the labial wall. Having thus a support of gold immovably



fixed by its relations with the neck and base of the cavity, pellets are taken up, piece by piece, and worked into it until the cavity is full.

Still another plan, practised, after a little experience, with all satisfaction, consists in taking a single ball, prepared as just described, and, after carrying into place against the neck-wall, holding it in position by means of any convenient instrument until it is condensed and a sufficient addition made to render the mass self-supporting.

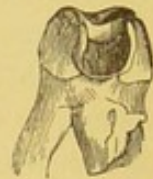Yet another plan is found in the employment of the matrix. This, as before suggested, is to be extemporized out of almost anything. A very simple mode consists in casting first a ligature of heavy well-waxed silk about the neck of the tooth. Between the tooth and its neighbor a piece of soft silver is next thrust and wedged into place by a slip of match-wood. Into the cavity thus formed the initial of the plug is placed. A temporary matrix of this nature is also provided, by the introduction between the teeth of a lath-shaped plugger, the initial gold being supported by the instrument until fixed and condensed.

Heavy foils, even those high as No. 120, are used by some operators in filling front teeth, it being claimed for gold so prepared that from being rolled instead of beaten it is rendered softer and more cohesive. Such gold, after being cut into delicate strips, is attached across the surface of the cavity, retaining-points being first prepared and filled.

Cavities in bicuspid teeth, approximal surfaces, are filled according as they may have been excavated. Where the V-cut has thrown the hole into an upward outlook,—that is, has given it more or less the aspect of a common crown cavity,—no special suggestions are required to be added to directions already understood. In the contour fillings, however, each case possesses its own peculiar indications. In preparing a bicuspid tooth for such a contour filling it is to be remembered that the cavity is cut from the grinding face, the tooth being, as it were, scooped out. This necessarily makes an open, free cavity, which requires some special means of support for the first piece of gold introduced. To obtain this support, it is found convenient to take advantage of an undercut, such point of fixedness being secured at any convenient spot about the base of the cavity. A first piece being by this means attached, the remainder of the plug is built upon it, the gold in mass becoming finally self-supporting as the cavity is packed. The use of a matrix is here found most conducive to convenience and success. (Fig. 185.)

A second means of filling such cavities, and one which is found easier of accomplishment by the inexperienced, consists in using a series of blocks or mats. After making a slight retaining undercut around the parietes of the cavity, a first piece is laid against the neck surface and loosely condensed into place. A second and third are next placed against the lateral walls, these also being loosely pressed into the undercuts. A fourth, fifth, and sixth, as

FIG. 185.



Cavity cut from grinding surface.



required, are now wedged into the centre, each wedge, as will be seen, tending more and more to consolidate and fix the first layers. Securing thus fixedness for the gold, the whole is to be carefully hand-worked or malleted solidly against the bottom; the upper part of the cavity (exposed by the condensation) is filled by working cohesive pellets into the anchored portion of the plug, precisely as in the case first described.

In filling lower teeth, it is common for an operator to be behind his patient, standing at such elevation as shall enable him to lean over the head or shoulder. Such a position is found to add immensely to convenience in manipulating. Another posture, practised and preferred by many, is to stand at the side, precisely as in operating upon the upper teeth,—a position that is found to answer a very good end where cavities to be operated upon occupy buccal face of the teeth, but which certainly cannot be compared for convenience to the first position for crown or approximal cavities. In manipulating upon a cavity in any part of the mouth, advantage is of course taken of the various movements permitted by an operating-chair or a head-rest.

Building up with gold the entire lost crown of a tooth is an operation frequently practised by expert workers with cohesive gold. Such operations, however, are too often to be viewed rather as exhibitions of nice smithery than as proper and judicious surgical performances, it being exceptional that the root built upon does not rebel against the treatment pursued. To practise operations of this class, the gold receives its fixedness either by anchorage in the pulp-canal,—the pulp having been removed of course,—or through means of gold screws roughened to attach and hold the metal worked into and about them. A plan that may be adopted with satisfaction is to ream out the root cavity precisely as for the accommodation of the tube of gold so frequently employed for the reception of artificial crowns, as in the process of pivoting. (See *Pivot Teeth*.) Into the canal, so prepared, is inserted a screw, which is to have close relation with it near the apex only. The screw is now built solidly into the canal, furnishing a support for the crown which the operator builds upon and about it.

In the case of molar teeth, the practice has been pursued of drilling several holes into the circumference of the surface to be built upon, making these act the part of slots for the fixing of bases of gold, or for the introduction of supports. Little gold retaining-screws known as Mack's answer here an admirable end.

**Contour filling.**—By contour filling is meant the building up of a carious or broken tooth into its original form after a general manner as just described. To do extensive contouring, gold being used, requires much endurance on the part of both tooth and operator. The practice, to be satisfactory, is to be measured by great good judgment. To do substantial contour work requires the perfection of operative dental skill; its understanding and practice is therefore to be commended to the student from an educational stand-point.



A tooth prepared for contouring is to stand with a cavity perfectly cleansed and of such form that every part is easily accessible by gold and pluggers. The walls are to be regular as possible, neither rounded nor absolutely sharp, while every edge is to be firm and resisting.

The tooth properly secured from moisture, even from that of the breath, an operation of contouring is commenced by anchoring immovably a first piece of gold in a retaining-slot prepared for it. (Fig. 198.) Then piece by piece the plug is built upon this into the required form. The manner of progress and performance, as suggested, is precisely that which one may familiarize himself with by practice on a gold or silver piece of money, and after such manner it is always to be first attempted.

FIG. 186.

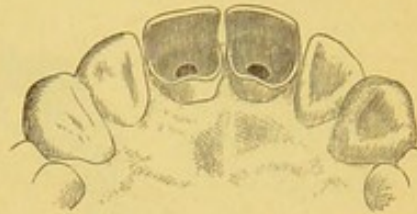
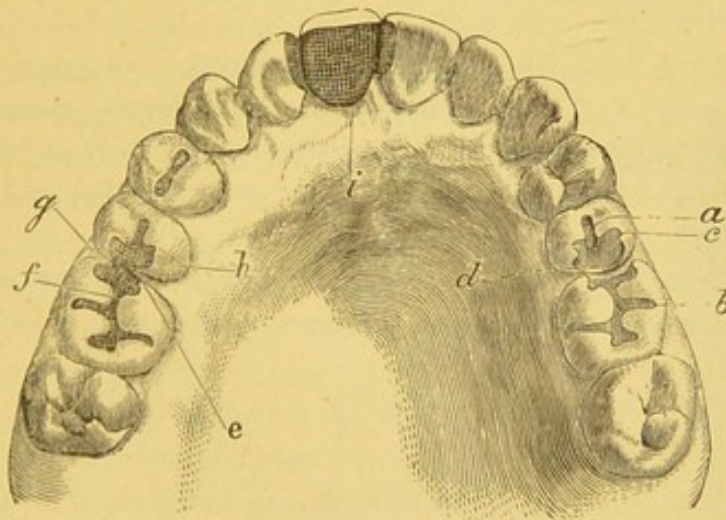


Fig. 186, after the late Dr. Marshall Webb, one of the most skilful of gold-workers, shows central incisor teeth prepared for contouring upon the palatal surface, the back and lateral faces of the organs being almost entirely lost. It is to be observed that absolute distinctness of outline distinguishes every point of the margins.

Fig. 187, also after Dr. Webb, shows, on one side, cavities made ready for contour plugs; on the other, plugs introduced and finished. The incisor

FIG. 187.



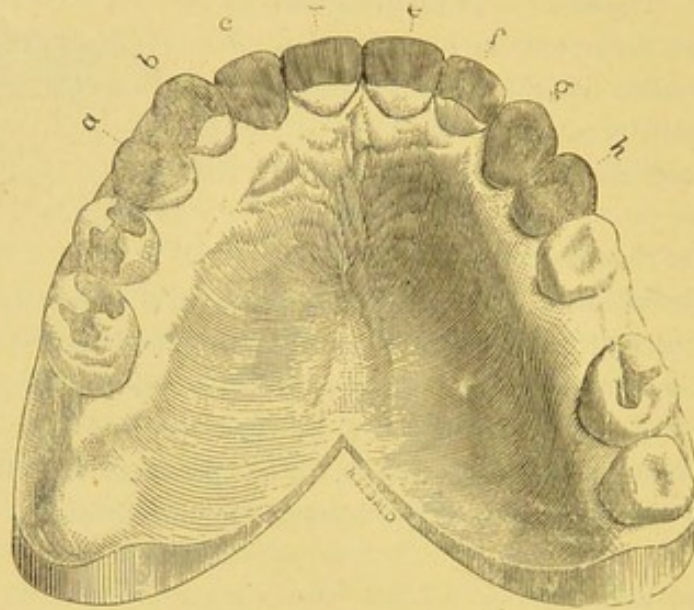
affords an idea of the completion of the operation, as one tooth is concerned, of that for which the cavity is seen prepared in the immediately preceding diagram. In the cut, *c* shows a groove made in the dentine, along each wall of the cavity; *a* and *b* show manner of treating fissures related with a main cavity; *d* shows a retaining-point. Upon the opposite side, *f* exhibits contouring to correspond with the anatomy of the tooth; *g*, the relation of two approximating gold surfaces, the metal being in contact,—a feature of approximal plugging insisted on by Dr. Webb,—shows also the strictly



defined surfaces of enamel as it should relate with gold; defines as well the original contour of the part. This same cut exhibits contouring of an approximal cavity in a lateral incisor. Also, a plug in the grinding face of a bicuspid defined as the metal should show in a perfect operation.

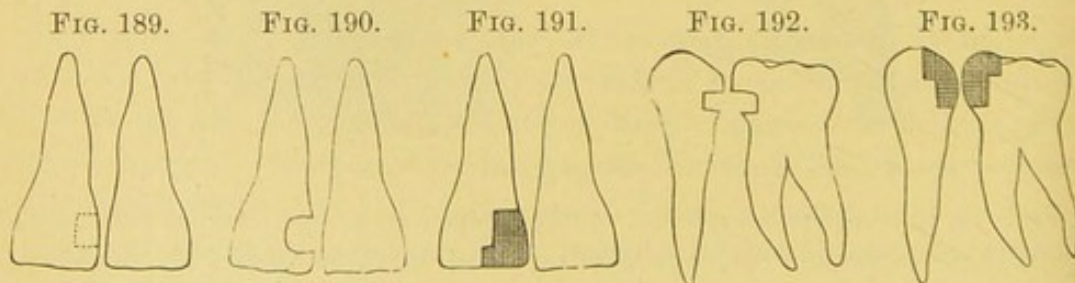
Fig. 188 exhibits a praiseworthy case of contouring done by Dr. Webb; it serves as an example of what is to be accomplished in this direction by skill

FIG. 188.



and patience. *A, b, d, f, g, and h* show pulpless teeth; *g*, a whole crown restored with gold; *a, f, and h*, almost entire gold crowns; the teeth *b* and *d* support the gold crown faced with porcelain, *c*; and fully one-fourth of the crown of each of these is restored with gold, as is also that of *e*, the pulp of which is living.

Figs. 189 and 190, after Dr. Weld, of New York, show studies where breaks extend on the continuity of the faces of the teeth, which breaks are



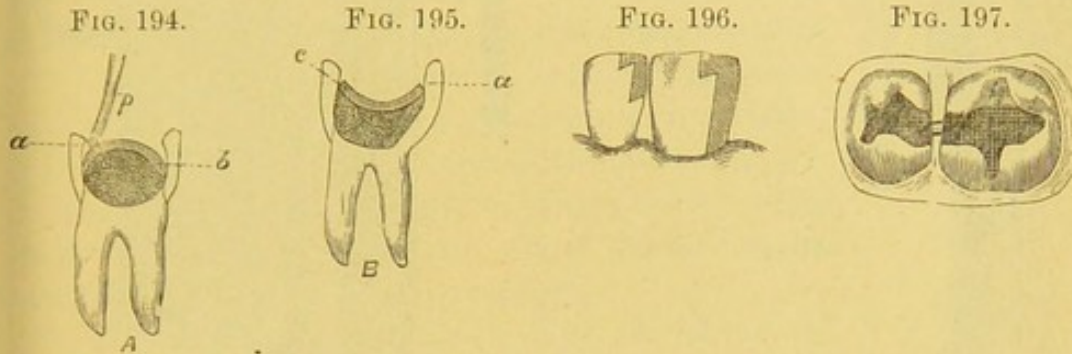
to be assumed, for our purpose, to affect both labial and palatal walls. To properly contour such teeth requires simply that they be cut and built up, as shown in Fig. 191.

Another illustration is furnished in Fig. 192; here the teeth affected are second bicuspid and first molar. Fig. 193 affords idea of the requirements.



A case commanding much skill is shown by Fig. 196. This exhibits front teeth decayed largely about their mesial faces. The procedure, securing result shown, lies in obtaining proper retaining-points, keeping the organ, while under operation, free from moisture, and, precisely as accomplished on the metal piece, building layer to layer until the lost parts are restored. Rubber-damming is an essential.

Figs. 194, 195 show contour work in progress. First, attention finds itself directed to shape of the cavity. Second, it is observed that in one the gold



(b) is being built of convex form; in the other the manner is concave. To the former mode is given the preference. The instrument with which the work is being done is *p*; the line of impaction is *a*.

Fig. 197, representing a bicuspid and molar, shows cavities which, to allow of the ends of contour work, are to have the grinding faces cut away until vertical walls exist. Teeth like these, being excavated as shown, and free from caries, are wisely filled with oxychloride, and when this has set secondary planes are prepared in the added material, the margins corresponding exactly with the enamel line. Such procedure affords a strength which it must be seen would be lost in cutting away the healthy operculum: the suggesting of an oxychloride lining implies, of course, that it be the case that the cavities are larger within than is measured by the margins; the zinc extends to the vertical plane.

Fig. 198 shows side view of an incisor crown almost destroyed by caries. The tooth is prepared for contouring,—nothing having been cut away that could be saved. Retaining-points, as seen, are slotted out in the dentine. In each of these slots is a twist of gold, the initial end, of which is assumed to be firmly anchored. Upon these anchorages the original form of the tooth is to be restored.

Contouring is done by hand or by mallet, preferably by the latter, as through such instrumental means the work is accomplished more easily and decidedly more firmly.

Automatic mallets used in contouring are of three general forms: 1. Hand

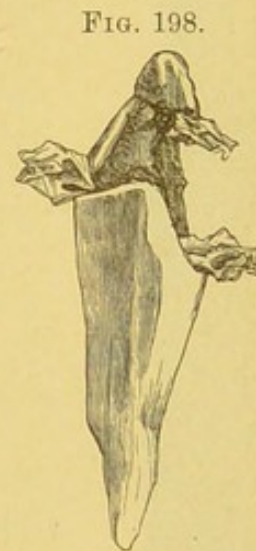



FIG. 199.

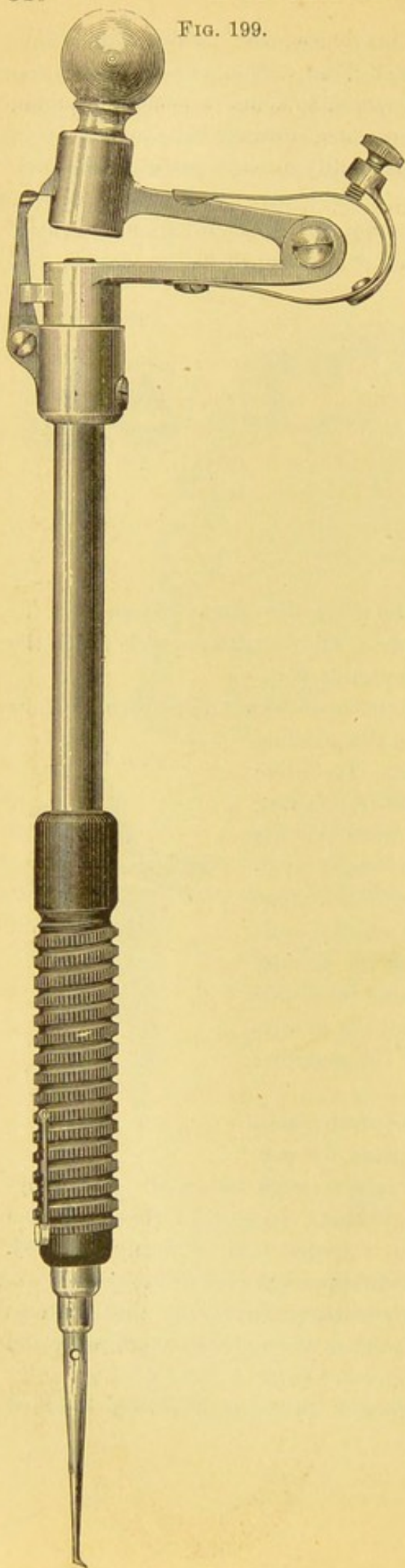
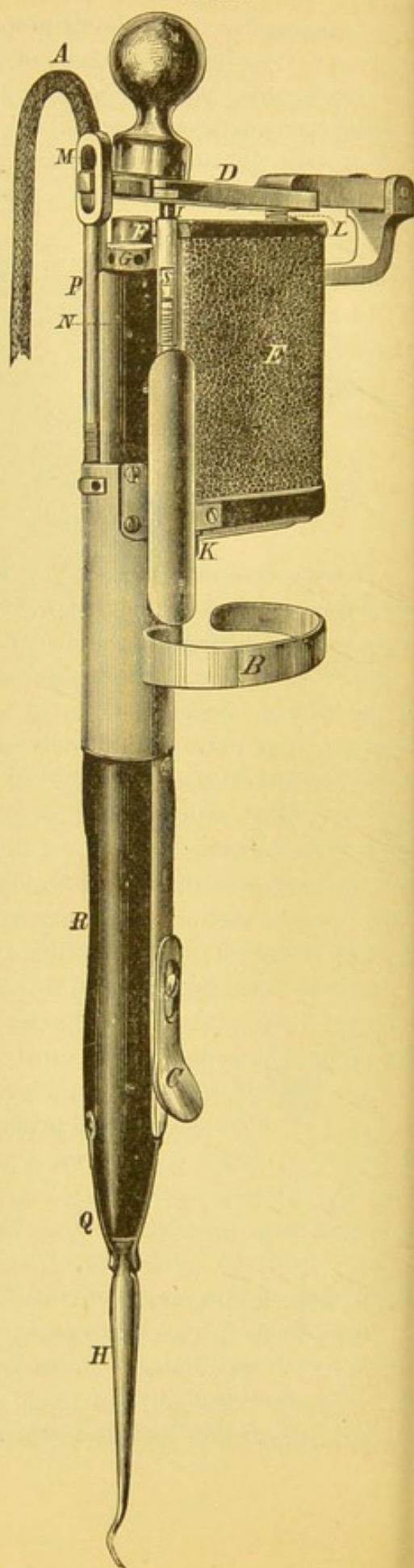


FIG. 200.—ELECTRO-MAGNETIC  
Mallet.





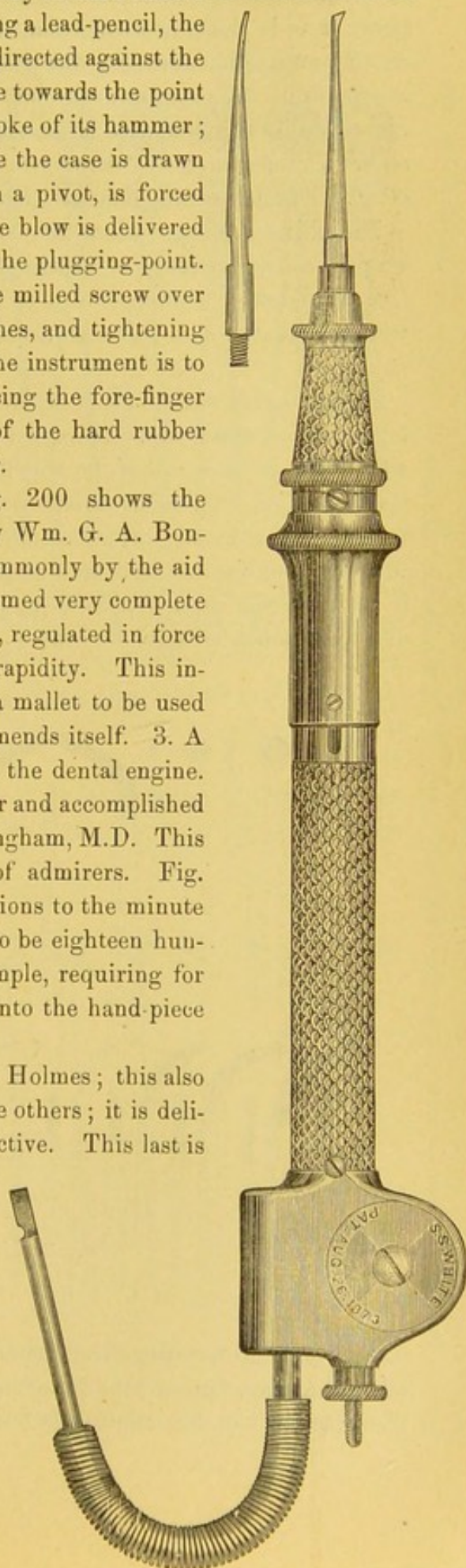
mallet, working by means of internal springs; Fig. 199 shows such an instrument. In use, it is grasped by its hard rubber case, somewhat after the manner of holding a lead-pencil, the point of the plugging instrument being directed against the filling to be impacted. Pushing the case towards the point exposes the end of the plunger to the stroke of its hammer; the trigger-latch holds the hammer while the case is drawn from it, until the latch, which works on a pivot, is forced past the lug, when the full strength of the blow is delivered upon the plunger, which transmits it to the plugging-point. The force of the blow is regulated by the milled screw over the spring; loosening the screw diminishes, and tightening it increases, the force. When desired, the instrument is to be used as a hand-plugger simply by placing the fore-finger on the spring-button at the lower end of the hard rubber case, which acts as a stop to the plunger.

2. **Electro-magnetic Mallet.**—Fig. 200 shows the electro-magnetic mallet, an invention by Wm. G. A. Bonwill, D.D.S. The instrument is run commonly by the aid of a Bunsen four-cell battery. It is deemed very complete by those familiar with its use. Its blows, regulated in force to suit, are given with a lightning-like rapidity. This inventor has also given to the profession a mallet to be used with the dental engine which fully commends itself. 3. A mallet also to be used in connection with the dental engine. This is an invention by the veteran teacher and accomplished mechanic and chemist, Thomas Buckingham, M.D. This instrument has secured a large number of admirers. Fig. 201 exhibits it. The number of impactions to the minute of which the machine is capable is said to be eighteen hundred. The use of it is exceedingly simple, requiring for the motion only that the bit be slipped into the hand-piece of an engine.

Still another mallet is the device of Dr. Holmes; this also is worthy of equal commendation with the others; it is delicate in construction and in every way effective. This last is the latest instrument of its meaning given to the profession up to the date of the issue of this volume; practical workers praise it highly.

With gold adapted to the end, and with absolute freedom from moisture, an operator possessed of requisite skill requires only patience to carry the build-

FIG. 201.—BUCKINGHAM MALLET.



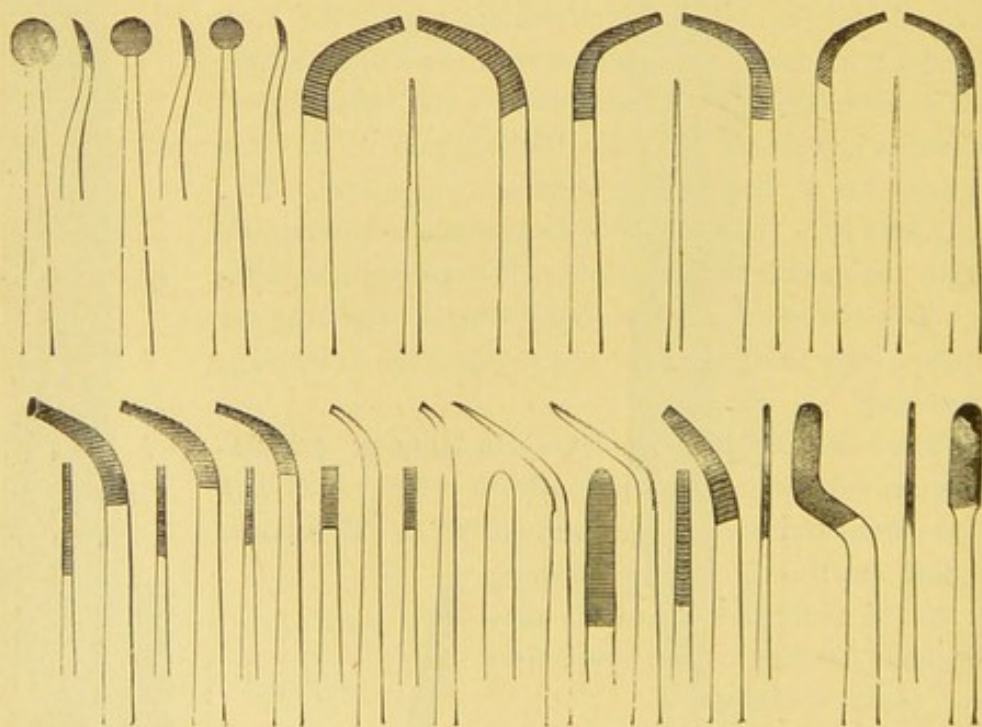


ing process to any extent. It is to be suggested, however, that if at any stage in the performance the mass in process of building is found to move, nothing better is to be done, as a rule, than begin again from the foundation. Still another suggestion considers the possibility of flooding. If this threaten at any point of the procedure, the half-accomplished work is to be at once burnished, to be recommenced, when dryness is secured, where left off. To resecure a proper surface, it is only necessary to scratch the gold and wash with ether. The use of the dam obviates commonly this accident.

**Finishing a Plug.**—From the consideration of the introduction of a plug, we pass to the processes of finishing. These consist in condensing the surface thoroughly, in filing the mass into such shape and relation as accord with articulation and other requirements, and in giving the gold a jewelry polish.

To accomplish these ends, an operator needs condensers, files, disks, burnishers, hard and rotten-stone, rouge, strips of tape or of wash-leather, pieces of wood, etc.,—that is to say, he will find useful any means which conduce to the ends. As condensing instruments are concerned, they find representation in pluggers with the serrations filed off. Much pressure, however, being brought oftentimes to bear upon such instruments, especially where the mallet is not used, the manufacturer in preparing them considers the requirements, and by so much enlarges the size of the shank over that of the pluggers.

FIG. 202.—FINISHING FILES.

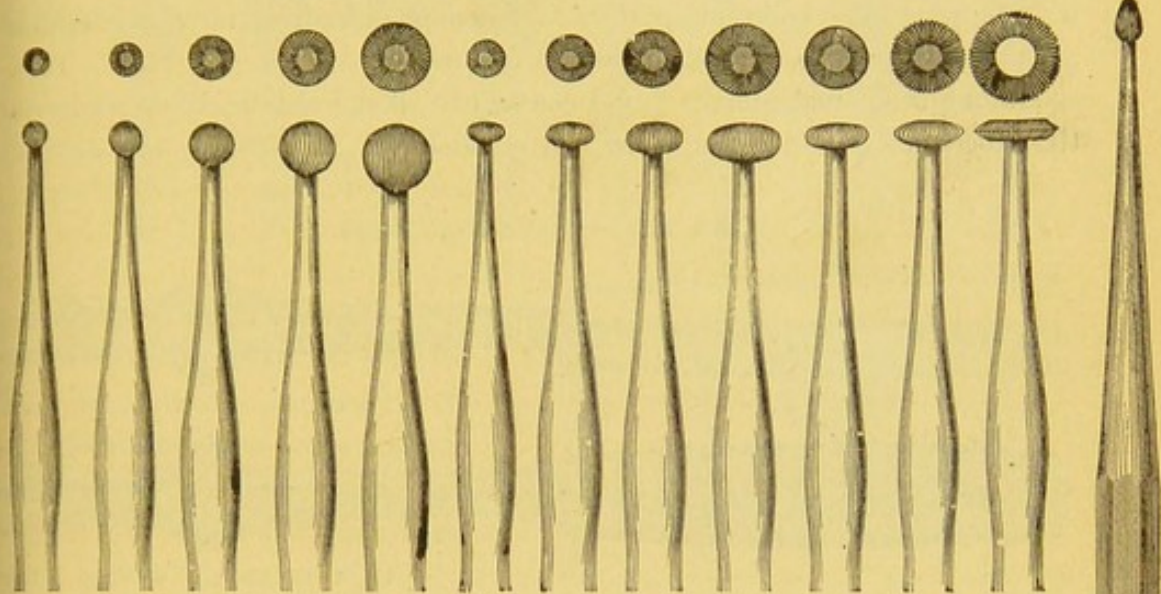


Files used in finishing are prepared in the greatest possible variety. The separating files, figured on a foregoing page, are indispensable for use on the front teeth. Fig. 202 represents forms of files that are found useful in almost



every position. Fig. 203 exhibits files prepared in the bur form. These latter have application in the cutting down of crown plugs, and accomplish

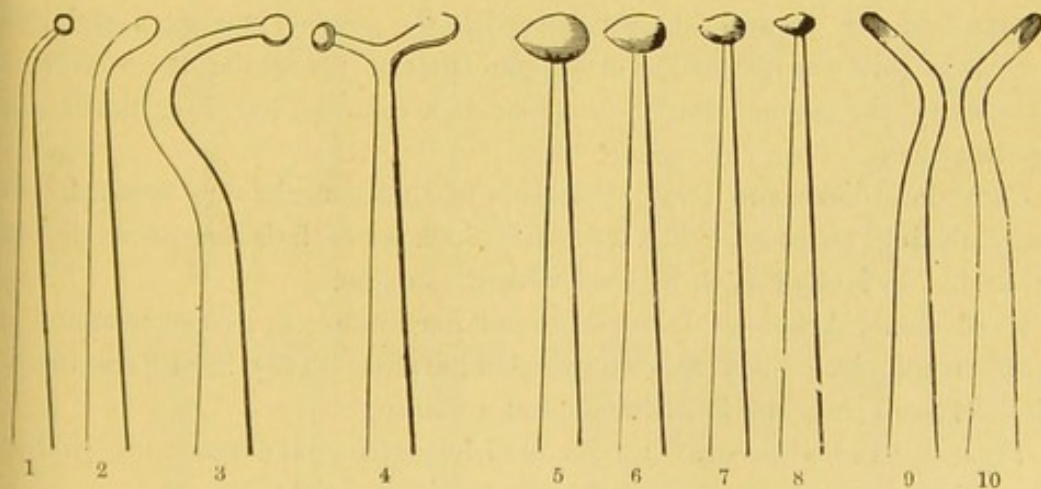
FIG. 203.—BUR AND WHEEL FILES.



their work with a nicety and finish which seem to prove them perfect; the figure shows also the handle. These bur files, of which there are every possible variety, when worked by the engine, are revolved with a velocity which enables them quickly to cut into shape the hardest-made plug, Dr. Bonwill claiming for his instrument a rotatory power of ten thousand to the minute.

Burnishing instruments are also found of many patterns, the designs corresponding with requirements. Fig. 204 represents a set of these instru-

FIG. 204.—SET OF BURNISHERS.



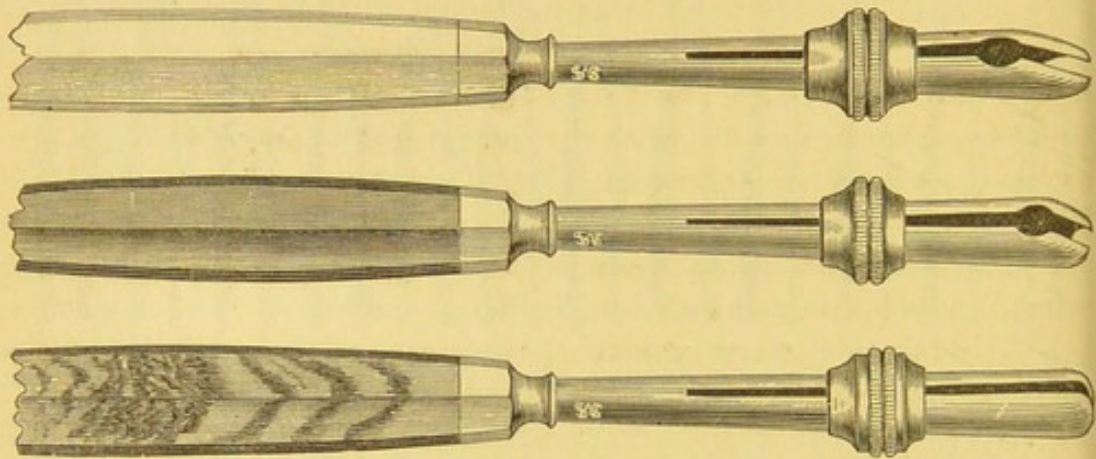
ments, for hand use, which will be recognized by the experienced to comprise all the forms for which there is real necessity. Indeed, it would be quite possible to do without Nos. 1, 3, 5, and 7: such a set costing, however, not



over six dollars, the outlay for the whole is soon found to be covered by the extra convenience. No burnishing instrument except that made from the very finest steel is worth possessing. The use of a burnisher is both to condense and polish the face of a filling. It is used in connection with the file, the plug mass being alternately filed and planished. The forms figured are prepared for use by both hand and engine.

Among other instruments found convenient, if not absolutely necessary, in the process of finishing plugs, are porte polishers. Fig. 205 represents a set

FIG. 205.—PORTE POLISHERS.



of three. These carriers, made for the hand, enable the operator to fix splints of wood, upon which he carries pumice- or rotten-stone, at any angle found convenient in working. The use of pumice-stone so applied represents the finest file, and is found of the highest import in securing a proper surface. A hand porte polisher of satisfactory yet inexpensive character is made by soldering together at right angles two tubes of silver or of tin of a size fitted to support a handle of wood and a splint. As a polisher, an arrangement invented by Dr. Bonwill, to connect with the engine, having a reciprocal motion, is quite the perfection of instrumentation. Circular heads of wood revolved by the engine after the manner of a common bur, save much time and trouble.

Corundum disks, and other appliances of that material, are invaluable for plug-finishing purposes. Fig. 206 exhibits a set of finishing-points devised by Dr. A. L. Northrop, to be used with the engine.

Hard stone, Arkansas, Hindostan, and Scotch, are to be had mounted on engine mandrels. These serve a valuable purpose. They are represented in Fig. 207, and their use is understood at a glance.

Tape, covered with corundum, or used by wetting and attaching pumice-stone to the surface, is required in many cases of finishing.

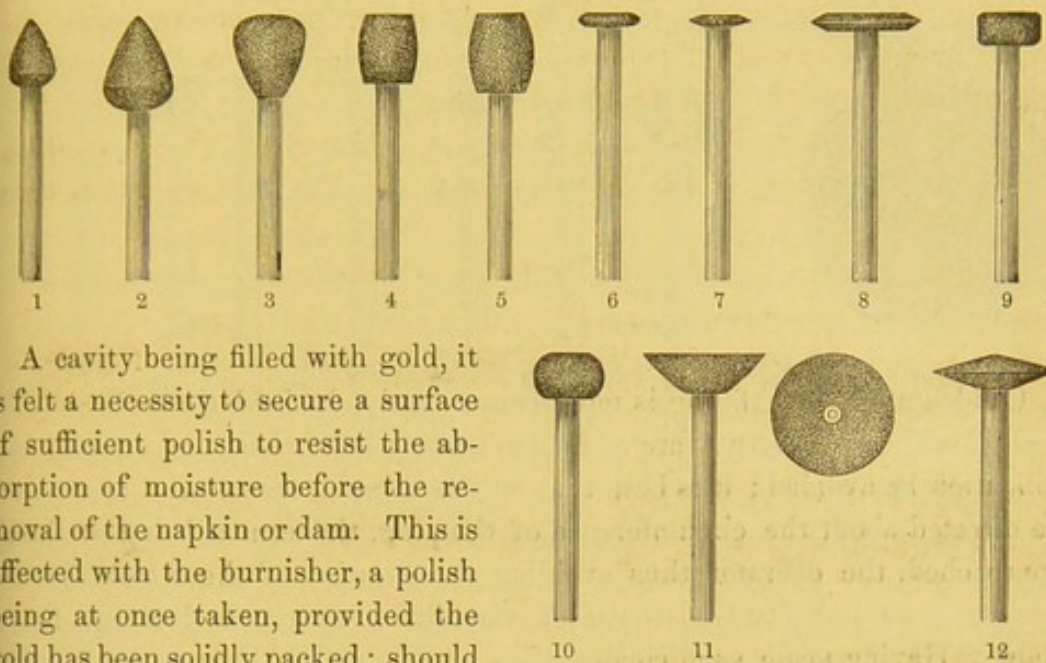
Corrugated disks, used for carrying powders, is another means yielding convenience to the practitioner. Fig. 208 shows such a disk.

Wood polishing-points, above referred to, illustrated in Fig. 209, are neces-



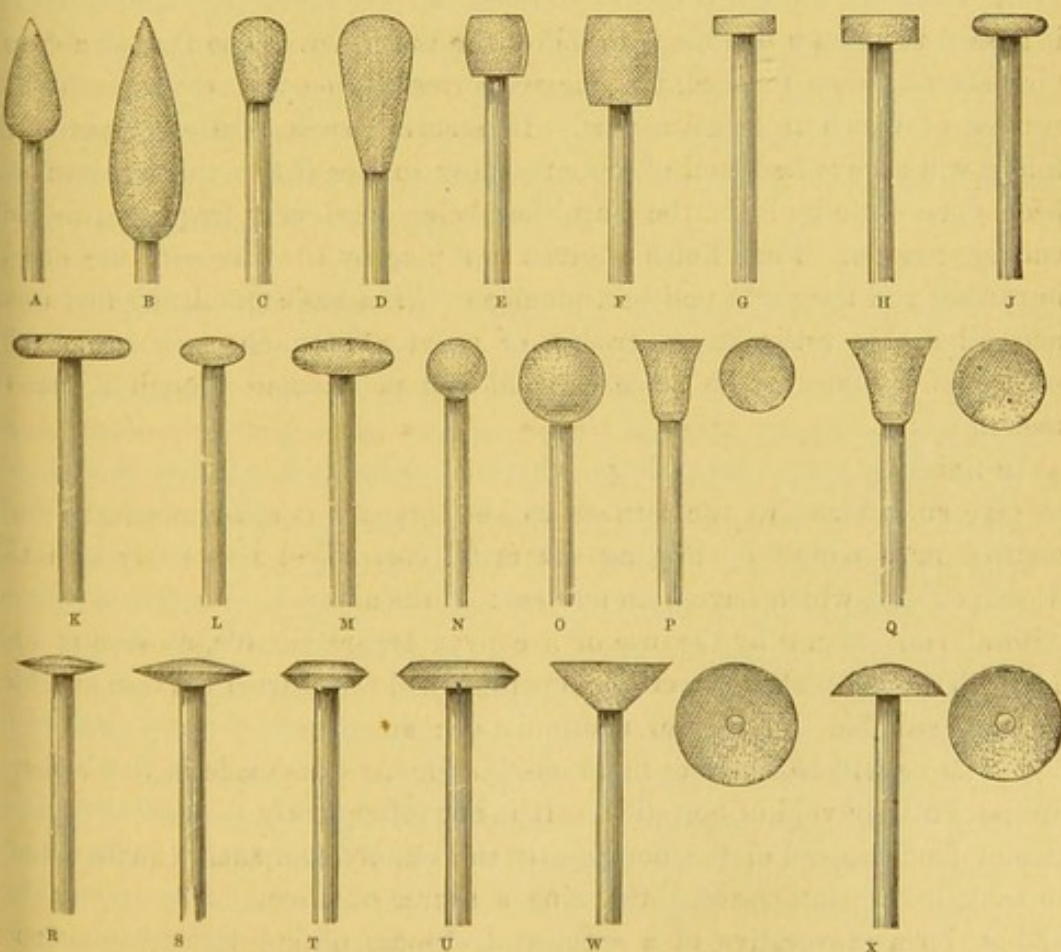
sary to the fine finish of a filling. Pumice, emery, rouge, and rotten-stone are used with them.

FIG. 206.—CORUNDUM POINTS, SET OF 12.



A cavity being filled with gold, it is felt a necessity to secure a surface of sufficient polish to resist the absorption of moisture before the removal of the napkin or dam. This is effected with the burnisher, a polish being at once taken, provided the gold has been solidly packed; should polish not be taken, then the operator is to go over the surface again and again

FIG. 207.





with the condenser, using either hand-pressure or, preferably, the mallet. The manipulations of burnishing and condensing in alternation are to be repeated until the protecting polish is secured.

FIG. 208.

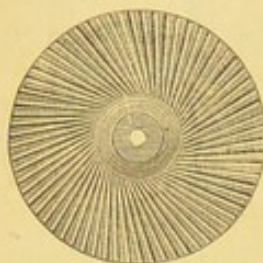
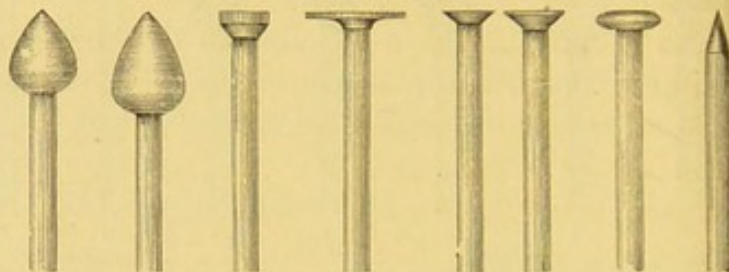


FIG. 209.



Condensation of a filling is most conveniently obtained through aid of a mallet. The blows struck are at first to be very light, that thus unequal consolidation be avoided; it is best that at the commencement the instrument be directed about the circumference of the plug, the centre being gradually approached, the operator thus avoiding the drawing of the metal from the parietes,—an important matter, as a very little experience does not fail to show. Having made such condensation of the surface, it is to be followed by the burnisher or file, as seems indicated. It is always important to avoid overhanging of the walls by the gold; this implies that a cavity be not over-full. In crown fillings, such over-fullness is a not uncommon fault. Where it is seen to exist, a bur file is to follow the burnisher. The face of a crown plug should, when finished, be concave, corresponding with the aspect of the surface of which it forms a part. In securing such relation of parts, the filling will always be found of more resisting surface if the cutting down has been done little by little, the burnisher being used very frequently as such cutting goes on. Final finish is given to a plug by the alternate use of the burnisher and the porte polisher, pumice or Arkansas stone being first used, and after this rotten-stone, crocus, or rouge. Through such means the surface of a plug may be made as solid and polished as though it were of molten metal.

In finishing approximal fillings, wherever situated, it is felt to be desirable to give such plane to the surface as shall render it self-cleansing; this is secured most simply by making the metal correspond reasonably with the V-shaped cuts which have been advised: in the anterior teeth this is effected with all convenience by the use of a convex separating file, as seen in Fig. 119. Treating posterior teeth, an operator will select from his case any files that are suitable and easy of manipulation; among the forms exhibited in Fig. 120 he will be likely to find himself suited. Cuts made in the V-shape are not entirely void of objection. It is not infrequently the case that particles of food, instead of passing quickly and cleanly over such a surface, tend to pack in the interspace, thus being a source of discomfort to the patient, and at times provocative of a species of chronic ulitis. Such jamming is,



however, oftentimes the result of the manner of filing,—a matter which soon comes to be corrected by a growing experience. In place of such packing of the ingesta being an objection, it is with force argued by many that it is a positive good, compelling, through the discomfort induced, that attention to cleanliness which is the object of the space.

An approximal plug filed into the required relation, the polishing and finishing follow as with the crown plug. Strips or points of wood, corundum tape, or strips of wash-leather wet and dipped into pulverized pumice, or twists of ordinary candle-wick used in a similar manner, are found valuable adjuncts, securing a fineness of surface which cannot, without a much greater amount of labor, be had through the instrumentality of partly-worn files. Strips are used by simply drawing them back and forth over a surface to be smoothed. Rotten-stone and rouge or the peroxide of tin are employed upon strips and points for the finish; the former is to have the preference.

In dressing contour fillings, regard is not to be denied to self-cleansing properties as related with the planes. Such plugs are to be filed into a shape corresponding with the natural irregularities of the tooth. That they may render prolonged service, they must have such relation as shall enable them to bear the strain endured by the original parts. The process of finishing is the same in principle as that employed in ordinary cases. In shaping the articulating face it is necessary, however, that special regard be given to the contact of the opposing tooth or teeth,—a matter which frequently demands much time and care. In shaping contour fillings, it is generally found convenient to use the Arkansas or similar stone, rubbing thus from the gold every scratch or indentation. Finish, it is to be remembered, is the expression of stability and force in a contour filling, as it is only a solid and reliable filling that is capable of taking a fine finish.

In concluding the subject of filling the decayed crowns of teeth with gold, the student is reminded that the principles which govern are, that all difficult cavities are to be converted into those of simple form; and that space is always to be secured, either by the file, chisel, or pressure, that shall afford the required room for manipulation. It is to be added that a fault, as the preservative virtue of gold is concerned, exists in a tendency to re-decay, which shows itself at the neck wall of a cavity; that is, at that boundary which immediately adjoins the gum. A gold plug being satisfactorily good, with the exception of the defect alluded to, it is now accepted as good practice to cut away the secondary caries and to fill the newly-made cavity with copper amalgam: Sullivan's being here peculiarly indicated. Explanation of the benefit existing in the relation of the two materials is suggested as follows by Dr. Register: "The combination is to be supposed to form a galvanoplastic which decomposes irritating acids, which would otherwise attack the lime-salts of the tooth. A primary battery of acids attached to a secondary one of metals will deplete itself in charging the latter, and then will, in

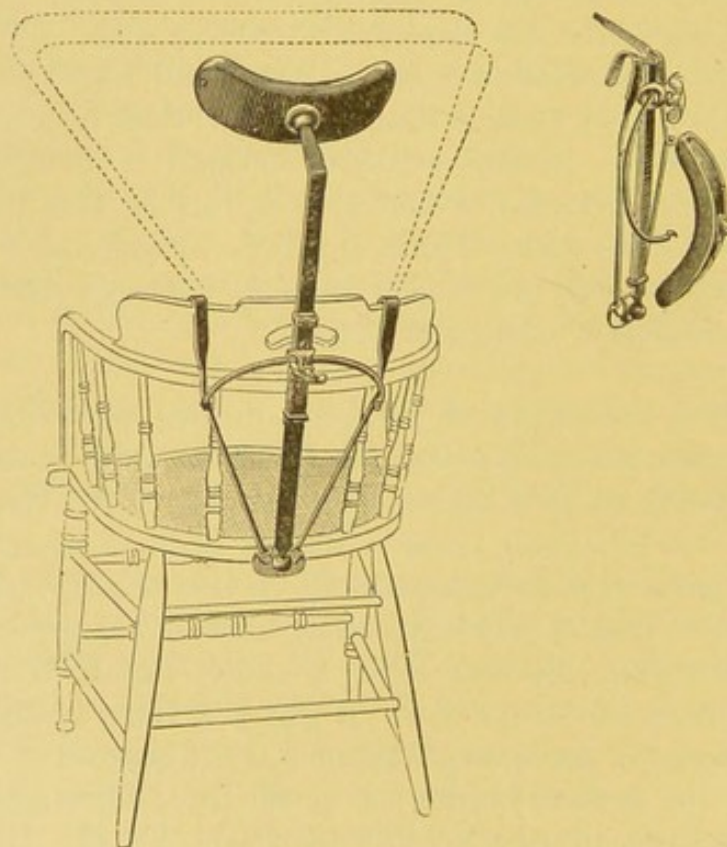


part, flow back until drawn off and used by interruption; and this flow continues back and forth each time, becoming less and less, until the current ceases and an equilibrium is established." Gutta-percha is a reliable agent in the direction of the same indication. If a patient can be watched, preference is to be given it. (See chapter on *Dental Therapeutics*.)

It is to be suggested in way of addendum that plugs made of cohesive gold may be defective, as the whole mass is concerned, by reason of a marginal defect not sufficiently great to admit at the imperfect spot the point of a cambric needle. This is ever to be borne in mind during the process of packing; it is always to have consideration when comparing the relative values of the two forms of gold, cohesive and non-cohesive, as a filling material.

**The Operating-chair.**—The chair upon which a patient sits while having teeth filled is to be of such height that it shall bring the head on a level with the breast of an operator. To this end there is great variety in construction. Where economy is to be consulted rather than elegance, a head-rest, the in-

FIG. 210.—WHITE'S HEAD-REST.



vention of C. C. White, D.D.S., is found most useful. This rest makes its own fastening to almost any chair, sofa, lounge, or settee. It has full movement in all directions on a scale for a tall person or for a child, and is securely fastened by turning a single thumb-screw. The accompanying cut represents the instrument applied to a common office-chair. The dotted lines show its



movement. Weight,  $4\frac{1}{2}$  pounds. Chairs of much elegance in construction, designed both for ornamentation and use, are to be seen in the catalogues of the dental depots.

**Conveniences.**—Upon an operator's tray there should always be found pellets of bibulous paper and twists of absorbing cotton, a bottle of Monsel's solution, either of the persulphate or chloride of iron, with a view of controlling trifling hemorrhages, a bottle of creasote, sticks of soft pine, cologne, brandy, tannic acid, atropia mixture to quiet pain, oil of cloves, and chloroform for the same end, ether for the purpose of provoking speedy salivation, belladonna and morphia with a view of controlling or arresting a too free flow of oral fluid, ammonia as an excitant or for blistering purposes, rubber rings, floss silk, a small cupping-glass, undeliquesced chloride of zinc, alcohol, a tongue-depressor, and a magnifying mirror.



## CHAPTER XXV.

### OPERATIVE DENTISTRY.

#### ARTIFICIAL CROWNS.

BROKEN teeth, when not contoured, are to be repaired by substitution. Plans of meeting the indications are by use of metal cap crowns, by pivoting, and by replacement with scales of porcelain.

**Cap Crowns.**—A metal crown is a hollow cap made to represent accurately a part to be replaced. To make such a crown an operator begins by recognizing that there is to be enough of the broken root proposed to be covered standing above the gum to permit of being encircled by a band of gold. Such accommodation existing, a first step consists in taking an impression in wax of the broken part to which it is proposed to adapt a crown, and in making an articulation. An impression is taken by softening a piece of common beeswax and moulding it over the part. Articulation is secured by shutting the teeth together upon this wax, thus getting the relation in which the artificial crown is to stand to teeth biting upon it. To make practical this bite, plaster-of-Paris paste is to be run over both surfaces of the wax, the paste being associated back of it. When dry, separation by section is to be made in such manner as shall preserve the relative positions of bite and root. The space left between is that to be occupied by the new crown.

Articulation secured, a succeeding step takes a strip of flat gold, and, laying it upon a piece of lead, strikes with a punch into its centre; this secures resemblance to the front face of an anterior tooth. Next anneal and bend the two ends round the root requiring a crown; when this is satisfactorily accomplished, solder the two ends together. The articulating pieces are now to be put together, and the superior face of the tube filed into a shape that permits proper closure with the tooth antagonizing. To finish, bend and fit a crown surface to correspond with the face of the articulating tooth and with the filed surface of the tube; the soldering together of the two completes the operation.

The above directions apply only to restoration of teeth anterior to the molars. To fit a crown to a molar base, the operator commences by striking up in a piece of lead a gold crown; this he stiffens by running solder into it. The crown ready, a succeeding step encircles the root with a stout gold band; crown and band are next soldered together, and the work is done.

Fig. 211 furnishes illustration of the manner of relating crown and root.

A root upon which it is proposed to graft a gold crown should be healthy.



To apply a crown, if the root stand but little above the free surface of the gum, it is found necessary, in order not to irritate the tissue, that it be forced

FIG. 211.

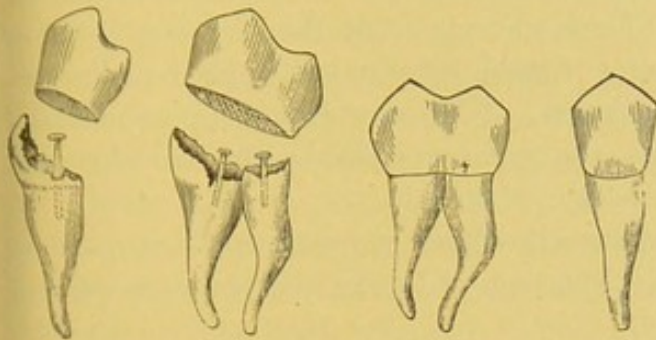
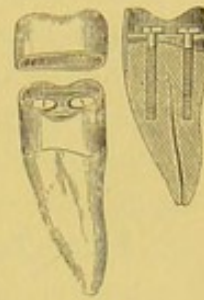
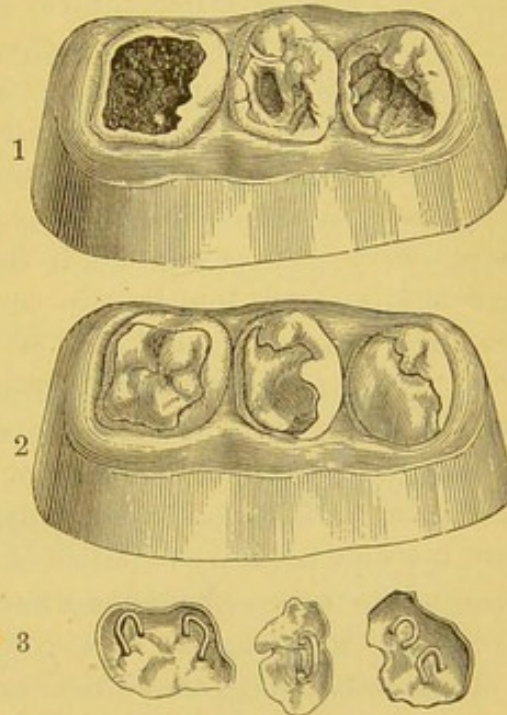


FIG. 212.



away from the tooth ; this is conveniently accomplished by using an ordinary gum lancet, or, more expeditiously, the instrument exhibited by Fig. 159. Next the cavity of the root is fully cleaned, as for the ordinary process of filling with a plastic. One or more pins, as deemed necessary, are now placed in the cavity, and secured in a desired position by means of gutta-percha or oxychloride of zinc. The same material being filled into the crown, relation of the parts is to be made during the state of plasticity. German *os artificiel* is highly commended by the inventor of the gold crown for making the relation.

FIG. 213.



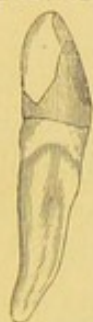A means of fixing a gold crown where the root is decayed upon either side or in the centre nearly to the alveolar process is to be practised with much success after the following plan : Cut down until a firm base is secured ; trim and put the rough edges in good condition ; next separate the gum from the neck of the root as low down as the alveolar process ; fit and solder the band, and proceed as before to secure a crown. The artificial part made ready, the operator reams out the pulp-cavity or cavities, and, fixing in these headed screws, grafts his crown as before described. Fig. 212, after a cut by Dr. E. S. Talbot, affords idea of the manipulations.

A manner of capping a broken tooth with gold is the device of a Dr. Bing, of Paris. The operation, more ingenious than promising, is accomplished as illustrated in the series of three accompanying drawings (Fig. 213). 1 shows molar teeth badly decayed and broken. These teeth are first to be excavated



as for ordinary plugging, the parietes of the cavities being made smooth and solid. Next an impression is to be taken in wax, out of which a die is gotten. Upon this die caps are to be struck up. A succeeding step tries these caps over the teeth, finishing them to suit. A next step solders rings to the bottom of them, as seen in 3. Teeth and caps ready, the cavities of both are filled with gutta-percha, and, being related, a warm iron applied to the surface of the caps melts the two together. Cold water is now applied, and, the gutta-percha being made resistive, the operation is finished by burnishing the edges of the gold about the parietes of the teeth.

**Pivot Teeth.**—A pivot tooth is a porcelain crown attached to a natural root. We commence with the simplest expression of the subject.



A pivot tooth is a crown of porcelain having a hole in its centre for the accommodation of a piece of rounded wood or metal; this wood or metal fits a hole of corresponding size reamed into the root of a tooth; the joining of the two, crown and root, constitutes the operation of pivoting. Fig. 214 shows a crown and root associated. Pivot teeth of every form, kind, and character are to be procured at the dental depots.

A case presenting itself as a pivoting operation will commonly be found in the condition of a half-destroyed crown with a pulp dead, or, it may be only semi-devitalized. The latter condition of the pulp found to exist, a first step resides in its full destruction. To accomplish this, as little disturbance as possible is to be provoked. If the pulp be exposed, the very best plan to pursue is to prick into it, with any convenient needle-pointed instrument, arsenic and morphia, equal parts of which have been rubbed up in creasote. (See *Nerve Paste*.) This is accomplished without pain, and is a simple operation, to be done by any person who possesses sufficient delicacy of touch. A pulp so treated limits irritation to the closest confines. When the pricking instrument is felt to strike against the foramen of the root and sensibility is lost, it is only necessary to introduce a barbed broach,—being careful to keep close to the tooth wall, and by a few turns in the canal the mangled pulp is caught and withdrawn.

In a broken tooth where the cavity of decay does not expose the pulp, such exposure is to be made by delicate manipulation with drill or excavator, otherwise the case is treated by the introduction of an arsenical preparation into the existing cavity, and the sealing up of the same for a period varying from twelve to twenty-four hours, according to the density of the tooth. A piece the size of an ordinary pin-head will be found sufficient to destroy a pulp. The pulp killed, the crown of the tooth may be cut off as now to be described. Previous reference, however, is to be made to accidents, not uncommon, which may have caused the fracture of a perfectly healthy tooth. If in such cases, as is most likely, the shock has excited pulpitis, and, it may be, periodontitis, a first attention is to be directed to the resolution of such



conditions; no immediate attempt is to be made to destroy the pulp, unless indeed it be exposed, when it is to be pricked as before described; but a local vigorous antiphlogistic treatment is to be instituted and continued until the practitioner is satisfied that resolution is not to be effected. Accepting resolution to be secured, the broken tooth is allowed to remain strictly at rest until all irritability has subsided, when a spear drill is to be used for the production of a receiving cavity, into which the arsenious paste is to be applied as before directed. Another way to employ the paste with such broken teeth is to build about the edges of the fracture a ring of gutta-percha, this to be accomplished by trailing a solution which has been made by covering parings of the plastic with chloroform; the chloroform, quickly evaporating, leaves the gutta-percha firmly adherent to the parts upon which it has been laid. Within a ring thus secured the paste is to be laid and covered in by the same solution. Teeth, from the accident of fracture, are sometimes made so sensitive as to render it impossible to use the drill. The means just suggested will meet the indication.

If gutta-percha be found not to adhere with sufficient tenacity by this method, it will be necessary to excavate a groove in the face of the organ, and, after thoroughly drying the parts, build on, piece by piece, the ring of "Hill's Stopping," or red gutta-percha, when the paste may be placed in position and covered with a portion of the same material.

Sometimes it happens that nodules of secondary dentine exist in the pulp interfering with the absorption of the arsenic; in such cases it is commonly found necessary to repeat the application a number of times, or else expose

FIG. 215.—EXCISING FORCEPS.



the organ and prick it. Resistance to arsenical applications is quite diagnostic of the presence of pulp-stones. (See chapter on *Odontalgia*.)

To cut the crown of a tooth from its root, the first instrument required is the excising forceps. This is used in anticipation of file or disk, the crown being cut away little by little until the neck is uncovered. This extent of excision being accomplished, it is prudent to give the part a rest of a day or

FIG. 216.—SAW FOR EXCISING CROWN.



two; it is a safe plan, although certainly not in all cases, or indeed even in the majority, a necessity.

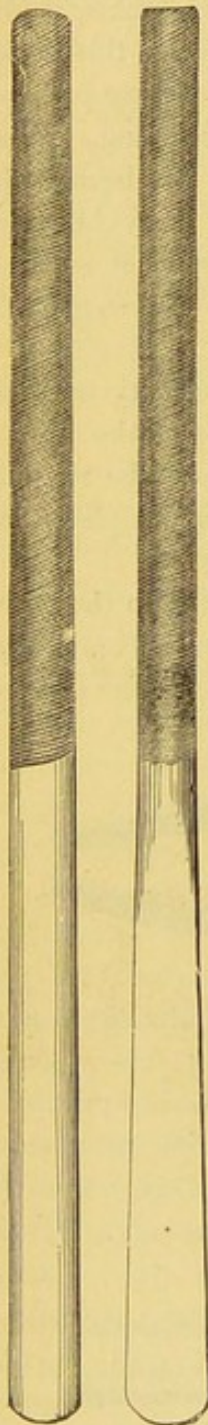
In place of the forceps some operators prefer the saw for excising a crown;



this will not, as a rule, be found so convenient of employment, and is more apt to provoke inflammatory response. It is not amiss, however, to have such an instrument, as occasionally it is found useful.

Following the excising forceps is the pivot file. This instrument, being half round, cuts a concave face on the neck of the root, which aspect of face is seen to correspond with the accommodation required by the neck face of the artificial crown, which, as it comes from the depot, and is used, is convex.

FIG. 217.  
PIVOT FILES.



In filing down a natural root, a judicious gentleness is to be combined with a necessary dispatch. The file first used is to be sharp, so as to accomplish the required work with the least irritation, and should be used until the gum is fairly reached; the sharp file is then to be exchanged for one comparatively dull, with which the now concave face of the root is to be smoothed until marked bleeding occurs from the abraded gum. The object of this abrasion is to insure an accurate covering of the joint between root and pivot tooth by means of new granulation-tissue. It is sometimes, though very rarely, the case, that with previously irritated roots this preparatory operation is profitably to be divided into several sittings, meanwhile an antiphlogistic treatment being pursued; but the cutting with the dull file which is to take off the root below the gum is to be the step immediately preceding the attachment of the new crown, otherwise the soft tissue is found to fall over the root and partially cover its surface.

During the process of cutting down a natural crown, or, to make a rule, we may say at that stage which is to employ the dull file, the preparation of the canal is to claim attention. To effect the requirements here demanded, rose, or bur, drills of various sizes are employed, commencing with one received into the natural canal, and increasing, seriatim, until a sufficient diameter is secured, such diameter being in correspondence with the size of the pivot used. The depth to which a canal may be reamed, and also the diameter, depend upon the size and density of the root; a rule applicable to all cases cannot be given: it is to be deemed necessary, however, that sufficient circumference and depth be secured to insure the retention of the pivot; half the length of a root may commonly be reamed with impunity.

The process of reaming completed, a delicate spear drill is to be passed into the continuation of the canal, and the parts cleansed to the apex. This secondary canal is then to be filled with gold



(see *Filling Pulp-Canal*); when accomplished, the root is ready for the crown.

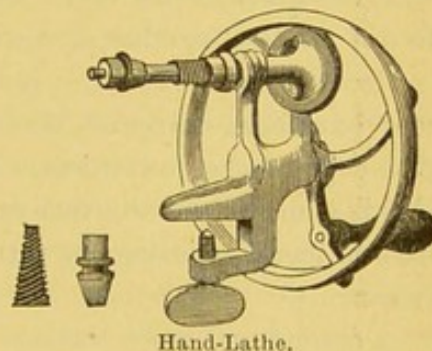
The introduction of the engine has done much to simplify the preparation of roots for reception of artificial crowns. Instead of the hand file, burs of corundum, barrel-shaped, used with the engine, are now almost universally employed by the experienced. These burs accomplish the concaving of a root with absolute accuracy and certainly with great dispatch. Drills for slotting and reaming are also used.

The selection of a crown for a root considers—first, shade, or color, this refers to correspondence with neighboring teeth; second, shape and adaptability, this being recognition of form. By having in one's possession a few hundred artificial crowns, it is quite possible to find among them many of such perfect match as to render the slightest alteration unnecessary. Third, it is requisite to have the pivot canal in the crown and that in the root so in correspondence that when jointure is made the two shall occupy a proper relation. To be satisfied of such proper relation of parts, the crown and root are to be put together for the moment with a pivot of round match-stick. It is suggested, and practised by some, that where there is lack of natural correspondence in the canal of the root, a required direction shall be given by the drill: this, however, is to be condemned as bad practice; it is much better to seek a new crown.

To have an accurate adaptation of crown and root is most desirable; this may require some grinding of the crown; and to know just where to grind makes it necessary that the touching points be recognized. Such information is to be secured by coating the surface with a film of wax; putting the parts now together, the wax overlying the points implicated will, of course, be found indented and displaced. A plan even better than that just described is, immediately upon having a root prepared, to take an impression of it and the contiguous teeth in wax (see *Taking Impressions*), and, having made a model of plaster of Paris, fit the crown to the model.

To grind the natural tooth, a stick of corundum is used by many. Such a stick is to be procured at the furnishing depots for a few cents. A better means is found of course in the employment of a lathe or the engine; of lathes used for dental purposes the greatest variety is offered; the smallest hand-lathe, however, is commonly found sufficient to meet requirements. Fig. 218 represents such a one: it may be attached temporarily to any stand conveniently at hand. This lathe is entirely noiseless. Having neither cog-wheels nor belt, it is free from oil, dirt, and the trouble of adjustment. The motive-power is communicated by friction gained by covering the small wheel, or

FIG. 218.

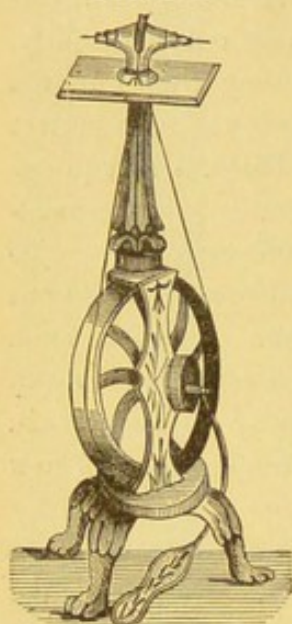




pulley, with a rubber ring which comes in contact with the inner surface of the driving-wheel. The driving-wheel is six and a half inches in diameter; the small wheel, two inches in diameter; and the weight of the lathe is two and three-quarter pounds.

A form of lathe which, being worked by the foot, leaves both hands at liberty, is represented in Fig. 219. Such a lathe is in many respects preferable to the first; it is certainly more convenient to the operator. This lathe has a movable column and table, and is capable of being elevated eight inches; it is made to accommodate the user in either a sitting or a standing posture.

FIG. 219.



Foot-Lathe.

As the grinding instrument, wheels of corundum are used on these lathes; the operator is to provide himself with five or six of varying sizes.

Crown and root prepared, a pivot is the next consideration.

A pivot is either of wood or of metal. A wood pivot is to be made only of thoroughly-seasoned and firmly-compressed hickory: a box of such pivot sticks, which are to be purchased at a depot at a cost of twenty-five cents, will set hundreds of teeth; it is best thus to provide one's self. To use a wood pivot, the operator commences by securing the exact length required; this he learns with least trouble from his temporary fixture of match-stick. One end of this pivot is now fitted into the crown, the other being of a size corresponding with the canal in the root. Everything being thus prepared, it only remains to put the two together, and the operation is complete.

Occasionally, however, it is found that, in defiance of the nicest care which may have been exercised, there is slight fault in the articulation of the cutting edge of the new crown with the corresponding tooth of the other jaw: this is commonly easily remedied by filing away the impinging point on the natural tooth, or, using the corundum stick, it may be taken from the artificial crown.

A second and more serious complication is periodontal inflammation, the root becoming sore and painful. When such inflammation supervenes all mechanical manipulations are to cease at once and the parts are to be treated until recovered.

Metal pivots are variously used. A common plan is to make a delicate tube of gold of such size as permits its introduction into a drilled opening of the root (which opening in these cases, is to be somewhat larger than is required for wooden pin pivoting, and is to be bell-mouthed), leaving sufficient space between tube and cavity for a packing of cohesive gold; a wire fitted into the tube prevents its compression. The tube fixed in place, the wire is



to be withdrawn, and the tube refilled either with wood or gutta-percha to prevent its injury, and the face of gold filed concave as though it were tooth structure; this leaves only a ring of cementum exposed, thus securing, from the exceeding durability of this substance, a permanent and desirable result. Next an impression taken in wax, a plaster cast is made, and from this metal dies. A thin plate of gold is now struck between these dies, which is to fit accurately the face of the root, being filed to the exact shape of the face and outlines of circumference. Following, the plate of gold—the cap having a hole drilled through its centre corresponding with the tube in the canal—being laid in place, a piece of gold pivot-wire is passed through it into its place in the tube, and secured with a small piece of adhesive wax. Cap and pin are now removed, are invested in plaster of Paris, and the two soldered firmly together. The tooth here to be used is what is known as a plate tooth,—a tooth having pins of platina in its back. Selecting one of this class to suit the case, the cap and pivot are slipped into place, and the crown, being held in the exact position required, is fixed by a particle of wax. The whole piece thus cemented together is now removed from the mouth; this last is accomplished by inserting the blade of an excavator beneath the plate, and thus lifting it. The tooth is next backed with a plate of gold having holes punched for the passage of pins. Backing, tooth, and cap are now soldered together, and the fixture stands complete, requiring only to be cleaned and introduced into the tube. If all is as desired, the gold pivot is then to be tapped laterally very gently with a pivoting hammer, when it will be found, upon introduction, to remain with all necessary firmness.

An improvement, as it is thought by some, on the plan just described consists in the replacing of the root tube by a hollow screw, a screw-tap being used to cut the thread on its inner wall; this screw, fixed in its place, is to be levelled with the face of the root and the operation completed as already described.

In roots having canals out of correspondence with the position demanded for the new body, the mode of using caps for the attachment of the crown seems to afford all that can be desired, inasmuch as when teeth are thus pivoted correspondence between the cavities of root and crown is of no importance.

A condition indorsing fully the employment of the tube is found in roots somewhat decayed. Here, the tube being in place, after excavation of the part, as in any case of caries, the seat of disease is occupied by gold placed on the principle of ordinary plugging.

A manner of pivoting which is to be esteemed a combination of the plans just described consists in passing through the centre of a wood pivot, which pivot has been drilled for the purpose, a second one of gold wire; such wire is found materially to strengthen the wood, and is thought by many to be the most desirable support that can be employed.

Still another plan is the employment of what is known as the vulcanized pivot. This process is as follows. The root being prepared by tubing as



previously described, a wire of length sufficient to protrude one-eighth of an inch or more beyond this tubing is flattened at one end and inserted into the tube; next a tooth (usually one made for vulcanite plate purposes) is fitted to suit and placed in position; wire and tooth being joined with adhesive wax. The wax cold, the adherent tooth and pin are carefully withdrawn. Moulds are next made of plaster, as for vulcanite work, the wax is removed, vulcanizable rubber is introduced in its place, and the pin and tooth are united by the vulcanizing process. This is a very neat, easy, and, as thought by many, an altogether desirable operation.

A means of setting a pivot tooth founded on the ease with which the Mack screws can be worked, and applicable particularly to bicuspid and molar teeth, consists in inserting into the filed face of the root three or more of the screws, and, having a tooth prepared for the purpose, of a box-like character, the chamber is filled with cement plombe, or any of the oxychloride preparations, and while the material is soft the tooth is put into place, being retained by the fingers until the cement hardens about the pins. A box tooth may easily be made by soldering a metal chamber to the pins of an ordinary plate tooth.

Another plan, pertaining, however, only to the treatment of a root where this has been weakened by decay, consists in first making proper excavation of the diseased dentine and replacing it with oxychloride or with amalgam. The material used having set, a pivot canal is reamed in its centre, and the operation completed by the use of the wood or wire-wooded pivot.

Flagg's method of pivoting anterior teeth is as follows: Select an ordinary plain plate tooth to suit. Grind and bevel the neck face. For the pin use platinum wire No. 14, U. S. gauge. Hammer this flat at end,—tooth end. Through this flattened end punch holes for tooth-pins. Rivet into union tooth and wire by means of the pins, and complete by soldering.\* To attach to the root the artificial piece thus made ready, the operator barbs the pin and drills out the canal bell-muzzle fashion. Next dryness is to be secured, and the barbed wire being thrust into the root (the crown being related exactly as desired), a quick-setting amalgam is packed until not only the canal is solidly filled, but a posterior face built to the tooth.

A method of setting a plate tooth on a root, and giving an additional support by a rim of gold, is practised thus by Dr. H. E. Dennet:

First cut off the crown; then tunnel out the root, by enlarging the pulp-cavity, making it very large at the orifice, and smaller as it goes in, cutting retaining-points at proper places. Solder a platina pivot to a suitable plate tooth, the pivot being large where it is soldered, and a gradual taper bring-

---

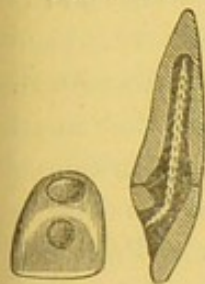
\* Soldering is a process accomplished by means of blow-pipe and a metal cement; in this case pure gold is used. Lay upon charcoal and partially imbed in sand and plaster. Next smear the parts to be united with a cream of borax. Place in this cream small pieces of gold, and direct over the imbedment, by means of a gas blow-pipe, the flame from a spirit-lamp until the metal melts and runs.



ing it nearly to a point; then make it barbed or rough, so that it will not pull out after the crown is set.

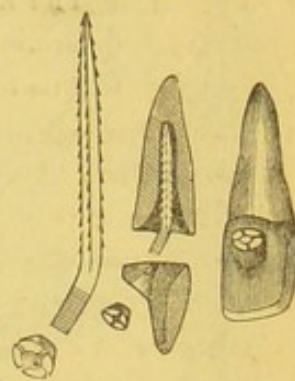
Having prepared the root and the tooth, put on the rubber dam; fill the root to the point where the end of the pivot will meet it; put on the tooth and fill around the pivot (turning the tooth in and out, and laterally, as convenience requires, the pivot being easily bent without danger of breaking); build out to the natural form of the tooth, using first soft gold, then that which is partly cohesive, then cohesive.

FIG. 220.



Tooth-pivoting has found very lately marked impetus through the inventive efforts of W. G. A. Bonwill, D.D.S., Marshall Webb, D.D.S., M. H. Cryer,

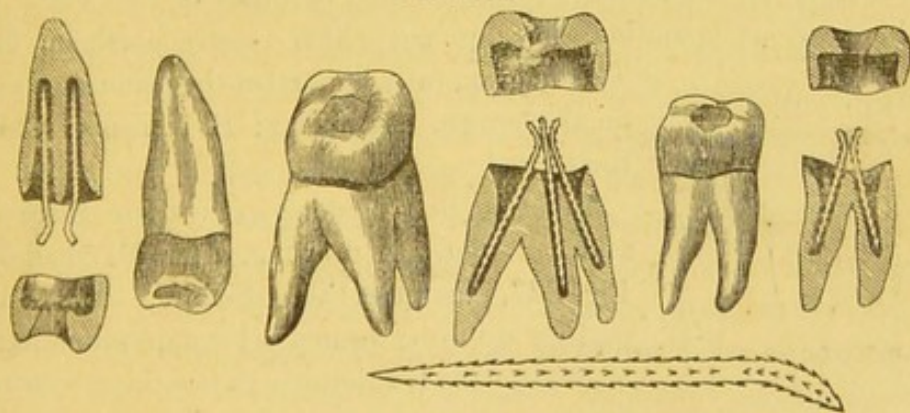
FIG. 221.



M.D., and others. Fig. 220 shows a pivot operation as practised by the first of the operators named. The principle consists in fixing a barbed, screw-headed pivot of platinum into a root-canal, using for the purpose of fixation a preparation of amalgam; the crown, previously fitted to the root, is placed upon this pivot and retained immovably in place by means of a gold nut. Fig. 221 exhibits the components of the operation separated.

A second method of this same practitioner, and one preferred by him, consists radically in a plug of amalgam capped with porcelain. Fig. 222 furnishes the idea. In the diagram sections of bicuspid and molar roots are shown into which are impacted the platinum barbed pins. Sections are also shown of crowns made hollow, an opening existing through the face surface. Placing one of these peculiarly-constructed crowns over a root surface prepared to receive it by means of a coating of amalgam, it will be seen that to make a perfect joint and strong bond of union the operator needs alone to

FIG. 222.




proceed by filling in at the crown opening a continuation of the amalgam already begun over the face of the roots.

Amalgam being a discolorer, attention is to be directed, in the use of this means, to a necessity for nice discrimination in the matter of shade.



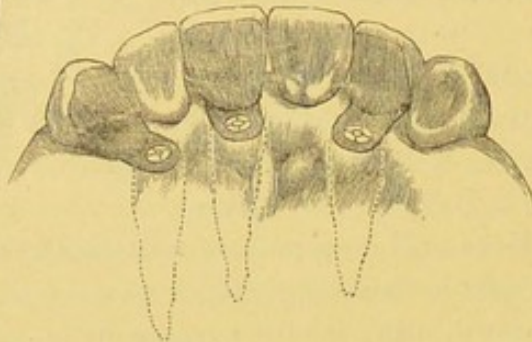
In the immediately preceding cuts the cases shown relate, all alike, with the supposition of a dead pulp; the canal or canals being the place of anchorage.

A reverse to this is expressed in Fig. 223, which shows, perfectly outlined, a mode of procedure in living roots; a procedure not, however, to be indorsed or recommended.



The adaptation of the plan of pivoting to the correction of deforming irregularity finds illustration in Fig. 224. Here, as will be inferred, the natural crowns are first to be cut off and the

FIG. 224.



pulps destroyed. Next, plate teeth are to be backed with stays of gold, the metal reaching to the location of the different roots and being fitted to them. From this point the procedure finds modification as in illustration, save that the manner of fixing is by means of nut and screw. Fig. 225 shows

forked screw-driver. The plan is commendable, the pulps being first destroyed and the canals used for the pivot.

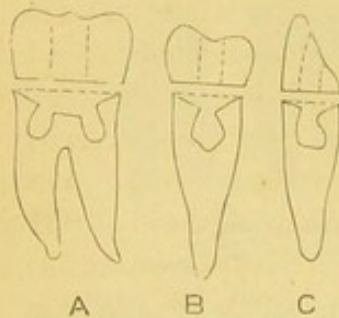
FIG. 225.



A manner of pivoting crowns of porcelain known as the Gates method is about the same as that by Bonwill; indeed, credit for the common invention seems to lie with the two.

Still another manner, closely corresponding, is shown in Fig. 226. Here, as in the previous operation, slots are cut which receive amalgam fillings.

FIG. 226.



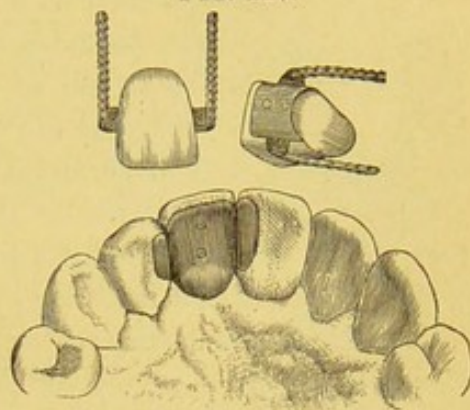
The diagram fully illustrates the manner of putting on the crown. A, molar; B, bicuspid; C, lateral incisor.

Pivoting may be done even where there is absence of root. A drawing, after Marshall Webb, Fig. 227, illustrates the procedure. First, suitable cavities are to be formed in the approximating faces of the two teeth adjoining the toothless space to be filled. An impression of the parts is next to be taken, and a plain porcelain crown selected of a form and shade corresponding with requirements. This tooth is to be backed, which backing is to extend about one and one-half lines from each



side the crown for insertion in cavities prepared in the adjoining teeth. To these wings barbs are to be soldered for introduction into the pulp-canals. A next step considers an impression of the parts which secures the ability to prepare a delicate cast of gold accurately fitting the gum upon which the porcelain tooth is to rest. Everything thus made ready, the parts are respectively placed in position, and secured in relation by means of a piece of wax. Being next carefully lifted from the mouth, all are included in a matrix and soldered. The operation is completed and made permanent through fixing the barbs by means of fillings made of cohesive gold. To secure temporary fixedness for his pins, Dr. Webb uses first a packing of oxychloride, cutting most of this subsequently away, replacing it with gold.

FIG. 227.

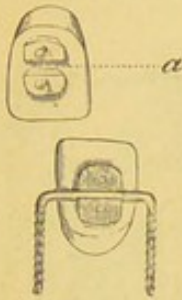


What is termed "grafting crowns" is an operation attracting at the present time considerable attention. The principle of the performance is the same as that just described. To illustrate it reference may be made to a mouth where the first and second molars, say of the upper right side, have been lost. The abutting, or adjoining, teeth—that is, the second bicuspid anteriorly and the wisdom-teeth posteriorly—are to be supposed to have cavities in their approximal faces, the first in the distal, the latter in the mesial, face. An operator preparing these cavities for plugs of amalgam, concludes to use them as abutments to a bridge of the plastic, which he builds in the intervening space, moulding and shaping it nicely to fit the gum and to articulate with the teeth of the inferior jaw. Grafting is nothing different from replacing amalgam with teeth. Different manners are practised in securing the organs. One way consists in taking crowns that represent fully the teeth to be replaced. These crowns possess double longitudinal perforations for the accommodation of a stiff gold wire which is to occupy them, stringing as it were the teeth together. Before being placed on this double string the base of the crowns are to be ground into accurate fit with the gum upon which they are to rest, and as well so fitted as to fill the space to be occupied, leaving, however, room for the necessary side, or anchoring, attachments. Mode of attachment will be understood by glancing at Fig. 227. To the extremities of the horizontally placed wire of either side vertically placed roughened gold wires, or wings, are soldered, and these, as understood, are accurately fitted and plugged into cavities existing or prepared for their reception in the adjoining teeth. Another mode consists in attaching the crowns to a delicate plate, fitted through impression and swedging (see *Prosthetic Dentistry*), to the face of the gum, precisely as ordinary plate teeth are manipulated, and in turn relating the fixture with the natural teeth, as understood.



The plan embraced in these various manipulations is mechanical rather than surgical; it is ingenious but not to be commended except as special cases are concerned; experience will safely venture where sciolism would meet with nothing but disaster.

FIG. 228.



An improvement, so considered, on the above manner of fixing a tooth to the backing,—a manner tending to prevent breakage of the porcelain face,—consists in cutting, with a disk of corundum, a groove along each side and across the cutting face of the tooth and another between the pins. A wire to connect the barbs is now laid in the groove and soldered in place as shown by cut, Fig. 228.

**Ferruling.**—A manner of attaching an artificial crown to a natural root is done by means of a gold ferrule. This is a suggestion by Dr. Buttner, of New York; the procedure as discussed by the inventor is as follows. Counter-reamers with counter-pins to level the root, and trephines with centre pins to turn a shoulder on the exposed end of the root, are used.

The instruments prepare the root as required, hence nothing prevents applying ferruling, which is recognized in mechanics as the most accurate and reliable system for combining two parts.

The ferrule used is of stiff plate gold, struck up on steel dies. It is a single piece of gold, closed at one end with a pivot soldered in its centre. The accuracy and strength of a ferrule constructed in this manner insures double the strength needed.

The first step in the practical application of the method is to enlarge the pulp-canal with one of the drills. The next is to level the root by aid of the counter-reamer, the centre pin of which fits the hole in the root. The trephine is used to turn a round shoulder on the exposed end of the root. This completes the preparation of the root. An accurately fitting straight wire is now inserted into the canal, and an impression taken; the impression cup is to be open opposite the root so as to allow the wire to protrude through impression material and cup. Next withdraw the wire, then remove the impression from the mouth, and return the wire to its hole in the impression.

A set of brass root models accompany the set of instruments, which correspond with the trephine and gold caps in size. These represent the prepared end of the root on the plaster model, and serve to guide the gold cap in being placed on the model. One of these models, corresponding in size with the trephine used, is placed over the pin in the impression; now the model is passed in plaster-of-Paris.

In removing the impression material from the model, the root model is found accurately in place of the root, representing the prepared root end. The corresponding gold cap is now placed on the root model, a porcelain crown prepared for the cap, and waxed into the same in such a way as to cover the gold in front. The united parts are now withdrawn from the model, imbedded in plaster and sand, and are soldered and finished.



The operation is completed by forcing the cap, with pivot and crown combined, upon the root by repeated blows with a suitable mallet.

**Porcelain Facing.**—A porcelain face is a scale or full tooth-surface of the material used for correcting a dental deficiency. Fig. 229 furnishes an illustration. A crown, *b*, is fitted to a root; *a* represents an open tube which has been soldered to platinum pins. On either side grooves are seen, cut by means of corundum disk into the substance of the porcelain. This crown, consisting of an ordinary plate tooth, is made to take the place of a lost tooth-face by closing the tube, slipping it over a pin fixed in the root, and building up the back surface in cohesive gold.

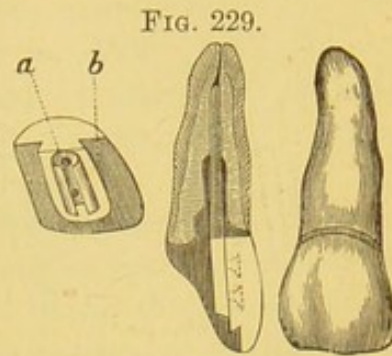
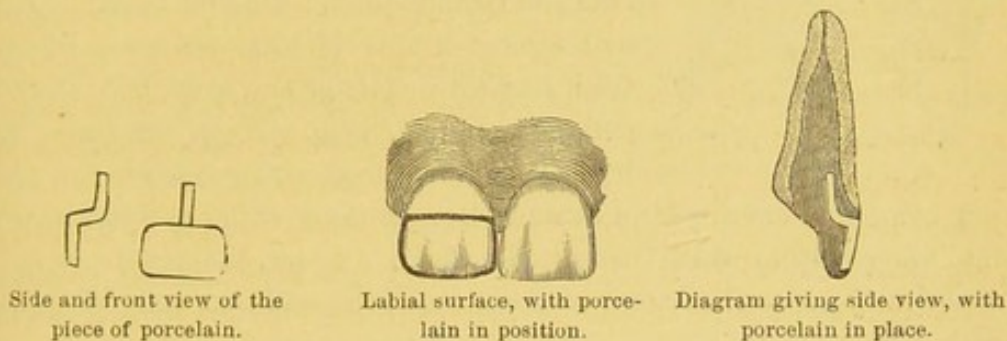


FIG. 229.

Fig. 230 shows another class of operations. The centre drawing exhibits a square of porcelain built into a broken tooth-face, being retained in its

FIG. 230.



Side and front view of the piece of porcelain.

Labial surface, with porcelain in position.

Diagram giving side view, with porcelain in place.

position by means of a pivot combined with a circumferential rim of gold worked into place by the impacting qualities of an automatic mallet.

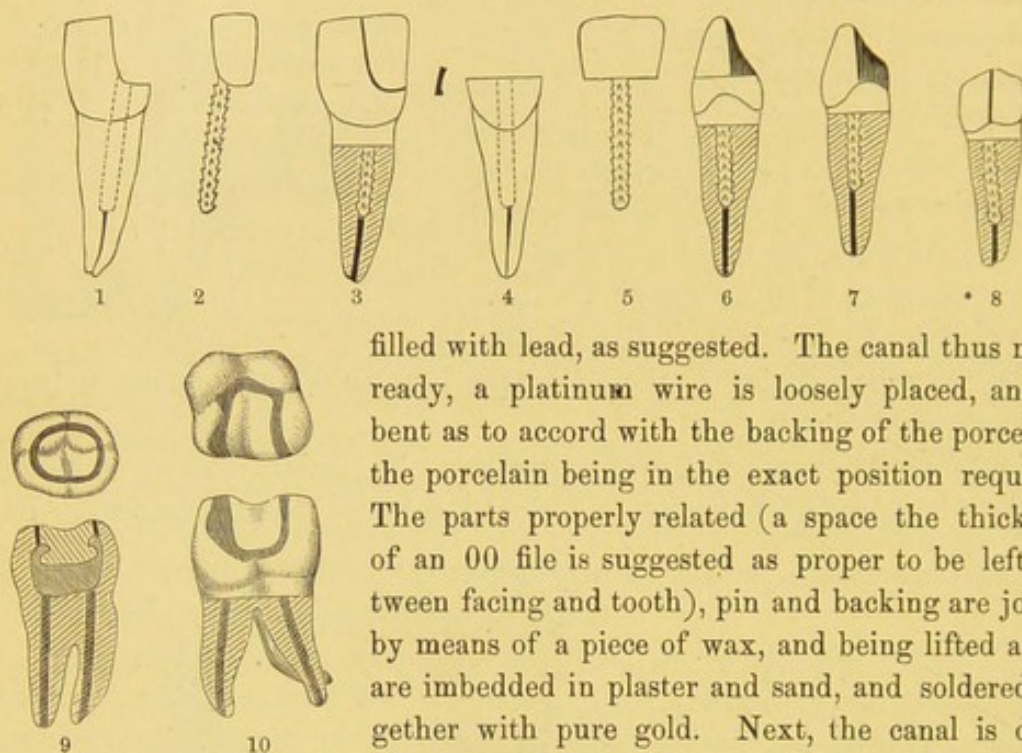
A very pretty, and as well commendable performance in this direction relates with incisor teeth, where, for example, the mesial angles of, say the two centrals are broken away. Here, after cutting a square into the two faces, or, if preferred, curving the surfaces, scales, having pins burnt into them, are nicely ground, and are related with these surfaces so as to constitute an accurate fit, and restore as well the lost contour. Next, an impression being taken, dies are prepared and delicate backings are fitted to the teeth. Succeeding this, the scales are put in place, and being attached by means of the pins to the backings,—soldered,—the contrivance is fixed by drilling countersunk holes through the backings, making slots in the teeth, and in uniting the two by rivets made of cohesive gold.

Subfigs. 1 to 10 (Fig. 231) illustrates operations in porcelain facing, all of which explain themselves. Dr. S. D. Rambo, whose practice furnishes the drawings, fills the extreme end of the pulp-canals with lead. The facings used are simply cut artificial plate teeth, selected with regard to shade and fitness. A piece or pieces being ground into absolute adaptation, the pins



are backed with platinum; the backing being held in place by splitting the pins. Next, the canal of the tooth to be fitted is reamed out, the apex being

FIG. 231.



filled with lead, as suggested. The canal thus made ready, a platinum wire is loosely placed, and so bent as to accord with the backing of the porcelain, the porcelain being in the exact position required. The parts properly related (a space the thickness of an 00 file is suggested as proper to be left between facing and tooth), pin and backing are joined by means of a piece of wax, and being lifted away, are imbedded in plaster and sand, and soldered together with pure gold. Next, the canal is dried by means of a hot-air syringe, when the platinum pin, being well enveloped in heated gutta-percha or with oxychloride, is thrust into the cavity to which it had been fitted. Later, the plastic is cut from about the joint to the extent of about two lines, and that material is replaced with gold.

No. 4 represents a central incisor with parallel break of crown. No. 5 shows piece of porcelain tooth pivoted and made ready for the repair. No. 6 is a side view of the restored crown. Nos. 7 and 8 show operations where nearly the full crowns have been restored. Nos. 9 and 10 show a bicuspid and a molar tooth where portions of the crowns are replaced with porcelain. If, in these cases, the pulp lies dead, it is recommended to pivot as in the previous examples, and fill in with plastic and gold; but if the pulp be vital, the porcelain is to be fitted with a view to its sole retention by a circumferential packing of gold.

The placing of diamonds in the front faces of the teeth as ornaments has been accomplished with a great deal of satisfaction to the possessors. To do this, using cohesive gold, little more skill is required than in making common crown plugs.

**Plastic Facings.**—The use of the plastics as a facing material, in the repair of deficient labial walls, is at the present time attracting a good deal of attention. A zinc amalgam accomplishes this work excellently well. (See *Amalgams*.) In such a situation the material keeps peculiarly clean, the moving lips acting as a constant cleanser and polisher. A happy manner of



making a facing consists in building up the deficient part with a tough, sharp-edged amalgam, standard alloy, for example, and while it is in the act of setting cutting away this material on the face surface until none is left except a delicate rim leading to an undercut. When setting is accomplished the place of the removed amalgam is to be occupied by facing alloy. With skill, and patience to secure shade, a tooth may be faced after this manner to the satisfaction of all concerned. When the less dense plastic fails it is replaced with little trouble.

Another manner of facing relates with the use of oxychloride as a material. This preparation is not very permanent, as is understood, but then it is easy and convenient of re-application. A tooth defective on its anterior face is improved wonderfully in appearance by a skilful employment of oxychloride.

Examples illustrating facing with the plastics would need to be given alone in connection with the preparation of special cavities. To accomplish himself in such directions a student is to give much time to practical studies made out of the mouth.\*

---

\* As an addendum concerning the use of plastics, more properly in place, however, in the article relating to the use of amalgam for tooth-plugging purposes, the author calls attention to an ingenious carrier of the alloy designed to take the place of cup and file-flat; see Figs. 162 and 163. The apparatus consists of a tube attached to the end of a shank, which tube, being filled with amalgam, is carried to the cavity to be occupied; arrived at which it is emptied, and the material partially packed into the cavity by a simple act of pressure which calls a spring into motion. Two or three forms are to be found figured in dental catalogues.

DENTAL CATALOGUES.—For the benefit of students it is to be mentioned that dental catalogues, to which reference is frequently made in this work, are book-like issues, to be obtained free of charge by addressing a postal to any of the various dental depots. These contain drawings and descriptions of all instruments used in dentistry, and by means of them the practitioner keeps himself informed as to new devices.



## CHAPTER XXVI.

### OPERATIVE DENTISTRY.

#### IRREGULARITIES OF THE TEETH.

##### ORTHODONTIA.

TEETH irregularly related to the common arch are, under favorable conditions, capable of having the malposition corrected without ill results.

Conditions to be appreciated are: 1st, general and local health; 2d, age of patient; 3d, nature of alveolar process.

A patient of extreme nervous temperament, or one laboring under a dyscrasia, is scarcely a proper subject for the endurance of details necessary for the correction of misplaced teeth: the latter, by reason of a degenerating inflammatory action almost certain to be provoked; the former, because of nervous excitability aroused, which involves a risk to the health at large, of greater import than any local good to be attained.

A patient over twenty-five years of age may, as a rule, be deemed to have attained a solidity and fixedness of stature which render the risk of change overbalancing the promise of good. The period intervening between twelve and seventeen years of age is found by experience to be the time of election for this class of operations.

An alveolar process of loose structure is more capable of affording response to a mechanical impression than is one of solid character. In the first, a tooth may be quickly changed in its position; in the second, not only is more time required, but great increase in the moving force.

Treatment which pertains to regularity and harmony in the second denture commences with the first, the rule being that a deciduous tooth is not to be extracted, save by compulsion, until a successor is ready to take its place. (See *Anomalies of Dentition*.)

A tooth is to be changed in its position by the application of force drawing in the required direction. The physiological changes induced in the alveolar process are, first, absorption of the parietes of that aspect of plate pressed upon; second, the exudation and organization of plasma in the part relieved. Change too rapidly effected excites inflammation, or otherwise draws the tooth from its cavity; haste in the correction of an irregularity is never safe.

In orthodontia, as in every other department of art, familiarity simplifies practice. To move teeth, but few means are really requisite. Complexities in appliances commonly signify lack of skill.



A full consideration of the associations of a case is to precede operation upon it. Such consideration embraces, first, age. As a rule, it is not found good practice to attempt the moving of an undeveloped tooth, the parts being too susceptible and irritable. (See *Dentition*.) Second, condition. Not only are dyscrasic and nervous conditions adverse to operation, but the more immediate expressions are to be taken into account. Teeth, from the shape and direction of their crowns, are sometimes to be recognized as possessed of peculiarities of fangs, which, in a proposed change, must compel the piercing of the alveoli. Again, teeth of bulky crown may have stumpy roots of such limited relation to their alveoli that very slight traction will drag them from their sockets. A tooth out of the arch may be a supernumerary; it may in every respect simulate the true teeth and yet not belong to the denture. Here, to avoid error, it is alone necessary to possess proper familiarity with the characteristics of the common denture. Mention as well is to be made of retained deciduous teeth which deny proper place in the arch to their successors. The writer has often met with such retentions in persons of advanced years.

The inferior anterior teeth of the second set are in nearly all instances found, in the earlier stages of the eruptive act, more or less irregular in the manner of their eruption; if not unduly crowded from narrowness of the arch it will be the exception to a rule where they do not prove self-correcting. Also is it found the case that in nearly every instance where accommodating space exists, irregularly developing teeth, wherever situated, will of themselves seek proper relation. Early interference is therefore, because of such natural tendency to self-correction, to be deprecated, except where it is evident that mechanical relations render such self-correction impossible. A single example may illustrate. Suppose a case where the superior central incisors develop with their cutting faces so inclining inward that in occlusion of the jaws the inferior teeth close against the labial surfaces: here it must be seen that time, instead of serving to correct the deformity, will only increase it. In such a condition, correction as immediate as possible is desirable; judgment must direct the means and the manner: the superior teeth should certainly be placed outside of the inferior: if this be done without provoking inflammatory resistance, however accomplished, the means employed have necessarily been judicious. (See illustrative cases.)

Instances, again, are met where certain teeth have completely changed position: a lateral incisor appearing in the situation of the central, the central occupying the place of the lateral. Here there is no correction possible, except it be found in transplantation, in the pivoting process, or in extraction of the teeth and their rearrangement upon a plate.

Teeth irregular to the arch, being held in the false position only by pressure from articulating teeth, find easy correction; forced into proper place, the same teeth which continued the deformity will prove the instruments of permanency to the new relation.



Apparatus used for correcting irregularities are to be as delicate as regard to a necessary strength will allow: they are to permit of ready change of form or relation to suit the constantly varying requirements of cases; the construction and application are to be as simple as practicable, that thus, as much as possible, the assistance of the patient be engaged; they are to be easy of removal and replacement, that thus a necessary cleanliness be maintained.

In the relation of plates to the necks of teeth, care is to be exercised that unduly sharp edges shall not cut the enamel; while in the employment of rubber rings, now in common use, attention is demanded to the avoidance of injury to the gums so apt to ensue from the sliding of the ring, a result easily avoided by placing between the gum and ring a thread of waxed silk tightly tied around the tooth.

Teeth changed in position, through mechanical means, are to have support in the new location until the required alteration is effected in their alveoli. This support is commonly seen to be given by nature: as for example, where a tooth being inside of the arch and so retained by overlying teeth, being forced outside, is equally compelled to retain the new place by the pressure of the same teeth. In all cases, however, where circumstances deny natural support, advantage is to be taken of mechanical appliances; such appliances being found in ligatures, metal bands, or plates.

With such appreciation of the simplicity of the principles underlying the practice of orthodontia, a few illustrative cases in practice may be presented as hints to the ingenuity of the practitioner.

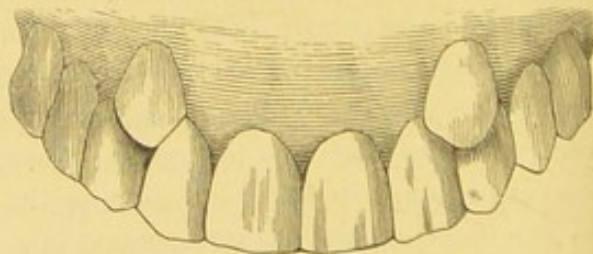
ILLUSTRATIVE CASES.—Fig. 232 exhibits a cast taken from the living mouth, in which, as is seen, the bicuspidati and lateral incisors approximate. Age of patient, ten years.

Studying this case, it becomes recognized that a required space is absent, namely, that for the accommodation of the cuspis of either side. At eight years of age, the incisor found its place; at nine years, the bicuspid. Most important was it that the space occupied by the deciduous cuspis should be preserved by the retention of that tooth until the eleventh year, the period

FIG. 232.

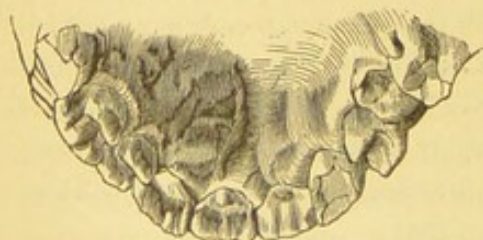

FIG. 233.



of eruption for the permanent. Not preserved, the room naturally became occupied by adjacent teeth; hence irregularity was inevitable: unless, indeed, it should have happened that the second cuspis remained unerupted,—a



matter which must always necessarily occasion more concern than even a deformity. Fig. 233 exhibits a front view of a similar mouth, the cast being taken in the fifteenth year, four years after the eruption of the cuspidati. This irregularity is the one most frequently met with.

**TREATMENT.**—If an arch so presenting exhibit the proper articulation, practice lies between the removal of the projecting cuspidati, and that of the immediately adjoining bicuspidati.

As facial expression is concerned, it is to be remembered that much of character resides in the eye-teeth. Many mouths from which these teeth have been removed show a flat, expressionless appearance, most undesirable. Again, it is found that these teeth serve as keystones to the arch: hence it frequently follows that secondary irregularity associates with their removal.

Where a mouth with overriding eye-teeth possesses proper articulation,—that is, where the superior incisors fully override the inferior; where the bicuspidati resemble in their labial outlines the cuspidati, and where the approximation of these teeth with the lateral incisors is complete and regular; where the cuspidati are situated well forward, and not over the bicuspidati, or even over the interspaces; where the patient is advanced in years, the process having become fixed in its relations; it is, in case of this kind, the proper practice to extract the eye-teeth. On the contrary, where the patient is young, where the articulation is harmonious, where the projecting teeth are situated over the interspace, or, still better, posterior to it; where the bicuspidati do not simulate in appearance the cuspidati: the practice proper to be pursued consists in removing the underlying premolars.

Experience exhibits that the developing tendency of the teeth is always in a forward direction; the extraction of a first molar, therefore, a plan often recommended for the correction of this irregularity, does not favor to any extent the accommodation of the cuspis: the second bicuspis will not fall back into the space made. On the contrary, a second irregularity is favored in the immediately manifested inclination of the second molar to fall obliquely forward, thus breaking the harmony of the posterior articulation. The preservation of the first molar teeth is of great importance to the process of dentition. It is a misfortune where they have been neglected.

A third condition of this special deformity is met with where it is evident that the slightest curtailment of the superior arch would destroy the harmony in articulation,—that is, the overriding is so slight that the extraction of two teeth might possibly result in the interior organs closing directly upon each other, or perhaps, indeed, in the inferior teeth closing outside. Two lines of practice here offer. The bicuspidati may be removed as before directed, and by the employment of an occipito-mental elastic sling, exhibited and described on a succeeding page, the inferior arch may be retracted; or the superior arch may be enlarged to an extent which shall afford the required space through the aid of instrumental assistance; or, still again, equality may

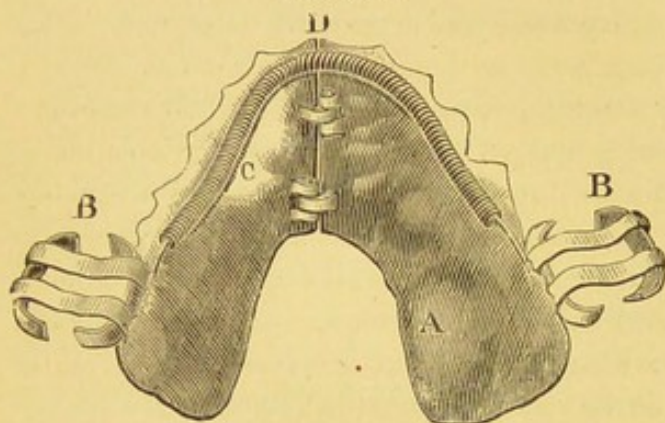


be maintained by the extraction of corresponding bicuspidati from the lower jaw.

Of appliances used in the correction of irregularities, every variety is to be met with. The operator will always, however, find himself best served in employing the most simple means capable of meeting indications.

Fig. 234 represents an apparatus devised by Dr. J. D. White, the office of its mechanism being the enlargement of the whole superior arch and the consequent accommodation of any outlying tooth or teeth. Taking an impres-

FIG. 234.

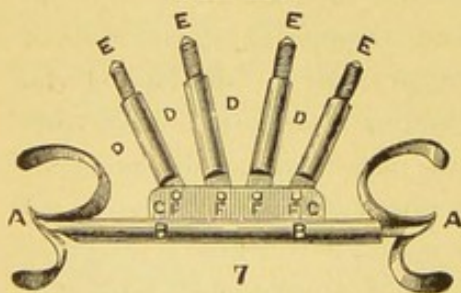


sion of an arch, a plate, in shape as shown, A, is made; this plate, separated into two parts, has its association preserved by a spiral spring, C, so arranged as to lie directly back of the teeth, being thus as much out of the way as possible. B, B represent crib bands for attachment to the first or second molar teeth, as may seem advisable. D, a hinge,

joins the parts in front,—a device, however, which, for the purpose now considered, is to be replaced with advantage by any arrangement admitting of lateral separation on the line of division. It is to be recognized that in the tendency of the spring to straighten itself the plate is separated, outward pressure being thus exerted against each tooth.

A second appliance, having similar import, shown in Fig. 235, is a device

FIG. 235.



by Dr. A. Westcott. This apparatus possesses in its construction the ability to move outwardly any tooth or teeth requiring change of position. The instrument may thus be described: First, a double clasp (A, A), these clasps connected by a straight bar made of tubular wire. This tube has a screw cut in its inside the whole length, and is soldered

to one pair of the double clasps; the other pair of clasps are soldered to a wire which screws into the tube, the object being to lengthen or shorten the bar at pleasure. Next a flat piece (C, C) of sufficient width for hinge-joints is soldered to the bar. To these are connected by hinge-joints (F, F, F, F) a series of tubes (D, D, D, D), each having a screw cut on the inside, these receiving and accommodating an equal number of spurs (E, E, E, E). These spurs, as is recognized, screw back and forth as may be desired, and are therefore capable of pushing (in time) any tooth from its socket.



Such an apparatus prepared, the clasps are slipped about the teeth for which they have been adapted, and, slight depressions being reamed upon the posterior faces of such teeth as it is designed to move, the spurs are screwed forward, the point of each thrusting upon the depression prepared for it.

Examining the construction of this piece of mechanism, its peculiar adaptability to the end designed must certainly strike any one; a single weak point is the reamings used as supports to the spurs,—an objection which may, however, in many instances, be obviated by receiving them between a double ligature of gilling or bookbinder's twine.

The moving of the teeth accomplished, the apparatus is at once to be removed, the parts being maintained in their new position by fitting a plate covering the whole roof of the mouth, so constructed as to act like a wedge in its relation to the common arch. Fig. 248 exhibits such a retaining plate.

Still another means of enlarging an arch so as to afford room for outlying cuspidati consists in adapting to the lower denture an accurately-fitting envelope of metal, from the articulating face of which pass upward and inward springy flat spurs, against which, in the act of occlusion, the superior teeth close, thus being directed outward, and to such extent spreading the parts. A spur, of course, is not to strike either of the eye-teeth.

Coffin's system differs nothing in principle from that employed by Dr. White; its distinguishing feature depending on the principle of permitting a relative motion, or maintaining a particular controllable reaction, between two semi-independent parts, usually its symmetrical halves.

The general form of Mr. Coffin's apparatus, as described by himself, consists of a thin vulcanite plate capping or clasping some or all of the bicuspidati and molars, and fitting the lingual surfaces of anterior teeth, but divided along the median line (as shown in Fig. 234), into two distinct halves, connected, however, by a slight steel wire, so disposed that, while guiding and limiting their relative motion, its tension exerted between them may be perfectly determined and varied in direction and magnitude. Perfection of the model is insisted on, as an entire plate may fit well and securely, and yet both halves be so loose when divided as to be useless; while, on the other hand, the halves of a split plate may be easily fitted, which, before division, could not possibly be inserted.

As a means of dispartment, Mr. Coffin recommends piano-forte wire of a diameter varying between three- and four-hundredths of an inch. The extremities of this wire being buried in the lateral plates and bowed like to the spring C in Fig. 234, the character and nature of the tension becomes self-demonstrable. A modification of the bow suggested as an upper general expander is a three- or five-curve serpentine figure, like a rounded capital W.

The experience gained of steel wire, says Mr. Coffin, referring to his own practice, has led to its almost exclusive adoption for ordinary regulating purposes, as spring levers acting directly on the teeth, for pulling, pushing, or



rotating; and, being permanently fixed to the plate, their convenience, adjustability, and many adaptations are remarkable. Combined with a split plate, they are found to replace, with advantage, screws, inclined planes, wedges, levers, and ligatures, in their many local uses, and, moreover, are practicable, where nothing else can be applied.

The means just described is recommended equally as a widener of the inferior arch, and on trial is found to work satisfactorily. It is also recommended by its deviser as a means of securing room for the treatment of approximal cavities, it being maintained that less discomfort relates with such manner of dispartment than associates with simple wedges of wood or rubber even, as in the latter way the separation of two teeth is implied.

Passing here to another study, a case may be presented where, with room in the arch, the lateral incisors maintain a posterior position.

Fig. 236 exhibits such a condition. This is an irregularity capable of quick correction, as exemplified in the use of the bar (Fig. 237). This bar,

FIG. 236.

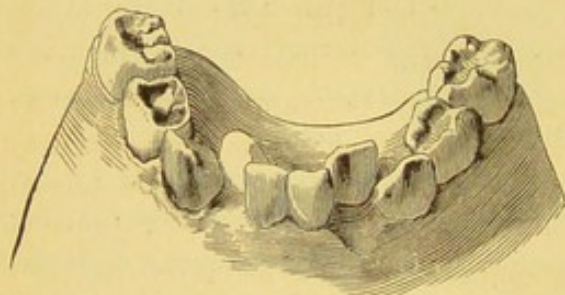
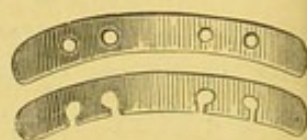


FIG. 237.



being adapted to the labial face of the teeth, is held in position by silk ligatures bound tightly to the misplaced teeth. A great improvement on the silk, however, as has been shown by Dr. J. H. McQuillen, consists in the substitution of india-rubber rings, applied, as will be understood by referring to the diagram, by being slipped into the holes through file cuts made from the face of the bar.

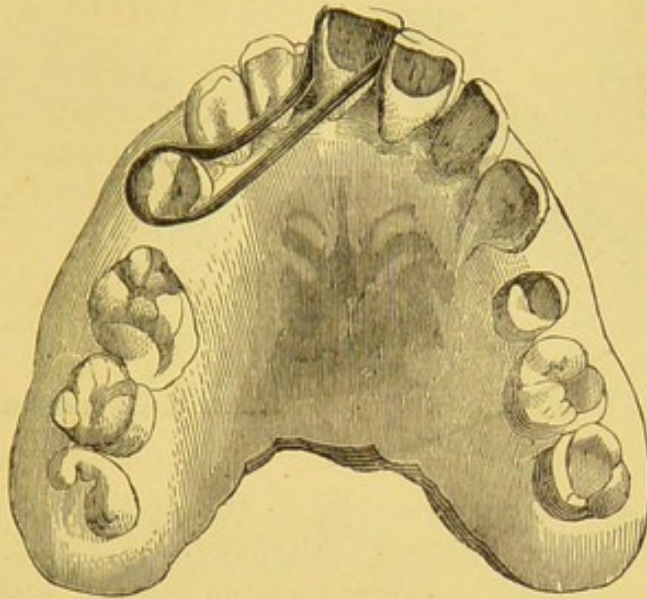
Another study is presented in Fig. 238. Here, it is seen, a central incisor is out of the arch. To correct this deformity a very common and very satisfactory practice is that exhibited. This consists in an india-rubber ring thrown about the projecting tooth, being stretched back until it reaches a bicuspid, around which it is placed. In thus employing the elastic ring, it will not infrequently be found that undue strain is exerted upon the base-tooth, making it quickly very sore. In these cases the ring is to be changed to other teeth, or assistance may be rendered by relieving the first tooth of an excess in strain by dividing the work by means of a ligature carried to some back tooth.

Fig. 239 exhibits another deformity. Here, as is seen, irregularity exists in both arches. The treatment consists in removing all the second bicuspidati, above and below, and throwing india-rubber tubing ligatures around the six-year molar, and the left inferior first bicuspid and cuspid, drawing the two



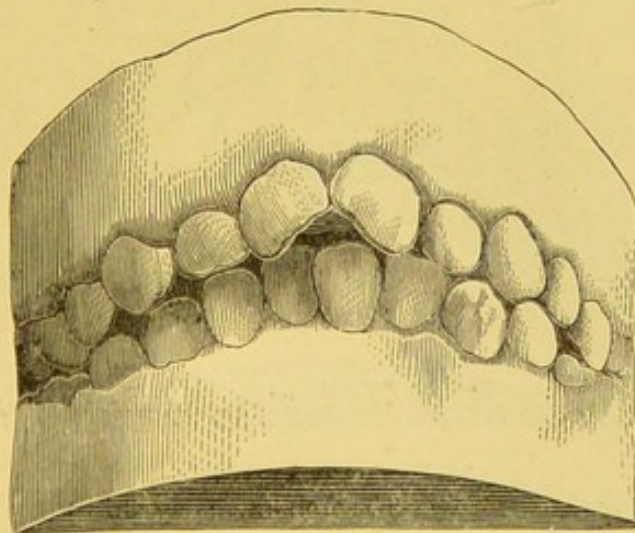
latter backward into the arch, at the same time passing a silk ligature around the lower incisors (Fig. 240) in such manner as to force into position

FIG. 238



an overlapping central. In the upper jaw a plate (not a necessity) may be adapted to the palate, secured by silk ligatures to the first permanent molars. Pins are to be placed in the plate in such manner as to allow of

FIG. 239.



the attachment of two elastic bands, which are secured by silk threads to the central incisors (Fig. 241), drawing thus upon the mesial face. Other bands are so arranged as to draw upon each lateral angle of the centrals, passing between these and the laterals from their palatine faces, and running along the labial and buccal faces to the first molar of either side. Tubing is now to be thrown around the remaining superior bicuspid of either side and the molar, for the purpose of approximating these teeth, thus affording space for



the proper placing of the irregular centrals. By this arrangement, nine ligatures will be exercising traction at the same time, gradually and beautifully

FIG. 240.

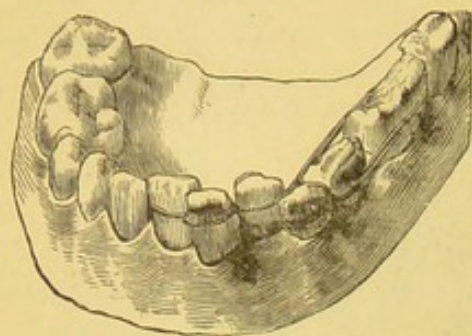
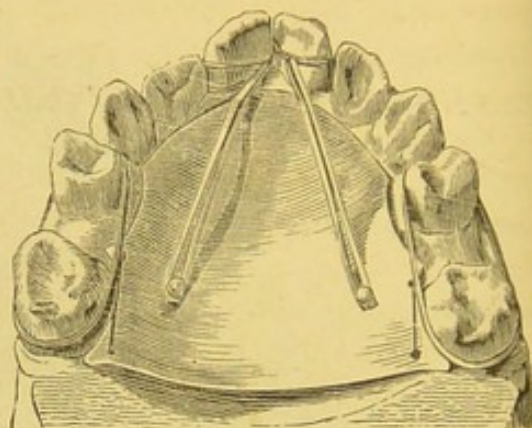
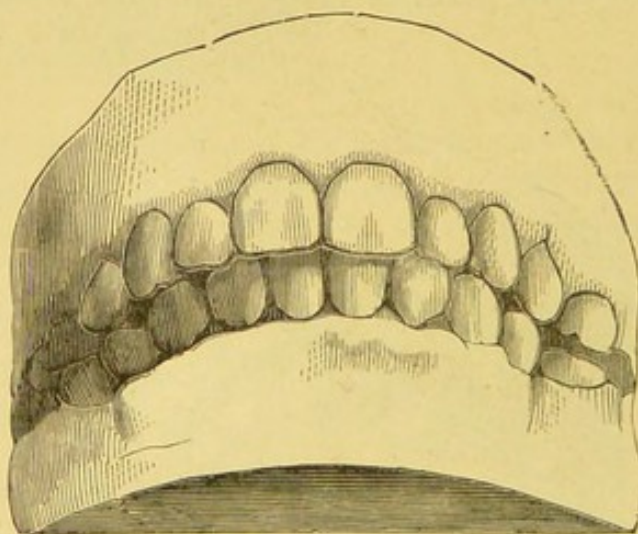


FIG. 241.



performing their work of correction. With the view of preventing periosteal irritation from becoming periostitis, both local and constitutional treatment may be required. A simple manner of turning incisors, related as shown in Fig. 241, is to lay across the labial faces a simple bar, which is attached by

FIG. 242.



means of elastic to a second, which, when in place, will pass across the mouth from bicuspid to bicuspid.

Another study, to which attention may be directed as being a quite common condition, resides in that articulation in which the anterior teeth of the superior jaw, in place of overriding the inferior, close directly upon them. This manner of bite, when found in elderly persons, is not to be remedied by any change in the position of the teeth, but by the adoption of some mechanical device, which shall relieve the organs of the abrading influence to which they are subjected, and which, unrelieved, will wear them to the gums.

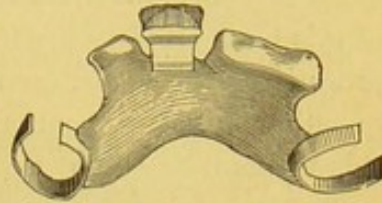


To treat such a malarticulation, three modes have been employed: one consisting in a metal cap inclosing the molar teeth, this keeping the anterior organs apart and taking the strain of mastication; second, a cap to be worn over the front teeth while eating (Fig. 243); and third, the cutting of cavities in the antagonizing faces of the abrading teeth, and building thereon faces of gold.

Fig. 244 exhibits a malarticulation known as "underhung,"—the teeth of the lower arch closing beyond the upper. To correct this deformity, different operators employ different means. A first consideration is as to the nature and cause of the condition.

Protrusion of the inferior teeth may exist in a variety of reasons. The jaw itself may be elongated, the angle being too obtuse for the age. The

FIG. 243.



Cap for Front Teeth.

FIG. 244.

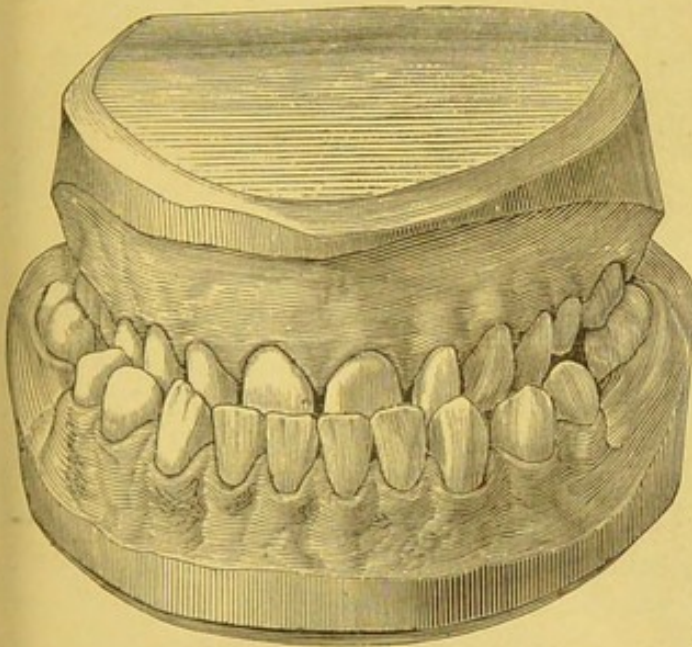
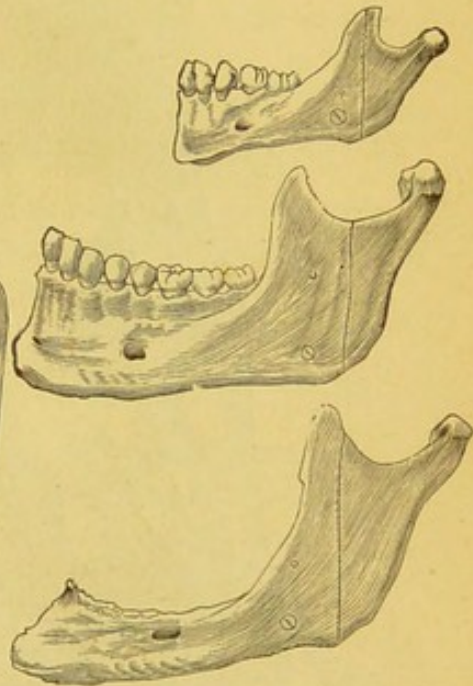


FIG. 245.



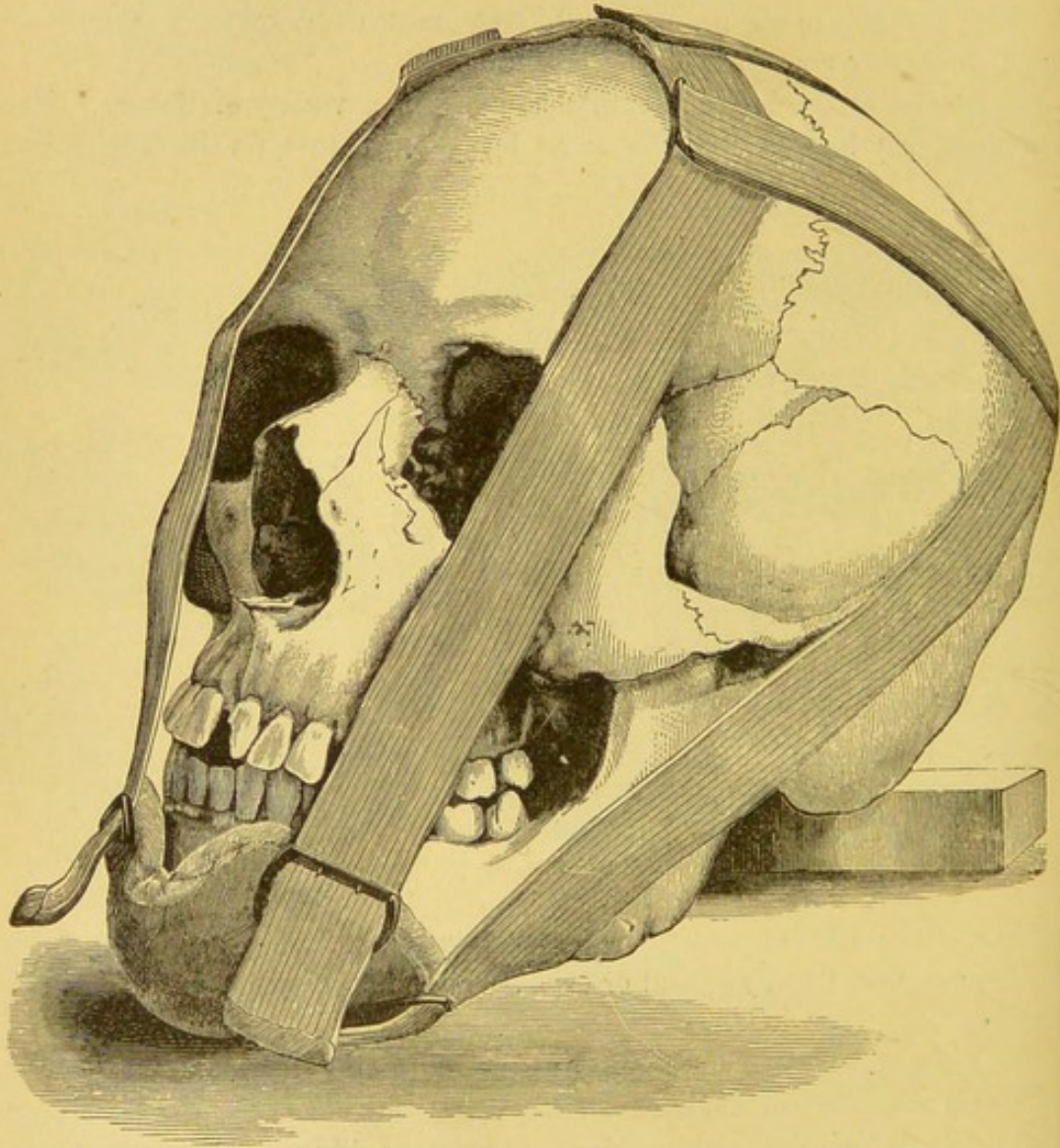
body of the lower jaw may be out of proportion to the upper. The teeth themselves may unduly spread or evert. The fault may be in the superior denture.

An anatomico-physiological examination of the inferior maxilla exhibits a body and ramus whose angle of relation varies with the age of the patient, or some other influencing circumstance. At a very obtuse angle in young life, it passes to the right angle in adult life, to fall again into obtuseness on the approach of old age and the loss of the teeth. The three illustrations (Fig. 245) represent these varying conditions,—the first, the infant bone, being very obtuse; the second, the adult, being at a right-angled relation; the third, the bones of an edentulous old person, having the ramus almost on a plane with the body.



In a young patient having a protruded under jaw, the size of the upper and the position of the teeth being normal, advantage is to be taken of the natural tendency of the parts to retire; a sling,—the occipito-mental,—the straps being of elastic material, is to be used, as represented in Fig. 246. A sling of this kind, properly made and applied, will be found to exert such constant pressure on the angle, forcing, as it does, the body backward, that not infrequently a very few months will suffice to correct such a malarticulation, and this without discomfort or the possibility of ill consequences.

FIG. 246.—OCCIPITO-MENTAL SLING.



Where fault resides in the superior arch, the jaw itself being small, or the teeth being possessed of inlooking cutting faces, the appliance represented in Fig. 241 may be used, or the envelope, with the flat spurs, may be employed, as directed for use upon the lower denture (Catalan's inclined plane).

A mode of treating a case of malarticulation such as is exhibited in Fig. 244 is as follows: Pull back lower jaw by means of occipito-mental sling

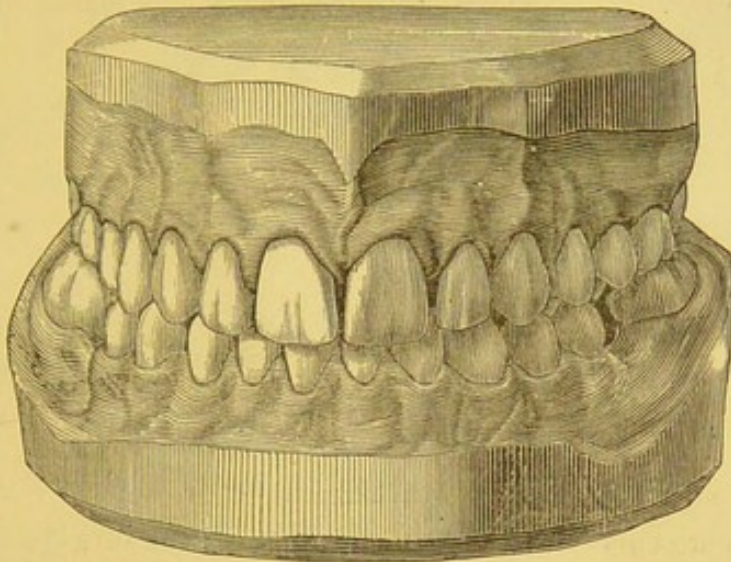


(Fig. 246). Wedge upper arch as shown in Fig. 249. To retain advantage gained by wedges, apply plate as shown in Fig. 248.

Fig. 247 shows a result obtained, after this manner of operating, in twenty days by Dr. N. W. Kingsley.

A very simple, and not infrequently effectual, mode of correcting the de-

FIG. 247.

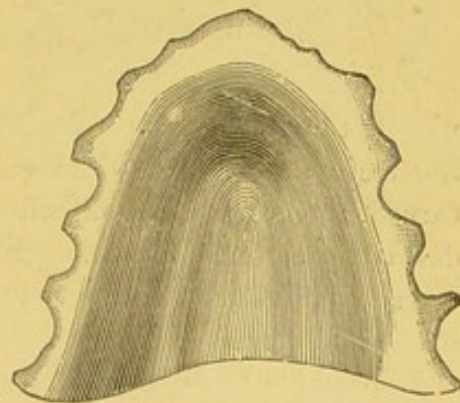


formity of protruding lower teeth in young patients, applicable particularly where the organs close directly against the upper, consists in removing from the inferior arch the first bicuspidatus of either side, and advising the cultivation by the patient of a habit of pushing the chin backward; or the latter purpose will be answered by using the occipito-mental sling during mealtime.

Among the various appliances which ingenuity has suggested for the treatment of dental irregularities is a plate devised by Dr. Redman, of Cincinnati. This is a rubber cap fitting accurately the palatine arch and carried across the anterior face of the teeth, having thus, as is seen, a most secure relation. Where it is desired to move a particular tooth, the plate is cut away in the direction which it is desired the tooth shall take, pressure being brought to bear from the opposite point by wedges of wood forced through holes in the plate.

In correcting irregularities of the teeth it is always necessary to bear in mind an antagonism which may exist to the moving force as relation is had to articulation. A tooth bound in place by one overlying it is to be moved only through relief from the existing pressure. To insure such relief it is found necessary, in almost all cases, so to cap neighboring teeth as to compel a space between the two arches,—such space to be preserved until the tooth is changed to its new position, when the removal of the cap and the restoration

FIG. 248.





of the articular bite will, in many instances, prove the best means that can be adopted for securing permanency to the change.

FIG. 249.

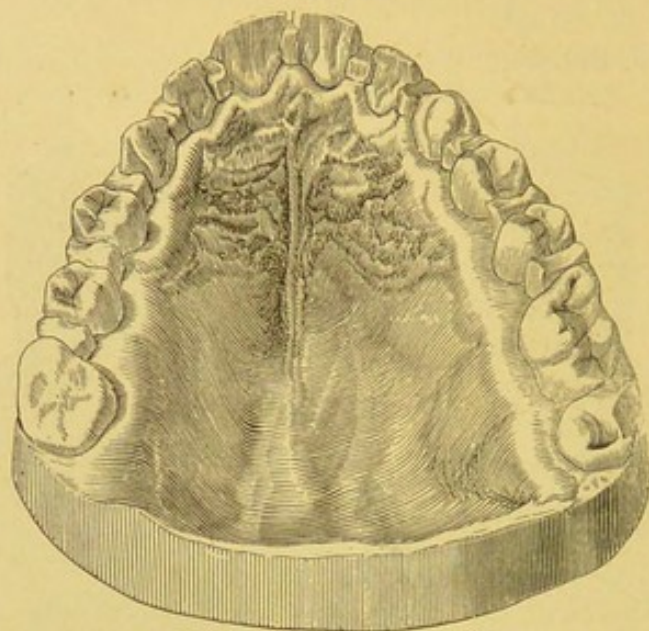
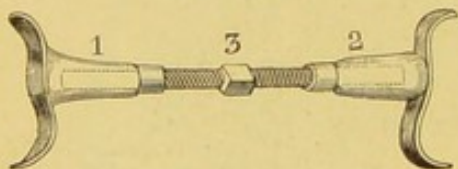


Fig. 250 represents a principle found most useful in a great variety of cases of dental irregularities. An example of its application may be given as follows:

CASE.—*Two central incisors turned upon their axes and overwrapping; arch narrow and crowded.*—To turn teeth so situated, a first necessity is room. To secure this room the arch must be widened. Examination of the

FIG. 250.



instrument exhibits double collars for resting against teeth on opposite sides of the arch: these collars are attached to screw-cut tubes 1, 2, which tubes are associated by a common screw, 3. Desiring to widen the arch and thus afford facility for manipulating the crowded incisors, the collars are placed against the inner faces of the teeth designed to be moved, when, by means of a wrench, the screw is turned, the arms being extended day by day as circumstances permit. The desired space thus secured, a plate is fitted to insure retention of the teeth in the new position, when the twisted teeth may be turned into proper position, by means shown in Fig. 241.

Illustrating the use of this means in another instance, reference may be made to lateral incisors, or other teeth fallen within the arch and overlaid by their fellows. Here application of the enlarging force is directed after the same manner. When the proper room has been secured, the misplaced tooth or teeth may with all facility be drawn into place by the labial plate and elastic ring as before described,—a manipulation which would be impossible without the previous expansion.



Fig. 251, after a cut by Dr. N. W. Kingsley, exhibits a case of protruding jaw treated as follows: First, a vulcanite plate with jack-screws, across the mouth against the bicuspidati, as shown in Fig. 252, the plate

FIG. 251.

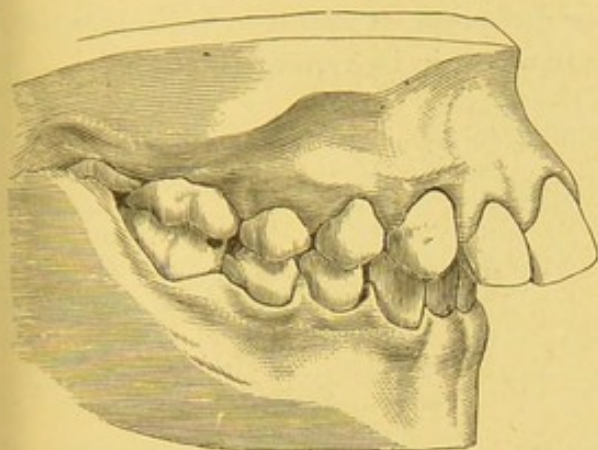
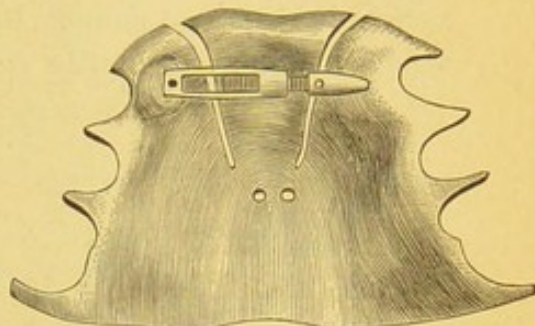


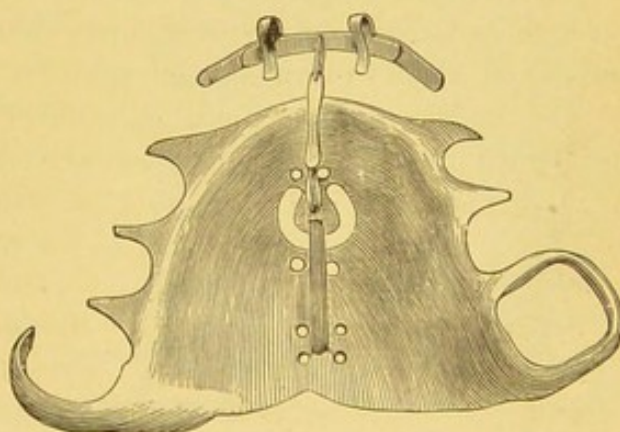
FIG. 252.



being split to allow of expansion under pressure. Second, a bar with elastic band acting upon the front anterior face of the arch, Fig. 253. The rectification was made in just five weeks.

A system of regulating, claiming attention through the efforts of J. N. Farrar, M.D., is known as the positive. Not entirely new, this system yet claims a study that shall fully appreciate it from the fact that it embraces its subject from a philosophical stand-point. The student who familiarizes himself with the positive system, even though he may not be disposed to accept all its practice, will find that he is master of the situation.

FIG. 253.



In regulating teeth the positive system accepts the dividing line between the production of physiological and pathological changes in the tissues of the jaw to lie within a movement of the teeth acted upon, allowing a variation which shall cover all cases, not exceeding one-two-hundred-and-fortieth or one-one-hundred-and-sixtieth of an inch each twelve hours; the application of the force to be intermittent, not a continuous motion.

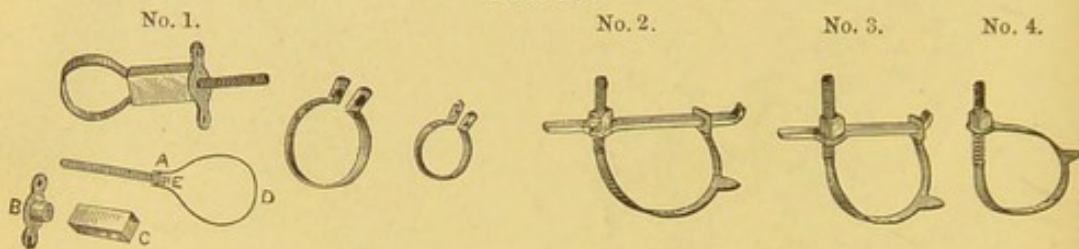
For motive-power, movement of the screw is accepted as expressive of the positive, the drum and belt as typical of the probable. For measurement, the action of a screw is recognized as unerringly calculable, the slippings of a belt over a drum as incalculable. Regulating apparatus con-



constructed purely on the screw principle are capable of intermittent motion. Elastics and springs are necessarily of continuous action.

Instruments used in the positive system by Dr. Farrar are simple when appreciated. They consist really of two pieces,—*i.e.*, a band to encircle the tooth or teeth to be moved, and a screw to act on this band. Teeth being various in shape and position, the band requires, of course, to have other than a single meaning. Fig. 254 shows the band in its varieties.

FIG. 254.



No. 1 is the box wrench, with lever. The separate parts A, B, and C, of which it is composed, are shown for a better understanding of it.

Nos. 2 and 3 are the bar and loop wrenches, the bar prolonged at both ends being the only difference in them.

No. 4 is the rotating loop, used to turn teeth in their sockets.

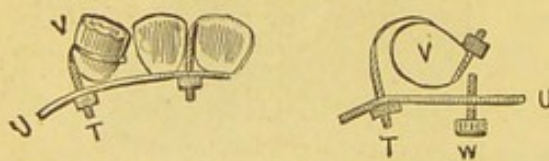The lugs, or ears, shown on all these bands and loops, are to be bent into fissures of the crowns of teeth to prevent them from slipping too far on the necks, and so irritating the gums, or causing misdirection of the screw-power.

A first matter in this system considers the application of a band to be acted upon, and which in turn is to act upon the tooth it encircles. Fig. 255 will supply the idea to a mechanical mind.

The cut represents rotation. The nut T, when tightened, draws the bolt through the bar U, and being attached to the band-clamp V on the opposite

side of the tooth causes it to rotate, and at the same time fall backward if desired. Should, however, this latter movement be undesirable, it may be prevented by a little screw, W, passing through a

FIG. 255.



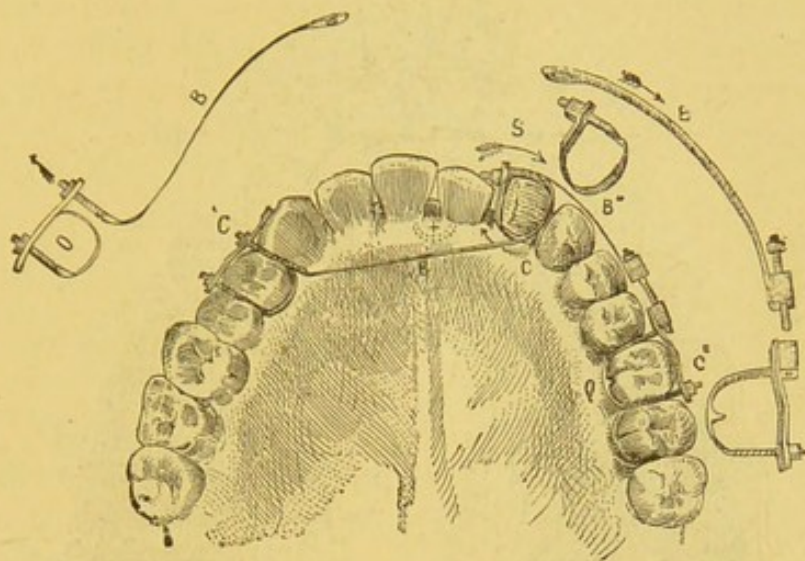
threaded hole in the bar U, which, impinging against some point (or not), as shown, holds the tooth in position. Should it be necessary, this screw may be made an assistant rotator; but a proper shaping of the bar by bending or filing will generally be sufficient for this purpose.

Fig. 256 shows the application of positive movement to a cuspid tooth out of the arch anteriorly, and somewhat overriding the lateral. The requirements are, 1, to drag the misplaced organ backward; 2, to pull it into the line of arch. C, left side of cut, and C, right side, exhibit bands or clamps placed about teeth as supports from which traction is to be exerted; these same bands are also shown separated from the teeth. In front, encircling



the eye-tooth, is a similar band. Q shows bolts and nuts. The design explains itself.

FIG. 256.



Figs. 257 to 263, after Dr. Farrar, exhibit ideal cases of application. In the diagrams, the arrows indicate the direction of the movement of the teeth operated upon.

Fig. 257 illustrates a form of apparatus which acts upon the teeth collectively, also by means of a band (*m*) extending along the outer surfaces, and which is made to force against the teeth to be moved by tightening of bolts which pass through smooth-bored nuts (*i, i*) soldered to the ends of the band (*m*), and which enter threaded nuts soldered to anchor-bands (*h, c*) secured around the back teeth as shown. The band *m* is to be prevented impinging on the front gum by passing through the eye of a clamp-band, *o*, secured to a front tooth, or, better still, by having a T (Fig. 258) soldered to the inside, so that the top of the T shall rest on the lingual surfaces of the central incisors.

FIG. 257.

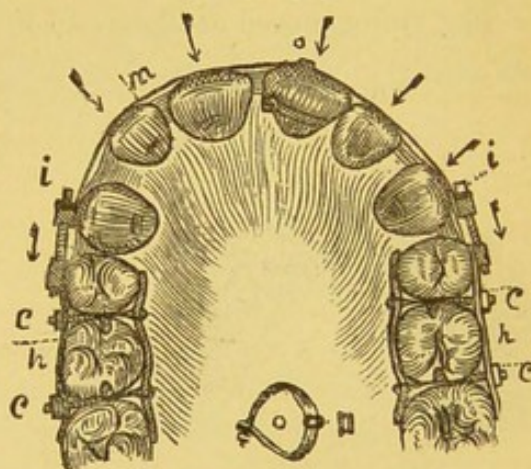


FIG. 258.

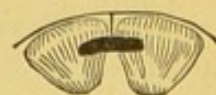

Fig. 259 illustrates a case of the lower jaw having the incisors in the posterior position, and which are being forced forward and into position by a compound variety of jack-screw devices. This appliance does its work by pushing against a bar situated immediately behind the teeth to be moved.

The jack-screws are secured posteriorly to anchor-clamp bands (*c, c*) around



two of the back teeth by a hook or rivet-hinge joint (*e*), and anteriorly into little pits made in the bar (*f*) by counter-sinks or cups soldered to it.

FIG. 259.

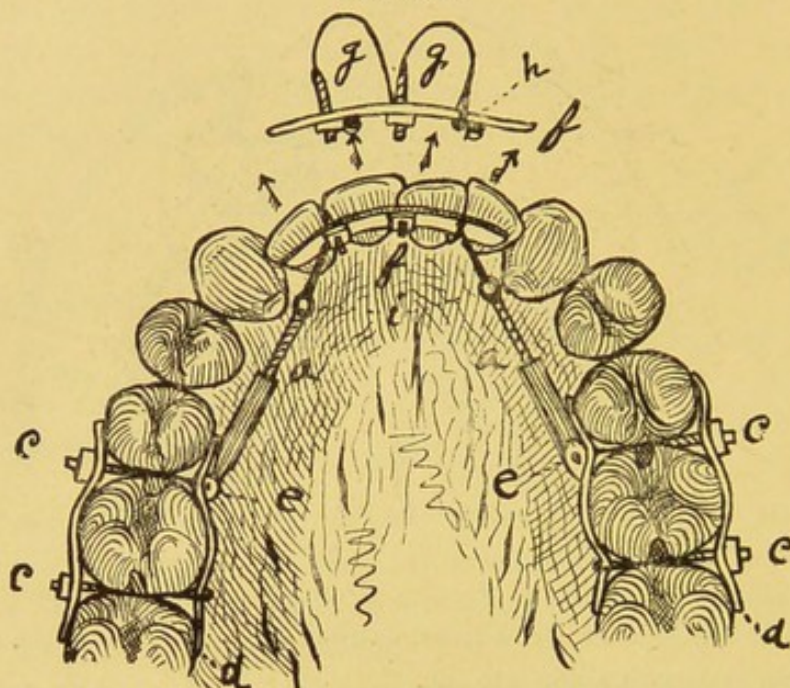


Fig. 260 represents a device made up of the same form of bar (*a*) behind the teeth, to be moved as illustrated in Fig. 261, but which is made to force

FIG. 260.

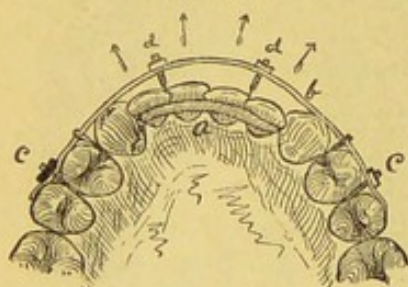
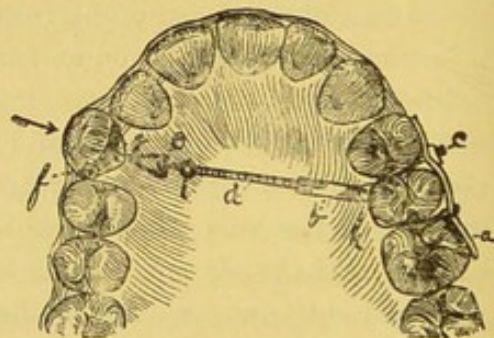


FIG. 261.



the incisor teeth forward by attachment to little bolts (*d, d*) which pass through a bridge-bar (*b*), which is tightened by nuts on the front sides.

Fig. 261 illustrates a device in the form of a drag- or swivel-jack (*d*) in the act of drawing upon to move a cuspid (*f*) tooth by forces based at the opposite side of the mouth (*c, c*). The cut so clearly shows its construction that it needs no further explanation.

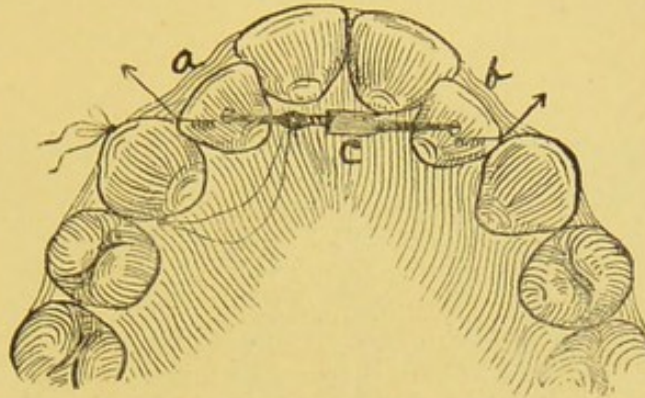
Fig. 262 represents the application of a spindle jack-screw (*c*) in position to force outwardly the two upper lateral incisors (*a, b*), which have erupted in the posterior position.

Fig. 263 illustrates the application of a compound jack-screw (*f*) made of the spindle and fish-tail varieties combined. The spindle-points should



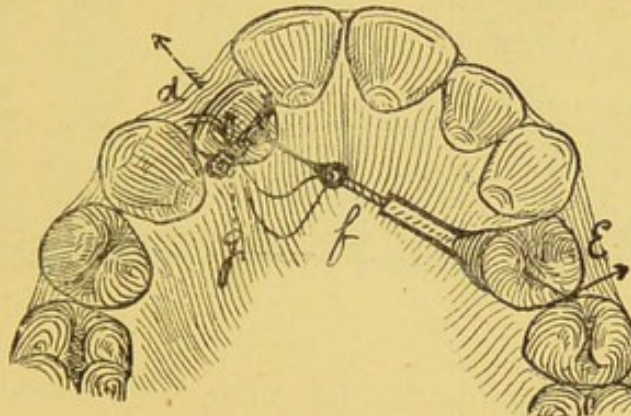
rest in pits, made in the teeth by a drill, or in cups or pits made in or upon a clamp-band secured around the tooth.

FIG. 262.



To avoid the swallowing of small pieces of regulating apparatus which may get loose, they are to be secured to some convenient teeth by threads, as shown in Figs. 262 and 263.

FIG. 263.



In conclusion, it is to be added that the health of a multitude of mouths has been ruined and patients rendered uncomfortable for life by ill-advised attempts in the direction here described. *To do nothing unless the way to an end is clearly, fully, and practically perceived, is a rule of practice from which the experienced practitioner never departs.* (See for surgical expression of this subject, chapters on *Anomalies of Dentition and their Relations*, on *Alveolar Abscess*, and on the *Odontomata*.)



## CHAPTER XXVII.

### THE EXTRACTION OF TEETH.

**Indications for Extraction.**—1. Teeth, or roots of teeth, which have lost their vitality, and which have become so much loosened as to be agents of offence and injury to surrounding parts.

2. Posterior teeth which, from absence of antagonizing teeth, are rising from their alveoli, and, through the displacement, have become a source of pain or inconvenience.

3. Teeth having fungoid excrescences growing from the pulp-cavity, not responding happily to curatives.

4. Teeth having associated with them incurable abscesses, threatening complications.

5. Teeth, particularly the premolars, so crowded and wedged into the arch as to contribute to undue lateral pressure.

6. Posterior teeth inferred to contain nodules of osteo-dentine, being themselves painful, or involved with sympathetic neuralgia.

7. Teeth recognized as associated with antral disease.

8. Teeth which are worn down to the pulp-cavities, or so close upon the gums as to render mastication painful, and where periodontal irritability renders the application of artificial crowns objectionable.

9. Teeth so badly affected by caries—being painful or offensive—as to afford no prospect of usefulness.

10. All roots of teeth about which the gums are congested and debased.

11. All roots which are sources of unrelievable pain or discomfort.

12. All roots in which badly putrescent decay is progressing.

The removal of a tooth is an easy or difficult matter according as the principle involved in the operation is clearly or obscurely appreciated. In the adult mouth there are thirty-two teeth, and these, as the study of their extraction is concerned, are comprehended under six classes.

The first of these classes embraces the eight central and lateral incisors, teeth with cone-like roots, and accommodated in alveoli representing hollow cones.

The second class embraces the cuspidati, represented by the partly flattened cone.



The third class embraces the bicuspidati, represented by the flattened cone.

The fourth class embraces the superior first and second molars, teeth having three roots,—two external cone roots, situated antero-posteriorly, with the interspaces looking toward the cheek, and the third, generally a flattened root, looking toward the palatine arch.

FIG. 264.—PERMANENT TEETH OF UPPER JAW.

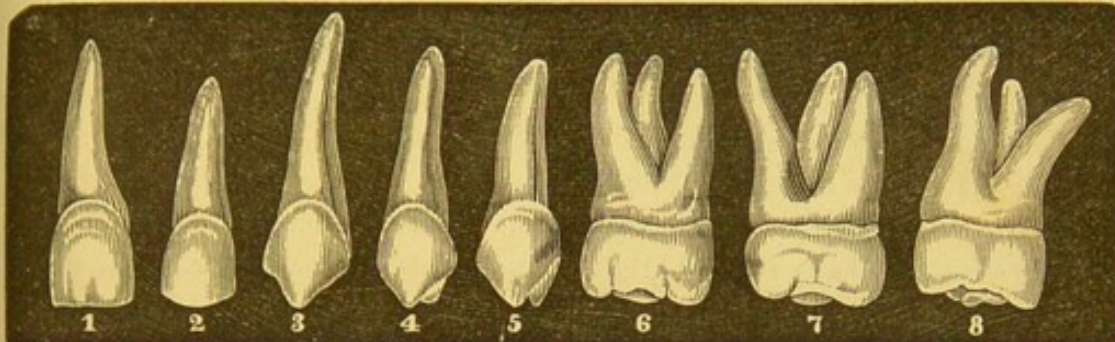
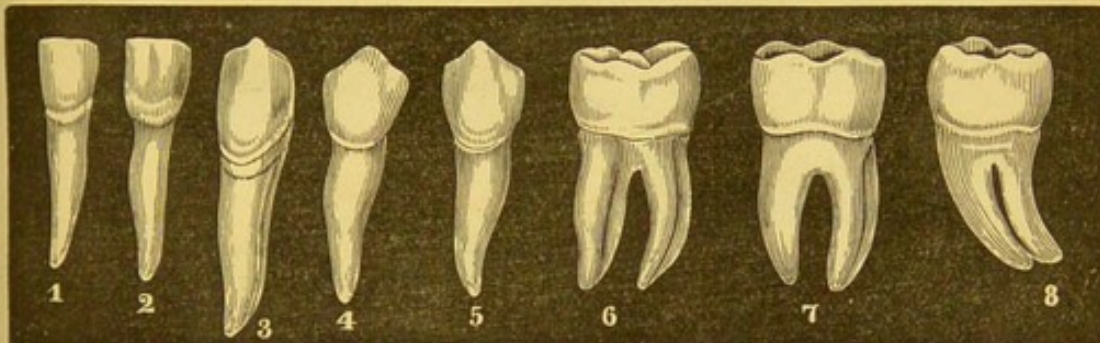


FIG. 265.—PERMANENT TEETH OF LOWER JAW.



Figs. 264, 265, DIAGRAM OF TEETH.—1, 2, incisors; 3, 4, 5, bicuspidati, or small molars; 6, 7, 8, large molars, or grinders.

The fifth class embraces the inferior first and second molars, teeth having two roots, one looking anteriorly, the other posteriorly; the interspace looking outward and inward.

The sixth class embraces the four wisdom-teeth. These are single-rooted as a rule, with a curve looking backward.

To extract a tooth of the first class, the application of the force is required in a twofold direction, rotary, and downward or upward, as the case may be.

To extract a tooth of the second class, the force is required in a threefold direction, downward or upward, lateral, and rotary.

To extract a tooth of the third class, upward or downward, and lateral, or inward and outward, as one loosens a nail.

To extract a tooth of the fourth class, the same application of the force; one-half of such a tooth is, however, to be extracted at a time,—that is, we first break the attachment of either the inner or outer roots, and feeling these yield, the force is instantly brought to bear upon the other. In extracting teeth of this class after such manner, much care is necessary in guarding against



a too great extent of lateral motion; otherwise the roots, instead of yielding, will be found to break, thus complicating matters very seriously.

Teeth of the fifth class require the lateral and direct application of the force; they are to be gently rocked inward and outward until felt to yield, when they are at once to be lifted from their sockets.

Teeth of the sixth class are to be carried backward and upward, or downward, in the line of the axis of their single curved root. Such applications will make easy an extraction which might otherwise be attended with much risk.

### INSTRUMENTS.

Instruments are now made in consideration of the anatomical peculiarities of the teeth for which they are intended. The better class are nickel-plated, to insure against rust, and are of such temper, as the character of the steel is concerned, that they will retain the outline and sharpness of blades through much service. No forceps but those of this quality are worthy of purchase. We now describe, together with manner of use, such as have most commended themselves.

FIG. 266.—UPPER INCISOR.

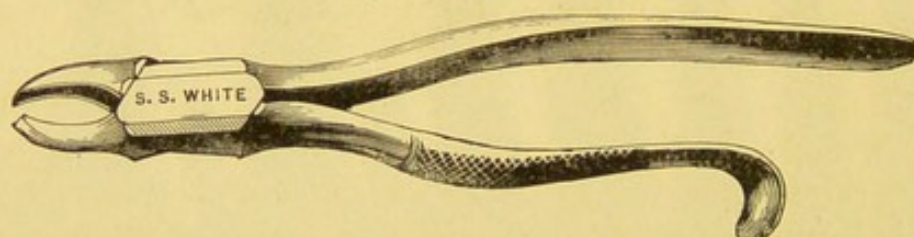
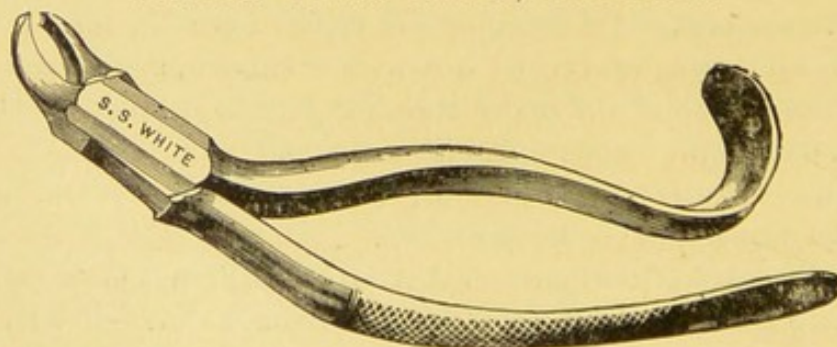


FIG. 267.—UPPER LATERAL INCISOR.



FIG. 268.—LOWER INCISOR, HAWK-BILL.



Figs. 266 to 270 represent forceps designed for the extraction of the incisor teeth. Referring to Figs. 264, 265, Nos. 1 and 2, or, what is practi-



cally much better, examining the organs themselves, the reader will perceive that these teeth fully represent, as has been stated, double cones, the bases

FIG. 269.—LOWER INCISOR AND BICUSPID FOR EITHER SIDE.

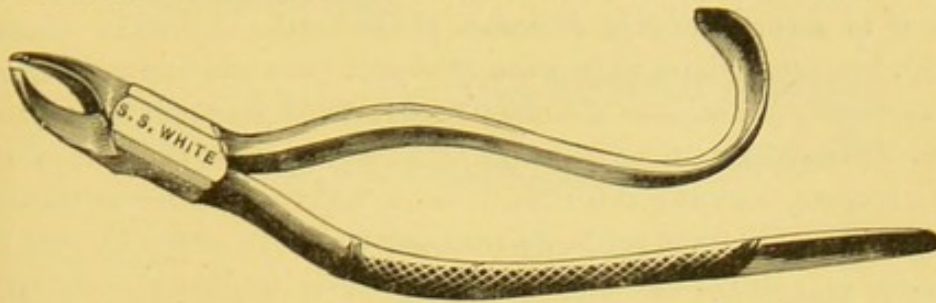
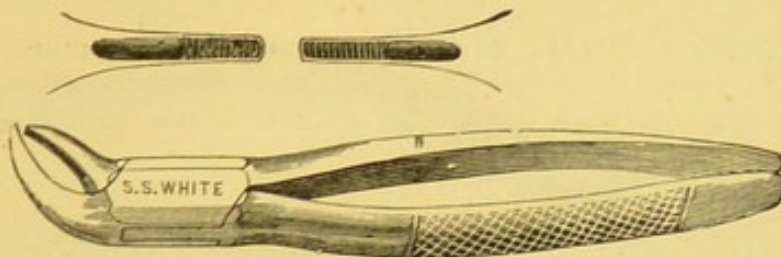


FIG. 270.—HAWK-BILL, LOWER INCISOR, AND CROWDED TEETH.



abutting just beneath the free margin of the gum. To secure a fixed, unyielding hold of a body so shaped, it would strike the intelligence of any operator that the forceps should be so constructed as to accommodate the width of the base, yet at the same time grasp firmly the retreating cones. Turning here the examination to the forceps, these indications are found fully met. The fenestra, made when the blades are closed, forms an ellipse, the widest part of which agrees with the base of the teeth. The apices correspond so in form with the cones, and the concavities of the blades so adapt themselves, that, applying the instruments, they are found fitted to the teeth with the nicest accuracy; indeed, as suited to the purpose, nothing seems left to desire.

Fig. 266, upper incisor, is a straight forceps, designed for the superior incisors, and which, where the under jaw is well withdrawn, answers very well for the cuspidati. The roots of the incisor teeth are understood to be rounded cones, having corresponding alveoli. These teeth are, perhaps, the most easily extracted of any in the jaws. Thrusting the blades well beyond the neck of the tooth, the curve in the handle receiving the little finger, and looking toward the body of the patient, having the head resting either in the support of the ordinary dental chair, or against the chest of the operator, whose left arm is to be thrown around it to secure fixedness (and which position applies to all the upper teeth), a force is to be exerted, which, while drawing downward, rotates or twists the organ from its socket. If, however, the resistance prove too great for a single twist,—which, in heavy jaws, is almost certain to be the case,—then the motion is to be reversed, the direction



of the twist being alternated until the tooth is felt to yield, when, without further effort, it may be drawn from its socket.

Fig. 267 represents a forceps designed for the upper lateral incisors. The ellipse is seen to differ a trifle from that of the preceding instrument; this adapts it to a corresponding difference in the tooth. It differs principally, however, in having the blades made narrower. The application of this forceps is precisely the same as that employed in the case of the central.

Figs. 268 to 274 represent forceps, all of which are found adapted to the inferior incisors, central and lateral, to the cuspidati, and the bicuspidati.

When extracting these teeth, the operator may stand either in front of his patient, or (a position more commonly preferred) he may seat the patient upon a low chair, leaning over his head, or over the right or left shoulder, as found most convenient.

FIG. 271.—UPPER AND LOWER ROOT, HALF CURVED.

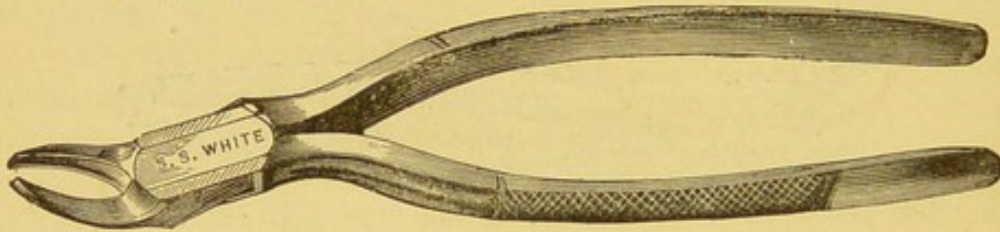


FIG. 272.—LOWER ROOT, FULL CURVED.

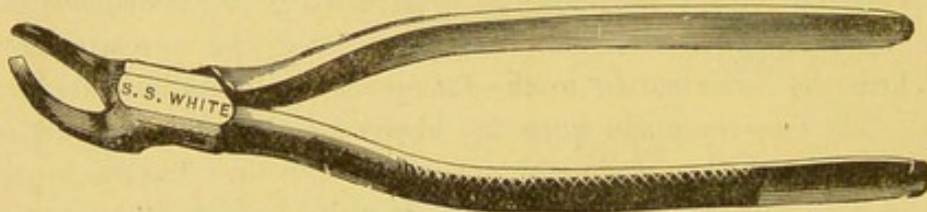


FIG. 273.—UPPER AND LOWER BICUSPID, HALF CURVED.

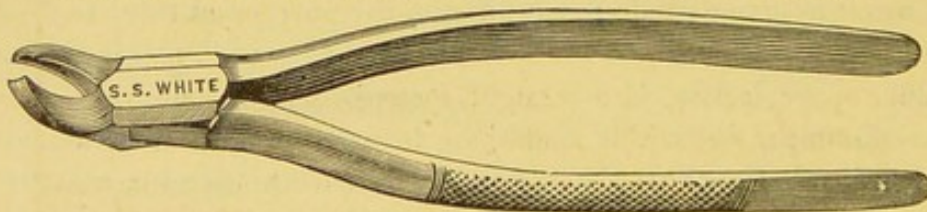


FIG. 274.—UPPER BACK ROOT (universal).

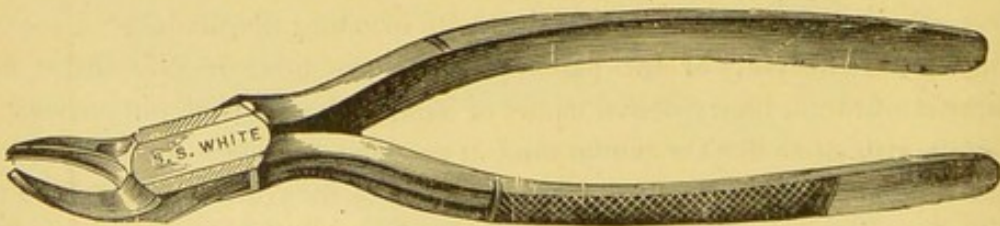
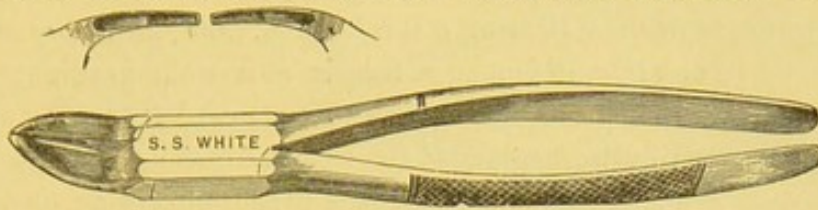


Fig. 274 is a forceps particularly adapted to the extraction of the inferior incisor teeth. Grasping the tooth by forcing the blades as far down as possible, keeping them confined closely to the organ, that thus they may be directed



between the tooth and its alveolus, the rounded root of the central may generally with much ease be broken from its attachments by an upward and

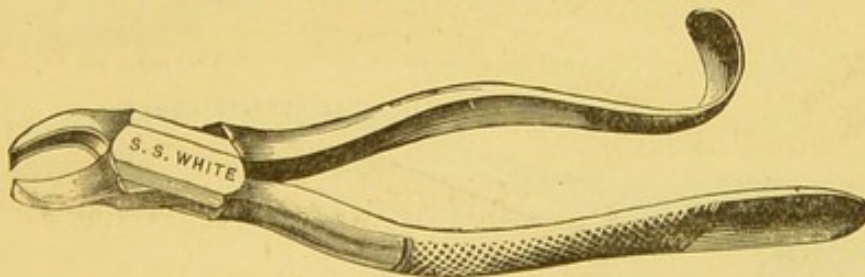
FIG. 275.—HALF CURVED, NARROW BEAK, FOR CROWDED TEETH.



rotary movement. If, however, with a very reasonable exertion of force so applied it is not felt to yield, the strain is not to be increased to a risk of breaking the tooth, but a lateral motion inward and outward may be tried, or this conjoined with the rotary. This root being sometimes considerably flattened, makes such lateral motion necessary. If very narrow or crowded, the forceps represented by Fig. 275 may be used. In removing the inferior lateral incisors the rotary movement is to be employed, which may have combined with it slight lateral motion, although this latter will not be found of much import, unless in exceptional cases, where the roots happen to be markedly flattened. The bicuspidati all have flat roots, and, so far as the conditions of extraction are concerned, are to be viewed as possessing but a single root. These teeth are removed just as a nail is worked from a board into which it has been loosely driven,—a motion inward and outward quickly breaking the attachment. The position of operator and patient is the same as just suggested.

Fig. 276 designates a forceps adapted equally well to the ten anterior upper teeth. It may justly be termed a faultless instrument. The writer cer-

FIG. 276.—UPPER BICUSPID AND CANINE.



tainly gives it the preference over all that he has seen used for the purposes intended: indeed, he inclines to think that with it any tooth in the mouth could be extracted in an emergency. Applying this instrument to any one of these ten anterior teeth, it is seen to be possessed of most satisfactory adaptation, the curve in the blades and handles clearing the lower lip to an extent affording the greatest freedom in motion, while the support curve in the handle prevents the possibility of change in the grasp.

The root of a cuspidatus is perhaps the most firmly fixed in its alveolus of



all the teeth of the jaw. Occupying as it does the position of a keystone to an arch, to extract it requires both strength and skill. In shape, the root is found to be a partly rounded, partly flattened cone; its alveolus, of course, corresponds. In length it is greater than the adjoining teeth,—in many instances to the extent of a third,—and, while generally straight, is yet frequently to be met with having an apex curved at varying angles, such curvature, however, being confined to the extreme end. To extract this tooth, the organ is grasped by working the blades of the forceps as much below the edge of the process as possible, and, while a firm compressing force is maintained, the tooth is gradually rotated, and also worked inward and outward. If, after a moment, it should be felt to yield, and yet, while moving with more or less freedom in its socket, seem to be held by some attachment, the operator is to cease his efforts, that he may satisfy himself that the loosening resides not in a fractured alveolar process nor in a retaining flap of gum. If neither of these complications exists, he may again seize the tooth, and, understanding that the retention depends on curvature of the fang, attempt to get it away by finding, through various movements, the direction which affords the least resistance: this discovered, the organ is to be worked out even at the risk of fracturing the curved apex. No tooth requires to be more thoroughly and deeply lanced than the canine.

FIG. 277.—UPPER BICUSPID AND INCISOR.

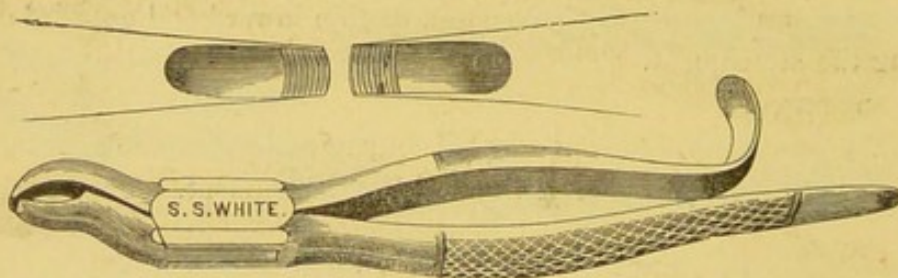
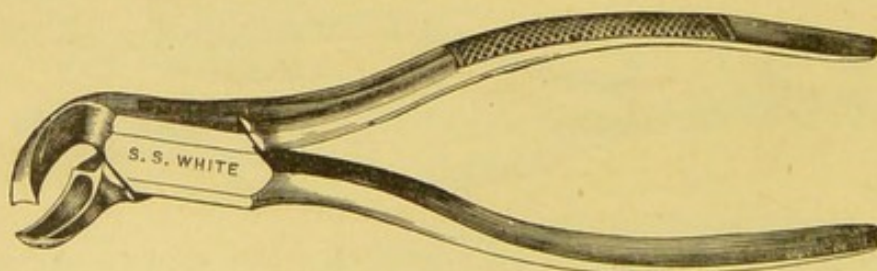


FIG. 278.—LOWER BICUSPID AND CANINE.



Figs. 277 to 279, are instruments devised by different operators for the extraction of the bicuspidati and cuspidati. These forceps are remarked to vary considerably in shape. Fig. 279 is one found to have most frequent application, being useful alike in the superior and the inferior jaw. Unless it is designed to furnish a case with all the numbers, this may with most satisfaction be selected. Fig. 280 is an excellent instrument, particularly



applicable to the lower jaw when the teeth are set well back and the commissure is small and unyielding.

FIG. 279.—LOWER BICUSPID, SAFETY.

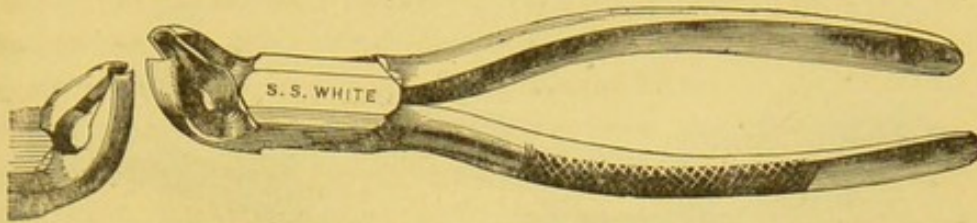
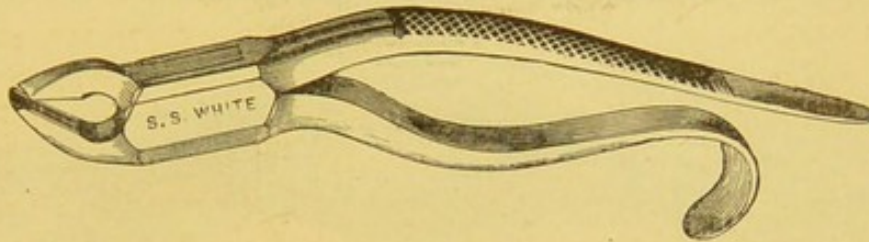
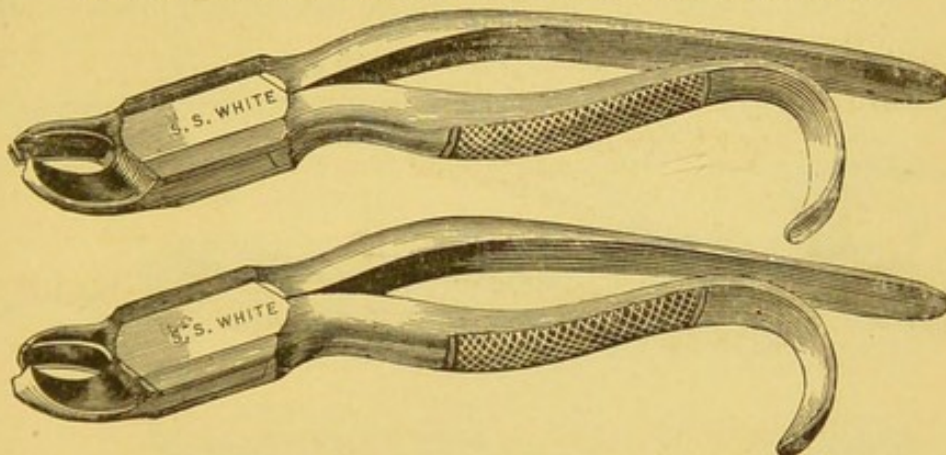


FIG. 280.—UPPER BICUSPID, SAFETY.



Figs. 281 to 283 represent forceps designed for the extraction of the superior molar teeth. On examining the blades of any of these instruments,

FIG. 281.—UPPER MOLAR, RIGHT AND LEFT (HARRIS'S).



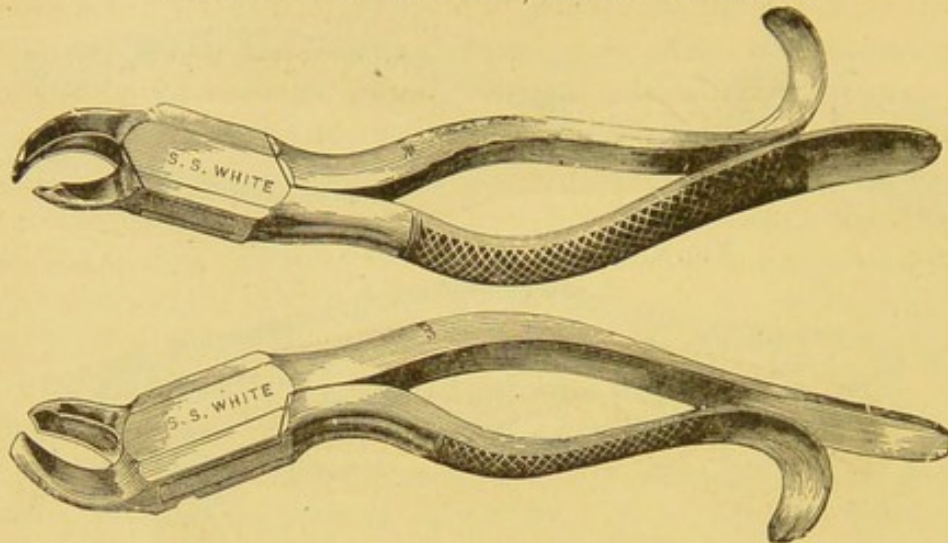
the outer will be seen to run to a nib at its centre, while the inner is plain. These correspond with the anatomical indications of the teeth upon which they are to be used, as is seen by glancing at Figs. 264, 265, Nos. 6 and 7. To apply these forceps, the triangular blade must correspond with the outer face of the tooth. Having the instrument well in position, which, it will be recognized, places the point of the outer blade in the interspace made by the bifurcation of the buccal roots, and the concave plain inner blade against the palatine root, the force is to be so applied as to break the attachments at separate motions; this is easily accomplished by the process of rocking the tooth outward and inward. Lateral movement is not to be great, that fracture be avoided. The position of operator and patient is as before designated for other upper teeth.

It is not always the case, however, that these teeth are found as represented



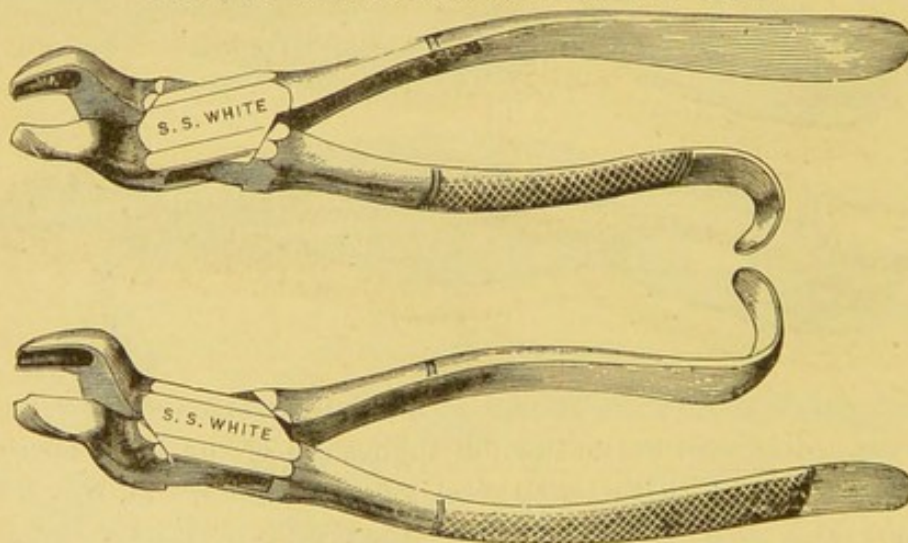
in the drawing. Sometimes as many as five roots exist, and these so diverging as to render the removal of all of them, without fracture, a very difficult

FIG. 282.—UPPER MOLAR, RIGHT AND LEFT.



matter, perhaps indeed impossible, particularly if the jaw be heavy and the alveolar process dense. At other times it will be seen that the roots have commingled, forming an irregular conical fang. This latter condition facilitates, of course, extraction. Another condition not infrequently met with is a

FIG. 283.—UPPER MOLAR, RIGHT AND LEFT.



convergence of the apices of the roots, these so grasping the inclosed process that, in the coming away of the tooth, either the fangs must spring to such extent as to permit the passage, or this piece of bone must come away with it.

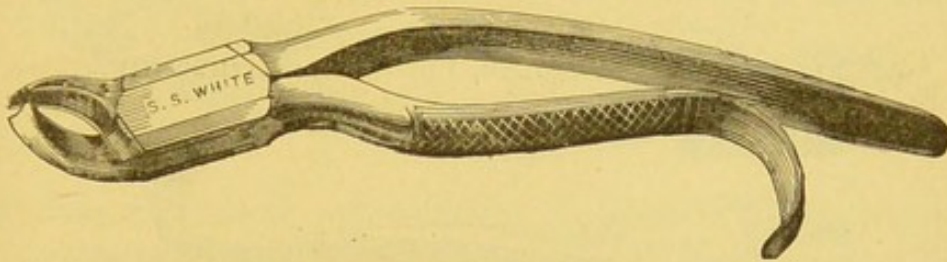
Again, it is sometimes seen that a molar tooth—although this is much more common to the bicuspidati—stands to the inside of the arch, being wedged, as it were, out of its place. Here the rocking motion is necessarily modified. The tooth is first, with gentle yet steady force, to be carried inward, then back to the point of departure. This is to be repeated until the attachments are broken. Cases also present, but they are very rare, where a



tooth desired to be removed is more or less overlaid by its fellows. Here it will most likely be necessary to resort to the use of the file, or recourse may be had to wedging away the opponent teeth by means of slips of india-rubber worked, while held on the stretch, between the teeth. Such wedges, after being retained for a few hours, will not infrequently be found to have secured room quite sufficient for the passage. Where undue crowding is seen to depend on approximal caries of the tooth to be extracted, it will be all-sufficient to chisel away the part intruded upon.

Instrument Fig. 284 is of such construction as permits its application to the superior molars of either side. It is not, of course, an anatomical forceps,

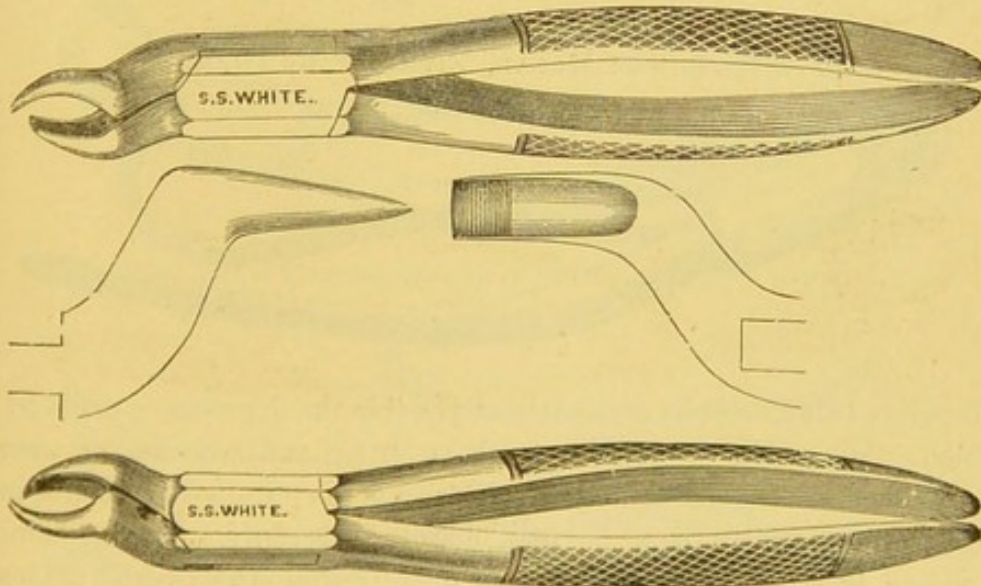
FIG. 284.—UPPER MOLAR, FOR EITHER SIDE.



but when the teeth to be extracted are solid and resistive as to structure it answers its end tolerably well. It is not, however, to be commended.

Fig. 285. These are instruments, in pairs, designed for the extraction of the superior molar teeth. They are known as the Maynard, or cow-horn.

FIG. 285.—UPPER MOLAR, RIGHT AND LEFT, COW-HORN, WITH OR WITHOUT HOOK ON HANDLE.



Than these forceps, it would seem that none could be devised meeting more happily the anatomical requirements of Class IV.

The outer beak, horn-shaped, is designed to enter the interspace between the buccal roots; the inner—flat, square of blade, and grooved—adapts itself accurately and firmly to the palatine fang.



To apply these forceps, the operator stands to the right of his patient, precisely as in the case of teeth of the first three classes, the left arm passing around the head, the fingers of the left hand holding the lip out of place. In using the Maynard forceps, care must be taken to thrust the point of the horn directly into the interspace, otherwise the operator would have no hold on the tooth; this being in position, the flat blade is carried along the palatine fang as high as possible. A few rocks of the tooth inward and outward, combined with a direct force in the line of its long axis, and it will be found to give way.

Fig. 286 is an instrument of similar construction, differing, however, in an arrangement of blade-curve which permits of its application to the teeth of either side.

FIG. 286.—UPPER MOLAR, COW-HORN, EITHER SIDE.

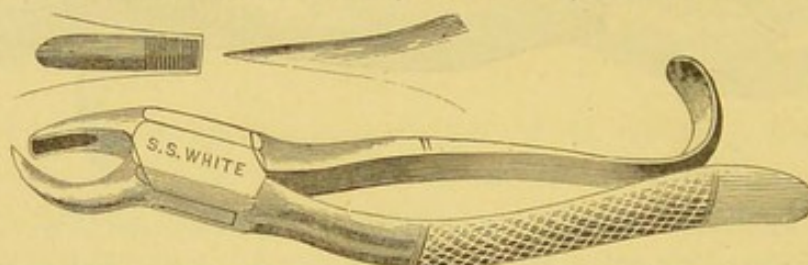
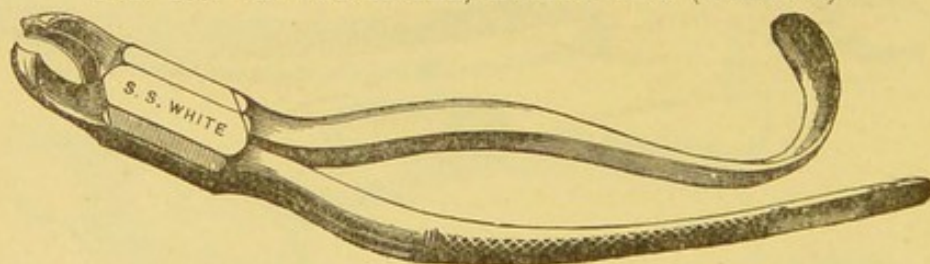


Fig. 287 is a forceps intended for the lower molars and the dentes sapientiæ of either side. The molars of the inferior jaw are two-rooted (see Figs. 264, 265), with the interspace looking outward and inward. Examining the instrument; it is seen that the blades terminate in sharp, central nibs, the design of

FIG. 287.—LOWER MOLAR, EITHER SIDE (HARRIS'S).



such points being to fit as accurately as possible the depressions made by the division. When the crown of a tooth is strong and resisting, or where a loose process permits of a hold which carries the nibs well into the interspace, this instrument is to be used most satisfactorily. Where, however, the crown is much decayed, and consequently frail, the cow-horn forceps, next to be described, are found better adapted.

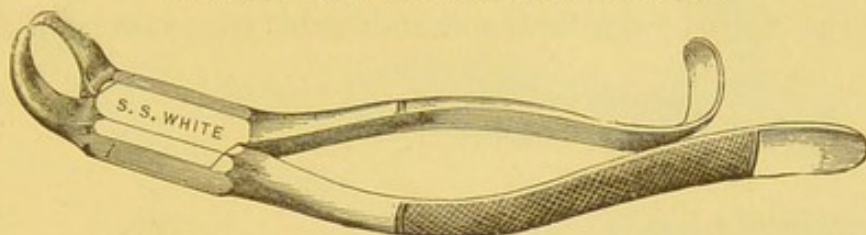
The wisdom-teeth of the lower jaw have the single curved root corresponding with the upper, bending here toward the rami of the jaw. Instrument Fig. 287 allows of the proper application of the force demanded for their extraction; they are to be lifted upward and backward. Wisdom-teeth



crowded under the rami, and thereby unable properly to erupt, not infrequently become the occasion of grave lesions. (For instances of such complication, together with mode of treatment, see *Alveolar Abscess*.)

Fig. 288 is the lower cow-horn forceps. This instrument, designed to be used in the extraction of the lower molars, is one of the most effective in the collection. To employ it, care is taken so to apply the points that the closure of the handle forces them into the interspace. Referring to Fig. 265, this interspace is seen to correspond with the exact centre of the buccal and

FIG. 288.—LOWER COW-HORN FORCEPS.



lingual faces of the tooth, and, examining its relation with the alveolar process, it is seen to be on a level with the border. When the blades of the instrument are in position, it will be recognized that the points are to occupy this interspace; thus the pressure is exerted from below, and not at all upon the walls of the crown, affording, in this respect, such advantage that extent of decay or brittleness amounts to very little. The lifting power and leverage of this forceps are of such character that it frequently happens that the

FIG. 289.—LOWER MOLAR. COW-HORN, RIGHT SIDE.

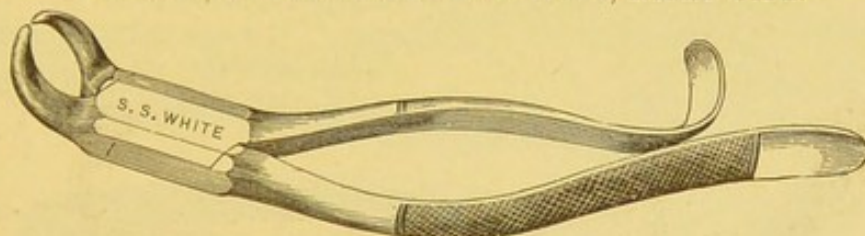
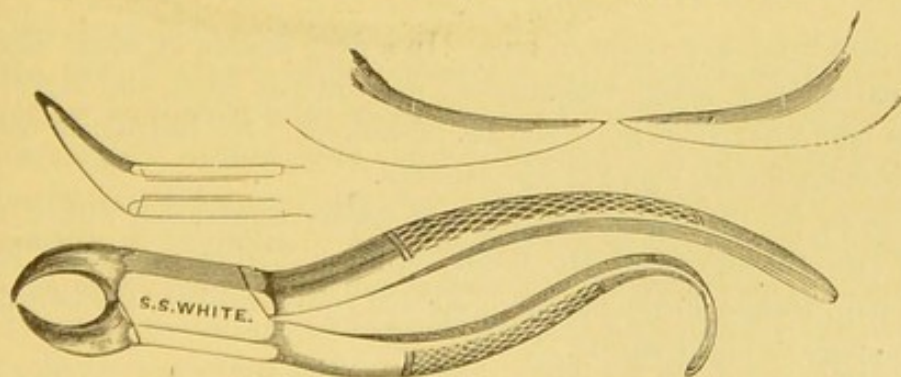


FIG. 290.—LOWER MOLAR, COW-HORN, LEFT SIDE.



mere closing of the handle loosens the tooth. When, however, this does not occur, the organ is to be rocked until the connection is felt to break. Examining a tooth held in the grasp of this instrument, the points of the



blades are found met in the interspace. Before applying the force it is well always to have the points thrust as deeply as possible below the free edge of the gum. When such precaution is not taken, and the sharp points do not reach the interspace, they are almost certain to produce fracture. This instrument is, of course, not applicable where caries has proceeded to such an extent as to have separated the roots. Figs. 289 and 290 are the cow-horn forceps in pairs: the shape of the handles, and the curve for the rest of the little finger, add much to convenience of employment. Together, they make a very efficient set for lower molars.

FIG. 291.—LOWER MOLAR, EITHER SIDE (WOLVERTON'S).

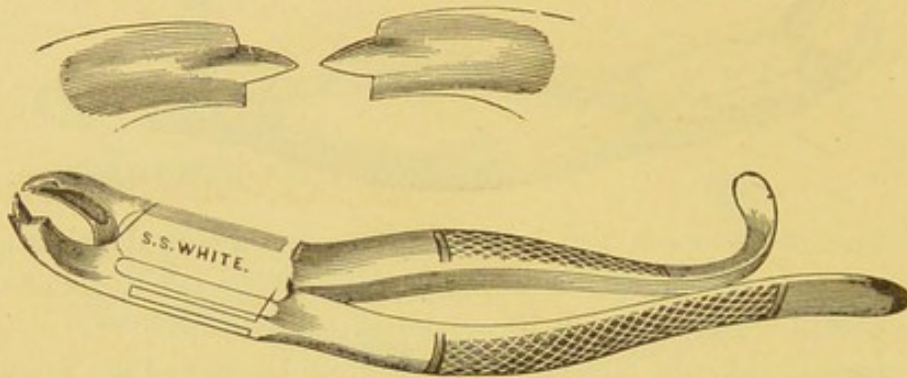


Fig. 291 is a forceps designed for the inferior molars; it is known as Wolverton's instrument. It is preferred by many as combining the advantages of the Maynard and Harris.

FIG. 292.—LOWER MOLAR (HUTCHINSON'S).

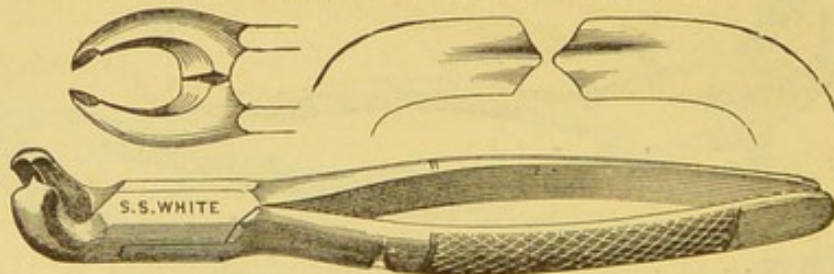


Fig. 292 is a lower molar forceps. In a deep mouth, or where the tooth to be extracted is much concealed by one anterior to it, the curve of the blade is found to render great service. Admirers of the instrument commend it particularly for the shape of the fenestra.

A forceps for the extraction of lower molars constructed with a double-clawed face, the device of Dr. Booth, of Iowa, highly commends itself; a second pair, clawed on the palatal blade and cow-horned for the buccal interspace, applies to upper molars.

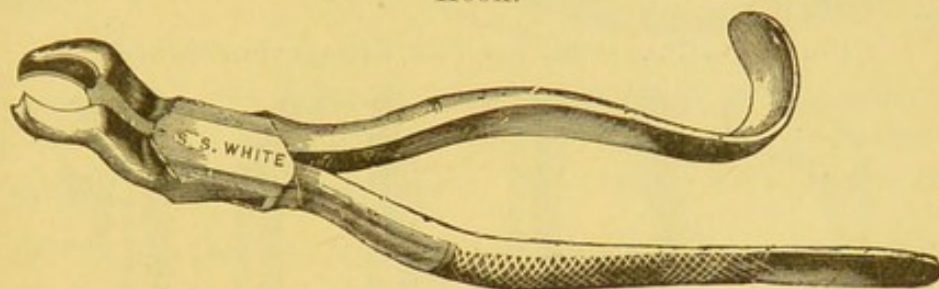
Fig. 293 designates forceps for dentes sapientiæ of upper jaw, either side. As a rule, these teeth are found to have but a single root. This, in shape, is conoidal, with a curve which directs the apex toward the tuberosity of the bone. To remove them with least effort and risk, this curve of the



root is always to be considered; requiring the extraction to be in the line of its axis. To accomplish such a requirement, the crown of the tooth, after being grasped in the beak of the instrument, is to be directed backward. This rolls the organ wheel-fashion, as it were, from its socket. The forceps Fig. 292 is adapted for the removal of these teeth when they are small.

It happens, however, that in many instances the superior wisdom-teeth have three, or even more, bifurcating fangs: when this is the case, it is


FIG. 293.—UPPER DENTES SAPIENTIE, FOR EITHER SIDE, WITH OR WITHOUT HOOK.



quickly to be recognized by an undue resistance offered to the employed force, and its direction. No rule may here be given outside of that which applies to the neighboring molars: the operator, if the irregularity be peculiar, feels his way by testing for the aspect of least resistance.

Fig. 294 represents a forceps designed by the late Professor Physick for the extraction of wisdom-teeth. The instrument is seen to represent a double

FIG. 294.—PHYSICK'S DENTES SAPIENTIE, EITHER SIDE.



inclined plane, and, in consideration of the necessity for throwing these teeth backward, is designed to be applied between the tooth to be extracted and the one directly anterior to it. The closure of the handle is expected to throw the organ from its socket.

In the case of wisdom-teeth possessed of several roots, as referred to in a preceding paragraph, these roots, instead of being inclined in a common axis, being spread irregularly in various directions, it is plain that the instrument would not apply, and that, more than this, it is entirely incapable of being used in the direction. Another difficulty in the way of its use lies in injury apt to be inflicted on the anterior, or fulcrum tooth; this not infrequently having the enamel so crushed and broken as to expose the more susceptible dentine, and thus lead to caries. Still another objection lies in the contusion inflicted on the periodontium, this membrane being occasionally so injured as to result in severe inflammation.

• The ordinary key instrument, when lightly and delicately made, answers a

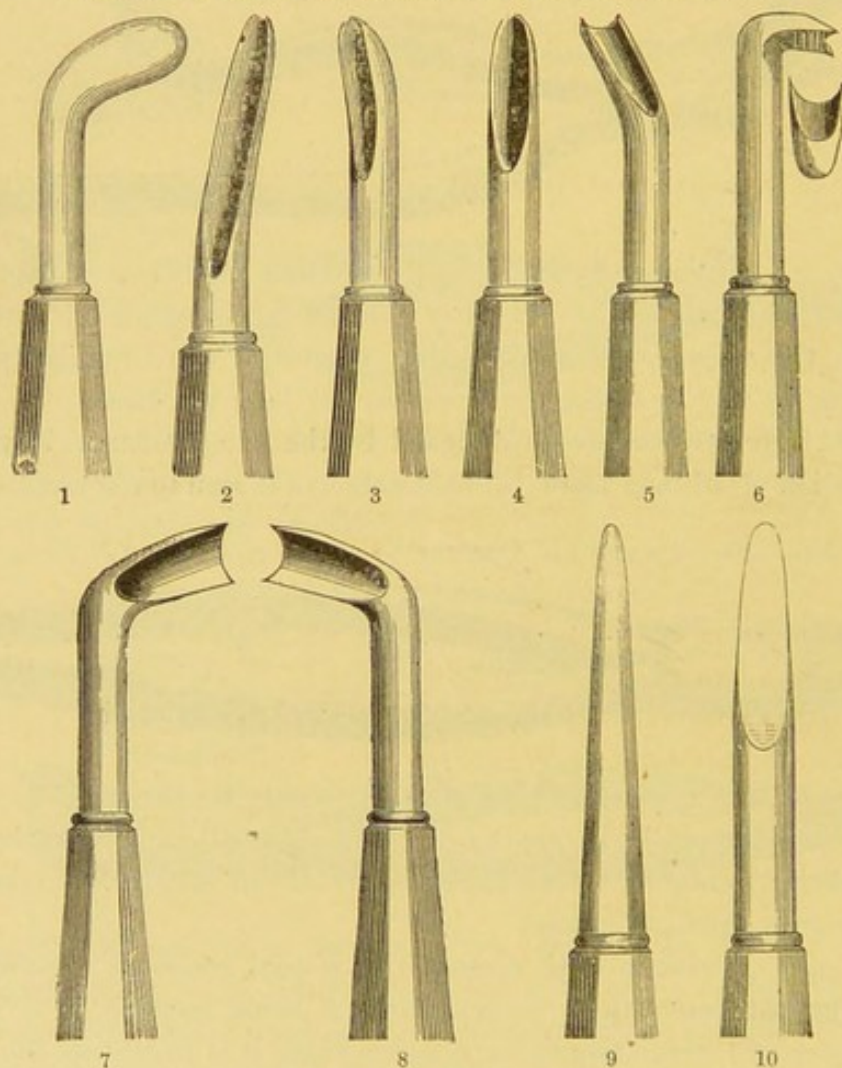


very admirable purpose with this class of teeth. The roots being generally quite short, there is little of the common danger of alveolar fracture, and being but lightly set in their sockets, and easily yielding, the application of but very trifling force is required.

In using the key, the fulcrum is to be placed on the inner face and well back upon the tooth, the claw being upon the opposite face and well in front; this application allows of the proper direction of the force, and admits of the easy and natural removal of the organ.

Still another instrument employed in the extraction of these teeth is the elevator.

FIG. 295.—ELEVATORS USED IN EXTRACTING TEETH.

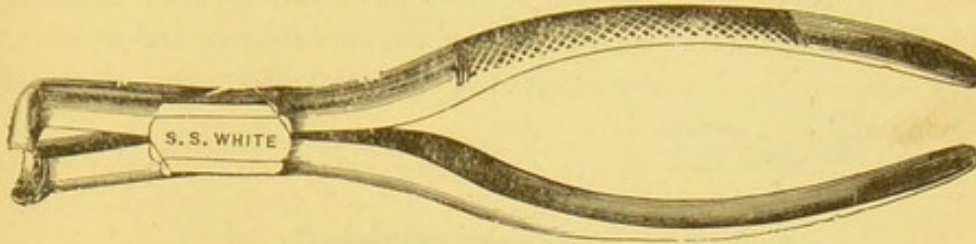


To apply this means, the grooved face is laid against the antero-lateral aspect of the tooth, and the blade being carried down to the process, the hand is depressed so that the free edge alone impinges; the tooth is then pushed outward and backward from its socket. When wisdom-teeth are but ordinarily adherent, this is a reliable instrument for their removal; care, however, is necessary that it shall not slip from the tooth and inflict injury on the neighboring soft parts. Elevator No. 5 (Fig. 295) is the one most commonly employed.



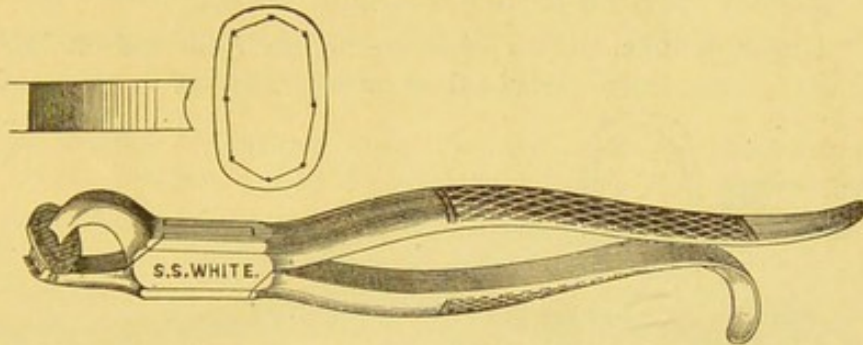
Another instrument yet is Fig. 296: long of shank, and with blades curved at right angles with the handle, it answers an excellent purpose in the case of the inferior wisdom-teeth.

FIG. 296.—LOWER DENTES SAPIENTIAE, EITHER SIDE.



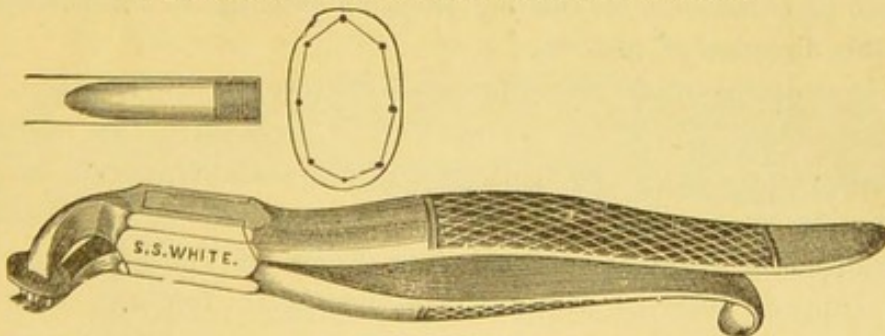
FULCRUM FORCEPS.—These instruments, of which seven constitute a set, act on the principle of the key and elevator. A glance at their construction will exhibit the mode of application. That when skilfully used they are

FIG. 297.—UPPER INCISORS, CUSPIDS, AND BICUSPIDS, FOR EITHER SIDE OF THE MOUTH.



capable of meeting many emergencies, is not to be doubted. The forceps of this class here figured are the invention of Dr. E. M. Jones, of Richmond, Va. Another instrument of the same general character, which, in respect to the fulcrum, highly commends itself, is the invention of Dr. H. H. Perrine, of Maryland.

FIG. 298.—LOWER INCISORS, CUSPIDS, AND BICUSPIDS. (Two pairs, one for the right and one for the left side of the mouth.)

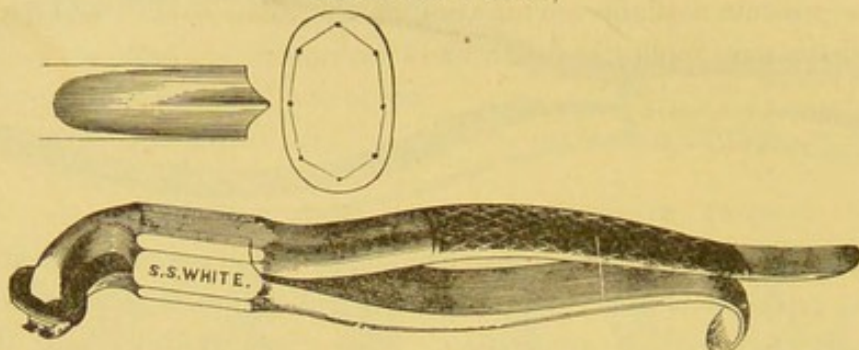


All forceps of this class are modifications of the key of Garengheot and of the elevator, and, in the deserved commendation they receive, serve to exhibit the virtue of the instruments they represent. The key, so long



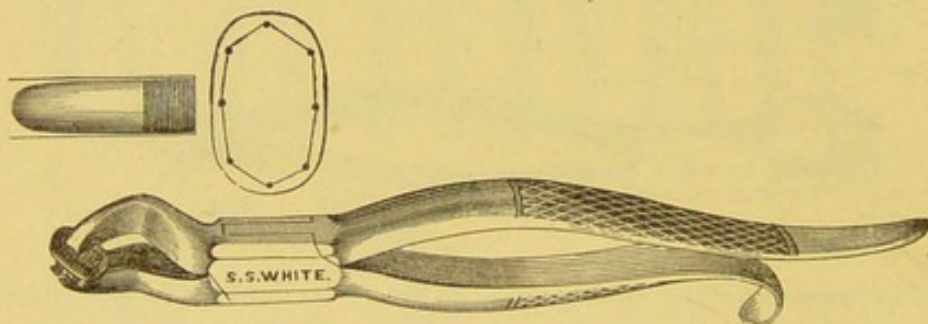
and so almost completely abandoned, should not be without its place in an operating-case. With a variety of claws to fulfil the diversified indications, and with skill and care in the adjustment of the fulcrum, it is a most valua-

FIG. 299.—LOWER MOLAR. (Two pairs, one for the right and one for the left side of the mouth.)



ble addition. An advantage possessed, however, by the fulcrum forceps, is easier adaptation of the claw, together with a more direct oversight during

FIG. 300.—UPPER MOLAR. (Two pairs, one for the right and one for the left side of the mouth.)



the act of extraction. In applying either this forceps or the key, it is necessary to force the blade as deeply as possible along the root of the tooth, and so to arrange the pad that the pressure upon the soft parts shall be as little injurious as possible. Bruising and crushing the gums are the objections.

Concerning the fulcrum forceps, much commendation has been received,—gentlemen of experience considering them an essential to a satisfactory success in this direction of practice.

The latest device in the way of forceps is an invention by Dr. Hurd. Five instruments constitute the full requirements of an outfit. The introduction of a spring which drops the tooth is a valuable addition. The set cannot be overhighly commended.

**Extraction of Fractured Teeth and Roots of Teeth.**—It not infrequently happens that, in attempts to extract teeth, fractures result; and such fractures must, of course, present the greatest variety of aspect, and require various resources for the removal of the parts left.

Fractures of the first, second, and third classes present the same common features, and are to claim a first attention. Fig. 301 represents the alveolar

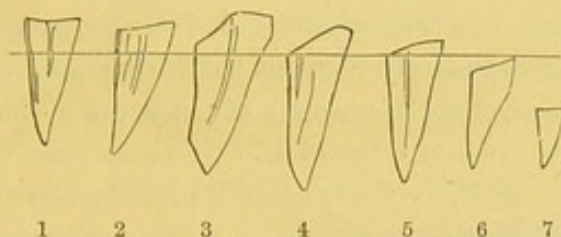


line, and the various relations held to this line, or free border, by fractured teeth or roots.

A fractured tooth, as represented by No. 1 in Fig. 301, is placed in no worse condition for easy extraction than before the occurrence of the accident. The same forceps and the same manner of its application apply.

No. 2 represents a slight modification of the same condition. The one forceps and the one application still, however, apply. It is advisable, if the

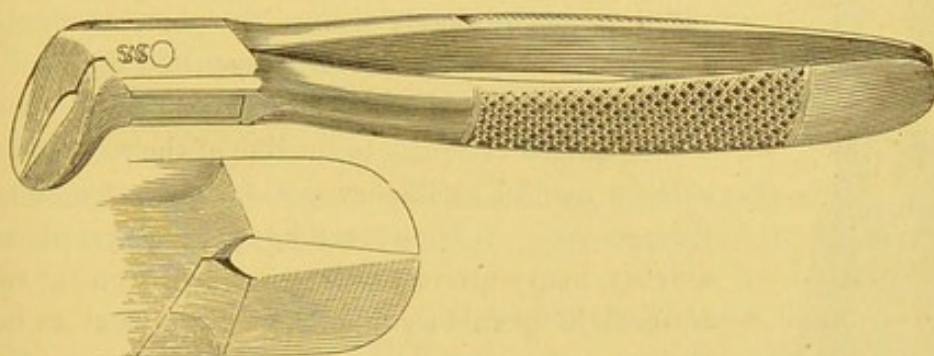
FIG. 301.—RELATION OF FRACTURE ROOTS TO ALVEOLAR LINE.



tooth be at all brittle, to work the blades of the instrument well beneath the alveolus. This affords greater support and yields increased security.

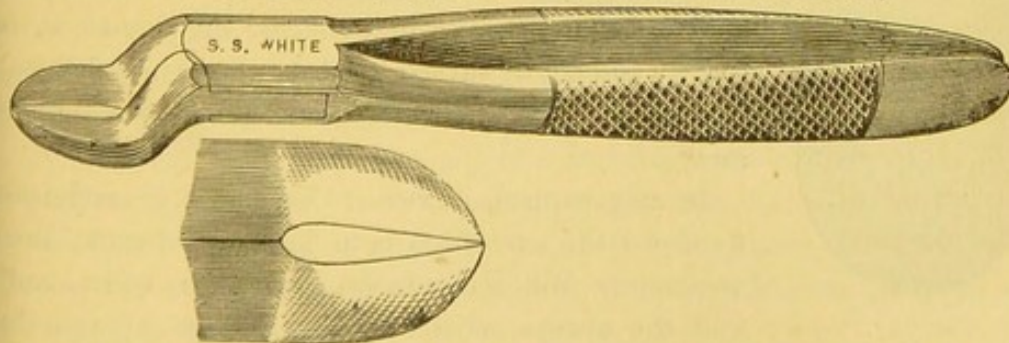
No. 3 represents a bicuspid tooth with the crown half broken away. In such a case, if the remaining portion be not at all brittle, and if the process

FIG. 302.—INFERIOR COMBINED ROOT INCISING, SEPARATING AND ELEVATING FORCEPS. (DR. T. C. STELLWAGEN'S PATTERN.)



be soft and spongy, the forceps, as described, having well-sharpened blades, may again be tried, working them well beneath the festoon, and securing all

FIG. 303.—SUPERIOR COMBINED ROOT INCISING, SEPARATING, AND ELEVATING FORCEPS. (DR. T. C. STELLWAGEN'S PATTERN.)

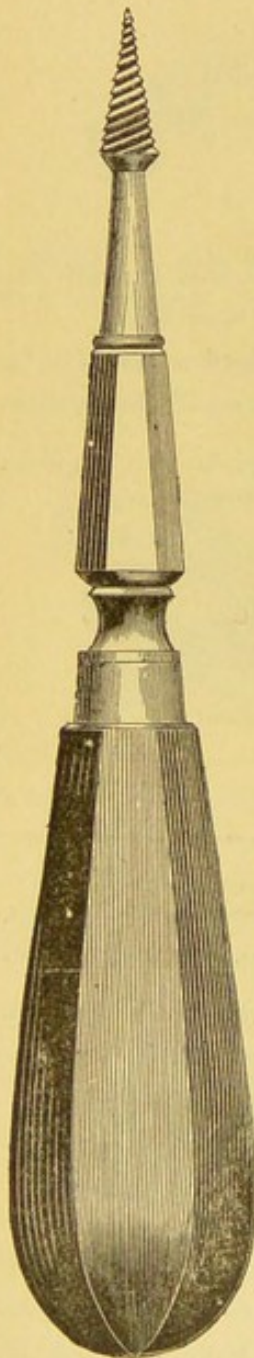


the hold possible on the root. If fracture again occur, which is very likely, simulating Nos. 4 and 5, the cutting forceps may have to be employed.



To use a cutting forceps, make, with a scalpel or other blade, an incision on either side of the root through the soft parts directly down to the process; these cuts must correspond with the exact centre line of the root. The forceps is now to be applied scissors-fashion, cutting directly through the bone. Being thus brought in contact with the root, and grasping it perhaps full half its length, the removal is a simple matter.

FIG. 304.—THE  
SCREW.



Some operators prefer to precede the cutting forceps with trial of the elevator, and this instrument, in many cases, certainly effects the end very well.

In the application of the cutting forceps, it not infrequently happens that, from want of care, the blades, instead of coming directly upon the root, slip to the back or front of it. In these cases the fang may generally be easily enough picked out with the ordinary root forceps. A form of cutting instrument used by many, consisting of a double curved blade, avoids this accident, but it is to be objected to on account of the wound it makes.

Roots represented in Fig. 301, Nos. 4, 5, 6, and 7, are removed on a common principle. The first attempt is to be made with the elevator: laying the groove of this instrument closely against the root, its sharpened knife-like edge is insinuated between the fang and process, being worked down as far as possible. The handle is now carried obliquely to the line of the root, and thus, using a careful oscillatory motion, the piece is forced from its bed. It is very well known, however, that with a dense, heavy alveolar process, this instrument cannot be made to operate so happily, it being next to impossible to insinuate it between the bone and tooth. Under these circumstances, another instrument, the screw (Fig. 304), may be brought into requisition.

The screw is designed to operate upon the tooth-root as the spiral operates upon the cork. Well tempered, and very sharp, it is introduced into the pulp-canal, and quietly and gently turned until it has taken a firm hold. A simple direct movement, and the root is brought away.

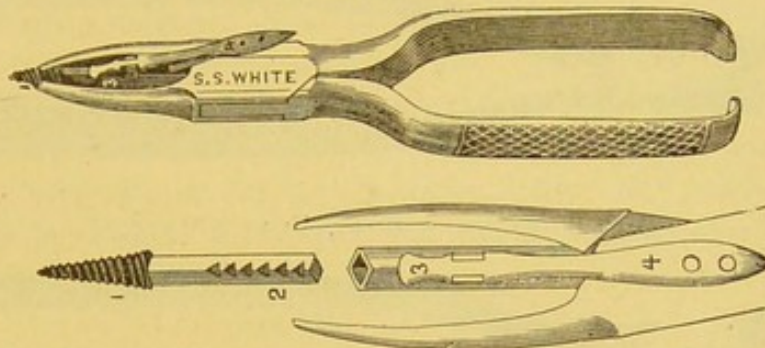
It may happen, however, that no hold sufficiently fixed for the extraction is to be obtained with the instrument. When this is the case, it may be laid aside, and the always reliable cutting forceps brought into requisition. If preferred, however, the screw can be bored into the tooth until fracture is produced, and this will sometimes enable us quite easily to



pick away the splinters; particularly will this be found the case when the line of the fracture divides the root in its length. Forceps known as Dubs's and Hullihen's represent the combination of the screw with the forceps. In the Hullihen instrument the screw is designed more especially to afford support, preventing the blades from crushing the root. In the Dubs's forceps the spring trigger corresponds with the two forces, affording thus not only support, but allowing the extracting force to be divided between the two means.

In using these instruments (their employment being confined to the single-root teeth), the shank holding the screw is to be confined in the grasp of the blades, and, thus controlled, it is to be screwed into the pulp-cavity: a proper hold secured, the blades are to be expanded, and thrust, as in the ordinary application, about the root, which is then extracted *secundum artem*.

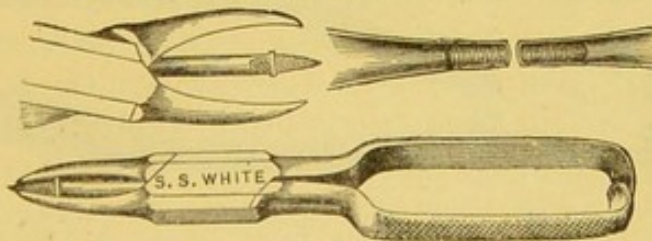
FIG. 305.—DUBS'S SCREW FORCEPS.



1, conical screw with square ratchet shaft; 2, beaks of forceps, grooved inside; 3, socket with square hole to receive shaft; 4, spring trigger by which the screw can be detached at pleasure at any given point.

In many instances, however, the immediate employment of the screw is found impracticable, owing to the shape of the canal or the density of the

FIG. 306.—HULLIHEN'S SCREW FORCEPS.



dentine: in these cases the fang may be reamed out of its bed, which manipulation is accomplished without effort by the use of drill and engine.

Roots of the molar and wisdom-teeth, superior and inferior, are removed on a common principle. In the use of the elevator, a very happy result is not infrequently secured by applying the blade to the inner face of the root, carrying the shank across the mouth, and making a fulcrum of some convenient opposite tooth.

Where the roots of a molar tooth are so firmly fixed as to seem incapable of removal with the application of an ordinary amount of force, it is better to



divide them. This is easily done with the cutting forceps, and after the separation each root may be picked out singly, and generally with comparative ease.

Forceps of delicate beak are much in favor for the extraction of roots of teeth: indeed, it is a common practice to exhaust their capability before resorting to other means. Fig. 307 to 312 exhibit different forms of such

FIG. 307.—UPPER FRONT ROOT, STRAIGHT.




FIG. 308.—UPPER AND LOWER ROOT, HALF CURVED.

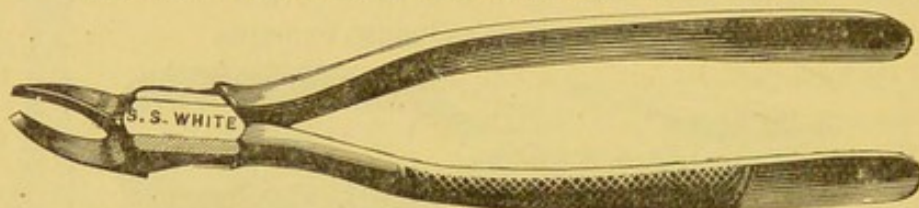


FIG. 309.—LOWER ROOT, FULL CURVED.

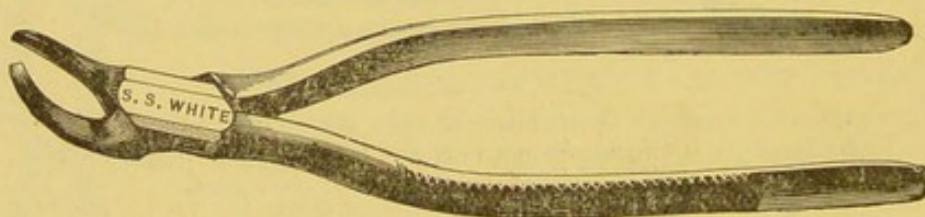


FIG. 310.—BAYONET-SHAPE ROOT.

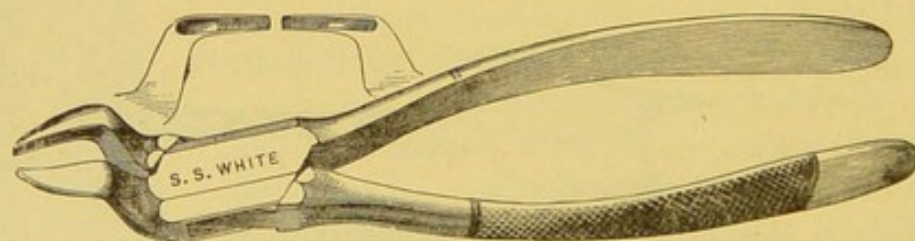
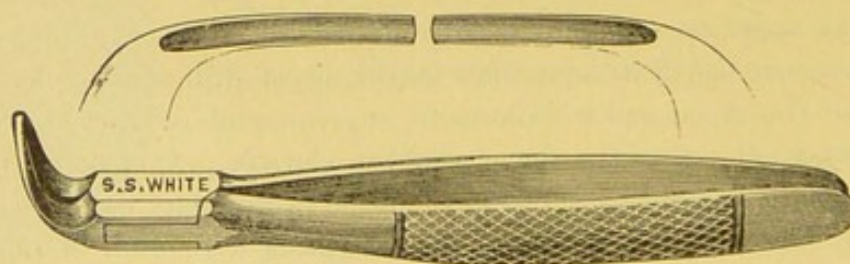


FIG. 311.—HALF CURVED, LONG BEAK, ALVEOLUS.

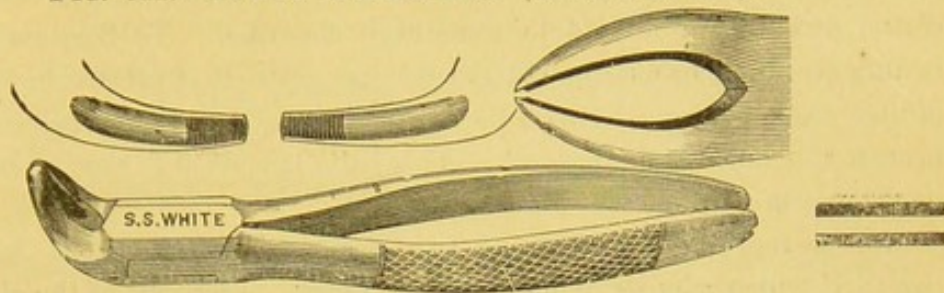


forceps. Figs. 307 and 308 are to have the preference,—these being quite capable of performing the work of the others.



Mention is to be made of what is denominated the sub-alveolar, thin-

FIG. 312.—LOWER MOLAR ROOT (WITH CROWNS).

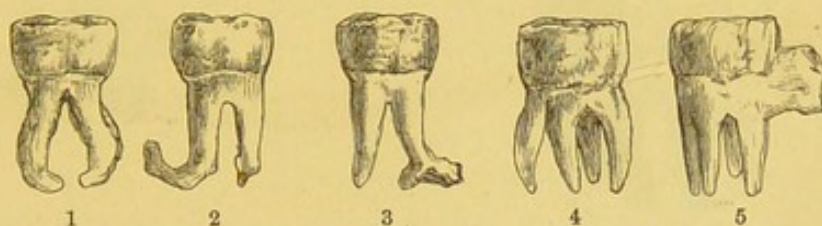


pointed forceps used in the extraction of roots. Where an alveolus is of loose structure, this instrument accomplishes its purpose admirably.

**Deformed or Anomalous Teeth.**—Understanding the principles on which teeth of ordinary character are extracted, the practitioner will need but little instruction so far as anomalies are concerned.

In Fig. 313, Nos. 1, 2, 3, 4, and 5 represents five anomalies, and these may very well stand for the class. In removing such teeth from the mouth, the matter of greatest importance is to recognize them. Now, while this cannot in all cases be done so as to appreciate exactly the condition of the roots,

FIG. 313.—ANOMALIES.



yet we may always see that some impediment to the removal exists; and this, after all, is the most important matter, as it influences the amount of force exhibited, which, too freely rendered, might result in fracture of the bone, or still greater injury to surrounding parts.

A tooth, as represented in No. 1, will generally yield in its roots so as to pass the intermediate piece of process. If it do not yield, then this wedge of bone will fracture and be brought away. Such fracture, however, results in no harm, and is to be deemed of little consequence.

No. 2, by the great curve in the root, is made incapable of passage, unless, after being loosened, it is carried outward in the direction of the axis of the curve. In this way it is easily removed. The character of the curve is recognized by the resistance offered when the tooth is inclined in certain positions, and by the absence of such resistance when it is directed in the proper line. The attempt to extract such a tooth by simple force would result either in fracture at the curve, in lifting out a neighboring tooth, or in fracture, more or less extensive, of the alveolar process.



No. 3 represents exostosis of a root. A fang so enlarged will not pass through the process unless the bone be very open in its structure. Such a tooth may be made quite loose, but, while it moves freely enough in its socket, it is felt to be held by something abnormal. To free such a root it is only necessary to use the cutting forceps, or, what is preferable, to take the ordinary small surgical chisel or engine-drill and cut away sufficient of the process to admit of the passage. This little operation is easy of accomplishment, and must prove adequate to the end.

No. 4 represents a form of twin teeth. The two must be removed together, which may be difficult or the reverse according to the character of the process. It is well, before making the effort to extract, to free the process from the teeth as thoroughly as possible: this is done by a sharp and flat elevator or by use of the chisel or drill.

No. 5 represents a second form of twin growth, the result of original germ union. If the offshooting bulb be situated within and covered by the process, it is to be treated as if it were a case of exostosis of the fang. These germ unions are exceedingly rare, and one might not be met with in a lifetime.

Among other curious examples of anomalous teeth to be seen in the Museum of the Philadelphia Dental College is one exhibited by Fig. 314. A

FIG. 314.

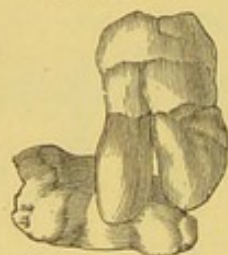

FIG. 315.



practical feature in the anomaly concerns the *extraction*. This was effected with less trouble than might be supposed. In the attempt to remove the one standing upright, it soon appeared that there was something wrong, and the effort to extract was suspended, and a thorough examination made. In the second attempt, the force was very cautiously applied, in order to find what direction the tooth would take. It yielded most to an inward motion, and by a continued effort in that direction the removal was secured with only a slight fracture of the lingual border of the alveolus.

The second specimen (Fig. 315) is a union of three of the anterior teeth.

An anomaly is, of course, a condition outside of rule. A practitioner familiar with normal tooth anatomy will find little difficulty in dealing with the exceptions; the plan is to feel one's way to a result.



## CHAPTER XXVIII.

### GENERAL REMARKS ON EXTRACTION.

THE relationship of the teeth with the jaws is through the medium of a cellular process known as the alveolar. Each tooth is lodged in an alveolus or alveoli corresponding to the number and character of its roots: thus, the central and lateral incisors, the cuspidati, and the bicuspidati, having each but one root, have each but one alveolus.\*

The molar teeth of the superior jaw have three roots, consequently a three-fold relation to the alveolar process.

The molar teeth of the inferior jaw have two roots and two alveoli.

The wisdom-teeth, as a rule, have a single short curved and stumpy root, consequently a similar alveolus.

The association of the teeth with their alveoli is through the medium of a fibro-cellular tissue; this membrane is coarse and resisting about the free edge of the bone, loose and cellular as it gets deeper. A properly-shaped lancet may be made to excise the coarse fibres; consequently, the operation of extraction is always to be preceded by that of thorough lancing. In this way much of the strength of the relationship of a tooth with its socket is to be overcome.

A tooth extracts with difficulty or easily as influenced by the character of its periodontium, and the loose or firm structure of its alveolus.

A limited fracture of the alveolar process is not generally found to be a matter of much consequence. If an extensive fracture should associate with an extraction, the tooth and bone may be laid carefully back in place, and treated as any common fracture; or, if this do not seem desirable, the fractured piece may be dissected from the soft parts, and the wound treated on general principles. Sometimes, when too much force is injudiciously used, a fracture may occur, including several teeth. In such accidents the circumstances of each particular case are to direct the practitioner; they are ugly and generally unnecessary troubles, and not apt to occur where proper care is exercised. Meeting with such an accident, effort is to be made to reunite the parts; failing in this, there is no resource but to dissect away the piece, or otherwise wait on nature for a process of expulsion; dissecting it away is the preferable plan.

Laceration of the gum is an accident frequently associated with the careless extraction of teeth. Such laceration may be trifling or it may be serious;

---

\* The student will here turn to the chapter on the "Surgical Anatomy of the Mouth and Face" and make himself acquainted with the nature and meaning of the alveolar process.



it is always to be guarded against by attention to proper lancing. A small piece of gum torn by a tooth as it comes away had best be removed; left in the mouth, it is a source of annoyance, and reflects, in the mind of the patient, on the practitioner. Large strips are to be carefully laid back in place, and secured by one or more stitches, or other convenient means of retention.

**Hemorrhage.**—Hemorrhage after extraction is influenced by two circumstances: the state of the parts, and the predisposition of the patient. An ordinary tooth extraction is followed by hemorrhage lasting but a very few minutes. In extraction for periodontal trouble the bleeding is more profuse. Such hemorrhage, however, if at all reasonable, is not to be interfered with; it expedites the cure of the case wonderfully, relieving, as it does, the general congestion of the parts.

Undue hemorrhage, of local signification, is found to depend either on non-contraction in the foraminal and circumferential vessels, or on excessive vascularity in the alveolar walls. Where the bleeding is from an artery, it is more or less *per saltem*; where venous or capillary, it is continuous. Hemorrhage of constitutional expression is associated with the defibrinating condition, or with hereditary predisposition. Anæmia as a cause is perhaps the most common of the systemic vices; next to this may be ranked a typhoid state; after this, purpura. Plethora conjoined with laxity of the tissues is another of the constitutional causes. Vicarious relationship is a condition met with sometimes.

In cases where a hemorrhagic diathesis exists, alveolar hemorrhage is not infrequently of profuse character, making necessary energetic treatment for its cure. Two cases, occurring with the author in the persons of a father and son, may illustrate such direction of practice.

Mr. B., aged 19, applied to his dentist for the removal of the second superior molar of the right side. The operation over, the bleeding seemed not excessive, and the patient was dismissed as usual. On the same day, in the latter part of the afternoon, bleeding recommenced; Monsel's solution of the persulphate of iron was employed, and the patient dismissed.

During the night hemorrhage recurred, and the family physician was sent for; the solution of iron was re-employed, and a temporary arrest again secured. The next day the bleeding reappeared, and nitrate of silver was applied in the alveolus. This controlled the hemorrhage until the succeeding day, when it again appeared: and so off and on over a period of eight days. At this time the case was first seen, in consultation, the patient being unable to swallow any other than liquid food, owing to the swelling of the fauces and of the œsophagus, from the effects of an over-free use of the silver nitrate.

In examining the case, the cavity was found filled with a half-coagulated clot, which was taken away, thus discovering that the bleeding came not alone from the socket of the tooth, but from about the margins which had been ulcerated and degraded by the various applications. Hemorrhage was entirely capillary.



In a treatment which resulted in the immediate control of this case, the following course was pursued. First, an impression in wax was taken of the roof of the mouth, inclusive of the bleeding part. From this impression a model was made, to which was struck a silver plate. This accomplished, which consumed about two hours, the bleeding cavity was packed with alum-saturated lint, the lint projecting and overlying the ulcerated margin. Over and upon this was now placed the accurately fitting and compressing plate. Upon the plate, raised to the common level of the adjacent teeth, was laid a fold of linen: the lower jaw was next closed upon this compress and kept in position by a bandage. Tincture of *erigeron canadensis* was administered, and the feet of the patient were placed in hot water. Hemorrhage ceased entirely in the course of an hour, and did not recur.

Mr. B., the father of this young gentleman, aged perhaps 50, suffered five days from hemorrhage, under the following circumstances: A wisdom-tooth of the left upper jaw troubling him because of its great looseness, he applied to his dentist for its removal. Not deeming it necessary or desirable to wound the gum, the practitioner extracted the tooth without the preliminary step of lancing, and in the act was so unfortunate as to tear away a small strip. Hemorrhage was immediate, and more or less continuous. Monsel's solution being prescribed by his physician, it was employed, but with somewhat the same result as in the son's case. On the evening of the fifth day the case was first seen by the writer. The patient was much weakened from the excessive discharge, and was exceedingly frightened and nervous. The clots washed away, it was discovered that the blood oozed from the torn gum, and not at all from the tooth-socket. *Erigeron* in drop doses, repeated every minute, was directed, and a tuft of alum-saturated cotton was ligated against the wound. The hemorrhage ceased entirely within ten minutes, and did not recur. As an assurance, wine of iron was prescribed, which the patient continued to take to the amount of four ounces.

Tincture of *erigeron canadensis*, in cases of this character, seems to be a reasonably reliable hæmostatic; not entirely so, however, as it is frequently prescribed where it fails to exert the slightest influence.

Hemorrhage dependent on the typhoid condition is to be treated with most success by conjoining with the local medication the internal administration of acids, than which none seem to answer so good and reliable a purpose as the dilute hydrochloric, in doses of fifteen drops in a wineglass of water, repeated each four hours. Purpura, as a predisposition, demands its own peculiar class of remedies. Anæmia is best treated for immediate ends with the tincture of the chloride of iron. Vicarious hemorrhage requires an attention which shall dispose to the restoration of the lost harmony. Whatever the systemic vice, appreciation of the requirements and the meeting of the indications constitute an important direction in the treatment.

Depressing the action of the heart is, under almost all circumstances, a valuable means for the arrest of hemorrhage. To this end the tincture of



veratrum viride is always given with satisfaction; the dose is five drops for an adult, given in a tablespoonful of water. Conjoined with this, and indeed in many instances quite capable of taking its place, is the hot foot-bath,—the impression to be continued until the patient shall either grow faint or break out into profuse perspiration.

Lead and opium prescribed in conjunction form a reliable hæmostatic; two grains of the first to one of the latter may be given every two or four hours, according to the urgency of the case.

Rest is a reliable means of cure. A patient is to be kept quiet, both as motion and anxiety are concerned.

Local treatment of dental hemorrhage has the threefold signification of mechanical, vital, and chemical. The first considers means which, through compression or clot, shall confine the blood to its vessels; plugging the alveolus is a common practice in this direction; the plug to be of almost any convenient material, as raw cotton, or shreds of lint made by scraping linen. When hemorrhage is *per saltem*, a splint of soft pine wood, shaved to a point corresponding with the apex of the alveolus, being carried and retained in place, will almost of a certainty control the hemorrhage. Plates of metal or of gutta-percha, so moulded as accurately to close the cavity, thus favoring the formation of a clot, are frequently employed with success. Spider-web as a clot-holder is another means, the web being packed into the cavity and there retained. Compressed sponge is still another of the mechanical means. This last, when thoroughly coated with wax and of delicate point, is to be carried to the very apex of a cavity, and, when forced into itself and maintained in position by an overlying compress, constitutes one of the most reliable of this character of agents. Preference, however, is to be given to a delicate strip of old and soft linen packed into a bleeding alveolus after full saturation with phénol sodique; such packing, when tightly done and the pledget kept firmly in place by means of a compressing pad, has never failed in the hands of the writer.

Of the medicinal agents having the signification of forming a clot, preference is to be given tannic acid. The persulphate of iron, a preparation much used in general practice, is to be denied application in the mouth. Without doubt a clot is to be formed more speedily and solidly with this agent than with the tannin, but the danger from secondary hemorrhage overbalances all its virtues. A tannin clot is not soluble by the blood, and needs but support to possess all required attributes.

Of the astringents and stimulants, acting by exciting responsive force in the tissues to which they are applied, and controlling hemorrhage through contractility, we have alum, zinc, lead, capsicum, iodine, turpentine, and most of the dilute mineral acids; of these preference is to be given to a dilute tincture of capsicum.

Alum, in full saturation with water, is a reliable hæmostatic, and, when properly supported by a mechanical adjunct, is seldom found to fail; it



is injurious to enamel, on which account it is not to be used without care.

Of agents acting chemically to the control of hemorrhage, mention is to be made of catechu and kino among the vegetables, and nitrate of silver among the metals; the latter, however, is an objectionable preparation, because of the destruction of tissue so common to its employment, except when used in dilution.

All ordinary means failing for the arrest of an alveolar hemorrhage, the actual cautery may be applied. A control thus secured, however, is to be seconded by anti-hemorrhagics of internal expression, as it is frequently found to be the case that separation of the slough made by this means re-excites the original trouble.

Compression made to a bleeding alveolus is to be moderate, not severe; and when made, and the hemorrhage controlled thereby, the packing is not to be too hastily removed; a good rule is to wait for expression of suppuration.

**Luxation of the Inferior Maxilla.**—Occasionally, in efforts at tooth extraction, as a result of sudden movement, or an abnormal laxity of the ligaments of the temporo-maxillary articulation, the condyloid process falls forward over its glenoid boundary. The patient is thus rendered unable to close the mouth, and is said to labor under luxation. (See chapter on *Luxation*.)

**Local Anæsthetics in the Extraction of Teeth.**—The employment of various local agents to secure exemption from pain in the operation of extraction has of late commanded so much attention that no chapter treating of the subject would be complete without reference to them.

The most simple and elementary application in this direction consists in enclosing in a piece of bladder, or other convenient skin, a small portion of pounded ice and salt, and enveloping, for a few moments, the part to be operated on. To secure most conveniently the effect of such a process of refrigeration, various instruments have been devised, but none, so far as the application of the ice and salt is concerned, have been found to answer any better purpose than the bladder or skin enclosure. Such skins should consist of two little bags, one to rest upon the outer, the other upon the inner side of the gum. To prevent pain from the application of the cold, the bags should be brought gradually in contact with the gums; or, what answers a similar purpose, the application may be preceded by ice-cold water held in the mouth for a few moments.

An apparatus designed and manufactured by Messrs. Horne & Thornwaite, of London, is said to answer a very good purpose, and is thus described:

A required amount of water is cooled down, by means of ice and salt, to about zero, in a vessel called a refrigerator. To this vessel is attached another, called a graduator, containing warm water at about 100°, and so constructed as to allow the slow admixture of its contents with the chilled water in the refrigerator, and thus produce a gradual diminishing tempera-



ture, for the purpose of preventing sudden shock and pain to the teeth, which a direct application of cold would inevitably cause. A tube conveys this graduated current into a terminal portion constructed of very fine membrane, which adapts itself to the form of the gums, and wholly surrounds the tooth to be extracted. The fluid then passes away through an exit tube. In this manner a constant current of cold, at a decreasing temperature, is made to pass over the part, abstracting therefrom all heat, and consequently all feeling.

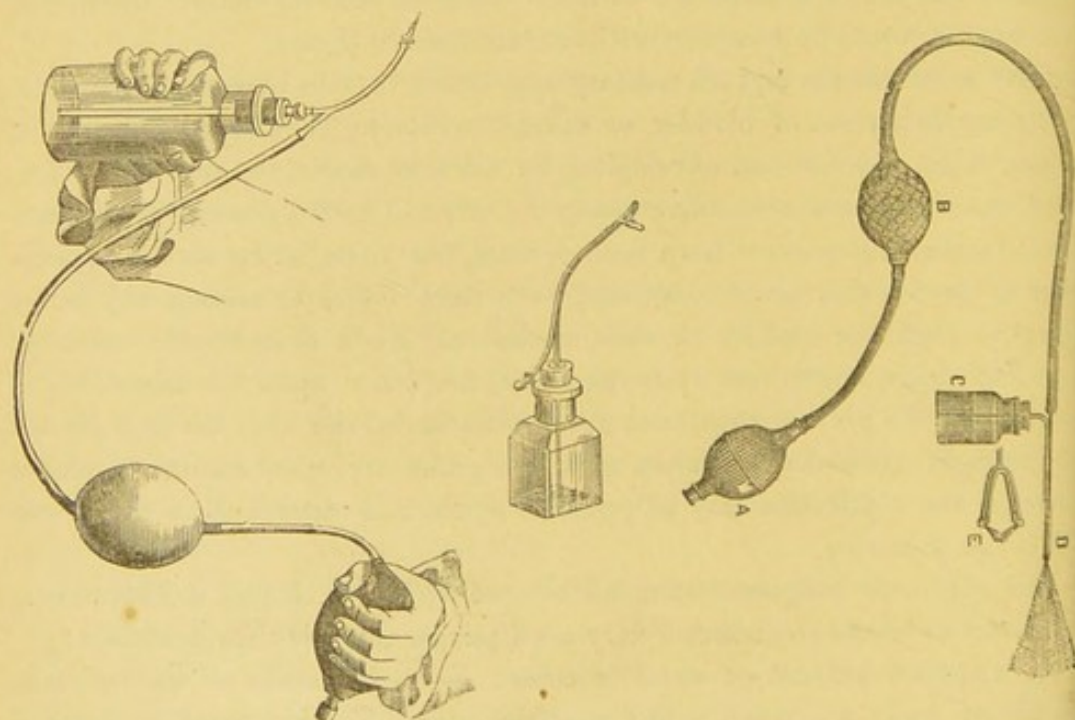
The concentrated tincture of aconite is a useful local anæsthetic, but one that is to be used with a great degree of caution. If a portion of this tincture be applied to one-half the lip, sensibility is likely to be found so interfered with that a goblet placed to the part feels as if broken.

A mixture of chloroform and laudanum in equal parts is lauded by some. To apply this, it is only necessary to saturate a tuft of cotton and lay it against the tooth to be extracted.

Another means, serving to attract the attention of the patient from the operation, consists in painting the gum heavily with tincture of iodine. After such painting, people are often heard to say that the pain has been much ameliorated.

Electro-galvanism claimed at one time a large share of attention. The application of this consists in attaching one pole of a battery to the forceps,

FIG. 316.—SPRAY APPARATUS—HAND-INSTRUMENT.



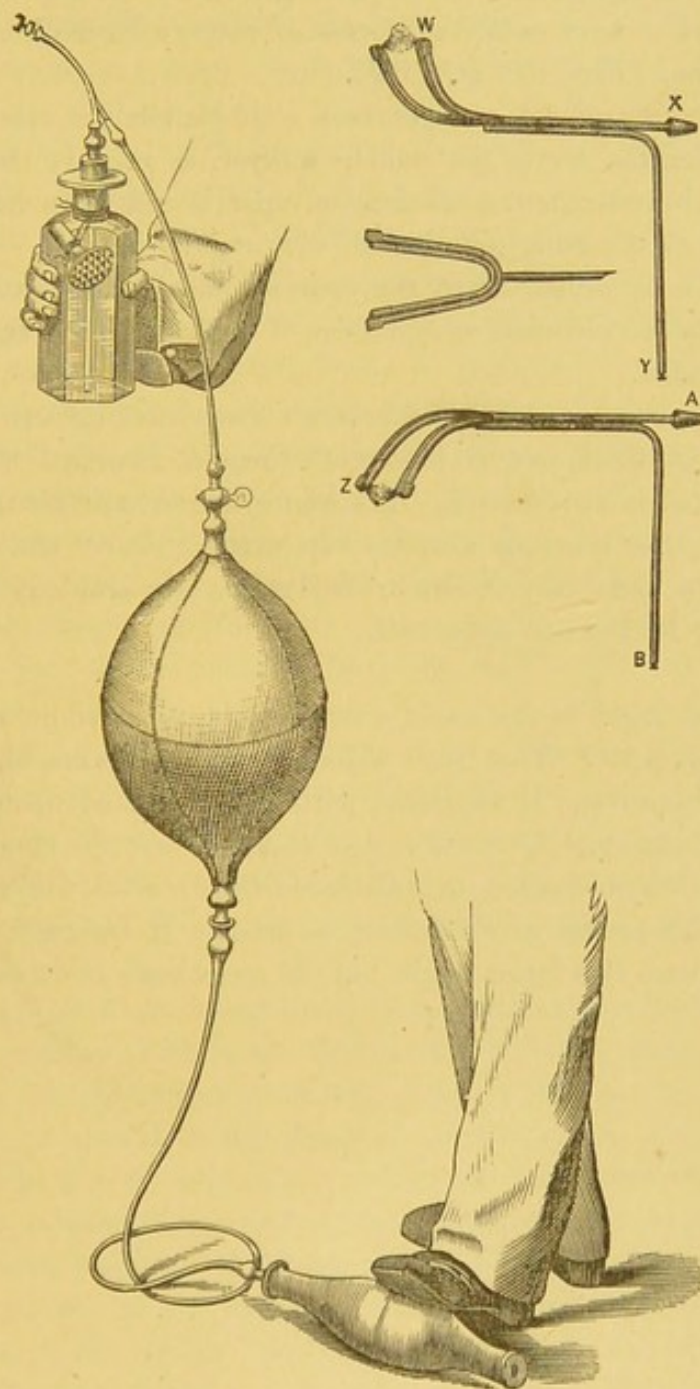
while the other is held in the hand of the patient; a gentle current is next let on, during the passage of which the tooth is extracted. This mode of effect-



ing local anæsthesia is still practised by many; but the writer has to say that in his hands and in the hands of experienced friends it has proved a failure. Not that it is to be denied that in certain cases it does seem somewhat to obtund sensibility, but in the majority of instances it either does no good at all, or adds the discomfort of shock to the pain of the operation.

The use of the spray of ether or of rhigolene is a late and not entirely unreliable means for the production of local anæsthesia; certainly one reasonably

FIG. 317.—SPRAY APPARATUS—FOOT-INSTRUMENT.



acceptable when employed for operations of limited extent about soft parts, but as to an availability in tooth extraction experience has not so fully in-



dorsed it. With these agents as thus locally applied, incisions, in the way of the removal of sebaceous and other superficial tumors, the opening of abscesses, carbuncles, and similar operations, are assuredly to be made with fair satisfaction; but in their application to the teeth the obtunding of the sensibility has not by any means been so marked, and particularly has this been found the case where rhigolene was used.

The process of freezing a part through the known refrigerant power of evaporating ether seems first to have suggested itself to Dr. Richardson, of London. An instrument invented by this gentleman for the accomplishment of such an end is here exhibited, forms of bellows for both hand and foot being represented (Figs. 316 and 317).

For the spraying of any plain surface, a simple straight tube is all that is necessary. For the teeth, the double sprayer, as seen in the drawing, is used; with this instrument a continuous vapor is cast upon both the outer and inner face of the gum, congelation being rapidly induced.

In using the hand-instrument the operator should not himself work the pump. A very few moments' compression of the ball renders the hand shaky and unmanageable.

Upon this instrument of Dr. Richardson's many modifications have already been made. Of these, one by Messrs. Codman & Shurtleff, of Boston, has perhaps attracted most attention. It certainly seems to divide the ether more infinitesimally, thus insuring complete vaporization; but it has a weak point, in that the tube frequently freezes or chokes up,—an accident that does not occur with the Richardson apparatus.

An objection urged to the use of extreme cold, as above induced, is injury done to the soft parts. That such objection is valid seems, however, not to be satisfactorily proven; if anything, parts thus operated upon unite better and with less inflammatory reaction than obtains where the spray is not used.

Rhigolene, or hydrocarbon, manufactured from coal-oil, and much vaunted by some, has not proven so satisfactory as ether. It certainly freezes a part more quickly than this latter agent, but the anæsthesia is not so complete.



## CHAPTER XXIX.

### PROSTHETIC DENTISTRY.

PROSTHETIC dentistry treats of the replacement of lost natural teeth by artificial ones set upon a plate. It is what is generally known as mechanical dentistry.

A full set of artificial teeth is called a denture. A plate having one or several teeth attached is commonly called a piece.

**Preparation of Mouth.**—The preparation of a mouth for the reception of a plate implies that the operator consider in the relations of each case the hygienic, mechanical, and artistic considerations therewith necessarily associated: one mouth, the lips being long; the process full, the arch markedly concave, and of some depth; the gums solid and resisting; the submucous structure neither deficient nor excessive; the teeth all absent, or such as may remain having harmonious relation; temperament lymphatic,—such a mouth the merest tyro will accommodate. On the contrary, lips short; process absorbed to a line; arch flat; gums irregularly flaccid and hard; teeth all gone or, where some remain, inharmonious to a common articular relation; temperament nervous,—such a mouth the most skilful will scarcely serve to satisfy.

A mouth before prepared to receive a denture, full or partial, is to be free from all roots which may have association with the parts to be occupied; teeth irregular to the arch, and thus the source of deficient symmetry, or such as may interfere with a successful fitting of the artificial piece, or such as may be diseased and lacking in promise,—these are to receive attention and judgment.

As a rule, a plate is not to rest upon a root, healthy or unhealthy. The retention of an isolated tooth in the dental arch (all the others having been lost), however healthy and symmetrical, except it be in a position where a plate is not to go back of it, will be apt to antagonize the merits of any denture, however perfect its construction. Soft teeth are not to be clasped. A cachectic mucous membrane is to be covered alone with a gold plate which has been alloyed with platinum, the baser materials being irritative. A turgid congested membrane is not capable of affording an impression which will allow a denture to be useful. Scorbutus, pyalism, all unhealthy conditions are to find correction before an impression is taken. Clasp teeth are to be freed from tartar, and (except when the denture is to be temporary) alveoli are to be absorbed.

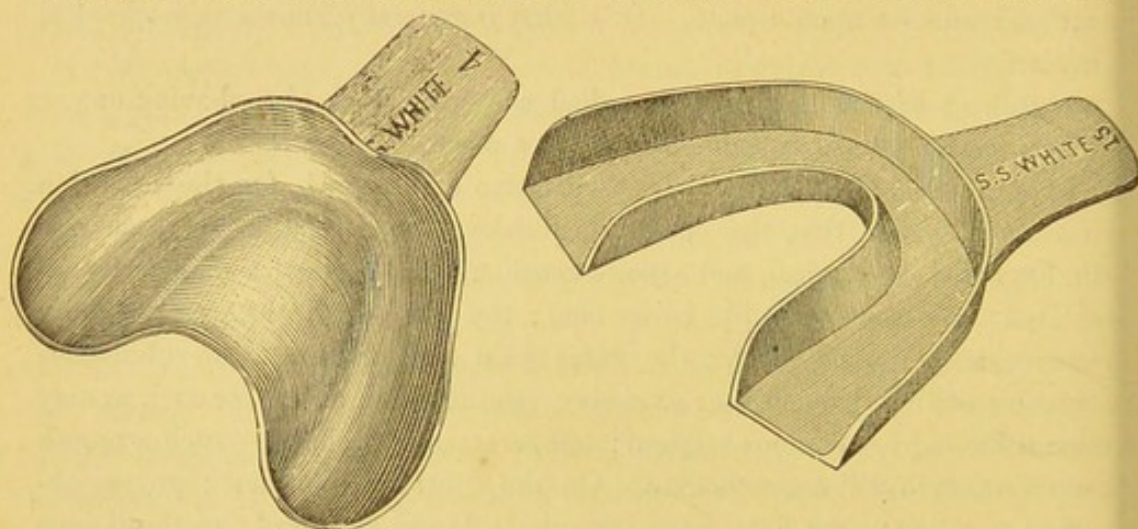


**THE IMPRESSION.**—The first step in the construction of an artificial denture or piece is the taking of an impression, or measure. This consists simply in filling a tray (of which every size and variety is supplied at the depots) with softened wax, plaster, or other impression material, and pressing it over the parts to be modelled.\*

Trays are of two general forms, the one being designed for the superior arch, the other for the inferior.

In selecting one for use in any special case, regard is to be had to the

FIG. 318.—TRAY FOR SUPERIOR JAW. FIG. 319.—TRAY FOR INFERIOR JAW.



requirements. First, such a tray is to be employed as shall admit of easy passage through the labial commissure. If an arch be deep in its palatal aspect, the one used will require to have marked convexity; otherwise a common cup may be made to answer equally well for deep or shallow arches by means of a false bottom. For application to the lower arch, a deep or narrow rim is demanded, as the alveolar process may happen to be prominent or the reverse. In many mouths the site of the original process is found to have entirely disappeared, leaving a perfectly flat surface that will require a tray without any flange.

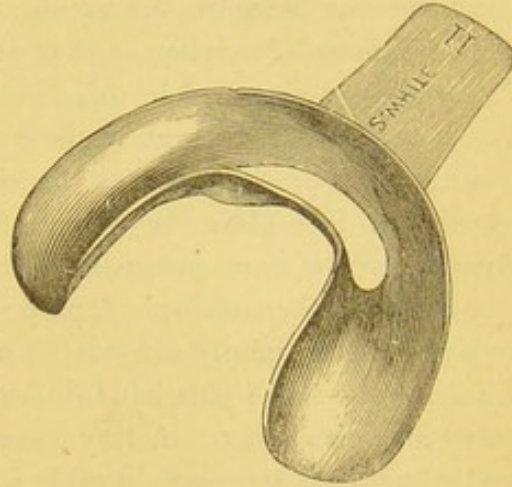
A tray is to be large enough to embrace the alveolar arch, leaving a space between gum and rim of about a quarter of an inch: it is to be deep enough to include the tubers of the upper jaw, or to touch the rami of the lower. If teeth long and prominent stand in either jaw, particularly the anterior in the lower, as is very common, it may be found more convenient to use a tray so cut as to admit of such teeth passing through it (Fig. 320); this, however, is not a necessity, and not always even a convenience.

\* A case presenting where irritability is so great as to cause retching and sick stomach is commonly to be corrected by means of a gargle made by mixing two drachms of bromide of potassium with an ounce of water. Another plan is to prepare the parts by practice of irritation, anticipating the impression by at least a week.



Modifications on these common trays are numerous; few practitioners, however, recognize sufficient merit in them to feel their consequence, finding rather in skill, the result of practice, that which meets the various requirements. An impression, good as requisite, has been taken with a piece of shingle whittled for the occasion; but the hand that secured the cast was experienced. The author has never, in his own practice, employed other than the character of trays here shown, and takes it for granted that his trouble in getting satisfactory impressions has been about of a common experience with others. As suggested, however, it is well to employ for the palatal arch the tray with a false bottom. Any one can make such false bottoms for himself by replacing, with pieces of tin or other metal, bent into shape, the centre which is to be cut from the tray. Having a number of these bottoms (which should be somewhat larger than the piece removed), an operator finds himself requiring very few cups; half a dozen, or certainly a dozen, will be sufficient. This false bottom may be duplicated by building the centre of a tray to the required height by means of wax or plaster.

FIG. 320.—TRAY FOR PASSAGE OF TEETH.



Materials elected for taking impressions are wax, plaster of Paris, gutta-percha, and modelling compound, either being used alone or in combinations. The inexperienced should begin with wax, as this is most simple and easy of manipulation, and at the same time quite capable of meeting all indications.

*Wax.*—Two kinds of wax are employed, the white and the yellow: of these, the white is, on some accounts, to be preferred. It will take a sharper impression, and has not its shape so readily deranged. An objection, however, is a lack of plasticity as compared with the yellow, much more time and trouble being required to prepare it for the tray, while corresponding increase in pressure is demanded to force it into place,—the latter being a matter of importance where there is excess of the submucous cellular tissue.

Yellow wax, when pure, will, under all ordinary circumstances, afford a satisfactory impression. To soften it to a required consistency, which is about that of dough, it is only necessary to work it at the fire, or over a spirit-lamp, or in hot water. Having selected a tray and observed the requirements of a special case,—that is, having considered the matter of depth of mouth, position of remaining teeth, and character of mucous membrane, whether this latter be hard or soft, yielding or unyielding,—the wax is piled into the tray, being heaped in the middle if the mouth be deep, smoothed, and flat-



tened, on the contrary if it be shallow; the wax to be very soft if the membrane be flaccid, of greater consistence if it be firm. The operator, if to take an impression of the upper jaw, stands behind, leaning over the head of the patient; if of the lower, a position is assumed in front and to the right. Tray and wax being in the mouth, observation is demanded to see if such correspondence of relation exist as will allow the cup being carried into place. If care be not exercised in this direction, it will frequently be found that the cup is not far enough back in the mouth, or perhaps it is too far back, or too much to one or the other of the sides, so that, as this last is concerned, in pressing it into place, the sharp edge of some portion of the ridge comes down upon the gum, producing not only much pain, but rendering the impression good for nothing. A proper correspondence existing, it only remains to press the tray gently and steady upon the arch, throwing the lip off should it interfere,—a manipulation, this last, easily accomplished by running a finger between lip and wax. A tray is never to be rocked into place, but rather carried with all steadiness until it is felt to be fixed and firm. Such a bearing obtained and preserved, the finger of the operator is to press the wax around the external face of the alveolar process, and where the false bottom has been used this is to be forced into the roof of the mouth. If the impression be of the lower jaw, the wax is to be pushed with the finger against the internal face of the process as well as against the external. Before removing an impression of wax from the mouth, it is to be allowed to remain a few minutes to harden. If, in the withdrawal, suction is recognized, the impression will almost certainly prove a good one. A tray is held most steadily in the mouth by being supported on either side.

Some operators, skilful in the use of wax as an impression material, find it necessary to employ a strand of silk or thread run through the material just before introducing it into the mouth, that, after securing the cast, they may get it away by letting in air through withdrawal of the string; the accuracy of the fit they obtain resulting in a suction so powerful as to make it difficult to get away the tray without derangement of the plastic.

Before taking an impression, a mouth is to be cleared of saliva and mucus. This is most conveniently accomplished through rinsing with water and cologne, a teaspoonful of the latter to half a goblet of the former, or, if more convenient, the cologne may be replaced with alcohol.

It is occasionally found recommended that immediately upon withdrawal of a wax impression from the mouth it be plunged into ice-water, or otherwise that it be laid upon ice. This is a practice scarcely to be endorsed, the varying thickness of the wax rendering some change not unlikely. Unless hurry exist, it is best to leave the cast to the existing state of the atmosphere.

*Sulphate of Lime—Plaster of Paris.*—Plaster of Paris mixed with water into a paste, or batter, is very widely employed as an agent for taking impressions. Plaster to be useful for such purpose must be of the very best



quality; this implies that it has been well calcined and thoroughly pulverized. To employ it, the operator selects a tray, and, filling it with the plaster batter, it is passed into the mouth in such manner that bubbles of air shall not be caught in the depth of the arch,—that is, the pressure which carries the mass into place is to be exerted gradually from the front backward.

For plaster (employing it with the upper arch), cups or trays, as portrayed in Fig. 318, are commonly used. These cups are made of britannia and are easily forced into any change of form required. A plan preferred, however, by many, consists in first taking an impression in wax, precisely as has been directed. This secured, the surface of impression is indifferently cut away, simply with the view of securing what might be termed a fairly-fitting wax tray. Into this is now poured the plaster batter, and the whole is reintroduced into the mouth. Put batter first in concavity of arch where very deep.

Employing plaster for the lower arch, the tray as shown in Fig. 319, uncut, is found entirely applicable. The requisites of a tray holding the plaster batter are, depth of flange sufficient to invest the alveolar face to an extent required to be covered by the paste, and a relation to the arch which insures the plaster reaching every position of the part to be modelled.

To take an impression in plaster, a patient is to be seated upon a low chair, and the head inclined forward at an angle sufficient to prevent the falling of particles back into the throat. The batter is to be of a consistency which does not allow it to run from the tray, nor on the other hand is it to be so stiff and hard that it may not take the desired cast. The time required for setting is about three minutes; it may be shorter or it may be longer,—this depending on the character of the plaster used. The proper time for the removal from the mouth of a plaster impression is designated by the sharp, abrupt break to be seen by fracturing any inconsiderable and unimportant fragment, or by testing such portion as may be left in the mixing-vessel. The matter of the time for removal is of very marked importance; should the batter not have set, the impression is of course worthless. Should it, on the contrary, have become too solid, it may bring a portion of the mucous membrane with it; particularly in the case of the superior arch. Plaster known in the market as “superfine” is the best.

Plaster that is slow in setting finds the defect removed by the addition of a small portion of common table salt, or, what is thought by some to be better, the sulphate of potash.

Plaster of Paris as an agent for impressions finds its most convenient application to edentulous arches; that it is used, however, with all success for partial sets of teeth is daily demonstrated. To take a partial impression it is found convenient to have a tray with a false flange. After the batter has set, this flange is to be withdrawn, the bottom part of the tray being separated from the mass by means of the point of the knife-blade. Next, the impression is broken into pieces, each fragment being removed carefully and



preserved. When all are away, each piece is coaptated with its fellow, thus restoring the cast.

A second mode of taking a partial impression is found in the use of a wax cast; the cup thus detached, the wax is quickly and easily removed from the plaster; the exposed cast is now broken and treated as before described.

Occasionally, indeed frequently, it happens that if the proper moment be secured, a plaster cast, even although it enclose several teeth, may be removed with reasonable facility without occasion for the fracturing as suggested. It is a point with many operators to try and save themselves the trouble arising out of breakage, and with a reasonable experience this is oftentimes to be accomplished.

*Modelling Compound.*—This is a preparation composed of French damar, Venice turpentine, talc, coloring matter, and aromatics. As an impression material it is sharp and of firm fixation. The manner of use is the same as for wax.

*Gutta-Percha.*—This material, used alone, has never impressed the author as an agent of sufficient merit to warrant, in this direction, any special commendation. It is not only troublesome to manipulate, but from its tendency to undue hardening, as influenced by circumstances, is tedious to look after; it may not have comparison with either the wax or the plaster. As an agent of admixture with wax, however, it is at times found a not unsatisfactory adjunct, insuring, as it does, an accuracy and sharpness in outline which is the highest recommendation of an impression. Gutta-percha alone, or in combination with wax, is used precisely the same as the pure wax, being softened by moist or dry heat, placed in the cup, and thus applied. When the gutta-percha alone is used, trouble may be experienced in getting it from the mouth, particularly in cases where teeth stand in an irregular relation to one another in the arch.

**The Model.**—An impression of the mouth secured, a succeeding step is the making of a model. This model is to be a fac-simile of the parts taken in the impression, and is made in a very few moments, as follows: If the impression be of wax, or gutta-percha, or of the mixture of wax and gutta-percha, or modelling compound, the surface is to be thoroughly smeared with oil, the tray is placed upon a table, a strip of paper, or lead, or waxed cloth, —any convenient thing, being of a length sufficient to encircle the circumference of the impression, and of a width not less than one and a half inches,—is to be placed around the tray, forming thus a temporary cup, the bottom of which is the impression. Taking now plaster of Paris sufficient in quantity to fill this cup, it is mixed with water into a batter of the consistency of very thick cream, and in this state it is poured, with care, beginning at one corner, into the cup. When set solid, which will require two or three hours, the strip is to be taken away, the tray removed by heating it slightly, and the wax, being further warmed and softened, is picked off little by little, any convenient instrument being used, an ordinary pocket-knife answering the



purpose quite as well as anything else. This model is the cast to which the mechanic works; it is a perfect likeness of the mouth to which the teeth are to be fitted.

In the case of a plaster impression the manipulations for securing the model differ somewhat from the above. The impression is first to be thinly varnished, and when dry is to be oiled, and the cream batter poured as before. When solid, the plaster impression is to be broken by the taps of a mallet, and thus, in pieces, lifted away. Another plan is to put the cast and impression in water, where the impression, by reason of its greater dryness, will absorb the fluid and expand more rapidly than the cast, so that it can be lifted away without injuring the model, and in many cases saving the impression for secondary use in case accident should render this desirable.

To insure a plaster model against chipping it is commonly coated with shellac varnish; this is accomplished by repeated brushings, one coat being dry before another is applied. Where it is important to insure much resistance on the part of a model, it is a practice adopted by many to boil it for about half an hour in a strong solution of alum; the officinal, or potassa-alum, is the variety used.

**The Denture.**—At this point is to be considered the mechanical performance of making the denture. The student whose purpose it is to practise dental art exclusively will have to duplicate the present work by one on mechanism. Out of such a work, of which there are several to be had of the booksellers, he will find himself able to secure the proper details.

The procedure of an oral surgeon in this connection is as follows: Taking the model which he has made, he transfers it to the hands of a mechanical dentist, being judicious in selecting one who possesses an art appreciation of his work. This latter now makes what is known as a trial plate,—a plate made to prove the correctness of the impression,—which, being delivered to the surgeon, is placed in the mouth, and, if found right, receives the articulation. To make a trial plate is nothing more difficult, however, than taking a piece of sheet gutta-percha or modelling composition and, warming it into ductility, spread it over the face of the model. Sheet-lead, wax, or any convenient means may be used. One is to be moulded and trimmed into shape in five minutes.

Plates for the denture are of two kinds,—those supported by clasps, or bands, which pass around certain teeth, and those which depend on atmospheric pressure for support. Whether the one or the other of these is to be employed depends entirely on the state of the mouth. Where all the teeth are gone, there is, of course, but the single resource: the plate must be made to cover the full arch, and, if the case is for the superior jaw, a cavity, occupying the centre of the palatine face, is to be made in it. Where certain teeth are present, these being of good shape to support bands, and of vigorous health and solid structure, it may prove a matter of comfort to the patient to take advantage of such means to give him a plate which allows exposure



to a greater extent of mucous membrane,—a matter of little consequence to the comfort of the lymphatic temperament, but of much concern to the nervous.

The matter of holding a plate by means of atmospheric pressure demands both experience and thought. The usual manner consists in cutting from heavy sheet-lead a half-moon-shaped piece, which piece is moulded upon the palatine face of the plaster model, with a view of securing a similar elevation in the zinc cast to be made from it, and a counter-depression in the lead mould prepared upon this latter. As will be inferred, a metal plate struck between such casts would contain a cavity corresponding in shape and depth with the piece of sheet-lead. If a denture plate be celluloid or gutta-percha, the moulding of the plastic over the prepared face of the plaster model secures the same cavity.

The shape and characteristics of a palate have much to do with success in suction cavities. The best kind of a palate is one that is reasonably deep and not too soft. Sometimes it is found desirable to use no vacuum plate, but to cover the oral roof fully and accurately. On the other hand, cases are met where the plate is to relate solely with the alveolar arch, the suction cavity occupying the whole hard palate.

Cavities made on the principle of the leather sucker, a plaything familiar to every school-boy, are favorites with many; these being used alone or as adjuncts to the kinds described. A form of these is known as the Beer's disk. Attached to a plate prepared with a cavity, it requires alone to be pressed against the roof of the mouth in order to hold. Being made of pure gum, consequently being soft, any rocking occurring with the plate does not detach it. The manner of holding is absolutely that of the leather sucker, while it differs nothing in form from that toy, being round, saucer-shaped, with its middle occupied by a rivet instead of by a string, which rivet relates disk and plate.\*

A disk of this same meaning has been shown the author by Mr. I. E. Clifford, of Windermere, England; it differs, however, from the Beer instrument in being circularly corrugated, some on one, others on both faces. This disk, attached to a plate after the manner of the American device,

---

\* "Some members of the profession consider the disk a valuable invention for extremely difficult cases, but not necessary in the majority of mouths. In this they are seriously mistaken, for it is really of great utility in almost every case, and all who are compelled to wear artificial teeth should have the benefit of it. The large majority of plates made with the ordinary 'suction chamber' are likely to tilt during mastication, thereby admitting air beneath them and destroying the vacuum, and very often they are thrown down in coughing, sneezing, etc., to the great annoyance and embarrassment of the wearers. With the disk attachment it is impossible to dislodge a set of teeth by any movement of the mouth, and the wearer has a sense of security and satisfaction which cannot be enjoyed with a set made by the old method. We therefore claim that a set of artificial teeth is unfinished unless it has this improvement, which adds so much to the comfort of the patient."—*From advertisement of inventor.*



catches the oral roof with considerable tenacity. The pieces corrugated on both surfaces adhere alike, on pressure, to plate and arch of palate.

A manner of supporting dentures, now almost obsolete, consists in the use of spiral springs.

**The Articulation.**—Articulation considers bite,—that is, it is necessary to know how the natural teeth stand in order that the artificial shall be in harmony with them. To secure articulation the procedure is as follows :

*The Partial Denture.*—We take, as the most simple illustration, a plate upon which is to be placed a partial denture, say the six central teeth of the upper jaw. Try the plate in its place, and see if a fit has been secured ; fit is adaptability ; every part of a plate is to rest evenly and solidly upon its base. If bands have been used, these are to enclose with the nicest accuracy the special teeth to which they are related,—they are to hug the teeth. Where atmospheric pressure is the means of support, the relation of parts is to be so intimate that withdrawal of air from beneath the plate—effected through suction by the tongue—causes it to adhere to the parts with more or less tenacity.

Satisfied of the adaptability of the plate, a succeeding step consists in softening a piece of beeswax precisely as was done for the wax impression, and, moulding this upon that part of the plate to be occupied by the new teeth, the patient is directed to close his mouth. This, as is seen, bites the lower teeth into the wax, thus affording knowledge of how the artificial teeth are to be set ; leaning the head far back insures against false bite. Associated with this step is the trimming of the wax while in the mouth, into what shall seem the required length of the new teeth ; also the wax overlying that portion of the plate which covers the external face of the alveolar ridge is to be so trimmed and moulded as to give proper contour, or expression, to the overlying lip. In such partial cases, however, it is not at all a necessity that anything more be done by the surgeon than secure the bite as directed. The mechanician, if at all an artist, has every required guide in the surrounding relations ; the trimming and modelling he can do to suit himself. What is called a shade, is required, however, by him ; this is secured by matching in color the natural by an artificial tooth, of which latter the surgeon is to have at his command quite a number.

*The Full Half-Denture.*—A full half-denture implies the complete set either of the upper or the lower arch. We consider first the upper. Try the plate in the mouth to test its adaptability. If this be satisfactory, let the patient close the teeth of the lower jaw upon it. This affords information as to a general line at which these teeth will strike the plate. Take now the plate from the mouth, and build upon it a rim of wax of a height which, when in the mouth, will represent the required length of the new teeth. Such height is readily distinguished by trimming the wax little by little, until, in the various movements of the lips, as in talking, laughing, etc., it is seen to afford the promise of a natural expression. This secured, let the patient make a line of the impression of his lower teeth by slightly biting



into the wax. Next the support of the lip is to have consideration. This pertains of course to the gum portion of the teeth. To afford here the requisite information to the artist, it is only necessary to model the wax until the external parts are seen to have proper expression. This modelling is done by building upon the flange of the plate a rim of wax of such form and shape as are proved to be right by the impression produced on the contour of the lip. Accompanied by its shade tooth, the articulation is now ready to be again transferred.

An articulation of the full lower denture is to be secured in a manner precisely similar to that practised with the superior.

*The Articulation of a Complete Denture.*—A complete denture implies a set of teeth full above and below. Having the plates made ready, the surgeon first places them, each in its proper place, and causes the patient to close the mouth that thereby some general idea of the relation of the parts be obtained. Measuring now the size of the lips that notion be afforded of the required length of the new teeth, rims of wax are built upon the two plates precisely as before explained. This accomplished, each plate is to be placed in position and the relations studied; the lip is to be properly contoured, the wax is to represent the proper height of the new teeth, and the arches are to have such relations with each other that the tongue is accommodated with the room required for untrammelled movement: likewise is it to be observed that the line at which the rim of wax rests upon each plate is calculated to throw the centre of gravity of the new teeth on a bearing which antagonizes any tendency in the plate to tilt. This last, however, the mechanical dentist should himself know all about; it is not a necessity that the surgeon particularly heed it, it is of chief consequence, however, that such balance be secured. Finally, the plates, with their rims, having been accommodated, each to its special requirements, the two are put at the same time in place in the mouth. This done, the patient is directed to close naturally the jaw, and as now the rims of wax meet, and adhere to each other, the natural bite, or articulation, is secured. The operator next, with a knife or other convenient instrument, marks from plate to plate upon the united rims of wax a line which represents the exact centre of the mouth, and besides this central mark two others, one on either side. The plates may now, in their united condition, be removed from the mouth, and are ready for another transfer. If, however, it happen, as indeed is not unlikely, that in removing the plates they have separated, it makes but little difference, as by the lines which have been cut they are at any moment to be replaced in the original position.

Peculiarities in articular relations occasionally occur, the management of which requires experience to make easy. As an example, reference may be made to a condition in which teeth remaining in both the upper and lower arches hold such relation that in bringing the jaws together they pass each other, allowing those of either arch to strike the gum of its an-



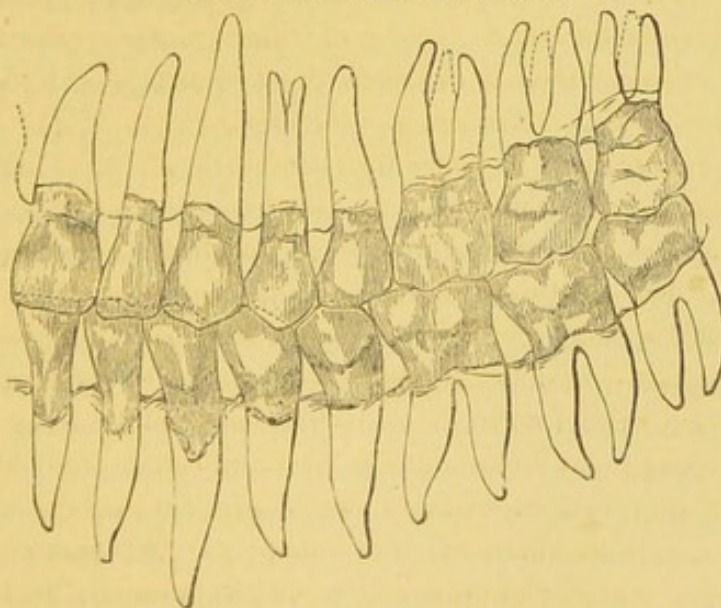
tagonist. Proper articular relation here resides in so arranging the artificial teeth that bite is restored to the original plane. In other words, in the arrangement of the wax the closure of the jaw is to show the impression upon it on that plane which would be natural, should the irregularly placed teeth strike instead of passing each other.

In an attempt to procure almost any but the most simple of articulations, the operator finds himself annoyed by false bites, the patient closing his mouth in every way but the right one; particularly does experience show this to be a result where special pains are taken to instruct a sitter as to the manner of closure. A proper bite, it is to be recognized, is the natural one. After arranging the wax, tell the patient to close the mouth. Having thus obtained an articulation, take the piece out, and after a few minutes replace it, procuring now a second bite. Should the two correspond, inference is in favor of correctness. Should, however, different impressions be made upon the wax at the different bites, one or the other must necessarily be wrong; the test is to be repeated until satisfaction is secured. The manner suggested a few paragraphs back, of having the patient lean the head far back while biting, seems to be the best corrective of false bite yet tried.

**Articulating a Full Denture in the Mouth.**—When an articulation, or bite, as just described, is faultless, the relations of an artificial denture should be equally perfect. It very frequently happens, however, that, from fault either in the surgeon or the artist, the desired and absolutely necessary perfectness of articulation does not exist, certain teeth being seen to strike unduly, thus denying a common occlusion; or it may be that the cusps are found wrongly placed as regard is had to their articulating neighbors.

To appreciate the character of a proper articulation, the student will refer to Fig. 321.

FIG. 321.—ARTICULATION.



Integrity and mechanical adaptability in articulation are essentials to usefulness and comfort. Artificial teeth which do not strike properly can never



be servicable or easy to the wearer. When, therefore, a finished denture is found to be so far out of the way in this direction as not to permit of a satisfactory correction, the very best thing to do is to have the piece made over. Such a necessity must come more or less frequently to the inexperienced; each mistake, however, has in it the compensation of a lesson more instructive than a dozen successes.

Artificial dentures slightly faulty in articulation constitute the rule rather than the exception. Relief here is found in recognizing the false touching points and by the use of the corundum stick, or preferably the wheel, cutting such points away.

Closing his own natural teeth, one recognizes solidity and regularity of occlusion. This is the secret of articulation. No tooth is to touch before its fellow; bite is to be common: an upper relates with two lower teeth.

**Addenda.**—Working to an articulation which has been furnished him (Fig. 323), the mechanical dentist attaches the teeth to his plate in general correspondence with such articulation. That it may be proven he returns it to the surgeon, prepared as designed by him, to be placed in the mouth. The teeth, however, in place of being solidly attached to a plate, are merely moulded into wax. Taking this denture, one who would convert the manufacture into an art proceeding places the set in the mouth, and, with aid of taste, he twists, turns, and alters special form and general contour until relation with physiognomical requirements is complete. The stones figured in connection with the insertion of pivot teeth are requisite in the work.

Arranged and ground to suit, the case is handed back to the mechanician, who, without in any way changing what has been done, proceeds to finish the operation; which being accomplished, it is again returned to the surgeon to be fitted into the mouth as just described.

Prosthetic dentistry, viewed as art work, is possessed of great interest. *Æsthetically* considered, it is a restorer of youth to age, comfort to discomfort. As work it soon comes to command great interest at the hands of him who engages in it. (See *Vulcanite and Celluloid*.)

An artificial denture is to consider many indications: it is to fit a mouth so as to be worn with comfort; it is to articulate after such manner as shall serve all the purposes of mastication; it is to restore lost expression.

Makers of artificial dentures are many, dental artists are few. It is possible, with appliances now at command, to replace lost teeth and symmetry with such perfectness as to deceive the closest observer. Every case is a special study; there is no rule of setting teeth that will apply to any two mouths. An artist may spend many hours not less pleasantly than profitably in physiognomically adapting a set of teeth to the mouth of a patient under charge. Adaptation consists in an appreciation of relations. This adaptation is to be practised at that stage of denture-making which precedes the fastening of teeth to a plate. The secret lies in arrangement.

**Illustrations in Arrangement.**—In the laboratory of the mechanical



dentist is an instrument known as an articulator; Fig. 322 represents one form; a great variety existing. That he may be certain of having a reliable model of the articular relation of the jaws to work by, the artist uses this apparatus, fixing the plates in their apposed positions by attaching them, each

FIG. 322.

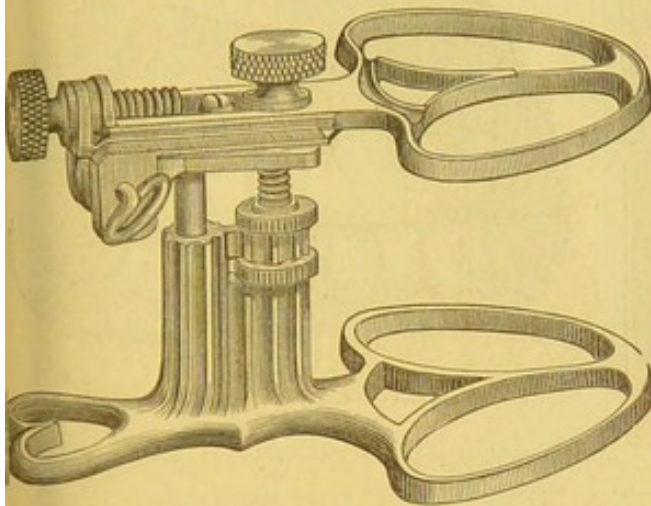
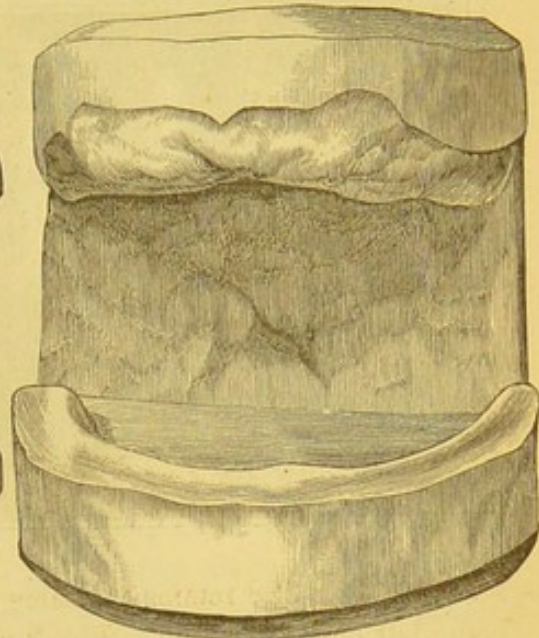


FIG. 323.



Arches in articular relation.

in its place, to the wings. These wings, before removal of the intervening wax which holds the plates in relation, are secured by means which allow of no change in position, so that on taking away of the wax the worker has assurance that relations are absolutely maintained, and that as the teeth are attached to his plates, so will they surely show in the mouth. Articulators have, as a rule, a joint which permits of a motion corresponding with that of the lower jaw, adding much to the convenience and facility of the dentist as he works at and studies his case.

The plates being attached, as explained, to the articulator, and the bite-wax removed, it is evident that a model as here exhibited, Fig. 323, would exist, and that the space between the two plates is that which requires to be correctly filled by the artificial teeth.

Fig. 324 illustrates a set of teeth as furnished for setting by the manufacturer.\* As here shown they reach the hands of the mechanical dentist, whose business it is to set or prepare them for the mouth. Fig. 325 shows this same set of teeth prepared for the mouth. As exhibited in the diagram, this denture appears handsome and finished. If so set for a patient about twenty-five or thirty years of age, possessed of great regularity of features and freshness of complexion, the arrangement might prove perfect.

We pass to a step in æsthetics. Fig. 326 shows this same set of teeth

\* This form of teeth is prepared and adapted for the celluloid base. Plate teeth, designed for ordinary soldering, are without roots.



triflingly altered in outlook by a cutting of the articulating faces expressive of abrasion. Fig. 327 shows these abraded teeth irregularly related in the

FIG. 324.

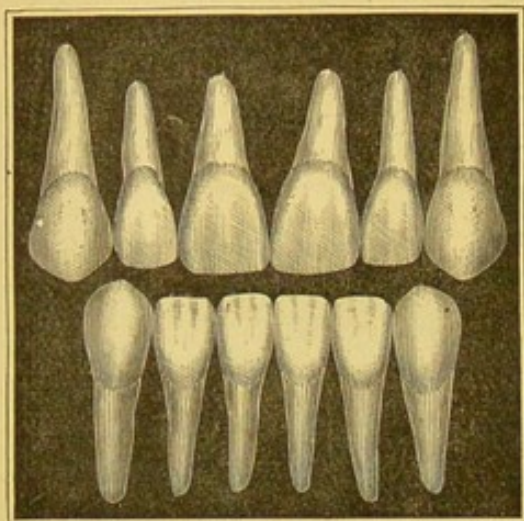
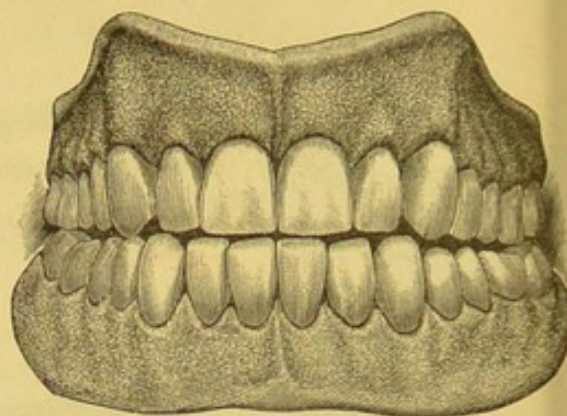


FIG. 325.



setting. Fig. 328 retains the same particular teeth irregularly set, a bicuspid being left out of the arch. Fig. 329 is a palatal view of the same case. Fig. 330, still the same teeth, is expressive; it shows a very common condition of recession in the gums. Great effect in the way of naturalness is gained in imitating this recession. Fig. 331 is a side view of the same denture.

FIG. 326.

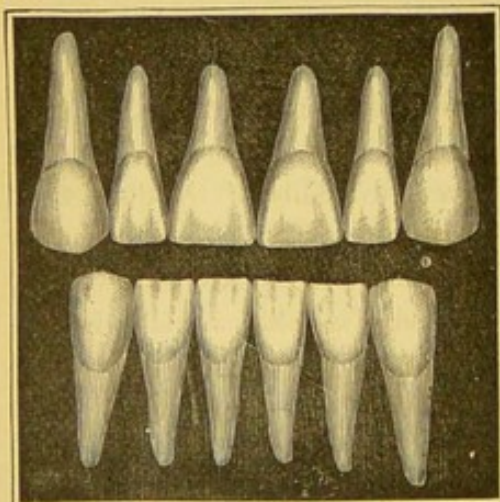
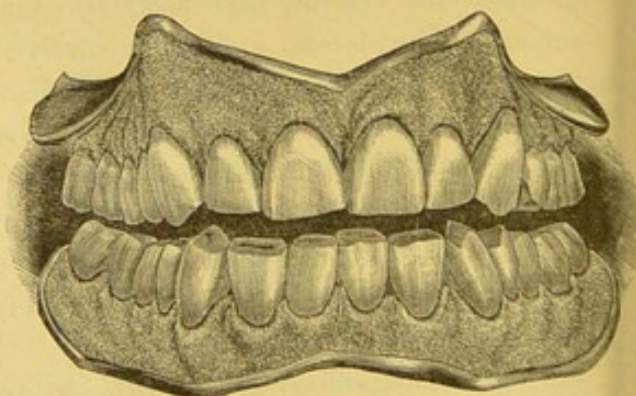


FIG. 327.



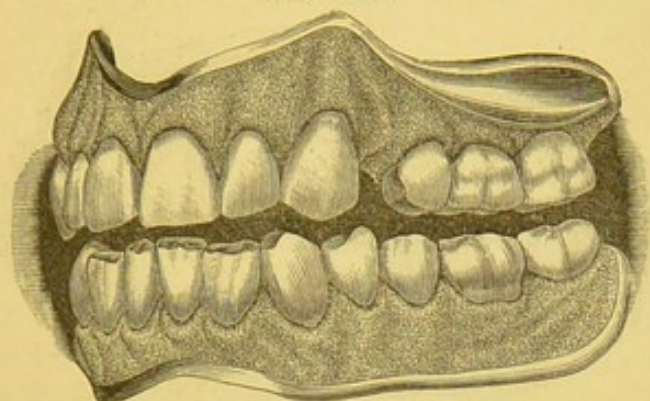
These illustrations, copied from studies by Warrington Evans, M.D., have the meaning of changes made to meet varying indications associated with features, age, etc. Seeing what results are to be obtained out of a single set of teeth, an operator will be led to infer that, with so great a variety before him as is to be found in a dental depot, he may effect anything within his inclination.

**Plumpers.**—What are known as plumpers consist simply in what has been



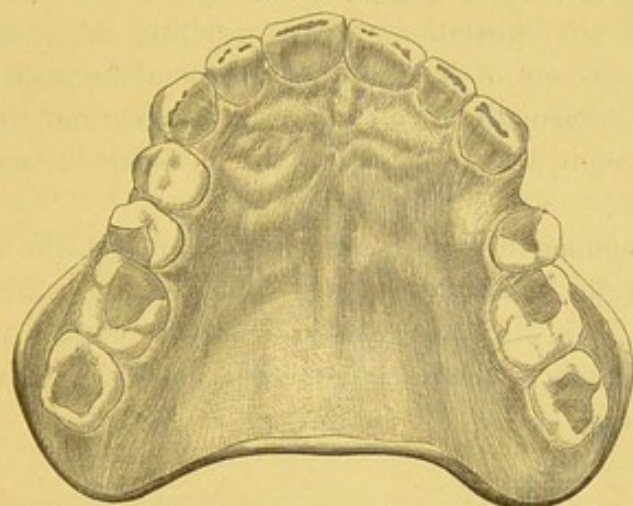
alluded to as contours, made by additions to the base of a denture; the object is expression. Plumpers are commonly associated with the cheek

FIG. 328.



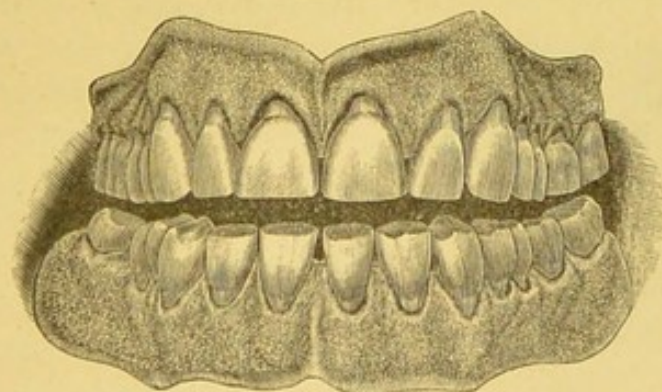
portion of the base. To make them nothing more is necessary than to

FIG. 329.



thicken this base by added material. Contouring is first to be accomplished

FIG. 330.

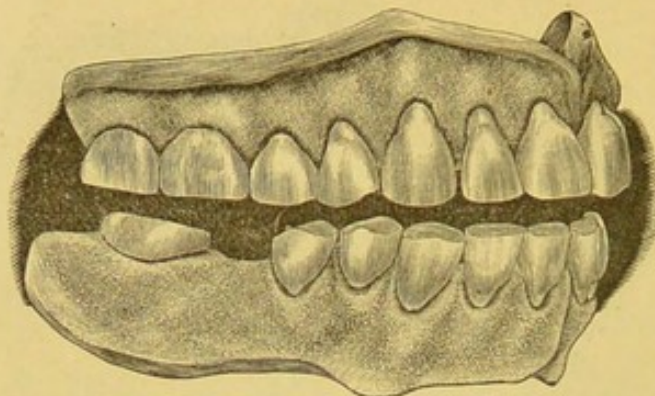


during the process of articulation, the operator adding layer after layer of wax until a desired restoration of form is achieved. It is in the experience



of the author to have secured such results in this direction that a toothless woman of seventy has found herself able, through a judicious use of

FIG. 331.



rouge, to compete with a sister forty years younger. An instance is familiar in which a mechanical dentist of celebrity in the art furnishes in his own person such an illustration of the capabilities of contouring that with teeth and plumpers out of his mouth he becomes instantly metamorphosed from a man full, apparently, of life and vigor, looking not a day over fifty, to one old and decrepit, whose age might be anywhere between ninety and a hundred.

A contour obtained by wax, it remains simply for the operator to pass the piece over to the mechanical dentist, who reproduces it in metal, in vulcanite, celluloid, or in whatever material it may be decided to use.

A full study of oral æsthetics is best made, and indeed is to be made only, in a study of faces.



## CHAPTER XXX.

### THE MATERIALS VULCANITE AND CELLULOID.

MANIPULATIONS with the materials vulcanite and celluloid are so exceedingly interesting, and, at the same time, so easy of being understood and accomplished, that the present chapter is introduced for the instruction of such as wish to enter upon the practice, either with a view to profit, convenience, or entertainment.

By vulcanizing is meant the conversion of a plastic material into a base of such solidity that it can be used for the attachment and support of artificial teeth, for obturators, and for a variety of similar purposes within the requirement of oral surgery. Vulcanite is a composition bought prepared at the depots; its components are india-rubber, sulphur, and sulphuret of mercury. It comes in form of sheets.

*Dental Plates as an Example.*—The author describes here the manner of making a denture, the example applying to the working of the material for any other purpose. First an impression of a mouth is taken, and an articulation secured precisely as described in the previous chapter; except that the test plate, on which the bite is received, is preferably made of wax for a reason shortly to be understood, and that also a layer of tin foil be made to underlie this wax as direct relation with the model is concerned. Teeth used are specially prepared for the purpose. Fig. 332 shows the peculiarity.

Let it be accepted that the worker has a set of teeth arranged as required, which teeth have their fixation by reason of temporary attachment to a base plate of wax, which wax, in its turn, rests upon a layer of tin foil: teeth and base rest in turn upon the plaster model. The wax of the base is required to be trimmed and formed that it shall represent accurately a base of vulcanite which is to take its place. The thickness of the wax is to vary according to position, and to requirements in general, from the twelfth to the twentieth of an inch. It is to be added that the joints between the gums are demanded to be as close as accuracy can make them.

To replace the wax base with one of vulcanite the operation is as follows:

FIG. 332.—TEETH USED WITH VULCANITE; FRONT AND SIDE VIEWS.

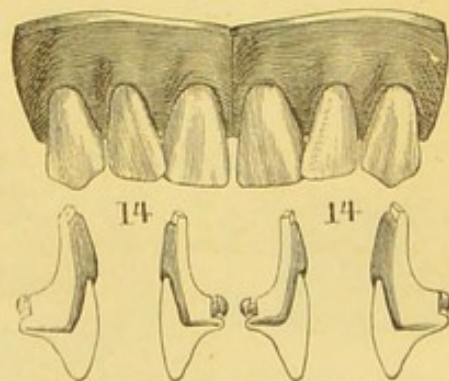
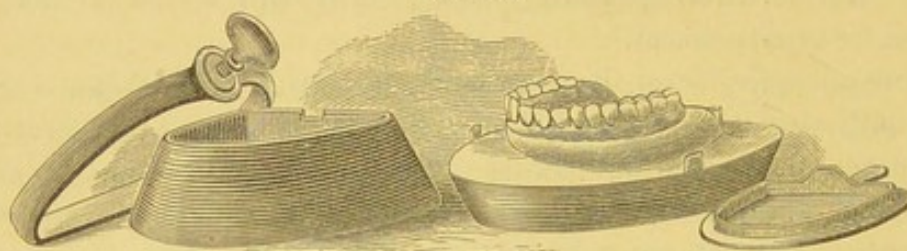




Fig. 333 represents moulding flasks, composed, as will be understood, of two horse-hoof-shaped cups. Into the lower one of these cups a thin batter of plaster is poured, when the model, holding the wax plate and teeth, is sunk in this batter until the base of the alveolar margin is on a level with the rim. (Points to observe relate to cutting away the base of the model so that it shall allow of the margin occupying the relation to rim alluded to, and as well the immersing of the model in water so that it shall not too hastily and unduly soak the fluid from the batter.) The model and batter becoming united through the setting of the latter, the worker trims up smoothly so that expression of model, teeth, the hardened batter, and the flask are as shown in Fig. 333. Here it is necessary to consider what is termed the draw, or sep-

FIG. 333.

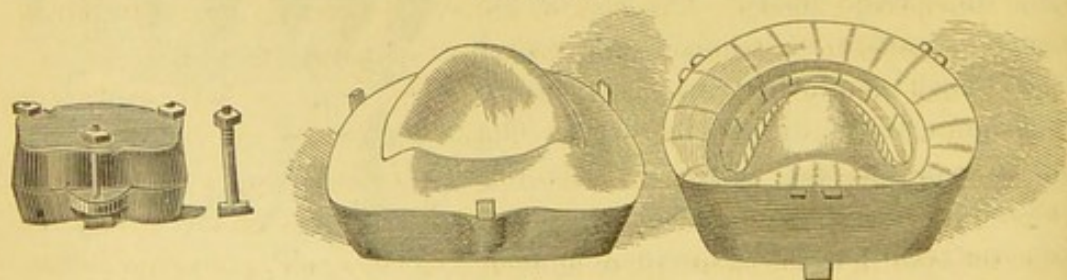


aration; that is to say, that as it is the intention to cover in this whole surface with batter-plaster, and that later this covering is to be lifted away, regard must be had to so placing the model that as little interference as possible exists in the way of the separation. Under, or receding, spaces are to be brought out as nearly as permissible to the level by means of plaster.

The draw provided for, a succeeding step varnishes or oils the whole exposed surface, as seen in Fig. 333, and, after placing the top portion of the flask, minus its cover (see same figure), fills up with thin batter: being most careful to avoid bubbles and to see that no interstice be left unoccupied. Next the cover is placed and the screw (see same figure) applied. Convenience is found in washing the batter-covered flask before the plaster has entirely set about the outside.

The plaster within the flask being allowed to rest until it has become

FIG. 334.



quite hard, the parts are separated (a matter insured by the precautions described), and the wax base plate is delicately picked away. Fig. 334 shows



the expression resulting; the model is in the portion of flask to the left; the teeth, together with the space secured by removal of the wax, are in that to the right.

As it is the intention in an immediately succeeding step to occupy the wax-space with vulcanite, and as the backs of the ground teeth abut on this space, it is recognized that imperfection in the grinding would necessarily permit the fluid gum, when brought under pressure, to insinuate itself into and between the spaces, thus destroying wholly the appearance of perfect jointure necessary to exist in a finished denture. Assuming, however, that inexperience, or undue haste in performance, shows the jointures at this stage as imperfect, the operator may, to an extent, antagonize the defect by insinuating dry plaster, touched with water, into the fissures; or, as is recommended by some experts, soluble glass may be painted into them; the manipulator being careful to clean every part, save the fissures, of the foreign material.

Turning again to Fig. 334, diagram of right side, the palatal reverse of the left is seen. Surrounding the palate, and corresponding with the curvature of the alveolar arch, the backs of the artificial teeth are seen, at least that portion of the backs which exposes gums and pins. Outside of the extreme tops of the gum a curved dig-out in the plaster is observed, the intention of this being room for that portion of gum-rim always seen on the boundary of a denture. The transverse cuts observed in the plaster are made with a view of accommodating surplusage, when the soft gum comes later to be crowded into the place of the removed wax.

Packing the vulcanite, for which the parts are now found ready, is accomplished by using gum made soft through means of a steam-heated surface. This gum, cut into strips for convenience of use, the first piece being of a size that shall cover the palatine surface, is laid upon the plate, the matrix being subjected at the same time to similar heat, and, when the flask has become warm and the gum is softened, the latter is taken up by any convenient means, and is packed into every part of the locality formerly occupied by the wax. An excess of this gum is allowed to be provided for by the transverse cuts, should it prove more than can be received. Here attention is to be bestowed on the experience that too little gum is the spoiling of the piece, too much is alike its destruction; the last owing to the undue pressure required to move it from the matrix, and most particularly does this apply where said transverse cuts are lacking in accord with requirements.

The packing completed, and the cups of the common flask being put together and the screws or clamp applied (a temperature of 212° Fahrenheit being maintained), the parts are screwed up as closely as is to be accomplished by aid of a wrench. This screwing process forces most fully the pasty contained mass into every locality, the excess escaping into the transverse cuts.

The last performance introduces the vulcanizer. Of these instruments, as of the flasks, there is a wide variety; the one shown in the cut (Fig. 335),



is quite equal, though perhaps in no way superior, to the many competitors found in the dental depots. A vulcanizer is an apparatus made up of a boiler and

FIG. 335.

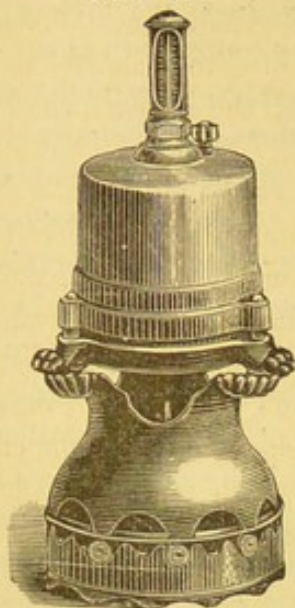



FIG. 336.



a furnace. In the one shown the boiler, surmounted by a thermometer, constitutes an upper half, the lower half is a furnace. Furnace-power signifies an ability to raise the temperature to  $326^{\circ}$  Fahrenheit, the means employed being gas, alcohol, or kerosene. Fig. 336 shows gas and alcohol, or kerosene arrangements. The boiler is rimmed internally about half an inch above the bottom, the object being support of the flask and accommodation of a few ounces of water.

The water being in place at the bottom of the vulcanizer, and being brought up to a temperature corresponding with that of the flask and contents, the latter are laid upon the rim, and the lid of the boiler screwed into place. Now begins the process of vulcanizing. Slowly the temperature is increased, it being a rule with many to expend an hour in obtaining  $310^{\circ}$ , and a second to advance it 10 other degrees; this last secured, and being held for five minutes, vulcanizing is to be accepted as accomplished. In college laboratories it is not common to spend more than a single hour in vulcanizing; the temperature being gradually brought up to  $326^{\circ}$  without an intervening waiting.

Cooling is to be gradual; a desirable plan is to leave things undisturbed until the flask is to be handled without discomfort to the fingers. The plaster, together with its imbedment, being allowed to stand a few hours after removal from the flask, is found to grow entirely crumbly, and is easily broken away from the denture; to remove it, tap the edges of the flask.

The gum vulcanized, or turned into a plate of horn-like consistency, a concluding stage refers to finishing the denture for the mouth. This performance relates to getting clear of all superfluous material, to thinning and shaping the piece into fitness and comeliness, and to compelling a polish



of the inferior surface and sides of plate, which is good in proportion as it is glass-like. Instruments employed are scrapers, files, sand-paper, rotten-stone, oxide of zinc, pumice, cone-burs,—any means found at hand and convenient. Spring callipers are necessary to measurement of the thickness of plate.

The conversion of the compound gum known as vulcanite into the hard substance distinguished as dental plate is of chemical meaning, and relates with a catalysis arising out of an intensified union of sulphur and caoutchouc produced through high heat; the difference as to softness or hardness being influenced entirely by that degree of temperature in which union is effected.

A concluding reference is to be made to the employment of the material from a medical stand-point. Ill effect upon the mucous face of the mouth is at times a result of the use of vulcanite plates, which effect is commonly attributed to the action of the vermilion, or sulphuret of mercury. The writer has given considerable attention practically to the subject, and desires to offer it as a conviction that trouble, exceptionable cases perhaps excluded, will be found to rest in the fact that the material, being a non-conductor, heats the parts, particularly as the locality of the suction cavity is concerned, thus engendering a passing inflammation, which is the nature of the offence. A vulcanite denture for this reason is not wisely kept in the mouth during sleeping hours.

Black vulcanite is preferred by many operators to the red. Here the gum is absolutely free from the coloring matter,—*i.e.*, the sulphuret of mercury. The process of preparing this form of the material is preferably by dry heat, moisture changing it to a dirty-brown color. The time required for vulcanizing is seldom less than five hours. Black base plates take a brilliant and durable polish. Objection to the preparation lies in an exposure of it when in the mouth, not at all times to be avoided.

**Celluloid.**—Celluloid is a pink-colored material, semi-brittle in consistency, possessed of greater conducting property than vulcanite, wholesome in nature, solid to an extent that denies soakage into it of fluids, and capable of being made into plates, buttons, etc., of ivory-like coolness and characteristics; its composition is gun-cotton, camphor, and collodion.

The making of a celluloid denture finds exact correspondence with vulcanite work until the stage of packing is reached. Here, instead of the warmed strips and heated flask, what is called a blank is taken (a blank being a mould of celluloid as furnished by the manufacturers, bearing fair resemblance to the ordinary denture plate), selection being made of a size corresponding nearly as may be to the requirements in the final plate. The teeth and base exposed, as seen in Fig. 334, the blank is laid loosely in its situation, and the other section of flask placed in position.\* Next the flask, with its

\* Celluloid flasks differ from those used in vulcanite, being heavier in structure and provided with rods and grooves on the sides of the sections, in place of screws, as in the rubber flask, for the purpose of guiding the sections into position during the process of moulding.



contents, is placed inside the boiler, and the screw (plunger it is commonly called) is turned sufficiently to lightly compress it. Consideration of the boiler refers us here to apparatus to be used, and of such instruments, as of the vulcanizer, manufacturers offer a considerable variety. Fig. 337 shows a new mode heater, an apparatus operated with moist or dry heat, and applicable alike to celluloid and rubber. The circular base, resting upon the

FIG. 337.



floor, is the gas-heating arrangement. The door, in the boiler portion, is a framed glass, permitting inspection of the flask-room. The screw-caps, four in number, three small and one large, seen on top, have their meaning understood by casting a glance at Fig. 338. To the right is a safety-valve. The left affords accommodation for a thermometer.


Fig. 338 is a sectional view of working parts of the apparatus, and affords, in its correctness, a full lesson of the manipulations to be described. The instrument, in its invention, is the outgrowth of what is esteemed by many the just view that perfect work, both as celluloid and vulcanite are concerned, is to be made only in a dry chamber, and that where a high degree of heat is used, such as is essential in the manipulation of celluloid, the temperature



must be kept uniform until the task is completed, and is not then to be allowed to change suddenly.

The blank, in place as described (occupying the loosely-screwed flask seen

FIG. 338.—SECTIONAL VIEW OF NEW MODE HEATER.



here under the screws within the boiler), it is the design and indication to begin its pressure only when a temperature has been obtained which is to be just below the burning-point; this is about  $320^{\circ}$ . It is common practice, however, to commence to turn the nuts when the blank becomes ductile enough to yield before a strength found in the fingers and thumb: about  $212^{\circ}$ . The mode of making pressure is understood in noticing that screws I, H, I, bear upon the top of the flask, and that compression is complete only when the divisions meet at the centre line. The screw-caps K, K, K, L, are used with a view of making the screw-holes steam-tight where moisture is depended on for the heating principle.

Observing the diagram, O, O shows a compartment separated from the flask- or packing-chamber; this is the water- and steam-box. Into this box put sufficient water to reach line A, and commence making steam by lighting the gas-furnace. Temperature, as it advances, is measured by the thermometer, C, in which connection it is to be noticed that the mercury-bath, B, is to be kept supplied with quicksilver (or what is found to answer equally well, iron filings) to an extent that covers the bulb. D is a screw-plug through which a compound steam-faucet works. E is a gum-nut for tightening the



packing of the steam-valve. F is stem of valve. G is a cap with a minute aperture, as seen, at one side. No probability of explosion lies with the apparatus.

Continuing to force the flask together, little by little as the temperature rises to the required average, the process is to be considered complete only when absolute apposition is secured, after which the furnace flame is extinguished and the case treated precisely as was the vulcanite.

An inexpensive apparatus replacing the one just described consists of a cylinder of iron large enough to hold a flask, glycerine being employed as the vehicle for the conveyance of heat. To use this means prepare and flask case. Next fix in clamp pertaining to the instrument, and, after placing the glycerine,—sufficient to envelop the flask,—put into cylinder. A subsequent step relates with the boiling of the fluid and compression of the blank. This apparatus presents, unfortunately, objection in the waste of time necessary to the preservation of a required cleanliness.

*Repairing.*—Breaks in celluloid dentures are repaired in the Philadelphia Dental College, under Dr. Cryer's plan, after the following very simple fashion: Remove all portions of broken tooth from the plate, taking care not to disturb the outlines of the socket. Select another of proper size and shade to replace the lost one. (If the tooth be numbered, a considerable part of the trouble of selection is saved by taking the number of the mould from the reverse impression in the plate, or from the broken pieces.) Having set the new organ partly in its place, hold it steadily over the flame of an alcohol lamp, carefully guarding the celluloid from contact with the flame. In a few seconds it will grow warm, and its heat will soften the plastic sufficiently to allow the placing of it in proper position. The attachment will cause, of course, a slight bulge, or raised spot, to appear in the celluloid opposite the oral aspect of the root of the tooth. Invest in plaster, in the deeper section of the flask, covering the whole plate and the teeth, except the small portion of the celluloid raised in pressing the tooth into place. Complete the investment, part the flask, and dry the case, after which insert a piece of rather thick writing-paper or heavy tin foil over the raised spot, and place in the oven. Heat up to the usual temperature for moulding and close the flask. When the case is cold the tooth will be found firmly fixed in its position, and there will be no mark to show that the plate had been repaired. In case a small portion of the celluloid is chipped away from the front of the socket,—enough only to expose the end of the root when in position,—drop a little wax upon the vacant spot, after placing the tooth, and carve to the shape desired. Without removing the wax, invest and mould as before described. The wax will pass off into the plaster, and its place will be supplied by the celluloid, of which there is usually enough to permit the flowing of the minute quantity required without damage.

If there is a similar deficiency on the inside of the plate, exposing the pins of the tooth, drop wax into the vacancy, and proceed as before, except that



in this case the wax is to be removed when the investment is made, and the bit of writing-paper or tin foil is to be placed just below instead of over the pins, so as to force the flowing of the celluloid to cover them.

To detach a tooth from a celluloid plate, *hold* the outside surface of the one to be removed in the flame of a lamp until the heat softens slightly the plastic about the pins, when it may be taken off without trouble, and it will come away clean, without any of the celluloid adhering to the metal. Do not move the plate back and forth through the flame, or others than the desired tooth may be loosened, or articulation may be interfered with. There is no danger of cracking a heated tooth so long as the flame does not come in contact with the pins.

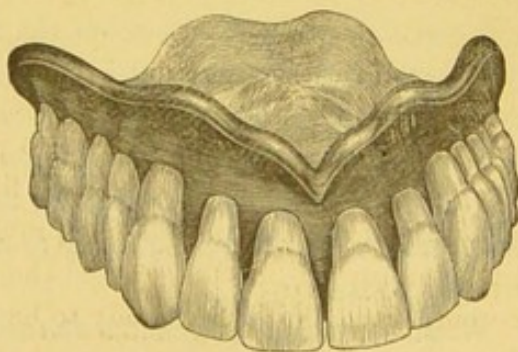
*Continuous Gum.*—The writer inclines to the conviction that continuous-gum work will, later on, be accomplished exclusively by means of celluloid. The agent allows imitation of the natural part, it is tenacious in its hold of teeth and plate, it denies all interspaces, it is in itself clean and sightly. Continuous-gum work is, undeniably, the highest accomplishment in artistic dentistry; each tooth is available for placing in any position desired and for study as expression is concerned. Objection to the plan, as the ordinary manner of preparing with porcelain is concerned, relates with weight, absence of elasticity, and expense in repairing accidents.

The following are the directions that apply to the new mode continuous gum, vulcanite being used as a base:

Employing teeth made expressly for continuous-gum or celluloid work (Fig. 324 shows such), set them up in wax after the usual manner, leaving the front, or outside, of the roots exposed. Cut a thin strip of the wax, warm, and attach it to the upper edge of the portion of the wax plate representing the gum, forming a rim which extends all around the outer margin. Finish the palatine surface to the form desired, invest in the flask in the usual manner, remove the wax, pack with rubber, and vulcanize. When removed from the flask, the case will present the appearance shown in Fig. 339, the front or outside of the roots being exposed and the narrow *undercut* rim extending all around, leaving a space with retaining-grooves between the teeth, for forming a gum of celluloid, looking very much as though the substance of the plate had been gouged out for the purpose. The vulcanite plate is now completed, with the teeth firmly attached to it.

To put on the gum, fill up the groove with paraffin and wax (this compound, not being sticky, does not adhere to the instrument, and is therefore more easily carved to the form desired) until all the space inside the rim, including the retaining-grooves

FIG. 339.—CASE READY FOR GUM.

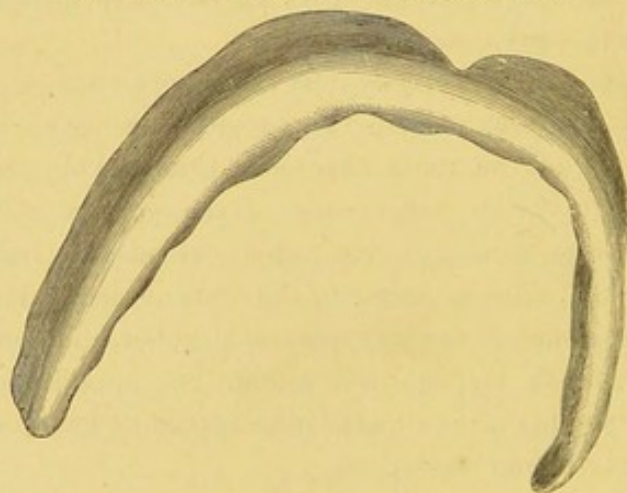




between the necks of the teeth, is occupied. After the wax has hardened, which may be hastened by placing in cold water, carve it into the desired form of gum. The wax may be made very smooth by throwing upon it the flame of a spirit-lamp with the aid of a blow-pipe, taking care not to destroy the outline of the carved gum. Cover the wax with heavy tin foil, burnishing it lightly, but smoothly, to the wax.

Invest the piece again in the following manner: Place the plate in one section of the flask with the teeth upward, and raised at the front at a greater or less angle, as may be necessary, so that when the investment is completed the upper part of the flask may be removed without dragging. Imbed in plaster to the rim, and pour batter over the palatine surface, covering the crowns, and taking care to fill the interstices between the necks of the teeth, but leaving their outer surfaces exposed. After the investment sets, pour more plaster around the inner edge of the flask ring, forming a ridge, leaving a groove or space between it and the plate. (See Fig. 334.) Complete the investment, and remove the wax from the groove and interstices between the roots of the teeth by pouring boiling water over it. Having selected a celluloid blank of proper size, saw off the outer rim; in other words, make a semi-circular rim; warm this rim of celluloid in boiling water, and with the hand

FIG. 340.—CELLULOID BLANK RIM.



and a cloth press it closely about the teeth, and hold it to its place until stiff; it will then remain there until the two parts of the flask are entered upon the guide-pins. Join the two parts of the flask together and place the investment in the oven of the machine, having previously heated up the chamber. When the temperature of  $280^{\circ}$  is reached the flask may be closed. As soon as this is accomplished the case is ready to be removed from the oven and placed in a clamp to cool.

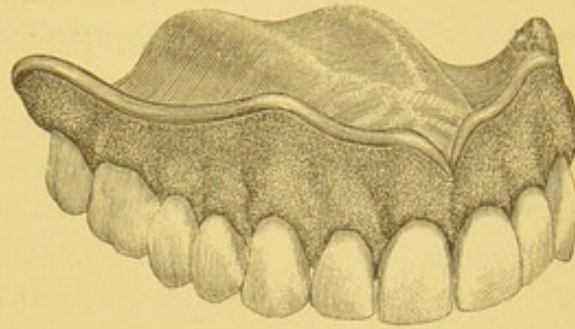
When entirely cold remove the plate. The tin foil will adhere to it, but can readily be removed by inserting the point of a knife under the edge and pulling it off. A surface produced by the above method presents a smooth, polished gum, but if the tin foil used be "stippled" a striking resemblance to



the natural part is produced. The adjoining edges of the celluloid and rubber will be found perfectly united, each preserving a sharp outline.

A second manner of making continuous gum out of celluloid relates to its use on metal bases. First an impression of a mouth is taken, and a plate of silver, gold, or platinum is prepared.\* This plate is tried, and, if found to fit, teeth like those shown in Fig. 324 are arranged on wax after a manner that secures both articulation and physiognomical adaptability. The piece, as it thus stands, is handed back to the dentist, who sets the case up in plaster, backs the teeth with metal, and solders the parts

FIG. 341.—METAL PLATE WITH CELLULOID GUM.



indifferently together. Taking the denture as now prepared, it is again tried in the mouth, a gum structure having been built out of wax about and around the teeth. This stage introduces the celluloid pack, which is accomplished and the piece finished precisely as described in preceding paragraphs. Fig. 341 shows a metal plate with stippled celluloid gum attachment.

\* Refer to description as to taking impressions and making metal plates on page 415.



## CHAPTER XXXI.

### OBTURATORS.

BREAKS in the continuity of the palate surface of the mouth, congenital or acquired, are treated by operation, or otherwise through the use of obturators and vela. The present chapter considers the mechanical means.

The instrument, or plate, called an obturator, gets its name from the Latin verb *obturo*, and signifies a something that shall close or stop up an entrance or break.

Obturators correcting breaks of the soft portion of the palate, being mobile in construction, are not improperly designated vela,—artificial vela.

Obturators are used in the treatment of palatine defects where operative surgical means do not apply.

As obturators are instruments designed to meet the most varying indications, so necessarily are they apparatus of great variety in construction. The simplest of them is nothing more than a plate of metal or rubber covering a break in the hard palate; it differs but little from the support of an ordinary denture. An obturator having the meaning of a velum is an attempted duplicate of missing part in the movable, or soft, palate; it is designed not only to fill a break, but to assist in functional performance.

A simple obturator holds the same relative position to one at the other extreme that is held by the Physick-Desault leg-box to the most complex of apparatus used in the treatment of fractures of the extremities. The simple is expressive of a principle; varieties express modification on the principle. A practitioner understanding the basal idea is at no loss to appreciate the genius of the instrument in its application to all kinds of cases.

A patient presents himself, let us suppose, suffering under a deficiency in the hard palate. We examine the condition, and find the walls of the break so heavily and solidly indurated as at once to perceive that any attempt to pare and bring them together would be futile. Palato-plasty naturally suggests itself, but observation of the surrounding parts convinces that the risks are too great for a good promised. Such is a case that not infrequently offers itself to the surgeon's judgment. Dieffenbach, whose name is so honorably associated with oral operations, evidently found himself much embarrassed with just such conditions,—cases here to be presented as the easiest of remedy by use of an obturator. To correct such defect the German surgeon suggested a stud of india-rubber. Two pieces of rubber the thickness of pasteboard are cut, being somewhat larger than the opening to be closed,



and between these is placed a small round piece; the whole is then securely fastened together by means of waxed thread: one of these pieces is intended to rest on the posterior, the other on the anterior surface of the opening; the small middle piece is for the intermediate space.

A moment's reflection will exhibit the inconveniences as well as the more striking faults of such an appliance. The rubber, unless vulcanized (and, to be so applied, it cannot be vulcanized), soon becomes offensive. It acts as a continual source of irritation, particularly as the posterior base of the cleft is concerned. The centre piece, which, to hold the parts with any degree of steadiness, must fit the opening with reasonable accuracy, soon, because of the presence of moisture and heat, expands, thus enlarging the canal. The apparatus is as well very inconvenient to remove for the purpose of cleansing, which cleansing it demands daily.

A case amply illustrative of the inefficiency of this mode of combatting palatine defects, and, indeed, of the absolute harm resulting from it, is recorded by Dr. J. H. McQuillen. The patient, who had an opening in the palate, the result of syphilis, was treated by Dr. Daniel Neall, who employed, in the first instance, india-rubber as a substance from which to construct an obturator. This was cut somewhat in a button shape, being large above and below, and contracted in the centre, thus constituting an apparatus which was retained in position by resting on the parts of the nares surrounding the orifice. After this had been worn a week or two, the patient returned, when it was found quite loose and the orifice somewhat enlarged, the rubber having acted as a source of irritation and induced absorption. Another apparatus was formed from the same material, and, after being worn a week, the orifice was found larger than at the previous meeting. The rubber was also found considerably affected by the fluids of the mouth. Satisfied that it would not answer the purpose intended, this material was abandoned, and a simple obturator of silver constructed, this covering both orifice and roof of the mouth. It was found to fulfil every indication.

There is another, a somewhat domestic treatment for these defects, which may be alluded to in passing. This consists in stuffing the break with cotton or wool. The material, unfortunately, not infrequently escapes into the throat, or, passing into the nares, it has sometimes produced ozæna by lodging in a meatus, quite extensive necrosis of the turbinated bones having been provoked in this way. The practice is not without marked danger.

A case of a different class, yet belonging to the same category so far as treatment is concerned, invites, in connection with the consideration of simple obturators, a moment's attention. This is the existence of a cleft or break associated with subacute or chronic disease,—cases not fit, of course, for operation.

Some time since, Mr. —, a French teacher of this city, had necrosis of the palatine arch, the result of venereal disease; the sequestrum that came away was quite large, producing a break in the continuity of the hard palate



at least an inch in diameter, freely exposing, of course, the nares. A result was, as might be anticipated, that his vocation as a teacher had at once to be relinquished.

This case was seen, in consultation with the attending physician, about a month after the patient had resigned a situation which he held in one of our principal private schools, and upon which, up to this time, he had mainly depended for his income. The necessities of the man were immediate; operation for the restoration of his speech was out of the question. The writer had the happiness of relieving this patient of his trouble so perfectly after three days, by the use of an obturator, that every time we have since met he laughingly asserts that he speaks better English than before his accident. It is certainly true that he speaks it quite as well.

An obturator for cases like this consists simply of a metal plate that fits accurately every part of the hard palate. Such a plate is to set with the greatest nicety, and is to be held in place either by bands placed around certain of the teeth, or by means of atmospheric pressure. The first plan of fastening is to be employed when disease is associated with the cleft. The latter is well adapted when the break is not too large, and where all disease is long passed away. To make such an obturator, first take an ordinary impression-cup, such as is employed in taking casts of the mouth for teeth. This cup is filled with beeswax, softened to the consistency of dough. Thus prepared, the operator takes his position behind the patient. The cup is now to be introduced carefully into the mouth, and carried just so far back as will allow of the teeth being included within the arch, or rim. This accomplished, cup and wax, in a body, are to be pressed firmly up into the roof of the mouth, and the wax worked around the necks of the teeth and about the alveolar border. The patient holding his mouth very wide open, the mass is to be removed even more carefully than it was inserted. This manipulation, if properly executed, gives the exact impression of the palate. The next step is to make a model. To do this, take the impression just obtained, and, surrounding it with a rim of paper, the rim to be, say, one and a half inches in height, stir into water the common calcined plaster—sulphate of lime—until a very thick paste is obtained. This paste is poured into the impression, and should be enough in quantity to fill from the wax, which lies at the bottom, up to the top of the rim. The model thus made is not to be disturbed for three or four hours; it must have time to set.

The next step in the operation is to remove, from about the plaster cast just made, the paper and wax. This is accomplished, first, by heating gently the cup in which the wax lies, which permits of its easy removal; and next by carefully trimming from about the necks of the teeth, by means of a knife-blade kept constantly warm, the wax which so closely surrounds and imbeds them; in this way it is all safely to be taken away. The paper is, of course, simply torn off. Comparing the face of the model thus made with the



mouth from which the impression has been taken, we find a common likeness to the minutest particular.

As the model expresses the break in the arch, and it is the intention to restore this arch to its original contour, so is it at this point in the procedure that the step is to be taken which insures such result. This step is easily accomplished by taking a little ball of warm wax, and filling with it the hole or break in the model. The natural concavity of the arch is in this way restored. Of course this is not at all difficult, nor is there any guess-work about it, as we have the inclinations of all the surrounding parts to guide us, and all we have to do is simply to model this wax to the proper curve. The cast is finished by bevelling the portion which rested against the paper; this bevelling to be so done that the greatest diameter of the model shall be its base, the object of the shape being to permit of easy drawing of the model if a sand cast be made.

This completes the model to which an obturator is to be made.

A next step is the preparation of dies.\* These are to be made, one of zinc, the other of lead; and the process of getting up such casts is precisely the same as that adopted by a moulder.

**Directions.**—Procure a moulding-flask or a circle of tin: a common tin cup, with the bottom broken out, answers the purpose well enough. Lay the model you have prepared upon the table, the palate face looking up. Now place the circle of tin over it, and with some moulder's sand, very fine, which you have previously moistened and tempered, cover in the model, packing and filling the circle completely. Now turn the circle, or cup, so that the base of the cast looks up. Next a penknife-blade or a small gimlet is to be inserted into a square of wood previously inserted into the plaster, and by striking it several light taps the cast will be loosened. It is now to be lifted from the sand. Thus we have a mould for a metal casting. The next step is the making of such a cast. To do this we have only to melt, in any convenient vessel, one or two pounds of common zinc, and pour it slowly into the mould. This done, let the whole remain undisturbed until cold.

Thus, it is seen, we have prepared, with little or no labor, a correct model of the mouth in metal. It is to this zinc model we are to fit and adapt our obturator. Now, this latter process is easy or difficult, according as one goes about it. One method is to take hammer, files, and pliers, and cut, file, and mallet until the adaptation is secured. Such a task is almost as hard as was the cleaning of the Augean stables; besides, it is next to an impossibility to accomplish the work properly. A second plan, and one which is as easy, simple, and interesting as the other is difficult, perplexing, and annoying, consists in making a counter-model in lead, between which and the model, or

\* A surgeon being the operator, the model, or even the impression, may be handed to a mechanical dentist, who makes the obturator ready to put in place, without further trouble to the practitioner.



male cast, as it is called, the palate, or obturator, is struck up. This counter-model is very easily made, as follows:

Take the zinc die and lay it upon a table, with the face or palate surface looking up; place about it the cup, or circle, precisely as in the case of the plaster model. Now, with the sand moistened as before, fill up the cup covering in the die, packing the sand as solidly as possible. Next, without disturbing the cup as it rests upon the table, take a knife and dig away the sand until the face of the die is exposed, together with a reasonable space between zinc and cup. You are now prepared to make the counter-model. Take a vessel (not the one in which the zinc was melted), and place in it two or more pounds of lead; when fluid, pour this over the face of the zinc die, filling up to the very top the cavity which you have dug out in the sand. When the lead has become cool, remove the castings from the sand, and with a hammer knock the two apart.

To make an obturator by means of dies thus obtained, the procedure is as follows: A piece of thin sheet-lead is forced with the fingers over the face of the zinc die, and with a sharp and delicate-bladed knife this lead is cut so as to cover accurately the hard palate, being festooned so as to adapt itself accurately about the necks of all the teeth. This palate of lead, being nicely and correctly fitted to the parts, is taken off the die and carefully spread. Next it is laid on a piece of gold or silver plate, and the outlines distinctly marked; using a pair of cutting forceps, the shape of the lead is repeated in this second piece of metal. A next step is the process of annealing, or softening the metal, so that it shall be as malleable as possible. This consists in subjecting it to a red heat, which may be done in any convenient manner. The mechanical dentist lays the piece upon charcoal, and throws over it, by means of a blow-pipe, the flame from his alcohol soldering lamp. Another manner is to lay it upon hot coals.

The metal being annealed, it is taken up and so bent with pliers as to fit the die tolerably; it is not, however, at all necessary, in this procedure, to give one's self much trouble. Next take up the counter-die, and lay it carefully over the zinc,—the plate being between the two. Employing a heavy hammer, the dies are now driven together. In this step of the operation it is desirable that the worker feel his way,—that is, hit the zinc model a few slight taps, and then, taking the two apart, see if the plate is going as required. If all be right, the casts are to be driven into each other with reasonable force. If, on the contrary, the metal is not taking a proper direction, it must be properly inclined by means of the pliers. To complete the finish of the plate itself, the festoons, which are to embrace the necks of the teeth, are to be cleanly cut out by means of a round file; polishing completes the manipulation.

Thus we have an obturator finished. If now it be placed in the mouth, we shall see that we have restored the arch, by our contrivance, to its original condition, at least so far as purposes of speech and mastication are concerned.



Nothing now remains but to secure the piece firmly to its place. This brings us to the consideration of modifications of the instrument.

If a patient, for whom had been made such an obturator as that the manufacture of which has just been described, had certain good sound teeth, we might proceed to fix the piece in the mouth as follows. Going back to the plaster model, we would fit around such teeth as might seem best adapted to the purpose delicate bands of metal,—gold is always to be preferred; these bands should fit the teeth with accuracy, and are to be fixed to their places while the obturator is lying on the model. Take next particles of wax, and stick the plate and bands together. Now carefully lift all from the model, and set in plaster. This last manipulation is accomplished by laying the piece on charcoal, and pouring over it, the wax alone excepted, the creamy plaster before alluded to. When this plaster sets, the wax is to be delicately picked away, and thus are exposed small portions both of plate and bands. These parts are to be soldered together.

This last process completes the piece for the mouth. In placing it in position, we have only to slip the bands over the teeth to find it held with all security.

Another plan of fixing the apparatus to the mouth is by means of atmospheric pressure. To accomplish this, a cavity is made in the piece. This is done by placing on the plaster model, before making the castings from it, a piece of wax: its shape may represent, in diameter and thickness, the ordinary half-dime. Or perhaps we cannot find a surface on the arch for a suction of such size and shape; if so, it may be lessened, or the shape modified so as to suit the case; what is wanted is a cavity in the plate, the size and location are not of special consequence. Such a piece of wax will, of course, be represented by zinc in the casting, and by a depression in the counter-cast. In forcing the plate between the dies, the portion represented by the wax is thrown up; thus, when the plate is in the mouth, a cavity is formed. The instrument is held, in this case, by making an air-pump, as it were, of the tongue, and sucking the air from the cavity. Obturators are seen thus dependent on atmospheric pressure for fixedness, held so tightly that it requires considerable force to effect their removal. The principle is the same as that employed for holding artificial dentures in place. The *modus operandi* will be perfectly understood at a glance by looking at any set of teeth made for the superior jaw.\*

Another modification of the obturator is that in which the piece is held to its place by a bulb, or rim which passes into the cavity of the break. This adapts the instrument to such cases as have neither teeth for clasps nor site for suction; where disease has destroyed the whole of the hard palate, leaving alone, as boundaries of the cleft, the alveolar processes and velum. Such an obturator and the character of cleft for which it is adapted are

\* Plates, whole or partial, for the support of artificial teeth, are made and fixed as here described. For repetition, after different manner, of the description, see page 415.



happily and truthfully exhibited in the accompanying drawings. Fig. 342 represents the mouth, Fig. 343 the obturator. This case, and others which

FIG. 342.

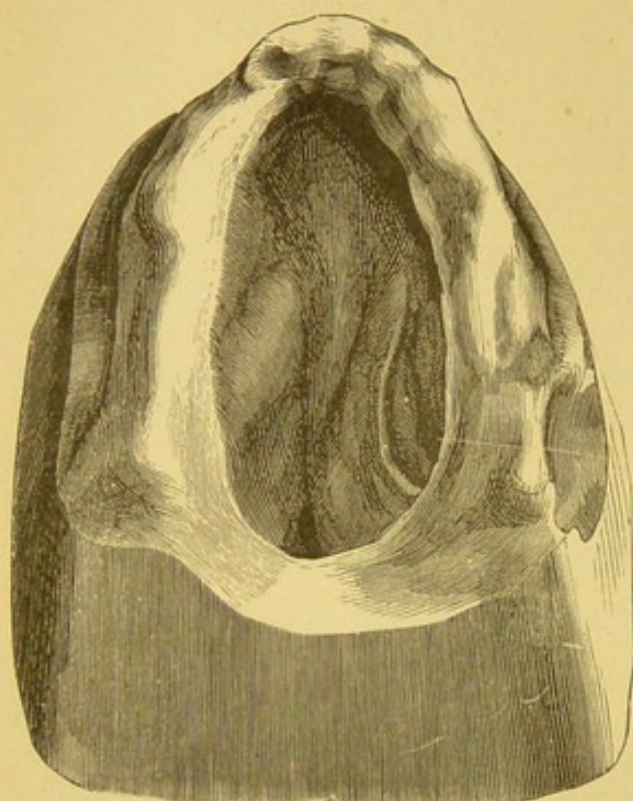
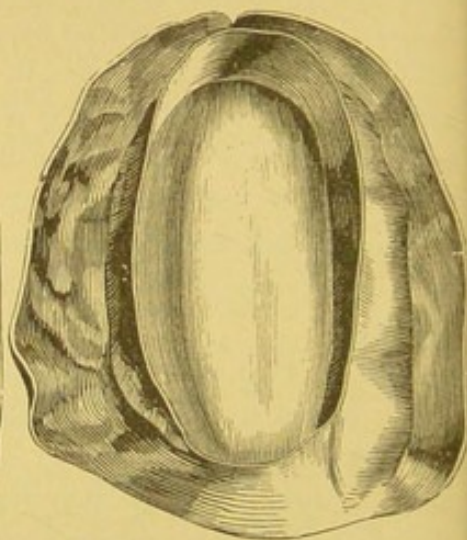


FIG. 343.



represent various modifications of the apparatus, are from life, having occurred in the practice of different dentists.\*

The first case, as seen in Fig. 342, from the practice of Dr. McGrath & Son, was that of a female over fifty years of age. In this instance the fissure was confined to the hard palate and was undoubtedly the result of syphilis. Of the history of the case, all that could be obtained was derived from answers to indirect questions which were put to her. The gentlemen learned that the defect was the result of a disease which commenced as sore throat and continued its ravages for over three years before it was arrested; this, together with the appearance of the pharynx and uvula,—these being covered with cicatrices, the result of old ulcers,—left them without any doubt as to the true nature of the complaint. The parts which had been destroyed during the progress of the disease were the palate-bones and the palatine processes of the superior maxillaries (making an opening into the nose nearly two inches in length and one inch in breadth), the turbinated bones with the exception of the middle one on the left side, which is represented in the cut as projecting from the side of the cavity), and the vomer, producing an enormous irregularly-shaped cavity, extending as high up as the nasal bones, which latter, however, bore no traces of ever having been affected by the disease.

\* Report by George T. Barker, D.D.S.



The patient, in order to prevent the passage of the food into the cavity during mastication, had been in the habit of filling the opening with a fold of muslin, which answered the purpose to a certain extent; the velum was entire; the patient had also lost all the teeth of the upper jaw.

The kind of obturator employed in this case was simple and uncomplicated in its mechanism, Fig. 343. A plate was made to fit accurately to the alveolar ridge, extending about one-eighth of an inch beyond the posterior margin of the opening; also passing in to a distance of nearly an inch, and fitting as closely as possible to the anterior and lateral sides of the cavity. The object of this latter arrangement was to render the piece firm in its position. From the posterior margin of the opening, and extending forward about half the length of the alveolar ridge, was a fold of mucous membrane projecting inward and upward, over this margin; that portion of the plate which was opposite to it was bent. This, together with the suction obtained by the plate fitting closely to the alveolar ridge, enabled the wearer to keep it in its place. The opening was then covered by soldering to this a second piece of plate, so fashioned as to represent as nearly as possible the form of the lost palate. The object in not extending the plate into the cavity on the posterior edge of the opening was to prevent a lodgment for the nasal secretions, which by their accumulations would prove offensive to the patient. The artificial teeth were then fastened in their proper position, and the apparatus was complete. This obturator the patient had been wearing for about three months; it remained in place and fulfilled the office of mastication as well as any ordinary suction plate in a mouth where no defect of the palate exists.

The second case, Fig. 344, was also that of a female, but the fissure was confined to the soft palate. This, as in the former case, was the result of syphilis. The break extended from the posterior opening of the nares through the velum looking backward, and was nearly an inch in breadth. The uvula was entirely gone, as well as the lateral half-arches, and along with them the palato-pharyngei and constrictores isthmi faucium muscles. In this case deglutition was impaired to a great extent; the food would get into the nares, and the fluids would also pass into the nasal cavities and out through their anterior openings. The disease had not confined itself to the palate, but, extending to the nose, had destroyed its internal structure, as well as portions of the nasal bones, to such an extent as materially to change the external shape of the organ. The obturator, Fig. 345, constructed for this case, was of one piece, and made to cover the hard palate completely, extending from the central incisors to the posterior wall of the pharynx, and passing a short distance beyond the edges of the opening on each side. The plate was made to press firmly against that portion of the soft palate which remained, yet not so firmly as to be the cause of irritation, the edges of the plate being slightly bent downward for the same reason; the object being to prevent the possibility of the soft parts being drawn above the palate, which would afford a communication with the nares. The posterior edge of the



obturator was bent downward at a right angle with the body of the palate, and curved so as to form, with the posterior wall of the pharynx, an oval

FIG. 344.

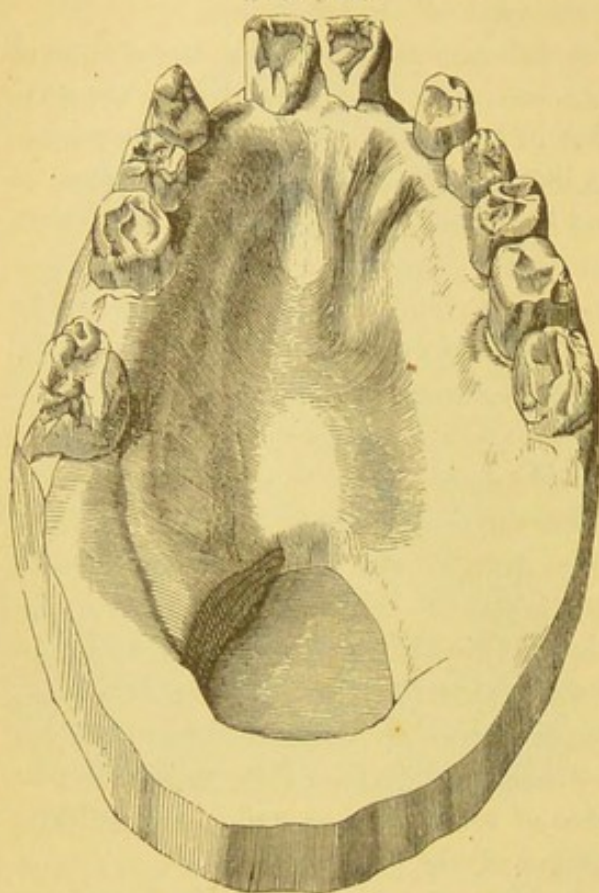
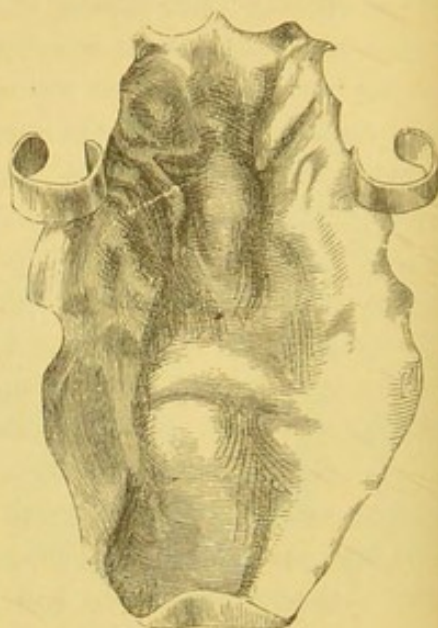


FIG. 345.



opening sufficiently large to permit the patient to breathe freely through the nostrils. In the act of deglutition, the muscles would contract and press against this portion of the plate, thereby cutting off the communication with the nares. To this plate were attached three artificial teeth,—two lateral incisors and one molar,—the whole being retained in position by means of clasps around the teeth.

This obturator the patient had been wearing a little over two months, and, like the former one, it had proved successful, deglutition being restored, and speech considerably improved.

The practice of Dr. T. L. Buckingham, Professor of Chemistry in the Pennsylvania College of Dental Surgery, offers the following cases:

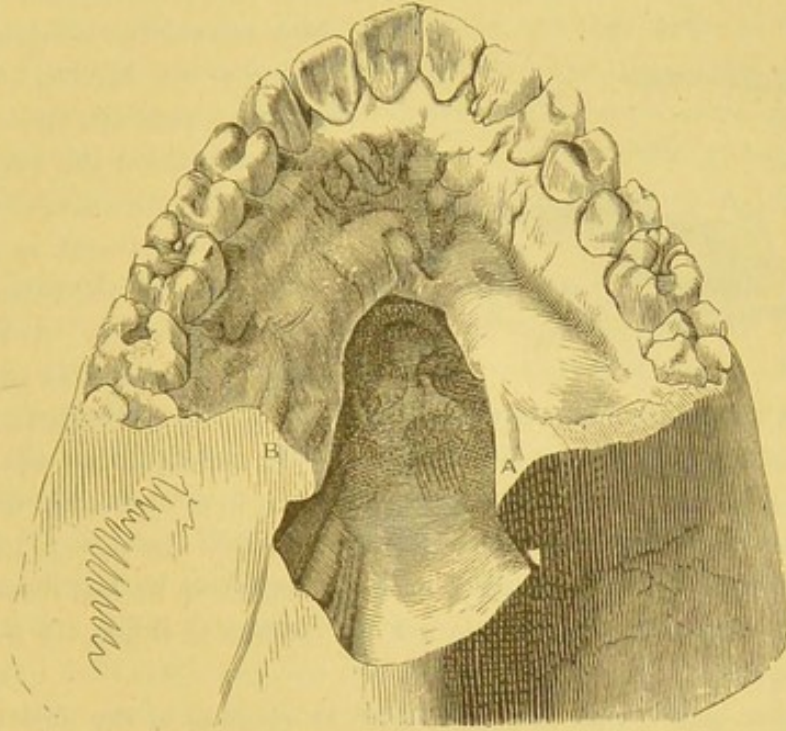
The first is that of a gentleman who had an opening through the hard palate, in the centre of the arch, about as large as a ten-cent piece. This patient had worn an obturator with a sponge attached to it, made in the following manner: A plate was modelled to fit the roof of the mouth, and a piece of sponge was sewed upon the palatine surface, to fill the break, and hold the plate in its place. Objections to this obturator were that the opening became enlarged from the absorption occasioned by the pressure of the sponge upon the sides of the cavity; the sponge would also become



very offensive, requiring frequent removal. In this case a plate was struck to fit the mouth, and attached to the teeth by means of clasps. This simple appliance answers better than any other that had been made for him.

The second case is one of a gentleman who had an opening into the left antrum, at the point where the second bicuspid and the first molar had been, but

FIG. 346.



on the outer surface of the alveolar ridge, or rather seat of original ridge,—for the alveolus was entirely absorbed opposite the opening, which was about half an inch in length by a quarter in width. The nasal bones were diseased, which caused an almost intolerable odor.

There was made for this case a small obturator to close the opening. This was left open at the top, to allow the placing in it of a small portion of chloride of lime, the intention being to correct, if possible, the offensive smell. The patient did not live long enough, however, to give it a fair trial. Dr. Buckingham remarks that while any of the chloride of lime remained in the obturator there was no unpleasant smell; but, unfortunately for the experiment, the gentleman had lost nearly all the sense of smell, and therefore could not tell when the agent had evaporated. The obturator was held in position, to a great degree, by a plate and teeth, to which it was attached.

In the two preceding cases voice was not altered when the appliances were in the mouth.

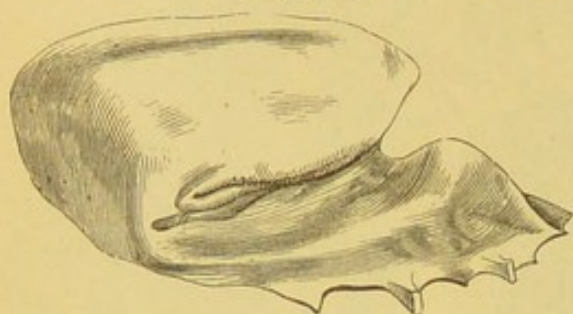
The third case is that of a gentleman who on a previous occasion had a tumor removed which covered a portion of the posterior surface of the hard and the anterior surface of the soft palate. The surgeon, in the ablation, had divided the velum and uvula, so that the case resembled a congenital de-



formity. The attempt had been made twice to bring the soft parts together by surgical operations, both of which failed. Fig. 346 exhibits the appearance of the parts very clearly,—the letters A and B showing the thickened muscles as they hung down on the sides of the pharynx.

For this case an obturator was constructed, Fig. 347, the plate of which covered the whole of the roof of the mouth, with a bulb attached, to extend up into the posterior nares and well back toward the posterior walls of the pharynx, leaving but a small space between the two. This obturator enabled the patient to eat and drink with convenience; without the instrument in place food would pass into the nares and occasion much trouble. It also greatly assisted the voice, as many of his

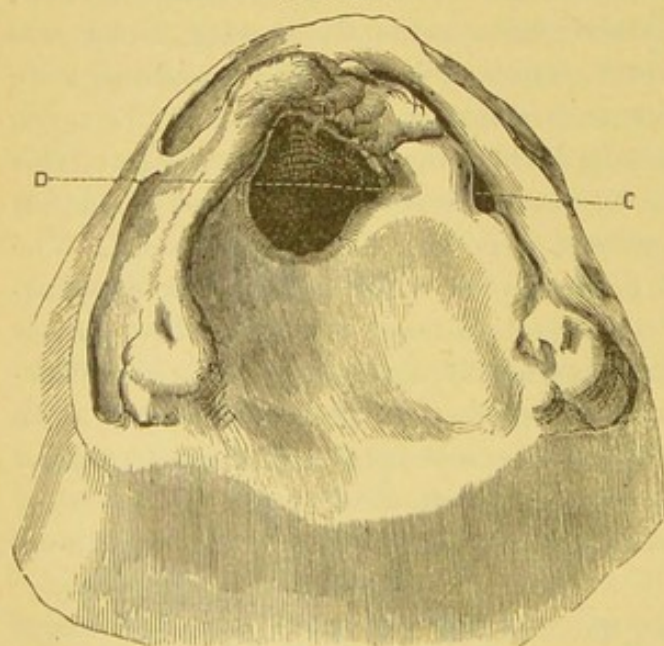
FIG. 347.



words could not be understood when it was not worn,—articulation was with great distinctness when it was in the mouth. Dr. Buckingham remarked that he had been more successful in restoring speech in this case than in any other he had treated, and attributes it to the fact that the person, having once had perfect voice, was always endeavoring to speak as he had formerly done. In the congenital cases patients do not, he inclines to think, try to overcome the difficulty.

The fourth case is that of a lady with an opening in the anterior part of the hard palate, a little larger than a ten-cent piece, and

FIG. 348.



also a second small one exposing the left antrum. All the teeth in the superior arch had been long removed, and absorption of the alveolar process, opposite the smaller opening, had progressed to such an extent as to present at that point a deep depression; the remaining part of the alveolar ridge had not been absorbed more than is usual where the teeth have been lost.

Fig. 348 shows the appearance of the different parts, C representing the smaller opening, and D the larger one; between these two points is the depression referred to.



This lady had never worn any mechanical appliance, but had been in the habit of closing the larger opening with loose cotton or pieces of linen. Without having it filled, she could scarcely be understood when speaking. For this case there was made, first, a plain plate to extend over both the openings, but not into them; upon this plate, at the point where the process had been absorbed, wax was arranged so as to restore the alveolar ridge to its natural fulness. By using the plate with the wax attached for a mould, metallic dies were obtained. A second plate was then made to fit over that part of the first one which was covered by the wax; these two plates being next soldered together. The object in forming a double plate was to fill up that part where absorption had taken place, so that the plate when worn would resemble the roof of the mouth, and not be deeper on one side than on the other.

This obturator was very successful; the voice was much improved, the patient was able to eat and drink as well as persons ordinarily can who use upper sets of teeth; and, what was more remarkable, she could wear the piece without springs, or any assistance whatever, to retain it in position.

A fifth case by this same practitioner relates to a gun-shot wound.

A gentleman was handling a gun loaded with buckshot, when it was discharged in his hands. The gun being pointed toward his head at the time, the load struck him at the angle made by the ramus and body of the inferior maxilla on the right side, passing upward and outward on the opposite side of the face. The only way the patient could eat or drink was to lie on his back and let the food run down his throat.

The teeth in the upper jaw were all gone, excepting the left second molar and dens sapientiæ; both antra were fully exposed, the remainder of the mouth being left almost flat. The lower jaw-bone was wanting on the right side, from the second bicuspid back, and also the condyloid process; about three-quarters of an inch of the coronoid remained, which was drawn in so as to partially cover the roof of the mouth. The molar teeth were lost on the left, and also all on the right side from the symphysis. In taking hold of the lower jaw it could be moved either backward, forward, or laterally, to a considerable distance.

Figs. 349 and 350 show this case,—the letters A and B are the openings in the antra, and C the end of the lower jaw-bone. The distance between the points A and C, with the mouth closed, was just two inches.

The gentleman had been wearing a partial upper set of teeth which had been attached to the molars, but the clasps of the artificial work had loosened these, and it was therefore necessary to replace the piece with a set that could be supported in some other way.

This was found a difficult case to treat. One of the obstacles encountered was the obtaining of a correct impression. To accomplish this the antra were first filled with loose cotton, to prevent the material used from passing into them; next as good a wax impression of both the upper and lower jaws



as could be got was taken; from these cups were improvised, to be used in securing the plaster moulds. There was found very little difficulty in obtaining

FIG. 349.

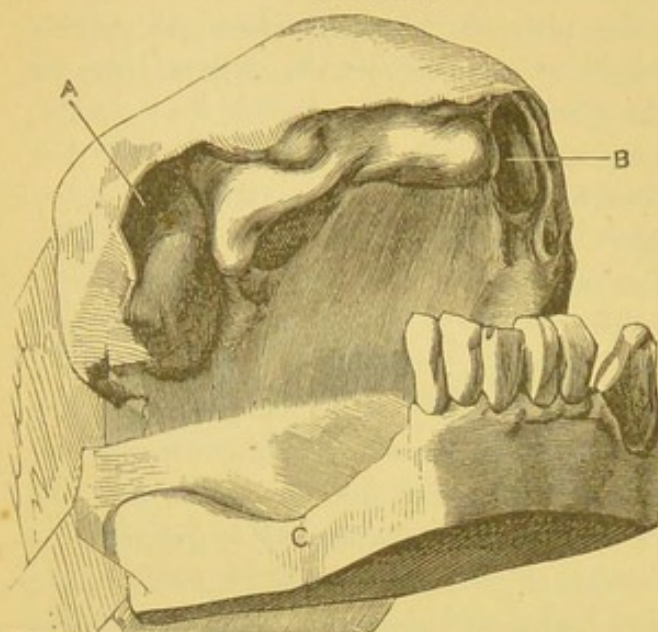
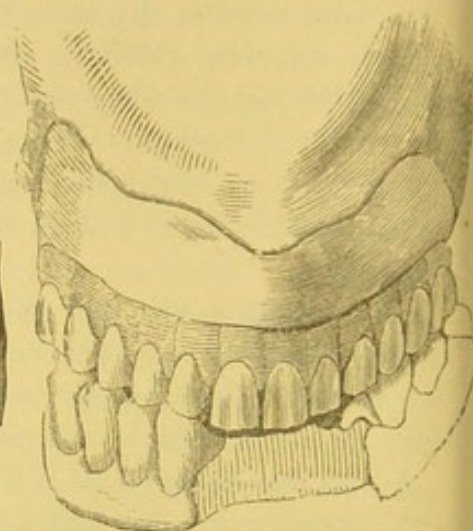


FIG. 350.



an impression of the upper jaw with plaster (the antra being filled with cotton as before), but it was far more difficult to secure a good one of the lower jaw. The distance from the points of the teeth down to the point marked C, as shown in Fig. 349, was so great that when any material was forced down to take the impression, removal was almost impossible without alteration that rendered it valueless. After several trials a fair one was secured with plaster. This, however, had to be broken before its withdrawal from the mouth; but, by carefully putting the pieces together, an answerable mould was obtained.

Next a plate to extend over the roof of the mouth and cover both the cavities opening into the antra was made; on this plate wax was arranged, bringing it down to where the alveolar ridge should have been; then, from a metal cast was struck another plate to fit over the first; these were soldered together, and upon them were placed single gum teeth as would have been done had there been no more absorption than is usually found in upper cases.

There was nothing peculiar in the formation of the lower teeth, except that these had to be very long on the right side (for this a block was made), and the plate not allowed to extend farther back than to the position once occupied by the second bicusps. The under teeth were put in more for the purpose of attaching springs for the support of the upper than for use.

What success attended this case the operator was not able to report, as the gentleman left the city immediately upon the insertion, and has not been seen since.

Vulcanite is the material now almost universally used for making obturators.



Advantages claimed are: its cheapness, its lightness, its capability of being moulded into the most irregular positions, and its resemblance in color and feel to the natural parts. Objection is its liability to become offensive. The manipulation of the material is so easy, as has been shown, that the surgeon attempting the manufacture from it of surgical appliances gives himself a source of recreation rather than work. To make an obturator from vulcanite, an impression of the mouth in wax is taken, and from this a plaster model is made precisely as before described. Gutta-percha is now moulded over this model to the form required. Plaster is next run over this first model, the gutta-percha plate being between. The model and counter-model thus made are separated, and the place of the original plate is supplied with vulcanite. The models are now put together, and the vulcanite between subjected to pressure. The whole, with a few ounces of water added, is then placed in an apparatus termed a vulcanizer, and the temperature is raised to about  $325^{\circ}$ . When taken from its steam-bath the plate is found as hard as bone. A finishing process consists in the polishing of the piece; this last is a simple manipulation, and requires only one or two files, a scraper, a burnisher, and some patience. (See previous chapter.)

M. Desirabode, a French surgeon, proposes a palatal obturator for congenital fissure, by which he thinks the sides of the alveolar border may be so approximated as to favor a union of the separated parts. This consists of a platina plate fitted to the vault of the palate and bent upon the alveolar borders in such a manner as to maintain the whole pressure. It is fastened to the teeth by means of three clasps soldered to each side, so as to cap the canines, the bicuspidati, and two of the molars. After the plate with these appendages has been well adapted, it is to be divided from before backward along the median line, and a piece removed from either side, so that the two edges are separated about half an inch. The two parts are now united by means of a thick and resisting band of caoutchouc, made fast by riveting. Thus united, the piece forms a smaller obturator than the plate before it was divided, so that it can only be applied by putting the caoutchouc on the stretch, which is effected by means of two sticks so contrived as to force the plates asunder. After the piece is properly adjusted, these sticks are removed, when, by the contraction of the caoutchouc, the sides of the alveolar borders are gradually approximated.

This contrivance of Desirabode looks very plausible, but, unfortunately, all experience is against its employment.


In the first place, to correct by pressure a fissure in the hard palate implies the very earliest use of force. A child is five or six years old before its first dentition is properly completed; and even at this period one would not dare apply any such apparatus, because of the physiological process of absorption, which has already commenced in certain of the teeth. Then if, on the contrary, he meant his instrument to apply to a more advanced period, he would have to wait until at least the sixteenth year, as before this age the



fangs of the anterior molars are not perfected. The bones by this time have, as a matter of course, become much less amenable to treatment. And again, even besides this, as the author knows from practical experience, his apparatus would in less than a week's time produce such ulitic and periosteal trouble that no human being would, or could, bear the continuance of the pressure; or, even admitting there should be found a patient resisting enough to endure the treatment, the apparatus would have its usefulness destroyed in less than two weeks by the teeth, to which it was attached, coming away. In other words, the instrument is useless, because the teeth, being the weaker and more yielding, would give way first.

The late Dr. E. Wildman, an able mechanical dentist, kindly furnished a description and cuts of a case which, as a study, will repay attention. The

FIG. 351.—THE FACE WITHOUT NOSE.



obturator in this instance holds in place an artificial nose, which in turn holds it in place. The description of manufacture affords the principle of constructing all such character of work.

Fig. 351 conveys an idea of the external appearance of the patient, but not fully, as the whole upper lip was cicatrized, and the left cheek depressed near the border of the cavity.

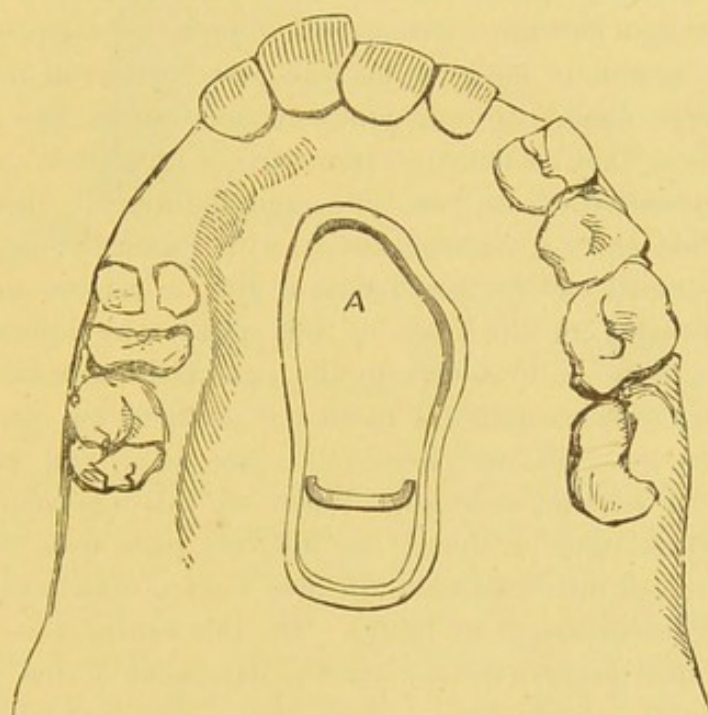
In May, 1863, a young man, aged twenty-six years, presented himself to Dr. Wildman for the purpose of having an appliance made to repair a loss sustained by disease. Upon removing the black patch which he wore upon his face, and the cotton with which the cavity was filled (without the latter



he could not articulate a word), it was found that the entire external nose was gone,—that the nasal bones, the nasal processes of the superior maxilla, also a large portion of their palatine processes, the approximal parts of the palatine processes of the palatine, and the turbinated bones, had been destroyed. The soft palate, the uvula, and the tonsils were uninjured. In looking into the nasal cavity, the walls of the antrum on the left side were found deficient, and ends of the roots of the incisors exposed and decayed. The tongue was visible through the opening in the palatine arch. The size and shape of this orifice are represented by the outer central line in Fig. 352.

Although desirable, it was deemed unsafe to remove the diseased roots, owing to the yielding nature of the superior maxillary bones. The disease

FIG. 352.—INTERNAL VIEW OF SUPERIOR ARCH.



appeared to be arrested, and the parts in a sufficiently healthy condition to warrant the application of the substitute; and time has verified this, as, with the exception of the exfoliation of a small scale from one of the superior maxilla, no change has taken place up to this date.

A first step in the operation for remedy was to procure an impression that would secure a perfect model of all the parts involved, and their surroundings, in their relative positions. For this purpose plaster was first used, but, its employment being found precluded by the acrid secretions in the nasal cavity, wax and paraffin were substituted. Owing to the rigidity of the upper lip, Dr. Wildman was unable to employ the ordinary impression-cup with success, and found himself obliged to take a rough impression of the palatine arch, from which a cast was made, and a metallic tray swaged.

A sufficient amount of paraffin and wax being thrown into warm water, and



an assistant aiding to keep the mixture at the proper temperature, the mode of procedure was as follows: A proper quantity of the compound was placed in the cup, introduced into the mouth, and pressed up firmly against the arch; the portion forced into the palatine fissure was at the same time pressed with the finger, introduced through the nasal cavity, so that it should give an accurate impression of the region. A groove was then cut in this to serve as a key, and, after oiling it, a piece of the compound was introduced through the orifice of the nasal cavity, and passed down to make the impression of the floor of the nasal cavity. When sufficiently hard, it was carefully removed, the upper surface trimmed, placed in cold water to secure its greatest firmness, then introduced into the cavity, and pressed into its proper position. The metallic cup containing the impression of the palatine arch was then removed. The next step was to take an impression of the sides of the cavity, then the top, using a curved wooden spatula to press the compound in proper position, being careful to mark or key the parts that came in contact, and have their surfaces oiled, to prevent adhesion; and also that the pieces should be thinner in front than in their posterior parts, so that when the four pieces forming the impression of the base, sides, and top were in their proper position, they would leave a tapering cavity, with its largest diameter at the front orifice. Into this orifice was forced a plug, or cone of the compound, filling it completely; in the front of this piece were inserted pieces of match-sticks, to cause it to adhere to the next piece, or mask. The head was now thrown back to nearly a horizontal position, wet tissue-paper was placed over the eyebrows and lashes, the face oiled, and plaster mixed thick was battened on with a brush. When set, this was removed, drawing with it the central plug or cone; the different parts were then carefully removed, and thrown into cold water to give them a consistency that would bear handling without danger of injury. On this central cone all the parts were placed in their proper position, and the impression of the palatine arch was adjusted in its proper place. From this a plaster model was made, giving the upper part of the face, cavities, palatine arch, all correctly in their relative positions.

Of the different substances—leather, wood, wax, metal enamelled, and porcelain—used for making artificial noses, Dr. Wildman gave the preference to hard rubber in this case, on account of its rigidity, strength, lightness, and less liability to injury by accident.\*

To prevent derangement, it was necessary to make the appliance as simple as possible; it consisted of two pieces: the external nose, septum, and floor of the nasal cavity constituted one, having a projection passing downward into the palatine fissure, as represented in Figs. 352 and 353, A; and the other, the obturator B, Fig. 354, with a projection rising upward into the palatine fissure. These projections were made hollow, so that when the two

---

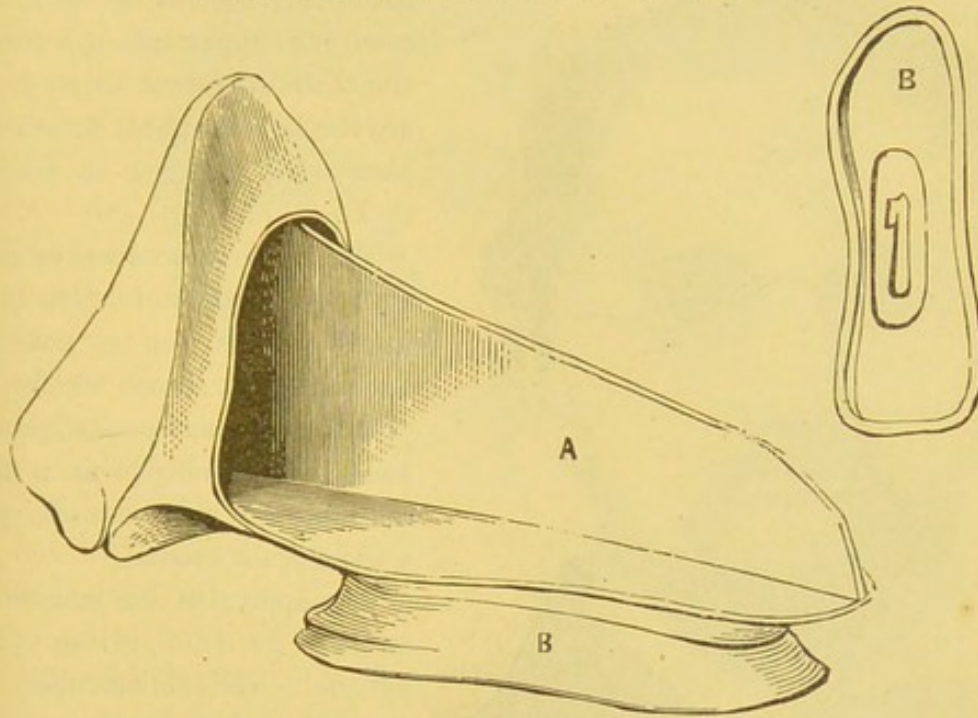
\* Celluloid yields a more natural appearance than does rubber.



parts were placed together, as in Fig. 353, there would be a cavity or box wherein the attachments could be placed.

Models were made of the compound of paraffin and wax, which were strengthened in the weaker parts by imbedding small strips of metal in their

FIG. 353, 354.—NOSE WITH ATTACHMENTS.



substance to give sufficient firmness to admit of the necessary handling without injury. The combined parts were then applied to the patient, and the nose trimmed so as to harmonize with his features. These were next imbedded in plaster in the usual manner for vulcanite work, with the exception that a stout curved wire passed through the artificial nasal cavities, extending beyond their borders, to give strength to the rods of plaster forming these cavities in the matrix, and thus to prevent their fracture in packing.

This appliance was vulcanized four hours, consuming one hour in attaining  $280^{\circ}$  Fahr., at which point it was held one hour, and occupying the third hour in elevating the temperature to  $320^{\circ}$ , where it was retained one hour. The work was rather overdone, but not so much as to injure it.

The two pieces were retained in position by a staple and slide-bolt. In the recess of the part of the floor of the nasal cavity projecting into the palatine fissure (A, Fig. 353) was inserted a gold staple. In the recess of the projection of the obturator passing into the palatine fissure (B, Fig. 354) were the gold catch and shield of the slide-bolt. The object of this shield was to prevent any foreign substances entering the slot and obstructing the movements of the bolt, also to give a base of support to the catch. The rectangular upright of the catch was soldered to the shield, passed through it and a longitudinal slot in B, and securely fastened to a rubber slide inlaid longitudinally,



and moving freely in the lingual surface of the obturator. On the anterior end of this slide was a small rounded projection, which enabled the patient, when the two parts of the appliance were placed in their proper position, with

FIG. 355.—THE FACE WITH NOSE.



the point of a finger introduced into the mouth, to force the slide backward, thereby to pass the catch into the staple and firmly secure the apparatus, or, by drawing the slide forward, detach the parts when desirable to remove them.

The external nose was painted with an oil color, to give it as nearly a flesh tint as possible, although this is not wholly attainable upon an opaque ground. Flesh being translucent, a true imitation can only be made upon a translucent ground.

The apparatus was introduced on June 30, 1863, giving to the patient great satisfaction and comfort. His appearance was much improved, as may be judged by comparing Fig. 351

with 355, both being engraved from photographs. The man breathes freely through the nose, and speaks with ease; the only imperfection in his speech is a nasal twang, and this is less now than when the instrument was first applied. The obturator at first extended too far back, and caused some irritation of the velum: this defect was readily remedied.

The operation proved entirely satisfactory, with two exceptions: first, the color of the nose was not as natural as desirable, for the reason already stated; second, in deglutition and speech, when the tongue pressed forcibly against the posterior part of the obturator, an unpleasant vibratory movement of the apex of the nose was noticeable. This could have been remedied by an elastic attachment coupling the two parts of the apparatus, but this mode was objectionable by reason of its producing constant pressure upon the delicate parts, and thereby endangering absorption. A safer plan was adopted by inserting a small steel pin in the nose as near as possible to its apex, to which was attached the bridge of a pair of spectacle-frames, these being retained in position by an elastic cord attached to the bows and passing around the head. This arrangement answered the double purpose of counteracting the vibratory movement, and concealing the upper part of the joint where the nose came in contact with the face.



This apparatus is worn at the present date (twenty years later) with ease and comfort by the patient.

FIG. 356.

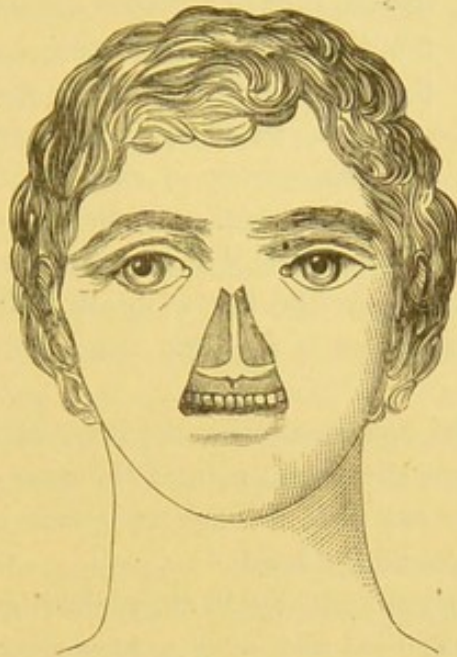


FIG. 357.



Fig. 356 is introduced as a study in mechanical appliances. This diagram represents a patient in the practice of the author as first seen by him.

Fig. 357, although not taken from life, is yet wonderfully correct as a likeness after treatment of the lip by operation.

Fig. 358 is from a photograph taken after treatment of the case was completed by adaptation of an artificial nose, which, with the assistance of the ingenious surgical artist, Mr. Kemble, was prepared for the lady. In this case the piece was temporarily employed in anticipation of a more promising condition of the general health for restoration of the organ by operation. The effect in life is quite as good as shown in the photograph.\*

FIG. 358.



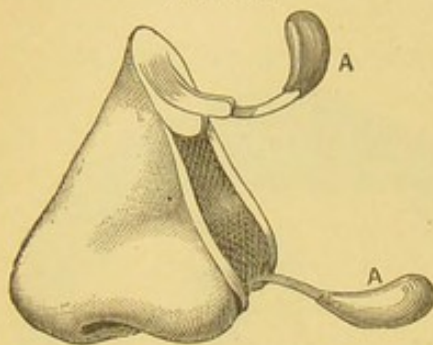
Fig. 359 represents an artificial nose, together with a common manner of hold-

\* The cut differs from the photograph only as parts aside from the seat of operation are concerned, it being necessary to prevent a recognizable likeness. This case is recited in previous editions of this work; the patient remains satisfied with her artificial nose, not yet having returned to have a natural one made by operation as contemplated.



ing such a piece in place. In employing springs, A, A, as here shown, great care is to be exercised that pressure be so applied as to insure if possible

FIG. 359.



against an irritation which is apt to result either in inflammation or absorption of the tissues, thus in a double direction rendering the piece useless. Better, however, than the upper spring for fixing the piece is the use of a pair of spectacles; these, through the employment of an elastic band passed around the head, not only prevent all motion on the part of the artificial nose, but also conceal the line of break. The author is

satisfied that the use of the spectacles is the best means of fixation yet devised.

In gentlemen wearing whiskers and moustache, the lower spring is also to be replaced by means of a delicate silver wire painted the color of the beard, and kept tense by relation of the two ends through an elastic bandage, concealed by the hair as it passes around the head.

Obturator for the mouth, although employed by the ancient Greeks, and by every succeeding generation of civilized men, seem to have attained to a reasonable completeness only in our own age. Before the time of Ambrose Paré, the appliances were all of a temporary nature, if we except mention of one suggested by Petronius, in the sixteenth century, although whether that surgeon ever really made such a plate as he described we are not informed. To Paré, however, we are indebted for a written description of the metal obturator, crude, without doubt, but embracing the principles of the present instruments. "Made," says this author, "like unto a dish in figure, and on the upper surface, which shall be toward the hair, a little sponge must be fastened, which, when it is moistened with the moisture distilling from the brain, will become swollen and puffed, so that it will fill the concavity of the palate, that the artificial palate cannot fall down, but stand fast and firm as if it stood of itself."

Garangeot, in 1715, made an advance on the idea of Paré,—although, it must be admitted, a very slight one. He describes his instrument as having a stem in the form of a screw, upon which ran a nut. To make use of it, he cut a piece of sponge in the form of a hemisphere, with a flat surface; through this sponge the stem was passed, the nut holding it in place. When about to introduce it, he wet the sponge, then squeezed it dry, and forced it through the aperture, or break.

After the period of Garangeot, no special advance seems to have been made until 1828, when obturators were constructed by a Mr. Snell, prepared on casts, which were correct representations, or impressions of the special cases. In a monograph published by this surgeon, he says, My method of constructing an obturator is with a gold plate, accurately fitted to the roof of the mouth,

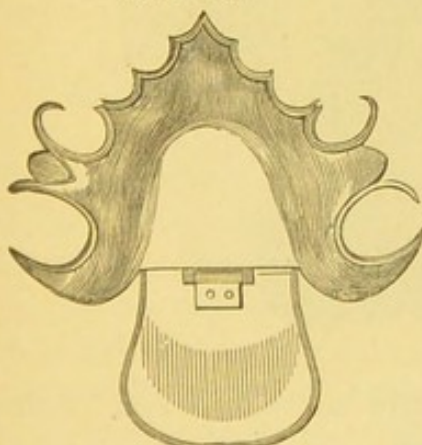


extending backward to the *os palati*, or extremity of the hard palate; a part of the plate, about an inch in length, being carried through the fissure. To that part of the plate, which answers to the nasal fossæ, are soldered two plates, meeting in the centre and carried upward through the fissure to the top of the remaining portion of the bones, to which it should be exactly adapted, and made to the natural shape of the nasal palatine floor: thus the fluids of the mouth will be carried backward into the fauces. A piece of prepared elastic gum is next attached to the posterior part of the plate where the natural soft palate commences, extending downward on each side as low as the remaining part of the uvula, and grooved at its lateral edges to receive the fissured portions of the velum; a movable velum is placed in the posterior centre of the elastic gum. That these may partake of the natural movements of the parts during deglutition, a sponge is affixed behind them, one end of which is attached to the posterior and anterior surfaces of the principal plate, and the other end rests gently against the posterior face of the india-rubber; this keeps it always in close apposition with the edges of the fissure during deglutition.

It is requisite to mention, he says, that the elastic gum should be placed in a gold frame, and not merely fastened to the posterior part of the plate, as it would shrink by remaining in the mouth. The frame should pass round its edges only, leaving the centre open.

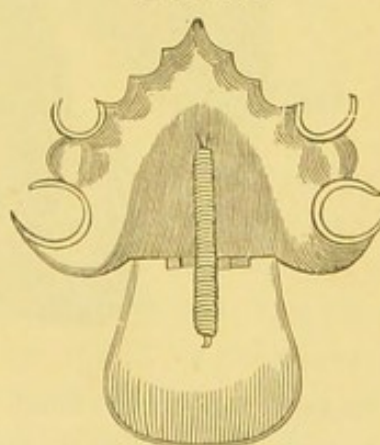
**Vela.**—Coming to the present period, attention is interested in the efforts made to compensate, through mechanical means, defects in the soft palate. The indication here is twofold: 1. To cover the break after such manner that food and drink shall be shut off from the nares and directed toward the throat. 2. To furnish ability for speech.

FIG. 360.



Palatine surface.

FIG. 361.



Nasal surface.

An obturator meeting the first of these indications reasonably well consists in an attachment to a metal plate of a flexible continuation made of rubber. Figs. 360 and 361 show the two surfaces of such a velum, and afford understanding of its construction.



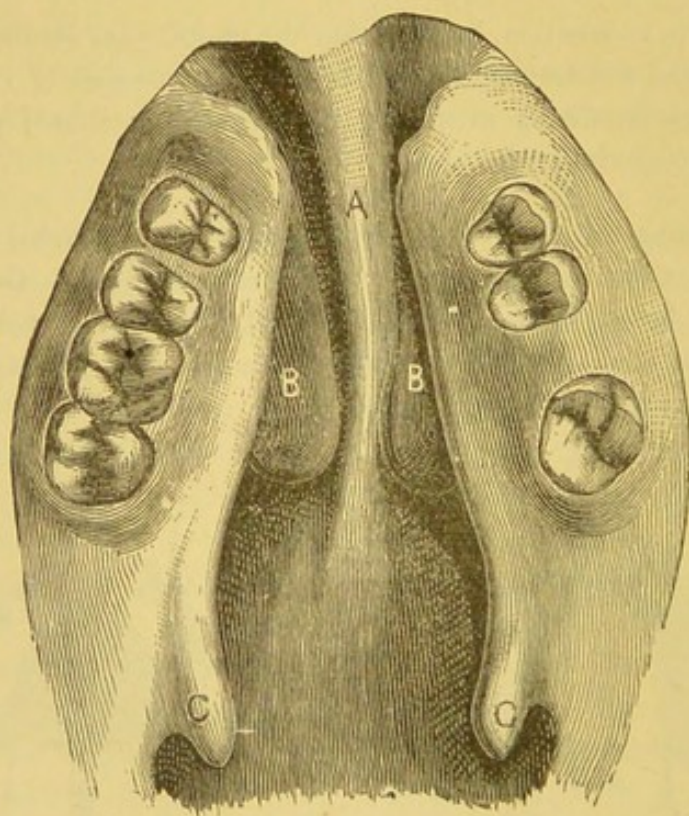
Obturator, here most justly called vela, designed to accomplish the second end, introduce the practitioner, in a study of them, to the complexities of prosthesis. Fortunately, the study leads in turn toward absolute simplicity.

In 1845, Mr. Stearn conceived the idea of a velum which should take the place of parts wanting in a soft palate, and be made movable by the parietes with which it was related. This appliance, as made by the gentleman, consisted of a gold plate fitted to the hard palate, having attached to it, by means of two spiral springs, an artificial velum of elastic rubber, composed of a body, wings, and grooved edges, to receive the margin of the cleft.

Succeeding Mr. Stearn is Dr. Norman Kingsley, of New York City, a practitioner who has been an enthusiastic worker in the direction for years. To follow and appreciate the steps taken in the work by this operator is to inform one's self very fully as to the principles of the practice.

Fig. 362 shows a case with which Dr. Kingsley commenced experimentation. The patient was a lady; the defect congenital. As is seen, the

FIG. 362.



break passes completely through both hard and soft palates. Indications directed an obturator and velum combined.

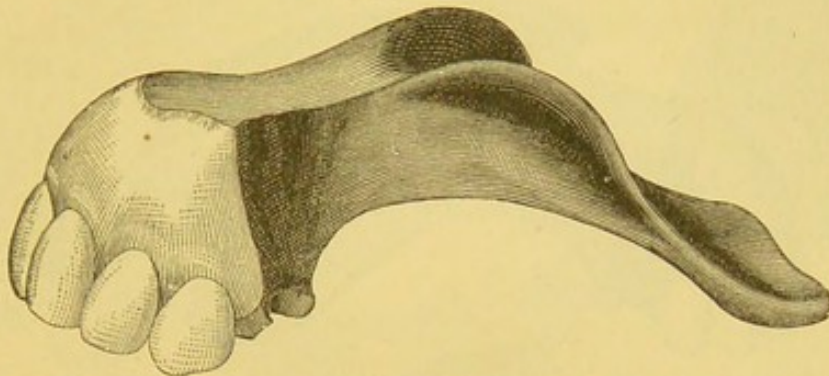
In the cut is exposed the perverted anatomy of the parts: A is the disarticulated vomer; B, B are the turbinate bones; C, C show the separated halves of the uvula, and afford an accurate idea of extent of deficiency in the soft palate.

"In my desire," writes Dr. Kingsley, "to benefit this patient, I re-read all



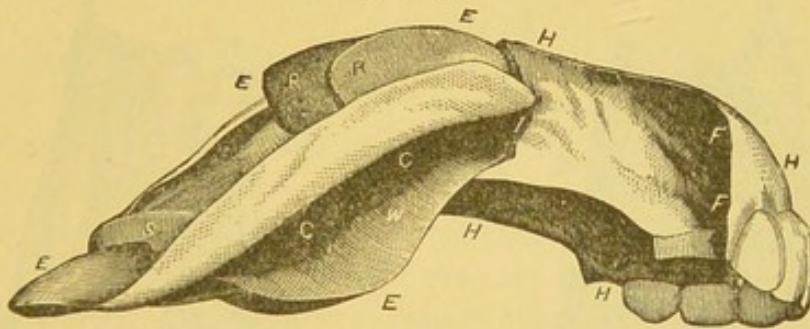
the literature I could find on the subject, with but little satisfaction, and ended in making a plate of vulcanite, of which Fig. 363 is an illustration. This obturator was worn for a few days with entire comfort, when my patient informed me that she had accidentally learned that there was a gentleman in the city engaged in manufacturing pursuits who had made a plate for himself which was a great success." Calling on the gentleman, Dr. Kingsley expresses his great surprise in finding him to be the veritable Mr. Stearn whose name, in connection with the invention of the artificial velum, is cited in previous paragraphs.\*

FIG. 363.



Mr. Stearn and Dr. Kingsley entered conjointly on the manufacture of a second apparatus. Fig. 364 shows the result of the work.

FIG. 364.



This velum proving unsatisfactory to Dr. Kingsley, believing, as he expresses himself, that one produced more after the manner in which a dentist would manipulate must do better, a second impression was secured (this being taken in plaster), and from it a model made. Upon this model a pattern was formed in gutta-percha, which, in turn, was copied in vulcanite. "This vulcanite model was carefully finished, and steps taken to make a mould in which to vulcanize duplicates of soft or elastic rubber." In this manipulation Dr. Kingsley claims to have been the first to use type metal, the mould used by Mr. Stearn being of wood. The instrument made is shown in Fig. 365.

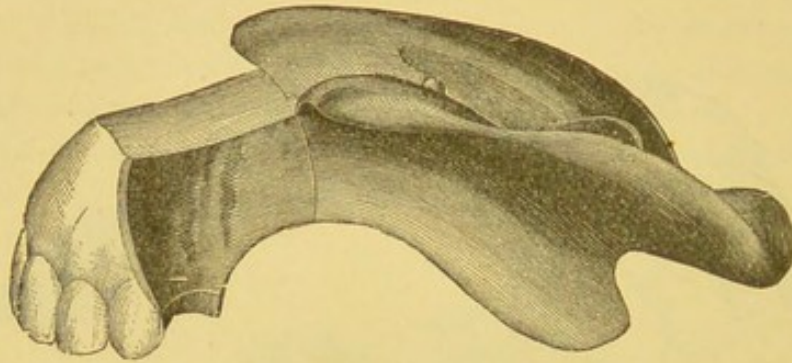
\* Desirabode, Snell, and Seracombe, as will be recognized, are not lacking in claim to a share in the conception of the possibilities of artificial vela.



Alluding to the two pieces, Dr. Kingsley suggests that the only advantage in the one constructed by himself lay in a nicer adaptability.

Improving on his original plate, Dr. Kingsley exhibits his second case, made in 1863. Figs. 366 and 367 show the oral and nasal surfaces. "A, A, A represent the groove which correspond to the border of the fissure. E, E show processes which lapped on to the floor of the nares and assisted in its support. C is the central flap, as used in the Stearn palate, and G, G are the two bows, or springs of rubber, which sustained it. In swallowing, the sides,

FIG. 365.



B, B, approached each other, sliding under the flap, C. This instrument was made of soft rubber in a type-metal mould, the mould itself being an intricate

FIG. 366.

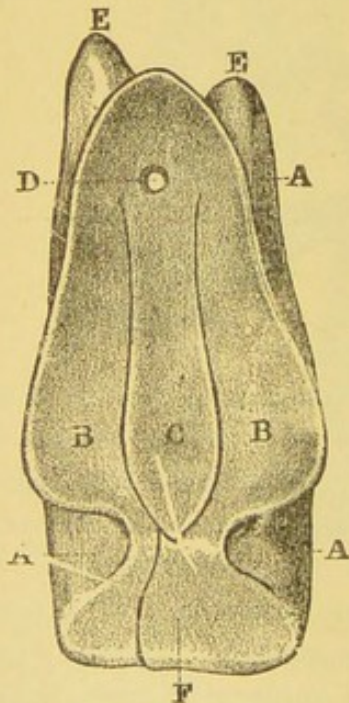
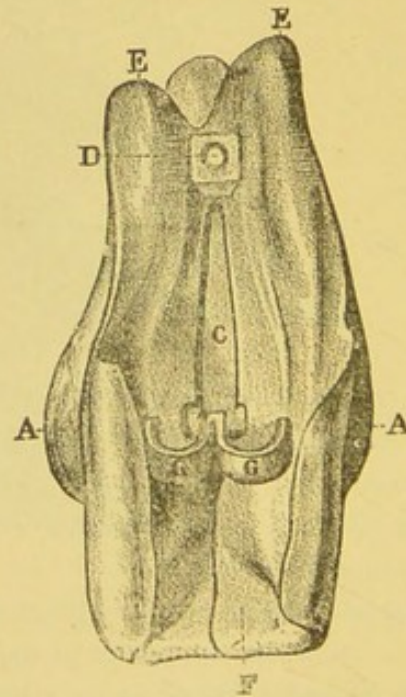


FIG. 367.



affair; but the instrument was simple in its application, and was of as much benefit in articulation as anything which has been produced since."

Objection to this apparatus, felt by Dr. Kingsley himself not less than by others, lay in its complexity, the instrument being both costly and liable to



get out of order. Here was an incentive to renewed effort. In 1864 a model was made of an instrument strictly original. The change consisted in abandonment of the triple form of construction, doing away with the central slip, the flaps, and all gold and other springs. These arrangements, it will be recognized, were in the former appliance to provide for the movements of the divided uvula and adjacent remnant of palate. The complexity is not hard to appreciate. Figs. 368 and 369 show the new instrument.

FIG. 368.

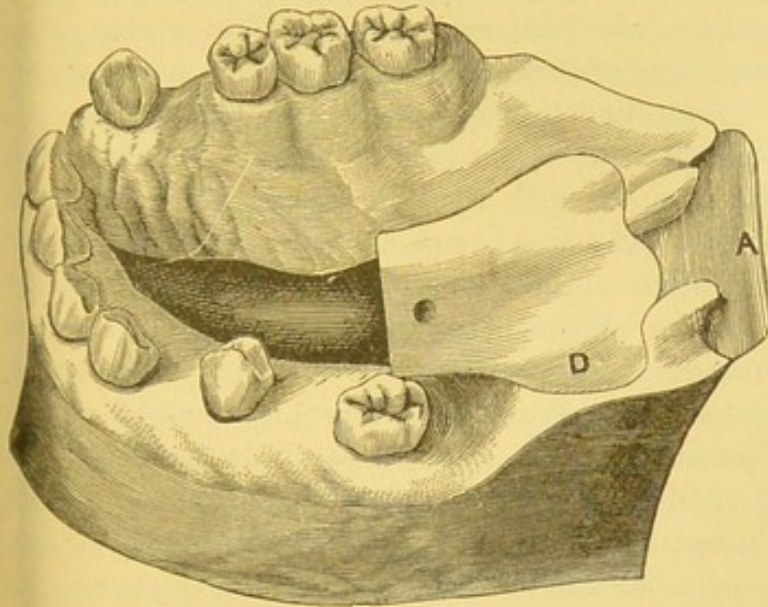



FIG. 369.



Out of his experience Dr. Kingsley remarks of this last construction: "For fifteen years I have used this form, and applied it in hundreds of cases of congenital fissure, and have made no improvement beyond simplifying the method of production. I know of no other form, or attempt at making an elastic velum, which fulfils the functions that this one does; nor do I believe it possible to make a flexible, yielding instrument which shall be of so universal application in any other form or by any other method."

In the cut (Fig. 368) D expresses the wings and A the posterior part of the velum; Fig. 369 shows an unattached instrument. Viewed *in situ* and distinct, the arrangement is easily appreciated. The hole in the front face of either velum is a means for attaching the piece to any arrangement required anterior to it.

Passing from the Kingsley experiments, reference is to be made to the velum and to the labors of William Suersen, Doctor of Surgery, a dentist practising his profession in Berlin. By this gentleman we have had advanced a new principle in the mechanism of speech. To pronounce distinctly it is necessary, he says, that the cavity of the mouth be separated from that of the nose by muscular interruption. That interruption is, under normal conditions, effected, on the one hand, by the velum palati, on the other by a muscle which has not, in such connection, received the attention merited,—namely,



the constrictor pharyngeus superioris. This latter muscle contracts itself during the utterance of every letter pronounced without the nasal sound, just as the levator palati does. The constrictive muscle contracts the pharyngeal cave, the wall bulging. On the action of this muscle is based the system of the new velum.

The palate, constructed in all its parts of caoutchouc, consists of a plate suitably attached to existing teeth, this being made as an obturator if indications exist in that direction. Where a fissure is related alone with the velum, this palate expands at the part into a process, or apophysis broad enough to compensate for the loss of the missing part. This process, or enlargement, is at the same time of such thickness as to keep up contact between the high edges constituting the sides of the apophysis and the two halves of the velum, even when the levator palati is active. To insure this contact in motion of the parts, the high edges do not rise straight, but obliquely, toward the outside. The lower surface of the apophysis, turned toward the mouth, lies on about an equal level with the velum, if the latter be raised by the lifting muscle. When, however, the levator is not in action, the velum loosely depending, the back part of the artificial palate lies over it. This back part fills up, accordingly, the pharyngeal cave, and in such manner as not to impede the entrance of air into the cavity of the nose when the pharyngeus constrictor superioris is inactive. Thus the patient can, without impediment, breathe through the nose. But, as soon as the constrictor contracts the cavum pharyngo-palatinum, this happening with the pronunciation of every letter, *m* and *n* excepted, the muscle reclines against the vertical back surface of the instrument. By this operation the air-current is prevented from entering the cavity of the nose and is compelled to take its way through the mouth, utterance being thus freed of nasal sound. To the existence of the vertical surfaces, and consequently to the thickness of that part of the apparatus which fills up the fissure in the soft palate and the cavum pharyngo-palatinum, special importance is to be attached. But for the thickness, the levator palati, when it rises upward, would not remain in contact with the side-edges of the instrument, nor would the pharyngeal constrictor be able to effect a sufficient termination if the portion of the obturator nearest it consisted only of a thin plate.

The author has to remark his great satisfaction with the Suersen design. Nothing yet made surpasses it for service, and for adaptability to requirements. It is his own plan, however, to make the portion covering the hard palate out of metal and to attach to this a velum, or box portion, constructed from celluloid.

Reference in connection with this form of obturator is deservedly to be made to what may prove an addition designed by Dr. Booth, of Iowa, in the shape of a box, or velum, portion related by means of a stop-hinge, and controlled in its upward movement by a delicate spring. The writer has not yet constructed such an apparatus, but its promise has much impressed him. The



instrument certainly has all required latitude of ascent and fall, and there is nothing to get out of order. To appreciate the construction of this obturator, it is only necessary to imagine a common plate fitted to the hard portion of the palate, to which a box, shaped something like the last phalanx of an index finger, is attached by a hinge of a character that prevents the part descending below the curvature of the arch, yet moving freely upward, except as such freedom of movement is controlled by a spring riveted at its fixed extremity to the nasal aspect of the common plate, and reaching back to the box.

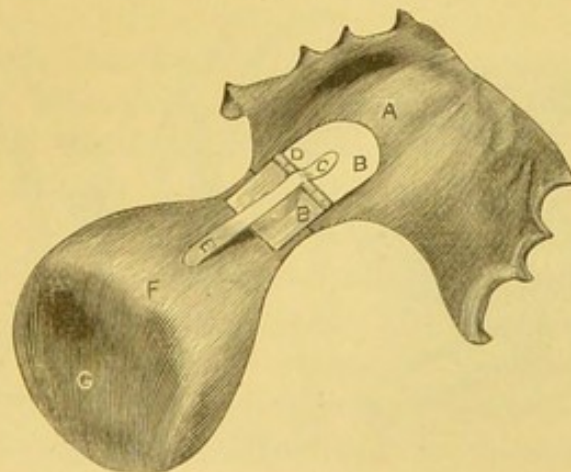
In a specimen of this design exhibited to the writer by its inventor, the roof-plate on one side was fixed by means of a groove slipped about the palatal process; a means of fixation not so desirable, it would seem, as the employment of the ordinary denture arch.

Similar in design and idea is an obturator made by Henry A. Baker, D.D.S.; like the last described, a modification of the Suersen instrument. Cuts here introduced afford an idea alike of the Booth and Baker apparatus.

Fig. 370, A, shows a gold or rubber plate fitted to the hard portion of the palate, its support being in clasps about the necks of certain teeth, as shown in the festoons. F is the velum proper; it is of chestnut shape and extends backward and downward, filling up completely the space between the separated parts, and being so embraced by the muscles and so restorative of the absent curvature that the movements of the palatal remnants reacquire, as nearly as may be, the meaning of original function.

Dr. Baker describes his velum as consisting of polished hard rubber, gold, or platinum. B, B exhibits hinge attachment to allow of part lifting

FIG. 370.



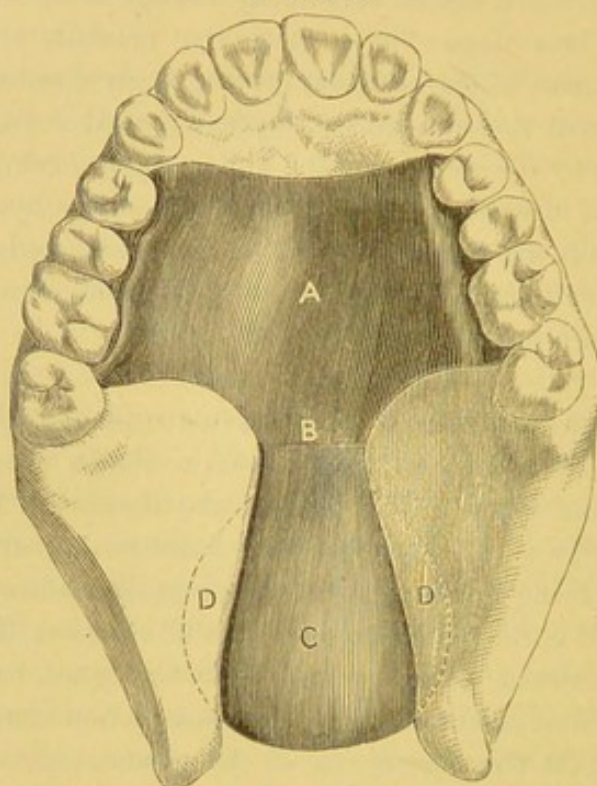
and falling in concert with constricting muscles. C is a delicate platinized gold spring, which, bridging the joint and resting on the velum at E with a slight downward pressure, serves to keep the latter in contact with the levator muscles when in action, thus giving them control of the appliance.

Turning here a glance at Fig. 371, the apparatus is seen in position.



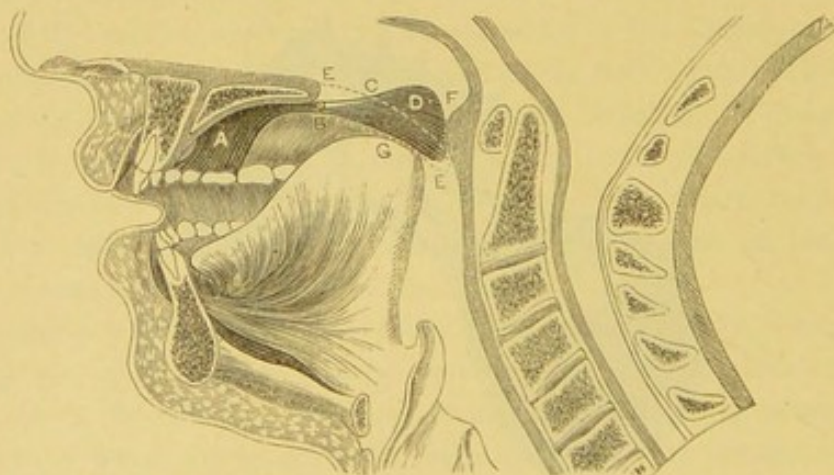
Attention is next directed to Fig. 372, which shows transverse section of obturator and of the natural parts to which it holds relation.

FIG. 371.



A, the plate; B, the stop, preventing downward motion when the muscles are in a relaxed condition; C, the artificial velum; D, D, muscles lying under it; the dotted lines show the appliance rests upon the muscles.

FIG. 372.



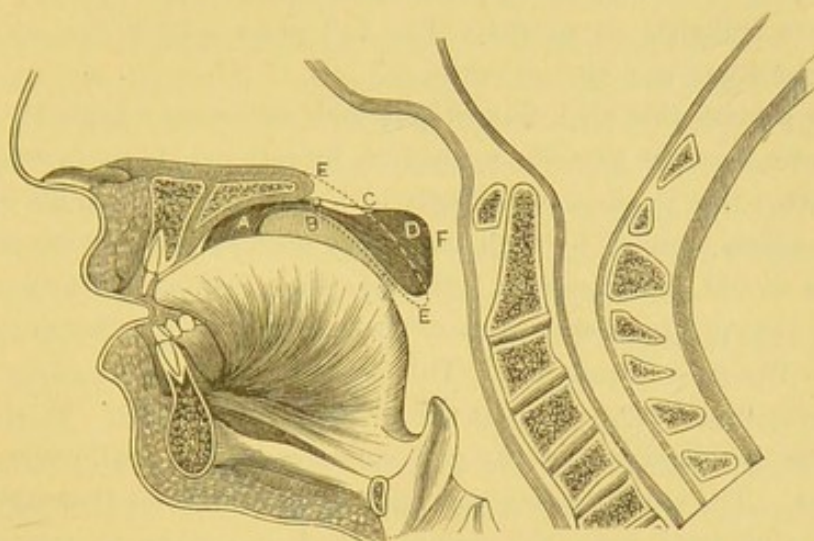
E, E, the artificial velum thrown up by the muscles as in all sounds requiring closure of the nasal passages; F, the superior constrictor muscle advanced to meet it; G, the tongue, raised, pressing hard against the appliance, as in pronouncing the letter *k* or *g*; A, the plate; B, the hinge-joint and stop; C, the spring resting on the velum.

Fig. 373 exhibits expression of velum and associate parts when out of office. Referring to the curvature, marked difference is seen as contrasted with Fig.



372. In the latter nasal respiration is shut off, in this it is uninterfered with. The letters refer alike in both diagrams to the same parts.

FIG. 373.



Showing muscles relaxed and the velum at rest, thus affording free passage for nasal sounds and respiration.

A valuable hint in connection with the velum or bulb portion of this obturator relates to making it hollow, so that weight shall not interfere with the necessary, or desired, movement. Manufacturers of rubber balls secure the result as follows: Take the vulcanite rubber in the soft state, and cut the sheets so that when joined the desired form is secured; then a little water (alcohol is added by Dr. Baker) is dropped into the cavity, the edges are sealed, and the piece vulcanized in the usual way. The steam produced by the water and alcohol inside creates sufficient pressure to keep the walls distended.

The well-founded claims for this obturator relate with assistance rendered the levator muscles of the palate, as the action of these contributes to freedom in speech. With all sounds requiring closure of the nasal passage the bulb is lifted (see Fig. 373, D) by the levator muscles, which muscles find their ability to act through the bridge-like relation with those of the velum (Fig. 372, D, C, D), nothing interfering with the action except the insignificant resistance offered by the slight spring (Fig. 370, C). The thickness of the velum, or bulb, relates its posterior surface in apposition with the superior constrictor muscle, F, thereby affording, in the pronunciation of the gutturals, firmer resistance to the tongue, C, than is to be obtained with a thin obturator. By reason of the presence of the hinge, B, the above movements are rendered so free and easy that there is no tendency to displacement of the plate. If a nasal sound immediately follow a guttural, the descent of the velum is rendered certain and timely by means of the spring.

**Masks.**—A mask is an obturator or cover designed to conceal facial de-



fects. Fig. 356 furnishes a good illustration of a defect suited for the mask ; it being accepted that the case admits of no correction by operation.

The principle of the mask is that of the common false-face ; difference lying in quality and adaptability of construction.

Masks are complete or partial. The full piece covers the whole face ; limited pieces apply to a part or parts.

To make a mask that shall fit perfectly and restore as completely as possible the lost contour, the surgeon commences by restoring to the face in wax the lacking parts ; this he does as perfectly as his artistic skill admits of. Harmony of features secured by such temporary means, a succeeding step is the taking of a mould, or impression. To take such cast, plaster being used, all hair of the region is to be shaved away ; otherwise closely flattened to the face through the free use of bandoline. This accomplished, a succeeding step provides means of breathing. Next is the getting of the mould. To secure this plaster batter is mixed in quantity and consistency that shall cover the face, yet not flow. The patient being now supine, and the parts thoroughly oiled, the batter is moulded upon the region ; care being taken to accomplish the intention perfectly.

When set, or hard, the mould is carefully to be lifted from the face and laid away for at least twenty-four hours. If, in the act of removal, difficulty be experienced in raising the plaster, the piece is to be broken and lifted in parts.

A succeeding step refers to the proper cast of the face ; it being recognized that the impression just taken is but a form in which this other is made.

The mould proper being arranged and built about so as to lie in the bottom of a cup, it is first varnished, and, after this has dried, it is very completely oiled. A second batter of plaster being mixed,—this time in the form of a thick cream,—the cup is filled by a pouring which commences and retains place at the lower portion of the mould. The batter is to rise gradually over the face surface, that absence of air-bubbles and absolute continuity of surface be secured.

Allowing time to elapse sufficient for the setting of the cast, a few hammer-taps against the mould suffice for the separating of the parts. A model thus secured represents perfectly the countenance from which it has been taken.

To fit a mask to this model, the whole or part being considered, a procedure is as follows : Taking the face (Fig. 356) as the block, and accepting the cast to have provided it with nose and lip, the operator commences by moulding over the restored parts a layer of absorbent paper, which performance he accomplishes by a free use of water. With this layer of paper he represents nose and lip, taking great pains that the boundary edges shall rest against their neighboring parts with the nicest accuracy.

The paper dry and hard, he proceeds to mould upon it either gutta-percha, other paper, or a sufficient number of layers of cotton stuff saturated with paste to accomplish the purpose of the requirements. This done, the proper



contour of the free surface of the lip and the nasal openings having been considered, succeeding steps relate to varnishing the piece, and to the manner of fixing it in place. In the case of a female such fixation is no easy matter; spectacles and flesh-colored string offer the best solution of the problem. The brush of an artist is necessary to give the final covering and color.

In this direction of practice an interesting example has been detailed to the author by Dr. Alfred Burne, of Australia; the patient being a medical gentleman and personal friend of the operator. The deformity in the case involved the superior maxillary region, bounded above by the transverse suture, below by the lower lip, extending from either oral angle backward and upward in curved lines to the temporo-maxillary articulations.

Having found, said Dr. Burne, that my own face corresponded in form and size with that of my patient, I had an impression taken of it. From this mould I made a cast, upon which, in turn, a mask was constructed. The completion of this mask showing it to be too large, I had a second impression moulded; this time also of my own face. Another mask was now made, this time being moulded into the mould, no cast being made. The fit secured is described as being so perfect and in every respect so satisfactory that whereas the gentleman never before its application ventured abroad without close concealment, he is now found mingling in society generally.

The steps of manufacture and fixation of the mask are given as follows: After the impression was hard it was thoroughly smeared with cosmoline; common paste flour and warm glue, eight parts of the former to one of the latter, were in turn laid over the cosmoline. Next, a piece of fine linen was taken, and by dint of much patience it was worked into the irregularities of the mould, the task being accomplished minus a single wrinkle. This being allowed time to dry, the glue-paste was in turn brushed over it, this receiving still in its turn a layer of blotting-paper. Again dry, again was repeated the layer of paste and paper.

Sufficient thickness obtained, the mask was removed from the mould and padded and trimmed to suit the face of the patient. The piece was completed by cutting out holes for the eyes and nostrils, adapting eyebrows and moustache to match hair and beard, and a final artistic painting of it.

Fixation to the face was after the following manner: When in place the mask extended from the line of the hair upon the forehead to contact with the inferior lip below, from the ear upon one side to that upon the other. Above and at the sides the hair was brushed over the edges, concealing these fairly well. Midway—that is, over the bridge of the nose—spectacles were fixed which passed around the ears with a spring. The artificial moustache mingled with a beard which concealed elastic flesh-colored strings passing among the hair around the head.

With the aid of the diagrams shown in the chapter, and with comprehension of the principles on which obturators and vela are constructed, the student or practitioner will surely be at no loss to continue experiments in the direc-



tion. The field is one inviting wide and generous competition. It is to be added, however, in conclusion, that the experience of the writer favors treatment of palatine defects by operation in all cases where such means applies. It is to be suggested, at the same time, that failures are, and will not unlikely continue to be, multitudinous. In a succeeding chapter the matter and manner of surgical operations upon the parts will be found fully considered.



## CHAPTER XXXII.

### THE GUMS AND THEIR DISEASES.

THE gums are simply an amount of fibro-cartilaginous tissue (the fibrous element predominating) placed as protecting cushions about the alveolar processes. The neck of each tooth is closely enveloped by a dental pit of this cushion; the mucous membrane, which covers the common surface, being reflected around the pit and rendered continuous with the periodontum of the organ.

The gums, in a healthy state, are remarkable for their insensibility, bearing, with very little or no response, the pressure and irritation to which, in the process of mastication, they are so continuously subjected. The mucous membrane, of which this tissue is largely made up, is very heavy and thick as compared with its continuity in other parts of the alimentary canal, and is underlaid by a network of vessels, which leads it to be esteemed of considerable vascularity as reference is had to operations involving it.

Inflammation is the disease of the gums; but such perverted vascular action, here, as everywhere else, has quite a variety of significations. These significations are—

1. Accumulations of tartar.
2. Periodontitis.
3. The mercurial impression.
4. Scurvy.
5. Syphilis.
6. Dead or loose teeth.
7. A crowded dental arch.
8. Use of improper dentifrices and brushes.
9. Improperly inserted artificial teeth.
10. Malignant impressions.
11. Anomalous conditions.—Neuralgia. (See *Neuralgia*.)

A comprehension of the diseases of the gums is found in the appreciation of these various conditions or influences.

1. **Accumulations of Tartar.**—Salivary calculus, a deposit from the saliva, combined with the various oral detritus, when attached about the necks of the teeth, becomes necessarily a source of offence, provoking inflammatory action, the grade of which is marked by the general condition of the individual. The most common type of inflammation thus induced is the chronic degenerative. The tartar, pressing upon the gums and insinuating itself about and around the necks of the teeth, soon interferes to such extent with



the proper circulation in the part as to yield the puffy, turgid condition so familiar in most of the cases. The mucous follicles associated with the dental pits have, of course, their secretive ability soon destroyed, and thus nothing prevents the insinuation of particles into these pits, and a consequent increase in the agency of offence. This irritation, uncombated, gradually progresses until the teeth become loosened and fall out, when, carrying with them the tartar, the parts recover.

All deposits, however, existing under the common name of tartar, or salivary calculus, do not have such a destructive history. Thus, it is very common to observe a greenish discoloration, particularly upon the teeth of the robust and uncleanly, which, so far as is observed, seldom results in any particular harm: it is æsthetically offensive, however, and is credited by many with being a corroder of enamel. Another kind, the black, rarely exists but in very limited amount, and as rarely or never does greater ill than slightly irritating the festoon; its situation is commonly the lingual face of the inferior teeth. It does happen, however, that this description of tartar, or something very analogous to it, is sometimes provoked, as it were, in depraved constitutions, to extensive deposit; it is a kind of mixture or agglutination related with sordes. The gums, very much depraved from a constitutional influence, are irritated not infrequently by this deposit into a state very little short of gangrene; the breath is made offensive, and the oral fluids, by admixture with the offensive mass, are rendered entirely unfit to be received by the stomach. The first two conditions of these stains, or deposits, if attempted to be removed with instruments or by means of pumice-stone, offer great resistance, but, as has been discovered by Dr. Dorr, a preliminary touching with tincture of iodine softens them most happily.

Yellow tartar, the deposit of the bilious and allied temperaments, is the kind most generally met with, and, as a rule, is most destructive to the integrity of the alveoli and gums. It is not at all uncommon to find this deposit of such extent as to inclose in a common mass half a dozen or more teeth, while its power of insinuation and destruction is so great that, before attention may have been directed to the process, the pits will be found destroyed and the teeth ready to drop from the mouth. The writer has, in his own practice, frequently been consulted in these cases, where nothing was of any avail but the removal of the implicated teeth. This description of calculus is evidently a direct deposit from the saliva, its situation corresponding with the location of the salivary orifices. It is found associated with a sluggish condition of the secretive action of the glands, and its reliable prophylaxis rests with their stimulation. This tartar has a rough, dry surface, and is generally easy of removal; flaking away in masses at the slightest touch of the instrument. The effect of its presence upon the gum is to force it away from the teeth, or rather, it might be more correct to say, to lift the teeth from the gums and their alveoli, destroying entirely any relation of attachment between the parts. The gums themselves, under its irritating influence, become puffy and soft,



and so tender occasionally as to render, in many cases, unbearable the ordinary pressure exerted in mastication, so that the patient is compelled to subsist exclusively on soft food, or to employ other than nature's process of comminution. (See chapter on *Salivary Calculus*.)

2. **Periodontitis.**—Ulitis arising out of periodontitis is not at all difficult to distinguish; it corresponds in character with the primary lesions in being acute or chronic. If a tooth be acutely inflamed in its periodontum, it is sore to the touch, and elongated. If it be chronically inflamed, it is loose or discolored. Inflammation in the gum is simply an inflammation of continuity. If the patient be in good health, the action is circumscribed; if the reverse, it will of course influence. To treat such an inflammation, the health of the tooth or teeth is to be restored. An inflamed periodontum is commonly associated with a dead pulp; this is the first source of offence for which the practitioner looks. If such a condition be found, and no cavity of communication exist with the pulp-canal, it will, in nine cases out of ten, only be necessary to make such communication, and the trouble quickly disappears. Tartar is the frequent source of chronic periodontitis. Fish-bones, or other foreign bodies, forced into the membrane in mastication, excite inflammation.

Acute periodonto-ulitis uncontrolled ends in parulis, and from such acute termination is very apt to pass to chronicity. Chronic ulitis presents the condition of continued turgescence, soreness, loose teeth or fangs; suppuration frequently occurs at the seat of the original abscess, and sometimes from the affected alveolar pits. Its cure, like that of the acute condition, resides in a treatment directed to the teeth. (See *Periodontitis* and *Alveolar Abscess*.)

3. **The Mercurial Impression.**—Mercury first yields decided evidence of its action by producing in the mouth a metallic taste, complained of as coppery. A little time, and this taste is accompanied with some increase in the quantity of the saliva; still later the festoons of the gums are found congesting, commencing generally about the necks of the lower central teeth. Succeeding this congestion we have the dull whiteness indicating the change in the epithelial tissue (a form of aphthæ). There now follow the elongation of the teeth, increased salivary flow, stiffness of the gums, enlargement of the tongue, foul breath, etc.

The effects which mercury is to produce on the mouth, or system at large, depend on the quantity administered and the susceptibility of the individual. The writer has exhibited the medicine in quantities of from fifteen to twenty grains in the course of three days without being able to perceive the local action; while, on the contrary, he has known five grains so to swell the tongue that it required much effort to prevent the patient being smothered. Children from five to ten years of age seem markedly susceptible. Some time back, there was removed at the Oral Hospital the whole of the left half of the body of the lower jaw, dead from but some three grains of calomel, as averred by the practitioner who administered the medicine. The patient was seven years of age. Mercurial ulitis, when confined alone to these parts,



signifies but slight effect on the part of the action of the agent; and the immediate cessation in its employment will generally result in the disappearance of these effects. If this should not, however, prove the case, nothing better is to be done than to scarify the gums, and paint them with tincture of iodine, the medicament to be graduated to each particular case, say, as a rule, half and half of the officinal tincture and water. Chlorate of potash as a wash, and used internally, is also to be employed. To an adult, ten grains of the salt, dissolved in a tablespoonful of water, may be given four or five times a day. As a local application, one drachm to the ounce of water is a very good strength. The bowels are to be kept in a lax condition by the administration of Seidlitz powders or other saline cathartics. Where mercurial ulitis passes to that stage which results in a breaking down of the tissue (and this is sometimes the case where even adjacent parts are not markedly affected), the treatment required is more imperative, and pertains, as a rule, quite as much to the constitution at large as to the mouth itself. Locally, the fetor will urgently demand attention; and one of the best means to correct this is found in the use of a solution of the permanganate of potash, such solution varying in strength from two to ten grains to the ounce of water. Constitutionally, vigorous tonic medicaments are required,—not the least important of which are the iron and bark preparations. If hemorrhage intervene, it may be necessary to employ opium and lead internally; or, as suggested in another part of this work, tincture of erigeron canadense, in doses of one or two drops, repeated frequently until such bleeding is controlled. Locally, cobweb saturated in alum-water may be used; laid carefully upon a bleeding part, and retained in position, it is seldom found to fail. Monsel's salts are not to be used. The tendency in extreme cases toward sloughing is a matter constantly to be borne in mind. When the tumefaction is very great and the tissue indolent-looking, the parts are to be incised and iodine applied; both remedies, however, are to be used with judgment and caution. The author has known gums in this condition which might perhaps have been recovered, sloughed in mass by applications of strong tincture of iodine. Always let the incisions be few at first, and the officinal tincture at least two-thirds diluted with alcohol or water. Aromatic sulphuric acid as a wash is a happy local remedy in these depressions: it may be mixed with water until the acid taste is comfortably bearable,—about  $\mathfrak{z}\text{i}$  to  $\mathfrak{z}\text{vi}$  of water. A combination for local use, occasionally employed with much benefit, is composed as follows:

R.—Potassii chloratis,  $\mathfrak{z}\text{ss}$ ;

Sodæ biboratis,

Aluminis pulveris,  $\mathfrak{aa}$   $\mathfrak{z}\text{ij}$ ;

Potassii permanganatis, gr. xxv;

Aquæ Coloniæ,  $\mathfrak{z}\text{j}$ ;

Tincturæ cinchonæ,  $\mathfrak{z}\text{ij}$ ;

Tincturæ myrrhæ,  $\mathfrak{z}\text{j}$ ;

Tincturæ capsici,  $\mathfrak{z}\text{j}$ ;

Tincturæ krameriæ,  $\mathfrak{z}\text{j}$ ;

Aquæ,  $\mathfrak{z}\text{viiij}$ . M.



There is a preparation of capsicum and myrrh, officinally known as *Tinctura Capsici et Myrrhæ*, which is used in this same direction with the most satisfactory of results by adding to it water until the latter fluid is changed in color to a bluish-white. A direction commonly given to patients in connection with this medicine is to take a goblet of water and add to it drop after drop of the combination until the shade required is secured, then to retain a mouthful for a few moments before ejecting it; this to be repeated several times a day.

If, in defiance of all that is done, the parts slough, one of three things occurs; the disease will seem to have exhausted itself, and the adjoining parts, after a little rest, give evidence of recovery; or the bone follows the ulcerative action, and sloughs as did the soft parts; or the patient dies from irritation and exhaustion. (For treatment of Caries and Necrosis, see other pages.)

4. **Scurvy.**—Scurvy proper, such as decimated the legions of Louis the Ninth, and in later days was so frequently the scourge of protracted sea-voyages, is a condition which modern science and judgment have so combated that it may be trusted that few will meet with or have occasion to treat it. Modified forms of the disease are still, however, prevalent enough, and exist with features which vary from simple indolent ulitis to general purpura.

Puffiness of the gums, scorbutic in nature, is fairly judged from its dull, purple aspect, independent of its varying constitutional conditions. This venous congestion compares pathologically with the effusions of purpura proper. It would not, however, be at all truthful, nor in accordance with the facts, to describe any particular train of constitutional conditions as constantly associated with the scorbutic sore mouth, as met with in ordinary practice, and for the reason that nothing else of the disease may appear but the local manifestation. That it is a constitutional affection and not a local disease, is proven by the fact of absence of any source of local irritation, and by the further fact of its constant presence in the mouth, let the disease possess whatever other manifestations it may.

Dr. Foltz, U.S.N., in a report made by him on the scurvy which appeared in the blockading fleet of the Gulf of Mexico, states that lassitude and indisposition to muscular energy, noted so frequently by authors as prodroma, were not among the symptoms which ushered in the disease, and that there was great activity, and not infrequently cheerfulness, good appetite, and sound sleep at night, after the teeth were loosened, the gums ulcerated, the limbs oedematous and discolored; and when at last the patient gave way, it was not an indisposition to corporal exertion, but an actual disability.

Authors, however they differ in their descriptions of the various cases that have come under observation, are all agreed that scurvy results from the absence of fresh fruits and vegetables, or of juices, necessary to furnish some principle required in the blood, which principle is not, in such absence, otherwise obtained. In the treatise published by Dr. Hamilton on Military



Surgery, the author says, "In regard to the pathology of scurvy, the belief prevails that it is due essentially to the absence of certain staminal principles from the blood, and especially potash. It appears to be a pretty well ascertained fact that all, or nearly all, of those remedies which have been employed successfully in the prevention or cure of scurvy, contain potash. Potatoes, cabbage, celery, lettuce, lime-, lemon-, and orange-juice, contain it in large quantity, unless their salts have been expressed by the application of heat, as in boiling, or other modes of cooking. Lime-, lemon-, and orange-juice contain nearly one grain of potash to every ounce.

"One ounce of potatoes yields one grain and a half, while one ounce of rice yields only .005 of a grain. The substitution of rice in an English work-house for an equal amount by weight of potatoes was followed in a short time by scurvy."

In the ordinary scurvy of the gums, which every practitioner is aware presents itself most frequently in the very early spring, when the old vegetables have been pretty well exhausted and fresh ones have not begun to grow, it is a common experience to discover that the patients have existed almost exclusively on salt meats; hence it is much the most frequently met with in the poorer class of farm-laborers. The gums, in these cases, are of a purple color, turgid, the dental pits discharging pus, the teeth loosened, the breath offensive, but the face not by any means pale, nor the habits languid; indeed, there is little or nothing to signify that the local manifestation is a systemic offspring. When the condition is extreme, it is not uncommon to have fungoid growths springing from the edges and depths of the dental pits.

**TREATMENT.**—It will be found good practice to treat these conditions locally, as directed in mercurial ulitis. Constitutionally, however, different indications are to be met; a something possessed by a vegetable and acid diet is required by the blood. Without stopping to discuss the question whether this something may or may not be potash, we act on the empirical conviction, and at once direct such diet. Then the depressed or perverted life-force is to be elevated or relieved, and to this end nothing can equal the sheet-bath, taken with water moderately warm and moderately salt. Saturating the sheet, it is quickly thrown around the body, and the patient or an assistant rubs the cloth over the flesh until the whole person is in a ruddy glow. This is repeated each morning immediately on rising.

As medicine, the vegetable acids are to be freely used. Lemonade is perhaps quite as good as anything that can be given. A combination which has some celebrity is known as Turner's antidote; it consists of ℥ij of nitrate of potassa, mixed in ℥viii of acetic acid, administered in tablespoonful doses three times a day. Conjoined with general medication, local attention is required by the teeth and gums. (See chapter on *Salivary Calculus*.)

5. **Syphilis.**—Syphilitic ulitis the writer infers, from his individual expe-



rience and observation, to be an inflammation, not of the gum-tissue proper, but simply of its mucous envelope: or, on the other hand, it is an inflammation commencing in the periosteum, and secondarily affecting the gum-tissue. He does not recall a case of pure uncomplicated syphilitic ulitis; while few conditions are more common than mercurio-syphilitic ulitis and osteo-ulitis of syphilitic origin. The appreciation of such lesions is, of course, not at all difficult; the history alone is sufficient to give a diagnosis, while to the experienced eye a moment's glance is enough to reveal the precedents. If the inflammation be confined to the mucous membrane, the full extent of its surface will be more or less affected, its color will be a dull red, it will be more or less tender to the touch, and most likely ulcerated. If, on the contrary, the bone or its periosteum be the primary seat of trouble, the gum may simply be thrown up by the effusion beneath it; or if it happen that the gum itself has become inflamed, the action seems inclining to localize itself as much as possible. This, however, depends on the state of the parts beneath, and on the treatment that is being pursued. If the condition be one of pure uncomplicated venereal ostitis, the excitement in the gum is found localized to the immediately overlying parts; but if there have been a mercurial treatment, any extent of complication may show itself. The treatment in these cases is founded on existing conditions.

**6. Dead or Loose Teeth.**—Pulpless teeth affect secondarily the gum structure through continuity with the inflamed periodontum. A tooth periodontally inflamed is always sore to the touch, is more or less elongated, and is discolored. A ulitis connected with such diseased tooth or teeth is plainly discoverable by the absence of other sources of irritation; relief follows, of course, the cure of the primary lesion.

**7. Overcrowded Condition of the Dental Arch.**—See chapter on *Anomalies of Dentition*.

**8. Use of Improper Dentifrices and Brushes.**—Many gums are subjected to continuous irritation and inflammation from the use of agents in the way of dentifrices, brushes, or other dental applications, which, either chemically, vitally, or mechanically, predispose and conduce to deterioration. Perhaps in the whole range of practice there is, in no single instance, less attention given to the requirements of the various cases than is manifested in the prescribing of tooth-cleansing powders and washes. Charcoal, a favorite agent with many, while excellent in its place, is one of the most frequently abused of these remedies. Very common is it to find, after a few weeks or months of the use of the material, the gums becoming pitted with black spots about the necks of the teeth and loosening from them. This is a result of the insolubility of the agent in the fluids of the mouth; gradually, but surely, it finds its way into the mucous pits, and, not being either washed out or dissolved by the secretion, it quickly destroys the integrity of the relation; hence follow chronic periodontitis and the eventual loss of teeth,—the mass of gum-tissue sympathizing during the whole period, producing chronic ulitis.



Pulverized coral and pumice are other agents mechanically destructive, although in their places very good, and, as will be remarked, recommended. Castile and other soaps, too freely used, degenerate the gum-tissue by the action of their alkalinity; a constant use of such agents is quite certain to be attended by puffiness and chronic turgidity of the parts, by degenerated mucous discharges, and by an offensive breath. Acids, on the other hand, employed of too full strength, inflame and irritate the gums, and put the teeth on edge by dissolving more or less of their lime-salts. A ulitis arising out of the irritation of acid agents differs, however, from that produced by the alkaline, in being of a free, generous, acute, or, at worst, subacute nature, easy of control, and much more injurious to the teeth than to the gums themselves. Irritation of the gums commonly associates also with injury to the teeth.

A very common cause of ulitis in persons with carious teeth results from the too free use of creasote. This agent, used pure, is a powerful irritant, and has been the cause of some of the most severe acute inflammations. Seen early, the cases exhibit the direct effect of the agent in the escharotic result that has been produced on the mucous membrane,—the part being white, pasty, and sloughing. Outside of the immediate local use of oil or butter, if it be inferred that free creasote remains about the mouth, such cases are to be treated on common principles. A case occurred, a short time back, in the writer's practice, where a girl, with the intention of committing suicide, swallowed two drachms of the agent. Called immediately, an emetic was used; the first thing at hand, namely, the soap on her washstand, being employed, and this was followed by making her swallow half a pound of common table-butter. No particular bad results occurred: the patient's mouth, œsophagus, and stomach were sore for three days, after which she seemed about as usual.\*

Chloride of zinc, used in the mixing of the oxychloride plugs, is another of the causes of ulitis. The action of this may be of a twofold character: either directly upon the gum-tissue, as by its careless use it may have been allowed to come in contact with this structure, or through a periodontitis excited by the action of the agent on the dental pulp. From abuse of this material many cases have occurred in which large portions of the gums are destroyed; and not infrequently the action extends to the alveolar process, necrosing the sockets of the teeth.

---

\* Dr. Theodore Husemann (*Journal of Applied Chemistry*) "opposes the use of fixed oils, glycerine, and similar demulcents in cases of poisoning by carbolic acid or creasote, but recommends, based upon experiments with rabbits made by himself and Ummethun, the saccharate of lime, the alkaline earth combining with the carbolic acid to form a non-irritating salt. Lime-water is less adapted to this purpose, owing to the sparing solubility of lime in water, and the large quantity of lime-water required for neutralizing the poison. Precipitated carbonate of lime does not combine with carbolic acid, but may be employed in case the saccharate of lime should not be procurable at once; the carbonate appears to act merely mechanically by absorbing the poison, and thus delaying its ill effects; sufficient time is thereby afforded to prepare the saccharate."



Causes of chronic ulitis, occasionally met with, exist in an undressed plug, in a wedge of gold, or in metal or other material forced into the dental pit while in the act of filling a tooth on its approximal face. Matters of this kind are apt to be overlooked by a general practitioner; hence an unappreciated stubbornness in his case. When ulitis is circumscribed, and the centre of the trouble seems to be a tooth filled on an approximal surface, attention may first be directed to the possibility of such conditions. To satisfy himself, let the physician take a strand of common ligature silk, and, passing it between the teeth, feel if it run freely about the necks; if it catch, the probability is that the trouble has been discovered. Remedy is found in dressing away by means of a file the bulging portion of gold, or otherwise removing what may be found.

The employment of arsenical paste in the destruction of the dental pulp is a frequent source of ulitis. In the use of this means, it is well to seal it in the cavity with a particle of wax, or, where this is not admissible (and there are certainly cases where to do it is impossible), then a tuft of cotton, saturated with gum sandarac, is placed over the application, and protected for a few moments until it hardens. (See *Odontalgia*.) In inflammation from this cause the immediate local use of the sesquioxide of iron has been recommended; but no good results come from it, the harm being established before the patient applies. Syringing the parts thoroughly, and a treatment directed on general principles, is all that may be done.

Brushes used in cleansing the teeth are frequently a source of offence from their excessive stiffness, tearing really the epithelium, at each cleansing, from the mucous membrane; the patient complains of the soreness and bleeding of the gums every time the teeth are brushed, yet fails to recognize himself as producer of the trouble.

**9. Improperly inserted Artificial Teeth.**—Ulitis, resulting in fungoid degeneration, and in troublesome chronic conditions, is frequently witnessed as a result of ill-adapted dentures and of ill-adapted material employed in their construction. Teeth inserted on plates held in position by clasps, or bands, attached to unsuitable teeth, are a prolific source of offence. Where the bearings of a plate are not accurate, the bands cut into the gums fret and irritate them, until, in the end, the teeth to which the clasps are attached are loosened, and the part passes to a chronic degeneracy, puffing up, and losing much of its vitality; otherwise a hypertrophied ring of the tissue, hard and callous, surrounds the diseased tooth, and serves as a sort of protection to the adjoining parts. A case comes to mind in which a lady, wearing an upper set of teeth, supported partially by atmospheric pressure and partly by a band passing around the only natural tooth in her mouth, had provoked, in this socket, an epulic growth of such threatening character that, failing to cure it by ordinary means, an operation was advised as the only hope of saving her life. In Mr. Heath's Jacksonian prize essay, drawings are given of certain papular hypertrophies (thought by the author to be quite



rare specimens) on the oral mucous membrane. These hypertrophies the author has frequently seen on the surface beneath the cavities of suction plates; they look like enlarged and indurated fungiform papillæ. Another form of such hypertrophy is induration of the membrane lying beneath the cavity; the parts are raised by sub-effusions, which organize and become as hard almost as cartilage. Still another form is the rugose,—several wheals running across the space; these indurations never degenerate or do any particular harm. In some instances they remain permanent after the removal of the offence; but, as a rule, are found to disappear in a few months after a plate is taken away.

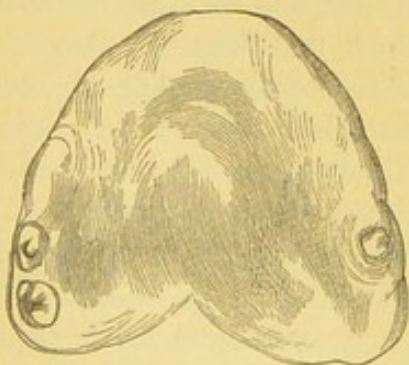
Hypertrophy of the gum in mass occasionally results from the mechanical irritation of dental plates. At the time of writing this page a case is being treated in the person of a lady suffering under such an enlargement; the trouble is in the upper gums, these seeming like thickened masses of gristle, and proving about as insensible as does this substance to medicinal impression.

Vulcanite, a material much employed in the construction of dental plates, is, to many mouths, a source of unbearable offence. The cases that come under observation are all alike,—soft, flabby, relaxed, congested, and very sluggish in recuperation, the gum-tissue seeming to be softened from surface to base. Acid and astringent lotions are adapted to the cure. The material called celluloid is to have preference over the former substance.

Silver is another material that it would perhaps be as well to dispense with in the construction of dental appliances; also gold too much alloyed with copper, running down, as it is sometimes found, to fourteen carats.

10 and 11.—In other parts of this work occasion is taken to treat, under what are deemed to be proper heads, various conditions, commonly associated under the common appellation of gum diseases. These diseases are of various expression, they associate with accidents, with idiosyncrasies, and with cachexia; examples are furnished in the epulic tumors, and in sympathetic disturbances.

FIG. 374.—VIEW OF GUMS INFLAMED BY VULCANITE PLATE.



Observation of Fig. 374 exhibits a congestion which has swollen the gums and tissues of the hard palate to an extent which conceals almost completely three posterior teeth which remain in the parts. The patient from whose mouth the drawing was made had worn a plate of vulcanite nine months; the parts were a dusky red,—flabby, relaxed, and exceedingly indolent. There was no particular pain,—simply a soreness, together with a tenderness on pressure, which tenderness had increased gradually until the removal of the piece became a necessity.

The cause of irritation from such a plate is variously ascribed: the most probable is the exclusion of atmospheric air, and a consequent heating which



follows. To cure such cases it is found, in most instances, a necessity to remove the denture, after which stimulating and astringent washes are to be prescribed.

A very excellent combination is as follows :

R.—Aquæ Coloniae, ℥j;  
 Tincturæ capsici compositæ, ℥j;  
 Sodæ biboratis, ℥j;  
 Tincturæ cinchonæ,  
 Tincturæ pyrethri, āā ℥j;  
 Aquæ, ℥vj. M.

A second application, which justly receives much commendation, is borate of zinc ℥i to water Oi.

Borate of potassa and water in like proportions with that immediately preceding affords also a reliable lotion.

Where an alterative is indicated, an excellent and tasteless ointment is made out of the subiodide of bismuth.

Cases of hypertrophy from ill-fitting clasps or ill-adapted plates are not infrequently met with; sometimes such an induration will be found circumscribing a single tooth to an extent which half conceals it, the band being accommodated in a space existing between the gum and tooth. The author has known such cases give much concern by the obstinacy of their persistence after the removal of the cause of offence; but such anxiety is seldom well founded, for even should the induration remain it will exhibit no tendency to degenerate. In the treatment it is only necessary to remove the offending agent, and leave the case to nature.

As general hypertrophy of the gums is concerned, illustration may be made by referring to a case at present under treatment. The patient, a lady in fine health, middle-aged, wears a plate of gold containing seven scattered teeth. Wherever this plate bears upon the gum, the parts are enlarged, indurated, and scirrhus-like. If it were not for the absence of associate expressions of carcinoma, one might very readily infer the presence of such disease. The explanation of such induration is to be found in an imperfect adaptation of the denture, conjoined, perhaps, with a cachexia. The treatment has been the very simple one of advising the patient not to wear the plate, nor any other, until a cure is obtained. No medication has been deemed necessary.

Still another class of cases exists in the hypertrophy of the mucous membrane lying beneath the surface of suction cavities. Sometimes this surface is found simply thickened and hardened; at other times it is seen broken into deep fissures; still again it is observed studded with papillæ, fungiform in character, and not infrequently possessed of a tendency to hemorrhage. Cases are met with where serious results threaten, yet seldom ensue. In one instance necrosis of the underlying bone exposed the nares.

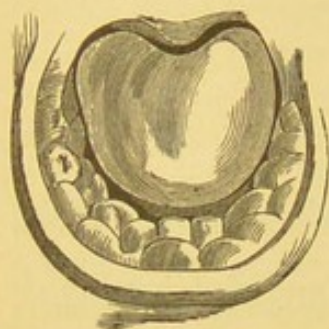
TREATMENT.—This is generally to be tentative; the plate is to be removed, or at least the suction cavity must be. If the parts do not recover after such



removal of the offence, it may be found desirable to touch with zinc, iodine, or capsicum. If caries or necrosis ensue, such conditions are to be treated as referred to in the chapter on these diseases.

Fig. 375 exhibits a form of general hypertrophy of the gum structure occasionally met with. Such condition is oftentimes

FIG. 375.

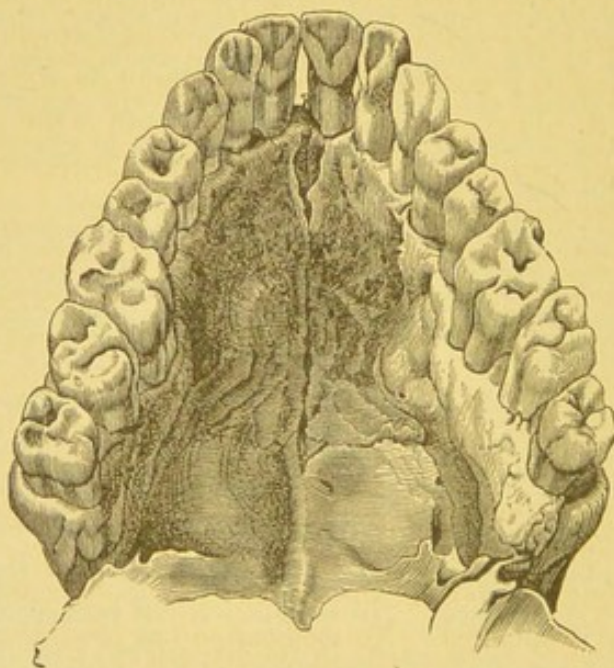


View of Case of General Hypertrophy.

found to be but an expression of unobserved local agents of offence, upon the removal of which the overgrowth disappears. Where, on the contrary, it is seen to be an expression of constitutional condition, the related vice is to be corrected. The best local treatment consists in frequent incisions through the parts, and the application of tincture of iodine. Removal of the overgrowth by the knife is seldom, if ever, found to be compensating.

Fig. 376, a case of chronic ulitis, with recession, is a type of a not uncommon condition, and has a great variety of meanings. The principal cause of such recession is found, according to experience, in the accumulation of small quantities of tartar

FIG. 376.—VIEW OF CHRONIC ULITIS, WITH RECESSION.



just below the free edge of the gums. A second cause, and a very prominent one, lies in a solidification of the tooth structure,—the equilibrium of circulation existing between the tooth pulp, periodontum, and gum being thus disturbed. Causes strictly local, however, need only give concern as they affect the appearance of the parts and the health of the teeth; they are susceptible of remedy, requiring only attention and the proper skill. It will be readily inferred, however, from what has been said on previous pages, that



local lesions are not alone to blame for such conditions. "In forming a judgment," says Mr. Bell, "upon cases of this description, and even upon those in which the loss of substance is associated with more or less of diseased action, it is necessary to recollect that the teeth in old age are removed by this identical process,—namely, the destruction of their support by the absorption of the gums and alveolar processes; and as this step toward general decay commences at very different periods in different constitutions, it may, doubtless, in many cases, even in persons not beyond the middle period of life, be considered as an indication of a sort of premature old age, or an anticipation at least of senile decay, as far as regards these parts of the body."

In depressed conditions of the life-force, as witnessed in the habitual drinker and debauchee, such recession is generally found conjoined with suppuration, and affects all the parts alike; the gums are turgid, sluggish-looking, and more or less purple; the mucous membrane lining the mouth and throat is of a dirty red; the tremor and prostration of the system at large show the constitutional nature of the offence.

Another form of this recession is associated with the sickly and weak; here the part is even lighter than in health, is shrivelled and shrunken, clasping the neck of the tooth tightly and closely,—seeming, indeed, shrinking within itself. These cases are always anæmic, being found usually in the female sex, or in males inclining to phthisis. Everything that tends to induce such a condition is to be regarded as a predisposing cause; such are bilious and inflammatory fevers, the excessive use of mercurial medicines, the venereal virus, anything occasioning deterioration of the fluids of the body. Persons of cachectic habit are far more subject to the condition, and generally in its worse forms, than individuals in the enjoyment of good health. Because of the truthfulness of such assumption it is seen that the condition is an occasion of warning. In the writer's experience, he has not infrequently had occasion to recognize in recession of the gums a first expression of declining health.

**TREATMENT.**—This is of course to be directed to cause. Where this is found to be of a strictly local nature excellent effects are secured by scarifying the affected parts three or four times a week, and touching them lightly with chloride of zinc; a solution in strength of about gr. xx to water ℥j. Sometimes the edges may be pared and brought together with a single stitch; this little operation, however, only applies where the tissues are reasonably loose and fairly healthy, and the recession is V-shaped. Compound tincture of capsicum is an excellent provocative of granulations; iodine also acts happily. The parts are always to be scarified to allow such applications to be of any use. The various washes recommended are, of course, serviceable or not, according as they are adapted to indications: of these, the stimulating and astringent will be found most frequently demanded. Where the teeth are thus exposed without apparent lesion, either of a local or a general nature, the trouble is to be deemed incurable.



**Congenital Union of Gums.**—Dr. W. S. Carter reports the following anomalous case, which, with a few others, is presented as an interesting study in this direction of oral troubles: Mrs. W. was delivered, after an easy labor at full term, of a living male child. The infant was perfectly quiet for a few moments after its birth, and then spasmodic respiratory efforts were made. Thinking the throat might be obstructed by mucus, endeavor was made, using the finger, to remove it. The finger passed readily between the lips, but could get no further than the gums, which both to sight and touch were found firmly united.

As it was necessary to act promptly, the tissue uniting the gums was divided. This tissue appeared to be about as thick as the gums, and was cartilaginous, extending as far back on either side as the angle of the jaw. Notwithstanding a free division, which enabled the child to breathe with more facility, the jaws were immovable.

After letting the patient rest a few hours, it was decided to use force to separate the jaws, and make a further careful exploration. This exploration showed a tough membrane, one-eighth of an inch in thickness, passing from the palate bone above, and inserted into the lower gum. Upon the division of this and the use of some little traction, the jaws were separated.

In two weeks the gums had healed, the child took nourishment readily, and was doing well.

Other malformations also existed in this case: viz., the fingers and toes were webbed, and the ears were in rather a rudimentary condition,—the integument passing from the head over the anterior surface of the upper third of each of these.

When the mother was about three months pregnant, her son, about six years of age, had a severe convulsion, the jaws being spasmodically closed. She was alone at the time, and her terror was excessive; and, indeed, since then, during all the remaining months of her pregnancy she states the frightful scene had scarcely ever been absent from her mind.

We have delayed, remarks the editor in whose journal this interesting communication appears, for some weeks the publication of Dr. Carter's extraordinary case, in order that we might, if possible, find recorded some similar cases or case; but after a diligent search we have been utterly disappointed. Even Saint-Hilaire, to whose study of the various anomalies of organization science is so greatly indebted, fails us in presenting any analogous instance.

While almost any one of the external openings of the body may be imperforate, yet this condition much oftener affects the inferior than the superior orifices: *e.g.*, closure of the anus as a congenital condition is more frequently met with than closure of the eyelids, closure of the vagina than of the external auditory meatus.

In regard to congenital adhesions of the mouth hitherto described, they have been from adherence, sometimes complete, in other instances partial,



of the lips. Even this malformation the illustrious Boyer spoke of as a possibility, never having seen it; but Velpeau discovered that Haller had pointed out its occurrence in the human species and also in the inferior animals, that Schenkus had met with cases upon which he had to operate, and that Desgenettes had seen a seven months' foetus with imperforate mouth.

In Saint-Hilaire's work, chapter iii., *Des Anomalies par Continuité des Parties ordinairement disjointes*, section i., *Des Anomalies par Imperforation*, will be found the following, which may be of some interest in connection with Dr. Carter's report: The imperforation of the nares is much less frequent than that of the eyelids; nevertheless, Litré and Jean Bianchi have seen it in subjects in whom other irregularities also were found, and Oberteuffer has also several times observed the same condition.

In a case mentioned by Litré, the closure of the nares was complicated with closure of the mouth, the skin passing over both apertures, an anomaly of still less frequent occurrence. The closure of the mouth has also been seen where the nares were unobstructed, but these cases presented various other deviations also.

As to the possible influence of the sudden and severe terror to which the mother was subjected, which Dr. Carter mentions, in causing the malformation, it probably is better neither to affirm nor still less to deny. Certain it is that the tendency of the observant and thoughtful in our profession is not to reject as "old wives' fables" all that is told of the very strong influence of maternal impressions upon the foetus, fables which have so long found such general credence with mothers and with the public. Those who are interested in the study of this question will find an admirable and philosophic discussion of it, by Dr. Alfred Meadows, in the seventh volume of the *London Obstetrical Society's Transactions*. It occurs in connection with the report of a case of *Monstrosity*, given by Dr. M., the mother attributing the deformities of her offspring to the fact that during the earlier weeks of her pregnancy she was greatly horrified by being shown some of Aristotle's plates, in which were exhibited deformities resembling this, and specimens of other monstrosities.—*Western Journal of Medicine*.

**Stomatitis and Pharyngitis Leucæmica.**—In *Virchow's Archives*, Dr. F. Mosler relates the case of a male forty years old, and previously of sound health, in whom, in the course of some fifteen months, there took place gradually a swelling of the glands on both sides of the throat, attended with inflammation of the mucous membrane of the mouth and pharynx, with flaccidity of and hemorrhage from the gums, followed by swelling of the axillary and inguinal glands, and finally of the liver and spleen. There was now an evident increase in the white particles of the blood. In the case described, the only etiological agent to which the morbid phenomena it presented could be referred was inordinate exertion of mind and body. The condition of the throat was of especial interest. Its mucous membrane was



red and swollen, and over its surface there were spread numerous medullary elevations having a smooth, shining appearance. Both tonsils were enlarged, and their surfaces presented the appearance of a congeries of large, dense, medullary knots. The secretions of the surface of the mouth and larynx and of the salivary glands were greatly increased by talking. After a thorough rinsing of the mouth, its secretions gave an acid reaction. The patient had not suffered previously from any disease of the mouth or throat. The person was attacked with this only after the lymphatic glands of the neck had become enlarged, and, at first, with their increase or diminution the throat affection became worse or better. Finally, under the use of quinia and iron, remedies which exerted a beneficial influence on the entire morbid phenomena, recovery resulted. Dr. M. believes that the form of stomatitis and pharyngitis here described is a specific disease resulting from a leucæmic dyscrasy. The inflammation of the mouth, which in its symptoms had a close resemblance to scorbutic stomatitis, was probably caused by an irritation due to some morbid chemical product in the blood and the secretions of the lymphatic glands, by which, also, according to Dr. M., is to be explained the affection of the mouth met with in cases of diabetes, the nature of which is still, however, unknown.

**Blue Line in Saturnine Affections, and its Pathognomic Value.** (*Archives de Médecine Navale, and Gazette Hebdomadaire.*)—Dr. Falot refutes the authors who believe that the blue line along the gums is formed by an accidental deposit on the buccal mucous membrane of lead furnished by dust contained in the air or food, or still more in fluids that have been adulterated or accidentally charged. According to M. Grisolle, among others, the blue line is the livery of the lead-worker, not a symptom of poisoning, but a simple deposit, and a sign of the worker's occupation. Dr. Falot quotes the observations of Beau, Barlow, Gregory, Smith, and Lecoq, all of whom observed the blue line in patients undergoing an internal treatment with pills of subcarbonate or acetate of lead; and he gives, in addition, the reports of some cases of his own, which were gathered in an epidemic of colic in a ship's crew at the Gaboon, the cause of which was lead-poisoning. Finally, after having established by experiment the impossibility of reproducing the blue line artificially by touching the gums corresponding to the incisor and canine teeth of the lower jaw with a brush dipped in acetate of lead, and after having proved that oxygenated water, and water sharpened by sulphuric acid, the ordinary reagents of lead, had no influence upon the blue line when it is plainly established, Dr. Falot proves that the line is the result of an elimination of the lead, and indicates by its manifestation that the lead, carried along by the circulation, comes to be deposited in the tissue of the gums, where it forms a combination which reveals its presence by a more or less intense blue coloration. Dr. Falot finishes his contribution by representing the blue line as a sign of penetration of lead into the economy, and he derives the important conclusion for forensic medicine, that its presence may denote lead-



poisoning, although an analysis of the viscera may not have revealed the smallest trace of the metal.

It will be remembered that a few years ago Dr. Hilton Fagge described, in an interesting paper, the microscopical characters of the lead line on the gums, and its dependence on the deposit of black pigment in and around the capillary loops. The same facts were described, almost at the same time, by M. Cras in the *Archives de Médecine Navale* (February, 1875, and May, 1876), and further observations by him were submitted recently to the Société de Chirurgie. He has examined the line in portions excised from the gums of many patients, and found that it was easy to demonstrate the presence of lead in all the capillaries by the action of chromic acid. This stains the whole gum of a yellowish color, but the capillaries are distinctly marked by a much deeper tint, in consequence of the formation of chromate of lead. If now the section be washed in distilled water, and treated with sulphide of sodium, the black tint of the capillaries is rapidly reproduced. Examination with high magnifying powers shows that the pigment is for the most part in the interior of the capillaries. M. Cras asserts that this line is not the only effect of lead upon the gums, and he describes another change antecedent to the lead line, and more constant, which he terms "saturnine gingivitis." The gums have two aspects,—the one free in the mouth covered with epithelium, the other adherent to the teeth and periosteum. These two surfaces unite at the narrow festooned border, which the epithelium covers as far as the place at which the gum adheres to the neck of the tooth by its periosteal surface. The interdental processes, which fill up the furrow between the gums and the teeth, present two surfaces adherent to the teeth. The capillary circulation of the gum is constituted by two plexuses: the one superficial, papillary, with fine vessels; the other, deep and periosteal. It is always the periosteal plexus which is the seat of the deposit of lead; the papillary plexus is normal. He asserts that every lead line is accompanied by a detachment of the gum from the tooth. On separating the loosened edge of the gum by a needle, a drop of pus, retained between the gum and the tooth, often escapes. The excision of the edge of the gum for examination is easy and painless, the interdental processes being especially convenient for the purpose. It will be seen, if the periosteal aspect be removed, that there, in the section, the line is replaced by a dotted area due to the black infiltration of the capillary loops. Thus, the line which is visible on the outer aspect of the gums is only the edge of the layer of blackened capillaries on the periosteal surface. The mechanism of the production of the line is, according to M. Cras, as follows: First, by the chronic inflammation of the gum, the edge is separated, and in the space between the gum and the tooth organic matters accumulate. The sulphuretted hydrogen disengaged during the decomposition of these organic substances passes, as soon as produced, into the walls of the capillaries, and, acting in them on the metal brought by the blood, a deposit of sulphide of lead takes place in the capillary network. The gingivitis and deposit extending around



the tooth often lead to serious consequences,—retraction of the gum, abscess, etc. The production of this change is variable. The presence of tartar unquestionably assists its production. M. Magitot at the same meeting contested the opinion of M. Cras as to the seat of the deposit, asserting that it is placed invariably in the deeper layers of the epithelium of the gum, adjacent to the Malpighian layer of the mucous membrane, not in the capillary network; and urged that the deposit depends on the elimination of the lead by the saliva, and was precipitated by the effect of the sulphur in the tartar of the teeth.\*

**Osteo-Gingivitis Gangrænosa Neonatorum.**—Klementowsky describes under this name three very similar cases, the first he ever met with during twenty years' practice among children in the Foundling Hospital at Moscow. *Case I.* A boy aged six days, well nourished, healthy, was taken ill, with high fever and an erysipelatous flush on the right cheek. The following day the latter had disappeared, but an oedematous dark swelling had appeared on the gums of the right upper jaw. Toward night two teeth broke through the swelling and fell out; the swelling diminished in size; ulceration set in four days later, and the child died. At the necropsy gangrene of the upper jaw and pyæmia were found. *Case II.* A girl aged one month and a half, badly nourished, had high temperature and a small gangrenous abscess on the gums of the upper jaw on the left side. On the second day a tooth broke through the abscess and fell out, the swelling diminished, the temperature rose, and a gangrenous abscess formed on the right side of the upper jaw. On the fourth day it began to heal; on the fifth peritonitis set in; and on the sixth the child died. The necropsy revealed purulent gingivitis, with ulcerations and diffuse purulent peritonitis. *Case III.* A boy aged thirty-eight days, well nourished, had gastric catarrh a short time ago. There was high temperature, with a purple swelling of the size of a nut on the gums, corresponding to the right upper eye-tooth. On the second day a tooth pierced the tumor and fell out; it was replaced by a dentiform granulation surrounded by necrotic tissue. On the third day the swelling and granulation diminished and suppuration set in. The wound healed during the following days; but on the fourth the temperature again rose, and a hard reddish swelling appeared on the left side of the gums, corresponding to the upper molar teeth. No pus escaped on incision. During the following days necrosis set in, the swelling beginning from the edges of the incision, gradually exposing the tooth and the bone in the alveolus. There were fetid suppuration and a gangrenous perforating abscess of the left cheek. Death occurred on the forty-seventh day. At the necropsy it was found that the two posterior thirds of the left half of the upper jaw had become one gangrenous cavity, the periosteum was detached from the zygomatic arch, and the latter was necrotic.†

\* London Lancet.

† London Medical Record.



**Gingivitis in Pregnancy.**—Since the publication of former editions of this work, it has come in the way of the author to see several remarkable illustrations in this direction. That inflammation of the gums is not an infrequent associate of pregnancy is a familiar fact to every practising physician. It is not so familiar, however, that epulic growths, bearing close likeness to cancerous tumors, occasionally start with and continue throughout the whole period of utero-gestation. In one such case the disappearance alone of the growth after birth of the child served to satisfy that the condition was not malignant. In the particular instance alluded to a fungous mass quite the size of a hickory-nut occupied the right side of the upper jaw, giving much pain, and bleeding at the slightest touch. Another case presented a tumor, fibro-cellular in appearance, occupying a space on the gums of the left upper jaw, extending from the cuspid tooth to the molar. These tumefactions are most likely to be met with in women whose health is not very robust. They appear most commonly from the fourth to the sixth month of pregnancy, and disappear from the second to the fourth after delivery. As an application, nothing as a palliative has as yet been found better than the following formula:

R.—Zinci sulphatis, gr. xii;  
Chloral hydratis, gr. xv;  
Aquæ, ℥iv. M.

The part to be touched three times daily by means of a camel-hair brush.

As a radical application, a preparation consisting of equal parts of caustic soda and quick-lime may be employed; this is used by mixing the powder into paste form with alcohol or water; a portion laid against the tumor will quickly slough it away. Upon return of the growth the cauterant is to be reapplied.

**Gangrene of Gums following the Exanthems and other Diseases.**—Any acute disease tending to impair the general health may be followed by, or have associated with it, ulceration or gangrene of the gums. Measles is the most common condition. The incipient ulcer expresses markedly the degenerative condition, the bottom of it being dirty and pasty looking. The treatment required pertains both to the constitution at large and to the immediate locality. Acid tonics commonly act admirably. The bowels are to be kept soluble, the skin clean and in a stimulated condition. Exercise in the open air, either passive or active, is to be insisted on. The sleeping room is to be kept well ventilated; the bed is not to be of feathers; the covering not too abundant.\*

A medicament of valuable tonic import in all such cases is prepared as follows: Take of red Peruvian bark one ounce, of Virginia snake-root half

\* A mineral-water that acts admirably as an aperient is to be made as follows: Take of sulphate of magnesia, ℥iss; of aromatic sulphuric acid, ℥ij; of sulphate of iron, gr. xv; of water, ℥vii. Of this combination put a tablespoonful in a goblet of water and drink half an hour before breakfast.



an ounce; put these into one and one-half pints of warm water, simmer to one pint, when cold strain and add one pint of Lisbon wine. The dose for a child is a tablespoonful three times a day; for an adult double this quantity. As a local remedy reliance is to be placed on the aromatic sulphuric acid diluted and used as a general mouth-wash, or applied, by means of a brush, full strength, to the ulcers.

Tincture of calendula, made stimulating by the addition of compound tincture of capsicum, furnishes an admirable wash when diluted one-half with water. Tar water, to which has been added indicated proportion of carbolic acid, is a trustworthy agent.\*

**Oidium Albicans.**—Upon most sores in the mouths of ill-nourished subjects are to be found cryptogamic spores shooting out thread-like plants. These spores are not the disease, but parasites finding habitation among the sores. To destroy them creasote or chloride of zinc, diluted, or in full strength, as indicated, may be employed. Cleanliness is a necessity. Phénol sodique mixed with the water used to wash the parts is found of profit. (See *Oidium*, *Aphthæ*.)

**Calcified Dentinal Tubules.**—A cause of chronic ulitis not yet mentioned lies in that calcification of the tubular material of one or more teeth by which equipoise of vital relation is interfered with. In this condition the tooth structure is found so solidified as to have its circulation disturbed to an extent which makes of it a foreign body. The receding and atrophied gum is expressive of nature's attempt at elimination. There is no cure outside of extraction. The common practice is to let such teeth alone until they drop out of themselves or become a source of discomfort.

---

\* Tar water, one pint; fluid carbolic acid, one drachm.



## CHAPTER XXXIII.

### THE APHTHÆ.

APHTHÆ is a term which every reader must have remarked to be associated (like the word *epulis*) with some degree of confusion.

In the Greek, from which the name is derived, there are two verbs with the same spelling,—*ἄπτω*. The meaning of the one is “to set on fire;” that of the other, to “bind to” or to “fasten upon.”

The mouth presents ulcers, or sores, of various signification,—some are characterized by pain of a burning, inflammatory character; others, chronic, or cold in nature, furnish an inviting soil to a very persistent and almost omnipresent parasite,—the *oidium*,—this fungus fastening upon and binding such sores in its necklace-like embrace. It has thus very naturally occurred that pathologists, seeking an expressive term by which to designate these varying conditions, differently employed the common name as it happened to them to observe or adopt the one or the other of the roots from which the nomenclature is derived. That such uses of the dissimilar verbs on the part of various authors must have been made, is necessary to be inferred to explain the differences which distinguish descriptions.

With such examples of liberty, intentional or unintentional, the author is to be excused in presenting to his readers the subject after his own manner and views.

For the reasons of the double derivation, and for others which will be presented, the term *aphthæ* cannot, in justice and pathological signification, be applied to a particular species of sore, but must, as a noun of multitude, apply to a class,—which class has many species. Thus we accept, as explained and dismissed, the various questions of ulceration and non-ulceration, exudation or non-exudation, the *oidium* or no fungi.

The type of the *aphthæ* is as follows: An *aphtha* or *aphthous* patch is a degenerate sore, to be seen, under varying circumstances, upon the mucous surface of the mouth, the fauces, the *œsophagus*, and, quite likely, upon any part of the alimentary canal, and perhaps also upon the respiratory tract. The most common seat of this patch is the uvula; next to this the lower lip; next the tongue. The sore varies in size, from the smallest point to a confluent mass which may cover a large surface; looks pasty or exudative, is generally oblong in shape, and varies in color from the misty white of hoarfrost to the dirty yellow of scrofulous pus. As most frequently seen, such a patch is one of several similar sores.



This, as described, is a typical case. From it we are prepared to pass to the general view of the subject.

An aphthæ is a canker; nothing more, nothing less. Thrush, follicular inflammation, cancrum oris, gangræna oris, are all species of a cancrum class, of the class aphthæ.

What, then, is the class aphthæ?\*

The modern microscopist exhibits and describes aphthæ as patches of a fungoid excrescence,—the *oidium albicans*. A pot of paste, a papered wall, a section of apple or other fruit, the leather back of a book or chair, exposed to a confined atmosphere, hot and moist, quickly produces, or rather gives attachment to, the *oidium*.

*Oidium albicans* is not a disease, is not aphthæ; neither is it the expression of disease. It is a fungous growth, accidentally associated with a soil and circumstances favorable to it as a habitat.†

Aphthæ is, without doubt, the expression of a cachexia, and is not likely to be merely a local disease. Neither is it possible for the fungus to be peculiar to a sore, as a something specific, any more than it is peculiar to the paste, the fruit, or the book. It must depend in the one instance, as in the other, on an accidental association. This accident, in the case of the sore, would seem to be the absence of a sufficient vitality to enable a part to resist the "fastening upon itself" of ever-present germs. The microscopist has, in his examinations and conclusions, accepted the accident and overlooked the disease.

**Thrush.**—Thrush, or muguet, one of the species, is an erythematic inflammation, degenerating after a few days into a condition of curdy exudation. The inflamed surface, after a longer or shorter time, presents small whitish points; these coalesce, forming exudate patches. These patches vary in color. As they remain moist and clear, they are considered with least apprehension; as they grow dry and brown, they are found possessed of dangerous import.

Dissections of the cadaver have exhibited aphthæ not only upon the œso-

\* The term is here employed as a noun of multitude.

† Parasite fungi (Hogg on the Microscope)—vegetable blights, as they are commonly called—have of late years become objects of earnest attention on account of the enormous damage done to our growing crops, and also of the many curious facts in their history which have been brought to light. *Oidium* is a common mildew.

It appears that at particular periods of the year the atmosphere is, so to speak, more fully charged with the various spores of fungi than it is at others. In 1854, the Rev. Lord Godolphin Osborne, during the cholera visitation, exposed prepared slips of glass over cesspools, gully-holes, etc., near the dwellings where the disease appeared, and caught what he termed *aërozoa*,—chiefly minute spores and germs of fungi.

From this same year (1854) to the present time, we have amused ourselves by catching these floating atoms, and, so far as we can judge, they are found everywhere, and in and on every conceivable thing, if we only look closely enough for them. Even the open mouth is an excellent trap. Of this there is ample evidence, since we find on the delicate membrane lining the mouth of the sucking, crying infant, and on the diphtheritic sore-throat of the adult, the destructive plant *oidium albicans*.



phageal mucous membrane, but also on other parts of the alimentary canal. They have not as yet been met with upon the respiratory tract; but there is no good reason why they should not have here a like existence.

In an acute attack of thrush, the mouth is hot and the general condition feverish. Milder cases, or those of easy progress, may, and do, seem—so far as observable constitutional sympathy is concerned—to have only a local signification.

But, if thrush be a distinct disease, could it be possessed of a double signification? Could it at one time be strictly local, at another, systemic? Thrush is common to children prematurely born or to those nursed by unhealthy women. It is a disease which belongs to hot, moist climates and to the situations of uncleanly hospitals; in fact, to any condition recognized to be depressive of the life-force; it is, in short, a systemic adynamic expression, seated on a mucous surface. That it differs from carbuncle or cancrum oris would not seem to be the case in fact, but only in degree. Thrush is, in other words, one expression of a common condition,—a species, not a class.

**Follicular Inflammation.**—Follicular inflammation—another form of stomatitis very likely to be asthenic—is a term used to signify that the abnormal vascular change is seated in the mucous crypts, or follicles. In passing the finger over a surface so inflamed, the studded irregularity produced by the engorgement of the glands is plainly evident. As such inflammation progresses, the bodies become recognized by the eye as papular eminences standing out from a common erythematic surface. In color they are of a varying red, such variations in shade expressing the constitutional conditions.

Follicular inflammation terminates either by resolution or ulceration: when in the latter way, the follicles soften in the centre, suppurate, and show a bottom filled with a whitish, pasty mass. When in this condition, they are the aphthæ of M. Billard.

Follicular inflammation appears most frequently in the infant during the dentitional period,—an explanation existing in a quickly and easily recognized combination of a predisposition and an excitant. In its most simple form,—that is, where there is no marked dyscrasia, or where the excitant is not of sufficient intensity to irritate to any extent,—the lancing of the gums, or the application of cooling local remedies, may be sufficient to combat or control the manifestations. Where, on the other hand, the conditions predisposing to the disease exist in a state of balance, as it were, with the natural resistive forces, the addition of a second depressant influence, as that resulting from the irritation of dental development, may very well be understood as giving the mastery to an agent or condition otherwise controlled or held fully in check. Thus we explain to ourselves both the real and apparent connection of dental irritation with the aphthæ.

From a simple form, or the inflammation of isolated follicles, the condition, in some ill states of the general system, becomes confluent, such extreme form being most frequently noticed in connection with the typhoid exanthems, or



in company with destructive organic diseases. In confluent follicular inflammation, a prognosis can only be justly made when every associate and collateral influence has been appreciated. The condition will nearly always be found an occasion for anxiety.

**Cancrum Oris.**—Cancrum oris, a species of stomatitis, generally accorded a special classification, differs in no wise from that just considered, except in being more localized; as if the force of an influence had concentrated rather than diffused itself.

The complaint known as cancrum oris is an asthenic degenerating ulcer. In appearance this sore differs from what has been given the special definition of aphthæ by most writers, only in being more depraved and threatening. It has the same pasty bottom of varying shades of white, the same association of pain, the same variation in persistence. Like other aphthæ, cancrum oris seems to be, and is, associated with dyscrasia, appearing most commonly in the infants of ill-conditioned charities, in the ill housed and poorly fed,—having, in all systemic associations, the precise history of the conditions alluded to as thrush and glandular inflammation. This form of stomatitis, although confined to no exact locality, is yet most commonly met with on the cheeks or gums. It may commence with a phagedenic expression, and very quickly destroy the patient; or a slight vesicle or pustule may first appear, to be followed by varying inflammatory associations, precisely as if some local poison was the source of the trouble.

The history of cancrum oris differs from that of other cancriform affections only in degree. This is fully proven in the facts that it is associated with the same causes; that any ordinary canker sore is capable of taking on an ulcerative action; that the fungus oidium is quite as common to the seat of this as the other affections. In fact, every analogy will demonstrate that the relation is like that which associates the phagedenic with the simple venereal sore, being a difference of degree and not of cause, or character.

**Gangræna Oris.**—Gangræna oris, sloughing phagedæna, is another expression, or species, of the common class. It may commence as an acute inflammation, quickly deteriorating; as a species of fatty degeneration of the epithelial tissue; as a submucous effusion; or as an eschar which falls from its relations with a rapidity that leaves us at a loss for an explanation, except on the inference that the materies morbi have had the most special concentration. The eschar, formed sooner or later, is ashy in color, or a deadish brown, while the still living parts, particularly the external cheek, if this location should be the seat of the ulcer, has an erysipelatous blush,—semi-livid and threatening in appearance.

Gangræna oris is markedly a disease of the dentitional period, occurring in ill-fed, ill-clothed, or ill-housed children. The constitutional nature of this affection is conspicuous. It is a general febrile or inflammatory disturbance, concentrating its intensity upon some part of the oral cavity, invited or directed, not unlikely, by an irritability existing thereabout. Foundation for this in-



ference lies in the fact that in nearly every case are to be found inflammatory complications; such associated inflammations being most frequently met with in the lung-tissue. It is to be taken for granted that the oral concentration modifies the impression showing in the other part.

Gangræna oris, where it does not quickly separate its eschar, affords support to parasitic fungi—the *oidium albicans*.

Oral gangrene varies, as will be inferred, in degree. When commencing as a single canker sore, or epithelial degeneration, and showing no complications, it is to be treated as the follicular, or other of the simple species. Concentrated, or in its malignant form, it destroys life without affording the physician any extended chance to combat it. In reasonably healthy children gangrene is very uncommon, the ordinary canker being generally the worst manifestation. In children exhausted under the exanthems, in a class maltreated with mercury, or those laboring under a syphilitic degeneration, the marked, or destructive, type exhibits itself.

The decomposition of mucus, or the *débris* remaining from food, when lodged upon an aphthous sore, forms the best nidus for the development of fungi; it is, as it were, a soil; and it is undeniable that epithelial scales in varying states of abnormal degeneration, inspissated mucus, and particles of decomposed food are general to all such sores. Thus, in sickly children, the fungoid association is most common from the fact of the weakened energy of the parts afflicted; this, favoring decomposition and the retention of the *débris* in the cavity of the mouth, and consequently producing the required soil or habitat of the *oidium*.

In foundling-hospitals, where the sucking-bottle is used, the spores of fungus find, through such vehicle, an easy passage to the mouth, being, indeed, incontestably in this way located and developed. In the nursing infant of an uncleanly mother, the accumulation and retention of the milk will, with favoring atmospheric influences, quickly develop fungi. It is the fungus and not aphthæ that is contagious, as must be plainly seen; hence one can but wonder at the disputes of Guersant, Billard, Valleix, Duges, and others.

REVIEW.—Having thus expressed his own views of aphthæ, committing himself to the admission that he fails to distinguish it as any special disease, the author may, with greater justice to so important a subject, present the opinions of others whose extended observations and judgment have long held them in the light and position of authority. Trousseau and Delpech both describe the aphthæ as being sores with the *materies morbi* deposited beneath the epithelium. Bamberger (*Krankheiten der Mund und Mundhöhle*) controverts these views, and explains the presence of the *soormasse* by the fact that it has insinuated itself between, among, and below the epithelial particles.

If we take, says Professor Bamberger, the *soormasse*, and place it under the microscope, we find it made up almost exclusively of epithelial scales, old and young, the *débris* of the food, and of inspissated mucus, which last is probably only a condition of epithelial formation. The color of the mass is



not to be hastily judged, as this might have been influenced by the débris of the mouth.

Upon these sores, however, very quickly appears a peculiar organization, which consists of round and oval spores which stick to one another, and in this way form a more or less ramifying series of threads. The longer the sore continues, the more marked is its penetration by these threads or spores. This new organization, or fungus, can never, however, originate or be generated by the organism itself, but is always the result of germs coming from outside sources. It is not peculiar to a particular sore, though it occurs most frequently on those of a certain order. Besides the two constituent parts, epithelial scales and fungus, there appears sometimes a third constituent, in the form of granules or granulated matter.

From this, continues Professor Bamberger, we see that aphthæ cannot be counted among the products of inflammational and exudational processes, as so frequently considered; the microscope has failed to discover an exudational appearance: also there are wanting the anatomical and clinical appearances of inflammation. True, it may be that it is found in association with a catarrh, but this is an accident, just as one may not say that the diarrhœa so frequently found in connection with the sore in the infant is the cause of the sore, as he might not say that the sore is the cause of the diarrhœa. There is, in aphthæ, no ulceration, the soormasse being capable of being peeled from the surface.

Professor Dewees thus refers to the aphthæ as exhibited in the infant:

This complaint is generally called the baby's sore-mouth: it consists of a greater or less number of white vesicles on the inside of the mouth. It very generally begins on the inner part of the lower lip or corners of the mouth, and much resembles a small coagulum of milk. From this point it sometimes spreads itself very rapidly over the inside of the cheeks, tongue, and gums; and, at others, it will appear in the same form, and at the same time, on several portions of the mouth; as inner portions of the cheeks, etc. The French, especially M. Billard, make it a different disease from what they term "muguet," but, from a careful examination of the two diseases, I believe them to be the same, differing only in intensity. I think we have not the disease which he terms "muguet," or I do not understand his description: so far as I have been able to compare them, they are identical. The difference may consist in the modification which a hospital gives it; if there be a difference, I think it must be owing to this cause. When this efflorescence is extensive, the child slavers very much, and is frequently embarrassed in its sucking; it cries, and evidently betrays that it is in pain; it is very restless and very thirsty, as it evinces by its frequent stirrings, and its disposition to be continued at the breast. The eruption in its mildest form is very white, and looks as if a stratum of milky coagulum were spread over the mouth. It sometimes confines itself to the centre of the cheeks, at others to the lower lip, or one side of the tongue. In its severe forms the appearance of the



eruption is of a dark-brownish color or extremely red, owing, most probably, to minute portions of blood; but both are evidently grades of the same affection, changed either by mismanagement, constitution, or the force of the remote cause.

This affection is thought to be altogether of a symptomatic kind, or very rarely idiopathic. It is almost uniformly preceded by a deranged condition of the stomach and alimentary canal, and always, we believe, by some disturbances of the stomach itself. The brain always shows signs of participating in this complaint, as there is almost always an unusual inclination to sleep, though the child is frequently disturbed in its nap by some internal irritation, perhaps of the bowels themselves. This disposition to sleep is so well known to nurses that they will frequently tell you "the child is sleeping for a sore-mouth." The bowels are often teased by watery, acrid stools, of a greenish color; their discharge is frequently attended with the eruption of much wind, and, to judge from the noise, it would be supposed there was a very large discharge of fæces, though, upon examination, it is found to be very sparing.

The alvine discharges are frequently very acrid, so much so, sometimes, as to excoriate the verge of the anus and nates very severely, especially when due attention is not paid to cleanliness or to the frequent changing of the diapers. But this never takes place until the disease is pretty well advanced, and has made some progress. It is generally fairly spread over the mouth, and always shows a violent disease. The stomach is also sometimes much deranged; vomiting the milk very soon after it is received into the stomach, in the form of a dense curd, mixed with a porraceous mucous substance. If the milk be not voided by vomiting, the stomach constantly discharges, by eructations, a gas with a very sour smell. The child, when the disease is severe, soon becomes debilitated, and rapidly emaciates; it is almost constantly harassed by severe colics and profuse diarrhœa; its stomach will scarcely retain the little it can swallow; the œsophagus sometimes becomes so loaded with aphthæ that it can no longer transmit the small quantity which is reluctantly admitted into the mouth; and the child dies, either from the exhaustion consequent upon the profuseness of the discharges from its bowels, or from inanition.

It is a popular belief that this apthous efflorescence passes from the mouth through the whole tract of the alimentary canal to the very termination of the rectum; and the excoriation at this part is offered as evidence of the fact. Whether this be true or not we do not know, for we are not in possession of any facts from dissection which decide the point. We once examined a body which certainly died from aphthæ, the examination of which would by no means tend to confirm this common belief. A child, on the tenth day after birth, was observed to have a number of white spots upon several different portions of its mouth, which rapidly spread over its whole surface. It had the usual premonitory and accompanying symptoms, which increased daily in severity, in spite of every effort to oppose them. It was a feeble, weakly



child, of a consumptive, feeble mother. Its sufferings were very great, though under some control from laudanum, so long as this could be taken by the mouth, or retained by injections. Coat after coat of aphthæ was thrown off, and each new crop appeared to be more abundant, and less amenable to remedies, until at last, at the end of two weeks of severe suffering, the poor infant could not swallow a drop of the thinnest fluid. Injections of bark and mutton-tea, in conformity with popular opinion, were resorted to, but all in vain; the child, in a few days more, died from absolute starvation, or, at least, the catastrophe was certainly hurried by the impossibility of receiving nourishment.

We examined the body after death: we found the whole tract of the œsophagus literally blocked up with an aphthous incrustation, to the cardia, and there it suddenly stopped. The inner coat of the stomach bore some marks of inflammation, as did several portions of the intestines; but not a trace of aphthæ could be discovered below the place just mentioned. This case would, therefore, create a doubt whether this affection besieges any other parts of the body than those just stated, namely, the mouth, posterior fauces, and the œsophagus to the cardia, since, perhaps, none could have been of greater severity; but it is with us a solitary case, and should not be received for too much. Dr. Heberden says, The aphthæ are supposed not only to infest the mouth and fauces, but to be continued down through the whole intestinal canal. In two who died of lingering fever, and whose mouths were covered with aphthæ, which hung in rags all over it, there was not the least trace of them that could be found in dissection beyond the fauces.\* The excoriations about the anus can certainly be accounted for, without the presence of aphthæ to produce them; in bad cases, the stools are always extremely acrid, and the parts over which they constantly pass and spread are, at such a tender age, very delicate, and very readily excited to inflammation.

Dr. Good seems to admit, without hesitation, the transmission of aphthæ through the intestinal canal; for he says, without reserve, the fauces become next affected, and it descends thence through the œsophagus into the stomach, and travels in a continuous line through the entire course of the intestines to the rectum, the fæces being often loaded with aphthous sloughs.†

We are afraid there is too much taken for granted in this account; we know of no decided evidence of the fact, nor does Dr. Good name any authority for the statement. The case alluded to was certainly one of death from aphthæ; but in it the aphthous efflorescence stopped at the cardia. Is it probable that any child could survive this affection did it travel the whole course of the intestinal canal? We think not: yet aphthæ is rarely a dangerous disease in infancy. Dr. Good's description of this affection would certainly lead to the conclusion that it is the ordinary march of the disease

\* Commentaries, p. 31. "It is well known, too, that in *smallpox* no pustules are traced beyond the pharynx and larynx, even in the most severe cases, when the mouth and tongue are thickly covered with the eruption."—*Tweedie's Illustrations*, p. 65.

† Study of Medicine, vol. ii. p. 391.



to pass through the bowels and manifest itself at the verge of the anus. This point is far from being settled in the minds of pathologists: even the French are far from having ascertained it with certainty: it is true M. Billard says he has seen evidences of it in the large and small intestines, as well as the stomach; but there is no mention of it lower than the ileum.

Now, this cannot be so; since it is in violent and long protracted cases alone that the anus discovers any signs of irritation from this cause, which would not be the case were Dr. Good's account correct.

Dr. Good and others suppose that aphthæ communicates itself by a specific contagion,\* and give as evidence the excoriations of the nurse's nipples. We do not hesitate to believe there is a discharge from these little pustules which may be highly acrimonious to the denuded skin; but we think this is perfectly innoxious to a sound one. We have never seen sore nipples produced by aphthæ, where the skin of these organs was perfectly sound. That they aggravate the tenderness and inflammation, when these parts are tender and abraded, we admit, and so would any other acrid substance, without having recourse to the belief of a specific contagion. If this were the case, why do not the lips of children laboring under this affection betray its influence?

That this complaint is occasionally epidemic there is every reason to believe; and this circumstance, among some others to be mentioned, renders the opinion so commonly credited (of its being a sympathetic affection) very questionable. We have always considered aphthæ as arising from some peculiar condition of the stomach; but, from some late cases and more mature reflection, we think it may be otherwise. Our reasons for *doubt* are,—

1. We have recently seen this affection in two cases where the stomach and bowels were in the most perfect order before the eruption, but became disturbed a little during the progress of the disease.

2. That this complaint has been very often removed by topical applications alone, where the efflorescence has been very considerable, and where there was no remedy of any kind addressed to the stomach and bowels.†

3. That we do not uniformly see this complaint where there has existed great disorder of both stomach and bowels, these being of a permanent kind.

4. That, however the stomach and bowels may be disturbed by acidity or other inconvenience, or however long these may continue, if the child has had this complaint, it is not renewed, though the individual is not exempt from a second attack, like measles or smallpox; for, in certain chronic affections, they may be again visited by aphthæ.

5. That this affection is sometimes epidemic, as stated above; for Dr. Good informs us that not only all the children of the same family, however cautiously separated from one another, but many of those of the same neighbor-

\* M. Billard declares it not to be contagious.

† QUERY.—Is, then, the unconquerable diarrhœa, sometimes present, a mere accident, or would it not be more easy to account for it by the presence of aphthæ?



hood, have been known, at times, to suffer from it simultaneously. (Vol. ii. p. 391.)

6. That this disease is almost always ushered in by some cerebral affection, as great drowsiness or wakefulness; the first is by far the most common.

7. That other portions of mucous membranes are liable to the same kind of eruption, without the condition of stomach or bowels being instrumental in its production; for we have seen it most plentiful within the labia pudendi, as well as on the internal face of the prepuce.

These facts have made us lately question the sympathetic origin of aphthæ: yet we admit they are not altogether conclusive in our own mind; but we thought it proper to suggest the possibility of its being an idiopathic disease of the mucous membrane.

This affection is not confined to early infancy; it shows itself in the more advanced periods of childhood, and from that to any period of human life. It is sure to attend the last stages of almost every long-protracted disease, especially those which may have wasting discharges, such as phthisis pulmonalis, dysentery, or diarrhœa; and when it does appear, it is almost sure to be a fatal harbinger.

This disease is not essentially accompanied with fever; if it accompany any chance affection which is attended by fever, we do not find it to heighten the existing one.

Weakly children, and especially those born before their full period, are more obnoxious to this complaint than the robust and those who have tarried to their full time in the uterus: the children of weakly women, and particularly those who make bad nurses from scarcity of milk, or from its not being of a sufficiently nutritious quality, are more disposed to this affection than the children of hale women, who have plenty of nourishment of good quality. The children fed much upon farinaceous substances are especially exposed to the attack of this disease, particularly when their food is sweetened with brown sugar or molasses.

In the work of M. Jourdain "On the Surgical Diseases of the Mouth" is a chapter on aphthæ, so unlike all that precedes it, as connected with modern pathology, that the reader finds himself inclining to think the book owes the presence of the chapter to the translator rather than to the author.

The term aphthæ, says this work, is used alike by ancients and moderns, but in quite a different acceptation. The former define aphthæ as superficial malignant ulcers, attended with heat, occurring especially in infants, and not confined to the mucous membrane of the mouth. It is at the present day universally applied to those whitish pustules which appear on the mucous membrane of the mouth, and sometimes of the adjoining parts. Inattention to this difference has led many to apply to the latter-disease a treatment based upon the definition of the ancients, whereas the two are palpably different.

Aphthæ have been regarded as ulcers; but ulceration implies solution of continuity, whereas in true aphthæ there is no erosion or decrease of sub-



stance, but, on the contrary, an increase; desquamation of the apthous crust leaves no trace of cicatrization. Theorists speak of white, red, and black apthæ, according to the nature of the generating humor; but during a long practice we have never seen them of any other color than white, whitish, or, especially when of an unfavorable character, ash-colored.

They commence by small white spots, usually on the uvula, thence spreading, sometimes over the veil of the palate, sometimes over the tongue, gums, and inside of the lips and cheek. Often they spread still farther into the pharynx and œsophagus. Of their extension beyond this we cannot, of course, have the evidence of sight; but we have other and unequivocal symptoms, which prevent us from regarding as an absurdity the idea of their presence in the œsophagus, stomach, and smaller intestines; as, for instance, in the difficulty of breathing and deglutition; also in the appearance of the discharges from the stomach and bowels, so frequent in apthous disease.

The description of apthæ is easier than their etiology. We maintain that they depend in all cases upon the same cause, differing, indeed, in degree of intensity, but never in its nature. We therefore differ from those who assign one cause in adults and another in infants. Nor can we agree with the many who make them to arise from excess of serum or of acid in the milk or nourishment given to the infant. The depleting, purging, and starving treatment based upon this hypothesis is most pernicious; moreover, experience tells us that this very acidity or astringency of aliment will frequently cure apthous eruptions, or prevent them from coming to maturity; and a serous flux, determining to the mouth, has caused the complete disappearance of existing apthæ.

What, then, is the true origin of this disease? We believe it to be found in the existence of a slow and imperfect *crisis*, and to arise from a sulphurous humor generated in the larger vessels, and determining to such parts as are, by position or structure, most impressible. Observe for a moment the circumstances and character of apthæ. In all fevers in the young and in the vigorous, their appearance is ever preceded by a crisis more or less distinct, and, according to the violence of the primary disease, marked by more or less severe symptoms. In one case nature struggles successfully with the acrimonious morbid principle, a favorable crisis occurs, and an apthous eruption brings great relief to the patient; in another case this morbid principle is too abundant, obstinate, or malignant,—no crisis occurs,—no apthæ,—nature succumbs, and the patient dies. Again, we have apthæ through the critical transfer of morbid action from some more or less vital and important organ. In some cases the change proves salutary; in others there is a reaction, the apthæ disappear, and if the *vis vitæ* be not destroyed, it is often greatly endangered.

Apthæ rarely occur in a perfect and favorable crisis, but, rather, as we have before said, in those which are slow and imperfect, such as are met with in a great number of diseases. Thus we find some apthous eruptions of not



only days', but weeks' and months' continuance. When, for instance, necessary evacuations have been neglected in the onset of disease, and a cachectic plethora has supervened, the cure is slow and incomplete without the occurrence of aphthæ. Diuretics and gentle enemas aid the recovery; blood-letting and purgatives retard it: the aphthæ disappear after fulfilling their sanative purpose, and the patient feels perfectly relieved. Experience, however, shows that the danger is not quite over: some lurking matter may take fresh increase, give rise to new aphthæ, in default of other means of escape from the system, and greatly endanger life; this may happen twice, or thrice, or oftener.

The causes or antecedent symptoms of aphthæ may be mild, and recovery take place without any or with very simple treatment; or they may be severe and lamentable, ending in suffocation, delirium, or obstinate diarrhœa. This difference we find explained by the varying state of the humors: at one time being crude, and by consequence irritating, at another time matured or concocted, by which process of concoction the more hurtful principles are expelled, a process aided in some inexplicable manner by the continued circulation of the animal spirits. Thus it happens that the aphthæ of seventh-day crises are usually more unfavorable than those which follow crises of a later date, when the morbid matter has had time to undergo a thorough concoction.

Although aphthæ are most generally preceded by febrile miasmata, they are not necessarily so. Cases are seen, both among adults and infants, in which they have been neither preceded nor attended by fever. In infants we may properly suspect impurity of the mother's blood.

Certain evacuants have been found more hurtful than beneficial in the treatment of aphthæ. This comes from the forgetfulness of the excellent advice of Hippocrates, who tells us to have regard, in the choice of depleting agents, to the channels of evacuation which nature points out in any given case. Now, the vessels concerned in the critical discharge of an aphthous eruption are the lymphatic rather than the venous or arterial. Therefore to the changes of the lymphatic fluid, rather than to those of the blood, is our attention to be mainly directed in the management of this disease. We have frequent evidence of serous or lymphatic engorgement at the outset of aphthous eruptions: in the fever, stupor, and restlessness during sleep,—indicating a fulness of the head and an acrimony of the humors.

Aphthæ are more common in certain countries than in others, which explains the almost total silence of some writers respecting them. This depends upon difference in climate and mode of living. In warm countries their course is rapid, from the increased perspiratory action of the skin. But in colder latitudes, where the food is coarser, the habit of body denser, and the humors thicker, their progress is slower, because the secretions of the system generally are more liable to obstruction. In these countries, especially, all discharges which tend to arrest perspiration, such as hemorrhoidal, intestinal, or uterine,



whether occurring spontaneously or artificially provoked, are very unfavorable in the treatment of aphthæ. On the contrary, a copious cutaneous or urinary secretion forms often a favorable crisis. This agrees with the doctrine that aphthæ are essentially serous, and most readily cured by a free discharge of serum or lymph. The cause of endemics we leave others to explain; each country bears in its womb the seeds of its own diseases, and also the means for their cure. External agencies may cause aphthæ, not, as the ancients supposed, by their direct action on the mouth, but indirectly, through the mass of the circulating fluids.

The diagnosis of aphthæ is easy; not so the correct interpretation of their premonitory symptoms. Painful deglutition, dryness of the mouth, a thick, husky voice, heat of the stomach, with rumbling noises, disturbed, unrefreshing sleep,—these often precede apthous eruptions. Urinary symptoms are not to be relied upon, though often useful in prognosis after the appearance of the eruption. In the different forms of fever, the obstinacy of the disease is often a precursory symptom; when, notwithstanding the intestinal, urinary, and other evacuations, there still exist great depression and embarrassment of the vital functions, the appearance of aphthæ will often in a single night bring calm and relief to the patient, as experience has abundantly testified. The physician should follow nature's hint, and seek to aid in the cure of the disease through the same channels. The above symptoms, be it understood, are by no means necessarily followed by apthous eruptions.

We should be careful in our prognosis: where the system is not weakened, the pre-existing morbid matter well concocted, or the extent of the eruption limited to the palate, we may anticipate a favorable issue. But if the patient be in a reduced and weakened condition, the morbid matter crude, or the aphthæ covering the entire membrane of the mouth and pharynx, the disease is much more to be feared. Again, suppression or derangement of the menstrual flux is unfavorable, from its tendency to draw the eruption from the place where alone it can properly mature. Profuse alvine or hemorrhoidal discharges are also hurtful; also any catarrhal attack falling upon the throat, causing the sudden disappearance of the aphthæ. Aphthæ occurring in diseases at the onset of which there was insufficient evacuation, are grave and dangerous. The disease may occur in persons of either sex, and be of tedious duration; but when the appetite returns, not only is the food highly relished, but it gives, by its new nourishment, relief and salutary benefit.

The term aphthæ, says Professor Wood, in his "Practice of Medicine," vol. i. page 501, was employed by the ancients to signify various inflammatory affections of the mucous membrane of the mouth. Willan proposed to restrict it to a peculiar vesicular eruption upon the membrane, but committed the error of confounding with this affection the thrush of early infancy. The two complaints are quite distinct, and should not be similarly designated. Aphthæ, in compliance with very general custom, is extended to all those small ulcers, with whitish surface, which so frequently appear in the mouth,



whatever may be their origin. The most frequent source of aphthæ is probably the vesicular eruption occasionally present in erythema. The vesicle is small, oval, or roundish, white or pearl-colored, and consists of a transparent serous fluid under the elevated epithelium. In a few days the epithelium breaks, the serum escapes, and a small ulcer forms, more or less painful, with a whitish bottom, and usually a red circle of inflammation around it. The vesicles are sometimes distinct and scattered, sometimes numerous and confluent. The distinct variety, though painful, is a light affection, continuing in general only a few days or a week, and is usually confined to the mouth. It produces little or no constitutional disorder, though it may be associated with fever and gastric irritation as an effect. It attacks equally children and adults, but is said to be very common in early infancy. In adults it is frequently occasioned by the irritation of decayed teeth. The confluent variety is much more severe and obstinate. This frequently extends into the fauces of the pharynx, and is said to reach even the intestinal canal, though it may be doubted whether the affection of the stomach and bowels is identical with that of the mouth.

The French fail in distinguishing, with Professor Wood, the difference between the pultaceous inflammation of thrush, or muguet, and the aphthæ, calling muguet the "*aphthes des enfans*." They recognize also that there are variations in the expressions of the condition, making a distinction between the *muguet bénin ou discret*, and the confluent, *muguet malin ou confluent*.

In Clymer's Aitken's "Science and Practice of Medicine," the subject is thus alluded to: Follicular inflammation of the mouth, follicular stomatitis, aphthous stomatitis, or aphthæ of the mouth, is a disease which usually commences as a simple stomatitis; but very soon small, round, transparent, grayish or white vesicles appear, and at the base of each is an elevated marginal ring, which is pale and firm. Fluid soon escapes from the ruptured vesicle; an ulcer forms, which spreads, bounded by a red circle and an elevated border. In some forms of the affection microscopical parasitic plants appear.

**TREATMENT.**—If we are content to view aphthæ simply as a fungous sore, originating from and maintained by the presence of a parasite,—the *oidium albicans*,—we would find a most admirable application in carbolic acid; admitting that the parasite had an external relation only. If, however, these spores come from within and are exudational, such local treatment would be of very temporary service.

Viewing the fungus simply as an accidental parasite external in its relations, attention is demanded primarily to the necessity for cleanliness, and the avoidance of all localities and circumstances favoring the development of fungi. Carbolic acid, acid nitrate of mercury, sulphuric acid, nitrate of silver, or chloride of zinc, will be found destructive to the parasite, and, of necessity, if the circumstances are changed, equal to the production of a permanent improvement in the appearance of the part; that is to say, the



application is equal to the removal of the envelope or cover of the disease, but, except by a happy accident, will not beneficially affect the underlying condition, or the disease proper.

In the treatment of aphthæ, the practitioner finds himself compelled, at the very outstart, to consider constitutional associations. Occurring in connection with acute diseases, it is generally the case that the local expression is found to disappear with the condition exciting it. Thus, in febrile attacks attended with stomatitis, remedies are directed to causes inducing such attacks; as the functions become harmonized, the expressions of the irregularity disappear.

Aphthæ, whatever its form, appearing in connection with the dyscrasic diseases, gives to the practitioner the greatest anxiety and trouble. In anticipation of what is to be done, he is not to forget that a task before him is the removal, or, at least, the amelioration, of the constitutional disease. If this should be syphilitic, tubercular, or cancerous, the magnitude of the task is evident: hence it is that patients are allowed so frequently and so unnecessarily to find themselves subjected to a series of disappointments.

Acute aphthæ, as manifested in *cancrum oris*, *gangræna oris*, and follicular inflammation, demands not infrequently the most attentive local treatment. This treatment has, however, nothing particularly special in it, and, without doubt, must be appreciated from the general expressions of the subject. Alterative and bracing applications are such as would naturally commend themselves. Sulphate of copper, in proportions varying from five to thirty grains to the ounce of water, is an excellent stimulant. Iron and quinine in combination are used to great advantage,—twenty-five grains of the latter to one drachm of the muriated tincture. A powder made by combining equal parts of red bark, chalk, and tannic acid is frequently found very serviceable. Solutions of alum, and the tinctures of capsicum and myrrh, are useful in their places; also borax, oxalate of cerium, powdered chlorate of potash, sulphate of iron, etc. Hydrochloric acid, applied by means of a feather or small brush, causes less pain than might be supposed, and is thought by many to be the very best local application that may be employed.

Where the parts seem angry and irritable, or phagedenic, combined with these alteratives, the more soothing means are to be employed: starch, gum, and slippery-elm water being found in such directions very serviceable. Tincture of hamamelis, much diluted, is a good preparation. Another is the phenate of soda. It is to be understood that while the principles which govern the treatment of the aphthæ are common to the species, the applications must vary to meet varying local indications. The ordinary white sores, for example, need little more in the way of such direct treatment than the continued application to them of some of the agents mentioned; which one is best, or, indeed, what would be best, we could not well say, unless considering a particular case. The local treatment is not, however, in any of these cases urgent, and it is the general experience that a practitioner



finds himself trying first one thing and then another; indeed, it is unfortunately too common that one is soon brought to the conviction that any local application is unreliable,—not that a sore cannot be made to disappear, but that to-day, to-morrow, or next week, another comes to take its place. Canker sores seem periodic in some persons; they come without perceptible cause other than what seems a persistent constitutional condition, defy all treatment, and finally disappear of their own accord.

Of the special conditions, thrush demands that the bowels be kept free from costiveness,—oil, the saline cathartics, or aloes being employed as indicated. Where fever attends the local manifestation, it is well to prescribe neutral mixture made by fully saturating lemon-juice with the carbonate of potassa; or, if more agreeable to the patient, ordinary lemonade may be drank. In diarrhœa, which is so frequent an attendant on thrush, some such combination as the following may be used:

R.—Hydrargyri cum creta,  
Pulveris opii,  
Pulveris ipecacuanbæ, āā gr. j;  
Magnesiæ carbonatis, gr. xij. M.  
Ft. chart. No. xii.

Of these powders, the infant may take one, mixed in molasses or other vehicle, every two hours, until the discharge is checked, or until the twelve are taken. In diarrhœa with green discharges it may be sufficient to use the magnesia alone; or lime-water, which is more convenient of exhibition, may suffice for the correction of the acidity: this latter can be rendered palatable by adding to it some of the aromatic waters. A combination, for a knowledge of which the author is indebted to his friend Professor Penrose, and which it would seem could scarcely be replaced by a better, is as follows:

R.—Bismuthi subnitratiss,  
Myristicæ pulveris, āā ℥ij;  
Cretæ preparatæ, ℥ij;  
Syrupi zingiberis, ℥iss. M.\*

Dose, from twenty-five drops to a teaspoonful, according to age, repeated every two hours.

In cases associated with much intestinal disturbance, it will in most instances be found satisfactory practice to combine laudanum or paregoric with olive- or castor-oil, administering in such doses as accord with the age of the patient. A child one year of age may take three drops of laudanum or twenty of paregoric, combined with a teaspoonful of the oil; for an adult a dose would be twenty-five or thirty drops of laudanum to a tablespoonful

\* The author is assured that his readers will recognize the obligation he places them under in directing attention to this palatable combination. As a medicine for the ordinary watery diarrhœa of summer, both in the infant and adult, it is seldom found to disappoint in affording speedily the desired cure.



of the oil. It is also found useful to drink freely of the demulcent waters, marshmallow and gum arabic being among the best of these. In debility,—and this is by far the most frequent of the conditions,—combinations of iron and bark, conjoined with the most nutritious articles of diet, will be found indicated: ferrated elixir of cinchona is a pleasant and very reliable preparation, and is freely taken by children. The dose for an adult is one teaspoonful, repeated three or four times a day; to an infant a year old, ten drops may be given.

Concerning the diet, if the patient be beyond the age of infancy, it will be found that the richest food is most advantageously received; juicy beef, oysters, malt liquor, wine, etc., being freely allowed. In the infant, the character of the milk of the mother is to be examined: in many cases it will be found needful to furnish a different nurse, or, otherwise, wean the child. Many cases of persistent thrush in the infant have quickly disappeared after a change of nurses.

Gangræna oris, the most degenerative and destructive of the aphthæ, requires persistent vigor in the treatment, both as regards systemic and local conditions. Sulphate of quinia and the muriated tincture of iron are, in the first direction, most to be relied on. This condition occurs most frequently between the periods of first and second dentition, and is, without doubt, more common to the miasmatic than to other regions, excepting always the location of ill-kept and ill-ventilated charities. Gangræna oris may have a local excitant, but it is never without a constitutional predisposition. It may commence as a simple sore, gradually degenerating, or, as in carbuncle, destruction may reside in the primary impression. A common form of sloughing stomatitis is its appearance as a whitish or ash-colored eschar situated upon the gums, lips, or cheeks. This eschar quickly falls out, being followed by degeneration of the associate parts; the breath becomes offensive, the saliva flows as in ptyalism, while, to add to the discomfort, the ulcer pours out an acrid, corrosive fluid, which not only excoriates the mouth, but seems to provoke the extension of the mortification. If not checked, the ulceration extends to the bone, quickly involving it in the general destruction, and bringing on the condition of necrosis,—necrosis infantilis, as the disease is, unfortunately, so frequently compelled to be named.

The treatment of gangræna oris is precisely that of a carbuncle. The practice is to endeavor to circumscribe the action by sloughing out the affected part with the aid of caustic; tonic stimulation of the general system associates. Where possible, all functional disturbances are controlled, and for the relief of the local sore such soothing means are used as seem indicated. The very best caustic for these and similar cases is found in the London paste; *i.e.*, equal parts of caustic soda and quick-lime made into a thick dough at time of application by mixing with water or alcohol.



## CHAPTER XXXIV.

### WOUNDS OF THE MOUTH AND ASSOCIATE PARTS.

WOUNDS of the mouth and associate parts have, of course, the signification of wounds in general. Thus, some are of an incised character, being slits or incisions made, accidentally or purposely, by sharp-edged instruments. Some are lacerated, contused, or torn, being made by dull and blunted instruments; some are punctured, a result of injury by pointed but not sharp instruments; some are penetrating, as when the offending agent passes through the lip or cheek into the vestibule. A wound may be of a compound, or complicated, nature, as, for example, in the case of blows or falls, where, while the lip or cheek is cut or contused, lesions relate at the same time with the teeth or jaw; gunshot injuries, lacerating or simply puncturing the soft parts, comminuting the hard; bites of rabid animals, introducing a virus; syphilitic inoculations, etc., illustrate complicated wounds. Complications may also be considered as embracing hemorrhage and shock as primary associations; inflammation, with its varied phenomena, erysipelas, pyæmia, tetanus, etc., as secondary associations.

Every wound presents a first indication. If an individual receive a hurt which covers the injured part with earth or other foreign substance, such substance is to be washed or taken away as a primary step. If hemorrhage be the feature, arteries are to be ligated, or other necessary means taken to control the bleeding. If shock be present, this is the most immediate feature, and is first to be combated. If a rabid, or poisonous, animal has inflicted the wound, the destruction of the virus is a first indication.

**Foreign Particles.**—To remove foreign matter, no better means is to be employed than simple sponge and water. Holding a basin beneath the injured part, squeeze water upon it from the sponge; if the particles be not washed away with the agent closely applied, let it be lifted, and the water allowed to fall from a distance. It is not, as a rule, at all necessary to rub a sponge directly over the surface of a wound. Bodies which are not to be washed away, no matter what their character,—splinters, shot, balls, particles of powder, spiculæ of bone, etc.,—are to be removed with forceps, scoop, or other convenient means, the rule being to allow nothing to remain that may interfere with the process of repair.

**Hemorrhage.**—A first matter to consider in hemorrhage is its character. Is it arterial, venous, or capillary? An arterial hemorrhage is known by its scarlet color, and by issuing from the wound in jets. Hemorrhage from a



vein is dark, and has a gradual and regular flow. Capillary hemorrhage is an oozing. Arterial hemorrhage may require that the bleeding vessel be ligated. To do this, it is only necessary to sponge away the blood until the part is to be plainly seen; it is then to be taken hold of by the forceps, or caught by the tenaculum, and a strand of waxed silk thrown around it. In tying this silk, one must be careful that he does not break his strand at either side of the knot; also that the tightening shall be sufficient to cut the middle and inner coats of the vessel. To prevent tearing the artery from its bed by the breaking of the ligature, the rule of holding the thumbs upon the strands close to either side is to be observed. After ligating a vessel, one end of the thread is to be cut off and the other brought from between the edges of the wound; this allows of easy future removal of the knot.

Torsion of a bleeding artery is a favorite mode of treatment with many surgeons. The end of the vessel is to be caught by the forceps and twisted. The author of the mode suggests that torsion be continued until the end is twisted off.

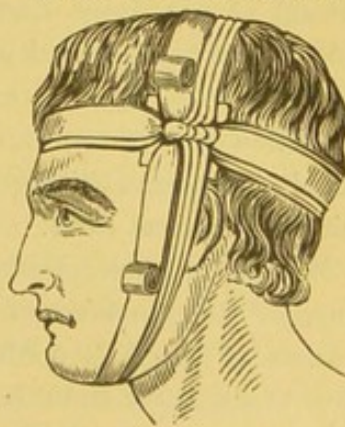Acupressure is another and a very common method of treatment. A steel or gold needle is passed beneath the vessel in such manner as to tightly compress it against neighboring parts.

Pressure by pad and bandage, when a hemorrhage about the face will not yield to simpler means, is a very satisfactory way of treatment, and one very reliable. All the vessels of the face region rest upon a bony floor, and all of them, at certain points, are sufficiently superficial for the purpose of compression,—the facial, at the notch in the inferior maxilla, in front of its angle; the temporal, just in front of the ear above the zygomatic process; the supraorbital, at the notch in the orbit; the infraorbital, at the foramen below the border. (See *Surgical Anatomy*.)

A bandage of common application for any of these vessels is the crossed, or knotted, circular. A glance at the drawing (Fig. 377) will afford understanding of the manner of its employment.

It is, however very seldom that any of these operations are necessary for the arrestation of hemorrhage about the face or mouth. Cold water thrown over the bleeding part from a sponge causes generally such contraction, both of vessels and tissues, as to control it quickly enough. If water alone do not answer the purpose, let alum be added, as much as the water will dissolve. If even this should not suffice, a syringe may be used, throwing a jet from a distance directly upon the bleeding part; this last will seldom disappoint. Monsel's salts, so warmly lauded for their styptic qualities, have exhibited to the writer more ill results than he has ever met with from any dozen other

FIG. 377.—CROSSED, OR  
KNOTTED, BANDAGE.





articles. If employed at all, the bleeding points alone are to be touched ; but of one thing any one using them may be assured : if the application do not control the hemorrhage instantly and permanently, he will have increased his trouble manifold.

A hemorrhage that is venous or capillary seldom requires more than the application of cold water. If this or an alum conjunction, or preferably phénol sodique, fail, astringent medicines are to be administered internally. Of the anti-hemorrhagic medicaments, a tincture of the erigeron canadense, one drop in a teaspoonful of water each minute, may be tried. This dose seems like a very small one, but a larger always appears to do harm rather than good. Opium and lead are to be used with much satisfaction, one grain of the former to two of the latter ; three or four of such pills may be administered at intervals of from one to six hours for each—if found necessary.

### SHOCK.

Depression generally attends, to a greater or less extent, the reception of wounds. Surgery divides shock into primary and secondary, or that which is immediate upon the reception of an injury, and that which exhibits itself at some later period. Shock is prostration : this may be simply of a nervous nature, implying functional disturbance ; or it may be organic, testifying to injury of a vital part ; it may, again, have the twofold relation.

In the author's experience he has found few things more important to observe than the differences between real and apparent shock. One person, heavy and lymphatic of temperament, receives an injury mortal in its character, and yet, as immediate or primary shock is concerned, shows less evidence of such injury than may some other of a different nature who is suddenly called to look on his wound. Mistakes in judgment of these limited expressions may readily influence a practice most adverse to the good of a person prescribed for.

Shock means interference with function. Interference with function arising out of the direct destruction of a part is not to be recovered from, that is, if the part destroyed be necessary to the functions constituting life. Interference with function extended over a lengthened period is dangerous in proportion to the continuance of the period. Functional disturbance, individual or general, arising out of simple shock, may reasonably be expected quickly to correct itself.

Shock is characterized by expressions varying all the way from tremor to collapse. Expressions of primary shock are paleness, trembling, faintness, sickness of stomach, giddiness, palpitation of heart, cold sweating, loss of office in sphincter and other muscles, disordered respiration, glassiness of eyes.

Primary, or immediate shock, has seldom the dangerous meaning of that which comes on in the later course of an accident. An intermediate condition, consecutive shock, not infrequently met with, is without dangerous import, as it implies simply a mental recognition, just arrived at by the patient,



of a situation in which he finds himself. Insidious, or secondary shock, is never to be absent from a surgeon's mind when injury is about the head region. Here the import refers likely to injury done the vascular system; the ill consequences arising out of hemorrhages or effusions. Many a blow ending fatally, received upon the head, has had as the primary expression nothing more than a slight bewilderment almost instantly recovered from.

A patient, being the receptive of a grave injury, yet showing little concern, either bodily or mentally, as to the harm received, is to be watched with anxiety. Here, as is frequently enough found the case, the system is in a state of stun. It has received a hurt which has destroyed or greatly interfered with sensibility. Gradual change shows in an icterode skin, in an albuminoid expression of the immediate subcutaneous tissues, cold extremities, a weak, but laboring pulse, occasional long-drawn sighs, progressive prostration.

To appreciate the subject of shock is to recognize its relations with the nervous, the vascular, and the common visceral systems. The first finds a familiar illustration in the effects of self-given blows over the locality of the solar plexus. The second is to be appreciated in watching the changes common to one undergoing the operation of venesection. Collapse belonging to the third is but an intensified expression of a history associated with splanchnic inflammations.

Accepting the above expressions of relationship, diagnosis and prognosis are divested of confusion. A person may die, persons have died, from nervous shock arising out of extraction of a tooth. Quite a number of instances are on record where similar fright in anticipation of taking an anæsthetic has resulted fatally. The trepidation associated in many persons with injury connected with surgical performances is infinitely of more evil import than the hurt itself. Some persons faint at the first spurt of blood from an opened vein, others require to be kept in an upright position and the vessel largely incised that they be depressed at all.

Idiosyncrasy is to be taken into account; a warrior shows paleness at sight of a coffin, a strong woman grows hysterical at approach of a mouse. Some particular child goes into spasms on putting a forkful of cabbage into its stomach.

To treat shock is to deal with varying conditions. Medicines required vary all the way from an assuring word to a dose of ammonia. A danger is from over-doing. In ordinary depression the abeyance in action tends naturally to over-excitation in the reaction. A patient doing well is to be let alone. Stimulation is not the indication; rather, indeed, would it be the better practice to exhibit depressants as reaction shows itself, wholesome fear being entertained of over-excitation. A best plan is to do nothing until indications make themselves clearly felt.

Shock of simple, but prolonged character, demands the treatment given a fainting fit: namely, recumbency as to position, fanned air, the dress loosened, cold water gently sprinkled or otherwise dashed vigorously over the face,



smelling-salts to the nostril. If continuing, in defiance of the employment of these means, recourse is to be had to swift blowing into the ear, the dropping of a few minims of raw liquor into the throat, or, in the absence of this, the use of ice-cold water. An excellent adjunct lies in the application of sinapisms; in this direction immediate result is to be derived from the use of pure chloroform poured over a handkerchief which has been folded into a small square, the application to be to the præcordial region, or otherwise to the calves of the legs; the agent is to be so covered that its vapor shall not reach the nostrils of the patient.

Prolonged shock having associated with the symptoms a continued retching is commonly to find its best treatment in the administration of an emetic; particularly is such a treatment indicated if it be known that a hearty meal has immediately preceded the accident; retching is almost invariably found associated with an ability to swallow.

Anodynes are not infrequently indicated after shock. An excellent and reliable combination consists of tinctures of valerian and gentian in equal parts; the dose varies from a drachm to a half-ounce. Another excellent means is found in a combination of bromide of potassium and veratrum viride; as a dose for an adult from twenty to forty grains of the first, four to eight drops of the second, may be administered in a wine-glass of water. In injuries having associated with them fear of secondary hemorrhage or effusion opium conjoined with lead is to be employed; the dose is one grain of the former to two of the latter, repeated as occasion requires.

Tendency to visceral determination is to be combated by cups, wet or dry; by hot foot-baths; by medicines directing the circulation to organs the most remote from the particular one threatened.

**Virus.**—If a rabid dog, or other animal, bite the part being considered, or any part,—if a poisonous snake strike its fang, or if the loose kiss of chancreous lips inoculate,—a first indication is to get clear of the poison. How? It is now very generally accepted that, as the first is concerned, the immediate application of the stick nitrate of silver to the part wounded will neutralize the poison, or that, at any rate, it will alter the status of the hurt to an extent which results in a slough and the prevention of absorption. If an escharotic be not at hand (and this, at the moment, would be not unlikely), such a wound may be cut away. Suction is also an admirable prophylactic. The danger to the person sucking such a wound would be trifling; danger, at all, depending on a casual abrasion that might at the time be present about the mouth or lips. Excision of bitten parts is frequently practised. The writer recalls an occasion on which, several years back, an enraged rattlesnake escaped from an experimenter, striking its fangs into a colored assistant standing by. Without a moment's hesitation, the gentleman excised the part: no harm came of the matter. Tiding a patient over the depression of rattlesnake-poison by the stimulus and specific effects of whiskey has received so many confirmations as to reliability as to have become a matter of common knowledge. As



the removal of hurts received from dogs, supposed rabid, is concerned, the author has, on several occasions, practised excision with entirely satisfactory result. Without exception, however, the wounds had been received through intervening substances, and such substances may have prevented the introduction of any poison. Syphilitic virus is best destroyed by use of London paste.

**Healing Wounds.**—Primary indications met, a second relates to the healing of a wound. Every break in continuity heals by granulation. The difference between a healing by first intention, as it is termed, and a healing by second intention is only a difference in degree. An incised wound, delicately and accurately approximated, unites with so little new inter-tissue that observers quote cases where no line of difference was discernible even under the microscope. A healing by second intention, so called, may require so much material to fill a gap that the new, or cicatricial, substance is observable at a great distance; frequently witnessed in scars from burns. An indication, then, of the utmost importance to be met in wounds about the face, is the avoidance of a necessity for new tissue. To meet such indication, every wound is to have its parts as nearly and as neatly approximated as possible, and the associated vascularity controlled.

How wounds are best put together is a matter which is always eliciting discussion. Common methods are by stitches, plasters, and compresses. An incised wound, of limited extent, about the cheek, seldom needs more than a strip of adhesive plaster thrown across it. If such a wound occupy the position of the lips, and complete separation has been made, adhesive plaster will not, perhaps, be found sufficient for the purpose. To insure the best result, a stitch is to be used, and increased support given by placing lateral compresses at the sides of the wound, relating these by a turn of the circular bandage; or it may be found that, after the stitch, the adhesive strips will answer the purpose. Pins, with a figure-of-eight turn about them, make a very nice, reliable, and accurate adaptation, and, if not kept in too long, leave very little scar.

A mode of approximation, which is found very satisfactory, consists in using a suture of silver wire, and bringing the edges of the wound together, as directed in cleft palate. An objection, however, it must be admitted, to all pins and stitches, lies in the fact of new wounds being made,—an irritation being begotten by the presence of the foreign body, which is very apt to provoke more or less suppuration, thus making other scars, as is witnessed so frequently in operations performed for hare-lip; it may therefore be set forth as the best practice, that a means which breaks the flesh is to be avoided, if any other can be made to answer. Silver or lead wire is preferred to the waxed silk only from the fact that these metallic agents seem to irritate less, and are, therefore, not so likely to make points of suppuration, and consequently scars.

When pins or stitches are used, they are to be left in place only so long as



is absolutely necessary; the time will, of course, depend much on circumstances. If an incised wound do as well as it may, twenty to seventy hours will usually be found sufficient for the union, while instances enough exist where, in that time, the process of repair seems scarcely to have commenced. A very good way of obtaining information is to sponge the wound, and to be instructed by the line of approximation: if this continue to show its incised nature, the pins are not to be disturbed; if, on the contrary, it is a fleshy line of comparative solidity, the pins are to be removed,—the parts will hold.

The withdrawal of a pin or ligature is a matter demanding delicacy of manipulation. It is frequently, and indeed generally, the case, that more or less blood-rust collects, making the removal a matter of such difficulty that, unless precaution be taken to scrape away such rust before making the attempt, disturbance of the cicatrix is inevitable. In the withdrawal of a pin, an important matter is the rotation of it; such rotation facilitates the getting away wonderfully. Metallic ligatures are generally disturbing on removal; the proper plan to take them away is to cut the wire at the side of the knot opposite that on which it seems desirable to withdraw it; the end is then to be carefully straightened, so as to place it on a line with the part through which it is to be pulled from the wound; support is to be given the cicatrix by a finger applied on either side, when, with a rotatory movement, the wire is taken away. In the use of the pin and figure-of-eight, a very excellent plan is, on the removal of the pin, to allow the blood-matted silk to remain glued to the wound; it serves to hold the parts together, and is entirely void of any offence as a source of irritation.

When plasters are used, it is a necessity to have all hairs shaved away and the parts perfectly dry. The ordinary adhesive kept on sale by every druggist, composed of resin and lead plaster, is perhaps open to as little objection as any. It is to be applied in strips of convenient length and breadth, and rendered sticky by holding, for a moment, the back of the strip in contact with a vessel of hot water. There are skins, however, which this plaster irritates and inflames; when cases of the kind are encountered, it is well to employ an isinglass plaster. This latter is applied by moistening the glazed surface with water.

In the use of plasters, it is a good rule to allow a space between each strip: this not only keeps the wound exposed to observation, but permits of easy drainage. The only exception to this rule is found in small cuts where it is thought desirable to use collodion. This mixture of gun-cotton and ether is applied either directly over a cut—first nicely approximating the edges, and holding the parts together until the ether has evaporated—or indirectly through the agency of saturated slips of gauze or other convenient material.

The removal of a plaster is to be effected by drawing the strip from either side toward the wound; such a removal being accomplished without any strain upon the cicatrix, the line of union being, of course, supported by the thumb and forefinger of the other hand. If a wound seems to be doing well



under plaster, there need be no special haste in the removal. It is usually the case, however, that such a dressing will not continue to do service longer than two or three days. In simple incised injuries, this is generally all that is needed, but in lacerated wounds, dressings are demanded an indefinite length of time, and require continued renewal. In reapplying a dressing of adhesive strips, a good plan is to displace and replace one at a time. In this connection attention is to be directed to a plaster prepared by Meade, of New York City; the author has never met with any that at all equals it; no heat is necessary to its application.

**Complicated Wounds.**—The history of a few cases may, perhaps, best serve to illustrate practice in the direction here considered.

**CASE I.**—Little girl, of remarkably perfect temperament,—temperamentless, it might be said,—about four years of age, brought into the office with a gash in the lower lip, and the six anterior teeth knocked directly back; considerable hemorrhage.

*Treatment.*—Checked the hemorrhage, and cleaned the parts by the free use of cold water applied through the syringe; pushed the teeth back into their unfractured alveoli, and retained them in place by laying a delicate roller over them, fixing it beneath the chin. A single stitch of waxed silk was placed in the wound of the lip. The case was dismissed for the day, with directions to keep the parts refrigerated through a continuous application of cold water.

*Second day.* Same treatment continued, the band over the teeth being replaced by a fresh one.

*Third day.* Wound in the lip healed sufficiently to remove the ligature. Teeth somewhat tightened; very little inflammation; continued the bandage, but left off the application of the water.

*Fourth day.* Removed the bandage. Teeth very sore, but doing well, and quite fast.

*Eighth day.* Patient dismissed; some soreness still in the teeth, but needing only time to bring them to full health.

This case was seen three months after the accident; there was no discoloration of the teeth, and not the slightest evidence that any harm had ever been done them.

**CASE II.**—Child six years of age. Four front inferior teeth knocked loose by a blow from a ball; some contusion of the lip, but no break in the continuity; very little bleeding.

*Treatment.*—Removed the injured teeth; absorption of the sockets having progressed to a considerable extent, applied to the lips dressing of cold water; case well enough to dismiss next day.

**CASE III.**—Little boy, five years of age, fell upon a curbstone, fracturing the superior alveolar process. Examination revealed six teeth movable in mass, the fracture extending from tuberosity of right side to canine fossa of left. The accident occurred nine hours before recourse to treatment.

*Condition.*—Child feverish and restless; pulse much excited; soft parts



about the seat of fracture considerably swollen, and so tender as to cause the patient to scream when the parts were touched.

*Treatment.*—A Seidlitz powder; hot pediluvia; the mouth syringed with cold water; iced lemonade *ad lib.*; spts. Mindereri, ℥ij,  $\frac{1}{16}$  gr. acetate of morphia. This was the treatment on the afternoon and night of accident.

*Second day.* Hot pediluvia; iced lemonade, made of crushed ice; mustard poultice at back of neck.

*Third day.* Swelling of gums very much abated. Fed the child freely with spoon food, then brought the fractured part to its place by reducing to proper articulation with lower teeth, and retaining in position by means of the yard strip modification of the Barton bandage; a fairly comfortable day was passed. In the evening the bandage was loosened, the child again fed, the bandage retightened, patient put to bed. A comfortable night was enjoyed.

*Fourth day.* Doing very well. On loosening the bandage there was very little tendency in the fractured part to move of itself; child fed with soup food; mouth well syringed with cold water; bandage reapplied. Patient played about the room most of the day, taking lemonade and rice-gruel very frequently; the fluid being placed within the lips and sucked between the teeth.

From fifth to tenth day did little more than continue the treatment of the fourth.

*Eleventh day.* Removed the bandage. Fracture fairly solid; able to hold of itself; liquid food continued; no other treatment.

*Fifteenth day.* Patient began to eat solid food; passing on, without further treatment, to a good cure.

CASE IV.—Little girl, three years of age, markedly scrofulous; lip cut through; fracture of process of central, lateral incisor, and cuspid teeth of left side inferior maxilla; cutting edges of teeth thrown backward.

*Treatment.*—The wound in the lip being quite extensive, a hare-lip pin was inserted, and the parts pushed together and held with a figure-of-eight. The fractured process was restored to position, and retained by tying the one end of a strand of waxed floss silk around the last molar tooth of the injured side; bringing it forward, passing it between the first molar and cuspis of the fractured part, back of the three teeth of the broken process, then out between the central incisors, and back to the first molar, where it was tied. This ligature supported the part in its place very well. The ferrated elixir of bark, in doses of twenty-five drops, directed to be taken three times a day.

*Second day.* Wound in the lip doing tolerably well; seat of fracture looking puffy and asthenic. Very weak solution of compound tincture of capsicum ordered to be thrown, *ter die*, over the part.

*Third day.* Looking worse; ligatures cutting into the gums; patient refusing both solid and soft food; took away the ligature; tempted the appetite with ice-cream and jellies; scarified the puffy gum.



*Fourth day.* Matter oozing from about seat of fracture; etherized the child; dissected down to the broken piece, and removed it.

*Sixth day.* Very much improved; wound healing fairly; continued to syringe with the dilute capsicum comp.

*Eighth day.* Case well enough to be dismissed. The pin in the lip had been removed on the third day. The wound gaped some little; but the removal was a necessity, on account of irritation produced by its presence; support was given by an adhesive strip. After the taking away of the pin, and the part being stimulated with capsicum, it healed very rapidly.

CASE V.—M. L., an iceman, aged perhaps thirty-five, brought into the office immediately after having been kicked on the mouth by a vicious mule. Patient very pale and faint. Examination revealed comminuted fractures of the alveolar process of both jaws, with the teeth knocked into every position.

*Treatment.*—First, stimulation with a little brandy. The patient revived. Incisions on either side of the teeth were made down to the bone, and some eight pieces removed, with the teeth associated. No hemorrhage of consequence attended the operation, and in the course of three or four days the man was going about his business,—no treatment, outside of the free use of cold water, having been indicated or employed.

CASE VI.—C. H., struck over the angle of the jaw by a minié-ball, which ploughed across the face, completely dividing the cheek, and grooving the right nasal ala. A first treatment employed on the field, where the injury was received, consisted in associating the several parts with a series of interrupted sutures, and the application of a poorly adapted bandage. In this condition the patient was sent several days' journey, to a hospital in which the writer happened at the time to be employed. A first observation of the case exhibited an immense wound, stitches all torn out; superior maxillary bone exposed, with groove cut into it; suppuration profuse; patient irritable and feverish, and much exhausted.

*Treatment.*—The weather being oppressively hot, a large basin of water was brought, in which the head and face were thoroughly, yet tenderly, washed. The matted hair was combed out and arranged. This refreshed the man very much. Examination of the wound was commenced. On the groove in the bone was found no splinter, nor other indication adverse to the direct and immediate overlying of it by the soft parts. Attention to the line of wound in the flesh exhibited that the slough, which must necessarily have ensued from the passage of the ball, had been completed, and that a process of repair was attempting to inaugurate itself. Indications being very plain, the whole of the cut and suppurating surface was slightly stimulated by an application of dilute tincture of iodine, and then carefully moulded into place and approximated. The maintenance of this apposition was accomplished by fitting a compress to the cheek, and also below the wound, and, by means of a bandage, carefully lifting and supporting it; no stitches, pins, or plasters being



employed. The success in way of adaptation of parts was perfect, the whole line of the wound being exposed, permitting full and frequent examination. In two weeks the parts had united so firmly as to allow of the removal of the compress and bandage. The only medication employed consisted in the administration of an occasional Seidlitz powder, and a glass daily of porter, with repeated applications to the wound of the dilute iodine, one part of the officinal tincture to four of water.

CASE VII.—Little girl fell over the shafts of a wagon, cutting, in some unappreciated way, her tongue directly in twain, for the distance of an inch down the middle. Hemorrhage was very profuse, requiring the ligature of a vessel. This wound was united by two stitches of the interrupted suture passed deep in the substance of the organ; cold water directed to be held in the mouth quite continuously, for the first day; patient fed on ice-cream and jelly. Third day, stitches removed, union complete, ligature loosened, and was pulled away on the seventh day.

CASE VIII.—Brigadier-General D., standing upon an outlook, was struck by a sharpshooter, the ball passing through the right ramus of the lower jaw, shattering the bone, passing forward across and through the tongue, emerging from and splintering the body of the bone on the left side. The treatment pursued upon the field had been to check an alarming hemorrhage from the region of entrance of the ball, by stuffing the wound with charpie saturated with Monsel's solution of iron, throwing a bandage over this, and hurrying the case to the hospital.

*Condition on entrance.*—Patient arrived, and was put under the author's care about eleven o'clock at night; complained, by writing on a slate, of great thirst, with entire inability to swallow, and of the painful effort required to breathe; had not been able to drink since the accident, which happened two days before.

*Treatment.*—Examination revealed marked displacement of the middle piece of the fractured bone. This, with the tongue being pulled backward by the hyoid attachment of the genio-hyoglossal muscles, sufficed to explain part of the difficulty in respiration and deglutition. The tongue itself, however, was much swollen, and had a ball wound through its base. Two primary indications thus presented: to restore the body of the bone and tongue to position, and to reduce the swelling in the soft parts. The external wounds were for secondary consideration: the patient had to breathe and had to be nourished. The mouth was first well syringed with cold water, which was found most refreshing; the bone was then brought forward, the inferior teeth in front of the superior; the jaws were closed, and held together by a delicate bandage, the middle fragment being thus retained even in front of its natural position, and pulling the tongue forward with it. This accomplished, the patient was propped up in an arm-chair, and his feet immersed in hot water, the application being continued until every vein and capillary was engorged. A local abstraction of blood was not thought desirable, as he had



already lost as much as he could well spare. The result of such a primary treatment was, that in half an hour the sufferer was able to swallow spoonfuls of lemonade. This drink, cold as it could be made, was continued during most of the night, serving by its refreshment to give much comfort, and by its refrigeration to abate the vascular excitement. About four o'clock in the morning the patient fell into a disturbed sleep, which continued until eight. At nine o'clock the tongue was examined by separating the lips and looking at it through spaces which existed between the teeth; the swelling and turgidity had very much diminished. The feet were again placed in hot water, and the blood held in the inferior parts until a sense of faintness was experienced. This gave increased relief. Immediate danger averted, attention was directed to the state of the external injuries, and the line of passage of the ball.

The wound at the external angle of the jaw was found to occupy quite a space in the parotid fossa, the ball having evidently been received as the general had turned his head to address some one behind him. The gap was stuffed with charpie, this being now a black and blood-infiltrated mass; it had evidently been thrust hard and solidly into the wound, and had swelled to double its former size, displacing the parts to a very marked extent. This plug being found firmly fixed, it was left to be removed or not, as circumstances should seem to direct, at a future time. The wound of exit was larger than might have been expected, spiculæ of bone having considerably torn the parts; from it were removed several small splinters. A probe, passed into this opening, revealed the line of the wound running through the base of the tongue obliquely across the mouth. The treatment consisted in a free use of permanganate of potash and water. The patient passed the day in a fair degree of comfort.

Sudden secondary hemorrhage being the next thing to fear, it was determined on the third day to remove the plug; this was accomplished only after a full hour of labor, the charpie having wedged itself into every imaginable space, the removal being effected by the very free use of milk-warm water and the most gentle traction with forceps and scalpel handle. The withdrawal was attended with considerable pain, but without the loss of a single drop of blood. The relief from the sense of pressure afforded was so very great as to change the whole appearance of the injured man, he now breathing and taking his beef-essence with great freedom. The appearance of the wound was really very promising, attempts at granulation being quite evident, while nothing especially threatening was to be observed. The day after this dressing, the patient, in opposition to advice or commands, insisted on being passed to his family in Washington. All the dangers of hemorrhage were exposed and explained to him, but he was possessed of a single idea, getting home. At five o'clock in the afternoon, being continued in charge of a surgeon who had been sent with him from the field, he was driven to the steamer plying between Fortress Monroe and Baltimore. At midnight, while on the



Chesapeake, profuse bleeding came on, which was controlled, as best it might be, by masses of ice held continuously to the wound. The patient died the next day at a hospital on the wharf in Baltimore, under what exact circumstances was not learned; most likely from exhaustion.

CASE IX.—J. B., middle-aged man, gash, from a blow, lacerating the cheek, opening the duct of Steno.

*Treatment.*—With a heavy-eyed needle, carried a loop from the bottom of the wound to the inside of the cheek: the silk, which was very loose, conducted the saliva into the mouth. Brought the external wound together by strips of resin plaster; no other treatment required, save an occasional dressing. In a week the loop had sloughed through into the mouth, preserving completely the track for the secretion, and the process of granulation had advanced almost to the stage of cure in the external wound. No after-trouble.

CASE X.—C. A., young gentleman, twenty years of age, deep punctured cut in the floor of the mouth just to left of middle line, made by the slipping of an elevator in the attempt to remove root of upper canine tooth. No hemorrhage, or immediate bad sign of any kind; patient very much frightened. Accident had occurred two days before first seeing the case; part very sore and tender; inflammation limited.

*Treatment.*—Directed arnica-water for relief of the soreness; nothing else indicated or required; the wound healed rapidly and kindly.

CASE XI.—Cut received by young lady, exposing and incising mylo-hyoid artery of left side in the groove; hemorrhage very great and persistent.

*Treatment.*—Upright position; tinct. erigeron as directed; strong alum solution held to the part on tufts of cotton; afterward thrown with the syringe; ice to the part, etc. No result on the bleeding. The patient becoming affected from loss of blood, enlarged the wound, picked out the vessel with the Liston forceps, and tied it. This, of course, controlled the hemorrhage. A comfortable recovery was made.

CASE XII.—Mr. C. Performed operation on the cheek for a peculiar erectile growth; cut well into the sub-tissue, making quite a deep wound, just as if the part had been scooped out.

*Treatment.*—Cold-water dressing; waited on nature to fill up wound with granulations; nothing else required, nothing done; the case progressed to a satisfactory cure, excepting as a raised scar remained.

CASE XIII.—Young man, shot through the cheek; the mouth being, at the time, fortunately open, the ball passed out, doing no further damage; no hemorrhage.

*Treatment.*—Applied cloths wrung out in cold water, for the purpose of controlling vascular action; nothing else done; wound suppurated until the compressed and devitalized tissues were sloughed; then kindly granulated, the patient being entirely well in a month.

CASE XIV.—Patient, young lady. In an attempt to extract the first



molar tooth of right upper jaw, a flap of gum had been torn, extending around the mouth to the left second bicuspid; this flap had been hanging loose some three hours before the patient presented herself.

*Treatment.*—Cut the piece off, and depended on granulations from the wounded surface for the filling up; patient comfortable next day; entirely well in a week; no other treatment of any kind required.

CASE XV.—Boy, twelve years of age; playing with powder contained in a bottle it unfortunately exploded, throwing the glass and burning grains into his face. When first seen, an hour after the accident, the patient was in the greatest distress; the eyes were completely closed, lashes entirely destroyed, hair singed, face raw and bleeding, pulse rapid, and very irritable.

*Treatment.*—First, Seidlitz powder, with half-grain of opium; second, removal of such pieces of glass as could be readily picked away with the forceps; third, cold-water dressing. In an hour the patient was fairly comfortable; at the end of which time a second half-grain of opium was administered.

*Second day.* Face very sore, but no burning pain; picked away several small pieces of glass and a number of the powder-grains. Continued cold-water dressing.

*Third day.* Reactive inflammation evidently aborted; water dressings dispensed with; used in place

R.—Olei lini,  
Aquæ calcis, āā q. s.

With this the surface was protected from the atmosphere until it cicatrized, —a period of two weeks. During the time of cure some little attention was given to the diet, the patient for the first day craving principally ice-cream, which answered very well, and served to allay a slight tendency to irritative fever which existed; the latter four days of the first week stimulating articles of food were interdicted; after this he ate what he liked.

CASE XVI.—Patient, young gentleman. Struck, while on a gunning excursion, by a buckshot, which passed through the lower lip, burying itself in the bone. Patient not seen until the next day; lip too much swollen to permit of examination.

*Treatment.*—Cold-water dressing to the lip. Mag. sulph. ʒss internally.

*Third day.* No diminution in swelling; slight erysipelatous blush; brushed the parts with the following combination:

R.—Tincturæ ferri chloridi, ʒj;  
Quiniæ sulphatis, gr. xxx;  
Tincturæ cinchonæ, ʒij. M.

In one hour the blush had disappeared.

*Fourth day.* Inflammation, with the swelling, disappearing very rapidly.



*Sixth day.* Probed the wound; discovered the shot lying near the root of the first bicuspid tooth; dissected away the gum from the inside, and with a very small curved gouge picked the lead away.

*Seventh day.* Inflammation back again, confined, however, rather to the inside of the mouth; reapplied the cold-water dressing, and directed a Seidlitz powder.

*Eighth day.* Better; inflammation rapidly yielding; a little pus escaping from the shot track in the bone.

*Tenth to thirteenth day.* Track of wound in the bone suppurating considerably; tinct. iodine used.

*Fourteenth day.* Discharge diminishing; iodine continued.

*Sixteenth day.* Discharge entirely ceased; patient dismissed.

CASE XVII.—Patrick T., laborer. While engaged in blasting rocks, the patient was struck with great force, just below the orbit, by a flying fragment, lacerating, in a frightful manner, the soft parts of the face, breaking and knocking into the naris the left nasal bone, and severely concussing the maxillary. No hemorrhage; heavy shock.

*Treatment.*—The patient being a strong, plethoric man, reaction was allowed to establish itself, which it did completely only after the lapse of several hours. Cold-water dressings were, however, at once applied to the parts, every deduction favoring the inference of severe inflammation. The accident occurred in the morning. At seven in the evening, a pine stick, whittled, to make its introduction easy, was coated over the end by dipping it in melted wax, and with this, insinuated into the nostril, the depressed nasal bone was thrust out into place, position being maintained by a tuft of wax-coated cotton, having attached a string for its withdrawal.

Examination of the injured face and maxillary bone revealed contusion and injury to such an extent as to make it evident that the process of cure must be that of exfoliation, sloughing, and repair by granulation; the only treatment was the expectant, and this was a simple water dressing.

*Second day.* Most decided reaction. Mag. sulph.,  $\mathfrak{zss}$  administered in a glass of water; water dressing, medicated with lead and laudanum.

R.—Plumbi acetatis,  $\mathfrak{z}ij$ ;

Tincturæ opii,  $\mathfrak{z}ij$ ;

Aquæ,  $\mathfrak{z}xxx$ . M.

Cloths wet with this lotion kept constantly upon the cheek.

*Third day.* Inflammation abating, but patient complaining of feeling hot and generally miserable. Lemonade ordered as a febrifuge, to be made by expressing the juice of an ordinary lemon into a goblet, sweetening, and filling up the glass with ice broken into a coarse powder. To be allowed *ad libitum*.

*Fifth day.* Wound suppurating; fever all gone; dressing changed back to simple water; waxed cotton changed in nostril,—the replacement giving much pain.



*From fifth to tenth day.* Water dressing continued; portion of external plate of the bone apparently dying; periosteum evidently destroyed.

*Eleventh day.* Stimulation commenced; parts wet three or four times a day with the following:

R.—Aluminis pulveris, ℥ij;  
Tincturæ capsici compositæ, ℥ss;  
Aquæ, ℥xvj. M.

*Fifteenth day.* Granulations being thrown out from around the edges of the wound; parts brought as closely together as possible, and retained with adhesive strips; nasal fracture doing very well.

*Twenty-fifth day.* Wound of face entirely healed, with the exception of a small place in the centre, which, when examined with the probe, discovered a sinus leading to diseased bone.

*Thirty-fourth day.* Piece of bone presented at the sinus; enlarged the opening, and withdrew a sequestrum rather larger than an ordinary finger-nail. Examination with the probe, after the removal, gave the fleshy feel indicative of repair. Case dismissed on the thirty-sixth day.

CASE XVIII.—Young man, struck on the side of the face, in a street-brawl, with a slung-shot; face severely cut and contused; outer boundary of the antrum driven backward into the cavity, not fractured apparently, but bent inward.

*Treatment.*—Cold-water dressing,—no other application for the first three days. After this, the patient being compelled to go out to his work, adhesive strips were employed; repair progressed rapidly, without a single adverse manifestation. The depressed plate of the sinus gave no trouble, soon accommodating itself to its new position; all sense of soreness leaving it by the end of the second week. External wound cicatrized in twenty days.

CASE XIX.—A young man slipped while standing on a stall in a market-house; falling forward and downward upon one of the hooks, the point entered his mouth, broke off three of his upper teeth, perforated his hard palate, and passed into the right nostril.

*Treatment.*—Seen first one hour after the accident. Pain in the broken teeth unbearably severe. Examination discovered the engorged pulps entirely exposed and bulging from their cavities. A probe introduced through the wound in the palate passed readily into the nares, giving little or no pain. No fracture of the bone, save a few trifling spiculæ about the circumference of the puncture. The roots of the broken teeth were at once extracted, and the case, for the time, left to nature.

*Second day.* No necessity for any interference; some soreness, but no actual pain.

*Third day.* Nothing required to be done.

*Fourth day.* Three trifling pieces of bone discharged into the mouth.

*Seventh day.* Wound granulating very satisfactorily.



*Fifteenth day.* Nature unable, evidently, to quite fill up the opening; assisted by scarifying the circumference of the wound, and touching with tincture of iodine.

*Seventeenth, twentieth, and twenty-second days.* Scarified and touched with iodine.

*Twenty-fourth day.* Opening completely closed. Case dismissed.

CASE XX.—Gentleman. While striking the iron handle of a chisel in the act of opening a box, a small piece flew off from the hammer, burying itself in the malar process of superior maxillary bone.

*Treatment.*—With probe, searched in the wound for the foreign body; found it in position as described, with very oblique track through soft parts. Introduced a sharp steel instrument, and, after some trouble, succeeded in working the piece loose; could not, however, get hold of it with forceps without such manipulation as would evidently enough contuse the parts. Introduced a director down to the body, and cut to it; removing it in this way without effort. Closed wound with two delicate sutures, and applied cold-water dressing. In three or four days the parts were entirely well, not the slightest suppuration having occurred,—no noticeable scar.

CASE XXI.—A little boy, Harry H., while playing with a wooden paddle which had been made for use in rendering lard, slipped while having one end of it in the mouth, the weight of his body carrying the stick through the soft palate, making a complete separation between the veil and hard parts. This patient was first seen three days after the injury. No inflammation of consequence existed.

*Treatment.*—Etherizing the child, the parts were stitched together by means of interrupted sutures of silver wire, the approximation being maintained by perforated shots clamped over the threads. Only a very limited union was secured, the two most important stitches sloughing out. On the fourth day from the introduction of the first stitches, those which had been lost were replaced, which last, by the eighth day, also sloughed out, yielding no increase in extent of the union, but happily being associated with such extent of granular face to the wound that, when the veil was pressed upward, it met the part from which it had been torn. An impression of the mouth was now taken with very soft wax. From this a model was secured, to which a silver plate was struck. This plate enveloped the back teeth of the upper jaw, but was cut to fit the palatal faces of the anterior. Impressions were next gotten of the inferior teeth, and caps made for the molars. Putting next plate and caps in place, they were related by means of wax, and the apparatus thus associated lifted carefully from the mouth, the piece being completed by soldering the parts together. Thus prepared, the apparatus was put in the mouth, and the two jaws held in relation by means of the author's strip bandage. In two weeks union was sufficiently firm to permit the removal of the splint.

CASE XXII.—Stout Irish lad, twelve years of age, shot in the face by a playmate. In this case the pistol was in the hands of a smaller boy, the



muzzle being directed obliquely upward. The ball, which was a good-sized minié, struck the centre of the nose, and, as it passed upward on the line of its projection, was deflected at an angle of about eighty degrees, by an influence exerted by the nasal bones, against which it struck. This boy was first seen on the second day after the accident. No inflammation, no evidence of shock, indeed, no anything that would lead to the inference of an accident of gravity; even the wound of entrance was scabbed over, looking nothing different from an insignificant sore.

*Treatment.*—Breaking away the scab, search was made for the course of the ball by means of the ordinary silver probe. As the instrument reached the nasal bones, the condition of deflection was recognized. Examining next the mouth of the patient, a solid projection was observed at the line of union of the palate plates of the maxillary and palate bones. Inferring this to be the missile, an incision was made through the soft parts; this exposed, however, not the ball, but a fractured portion of bone. Removing this, the lead, much flattened, was found immediately above it, being wedged in the site from which it had forced the bone. The boy seemed to require no treatment, and therefore received none. In no way had he a bad symptom.

CASE XXIII.—Michael M., car-driver. Separation from its maxillary attachment of left nasal bone. Deformity very marked; the whole nose looking as if it had been thrust upon one side of the face.

*Treatment.*—The parts being very much inflamed, application of the lotion of lead-water and laudanum was ordered, and continued until the condition was fully combated; two days being required to secure such desired result. Using now the handle of an ordinary scalpel, the displaced bone was lifted into position, and was retained by making a flattened roll of the common adhesive plaster,—the unspread side out; this, being dipped in olive oil, was directed into place, and retained for a week by a ligature, which kept it well in position by passing over each ear. At the end of this period the roll was withdrawn and the parts left to nature. A perfect cure resulted.

CASE XXIV.—From Langenbeck. Head of patient was caught between a locomotive and its tender. The eyelids were torn away from the orbit, and a deep wound ran down from the inner canthus to the upper lip. A probe could be passed into the antrum: not a trace of the eyeball could be found; while in the orbit was a bluish-black pulsating mass. The nasal bones comminuted. Patient conscious, but sleepy; pulse slow; violent pain on right side of head. A week afterward, as head symptoms disappeared, and the extravasated blood had been somewhat absorbed, a closer scrutiny could be made. The eyeball was discovered to have escaped into the antrum from the orbit by a hole in the orbital margin of the upper jaw, big enough to admit the finger easily,—the axis of the eye standing vertical, the cornea downward.

The fragments of bone were adjusted as well as possible, and the eyeball replaced in the orbit. It was uninjured, and vision was perfect.

About ten weeks after, by two blepharoplastic operations, the eyelids were



brought into tolerably good condition. They could be closed, and usually so remained, but could be opened enough to expose the cornea and permit sight. The globe was, however, perfectly immovable. About five months after the injury, ulceration and suppuration of the cornea occurred, and the globe atrophied.

CASE XXV.—A painter, engaged at some work in the line of his trade, fell from the roof of a three-story house to the street, striking against the rail of a car-track, producing, besides other fractures, compound comminution of the inferior jaw. The writer first saw this man at the Pennsylvania Hospital, several months after the accident. Despite the judicious care he had received, full half the centre of the body of the bone had been lost, the angles being pulled together by action of the mylo-hyoid muscles, the fragments having united just above the hyoid bone. A more lamentable condition it would be hard to imagine. The tongue, of course, was permanently fallen back into the throat. The treatment of the case being kindly transferred to the clinic of Oral Surgery by the surgeons of the hospital, attempt to restore the articular relations of the portions of lower jaw remaining was commenced by separating the united angle, using for this purpose the cutting forceps. This accomplished, reunion was prevented and a false joint secured through the interposing of a tuft of sponge kept in place several weeks. The parts recovered to a healthy condition, a succeeding step pertained to the restoration of relations. This was accomplished by means of metal plates made to fit accurately the lingual faces of that portion of the jaw remaining on either side. Passing across the floor of the mouth, acting upon the plate of either side, was a swivel screw. Elongation of this screw forced the parts into position.

Articular relations restored, a succeeding step was the securing of a wax impression of the parts representing the hiatus, or lost segment, of the jaw. From this impression a model was made in plaster from which, in turn, there was prepared a silver jaw, with teeth attached. This jaw, or segment, when slipped into place, restored and preserved the contour most satisfactorily. When last seen the patient looked not unlike people in general, and was using his artificial jaw and teeth to the required end of enunciation and mastication. (See, for illustration, *Fractures*.)

**Burns and Scalds.**—Burns and scalds imply injury done by heat. The former is a result of contact with hot solid bodies; whether through radiation, flame, or immediate touch. The latter results out of a relation with heated fluids; these being water, alcohol, ether, oil, or steam.

Burns and scalds classify themselves as simple and complicated, or according to extent of injury. 1. An impression made, either by dry or moist heat, including that of the sun, which has acted as an irritant to the surface of the skin. Result: simple erythema terminating speedily in delitescence. 2. Irritation resulting in inflammation. Result: vesication, the vesicles curing themselves by desiccation or suppuration. 3. Cauterization of tissues. Result: sloughing by dry eschar or demarkation.



The first indication in burn or scald relates with shock ; this, in proportion to the injury received, is commonly more severe than from other forms of casualties. It is a matter to be closely appreciated. (See *Shock*.)

As immediate application in burn, the one commonly most conveniently at hand is cold water. In ordinary cases no means insures so great an amount of comfort as fine handkerchiefs spread over the face and kept continuously wet. Such an application continued from one to two hours, or until it ceases to be comfortable, will almost surely relieve a patient of the agony attending on a burn. Where sanguineous reaction threatens, acetate of lead may be added to the water.

Vascular disturbance aborted or modified, a second step in treatment refers to prognosis. A burn or scald, superficial in its nature, may reasonably be expected to resolve itself without greater loss than the epiderm, and without scar. Where a burn has involved the skin proper, tardiness of cure and resulting deformity will be in proportion to the injury received. Lost skin is replaced by scar-tissue. In scar-tissue is deformity. Depth of destruction implies extent of eschar.

Where a burn is superficial, aim lies in the direction of immediate resolution of the induced vascular perversion. The treatment is : first, cold water ; second, soothing unguents.

The epiderm is not to be removed in surface burns. Where effusion occurs the vesicles are to be drained by pricks with a needle ; otherwise blebs and serum may be left to take care of themselves.

To protect burnt skin against the irritating effects of the air, it is highly recommended by some to paint the part heavily with gum-water and to form a coating by dusting into this subnitrate of bismuth. Common white paint is also highly commended. A varnish, lasting the necessary length of time, is prepared by mixing into tinctures of iron and cinchona a sufficient quantity of sulphate of quinia to thicken the fluid. Carron oil, a remedy much used in Scotland, consists of lime-water and linseed oil in equal parts. Carded cotton is a common and valued domestic remedy. The new preparations of petroleum, vaseline and cosmoline, are coming into much favor for use in superficial scalds or burns. A soothing application is found in starch prepared as a poultice. Scrapings of potato, apples, and carrot are good remedies. Fresh-gathered plantain leaves furnish a very satisfactory dressing. Earth, in the form of dry powder, dusted over the part, is highly commended by Dr. Addinell Hewson. Cod-liver oil is a good although an offensive means. As an immediate application to relieve pain much commendation has been given from various sources to an admixture with water of the bicarbonate of soda.

Deep burns, implying eschar, or slough, are treated primarily as the previous class. Inflammatory disturbance being modified, secondary indications refer to anticipated loss of tissue. Parts entirely dead are wisely cut away ; partly dead, being injured beyond possibility of restoration, poultices hasten a line of demarkation.



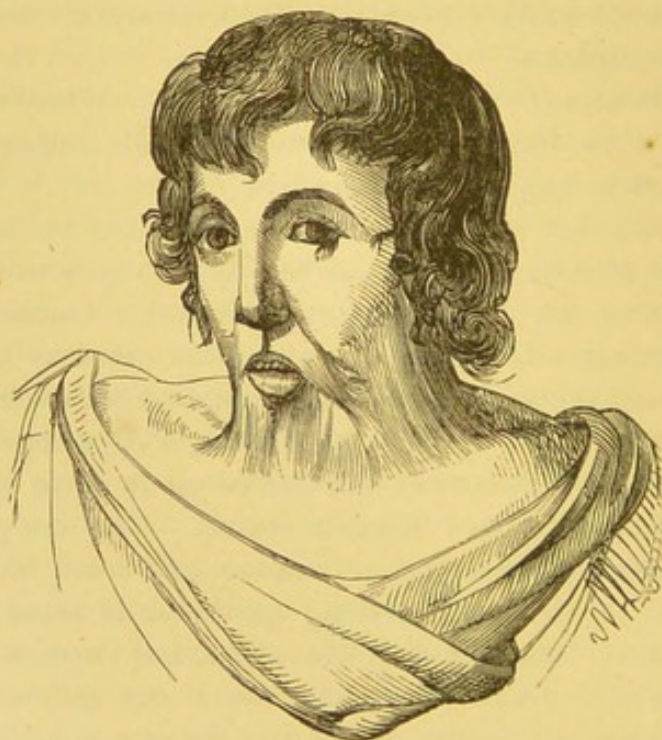
A good and comforting poultice is made of bread and milk or of ground flaxseed and water: whether to be applied cold or warm is best determined by the feelings of the patient. If vascular disturbance be present to an undesirable extent, great good is derived by admixture with the mass of lead-water and laudanum.

R.—Plumbi acetatis,  $\mathfrak{z}\text{j}$ ;  
Tincturæ opii,  $\mathfrak{z}\text{j}$ ;  
Aquæ,  $\mathfrak{vi}$ . M.

S.—The poultice to be thinned with this.

Where passivity or tardiness of condition intervene, the poultice is wisely replaced with a stimulating unguent. In this direction Kentish's ointment, mixed in equal parts with oxide of zinc ointment, highly recommends itself. In the way of fluid applications tincture of marigold is found serviceable; also almond or olive oil in which has been infused the fruit *Momordica balsamina* (balsam apple); also glycerine to which has been added a fourth part of red ointment; also, where passivity approaches deadness, the compound tincture of capsicum, used pure or dilute, as indicated.

FIG. 378.



Burn of neck; showing contraction; remedy lying alone in operation.

Where erysipelas threatens, absolute reliance is to be placed on the following combination, the application to be renewed each one or two hours, or oftener if found necessary; it cannot be repeated too frequently so long as the shiny blush and tension persist.

R.—Tincturæ ferri chloridi,  $\mathfrak{z}\text{j}$ ;  
Tincturæ cinchonæ,  $\mathfrak{z}\text{j}$ ;  
Quiniæ sulphatis,  $\mathfrak{z}\text{j}$ .



A sloughing part is to be kept both stimulated and disinfected. To this end carbolized fluids may be used ; or, if the part be irritable, phénol sodique answers a better purpose. Tar-water, to which has been added required proportions of the aqua chlorinata and tincture of capsicum, is found serviceable.\* Still another application is the permanganate of potash ; a solution being made of five grains to the ounce of water.

Where an eschar is large, a succeeding indication refers to the prevention of scar. Two means here apply: mechanical fixation and skin-grafting. From the first little good is to be expected. The second is seldom wisely omitted.

Skin-grafting includes the planting over the surface of a wound of points of skin removed from well parts, and the transference of flaps, having temporary relation by pedicle to neighboring parts, into the seat made vacant by the falling slough. The latter means promises greatest benefit. (See *Plastic Operations*.)

In operating for the relief of deformity from scar-tissue regard is to be had to the time intervening between date of proposed operation and that of reception of the injury. It is well to let months if not years elapse, except indeed the performance be attempted at the time of accident ; a matter, the consideration of which should imply the possession of a wide experience. No objection holds, however, to the immediate use of skin-grafts. To receive such grafts the ulcer is to be in a condition developing healthy granulations.

---

\* Tar-water, one pint ;  
Chlorine-water, one ounce ;  
Tincture of capsicum, one ounce.



## CHAPTER XXXV.

### THE TONSIL GLANDS.

THE tonsil glands, situated on either side of the oro-pharyngeal space, between the half arches, are readily exposed by depressing the tongue through the medium of any convenient means. An instrument made especially for the purpose, called a "depressor," is found well adapted to the purpose.\*

The tonsils, glandular organs, described by Virchow as an analogue of the lymphatic glands, are made up of many lobules, congeries of mucous follicles, with intervening sulci lined by involutions of the common mucous membrane. Inflammation, simple or acute, and chronic or morbid, is the disease of these bodies. With the first are associated the various features of vascular perversion, passing from the most transient of congestions to the most threatening of abscesses.

Simple tonsillitis—angina tonsillaris—amygdalitis—is an inflammation of the substance of the gland. Looking into the mouth, the bodies, one or both, are discovered unduly colored and swollen. If the inflammation be of any severity as to grade, the patient experiences pain and difficulty in swallowing, together with a sense of dryness, heat, and fever in the mouth and pharynx; and these discomforts, influenced by the character of the attack, may progress until it becomes impossible to swallow, and in many cases exceedingly difficult to breathe.

As a gargle, found useful in such cases,—or rather as an application to hold in contact with the parts, for the act of gargling may be impossible,—the following will be employed with satisfaction:

R.—Plumbi acetatis, ℥j;  
Tincturæ opii, ℥j;  
Aquæ, Ojss. M.

A second medicament, highly esteemed by many, consists in a combination of tannin and glycerine, the application being made to the parts with a brush.

In the cases in which congestion is associated with passivity, resolution is found oftentimes quickly effected by a gargle compounded as follows:

R.—Sodæ biboratis, ℥iij;  
Potassii chloratis, ℥j;  
Tincturæ capsici, ℥ij;  
Tincturæ myrrhæ, ℥j;  
Aquæ, ℥viij. M.

\* It is a singular fact that depression of the tongue is commonly most easily secured by simply laying the depressor upon it. When force is employed, the organ, in many cases, resists, spasmodically crowding against the roof of the mouth. Directing a patient to inspire exposes the tonsils.



Another practice, which the author has found happily applicable to these latter conditions, consists in first brushing the parts with a solution of nitrate of silver, four grains to the ounce of water, and afterward using a compound iodine and carbolic acid gargle.

R.—Tincturæ iodinii compositæ, gtt. xl;  
Acidi carbolicæ fluidi, gtt. vj;  
Glycerinæ, ℥j;  
Aquæ, ℥vij. M.

An application for the treatment of acute tonsillitis, recommended by I. H. Peabody, M.D., as a specific is as follows: Take of oil of turpentine ℥ij, of pulverized chlorate potash a like quantity, of white sugar and gum arabic ℥ss each, of water ℥v. These are to be mixed, and being well shaken and united, the patient is to slowly swallow a teaspoonful each hour or two until relieved. The writer's experience has not been satisfactory with it.

Phénol sodique diluted with water, in proportion of a tablespoonful of the former to a gobletful of the latter, affords a grateful gargle in acute tonsillitis. In very many cases the use of this combination is all-sufficient to a cure. In ulcerative conditions its employment is to be advised.

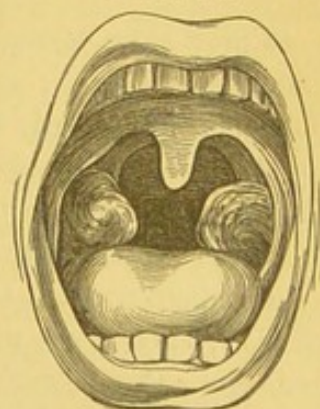
Tincture of belladonna has lately received much commendation as a remedy in acute tonsillitis,—being administered in from two- to fifteen-drop doses, repeated every two hours until the patient is relieved, or until contraindicated, either as dryness in the throat is induced, or as the pupils exhibit enlargement. Local applications are also highly endorsed, the medicine, it being affirmed, having the same action whether applied directly or given internally,—that is, diminishing the calibre of capillaries by its action on the vasomotor system of nerves. Still another means, one described as specific, consists in the use of aconite tincture; five drops first to be administered, to adult, to be succeeded by two drops each two or three hours, if found necessary.\*

Sympathetic inflammation of the tonsil glands is not infrequent. Among the most common of such relations, and where a treatment must of necessity consider the influencing lesion, are croup, scarlet fever, measles, diphtheria, typhoid fever, and syphilis.

Glancing at the diagram, Fig. 379, which exhibits the glands in a state of partial engorgement, it is plainly seen that the isthmus, the oro-pharyngeal space, would be closed in proportion to an enlargement: hence difficulty experienced in deglutition and respiration. Tonsillitis ends in either resolution or suppuration.

When the inflammation is met with in its incipiency, attempts are at

FIG. 379.



The Tonsil Glands.

\* The tincture of the leaves is one-half the strength of the tincture of the root; the medicine is to be used with caution.—See Dispensatory.



once made to resolve it by use of antiphlogistic remedies. Free scarification has occasionally been resorted to with the best results. Dry cups to the neck are invaluable; used in time these will abort almost every attack.\* Leeches applied externally between the angle of the jaw and the sterno-cleido-mastoid muscle,—to be used only, however, with the vigorous and plethoric, and blisters, directed to the nape of the neck, will be found of the greatest service. Hot footbaths, continued until the veins of the legs are engorged, or until diaphoresis results, or the patient grows faint, constitute a satisfactory and reliable means of relief. If the inflammation have advanced to a point where the system at large sympathizes, as exhibited by the presence of fever, hope is still to be entertained of recovery by resolution. In these cases it is found good practice to place the patient over a basin of steaming water, and, with the form enveloped up to the very mouth in blankets, secure diaphoresis by a plentiful exhibition of the spiritus Mindereri,—a tablespoonful every ten minutes until free perspiration is produced. This performance, if the patient be robust, may be succeeded by a saline cathartic. As a local treatment, much satisfaction is to be derived from lemonade, made by crushing ice in a towel or napkin; the small particles thus acidulated are to be taken little by little into the mouth, and allowed gradually to dissolve. Another application is found in a gargle of flaxseed tea, in which chlorate of potash has been dissolved. Tartar emetic, or the tincture of veratrum viride, administered internally, is of much use in controlling the circulation. A very useful combination, where vascular disturbance runs high and the system is irritable, is as follows :

R.—Liquoris potassii citratis, ℥iij;  
 Spiritus ætheris nitrosi, ℥ss;  
 Tincturæ veratri viridis, gtt. xxv;  
 Antimonii et potassii tartratis, gr. ss. M.

Sig.—From ℥j to ℥ss, according to age and requirements.

In most cases of tonsillitis where inflammation is excessive, the uvula is found participating; swelling of this organ occurring, through serous effusions, not infrequently to such extent as to threaten suffocation, the bulbous tip of the organ dropping into the chink of the glottis. In these cases it may be proper first to try an application of the tincture of iodine; but should this fail,—which, in the experience of the author, will be found most likely,—immediate resort is to be had to section of the mucous sac holding the effusion; such a cut will quickly cause the swelling to disappear through drainage. Circumstances sometimes arise where an opening into the larynx or the trachea affords the only chance to a patient for his life. (See *Uvula and its diseases.*)

\* Dry cupping is conveniently done by using a small wine-glass; applying this by means of a lighted wisp of paper, which paper has been touched to alcohol. The wisp lying in the bottom of the glass is fired by a match, and while blazing the rim of the vessel is quickly put to the skin.



Where, in defiance of all treatment, a tonsillitis, whatever its signification, determines toward suppuration, the best that can be done is to hasten the process as rapidly as possible, providing always, that the attendant swelling be not formidably extensive. The latter condition supervening nothing better is to be done than make incisions. Where the swelling is not extensive or threatening, a gargle of flaxseed tea will be found soothing to the parts and encouraging to the formation of pus, and may be used with all freedom.

Where pus has formed in a gland, it is a proper practice to void it with the knife as soon as recognized. This is to be done with most safety by using an ordinary tenotome.

In inflammation of the tonsil glands occurring in the weak and depressed, the abstraction of blood is seldom, if ever, advisable; too much care cannot be exercised in this direction.

Acute tonsillitis is accompanied by increase of temperature, the change being not infrequently as much as six degrees Fahrenheit. The tongue is coated, the bowels constipated, occasionally there is delirium, often much wandering of thought, the urine is diminished in quantity and is of increased specific gravity, the chlorides are deficient.

In a true appreciation of inflammatory disturbance of the region studied, it requires not to be overlooked that the arches themselves—namely, the palato-glossal and palato-pharyngeal folds—may be the seats of lesion; swellings occasionally occurring as the result of submucous effusion to an extent that throws these parts as an envelope over the gland. Remembrance not being borne of this fact, much confusion would exist when such condition is met with. Diagnosis is secured, first, by recognition of the smooth mucous face of the swelling; second, through means of a probe exposing the line of separation between the folds.

Another expression relates to inflammation associated with a number of glandular bodies situated between the tonsils and base of the tongue,—infratonsillar glands, as it has been proposed to call them. While not very subject to perversion, the writer has yet met with them in an inflamed state where great discomfort was produced in deglutition. Treatment is the same as for common tonsillitis.

An infrequent, yet not sufficiently uncommon disease of the tonsil to deny it mention, is known as herpes. This is a vesicular affection very familiar to the dermatologist, as it shows itself upon the skin surface of the body. Herpes makes its appearance in the form of little vesicles studding the surface of the gland, the body being of a scarlet-red color, and swelled to an extent that throws it well out into the oro-pharyngeal space. Maceration of the epithelium quickly converts the vesicles into open abrasions, which, in turn, cover themselves with an exudate that gives to them the expression of aphthæ. Characteristic symptoms are burning sensations in the throat, combined with sharp pain darting towards the ear. Care is to be taken that the condition considered be not confused with diphtheria. The treatment of herpes relates

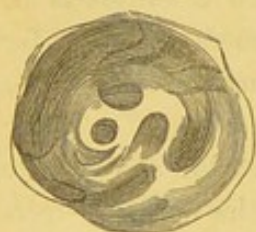

with the use of gentle laxatives, together with the employment of gargles, as directed in follicular pharyngitis. If febrile expression be marked, strong lemonade is found of service. Where the regions of the spinal column, the breast, and the abdomen are found with elevated temperature, the parts are to be laved with alcohol until cool. No specific treatment is demanded.

**Hypertrophy.**—Hypertrophy, or chronic enlargement, of the tonsils, is a condition most common to scrofulous children, and pertains, consequently, to early life, being, indeed, rare after puberty and never perhaps seen in old age: of the multitude of patients operated upon for the relief of this affection, few have been over thirteen years of age. The enlarged or hypertrophied tonsil differs very much in consistence and character in different cases, being in one patient indurated and smooth, in another spongy and lobulated. In color equal variety is presented, varying in appearance from the scarlet of an arterial injection to the dull blue of a passive venous stagnation. One of the inconveniences associated with enlarged tonsils is the effort required in respiration, particularly during sleep. Another is interference with hearing, pressure upon the Eustachian tube frequently occluding that passage, particularly when the patient takes cold. Speech is interfered with: to sing softly and finely with the tonsils enlarged is impossible.

Tonsillar hypertrophy being a systemic expression rather than a strictly local disease, very little true benefit has been derived from the employment

FIG. 380.



Hypertrophied Tonsil.

of the great variety of direct remedies which from time to time are recommended. A patient so afflicted is to be treated from the constitutional stand-point; and to this end nothing is found more conducive to good than cold salt-water bathing: indeed, as a rule, more attention will be found required in the direction of diet, clothing, exercise, and general mode of life than to the administration of medicine. Where, however, medication seems demanded, it is to be directed

to the correction of any observable constitutional defect or irregularity. Iodine and its preparations are not always, by any means, indicated; and not infrequently their exhibition, by a further debasement of the vital powers, does more harm than good. It does not seem possible to lay down rules that shall apply to the constitutional treatment of such cases, except so far as to suggest attention to all the functions, and to the general tonic medication mostly, if not always, demanded.

Among remedies professed to be possessed of specific signification, used for enlarged tonsils, sulphate of potassa holds the most prominent position. This preparation, given in doses of from five to fifteen grains, continued for a month or six weeks, will, without doubt, in some cases, cause the hypertrophy to disappear. It is usual to combine with it rhubarb and some of the aromatics, sufficient to insure laxity of the bowels.



Where enlargement of the tonsils associates with the rheumatic or gouty diathesis, colchicum is to be prescribed: to be taken internally, and applied externally as an alterative in combination with the linimentum saponis. The use of colchicum in such direction was originally introduced into English practice by a Mr. Harvey, he being led to his conclusions by observing the relationship of the contents of the tonsillar follicles with the concretions found in the joints of the rheumatic and gouty.\*

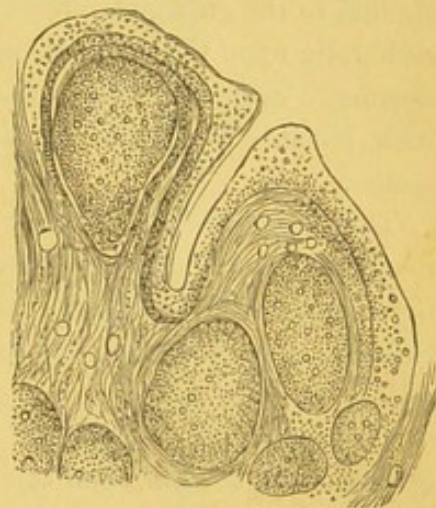
Another remedy, having the commendation which associates with frequent successful response, and particularly applicable where the condition is coincident with scarlatina, is found in the acetate of zinc: it is prescribed from  $\mathfrak{D}\mathfrak{j}$  to  $\mathfrak{3}\mathfrak{j}$  in from  $\mathfrak{3}\mathfrak{v}\mathfrak{j}$  to  $\mathfrak{3}\mathfrak{v}\mathfrak{i}\mathfrak{i}\mathfrak{j}$  of water and glycerine, given in tablespoonful doses every four hours, or in the acute, severe cases, oftener. It is well to retain it for a moment in contact with the tonsils before swallowing.

The local treatment of hypertrophied tonsil glands resolves itself into the threefold direction of the use of alteratives, destruction by cauterization, and amputation. Of the first of these means the iodide of zinc holds, perhaps, the most prominent position. It is used in solution of from ten to thirty grains, being applied with a brush two or three times in the twenty-four hours; or, as the treatment advances, it may be applied pure, that is, as it deliquesces when exposed to the atmosphere.

Pressure by the finger, frequently repeated, punctures with the point of a bistoury, gargles of capsicum,—means of such character may be tried, as judgment shall make preference for one or the other. It is to be regretted, however, that the promise by such mode of treatment is not the most satisfactory; and it is always to be borne in mind that if such agents are found to do good even by controlling the enlargement, it may be prudent to rest satisfied, as advancing age will generally be found to afford correction of the trouble.

The second mode of treatment—that by cauterant destruction—may be said to have been made practical by A. Ruppaner, M.D., of New York. A practice introduced by that gentleman, and whose successes have been verified in a large number of cases by the author in his own practice, consists in the use of the London paste recommended by Dr. Morrell Mackenzie.

FIG. 381.



Hypertrophied Tonsil laid open.

\* Foul breath, so frequently associated with the soft variety of tonsillar hypertrophy, arises from the degeneration of the sebaceous secretion retained within the crypts, and from the inspissated mucus enveloping the glands. The phenate of soda, chlorine-water, or a solution of the permanganate of potash, either of these being combined with diluted tincture of capsicum, will be found satisfactory for the purpose of temporary relief.



The following are the directions given for the preparation and use of this paste:

A quantity of equal parts of finely-pulverized and well-mixed *caustic soda* and *unslacked lime* is kept on hand. When an application is to be made to the tonsils, a little of the powder is put into a small porcelain cup; a few drops of absolute alcohol, which is kept near at hand, are added; the two are carefully mixed with a glass rod, when the paste is ready for use. Care must, however, be taken that it be of the proper consistency. If too thin, it is apt to find its way to parts which ought not to be touched; if too thick or lumpy, the paste will not readily stick, and little pieces might be swallowed. To apply the paste, a glass rod of sufficient length may be used. One end of it, which must be smooth and slightly funnel-shaped, is dipped into the paste, and a greater or lesser portion of the surface touched, as occasion may require.

To apply the paste, the patient is to be placed in the position for laryngoscopy. The tongue is then to be depressed with the spatula, and the paste applied to the enlarged surface for two or three seconds. The action of the escharotic upon the tonsil is rapid. The mucous membrane almost instantly assumes a deep flesh color, and presently a dark, blackish spot is seen streaked with blood. The following day the tonsil is covered with a whitish-yellow eschar.

The inconsiderable amount of suffering produced by this cauterant is noticeable. Children pay scarcely any attention to the pain, or make light of it. At the longest, the discomfort lasts only two or three minutes. Subsequent applications are accompanied with less, if any discomfort at all.

The operation is repeated each six days. The number of touchings required will depend upon the nature of the case.

Our author reports one hundred and twenty-three cases treated in this manner: the minimum number of applications of the paste, in any case, was six; the maximum, fourteen.

The good results obtained from the use of this paste are not exaggerated by Dr. Ruppaner. Still, the experience of the author makes him unwilling to agree that such mode of cure is to dispense entirely with the use of the knife. Over-commendation, however, is not to be given the process, it is above praise. It will disappoint nobody who properly practises the manipulation. In place of the glass rod the author employs the cup of an ordinary director. The practitioner, experienced or inexperienced in the use of the knife, may put full confidence in the London paste.

It is not out of place, perhaps, to refer to the possibilities of this London paste. Applied to a seed wart, the body drops away almost instantly. It is so little provocative of vascular response that the writer has made frequent use of it in the treatment of endometritic vegetations, using it freely over the whole inner face of the womb. Sloughs of the uterine os are quickly

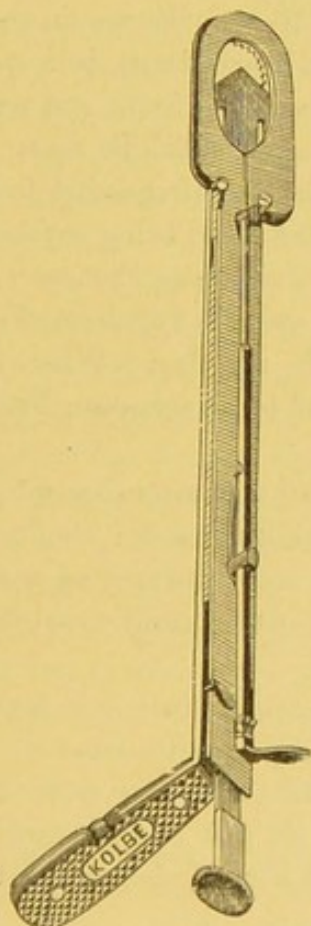


and safely made with it. In the treatment of chancres, familiarity with its virtues will quickly accord it the first place.\*

Dr. Rumbold, of St. Louis, Missouri (*Medical Archives*), claims to have treated successfully a number of cases of enlarged tonsils by means of hypodermic injections, using an iodine combination (R.—Iodinii, gr. ij; potassii iodidi, ℥ij; aquæ, ℥j). A slight inflammation—one, however, which soon subsides—is reported as following the injection. From twelve to seventeen applications—ordinarily two a week—were found sufficient to reduce the gland to its normal condition. An advantage claimed for this mode of treatment is that it saves the substance and function of the gland.

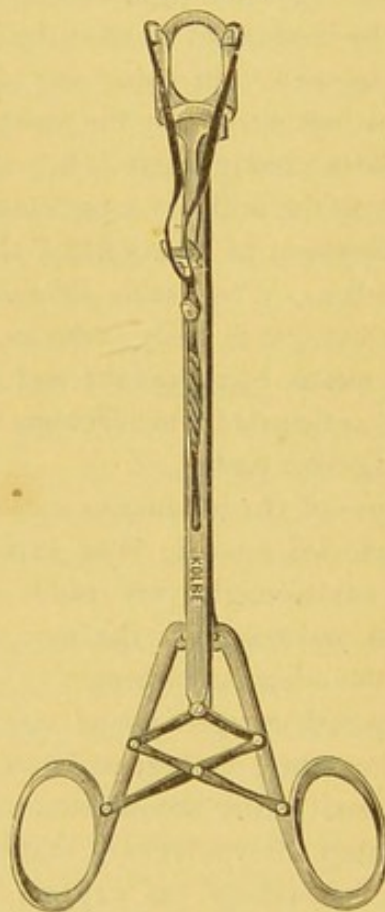
Amputation of an enlarged tonsil is to be effected either with a bistoury or the tonsillotome, the latter instrument being that which most recommends itself. Figs. 382, 383 exhibit forms of such instrument. The principle of

FIG. 382.



Tonsillotome—Physick.

FIG. 383.



Kolbe's Tonsillotome.

a tonsillotome is that of the guillotine. Of these instruments there are a variety, a single mode of operation being common, however, to all of them. The construction embraces, first, a fenestra, to encircle the gland; second, a slide-

\* In a conversation held by the author with Dr. Morrell Mackenzie, he learned with surprise of the substitution by that gentleman of the galvano-cauterant for the London paste.



pin, to catch and hold the organ ; and, third, a triangular blade, for the excision. Of these instruments, some cut by having the knife drawn forward ; this is the manner of that known as the Fahnstock blade. Others, as the Physick, have the motion forward. An improvement lately made on the Physick instrument, by Mr. Kolbe, consists in an addition of automatic fingers and ringed lever-handles. To use this instrument it is only necessary to carry the fenestra over the gland, when, by the simple closure of the handles, the fingers grasp and pull the gland under the blade, which, in a synchronous movement, cuts it off. Another valuable instrument in this direction is known as the Billings tonsillotome. Mr. Kolbe gives this device preference over his own, pronouncing it indisputably the very best of the class.

To apply the tonsillotome to the gland of the right side, the surgeon finds his greatest convenience in leaning over the thrown-back head of the patient. In using it for the left side, there is no better manner than to rest in front of the patient upon the right knee, thus placing the fenestra with facility, and, if the Kolbe instrument be used, holding it, while the handles are manipulated by an assistant. In using any of the slide-pin instruments, both pin and blade are best worked by the assistant, the surgeon both fixing and retaining the fenestra exactly where it is desired that the section shall be made.

In using the ordinary tonsillotome, occasion is not infrequently found for the employment of means which shall allow of the gland being enveloped by the fenestra. When such difficulty is met, it complicates the operation to some extent, yet is easily overcome through the use of a vulsellum, the gland by this means being caught and dragged within the ring. Where hemorrhage is anticipated, a tonsillotome is well replaced by an *écraseur* ; better still by the London paste.

The use of the bistoury as a means for amputation of a tonsil gland is only to be indorsed when in most experienced and skilful hands ; results of the gravest nature might very readily arise through some unexpected and unanticipated movement on the part of a patient,—risk entirely avoided in the use of the other instrument.

In operations upon young children with the tonsillotome, it is found best to employ ether, restlessness interfering with the proper introduction of the instrument. After the excision of one tonsil the child is to have its head immediately thrown forward, that the blood may not pass into the throat. As soon as hemorrhage has stopped, the anæsthetic is to be readministered, and the section repeated upon the opposite side.

Questions, however, will arise as to the advisability of the double operation at the same sitting,—questions of shock, of hemorrhage, of inflammatory sequelæ, of idiosyncrasy. The experience of the author favors decidedly two operations, the first to be in every respect recovered from before the second is attempted,—not, however, that it is meant to imply that such care and caution are always necessary, or that indeed the single operation is his own constant practice : it is suggested as that attended with least risk.



Many surgeons, immediately after this operation, and in many instances before it, administer, in anticipation of inflammatory trouble, a full dose of sulphate of magnesia. It is also thought well by many to protect the incised parts against the irritating influence of atmospheric changes by a confinement of several days in an even temperature. It may be accepted, however, that if the weather be moderately mild, it will be found sufficient to keep the parts lubricated by a coating of gum acacia, or of marsh-mallow confection, secured by simply holding the agent in the mouth until it dissolves.

Hemorrhage of marked character, after the operation, is not common; instances occur, however, where the tonsillar artery has to be compressed, twisted, or tied; but, as a rule, there is no trouble from this source which a simple gargle of alum-water is not quite sufficient to overcome.

Of other surgical conditions associated with the amygdalæ, ulceration is, without doubt, the most common. Of the non-specific ulcers, all will be recognized to have the expression as described under the head of "the Aphthæ" (which see). Specific ulcers are of two kinds, the venereal and the cancerous. A diagnosis of the former is readily to be made from the expressions found associated in other parts of the mouth.\* The cancerous ulcer, being of the epithelial variety, is to be recognized in the papilliform character of the granulation, with which its surface is always found studded. The treatment of the first is to be that directed to the cure of the influencing disease. (See *Ulcers*.) That of the second may only be founded on the most careful weighing of the circumstances of each case. Should such disease be recognized in its true character, when very circumscribed and non-infiltrated, it is justifiable to extirpate the gland. If not appreciated until the neighboring mucous membrane manifests its sympathy, an operation would be worse than useless. It has happened to the author to be consulted in several cases of epithelioma of the tonsil glands, but he has not seen one which warranted operation.

Complete extirpation of the gland, when indicated for a cancerous manifestation, is best practised by a procedure directed from the external parts. An operation so performed is recorded by Dr. Cheever, of Boston. In this case

---

\* "The syphilitic affections of the tonsils are difficult to diagnose, since even in relative good health considerable swelling, fissuring, partial loss, excoriations, follicular abscesses, and cicatrices may frequently affect these organs and yet remain unnoticed. The crypts of the tonsils sometimes form extensive fistulous passages, thus constituting a persistent cause of altered secretion and of increased sensibility. If the hypertrophied tonsils are not removed, the surgeon should at least slit up these fistulous canals or cauterize them to a sufficient depth. Of the ordinary caustics, Professor Sigmund prefers to nitrate of silver or bichloride of mercury the Vienna paste, immediately after the application of which the cauterized spot is to be washed with vinegar and water. Concentrated tincture of iodine may also be applied to ulcers with good results. Tannin is used principally as a wash after the use of caustics, or as a retaining agent after brushing over the parts with tincture of iodine. All these applications, however, may be spared if the surgeon at once removes the hypertrophied tonsils, the most certain means of alleviating and cutting short the course of syphilis in these organs."—*Schmidt's Jahrbücher*.



two incisions were made: one commencing within the angle of the jaw, and directed downward on a line parallel with the sterno-cleido-mastoideus; the second forward, along the base of the jaw. The dissection in this case revealed, first, an enlarged lymphatic gland, which was removed: second, the digastric, stylo-hyoid, and stylo-glossus muscles, these being cut and pushed aside; and, third, the superior pharyngeal constrictor, the fibres of which were disparted, thus allowing the finger to reach and retract the gland. Twelve ligatures controlled the hemorrhage of the operation, and the patient is reported as having recovered completely in a month. Extirpation of the gland from within the mouth has been successfully accomplished by both European and American surgeons. In a gland well solidified by the scirrhous expression, and possessed of a well-defined base, a catgut or wire *écraseur* might be used with satisfaction.

**Cystic Disease.**—The formation of a cyst or cysts within the gland is of rare occurrence. In his own immediate practice the author has as yet never seen a case. Virchow, in his volume on tumors, mentions them, however, as being of not infrequent occurrence. The treatment demanded is of such simple nature as applies to abscess or ranula. Should a cyst prove of malignant character, little harm results from mistaking it for, and treating it as, one of simple form: it will prove necessarily fatal. The diagnosis of a cystic tonsil is to be made by touch.

**Abscess.**—Abscess of strumous signification is frequently met with in the tonsil glands. These abscesses belong to the cold or chronic variety, being oftentimes two or three months in maturing, seldom attended with pain, and imparting to the overlying structure a dull white appearance, very characteristic. Such abscesses are to be treated from a constitutional as well as from a local stand-point. As a gargle, to be used several times a day, no medicament seems to equal the compound tincture of capsicum; ℥ij to ℥viii of water being employed.\* Internally, cod-liver oil, combined with a chalybeate, is found of the greatest service, and may be prescribed with great freedom.

An anomalous case of tonsillar abscess having the following history was treated and cured by the author some few years back. The patient, a young married woman, was troubled by a swelling that made its appearance on the side of her neck just below the ear. After some three months, the enlargement extending down her neck, an abscess formed and discharged itself just above the clavicle. This abscess was under treatment by her medical adviser over two years, injections of different kinds being used daily. Examination for diagnosis was commenced by the use of a long and very soft silver probe, which, after repeated attempts to trace the track of the fistula, was finally brought in contact with a tonsil gland. Cure was immediate on the removal of the body, this being effected by an *écraseur*-like operation. No hemorrhage of consequence attended the ablation.

---

\* Tinctura capsici et myrrhæ.



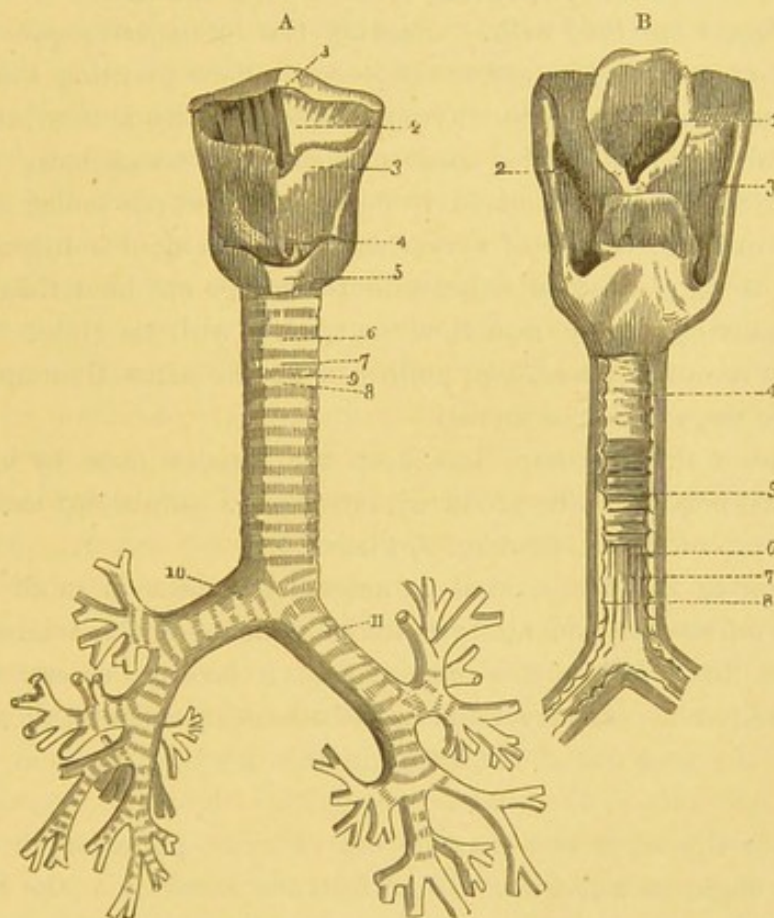
Scrofulous abscess related with the body of a tonsil gland commonly approaches the surface in the shape of a yellowish bulb; if not breaking readily the pus is to be voided by employment of a tenotome or a guarded bistoury.

As a gargle to be used for correction of offensiveness attending tonsillar abscess phénol sodique, much diluted, may be used.

**Laryngotomy.**—Occasions are found to offer, where, in acute tonsillar disease, as in other throat affections, the surgeon, called in an emergency, is compelled quickly to decide on means which involve life. For such emergencies a judicious practitioner fully prepares himself.

When convinced that a patient is not otherwise to be relieved, suffocation being imminent, the surgeon may, without hesitation, thrust a bistoury or

FIG. 384.—VIEW OF THE AIR-TUBES.



A. Larynx, trachea, and bronchial tubes, viewed in front. 1, hyoid bone; 2, thyro-hyoid membrane; 3, thyroid cartilage; 4, crico-thyroid membrane; 5, cricoid cartilage; 6, trachea; 7, 8, two cartilaginous rings; 9, membrane which separates them; 10, right bronchus and its divisions; 11, left bronchus.

B. Larynx, trachea, and commencement of bronchial tubes, viewed from behind. 1, upper opening of larynx; 2, 3, lateral grooves of larynx; 4, fibrous membrane of trachea, interspersed with small glands, beneath which are seen, 5, muscular fibres; beneath this last are, 6, 7, small fibrous bands; 8, mucous membrane seen between them.

scalpel directly through the crico-thyroid membrane. This operation, if no middle thyroid artery run over the part, is one of simple character; and if the membrane be separated after the puncture and kept so, either by the



introduction of a tube, or by hooks of wire, which pass around the neck, the patient will experience the greatest relief. When the artery crosses the membrane, and has been cut, blood is to be prevented from entering the lungs by leaning the person forward, the face downward; the vessel is then to be secured in the most convenient manner, with ligature if possible.

**Tracheotomy.**—Tracheotomy, an operation often found compulsory in such connection, while seemingly complex, is yet not difficult of accomplishment: at least the author has found himself able to perform it upon the living subject without assistance. Having the patient upon his back, with the neck extended, an incision is made directly in the middle line: this incision may be quite short, and is to be commenced immediately below the cricoid cartilage. Dividing skin, superficial fascia, and the delicate layer of the deep fascia, the muscles running from the sternum to the os hyoides and thyroid cartilage are met with. Seeking the interspace separating these, they are thrust and held to either side,—easily done by using the handle of the knife and retractors. The thyroid plexus of veins is now brought into view, and this is to be carried aside or ligated, as seems most convenient. The isthmus of the thyroid gland if found in the way is pulled upward, or, if necessity exist by reason of a very short neck, a double ligature may be passed, and being secured on either side, the bridge can be divided between. These manipulations bring into view the trachea with its rings. Steadying the tube by use of a tenaculum, pulling it at the same time upward, one, two, or three rings are to be incised.

The operation thus accomplished, keep the incision open by use of wire loops, or, what is much to be preferred, introduce a canula and maintain it in place by a strap of tape. (Subfig. 6, Plate I.)

In performing the operation, it is necessary to bear in mind that occasionally the inferior thyroid artery is found lying upon the trachea, directly in its middle line. When this vessel is seen, it becomes necessary to throw a ligature around it. Observations in the dissecting-room would lead to the inference of the presence of the artery in this position in about one out of six cases.

A superior thyroid artery may be out of exact place, or an anomalous distribution might be met with. In an instance occurring at the Hospital of Oral Surgery, much anxiety was induced by reason of hemorrhage arising out of an anomalous position supposed to be related with the vessel just named. The patient in this case was a man seventy years of age, where an operation was made necessary by a rapidly-growing tumor enveloping the larynx.

A complication occasionally met with in tracheotomy exists in the intrusion of a prominent thymus gland. In one particular operation done by the writer on the person of a child that body swelled with such prominence into the wound as to convey a momentary impression that the tissue to be dealt with was the lung. After some manipulation the gland was gotten rid of by



being crowded beneath the manubrium of the sternum. In the subsequent treatment of the case it gave no trouble.

With a view to convenient reference Plate I. is inserted. The anatomy of the parts involved, together with the several features of a tracheal operation, are so perfectly displayed as to render the hints afforded invaluable. Regarding the tube, seen in place, with its retaining tape bands (Fig. 6), it requires to be remarked, that, as furnished by the manufacturer, this is a double canula, the object of the inner tube being to permit of easy cleansing. The author being possessed of considerable experience in the direction of these operations, advances it as his opinion that this inner tube is seldom a convenience but often an obstruction. By reason of occupying a space within the outer tube it will readily be recognized as interfering to an extent with free breathing. By reason of this same interference it invites the clogging it is intended to correct. In removing it, in cases where secretions are tenacious, the first tube is occasionally withdrawn; a matter, this last, of little consequence in the later treatment of a case, but demoralizing to a patient when occurring immediately after an operation. To remove the secretions a mechanical plan suggested originally to the author by Dr. Cohen will not soon be superseded; this consists in the use of a common wire brush such as is employed by smokers to clean their pipes; thrusting this into the canula a single turn catches among the bristles the sticky glutinous mass, bringing it cleanly away. These little brushes, made on the end of a long strand of wire, are to be bought in tobacco stores. The brush applies only when the secretions are fresh.

A canula is to correspond in diameter with the trachea into which it is to be introduced: a common length is one and one-half inches. The windpipe opened, a tube is most conveniently introduced by means of a rubber bougie, the point of this leading the way, the tube following on the principle of a trocar and canula. The tube in the trachea, the bougie is quickly to be withdrawn, it being recognized that while in, the patient is unable to breathe.

A point of practical importance in operations of this kind pertains to absolute exposure of the trachea before incision. Covering the tube is a sheath of cellular tissue; if this sheath be simply incised, without being scraped fully and completely away from the circumference of the canula, a result sure to follow is, emphysema. From neglect of so simply an accomplished matter the earlier experiences of the writer confounded him more than once with windy expansions puffing out the integuments of the whole breast region.

A source of inexpressible comfort to a patient who has undergone the operation of tracheotomy, is found in relieving the bronchial dryness, and irritability arising out of the new manner of respiration, by means of frequent atomizing of water or other grateful fluids. The practice is deemed a necessity by the writer to the successful carrying through of his cases. To this end a steam atomizer is to be kept quite continuously at work, the



vapor being directed to the neighborhood of the patient, care being taken not to wet him. In the absence of the steam apparatus an ordinary cologne sprayer is made to take its place. Fluids found grateful are tincture of hamamelis, tar-water and glycerine, phénol sodique much diluted, and very weak chlorine-water. Steam applied by the spout of a kettle of boiling water affords great relief to a patient; the application at first to be repeated every hour or two. Close attention is to be paid to clogging of the tube, sure to occur where not combated by moisture. The writer has been hurriedly called from his bed at midnight to find a patient running frantically about a room gasping for breath, examination revealing a tube so clogged with tenacious mucus as to almost entirely obliterate its calibre. Such a case is relieved by supporting the canula in place by means of a finger placed against either wing, in using steam freely, and in picking away the glutinous mass by means of an ordinary hoe-form dental excavator. A tube, after having been in place two or three weeks, is to be taken out and replaced without difficulty or risk. Here it is cleaned without trouble.



Fig 1.

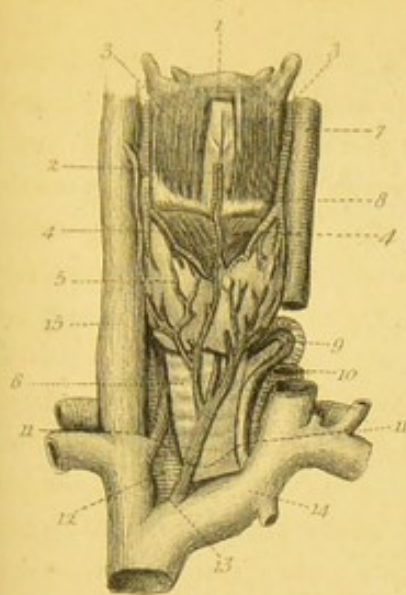


Fig 3.

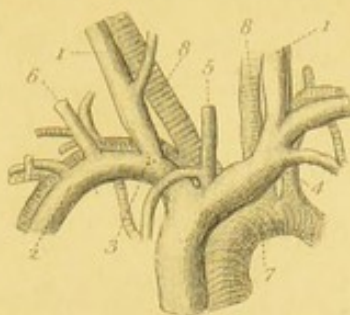


Fig 2.

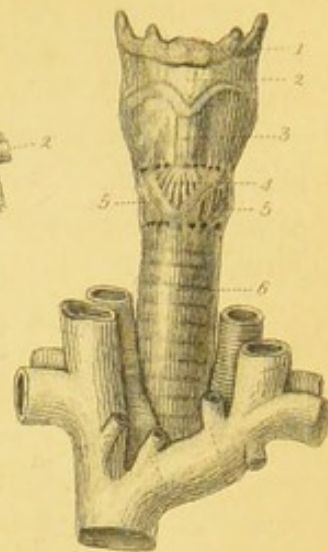


Fig 4.

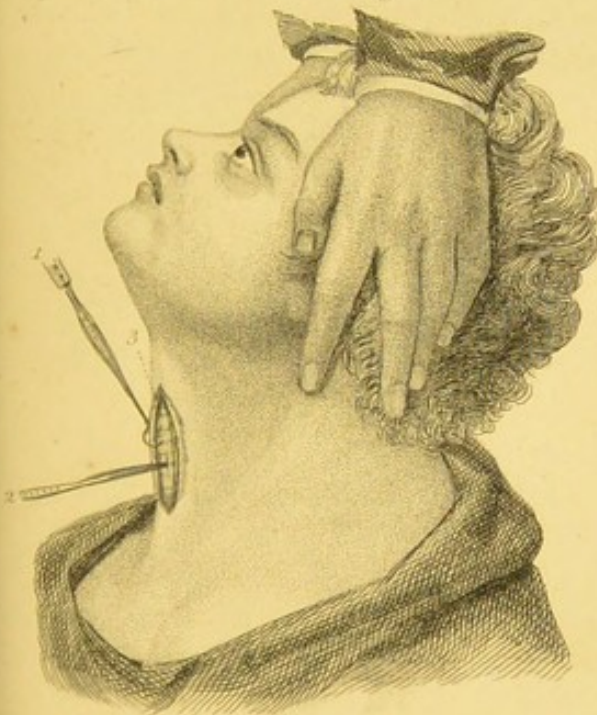

Fig 5.

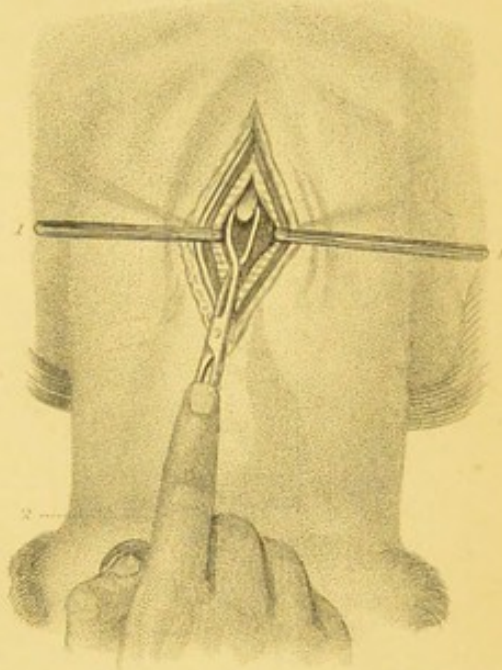


Fig 7.

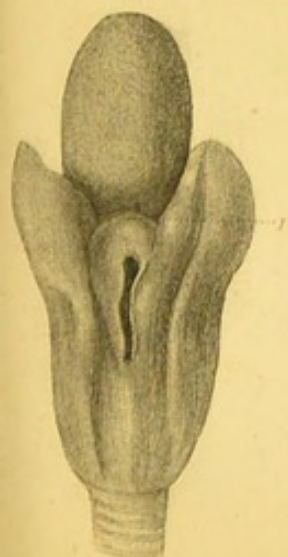

Fig 6.

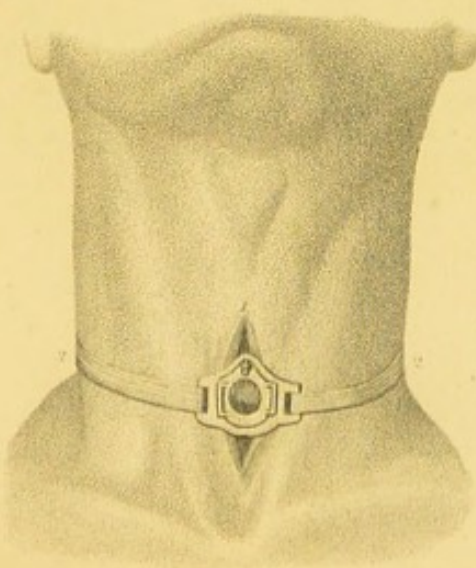
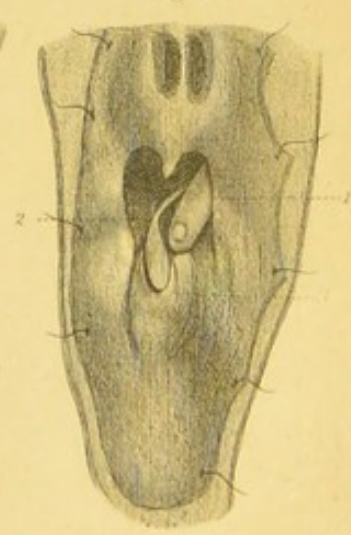



Fig 8.









## CHAPTER XXXVI.

### THE TONGUE AND ITS DISEASES.

EXPRESSIONS of the tongue indicative of systemic conditions are not to be confounded with lesions of the organ itself.

Of medical diseases the part has long been esteemed a reliable sentinel. As an index, pointing, through sympathy, to a wide range of morbid affections, physicians have learned through experience to confide in it as among the most useful of guides.

Changes in the tongue, associated with systemic derangement, relate to size, form, color, temperature, moisture, taste, motion, and coating.

Increase in bulk, recognized, while very moderate, by lateral indentation made by pressure upon the teeth, affords not infrequently the first sign of salivation. Pointing, or elongation, is expressive of irritation in the alimentary canal and of determination of blood to that region. A shrunken tongue is met with where atony exists in the digestive organs. Color varies from white to livid: whiteness indicates anæmia; floridity implies, either inflammation of the stomach, or an unduly arterialized state of the blood: redness relates with vascular excitement, particularly as associated with the alimentary canal; lividity signifies prostration. Temperature is influenced by that of the body at large; heat denotes fever; coldness implies diminution in vital force. Moisture, or its absence, is highly significant; a moist tongue in sickness is a good sign; dryness implies congestion or otherwise that force is failing. Taste, or its absence, depends on derangement of the tongue's surface; the cause is commonly found in a coating covering the surface of the organ. Motion affords important indications; inability to control the part implies prostration or cerebral complications; loss of motion on one side points to hemiplegia. Coating is a principal element in tongue diagnosis: a furred condition signifies fever; allied with disease this fur distinguishes itself from that habitual to certain persons by resistance to local means employed for its removal; a white, uniform fur, accompanied with moisture, indicates an open active febrile condition without complications; short and tenacious, showing through the coating a florid base, a typhoid condition is indicated; yellowish fur implies bilious disorder; a brown or black coating implies blood-poisoning, and as well diminution of vitality.

**Illustrations.**—*Diabetes Mellitus*: Tongue dry, generally red, abnormally clean and fissured; sometimes covered with a whitish and dry coat; sometimes streaks of fur appear in a longitudinal direction along the dorsum;



sometimes covered with rough papillæ; sometimes sticky to the touch. *Abscess of Liver*: Tongue covers itself with a coat grayish yellow in color. *Congestion of Spleen*: Tongue sometimes as if transparent; is pale, commonly thinly coated with a whitish fur. *Diarrhœa*: Tongue dry and stiff. *Atonic Dyspepsia*: Tongue flabby, broad, pale, and enlarged. *Enteric Fever*: Tongue rough, fissured, and dry, indicating ulceration of the Peyer glands. *Malarial Poisoning*: Tongue coated down its middle with a dirty-brown fur thinning towards the tip where the color of the papillæ is to be seen through it; edges flattened, pinkish in color, and traversed by sharp lines conveying an impression of puckering, or corrugation.

The local, or surgical, injuries and diseases of the tongue are many. These lesions are of twofold relation: direct, as reference is had to some immediate cause demanding local attention only; indirect, as constitutional offence is the predisposing or exciting agent requiring to be antagonized.

Local injuries find examples in ulcers caused by jagged and projecting teeth, in cuts and contusions from falls or blows, in bites inflicted by one's self, in insect stings, in burns, scalds, the incautious or accidental mastication of acrid and irritating substances, etc. Local diseases are to be illustrated by reference to hypertrophy, atrophy, erectile, papillary, fatty, and benign cystic tumors, to chancres, to nerve lesions constituting neuralgia, etc.

**Localization of Diseased Action.**—In his admirable monograph "Studies in the Facial Region," Dr. Harrison Allen divides the subject most happily, as it seems to the writer, into four portions: (*a*) diseases confined to or appearing on the mucous or epithelial surface; (*b*) those appearing in the submucous or muscular tissues; (*c*) diseases of the anterior two-thirds of the dorsum, as contrasted with the posterior third; (*d*) diseases as influenced by symmetry.

(*a*) Psoriasis, ichthyosis, keloid, furring, papillary hypertrophy, epithelioma, fissure.

(*b*) Syphilitic gumma, fibrous tumors, tubercular deposits.

(*c*) Ulcers of local expression, bites, stings, burns, fatty tumors, cancer.

(*d*) Hypertrophy, atrophy.

Tongue diseases of systemic relation are venereal manifestations, scrofulous ulcerations, carcinoma. Changes arising from emotional influences are witnessed.

**Local Injuries.**—Local injuries imply a treatment as directed by indications. Where a cause of offence is seen to be present, the first thing is the removal of such cause; this refers to the extraction of irritating teeth and roots of teeth, to the withdrawing of splinters, the removal of masses of calculus, the antagonizing of acrid agents, etc.

Inflammation arising out of falls, blows, the accidental biting of the parts, burns, and scalds are to be treated on common principles. Ordinary hurt done to the tongue is commonly quickly cured by the remedial power of nature. For the relief of trouble arising out of sting by an insect a mould of mud



applied to the part constitutes a specific application. Burns and scalds are wisely left to nature except where the saliva is found unduly acid; correction of this condition resides in the use of lime-water. Cuts are to be sewed with stitches of the interrupted suture; note of the point being made, that such stitches are to be taken deeply. A manner of treating a cut when it is lengthwise consists in slipping around the organ a wide rubber ring. Vincent suggests the use of a roller, which, binding the jaws together, compels the tongue to lie in place within the lower jaw. The experience of the author commends the suture.

The most frequent disease met with about the tongue is syphilis. Syphilitic ulcers, the commonest of the manifestations, successors to the gumma, appear on any part of the organ, but are most frequently met with on the sides and under surface. Such ulcers are almost invariably accompanied by associations pointing to their origin,—psoriasis on the body, nodes, falling of the hair, lymphatic induration of the posterior cervical ganglia, etc. A syphilitic ulcer on the tongue has the appearance of chancre, hard or soft: such are to be met with where the ulceration is quite deep and the edges heavily indurated. Again, where there is neither excavation nor induration, we nevertheless know, from the associations, and from the peculiar characteristic appearance of the surroundings, that an ulcer is venereal.

A second form of syphilitic disease of the tongue is observed in the induration and hypertrophy of circumscribed patches of mucous membrane. The induration in these cases is so markedly localized that, were it not for their varying locations,—being always, however, on the dorsum,—one might readily believe them to be enlarged vallate papillæ; the patches are quite as large as a dime piece, are elevated, and are as isolated as a fungiform wart. The author has seen two such patches on the dorsum of a tongue, and at the same time a large ulcer on its under surface.

Cracks and fissures are other syphilitic indications met with on the tongue. It may happen in some instances that these fissures are so deep as to seem to divide the organ into a number of parts; they always, so far as the author has observed, run lengthwise. These fissures are at times unbearably sore, denying the patient comfort either in eating or at rest.

Indurations of the mucous membrane of the sides of the tongue from this cause are occasionally observed, or it may be that a general thickening exists, or, indeed, that the whole organ is indurated. In this latter condition the disease has sometimes been mistaken for cancer; but such an error could arise only from a failure to observe the associations of the case.\*

---

\* *Syphiloma (Gummata Syphilitica) of the tongue.* Dr. Neumann, of Vienna (*Allgemeine Wiener Medizinische Zeitung*, and *Half-Yearly Abstract*).—The dorsum of the tongue, as is well known, is frequently at its centre or lateral portions, more rarely at the root of the organ, the seat of infiltrations,—the so-called syphilitic gummatous tumors, the size, superficial aspect, and progress of which undergo many variations. These tumors, which are of firm consistency, are seated partly under the mucous membrane, partly in the mus-



Sometimes the dorsum presents red patches, the result, evidently, of a loss of the epithelial covering. These patches show papillæ but are not ulcerated. They are painfully sensitive to hot or cold impressions. The condition is to be met with where the dorsum seems literally skinned. By those familiar with the diagnostic description of the tubercular ulcer as insisted on by M. Tielert, it will be seen that with such a condition his premises become to a marked degree confused. Bald tongue, recognized in the existence of smooth, glossy patches entirely disassociated with fur, is an expression of specific psoriasis.

To Professor Sigmund we are indebted for knowledge of the fact that the raw ulcerations on the sides of the tongue called syphilitic psoriasis are very contagious, a diseased child poisoning a nurse, and a diseased nurse poisoning a child by chewing its food first in her own mouth.

The treatment of syphilis in the tongue has, with one special exception, the twofold signification of constitutional and local,—the exception being that of chancre. It has without doubt occurred that a man has gotten a chancre upon his tongue. Mercury, in some of its various forms, seems to be looked

---

cular tissue of the tongue, and are developed from small infiltrations of the size of a pea to prominent nodules as large as a bean or hazel-nut, or even larger. The growth sometimes extends laterally, so as to form level patches; in cases of this kind a greater part of the tongue, especially its edges, feels thickened, infiltrated, and hard as cartilage. In this affection the mucous membrane covering the growth is either smooth or covered by numerous papillary growths, which occupy a large portion of the tongue in the form of broad-based watery formations, or the surface of the dorsum may be traversed by shallow furrows, or by deep fissures crossing in various directions,—rhagades; or, again, if the mucous membrane be irritated by the sharp edge of a decayed tooth, it may present superficial patches of gangrenous tissue.

The whole volume of the tongue is increased to a considerable extent. Finally, the disease may proceed by softening of the nodules to a more or less extensive and deep loss of substance, in consequence of which the tongue on the affected side presents large cavities, which, when the loss of substance has affected the root of the tongue, exert a considerable influence upon the consonance of the speech. The movements of the tongue, also, as in speaking, masticating, and swallowing, cause much pain. These new formations, consisting partly of granulation-tissue and partly of connective tissue,—which tissue, in its further development, becomes either soft and jelly-like, or is converted into adipose tissue, and forms dry yellow lumps,—were described by Robin and E. Wagner as syphiloma. They present granular cell contents, and their cells and nuclei lie in peculiar hollow spaces—alveolar formation.

In cases of this kind one has to distinguish the infiltration of syphilis from that of cancer. Hardness, rapid growth, painfulness, and an uneven surface, are, indeed, symptoms which speak more for cancer than for syphilis; the existence, however, of a sharply-defined loss of substance, and the presence on the dorsum of the tongue of warty or condylomatous growth, are indicative of gummatous deposit. In cancerous growths of the size of syphilitic gummata, the submaxillary glands would certainly be enlarged. In doubtful cases the diagnosis might be determined by means of the microscope. In some cases the distinction may be indicated by the course taken by the disease. In syphilitic gummata the breaking down of the tumor commences deeply, and proceeds to the surface; in cancer the opposite takes place, loss of substance commences superficially, and gradually extends to the centre of the growth.



upon by most practitioners as having in this direction something specific in its nature; without doubt, however, it is a greatly abused medicine, and should be used with more caution and judgment than generally characterize its exhibition. A chancre is to be burned out,—London paste being employed.

Where ulcers or other manifestations upon a tongue are secondary in signification, and mercury has not been used upon the case, it is marvellous how at times, under its influence, such manifestations can be made to disappear. How this medicine is to be used is perhaps best left to be directed by the apparent requirements of individual cases. Of one thing, however, we may be sure: its best effects are not to be obtained by salivating the patient. Mercury in the form of the bichloride is a favorite preparation; it is to be given in doses of the tenth to the twentieth of a grain dissolved in water or the fluid extract of sarsaparilla, three times a day. The hydrargyrum cum creta, combined with Dover's powder, is a combination which is used with benefit where dryness and other lack of function is found in the skin. Impression by inunction is still another mode of exhibiting the medicine. A lump of mercurial ointment, the size of a large pea, may be rubbed into the inner face of the thighs night and morning. Calomel in quarter-grain doses, combined with small quantities of sugar to render it palatable, may be given every two or three hours, until the patient remark the coppery taste. Blue pill, in five-grain doses, answers very well if there be hepatic disturbance, as manifested by gastric derangement and sick-headache.

Of the various mercurial preparations, preference will be found to reside with the bichloride: in this form the impression of the medicine is gradually secured. If necessary, it may be given continuously for a month.

It is a common experience that tonics combined with the mercurial are generally found indicated,—a something to counteract the degenerative tendency which appears to reside in every dose of mercury administered. Iron, quinine, gentian, and the red bark are excellent preparations. A prescription found to be a very good one is as follows:

R.—Hydrargyri chloridi corrosivi, gr. vi;  
Tincturæ cinchonæ compositæ, ℥vj. M.  
Sig.—A teaspoonful three times a day.

A second, admirable in cases associated with nervous disturbance, is the combination with the mercurial of the pyrophosphate of iron:

R.—Hydrargyri chloridi corrosivi, gr. vj;  
Syrupi ferri pyrophosphatis, ℥vj. M.  
Sig.—A teaspoonful three times a day.

In syphilitic disease of the tongue, tertiary in its type, mercury will seldom be found admissible; the system is broken down: the process of cure is to be one of repair. These are the patients for the seashore and the hill-side. You will not get them well if you do not build them up.

Conjoined with tonic medication in these cases, very experienced authori-



ties commend, for its alterative influence, the use of the iodide of potassium. Where it is thought desirable to use this medicine, ten grains as a dose for the adult may be given three times a day. It is most conveniently exhibited in water, or, if taste is to be consulted, in the fluid extract of sarsaparilla.

Tertiary symptoms, as M. Ricord observes, do not inevitably occur in the course of syphilis, but they are very likely to do so if the treatment of the primary and secondary symptoms be not conducted with the greatest care. As soon as the tertiary period has set in, mercury is to be abandoned, and iodide of potassium given. Nay, further, as mercury taken in time may prevent or retard secondary symptoms, and so may be regarded as prophylactic against them, so may iodide of potassium be esteemed as prophylactic against tertiary symptoms; and therefore M. Ricord, from the premises of his great experience, teaches that to render the treatment of secondary syphilis complete and rational, it should always be followed by the exhibition of iodide of potassium. This substance is, however, not only useless when employed against secondary symptoms and those of transition, but very often hurtful; yet, when secondaries have been of long standing, it may produce beneficial effects; it is also useful as an adjuvant of mercury in those affections which in some degree lie between the secondary and strictly tertiary manifestations; and, finally, it is indispensable for combating the symptoms of a decided tertiary nature. In order to become well acquainted with the proper manner of administering the iodide of potassium, we should take the trouble of studying its effects, independently of its curative action. First let us see how it acts on the skin. It may produce on the cutaneous surface diverse psyrdracious and acnoid eruptions. The pustules are generally surrounded by a vividly red areola, and the usual seat of these eruptions is *below* the umbilical region, as the nates, thighs, etc., whereas the common acne (not to mention its other characters) is mostly situated in the upper half of the body. To these peculiarities, it may be added that the pustules will fall in immediately the administration of the iodide is interrupted. Exanthemata, impetigo, and lichen are very apt to be produced by the use of this salt; and what you ought especially to keep in mind is, that ecchymosis and purpura in the inferior extremities are sometimes caused by the action of the iodide of potassium. The effects of the latter on mucous membranes should also be carefully observed. It may cause inflammation of the conjunctiva; the submucous cellular tissue gets infiltrated and puffed up; the eyelids turn red and oedematous, and, when the inflammation and effusion are not arrested, the internal parts of the eye become involved in the affection, and photophobia is the result of this state of things. The normal mucous secretion is always a little increased, but it does not take the muco-purulent character, as in the case of catarrhal ophthalmia. Coryza, of a more or less severe nature, often exists at the same time; it is preceded and accompanied by headache, and a pretty abundant mucous secretion; but this coryza never reaches the suppurative



state; it seldom produces more than a catarrho-serous flux. These affections never give rise to any fever, and they disappear as soon as the iodide is given up. This coryza is an accident which we should not overlook; for it is of importance to avoid it when we have to treat a tertiary affection of the nasal fossæ. As for the effect of the iodide on the intestinal canal, I have to state that persons enjoying good health can bear very large doses of it; I have given as much as fifteen drachms a day. M. Puche has often given ten drachms per diem, after commencing with six; and it has been noticed that it improves the appetite of the persons who use it. With some patients a certain pleurodynic sensation, corresponding to the cardiac extremity of the stomach, is felt after its ingestion; but it never causes vomiting. The sub-mucous cellular tissue of the stomach may, by the use of this iodide, undergo the same modifications to which we have noticed the conjunctiva to be subject; a sort of hyper-secretion and intestinal ptyalism takes place, and much of the fluid which ought to have been secreted by the skin is rejected by the mouth. This liquid has a slight taste of iodine; it is not fetid in the least; the gums are not swollen, and there is no feter in the breath, as happens in mercurial ptyalism. The same effect may be produced on the other portions of the intestinal canal; the patients are then seized with abundant serous diarrhœa. The iodine is eliminated from the system by the kidneys; half an hour after the ingestion of it, its presence may be ascertained in the urine; and it should be remembered that the presence of iodine in the blood increases the renal secretion. I have even observed a case of polydipsia which went on as long as the iodide was used, but disappeared when the latter was discontinued, gradually springing up again as the use of the salt was resumed.

"The effects of the iodide of potassium on the circulation are of a sedative kind; it diminishes the number of arterial pulsations, and lowers their force, but they may regain their normal standard if the remedy act beneficially on the system; the same arterial energy may also reappear when the iodide causes a slight phlegmasia. This salt is somewhat antiplastic; for it has rather a tendency to liquefy the blood, and may even produce the peculiar hemorrhages of purpura. When the effect of the iodide on the nervous system is carefully watched, it is found to cause a certain excitement of the nervous centres, followed by a little uncertainty in the movements and in the intelligence."

A combination much employed by Sir Astley Cooper, in cases where the iodide of potassium did not seem to favor the patient, was the liquor arsenici et hydrargyri hydriodatis,—Donovan's solution.

Concerning the local treatment of the venereal affections of the tongue, with which, in a work like this, we would seem to have most to do, little is to be added outside of the suggestions offered in the previous paragraphs. The treatment has principally to be constitutional in character: direct medication is perhaps to be esteemed simply as palliative.



As a local application of a common signification, lactuca sativa five ounces, honey one ounce and a half, and alum one drachm and a half, is a favorite with Ricord. Another consists of a decoction of hemlock, six ounces and a half, to bichloride of mercury, three grains. The use of acids applied to the ulcers in cases where the dyscrasia has been corrected or nearly so is to be recommended. It is surprising with what rapidity a syphilitic ulcer will frequently respond to occasional touches of almost any of the mineral acids.

In a bad case of mucous tubercles the author once treated, he got his patient well by daily salt-baths and the local use of a paint composed of sulphate of quinia and iron; twenty-five grains of the former to two drachms of the muriated tincture forming the combination. The tubercles were painted twice a day for two months.

Borax is a soothing application; it may be rubbed with water into a cream, and applied *ad libitum*.

A species of local specific, to be used on the part and rinsed away after a few moments, is composed as follows:

R.—Aque destillatæ, ℥ixss;  
 Ferri perchloridi,  
 Acidi acetici,  
 Acidi hydrochlorici, āā ℥j. M.

This may be repeated three times a day.

Fissures and fistulæ are sometimes, in their chronic form, to be cauterized, nitric acid, pure or dilute, being used for the purpose. In a case of long-standing fissure of the tongue, the author on one occasion cut out the bordering induration, the patient making a rapid recovery.

Chloride of zinc, twenty grains to the ounce of water, is found a useful application in chronic syphilitic conditions, whether of ulcer, fistula, or fissure.

In smokers, and in persons addicted to strong drinks, or with such as feed on irritating diet, the lips, cheeks, tongue, and especially the fauces, as pointed out by Dr. Charles Drysdale, and as has frequently been observed by the author, become the seat of interminable eruptions of mucous syphilitic lesions. These habits are not to be indulged by persons afflicted with the general disease.

Mercurial enlargement and induration of the tongue are conditions frequently demanding treatment. One of the first effects of mercury is often seen in the markings made upon the sides of this organ by an otherwise not observed swelling which has crowded it against the teeth. A tongue, tumefied by the impression made by the medicine, may become so enlarged as to fill the whole mouth. One particular case is just here recalled, where, to prevent the patient from being smothered, the writer was compelled to string the part and drag it forward over the lower jaw, fixing it until relief could be otherwise secured.

Mercurial ulceration of the organ is another of the offences of that medicine. Such ulcerations are in appearance indolent and yet irritable, and are



associated with similar conditions of the gums, and with salivation: the diagnosis is plainly marked.

The rational treatment of mercurial conditions refers to the correction of local impressions, together with elimination of the agent from, and support applied to, the system at large. In rapid swellings of the tongue, it may be found necessary to resort to the use of leeches combined with most marked derivation.

Such treatment, combined, if the circulation be sthenic, with some arterial depressant, as aconite, or veratrum, will commonly relieve from immediate danger. Unless, however, the ptyalism has been acutely excited, and the subject be strong and vigorous, the means of cure employed will be succeeded by much lassitude and depression; such result is, however, a necessity, and the treatment will, perhaps, have saved a life.

Local medication in cases of this kind is simply palliative and soothing. *Lactuca sativa* and honey, recommended in the syphilitic sore-mouth, is an excellent gargle. Sage-tea combined to a full saturation with chlorate of potassa, is another agreeable application. Common table-tea is very grateful to a patient. In combination with these, or any similar demulcent gargle, great relief is to be afforded by the free exhibition, internally, of bromide of potassium.

R.—Potassii bromidi,  $\mathfrak{Zss}$ ;  
Aque,  $\mathfrak{Zviiij}$ . M.

Sig.—Tablespoonful repeated occasionally as the patient is found nervous. Twenty grains, as here directed, may be prescribed three times a day at the least. The author has given eighty at a single dose.

The acute conditions of a mercurial glossitis combated, the practitioner will find it desirable to attend to the general requirements of the case. The system is to be protected against further impressions of the offending agent, while at the same time it is generally found that a present support is demanded. Chlorate of potassa, the antagonist of the mercurials, has now obtained in this direction an almost universal use: it is to be administered in full saturation, in tablespoonful doses, three or four times a day. A very good way to prescribe this salt is to order two ounces placed in an eight-ounce bottle, the vessel to be kept filled with water until all the salt is dissolved. As each dose is taken, the patient replaces it with fresh water.

In the treatment of mercurial ulcers, the local applications suggested have been various. Bismuth, red bark, and borax, in equal proportions, act sometimes happily. Chlorate of potassa, tannic acid, and glycerine form an excellent combination. Solutions of sulphate of copper or of zinc, one grain to the ounce of water, are cleansing and stimulating applications. Iron, opium, chalk-powder, aromatic powder, are all, in their turn and place, useful. If phagedæna intervene or threaten, the potassio-tartrate of iron, as recommended by Ricord in the similar ulcers of syphilis, is not to be omitted: this may be used in the strength of thirty grains to the ounce. It is also



to be administered internally in doses varying from five to ten grains repeated each two hours.

Chronic phagedæna, which in some degree associates itself more or less frequently with mercurial ulcers, is best treated by potential cauterants. Of these, a favorite is creasote: this is to be applied with care, however, as it may provoke secondary inflammation. Carbolic acid is a useful article, and sometimes proves very reliable. Nitric and hydrochloric acids are highly commended by many practitioners: when applied, every recess of a sore is to be burned, and this is to be repeated daily until healthy granulations appear. Phénol sodique, used full strength, is an admirable application.

**Scirrhus.**—Of the third form of constitutional impressions, scirrhus carcinoma may now invite consideration. The scirrhus of the tongue, from the circumstances of its association and position, is to be deemed a necessarily dangerous, if not fatal, disease. Scirrhus in other parts may be cured; that is to say, being removed, it may not reappear in the part of removal,—although the disease is seldom, if indeed ever, permanently combated. That scirrhus carcinoma is not, however, at least in its incipency, so formidable an expression as the encephaloid, seems to be the universal impression: there is a fixedness, an apparent isolation, about it, which always invites operation.

Situated in the tongue, such isolation is, however, unfortunately, not so marked as when found in many other parts: the disease appears here as an induration rather than as what might be termed a lump, and this induration has not, commonly, a definite boundary; hence, if it be removed by operation, one is at a loss to say whether such removal has been complete.

A carcinomatous scirrhus is to be distinguished from scirrhus of local signification,—first, by its resistance to treatment; and, second, by the peculiar darting, lancinating pains which, sooner or later, always appear in it; these pains are markedly diagnostic. Again, a scirrhus carcinoma is apt to have a hereditary history: a generation may have escaped, but it is apt to be discovered somewhere in the family.

Local medication to a carcinomatous scirrhus is perhaps worse than useless. If the lesion be not widely cut away, it is better, a hundred times better, to let it alone. Many a tumor of this class that would have remained dormant for years has been excited to destructive malignancy by over-officious meddling with it. If a practitioner do not know the character of a tumefaction upon a tongue, he cannot act more wisely than in letting it alone until continued observation has secured to him the proper diagnosis.

At a period very various as to time, a scirrhus carcinoma ulcerates. If the tumor have attained any size, fungous granulations sprout forth, giving that expression known as fungus hæmatodes; if, on the contrary, the tumor ulcerate while small, it is irregular, puckered, everted in its edges or elevated, and covered with abundant granulations: the discharge may be thin and sanious, or purulent, the latter character being, however, rare: it differs from the syphilitic sore in its granulative bottom.



A section of scirrhus carcinoma presents a stroma dense, abundant, and closely meshed. A fibrous structure is always more or less marked, particularly in its occult state, such structure assimilating both the white and yellow tissues, being perhaps really these tissues. A diagnostic sign is a peculiar creak or cry given under the knife. Another is a shrinkage or contraction in the centre of a section. Still another is a creamy juice, which may often be scraped from it.

In looking at a microscopic slice of scirrhus carcinoma, the areolæ existing in the stroma are found filled with granules, nuclei, and nucleated cells. These cells being of diversified form and common to no tissue, the term heteroclitic is justly applied to them. The appearance of such a section is exhibited in the engraving (Fig. 385).

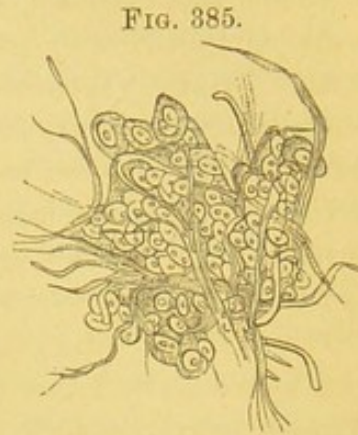


FIG. 385.

A microscopic view of the cancer-cells filling the interstices among the bundles of the fibro-cellular tissue. Magnified about two hundred times. (After Paget.)

As scirrhus carcinoma commonly begins upon the sides of the tongue, jagged and sharp teeth irritating the parts may be supposed to have some influence in its localization; such teeth, under all circumstances, are to be removed or smoothly dressed. See *Epithelioma*, which is now most commonly affirmed to be the same expression of the cancer vice as this considered.

In the treatment of scirrhus of the tongue by amputation, several modes are employed. One, that of the French school, is by means of an instrument known as the *écraseur* of Chassaignac. This is simply a delicate chain arranged from a handle, which little by little crushes off the part. Another mode, that of strangulation, consists in the introduction of circumscribing ligatures, which, being drawn tightly, cut off all circulation from the diseased part, thus compelling its separation. Another means of treatment widely employed, and in instances recommended by very high authority, consists in the use of caustic remedies; of these there is a great variety,—arsenic, however, forming the base of most of them. No remedies require to be used with more judgment and caution. If the practitioner desire to try a caustic, the author's experience would suggest chloride of zinc:

R.—Zinci chloridi,  
 Aluminis pulveris, āā gr. v;  
 Acidi tannici, gr. ij;  
 Ferri persulphatis, gr. iij;  
 Glycerinæ, q. s. for a paste. M.

To apply this paste, draw the tongue forward, hold, and dry it carefully in a napkin. Lay some crystals of zinc on the part, and cover over with the paste. This may be allowed to remain as long as the tongue can be kept dry. Finally, wash the *débris* away, and the application is completed.

It may happen, after such an application, that severe general glossitis will



supervene ; this is unfortunate, and implies that harm rather than good has been done. In making a caustic impression under such circumstances, the parts should be quickly killed, not excited nor provoked.

The galvano-cauterant, a means suggested originally by Heider, and lately made quite practical by Hilton, is thought by many to be greatly preferable to the potential cauterants: this consists of a long, delicate-bladed forceps transmitting copper wires, which, being applied to the part to be acted upon, are heated to whiteness by the galvanic current, and destroy it instantly.

Injection of persulphate of iron is still another means employed and commended. The writer's experience with the agent has not led him to look upon it as a specific.

The arrows of Maisonneuve, points tipped with chloride of zinc, may be used by those who do not fear a resulting inflammation. Two, three, or more of these arrows are made to circumscribe a tumor, precisely as practised by that surgeon in his operations upon the mammary gland.

The author desires to emphasize caution as to meddling over-officiously with cancer of the tongue, affirming, without hesitation, that, as a rule, very much more harm than good attends attempts at radical treatment.

**Epithelioma.**—Except as the lower lip is concerned, in no situation has the writer more frequently met with epithelioma of cancerous expression than upon the tongue. Situated at the sides and along the frænum, the disease is commonly first noticed as an irregular puckered patch of more or less hardness, and almost from the very beginning has associated with it a characteristic pain. More frequently than otherwise, instead of one patch, a sufficiently close observation will discover the affected side studded,—a matter which is not long in being made evident enough to the patient. After a time, differing in individuals, these patches sprout forth the giant granulations so characteristic of the disease, the surface of the sore becoming foul and ragged, and inclining to spread over neighboring parts. In a case at present under care, in which preparation is being made for the amputation of the full tongue, the disease exists as an infiltration, involving the entire right half, but not passing the raphé.

In no cases of disease does there seem to exist greater reluctance on the part of a general practitioner to the admission of the existence of a fatal malady than in that of epithelioma of the tongue ; and this, perhaps, is not to be wondered at, seeing that not infrequently an ulcer of such signification will lie in a dormant condition for a period of several months, looking to the inexperienced scarcely as formidable as a syphilitic sore.

Cancerous epithelioma, so frequently confounded with syphilis, is to be distinguished from the latter expression not only by its location, but with most assurance by its appearance ; the first being characterized by isolated giant granulation of rough surface, the latter by a soft, pasty base. The two are really very unlike, and should deceive no one : even the primary chancre sometimes found here bears no resemblance to epithelial carcinoma.



The progress of lingual epithelioma is of most distressing character; the organ enlarges and stiffens, mastication and deglutition become functions of difficult and painful performance, the saliva dribbles constantly over the chin, and the patient finally perishes from exhaustion.

Cancerous epithelioma of the tongue must either have attempted with it the most radical extirpation, or be soothed into quiet, and into such abeyance as is possible to be secured. Of the latter means, advantage has been taken of a partial paralysis, securing immunity from pain through section of the lingual nerve; while it has also been deemed that much control over the progress of the disease has been secured by ligation of the lingual artery of the affected side.

In the practice of the author, where, in certain cases, operative means of any class have not been thought advisable, the patients have expressed themselves as receiving great relief from the local employment, by means of an atomizer, of the following combination:

R.—Acidi carbolic fluidi, ℥j;  
Sodæ sulphitis, ℥j;  
Aquæ, ℥x.

Lingual epithelioma most frequently makes its appearance either at the side of the base of the organ or under the tip. Frequently, however, where jagged teeth exist in the arch, it may arise as an abrasion, the location being without doubt influenced by the irritant. Such a lesion is not apt to be appreciated in its true character until its refusal to heal is noticed, after the extraction of the offending tooth. Still another cause of localization in this direction arises from a malarticulation of the posterior teeth, the tongue on each occlusion being caught and fretted. The peculiar articulation referred to is to be seen when the molars of both jaws incline inward, striking above at the buccal angle and leaving a space with the base looking inward. The author has at the present time under his care two cases of epithelioma which apparently have been thus located.

The oneness of scirrhus and cancerous epithelioma of the tongue is beyond dispute; that is, as a common specific nature is concerned; histological differences, when existing, have the meaning in anatomical relations. The treatment differs certainly in nothing: a cancer locating itself in the tongue implies a fatal result.

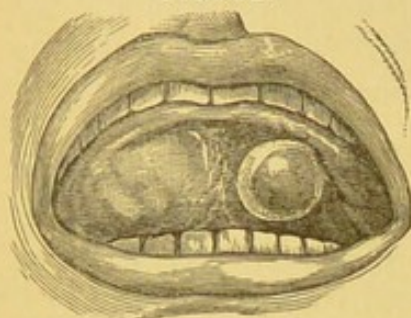
**Tobacco Tongue.**—Inveterate smokers and chewers of tobacco are not unapt to be found with a tongue that is somewhat enlarged, dry, and fissured, and yellowish-brown in color. Complaints on the part of patients refer to stiffness, to harshness of surface, and to diminished motion.

**White Tongue.**—A condition of the organ where the extreme tip and edges maintain a natural appearance while the centre is a dead white has been met with by the writer as the result of presence in the alimentary canal of tape-worm.



**Tubercle.**—Tubercle, to the apprehension of the writer, signifies a catalytic result arising out of lymphangitis; this, whether the tubercle be found in the tongue or in the lungs. Lymphatic obstruction implies stasis in tissue metamorphosis; out of this, or associated with it, is the *materia peccans*. Lymphangitis is not common to the region of the tongue, consequently tubercle is

FIG. 386.—CYSTIC TUMOR OF TONGUE.



as rare to the situation as it is common to the lungs. That it exists occasionally, however, has been fully illustrated in the studies of Langham. Tubercle of the tongue tends to self-cure through abscess. Where abscess terminates in an indolent ulcer, iodine or light touches of the actual cautery may be used.

**Cystic Tumors.**—Cystic tumors of the tongue, while not frequent, are yet not sufficiently rare to make allusion to them unnecessary.

That known as *meliceris* is round, free from pain, and filled with a glutinous, honey-like substance. A peculiarity of this cyst is the fungiform character of its bottom, this portion looking pyogenic. A second order of cysts contains lymph, sometimes fairly colloid in consistence and appearance, at other times flaky, tubercular, or, it may be, puriform.\*

\* "There is a disease of the tongue which I have seen every now and then, and which I am sure is very often mistaken for cancer, though it is of a different nature. It is a curable disease, although it looks like a malignant one in many respects. The first thing of which the patient complains is enlargement of the tongue, with some pain. On examination, you find a tumor in one part of it, not very well defined, nor with any distinct margin. It is a softish tumor, and increases in size, and perhaps a second appears in a different part of the tongue, and that increases also. There may be three or four of these soft elastic tumors, with no very defined margins, in various parts of the tongue. This is the first stage of the disease.

"In the second stage there is a small formation of matter in one of these tumors,—a little abscess, which breaks externally, discharging two or three drops of pus. When the abscess has burst it does not heal, but another forms in one of the other tumors. These abscesses may assume the form of ulcers, and the ulcers have a particular appearance. In the first instance it is a very narrow streak of ulceration, but on introducing a probe you find that the ulcer is the external orifice to a sort of fissure in the tongue. The probe passes in obliquely: the tongue is, as it were, undermined by the ulcer, a flap of the substance of the tongue being over it.

"The disease now becomes more painful, and at last the ulcers may spread externally. In some instances they occupy a very considerable portion of the surface of the tongue, but generally they burrow internally, and do not spread much toward the surface. This is a very distressing state of things, and a man may remain in this state for a long time. The glands of the neck do not become affected, nor does the general health suffer, except from the difficulty of swallowing food. This is one inconvenience experienced by the patient; and he also labors under a difficulty of articulation. The tongue, from its enlarged state, may become stiff, not sufficiently pliable for the purposes of speech, and the patient either speaks thick or lisps.

"In some instances the disease may be relieved by a course of sarsaparilla, with small doses of bichloride of mercury. A strong decoction of sarsaparilla, with from a quarter to



A form of cystic tumor, being a cystiform hypertrophy of a circumvallate papilla, is met with occasionally on the back part of the dorsum. These tumors have been known to attain the size of a walnut. To the touch they are quite solid, the walls being greatly indurated. If satisfied that there is no malignant association, the practitioner may puncture the sac and introduce a tent. Iodine is to be used both externally and by injection. Ranular cysts, frequently described as lingual cysts, are classified by themselves. (See *Ranula*.)

**Acute Glossitis.**—Acute inflammation of the tongue, whether of idiopathic or of traumatic character, is always to be looked on with concern. The causes inducing the condition are various.

Viewed as a distinct lesion,—and this view, no matter what the cause, will ever force itself on the attention of the practitioner when called to a case,—urgent necessity is always felt for a treatment that shall abort or resolve the phenomena quickly as possible. It is true that all glossal inflammations are not dangerous; but it is the case that all inspire with a sense of danger.

Acute glossitis, idiopathic in form, commonly begins with a sense of enlargement and stiffness of some part of the organ, generally the anterior part; this soon becomes red, painful, and perceptibly swollen. At this stage the condition may rest, and after some little time begin to decline. On the other hand, a single hour may witness the spread of the inflammation to an extent which threatens, or perhaps produces, suffocation. In still other instances advance is gradual; the general circulation sympathizing, the pulse grows

---

half a grain of bichloride of mercury, may be taken in the course of the day. Of course, if there be anything wrong in the general health, you should endeavor to get that corrected and attend especially to the state of the bowels and the secretion of the liver. If the secretions of the digestive organs be unhealthy, a dose of senna and salts may be given every other morning, and blue pill every other night. When the patient is brought into this state, one remedy, as I have said, is sarsaparilla with bichloride of mercury; but, according to my experience, this is not the best remedy. The remedy best adapted for these cases is a solution of arsenic. Give the patient five minims three times daily, in a draught, gradually increasing the dose to ten minims. It should be taken in full doses, so that it may begin to produce some of its poisonous effects on the system. When it begins to act as a poison, it will show itself in various ways. Sometimes there is a sense of heat, a burning pain in the rectum; sometimes griping, purging, and sickness, and nervous tremblings. A patient who is taking arsenic, especially in pretty large doses, ought to be carefully watched. At first you may see him every two or three days, and then every day; and as soon as the arsenic begins to operate as a poison, leave it off. When this effect is produced, the disease of the tongue generally gets well; but at any rate leave off the arsenic, and the poisoning will not go too far; it will do no harm. If, after a time, you find that the disease is relieved, but not entirely cured, you may try another course of arsenic. Perhaps it may take a considerable time to get the tongue quite well. Sarsaparilla, with the bichloride of mercury, may be given at one time; and at another, arsenic. You cannot give either of these remedies forever, and indeed the arsenic can only be given for a very limited period; but it is astonishing what bad tongues of this description I have seen get well under these modes of treatment, especially under the use of arsenic.”—BRODIE.



rapid and irritable, the skin becomes hot, to decline, however, to the cold sweating stage; suppuration or perhaps gangrene terminates the action.\*

\* GLOSSITIS, ACUTE.—“Michael M., aged thirty-six years, employed as a boatman by the Barrow Navigation Company, presented himself at the Meath Street Dispensary, Dublin, on the 14th of January, 1871. His appearance was characteristic of the affection from which he suffered. His countenance was anxious, the tongue protruded between the teeth, his speech was thick, or what might be termed the glossitic speech; his breathing was distressed. On inquiry, he (Mr. Croly) ascertained that the man had got a severe wetting some days previously, and had his feet also immersed in water. He shivered, and felt a soreness at the root of the tongue. He had not been taking any medicine, and up to the time of severe wetting was in robust health. In addition to the symptoms detailed, he had a dribbling of saliva from the mouth, with headache and dysphagia. The pain in the tongue, as the disease advanced, was described by him as of a stinging nature. On examination, he found the tongue covered with a white exudation, like a false membrane. The organ was large, protruded, and exquisitely tender to the touch. The sublingual space was infiltrated and chemosed, and the fringe beneath the tongue resembled a cock's comb. The tonsillitic regions were natural, and bore pressure without causing any uneasiness. He got the patient to open his mouth sufficiently to enable him to introduce his little finger, and the man winced when he depressed his tongue. He observed that the palate and tonsillitic regions, as seen internally, were not in the slightest degree altered. He considered from the patient's general symptoms, and the infiltrated condition of the tongue, caused by the exudation of lymph in addition to the engorgement with blood and serum, that no time should be lost in giving him relief by the knife. He accordingly introduced a sharp-pointed bistoury far back, and made a free incision at each side, parallel with the raphé. The wounds gaped and bled freely, and the patient's speech became suddenly better. He next punctured freely the chemosed sublingual space. A warm bath and a purgative draught were prescribed, and he warned the man against cold, and recommended him to come into hospital, but he declined. On the following day he called at the dispensary, and was much improved. The tongue was still tender to the touch, but the symptoms were so much relieved that, notwithstanding his advice to the contrary, he returned by boat to the country that evening, and he had heard nothing of him since. The notes of the next case to which he would call their attention were sent to him by Dr. Barry, of Kanturk. He visited a man, aged forty, whose respiration, articulation, and deglutition were very painfully affected. His tongue protruded between his teeth, and was so engorged as to fill all the space up in the palate; and the tissues from the chin to the larynx were infiltrated. With some difficulty, Dr. Barry introduced a long and narrow bistoury on the flat, and, having turned the blade on its edge, he made two longitudinal incisions parallel to the raphé, with instantaneous relief. There was a copious flow of blood, which relieved the danger of impending suffocation, and the patient recovered in a few days, and was now in good health. The notes of the following three cases were kindly given to him by Dr. Leeper, of Keady. Dr. Leeper called the cases ‘Glossitis.’ The first was followed by an attack of delirium tremens, and after that by diffuse inflammation of the left leg. Mr. —, of full habit of body, a free liver, of intemperate habits, dined at a club with seven friends on New Year's eve. He left the hot dining-room late, and drove home, a distance of six miles, the night being bitterly cold and frosty. Next morning he awoke with sore throat, some difficulty of swallowing, and had a dry, parched, and swollen tongue. These symptoms rapidly increased, and Dr. Leeper was asked to see him at ten o'clock A.M. The tongue was then greatly swollen, filling up the mouth, and protruding an inch between the teeth. It was of a dark-brown, almost mahogany color. The sublingual glands were swollen, and the sublingual spaces filled up to a level with the incisors. The submaxillary glands were not much affected. It was impossible to see either the tonsils or fauces; but the roof of the mouth was covered with red erythematous patches. When the tongue was well moistened he could swallow and speak without much difficulty. Six leeches were applied to the under surface of the tongue and



The dangerous character of a severe glossitis demands energetic treatment. Leeches direct to the organ, or better, beneath the jaw, bleeding from the arm,

sublingual space. They rapidly filled themselves, and from the bites there was a very considerable flow of blood, which gave immediate relief. Before two hours he could keep the tongue in the mouth, and swallow with ease. Dr. Leeper considered that the leeching, purging, and sudden withdrawal of his accustomed stimulant and food brought on an attack of delirium tremens. The next case was one of acute glossitis, treated by free incisions on the dorsum of the tongue. P. R., a farm-laborer, was attending a corn-mill, getting oatmeal prepared. When there, he assisted the kilnman in turning the oats when drying, got into a profuse perspiration, and soon afterward exposed himself, on a cold, biting day in March, and was chilled. This was followed by swelling of the tongue, and difficulty of swallowing. Dr. Leeper saw him the next day. The tongue was greatly swollen, especially at the back part; there was an abundant flow of saliva from the mouth, and the surface of the tongue was covered with a dirty-white, creamy-looking paste. He was speaking thick, and said he would soon choke if not relieved. There was no enlargement of the tonsils or the submaxillary glands. Dr. Leeper made with a lancet, the only instrument he had with him, two incisions on the dorsum of the tongue, parallel to the raphé. There was a discharge of four or five ounces of blood and serum from these incisions. He received a message next day to say that the man was much worse, and on visiting him found the tongue more swollen, protruding from the mouth, and that deglutition and speech were more difficult than on the day before. He introduced a sharp-pointed bistoury, and made two long and pretty deep incisions on the dorsum from the base to the tip of the tongue. These bled profusely, and gave immediate relief, and the next day the patient could swallow without difficulty, but the speech was thick. His recovery from this time was rapid. In the third of Dr. Leeper's cases, the patient was forty-five years of age. After exposure to cold he complained of pain and deafness in the right ear, and these were soon followed by difficulty in speaking. These symptoms, after having lasted upward of a fortnight, were succeeded by rapid swelling of the right side of the tongue. When Dr. Leeper saw him, there was a profuse flow of saliva, so much so, that he thought he must be laboring under the influence of mercury; but there was no mercurial fœtor, nor were the gums affected. The right side of the tongue was as much affected as it could be, but the left was not engaged. The tonsils were not enlarged; neither the salivary nor the submaxillary glands were swollen. The root of the tongue was hard and swollen. Any attempt to swallow was followed by a squirt through the nose and mouth, with coughing. It seemed as if the epiglottis could not act, and that the fluid passed into the larynx. Some milk was injected (by means of a large elastic catheter attached to an elastic bag) into the œsophagus. He sometimes succeeded in swallowing, but the attempt far oftener failed, and was very distressing to him. Dr. Leeper made a free incision, on the dorsum, from the back to the tip of the tongue on the right side, but the discharge of blood was inconsiderable, less than he could have supposed from the extent of the incision. Fomentations with hot chamomile-tea were used and kept in the mouth, and his health supported as well as possible with milk and beef-tea. Next day he was worse, and Dr. Leeper made a still deeper and more extensive incision on the right side of the tongue. There was no discharge of blood or serum, at least not more than two ounces, and no relief from it. Mr. Young, of Monaghan, saw the patient the next day, and advised leeches to the side and under surface of the tongue. These induced profuse bleeding, which was kept up by cold water in the mouth, Dr. Young thinking that cold water promoted bleeding from leech-bites better than hot. The swelling of the tongue subsided at once after the leeching, but the right side of it remained thicker and harder than the left, and the man's speaking was still difficult and imperfect. Mr. Croly proceeded to say that it was superfluous to go into the subject more fully, as it had been already discussed at a previous meeting. He would only state that he thought the case he had detailed was a very well-marked case of idiopathic glossitis. The man working on a river and getting a severe wetting, not taking any mercury, the tongue becoming greatly swollen,



catharsis, diaphoresis,—any or all of these means are successively to be brought into requisition. A plan of treatment, as reliable as any in character, is as follows: place on the back of the neck a cataplasm of mustard and red pepper; put the feet in water, as hot as can be endured; give a full dose of sulphate of magnesia. If now the disease be not held in check, wrap the patient in shawls or blankets and administer spirits of Mindererus until full diaphoresis is secured. If even yet control be not secured, let ten, twenty, or thirty American leeches, or a third of the number of Swedish, be placed beneath the jaw. If the action be still unconquered, blood *pro re nata* is to be taken from the arm, and the tongue itself freely incised. If yet the swelling go on, and suffocation is threatened, laryngotomy or tracheotomy becomes a necessity.\* (See these operations.)

the characteristic voice, the absence of any tonsillitic inflammation,—all these features showed that it was a typical case of idiopathic glossitis.

"Mr. Richardson said he had a case of this kind a short time ago in the Adelaide Hospital. There was rapid swelling of the right side of the tongue and chemosis of the floor of the mouth. In that case he not only made an incision from the base to the point of the tongue, along the dorsum, but he also made a few punctures in the chemosis on the floor of the mouth, and the man was well in a few days. An exfoliation of mucous membrane followed, which, however, did not interfere with recovery. As there was some doubt regarding the period at which the treatment by long incisions was introduced, he wished to state that he had found in the *Memoirs of the French Academy of Surgery* several cases of this kind recorded. In one of these cases, published by De la Motte in 1725, the tongue became greatly swollen in less than five hours. It soon filled the mouth, and protruded from between the teeth. Bleedings from the jugular vein, arm, and foot were performed without relief, but a rapid cure followed three deep incisions along the dorsum, extending from base to apex. The patient could speak in an hour after the incisions were made. In another case, that occurred in 1744, rapid swelling of one side of the tongue took place in a woman; respiration was obstructed, and deglutition impossible. It was cured by one long, deep incision. Louis mentions a case that occurred in the military hospital at Metz in the year 1740. The tongue became spontaneously swollen. Alexander Benedictus, who published the case, mentioned that M. Casteras, the senior physician of the hospital, directed him to scarify the tongue lightly. This, however, was not sufficient, and the patient died in two days in consequence of the swelling. As Louis truly observes, life might have been saved by a couple of deep incisions along the dorsum of the tongue."

\* "Mr. J. Z. Laurence exhibited before the North London Medical Society the tongue of a woman who had died of acute inflammation of the organ. She had been under Mr. Laurence's care for acute rheumatism, when, on the evening of the 5th November, he was called to her, and found her sitting up in the bed, with a countenance expressive of the greatest anxiety, her face pale and bedewed with sweat; she breathed at long intervals, and laboriously; pulse 130. The cause of this was evident; she could not open her mouth to speak, for a swelling of the left half of the tongue, which was red, dry, and glassy. On the night of the 2d and 3d she had had severe rigors. Mr. Laurence at once made three free incisions into the tongue, and about half a pint of blood escaped. About two hours after the bleeding had ceased, the submaxillary region began to swell, twelve leeches were applied, and on the following morning the *right half* of the tongue began to swell, and by the afternoon it had attained full as great a size as the left. With this was a corresponding engorgement of the tissues about the jaw; the local depletion had had very little effect in reducing the swelling of the left side of the tongue; generally she was worse; rigors now came on, and the pulse intermitted three or four beats. Mr. Quain saw her, and proposed incising the right half of the tongue, but both patient and friends objected. Mr. Laurence saw her the last time



**Abscess.**—In depraved and tainted conditions of the system, abscesses, of what might be called a cold character, occasionally form among the deeper muscles of the tongue; such abscesses are not necessarily associated with any marked inflammatory phenomena, but may have attention first directed toward them by the swelling which appears on the under surface.

The proper treatment is found in voiding the matter through puncture as soon as fluctuation is perceived; otherwise it has happened that the pus has dissected its way down the neck, pointing in front of the hyoid bone, creating much derangement, and threatening even a fatal result. Treat these cases by local stimulating injections and the internal administration of tonic medicines. Acute abscess is one of the terminations of glossitis. (See foot-note for illustration.)\*

---

alive the same night; her surface was deadly cold; pulse not perceptible at the wrist, yet, strangely enough, the respiration went on tranquilly, though feebly. Mr. Laurence at once perceived that she was dying of slow asphyxia, and that her only chance was in tracheotomy; this was proposed with more impressive force than a surgeon almost dare do. She and her husband doggedly refused. Next morning she was dead.

*Autopsy.*—No organic disease was discoverable. The whole of the tongue was swollen, pale, and soft from maceration in a puro-serous fluid, which infiltrated the substance. The superior aperture of the larynx was greatly narrowed by serous effusion; the rima glottidis to a less extent; below this point the whole of the trachea was perfectly unobstructed; the submaxillary region and anterior triangles of the neck were infiltrated with a serous fluid, which, among the suprahyoid muscles, had assumed a purulent aspect. The lungs were singularly healthy; the heart, kidneys, and bladder presented no signs of disease.

"From the above facts, it follows that tracheotomy would in all probability have saved the woman's life; and Mr. Laurence believes he proposed it at the proper time. It is true there was, throughout the case, not one fit of suffocation. On the contrary, she died choked in the most gradual conceivable manner; and were he to meet with another case, he would not defer the operation until the patient was in his last gasp, as was too commonly the case, but resort to it as soon as he saw the patient sinking, previous measures not having ameliorated his condition. A curious pathological fact, which Mr. Laurence noticed and pointed out to Mr. Phillips, who attended the case with him, was the successive and separate invasion of the two halves of the tongue by the inflammatory action, offering a remarkable instance of the dependence of pathological changes on the anatomical distribution of the blood-vessels."

\* The following suggestive case of abscess of the tongue, ending fatally from hemorrhage, is related by Mr. Ward, being presented before the London Medical Society:

"E. T., aged seven, was born with a slight red enlargement in the centre of the tongue. No inconvenience or difficulty in the ordinary motions of the tongue, or in swallowing, had ever been experienced; the general health had always been good. In the night of Sept. 27, having been in her usual health at bedtime, she was attacked with pain and swelling under the chin and both sides of the lower jaw; slept very little, and the following morning had pain in the tongue, with great difficulty in speaking, or swallowing anything but liquids. She had an aperient powder at night, and the lower jaw was fomented frequently. In this state she continued for two or three days, and was visited by me on Oct. 1, when the following appearances were noted:—Face flushed; eyes very bright; countenance anxious; great swelling, redness, and extreme tenderness of the parts under the lower jaw; very slight swelling of the tongue itself, which is covered with a thick, brown fur; is unable to open the mouth wide, or move the tongue beyond the teeth, or to speak, and has great pain in the mouth; pulse very quick and sharp; great heat of skin, and thirst urgent; bowels confined. Ordered eight leeches to be applied under the chin; to



**Neuralgia of the Tongue.**—The only neuralgia of the tongue which seems special and peculiar to the organ has its seat about the extreme tip ; the

take, at bedtime, four grains of calomel ; James's powder and sugar, of each three grains ; a saline mixture, containing a scruple of nitrate of potash ; one tablespoonful every three or four hours.

"Oct. 2. Slept more last night than since first attacked ; fever great ; pain slightly relieved ; swelling and redness less ; mouth nearly closed ; was able to swallow the powder in jelly, but refuses the mixture, of which very little has been taken ; bowels freely relieved, evacuations dark and offensive ; to take calomel and James's powder, of each three grains, and jalap, five grains, at bedtime ; use a chloride-of-soda gargle, warm, to the mouth, by means of a syringe. Fluids taken in the mouth return by the nose.

"4th. Less fever ; rests better at night ; difficulty in swallowing or speaking the same ; can open the mouth sufficiently to allow the tongue to be seen, which is nearly fixed, very little swollen, and still thickly coated ; the breath extremely fetid ; external redness and swelling still considerable ; the tenderness great ; pulse soft, quick, and weak ; the bowels act freely ; was able to pass my finger into the mouth ; under each side of the tongue distinct fluctuation can be felt ; while pressing on the left side the lining membrane gave way, and was followed by a profuse discharge of fetid pus, mixed with blood ; the point of the finger passed easily to the depth of the first joint, under the tongue, giving the sensation of a large pulp-cavity ; the tongue not very tender, can be moved from side to side by means of a small teaspoon, but not voluntarily. Apply strong poppy fomentation frequently, and linseed poultice ; continue the chloride-of-soda gargle under the tongue, with the syringe, and take, of a mixture consisting of six grains of quinine, a teaspoonful every four hours ; give a little port wine and water frequently, and milk or thin arrowroot for drink.

"6th. The pain less since the use of the poppy fomentation, generally sleeping for some hours after using it ; the discharge of pus and saliva very copious and offensive ; lies with the head on the left side to allow the free exit of the discharge, otherwise the mouth is constantly filled ; fever less, as also the swelling and tenderness ; redness gone ; great debility and considerable wasting of the body already ; can swallow fluid, and is eager for the wine ; very little quinine has been taken ; bowels act twice a day ; can open the mouth wider, but is still unable to protrude the tongue, which is cleaner and moister ; on slightly raising it by the handle of a spoon, a large jagged opening may be seen on the left under side of the lower jaw, from which, by gentle pressure under the chin, a profuse discharge of thick pus wells up, of which I pressed out at least two ounces ; pulse soft and weak. Continue the external applications ; apply the chloride-of-soda gargle frequently to the mouth and under the tongue, with the syringe ; take a mixture consisting of two ounces and a half of decoction of bark, syrup of orange-peel, and tincture of bark, of each two drachms, a fourth part three times a day ; continue the wine, and give strong beef-tea and arrowroot frequently.

"9th. Altogether improved ; discharge less, but still fetid ; takes fluid nourishment frequently, and the wine ; the general swelling and the tenderness reduced ; more on the left side under the jaw than the right, and is unable to protrude the tongue further. Continue all the applications and the mixture.

"11th. Has not rested so well the last two nights, and has had more pain, particularly on the right side, which is more swollen and very tender, the left side being almost in its natural state ; the discharge has been profuse, but thinner ; the tongue is moist and clean ; not very tender, but less movable ; the opening under the left side of the tongue smaller ; fever returned ; has constant hacking cough ; not able to swallow so well, or to speak so as to be understood. Apply six leeches under right side of lower jaw ; continue the fomentations and poultices ; also, bark mixture and port wine.

"12th. Has slept very little, from the frequent coughing, which tires her very much ; discharge from the mouth less and thinner, but still fetid ; emaciation extreme ; has changed



pain, which is very irregular in its coming and going, is of the most acute character, seeming indeed as if the organ might be in the grasp of red-hot pincers. This neuralgia is most frequently encountered in the persons of middle-aged men. Vanzetti, for the cure of such a trouble, has recommended and practised the operation of section of the lingual nerve,—accomplished by first drawing the tongue forward and to one side, and exposing the nerve, through incision of the mucous membrane on the border of the internal pterygoid muscle. An excellent obtunder is found in the combination suggested in the paragraph on Epithelioma. Lingual neuralgiæ originating in the offence of jagged teeth have their cause too evident to need comment. The causes of many cases seem beyond finding out. (See *Neuralgia*.)

the position of lying to the right side; left angle of the mouth drawn down; the swelling and tenderness on the right side very much increased since yesterday; feels soft; is more prominent in the centre, and appears pointing here; the finger in the mouth can detect very distinct fluctuation under the tongue, which is thickly coated and very tender; takes very little nourishment, only a teaspoonful at a time: prefers wine to other things. Continue the fomentations and poultices.

"13th. Has had a bad night; is very irritable and feverish; mouth nearly closed; unable to examine the tongue; the swelling about the same; the right cheek and under side of the jaw of a dusky red color, and very shining; so tender that she has again changed the position; lying on the left side; cough less; pulse very small and weak; takes scarcely anything; discharge more copious, thicker, and slightly tinged with blood; it now appears to come from the right side. In the evening, while coughing, a large gush of blood took place from the mouth, mixed with pus, and flowed freely for more than ten minutes. By applying ice internally and externally (which I had directed to be in readiness), the hemorrhage was arrested. A cold lotion was applied externally, and an alum gargle frequently to the mouth.

"14th. Has slept very little; unable to lie down, from the constant discharge of fetid pus and saliva from the mouth; the swelling of the right cheek and side of the jaw less; very tender, of a dull, yellowish color; able to open the mouth so as to examine the tongue, which does not appear enlarged; no power of moving it herself; is thickly coated with a dark fur, and when pressed upon, a profuse discharge of thick pus fills the mouth immediately; no return of the hemorrhage; is very pale and faint; pulse very small and weak; has taken more nourishment since last night than for some days before, such as port wine, isinglass in milk, beef-tea, jelly, etc. Continue the lotion and alum gargle to the mouth with a syringe. At half-past seven P.M., in the act of swallowing a small piece of bread-and-butter, profuse hemorrhage occurred from the mouth, and more than a pint of blood was lost before it was again arrested by the free application of ice; it was of a bright arterial color. She became faint, and expired at nine P.M.

"On the day following I made a post-mortem examination of the parts affected. The parotid, submaxillary glands, and other parts, having been brought into view, were found (on the right side) so much softened, decomposed, and mixed with coagulated blood and pus, as to be recognized with difficulty, and it was impossible to trace from what vessel the hemorrhage proceeded, such was the destruction of the parts. On the left side, the glands were of a greenish color, very much softened, and bathed in pus. A probe passed readily by the side of the jaw into the mouth. I divided the trachea just above the sternum, and dissected the larynx and tongue carefully out. The morbid state of the tongue is shown in the preparation before the society."

In the discussion which ensued, the case was considered a very remarkable one. The remarks had reference chiefly to the cause of the disease, respecting which various opinions were expressed.



**Effusions.**—The tongue is occasionally the seat of formidable congestions or effusions. The writer has known an inflamed tongue so swell in a single hour as almost to prevent respiration. The organ, when enlargement increases to an extent which threatens suffocation, looks so vascular that one hesitates to use the knife. The practice is to incise freely,—cut deeply from behind forward, on each side of the median line, avoiding, however, in the depth of the cut, the ranine arteries. A wound thus made will bleed for a time freely, even alarmingly; but the common experience is that such cuts soon close, and are devoid of danger. Velpeau has recommended the opening of the ranine veins in congestion. Leeches may also be applied direct to the tongue.

**Erysipelas.**—A formidable danger in the tongue is the presence of erysipelas: this may be idiopathic, but is most frequently traumatic, operations about the jaws being, occasionally, provocative of the condition. The treatment of erysipelas in the tongue is the same as treatment of the condition elsewhere. Iron and quinia, internally and locally, are to be freely employed. If this be not found effective, then make incisions. The practitioner is, however, never to forget to extend his observations over any functional disturbances which may exist.

**Bites of Insects.**—The most severe and threatening glossitis ever met with by the author was the result of the sting of a wasp taken into the mouth while the patient was eating blackberries. The tongue in these accidents is apt to swell enormously, but, happily, tends to a rapid self-cure. If seen immediately, no better application is to be employed than common mud; phénol sodique is a favorite preparation: later, we can only treat such an inflammation like any other of the sthenic type. It is well, however, to remember that the swelling in these cases is from effusion rather than a congestion; incisions, if necessary, are always to be made freely. Iodine, in these instances, sometimes acts happily; paint the tongue thoroughly, and hold cold water in the mouth. If, unfortunately, erysipelas supervene, the iron and quinia combination is at once to be resorted to.\* In these cases the pain becomes excessive, the parts may assume a livid hue, and there seems to be a decided tendency to gangrene; particularly does this occur in depraved and broken-down persons. Free incisions are never to be neglected: the degraded expression of the erysipelas depends upon the separation of the molecules—if the expression may be used—from their base of supply; the incisions, draining the organ, allow contraction of the parts, and thus restore the circulatory relationship.

---

\* R.—Tincturæ ferri chloridi,  $\bar{3}j$ ;  
 Quiniæ sulphatis,  $\bar{3}j$ ;  
 Tincturæ cinchonæ,  $\bar{3}ij$  to  $\bar{3}ss$ . M.

The author believes that this combination, as a local application, is an approach to, if it is not indeed an absolute specific in erysipelas. It will be noticed that the proportions of the combination as here given differ from that on a preceding page: this relates to application of the mixture as location is concerned.



In ulcers or tumefactions of the tongue provoked by irritating teeth, it is seldom necessary to do more than remove the source of offence. Cases occur, however, where some after-treatment is demanded, the provoked ulcer being indolent, or, in some instances, even semi-gangrenous. For all such sores, one of the best washes to be used is water changed in color to a milky blue by the addition of the compound tincture of capsicum. Where a part is simply indurated and not ulcerated, presenting no evident cause, it is better, for a time at least, to leave the case to nature. The writer's rule is, never to interfere with a non-explainable induration except from necessity. In all these cases injudicious meddling is bad practice.

**Erectile Tumors.**—Of this character of lingual tumors the author has met thus far with some five cases. Of these, the most marked was in the person of a babe nine months of age, for whose relief an operation was successfully performed at the hospital clinic. This tumor, which was congenital, occupied the whole anterior third of the tongue, protruded from and filled up the oral fissure to a considerable extent, was of a dark-red or purple color, enlarged very much when the child cried, was soft and fluctuating, and through manipulation could be made temporarily to almost disappear.

A mode of operation which in two weeks resulted in a perfect cure, consisted in first strangulating the mass with a double ligature, and, after three days, effecting separation through the instrumentality of a wire *écraseur*.

The principle of the treatment of erectile tumors of the tongue is that common to this class of tumors wherever found. (See *Erectile Tumors*.)

**Fatty Tumors.**—These, like the erectile, are uncommon. A peculiar case met with by the author exhibited the growth looking like a mass of very smooth fat, overlaid by the mucous membrane: the situation was the inferior left surface of the organ. As the patient spoke, the tumor would bulge out over his lower teeth, presenting a most unsightly appearance.

**Metastatic Disease.**—An example herewith given explains, without other remarks, a character of trouble rare, yet sometimes met with, upon the tongue. We may recognize in the disappearance and reappearance of the various exanthems an explanation of the condition. I have been consulted, says Mr. Wm. McClure, in a paper read before the Harveian Society, by a young married lady, for rather a curious affection. She informs me that her tongue becomes occasionally bestudded with small ulcerations, and, afterward, when these get well, the palm of her left hand becomes affected with a sort of psoriasis palmaris. The tongue is at present quite well, but the palm of her hand is covered with the eruption. When this gets better, however, she expects her tongue to become again the seat of disease, for thus they have alternated for a considerable time past,—she says about two years. The chief reason for which she consults me at present, however, is that she has gout in one of her feet. I believe that the whole series of her complaints depends on some derangement of the digestive organs, though that is not made very apparent by external symptoms. I gave her an alterative pill and a tonic mix-



ture, combined with colchicum and an alkali. The gout has already disappeared, and even the hand is much improved. As soon as the gout was got rid of, I substituted for the tonic mixture—in which, as I have just said, were wine of colchicum and carbonate of soda—a mixture composed of the extract of sarsaparilla combined with the iodide of potassium. As a local application to her hand I prescribed an ointment composed of pure iodine, iodide of potassium, and hog's lard; but this was found, upon trial, to give her so much pain, and produced so much irritation, that I was forced to abandon its use after a few days' trial. For it I substituted the following ointment, viz.: white oxide of mercury four grains, and extract of conium a drachm, rubbed up with seven drachms of prepared hog's lard. This ointment was ordered to be rubbed into the palm of her hand every day, both morning and evening. Besides these remedies, local and general, she took occasionally an alterative and aperient pill, made up of blue mass and the compound extract of colocynth. The consequence has been, after a month's steady use of the remedies, that the hand has become quite well, the skin being now, for the first time these two years, soft, white, flexible, smooth, and completely free from itching, heat, and every unpleasant appearance and feeling. Nor has the tongue as yet shown any tendency to alternate disease, as before; so that we have reason to hope—the constitution having been set to rights by the means employed—the former chain of morbid sympathy between the distant organs of which we have been speaking, and by which a metastasis of the psoriasis, from the one to the other alternately, took place so often, for so long a time, has been at last broken and destroyed, permitting both to remain in their healthy condition.

Urticaria, a very common skin-trouble, has similar metastatic relation. In a case encountered a wheal would appear either upon the cheek or the tongue whenever ice-cream was eaten.

**Hypertrophy.**—This condition has been met with and described by various writers.\* Hypertrophy may be complete, involving the whole organ, or the enlargement may pertain to particular tissues alone. A case is described by Mr. Paget, involving the muscular substance exclusively, the primitive fasciculi being found to divide in a dichotomous manner. The epithelium is another of the tissues most frequently found affected, instances being on record where this structure has thickened so as to resemble a coat of mail. Granular hypertrophy,

---

\* "A case is related by Zacchias, of a male infant well made except that the tongue projected three fingers' breadth from the mouth: the child could suck, and it lived until the age of fourteen months. Bertholin mentions a case of *linguæ portentosa magnitudo*, where a male infant was born with the tongue out of its mouth as large as a filbert: as the child grew its tongue enlarged to the size of a calf's heart. A case is recorded by Dr. Humphrey of a child, eleven years of age, whose tongue from the upper lip to its tip measured three and a half inches; from the under lip to its tip, one and a half inches; from the angle of the mouth round the sides and tip to the opposite angle, six and a half inches. The circumference of the widest part, which was about the middle of the protruded portion, measured six and a half inches circular measurement."—HOLMES.



a condition of enlargement of the papillary structure, is sometimes seen in the form of a mass of warty excrescences covering the whole body of the tongue; at other times it is confined to some portions more or less limited in extent.

The treatment of hypertrophied tongue is to be governed by the circumstances and character of each particular case. In epithelial hypertrophy the best results seem to have been secured through the use of arsenic,—from the thirtieth to the twentieth of a grain administered three times a day, its effect being carefully noted. Donovan's solution, the liquor arsenici et hydrargyri hydriodatis, given in five-drop doses, has been highly commended; also the solution of Lugol. These doses are for adults.

In a true hypertrophy of the organ—prolapsus, as it is frequently miscalled—that is, where the body has enlarged as a result of congenital impressions, medicinal appliances are of little service. This disease is markedly one of young life, commencing generally very soon after birth, and progressing tardily but surely until death or an operation gives relief. Unaccountable though it may seem, hypertrophy is confined almost exclusively to female children,—this sex being affected in the proportion of five to one of the other.

As may be inferred, hypertrophy of the tongue presents various degrees of enlargement; cases are on record where the organ has hung from the mouth, resting upon the breast. In the instance of elephantiasis, the mucous membrane looks more like the bark of a tree than anything else, being rough, dry, and crusted.

In the treatment of hypertrophy we consider the character of the trouble from the aspects of activity and chronicity. Where the first of these exists, most is to be hoped for from medication; where the latter obtains, little is to be expected except from operation.

Compression, recommended by Lasser and indorsed by Professor Syme, it may not be amiss to try before proceeding to excision or ablation; but the treatment will certainly be found to have much more of failure than of success in it. The author lately had at his clinic a boy in whom congenital hypertrophy had enlarged one side of the tongue to a bulk fully double that of the other; compression had no effect whatever. Ablation of redundancy is accomplished by cutting away a V-shaped piece, as shown in Fig. 4, Plate II. The manner of relating the parts after the section is explained in Fig. 5 of same plate.

**Atrophy.**—As the opposite to hypertrophy, reference is to be made to a condition sometimes, though infrequently, met with, of atrophy. A case described by Dupuytren found its explanation in a post-mortem, which revealed the presence of hydatids at the base of the cerebellum; one of these parasites, wedging itself into the anterior condyloid foramen, had compressed the lingual nerve and thus obliterated its function. Paget has reported a case arising out of pressure, by a piece of dead bone near the anterior condyloid foramen, on the hypoglossal nerve. Allan refers to a third instance where a physician in opening an abscess, which had formed beneath the jaw, is sup-



posed to have severed the nerve, as from the time of operation deflection and atrophy of the corresponding half of the tongue were observed; these were found to continue twenty-five years later. A case reported by W. Fairlie Clark details the particulars of atrophy of the organ, confined to its anterior two-thirds, where the lesion seemed to lie in carcinoma of the breast.

Errors of nutrition being the cause of asymmetrical conditions, it is to be appreciated that deficiency may be to such extent as insures loss of the organ. A case quoted by Dr. Allan refers to a male aged seventy-eight, who suffered from neuralgia of the occiput. The patient complained at the same time of dysphagia and excessive flow of saliva. By the eighteenth day the tongue became flabby, insensible, and began to mortify. By the thirty-first day a line of demarkation had formed, which included the right half of the tongue and the tip of the left half. The patient recovered.

**Papilloma.**—A papilloma of the tongue, as commonly met with, bears close resemblance to a common seed wart. A very simple and easily practised method of removing such a growth consists in drying the parts by means of napkin or rubber dam, and making an application of the London paste. A second means is found in transfixing the base by means of a curved needle and strangulating the pedicle. Papillomata, if unduly vascular, are to be looked on with concern; a common seat is the side of the organ well back.

**Venous Tumors.**—A case treated by the writer showed a bulbous vein not much less in size than an ordinary hickory-nut; cure was effected through strangulation.

**Arterial Nævi.**—Growths of this nature are most frequently met with about the tip; treatment is by ligature. (See *Nævi*.)

**Cartilaginous Tumors.**—Cases of enchondroma are reported as being met with. These growths must be very rare; the author has never seen one. Treatment would be by excision.

**Immobile Tongue.**—Immobility arises out of inflammatory changes attended with plastic deposits. The condition is uncommon except in connection with carcinoma, and, to a degree, with syphilis. The cure employs sorbents, aided, as the second of the causes is concerned, by a specific.

**Operations practised upon the Tongue.**—From medical necessity, or from accident, it sometimes becomes necessary to amputate a part or even the whole of the tongue. Surprising as it may seem, such amputations, even when of the complete organ, interfere very little with speech, and do not entirely obliterate the sense of taste. Mr. Nunneley, an English surgeon, lately exhibited to the Pathological Society of London a patient from whom he had removed the whole of the organ, this being effected by a submental opening, the patient, a man aged thirty-five, recovering without a bad symptom. The disease, which had existed sixteen or eighteen months, became worse eight weeks before the operation, and, from the pain and difficulty of speaking, the impossibility of mastication, and the difficulty of deglutition, was fast wearing the patient out. When shown to the society, the man had regained



strength and flesh ; indeed, said that he felt as well as ever : he talked with distinctness, and swallowed with facility.

A second interesting case is reported by the late James Syme, F.R.S.E., Surgeon-in-Ordinary to the Queen in Scotland, and Professor of Clinical Surgery in the University of Edinburgh.

About twelve months ago, says Mr. Syme, I communicated a case in which the tongue had been completely removed by excision, on account of extensive disease that threatened to prove fatal by preventing the admission of nourishment. This account was necessarily limited to the operation and its immediate effects, as sufficient time had not elapsed for determining whether or not the relief afforded would prove permanent, or how far the powers of deglutition, articulation, and taste would be restored. After his return home to Manchester, the patient sent me favorable reports of his progress, but certainly not such as to convey any adequate idea of the improvement that had taken place since he came under my care. He was then emaciated and bent down by long-continued suffering, unable to articulate, so as to require a slate and pencil for expressing his wishes, and swallowing even fluids with such extreme difficulty as to feel on the point of starvation. My surprise may, therefore, be imagined when, on the 10th of September last, he unexpectedly made his appearance, erect and vigorous, and, seeing that I did not recognize him, announced his name in a loud, clear voice. The feeling thus excited was not lessened by learning that, while travelling in the Highlands, he had dined at *tables-d'hôte* and entered into conversation without betraying the deficiency under which he labored. Very much astonished by a result so much better than could have been anticipated, I requested a number of my medical friends to join me in examining the state of matters. Professor Goodsir and Mr. Nasmyth having satisfied themselves that no vestige of the tongue remained, various observations were made with regard to articulation and other functions of the absent organ ; and Mr. Annandale afterward instituted a more particular inquiry, of which he has given me the following report :

“ The lips and jaw-bone, where divided, were soundly united without any deformity. The opening between the mouth and pharynx was much diminished in size and irregular in shape from contraction of the fauces and soft palate, which were drawn downward and forward more to the right than the left side, from the mucous membrane at that part having participated in the disease and been removed along with the tongue. Mr. W. says that he can swallow as well as ever, provided that the food is either finely divided or fluid. He is also able to masticate solid substances, although difficulty is sometimes experienced from their getting into awkward parts of the mouth. In ordinary speech his words are wonderfully clear and distinct, and he can sing without any difficulty. All the vowels and words composed of them are articulated perfectly, and also the following consonants : B, C, F, H, K, L, M, N, P, Q, R, V, W. D is pronounced ‘ dtbe,’ J ‘ the,’ G like ‘ sjee,’ S is



a lisp. His taste is impaired, but still enables him to distinguish different articles and their respective qualities, as grouse from partridge, bitters from sweets, good beer from bad beer, etc. He has remarked that the seat of sensation lies somewhere in the throat, since there is no recognition of taste previous to the act of swallowing; and, in order to ascertain the truth on this point more precisely, the following experiments were made:

"1. A strong solution of salt was applied by means of a camel's-hair brush to the fauces, palate, floor of the mouth, lips, and inner surface of the cheek, with the result of something being felt in the mouth, but no idea formed as to its nature.

"2. About a quarter of a teaspoonful of finely-powdered sugar was placed on the floor of the mouth, and, having been allowed to remain there a few seconds, was then brought thoroughly into contact with every part of the cavity without any recognition of its nature; but when a little water was added and swallowed, the taste was immediately perceived.

"3. The same experiment was repeated with another substance (salt), and with the same result."

It has long been known that large portions of the tongue may be removed without destroying or materially impairing the power of articulation; but I am not aware of any case on record in which it has remained so perfect after complete removal of the organ.\* Of the facts above mentioned, the one that

---

\* Complete extirpation of the tongue has now been practised with success by a number of surgeons, among them by Fiddes, Heath, Nunneley, Annandale, Rizzoli, and Sedillot.

EXCISION OF TONGUE.—"The removal of the entire tongue is altogether a modern surgical operation. Though, for time out of mind, greater or less portions of the tongue have been removed by cutting instruments, escharotics, actual cautery, or ligatures, the importance of the organ in deglutition and articulation, the difficulty of reaching its base, and especially the fear of not being able to arrest the hemorrhage, owing to the depth of the wound, the size of the arteries, and their near origin from the carotids, have not unreasonably deterred attempts at more than partial amputation of it. I believe it was Mr. Syme who first suggested an operation for its entire removal, and performed it in the presence of many members of the Association, when its meeting was held in Edinburgh. Unfortunately, that patient, as well as a second, died a few days after the operation; and a solemn warning was published by Mr. Syme, who declared that the operation was so serious that further attempts were not justifiable, as no one could recover from it. Subsequently, I believe, in a third case, Mr. Syme was, by a like proceeding, rewarded with success; and Mr. Fiddes, in Jamaica, and Dr. G. Buchanan, in Glasgow, have also succeeded by the plan laid down by Mr. Syme. However, believing that the severity of the operation depended far more upon the method of proceeding than upon the mere removal of the tongue itself, I devised what I hoped would prove to be a less formidable one, and which experience has proved to be so. Up to the present time I have removed the entire tongue nineteen times, and Dr. Fenwick, of Montreal, has done the same operation once, without any untoward symptom following in a single instance. In most cases the patient has not required any after-treatment, being able to sit up the following day, and in ten days to be considered well. In the majority of operations not a drachm of blood has been lost. In two cases only has there been any hemorrhage, and in those not more than half an ounce of blood was lost. In one a point of hot wire, and in the other a ligature, at once arrested the bleeding. The little constitutional disturbance which follows this operation is surprising; indeed, in the majority of cases there is none."—THOMAS NUNNELEY, F.R.C.S.



seems most curious is the connection between taste and deglutition; from which it appears that the latter is essential for the full perception of the former. If the pleasure of taste could be perfectly gratified by mastication without deglutition, there would be no limit to the consumption of food; but the instinctive desire to swallow an agreeable morsel affords a check to any such abuse.

Mr. Paget reports the following case:

On the 20th of February a little girl, about three years of age, was brought into the operating theatre of St. Bartholomew's Hospital with hypertrophy and prolapsus of the tongue, which commenced when she was some six months old. It now protruded nearly two inches, and hung downward, completely filling the circle of the lips; its end was dry, and excoriated with hardened epithelium, a sort of crust having formed of the size of a shilling; several of the papillæ also were enlarged, and in places gave to the tongue a warty or granular appearance. The lower jaw had already begun to be deformed, and expanded downward and outward; the teeth were gradually separating from one another in the mental portion of the jaw, and there was dripping of saliva. An examination of the tongue by Mr. Paget showed that the organ was truly hypertrophied; the part not prolapsed completely filled the cavity of the mouth.

Chloroform was carefully given to the child, and the chain of an *écraseur* was passed around the tongue within the mouth, the jaws being kept open by a metal gag. The chain was slowly drawn home, and the prolapsed and hypertrophied portion was detached with little or no bleeding. On examination of the piece removed, its structure was found to be similar to that of the natural organ, both in texture and color: it was simply a redundancy of growth from hypertrophy. The subsequent progress of the case was reported as most satisfactory, a good recovery being recorded.

Partial amputations of the tongue have been very frequent. Union, in many of the cases, is very rapid and perfect. In one instance, that of a child, where a kind of a flap operation was made by the writer, reliable union resulted in a single day.

Amputation of the tongue, complete or partial, is practised with ligature, knife, or *écraseur*. The author, from his own experience, gives the preference to the last means.

**Operations.**—For a surgical study of the tongue, and the operations practised upon the organ, the reader will turn to Plate II.

Subfig. 1, in plate, is a front view of the anatomical relations of the parts about the fauces, as shown with the mouth wide open. 1, the dorsum of the tongue; 2, 3, the tonsils; 4, the uvula; 5, the anterior half arch; 6, the posterior half arch, with the tonsil between it and 5; 7, the soft palate.

Subfig. 2 represents a side view of a vertical section of the mouth and tongue, showing the relations of the vessels and nerves of the tongue. 1, the lingual artery; 2, its sublingual branch,—the veins accompanying the ar-



teries; 3, the hypoglossal nerve; 4, the ranine terminations of the lingual vessels.

Subfig. 3 represents the situation and associations of a disease compelling amputation of a section of the tongue. The lines, 1, 2, 3, form a V, which is to circumscribe the growth; it should, however, have been placed much farther back.

Subfig. 4 exhibits the operation of excising the tongue, as practised with scissors. When the knife is used the sections are similarly made. If, in such an operation, the hemorrhage be threatening, it is better to ligate quickly the vessels of one side before making a section of the other; this suggestion, however, only holds good when the bleeding orifices are freely exposed and can be reached without effort or difficulty.

Subfig. 5 shows the preceding operation completed, and the flaps united by ligatures. 1, 2, represent the sutures: wire pins or waxed silk may be used. Let them be left in only long enough to secure the union; this, if no undue inflammation supervene, will be accomplished in from twenty-four to forty-eight hours.

Subfig. 6 is the *lingua vitula*, or lingual hypertrophy. The particular case here represented was a patient of Dr. Harris, of Philadelphia, and the operation was the first performed in the United States. The case is thus described by Professor Henry H. Smith in his "System of Surgery":

The patient, aged nineteen, had the tongue enlarged at birth. A short time previous to the operation it projected beyond the upper incisors at least three inches. Its circumference was six inches, and its vertical thickness one inch and a half; it filled up the jaws so completely that it was necessary to have the food cut into small pieces and introduced at the side of the tongue.

The operation practised by Dr. Harris was accomplished as follows: The tongue being elevated, a strong ligature was passed through its tip so as to control its movements. The under surface was then dissected from the floor of the mouth about three-fourths of an inch behind the anterior part of the jaw, and a strong, straight bistoury introduced into the organ at a point where the dissection terminated, whence it was pushed through between the median line and the left ranine artery, and, being drawn laterally and forward, was made to cut a flap, which terminated near the first bicuspid tooth. The left ranine artery being then secured with a ligature, the bistoury was again introduced in a corresponding position on the right side, and the opposite, or right flap, made in a similar manner. The artery of this side being now secured, and the space intervening, or central portion, divided by strong scissors, the incisions, or flaps, resembled the letter V, and, being approximated by these interrupted sutures, made a pointed, well-formed tongue of the ordinary length. A year subsequently the patient articulated distinctly, and continued relieved of all deformity.

In another case, somewhat similar to this, under the care of the same surgeon, a ligature was applied to the enlarged portion, in order to cause it to



Fig 1.

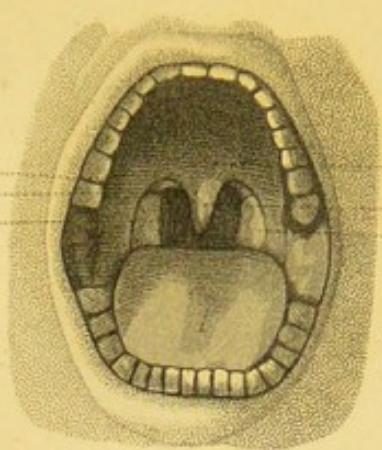


Fig 2.

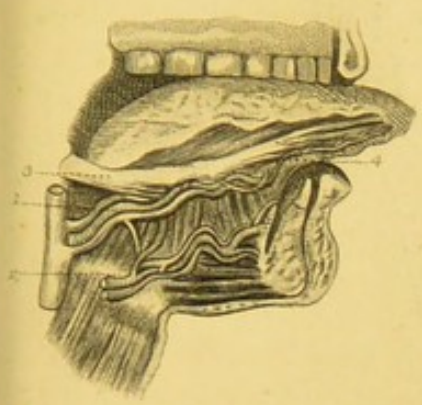


Fig 5.

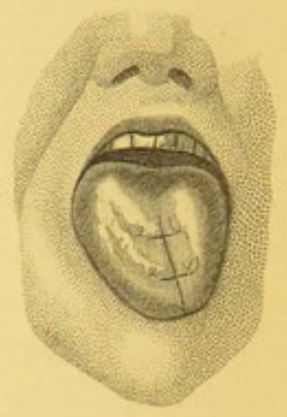


Fig 6.

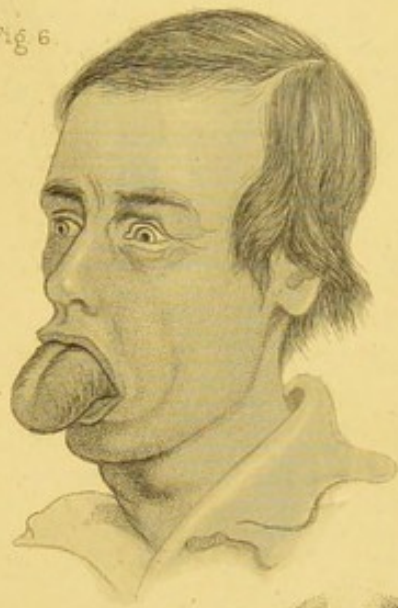


Fig 3.

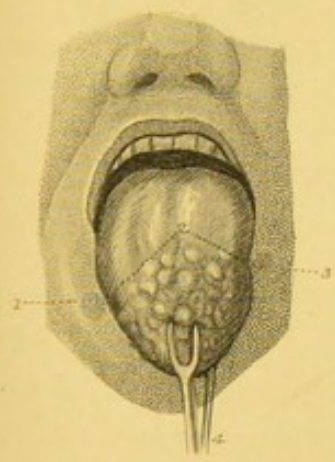


Fig 4.

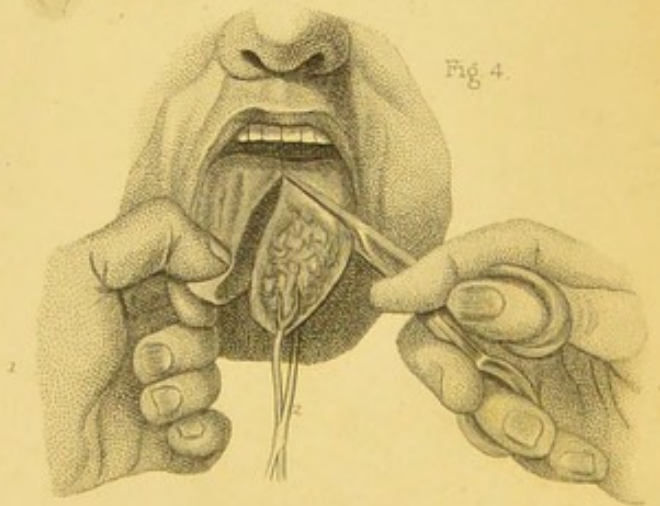


Fig 7.

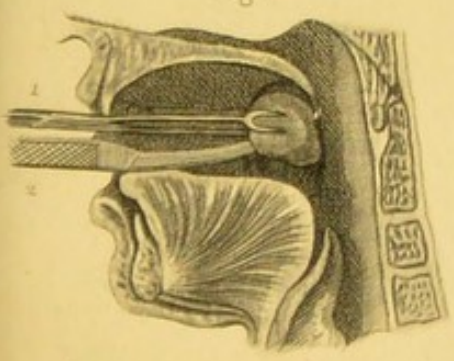
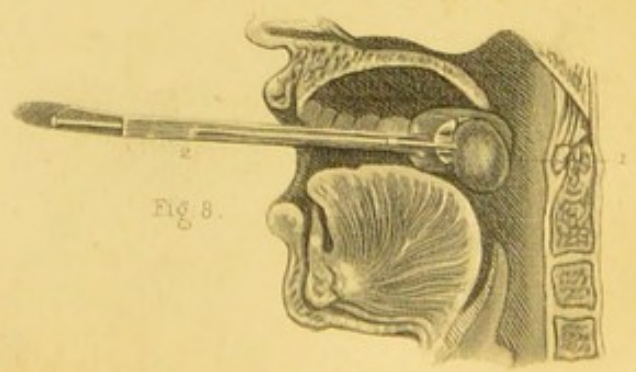


Fig 8.



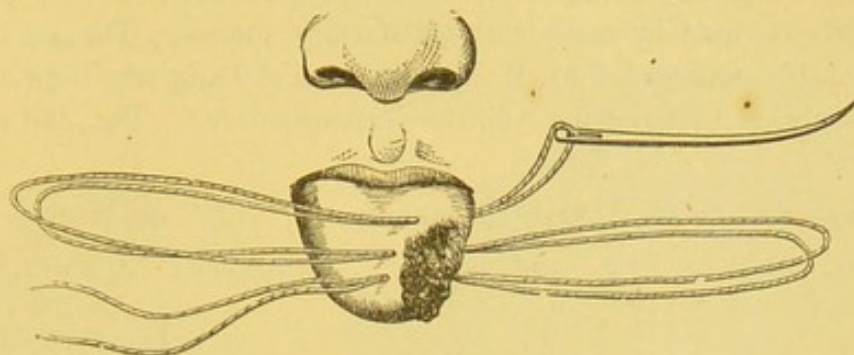






slough off; but the irritation, Professor Smith informs us, was so great that Dr. Harris found himself subsequently compelled to amputate the end of the

FIG. 387.—AMPUTATION BY STRANGULATION.

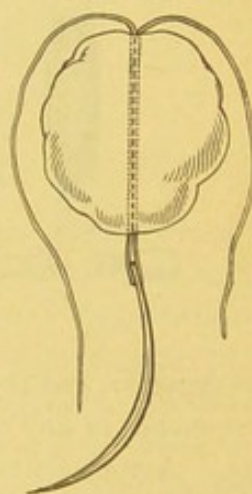


tongue with a catlin. In this patient the organ protruded four inches; its circumference was over six inches, and its vertical thickness nearly two inches.

Other figures upon the plate show manner of excising the tonsil glands, the bistoury and tonsillotome being used.

Fig. 387 represents a condition of resisting ulcer, together with a manner of treatment by strangulation. With such ulcers and such manner of treatment the author has had quite a large experience, but, as before remarked, he gives the preference to the *écraseur*. A mode of using the ligature, more convenient than that exhibited in the diagram, and quite as effectual, consists in the passage of the double thread, exactly as is represented in this case by the threads occupying the middle position; separating this double ligature, it may be made to circumscribe any portion of the tongue simply by the passage of pins: as, for example, if in the places of the first and second threads, as shown, pins were placed, it must be seen that by separating the double middle ligatures and casting them back of the pins, the part included would be precisely the same as found here with the six ligatures. By such use of the double ligatures the author has amputated full half the tongue twice within four months. Such a mode of employing the double ligature, not alone for the tongue, but in any other situation, is shown in Fig. 388.

FIG. 388.



**The Écraseur.**—Fig. 389 exhibits the *écraseur* of the inventor of the instrument, the French surgeon M. Chassaignac. Of the two forms shown, the one to the right will be found most to commend itself, the direction of the chain being best controlled by it. To use the *écraseur*, it is simply necessary to arrange the chain back of the part to be amputated, the handle being next slowly worked, whereupon the chain, little by little, is retracted, until finally—the time should seldom be less than a quarter of an hour—the portion



of tissue drops off, without, quite as likely as not, the loss of a single drop of blood. Such a bloodless ablation of the tongue was lately performed by the author before his class.

As a substitute for the chain of the Chassaignac instrument, a common annealed wire is used by many with satisfactory success. The use of such a wire is highly commended by M. Maisonneuve, of Paris, who has published a memoir on what he terms the "*ligature extemporanée*." Fig. 390 exhibits

FIG. 389.—CHASSAIGNAC'S ÉCRASEUR.

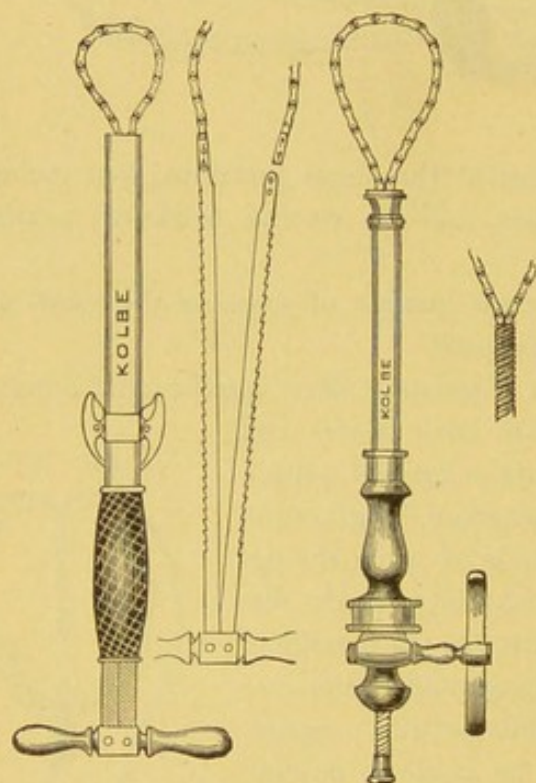


FIG. 390.

LIGATURE EXTEMPORANÉE.



this écraseur, and the mode of its application. A screw like that of Graefe's serre-nœud, or any other convenient means, may be employed to tighten the wire. A very convenient instrument of such character is manufactured at a trifling price by Mr. Kolbe, of Philadelphia, and is to be procured of most surgical cutlers. With such form of écraseur, the author has succeeded in amputating, without trouble, fully two-thirds of the organ.

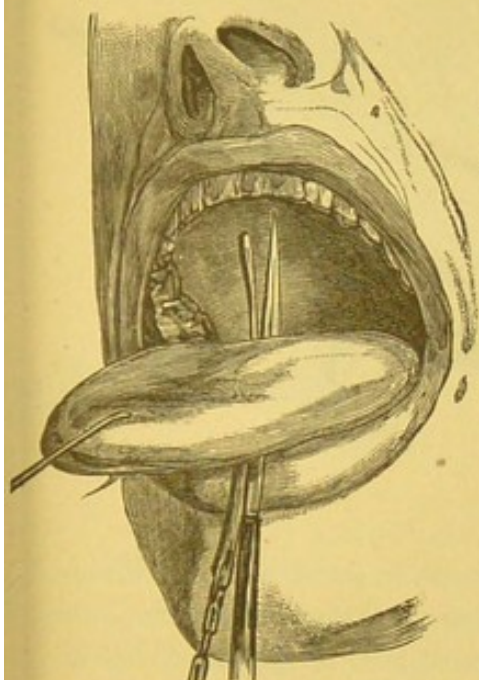
Ablation of the tongue in part by means of the écraseur is fully demonstrated by Figs. 391 and 392. In the first of the cuts is exhibited the manner of applying the instrument, which, as seen, has been threaded, or attached, to the eye of a silver probe, the probe following the thrust of a bistoury and being in place before the knife is withdrawn. In the second of the cuts, two chains, belonging to different écraseurs, are seen ready fixed for the strangulation; the retraction of the chains within the handles cuts the piece out; the loop held by the finger in this diagram is a replacement of the



tenaculum seen in the other; either being used alike with the common purpose of securing control of the organ.

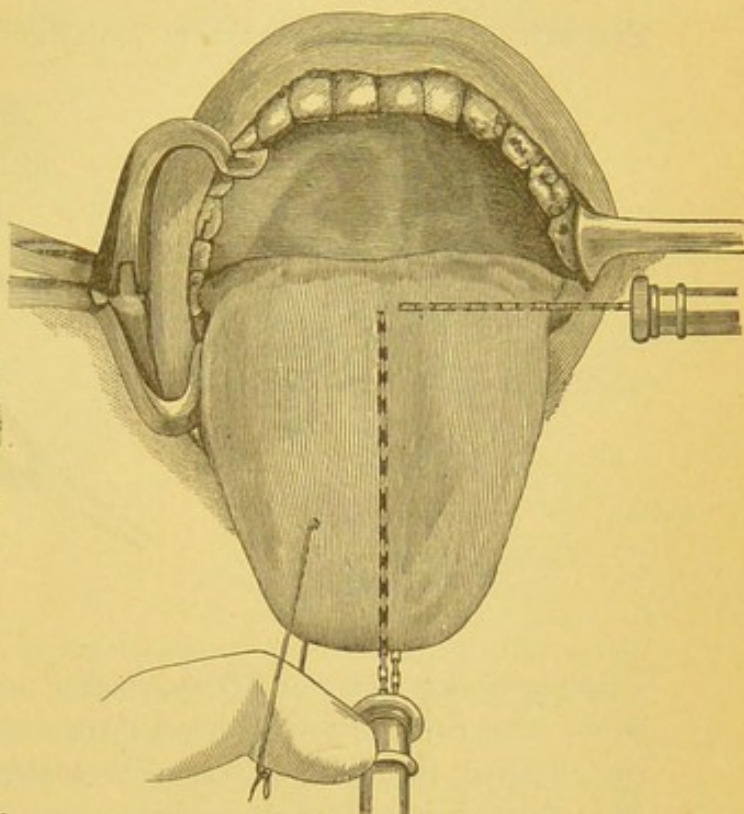
Ablation of the tongue in full, an operation now attracting considerable

FIG. 391.



Application of écraseur with a view to limited section.

FIG. 392.



Two écraseurs used in making sections.

attention, is variously practised. A mode known as that of Regnoli, shown in Fig. 393, consists in opening into the oral cavity from the neck, and, by means of a loop in the tip, drawing the organ downward. To open into the cavity by this plan, the operator commences by making a curvilinear incision corresponding to the arch of the jaw, extending nearly from angle to angle. Joining this first incision is a second of vertical direction, extending to the hyoid bone. The flaps are next to be reflected, and, after incising the lingual muscles from the bone, the tongue is caught by the tip and drawn out of the mouth. Control of the organ being thus secured, the knife or écraseur is employed to make the separation.

A second manner of operation is that which was practised by Mr. Syme. This is shown in Fig. 394, and is as follows. A first incision divides the lower lip in its exact median line, being carried down to the hyoid bone. Next the maxilla, by means of a saw, is separated at the symphysis; this may or may not necessitate the removal of the two front teeth. Placing the finger as a guide beneath the tongue, the surgeon next incises the mucous membrane, together with the muscular attachments. At this stage attention is to be given to hemorrhage. The tongue, as shown, is to be drawn forward and the amputation made by the écraseur.



Statistics favor the Regnoli operation rather than that by Mr. Syme; the section of the jaw made by the latter complicates to a marked extent the process of cure.

Still another operation, one practised by Mr. Nunneley, of Leeds, has

FIG. 393.—REGNOLI'S OPERATION.

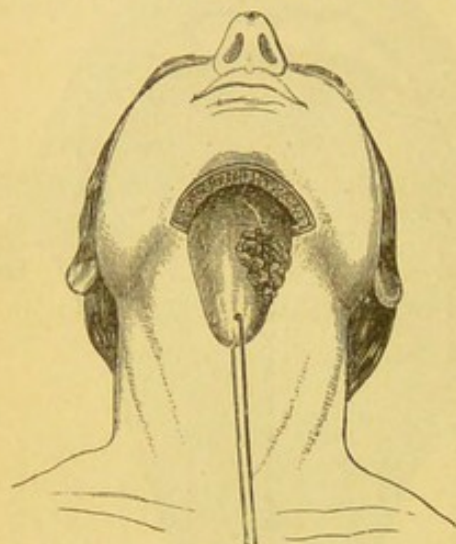
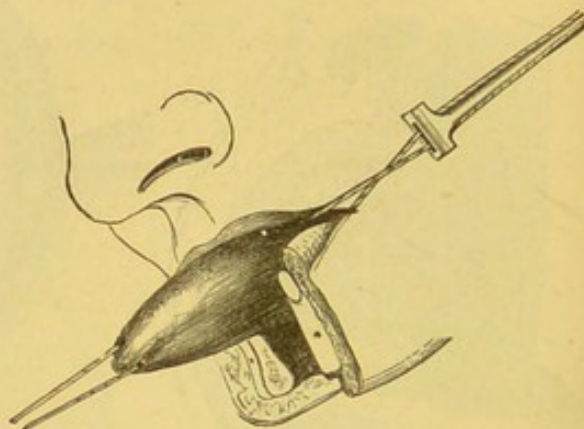


FIG. 394.—SYME'S OPERATION.



yielded a success most satisfactory, since of nineteen cases in which this surgeon has operated, removing the whole or a large portion of the tongue, every one survived the performance. The manipulations, as practised by Mr. Nunneley, consist in a slight incision, a puncture, indeed, made in the exact middle line of the throat,—a little nearer the base of the jaw than the hyoid bone, the bistoury being passed upward until it emerges at the frænum. Through this wound is drawn up the chain of the *écraseur*, the loop being cast about the base of the tongue. Next, with a *volsella*, or by any other convenient means, the organ is pulled outward and upward. To control and secure the loop of the chain about the base, two strong curved pins are passed from below, through the tongue, to the base; the loop thus controlled, ablation is made as in the previous cases. See Fig. 395.

A fourth process is that practised by Mr. Paget. Separating first the general attachments of the *genio-hyoglossal* muscles, this surgeon dissects along the floor of the mouth, thus liberating the tongue, whereupon the organ is caught, drawn forward, and removed with the *écraseur*. See Fig. 396.

In limited ablations, the surgeon, not having at his command the *écraseur*, may use with satisfaction the ligature as illustrated a few pages back. A point of importance, however, to consider in the use of that means, is the danger of cutting the string out; it is really a nice point to draw it tight enough, yet not too tight. The author has seen a ligature cut through a tongue almost with the facility of a knife, complicating matters most seriously by the hemorrhage which followed. Another matter is correspondence in size of the thread with the needle used. A needle, larger than the thread which



is to occupy the line of its passage, will not infrequently have its use associated with an oozing of blood, so persistent as to compel the repetition of an operation.

In the use of an *écraseur* the surgeon will also not infrequently find him-

FIG. 395.—NUNNELEY'S OPERATION.

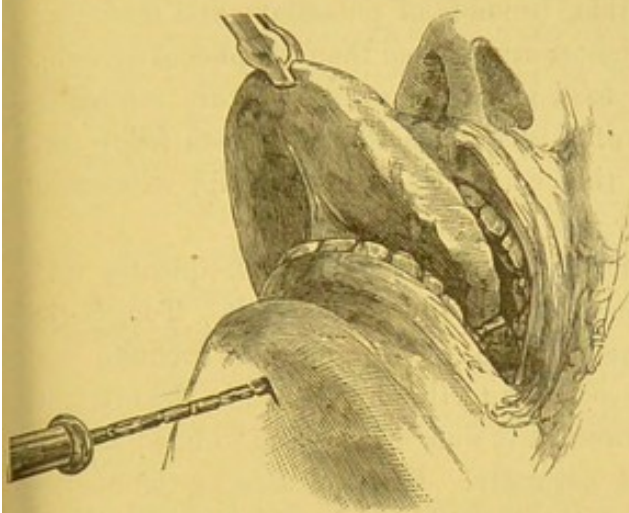
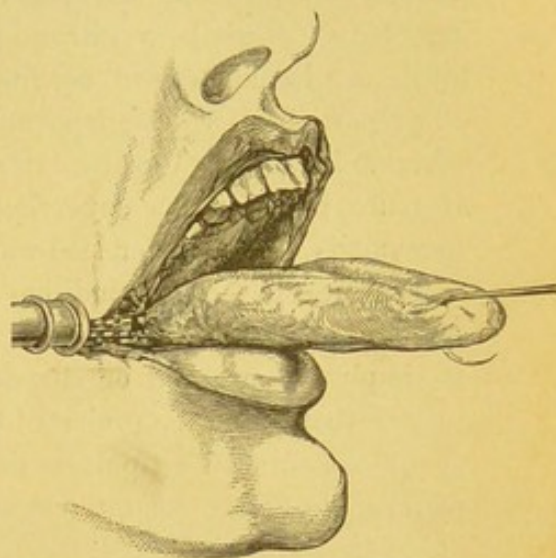


FIG. 396.—PAGET'S OPERATION.



self confronted by hemorrhage, and particularly is such a result to be anticipated where abundance of time is not allowed for the ablation: the rule with this instrument should be, "make haste slowly."

Billroth's method of amputating the tongue, a method in favor with many surgeons, begins with the ligation of both lingual arteries, the vessels being reached by a curved incision upon the submaxillary region of the neck, which starts below the anterior border of the masseter muscle, is carried down to a level with the hyoid bone, and is extended from this to the locality of the genial tubercles. The cut passes through the integuments, exposing and opening the envelope of the submaxillary gland, which body is pushed out of the way, and an incision made through the hyoglossus muscle, the vessel being exposed and lifted in a triangle formed above by the hypoglossal nerve and below by the converging bellies of the digastric muscle. The arteries secured, and the circulation thus shut off from the tongue, the jaws are widely separated by means of a convenient gag, following which a strong ligature is passed through the organ, and looped, with a view of securing control. Ablation here commences, a pair of stout and sharp scissors being used. First the *frænum* is divided. Next a blade of the instrument is thrust through the hole thus made, below the mucous membrane relating the tongue and floor of mouth, which membrane is divided back to the epiglottis. A succeeding step disparts the hyoid muscular attachments from before backward, following which the organ is freed and lifted from its bed. Limited bleeding attends the operation, a compress of sponge being found sufficient for its control. Nutrition is effected for five or six days after the operation by means of an india-rubber tube passed through a nostril into the *œsophagus*.



Whitehead's operation differs from the one just described in that the English surgeon does not preliminarily ligate the lingual vessels.

Hemorrhage, shock, inflammatory perversions, and septicæmia are the dangers associated with operations upon the tongue, which dangers the prudent surgeon guards against by every precaution known to the science. After an operation of magnitude upon this organ, it is always prophylactic practice to prescribe *veratrum viride*, bromide of potassium, and morphia; while as a local detergent, nothing better can be used than the *phénol sodique*, in proportion of a dessertspoonful to a goblet of water, *tinctura capsici et myrrhæ* being added to the extent of a teaspoonful if suppuration follow, or, if acute inflammation supervene, this conjoined with the fluid extract of *hamamelis Virginicus* or lead-water and laudanum.

**Tongue-Tie.**—The condition denominated tongue-tie is frequently met with in young children, and, indeed, occasionally in the adult. Tongue-tie is simply a shortening or curtailment of the anterior mucous *frænum*. A tongue that cannot be projected beyond the teeth, and which, in the attempt at projection, has its tip turn downward, is tied. A tongue so fixed cannot perform its offices comfortably and naturally. Upon examining the mouth of a person thus afflicted, the tip of the organ is not infrequently found set to the floor of the mouth, incapable, indeed, of any movement. This, however, is an extreme case, the usual condition being simply curtailment of ordinary motion.

Tongue-tie is of two kinds, adventitious and congenital. Of the first, that arising from ulceration is the most common. A person having a bad ulcer under the tongue, particularly if on the side of the *frænum*, is almost sure to have the fold shortened as the result of cicatrization.

A second expression of this first form is one described by Professor Dewees; exceedingly rare, but necessary to note.

There is found, says Dr. Dewees, attached to the *frænum* of the tongues of new-born children a nearly transparent, whitish membrane, which pursues the bridle through its whole course, continues beyond the point where it stops, and terminates near the extremity of the organ itself; so that the tongue is tied down, as it were, to its proper bed.

In consequence of this disposition of the *frænum* the child cannot elevate the tongue nor protrude it beyond the lips, and in attempts to suck cannot apply it with sufficient force or certainty to the nipple to make a complete exhaustion; therefore it sucks but imperfectly, and the act is accompanied by a clucking kind of noise. Whenever this is observed the mouth should be examined, and it will almost always be found in the condition just described, but not necessarily, as there may be clucking without this membrane; but the membrane, we believe, is never without the clucking.

This membrane is easily discovered by provoking the child to cry or by elevating the point of the tongue by the extremity of the little finger. In making the attempt to raise the tongue the child is almost sure to



cry; and then this tissue is readily discovered, as it is put fully upon the stretch.

The defect is easily remedied, being corrected in the following manner: Let the child be laid across the lap of the nurse, with its face toward a proper light, the operator standing behind the head so that he does not intercept the light. The chin of the child must be gently depressed by the forefinger of the nurse. When it is thus lowered the little finger of the left hand of the surgeon is to be insinuated between the side of the tongue, near its tip, and the inner corresponding portion of the jaw, until it can lift up the point of the tongue, which being done, the membrane is immediately brought into view and put upon the stretch; or, should the child now begin to cry, as it almost always does, the operator can easily place his finger under the tongue and keep this false frænum tense, while by a single stroke directly across it by a sharp gum-lancet he divides it to the true frænum; the operation is then finished. We have never known it necessary to repeat this operation. The incision through the membrane never yields more than a small drop of blood; no hemorrhage can ensue, as the tissue is but very slightly vascular.

A third of the adventitious forms, occurring in the adult, is the result of induration of the frænum. This is occasionally venereal in character, or it may be cancerous. In these cases the band gradually thickens until the motion of the tongue is markedly impaired. The cancerous is distinguished in its incipency from the venereal disease by the greater pain associated with the movements of the parts; in the first the pain is acute and sharp, in the second it is soreness rather than pain. If the induration be malignant the parts may be excised, still better, let alone, the hope of cure being very slight; if venereal, a specific treatment conjoined with such general and local combinations as may seem demanded by the circumstances of the case is to be pursued. The practitioner is to avoid over-irritation.

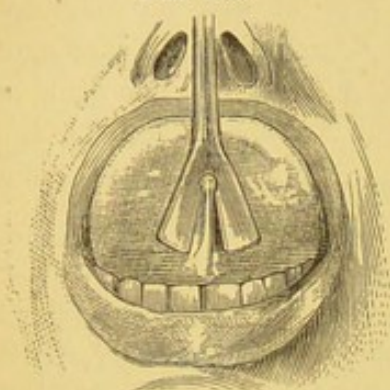
Congenital tongue-tie is quickly appreciated by lifting the tip of the organ. These cases differ very much, the frænum at times being observed to run as in the normal course, except that it is much shortened. In other instances the fold passes forward almost to the apex. It may be free or tight. If the first, it forms a septum between the lateral aspects of the floor of the mouth, but is not otherwise inconvenient; if the latter, it ties the tongue more or less closely.

The relief of a congenital tie consists in nicking, or cutting, the contracted frænum. This operation, although of the simplest nature, requires to be performed with some care. A frænum too freely cut permits of the tongue being pulled quite far back into the fauces; cases are on record where suffocation has nearly resulted from such accident. Again, it is not to be forgotten that the ranine vessels inosculate just in front of the frænum on the under surface of the organ, and that they might very easily be divided in an operation. Many children have lost their lives from such an accident.



A proper operation consists in making a simple nick midway between the tongue and the floor of the mouth; a rupture of the parts thus effected, the motions of the tongue will quickly secure all the latitude required. Should

FIG. 397.



Division of the frænum while held up  
by director.

an operation unfortunately open a vessel, the best practice would be to secure it with a ligature; but this is not always easy of accomplishment, the artery retracting within its loose sheath. An instrument devised by M. Petit to control such a hemorrhage consists of a piece of ivory, cut fork-shape, the prongs, of which there are two, passing on either side of the frænum, the short handle resting against the inside of the jaw. To apply this instrument introduce against the bleeding vessel a tuft of lint saturated with alum-water or other astringent, then place the fork about

it and secure it by pressing it down with the tongue, over and around which and the jaw a roller is to be thrown. A much better means, however, would be the use of the Morrison Compressor, which see. Guersent, in his "Surgical Diseases of Children," recommends the *serre-fine*, or the retention, for a time, of agaric against the part. Another means, where the wounded vessel is not too far retracted to be caught, is the employment of torsion. The use of nitrate of silver or of Monsel's salts in these cases cannot be too forcibly discountenanced, the injury done by either to the tender parts making secondary hemorrhage almost a certainty. The position of the lingual vessels in danger from operation for tongue-tie is seen by reference to Plate II., Fig. 2.

**Swallowing the Tongue.**—Swallowing the tongue, as it is called, is a disagreeable accident, and may occur without section of the frænum. Dr. Dewees mentions one case in which a child became choked several times a day from such a recession. This case was always, however, relieved by the nurse, who would press the organ down with the handle of a spoon and then draw it forward.

**Operation for Tongue-Tie.**—To operate for tongue-tie it is best to place the body of the infant upon the lap of the nurse, the head being received upon or between the knees of the surgeon; the tip of the tongue is then raised, and the cut, or nick, made with a pair of curved scissors. Fig. 397 shows the frænum exposed and held by means of the nick in a director.



## CHAPTER XXXVII.

### THE UVULA AND ITS DISEASES.

SURGICAL anatomy recognizes the uvula as muscle inclosed in a bag of mucous membrane, the connection between the two being a varying amount of loosely related cellular tissue.

The frequent and only common local disease of the uvula refers to enlargement of the organ. Enlargement is by reason of relaxation, by cellular engorgement, by hypertrophy, by neoplastic associations.

Persons of lax tissues are not unapt to possess a uvula of such undue length that serious irritation of the fauces is provoked, phthisis pulmonalis being too often a consequence. Examination of the condition reveals a pale relaxed apex, the distinction between muscle and membrane being very marked.

Enlargement by cellular engorgement finds explanation in serous infiltration. The writer has encountered cases where, in a single hour, the organ has swelled to the size of a shell-bark, and where immediate relief was necessary to the saving of life. Cases of this kind relate with laxity of tissue associated with acute inflammatory attacks, although, as a reverse to this, instances are met with where tonicities is the characteristic of the individual at large. The organ, when this condition exists, has much the appearance, and certainly all the characteristics, of a water-bag.

Hypertrophy, as an uncomplicated condition, is not at all common, and when met with, has its meaning in organization of plastic lymph exuded between muscle and envelope. The subjective symptoms are described by the patient as a lump in the throat and interference with swallowing.

Neoplasms refer to new formations of cancerous relation, and are always of secondary signification, the disease extending to this from neighboring parts; the signs are pre-existence of the vice, local enlargement, hardening, nodulation, specific pain, progressive degeneration.

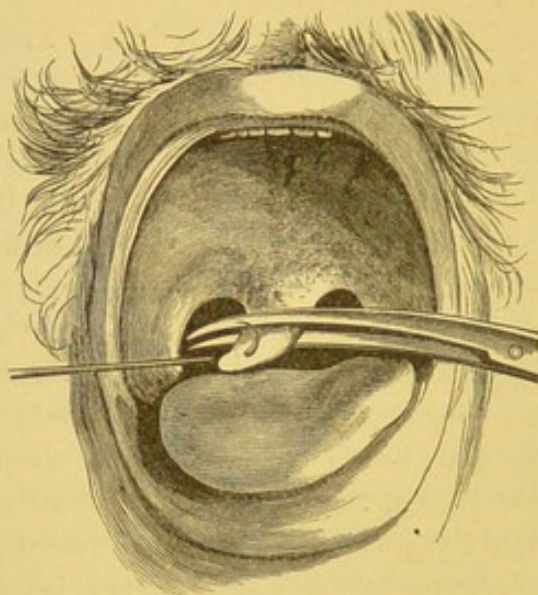
Tumors, analogous to those so often produced in the lobes of women's ears by the wearing of rings, are occasionally found pendent from the tip of the uvula. Fatty growths are also alluded to as having been met with. Defined cysts are described as of occasional occurrence.

**Treatment.**—Treatment of uvular disease is according to indications. When the organ is simply relaxed, the mucous bag being the tissue involved, no cure equals amputation of the redundant part. To accomplish this the author now universally employs the plan of empaling the tip upon a tenaculum (Fig. 398), and incising with scissors curved flatwise. The use of a tenaculum



for fixation and control is so superior to all other means as not to allow of too much commendation. In the case of children ether is to be given, and the

FIG. 398.



mouth held apart by a Kolbe or other gag. Fig. 399 shows a form of scissors much used; the teeth have the intention of catching and holding the excised part.

Enlargement from serous effusion demands effective treatment. Iodine, muriate of ammonia, and other sorbefacients are recommended, yet are tried

FIG. 399.—UVULA SCISSORS.



only to be found unreliable. Every cell of the connective tissue communicating the one with the other, accommodating the serum, it is alone necessary, in order instantly to drain the tumor, to snip off the apex, otherwise to slit the uvula; preference to be given the first of the operations.

Hypertrophic enlargement of the uvula is treated by the use of sorbefacients, and by pressure applied through the daily use of forceps faced with rubber; fifteen minutes are required for the latter purpose, the handles of the instrument being retained in the grasp of the operator's hand. A second manner of exerting pressure employs a rubber ring, applying it by means of forceps not unlike those used with the rubber dam. To avoid accident, a string is attached to the ring, which string is brought out of the mouth, and may be



attached to a button-hole. Still another plan employs collodion; the uvula, after being dried by means of bibulous paper, is thoroughly coated, the performance being repeated several times daily. If the lower half alone be involved, amputation is the remedy.

Simple fibromata, lipomata, and cysts may be cut away even to the extent of removal, along with them, if necessary, of the whole uvula.

**Restrictions.**—As one of the offices of the uvula is to convey the mucus and saliva about the base of tongue and epiglottis, acting thus as an agent of lubrication to these parts, it is objected that ablation of the organ results in a dryness of the parts more irritating than the offence removed. Objection is also advanced that as the uvula possesses the function of holding the soft palate tense and firm in the median line against the pharynx during the act of deglutition, thus preventing the passage of fluid or of solid substances toward the nose, amputation of it must result in serious inconvenience. As loudness in speech is concerned, the organ is credited in exercising much influence through its capacity as a levator or shortener; this as the muscular portion is involved. Speech, according to Sir Duncan Gibbs's experiments, is modulated by the soft palate and uvula, and the motor power of the latter is unquestionably exerted, he maintains, in pronouncing the letters K, Q, and X, with their associations, more especially in the gutturals of the various languages. Concerning these objections the writer has to note a clinical experience which in no way indorses them. Caution in performing operations of the kind on the persons of public singers or speakers is, however, not unwisely considered and practised.

Hemorrhage from amputation of the uvula is seldom found to require attention. The author has operated a great number of times, and never, except in a single instance, met with bleeding to an extent demanding treatment; in this one case it yielded to a gargle of alum-water. A feeling of rawness associated with the excision, and which is the principal complaint, will be found corrected through the use of crystals of gum arabic held in the mouth, or, if preferred, marsh-mallow or jujube paste may be used,—solid food is to be excluded from the diet for a short time.



## CHAPTER XXXVIII.

### DISEASES OF THE FLOOR OF THE MOUTH.

ENCIRCLING the tip and sides of the tongue is a space bounded externally by the inner face of the maxillary alveolar process, which space constitutes the lower boundary of the mouth; its floor is the mylo-hyoid muscle; its carpet a plane of mucous membrane. Anteriorly this space is divided into two parts by the *frænum linguæ*. Floor and carpet are separated by cellular tissue which might not inaptly be likened to a single layer of wadding related by one face to the first, by the other to the second, structure.

Imbedded in this cellular tissue are the sublingual glands, together with their vessels of outlet. Passing through it are the Whartonian ducts. Lying beneath the floor of the region are the submaxillary glands. A large vein crosses it. The most common of the diseases of the locality, as the author has met with them, is tumefaction arising out of sympathetic disturbances; notably, alveolo-dental inflammations. Cases will be encountered where the mucous membrane is so thrown upward, as a result of effusion into the underlying cellular tissue, as to assume a place on a level with the teeth. In glossitis such infiltrations are not infrequently of an extent that throws the membrane as a partial envelope about the sides of the tongue. Treatment is to be directed to the primary lesion.

The second most common disease arises out of obstruction in the salivary ducts. The trouble shows itself either as a raised roundish line running from an inflamed point beneath the tip of the tongue; as a cystoma; or as a tumor, lesser or greater in size, of stony hardness. The swelling known as frog-belly ranula is an example of salivary obstruction.

**Ranula.**—The term, not a good one, is retained because of the familiar position it holds in surgical nomenclature.

The subject is one easily comprehended. A ranula is the analogue of a sebaceous tumor, being simply a cyst of retention; a collection, the result of the closure of a tube of outlet. The tumor thus designated is found principally beneath the tongue; it is a swelling varying in size and in expression according to the circumstances of its existence, at times being observed when not larger than a pea, at others so great in bulk as to throw the tongue back into the fauces. *Ranulæ* are occasionally met with which fill the whole oral cavity; such dimensions, however, are uncommon.

If we were to tie or otherwise obstruct one of the tubes just alluded to, it would be natural to expect that the secretion accumulating back of the ligature



would expand and bulge out the duct into the form of a tumor. This is really the very simple history of the formation of a ranula.

Ranula, thus provoked and formed, varies as much in appearance and character as in size. In one case it looks and feels almost precisely like the belly of a frog, the enveloping cyst being thin and attenuated. In other instances the walls are thick. The contents present varying characteristics, being watery, semi-solid, or solid even to the hardness of stone. Commonly it consists of a yellow albuminous-like substance, which, for evacuation, requires pressure upon the tumor after an incision has been made.

A ranula, the contents of which are watery, implies, as a rule, that the disease has been of short existence, the fluid being simply the secretion from the gland unchanged in character. In the ranula of semi-solid consistence an explanation is found in the partial absorption of the more fluid portion, leaving an inspissated mass. In the solid ranula the encystment is the common salivary calculus,—being precisely the same as is seen upon the sides of the teeth, except in the absence of the common detritus of the mouth. Such a ranula as the last is found to be of long standing; absorption of the watery part has gone on until what remains is the limy portion of the secretion.

A thin cyst implies a rapidly-formed tumor unattended by vascular excitement, the envelope being a simple attenuation of the walls of the duct and overlying parts. This form of ranula very frequently ruptures, and thus effects a self-cure. Cysts, thickened and hard, imply tumors of slower growth and the association of vascular changes resulting in the effusion within the cyst-wall, and the organization of a greater or less amount of lymph. Cysts thus thickened may compose the bulk of ranulæ, the cavities being small in comparison.

A ranula gives trouble from its size and location, seldom or never degenerating. It does not seem true, either, that harm results to digestion from the loss of the secretion, such loss, indeed, being more apparent than real, the associate glands performing excess of work. A ranula attaining great size would necessarily intrude upon all the surrounding parts, thereby provoking secondary lesions which might very well prove of more serious character and consequence than the original disease: thus, cases are on record where the teeth have been forced from their sockets, where large ulcers have formed against the inner face of the lower jaw, where necrosis of extensive character has been provoked, etc.

TREATMENT.—This, in principle, consists simply in opening the tumor, evacuating its contents, and so conducting cure of the wound that it shall not entirely close, securing and preserving in this way an orifice of exit for the secretion.

In the frog-belly tumor it is found sufficient to catch up with tenaculum or forceps a portion of the sac, and with the scissors or bistoury cut it off: the edges of the wound then to be cauterized, and the case left to nature.



In the thickened cysts an operation as just suggested might not be easy to accomplish. In such a case take a strand of ligature wire (silver is to be preferred), double it upon itself half a dozen times, to the extent of the supposed thickness of the sac of the tumor to be operated upon. Take next the continuation of the length of the wire, and closely, yet spirally, bind with it the thickness just secured by the half-dozen reflections. Next take a curved needle, and thread the wire to it. Now pass it through the tumor, entering at the centre. When the thickened part of the wire—which is to be bulbed by a perforated shot compressed on its extremity—is brought in contact with the cyst, an incision is to be made just large enough to allow the passage; pull it now in until checked by the shot; fix the needle-end so as to retain the thickened part in place, and the operative part of the proceeding is completed.

A second mode, founded on the same principle of drainage, consists in taking a delicate rubber tube, and, after cutting through its walls a number of outlets, passing it through the tumor. To retain it in place, the extremities are tied together, having an opening made between the ligature and the tumor.

If, when making the little section in the tumor for the passage of the wire or tube, the contents should not at once escape, they are to be pressed or syringed out. If the parts seem particularly indolent, there is no objection to the introduction of a stimulating injection. The presence of the drain will, however, in ordinary cases prove sufficiently provocative of a desired inflammatory action. Iodine, in tincture, may be used externally over the face of the tumor.

In a ranula holding a calculus nothing is to be done without the knife, except, indeed, in certain occasional instances where the orifice of a duct has become patulous and the stone can be seen or felt. In these latter cases the operator may succeed in drilling or breaking the mass in pieces, and thus securing its removal. It is much easier, however, even here, to incise down to the stone and take it away. See for interesting case chapter on *Salivary Calculus*.

All cysts or tumors found beneath the tongue are not, however, to be esteemed as of the character just described. Inflammation of the sublingual gland is not infrequently met with, and the tumefaction is, at times, so considerable as to very closely simulate ranula. Cysts within the substance of the gland, not salivary in character, are other of the conditions encountered, and these more closely imitate the ordinary ranula than the first, particularly when the cyst is simple. Papillary indurations are sometimes met with in the same situation.

Lipoma simulating ranula is found occasionally referred to.\* Writers,

\* "LIPOMA SIMULATING RANULA.—Mr. F. Churchill exhibited a specimen of lipoma simulating ranula. He said this tumor was removed from under the tongue of an old man eighty-six years of age. The specimen is unique, so far as the Society is concerned. I



prominent among whom is M. Marrant Baker, are found, who incline to doubt the common relation of the ranulæ with the salivary ducts, but upon such premises, as must appear to any one who shall see much of the disease, that the arguments advanced carry no weight: the true ranulæ arise from salivary lesions influencing the relations of the discharge: tumors of kindred position may have the signification of muciparous cysts, or may be expressive of a systemic vice. Because a tumor is beneath the tongue it is not necessarily a ranula.

Ranulæ are found superficially seated, or deep, according to the part affected and the location of the lesion: thus, ranulæ associated with the tubal outlets of the sublingual gland are always entirely superficial, because the part affected is covered only by the mucous membrane. Obstruction of the duct of Whar-

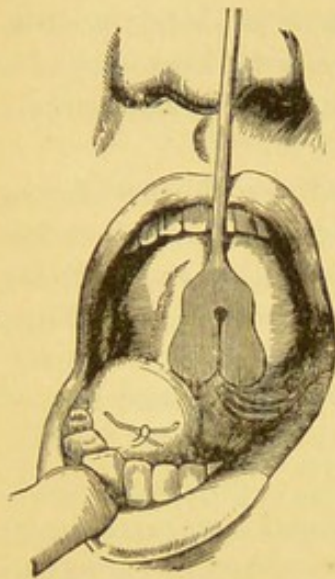
---

have been unable to find in the *Transactions* any records of a lipomatous tumor removed from this situation, and there is no such tumor in the Museum of the College of Surgeons. Mr. Liston refers to the removal of fatty tumors under the tongue in his work on Practical Surgery. Mr. Pollock removed a fatty tumor from below the jaw of a lady forty years of age, enveloping the mylo-hyoid muscle; but in this case the intrinsic muscles of the tongue do not appear to have been encroached upon by the tumor. In several cases, hardened, putty-like masses have been removed from a ranular cyst, as also phosphatic concretions. During the last session of the Society, Mr. Warren Tay exhibited four or five butter-like masses, which he had removed from a ranular cyst, but 'under the microscope no definite structure could be detected in them. Entangled in the substance composing the masses were some cells and portions of cells looking like *débris* of epithelium.' Dr. Meymott Tidy, after a careful chemical analysis, 'was disposed to regard the bulk of the deposit as adipose.' The history of the case was as follows: H. T., aged eighty-six, was admitted to the Westminster General Dispensary, under the care of my colleague, Dr. Waite, who treated him for eczema rubrum of the leg. After consultation with Dr. Waite as to the nature of the tumor beneath the tongue, supposing it to be a ranula, I suggested that it should be removed in the usual way. He stated that on several occasions fluid had issued from the tumor, after which it was distinctly smaller. The incisive teeth in the lower jaw were intact, and situated just behind these was a movable (apparently pedunculated) tumor, about the size of a walnut, covered by the smooth, glistening mucous membrane of the floor of the mouth. The tumor was also, in part, covered by the sublingual gland; it was soft and yielding, and I was under the impression that I could detect fluctuation. The distended mucous membrane was being chafed by contact with the sharp edge of the teeth during mastication. The old man had noticed the swelling for twenty-two years. It had gradually increased up to the present time. During the past twelve months, however, it had given him pain, in consequence of chafing against the teeth; he much feared that it was a cancer. From its size it had also interfered with mastication, and acted as a serious impediment to his speech. Having removed a portion of the anterior wall of the tumor, I proceeded to turn out the contents, but found, underlying the mucous membrane, a bright, glistening mass, resembling a cyst-wall; this was seized with a pair of clutch-forceps and drawn forward, a small portion of it being removed, but still no fluid escaped. I proceeded then to separate the adhesions to the mucous membrane with the spoon-end of a director, but the deep connections were too firm to separate in this way; the finger also failed to enucleate the mass. The tumor was forcibly drawn forward, and these deep attachments cautiously divided with the knife. In this way the tumor, which was lobulated, and enveloping (probably) the genio-hyoglossi muscles, was removed. Exploring the cavity afterwards, I could feel the sharp borders of the vertical muscles, and I was satisfied that the growth had been entirely removed. There was very little hemorrhage after the operation, and the cavity had completely closed in the course of a week."—*Proceedings of the Pathological Society.*



ton at its orifice yields also a superficial tumor, lying as it does between the mucous membrane and the mylo-hyoid muscle; occurring, however, beneath that muscle, the tumor resulting is deep-seated.

FIG. 400.



Superficial Ranula, showing  
seton introduced.\*

Ranulæ are of temporary or of permanent signification: thus, where only a limited obstruction exists, a tumor may form suddenly during the excess of secretion at periods of mastication, to drain gradually away as the superexcitation passes off. Cases are met with where, as the result of accidental inflammatory conditions, the outlets become obstructed from neighboring exudates, the tumor disappearing as the exudates are absorbed.

The existence of true ranula does not necessarily imply that the tube affected is absolutely closed: a ranula may exist where observation discovers the canal patulous and the secretion discharging; here an explanation is found in well-known similar stricture as met with in the relation of the bladder and its urethral canal, urine constantly dribbling from the meatus, yet the patient suffering from retention; or, again, a probe may be passed with all ease into the orifice of a salivary duct, yet a true tumor of retention exist,—here, as referred to, a stricture being deep-seated.

The sublingual gland itself is occasionally the seat of an inflammatory enlargement which protrudes a tumor upon the floor of the mouth. These enlargements are not infrequently of most indolent character, as many as five or six months being required to resolve them. The submaxillary, however, seems to be the gland most disposed to take on such condition, the tumefaction thus produced being without rather than within the mouth, although it occasionally happens that it is first observed by the patient as a swelling on the inner side of the jaw.

**Illustrations in Ranula.**—CASE 1. A gentleman having a tumor the size of a hen-egg, situated upon the floor of the mouth, applied to the author, having been assured that his disease was cancer and that nothing could be done. The growth seemed semi-solid, and was fixed to the underlying parts with great firmness; the vault of the swelling was smooth and non-vascular; darting pains associated with it.

Examination of the centre of the tumor made by means of a syringe and large aspirating needle afforded the diagnosis of ranula. Cure was secured by section of the cyst and complete cauterization of its inner face. The walls of

\* This is but a single expression of the superficial ranulæ. One treated this very day of writing by the author—being a double tumor—presented the appearance of the whole floor of the mouth raised on a level with the teeth.



the sac were quite a quarter of an inch in thickness; the contents were semi-fatty.

CASE 2.—Lately, at the Imperial Society of Surgeons there were exhibited by M. Paulet two salivary calculi found by him in Wharton's duct. In connection with the presentation was reported the unique fact—for such it was thought to be—that the submaxillary glands of both sides were found stuffed with stones. See in this connection case of Mrs. B., described in chapter on *Salivary Calculus*.

CASE 3.—*Obstruction of both Submaxillary Glands.* December 17, 1847, John C. Lyons, aged twenty, Benton Centre, Yates County, consulted Dr. Hamilton. He stated that in the latter part of July, while harvesting, the weather being very warm, he discovered in the morning a soreness under his tongue upon the left side, and before night he found there was a tumor at this point. This was oblong and about half an inch in length. His physician, Dr. Wolcott, opened it the following day, and it discharged a glairy matter. Since then it had been opened four times; but, a few days before calling on Dr. H., he discovered that there was a swelling on the opposite side, externally, in the region of the submaxillary gland. When seen by Dr. H. the gland was of the size of a pullet's egg, oblong, not painful or tender. It was increasing in size, but he noticed that it was larger in cold and damp weather. His health was good. He was advised to submit to a low diet, take physic, and apply externally the tincture of iodine. Patient was never seen again, and the result is unknown. During the winter of 1847 and 1848 two similar cases of enlargement of the submaxillary gland were presented in Dr. Hamilton's surgical clinic, at the Buffalo Medical College, one of which had resulted in an external salivary fistula.

The third most common affection met with about the floor of the mouth relates with muciparous cysts. The meaning of such cysts is obstruction in outlets of mucous glands. Diagnosis lies in limited size and in the superficiality of situation. Treatment consists in puncture and cauterization.

Cysts apparently non-mucous are met with in the region, the contents of which are various: cheesy, pultaceous, jelly-like. The sebaceous form has been most frequently described; one of these cysts seen by the writer was as large as a pullet-egg. A condition, simulating a cystic tumor, treated by W. Fairlie Clark, had its meaning in the symmetrical enlargement of the sublingual folds; the trouble arising out of irritation caused by a carious tooth. The tumor is described as being of a horse-shoe shape and surrounding the free portion of the tongue.

The fourth in classification, as frequency is concerned, are cysts simulating ranula: that term being restricted to tumors arising out of obstructions in salivary ducts. The seat of such cysts is Fleischman's synovial sac,—a bursa closely adjoining the outer side of the genio-hyoglossus muscle, beneath the mucous membrane. Cases of this kind are frequently mistaken for the true ranulæ. An interesting example was lately reported to the Pathological Society



of Philadelphia, by Professor J. G. Richardson, where the sac was filled with seed-like bodies similar to those met with in bursæ of the wrist-joint.

Convinced by personal experience that this form of cyst is not uncommon, the author is led to infer that the bursa described by Fleischman is very much more constant as to presence than generally admitted. Diagnosis of this special cyst is forwarded in remembering that the tumor is to be felt upon the neck adjacent to the middle line. A post-mortem made of such a cyst by a Dr. Müller, of Moscow, showed a cavernous tumor the size of a pigeon-egg, the contents of which were a clear, transparent fluid. The subject was an infant.

Epithelioma of the floor of the mouth commences as a primary affection at the lingual frænum, otherwise it is an extension of the disease from the side of the tongue or gum.

Venous aneurism, or nævus, of the location, has been met with in the author's practice but in a single instance. The case was successfully treated by exciting inflammation in the growth.



## CHAPTER XXXIX.

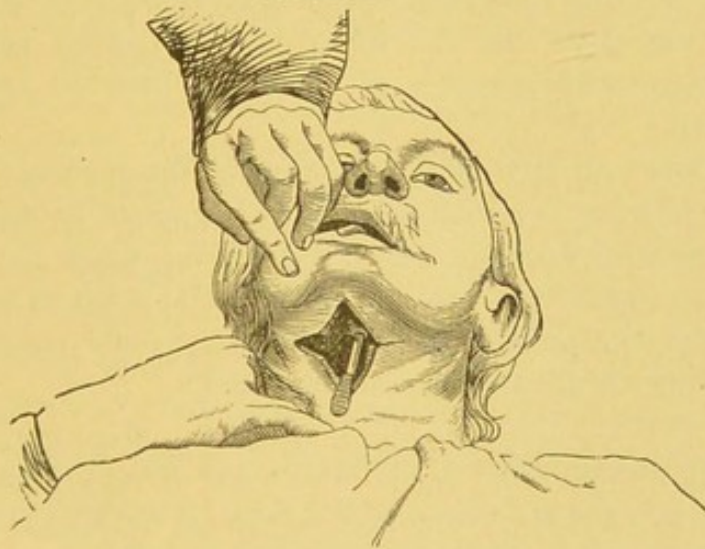### HYGROMATA OF THE NECK.

A CLASS of cysts indirectly associated with the oral floor may at this point claim attention.

The front of the neck holds several bursæ. The first of these, commencing from above, is known as Fleischman's. The second is situated between the thyro-hyoid membrane and the posterior face of the hyoid bone. The third has its location between the skin and pomum Adami; this last is sometimes double. Any of these cysts may become the seat of a hygroma, the contents of which may be either clear and viscid, or sanguineous and grumous. Any one of them may furnish location for a true ranular deposit.

**Example of Ranula situated in Front of Neck.**—Fig. 401 represents a case and operation, occurring in the practice of the author, having the

FIG. 401.



following history. First, it was noticed by the patient that the parts beneath the chin began to soften and broaden, and that gradually freedom of motion in the jaw was lost, while a slight sense of difficulty was experienced in speech, as the result of stiffness about the tongue, the floor of the mouth being quite indurated. In the course of four months, a tumor, evidently cystic, and fully the size of an ordinary orange, occupied the front of the neck, but was happily concealed by a long and heavy beard worn by the patient.

Presenting himself for a cure, a diagnosis as to the general nature of the



tumor was secured through the aid of an exploring-needle; this valuable instrument demonstrating not only that the tumefaction was cystiform, but affording an idea of the contents.

Treating the tumor as a cyst of immediate signification, a bistoury, making a reasonable incision, was passed into the most pendent part; the contents, a mass of lymph-like fluid, filling a large goblet, issued as a continuous rope; in color and in consistence this would have been well likened to thin calves-foot jelly. The cavity having been thoroughly washed with warm alum-water, compresses were carefully adjusted to the parts and sustained by a strip bandage. In two weeks, and without any trouble, the parts had united, and the cyst seemed permanently obliterated.

One month later the patient again presented himself. The tumor was reforming: the sac apparently had not been obliterated; already it was the size of a walnut. A few days later a second operation was performed precisely as in the first instance; the contents of the cyst differed, however, at least in color, having the same colloid consistence, but being blood-red. After the incision, and after evacuating the cavity, determined on obliterating the cyst, it was treated with the officinal tincture of iodine, and stuffed loosely with cotton. This time a perfect cure was obtained; but the swelling, associated with the inflammation produced by the injection, was so great that it was only with the aid of leeches, and by a free use of cathartic and diaphoretic medicines, combined with the closest attention, extending over four days, that the man's life was saved: for two whole days the patient was unable to swallow even teaspoonful measures of water, and breathed only with the greatest difficulty.

This tumor was evidently enough a hygroma, the starting-point of the lesion being, as inferred, in a sublingual gland. It might be suggested that, had it been associated with this gland, the swelling would have exhibited itself more in the mouth. A reason for inferring that it was so associated lay in the fact that a blunt probe passed into the cavity could readily be felt in the position of the left of these bodies in the mouth.

\* \* \* \* \*

The preceding history is one of the illustrations offered in the chapter on *Ranula*, published in the first edition of this book; it was written four months after performance of the operation, every evidence existing as to the completeness of a cure.

As a coincidence, it occurred that, on the very day the perfected proofs of a succeeding edition were put into the writer's hands (the form being struck off), this patient again presented himself, the neck exhibiting evidence of a return of the tumor.

Now was determined on, and practised, an operation which shows the case in its most instructive light.

As illustrated in the diagram, a crucial incision was made, exposing, in the retraction of the flaps, the common deep fascia of the neck, which fascia con-



stituted the floor of the cyst, and was, in appearance and consistence, apparently natural.

Passing into a sinus in this deep fascia, and emerging from the mouth, the reader observes a probe. The orifice of this sinus was very small, and was only seen after the parts had been thoroughly cleansed; the track was exceedingly tortuous, and was not passed until after several attempts, and only at last by an experimental bending of the probe.

On reaching the floor of the mouth, it was evident enough that the instrument struck the sublingual gland, as without effort that body could be thrust upward from its bed. To thus elevate and dissect out the organ, which was done, was a matter of no difficulty.

To complete the operation, the walls of the cyst were slightly cauterized with the solid stick of nitrate of silver, the flaps laid in place, and secured with the necessary stitches of interrupted suture; adhesion was secured by compresses continued in place over a month.

Examination of the removed gland discovered upon its under surface a break in the continuity, evidently pathological and of long standing; thus was demonstrated the salivary character of the tumor. Little by little the secretion had worked a passage downward, securing, by slow progress, an adventitious tissue, or walled sinus.

Looked at from the cervical base, one would naturally have viewed the sinus as being made by a prolongation of the fascia, so precisely did it look as though a tubular cul-de-sac had elongated itself until it had met and associated itself with the base of the gland.

The question of the location of this tumor is not without a special interest.

Does it not prove the existence of a supra-hyoid bursa, described by some anatomists and searched for in vain by many others? If such bursa had not, in this particular case at least, an existence, how shall we explain so naturally the presence of the perfect cyst which formed the tumor?

A second point of interest lies in the fact of reaching the gland described in the first diagnosis made months before. This, it would seem, could only have been the result of a rare accident, which on that occasion directed the probe into the sinus, and gave to the parts such favorable position as made the passage a direct one.

This case, viewed from the stand-point of fistula, is one of great interest and instructiveness: had the tumor been allowed to enlarge and attenuate the walls, and thus to rupture, it is evident that the case would have become one of salivary fistula proper.

An example of hygroma, very suggestive as a study, is recorded in Bell's "Principles of Surgery." The attention of the reader is directed to it:

The case was that of a young woman of Berwick, whose native peculiarity of accent had received a singular aggravation by such an uncouth obliquity and imperfect motion of the tongue as conveyed the notion of her attempting to chew and turn each vocable with her tongue before she proceeded to swal-



low, in place of uttering it. This was produced by a tumor of very great size, and of an appearance so peculiar as plainly to denote its character. It consisted in a vast collection of matter in the sublingual gland; and as that gland is covered by the whole thickness of the tongue within, and by the mylo-hyoid muscle without, and is bounded by the line of the jaw-bone, it had the following singularities of character. It could not be distinguished as a tumor, but had rather the appearance of a general tumefaction of the lower part of the face, jaw, and neck, such as often accompanies severe toothache or mumps. On laying the hand upon the outside of the neck, below the lower jaw-bone, it was filled with a swelling, apparently solid, but so little convex or circumscribed as to resemble in no degree a tumor of any particular gland, and yet so limited and so firm as not at all to simulate the general enlargement proceeding from periodontitis. On introducing the finger into the mouth, the tongue was found raised, turned edge uppermost, and pressed entirely toward the left side of the mouth, the external tumor being upon the right side. On pressing the fingers very firmly down by the side of the tongue, and reaching from without, one could sensibly perceive not so properly a fluctuation as an elasticity, which implied the presence of a fluid; the tumor seemed elastic like a football, but with a degree of tension which made it appear almost solid. It was by comparing a variety of circumstances, especially the original place and slow growth of the tumor, that the surgeon confidently referred it to the sublingual gland. The patient being placed in a chair, a fine bleeding-lancet was struck deep into the growth by the side of the frænum of the tongue, when, from the firm compression of the surrounding parts, the matter, though too gross to pass freely through such an opening, was spewed out from the orifice, in a manner expressly resembling that in which yellow paint is squeezed from the bladder upon a painter's pallet. It was of a deep saffron color, thicker than mustard, mixed like gruel with seed-like particles, and exceedingly fetid. Next day the point of a probe-pointed bistoury was introduced into the orifice made by the lancet, when thick yellow mucus flowed freely, or was raked out with the points of the fingers and the handle of the bistoury, the tongue descending to its natural level.

So tense and apparently fixed was this tumor, in consequence of the compression by so many surrounding muscles, that it was at one time mistaken for a solid and strumous swelling.

It is found, in all such cases, a matter of some importance, especially in girls, to anticipate the outward suppuration of any sacculated tumor, by puncturing it, though to a great depth within the mouth and under the tongue, and equally necessary to be at pains in preserving the opening and in obliterating the sac: a slight misconduct in this respect occasions much distress to the patient and much superfluous labor to the surgeon.

An expression of deep-seated ranula is exhibited in Fig. 402. Cases of this kind are met with where the swelling is associated exclusively with the submaxillary region; more commonly the tumor shows alike within and with-



out the mouth. Abscess of the gland, the pus being confined between the triangular leaves of its fascia, is distinguished from hygroma by its history; the one being an inflammatory disease, the other not.

Hygromata of the neck, in no way related with ranula, are frequently

FIG. 402.



Deep-seated Ranula.

to be met with. The writer has dissected out such cysts of sizes varying from that of a hickory-nut to that of the largest orange. In a case under observation at this time of writing the tumor occupies the full square of the neck, it is quite the size of the largest cocoanut. Removal by operation is the only manner of cure.



## CHAPTER XL.

### DISEASES OF THE PHARYNX.

THE pharynx is the pouch entered on passing through the oro-pharyngeal space. Its boundaries are as follows: above, the base of the skull; posteriorly and laterally, the constrictor muscles; anteriorly, the plane of the opening which associates it with the mouth.

The pouch communicates with seven associate parts; namely, with the mouth, the larynx, the œsophagus, the two nares, the two Eustachian tubes.

Dissection of the pharynx exhibits it as a muco-musculo-aponeurotic bag held open by attachment above to the petrous portion of the temporal bone, and laterally to this same bone, to the pterygoid processes of the sphenoid,

FIG. 403.

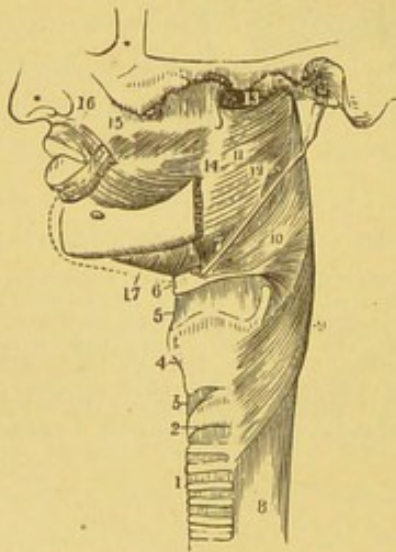


FIG. 404.

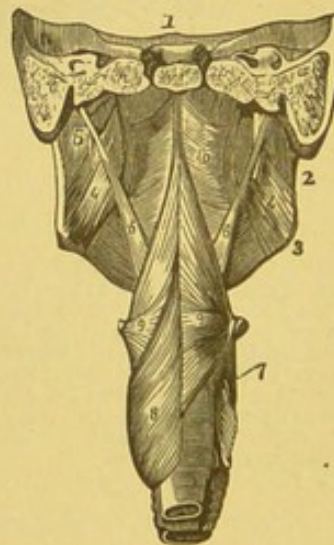

FIG. 403. SIDE VIEW OF PHARYNX AND ITS MUSCLES. 1, trachea; 2, cricoid cartilage; 3, vocal membrane; 4, 6, thyroid bone; 7, stylo-hyoid ligaments; 8, œsophagus; 9, inferior constrictor; 10, middle constrictor; 11, superior constrictor; 12, portion of stylo-pharyngeal muscle; 13, upper extremity of pharynx; 14, pterygoid-maxillary ligament; 15, buccinator muscle; 16, oral orbicular muscle; 17, mylo-hyoid muscle.

FIG. 404. POSTERIOR VIEW OF THE MUSCLES OF PHARYNX. 1, vertical section transversely of the base of the skull just in advance of the cervical vertebræ; 2, 3, posterior border and angle of lower jaw; 4, internal pterygoid muscle; 5, styloid process, giving attachment to, 6, stylo-pharyngeal muscle; 7, pharynx; 8, inferior constrictor of the pharynx; 9, middle constrictor; 10, superior constrictor.

the pterygo-maxillary ligaments, the angle of the lower jaw, the hyoid bone, and to the larynx.

The base, or framework of the pouch, is an aponeurosis. This is a fibrous structure internal to the muscular layers; thick above, where it is attached



to the skull, thin below, where it proximates the apex. The muscles are ten in number; these being fairly separable into five pairs. Figs. 403 and 404 show and name these muscles; affording as well appreciation of the posterior and lateral relations of the pouch. Fig. 27 shows an inside view of the pharynx. The mucous lining, seen in the last-named diagram, is soft and brownish red. The epithelium covering it is of the columnar ciliated variety above; below it resembles that of the mouth in being squamous.

Membrane and underlying parts are related by much submucous tissue in which are imbedded a large number of glands, these being of the racemose and follicular varieties.

The blood-vessels of the pharynx are derived indirectly from the internal maxillary and thyroid arteries. The nerves issue from the glosso-pharyngeal, the pneumogastric, and from the sympathetic system.

The pharynx is partly divided into an upper and a lower portion by the soft palate which extends incompletely across it. The part above the velum is termed the naso-pharynx; its immediate relation is with the nose. The part below is named the oro-pharynx; its association is with the mouth.

The soft palate, or veil, is a musculo-membranous curtain concerned in the processes of deglutition and speech. It may not inaptly be described as a fold of the common oral mucous membrane extending backward for some distance from the ledge of the hard palate, then turning upon itself, after dropping a pouch—the uvula—and passing forward to line the nares. Between these layers, relating with each other at a median raphé, are five pairs of muscles. These muscles are elevators, depressors, lateralizers. A special pair—azygos uvulæ—arise from the spine of the conjoined palate bones and extend into the uvula pouch.

**Diseases.**—The diseases of the pharynx relate to the mucous membrane and elements of the submucous tissue. Affections of the muscular and aponeurotic structures are uncommon.

**Pharyngitis.**—Pharyngitis, active, passive, or chronic, is the pathological condition most frequently met with. The aspect of phases presented in inflammation of the parts depends partly on the nature of the cause, partly on the state of health of the patient.

Angina simplex, common sore throat, inflammation arising out of taking cold, is ushered in by a sense of irritation about the throat which later progresses to a condition of huskiness in voice and pain in swallowing. Examination reveals a swollen state of the parts, a bright-red color, velvety appearance of the surface, a uvula more or less elongated and œdematous. Result: commonly resolution; sometimes laryngitis, trachitis, œsophagitis, and inflammation of Eustachian tube by extension through continuity. Treatment: feet in hot water, dry cups to neck, saline cathartics, refrigerant diaphoretics or diuretics, a gargle composed of one grain each of hydrate of chloral and sulphate of zinc to the ounce of water. A medicine found frequently to break up at once a sore throat, consists of twenty to forty grains of bromide



of potassium combined with five drops of tincture veratrum viride and the one-quarter of a grain of elaterium; the whole to be taken in a wineglass of water on going to bed. Phénol sodique, a tablespoonful to a goblet of water, is an admirable gargle in all conditions of sore throat; in diphtheria it is reasonably specific, while the use of it is to be recommended prophylactically wherever this disease is prevalent.

In ill constitutional conditions pharyngitis may rapidly advance to a state of ulceration or even gangrene. Indications here direct special systemic medication. In diphtheria the congested pharyngeal membrane is commonly covered with patches of exudate which have extended from the palato-pharyngeal fold, requiring a special local as well as systemic medication; local remedies are tincture of iron and chlorine-water, these being alternately applied by means of mop, brush, or atomizer, every one, two, or three hours according to urgency. Constitutional remedies are found in the direction of the chalybeates and preparations of bark. (See works on Practice of Medicine.)

Follicular inflammation of the pharynx limits itself chiefly to the crypts; these, however, commonly ulcerate and cause a very great deal of pain and nervous disturbance, although not commonly exciting the febrile condition. A continuous desire to hawk or spit is the first sign of follicular inflammation. Examination of the throat reveals the pouch reddened and studded with oval granular patches lying within areolæ of congested tissue. The patches are the diseased follicles. The summit of each presents a whitish translucent appearance which is apt quickly to change to the condition of ulceration. Where the general health is unimpaired this ulceration is found to be the point at which turn is taken towards cure; the sores healing commonly within a few days. In bad states of the system the ulcers oftentimes exist for a long time; taking on a chronicity and an indolency which render them the source of much distress.

Treatment of follicular inflammation differs nothing as the active, or first stage, is concerned, from that employed for angina simplex. Becoming chronic, the ulcers remaining stationary or enlarging, local and general stimulation is indicated; the former particularly. As a gargle no medicine surpasses the tinctura capsici et myrrhæ used in dilution; enough being dropped into water to change the color of this fluid to a bluish white. Chloride of zinc in the proportion of two grains of the salt to an ounce of water is another valuable means. Still another is found in a formula as follows:

R.—Acidi carbolici fluidi, gtt. xii;  
Tincturæ calendulæ, ℥iv;  
Aquæ, Oj. M.  
S.—Gargle frequently.

Dilute chlorine water—Watson's formula (see *Dublin Pharmacopœia*)—is an invaluable application in association with stimulants; being used with the atomizer. In diphtheritic sore throat this remedy plays an invaluable



part as a solvent of the exudate and a preventive of blood-poisoning. In the estimation of the writer it approaches a specific.

Other means of treating ulcers in follicular pharyngitis refer to touching them with solid caustic or alterative preparations: agents of this class are nitrate of silver, sulphate of copper, alum, etc.

**Pharyngitis Sicca.**—Pharyngitis sicca, atrophic pharyngitis, senile inflammation of the pharynx is an atrophic condition esteemed commonly as associated with age or as the ultimate of chronic pharyngeal or naso-pharyngeal catarrh, or as a state dependent on constant contact with dust or other foreign agents of offence. A case of this nature, lately under care of the writer, in the person of a gentleman aged eighty, presented the single disagreeable symptom of dryness, this being so great and persistent as to necessitate the continuous use of glycerine as a lubricant. Dr. E. L. Shurly, of Detroit, in an able monograph on the subject, lays stress on systemic conditions influencing and keeping up the condition; these being functional or organic derangements of the stomach and allied parts, rheumatism, enfeeblement of the circulatory apparatus, etc.

The principle of treatment lies in accepting the expression of local paralysis. Means of relief or cure refer to the correction of systemic defects, particularly as nervous derangement is concerned, and in the employment of local lubricants and stimulants. The use of a constant electric current as applied through a Grenet battery is credited with some virtue by Dr. Shurly. The prominent feature in the diagnosis refers, in the estimation of the writer, to interference with the nerve supply of the parts; the sympathetic system being most apt to be found at fault. In this connection, and as well in relation with all local expressions of enervation, the author finds that great reliance is to be placed on the use of Volta's pile, applied by taking pieces of sheet-zinc and copper and securing galvanic action by placing between the two a strip of woollen cloth saturated with cider vinegar.

**Effusions.**—Effusions into the submucous tissue of the pharynx are frequently met with. These are semi-plastic in character, and tend to limit themselves to one side of a vertical line, principally to the right side as met with in the experience of the writer. When extensive, the membrane is thrown forward to an extent that sometimes interferes markedly with deglutition. If not resolved, such effusion may result in abscess. Primary treatment is by local stimulation. If pus form, speedy vent is to be given it.

**Post-Pharyngeal Abscess.**—Retro- or post-pharyngeal abscess is a form of disease differing from that just alluded to alone in situation, the effusion and pus being situated between the pouch and vertebræ. The subjects of it are generally children of scrofulous habits; the cause, acute pharyngitis or disease of vertebral column. Diagnosis refers to subjective and objective symptoms. The abscess being situated high up, the bulging of the pouch is plainly to be seen. When the position is low down, judgment is to be formed by the seat and nature of obstruction. A diffused abscess may baffle the very



experienced. The condition is always to be looked on as serious, being of constitutional import. Treatment consists in venting the pus as soon as discovered, and in ministering to the patient supporting cordials and tonic medicines. Iron and cod-liver oil are always indicated.

**Specific Conditions.**—Syphilitic ulcers of the pharynx, while not common, except as relation is had with the soft palate, are yet not sufficiently infrequent to deny them notice in connection with diseases of the part. The affection is among the earliest of the series of secondary phenomena. Syphilitic erythema is very much more common to the pharyngeal walls than are ulcers; indeed, it is to be asserted that any secondary or tertiary expression manifesting itself about the tonsils, uvula, or palate will have associated with it this blush of the pouch.

Syphilitic ulcers of the pharynx differ nothing in appearance and character from such sores when affecting mucous surfaces generally. There are two varieties, the superficial and the excavated. Superficial sores are commonly multiple; they simulate abrasions, showing, in many cases, no other expression than that of lost epithelium; in others, being of ragged, or, it may be, of undermined edge. Sometimes the sore assumes a serpiginous form. An excavated one is the analogue of a Hunterian chancre. It is deep, has a pasty bottom, and is indurated.

**Tubercles.**—Specific tubercles are occasionally met with in this location; these are irregular elevations of the mucous membrane, generally of oval form, and of whitish color. To the touch they are not unlike chancres. When becoming confluent, as is sometimes the case, the degenerated surface may break down with the result of an open ulcer of the second class as above viewed.

**DIAGNOSIS.**—Diagnosis of venereal affections of the throat relates to color of the parts,—which is that of copper,—to the peculiar feel, and to co-existence of the disease in the system at large.

**TREATMENT.**—Treatment concerns itself with prescribing; first, for the vice at large; second, for local indications.

An anti-venereal of satisfactory import in secondary syphilis is a formula as follows:

℞.—Hydrargyri chloridi corrosivi, gr. ij;  
Potassii iodidi, ℥ij;  
Sarsaparillæ fluidi extracti, ℥viii. M.  
Dose, tablespoonful three times a day.

Where the disease is of tertiary form it is usually found well to omit the mercurial, replacing it with a medicine of anti-scorfulous signification: cod-liver oil, having combined with it the hypophosphites of iron, lime, and soda, is hardly to be used but with profit.

Local treatment differs little from that employed on chancre of the penis. If the sore be of the superficial variety it may be all-sufficient to touch it lightly with a dilute mineral acid. Nitrate of silver, in stick or solution, is an admirable remedy. Acid nitrate of mercury, diluted in eight or ten parts of



water, is highly commended, being brushed over sore and neighboring parts once each day. Phénol sodique, diluted one-half with water, is never found otherwise than useful. This last remedy not being at hand, an admirable substitute is found in common tar-water, made by stirring a tablespoonful of tar in a goblet of water, adding to this carbolic acid to suit indications. Where the sore is of excavated character it may be touched moderately with the London paste, or, what answers an admirable purpose, crystals of zinc chloride may be laid in the part and allowed to deliquesce, care being taken that the fluid do not run over adjoining localities, and that as soon as permissible it be mopped from the ulcer with bibulous paper. Plethoric persons require depression; the anæmic are to be stimulated.

**Wounds.**—Wounds of the pharynx demand attention in consideration of indications. A case treated by the author, where the pouch was opened just above the larynx in an attempt at suicide, resulted in permanent aphonia. In a second case of injury to the region a stick in the hands of a boy passed through the posterior wall and struck against the vertebral column. The recovery was without a bad sign, soothing gargles being alone used.

Gun- or pistol-shot wounds are the commonest injury to the region. Primary indications relate with the removal of the missile, the control of hemorrhage, and the recovery from shock. Treatment of the hurt implies little more than the directing of fluid food and the prescribing of antiphlogistic lotions.

An ugly complication of wounds perforating the mucous membrane of the pouch is emphysema of the neck; the areolar tissue of the region sometimes becoming so much distended as to be a cause for much alarm; the swelling not at all times disappearing with a rapidity to be desired.

Incised wounds of the pharynx require to be closed with stitches of the interrupted suture where such stitching is conveniently to be accomplished; the ends of the ligatures are to be cut off close to the knots so that, when ulcerated free, the thread may fall into the throat. Thread of catgut replaces happily that of silk. The staphyloraphy needles apply (which see).

**Stricture.**—This condition, as affecting the pharynx, has never been met with by the author except as associated with carcinoma.

**Imperforate Pharynx.**—Cases of imperforate pharynx, as relation is had with the œsophagus, are on record. If met with, a practitioner could do nothing apart from a practice directed by common experience derived in analogous directions. A case lately under the care of the writer showed such an imperforate condition of the naso-pharyngeal opening, ulceration of the nasal surface of the velum having attached that part immovably to the region above it. No opening existed between nose and pouch.

**Neoplasms.**—Cancer of the pharynx proper is rare. A case in the Hospital of Oral Surgery showed the sac so completely occupied by a sarcoma growing into it from the maxillary sinus that the patient was unable to pass any but the most fluid food. Another case in the same hospital



exhibited the soft palate so involved that a pendent mass completely filled the oro-pharyngeal orifice, extending back to the posterior wall, interfering not only with deglutition but with respiration.

Cancer occurring directly in connection with the pharyngeal walls is apt to start in the submucous cellular tissue close to the œsophageal locality. A first expression is in the form of an infiltration which is apt to afford primarily idea of cold having been taken. Stricture arising out of the condition is incurable; operation is only a prolongation of misery sure to end fatally.

Fibromata, of which mention is to be found in connection with the soft palate, are always to be associated with doubtful prognosis. Fungiform papillomata, except where of pronounced venereal character, are not unjustly to be regarded with like concern.

Polypi falling from the naso-pharyngeal space back of, and below the velum, are not infrequent. These are to be caught from the oral opening and twisted off. A second means of evulsion employs a wire *écraseur* passed through the nostril. (See *Polypi*.)

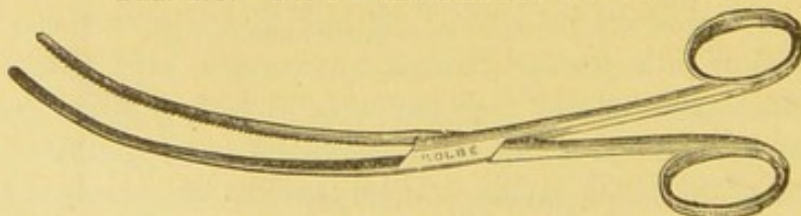
**Uvula.**—Tumor of the uvula, caused by hypertrophy, may be of such bulk as to interfere with respiration by descending into the laryngeal opening. Treatment is by amputation. (See *Uvula and its Diseases*.)

Irremovable causes of interference with the pharyngeal openings, either of larynx or œsophagus, are to find all correction possible in the operation of tracheotomy or œsophagotomy. (See *Tracheotomy*.)

**Foreign Bodies.**—Pertinent to this direction of our study is a reference to the probability of foreign bodies lodging about the parts considered. First: artificial teeth and plates. Pivot teeth falling from their sockets are commonly swallowed; no harm results where the pivot remains in the root. A tooth of this class carrying with it into the intestines a pivot of wood or metal is not disassociated with danger existing in the possibility of perforation. A guard is found in feeding the patient largely on mush with a view to distending the intestinal tract as much as possible.

A plate commonly lodges about the orifice of the œsophagus or descends into that tube. Very lately the writer was called to an accident of such nature where a piece of quite an inch across had worked along full half-way down

FIG. 405.—BOND'S ŒSOPHAGUS FORCEPS.



the canal. Removal was effected with very little difficulty by use of forceps as here shown, Fig. 405.

A plate lodged in the apex of the pharynx is to be felt with the finger, and, if no forceps be at hand, is not infrequently to be dislodged and thrown from the mouth through the production of emesis.



A plate in the œsophagus is commonly to be located by pain induced from pressure made over its seat.

Bones swallowed in eating may be stayed in the œsophagus. An instance of this kind under observation by the author showed the obstruction fixed at the cardiac orifice of the stomach; the body could not be made to descend and it seemed alike impossible to withdraw it. Manipulation with long forceps continued, at varying intervals, over two or three days, resulted in catching the piece at a proper axis and getting it out. Œsophagitis followed, but quickly resolved itself.

One of the very immediate results of the presence of a body impacted in the apex of the pharynx is spasm, this being at times so severe and persistent as to smother the patient quickly if relief be not afforded. Opening of the crico-thyroid membrane is the indication; to be followed by tracheotomy, if necessary. If chloroform be at hand it may be employed with hope of relief from the effects of the stricture. Moments are, however, as hours.

Fish-bones, bristles from a tooth-brush, and similar small particles, are the not infrequent causes of great suffering from lodgment in the throat. A first place to look for all such bodies is in the lingual sulci found on either side of the frænum epiglottis; failing in discovery here, examination is to be directed backward. Small bones incapable of being dislodged are to be rendered flexible by the free use of acids.

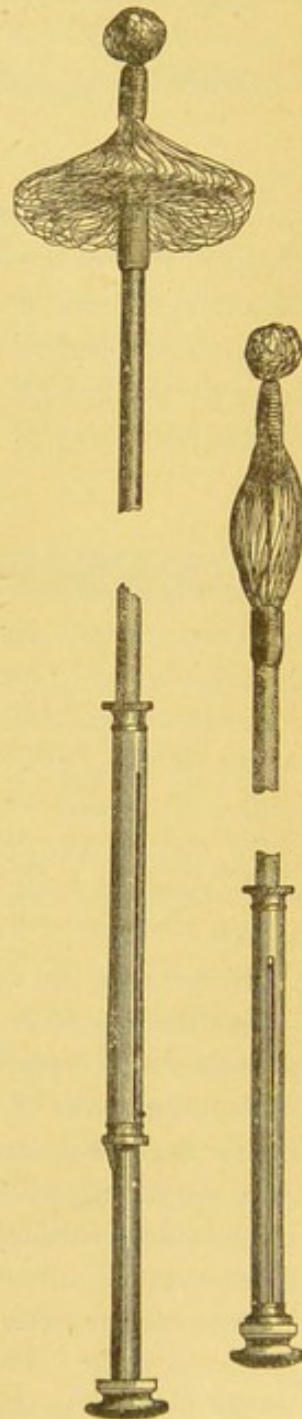
Instruments used in search of such bodies, known as bristle probangs, are exhibited in Figs. 406 and 407. As will be recognized these probangs fold the bristles on introduction into the œsophagus, spreading them out, thus searching the circumference of the tube, on withdrawal.

The swallowing of a pin is a not infrequent event; the writer has occasionally been called to these accidents without finding the body; in no case has there been any serious result.

A fish-hook attached to its line has been swallowed into the œsophagus where withdrawal was effected by means of a lead ball perforated and slipped over the string. Extending the twine and allowing the ball to drop a dislodgment was secured and the hook brought up, its point being caught in the metal.

Soft bodies in the œsophagus, if at all impacted, are to be helped to their

FIGS. 406, 407.—BRISTLE PROBANGS.

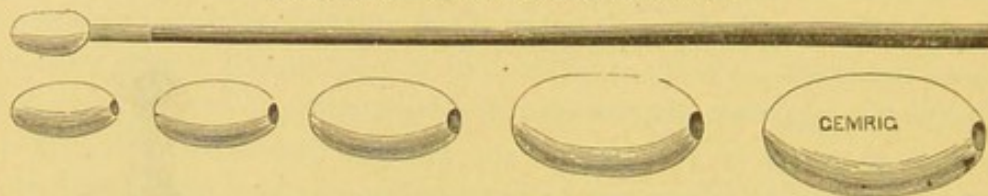




destination by means of a bougie or flexible probe. Fig. 408 represents such a probe having bulbs of varying size; these are used also in strictures of the œsophagus. Bodies in the trachea will almost certainly require for their removal opening of that tube.

In considering the subject of foreign bodies about the throat it is always to be borne in mind that feeling is not evidence of presence. Lives have

FIG. 408.—ŒSOPHAGEAL BOUGIE.



been destroyed in efforts to dislodge bodies which dissection showed to be absent. It is in the experience of the author to have a patient maintain for days the existence of presence where certainty existed as to absence.

Sharp and jagged bodies in the œsophagus may occasion speedy death by being forced through a blood-vessel, or, if remaining some length of time, a similar result may be brought about through ulceration.

#### NASO-PHARYNGOSCOPY.

Examination of the naso-pharynx is made by employing the means known as posterior rhinoscopy. Rhinoscopy is the manipulation designed by Czermak for exposure and illumination of the naso-pharyngeal space.

A rhinoscope differs nothing from the mouth mirror used in dentistry. Adjuncts used with the mirror are: 1, the flame of an argand burner; 2, a glass of concave face.

To make a naso-pharyngoscopic examination implies lighting up of the space together with an ability to see into it when looking directly into the mouth.

Recognizing the double requirement of reflecting a flame and catching an image, the operation is ordinarily commenced by placing a light to the back and side of the patient. This light is variously modified to suit the convenience or views of the surgeon. Tobold, Voltolini, Czermak, Morrel Mackenzie have each devised apparatus. (See works on the Laryngoscope.)

A simple means of illumination consists of an argand flame enveloped by a cone made of tin, which cone is so fenestrated as to allow of its being slipped in a horizontal direction over the glass; the base of this cone is a common circular mirror; the apex, which is cut off so as to give a diameter of two inches, is open. The instrument stands upon a pedestal, which raises and lowers to suit examinations made standing or sitting.

Light and patient in relation, a succeeding step considers reflection of the flame. To accomplish this the operator uses a concave mirror; this being



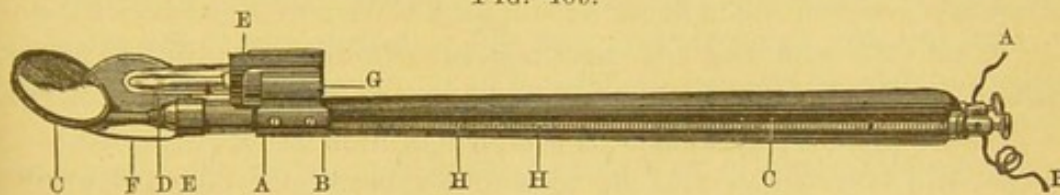
employed attached to the forehead, or otherwise held. Catching the ray upon this glass it is appreciated that it can be directed at will.

Step three refers to the employment of the throat mirror: Here is the difficulty of the operation. A deep velum associated with irritability of the region seriously complicates the matter; rendering, indeed, in occasional instances, the performance an impossibility. A short velum and an unirritable throat favor in every way the examination, exposure of the parts being secured without even discomfort to the patient.

A throat lined with tenacious glairy secretions is to be preliminarily treated by gargles of Watson's chlorine-water diluted to suit requirements. An irritable throat may be partially schooled into hebetude through frequent handling, or by use of a potassium bromide gargle.

**Electric Illuminator.**—The conspicuousness of separate mention is made of this illuminator because of special merit; the design is by J. S. Dicken, L.D.S., of Southport, England; introduction of the light into America was by M. H. Cryer, M.D. Employment of the instrument relates alike with mouth, throat, and naso-pharyngeal surgery. It illumines perfectly. A too frequent absence of battery conveniences is the single offset.

FIG. 409.



DESCRIPTION OF DIAGRAM.—C C, an ordinary mouth mirror, or laryngoscope. A B, two binding-posts. D E, a small Swan's electric lamp. H H, two wires running in grooves along the handle C, from A B, to a silver sleeve, G, made in two sections, insulated from each other, in which the lamp is held. E, a brass plate on each side of the insulated portion of the lamp; from these plates run the platinum wire into the lamp D and back when the lamp is held in the sleeve, and the wires of a battery, consisting of two Bunsen's cells, attached at A and B; the current is then formed from A to sleeve G on one side, connecting with E through the platinum wire, back again to E and G on the other side, thence to B, or *vice versa*. F is a silver shield and reflector combined, highly polished, to protect the cheeks or any portion of the mouth coming in contact with the instrument.

Referring to the diagram, complete understanding of the apparatus is received in recognizing that it consists simply of an ordinary mouth, or laryngeal, mirror, to the handle of which is attached a circular glass lantern holding the platinum points of an electric light. Associate fixtures refer to transmission of wires from battery, to reflection, and to lifting and protecting surrounding parts. The heat evolved is so trifling that the writer has allowed the uvula to rest against the lantern, the patient being unconscious of the fact; it is yet sufficient to keep the glass entirely free from moisture however long it be continued in the mouth.

Dental practice is perfectly served by this illuminator. Placed back of the teeth, these organs are rendered nearly transparent. Pulp-canals can be seen almost to their apices.



In connection with Mr. Dicken's apparatus attention is directed to Trouvè's polyscope, an instrument differing nothing at all in principle from the former but not comparable with it in adaptability to oral requirements, the light in the latter being exposed in a porcelain saucer. An illuminator of similar signification is a design by Mr. Margetson, a surgeon of Dewsbury, England. This gentleman uses carbon filaments varying in size from one by half an inch to one-eighth by one-quarter inch. Mr. Stern, of the Swan Electric Company, has brought out an instrument of this same class, while still another, concerning which large confidence is entertained, is at the present time in course of construction by the Messrs. Queen & Co., opticians, of Philadelphia.

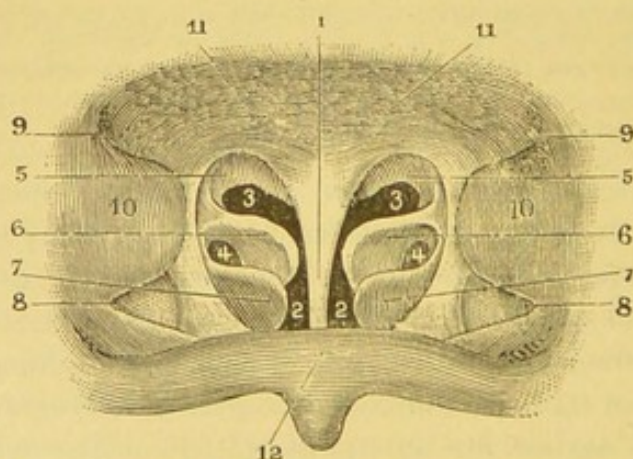
To employ a rhinoscope requires depression of the tongue and relaxation of the velum. The first is accomplished by means of an instrument known as the depressor; the handle of a spoon practically represents this. The second is secured by directing the patient to breathe entirely through the nostrils; in which act the veil falls towards the tongue.

A common rhinoscope is to be introduced warm; this with the double purpose of avoiding moisture upon its face and sparing irritation to the throat.

Everything being ready the glass is passed gently into the pharynx, the face being directed at a proper angle toward the space to be examined. Upon this glass is received the light reflected by the hand mirror; to be cast by it in turn into the naso-pharynx; and still in turn to give to the eye of the looker an image of the part illuminated by it. Practice is required to afford proficiency. Dicken's instrument is complete in itself.

What will be seen in naso-pharyngoscopy depends on the manipulative tact of the surgeon. What should be seen, the parts being healthy, is beautifully outlined in the accompanying diagram.

FIG. 410 (after Cohen).



- 1, septum; 2, free space of nasal passage; 3, superior meatus; 4, middle meatus; 5, superior turbinate bone; 6, middle turbinate bone; 7, inferior turbinate bone; 8, position of the opening into Eustachian tube; 9, fossa of Rosenmüller; 10, lateral wall of pharynx; 11, superior wall of pharynx; 12, posterior surface of velum.



## CHAPTER XLI.

### PALATINE DEFECTS, AND THEIR TREATMENT BY OPERATION.

IN the treatment of palatine defects, the first consideration refers necessarily to cause and condition. Thus, it is found that such defects or deficiencies may, by influencing circumstances, require treatment so modified or changed as to seem, in cases apparently similar, quite at variance with each other. For example, take two perforations exposing the nares; one congenital, the other the result of disease. In the first of these cases any operation or appliance which would seem to promise relief might be adopted; in the second we might justly pause at any interference. No one would attempt staphyloraphy on a patient laboring under acute syphilis, or where a mercurial course had so broken down the crasis of the blood as to make a union by the first intention impossible, or even doubtful. No more would one be justified in attempting this or any other of the operations of expediency, with the constitutional conditions adverse to success, than he would be justified in avoiding the responsibility where such influencing associations were favorable.

**Cleft Palate.**—The condition known as cleft palate, to which we at once pass, may, from its exceeding frequency, be the first to claim attention. A cleft may be partial or complete; that is, there may be a simple lengthwise division in that portion of the mouth known as the soft palate, or the cleft may be so extensive as to extend from the uvula to the lip, a fissure separating both hard and soft parts. The first of these conditions is found sometimes as the result of disease; the latter is always congenital. Fissures produced by syphilis are constantly treated where there are breaks both in the bone and in the soft palate, but never where there is a coexistent one in the continuity of the lip.

Fissure of the hard palate, a result of disease, differs from the congenital form in a particular which would scarcely allow of the surgeon's being deceived. A fissure the result of disease exhibits an irregular break in the continuity of one or both palatine processes; a fissure having congenital origin exhibits the deficiency harmonious to the line of contiguity; that is, to the palatine raphé.

Let first be considered the condition and treatment of a congenital cleft. A child is born, toward whose mouth attention is directed either by the nasal character of the cry, or, a little later, by inability to take the breast properly; or the condition is marked, perhaps, by the break continuing through the lip, giving the deformity known as hare-lip.



When a child is thus unfortunate and the attention of the surgeon is called to the case, a single question presents itself; namely, how is the deformity to be corrected? If suffered to continue, every day increases the difficulty of the cure; that is, as the most formidable part of the operation is involved, while if its correction be at once attempted, the prospect of complete success is very great.

Fissure of the hard palate has generally been deemed irremediable as operative means are concerned, and the surgeon has been taught to consider his whole duty done in describing to the parents the mechanical method which in after-life is to conceal and correct the defect of his patient. Now, in this connection will be presented a remedial surgery which is as practicable and feasible as any other of the operations of expediency, and perhaps one is justified in going so much further as to say that the modes of procedure will be found much more promising than the majority of such operations. Through the proper application of mechanical allied with the more strictly surgical means, the writer has not infrequently succeeded in effecting changes in the young maxillary bones, a simple description of which might cause his veracity to be doubted; yet this ability to effect such changes becomes very evident if for a single moment we pause to consider the difference between the composition of the young and that of an old bone. Young bone, or bone at birth, as is well known, is almost if not quite half made up of animal material; while in the osseous structure of the adult there is excess in the inorganic or unyielding material representing from seventy-five to perhaps quite eighty-five per cent. of the substance of the part.

To illustrate more familiarly this yielding constituent of young bone, reference may be made to the old experiment of maceration in dilute muriatic acid. We know that if a rib bone be subjected to the action of this acid for one or two weeks, we may tie it like a whip cord. This is done simply by reducing an old bone to the condition of a young one. As has been shown in the chapter on dental irregularities, one may take an inferior maxilla, even in a child of fifteen years, where the projection of the chin is so great as to produce deformity, and with a properly-constructed vertico-mental elastic sling can, in a period varying from three weeks to as many years, so change the angle as to do away entirely with the deformity. One may take the projecting myrtiform border, and through the instrumentality of the occipito-alveolar sling compel it in quite a short period to a natural relation. On this known yielding character of young bone operations for the correction of congenital fissures of the hard palate are founded.

A congenital fissure of the hard palate may be corrected instantly, or the cure is to be effected slowly. The first of these procedures is applicable to such cases as present but a limited separation of the bones; the latter, when the break has considerable width.

The operative procedure for immediate cure is as follows: an instrument, a modification of the Hoey clamp, ordinary arterial compressor, or a Hainsby



compress, is to be made by so arranging the pads that they shall apply to the sides of the jaws and allow of the force being so directed that the pads can be approximated without undue facial pressure. The clamp of Hoey, it will be seen, needs alteration only so far as the pads are concerned, and is quite easy of adjustment to this purpose.

The instrument ready (the infant being in proper condition), the operator commences by paring the soft parts and bone on both sides of the fissure, beginning on the approximal faces of the palate bones, and cutting forward to the alveolar face of the chasm. This part of the operation completed, the little patient is to be allowed to rest until the bleeding ceases. A succeeding step is to re-etherize and apply the compressor; the curved pads to embrace the buccal faces of the alveolar arch. By now gradually turning the screw of the instrument, the yielding bones are brought together. The next and last step in the operation is to retain the parts in position by the use of compresses placed upon and below the malar bones, and secured by adhesive strips applied as in the occipito-labial cravat of Mayo.

It may be urged against these manipulations that they are formidable and entirely too heroic; that fractures may result, etc. On these points the surgeon must decide for himself. If carefully performed, the operation is not dangerous; fracture of the bone, even if it occur, is of little consequence, the parts having to be kept, as it were, in splints, consequently the treatment of the one would be the treatment of the other. The marked risk is from inflammation that may be provoked; but a surgeon not infrequently has to run far greater for even a less result.

Another mode of securing the same end is as follows: take a circle of india-rubber tubing, the circumference of which shall be about one-third or one-half that of the child's head; next prepare two firm compresses, of a size adapted to the case under treatment; place these pads, or compresses, one on either cheek, in such position as will give them their rest on the buccal faces of the alveolar border, and secure them in place by one or more delicate strips of adhesive plaster; next take up the ring of rubber and pass it over the pads and around the cervico-labial diameter of the head. Resting upon the compresses, the ring will exert, as is seen, a gradual pressure, serving to push the bones toward a common centre, this centre being the mesial line of the palatine arch. This process is a gradual one; but, if the patient be young, it will be likely to succeed; the only real objection to the manipulation is the constant care necessary to prevent excoriation of the tender skin.

When, by this procedure, the bony parietes have been brought into contact, the operation, as the hard palate is concerned, is completed by simply paring or cauterizing the adjacent mucous surfaces. If the bones have been brought very close together, the granulations will bridge the slight remaining chasm.

In either of these operations it is seen that the break, both in the soft palate and in the lip, is not remedied. It is well not to attempt operation on



the face until the patient has entirely recovered from the foregoing treatment. It may at such time be performed, and, if done according to rules given, will secure a lip so perfect that, in adult life, little or perhaps no mark of the manipulation will exist. The operation for the cleft in the soft palate is to be left to a period later in life, for reasons alluded to presently.

These suggestions for the cure of cleft in the hard palate were, it was thought by the writer, original with himself,—though it is of slight consequence who invents an operation, so that it be good; but in the periscope department of the *Dental Cosmos* is to be found the following extract, taken from the *Australian Medical Record* and *Dublin Medical Press*, which shows that the performance was conceived by another. The extract is a short one, and so *apropos* to the matter that it may be presented entire:

*Pressure in the Treatment of Cleft Palate.*—I am not aware, says the author, that the subject of using pressure in treating fissure of the palate has been before suggested. I am inclined to think that it has not; for when the plan first presented itself to my mind, in 1851, I carefully examined French, German, English, and American works to see whether it had. I was first led to try it on the dead body of a child, which had died three weeks after birth. The fissure was longitudinal, and large enough to admit the extremity of the little finger; fissure of the lip also existed. By means of a pair of clamps, the sides of the fissure were brought readily in contact, without any fracture or displacement of the bones; the only fault was that the gums of the upper jaw were within those of the lower; but nature would modify this as the living child grew up; the use of pressure on the lower jaw would remove a great deal of this deformity; of course the amount of deformity would depend on the size of the fissure in the palate. I several times repeated the experiments on young dogs, removing a piece of the palate bone by means of Hey's saw, and then applying the pressure. The animals did well.

The operation should be performed as early as possible after birth, when the bones are in their softest condition. The following is the plan which I would suggest: the edges of the fissure having been pared, the superior maxillary bones are to be embraced by a horseshoe-shaped clamp, with a shelf on its lower border to receive the gums and prevent it slipping. It should be padded with india-rubber or some other material, to prevent the germs of the teeth being injured. The clamp should work on a joint, and possess arms. It may be said to resemble a large pair of pincers with horseshoe-shaped blades. A screw may be attached at the extremities of the handles, for the purpose of bringing the blades in contact, or the hands may be used: the former would be, I think, preferable, as the force could be applied gradually, and not be likely to be carried too far. It may also be employed in grown-up children, when the bones are so widely separated as to render it difficult to get soft parts enough to close the opening, but in a gradual manner and at intervals more or less prolonged, according to the

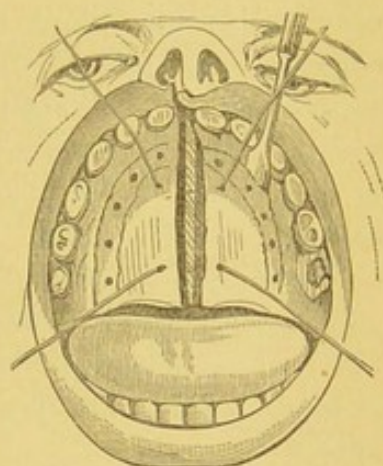


amount of pain it excites. If it were used suddenly it might produce inflammation, and subsequently abscess, which would prove troublesome to treat. From the foregoing it will, I hope, be understood that the younger the child the safer the operation is likely to prove, and that even in grown-up children it may be adopted, with precaution, with decided benefit.

The pads and the ledge to rest the teeth upon should be made to slide in the sides of the clamp: the former, that the pressure may be directed on any part of the bones; the latter, that the edges of the teeth may rest on it, without the pressure being directed either too high or too low, but at the point where the palate bone joins the superior maxillary.

Fig. 411 shows the steps of an operative procedure for closing breaks in the hard palate, which is not unworthy close consideration. First, an incision is to be made through the soft parts upon either side, midway between the fissure and alveolar ridge. From the line of this incision, the periosteum is to be dissected inward or outward, as found most convenient. Or, as preferred by some, the strip seen between the two lines in the diagram may be cut away. Next, using a spear-drill, a series of closely-related holes are made through the bony parts which the previous steps have exposed. (The writer employs a circular-saw, revolved by the engine.) A concluding process pares the edges of the fissure, introduces two wires through soft parts and bone, applies a wedge instrument, as shown in the cut, and forces the edges into contact. Granulations springing up in the seats of the lateral separations quickly fill up the breaks, thus completing a cure.

FIG. 411.



**Cleft of Velum.**—We pass now to the consideration of treatment of fissure in the soft palate. The operation, done for the cure of this deformity, is known as staphyloraphy, a term derived from two Greek words, signifying suture of the uvula. As generally practised, it is rather difficult of performance, and so frequently unsuccessful that surgeons seem disposed to avoid the responsibility of it. It is proposed here to suggest for consideration a new mode, which renders the manipulations as easy of accomplishment as by the old they are tedious and difficult.

*Preparation of the Patient.*—For weeks before it is designed to perform staphyloraphy, preparations are made for it by subjecting the parts to such daily manipulations as shall educate to forbearance the natural sensibility of the throat. In the absence of such preliminary manipulation, the retchings and spasmodic twitchings are such as to render a proper performance of the operation, without the use of an anæsthetic, almost an impossibility. With such education, the parts are found to assume, in a reasonable time, quite



a stoical indifference to even severe irritants. This forbearance is secured by roughly fingering the velum daily. Some surgeons are in the habit of daily tickling the parts with a fine brush; this answers a very good purpose. A very admirable idea, and a most successful one, is to have made an obturator,\* which shall extend back to the palate border, or nearly to it. This is to be placed in the mouth, and, as soon as the irritability produced by it is so far overcome as to permit of its permanent retention, the bands attached to it are clasped firmly about the necks of the teeth, and it is worn continuously for one or two months. When the parts have thus submitted to the presence of an obturator, they will be found quite ready for an operation.

On the evening before the day of performance a saline cathartic is to be given the patient, particularly if he be robust and strong. In operating on a depressed and anæmic person, the deficiency in vital force is to be first considered, and, as far as possible, corrected. If such attention be neglected, failure is almost certain to result; the parts will not unite. Exercise in the open air, generous living, iron tonics are to be prescribed. To sum up in a single sentence, preliminary treatment is to meet the indications of each particular case. If, for example, one should operate on a scorbutic patient, or a patient disposed to purpura, without correcting such dyscrasia he would be no more likely to gain union of the parts brought together than in an operation done on the cadaver.

The surgical anatomy of the region is to be fully understood. So much of success depends on a thorough knowledge of the muscular relation to the cleft that such acquaintance gives a success where otherwise failure would be sure to result. This anatomy we may look at before taking up the steps of the operation.

To get a correct idea of the soft palate, we commence the study by first carefully examining the parts on the living subject. When we look into a mouth, we see an arch, stretching from every portion of the alveolar ridge inward and backward toward the pharynx, terminating in a tongue or uvula, pendent in a vertical direction from its centre. One-half of this arch is seen to be fixed, the other—the posterior half—in almost constant motion. If now the finger be called into service, the fixed part is found to correspond with the boundaries of the palatine faces of the maxillary and palate bones; that is, for a certain extent the parts are felt to be solid, as if the finger passed over an arch of bone which might be covered alone by mucous membrane; and this is, in fact, about the case. The finger traverses the anterior bony border of the mouth, or the hard palate. As now the finger is passed backward, it falls over a hard ridge upon parts that are soft and yielding; the hard ridge is the posterior face of the palate bone, and terminates the hard palate. The part upon which the finger has fallen is the veil, or soft palate, the part observed to be movable. This is the region in which occurs

---

\* A description of this instrument and of its proper use will be found on page 442.



the rent, or cleft, for the cure of which is demanded the operation about to be considered.

The mobility of this part, which pertains to its function, depends, as will be anticipated, on an associated muscular structure. To study properly this structure, which it is all-important to understand and appreciate practically, the student is to take up a scalpel and pass to the cadaver; it is, perhaps, only by dissecting that a really satisfactory idea of these muscles is to be secured,—that is, as pertains to that kind of knowledge which gives confidence when one comes to perform operations upon the part.

The external coat, or covering, which is seen on every mouth, living or dead, is the mucous membrane,—simply the continuation of that which covers the hard palate; but while in the case of this part the underlying structure is found osseous, in the soft palate the deep tissue is made up exclusively of muscular substance,—at least as a surgical anatomy is concerned, or as it serves the present purpose to study it.

Commencing with the mesial line, one can dissect out the attachment of five muscles, each of which is of course duplicated on the opposite side, and each of which has such relation to a mesial line that, in case of cleft, or split, it serves more or less to draw away the parts postero-laterally.

These muscles, mentioned in the order of their signification to such lateral displacement, and consequently in their relation to the operation of staphyloplasty, are the tensor palati, palato-glossus, levator palati, palato-pharyngeus motores uvulæ. Of all these structures the tensor palati plays the most important part, and is therefore entitled to the first consideration.

This muscle arises from the scaphoid fossa at the root of the internal pterygoid plate, from the anterior surface of the Eustachian tube, and from the spinous process of the sphenoid bone. If the student carry his finger (in his own mouth) back to the wisdom-tooth of the superior jaw, and let it drop over and back of this organ, it will fall on the tuberosity of the maxillary bone; carry it now half an inch farther back, and it will come to a second prominence; this is the hamular process of the pterygoid plate of the sphenoid bone. The tensor palati muscle descends from the origin of which we have just informed ourselves, and, meeting this hamular process, it winds—as a tendon—around it, and then, by a fan-like expansion, spreads itself into the substance of the soft palate. Its action is evident: it expands the palate laterally.

To perform successfully the operation for cleft palate, it is perhaps desirable, in every case, that the strain made by this muscle be taken off. A moment's reflection will show that the action of the muscle, in case of a cleft, would, when the parts are brought together, be much increased over its natural capability, not only because it would be put considerably on the stretch, but also because such stretch would, more than likely, excite to spasmodic contraction. The muscle of course is then to be divided: as well here, as anywhere else may be considered the easiest point at which such preliminary operation is to be done.



It is remarked that the muscle is found winding—as a tendon—around the hamular process. It winds from the back, outwardly, inward, and forward, so that just in front of the process, between it and the tuberosity, is the place at which its section may be best accomplished; there are here no important vessels to be wounded, if we except the posterior palatine artery and nerve, and these hug the base of the tuberosity so closely that it would have to be a very badly-managed knife that should interfere with either of them. The cut is to be a little oblique. The interference with function, as in most cases of myotomy or tenotomy is, of course, but temporary. The action of the muscle will be found recovered quite as soon as the cleft operation is ready for it.

The next most important muscle is the palato-glossus; this is simply the anterior half-arch, the constrictor isthmii faucium. It arises, as will be seen, from the soft palate on either side of the uvula, and, passing outward, is inserted into the sides of the tongue, blending with the fibres of the styloglossus muscle.

The palato-pharyngeus arises from the soft palate by an expanded fasciculus, and, passing outward, goes to be inserted into the posterior borders of the thyroid cartilage. These muscles constitute the posterior half-arches. Section of the palato-pharyngeus and the palato-glossus is to be made through the substance of the muscles, and is accompanied simply by nicking, somewhat deeply, the arches, four cuts, one to each arch. These nicks are best made with curved scissors.

The levator palati muscle arises from the petrous portion of the temporal bone, passes into the interior of the pharynx, and then descends obliquely downward and inward, spreading its fibres out over the posterior surfaces of the soft palate as far as the raphé.

The action of the fifth and last muscle, the azygos uvulæ, it is perhaps not absolutely necessary to consider,—its influence, for separation of the wound, being very trifling.

Section of the levator palati is thought to be easiest of performance after a manner suggested by Mr. Pollock. This gentleman first puts the flap on stretch, and then, with a double-edged knife, makes an incision through the soft palate just on the inner side of the hamular process. The handle is now alternately elevated and depressed, a sweeping cut being made along the posterior surface of the soft palate.

The other anatomical elements of the soft palate are glandular structures, vessels, nerves, etc., all associated, more or less intimately, by connective tissues; but these need not be particularly referred to, as one could not well dissect out the muscles without necessarily familiarizing himself with them. Thus, then, we understand the surgical anatomy proper of the parts,—the anatomy as it has relation to cleft palate.

The operation of staphyloraphy was first practised by a dentist of Paris,—La Monier. It has for its object the bringing together of the separated



portions of a cleft soft palate and the retention of the parts in apposition until nature shall unite them.

The operation consists of four different stages, with an object to be attained by each stage :

- 1st. The paring of the edges of the cleft.
- 2d. The introduction of ligatures.
- 3d. The bringing together of the freshened edges, and fixing the ligatures.
- 4th. The relief of any tension on the ligatures that may attend the approximation of the parts.

These are the steps or stages, and to accomplish them various means and instruments have been devised,—some good, some bad, some indifferent. The reader curious in such matters will find an admirable and most instructive chapter on the subject in a *System of Surgery*, published in 1851, by Professor H. H. Smith. In the chapter therein devoted to staphyloraphy is given a synopsis of the operations as practised by surgeons whose names have been and are particularly associated with the subject.

An epitome may be made of this chapter by noticing that the operation first suggested by La Monier, in 1764, was revived by Graefe, of Berlin, in 1817, but first methodized and published, with the rules for its accomplishment, by Roux, of Paris, about 1819. In 1820 a nearly similar operation was performed by Dr. John C. Warren, of Boston, he being at that time ignorant of the views or operations of other surgeons. In many respects the steps proposed by Drs. Warren and Roux correspond, though the means suggested by Dr. Warren are simplest, the operation of the latter being generally regarded as the basis of the various modifications that have since perfected the proceeding.

The instruments prepared by Roux for performing the operation are alluded to as being sufficiently complicated. To execute the manipulations, that surgeon seated his patient before a strong light, the head being thrown back and supported against the chest of an assistant, the mouth kept wide open by means of a cork placed between the molar teeth. The operator then placed himself in front, and, with forceps held in the left hand, seized the right lip of the fissure. With his right hand armed with a needle-holder, he next introduced the point of a needle from before backward behind the uvula, in order to traverse the flap from behind forward, at three or four lines from the free edge of the fissure. The needle, being thrust in as far as its head, was then freed from the holder, and seized at its point by forceps, which drew it, and the ligature, through into the mouth. After permitting a few minutes of rest to the patient, the same manœuvre was practised on the left side of the fissure with the other needle of the same ligature, the two ends of which were thus brought out of the mouth. In passing these ligatures, M. Roux commenced with the lowest, next passed to the highest, and ended with the middle.

The next step in the operation of Roux was to freshen the edges of the



fissure. This he accomplished by seizing the margins, as before, with his forceps, and paring from behind forward. To tie the ligatures, he commenced by knotting the middle one with the fingers, and, after making a simple tie, confiding it to an assistant, who held it with an instrument termed by the French a *serre-nœud* (knot-tier); he then passed on to the second ligature, and from that to the first, drawing them tighter than was necessary to approximate the edges of the wound, in order to prevent any separation. Eating, drinking, and speaking were interdicted the patient for from two to three days, the ligature being removed on the third or fourth day, excepting the lowest one, which was allowed to remain twenty-four hours longer than the other.

Dr. John C. Warren performed the operation as follows: The patient being well supported and secured, a piece of wood, an inch wide, a little curved at the end, and with a handle to be held by an assistant, was placed on the molar teeth of one side to keep the mouth open. A sharp-pointed curved bistoury was then thrust through the top of the palate, above the angles of the fissure, and carried down on one edge of the cleft to its extremity, and the same was done on the opposite side, so as to cut out a piece in the form of a letter V, including about a line from each edge. Next a hook, or curved needle, fastened in a handle, with an eye on its extremity, and a movable point, armed with a triple thread of strong silk, was passed doubled into the mouth through the fissure behind the palate, and the latter pierced by it one-third the length of the fissure from the upper angle of the wound, so as to include about three lines of the edge of the soft palate. The eye, with the ligature, being seen, was seized with a common hook and drawn out. The eyed hook was then drawn back, turned behind the palate, and the other edge transfixed in a similar manner. A second and a third stitch were now passed in a similar manner, the third being as near as possible to the lower end of the fissure. Then, seizing the upper ligature with the finger, the knot was tied without using a *serre-nœud*, and placed on one side of the wound in order to prevent its pressing on the fissure, the other being tied in like manner, and the fissure closed.

After the first operation of Dr. Warren, Dr. A. H. Stevens, of New York, in September, 1826 (see *North American Medical Journal*, vol. iii. p. 233), operated successfully, by first inserting the ligatures and then paring the edges.

In 1827, Dr. Mettauer, of Virginia, operated for staphyloraphy, and in 1837 published an excellent essay. Dr. M. employed leaden ligatures. (See *American Journal of the Medical Sciences*, vol. xxi. p. 309.)

Allusions are made in this chapter to other operators and operations; but as they are all only modifications of the methods of Roux and Warren, it is not necessary to refer to them.

Several years back the author had in his possession a monograph on the subject of staphyloraphy from the pen of the late Professor Mütter. He regrets



that he cannot now lay hands upon it. Dr. Mütter was much interested in the operation, and his pamphlet abounded in cases illustrating his success in the direction.

To Sir William Fergusson, of England, more than to any other man, are we perhaps indebted for a scientific appreciation of the requirements in staphyloraphy. The cutting and sewing parts of the operation are simple mechanical manipulations, which are of consequence only as they tax the ingenuity of an operator. The proper surgical understanding of the subject consists, as we are prepared to see, in an acquaintance with the muscular relations of the parts. These relations we have just studied. To Mr. Fergusson belongs the credit of first making the demonstrations. It is very true that before his time incisions in the soft parts had been advised. Roux, Dieffenbach, Mettauer, Liston, and Warren all practised them where difficulty was met with in approximating the fissure; but the sections made by them, as remarked by Mr. Fergusson, seem to have been without reference to the anatomy of the parts, and, as a consequence, rendered success somewhat a matter of accident. The operation of Mr. Fergusson, as the paring and bringing of the fissured parts together are concerned, is much the same as that practised by Dr. Warren. He pares the cleft before inserting his sutures, and his knots are made about as Dr. Warren's.

In looking over the history of staphyloraphy, the reader will be struck with the likeness in complaints, the three principal of which seem to be the difficulty in tying the ligatures, the great tendency of the ligatures to slough out after they are once nicely secured, and the concealment of the parts during operation both because of deficiency in light and the accumulation of the viscid muco-saliva which in mouths thus affected is secreted in great abundance.

Now, in the direction of operations in and about the oral cavity, the writer has had an experience which will, perhaps, justify him in asserting that there is an easier and more philosophical mode of performing the operation of staphyloraphy than has yet been described. To sit in front of a patient and operate in the mouth is most unhandy. The operator is in his own light; besides, it is certainly much more difficult to operate sitting than standing: motion is cramped, freedom is interfered with. To perform on the mouth of a patient, when the surgeon is seated in front, renders necessary an assistant, whose office it is to manage the head. This has a twofold objection. In the first place, the assistant cannot follow in all those little changes which are so necessary to success. He does not see quickly the shiftings and turnings which so help in the manipulations. Again, one is more naturally ambidextral when the arms are supported than when they are unsupported. In operating sitting in front of a patient, the surgeon must work at arm's length; he has nothing to steady him,—no guard which shields against any sudden awkward movement on the part of either assistant or patient.



To make a knot deep in a canal, such as the mouth or the vagina, is not easy. To fix a ligature by compressing something upon it is very simple.

Silk is not unapt to act as an irritant to human tissue,—silver or lead is less worrying; therefore, where it is desirable to retain a ligature for several days or weeks, without irritation, metal is best adapted to the end.

Instruments perfectly suited to a performance simplify it greatly.

Predicating an operation on these self-evident truths, the following manner is commended as being the best and easiest mode of manipulating. Where once practised it will take precedence of all other modes.

The instruments required are those belonging to the ordinary vesico-vaginal case,—a long-handled knife, needles and needle-carrier, shot-carrier and compressor, tenaculum, cutting forceps, silver or lead wire, the perforated flat shot of McLean, and mop-sticks. Better instruments than these for the operation of staphyloraphy will not soon be devised. The instruments arranged on a tray in the order in which they are to be used, the patient, having had the steps of the operation explained to him,—for much is expected from him,—is seated on a chair having a movable head-rest: it is well if this rest move in a ball-and-socket joint; at any rate, it must be movable backward and forward. The ordinary dental chair answers the purpose admirably. When the head is placed on this rest, the mouth will be found to look directly upward. The surgeon now takes his position back of the patient, standing on a footstool of such height that his breast shall be brought on a level with the head. If the reader be disposed, he can thus seat a friend, and, taking a position back of him, by leaning over his head he will find that when the mouth is opened he not only has a perfect view of a thoroughly lighted cavity, but by leaning against him, and passing his arms around the head so as to bring the hands to the mouth, he will perceive that, besides having his own arms so steadied as to allow of the easiest manipulation, he has the movements of the sitter completely under control.

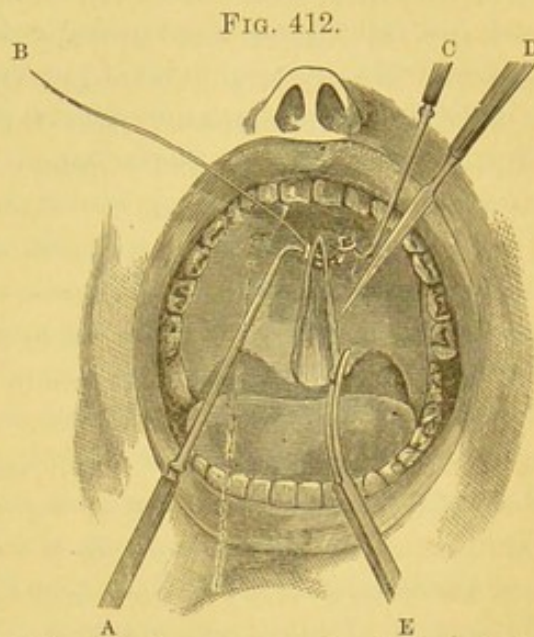
This relative position of the surgeon to his patient gives not only the advantages enumerated, but places him out of the way of ejective spasms. If saliva and blood accumulate about the parts, he can and will, almost unconsciously, and certainly without effort, so turn the head that, while he does not at all interfere with his own manipulations, he throws the fluid into some more convenient part of the mouth. This is to be done so readily that each step of the operation may be accomplished without the annoyance and delay experienced in using the mop. Certainly, a patient so held cannot make any movement too quickly or too unexpectedly for the surgeon. True, he might be so obstreperous that the operation could not be accomplished; but he could not make any change which the knife of the operator would not intuitively follow, and therefore accidental harm could not be done.

Patient and surgeon being in position, a tenaculum is taken up and carried through the very point of the cleft pendulum, or, if preferred, the forceps




may be used. (See Fig. 412.) The part is then put on stretch, and a paring (as shown in the diagram) of about a line is taken from the whole of that side, cutting from behind forward. The manipulation is repeated on the opposite side. The first stage completed, very dilute compound tincture of capsicum,  $\mathfrak{z}\text{j}$  to  $\mathfrak{z}\text{xvj}$  of water, or water medicated with potash, or ammonia, is given the patient, with which to gargle and wash the mouth. These cleanse the part admirably, besides acting as healthy stimulants.

The bleeding arrested and the patient a little recovered, the second step, that of passing the ligature, is to be practised. Take up one of the curved needles, Fig. 413, and, threading it with the silver wire, thrust it through one side of the cleft, about three lines from the margin and about half an inch from the apex of the cleft or hard palate. After passing it to this point the wire is unthreaded by means of an excavator. This accomplished, the needle is withdrawn, rethreaded, and carried after a like manner through the opposite side; the two ends are next brought from the mouth and their relaxation secured by one or two twists. This completes the first ligature. A second is now passed half an inch farther on, also a third, or more, as may seem needed. The manipulations required are of course the same as for the first. This completes the second stage, and the patient is allowed to rest as before. If he need to wash his mouth, which is very much more than likely, the surgeon must look carefully after the ligatures.



The author's operation as described. A, is the curved needle; B, the wire-thread; C, is an ordinary dental excavator used in unthreading the eye; D, is the knife paring the cleft; E, is tenaculum or forceps putting the part on stretch.

FIG. 413.



The Author's Curved Needles.

The third stage, or approximation of the edges, is next to be accomplished. Take up the shot-carrier, and, slipping through its fenestra the twisted ends of the last ligature introduced, push the carrier down the wires, and it is found that as it approaches the palate, the edges of the cleft approximate. This will always be found to be the case with the ligature nearest the



uvula: the parts are closed very easily. Now slip off the carrier and take up one of the perforated shot; put this on the wires, and with the carrier force it down to the palate. Holding this in place, which is done by simply laying the wire against the carrier and shifting a finger over it, take up with the right hand the forceps, and compress the shot tightly upon the strands. The parts up to this ligature will now be found nicely approximated and fixed. This completed, repeat the operation on the second ligature. This, however, may be found impossible, without greatly overstraining the parts and risking the tearing out of the wire.

If this be the case, the operator at once desists from the attempt, and makes the section as described of the tensor palati muscles on either side. Now most likely the parts will come together conformably: if so, fix them with the shot as before; if, however, an approximation has not yet been secured, nick the anterior half-arch; and if this do not suffice, cut the posterior and as well the levator palati muscle: the ligature may then be fixed, and, as well, those still farther front. Each shot firmly compressed, the wires are to be cut off as closely as possible. Thus the third and fourth steps of the operation are completed, and nothing remains but to enjoin on the patient reasonable quiet. In this rest lies half the secret of success: the patient should move warily for two or three days; certainly he should not be permitted any food that would demand for its comminution the slightest effort at mastication. He is to be directed to allow the liquids taken to trickle down his throat, rather than attempt to swallow them. These restrictions need not, however, be made quite so stringent if in the operation myotomy of the half-arches has been employed.

In the old mode of performing the operation, it was found necessary after the first day or two to remove the ligatures, because of their tendency to slough out: the use of silver wire obviates this necessity to a great extent, as the metal seems to provoke little inflammation. These ligatures may therefore, if they seem useful, be allowed to remain a whole week. This non-irritating quality of metal ligatures is so marked that they have been seen, when applied to varicose veins, as firmly fixed after four months as on the day of application. This is the feature which adapts such ligature-material so admirably to staphyloraphy.

The wounds made in dividing the muscles may be left to nature. If the patient be in condition for the principal operation, he is in a condition which does away with any necessity for care in trifling flesh-wounds; if, however, trouble should arise in such a direction, the practice is that which applies to similar wounds, however made.

It is seen that the manipulations here suggested for the cure of cleft palate are precisely the same as those practised in vesico-vaginal fistula, and that the instruments adapted to the one operation are exactly suited for the other.

The position in operating together with the employment of perforated shot



and carrier was first suggested and practised by the author twenty years back.\*

From this consideration of cleft palate proper, we now pass to the study of other defects of the parts.

**Holes in the Palate.**—Breaks in the continuity of the palate may be treated in two ways: either by an operation strictly surgical, as reference is had to the use of the knife; or by means which are to be denominated surgico-mechanical. If the knife is to be exclusively used, we have simply to pare the edges of the break, and then get the parts in apposition as best we can. Herein consists, however, the difficulty of such operations; and the tact and knowledge of the surgeon will prove his best guides. If the breaks are in the soft palate, any resistance that may be met with is to be overcome precisely as in staphyloraphy: let the surgeon consider what muscle or muscles oppose him, and divide them as before suggested; or, if myotomy seem scarcely necessary, he can in all probability accomplish his purpose by making lateral slits through the mucous membrane alone, or otherwise he may go a little deeper, making a kind of semi-myotomy.

If the break be small, one ligature will perhaps be all that is necessary to secure the approximation of the pared edges; this suture is to be made and fixed precisely as in the previous operation. If more than one seem indicated, of course more are to be employed.

Defects in the hard palate are also amenable to surgical skill: they may be remedied by the use of the knife and stimulating local applications, or, if these fail, an artificial palate, properly constructed, will so admirably supply the deficiency that the patient is rendered almost as well off as his fellows. (See *Obturers*.)

Using the knife alone, most successful results are frequently attained by first paring the edges of the break and afterwards dissecting the parts freely from the bone. This mode of operating is suited to such hard palates as have a thick, soft, mucous membrane. Through this manner of manipulating, and with such character of mucous membrane, quite wide chasms may be spanned.

With such mucous membrane, plastic operations are found to answer very well. It is quite easy to get a flap without disturbing the periosteum, and such a flap may be twisted on its pedicle without any special interference with its function. The pedicle, however, should be as wide as possible, remembering that the circulation pertains to the basement membrane alone. An objection, however, to such operations in the mouth is the difficulty that attends the fixing of the flap in its new place.

The next mode of relieving these defects which may be alluded to is that originally suggested by Dieffenbach. This surgeon commends the pencilling of the edges of the break with tincture of cantharides, hoping thereby to

---

\* These manipulations were first practised in 1861, and were described in papers published by the author in the *Medical and Surgical Reporter of Philadelphia*.



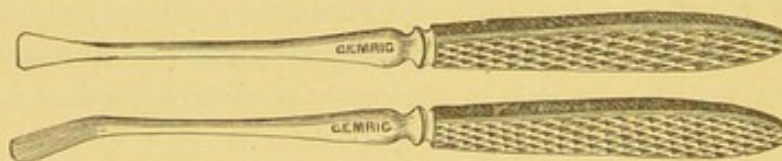
excite granulation to an extent that shall fill up the cleft. The use of nitric acid is advised in the same direction.

Now, while this does very well for small holes, it seldom succeeds with the larger. The granulations, having nothing to support them, break down before connecting in the middle.

This defect in the treatment is to be remedied, and success almost warranted, by the following modification: make a simple obturator, or artificial roof; after fitting this so as to cover accurately every portion of the hard palate, it is to be removed and the cleft pared; next touch the parts with cantharides, nitric acid, or tincture of iodine,—the latter is preferred by the writer. The plate is now to be replaced, and will be found to act most completely as a support to the granulations which form. The process of freshening the edges is, of course, to be frequently repeated; but after the first paring the cuts may be made from the circle on, and not around, the cavity.

**Uranoplasty.**—To Dr. J. Mason Warren seems justly due the credit of the conception of this operation. His plan of manipulation is as follows: Incisions are first made on either side of the cleft down to the submucous cellular tissue, being midway between the borders of the break and the alveolar processes, these incisions extending back to the extent of the break. Next, using a double-edged knife, these flaps are dissected towards the cleft,

FIG. 414.



Instruments for raising soft tissues from hard palate—two patterns.

and, falling, are united in the middle line. Another plan practised by this surgeon consists in dissecting the mucous membrane from the edges of the cleft toward the alveolar processes, and, as they are thus made loose and pendulous, uniting them along the centre line.

A modification by Langenbeck on the operation of Warren consists in including in the dissection the periosteum, thus taking advantage of the osteogenetic qualities of that membrane to secure the filling of the break by a deposit of bone.

The use of a gag to keep the jaws separated, both in the operation of staphyloraphy and in that of uranoplasty, will be found to add to convenience in the operation. The instrument of Kolbe, shown in Fig. 415, the author occasionally uses with much satisfaction. A means, however, more commonly employed is known as Whitehead's Gag and Tongue-Depressor; this consists of two curved bars, one supporting either jaw, kept separated by a ratchet lever; to the lower bar being attached the tongue-holder. A modification of this gag (or, more properly speaking, of the Smith gag, which is



much like it), made by Dr. Louis Elsberg,\* of New York, is preferred by many.

Another form of gag is a very simple, but yet quite effective, apparatus devised by Dr. Goodwillie, shown in Fig. 416: this consists of two arms

FIG. 415.—SCREW LEVER.

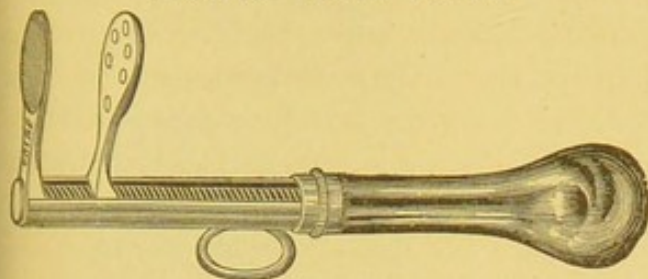
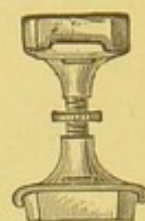

FIG. 416.



covered with elastic rubber, with a central screw which increases or diminishes the length of the piece as required. Gags of this class require, however, to be held in by the finger of an assistant.

Still another form of this instrument is one devised by John Wood, of King's College Hospital, and which was used exclusively by Sir William Fergusson in his operations about the mouth; this consists of a double bar, having rests for the support of the teeth, and which are separated on a principle precisely the same as that employed with the bivalve speculum.

In concluding the subject of treatment of cleft palate by operation, reference is to be made to uncertainty in success both as regards result of manipulations and improvement in speech. Cases operated on by the writer have proved to the fullest degree satisfactory; a greater number have ended in failure.

Where the remnants of a velum are plentiful, and the patient is in health, operation promises most, and is to be recommended. Where, on the contrary, the parts are scanty, and these scanty parts fixed, little good is found in trying anything outside of mechanical means.

Section of the velum, as shown in Fig. 5 of illustrative plate, is only to be practised when impossible to be avoided. As a result of such section, a tumidity of the parts is almost certain to show itself, which proves very adverse to union of the pared edges.

Fig. 1 (see plate) shows the operation of Roux.

Fig. 2 shows paring of edges of cleft.

Fig. 3 shows the operation of Warren; the knife freshening the edges of the fissure from above downward; the forceps steadying the margin so as to favor its regular incision.

Fig. 4 shows manner of introducing sutures, Physick's forceps and a curved needle being used.

\* A sponge-holder of most convenient form and construction, and of great service in operations about the mouth, is known as Elsberg's sponge-forceps.



Fig. 5 shows Dieffenbach's operation of staphyloplasty. In this case silk has been used and ties made.

With the understanding now secured of the mouth, the pharynx, and their diseases and deformities, we may carry our observations from above forward through the nose.



Fig. 1.

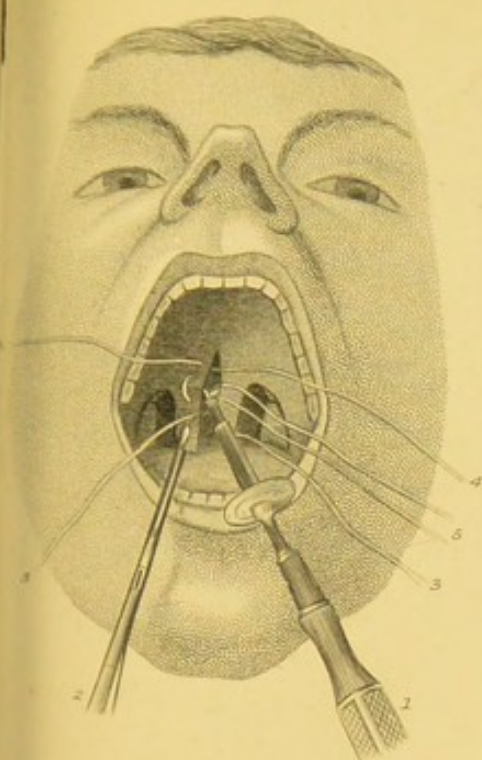


Fig. 2.

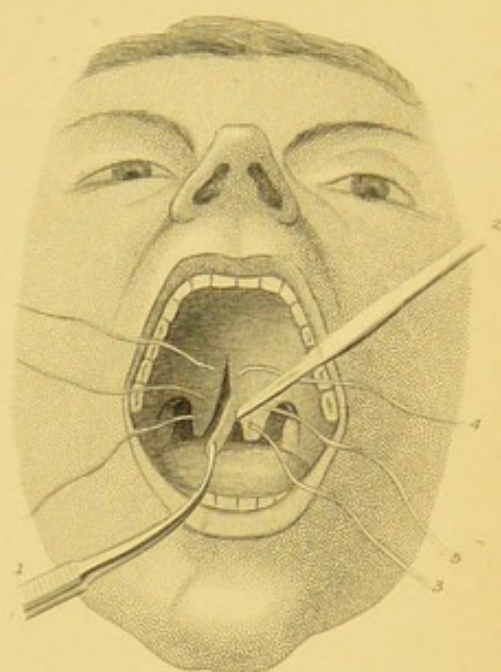


Fig. 3.

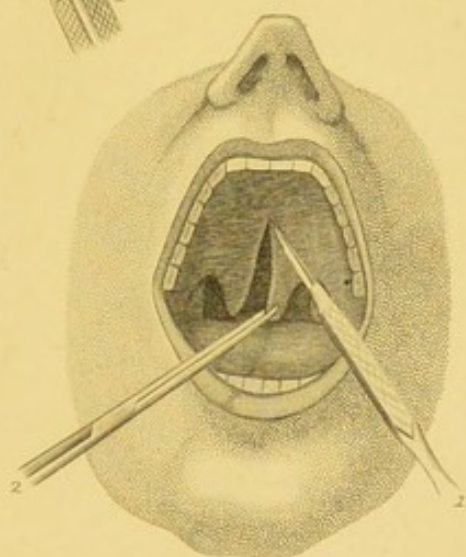


Fig. 4.

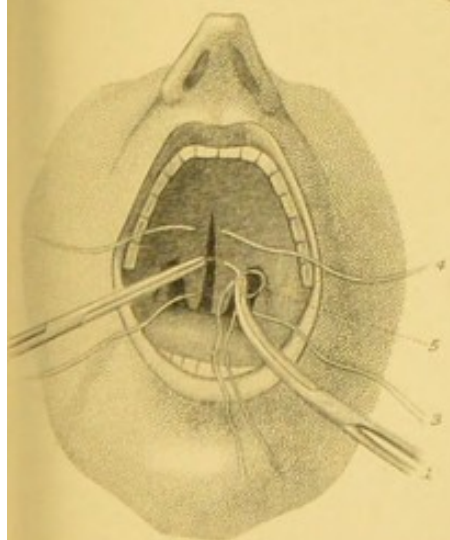
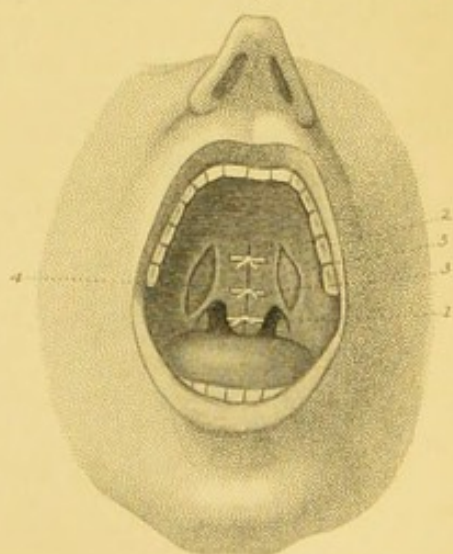



Fig. 5.







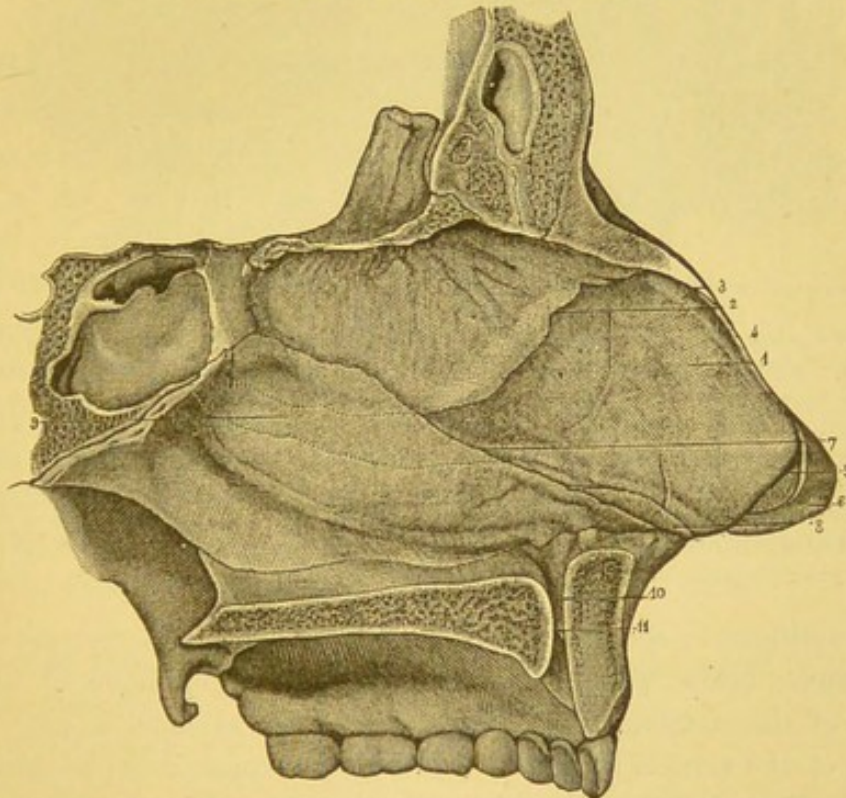


## CHAPTER XLII.

### THE NOSE AND ITS DISEASES.

**Anatomy of Internal Nose.**—The nose is a symmetrical organ, occupying the exact centre of the facial region. Looked at from below it is seen to be divided into two cavities, or canals, by means of a vertical septum. These canals are called nostrils, or nares (*naris*, singular); they constitute the nasal fossæ.

FIG. 417.—VIEW OF NASAL SEPTUM.



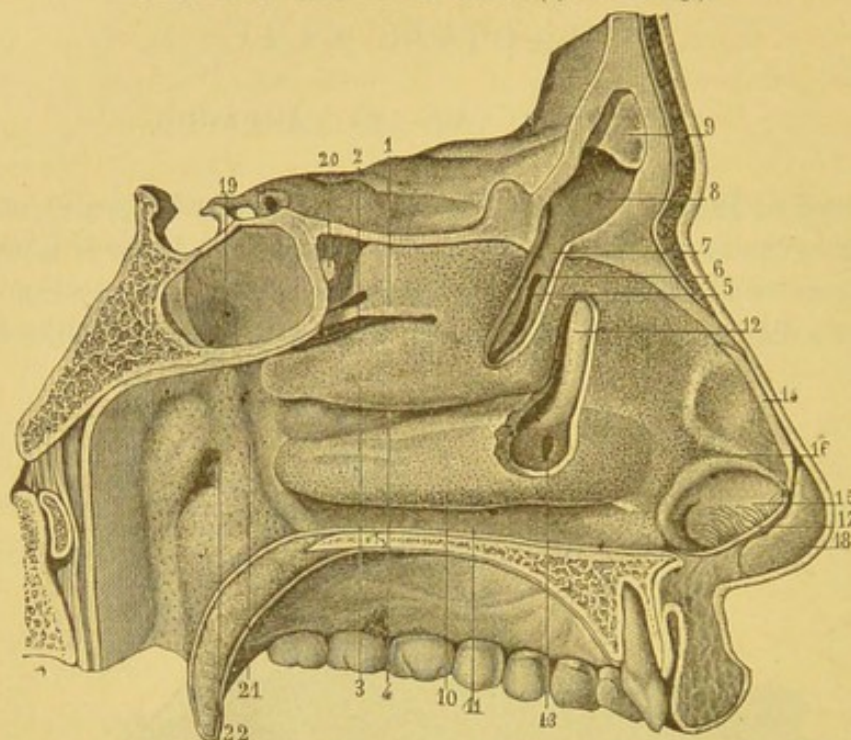
1, cartilage of the partition; 2, its junction with the nasal plate of the ethmoid bone; 3, its junction with the nasal bones; 4, margin of continuation with the upper lateral cartilage; 5, fibrous membrane connecting the cartilage of the partition with the lower cartilage; 6, inner portion of the left lower lateral cartilage; 7, anterior border of the vomer; 8, an accessory cartilage; 9, prolongation of the cartilage of the partition in a groove between the vomer and nasal plate of the ethmoid bone; 10, naso-palatine canal of the right side opening into the anterior palatine foramen; 11, palatine process, osseous floor of nose.

By the nasal fossæ is meant the whole inside of the nose. By a nasal fossa is understood either lateral cavity; the one being separated from the other by means of a division composed of bone and cartilage, known as the septum narium. Fig. 417, representing a vertical section of the nose, the septum being left in position and relation, affords accurate understanding of this anatomy.



The vault of the nose is supported, posteriorly, by the vomer and by the nasal plate of the ethmoid; anteriorly, by a cartilage. The vomer is a single

FIG. 418.—INSIDE OF NOSE (*after Leidy*).



OUTER WALL OF THE LEFT NASAL CAVITY.—1, superior turbinated process; 2, superior meatus; 3, inferior turbinated process; 4, middle meatus; 5, portion of the turbinated process of the ethmoid bone removed to show the orifice of communication (6) with the anterior ethmoidal sinuses; 7, communication with the frontal sinus; 8, left frontal sinus; 9, part of the unsymmetrical partition which separates the frontal sinuses; 10, turbinated bone; 11, inferior meatus; 12, lachrymo-nasal duct exposed by removing a portion of the bones; 13, its termination; 14, edge of the upper lateral cartilage; 15, outer part of the left nostril; 17, cut edge of the partition; 18, inner portion of the left lower lateral cartilage; 19, sphenoidal sinus; 20, its orifice; 21, pharynx; 22, orifice of the Eustachian tube.\*

bone, ploughshare in shape. Above, it articulates with the rostrum of the os sphenoidum; below, with the crest formed by the conjunction of the palate processes of the maxillæ. The nasal plate of the ethmoid is simply a prolongation of the vertical lamina of that bone; it constitutes one-third of the partition. Posteriorly it articulates with the sphenoidal crest, inferiorly with the vomer, superiorly with the nasal process of the frontal bone. The cartilage constitutes the anterior portion of the division; its connection above is with two lateral cartilages, associated with the free edges of the nasal bones and nasal processes of the superior maxillæ, posteriorly with the vomer and ethmoidal nasal plate, and inferiorly with the vomer. (See cut.)

The inside anatomy of the nose, nasal cavity, or fossa, is to be thoroughly appreciated through a study of Fig. 418. Also is it to be suggested that, with aid of a pencil and this diagram, a student may draw figures of nasal

\* The student will do well here to turn back to the special descriptions found on pages 39 to 42, inclusive of both.



polypi in position and relation, thus affording to himself thorough comprehension of a most important subject. (See also Fig. 427.)

The communication of a nasal fossa is with six cavities; above, with the frontal sinus, the relation being by means of the ethmoidal cells; behind, with the sphenoidal sinus; laterally, with the antrum of Highmore and the posterior ethmoidal sinus. The first of these communications is related with the middle meatus; the second and fourth with the superior meatus; the third with the middle meatus. Communication also exists between the nose and orbital cavity through nasal duct.

Each nasal fossa is of like form and characteristics. The irregularities seen upon the outer wall are resultant of the turbinated scrolls. These represent the meatuses, of which there are three,—superior, middle, and inferior. The common covering is mucous membrane.\*

Each fossa is physiologically divisible into a superior and an inferior canal; an upper, which relates with the olfactory region (olfactory channel); a lower, which pertains to respiration (respiratory channel, Schneiderian region). The septum, described by Meyer as the *agger nasi*, is simply a duplication, or fold, of mucous membrane prolonged anteriorly upon the middle turbinated bone. Division of the common naris is made by action of the compressor naris muscle.

The functions of the nose divide it into four different aspects (Watson): 1, a sense organ; 2, a respiratory apparatus; 3, as a part of the face and of the mechanism of expression; 4, as part of the vocal mechanism.

Surgically studied, regard is to be paid—1, to the cavities and irregularities arising out of the presence of the scrolls; 2, the regularity or irregularity of the septum; 3, the peculiar thickness and softness of the mucous membrane lining the olfactory channel when compared with that found in the Schneiderian region; 4, association with the sinuses and orbit.

**Diseases of the Nose.**—Diseases of the internal nose named in the order of their frequency are:

1. Simple Nasal Catarrh.
2. Hemorrhage.
3. Ulcers.
4. Polypi.
5. Strumous Abscess.
6. Conditions associated with Ozæna.
7. Neoplasms.

1. **SIMPLE NASAL CATARRH.**—Simple nasal catarrh is the so-called “cold in the head;” the meaning of it lies in vascular perversion congesting the mucous membrane of the nose, particularly that portion associated with the

\* Asymmetry of the nares relates with deflection in the septum, or is a natural inequality. Congenital interference in respiration has not by any means its constant cause in deviation of the partition.



olfactory channel. Fulness felt in the front and base of the forehead region finds explanation in the continuation of this membrane which lines the frontal and ethmoidal sinuses. Treatment lies in applications directed to the production of resolution. Such applications consist in hot foot-baths, and in the inducing of free catharsis, diaphoresis, or diuresis. A large dose of sulphate of magnesia dissolved in a goblet of water is an admirable remedy; to be taken at bedtime. A means in the second direction is found in tablespoonful doses of spirits of Mindererus repeated each fifteen minutes until free sweating is induced. Spirits of nitric ether is a reliable medicine in the third direction; the dose is a teaspoonful repeated each two hours.

A combination freely used by the author, being prescribed, indeed, in nearly all cases which he is called to treat, is as follows:

R.—Liquoris potassii citratis, ℥iij;  
Spiritis ætheris nitrosi, ℥ss;  
Antimonii et potassii tartratis,  
Morphiæ acetatis, ʒā gr. j. M.

Dose from a dessertspoonful to a tablespoonful repeated each two, three, or four hours according to urgency.

An admirable plan to pursue with a view of breaking up a cold in the head consists in prescribing from twenty to forty grains of bromide of potassium in conjunction with five drops of tincture of veratrum viride; the two to be combined in a wineglass of water. To be repeated, if found necessary, after four or five hours.

2. HEMORRHAGE.—Nasal hemorrhage is direct or indirect; the first referring to a lesion of the fossa, the second being related with the sinuses of the dura mater, and with constitutional conditions. A division made by Watson\* is: 1st, the traumatic, or lesional; 2d, the plethoric, or active; and, 3d, the adynamic, or passive.

Lesional epistaxis arises out of erosions and external injuries; the first may have the expression of a polypus, of an ulcer or, viewing it as a traumatic, may result from accidental injury to the part. The second is commonly associated with fracture of some portion of the osseous parietes of the part, compound in character, the opening being internal.

Plethoric, or active, epistaxis, is the hemorrhage so commonly met with in growing children of robust constitution; the expression is that of relief to vessels over-full. In the apoplectic it means rupture of a vein associating the brain sinuses with the nose; it is to be looked on here as a safety-valve, and, unless excessive, no attempt should be made to control it.

Passive epistaxis occurs in the depressed and ill-conditioned, it is not usually preceded by precursory molimen. The condition of defibrinization as existing in the typhoid condition is a common antecedent. Scurvy and purpura, as

\* Diseases of the Nose.



noted by Watson, are other associations. The blood coming from this kind of hemorrhage is dark, serous, and lacks in coagulable quality.


Traumatic nasal hemorrhage is commonly left to take care of itself. When excessive, the bleeding point or space is to be looked for, and if discovered, direct pressure is to be applied by means of a ball of lint-cloth which has been saturated with alum-water, or preferably, with phénol sodique. The search implies anterior rhinoscopy, which see.

Where the immediate seat of flow in traumatic epistaxis is not to be discovered the treatment is to be upon general principles. Holding the hands high above the head, after the manner of Negrier, while the bleeding nostril is compressed, will oftentimes control it. Ice-cold water drawn into the nares is a favorite means. Upright position. Hot foot-baths. Ice to nape of neck. Strong solutions of lead, or of phénol sodique, snuffed up the canal. Ice applied upon the external face of nose. Hot or ice bags to the spine (Chapman) with a view to stimulating the sympathetic ganglia. Tannic acid thrust into the nostril.

Ordinary means failing the practitioner is driven to operative measures; these imply the employment either of a Cooper Rose gum-tube, or Belloc's canula. The former instrument has never been used by the writer, but strikes him most favorably; a description of it by Watson is as follows: It consists of a gum-elastic tube about five inches long, with lateral perforations near the end, and covered with thin caoutchouc membrane in the form of a spirally-twisted bag for the last three or four inches of its length. The cavity of the bag can be injected with air or water from the gum-elastic tube, the end of which has fitted to it a piece of india-rubber tube for the purpose of connecting it with a syringe. This instrument is used by folding smoothly the membranous bag over the contained tube, and, after oiling, passing it along the floor of the naris until the pharynx is reached. The bag is now to be inflated, its inflation, before and behind, serving to close completely both apertures.

Belloc's canula, exhibited in the cut, is a means familiar to practitioners at large. To use this instrument the curled spring is withdrawn, and the

FIG. 419.—BELLOC'S CANULA. (See for application Fig. 436.)



instrument, being warmed and oiled, is passed along the floor of the nose until seen in the pharynx. A succeeding step forces the spring forward, which, as is recognized, must throw it into the mouth. The eye is now double threaded, the terminal end being retained without the mouth, the initial portion being



carried through the nostril by retraction of the spring and withdrawal of the canula. To the mouth end of the string there is now attached a plug sufficient in size to occlude fully the posterior naris. This plug is now drawn into place, being directed by a finger of the surgeon; its impaction against the outlet of the opening being secured by a second plug forced into the anterior naris and held in place by tying about it the double strand of which the common string is composed. This manipulation controls hemorrhage by clotting the blood in the canal. Removal of the plugs is to be effected with great care. For convenience in removing the posterior plug it is common to tie about it at time of introduction a second ligature which remains in the mouth, being fixed to the initial end related with the anterior plug, during time of treatment.

The use of the tampon, as here described, is attended with danger, both as to delay in its employment and results arising out of its use. The first refers to a procrastination in plugging, which has allowed the patient to become exsanguined beyond the ability of the system to recover. The second relates with irritative fever and to pyæmic conditions begotten of the confined and decomposing blood in the naris. This last involves lack of judgment, or otherwise carelessness on the part of the surgeon. In placing the anterior plug the knot retaining it is to be of a character easily untied. On the second day this plug is to be carefully lifted and the cavity syringed with permanganate of potash, or preferably, phénol sodique; disinfection attained the plug is put back in place, to remain until the following day, when it most likely can be dispensed with. The immediately succeeding day permits, most commonly, of the removal of the posterior plug. The withdrawal of the string through the clot is always a matter of concern as regard is had to the possibility of re-exciting the bleeding. Both as pertains to secondary hemorrhage and disinfection the writer has learned to rest strongly on the phénol sodique.

Nasal hemorrhage of active or plethoric character requires, in instances, a very immediate attention to constitutional conditions. Over-fulness of the stomach, and costiveness, are common associations. Nasal hemorrhage immediately after a hearty meal is apt to find quick cure in the production of free emesis. Costiveness is wisely treated by the administration of purgatives. Bleeding from the arm is a means of cure sometimes found a necessity in the hemorrhage of plethora. An important matter in the after-treatment relates with diet. Rare meats and much stimulating food are to be avoided.

Nasal hemorrhage of passive signification implies lack of resistive force on the part of the containing vessels, not excess in the propulsive power of the heart. A case of this kind shows a lymphatic temperament, atheromatous vessels, otherwise debility from disease or improper living. A case some years back under the observation of the author, the patient being a young man, had its origin fairly in excess of candy eating; it seemed as though a finger might be punched into the tissues at any point. Persons ill fed, syphilitic, or scrofulous are subjects of passive hemorrhage. Out of thirty



cases of diphtheria in an epidemic at the Stafford Infirmary (Watson) twelve were lost from passive hemorrhage.

Epistaxis of vicarious meaning is not to be meddled with without appreciation of exciting conditions. Common relations are with piles and with the menstrual period in women. The writer has had under his professional care for over ten years a lady who, whenever she misses the regular monthly menstruation, bleeds from either the lungs or the nose.

Epistaxis associated with the hemorrhagic diathesis finds its best treatment in the occasional use of quinine, iron, strychnia, and hydrochloric acid. The condition is commonly that of super-alkalinity of the blood combined with vaso-motor debility.

3. ULCERS.—Ulcers of the nose are of traumatic, scrofulous, syphilitic, or cancerous origin.

A traumatic ulcer implies injury done to the part by some accidental source of offence. A not infrequent cause of such condition, as met with in early childhood, has its existence in foreign bodies that have been thrust into the nostril. In congenital breaks of the hard palate ulcers of the Schneiderian nasal region are not uncommon, portions of articles taken as food lodging and proving sources of irritation. The escape of cotton plugs which have been inserted into the anterior nares is to be credited for much offence in the direction. Adenoid vegetation is another cause; the location of this ulcer is toward and in the naso-pharyngeal region; posterior rhinoscopy discovers it.

Treatment of ulcers of local signification arises out of the indications of each particular case; cure is commonly found in removing a source of offence. In the adenoid vegetations a nasal curette, dull or sharp, may be used. A plan of treatment more commonly preferred consists in locating the lesion and making daily applications to it of a powder composed of equal parts of iodoform and subnitrate of bismuth. Injections of zinc sulphate and chloral hydrate in the proportion of grains two of each to ounces one and a half of water are never out of place in nasal ulcerations.

Scrofulous ulcers are most frequently met with in yellow persons; diagnosis lies in collateral associations. It is perhaps never the case that a scrofulous ulcer of the nose is disassociated with an easily distinguishable dyscrasia. As a rule phthisis pulmonalis is found to exist. Scrofulous, tuberculous, or lymphatic ulcers, as sores of this class are indifferently to be termed, seldom, if ever, extend their ravages beyond the submucous tissue. A common location is the septum. A good local application in treatment of them is found in the formula last given. Another is *tinctura calendulæ*. Still another, particularly useful if odor be present, is *phénol sodique* much diluted. Where marked indolency exists the compound tincture of capsicum used in the proportion of five drops to a tablespoonful of water answers an admirable purpose. As constitutional medicaments unskimmed milk, cod-liver oil, and iodine in limited quantity are to be used. No better course of treat-



ment is to be prescribed for a person afflicted with, or tending toward, tubercle than the following: A sheet bath, prepared with Turk-island salt, immediately on rising in the morning; the act to be accomplished within a minute. Succeeding this is to be a self-rubbing of the skin until the surface is aglow. After this a goblet of milk containing a raw egg together with a tablespoonful of alcohol. This to be followed by a walk; breakfast finishing the performance. In the case of a patient weakened from disease the milk and egg are to be taken fifteen minutes before getting out of bed; bath and rubbing are to be given by a nurse; the tablespoonful of alcohol concludes the breakfast; exercise may be passive.

Strumous rhinorrhœa and ulceration as a disease of childhood is found in connection with hereditary taint, and in a dyscrasia related, as in the previous recital, with disease of the lymphatic system. The ulcers are of the pasty variety, the discharge commonly somewhat offensive. Obstruction of the nostrils exists in a swelling of the mucous lining and in the formation of yellowish scabs. Attention is to be directed in connection with strumous ulceration of the nose to a congestive infiltration of the membrane covering the inferior turbinated bone, which oftentimes results in a pouch-like projection of that tissue from the nostril, which, while it obstructs respiration, so simulates polypus in appearance as not infrequently to beget mistakes in diagnosis.

Treatment of scrofulous ulcers in children differs nothing from that just suggested. Importance is attributed by some to frequent removal of the scab, this being recommended to be done twice a day. To accomplish such removal glycerine and water in equal proportions combined with carbolic acid, one part of the last to sixty or eighty of the first, is highly commended by Watson: application is made with a camel-hair brush. A means used by the writer is cod-liver oil; this softens the scab nicely. Still another admirable local application is found in benzoated zinc ointment, to which have been added small quantities of iodoform; two grains of the latter to one drachm of the former. Where a general passive congestion of the parts exists the injection of zinc and chloral, noticed a few paragraphs back, will be found of great service.

Syphilitic ulcers are, in like manner with the scrofulous, recognizable by associations. A syphilitic ulcer is a dangerous sore; once started its ravage might not be stayed until mucous membrane, cartilages, and bone-structure are involved in a common destruction. The start-point of this ulcer, excepting when of primary signification, is commonly, if not exclusively, in the form of a gumma. The symptom first noticed is interference with free nasal respiration; a later sign is a thin muco-purulent discharge of offensive character; still later, greenish slimy clots are formed and thrown off. Ulcers associated with the tertiary form are most formidable.

Correct treatment is founded on general principles: the disease is syphilis, syphilis requires to be prescribed for; the local expression is a rhinorrhœa,



or coryza, associated with ulceration, local expressions demand exhaustive attention.

The offensive, and indeed poisonous, nature of the discharge relating with syphilitic coryza renders cleanliness a matter of special consideration. Nostrils so diseased are to be washed, disinfectants being used, several times daily. This is accomplished by a douche bath prepared by adding to the zinc-chloral water a required quantity of phénol sodique or Watson's chlorine-water; this last much diluted.

Application to ulcers is to be direct. To discover the seat of such ulcers anterior rhinoscopy is employed (which see).

Syphilitic ulcers of the nose are treated the same as those found in the mouth or pharynx (which see).

*Neuro-paralytic Ulcers.*—Ulcers of this class are to be looked for in conditions of paresis of the fifth nerve. Treatment is in stimulation.

*Scorbutic Ulcers.*—These are undoubtedly to be met with situated within and about the nostrils. Diagnosis and treatment refer to the general condition.

*Glanders.*—This is an ulcer of contagion. The period of incubation is commonly twenty-four hours. The primary nasal expression is a discharge of thick yellowish fluid streaked here and there with blood. The disease is almost necessarily fatal. (See works on Practice of Medicine.)

Cancerous ulcers of the nose are of fatal signification. They are recognizable in the giant granulations studding the surface. No cure is known. Treatment considers free excision of the part involved.

Nasal ulcers associated with the ordinary exanthems of childhood find proper treatment in that which considers the disease at large. The same is to be remarked of diphtheritic ulcers. Local treatment of the first class consists alone in the employment of simple soothing unguents or fluids. Ulcers of the last kind require that the exudate forming over them be both dissolved and disinfected. Watson's chlorine-water will be found invaluable.

4. POLYPI.—Polypus is the fourth most common disease of the internal nose. All polypi are to be looked on with concern as reference is had to the neoplastic meanings. Two general forms are met with: the gelatinoid and fibrous.

A gelatinoid polypus resembles closely, in color and general appearance, a common oyster; it is moist, translucent, occasionally jelly-like, infrequently fairly solid. Shape varies to a degree that places it out of the way of comparison, although, as a rule, the growth is pedunculated. "Pyriform" is the expression of form commonly used by writers.

The origin of this growth is almost invariably from the middle turbinated bone, while yet it is quite well known that it may spring from any part of the cavity, the nasal septum not excepted. Origin is single or multiple, one or several occupying a naris. Gelatinoid polypus, looked on as a mucous tumor, is to be esteemed as an hypertrophy of that structure, otherwise as a




submucous development carrying and attenuating the membrane; a variety is undoubtedly modified adenomata. Papillomata is a variety made by certain writers.

The hygrometric character of a gelatinoid polypus finds explanation in its structure; this is cellulo-fibrous, the meshes being filled with a sero-albuminous fluid. The growth is commonly much affected by the state of the atmosphere, being smallest in dry, largest in wet weather.

Treatment of mucous polypi is by desiccation, evulsion, abscission, the electric cauterant, and the use of potential cauterants. The first is to be tried with the smaller varieties. In this direction a powder composed of tannin and iodoform, in equal parts, is to be recommended; application is made by means of a glass tube charged with the medicine, this being blown over the growth. A second means employs an insufflator composed of bellows and tube: Kolbe's instrument (Fig. 420) is a good one. Strong alum- or lead-

FIG. 420.—KOLBE'S POWDER INSUFFLATOR.



water, as an injection, is found to afford much comfort; it is to be used two or three times a day.

Cure by evulsion, tearing away, or by strangulating is most relied on; to this end a polyptrite, or double canula, is used. Fig. 421 shows a modifi-

FIG. 421.—THE ARELING-HODGE POLYPTRITE.





FIG. 422.—GOOCH'S CANULA.

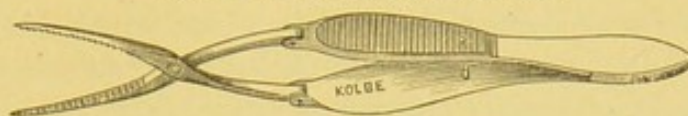


cation on Hodge's modification of Areling's polyptrite. This instrument, though best fitted for use in another location, is yet found at times to act well in the nostril. Fig. 422 represents Gooch's double canula applied.



Still another instrument, one the writer would recommend, is shown in Fig. 423. An advantage consists in the forceps having the grasping part

FIG. 423.—TORSION FORCEPS.

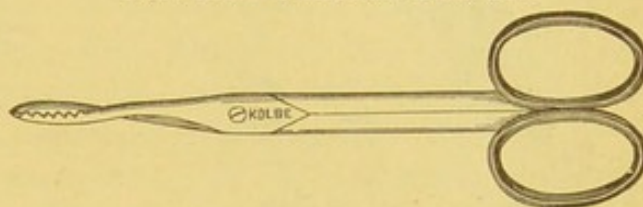


connected by three joints; thus, in seizing a tumor the points cannot slip or twist laterally; the leverage is also increased, while the strain of the fingers is diminished. Another instrument still is that illustrated in Fig. 424. This, where the pedicle is tough and resisting, plays a most satisfactory part.

To use the snare or forceps requires that the operator possess himself of an accurate knowledge of the position of the base of the tumor; using the loop,

the wire is to be placed by means of a notched guide; the forceps employed, the pedicle is to be grasped immediately adjoining the part from which the growth originates. A polypus associated

FIG. 424.—POLYPUS FORCEPS.



with the posterior nares, or naso-pharynx, falling backward into the throat, is to be caught from below and twisted off, otherwise it may have its pedicle encircled by a double wire passed through the nostril, being extended until it can be caught in the pharynx and slipped over the tumor. In ablating a polypus after this latter manner it is desirable to save the mass from slipping into the apex of the pouch through means of a ligature passed through it previous to the strangulation.

After removal of one of these polypi the base, where possible, is to be deeply cauterized with London paste, chromic acid, or other agent. The preference of the writer is for the paste.

*Fibrous Polypi.*—Fibrous polypi, unlike the form just described, which is rarely met with in the young, is a condition associated with all periods of life. It is less common than the gelatinoid, is rarely multiple, and, unless markedly pedunculated, is to be esteemed of threatening import. The composition of these growths consists of fibres intricately arranged, among which arterial and venous vessels, possessed of brittle coats, freely circulate. Microscopic examination too often distinguishes a sarcomatous element.

Fibrous polypi of pedunculated base are to be snared or twisted precisely as the gelatinoid. Where the base is broad experience has shown the futility of all operations. Great care is to be exercised in distinguishing these growths, that they be not confounded with others coming from the base of the skull.

Diagnosis of simple fibrous polypi lies in obstruction and in the movable nature of the tumor, as well as in complexion, which differs from the gelatinoid



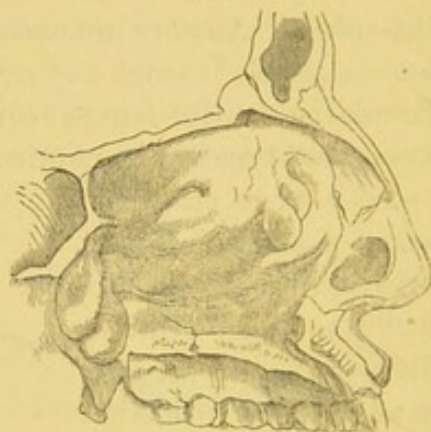
in being of flesh-like appearance. The sarcomatous form of polypus is commonly of rapid growth, quickly making its presence recognized upon the external face. Frog-face, as it is called, deformity growing out of lateralization of polypus, is diagramed in the cut.\* (Fig. 425.)

Polypi of the sarcomatous variety are found little amenable to treatment, even the most radical removal affording seldom any but a temporary relief. Injections of ergot, of iron, of different acids are not, as has been suggested, of questionable advantage; they are injurious to the greatest extent. The

FIG. 425.—FROG-FACE.

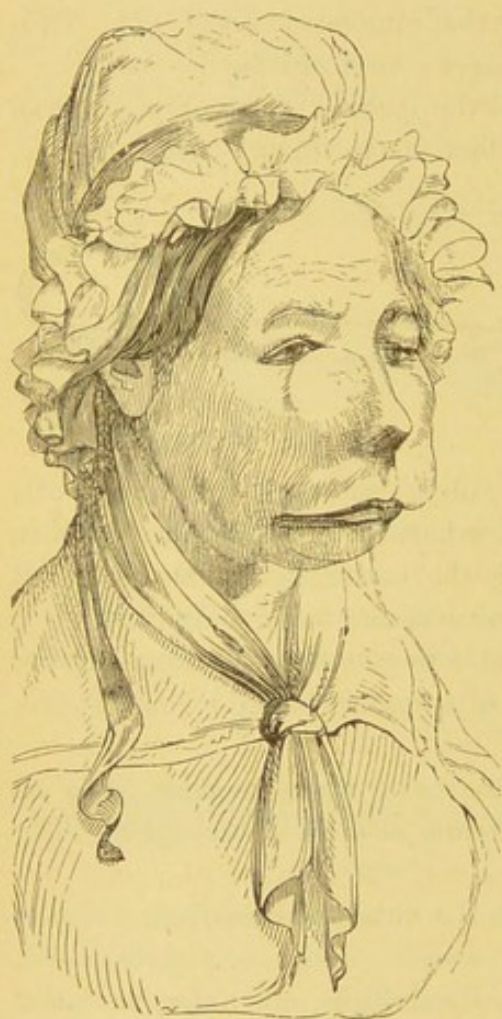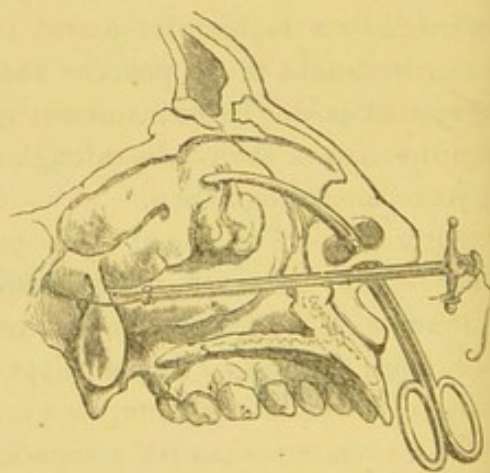


FIG. 426.



Polypus related with turbinated bone.

FIG. 427.



Illustrations of removal of polypi with the forceps, and with the canula and loop. See Fig. 437.

galvanic *écraseur* is alike objectionable, except with the markedly pedunculated growths.

Extirpation of sarcomatous polypi is practised variously. When situated well back in the naso-pharyngeal region, the origin being from the base of the skull, Langenbeck's procedure may be imitated; this consists in a depression

\* A cartilaginous tumor associated with the septum nasi or lateral cartilage finds an exact representation in this tumor. The two forms of growth are not to be confounded.



of the upper jaw. The writer on one occasion succeeded most satisfactorily in an operation performed in the naso-pharyngeal space by slitting the soft palate. Nélaton, the French surgeon, records operations practised by dividing both soft and hard palates. To do the operation of Nélaton, an incision is commenced in the soft parts and carried through mucous membrane and periosteum of the hard palate. Next the periosteum is carefully raised, a triangular exposure being made of the bone. A succeeding manipulation removes the bone to an extent necessary to reach the tumor.

Where a polypus of the naso-pharynx is not large, yet of a nature not to be excised from the nares, the "palatine button-hole" of Maune may be made. This "hole" consists of a simple section through the velum, leaving the uvula intact.

The operation of Langenbeck is done as follows: 1. An incision commenced at the base of the nasal ala and carried outward until it reaches midway of the zygomatic arch. 2. A second incision beginning at the centre of the root of the nose directed just below the inferior margin of the orbit, continuing over the frontal process of the malar bone until it meets the first at an obtuse angle. Beginning now at the apex of the triangle seen to be included in the incisions, the flap is dissected from its bed. Succeeding this, section is made of the periosteum in the line of the cuts, while the masseter is lifted from its malar origin. Using now the circular-saw of the surgical engine (though Langenbeck employs a narrow blade), the bone is to be cut horizontally from behind forward, leaving intact the nasal process. With the engine-saw no occasion exists to introduce the finger into the posterior nares as a guide, the position of the cutting edge of the saw being instantly recognized in the cessation of obstruction. The bone thus freed, except as regard is had to its relation with the central line of the face and its covering of soft parts, is to be pried out of its bed by a lever inserted between it and the os malare. The tumor, thus exposed, being removed, the bone and overlying parts are restored to their original location.

Fibrous polypi are secondarily dangerous as the cause of intra-cranial disease, being an excitant of coma, convulsions, abscess, chorea, asthma, emphysema, and cerebral affections.

5. NASAL ABSCESS.—As met with in the practice of the writer, nasal abscess has its seat most commonly in the septum. Cause is so persistently a strumous diathesis as to imply, for such cachexia, consideration in every case. Patients are almost invariably of the yellow class. Diagnosis is found in protrusion from the nares of a fluctuating sac. Treatment is both constitutional and local. The first is as heretofore directed; the second implies venting of the accumulated pus and the injection of stimulating lotions.

6. CONDITIONS DIRECT AND INDIRECT ASSOCIATED WITH OZÆNA.—Ozæna is an opprobrium of surgical practice. By some it is esteemed and treated as a parasitic disease; by others as an expression of a dyscrasia. At the head of the first of these schools is Dr. Massei, an Italian. Treatment



advised by that gentleman is as follows: *a.* Gradual dilatation of the obliterated nasal passages by means of elastic bougies; *b.* Cleaning and disinfection of the diseased regions by a very weak solution of salicylic acid (one part to five hundred parts of water), applied by means of a syringe; *c.* Modifying local medication, by blowing calomel powder through a nasal speculum on the ulcerated surfaces. The author says that there is always an arrest in the process of healing at a certain period, but advises strongly not to give up this treatment, but to continue it patiently until total cure is obtained. Dr. Fränkel (*Virchow's Archives*, vol. lxxxv.) gives a number of cases which he thinks will confirm the views of those who believe that ozæna always owes its origin to a dyscrasia,—two of his patients were phthisical, two syphilitic,—but he does not believe, though admitting the frequent coincidence of ozæna with pharyngitis sicca, that the diseases are in causal connection with each other.

To understand ozæna is to appreciate a circle of associations. The accompanying study is presented for the instruction of the student and the consideration of practitioners.

The term ozæna, like that of epulis, is a somewhat indefinite one, and is to be first viewed from the stand-point of its common signification.

Ozæna is from the Greek *ὀζη*, signifying "stench," and the term is, therefore, in reality, applicable to any ill-smelling condition. By universal consent, however, it has been restricted in its application to foul expressions about the nares and associate parts, accompanied with offensive discharge. The study of ozæna, then, it will be seen, is, necessarily, a study of various conditions, and these conditions, experience will show, are classifiable under the following heads:

1. Accumulation and degeneration of the common antral secretion.
2. Degenerated pus from tooth-abscess discharging into the antrum, and from this appearing in the nose.
3. Ulceration of mucous membrane of the antrum.
4. Deteriorated secretions from constitutional causes.
5. Caries of the osseous walls of the antrum.
6. Ulceration of the mucous membrane of the nares.
7. Caries and necrosis of the osseous boundaries of the nares.
8. Lodgment and retention of foreign bodies.

1. The first of these conditions is most frequently observed in connection with the ordinary cold in the head. The outlet of the antrum, it will be remembered, is by an opening about the size of a goose-quill into the middle meatus, which opening is circumscribed by mucous membrane, and which membrane, as the result of congestion, can very readily occlude this outlet; the parts being in this condition, it may happen that the pent-up mucus degenerates and decomposes, so that, on the subsidence of the swelling, the escaping discharge presents an offensive odor. To diagnose this character of ozæna, it is only necessary to connect it with the preceding inflammation, with the absence of specific conditions, and with the readiness with which it



yields to simple treatment. Of course there would have been a preliminary feeling of the sense of congestion on the part of the patient; he would have had, to express it most simply, a cold in the head, and this cold, with its accompaniment of dryness and constriction, would have grown worse, until, with the appearance of the discharge, relief would have been experienced,—the discharge implying the passing away of the congestion and the restoration of a normal circulation and secretion.

To cure this form of *ozæna* requires very little treatment,—indeed, in most cases no treatment at all. The author is in the habit, when the discharge continues longer than two or three days, of directing the sniffing up the nostril of the affected side some such combination as the following:

R.—*Ætheris sulphurici*, ℥j;  
*Tincturæ iodinii*, ℥ij;  
*Olei juniperi*, ℥j. M.

If this fail to check the discharge, such constitutional treatment as seems indicated is to be directed. Patients in whom such drain exists belong to one of two classes, the plethoric or the anæmic. With the first, the treatment demanded is depletory: a dose or two of sulphate of magnesia will generally be all that is demanded; although in a few instances it is found necessary to bleed from the veins. With the second class—and this is by far the more numerous—the mucous membrane of the part is found fallen into a condition analogous to the urethritis of chronic gonorrhœa; in these cases tonics are at once to be resorted to; the common combination of iron and quinia is perhaps the best that can be prescribed:

R.—*Tincturæ ferri chloridi*, ℥j;  
*Quiniæ sulphatis*, ℥j. M.

Sig.—Fifteen drops in water every three hours.

2. Fetid discharges depending on tooth-abscesses—abscesses which vent into the antrum—find their cure, as a rule, immediately on the extraction of the diseased organ. If this prove not to be the case in any special instance, then injections are to be made through the tooth alveolus. Iodine is an admirable base for all such injections. It is desirable practice to control the odor with the permanganate of potash.

R.—*Potassii permanganatis*, ℥ss-j;  
*Aquæ*, ℥viiij. M.

Inject as occasion requires.

It would most likely be quite sufficient to use the disinfectant three times a day. After it the following may be thrown in:

R.—*Tincturæ iodinii*, ℥j;  
*Glycerinæ*, ℥j;  
*Acidi tannici*, ℥ss;  
*Aquæ Coloniæ*, ℥j;  
*Aquæ destillatæ*, ℥iiij. M.



Or,

R.—Tincturæ capsici compositæ, ℥ss;  
Aquæ rosæ, ℥viij. M.

Or,

R.—Argenti nitratis, gr. xxx;  
Aquæ, ℥vj. M.

Or,

R.—Vini opii, ℥j;  
Vini aromatici, ℥j;  
Aquæ, ℥vj. M.

Indeed, any stimulant preparation may be resorted to, although experience favors particularly the use of iodine.

3. Ozæna from ulceration of the mucous membrane of the antrum is not a condition of frequent occurrence; without doubt this is the case where no specific disease, as syphilis, scrofula, or scurvy, exists, so that, meeting with such ozæna, we naturally at once revert to the constitutional condition. To discover an ulcer within the antrum is a matter for diagnosis by exclusion, and thus to expose it is not at all a difficult matter. If there be no diseased teeth or teeth-roots, no nasal ulceration, no antral dropsy, no acute preliminary conditions; if the fetid matter flow most freely when the suspected antrum overlies its nasal outlet, then we will generally be right in inferring an ulcer of the antrum; but an ulcer in the antrum is not necessarily a cause of ozæna. To give this fetid odor, it must be an unhealthy ulcer, by which is meant that it tends to degenerate its granulations, rather than to organize them. An ulcer, says Mr. Cooper, may be defined to be "a granulating surface, secreting matter;" and this is certainly true of most ulcers, particularly if we replace the term secreting with the term making; for the matter given off is nothing but degenerated lymph-corpuscles, to which the parts lacked strength to give force of organization. A healthy ulcer is to be seen in any accidental sore tending to rapid self-cure: there is in these cases little or perhaps no pus, for the reason that every particle of the exuded lymph of repair has in it vitality sufficient for its organization. An unhealthy ulcer, on the contrary,—and by such an ulcer we mean an adynamic one,—gives off more or less matter; it throws out its reparative lymph just as does the healthy one, but the viability of such lymph differs materially from the exudation of the former ulcer. Thus, according to the nature and character of such degeneration, we have the produced pus: ichorous, a thin, watery, acrid discharge; scrofulous, a cheesy, curdlike pus; sanious, a thin, sisy discharge; glutinous and viscid, as in sordes, etc.

Now, whether any or all of these kinds of pus give the fetor of ozæna, depends on circumstances; not the least important of which is the state of the atmosphere, and the condition of cleanliness preserved. Laudable pus, issuing from a healthy wound, will, in hot weather, become quite offensive in a very short time, as is, unfortunately, too freely illustrated in hospital practice. Certain ulcers are, however, in themselves offensive. Every one has



had occasion to observe, at some time or other, the disgusting odor arising from the saliva of particular persons,—constitutional ozæna it may with most propriety be termed. The writer recalls, even to this day, a certain school-master, the stench of whose spittle, employed to rub sums from his slate, always made him sick. This kind of saliva, and this odorous ulcer, belong to the alkaline class of people. Give such persons acid: they always need it; there is no exception.

A simple ulcer of the sinus—that is, one not associated with osseous diseases—is to be treated in the twofold direction of its constitutional and local requirements. To treat an ulcer scientifically, calls for an understanding of the conditions on which ulcers in general depend; and as ulcers of various signification so frequently present themselves about the mouth and throat, it is not a digression to make a hasty review of so enlarged and important a subject.

Ulceration is the absorption or the breaking down of some constituent part of the body. Its great cause is inflammation. Inflammation is always preceded and excited by irritation. The term irritation is a comprehensive one, and covers every source of offence to which the human body is subject. Thus, one man has an ulcer, the result of an inflammation excited and perhaps kept up by the presence of some foreign body, as, for example, a ball, a splinter of wood, a particle of dust, etc. A second man has an ulcer, the result of a localized inflammation, predisposed by the presence within his system of some specific taint. These ulcers, a glance would exhibit, must vary widely in their character, and even more so in treatment demanded for their cure. Thus it is that we speak of, and think about, ulcers in the way of their signification. We have simple purulent ulcers, venereal ulcers, scrofulous ulcers, scorbutic, varicose, and cancerous ulcers; the character of each being expressed by its adjectival prefix. A simple purulent ulcer is a sore, the result of some local accident, and is, most likely, self-curing; a venereal ulcer is one excited and kept alive by the presence in the system of the venereal poison; the scrofulous, scorbutic, and cancerous alike depend on dyscrasic conditions; the varicose on certain obstructions in the venous system, etc. To secure a cure in the first of these classes of ulcers, nothing more is necessary than to protect them from adverse influences. A varicose ulcer, to be cured, must be converted into a simple one by treatment directed to the trouble in the circulation; a cancerous, scorbutic, or scrofulous ulcer is only to be permanently cured by obliterating the cachexia. There is nothing obscure in the appreciation of these facts; the difficulty is in meeting the indications. Ulcers, it is true, are presented under a great variety of names; but these variations have reference only to differences in expression. Thus, a carious ulcer implies that the condition is dependent on the presence of dead or dying bone; a callous ulcer is one having indurated circumference; a fungous ulcer is one where the granulations of repair are in excess; a sinuous ulcer is one constituting the orifice of a canal leading to a deeper than the manifested disease; an irritable ulcer is one that, from internal or external causes, has



become tender and excitable; a phagedenic ulcer is one that tends to take on gangrenous action; a sordid ulcer is one discharging a dirty-looking glutinous matter; and so on, each of the many appellations being simply expressions of distinctive peculiarities. Now, one man, having syphilis, gets a rheumatism in his joints; another an ulcer on his tibia. In these two cases the important features of treatment are alike: both patients must have antisypilitic medication; local applications are simply adjuncts. An ulcer, simple in its character, situated over or upon some part in frequent motion, is apt to assume the irritable aspect; an ulcer the result of an idiopathic influence, if occurring on a person of weak or typhoid condition, is almost certain to assume the chronic or indolent form; an ulcer engrafted by external cause on a depraved constitution as always more or less influenced by the vice, and such vice is to be considered in its treatment; and so, whatever the extent of the review, this wide collateral relationship keeps itself in the foreground.

To return to ulcers in the antrum. We are prepared to recognize that such sores may be of various signification, and may, for their cure, demand a various character of treatment. So far as odor is concerned, all will alike be benefited by a primary treatment of cleanliness and antiseptic injections. To correct the fetor in a chronic case, it generally becomes a necessity either to trephine the canine fossa, or to extract one of the underlying teeth and get into the cavity through its alveolus: the latter mode is decidedly to be preferred. A plan, however, that may be tried, consists in keeping a tuft of cotton or fine sponge in the nostril, and frequently saturating it by the sniffing into it of an antiseptic. The entrance into the cavity, however, through the alveolus of a tooth is one of the simplest procedures in surgery, demanding only that the operator shall recognize the position of the sinus as influenced by the shape of the jaw. Any spear-shaped instrument will answer to make the opening: to keep it patulous, it is only necessary to introduce, after each operation or injection, a tent of cotton or sponge. As a medicament, the following combination may be employed:

R.—Acidi carbolici, gtt. xx;  
Glycerinæ, ℥ss;  
Acidi tannici, gr. v;  
Aquæ, ℥vj. M.

Or,

R.—Spiritus vini, ℥j;  
Creasoti, gtt. x;  
Aquæ, ℥vj. M.

Or, as suggested on a previous page, the permanganate of potash in the proportion of from two to ten grains to the ounce of water, as indicated.

Phénol sodique, combining as it does antiseptic and alterative virtues, is one of the very best injections that may be employed in these cases. It is used diluted, as required.

Associated with such antiseptic treatment, and which is to be used in every



case of ozæna whatever its origin, we connect the specific or peculiar treatment demanded by each special case,—the appreciation of which treatment presupposes and necessitates the understanding of therapeutics in general, and can conform to no special rule.

It is true that for certain diseases certain remedies have come, perhaps unadvisedly, to stand too much in the light of specifics. Thus, in syphilis, the mercurials are depended on; so that, having an ulcer of such origin to treat, a medicine ordinarily prescribed is as follows:

R.—Syrupi ferri pyrophosphatis, ℥vj;  
Hydrargyri chloridi corrosivi, gr. iv. M.  
Sig.—A teaspoonful three times a day.

Or,

R.—Hydrargyri iodidi, gr. ij;  
Potassii iodidi, ℥ij;  
Syrupi sarsaparillæ compositæ, ℥viiij. M.  
Sig.—A tablespoonful three times a day.

Mercury is to be considered as an active force, striking at the condition of syphilis, destroying it; and while it is very well thus to kill such a condition, it is quite as well to remember that the harm of the agent employed requires to be constantly met and antagonized. This is done by keeping up and supporting the system, so that it will commonly be found that syphilitic ulcers require, quite as much as a specific medication, wholesome food, fresh air, proper exercise, judicious bathing,—in short, the employment of every means that tends to the maintenance of general health.

In the mercurial ulcer of the antrum—which is far more common than the syphilitic,—the general and local use of the chlorate of potash is found to act very well. The medicine, dissolved in water, may be given in doses of ten grains, repeated four or five times a day; the injection is not to be less in strength than a saturated solution. The mercurial character of an ulcer is discovered by association of a local lesion with an existing dyscrasia.

Scrofulous ulcers are judged by the appearance of the sore, the nature of the discharge, and the existence of depression in the patient at large. A scrofulous subject, while not always bearing the clearest general evidences of the disease, usually has some one or more features that will allow of it being distinguished. Common features associated with scrofula may be enumerated as follows: the first manifestation occurs generally, not always, at the period of milk dentition, the symptoms being irregular appetite, an ill-smelling, inspissated mucus, and swelling of the superficial glands of the neck. Continued manifestations advance with age, presenting subcutaneous lymph effusion, particularly about the calves of the legs and the outside of the thighs; various eruptions, inflammation, and suppuration of joints, especially those of the hip, knee, and thumb; a flaccid, enlarged condition of the tonsil glands, susceptibility to atmospheric changes, inability to endure physical fatigue, impoverishment of the blood, general asthenia. Scrofulous



subjects are generally languid in their movements and without much impressibility; not always this last, however, for it is well known that many precocious and bright persons end their effulgence in phthisis. In short, the history of scrofula may be viewed as the history of phthisis: it matters little as a principle is concerned, whether tubercle deposits itself in the lung or in the ganglia, or whether there be or be not a deficiency in the developing force.

Scrofulous ulcers are unhealthy in appearance, being covered with a dirty-yellowish aplastic matter, irregular about their edges, generally bluish or purple, more or less undermined, and discharging an ichorous, flaky pus. Local stimulation meets with little or no response, and, for the reason of the general deficiency in vitality, the parts around are usually indurated from interstitial deposits, chronically congested, and looking altogether indolent and ill conditioned.

The treatment of scrofulous as well as of the true tuberculous ulceration is (in our present knowledge of the disease) simply a treatment of building up. Unacquainted with any special *materia peccans*, we direct our aim so to lift up the life-force that a sufficient inherent vitality may be developed to throw off or master the depressing influence. Exercise, tonic medicaments, cold bathing, salt and mountain air, rare or raw meats, generous liquors,—all are useful means to such an end. Iodide of potassium has long had a reputation in this condition; also barium, iodide of iron, syrup of the phosphates, cod-liver oil, phosphoric acid, etc. The individual experience of the author is, that wrapping one's self in a wet sheet on getting out of bed, and securing vigorous reaction by a good hand-rubbing, and, after such operation, drinking a fresh-laid egg drowned in good brandy or whiskey, is better than any medicine proper yet prescribed.

We always, however, do something for a local disease, from mere force of habit, if for no other reason. We can use with these ulcers any of the applications referred to a few pages back, and any one of them is about as good as any other, or we may use them one after another.

Syphilitic ozaena from ulceration of the antral mucous membrane must be, as has been remarked, an exceedingly infrequent affection. Not so, however, with ulceration from such cause in the naris; such a condition is quite common. When a practitioner has a case in which dirty clotty scabs are constantly being received into the handkerchief, and much offensive sanies is discharged from the nose, he may feel well satisfied that he has a case of syphilitic ulceration, and particularly may he rest satisfied in his diagnosis if any evidences of the disease exist in other parts of the body. Syphilitic ulceration of the nose has frequently been confounded with a commencing polypus; but the conditions are so dissimilar that only the most culpable carelessness could fail to distinguish them. In the first there are the fetid discharge, and the association with the anterior train of accidents; a scab soon comes away, and a temporary cessation of the obstruction ensues. In the



latter the obstruction is apt to be gradual and continuous; there are no fetid clots, and no anterior accidents of association: blowing the nose, in the one case, most likely relieves for the moment; in the second, it throws forward the polypus so that we can see and feel it.

Syphilitic ulcers within the nose, commencing commonly as gumma, attack equally any location, and possess the most unfortunate tendency to extend to neighboring parts, so that, if not successfully combated, in a very short time the bony framework is involved, thus producing the deformities so common.

A patient with a syphilitic ulcer developing in his nose complains first of a feeling of congestion. Diagnosis is arrived at by observation of associations. A few weeks later he is troubled with a discharge; this, at first, is very slightly and perhaps not at all offensive. Soon, however, odor is remarked, and the discharge, which continues to increase, frequently becomes so profuse that twenty or thirty pocket-handkerchiefs are necessary for daily use. Occasionally, and sometimes very frequently, dirty gluey clots or scabs come away, and the ulcer, if seen, is noticed to present a reasonably healthy look,—something, for example, as a chancre would look when only half destroyed and casting off its slough. If uncombated and unconquered, the ulcer extends deeper and deeper, until the bone is reached, which, in its turn, succumbs, yielding caries, or, more likely, necrosis. Arrived at this stage, the condition is formidable; not at all infrequently, in defiance of every effort, more or less deformity results.

An ulcer situated in the anterior part of the naris is indicated by the forced expirations of the patient. Situated well back, he relieves himself by strained inspirations; occasionally, however, in the very beginning, the mucous membrane becomes so thickened and engorged that the passage of air through the tube is almost shut off: in these cases excessive restlessness is found associated.

It is not by any means always the case that nasal ostitis is secondary to gumma: on the contrary, cases are frequent enough where the bone becomes primarily diseased and where the ulcer is simply an associated lesion. Syphilitic ostitis very frequently ends in necrosis, and more particularly is this likely to be the case where the turbinated bones are the ones affected. The vomer, however, is the bone most frequently necrosed in syphilis,—that is to say, is the most frequently attacked. This is brought about in three ways: first, from a primary ulceration of its mucous covering; secondly, by the deposition of submucous tubercles; thirdly, by the direct affection of the bone. Next to the vomer the inferior turbinated sympathizes most in syphilitic affections. When ostitis attacks the vomer or any other bone, efforts are to be directed to the resolution of the inflammation. To secure this end resort is had to such local means as seem indicated by the peculiar features of the case. The treatment would be that applicable to inflammation anywhere; it is to be influenced by the temperament of the patient and the stage of the disease. Locally we have at this time nothing to do with its specific char-



acter: we have simply to treat a perverted condition of the circulation of the part. Constitutionally, however, its origin is to attract closest scrutiny; and, in connection with the local remedies employed, anti-venereals are to be depended on as strong supports.

Diagnosis of inflammation of the nasal boundaries is not difficult to make out. When the vomer is the bone attacked, the patient suffers from sharp spasms, referred to the root of the nose; he has headache, always increased by the recumbent position. If the inflammation exist in the anterior part of the cavity, pressure on the cartilage increases the pain.

The nasal bones, when affected, exhibit an overlying congested skin, gumma; pressure on the bridge is responded to by much pain; the lachrymal secretions are affected, and not infrequently, because of the congestion in the ductus ad nasum, run over the cheek. The turbinated bones, when they are the seat of the inflammation, yield a soreness to the lateral aspects of the canal, and respond quickly to pressure exerted thereon.

Whichever of these bones may be affected, the prognosis, as ozæna is concerned, is the same in signification. If the inflammation be not arrested, necrosis or caries, partial or complete, results. Soon a discharge makes its appearance, disgustingly foul if the case be one of necrosis, and more or less offensive, and mixed with osseous particles, if it be caries.

Anti-venereal treatment is a process of strengthening. One cannot hope to arrest syphilis in any other way, when it has passed to its tertiary manifestations. Limit and circumscribe the local inflammation as much as possible. To do this stimulants act a better part than depressants. An excellent local medicament is a combination of iron, iodine, quinine, and glycerine:

R.—Tincturæ ferri chloridi, ℥j;  
 Quiniæ sulphatis, gr. xxv;  
 Tincturæ iodinii,  
 Glycerinæ, āā ℥j;  
 Aquæ, ℥iv. M.

Sig.—Inject, or brush over and about the parts, three times a day.

Give iron and quinia internally. It is scarcely probable that a patient having syphilitic necrosis needs a mercurial course; indeed, it is much more likely that he has already been so over-drugged with this medicine that his trouble is mercurio-syphilitic, rather than syphilitic alone. Any use of the agent in such a case is almost certain to prove an abuse of it. Iodide of potassium is recommended and freely prescribed in these tertiary conditions; it may be given in doses of from ten to twenty grains dissolved in water or in the fluid extract of sarsaparilla. Good rare roast beef, poultry, a daily glass of malt liquor, boat-rowing, wrestling, horseback-riding, systematic bathing, these are reliable means, and may elevate the vital forces to an ability, *per vias naturales*, to throw off the disease. It is confessedly hard to cure syphilis when it has fully taken hold of a system; when it inflames a bone, par-



ticularly a small one, the patient is lucky if he escape without the complete destruction of the part.

Necrosis, partial or complete, implies, of course, the existence of a sequestrum; and the getting away of this dead part implies very generally the cure of the ozæna. Particularly is this the case when the death is limited to a single bone, or piece. To get away this piece is, then, one of the most important features in treatment. How is it to be done? Simply wait until the probe reveals that it is loose; if it may not be taken away through the orifice of the sinus it has itself created, it is only necessary to enlarge in any convenient manner such sinus, and then lift it out. If, after the removal of such dead bone, the discharge be found to continue, yet modified as to character and odor, necessity exists for stimulation. Iodine, or iodine and iron, or the combination with tannin and glycerine, is employed, as seems indicated. It may be, however, that neither the discharge nor the odor decreases; in such cases the practitioner is seldom wrong in inferring that more dead or dying bone is in the nose; the treatment first employed is to be renewed. When tertiary syphilis has associated with it severe nocturnal pains, great relief is frequently secured from the administration of the iodide of potassium, particularly if combined with minute doses of phosphorus,—say five drops of the diluted phosphoric acid; it is to be remembered, however, that because of the relationship of the potash with the mucous membranes, it is the case that in many persons even very small doses will excite much irritability in the air-passages, thus seeming to increase instead of allaying the trouble. With such patients we must diminish the dose of the iodide *pro re nata*.

Bromide of potassium is now frequently employed to procure rest and tranquillity. It is commonly prescribed in doses of ten grains; but forty or fifty will be found the better dose. It is best given in a little water just as the patient is about to get into bed.

*Lodgment and Retention of Foreign Bodies.*—In the use of cotton or sponge about the nares, care is to be taken that the pellets do not escape attention and become lodged in the passages. Some of the most offensive and resisting discharges occasionally have their cause in this direction. Rhinoliths—calculi varying in size from that of a pea to that of a pigeon's egg—sometimes form in the canals, and, by inducing ulceration and collecting detritus, come to be a source of ozæna. Peas, rags, buttons, and sundry other articles are not infrequently found in the nares, thrust there by children of experimental proclivities: any of which may, of course, become a source of offence.

The removal of foreign bodies from the nares is always to be effected as speedily and with as little injury to the parts as possible. A plan that may first be tried is to place the patient in a strong light and search the parts with very delicate forceps: if the body can be seen, it may thus generally be removed. Another plan consists in giving a pinch of snuff and compressing the unobstructed nostril; the effort of sneezing will not infrequently throw



the body a considerable distance. Still another plan is to compress the unobstructed nostril and blow into the mouth. An annealed wire, bent into the form of a loop and passed over the lodgment, is very frequently employed with satisfactory success; a flexible, blunt, double hook is also used with advantage. A syringe is sometimes found beneficial, the obstruction being washed back into the throat.

The convenience of the douche bath in ozæna is acknowledged. Thudichum's apparatus\* highly commends itself in such direction. Another means of great service is the rubber bulb atomizer: this is used by the patient without effort or trouble of any kind, and carries the spray to every part of the nostril. This latter instrument may be charged with a solution of permanganate of potash, with chlorine-water, or with other disinfectant, and may be kept about the person, ready for use at any required moment. In cases which emit much fœtor, employment of this means will avoid many seasons of mortification.

Syphilitic coryza in infants, characterized by snuffling and by difficulty in holding the breast, is not infrequently associated with offensive discharge. Here the excessive delicacy of the affected membrane is not to be overlooked. While it is a necessity to keep the parts well cleansed, it is not permissible to employ any but the gentlest of medicaments. Borax-water associated with a little glycerine is a nice preparation, or a weak solution of the phenate of soda may be used satisfactorily. Fissures of the membrane are to be touched with dilute chloride of zinc, or with iodine ointment made very weak.

**Anterior Rhinoscopy.**—The employment of the rhinoscope in rhinorrhœa or ozæna is to be commended as of great value in making a diagnosis. Anterior rhinoscopy is performed most simply by using two delicate ivory spatulas and placing the patient in the full sunlight. Or, placing his back to a bright gas-flame, a stream of rays is thrown up the nostril by means of a reflector. A mode of anterior illumination frequently employed by the author consists in extending the ala, and passing the light through a silvered speculum.

The nasal reflector of Metz differs from the ivory blades in being made of highly-polished metal. A speculum known as Duplay's anterior is the analogue of the common bivalve vaginal instrument, the valves being separated by means of a screw.

---

\* Some years ago it was discovered by Professor Weber, of Halle, that when one side of the nasal cavity is entirely filled through one nostril with fluid by hydrostatic pressure, while the patient is breathing through the mouth, the soft palate completely closes the choanæ, and does not permit any fluid to pass into the pharynx, while the fluid easily passes into the other cavity, mostly round and over the posterior edge of the septum narium, and escapes from the other open nostril, after having touched every part of the first half of the cavity of the nose, and a great part—certainly the lower and median canals—of the second half."—THUDICHUM: *Polypus in the Nose, and Ozæna*.



Another instrument, known as Frankel's, working admirably in exposure of the anterior nares, is shown in Fig. 428; application of this speculum is explained by the cut.

Certainly, in anterior rhinoscopy, it is not to be doubted that sunlight surpasses all other sources of illumination. In cloudy weather, besides the means explained in connection with posterior rhinoscopy,—which see,—use is to be made of artificial light.

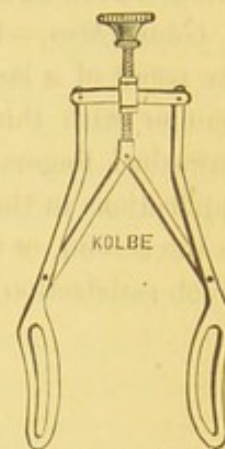
As a means of such artificial illumination Tobold's apparatus carries in itself much recommendation. Fig. 429 exhibits the instrument, affording at the same time idea of its use. Besides this device many of various forms and attributes have been invented by specialists, and are to be met with at the stores of instrument-makers.

7. NEOPLASMS.—By neoplasm is meant a new formation. By a new formation is commonly implied cancer. To put this in other words, any growth of the nose not having identification in a history is to be looked on with doubt as relation is had with benignancy. Treatment of neoplasms of the nose is not apt to yield satisfactory results. (See *Fibrous Polypi.*)

*Hypertrophy of Nasal Mucous Membrane.*—A nasal condition allied with persons of the scrofulous diathesis, being most commonly met with in children, shows a tumorous projection of reddish appearance projecting from one or both nares. This projection is liable to be mistaken for polypus, from which it differs in being a hypertrophy of the mucous membrane. To distinguish the one growth from the other requires the use of a probe; this means enabling the practitioner to see the seat and character of origin as these relate with the inferior turbinated bone. Treatment pertains to the employment of both local and constitutional means. (See *Scrofulous Conditions.*)

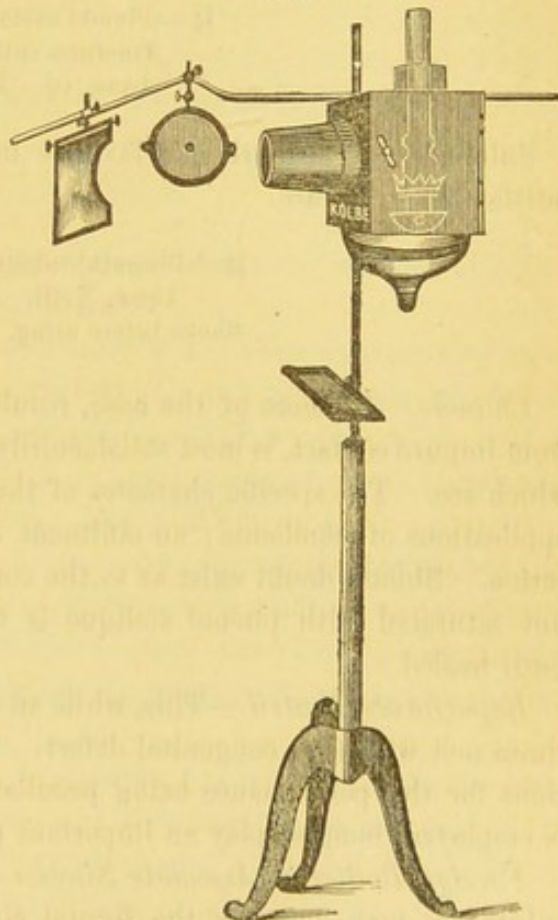
*Deviation of Septum.*—Deviation of septum to one side or the other is a source of great discomfort. If a patient be young a means of correction frequently found beneficial consists

FIG. 428.



Frankel's Nasal Speculum.

FIG. 429.



Tobold's Illuminating Apparatus.



in the continuous use of a pledget, saturated with glycerine, introduced and retained in place between the central and alar cartilages. Where the sufferer has reached adult years the knife is the only remedy; the projecting part being shaved away. (See *Fracture*, page 658.)

*Gonorrhœa*.—Gonorrhœa of nares is an occasional condition met with as the result of a lack of care on the part of persons afflicted after the ordinary manner with this disease; the virus having been carried to the parts by unwashed fingers. Treatment is that used for the penis; namely, emollient applications in the primary, or acute stage; specific and stimulating remedies in the second, or suppurative stage. A combination used by the author with much satisfaction as a curative of the disease considered is as follows:

R.—Zinci chloridi, gr. iv;  
Chloral hydratis, gr. vi;  
Aquæ destillatæ, ℥iv. M.

To be injected into penis or nostril three times a day.

As an application in the first stages of nasal gonorrhœa sulphate of zinc in the proportion of three grains to the ounce of water may be used. Common tea as prepared for the table is a good wash. When much inflammation is present lead-water and laudanum are to be employed.

R.—Plumbi acetatis, ℥i;  
Tincturæ opii, ℥i;  
Aquæ, Oj. M.

Subnitrate of bismuth is a favorite injection and commonly affords much satisfaction in its use.

R.—Bismuthi subnitratis, ℥ss;  
Aquæ, ℥viii. M.  
Shake before using.

*Chancre*.—Chancre of the nose, resulting in like manner with gonorrhœa from impure contact, is most satisfactorily treated by the use of London paste, which see. The specific character of the sore destroyed, it is healed through applications of emollients; an ointment of the oxide of zinc is a good application. Should doubt exist as to the complete destruction of the specificness, lint saturated with phénol sodique is to be kept in contact with the part until healed.

*Imperforate Nostril*.—This, while an extremely rare condition, is yet sometimes met with as a congenital defect. Treatment is by operation, the directions for the performance being peculiar to each case; where incision alone is employed, bougies play an important part in the cure.

*Foreign Bodies in Associate Sinuses*.—Balls and other foreign inanimate substances may lodge in the frontal sinus, resulting in abscess which discharges through the nose. Of animated objects, many illustrations are to be found recorded where persons have disgorged caterpillars and other worms



after having experienced discomfort in the region of the sinus, pointing to it as a seat of habitation by the parasites. M. Saint Pierre instances six cases of deposits of fly-larvæ: In one of these more than three hundred were washed out by means of injections, the patient dying eighteen days later from invasion by the worms of neighboring parts. Dr. Raoure, of Nismes, records the case of a woman attacked with fever and violent headache, which, in spite of remedies, made continual progress. About the fourth or fifth day she began sneezing, and expelled some small white worms. The headache diminished as the parasites came away. Seventy-two were expelled in the course of a few hours, and the patient found herself well.\*

During the war of the American rebellion the author, who for some time was on surgical duty at the Fortress Monroe hospital, in a hot summer, had wide opportunity for witnessing the destructive inroads of the fly-larvæ: these were literally everywhere; the stump of an amputation guarded to the extreme of caution and of prophylactic care would sometimes be found filled with maggots at the stage of a first dressing; petroleum and chloroform proved the best remedies. Insufflation of snuff is recommended as a parasiticide where maggots are located in the nose or sinus.

A means of diagnosing nasal parasites consists in the free employment of a syringe, salt water being used; detection of a worm is proof of presence. General signs refer to uneasiness in the region, pain more or less constant, sometimes localized, sometimes darting about in various directions; spells of fainting, an aura starting from the region of the frontal sinus; vertigo, mania.

#### EXTERNAL NOSE.

Surgical conditions of the external nose relate with tumors, epitheliomatous ulcers, injuries, and loss of substance.

Tumors are infrequent; they are embraced by the sebaceous, cartilaginous, and neoplastic. The first are readily treated through an incision which permits of enucleation; the second, through extirpation; the third, if it be deemed advisable in any particular case to touch them, are to be thoroughly and widely removed by the knife. (See *Rhino-Scleroma*.)

**Ulcerations.**—The writer desires to be impressive in the suggestion that ulcers appearing upon the external nose without explainable cause, proving at the same time resistive to simple means of cure and showing giant granulations, are to be looked upon as epithelial cancer, and considered accordingly. (See *Lupus of Face*.)

Treatment of epithelial nasal sores by caustics implies commonly the death of the patient. Removal of the sore and surrounding parts by use of the knife, and replacement by healthy tissue transferred from immediately neighboring, or, preferably, from distant parts, insures a cure. This means of remedy the writer claims as a discovery made fifteen years back from the date of

\* Diseases of the Nose, Watson.



this writing, he having lost no case of epithelial cancer in the interim where such operation could be perfectly practised. (See *Epithelioma*.)

**Fracture.**—Fracture of the nasal osseous arch is a common accident. Diagnosis lies in history of injury, in crepitation, and in character of deformity.

A broken nose expresses one of two conditions: depression arising out of a bending of the anterior or cartilaginous portion, otherwise irregularity in position, and crepitation of the nasal bones.

Treatment refers alike to the combating of an inflammation sure to associate with the accident, and to the setting and retaining in place of the distorted parts.

Where displacement is in the septum nasi, broad and flat-faced forceps apply to the restoration of symmetry; glycerine-saturated pellets being applied to preserve the position. An instrument used in English surgery consists of two smooth-faced triangular blades hinged at the middle, somewhat like a pair of scissors, these plates corresponding with the arch of the nose when considered from the inside. The thrusting of these blades into the nostrils restores symmetry; the blades are made to lie flat against the broken or twisted septum on either side, and to grasp it between them, thus holding and being held. Change of the blades is secured through means of a screw working external to the joint. (See Figs. 438 and 439.)

Displacement of the nasal bone is much the most comfortably combated by external means, internal appliances being endurable by the very phlegmatic only. A practice employed by the writer consists in the use of a splint of gutta-percha, moulded over the part after setting the fracture. To make such a splint it is alone necessary to warm the material until a consistency of dough is secured; it is then moulded over the region without effort on the part of the surgeon or pain on that of the patient: suffered to remain two or three minutes, it is found sufficiently hard to be removed without change of form, when, to complete the hardening process, it is dropped into cold water. Retention of the fixture is secured by placing over it a strip of adhesive plaster.

Gutta-percha not being at hand, an admirable substitute is found in a piece of common pasteboard softened in hot water.

Complication in nasal fractures is the rule rather than the exception. The relation of the arch to the ethmoid bone not infrequently results in fatal injury to the brain by the driving upward of the crista galli. The nasal bones are sometimes torn from their place, being so comminuted as to render replacement impracticable, if not impossible. Wounds of the soft parts are at times extensive and formidable, requiring much placing and stitching. Separation of the nasal cartilages is not an uncommon event.

The principal cure in all complications consists in putting displaced parts into position, and combating vascular perversions.

**Loss of Substance. Rhinoplasty.**—Defects of the nose, requiring relief through plastic operations, vary markedly in character: thus, the parts may








Fig 1.



Fig 3.



Fig 2.

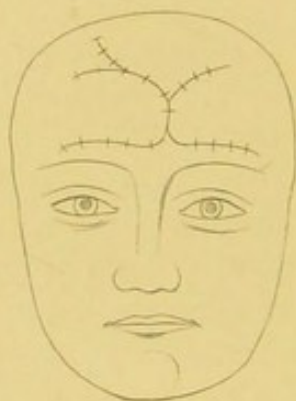

Fig 4.

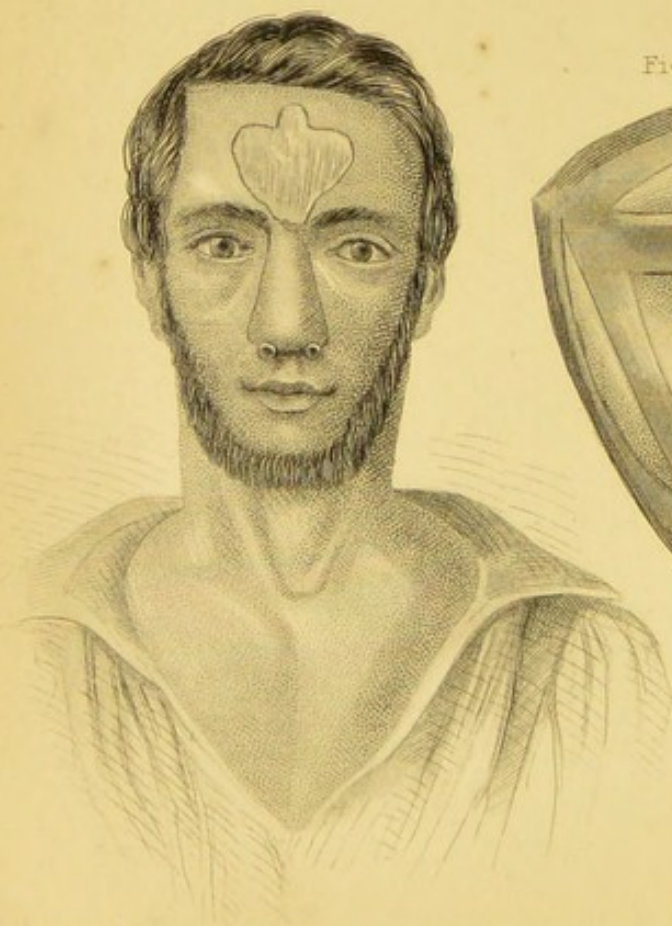
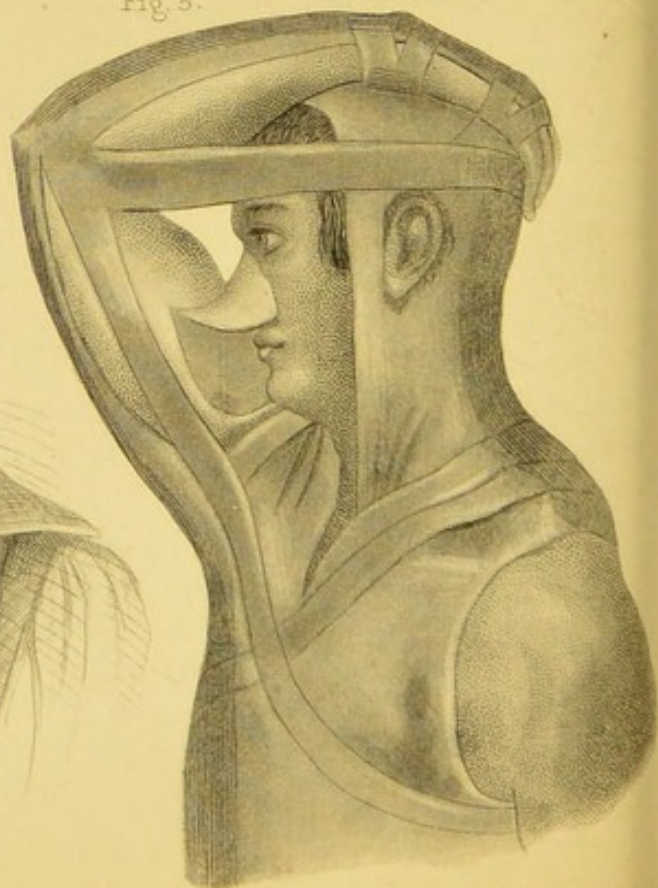
Fig 5.





be completely lost, or only one ala may be absent; a break in the continuity exist, as shown in Fig. 430, or with the loss of one side may be conjoined a misshaped and sunken condition of the opposite, as seen in Fig. 432; nose and lip may both be wanting, as exhibited in Fig. 356; or, as is often seen, V-shaped breaks may exist in the continuity of the free surface of one or the other of the alæ.

Four general features associate with the operations of rhinoplasty, namely: the Italian, the German, the Indian, and the English method.

The Italian method is that known as the operation of Tagliacozzi. This is practised by marking upon the inner and middle portion of the integuments of the arm two longitudinal lines four inches at least in length by three and a half in breadth; the flap thus outlined is raised, and, while allowed to remain attached at either end, is separated its length from the underlying parts by well-oiled linen or sheet-lead passed beneath it. Allowed thus relation until it become thickened and indurated, a period of some two weeks, the one end is detached, and the oblong flap, being pared into shape, is stitched to the face, which has been prepared for its reception.

The German method, being a modification of the preceding made by Professor Von Graefe, of Berlin, consists in the performance of the whole operation at a single sitting. This plan, while advantageous as regards the comfort of the patient, yet fails to secure that thickness of substance in the flap which was the object with Tagliacozzi in subjecting it to such long-continued irritation; also the shrinkage has to occur in the part, as a nose, rather than as integument.

The Indian manner, the one most generally practised, consists in taking the flap for the bridge and alæ from the forehead, and the columna from the lip.

The English operation, devised and first practised by Professor Syme, of Edinburgh, consists in taking flaps from the cheek, as is shown for one ala, in Fig. 432. In this operation the columna is also to be obtained from the lip.

Fig. 5, Plate IV., exhibits the flap, as made after the manner of Tagliacozzi; also the manner of attachment to the face, together with the means practised by that surgeon to fix the forearm over the head.

Fig. 4 of the plate shows the Indian operation; the general V-shape of the flap, conjoined with the strip for the columna, is recognized in the ulcer on the forehead; the flap, rotated on its pedicle, is seen to be raised in its new position into the shape of the nose by bougies introduced into the nostril-spaces.

**Studies.**—Fig. 430 exhibits a case in which the alæ and cartilaginous septum of the nose have been lost. In this case the defect is proposed to be remedied by material taken from the forehead, after the Indian method. First, the size and shape of the new wings are dotted out with ink, as shown. To so map out the organ it becomes necessary, first, to have a complete idea of what is needed; this is obtained by using a thin sheet of gutta-percha, which, on




being warmed, may be moulded as desired. Obtaining thus a measure, the material is spread out upon the forehead, as shown in the cut. It now remains to freshen the circumference of the parts to be restored, and, dissecting the flap from the forehead, plenty being allowed for shrinkage, twist it upon the

FIG. 430.



FIG. 431.



pedicle, which of course is allowed to remain, and by means of ligatures fix it in the new position.\*

The separation of the pedicle is only to be practised after full relationship of circulation is established in the newly-related parts,—a period varying from ten days to as many weeks.

Convex position of a new nose and maintenance of the orifice are to be secured by tubes of silver, worn for several months. Fig. 431 shows a frequent result of such a rhinoplastic operation.

FIG. 432.



FIG. 433.

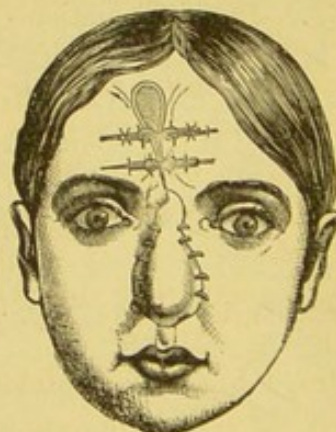

Fig. 432 being a case from the practice of Professor D. Hayes Agnew, in

\* A manner of relating the parts, devised by the elder Pancoast, is known as the tongue-and-groove suture: this consists in associating two surfaces by means of convex and concave faces.



which the author had the pleasure to assist that gentleman, exhibits the loss of fully one-half the nose. In this instance it is perceived that, besides the absence of the ala, the remaining nostril, as the result of a cicatricial depression at the bridge, has been made to look unduly outward, the organ being converted into a very decided pug. Two indications are here seen to exist: first, the body of the nose is to be let down; secondly, a new ala is to be made. Turning now to the lines of incisions, it is perceived how these indications were attempted to be met. Across the bridge is seen the first cut made; this incision, with a little dissecting, allowed the part to drop as required; secondly, commencing upon the nasal prominence, as remarked in the diagram, an incision was brought down, and, after extending a very short distance, was made to assume a triangular form, thus affording a pyramidal slip to occupy the space necessarily resulting from the dropping of the nose; thirdly, continuing the line of incision, the cut was carried into the substance of the cheek, as shown in the drawing, the form of flap created being in accordance with the wants of the part to be restored; fourthly, the edge of the nose was freshened, and the triangular flap seen below was dissected to its base. All being thus made ready, the alar flap was brought into place and attached, while the inferior one was forced outward to help fill up the space left vacant by the removal of the irregular apex of the alar flap.

Fig. 433 exhibits an operation similar to that shown in Fig. 430, the new nose being here seen stitched in place, and the wound on the forehead approximated.

Fig. 434 exhibits a facial loss of substance, together with a proposed mode of correction.

FIG. 434.



FIG. 435.

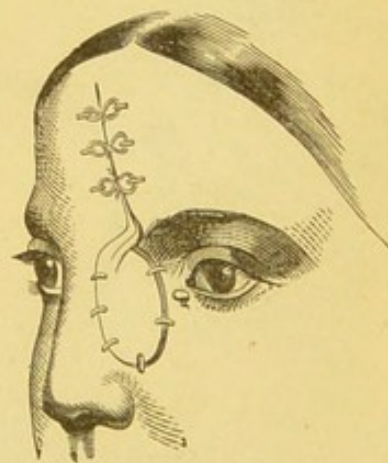


Fig. 435 exhibits the flap, as made in Fig. 434, in place, with the wound of the forehead approximated, the various pins and stitches required being shown.

Plate V. is one representing a combined operation in rhino-cheiloplasty,



## PLATE V.

## RHINOPLASTIC AND CHEILOPLASTIC OPERATIONS.

Fig. 1.—Appearance of John Glover prior to the operations of cheiloplasty and rhinoplasty.

Fig. 2.—View of his face with the chin depressed. The mouth, being contracted into a rigid orifice, was enlarged laterally by the stomato-plastic operation of Dieffenbach for atresia oris, after which two flaps were made, as marked in the lines upon the cheeks, so as to form the upper lip.

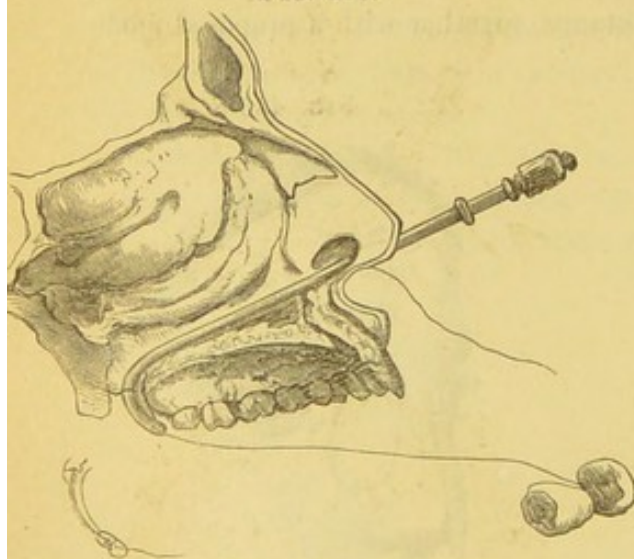
Fig. 3.—Appearance of his face after this operation, showing the position of the sutures and the improvement in the mouth.

Fig. 4.—Shows the steps of the rhinoplastic operation performed upon him subsequently. The edges of the nasal cavity being freshened by a grooved incision, the outline of the new nose was marked on the forehead before cutting the flap. The dots indicate the position of the sutures.

Fig. 5.—The wound in the forehead being closed by the hare-lip sutures, the flap was reverted, and attached in the groove on the edge of the nasal cavity by three stitches of the interrupted suture, which were tied over little rolls of adhesive plaster, after Graefe's method. The edge of the septum is also attached to the upper lip. The twist in the pedicle is seen in the root of the nose.

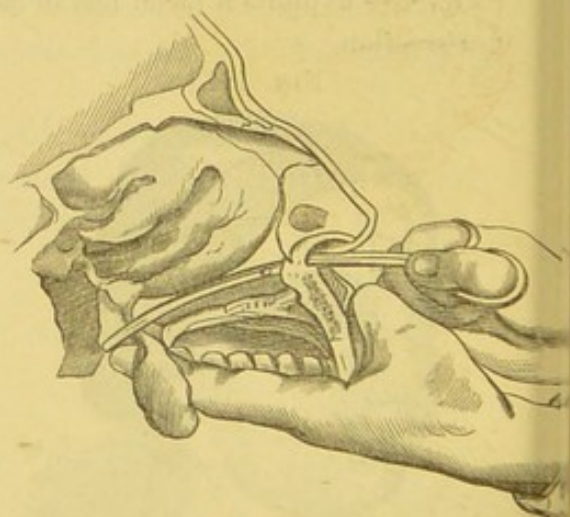
Fig. 6.—An accurate likeness of John Glover, sixteen months after the operation.

FIG. 436.



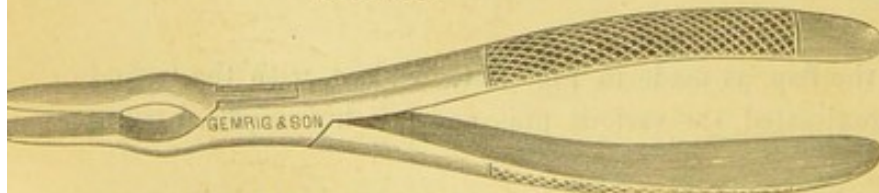
Belloc's canula applied.

FIG. 437.



Removal of polypus by means of forceps and finger.

FIG. 438.



Adams's forceps for straightening nasal septum.

FIG. 439.

Adams's screw plates for  
ing septum straight.



Fig 1.

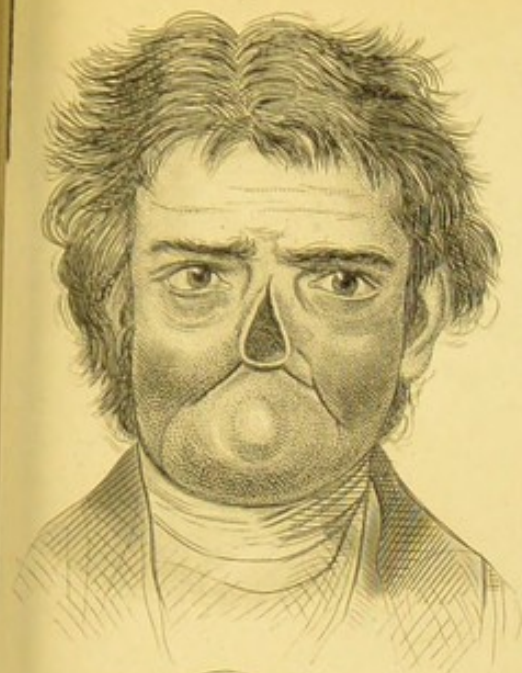


Fig 2.




Fig 3.

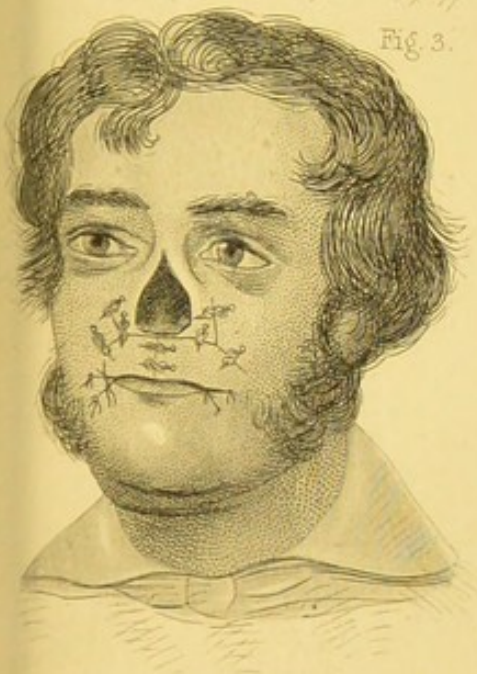

Fig 4.

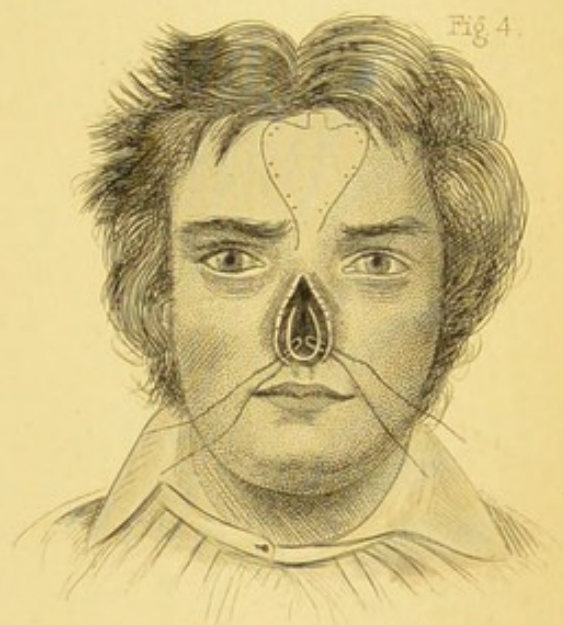



Fig 5.

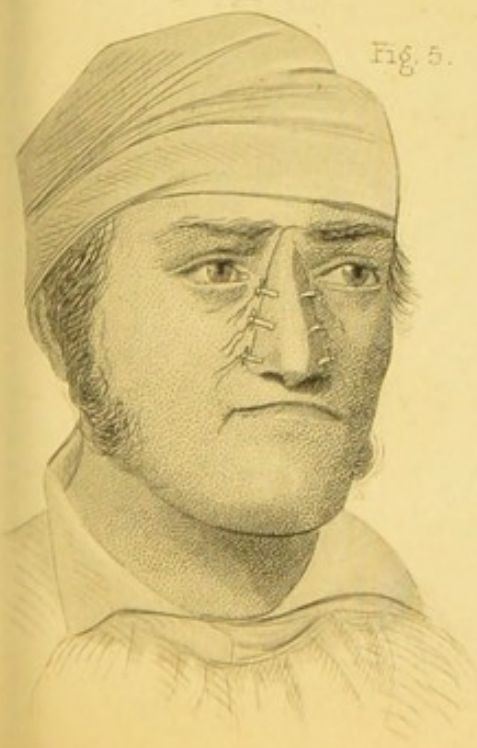

Fig 6.









with the original appearance of the patient, the steps of an operation devised and executed by the elder Professor Pancoast, and the result obtained as exhibited by an accurate likeness of the patient taken sixteen months after the operation.

**History of the Case.**—The recital of this example, having the advantage of illustration, will serve as a type and study of similar cases. A man aged fifty-three had lost all the soft part of the nose and the whole of his upper lip, from the commissures of the mouth to the canine fossa of each side, as well as the septum narium and the turbinated bones; the cavities of the antra Highmoriana and of the sphenoidal sinuses being exposed. His appearance with his mouth closed is shown in Fig. 1 of the plate. The mouth, when opened, presented a rigid circular orifice three-fourths of an inch in diameter.

**OPERATION.**—The mouth being widened after Dieffenbach's method (see description on a preceding page), the free surface of the gum was freshened, and an incision made obliquely upward and outward for a quarter of an inch from the point where the gum was covered by integuments, and from the end of this another cut was made for about the same distance, nearly parallel with the incisions for widening the mouth, but inclined a little downward. The cheeks being now loosened from the gum and malar bone by incisions on the side of the mouth, the flap of skin and subcutaneous fatty matter was raised from the surface of the muscle by beginning the dissection at the angle next the nose, Plate V., Fig. 2.

The arterial branches, which were divided, having been twisted, the flaps were drawn downward and forward over the raw surface of the gum, and fastened together with the hare-lip suture, Plate V., Fig. 3, the inner edge of the rotated flaps being thus united in the middle line of the lip. The face was dressed with lint wet with lead-water and laudanum. The patient recovered in about two months. The nose was subsequently formed as follows:

The hair being shaved from the temple and forehead, the nasal orifices closed with lint to prevent the entrance of blood, and the patient lying down with the head supported by a pillow, a flap was raised from the forehead, as shown in Plate V., Fig. 4, the skin being divided at a single sweep of the knife, the blade of which was inclined outward so as to cut a bevelled edge. The apex of the flap, which was about five-eighths of an inch wide, rested between the eyebrows, and the tongue-like portion which was to form the columna nasi extended up into the scalp. The base of the flap was nearly three inches wide, in order to allow for its subsequent contraction. The flap, after being dissected up, was then turned down on the left side and wrapped in linen, while the wound in the forehead was closed by four interrupted sutures, after which the flap was applied to the freshened edges of the new lip and gums, the whole being held in position by the plastic suture before described, and tied over rolls of adhesive plaster, as in Graefe's method, Plate V., Fig. 5. Union having occurred, the pedicle of the flap was divided,



five weeks subsequently, by passing a director under it, after which it was smoothly fitted down to the roots of the ossa nasi, in a cavity which was made for its reception by excising a portion of the sub-jacent integuments. By the twelfth day union was perfect, and the patient left the hospital so much improved that, sixteen months subsequently, his likeness was taken, as represented on Plate V., Fig. 6.—*Smith.*

FIG. 440.

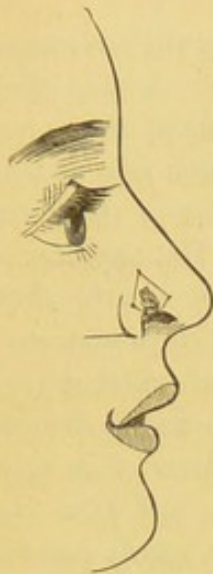

Fig. 440 exhibits a case which was of much interest to the author, inasmuch as the defect deformed the face of a fine-looking person, and had twice been attempted to be cured by a plastic section from the cheek; the flap in both instances having sloughed. Examining the diagram, an irregular V-shaped break is seen to exist in the right ala; this had been produced by the improper application of caustics for the cure of a supposed cancer. The character of operation seen in the diagram yielded a most satisfactory result; this consisting in the employment of a double

V-incision, conjoined with a second loosening of the ala at its external inferior angle from the cheeks; these cuts made, the ala was slipped toward the mesial line and fixed in its new position by a pin. Passing now to the comparatively lax nostril, a delicate hare-lip pin was passed through the apices of the two lesser triangles, and by means of the figure-of-8 ligature these apices were brought into contact, thus necessarily securing a proper curvature to the free border of the nostril.

Referring to Plate IV., Fig. 1, is seen the front view of a patient operated on by Dr. Watson, in the New York City Hospital, for the relief of a large ulcer, accompanied with syphilitic caries of the frontal bone; the ulcer is represented with thickened and inverted edges, and as retaining a portion of the diseased bone. A fistulous orifice is also described as existing at the upper border of each orbit, with another in the left temple, through which pus escaped freely. The superior eyebrows and eyelids are shown as slightly elevated and deformed by the adventitious adhesions existing around the fistulæ.

Fig. 2 represents the lines of incision practised for the securing of flap-tissue to cover this ulcer, together with the approximation secured, and the appearance of sutures in place.

Fig. 3 exhibits the relief secured by the operation.

Another manner of treating a facial ulcer, or indeed any ulcer, consists in the transplantation of particles of skin, as referred to on a previous page. These islands serve as points of cicatrization, and not infrequently succeed most happily in covering an ulcer, and in limiting to marked extent the boundaries of a cicatrix.\*

\* The study of the subject of transplantation of tissue has recently received fresh impetus from the experiments which have been made in the direction of attempts to compel inde-

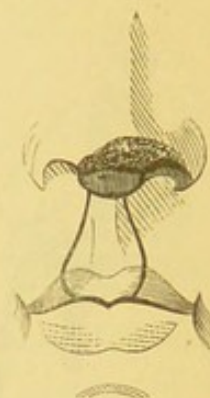

An accident occasionally met with by persons who indulge in street-brawls, consists in the loss of the tip of the nose by the teeth of an antagonist. Fig. 441 affords idea of the appearance of the part after such incident.

To treat a case of the kind implies, first, consideration of the state of the lesion. The incisor teeth of people differ very markedly, being in some of such knife-like edge that a bite made by them would really represent the ordinary incised wound, and might be expected to heal with little or no slough; on the other hand there are teeth, known ordinarily as double, where the surface is so broad and jagged that sloughing to a greater or less extent would necessarily associate with an injury done by them.

In the case of a portion of nose bitten off, it is good practice, if the piece be quickly found and is not too much injured, to stitch and bind it in position. Nothing can be lost by doing this, and a happy repair may possibly be secured. Should such result not ensue, the loss is to be replaced by modifications of some of the various operations suggested. Or, most conveniently, it is to be done from a flap secured from the lip as shown in the diagram; this flap, shaped to fit the part, is twisted on its pedicle, and attached after the usual manner. The gap left is simply an expression of hare-lip, and is to be so treated. (See *Operations for Hare-lip*.)

FIG. 441.

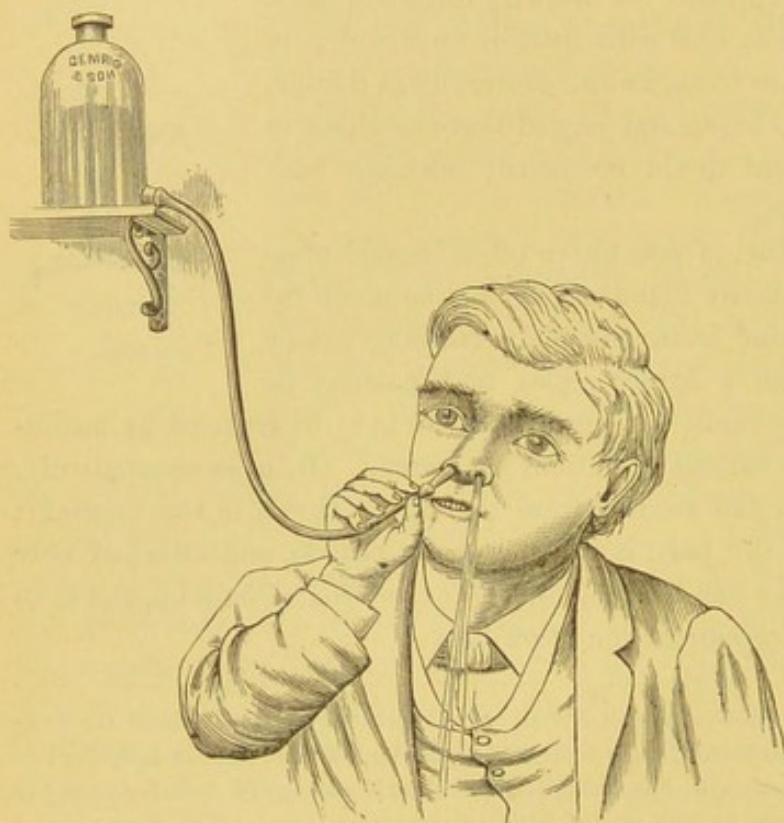


pendent islands of skin to unite with and live upon an ulcerated surface without the support of a pedicle. The nutrition of such a piece of transplanted skin, and, in fact, the immediate union of any transplanted flap, necessitates the rapid passage of vessels across the intervening space and the production of but little intermediate tissue. The formation of new blood-vessels in tissue is a subject so wonderful that it is well worthy of careful study. At some point on an existing vessel the wall dilates; a pouch is formed; it deepens, and a blind canal results. At the same time, at a point not far distant from the first, a similar action is going on,—one diverticulum projects backward, the other forward, each taking its course in the direction of the new tissue to be nourished or formed; they extend, meet; the intervening walls which closed their ends are removed, and a continuous arch is formed, through which the blood freely courses. Thus at every place these little offshoots or arms, microscopic in size, unite with similar ones from the same or adjoining vessels, until multitudes of small arches and natural anastomoses are formed, and nutrition is accomplished, every step being taken with precision, regularity, and despatch. Thus marvellous are the actions constantly taking place in our bodies to subserve the process of repair; and although man's capacity for the reproduction of lost tissue is infinitely less than that of lower beings, yet all of us must frequently be astonished at the extent of reparative power exhibited by him. As we descend the scale to creatures incapable of self-defence, self-preservation, the provision for the sustenance of existence becomes more marked, until, in protozoa, self-mutilation is but a common occurrence in case of danger, repair being so active that a short time suffices to replace any member which may thus have been cut off. Man, endowed with powers of reasoning and defence, requires such provisions to a correspondingly less degree, and in him we find that repair exists in its least expression. Still, with our advancing knowledge, we may hope to assist nature even in this process, as exemplified, for instance, in the reproduction of bone from preserved periosteum.—*From Clinical Lecture by the author in the Hospital of Oral Surgery.*



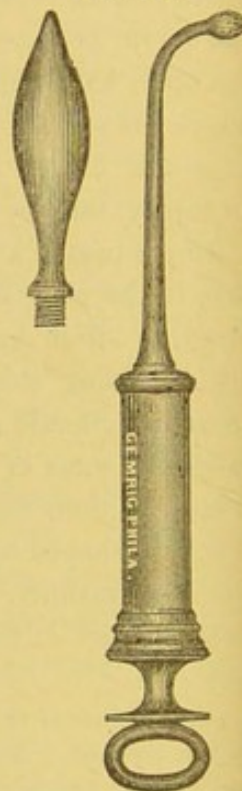
From the studies and illustrations offered, it is to be taken for granted that the ingenuity of the practitioner, directed by the hints afforded, will enable him to meet such varying indications as may from time to time be encountered. The subject is very interesting, and will repay attention given it.

FIG. 442.



Use of Nasal Douche. (See foot-note, page 654.)

FIG. 443.



Naso-pharyngeal Syringe with spray-nozzle; also nozzle for anterior nares.



## CHAPTER XLIII.

### DISEASES OF THE FACE.

THE most common diseases of the face arrange themselves under a dermatological signification. A division is into affections of the epiderm, of the corium, of the epiderm et corium, of the sebaceous glands, of the sweat-glands, of the connective tissue, and of the blood-vessels. A subdivision is into immediate and mediate diseases.

By immediate disease is meant anatomico-physiological perversion resulting in lesion of a part involved. Illustration: Sebaceous tumor arising out of duct occlusion.

By mediate disease is meant lesion originating in an indirect source of perversion. Illustration: Syphiloderma existing in constitutional condition.

Immediate diseases associated with the facial epiderm are callositas, cornu cutaneum, lichen pilaris, vitiligo, nævus pigmentosus, lentigo, chloasma.

Immediate diseases associated with the facial corium are nævus pilosus, scleroderma, dermatolysis, elephantiasis, atrophy, morphœa, framboesia.

Immediate diseases associated with the epiderm et corium are verruca and ichthyosis.

Immediate diseases of the sebaceous glands are seborrhœa, comedo, milium, molluscum sebaceum, sebaceous tumors.

Immediate diseases of the sweat-glands are hyperidrosis, chromidrosis, anidrosis, sudamina.

Immediate diseases of the connective tissue are keloid, molluscum fibrosum, xanthoma, rhino-scleroma.

Immediate diseases of the blood-vessels are nævus vasculosus and telangiectasis.

Mediate affections of the facial skin are the various manifestations of scrofula, of syphilis, of the exanthems, of the cancer vice.

#### EPIDERM.

**Callositas.**—A callus finds its best illustration in the horny hand of a workingman; it consists simply of hypertrophied epiderm. Callus upon the face is as rare as are indurating causes to the region. Splints used in jaw-fractures may excite the condition.

**TREATMENT.**—Remove the cause.

**Cornu Cutaneum.**—A cutaneous horn is a hyperplastic growth of the deeper strata of the mucous layer of the epidermis. These excrescences



vary much in size, but are alike in being largest at the base and of laminated, roughened appearance. Rare at all, they are yet rarer in the young than in the aged. A cutaneous horn, when developed, is to be accepted as differing little, if at all, from the horns of the lower animals. Microscopic examinations show the prolongation to be made up of small columns, or rods, so blended by an intermediate plasm organization as to present the appearance of a homogeneous mass. The arrangement of the epidermic scales is after the imbricated manner. A specimen in the British Museum is eleven inches in length. A case recorded in American practice describes the horn as measuring fourteen inches in circumference, and branching into three divisions. (See Figs. 454, 455.)

**TREATMENT.**—The radical cure of a cutaneous horn is achieved by extirpation of the mass and cauterization of the base.

**Lichen Pilaris.**—This is a hypertrophic affection, characterized by the formation of pin-head sized, conical, whitish, solid epidermic elevations seated about the apertures of the hair-follicles. The condition is liable to be mistaken for cutis anserina, from which it differs, however, in being of a non-acute character; it may also be confounded with miliary syphiloderm when this is in the desquamative stage, but difference lies in a history of the condition. The course of the disease is chronic; it is unassociated with itching; it is often related with ichthyosis.

**TREATMENT.**—Cosmoline is found serviceable. Glycerine, medicated with the compound tincture of iodine and carbolic acid, serves a good purpose. Dermatologists recommend the free use of warm or vapor baths.

**Vitiligo.**—This is a rather rare affection; it is commonly known as white, or bald spot. Its origin is in pigmentary perversion. As met with upon the face, the lesion consists of round, oval, or irregular patches of blanched skin, which patches commence as points, or dots. A diagnostic feature is the abrupt line at which the whiteness terminates; no matter what the shape of the patch. A second feature in recognition refers to an areola, never absent; this areola is most distinct at the line of its internal surface, and fades gradually away into the surrounding skin. In the black race the disease is more common than in the white; a piebald negro is met with frequently. When congenital, the condition is to be accepted as permanent; the acquired lesion is occasionally found to disappear spontaneously. Microscopic examination shows deficiency of pigment in the white spots with excess in the surrounding areola.

**TREATMENT.**—This is to be directed, if any attempt at cure be made, to the correction of adverse constitutional conditions. Hebra recommends the removal of the areola. Duhring refers to the propriety of treating the hypertrophy, rather than the atrophy, of the pigment. Balmanno Squire associates little worth with any means. Where unseemingly deformity exists it has impressed the writer that advantage might be gained by a judicious coloring of the part with skin-red india-ink.

**Nævus Pigmentosus.**—A circumscribed deposit of pigment without alter-



ation in bulk or feel of the surface is called *nævus pigmentosus*. Such *nævi* may be simple or multiple. The face is a common situation. *Nævus pigmentosus* is indifferently illustrated by a patch of dark-blue india-ink which a boy pricks into his hand. Simple flat pigmentary *nævi* are almost always acquired. (See *Nævus Pilosus* and *Vasculosus*.)

**TREATMENT.**—A pigment stain may be removed, when not too extensive, by a dissection extending to the structure of the corium. Another plan employs caustics. Still another, frequently found successful by the author, consists in occasional prickings up of the epiderm through use of a needle. The location of the pigment cells and granules being in the mucous layer of the epidermis, any treatment employed is to reach that layer.

**Lentigo.**—This is the common freckle. It is found to consist of normal pigment deposited at points in excess. Most common to childhood, it is yet met with at all ages. It is not necessarily confined to parts exposed to the sun, for which reason its pathology is somewhat obscure.

**TREATMENT.**—See *Chloasma*.

**Chloasma.**—This is a pigmentary affection, exhibiting itself as a smooth, yellowish, brownish, or reddish-brown defined patch. It differs from lentigo, or the common freckle, in appearance, as form and size are concerned.

Chloasmata are of both immediate and mediate meaning, arising, in the first case, out of direct sources of irritation, as exposure to the sun, the action of chemicals, scratching in skin affections, etc.; in the second, being symptomatic. *Chloasma uterinum* is specially noted. A second illustration is found in Addison's disease. In the first of these symptomatic expressions the whole face may be occupied by a diffused, blotchy discoloration resembling a mask; more commonly it shows itself as one or several patches about the forehead. Pregnancy is still another of recognized causes. In non-pregnant women its association is mostly with dysmenorrhœa, chlorosis, anæmia, and hysteria. The seat of the affection is the mucous layer of the epiderm. The lesion consists essentially in an increased deposit of normal pigment.

**TREATMENT.**—This is directed, first, to removal of cause. To destroy the pigment various lotions and ointments are used. Favorite among such preparations is an application of corrosive sublimate, from one to three grains of the salt to an ounce of water. Ointments are made with sulphur, zinc, ammoniated mercury, subnitrate of bismuth, etc. Acetic acid in solution is commended by Squire.

#### CORIUM.

**Nævus Pilosus.**—Hair mole differs from the macula described in connection with the epiderm in being of deeper origin and relation. The same distinction applies to the flabby hypertrophies known as toads or toad-marks. Hair, or mouse, moles are exceedingly common to the face. They vary in size from that of a small shot to a hand's breadth. Their relation with the skin is that of comparative flatness. In occasional instances they are met



with raised from the surface quite a finger's width. The hair covering them is found to differ in almost every case; the term *fur* expresses fairly well the appearance.

**TREATMENT.**—The inert and lifeless character of most of these growths defies all curative means except the knife, ligature, or cauterant.

**Scleroderma.**—Leather skin, as this affection has been not inaptly termed, is a hard, fixed condition of the corium, unaccompanied by either constitutional disturbance or expressions of local vascular change. The affected part is neither raised above nor depressed below the ordinary skin surface; neither is the lesion expressed by a defined line of demarkation, the hardness shading off into the normal skin. The author has never met with a case. Professor Duhring, who enjoyed opportunities of observing the disease at the clinic of Hebra, in Vienna, has described it to the writer as commencing by an apparently simple induration of the integument, which goes on until the part becomes almost as hard as wood or stone. The color of the skin is referred to as varying considerably, more or less pigmentation being present; a waxy appearance is alluded to as occasionally showing itself. The disease, according to the experience of the Vienna clinic, may appear at any period of life, but is most rarely encountered in youth. Women are more frequently affected than men. From studies made by such eminent dermatologists as Kaposi, Auspitz, and others, it is to be accepted that the condition consists in a lymph stasis occurring in the cutis. Kaposi suggests by way of explanation, in consequence of the thickening of the lymph, which results, not from local cause, but out of a general abnormal state of the nutritive process, that this stagnates in the interstices of the tissue, which, according to the views as to the commencement of lymph passages, are considered to be lymph spaces. Hence the rigid infiltration of the cutis. A return to health of the parts would imply that circulation of the lymph has been restored. Stagnation continuing, connective tissue comes to be formed in excess, this structure growing at the same time denser and denser. The interstices of the tissue become more and more narrowed. The whole structure diminishes as to juiciness, at the same time retracting and shrinking. Diagnosis is expressed as lying in the solidified, rigid, hard, more or less pigmented condition of the integument, apparently unaltered in structure.

**TREATMENT.**—Practitioners familiar with the disease agree that little is to be done. Galvanization is recommended by Fieber. Constitutional remedies that have been most used are iron, arsenic, cod-liver oil, and iodine.

**Dermatolysis.**—Fig. 444 shows a marked case of this rare disease in the person of a young man aged eighteen years, recommended to the author for consultation by Dr. A. R. Begun, of Iowa.

The condition consists in a hypertrophy of the integuments apt to extend to the sublying structure, the characteristics of which are a laxity and pliability suggestive, to the touch, of adipose tissue. The surface is commonly rugose, is apt to assume the form of folds, and is generally more or less pigmented.



Difference in views exists as to the features of the disease. Cooke describes it as an affection not making its appearance until after puberty. Hebra and Kaposi write of it as of purely congenital origin. Duhring classes it with molluscum fibrosum, and implies that it may appear either as a congenital or an acquired affection. The example here presented made its appearance when the patient was in his third year, and the hypertrophy has continued to advance to the present time. A remarkable case of this disease occurring in the practice of Nélaton showed a huge fold extending, in the form of a cloak, from the neck to the buttocks.

**TREATMENT.**—The knife offers the only present known means of relief, yet applying, unfortunately, to a very few instances. In a case somewhat similar to the photograph shown, the author excised the redundant skin with considerable satisfaction both to the patient and himself.

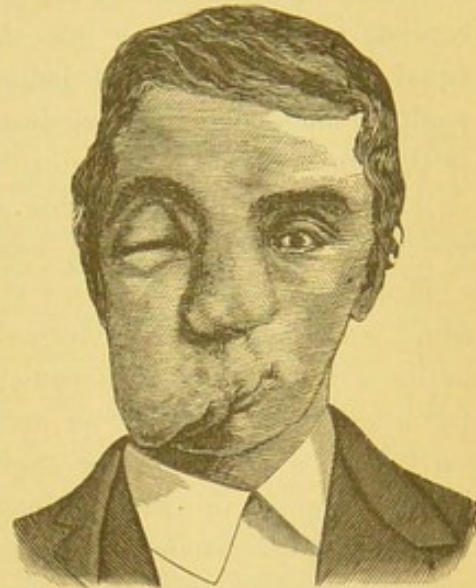
**Unilateral Atrophy.**—A disease of the cutis, the reverse of that just considered, is known as atrophy (*atrophia cutis propria*). The affection of unilateral facial atrophy is expressive of arrest in development. The skin of the side involved presents a shrunken, yellowish, lardaceous aspect. Structural alterations exist without actual loss of substance. The condition is one of undergrowth, as dermatolysis is one of overgrowth.

**TREATMENT.**—No line of medication affords any promise. The lesion may, however, incline to improve of itself. A case familiar to the author verifies this.

**Elephantiasis.**—Repeated attacks of erysipelas about the face not infrequently result in a cutaneous hypertrophy not dissimilar in appearance and characteristics to elephantiasis Arabum. The parts become swollen, pit on pressure, are pigmented, are sometimes rough, sometimes smooth, at times scaly, in instances ulcerated. The condition, as met with upon the face, is undoubtedly a lymphatic disease; a stasis in this circulation the judgment of the writer would denominate it. Practically it differs little, except in origin, from dermatolysis; indeed such likeness has struck both Hebra and Kaposi with a force that has led these able authorities to denominate the last-named disease elephantiasis telangiectodes. Diagnosis lies in origin, in history, and in the appearance of the enlargement; this last having the characteristics of parts chronically inflamed and semi-solidly indurated.

**TREATMENT.**—If met with while at all possessed of active expression no treatment is found so efficacious as a combination of muriated tincture of iron, tincture of cinchona, and sulphate of quinia applied locally. The writer

FIG. 444.





recommends a mixture made of these medicines as absolutely specific in facial erysipelas; application to the parts being often enough repeated. \* Specificness in the inflammation being destroyed, succeeding steps consider the use of sorbefacients and softening cataplasms. A very satisfactory course to pursue consists in daily rubbing into the induration an embrocation consisting of equal parts of tincture of iodine, tar, and olive-oil; following this with a poultice, made very light, medicated with a chloral solution; this last being in the proportion of five grains of the salt to an ounce of water.

As an adjunct of great value, where the induration is heavy and resisting, bandaging, judiciously done, deserves to command much attention.

**Morphœa.**—This disease, a synonyme of which is "the keloid of Addison," is a condition characterized by much variety in expression. As ordinarily seen it consists of irregularly rounded or elongate pinkish or purplish patches circumscribed by an areola made up of minute capillaries. In its early stage a patch may be slightly elevated above the surrounding plane, later it is on a level, when of long standing it is likely to be depressed. The surface is usually smooth and shining, looking sometimes as if polished, otherwise it may show a dry, shrivelled appearance.\* In the early stages minute and anastomosing blood-vessels are not infrequently seen ramifying over the affected part. Pigmentation is rarely absent. As a rule subjective symptoms are lacking; occasionally itching and tingling pain are present. Common seats of morphœa patches are the regions holding the tracts of the fifth nerve. Duhring and Hutchinson, who have closely studied the pathology of the disease, agree in pronouncing it a trophoneurosis.

**TREATMENT.**—Arsenic continued in small doses over a period of months promises most. Iron and cod-liver oil are thought highly of by some practitioners. \* Prognosis is not encouraging.

**Frambœsia.**—This is an endemic disease peculiar to South America and the West Indies; known in the region of its occurrence as yaws. Drs. Milroy and Imray, of Dominica; Dr. Bowerbank, of Jamaica; Mr. Hutchinson and Dr. Ward, of Peru, describe the cutaneous symptoms as consisting of variously-sized reddish papules, tubercles, and tumors which are usually present in all stages of development. These begin as pin-head sized, hard, red points, and enlarge gradually to the size of cherries. As they grow they incline to become flat on their summits and to be studded with yellow points; they grow soft in consistence, and are apt to break down and ulcerate, discharging a thin, fetid, yellowish fluid. The lesions, although roundish and semi-globular, may be of any shape; at times they coalesce, forming a patch of a vegetating, or fungoid nature. Dr. Imray likens a yaw to a piece of coarse cotton wick, a quarter of an inch, more or less, in diameter, dipped into a dirty yellow fluid and stuck upon the face in a dirty, scabby, brownish setting. The author has met with a single case of the disease.

---

\* Duhring graphically likens one of its expressions to a piece of bacon which has been cut out and laid in the skin.



**TREATMENT.**—Dr. Imray pronounces a treatment most effective which employs the local use of carbolic acid solution or a weak nitrate of mercury ointment combined with the internal use of tonics. Cleanliness, hygiene, and good food are alluded to as essentials.

#### EPIDERM ET CORIUM.

**Verruca.**—Warts are excrescences familiar to everybody. The signification of a wart is that of papillary hypertrophy. Five varieties are known to dermatology: namely, *verruca vulgaris*, *v. plana*, *v. filiformis*, *v. digitata*, *v. acuminata*. The first is the form seen upon the hands and is not common to the face; a split pea thrust beneath the epiderm would fairly represent it. The second is of flat aspect, being frequently met with about the cheeks of elderly persons; in structure these are more or less sebaceous; elevation above the skin is slight; size is about that of a small finger-nail. The third variety is commonly found upon the lower eyelid; the wart consists of a single thread-like projection of slightly conical form. The fourth form is allied with the second, differing from it in possessing a surface broken up into rugæ, or claws. The fifth affects the face at points where skin is in contact with mucous membrane; acuminated, well expresses the appearance of its surface. A common name of the variety is moist, or cauliflower, wart.

A wart situated upon the side of the nose is not unwisely looked on with concern. Degeneration is not uncommon. When a growth assumes a vascular aspect about its base a judicious rule of practice is, *not to irritate*.

**TREATMENT.**—Ordinary warts are removed by means of ligature, or preferably, by caustics. In the fungiform varieties an application of London paste destroys one almost instantly. A thread wart is quickly got rid of by use of scissors. Flat warts are to be dissected out, or may be transixed and strangulated.

**Ichthyosis.**—Fish-skin is a condition sometimes met with upon the face expressive of excessive proliferation of the epidermic scales combined with hypertrophy of the papilla of the corium. A space, greater or lesser in extent, shows itself covered with fish-like scales. A variety is distinguished as *xeroderma*; here there is simple dryness with furfuraceous exfoliation. A second phase has the designation of *ichthyosis corium*; this shows a greatly thickened derm, the parts being hardened and fissured. *Ichthyosis* is unaccompanied either by redness in the skin or sensibility. Diseases with which it might possibly be confounded are *psoriasis* and *pityriasis*.\*

**TREATMENT.**—This is palliative rather than curative. Scales are to be removed and the part kept continuously anointed with cosmoline. Ointments of the alkaline carbonates are recommended. Where the scales tend to ad-

\* A condition met with upon the inside of the cheeks where the surface is checkered and scale-like seems not unjustly classifiable with ichthyoid expressions; it is not, however, a congenital disease, and not infrequently yields, after some resistance, to iodide of potash, administered in ten-grain doses thrice daily.



here closely a blister serves an admirable end. Cod-liver oil and arsenic are to be employed internally.

#### SEBACEOUS GLANDS.

**Seborrhœa.**—This is an expression of functional derangement on the part of the oil-glands, showing, over the region affected, an excess of sebum. As the face is concerned the localities particularly involved are the forehead and nose. Two varieties of the disease are *s. oleosa* and *s. sicca*. The first of these exhibits a coating of oil, the second a covering of dirty greasy scales. Looked at as it exists upon the forehead of the young, the asthenic character of the condition is clearly recognized in the patulous mouth of the ducts and in the general sluggishness of the parts involved.

**TREATMENT.**—This is both local and general, the first being stimulating, the second tonic. A local application used satisfactorily by the author consists of equal parts of zinc, tar, and iodine ointments. Dusting the parts with flour of sulphur is good. Hebra has introduced and highly commends a wash composed as follows:

R.—Saponis viridis, ℥viii;  
Spts. vini, ℥iv. M.

Eau de luce, a liquid soap made by mixing oil of amber and balsam of Gilead with water of ammonia, commends itself. Duhring claims good results from a combination of red oxide of mercury and vaseline, five grains of the first to an ounce of the second.

Cold salt-baths taken in conjunction with iron medicaments afford the best systemic results. The face, before being vigorously rubbed after the bath, is, advantageously, to have a second washing with cologne or alcohol.

**Comedo.**—This, like the immediately preceding, is a disease of the sebaceous glands. It is the familiar *pimples*, containing as their centre a black point, seen over the faces of young people of both sexes. The affection implies indolent distention of the sebaceous outlets, and indicates absence of vigor in the oil-glands. The so-called worm squeezed from a comedo is, of course, nothing but the accumulated sebum. Comedo is distinguished from acne by the absence of inflammatory associations, and from milium by a non-presence in the latter of the characteristic black point.

**TREATMENT.**—Comedos are treated by expressing the contents of the ducts and employing stimulant remedies. Tar ointment having rubbed up with it a little oil of cloves is an excellent application. As with seborrhœa, advantage arises out of local invigorating influences. To wash the face in salt water and afterwards rub with a coarse towel until a glow is produced is commendable practice.

**Milium.**—A milium is a distended oil-duct, the orifice of which has become obliterated. Milia are mostly seen about the eyelids, where they appear as papilliform whitish elevations, covered, seemingly alone, by the epidermis.



**TREATMENT.**—The pathology appreciated, it is seen that treatment of a milium differs from that of comedo in requiring incision of a sac.

**Molluscum Sebaceum.**—This is a little tumor arising, perhaps, out of sebaceous perversion, having the face as one of its localities. In color it is whitish or pinkish. Its size varies from that of a pin-head to that of a cherry. A glistening appearance is characteristic. Sometimes the expression is dead white. The condition, as known to the writer, is without constitutional relation. Duhring associates its existence with the ill-nourished and neglected. Virchow does not accept the relation of this tumor as being with the oil-glands, but regards it as a hyperplastic formation of the cells lining a hair-follicle. Others are led to esteem the disease as associated with the rete mucosum.

**TREATMENT.**—Incision, expression of the contents, and cauterization are the means of cure employed. Ligation sometimes applies most happily. The necessity for cauterization supports Virchow's view.

**Sebaceous Tumors.**—As a result of some unremembered cause, or in the absence of recognizable explanation, the orifice of one or more of the ducts of the sebaceous glands becomes obstructed; the secretion continuing and having no outlet, necessarily accumulates; hence the gradual expansion of the duct and formation of a tumor. As this tumor enlarges, it becomes more and more solid, the result of the absorption, or, if not this, at any rate the disappearance, of its more liquid contents, until finally, by the touch, it is found springy and elastic. A section of such tumor exhibits a delicate cyst wall or envelope, and cheesy or semi-cheesy contents. The cyst is seen to lie among the integuments as distinctly as a walnut within its hull.

Sebaceous tumors are found of sizes varying from that of a hazel-nut to that of a foetal head; they are generally spheroidal in shape, but frequently, because of influences exerted by neighboring parts, or by reason of semi-patulous ducts, become changed, even to a lobulated character.

The diagnosis of a sebaceous enlargement is generally not at all difficult: the tumor rolls under the touch, can be circumscribed by the grasp, and has a detached feel, as if confined to its place alone by the skin. The tissues enveloping it are perfectly healthy, while however large it may be, no evidences are given of constitutional association. Exceptions, however, exist to this simplicity in some special cases, as, for example, where the presence of the tumor has excited inflammation in the surrounding parts, where attachments have formed, where an attenuated skin has ulcerated, or where the contents of the cyst have degenerated.

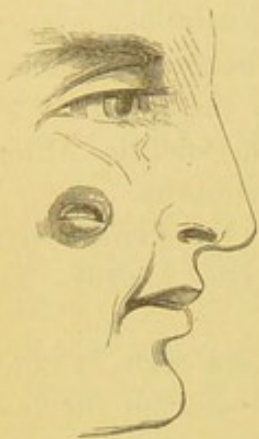Sebaceous growths are most easily gotten clear of by operation. In a majority of cases it is only necessary to make a sufficient cut in the skin, and the tumor can be enucleated, just as the crystalline lens is removed in the operation for hard cataract.

In other cases it is necessary to incise the tumor through its centre down to the base; this divides the cyst, or sac, each portion of which is to be dissected away. In instances of moderate or of large growths it is the practice



to commence with an elliptical incision, making the skin removed correspond with the requirements of the parts after the tumor shall have been taken away. In doing this it will be found better to have too much than too little integument: even very redundant flaps are seen to accommodate themselves to the parts beneath.

FIG. 445.



Small Sebaceous Tumor, showing its sacculated condition.

The contents of sebaceous tumors, while uniform in character, vary greatly not only in consistence but in appearance. Yet, whatever the expression, the springy, elastic character, as touch is concerned, is preserved. These tumors, while frequently multiple when appearing upon the scalp, in which position they are known as the common wen, seldom appear but as single upon the face.

Sebaceous tumors have little vascularity, the supply of vessels being confined to the sac, which, as will be inferred, is the attenuated duct and glandular substance. Little or no pain attends their development. The enlargement is entirely devoid of danger, as tendency to malignant degeneration is concerned. To prevent the possibility of return on the part of a removed sebaceous tumor, particular care is to be observed that no particle of the sac be allowed to remain. Cauterization is not required nor is it permissible.

#### SWEAT-GLANDS.

**Hyperidrosis.**—This affection finds its diagnosis in greatly increased perspiration. The condition relates with both systemic and local disease; is of acute or passive signification. General sweating is identified with febrile maladies; it arises also out of a high atmospheric temperature. Local sweating signifies abnormality on the part of the sudoriparous glands of the region implicated; it is a special condition. When associated with the face hyperidrosis confines itself markedly to the forehead.

**TREATMENT.**—Inferring the cause of local hyperidrosis to lie in deficient innervation, out of which arises passive congestion of the sudoriparous plexus, faradization commends itself as an application to be repeated daily for weeks, and after that, interruptedly for months. Stimulation excited by the use of dry handkerchiefs which have been wrung out in salt water is a promising remedy if continued long enough. Astringents and alteratives apply. In the first direction alcohol medicated with tannic acid is to be commended; in the latter few means are found of more satisfactory import than a combination of chlorate of potash, sulphate of zinc, and hydrate of chloral.

R.—Potassii chloratis,  $\mathfrak{z}$ ss;

Zinci sulphatis, gr. xxiv;

Chloral hydratis, gr. xv;

Aquæ rosæ,  $\mathfrak{z}$ viii. M.

Sig.—To be applied pro re nata.



**Chromidrosis.**—This is an affection of the sweat-glands, emotional and vicarious of signification, in which a watery fluid, variously colored, is seen to issue directly from the tubal outlets. At the present time the writer has under observation a lady of marked hemorrhagic diathesis where these glands, on the intervention of an hysterical attack, will sometimes throw out a fluid of venous darkness. Causes are idiosyncrasy, chlorosis, irregularity in the menstrual relations, nervous prostration.

**TREATMENT.**—This is to be directed to any derangement seen to exist, and to a general building up of the constitution.

**Anidrosis.**—This condition is the opposite of that just considered. It may occur as an idiopathic condition, but is most commonly an associate of chronic skin affections. Dry face is met with where moisture is absent in the hottest weather.

**TREATMENT.**—This is directed by the circumstances of each particular case. Where the cause is not recognizable nothing is to be done outside of administering nerve tonics.

**Sudamina.**—This affection occurs in hot weather and during the continuance of such diseases as typhoid and typhus fevers, phthisis, and rheumatism; its subjects are alone thin-skinned people; commonly women. The characteristics of the lesions are crowded, transparent vesicles, pin-head in size, raised somewhat above the level of the skin and felt as elevations. The vesicles never run together nor become puriform. Pathology of the condition is explained in an excess of secretion over discharging ability of the tubal outlets. Sudaminae disappear with the occasion excitiv of the condition.

**TREATMENT.**—This affection being received as an expression of debility, remedy lies in the direction of stimulation.

#### CONNECTIVE TISSUE.

**Keloid.**—*Kéloide*, the French term, signifying a disease resembling scirrhous, is the name given to one of the most peculiar and individualized of skin affections. This condition, first described by Alibert, is characterized by nodules, or more generally wheals, scattered irregularly over the body,—usually, however, confined to the breast, arms, neck, and face. It occurs in both sexes, may appear at any time of life, and is more common to the black than to the white race.

Keloid is a disease of the corium and subcutaneous cellular tissue. That it is an atonic condition is to be inferred from the fact that in every individual case in which the author has met with it there appeared to be present a serofulous association. This, however, is a feature not referred to by dermatologists.

As to the exciting causes of keloid, writers on skin diseases express no opinion: it is traumatic and it is idiopathic; it appears upon a skin which before has seemed entirely healthy, and it springs up in the cicatricial tissue

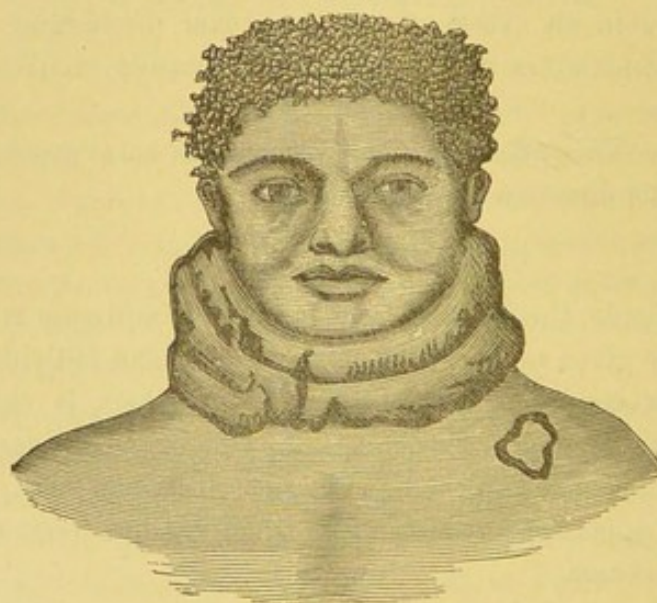


of a wound. The cicatrices of bad burns from dry heat very frequently so simulate this disease that one might be readily mistaken for the other. Keloid certainly constitutes a diathesis: the writer has seen it develop after a simple puncture which opened a boil, while others have remarked it appearing in the cicatrices of smallpox, after scarification in cupping, after vaccination, blistering, etc. Processes, or roots, pass into neighboring parts, thus extending the disease. The excrescences, to the touch, are hard, semi-elastic, and rough; the color differs from that of the surrounding region—varying as do the cicatrices of burns. According to some observers, the parts itch and are more or less uncomfortable. Complaints of any peculiar sensation are seldom heard, however, except as the location of some wheal may interfere by its stiffness with free motion.

Keloid is an imperfect fibrous development, a species of cellular fibroma. Warren, of Boston, has demonstrated the origin of the disease to be in the walls of the blood-vessels, numberless cells accumulating and in time becoming converted into dense connective tissue. Microscopic studies made by Langhans, Kaposi, and others, exclude from connection with the lesion both the epiderm and papillæ.

**TREATMENT.**—This has, in every instance, proved so unsatisfactory, that surgeons are agreed in the practice of letting the deformity alone: even the

FIG. 446.—KELOID OF NECK.



knife is useless, or worse than useless; if a nodule or wheal be removed, one, or perhaps half a dozen, will spring up in its place. Where the tumors interfere much with motion, they may be lubricated with glycerine or oil, but otherwise nothing is to be accomplished: the only comforting reflection for the patient is that keloid seldom, if ever, kills.

**Molluscum Fibrosum.**—This is a connective-tissue proliferation exhibiting itself as multiple, sessile, or pedunculated tumors varying in size from a



common pea to that of an egg; the situation is immediately beneath the skin or it may be in the skin itself. Appearing occasionally single it not infrequently multiplies itself by hundreds. When single the measurement is not unapt to be that of an olive or a small pear, the shape corresponding with that of the latter-named fruit; existing in numbers the growths are seldom larger than a pea or cherry, and are not unlikely to be dome-shaped.

Section of a tumor differs with its age and size; all, however, show a white fibrous stroma from which, on pressure, a yellowish exudate may be pressed. A marked clinical difference between this tumor and the molluscum sebaceum lies in the oneness of the latter with associated parts; this is not to be expressed. Old growths frequently show much vascularity about the base. These have a twofold termination; they become arrested in development after attaining a certain size and remain through life, or, they ulcerate and become troublesome sores. The latter is uncommon.

**TREATMENT.**—This relates strictly with operative proceedings; common manners of extirpation are by means of knife and ligature.

**Xanthoma.**—This is a common affection, seen most frequently upon and below the under eyelid, and upon the region of the malar bone. It is a connective-tissue new growth, yellowish or saffron in color, irregular in form, showing itself in the two forms of tubercle and an inlaid patch or streak. In a case long under observation of the writer, the characteristics are saffron-colored, distinctly demarked strips, running horizontally along either eyelid, together with a number of tumor-like bodies situated between the lower orbital border and position of infraorbital canal. The patient is a lady possessed of dark and somewhat delicate skin; the general health is perfect. Microscopic examination of a patch removed from an upper eyelid by Professor Duhring showed a structure related with the corium consisting of connective tissue, which, to use the words of the examiner, "had undergone fatty degeneration, oil-globules and fat being present." This result agrees with that obtained by Tilbury Fox and others.

**TREATMENT.**—If not deforming, these strips and tubercles are best let alone. Excision is the only remedy.

**Rhino-scleroma.**—This is an exceedingly infrequent affection. It is described by Duhring, who possesses the experience of having seen two cases in Europe, as a circumscribed, irregularly shaped, flattened, tubercular, remarkably hard and dense cellular new growth, having its seat about the region of the nose. Beginning as an induration, or hypertrophy, of the nasal alæ, the disease extends to the septum and from that down the lip. Upon pressure the growth shows elasticity, it is free of all acute inflammatory expression, the color of the skin is unchanged, or if not so, only slightly pigmented a reddish or brown. The line of demarkation is diagnostically distinct. Kaposi, who, together with Geber and Mikulicz, has microscopically studied the affection, remarks a surprise begotten by cutting into the growth at the ease with which a blade passes through it as comparison is made with the



hardness to touch; that observer describes a section as showing the epidermis and rete as normal, the papillæ being filled with cells closely packed, the cellular infiltration, here and there, extending deeply into the corium, which structure is uniformly dense throughout, the vascular stratum and the papillæ being especially crammed with cells; Kaposi associates the disease with the small-cell sarcoma: Geber and Mikulicz consider it as a chronic inflammatory process.

**TREATMENT.**—If allowed to run its course, rhino-scleroma is found to eventuate in occlusion of the nostrils. Caustics are recommended, but the inference drawn by the writer from a clinical examination of the cases treated at foreign clinics begets a very positive conviction that a remedy proper to use has not yet been discovered. Prognosis is most unfavorable. No case is known to have occurred in the United States.

#### BLOOD-VESSELS.

**Angeioma. Nævus Vasculosus.**—A vascular nævus is a disease of the blood-vessels; arterioles, venules, or capillaries being individually or collectively involved. Varieties of the condition show many aspects; extremes are flat discoloration, and extensive tumors. Under the designation are included the nævi materni, mother-marks; also, justly, the acquired lesion, telangiectasis.

A mother-mark is commonly a small reddish or brownish flat or raised defect situated upon the face or other part of the body. Such a mark is various as to size and characteristics, being, in instances, a mere point, in other cases, as in that known as the port-wine stain, covering a large surface.

Although to the eye such lesions do not in all instances appear vascular, they certainly differ only in degree from the telangiectases, being commonly capillary hypertrophies, as is sufficiently witnessed when wounds occur in them. That such vascularity does not, however, shade off into the adjoining tissue is sufficiently well recognized; on the contrary, the connection is very limited. Such marks are supplied by two or three large vessels, the hypertrophy of whose radicles may, for practical purposes, be viewed as constituting the disease: hence, in operating on them, if the incisions be made wide of the growth, there is no more than ordinary hemorrhage,—only one or two vessels, if any, requiring the ligature.

**Arterial Tumor.**—This is a form of the erectile growths which has an individuality, inasmuch as it consists of a congeries of vascular twigs, held together by the more or less imperfect remains of the associated skin or cellular tissue. That it is not, as has been suggested, an aneurism, but rather a simple enlargement of terminal vessels, is proven by the fact that such enlargement accompanies the vessels of supply for a greater or less distance; that it differs, however, from the nævi, just described, few are prepared to admit. It is, perhaps, a formidable nævus, nothing more, both being, in varying degrees, erectile tumors.



These growths, while in many instances referable to local injuries, are in most cases fairly presumed to be of congenital character. It is quite true that they may appear late in life, yet the impress has existed not unlikely, although it may have been in the form of a point not larger than a pin-head, and may have entirely escaped attention.

The growth of such tumors is markedly variable. The writer has met with them where twenty years seemed scarcely to have changed their character, while in other instances a single week has exhibited alarming progress. In some cases the attenuation of the coats of the vessels is so great that one might well imagine he can see the flow of the blood, while in other instances hypertrophy of the associate tissues is so marked as comparatively to solidify the part. In color also, as will be inferred, the arterial tumors are found to vary, the shading being influenced by the conducting facility of the associate veins. Pulsation exists in many of the growths, and is synchronous with ventricular systole. To the touch the tumors are soft and doughy, almost disappearing under pressure, yet filling up the moment such pressure is removed. Form is without absolute definition, the outline being modified by circumstances of which we know nothing. A marked diagnostic sign is the effect produced on the size by the condition of the circulation. *Veratrum viride*, or *aconite*, by lowering the action of the heart, will cause those of moderate bulk to almost disappear. Even the quietude of sleep and of recumbency markedly affects them. Passion, on the other hand, excitement, or any mental emotion disturbing the pulse, causes them to enlarge, even in some instances to bursting, such enlargement being most pronounced in cases where a state of atrophy characterizes the connective tissue. The common danger from these tumors is ulceration, which, in many instances, resulting in severe hemorrhage, has gradually, yet sometimes suddenly, exhausted the patient.

A case of arterial *nævus*, the largest ever treated, or indeed ever seen, by the author, is perfectly shown in Fig. 447. The patient, a negro baby from Maryland, was brought to Professor D. Hayes Agnew, who, for the service of the oral clinic, kindly placed the child in that department. The growth, as exhibited in the cut, involved the full side of the face and looked as if it might give way at any moment. The whole substance of the cheek was involved, the mucous membrane excepted. The tumor is shown uncovered, its base being transfixed by two needles. A complete cure was made.

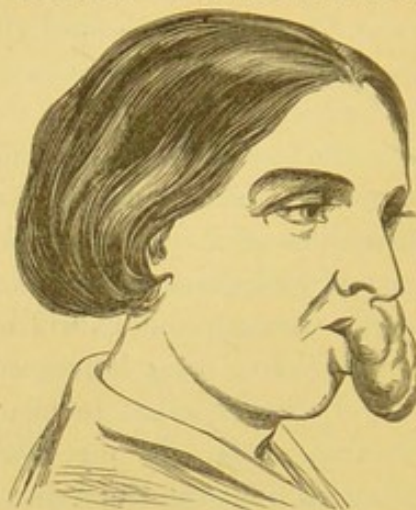
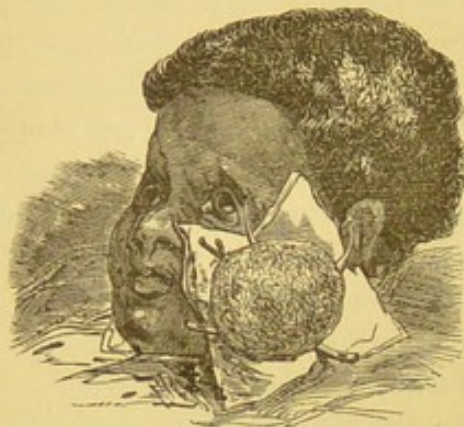**The Venous Tumor.**—This is another form of the erectile growths, differing, however, from the one just described, in the fact that the venous rather than the arterial twigs are in a state of enlargement. A description of the one is a description of the other, save in the matters of color and pulsation, the latter being generally dark, almost to a dull purple or grayish-black, and of course deficient in movement. Like the arterial, the venous tumors are sometimes slow of growth, at other times rapid; they appear without assignable cause other than the congenital impression.



Fig. 449 shows a form of nævus, or, as it is more commonly called, venous varix, which is met with in varying facial locations not infrequently by the

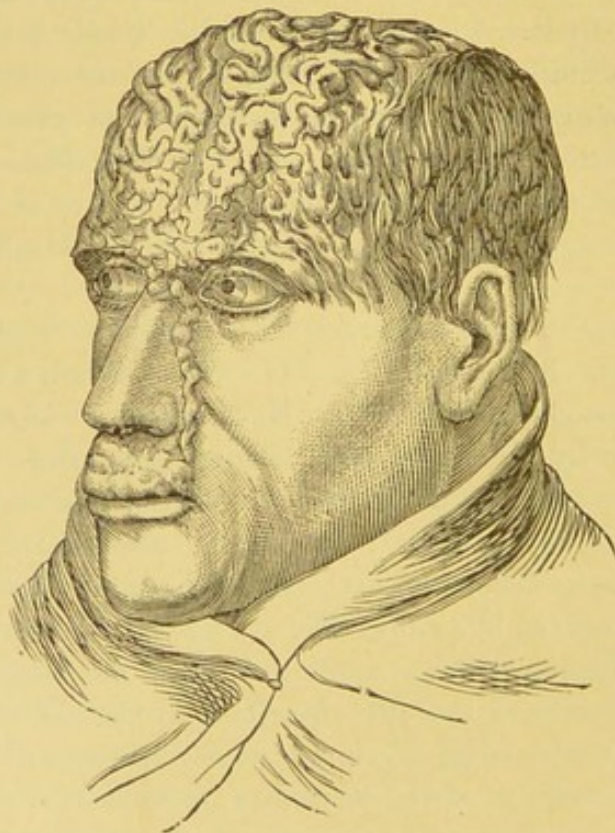
FIG. 448 — VENOUS NÆVUS.

FIG. 447.—ARTERIAL NÆVUS.



writer. The condition, as will be appreciated, consists of a congeries of enlarged veins. A common seat of the affection is the cheek, where, the

FIG. 449.



overlying skin becoming more or less atrophied, the appearance presented is that of a divisioned sac filled with darkish blue blood.


Fig. 450, being a case illustrated by the elder Pancoast, represents a large



nævus met with upon the lip of a black man. It was successfully removed by acupressure, after a manner shown in the cut.

A case of nævus about to be dismissed from the observation of the writer, is in the person of a white babe, the right half of whose lower lip was but

FIG. 450.



lately a vascular mass, the disease extending well into the cheek. The condition was congenital, the nævus having enlarged, however, very much and rapidly after birth. (See page 688.)

**Capillary Nævi Maculæ.**—A capillary nævus may involve the deep structures or it may be of superficial import; the signification of it lies in the capillary tissue. Under this head are to be classed not only small and unimportant phases of the disease, but tumors which threaten life.

**Port-Wine Stain.**—This is a nævus of such marked and peculiar expression, and withal so common, as to merit special naming. In color a reddish purple, the extent of parts deformed by it varies from an aspect known as araneus (epides clavus) to the whole side of the face and neck, the patient looking as if stained by dark wine. So superficial is this discoloration that a touch of the finger will cause its temporary disappearance.

**TREATMENT.**—Nævi are treated on a common principle: by ablation with the knife, by strangulation, by starvation, by compression, by injection, by electrolysis, and by the application of caustic remedies.

Excision is chiefly confined to small tumors, this being the easiest and quickest way of getting clear of them. The general experience to cut as wide of the growth as convenient is the principal rule to bear in mind. As



the vessels of supply are cut, an assistant compresses them with thumb or finger; and while such vessels are frequently very formidable-looking, yet it may happen that when the tumor is entirely away not a single ligature shall be required. Should the hemorrhage not cease, it will be found convenient practice to ligate.

Removal of a growth effected, and the bleeding controlled, nothing remains but to close a wound, that may have been made, with a few stitches of the interrupted suture, and to support it with adhesive strips.

*Strangulation* is a means of treatment familiar to every practitioner. Such manner of cure implies transfixion of the base of the *nævus* and the application of ligatures that shall cut off the circulation. Simple strangulation uses one or more curved needles and a strand of waxed silk; skin is included in the strangulated circle. A step more complicated cuts around the disease, the incision passing through the skin; this circular channel receives pins and ligature. Another operation (Fig. 447) demands uncovering of a tumor that skin may be secured or saved to cover in the part from which a *nævus* has been removed. In the case of the child portrayed four flaps were commanded by means of a crucial incision. The mass thus exposed, it was worked into as ball-like an aspect as possible, fingers and the handle of a knife being used to tear the adhesions. When hemorrhage could no longer be controlled by ligatures, two large curved needles were passed, as shown in the cut, and strangulation effected by means of several strands of gilling twine twisted together and well waxed. The pedicle controlled by a single tie of the ligature, the vascular fungus was freely depleted by deep pricks from a lancet. This last step allowed such a knot to be made as turned the tumor quickly black by reason of absolute shutting away of all circulation. To render the case as suggestive as possible, it is to be stated that union of the base of the growth with its vital bed was prevented by interposing layers of linen saturated with an antiseptic. Four days later the now degenerating and offensive mass was lifted away and the flaps, which had changed surprisingly little, were laid down and delicately stitched and compressed into place. Recovery was without a complication. Four years later, the baby, grown into a rugged child, was brought to see the operator, scarcely a scar designating the locality of the formidable performance.

Still another class of strangulation refers to the manipulation practised subcutaneously. Cases demanding this operation have the disease situated beneath the skin, circumstances existing which contra-indicate an uncovering. In these instances, not always satisfactory as to results, a threaded needle is passed over one surface of the pedicle and brought under the other by being returned through the opening of exit, the needle finally emerging at the point of entrance. The principle is that employed in the treatment of varicocele.

The strangulation of *nævi* requires not infrequently the exercise of considerable ingenuity in the arranging of ligatures. Figs. 451 and 452 exhibit complexities in transfixion, and will serve as hints to practice.



*Compression.*—Compression applies to pressure, however made. Take a piece of ivory, metal, or other convenient material, adapt it to the part, and confine by means of bandage or adhesive strips. This mode of cure is rarely applicable, being used only over bony surfaces and where a tumor is quite

FIG. 451.

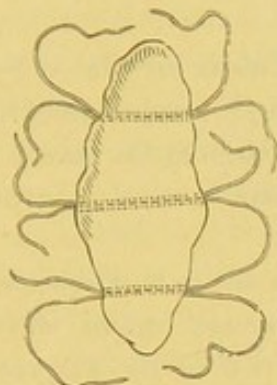


Diagram of tumor with its base transfixed by a number of threads.

FIG. 452.

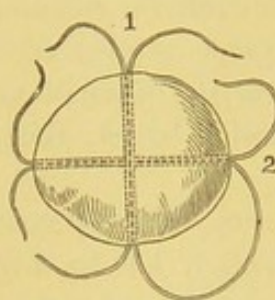


Diagram of tumor with its base transfixed by threads at right angles to one another.

small. A practice which in one instance, where the tumor was situated upon the finger, answered a satisfactory purpose, consisted in the daily application of tincture of iodine four times the officinal strength, together with the use of an india-rubber ring. Collodion, daily applied, is recommended with similar intent.

Injections have some few advocates: of agents thus used, the principal are iodine, Monsel's solution of iron, nitric acid, and creasote. Such mode of treatment is always, however, attended with more or less risk, and is not to be commended. The practitioner disposed to try the plan has only to use the ordinary subcutaneous syringe, break up, with its point, the structure of the tumor or some portion of it, and follow with the injection. Several cases of death are on record from this manner of treatment; the danger lying in emboli.

Caustic remedies, used to destroy nævi, are of various kinds,—Vienna paste is a wide favorite; this is the potassa cum calce of the Pharmacopœia: it is used by continuing an application from ten to twenty minutes, following it with an emollient poultice. London paste, composed of equal parts of quicklime and caustic soda, replaces this in the estimation of the author; it is used by being mixed into a thick paste with water or alcohol.

Another method is to paint the part with blistering collodion, and, after the cuticle is raised, apply crystals of the chloride of zinc. An application recommended by Richardson, of England, consists in the ethylate of sodium used upon the nib of a quill pen.

In the application of any caustic, trouble, more or less severe, from a resulting inflammation, is always to be apprehended; this every patient, or the friends, are to be made to understand, as it is impossible to know just how a



case may come out. After the use of a caustic, and the slough of a part, the resulting wound is to be treated as a simple ulcer.

*Starvation.*—Starvation is still another method of treating the erectile growths. This consists simply in finding the vessel or vessels of supply, and cutting off the circulation by ligation; this mode has many advocates, and is certainly a good one where the arteries are in a position to be surely recognized and conveniently operated upon.

*Seton.*—The seton is still another mode. This is introduced by threading a needle with tape or other material, and passing it beneath the growth. The seton, whatever the material used, is to be as large as the needle which carries it, preferably larger; thus, by the pressure secured, guarding against hemorrhage.

In considering the treatment of nævi, it is not to be forgotten that there are cases which, if left to themselves long enough, might effect self-cure. Young children afflicted with nævus are hurried to the surgeon, under an impression that the disease must necessarily spread, and that therefore the sooner an operation is done the better. Such haste is not always found necessary, nor even prudent. For a short time after birth a nævus may continue to grow,—for several weeks, perhaps; then it may cease to enlarge. If it be of a simple cutaneous variety, it may become the seat of ulceration; this may spread, but it will destroy the nævus. In other instances, a nævus, after growing to a considerable size, will become the seat of atrophy,—will dwindle, shrink, and degenerate, until little or nothing of it is left.

*Electrolysis.*—Treatment of the vascular nævi by the galvano-cauterant is at present in much esteem. Dr. Maas, of Breslau, has collected in the *Archiv für Klinische Chirurgie* (vol. xii.) the histories of one hundred and twelve cases of nævi treated by this method. The results were as follows: *Capillary nævus*—cured, 32; improved, 1; result unknown, 1. *Cavernous or venous nævus*—cured, 72; improved, 8; result unknown, 1; died, 3. *Arterial or racemose nævus*—cured, 2; improved, 1. *Nævus combined with other tumors*—cured, 6; improved, 1; result unknown, 2. This surgeon deduces from the examination of his cases the conclusion that the galvanic cautery is followed by the best results, and is much safer than the injection of perchloride of iron or other coagulating fluid. It would, however, be wrong to say positively that the remedy is indicated in all cases of nævi. As Virchow has well remarked, the physician is to take the circumstances of each lesion into consideration. The battery used in the cases referred to was that of Middeldorpf.

In the use of the means of electrolysis, a difficulty encountered arises out of the experience that occlusion of one venule or other radicle seems to have but little influence on its neighbors, thus necessitating repeated operations until the electrolytic action has directly influenced almost each individual vessel. Moreover, since galvano-puncture thus cauterizes the tissues as well as coagulates the blood, it is evident that a slough must ensue, provided the



superficial portion be much affected; and if such an occurrence must take place, with its consequent cicatrix, it is preferable to have it occasioned by the more speedy action of a ligature. The slough of galvano-puncture is, however, perfectly devoid of hemorrhage, since it is tardy in its separation, and remarkable for its extreme dryness.

These objections to the use of this means apply only to cases which are superficial, or where the skin is implicated. In subcutaneous nævi the operation possesses the advantage of being safer and more certain than injection, and in cases where no slough is necessitated the scar of an excision or ligation is avoided,—that is, provided insulated needles are employed. A Bunsen or other battery may be used, the number of needles varying with the size of the tumor; but in all cases care is to be taken not to carry the action beyond the whitish hue indicative of cauterization. In regard to the introduction of gas into the circulation by this method, little danger is to be apprehended, notwithstanding the opinions of Rutherford and other able writers on electro-therapeutics. In cases of huge nævi or vascular tumors, the practice is to be pursued with advantage, especially when excision is hazardous.\*

*Tearing.*—A method of treating nævi practised and highly commended by certain English surgeons is that of "piecemeal" removal; *i.e.*, tearing the mass away fragment by fragment, the object being to prevent hemorrhage, on the same principle as in torsion of arteries.

The repeated use of a needle, heated to redness by means of an alcohol-lamp, thrust a sufficient number of times and on a sufficient number of

---

\* "ELECTROLYSIS.—Drs. Beard and Rockwell, in the *Medical Record* for July 15, 1872, publish some of their results in the use of electricity in surgery:

"In the treatment of erectile or vascular tumors, they claim for electrolysis the following advantages over the knife or other methods: there is no hemorrhage; there is no scar; by proper management, the effect produced is solely upon the blood in the tumor; the operation is easily performed.

"In proof of this, they adduce cases.

"1. A child aged eight months, with an erectile tumor in the cheek. Four needles introduced for eight minutes. A clot was produced, which was wholly absorbed in four months.

"2. A large tumor in the back, in a weakly child aged one year. Same operation. Result unsatisfactory, as some ulceration followed, and the tumor remained.

"3. A child aged fifteen months, with a tumor near the angle of the mouth. Four needles introduced for ten minutes. In four months the tumor had disappeared, and no scar was left.

"4. A subcutaneous erectile tumor at the inner angle of the eye, in a child aged sixteen months. Three needles introduced for twenty minutes. Some sloughing occurred afterwards, and deformity was left. The authors think too strong a current was used, and for too long a time.

"5. A child aged eight weeks, with a nævus on the neck, just below the chin. One needle introduced and a sponge electrode applied externally for four minutes. Two and a half months afterwards there were signs of reappearance of the growth.

"6. Bronchocele of four years' standing, in a girl aged fourteen years. External galvanization twice a week for two months failed. Needles introduced; in four months, after about twenty applications, a great decrease in size in the tumor."



occasions into a *nævus* is a means that has yielded great satisfaction in the practice of the author. This applies particularly to *nævi* involving the skin under circumstances not permitting excision of the parts. The case of the white baby with *nævus* of lower lip and cheek, alluded to on page 683, furnishes an example. In that case heated needles were used each one, two, or three weeks for some four months, the child being etherized on each occasion. Cure of a complete type has resulted, and little trouble was experienced either by child, operator, or nurse.

Port-wine *nævi* are treated by ligation of supplying vessels, by the formation of points of issue, or by cross-sections. In a case of *nævus* of this character, involving a whole cheek, a second and isolated mark being related with the scalp of the temporal region, cure of both resulted from an inflammation provoked in the latter. The cross-sections proposed by Squire consist of a series of obliquely-directed cuts crossing each other at right angles, so as to divide a surface into many small squares; the operation to be repeated in one or two weeks if found necessary.

#### MEDIATE AFFECTIONS.

**Scrofuloderma.**—All facial skin affections traceable to scrofulosis are, clinically, to be denominated *scrofulodermata*. These affections vary in characteristics and find in the classifications of the dermatologists arrangement after different order. Treatment being, however, of a common expression, the disease is proved thereby individual.

Diagnostic features in the *scrofulodermata* relate with history and certain common features. Out of lymphatic stasis, and a consequent arrestation in tissue metamorphosis, arise all scrofulous manifestations let the forms be what they may. The disease may be inherited or acquired. Inheritance is more common than acquirement. Causes related with inheritance are syphilis, intermarriage of near blood-relations, impoverishment of tissue. Conditions pertaining to acquirement are insufficient or bad blood, lack of proper cleanliness, want of protection against atmospheric changes, malarial influences, living in sunless and damp rooms, depressing associations.

Accepting a common type of local manifestation for description we consider an indolent swelling, much in general appearance like the syphilitic gumma, which shows itself upon the face, remaining for a long time stationary, breaking down, not unlikely, eventually into an ulcer. The meaning of the process from beginning to ending is in tissue stasis, by which is meant, repeating for emphasis our definition, interference with, and arrestation of, nutritional activity.

The commonest expression of *scrofuloderma* is that so frequently met with upon the sides of the neck and beneath the chin. Here the condition of stasis is most appreciable, the organs primarily involved being the lymphatic glands. The breaking down of a gland, and of its overlying tissue, is a direct phase of the lesion.



A scrofulous ulcer is usually of uneven, undermined, ragged edge, has a bottom covered with a flaky deposit among which indolent granulations of a palish red show themselves, gives off a curdy pus, is not unlikely found incrustated with scabs, and is painless. Diagnostic concomitants are coryza, otorrhœa, palpebral conjunctivitis.

**TREATMENT.**—Cure of the scrofulodermata lies in a medication directed to the lymphatic system. Toward this end nothing in the estimation and experience of the author equals "roughing it,"—salt baths taken as directed at page 106, deep breathing induced by running up-hill, the temporary drinking of alcohol, working in a horse-stable or in a butcher's yard, arousing the system to vigorous action and feeding it with pure air as found among mountains or by the sea-shore. Medicines used are iron, iodine, arsenic, nux vomica, cod-liver oil. Local applications are benzoated zinc ointment, tincture of calendula, tar cerate, solutions of iodine, mercurial preparations.

**Syphiloderma.**—By the syphilodermata are meant all skin manifestations arising out of the syphilitic vice. These are met with in the forms of macules, papules, pustules, tubercles. The forms succeed one another, or, what is more likely, are met with upon the same surface at the same time.

Like the scrofulodermata the syphilodermata find diagnosis in history and in local peculiarities. The syphilides are always preceded by a primary stage of the disease. Appearing upon the face the form is almost constantly that of erythematosum. The blush is persistently copper-color. No pain, itching, or other subjective symptoms are present, except at times when the patient finds himself over-warm in bed.

Facial syphilitic tuberculosis, a condition allied with tertiary manifestations, consists of one or several prominences varying in size from a split pea to a finger-point, hard and resisting to the touch, rounded and conical in form, copper-colored, usually of smooth and glistening surface. Progress in development is slow, several weeks commonly elapsing between time of appearance and suppuration. A resulting ulcer is differentiated from one of scrofulous nature in not being undermined nor ragged.

Gumma is markedly peculiar to the forehead as the facial region is concerned; two, seldom over three are found together. A gumma is in shape and size not unlike the dorsum of the middle phalanx of a finger; more rounded perhaps. Cases, however, are recorded where the size of a hen-egg has obtained. The skin is more or less involved, is of a coppery purple, and looks apparently toward pointing. Consistence of tumor is that of tough dough; at times it is quite elastic, sometimes markedly fluctuating.

A gumma tends to break down; skin, cellular tissue, and deeper structures giving way before it. The ulcer resulting is of perpendicular edges and abrupt as related with associate parts. In place of disintegrating a gumma may disappear by absorption.

Other forms of the syphilodermata are the papular, large, small, and lenticular, these being of dry and moist varieties; the vesicular; the pigmental;



the pustular, these being of the acuminate and miliary kinds; last, those pertaining to hæreditarium infantile.

**TREATMENT.**—All syphilitic manifestations are prescribed for on the principle of specificness: the antidote is mercury. A recipe directed toward the constitutional condition most frequently used in the practice of the author is as follows:

R.—Hydrargyri bichloridi, gr. ij;  
Potassii iodidi, ℥ij;  
Extracti fluidi sarsaparillæ, ℥viiij. M.  
Dose, tablespoonful three times a day.

If judiciously directed, this combination may be continued over a period of weeks, if found necessary, without touching the gums. In sickly subjects it is well to combine with it a bark tonic. (See *Treatment of Syphilis of Tongue*.) Locally, a syphilitic ulcer is to be treated in consideration of whatever may be the peculiar indications. Much benefit generally ensues from touches of caustic application, chloride of zinc, acid nitrate of mercury, London paste, and iodine, being valuable remedies in this direction. It is a habit with the writer to apply the cauterant and afterward to keep the part packed with absorbent cotton or, preferably, lint, saturated with a solution, made to meet indications, of tar-water, glycerine, and carbolic acid.

A syphilitic tubercle, papule or gumma, met with in the non-ulcerous stage commands effort for its cure by absorption. The recipe given above is almost surely curative.

**Parasites.**—Certain skin affections exist in the presence of parasites; of such parasites there are two general forms, animal and vegetable. The animal parasites are *acarus scabiei*, or itch-mite; *pediculus capitis*, or louse; *acarus folliculorum*, or gland insect; the *pulex irritans*, or common flea; the *cimex lectularius*, or bedbug; the *pulex penetrans*, or sand-flea; the *filaria medinensis*, or Guinea-worm; and others of unimportant relation.

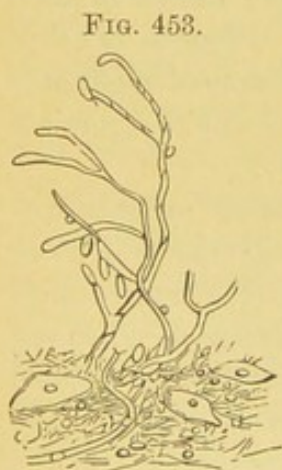

FIG. 453.  
Illustration of a parasitic growth, *oidium albicans*.

Vegetable parasites are *achorion Schönleinii*, the fungus giving rise to *tinea favosa*; the *trichophyton*, out of which arise three diseases, namely, *tinea circinata*, *tinea tonsurans*, and *tinea sycosis*; the *microsporon furfur*, the fungus of *tinea versicolor*. *Tineæ* is a generic term, signifying vegetable fungoid disease.

The origin of parasitic diseases is accident or want of cleanliness. All of them are contagious. The course is chronic. Medication lies in the employment of parasitocides. Cure is assurable.

Parasitic diseases met with upon the face, named in the order of their frequency, are *tinea sycosis*, *tinea circinata*.



**Tinea Sycosis.**—This is the familiar “barber’s itch.” It commences as a reddish, slightly scaly patch, followed in a week or two by desquamation and induration. The hairs of the part involved grow dry, loose, and brittle, showing points of pustulation about the follicles. From this condition the course of the disease is rapid, the skin becoming nodulated, and the deeper parts indurated. The surface, which has assumed a deep reddish color, becomes pustular, scabs of offensive appearance forming over the parts. A crust removed, the sore beneath shows a granulated face not unlike that of a broken fig: whence the name sycosis. The lesion generally involves the whole of the region of the lower jaw.

(Some dozen cases of a disease appearing upon the face met with by the author which is to be classified with the tinea, possess the following clinical features. There appears first an induration about the size of an almond; this, after a time, turns a purplish red and softens; affording fluctuation, it yet yields no pus when opened, but is seen to be composed of a watermelon-like stroma. Still later the original tumor lessens, but in proportion as it diminishes a second arises to take its place. The history of this second is that of the first, and so one after another come and go indefinitely. Relation of the hairs with the condition is that of tinea in every particular. The author has found these tumors invariably respond either to creasote daily brushed lightly over them, or a solution of corrosive sublimate, two grains to the ounce of water. The latter to be applied several times a day.)

**TREATMENT.**—The cause lying in the trichophyton fungus, the seat of which is the hair-follicles, treatment is necessarily specific. The practitioner, distinguishing the condition from that of sycosis non-parasitica, a matter not difficult, as this latter confines itself markedly to the hair-follicles, implicating the surrounding skin but comparatively triflingly, remedies known as parasitocides are selected. An application destructive of the particular fungus considered is the yellow sulphate of mercury, an ointment being used composed of fifteen grains to an ounce of simple cerate or of cosmoline. The bichloride is another mercurial of great value; one to two grains to the ounce of water as indicated. Still another remedy, one much employed, is sulphurous acid, one part to three of water.

A point is the manner of application: crusts are to be removed by means of poulticing. Hairs at all loose are pulled away. Shaving is to be practised to all the extent possible. Absolute cleanliness is to be preserved. Using an ointment, the medicine is to be gently but thoroughly rubbed into the parts. Employing a lotion, contact is to be continued for at least half an hour. Cure is slow; relapse frequent: treatment is to be persevered in for a long time.

**Tinea Circinata.**—Ringworm is a not unfamiliar condition. Its characteristics are one or several circular patches of varying size, commonly not larger than a twenty-cent piece, occasionally the size of a hand, appearing upon any part of the body.



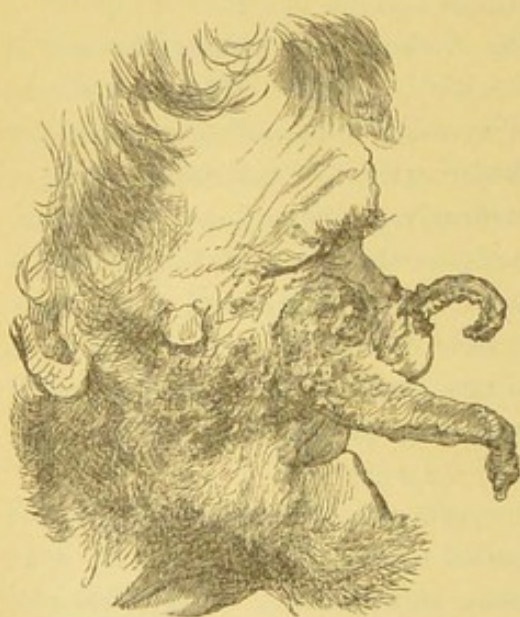The commencement of the disease about the face, as in other regions, is as a small red spot, which enlarges until the ordinary dimension and circularity are attained, the skin becoming, in the mean time, hyperæmic and desquamative.

A vesicular association is not uncommon, this arising out of a more than common irritability of the parts. The course of the disease is variable. In the child it is more amenable to treatment than in the adult. Cold favors cure; heat retards it. The affection is contagious. It is most frequently met with among the poor and ill nourished. Improvement is from the centre outward.

**TREATMENT.**—A domestic remedy that frequently proves successful consists in binding over the part a copper penny, which has been immersed in vinegar. Duhring commends an ointment composed of ten grains of ammoniated mercury to an ounce of simple ointment. Common black ink is a popular remedy. Goa-powder ointment is highly prized; this is an Indian remedy, consisting of the pith of a leguminous tree found in Brazil, rubbed up in a five-per-cent. admixture with cerate.

The general principle of cure, it is to be recognized, lies in detaching the scurf, and with it the superficial epidermic scales among which the parasite vegetates.

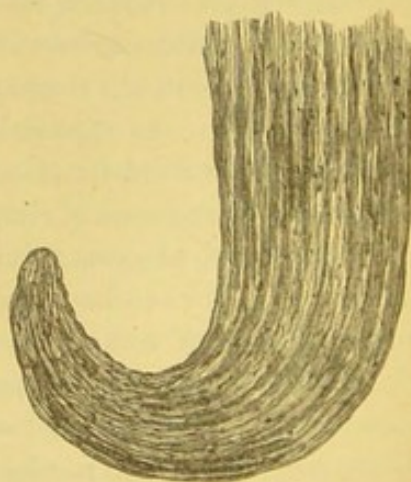
FIG. 454.



Horns growing from the nose and face.

(See page 668.)

FIG. 455.



Section of a horn, showing its laminae.



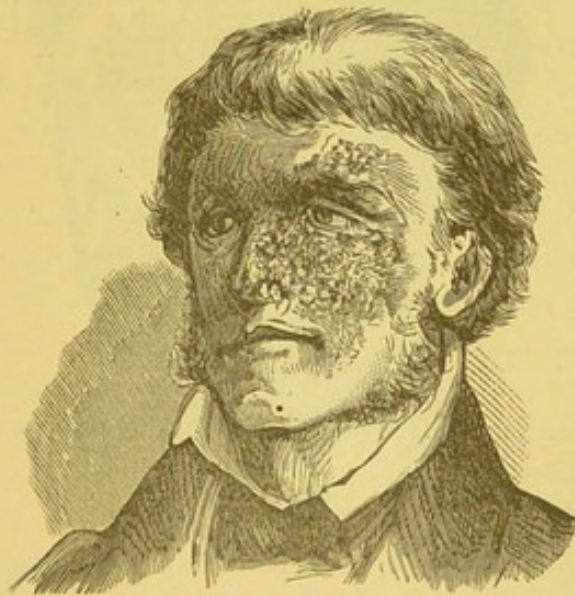
## CHAPTER XLIV.

### LUPUS.

THERE are two general expressions of lupus: One of these, seen most commonly in the adult, is known as lupus erythematosus; the other, met with more frequently in the young, is designated lupus vulgaris.

**Lupus Erythematosus.**—The characteristic of this condition is an irregular, yet more or less roundish dry sore, appearing upon the face, having its situation most commonly either about the bridge or ala of the nose, or over the location of the infraorbital foramen, the surface being covered with adherent scales. Lupus presenting itself in this form is commonly of most chronic condition; if untreated, not being irritated through caustic applica-

FIG. 456.



Lupus erythematosus.

tion nor by scratching or picking off the scabs, it may remain a lifetime in the state described.

This expression of lupus begins in one of two ways: first, and most commonly, as a dry patch toward which attention is directed by the formation of scales; second, as several unepitheliated, isolated, patches which later enlarge and coalesce, forming in this way one large patch, or, it may be, two or three.

The scales of lupus erythematosus show in their abundance that the disease is a cellular new growth; also, out of a grayish or yellowish aspect sometimes pertaining to them, that it is associated with the sebaceous glands.

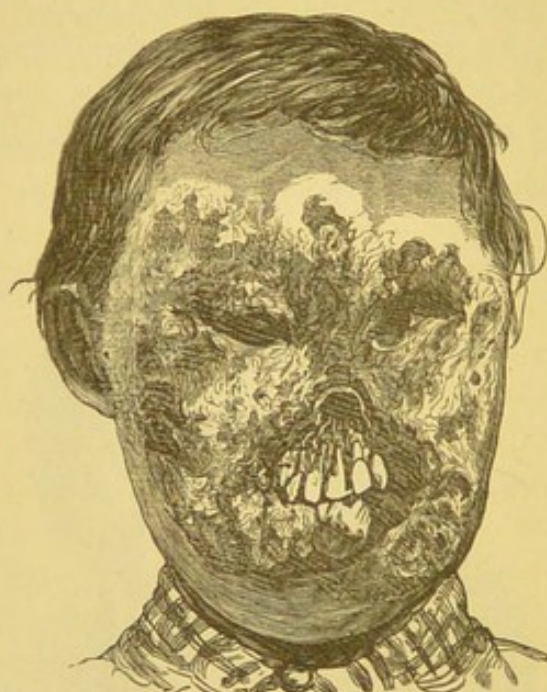


Hebra, because of this last-named association, and for the reason that the origin of the disease is not infrequently that of seborrhœa, inclined to give it the name of seborrhœa congestiva. Kaposi and Thin show that the sweat-glands as well as the sebaceous may be the seat of the disease, while, according to Duhring, to Geber, and to Stroganow, all the structures and every layer of the skin may be the centre of the morbid process.

**Lupus Vulgaris.**—Expressive synonymes for this condition are, wolf-gnaw, corroding tetter, malignant herpes.

This expression of lupus begins in one of several ways: as a papule, as a tubercle, or as a flat infiltration. That, like the form just considered, it is not a condition of scrofulosis exclusively is proven by the fact of its exceeding rarity when compared with that condition, statistics of the American Der-

FIG. 457.



Lupus vulgaris.

matological Association showing but 42 out of 16,863 cases of skin diseases reported.

Commencing in papular form, lupus vulgaris is first observed as a number of points situated beneath the epiderm, these being of a reddish or brownish color, and associated by intervening tissue not entirely without induration; a variety is the verrucous, or scaly wart, form.

Lupus tuberculosus is the disease in the shape of one or several tubercles; this is a stage progressive on the first, or, tubercle may be a primary expression.

Infiltrating lupus begins as an effusion among the sub-epidermic structures, the corium being the commonest seat: a synonyme for this expression is lupus hypertrophicus.



However commencing, the history of lupus vulgaris is that of progressive ulceration. First, from the breaking down of papule, wart, tubercle, or infiltration, a sore of resistive, angry, and threatening appearance shows itself; this may not be larger than a pin-head, it may not be smaller than a silver dollar. A peculiarity about the sore is absence of indication. In its origin a lupus ulcer aims to cover itself with a scab, this grows out of a plastic exudate which concretes into a yellowish or dirty grayish crust. Extension of the ulcer is from the circumference of this crust, fresh pustules or, not unlikely, blebs appearing, forming, as it were, new nidi of the disease.

Extension is also in the direction of the deep structures; a lupus commencing upon the side of the nose not infrequently destroys, not only all surrounding parts of the face, but erodes the osseous structure beneath until the arch is completely destroyed. (See Fig. 457.)

Dermatologists apportion the disease to the poor, the scrofulous, and the uncleanly. The author has seen a fair share of cases, and it is his testimony unhesitatingly written that the class of people affected are likely to be just the reverse of these.

The pathological anatomy of the lesion is interesting but not pertinent clinically. The subject has been elaborately studied by the European histologists, but nothing germane to a scientific treatment has come of the studies. What the writer learns from these investigations only serves the more to confirm him in a conviction of the likeness of the condition—certainly of lupus vulgaris—with cancer. Using a low-power microscope Kaposi exposes a recent nodule to consist of variously sized, roundish, nest-like masses of neoplasm distributed through the lower part of the corium. Lang, Thoma, and Friedländer present varying results as influenced by the stages of the diseased part studied by them. Schüppel lays stress on the existence of giant cells containing numerous refractive nuclei, deemed by Thin, who has examined them exhaustively, to consist of diseased blood-vessels. Duhring, grouping the studies, pronounces the etiology of the disease obscure but persistently refuses to identify it with carcinoma; he favors, but does not commit himself to, the scrofulous origin.

Lupus erythematosus separates itself from lupus vulgaris in that it is not accompanied by ulceration, and that it confines itself to the surface of the skin; also in its relation with age.

Tertiary syphilitic ulcers are not unlike the erosions of lupus vulgaris; distinguishing marks lie in histories of the two conditions, and absence, in the latter, of an offensiveness as to odor so characteristic of the former.

Acne rosacea is still another disease of resemblance; distinction lies in the pustules of acne, in the dilated vessels, and in the rose red of color when compared with the purple of lupus. In assuming a cancer origin for lupus vulgaris the author is not to be understood as confounding it with forms of the lesion possessed of familiar description. What is meant to be implied is existence of close likeness as to clinical histories.



TREATMENT.—This aims to be alterative. Absence of knowledge of cause denies any but empirical practice. Attention is to be given to any systemic derangement that exists. Local remedies relate with iodine, iodide of potassium, the mercurials, sulphur, carbolic acid, zinc, chloral hydrate, bismuth, and similar preparations. Tar has been found serviceable. A mixture composed of equal parts of oil of cade, alcohol, and soft-soap is recommended. Hebra favors the use of iodine, alone or in combination with glycerine, painted over the part until a scab is formed. Cutting away of the surface by means of a curette is endorsed by many. Multiple scarification is recommended by Volkmann. Burning with the ordinary sun glass has been tried. The treatment employed by the author is the same as used by him in cancerous epithelioma, which see.



## CHAPTER XLV.

### EPITHELIOMA.

EPITHELIOMA as a term, when properly applied, is expressive of a variety of conditions: A cutaneous horn, an epidermic neoplasm, a subcutaneous scirrhus are alike justly to be grouped under the single name. There are epitheliomata.

Epithelioma means relation with epithelial tissue,—that, and nothing more. Pathological signification of any special condition compels the prefix to the substantive of an adjective.

The present chapter deals with cancerous epithelioma.

By cancerous epithelioma is meant perversions, related with epithelial structure, arising out of the cancer vice.

Cancer is the terra incognita of surgery. A question of large clinical import relates with the origin of the disease. Is carcinoma primarily of local origin? Is a local manifestation simply an expression of a vice lying back of it? These questions wait solution. An English school contends for a primary constitutional meaning. The German, and an American school, the latter headed notably by the distinguished histologist, J. J. Woodward, of the Surgeon-General's Department at Washington, maintain the origin to be local. Accepting the latter authorities to be right, cure of cancer is found in immediate recognition and abortion of a local manifestation. The difference between the two views is separation between life and death,—a specific remaining undiscovered.

A cancer sore *accepted* as holding similar relation to the constitutional condition as is held by a chancre to systemic syphilis, treatment of the two becomes identical. Immediate recognition and destruction of a chancre is the abortion of syphilis; to possess a diagnostic acumen capable of distinguishing the incipency of cancer is to hold in one's hands the means of cure.

Certain experiences of the author, had within the past twelve years, have introduced into his mind some doubt as to the humoral theory. He has cured epithelioma diagnosed to be cancerous. He is led to think that skin cancer, if taken in time, is to be aborted precisely as is syphilis.

Granting the success assumed: Are carcinoma and epithelial cancer the same disease? This dispute is gotten clear of in the exclusion which characterizes the diagnostic data of the chapter. All epitheliomata are not carcinoma. Some epitheliomata are necessarily carcinomatous, for the reason that exclusion shows they can be nothing else. Cancerous epithelioma is what has been successfully treated by a practice to be described.



The author of this work, in absence of better data, defines and treats as cancerous epithelioma every lesion upon the face that he cannot determine to be something else. (See *Tumors*.)

Whether primarily of local or of systemic expression, cancer, like syphilis and scrofulosis, is a vice of varying attributes, being, in some cases, mild and tractable, in others, strong and uncombatable.

An epithelioma, possessed of a history, classifies itself. In absence of history, or of likeness with known benign affections, a practitioner places, compulsorily, a disease before him with the neoplasms.

Accepting the reader as one able to distinguish a self-explainable condition, we proceed to a study of cancer seated in the skin of the face.

Viewing first the histogenesis, the idea is to be conveyed, that out of an impression made by the vice considered, abnormal epithelial evolution results. The vice intensifying, local expression enlarges; being in abeyance, change is at rest; being dead, cure takes the place of destruction.

Cancerous epithelioma seldom shows itself before middle life. It is more common to man than to woman. Its seat of predilection is the face, markedly the lower lip. Exceptionally it is met with in the superior lip. It is rarely seen multiple.

Three general forms of origin characterize the condition; these are, the superficial, the infiltrated, and the papillary. A form of epithelial cancer met with by the writer first showed itself as a series of delicate blebs in front of the ear, these being surrounded by a network of enlarged capillaries.

The superficial, or flat variety, presents itself as an irritation of the epiderm which assumes the form of scales, or of a grouping of papules, or of an inflamed sebaceous outlet.

The infiltrated variety is illustrated in the indurations begotten of chronic inflammation. Difference lies in absence of cause to explain the effusion. Another beginning of this diversity is in the form of indurated points, which later enlarge and coalesce until considerable surface is covered. This surface may be raised, but is more commonly as if bound and held down by the associated connective tissue.

The third form varies greatly, being in instances not dissimilar to the common wart, again presenting a cauliflower-like excrescence.

Commencing in the skin proper, epithelial cancer is apt to assume the papillary shape. Upon a mucous surface it is most commonly met with as an ulcer; at juncture of skin and mucous membrane, it is seen in either of these states.

All warts of vascular type, all pigmental and other nævi, all single and defined scaly patches, all persistent and unexplainable indurations, all cracks and fissures refusing to heal, are to be looked on with concern as of possible relation with the cancer vice.

In microscopic character epithelial cancer differs somewhat with location and stage of the disease. Primarily and characteristically, it is made up of



proliferation in epithelial cells, which cells range themselves in groups, and are found pushing their way into adjacent parts. These differ but little from the ordinary cell of the part implicated; when young they are round and succulent; when old they are caudate or elongated. Not infrequently they degenerate, undergoing a fatty metamorphosis.

The cut surface of an epithelial cancerous tumor shows a face not unlike that of a split turnip; it is hard, white, succulent.

An epithelial cancerous ulcer is fissured, vascular, and proliferating; its face is covered with giant granulations.

Epithelial cancer is not debarred by depth of surface, the signification lying in the presence of epithelium. Parts histologically connected with skin or mucous surfaces, wherever situated, as, for example, the liver, pancreas, frontal sinus, vermiform appendix, being attacked by cancer, would or would not show the epithelial expression according to tissue implicated. Parts histologically disconnected, as the subcutaneous connective tissue, find involvement in contiguity of structure.

Epithelial growths, as suggested by Billroth, "gland-like ingrowths," might be inferred not infrequently to diffuse into the spaces between the connective-tissue bundles, where lymph circulates, for there the structure offers least resistance. These are the tubes and cylinders which Koster thinks he has proved lie solely in the lymphatic vessels.

The epithelial pearls, described by histologists, are a result of a globular union of cells of the flat variety; their development being, most likely, as has been suggested by Billroth, from the increasing division of a number of conglomerate cells, the peripheral layer being flattened by pressure against not very distensible surrounding parts.

**Treatment.**—This, as will be inferred, is much at odds and ends. The humoral theory being that commonly accepted for the epithelial, as for all other forms of cancer, and nothing in the direction of a specific being known, practice has been purely empirical. To avoid doing harm has had more of signification in it than has hope of affording a cure. In every case in which the author is at all in doubt, the treatment adopted by him is that of a soothing nature. Cerate of oxide of zinc, thickened with oxalate of cerium, does no ill if no good; the combination is judiciously directed on occasion of a first interview. To feel one's way is the meaning of prescribing by exclusion; a placebo affords time for the making up of a conclusion.

Caustics hold prominent place in the practice of the day. If used at all, there is to be no half-way measure in the application. Nothing is so provocative of malignancy in the cancer vice as the application of a means not fully and completely radical as an extirpative destruction is concerned. Caustics used to destroy epithelial lesions are of various kinds; the Vienna paste is widely preferred; this is the potassa cum calce of the Pharmacopœia. It is used by retaining an application in place from ten to twenty minutes, succeeding it with an emollient poultice. Landolfi's caustic is as follows:



R.—Bromin. chlorid., 3 parts;  
Zinci, 2 parts;  
Antimon., 1 part;  
Pulv. rad. glycyrrh., 1 part.

Still another is called Fell's:

R.—Pulv. rad. sanguinar. Canaden.,  $\mathfrak{z}\text{j}$ ;  
Zinci chloridi,  $\mathfrak{z}\text{ij}$ ;  
Aquæ,  $\mathfrak{f}\mathfrak{z}\text{ij}$ .

A thick paste is formed.

A cauterant used by Dr. Mackey, of Edinburgh, consists of four parts of corrosive sublimate combined with thirty of glycerine. This makes a paint which is allowed to remain in contact with the part four hours; the application being followed by a warm water dressing; the eschar sloughs in from three to six days.

The author desires to express great personal fears of any and all cauterants; repeating, and laying decided stress on the injunction "to use with radical freedom or not use at all."

Epithelioma appearing in tumor-form upon, or in the substance of, the lower lip, invites removal by the knife in proportion as a condition of concentration is expressed by hardness and non-infiltration. Fig. 458 shows such a tumor. In the instance illustrated, the lesion, together with almost the whole of the lip, was removed by a triangular-shaped section. Such section is the common manner of ablating these growths; to promise anything, a wide margin is to be cut away.

FIG. 458.

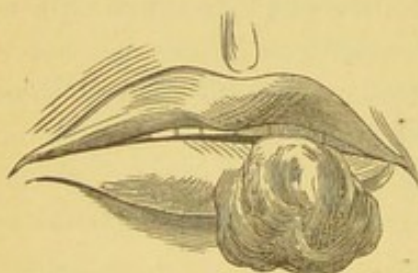
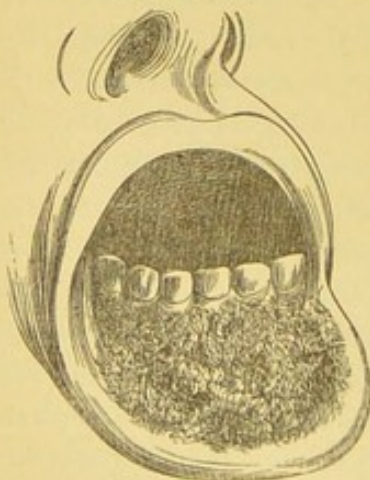


Fig. 459 shows one aspect of a case having the following history: Col. W., merchant. Epithelioma involving, when first seen, lip, tongue, and cheeks,—state hopeless. The disease in this instance began as a minute tubercle just over the genial bodies of the inferior maxilla; little was thought about it, and it received attention only when found ulcerating, such attention consisting in the application of caustics. Aggravated by the treatment, the ulcer commenced rapidly to spread, defying, when too late understood, every means employed for its arrest. Shortly after coming under care of the author, the lip fell off in mass, the root of the tongue became indurated to such extent as to interfere with both respiration and deglutition, and the sufferer, who had been a fine robust man, died from prostration.

FIG. 459.



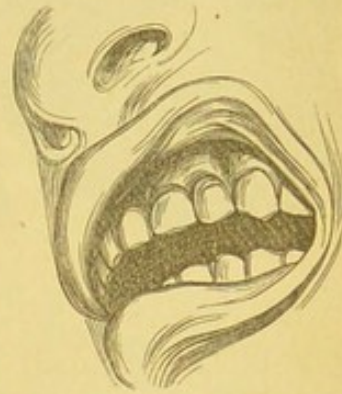

In this instance the patient had, for many years, been in the habit of holding the tip of his cigar between the tongue and floor of the mouth. Many persons, however, so hold cigars without cancerous disease resulting.

Fig. 460, being from life, has the following history: M. G., aged about twenty-one, farmer by occupation, was sent for consultation by Dr. Edward Townsend, whose dental patient he was. Dr.

T., while treating a bicuspid tooth, remarked at the neck a slight ulceration, which lesion, appearing of little consequence, commanded scarcely more than a passing thought. Attempting, however, at a later period, a cure, the obstinacy of the sore excited his suspicions, and, being unwilling to assume the trouble of the case, he directed the patient to the writer's care. Examination made on first meeting the case exhibited a small ulcer on the left superior gum between the bicuspid teeth, in size about half as large as the silver three-cent piece, jagged, covered with a whitish gummy secretion, and apparently superficial. The passage of a sharp probe through the centre

FIG. 460.—VIEW OF CASE AS FIRST SEEN.

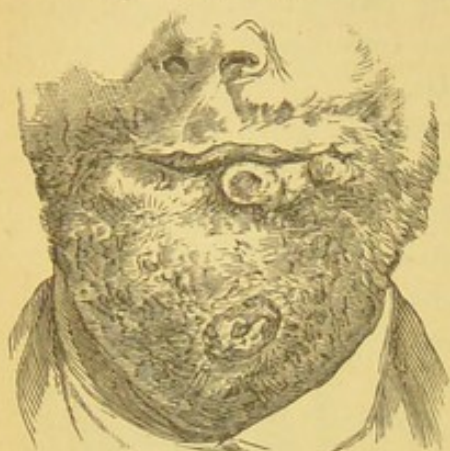

of the ulcer revealed carious, softened, and periosteally denuded bone. Impressed with the character of the ulceration, yet unwilling while there might be an unrefuted doubt, however slight, to depress the patient by informing him of the nature of his disease, he was placed under ordinary treatment for a period of two weeks, at the end of which time, finding the experience in treatment to agree with that of Dr. Townsend, his condition was laid before him, immediate resection of the affected and adjoining parts being advised. Refusing to submit, the patient desired consultation, and in turn the advice of every prominent surgeon in the city was obtained. Opinions differing, he, by advice, submitted himself to various proposed remedies, being treated two weeks by one gentleman, eight weeks by a second, and nine by a third, the disease progressing, though slowly, all these weeks. At the end of this time, operation was again proposed and insisted on, the gentleman being informed of the necessarily increased magnitude of the portion of bone and soft parts to be removed; on his still refusing, further responsibility in the case was declined. The patient making the author a visit at a later period, the ulceration was found involving the Stenonian duct and extending from the symphysis to the tuberosity of the bone. At this visit he was told of the utter hopelessness of any operation for his relief, the disease being too extensive. From this time until his death, which happened in a few months, he was in the hands of different advertising impostors. Whether or not an early operation would have saved the person from his doom one may not say, but from a reasonable experience in the direction, it is to be asserted that without the performance of such proposed operation he had no possible chance.



Fig. 461 is from a photograph. It shows a patient under care of the author six months after commencement of an infiltrating epitheliomatous cancer;

FIG. 461.



three months later death ensued from exhaustion. In this instance the first trouble from the disease was in stiffness of the lower lip; a very short time after papillary protuberances showed themselves; these, in instances, coalesced, forming the more prominent of the tumors seen. The infiltration extended rapidly to neighboring parts, the neck becoming indurated; a choked disk showed itself to ophthalmoscopic illumination. Vascularity was excessive. In this case the choked disk, and as well the entire condition, contra-

indicated the trial of any direct means of cure. The patient died without attempt being made to save him.

Treatment of cancerous epithelioma by injection of bromine is commended by Dr. Wynn Williams; a patient exhibited by this practitioner to the Obstetrical Society of London, was a person nearly the whole of whose lower lip had been removed for epithelioma eighteen months previously. The disease shortly appearing in the cicatrix, the growth was successfully treated by two injections of bromine, twenty drops to a drachm of spirit. There was later no appearance of any return.

Injections of glacial acetic acid and of Monsel's solution of iron, both of which have been highly recommended, have been submitted by the author to exhaustive tests. No good results ensued.

Treatment by the knife consists in complete ablation of the diseased mass. Unless an extirpation can be thorough, there is no excuse for attempting such mode of treatment.

In the numberless cases of epithelioma where the most superficial observer would recognize the impropriety of attempt at cure by operation, it becomes a necessity to support the strength and contribute to the comfort of the patient. Here medicines found most antagonistic to the disease are by all means indicated. Of such local means the author would highly recommend the daily use, by means of an atomizer, of the following combination:

R.—Glycerinæ,  $\mathfrak{z}\text{j}$ ;  
Acidi carbolici,  $\mathfrak{z}\text{j}$ ;  
Sodæ sulphitis,  $\mathfrak{z}\text{j}$ ;  
Aquæ,  $\mathfrak{z}\text{x}$ . M.

Not only will this preparation be found to afford much relief from pain, and to be softening and soothing, but it has seemed to possess marked influence in retarding the progress of the disease. It may also be administered internally



in teaspoonful doses. The American drug *hydrastis canadensis*, used in lotion, is highly commended by Dr. Edwin Payne, of London, for its painlessness and for its power in keeping the surface in a more healthy condition and free from offensive odor. The strength used is a drachm of the tincture to eight ounces of water. In this connection *phénol sodique* is to be mentioned, the author has tried no remedy that seems more grateful to a patient: it is not only an obtunder, but the most reliable of disinfectants. It is employed diluted *pro re nata* with water.

Vallet's mass, administered in doses of from five to ten grains a day, is highly recommended by Professor H. H. Smith. One case, as an example, is mentioned by this surgeon, where, having been consulted with a view to operating, and having declined on account of the rapid advance of the disease, he suggested the use of the medicine, conjoined with the application of the powdered carbonate to the sore, and the patient lived eight years without the disease having made any very great progress.

Justamond, of London, also favored the internal use of iron, and was in the habit of giving from sixty to one hundred and twenty grains of the ammonio-chloride a day. Dr. Carmichael, of Dublin, expressed himself as having derived much benefit from washing the ulcerations with a solution of sulphate of iron.

Chloride of zinc in solution is, in this direction, a favorite preparation: the power of this salt to arrest phagedenic action is remarkable: it is peculiarly alterative. Judiciously applied to any indolent, irritable, or bad ulcer, it will be found to influence markedly to a change for the better.

Concerning the use of this agent in cancer, we have many commendations, particularly from European surgeons; but, as can be very readily apprehended, nowhere in the range of its application is more judgment required for a judicious employment than here, for it is a cauterant, a stimulant, an antiseptic, and an alterative. Dr. Zuerine, of Vienna, relates a case of cancerous ulceration of the septum nasi which threatened to destroy the whole nose; one grain and a half of the chloride of zinc, he says, were dissolved in one ounce of distilled water, and, the scab being removed, the sore was pencilled over several times a day with the solution; at the end of a fortnight a healthy granulating surface was found underneath the thick crust which covered the sore, and this being occasionally removed, and the solution reapplied, it cicatrized in five weeks.

Mr. Tuson has published some cases to show the value of certain preparations of chlorine in cancerous affections. In one which he refers to there was an extensive cancerous disease of the right breast and neck, which was treated unsuccessfully for a long time, till a paste was applied, made of one part of chloride of zinc to three of flour; this was well mixed, and moistened with water, and then applied over the ulcerated part. The zinc was also given internally; half a grain was ordered in a wineglassful of caraway-water every morning. The chloride of zinc paste was applied again, and when the slough



separated, the ulcerated surface healed kindly. The cancerous deposition continued for some time, and the dose of the metal was increased to three-quarters of a grain and continued for three months. The improvement, although very striking, was not permanent, as the patient suffered a relapse which ended fatally. The case, however, was sufficient to show that the treatment had made considerable impression on the disease, and especially in healing the open cancer, which Mr. Tuson had found to be the result in several other cases.

The great suffering associated with carcinoma makes necessary the free use of opiates, both locally and internally. Stramonium, belladonna, aconite, opium and its preparations, hamamelis, are highly recommended. As much as twenty grains of sulphate of morphia have been administered during the course of a single twenty-four hours in certain rare cases. Injection by the subcutaneous method, where morphia is to be long continued, is now generally resorted to. Batley's solution answers well for this manner of use. For continuous stomachic administration of the opiate preparations, preference is to be given to the bi-meconate of morphia; the officinal strength of this medicine, prepared in solution, is that of laudanum, twenty-five drops representing one grain of opium.

A complication sometimes occurring with epithelioma about the mouth is the supervention of erysipelas. A peculiarity of these cases is that the inflammation does not exhibit its specific complexion, but a patient is found to look as if in a few hours his disease had made more progress than before in months, or perhaps in years. The best treatment the author has found for such a complication consists in the use of what on a previous page has been alluded to as almost a specific, the proportions being varied to suit cases:

R.—Tincturæ ferri chloridi,  $\mathfrak{z}\text{j}$ ;  
 Quiniæ sulphatis,  $\mathfrak{z}\text{j}$ ;  
 Tincturæ cinchonæ,  $\mathfrak{z}\text{ij}$  to  $\mathfrak{z}\text{ss}$ . M.  
 S.—To be brushed over the parts every hour.

Another complication occasionally met with is the existence of salivation. The author once had as a patient a lady who was compelled to keep a wash-bowl constantly upon her lap; the water literally flowed from her mouth. (See *Dribbling*.)

In doubtful cases, as will bear to be repeated, great caution is demanded that a practitioner do not more harm than good. A safe rule is to do nothing unless one knows exactly what to do. More patients have the fatal termination accelerated than retarded by treatment of epithelial cancer. That which is the treatment of lupus erythematosus in its milder aspects is good practice to pursue in doubtful cases. The affected part may be sprinkled with iodized starch, ten grains of iodine to an ounce of finely pulverized starch. Another most excellent powder is composed of subnitrate of bismuth, calomel, and oxide of zinc in equal parts. Still another is found in



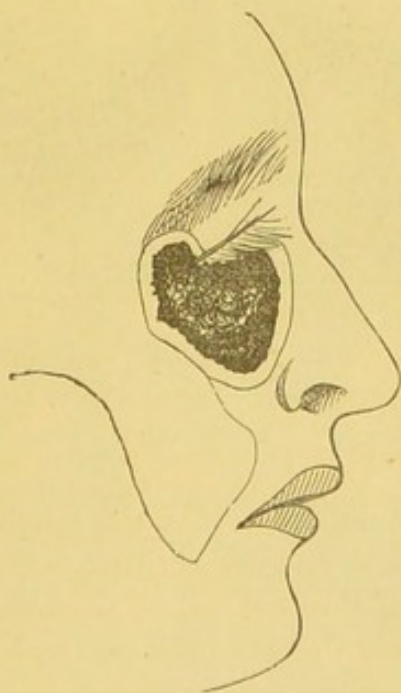lycopodium. Tar and zinc ointments in like proportions constitute an excellent application. Sulphur proves at times serviceable. Iodide of potassium and iodine, of each half a scruple, mixed up with a drachm of glycerine, is highly commended by Anderson. Duhring, in the treatment of lupus erythematosus, thinks favorably of an ointment made by mixing up with an ounce of simple cerate from a scruple to a drachm of chrysophanic or pyrogallie acid.

Treatment of strictly surface cancer may try the method of erosion by the curette as practised with much satisfaction in surface lupus; recommended for this last by Auspitz, of Germany, and by Wigglesworth, of our own country.

The author concludes the chapter by reserving a place of prominent signification for a treatment to which special attention is directed,—a treatment which, in every individual instance where he has found the operation practicable, has resulted in cure. It is desired to lay stress on the suggestion as being the most promising means of treatment yet tried. The practice is founded on an inferred catalysis resulting from bringing in contact and vital apposition tissues differently related. That is to say, a patient laboring under epithelial cancer of the face is to have the disease thoroughly and widely removed by the knife, and the seat of the ablated part occupied by structure brought from neighboring or distant parts.

EXAMPLES.—Fig. 462 exhibits an operation practised by the writer for the relief of an epithelial ulceration involving the full lower eyelid and a

FIG. 462.



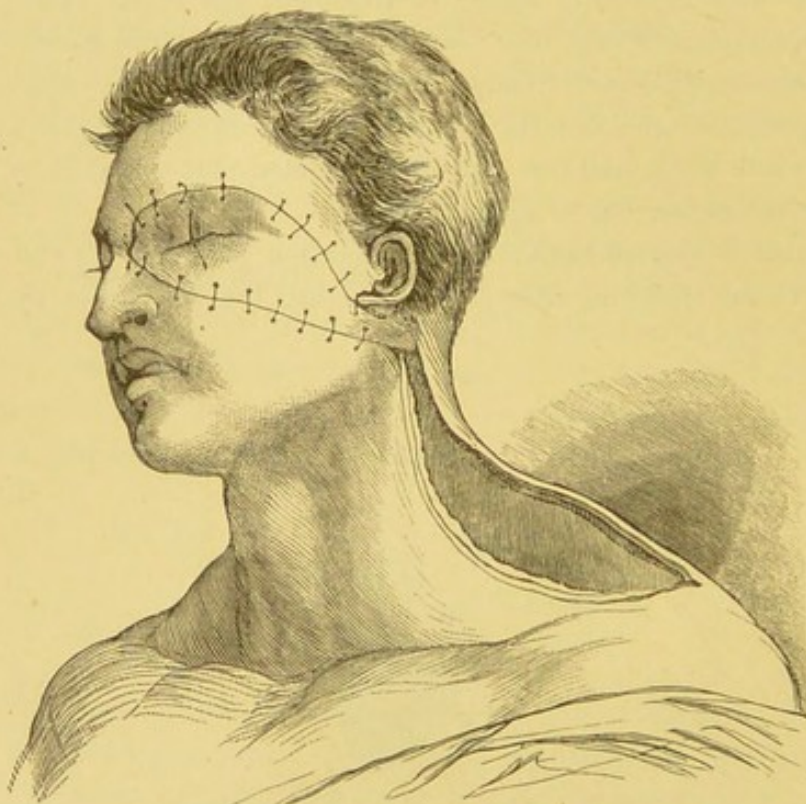
limited portion of the upper. The study of this operation illustrates a class in the direction. First, as seen in the diagram, the diseased structure is fully removed through incision associated with the uninvolved surrounding parts.



Second, the hemorrhage being entirely controlled, a flap to replace the lost part was made, as shown in the inferior lines; this flap being raised was carried upward, the convex portion being associated with the concave break resulting from the section of the upper lid,—the slightly concave portion representing the superior line of the lower lid. The triangular portion, seen in the diagram to exist at the side of the ala between the two incisions, was next dissected from its apex toward its base, and being directed below what, in the diagram, is seen to be the inferior flap, was thus brought into relation with healthier influences, while a similar good was secured for the new eyelid, in making it of tissue which had not been in immediate juxtaposition with the diseased part removed.

The position of this cancer is seen to be of most unpromising relation. The operation was done in 1869. There has been no return.

FIG. 463.



Flap operation in treatment of carcinoma.

In 1875 an epithelioma situated on the side of the nose of a nephew of the gentleman whose case is referred to above, was treated by a flap transferred from the hair-line of the forehead. Cure remains complete.

An operation of extensive transplantation was made by the author at the Hospital of Oral Surgery, where the disease involved both eyelids, the contents of the orbit, including the eye, the nasal arch, and the cribriform plate of the ethmoid bone, all the parts named being removed, and their places occupied by a flap taken from over the scapula, its pedicle being at the mastoid process of the os temporis. Being fitted into its new place, this pedicle



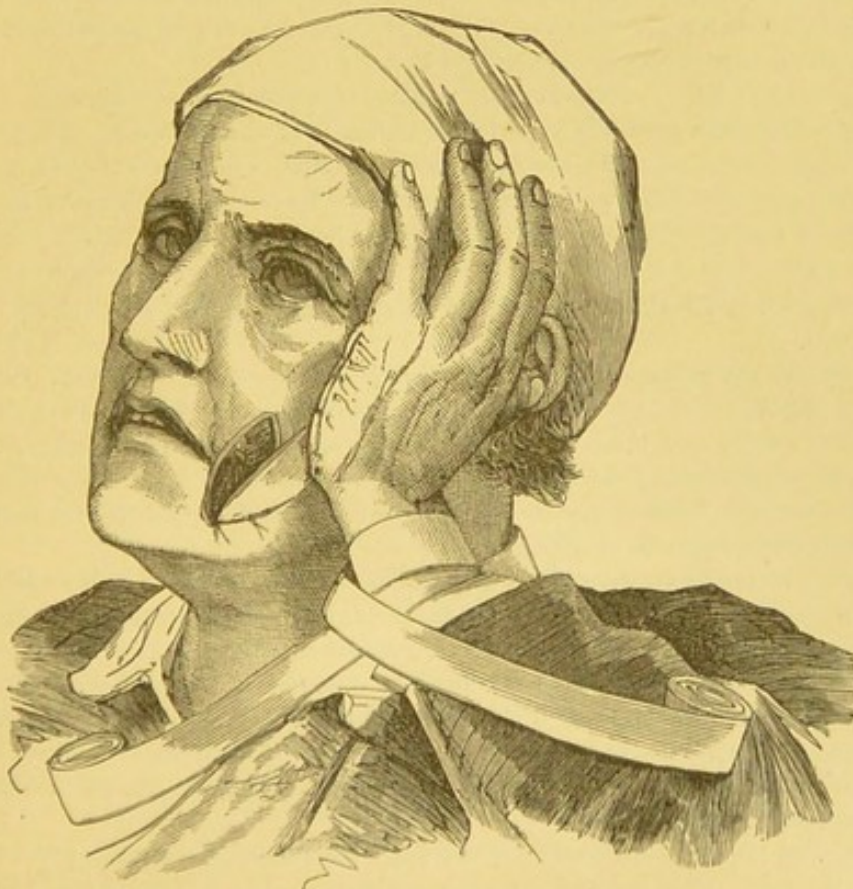was crucially incised where it overlay the circumference of the orbit, and the flaps thus secured were turned into this cavity. Unfortunately, some

FIG. 464.



sloughing occurred which interfered with the æsthetic results of the performance; but aside from this a good was secured which delayed the progress of the disease for over a year.

FIG. 465.



This case was not a practicable one as to prospect of permanent cure, the



disease being of too complicated ramification and relation. Repeating the performance, two flaps would be made; one to be taken from the neck, the other from the forehead. The sloughing in the case was adverse to a fair trial of the influence in cases of such magnitude, but further tests are encouraged by the result obtained. (Fig. 463.)

Fig. 464 shows steps of an operation performed upon the person of a lady who had submitted to three previous ablations of a diagnosed epithelial cancer situated as shown in 1, the disease in each case by its immediate return preventing the healing of the wound made. The lines marked upon the side of the face designate the part removed. Sub-figure 2 marks a flap of replacement. Four years have elapsed, cure remains perfect.

Fig. 465 shows an operation where a flap of replacement is taken from a distant part. The cut explains the details. The cap seen upon the head, and the rollers attached to the wrist, are to the end of securing fixation of the hand to the face. Union secured, the pedicle is to be cut. Three days suffices for the hand to be retained in the position shown. This case being one pertaining to the practice of the Hospital of Oral Surgery, a clinical report of the procedure made at the time, and published, is appended as a footnote, with the idea of affording a lesson to students.\*

\* The gentleman before us has an epithelioma involving his lower lip where that part relates with the cheek. Already has the condition been treated after the ordinary manner of operating, and already has the disease returned. It is a peculiar satisfaction to approach a case of this kind with a confidence inspired of success. I have told the patient I will cure him, and I am assured out of my experience that I will.

What I propose to do is,—first, cut away the ulcer from its base; second, replace the part removed by a flap taken from the hypothenar eminence of the left hand. The gentleman, himself as much interested in the operation as I am, proposes to endure the cutting without an anæsthetic: he wants to understand the matter. I refer you to him as an example encouraging to men pursuing an object under difficulties.

\* \* \* \* \*

We are now ready for the operation, and to the features of it I particularly commend your attention.

First, I remove the portion of face upon which the disease has fixed itself. I do this by means of an elliptic-shaped cut. . . . This is now done, and I show you clearly exposed the depressed anguli oris muscle. The parts, as you see, are extra vascular; this they always are where cancer is present: vascularity is diagnostic. Three vessels are bleeding with a freedom which requires the use of ligatures. We tie them and dry the parts. This done, we wait for the process of glazing.

The courage of the gentleman not being abated by this first step of the operation, we pass to the second. Having the hand firmly held, I repeat the incision by ellipse along the hypothenar eminence. Observe, however, I do not cut the piece entirely away from its attachments, as upon the face. I leave a pedicle: this with a view of temporarily feeding the ellipse. To cut about the hand is excessively painful. Our patient is without feeling, or, what amounts to about the same thing, is possessed of endurance stronger than pain. If, however, he can stand this work, assuredly we can; the courage is not at all in cutting, but in submitting to be cut.

The third step implies the stitching of the flap from the hand into the place prepared for it upon the face. This is a feat not without difficulty. First, I place over the vault of the head a cap made to fit accurately. Next I attach a double bandage about the wrist of



The author commends the same plan of treatment for the radical cure of lupus.

The following combination seems to control the progress of carcinoma: iodoformi, gr. x; olei eucalypti, gtt. xx; ung. aquæ rosæ, ℥j. Belladonna

the hand operated upon. I now close with stitches of the interrupted suture the wound of the hand, leaving the flap pendent. Lifting the hand to the head and directing the palm to the side of the face, observe with what nicety I find myself able to adapt part to part. You wondered, perhaps, why I cut so long a pedicle. Had I not done that, I could never, as you must see, have accomplished the stitching now attempted. . . . The stitching is now finished to my entire satisfaction.

The hand is next to be attached immovably to the side of the face. This with the means prepared is no difficult matter. I pass one roller obliquely over the vault and a second beneath the chin. I now proceed after the manner of a double Barton bandage,—a style of dressing with which you are all familiar.

The hand and wrist firmly fixed, a succeeding step is the support of the elbow and forearm. A simple manner of accomplishing this is to button the patient's vest over the parts. A second plan—one I shall adopt this morning—is found in the use of the third roller of the Velpeau bandage. This done, nothing remains but to hope for the life of the flap and to separate it from the hand at the proper time,—a period that will vary from forty-eight to seventy-eight hours.

Restlessness and irritability being associates of plastic operations, sedatives are indicated. In the present instance I will wait, however. The strength of resistance possessed by our patient may be proof against irritability. Opiates, where they do no good, always do harm; never use them unnecessarily. If restlessness supervene, I will prescribe thirty-grain doses of bromide of potassium. If the pulse run up, I will conjoin with this five-drop doses of tincture of veratrum viride. If fever show itself, I will direct tablespoonful doses of a formula as follows:

R.—Liquoris potassii citratis, ℥iij;  
Spiritus ætheris nitrosi, ℥ss;  
Antimonii et potassii tartratis,  
Morphiæ acetatis, āā gr. j.

Sulphate of morphia you all know as the great sedative; with it you can quiet to any degree, even down to the stillness of death itself. The dose is from one-eighth to half a grain repeated *pro re nata*. Many surgeons recommend that immediately after all operations of consequence a one-grain pill of morphia be given. If the medicine be exhibited in a vehicle of judgment, the prescription proves no bad one.

In doing plastic operations, where immediate union is the *summum bonum*, never use chloroform. Chloroform interferes with the process of glazing, and without the glaze the promise is little.

Another matter to look after in operations of the kind just done is maceration. Between the palm of the hand and the face I will lay a piece of old and soft linen. Maceration comes on very rapidly where the weather is warm enough to excite perspiration. From lack of such simple care as is expressed in the use of this little strip of cloth many otherwise perfect operations have proved blank failures. Do not overlook the fact that a flap does its utmost in preserving its vitality; never put unnecessary work on it.

A flap doing well is to be let alone. Think not to make a well thing better. Where a diminishing vitality is seen, as shown by a flap growing dark, dry heat and other stimulants are to be employed: not only local but constitutional stimulants.

Preparation of a patient for a plastic operation is a matter not to be left unconsidered. A plethoric man is to be reduced, an anæmic one built up. With the first the lancet, or preferably, as a rule, sulphate of magnesia is to be used: the latter demands iron, gentian, and similar tonics.

Another very important—indeed, in a sense, all-important—matter associates with

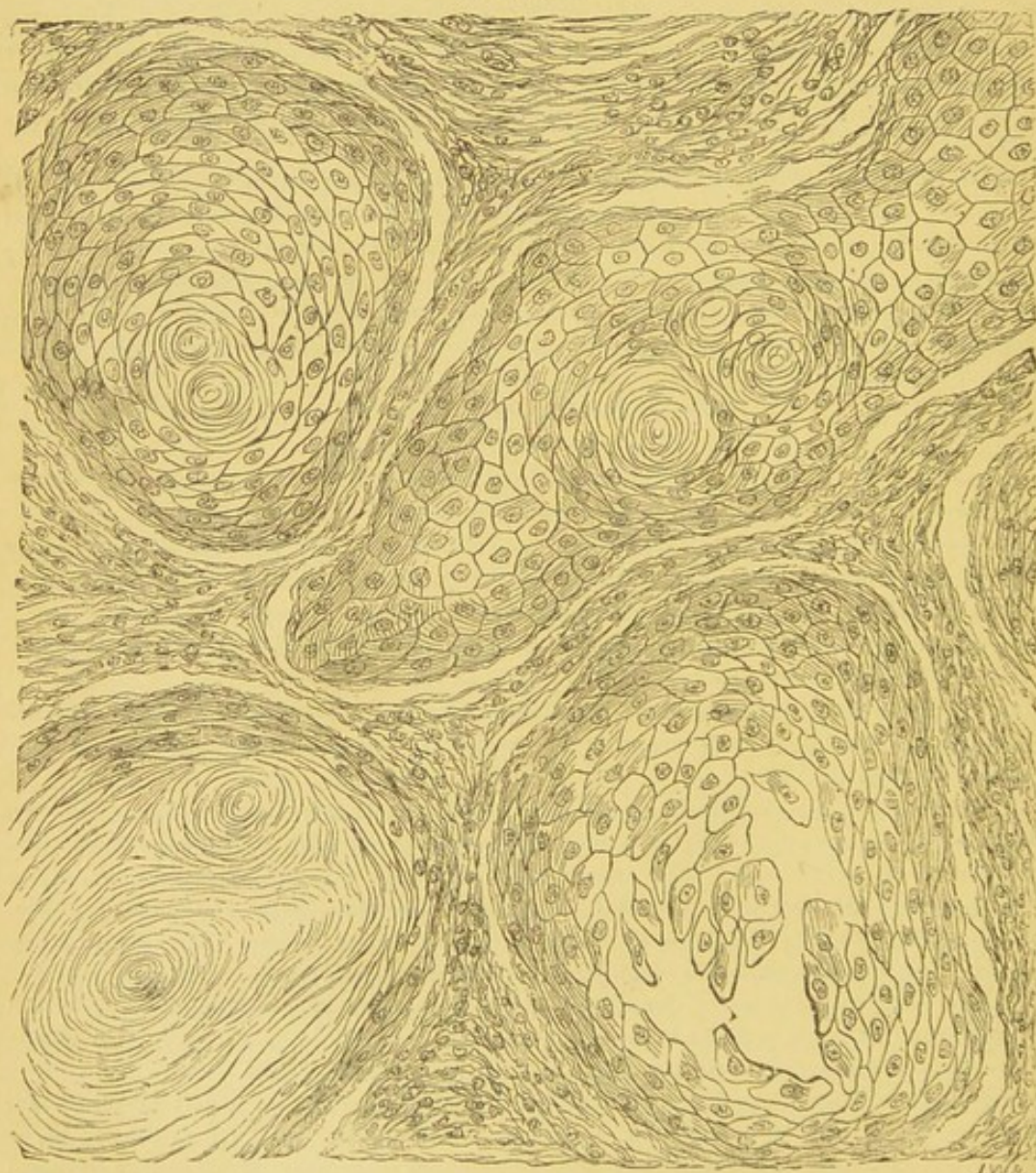

ointment applied about the circumference of a sore is obtunding. In inflammatory accidents the accompanying indorses itself: plumbi acetatis, 3j; tinct. opii, 3j; aquæ ferventis, Oj. Apply by means of a baker's-bread poultice.

plastic surgery; namely, calculation. Never do a new or untried operation on a living face until after you have done it on a dead one, or, if this last be impracticable, do it upon a paper face. I have seen in my time a surgeon standing utterly confounded in the presence of a large class, a great wound before him, a flap and pedicle too short to fill up; nothing fitting. Make a blunder of that kind once, and you will never get over it; it will be found to have undermined your confidence, and without that quality a surgeon is nothing.

[NOTE.—The flap was separated from the hand forty-eight hours after the operation. Two weeks later the patient was shown to the class, the union and relation of the parts being complete. The wound in the hand was getting well rapidly, part of this latter cure being necessarily by granulative action. The scar upon the face promises to be almost unobservable after a very short time.]

FIG. 466.



Microscopic view of a section of a squamous epithelioma. The cells are seen to be massed in isolated groups. On the left side are the pearly bodies showing a concentric or laminated arrangement.








Fig 1

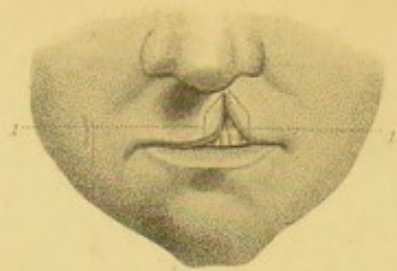


Fig 2

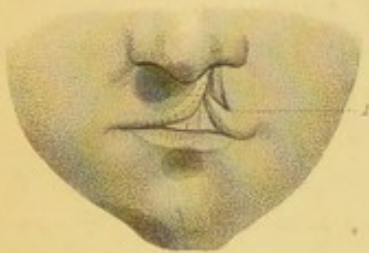


Fig 3

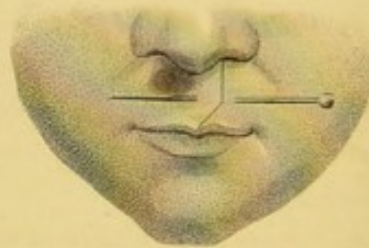


Fig 4

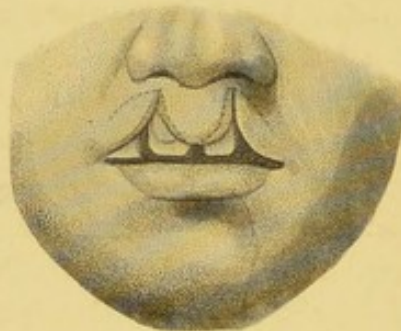


Fig 5

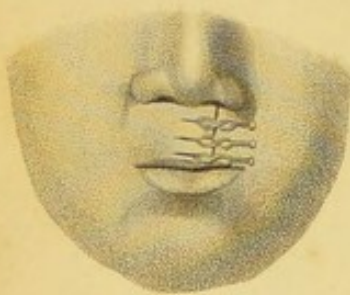


Fig 6

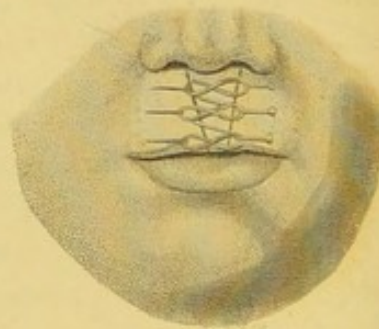


Fig 7

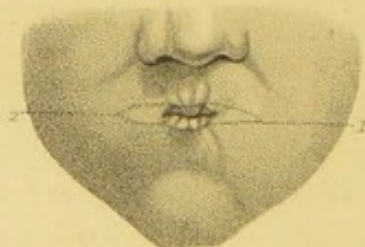


Fig 9

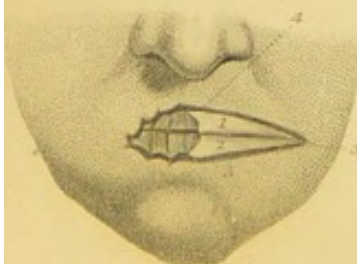
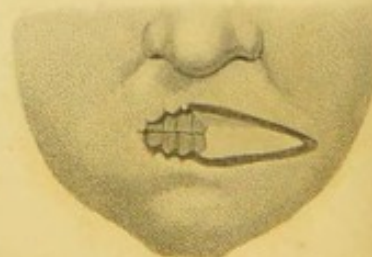


Fig 8





## CHAPTER XLVI.

### OPERATIONS UPON THE LIPS AND CHEEK.

**Hare-lip.**—This defect consists in a break, single or double, in the continuity of the lip. The deficiency in its typical form is almost precisely similar to that which exists naturally in the hare and rabbit, having from this resemblance taken its name. When congenital, it is always found associated with the superior lip.

A general idea of the operation for the relief of hare-lip, and indeed the one which comprises the principles of the cure, is, that the margins of the cleft, or break, be pared, be brought together, and held in apposition until nature shall secure a union. There are, however, nice surgico-artistic associations which are to be studied in connection with such principles of operation. Cutting manipulations upon the face, and especially about the lips, claim more than ordinary skill and judgment. Such skill and judgment the practitioner is to be prepared to exercise, if not for humanity's sake, at least for that of his own credit and reputation. As truly remarked by the skilful surgeon, Mr. Skey, "on the more or less perfect result of such operations depend the appearance and expression of the patient for life." Surely, just so far as an operator shall beautify or mar, is the comfort of the patient, as well as his own satisfaction, influenced.

A proper and comprehensive study of hare-lip divides itself into three subjects of special signification :

- 1st. The time of life best suited to the operation.
- 2d. The condition of the patient.
- 3d. The mode of operating.

In making up the sum of an operation, a surgeon is to consider, regardless of the age of the patient, the amount of shock such operation is to give, and the ability of the patient to bear it. This at once brings up the character of the defect, and the amount of manipulative proceeding necessary to a cure. A bad double cleft would inflict a greater amount of pain than a simple single one, consequently would inflict a shock double or treble in measure. Now, every man, woman, and child in the world has a certain amount of physique, and no more. The experience and physiological knowledge of the surgeon should enable him to weigh this life-force. He must decide, in the first place, whether or not his patient be equal in such force to the demands of a proposed operation. He must consider the condition of the patient. This brings up the second of the special propositions, or



stand-points, from which the operation is to be studied. The possession of a capable physique does not imply that life-force has not, like the tide, its ebb and flow. A child may have proper development, yet at the time when presented for operation may labor under temporary depression, the result, perhaps, of functional disturbances. One, for example, just convalescent from cholera infantum, or just recovered from some of the exanthemata, would certainly not be so fit a subject for cutting as though it had not suffered; it may have borne the demands made upon it very well, and come out of the ordeal looking strong; but then it is the last feather that breaks the camel's back; the physique that endured bravely the one demand may not have a residue of force on hand that will just then meet another. Give such a system time; get it back to the condition in which the first demand found it, and you then have it certainly capable of the same resistance and of the same endurance. Again, a patient may not be up to the required tone, and yet circumstances render a speedy operation desirable. We can assist nature. Exercise, fresh air, and proper food will do much. The last may imply that the milk of the mother, if the child be nursing, is exchanged for that of a nurse. Who has not examined the milk of a mother or wet-nurse and found it greatly deficient in some important constituent? The author has seen babes growing weaker and more puny day by day; has seen physicians baffled because they could find no one portion of the economy less healthy than another. He has seen the microscopist take the milk on which such a babe has been feeding, and, looking at it through his glasses, find large quantities of cholesterin. A change of milk has effected an immediate change in the health of the child. A babe may have fibrinous blood to excess, tending to undue circulatory excitement, or the lymph which such blood would exude might be so corpuscular in character that a wound would at once take on suppurative action. Either condition is adverse to an operation. We have, however, alteratives for the one, and tonics for the other. A seemingly strong child can be in a typhoid state, and a blushing cheek may be but the effect of hectic or excitement; typhoid blood has, comparatively, no fibrin. If you were to perform an operation on a patient so conditioned, you would be sure to have a failure for your pains. The writer has had under care children in just such a typhoid state; the pulse would be bounding and the face always flushed: such quick pulse and flush are, however, resultant of very deficiency in blood. A child may be cutting its teeth, yet this does not necessarily contra-indicate an operation. It is not every child that has convulsions and kindred troubles with the cutting of teeth; many an infant goes through the whole process of dentition without cause on which to ground a sob. If a child be brought to the surgeon, cutting teeth, with an operation for hare-lip to be performed, and there be associated with the dentition no general or special local disturbance, why should he not proceed, *cæteris paribus*, at once to operate? There are no objections to so doing.

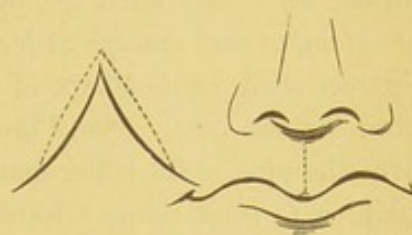


The author, who has operated on such number and conditions of hare-lip cases as to afford confidence in his experiences, prefers that period which precedes the eruption of the first teeth. In babes of such age he has frequently been able to remove the first pin in twenty-four hours, and the remainder at the end of the second day. Any time between the eighth week and the sixth month is to be esteemed a period of selection. Operations have been performed by him after the thirtieth year.

The next consideration is the performance itself,—the modifications of the one principal operation, and the variety of clefts influencing modifications.

A basis operation is best represented by a simple V-cleft, having the mesial line of the lip as its centre,—the indication being to restore such lip to a normal contour. (See Fig. 467.) On exam-

FIG. 467.



V incision in the operation for hare-lip.

ination, we find that a normal lip has no break in its continuity; we find what may be termed the centre lip represented at its free margin by a projection of more or less graceful curve. We find, extending from this free margin up to the septum nasi, and bounded laterally by the alæ, a fossa,—the fossa labialis. From this fossa we find the lip on either side spreading itself out to be lost in the cheek. To meet the indications of this case we are to remedy the break in the continuity, create a mesial projection, and give to the centre a fossa. To fulfil such indications requires a study of the conditions from a surgico-artistic stand-point. We want, first, to correct the cleft. This in itself is easy of accomplishment; we have only to pare the edges and sew, or pin, the raw surfaces together. In viewing this first step a little more closely, we perceive that a common V-paring from the edges of the V-break would defeat our purpose in securing either a centre fossa or a mesial projection; the mode of bringing the parts together would put on the stretch such fibres of the orbicular muscle as are associated with the margin of the lip, while all that portion farther up would be comparatively relaxed; thus our fossa would be a promontory and our soft median swell a stretched mucous membrane. Such an operation would, then, in meeting the first indication, defeat the two others. We must, therefore, instead of the V-cut, seek a better; for on the way in which we pare our edges depends the fulfilment of the three indications. An ellipse suggests itself, and such a paring will, measurably, meet our wants. 1st. It enables the edges of the cleft to be brought together. 2d. The centre of the ellipse is its transverse greatest diameter, and this centre is the centre of the lip. When we bring together this most widely separated part, it necessarily projects the most yielding surface,—and such surface is the free symphysis of the lip; thus the second indication is met. 3d. The greatest stretch on the muscle is in the site of the myrtiform fossa, with a necessary relaxation above and below; and thus the last indication is met; for, as the



result of such a condition of the parts, we have a fossa formed and a promontory at the free mesial line.

REMARKS.—The paring of a cleft is always to be constant in the one feature of being V-shaped, as reference is had to the base of the V looking toward the throat; this allows for excess in the retraction of the skin over the mucous membrane. If this precaution be neglected, a difficulty is likely to be experienced in the gaping of the cutaneous portion of the wound.

The subject of retaining the parts in apposition, with regard to suture material, has elicited much controversy. The ordinary operation is as follows. After you have pared the edges of the cleft, take up a needle threaded with the ordinary waxed silk, pass this through the free margins of the lip and bring the parts together; this is to insure a satisfactory approximation at this point. Next take three ordinary steel pins and pass them at equidistant points on the lip,—they must go, in depth, at least half its thickness; these pins are to enter and emerge at least five lines on each side of the fissure. Silk ligature stuff, in the shape of the figure-of-8, is now to be passed about and around these pins. (See Plate VI., Fig. 5.) Adhesive strips are next passed over the pins, a slit being made for their accommodation; the object of these strips is to press tissue toward the wound, preventing, through such support, undue tension. If blood oozes out and clots upon the ligatures, it is considered favorable rather than otherwise, as it is thought to add to the support of the parts. After two or three days the pins are carefully removed by a rotatory motion; the ligature material and adhesive strips are allowed to remain from four days to a week longer.

Various means have been suggested to be employed in lieu of the pin and figure-of-8 dressing, objection to such dressing certainly existing in ulceration apt to associate with the pressure induced by swelling. Professor Agnew uses silver wire. He simply sews the parts together with a greater or less number of interrupted sutures. He thinks such sutures possess great advantages over the pins.

Another means of bringing the parts together which has been suggested, consists in the employment of the interrupted suture of silk used from the under surface of the lip. In such use of the hidden suture nice approximation and support are to be given the face of the wound.

Dr. Washington Atlee has suggested a suture which differs from the ordinary pin and figure-of-8 only in that he employs rings of india-rubber, which are stretched over the pins. This suture for many purposes must prove an admirable addition to the armamentarium chirurgicum; but in hare-lip operations it has no advantage over the ordinary figure-of-8, inasmuch as the same strain, if not a greater, is exerted upon the points at which the rubber is supported by the pins. The merit claimed for this suture is, that whether a part swell or remain normal, the compressing force continues the same.

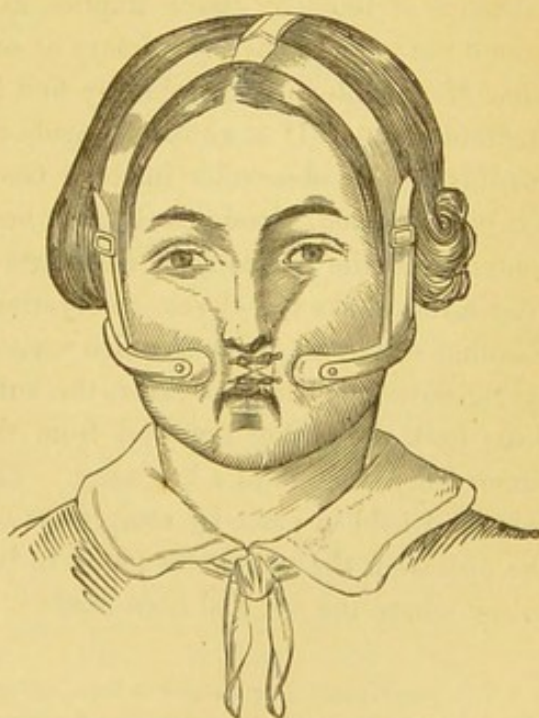A mode of securing apposition of the parts, which will be found very satisfactory, is to take three, four, or more threads of silver wire,—the fewer



you can get along with the better,—the gauge being the most delicate that can be procured; pass these and let them emerge at lines which shall very nearly correspond with the commissure of the lips. Next take a strip of common sheet-lead, and, cutting it to an appropriate size, make in it as many little holes as you have threads to either side; pass the threads through these holes, and compress on each a McLeon button,—*i.e.*, a simple flat shot having a hole through its centre. Now, with the fingers, nicely approximate the wound. This satisfactorily accomplished, draw up the wires and fix them on a second piece of sheet-lead, as in the first instance. If the centre, which is the line of the wound, tend to bulge forward, a delicate compress is to be placed over it, and bound to its place by an adhesive strip. The advantages of this dressing are, that it may be retained for weeks, if necessary; it is entirely unirritating; the wound is exposed to examination; and, more than all this, the threads, being unirritating and very slight, when taken away leave no scars.

A still happier dressing, but one which can be applied only on such patients as have reached the age of intelligence, is a modification on Dewar's dressing. Hainsby's compressor may be likened to the ordinary double hernia truss. It consists simply of a spring which passes around the head, having a small pad at each extremity. The piece is of such circle and character as to bring the pads to the labial commissures. The instrument is held in position by any convenient means. Dewar holds it by what might be termed a fronto-sagitto-lambdoidal sling. The process of dressing with this instrument is as follows. After making the paring of the cleft, cleanse the parts well with cold water (controlling hemorrhage by pressure on the facial arteries); next take a strand of the common silk ligature material, and nicely approximate the free edges of the lip, passing the needle on the under side. The next step is the application of the compressor. With the thumb and finger force the tissue of the cheeks toward the mesial line of the lip, —this approximates perfectly the edges of the wound; replace your fingers by the compressor, and the parts are held *in situ*. If the approximation of the wound thus made should not be satisfactory, secondary compresses of linen are to be placed more immediately about the cut, and fixed by a delicate roller. The

FIG. 468.—HAINSBY'S COMPRESSOR.





advantages of this dressing will be at once apparent. There are no pins or ligatures used, consequently there is nothing to interfere with direct union; there are no punctures made in the skin; of course there is no risk of having any but the single linear scar, and even this, if direct union be secured, must be slight indeed. The parts can be examined at any time without important interference with the apparatus.\*

In some individuals the coronary arteries are quite large. To suppress the hemorrhage from these vessels, dependence is generally placed on the pressure exerted in bringing together the edges of the wound. If such pressure fail to answer, or if we should prefer some dressing that will not make it, light ligatures may be thrown around the vessels, one end to be cut off, the other to be brought out at the back part of the wound. Ligatures, however, are to be avoided where possible, as they interfere with proper union.

A much better means than resort to the ligature is compression of the facial arteries. Such compression needs to be kept up but for a short time, as the smaller vessels soon contract. Hainsby's compress controls the hemorrhage by its pressure on the coronary arteries, and its action may be very readily imitated with a common roller.

There is a feature associated with the formation of the linear cicatrix, and the unsightly notch which so commonly deform hare-lip patients, that is not enough considered, being of a consequence to merit the closest scrutiny. Is it the fault of nature or the fault of the surgeon that the operation gives any cicatrix at all? Cicatricial tissue—*tissu inodulaire*, as Delpech more happily terms it—means accidental tissue,—new tissue formed from granulations. The existence of inodular tissue implies, as it is greater or less in amount, that a wound has healed either by primary or secondary adhesion, and certainly not by what Mr. Hunter terms union by first intention, or what Mr. Paget calls immediate union. If a wound be made to unite by first intention, there cannot possibly be any observable inodular tissue, or scar, because so little new tissue has been formed, blood-vessels and nerves have been brought into perfect contact, and the harmony of the parts has been so completely restored that after a few weeks the closest observation fails to discover the seat of accident. Familiar examples of such union exist in the slight cuts we are constantly giving ourselves with the razor, the cuts we get about the fingers, etc. Some years back the author removed from the parotid region of a young man a tumor fully the size of a hen's egg. The flaps were adjusted with the greatest care, and held in place by compresses of old and fine linen. Ten weeks after the operation the union was found to be so immediate that it was impossible to say where the cut had been made.†

\* This description does not, as is seen, accord fully with the diagram; the pin and figure-of-8 being shown. The drawing has been utilized to show the feature of the ordinary dressing. In depending on a Hainsby compressor, much skill and a continuous oversight of the case are required.

† Mr. Paget mentions very large wounds that not infrequently heal in this perfect



The union of a wound, either by adhesion or by granulation, implies a certain amount of inflammatory action, and the exudation and organization of lymph. This is the way in which hare-lip operations are healed, and this is why we have the linear cicatrix; and not only the cicatrix, but, according as the union has simulated or departed from the immediate type, we have necessarily a small or a great notch.

But how is the notch formed? The explanation is simple enough; but it is not that generally given; at least, that will be assumed. The notch is the result of the natural contraction which belongs to fibrous tissue, of which fibrous tissue the cicatrix is formed; and if we observe, it will be found that where this linear inodular tissue exists in excess, a large notch is always associated with it. If proof be needed that out of such contraction is the notch, we have only to remark that in cases of large cicatrices destruction of symmetry in all surrounding parts invariably occurs; contraction puckers, as it were, the whole part. When a linear cicatrix is very limited, the notch is correspondingly small. These conditions could not so uniformly exist associated, if it were the manner of the paring exclusively that gave the notch, and not the contraction, as described.

The nearer, then, approach to a union by first intention can be secured in hare-lip operations, the better for success will be the result. But can we not get immediate union in full? This would imply that we have artery to artery, vein to vein, nerve to nerve. Well, the artery is a prominent point of reference, and the relations of surrounding parts are in perfect unison. If we can get the mouths of the two arteries together, will not all other vessels assume, by compulsion, inosculation? We may try for this, at any rate; such care will

---

manner. One case, that of a lady who had been operated on for scirrhus of the mammary gland, may be specially alluded to. Speaking of the operation, he says,—

"The flaps, which were very large, had been carefully laid down, strapped with isinglass plaster, and well tended. After death, which occurred in three weeks, from erysipelas and phlebitis, I cut off the edges of the wound with the subjacent parts, expecting to find the evidences of union by organized lymph, or, possibly, blood; but neither existed; and the state of the parts cannot be better described than by saying that scarcely the least indication remained of either the place where the flap of skin was laid on the fascia, or the means by which they were united. It was not possible to distinguish the relation which these parts held to each other from that which naturally exists between subcutaneous fat and the fat beneath it. There was no unnatural adhesion; but the subcutaneous fat which did lie over the mammary gland was now connected with the fascia over the pectoral muscle. The parts were altered in their relations, but not in their structure. I could find," continues Mr. Paget, "small points of induration where, I suspect, ligatures had been tied, or where possibly some slight inflammation had been otherwise excited; and one small abscess existed under the lower flap. But, with the most careful microscopic examination, I could discover no lymph or exudation corpuscles, and only a small quantity of what looked like the débris of such oil particles or corpuscles of blood as might have been between the cut surfaces when the flaps were laid down. In short," says Mr. Paget, "this was union by first intention; it was immediate, at once in respect of the absence of any intermediate substance placed between the wounded surfaces, and in respect of the speed with which it was accomplished."



necessarily insure to us the very nicest approximation of parts, and, if what is termed immediate union cannot be obtained, we will at least secure to our patient, by such care, the smallest possible scar. To insure the most perfect union, a wound should never be approximated until all hemorrhage has ceased and the raw surface becomes glazed with a film of lymph.

Fig. 469 represents a modification on the ordinary operation for simple hare-lip which the author has now performed many times, and always with the most satisfactory success. This operation, as is seen, differs from that shown in the preceding figure in having the parings utilized in place of being cut away. Studying the diagram, it is seen that the parings, being commenced at the nasal septum, have been cut to the free border of the lip, from which, supported by their attachment, they hang. From the septum to the apices of the flaps it is seen that raw surfaces approximate: the parts in this

FIG. 469.

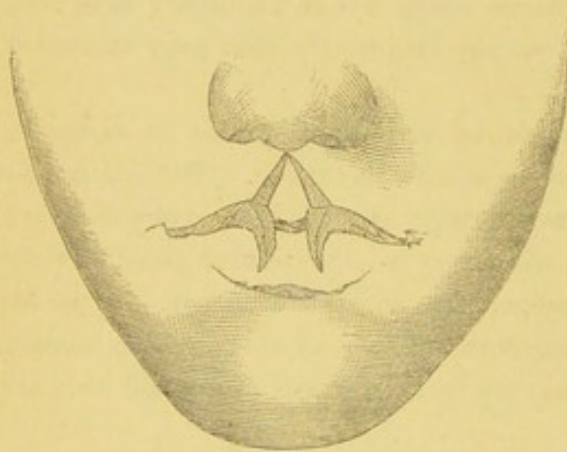
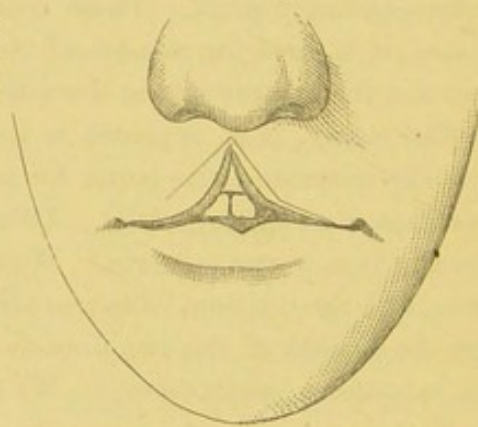


FIG. 470.



condition are now brought and retained in apposition, the pendent portion being trimmed to that shape which considers the labial swell. This operation performed properly, a notch cannot result.

A second modification on the basal operation is shown in Fig. 470. Here, as is seen, one side of the break (the left) is most extensively pared, the section taking off quite a portion of the free border of the lip. Upon the opposite side, however, the paring is compensatory. Study of the section will exhibit that the flap of the right side of the face restores the removed part on the left, affording, at the same time, complete continuity of the free border of the lip at the mesial line.

**Complications.**—The first modification of the simple mesial cleft, which has been described as a type, is where the break is to the one side or other of the labial centre, this centre constituting one of the lateral boundaries. This character of cleft, particularly as the left side is concerned, is by far the most common form; indeed, it is to be denominated the type proper of hare-lip.

In operating on a case of single break, laterally related, as thus described,



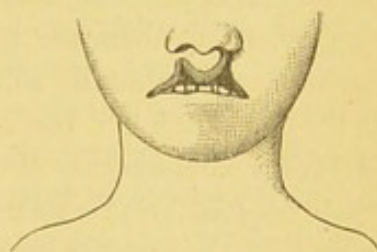
certain variations, as must be seen, are demanded. Employing the ellipse, it is recognized that the labial prominence would necessarily be thrown out of that exact central position which is its place. The same defect would reside in uniform pendent parings. To meet the objections, using the ellipse, a modification, as practised by Malgaigne, is employed. The surgeon makes the one side of a simple V-cut upon the outer flap; upon the mesial is practised the ellipse. The bringing together of two surfaces so related throws down, as is seen, the free border of the mesial flap.

A modification on the operation of the French surgeon, suggested by Dr. Richard Levis, consists in making a double V on the mesial flap. Entering the knife just below the nostril, a first incision pares the flap; a second removes from this surface a small V-shaped piece, having its apex looking toward the cheek. In bringing the parts together, which is done by inserting a pin at the apex of the second V and passing it through the opposite flap, it is seen that the free border of the mesial flap is alike bulged downward.

Better, however, than the operations either of Malgaigne or of Dr. Levis, is the modification shown in Fig. 469; this, however, being on a precisely similar principle, the paring from the mesial flap being to such extent heavier than its fellow, as shall place the desired prominence in its right position.

Another variety in hare-lip, and the next most common, is that in which the break is double,—that is, the single break is divided into two parts by a teat which starts out from the apex of the cleft; this teat is seldom more than half the width of the lip. Fig. 471 exhibits very satisfactorily an example of the most simple of such double breaks. A second is shown in Plate VI., Fig. 4. For the correction of this defect, various means are resorted to. Some surgeons cut out the teat, thus converting the double into a single break, making the basis cleft as described. Others, on the contrary, after paring all the four sides, tease and strain the centre piece or teat until they get it on a level with the rest of the lip. Both operations are objectionable. The first takes away an unnecessary amount of substance from the lip, thus giving a tense, stretched appearance to the part, while from the second manipulation, the natural resiliency which belongs to most tissue compels a character of notch or central depression almost as unsightly as the original deformity. In this simple form of double hare-lip it is found the most satisfactory operation to pare the lateral flaps in the form as shown in Fig. 469, while the centre teat should be pared into the V-form, the base being to the septum narium; all the parts will thus be found capable of a neat approximation, the teat doing its share more or less in filling up the break. The approximation is to be made in the manner described.

FIG. 471.



A second form of double hare-lip is that in which alveolar process is asso-



ciated with the teat. This is termed complicated hare-lip. The portion of process projecting into the cleft is generally an intermaxillary formation, and holds the germs or developed incisor teeth. The correction of this defect implies a somewhat formidable operation. The first step consists in dissecting well the lip from its reflection over the process, should attachment exist. Next the gum is separated thoroughly from the projecting bone, which bone the third step in the operation removes down to the natural curvature of the parts, this last being effected either by means of revolving saw, chisel, or cutting forceps. If in this third step of the operation the anterior palatine artery be wounded, the resulting hemorrhage is controlled, either by taking up the vessel or by touching it with one of the astringents; or, if neither of these means suffices for the arrestation, the artery may be touched with a red-hot cauterant needle, or better, may be plugged with a point of pine stick. The bone removed, the flaps of gum are to be laid back in the cavity, where they will remain sufficiently approximated without the employment of sutures. The operation upon the lip may now be performed at once in any of the manners described; or, if the force of the patient be too much exhausted, it may be left for a future period.

These are the two principal forms of double hare-lip. An appreciation of the operations required for their cure will enable the surgeon to meet satisfactorily any modifications that may present on either of them; and these modifications, it is to be suggested, are constantly occurring. Let us, for a single moment, refer to an uncomplicated double hare-lip, where the centre piece, or teat, is found so large and square as fairly to divide the lip into three parts. Now, here the mesial line of the lip is found in the centre piece; it suggests itself, therefore, to any one, that either side of the cleft is to be treated as a separate hare-lip,—that is, the whole manipulation is to be done at the one sitting and there are to be symmetrical parings made of either cleft. In such a case, we have also to take into account the concavity made on either side of the fissure, as reference is had to the influence exerted on the free margin of the lip; for here of course no swell is required. Whether, again, in these really double cases, we would first operate on the one side, and, when that is cured, on the other, is a matter to be decided by the judgment of the operator. Many surgeons prefer to correct the whole deformity at once. If it be decided to do this, the operation deviates from the principles laid down, only as regard is had to approximating the parts. If the centre piece be small, it is found the most satisfactory practice to pass the pins, wire, or whatever suture material is used, directly from one lateral flap, on through the centre piece, to and through the other, thus uniting all the parts by a common suture. If, on the contrary, a centre piece be broad and well covered by skin, the greatest good is found in using two sets of ligatures. As regards the single or double operation, the author is influenced by the width of the middle piece, the tenseness or laxity of the tissue of the lip, and the endurance and condition of the patient.



A modification of the double hare-lip is one in which there is a projection, into the cleft, of the incisor teeth; the alveolar process itself being sufficiently normal to allow of non-interference with it. This modification is commonly met with in the adult, or at least after second dentition. The projection of the teeth is the natural result of the lack of external support from the labial deficiency; the tongue has actually pushed them outwardly. In a case of this kind, a preliminary operation is the removal of the teeth. If, now, six months be allowed to intervene before attempting the operation on the lip, the alveoli of the extracted organs will be found to have receded, through absorption, quite the eighth of an inch. The second operation is then to be done *secundum artem*. This waiting on the process of absorption will be found to conduce to a successful result.

A still better, though a more tedious, mode of correcting such deformity is by first bringing the projecting teeth back to their normal place in the arch, through the agency of elastic ligatures. This is a perfectly feasible operation, and not at all difficult of performance. By such a preliminary procedure we not only get the teeth out of the way, but save to the patient these valuable organs. To make and apply such a ligature, we have only to take a slip of common india-rubber and attach at each end a loop of silk. We next place these loops over certain of the molars; it is entirely immaterial which: the centre, or rubber part, is then stretched forward and laid over the labial faces of the teeth to be pulled back. It is astonishing how quickly and powerfully such a force acts upon them. In two or three weeks, at most, the organs are brought into their proper line. To secure them *in situ*, and prevent their being again pushed forward, we have only to keep them ligatured in any convenient manner until the operation on the lip is made, and union secured. (See *Correction of Irregularities*.)

Cleft of the lip, as previously remarked, is common to perhaps a majority of the cases of cleft of the hard palate. It has always been deemed very important in these cases that an operation on the lip be performed as early as possible; it favors approximation in the bony cleft. In these cases the manipulation differs from that suited to an ordinary one only when there is projection of one or both alveolar prominences into the break. (See *Cleft Palate*.) In such instances, if the intrusion be very marked—that is, so much so as to prevent the bringing together of the lips—we may perhaps be able to do nothing better than cut away the parts. This, however, is always to be avoided where possible: first, because thus we destroy the germs of the teeth; and, secondly, because, if by any means we can get union of the lip, the parts in their development will come mutually to accommodate themselves to each other. In such cases it is recommended by some authors that we endeavor to bend back these juttings of bone, turning them in toward the mesial line. Where this can be done, it answers a very admirable purpose. Still another mode—after the method suggested for the complete relief of



this character of cleft—consists in the employment of the fronto-occipito-labial elastic sling. This sling is so applied that it pulls from the occiput upon the projecting process. It will certainly fulfil the indications; but its employment is not unattended with trouble.

Cases of double hare-lip not infrequently occur where the centre slip is so associated with the septum of the nose as to make the parts seem as one: if there was not the loss of material from the lip, the septum would bear being described as in a state of hypertrophy. Again, the lost part from the lip is sometimes found attached to the very tip of the nose, giving to the patient somewhat the appearance of laboring under lipoma. These, together with all the anomalies in this direction, are first to be studied, as regards their cure, from the artistic stand-point. The surgeon knows where and what he can afford to cut; he judges what nature will do in the case; it only remains for him to consider well his incisions, where he shall make them, and what is to be the æsthetic result, before the operation is attempted.

A useful study is found in the examination of examples. If one familiarize himself with all kinds of cases, and if—what is commonly found more at command—he represent the morbid anatomy in india-rubber, and thus devises and tries experimental operations, he finds the subject of hare-lip grow simple enough.

**Addendum.**—In operating for hare-lip, always first dissect the lip well off from its attachment to the gum.

In paring the fissures, the young surgeon is much more apt to remove too little than too much.

In paring out the apex of the cleft, be sure to freshen perfectly the extreme point of such apex. This is oftentimes neglected; and an ugly pucker is the result.

The paring for hare-lip is, perhaps, best made on a wooden spatula.

Few instruments are really required in this operation. A bistoury and forceps, or tenaculum, together with such coaptating means as it is designed to employ, will answer the purpose well enough.

A mode of operating on the infant is for the surgeon to seat himself face to face with an assistant. The child being etherized, the surgeon lays its body over his own knees, the head being supported by the helper. On incision being made upon one side, the assistant grasps the lip between the thumb and finger, compressing the coronary artery. When the vessel of the opposite side is cut, he secures this. Both are steadily held until the operator is ready to coaptate the wound.

In operating on the adult, it is found convenient to stand behind the patient; such a chair being used, and the head being placed in such position, as recommended in the operation of staphyloraphy.

Another very convenient manner is to sit in front of the patient, the head being supported against the breast of an assistant.

When plaster is used to assist the ligatures, silk gauze and collodion are to



be preferred; this leaves the wound exposed to inspection, and is a light and most effective dressing.

#### STUDIES IN COMPLICATED HARE-LIP.

Fig. 472 is a dissection showing the nature and character of an intermaxillary projection. Where such bone interferes with the ability to obliterate a cleft, it is plainly proper practice to cut it away.

Figs. 473, 474, 475, 476, which are strictly true to cases constantly being met with, exhibit aspects of intermaxillary complication. Whenever such intermediate projections are found unyielding, and may not be utilized, the author pursues the practice of amputation; this converts the case at once into simple hare-lip, with the complication, however, of a very great loss of substance from the centre; this may not be helped; and if the parts be found too widely apart to be brought together, as directed in the ordinary cases, the surgeon is compelled to resort to the cheeks for the required material. (See *Making Upper Lip*.)

FIG. 472.

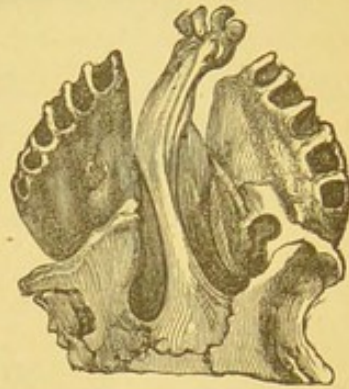


FIG. 473.

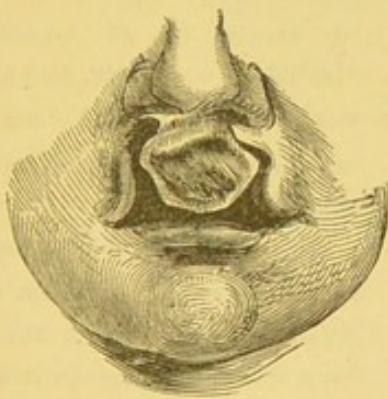


FIG. 474.

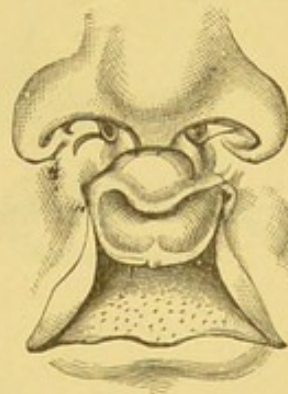


Fig. 477, being from life, represents the appearance of a child operated on by the author at one of his clinics. In this babe complete cleft existed not only in the lip but in both hard and soft palates, while pendent from the nasal septum was a mass half cartilage, half bone, which, as shown in the drawing, was the complete representation, in shape, of a door-knob.

In examining the case, it will be seen that the removal of the pendent mass is to be effected by section of the pedicle. This was done, exposing the cleft in the lip, which, as recognized, was very extensive. To make raw and bring the boundaries of the cleft in apposition was now the indication. This was met after the manner of utilizing the parings. The strain on the pins being very great, extra support was given by placing a delicate compress on



either side and dragging all the lateral aspect of the parts toward the mesial line by means of adhesive strips.

FIG. 475.

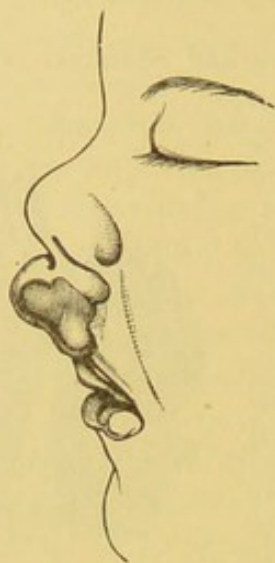
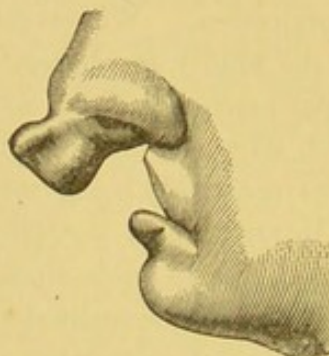
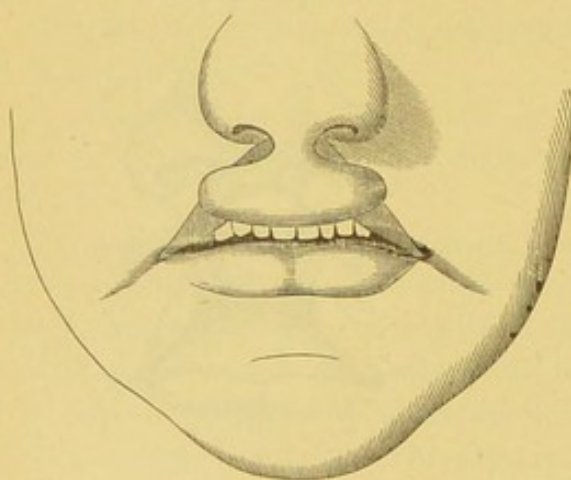


FIG. 476.



In this case traction on the pins necessitated their removal earlier than was desirable; but moderate union was found to have been secured at the

FIG. 477.



free border of the lip,—that is, with the parings. Taking advantage of this, support was kept up by means of an extemporized Hainsby's compress, and after two weeks the cleft was found obliterated, having been filled up by granulation.

This case is selected as an example, because it is an instance where nothing better might have been done than the operation practised, the child not having force to endure a more complicated

means of treatment. It was not desirable to have a cure by granulation; but it was better than taking risks overbalancing the good to be secured.

Fig. 3, Plate VI., exhibits the manner of placing a pin.

Fig. 5 exhibits three pins in place, the points being cut off, and the parts retained in apposition by means of the figure-of-8.

Fig. 6 exhibits the dressing of a simple, uncomplicated double hare-lip.

**Pins.**—Until very familiar with the operation, it is advised that in approximating flaps the ordinary steel or gold pin be used. Such means, while having the objections noticed, will yet be found of ready, easy, and convenient application.



In passing a pin, it is to be carried forward until within about three lines of the head.

In casting the figure-of-8, no more strain is to be employed than suffices to hold the denuded surfaces in contact; more than this is almost sure to result in strangulation of the compressed parts, a consequent ulceration marking the line of the pins. Cotton twine is to be used.

Pins are always to be removed as quickly as parts are found sufficiently self-supporting, their presence interfering necessarily with the process of union.

In withdrawing a pin, support is demanded by the lip. A rude removal is apt to tear asunder the delicate granulations.

FIG. 478.

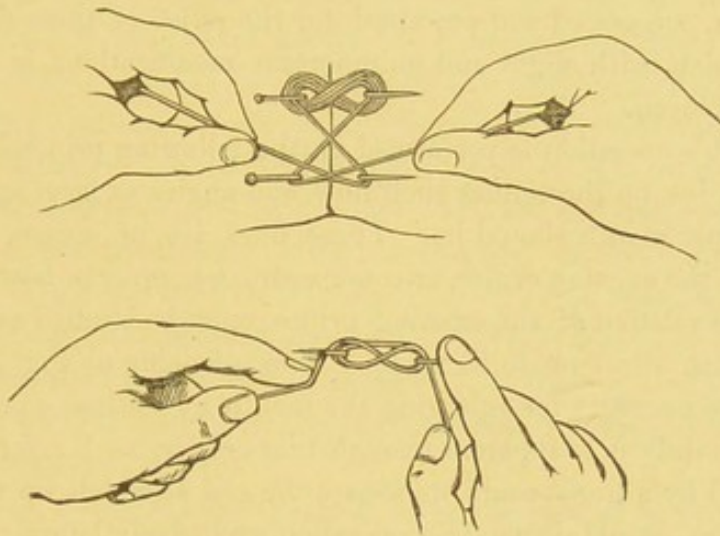


Fig. 478 exhibits the twisted or hare-lip suture, together with the manner of making it.



## CHAPTER XLVII.

### OPERATIONS UPON THE LIPS AND CHEEK.

As the result of disease or of accident, persons occasionally suffer from contraction of the orifice of the mouth,—a most unhappy condition, both as regards appearance and comfort. Such contractions are represented in Plate VI., Figs. 7, 8, and 9.

Dieffenbach, of Berlin, who interested himself very much in the surgery of the mouth, suggested and practised for the relief of these deformities an operation, which, with slight and unimportant modifications, is the one still generally employed.

Dieffenbach's operation is performed on the following principles: Map out with pen and ink on the tissues such lines and angles as meet approbation of what the proper mouth should be. These lines are, of course, to be in conjunction with the existing orifice, or commissure, wherever or however situated,—that is, the relation of the existing orifice must be studied as it is to have association with the cuts to be made. Thus, glancing at Fig. 7, we at once appreciate the necessity for enlarging the mouth by sections equilateral to the centre, as certainly it is apparent enough that only by such a form of incision—represented by a line—could we secure the end at which we aim. Fig. 8, on the contrary, would demand an operation exclusively lateral; for here the mouth at its right side is as perfect as one would hope to make it. Fig. 9 presents a complication on these simple conditions. This complication might be multiplied almost indefinitely; for who may say in what condition a wound or other injury shall leave a part? At any rate, the surgeon is to be prepared to meet all kinds of modifications. The three figures give, however, as just an idea of the mechanico-surgical indications of such cases as any others that might be drawn. Figs. 7 and 8 are from life; 9 is one made up to represent a not unlikely aspect.\* It exhibits, as is seen, a combination of a cicatrix and hare-lip. In this last case is suggested of itself the necessity for a double operation. The mouth is to be made smaller before it would be at all proper to attempt making it larger. We must first perform a hare-lip operation. Imagine this done, and then, further, the condition in which such operation would leave the orifice. If we refer to the drawing, we see that the opening is now at what is fairly the right angle of the mouth; and an operation for the making of a proper commissure, if there were no hare- or cleft-lip, would be precisely the same lateral incision as that

\* Fig. 9 is not correct to the text: add to it the defect in Fig. 1, and it will be right.



indicated in Case 8. But then it is to be remarked that, after the first operation was performed, the orifice would not be, as now, at the proper right angle. The bringing of the cleft together would pull it naturally toward the mesial line. Thus, then, it is made a cross between 7 and 8; it is not like 7, because it is not exactly in the mesial line, and it would not be like 8, because it has been drawn from the proper right angle toward the mesial line. Here, then, the complication has materially changed the indications of the principal operation. The incisions are to be bilateral, yet not equally so as reference is had to the false commissural centre, but only as reference would be made, say to the septum narium or to any other fixed mesial line proper. The space between the central incisor teeth would be a good mesial centre to adopt.

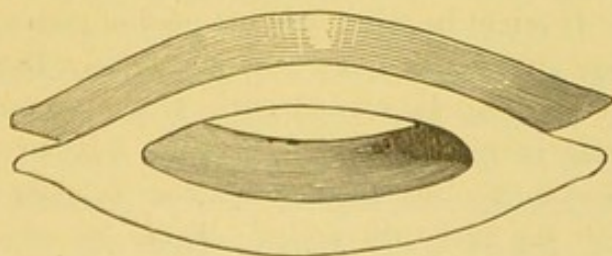
These features well considered, the surgeon takes up a pair of sharp-pointed scissors, and, passing a finger of the left hand into the mouth, enters one blade down through the tissues toward the finger, sparing alone in the puncture the mucous membrane; the blade is now pushed forward toward the mesial line, and the tissues incised, as indicated by the superior right lateral half of the ellipse represented by the line in Fig. 7. The blade is now reintroduced at the previous point of entrance, and the cut made on the inferior lip precisely as was done above. Next is dissected out the triangular piece. These incisions are repeated on the opposite side. A succeeding step considers the cutting of the mucous membrane. This is done simply by dividing it down the centre to within two or three lines of the angle of the wound; it is then to be brought over the raw surfaces and attached by means of the interrupted suture to the skin.

This mode of re-establishing the oral orifice is deemed to be the best that can be employed.

A modification on the manner of Dieffenbach, which the author would suggest, and which he is confident will be found to add to the good results, is an association with the surgical means of a mechanical appliance.

After the operation, as described, has been performed, and time has been given for union of the reflected mucous membrane, let such an appliance as

FIG. 479.



is here figured (mouth-stretcher, it might be called, Fig. 479) be prepared, and slip it between the lips. This stretcher represents a properly-shaped mouth; the lips in the whole of their circumferences are caught and held by the gutter



of the apparatus, and thus not only is the healing influenced to a desired shape, but undue cicatricial contraction is prevented.

If it be objected that such an instrument looks ungainly in the mouth, it is to reply that after the first week or two there would exist no occasion for its constant wearing; it might be entirely dispensed with during the day and be worn alone at night. Use of it is to be continued, however, for at least six months, if cure is to be perfected. An advantage yielded by such an appliance to a bungling operator lies in the fact that it naturally corrects any imperfection in his manipulations; the character of the apparatus compelling the regular healing of the wound. Indeed, the writer is not sure but that in this way a proper mouth might be made if the strictly surgical part consisted only in a simple incision to enlarge the parts to a proper capacity; for in the operation it cannot be said that the reflection of the mucous membrane is an absolute necessity; whether that membrane should be carried over the cut surface or not, we would very soon have it clothed with such tissue, or at least with that found sufficiently analogous to fairly represent it. The great difficulty, as has been remarked by Dr. Mütter, in all these cases arises from the constant tendency to contraction manifested by the cicatrix, which occasionally goes on to such an extent that the orifice of the mouth is almost closed. At the first examination of such a deformity, the remedy which seems to promise most success, says Dr. M., is mechanical dilatation. Unfortunately, this is productive of but temporary relief, and has never, I believe, effected a permanent cure. Next to this method comes incision of the commissures. We might naturally expect such a course to be sufficient to effect the ends desired; and in all probability this would be the case, could we by any means prevent reunion of the edges of our incisions. But this, it would appear from statements of the best authorities, has hitherto been impossible: for, notwithstanding introduction of tents, leaves of sheet-lead, cerate cloth, etc., between the lips of the wounds, adhesions, more or less complete, are sure to take place.

The instrument here suggested will master indications which the appliances heretofore used have not been able to meet. A tent, or cerate cloth, or strip of easily yielding sheet-lead cannot resist the great contractile force existing in these conditions; something fixed and immovable is required. One would not be willing to trust to a less resisting body than the catheter, after urethral section. It might be asked, "What need of such appliances, if Dieffenbach's operation will effect a cure?" Unfortunately, Dieffenbach's manipulations cannot in all cases be carried out. If the mucous membrane, for example, participate in the lesion, the operation cannot be successfully performed. Or who can say that flaps of mucous membrane, however nicely approximated with the skin, will unite? There are several things which are apt to come between the surgeon and success. There are, at least, cases which Dieffenbach's nice operation will not cure.

A preliminary performance, having the object of obviating the tendency to closure of the mouth, consists in first passing through the tissues, at the pro-



posed sites of the angles of the lips, setons of delicate india-rubber tubing. These are to remain in place until the orifices are cicatrized, precisely as in the case of the ringed ear. No trouble after this is experienced in preserving the mouth as formed.

**Studies.**—Plastic operations about the lips are embraced under the general name of cheiloplasty; those upon the cheeks are termed genioplastic.

The necessity for such operations arises from various causes, not the least frequent of which are sections made by the knife of the surgeon. Reference to Plate VII. exhibits five cases; the first resulting from salivation, the second from an ulcer, the third, fourth, and fifth due to operations for the removal of cancer.

The first of these (Fig. 1) is described as having been a shocking deformity. The operation for its relief was performed by Professor Mütter, the practice being as follows. Having first extracted the useless teeth of the upper jaw, which would have prevented the proper adjustment of the flaps, or induced their ulceration, the edges of the ulcer were freshened, and the integuments detached from the side of the jaw. Two incisions, one above and one below the break, as seen in the figure, were made, so as to form four flaps. These were now allowed to fall together, and were united in the line of the teeth as far forward as the natural angle of the mouth. The result was entirely satisfactory.

In studying this case, the reader will remark that while the mode of section, or making the flaps, most happily meets the indications as filling up the seat of the original lost tissue is concerned, yet this is only done by making two other defects, one above, the other below. Such defects, however, prove, in healthy tissue, of no great consequence; granulations, quickly springing from the whole circumference of such wounds, supply the lost tissue: indeed, in the author's experience he has found that, as a rule, the tendency in these fresh parts is to so rapid a repair and cicatrization that frequently the line of the artificial union is torn apart.

Fig. 1 may be studied from another stand-point. In a case operated on lately, very similar to the drawing, where the neighboring tissues were loose and free in character, the writer secured an admirable result by simply dissecting the parts from the bone, freshening the edges, and uniting them by the ordinary hare-lip pin, supporting the whole with straps of adhesive plaster passed from beneath the jaw to the side of the head; the parts at first looked much stretched, but soon accommodated themselves.

Still another mode of performing such operations is after the manner of Tagliacotius. Freshening the edges as before, map out, by means of a piece of card-paper, the size of a flap required to fill up the gap; next lay this upon the arm, and, dissecting from the integuments its size, supported by a pedicle, fix it in the break by means of stitches of the interrupted suture. To do this, the arm is to be brought over the head, and thus supported until union is secured, when the pedicle is to be detached, and the parts trimmed to suit.



Subfig. 2, constituting a second study, represents an operation performed by Mott for the relief of an ankylosis of the jaw dependent on cicatrization of the mouth, together with the restoration of a part of the cheek. 1, exhibits cicatrix arising from an ulcer. This was entirely excised, leaving an opening in the cheek. 2, tongue-shaped flap cut to fill up the opening, this being rotated upon its base.

Subfig. 3 represents an operation performed by Professor Pancoast for the removal of an extensive cancer, and the formation of a new lower lip. The disease is shown circumscribed by a curvilinear cut. A vertical incision in the median line of the chin extended from the cut nearly to the os hyoides, and another, which was horizontal and parallel to the base of the lower jaw, formed four flaps. The angles of the flaps being removed, the upper (1, 2) were raised to the proper level, and united by the twisted suture on the median line, when the lower (3, 4) were also united on the median line so as to cover the front of the chin.

Subfig. 4 represents a similar case, treated by the operation of Chopart. The lines show the idea of the incisions. 2, 4, circumscribe the disease. 1, 5, 3, 6, show vertical cuts. The diseased part, all above 2, 4, being removed, the integuments are loosened from the lower jaw, and simply lifted, being retained in the new position by hare-lip pins, or by other convenient means. This operation occasionally answers very well. In certain instances, however, where, for example, it has been necessary to stretch the parts, much cicatricial evulsion is apt to occur.

Subfig. 5 represents the same position of the disease, treated after the manner of Lallemand. 1, the remaining portion of the lip, which is to be drawn over to the angle of the mouth at 2. A flap, formed of the integuments of the neck, having been dissected off, is shown as being partially rotated on its base, and about to be carried up to cover the deficiency. The wound on the neck may either be approximated at its edges or be left to heal by granulation.

In epithelial cancers quite as large as those represented in Figs. 3 and 4, the author has succeeded in making perfect operations by practising the manipulation of Malgaigne. This consists in removing the diseased mass by a simple V-incision; the angles of the mouth are next enlarged by horizontal cuts, and the V drawn together and united in the middle line of the face. In the cases alluded to, a pin was always placed at each corner of the mouth; as the result of this, some little puckering is produced, but, in return, it eases the strain on the middle line, and itself disappears after a very few months.\*

---

\* The lower lip, from its conspicuousness, its utility in articulation, and also in the prevention of an involuntary and incessant flow of saliva, forms a very important portion of the face. Unfortunately, it is exceedingly prone to diseases of various kinds, especially tumors and ulcers, requiring for their relief the removal of the whole, or a portion, of the organ involved. It would be worse than useless to enter into a description of all the operations that have been devised to remedy its loss, but a brief sketch of the most novel and



Fig 1.

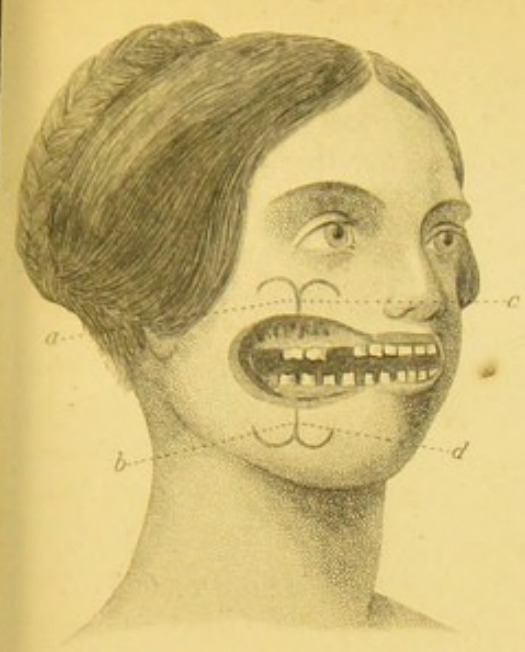

Fig 2.

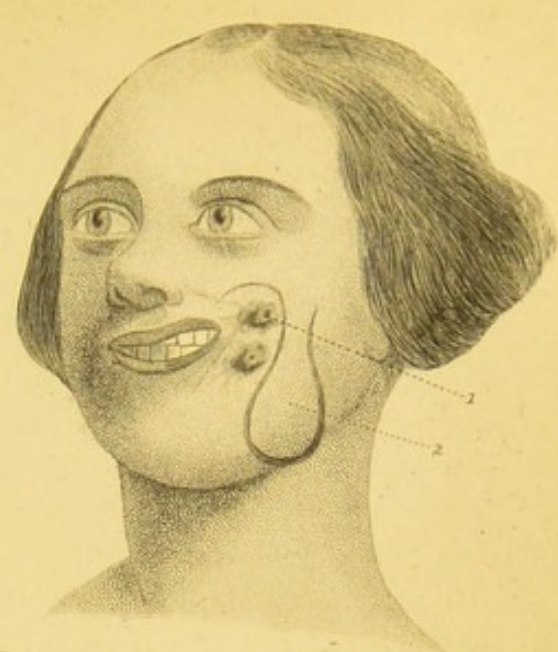


Fig 5.

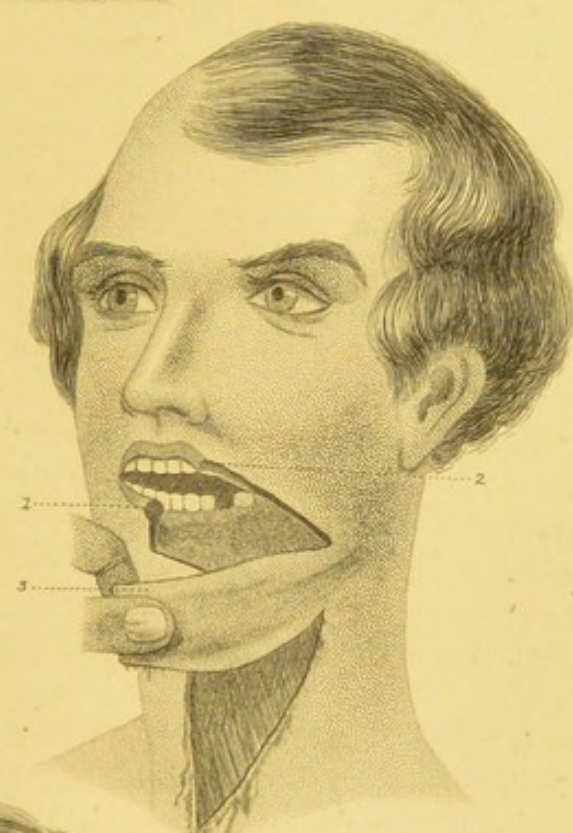


Fig 3.

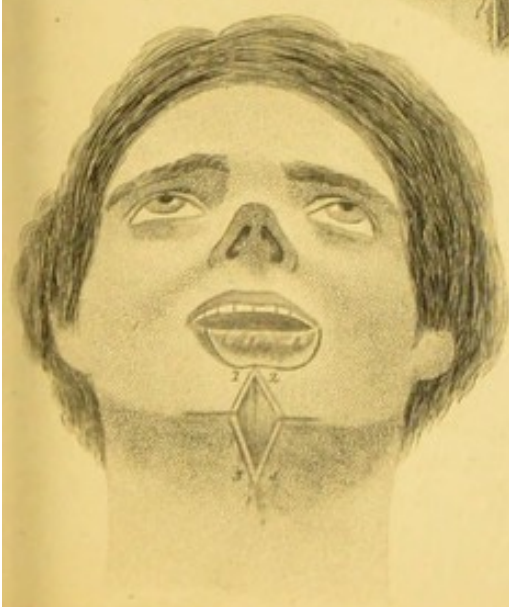
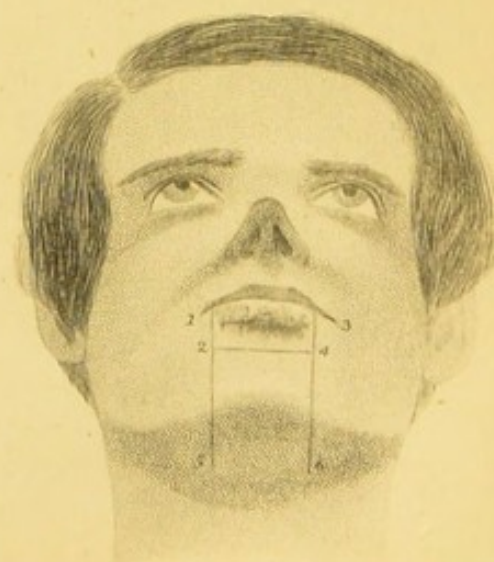


Fig 4.










Fig. 480 exhibits conditions met with almost every day. Such ulcerations being esteemed of cancerous signification, are commonly treated by excision.

important may prove useful and interesting to those not familiar with this department of plastic surgery.

*Chopart's Operation.*—This operation consists in making, on each side of the diseased tissue, a perpendicular incision, extending from the margin of the lip to a point below the base of the lower jaw. Dissecting up the flap inclosed between the incisions, he carefully removed from its upper margin all the affected tissue, either by a *transverse* or a *curvilinear* cut. Then, pulling upon what remained of the flap, he brought its upper edge to the level of the margin of the natural lip, and there retained it by suture, straps, and placing the head of the patient in such a manner as to prevent all strain upon the part. This method, though apparently simple and easy of execution, does not generally answer, in consequence of the subsequent contraction of the tissue.

*Horn or Roonhuysen's Operation.*—If the part to be removed be small, the common V-shaped incision is sufficient, and the parts may be brought together as in the operation for hare-lip; but where the mass is large, this process is sure to diminish the orifice of the mouth and thus give rise to deformity and inconvenience. To obviate all this difficulty, it was proposed by Horn to detach the adjacent parts by free dissection from the maxillary bones, which would of course afford more material for the lip. The objection to this method is, that in many cases the orifice of the mouth is rendered so small as to be almost useless, besides presenting great deformity.

*Operation of Dupuytren.*—This, in ordinary cases, is nothing more than cutting away by a semi-elliptical incision all the diseased tissue. Granulations spring up from the margin of the healthy skin, occupy in part the place of the original lip, and conceal to a certain extent the deformity. It is only in mild cases, however, that such a measure could succeed.

*Celsian Operation.*—Having carefully removed the diseased part by a V-shaped incision, he proposed to divide the tissue remaining *horizontally*, carrying the cuts as far into the cheek on each side as might be deemed necessary, after the manner of Horn; but, in order to take off the strain from the flaps, he made a *semilunar incision* in the cheek, just beyond the base of each. This enabled him to bring the parts together without difficulty; and the only objection to this operation is the danger of wounding the larger vessels, nerves, and ducts of the cheek, in making the semilunar incisions.

*Operation of M. Serres.*—If the disease, as is sometimes the case, be confined to the integuments and subjacent muscles, leaving the mucous lining of the lip sound, Serres cuts away only the affected part, and then turns the mucous membrane over the margin of what is subsequently to form the lip. A few stitches are sufficient to hold it in place, and, as union by the first intention usually occurs, a very natural and useful organ may thus be made. This method, however, will only answer in cases of superficial and recent disease.

*Operation of T. W. Roux.*—After removing the affected tissues, and forming suitable flaps of the adjacent parts, M. Roux takes away with the saw or cutting instruments the prominent centre of the maxillary bones, so as to make room for the proper and easy adjustment of the integuments intended to replace the organ destroyed. This operation is barbarous, because unnecessarily severe.

*Operation of P. Roux.*—Professor Roux, determined to surpass his namesake, saws out an inch or more of the bone, and then, by drawing the lateral flaps toward each other, diminishes the breadth of that part of the face involved in the disease. Then, detaching the flaps, he draws them across the opening in the bone, and the sutures which hold the soft parts are generally sufficient to hold the bones in their proper places.

*Operation of Mr. Morgan.*—This consists in *first* removing the entire lip by a semilunar incision, the concavity of which is uppermost; and, *second*, in making an incision also curvilinear and parallel to, and about an inch or more below, the first. The skin included between the two is then carefully detached, except at its extremities, and lifted into the place occupied by the diseased lip.



Taking as example the two shown in the diagram, the manner of removal is portrayed in the circumscribing lines, the remark being to add, however, that such lines are to be twice or thrice as widely separated from the lesion. The after-treatment consists simply in approximating the parts by the use of the pin and figure-of-8; adhesive strips being used, or not, as may be found indicated.

Fig. 481 exhibits disease involving the entire lower lip, and compelling its removal. To accomplish the necessary end, namely, to ablate the lesion and restore the lip, various means are employed. (See foot-note.) By the

*Operation of M. Blasius.*—M. Blasius has performed a very simple operation when the tumor was large; and, according to his statement, with decided success. After removing the diseased mass by a common V-shaped incision, he next divided the integuments along the base of the lower jaw by two incisions, which commenced at the entering angle of the V, and extended an inch or more in the direction specified. Lifting the flaps, he made them occupy the place of the original lips.

*Operation of Dieffenbach.*—This surgeon has recommended an operation apparently hazardous and severe.

"Having pared away the useless remains of the former diseased lip, or separated the cicatrized margin, a horizontal incision, about two inches long, is carried from either angle of the mouth outwards, through the cheeks, so as to throw the mouth widely open. The length of these incisions must be regulated according to the width of the mouth; or, as a general rule, the combined incisions must somewhat exceed in length the breadth of the upper lip. From the outer point of each of these, another incision is next carried obliquely downwards and toward the median line; the section in this case likewise extending through the whole thickness of the cheek. Thus by means of the first operation for paring the cicatrix, and by the succeeding horizontal and vertical incision, a flap will be prepared on either side to replace the defective lip; this flap is of a quadrangular form, and maintains a connection of more than one inch wide with the soft parts covering the tissue of the lower jaw. It may be useful further to separate the mucous membrane at its attachment to the gums, to allow of the more ready traction of the flaps."

The severe injury inflicted on the facial nerve, the large arteries and veins, and possibly the parotid duct, has rendered this operation anything but popular.

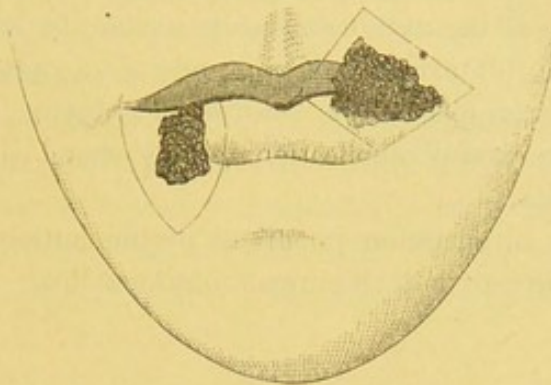
*Operation of Liston.*—This consists in first removing the diseased mass by a horizontal and two perpendicular cuts, or by one curvilinear in shape; and, second, in detaching a flap from the chin and neck, twisting it on its pedicle, placing it in the seat of the original lip, and there retaining it by suture. After adhesion has taken place, the pedicle is divided, and a wedge-shaped piece removed so as to allow the flap to be laid down smoothly. This method, it is obvious, is frequently applied to the restoration of other parts, and will answer here exceedingly well in many cases. Dr. Mütter, however, prefers the following operation, "as there is *less scar*, and less risk of sloughing of the flaps."

*Dr. Mütter's Operation.*—Having first removed the diseased mass by a semi-elliptical incision, two slightly curved incisions are carried from the centre of this line, downwards and outwards, to the base of the inferior maxillary bone. Then, from the terminal extremities of these incisions, two others are carried upwards and outwards along the base of the lower jaw until they reach a point opposite the initial and terminal points of the original semilunar incision. Two quadrangular flaps are thus marked out, and immediately detached from the subjacent bones. These flaps are then raised and placed in the position originally occupied by the lower lip, and then united to each other at the median line, and also by their lower thirds to the triangular piece of integument (as between the two lines which started from the centre of the semi-elliptical incision), by means of the twisted suture. By the elevation of these flaps, a raw surface is left on each side to heal by the modelling process or by granulation.—MÜTTER.



diagram are shown the outlines of an operation known as Serres's. In this mode it is seen that the tissues of the cheeks are utilized. Fig. 482 shows the disease removed, and the wounds dressed. A marked objection to this

FIG. 480.



operation is inability to gain such character of lower lip as shall control the direction of the saliva, or permit of true and full approximation with the superior lip. In looking at the restoration, the reader is to observe the

FIG. 481.

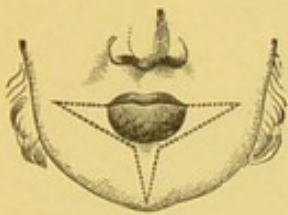
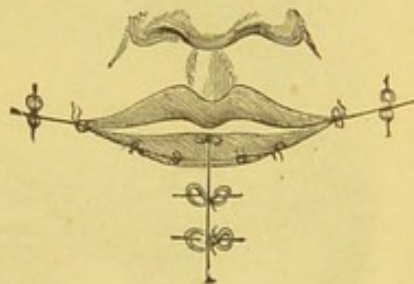


FIG. 482.



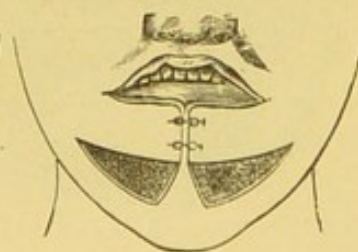
manner adopted of covering the same surface of the free border by stitching to the skin the mucous membrane.

Fig. 483 exhibits a lower lip removed, and lines of incision practised by Mütter for the restoration of the lost part from the chin. Fig. 484 shows

FIG. 483.

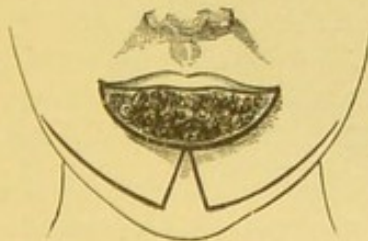

FIG. 484.



the flaps dissected and raised into place; the triangular spaces being left to heal by granulation.

A modification made by the author on the sections of Mütter—cuts of which are shown in a clinical report published in the *Medical and Surgical*

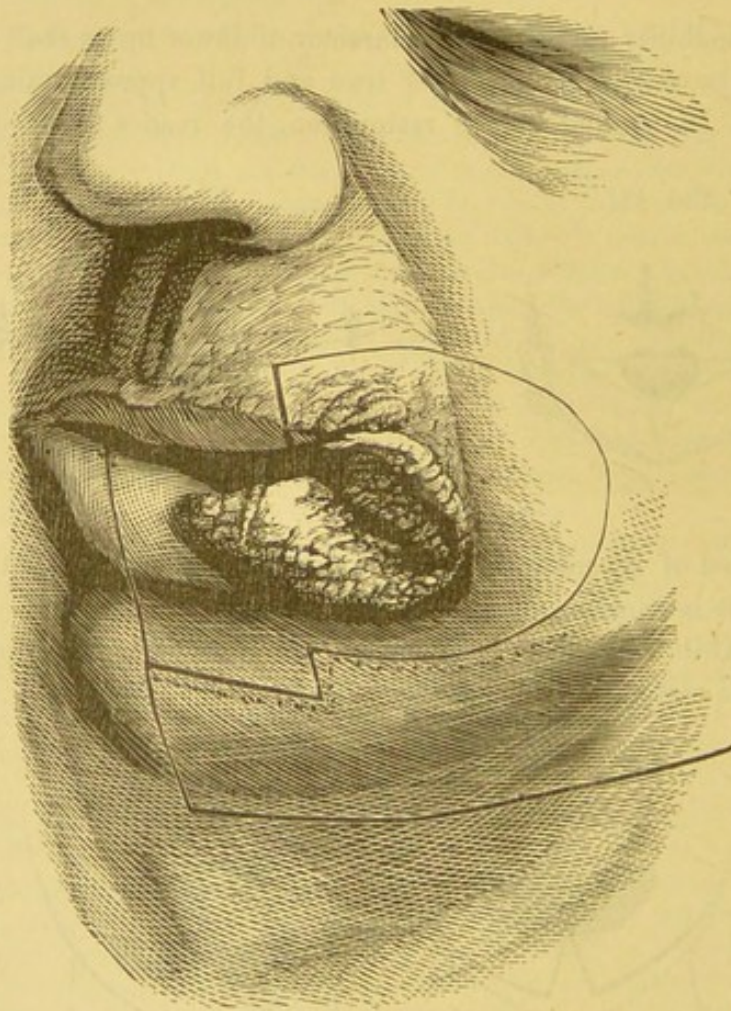


*Reporter*—consists in carrying the vertical lines beneath the jaw, so that the flaps when put in place show but the single central line upon the face. By this modification not only are observable scars avoided, but the lip is not apt to be shortened by the cicatrization: indeed, it is possible by such manner of cutting to obliterate the triangular breaks left in the operation shown, the yielding integuments of the neck being made to close the breaks.

The transplantation of particles of skin, now an accepted means, may be practised in the Mütter plan: this consists in snipping from sound parts small pieces, and by careful application uniting them with the uncovered surface of the triangles.

Fig. 485 exhibits an operation practised by the author for the removal and restoration of parts of both the upper and lower lips.

FIG. 485.



At the angle of the mouth is seen the lesion designed to be removed, circumscribed by lines which fully include it; all tissues within these lines are ablated. Commencing now at the angle of the wound in the mesial centre, an incision is carried downward beneath the jaw, and outwardly—as



shown in the diagram—as far as the line of the facial artery;\* this flap being next dissected from its base is lifted until it meets the free border of the natural half of the lip; to this it is pinned. The angle seen back of the mesial incision will be recognized as receiving accommodation in the second angle in the upper lip; this relationship limits the size of the commissure on the side, which limitation, however, is to be corrected by a subsequent operation practised after the manner of Dieffenbach.

Remedy for disease thus situated is of frequent necessity. The operation shown is one that may be practised with entire satisfaction. With various required modifications the author has repeated it many times.

Fig. 486 exhibits lines of section demanded for the restoration of a lost upper lip. The case here shown, represents a case in which the author found

FIG. 486.



himself compelled to remove the upper lip on account of the rare affection, as here located, of epithelial cancer. Imagining the lip away, the reader will perceive that lateral flaps dissected from the cheek, as shown in the diagram, must admit necessarily of being brought down and stitched together in the place of the lost part.

Fig. 487, demonstrative of the same operation, as the making of a lip is concerned, shows the face of a patient when first presenting for treatment.

Fig. 488 exhibits the appearance of the face immediately after the completion of an operation for a new lip, practised precisely as shown by the lines marked upon the face of Fig. 486. The triangular space, left necessarily on each cheek, as must be appreciated by a study of the drawing, on the left side is shown obliterated by compelling the cheek to override the space. On the right side it has been allowed to remain. The artist, however, should have represented this space by a dark rather than by a light surface.

Fig. 489 shows what is known as the Dieffenbach operation for removal and

\* Mistake has been made by the artist in not giving width enough to the flap; it is to be one-eighth in excess of the part removed.



restoration of an upper lip. The inferred diseased part, *d*, being ablated, an incision, *b*, is carried upward, outward, and downward, as seen. Fig. 490 exhibits *b* carried to the place of *d*; the line on either side, with its double dots, representing the seats of flaps after approximation.

FIG. 487.

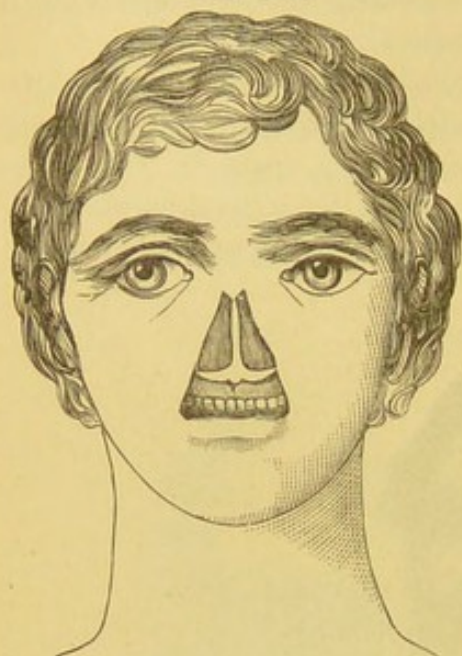
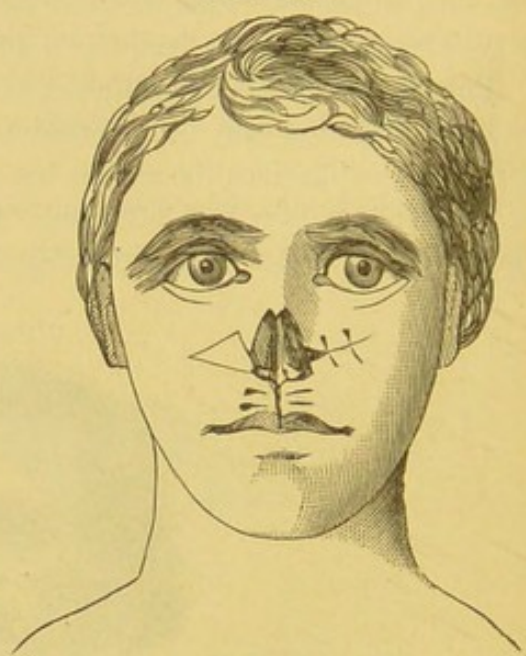


FIG. 488.

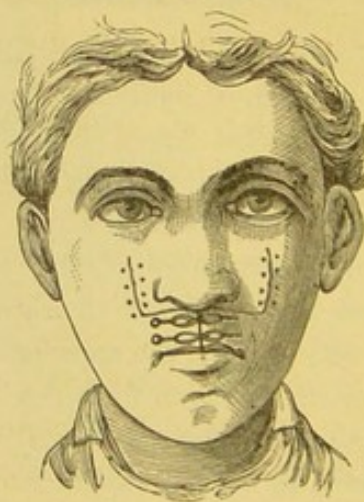


Another manner of making an upper lip is known as Leidillot's. Fig. 491 shows the lines of incision. Fig. 492 the flaps in place.

FIG. 489.

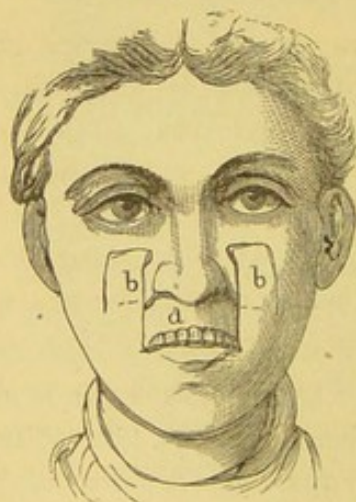

FIG. 490.



The lady represented in Fig. 493 applied to the author for relief from the deformity exhibited, the irregularity of features being dependent on injury done the facial nerve in an inflammation and necrosis of the temporal bone from accident met with in childhood. Paralysis was complete; not the slightest power existed in the muscles of the affected side.



The desire of the patient was for a symmetrical mouth and face; the question was, the accomplishment of such an end.

TREATMENT.—A case of this kind is treated strictly from an operative stand-point. The indications are threefold:

FIG. 491.

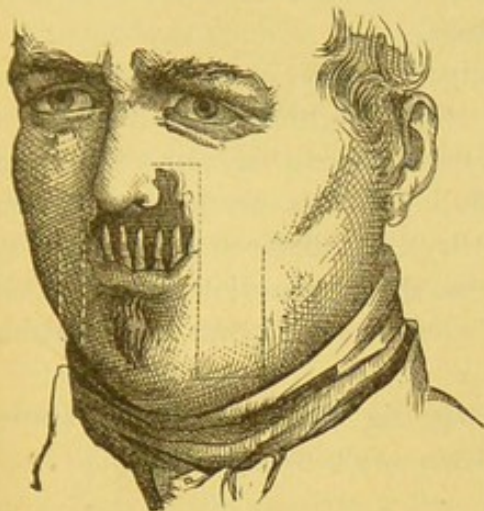
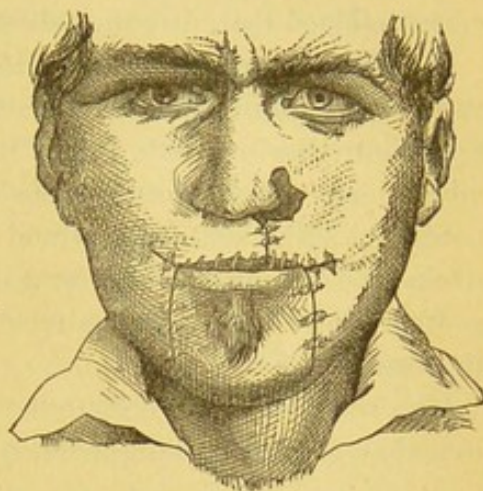


FIG. 492.



- 1st. To reduce the flabby redundancy of the paralyzed cheek.
- 2d. To give comeliness and regularity to the mouth.
- 3d. To antagonize the muscular action (when in play) of the vital side.

FIG. 493.



In this case these indications were attempted to be met by means as follows: A study was made of the cheek, and what was deemed to be the re-




dundant tissue was included in an ellipse drawn with a lead-pencil, one of the apices being at the middle of the nose, the other at the angle of the lower jaw, —such direction of the ellipse being with a purpose of raising the angle of the mouth. Satisfied that the removal would be found rightly placed to meet the first two indications, the part was cut out. In the operation the facial artery was the only vessel which needed a ligature, and even this ejected no more blood than does an ordinary coronary.

To bring the parts together, three hare-lip pins were used, and, somewhat surprisingly, so direct and immediate was the union, that it was found permissible to dispense with two of them on the following day; the third, the middle one, was left in until the fourth day; but this, not seemingly from necessity. The ligature, a strand of ordinary silk, remained firm for three weeks, and was finally taken away only by the use of a traction quite as great as would have sufficed for its removal the moment after it was placed about the vessel.

The result of this procedure is exhibited in Fig. 494. With the features in a state of rest, nothing more, it would seem, could be desired.

FIG. 494.



The third indication, however, showed itself a most important one. Emotion of the face altered this mechanical harmony of the parts, and exhibited the non-vitality of the side operated upon; that is to say, in laughter, for example, the superior and lateral levators would pull up the well angle, with no corresponding action on the diseased side. This was, of course, a matter which had been originally considered. The indication was met with remarkable success, as follows: A piece of rubber tubing four inches long, possessed



of an elastic power adapted to the requirements of the case, was attached by one of its ends to a hair-pin (the ordinary pin used by ladies in dressing the hair). With its other end was united a piece of strong, but delicate, gill-net string, and this, in turn, was connected with a small strip of flesh-colored court-plaster.

The application of this piece of mechanism—an artificial muscle, let us call it—was made as follows: The plaster was softened and applied to the dead side of the face, as far back upon the cheek as would answer the purpose. The lady, standing before her glass, would excite the displacing muscles into play, and antagonize them by drawing slightly backward the dead side by means of an artificial muscle, holding a required tension by the pin fixed into one of the coils of her hair, the rubber lying entirely concealed by such coil. When applied, only the plaster could be seen, the string being hidden by the hair.

This rubber muscle answered its purpose admirably. The fear that the plaster would irritate, and perhaps ulcerate, the skin, seems to have been without foundation. At any rate, this held good for six months of use, which was as long as the case was under observation; the lady living in a distant city. Should this accident have supervened, it was evident that, after a very few days of experience, a habit might be attained of accomplishing the same object by the use of the fingers applied in such manner as not to elicit attention.

This operation, the only one of the kind done by the writer, gave results which warrant its repetition. It is recognized, however, that a continued and proper employment of the artificial muscle is a necessity, otherwise the use of a finger, as suggested.

**Burns.**—Plastic operations practised for the relief of cicatricial deformities must always be of special signification. Of such cicatrices there are of course an endless variety, and it may only be that each case shall command a special operation.

Cicatricial tissue, always the result of suppurative inflammatory action, is a species of imperfect fibrous formation, dull white in color, hard, its fibres running in every direction and possessed of a contractility which, in many instances, requires years for exhaustion. In vital force this structure is of low organization, peculiarly susceptible to degenerating influences, rarely, if ever, developing to full likeness with its associated parts.

The surgeon on treating a cicatrix will find himself wisely influenced in heeding the maxims of Dupuytren:

1. Never attempt the correction of a deformity until months, and in many instances years, have passed after its production.

2. Never operate unless certain of obtaining a larger cicatrix than that which is wished to be removed.

3. Be certain that the operation can restore the parts to their shape.

Dermoplasty, as this operation is called, is never to be undertaken without



full consideration of the shock to be entailed by the cutting and suppuration, and the ability of the patient to endure such shock (see page 514). In removing a cicatrix, it is to be recognized that not only may a prolonged dissection be necessitated, but the cutting is not at all unlikely to be of the most hazardous nature, requiring on the part of the surgeon not only an accurate knowledge of the anatomy of the parts involved, but a patience and a manipulative skill which are by no means a common possession.

A secondary danger associated with these operations lies in the supervention of erysipelas, a contingency to be guarded against by that preliminary attention which has taken into consideration every functional irregularity which can have a tendency to lower the resistive force of the individual locally or at large.\*

A flap is always to be at least from a quarter to a third larger than the cicatrix to be replaced; such increased size will be found necessary to counter-balance shrinkage.

A flap is always to be taken from the nearest healthy neighboring part. It is to have the widest pedicle the circumstances of the case will permit, and is not to be laid in its new situation until all hemorrhage has been fully suppressed and both flap and base are covered with a film of plasm.

In fixing a flap, unnecessary stitches are to be avoided, while compression of the most gentle nature is to be used in holding the parts in apposition.

No dressing except of the simplest character is to be employed after an operation; the surgeon is to take it for granted that no complication will arise and that the union is to be immediate and full: should, however, such results not accrue, then indications are to be met as they arise.

Concerning the wound left by the transfer of the flap, this is best treated in the endeavor to close it by the overdrawing of neighboring parts; with large surfaces, however, where the practice may not avail, the process of skin-grafting is had recourse to; this, while not so reliable as is to be desired, serves at times a satisfactory end. For further illustrations in plastic surgery see chapter on Epithelioma.

---

\* Erysipelas would seem to be a parasitic disease; the fungi finding habitation in a part incapable of self-defence. Repetition of the combination of a medicament always used by the author is made:

R.—Tincturæ ferri chloridi,  $\overline{3j}$ ;  
Tincturæ cinchonæ,  $\overline{3ij}$ ;  
Quiniæ sulphatis,  $\overline{3j}$ .

Sig.—Apply hourly until blush and tension disappear. Decrease or increase tinctura cinchonæ according to delicacy of skin.



## CHAPTER XLVIII.

### VASCULAR SYSTEM OF EXTERNAL AND DEEP FACIAL REGIONS.

#### LIGATION OF ARTERIES.

THE arteries of the face, external and deep, arise out of the external carotid. The external carotid is one of the two terminal divisions of the common carotid. A line upon the neck, laid from the sterno-clavicular articulation to the mastoid process of the temporal bone, marks the position of the common vessel in the length of its course from emergence above the clavicle to termination opposite hyoid bone. (Refer to Fig. 23.) A line drawn from a point of meeting with the first, opposite hyoid bone, to angle of lower jaw, locates the situation of external carotid. (Refer to same Fig.) A line starting from the notch upon the face of lower jaw anterior to masseter muscle, being carried to internal canthus of eye of the same side, distinguishes the course of facial artery. (Refer to same Fig.)

The external carotid artery breaks up in the substance of the parotid gland into the internal maxillary, the temporal, and the auricular. (Fig. 22.) The first passes the head of the jaw and supplies all the deep parts of the face. The second has its pulsations felt just in front of the ear, it continues upward supplying the temporal region and side of forehead. The third runs back of the ear, assisting to vascularize the posterior auricular locality.

Associated with the surgical signification of the face is the lingual artery; this is the second branch of the external carotid. It supplies the tongue, and is the not infrequent seat of ligation.

Arterial blood having passed through the capillary system is returned to the common circulation by office of the veins. A dissection of the facial venous system, one of the most perfect the author has ever seen, is here introduced as a study. (Fig. 495.)

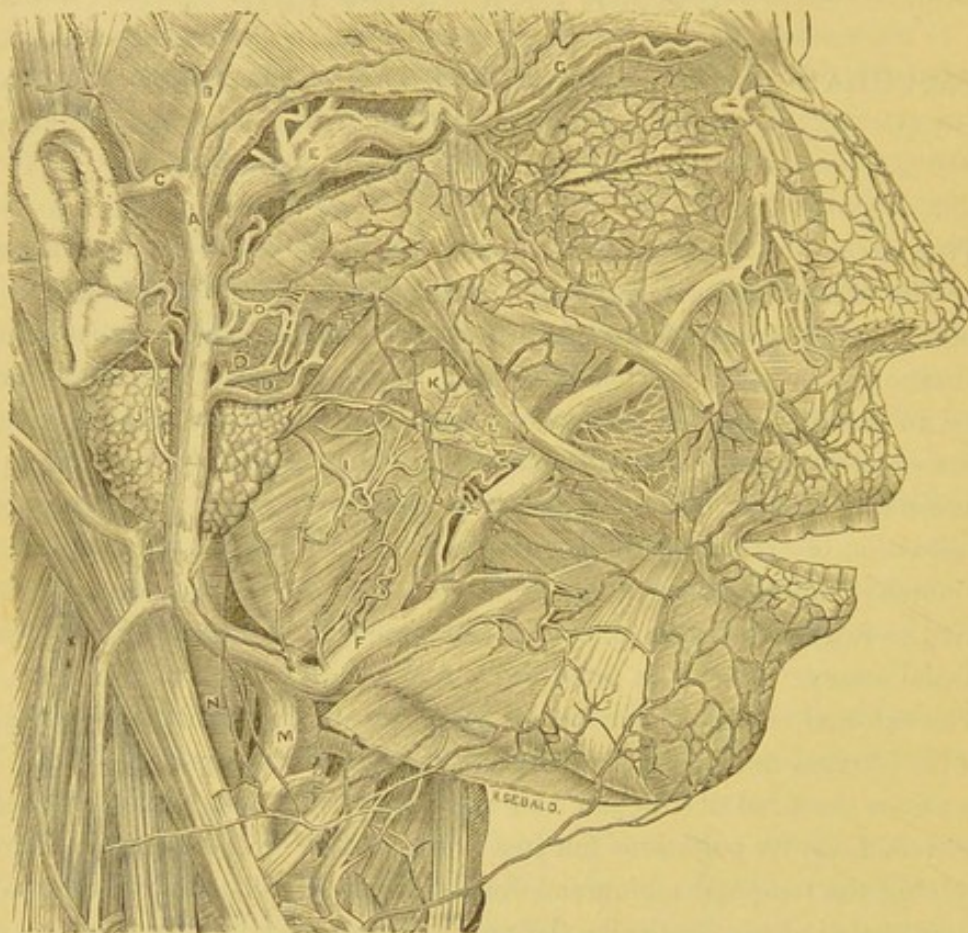
**Arrestation of Hemorrhage.**—Ligation being found necessary for the arrestation of hemorrhage, the vessel indicated for operation is that one most directly associated with the lesion.

1. **LIGATION OF FACIAL ARTERY.**—Feeling for the anterior border of the masseter muscle, the finger is allowed to drop until resting upon the notch occupied by the artery in its passage over the jaw. Position discovered, a pencil-mark, half an inch in length, is made to designate the direction of the vessel. An incision, one inch in length, is cut oblique to this line. The artery is reached by incising skin, the subcutaneous and adipose tissue, platysma myoid



muscle and deep fascia. Along the outer border of the facial runs its associate vein, which is not to be included in the ligature.

FIG. 495.—VIEW OF THE REGION OF THE TEMPLE, ETC., DESIGNED ESPECIALLY TO SHOW THE TEMPORO-MAXILLARY VEIN AND ITS TRIBUTARIES. (After Allen.)



A, temporal vein receiving the anterior and posterior temporals B, C; D, D, the internal maxillary veins, emptying into the temporal to form the temporo-maxillary vein; E, the middle temporal vein (slightly enlarged), to display which the deep temporal fascia over it has been removed; F, the facial vein; G, the supraorbital branch, uniting with the middle temporal vein; H, the inferior palpebral vein, uniting with the same; I, the masseteric vein; J, the parotid vein; K, the socia parotidis; L, the parotid duct; M, the external jugular vein; N, the temporal vein.

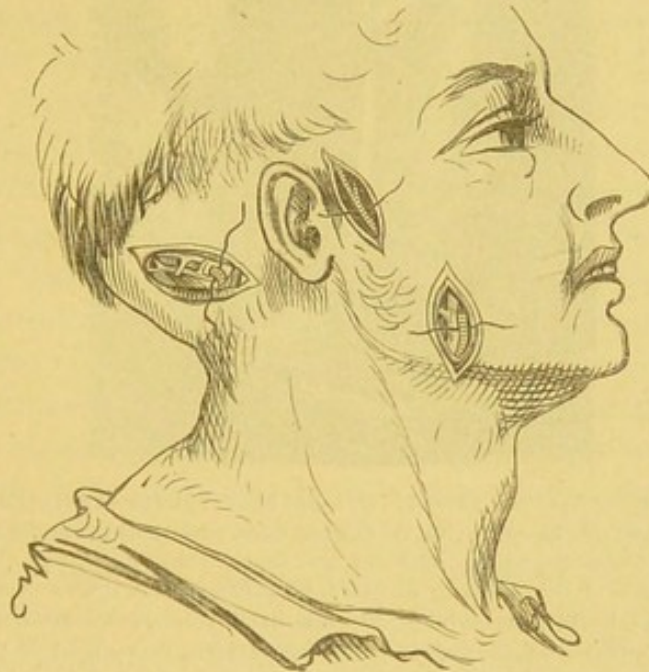
2. LIGATION OF TEMPORAL ARTERY.—The seat of selection for ligation of the temporal is immediately above the zygoma and one-quarter of an inch in front of the cartilage of the ear. The vessel lies quite superficial, being covered alone by the integuments. Its pulsations are to be felt, and constitute a reliable guide in the operation. A feature of obstruction is met with in the resisting character of a connective tissue which ties the vessel closely to its bed; this tissue is to be torn by means of a director. Not infrequently one or more lymphatic glands are found in the line of incision; these are to be pushed aside. On the ear side of the artery runs its vein, while both anteriorly and posteriorly are seen nerves (branches of the facial and inferior maxillary) all of which are to be carefully excluded in passage of the thread.



3. **LIGATION OF OCCIPITAL ARTERY.**—The occipital is a vessel of considerable import coming off from the external carotid just opposite the facial. (See Fig. 22.) Ligated in the scalp, which is the seat of selection, an incision two inches in length, which commences at the mastoid process, is carried outwardly in the direction of the occipital protuberance. The operation is more involved than the two preceding. The layers to be gone through are skin, subcutaneous tissue, some fibres of the sterno-cleido-mastoid muscle, the splenius and complexus. Reaching thus the locality of the artery, search is made for the vessel by means of a finger introduced into the wound. Casting of the ligature implies the avoidance of accompanying vein, and, most importantly, of the large mastoid vessels which in this neighborhood join the occipital vein, forming communication with the lateral sinuses of the dura mater.

Fig. 496 shows the various lines of incision described together with ligatures in position.

FIG. 496.



**Lingual Artery.**—Wounds and diseases of the tongue make necessary, occasionally, the ligation of the lingualis. To do this operation requires much skill and thorough anatomical knowledge of the parts. The seat of selection is where the vessel runs beneath the hyo-glossus, immediately above the greater cornua of the hyoid bone. Feeling for this extension, the cutting is commenced by an incision running inward from the anterior border of the sterno-cleido-mastoideus parallel with, and just above, the horn. The tissues to be gone through include the skin, platysma myoid muscle, superficial fascia, deep fascia. Arrived at this locality the hypo-glossal nerve is found directly in the line of the cut, overlying the hyo-glossus muscle, the lingual



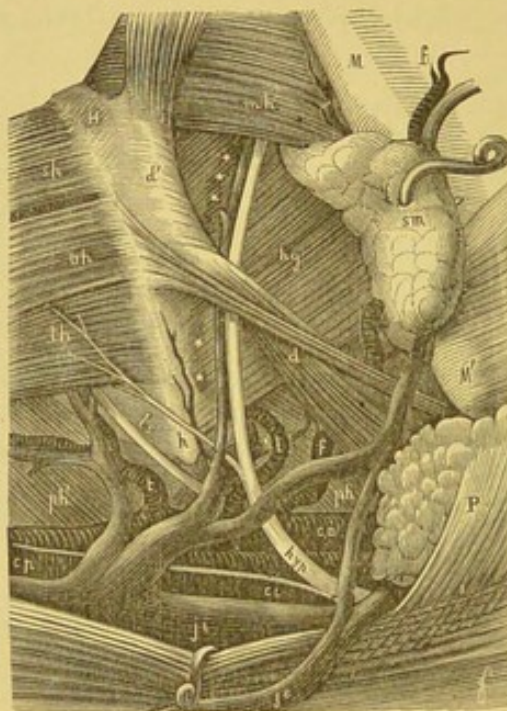vein being in immediate relation. Supporting these vessels and covering the artery is the muscle named. This is to be incised; a director being used.

Fig. 497 is introduced as a study. The author has repeated the dissection a great number of times. The block is more than good.

A hemorrhage uncontrolled by any one of the ligations described, a succeeding recourse is to the external carotid; this failing, in turn, the primitive, or common, carotid is to be tied.

4. LIGATION OF EXTERNAL CAROTID ARTERY.—The patient being placed upon his back, with the head extended, an incision is made obliquely over

FIG. 497.



RELATIONS OF THE LINGUAL ARTERY. H, hyoid bone; h, its great horn; M, the body of the lower jaw; M', its angle; sh, oh, th, insertions, into the body and horn of the hyoid bone, of the sterno-hyoid, omo-hyoid, and thyro-hyoid muscles; ph, the inferior constrictor muscle of the pharynx; sm, the submaxillary gland drawn over the jaw, with (f) the facial artery and vein; je, the external jugular drawn aside, along with the sterno-cleido muscle; d, the digastric muscle perforating the stylo-hyoid, and looped down to the great horn of the hyoid bone by its fibrous pulley, d'; hyp, hypoglossal nerve running alongside the lingual vein, and disappearing under (mh) the mylo-hyoid muscle; l, the lingual artery passing beneath (hy) the hyoglossus muscle; t, the superior thyroid artery; f, the facial artery, behind which lies the external carotid; ci, the internal carotid artery; ji, the internal jugular vein, into which are seen emptying the facial, the lingual, and the superior thyroid tributaries. The white stars mark the point where the artery is cut from, as described in the text.

the line of the vessel as located; this incision to be one and one-half inches in length. The overlying tissues consist of skin, platysma myoides, superficial fascia, deep fascia. Section of this last exposes more or less connective tissue in which the sheathed vessel lies; the facial and lingual veins, and commonly one or more lymphatic glands, being in close association. The artery is crossed by the hypoglossal nerve and by the digastric and stylo-



hyoid muscles. Close to its outer border lie the internal carotid and deep jugular vein. The situation of the part being quite deep, much dexterity is required in manipulating about it. The ligature is to be passed between the two carotids; that is, from without inward.

5. LIGATION OF PRIMITIVE CAROTID ARTERY.—The study of the topographical anatomy of the neck shows it first as an oblong square, which is divided primarily into an anterior and posterior triangle by reason of the oblique crossing of the sterno-cleido-mastoid muscle. A second muscle, passing obliquely in a reverse direction, the omo-hyoid, subdivides the two triangles into four, these being known as the anterior inferior and superior, and the posterior inferior and superior cervical triangles. The primitive carotid is ligated in either of the anterior triangles; in the superior preferably.

*In Superior Triangle.*—The patient in position as described in connection with the external carotid, an incision from one to two inches in length is made upon the line described. Overlying tissues are skin, platysma myoides, superficial fascia, deep fascia, sheath of vessel. Upon the sheath is the descendens noni nerve; within it are the artery, the pneumogastric nerve and deep jugular vein.

*In Inferior Triangle.*—Position of patient is the same. The line of incision approaches the trachea along with the anterior border of sterno-cleido muscle. Overlying structures are skin, platysma myoides, superficial fascia, deep fascia. In place of coming here, as in the previous dissection, upon the sheath of the vessel, muscular structure is met with: this structure is, on the outside, the sterno-cleido-mastoideus; on the inside, the sterno-hyoid and thyroid muscles. To get at the artery requires separation of these muscles at the interspace, retractors being used to hold them out of the way. Exposure of the sheath reveals an anatomy as before described. The passage of the needle in both operations is to be from behind forward, great care being taken that neither nerve nor vein be included in the ligature. Fig. 498 is a study from dissection. It shows most fully the relational anatomy of external carotid artery and that of the superior cervical triangle as reference is had to seat of election for ligating primitive carotid. The anterior inferior shows upper boundary of that triangle as made by the crossing of the omo-hyoid muscle, also outer and inner boundaries as made by sterno-cleido and sterno-hyoid and thyroid muscles. At the bottom of the space exposed are the artery, vein, and nerve enveloped in the common sheath. It is understood, of course, that the two muscles named have been removed. Fig. 23, as well as Fig. 498, shows them in place and surgical relation.

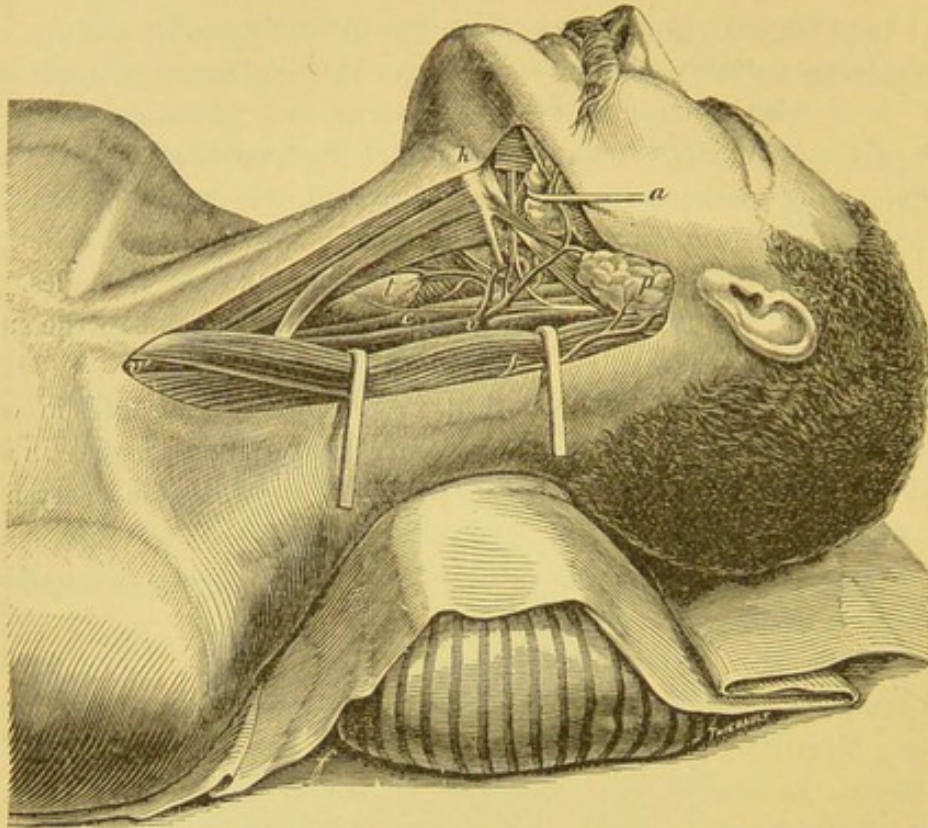
Fig. 498 enlarges the dissection shown in Fig. 23. Combination of the two affords an anatomy which furnishes a sufficient guide to the performance of the ligation.

Concluding the subject, it is to be added that a comprehension of the surgical anatomy of the neck region is best secured by first viewing the



part as a square, the boundaries of which are the mesial line in front, the trapezius muscle behind, the base of the jaw above, and the line of the

FIG. 498.



V, internal jugular vein with its tributaries, the facial, the lingual, and pharyngeal; p, parotid gland; h, os hyoides to which is attached the stylo-hyoid muscle, through which is seen running the tendon of the digastric, under which passes the hypoglossal nerve after crossing the external carotid; a, hook raising the submaxillary gland in order to expose contiguous parts.

clavicle below. This square is divided into two great triangles, known respectively as the anterior and posterior cervical, the separation being the sterno-cleido-mastoid muscle. These triangles are subdivided by the passage of another muscle, the omo-hyoid, into four, namely, anterior superior and inferior, and posterior superior and inferior cervical triangles. Desiring to inform himself as to a special operation, or as to detail, the practitioner isolates the particular triangle and makes his study, or diagrams, without reference to any other part.



## CHAPTER XLIX.

### THE ANTRUM OF HIGHMORE AND ITS DISEASES.

MANY years spent in a practice which should have afforded every opportunity for observation, as well as a scope of view which necessarily offers to one who is himself a hospital surgeon and a frequent visitor at hospitals, combine to impress the writer with the truthfulness and propriety of a conclusion, that the immediate diseases of the antrum are, for the most part, simple in character, easy of diagnosis, and, as a rule, not at all difficult of treatment. Indeed, for the purpose of general study, one would not be entirely without justification in asserting that there are but two sources of trouble to be found in this cavity: the first, and prominent, being lesions secondary to the diseases of the teeth; the second, the lesions common to mucous membranes, wherever situated. Certain it is that the great majority emanate from the first of these directions; while the atonic conditions, represented by the dropsies, the puruloid secretions, the mucous engorgements, and the ulcerations, are in no wise different from ordinary mucoid affections, except as modifications are made by situation; the last being conclusively proven by the fact that what is the cure of the one is the cure of the other.

While accepting, however, that in these two directions lie the chief sources of trouble, it is not by any means to be understood that the subject is unworthy investigation outside of such considerations; on the contrary, there is found recorded more than one description of diseases of the cavity, which, to the author, at least, are as anomalous on principle as they are in description, and which he can only explain to himself on the ungenerous supposition that the authors have drawn on their descriptive powers, or else that the antrum has some strange anomalies.

Again, as a class coming between these uncommon and the common affections, it follows, not at all indirectly, that there exist sequelæ of certain of the exanthemata which have a special and peculiar affinity for this cavity; while, in syphilis, it may be the case that the very first event in the secondary train exhibits itself in a disturbance of the sinus. That this latter, however, is rare, observation certifies. Indeed, syphilitic troubles of the antrum are so infrequent even in the tertiary stage of that affection, that experience will lead to the inference that the cavity never takes on the disease unless when, from continuity of structure, it has the trouble absolutely forced on it, this either from its relationship with the hard palate in the oral direction, or with the turbinated bones in a nasal; for, while the practitioner will surely hear



complaints, yet, if he investigate the cause of trouble, he will find that mercurial inflammation of periodontal membranes is the source of offence, rather than the specific condition. Clumsily performed surgical operations are also occasional causes of morbid conditions being set up in the cavity, which, when forerunning, would of course be so evident as to force the consideration of them on the attention,—the most common of them being the breaking of the fangs of teeth in attempts to extract these organs. (See *Tumors*.)

With these preliminary remarks, we pass to a consideration of the premised principal cause of antral trouble,—diseased teeth.

In the chapter treating on "Anomalies of Dentition," attention was directed to the close relationship of the fangs of several of the teeth with the floor of the antrum, and to the fact that it was not uncommon to find these fangs—particularly the palatine of the second molar—penetrating the sinus, thus associating their membranes, and furnishing a contiguity, if not a continuity of structure.

In the same chapter attention was also called to such diseases and conditions of the alveolar border as are apt secondarily to affect the antrum; means of diagnosis and treatment being suggested. The reader who feels sufficient interest in the subject will do well to review the chapter alluded to before proceeding to the consideration of the clinical cases here presented. (See, also, chapter on *Tumors*.)

CASE I. *Indolent Tumor on the Right Cheek*.—A woman had an indolent tumor on the right cheek, about the size of a pigeon's egg, occasioning much disfigurement, but altering the color of the skin very slightly. The patient had often suffered violent toothache on this side, and, though young, had few teeth now remaining, and these all carious; otherwise she was in very good health. The tumor was prominent toward the cheek, palate, and nostril, yielded on pressure, and gave a slight noise as it returned to its position.

The symptoms caused the practitioner to suspect the existence of some fluid, which it was necessary to evacuate and follow with suitable injections. For this purpose, the cheek was drawn aside, and an incision made into the bone above the gum, with a bistoury, enlarging it before and backward, till a sufficient opening was obtained, from which escaped an inodorous mucous fluid. The bone was at no point denuded of its periosteum. The wound was dressed with a pledget of lint saturated with spirits of wine, and the next day the patient was better. On the third day she was feverish, the sinus was swollen and painful, and the discharge acrid and fetid. These symptoms were controlled by proper remedies, and, after twenty-four days, the walls of the sinus were nearly restored to their normal condition.

The canine tooth of this side being very obliquely situated, it was thought proper to extract it, and thereupon followed an escape, through its socket, of fluid contained in the sinus, though the tooth itself seemed perfectly sound. Through this orifice injections were made. The opening made in the exter-



nal wall healed promptly, without any exfoliation; in six months the tumor entirely disappeared, and the patient was cured. (From Baron Haller's Collection of Medico-Chirurgical Theses.)

The translator of the above case, in commenting upon the treatment, pointedly remarks, "One cannot fail to see the uncertainty, not to say obscurity, of the treatment adopted. Though all the teeth were carious, and their extraction plainly indicated, an incision in the external wall of the antrum, or, more correctly, its destruction, was determined on. The result is seen in the symptoms which supervened on the third day, which were, perhaps, hastened by the spirits of wine. We have here a canine tooth quite displaced and involved in the tumor; yet it was long before the idea of its extraction occurred, though the subsequent discharge, through its socket, proved how advisable it would have been at the commencement of the treatment. In this way the time of cure might have been shortened by half."

CASE II. *Distention with Softening of the External Walls of the Sinus.*  
—In —, says the same surgeon, I was consulted in the case of a large tumor of the right cheek. The external wall was much distended and softened, and yielded to pressure, upon the removal of which it gave a sound resembling the crushing of an egg-shell. The nose was turned to one side, —the nostril was obstructed,—yet the patient suffered no pain, and the skin, though distended, preserved its natural color. On examination of the mouth, I found that the crowns of the bicuspidati and molars were destroyed by caries, which induced me to advise the extraction of their persistent fangs; the patient consenting, this was immediately done. The shock occasioned by the removal of each of the fangs, caused a portion of fluid to escape from the sinus through the natural opening: it was thin, reddish, saline, and inodorous, and, in all, about three spoonfuls. The tumor could now be made to disappear by pressure, but would again return to its full size. Pressure caused no escape of fluid through the nasal, and but slight through the alveolar, opening, which latter was at the bottom of the first molar socket, and large enough to admit the finger.

The internal membrane of the sinus was entire, except at the alveolar opening: through this I made injections of warm water, strengthened with a little gently alterative fluid. The next day I injected the sinus repeatedly with a decoction of agrimony\* and honey of roses, meanwhile not neglecting external compression. In fifteen days the parts returned to their natural condition, all crepitation of the bone ceased, and the discharge was very slight. I now had recourse to stimulating solutions. On the second day the discharge had ceased, and the alveolar opening was reduced to a mere fissure, and in a month from the extraction of the teeth the patient was fully restored.

\* A mild tonic and astringent. An injection of more character would be as follows:

R.—Glycerinæ, ℥j;  
Tincturæ opii camphoratæ, ℥ij;  
Aquæ Coloniæ, ℥iv. M.



CASE III. *Periodontal Abscess affecting the Antrum.*—A patient was brought to the author who, for more than three months, had suffered with a tumor, like the last, on the right side. The maxillary cavity was distended to a level with the orbital margin; the nose was turned to one side, and the vault of the palate was remarkably prominent. The treatment pursued consisted in removing the fangs of the first two molars, the crowns having been destroyed by caries, which fangs seemed to be the immediate cause of the disease. Next, the opening at the bottom of one of the sockets was enlarged, and through this there escaped a large quantity of a serous inodorous fluid. Pressure upon the palate and external wall caused this fluid to pass through both the alveolar and the nasal openings: this compression, together with suitable injections, soon terminated the disease.

The teeth on the left side being in bad condition, their removal was urged; but to this the patient would not consent. In three months she came back with a precisely similar swelling of this side, which, having the same cause, was cured in the same manner.

CASE IV. *Abscess of the Antrum caused by a Tooth.*—The following very interesting and instructive case is from the practice of Dr. J. D. White, and was reported for the *Dental Cosmos* by his son, Horace Meredith White, M.D.:

Mr. S., aged twenty years, light complexion, peculiar whiteness of the skin,—a characteristic of the family,—had been complaining for some time of a fetid discharge from the right nostril; of heat, and a sense of tension, in the right superior maxilla.

He applied to his physician, who gave him a wash, with the belief that the parts would speedily return to their normal condition, the practitioner supposing the affection to be merely an increased discharge depending on a slight local hyperæmia, the result, perhaps, of the bad state of the weather at the time. The parts, however, did not recover; the discharge became much more fetid, and evidently was principally composed of unhealthy pus, though it was not as copious as it had been previously; the pain was not severe, but the heat of the parts more elevated, and the sense of tension increased. The patient was irritable and pale; the heat of the body was above the average temperature. This was the condition of the sufferer when he came under the care of Dr. W.

Upon examining the anterior naris, nothing was to be discovered to account for the discharge; the mucous membrane being a little inflamed, but not sufficiently so to explain it. A diseased state of the antrum was suspected, and the mouth was looked at to ascertain if diseased teeth could be the cause. The second molar, upper jaw, right side, was unsound. Part of the crown was decayed away; the bulbous portion of the nerve, and the filaments of the buccal roots, were dead, but that part in the palatine root was living, and occasioned the patient pain. A little arsenical paste was applied to destroy it. No sign of alveolar abscess was present in this or any other tooth. The next



day the nerve in the palatine fang was removed without trouble; a careful inspection was now made, and important information received. On examining the right nostril by means of the speculum, a little pus was seen in the middle meatus. The patient was requested to incline the head toward the left side; he did so, and on looking at the parts again, a large amount of pus was found. This together with the facts stated already, and that there was no other assignable cause of the discharge, was deemed sufficient to establish the diagnosis,—abscess of the antrum, caused probably by the unsound second molar tooth.

Extraction was advised and submitted to. On the removal of the tooth no pus escaped. A probe was introduced into the alveolus previously occupied by one of the buccal roots, and readily passed on into the antrum; matter followed the withdrawal of the instrument.

The cure was completed on general principles.

Dr. White concludes the description of his case by remarking a coincidence which it will not be at all amiss to repeat here,—a coincidence which must have been very alarming to the patient. The gentleman had repeatedly visited a horse belonging to his father, which had a profuse discharge from the nose, thought to be glanders. The date of the horse's malady was prior to that of the patient, and, of course, an inference as to infection was not unnatural.

**Dropsy of the Antrum.**—This, which is only another name for mucous engorgement, is not infrequently the result of a reflected chronic periodontal inflammation. In such cases, we have the analogue of a similar inflammation in the cavity of the mouth: the membrane becomes puffy and thickened, the mucous secretions grow inspissated, and the natural opening of the sinus (simply through this thickening of the mucous membranes, the folds of which are the natural outlet of the cavity) is found obliterated. All egress being closed, the result is not difficult to surmise: if there should not occur atresia of the occluding membranes, and no correct surgical assistance be afforded, there must, of course, result either the gradual attenuation of the weakest portion of the parietes of the cavity, or the setting up of active and severe inflammation. If, on the contrary, the natural outlet has a partial restoration, it is not at all unlikely that a troublesome and, if misunderstood, tedious and unmanageable puruloid discharge will ensue: this being the result of a continuance of the cause of trouble. Recalling illustrative examples from his own practice, the writer remembers particularly the case of a child who, previously to coming under care, had been treated nearly two years for the occasional discharge of muco-purulent matter from the left nostril; the subject was of bad temperament, being a cross of the bilio-lymphatic. This patient was relieved in a single week, the treatment being directed wholly to the dental arch, if a course of salt sheet-baths—continued long after the local cure, and which had been directed in consideration of the relaxed condition of her general system—be excepted.



The relation of temperament and conditions is to be closely considered in connection with diseases of the antrum: it is, of course, far from being every one who is troubled with a bad tooth, the fangs of which penetrate the cavity, who has secondary disease of that cavity as a result. The author has just now under treatment a patient suffering from necrosis of the whole roof of the mouth, the result of a syphilitic cachexia, the exciting cause of the local trouble being an incisor tooth anomalously developed. This tooth, the extreme point of which presented just back of the incisive foramen, had been mistaken by a practitioner for the point of a sequestrum, and, being worked and cut at, periostitis had developed; and when the dead bone, which is the result, is ready to come away, both antra will necessarily be exposed.\*

A purulent condition of the secretions of the antrum is to be viewed as one considers a gonorrhœal discharge; indeed, Mr. Bell, the English author, has, not at all unjustly, referred to the two conditions as being similar, "both diseases," he says, "consisting equally of an altered secretion,—in the one, of the pituitary membrane, and in the other, of the muscular lining of the urethra, which in neither instance possesses any of the characteristics of abscess, though the matter in both is purulent."

Certainly, if we allow for some differences, as influenced by cause and location, the description of the one answers very well for the other. In both there is the same perverted secretion, the same molecular change, the same sthenic and asthenic modifications.

As a gonorrhœal discharge is always preceded by certain inflammatory conditions, and as, after the subsidence of the acute attack, the discharge may long continue profuse, or, on the contrary, may decline to a scarcely perceptible minimum, so, in antral purulency, we have the antecedent inflammation, and may have the profuse or limited secretion.

In antral diseases, however, as is readily to be inferred, very much depends on the nature and associations of the secretion. A profuse discharge, with closure of the orifice of the sinus, must necessarily entail untoward consequences: the walls of the cavity will attenuate until (unless surgically relieved) the weakest point gives way, the rupture being most apt to occur either into the orbit or the mouth. Not infrequently, however, this weakest portion seems to be the canine fossa; the opening has also occurred at the tuberosity. The author's experience leads to the inference that the hard palate is by far the most common point at which such matter seeks egress. The tumor will be seen bulging from one side of the mesial line, the swelling advancing more or less rapidly, until fluctuation becomes distinct. A sign diagnostic of this class of tumors is, that the internal boundary is apt to be quite abrupt, and that it does not pass the line of the mesial division. The establishment of a fistula relieves at once the sense of distention, and, if such sinus has opened in a convenient place, as within the mouth, the patient

---

\* This proved to be the case. The lost process is now replaced by an obturator.



feels disposed to congratulate himself on having come to a sufficient cure. Unfortunately in the majority of cases, this satisfaction is of short continuance; for, independently of the fact that the disease at once takes on chronicity, making the sufferer an object of disgust to those with whom he is brought into immediate contact,—the fetor of the discharge, under some circumstances, being really unbearable,—the undue retention of the secretion within the cavity is a source of such irritation to the parts that not infrequently the most serious lesions result. In some instances—happily, rare—all the bones of the face are destroyed.

The causes influencing retention of these secretions are twofold: First, an external wound is apt to heal, and to continue impervious until increase of the collection induces sufficient pressure to cause absorption, as in any case of abscess. In the second place, the passage is blocked up by flocculi within the cavity.

Puruloid secretion in the antrum may, from the onset, be of so limited a character that, like secretions in certain of the ovarian cysts, years pass before marked inconvenience results. The writer is acquainted with a case, that of Mr. C., late a merchant of Philadelphia, in whom, after five years of great mental and physical suffering, a disease of the antrum, supposed to be malignant, was found to be nothing but simple muco-puruloid engorgement depending on a dead tooth. In this case the trouble had commenced with a feeling of heaviness and oppression in the body of the jaw; the parts had gradually enlarged until finally there was distention of the cheek to the size of a large fist, the eye being thrown entirely out of position from the rising of the roof of the antrum. Much treatment had been given the case, without the slightest benefit accruing. No attention, however, had been directed to the dental arch,—the teeth, although the patient was sixty years of age, being apparently in the most perfect condition. The result of this case was the diagnosis, on the part of a surgeon to whom he finally applied, of a dead nerve in one of the bicuspid teeth. The organ, although as healthy-looking as any of its fellows, responded to the stroke of an instrument in the manner described in the chapter on alveolar abscess; the tooth was extracted, and in six months the health of the patient was perfectly restored. A circumstance connected with the extraction offers an example of practice of which it is well not to lose sight. The practitioner informed the reciter that he expected to find associated with the tooth-fang a pyogenic membrane, and to have the extraction followed by a gush of pus, in both of which expectations he was disappointed. The fang was clean, and the blood which followed the operation had nothing peculiar about it. Not to be thus balked, a probe was passed up the alveolus of the extracted tooth, which, meeting a resisting yet yielding body, was thrust onward in the direction of the antrum; the withdrawal was followed by profuse discharge. Such a resisting body may be simply flocculi or it may be the mucous membrane proper to the parts: most likely it would be found the latter, for we are to remember that it is not alveolar or



antral abscess with which, in these cases, we are dealing, but simply what might be termed a mucitis, and, of course, a break in the continuity of the membrane is not necessarily to be inferred. The practitioner, in this case, only approximated to the exact condition; he thought, evidently, that the trouble was tooth-abscess discharging itself into the sinus, whereas (while the treatment was perfectly adapted to the requirements) the case was one of simple mucous or muco-puruloid engorgement, the result of reflected irritation.

The diagnosis of mucoid or puruloid engorgement of the antrum is not, as a rule, difficult to make out. At first there is inflammation, and this, as has been suggested, is found most likely to have origin with the teeth. As the trouble advances, the patient begins to complain of a sense of heaviness about the body of the cheek. If the secretion be active, there is much pain, sometimes sharp in character, but more frequently heavy and unbearably dull. In all chronic periodontal inflammation we have this same character of pain, but then it differs from that of engorgement in being confined to the alveolar arch; in this latter trouble the greatest distress is found associated with the floor of the orbit, which, as will be remembered, makes the roof of the antrum. At length, as the secretions accumulate, the parietes of the cavity begin to attenuate and expand. The tumor now forming may be distinguished from others,—first, by the history of the case; second, by dryness of the naris of the affected side, the result of the closure of the orifice of the antrum; third, by the gradual and regular enlargement; fourth, by the non-association of the integuments of the cheek; and, fifth, by a fluctuation which it will finally yield.

To treat successfully such a disease, we have only to search out the source of offence, and, where it is possible, remove it. If this should prove to be a tooth, we may, if necessary, secondarily treat the antrum through the alveolus. Where the offence is thus of strictly local origin, we shall find little more needed than the daily employment of some stimulating application, such as diluted tincture of iodine, zinc-sulphate, or a carbolized solution. Where the acrid character of the retained secretion has provoked degenerating ulcers, the very happiest effects are to be obtained from injections of chloride of zinc: *zinci sulphatis*, ℥j; *aquæ*, Oj.

If, on the contrary, such bad conditions of the antrum be associated with constitutional causes, it need not be suggested that these are to have a required attention. In these latter cases, where the cure inclines to be tardy, complete relief is to be given a patient locally, by making an opening into the cavity, and keeping it patulous by means of a cotton tent; this, combined with the daily use of such injections as may seem indicated, yields great satisfaction.

In parenthesis, it is here to be remarked that the antrum once opened in the floor region, absolute closure is not to be expected; this certainly as the rule; neither, in the experience of the writer, is closure of consequence, no



harm resulting from the opening. If the orifice be large enough to admit particles, syringing corrects the difficulty, or a plate may be made to cover the break.

Concerning abscess proper of the antrum, it is to be set down as the rarest of rare diseases. Abscesses, described so frequently as occurring in this cavity, will commonly be found to have origin in the alveolar border, and, if treated like any ordinary case of alveolar suppuration, will generally at once succumb. (See *Alveolar Abscess, Anomalies of Dentition.*)

While, says Dr. Richardson, we cannot trace out the nature of that condition of the blood which gives rise to purulent formations, we are informed by observation of the external conditions which foster it. We learn that the pus-producing disposition is an indication of deterioration of blood. We see that when the system is enfeebled, whether by diathesis hereditarily supplied, as by the strumous diathesis,—whether by epidemic influences, or whether by deprivation of nitrogenous food, or the inhalation of bad air,—that under these circumstances the tendency to purulent formations in local structures is marked, and that, in extreme instances of the kind named, the act of suppuration may take its absolute origin from blood thus depressed.

Hence we have reduced almost to a principle in medicine the saying that suppurative tendency is a sign of an impaired or vitiated nutrition. Hence, also, we reason in speculative argument, that pus is lymph transformed into a lower form of organization, and we adduce, in evidence of this view, that the purulent fluid is incapable of organic construction, and that in animals in which the respiration, the circulation, and the animal temperature are more than ordinarily active, the formation of pus, even in an open wound, is an occurrence almost unknown.

These remarks, from a lecture by Dr. Richardson, cannot fail to be suggestive; they have indeed much meaning; the student reader, however, is to be reminded that their signification is limited. Puruloid conditions are, without doubt, and as the rule, perhaps, indicative of asthenia; but it would be very wrong to jump from such data to the conclusion that every puruloid disease requires treatment from a constitutional stand-point; and particularly will this hold good as suppuration of the antrum is concerned.

All diseases are to be treated on principle. M. Ricord, as many readers will remember, has a favorite prescription for gonorrhœal purulency, which runs as follows:

R.—Pulveris cubebæ, ℥vj;  
Ferri carbonatis, ℥iij. M.

Now, anybody can understand that such a combination would naturally act well on a debilitated system; it is, perhaps, a happy prescription for half the roués of Paris. Where applicable, it would answer as well for a puruloid antrum. The author recalls treating a gentleman for a gonorrhœal difficulty, which had been contracted almost immediately after getting over an attack of syphilis. This patient was medicated locally over six weeks, a defying dis-



charge constantly increasing in quantity. At the expiration of that period he was put on copaiba, tincture of iron, and quinia, and sent to the seaside for a few days. The discharge quickly began to diminish, and after the eighth day disappeared entirely. A success of this kind would not, however, lead to the inference that every man afflicted with a purulent discharge is to be treated with tonic stimulants. On the contrary, though large opportunity has been enjoyed by the writer in prescribing for this condition,—gonorrhœa,—it is seldom that indications have seemed to call for anything more than a strictly local treatment; at any rate, to such treatment the disease has been found quickly to succumb.

On a previous page it was suggested that puruloid conditions of the antrum had origin chiefly from two directions: first, from diseased teeth; second, from constitutional disturbance. It was also desired to convey the inference that where the fault is markedly in the first of the directions, the practitioner would err on the right side if, in his consideration of the case, he should incline to look on the tooth only in the light of an exciting cause, searching farther for what might be a predisposing condition. It is, however, to be inferred that lesion of the cavity may exist, while yet constitutional condition has nothing at all to do with the matter, and is not to be taken into account in the treatment. As a line in practice running between the two states, allusion is to be made to the fact that cases are met with where inference of constitutional association seems most marked, and yet where patients are quickly cured without resort to other than local treatment. These are the kind of cases in which the medical man is to feel his way: if he be an observer, it is not likely that more than a week will pass without his arriving at a just conclusion.

Coming now to the investigation of cases where the cause is to be found in cachexia, we have to refer back to the general features of disease as manifested on mucous membranes.

The most common, and indeed not very infrequent, cause of engorgement of the antrum—particularly mucous engorgement—is simple catarrh of the Schneiderian membrane. The patient takes a cold, the excitement expends itself about the nares; by simple continuity of structure the lining membrane of the sinus becomes vascularly excited; perhaps the duplication at the orifice, because of greater nearness to the central ring of inflammation, becomes congested to such extent as to close the opening: thus we have the elements for retention, and the mucus thus confined will, if not vented, sooner or later act as such a source of irritation that it becomes to the membrane of the cavity almost precisely what the virus of gonorrhœa becomes to the same character of membrane lining the urethra. Trouble from this cause is, however, generally so slight, and so quickly over, that it is seldom prominently marked, either to patient or practitioner.

The symptoms designating this condition are, first, simple vascular excitement of the membrane lining the nares, accompanied with increase of mucus.



As the grade of inflammatory action advances to complete congestion, the excess of mucus associated with the immediately preceding stage is succeeded by a most uncomfortable deficiency in the secretion.

This dryness is associated with all nasal inflammations of advanced grade, but when the trouble is to implicate the antrum it is even specially marked.

A single moment's consideration of the parts makes this plain: the nares are the natural outlets for the antral secretions; in ordinary Schneiderian catarrh the extensive secretory surfaces of the antra are comparatively unaffected: of course they serve to lubricate, to a greater or less extent, the passages. When, however, the grade of inflammation is of sufficient extent to congest the duplicatures of membrane which form the nasal outlets, then, because of the retention of the mucus, the extreme dryness is induced. This excessive dryness may be said, therefore, to offer the first diagnostic sign of antral engorgement from simple catarrh. From this point the disease advances or declines. If it decline, the trouble will have proved of such trifling inconvenience as scarcely to have attracted attention. If, on the contrary, it advance, the patient is soon made conscious of the engorgement by a sense of growing heaviness in the cheek, this being attended by soreness of a dull, sluggish character. The progress of the disease, from this condition, is precisely the same as that described as accruing from dental lesions.

**TREATMENT.**—This is to be conducted on general principles. Where the disease is met in its incipient stage, it will, perhaps, be found unnecessary to do more than administer a saline cathartic; or, what is found most satisfactory treatment, to give the patient at bedtime one-sixth or one-quarter of a grain of sulphate of morphia dissolved in an ounce of the liquor ammoniæ acetatis. This latter treatment is seldom found to fail in breaking up a limited congestion.

Where, however, the disease has advanced to engorgement, and the antrum is found to be enlarging, it may be necessary, in order to insure against more serious lesions, that treatment be directed immediately to the cavity. To accomplish this the second molar tooth is to be extracted, and penetration of the cavity effected through the alveolus of the palatine fang; in this way such medication as may seem indicated is readily employed. Indeed, for a cure it may be only necessary to keep the wound patulous, leaving the rest to nature.

**Furuncular Epidemics.**—It will be found the experience of every one who has observed in the direction, that during the existence of furuncular epidemics, mucous and purulent engorgements of the antrum are more than usually common. This is not strange, if we consider the epidemic condition in the light of an exciting cause alone; for in no single instance where his attention has been called in such direction has the writer been unable to discover a predisposing cause in a dead or diseased tooth. The same state of things exists in regions where the intermittents are endemic. All the odontalgias and cephalalgias of the country are apt to be quotidian, tertian,



or quartan. Furuncle is a condition associated, it would seem, with some derangement of the digestive or cutaneous functions. When epidemic, it would be in proof that a condition exists adverse to the performance of certain physiological functions. With the existence of a predisposing cause of disease about the antrum, it is not at all strange that the addition thereto of an exciting cause should at once increase the effect of the irritant even to the production of acute disease: and this, in truth, is the case: the patient escapes the purulency of boils, but he has purulency of the antrum.

**TREATMENT.**—This need scarcely be referred to: it consists, first, in removing the source of local irritation; secondly, in combating the constitutional disturbance.

**Scorbutus.**—This diathesis, as may be inferred, predisposes to antral purulency and ulceration. To understand the local condition thus induced, it is only necessary to examine the gums in an individual so afflicted. The state of the antrum is akin to that of the mouth. Treatment, to be successful, must be from the constitutional stand-point. If injection of the cavity be indicated, it is to be gotten at as before directed, or a canula can be passed into it through the natural opening in the middle meatus: the latter is, however, difficult, and therefore liable to objection. A delicate trephine used upon the wall of the canine fossa is the preferable way.

*The Exanthemata* are said to associate, not infrequently, their sequelæ with this cavity. Treatment thus demanded could need no special consideration: it would be a treatment founded on general principles.

**The Mercurial Diathesis.**—Reference has been made to troubles of the cavity thus provoked. Mercury holds a double pathological relation to the antrum; it predisposes from its constitutional relations, and actively and locally excites, through the periosteal inflammation it induces in the alveoli of the teeth. (The same is to be remarked of the condition known as scurvy.)

**TREATMENT.**—The indications here are twofold. Resolve, if possible, the inflammation about the teeth (see chapter on *Periodontitis*), and eliminate the mercury from the system. Chlorate of potash and the common muriate of soda are valuable medicines in the direction.

**Syphilis.**—This is a disease which it might be inferred would have affinity for such mucus-lined surfaces as the antrum. Now, the author's may be a singular experience, but, in contradiction of many who have written on the subject, he must say that, with the wide scope afforded by such a hospital as that of Blockley (in which, for over a year, he gave the study of the venereal disease a very close attention), he was unable to find a single case of disease of the antrum which could with justice be attributed to the vice. As remarked on a previous page, instances are met with where the origin has been traced in such a direction; and it will not do to deny that, in some cases, it has been justly so traced; but, in every example seen, the mercury administered for the cure of the syphilis seemed to have much more to do with the condition than any dyscrasia induced by the virus.



Among what may be termed anomalous cases of antral disease, mention is to be made with benefit, perhaps, of one presented at the author's clinics, the child being under charge of Dr. Cruise.

Patient, infant, two weeks old. Six days after birth the attention of the mother was called to an uncommon restlessness, which quickly associated with a growing swelling of the right side of the face, the eyelid being soon closed from œdema. Examining the case closely, discovery was made of a distending antrum, every portion of the common wall gradually bulging. Pressure upon the roof of the mouth, with counter-support to the cheek, caused a slight ejection of bloody pus from the nose. Diagnosis secured, a bistoury was passed through the attenuated, softened wall of the canine fossa, the withdrawal of the blade being followed by much pus and blood.

The treatment of the case, continued by Dr. Cruise, consisted in the frequent injection of black tea, of a strength as prepared for the table. Several spiculæ of bone came away, leaving the little patient, after two or three weeks, in what might be termed a common state of health. No injury was known to have happened this child in its passage through the pelvic straits. The mother was quite hearty; the father, however, was scrofulous. Three still-births had preceded the present live one.

Cases of what may be termed mechanical disease of the antrum will be encountered by every surgeon in the persons of those who, having met with the accident of limited exposure of the cavity, are in the habit of wearing plugs of cotton, wax, or wood in the break, which plugs escape into the cavity. The treatment required is, of course, the simple one of getting away the foreign body,—a matter, however, not always easy to accomplish.



## CHAPTER L.

### SALIVARY FISTULÆ.

By a salivary fistule is meant a break in the continuity of structure, either of a salivary gland itself or in its tube of outlet, through which break the secretion is poured over external parts rather than passing into the mouth to fulfil its recrementitial offices.

The causes of salivary fistulæ are various. In children, cancerum oris has frequently so sloughed away portions of the cheek as to produce the most intractable of sinuses, necessitating, indeed, plastic operations for their cure.

Wounds of lacerated character, and burns, are other causes of such fistulæ. Abscesses, osseous and dental, venting through the cheek and involving in their course the Stenonian duct, are origins with which the author has several times met. Epithelial cancer eroding the cheek is a condition encountered. Salivation, once a most common cause, is fortunately now infrequent. Surgical operations exposing the glands or ducts are to be enumerated among causes.

A rare cause of salivary fistula met with by the author on two different occasions, the diagnoses of which have been verified by removal of the organ, consists in an apparent subcutaneous ulceration of several lobules of the gland, the secretion being thus in small quantity continuously discharged and forming hygromata. In one of these instances—detailed, in the section on ranula

—an adventitious sinus led the secretion from the sublingual gland to the supra-hyoid bursa, forming a cyst as large as the fist.

The cure of salivary fistule is found in restoring by any capable means the original tube of passage.

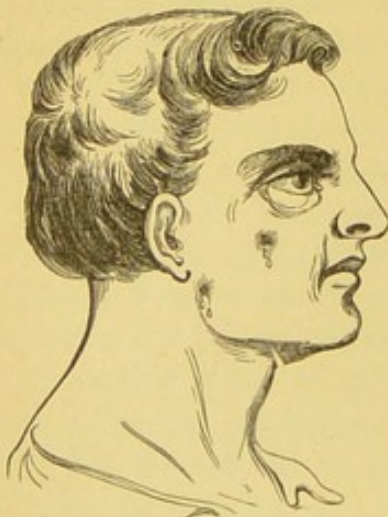Fig. 499 exhibits a fistule upon the cheek, the break being into the duct of Steno near its outlet. On the same diagram, situated just above the angle of the jaw, is shown a second. This represents the condition as connected with the gland proper.

Fistulæ are treated by cauterization and by operation. The first manner has its application particularly in exposure of the substance of a gland, and in most instances invites to a

trial which shall precede operative measures.

A mode of cauterization, which has the commendation of many successful cases reported, consists in pointing a stick of nitrate of silver, and forcing it

FIG. 499.—SALIVARY FISTULE—FROM LIFE.



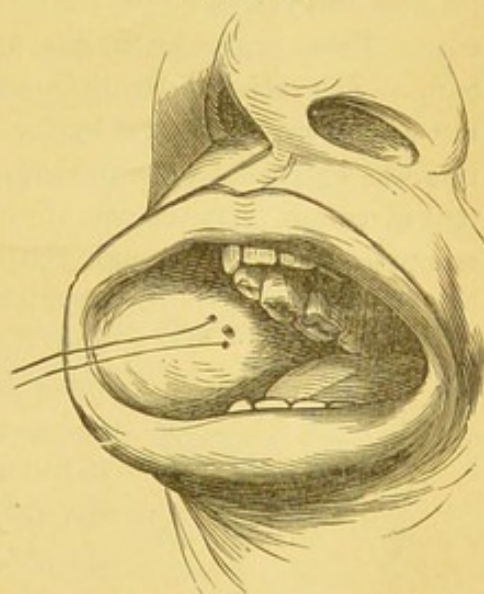


through the track of the sinus down to the gland. When a sinus is straight, and the caustic may thus be made to reach the place of disease in the organ, the practice is to be commended. In the tortuous track, however, such means do not apply; the line may be closed, but, the surface of secretion being unobliterated, the accumulating secretion needs but a very short time to re-establish its channel. Fistulæ of irregular track, connected with the glands, are, with most hope of success, treated by injection. Injections are to be saturated solutions, if deemed necessary, and may be either of the nitrate of silver, of chloride of zinc, or of iodine.

Of the operative means resorted to for the cure of salivary fistulæ quite a variety have been practised. A common manner, and one most easily performed, applicable particularly to breaks in the continuity of the Stenonian duct, consists in taking a strand of well-waxed ligature silk, threaded at each end to straight or curved needles, as preferred. Seeking the bottom of the fistule, the first needle is thrust through the cheek into the vestibule, and brought out at the orifice of the mouth; the second is now passed to the bottom of the fistule precisely as the first, and is also thrust through into the vestibule, but leaving some little tissue between its exit and the line of the first. The two ends being out of the mouth, a single knot is made, drawing it close up to the mucous surface of the cheek, strangulating the contained tissue. The strangulation, however, is not absolutely necessary, many surgeons, indeed, preferring the knot loose, and to have the new passage resultant simply from the presence of the silk. With such a new passage, the original fistule will frequently tend to close. Particularly will this be found the case where it has been so made as to afford easier exit for the fluid than does the fistule.

A second plan of operation is one devised by the late Professor Horner, of the University of Pennsylvania, and is that preferred and practised by many surgeons. Employing a punch, a simple incision is first made from the surface of the cheek down to the line and position of the duct: placing now against the mucous aspect of the part a wooden spatula, the instrument is directed to the bottom of the superficial wound made by the knife, and then pushed through to the spatula, thus, as is seen, cutting out a section of the tissue, and affording a track to the discharge.

FIG. 500.



Agnew's method of treating salivary fistule. The cheek is represented as everted, showing the orifice of the duct of Steno, and the seton deposited between the duct and outside of the cheek, with its two ends brought out at the corner of the mouth. As the threads cut their way out by absorption, the duct is detached from the external opening in the cheek.



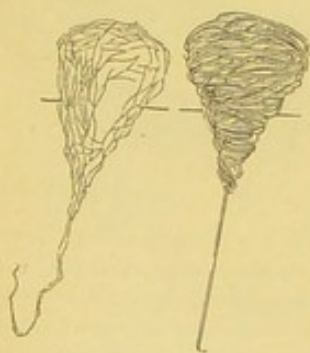
The external incision is next closed, and attempt made to secure immediate union.

As a study in a class of cases oftentimes found quite defying, the following may be offered.

The patient, a gentleman of excellent constitution and in easy circumstances, suffering from a carious dens sapientiæ, had sought relief in its extraction. The dentist, however, had the misfortune to break the tooth, and was unable to remove the fang. From the resulting irritation, conjoined with that residing in the broken and inflamed root, caries of the bone was induced; this, in its turn, inflaming the cheek an abscess formed which opened externally, involving in its passage the duct of Steno, thus producing fistule. The condition of the patient was as follows: the natural outlet of the gland continued patulous; consequently, to the comfort of the case, much of the secretion found its way into the mouth. Through the artificial channel enough of the fluid escaped, however, to keep the cheek constantly bathed with saliva and pus, the orifice being continuously covered with a large, but soft, pasty, and imperfect scab. Of course, so long as the channel passed saliva, it was impossible for nature to close it.

In this case,—which had been under the treatment of different surgeons for over two years,—three weeks, lacking three days, were required for the cure. First, examination was directed to the condition of the underlying parts. The caries of the bone being found cured, the depth and course of the sinus were discovered by the use of an ordinary silver probe. This fistule was enlarged by the introduction, repeated for several days, of a twisted tent of cotton. At the end of this period a slender, straight-bladed bistoury was passed directly through the cheek into the mouth. An eyed probe was

FIG. 501.      FIG. 502.



next threaded with a cotton tent (Fig. 501), large and thick at the part which was to occupy the inner half of the thickness of the cheek, delicate and as thread-like as it could be made where it was to be lodged in the external track of the fistule. By the aid of the probe this tent was carried through the cheek, and was then fixed in position by a little slip of adhesive plaster, attaching it to the cheek. The cotton, being kept clean and disinfected by daily syringing, was retained in position one week, the swelling of the inner bulky portion having by this time resulted in the formation of quite a channel, with a corresponding diminution in the diameter of the fistule. At this stage it was replaced with a wire seton (Fig. 502), made by taking the most delicate of ligature iron wire, and coiling it upon itself a number of times to half the thickness of the cheek, a single strand continuing the length designed to occupy the line of the fistule. To replace the one with the other it was only necessary to attach them by an intermediate strand of silk: as



one was withdrawn, the other took its place. This wire seton was thus inserted, and was held in place by perforated shots clamped on each extremity. In one week the external, or original, fistule had closed so as to hug the wire, the discharge being entirely into the mouth. The seton was now withdrawn, and on the next day complete closure was found to have resulted. The case was dismissed cured, and has remained so.\*

A fistule of the parotid gland proper, failing to close upon cauterization, is to be treated precisely as the case just detailed. In place, however, of the pyramidal coil, a rope of wire is used, three or more strands being twisted together; the track leading to the mouth is to be the shortest that can be selected.

The surgeon, on meeting with a case of uncomplicated fistule, is to make the attempt, before resorting to the more formidable means, to restore a patulous condition of the obstructed duct. This he does by a free use of probes, passing these, of gradually increasing size, from the orifice to termination in the gland. The turning of the canal over the buccinator muscle offers the only complication.

Foreign bodies in the canal are the not infrequent cause of fistule. From the Stenonian duct, of a patient in the Oral Hospital, the author removed a short time back a splint of broom corn measuring over an inch in length. Earthy concretions, when met with, are to be crushed, otherwise removed by an incision made upon them from the mucous surface.

**Dribbling.**—This condition associates with deficiencies of the oral boundaries. Cure is by operation.† (For studies, see *Plastic Surgery*.)

---

\* The cross line upon both cotton and wire tents marks the proper size for use. The single strand associated with the base of the wire twist has been overlooked by the artist.

† DRIBBLING.—Patients infrequently are seen where constant dribbling, or at least constant desire or necessity to spit, exists. Persons so afflicted are met with who are debarred society, and who are an offence to themselves and to their families. Examination reveals that this dribbling is not generally associated with the salivary glands, but that it is excess of secretion on the part of the mucous bodies. Cathartics given such patients show a glairy mucous discharge suggesting the existence of worms, yet exhibition of anthelmintics fails in supporting the suggestion. Treatment is by tonics directed to the mucous tissue. Pilocarpine hypodermically used is a late application highly lauded: dose gr. 1-60. Any systemic derangement existing is to receive attention.



## CHAPTER LI.

### CARIES OF THE MAXILLÆ.

CARIES of bone, practically viewed, is a disease very analogous to ulceration in the soft parts, and is possessed of the threefold expression of simple, strumous, and specific. As the jaws are concerned, the condition is confined almost exclusively to the superior bones. The causes which act as provocatives are, of course, various; yet dead teeth and roots of teeth are found far to preponderate.

Caries of the jaw presents commonly, yet it may be in aggravated form, the external features which characterize the ordinary alveolar abscess, whether in its acute or chronic state. This, however, would be inferred, such lesion being so commonly its origin. When the attack is acute in its nature, ulitis or periostitis will always be found associated with it. If the disease originate as a pure ostitis, then the gum in turn quickly sympathizes; if, on the contrary, the inflammation arise from a tooth, periodontitis will distinguish the offending agent. In all inflammations about these parts, whatever their character and cause, the abortive treatment cannot too quickly be attempted. From failure to attack with sufficient vigor such perversions, the whole bone is sometimes destroyed.

Caries once established, a diagnosis is made easy through the instrumentality of touch. One or more fistulous openings will be found to exist in the gum, or it may be in some neighboring part, the orifices of which are surrounded usually by fungous granulations; it is only necessary to carry a probe through these sinuses when the bone is found riddled, honeycomb-like, and easy to break down, either as the surface is implicated, or as, in the strumous expression of the disease, the deeper parts are involved. In such examinations it is always found advantageous to replace the ordinary probe with the common dental excavator, as otherwise, from the less accurate touch attained through the first instrument, it is possible to mistake the denuded bone of ordinary alveolar abscess for the more formidable and extensive disease, thus being misled as to treatment. In carrying the instrument through the opening of an alveolar abscess, it is remarked that the bone is bared; but the touch differs from that peculiar to caries, in the fact of this uncovered bone being hard and resisting. Not always, however; for it has just been remarked that periodontitis and dental abscesses are the most common causes of ostitis and caries, reference being had only to the pure, uncomplicated cases of alveolar abscess. As a rule, when a sharp instrument can be made



to pass readily into the substance of the bone, and to break it down, caries is present. If, on the contrary, the bone be solid and resisting, even although denuded, caries does not exist. Carious bone is frequently, however, found associated with exuberant granulations, which deceive when the probe used is not of sufficient sharpness readily to penetrate the fungus. As a rule, no harm is seen to result in boldly thrusting knife or probe through soft parts inferred to mark benign maxillary disease.

An ostitis, however provoked, does not by any means necessarily run into osseous ulceration, any more than ulceration is necessarily a result of an inflammation in the soft parts. There are, however, certain conditions which markedly predispose to such degenerations: of these the strumous is without doubt the most common. The bones of scrofulous subjects break down easily, also those of persons who have received the mercurial impression. Cancerous caries of the upper jaw is not infrequently met with; while, aside from such lesions, it seems to be true that, in persons of the most robust and vigorous health, a slight cause has been sufficient to develop the disease. A case this moment recalled (a very expressive one) will serve to illustrate the probability.

In the autumn of 1867 a gentleman from a distant State visited Philadelphia for the purpose of having an opinion concerning a fistule that existed over the apex of the right upper lateral incisor tooth, and which had long resisted the ordinary applications and injections used by his professional adviser at home. This fistule had originated from the tooth named, a dead one, and was considered simply an alveolar abscess, the only question thought to be involved being the loss of an organ, which the patient was most desirous to save. The gentleman coming first under the care of a personal friend, opportunity was afforded the writer to see him in consultation, when examination revealed a softened, honeycomb-like condition not only of the right but also, partially, of the left jaw, necessitating an operation of very extensive character as the removal of bone was concerned.

In this case nothing wrong was recognized with the general health of the patient, he being young, and of more than commonly vigorous habits.

The primary lesion here was, without doubt, the dead lateral incisor. Why this should have provoked such extensive trouble one is at a loss to say. In this particular instance, as in other cases, the disease was developed and advanced without any very marked acute manifestations, a not uncommon feature in caries, and one which is of much importance to be borne in mind. A whole jaw may be softened and destroyed, while the patient rests under the impression that he has no lesion beyond cure through the loss of a tooth. Cases of this kind are occasionally met with, where the adviser and advised have been alike deceived.

The slowness or the rapidity with which caries of the jaw progresses is influenced by individual conditions. Thus, in the periods of dentition, the disease will commonly be found to make rapid progress, unless, indeed, the



vital forces are very resistive; while in the mercurially weakened bone, caries seems sometimes analogous to simple disintegration, as if, indeed, the particles had lost the power of cohesion.

The peculiar affinity existing between this disease and the cellular tissue of the bones leads to the inference that it is more common to persons whose skeletons are loose and spongy in character than to the reverse class; and this is markedly true: hence strumous children are very subject to caries, as is so often witnessed in their articular complaints.

In many subjects the condition seems to be that of a semi-fatty decomposition, the animal portion of the bone becoming quite soft and greasy; indeed, even the osseous particles thrown off present the same aspect. The relationship of the disease with tubercular deposits is so fully established in the minds of many that they incline to the conviction that such tubercle is present at all points of the manifestation of caries. That this is not fully true, is proven by examples such as have been presented. That constitutional causes have, however, quite as much to do with the development of caries as have local injuries, is made sufficiently evident in the immunity of the numberless persons who have been brought, without ill result, under the influences of similar local sources of irritation.

It has been suggested that caries may exhibit itself in various ways. Yet, however and whatever the manifestation, an *ostitis*—chronic or acute—must precede the ulceration. About the jaws the great majority of cases have, in their incipency, nothing to distinguish them from ordinary *periodontitis*; and it is by far most frequently the case that the acute attack has been long past before this peculiar ulceration is developed, it seeming to be that the resistive power of the bone is gradually worn out by the presence of chronicity; the inflamed tooth has died, and its devitalization is the source of offence. Nearly every case of caries of the jaws met with could have been aborted by the timely removal of a certain tooth or teeth,—not, of course, all, but that great majority which have dental irritation as the exciting cause.

A carious bone presents clinical peculiarities according to the duration of the disease and the several phases of the cause inducing it. If seen early, there is to be observed simply the increased vascularity and congestion of the inflammation. A little later, and a *cacoplastic* exudate occupies the cells, which cells, in their turn, have become enlarged, and their walls decalcified; these, still later, commence gradually to break down, together with the semi-organized lymph exuded into them; in proportion as such exudation has been, and is, extensive, and the breaking down is rapid, the caries may be said to be dry or moist. Such exudation and degeneration are markedly exhibited in many cases of hip disease, or in white swelling of the knee-joint, where the discharge may amount to quite as much as a pint a day. On now looking at the bone, we find it riddled with irregular cavities, many or all of which are lined by a sort of imperfect secretory surface, or perhaps it would be more



correct to say, a glazing of semi-organized exudate corpuscles.\* If the disease is to involve the whole bone, such will be its general condition. If, however, there reside in the part the vital force capable of resisting the lesion, then from the central point of the disease outward will be observed a change in the character of the lymph exuded. The farther we get from the centre, the more bland and healthy is the exudate; while the complete filling up of the cells (structural consolidation) exhibits the wall of protection present in circumscribed healthy inflammation of the soft parts. It is to be observed, however, that this protecting wall is most apt to give way before the advance

\* "The whole essence of caries consists in this: the bone breaks up in its territories, the individual corpuscles undergo new developmental changes (granulation and suppuration), and remnants composed of the oldest basis-substance remain in the form of small, thin shreds in the midst of the soft substance. In ossification (in cartilage) there is a portion of the original intercellular substance of the cartilage cells (secondary cells) which, though it belongs to the group as a whole, yet when these, in the course of ossification, are transformed into a number of isolated bone-cells, becomes, comparatively speaking, almost entirely independent of those cells individually (which have their own immediate intercellular substance to attend to, and from most of which it must be separated by a considerable interval), and therefore escapes the changes which befall them. It is this portion which remains behind in caries, while the secondary intercellular substance perishes. In other processes, however, which run a more chronic course (in cancer, for example), everything is destroyed.

"At the moment a periosteal tissue quits the surface of a bone, and the vessels are drawn out from the cortex in inflammatory condition, we see, not as in normal bone, mere threads, but little plugs, thicker masses of substance; and if they have been entirely drawn out, there remains a disproportionately large hole, much more extensive than it would be under normal circumstances. On examining one of these plugs, you will find that around the vessel a certain quantity of soft tissue lies, the cellular elements which are in a state of fatty degeneration. At the spot where the vessel has been drawn out the surface does not appear even, as in normal bone, but rough and porous, and when placed under the microscope, you remark those excavations, those peculiar holes, which correspond to the liquefying bone-territories. If it be asked, therefore, in what way bone becomes porous in the early stage of caries, it may be said that the porosity is certainly not due to the formation of exudation, seeing that for these there is no room, inasmuch as the vessels within the medullary canals are in immediate contact with the osseous tissue. On the contrary, the substance of the bone in the cellular territories liquefies, vacuities form, which are first filled with a soft substance, composed of a slightly streaky connective tissue with fattily degenerated cells. If round about a medullary canal the territory of one bone-corpuscle after another liquefies, you will, after a time, find the canal bounded on all sides by a lacunar structure. In the middle of it, the vessel conveying the blood still remains, but the substance around about it is not bone or exudation, but degenerate tissue. The whole process is a degenerative ostitis, in which the osseous tissue changes its structure, loses its chemical and morphological characters, and so becomes a soft tissue which no longer contains lime. The tissue which fills the resulting vacuity in the bone may vary extremely according to circumstances, consisting in one case of a fattily degenerating and disintegrating substance (the bone-corpuscles perishing), and in another of a substance rich in cells, and containing numerous young cells; this latter is formed by the division and proliferation of the bone-corpuscles, and the newly-produced substance is very analogous to marrow. Under certain circumstances this substance may grow to such an extent that—if we may again borrow our illustration from the surface of the bone where a vessel sinks in—the young medullary matter sprouts out by the side of the vessel, and appears as a little knob filling one of the pits in the surface. This we call granulation."—VIRCHOW.



of the trouble,—seeming to retard but not to check it. In other words, nature seems seldom able, unassisted, to complete a line of demarkation, as witnessed in necrosis.

**Treatment.**—To do all that can be done in these cases is not at all difficult. If inflammation of the bone exist in an acute stage, it is to be treated on general principles: cathartics, diaphoretics, counter-irritants, hot pediluvia, leeches, dry or wet cups, the general abstraction of blood, any or all of these means being brought into requisition, the practitioner being influenced alone by the resistance of his case. If a tooth, irritated in its enveloping membrane, be the cause of the inflammation, as is most frequently the case, such tooth is to be removed, or treated. Generally, in such an inflammation, it is found sufficient to scarify the gums, give a hot foot-bath, apply a blister to the back of the neck, and administer a saline cathartic. If such a course should not abort the trouble, then three or four Swedish leeches are to be applied directly to the inflamed part, this being easily accomplished by introducing a napkin back of the middle of the roof of the mouth. If even this should not succeed, and the patient be plethoric, blood is to be taken from the arm. Dry cups are invaluable.

It is, however, frequently the case that even what may be viewed as the acute stage will be found of an asthenic type. In these cases, conjoined with the local depletion, tonics are demanded: iron, quinia, beef-essence, cod-liver oil, etc., being indicated. If, when a case be first seen, the caries has become established, the acute action having ended, as recognized by the existence of fistulæ, the honeycomb-bone, etc., vigorous tonic medication, conjoined with stimulating injections, is to be used. Of such injections, the tincture of iodine, carbolic acid, compound tincture of capsicum, and chloride of zinc, will be found as promising as any. Of the tonics, a common experience gives to the chalybeates a preference. It is not, however, from the medication alone that a cure is to be expected. In caries nature seems unable to throw off the incubus of the disease; and the cases are rare indeed where relief by operative means is not found imperatively demanded. Such operative means, however, to be of profit, are to be well considered.\*

---

\* "Prevention is obviously the paramount indication. With this view, if symptoms of interstitial absorption be present, our attention will be directed to the arrest of this by counter-irritation and constitutional care. If a simple abscess or ulcer occurs on the surface of bone, it will be our object to effect the healing of this as rapidly as possible, in order to prevent degeneration. When mere osteitis is present and demands our aid, we shall treat it actively yet warily: actively, in order to arrest the inflammatory process ere yet the untoward results of suppuration or ulceration have occurred: warily, avoiding exhaustion of the system, and still more the poisoning of it by excess of mercurial and other active antiphlogistics; careful not to induce a state favorable to the occurrence of destruction in bone. And seeing that caries is usually so much connected with taint of system, our attention will be directed throughout toward constitutional care in connection with both prevention and cure.

"When caries has occurred, the indications of local treatment are abundantly simple. We are to take away the two portions which are incapable of healthy effort,—the intersti-



To operate for caries of the jaws the author now employs universally the surgical engine and stoned rose drills. The rapidity and painlessness with which such operations can be performed must be witnessed to be appreciated. One not possessed of an engine gets along very well, however, with two or three delicate chisels, a scalpel, and a syringe. Taking the fistula for a guide in an operation, the bone is exposed by a simple incision. Next, with rose drill or chisel, the softened structure is, little by little, cut away.

The extent to which caries is occasionally found to have progressed is a matter of surprise. One can do no better than follow the softened bone, wherever it leads. The author very frequently, in this way, has been led from an apparent simple beginning, to remove nearly or quite all of the upper jaw. Danger from hemorrhage affords no special occasion of anxiety; indeed, cases are few in which the injection of alum-water or phénol sodique is not found all-sufficient for its control. When healthy bone is reached in an operation, it is distinguished from the carious by both touch and sight. Under

---

tially absorbed as well as the truly ulcerous; leaving a solid foundation of normal texture, not only capable of, but already engaged in, the business of efficient repair. Afterward, the part is to be treated as a simple ulcer; our anxious care being directed to speedy yet efficient and certain closure, lest renewed degeneration supervene; not resting satisfied with a blue, elevated, soft, and spongy cicatrix, but insisting on the establishment of one which is firm, white, depressed,—plainly incorporated with the bone.

"For effecting the removal, cutting instruments are infinitely preferable to escharotics, in all situations where excision is practicable. But as a general rule, no operation of any kind should be performed on the bone unless the adjacent and superimposed soft parts are in a quiet state. They may be undergoing the acute inflammatory process; they may be the seat of acute suppuration, of acute ulceration, or of both; and removal of a portion of bone, imbedded in such soft parts, is almost certain not only to prove futile as a means of cure, but actually to aggravate and extend disease. The then carious portion of bone may be taken away, but ulceration instead of reparation is certain to ensue; and by rapid degeneration the carious condition is renewed; or a more general and intense osteitis is kindled, and the partial caries is merged in general necrosis. And even supposing none of these untoward events to occur, still the time of operation were inexpedient, as causing an unnecessary and therefore unwarrantable amount of secondary inflammation.

"The soft parts being already quiet, or having become so under suitable treatment, free incision is made through them, so as effectually to expose the diseased portion of bone,—previously tolerably well explored by judicious use of the probe. The extent of the doomed parts having been satisfactorily ascertained, their thorough removal is then to be accomplished.

"Escharotics in some cases are employed; as, for example, when a patient resolutely objects to any other mode of removal. Or when cutting instruments have been used, and yet a border of suspicious character remains, the extinction of such a suspected part may sometimes be conveniently enough intrusted to cauterization. The actual cautery may be applied, but unwisely. It effects too much. The carious part is at once and satisfactorily killed; but, as in all severe burns, the texture immediately surrounding the eschar, though escaping with life, has its vitality very much impaired, and is more prone to disintegration than to repair. The potential cautery is infinitely preferable. It destroys the diseased part just as effectually, though, perhaps, with less rapidity, and at the same time the immediately adjoining parts do not in any wise suffer, but at once institute a healthful line of demarkation for removal of the dead part, and are well able to commence, at the same time, a sthenic action of repair."—MILLER.



the steel the first is hard and springy, the latter soft and brittle; passing, with the instrument, from the diseased to the healthy tissue, one could not fail to remark a difference. To the sight, healthy bone is white and vascular; carious bone is dark and non-vascular, or it is a deadish white, or oleaginous. A very observable difference between caries and necrosis consists in the absence, in the former, of the odor associated with the latter, caries running its whole course without necessarily giving the slightest annoyance from this cause; at least, where proper cleanliness is observed.

The use of the syringe, after an operation for caries, is of the greatest moment; the capacity is not to be less than of one gill, and every particle of detritus is to be carefully washed away. In the after-treatment, this instrument will also be found to perform good service,—repeated washings with proper medicaments being very conducive to a cure.

The use of sulphuric acid in the treatment of caries, designed to unite with the base of the phosphatic salts of the bone, and thus remove it, introduced into practice by George Pollock, F.R.C.S., surgeon to St. George's Hospital, has justly attracted much attention. Used in that state, in which nature, possessed of the requisite resistive force, has compelled the line of demarkation, and needs only the assistance of relief from the dead tissue, sulphuric acid employed in a required strength will undoubtedly dissolve such dead bone and thus allow a cure. Again, employed as a local stimulant, it exerts most excellent influence, exciting into action, and seeming to afford support to all the abeyant force of the parts. Still again, used as an antiseptic, its effects are very beneficial, assisting in keeping the parts fresh and clean.

In using sulphuric acid with a view to the solution of dead bone, one part of the officinal is to be diluted with eight of water; or, if preferred, the aromatic acid may be used pure. Mr. Pollock himself uses this latter, at first diluted with equal parts of water, and then more and more nearly pure, pencilling the surface which he exposes by turning aside the soft parts. When the acid is employed simply as a stimulant or antiseptic, the circumstances of each case will govern the strength of the application.

Aromatic sulphuric acid is used undiluted by the writer, being applied and retained against the part to be dissolved on tufts of cotton wool fully saturated. No harm results to the soft parts.

The employment of caustic potash for destroying quickly disintegrating bone has the recommendation of no less eminent authority than Dr. Fitzgerald, of Dublin. When tested, however, by the side of sulphuric acid, it is to be agreed that there is no comparison. With the former agent, secondary injuries may associate; with the latter, nothing but good is to be anticipated.\*

---

\* "Acid does not affect or injure the soft tissues when used in the diluted form: acting chemically on the *diseased bone alone*. It does not affect the living bone, and its application is seldom followed by any great degree of pain.

"That, in the diluted form, it will only act on dead or diseased bone, and not on healthy bone, is a point of very considerable practical importance, and is the great advantage sul-



**Illustrations in Practice.**—Mary B., girl of weakly constitution with caries of inferior maxilla involving the body of the bone from the second bicuspid of one side to the first molar of the other, the teeth being in place, but very loose, three sinuses existing in the gum overlying the disease, which sinuses were in constant discharge. Examination with a sharp-pointed steel probe exhibited the bone as so honeycomb-like that the instrument could be pushed through it without difficulty.

**TREATMENT AND RESULT.**—Patient kept on a chalybeate tonic for three weeks, then operated upon before hospital class. Desirous of testing the reparative powers, a cut, uniting several sinuses, was made below the apices of the roots of the teeth, and with delicate gouges the softened bone was scraped away, allowing the teeth to remain supported almost exclusively by the gum. After the operation the parts suppurated from the superficies of the bone more or less for three months, the left cuspis being thrown off by a slough of the immediately overlying gum. At the end of this period, an osteophytic sequestrum was exfoliated, after which the wound closed, the teeth gradually became firm, and a cure, with the teeth preserved, was happily secured. Locally, sulphuric acid alternated with the chloride of zinc was used. Systemically, advantage was endeavored to be taken of all tonic influences: exercise in the open air and sunshine, salt-water sheet-baths, juicy undercooked meat, the compound tincture of gentian as an appetizer, etc.

The use of sulphuric acid in caries, acting to the chemical decomposition of bone, may readily be conceived as possessed of much good import; indeed,

---

phuric acid possesses as an application, under the circumstances quoted, over the use of the gouge, or of the actual cautery, or of caustic potash. The following experiments, conducted at my request by Mr. Henry M. Noad, lately my clinical clerk, satisfactorily prove the correctness of this statement.

“Portions of dead, diseased, and healthy bone were selected and subjected to the action of sulphuric acid, viz.:

- “1. Dead bone, 10 grains.
- “2. Diseased bone, 10 grains.
- “3. Healthy bone, middle age, 10 grains.
- “4. Healthy bone, old age, 10 grains.

Exposed to the action of a mixture of sulphuric acid and water, one part in four, for three days, at a temperature of 100°, the following were the results:

- “1. Dead bone: Phosphate of lime, 2 gr.; carbonate of lime, 3.30 gr.; dissolved in the mixture.
- “2. Diseased bone: Phosphate of lime, 2 gr.; carbonate of lime, 1.3 gr.; dissolved in the mixture.

“3 and 4. In both specimens of healthy bone, *no action took place.*

“The process of disintegration or dissolution, with the commencement of healthy granulation from the surface of the living bone, may be observed simultaneously progressing, in any exposed surface of dead or dying bone to which the acid may have been applied. When its action and effects are compared with those of the gouge, the bruising which is necessarily produced by the use of the latter, the pain and frequent subsequent inflammation, and, even under the most favorable circumstances, the time required for the rough lacerated surface to recover itself, throw off its small bruised fragments, and become covered with granulations, the treatment by sulphuric acid will be found far preferable.”—POLLOCK.



it may very well be recognized as possessed in itself of power sufficient to a cure, doing chemically that which the gouge or bur does mechanically. The strength in which an acid is to be used depends entirely on the effect desired to be accomplished. If employed in the anticipation of decomposing carious bone, the undiluted aromatic sulphuric is never found over-strong. Personally, the author has frequently made a test strength much greater, using, indeed, the officinal ordinary sulphuric acid, taking, however, the precaution to make direct applications by means of a stick brush. Where acid is used merely as a stimulant, the aromatic is to be preferred and is to be used diluted *pro re nata*.

CASE II.—French lady, about twenty-three years of age; caries of base of alveolus of right cuspis of superior jaw, involving the palatine process, with discharge beneath the covering of the hard palate; two tumors, one the size of a hickory-nut, the other that of a hazel-nut, existing.

*Treatment*.—First opened the sacs, giving vent to the accumulated pus, the bone being found denuded quite the size of a dime piece. Once each day, for the period of two weeks, the sacs were injected with commercial sulphuric acid and water, one part of the first to twelve of the second. At the end of this time the cure was complete, granulations after the sixth day being recognized as covering the exposed bone.

In this second case, observation elicited the fact that the acid acted just as any other stimulant would have done. Iodine or zinc might have been used with a precisely similar result,—power existing in the natural force of the patient to overcome the destructive condition, requiring only the aid of slight stimulation.

CASE III.—Merchant from New York City; caries of both palate plates of superior maxillæ. In this case, while two sinuses existed, the mucous envelope of the hard palate was found separated from its bony base, forming a tumor which half filled up the mouth. Examination revealed the palatine processes riddled with holes. This was a character of case most admirably suited to acid treatment, and which was recommended. A diagnosis of different character afterward offered in another city resulted, however, in resection of the jaws; a performance as unnecessary as the diagnosis was faulty, and from which operation the author is under the impression the patient died.

CASE IV.—A very delicate lady, about twenty years of age; caries arising from presence of a lateral incisor tooth containing a dead pulp. When this patient first presented herself, no external evidence of disease existed, except that implying chronic inflammation of the membrane surrounding the root of the tooth, the organ being loose, slightly elongated, and sore; the gum, however, over the apex of the root was healthy-looking. Treatment directed to the cure was commenced by drilling an opening into the pulp-chamber, through the palatine face of the tooth; the cavity entered, a discharge of pus was the result. A succeeding step was an exploration of the parts about the



apex of the root, effected by passing a sharp steel probe through the soft tissues. The probe, meeting bone, was thrust forward, revealing a cavity the size of a hazel-nut, the parietes of which were found spongy and disintegrating. This cause, condition, and character of caries are most frequently met with in the upper jaw. Treatment of the case, which resulted in a cure in ten days, was as follows:

The pulp-chamber was thoroughly washed out with water medicated with creasote. The length and circumference of the pulp-canal were measured, and a delicate pyramidal cylinder of gold was passed and consolidated to the apex. This manipulation was not, however, a necessity, but had reference to the preservation of the future usefulness and color of the tooth. This accomplished, the parietes of the carious cyst were well broken up by means of a sharp excavator, and the detritus removed through the aid of a syringe. Injections of sulphuric acid and water, one part of the first to eight of the second, were now used for ten successive mornings, when the cyst was found filled with organizable material, and the cure remained complete.

Since penning the above illustrations, which pertain to the first of the preceding editions of this work, the author has operated on many cases of caries. There seems nothing to add except to commend aromatic sulphuric acid, employed pure, and freely, and to indorse the surgical engine and its appendages as being worthy to take the place of all operative means in common use.



## CHAPTER LII.

### NECROSIS.

NECROSIS, signifying death of bone, while a disease common to both the superior and inferior maxillæ, exhibits decided preference for the latter, attacking it, as the author is led to infer from the experience of his own practice, in twenty cases to five of the former. The lesion presents a twofold primary expression. It commences as a general ostitis: stasis of the circulation quickly antagonizing nutrition, thus killing the bone outright; or, as commonly witnessed, it arises out of periosteal disease, the membrane affected being the periosteum proper, or, as recognized in a great majority of instances in which the condition is met with, the alveolo-dental tissue,—periodontium. In such primary membranous associations, either the tissue, as it reacts on the bone life, is found dead, or it is seen separated from the bone by a degenerating plastic exudate.\* In such inflammations and separations, it is to be inferred that the layer of bone immediately adjacent the membrane would be the first affected; this is so truly the case that timely incisions and the combating of the inflammation are most influential in the limitation of the disease,—this being markedly exhibited in periodontal inflammation. The superior jaw, however, is much more liable to take on a general inflammation than the inferior; but the higher vascularity and resistive force of that part seem to enable it to resist the destructive action and to limit the part overwhelmed.†

---

\* In necrosis confined to part of a bone, the increase in the vascularity of the parts is apt, especially in young persons, to result in hypertrophy of the remainder.

† Necrosis signifies death, and, as the human body at large is concerned, death relieves the surgeon of his duties. Partial death, because of the relation of a lifeless to vital parts, and because the changes of separating the dead from the living differ as to the situation and circumstances of parts, demands a close and very practical consideration on the part of a practitioner.

A particular portion of bone being deprived of its nutrition, attempt at separation and exfoliation is an immediate consequence. The phenomenal expression of throwing off a portion of dead bone and as well the destroying of an offending part is found in the inflammatory act. Circumvallation is the rule as to slough and sequestrum. To appreciate the process, it is only necessary to consider the blood supply to a part interrupted by an effusion of lymph, which lymph proceeds to coagulation, and which consolidation compresses little by little the vessels, until finally obliterating them. In traumatic sequestrum, *i.e.* where a piece of bone is broken from its bed, the signification is the same, the clinical difference being that in this latter case the nutritive interference is by reason of laceration of the vessels. Purulency is an associate of exfoliation. To appreciate this consists in a



Inflammation of the jaws, whether osteal or periosteal, is primarily to be treated on general principles. If acute in character, we may first try the effect of the hot pediluvia and saline cathartics. These failing, the parts are to be well scarified, or leeches may be applied, or blood taken from the arm. Diaphoresis can be employed. In short, antiphlogistics of any and every nature, promising control of the excitement, may be pressed into service. If all, however, fail, and pus form, vent cannot too soon be given that fluid. When, on the contrary, an inflammation is chronic and asthenic in character,

---

recognition of a mass of circumferential exudate unable to do more than partially organize itself, falling back quickly into a degeneration expressive of pus, pus being nothing else than abortions of granulation-corpuscles. Purulency is the act of floating. A dead part is lifted or floated by means of pus. Pus continues to form so long as a dead part remains in contact with a living seat.

A pyogenic membrane is a sheet of granular lymph making effort to organize itself. A pyogenic membrane ceases to be the moment sufficient power accomplishes the act of organization. A pyogenic membrane does not secrete. Pus is not a secretion, but a degeneration.

Demarkation is a line expressive of a surface of separation; all in front of this surface is the sequestrum; all back of it is vital.

To demark a part is an act related with varying time and systemic energy. The process may extend over months or it may accomplish its end in a very few weeks. Nine months is the ordinary time required for exfoliating a lower jaw.

A sequestrum prevented by the circumstances of situation from being thrown off becomes enveloped by a case of new bone. This is found markedly with the instance of the inferior maxilla, it being, as a rule, necessary to break through a case in order to get at the dead part.

Osteophytes are expressive of attempts at ossification. As a rule, osteophyte after osteophyte dies before sufficiency of force is found to complete organization. At a certain stage in the processes of exfoliation and repair osteophytes are to be met with irregularly interspersed throughout the affected region, and too often are found converted into loosened sequestra, which require to be removed.

Periosteum, as well as bone itself, constitute the osteogenetic agencies. Both are no sooner relieved of the incubus of a dead part than evidences of repair are exhibited. Both exude and organize bone pabulum, both enter the work as repairers of damage.

The student familiar with the processes of exfoliation and repair, as flesh lesions are considered, has nothing different to learn as concerns bone surgery. There is first, as the result of injury, extravasation into the cellular structure, into the cortical substance perhaps, and certainly beneath the periosteum. As a result of such extravasation, nutrition is entirely cut off from the lymph-surrounded island. The death of the island following, the most immediate layers of lymph degenerate, thus affording pus, which is the eliminating or rather the extruding agent. Repair of bone and of soft parts are the same, save as difference of tissue is concerned.

Granulation material, incapable of organization, needs assistance in the shape of stimulation. Cleanliness is an essential, and dead osteophytes are to be picked or washed away as soon as discovered.

As an injection acting peculiarly happily where osteophyte degeneration exists, no agent known to the writer acts so happily as aromatic sulphuric acid, the strength used varying with the indications; equal parts of the acid and water is an ordinary injection, or the medicine may be used on cotton, a cavity being loosely stuffed.

A second stimulant and antiseptic of most satisfactory response is found in a combination of capsicum and myrrh (the *tinctura capsici et myrrhæ* of the *Pharmacopœia*). This is used diluted with water, the proper strength being expressed by a bluish-white color.



as marked in the puffy, debased character of the parts exhibited in the dyscrasic, with the necessity for free scarification will exist a demand for local stimulating douches and the administration of tonics. Of the supporting medicines applicable to these cases, the very best is found in the union of sulphate of quinia with the muriated tincture of iron. A combination very frequently employed is as follows :

R.—Tincturæ ferri chloridi, ℥j;  
Quiniæ sulphatis, ℥j. M.

Sig.—Fifteen drops in water four times a day for an adult.

Ostitis, as a primary expression, exhibits its most intractable cases in the periods connected with dentition, whether first or second; the irritability being increased and kept up by the excitability associated with this process. Hence the care necessary to guard against any increase in the vascularity natural to such age. The trouble aroused, nothing can be done, however, beyond using such treatment as applies to ordinary cases: except, indeed, it will be found that there exists a greater necessity for the use of sedative medicaments.

In directing treatment to a condition of ostitis or periostitis, as relation is had with necrosis, an indication of principal signification lies in the discovery, and removal when possible, of the exciting cause or causes. That such causes may have proper and definite signification, we proceed to the division and study of the subject as clinically it presents its diversified phases and aspects.

In the order of frequency in which maxillary necrosis is met with, the following table may be accepted and studied :

1. Dental necrosis.
2. Alveolar necrosis.
3. From lack of room for eruption of wisdom-tooth.
4. Syphilitic necrosis.
5. Mercurial necrosis.
6. Necrosis from injuries.
7. Exanthematous necrosis.
8. Phosphor-necrosis.

**Dental Necrosis.**—Dental necrosis—death of a tooth or teeth—may claim a first attention as being the most common of all the troubles of the ossa corporis.

A tooth has a threefold source of vitality,—an internal, or tubular, secured from its pulp; a middle related with the vessels of the tunica propria; and an external arising out of its periodontum. The destruction of the internal circulation, through the killing of the pulp and filling the root-canal with metal, is so common an occurrence as to be familiar to almost every one.

By the majority of teeth, if properly treated, such destruction of one source of the nutritional supply seems to be sustained without much apparent



inconvenience. The treatment consists, as we have learned, in extracting from the cavity every particle of dead pulp, and so filling the chamber with gold or other material as to prevent the introduction of more irritating matter. (See *Treatment of Pulp-Cavity*.) Where teeth, however, are not properly treated, or where there is great susceptibility in the system to vascular perversion, the destruction of the pulp results in an extension of irritative action to the periodontal membrane, yielding the lesion known as periodontitis; this, if not aborted, terminates in the death of the tooth.

A dead tooth is not, however, fortunately, treated in all cases by the system, or even in the majority of cases, in so summary a manner as a piece of dead bone. As a rule, there exists a wonderful forbearance on the part of nature to its presence, and the organ may be retained in its cavity and made to serve useful purpose for a long time. True, it is discolored, and, provided there be no decomposing pulp in the canal, in proportion to this discoloration may the degree of degeneration be judged. A tooth lowers in the scale of vitality in degrees. It may be deteriorated as the death of part of its pulp is concerned, or as the death of all of it is implied,—or as regards the whole or any part of its enveloping membranes. When both pulp and membranes are dead, the tooth, of necessity, must be dead with them; and in proportion to their destruction, so is its destruction.

Fig. 503 is introduced with a view of exhibiting the refinements in tooth-nutrition, and the possibility of a retention of vitality on the part of an organ, its pulp and periodontum being dead. Glancing at the diagram, it will be seen that the dental artery gives off three branches, the first passing through the apical foramen to be distributed to the pulp, the second going to the tunica propria, the third supplying the periodontum. (See *Tunica Reflexa*.) It seems quite possible that one or two of these branches might be obliterated, the third remaining intact, and, accepting this third as the vessel distributed to the tunica propria, it can be understood that, though seemingly deprived of nutrition, the tooth-structure is yet not without pabulum.

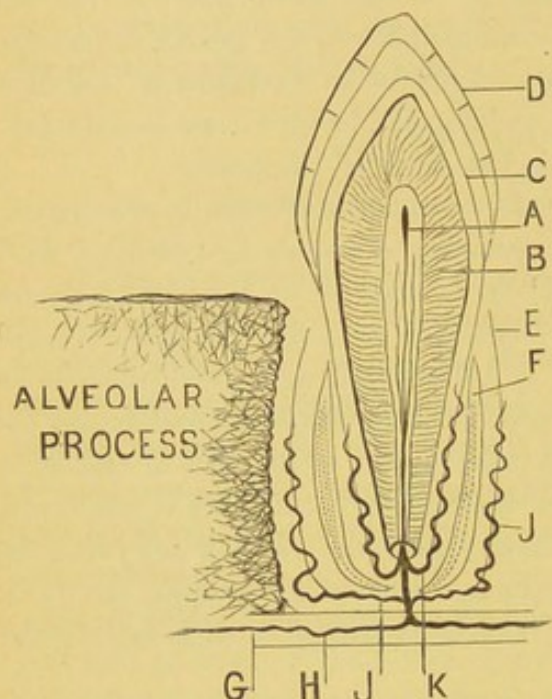
Some systems are so irritable that any amount of skill fails to make the mouth retain a tooth in which simply the pulp is dead. Others, on the contrary, are so unimpressible that half the teeth in an arch might be utterly necrosed, and yet no complaint be made. The author once, as an experiment, replaced in the mouth a central incisor tooth which had been extracted twelve hours before, and although it had been carried in the pocket, enveloped in the usual collection of dust, tobacco, keys, knife, etc., the whole intervening time, it was kept in its socket until the parts became reconciled. Many years have since passed, and it seemed, when last seen, as useful as in its palmiest days. The repetition of this experiment is now common. (See chapter on *Replantation*.)

The irritation, inflammation, and death of a tooth are generally the result of caries which exposes its pulp. The first stage in the destructive process



is the death of this part;\* here it may end, the pulp sloughing off at the foramen, the periodontum and middle membrane assuming the full duties of

FIG. 503.



A, dental pulp and its artery; B, dentine; C, tunica propria; D, enamel; E, periodontum; F, cementum; G, canal in lower jaw; H, dental artery; J, branch of dental artery supplying periodontum; K, branch of dental artery supplying tunica propria.

life, yet, as a principle of nutrition is concerned, it assuredly would have a chance, and perhaps the agency we consider is of greater consequence than a first thought would incline to give it. Because an artery entering a foramen is occluded, it does not at all follow that an immediately adjoining one meet with the same fate. A glance at the diagram shows that the vessel of the tunica propria has nothing to do with another, or others, intended for the periodontum. The spiral lines represent the vessels or their equivalents.

The diagram shows another feature in tooth nutrition. Referring to, and considering the vascularity of, the alveolar process, it is not difficult to appreciate that a tooth can be nourished, even though the maxillary artery itself be dead. Vessels pass from the process into the periodontum, and this blood can be passed in turn through the Haversian system of the cementum into the tunica propria, and from this tunic dentine and enamel may be fed.

A dead tooth is not, however, necessarily associated with caries. Inflammation, resulting in its destruction, may be induced by atmospheric changes,

nutrition. If this be not the case, the membranes become involved; if these too die, the tooth is dead. A dead or partly dead tooth is recognized by its loss of translucency, the opacity varying from the slightest discoloration to complete blackness.

The writer is not aware that clinical signification has before been called to the vascular relation of the tunica propria. Analogy with such circulation is found in the response existing in the anastomosis of vessels of pericranium, diploë, and dura mater. It seems not at all doubtful that the three-fold circulation related with tooth-structure finds its meaning in the law of compensation. Assuredly it would be the case that a tooth deprived of pulp and periodontal supply would have little chance for

\* The pulp of a tooth is composed of most delicate connective tissue, in which ramify the vessels and nerve. (See Figs. 41 and 42.)



by blows, etc. This is to be recognized, so that by reason of the absence of decay a diagnosis be not obscured.

A dead tooth is thrown off in one of two ways: either by chronic or by acute action. When by acute means, violent inflammation is set up in all the surrounding parts, the tooth is elongated and loosened, much pus is discharged, and eventually the organ drops from its socket; this accomplished, the trouble commonly subsides. In chronic exfoliation, the parts indurate, one or more sinuses form as in ordinary abscess, all the region about the tooth is thickened and rough, as if some ugly disease were in process of development, the enamel grows dark, perhaps black. The tooth does not get loose, but is apt to frighten into its removal. If such extraction be not resorted to, the lesion involves the bone, and tooth and alveolus become eventually cast off as a common sequestrum. Another, and more chronic form, consists in the gradual absorption from about the roots of a dead tooth of its alveolar process. This is most frequent with old persons, although not by any means so confined. This form of exfoliation is usually very slow in its progress, extending over a period sometimes of several years. Cases, however, frequently present—confined to young persons—where several teeth are cast off in this manner within a few months.

Teeth sometimes die as the result of structural consolidation. This never occurs but in what are recognized as dense teeth, and is seldom found associated with caries. Such teeth loosen day by day, and finally—it may be after a period of years—drop from their cavities. The condition is seen seldom but in old persons, or in those beyond middle age. To arrest this trouble seems impossible. No treatment appears to do any good.

**Alveolar Necrosis.**—The membrane enveloping the root of a tooth is associated, as a nutritional vehicle, with its alveolus; hence it is commonly termed “alveolo-dental membrane.” As the result of such relationship of structure, an inflammation originating in a tooth extends to the surrounding bone, and, according to its severity, affects the parts involved; hence portions of alveolus, overwhelmed, as it were, by the force of an attack, sometimes die and sequester. This form of necrosis, while very common, would perhaps, with proper treatment, seldom occur. (See Fig. 503.)

The dentist, for the purpose of destroying a pulp, applies an arsenical mixture. This is placed in a cavity of decay, and covered with cotton or wax. It happens, however, occasionally, that from carelessness in application, or out of difficulty in retention, the paste oozes around the neck of the tooth, and thus acts on parts not intended. In this way alveolar necrosis is sometimes induced; the portion destroyed is seldom, however, very considerable, and generally exfoliates in from two to four weeks. The local application of the sesquioxide of iron has been thought by some to exert a happy effect, applied immediately on the discovery of the accident. Repeated syringings are not to be neglected. A case, occurring in the person of a physician, has, at this date of writing, been treated by the author, where arsenic had been



sealed in a tooth-canal having a drill-hole through it communicating with the alveolus. As a result, all the bone forming the envelope of the tooth was destroyed and came away.

Alveolar necrosis is sometimes induced by the application of chloride of zinc (used as an obtunder of dentinal sensibility, and also for the purpose of controlling the slight hemorrhages caused by the slipping of instruments in the operation of filling). The first result of contact is of course on the gum, inflaming and engorging it, the effect upon the bone being secondary. Nothing better than the ordinary antiphlogistic applications can be employed. The action here is much more tardy than in the destruction induced by arsenic; the sequestrum is seldom very considerable, the alveolus perhaps of a single tooth. The action of nature in the separation is always to be awaited.

Cases which, for want of classification, may be termed anomalous, sometimes occur. An instance will illustrate. I. B., an Irish laborer, consulted for pain in the two inferior incisor teeth. No caries, no periosteal inflammation, nothing indicating disease, was observable. The pain increased day by day, until at the end of the second week the two teeth and their alveoli had become detached, and were dissected from the gum. This case is one of a very few of the kind that have been met with, and may well be termed anomalous. The pulps of such teeth are not found dead if examined at the time, as under ordinary circumstances one would expect to see them. There is no soreness on pressure, and, strangest of all, the absence of every phenomenon of inflammation. The practitioner in these cases is to be guided by such indications as he may be able to seize on.

Reference is here to be made to the fact of entire destruction of the thickness of the jaw, arising out of ill directed dental performances. In a case just dismissed, an operator in drilling out a root had allowed the instrument to pass, not only out of the apical foramen, but to enter the dental canal, where both nerve and artery had been wounded. As a result ostitis set up, which eventuated in a sequestrum one and a half inches in length, involving the entire continuity of the bone.

Two cases now under treatment are making sequestra implicating the continuity, cause in both instances lying with diseased teeth.

Principles of treatment consider, outside of medication as commonly directed to such cases, the relation of the extremities after separation of the sequestrum. To insure preservation, or restoration, of continuity, cotton is to be worked between periosteum and bone, and the part kept cleansed and stimulated by free use of the *tinctura capsici et myrrhæ*.\* As a rule an arch of bone extending externally over the dead part and associating the living parts is to be secured. The author has had a number of happy experiences in the direction.

---

\* A teaspoonful to a wineglass of water; stronger if indicated.



**Necrosis from Lack of Room for Eruption of Wisdom-Tooth.**—This is found most commonly associated with the lower jaw. The close relationship of the second molar with the ramus frequently makes the egress of the advancing wisdom-tooth an impossibility; hence an irritation resulting in inflammation. The serious extension of the trouble to the bone is always, however, preceded by more or less trismus and difficulty in deglutition: thus every chance is given for an anticipating surgical relief. This form of necrosis is to be looked for between the seventeenth and twenty-fifth years. The extraction of the second molar allows the wisdom-tooth to fall forward; thus remedying the irritation and effecting a cure. These cases, if rightly treated, are as simple and harmless as they are found severe and prostrating if left to chance or if improperly managed. Extract the second molar tooth, and do not attempt the removal of the offending one,—that is, if such extraction threaten difficulty.\*

---

\* "The advent of the wisdom-teeth is very often accompanied by painful and distressing symptoms, that may be protracted through many months, or it may be even years, unless relieved by surgical interference. These circumstances arise from the position occupied by these organs, so close to the joint of the lower jaw, where the mucous membrane is reflected from the gum to the cheek and fauces, combined with the very common condition that the jaw is not sufficiently elongated backward to allow them to range in the horizontal series with the other teeth. This mechanical difficulty not only prevents the proper evolution of the teeth, holding them back in their bony bed, but it often perverts their direction of growth and dislocates them. Annoying and very painful as are often the symptoms attendant on difficult cutting and misplacement of the upper wisdom-teeth, they are trivial in comparison with those which occur in similar conditions of the lower."—*Salter*.

Necrosis arising out of impaction of a wisdom-tooth is associated as a rule with inflammatory phenomena and with false ankylosis of severe type. The trouble begins commonly with a sense of stiffness about the articulation, which is quickly accompanied by swelling and pain. Enlargement of the face is in the sense of induration, the hardness being sometimes scarcely less than that of a board. Diagnosis associates with the age of the patient and with relation of the second molar tooth to the ramus of the jaw. The dens sapientiæ erupt at a varying period between the seventeenth and twenty-fifth year. A second molar jammed directly against the ramus leaves no room for a succeeding eruption. Examining a mouth in which this trouble exists, it is not unlikely that a pearly point be seen back of the developed denture, no room at all existing for accommodation of the rest of the crown. Unrelieved, such a case is almost certain to develop an otitis of a grade in severity that shall quickly advance to the suppurative stage, which result implies death of parts, small or great in extent.

Condition of mal-eruption in the wisdom-teeth is another cause of necrosis. It occasionally happens that the long axis is in horizontal relation with the body of the bone, and hence eruption may not take place, while pressure exerted against the immediately neighboring tooth excites an irritative condition of all the teeth of the side.

Burrowing of pus in connection with imprisoned wisdom-teeth is a familiar condition. An inflammation sets up, and lymph becomes deposited sub- and supra-periosteally, not unlikely as well in the cellular structure of the cheek. Degeneration following, pus burrows and makes openings, which are a source of much distress and not unlikely of deforming scars.

Cases of this kind demand, primarily and imperatively, that room be made in the deficient arch, and to secure this it is seldom the case that anything else is to be done than



Exfoliations of laminæ of bone are very common after the operation of extraction of teeth. Such scales vary in size from the dimension of a pin-head to that of a finger-nail. They seldom require particular attention, coming away, generally without pain or trouble, of themselves.

**Syphilitic Necrosis.**—The hard palate, the turbinated bones, and the external plate of the cranial vault seem particularly liable to suffer from attacks of this specific disease, the venereal ulcer of the overlying soft parts, as of the structure of the soft palate, being observed as among the most common of the constitutional affections. That these ulcers are, however, strictly venereal, one is oftentimes led to doubt; certain it is they appear and exist with greatest virulence where mercury has been used with unnecessary freedom. Venereal ulcers of the mouth are of two kinds: the superficial, and the ordinary ulcer of necrosis. The superficial ulcer may be found both upon the hard and soft palates, but is much more common to the latter. These ulcers

FIG. 504.

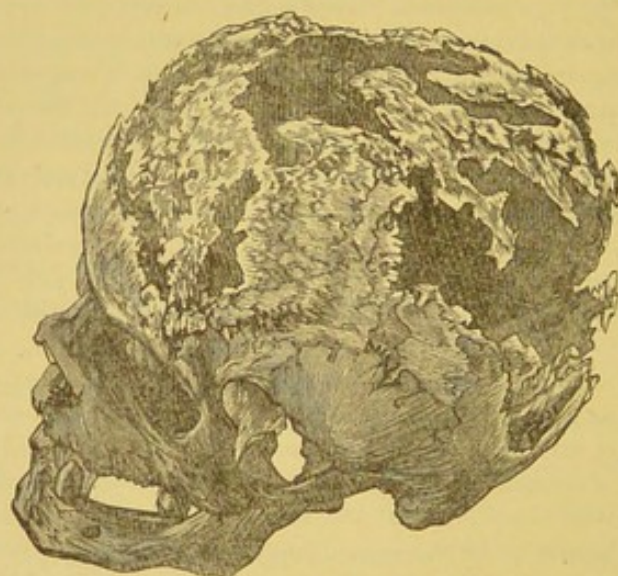

Diagram illustrative of a bone surface broken and in process of being broken up into sequestra. The picture is particularly expressive, it shows appearance of the conditions perfectly.

—as the chancres—vary in size and character, being sometimes very amenable to treatment, at others resisting and phagedenic. Their treatment is to

extract the twelve-year molar. Just here, however, arises a question where the six-year organ is decayed, the other being good. Will extraction of the former meet the indication? If the inflammation be of high grade and threatening, the question is to be answered negatively. If, on the contrary, irritability rather than marked vascular perversion exist, the reply may be affirmative. Where the wisdom-tooth itself can be drawn, such removal is to take precedence as a line of practice.

Cause removed, subsequent steps of treatment in these cases relate with the use of sorbents and the healing of any sinuses that may have formed. (See chapters on *Periodontitis* and on *Alveolo-Dental Abscess*.)



be conducted on general principles; few surgical conditions require nicer general judgment or more attentive care; it is, really, to blow hot to-day and cold to-morrow, and *vice versa*. As a rule, such ulcers are oblong in form, from an eighth of an inch to an inch or more in length; more or less excavated, the cavity being filled with a dirty-white semi-solid paste; the truest practical comprehension of the lesions is found, as the experience of the author leads him to infer, in looking at them as one looks at scorbutus. Met with in the scalp, the history is most likely that of gumma.

Touching locally with the acid nitrate of mercury, with the nitrate of silver, or with a mixture of equal parts of iodine and creasote, not infrequently causes such sores speedily to assume healthy action. A case will seldom be met with where the internal exhibition of a mineral acid does not seem in some degree useful; particularly is this found to be the case where a phagedenic tendency exists. Whatever remedies be employed, the venereal basis of the trouble is always to be kept in mind. Syrup of the pyrophosphate of iron, conjoined with minute doses of corrosive sublimate and iodide of potassium, will, under certain conditions, compel such ulcers to disappear as if by magic; or a combination which may be employed commonly with a happy effect is as follows:

R.—Hydrargyri chloridi corrosivi, gr. ij;  
Potassii iodidi, ℥ij;  
Syrupi hypophosphitis, ℥ij;  
Syrupi sarsaparillæ compositæ, ℥vi. M.  
Sig.—Tablespoonful three times a day.

The ulcer of necrosis, looking like the preceding, differs from it in having the pasty mass, which constitutes the apparent bottom, associated with dead or dying bone beneath. The ulcer in this case is not the trouble to be cured,—indeed, could not be cured while the underlying disease exists. Ulcers of this class, being an attendant condition, are always, of course, situated over the bones, generally about the maxillary and palate sutures; they are always preceded by an engorged and tumid state of the parts in which they are situated, indicative of the osseous trouble beneath. The character of this tumidity is a matter of much concern, as in proportion to its solidity will generally be found the extent of destruction in the soft parts; the variability of such destruction is seldom, however, in proportion to the disease below. The author has seen the whole palatine process die while the indicative ulcer has not been larger than the eighth of an inch in circumference; on the contrary, the smallest sequestrum will sometimes be found attended with the largest ulceration.

Incision into and through this tumid engorgement is always found satisfactory practice. The cuts, however, are to be made, not carelessly, but with judgment; always taking into consideration the vitality of the part. Such incisions, if made through the periosteum, will frequently be found to exercise quite a controlling influence on the osteitis, just as in cases of ordinary



inflammation; the effect upon the soft parts is always good. The treatment which should succeed the incisions is only to be determined by the circumstances of each particular case; not infrequently it will be found amply sufficient to keep the parts well cleansed, and await the coming away of the sequestrum; never, however, forgetting to meet the constitutional indication. In other cases, as when, for example, the phagedenic type is assumed, the most vigorous and well-directed local treatment is necessitated. When cases are first seen in the open ulcerated condition, semi-indolent, as is frequently the case, no treatment seems superior to packing the sore with cotton saturated with creasote and iodine, with phénol sodique, or with dilute aromatic sulphuric acid. Cases have come to the writer for treatment where the bone would be found exposed to the size of a silver three-cent piece, and where all the consequences of a large opening into the nares were to be apprehended, yet, by such applications, repeated every other day, allowing the cotton to remain in the ulcer the intervening time, in the course of two weeks the denuded bone would be entirely granulated over, and the parts remain permanently cured.

Breaks occurring in the hard palate, associating the oral cavity with the nares, are easily remedied by a covering of gold or silver plate. An impression of the full roof of the mouth is taken in wax; into this is poured plaster in a cream form; to the cast thus procured is fitted the plate of metal, supported by the teeth, or by atmospheric pressure, precisely as in the case of a plate for the attachment of teeth. Any reasonably ingenious mechanical dentist can meet the indications. (See *Obturbators*.)

In breaks of the soft palate a simple wad of cotton may be temporarily used with a considerable degree of satisfaction. Astonishing results in the way of diminishing or closing breaks, both in the hard and the soft palates, are not infrequently secured by freshening the edges and touching every second or third day with iodine, zinc, dilute sulphuric acid, or the compound tincture of capsicum. Great care is, however, to be exercised in this practice not to over-stimulate, very troublesome degenerating inflammations being sometimes the result of over-excitement.

An ugly feature in a syphilitic ulcer is its tendency to recur: a palate, looking healthy to-day, will assume to-morrow an indolent relaxed type, becoming semi-yellowish; some point or other will take on a fatty look, and in a few hours break down into an ulcer. This may recur a dozen times; explanation lying in the systemic condition. Such recurrence of ulceration may extend over a period of six or eight months, in defiance of the most careful attention. The author has certainly found it so in his own practice, and believes it to be a common experience. The salt-bath is found in these cases invaluable, affording, as it does, increased vitality.\*

\* To Professor Sigmund, of Vienna, are we indebted for an appreciation of syphilitic manifestations occurring where there is associated with the disease nothing of the ordinary history. Syphilis of the mucous membrane of the mouth and jaws (*Wiener Med. Wochen-*



**Mercurial Necrosis.**—Ostitis, and exfoliation from the undue use of the mercurials, are so common as to have come under the notice of almost every physician. These cases have generally a history regular and distinctive in progress. First is observed by the patient, while the medicine is being taken, a coppery or metallic taste. Quickly associated with this is an enlargement of the tongue, recognized through the indentations made by the teeth as the organ encroaches on these bodies. The next stage is puffiness remarked about the necks of the teeth, commencing generally with the inferior incisors; the congestion of the oral mucous membrane, which soon extends over the entire cavity, produces a sense of dryness, and not infrequently of burning; the tumefaction, which has now become general about the necks of the teeth, assumes a livid color, and presents a grayish, œdematous surface, which extends more or less widely throughout the mouth; the inflammation, attended with cacoplastic exudate, next intrudes on the alveolo-dental membrane, and the teeth soon become so loose as readily to be lifted from their cavities, and when so thrown off are found covered with the sticky, grayish lymph in abundance.

Uncombated, the effect of the metal passes rapidly to the alveolar processes, this tissue seeming to undergo a process of liquefaction and absorption.

*schrift*) is recognized as a secondary or tertiary form of the disease commencing in the genitals or region of the anus. Those cases, on the other hand, are rare in which syphilis most undoubtedly, or with a probability amounting almost to a certainty, occurs as a primitive affection of the oral mucous membrane, especially the lips, and thence extends to the general system. Professor Sigmund, long ago, called attention to the increasing frequency of affections of the lips of primitive syphilitic forms,—indurations, papulæ, ulceration,—and this opinion has been confirmed by subsequent experience in his own private hospital practice. This observation has, in addition to its importance with regard to pathology and treatment, a deep social significance. During a given time seventy-three cases of these primary affections of the lips came under the notice of Professor Sigmund. Of these, thirty-two were presented at the hospital, and forty-one in private practice. These seventy-three cases of syphilitic affections of the lips occurred out of 5551 patients. The disease was observed much more frequently in the upper than in the lower lip. The most frequent explanations as to the cause of its having been contracted were, in males, smoking, and the use of certain tools, and in women, the rubbing of a spoon against the upper lip, and also the habit of holding between the lips thin, sharp, and pointed instruments, such as are used in sewing, arranging flowers, drawing, painting, working in cardboard, and similar occupations. It is worthy of remark that these affections of the lips occur in all ranks of society. Professor Sigmund passes over the special etiological reports appertaining to these affections, as they are in many cases doubtful, and, moreover, savor of scandal. Labio-genital coitus could be clearly proved in some cases, and in others contagion by means of paint-brushes, tobacco-pipes, drinking-vessels, etc., was made out. The syphilitic affections of special importance to the practitioner are those produced through kissing. Any method of transferring syphilis to a healthy individual from one previously affected at an earlier or later period, but evidently, and to a superficial observer, cured of the disease, is of the greatest importance; and even these methods have, according to Sigmund's experience, occurred with great frequency, and form a very noteworthy, but often neglected, mode of origin of the affection.

Interesting cases of specific inoculation by kissing are recorded in considerable number in American medical publications.



Necrosis, when it ensues, may be partial or complete. Many interesting cases of such condition have come under the notice of the author, some of which will be found alluded to in other parts of this volume. Children, during the dentitional period, are found most in danger of mercurial necrosis, the parts seeming preternaturally susceptible; a result, without doubt, of the excitement related with dental genesis. When the mercurial poisoning is conjoined with a scrofulous condition, the ravages are found most marked. The writer has known a single two-grain dose of calomel given a child of this cachexia kill half the lower jaw. Inflammation accompanying mercurial necrosis is apt, from its sloughing tendency, so to destroy neighboring soft parts that not infrequently the mouth is permanently closed, requiring for relief plastic operations of the most difficult and complicated character; and, unfortunately, even these proceedings are not always able to restore to the patient the lost offices of parts. (See *Atresia Oris*.)

The state of salivation, so characteristic of the mercurial poisoning, comes on at varying periods, the susceptibility being influenced by different conditions: the increase of saliva changes, also, from that which may scarcely elicit attention, to a secretion which shall keep the mouth of a patient constantly over a vessel. Persons occasionally are to be met with who will be salivated by the simple smell of a mercurial; there are others, on the contrary, who appear unimpressible. It would seem to be a just experience that mercurials, as a rule, are not wisely given to teething children, or to scrofulous subjects, and assuredly it can never in many cases be productive of good to push the medicine, let little or much be demanded, beyond that point at which its effects are observed on the festoons of the gums.

In the treatment of mercurial ulitis (which see) attention has been called to a practice by free scarification and the local use of iodine. Many cases of threatened necrosis have by these means been aborted; but very great care is to be exercised that a low vital force be not still further depressed.

Medication that applies to ulitis applies also to ostitis.

In the special treatment of the mercurial, as of any other sequestrum, it is to be looked on as a matter of importance that the dead piece be detached by nature alone, assisted by the surgeon only as in other paragraphs described. Particularly does this seem important in the young jaw, as thus it may happen that we shall not disturb, unnecessarily, the germs of developing teeth.

Much stress has been laid by some practitioners on the preservation of such teeth as are associated with the sequestrum, and advice given that incisions be made through the soft parts which shall allow the bone to be drawn away from the loosened organs. Such treatment can certainly only apply to very few and peculiar cases. As a rule of practice, the author is confident it will be found of little signification.

The ill odor and putrescence associated with mercurial necrosis are to be antagonized by the free use of antiseptic injections.

**Necrosis from Injuries.**—Accidental injuries received by the jaws are



not infrequent causes of necrosis. Having such origin, the recognition and comprehension of the condition are but the apprehension of the common pathological expression. Traumatic influences capable of provoking an osteitis or periostitis which may result in necrosis, can be independent of external wound; depending entirely on concussion. The treatment of such a case is the treatment of inflammation anywhere. Death of the bone, in whole or in part, resulting, the case has the common history of necrosis.

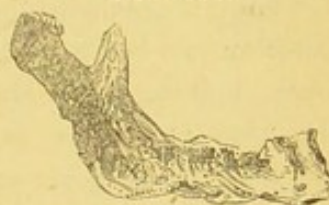**Exanthematous Necrosis.**—As a result of the exanthemata, it occasionally, though fortunately quite infrequently, happens that a subacute inflammation of the jaw occurs, resulting in limited or, it may be, in extensive necrosis of the part affected. To this form of disease, as the recognition of its associations is concerned, attention seems first to have been directed by S. James A. Salter, of Guy's Hospital, who records twenty-three cases as being met with in the associated population of that institution. The author in his own practice has seen quite a number of examples.

The accompanying cut is from a photograph of pieces, constituting the full half of the lower jaw, removed from the mouth of a German boy six years of age, the bone being in the museum of the Hospital of Oral Surgery. The earlier history of this case could only be procured to the extent of learning that some time after an attack of measles the child commenced to complain of a sore mouth, the gums swelling as in an attack of periodontitis, the swelling after a few weeks being followed by the continuous discharge of pus, which the parents stated had been troubling the child for several months; could not say whether it might be two or four. When first presented at the clinical service, the boy was so emaciated that little hope was entertained of saving his life; but, after having been placed on vigorous tonic medication for two weeks, taking iron and quinine, drinking beer, using salt-baths, and having the parts almost hourly syringed, thus washing away the offensive semi-putrid pus in place of allowing it as before to pass to the stomach, and at the same time using local means of a stimulating nature, the reaction was of the most promising character, and invited and indorsed the attempt to remove the sequestrum.

Making at a second clinic thorough examination, it was evident that the body of the bone in mass was dead, and that not the slightest attempt had been made toward the formation of any new osseous structure. In this instance, all proper attempt was made to excite the production of osteophytes, the necrosed structure only being removed when to leave it longer in its bed would have been to risk life.

The removal of the sequestrum in this case resulted in a considerable immediate deformity, but which, after two years, had so completely disappeared as to be scarcely observed, while the natural motions of the jaw seemed quite as good as in other children.

FIG. 505.



Sequestrum after measles.



In a second case, the disease attacked the upper jaw, resulting in a repetition of small inflammatory sequestra, together with the crowns of the undeveloped bicuspidati of the side affected; the trouble continuing, in defiance of medication, for over a year, and yielding finally only to a summer spent by the patient among the mountains.

In the treatment of such cases, nothing special seems demanded, unless it is that we be able to recognize and administer the specific for the peculiar poison. Lacking such knowledge, the cure is to be conducted on general principles: great cleanliness, conjoined with stimulating and antiseptic injections, constitutes the principal local demand; while systemically, the patient is to be supported under the drain which, to a greater or less extent, always attends the process of exfoliation.

In cases of slight signification where the exfoliated part may involve the edge of the alveolar process only, so little attention is demanded as to deny the surgeon not unlikely even opportunity to see the condition.

**Phosphor-Necrosis.**—This is a term applied to that lesion of the maxillary parts dependent on phosphorus-poisoning, being a disease peculiar to workmen in match-factories, and confined here almost exclusively to such as are engaged in the processes of dipping and packing. How phosphorus affects the maxillary bones, whether from a systemic or a purely local relation, continues to excite discussion. That persons possessed of carious teeth are alone affected, seems sufficiently verified; while, on the other hand, as shown first by Dr. Letheby, of London, phosphorus has a systemic relation, as exhibited by its detection in excess in the urine of the poisoned patients. Von Bibra and Geist, holding to the theory of a local contamination, direct attention to the fact that "toothache invariably precedes the more severe affection," that a carious state of some tooth or teeth is a "*sine qua non*," and that "so long as the teeth remain good the affection does not show itself." Lorinser, who was the first to describe the phosphorus-disease, holds to the analogy of the affection with mercurial poisoning,—a view which the experience of the author of this volume leads him to sympathize with, although it is not to be denied that it is in opposition to that which at the present time is generally held: this common view being that phosphorous oxide, in a low form, finds a way to the periosteum through the dental pulp-canal, producing, as a result, the peculiar and specific inflammation.

A jaw, however, fretted and vascularly excited by teeth in a state of disease, would naturally be expected to be in a more susceptible condition than one strictly healthy: hence it may very well be that such special susceptibility can explain the attack, the natural resistive force of the part being to such extent lowered. Such supposition certainly tends to add force to the views of Dr. Lorinser, "that the fumes act by infecting the blood, laying the primary foundation for a disease which remains dormant until an exciting cause fixes the spot for the outbreak." In proof of his inference, attention is directed to the peculiar sallow skin, combined with a dull expression, together with



the gastric derangements, which are prodromous to the local affection; expressions which the author has observed as characterizing his own patients. In certain Nuremberg cases, however, mentioned by Von Bibra and Geist, these prodroma were not only lacking, but, on the contrary, the majority were seen to be of healthy, florid complexions, which some retained to the last stage of the disease. Let the true expression of the condition be as it may, a prophylactic always to be commended to workers in phosphorus is found in that continuous attention to the mouth and teeth which insures the most perfect cleanliness, combined with the immediate filling of every tooth which becomes carious, thus preventing exposure of the pulp. A second prophylactic is one suggested by Mr. Salter (see Holmes), who expresses the belief that by keeping the atmosphere of the factories ammoniuretted, and thus neutralizing the acid vapor, few, if any, cases of the disease would occur.

Still another means having general commendation is found in the employment of a respirator, of which perhaps the best is that devised by Mr. Graham for persons exposed to carbonic acid vapor. This consists of a mixture, in equal bulk, of fresh-slacked lime and sulphate of soda, worked into a cushion, through which it shall be easy to breathe. Carbonate of magnesia, used in teaspoonful doses twice each day, and applied with all freedom locally, will be found of great service in antagonizing the acid.

Outside of the association of the patient with phosphorus, there is nothing which, to an ordinary observer, would distinguish the incipient condition of this loathsome disease from a case of chronic periodontitis.

The first sign of a commencing phosphor-necrosis is found commonly in one or more teeth becoming sore to the touch, feeling, on occlusion, as if raised in their sockets; in a short time the surrounding gum begins to swell: in the character of this swelling is the first distinctive sign. It is not the acute, firm, inflammatory swelling of periodontitis, or of traumatic ostitis, but from the beginning has a puffy, debased, and degenerating look. One feels as if he might hesitate in adopting any very decided antiphlogistic treatment, or, indeed, in employing any other than an expectant one.

Phosphorus acts on both the upper and the lower jaw-bone, but seems to have a decided predilection for the latter; as twelve to nine, perhaps.\*

The history of a case of phosphor-necrosis is to be epitomized as follows: a degenerative inflammation commences in the alveolo-dental membrane, or in the substance of the bone; the author inclines most strongly to the belief of its commencement in the latter. The degeneration of this bone progresses until its enveloping periosteum—which remains unaffected as its vitality is concerned—separates from it. The bone dies in bulk, or in part. In the

\* Of twenty-two cases reported by Dr. Lorensen, nine were of the upper jaw, twelve of the lower, and one in which both were affected. Of fifteen cases occurring in Nuremberg, five were in the upper, nine in the lower, and one in both. Of eight cases recorded by Dr. Neumann, three were of the upper jaw, four of the lower, and one of both.



lower jaw, the body alone commonly dies, the rami remaining unaffected. In the upper, one cannot well infer where the demarkation will occur. During the process of dying, the periosteum, particularly in the lower jaw, is most active in the reproduction of new bone, of osteophytes, so called; this new material exhibiting markedly its endeavors to envelop and replace the old. The separation of the dead from the living bone, in the lower jaw, when the dead part is at all extensive, is found to occupy a period of from seven to nine months. It is attended with the formation of many sinuses, both in the mouth and about the neck, and is very exhaustive to the patient, on account both of the great suppurative drain and of the nauseating character of the discharge. All the soft parts associated with the affected jaw, the periosteum perhaps excepted, sympathize warmly during the process of decomposition and separation, looking, indeed, as if very badly affected with scurvy. At the period above alluded to, exfoliation being complete, the surgeon may remove, with little effort, the sequestrum; the sinuses then heal, and the parts may recover with as little deformity as attends the extraction of the teeth and the ordinary absorption of the alveolar process.

This will be found a common history of the disease. The author has seen and treated quite a number of cases, and it is thus that it has presented itself to his observation. It might perhaps be added that the teeth, influenced by the advancing disease, loosen one by one, so as to make necessary their removal long before the bone is ready to come away.

In phosphor-necrosis the death of the bone seems to be a result of morbid porosity, the loosening and expansion of the structure proving antagonistic to its nutrition; as vitality diminishes, so, as the result of a cacoplastic exudate, the periosteum is found to separate itself, such exudation explaining, in its degeneration, the characteristic abundance of fetid pus. Indeed, it is to be seen, almost from the earliest affection of the bone, that the periosteum is aroused to efforts for self-protection; so marked is this in many instances that attempts at the formation of new bone, made by separating the periosteum from the dead tissue, result in numberless osteophytes, if indeed a perfect wall be not secured. The writer has seen not infrequently the whole floor of the mouth, back to the base of the tongue, occupied by such new bone.

As is to be readily recognized, the tendency of this exudate to degeneration is marked: thus, the osteophytes are found in inverse proportion to the quantity of pus. These osteophytes, in characteristics, are seen also to be greatly influenced by a treatment employed in a case: in the beginning they are, it is to be inferred, uniform; from such uniformity we see them as slender shreds, in masses, and indeed in every irregularity of form and feature; decidedly disposed also are they to break down and disappear, and this particularly where extreme cleanliness is not observed, or the system at large is left without the support of tonic medication. It is, indeed, simply the common



history of lymph degeneration,—an inability on the part of the plasm to the maintenance of a self-supporting organization.

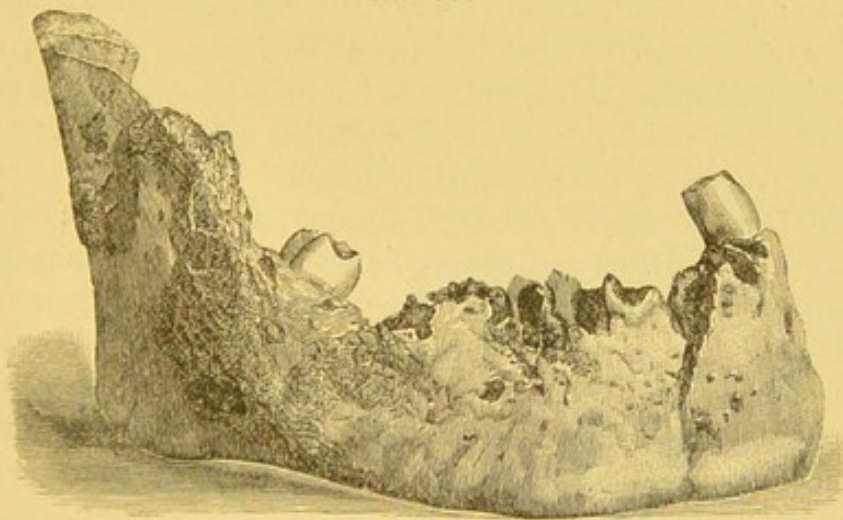
A dull, dirty-yellow complexion is almost universally associated with phosphor-necrosis: this has been variously attributed to dyscrasia, to the pain, the impeded ingestion, and to the immense drain made on the system in the progress of the exfoliative process. The most reasonable hypothesis is that all these causes are alike implicated: certain it is, that to get a patient clear of such a complexion, all require to be considered in a treatment.

The tendency to the burrowing of pus in acute phosphor-necrosis is remarkable, and to a great extent such burrowing will occur in defiance of treatment: if the lower jaw be the seat of the disease, the sinuses will riddle the neck: if the upper, the antrum tends to receive the pus, while in grave cases the matter not infrequently finds its way to the ear and to the mastoid cells of the temporal bone.

Salivation is another of the marked characteristics of the condition: the author has had patients who were compelled to have a handkerchief constantly at the mouth to receive the drainage. Another source of discomfort resides in vomiting: particularly does this tend to occur in the morning; the result of the pus swallowed during the night. Fever, diminution of appetite, and derangement of the bowels follow the progress of the disease, and, if not vigorously combated, are apt to end in an inanition fatal to the patient.

The sequestra of phosphor-necrosis in the lower jaw look somewhat like

FIG. 506.



Phosphor-necrosis sequestrum.

pieces of rotten sponge, being almost as light and porous; this arises from the suppuration and discharge of the primary exudate which was the cause of the original enlargement: the organic material being all discharged, nothing remains but the cell-riddled, inorganic structure.

**TREATMENT.**—The treatment pursued in phosphor-necrosis is to consist in the employment of means that shall circumscribe as much as possible the disease, that shall hasten the process of limited death and the accruing sep-



aration, and that shall support the patient under the drain to which he is necessarily subjected.

When a case presents in its incipency, that is, simulating a developing periodontitis, we commence the local treatment just as we would that of the tooth lesion. If the inflammation have about it anything of a healthy acuteness, we limit as much as possible all external irritation, by softening in a gas-flame or by the stove a piece of gutta-percha, and moulding it over some opposite organ, or tooth farthest removed from the seat of disease; a mouthful of cold water hardens this cap, and thus occlusion against the sore tooth or teeth is prevented. A dose of Epsom salts or other saline cathartic is ordered, and a sinapism is applied to the back of the neck. A hot pediluvium is found sometimes to act very happily as a derivative; or a diaphoretic, such as the spirits of Mindererus, may serve a very good end. Depletion by leeches, however, has never seemed to the author to be an indication: the affection has its foundation in asthenia.

If we first see the case—and this is most apt to occur—when a discharge has made passage for itself by opening through the gum at the neck of a certain tooth or teeth, we immediately make a free incision through the soft parts down upon the bone, and syringe thoroughly with some medicated water, stimulating or antiseptic, or both, as indicated. Having the parts well cleansed, the wound which has been made is stuffed with cotton or sponge saturated with aromatic sulphuric acid. This is repeated the next day and the next, until, particularly as the syringing is concerned, it may be absolutely necessary to repeat it a dozen or twenty times per diem, the progress of the disease being so marked by discharge and offensiveness. As day by day the cotton or sponge stuffing is renewed, it is insinuated gently between the separating periosteum and bone. This manipulation will be found to hasten the separation wonderfully; it may abort the disease.

It might here be asked, perhaps, by some one, Is not this process of working off the periosteum an unsurgical proceeding, compelling an extension of the destruction beyond that which would have been a result if the bone was let alone? The author can only answer from his own experience in different modes of treatment, and say that he is perfectly satisfied that this is not the case, and that the result is for the good of the patient in every way: the portion of bone destined to die has the destruction markedly hastened; the sooner the death, the sooner the separation; the sooner the separation, the less the exhaustion.

The compound tincture of capsicum, with an excess of myrrh and an addition of the permanganate of potash, is an excellent wash for the mouth in these lesions. Dilute phénol sodique is almost indispensable. Cold water, with a little salt and magnesia dissolved in it, can be used *ad libitum*.

The sinuses which are so apt to form upon the neck, in defiance of all treatment, and which greatly annoy by their discharge, are most comfortably treated with dressings of patent lint. Once formed, it is a waste of time to



attempt the healing of them: they will get well only when the source of offence in the dead bone is away.

It has been remarked that the death is limited in the lower jaw to the body of the bone, the horizontal portion, the demarkation occurring at the angle. This, in the majority of instances, will be seen to be the case, particularly if the treatment has been properly directed. Seven months has been found, in the practice of the writer, the minimum required for the course of the disease, nine months the more common time, and fifteen the maximum, although this latter does not accord with German experience, cases being reported of two years and a half standing. The drain during most of this time is immense, the patient requiring generous tonics and substantial fare. Attention to repair of wear and tear is, perhaps, of greater consequence than any local treatment; certainly, if one could not have both, his chances would be best with the former. Both are to be esteemed of vital consequence. To commence, however, with the ordinary medicinal tonics, is ill advised. One cannot well keep on with them, and by employing such means in the beginning of the disease their powerful assistance is lost at a time when every help is found weak enough at the best. Good underdone roast beef is enough for the first two or three months; then addition is to be made of generous malt liquors, together with the salt-bath. The latter portion of the time demands iron, quinine, brandy. The hemorrhages, sometimes profuse, are held in check by exhibitions, once or twice weekly, of five-drop doses of tincture of *Erigeron Canadensis*; otherwise the bleeding points are to be packed.

The period at which a sequestrum is ready to be taken away can only be known by repeated examination, the proper treatment being to wait always until exfoliation is complete, be such time longer or shorter. Nothing is gained by expediting the removal through operative proceedings, as by breaking away the bone, using the chain-saw, etc., while the risk to life is very considerable. To wait patiently, keeping the system equal to the demand on it, is the surgeon's highest duty; to do more is to do harm.

The removal of the bone is always to be effected from the inside; it does not seem that an outside incision could ever be found necessary. If the opening along the gum, obtained in the treatment, be not great enough, it is easily enlarged to an extent desired.

A step preliminary to the removal of the body of the lower jaw is its division at the symphysis. This is easily accomplished by means of a straight-cutting forceps, or still better by the engine and drill. It is better to cut little by little, from above downward, than to crush through the bone with a single cut; it does not hurt nor shock nearly so much. The operation with the drill pains little or none, never demanding the patient to be etherized.

To take away the bone, no instrument is found better than ordinary tooth forceps, such as is in common use for the extraction of the inferior incisors and bicuspidati. With such forceps, complete control of the part is secured, and the removal, as a general thing, is quickly effected.



A trouble frequently encountered, and one which, undistinguished, proves confusing and deceptive, consists in the grasping of the sequestrum, when extensive, by lateral overlying tissues,—not new bone, but indurated soft parts. The writer recalls a case which he once had under treatment, where, the dead bone being thus held, a practitioner had been waiting for the separation a period of over two years, being deceived entirely as to the relation of the part. To satisfy one's self as to the condition, pass a small hook under the bone, and lift: if it yield, the sequestrum is only thus held, and is with safety to be pulled through; if, on the contrary, it be firm and unyielding, it is to be let alone,—separation not yet having occurred.

In the reproduction of new bone, which, at the period for the removal of the old, should be found to have obtained such character as to keep up perfectly the shape of the parts, the observer will be struck with the excess deposited along the middle line of the mouth; it seems, oftentimes, as if the floor was a mass of bone,—which, indeed, it really is. It is not found necessary, however, to do anything with this excess, nature taking all proper care of it.

Phosphor-necrosis attacking the upper jaw seems not so much to be dreaded as that associated with the lower. It is seldom so formidable in its nature or so destructive in its progress, the disease in these parts being sometimes found to run its whole course with an entire absence of acute action. A portion of bone dies, and the surrounding soft parts seem utterly indifferent. One would scarcely know anything abnormal was going on, were it not for the indication given in the loosening of the teeth; these drop out somewhat as they would out of a dried skull, while the soft parts eventually present the appearance of shrinking away from the bone, which structure becomes fully exposed,—as dry and lifeless, apparently, as a portion of dead wood. This, however, is, of course, not the common history. The inflammatory action is of the same type as that associated with the disease in the lower jaw, but more limited in extent and consequence, and much more susceptible to remedial measures. A bad feature consists in a marked tendency to recurrence of the trouble; but this, perhaps, will mostly be found within the control of the surgeon. The removal of a sequestrum here is a trifling matter, comparatively little effort allowing the piece to pass. If the bone seem grasped by the contracting soft tissue, the easiest plan of removal is found in the introduction between the parts of pellets of cotton: these quickly swell, and thus effect loosening.

At a Medical Congress in Zurich, Switzerland, Professor Billroth, in citing his experience with phosphor-necrosis, remarked that in attacking the upper jaw it seemed to act with greater and more destructive force, and was more unmanageable.

The author does not know how to reconcile this difference in clinical observation, unless an explanation is to be found in an implied greater tendency to return which exists on the part of the disease when situated in the upper



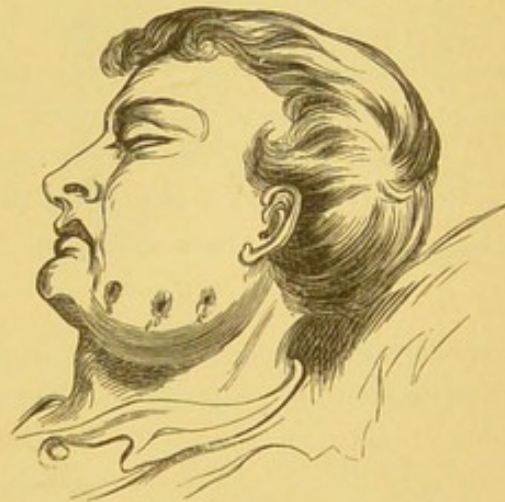jaw. In the lower jaw, the full part that is to die seems impressed from the beginning,—that is to say, a certain portion seems predestined, and it dies in defiance of all surgery can do. Not that the evidence of the disease is general over all the involved part from the beginning: on the contrary, the incipient stage is markedly localized; but then, day by day, and week by week, the trouble is likely to extend over the apparently predetermined or preimpressed part. When the death occurs, it is a single death; and when the piece is cast off, there is not apt to be any renewal of the trouble. The sequestrum of the upper jaw, on the contrary, is generally small, some portion, most likely, of the alveolar process; but unless the treatment is of a most supporting and specific kind, it is apt to repeat itself again and again; but your treatment is responded to here, and for this reason, with care and attention, the extent of destruction is comparatively under control. If it be found more unmanageable in Zurich, then the means would not seem to be so well adapted to the end as those here employed, otherwise the circumstances must be different.

Again, at the same Congress resections are strongly commended. To be so indorsed, they must, of course, have been found to answer a good purpose. The patients who have their jaws resected for phosphor-necrosis disease in this country generally die, or, if happily they escape death, they do not find their disease cured without an inflammatory sequestrum at last.

The picture (Fig. 507), taken from life, represents a patient as he appeared with the disease five months in progress. At the end of eight months the writer removed the jaw at the articulation: the loss was very fully repaired at the date of operation, the parts having excellent motion.

An important objection to the operation of resection, even were the question of life not involved, is the great resulting deformity. Let nature take her course, and of such deformity there may be little or none. A late patient was a gentleman for whom the author removed—or rather from whose mouth nature cast out—the whole body of the inferior maxilla, and no one might tell whether it had been a case of necrosis or of simple extraction of all the inferior teeth, with the consequent alveolar absorption, so perfect has been the repair in accordance with the destruction. The objection that this new bone keeps up the trouble, by becoming involved in the diseased action, is not according to the experience of the writer. If it become implicated it would seem to imply that it has not

FIG. 507.—APPEARANCE OF PATIENT WITH PHOSPHOR-NECROSIS.





been properly cared for. Careful and properly repeated syringings with water medicated with iodine or capsicum will protect it. This experience does not, however, include the isolated osteophytes; these do without doubt incline to degeneration and decomposition, but by care the many may be stimulated to a self-supporting combination to which the periosteum becomes what it was to the bone exfoliated.

It is certainly most unfortunate that in the case of the upper jaw no osseous repair seems attempted, but it is not the experience of the author that the horrible deformities mentioned by various writers are at all common. Local and systemic stimulation combined with a tonic treatment insures more or less attempt at supporting the surrounding parts by an exudate which assumes a fibro-cartilaginous aspect, and which takes on itself the duties of the structure lost, to very good purpose.

In loss of structure in the lower jaw the most vigorous efforts are seen to exist on the part of the periosteum almost from the beginning to reproduce the impressed part, disproving to such extent, as it would seem, the deduction of Dr. Geist, that the phosphorostitis is secondary to periostitis, for assuredly is it the case that under no circumstances of excitation does that tissue exhibit higher vitality. That this secondary deposit differs from the original bone, in possessing an excess of organic structure, implies perhaps only that the deficiency in inorganic substance has its explanation in the presence of the corroding acid of the disease. That the capsule of new bone is so frequently found to atrophy may have similar explanation with the primary osteophytic degenerations, requiring, if not a local, yet a constitutional care. A suggestion made by Mr. Salter that the new bone be supplied with function by using it as soon as possible as a base for artificial teeth may be found to have in it much practical import.



## CHAPTER LIII.

### DISLOCATION OF THE INFERIOR MAXILLA.

THE frequency of this accident, the terror it excites, and the harm resulting when it is not properly cared for, give an importance that renders appreciation of the subject a matter of necessity.

There are four forms of submaxillary displacement: complete dislocation, incomplete, bilateral, and unilateral. In the first of these, one or both condyloid processes have slipped fully out of the glenoid fossæ and rest entirely in front of the articulating eminence, as exhibited in the view.

In the second, the condyles rest upon their interarticular fibro-cartilages, directly over the articulating eminence, and will remain fixed, or may fall backward or forward as directed by accident, not being retained in their position, as is frequently thought, by the coronoid processes being hooked under the malar bones, but resting, as it were, upon points with complete balance in the muscular structures. The forms described are bilateral, the articulations of both sides being involved.

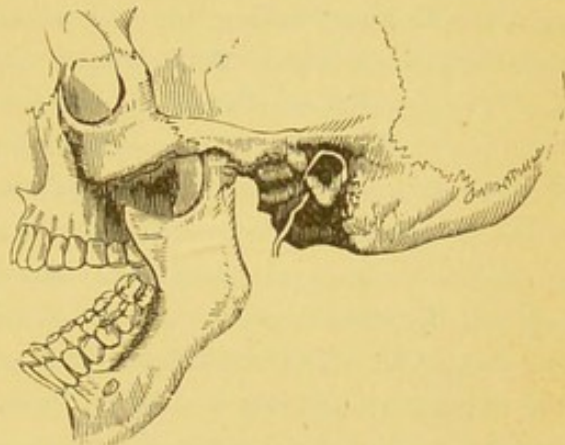
A unilateral dislocation relates to one side.

The diagnosis of a luxation is an exceedingly simple matter. An open mouth, with inability to close it, the lower jaw thrust forward in a straight line, or otherwise turned to the right or the left, according to the accident, indicates a luxation of bilateral or unilateral character.

The exciting causes of dislocation are various: laughing, yawning, vomiting, putting large bodies into the mouth, blows received upon the chin from above downward, or in front, while the mouth is open; the extracting of teeth, or extending the jaws widely for the convenient filling of them, etc. The first case ever met with by the author occurred with a middle-aged man while he was laughing immoderately.

A predisposing cause of the accident resides in a general or a special laxity

FIG. 508.—COMPLETE DISLOCATION OF JAW.





of the articular connections: thus, all are acquainted with persons who without effort will dislocate a finger or a toe. Rare instances exist where the operation of removing teeth is almost certain to be attended with unilateral luxation unless a mento-occipital sling be used.

What is the condition of parts in this luxation? By placing the finger immediately in front of the tragus of the ear when the mouth is closed, and carrying it forward along the zygoma, the surface is felt to be a plane. If the finger be kept on the surface, and the mouth opened, it drops into a fossa. This is the glenoid fossa; the concave rim above is the border of the cavity; the rounded prominence below is the condyle of the lower jaw. Placing the maxilla of the cadaver in this position, and dissecting down to the articulation, the condyle is seen slipped forward, resting upon the interarticular fibro-cartilage; the fossa has been partially vacated, and the bone lies against the articulating eminence. If now the condyle be dragged downward and forward over the eminence, the glenoid cavity will be found completely vacated, and, unless by manipulation, the condyle cannot be restored. Laying back now the soft parts, the cavity in front of the tragus is remarked greatly increased, the finger falling into the unoccupied fossa. (An added diagnostic sign is found in increased depth and size of the fossa in front of the ear: this it is desirable to remember, as a fracture of the neck might simulate a luxation.) Returning to the examination, we see that to reduce the luxation it is necessary to depress the head of the bone below the level of the articulating eminence, which, being back of the condyle, serves to fix it in its abnormal position, as originally it was the means of its retention in place. The capsular ligament is not usually found torn in a jaw dislocation, but stretched and elongated. The lateral ligaments do not seem particularly interfered with, and impress an observer as having little influence in the matter one way or another. The temporal muscle shows itself stretched and dragged forward, but is seldom lacerated. The pterygoid and masseter muscles are relaxed.

Dislocation is of more frequent occurrence in women than in men, is uncommon in children, and is rare in the robust. When a dislocation has existed for a long time, there seems a tendency on the part of nature to make compromise with the condition; the jaw will gradually recover considerable of the lost motion. Cases are met with where patients seem able to masticate without the least trouble. The original contour of the face is never, however, entirely restored.

A luxation of the lower jaw, like that of any other bone, if left unreduced, even for a very few days, is found difficult to correct; the muscles contract, the condyle settles itself in its new position, lymph is effused and coagulates, the general aspect and relations of the joint are changed. A patient so situated, is not, however, to be left unassisted, or to the relief afforded by nature. A satisfactory practice in cases of this kind, where a luxation may not be immediately reduced, is found in wedging corks between the teeth, forcing the back part of the jaws as far asunder as possible, and then with a properly



directed compress and bandage approximating the anterior teeth, and at the same time forcing the lower jaw backward. This manipulation, assisted by the employment of sorbefacients, not infrequently results in a removal of the semi-organized lymph and a consequent ability on the part of the bone to reoccupy its original cavity.

Reduction of a luxated jaw has been accomplished as long as ninety-eight days after occurrence of the accident.

Subluxations are of common occurrence, particularly among weak women of easy and luxurious lives. In England attention was first directed to the condition by Sir Astley Cooper; in this country it certainly has needed no particular one to discover it,—a proof, perhaps, of the physical superiority of English over American ladies. This condition depends, evidently enough, on laxity of the ligaments, and on the weakness of the muscles of the part. In yawning, or not infrequently in ordinary mastication, the condyle will slip forward on the articulating eminence, and, for a moment, the mouth cannot be closed, requiring, in many cases, the assistance of the hand to shut it. Depending on weakness, a permanent cure is only to be looked for as a higher and stancher vitality is secured. Thus, such tendency and condition are to be treated by cold bathing, tonic medicaments, exercise, etc. In the case of a lady liable to the luxation, and who was made very nervous by its occurrence, the accident was entirely guarded against by wearing the occipito-mental caps and bands. The writer was once consulted by a person who was awakened almost every night by the peculiar and unbearable pain attendant on such slipping of the condyle during the relaxation of sleep.

Dislocations associated with fracture are, happily, of rare occurrence. Delamotte records a case where, in the person of a girl, double luxation existed with fracture of the body of the bone. Another is mentioned by Roberts, where the body was broken in front of the right ramus, and the condyle dislocated outward. A third case (Heath) is reported in the *Dublin Medical Gazette*, and "occurred in a boy of eight, who suffered a fracture at the symphysis, with dislocation of the left condyle upward and backward. There was bleeding from the ear, and the chin was much retracted and turned to the left; the mouth was open, but could be closed, and it was then observed that the lower molars overlapped the upper, but that the lower incisors were at least one inch behind the upper. Reduction was easily effected, and the case did well."

Luxations are sometimes congenital. The first case of this kind was noticed by Mr. Robert Smith, of Dublin, who gives with minuteness the results of his dissection. The patient, an idiot from infancy, died at the age of thirty-eight. The displacement existed on the right side, which was remarkably deformed, having a singularly hollow appearance, which strikingly contrasted with that of the sound one, which was unusually full and plump. The extremity of the finger could be readily pressed between the posterior margin of the jaw and the auditory canal, owing, as was found on examination, to the



absence of the condyle of the bone, which was, in fact, greatly atrophied nearly as far forward as the ramus proper. There was no interarticular cartilage nor distinct capsular ligament, and the masseter, pterygoid, and temporal muscles were much wasted. The temporal, malar, superior maxillary, and sphenoid bones were imperfectly developed, and the glenoid cavity existed merely in a rudimentary state.

**Treatment of Luxation.**—By referring to Fig. 508, it will be plainly evident that the reduction of a disarticulated condyle consists in getting it back of the eminentia articularis. How best to do this is the question.

1st. Wrap the thumb in delicate napkins, seat the patient on a strong chair, and, standing behind him, rest his head against your person; place now the protected thumbs upon his inferior molar teeth, and with main strength force the jaw directly downward and a little backward: the moment you have depressed the articulating face of the condyle, it will be felt to be dragged into place. The amount of force required to do this depends on the muscular tone of the individual. In some cases the reduction is effected almost before you are aware of having exerted any pressure; in others it cannot be secured without the assistance of mechanical appliances.

FIG. 509.

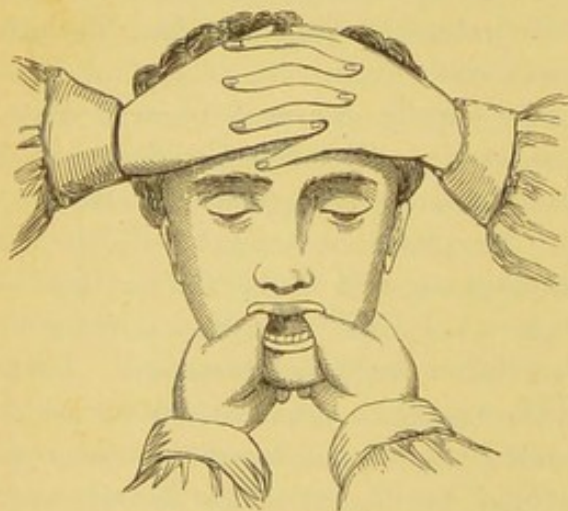
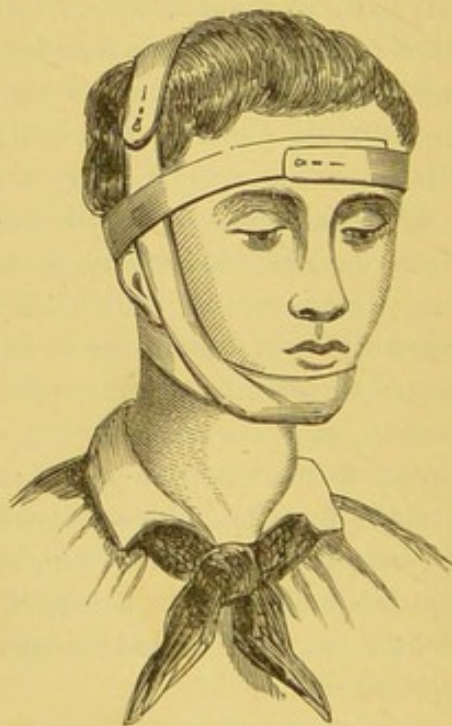


FIG. 510.



Vertico-mental sling or cap.

2d. Failing to reduce a luxation standing behind a patient, reverse the position, resting the head against an assistant.

3d. Take corks, one or two, according as the luxation is single or double, force them between the wisdom-teeth of the upper and the lower jaw as firmly and fixedly as possible; now gradually push the chin forward and upward, using either the hands or a tourniquet applied around the head.



4th. Take a piece of wood about a foot in length, place one end upon the molar teeth of the luxated side, make a fulcrum of the molar teeth of the upper jaw of the opposite side, and elevate the end held in the hand. If the luxation be double, reduce one side at a time. In the use of this lever, the results are most easily secured by resting the centre of the piece of wood upon the teeth of the side to be reduced, carrying the end downward.

The forceps invented by Stromeyer yields a powerful leverage. This consists of two blades so expanded at the extremities as to fit, as well as may be, the dental arches, these blades being covered with leather; a spring between the handles throws them apart, thus closing the blades. Reduction is attempted in two ways. So introducing the padded blades that each shall rest upon its proper tooth or teeth,—the third and second molars,—the handles are grasped in the hands of the operator and gradually brought together; when the blades have thus been so far separated as to lead to the inference that the face of the condyle is below the level of the obstructing eminence, the jaw is to be pushed forcibly backward into its place by an assistant.

Another method of using this instrument is the employment of a screw and nut which passes between the blades: a delicate wrench fits the nut, and through its instrumentality the handles are gradually screwed together, separating of course the blades. The manipulation of pushing back the jaw, Stromeyer suggests, should be effected at the same moment with the sudden closing of the blades. Even better, however, than the Stromeyer forceps is the instrument shown in Fig. 415. With this it is easy to secure the required depression, when the condyle, not unlikely, is found to slip into place of its own accord.

5th. Still another manner is that known as Nélaton's. To practise this, the patient is seated upon a common chair, and the surgeon, standing behind, fixes his thumbs upon the nape of the neck, while with his fingers he pushes the jaw forward and downward by pressure exerted upon the coronoid prominences.

6th. ANÆSTHESIA.—In recent cases the anæsthetic agents may not be required, although there is seldom objection to their employment. In cases, however, of any standing, or in muscular persons, it often happens that it is impossible to succeed in the reduction without the aid of relaxing agents; while, again, the formation of adhesions will be found to make attempts at reduction both painful and formidable.

A luxation having been reduced, it becomes necessary to give support to the parts, and insure for a time against the possibility of the mouth being too widely opened. This is most conveniently insured through the use of a vertico-mental sling made with elastic straps.



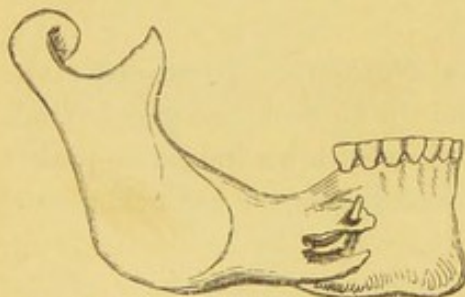
## CHAPTER LIV.

### FRACTURES OF THE MAXILLARY BONES.

FRACTURES of the maxillary bones are to be divided into two classes, simple and complicated. The first relates with such cases as are without external or associated injury, implying a single break in the continuity of the bone. The second embraces all conditions associated with comminution of the bone, with external lesions, injury to vessels, to teeth,—in short, to any relation which alters the fracture from one of a simple to one of a compound character.

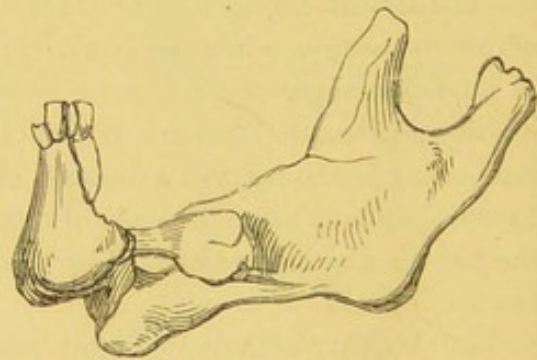
The inferior maxilla, from the exposure of its position, from its shape, and from its office, is more liable to the accident of fracture than the superior,—the lesion being commonly the result of blows, falls, kicks, etc. These fractures will, in the majority of cases, outside of gunshot injuries, be found associated with the body of the jaw, the rami escaping, from the fact that a

FIG. 511.



Simple fracture through the body of the lower jaw near the mental foramen.

FIG. 512.



Compound fracture of lower jaw.

force brought to bear upon them slips the articulation more easily than it breaks the bone.

In most inferior maxillæ a weak point exists in the line of the roots of the canine teeth; hence here is the most frequent seat of fracture. This, however, as will be inferred, applies to an unbroken dental arch. When teeth have been lost, and the process absorbed, the situation of this weak part is materially changed. In gunshot injuries, accidents from the passage of a wheel over a jaw, or similar applications of force, fractures occur at the seat of such applications, and follow no rule.

It is singularly the case that most fractures of the body of the lower jaw are compound, the opening existing on the lingual aspect: this is a result of



the easy lacerability of the gum-tissue, combined with a quick displacement inward of the fractured part. This exposure of the bone seems, in many mouths, to be of little consequence. In others it is quite the reverse, the saliva thus allowed to come in contact with the structure degenerating and deteriorating it.

Fractures from blows of the fist, or from similar concentrated forces, are apt to be single; from falls, they are not unlikely to prove multiple; from kicks of animals, comminuted. A common cause of fracture, familiar to every dentist, is found in the extraction of teeth having large and bifurcating roots; luckily, however, such breaks are not of serious nature, being confined to the alveolar process, although cases are on record where the accident has been so extensive and severe as to cost the life of a patient. Complete division in the continuity is, however, rare, very few cases having occurred.

The symptoms denotive of fracture in this bone are seldom or never obscure. There are, first, the mobility at the break, and the crepitation; second, loss of harmony in the line of the teeth. If the fracture be multiple, irregularities are produced in the general contour of the arch, and in the articulation. If the freed portion be the anterior or chin part, it will be dragged downward and backward by the action of the genio-hyoid, genio-hyoglossus, and digastric muscles. If it be at the line of the cuspid tooth and at the upper portion of the ramus, the fragment will be displaced inward by the action of the mylo-hyoideus, upward by the action of the masseteric, and forward by the action of the external pterygoideus. If the fracture be single, and beneath the attachment of the masseter, crepitation will be present, but little displacement. If the neck of the bone be broken, the body is dragged forward by the action of the external pterygoideus; much pain will attend the movements of the jaw.

Pain, soreness, inability to masticate, inflammatory phenomena, impediment to speaking or swallowing, associate with and characterize jaw fracture.

In short, the history of a broken jaw is the history of fracture anywhere else, allowing for differences in office.

Fractures of the superior maxillæ are quite infrequent, and when occurring, except from extraordinary causes, demand little attention outside of that which pertains to the injury as a contusion. Of such fractures the author has treated a number which surprises him in the count, considering the rarity of the accident; in no instance, outside of the alveolar breaks, has he met with a displacement requiring special apparatus for its cure. Indeed, the cellular character of these bones, and the existence of the antra, permit of such yielding that depression of the substance forms commonly the displacement: hence the associated frequency of caries with such accidents, the vitality of the part being lowered or destroyed. It is not, however, to be understood that derangement does not occur; the force of an injury may be great enough, as cases are on record to show, to luxate the bones in mass. In Mr. Heath's work is the record of a case taken from the Chirurgical



Treatise of Richard Wiseman, which is a marked example of such displacement. The patient was a lad eight years old, who had received a blow on the middle of the face so severe that he appeared at first to be dead, and afterward lay in prolonged coma. "When," says Mr. Wiseman, "I first saw the boy he presented a strange aspect, having his face driven in, his lower jaw projecting forward. I knew not where to find any purchase, or how to make any extension. But after a time he became sensible, and was persuaded to open his mouth. I saw then that the bones of the palate were driven so far back that it was impossible to pass my fingers behind them, as I had intended; and the extension could be made in no other way. I extemporized a retractor curved at its extremity, which I engaged behind the palate, and, having carried it a little upward, used it to draw the bone forward, which I did without any difficulty; but I had hardly withdrawn the instrument when the fractured portions went back again. I then contented myself with dressing the face with an astringent cerate. I likewise prescribed bleeding, and some hours afterward I had an instrument better constructed to reduce the large mass of displaced bone to its proper position. I had it held by the child's hand, by that of its mother or of an assistant, each for a certain time. Nothing else was done. Thus, by our united attention, the tonicity of the parts was maintained, callus was developed, and in proportion as this last became solidified the parts grew stronger, the face assumed a good appearance, —certainly better than could have been hoped for after such marked displacement. The child was entirely cured."

A case in the Westminster Hospital, of a frightful deformity produced by the passage of a wagon-wheel over the face of a man who fell in the street, may be alluded to. Here the bones were completely shattered, and the maxillæ torn from one another, death being instantaneous. A case is also recorded, admitted into the same hospital, the accident resulting from the overturning of a cab upon the face of its occupant, who at the moment was leaning out of the window to direct the driver. Here, in addition to a fracture of the lower jaw, a little to the left of the median line, the nasal bones were broken, both malars were loosened and separated from their attachments, and the left bone was fractured, as also the external angular process of the os frontis. Though not positively ascertained, the vomer was no doubt fractured, and probably the vertical plate of the ethmoid. The case is reported by Dr. Fyfes. It was remarkable, says this gentleman, to observe how movable the bones of the face were. On watching the profile of the patient while he was in the act of swallowing food, the whole of the hard parts could be seen to move up and down upon the fixed part of the skull, as the different portions were brought into motion. It appeared as if the integuments alone retained them in position. It was a curious feature that notwithstanding the very extensive injury done, and the violent character of the force, not a single tooth was fractured or misplaced. The patient is reported as having made a perfect recovery.



A case of similar signification, which the kindness of Professor Agnew enables me to illustrate, is shown in Fig. 513. The patient, a lad, who had been

FIG. 513.


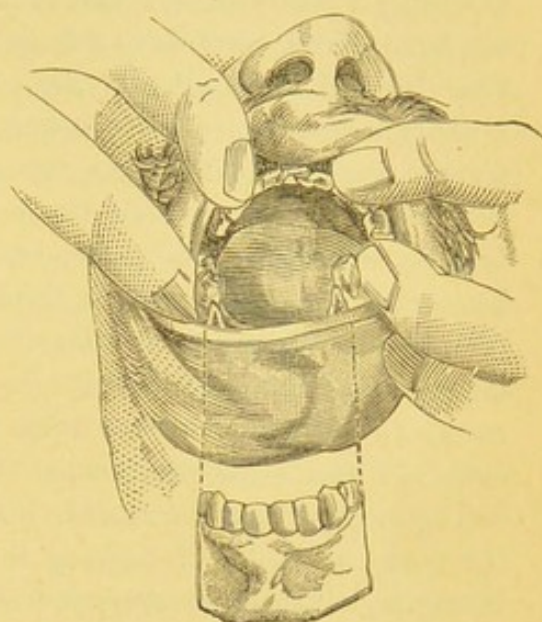


FIG. 514.



caught between the bumpers of two railroad cars, was brought to the hospital, the whole face being disjoined from the head. The upper jaws were greatly comminuted, the inferior maxilla was broken in four places, and a number of ragged wounds involved the soft parts of the face. Notwithstanding this extensive mutilation, Dr. Agnew speaks of all the upper fragments as uniting, a portion of the lower only becoming necrosed and requiring to be removed. The drawing shows the appearance of the patient after recovery.

A case of complicated fracture, treated by the author in conjunction with the service of the Pennsylvania Hospital, has the following history:

The patient, a painter, while passing over the roof of a house, had the misfortune to slip, falling all the way to the street. As a result, besides fractures of both legs and arms, the superior and inferior jaws were broken into many pieces.

Comminution being very great, a number of splinters were necessarily removed; this, as the lower maxilla was concerned, allowed the lateral remnants to fall together, the symphysis of junction being midway between its former position and the hyoid bone.

The patient being recovered, this adventitious jointure was incised and the



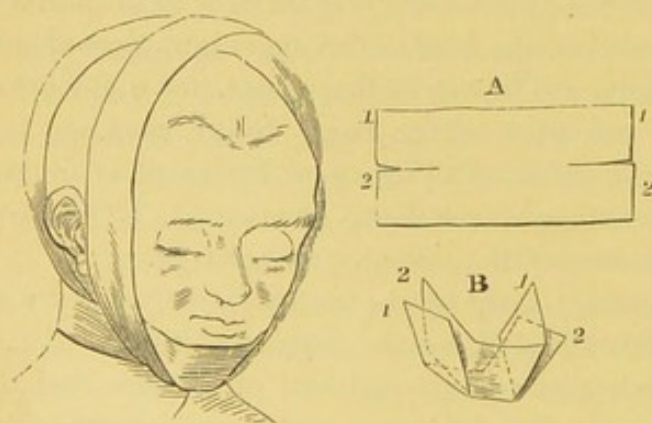
parts separated by means of a jack-screw; some three weeks being required to accomplish the task. Being held in place an impression of the parts was secured in wax from which was finally prepared the section shown (Fig. 514). This slipped into the hiatus, restored most happily the continuity; the great deformity being corrected and the patient eating with almost his ordinary comfort. Teeth in place in the upper jaw conceal the defects in that arch. (See *Wounds of Mouth and Associate Parts*.)

Of gunshot injuries the writer has had opportunity to see many and marked examples. In comminuted fractures it is his practice to pick away such pieces as are completely detached, but to leave and mould in place, when feasible, all others. He has never met with the trouble of uncontrollable hemorrhage, and generally has found the reparative energy sufficient to unite parts much broken. In Circular No. VI. of the Surgeon-General's Department, secondary hemorrhage is noted as the principal source of fatality in the cases: 1579 fractures of the facial bones are reported; of these 891 recovered, 171 died,—the terminations of 517 cases were left unaccounted for.

The treatment of a fractured jaw involves the indications to be met, and the mode or modes of meeting them. These indications and modes vary, of course, with almost every individual case. For a simple fracture of the inferior maxilla, or, indeed, for most compound fractures, the common pasteboard or gutta-percha splint is generally found sufficient and reasonably satisfactory.

To make this splint,—which constitutes the basal idea of dressings for jaw fractures,—take a piece of binder's board, or gutta-percha, and cut it as shown

FIG. 515.—BARTON'S BANDAGE.



A. Shape of the piece of pasteboard or gutta-percha for the chin.

B. The same moulded to the part,—the ends, 1, 1, being turned upward, and the sides, 2, 2, turned from before backward.

in Fig. 515. The board thus shaped is soaked in hot water until it becomes soft. The fracture is then set, the jaws approximated, and the splint moulded into shape and position over the parts. To accomplish this last it is only necessary to lay the centre of the board beneath the chin, one-half projecting; the wings are next brought up and pressed about the cheeks; next the projecting portion of the board is laid against and around the chin and sides of the face. This makes a complete cap, fitting accurately the region, and, when dry, it is uniform and unyielding.

A manner of splinting, as perfect as it is simple, and which, as the author's



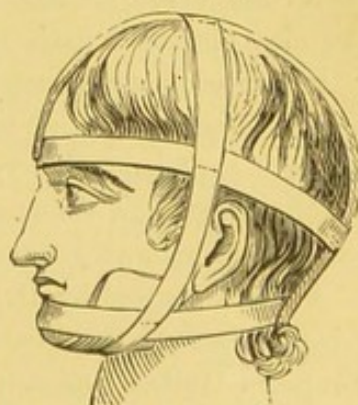practice is concerned, commonly relieves him of all trouble, as complicated apparatus are concerned, consists in putting into dough form ordinary gutta-percha (used in dentistry for the purpose of taking impressions), by means of hot water, and, after setting the fracture, model out a rim corresponding with the jaw, and allow the patient to bite into it. If delicately and properly done, no excess of material being allowed, this holds the parts firmly, and may be allowed to remain, without being disturbed, for two or more weeks, or even, indeed, until splinting is no longer a necessity. After the first week, a patient wearing this splint may be allowed to rest himself frequently by opening and shutting the mouth.

A perfect double interdental splint (see succeeding paragraphs) is to be made in a few moments by means of this preparation, the mouth being held open at any angle desired. Such a splint is made simply by placing the material, in required bulk, on both sides of the jaw and allowing the patient to settle the teeth into the masses to that extent which preserves the necessary opening in front. A sponge, wet with cold water, hardens the splint instantly. Fig. 521 affords the idea, the middle portion being supposed absent.

To hold splints in position, a bandage is to be applied. The most simple is a modification of Barton's, which suggested itself to the author several years back, and which has since been used by him with much satisfaction. The Barton bandage, so generally employed in fractures of the lower jaw, consists of a roller six yards in length and from one and a half to two inches in width,—following in this latter respect the taste and idea of the operator. To apply this dressing, place the initial extremity behind the left ear; carry it around the side of the head, over the opposite parietal bone; cross to the right over the neighborhood of the fronto-parietal suture; carry down beneath the chin; carry up on the opposite side; cross on the forehead; carry around the left parietal bone, and meet the beginning of the roller at the occipital prominence, or a little below it. Repeat the turns until the roller is exhausted.

Gibson's bandage, used in the same and similar fractures, employed mostly when the break occurs at the angle, consists of three distinct turns. First. Place the initial extremity in front of the ear; carry beneath the chin; pass up on opposite side, and meet the beginning by passing over the fronto-parietal region far enough back to prevent slipping; repeat this turn three times. Second. Reverse in front of and a little above the ear, and make three turns around the circumference of the vault. Third. End the third of these last turns at the occiput, and carry three times around the occipito-mental circumference. This is also a six-yard roller.

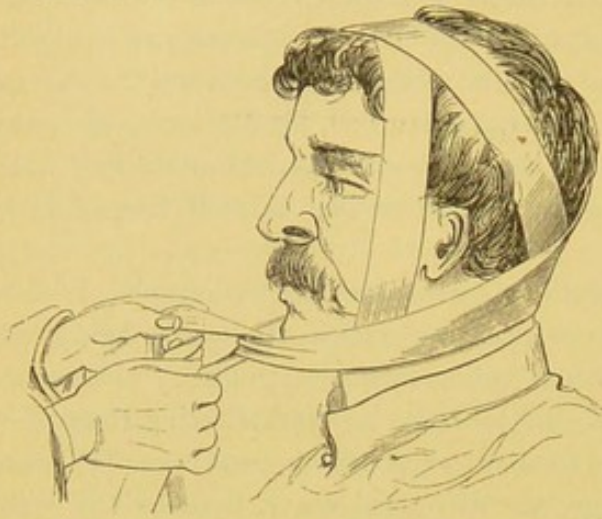
FIG. 516.—GIBSON'S  
BANDAGE.





The modification of Barton's bandage, known by the author's name, is applied as follows: Take a strip of roller material, one and one-half or two

FIG. 517.—THE AUTHOR'S BANDAGE.



inches wide, one and one-half yards in length. Standing behind the patient, rest the chin on the centre of this strip; carry the ends up, cross on the forehead, carry around the sides of the cranium, cross again at the occiput; carry forward, and tie, or otherwise fix, in front of the chin.

In the application of this dressing or strip, if the parts about the jaws be tender, it is better to make the termination somewhere on the side

of the neck. To effect this, it is only necessary to place the chin, when first resting the strip, nearer to one or the other of its ends. This bandage is shown in Fig. 517.

A second method of dressing a fracture, applicable to both simple and complicated cases, one which allows the mouth to be partially open, consists in making two plates, one to fit the upper teeth, and in part the roof of the mouth, the other to cap a certain convenient number of the lower teeth. After setting the fracture, these plates are put in position, and attached to each other by means of a piece of wax; the related plates are next removed from the mouth and soldered together. This done, the piece is replaced, and the teeth closed into the metal sockets. The strip bandage being applied the dressing is completed. This mode of treating a fracture of the lower jaw the author thought original with himself, but has found it employed by Mr. Liston, of England, some twenty years or more back, a splint entirely similar having been constructed for that surgeon by Mr. Nasmyth at least five years before the idea suggested itself to his own mind.

In any ordinary fracture of the lower jaw, the mode of dressing described will be found to meet all indications. In complicated injuries, it has been the common experience that rules are of little consequence; a surgeon finds himself governed and directed by the peculiarities of each case, and is thrown entirely on his own judgment and ingenuity.

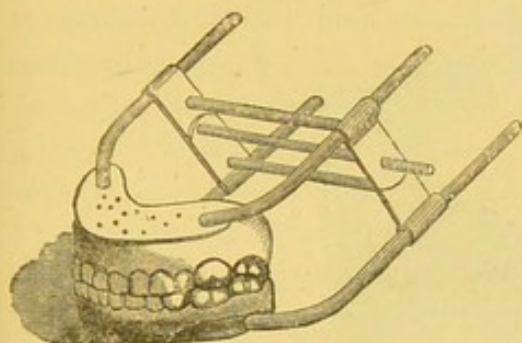
A splint devised by Dr. Bean, of Georgia, and used during the war of the rebellion, among the Confederate troops, is, seemingly, much regarded in the Southern United States. This apparatus consists simply of a piece of light wood, four and a half inches in length, three-sixteenths of an inch in thickness, and one inch and a half in width in the middle, tapering to seven-eighths of an inch, and round at the ends, to each of which is attached a



metallic side piece four or five inches in length and from three-quarters to one inch in width, also a shallow cup, fitting the apex of the chin. Incasing these side pieces are temporal straps, made of stout cloth, and secured by a strong cord at the base of each piece.

A bandage, occipito-frontal, is composed of a band passing around the head from the forehead to the occipital protuberance, and secured by a buckle, one inch to the right of the median line behind, of another strap secured to the band in front and behind, and a third, extending from the temporal buckles on either side and secured to the middle strap at the point of crossing. Figs. 518, 519 show this splint.

FIG. 518.



Bean's interdental splint.

FIG. 519.



Bean's splint applied.

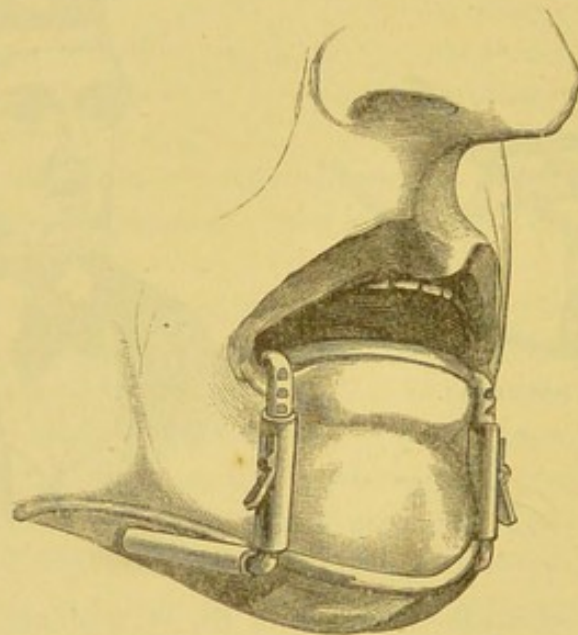
A mento-dental splint, the invention of Dr. W. Sudduth, of Bloomington, Illinois, is shown in Fig. 520. This apparatus carries its own commendation, and no doubt will come into wide use by such as have the ingenuity to make and the tact to manage it. The especial points claimed for the splint are, 1st. That it is universal in its application. 2d. That by its use a perfect articulation is insured (upon recovery). 3d. Cleanliness. 4th. Comfort in wearing. 5th. Ease of adjustment. 6th. Absolute firmness, so that no crepitation of fractured ends of jaw can occur at the posterior portion of the splint. This is insured by the arms of the ratchet-clamp extending nearly to the rear of the splint. This last point has not been touched by any other device. Also, the attaching of the clamp to the sides of the cups allows the jaws to move nearly approximate, insuring comfort to the wearer.

**DIRECTIONS FOR USE.**—Adjust the fractured portions of the inferior maxilla, and take impression in wax of both maxillæ (upper and lower), fill impressions with plaster, place the upper cast of the teeth thus obtained in the superior portion of an articulator. Break the cast of inferior maxilla at such points as correspond to the fractures of the jaw (if you have not



been able to secure an impression which will articulate its cast, which in all probability you will not), articulate the fractured portions with the cast of superior maxilla. When you have the articulation correct, cement the fractured portions by the addition of fresh plaster to the breaks. Next warm some impression compound and place in the upper tray of splint, then press the articulated cast of inferior maxilla into the impression material, thereby getting an impression of the jaw as it should be to articulate with the superior. Insert the cup into the mouth, and carefully work the natural teeth into the impressions made for them by the cast. Adjust the clamps and the lower cup, placing a little plaster in the lower cup to fill up any inequalities in the

FIG. 520.—SUDDUTH'S MENTO-DENTAL SPLINT.



jaw not met by the lower cup, thus making a *perfect splint*, holding the teeth above and the lower portion of the inferior maxilla below. If it be found that the circulation of the facial artery is interfered with, a groove can be cut in the plaster in lower cup to accommodate the vessel.

It is sometimes the case that from comminution, or other causes, fractures of the inferior maxilla, like fractures of other bones, fail to unite. In treating these cases the practitioner finds each one possessed of special indications. If necrosis exist, exfoliation of the sequestrum is to be awaited. If the vital force seems at fault, this is to be stimulated and elevated. If it occur that the ends of the fragments have become rounded, and perhaps tipped with a species of cartilage, operative means are demanded,—such means varying with circumstances. One plan, considering this last condition, much approved, is to pass through the parts a seton, composed of several strands of wire, to be removed thread by thread, as inflammation requires to be modified. Or, in place of the wire, other material, as silk, twine, tape, etc., may be used. An



operation consists in boring one or more holes through each of the fragments, and the tying of them together with sutures of wire. Resection is a means successfully employed by many. Irritating the ends by rubbing the fragments together, thus provoking the desired inflammatory action, is still another plan.

Attention to the circumstances of a patient suffering from ununited fracture is important. A case exhibited at one of the clinics of Professor Henry H. Smith was plainly enough due to the individual having confined himself exclusively to a diet of potatoes, such food, in this case at least, being insufficient to accomplish the repair.

Complications, whatever their character, are to be treated on general principles. It is impossible to direct any special course, for the reason that such conditions are constant to no rule. Hemorrhages of moment, so frequently alluded to, have not been met with by the author. Those occurring, are nearly always secondary in character, and it is well, where possible, to treat them in anticipation: for example, an injury which has lacerated the facial artery would perhaps yield little or no hemorrhage at the time of accident; yet, as the process of sloughing should expose the sound part of the vessel, hemorrhage might be profuse and alarming enough. In these and corresponding cases circumstances, in special instances, justify one in searching for the ends and ligating them, otherwise cutting down upon them. (See *Ligation of Arteries*.) Injuries to the dental organs are to receive due attention: it is not by any means every loosened tooth that is to be removed, nor every displaced one that is to be looked on as lost to usefulness. The proper plan is to wait on nature's indication. The practice of the writer is to remove no important tooth or teeth under circumstances of accident until shown by the extent of suppuration or by a threatening appearance of the parts that retention is impossible. As a means of support to loosened teeth, apparatus of the least irritating nature is to be employed.

In cases where teeth have been broken off, parts of roots remaining in the gum, indications demand the removal of the crowns should these be hanging attached to the gums. It is desirable also that the roots be removed, but this, as a rule, it seems impossible to accomplish, so that nothing better is to be done than to combat the associated inflammation and wait. Acute manifestations having been mastered, the most satisfactory results possible to be secured are found in the use of the *tinctura myrrhæ et capsici*; teaspoonful to half-goblet of water; gargle frequently. Fractures occurring about the neck of the inferior jaw are to have the displacements corrected by the application of such compresses as are found to answer the purpose, no matter how closely such applications follow any special rules, nor how far they depart from them. The author does not remember ever to have treated, in the course of his professional life, two fractures precisely in the same way. (See *Inflammation*.)

In breaks of the superior jaw, complications, while rare, are still more



anomalous. Thus, a case is recalled where it was necessary to remove the whole alveolar process of both maxillæ, the accident being resultant of a kick received from a mule. In this case the patient was a man broken down by drink and dissipation. A process was anticipated which was sure to have resulted, but which, to have been accomplished *per vias naturales*, would have cost the patient weeks of suffering, not unlikely, life. The writer has seen a case of fracture of the right upper jaw, where the alveolar process (the fractured part) hung at least a quarter of an inch below the common level. In this case the part was moulded into its place and supported by a simple strip passing across the jaw and fixed a little beyond the fronto-parietal suture. In three days the piece became self-supporting, and in two weeks the patient was eating comparatively solid food.

Gunshot injuries of the face and jaw are of every conceivable variety. The surgeon does primarily, in such cases, what he can, and leaves the rest to nature. (See *Obturbators*.)

With Hamilton, the author has to remark that it is impossible to discuss in detail the varieties of accidents to which the complicated structures of the face are exposed from balls or other missiles. Certain general rules are, however, to be observed. For instance, as suggested by that surgeon, missiles entering and lodging in the face are to be extracted as speedily as possible; and, whenever it is practicable, they are to be removed through the mouth. If permitted to remain, they expose to the danger of secondary hemorrhage, and increase chances of subsequent disfigurement.

Loose fragments of bone are to be replaced, unless much detached from the flesh and periosteum, experience proving that these unite in most cases with facility.

No piece of skin which is torn up is to be removed unless it be absolutely dead; it is to be laid back carefully in place, and retained either by a few delicate sutures, or by some gentle means of support. Tight ligatures and firm straps of adhesive plaster, being apt to bind the tissues and destroy their little remaining vitality, are not to be employed. The best means of supporting a fragment of skin in place, in many cases, is to lay upon it a thin piece of lint smeared with cerate, and over this a pledget of cotton-batting, securing the whole with adhesive plaster or a roller.

As soon as the inflammation and consequent induration have completely disappeared, and not before, it will be proper to make the final anaplastic operations.

An addendum to these suggestions of Dr. Hamilton is to be made by directing attention to the necessity of controlling and combating inflammation. To this end cold water is freely used locally, saturated cloths being renewed as the temperature is elevated; or the water may be medicated; acetate of lead and laudanum being generally employed. An admirable antiphlogistic application is prepared by adding to Oj of water ʒij of the former and ʒij of the latter. If a patient be robust and plethoric, it is, in most cases,



advisable to assist local treatment by cathartics,—sulphate of magnesia or the ordinary Seidlitz powder being prescribed.

Imperfectly treated fractures not infrequently induce so much discomfort as to warrant secondary breaks. As an illustration, the following case may be cited: T. H., an employé on the Camden and Amboy Railroad, received a double fracture of the inferior jaw, by being in some way jammed between two cars,—one break being on the line separating the second and third molar teeth, the other, the line of the cuspis root of the same side. A treatment resorted to in a hospital to which he had been carried failed in retaining the intermediate part in place, so that, on uniting, the teeth lay flatwise, presenting the buccal as an articulating surface.

Deciding on the propriety of an attempted correction, the bone was rebroken through the imperfectly solidified callus, and the depressed portion, being raised into position, was retained by a silver splint,—this splint being made and applied as described and illustrated. (Fig. 521.) As a consequence of the injury inflicted, several pieces of the callus necrosed and came away; but the daily injection of a much-diluted tincture of capsicum and myrrh resulted in such solidification of the parts in their new position as to permit the disuse of the splint,—terminating in a cure most satisfactory to all concerned.

**Description.**—The bone being rebroken the fragment was raised into position, and while held by the tongue of the patient upon the inside and the fingers of an assistant upon the outside, an impression in wax of the whole lower arch was secured. From this mould a silver plate, C, was prepared,\* which fitted accurately the lower arch when the disjoined piece was in position. A succeeding step secured a wax mould of the upper jaw, from which model a second plate, H, was made. This plate, as seen, covers the side but not the front teeth; it covers as well the roof of the mouth.

The two plates ready, a succeeding step placed them in position, exactly as seen in the diagram. The jaws being separated to an extent permitting of the convenient passage of food, relation was secured temporarily through the use of adhesive wax thrust against and between the plates on either side in the spaces existing between E, G, and D, F. The plates thus related were lifted from the mouth and being placed in a plaster matrix were soldered together at the seats of the wax application. Afterwards cleaned by being dropped into a dilute sulphuric acid bath, the fire coat being thus removed, they were polished with pumice and rotten stone. The fracture was now again set and the piece put in position. The patient went at once about his business and in six weeks was well. This splint is the one referred to a few paragraphs back. To hold it in place, or rather to secure fixed relation of the jaws with it, the bandage already described and figured is to be used.

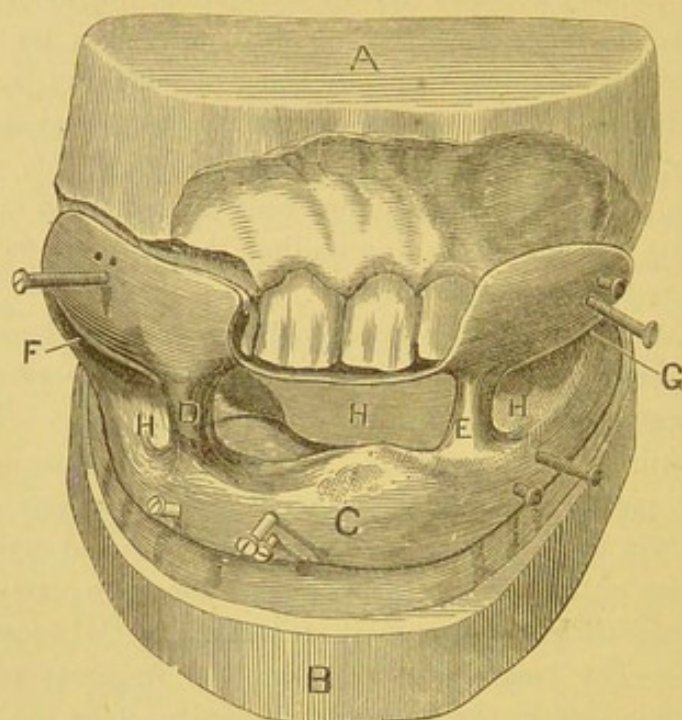
As a means of dressing in any complicated jaw fracture the inter-dental splint is as invaluable and reliable as it is simple of construction and easy of

\* For manner of making see *Prosthetic Dentistry*; also *Obturbators*.



application. The screws passing between the teeth—shown in the cut—are not longer found necessary. A bandage, tightly enough applied, prevents

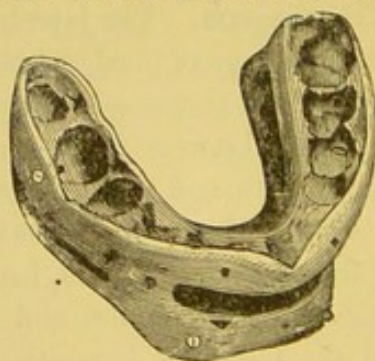
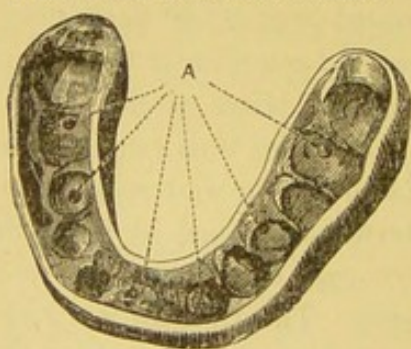
FIG. 521.—THE INTER-DENTAL SPLINT.



all motion. It will be understood that the plate line seen below the superior incisor teeth is, in the cut, with a view of showing its relation with the palatal faces of these organs; when the plate is in place the line is, of course, resting upon the gum adjoining the necks of the teeth.

FIG. 522.—DENTAL SPLINT.

FIG. 523.—INTER-DENTAL SPLINT.



Inter-dental splints are now, in America at least, more frequently made of gutta-percha than of metal; this, presumably because of the easier working of that material. Metal, however, is, in the estimation of the author, most decidedly to have preference; gold to be used, if the patient be rich enough to bear the expense. Silver, when fire gilded, is an admirable substitute.

Fig. 522 exhibits a splint of gutta-percha which is made most simply by



warming and moulding the material over a cast secured from a wax impression obtained as described. Being hardened by the use of cold water, and trimmed, such a splint is prepared and applied in a little time. A represents alveoli accommodating the teeth. Fig. 523, after model by Dr. Gunning, shows an inter-dental splint, made of this same material, fitting both jaws.

An inter-dental splint of satisfactory character and entirely general in application is to be prepared and applied as follows: Make a curved tin channel corresponding to any inferior jaw that may be selected. Upon the base of this first set and attach second channels made to loosely correspond to the molar regions of the superior jaw. Putting the three in place, attach them by means of wax, the jaws being separated to the width of a finger. Remove carefully from the mouth and solder. Make several to correspond reasonably with the varying curvatures of different arches. To apply, fill the channel with softened white beeswax, set the fracture, and, placing the apparatus in correspondence with the arches, let the patient bite into the wax until the plates are reached. Instantly bandage to prevent movement, and, this accomplished, harden the wax by cold water held in the mouth. This apparatus proves as satisfactory as it is seen to be simple.



## CHAPTER LV.

### EXSECTIONS OF THE MAXILLARY BONES.

THE history of experimental surgery on the bones of the face constitutes one of the most interesting of the chapters in surgery. The formation about and within these bones of such tumors as seemed to make desirable their removal, necessarily directed, from a comparatively early period, the attention of surgeons to the feasibility, propriety, and promises of such operations.

It is not at all unreasonable to infer that surgery gained its first lesson in this direction by observing, in the results of accidents, how extensive could be an injury done to the parts without fatal, or, indeed, even threatening consequences. As early as 1693, Acoluthus, a surgeon of Breslau, attempted the removal of a portion of the upper jaw for a tumor, in which operation he succeeded very satisfactorily. Jourdan, according to his translator, removed, at various times during his century, portions of the jaw. To Dr. Jameson, an American surgeon, belongs the credit, however, of having made the first complete exsection, or removal of the upper jaw,—this having been done in 1820, although to Lizars, of Edinburgh, belongs the higher credit of having first suggested the possibility and advantage of the operation. In 1824, four years later, Dr. David Rodgers, of New York, exsected both superior maxillæ. Afterward this was attempted by Lizars, and in the same year by Gensoul, of France. After this the operation may be considered as having become commonly recognized, surgeons of ability performing the various sections throughout England and France, and especially in the United States.

While the operation of exsection has been frequently performed, it cannot but surprise the surgeon of to-day to notice how slowly its lessons were learned. At present it is practised with little preliminary caution, being esteemed a matter that is to be attempted with trifling danger to the patient, and even without much damage to the appearance. Formerly, and, indeed, not very far back, it was considered necessary to ligate, as a preliminary step, the primitive carotid artery; and when, as experience advanced, this was seen not to be a necessity, the actual cauterants were always held in readiness, a means of controlling the hemorrhage which, much to the detriment of a happy cure, obtains in some regions even to the present day.

Exsections of the maxillary bones are practised for various diseases, the principal of which are the malignant tumors. That such exsections are so often reported as resulting unfavorably, has not explanation in shock, or in local injury done, but in the fact that the disease for which operations have been performed is in itself fatal.



In looking, after an interval of months, and, in cases, of years, at individuals on whose jaws the author has personally performed exsections, he has been astonished at the correction, on the part of nature, of deformity. The little German boy, alluded to in the chapter on Necrosis as having lost the left half of the inferior maxilla, without at the time any reproduction, looks to-day as though no such loss had occurred; his face is exactly as it was before the operation, and, so far as may be judged, the ability to masticate, allowing for the loss of the teeth on that side, is about as good as ever. This, however, is an uncommon case, the result without doubt of the youth of the patient. A young lady allowed herself to be exhibited by the author to a few gentlemen during a meeting of the dental profession of New England, held at Providence (1883), from whose person he had removed, a year before, the right superior maxilla in its entirety. A denture made for the case by her dentist, Dr. Buckland, of Woonsocket, which differed little from an ordinary tooth-plate, corrected the loss so absolutely as appearance was concerned, that every external evidence of an operation was absent. The bone had been removed from the inside.

Ollier, by his experiments upon the osteogenetic properties of the periosteum, has done good service to oral surgery. It is now a common practice in exsections to spare and save all this tissue possible. In the chapter on Necrosis the author has alluded to his own success in this direction, having replaced entirely (now several times), with the exception of the alveolar process and teeth, the whole of the lower jaw; the process adopted being that of enucleation.

It is not to be forgotten, however, that the seeds of a disease, so to speak, may be left in a part by an attempted preservation of periosteal tissue. This fact is always, in all classes of exsection, to be borne prominently in mind: periosteal tissue is not to be saved unless healthy.

To make a complete exsection of either maxilla implies, ordinarily, a preliminary uncovering of the affected bone. The incisions to such ends are necessarily various, being influenced by the condition of the parts beneath. Exposure is not, however, always necessary. Professor Horner, as exhibited in Plate VIII., has removed the upper jaw of the left side without preliminary incision; and in several favorable cases the writer has himself succeeded, even without difficulty, in doing the same thing.

In the case of tumors of magnitude these sub-integumental operations are not, however, to be commended. A wound, or incision, made to expose such tumors, may be united by the first intention, leaving little or no scar, while certainly the exposure obtained through such incisions compensates by the liberty and rapidity of movement allowed in the subsequent steps of an operation.

Subfig. 1, Plate VIII., exhibits the mouth of a patient of the late Dr. Horner, immediately after the removal of the superior maxillary bone without external incision. Fig. 2 is a side view of the bone removed, and Fig. 3



is the likeness of the patient taken three years after the exsection. The operation, as practised by Dr. Horner, is thus described by his son-in-law, Professor Henry Smith: Having determined to avoid cutting through the cheek, as commonly practised, the patient was seated in a chair, with his head well supported, and partially etherized. The assistant, supporting the patient's head, then raised the angle of the mouth on the left side,\* and held it widely open, while the upper lip and cheek were dissected from the superior maxilla as far back as possible, in a line parallel with the superior margin of the buccinator muscle. The two incisor teeth on the left side being then drawn, the corresponding alveoli were cut through in the middle line by a narrow saw, which worked its way from the mouth into the left nostril; then a pair of strong hawk-bill scissors, such as are used by gardeners for lopping off twigs, took out the two vacated alveoli at a clip.

A thin, flat, well-tempered knife, with a strong, round handle, was now struck through the roof of the mouth into the nose, at the junction of the palatine processes of the palate and superior maxillary bones (posterior middle palate suture), so as to cut forward and separate the maxillary bones from each other in the middle, when the narrow saw was again used to cut through the root of the nasal process of the maxillary bone, and strong scissors, curved on the flat, made to cut through the orbital plate at its margin, the incision being carried back to the pterygoid process of the sphenoid, around and below the malar bone.

The base of the soft palate being then separated by a short triangular knife, curved on the flat, so as to leave the part associated with the palate bone, a few touches of the knife freed the remaining attachments.

The pterygoid process, malar bone, and the orbital plate of the maxilla were not disturbed. The tumor,—which was a scirrhomia,—besides its bony connection, was also attached to the posterior part of the cheek, and to the external pterygoid muscle. The gouge and scissors, however, sufficed to remove every part that could be detached.

The bleeding was profuse, especially from what was believed to be the posterior palatine artery, but the vessel was readily secured by means of a ligature and Physick's needle. A few other ligatures, together with the use of charpie, arrested the remainder of the hemorrhage.

The ordinary operation for the removal of the superior maxillary bone may now be described in detail.†

If the disease for which such an operation is to be performed is a tumor of moderate dimensions, say scirrhus, as in Professor Horner's case,—which

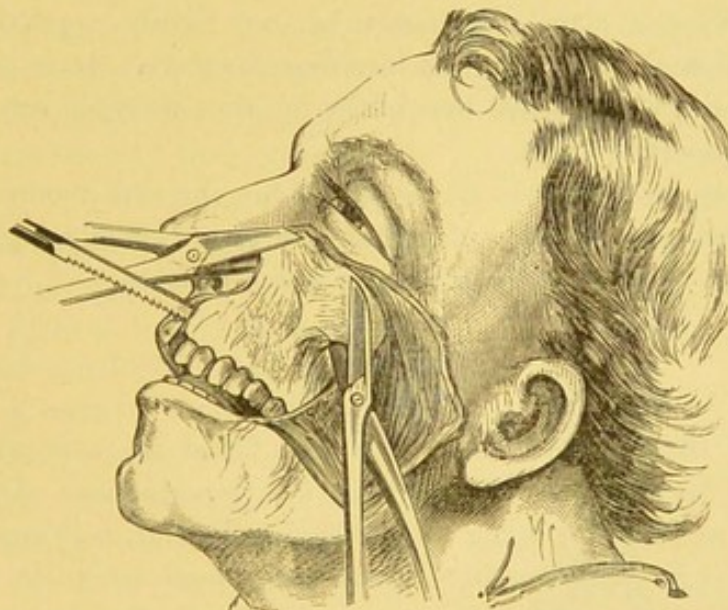
\* The figure, by an error, is made to show the operation on the right side.

† An arrangement in the shape of a double tracheal canula has just been introduced into German surgery, and has received much encomium; this, of course, necessitates the preliminary operation of tracheotomy. The canula being put in place, the breathing of the patient is said to be in no way interfered with by the hemorrhage, thus permitting the exsection to be made without that haste generally found so necessary. A later design of tube enters the trachea from the mouth. The author uses neither.



seldom attains to large size,—the uncovering of the part is effected by dividing the superior lip in the middle line, carrying the incision upward along the base of the ala of the diseased side to the inner canthus: the flap thus secured, which is triangular, is dissected off as far as the malo-maxillary articulation. Next remove the central teeth, and, with a scalpel, make an incision along the middle line of the hard palate as far back as the palato-maxillary articulation. At right angles with this incision make a second, extending to the tuberosity of the bone, the cut to be as nearly as possible on the line of the articulation named. Examining at this stage a skull,—which it is never amiss to have by,\*—take up a Hey or a metacarpal saw, and, with delicacy and accuracy, cut across the nasal process, leaving, if possible, the orbital plate. Next, with the same saw, cut across the maxillo-malar articulation; this completes the two upper sections. The third, the intermaxillary, is quickly effected by introducing within the nostril one blade of the large cutting forceps, the other being placed on the line of the articulation within the mouth, as far back as the point of union with the palate bone; the incision is now made, and the separation, as cutting is concerned, is completed. Take now a pair of strong forceps, and, seizing the bone, twist

FIG. 524.



Excision of the upper maxilla. Instruments applied to parts requiring division.

it from its bed. Fig. 524 shows an uncovered superior maxilla, with forceps and saw in the act of making separations.

In place of the instruments here shown the author now employs a circular-saw, revolved by the surgical engine. This latter means, while accomplishing

\* In a review of the first edition of this book, "Diseases and Surgery of the Mouth, Jaws, and Associate Parts," fault was found by a critic with this suggestion. To some, such reminders may not be necessary; the author, however, has always found them serviceable as immediate hints for delicate and accurate manipulations. With a patient etherized, there can be no objection to the presence of such models.



the object neither more effectually nor quickly, is yet attended by such diminution in shock, and of injury to associated parts, that no hesitation exists in according decided preference to it. (See Figs. 531 to 533.)

Succeeding immediately the removal of the bone is a required attention to the hemorrhage. It may be that twenty arteries will jet their blood into the face of the operator, or, on the contrary, only two or three may require artificial means for their control. One need not be over-hasty or timid about this bleeding. Neither is he to be over-easy or too confident. The circumstances pertaining to the arrestation of such hemorrhage are most influenced by the nature of a tumor occupying the bone; a sarcoma being of great vascular relation, a fibroma only very moderately so. The author, depending first, and most prominently, on ligation, resorts at once, on failure of this, to packing.

Packing has the double signification of stanching the bleeding and affording support to the overlying integument which is to rest upon it. Using first a square, this is to be fully saturated with phénol sodique and laid in the bottom of the wound. Next a strip of linen is soaked with oil, and the cavity is solidly filled; the end of the strip being so placed as to be easily found when removal is demanded.

The hemorrhage controlled and sub-integumental form considered, the flap is laid carefully into place, and closely, but not tightly, approximated by a sufficient number of stitches of the interrupted suture. It is generally the best plan to put a pin or stitch first in the lip, thus insuring correct relation at that most important point.

As a dressing, in this, as in all his operations, the author now uses phénol sodique, cloths kept wet with it overlying the part. Should high inflammation supervene, the following combination is a favorite:

R.—Plumbi acetatis, ℥ij;  
Tincturæ opii, ℥ij;  
Aquæ, Oj. M.

Concerning the pad and strip inside, it is found the best practice not to allow them to dry from the time of their first introduction. This is to be prevented by repeated syringing with phénol and water, half and half.

Stitches used in approximating the external wound are to be removed as soon as possible: three or four days generally allows of such removal. It is well to cut them cautiously, taking away intermediate ones.

The withdrawal of the packing is to be effected leisurely: indeed, the idea is to consider it as a tent, to be thrown out as the wound granulates and fills up below. The plan of the author is to withdraw a very little portion each day, cutting off the part extracted by means of sharp scissors.

Many cases occur where the external incision here suggested might not be the best one, and, indeed, where it might not be sufficient to uncover the disease. Certain surgeons prefer to expose the bone by an incision, commencing at the angle of the mouth, and passing obliquely in front of the Stenonian duct to the centre of the malar bone, throwing thus the flap upward and



inward from below. Another mode is to use both these incisions upon the same subject, a necessary proceeding, in many cases, where the tumor is large.

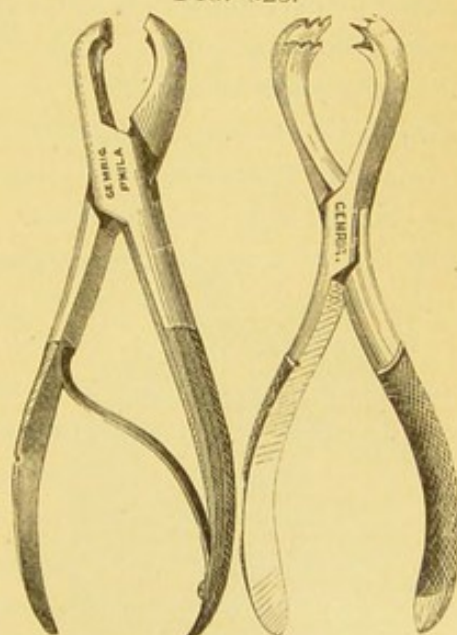
Sir William Fergusson, who during his years of practice was particularly successful in oral surgery, in remarks after an operation for the removal of disease affecting the alveolus and antrum, made some important and interesting observations, having reference generally to the exposure of such parts prior to the removal of the actual disease. He said that formerly, and even now, some surgeons divided the integument of the cheek, lip, etc., trying to get at the disease from various points: that one method he pursued with advantage (as in a case of removal of malignant disease of the upper jaw) was to divide the upper lip in the median line, and then by carrying the incision on one or both sides, as the circumstances of the case required it, into the nose, to dissect back the upper lip, ala nasi, and cheek, and thus expose the parts freely, avoid the deformity of scar on the cheek, or, to use his own words, "to leave as few marks of the surgeon's doings on the face as possible." In a case before him at the time the remarks were made,—a young woman,—he was able to remove the disease without interfering with the lip. It affected the alveolar ridge of the right side, extending from the second incisor to the second molar, and was continued into the antrum; but whether it first arose in the sinus or in the alveolus, he did not know. Mr. Fergusson attributed the success attending this method of removal, in a great measure, to the instrument he used, viz., a pair of clipping forceps. He first clipped away the alveolar ridge, and then attacked the portion of disease situated in the neighborhood; by this means freely laying open the antrum and nostril. He alluded to a case in which Mr. Bowman successfully removed a large tumor from the cavity extending into the mouth, without dividing the lips.

Such a mode of uncovering a tumor of limited size is admirable: the section will be found to make a large exposure, but the scar left is scarcely to be remarked.

**Operation for Removal of both Superior Maxillæ.**—It has never fallen to the lot of the author to exsect, or to see removed, both maxillary bones at one operation. Several such performances are, however, on record; and from among them may be selected that of Heyfelder, as being the one most practicable and easy of accomplishment.

The patient is to be seated in a chair, with his head supported by an assistant, or, better, he may lie down. An incision is made on each side of the face, from the external angle of the eye to the labial commissure; the included parts are now

FIG. 525.

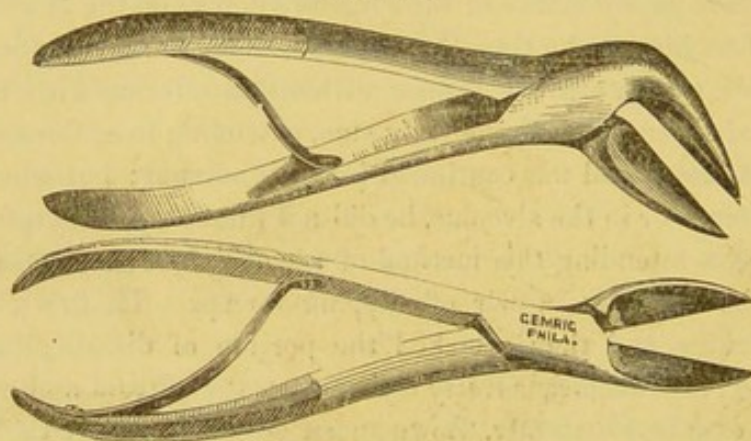


Lion forceps.



reflected upward toward the forehead until the infra-orbital ridges are exposed. This uncovers the whole of both bones. The chain saw is now passed through the speno-maxillary fissures, the malar bones are divided, the maxillæ separated from the ossa nasi, and the vomer and thinner bones are cut with strong scissors. These steps complete the separation, when the bones are to be pried from the cavities with elevators or twisted away with the lion forceps of Liston. The result of an operation thus performed by the deviser himself is described as follows: Very little blood was lost, torsion and compression sufficing to arrest the hemorrhage. Two hours afterwards, the edges of the wound, from the angles of the eyes to the corners of the mouth, were united by twenty-six stitches of the interrupted suture; cold lotions were applied: there was no reaction or swelling, and the patient could swallow water and broth. Four days

FIG. 526.



Cutting-bone scissors.

subsequently, the wound had nearly healed by the first intention, and in six weeks the patient was exhibited to the Medical Society of Erlachen. At this time there was no deformity of the features: a fissure, thirteen lines long and three wide, was seen along the median line of his mouth; the soft palate and uvula were in their natural place; deglutition was free; the nose had assumed its original form and direction. The face, which, before the operation, was like that of a monkey, again possessed a human expression; a firm and solid tissue replacing the extirpated parts.

For the removal of a class of tumors having origin back of the superior maxilla, the means known as the osteo-plastic resection of the jaw is employed. This operation consists in detaching the bone from its relations, except at one side, and then forcing it in the direction of the attached part,—that is, turning it out of place. The tumor is removed, and, after controlling the hemorrhage, the jaw is replaced.

Where, in this operation, may be the related part, is somewhat a matter for the preference of the operator, or otherwise is directed by the peculiarities of special cases. Langenbeck, the deviser of it, after exposing the bone, as in the ordinary performance, passes the saw through the maxillo-



Fig. 1.

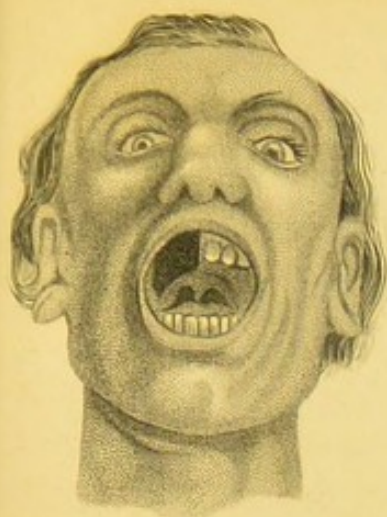


Fig. 3.



Fig. 2.

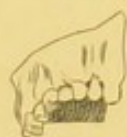

Fig. 6.

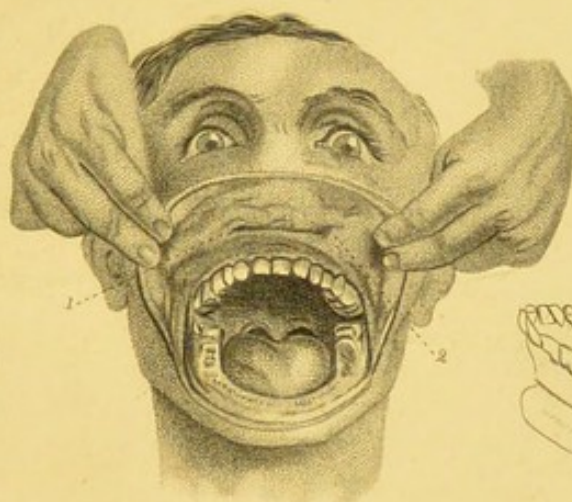

Fig. 4.

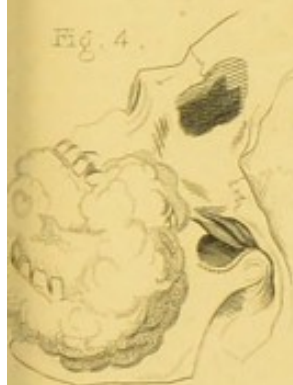

Fig. 5.

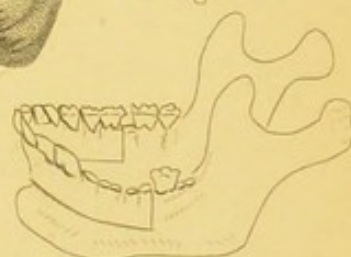


Fig. 7.

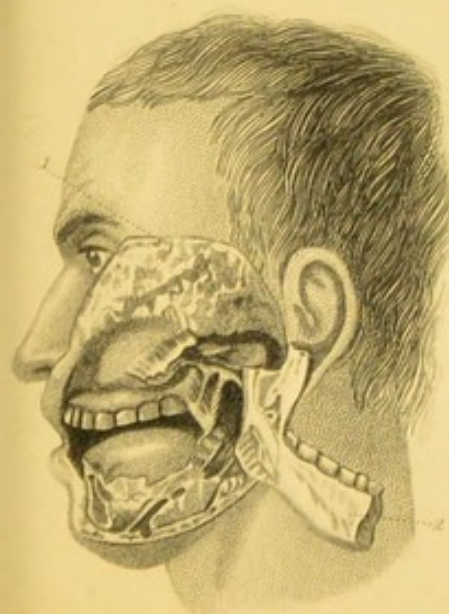
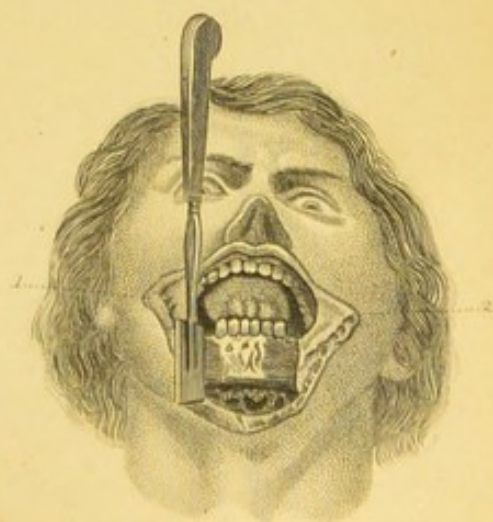
Fig. 8.









malar articulation, along the orbital angle, and then without further section turns, if possible, the bone toward the mesian aspect: if this may not be done, he then makes section of the palatine raphé. As a modification of this operation, Dr. Cheever, a Boston surgeon, separates the nasal and malar attachments, leaving in relation the palatine, thus throwing the bone downward.

In the removal of large and threatening nasal and naso-pharyngeal polypi, osteoplastic operations of the most severe character find commendation in the greater risk they are designed to avoid.

A mode of getting at such tumors, when they spring from the sphenoccipital base, and one which, on a single occasion, was practised with most satisfactory results by the author, consists in splitting the soft palate, and by a ligature passed through the apex of either flap drawing the veil aside.

Still another mode, one used by Ollier, applying more particularly where tumors are situated well back in the nares, consists in making a U-incision over the bridge and along the sides of the nose, having the apex looking toward the forehead; the flap, which is the nose, is now turned downward. Should space enough for the manipulations needed be not thus obtained, Ollier uncovers by a second incision the maxillæ, and saws away such portions of the bones as may be found necessary. (See *Polypi*.)

**Exsection of Inferior Maxilla.**—Figs. 6, 7, and 8, Plate VIII., exhibit various steps in section and removal of the inferior maxilla.

Complete section of the lower jaw is one of the most disfiguring and comfort-destroying operations that is practised on the living being, and is never to be performed without the existence of a well recognized or proven necessity. Section of the alveolar process is not a difficult matter, and is generally easily accomplished without external wound, the lips being held out of the way by such a mouth-stretcher as is used in the performance of dental operations.

Fig. 527 shows a form of mouth-stretcher commonly employed. A second form, one devised by Dr. Goodwillie, is shown in Fig. 528. This latter instrument takes up less room, and on that account is, in many cases, to have preference over the former. Quite as good as any is the common retractor found in every surgeon's operating-case. Still another, and a most excellent one, is known as Doyle's.

In instances where section of the lip may be thought desirable, as when the practitioner, from inexperience, is not able to accomplish ablation without such uncovering, various cuts are proposed. These are to be fully appreciated by the studies presented. Subfigure 8, Plate VIII., represents exposure of the mental portion of the bone. The flaps, 1, 2, are made by a single vertical incision through the median line of the lower lip, crossed by a second at right angles at the base of the jaw, extending on either side, laterally, as far as the bone is required to be removed.

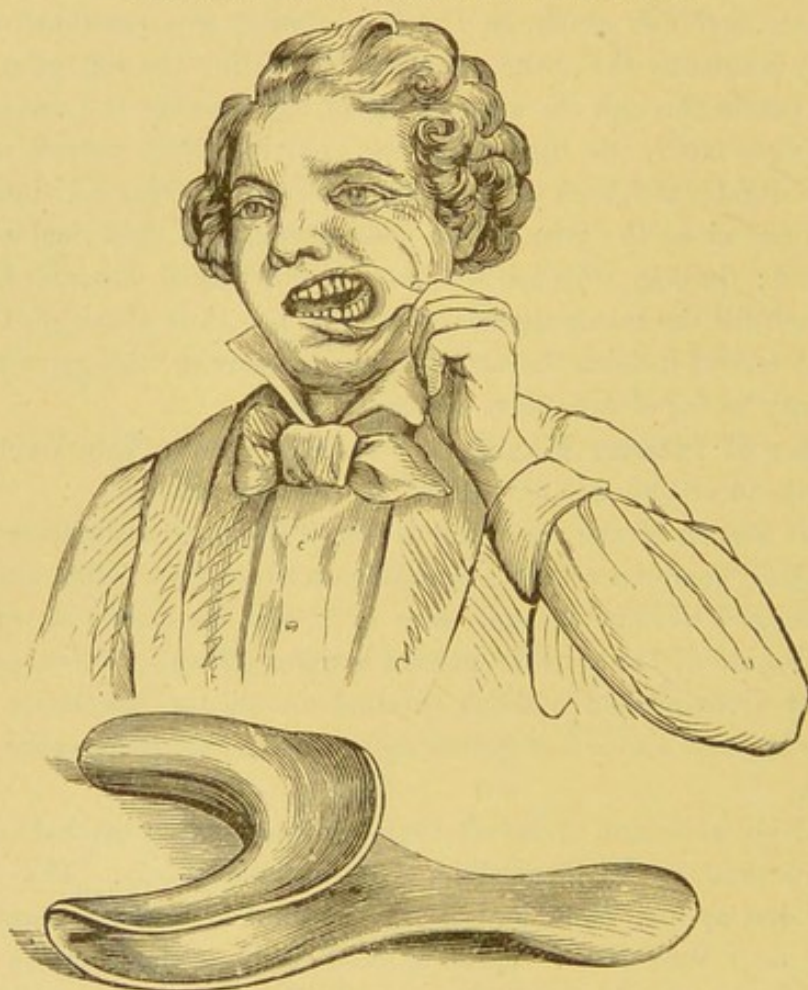
Subfigure 7 represents an exposure of the whole left half of the jaw. To accomplish this, make a first incision in the median line to the under border



of the bone. From this carry a second under the jaw—although along it—to the temporo-maxillary articulation. Dissect now the flap upward. In the horizontal cut here made it will be perceived that the facial artery is divided; this is a large vessel, and requires a ligature. It will be found the better practice to tie both ends before proceeding to the operation upon the bone. The coronary artery, cut in the vertical incision, will often compel a ligature.


Subfigure 6 exhibits an exposure of the whole body of the bone. This is

FIG. 527.—MOUTH STRETCHER APPLIED.



accomplished, as seen in the drawing, by a simple horizontal incision along the base of the jaw, being carried from angle to angle, and the flap, including

FIG. 528.



the mouth entire, thrown up; or it may be secured by joining the horizontal to a vertical incision made from the angle of the mouth; or, as in Fig. 8, by the median, vertical, and horizontal incisions. These sections understood, any required modification will suggest itself.



Subfigures 4, 5, 6, represent an operation practised by Dr. J. Rhea Barton : 4 exhibits the tumor, which will be seen to be of great bulk, being described as having complete possession of the mouth, forcing the tongue into the pharynx, and stretching the jaws widely apart. It also rose up outside the superior maxillary bone, protruding the lips, cheek, and neck on the left side.

Finding, by examination, that the base of the bone might be left with promise, Dr. Barton made the exsection as exhibited by the lines in 5. This was accomplished by sawing horizontally from without inward, commencing at the middle line below the canal, and extending the section bilaterally. The removal of the bone, in this particular operation, gave no hemorrhage requiring attention. The flaps being replaced and stitched, the patient was well in a month.

Complete section of the jaw, as exhibited in Fig. 8, after the practice of Dupuytren and many successors, destroys forever the articulation of the jaws, and interferes not only with mastication, but seriously with deglutition and speech. Exposing the bone as directed, the section is most easily made with either the Hey, metacarpal, chain, or circular-saw. Before, however, shaving from the bone its inner attachments, a loop of waxed silk, or silver wire, is to be passed through the tip of the tongue, that this organ may be prevented from being drawn back into the pharynx by the hyo-glossi muscles.

Subfigure 7 exhibits the removal of one-half the maxilla. Exposing the bone as directed, extract one or more of the centre teeth ; next, from without inward, saw through the bone, or if preferred, use a chain saw, carrying it around the part by the aid of a curved needle. Catching now the bone in the grasp of the forceps, or using the fingers, detach the inner soft parts, turning it outward and downward. Arriving, in the dissection, at the coronoid process, the temporal tendon is to be detached by a chisel-shaped knife, care being taken not to wound the maxillary artery or internal carotid. The process freed, the condyle can be twisted from its ligaments, or, better still, twisted and at the same time cut away. This operation, apparently so formidable, the author has succeeded in doing without external incision. With the section of the soft parts, as represented in the figure, it is not nearly so difficult as might be supposed. A diseased bone is seldom as troublesome to disarticulate as a sound one.

Professor Smith, in his *System of Surgery*, gives the credit to Dr. George McClellan of having been the first to attempt more than a limited section of the inferior maxilla,—this surgeon, in 1823, having removed all the parts anterior to the angles. In this, however, he was preceded by Deadrick, of Tennessee, who, in 1812, made an exsection which extended from the symphysis to the angle. Professor Mott, of New York, also made an operation similar to Deadrick's, in 1821. Dr. Ackley, of Cleveland, Ohio, is reported as having, in 1850, removed the bone entire. In Europe, priority of the operation performed first by Deadrick is awarded to Dupuytren. Mott, according to Professor Smith, disarticulated the bone,—Deadrick and Dupuytren



did not. Professor Mott thought it necessary to ligate the primitive carotid artery a few days before making his exsection, a step long since proved to be uncalled for.

The performance of Dr. Deadrick, deservedly famous for its priority, was done on the person of a lad fourteen years of age. The operation was for the removal of a cartilaginous tumor on the left side of the jaw, which tumor filled up nearly the whole of the mouth, causing the greatest difficulty in swallowing, and, at times, even in breathing. To accomplish his exsection, Dr. Deadrick commenced an incision under the zygomatic process, and carried it across the tumor, downward and forward, to nearly an inch beyond the middle of the chin. From the centre of this first incision, and consequently at right angles with it, a cut was extended a short distance upon the neck; the flaps thus secured were dissected from the diseased mass, and the bone next sawed off at the angle and symphysis. The flaps were laid back in the usual way, the boy making a speedy recovery.

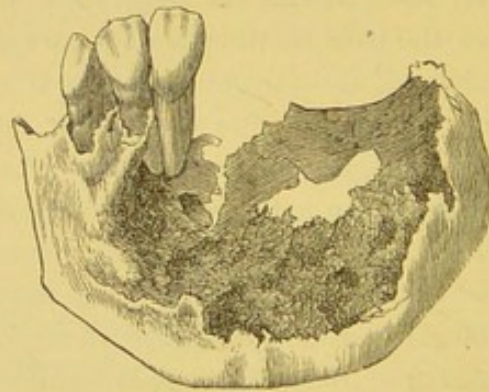
The author's manner of exposing the lower jaw and removing sections from it will be understood by reference to the illustrations given.

CASE 1.—Operation in this case was required for a cysto-sarcoma which extended from the first molar tooth of the left side to the first bicuspid of the

FIG. 529.

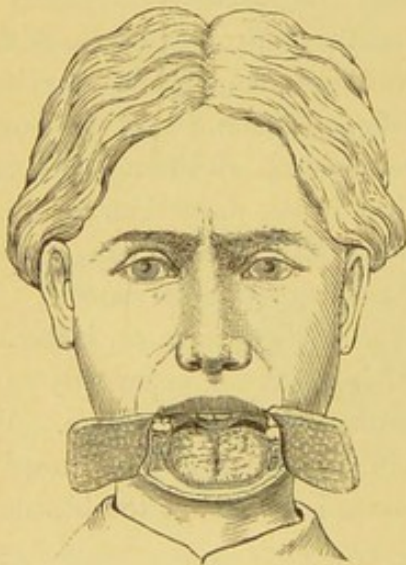

FIG. 530.



right. Patient, a young lady, seventeen years of age. Tumor had been twice removed by internal section, quickly recurring in both instances.

An exsection from which the lady quickly recovered, and which leaves her to-day (eight years having passed) without disfigurement of any kind, was done as follows. An incision, commenced at the free border of the lip, was carried directly in the vertical line until it passed beneath the chin. Next the neck tissue was drawn upward until it rested upon the jaw; it was then incised outwardly upon either side as shown in the cut. The bone thus exposed was sawn with great delicacy from side to side, a rim being left to pre-



serve the convexity of the chin. The tumor removed, a succeeding step replaced the soft parts and stitched them in position. On completion of the cure, which was very rapid, an artificial substitute for the lost teeth and portion of jaw removed was made, which, together with the immediate union of the lip wound, have placed the patient in as good a position, as appearance is concerned, as before the operation.

FIG. 531.

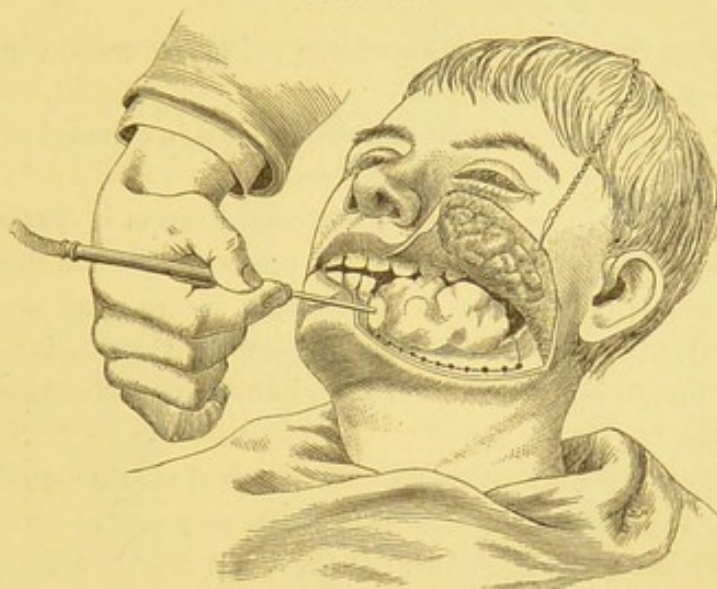


Fig. 531 exhibits an operation performed now many times by the author both before the class of the Philadelphia Hospital of Oral Surgery and in

FIG. 532.

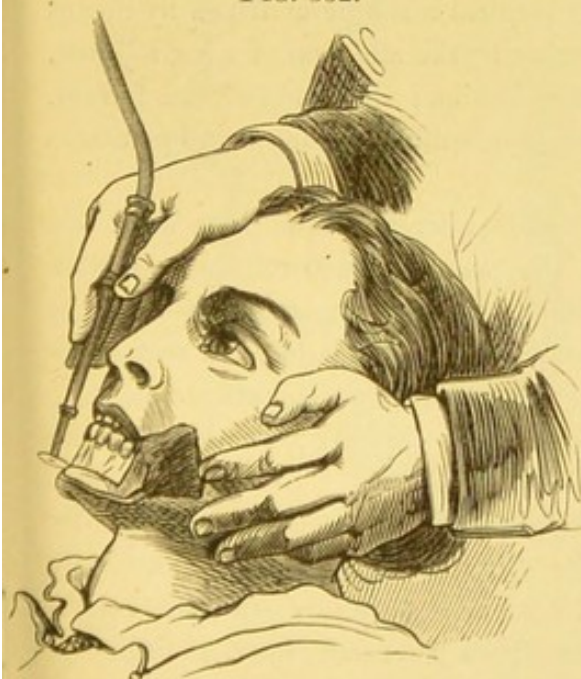
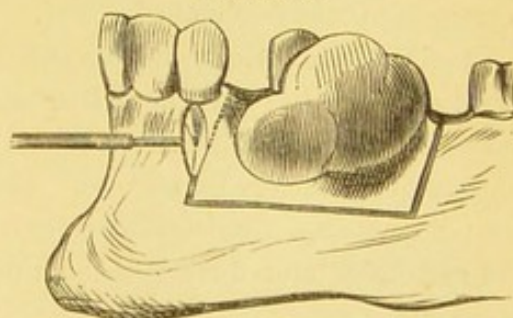


FIG. 533.



private practice. As is seen, the instrument used is a circular-saw revolved by an engine. The removal of bone after a manner that retains the con-



tinuity, consequently preserves the contour of the face, is understood by observing the dotted line.

The manner of making a section of the lower jaw, as here shown, is one always to be selected when circumstances permit. The circular-saw is not, of course, a necessity for accomplishment of the performance, but it is a help only to be appreciated by a surgeon familiar with its use. In the absence of an engine, Hey's saw is to be used. An exsection thus made leaves no deformity.

Fig. 532, taken from the practice of the writer, shows the use of engine and saw used on front of lower jaw.

Fig. 533, shows manner of applying circular-saw in removal of small epulic growths. The diagrams explain themselves.

In doing operations upon the jaw-bones consideration is demanded by any undeveloped teeth that may happen to be present. To cut through a tooth with the Hey saw is impossible. It is difficult, and in cases cannot be done, where the circular instrument and engine are used. Caution is to be observed as reference is had to making the horizontal cut as near the base of the jaw as safety permits.

**Addendum.** **SURGICAL ENGINE.**—A surgical engine differs from the instrument used in dentistry proper principally as power is concerned. The invention is by Wm. G. A. Bonwill, D.D.S., and the introducing of it into general surgical practice is claimed with much satisfaction by the writer.

The reader, by referring to the cut (Fig. 534), will obtain correct understanding of the apparatus, and of the tools used with it. While a dental engine is worked with the foot, or by an electric, steam, or water motor, and possesses but a single driving-wheel, the surgical machine is driven by means of a hand-crank, and is intensified in motion by the addition of a cog adjunct. The shaft of the latter is always of arm fashion; the cable of the former, as at present constructed, being too weak to accomplish other than operations demanding little mechanical power.

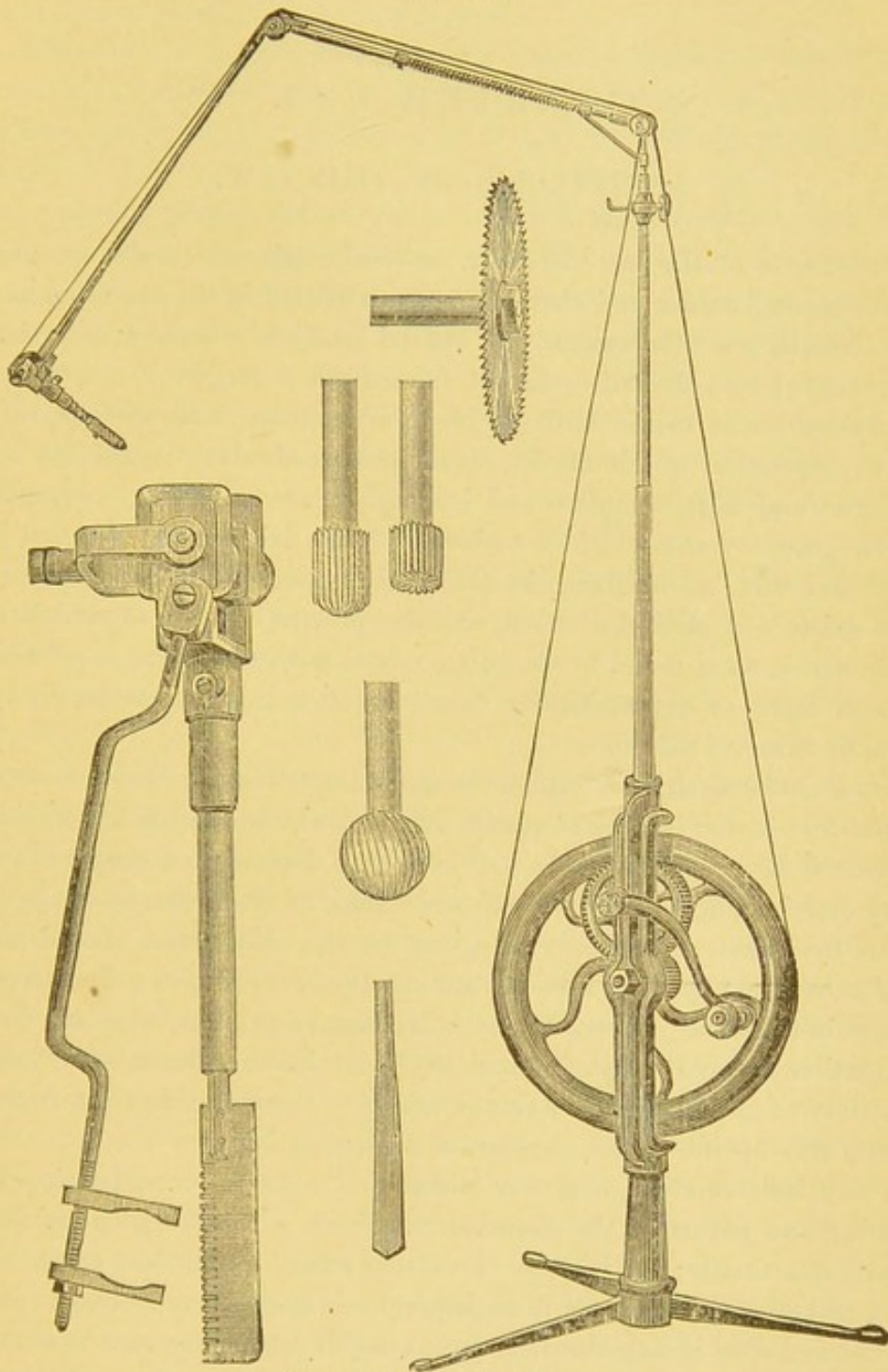
The middle pieces in the engraving show a circular-saw, three sizes and forms of burs, and a drill. These are the principal instruments used with the engine, and they possess the capability, individually and collectively, of doing a great variety of service. The contrivance to the left is a reciprocal-saw; it possesses a latitude of motion to the extent of one-quarter of an inch, and runs back and forth with an unrecognizable rapidity; its use applies in exsections.

In oral practice the surgical engine is a convenience above praise. By means of the capability furnished by the apparatus operations of magnitude and danger are accomplished with all ease and at greatly diminished risk. Instruments are used precisely as one handles a pen; saw, burr, or drill slipping, by means of a shank, into a hand-piece, or handle, and made to perform revolutions to the extent of several thousand to the minute, while, at time of greatest movement, a thumb and two fingers controls the cutting tool with all



the facility of an act in drawing. (See for illustrations in practice various diagrams showing operations.)

FIG. 534.



Surgical engine and appliances.



## CHAPTER LVI.

### ANCHYLOSIS OF THE JAW.

ANCHYLOSIS of the jaw (*αγκυλος*, crooked), trismus (*τριζω*, to gnash), finds its general nature and characteristics exhibited in the condition as seen in the common articular system. A special study is therefore to be beneficially preceded by a limited review of the subject at large.

By ankylosis is meant stiffness in an articulation, such stiffness varying from an expression of simple inconvenience to absolute immobility. The terms true and false, complete and incomplete, are employed to express two common groups under which a variety of forms are classed; the first being applied to a state of fixedness in the joint, the second where more or less motion exists. A clinical division, one the practical utility of which every practitioner is soon found to recognize, relates with the lesion as reference is had to an intra- or extra-articular character; that is, whether the disease be within, or without, the joint.

Intra-articular ankylosis implies change in the articular relations,—arthritic inflammatory action leading to plastic effusion, which effusion has necessarily a varying history. Imprimis, a stiff joint may depend on a simple synovitis. It may associate, again, with lengthened disuse of the joint, as compelled in fracture-treatment, such fixedness acting as the abstraction of the natural stimulus of the part found in its motion, thus resulting in a dryness which becomes in time the excitant of an inflammatory exudate, with tendency to organization favored by the immobility. Arthritic inflammatory lesion is the history of all inflammatory action, and is to have consideration from such common stand-point. (See chapter on *Inflammation*.)

In any inflammation, a matter which first calls for consideration is the character and nature of the disturbance. Such a consideration applies particularly to arthritis; for whether the action arise from local or constitutional causes makes great difference in such prognosis as one may incline to offer.

Local arthritis is explained by any cause of local character that may be discovered to have provoked the lesion; of such offences we may instance blows, luxations, fractures, immediately neighboring lesions, inter-articular bodies.

Arthritis of constitutional relation finds its diagnosis in the absence of local sources of offence, and in the presence of cachexia: scrofulosis, syphilis, rheumatism, gout, cancer, and the sang calciné. Rheumatic, gouty, and scrofulous arthrosia are familiar exhibitions in such direction.



**Complicated Arthritis.**—This refers to a provocation into action, by some direct irritant, of an abeyant cachexia. Enough instances of such complications are found in the hip diseases of children arising from falls, and of cancers located through immediate injuries.

Inflammation in a joint has primarily a double diagnostic signification of concern to the surgeon; that is, it may involve the joint proper, the bones, cartilages, and synovial membrane; or it may be confined to the latter exclusively.

In synovitis proper, the prognosis is much more favorable than in true arthritis, provided the attack be acute in character and the treatment timely. Synovitis, in its incipiency, is attended by excess in the natural secretion of the membrane; such excess, by producing overfulness of the articular cavity, interfering markedly with freedom of motion. Passing into a chronic state, the neighboring parts are soon involved, and what is to be the result depends as much on the circumstances of the case as on the care and skill employed in the treatment. Effusions in synovitis are readily distinguished, the serous, associated with all the phenomena of acute inflammation,—the parts being red, heated, painful, elastic, and fluctuating. The plastic, appearing after the acute action has passed, this being dull, doughy, and pitting, and divested of active associations.

An attack of synovitis may be, and indeed commonly is, subacute in character, that is, it may be a long while in developing itself, and this, even when it is the result of local injury. The first symptom attracting notice is apt to be a sense of stiffness after rest, this being most observed in the morning; succeeding this is pain, with the stiffness prolonging and fixing itself; swelling will now perhaps be first observed, the heat of the part increasing with the distention; suffered to progress, suppuration of the membrane may be the result, and with it the complete destruction of the joint. A better and, happily, more frequent result is found in a cure of the inflammation through the exudative process, such exudation seeming to afford the necessary relief to the over-distended vessels. With such a result obtaining, the care of the surgeon becomes directed alone to the exudate, absorption is to be compelled, and through passive motion and the judicious employment of the sorbefacients, the plastic lymph will not be able to associate its bands with parts that shall afford it the capability of organization.

Acute synovitis, if disassociated with cachexia, may commonly be quickly resolved into a subacute condition; to obtain such result, however, treatment is to be directed with much judgment; if purely local, the attention required will most likely be one vigorously antiphlogistic;\* if conjoined with cachexia, local sedation is to have associated with it a constitutional specific medication, or, stimulation and invigoration may be indicated. A common treatment for

---

\* A cure almost magical in the rapidity with which it results is sometimes secured by cauterizing the surface with the solid nitrate of silver.



an acutely inflamed joint, whatever the parts involved, may be laid down as follows: Put the feet and legs of the patient in water, as hot as can be borne; administer a full saline cathartic, or a diaphoretic; apply a lead-water and laudanum lotion to the inflamed part; bleed with the lancet, or, locally, by leeches; depress the circulatory force by the administration of arterial sedatives, aconite or veratrum viride, and restrict to a low diet; use counter-irritants; any or all of these means being employed according to the indications of the case, an exception to the use of the pediluvium existing in inflammation of the inferior joints. An inflammation, once having its acuteness broken, is often happily terminated by painting the parts with the tincture of iodine, or with the muriated tincture of iron combined with quinine and the tincture of cinchona, as recommended on another page for erysipelas, and afterwards, if deemed necessary, enveloping the part in the lead and laudanum lotion. Where structural change is feared as the result of effusions, the mercurials may be administered and pushed to the least perceptible evidence of their impression. It is seldom the case, however, that a result is not better without than with these: it is not to be doubted that through the injudicious use of mercury many joints have been depressed to suppuration, which, without it, would have escaped.

When, in defiance of treatment, suppuration occurs in a joint, the pus formed is to be got clear of as speedily as possible. To effect this, aspiration is to be resorted to. At this stage it is that stimulation is directed with prospects of good results. Yet what is to be the precise nature and extent of such medication is not so easy to suggest, each case having, most likely, some special indication. The principle of the means, however, is to be found in anything that shall arouse the parts to a higher and healthier grade of action; embrocations, hot or cold douches, strapping, painting as before suggested, passive motion, or even, it might very well be, injections into the joint itself,—a means, this last, that might save an articulation where all others should fail.

Synovitis of systemic origin demands that the treatment consider the specific indication. If syphilitic, gouty, rheumatic, or strumous, medicines which experience characterizes as most antagonistic to the particular condition are to be conjoined with the local means. Thus, while giving every attention to the affected joint, we direct a medication to the cause at large.

**Arthritis.**—By arthritis is meant the inflammation of the common structures of the joint; here the danger of ill results is proportionally greater than synovitis as extent of parts is involved. An arthritic inflammation may be general, involving all the components of a joint, and of such severity of grade as to run quickly into suppuration and destruction of the parts; on the contrary, it may prove so slight as to amount to nothing more grave than a temporary congestion resolvable by a few hours of rest and sedation. Between these two extremes are found all the phenomenal associations of inflammatory action. An arthritis in the fulness of its history is thus to be



described: First, a sense of stiffness in the joint, with increasing uneasiness,—the stage of simple vascular excitement. Second, the development of the sense of heat, the parts swelling and becoming intensely painful on the slightest motion,—the stage of active congestion. Third, fixed engorgement, the pain persistent and of a heavy character, skin a dull red or white, according as the inflammation may or may not have travelled to the surface,—the stage of stagnation. Fourth, the destruction and breaking down of the involved parts,—necrosis, as evidenced in *morbus coxarius*,—the stage of suppuration and devitalization. Fifth, hectic fever from exhaustion, or pyæmia from pus-poisoning. Sixth, death.

The treatment of arthritis proper is precisely that indicated and employed in synovitis. To limit and control inflammatory action is the principle of the cure. The vigor with which such a treatment is to be directed depends, of course, on the indications of each special case, these presenting, as suggested, every shade of character. If an inflammation, in defiance of the immediate antagonists employed for its control, pass onward in its grade to the effusion of lymph, as recognized by the doughy, pitting character of surrounding parts, then the danger of anchylosis, on the one hand, or of the degeneration of this agent into pus, on the other, is the matter which presses for attention and concern. Passive motion of the gentlest character is to be resorted to, together with the employment locally of sorbefacients, combined with such general medication as the particular case may appear to demand. If the mercurials seem essential, the practitioner will seldom find himself at fault in combining tonics with them. This will most certainly be found to hold true in all cases associated with asthenia. The character of cases in which it would seem to the writer's judgment that mercurials are admissible, and, indeed, in some instances, positively necessary, is where the trouble occurs with the robust and vigorous. In cases of this class their good effects are occasionally markedly observed; but even here, if employed too freely, the harm done quickly overbalances the good. When a mercurial is used, the effects produced are to be watched with the closest attention, and never is it to be inferred that, because good results are observed from the gentlest of ptyalisms, pushing the medicine will expedite a cure. No greater error than this can arise; a result is not unapt to be pus, and destruction of the joint. Another matter, not to be overlooked in the employment of the medicine, is its cumulative nature. A man may take a mercurial for a week or a month without apparent effect, when suddenly most profuse ptyalism exhibits itself.

**Rheumatoid Arthritis.**—For a medical paper treating most fully on this condition, the reader is referred to Reynolds's *System of Medicine*.

**Trismus.**—This term has its application alone to the anchylosis of the temporo-maxillary articulation; it expresses the simple locking or fixing of the jaw. As there are many causes or conditions involved in such locking, so, of course, are there conjoined terms expressive of such different lesions: tris-



mus traumaticus, including tetanus,—the locked jaw from wounds and other local external injuries: trismus dentium, arising from associative dental lesions; trismus nascentium, or trismus neonatorum,—infantile tetanus. In strictness of application, the term trismus, however, applies only to gnashing, spasmodic, or nervous lockjaw, and is without true expression or meaning when applied to other forms. It might be best viewed as referring to the medical rather than to the surgical aspect of the lesion.

**Tetanus**—from *τείνω*, to stretch—is a disorder of the nervous system, presenting its manifestations in spasms, and affecting in nearly every instance the muscles of mastication, thus producing gnashing, or, it may be, locking of the jaw. Tetanus is decidedly a nervous disease, and is primarily confined to the true spinal system, being produced in some individuals by the most trifling injuries, many cases being on record where the simple extraction of a tooth has sufficed to provoke it. A bath, unduly prolonged, produced it in one of the author's surgical students. The terms opisthotonos, emprosthotonos, and pleurosthotonos are employed, together with trismus, to designate the groups of muscles implicated in the derangement.

Tetanus is divided into traumatic and idiopathic, and into acute and chronic; the first following wounds and other injuries, the second arising without assignable cause. The first form is usually acute in character; the later is likely to be chronic, and, to the extent of its chronicity, amenable and responsive to treatment.

As predisposing causes of tetanus, the experience and observations of Baron Larrey would seem to give cold and dampness prominent positions. Dr. Kane, in his Arctic Explorations, alludes to the death of two of his men from tetanic spasms, after being exposed to intense cold. Extreme heat is certainly another of such predisposing causes, tetanus being as common in very hot as in very cold temperatures, both extremes acting, most likely, by provoking centric nervous irritation.

**SYMPTOMS.**—Tetanus, although sometimes coming on suddenly, has more commonly a premonitional history. Instances are recorded where the spasms have arisen almost simultaneously with the reception of a wound. Such cases are, however, exceedingly rare, and indicate a predisposition which renders the disease almost necessarily fatal. On the other hand, it is exceedingly common to find the condition remaining in abeyance until the external wound has completely healed. A case of this latter character came only a short time back under the author's own observation, where a lady, while searching in a barn for eggs, accidentally ran a rusty nail into her knee, not, however, involving the articulation. Four days after the reception of the injury, with the break fairly healed, emprosthotonos supervened; yet the spasms quickly disappeared on opening the wound with a bistoury and the introduction of a delicate tent, thus compelling a filling up of the parts from the bottom. The irritation of a nerve radicle by its being caught and compressed in a cicatrix is a reasonable explanation of neuralgia and tetanus supervening on the heal-



ing of a punctured or lacerated wound, and seems to have had an example in this case.

Commonly, tetanus exhibits its approach, as suggested, in a gradual manner. Attention is first directed to a sense of general malaise; then stiffness of the movements of the lower jaw supervenes, as though the muscles were exhausted. This stiffness, increasing to soreness, extends to the muscles of the neck. The mouth becomes dry and sore; mastication grows painful, and swallowing difficult, a sense of spasm and suffocation resulting when these offices are attempted. Eventually the masseters, temporals, and pterygoid muscles become stiffened and bulging; the orbicularis puckered and contracted; the eyelids are closely approximated; the zygomatici are liable to become fixed, thus giving a peculiar expression known as the *Risus Sardonicus*. Following these symptoms, almost any of the voluntary muscles may become implicated, the abdominal group, particularly the recti, corrugating and knotting themselves. Colicky symptoms soon supervene, induced by spasms of the muscular coat of the bowels; or difficulty in respiration may arise, from spasms of the diaphragm. Opisthotonos, emprosthotonos, pleurosthotonos, or, it may be, a most unyielding trismus now develops, according as the force of the irritant may select special groups of the muscular system on which to expand itself. That tetanus does not implicate the ganglia of special sense, but is confined to the spinal cord, medulla oblongata, and cerebellum, is demonstrated in a clearness of the intellect which continues during the attack.

The bowels, in tetanus, are commonly found obstinately constipated, depending on the general derangement of the alimentary canal; and motion, when it does obtain, is commonly accompanied with fetor of a most offensive character and of great persistence. The bladder may be closed by spasm of the muscular fibres of its neck, or these may be so relaxed that complete incontinence exists. The tongue, when involved, tends to be thrust forward, and is thus often lacerated in the spasmodic occlusions of the teeth.

Acute tetanus seldom has a greater duration than four days, the patient perishing either from asphyxia in a spasm, or otherwise from exhaustion. Chronic tetanus, on the contrary, runs on day after day, most frequently eventuating favorably. One is impressed with the sense of a battle, in which nature properly supported may reasonably be expected to win.

**PATHOLOGY.**—Because of the absence of definite pathological lesions, more or less diversity of opinion exists concerning the conditions of this disease. Sporadic or traumatic cases, where tetanus has shortly supervened upon injury to a nerve, naturally direct attention in such direction. Investigations into nerve-relations, however, prove so unsatisfactory that there seems now quite a tendency to revive the humoral origin, a view maintained with all earnestness by Rose, and favored by both Billroth and Dr. Richardson, the latter suggesting that it may eventually prove to be the result of the absorption of some septic material. "In the disease," says this author, "the poison, in my opinion, is first developed in the wound as the result of decomposition.



Thence carried into the circulation, the new substance, without any necessary increase of its own parts, excites a zymosis, ending in the production of an alkaloidal or alkaline body, which has all the power of exciting the symptoms of spasm as much as strychnine itself." Billroth inclines to ally the condition with the infectious phlogistic. "It is known," he says, "that, by blood-poisoning with strychnia, severe spasms, and with alcohol, psychical disturbances (drunkenness), may be induced; hence it is very possible that this disease may result from poisoning with a peculiar substance, only very rarely formed in wounds, and thence absorbed."

The symptoms of tetanus indicate irritation of the spinal medulla. Rokitsansky describes, from autopsies made by him, evidences of vascular relations of this substance as exhibited in the development of young connective cells. Other observers, however, have failed to find these expressions.

The reviewer of the article Tetanus in Reynolds's System of Medicine (see *British and Foreign Medico-Chirurgical Review*, vol. xiii.) says, "The author does not attempt to trace any connection between the acknowledged causes, cold and damp and wounds, and the production of such a fearful consequence in only a few cases. With regard to its relation to hydrophobia and analogy of the latter to that of snake-bites, may not the connecting link between chilled wounds and spasmodic paroxysms be an animal poison generated in the wound during the process of healing? and being an animal poison, therefore poisonous in extremely minute doses? and being an animal poison, therefore latent in the system for long periods? and being an animal poison, therefore specially fatal to the nervous system? The greater tendency in punctured and closed wounds to cause tetanus is very suggestive of the needle-like serpent's fang, and the frequent triviality of the dog's bite, which are more deadly the less blood flows."

Holmes (in his chapter on Tetanus; see vol. i. p. 330), after a review of the morbid anatomy, as referred to by various observers, remarks the obscurity in which the pathology is involved. "Some," he says, "are seen to affirm tetanus to be an irritation of a peculiar kind, affecting the excitatory apparatus; that the irritating cause may be excentric at the extremity of, or in the course of, the afferent spinal nerve, or it may be centric within the spinal canal itself. Some consider it to be an exaltation of the polarity of the cord and medulla. Others, again, maintain it to be identical with inflammation of the spinal cord and medulla oblongata, and adduce cases of inflammation of such structures as inducing symptoms of tetanus."

PRINCIPLES OF TREATMENT.—"If the difficulty of ascertaining pathological conditions, on which all rational indications of cure should be based," says Dr. Copland, "be so great in this malady as not to have hitherto been overcome, can it be a matter of surprise that the means which have been resorted to, by both physicians and surgeons, in this treatment, have been most opposite in their effects, the most different in their nature, and in every respect most empirical and uncertain? In this state of our knowledge it would be



better to leave nature to her unaided efforts, to observe closely and accurately what is the true procession of changes and of their manifestations, and to ascertain the seats and the extent of lesion as soon after death as may be attempted with propriety."

The treatment that has most commonly suggested itself seems to be that of anæsthesia; opium and chloroform being much depended on. Of the former medicine as many as twenty or more grains have been used in the course of a day, or a correspondence in the subcutaneous use of morphia. The greatest gain in treatment seems to be to prolong the disease into chronicity, thus wearing out, as it were, the force of the active cause. Billroth refers to the use of warm potash baths, and the application of strong irritants along the spine, large blisters, moxæ, but does not feel that experience tends to indorse any of them. On the contrary, referring more particularly to the chronic cases, he suggests that the patient be allowed to remain as quiet as possible, guarded against all injurious influences, especially from physical or mental excitement, the general aim of the treatment, he thinks, being to alleviate the acute course and make it more chronic, as this adds to the hope of recovery.

Of the internal remedies that have been employed, almost every class and description has been tried, without, as yet, any result in the way of a specific or an approach in such direction. "Alteratives, in the shape of the varied preparations of mercury, large doses of fixed alkalies, solutions of arsenic, etc.; diuretics, in the form of tincture of cantharides, oil of turpentine, given in frequent and large doses so as to irritate the urinary passages or to occasion bloody urine; sedatives, such as digitalis, tobacco, nicotina, hydrocyanic acid, aconitina; anodynes and narcotics, as opium, morphia, belladonna, colchicum, cannabis indica, ether and chloroform internally and by inhalation; stimulants and antispasmodics, including musk, ammoniacum, camphor, turpentine, assafoetida, castor, wine, and other stimulants; tonics, such as quinine, bark, strychnia, iron, zinc, etc.; hygienics and dietetics, as support, milk-diet, etc.; injections into the veins of solutions of opium, stramonium, etc.; tracheotomy and laryngotomy. The calabar bean in sufficient doses to paralyze the voluntary muscles has been affirmed to be attended with marked success, although it has, on the other hand, failed very frequently." (Alfred Poland, Holmes's System of Surgery.) The writer directs attention to belladonna as a remedy with which he has resolved tetanus. The dose of the tincture as employed by him is half a teaspoonful repeated *pro re nata*.

The treatment of tetanus by woorara has of late excited some attention, mainly through the work of Mr. Morgan. According to Demme, this most powerful poison has out of twenty cases resulted in eight cures. It is recommended by Spencer Wells, Broca, Chassaignac, and others; the dose is given as from one-eighth to one-half grain to an adult. To one not familiar with the action of woorara, it would seem necessary to recommend great caution in its employment. Most interesting experiments have been performed with



the agent upon the lower animals, particularly a series in 1858 by Dr. J. J. Woodward.

The use of the calabar bean has come to be much relied on in the United States. Eighteen cases are reported by Dr. Eben Watson in which this medicine was used, yielding ten recoveries. The dose varies with the effect produced in controlling the spasms. The action seems to be that of a direct sedative to the spinal cord, patients, while under its influence, commonly taking food with ease. One grain may be commenced with as a dose, increasing the quantity as seems warranted.

The preparations hydrate of chloral and croton-chloral have in them considerable promise in this direction. A peculiar action from this latter agent is found, that at first a high degree of anæsthesia in the head is produced, while sensibility in other parts of the body remains intact. The second stage is, that the spinal cord loses its function, and reflex excitability is everywhere extinguished. During this stage, pulse and respiration remain unchanged. The third stage, which is induced by large doses, is characterized by paralysis of the medulla oblongata, and death. Animals may, however, be kept alive by artificial respiration, because the function of the heart is not interfered with; while the ultimate effect of hydrate of chloral is to paralyze the heart.

The local treatment to which recourse has been had in tetanus consists in laying open wounds, their thorough cleansing, and the application of antiseptics; division of nerves, the application of counter-irritants, the employment of sedatives, ice-bags to the spine, cold and warm shower-baths, electricity, attention to inflamed and suppurating wounds, etc.

**Trismus Nascentium.**—**Lockjaw in New-born Children.**—The frequency of this condition, and its fatality to a particular order of infantile life, make its study one of interest and importance to the practitioner. It is decidedly a disease associated with the period of the desiccation and phenomenal change occurring with the cord and umbilicus, and is found confined, therefore, to the time associated with these changes,—never happening before the second day after birth, and seldom after the fourteenth.

Tetanus, of which this is a form, has its expression and association exclusively with the nervous system of organic life,—the excito-motor. That trismus nascentium is therefore a special disease, is not an idea to be entertained for a single moment; it is simply tetanus occurring from generally evident causes in the newly-born, and is to have the consideration and treatment of the disease as found anywhere else. Wherever the nervous system of organic life exists in exquisite development, and wherever it is excited from any cause to excess of expression or action, there, also, is found the danger of trismus. Hence in infants of the negro race, and particularly those born of parents of less than average intelligence and resident in hot climates, the condition is found most widely to prevail. In the southern section of the United States, and in the West Indies, the mortality of infantile deaths from



this single cause is estimated by some observers at not less than twenty-five per cent.; while it is affirmed that in the equatorial regions of South America in some years more than half the infants born fall victims to this disease. In an epidemic form in which it is found occasionally to prevail, the mortality of certain neighborhoods has amounted to four-fifths of the births.

That trismus nascentium is not confined, however, to the hot latitudes, is to be inferred, not only from the report of many cases elsewhere, but from its oneness with tetanus proper. According to Dr. Holland, it is very prevalent on the southern coast of Iceland, also at St. Kilda, one of the western islands of the Scottish coast. In Elbing, Prussia, cases are announced as occurring frequently, thirty-seven being recorded from 1863 to 1865 in a population of twenty-seven hundred. In Dublin the disease has prevailed so alarmingly that at one time, for a limited period, nineteen-twentieths of the infantile deaths occurring in the Lying-in Hospital of that city were from this cause, the death-rate being one to every sixth child born. Being attributed to ill ventilation and the absence of proper hygienic requirements, attention was at once directed to these prophylactics, with the result of decreasing the rate to one in nineteen.

**SYMPTOMS.**—Like the manifestations of the disease as exhibited in the adult, the prodromous period may be deficient in signs sufficiently marked to attract ordinary observation. The child may seem restless and more excitable than usual, but this is apt to be attributed to any other than the true cause. A few hours, or perhaps days, intervene, when the infant, apparently anxious for the nipple, is found unable to take hold of it. This, together with an occasional smothered cry, as if the child were in distress, first brings it under the notice of the physician. If now the jaws be examined, more or less rigidity is found to exist, the masseter muscles seeming the ones principally affected. From these the expression may extend to any others, and does so, not unlikely, in a very few hours; or it may be that the first manifestation of muscular involvement is exhibited in spasm, the jaw being shut with a snap which has, in instances, partially amputated the tongue; or the spasm may affect some muscle of the limbs or trunk. Such commencement of the active stage of the disease is, however, infrequent.

In the fully developed stage of infantile trismus, the spasms are found quite frequent. The agitation of the child is very great. The smothered scream which it emits is peculiarly painful,—itself spasmodic in character from affection of the respiratory muscles. The little sufferer foams at the mouth; the fists are tightly clinched; the feet are flexed upon the ankles, with the great toe abducted; the head is drawn back by the cervical muscles; the surface grows livid, the infant dying in the paroxysm, or, otherwise, either receiving respite in which relaxation ensues, or sinking into death through coma. The duration of the disease is commonly about two days; but cases are recorded where death has not occurred until the third week of the attack.

**CAUSES.**—First, there may be assumed to be a predisposition (though this



need not of necessity exist), such predisposition being impressed on the child in utero by the hot and foul air and common filthiness of habit which, from its inception, have attended it in the person of the parent who has borne it: this finding proof in the fact that as the condition of parents has been improved, so has trismus diminished, the disease seeking its habitat almost exclusively amidst the squalor and poverty of the lowest and least intelligent classes. Other predisposing causes are found in any and all relations of depressing character. Thus, hot moist days, followed by cold nights, have been sufficiently recognized to be among the most efficient of the predisposing causes, the explanation being found in the interruption of the functions of the skin. Miasma, no doubt, contributes its quota through its depressing action on the nervous system,—tetanus being associated with the period of reaction.

In papers published by Dr. J. Marion Sims, this practitioner advances the view that the cause of trismus nascentium lies in a pressure exerted on the medulla oblongata and the nerves originating from it, produced by displacement of the cranial bones, and especially the occipital, such displacement occurring in the parturitive effort, and capable of being corrected; but, that the cases observed by him were exceptional, and not common, seems clear enough by the universal denial of his premises, following observations elicited by the publication of his views.

Whatever, then, may be a predisposing cause of infantile trismus, the chief exciting one is found in association with the umbilical cord: and first this associates with the tying and excision of it. A cord cut with a dull blade is thus to be put into a condition of irritability, which, reacting on a highly predisposed system, might bring on an immediate attack of spasm. An ill-strangled cord is to be classed as the second of the offending causes. A common habit with midwives, among the poorer classes, is to wrap the parts with packthread. This is not only an inadequate protection against hemorrhage, as in his experience the writer has several times had occasion to witness, but it is irritating even in the remote aspect of its relation with the general system, and may readily arouse the abeyant irritability.

The umbilical vessels separate from the body, physiologically speaking, as does the stem from the ripe fruit. When such is not the character of the disjunction, the conditions are to be expressed as pathological, being associated with more or less inflammation, ulceration, and local irritation. The ordinary period required for the separation of a funis is from three to six days. During this period the parts should be kept enveloped in a fold of old half-worn linen, prepared as a dressing by snipping a piece out of the centre after the manner of a Maltese cross; the cord to be passed through this hole, and thus, by its envelopment, separated from contact with the person of the child. In hot climates, such dressing, combined with oil, or antiseptics, is the more necessary, as the danger is to be guarded against of having the parts serve as a habitat for the deposit of larvæ,—a not infrequent cause in itself of tetanus.



TREATMENT.—From the constitutional stand-point, nothing more may be done than is to be inferred from the directions given in general tetanus. Anodynes, antispasmodics, anæsthetics, and alteratives may be tried *ad libitum*, but the result will amount to very little if any unappreciated or unremoved cause exists in the way of local irritation. Attention is therefore to have a first direction to the umbilical region, and such attention, if thus given in the incipient stage, will not infrequently result in aborting the attack. If an ill-incised cord be found, let a fresh and clean cut be at once made nearer the body. If the cord be indifferently strangulated, remove at once the ligature, and replace with a well-waxed silk thread, or otherwise place the new ligature nearer the body. If separation be not progressing with its usual physiological harmony, treatment will be needed as indicated. Cleanliness is to be strictly enjoined, and vascular action is to be stimulated or depressed, as required,—not as indicated by the pulse, for this in tetanus affords very little guidance, but, as implied, at the seat of local offence. Among negroes, as remarked by Dr. James S. Baily, whose opportunities for observation seem to have been extensive, “the uncleanness and unsuitableness of the umbilical dressings are by far the most common of the exciting causes of the disease. Among these people infants are found not only fetid with the ammoniacal smell of the urine with which they are wet from morning until night, but are loaded with fecal matter, so thoroughly saturating the appendage of the funis as to render its drying impossible. In consequence of the sphacelated condition of the cord, it gives off the material of death and decay, which, being deposited in direct contact with the active absorbents, must necessarily act as a fearful causation.” This gentleman, who, during a residence in Texas, was able to collect and make notes of two hundred cases, tells us that in his experience he has never observed a case of lockjaw when due regard was paid to proper instructions in reference to the management and dressing of the umbilicus. Tumefaction and redness without suppuration are always, he thinks, expressions to excite apprehension, and are to receive immediate attention. Quoting a Mrs. O., a lady living on the Brazos, in Texas, observation is directed to the value of a mush poultice applied to the navel immediately after birth, to be continued until the falling off of the cord, or while any signs of inflammation exist, the lady asserting that with such practice employed with her own servants she has never lost a case. This, however, evidently applies to the use of the poultice as a prophylactic,—a direction, indeed, in which the physician finds his advice most useful. Mixed with such a poultice an antiseptic would certainly add to its effectiveness.

#### TRISMUS DENTIIUM.

In the chapter on Dental Anomalies we studied the process of maxillary enlargement, and understood how that process was, in part, counterbalanced by an untimely extraction of the deciduous teeth. It was further shown how certain derangements of the dental organs are a common, if not a necessary,



sequence to such abridgment of the arch; and, among other ill effects, reference was made to the impossibility of a natural and healthy evolution of the wisdom-teeth, and to conditions favoring periodontal inflammation. In this section we are to consider lockjaw as it has a signification exclusively surgico-dental.

Such dental signification, however, will, it is apprehended, outside of tetanic conditions proper, be recognized as having widest relationship to the lesion, and, indeed, if experience has not been uncommonly one-sided, it will be found to have the very closest relationship; in every twenty cases of local trismus, eighteen have, as the primary lesion, periodontitis, in some of its varied forms.

We have considered the retraction of the dental arch. We will now look at such lesions as this retraction engenders,—lesions pertaining to the subject under consideration.

The troubles of an individual afflicted with a contracted dental arch are most apt to begin at about the fifteenth or sixteenth year of age. If you look into such a mouth you find the teeth crowded into most uncomfortable-looking positions. The last molar of the lower jaw you will see, quite likely, jammed into the ramus; while the same tooth of the superior jaw is found occupying the very extreme of the tuberosity of the bone.

At this period, unless, fortunately, the teeth are possessed of uncommon resistance, they will be found breaking down from approximal caries; while, as the result of such caries, combined with the crowded condition of the fangs, the alveolo-dental membranes enter into a subinflammatory state, and become as ready to take on acute disease as is tinder to respond to a spark.

If, then, interference with the elongatory process has been such as to yield these troubles when only twenty-eight teeth have erupted, it is plain that the development of the four *dentes sapientiæ* must proportionally add to the difficulties. Only by appreciating the character of such trouble can we fit ourselves to abort its lesions.

These lesions are periodontitis, alveolar abscess, stomatitis, ostitis, caries, necrosis, trismus.

In the chapter on Anomalies, it was remarked that all dental troubles arising from retraction and diminution of the maxillary arch are to be guarded against by a timely extraction of certain of the permanent teeth; and from this we are to infer that a lesion arising from an advancing wisdom-tooth is also to be provided for on the same principle, namely, by extracting the second molar, thus securing a required alveolus.

These pathological conditions, and the remedial and prophylactic indications so plainly written over them, it would seem impossible, because of their very simplicity, to overlook; that they are overlooked, however, is too evident, from the many secondary associate lesions which the surgeon finds himself constantly called on to treat.

The view has been advanced that the majority of the cases of trismus will



be found to have, as the primary irritant, some periodontal trouble. Of course this is to be understood as not including trismus neonatorum, or any trismus traumaticus, the lesion of which is of different signification and self-evident. A child might get a severe burn on the cheek, and trismus be a result of the innodular tissue, which would close up the break in the continuity. Anchylosis might exist, the sequence to articular disease, as we have studied. Traumatic tetanus affecting the muscles of the jaw has, as we know, a primary cause combined with peculiar nervous disturbances, which would give the diagnosis. But it is to the numberless cases of so-called idiopathic trismus that allusion is made, and to the cases of trismus which have evidently a local signification alone; that signification not being always very evident, or otherwise being associated with so many complications as not to be readily distinguishable.

Reports of case after case of unappreciated local trismus come to our attention,—of the lesion being referred to this cause and the other cause,—the treatment being as various as the diagnoses. Many of the inferences thus presented are, without doubt, just and acceptable; but it is to be offered as a reliable experience that where, personally, the author has had the opportunity of seeing such examples as would seem to be their parallel, he has mostly been able to point out some dental disturbance, simple or obscure, constituting the primary lesion.

In the epitome of Braithwaite, vol. ii. page 191, is a case, the diagnosis and treatment of which will serve as an example. Dr. S., the practitioner who reports it, ascribes the trismus to a complication of inflammatory and nervous derangements. Now, while the inference may be wrong, yet from the history, and from the age of his patient, the writer would have expected, had he seen the case with him, to have been able to show that an ulcerated sore throat, to which Dr. S. alludes, had its primary lesion in a trouble of the alveolo-dental membrane; the reader, however, can draw his own inference. The case is compared with one from the author's practice.

DR. S.'S CASE.—*Acupuncture in Protracted Lock-jaw.*—The patient, twenty-five years of age, unmarried, had for years been subject to attacks of suppurating sore throat, in which the jaws often became nearly immovable for two or three days before the discharge of matter. In 1826 she had a severe attack, from which resulted complete lockjaw, accompanied with hysterical symptoms, which attack yielded, after six weeks of treatment, so far that she could put a teaspoon in her mouth. After nearly a year, the jaw again became completely fixed, without accompanying sore throat, and the same treatment, with galvanism, was tried without effect. Although unequivocally connected with hysteria, there was reason to think, from the inflammatory action with which the disease set in, that the affection was not purely spasmodic, but was kept up by the rigidity of the muscles closing the jaw produced by inflammation; in consequence of which the antagonistic muscles had become inadequate to the effort of opening the mouth under the mere influence of volition.



It was this view of the case which made Dr. S. think it more reasonable, in making trial of the needles, to insert them into the muscles opening the jaw, in the expectation of exciting them to such a contraction as might overcome the rigidity of their antagonists.

On each of the two following days two needles were inserted, one on each side of the mesial line between the chin and the hyoid bone, the effect being short, conclusive efforts. The teeth began to grate on each other, and the jaw was drawn from side to side, not by single alternate attractions, but by severe convulsive movements on one side, followed by a nearly equal number toward the other side, interrupted occasionally by a momentary opening of the mouth to the extent of about two fingers'-breadth.

The convulsions continued after the needles were withdrawn; ceased and became renewed again after a few minutes, and returned spontaneously in the evening on both occasions. Some increase of voluntary power over the jaw followed both applications of the remedy. After each trial of the acupuncture some improvement was observable; but, as the spontaneous convulsion was almost always followed by a slight loss of motion, the progress made was slow.

The needles were usually inserted to the depth of half an inch, and sometimes to the depth of an inch.

The acupuncture, together with leeches, was used for ten days, by which time the patient could open the mouth two fingers'-breadth and chew soft substances. She then went into the country for five weeks, by which she derived great benefit; but, being exposed to cold and wet on her return, had another severe attack, the consequence of which was the loss of much of the voluntary power over the muscles of the jaw. The needles were again resorted to, with the same effect as before; but the pain produced by the spasms was greater, and lasted longer, while the spontaneous convulsions recurred several times in the evenings after each of the first trials. As leeching did not succeed in mitigating these convulsions, the temporal artery was opened with the desired result, and with the effect at the same time of restoring, to a considerable extent, the sight of the right eye, which she almost lost with the first attack of lockjaw. A second detraction of blood from the same vessel diminished the force of the attack so much as to permit the acupuncture to be used twice a day. Nine days after the renewal of the operation, the jaw had recovered its natural extent of motion.

The aphonia, which had come on at the same time as the affection of the eye, was completely cured by a smart shock of electricity.

The case referred to as from the author's experience occurred in the practice of a friend,—relation with it being through consultation. Its history is as follows:

For a period of several years the patient, Mary C., twenty-four years of age, had been troubled with attacks of sore mouth and throat whenever she unduly exposed herself; these attacks had always associated with them partial



loss of voice and general excitation of her whole nervous system, while her jaws were invariably stiffened to a greater or less extent, according to the severity of the attack.

On each of these occasions she had depended for relief on domestic treatment or on homœopathy. At the period, however, of her coming under the care of Dr. W., she was suffering from such severe trouble as to have decided her usual attendant into dismissing the case. The jaw had remained so firmly locked for a period of six weeks that it was with difficulty a knife-blade could be introduced between the teeth. This particular spell had come on as usual; but the patient said there was something about it which made her think that her teeth were implicated; she could not say what tooth or teeth, but thought it was one or more in the lower jaw.

Now, whatever was to be discovered as the primary lesion in the case, its surgical feature, as it presented itself to our attention, was an extra-capsular mass of coagulated lymph about the temporo-maxillary articulation, which overbalanced the influence of the depressor muscles, holding the parts, of course, in a state of false ankylosis.

We asked the patient if, when these attacks came on, her face had not always swelled more or less. She said that it had. We asked her if the cheek had not always a stiff, hard feeling in it, which wore away gradually after such attacks. It was so, she told us.

Dr. W. coinciding that the speediest way of overcoming the trismus was by mechanically breaking up the adhesions, we procured a pine stick about a foot in length, tapering, wedge-shape, from an inch and a half base. The thinnest portion of this wedge was, after much trouble, passed between and across the dental arches, and, after being forced a little farther on, the stick was turned on its axis, the adhesions yielding before the strain. Thus the mouth was opened at least an inch, and we were enabled to explore the cavity in search for the lesion on which the trouble depended.

So far this case will be seen to simulate closely that of Dr. S.'s: sore throat, aphonia, hysteria.

Now, here we found all the trouble emanating from a wisdom-tooth projecting, as it were, from the very angle of the jaw, and half covered by an operculum of gum drooping over on it from the ramus. The tooth of course we at once removed. The patient was then dismissed for the day, a sorbefacient being directed for external application.

The next afternoon, at four o'clock,—no inflammation having supervened,—we completed, by our mechanical appliance, the unlocking of the jaw. In a week the patient was dismissed well. She has since had no return of her spells, and will not have.

Parallelism between these two cases will be recognized; but should the reader disagree, study of them will not be without its profit.

One of the most severe examples of inflammation of the mouth, throat, and face, combined with a bad trismus, ever seen by the author, was in the



person of a medical student in the office of a Dr. C., of this city,—the primary lesion being such a half-erupted wisdom-tooth as has been alluded to as being found in the preceding case. This gentleman, when first seen, had been suffering for two or three weeks. The operculum of gum had been split up on two different occasions. Antiphlogistics in every form had been resorted to. The patient consulted under the anticipation that nothing was to save him from necrosis of the angle of the bone.

We gave this man one and a half pounds of ether; it seemed impossible to get him into an anæsthetic condition, his physical suffering was so great. Prying his mouth open, just sufficient to introduce the key of Garengéot, the offending tooth was extracted with much difficulty. In three days the man was attending to his studies.

This peculiar lesion of a half-erupted wisdom-tooth may well claim more than a passing attention. Many a practitioner has been so deceived by the anomaly as to have been led widely astray in the study of his cases.

Where the condition exists, it is to be noticed, on looking into the mouth, that only the anterior face of the tooth has fairly erupted, the other two-thirds being overlaid by the integuments of the ramus. You infer that the development is not yet perfected, and consequently it does not even occur to you to associate disease with the parts; but this tooth, only a single cusp of which is through the gum, may have caries extending into its pulp-cavity, or may be the seat of the most aggravated periodontitis. It is the common impression that wisdom-teeth decay early; that they are not a substantial class of teeth. The fact is that four-fifths of these organs which decay so soon have been destroyed by this operculum of gum. The explanation is very evident. The decomposing epithelial scales, and other débris of the mouth, combine in the acidity engendered of their disintegration to corrode the structure of the tooth, thus quickly destroying its integrity. The writer is sure that he has seen more than a thousand cases illustrative of this fact; and if any practitioner will take the trouble to dissect off this fleshy lid—the proper treatment by the way—and examine with a delicate probe the sulci of such teeth, in nine cases out of twelve he will find caries.\*

Such a lesion will at once be recognized to have important secondary relations. For example, the writer has been consulted time and again by persons who have been sufferers for a considerable period from what has been pronounced and treated as neuralgia. Their teeth had not escaped observation,

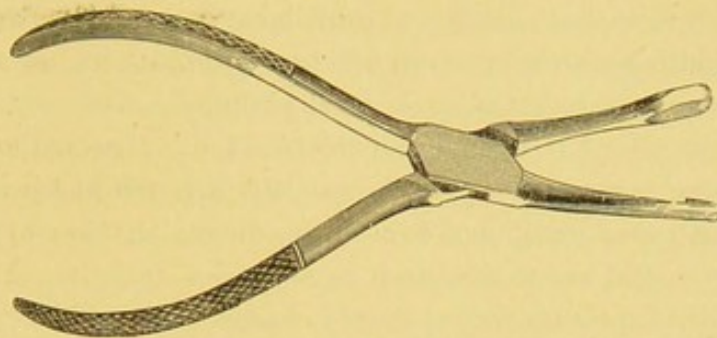
---

\* **FORCEPS FOR INCISING OPERCULUM OVERLYING WISDOM-TOOTH.**—The lesion of an operculum wholly or partially covering a half-erupted wisdom-tooth is one presenting very frequently to practitioners. The indication in every one of these cases is removal of the fleshy projection. To accomplish this a punch forceps furnished by Ash, of London, and introduced into this country by Dr. Sheppard, of Boston, offers itself as better adapted to the purpose than any other means familiar to the writer. This forceps consists of a blade the shape and size of the operculum, which blade is slipped between the flesh and the grinding face of the tooth. Closure of the handles catches the flesh in a fenestra, fully and cleanly and instantaneously excising it. (See Fig. 535.)



but had been examined and pronounced sound. There has been found in such mouths not infrequently this operculum of gum overlying the wisdom-tooth.

FIG. 535.



Operculum excising forceps. (See foot-note on opposite page.)

This has been dissected off, exposing compound caries. Such teeth have been extracted and the patients have been instantly relieved of their odonto-neuralgia.

Again; these fleshy cups, catching, and holding in contact with the soft parts, insoluble particles, as often found mixed with the food, will provoke periostitis, or even ostitis of the angle and ramus of the jaw. The writer has seen most alarming inflammatory attacks thus aroused. The tooth in these cases, as is somewhere else remarked, will always be found responsive to the stroke of an instrument. Its periodontum being inflamed, common sense would direct that the organ be at once extracted. Such extraction, however, is occasionally among the almost impossible things. A tooth so affected will not infrequently have but a point erupted not larger than the head of a pin. In these cases the best thing to be done is to take out the adjoining molar; this relieves the pressure on the ramus of the jaw, and gives room for the posterior tooth. It commonly yields a cure.

Trismus, depending on such lesions, is not infrequently the only external evidence yielded of the existence of the condition. The jaw stiffens and relaxes, as an odontalgia comes and goes. In such ephemeral cases it is not at all unlikely that the locking is exclusively a nervous action, or reflected irritation,—slight and ephemeral local inflammatory action being the irritant.

Wisdom-teeth erupt from the seventeenth to the thirty-fifth year; commonly, however, at about the eighteenth year.

Some years ago the author treated a case of trismus, the history of which is to be given as a very common one:

The patient, David B., a farmer, after doing a hard day's work, and being much overheated, threw himself down at early evening, in a cool outhouse, to rest. Here he fell asleep, not waking until near midnight. The next day he felt a soreness in the left superior alveolar arch, which soreness increased for two or three days; after which it deserted the teeth and passed to the antrum. Then commenced a swelling in the integuments of the face, which



advanced until it shut up the left eye. The jaws began to stiffen, and ended, after three or four days more, in complete immobility.

The call to the case was after the lockjaw had existed nine weeks, the patient having barely been able to support life by putting his mouth into a basin filled with soup, and sucking the nutriment through his teeth. During this time he had been seen by seven different practitioners, no one of whom had seemed to appreciate his case, or, what perhaps is more probable, none of whom had been willing to assume the trouble of it. The patient had never told any of these gentlemen about the soreness first felt in his teeth, and no one of them had ever questioned him in the direction; his single complaint was of a great weight about the cheek.

The diagnosis of the case was, primarily, periodontitis. This inflammation, by a double continuity of structure, had extended into the maxillary sinus, and to the integuments of the face. The inflammation of the antrum had been sufficiently severe to result in abscess; abscess of the alveolo-dental membrane, and of the lining membrane of the cavity. The inflammation of the face had resulted in an exudation of lymph, which lymph in a state of coagulation was the cause of the trismus.

A first effort was directed to getting into the antrum, which it was felt assured was filled with pus. This was done by prying out a second molar tooth with an elevator, pushing it into the mouth (from which, with some trouble, it was afterward gotten out); the extraction was followed by profuse discharge. The patient described the relief as being immense.

This particular tooth was removed, not because it was more carious than its fellows, but because it was somewhat loose, and thus gave evidence of the diseased condition of its roots. Again, it is through the alveolus of the palatine fang of this tooth that we find our easiest and best road to the antrum; in this case, as is seen, the fang communicated with the cavity.

On the day succeeding the evacuation of the abscess, the patient expressed himself as entirely free from pain, his only trouble being the anchylosis, which had not, as yet, relaxed in the least.

To the touch, all the parts about the articular extremity of the inferior maxilla seemed completely indurated. Hesitation existed as to attempting the breaking up of the parts mechanically, fearing injury to the important vessels which are associated with the head of this bone,—the maxillary nerve and internal maxillary artery. The induration was of course extra-capsular, and of sufficient extent to have bound the jaw from the glenoid cavity to the anterior border of the masseter muscle; passive motion was resorted to, but employed very gently. Blisters and sorbefacients were depended on. The case progressed very slowly, the patient having to come to the office every day for half a month; at the end of this time, but after removing other diseased teeth from his mouth, he was dismissed cured.

When one is called to a case of trismus of any standing, the anchylosis being the result of inflammatory action, question may arise as to the pro-



priety of mechanically breaking up the adhesions. The condyloid extremity of the maxillary bone is assuredly not the stanchest part of the body, and there are anatomical relations which it would not be at all pleasant to disturb: these things are for the surgeon to decide. So far, individually, as the writer is concerned, he now uses mechanical force in all cases that come under his care, premising of course that the condition is one where, from inflammation, the trismus depends on effused lymph. He is willing to run the risk for the great and immediate good yielded; some considerable experience in this direction assuring him that such risk is materially influenced by the manipulations. Of course it is not meant to recommend that attempt be made to open the mouth to its greatest capacity with a single turn of the lever employed, although there are cases where such practice would be very commendable. The author has so opened the mouth many a time, but not in cases of long standing. Generally, the force should be applied with gentleness, gain a little one day, and a little the next; it takes but a very short time to open a mouth in this way; besides, if your force be applied with such judgment as not to provoke vascular response, you will arouse to co-operation the absorbent system, the excitement acting as a stimulus to it, and it will be found to do its part vigorously.

A person will not infrequently be attacked with trismus after the dental operation of inserting a pivot tooth. Here the lesion is more than likely inflammatory in character, and the treatment is to be directed accordingly; the root of the tooth is in a state of periodontitis. Cases of pure tetanus, however, have had origin in such an operation. Where the lesion is inflammatory, the parts are sore, and tender to the touch.

A person will sometimes be attacked with trismus after the plugging of a tooth with metal; the attack comes on suddenly; it is a reflex nervous action, and is always to be esteemed of dangerous import. The conducting facility of the metal irritates the nerve periphery in the pulp; this irritation is referred to the medulla, and thence reflected to the muscles of mastication. To prove the existence of the lesion, direct the patient to hold cold water in contact with the organ.

To treat a case of this kind, remove the metal; when the irritation has subsided, be sure that before refilling, a non-conducting substance be placed between the plug and floor of the cavity; or, because of the thinness of the bony septum, it may be desirable to destroy the pulp.

Spasmodic trismus, very persistent, may result from the employment of different metals in the operation of a single tooth-plugging; galvanic action being a consequence, and the nerve subjected to a most harassing irritation. To test for this trouble, increase the action by holding silver and zinc against the plug. This test, however, will irritate any super-sensitive pulp into a state of excitement, and is an admirable search-warrant for obscure lesions of the organ. The treatment consists of course in the removal of the plug, and the medication, if required, of the irritated pulp.



So over many pages might be extended the consideration of dental lesions in connection with trismus. Enough, however, has been written it is presumed, to direct proper attention to the subject.

To recapitulate: It is suggested that many of the cases of so-called idiopathic or obscure trismus will be found to depend on conditions associated with the dental arch.

That to insure permanent relief, the treatment must include the primary lesion.

That such primary lesions as are described in the chapter on Anomalies are always distinguishable.

That where it is desirable to extract an offending wisdom-tooth, and such extraction seems too difficult to attempt, the removal of the tooth immediately anterior to it will, as a rule, meet the indications.

That the immobility of the jaw, where acute inflammatory action exists, is to be treated on general antiphlogistic or phlogistic principles, according as it seems probable or improbable that the inflammation may be resolved.

That when the acute action has passed, adhesions are to be broken up by mechanical force carefully applied.

That mechanico-dental lesions are not to be overlooked, but are to be searched for, and discovered *secundum artem*.

**Trismus Traumaticus.**—This is that ankylosis, true or false, intra- or extra-articular, dependent on local injury. Blows inducing inflammation are among the common causes; a not infrequent origin, one difficult to combat, resides in severe burns; sloughs from the undue use of mercurials are to be named; in short, enumeration might instance any lesion in which the locked jaw associates with conditions of local signification attended with solutions or irregularities in the continuity of the structures. A case just dismissed from the writer's practice, in the person of a boy twelve years of age, had the ankylosis dependent on false articulation, the result of injury done the glenoid fossa three years before by a blow upon the chin. The force of this blow being carried to the joint, a chronic inflammation had resulted in a filling up of the cavity to a level with the articular eminence. While in this peculiar situation, a species of irregular cavity had formed, which partially accommodated the condyle, permitting, however, dislocation whenever the jaw was opened beyond a certain point. In this case a fair cure was obtained by a tri-weekly manipulation of the bone, which resulted in a better-adapted fossa through absorption. To procure such motion as seemed demanded, frequent luxations resulted,—causing at first not infrequently much trouble in the reduction. This patient has been advised to watch any tendency to contraction which may appear, and to keep it counterbalanced by rolling corks between his teeth,—an excellent means, by the way, where the expense of instruments prevents their purchase.

The use of common bottle-corks as a means of overcoming false ankylosis is employed with satisfactory success. Beginning an operation with one of a



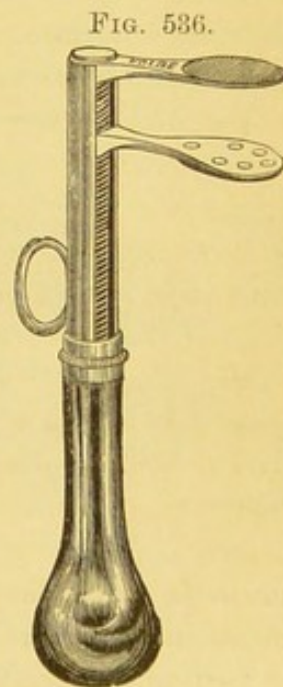
diameter to be readily introduced, increasing sizes are to be rolled, one after the other, between the teeth, into place. Timid children who resist the screw will permit the use of corks.

At a late clinic, a young man presented himself with the lower jaw so fixed that only by profoundly etherizing him was it possible to pass the blade of a common table-knife between his teeth. This condition, which had existed for two years, had resulted from a blow received on the cheek, involving, in an inflammatory fixedness, the masseter muscle. This case was treated by subcutaneous section of the muscle, associated with the daily use of the screw. Through the use of this instrument there is no doubt of his being kept comfortable; he is directed to employ it daily, and never to allow the jaws to deny the introduction of two fingers. Without doubt, it will be found that eventually such modification of the contracted muscle results that a fair cure shall be obtained. The section of the muscle in this case had of course but the meaning of affording the use of the second and true means of cure, namely, the daily stretching of the part.

Fig. 536 represents the instrument employed in the stretching process, and which has been furnished the patient for daily use: it is one devised or modified by the ingenious cutler to the Hospital of Oral Surgery clinic, Mr. Kolbe, and surpasses any other form with which the writer is acquainted: by simply turning the handle, the blades, as seen in the drawing, are gradually separated. The power residing in this instrument is sufficiently great to break up any ankylosis, true or false; a jaw is easily to be broken with it. A necessary addition to the instrument, as felt, is a transverse bar in the handle to afford a more convenient application of the force. The apparatus is to be recommended as the best in use; it will fulfil the requirements of any case to which such application of force is indicated, while the most careless patient may be intrusted to use it on his own jaws.

Cases of false ankylosis are most frequently found extra- rather than intra-articular; or where the condition has existed for a long time, say for a year, then it is reasonably to be inferred that the two conditions combine, that is, that portion of the articular cavity which is not used has been modified by nutritional changes. Wherever the lesion of a false ankylosis is situated, the philosophy of its relief consists in the practice of passive motion,—it is really only another expression of the mode of cure of urethral stricture: operation may be necessitated, but it is only to be practised in cases of urgent necessity.

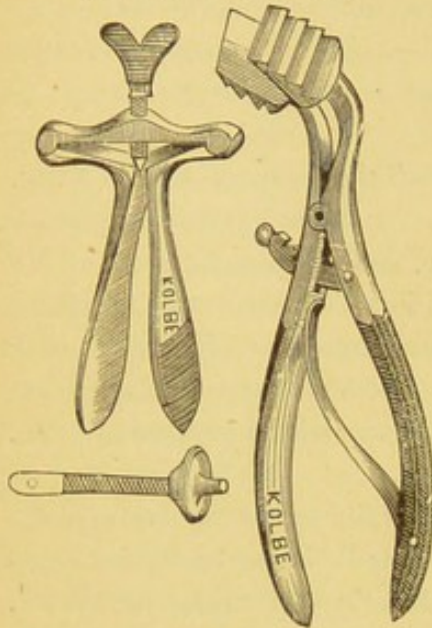
Besides the instrument commended, various others have been devised for the purpose of passive motion. Figs. 537 and 538 show forms. Fig.





537 is that known as the wedge of Scultetus. Fig. 538 is a modification, as is seen, of such instrument: neither of these deserves mention as compared with that devised by Mr. Kolbe.

FIG. 537. FIG. 538.

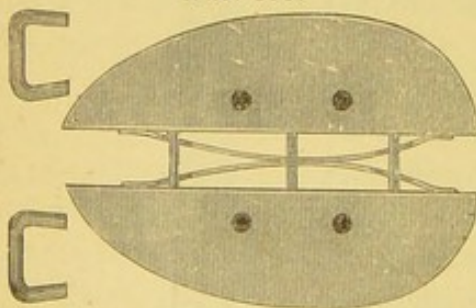


In sections of the country where the mercurials are freely used, ankylosis as a result of sloughing is not uncommon; it is frequently found in these cases that the mucous aspect of the cheek has been converted into a dense unyielding fibro-cellular cicatrix, which cicatrix resists all attempts on the part of the depressor muscles to antagonize it. In cases of this kind, instrumental aid applies most happily, and, if properly and judiciously persisted in, will eventuate in a reasonably satisfactory relief.

A form of instrumentation applying in this direction finds its suggestion in the deep, yet perfectly healed cuts existing in the mouths of patients who have worn for considerable time dental plates which impinge unduly about the vestibular base. Acting on such hint an impression of the parts is taken, and an apparatus constructed possessed of dull edges, which impinge continuously and increasingly upon the cicatrix where it relates the cheek and gum surfaces. This plate is to be worn for months. Success in securing permanent division of the cicatrix by this means is sometimes very satisfactory.

Fig. 539 represents an instrument of this class, the mutual device of the

FIG. 539.



author, and of Mr. E. B. Buckland, a student of the Philadelphia Dental College, by the latter of whom it was made. It consists, as seen, of two wings constructed of vulcanite and separated by pieces of watch-spring. The uprights, of which there are three, have the single office of steadying the wings. The clamps, seen to the left, are with a view of holding the wings together until fixed in place

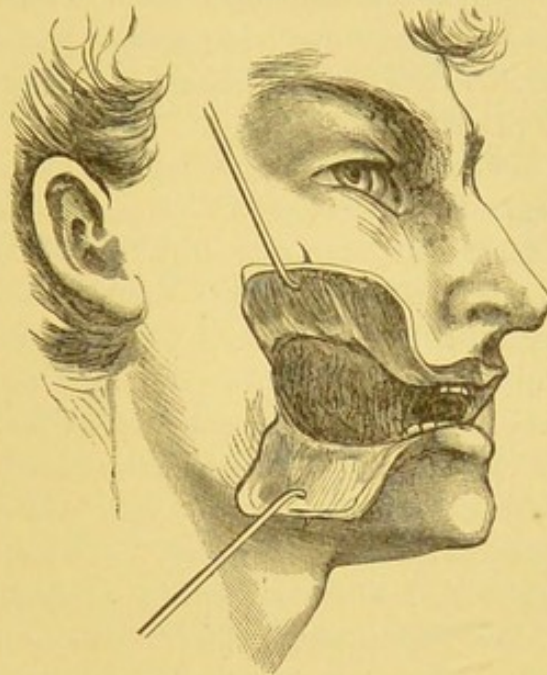
in the mouth. They fit in the holes seen. This instrument accomplishes its intention with great satisfaction.

Cutting the face open with a view of getting at the cicatrices is an operation to be avoided where possible. Fig. 540 shows a mouth so cut, where, after the structure has been removed and the teeth separated, an interdental splint, with attached vestibular wings, made from celluloid, has been inserted. Here are met the double indications of holding the jaws apart and preventing



reunion of the cicatrix to the gums. In principle the manipulations work beautifully, not so well, however, in practice, objection existing in a degenerative action which is found most apt to interfere with union of the cut cheek. Instruction exists in the diagram, as it exhibits the relation of the interdental splint. Where it is possible to get such apparatus in place by separating the cicatrix from the gum without external incision, the performance is not too

FIG. 540.



highly to be commended. If attempt is to be made, the surgeon incises freely above and below, and, after forcing the teeth apart by means of a Kolbe gag, he moulds softened gutta-percha between the teeth and into the vestibule, hardening this by use of ice-water. Celluloid requires to be prepared upon an impression, a difficulty in procuring which stands in the way of the use of the agent. When, however, a mouth can be so opened as to permit of the introduction of impression cups and material, a vestibulo-interdental splint of this material is the least irritating of the different kinds used in the direction.

The use of modelling compound, as employed in dentistry, is not permissible in the direction here considered. As an agent ductile under a low degree of moist heat it peculiarly commends itself, but it is not in the mouth more than a day when it begins to crumble and lose its supportive power.

Another expression of ankylosis is found in bridges of bone associating neighboring parts, commonly the edges of the glenoid cavity, with the neck of the lower jaw, or it may be that the relation is between two maxillary bones. These bridges are not infrequently to be broken and their absorption secured through dilatation conjoined with passive motion and the use of sorbent facients. In no cases, however, is it more desirable to guard against inflammatory results, and therefore such procedure is to be conducted with the same care as obtains in breaking up ankylosis in the knee- or elbow-joints; a principle



being, to make haste slowly: fracture of the neck may readily attend rough manipulation. Should such fracture occur, the desirability of making a false joint is to have consideration: if a diagnosis exhibit complete fixedness of the head of the bone by an osseous relation, then nothing better is to be attempted than the creation of such false joint, union of the parts being prevented by passive motion, and inflammation combated through antiphlogistics. Cases offer where the only possible prospect of relief exists in the production of such a false joint by operation particularly directed to that end. The author has met with success by excising from the posterior part of the body of the bone a V-shaped piece. A flap raised, the engine quickly removes the section. Saw or bur is used; the latter preferably.

In such conditions of ankylosis as depend strictly on superficial cicatrices, the propriety is always to be considered of a plastic operation, which, removing the deformed tissue, shall replace it with that which is normal, secured from some convenient part in the immediate neighborhood. If the cicatrix to be replaced be small, adjoining portions of the cheek may furnish the required material; if, on the contrary, it be large, the neck will have to be depended on, or it may seem preferable to employ the Italian method of taking a flap from the arm. The principle of the operation consists in mapping out on the part from which the flap is to be made such extent and shape of surface as shall replace that designed to be removed. The cicatrix being dissected out, and all bleeding checked, the flap as marked is raised, leaving it attached alone by its pedicle; and when hemorrhage in this also has been controlled, and the surfaces begin to glaze, it is carefully to be turned on the pedicle into its new position, and, being fixed by stitches, is to receive the attention required by wounds in general. The space left by the removal of the part is to be drawn together by stitches, adhesive strips, or other convenient means. Before undertaking a plastic operation, however, nothing is more necessary than to possess an appreciation of the reparative and nutritional powers of the patient. To operate on a person in a typhoid state, or on one the plasticity of whose blood is destroyed by the influences of syphilis, scrofulosis, scorbutus, or mercurialization, would be simply to court failure. (See *Plastic Surgery*.)

Concluding this consideration of fixedness in the jaw, a résumé of the subject exhibits as causes of the condition,—

- 1st. Spasm; the treatment being of constitutional consideration.
- 2d. Ankylosis by muscular induration; the treatment being by local medicaments, combined with the employment of the dilator.
- 3d. Osseous ankylosis; the treatment being the breaking up, by section or otherwise, if permissible, of the bony bridges.
- 4th. Cicatricial ankylosis; the treatment being by dilatation and by plastic operations.



## CHAPTER LVII.

### NEURALGIA.

THE term neuralgia is from the Greek roots *νεῦρον*, a "nerve," and *ἄλγος*, "pain." It signifies a condition, or an effect, not a cause; or, if this definition be not an absolutely correct one, the exceptions to the rule it would form are exceedingly few. For such reasons it is, as commonly employed, a meaningless term, expressing a condition about as definitely as the word suppuration conveys idea of the meaning of inflammation.

Neuralgia, as the appellation has definite application, refers to paroxysmal pains, localized or metastatic, presenting no manifestation of any lesion at the seat of pain outside of the single phenomenon.

The pains of neuralgia are mostly, although not exclusively, acute in character, are confined to the tract or to the periphery of a certain nerve, remit, or more commonly fully intermit, and are accompanied with tenderness of the part involved only when an accidental associate lesion may exist, or when an irritation is so severe or has been so long continued as to have reacted on the neighboring vascular system.

When, then, a practitioner has his attention directed to a seat of pain without apparent lesion, the matter of first importance is an appreciation of cause. To say that such a one has neuralgia, and to treat him with nervines, is to say just nothing, and certainly is to do nothing in the way of good except indeed by accident. A first duty is to search for cause, and, if discoverable, to remove it, if this be possible. Now, the causes of neuralgia are, as farther on will be shown, sometimes very evident, and very easy of removal; and it will be seen, from illustrations offered, that one, from lack of observation, may utterly fail in giving a relief very easily and naturally afforded by another.

Correctly speaking every pain is a neuralgia. It is quite proper to say rheumatic neuralgia or gouty neuralgia. The suggestion affords a lesson in diagnosis. Rheumatism is always accompanied with vascular perversion; the pain is not distinctly localized, but is diffused over a part involved; as a general thing it is a soreness rather than sharp, acute, concentrated pain. Movement aggravates this soreness, changes in temperature affect it; it is not paroxysmal, although it may be, and generally is, remitting; in short, it has a history, and this history is not difficult to read. Gout exists in heredity and in over-generous living. It is decidedly inflammatory in its local manifestations. It attacks in preference small joints. It is accompanied by œdema, by congestion, and by enlargement of the veins. If it prove metastatic, the seat



of transfer presents like vascular phenomena with the original inflammation. The cause to be removed in rheumatic neuralgia is rheumatism, in gouty neuralgia, it is the gout.

But is there not a condition—a disease—which is, or might be, termed neuralgia?—as, for example, gout is a disease with an individuality, or rheumatism is a disease. If, without being influenced by other than his own observations, the writer were to answer the question, he should say decidedly there is not; and his reasons for the denial would lie in the fact that in one way or another he has become conversant with many cases which have stubbornly resisted a long course of treatment founded on an abstract neuralgic theory, but which have rapidly and readily yielded on the discovery and removal of some lesion of which the pain proved to be simply a sympathetic connection,—as, for instance, otalgia, hemicrania, or even sciatica, from an exposed tooth-pulp, from a splinter of foreign substance, or from the pressure of an exostosis. It is certainly true that there is a class of persons who might be termed neuralgic; these do not belong strictly to what is called the nervous temperament, but are the anæmic and prostrated. A plethoric temperament disposes to inflammation, but plethora is not inflammation; it is only a predisposition; the nervous temperament is only a predisposition. It cannot be denied that cases called neuralgia, and treated without ideas of specific lesion, do very frequently get well; but has not the indication been accidentally met, just as with the Dewees' carminative a restless child is often prescribed for and cured, no definite idea of the ailment being entertained, a single medicine possessing the requirement of various conditions?

If neuralgia, then, be simply a phenomenon,—simply the expression of an immediate or distant lesion,—scientific preliminary treatment lies in search after cause. But is cause always evident? Not certainly to our present acquirements. Cause, nevertheless, exists, and, failing to discover it, a practitioner is compelled to desert principles and treat experimentally.

Are there predisposing causes of pain-radiation? Undoubtedly. These may, and always are to, receive a proper degree of attention, as, in antagonizing them, it may prove to be the case that the proper lesion is not in itself of sufficient importance to inaugurate or maintain a neuralgia. Thus, of predisposing causes, a damp, cold atmosphere is to be named, fatigue, over-excitement, excess in drinking, poor diet, the too free use of coffee or tea, loss of

---

\* Dr. Anstie, whose monograph on Neuralgia has attracted much attention, as well as criticism for and against, advances and defends the position that as regards both the seat of what must be the essential part of the morbid process, and the general nature of the process itself, we must possess very definite information indeed. In the beginning of his third chapter he says, "I expect to convince most readers that the essential seat of every true neuralgia is *the posterior root of the spinal nerve in which the pain is felt*, and that the essential condition of the tissue of that nerve-root is *atrophy, which is usually non-inflammatory in origin*." There can be no doubt that such condition is to be met with as an explanation of peripheral pain; but such a condition is merely one *cause* of the neuralgiæ.



sleep, costiveness, diarrhoea,—in short, anything which interferes with the easy and proper performance of functional life.

In miasmatic neighborhoods, neuralgia frequently assumes a periodic type, influenced evidently by the malaria. It is without doubt true that the exhibition of quinine will and does, not infrequently, cure such cases. Whether such cure is because the medicine controls the full and complete cause of the trouble, or only removes an exciting cause in the absence of which nature gains the mastery, need not be discussed, it being a matter of certainty that it is by no means always the case that in the destruction of periodicity pain is removed.

Syphilis is another of the exciting causes of neuralgia. Patients have sometimes great pain in diseased teeth, which can be held completely under control, although not cured, by iodide of potassium. The pain undoubtedly is from the teeth, as with a subsequent removal of these organs the trouble disappears.

To epitomize the subject is to advance that in a state of health the nervous system represents a poised balance: it is neither excited nor depressed; it works in entire harmony with its requirements. Apply a source of irritation, and this harmony is destroyed. According as the amount and extent of irritation, so the amount and extent of derangement. Life, happily says Bichat, rests upon a tripod of innervation, respiration, circulation. What affects one of these legs affects the whole body. To appreciate the phenomenon of neuralgia is to appreciate relations,—is to search over the economy until wherever a lesion exists it is exposed and comprehended.

If after such manner of studying diagnosis a first view be directed to the nervous system, we look for a lesion in that part which, by the expression of pain, seems most markedly implicated. The most decided cases of neuralgia are, without doubt, odontalgic. A tooth decays until the cavity containing the delicate nerve is exposed; the neuralgia has the simple, single signification of a direct irritation. Exostosis of a tooth-root presses on nerves ramifying in an alveolo-dental membrane; the signification is similar.

Let reference be made to a neuralgia occurring in a part after amputation. Is cause not most frequently found in the squeezing and pinching of a nerve caught in the cicatrix? Is it not the same history where tumors grow about and press upon some nerve-periphery? May there not be instanced neuro-matous expansions found in stumps, evidently enough sources of pain? Let a different view be considered. Are there idiopathic inflammations of nerve-substance? Do nerves in themselves degenerate and ulcerate? The subject may be looked at from a still wider stand-point. There is no doubt that a pure nervous irritation of the system at large can exist. There is certainly an individuality living in this system. It has a mode of action of its own, and this action, as remarked by Dr. Wood, is susceptible of exaltation, depression, or deprivation in itself, and from the influences of its own peculiar agents. But can or do these vicissitudes express themselves ever, or even



occasionally, in sharp neuralgic pains? Connected with the digestive function we have often nausea and vomiting; with the secretory, disorder of the liver and kidneys; with the respiratory, hurried and otherwise irregular breathing; with the circulatory, a frequent and agitated, though seldom full or energetic, pulse. As the offices of the brain, suggests Professor Wood, are various, so also must be the signs of its excessive excitation. Irritation in the brain obeys the general laws of that morbid affection. If moderate, it exalts the healthy functions without otherwise altering them; if stronger, it more or less degenerates the functions; in great excess, it entirely changes or abolishes them. Thus, sensation and perception may be rendered simply more acute, or may be deranged, producing vertigo, pain, and every variety of disorder in vision, hearing, touch, etc., from buzzing in the ears, unnatural coloring of objects, a sense of tingling, formication, etc., to complete hallucination. The intellectual faculties and the emotions may be excited into increased vigor, or may be completely perverted, as in delirium and insanity. The general over-seeing faculty of the brain may be simply stimulated to increased vigilance, to a more ready and rapid response to all the intimations of its dependent functions; or it may be thrown into excessive disorder, evinced by restlessness, jactitation, obstinate sleeplessness, etc. The motor faculty may merely impart increased activity and energy to the muscles under the influence of the will; or it may throw off more or less completely subordination to that principle, and give rise to every variety of spasm and convulsion. Finally, all the functions above referred to may be overwhelmed by an excess of irritation, and more or less completely lost in stupor and coma. This is nerve-irritation, from causes or influences which reside in, or in association with, the system, and to be considered alone in connection with the system.\*

Reactions of vascular perversion on the nervous system are to be considered. Coup-de-soleil and apoplexy may be esteemed opposite conditions in such reactions. How frequently have all the phenomena of partial compression—headache, giddiness, buzzing in the ears, disordered vision, tingling, formication, numbness, drowsiness, mental confusion, spasms, convulsions, etc.—been quickly resolved and removed by the accidental rupture of a nasal vein having communication with a meningeal sinus! And how happily, when similar conditions have come on from long-continued chlorosis, has a course of iron relieved them! Every portion of the encephalic mass, every portion of its continuation in the spinal canal, every nerve-periphery, requires a certain amount and a certain character of blood to keep it in proper poise and nutrition. Too much blood, and too nutritious, and we have derangement from over-stimulation; too little, and too poor, we have it from lack of pressure, lack of nutrition, and, in many cases, from effusions.

Derangements in respiration act as predisposing causes to neuralgia. A patient who labors under an inability to aerate his blood, whatever the cause,

---

\* Practice of Medicine, George B. Wood, M.D.



fails to relieve that fluid of certain poisonous qualities, which, of necessity, sooner or later disturbs the nervous economy.

Anything and everything, in short, it is to be said, which acts as a depressant in the vital economy, whether by over-stimulation or by under-nutrition, is to be thought of, and considered, in neural derangements; overstudy, sensual excess, indigestion, hepatic and nephritic diseases, repression of the cutaneous circulation, the depressing passions, as fear, grief, melancholy; the employment of sedative poisons, as opium, tobacco, chloroform; living in an atmosphere impregnated with irrespirable gases,—any of these may assist some otherwise incapable lesion in determining an attack of neuralgia.

Definite note is to be made of the fact that poison long continued proves so great a depressant of the vital economy that, though a lesion be fully and undeniably exposed and removed, secondary relations are apt to show themselves, which prove, not infrequently, of worse offence than the first. The writer directs particular attention to the clinical fact that sooner or later, after the cure of some special, severe, and long-continued neuralgia, the general health is found to become deranged, this derangement showing itself as of common systemic import, otherwise as associated directly with some vital organ.

The most extreme case of nervous mania that has ever come under the observation of the writer, this being accompanied with general hyperæsthesia and local neuralgia, was in the person of a carter, addicted to excessive smoking. For three days this man was uncontrollable by any but physical restraint; at the end of which period, having secured a short interval of sleep and quiet, there was placed between his lips a pipe of the strongest tobacco. The patient was finally cured by making the section of a nerve, and treating him with tobacco and sedatives, just as one treats delirium tremens with whiskey and narcotics. In this case there can be no doubt that the local neuralgia was goaded to its intensity by the perverted condition of the general nervous system. Similar cases associate with the improper use of opium, and with the abuse of the sexual instincts.

In cases of persons long habituated to the use of opiates as a relief in neuralgic pain, operations which have considered and which have truly relieved the system of the lesion of offence are not apt to be followed by the immediate relief anticipated. Here is a point in which clinical observation agrees with deductions of Dr. Anstie, that "pain involves a lowering of function;" on the other hand, it is not unreasonable to suggest that the condition is one of "hyperæsthesia." Pain is of both conditions, and is to have such appreciation if it is to have cure.

The first of the propositions quoted finds demonstration, plain enough, in the exhibitions of the inebriate, who manifests the first symptoms of delirium only on the deprivation of the wonted stimulus, his aberration having the meaning of exhaustion consequent on over-stimulation, as shown in what might be termed the synthetical proof of the primary demand for stimulation.



From his own practice the author might cite many interesting cases illustrative of the difficulty of affording ease to a patient addicted to, and long dependent on, opiates, even where the original disease undoubtedly has been cured,—as, for example, in such instances as the removal of cicatrices or of foreign bodies; these cases, however, are not at all in proof of neuralgia being a disease in itself, the reverse rather: pain being the expression of exhaustion consequent on long-continued over-stimulation. No direct lesion remains in such instances to be considered. Cure lies in getting back a lost equipoise. Exactly what this lost equilibrium may be called is entirely immaterial. Let it be named vaso-motor paralysis, as designated by Dr. Anstie, and let it be said that the paralysis is a “direct extension of the original morbid process from the sensory root to the motor, affecting the original fibres in the latter, which are destined to control the calibre of the ocular and facial vessels.” Granting the premise of neuralgia being an expression of the presence of an irritant, or accepting the hypothesis of Anstie as to its being a condition of diminished vitality, it must certainly be felt that the hypodermic injection of morphia,—of obtunding agents,—so continuously practised and recommended, has in it only the virtue of covering a wound temporarily from sight and calling it well; indeed, it is much worse than this, it is exhausting more completely that which is already weak; it is making neuralgia; it is treating effect,—taking no heed of that which is the cause of effect.

It is not designed to convey an idea, however, that opiates are unjustifiably used in neuralgic conditions; pain in itself is, as has been suggested, a cause of exhaustion, and it may prove the lesser of two evils to moderate or annul pain. But opiates are to be employed as adjuncts. When a practitioner finds himself forced to rely upon such medicaments, the confession is extorted commonly that he knows solidly nothing of what he is treating.

It is to be accepted then as the proposition of this chapter that neuralgia has its existence in a lesion. As a corollary it is deduced that treatment of neuralgia is treatment of a lesion.

Lesions resulting in neuralgia are of every possible kind and situation. The illustrations appended have the meaning of propositions in diagnosis.

**1. Tooth and Uterus.**—Miss A., unmarried, thirty-five years of age, neuralgia situated in a bicuspid tooth of lower jaw; pain of nine weeks' standing; unbearably severe.

**TREATMENT.**—Tooth being carious and of little value, removed. No benefit. Examination directed to all the teeth of the mouth showed no associate lesion in any of them. Search for cause, extended over the system at large, discovered an ulcer upon the inner face of uterine fundus. The cure of this ulcer resulted in cure of the jaw pain. Later this same patient applied to the writer for treatment of a defect in refraction; this defect being so great as to require for its correction glasses ground as follows:

R.—Right eye + 48 = c × 60 ax 35.

Left eye + 32 = prism 4 ax 0 = c + 48 ax 145.



The lenses, constructed to order, worked so perfectly as to elicit from the patient the remark that she had never before seen the world as it is. Six months later they ceased to work at all; the lady being returned for consultation by her physician under an impression that she was going blind. Satisfied as to the correctness of the glasses, attention was at once redirected to the uterus; ordinary sponge tents being used for the exposure. The ulcer was back. Cure of it corrected the amblyopia.

**2. Tooth and Eye.**—Mr. —, thirty years of age, mydriasis and pain of two years' standing. Cause, in this case, lay in an encystment of a cuspid tooth. Cure, which was so immediate as to be almost complete before the patient left the office, was found in breaking up the cyst and taking away the enclosed organ.

**3. Tooth and Ear.**—Patient, a medical student. Otalgia of five weeks' standing. No expression of local cause. Examination directed to the teeth discovered a nodule in the pulp of the most immediately neighboring *dens sapientiæ*. Instantaneous cure resulted from extraction of the tooth.

**4. Tooth and Ear.**—Patient, a professor of otology. Pain and ringing in the ear constant. Cause found in an undecayed wisdom-tooth which nature was making an effort to throw off. Extraction was succeeded by immediate cure.

**5. Maxillary Nerves and Head.**—Mrs. B., wife of an undertaker, suffered for a long time from periodic attacks of pain about the face and head. This person, exceedingly quiet and retiring, spent most of her life in sunless rooms surrounded by the melancholy paraphernalia pertaining to the business of her husband. She was anæmic, and of poor general health and spirits. Although she had certain bad teeth, yet the pain from which she suffered had never seemed associated with them; indeed, so insensible were these organs to ordinary agents of irritation, that a diagnosis was founded alone on her general condition and surroundings, and remedies applied entirely in such direction. Tonics were administered, window-shutters unbowed, exercise and amusement, conjoined with generous living, were advised; even with this entire change the patient failed to improve, but, on the contrary, grew worse. The diagnosis thus discovered at fault, the teeth were extracted; still the condition persisted, the pain increasing. The lady was now treated for over a year, the pharmacopœia being exhausted in her case. Called in consultation, and acting on the belief of the existence of a special lesion in all such cases, the author determined, with the concurrence of the gentleman in attendance, to make a most careful exploration of her whole system. At this period the pain had assumed, and continued, the impression of an iron clamp about the head, terminating beneath the chin, which clamp seemed daily contracting itself. The terror and pain of this impression had become so great as to convert the patient almost into a lunatic. On inquiry, it was found that her internal organs had been most carefully examined, and inferred not to be in fault. Investigations, therefore, were commenced externally.



First, was there any remaining tooth or teeth implicated? The organs were examined for caries, for pulpitis, for nodules, for necrosis, for exposed cementum. The teeth were in no wise involved. Next the spinal cord was explored, and, through its expressions, the encephalic mass; organically, the trouble could not be found reflex from these points. Every articulation, the line of every artery, vein, and nerve was looked at so far as these could be followed. Every observation and fact which might throw light on the case were considered without success, as any discovery of an exciting cause was concerned. Finally the oral cavity was returned to. The teeth which had been extracted the year before were the molars and premolars of the left superior jaw. Might there not possibly have been just the smallest particle of one of these teeth left in its socket? Pressure was being made in the canine fossa, when the patient made slight complaint; it was the only point which had yielded difference in sensation. Now, what was this sensation, and what did it mean? It was not pain of which the patient complained, not discomfort; it was simply difference of sensation. It was a point, however, which had yielded expression. It was in the line of the diagnosis to infer that here existed something,—the lesion, perhaps, of which we were in search. Acting on this hint, an exploratory trephine of the antrum was made. This discovered that branches of the infra-orbital nerve running across the cavity had enlarged to the size of knitting-needles. These enlarged nerves, of which there were two, were cut away. The patient was immediately relieved, and, although ten years have passed, she has had no recurrence of her neuralgia.

**6. Tooth and Scalp.**—Patient, a young lady, who shortened a summer and fall campaign to come to Philadelphia for advice concerning neuralgia of the face, and of the ear and scalp. She described her agony as being sometimes so great that only from chloroform could she get even a temporary relief; had been taking tonics and opiates throughout the summer; had no pain in any of her teeth, although on the upper jaw was a pulpless molar. Examining her mouth, attention was attracted to a peculiar overriding of the second bicuspid tooth of the lower jaw by the first molar; the employment of a delicate curved probe revealed caries of the first of these teeth exposing the pulp; the tooth was extracted, and the distant and apparently dissociated neuralgia instantly disappeared.

A tendency to nervous irritability which exists in this patient may very well be re-aroused by the presence of the upper dead molar; if this should prove to be the case, she is advised to have it extracted.

**7. Urine and Nervous System.**—During a late midday meeting of the class of the Oral Hospital, convened for the purpose of experimentation in analyses of human fluids, the urine of one of the students, a martyr to neuralgia, was offered for examination, the heat test of which exhibited an opalescence quickly passing to the showing of (apparently) albuminous threads startling as to quantity. The addition of nitric acid dissipated instantly both



opalescence and threads, proving the coagula to be not albumen, but lime salts, and directing attention to the immense waste going on in the nervous system as a possible, not to say probable, cause of the young gentleman's disease. As this person has had his case under examination from time of entering the school, a year and a half back, without having come either to cure or to a satisfactory understanding of his condition, he was put at once on the syrup of the hypophosphites with a view of finding correlative proof, if such existed, as to inferences arising out of the condition of his secretion. The specific gravity of the specimen was 1030.

**8. Inferior Maxillary Nerve and Face.**—Lesions of the inferior maxillary nerve, where it lies in the maxillary canal, are assuredly more common than is generally supposed. Diagnosis of such lesions lies in the fact that pain, however it may shift about, is distinctly referable to the locality, and to evidence as afforded by a certain obscure tumidity never, perhaps, entirely absent. As a rule, the origin of these lesions is to be traced to some periodontal affection, although not infrequently direct injury has been inflicted on the nerve by an unskillfully directed dental drill. It is in this connection to be mentioned that cases seem to exist where a peripheral nerve of one side of the jaw passes to the other side, and where the mylo-hyoid nerve penetrates the bone and associates with the maxillary. At the present moment of writing there is a patient in the Oral Hospital whose inferior maxillary nerve was removed a week back from mental to dental foramen; to the present moment, from the time of coming from under ether influence, the man suffers as profoundly as ever from pain in that side of the lip supplied by the nerve removed.

Reference is also to be made in this connection to a neuralgia of the lower jaw, which close examination shows to be associated strictly with the gums. Here is to be borne in mind that the part is supplied by branches accompanying the gustatory nerve, and that consequently the trouble is not—save accidentally—to be reached by a section that considers the dental nerve. The writer has in his experience verified this in cases where the dental nerve has been removed from the whole length of the canal, yet where cure has been secured only by a second section made near the oval foramen, and which included the lingual. Attention is to be particularly directed to this complication.\*

---

\* NEURALGIA OF GUMS AND TIP OF TONGUE.—Neuralgia, situated in the gum tissue, invites, in a search of its cause, to a consideration of the following: The gums of the lower jaw are supplied by branches of the gustatory or lingual. This is a branch of the third division of the fifth, and comes off from that nerve just above the inferior dental branch; communicating, not infrequently, with this last-named just before it enters the posterior dental foramen to be distributed to the teeth. The lingual, in its continuation, supplies the tip of the tongue, at which point it associates with filaments from the hypo-glossal. The tip of the tongue is a frequent seat of paroxysmal neuralgia of an almost unbearable type.

Experience has yielded the lesson that neuralgia situated in the substance of the lower gum is not to be cured by section of the dental nerve, unless, indeed, it happen that the



**9. Foot and Knee.**—One of the most impressive cases of neuralgia ever treated by the author has the following history. A Mr. B., serving in the war of the rebellion, received, as near as memory serves to recall the case, three gunshot wounds,—one in which a small minié-ball passed through the tarsal bones, a second into the arm, a third lodged in the chest; the exact locations of the two latter are not distinctly recalled, as they did not associate with the case. After dismissal from the service, and after being engaged for a long period in the occupation of a carter, the patient commenced to suffer pain in the knee-joint and down the back of the leg, this pain increasing during a period of months to such extent as to require a constant watch being kept to prevent suicide. The author feels justified in asserting that seldom is witnessed greater expression of agony in a human being than was the almost constant condition of this man. Spending two months in observation and clinical study of the case, a conclusion eventually forced itself upon the mind that associated with the track of the ball through the foot existed some lesion of the dorsalis pedis nerve. Not that at this point there was pain, tenderness, or indeed expression of any kind, but a diagnosis by exclusion seemed to locate the trouble here: the author mentions particularly the absence of all signs, because he could find no one to second his conclusions or to indorse a proposition to make section of the nerve above the ankle. The nerve, however, was exposed and the length of an inch removed. From the moment of the operation the patient was entirely free from his neuralgia, although tenderness about the knee upon pressure continued for some little time, while the superficial portions overlying both malleoli sloughed and remained in an ulcerating condition over three months.

Dental surgery affords countless instances of immediate pain radiation. This radiation commonly relates to teeth having a common period of eruption, a diseased bicuspid of one side expressing itself in a healthy bicuspid of the other, a molar in a molar, etc.

It is to be accepted that a diseased tooth may express itself in almost any part of the body, on the other hand that disease in any part of the body may express its discomfort through a tooth. (See *Odontalgia*.)

**Treatment.**—The idea is advanced that there is seldom or never what is termed idiopathic neuralgia but that pain is always a symptom. It is unfortunately the case that too often as practitioners we discover weakness in search after cause, and thus find ourselves unable to treat a case scientifically, being driven to empiricism. Even yet, however, medicine is able to render more than an accidental service; and the principle on which treatment is founded is that of soothing and quieting, either as applications refer to the

---

pain is reflected from a lesion related with this nerve. Neuralgia of this situation and of the tip of tongue demands consideration of possibilities associated with the lingual nerve and with the hypo-glossal,—not overlooking, at the same time, probabilities connected with more distant anastomosis. Section of the lingual nerve at base of skull is made by means of same operation practised for dental. See Diagrams, Figs. 541 and 543.



system at large, or to a particular part involved. Sedatives, where there is general nervous disturbance, independent, so far as we discover, of other derangements, are found sometimes to act very happily. The tinctures of valerian and gentian in equal proportion, given in tablespoonful doses, make a fine combination. Bromide of potassium, where it seems necessary to keep up a continuous impression, is given with advantage in doses of ten grains, dissolved in a wineglass of water, from two to ten times a day. If administered, however, in a paroxysm, forty to sixty grains are found not too much, and it is sometimes well to combine with this small doses of opium or morphia.

R.—Potassii bromidi, gr. xx;  
Morphiæ acetatis, gr.  $\frac{1}{4}$  to  $\frac{1}{2}$ , according to severity of pain;  
Aquæ,  $\mathfrak{z}$ j. M.  
The dose to be repeated in five or six hours, if required.

Valerianate of zinc is a favorite preparation; it may be made into pills with conserve of rose, or any preferred vehicle, each pill to contain from one-half to a full grain, to be given twice or thrice a day.

Tincture of Indian hemp is prescribed in doses of five drops, repeated three times a day.

Where there is disturbance of the visceral health, it has been found occasionally successful to produce rapid but moderate salivation. Compound tincture of benzoin administered in fifteen-drop doses three times a day acts happily in those wandering abdominal pains which sometimes put at fault in way of explanation.

Aconite, made into quarter-grain pills, and administered cautiously, three or four times a day, is recommended.

Digitalis in tincture, or the tincture of veratrum viride, in conditions of undue circulatory excitement, exhibited in five-drop doses until such excitement is subdued, will sometimes quickly relieve the pain.

Colchicum, where there is a supposed gouty association, is always wisely employed. The wine of the root is the best preparation.

In rheumatic neuralgia, or pain associated with a rheumatic condition, the following formula will be found very reliable; certainly so, if some other existing lesion be not too antagonistic:

R.—Potassii iodidi,  $\mathfrak{z}$ ss;  
Extracti belladonnæ, gr. vj;  
Vini colchici radicis,  $\mathfrak{z}$ ss;  
Tincturæ guaiaci ammoniatæ,  $\mathfrak{z}$ vj;  
Aquæ cinnamomi,  $\mathfrak{z}$ vj. M.

Sig.—A tablespoonful to be taken in a wineglass of water three times a day; if it purge, five drops of laudanum is to be added to each dose.

Arsenic is frequently used with benefit. It may be exhibited in granules of the twentieth of a grain three times a day. It acts well in cutaneous neuralgia.



Donovan's solution—the liq. hydrarg. arsen. et iod.—is a favorite with many practitioners. Dose, five drops three times a day; avoiding salivation. This is an alterative, having a variety of significations.

In all cases associated with lassitude and anæmia, the following may be prescribed with benefit:

R.—Elixirii gentianæ ferratæ,  $\bar{z}$ vj.  
Sig.—Teaspoonful four times a day.

Or,

R.—Tincturæ ferri chloridi,  $\bar{z}$ j;  
Quiniæ sulphatis,  $\bar{z}$ j. M.  
Sig.—Fifteen to twenty drops three to four times a day, in water.

Or,

R.—Syrupi ferri pyrophosphatis,  $\bar{z}$ vj;  
Quiniæ sulphatis,  $\bar{z}$ j. M.  
Sig.—Teaspoonful four times daily.

Opium and ether, given in full doses before a paroxysm, with ten or fifteen grains of quinine administered after the pain has ceased, will commonly make an impression, and frequently abridge the next attack. Success is claimed for the exhibition of opium to the production of narcotism. Such treatment is only, however, commendable as an occasional expedient.

Muriate of ammonia, in doses of half a drachm three or four times a day, has been given with advantage; a soothing effect is produced by placing a lump of the salt on a burning coal, thus impregnating the atmosphere of a room.

Oil of turpentine is frequently applauded by English practitioners. It is to be given in doses of from one-half to a full drachm.

Chloroform, or chloroform combined with camphor, is recommended. A formula used by Dr. George B. Wood is as follows:

R.—Chloroformi, f $\bar{z}$ ij;  
Camphoræ,  $\bar{z}$ j.

Mix with the yolk of an egg and  $\bar{z}$ vj of water, and direct a tablespoonful to be taken every half-hour, every hour, or every two hours, according to the urgency of the case, until relief is obtained, or some decided effects are experienced from the medicines, either on the stomach or brain. Chloral hydrate, in ten-grain doses, may replace this, commonly happily in the case of the plethoric.

Vermifuge medicines are frequently prescribed with benefit, particularly in the case of children, parasites frequently keeping up an irritation, although presenting no definite signs. Of these medicines, one of the very best is the combination of spigelia and senna:

R.—Syrupi spigeliæ et sennæ,  $\bar{z}$ iv.

Sig.—Teaspoonful doses three times a day. Four ounces will commonly be found enough to destroy any worms which may be present in the intestines, or to show error in diagnosis.

Cathartics are generally indicated in spasmodic attacks of neuralgia; especially is this the case when there is costiveness, furred tongue, sick headache



or stomach, giddiness, etc. It is generally satisfactory practice to precede the purgation with a few quarter-grain doses of calomel. The character of the purgative is to be influenced by the condition of the patient. Sulphate of magnesia is generally found applicable. The compound cathartic pill is mostly found objectionable. The ordinary Seidlitz powder, repeated three or four times within the day, is a very happy and really refreshing medicine. If it should do no good, it certainly does no harm.

Strychnine is an empirical anti-neuralgic medicine of much reputation. It may be prescribed in quantities of two grains, divided into eighty pills, one to be taken three times a day.

Of local remedies there is a great variety. A formula long celebrated under the name of Rauque's liniment, is as follows:

R.—Extracti belladonnæ, ℥ij;  
 Ætheris, ℥j;  
 Aquæ lauro-cerasi, ℥ij. M.

Sig.—Let it be rubbed on the part and saturated flannel be applied.

The endermic application of morphia is a common practice. The medicine may be used on a blistered surface, or be injected subcutaneously. To make the injection, it is only necessary to thrust the needle-point of the syringe into the rete mucosum, or it may be passed completely beneath the skin into the underlying cellular structure.

Hot and moist applications are generally found of much service in quieting pain,—the part to be enveloped in old and loose flannel, and evaporation prevented by an investment with oiled silk or other material.

In affections of the fifth pair, Dr. Richab, of Strasburg, attributes great good to one grain of quinine and two of common snuff, introduced into the nostril of the painful side. It is said in many cases "to act like a charm."

Prof. Charles Meigs introduced, several years back, a plan of treatment with sulphuric ether, which yields at times great temporary relief. He confused the nerve-currents by taking a piece of sponge saturated with ether, and, by a continuous but irregular round, touching, here and there, different neighboring surfaces, until the pain would disappear. If, for example, it was in the forehead, he would touch over the supra-orbital nerve, over the infra-orbital, over the anterior dental, over the facial, over the cervical,—alternating the touches to these parts for a period varying from five minutes to half an hour. In most cases the pain is, for the time, relieved.

Creasote, much diluted in simple cerate, is sometimes found very useful as a local obtunder,—five drops of creasote to an ounce of cerate or lard; to be rubbed over the affected part, little by little, until relief is obtained.

Dr. Kirby directs a liniment made of one drachm of tincture of aconite to seven of fresh palm-oil, or with two ounces of camphor liniment,—a half-drachm of the former, or double the quantity of the latter, to be rubbed in twice or thrice a day, according to its effects. It must be watched, however,



as the medicine is cumulative; if its poisonous effects appear, stimulants are to be given.

Dr. Grave's neuralgic plaster is compounded as follows:

R.—Pulveris opii, ℥ij;  
 Camphoræ, ℥ss;  
 Picis Burgundicæ, q. s. M.  
 Stupe the parts with warm water before applying it.

Cazenave's pomade is thus made:

R.—Chloroformi, ℥j;  
 Potassii cyanidi, ℥ijss;  
 Adipis, ℥iij;  
 Cerae albæ, q. s.

Rub into the part a piece of the ointment the size of a pigeon's egg, and cover with oil-skin.

Hydrate of choral in the proportion of ℥ss to ℥viii of water furnishes an admirable local obtunder.

A writer in *The American Practitioner* recommends dropping into the meatus auditorius from four to ten drops of the following mixture, remarking it to be "very rare, with the use of this liquid, that relief is not obtained in a few minutes, and the patient asleep in half an hour, whatever may have been the severity of the pains."

R.—Extracti opii,  
 Extracti belladonnæ,  
 Extracti stramonii, āā pars j;  
 Aquæ pruni Virginiani, partes xij.

If it should happen, says this writer, that at the end of eight or ten minutes the pain does not yield to the remedy (which sometimes happens when the quantity used has been too small, or when we have to treat a neuralgia which has already required the use of narcotics in any way), it is necessary to use a second dose, at least equal to the first.

Alluding to the extemporaneous character of the preparation, it is suggested that it may be preserved, if care be taken to keep it cool, by pouring on its surface from two to four drops of sweet almond oil.

Among the recipes found in Dr. Napheys's "Modern Therapeutics," which have been selected from the prescriptions of eminent practitioners, are the following, which may not be without service to many readers:

Wm. Aitken, M.D., Edinburgh:

When the neuralgia is superficial, compresses steeped in the following solution:

R.—Atropiæ sulphatis, gr. v;  
 Aquæ destillatæ, f℥iij.

Renew the compresses several times in twenty-four hours, continue them for at least an hour each time, covering them with oil-skin to prevent evaporation.



## Brown-Séquard :

R.—Extracti belladonnæ, gr.  $\frac{1}{2}$ ;  
 Extracti stramonii, gr.  $\frac{1}{2}$ ;  
 Extracti cannabis Indicæ, gr.  $\frac{1}{2}$ ;  
 Extracti aconiti, gr.  $\frac{1}{2}$ ;  
 Extracti hyoscyami, gr.  $\frac{3}{4}$ ;  
 Extracti conii, gr. j;  
 Pulveris glycyrrhizæ, q. s.

For one pill. To be used with care, and not over four a day.

## Dr. Da Costa :

R.—Aconitiæ, gr. ij;  
 Veratriæ, gr. xv;  
 Glycerinæ, f℥ij;  
 Cerati adipis, ℥vj. M.

To be rubbed over the painful part, care being taken to see that there is no abrasion of the skin.

## Dr. Wm. Hammond :

R.—Extracti belladonnæ, gr. v.  
 Divide into twenty pills. One three times a day.

## Liniment of Guy's Hospital :

R.—Liquoris plumbi subacetatis,  
 Tincturæ opii,  
 Mellis, āā ℥ij;  
 Confectionis rosæ, ℥j.  
 Fiat linimentum.

## London Hospital :

R.—Tincturæ aconiti,  
 Linimenti saponis, āā f℥j.  
 To be used as an anodyne liniment.

A liniment recommended by Dr. Napheys as an elegant sedative is as follows :

R.—Atropiæ sulphatis, gr. viij;  
 Morphiæ sulphatis, gr. xvj;  
 Aconitiæ, gr. ij;  
 Acidi sulphurici diluti, ℥v;  
 Alcoholis, f℥ss;  
 Olei olivæ, q. s. ad f℥iv. M.

Or, if a stimulant effect be also desired :

R.—Chloroformi, f℥ss;  
 Spiritus terebinthinæ, f℥j;  
 Camphoræ, ℥j;  
 Olei lavandulæ, ℥xx;  
 Olei olivæ, q. s. ad f℥vj. M.

The first four ingredients are to be mixed before adding the oil, and the liniment to be well shaken before being applied.



Dr. Felix von Niemeyer, University of Tübingen :

R.—Extracti hyoseyami,  
Zinci oxidi, āā ʒij. M.

Divide into eleven pills. Begin with one pill morning and evening, and increase to twenty or thirty of them daily. These, known as the Meglin pills, have a good reputation in Germany.

One of the most intractable of the neuralgiæ of the scalp ever met with in the practice of the author, yielded to compression of the facial arteries.

Methodical rubbing, massage, of a neuralgic seat is recommended by Dr. S. Weir Mitchell.

In a case, noted by that author, of contusion of the ulnar nerve subject to intense neuralgia, the nerve being hardened and enlarged, tender, and enduring no application of electricity, the pain was relieved by hypodermic injections; but after using many remedies, and at last the actual cautery over the nerve-trunk without altering its size or tenderness, slow and careful manipulation was tried to test if it could be enabled to bear pressure. After a course of gentle friction, lasting half an hour, the object was attained, three sittings enabling the parts to be rubbed and even kneaded quite roughly.

A case of neuralgia of seventeen weeks' standing, the seat of pain being the lumbar muscles, was instantly cured by the author on relieving the pregnant uterus found caught by the promontory of the sacrum. The patient, when met, was found propped on all sides by pillows, not having been able for the period named to touch a foot to the floor. Correction of the misplaced womb allowed her at once to go about as usual.



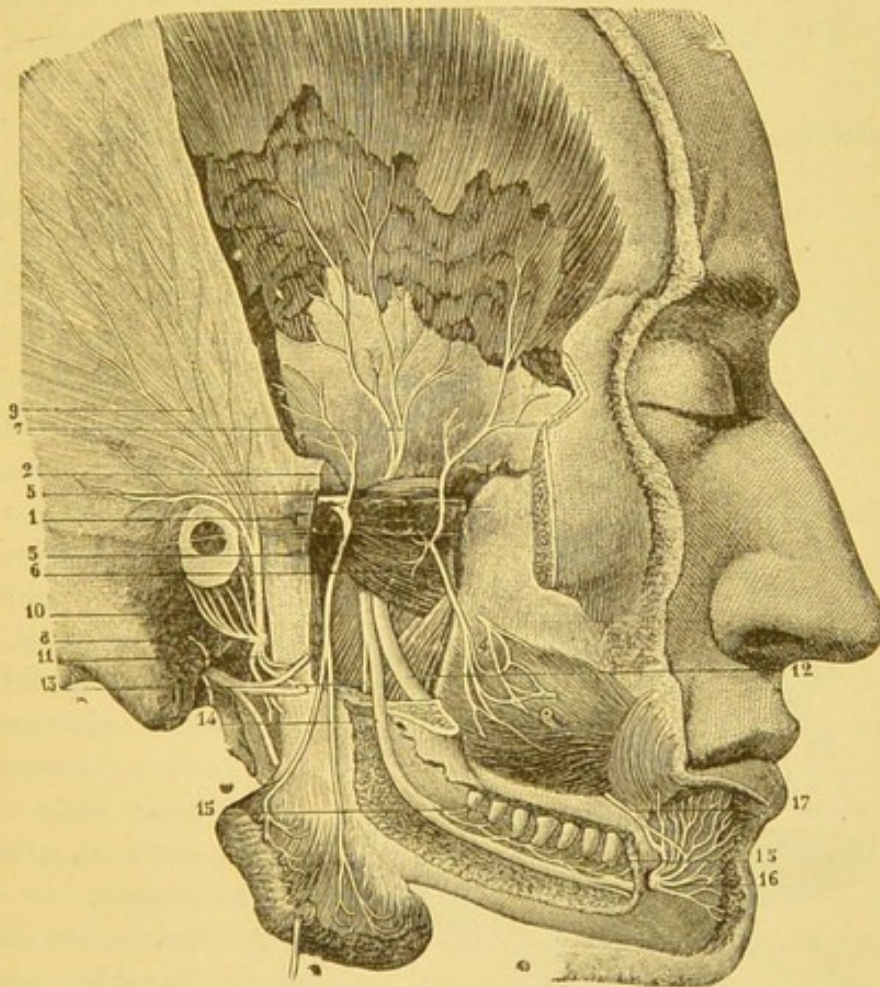
## CHAPTER LVIII.

### NERVE LESIONS PROPER AND THEIR TREATMENT BY SECTION.

NEURALGIA arising out of disease of a nerve incurable by medical means finds remedy in removal of the affected part; otherwise, by section made between the seat of lesion and sensorium. (See *Neuralgia*.)

**Inferior Maxillary Nerve.**—Fig. 541 shows the location of this nerve

FIG. 541.



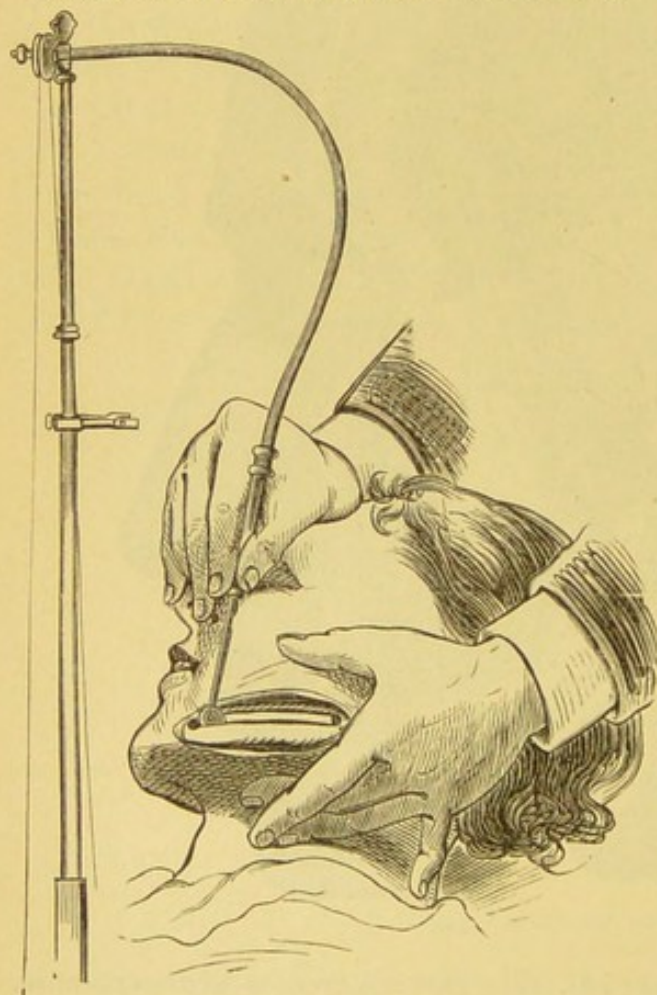
Refer for description to page 75.

as situated in the maxillary bone (14). The part removed, to secure exposure, is the external plate. The old ways of uncovering this nerve have been so surely succeeded, as the writer cannot help but feel, by an operation devised by himself and practised now on many occasions, that the single manner is presented.



Having a patient seated in a reclining chair with the body thrown back at an angle of about fifty degrees, the side of the face to be operated on being turned toward the light, the operator feels for the notch upon the jaw, over which runs the facial artery. The vessel found its position is marked by a line corresponding with its direction. Next a second line is made upon the neck parallel with the plane of the lower jaw and immediately beneath it. A succeeding step draws this line upward until it rests upon the body of the bone, when, the finger-nail guarding the artery, an incision, reaching to the bone, is cut as far forward as the position of the cuspid tooth. The wound thus made is separated by retractors, and search is made for the anterior, or mental, foramen. This hole exposed and the terminal position of the nerve thereby accurately ascertained, a succeeding step lifts the roof from the canal in which the nerve lies. This last manipulation is accomplished in one of two ways. Using a raspatory to scrape away the periosteum the operator

FIG. 542.—THE AUTHOR'S OPERATION FOR EXPOSURE OF INFERIOR MAXILLARY NERVE.



employs a circular-saw revolved by the engine, or, he may gain the same end with chisel and mallet.

Adopting the first means the saw is put in rapid motion, and two lines, corresponding to the width of the canal, are made, as shown in the cut, from the circular black opening in front, representing the foramen, as far back as it is desired to go. These lines are joined posteriorly by a trephine-cut. The roof of the canal, as will be understood, has thus been freed and it only remains to lift it away; the vessels and nerve lying freely exposed by the operation to the eye of the surgeon.

A modification of the above-described operation consists in employing a bur. The bone being denuded of its periosteum, and the foramen exposed, the canal is opened by burring away its roof. This latter performance is easier of accomplishment by the inexperienced than is the former; the exposure of the nerve can be made equally perfect.



The second manner employs a sharp chisel, the lines shown in the diagram being cut with that instrument propelled by blows from a mallet.

Exposure thus secured the cord is lifted and severed ; otherwise treated as indicated.

Where bleeding results from the cutting of the dental artery it is readily controlled by the use of a pledget of sponge thrust into the canal ; an attached string hanging from the wound to facilitate subsequent removal.

The immediate operation done a succeeding step rounds the two edges of bone, and, after well washing the parts with a view of getting away all *débris*, closes the external wound, which, when the stitching is complete, is found to be upon the neck and in a situation that shows no scar.

The author assumes that the diagram serves fully to familiarize the surgeon with the manipulations, and further that the operation is of a character to show and speak for itself.

SECTION OF INFERIOR MAXILLARY NERVE AT OVAL FORAMEN.—The author practises and highly commends the following manner of exposure : Open the nerve-canal in the inferior maxilla as just directed. Pick up the nerve on a tenaculum and cut it. Seize next with bull-dog forceps, and, preserving the continuity, follow the line of nerve and canal until the dental foramen is reached. Enlarge now the foramen, using bur and engine, and follow nerve to dental foramen. At that point in the operation where enlargement of the foramen has been secured any convenient instrument is taken up with a view of isolating the nerve from its surroundings ; a delicate knife-handle has been used by the writer. When the base of the skull is reached, and the nerve seen to stand clear, a pair of eye-scissors or the blade of a tenotome completes the section.

If not thought necessary to open the canal in front of the masseter muscle a line vertical with the posterior border of the ramus may be cut. Fig. 543, a drawing of much merit made for the author by Mr. Faber, allows the performance to be clearly understood. The isolation of the nerve, after the dental foramen is enlarged, is seen to carry the instrument of the operator between the external and internal pterygoid muscles. (See Fig. 541.)

The enlargement of the dental foramen does not interfere with either the health or the offices of the condyloid or coronoid processes, while it exposes the nerve quite as freely, as exhibited in the diagram, as when these bodies and as well a portion of the ramus have been removed.

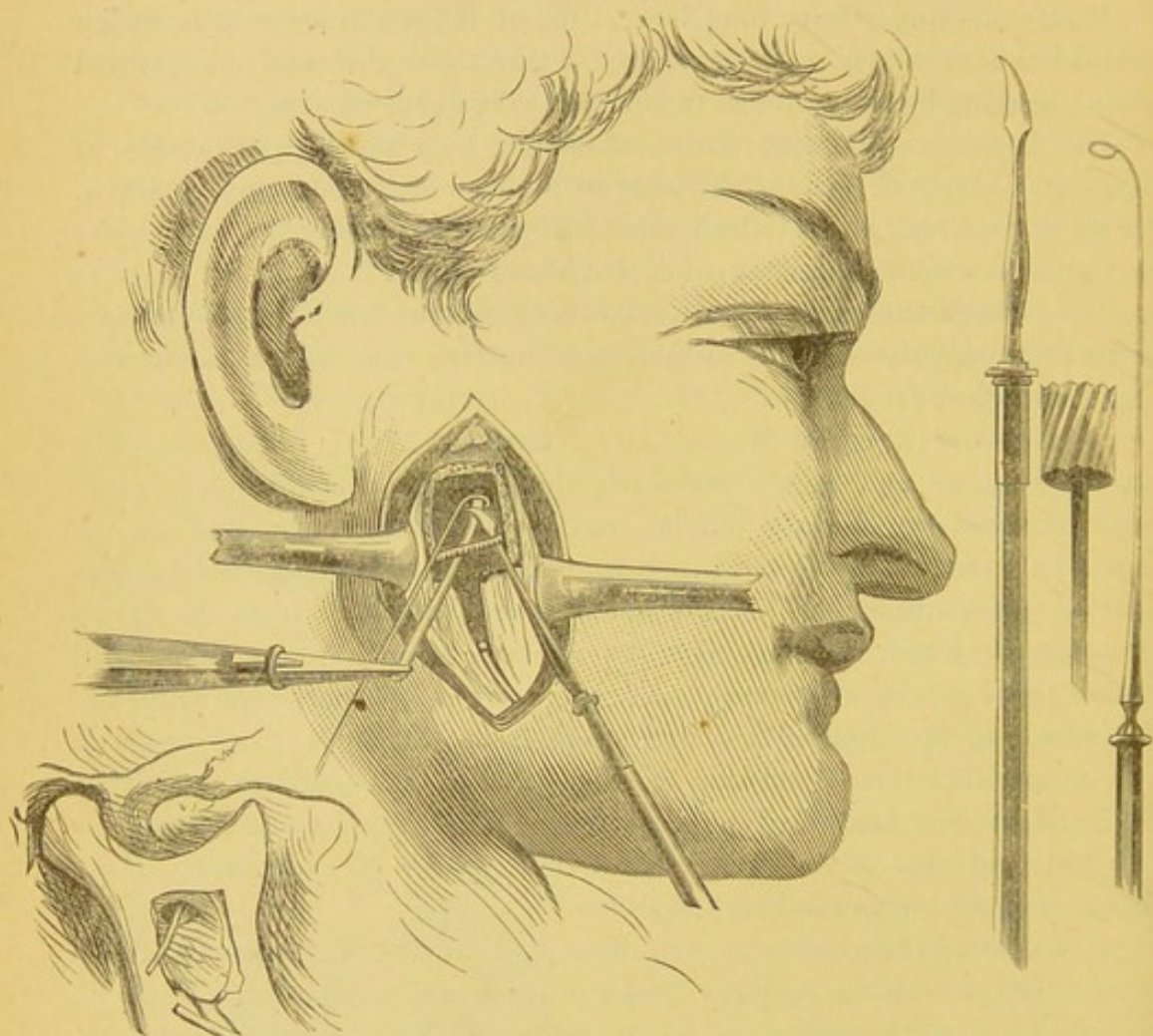
Referring to the diagram the anatomy as well as the operation are to be clearly appreciated. The opening in the bone shows the nerve up to the point of emergence from the oval foramen. Crossing it externally is the internal maxillary artery. Accompanying it is the dental vessel. Running parallel with it (see Fig. 541), is the lingual nerve. In the operation, as here shown, the nerve, after being cut, is passed through the fenestrated instrument exhibited, and by means of which it is isolated up to the base of the skull. The knife used to cut it is very small and of sickle shape. To



cut the lingual nerve implies simply the use of a hook with which to pick it out.

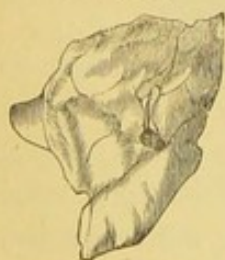Neuralgic pain persistently located in the lower lip, one side or the other

FIG. 543.



of the mesian line, is oftentimes successfully treated by section of the affected nerve at its exit from the mental foramen. The operation is accomplished by sinking a bistoury to the proper depth adjoining the second bicuspid tooth and shaving the bone as far forward as the cuspis.

FIG. 544.



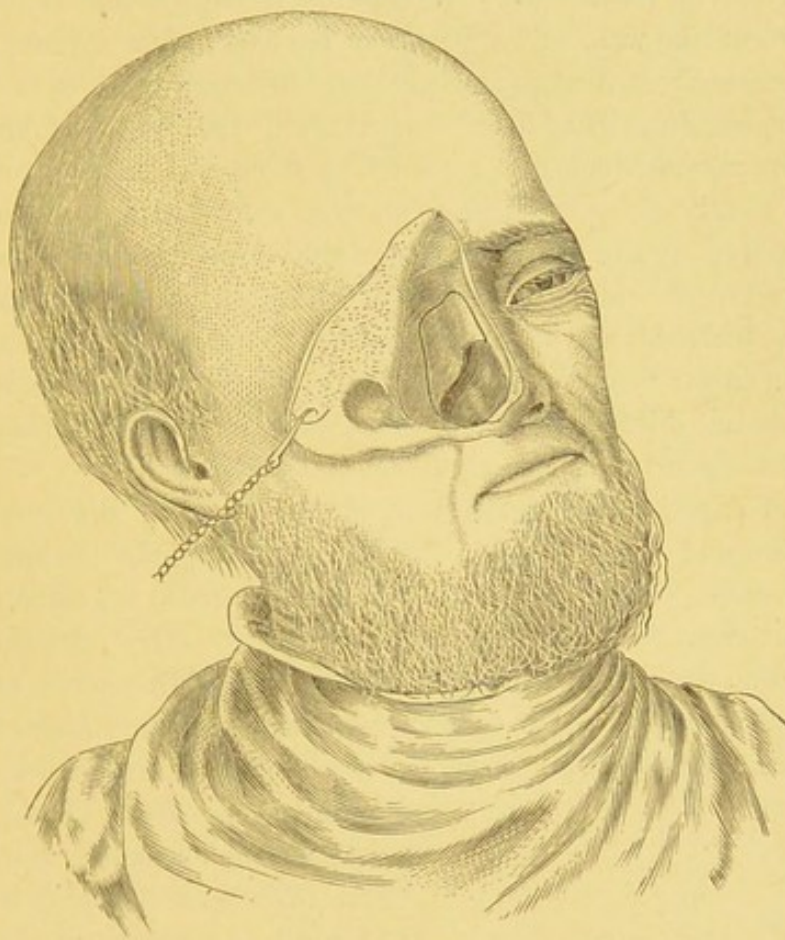
**Superior Maxillary Nerve.**—Section of the branches of the second portion of the nerve is made at various points as indicated by various conditions. Fig. 544 shows a neuroma diagnosed by the writer as existing upon the under surface of the nasal arch. In this case the neuralgia was of twenty years' standing. Fig. 545 exhibits the steps of an operation which exposed and removed the bone with which the tumor was related; the circular-saw and engine were used.

Neuralgia of parts supplied by branches external to the infra-orbital may find relief by section made at the foramen.



Parts innervated by branches coming from the canal demand section of the nerve within that channel. To expose the part the operator commences by dissecting a flap from the region of the antrum. The anterior wall of that cavity is next trephined. A succeeding step chisels away that portion of the orbital floor which makes the inferior boundary of the canal. The nerve, now laid bare, is to be excised. The section can be made from the inside of the mouth by trephining.

FIG. 545.



Nerve lesions existing in the maxillary sinus are exposed by dissecting the overlying parts within the mouth and trephining. Illustration 5 in the previous chapter is an example of a lesion so situated and treated.

Cases of neuralgia occur, where pain is so diffused over the track of the second division of the fifth nerve, and where the suffering of the patient is so intolerable, as absolutely to force the surgeon into operation even in the absence of a perfectly reliable diagnosis, and when it is felt that no section outside of the main branch may promise any good. In these instances, the results too frequently prove the worse than uselessness of what has been done; too often does continuous pain, transferred to some other part, show that the lesion is still back of the seat of operation. The author does not, however, condemn these operations: desperate evils call for desperate remedies. He would only enjoin that it be well understood that a desperate remedy is not to be unnecessarily employed, and that no man is to undertake the



section of the superior maxillary nerve until assured that he has mastered all that can be known of his case.

The exposure of the second branch of the fifth nerve was first practised in this country by Dr. Carnochan, of New York, and the plan originally adopted by that surgeon for the exposure is the same, with unimportant modifications, as is still employed.


Commencing this operation, a Y-shaped or simple curvilinear flap exposes the anterior wall of the antrum. A trephine, as large as may be used, is now made to cut out the wall. The posterior boundary thus exposed, a second trephine, necessarily somewhat smaller than the first, removes a section of this. The speno-maxillary fossa thus exposed, the nerve is found and isolated from its surroundings and as much of it excised as may conveniently be effected. If, in the opening made through the antrum, space enough has not been secured by the trephine, the operator finds himself compelled to remove, by means of chisels and cutting pliers, the lower boundary of the infra-orbital canal; this will be found to enlarge the working space considerably.

In seeking in the fossa for the nerve, too much delicacy cannot be exercised, as above all things is it desirable to have, if possible, a healing of the parts without degeneration or destruction of the tissues.

A mode of exposing the antral wall, affording greater convenience in the succeeding steps of the operation, consists in dividing the lip and cheek by an incision leading directly from the labial commissure to the malar bone: two flaps are thus created, one being directed inward, the other outward.

An operation devised by Langenbeck for section of this nerve, being, however, one that is scarcely likely to meet with much favor, consists in the use of a stout tenotome, which is thrust, with its point directed downward and

backward, immediately beneath the external palpebral ligament, being kept in close contact with the outer wall of the orbit until it reaches the speno-maxillary fissure, this being recognized in the cessation of resistance. The edge of the knife is now turned so as to shave the surface of the bone, the nerve being cut by a sawing motion as it enters the orbital canal. A cut opening the canal is now to be made through the floor of the orbit, and with a hook the nerve is to be caught and pulled from its bed.



The elder Pancoast's operation for exposure of the second and third branches of the trifacial is performed as follows: First, as exhibited in Fig. 546, a trap-like flap is made across the ramus of the lower jaw. This being raised and



reflected, the masseter muscle is shaved from its attachment, and the coronoid process exposed; this process is next sawed off at its root, and, having detached from it the temporal muscle, is removed; the muscles being thrust upward out of the way. This series of manipulations exposes the zygomatic fossa, across which, but overlaid with some fatty tissue, passes the internal maxillary artery, which a succeeding step picks out and ligates. The next use of the knife is found in detaching from the great ala of the sphenoid bone the external head of the pterygoid muscle; this accomplished, any soft parts found in the way are to be pushed aside with the finger, after which attention is to be given to stanching the hemorrhage and oozing.

The parts thus exposed and dried, the nerves of the spheno-maxillary fossa are plainly visible, and may be excised by using a pair of curved scissors.

An operation practised by the author for making section of the second branch of the fifth nerve immediately as it emerges from the foramen rotundum, being a manner superior to, and easier of accomplishment than any described, is as follows: Place the patient on a pallet and etherize. Next expose the anterior face of the antrum by a trap cut in the cheek, which trap is to open towards the eye, and is to hold the branchlets of the infra-orbital nerve, which nerve is dissected out, and held uncut out of the way. Hemorrhage being controlled by ligatures, styptics, or other means, the face of the antrum is cut away by use of bur (Fig. 547) revolved by the surgical engine. Following this, the infra-orbital nerve is caught and held in the grasp of bull-dog forceps. With the nerve thus secured for a guide, the floor of the infra-orbital canal is cut away, and the guide followed to and along the floor of the orbit. The posterior wall of the antrum reached, the bur is passed backward through it; the nerve still being preserved intact. A succeeding step removes, by means of the bur, such extent of posterior wall as to allow isolation of the superior maxillary nerve, thus exposed, to a diameter that permits the passage of a tenotome beyond Meckel's ganglion, when the section is made and the nerve withdrawn. In performance of this operation, great care is required to avoid cutting the nerve prematurely by the rapidly revolving bur. The figure shows the stage of operation when the bur has reached and perforated the posterior boundary of antrum, and where a fenestrated instrument encircles the nerve and has been pushed along it until stopped by the base of the skull.

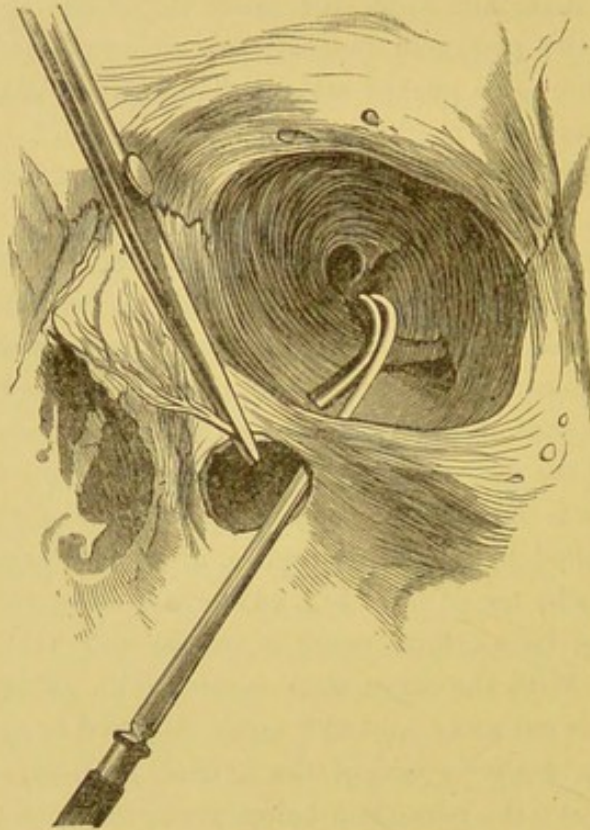
If, turning from this cut, the student will take up a skull, he will find that the spheno-maxillary fissure, seen by the side of the optic foramen at the apex of the orbit, leads directly into the spheno-maxillary fossa, and that by means of a fenestrated hook he could isolate a nerve from its associations and that he could reach the base of the cranium.

Referring to the author's operation for exposing the zygomatic fossa and its nerves, it is seen that the same exposure can be followed to the spheno-maxillary. It implies simply detachment of external head of pterygoid muscle. (See Fig. 541.)



A nerve-section is to possess the feature of a cut absolutely clean. Section made after any manner, or by means of a form of instrumentation, that gives a fringed or frayed expression is apt to be associated with bad results. An experiment, original with, and performed each session before the class of

FIG. 547.



Author's operation for exsection of superior maxillary nerve at base of skull, using engine and bur.

the Oral Hospital by Dr. M. H. Cryer, seems worthy of close consideration. Two insulated wires, extending the length of one of the lecture-rooms, are related with a bell and a battery. Making a clean cut of one or both of these wires lengthwise, contact elicits no response by the bell. Scraping the wires, so as to interfere with the insulation, touch results in vigorous ringing, continued so long as contact and non-insulation exist. Relating the experiment with nerve fasciculi deprived by accident of the insulating neurilemma, inference is drawn that cause of pain exists, under all circumstances, in absence of insulation, and that it is to be recovered from only when nature or the physician cures such a defect. It is argued that in inflammation neurilemma is destroyed, allowing contact of immediately related fasciculi, hence continued worrying of the sensorium, as a principle, if not similar with, yet analogous to continued ringing of the bell. As corroborative of the experiment, a case lately offered in the clinic of the hospital service where a median nerve, much frayed, and imprisoned in a cicatrix, afflicting the patient with



persistent pain, cure of complete character resulted from dissecting out and sharply incising the cord some little distance from the frayed end. Accepting contact as an explanation of pain, interest in the subject invites to consideration in every individual case as to probabilities and possibilities in this direction.

For exposure of other nerves of the region under consideration, see succeeding chapter.



## CHAPTER LIX.

### NERVE LESIONS PROPER AND THEIR TREATMENT BY STRETCHING.

STUDY of the preceding two chapters has prepared the reader to pass to a consideration of the present one.

Nerve-stretching was introduced as a surgical performance some twelve years back by Nussbaum, and, by reason of an occasional success found in the practice, has established for itself a position which attracts a certain amount of attention.

By nerve-stretching is meant the exposure of a painful nerve, the lifting of it from its bed, and the pulling of it.

Nerve-stretching, when practised, is to find signification wholly in diagnosis. To do the operation simply on the data of statistics is to engage in an unjustifiable procedure. The scientific meaning of the performance lies in breaking up areas of obstruction existing somewhere along the line of a nerve-cord, and not in the fallacy that a transmitting capacity is lessened, or that new impressions are made on the centre of origin. As illustrative, reference is to be made to an example of lesion of anterior tibial nerve referred to on page 864.

It happened in this case that an absolute cure of several years' standing was but comparatively lately replaced by a recurrence of the old pain, and, on application of the patient, arrangements had been about completed for repetition of the exsection. Apart from sympathy for the sufferer, much interest was excited in the mind of the writer, as he regarded the condition as identical with inflammatory obstruction, and one where stretching—*i.e.*, breaking up adhesions—was the indication, a conclusion which he expected the operation fully to indorse.

A few days before the one set apart for the meeting the patient, while descending some stairs leading from a chamber, caught his toes in an irregularity of the carpet, which accident compelled his foot to extreme extension, throwing the man forward on his face. A draggy snap is reported as being both heard and felt. There has not been a twinge of pain felt since.

Nerve-stretching, to be effective, must associate with extra- and not with intra-lesions. Where a distinction is recognizable, good will be found to attend operations practised in relation with the first, evil when in connection with the latter. The author is compelled to recognize out of his experience that a great many cases of neuralgia indicate a requirement for nerve-stretching. Unfortunately, in a majority of the cases, the reading of the indication



is very difficult. The writer has to admit mistakes or failures, as it may be thought well to distinguish them, which furnish him with sufficient reasons to recognize his lack of personal judgment in the direction. No diagnoses are more difficult, as a rule, to make out than these that relate with neuralgia.

Exposure of the main branch of a plastic-caught nerve, and the stretching of this, is not at all the indication. Recognition of the seat of lesion is to go before operation, and the exposure of a nerve is to be not farther away from the obstruction than permits the lesion being acted on by the force exerted; this applies particularly to nerves running at obtuse and at right-angled relations.

Nerves, like arteries, are exposed according to directions furnished by the anatomy of a part.

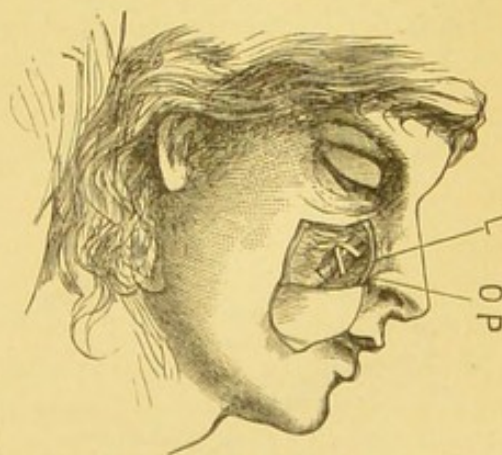
**Infra-orbital Nerve.**—The infra-orbital is the main continuation of the superior maxillary division of the trifacial nerve; its entrance upon the face is from the infra-orbital canal; the direction of change at the foramen is at a right angle; seat of lesion exists not infrequently at the orifice of the canal, being resultant of blows received upon the face.

Referring to Fig. 34 as a study, the student will recognize the nerve as breaking up, immediately on exit from the foramen, into three sets of radicles, which supply respectively the palpebral, nasal, and labial localities, consequently pain met with in these regions is plausibly referred to as related with the sensorium by the cord found at the foramen, and an inference is most likely to be indulged that exposure at such point affords command of the lesion. Here it is necessary to look beyond and consider that in the infra-orbital canal a branch is given off which supplies the anterior teeth, and that farther back is a second innervating the bicuspidati and molars,—situations much more likely to afford lesions than either of the first named. (Turn also to Figs. 26 and 36.)

To expose the infra-orbital nerve at its exit from the facial foramen, it is the practice of the author to feel for the depression, using the pulp of the little finger, and, when found, dissecting carefully to it by means of a single incision carried in the direction of the lip. The body exposed, a tenaculum is passed beneath it and the stretching accomplished, or it may be excised, as preferred.

A means of exposing the infra-orbital nerve, suggested by Professor Agnew, is shown in Fig. 548. Although the author disagrees with his valued and learned friend as to necessity for more than a single cut where

FIG. 548.



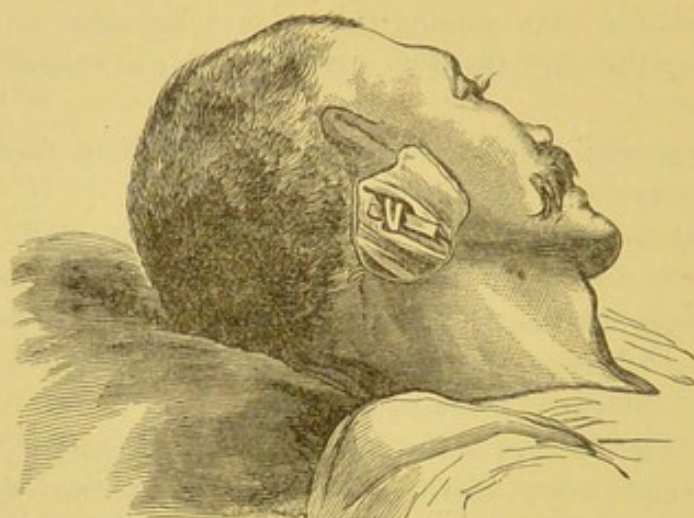Exposure of infra-orbital nerve.



the object is simply stretching, he yet regards the experience sufficiently to know that his readers will find profit in study of the diagram.

**Inferior Maxillary Nerve.**—This nerve, which is distributed to the muscular and cutaneous portions of the lower lip, emerges from the dental canal of the inferior maxilla at the mental foramen. (See for study Fig. 37.) To reach it within the canal an operation is practised as shown in

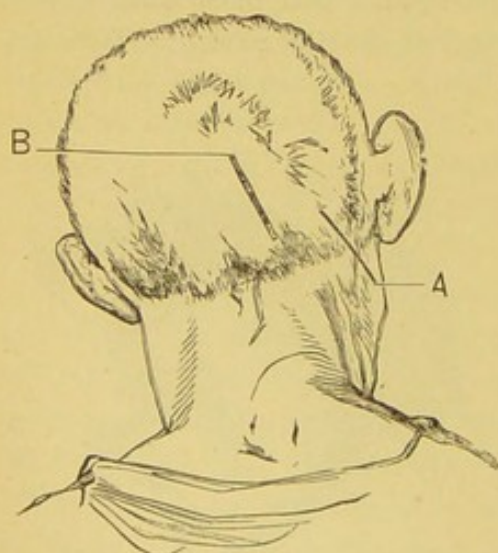
FIG. 549.



Auricularis magnus nerve exposed.

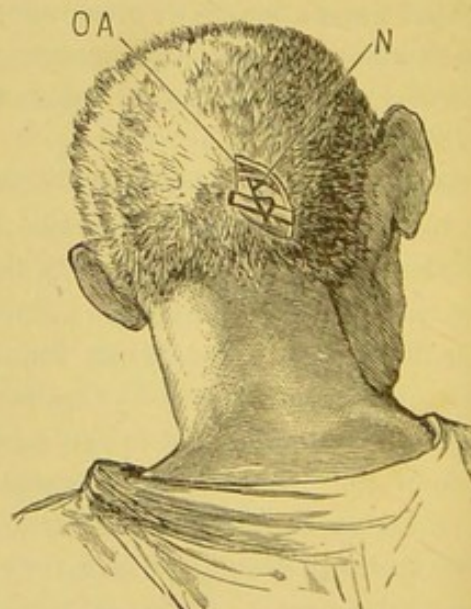
Fig. 549. To expose it superficially an incision is to be made, beginning at a point opposite the inferior second bicuspid tooth and continued forward to

FIG. 550.



Line of incision for exposing auricular and occipital nerves.

FIG. 551.



Exposure of occipital nerve and artery.

the cuspidatus; the situation is to correspond with the apices of the tooth-roots. A second manner of exposure excises the alveoli-labial floor, and finds



the nerve by aid of tenaculum and knife; difficulty lies in interference by the free hemorrhage.

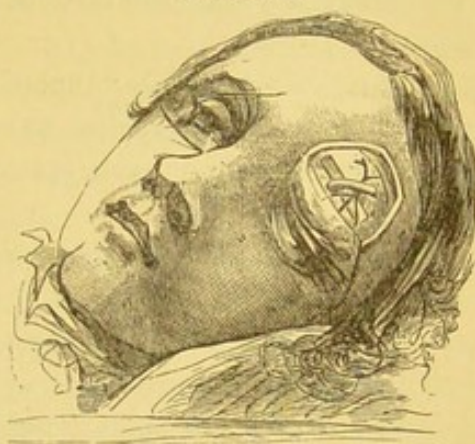**Auricularis Magnus Nerve.**—Fig. 550 exhibits an exposure of the part. This nerve, a branch of the superficial cervical plexus, which supplies the auricle and the parts about the mastoid process, is found least covered at a point about half an inch posterior to the lowest point of the lobe of the ear. (See for study Fig. 26, 2, 3, 29, 31.) The cut shows a manner of exposure; a single curvilinear incision corresponding with the line of the lobe as it ascends to join the tragus. (See Fig. 550, A.)

**Great Occipital Nerve.**—Taking advantage of still another cut furnished by the publishers, location and exposure of occipital nerve and artery are shown: Fig. 551. N, nerve; OA, artery. The occipital is a branch of the cervical; it supplies the integument of the scalp as far forward as the vertex.

**Lingual Nerve.**—See Vanzetti's operation, page 569, also see page 874.

**Supra-orbital Nerve.**—The supra-orbital is the continuation of the ophthalmic division of the fifth nerve; its branchlets supply the upper eyelid, the orbicularis palpebrarum, occipito-frontalis, and corrugator supercilii muscles, also the periosteum of frontal and parietal bones; neuralgic phenomena are frequent associations with it; diagnosis is apt to be very confused. The situation of this nerve upon the forehead is at the supra-orbital notch. It lies, as its trunk is concerned, upon the periosteum, being covered by skin, fascia, fibres of occipito-frontalis and corrugator supercilii muscles. Exposure is effected by means of an oblique incision. Direction of cut, and anatomy of relation, are shown in Fig. 552.

FIG. 552.



Exposure of supra-orbital nerve.



## CHAPTER LX.

### THE CLASSIFICATION OF TUMORS.

IN the following pages the author proposes, after proper reflection, and after a thorough study of the views and observations of the latest writers, German, English, and American, to present to his readers the subject of tumors, precisely as in his own clinical service he meets with, classifies, and treats the lesions. He assumes, to a certain extent, a disregard of the arrangement of others, because one here adopted seems most rationally to introduce and evolve the subject. The classification opens, it is believed, the study to the ordinary practitioner with a clearness and simplicity which permits of easy and of full clinical understanding, while at the same time it is not seen to limit in any way the examinations and inquiries of the most inquisitive histologist.

The surgical expression "tumor" is a term having origin in the Latin verb *tumeo*, to "swell;" it applies necessarily to any unnatural enlargement of a part, no matter where such enlargement is met with or from what cause it arises.

A tumor is a swelling which varies in signification from that which has a meaning in some accidental and, it may be, evanescent functional derangement—as, for example, a foot œdematous from exhausting exercise, an abdomen swollen from accumulated flatus, a duct expanded from obstruction of its outlet—to that character of an outgrowth which is without explanation in itself or in any immediate physiological or anatomical perversion—a something which, by exclusion, is to be classified as an expression of a mediate, or systemic, antecedent.

(A study of tumors to be exhaustive is to be pursued from a twofold standpoint,—clinical and histological. The first has to do with that classification of the conditions which directs the practice demanded. The second analyzes under the microscope the histogeny of a growth, and describes the expressions of its minute anatomy.)

Clinically, experience fairly demonstrates that a rational primary distinction of tumors is found by separating them into two classes. One class embraces every lesion that possesses a local self-explanation, as, for example, a sebaceous tumor, a ranula, a hernia, a hydrocele. The other comprises all that remainder, the explanation of which lies outside of local conditions; examples in this latter direction being recognized in the nodes of syphilis, the degenerating glandular enlargements of tuberculosis, the multitudinous expressions of cancer.



All tumors of the first class are, *in themselves*, of a necessity, benign. All tumors of the second class are to be viewed, not in themselves, but in a dyscrasia of which they are simply phenomena.

Tumors of the first class, having only a local signification, demand only a local treatment; tumors of the second class, having, save in the accident of the habitat, no local signification, but being of constitutional meaning, receive scientific treatment only through remedy directed to the vice in which they exist.

Tumors of the first class are to be termed homologous, indicating by the term, not likeness to associated tissue as exhibited by some of the neoplasia, but that a tumor is wholly part and parcel of a location in which it exists.

Tumors of the second class are to be distinguished as heterologous, the expression indicating neoplasia, no matter what the likeness; a something which is more or less foreign to the *part in which it is found*.

**Clinical Illustration in Diagnosis.**—A patient having a tumor in his groin presents himself to a surgeon. What is the nature of the tumor? It may be a hernia; an undescended testicle; a hydrocele of the spermatic cord; an inflamed lymphatic gland. It may have the constitutional meaning of a syphilitic or of a tuberculous bubo. It may be an expression of cancer. To satisfy himself as to the nature of the particular condition represented, the practitioner can only proceed as follows. First, he must recall the anatomy of the part. In the groin of the human male is a canal,—the inguinal. This canal is entered by a ring from the abdominal cavity, and has an outlet through a second existing in the aponeurosis of the external oblique muscle. In this canal lie, enveloped in a sheath, the spermatic vessels. This canal constitutes the passage transmitting the testicle from the abdomen to the scrotum; the entrance to it may permit of the insinuation of a knuckle of omentum or of intestine. In this inguinal region exist a number of lymphatic glands. This, then, is the anatomy, and these are the data. Is the tumor a hernia? There is no impulse on cough; no doughy feel; no diminution in size when the patient lies down; no ability to thrust the tumor into the abdomen; no enlargement of either inguinal ring. The tumor is not a hernia. Is it an undescended testicle? The testicle is to be felt in its place in the scrotum. The tumor is not an undescended testicle. Is it hydrocele of the spermatic cord? There is no fluctuation on percussion; no ability to change the position; no fluid as test is made with an exploring-needle or aspirator. It is not hydrocele. Is it an inflamed gland of a local inflammatory signification? There is absence of history. The tumor, then, is not of immediate signification; this, it would seem, the explorer must know to a certainty. By exclusion, then, such tumor is exhibited as belonging to the second class. The question remaining is as to the vice represented. Of these vices there are three, syphilis, tuberculosis, cancer. The former two have histories. The last is an arcanum. If the knowledge of the surgeon enables him to exclude the first two his diagnosis is made,—the tumor before him is cancer.



EXAMPLE.—At a late hospital clinic there appeared before the class of the author five patients. These patients, suffering alike from swollen, enlarged cheeks, were ranged side by side for diagnosis. Patient 1 was found to have the tumefaction dependent on a periodontitis; patient 2 was laboring under caries of the jaw, originating from a dead tooth-root; patient 3 suffered from necrosis, the result of injury; patient 4 had a lymph effusion consequent on a fracture; patient 5, with very limited swelling of the cheek, associated with enlargement of the maxilla, presented in his case no local nor common systemic explanation; out of exclusion the lesion, in the last case, pronounced itself cancer. The first four patients, their lesions being self-explaining, were quickly made well; the last—whose case was without an accounting explanation—died, and died from that condition which, in its developed state, was by all called carcinoma.

With the premises of the preceding pages, for the purposes of the chapter, assumed, it is to be understood that any tumor, wherever situated, being without a history which explains it, is to be called and treated as cancer. But here at once may seem to rise insurmountable objections to such classification. It might be urged, for example, that a fibroma which does not destroy life has no more explanation of its origin than has an encephaloma, which in a single year runs to a fatal end. Such objection, however, influences only the histologist; the clinician recognizes no practical difference between the conditions: they are, he assumes, expressions of a common vice. But the one kills, the other does not. If this be urged, the objection will be admitted; but it has an explanation which is easily made evident. There is, we say, but one non-self-explaining vice; this vice puts on various phases. These phases are influenced by the malignancy of the crisis, or by relation with the conditions of the individual into whose system the malady has found ingress. This we may illustrate by an example. Four men go from a healthy to a malarious district; all live in the same house, and all impregnate their systems with the same poison. In a week one succumbs to a quotidian; in two weeks the second has a tertian; in three weeks the third dies from a congestive chill; while the fourth, preserved by an inherent resistive force, antagonizes the miasma entirely. Thus also in the cancer vice: one man, either from the concentration of the virus, or from the absence of antagonizing power, dies quickly from a medullary expression; while another maintains a tumor for years, in the expression of simple sarcoma, succumbing finally in the battle by reason of some accident out of which force becomes diminished, affording thus mastery to the abeyant vice; the sarcoma quickly degrading into that which the microscope distinguishes from it as encephaloma.

The premise, then, is assumed, that any and every tumor which cannot be proved benign is to be deemed malignant. A self-explaining tumor expresses its nature and indicates its name; a non-explaining tumor demands from us no special regard for the distinctions of nomenclature, except as in an adjectival way the distinctions classify, for convenience in description, what



are to be regarded as varying expressions of a common disease. (See *Fibroma*.)

Urging the conviction that in the preceding few and very simple rules lie the fulness of a proper clinical distinction of tumors, applicable to any and all cases, the student may now, without the chance of becoming confused, proceed to acquaint himself with the growths pertaining to the parts which it is the special object of this volume to study. Before doing this, however, a comprehensive discussion of distinctions at large is to engage his attention.\*

1. **Relationship.**—Homologous tumors tend, as would be inferred, to preserve isolation and individuality; a malignant growth, on the contrary, representing simply the nidus of a vice, is seen to tend to infiltration and to a commingling with adjacent tissues.

2. Homologous tumors progress regularly, are apt to remain stationary after attaining some certain size, as in an odontocoele; or they may degenerate and slough, as seen frequently in the sebaceous growths. In structure, homologous tumors are akin with the parts in which they are found; they do not possess other than a single formative capacity. Treatment of them is purely local. The tumors of a vice, on the contrary, have, as a rule, the evidences of their systemic character associated with them. They are not amenable to a local treatment: if one be removed, a second comes to take its place, appearing either in the site of removal or in some other locality.† The cure of a vice tumor resides either in the use of a specific, antidoting the poison of the vice, or in affording such increase of the natural resisting force that the destructive tendency is retarded or overcome.

3. Homologous tumors are commonly single, or, if multiple,—for example, sebaceous cysts,—are confined to a common tissue and a common association. The vice tumors exhibit their constitutional relation in the tendency to reproduction, not only in various parts, but in different tissues.

4. Homologous tumors, if painful, express common pain. Vice tumors have a character of suffering peculiar to themselves.

1. **SIMPLE INFLAMMATORY TUMORS.**—A simple inflammatory tumor refers to a swelling (which is of varying nature), associated with an inflamma-

---

\* But it is to be asked whether or not, outside of the negation of the self-explaining tumors, there is not a something that may distinguish cancer? If there be, the author knows nothing about it. The negation has, however, a wide meaning. According as a man knows of a certainty what is not cancer, his inference as to the existence of that condition becomes reliable and valuable: he calls that cancer which he proves to be nothing else.

But is there not some special histological expression which characterizes cancer,—some peculiar heteroclitic cell? Once it was thought so; but now it is known that certain caudate cells, deemed a few years back entirely diagnostic, are also found in foetal connective tissue. Heteroclitic cells afford information to diagnosis from location and combinations alone. The histological aspects assumed by a cancerous tumor originate out of relation. No special cell exists.

† This is attempted to be explained by Virchow on the principle influencing syphilitic absorption, or rather, to express him more critically, by embolism.



tion: thus, it may depend on simple excess of blood in a part, or on effusion of serum or of lymph.

Vascular excitement, of a grade which brings a perverted circulation under cognizance as inflammation, never increases the dimensions of a part through excess of nutritive or formative action; on the contrary, the nutrition of an inflamed part is always diminished, this being amply demonstrated by the disorganization of suppuration. Even, however, in cases where resolution occurs, the tissues are always left relaxed and degenerate, and in themselves are, without doubt, of less consistence by weight or bulk than before the attack.

It is, as well understood, a characteristic of vessels involved in inflammatory action to relieve their distention through effusion, and thus, as such effused material may be serum, fibro-serum, blood, or lymph, tumefaction is produced, which tumefaction is persistent or otherwise according to character and associations.

Concerning the first,—the simple, unmixed watery effusions,—they are found most frequently associated with lower degrees of inflammation, as in certain articular affections, in encephalocoele, hydrocele, etc. In such effusions there can be no tendency either to coagulation or to organization: a tumor is formed, but it is simply a water-bag. Fibro-serum, or serum containing fibrin, has in it an organizing force proportioned to the quantity of fibrin contained, approaching to this extent the nature and character of lymph. Such fibro-serum is seen, on withdrawal from the body, to differ from serum proper in the ability it possesses to assume a jelly-like consistence, and to show the fibre-cell, as exhibited in peritoneal and pleural effusions. Fortunately, however, while excluded from the air, fibro-serum seldom manifests any tendency to coagulate, thus remaining as susceptible to the action of the absorbents as the more simple effusion.\*

Lymph, another of the exudates of an engorged vessel, finds its most practical expression when viewed as the agent of nutrition; it is that pabulum in which reside the elements of life, and is in a state of constant relation with every part of the organism. Only as the result of over-pressure or engorgement, however, is it likely to be found in excess in any one part; but when so found it compels a tumefaction, measured by the undue amount present.

Between lymph and the vitalizing principle—the *vis vitæ*—there exists a marked affinity, so that circumstances must be adverse indeed where exuded lymph does not tend to organization. Corpuscular lymph, as a kind is sometimes termed, is a physiological misnomer,—difference lies in perversion, not in character: thus, while lymph exuded by a vigorous system tends always to immediate organization, exuded in a specifically diseased person, or

---

\* Fibro-serum is the liquor-sanguinis of Babington, the plasma of Schultz, the mucago, or mucilage, of Harvey.



in one deficient in the vital element, the recognition of cause for degeneration is sufficient explanation of the variety considered. Corpuscular lymph is protoplasm the grade of organization of which fails to rise to a proper development. A common admixture of the two varieties is evidence enough of oneness.

Lymph tumors have associated with them a threefold sequelæ: the contents are absorbed; or they organize; or they degenerate and are gotten clear of in suppuration: or the three conditions may coexist, part of the lymph being absorbed, part being thrown off, and a portion affiliating itself with the surrounding parts.

2. **HYPERTROPHIC TUMORS.**—Hypertrophy is an expression of unbalanced nutrition,—a part developing in excess of its fellow-parts. Hypertrophic tumors differ from all others by conformity with regions with which they are associated. So marked and characteristic is this that it is only through comparison with neighboring parts that such enlargement is to be measured. Hypertrophy may ensue from the opposite conditions of excessive supply or of diminished waste. The enlarged biceps muscle of a blacksmith, and the gastrocnemii of the ballet-dancer, are illustrations of hypertrophy from super-nutrition. Enlarged glands from tuberculosis are not unjustly to be instanced as illustrations of the second condition.\*

3. **TUMORS WHICH RESULT FROM INTERFERENCE WITH FUNCTION.**—The appreciation of this class of tumors, of which there are a great number, is commonly without confusion or difficulty. It is, of course, required that the observer draw his inferences from the data of anatomical and physiological knowledge. The deficient spinal canal gives the protruding meninges,—the fluid of the subarachnoidean space filling the fluctuating cyst. Obstructed sebaceous ducts yield wens. Relaxed veins afford varices. Occlusion of the antral foramen compels engorgement of that cavity. An umbilicus, unclosed, or its boundaries attenuated, hernia follows. A tooth out of the dental arch, yet developing within the structure of the bone, odontocoele exists. So of all this class of tumors, similar simple and single signification is found.

**Histological Distinctions.**—A classification of tumors, employed by writers generally, is founded on histological anatomy. The philosophy of such classification finds condemnation in changes constantly occurring. These namings are good, bad, and confusing, in the phases of neoplasms, and in the fact that the clinical history of the conditions demonstrates expressions to be phenomenal, just as, though in more marked degree, the expressions of vascular perversion which we denominate inflammation are phenomenal. Histological definitions are not, however, without great usefulness and interest.

Tumors, as histologically classified, are as follows:

---

\* The meaning of scrofulous induration lies in stasis of tissue metamorphosis, the direct cause being lymphatic obstruction. Lymphangitis and tuberculosis are identical.



Cystoma.....	Cystic.	Adenoma.....	Glandular.
Enchondroma.....	Cartilaginous.	Angioma.....	Vascular.
Fibroma.....	Fibrous.	Sarcoma.....	Fleshy.
Lipoma.....	Fatty.	Neuroma.....	Nerve-like.
Osteoma.....	Osseous.	Hygroma.....	Water-like.
Dentinoma.....	Dentinal.	Steatoma.....	Lard-like.
Hæmatoma.....	Blood.	Myeloma.....	Marrow-like.
Encephaloma.....	Brain-like.	Meliceroma.....	Honey-like.
Scirrhomia.....	Marble-like.	Atheroma.....	Gruel-like.
Melanoma.....	Like black pigment.	Chloroma.....	Like green pigment.
Myxoma.....	Mucus-like.		

No conflict exists, however, between the two manners of classification, as a single moment's reflection will show. An angioma may be homologous or heterologous. A hæmatoma may be benign or malignant. It will serve the purpose of a study to analyze, in illustration, some of the terms.

We say, for example, of a certain tumor, that it is a cystoma. Using this descriptive expression, we imply by it a cystiform character of the growth spoken of,—this, and nothing more. The tumor may readily enough be what we have called homologous; for should it be in a jaw-bone, and should we make examination, we might remark the absence of certain teeth from the arch affected, and, on chiselling off the vault of the enlargement, might find the lost teeth as an explanation of the growth: the cyst would be a self-explaining odontocoele.

Again, examining a maxillary cyst, we find no teeth absent from the arch; none of these organs diseased, no anything of local signification that has in it the semblance of explanation; accurate inspection, founded on a thorough knowledge of the parts, reveals no cause why a cyst should have developed in such a place and at such a time. Here the most experienced surgeon has but a single resource. He must act on the premise that the condition is an expression of constitutional meaning. In his investigation he passes to examination of vices possessed of a history. Discovering still nothing, he has left him but assumption of the condition of cancer. Certainly he has been able to secure nothing outside of such assumption. If he treat not his case as cancer he is without data for treating it as anything else.

Take a third condition of cyst,—a cyst in the substance of the lip. Is this a self-explaining condition, or does it express a vice?

In the substance of the lip are secreting glands of three characters, mucous, sebaceous, and sudoriparous; each of these, for the purpose of clinical study, may be described as a secreting cyst-like body with a patulous tube running from it to a free surface, through which tube is constantly being discharged the fluid formed in the cyst. Suppose now any one of these tubes to be accidentally occluded, we find ourselves led at once to an apprehension of a diagnosis. Should a labial cyst be mucous in its character, it will be a soft, more or less elastic tumor, will be situated upon the oral aspect of the lip, and if explored by the needle will yield the characteristic discharge. Should it, on the contrary, be of a sebaceous nature, it will be related with the external



tissue, will roll loosely under the touch, and if explored will exhibit cheese-like contents. The sudoriparous cyst is, of course, of very rare occurrence; if existing, it would also lie in the external tissue, and would be found to have much more elastic walls than either of the others. A cyst is sometimes found in the lip dependent on dental abscess. A case is at the present time under treatment by the author where such a cyst was of eleven years' standing; during all that period the tumor has not been of less size than an ordinary shellbark-nut. The sac was found very thick, and the surface ulcerated. A treatment which consisted simply in the extraction of two dead teeth, has resulted in the entire disappearance of it.\*

We pass to other of these synonymes. Let us take the terms scirrhomia, myxoma, encephaloma, myeloma: these are names given to tumors because of peculiarities in structure. The clinical placing of them, however, is the practical matter. Whatever name the histologist employs for the designation of a tumor, whatever may be the histogeny of a growth, if no local nor common vice explanatory of presence exists, its place is with cancer. Here only may it be placed as treatment is concerned. It is to be cut away or let alone. That is the sum of its treatment.

Scirrhomia is a term employed to designate solidity, hardness; the cancer vice. Influenced by the associations of a part in which it is found, by its own character, or by some peculiarity or idiosyncrasy of the individual, it exhibits itself as a hard nodule; remove this nodule, and not unlikely the return of the disease—particularly if appearing in another locality—is in the form of a brain-like substance,—encephaloma; or that might come, which, cut into, would exude a mucus-like substance, and we might call it a myxoma; or perhaps a section would exhibit marrow-like contents,—myeloma; or there might be a cyst with gruel-like contents,—atheroma. Or, diffused throughout the substance of any of these differently appearing conditions, there might be a black coloring-matter,—then we might express the tumor as a melanoma; should the pigment be of a green shade, we would call it chloroma; or should we designate the growth for the first time, on seeing it in a state of fungous proliferation, we should call it a hæmatoma. Yet, with all these various significations, we would mean, in truth, but a single thing; and to clinically classify any or all of these phases we would need but a basal term,—that is, taking it for granted that the tumor was without local or common vice explanation.

In such exposition of names, which are seen to be simply expressive of types,—synonymes we may with all propriety call them,—any confusion must certainly be found dispelled. These various terms, as employed in writing, are, however, as has been suggested, of great assistance in expression; it is only necessary to bear in mind that their meaning and relation are adjectival.

---

\* The hydatid, being a cyst of parasitic origin, is not introduced. Such a cyst, being an accident, as it were, can be conformed to no rule. Diagnosis is through aspiration.



## CHAPTER LXI.

### THE TUMORS OF THE MOUTH.

#### THE EPULIDES.

TUMORS of the mouth most frequently met with are those seen growing upon the gums, and known as the epulic. These growths are, in almost all instances, first to be observed making their way from about the neck of some particular tooth, pushing out apparently, from the socket, being found to originate from the odonto-periosteal membrane.

As the epulides, like other tumors, classify themselves into self-explaining and non-explaining, the term epulis, still in quite common use, is without proper signification when employed as a noun substantive. It is derived from the Greek words ἐπί and ὄβλα, signifying "upon the gum;" it is to be accepted as distinctive of situation only, so that, in using it, one expresses simply that a growth spoken of is upon the part classically designated.

Histologically expressed, the epulic tumors are to be arranged as follows: epulo-fungoid, epulo-erectile, epulo-fibroid, epulo-fibro-recurring, epulo-sarcomatous, epulo-myeloid, epulo-myxomatous, etc. Clinically classified, we have to concern ourselves only with benignancy or malignancy, as thus alone we are led to a required treatment.

The single epulic tumor which may *with certainty* be known as benign is the pulp-fungoid. A second form, which is usually found so, is the erectile. Any of the epulides which does not exhibit itself as one or the other of these forms is to be deemed cancerous, and treated with the latitude given to cancer. No other inference insures the best good to the patient.

A pulp-fungoid growth is self-explaining. An erectile tumor is fairly so from analogy with the common vascular nævi: it is, in fact, a nævus. Besides these two *no other* of the epulides possess explanation of their presence or of their development. The epulo-fungoid growths demand a treatment peculiar to themselves; so, also, do the erectile. All the other epulides are to be treated on a common principle. From such data, which may be accepted as solidly reliable, the surgeon is led to perceive that an appreciation of the first two insures clinical understanding of all the other conditions. That is, knowing two, he knows all the rest.

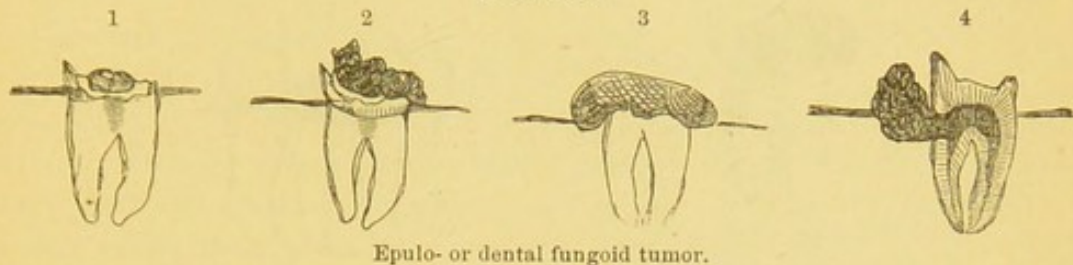
**The Epulo-Fungoid Tumor.**—By an epulo-pulp-fungoid tumor is meant a fungoid growth of an exposed degenerating tooth-pulp. This tumor is as common as it is simple and harmless, and is certainly to be seen in a thou-



and cases to one of any other form. The fungoid pulp tumor is met with under the various aspects exhibited in Fig. 553.

Referring back to Figs. 41, 42, and description, the dental pulp is recog-

FIG. 553.



Epulo- or dental fungoid tumor.

nized as a stroma of delicate connective tissue, in which stroma ramify blood-capillaries and nerve-fibrillæ; this structure occupies the cavity of a tooth, and is liable, through the accidents of decay or fracture, to become exposed. When so exposed, it is not unlikely to undergo fungoid degeneration.

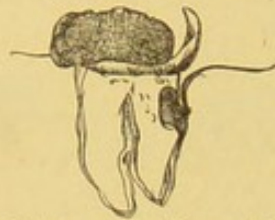
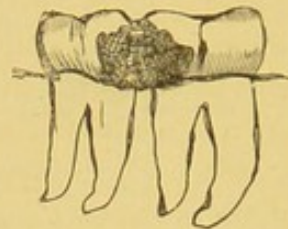
Fig. 553, Subfig. 1, is an outline drawing representing the walls of a tooth-root enveloping its pulp, which pulp, slightly fungous, projects a trifle above the level of its cavity. In molar roots, the crown being gone, such form of pulp-tumor is very common. No difficulty exists in its recognition, as the boundary-walls of the cavity are plainly to be observed. A form of such tumor, a trifle complicated, is exhibited in Subfig. 2: here, as is seen, the fungus is of such extent as to overlie the boundaries of its cavity; any confusion is avoided, however, by thrusting the mass aside, when its character is at once made evident. Subfig. 3 represents another condition: here the mass has increased to such extent that it not only conceals the cavity, but also rests upon the surrounding gum, to which, not unlikely, it will be found to have formed attachments. Still another form is exhibited in Subfig. 4. Here a tooth-root may be below the border of its socket. No pulp projects from nor is seen upon the face of the canal; a break exists, however, upon one side of the root, out of which grows the fungous mass. Such a growth, little by little, insures the absorption of the alveolus on the side at which it projects, and rising, finally, above the free face of the gum, exhibits a condition well calculated to mislead. This tumor is readily distinguishable from the odonto-periosteal growths by the nature of the proliferations, these being of a livid asthenic appearance, not common to any other of the epulides. This last form of tumor is not at all frequent; it depends for its existence on such a break in the continuity of a tooth-root as seldom occurs. It is to be remembered, however, that a decay commencing at the free surface may run along the root of a tooth, and that out of this track the fungus may project.

Fungus of the dental pulp, of an extent and character described in conditions 3 and 4, is, however, as infrequently to be met with as conditions 1 and 2 are common.



A form of epulides simulating, as location is concerned, the pulp-fungus, is exhibited in Fig. 554. In this instance the tumor, while seen to arise from the pulp-cavity of the fang, when traced, is found to be an outgrowth of that

FIG. 554.

Odonto-periosteal growth  
simulating pulp-fungoid.FIG. 555.—ULITIC  
TUMOR.

aspect of the odonto-alveolar membrane which adjoins the bone; the growth has passed through an opening in the root, and has progressed, as shown in the dotted lines, until, reaching the margin, it becomes exposed. The drawing should show the tooth in section.

To mistake this last form of tumor for the ordinary pulp-fungus would be to err necessarily in the treatment, the four conditions represented in Fig. 553 requiring either the destruction of the fungus by means of cauterization, or the extraction of the affected fang; while this last necessitates removal of a portion of jaw found implicated.

Still another form of epulic tumor\* consists, as exhibited in Fig. 555, of an ulitic outgrowth, the result of irritating influences associated with double approximal dental caries; the gum-tissue, semi-strangulated, rises and fills the cavities. A similar expression of tumefaction is not infrequently met with in the interspace existing between teeth in which the V-cut has been made; indeed, these growths are encountered where they have not only completely filled such interspace, but so projected above the grinding face of the teeth as to be injured at every occlusion of the organs. The treatment consists either in extracting one of the approximating teeth, in so altering the relation of the necks of the teeth as to obviate the strangulation, or, after cutting away the mass, and by means of cotton wedges forcing the structure entirely clear of the cavity, in restoring by contour filling to the original relation of the parts. A temporary curative consists in keeping the sites of projection stuffed with plugs of cotton saturated with gum sandarac.

Reviewing the tumors just described, it is seen that, with a single exception,—that shown in Fig. 554,—all are, very simply, self-explaining.

**Epulo-Erectile Tumor.**—This is a vascular growth, the analogue of the nævi; it is commonly associated with the capillary system, and has its character marked by its variation in size and appearance as influenced by the conditions of the circulatory system at large,—excitement increasing its turgescence, quiet reducing it. Turgid in a general appearance, epulo-erectile

\* This, from its simplicity, is to be classed with the pulp-fungoid, as it is equally self-explaining.



tumors present, however, decided features of variation. Thus, some represent a congeries of vessels which would seem to need the merest scratch to result in profuse hemorrhage. A common feature of vascularity exists in a likeness with the tissue of the corpus cavernosum penis, the cellular stroma being thinned into a series of communicating cells, which are found congested or otherwise, as circumstances control. Erectile tumors are also not infrequently found quite solid, simulating fibrous structure: this depending on some vascular perversion which has produced excess of the fibro-cellular element; indeed, it sometimes happens that spontaneous cure is effected through solidification. The surgeon, acting on such a hint, employs the process as one of his means of cure. Of the various forms of epulo-erectile tumors, the spongoid is by far the most common,—is, indeed, to be placed as the type; stimulation of the circulation will fill it at times to bursting; pressure may almost completely empty it.

Whether an erectile tumor come under the definition of arterial, venous, or capillary, depends simply on the vessels most involved. A term, aneurism by anastomosis, applied to these growths by John Bell, had its foundation without doubt in that variety in which the arterioles are implicated. This species, when congested, presents the scarlet hue, and, if accidentally wounded, is most troublesome, as control of hemorrhage is concerned. The venous variety is made up of a congeries of venules: the tumor is dark and commonly sluggish in aspect. The capillary form is intermediate between the arterial and the venous, and constitutes the spongoid form. The underlying bone of the erectile epulides will almost invariably be found involved, being softened and spongy. Erectile tumors sometimes, though rarely, make their first appearance as a red pimple upon the gum, growing in a polypoid form until they may attain the size of a cherry.

**TREATMENT.**—Tumors of this class involving the bone as they do, can be cured only by a section which includes that structure. A diagnosis is easily secured by passing an exploring-needle through the soft tissue: if the hard parts be implicated, the needle is found to enter freely, and may be moved about among the loose stroma; if the needle do not pierce the bone, and the tumor be at all pedunculated, it may be strangulated; or, even where the base is broad, the ligature may yet be used, transfixing first the base with one or more needles for the proper directing of the thread.

A second mode of treatment, applicable when the bone is not involved, is by injection; the ordinary hypodermic syringe being employed, charged with one of Monsel's solutions of iron, with a very concentrated tincture of iodine, or with the glacial acetic acid. Any substance which will coagulate the blood may be used, and not infrequently is found to answer a satisfactory end. The employment of this means of cure is not, however, unattended with risk from emboli. Still another method consists in the application of caustics, such as chloride of zinc, Vienna paste, the London paste, or the strong mineral acids. An anxiety, however, which must always accompany the employ-



ment of these agents, is the fear of hemorrhage on the casting of the slough ; and such anxiety is so well grounded that experience soon teaches that the means of cure is applicable only in the least vascular of the growths.

The seton, as an agent, finds not infrequently happy service in the erectile epulides. The needle used is that employed by the surgeon in passing ordinary ligature silk. The seton may be soaked, or not, in some caustic solution ; the thread is always to be the thickest that the eye of the needle will admit, in this way insuring the occlusion of the transfixed vessels and guarding against bleeding. When hemorrhage associates itself with such transfixion phénol sodique may be freely applied to the points of puncture ; or, if this do not answer, tannic acid is to be drawn into the wound by coating the seton and moving it gently backward and forward. Should even this not control the bleeding, a knitting-needle heated to whiteness may be thrust through the wound, or the saturated tincture of iodine be injected. On two or three occasions the author has found himself enabled to control such a hemorrhage by casting a ligature around the parts, as best might be done, thus cutting off the circulation ; indeed, the practitioner, using the seton, will on some occasions find the employment of a strangulating ligature forced on him. Such hemorrhages are, however, very infrequent, and may not be met with in one out of a hundred cases. They are most commonly associated with the arterial variety of tumor.

Electrolysis is another means of treatment sometimes employed (see *Treatment of Nævi*), and is highly lauded in its application ; the object should be the coagulation of the blood, rather than a cauterization of the stroma of the tumor. Although destruction is preferred by many as the best service of electrolysis, it is to be recognized that the mode of using the agent suggested has the advantage, inasmuch as it is a certain assurance against hemorrhage.

A practice of "piecemeal removal" has been introduced into English surgery, consisting in teasing or tearing or twisting away fragment after fragment ; the principle being to avoid hemorrhage, as in the torsion of arteries. This is a practice, however, which the inexperienced will do well to avoid ; not but that, in certain cases, it is a good plan of treatment, but frequently it has troublesome associations, not the least of which is active hemorrhage.

Still another treatment, employed where a tumor has no association with the bone, is the application of the serres-fines : these are spring-wire forceps ; they are to be made of a size proportioned to the requirements, and are to be clamped over the mass. In using these clamps, regard is to be had to the nature of the serrations, these being used deep or shallow according to the vascularity of the part to be grasped ; the pressure of these clamps will not infrequently result in a coagulative and inflammatory action, which proves the cure of the tumor.

An application somewhat on the principle of the serres-fines is the employment of pressure. The parts having first been emptied by forcing out the blood, a well-adjusted compress is to be bound tightly over the tumor, and



retained in place continuously for several days: this treatment, when the growth is small, will often effect a cure. An admirable plan of securing a desired pressure is to take an impression of the jaw on which the tumor is situated, and, obtaining thus a model, make a plate precisely as for an artificial denture, having bands, to hold it firmly in place, fitted to clasp neighboring teeth; by now placing over the tumor a layer of cotton-wool, and compressing it by fitting the plate in place, pressure of a very effective type will be found to have been secured. Advantage is gained by employing astringents in conjunction with the plate; saturating the wool with a diluted preparation of Monsel's solution of the persulphate of iron answers a very good purpose. Tannic acid may be used.

The erectile forms of the epulides, while not so clearly explainable as the pulp-fungoid, are yet to be esteemed as of local signification and of innocent type. An analysis of an erectile growth exhibits it as a tuft of vascular tissue. In it is to be recognized vascular anatomical perversion.

From the consideration of the epulides of self-explainable character we proceed to that of forms, all of which experience assures us are best esteemed, and most wisely treated when accepted, as belonging to the second class. The author so treats them because, while they may not all express the cancer vice, he cannot prove that they do not. By treating them with the latitude given to carcinoma, nothing detrimental to an innocent growth is done, but everything in the way of cure possible (with our present knowledge) should the disease be malignant. This practice the writer himself shall continue to pursue—finding in it the commendation of his highest intelligence—until the typical something is discovered which shall allow him to know a cancer in all its expressions, just as to-day one might not easily be deceived in a hernia or in a ranula.

**Epulides not Self-explaining.**—We pass now to that consideration which includes every other epulic tumor met with in the mouth: histologically, we would class these as myeloid, sarcoid, myxoid, fibroid, etc.; clinically we are not interested in giving them any name at all; the single concern with our classification being as to self-explainability or non-explainability. With the epulides the author has had much to do; he may be pardoned in suggesting that in the direction few have had, perhaps, wider opportunities of observation; as the result of such an experience, he believes that he advances the highest truth, and that which will be found to redound to the greatest good of patients, when he teaches *that a growth is to be called, viewed, and treated as cancer which cannot be proved not to be cancer.\**

\* The author of course sees that here are involved the learning, experience, and judgment of an observer. But with all grades of intelligence, he must perceive his position equally to hold. A man can handle and treat a matter only as he comprehends it; it is the fatal misfortune of all cancer afflicted patients that the highest intelligence has not yet arrived at the apprehension of what cancer is. It is a great misfortune for a patient to fall into the hands of a man who does not know—to the extent of the known—what is not cancer.



Cancer is treated in consideration of a twofold expression belonging to the condition. When infiltrated, that is, when parts adjacent to a tumor are in marked sympathy, being engorged and shading dimly into healthy structure; when glands are indurated and dyscrasia is marked; then, not knowing any antidote to the virus, a surgeon can do nothing for a patient. When, on the contrary, a cancer lesion is strictly localized, when a tumefaction does not shade gradually away, but possesses a strict individuality, like, for example, the concentric fibroma, then, let it be epulic, or of whatever situation, ablation is indorsed, on the principle of assistance rendered to a something which offers expression of attempt to help itself.

Accepting the premise, we find in the character of an epulic tumor the practice pertaining to it. If the premise be right, indecision or confusion has no occasion for existence.

Presenting Figs. 556, 557 as illustrations of some of the various expres-

#### EPULIC TUMORS.

FIG. 556.

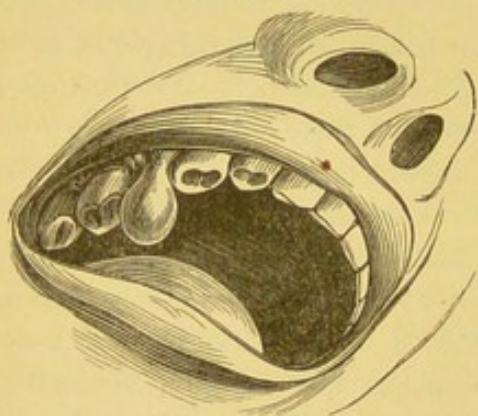
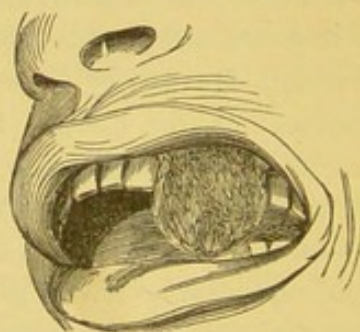


FIG. 557.



sions of the epulides, attention is to be directed, with benefit to many, perhaps, to a description of the cases, together with the practice adopted, and the results.

FIG. 558a.

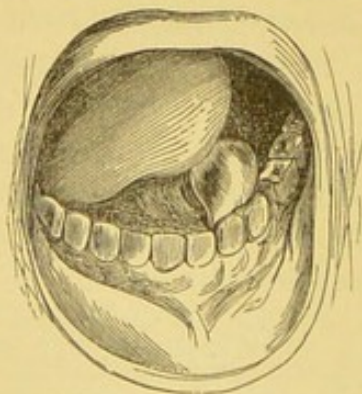
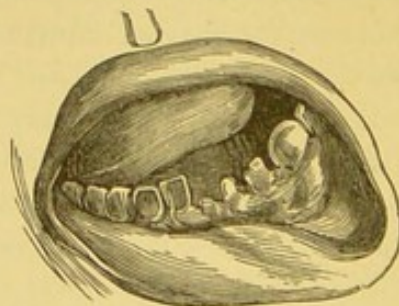


FIG. 558b.



CASE, FIG. 556.—Some four years ago, Mrs. T., the sister of a medical friend, was brought by the brother to the office of the writer for consultation on a tumor (about the size of an ordinary pea) growing from the alveolus of

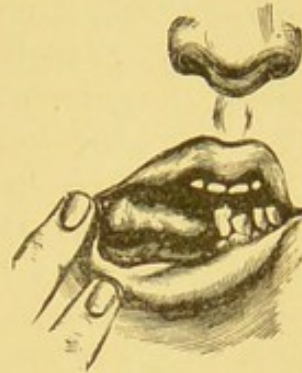


an upper molar tooth. This tumor was thought to belong to the class pulp-fungoid. There was a broken palatine fang in the jaw, but so deep as to be

FIG. 559.

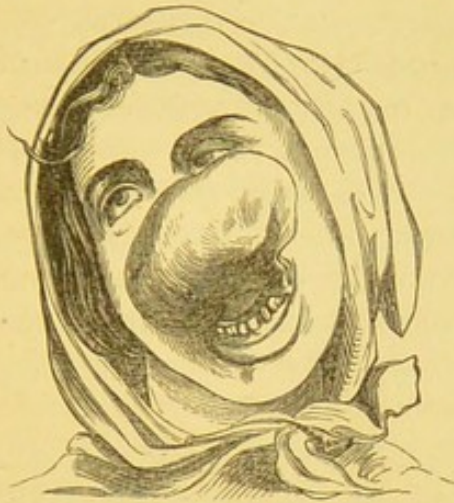

FIG. 560.



only fairly discernible to the probe; the origin of the growth could not be seen, only inferred; by separating carefully the alveolus from the fang, the root, after some little trouble, was gotten from its bed. The little tumor proved to be an outgrowth of the periodontal membrane, and not an excrescence from the pulp; in character it was distinctly and decidedly fibrous—it was, then, histologically to be classified as an epulo-fibroid tumor. It did not look like a growth from the periodontum, but rather as if its origin was in the crusta petrosa, and as if it had carried the membrane before it, somewhat as the infundibuliform fascia is made a tunic to a descending intestine in an oblique inguinal hernia. The removal of the fang brought the growth cleanly away. Of course, no scraping or cutting of the parts was necessary: the growth was evidently an emanation of the dental aspect of the periodontum, and had in no way involved its alveolar association. No treatment of any kind outside of the removal of the tooth was employed. The patient remains perfectly cured. This is the only growth of just such relation ever met with by the author.

CASE, FIG. 557. EPULO-ERECTILE TUMOR.—Mrs. J., presented herself with a livid, threatening-looking tumor, the size of a hickory-nut, occupying the left alveolar face of the upper jaw, the growth extending from the lateral incisor tooth back to near the tuberosity. This tumor diminished in size during sleep, and increased at the time of any excitement which tended to accelerate the circulation; sometimes it seemed like a solid body, at other times like a spongy mass; it was evidently erectile in its nature, the analogue of an ordinary *nævus*. It was an epulo-erectile tumor.

Separating the growth from the gum, its association with the periosteum was plainly evident; the probe revealed involvement, as well, of the neighboring bone. An operation, which resulted in complete cure, was performed as



follows. The lip being held well out of the way by an assistant, an incision was made, extending from the central incisor tooth of the affected side back to the tuberosity, a similar cut being carried back on the palatine face of the tumor to the place of beginning: these cuts passed freely through the soft parts down to the bone, and circumscribed the tumor, with a reasonable margin to spare. The central incisor was next extracted, and, with the ordinary cutting-forceps, section was made through its alveolus, extending almost to the labio-nasal angle. A second pair of forceps was now taken up, and, by two cuts, the width of its blades, the involved bone was removed; the section extending, as is evident, from the situation of the left central incisor tooth to the tuberosity. Considerable hemorrhage attended the operation, although the section was well outside of the vessels involved, three ligatures being required. Treatment by excision of the bone was here necessitated from the implication of this structure.

*After-Treatment.*—The lady being of very full habit and of markedly sanguine temperament, magnesia sulph.  $\mathfrak{z}$ ss was ordered the evening of the operation. As an opiate, morph. sulph. gr. ss.

*Day after Operation.*—Marked inflammatory action, attended with considerable swelling of the tissues of the face. Prescribed,

R.—Plumbi acetatis,  $\mathfrak{z}$ ij;  
Tincturæ opii,  $\mathfrak{z}$ ij;  
Aquæ,  $\mathfrak{z}$ xvj.

Ordered a cloth wet with this preparation to be kept continuously upon the part.

*Third day.* Inflammation increasing; eyes completely closed from the great œdema of the lids; mag. sulph. reordered, together with hot pediluvia; eyelids heavily painted with tincture of iodine.

*Fourth day.* Erysipelas set in; the face looking like a glistening red ball; patient restless, nervous, and frightened; painted the whole face with tincture of iodine, officinal strength; the lead-water and laudanum continued; iron and quinine internally.\*

R.—Tincturæ ferri chloridi,  $\mathfrak{z}$ ij;  
Quiniæ sulphatis, gr. xxv.

Sig.—Fifteen drops in water every three hours.

\* The author, for such erysipelatous inflammations, now always employs for local use the combination recommended of iron, quinia, and cinchona, recognizing a parasitic relation of the disease, and finding the application specific.

The micrococci of erysipelas have been demonstrated by Fehleisen (of Bergmann's Berlin clinic). A patient had been inoculated forty-five hours previously, and when showed displayed a typical erysipelas. The micrococci which had been here implanted were the product of more than thirty generations cultivated on gelatine, and could be considered entirely free from extraneous matter or germs. Of eight thus inoculated, only one failed to show typical results. The last trial in April was just as successful as the first during the previous August, and with the same culture. The one person on whom the experiment failed had suffered from an idiopathic attack but a short time before.—*Annals of Anatomy and Surgery.*



Also a diaphoretic :

R.—Liquoris ammoniæ acetatis,  $\mathfrak{z}$ ij.

Sig.—Tablespoonful every ten minutes until the induction of profuse perspiration.

*Sixth day.* Erysipelas evidently yielding ; iron and quinine ; painting with iodine, lead-water and laudanum, continued.

*Seventh day.* Much improved ; the erysipelatous redness gone ; skin wrinkling ; patient can see a little from one eye ; continued the painting with the iodine, and the application of the lead-water lotion.

*Ninth day.* Inflammation all gone ; patient quite comfortable ; the exposed bone covered with a thin layer of healthy granulations ; case progressing well.

*Twelfth day.* Patient attending to household duties ; mouth of course very tender, but advancing rapidly toward a cure.

*Twenty-fifth day.* Patient may be called well ; needs no further attention.

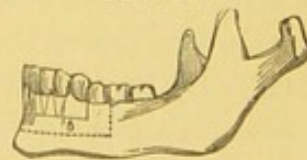
To complete the case, artificial teeth have been inserted, the plate being made to fill up the place of the lost bone. No one would suppose, in looking at the lady, that she had lost such a portion of the jaw. She remains well.

CASE, FIGS. 558*a* AND 558*b*. RECURRING EPULO-FIBROUS TUMOR.—These two views, from life, represent the case of a young lady as an epulic tumor appeared when first operated on, and as it reappeared and was reoperated on some four months after the first time.

The patient, nineteen years of age, and of much more than ordinary personal attraction, applied for treatment of the growth as represented in the first view. The necessity for an operation having been explained, the following suggestions were made. That a section be first cut which should simply remove the tumor and the alveolar process connected with it. If this should succeed, no deformity would result. If the growth reappeared, a second operation to be performed, this to ablate the bone proper, except a simple rim of continuity. Third, if this, too, failed, then complete section of the jaw to be made ; this, of course, would be deforming, but it would be the only resource.

The first of the operations was performed ; the bone outside the section looked healthy, and gave every promise of a satisfactory result. In two weeks healthy granulations had covered the part, and in one month the patient was dismissed cured. The following March—the operation having been done in December—a small tubercle appeared in the centre of the site of the original tumor, and in the course of three weeks half a dozen new lobules had sprung up. The second operation, as proposed, was now performed, the continuity and natural arch of the bone being preserved unbroken. This was successful. The patient remains perfectly well. The site of the removed bone is occupied by artificial teeth ; not the slightest deformity is to be observed.\*

FIG. 561.



Section of bone as first and afterward made.

\* Sixteen years have elapsed.



Fig. 559.—This figure exhibits a case operated on by the celebrated English surgeon Mr. Liston. The following is a summary of it, given by that gentleman in a paper on "The Tumors of the Jaws:"

The patient had labored under the disease for eight years, and had been subjected to a partial removal of the growth when of inconsiderable size. The tumor was of fibrous nature as regards its disposition, form, and intimate structure. It differed somewhat, however, in outward appearance, in consequence of its exposed situation. The growth sprang originally from the gums and sockets of the incisors and canine teeth of the left side; at an early period it protruded from the mouth, unconfined and uninfluenced by the pressure of the lips or cheek. It had assumed a most formidable size and appearance, concealed the palate and pharynx, and gave rise to great inconvenience and suffering. The surface had been broken by ulceration, but on close inspection of the projecting part, and of that covered by the cheek, it was found to possess a firm consistence, and to present a peculiar botryoidal arrangement of its parts.

An operation proved perfectly successful.

CASE—not illustrated.—Mrs. S., of Camden, New Jersey; epulo-fibroma of left superior jaw. This growth was the size of a large walnut; it was of some eighteen months' standing; the bulging of the cheek quite deformed the patient. Lady had been confined with her fourth child five weeks before presenting herself.

*Operation.*—This was performed three weeks later. The tumor, or all that portion of it which was free of the bone, was cleanly excised with the scalpel, together with a margin of surrounding healthy tissue. This step exposed the bone, which was found carious. This was removed by the use of the gouge, little by little being cut away until healthy structure was reached. The surgeon recognizes such healthy structure both by its feel under the instrument and by its appearance; healthy living bone being white, studded with minute bleeding points. Hemorrhage during the operation was considerable, but was controlled, without ligature, by throwing alum-water into the wound from an ordinary syringe.

*After-treatment.*—Very little required; a wash of the permanganate of potash, five grains to the ounce of water, was given as a disinfectant, there being for a few days a somewhat disagreeable odor from a decomposing blood-clot. No antiphlogistic or systemic treatment of any kind was required, not a bad symptom having appeared, the patient being entirely well three weeks after the day of operation. In this case the floor of the antrum was removed and the cavity wholly exposed. At the completion of the cure the break was closed up.

CASE—not illustrated.—Mrs. T., of Philadelphia. Tumor of four years' standing; loose in structure, occupying one-half of the roof of the mouth, giving a most disgusting and threatening appearance. The growth had first appeared between the bicuspid and first molar teeth, and at the time of presen-



tation had entirely destroyed the inner alveolar plate of the portion of jaw with which it was associated. In raising the mass from its bed, all the underlying palatine process, so far as could be seen, was found diseased.

*Operation.*—This consisted in cutting away with the scalpel as much of the growth as possible, and completing the operation on the bone with the gouge; hemorrhage very profuse, the use of a compress being necessary for its arrestation, and this only effected after several hours.

*After-treatment.*—Very little required; some over-inflammatory action, which quickly and readily yielded to low diet for a few days, and a single dose of sulphate of magnesia. In three weeks the case was in condition to be dismissed.

These special illustrations, all of them, with the exception of the third, being without the pale of our first classification, are given because they serve to show that there is an order of fibrous tumors; or, on the other hand, an antagonizing condition of the system, which, fully appreciated, would afford to the surgeon an ability to prognose the result of operations on them with the same certainty as in the removal of a pulp-fungoid. To be able to distinguish this class, or species, or condition, would certainly signify a step gained,—one of the many to be made, without doubt, by those who shall come after us. But such ability to distinguish does not yet exist. We may infer, but we are not certain. No treatment is known but that of radical ablation.



## CHAPTER LXII.

### THE TUMORS OF THE MOUTH.

#### EXOSTOSIS AND SUBACUTE INFLAMMATORY TUMORS.

THE term *ostosis* is derived from the Greek words  $\epsilon\kappa$ , "out of," and  $\sigma\sigma\tau\epsilon\sigma\nu$ , a "bone:" it denotes an osseous tumor which forms on the surface of bones, or in their cavities; the first is called *exostosis*, the latter *enostosis*.

The following varieties have been named: Ivory *exostosis*, that which is ivory-like; lamina *exostosis*, that which is made up of distinct fibres or layers; spongy *exostosis*, that which is like the spongy tissue of bone.

*Hyperostosis* is precisely the same thing as *exostosis*, both being hypertrophies. Inflammatory osseous tumors are *hyperostoses*.

Because, however, there are great differences in the expressions of these conditions, they may be written of under special heads.

*Exostosis*, as commonly met with in the mouth, is strictly benign. It is generally recognizable by its extreme slowness of growth, the entire absence of pain,—except when it meets with some peculiar obstruction,—and freedom from disease in surrounding parts. It does not tend markedly to ulceration, and does not, except mechanically, affect the regions even most directly associated with it.

True *exostosis* has its origin in local irritation, perhaps always. It is true that reference is made by authors to an ossific diathesis, but, as is significantly remarked by Miller, a skeleton so susceptible is prone rather to the more common inflammatory products of caries, abscesses, ulcers, and necrosis.

That local irritation is the chief cause of *exostosis* is satisfactorily proven by reference to parts most subject to the lesion. The teeth, for example, are found affected in a thousand instances to one of any other bone, and certainly no bones are so constantly found in irritative conditions. The term bone is used, the reader being reminded that the portion of a tooth which takes on this morbid action, the *cementum*, is, in a surgical sense, that structure.

Non-specific *exostosis*, occurring on any portion of the maxillæ removed from the alveolar borders, is an exceedingly infrequent disease. With every opportunity for observation, the author is surprised at the small number of cases met with by him; and these, with a very few exceptions, have been of little consequence.

Around the base of the alveolar processes, however, and particularly on the lingual aspect of the lower jaw, the affection, in a minor form, is exceedingly



common; the enlargements vary from the size of a small shot to that of a rifle-ball. As pathological relations are concerned, the growths seem of little consequence; the treatment is, commonly, the very simple one of letting them alone.

It is not improbable, though, that cases may occur upon which operations will be demanded. The mode of procedure is simply to lay off from the tumor the soft parts, and, with a chisel or bur, cut away the mass; there is no hemorrhage or other trouble attendant on the operation. (See *Hyperostosis*.)

Exostosis of the fangs of the teeth—*exostosis dentium*—finds location in the cemental structure of the organs; for while the writer has seen two or three cases where the crowns of the teeth were enlarged, as if from a species of hypertrophy, yet these were so anomalous that the growth is to be described as associated exclusively with the fangs; and even here it is found in the majority of instances confined mostly to the apex, growing, bulb-like, as it were, about the end of the root.

The diagnosis of exostosis in these situations is not always without confusion. The most frequent pathognomonic feature is a sense of continued uneasiness about the parts, this not amounting to pain, but serving as a constant reminder of the presence of the tooth. The organ itself may or may not be carious. Pressure, or the stroke of an instrument, does not, in ordinary cases, either increase or diminish the soreness; the sense of fulness about the parts is particularly observed where the absorption of the alveolus is not proportionably active with the exostosis. In these latter cases, the extremest symptoms of neuralgia are not infrequently produced, and, if not comprehended, are of course treated without avail.

One of the most remarkable cases of dental exostosis on record is related by Mr. Fox. The subject was a young lady, who, at the time she sought the professional aid and advice of this practitioner, had suffered so severely and so long that the palpebræ of one eye had been closed for nearly two months, and the secretion of saliva had for some time been so copious as to flow from the mouth whenever opened. The patient had tried every medicine recommended by the ablest professional advisers, without deriving any permanent benefit, and was only relieved by the extraction of every one of her teeth.

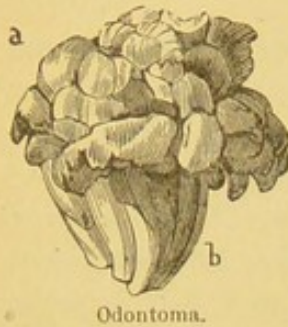
The surgeon may infer from the mention of this case that he is likely to meet with many gradations of the trouble. Such inference is right. Cure is found in the removal of the affected member. This is easily accomplished with the aid of a pair of cutting-forceps, or by means of an engine drill.

**Warty Teeth.**—In this association reference is to be made to an anomalous confusion and development of teeth-germs to which the term warty has been applied. On another page has been discussed the aspect of dentigerous cysts. The rarity of these warty teeth permits few the opportunity of seeing them. Among recorded examples familiar to the writer are four by S. J. A. Salter, one by Mr. John Tomes, two by Wedl, two by M. Oudet, two by M. Forget, and one by Mr. Harrison.



To teeth of such anomalous development M. Broca has applied a name that has now come into somewhat general use, namely, odontomata. These

FIG. 562.



he, with all propriety and clinical justice, has classified into circumscribed and diffused,—the first including all masses in which recognition of the tooth exists; the second, where it is lost in an anatomical confusion of the structures. The odontoma described from the practice of M. Forget, on a succeeding page, constitutes the most marked example of the latter on record. Fig. 562 is an example of the former.

A form of dental exostosis termed by Mr. Salter the enamel nodule exhibits a pearl-like protuberance growing from a tooth. Excrescences of this kind are considered to be essentially submerged cusps, being composed of a cone of dentine enveloped by a cap of enamel.

As an illustration of extreme dental hypertrophy, combined with the existence of an enamel nodule, attention may be directed to a specimen belonging to the Philadelphia Dental College, exhibited in Fig. 563. This mass is two and a half inches in length by two and five-eighths inches in circumference; it was associated with the roots of a left superior molar, and was extracted from the mouth of a laborer by Dr. S. H. Whitman, of Newport, Perry County, Pennsylvania.

In examining this specimen, it is observed that to the right of the palatine root, and connected with it, is a portion of enamel; being an outgrowth, as

FIG. 563.

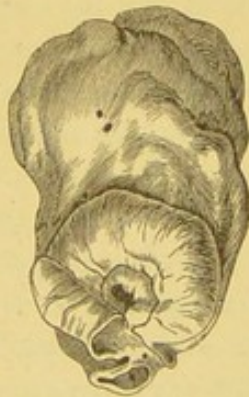
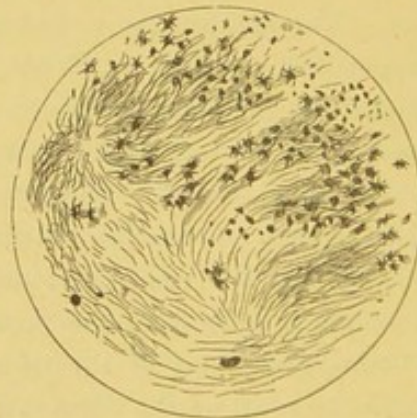


FIG. 564.



has been inferred, either of a wisdom or of a supernumerary tooth,—most likely, however, a production of the tunica propria of the tooth itself. Mr. Salter describes such cusps as being clothed with a pulp,—the *enamel pulp*.

A microscopical section of this growth is figured (Fig. 564) and described by Dr. J. H. McQuillen, through whom the specimen was received as a donation to the museum:

A first or outer section presents only the lacunæ and canaliculi charac-



teristic of cementum. A second cut differs somewhat from this, in having, in addition, certain spaces of no definite shape, and apparently being the blending of a number of the lacunæ. In a third section the lakes are quite numerous, and the canaliculi starting from them are of considerable length, and pursue a tortuous or curved direction, resembling very much the appearance and course taken by the dentinal tubuli in secondary dentine. Fig. 564 is from a drawing of one of the preparations as seen under the microscope. A few canals (cut transversely), evidently existing for the passage of blood-vessels, are observed, but no Haversian canals, as in bone, with the lacunæ and canaliculi arranged in concentric layers around them.

In the venereal, scorbutic, and tubercular hypertrophies or exostoses of the maxillary bones, the features of the common disease become quickly evident in the local trouble: so remarkably so, indeed, that no one would be likely to misunderstand the condition; presupposing the general disease to be recognized. The growths are rapid, painful, and almost always more or less amenable to constitutional treatment.

Scrofulous and scorbutic tumors differ from the venereal in being more loose and spongy in structure, and, in consequence, more apt to run into abscess, being possessed, as it were, of elements for their own destruction.

In these forms of maxillary disease, the lesion is commonly heralded by deep-seated, dull pains, which precede by some time the visible enlargement of the part. After the tumefactive process sets in, it goes on, if uncombated, until the parietes of the bone are completely disparted. Associated with this enlargement is an unhealthy condition of the soft parts.

As the disease advances, the centre of the tumor softens, while the character of pain changes, becoming sharp and throbbing; as pus forms, sinuses are created, and thus ulcerations occur on the face of the tumor. Enlargement of the maxillæ from these causes is, however, very uncommon, and might only escape being confounded with cancer by observation of the association with the disease at large.

The treatment of inflammatory tumors of these and similar types is to be conducted in consideration of their twofold requirements. The systemic influences are to be corrected, while, locally, as a rule, they will be found to succumb to the treatment commonly directed against similar lesions of the soft parts. Great confidence is to be entertained in the use of tents and stimulating injections.

There is a simple inflammatory tumefaction of the maxilla sometimes met with, which might be mistaken for specific exostosis. It is to be distinguished, however, by the rapidity of the formation and by the greater soreness attendant on it; it comes as a cold in the head, or on the chest, comes,—without, in the majority of cases, the patient being able to assign any cause,—and it is found soon to give way to antiphlogistics. This tumefaction is extra- rather than intramaxillary; it is simply a periosteal exudate, and has no constitutional association.



In this connection, attention is to be directed to a form of tumor frequently found in the mouth, which, clinically, is classifiable with the exostoses. Allusion is made to an apparent expansion of bone frequently found in association with a strumous diathesis, and invariably in connection with periodontally diseased teeth or roots of teeth.

These tumors have a common history. The nerve of a tooth dies, and the periodontium takes on a chronic irritative condition, or perhaps a tooth has been fractured in attempts at extraction, and the root, or some portion of it, has been left in the socket. After a time, sooner or later, a slight swelling, apparently of the gum, is observed. This may readily be taken for a chronic alveolar abscess; there is no pain, however, associated with the enlargement, which is soon seen to differ from abscess in the slowness of its evolution; it is also hard, being perfectly unyielding under pressure. As we watch such a case, month after month, we find that it gradually grows, giving the impression of an expansion of the bone under the gum, although, as we understand, there are no special or marked signs of such cystiform condition. If we pass an exploring-needle into the tumor, it feels as if it were cutting its way through spongy bone; and so indeed it is, as dissection reveals that the cancellated structure has taken on hypertrophic action. It is such spongy enlargement that bulges out the overlying parts and makes the tumor. The author has treated quite a number of these growths, invariably in connection with the inferior jaw. He does not think they are often to be found in the superior, such chronic conditions being in the latter relation more apt to induce caries, which disease is known to be as uncommon to the lower as it is common to the upper jaw. These tumors either remain fixed in character, after growing to the size of half a walnut, or, in very bad subjects, they degenerate into abscess, and discharging thus the offending body, correct themselves. Such spontaneous cure is, however, not common.

The surgical treatment of the growths is both simple and effectual. It is enough, not infrequently, to remove the tooth or root, particularly if, in connection with such removal, the socket is kept open for a few weeks with a tent of cotton or sponge. A certain method of cure consists in cutting away, with a bur or gouge, the enlarged mass: this is easily accomplished by using the opening made in the extraction of the tooth as a means of ingress to the mass; the disease can, in this way, be taken out, particle by particle, without external incision, and with a wound not larger than that made by the preliminary extraction. After such operation the parts are to be well syringed, and a tent kept in the tooth-socket, to insure granulations from the circumference of the wound. In two or three weeks cure will be found complete.

In this connection attention is to be directed to an obscurity which sometimes exists in the diagnostic relationship of diseased teeth,—that is, no teeth or roots of teeth seem to be present. A sufficiently close observation, however, will always detect in the neighborhood a fistulous opening; it may be



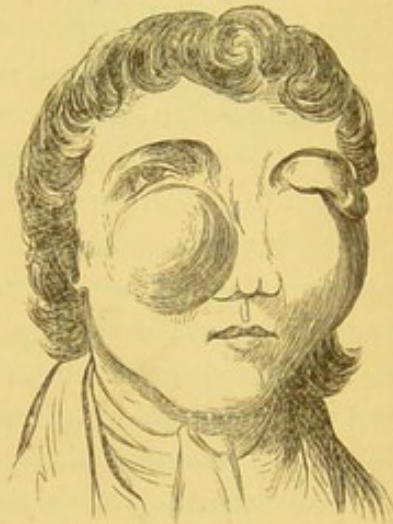very minute, but it is seldom, if ever, absent. If a probe be passed into the orifice, it will lead to the offending agent.

#### HYPEROSTOSIS.

In connection with the simple tumors, reference is now to be made to general facial hyperostosis sometimes existing. In a work published by Mr. Heath, being a Jacksonian prize essay of the Royal College of Surgeons, England, the following illustrative diagram and description of a case are given :

The patient, when about forty-five years of age, and apparently in perfect health, was exposed to a cold wind ; immediately after which he perceived an itching and heat in the eyes, a swelling of the face rapidly supervening. A small tumor formed just below the inner angle of each eye, which burst, and after twelve weeks he was able to resume his employment. He suffered from inflammatory attacks in the growth, with much pain in the head on more than one occasion. He consulted many medical men ; but no treatment relieved the disease nor retarded the growth of the enlargements, which increased slowly and were of stony hardness. The eyes were projected from the orbits by the tumors. The right inflamed and burst. The left was accidentally ruptured by a blow. The patient lived to be over sixty years of age, and died of apoplexy, having been occasionally maniacal during the last two years of life. The portrait is taken from the work of Mr. Howship (*"Practical Observations on Surgery"*). The skull of the patient is preserved in the College of Surgeons, and shows, as might be anticipated from the portrait, two large masses of almost exactly symmetrical form and arrangement, which have partially coalesced in the median line. The tumors are as hard as ivory, and consist of very close, cancellous structure. They project more than three inches from the face, and an inch beyond the malar bones on each side. The man attributed the growths to repeated blows received on the face in fighting.

FIG. 565.—HYPEROSTOSIS.



The skull of the patient is preserved in the College of Surgeons, and shows, as might be anticipated from the portrait, two large masses of almost exactly symmetrical form and arrangement, which have partially coalesced in the median line. The tumors are as hard as ivory, and consist of very close, cancellous structure. They project more than three inches from the face, and an inch beyond the malar bones on each side. The man attributed the growths to repeated blows received on the face in fighting.

The skull of a Peruvian (3093, College of Surgeons, London) is also alluded to by the same author. In this case the lesion is of a more diffused character, all the bones of the face, as well as the frontal and the adjacent parts of the sphenoid and parietal, being enlarged and thickened in a remarkable manner. The nasal fossæ and orbits are nearly closed, the superior maxillary bones having grown into great knobbed and tubercular masses, in which their original form can hardly be discovered. The hard palate is similarly diseased. The lower jaw is enormously enlarged at its right angle, and in



the greater part of its right half it measures upwards of five inches in circumference; all but three of its alveoli are closed up. A section of the lower jaw shows that its interior is composed of an almost uniformly hard and compact, but finely porous, bone. There is no history attached to the specimen.

Hyperostosis is simply exostosis or enostosis. It is analogous to hypertrophy of the soft parts, and has a similar meaning.

As can be very well understood, varieties in form and character present themselves. These growths are sometimes associated exclusively with the face of a bone, as in the ordinary exostosis. In these cases the periosteum may separate the two bodies. In other instances there is hypertrophy of the bone proper. The condition is one of disease only as there is a lack of correspondence in other parts. Any section of a hyperostosed bone exhibits the peculiar features of bone-substance; it may be, as is often seen, that the cellular substance is compressed and much altered, but there is the distinction to be observed between it and a cortical boundary, and the analysis remains the same,—that is, as the constituent parts are concerned. When these hypertrophies associate exclusively with the medullary canal, as in long bones, they obliterate or diminish the cavity, and, if of sufficient size, expand the external parts into a tumor, greater or less in size.

The history of any form of hyperostosis is the history of certain of the phenomena of inflammation; there is, from some cause or other, irritation attended with vascular changes, the effusion of plastic matter being associated with osseous transformation. What this source of irritation is, and how to control it, are matters which necessarily invite the attention of the surgeon.

Reference has been made on a preceding page to the hypertrophies of the specific conditions; such enlargements are easy enough to understand, even if not so easy to remove. But the hyperostoses here considered are not of such character, but are entirely of local signification; hence a local source of offence is not to be sought for in vain, as, for example, in Mr. Howship's case, where the osteitis was justly attributed to blows received. The inflammatory thickening of bone, alluded to a few pages back in connection with diseased teeth-roots, is but another illustration of the results of local irritation.

That the hyperostoses are to be viewed, and in every way treated, as simple overgrowths, is certainly well exhibited by Mr. Quekett, who, submitting to microscopic examination portions of all the osseous tumors in the Royal College of Surgeons, confirms the position in all particulars. The rates of the growths of such tumors are influenced by individual susceptibilities or peculiarities. There is certainly in this respect the greatest possible difference. In the *Osteographia* of Mr. Cheselden is an engraving of an osseous tumor surrounding the head of a tibia, which measures exactly one yard in circumference. An imposing growth is also figured in Mr. Paget's *Surgical Pathology*.

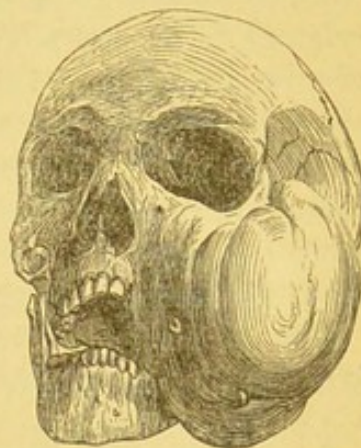


In this latter case, as Professor Clark describes the tumor, the hardest parts have neither Haversian canals nor lacunæ. In the less hard parts the canals are very large, and the lacunæ are not arranged in circles around them; everywhere the lakes are of irregular or distorted form.

A remarkable specimen of an osseous tumor of the left upper maxilla (Fig. 566), from the *Traité de Pathologie Externe*, found in the Musée Dupuytren, is described in Mr. Heath's essay

FIG. 566.—OSSEOUS TUMOR.

as being limited behind by the pterygoid process, internally by the intermaxillary suture, above and externally by the malar bone. The tumor encroaches considerably upon the cavity of the mouth, and reaches back as far as the front of the spine. Its form is bilobed, and in the deep sulcus between is to be seen a molar tooth. All the other teeth of the jaw have disappeared, and there is no trace of alveoli. The left orbit and the nasal fossa are not sensibly diminished in size, but the cavity of the mouth is almost entirely occupied by the posterior lobe of the tumor. The lower jaw has, in this case, un-



dergone several remarkable alterations. It must at first have combated the growth and produced the deep sulcus between the lobes; but in its turn the tumor has reacted on the jaw with the following effect: it has caused a double luxation, the left condyle resting against the root of the zygoma, and the glenoid cavity being filled with soft material. The teeth of the left side have disappeared, and absorption of part of the coronoid and the whole of the alveolar process has taken place, so that only the base of this part of the bone is left. The outer surface of the growth is smooth, and presents numerous vascular grooves of good size; at many points it is perforated with holes. The vascularity of the other bones of the face does not appear to be augmented.

In Guy's Hospital Reports a case is described by Mr. Hilton in which a tumor similar in signification to the one just referred to spontaneously separated from the face. The patient was a man aged thirty-six, who, twenty-three years before Mr. Hilton saw him, noticed a pimple below the left eye, close to the nose, which he irritated, and from that spot the tumor appears to have originated. The disease, in its growth, displaced the eyeball, giving rise to excruciating pain, which subsided on the bursting of the ball. It began to loosen by a process of ulceration around its margin six years before it fell out, which event was unattended by bleeding or pain. The tumor weighed fourteen and three-quarter ounces. It was tuberculated externally, and an irregular cavity existed at the posterior part. A section presented a very hard, polished surface, resembling ivory, and exhibited lines in concentric curves, enlarging as they were traced from the posterior part.

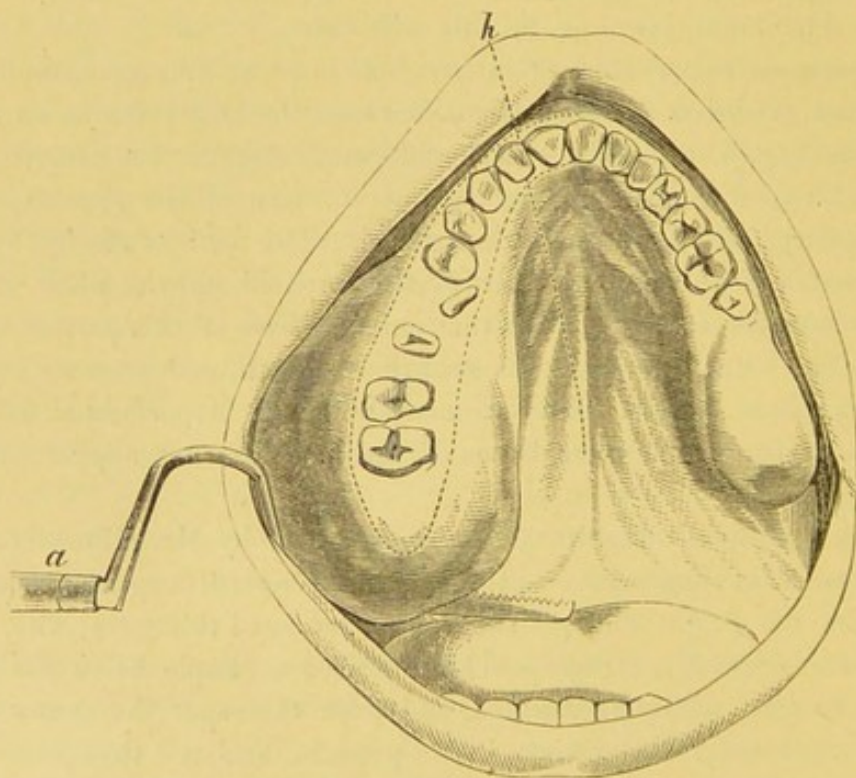


The huge cavity left by the separation was bounded below by the floor of the nose and antrum, above by the frontal and ethmoid bones, internally by the septum nasi, and externally by the orbit, which last had been considerably encroached upon by the growth.

Among several rare and interesting cases in this direction described by Mr. Hilton, particular mention is to be made of that of a lad, William Mars, born with a general enlargement of the whole left side of the face,—cheek, jaw, teeth, tongue. As the boy grew, so in a relative proportion enlarged the left side. The exact mesian line of distinction was curious to observe: the left side of the tongue was quite one-third larger than the right, the papillæ likewise showing the distinction. Commencing with the left central, the teeth were also one-third larger than their fellows of the opposite side. The ears, also, differed in size. No sense of discomfort was experienced by the patient. This congenital peculiarity was confined strictly to the head, all other parts being in correspondence.

The cut of a case of osseous hypertrophy—being the exact duplicate of an impression in plaster in the cabinet of the Hospital of Oral Surgery, taken by a

FIG. 567.—HYPEROSTOSIS OF TUBEROSITY OF MAXILLA.



practitioner of a distant county, in whose own mouth also the tumor exists—is kindly sent the writer by D. H. Goodwillie, M.D., of New York, the following description accompanying:

**Osseous Tumor of the Right Superior Maxilla.**—Mrs. B., aged forty-four years, has always enjoyed good health. About six years ago she noticed that the alveolus of the right superior jaw began to enlarge,



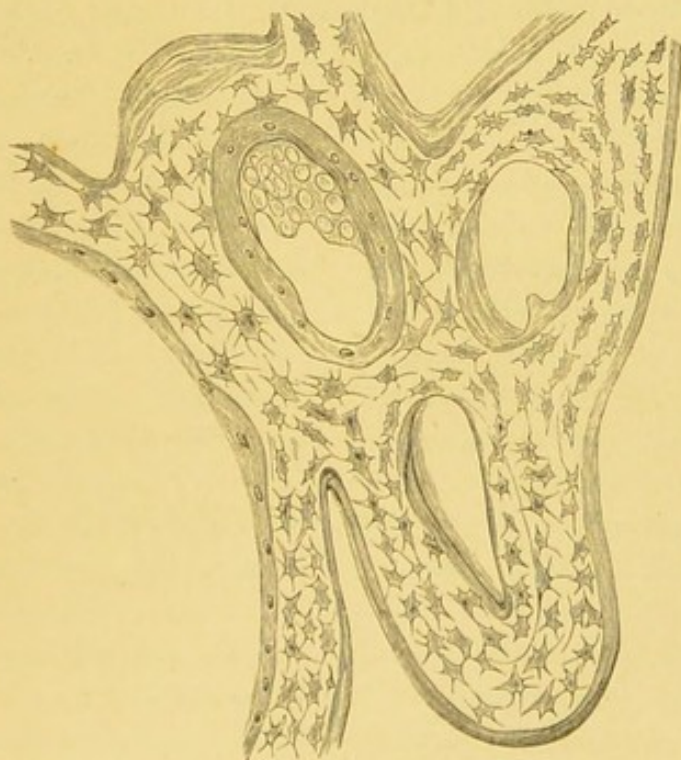
and has gradually increased to the present time. In size and shape it very much resembles a hen's egg, the large end presenting posteriorly. It extends antero-posteriorly from the right superior canine to the internal pterygoid process, laterally from near the centre of the palate to the maxillo-malar fossa, forward to the canine fossa, and to a slight degree into the antrum of Highmore.

The mucous membrane over the surface of the tumor appeared a little lighter in color than normal; this, no doubt, was due to the tension on it by the parts below. On the face of the enlargement could be seen the fangs of the first and second molars. The canine and bicuspidati were not decayed. First bicuspid and canine retained their normal position in the jaw, but their crowns were somewhat buried in the tumor. The crown of the second bicuspid could all be seen above the surface of the tumor, but the whole tooth was raised out of its natural position, and thrown inward about one-half an inch. One of the roots of a molar was lying longitudinally in the soft parts on the surface.

Patient has experienced no pain, nor discharge from the mouth or nose, during the long period of growth; from its apparent firm texture, together with the excellent health the lady has always enjoyed, there appears no doubt of its benignant character.

**PATHOLOGICAL APPEARANCES.**—On making a section of the tumor

FIG. 568.



through the longitudinal direction of the teeth, the following was to be seen: At the apex of the second molar tooth there was a small, soft cyst,



containing some pus, and for a short distance surrounding this the bone appeared quite cancellated, but the rest of the tumor was quite dense in structure. The pulp of the canine and of first bicuspid had still some vitality, but that of the second bicuspid was dead. The pulp-chambers were decreased in size by a deposit of osteo-dentine upon their walls. Slight hypertrophy existed of the cementum around the fangs. A large nerve entered the growth on its buccal side.

The microscopical examination of this tumor, as made by Dr. J. W. S. Arnold, and as shown by his drawing (Fig. 568), exhibits cancellated tissue almost entirely; the outer edge being a thin layer of more compact bony tissue. In the spongy part is a small amount of soft marrow, containing the usual constituents of foetal marrow,—*i.e.*, medulla-cells, and myeloplaxes with oil-globules.

Exostosis, or, more correctly speaking, hypertrophy, of the tuberosity of the maxillary bone, the condition shown in Fig. 567, is a quite frequent affection, being associated, as the author infers, with the continuous excitability engendered in this part by that elongatory process which terminates only in adult life. The propriety of operating upon these cases is to be determined by the individual conditions. The majority of such tumors are safely to be let alone, as they exhibit little or no disposition to change from year to year. Associated with these hypertrophies the author has met with neuralgia of such severity that only through section of the affected part could relief from suffering be procured.



## CHAPTER LXIII.

### THE TUMORS OF THE MOUTH.

#### SELF-EXPLAINING CYSTIC TUMORS.

THE self-explaining cystic tumors of the jaws are, all of them, dental: of this the author is now entirely satisfied. In a former edition of this work\* these cysts were described as being of two kinds, simple and compound: the first, the simple, were alluded to as mere expansions of the outer plate of the bones,—wind-bags, the old writers called them. The second class, the compound, were described as cysts containing peculiar contents, which contents induced the cysts and constituted the lesion to be studied; such contents being teeth in a state of full or partial or anomalous development, the tumor being the odontocoele, or, as it might as well be termed, the dentigerous cyst.

**The Simple Cyst.**—All writers on surgery have remarked the existence, in the mouth, of this form of tumor,—a simple expansion of the bone, with varying fluid of gaseous contents. Different authors differently describe and name them. The term *spina ventosa* is, perhaps, about the most unmeaning that has been applied. As the author *knows* them, their history may be written as follows: there is first remarked on the side of the jaw, either superior or inferior (no preference seems to exist), a slight flattened enlargement; this increases slowly, until the swelling reaches the size of half a hickory-nut; they are seldom seen larger. No pain attends the growth, and, outside of the mental disquietude induced, no functional or other disturbance associates. The slowness of growth is such that it may require from one to three years to reach the size alluded to. This tardiness, absence of pain, and of constitutional disturbance form marked diagnostic signs. Another sign, one on which most writers lay particular stress, is the giving forth, on pressure, of a parchment-like crackling; with this last the author seems to have had a peculiar experience, for, while he has treated quite his share of such cases, it has not been his experience to find such crackling sound in any one of them, and while of course it would ill become any individual to assert that such a crackling is never to be heard, yet it is to be impressed that the sign is not by any means a constant indication, consequently is not to be given a heed demanded for it. In most of these tumors, septi, more or less in num-

---

\* Diseases and Surgery of the Mouth, Jaws, and Associate Parts.



ber, have been found supporting the vault ; with the presence of such pillars, it is evident that yielding would be out of the question, so that the practitioner is not to be deceived by the firm character of the growth. The gum covering such cysts is always perfectly normal,—no congestion, nothing indicating implication ; a matter important to observe, as, should the diagnosis be in any wise obscured, the practitioner has at least the satisfaction of feeling a tolerable assurance as to the benign character of the disease as well as of its non-acute character.

Of the number of cysts of this class treated by the author, every one has been situated in the outer or vestibular walls of the bones. Why they should have been so located, or indeed whether it is always the case that they are so found, he does not know. An individual experience alone is offered.

A diagnosis made out, correction is simple. A common treatment, and one generally practised, because of its little trouble, is to make a crucial incision through the body of the tumor, and, breaking up such septi as may exist, stuff the cavity with lint saturated with the tincture of iodine : this, if there be no foreign body in the cavity, as, for instance, the root of a dead tooth, will invariably cause the base to throw out granulations, and thus obliterate the cyst.

Another mode not infrequently resorted to, is to dissect from the tumor, in flap-form, the overlying gum, and with a chisel or the bur of an engine cut away the vault of the cyst. The parts are next carefully syringed and the flap laid back. This latter operation requires much more time, more skill, and gives more pain than the other. The first is not nearly so objectionable to the patient, and is likely to be equally effectual.

Concerning hemorrhage, little anxiety is to be felt ; it may be necessary to syringe the cavity with a little alum-water, or some other astringent, but even this is not commonly necessary.

CASE.—Mrs. C., aged about twenty-one, applied to the author for treatment of a tumor occupying the canine fossa of the left superior maxillary bone. The growth had been eighteen months in progress ; was about the size of half a walnut, perfectly solid to the touch, painless, and entirely healthy-looking ; the disquietude of the patient was purely mental, her mother having died from scirrhus cancer.

*Diagnosis.*—Simple cyst.

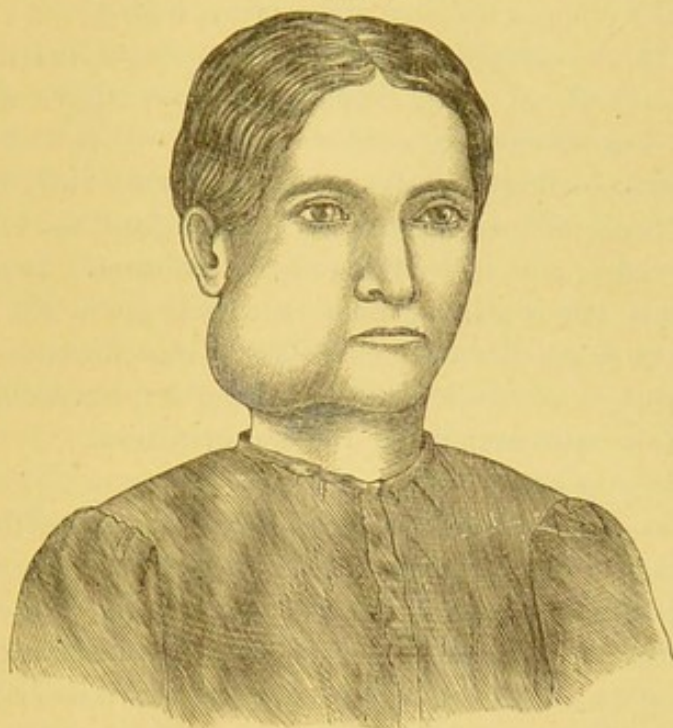
*Treatment.*—Crucial incisions were made ; several delicate septi of bone, which the cuts revealed, were broken up ; the cyst was injected for the first three days with weak stimulating liquors. No inflammation developing, tufts of cotton were saturated with tincture of iodine, and the cysts stuffed with them. In one week the site of the cavity was occupied by healthy granulations ; in three weeks the patient was entirely cured, and left the city for her home in an adjoining State.

CASE.—About nine months back, a German woman applied with a cystic tumor, similar to the above ; it was certainly as unyielding as solid bone.



This tumor was treated by making a crucial incision through the soft parts alone; the flaps were then dissected off, and the cyst, being exposed, was cut away with a chisel-shaped instrument. The flaps fell naturally into the

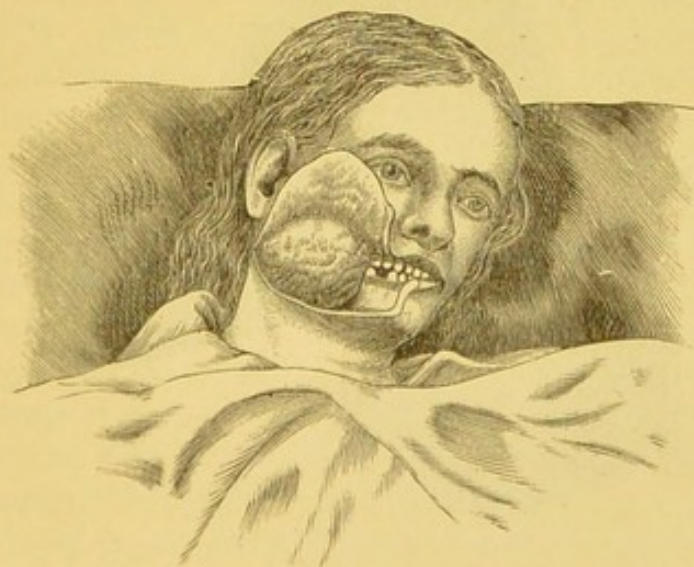FIG. 569.



cavity, and were left, even without a stitch, to take care of themselves. The cure was complete in about a week.

Figs. 569 and 570 show the external and the uncovered appearance of a

FIG. 570.



cystoma successfully removed by the author at one of the clinics of the Philadelphia Hospital of Oral Surgery. This tumor had been some two years in progress of development. It presented certainly a threatening appearance and



was variously diagnosed by different surgeons. The origin was in a diseased wisdom-tooth. In the extirpation it was found to involve all the body of the bone extending from the cuspid tooth to the sigmoid notch. Internally were several septi. The feature of the cyst was that of osteo-enchondroma. The patient recovered without a bad sign and remains well.

The above, with the exception of the last case, constituted the description and the illustrations offered of the simple cysts in the edition alluded to; but in the mind of the writer there existed a degree of confusion, because in some of these cysts nothing was found, and a tumor strictly local, as these always prove to be, should not be without local explanation. This explanation has been found in a more careful study of the cases. In every instance over which proper inquiries have been extended, origin has been demonstrated to exist in dental disease. Close observation, in most of the cases, discovers some part, it may be a mere particle, of an unabsorbed tooth-root.

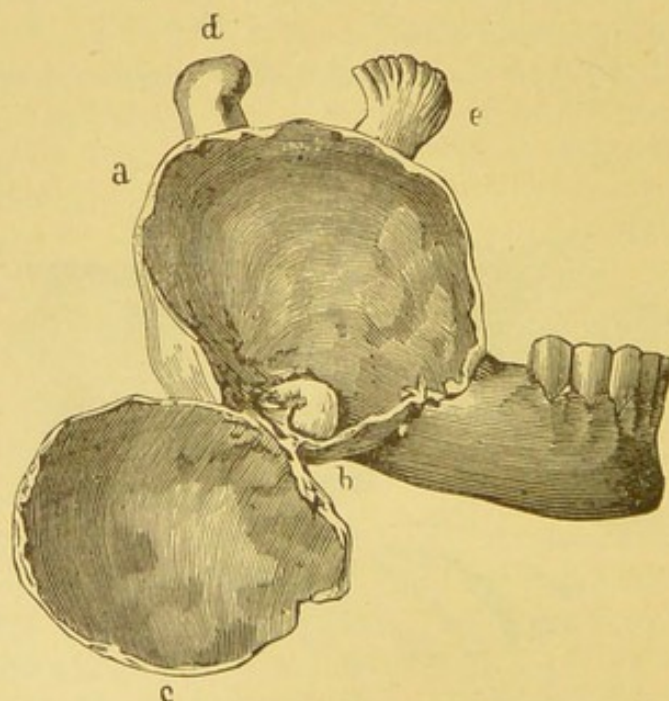
Odontocoele is the most common of the oral cystomata.

An odontocoele proper is exhibited in Fig. 571.

In the diagram a large tumor is recognized to have existed in the body of the lower jaw, cystic in character, as seen by the section *c*, the exciting lesion of which, *b*, a tooth-crown, is seen lying in the cavity.

The diagnosis of an odontocoele is seldom a matter of difficulty. The illustration last presented is the subject in its simplest expression; from this the

FIG. 571.



lesion varies to the complex dentigerous tumor, an example of which is presented on succeeding pages.

An odontocoele may present itself in any part of the ossa maxillæ, and,



what is of much consequence to be remembered, may have, as the lesion of departure, a supernumerary tooth.

The absence of a tooth or teeth from the arch through non-development, conjoined with the presence of a non-vascular tumor, affords inference of the existence of odontocèle.

In the case of supernumerary teeth, or of doubt as to absence of teeth through non-development, the use of the exploring-needle, striking the glossy, slippery enamel, will always explain the ordinary condition.

EXAMPLE.—A young lady, aged sixteen, presented herself, having a tumor, intramaxillary, evidently, occupying the anterior left side of the hard palate. Her exact condition was as follows. She had never had a tooth of the permanent set extracted, yet she lacked, to make up the complement common to her age, the canine of the affected side. The tumor was, of course, an odontocèle, or at least so great was the probability of such being its character, considering the absence of the tooth from the dental arch, that any surgeon would feel justified in founding a proposed operation on such conviction. An exploring-needle verified the conclusion.\*

A few years back the following interesting case of odontocèle came under observation of the author. The patient, desiring a set of artificial teeth, had, about a year previous, all the teeth of the upper jaw extracted, and, as is customary (not desiring to wear a temporary denture), had been dismissed for a period of some four months to await alveolar absorption. At the end of that time the impression of his mouth had been taken, the parts being in healthy condition. The teeth were made, placed in position, and worn with entire comfort for a period of a year.

About eight weeks before presenting himself, these artificial teeth had been found getting loose, as if from some projection at the right border of the myrtiform fossa. Applying to his dentist, surprise was expressed at the occurrence, and advice given that developments be awaited. At this period the gums were more or less congested, and were putting on quite an angry appearance; a few days later a fistula formed. His adviser, confident that no portion of the roots of any of the teeth had been left in the jaw, now dismissed the case, advising him to seek surgical assistance. In this condition he came under observation of the author.

The case now presented the following features: much engorgement of all that portion of the gum and lip covering the incisive and canine fossæ, which engorgement extended in a triangular direction to the inner canthus of the right eye; much soreness on pressure over all the affected parts, the fistula discharging thin and occasionally bloody pus.

Examination with the probe gave the impression that it struck against the root of a tooth, which would certainly have influenced the making up of

---

\* Refer, for proper appreciation of the subject, to chapter on Anomalies of Second Dentition.



the diagnosis if experience had not suggested that no tooth could, under ordinary circumstances, have a fang extending such a length.

Deducing from the conditions present the imperative necessity for an exploration, and the patient willingly acceding to the conclusion, the following course was pursued. The parts being exposed, a pointed and somewhat delicate-bladed bistoury was passed from the superior fleshy boundary of the canine fossa to the inner canthus. The cut passed not only through the soft parts, but, in the return, sunk readily into the bone. A first flap was now dissected posteriorly from the dead mass: a second was bounded mesially by the nasal bone, ala, and left prominence of the myrtiform fossa. The blood being sponged away, there was discovered, lying in the very centre of the carious bone, a cuspid tooth of ordinary size and development, the apex being in immediate relation with the floor of the orbit.

That this tumor had existed for a long time is, of course, not to be doubted, but it attracted the attention of the patient only on setting up acute inflammatory action. This inflammation soon destroyed the integrity of the vault of the cyst: hence the softened carious state in which it was found. The interest associated with the lesion lies in the absence of all the teeth by extraction, and the consequent loss of data for a diagnosis. A tumor precisely similar is described by Dupuytren.

A case of odontocoele, deserving to be put forward as illustrative, occurred in the practice of Dr. David Roberts, treatment being conducted by the writer in consultation with that gentleman.

Mr. T., a person of wealth and leisure, wearing a partial set of artificial teeth, noticed that the four natural incisors of the superior jaw were loosening. This trouble increased until the living teeth were about to drop out. Anticipative of that accident the organs were extracted. Following the removal exuberant granulations filled, and depended from, the cavities. Examination with a probe revealed the bone to be in a condition of caries. Development showed the expression of fungus hæmatodes. Diagnosis being in abeyance the concern felt was very great.

The meaning of the case turned out to lie in an encysted canine tooth of uncommon size, occupying a position in the floor of the nasal fossa midway between the anterior and posterior openings. The writer, in an experience of thirty years, has met with no case more confusing. A diagnosis was secured only by cutting away the carious bone on the supposition of an existing local lesion; this supposition arising out of absence of dyscrasic expression.

Osteo-dental tumors dependent on the development of supernumerary teeth are not uncommon; they are generally easily recognized from their position and size, being seldom larger than an ordinary pea, and mostly situated in some part of the palatine processes of the superior maxillæ. Any obscurity, however, is readily dispersed by thrusting a bistoury into them, or, as suggested, the exploring-needle. The dental surgeon, particularly, would remark from the sense of touch whether or not the contents are tooth-substance.

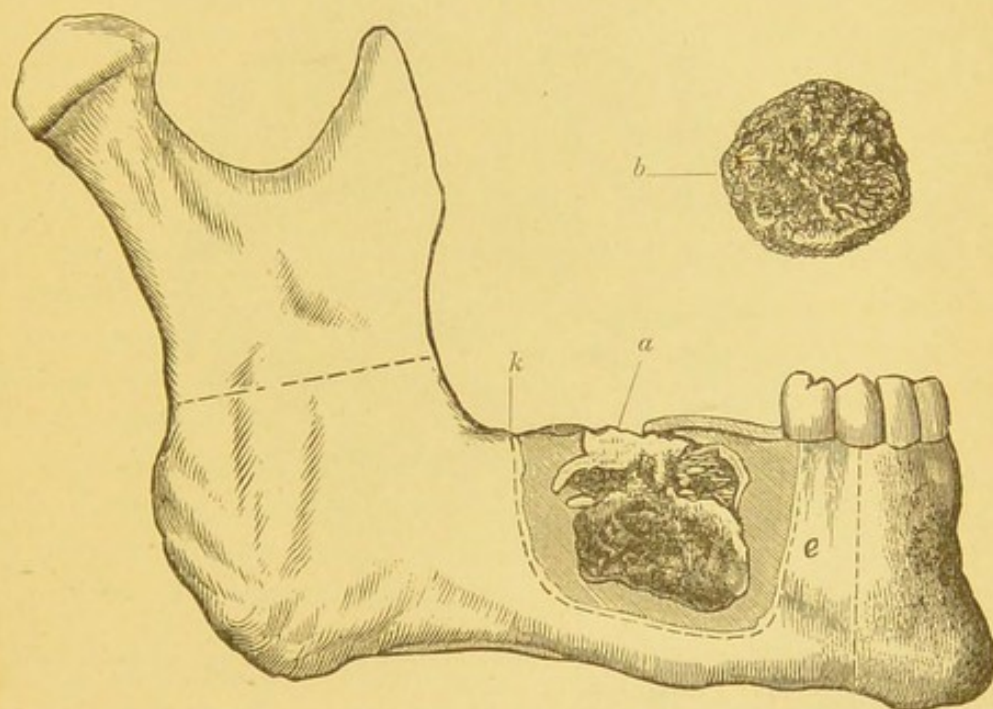


Osteo-dental tumors not infrequently have as their cause undeveloped teeth. Only a few days ago the author saw a couple of bicuspid crowns, evidently long dead, which had been removed from one of these oral compound cysts.

Such osteo-dental tumors, then, as just illustrated, may be viewed as the most simple of these compound cysts. Another class, the complex osteo-dental, may now claim attention.

Taking advantage of illustrative cuts kindly furnished by writers and publishers, two cases are shown which cover the ground of a required study perfectly; both being anomalous, indeed almost unique. Fig. 572 shows an

FIG. 572.—AN ODONTOMA.



odontoma, or tooth-tumor, in position. The outer, enveloping, plate is removed with view to the exposure. This growth, looking in its bed, *k*, *e*, so indistinguishable, and not less so when isolated, *b*, is yet easily demonstrated by microscopic section to be an expression of odontocoele.

On the top of the tumor, as is seen, is a portion of the enamel of the crown of a tooth, *a*, very much like a half-decayed deciduous molar. The part below this, in external appearance, was rough on the surface, and seemed dense in structure, with the exception of a concave surface on the bottom of the tumor, which was quite porous. Sticking out from this surface were a number of spines, between which were minute openings into the centre of the tumor for the passage of these vessels.

Alongside of this were two other concave surfaces, not so deep, but dense and somewhat smooth, produced by the cusps of a molar tooth found below the tumor at this point. These cusps were probably a part of the first per-

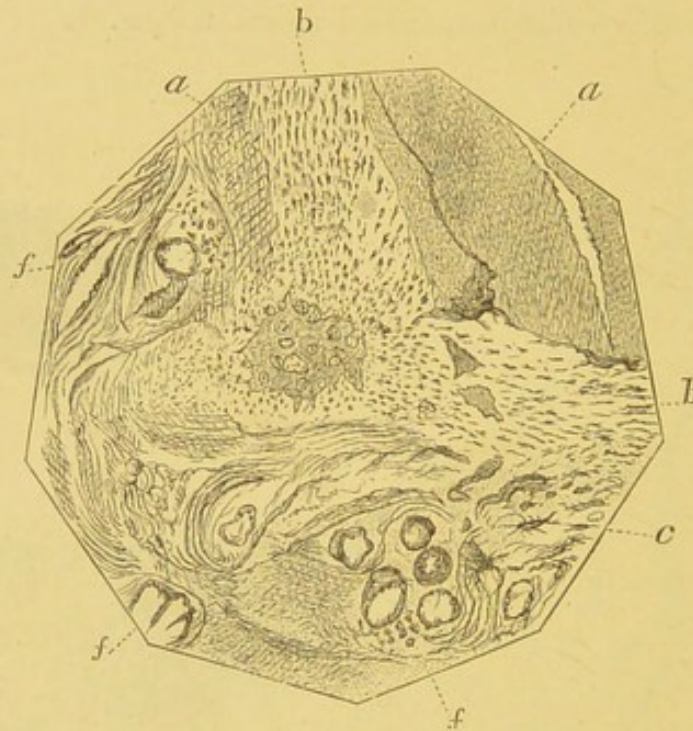


manent molar, and the tumor was composed of the elements of the last deciduous molar. No other teeth were found.

On making a section of the tumor, there were seen columns or spiculæ running from the circumference to the centre, forming quite a net-work, in which the pulp was held, so that, instead of there being one pulp-chamber, there were many.

Fig. 573, drawn from a section of this tumor, made by Drs. Goodwillie and

FIG. 573.



*a, a,* represents the enamel at the top of the tumor penetrating into fissures, or depressions, in the mass below.

*b, b.* Here is represented the dentine; passing from the centre in two directions,—in one instance passing between two layers of enamel, and in the other between enamel and cement.

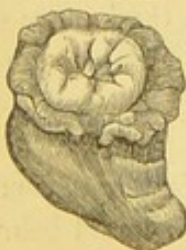*c.* The cement is here seen, recognized by the presence of lacunæ.

*f, f, f,* represent the fenestræ, once occupied by the dental pulp. Around some of these may be seen distorted dental tubuli.

Arnold, represents the dental tissues in their deranged and distorted condition. The internal structure is seen to be very much fenestrated.

A curious case, diagrammed for the *Dental Cosmos* by Dr. C. N. Peirce, the

FIG. 574.



tumor having been ablated by Dr. A. B. Eastman, of Wellsboro', Pennsylvania, will command interest. In the preceding chapter reference is made to a condition evidently of similar signification, but another periodontal proliferation, or hypertrophy, so extensive as that here shown is not familiar to the author as being on record. Histologically the growth is described as not being very widely differentiated. Its upper part, or that portion which surrounded and almost buried

the crown of the tooth and which presented a somewhat granular appearance,



is delineated as being composed largely of a proliferation of impacted epithelial cells so dense that quite an effort was required to separate them sufficiently for an accurate examination.

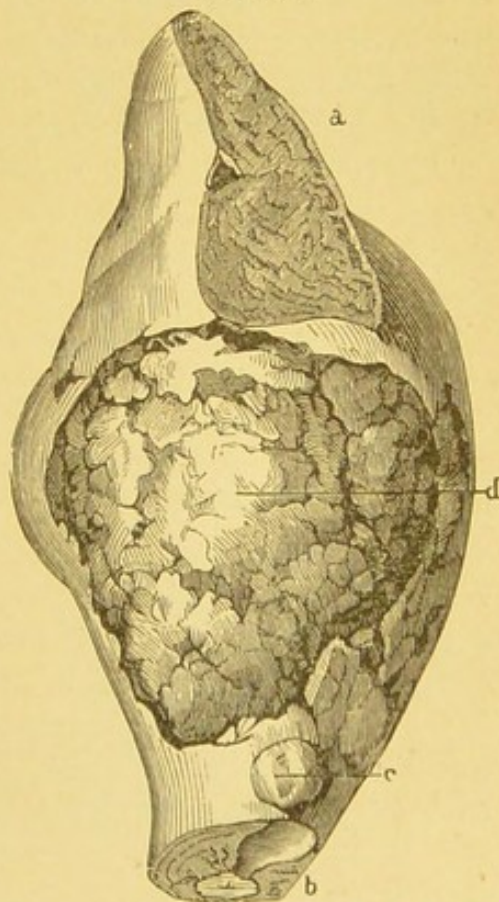
The lower part of the tumor, or that division which was entirely within the walls of the alveolar process, was still more dense, forming a structure hard and leathery in appearance; like the upper part it was composed of epithelial cells, with a tendency to a linear arrangement containing various amorphous patches of the salts of lime, showing quite an effort at calcification,—a condition occasionally presenting itself in the periodontal membrane without causing much deviation from normal appearance of function.

The feature of interest lies in the fact that the envelope is part of the tooth. Periodontal thickenings are not at all rare, the writer has seen cases counting by hundreds, but accepting that here shown as photographically correct it is exceptional. It is only, however, in a special sense that the condition is to be allied with the odontomata.

An odontoma, the most heterologous example found illustrated in surgical literature, was presented, together with a prize essay thereon, by M. Forget to the French Academy. Fig. 575 shows the tumor as it lay in the section of jaw removed. The commencement of the disease was by pain, at first intermittent, afterwards continuous and acute. When the patient was seven years of age, two small healthy molars were extracted, under the impression that they were preventing the evolution of the second teeth. The operation gave great relief, and the pain ceased. Shortly afterward a small, round, hard tumor appeared on the external face of the jaw, near the alveoli of the teeth that had been removed. The growth caused no suffering to the patient, and made no sensible progress for a period of eight years. After this the left side of the jaw became tumefied, and the bone, in the language of the patient, broadened and rounded. He also observed, at this time, that the large molars, which were regularly developed on the right side, were wanting in the diseased part.

This morbid enlargement was accompanied by frequent fluxions of the gums, cheek, and whole left side of the face. The recurrence of this perversion was attended with great pain, and caused an increased tumefaction in the

FIG. 575.





soft parts to such an extent that the difference between the sides of the face became absolute deformity.

Later a violent inflammation occurred in the base of the jaw and the cervico-maxillary region. Antiphlogistic treatment was employed, two applications of leeches were made, and the inflammatory symptoms decreased, and, fifteen days afterward, purulent matter formed. The thick part of the cheek opened spontaneously, allowing the issue of a large quantity of fetid pus. The opening of the abscess became fistulous, the surrounding tissues then detached, and the bone under them was naked for a very considerable extent.

The case is thus described in the memoir. The disease appears externally in a considerable tumefaction of the left cheek, which is more than three times its natural size, and the tumor has caused a very marked eccentric development of the corresponding maxillary bone.

When the patient opens his mouth, which he does without effort, the whole left side of the bone is seen to resemble a large turkey-egg,—the base of the jaw being confounded, without appreciable line of demarkation, with the internal and external faces, which describe a very considerable curve.

The tumor is uniform, without depressions or any irregular swellings upon the surface. It does not yield to pressure, and no part of it gives that sound of crepitation which is characteristic of attenuation of the osseous tissues. The external swelling hides the superior and lateral parts of the neck; the enlargement of the bone has forced the tongue from its true direction, and the floor of the mouth has been driven from the left to the right.

The alveolar ridge, singularly enlarged, contains none of the grinding teeth, except the first bicuspid, which stands regularly in its socket. The tissue of the gums is dark-red, and unusually thick and hard. In a circumscribed spot, about the size of a twenty-centime piece, the tissue is broken, and exhibits an unequal, wrinkled, grayish surface which gives a dry sound when struck with a metal, as if the crown of a tooth were hidden in the cavity.

In order to complete the symptomatic description, it is added that there are many ossifluent fistulous openings at the base of the tumor, and much hypertrophy and hardening of the submaxillary lymphatic ganglia.

The functional disorders arising from the pathological condition, at first very slight, are noticed at this stage as increasing every day: embarrassment of vocal utterance, mastication painful and incomplete, deglutition effected with difficulty, and respiration much impeded every time inflammation is renewed in the tumor; lastly, the patient suffering from two serious inconveniences,—one, the very marked deformity of the face; the other, the incessant flow of fetid pus, proceeding from the complicated fistulæ of the osteo-dental caries.\*

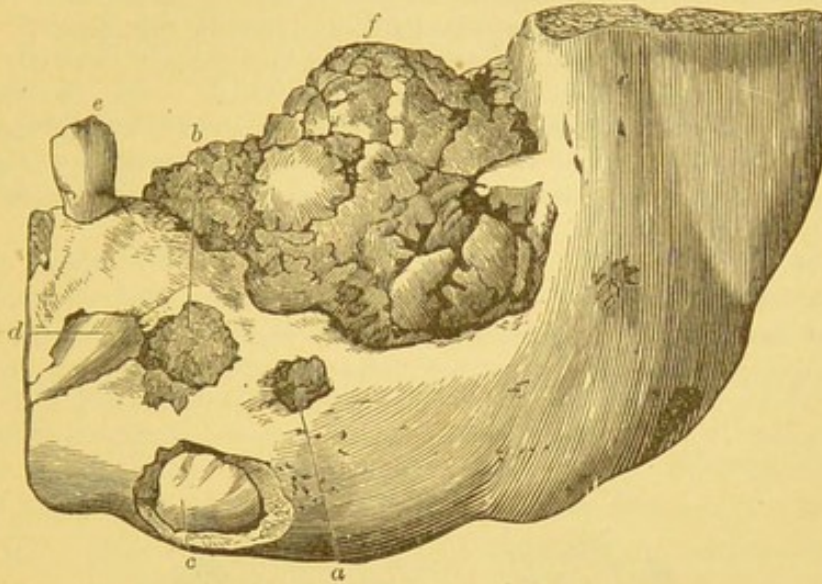
\* ANATOMICAL EXAMINATION OF TUMOR.—With the surrounding soft parts, the tumor is described as being an exact ovoid. The tissues, adhering to its external face, were found marked with many fistular passages, ending at inflamed and ulcerous points of osseous structure. This tissue was thin, soft, and depressible, and perforated by two orifices leading into the interior of the cyst, from which exuded a purulent, viscid, reddish liquid. A stylet



M. Forget, in presenting his case to the French Academy, remarked that it was a duality of anatomical and pathological lesion, so rare that, after the

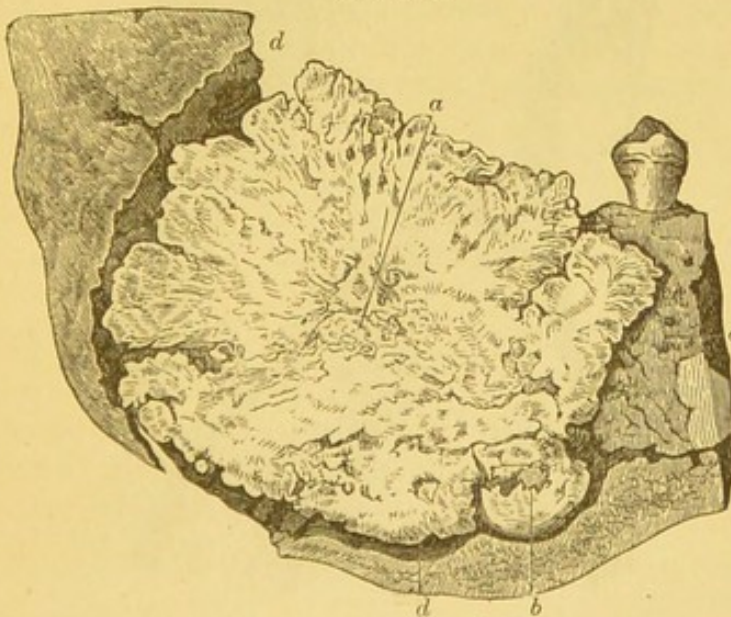
introduced into one of these passages was stopped by a hard body, which, under percussion, sounded like a compact tissue deprived of its periosteum. This object was reached by dissecting off the gums, which, condensed into a thick bed, formed a sort of operculum for the upper part, completing the cyst in which the morbid product was situated. The

FIG. 576.



dissection exhibited that the jaw from the ramus to the premolar had been changed into a cavity containing a compact, saxiform, ovoid mass, the size of a large egg, grayish, unequal surface, studded with small tubercles, surrounded by a bed of enamel, and completely buried in the thick part of the bone. (See Fig. 575.)

FIG. 577.



Next, the tumor was divided along its axis into two unequal parts, each confined to the corresponding half of the osseous cyst that was comprised in the division. This revealed the composition of the tumor: it was formed of a smooth, glossy, compact, homogeneous, ivory-like tissue, of a whitish-brown color. In the centre of it a kind of regular disposi-



strictest research, he was led to believe it unexampled in the human species. Accepting this, we have here, side by side, extremes. Understanding each,

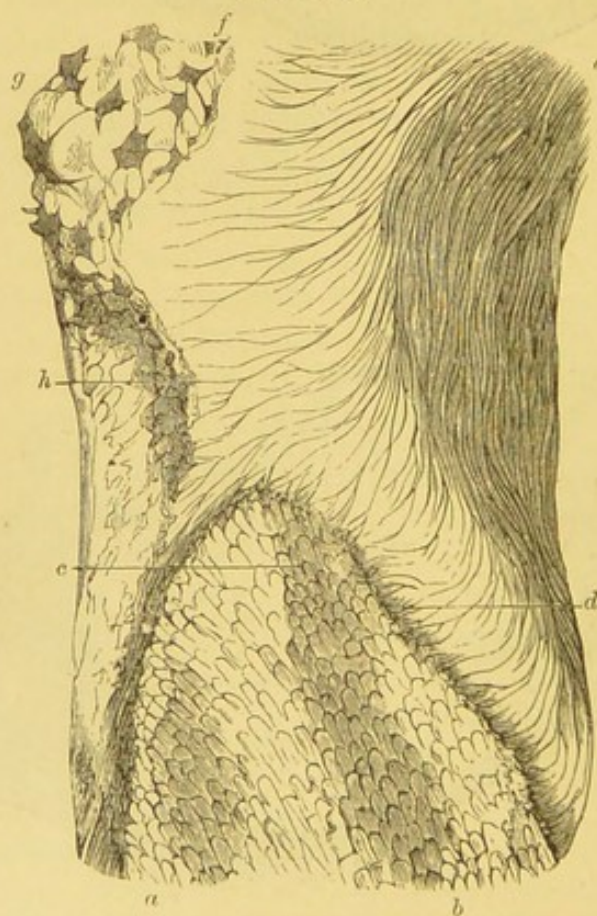
tion of its elements is described as existing, discernible by the naked eye. (See Figs. 576 and 577.)

Between the tumor and the wall of the cyst was a thick, fibro-cellular tissue, free on the side of the former, where it covered the whole intramaxillary portion, and was joined to the latter by filamental prolongations of a cellulo-vascular appearance,—these being attached to the numerous openings that covered the face of the cyst. The external surface of this membrane was bathed with a muco-purulent liquid, smelling like dental caries.

At the base and anterior extremity of the tumor, an indentation is described fitting the crown of a large molar that stood between it and the maxillary bone. (See Fig. 577, *b*.) A portion of the same tooth caused a slight elevation on the external face of the jaw. (Fig. 576, *c*.) M. Forget also describes the tooth encountered in the operation. (Fig. 576, *d*.) Its location, as will be seen, is directly beneath the alveolus of the first molar, which is standing in its true position. (Fig. 576, *e*.)

All the teeth, with the exception of the last two molars, it will thus be seen, were found, and the space appropriated for them was filled by the tumor. What, then, queried M. Forget, could have become of these two great molars? It could not be, he argued, that the bulbs, compressed from their very origin, had disappeared without leaving a single vestige of their existence. The numerous instances, he held, that had occurred of the simultaneous development of teeth and anomalous productions in the very centre of the maxilla

FIG. 578.



would not allow him to think of accepting such an explanation. In all the analogous cases that had fallen under his observation, the teeth were of the ordinary dimensions, and complete in number, although removed from their normal position, and sometimes buried even in the morbid substance itself.



there is not likely to come anything between that we may not be able readily to explain.

A dental germ assuming or compelled to an abnormal position may have various sequelæ. It may make a mal-eruption; it may remain encysted; it may die after partial development, or it may present heterogeneously.

We have, then, but to consider heterogeneous development, and we have mastered the pathology of the lesion and all its various phases.

First, let us dissect a tooth,—for the parts of a tooth are the parts of such tumor. A tooth is made up of enamel, dentine, cementum, pulp-substance, periodontium, and tunica propria.

**Enamel of the Teeth.**—Cortex strata, adamantina dentium; crusta dentium adamantina; substantia vitrea.

The enamel of a tooth is that portion which caps the crown. In structure it is fibrous; its fibres radiating from the centre to the surface.

In microscopic structures, the enamel (Owen) consists of long and slender, solid, prismatic, for the most part hexagonal, fibres of phosphate, carbonate, and fluorate of lime; which are essentially the contents of extremely delicate membranous tubes.

**Dentine.**—Os dentis, substantia ossea ebur dentis. This is the portion of the tooth between the pulp and the cementum and between the pulp and the enamel, the tunica propria intervening. It makes up the great body of the organ. Dentine is composed of numberless tubules, these being not smaller than the one-four-thousandth of an inch in diameter; their course is waving, each tubule having several curves resembling, according to Retzius, the Greek letter  $\vartheta$ . "Professor Retzius confirms the observation of Müller, that the tubes contain an organic earthy matter in granular masses, which disappears under the action of dilute muriatic acid. The cells, and the small

Let us now, that we may fully comprehend such a class of cases, pursue the study of this particular one.

Fig. 575 represents the left half of the body of the inferior maxillary bone, hollowed into a large cavity, containing an ivory-like bony tumor.

*d.* Side view of the alveolar edge.

*a.* Orifice of the dental canal upon the surface of the resection of the bone in the continuity of the ramus.

*b.* Plane of the cut in front, showing the second small molar which was found in it.

*c.* Crown of the first molar, in regular position.

Figs. 576 and 577. The two halves of the anatomic section, divided according to its axis (osseous cyst, and included tumor).

Fig. 576.—*c.* Crown of great molar, seen through a notch in the outer wall of the cyst.

*d.* Second small molar.

*e.* First small molar.

*a* and *b.* Points of the same wall, perforated by the prolongation of the tumor.

*f.* Summit of the most elevated of these.

Fig. 577.—*a.* Interior aspect of the tumor.

*b.* Great molar inverted.

*c* and *d.* Cellulo-fibrous membrane, interposed between the osseous cyst and tumor.

Fig. 578. Microscopical appearance.



tubes which radiate from them, also contain earthy matter, as in bone. They are naturally white and opaque, but, after maceration in dilute muriatic acid, become colorless and transparent."

Chemically, dentine differs from enamel principally in the absence of the fluorate of lime.

**Cementum—Crusta Petrosa.**—The cementum of a tooth is that portion which invests the fangs. In character, it corresponds quite closely to the osseous structures. The microscope demonstrates clearly the existence of Haversian canals, and the so-called corpuscles of Purkinje, or, as Robin prefers to term them, osteoplasts.

In growing teeth, with fangs not fully formed, the cement is so thin that the Purkinjean cells are not visible; it looks like a fine membrane, and has been described as the periosteum of the fangs, but it increases in thickness with the age of the tooth, and is the seat and origin of what are called exostoses of the fangs, which are wholly composed of it. It is the presence of this osseous substance, says Professor Owen, which renders possible many well-known experiments of which the human teeth have been the subject; such as their transplantation and adhesion into the combs of cocks, and the establishment of a vascular connection between the tooth and the comb, etc. Under every modification, the cement is the most highly organized and most vascular of the dental tissues, and its chief use is to form the bond of vital union between the denser constituents of the tooth and the bone in which the tooth is implanted.

**Dental Pulp.**—The pulp is that vascular, reddish-gray, highly-sensitive substance occupying the cavity of the tooth. It is made up of delicate connective tissue, in which ramify the dental nerve, artery, and vein.\*

When, says Mr. Nasmyth, the internal structures of a dental pulp are examined, the number of minute cells which present themselves in a vascular form is remarkable; they seem, indeed, to constitute the principal portion of its bulk. Mr. N. describes them as "varying in size, from the smallest microscopic appearance to one-eighth of an inch in diameter; and as being disposed in different layers throughout the body of the pulp." This tissue is highly endowed, and, perhaps, more liable than any other portion of the body to take on morbid action; fungoid degeneration is, perhaps, its second most common disease.

**Periodontal Membrane.**—This is the periosteum of the tooth. Anatomically and physiologically it differs little from this general class of membranes. Pathologically, it may be remarked as being more susceptible to disease, and more disposed to assume quickly acute perversions. For example, inflam-

---

\* Exception is taken by so eminent an observer as Dr. Atkinson, to the existence of vessels proper within the pulp. This gentleman, whose learning and keen sense of observation commend his inferences to the professional reader, prefers to consider the nutrition as of capillary signification.



mation of the periodontal membrane is easily provoked, and, once inflamed, the part is ever after surprisingly prone to reassume morbid action.

Familiar with tooth composition, we turn to Fig. 578, and trace a perversion of development in the structures,—see them forming a tumor, strictly dental, yet to the last degree anomalous and abnormal.

We refer here to the microscopic examination of M. Forget's odontoma, made and noted by Professor Ch. Robin, Fig. 578 (400 diameters). This figure represents a portion of a slight cut made into the tumor represented in Fig. 577, *a*. The preparation is taken from near the free edge, or the irregularly mammillated surface of the tumor. The latter is formed principally of the ivory or dentine, easily recognized upon the thin section by its very fine tubes, disposed in parallels, or nearly so, through part of their extent (Fig. 578, *e*).

These tubes, radiating more or less regularly from the little depressions or cavities observable in the mass of the tumor (Fig. 577, *a*), very near to each other through part of their extent, become more rare, fine, and ramified as they approach the surfaces of the dental tumor (Fig. 578, *d, f*), and end in a very sharp point toward the lines of junction between the ivory and the enamel (*a, b, c*), and the cement (*f, g, h*). The presence of the ivory, which forms the greater part of the tumor, demonstrates its dental nature very clearly.

**Enamel.**—Another important particular is the presence of the enamel on the surface of the tumor, where it in some measure covers the irregularities with a varnish which moulds itself upon them in order to penetrate more or less deeply into the fissures or depressions that divide the growth superficially into lobes.

This bed of enamel varies in thickness from microscopic dimensions to a millimetre (.03937 inch), or near it, and is as irregular in places on the lower or adhering face as it is on the free surface, which the microscope alone allows to be seen. The portion of the section of the tumor that is here delineated (Fig. 578) is taken at the level of one of the points where the enamel (*a, b*) in a manner penetrates (*c*) into the body of the ivory mass of which the tumor is principally formed.

The enamel is easily recognized by its narrow prisms, from six- to eight-thousandths of a millimetre in width, which are in immediate juxtaposition (Fig. 578, *a, b*). The figure shows them inclined, as by the accidents of the cuts in making the section. When the cut is perpendicular, or nearly so, to their greatest axis, their prismatic form, with five or six faces, is easily seen; this is shown in the neighborhood of *b*, Fig. 578.

**Cement.**—In the depth of the fissures, and here and there in the mass of the tumor, near its surface, and especially that part of the surface hidden in the adventitious cavity of the maxillary bone, the microscope discovers some trails or beds of variable thinness, formed entirely of the substance of the cement (Fig. 578, *g*).



The cement is inclosed between masses of ivory, and is consolidated by the immediate contact (Fig. 578) with the masses between which it lies. It extends itself in places with the surface of the tumor to the neighborhood of, and even to contact with, the enamel. The section represented in the plate is taken at a point that shows this arrangement (Fig. 578, *f, g, h*). There are, besides, thin pieces of cement extending far forward into the body of the tumor.

The cement is known to be no other than the osseous substance. The figure before us exhibits the characteristic elements belonging to it. These are the microscopic cavities, called osteoplasts, or, incorrectly, osseous corpuscles, for they are excavations. The air that fills the dry bone makes these cavities appear black under the microscope (Fig. 578, *g*); but in the fresh state they are full of liquid, and are pale and more difficult to observe than in the dry pieces.

These cavities, which are in breadth and length from one- to three-hundredths of a millimetre, are always of very irregular shape, on account of the presence of the fine tubes that start from all their peripheries and traverse even the substance interposed between the osteoplasts.

The best-joined pieces show that these little canals are subdivided two or three times, and are then inosculated with those of neighboring osteoplasts. The portion of cement shown in the plate does not exhibit this arrangement, which was visible, nevertheless, in the parts close to it.

The cuts in the tumor exhibit, moreover, little openings, that are either full of a grayish or brown pus, or empty. These small orifices are from two- to six-tenths millimetre and upwards in width, and from about one to two millimetres apart. The microscope shows that these orifices accompany the narrow, irregular cavities, sometimes in the form of elongated conduits, hollowed out of the ivory through which they pass. The instrument shows also that the tubes of the latter start from these cavities to radiate toward the surface of the tumor, in the same manner as those of the ivory in the normal tooth start from the natural cavity of the dental pulp. These narrow, irregular cavities, more or less elongated, traverse the mass of the growth, and some of them even reach within a few millimetres of the surface.

These cavities are, in reality, nothing more than the pulp-canals of this morbid product, either rugous from desiccation, or still containing some remnant of the dried organ in the form of a brownish or grayish powder.

**Recapitulation.**—The result of the observations of the case is thus epitomized by M. Forget :

1st. An original union of the follicles of the last two molars, followed by an intimate union of them, caused by phlegmasial or other action.

2d. Under the same morbid influence, the excess of vitality in the organic elements of the follicles has produced hypersecretion of an ivory-like osseous substance.

3d. That the irregular aggregation and diffusion of these constitutes the pathological growth.



4th and lastly. Its growth has formed in the cyst, and it has maintained therein a permanent inflammation which has disorganized the osseous tissue and altered the structure of the adjacent soft parts to such an extent that a radical operation is necessary.

Many curious illustrative instances might be mentioned of anomalous incongruities in dental evolution; but, as we are prepared to understand, all would be found in character the same,—enamel, dentine, cementum, pulp structure; arrangement only would differ. A practitioner using his eyes, or assisted by the microscope, is to be able to pronounce concerning any of them.

Ability to distinguish a dental from a malignant osteoid tumor must certainly prove a source of much satisfaction: for, as M. Forget has remarked, if intervention cannot be too radical in an instance of cancer, it is certain, on the contrary, that more caution and moderation are desirable when it is a question of a lesion which is essentially local and of a benignant nature, and allows the surgical operation to be restricted to the precise limits of the lesion, without its being necessary to provide against an improbable repetition by encroaching upon the osseous tissues that border it, thus subjecting the patient to a mutilation which could not be justified.

**Data.**—1. There are twenty teeth in the deciduous denture, which twenty are to be replaced by thirty-two, each of which is to be at least twice the size of its predecessor.

2. A contracted maxilla, having no accommodation for certain teeth, the germs of which are in the jaw, gives us, among other lesions, irregularity in dental evolution.

3. Irregularity in evolution yields morbid conditions, as described, which conditions are influenced, not unlikely, by peculiarities of the general organization and by manner of interference with development.

4. An overcrowded arch will surely yield periodontal and other minor troubles, and may produce lesions of grave character. The extraction of the bicuspid teeth of the permanent set is therefore to be practised, whenever time makes evident the existence of contraction on the part of an arch.

5. Dental tumors vary from simple cystic growths to such perverse and anomalous evolutions that the microscope alone is capable of explaining them.

6. A dental tumor is an abnormal growth, having its point of departure and development in irregularity of tooth evolution.

7. Dental tumors are benign; operations for their cure promise all success, and are to be practised in exclusive consideration of the disease as it locally exists.

8. The existence of a dental tumor is to be inferred, *cæteris paribus*, in case of deficiency and derangement in the dental arch.

The extent of very large cysts, as occasionally found in the lower jaw, involves in a treatment the preservation of the contour of the parts,—complete



section of the bone being never, as a primary operation, permissible. Such required precaution is best secured through the preparation of a plate fitting the teeth precisely as directed for fractures when the inter-dental splint is used. (See *Fractures*.) This plate, before the cyst is at all interfered with, is to be placed in position, and the jaw fixed in its place. This accomplished,—although it adds to the inconvenience of the treatment,—a cyst may be crucially incised and stuffed with very little danger of fracturing the continuity of the parts. Cysts of such delicate attenuation are, however, not at all common, a consolidating and supporting periosteal exudate counterbalancing to a marked extent the attenuation. The author, at the present time, has under treatment a cyst of the lower jaw quite the size of an ordinary orange, yet the bone seems as solid as iron. The patient in this instance, however, is a remarkably vigorous laboring man.

Cysts may have a self-explaining origin, yet, from the presence of a systemic vice, depart from their homologousness. As heteroclitic contents are met with, so will be found want of success in attempts at cure by the granulative process. The septi alluded to as seen so frequently in the simple cyst will be found at times replaced by what is known as the soft multilocular cyst. Again, the cavity will be found filled with a pulpy, liver-colored, turgid mass. It has been the experience of the author that exactly in the degree in which these cysts depart from simplicity, do they afford evidence of the change by the sympathy expressed in the overlying mucous membrane. (See *Cysto-Sarcoma*.)

In accounting for the formation of the ordinary dentigerous cyst, the hypothesis has been advanced that the condition is due to a morbid secretion into and enlargement of the capsule of the enamel organ: this, however, is certainly not the explanation, as the true enamel membrane—the tunica propria—is always found in a normal relation and position. That an effusion might have occurred between the enamel and its matricial membrane—the tunica reflexa—is barely probable, though possible; the enamel of the crowns of the encysted teeth being commonly too perfect to warrant inference of interference of any kind in the process of development.\*

---

\* The exciting causes are often unknown, and probably are various. The attempts of the impacted teeth to reach the surface have an exciting action in certain cases; but, on the other hand, such teeth may lie quiet in the jaw during the entire life, and cause no trouble, or may be found inclosed in a cyst after all attempt at growth had been given up for years. That the disease should follow the extraction or aching of carious teeth is not remarkable, considering how common these are at all ages; yet such irritation in some cases may have been the exciting cause as well as the obstinate resistance of a milk-tooth to the advance of its follower. In the first and second cases given in the tables the disease was evidently excited by the blows which preceded. The additional presence of undeveloped teeth in the jaw is, of course, essential in all these cases, for without these the affection *cannot exist*.

Whatever may have been the exciting cause, the pathology is essentially the same. The disease is due to a morbid secretion into and enlargement of the capsule of the enamel organ of the unfortunate tooth. This is shown by the position of the latter, whose crown lies exposed in and to a certain degree faces the cavity. This position serves to distinguish



The teeth most frequently found encysted are the cuspidati; this would be inferred from the relation of these organs. After the eye-teeth, the next in frequency are the dentes sapientiæ. According to the observations of Dr. Bolles, the sexes seem nearly equally liable. Most of the instances collated by this author are noticed as having occurred between the ages of ten and forty: one to ten, one case; ten to twenty, nine; twenty to thirty, nine; thirty to forty, three; forty to fifty, none; fifty to seventy, three;—the duration being between four months and thirty years; the lists of ages being at time of operations.

Dentigerous cysts, as would be inferred, are related with the permanent (or, as they would in this connection be better named, the successional) teeth. One or two exceptions, however, are related: one from the practice of Mr. Alexander Edwards, of Edinburgh, being in the person of a young man in whose upper jaw, just below the orbit, a tumor had developed. This tumor consisted of exostosis from the maxilla, combined with a bony cyst, containing a tooth which was pronounced by Professor Goodsir to be a temporary molar.

Of the various preparations in existence of cyst of the jaws, the largest with which the author is familiar is one in the Museum of St. George's Hospital. This immense tumor rested upon the clavicle when the head of the patient was thrown as far back as possible. It may be found figured in Holmes's System of Surgery, vol. iv. p. 459. An example in the author's practice showed a cyst eight inches in diameter.

**Cystiform Antra.**—Fig. 579 represents a cystic tumor, or, rather, expansion of the walls of the antrum, as occasionally met with. The cyst represented in the view occurred in the person of a young gentleman some twenty years of age, from whose jaw it was removed two years back. This cyst, the size of an ordinary orange, was successfully treated without external incision, the soft parts being dissected off by pulling outward and upward the angle of the mouth; the wall of the cyst, about the thickness of ordinary parchment, was cut away with a chisel. This particular cavity was without contents of any kind. After the removal of the vault, the soft parts were permitted to

---

this cyst from those instances where innocent teeth, before eruption, have become displaced by the growth of solid or even fluid tumors in which their own enamel organs bore no part, or other cavities which stimulate it, but are as distinct from it as hydrocele from serotal abscess. *If the fang instead of the crown project, it is not a true dentigerous cyst.*

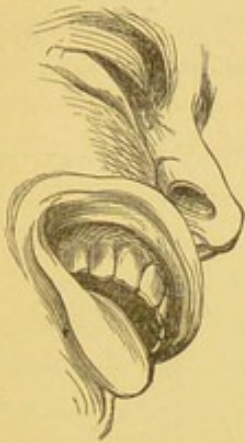Probably the reticular parenchyma of the enamel organ is destroyed by its expansion, but in the multilocular forms this may possibly aid in forming the partitions. The whole inclosure is lined with a serous membrane, which is sometimes considerably thickened and vascular, and continuous over the crown of the tooth, as would be expected from its origin. A microscopical examination of such specimens would be very interesting; it should show an absence of the "cuticula dentis" from the tooth and the continuousness of its covering, the enamel membrane, with the rest of the wall. The fluid is usually serous, but may be purulent,—contain cholesterine, flakes of lymph, or shiny matter, or vary in other respects. A bony exostosis in one case accompanied the cyst, and may have been the exciting cause of it. Other complications have occurred.—*Extract from a Prize Essay on the Dentigerous Cysts*, by W. S. BOLLES, M.D.



fall into the sinus: no deformity resulted, and no trouble has since been experienced.

An interesting feature in this character of cases is found in the tenacity on the part of the antrum, after operation, to maintain its office. The author

FIG. 579.—ANTRAL  
CYST.



has tried his best to obliterate a sinus by compelling granular activity about its walls, but so long as he has been enabled to watch cases (and in one instance seven months elapsed before the overlying tissues so covered in the parts as to conceal it from observation), in none of them has he been able to satisfy himself as to what was the subsequent condition of the part. His impression is, however, that the mucous membrane maintains itself, and that a species of cavity continues to exist.

Hydrops antri is another form of cystiform enlargement of this cavity. The dilatation in these cases is gradual and painless, and when the bone becomes expanded to any considerable extent, fluctuation is commonly apparent, the vault of the cyst yielding readily to pressure. If obscurity exist, it is to be removed by the use of an exploring-needle. It sometimes happens in these cases that the floor of the orbit becomes the yielding point, or it may be the canine fossa, the tuberosity, or the hard palate; the latter boundary, however, according to common observation, is the most frequent seat of the enlargement, forming a tumor within the mouth.

Hydrops antri depends, in many cases, on the formation of a cyst within the cavity. In others it is to be recognized as a simple mucous engorgement, the natural outlet into the meatus being, from some cause or other, obliterated. A very expressive illustration of the first of these conditions was exhibited in a specimen taken some three years back by the writer from the antrum of a young man. In this case the cyst seemed to spring from the root of the second molar tooth, or from its immediate neighborhood; the mucous membrane being dissected up, and covering the cyst as a kind of reflex tunic. Although this particular tumor was not large enough to exhibit external evidence of its existence, yet there are no reasons for inferring that more extensive tumefaction would not eventually have resulted. A case of interest in this direction is recorded in the practice of Dr. Chase, of Iowa City, who reports it in the *Dental Cosmos*, accompanying the account with a diagram.\*

\* DESCRIPTION OF CASE.—An Irishwoman, aged forty years, came to have the right first upper molar extracted. I found her teeth in a bad condition generally: they were decayed and loose, and the gums congested. This particular tooth was decayed and very loose. On pressing it, the alveolus seemed to move with the tooth. Adjoining it in front was the root of the second bicuspid,—the crown gone.

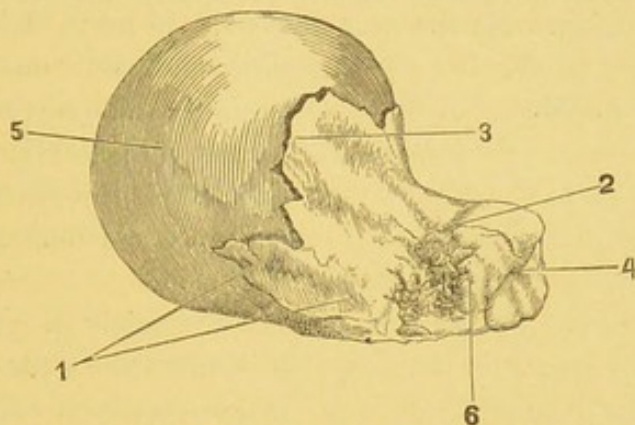
As she was of that class who make no attempt to preserve their teeth, I extracted the molar without hesitation. She had told me that her "jaw" had ached for three or four months previous to this time. On applying the forceps, the beaks readily passed under the gums



M. Giraldes refers to multiple cysts of the antrum ranging in size from a pea to that of a pigeon's egg. These cysts he describes as being found filled with a fluid, sero-albuminous, thin or glairy, and differing in color in different cases, being brown, yellow, or blood-shade. To the suppuration of them is

without lancing, and the tooth, much to my surprise, came away with a very slight application of force. But this surprise was not equal to my astonishment when I saw what I had brought away with the tooth,—namely, a large quantity of alveolar substance, the bicuspid root, and a fibrous connective-tissue tumor, nearly an inch in diameter, attached to the tooth, and inclosing two of the roots, namely, the posterior buccal and the palatine root.

FIG. 580.—SECONDARY CYST OF THE ANTRUM.



1, root of second bicuspid attached to alveolus; 2, neck of tooth and border of alveolus; 3, walls of antrum, palatal side; 4, centre of crown of tooth; 5, tumor; 6, tartar, covering the cavity of decay. The buccal aspect of the tooth was similar in appearance to the palatal surface which is seen in the engraving.

After being in alcohol three days, the tumor was nearly white, and had shrunk to one-third its original size. On cutting it open, it was found filled with a solid structure. The consistence was that of tubercle, or pressed cheese-curd; the color, light yellow, tinged in most parts with red.

The roots within the tumor were nearly free, and covered with their periosteum, which had thickened into a loose, spongy mass, extending even to the base of the body of the tooth. The appearance was like that of roots involved in alveolar abscess. The walls of the tumor were not composed of detached dental periosteum. There were apparently two coats, the outer fibrous, like periosteum; the inner a mucous one, like the lining of the nasal cavity.

The pathology of the case, as inferred by Dr. Chase, is that the tooth decayed to the pulp-cavity, and that the pulp, after repeated inflammatory attacks, died. Putrefaction occurred, provoking periodontitis; after a while suppuration occurred, and the disease became chronic. The periodontium became thickened and spongy, and continued irritation caused a proliferation of connective-tissue corpuscles, thus eventuating, finally, in the formation of the cyst.

This inference is, probably, the true explanation of the tumor. The trouble, however, seems to have been seated primarily upon the bicuspid and not upon the molar roots,—involving the latter secondarily. This tumor, although it possessed not the contents of the one operated on by the author, has a similar pathological signification: it constitutes an instructive example.

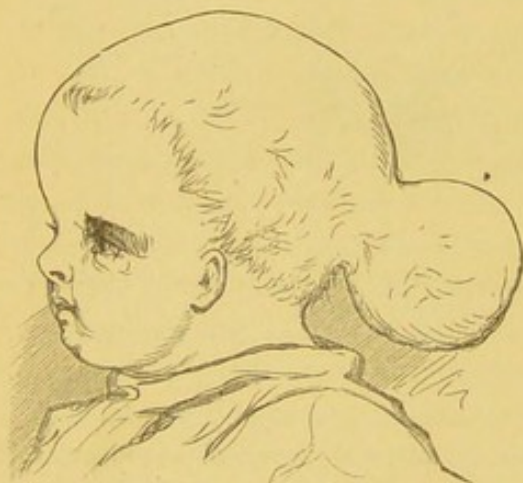In cases of this kind it will be seen at a glance that, however patulous the natural outlet might be, the contents of the tumor could not by such means find egress. In the second character of cases, the contents are just within the cavity, but the engorgement of the tissue bounding the outlet has closed the foramen. A case described in the chapter on Diseases of the Antrum exhibits the dangerous and destructive effects of such accumulations when unappreciated and untreated.



attributed the occasional resistance of abscess to treatment. These cysts this author believes to be quite common, and that they are the explanation of many of the enlargements encountered. Their origin he locates in morbid changes of the mucous glands.\*

A cystoma, meningocele, of grave nature—a self-explaining cyst of an entirely different nature from any referred to—is shown in Fig. 581. The tumor expresses a congenital deficiency in the occipital bone, and exists in a protrusion of the meninges of the brain. An operation being rendered necessary in this special case shown by reason of rapid increase in the size of the cyst, attempt was made by the author to strangulate at the pedicle by means of subcutaneous ligation. No shock or immediate ill result attended the accom-

FIG. 581.



Meningocele.—From a patient in the author's clinic.

plishment, but on the fourth day coma gradually came on, in which condition the child died three days later, without, apparently, having experienced a pain. Age of babe, ten months.

Very lately a patient presented himself to the writer having an immense cystiform enlargement of the lower jaw. The tumor was quite the size of a foetal head. Examination revealed an aneurism.

Fig. 569 exhibits the external appearance of an osteo-enchondroma operated upon at the Hospital of Oral Surgery. Fig. 570 shows the cyst uncovered. In this case the trouble

originated about the roots of certain diseased posterior teeth. The tumor is, of course, classifiable with the cystomata. It belonged to the self-explaining growths, although obscure until exposed by operation. Treatment consisted in removing the vault and scraping out the floor. Recovery was rapid.

**Hydatid Cysts.**—A tumor occupying the extreme end of the self-explaining growths is found in the hydatid cystoma. Here the origin, not being in a perversion peculiar to a part, is not without confusion in the way of diagnosis. The tumor is to be placed, however, in remarking the absence of all signs which relate it with common vice expression, and in observing that, unlike cancer, there is no disposition to invade neighboring parts. Local diagnostic signs lie in a peculiar resiliency and in the not infrequent presence of a fremitus. The treatment of a hydatid cystoma is by radical removal with the knife, otherwise by absorbable parasitocides or by injection of like agents.

\* Recherches sur les Kystes muqueux du Sinus maxillaire.



## CHAPTER LXIV.

### THE TUMORS OF THE MOUTH.

#### NON-EXPLAINABLE TUMORS.

**The Neoplasms.**—Assuming the student as now appreciative of the principle on which all tumors belonging to the first division of our classification are diagnosable, we pass to those of the second.

As all lesions of the first class have their meaning in derangements purely local, after a like signification all growths of the second division are found of constitutional import. That is to say, repeating the basal principle of the arrangement. There are two kinds of tumors; only two kinds: 1, tumors arising out of local causes; 2, tumors arising out of constitutional causes.

There is one constitutional cause of tumors that is an arcanum. Besides this one there are other constitutional causes of tumors. These others, however, are understandable and appreciable; examples lie in the manifestations of syphilis, of scrofulosis, of scorbutus, of gout.

Accepting a tumor to be of constitutional import, diagnosis proceeds on the ground of getting accurate conception of the lesion through a process of exclusion. 1. In what systemic vice does the condition exist? 2. No appreciable vice existing, the growth pertains to the arcanum. The arcanum is carcinoma.

We pass to the study of carcinoma.

*Every tumor is a cancer that is not something else. Learning and experience are capable of distinguishing the "something else."*

Another aspect of diagnosis relates with treatment. All self-explainable tumors, whether of local or of systemic signification, possess in themselves the meaning and manner of cure; all such tumors are treatable on a purely scientific basis; cause is understood, cause is managed.

Unexplainable tumors are treatable alone mechanically; nothing being appreciated as to cause, medicine is not to be rendered applicable. To let such tumors alone, otherwise to cut them away, is all that surgery has yet learned.

Clinically: Tumors which are of a common manner of treatment belong under a common head:—Deduction: Fibroma and encephaloma having a single and common manner of treatment are—as treatment at least is concerned—identical.

Histologically: Tumors found to run into each other, no absolute line of



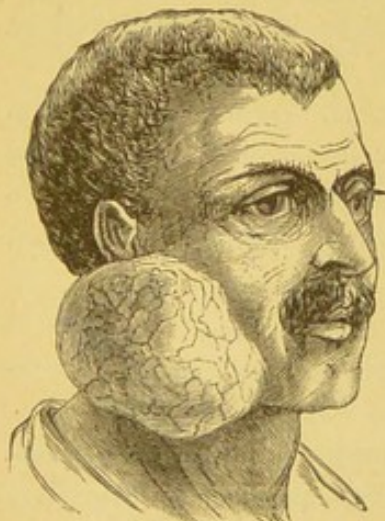demarkation existing between the extremes, are to be classed under a common head. Simple fibroma cannot be demarked, as extremes are concerned, from recurring fibroma. Recurring fibroma cannot be demarked from sarcoma. Sarcoma cannot be demarked from encephaloma. Deduction: The most simple of fibromata differ from the most complex of encephalomata alone in features of expression. The family is a common one. The reader interested in the subject will wisely at this point observe and study closely the diagrams introduced illustrative of distinctions in the neoplasms as taught by the microscopist, but he is to hold in his mind the differences which exist between histological and clinical definitions.

In a record of 307 cases of tumors of the jaws made by Professor C. Weber, the histological varieties noted are as follows: Carcinoma, 133; sarcoma, 84; osteoma, 32; cystoma, 20; fibroma, 17; enchondroma, 8; gelatinoid polyps, 7; melanotic sarcoma and carcinoma, 5; angioma, 1.

Upon such a record it would seem that in all solidity a classification might be founded. This indirectly we may receive; directly, however, it is not a matter that concerns us. Our classification recognizes, as is understood, but a single condition,—a condition of many expressions, these expressions being accorded the title of *the destructive disease*. Indirectly, however, we must accept a histological classification, as thus with most convenience we find data

for a study, the understanding of which is of great service, and certainly of large interest.

*First. Fibrous Tumors—Fibroma.*—The study of the fibromata begins with—1. A tumor, the most common seat of which, as the whole body is concerned, is, beyond comparison, about the jaws. These tumors, which to the eye are composed of firm, interlaced fibrous tissue, are, to the touch, hard, yet to an extent elastic. Such growths spring from the periosteal tissue, and find a favorite location in the antrum. When unmoulded, as where springing from a free surface, they are superficially lobed, and, as a rule, are ovoid in form; when occupying the sinus, they conform very much to the shape of the cavity, and are apt to retain the bony



Fibrous tumor over parotid gland.

covering until they attain a size many times greater than the site from which they originate. In color, these tumors are a faintly yellowish white, pure white, or a very pale red; in arrangement, the fibres are concentrically related, affording an expression of focalizing, as if growing towards, rather than from, a centre.

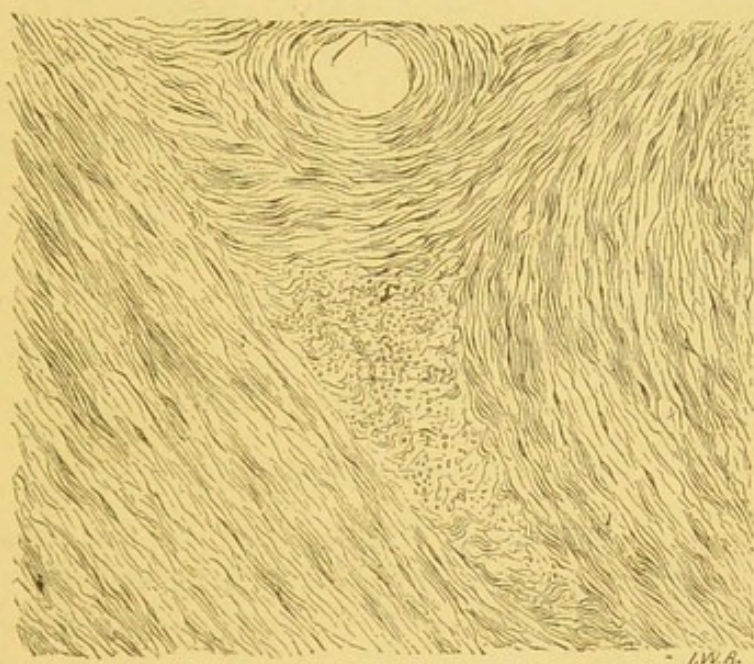
The diagnosis of this form of the fibromata lies in the isolation of the growth; in its elastic hardness; in the perfectly healthy and non-implicated appearance of the associate parts; in the absence of pain; and in the tardy



growth. Such a tumor is to be removed with reasonable assurance of its non-return.

2. A second form of the fibromata is found in such close alliance with the first that no one might doubt the intimate relationship of the two, differing really alone in the presence of a looser stroma, being what Rindfleisch, in his classification, would term "a connective-tissue tumor." This tumor, or rather this expression of a common tumor, has not the same concentric development, seeming, in this respect, to be less resisted by the neighboring parts; it does not infiltrate, yet is of eccentric rather than of concentric growth; or, if not this, then the fibrous relation is irregular. This is the first expression of the fibro-plastic tumor of Lebert. It differs from that shown in Fig. 582 simply

FIG. 583.



Microscopic appearance of fibroma.

in possessing a freer amount of cellular tissue; advancing after such expression toward the myomata.


3. THE MYOMATA OF VIRCHOW.—Advancing one step farther in the appreciation of the fibromata, we meet with those spindle-shaped cells, which induced Virchow to give to the expression the name of myoma, and which, when possessed of more marked characteristics, constitute the fibro-sarcoma of Rokitsansky. This is truly the fibro-recurring tumor, an expression of which Mr. Miller speaks—see his "Principles of Surgery"—"as of a tumor ill defined, one which it may be doubted if it be not more properly classed when placed among the malignant condition, seeing it is found prone to return, after excision, with singular obstinacy."

The eccentric fibrous tumor—fibro-plastic, fibro-recurring, myoma, fibro-sarcoma—presents alterations of structure, from which, at a point of some confusion, it passes into classification as sarcoma.



*Second. Sarcoma.*—The sarcomata are so called from presenting on section a fleshy look. A sarcoma is what Billroth designates “a tumor con-

FIG. 584.



Microscopic appearance of fibro-recurring tumor.

sisting of tissue belonging to the developmental series of connective-tissue substances (connective tissue, cartilage, bone, muscles, and nerves), which, as a rule, does not go on to the formation of a perfect structure, but to peculiar degenerations of the developmental forms;” in other words, it is an expression of imperfect fibroma. Rindfleisch distinguishes the sarcomata into “the round-celled sarcoma, the spindle-celled sarcoma, and the fibroma.”\* These

\* The *granulation-like* round-celled sarcoma (sarcoma globo-cellulare simplex) in its textural and structural relations is allied to the model of the tissue of granulations. To the naked eye, a yellowish or reddish, thoroughly homogeneous, elastically soft mass, at times extraordinarily like the roe of fishes, presents itself from the cut surface; by scraping with a knife-blade, we can obtain a scanty amount of juice, which is almost entirely clear, or contains but few cells. The cells are small, round, and possess comparatively large nuclei, of sharp contour, and provided with nucleoli. The protoplasm, as a rule, is present only in small amount, therewith entirely naked; we must have recourse to hardening the tumor and coloring it with carmine, in order to make it generally distinct, and to convince ourselves that a cell-body actually belongs to each of the apparently free nuclei.

The structure of round-celled sarcoma deviates only in a quantitative relation from the structure of granulations. The vessels in part are wider, thicker walled; where these, however, break up into capillaries, they are just as delicate, frequently only built of a simple cell-layer, such as we saw in the vessels of granulations. The interspaces between the vessels are everywhere uniformly filled by the round cells and the scanty, soft, and



tumors grow to an immense size. Fig. 585 shows a not infrequent clinical expression of the disease.

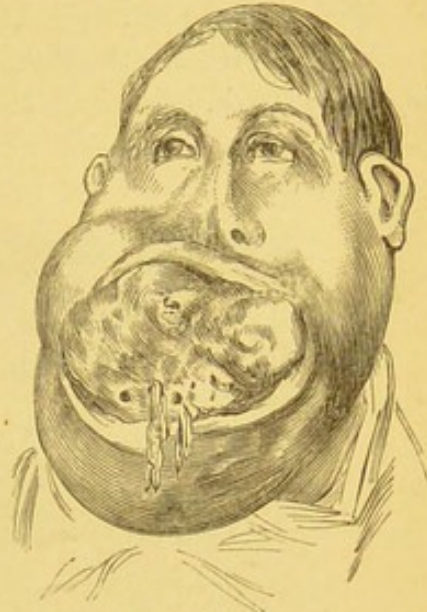Tumors denominated in this chapter neoplasms, are coming to be commonly accepted as conditions expressive of arrest in development, a conclusion which is no doubt just enough, but yet it does not touch the cause in which the arrest has its meaning.

Another expression of this tumor is that classified and described by Mr. Paget as the myeloid,—so called from its resemblance to marrow,—an expression so lacking in persistent individuality that, even according to the classifier himself, the features vary from simple semi-fibrous, semi-marrow-like structure to those so heteroclitic that they “seem to merge into the medullary.” A myeloid, as suggested by the English surgeon, like a fibrous tumor, may be either inclosed in a bone whose walls are expanded round it, or more rarely, it is closely set upon the surface of a bone confused with its periosteum. The sketches of fibromata pictured in the “Surgery” of that author are readily to be received as illustrative of myeloid.

These two kinds of growths are equally common to superior and inferior jaws.

A myeloid inclosed in bone affords a tumor ovoid in shape, well defined, not infrequently invested with a distinct capsule. Situated externally it is apt to be lobulated and of irregular roundish form. Mr. Paget describes the growths as feeling like uniformly compact masses, but in different instances variously consistent. The most characteristic examples are firm, and (if by the name we may imply such a character as that of the muscular substance of a mammalian heart) they may be called fleshy. Others are softer, in several gradations, to the consistence of size gelatin, or to that of a section of granulations. Even the firmer are brittle, easily crushed or broken; they are not tough, nor very elastic, like the ordinary fibro-cellular or fibrous tumors, neither are they grumous nor pulpy, neither do they show a fibrous nor granular structure on their cut or broken surfaces; these tumors are smooth, uniform, compact, shining, succulent, with a yellowish, not a creamy fluid. A peculiar appearance is given commonly to them by the cut surface presenting blotches of dark or livid crimson, or of a brownish or a brighter blood color, or of a pale pink, or of all these tints mingled on the grayish-white or greenish

FIG. 585.



A clinical expression of sarcoma.

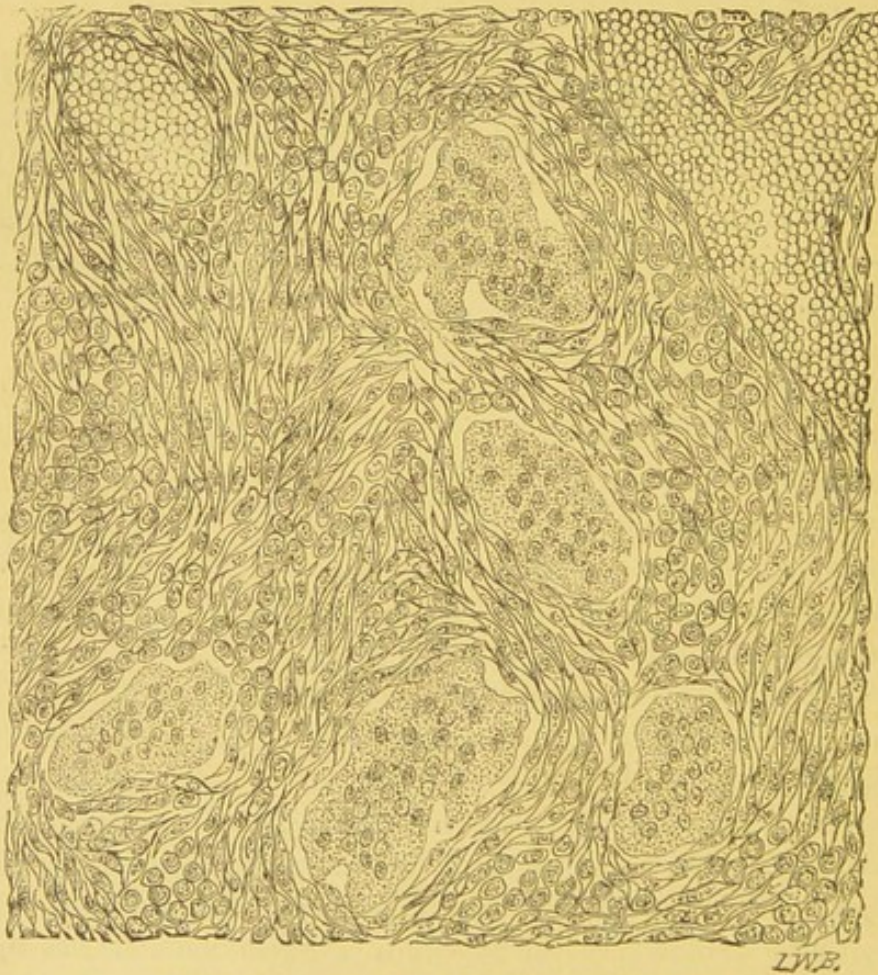formless basis-substance of the germinal tissue. In rare cases one observes a higher organization of the whole, which reminds of the papillosities of granulations, namely, a radiated striation and a decided disposition of the mass of the tumor for cleaving in radiating directions.



basis-color. (In a foot-note, Mr. Paget quotes from Lebert, who says the greenish-yellow color they may show depends on a peculiar fat, xanthose.) The tumors may all be pale, or have only few points of ruddy blotching, or the cut surface may be nearly all suffused, or even the whole substance may have a dull modena or crimson tinge, like the ruddy color of a heart, or that of the parenchyma of a spleen. Many of what have been named spleen-like tumors of the jaws are of this kind. The color they present is not due merely to blood in them; some of it is appropriate to their texture, as is that of the spleen or that of granulations, and it may be quickly and completely bleached with alcohol.

The following are the histological appearances pronounced peculiar to the myeloid growth, being imitated in no other morbid structure:

FIG. 586.



Microscopic appearance of myeloid,—i.e., of sarcoma.

1. Cells of oval, lanceolate, or angular shape, or elongated and attenuated like fibre-cells, or caudate cells, having dimly-dotted contents, with a single nucleus and nucleolus.

2. Free nuclei, such as may have escaped from the cells, and, among these, some that appear enlarged and elliptical, or variously angular, or are elongated



toward the same shapes as the lanceolate and caudate cells, and seem as if they were assuming the character of cells.

3. The most peculiar form: large, round, oval, or flask-shaped, or irregular cells or cell-like masses, or thin disks of clear or dimly-granular substance, measuring from one three-hundredths to one-thousandth of an inch in diameter, and containing two to ten or more oval, clear, and nucleated nuclei.

Corpuscles such as these, irregularly and in diverse proportions embedded in a dimly-granular substance, make up the mass of a myeloid tumor. They may be mingled with molecular matter, or the mass they compose may be traversed with filaments or with bundles of fibro-cellular tissue and blood-vessels, but their essential features (and especially those of the many-nucleated corpuscles) are rarely observed.

Many varieties of aspect (as remarked by Mr. Paget in his histological studies) may thus be observed in myeloid tumors, and beyond these they may even be so changed that the microscope is essential to their diagnosis. After they partially ossify, well-formed cancellous bone being developed in them, cysts, also filled with bloody or serous fluids, are to be found occupying much of their volume, or even almost excluding the solid texture.

This author notes a case in which he amputated the leg of a woman, twenty-four years old, for what was supposed to be a cancerous tumor growing within the head of the tibia. She had pain in the part for eighteen months, and increasing swelling for ten months, and it was plain that the bone was expanded and wasted around some soft growth within.

On section, after removal, the head of the tibia, including its articular face, appeared expanded into a rounded cyst or sac about three and a half inches in diameter, the walls of which were formed by its flexible bone and periosteum, and by the articular cartilages above; within there was little more than a few bands or columns of bone, among a disorderly collection of cysts filled with blood, or blood-colored serous fluids. The walls of most of the cysts were thin and pellucid; those of others were thicker, soft, and brownish-yellow, like the substance of some medullary cancers, a likeness to which was yet more marked in a small solid portion of tumor, which, though very firm, and looking fibrous, was pure white and brain-like.

No one, Mr. Paget says, who examined this disease with the naked eye alone, felt any doubt that it was an example of medullary cancer, with cysts abundantly formed in it. But, on minute investigation, none but the elements of the myeloid tumors could be discovered; these, copiously embedded in a dimly-granular substance, appeared to form the substance of the cyst-walls, and of whatever solid material existed between them. The white brain-like mass was apparently composed of similar elements in a state of advanced fatty degeneration, but neither in it nor in any other part could be found a semblance of cancer-cell.

No mention is made of the return of the disease; it would seem that, *in the present state of our knowledge of cancer-growths*, it would have been no



difficult matter to class such a tumor with the malignant. Not consuming time in a discussion of the subject, it is evident that even so able an observer was not at all clear with his case. *There is no special cancer-cell.*

An epitome of the myeloid may thus be presented :

They are a class of fleshy tumors called by M. Lebert fibro-plastic, because, he says, they are made up of fibre-cells. They are called myeloid by Mr. Paget, because he thinks they resemble marrow much more than they do fibrous tissue.

In character, they vary from simple semi-fibrous, semi-marrow-like structures to those so heteroclitic that they seem to merge into the medullary.

Their favorite seat seems to be about the bones, either intra or extra, being perhaps more common to the maxillæ than to any other of the ossa-corporæ.

They are growths which usually occur singly; they are most frequent in youth, and very rare after middle age; they generally grow slowly and without pain, and usually commence without any known cause, such as injury or hereditary disposition.

According to Mr. Paget's observations, they rarely, except in portions, become osseous; they have no proneness to ulcerate or protrude; they seem to bear even considerable injury without becoming exuberant; they may shrink or cease to grow; they are not apt to recur after complete removal, nor have they in general any features of malignant disease. These observations as they relate to non-return of the disease after ablation of the tumor are the reverse of the writer's experience.

Since penning the above the author has accidentally fallen on a classification of the tumors of the upper jaw, made by Mr. Hancock. After alluding to various classes, he says, "In addition to these, Mr. Paget adds what he terms myeloid tumors of the part; but while the examples he quotes resemble on the one hand so much the fibrous, on the other the medullary tumors, their true character, whether innocent or malignant, is so very doubtful that I should hesitate in admitting them as a distinct class."

**Epitome.**—Fibrous tumors proper, and the fibro-plastic, have general features in common,—that is, they belong to the expression of sarcomatous growth; but then in a histological sense they have such differences that an epitome, at least, of their history should be reviewed by us.

In some instances, fibrous tumors are seen under the microscope to have a concentric development: this species is slowest of growth, is least malignant, never attaining any great size.

In another species the fibres interlace in a most complicated and irregular manner. This kind attains the largest size, and strides toward the heteroclitic.

A third class consists of an aggregate of nodules, and is compared by Dr. Humphrey to a conglomerate gland; the tumor being made up of small masses closely compressed, having an uneven, knotty outline.

Fibrous tumors affecting the bones (Braithwaite) are usually found upon



those of a spongy nature, upon the ends of the long bones, the phalanges, pelvis, and in the jaws. So far, says the author, as I have met with them, they are confined to the exterior of the lower jaw, growing from the periosteum and creeping along the surface of the bone in such a manner as to prove almost to a certainty that they originate in some morbid condition of the periosteal fibres. The bone underneath these tumors may suffer absorption in consequence of the pressure produced, but does not seem to be affected in any other way. The growths appear upon the maxillary bone more frequently than upon any other part of the skeleton. On the lower jaw they spread along the ramus, encircling it beneath and on the sides, so that the bone is almost concealed by the tumor. In some instances they form within the substance of the jaw, probably from the alveolo-dental membrane, and as they increase, the walls of the bone become spread out over them. They grow up around the teeth, and when they project into the mouth may be soft and fungous.\*

In some instances the fibrous tumors of the jaws exhibit a semi-cartilaginous structure, and now and then fibres or plates of bone are formed in various parts of them. The progress of the disease is well illustrated by a series of maxillary tumors in the College of Surgeons, London, from the museum of the late Mr. Liston. These preparations serve to show how necessary it is to bear in mind the mode of growth of periosteal fibrous tumors of the jaws, because from their disposition to creep along the surface of the bone, whether it be an endosteum or periosteum, they are liable to return after removal, unless the immediately adjacent as well as affected parts be excised. The histories attached to the specimens teach that very large fibrous tumors, both of the upper and lower maxillæ, together with the bones on which, or in which, they grow, may be successfully removed.

A cysto-sarcoma, as implied by the prefix, is a tumor of only semi-solidity, its interior, or stroma, being made up of cysts and fleshy substance. These cysts are original formations, and not of secondary character,—that is, they are not the result of molecular disintegration. They are lined sacs, having a distinct secretory membrane. Miller describes the contents as widely differing, which difference every surgeon must have observed: They are more or less fluid, as noted by him, sometimes a clear gluey liquid, sometimes a gelatinous, pale mass of semi-solid consistence, elastic, and projecting beyond the level of the cut cyst on a section being made; sometimes a solid, consisting of a fibrous deposit, organized very imperfectly, if at all; sometimes of a pulpy consistence, as in many encysted tumors; sometimes, but more rarely, a dark fluid, like printers' ink, is contained; sometimes blood is mingled with the contents, either in the solid or in the coagulated form.

The very nearest approach made by cysto-sarcoma to the self-explainable

---

\* Presenting this phase, the tumor may be classed with the epulic, but it will be seen that on this account there need be no confusion. An epulic tumor may be sarcomatous.



cysts, is in that class, very well named the "cysto-succulent." These are sarcomatous tumors, the stroma of which is made up of very loose fibro-cellular tissue. They might well, in their contents, be likened to a watermelon, solid enough on section, but compressible to a few shreds. The fibrous contents of the stroma are, however, always a distinguishing sign. These tumors are very rare, and particularly so about the bony structures.

Müller thus described a variety of these cysts of sarcomatous growth, which he calls cysto-sarcoma phyllodes. The tumor forms a large firm mass, with a more or less uneven surface. The fibrous substance, which constitutes a greater part of it, is of a grayish-white color, extremely hard, and as firm as fibro-cartilage. Large portions of the growth are made up entirely of this mass, but in some parts are cavities or clefts, not lined with a distinct membrane (an exception to the rule in cystic tumors). These cavities contain but little fluid, for either their parietes, which are hard, like fibro-cartilage, and finely polished, lie in close apposition with each other, or a number of firm, irregular laminæ sprout from the mass and form the walls of the fissures, or excrescences of foliated or wart-like form spring from the bottom of the cavities and fill up the interior. These excrescences are perfectly smooth on their surfaces, and never contain cysts or cells. The laminæ lie very irregularly, and project into the cavities and fissures like the folds of the psalterium in the interior of the third stomach of ruminant animals. Sometimes the laminæ are but small, and the warty excrescences from the cysts are very large, while in other instances both are greatly developed.

Cartilaginous, or the enchondromatous, tumors of Müller, are, for all practical purposes, to be classified with the sarcomatous, for while it might demand some little stretch of the imagination to convert a cartilage into a fleshy mass, yet surgically the species are very much alike,—that is, both are little amenable to the action of sorbefacients, and both are better treated by the knife than in any other way.

As we understand the osteo-sarcomatous tumors proper to be outgrowths associated commonly with periosteal membranes, so we are led naturally to ask ourselves as to the cause of their formation. This may be conceived to be of twofold relation: first, as a result of local irritation; second, as a relation of constitutional condition; and, still again, we may combine the two, laying the predisposing cause on the one, the exciting on the other.

The attention of the author was once directed by William Gibson, late Professor of Surgery in the University of Pennsylvania, to a case markedly illustrative of this latter condition. An old gentleman, Mr. F., seventy years of age, was struck on the cheek by a stone. Soon he had growing from the site of the injury a tumor, diagnosed by Professor G. as osteo-sarcomatous. The growth of the body was so rapid and so formidable as to incline to the view of its intimate relationship with malignancy. Later the patient died from it. No one would doubt the twofold relation of such a tumor.

When osteo-sarcoma takes on this rapid growth, its malignancy is not to be



doubted; when the development is slow and regular, and particularly if the origin can be traced to some local irritant, extirpation may be expected to result in relief.

Osteo, and simple fibrous tumors of the sinus maxillare, must not be mistaken, as has too often been the case, for polypi of the nares. It sometimes happens that these tumors, particularly the softer kinds, find their way through the outlet of the sinus into the nostril, and there simulate very closely a common fibrous polypus; such tumors have been often highly aggravated by operations founded on such mistaken diagnosis. Again, polypi of the nostrils may find their way into the sinus by absorbing, through pressure, a passage, and, enlarging, represent very fairly the ordinary fibrous tumor of that cavity. Now, pathologically speaking, being about one and the same thing, it would be little difference where or how the growth should develop, but as operative proceedings are concerned, a mistake of the kind becomes an awkward matter.

As regards changes common to sarcomatous tumors, they may be considered under the heads of softening, suppuration, and malignant degeneration.

Softening, as described by Dr. Humphrey, appears to take place in two ways:

First, as a chronic process, affecting some circumscribed portion of the tumor, which is usually at or near the centre. The change is observed to commence with a slight discoloration, a yellowish or dark tinge, which is followed by loosening or by incipient disintegration of the structure; at the same time a line of demarkation is formed around the altered portion, which portion becomes separated, like a sequestrum, from the surrounding mass. Both the detached part and the cavity are at first rough and thready on their opposed surfaces; the former undergoes still further disintegration and solution, becoming broken up into a number of smaller fragments, these floating about in a dark, dirty, turbid fluid, and likely ultimately disappearing.

The process of destruction may go on in the adjacent portion of the tumor, enlarging the central cavity till the whole is reduced to a fluid or a semi-fluid mass, walled in by the capsule of the tumor, which now stands in the relation of a cyst-wall to the disorganized contents.

In some cases the softening operation is completed without extending the circumference; the ragged processes hanging into the interior of the cavity being removed. The excavation acquires a smooth lining, and looks like a simple cyst lying in the centre of the tumor.

A second mode in which softening takes place is more rapid and diffused, the whole or the greater portion of the tumor being affected at once. The change commences with the infiltration into the mass of a serous fluid, whereby its texture is loosened and its components separated; at the same time the tissue of the growth is softened, and interstitial absorption is set up in it.

As the result of these processes combined, a tumor is soon broken up into detached fragments, and reduced to a diffuent pulp, or it may be com-



pletely liquefied. These changes, Dr. Humphrey suggests, are occasioned by some altered nutrition analogous to inflammation; they may be induced by

FIG. 587.—OSTEO-SARCOMATOUS TUMOR.

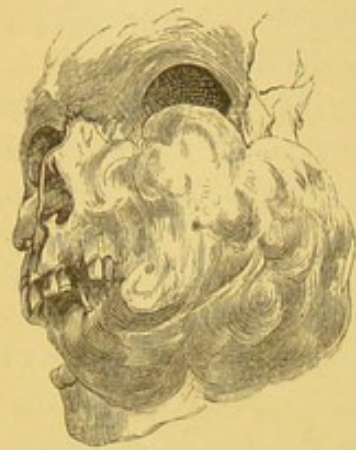
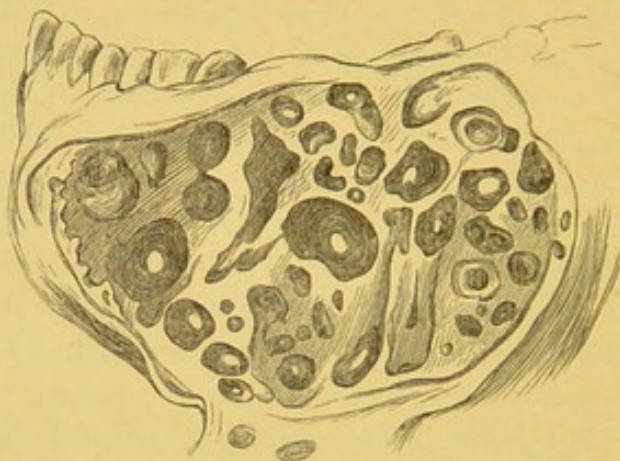
FIG. 588.—CYSTO-SARCOMA.



some accidental cause, as an injury; nevertheless they are not necessarily attended with any constitutional disturbance at all corresponding with the extensive destruction which is in progress.

**SUPPURATION.**—This is very rare; it may begin internally, or may progress from without inward.

The tumor represented in Fig. 587, from the person of an old woman, commenced within the antrum, and progressed four years before causing death. In character it was fibro-plastic, with here and there osseous masses.

Fig. 588 represents a cysto-sarcoma. It is a section of the diseased lower jaw of a man aged about thirty. Death occurred within a year, from return of the growth after operation.

**Histoid Mixed Tumors.**—The tumors described as fibromata, sarcomata, etc., possess their appellation from a distinctiveness of tissue which characterizes them in their purest expression. In the histoid mixed, two or more elements are found conjoined, thus as is seen, confusing necessarily—not a *clinical*, but the histological—classification. When, as has been queried by Rindfleisch, besides distinct lipomatous constituents, distinct chondromatous features are found; when sarcoma nodes and nodules are deposited in an enchondroma, we do not know whether we should name the thing enchondroma lipomatodes, or lipoma cartilagineum, or sarcoma cartilagineum, or chondroma sarcomatosum. This embarrassment recurs with the question as to the clinical character of the sort of tumor, the prognosis, etc. The histoid mixed tumors will, in the mouth, be found more common than the pure histoid; their nature and character are to be appreciated from what has preceded.

**SCIRRHUS.**—Although the very rarest of the expressions of the cancer vice as met with inside the mouth, except as relation with the tongue is concerned in shape of epithelioma, yet as a form of the dyscrasia clinical attention will



occasionally be directed to the condition. Scirrhus is a disease of adult life, rarely appearing before the age of forty, and even then seeming, in its isolation, a something concentrating itself for purposes of operative relief. Commencing in the gum or alveoli, and secondarily affecting the bone, scirrhus appears as a small nodule, incompressible, having indeed a lead-like feel. What now is to be its progress depends pre-eminently on circumstances. The author has at the present time under charge a scirrhus tumor associated with the periosteum immediately beneath the left malar bone: this tumor grows neither larger nor smaller, being held in abeyance either by the lightness of the dyscrasia or—what amounts to precisely the same thing—by the resistive powers of an antagonizing life-force. A second case is a lady, still under observation, from whose under lip, two years back, was removed a tumor yielding the microscopic expression of scirrhus carcinoma, and with whom there has been no return of the disease.

As a scirrhus advances in its development, there associates with it a lancinating character of pain particularly diagnostic, the presence of which is commonly admitted to decide any existing doubt. Still advancing, the overlying structures become implicated, the skin contracts and adheres, and soon shows an increased vascularity; later in its progress the tumor puts on the character of a pointing abscess, or ulcerates with a lupoid expression, or it cracks; finally the telangiectatic expression is assumed, exuberant granulations springing forth, giving to the patient the disgusting and depraving associations of the fungus hæmatodes, soon wearing out vitality.

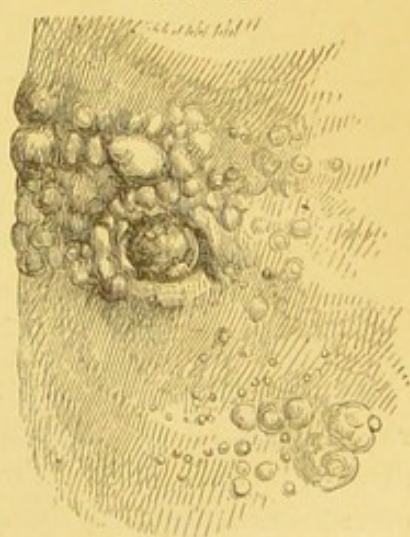
The meaning of the multiplication of scirrhomata is one of the most interesting, as it is certainly one of the most important, matters of surgery. First appearing as a solitary nodule, the tendency in the condition to increase its expressions is a sufficiently recognized fact.

After the removal of a single scirrhus nodule, the recurrence, if it take place, is apt to be in the form of numerous secondary papules, or else with a medullary expression. Fig. 589 exhibits photographically this disease as it made its reappearance over the mammary region of a lady from whose axilla the author had removed a scirrhus gland.

Concerning duration, scirrhus is apt to complete its history in from twenty to forty months, although, as has been remarked, cases may remain in abeyance for many years.

Section of an amputated malignant scirrhus shows a concave surface, deemed to be diagnostic of malignancy; it is smooth, being indeed very similar to the section of a fresh turnip; scraping the surface affords what is commonly called the cancer-juice, the microscopic cell aspects of which are portrayed in Fig. 590.

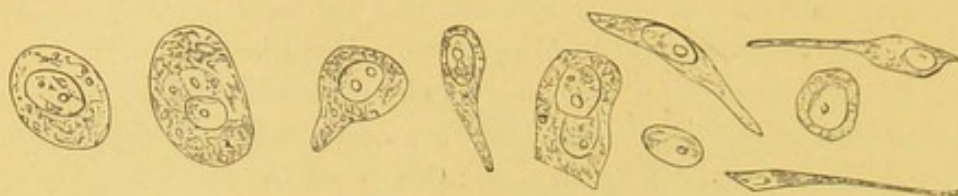FIG. 589.





It will be seen from the great variety of feature exhibited in these cells that there is here no characteristic cancer-cell. Judgment of such growths is

FIG. 590.



A microscopic view of the cells of hard cancer, showing their varied shapes, with the numerous free nuclei, as seen in scirrhus of the breast. Magnified 500 diameters. (After Paget.)

to be founded on the common heteroclitic expression. Fig. 591 shows a section of a scirrhus taken from the centre of a cancer of this form undergoing atrophic changes. A common shape of the cells seen is the caudate.

FIG. 591.



Microscopic appearance of scirrhus carcinoma.

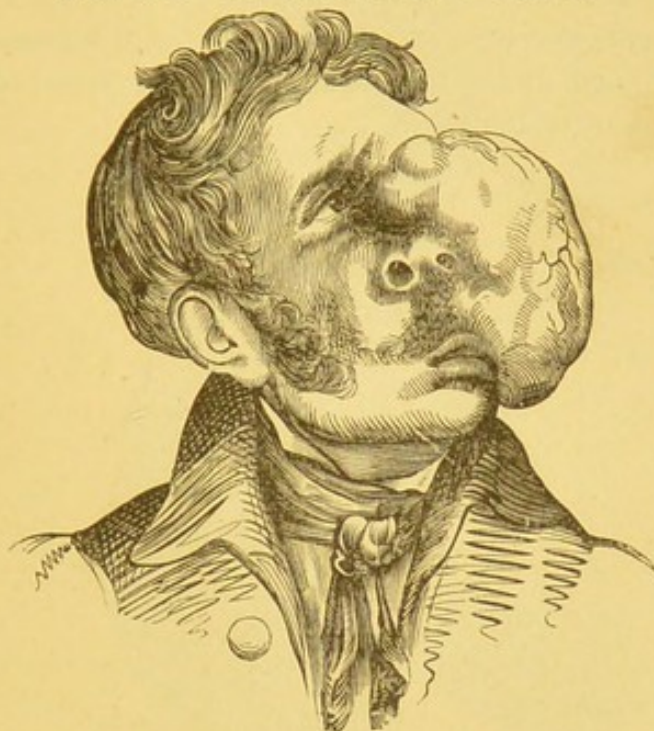
**ENCEPHALOMA.**—To the mind of the writer, encephaloma expresses the very fulness of the meaning of malignancy. It is crasis, which, either through its own force, or through non-resistance on the part of the patient, overwhelms and quickly destroys; all tissues melt before it, for none may combat it. Early ulceration and the protrusion of fungus hæmatodes form the common history of encephaloma, the cases being exceptional where a patient survives over two years.

Pure encephaloma of the jaws has, in its inception, nothing to distinguish



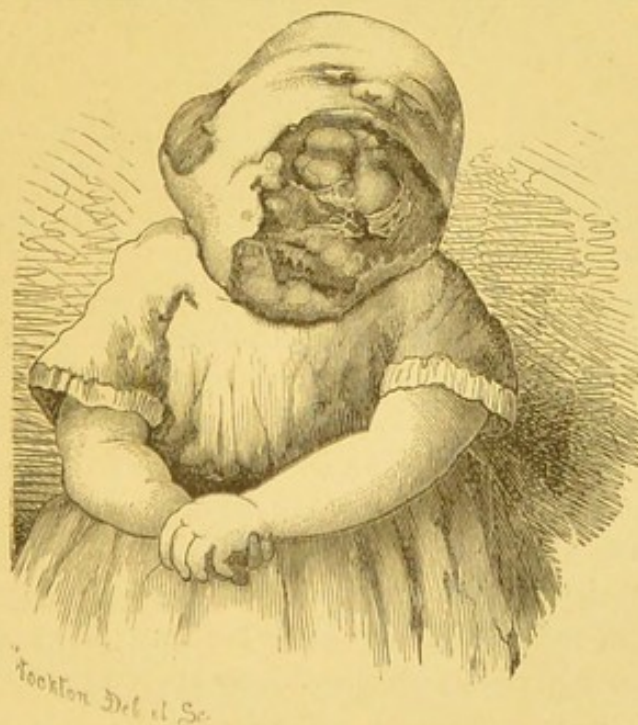it from the most simple of sarcomata; once started, however, the greater activity of the expression exhibits itself, showing futility of treatment; par-

FIG. 592.—AN ENCEPHALOID TUMOR.



ticularly does this find illustration in the infiltrated appearance of surrounding parts. If the idea of cutting has suggested itself, it is quickly enough

FIG. 593.—AN ENCEPHALOID EXPRESSION OF CANCER IN A YOUNG CHILD.

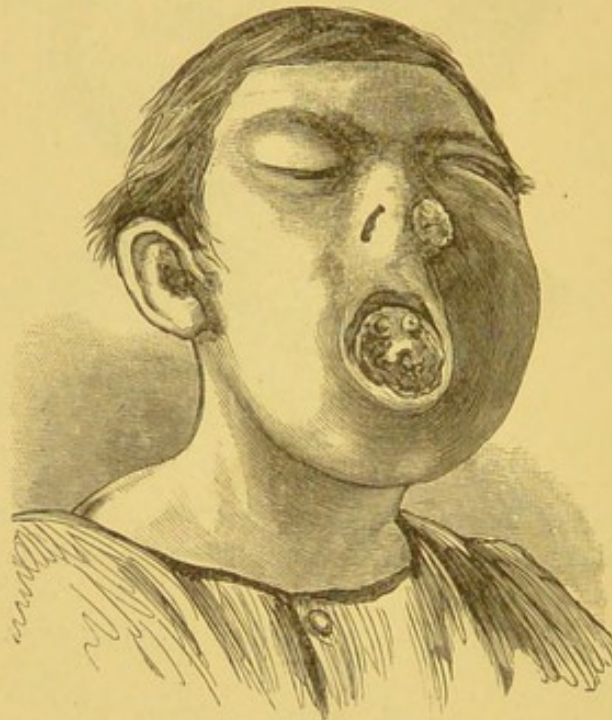

abandoned by reason of the absence of any distinct line of demarkation. One is made to feel that in the lack of a specific he is powerless for good.



Encephaloma does not seem to the author justly described—certainly not at all so from the clinical stand-point—when an impression is conveyed as to encapsuled character, for never perhaps is it the case that inside of any capsule is confined the heteroclitic expression, cells, differing from the normal tissue, being found infiltrated not only throughout the substance of such capsule, but also through all the neighboring parts. Presence of capsule is apt to signify absence of malignancy.

FIG. 594.



Encephaloid tumor.

Fig. 594 shows a case in the Presbyterian Hospital at this present time of writing which has the following history. Four months back the patient, a boy thirteen years of age, was attacked with pains in the jaw, his face and general condition being, apparently, in every other respect normal. Examination, made by his physician, revealed a molar tooth considerably carious, which tooth, under the impression that it might be the cause of the discomfort, was extracted. The socket, in place of filling up after the ordinary manner, threw out a fungous mass, disease being then discovered in association with the antrum of Highmore. From the day of the extraction to the present one proliferation has run riot. As seen, the whole side of the face is projected, the eye of the affected region has gone blind, the nostril is filled with the growth, which shows from it, while the oral cavity is so completely crammed that scarcely more than breathing-room remains. The patient, as will be inferred, is in a state of inanition rapidly approximating death. Microscopic examination will surely reveal the histological expression of the tumor as that of encephaloma. No other form of carcinoma advances so



rapidly. The writer attended a consultation on the case, the conclusion being adverse to an operation.

FIG. 595.

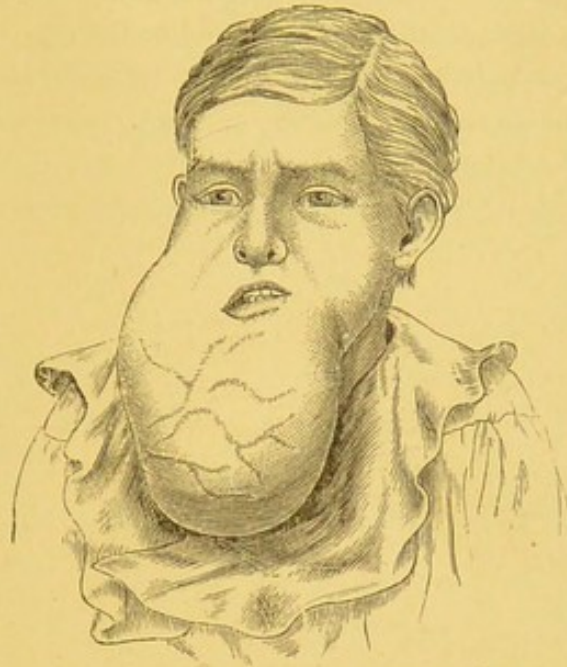
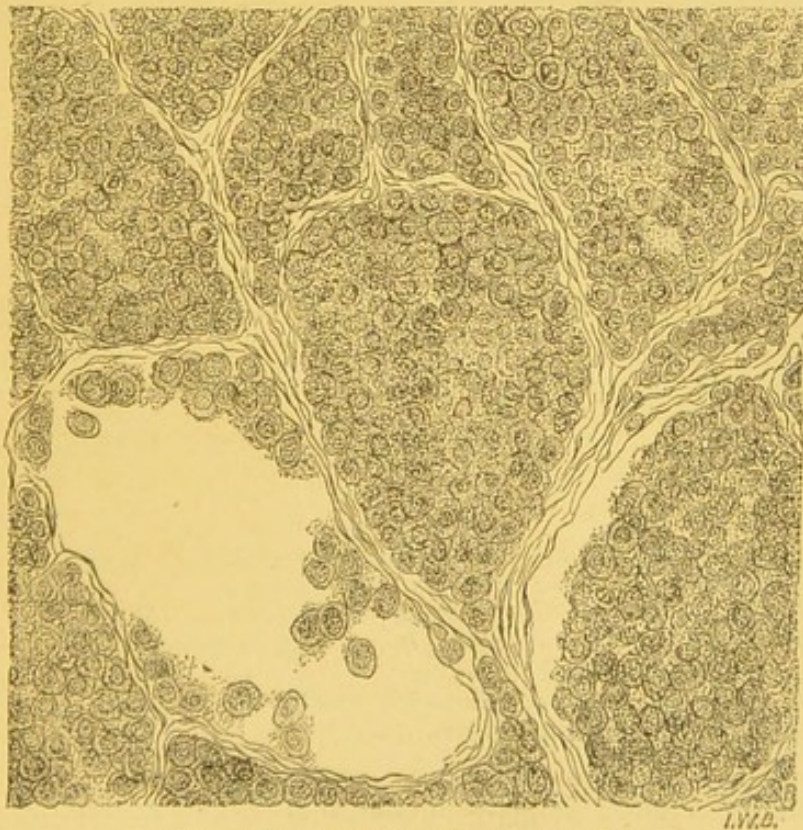

Fig. 595 exhibits the case of a child six years of age, brought to the Hospital of Oral Surgery, where the growth was of the usual rapid extension,

FIG. 596.



Microscopic appearance of encephaloid cancer.

and attended with the pain and expression of dyscrasia, so characteristic of



encephaloma. The neoplasm, as seen, is about the size of the head itself. To the touch it was semi-elastic; it was marked by veins of large size irregularly distributed over the surface. Progress was as regular as it was rapid. Patient died two months after being exhibited at the clinic.

Section of an encephaloid tumor, as is to be inferred, presents varying expression: it is sometimes quite brain-like or it may, as it shades into less malignancy, simulate scirrhus: occasionally it will be colored, such coloring being the pigment-granules of melanosis,—melanoid cancer.

FIG. 597.

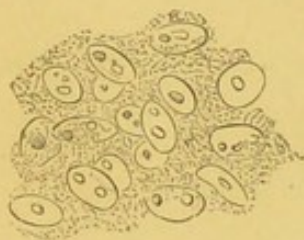


FIG. 598.

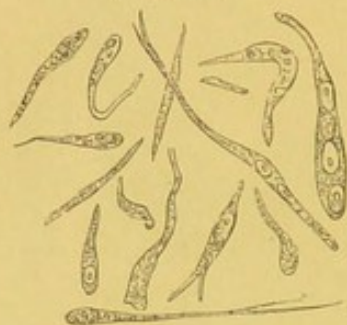

FIG. 599.

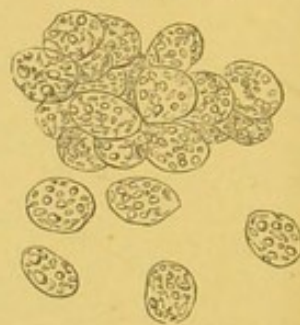

Fig. 597. A microscopic view of the nuclei of soft medullary carcinoma embedded in a molecular basis substance or stroma without cancer-cells. Magnified 500 diameters. (After Paget.)

Fig. 598. A representation of various fully-developed cells and nuclei of medullary carcinoma, as seen under the microscope. Magnified 500 diameters. Some of them are larger than the average, others more peculiarly slender, elongated, strip-like, or caudate cells, with a darkly-dotted granular nuclei. (After Paget.)

Fig. 599. A representation of the dotted nuclei of medullary carcinoma of the breast. Magnified 500 diameters. (After Paget.)

FIG. 600.

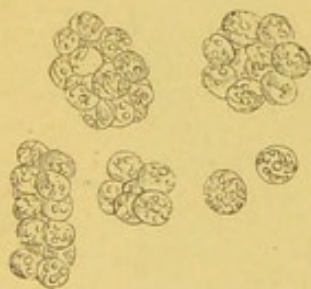


FIG. 601.

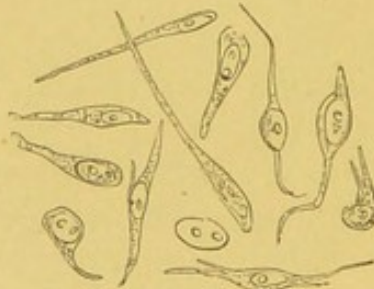

FIG. 602.

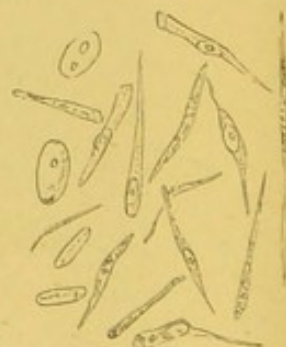

Fig. 600. A representation of the clustered nuclei of medullary cancer, composed almost exclusively of round, shaded nuclei, with three or four shining particles, arranged in groups or clusters of five to twenty or more. Magnified about 400 diameters. (After Paget.)

Fig. 601. A representation of the caudate and variously elongated cells of a firm medullary cancer. Magnified 450 diameters. (After Paget.)

Fig. 602. Small elongated cells and nuclei with a nucleus of the ordinary shape, from a firm medullary cancer. Magnified 500 diameters. (After Paget.)

Plate IX., introduced simply as a clinical study, represents the appearance and position of some of the various tumors met with about the neck. All of them are extreme cases as size is concerned.








Fig. 1.



Fig. 2.



Fig. 3.

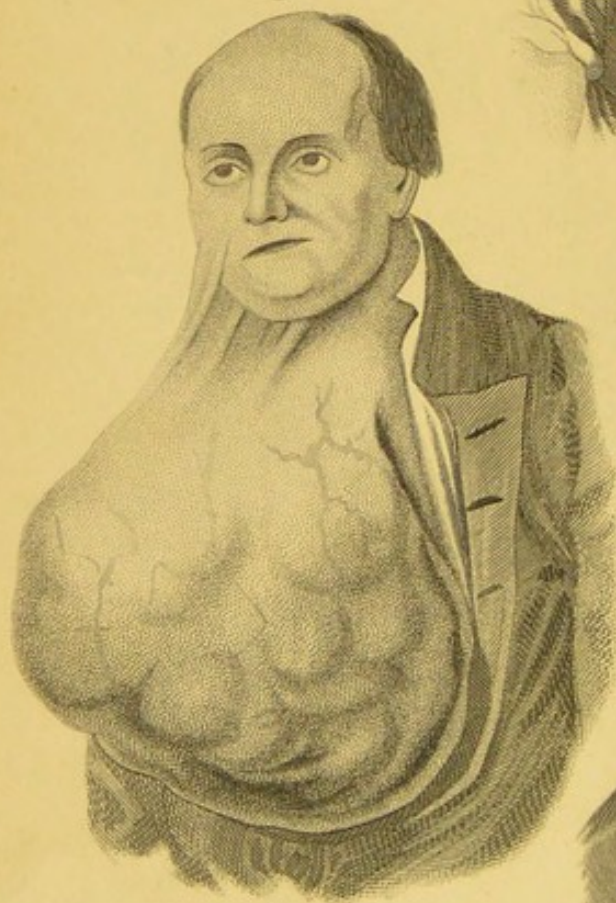

Fig. 4.

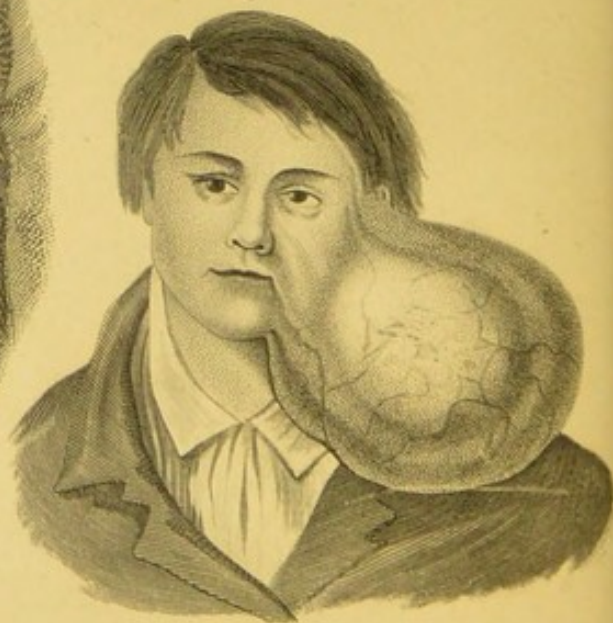




FIG. 1.—A large cystoma of the right parotid region, caused by the development of a sebaceous follicle in consequence of a blow upon the part. Commencing as a lump the size of a nut, this tumor gradually increased to nearly the size of the head; gave exit at one time to sebaceous matter; had a broad base; was nearly immovable; had the veins enlarged upon its surface, and showed a small ulceration in front, from which, fetid, acrid, and bloody sanies had escaped. As the tumor enlarged, the jaw became closed, sensation of the face diminished, and there were all the other symptoms due to pressure on the vessels and nerves of the part. The tumor differs in appearance from scirrhus of the parotid gland in its size and period of development. It was readily removed, and is represented as an example of one of the class of growths of the parotid region not involving the parotid gland.—*After Auvert.*

FIG. 2.—Large adenoid tumor of the neck dependent on degeneration of the lymphatic glands of the neck. Arising as a small swelling caused by an enlarged gland below the angle of the jaw, it gradually increased until it occupied the entire side of the neck, involving many glands, and reaching from above and behind the ear to below the clavicle, so as to turn the head to the opposite side. Its appearance was that of an irregularly lobulated mass; it was unaccompanied by pain, was perfectly firm and hard, and gave no sense of fluctuation at any point. Under the use of chloroform it was successfully removed by Mott.—*After Mott.*

FIG. 3.—Appearance of an immense adipose or lipomatous tumor of the neck. This tumor was not painful; had no pulsation; was formed of numerous large lobes, with the superficial veins distended over them, and was attached to the neck by a large pedicle which extended from the angle of the lower jaw on the right side down to the sterno-clavicular articulation, its weight being so great that the patient could hardly retain the erect position. The tumor was found to be covered by a strong capsule formed of the surrounding cellular tissue, and to have originated in a hypertrophy of the surrounding adipose tissue.—*After Auvert.*

FIG. 4.—A large cystoma of the left parotid and submaxillary regions, which was to the touch semi-elastic, unequally lobulated, and due to a chronic irritation of one of the sebaceous follicles, the duct of which had become closed, and thus caused a retention and degeneration of its secretion.—*After Auvert.*



## CHAPTER LXV.

### ANÆSTHESIA, AND ANÆSTHETICS.

ANÆSTHESIA means the obtunding of sensibility. Obtunding agents used ordinarily in the sense implied by the heading of the chapter are sulphuric ether, chloroform, nitrous oxide, and bromide of ethyl.

**Ethylic, Absolute Ether, Sulphuric Ether.**—When equal weights of rectified spirits and oil of vitriol are mixed in a retort, the latter being connected with a good condensing arrangement, and the liquid heated to ebullition, a colorless and highly volatile fluid, long known under the name of ether, or sulphuric ether, distils over. The process must be stopped as soon as the contents of the retort blacken and froth, otherwise the product will be contaminated with other substances which then make their appearance. The ether obtained may be mixed with a little caustic potash, and redistilled by a very gentle heat.

Pure ether is a colorless, transparent, fragrant liquid, very thin and mobile. Its specific gravity at 60° is about 720; it boils at 96° under the pressure of the atmosphere and bears, without freezing, the severest cold. When dropped on the hand, it occasions a sharp sensation, from its rapid volatilization. Ether is very combustible; it burns with a white flame, generating water and carbonic acid. Although the substance is among the lightest of fluids, its vapor is very heavy, having a density of 2.586. Mixed with oxygen gas and fired by the electric spark, or otherwise, it explodes with the utmost violence. Preserved in an imperfectly-stopped vessel, ether absorbs oxygen and becomes sour, from the production of acetic acid. This attraction for oxygen is increased by elevation of temperature. (*Fownes.*)

Dr. Jackson's formula for the preparation of ether for anæsthetic purposes is, we believe, as follows: Procuring the strongest and purest rectified sulphuric ether,—that just described,—wash it well, to get clear of any acids; then decant from the water, drying it with chloride of calcium, to free it of any water that might otherwise remain from the washing.

This, however, is but a single formula for the anæsthetic ether. Different chemists arrive at the same end through different processes. The surgeon should buy of a reliable druggist rather than attempt the preparation for himself.

To exhibit ether successfully, four essentials seem necessary:

1st. That the ether be very pure.

2d. That the vehicle upon which, or with which, the agent is exhibited,



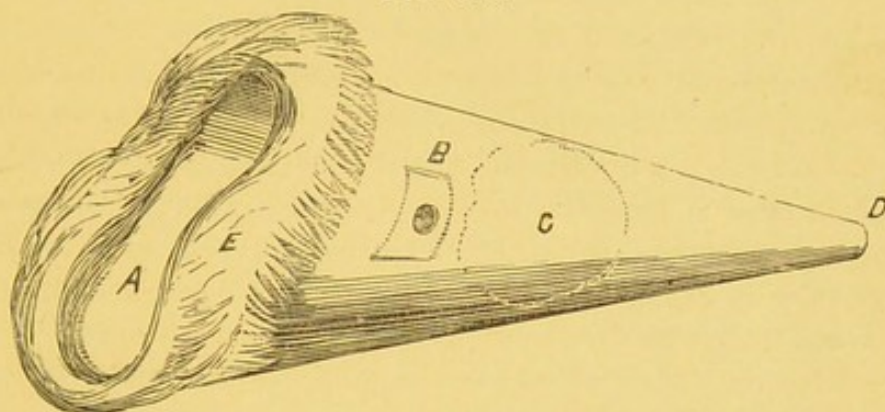
be of such character that full volume of atmospheric air is allowed to pass with the ether into the lungs.

3d. That the vapor of the ether be properly diluted, given for the first few inspirations comparatively weak, and increased in strength as the glottis, air-passages, and lungs are found able to receive it.

4th. That insensibility be produced as quickly as the system will bear, as evinced by obvious signs.

A cone-shaped, close sponge is a good means for administering ether. This possesses every advantage, except that of economy in the exhibition.\* From

FIG. 603.



two to five minutes is found the average period necessary to produce the full effect of perfect sleep; though cases present themselves where double this time is required, and where, indeed, it may be necessary to combine with the ether the more powerful agent, chloroform, or even, indeed, to employ pure chloroform.

Ether acts well in proportion to vigorousness of employment. Rapidity of breathing, not the quantity of the agent respired, is the secret of easy and quick narcotism. It is quite possible to get out of one part of an anæsthetic an effect to secure which ten are commonly used; not only this but every relation is of healthier and more agreeable character.

Over-dilution, and a consequent protracted inhalation, is the cause of excitement which supervenes in the experience of many practitioners while it so rarely shows itself in that of others. In these cases a patient is made drunk; drunk in the first degree, but not, as remarked by Mr. Snow, dead-drunk, the condition required for surgical purposes.

It will be remarked, it is to be noticed in passing, that one of the objections of the opponents of ether lies at this door,—this supervening state of excitement

\* Fig. 603 represents an instrument devised by the writer twenty years back; he has been able to find nothing better. As seen, it is simply a common cone, open at both ends. A is the mouth-piece enveloped by a napkin, E; B is a valve for escape of respired air; C implies a sponge placed within the cone with a view of holding ether; D is to furnish air (which necessarily must pass through C) for inspiration. A tinner will make the apparatus in a few minutes.



instead of that of stupor. The fault is not with the agent, but with the operator?

The idea is to be conveyed that the effects of sulphuric ether and of the common alcoholic beverages are the same. The results of the latter are too well known to require description. There is, first, the state of exhilaration, which gradually changes to complete stupefaction, or narcotism: the second condition, the result probably of narcotism of the brain. Just so acts ether, yet passing through its various stages more quickly, the effects of its being poured in a continuous and undiluted stream upon the heart and brain. Ether is no sooner absorbed than the blood charged with it passes to the left side of the heart, and immediately thereafter is circulated through the coronary vessels, the carotid and vertebral arteries, and thus pervades the tissue of all parts of the heart, as well as of every portion of the brain. A writer, in an influential dissertation, presents an example in this wise: Suppose, to take an extreme illustration, that the blood was as capable of absorbing as much ether as water can combine with, or one-tenth its own weight. If, then, we suppose the blood in the lungs was impregnated to this extent, it would be applied in that state to the heart and brain; whereas, if the blood in the stomachic vessels was impregnated to the same extent with ether, before reaching the liver it would have mingled with more than its own mass of pure blood from the splenic and mesenteric veins. The tenth would then become a twentieth, and, on the blood leaving the liver and joining the larger current of the inferior cava, the twentieth would become a fiftieth or sixtieth; a further dilution would take place at the confluence with the superior cava, so that the blood, on reaching the heart and brain, instead of containing one-tenth part of absorbed ether, could not contain as much as one-hundredth. When, therefore, the same quantity of ether, or any absorbable substance, is taken up from the lungs and from the stomach, it must, in the former case, be applied to the tissue of the heart and brain in a state of concentration at least ten times greater than the latter, and will therefore act on these organs with more suddenness and energy.

The evanescence of the influence of ether, as compared with that of alcohol, is explained by a momentary consideration of the different manner of absorption. During the inhalation of ether, as we have just seen, the charged blood is applied to the heart and brain, while that circulating in the lower parts of the body contains a much smaller proportion of it. Now, on stopping the inhalation, the blood in the heart and brain speedily passes off by the veins, and is succeeded by that which is comparatively pure coming from the lower regions of the body, and so the narcotic symptoms disappear.

It is far otherwise when alcohol is absorbed from the stomach, for the whole mass of blood must be impregnated with it before a highly-charged fluid can be applied to the heart and brain; and then the effect continues for many hours, till the alcohol has been thrown out of the system by the lungs and skin. With respect to ether, it must not be supposed that on the subsi-



dence of the narcotism it disappears from the body ; for it is merely weakened in its effects by being diffused over the whole mass of blood. This is obvious, from the smell of the breath for many hours, and from its frequently causing copious perspiration.

Does not the question here suggest itself, If the effects of ether and of the common alcoholic beverages be so nearly alike, why any dread of the one and entire fearlessness with the other? Would not the answer seem to be something of this kind? Men when etherized are as dead-drunk ; our eyes are accustomed to seeing them only partly drunk. In this state they excite amusement : in the state of profound drunkenness they have always aroused our fears for their recovery. Associations have great weight.

The immediate and obvious effect of ether on one to whom it is administered in anæsthetic dose is almost too familiar to justify the use of a paragraph for its description. First, there is commonly exhilaration, this shading gradually into stupor. Second, and finally, there is narcotism, which differs much as to the time which it lasts ; one person recovering almost instantly on the cessation of the exhibition of the agent, another continuing drowsy, or, it may be, remaining in the deadness of profound sleep for many hours.

The progressive effects of the medicine as relation is had with the various nerve-centres are markedly shown in the course of an etherization. A first effect is on the intellectual faculties, these being, 1, stimulated ; 2, degraded ; 3, negated. Second, the influence shows itself in relation with the spinal cord ; on the anterior column first, motion being affected, soon temporarily destroyed, successively on the posterior segment ; sensation, little by little, being obliterated. The point of danger is intermediate to brain and cord ; namely, the medulla oblongata, the respiratory centre. So long as an ether patient breathes undisturbedly there is no necessity for apprehension. Disturbance of respiration is a signal for caution.

Throwing out of immediate consideration the idiosyncrasies, let us for a moment consider the question of the general harmless exhibition of the agent.

The safest means may be made a source of ill. As the intruder on the physical laws of his organism must suffer the consequences of ignorance or of temerity, so may any agent, however good, become an evil by its abuse. As the drinking of alcoholic beverages can be carried to a point beyond which the life-principle will not react, just so, and as the warmest supporters of the anæsthetics would have impressed, may ether be made an instrument of irreparable injury, blasting and destroying where it was designed to refresh and save.

To lay down certain reliable rules, applicable in all cases, for the process of etherization, is an impossibility. The presentment of conditions in various individuals differs so materially, that it would be charlatanism to act on any but rules resulting in a general knowledge of the agent and a comprehension of physiological laws and pathological alternations. One person, as Dr. Snow has remarked, shall become impassable as the subject on the dis-



secting-table; another talks incoherently or mirthfully, replies to questions, or obeys directions; others utter exclamations of pain, which they afterwards retain no reminiscence of having felt; others again declare that they have suffered pain but felt themselves powerless for its expression. Finally, in the exceptional few, ungovernable violent or convulsive action takes place, quite adverse to the performance of any delicate surgical operation. With some an utter oblivion is induced; while others, though undergoing all the apparent torture of a prolonged dissection, are revelling in the realms of memory and in the fields of imagination. M. Jobart and other observers have attempted to lay down three distinct stages in the effects of the agent, according to the prolongation of the etherization. 1. That of incoherence, agitation, or delirium, as the case may be. 2. Acceleration of the pulse, with loss of sensibility and loss of power. 3. Exhaustion and coldness of the surface. The matter cannot thus be methodically stated, for it is quite certain that any of these conditions may be induced, in different individuals, by very various doses of ether; while others, again, are susceptible of only the first degree, to appearances, and yet enjoy an immunity from suffering during operations. Even the quickened condition of the pulse and respiration, and that almost universally employed criterion, the insensibility of the pupil, may deceive in the supposed impression produced.

A number of the French Academicians some years back instituted a series of experiments on animals, for the purpose of determining the mode and order in which the various portions of the cerebro-spinal system were influenced during inhalation. The following are some of the conclusions arrived at as stated by the veteran vivisector, Baron Flourens:

The action of ether on the nervous centres follows in a given course. It acts, first, on the cerebral lobes, disturbing the intellect. It acts, secondly, on the cerebellum, deranging the equilibrium of the movements of the animal. Thirdly, it acts on the medulla spinalis, in which it extinguishes, successively, the sensory and motor principles; and, lastly, it acts on the medulla oblongata, where arrived, life becomes extinct.

To produce the best effects of sulphuric ether, it is of the first consequence that an entirely reliable article be employed. Not only this, but that it be employed heroically, yet persuasively. In the Hospital of Oral Surgery, where ether is used almost exclusively, and under circumstances the most trying to such agents, it will be testified that trouble of any kind has yet to be experienced. A patient is assured, not forced. The agent is administered in full doses, not in dribbles. Instruction is given to make full respiration, persons are not allowed simply to sniff and smell.

The effect of a bad article of ether is not only to deny anæsthesia but to provoke sick stomach, headache, and derangement generally.

Concerning the dose required, this is a matter special to each patient. Persons are met with—trusting and confiding people of lax fibre—upon whom a single inhalation will produce the anæsthetic impression. A differ-



ent class—the vigorous and lusty, of untrusting nature—will consume it as some men do spirituous liquors. The writer has given a whole pound before getting the primary impression.

The criterion in ether exhibition relates, as the state of narcotism is concerned, to the effect of touch upon the eyelashes or eye; these insensible, an operation is to be proceeded with. The point of danger, as has been suggested, relates with respiration. Easy breathing is assurance of safety.

Respiration is not, however, to be misjudged. In some persons a peculiar repugnance to the agent exists. Others find much momentary irritability of the air-passages induced. Cure of both is found in a few minims of chloroform dropped upon the sponge.

Sick stomach, another not infrequent associate, finds treatment, alike with cough, in a drop of chloroform, the agent being mingled with a spoonful of water and drunk.

Another specific is coffee. Dr. Stiles, of Conshohocken, a practitioner of experience, assumes failure of this latter remedy to be uncommon; he prescribes it in small, but strong, doses. Carbonic acid is a grateful means of relief. A spice plaster placed over the stomach will seldom disappoint. Creasote is another cure; the dose and manner of administering is the same as that of chloroform.

As to the question of the continuance of a patient in the anæsthetic condition, it is the practice of the author, and that of the Oral Hospital, to make the time just as short as possible; that is to say, as the continuance of the agent is concerned. If an operation to be performed may be completed in five, ten, or fifteen minutes, it is not good policy to prolong it, and with it the continued administration of the ether, to a half or a full hour. That there is, however, any imperative or absolute necessity to hurry through an ether case is not at all implied. The author has kept a patient profoundly under ether for two and a half hours; and in obstetrical practice half a day of intermitting anæsthesia is not at all infrequent. It is contended only that it is neither desirable nor prudent to unnecessarily prolong the condition. Where, however, such lengthened action is demanded, it is to be secured, not by keeping the saturated sponge constantly applied over the air-passages, but by using the agent at such intervening periods as may be necessary to preserve its effect.

The condition of the temperature, as might be inferred, has much to do with prolonging or shortening the time commonly considered necessary to place a patient in a state of sleep. Dr. Snow obtained, from experiments, the following results:

One hundred cubic inches of air, saturated with the vapor of ether, at a temperature of

44°	would contain	27.0	cubic inches of vapor.
54°	“	24.3	“ “
64°	“	43.3	“ “
74°	“	53.6	“ “
84°	“	66.6	“ “



Being doubled by a rise of only thirty degrees; or, in other words, if at a temperature of  $84^{\circ}$  Fahrenheit we employ two or two and a half minutes in affecting a person to the state desired, at a temperature thirty degrees lower we would require from four and a half to six minutes to obtain the same result.

Concerning the idiosyncrasies, the author would speak his own experience by saying that he has never yet met with a person who might not take ether, or ether in combination with chloroform. The London *Medical Gazette* considers its use inadmissible where there is a tendency to apoplexy or epilepsy, and also in plethoric individuals. Another intelligent source says that persons presenting the slightest signs of being cataleptic should be viewed as idiosyncratic. Persons under the influence of liquor, it is generally thought, are to be esteemed for the time as not fit subjects.

In conversation with the elder Dr. Flagg, had several years back, that experienced man implied that he believed in no idiosyncrasies, except it might be a very high, nervous temperament; that he had administered ether to the infant of thirty-six hours and to persons in extreme old age; had given it to the robust and the weak, the plethoric and the consumptive; had used it in all stages of pregnancy, except that known as quickening; might also exhibit it here, but would feel called on to exercise more than ordinary care. Seeming idiosyncrasies could generally, he thought, be explained by an examination of the operator's ignorance of the agent. The faith of that gentleman in the perfect safety of the use of ether was so great that he remarked he would not hesitate to use it where there had been, or was, aneurism of the aorta. The opinion of Dr. Flagg concerning the non-existence of idiosyncrasies is to be taken before that of most persons, either of this country or Europe. His opportunities for observation were not surpassed by those of any other physician, and perhaps equalled by few. A work published by him in 1854, long before his retirement from practice, has not, up to the present day, been advanced on, and is an heirloom to be valued by those to whom his industry has left it. The experiences of the author coincide with those of the gentleman quoted. He has administered ether under every possible variety of circumstances as to age, condition, time, and apparent idiosyncrasies, and has never met with any cause for anxiety. In the labor of childbirth ether is absolutely temporary euthanasia. The author, speaking out of an experience arising from a connection of several years with a large obstetrical clinic, bears witness to the entire absence of any objection to the free employment of the agent in the direction. The indication is to have the ether in full strength at the mouth in the commencement of a pain. Two or three inhalations suffice for each contraction.

**Chloroform.**—From the consideration of sulphuric ether we pass to an investigation of the character and merits of the perchloride of formyle, or chloroform. This agent is, without doubt, the most powerful and reliable of the anæsthetics; but, unfortunately, it possesses qualities which render it not



infrequently fatal to life, and therefore make it of less value than the one just considered. No person is to employ chloroform who is not prepared to meet formidable emergencies.

To procure chloroform, the chemist takes of chlorinated lime say (to take a common formula), lb. iv; rectified spirits, Oss; water, Ox; chloride of calcium, broken in pieces, 5j. Put the lime, first mixed with water, into a retort, and add the spirits, so that the mixture may fill only the third part of the vessel. Then heat them in a sand-bath, and as soon as ebullition begins withdraw the heat as quickly as possible, lest the glass be broken by the sudden increase. Let the liquor distil into the receiver so long as there is nothing which subsides, the heat being reapplied if necessary. To the distilled liquid add a quarter of the water, and shake them all well together. Carefully separate the heavier portion, which falls, and add the chloride to it; for an hour frequently shake them. Lastly, let the liquid distil again from a glass retort into a glass receiver.

In appearance chloroform resembles the freshest water of the mountain-spring. To the taste it is hot and very sweet; to the nostril it has much the odor of the common strawberry. When dropped upon linen it evaporates very quickly, leaving, if pure, no stain or sign behind. In weight it is quite one-half heavier than water, and, as its vapor is concerned, it is four times as dense as atmospheric air.

The smell of chloroform is esteemed by Dr. Snow, a practitioner widely experienced with the agent, one of the best tests of purity and identity. If a disagreeable scent remain on the hand after the evaporation, the chloroform has probably been made from impure spirits, or even from wood or acetone, and is therefore unfit for medicinal purposes. When dropped on the skin it should quickly evaporate, leaving not the least odor or moisture behind. When chloroform becomes decomposed from any cause, it acquires a greenish-yellow color, and gives off chlorine and hydrochloric acid, so that the alteration is at once apparent. When it is pure, it has no reaction on test-paper, but is quite neutral. The best way, according to the writer quoted, to detect a small quantity of hydrochloric acid in it, is to moisten a slip of blue litmus paper with distilled water, and hold it just within the neck of the bottle, exposed to the vapor. If sulphuric acid be present, it may be discovered by agitating the chloroform with distilled water and adding nitrate of baryta.

Chloroform is degraded by admixture with alcohol, and this can be done without making any perceptible change in its appearance: its specific gravity, however, is thereby lowered. According to M. Mialhe, the foreign presence is most easily detected by adding to the suspected fluid a small quantity of water, when a milky opacity results.

Chloroform, as the heart's action is concerned, is a powerful sedative. In nearly if not quite all the fatal cases resulting from its administration, cardiac syncope has been the cause of death; and in a very small minority of the cases indeed has there been any evident interference with the process of respiration.



This latter fact is always to be held in strictest remembrance when exhibiting the agent.

In oral surgery, where it is desirable to secure the profoundest and most prolonged primary impression, chloroform, if it were without danger, would be the anæsthetic most indicated and required. Indeed, in the writer's practice he finds many cases where he does not seem able to get along without it, using the agent in association with either brandy or ether. Because its use is so frequently necessary, the oral surgeon is to make himself as familiar as possible with all that concerns its defects as well as its virtues.

Experiments have demonstrated that eighteen minims of chloroform is the average quantity necessary to put an adult in a condition of insensibility,—that is to say, this amount is to be absorbed and carried to the nerve-centres.

It has also been shown that chloroform vapor has the effect of suddenly arresting the action of the heart, when it is mixed with the respired air to the extent of eight or ten per cent. or upward. With these two lessons appreciated, it is seen that the matter and manner of the exhibition of the agent have much to do with the result: not everything, however, as it is undeniable that fatal accidents have occurred in the best and most skilful hands.

Eighteen minims, according to Dr. Snow, are to be absorbed from thirty-six breathed; allowing thus that one-half is lost in expiration. But atmospheric conditions, as in the case of ether, has much to do with the taking up of quantity. The following table comprises experiments in this direction. At a temperature of 40° Fahrenheit, one hundred cubic inches of air will take up but seven cubic inches of the vapor.

At 45°	8 cubic inches.	At 70°	24 cubic inches.
50°	9 “	75°	29 “
55°	11 “	80°	36 “
60°	14 “	85°	44 “
65°	19 “	90°	55 “

This table exhibits the fact that anæsthesia by the use of chloroform must come on at varying periods, and that therefore no judgment of its proper exhibition is to be derived in the direction. Again, outside of these atmospheric associations, the manner of the exhibition has much to do with the minims inspired. Where, for example, the agent is exhibited poured upon a single layer of linen (as upon a handkerchief laid over the face), quite as much is lost in the surrounding atmosphere as is inhaled into the lungs.

Recognizing the danger as arising from the direction of cardiac syncope, advantage is to be taken of means antagonistic to such depression. In blood-letting, it is known that such a condition is much the most readily brought about when the operation is performed on the patient standing, and when the primary impression is made most marked through a large exit for the blood. In states of depression arising from whatever cause, either of physical or mental disturbance, such tendency is increased. A surgeon always hesitates to bleed a depressed patient; or, if such bleeding seem a necessity, support-



ing means are employed and continued in conjunction with the depletion. Advantage is taken also of all collateral indications, as, for example, position, the patient lying down, the head perhaps being placed on a lower plane than the body, the orifice of exit being made very small, intermissions in the flow of the blood, stimulants, as the pre-exhibition of brandy or wine, kind and encouraging assurances, etc. The depressing effect of fear on the heart's action is never to be lost sight of in the administration of chloroform. How many patients faint even while preliminary arrangements in anticipation of an operation are going forward! indeed, how many are the cases on record of death from such fright! It would seem, then, that one would never be justified in administering chloroform to a patient laboring under marked depression; at least such is the author's conviction, and on such impression has he always acted. All persons, or nearly all, approach a surgical performance with a certain amount of trepidation, but such fear may, in the majority of cases, be dispelled; or if this be impossible, then a preliminary artificial courage is to be given by the use of stimulants; or cerebral consciousness may be confused by the inhalation of a few drachms of ether.

The objection that chloroform is not to be given a patient in a sitting posture does not seem to hold entirely good. In oral surgery this is nearly always the necessary position; and the agent is thus administered in hundreds of cases without ill result. A difference in the character of cardiac syncope is here to be recognized. The paralysis may arise from two sources, and exhibit, as the state of the heart is concerned, quite different appearances; that is, there is a syncope of anæmia and a syncope of narcotism. Now, while there is between these two conditions much relationship, as the question of a vital propulsive force is concerned, yet there are also certain differences, of which, as surgeons, we are to take advantage. Paralysis of the heart occurs when, from any reason, the organ is deprived of the effect of its natural stimulus, the blood: this is the syncope, or paralysis, of anæmia. It occurs again when, through the action of a common or a specific narcotic, its muscular fibres are relaxed and deadened. The two causes may exist and act in conjunction. Chloroform is a specific narcotic, as the heart is concerned; at least this is the deduction from post-mortems made in the fatal cases of its exhibition. In anæmia, syncope is partly a mechanical production; the patient, in a standing position, faints, as the result of gravity counterbalancing the natural distribution of the blood. In narcotic syncope, position is, perhaps, of little consequence, at least as the action of the producing cause is, of itself, concerned. The question, then, of sitting or of lying, as the exhibition is concerned, resolves itself into a consideration of the state of the general health of a patient: if there be deficiency either in quality or in amount of the vital fluid, then the erect or even semi-erect station is not to obtain. If, on the contrary, a patient does not present such conditions, then it would seem that there is no special danger in the position.

Prefatory stimulation, if not contra-indicated, is happily employed in con-



junction with chloroform. A tablespoonful or more of brandy given to a patient some five or ten minutes before exhibition of the agent, will frequently support the natural action of the heart through a prolonged operation, and thus antagonize the common source of alarm.

In his own practice the author never likes to use chloroform but in conjunction with ether; not mixing them, as in the common chloric ether, but alternating, as the case seems to require or allow. Thus, employing the cone, the process is commenced by pouring within it a quantity of ether, when it is gradually, and yet as rapidly as possible, brought to cover the mouth and nostrils. If now the pulse rapidly increase, or even remain fixed and steady, and particularly if undue cerebral excitability manifest itself, ten or twenty drops of chloroform are dropped into the sponge. This is found to quiet the patient almost instantly. From this point the surgeon proceeds, using chloroform or ether, according to the result to be secured. If an operation be one of simple character and of quick performance, as the extraction of teeth, or the making of a puncture or incision, then it is not wise to risk anything with chloroform. If, on the contrary, it be some difficult and tedious case about the mouth, where, after commencing, the operator cannot well stop to readminister the anæsthetic, the risk of the excess of chloroform may be taken for the prolonged effect yielded and the greater profundity of impression secured.

The manner of the exhibition of the agent has, as one would infer, much influence, as result is concerned. Thus, of the various apparatus that have from time to time been devised to assist in the use of chloroform many are deserving of no better name than life-traps; and in this connection one naturally finds himself wondering at the character of contrivances which, particularly in the earlier history of chloroform, were employed, even by the ablest men, in experiments directed to the testing of the general safety and results of the agent. One cannot read of the white mice, guinea-pigs, cats, and bell-jars of these pioneers, without wondering that it should never have occurred to the experimenters that animals might as readily die from lack of proper respirable air as from effects of anæsthesia.

In using pure chloroform, it is most desirable that there be the fullest admixture of air; with this intention the sponge is used, first softening it with warm water, which water is to be well squeezed away. The respiration should be easy and natural, and the patient fully *en rapport* with the operator. He should be given to understand that anæsthesia is but a gentle and harmless sleep, and that one is to enter on it as he does on natural slumber. If such confidence be secured, there will be found little trouble in producing narcotism. Another plan of using the agent, and one which has many advocates, is to let fall drop after drop upon a napkin, laid loosely over the air-passages. The tin cone shown will not disappoint.

However employed, the principal indication is to have the agent in proper dilution and combination with atmospheric air: this secured, any mode of



inhalation must be a proper one. Insensibility, as wisely remarked by Dr. Snow, is not caused so much by giving a dose as by performing a process. Nature, continues this gentleman, supplies but one mixture of diluted oxygen, from which each creature draws as much as it requires; and so, in causing narcotism by inhalation, if a proper mixture of vapor and air be supplied, each patient will gradually inhale the requisite quantity of the former to cause insensibility, according to his size and strength. It is desirable to vary the proportions of vapor and air, but rather according to the purpose one has in view, whether medicinal, obstetric, or surgical, than on account of the age or strength of the patient; for the respiratory process bears such a relation to the latter circumstances as to cause each person to draw his own proper dose from a similar atmosphere in a suitable time.

The induction of insensibility varies with the individual, or rather, it is to be suggested, with classes of individuals. One class will breathe quietly and slowly, until unconsciousness supervenes as if by a natural sleep: persons of this kind are of the lymphatic temperament. The nervo-sanguine or bilious class are apt to become restive and frightened, and require a great amount of care and attention, being the most difficult to impress. The true and full nervous man, while timid and frightened, is yet apt to be impressed by a very few inhalations. There is one question that here arises in regard to an exhibition of timidity. When a patient becomes excited, shall the chloroformization go on? Yes, is to be answered, if such exhibition be associated with mental disturbance produced by the agent; for here it is not as the condition previously named, but is rather an hallucination. These patients are to be forced rapidly beyond the state of excitement. Here is the point in which the production of anæsthesia demands skill, courage, and judgment. Over and over again incompetent operators worry poor creatures into most wretched conditions simply by fearing to pass the Rubicon of excitement. If assured that all be right (and such assurance is to be derived from noting closely the circulation), we are to get over this intermediate excitable stage as quickly as possible, and get over it by concentrating the chloroform. Patients laboring under such excitability will, often enough, assure you that they feel that another inhalation will kill them; that it is impossible to breathe; that the heart is laboring under woful depression; with many complaints of like character. Such speeches are mostly to be taken *cum grano salis*; the practitioner is to judge for himself. Danger is, however, at the bedside, let it not be *overlooked*. Chloroform is more treacherous than is Mephistopheles.

Before an operation of magnitude is commenced, it behooves a surgeon to assure himself that his patient is in the proper anæsthetic condition. Entire paralysis of the muscles of animal life is commonly received as indicative of such a state,—this being manifested in the lifeless falling of an arm when raised. But this is not strictly reliable, as to obtund sensation we are aware the posterior column of the spinal cord is to be affected, while loss of motion implies only anæsthesia of the anterior. So quickly, however, does the action



of the agent pass from the one to the other of these parts, that this sign is found to be one most convenient of acceptance.

Three degrees of narcotism are described. The first includes all the effects of chloroform that exist while a patient retains a perfect consciousness of where he is and what is occurring. In the second, there is no longer correct consciousness; the mental functions are impaired, but not necessarily suspended. In the third there are no longer any voluntary motions.

The circumstances which influence or modify the effects of chloroform are thus considered by Dr. Snow, than whom, perhaps, there is no one whose observations have been of a more extended or thorough nature; although it is not to be overlooked that he was so enthusiastic in his direction that perhaps, in some instances at least, his prejudices may have influenced somewhat his judgment. The writer puts it on record that he discountenances the employment of chloroform. He uses it, never save under compulsion, and fears always while he uses. *He never administers it without the conjunction of a prophylactic—ether or brandy.*

I arrived at the conclusion, says Dr. Snow, after much careful observation, that chloroform might be given with safety and advantage in every case in which the patient requires, and is in a condition to undergo, a surgical operation. And having acted on this conclusion for several years, I have found no reason to change it. It is desirable, however, to pay attention to every circumstance connected with the health and constitution of the patient before exhibiting chloroform, as many of these circumstances influence its effects.

The conclusions arising out of Dr. Snow's experience concerning circumstances of exhibition are thus to be epitomized. Those of the writer accord with them.

AGE.—The age of a patient has considerable influence in modifying the effects of chloroform. It acts very favorably on children. These sometimes oppose the inhalation of it as long as they are conscious, but it does not occasion the rigidity and struggling, after loss of unconsciousness, which are sometimes met with in the adult. Anæsthesia is generally induced with a less amount of narcotism of the nervous centres in children than in grown persons.

The effects of chloroform are produced more rapidly, and also subside more quickly, in children than in adults, owing, no doubt, to the speedier breathing and circulation. It often happens, however, that when the insensibility has been kept up for some time, say twenty minutes or half an hour, in a child, it is followed by a natural sleep of a few hours' duration, provided there be no painful wound or other cause to prevent the sleep. It is worthy of remark that none of the accidents from chloroform which have been recorded have occurred to young children.

There is nothing peculiar in the effect of chloroform upon people advanced in years, except that its influence subsides tardily, on account of the slower breathing and circulation.

STRENGTH OR DEBILITY.—The comparative strength or debility of a



patient has considerable influence on the way in which chloroform acts. Usually the more feeble the person, whether from illness or any other cause, the more quietly does he become insensible; while if he be strong and robust, there is very likely to be mental excitement in the second degree of narcotism, and rigidity of the muscles, and probably struggling, in the third degree. Patients in a state of debility resemble children, not only in coming quietly and easily under the influence, but also in the circumstance that the common sensibility is suspended with less narcotism of the nervous centres than is generally required in robust people. Children, and persons in a state of weakness, have usually an acute sensibility, which causes them to suffer pain from very slight injuries, but this sensibility is more easily suspended by chloroform than the less acute sensibility of the robust.

**HYSTERIA.**—Patients who are subject to hysteria have sometimes symptoms of the complaint, such as sobbing, crying, or laughing, as soon as consciousness is suspended, or even impaired, by the chloroform; but these symptoms can always be subdued by proceeding with the inhalation.\*

In some persons who are subject to hysteria the breathing becomes excessively deep and rapid while inhaling chloroform.† This usually occurs just as the patient is becoming unconscious, but in a few cases even earlier, and the subject is aware of the impulse to breathe in this manner. After this kind of hysterical breathing has lasted a little time, the individual generally rests nearly a minute without breathing at all, after which the respiration becomes generally natural. Chloroform is to be given very sparingly during the violent breathing, or else withdrawn altogether for a moment or two.

**PREGNANCY.**—It is not generally thought that there is anything in this condition objectionable to the use of chloroform.

**THE MENSTRUAL PERIOD.**—This time is certainly not to be preferred or selected as an occasion of chloroform exhibition. Yet there is nothing at all in it adverse to the administration. The controlling effect of the agent over hysterical symptoms has just been remarked, and such irritability of the system is a peculiarity of the state. Indeed, it is very common that the hysterically inclined female is compelled to resort to chloroform, particularly in conditions of dysmenorrhœa.

---

\* Chloroform in hysteria is one of the most valuable medicines of the *Materia Medica*, while, on the contrary, sulphuric ether is most decidedly objectionable to such patients. The writer has treated females afflicted in this way where ether had been used by the pound with no other effect seemingly than increasing, intensifying, and prolonging the paroxysm; yet with a very few inhalations of chloroform has had the pleasure of seeing the persons fall into the most natural slumber, and after resting quietly for hours, the sleep prolonged, perhaps, as sometimes has seemed indicated, by occasional repetition of the inhalation, has again and again seen them awake perfectly recovered.

† Dr. Snow, in his paragraph, remarks the supervening of this condition after the first few inhalations, but, according to the writer's experience, it is as uncommon when chloroform is used as it is common in the employment of ether. When, in administering ether, the slightest signs of hysteria are seen either in male or female, control is to be secured by replacing the ether with chloroform.



**DISEASES OF THE LUNGS.**—Affections of the lungs sometimes cause a little difficulty and delay in the administration of chloroform, as the vapor is liable to excite coughing when the mucous membrane of the air-passages is irritable. The inconvenience is, however, confined to the time of inhalation, for the cough is generally relieved afterward.\*

I have given, says Dr. Snow, chloroform for surgical purposes in many cases where phthisis was present, and in several patients who had suffered from hæmoptysis, and have not seen any ill effects from its use. Chloroform is, indeed, often inhaled with advantage to relieve cough in consumption. The instances of chronic bronchitis in which the agent is administered for relief of the condition and for operations are still more numerous.

**DISEASE OF THE HEART.**—There is a very general impression that the use of chloroform is unsafe when disease of the heart exists, more particularly fatty degeneration of that organ. This belief has been encouraged by the circumstance that the affection has been present in a few of both the real and alleged deaths from the agent, and also by the fact that, in the accidents that have been really due to chloroform, the heart has been the organ on which it has exerted its fatal influence. When we come to investigate these cases, however, we shall find reason to conclude that the heart has probably been diseased in quite as great a proportion of the patients who have taken chloroform without ill effects as of those who have succumbed under its influence. As regards my own practice, says Dr. Snow, the only case in which death could in any degree be attributed to the chloroform, was one in which there was extreme fatty degeneration of the heart; but, on the other hand, I have given chloroform in numerous cases without ill effect where the symptoms of this, as well as of other affections, were present in a marked degree. Indeed, I have never declined to give chloroform to a patient requiring a surgical operation, whatever might be his condition, as I early arrived at the conclusion that this agent, when carefully administered, causes less disturbance of the heart and circulation than does severe pain. Wherever, continues Dr. Snow, I have had an opportunity of seeing an operation performed without chloroform, I have carefully examined the pulse, and although none of these operations have been of a very severe nature, I have found the circulation to be much more disturbed than it would have been by the agent carefully administered. The pulse, in most of the cases, has been exceedingly frequent during the operation, and in some instances it has intermitted to an unusual extent.

In one case, this gentleman says, I had an opportunity of witnessing a similar operation on the same patient, first without chloroform, and afterward under its influence. In the first, which was lithotrity, I began to feel the

---

\* This difficulty, as observed not only by Dr. Snow, but also by nearly all writers on anæsthesia, is found to be almost, if indeed not entirely, obviated by preceding the exhibition with a tablespoonful of thick mucilage of gum acacia, the patient allowing it gradually to lose itself over the mucous surfaces.



pulse just when the patient saw the lithotrite about to be introduced. It was 120 in the minute. As soon as the instrument was in the bladder the pulse increased to 144, and immediately afterward it became uneven, irregular, and intermitting. I could not count more than three or four beats at a time; and occasionally, when the pain seemed greatest, and the man was straining and holding his breath, the pulse was altogether absent for four or five seconds. In order to ascertain whether the loss of beat at the wrist might not depend on the pressure of the muscles of the arms, caused by grasping the table, I applied my ear to the chest, and found that there was no sound whatever to be heard during the intervals when the beat was imperceptible. It was evident that the patient held his breath till the right cavities of the heart became so distended as to stop the action of the organ till the respiration returned. The man did not complain or cry out during the operation.

A week afterward the lithotrity was repeated, but on this occasion I administered chloroform. The pulse was 120 in the minute when the patient began to inhale the anæsthetic, but it became slower as he was made unconscious, and it was regular during the operation. It was only toward the end of the performance, when the effect of the agent was allowed to diminish, and when the man began to strain a little, though not yet conscious, that the pulse intermitted slightly, passing over a single beat occasionally. There were none of the long intermissions observed on the former occasion.

It is very evident that if the above-mentioned patient had been the subject of any affection of the heart which weakened or embarrassed its action, he would have run a much greater risk from the pain of the first operation than from the inhalation of the chloroform in the second one.

In a few of the patients having the arcus senilis of the cornea, a weak, intermitting, or irregular pulse, and other signs of fatty degeneration of the heart, there have been a feeling of faintness and a tendency to syncope as the effects of the chloroform were subsiding, especially when the operation had been performed in the sitting position; but these symptoms have soon subsided, in all cases I have met with, on placing the patient horizontally, with, or without, the help of a little ammonia to the nostrils.\*

CEREBRAL DISEASES.—Affections of the head, according to this same authority, offer no obstacle to the administration of chloroform. I have given chloroform, he says, to several patients who had suffered previously from an attack of apoplexy; some of them still retained the paralysis resulting from the attack, but the exhibition has not been attended or followed by ill effects in any of these cases.

The following interesting and most instructive case is mentioned in this direction:

The 31st of October was a day appointed by Mr. Fergusson to perform

---

\* However imposing and authoritative the testimony favoring the exhibition of chloroform where organic heart derangements of any kind exist, the writer puts in his own word of warning. He believes the agent full of risk.



lithotrity on a gentleman seventy-eight years of age, who had a phosphatic calculus in his bladder. He was a patient of Mr. Propert, and Mr. Fergusson had removed a similar calculus by lithotrity, and I had given him chloroform at each of the operations, and it was arranged that he should have it on the present occasion. Mr. Propert informed Mr. Fergusson and myself on our arrival that his patient had, the night before, an attack resembling apoplexy; he had been insensible; the breathing had been stertorous, the pupils dilated, and the face very red and congested. Mr. Propert had caused him to be cupped to fourteen ounces, and had given him twenty grains of calomel in the course of the night, and in the morning he was as usual, and remained so at the time of our visit. We considered the case with his attendant, and, as there were no reasons for postponing the operation, it was determined that the man should inhale the chloroform rather than be subjected to pain. The vapor acted very favorably: he recovered his consciousness a few minutes after the crushing, and expressed himself as feeling quite well.

INSANITY.—Chloroform acts on insane patients just as it does on others; when the effects subside they are in the same state of mind as before. Mr. Snow remarks the suspiciousness of the insane, but gives his experience where teeth have been extracted and other operations performed which it would have been impossible to accomplish in the same individual without resorting to inhalation. The employment of chloroform in the delirium of mania a potu has, through the experiments of Dr. Ely McClellan, of the United States Army, lately been revived, and commands much attention, the success of this gentleman being verified by practitioners in every part of the country. Given in drachm doses, *pro re nata*, chloroform seems to break the paroxysm completely, causing the patient to fall into a profound sleep, from which, after eight or ten hours, he awakes, commonly entirely relieved. In delirium, however, the chloroform is to be taken into the stomach, not breathed.

This consideration of chloroform may be closed by remarking, as alluded to in the commencement of the chapter, that the agent, if one feels justified in using it, is far to be preferred in oral surgery to the ether; a profound impression created through chloroform will not infrequently continue through quite a prolonged operation; or, if it be necessary to renew the inhalation, the desired impression is generally made with great rapidity. Performances about the mouth, unlike most other surgical services, require to be executed with rapidity; therefore it is a necessity to be as little interfered with as possible: an impression, apparently very profound, made with ether, is apt to be broken in the very first shock of an oral operation. This first step may be of a character starting, in some instances, frightful hemorrhage, and which is to be combated only at the completion of the service. To have a patient pass from control at such moment, and under such circumstances, is sometimes a matter of serious concern. If one has not used chloroform up to this



time, and the article be at hand, it is apt to be given the patient in a quite free manner.

The author in this chapter has used in many instances the strong authoritative experiences of Dr. Snow. He is convinced of the truth of all that is maintained; personally, however, he is afraid to use chloroform except in conjunction with ether; and while such fear may not be solidly grounded, yet, as it exists, he cannot do otherwise than give expression to it. At this day it were certainly idle to attempt to deny that many deaths, a great many, have resulted from the use of chloroform; and a large proportion of these accidents have happened in the hands of eminent and skilful men, and where every possible scientific precaution had been taken.

Again, the accidents have seldom if ever been traceable to an overdose of the agent; the deaths have never occurred from narcotism, but from a direct and unforeseen paralysis of the heart. The author has not overlooked the fact that fatal results happening while chloroform was being used might not be owing to the agent. Certainly there are cases enough on record justifying such a conclusion,—cases with which every surgeon must be familiar; but, on the other hand, there are instances of such doubt, or perhaps it is better to say, of such certainty, that one may incline to err on the side of discretion.

Treatment of chloroform narcosis relates with restoration of the abeyant circulation. To this end a cloth wrung out in cold water is to be slashed over the chest. Inhalations of ether may be given. The head is to be placed on a lower level than the body. Artificial respiration is to be maintained. Tickling the nostril is a favorite means.

In the *Vierteljahresschrift für Gericht. Med.*, Dr. Wachsmuth, of Berlin, makes the important statement that if one-fifth part of oil of turpentine be added to chloroform, the latter can be administered to the fullest anæsthesia without the slightest risk, as the turpentine prevents, by its stimulating properties, the pulmonic paralysis, which is the proximate cause of death in fatal chloroform narcosis.

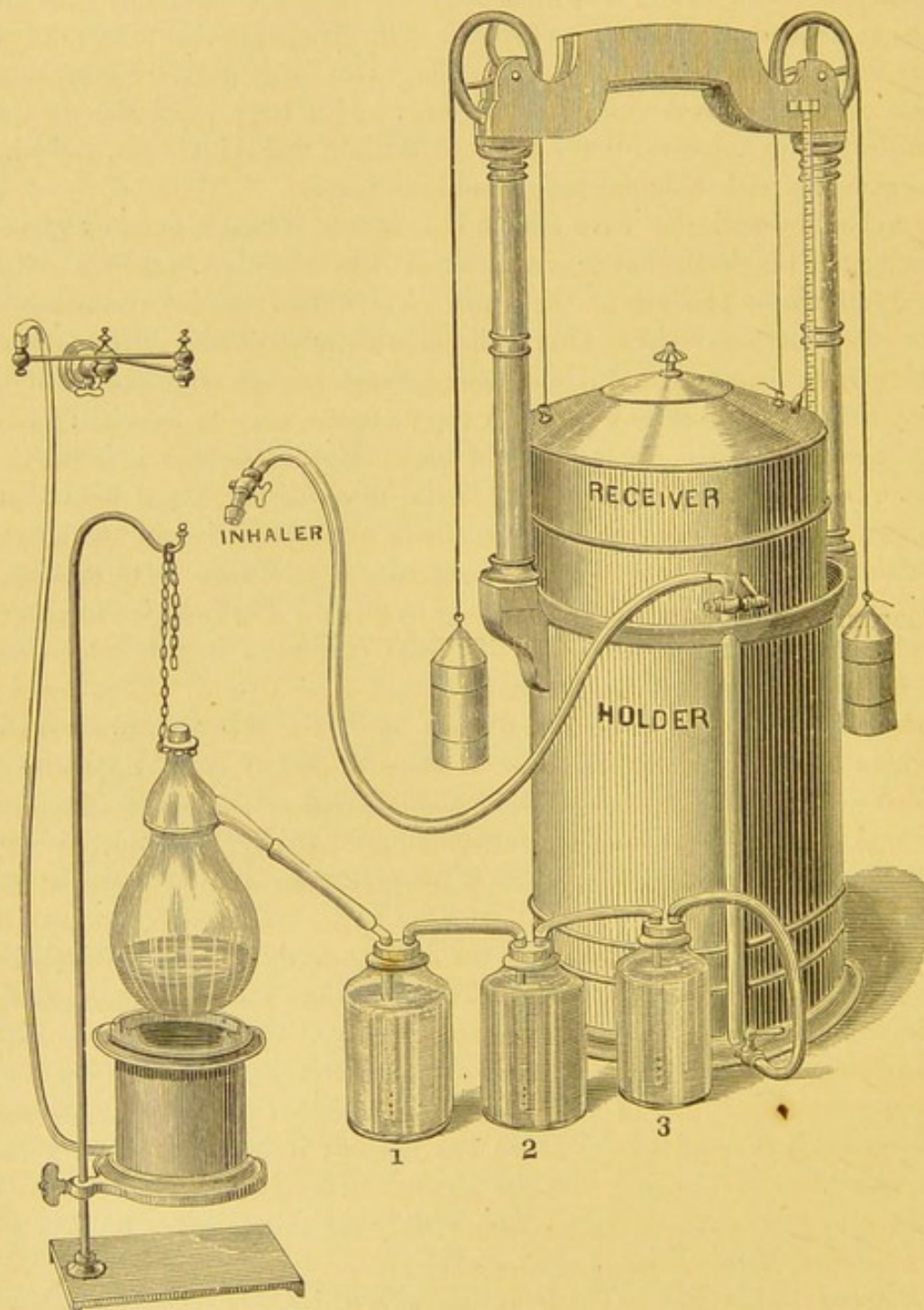
Apparent death from chloroform has found remedy in turning the patient for a few moments head downward. The author has had occasion to practise this, and it has proved successful; it applies as well to ether syncope. Artificial respiration, continued for from half to a full hour, is on record as proving restorative. Nitrite of amyl, ten drops poured on a cloth and applied to the nostril, is an antidote. Look to the tongue; if this be fallen back pull it forward. Give fresh air. Fan the patient. Use smart strokes of a battery. Dash cold water over the face. Rub briskly the extremities. Blow in the ear. Insert a lump of ice in the rectum.

**Nitrous Oxide Gas.**—The frequency with which this agent is now used, and the immunity from accident indorsing its employment, has begotten acquaintance with and confidence in it on the part of the people at large. Application of it is with minor and quickly-performed operations. Dentistry proper, as it relates to tooth extraction, is particularly served by it.



Nitrous oxide gas owes its discovery to Priestley, 1776. Credit for its use as a pain-obtunding agent is due both to Sir Humphry Davy and Dr. Horace Wells; to the latter, particularly. The gas is secured simply by boiling nitrate of ammonia and collecting the vapor evolved in the process.

FIG. 604.



PREPARATION.—Fig. 604 shows a nitrous oxide gas apparatus. It consists, as seen, of a stove and retort, three bottles connected by means of pipes and tubing, and a holder and receiver.



To make the gas an operator provides himself with a quantity of pure nitrate of ammonia (a pound produces thirty gallons of the vapor). This he tests by a procedure as follows: A teaspoonful is placed in half a goblet of distilled water. If admixtures containing chlorine be present the fluid will be rendered milky; if, on the contrary, the salt be pure the water will remain unchanged. Being found unadulterated, the required quantity—measured by the amount of gas needed, one pound to each thirty gallons—is placed in the retort\* and heat applied through a sand-holder in which the retort rests, until the fusing point be attained,  $250^{\circ}$  F. The salt melted, heat is to be increased to the boiling point,  $460^{\circ}$  F. If now the gas be disengaged and commences to pass over with freeness, the temperature is to be maintained, otherwise it is to be advanced, the maximum being  $482^{\circ}$  F. Heat higher than this is productive of a poisonous element.

WASHING.—The bottles employed are for the purpose of cleansing, or washing, the gas. Bottle 1 is furnished with a pipe having a hole-riddled terminus, the external end being associated with the retort by medium of rubber tubing; it may or may not contain a little water, never enough, however, to be in contact with the tube. The office of this first bottle is simply to catch the drip. Bottle 2 is partly filled with water: beside that fluid it commonly has put into it three or four ounces of sulphate of iron or copperas. Bottle 3 is to have a stick of caustic potash placed in it, this as a guard against the possibility of chlorine being present. The contents of the wash-bottles are to be renewed after each running.

Before starting the distillation it is desirable to prove the existence of communication between retort and receiver. To do this it is only necessary to blow in the retort end of the connecting tubing: the passage being unobstructed the water in the middle and third bottles is made to bubble.

COLLECTING.—To collect and preserve the gas implies a receiver. The one shown in the cut is highly commended by users of it. Connected with bottle 3 a tube, having a stop-cock, is seen. This conductor relates with the cylinder at a point above the surface of water with which the fixed portion, or holder, is filled. Forced through this pipe the gas enters the receptacle, the weighted and balanced receiver accommodating the collection. It is now ready for use.

DISPENSING.—This is by means of the outlet marked inhaler. A rubber bag receiving the gas, it may be disconnected and carried anywhere. To administer the agent, a mouth-piece, Fig. 605, is associated with the contents of the bag by means of a spiggoted tube.

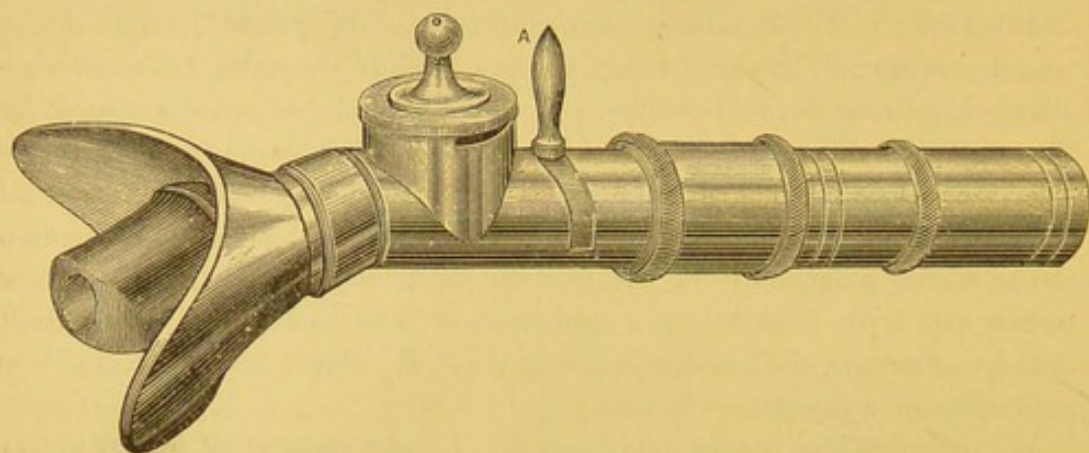
**Liquefied Nitrous Oxide.**—Nitrous oxide gas subjected to extreme cold and pressure is to be condensed in strong iron cylinders in the form of a liquid. Fig. 606 shows such a cylinder in the shape of a not unsightly piece of office furniture. A tube holding one hundred gallons of the gas weighs

\* The fused or granulated salt is to be preferred.



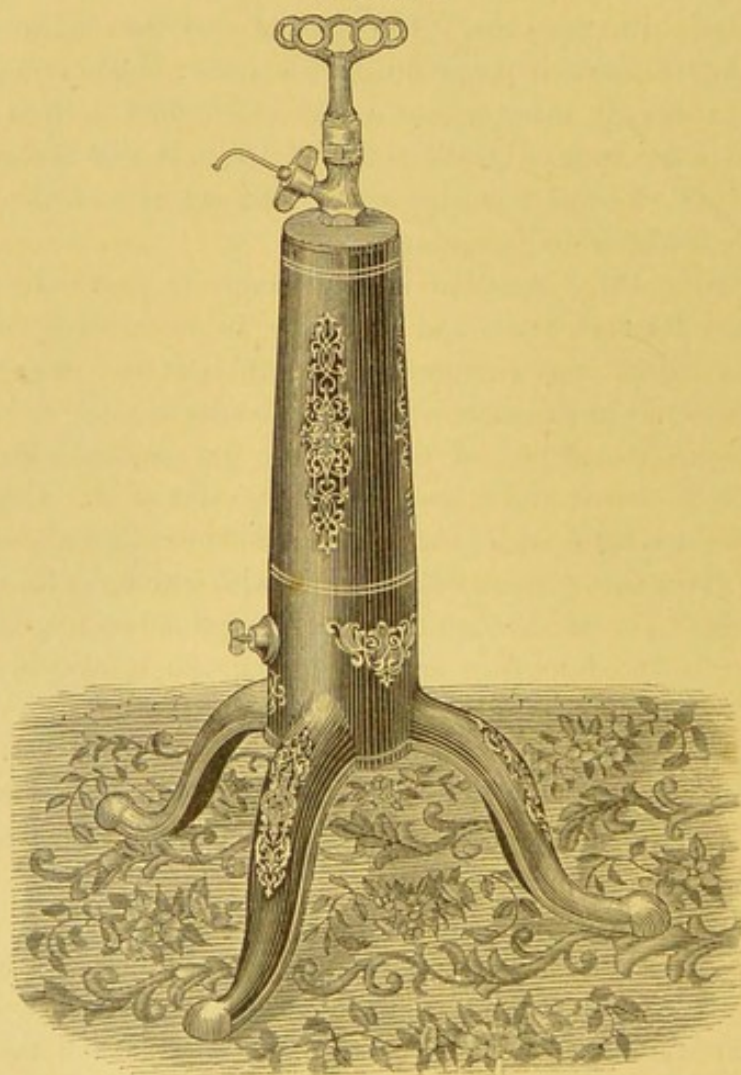
just ten pounds. With paper wrapped about it one would carry the shell

FIG. 605.



in his hand without attracting a passing glance. The surgeon's case, a

FIG. 606.



package containing the liquid, and conveniences for exhibiting it, is a most



handy, economical, and convenient arrangement for the use of general practitioners.

Fresh gas is to be accepted as being better than old. Twenty days is esteemed by many the maximum time that the agent should be allowed to stand over water. Differing, in the respect, as the antipodes, from ether and chloroform, nitrous oxide gas is to be given to the absolute exclusion of air. Bearded men require to this end the application of a hood. No condition or idiosyncrasy absolutely contra-indicative of the use of the agent is admitted.

Spasm of the glottis and syncope are the commonest of the interruptions. In both cases immediate attention is required to the tongue; the organ to be seized with a dry napkin and drawn forward. In spasm the placing of the tongue, combined with a few inhalations of air, is sufficient for relief. In syncope, the patient is put in a reclining position; fresh air is freely admitted; water is dashed against the face; smelling salts or ammonia fortior is applied to the nose; the ear is blown into or the nostril tickled.

Conditions demanding caution are plethora, hypertrophy, fatty degeneration and valvular obstruction of the heart, temporary or permanent systemic depression, as existing, the first, in the over-fatigued, the second, in drunkards.

**ACTION.**—While the agents previously described relax the muscular system, nitrous oxide gas stiffens it. Hence the necessity for a prop placed between the teeth as a preliminary to inspiration. Respired in association with a modicum of air the agent produces exhilaration; received absolutely pure, such state of excitement is commonly too quickly passed to be noticeable; particularly is this the case where complete *rappor*t exists between patient and operator. Insensibility is quickly induced and as quickly passes away. Judgment of the effect of the gas is derived from observing the mucous surfaces. Danger lies in venous congestion.

**Ethyl Bromide.**—A process employed by Dr. Lawrence Wolff to secure this agent is as follows: Twenty-four ounces of bromide potassii, coarsely powdered, are conjoined with a mixture of sixty-four of sulphuric acid and thirty-two of water. After cooling, sixteen fluidounces of alcohol (95 per cent.) are added, the whole placed in a large flask contained in a sand-bath and connected with a Liebig's condenser. The temperature is now raised to about 200° F. and maintained thereabout until reaction shall have ceased, and the ethyl, which has been gathering rapidly in a receiver, shall no longer come over. To know of this, about an ounce of water is put in the receiver before commencing the operation. The evolution has stopped when no further sinking to the under surface of the water is observed. The ethyl bromide so obtained will amount to twenty ounces, and is to be shaken with a solution of potassium bicarbonate, subsequently washed with water, and purified by redistillation.

Ethyl bromide, hydrobromic ether as it is as frequently termed, is employed in surgery by many professedly with much satisfaction. The occurrence of several accidents of late, has, however, somewhat modified the estimate of its



safety, and induced a spirit of caution as to its acceptance. Bromide of ethyl is a colorless liquid possessed of an agreeable odor and pungent taste. It mixes perfectly in all proportions with ether but sparingly with water. The action of the agent, from an anæsthetic stand-point, is even more quickly exerted than is that of chloroform. The manner of its use is the same as for ether, a sponge, napkin, or inhaler being employed. Recovery is more rapid than from the two agents just named. According to experiments by Dr. Laurence Turnbull, to whom the profession stands indebted for a knowledge of the anæsthetic quality of the preparation, the shortest time required to place a patient under its influence is thirty seconds; the longest, five minutes; average, ninety seconds. In the experiments, the smallest quantity used was that taken into the lungs by two inhalations from a sprinkled handkerchief; the largest was two ounces. Out of twenty-one cases, sickness of stomach, with vomiting, occurred in three, hysterical excitement in two, prostration in one.

**Bonwill's Method of Rapid Breathing.**—An anæsthetic effect, as has been shown by Dr. W. G. A. Bonwill, is produced when rapid and full breathing is indulged in for a few minutes. What may prove the result of greater familiarity with the means the writer is not prepared to say. That a condition is produced which allows of puncture being painlessly made he knows from observation. A feature undoubtedly lying in the practice is the diminished quantity of an ordinary anæsthetic required where this process has preceded, and is continued, with the exhibition. A danger connected with the performance seems, to the experiments and experience of the writer, to lie in the direction of venous congestion of the brain; a conclusion to which exception, however, is taken by physiologists whose opinions worthily command wide respect. Greater familiarity, and wider experimentation, with the means, may demonstrate the existence in it of a boon not surpassed by the other great discoveries in Anæsthesia.

**Medicines used by Hypodermatic Injection.**—"Gemischte narkose," mixed narcosis, is a term introduced by Thiersch of Leipsic to express a relation of means by which insensibility to pain is secured without entire abolition of consciousness. The means consists in the hypodermatic employment of morphia by an anticipation of some five minutes of chloroformization. This manner, while most recommendable, is yet not justly to be credited to the German surgeon; the author has been familiar with it assuredly for the last fifteen years, certainly wrote about it in connection with jaw operations quite that long ago. Advantage residing in the practice is that a semi-consciousness may be maintained which insures against the passage of blood into the larynx at the same time that it serves as a prophylactic to shock.

Sulphate of morphia used in conjunction with sulphate of atropia constitutes an admirable injection. The dose will vary from the eighth to a half grain of the first, from the one-hundredth to the seventieth of a grain of the second. To prepare the combination for use it is to be mixed with from seven



to ten drops of pure water. The spoon containing the solution is to be held over a flame for a single moment that a blood-heat of the fluid be secured. The means is not without danger.

Chloroform, subcutaneously used, is an excellent obtunder. In sciatica, ten drops, injected deep among the gluteal muscles, is efficacious in breaking up an attack. The remedy, and manner of employment, are indicated in obscure neuralgiæ generally.



## CHAPTER LXVI.

### INFLAMMATION.

THE author adds to the volume a chapter on the subject of inflammation, a chapter which is to find apology for its appearance in a work of the present character in consideration of being addressed solely to students, and in further consideration of the importance of the theme.

Understanding of the subject of inflammation is familiarity with surgery. No man has ever yet attained to over-knowledge of the matter. Many practitioners fail in apprehending the importance of it. A study of inflammation involves primarily a comprehension of principles. To appreciate principles is to secure understanding of associate phenomena. The present thesis, written in the most simple words at the author's command, and after a manner aiming to be demonstrative, is commended as designed to present the topic in an aspect which relates it with every-day practice. An analyzer starts on the study of inflammation properly only when he has arrived at recognition of the fact that it is the very corner-stone of that building which is expressive of the full meaning of a physician's life. Without a knowledge of the subject of inflammation no practitioner can be successful. Possessed of such knowledge, obscurity converts itself into simplicity.

By inflammation is meant perversion of the circulation. By perversion of circulation is implied derangement in that harmonious distribution of the blood to the organism at large, through which harmony every individual part has its proper share, and has no more than this share.

When the blood is not harmonious as to a general distribution it follows necessarily that some parts have more than their share, other parts consequently less. A part having more than its share (this being of other than temporary signification) is in a state of inflammation.

Inflammation defines itself as excess of blood in a part; an excess existing by reason of the presence of a something in the part which acts as an irritant. (See Fig. 607.)

The diagram exhibits the two ears of a rabbit, the left one inflamed, the other not.

Inflammation exists never but by reason of the presence of an irritant.

By an irritant is meant anything that worries. Examples of irritants are to be instanced in referring to a splinter pricking the finger, to an exposed tooth-pulp fretted by crumbs or other foreign particles coming in contact with it, to a broken jaw, to a burn, to a ball shot into the flesh, to virus mingled with



the circulation; in short, to anything of whatever nature that after any form or any method interferes with the natural condition of a part or of parts.

FIG. 607.


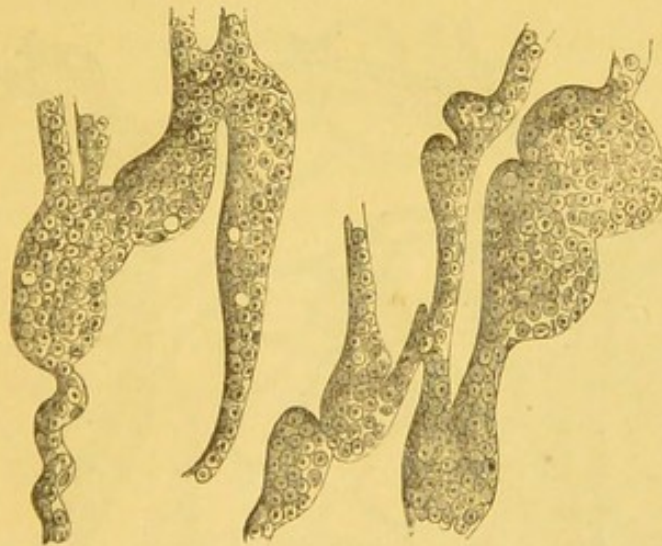


FIG. 608.



Capillaries enlarged and made varicose from blood engorgement  
in inflammation.

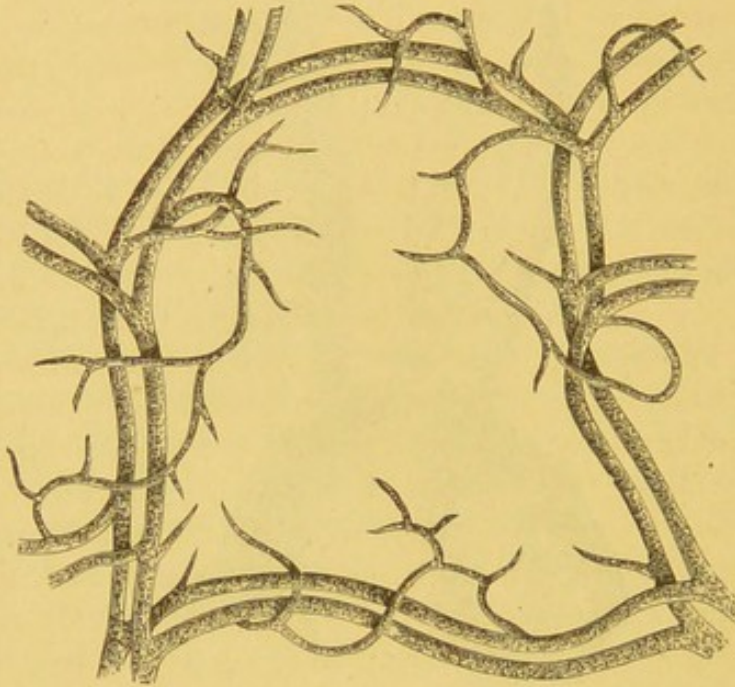
A splinter in the finger is to be seen, not unlikely, by the unassisted eye, A ball in the flesh is commonly to be located by the touch of a probe. Irritants, on the other hand, may be of a meaning, and be involved in an obscurity, that the widest examination to be made, in the light of modern science, fails to get comprehension of them.

An irritant not removed by being picked or lifted away, or by being an-



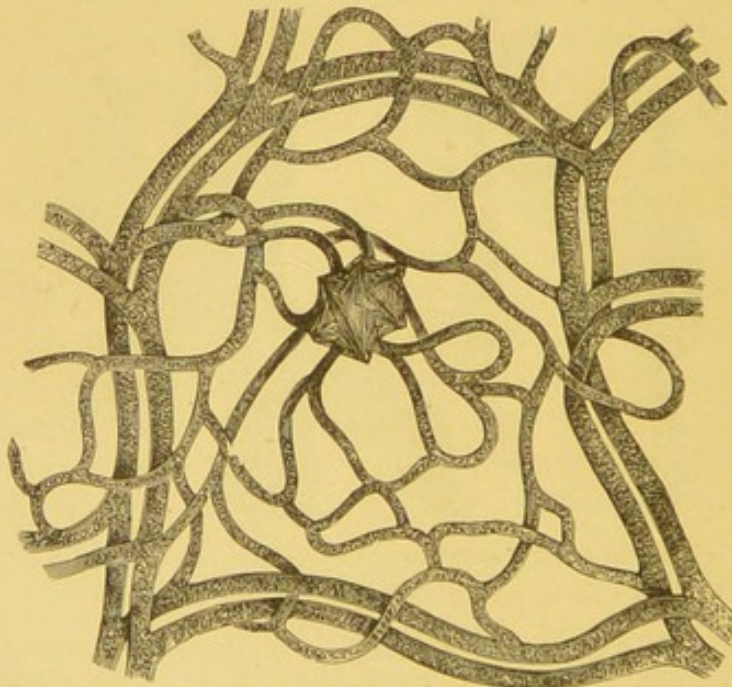
tagonized by means of medicine, or after other required fashion, is always attempted to be combated by nature, and it is the processes of this combat which medical science denominates inflammation.

FIG. 609.



Uninflamed wing of a bat.

FIG. 610.



Inflamed wing of a bat.

An irritant of strictly local signification arouses local phenomena, while one of general import, as, for example, syphilis, is seen to be expressive of disturbance throughout the system at large.



Wherever and whatever the irritant, nature will surely make an effort to rid herself of it. Inflammation is to be understood then as nature's effort to circumvent and to get clear of an offending body, and it is therefore to be looked on as a means of cure and not of hurt.

Local inflammation differs nothing in principle from general inflammation. In both is perversion of harmony in the circulation, both aim to circumvent an offending agent, both show an excitement in the circulatory fluid expressive of aggressive attack on something.

To understand the meaning practically of inflammation the student will consider that he watches with the writer a case possessed of purely local signification. First, it is seen that an agent of offence has fixed itself in the flesh. Let us assume this agent to be a lead ball. No sooner has such an agent intruded than the sensorium, having gained cognizance of the fact, calls for defence on the circulatory system. This system inaugurates an inflammatory attack; that is to say, it takes on itself the office of shutting the part off from surrounding parts by pouring around it a mass of lymph. This lymph is an ingredient, or component, of the blood. It would not be at all amiss to liken it to the white of eggs. It is first a thin fluid, but later coagulates and becomes hard. In its solidification it compresses all blood-vessels which it surrounds, thus cutting off nutrition from the parts infiltrated. These parts dying slough away, and carry the offending agent with them in a stream of pus significant of the death. (Fig. 611.)

The inflammatory act is described commonly as consisting of the stages of simple vascular excitement, active congestion, stagnation, suppuration. These terms have no other signification than that a condition inaugurates where excess of blood begins to run toward a part (simple vascular excitement), that it increases as to amount until the part is engorged (active congestion), that later the part has become so filled that circulation can no longer go on (stagnation), and that still later out of the stagnation has come the death of the part (suppuration).

It is seen that by the term suppuration is meant simply the breaking down of tissue by reason of absence of nutrition, and that such breaking down implies a lake, greater or less in extent, of pus (suppuration and pus being synonymous), which pus is a means to float an offence away; a common boil is illustrative. A boil exists by reason of some particle, that, to be gotten rid of, must be

FIG. 611.

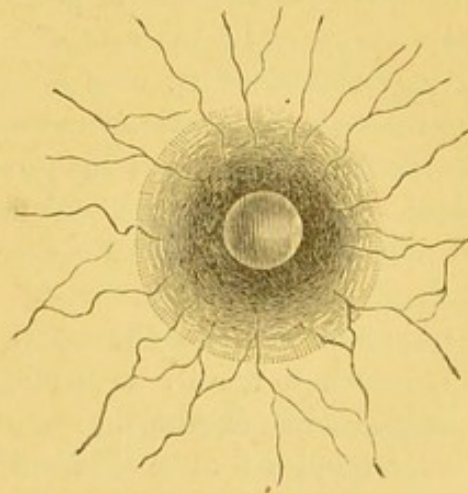


Diagram showing process of circumvallation. The centre shows the foreign body. The lines represent vessels. Circumscribing the irritant, compressing the arteries, and shading dimly away is the lymph.



circumvallated and finally floated off. (See diagram.) Repair is an inflammatory act. The meaning of this is to resupply a part lost in the pus lake. It means simply that such lymph as remains begins to organize, explanation of this existing in the fact that it is beyond that line of compression from which the circulation was cut off. The lymph organizing is vitalized; granulation after granulation springs out, until finally the destroyed part is renewed. The whole performance, as must be appreciated, is expressive of healthy effort, and is not to be interfered with except for reasons. (See diagram, which shows the expression of circumvallation.)

Inflammation of systemic import is illustrated in what is known as "taking cold." An individual exposes the whole or part of the superficies of his body to the action of a cold atmosphere. Cold contracts the capillaries of the skin. As a result of the contraction blood is driven from without inward. There is interference with equilibrium. There is too much blood among the viscera, too little with the integuments. The derangement implies perversion of the circulation. The perversion of the circulation is inflammation. A man who has a cold is in a state of inflammation.

A third and last illustration is found in considering irritants which mingle with the blood at large, proving a source of offence that shows perversion at many points. To express this most simply we are justly to accept that emboli, significant of a vice, are caught at varying localities, and that the perversions seen at these points are expressive of the phenomena of attempted circumvallation and expulsion. Syphilis stands as a prominent representative of the blood vices.

Appreciating the meaning of inflammation, it is understood that whenever the condition is met with in practice a primary question relates with purpose and intention. In the case of a ball, not to be removed otherwise than through natural effort, it is assuredly desirable not to antagonize, but to forward and assist nature's means. It is, however, to be considered that circumstances alter cases, and that while, on principle, the ball should be floated away, yet because of relation of a part with vital organs, it may be a necessity to limit the action of disturbance all that is possible, or even indeed to abort it altogether.

In perversion of the circulation arising out of "taking cold" it is always an indication to remedy the derangement speedily as possible.

In perversions existing by reason of presence of irritating agencies in the blood, treatment is to be as immediate as may be.

**Local Treatment of Inflammation.**—Inflammation meaning disturbance of equilibrium in the circulation, it follows that to restore equilibrium is to resolve inflammation.

Whatever means tend to restore a lost equilibrium in the circulation is the proper and scientific treatment of inflammation.

First, an inflammation being understood to exist never but in the presence of an irritant, attention to the irritant is a primary indication. A splinter



in the flesh is to be lifted away if possible, a ball or a diseased tooth is to be extracted, a broken jaw is to be set and quieted, a virus of specific nature is to be antagonized by specific remedies, influences of cold are to be corrected by repairing broken windows or assuming protective clothing.

An irritant removed, it is commonly the case that inflammation cures itself; that is to say, the cause of disturbance in equilibrium being away equilibrium comes back.

When, upon the removal of an irritant, an inflammation does not resolve itself, or when reason exists for modifying or aborting an inflammation, means are at once to be employed which tend to disgorge over-full parts, restoring the excess to parts under-full.

Over-full parts are in a state of distention. They are so because the office of contractility has been put in abeyance by reason of the unnatural afflux of blood. To relieve this distention implies simply removal of the cause. The cause away, the vessels regain of themselves their normal calibre, accommodating consequently only that amount of blood natural to the circulation of the part. The amount of blood natural to a part circulating in this part, it follows that no inflammation is present; if it existed it has been resolved.

Great variety in means and manner relates as regard is had to getting blood away from a region. If too much blood exist in a part above the lower limbs, a plan is to immerse feet and ankles in warm water; warm water relaxes. Feet placed in warm water are found quickly to grow red, to become engorged, really to assume the inflammatory condition. The excess of blood called to the part as the result of the relaxation invites from the seat of primary congestion such excess as has in it the meaning of the distention. Relieved of the distention the part recovers its contractility, and is thus found cured. The feet, by reason of being in a condition of perfect health, are seen to be able to take care of themselves and to drive the excess of blood from the capillaries, the process of self-relief commencing quickly after the removal of the irritant, *i.e.*, the relaxing water. The blood returning from the feet cannot throw the excess back on the seat of original engorgement, provided time and condition have allowed the part to recover its tone. When tone has not been recovered the inflammation is not found cured, and the foot-baths are to be repeated and other means of relief added, otherwise the other means employed alone.

Dry cups are an admirable agency of derivation. Assuming, for example's sake, that an inflammation is related with the enveloping membrane of a tooth, the placing of a dry cup upon the cheek and a second on the back of the neck, relief to the tooth is apt quickly to follow the abstraction of blood; the change of position in the fluid being witnessed in the red and engorged swellings formed under the cups.\*

\* DRY CUPPING.—To dry cup means simply to take a common wine or other glass and to put in it a wisp of paper saturated with alcohol. When ready to attach, that is, having one edge of the rim resting against the skin, a lighted match is applied and the full circumfer-



Wet cupping is another plan. This relieves by running blood out of a part. In the plethoric the means commends itself, in the anæmic it is oftentimes of doubtful propriety.\*

The use of leeches is another manner. Two kinds are used in practice, the Swedish and American. A Swedish leech sucks half an ounce of blood, the American a less, but an undetermined, quantity; the former is to be preferred. To apply the worms it is usually necessary to hold them against a part by means of a wine-glass or goblet. Where leeches refuse to bite sweetened water may be smeared over the part. Another plan is to prick the skin until a few drops of blood are obtained, this being spread after the same manner as the sweetened water.

Abstraction of water from the blood by use of a fly-blister is a means applicable to underlying inflammation,—of a joint, for example. Take of the fly-plaster, as prepared by druggists, a square or strip of size required and place upon the skin above the diseased part. This is allowed to remain from eight to twelve hours, according to susceptibility of the tissue. On being removed it is to be replaced by a poultice of bread and milk, which poultice is kept on until it is seen that much serum occupies the space between the epiderm and true skin. The object being to drain, the bleb is pricked with a needle and the poultice reapplied, pricking and poultice to be continued so long as water comes or until indications are met.

In inflammations of threatening import involving vital parts, bleeding from a vein is a practice not to be over-commended. A vessel commonly selected for the operation is one at the bend of the arm that does not occupy the centre line; this line being the position of the brachial artery, which, in the region, is separated from the veins by the thickness only of the bicipital aponeurosis. To open a vein the operator commences by placing a constricting band between the proposed seat of performance and the heart. Fig. 612 shows the anatomy of the parts. The crossed vessel is the brachial artery. The bicipital aponeurosis is seen passing between vein and artery; it is not thicker than foreign post writing-paper. The blood being dammed back in the locality through means of the constriction, and the veins swelling to a greatly increased diameter, it remains simply to open the one selected by means of an oblique incision; a curved bistoury of sharp point being employed, otherwise a lancet, thumb or spring, as portrayed by cuts 613 and 614. If an open vein refuse to bleed, the fist of the patient is to be opened and shut many times. If this fail, it is more than likely that the overlying skin inter-

---

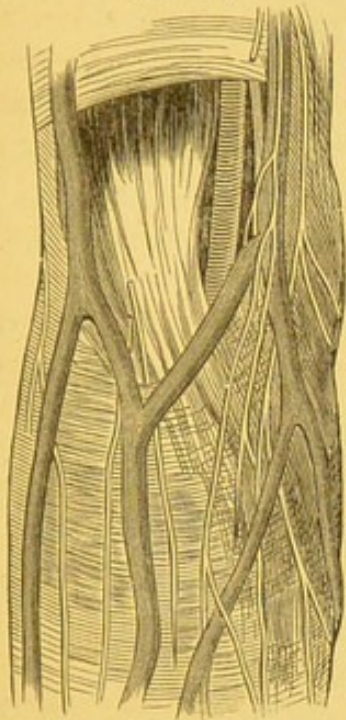
ence instantly pressed to the skin. To remove a cup, the integument is pressed from the outside away from the rim.

\* Wet cupping differs from dry in the use of a fleam, or lancet. A cup being applied after the dry manner, and excess of blood brought to the part, the knife is stuck into the skin and the dry cup reapplied. Here the vacuum made draws the blood from the wound, filling the cup. Surrounding parts are of course relieved of the excess, contractility being thus secured.




feres with the egress, or that a freer cut is required to be made in the vein. To check bleeding from a vessel the band is to be taken away, and a compressor, retained by a figure-of-8 bandage, is to be bound upon the wound.

FIG. 612.



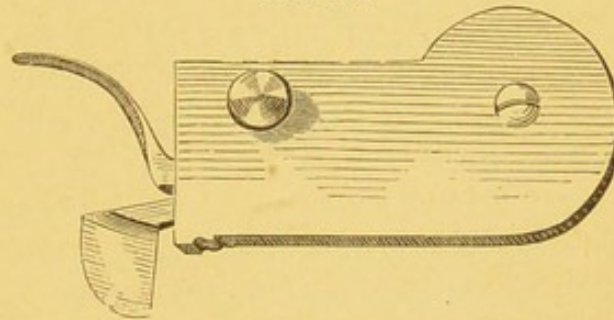
Arrangement of veins, brachial artery, nerves, and bicipital aponeurosis at the bend of the arm.

FIG. 613.



Thumb lancet.

FIG. 614.



Spring lancet.

In parts suffering from inflammation where exposure is immediate and direct, as, for example, a cheek, the neck, or ear, medicines known as antiphlogistics apply. Antiphlogistic remedies act after two manners: 1, constricting the capillaries, thereby driving the blood out of them; 2, sedating the nerve irritability of a locality, thus relieving the vessels of a fret that worries and goads them. In the direction of the first means are alcohol, so applied as to permit of rapid evaporation, cold water, hot water, and medicated water. A prescription known to surgical practice the world over is as follows:

R.—Plumbi acetatis, ℥ij;  
Tincturæ opii, ℥ij;  
Aquæ, Oij. M.

This is applied by means of cloths kept constantly wet, or thin poultices of bread-crumbs may be made with it. Where abscess is inevitable, perhaps desirable, yet where at the same time necessity exists for limiting as much as possible the inflammatory area, it is the practice of the writer to apply flax-seed-poultices, moderately cool, every portion of which, except the part im-



mediately overlying the centre which it is desired to break down, being fully saturated with the lotion; the centre being warm as well as unmedicated.

Another agent of valuable signification in the direction is phénol sodique. To use this cloths are saturated with the pure preparation and kept applied to the part. Phénol is antiphlogistic and antiseptic; it applies particularly in hospital practice where reason exists to fear the influence of septic conditions; it is markedly sedative. The writer always uses phénol in his surgical operations, depending on it wholly for what is called Listerism.

Hydrochlorate of ammonia in proportion of  $\mathfrak{Z}$ ij to Oiv is a good sorbent antiphlogistic, applicable particularly where, in the inflammatory act, an undesirable quantity of lymph—the circumvallating material—has been thrown out. It is not so good, however, as is lead-water and laudanum preceded by paintings of tincture of iodine.

Goulard's extract is a favorite antiphlogistic. To use it a mixture is made in proportion of  $\mathfrak{Z}$ ij to water Oj. It is placed by means of saturated cloths.

As applications acting from the stand-point of sedation, reference is to be made to tincture of hamamelis Virginiana, to be much diluted with water; to laudanum conjoined with an equal proportion of sweet oil; to moist plantain leaves; to decoction of poppies or of hops; to steam. All these are applied with reference to keeping the parts unexposed during an interim of necessary changing.

Rest is to be numbered as among the important features in treatment of an inflamed part; a broken arm is to be splinted; capping of neighboring teeth applies where periodontitis exists; a diseased stomach is to be spared to all possible extent in its functional work; a lung affected, the fewer respirations the better.

**General Treatment.**—Every inflammation implies disturbance alike of the nervous with the circulatory system. In every inflammation it may be necessary to direct remedies to the quieting of both systems. Considering as a type that perversion of the circulation which arises out of "taking cold," few combinations act more curatively than a mixture of tincture of veratrum viride and the bromide of potassium; the first affecting directly the circulation, the second the brain. A formula is as follows:

R.—Tincturæ veratri viridi, gtt. xx;  
Potassii bromidi,  $\mathfrak{Z}$ ij;  
Aquæ,  $\mathfrak{Z}$ ij. M.

Dose, a tablespoonful, to be taken on going to bed, and to be repeated twice or thrice the succeeding day, if found necessary.

A second valuable medicine in this same direction is found in Dover's powders:

R.—Pulveris ipecacuanhæ et opii, gr. xl.  
Chart. No. iv. M.



One to be taken at bedtime, and repeated twice or thrice next day, if required.

A free pulse, hot skin, and general febrile disturbance are treated happily by tablespoonful doses of the following mixture, repeated each three or four hours, according to urgency:

R.—Liquoris potassii citratis, ℥iij;  
Spiritus ætheris dulci, ℥ss;  
Antimonii et potassii tartratis, gr. ss;  
Morphiæ acetatis, gr. j. M.

Epsom salts is an admirable anti-inflammatory agent of constitutional expression; it reduces the volume of blood by reason of producing watery stools; the dose is a tablespoonful dissolved in a full goblet of water.

Another agent of this same class is elaterium:

R.—Extracti elateri, gr. j.  
Ft. pil. No. viii.

One to be given each two hours until copious watery evacuations are secured.

Another means, one acting as a diaphoretic, is a favorite with the writer:

R.—Liquoris ammoniæ acetatis, ℥iv.

Put the patient in bed, cover with blankets, and give in tablespoonful doses each fifteen minutes until profuse perspiration is secured.

Still another manner of sweating serum from blood is to place a patient upon a cane-seat chair beneath which a bucket of water kept steaming by means of hot bricks has been put; the patient to be wrapped about with a blanket which extends to the floor, enveloping the bucket, and supplied freely with hot drinks. Care is required in taking a person from such steam bath; he is to be rubbed dry by means of towels carried beneath the blanket, and is to be exposed for the shortest possible time while a change of clothing is being made.

Diet is an element in the treatment of inflammation; articles which never hurt are tea and dry toast. Water-ice, ice-cream, acidulated drinks, are found both refreshing and profitable.

Where much heat of surface exists no means familiar to the author equals sponging with pure alcohol. Generally it is the case that in febrile disturbance the regions of the spine, thorax, and abdomen are burning. A plan that yields commonly inexpressible relief consists in a few minutes of bathing, then drying by means of a soft towel; the bathing and drying to be repeated until the parts are entirely cool and remain so. The writer uses his hand in place of a sponge.

Placing the hands and wrists of a febrile patient in ice-water is an admirable means of refrigeration, the cooled blood being carried from the parts over the general system.



**DIURETICS.**—Diuretics commend themselves where a derangement is of such trifling import that it is justifiable to treat the patient without confinement to the house; in common colds, for example. Sweet spirits of nitre is a favorite preparation in the direction; the dose is a teaspoonful, repeated three times a day. Spirits of Mindererus is much employed by the author; as intended to act upon the kidneys the dose is a dessertspoonful, the external parts of the body being kept cool, so that its action shall not be invited to the skin.

**NARCOTICS.**—Opium and its preparations, used with a view to the narcotic quality, seems, to the experience of the writer, to be ill-advised practice. In the Oral Hospital the medicine is never given but in emergencies. Like with the use of chloroform, employed as an anæsthetic, inflammatory conditions seem impressed with characteristics of depression. It may be, and undoubtedly is, occasionally necessary to employ full doses of opium, but such necessity is a matter to modify anticipations of a generous cure.

Where inflammation associates with wounds, or exists in other causes, and where sedation is an indication, no medicine surpasses, if it equals, the potassium bromide. As a dose this may be pressed from thirty grains to one and a half drachms. A practice with the writer is to order a mixture containing ninety grains, and to exhibit this in three equal parts, if found required, at intervening periods of two hours. It is to be observed that the medicine is not to be taken until external circumstances favor the falling asleep of the patient.

Hyoscyamus and belladonna combined in a suppository act commonly favorably.

R.—Extracti hyoscyami, gr. xx;  
Extracti belladonnæ, gr. ijss.

The proportions are to be mixed up with cacao butter and divided into ten suppositories. The application is by rectum; one three times a day. In connection with this combination morphia has seemed to the author to be least objectionable; one-quarter of a grain of the sulphate added to each suppository induces speedy sleep; half a grain, if pain be great, as, for example, in phlegmasia of the skin or cellular tissue, in rheumatic or gouty inflammation, is not at all an overdose. In visceral inflammation, where control of movement is a necessity, there is nothing that seems able to do the work of opium. Being the only medicine to be used, it is best given in full doses. The writer has frequently met with conditions of irritable bladder where, to prevent the patient from being worn out, morphia had to be given; this, however, as must be appreciated, from the fact only of an inability to learn of and to treat the direct cause of the trouble. In conditions of pleuritis and of inflammation of the lungs morphia applies, and is to be employed where extreme irritability is not otherwise to be subdued.

Specific inflammation having existence by reason of the presence of a source of irritation specific in its nature, a treatment required is to be with



special signification; the poison, or agent of offence, is to be antagonized. Syphilis is a specific agent of offence that shows many expressions. Here local conditions are to be met on the grounds of common indications, but, associated with these common means, medicine specifically antagonistic to the virus is not to be omitted. The medicine required is mercury, an agent found too often not less full of evil than of good. The writer, deducing from the experiences of many years, recommends the bichloride. Where employed at all judiciously he has yet to fault the preparation in a single instance. His own usual prescription is as before given. (See page 690.)

R.—Hydrargyri bichloridi, gr. ij;  
Potassii iodidi, ℥ij;  
Aquæ, ℥iij. M.

Sig. Teaspoonful three times a day, before or after meals, as found least objectionable.

In all conditions of syphilis, primary, secondary, and tertiary, it is the practice of the author to give this combination in connection with whatever local remedies it seems necessary to employ; the iodide of potassium, if not useful in the first and second of the stages, has certainly never been found hurtful; on the contrary, it has always seemed to add activity and curative virtue to the mercurial.

In perversions of the circulation arising out of malarial poisoning the antidote is quinine. In acute attacks, where the disturbance associates with certain periods of the day, as in the instance of quotidian intermittent, the specific is to be employed only in the interim of attacks. Ten grains of quinia sulphatis, given in divided doses when the fever has passed off and before the chill comes on, being repeated during from two to half dozen interims, destroys the cause of the disturbance, consequently cures the evil.

In conditions of malarial disturbance, where the cause is not of sufficient force to produce paroxysms yet induces the state of malaise, no specific means better than the following is to be employed. Take of powdered red Peruvian bark (*cinchona rubra*) one ounce, of powdered Virginia snakeroot (*serpentaria Virginiana*) half an ounce, put the two together into one and one-half pints of water, simmer to one pint; when cold, strain, and add one pint of Lisbon or other red wine having an alcoholic strength of not less than twelve per cent. The dose is a wineglass, containing two tablespoonsful, before meals.

The specificity of diphtheritic inflammation, as of ordinary erysipelas, demands iron; this to be used externally and internally. In treatment of this inflammation it is a practice of the writer, resultant of his experience in the direction, to administer from five to twenty drops of the muriated tincture of iron each three hours, and to apply to the throat the iron, quinia, and cinchona mixture (see *Erysipelas*), by means of a camel's-hair brush, at least six times a day. With a view to dissolving the exudate as it forms, free local use is made of Watson's chlorine water, full strength, used with the brush, or,



when the deposit has reached the trachea, by means of a hand or steam atomizer. It is to be recommended that the steam atomizer keep the atmosphere quite continuously impregnated with chlorine. With this as the specific treatment, aided by adjuncts of a character suited to indications as they may offer, the writer finds himself able to claim a reasonable share of success in the direction.

Scrofulous inflammations demand special attention to the general lymphatic indolency which begets them. Treatment is tonic; salt sheet-baths, milk, drank in quantities of two quarts a day, cod-liver oil, ferrated wines, exercise, rough and exhilarating as it can be borne. In scrofulosis the perversions are always of indolent expression, no acute symptoms show themselves. As a local application to glands and parts indurating, the following combination is to be employed with much satisfaction:

R.—Tincturæ ferri chloridi, ℥j;  
 Tincturæ iodinii, ℥ss;  
 Quiniæ sulphatis, ℥ss;  
 Tincturæ cinchonæ, ℥ij. M.

Sig. To be painted over the part thrice daily.

Inflammation is to be considered from the stand-points of activity and chronicity. Active, or acute, inflammation signifies response, to the presence of an irritant, that runs a rapid course. It would not, perhaps, be easier to provide illustration of acute inflammatory action than is exhibited in the common boil. The phenomena are open, free, and follow each other successively, if not interfered with. Indications are always of an antiphlogistic nature. Chronic inflammation, on the contrary, is expressive of exhaustion and of sluggishness. It is that condition too often encountered on the subsidence of acute attacks where the irritability of parts seems worn out, where capillaries are over-full of blood, yet unable to contract upon and expel it. It is a condition where everything is in abeyance, growing neither worse nor better. It is a state where demand exists for external help, and this help pertains not to depression, but to stimulation.

The indication in chronic inflammation is for supply of lacking force. To accomplish the requirement demands the unloading of capillaries, and the putting into the parts of such activity as shall enable them to recover and preserve the lost equilibrium. An expression of chronic inflammation very familiar to the oral surgeon is seen in scorbutic gums. The parts are spongy, turgid with blood, are purplish-red in color, are fallen away from the teeth, about which organs pus is exuding, they look as if mortification was to terminate the condition. Ulcerations occurring in scrofulosis and in syphilis furnish other illustrations. In neither of the latter lesions is there any sign that is open and generous. Everything is indolent and expressive of degeneration.

To unload capillaries passively or chronically congested, depletion is almost always a necessity. Certainly the radicles cannot recover normality unless relieved of blood. This unloading is commonly to be accomplished by pricks



or slits, made by means of a bistoury. When depletion is obtained, a valuable succeeding performance consists in free painting with a sorbefacient of stimulating attributes. Of such medicines there is nothing superior, if indeed equal, to the ordinary officinal tincture of iodine. This tincture not only excites, but it favors attempt at renewed action, by arousing the lymphatics to removal of lymph and sero-lymph effusions with which such parts are found burdened. Aromatic sulphuric acid in dilution is an alterative stimulant of happy signification. Another, one of great virtue, is the *tinctura capsici et myrrhæ*, used pure, applied by means of a brush, otherwise diluted with water to meet indications. It is seldom that, in the practice of the author, this last is not pressed into service at some stage of the treatment of chronic inflammation. Mercury is to be commended when employed by the experienced with discretion. It is a remover of indurations, but is an agent capable of an evil far excelling any good that it may do. Tincture of *erigeron* is an expressive stimulant. Still another is the compound tincture of benzoin. Where it is desired to constrict, and at the same time to cover a surface, an admirable medical varnish is made by thickening muriated tincture of iron with sulphate of quinia. Touches with chloride of zinc or with nitrate of silver are sometimes found of valuable import in chronic conditions. A most excellent means for renewing vitality in a part is found in Volta's pile. To make this requires simply strips or squares of sheet-zinc and copper, between which is placed a piece of cloth kept wet with cider vinegar; care is to be exercised that it do not over-stimulate.

Conjoined with local cure chronicity, where of any extent of signification, requires systemic consideration. This is to be always a treatment of building up, and it varies necessarily with the disease and circumstances of a patient. A means of general import for good is found in the sheet salt bath. To apply this, Turk Island salt is put into a small tub of water (enough being added to give it the taste of the sea), and in this a coarse sheet is placed. The bath thus made ready, the patient steps into the tub, and the sheet being thrown quickly about him, he is rubbed, or rubs himself, until the skin is aglow. In the use of this bath regard is to be had to the immediate effect. If, instead of a glow, the patient comes from under the manipulations cold, depressed, the surface in the condition of goose-flesh, the cold water is to be changed for hot, or, the bath being taken in the morning, a goblet of milk in which a tablespoonful of whiskey or brandy, together with the yolk of an egg, have been placed, may be drank quarter of an hour before getting out of bed. Milk is an admirable medicine; two quarts may commonly be taken in the course of a day with benefit. Oils and oleaginous foods are indicated in every case of tuberculosis. Hill-sides and the sea-shore, and roughing it where air is pure and water good, are means not wisely neglected when a condition of depression is serious. Attention to habits is of consequence; excesses of any kind bear to be inquired into.

Massage is a means tending to restoration of lost general excitability most



worthy of careful study. To massage a person means simply to rub and to knead his flesh. Few better methods of dispersing indurations exist than is found in this practice. An induration is to be rubbed toward more vital parts. The acts of massage relate with both the vascular and lymphatic systems, meeting thus two indications at the same time.

A feature of chronic inflammation annoying and defying as to treatment relates with an inability shown by parts to retain advantages apparently secured. This is to be estimated in the treatment of a case that discouragement do not ensue. A part will hold its own when fully recovered from depression, not sooner.

Chronic inflammation associated with joints favors plastic effusion, apt to result in false, or possibly in true, ankylosis; related with the lymphatics, scrofulosis or tuberculosis ensues; if existing with the viscera, adhesions form; if in the tonsils, hypertrophy is developed; in mucous membranes sub-infiltrations and strictures follow.

**Suppuration.**—By suppuration is meant nothing different than that nutrition in a part showing the phenomenon is incapable of perfecting itself, consequently that food elements, brought to the locality, in place of accomplishing the process of organization, proceed a certain space in the direction, then undergo degeneration and roll away in the shape of pus-corpuscles.

**Redness, Heat, Pain, Swelling, Functional Disorder.**—Redness in an inflamed part signifies coloration by the excess of blood that is in it. Color varies. In syphilitic inflammation it is like to copper. In erysipelas it is a glistening red. In the skin, and associated with mucous membranes, being of non-specific character, it is scarlet. Affecting the iris, it is commonly brick-colored. In scrofulosis it is not unlikely to be yellowish-purple. When gangrene is threatened the color is brown or a brownish-black.

**HEAT.**—Heat signifies increased nutritional activity combined with evolution arising out of the friction of an accelerated circulation.

**PAIN.**—Pain is a factor not fully comprehended; that it is not an unmitigated evil is proven in the fact of its acting as a warner, affording understanding of the condition of diseased parts. Pain begins with a perversion, and accompanies it until the suppurative act is reached, when it gradually subsides. In an inflammation it is commonly greatest at the central point of obstruction, and shades off proportionably with the clearing of the circulation. Pain exists with the nerve radicles, consequently in relation with the nervous system are we to study the phenomenon. To pinch is to produce pain. Nerves related with inflamed parts are pinched by the effusions. Pain like color varies: associated with serous membranes it is sharp, with mucous membranes it is dull, in cellular tissue it is throbbing, in the bones it is gnawing, in the testicles it is sickening, in the urethra it is scalding, in the kidneys, spleen, liver, and lungs it is a heaviness or soreness, in gout it is twinging, in rheumatism it is constricting.

Pain is proportional with the temperament and irritability of a patient.



The lymphatic suffer little, the nervous much. That long continuance of pain wears out vitality is not to be doubted. Pain, when in excess, is to be narcotized. Being bearable, without too great discomfort, it may be left to its office of sentinel, affording information as to a patient's condition. To narcotize pain is not necessarily to be in the line of cure of a case. To cure a case, however, is to be certainly rid of pain.

Pain is not the associate of inflammation alone. There is the pain of spasm, the pain of neuralgia, the pain of colic, the pain of anæmia, the pain existing in the functional disturbance of organs, growing pains, reflected pains.

In inflammations of vital organs the sudden cessation of severe pain where no opiate has been used is a sign of threatening import, implying too often that mortification has set in.

Morphia is the most reliable of pain-obtunding agencies. A standard preparation is the liquor morphiæ sulphatis; the admixture is a grain of the salt to an ounce of water; the dose, from a tea- to a tablespoonful, according to urgency. The liquor morphiæ bi-meconate is another admirable mixture; the strength is that of laudanum; the dose, twenty-five to fifty drops. Paregoric (tinctura opii camphoratae) is used with children; the dose is five drops for each year. Morphia, hypodermatically injected, is in universal favor: quarter of a grain is dissolved in ten drops of blood-warm water, and by aid of a needle-pointed syringe is thrown beneath the skin. Dover's powder is an admirable medicine as an opiate; being a combination of ipecacuanha with opium, it is not less antiphlogistic than narcotic. In common colds, having painful associations, few agents are found superior to ten-grain doses of this preparation. Other formulæ of the medicine are known as vinum opii, acetum opii, confectio opii, extractum opii, morphiæ acetat, etc.

**SWELLING.**—Enlargement of an inflamed part has its meaning in simple engorgement, in effusions, and in expressions of hypertrophy. In every inflammation there is, primarily, excess of blood in a part, necessarily measurement is increased. Effusions are of two kinds, serum and lymph; the first is a condition of a simple oozing from attenuated blood-vessels of the water of the blood, the second is a vital act, and expresses intentions looking toward the act described as circumvallation. A watery effusion is elastic to the touch, and by manipulation is quickly to be pressed from a part into which it has flowed. A plastic infiltration, on the contrary, is of dough-like consistency, and is not to be gotten rid of without much trouble. Swelling is beneficial or the reverse. It is the former where the effusion has relieved the tension in blood-vessels and permits of a restoration of contractility; it is the latter where it is of a character choking and interfering with the functions of a vital organ. Hypertrophy means overgrowth; the liver, the spleen, and the heart furnish too frequently examples.

**Functional Disorder.**—By functional disorder is meant matters of local and of general import. All organs show exhilaration of function in the con-



dition of simple vascular excitement. On "taking cold," excess in the circulation being directed to the nostrils, "cold in the head" as it is termed, increase in the secretion of the Schneiderian membrane, is familiar in the "running of the nose." Vascular excitement, progressing to the condition of congestion, function is diminished, not unlikely temporarily suspended. Susceptibility is increased; parts that are almost without feeling when in health become vividly sensitive to impressions when inflamed. Special senses are modified; the ear, the tongue, the tactile papillæ, the eye, all show derangement influenced by the circumstances of each particular case. In the instance of the kidneys, an acute congestion may quickly result in uræmic poisoning by reason of suppression; a most dangerous condition, that, happily, is to be quickly and easily remedied by means of dry or wet cups used about the loins. Enlargement of the prostate gland results in retention of the contents of the bladder, an accident less formidable than the immediately preceding, but scarcely less alarming. Congestion of the lungs afflicts with dyspnœa, the inter-vesicular circulation being of an extent that compresses the cells. Irritability of the general circulation, if at all excessive, results in fever. Changes in nutrition necessarily relate with inflammation; this for the reason of variation in quantity of blood brought to a part. In simple vascular excitement, nutrition, as suggested, is increased, this solely for the reason that free feeding and ability to appropriate exist. On the contrary, where congestion is present, that cell-action in which resides nutrition is

antagonized; the work of assimilation cannot go on in presence of crowding.

Besides nutritional changes, alteration shows in the circulatory fluid itself. Examining the contained blood of vessels related with an inflamed part, great increase is found in the number of the white, or pabulum-carrying, corpuscles, while at the same time the tendency of these bodies is to secure place about the sides of the vessel, the red corpuscles being crowded, not only toward the centre, but also closely packed together by the flat sides of the discs, after the manner of a rouleaux of gold coin. The meaning of the excess in the white corpuscles, which is not relative, but real, is appreciated

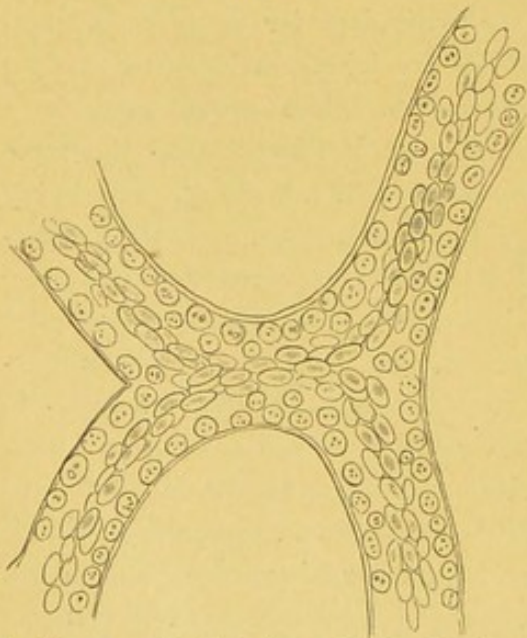


FIG. 615.  
Positions occupied in inflammation by blood-corpuscles; in the centre are the red, outside are the white.

in referring to their meaning as the circumvallating agency. The fibrin of irritated blood is increased commonly several per cent.; change being at times



as great as from ten to twelve per cent. over the ordinary amount of two and a half. The clotting of inflamed blood is slower than with the healthy fluid; this exists by reason of the close relation of the red corpuscles, the fibrin and the white bodies separating and not being caught and held in the coagulum. The buffy coat so characteristic in the blood of inflammation has its existence in the union of the white corpuscles and fibrin, contraction on the part of the latter agent explaining what is known as the cup, —*i.e.*, the sunk centre and the elevated circumference of the clot, or crassamentum.

Swelling and hypertrophy as associated with vascular perversion will be recognized as being antipodal. Swelling has its meaning, as has been described, in the simple increase of blood in a part, otherwise in effusions of serum or of lymph. Hypertrophy means growth; illustration is furnished in the second direction by the increased development of the biceps muscles of a boxer, and of the gastrocnemii of a ballet-dancer.

Evolved by the illustration just offered, attention is referred to a question as to the identity of excess of blood in a part with inflammation. Reference is to be made to the fact that erectile tissues engorge normally, and that out of the application of a constricting bandage much blood is dammed up in a part. Confusion as to this seeming paradox is avoided on the part of a student by his bearing in mind the subject of office, or meaning, as this refers to determination of blood to a part. If some words more explanatory seem needed, reference may be made to engorgement of the penis. Here irritation precedes the afflux not less surely than presence of a splinter invites excess to a finger; but the irritant is of a mental character. The removal of such an irritant resides with the act of seminal emission, otherwise with the passing away of a libidinous thought. An irritant is not less real by reason of being mental.

**Repair.**—Inflammation not terminated by resolution, destruction of a part involved necessarily follows. Repair, like to destruction, is an inflammatory phenomenon. Referring to diagram (Fig. 611), it is understood that destruction exists through compression by lymph. It is as well explained that lymph is the pabulum out of which structure is built, and that it needs alone relation with the circulation to establish it in vital meaning. An over-compressed part being sloughed away, all that remainder of the circumvallating lymph free of such over-compression begins to organize, and in the act accommodates extension of blood-vessels, which in turn supply to the new surface more lymph, which lymph repeats the acts of an underlying portion, until, in repetition, a cavity is filled.\*

---

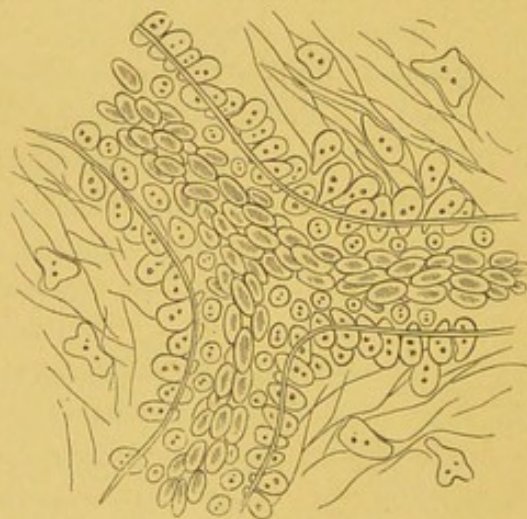
\* An experiment of much interest to the writer is at present being pursued by Dr. M. H. Cryer, with a view to the simplification of skin grafting. So far the process has been tried exclusively with horses, and results seem most promising. It is known to the reader that on limitation of the act of repair, where skinning of a wound fails to be effected, it is the not infrequent practice to lay upon the sore a particle of skin removed from a neighboring part. This implies an operation and inflicts pain. The present experiment consists in



Lymph, as now understood, breaks down in the form of pus, or it organizes, or it is absorbed, finding its way back into the blood whence it came.

The subject of lymph invites to and furnishes wide and curious study. Much objection is urged by pathologists to accepting it as a fluid exuded by the blood-vessels. It is a common view that cell proliferation, or segmentation by existing cells, is the meaning of repair after suppurative destruction. Cohnheim considers and teaches the identity of lymph and white blood-corpuscles. As seen by the clinical observer, lymph is a opalish-white plastic substance, differing little, when first exuded, either as appearance or apparent characteristics are concerned, from ordinary albumen. Continued to be watched, tendency in the fluid to coagulation is observed, which coagulation, or solidifying, increases until a part occupied by an effusion may come to feel hard as a board. The writer, not at all unwilling to commit himself, offers it as his view that the material called lymph is a combined expression of the natural succulency residing in parts, in addition with fibrin, albumen, salts, a certain amount of water, and an indefinite number of white corpuscles coming direct from arterial radicles.

FIG. 616.



Nutritional pabulum exuding through the walls  
of vessels.

To affirm that tissues are built out of lymph is not at all to dispute the doctrine of Virchow as to cell segmentation. Organization of lymph can mean very much what is meant by an egg mass, as out of this is built by the germinal spot a chick.

simply scraping over the wound particles of epiderm, the scraping being so decided that scales not fully devitalized be secured.



## CHAPTER LXVII.

### ON DIAGNOSIS.

THE author indulges in a parting word on the subject of diagnosis.

To diagnose a case means to find out what is the matter; this, nothing more.

Every person having occasion for the services of a medical man has *something* the matter with him, which *something* is to be esteemed as of physical import.

A person knows himself as having something the matter when he ceases to be in a state of ease. Ease is the normal condition. An individual being in a state of ease is possessed of parts and of wholeness undisturbed, and of exact equipoise.

When, from any reason, parts or whole are out of equipoise, and are disturbed, an individual is not in a state of ease, but he has passed over to a condition which requires a word of exact opposite signification to express it. Such a word is the preposition "Dis." To signify, therefore, that ease is no longer present with an individual medical nomenclature employs this preposition, placing it before the noun; thus, Dis-Ease, disease.

Disease is a generic term, it tells nothing of diagnosis, it expresses simply and alone, yet embracingly, general condition. Search after dis-ease means search after cause. Search after cause implies ability to recognize what is not natural out of a knowledge of what is natural. It is not natural for teeth to have holes in them; a practitioner who knows that perfect teeth are without holes perceives and recognizes a dis when he meets with such a defect. It is not natural to carry a cinder about in an eye; when, then, this organ is found inflamed and suffering, he who everts a lid and discovering, has understanding to know that the cinder is a foreign body, this one is a physician. Between the elbow and shoulder anatomy gives no joint; when, then, dis-ease shows itself in this locality and examination comprehends false, or unnatural, mobility, comprehension is alike gained that the dis and a fracture are one. Rapid breathing may mean pneumonia, or it may mean asthma. A dis is most evident. If it be pneumonia, it is not asthma, if asthma, it is not pneumonia. To distinguish the one from the other implies simply knowledge of a kind that has seen the hole or the cinder or that has felt the mobility. Lung structure is seen and felt, however, by use of the ear,—by auscultation, as the act is termed. A kidney, situated deep back of the lumbar muscles,



may be in process of degeneration, *dis* is present over the system at large, everywhere, perhaps, except at the seat of lesion; there is headache, loss of memory, the lungs are sore, the heart labors, the muscles deny their wonted elasticity, strength wanes. Is the *dis* not discovered and removed, death will surely follow. To discover it is to apply the common means. The thing is not, however, to be seen with eye, to be touched with finger, nor to be heard with ear. Here a microscope applies, or the practitioner, relying for his measure on a knowledge of normal urine, resorts to urinometer, to test-tubes, to flame, to nitric acid, or to other appreciated requirements. Chill and fever are other expressions of a *dis*. What *dis* is it that calls attention by means of chill and fever? Doctorly acumen is able to answer the question, and with a few grains of an anti-periodic to destroy such a *dis*.

Ability to diagnose is proportional with knowledge. What an eye sees it sees. With not less certainty does a brain understand what it comprehends. Understanding is resultant of experience. Thought and experience are one. There is certainly no thought without experience. Nothing different from an unwritten slate is a mind upon which no experiences are inscribed. Knowledge and experience being one, it follows necessarily that power to diagnose accrues out of observation, and that only a worker and looker may be a diagnostician. He who is without learning as to a subject does wisely when he turns a *dis* to where more knowledge exists than he finds in himself. To appreciate is to comprehend. To comprehend is to be able to say exactly what a thing is. Exclusion is something different. Diagnosis is not infrequently a matter of exclusion; this is to find one's self able to say what a thing is by being certain as to what it is not.

Above all things a student is to have commended to him the science of development. Surgeons are of professional stature as they are of physical height. A five feet man lifts not from a shelf a medicine reached easily by one who outmeasures him by a foot.

Study of diagnosis is the study of many things; among them, of anatomy; it learns where there are holes and where there are no holes, where there are joints and where there are no joints. It is a study of physiology; it inquires into sulci, into joint movements, into the functional meaning of uriniferous tubules. It is cognition; it measures the cavity of a pot by means of the very circumference that hides; it deduces unknown from known, it pushes ghost from behind substance.

A practitioner is not to hope to be useful in other measure than as he is learned; while to become learned implies simply that a man keep himself in the way of experiences.

Suggestions are never worse for illustration. The author directs the attention of the reader to the chapter on Tumors as a study in diagnosis. In most of the examples offered in that chapter the relationship and signification of growths are fixed by comparison, by anatomical, or by physiological exclusions. Undeniably, it is to be seen that in places the distinctions are entirely



without confusion, that diagnosis asserts itself. As undeniably is it the case that in places distinctions are not without confusion; with the neoplasms, for example. A point to be made is this: where a writer knows absolutely, there he is clear; where he does not know, he is not clear. It takes very little learning to appreciate all about a pulp-fungoid tumor, but, as carcinoma is concerned, a clinician has not yet appeared who shows himself able to explain the reason for presence of such a growth. Where there are definition and clearness in this chapter on tumors, it means learning; where definition and clearness are lacking, it implies ignorance. The lesson to the student is this: To know a matter is to understand it. To understand a matter is to work at it, and at its environment, until nothing remains to be considered.

Diagnosis is a matter of principles and of details; the first to come first, the second to follow. Making here another illustration, one that, like the former, is to be referred to by the student without change of book, attention is directed to the subject of inflammation. Every inflammation is a perversion of circulation, and every perversion has certain associate phenomena which are general to the common condition. Following this, every inflammation has phenomena peculiar to special relation of the condition. First, a student is to acquaint himself with the common phenomena; second, he is to inform himself of relations which modify these phenomena. A phenomenon of inflammation is swelling. A swelling about the skin is almost invariably an expression of relief. A swelling about the mucous lining of a trachea means danger, too often death. Reason for the difference exists. To understand all about the difference implies simply that one make himself acquainted with a relational anatomy of the parts.

A papilla, assuming a hypertrophic expression, turns into a wart. What is a papilla? An engorged antrum will not unlikely throw the eye out of its socket. What is the connection of an antrum with an eye? To expand the fauces with air is to learn by sound whether or not the drum of an ear be ruptured. What is the relation of a throat and the drum of an ear? To see copper-colored blotches over a man's face is to discover whether he has a chancre covered by his pantaloons or by the lapse of twenty years. What is the kinship between blotches and sore? To hear a person complain of his hair coming out by the handful is to get a suspicion. A surgeon learns of distant things by sight of a swollen joint,—of gout as to the little joints, of rheumatism as to the big ones. A missing, unextracted, tooth explains an odontocoele. Irritation about the head of a penis directs attention to the possibility of stone in the bladder. Petechial spots upon the abdomen or chest tell of irritation of the glands of Peyer. An exudate shows distinction between diphtheria and scarlatina. A cornea that is the segment of a cylinder, and not of a sphere, gives understanding of astigmatism. In short, things tell of themselves, tell commonly everything about themselves. To read narrowly or widely, little or much, is with a man's self.

Diagnosis in any given case secured, treatment follows after a common



simple principle: holes are filled, cinders are lifted away, broken bones are splintered, congestions are resolved, spasms relaxed, poisons antidoted, errors in refraction antagonized. Complexity resolves itself into simplicity through understanding; to see into a pot requires never anything but the lifting of its lid.



# INDEX.

## A.

- Abbot's pluggers, 329.  
 Ablation of jaws, 816.  
     of tongue, 581.  
         Nunneley's operation for, 582.  
         Paget's operation for, 582.  
         Regnoli's operation for, 582.  
         Syme's operation for, 581.  
 Abortion of alveolar abscess, 226.  
 Abrasion of teeth, 267.  
 Abscess, 225.  
     abortion of, 226.  
     alveolar, 226.  
     associated with temporary teeth, 234.  
         with wisdom-teeth, 231.  
     caused by imprisoned teeth, 234.  
     complicated by opening into Steno's duct, 231.  
     dental, 225.  
     of antrum, 129, 750.  
     of liver indicated by tongue, 550.  
     of tongue, 567.  
     of tonsil gland, 544.  
     relation of with imprisoned teeth, 234.  
     treatment of, 232.  
 Absolute ether, 956.  
 Absorbable parasitocides, 165.  
 Absorption and recession of gum and alveolus, 217.  
     treatment of, 217.  
     of alveoli, 218.  
     of alveolar plate in dental abscess, 217.  
     of dead pulp into dental tubules, 228.  
     of gums, 219.  
 Abutments at neck of teeth, 285.  
 Abutting teeth, 286.  
 Accessory parotid gland, 191.  
 Accidental injuries to face, 512.  
     substances found in saliva, 196.  
 Accidents in root-filling, 243.  
     in tooth-extraction, 407.  
 Accumulation and degeneration of antral secretions, 644.  
 Acetic acid in ether, 956.  
 Acid in treatment of osseous caries, 770.  
     of salivary calculus, 265.  
     of typhoid fever, 161.  
     nitrate of mercury in treatment of ulcers, 783.  
     oral secretions, 165.  
 Acne rosacea, 695.  
 Aconite as a local anæsthetic, 412.  
     in toothache, 200.  
 Action of ether on nerve-centres, 960.  
     of nitrous oxide, 977.  
 Active inflammation, 992.  
 Actual cautery in dental hemorrhage, 411.  
     in sensitive dentine, 200.  
 Acupressure in hemorrhage, 573.  
 Acupuncture in trismus, 843.  
 Acute aphtha, 509.  
     glossitis, 563.  
     periodontitis, 219.  
     synovitis, 831.  
 Adamantina dentium, 927.  
 Adaptation in dentures, 426.  
 Adenoid tumors, 955.  
 Adenoma, 890.  
 Adhesion of the gums, 488.  
 Adhesive gold, 326.  
 Administration of ether, 596.  
 Advent of wisdom-teeth, 781.  
 Adventitious tongue-tie, 584.  
 Adynamic stomatitis in infants, 500.  
 Æsthetic aspect of amalgam, 311.  
     dentistry, 426.  
 Age and dental irregularities, 366.  
     in dentition, 100.  
     in relation to orthodontia, 366.  
     relation of, to use of chloroform, 968.  
     to scirrhus, 949.  
 Agents in contact with the teeth, 160.  
     excitative of dental caries, 135.  
     of calcification, 188.  
 Agger nasi, 633.  
 Agnew on hare-lip, 714.  
     on salivary fistula, 761.  
 Air and diet in dentition, 119.  
     tubes, view of, 545.  
 Albumen, albuminoids, and teeth, 193.  
     in saliva, 196.  
 Albuminoid degeneration and cadmium, 306.  
 Alcohol in febrile conditions, 108.  
     and sulphuric ether, 958.  
     sponging in inflammation, 989.  
 Alimentary canal during dentition, 101.  
 Alkalinity and dental caries, 161.  
 Allport's operation on dental pulp, 247.  
 Alteratives in tetanus, 837.  
 Alum and the teeth, 193.  
     in dental hemorrhage, 410.  
 Alveolar abscess, 225.  
     abortion of, 226.  
     anomalies of, 227.  
     arising out of imprisoned teeth, 234.  
     chronic conditions of, 232.  
     discharging into nostril, 230.



- Alveolar abscess, gout an associate of, 233.  
 illustrative cases of, 227.  
 meaning of, 225.  
 objections to use of warm fomentations in, 229.  
 opening into Steno's duct, 231.  
 prophylaxis of, 226.  
 rheumatic diathesis a predisposing cause, 232.
- Alveolar process, 28, 87.  
 and extraction of teeth, 407.  
 development of, 93.  
 fractures of, 407, 802.  
 necrosis of, 779.
- Alveoli of teeth, 28, 86.
- Alveolo-dental periosteum, 28, 225.  
 odontal membrane, 97.
- Amalgam, 303.  
 Arrington's, 303.  
 cadmium in, 306.  
 Caulk's, 304.  
 cause of failure as a tooth-filling material, 307.  
 Chase's, 305.  
 chemistry of, 312.  
 chloride of zinc as a cleanser of, 306.  
 composition of, 303.  
 contour, 304.  
 copper in, 305.  
 cupped carriers for handling, 309.  
 different preparations of material, 303.  
 discoloration of teeth caused by use of, 310.  
 facing, 304.  
 file flats for handling, 809.  
 front tooth, 304.  
 gold as an element of, 305.  
 Holmes', 303.  
 illustration in working, 309.  
 indications for use of, 310.  
 instruments used for, 308.  
 Johnson & Lund's, 304.  
 Lawrence's, 303.  
 Oliver's, 303.  
 platinum as an ingredient of, 306.  
 pluggers, Arrington's, 309.  
 silver in, 305.  
 standard alloy, 304.  
 submarine, 304.  
 Sullivan's, 304.  
 therapeusis of, 310.  
 Townsend's, 303.  
 usual, 304.  
 Weston's, 304.
- American leeches, 986.  
 in angina, 107.
- Ammonia in angina, 108.
- Amputation of tongue by the *éraseur*, 579.  
 by strangulation, 579.  
 of tonsil glands, 541.  
 instruments used for, 541.  
 Billing's tonsillotome, 542.  
 Kolbe's tonsillotome, 542.  
 of uvula, 588.
- Amygdalitis, 534.  
 acidulated ice in treatment of, 536.  
 dry cupping in treatment of, 536.  
 herpes in association with, 637.  
 hot foot-bath in treatment of, 536.  
 leeches in treatment of, 536.
- Amygdalitis, medicated gargles in treatment of, 534.  
 phenomenal expressions of, 534.  
 pus forming in gland, 537.  
 spirits of Mindererus in treatment of, 536.  
 veratrum viride in treatment of, 536.
- Anæmia and dental caries, 135.  
 and hemorrhage, 409.  
 as a cause of dental hemorrhage, 408.
- Anæsthesia and sensitive dentine, 202.  
 by chloroform, 962.  
 by ether, 956.  
 by ethyl bromide, 977.  
 by nitrous oxide gas, 973.  
 by rapid respiration, 978.  
 by rhigolene, 414.  
 by subcutaneous medication, 978.  
 general, 956.  
 in jaw luxation, 801.  
 local, 411.
- Analogy of teeth in parent and child, 135.
- Analyses of amalgam, 304.
- Analysis of blood, 148.  
 of cementum, 92.  
 of dentine, 92.  
 of enamel, 92.  
 of Indian corn, 156.  
 of milk, 150.  
 of potatoes, 153.  
 of saliva, 190, 258.  
 of salivary calculus, 258.  
 of the oral fluids, 190.  
 of tooth-substance, 92.
- Anatomy in nerve operations, 872.  
 of bend of arm, 987.  
 of facial region, 25.  
 of internal nose, 631.  
 of soft palate, 618.  
 of the teeth, 83.
- Anchorage slots, 339.
- Anchor-clamp bands, 381.
- Anchylosis of the jaw, 830.  
 complication, 831.  
 definition, 831.  
 inflammation a cause of, 830.  
 lockjaw in new-born children, 838.  
 rheumatoid, 833.  
 tetanus, 834.  
 trismus, 833.  
 dentium, 841.  
 nascentium, 838.
- Aneurism by anastomosis, 895.
- Angelioma, 680.
- Angina, 107.  
 aphthosa, 107.  
 simplex, 107, 603.  
 tonsillaris, 534.
- Angle of lower jaw at varying ages, 375.
- Angular artery, 54.
- Anidrosis, 577.
- Annealing gold foil, 326.  
 silver and gold plate, 446.
- Anodynes in shock, 516.
- Anomalies in alveolar abscess, 234.  
 in second dentition, 124.  
 in situation of salivary calculi, 259.
- Anomalous case of antral disease, 759.  
 of salivary calculus, 259.  
 of jaw fracture, 805.  
 of necrosis, 780.



- Anomalous teeth in relation with extraction, 405.  
     tonsillar abscess, 544.
- Anstie on neuralgia, 856.
- Anterior nares, 631.  
     palatine canal, 27.  
     pillars of oro-pharyngeal space, 50.  
     rhinoscopy, 654.
- Antero-posterior section of cranium, 49.
- Antiphlogistic prescription, 536, 987.  
     remedies, 987.
- Antiseptic injections in mercurial necrosis, 785.
- Antral outlet, 40.  
     ulcers, 647.
- Antrum of Highmore, 30, 747.  
     abscess of, 129, 750.  
     cystiform, 748.  
     diseases of, 747.  
     distension and softening of walls, 749.  
     dropsy of, 751.  
     puruloid secretion of, 753.  
     relation of anomalous dentition with, 748.  
         of furuncular epidemics with, 757.  
         of scorbutus with, 758.  
         of syphilis with, 758.  
     tooth-hills in, 30.
- Aperient mineral water, 493.
- Apex plugs in tooth-bleaching, 248.
- Aphthæ, the, 595.  
     Bamberger's views of, 499.  
     Delpech's views of, 499.  
     Dewees's views of, 500.  
     Good's views of, 502.  
     Jourdain's views of, 504.  
     Trousseau's views of, 499.  
     Wood's views of, 507.
- Aponeurosis of pharynx, 602.
- Apparatus used in correction of dental irregularities, 368.  
     (Farrar's) in orthodontia, 379.  
     in preparing nitrous oxide gas, 974.
- Appearance of dead teeth, 228.
- Application of dental napkin, 293.  
     of rubber dam, 279.
- Appreciable tumors, 884.
- Approximal dental cavities, 285.  
     and the rubber dam, 301.  
     tooth plugs, 346.
- Approximation of wounds, 517.
- Arbuthnot on infant mortality, 100.
- Arkansas stone, 344.
- Aromatic sulphuric acid in mercurial diseases, 477.  
     in treatment of osseous caries, 770.
- Arrangement of artificial teeth, 426.  
     of gold for filling teeth, 319.  
     of teeth in dental arches, 424.
- Arrestation of hemorrhage, 741.
- Arrested dentition in rickets, 143.
- Arrows of Maisonneuve, 560.
- Arsenic as a pulp devitalizer, 208.  
     relation of, with necrosis, 779.
- Arsenical paste, 208.  
     in sensitive dentine, 199.
- Art treatment of dental caries, 268.
- Arterial hemorrhage, 513.  
     hemorrhage after tooth extraction, 408.  
     nævi of tongue, 574.  
     sedatives and periodontitis, 222.
- Arterial tumors, 680, 895.
- Arteries of face, 53.  
     of neck, 53.  
     of tongue, 63.
- Artery, lingual, 61.
- Arthritis, 830.  
     complicated, 831.  
     from constitutional disease, 836.  
     from local cause, 830.  
     rheumatic, 833.
- Articulation, 427.  
     of complete denture, 424.  
     of full half denture, 423.  
     of head bones, 26.  
     of inferior maxilla, 66.  
     of nasal bone, 47.  
     of palate bone, 39.  
     of partial denture, 423.  
     of pivot operations, 350.  
     of superior maxilla, 34.  
     of teeth, 99.  
     of turbinated bone, 40.  
     of vomer bone, 39.  
     proper bite, 425.  
     test bite, 425.
- Artificial dentures, 415.  
     as a cause of ulitis, 475.  
     nose, 462.  
     pivot crowns, Bing's, 351.  
         Bonwill's, 359.  
         Gates's, 360.  
         Talbot's, 351.  
     support of lip and cheek, 428, 738.  
     teeth, 415.  
     tooth crowns, 350.  
     vela, 463.
- Artistic dentistry, 526.
- Association of teeth with alveoli, 86.
- Associative lesions of first dentition, 100.  
     of second dentition, 124.
- Asthenia and purulency, 755.
- Astigmatism, 1001.
- Astringents in dental hemorrhage, 410.
- Asymmetrical condition of tongue, 572.
- Atkinson's burnishers, 328.  
     pluggers, 267.
- Atlee's elastic suture, 714.
- Atmospheric changes a cause of pulpitis, 206.  
     of gelatinoid polypi, 640.  
     of tetanus, 840.  
     pressure in dentures, 421.  
     relations with chloroform, 964.  
     with ether, 961.
- Atomizers, 412.  
     foot instrument, 413.  
     hand instrument, 412.
- Atonic dyspepsia and tongue, 550.
- Atresia oris, 725.  
     Dieffenbach's operation for, 726.  
     Mütter's operation for, 729.
- Atrophic change in teeth, 145.
- Atrophy of tongue, 573.
- Atropia in neuralgia, 864.  
     in odontalgia, 205.
- Auriculo-temporal nerve, 57.
- Author's inhaling instrument, 957.  
     jaw bandage, 808.  
     operation for radical treatment of epithelial cancer, 705.



- Author's operation for resecting nerves at  
base of skull, 874, 878.  
for salivary fistula, 761.
- Automatic pluggers, 340.  
Buckingham's, 341.  
electro-magnetic, 340.  
hand instrument, 340.
- B.
- Baby's sore mouth, 495.  
Bacilli, 165.  
Bacteria, 165.  
Bad breath, 163.  
ether, 960.  
taste in mouth and amalgam, 311.
- Baker's velum, 469.  
Bald tongue, 552.  
Bamberger's views on the nature of the  
aphtha, 499.
- Bandages, 806.  
Barton's, 806.  
Garretson's, 808.  
Gibson's, 807.
- Bands and loops in orthodontia, 380.  
used in support of artificial teeth, 421.
- Barber's itch, 691.  
Barks, bitter, in angina, 110.  
Barnum's rubber dam, 297.  
Bars for removing teeth, 372.  
Bartholin's duct, 66.  
Barton in exsection of the jaw, 825.  
Barton's jaw-bandage, 806.  
Basal nutritive agent, 139.  
Basc's operation in hare-lip, 713.  
Base of skull, 49.  
of tongue, 64.  
Batley's solution in cancer, 704.  
Bayberry powder in hemorrhage, 103.  
Bean's interdental splint, 808.  
Bearing of impression material, 418.  
Beer or wine in rickets, 144.  
Beer's rubber disk, 422.  
Beeswax as an impression material, 417.  
Bell's case of hygroma, 599.  
Belladonna in angina, 109.  
in dentition, 102.  
in epithelial cancer, 710.  
in infantile spasms, 116.  
in tetanus, 257, 837.  
in tonsillitis, 535.
- Belloc's canula, 419.  
Benign tumors, 885.  
Bicarbonate of soda in burns, 531.  
Bicuspid approximal cavities, 335.  
forceps, 388.  
Bicuspidati teeth, 89.  
filling of, 288.
- Bilateral luxation of jaw, 797.  
Billing's tonsillotome, 542.  
Billroth on phosphor-necrosis, 794.  
on tetanus, 835.  
Billroth's operation on tongue, 583.  
Bing's gold crown, 351.  
Bite in denture-making, 423.  
of rabid animals, 512.
- Bitter barks in angina, 110.  
Black tartar, 264.  
teeth, 248.
- Black tongue, 549.  
vulcanite, 435.
- Blank's celluloid rim, 440.  
Blasius's lip operation, 732.  
Bleaching teeth, 248.  
Blindness in antral disease, 27, 753.  
Blisters in periodontitis, 223.
- Blood, composition of, 148.  
and tooth health, 147.  
and typhoid condition, 161.  
in typh fever, 162.  
vessels, diseases of, 680.  
angioma, 680.  
arterial tumors, 680.  
capillary nævi maculæ, 683.  
erectile growths, 680.  
macula, 680.  
nævus vasculosus, 680.  
port-wine stain, 683.  
venous tumors, 681.  
of the pharynx, 603.
- Blotting-paper in mask-making, 471.  
Blue line in saturnine affections, 490.  
teeth, 181.
- Blunt files, 276.  
Boiler of vulcanite apparatus, 434.  
Boiling-point of ether, 956.  
Boils, 983.
- Bolles on exciting causes of dental tumors,  
932.
- Bond's œsophagus forceps, 608.  
Bone scissors, 822.  
Bones of head, 26.  
ethmoid, 41.  
hyoid, 48.  
inferior maxillary, 35.  
lachrymal, 48.  
malar, 47.  
nasal, 29, 46.  
palate, 36.  
sphenoid, 43.  
superior maxillary, 30.  
turbinate, 40.  
vomer, 39.
- Bonwill's dental engine, 272.  
diamond reamer, 186.  
mallet, 341.  
method of rapid breathing, 978.  
pivot tooth, 359.  
surgical engine, 828.
- Bony septi in cystoma, 915.
- Booth's claw-forceps, 396.  
velum, 468.
- Bottle corks in ankylosis, 850.
- Bougies in imperforate nostrils, 656.
- Brain-like character of encephaloma, 950.
- Branches of internal maxillary artery,  
55.
- Breaking up sac of alveolar abscess, 227.
- Breaks in hard palate, 442, 784.  
in soft palate, 784.
- Bridges of bone in ankylosis, 853.
- Bridgman's experiments, 167.  
on electro-chemical cause of dental caries,  
167.  
on filling materials, 167.
- Bristle probangs, 609.
- Brittleness in gutta-percha, 313.
- Broach, pricking with, for destruction of  
dental pulp, 209.



- Broach, use of, in dentistry, 244.  
 Broaching dental pulp, 206.  
 Brodie on disease of tongue, 563.  
 Broken jaw-bones, 802.  
 Bromide of potassium in angina, 119.  
   in dentition, 102.  
   in febrile conditions, 112.  
   in infantile spasms, 117.  
   in neuralgia, 865.  
   in periodontitis, 222.  
   in retching, 416.  
 Bronchial tubes, view of, 545.  
 Broom splint in duct of Steno, 763.  
 Brown-Sequard's neuralgic pill, 869.  
 Brown tongue, 549.  
 Brown's three-edged chisel, 274.  
 Brutes' teeth in human sockets, 255.  
 Buccal nerve, 57.  
 Buckingham's mallet, 341.  
   obturators, 451.  
 Buckman's rubber dam clamps, 299.  
 Building gold tooth crowns, 336.  
 Bulb support for obturator, 447.  
 Bullæ, 122.  
 Bur and wheel files, 343.  
 Burnishers, 328, 343.  
 Burnishing in sensitive dentine, 203.  
 Burns, 530, 739.  
   treatment of scars from, 531.  
 Burrowing of pus in phosphor-necrosis, 791.  
 Burs, diagram of, 201.  
 Buttner and pivot teeth, 362.  
 Butyric acid and teeth, 193.
- C.
- Cachectic mucous membrane, 415.  
   state and rickets, 140.  
 Cachexia in dental caries, 144.  
 Cacoplastic lymph, 139.  
 Cadmium in amalgam, 189.  
 Calabar in treatment of tetanus, 837.  
 Calcareous tumor upon floor of mouth, 259.  
 Calcification of dental pulp, 211.  
   of tooth, 94.  
   as a cause of chronic ulitis, 494.  
 Calculi in salivary ducts, 259.  
 Calculus, salivary, 258.  
   acids used in, 265.  
   instruments used in removing, 265.  
 Calendula as a mouth-wash, 494.  
 Callositas, 667.  
   treatment of, 667.  
 Campbell's new mode heater, 436.  
 Camphor and morphia in sensitive dentine, 200.  
 Canal, Fallopian (see *Temporal Bone*).  
   infra-orbital, 32.  
   interpalatine, 33.  
   lacrimal, 48.  
   naso-palatine, 33.  
   pluggers, 243.  
   pterygo-palatine, 33.  
   vidian, 46.  
 Cancer, 937.  
   encephaloid, 950.  
   illustration of, 951.  
   epithelial, 697.  
   juice, 949.  
   Cancer of cheek, 697.  
     of eyelid, 705.  
     of gums, 701.  
     of lip, 700.  
     of maxillary bones, 937.  
     of nose, 633, 641.  
     of throat, 550, 607.  
     scirrhus, 949.  
     treatment of, 699, 937.  
   Cancerous epithelioma, 697.  
     ulceration of lip, 698.  
       Blasius's operation, 732.  
       Celsian operation, 732.  
       Chopart's operation, 731.  
       Dieffenbach's operation, 726.  
       Dupuytren's operation, 731.  
       Horn or Roonhuysen's operation, 731.  
       Leidillot's operation, 736.  
       Liston's operation, 731.  
       Morgan's operation, 731.  
       Mütter's operation, 732.  
       operative treatment, 702.  
       Roux's operation, 731.  
       Serre's operation, 733.  
     ulcers of nose, 633.  
   Cancerum oris, 499.  
     and salivary fistula.  
 Candle-wick and pumice-stone, 347.  
 Canine forceps, 389.  
   fossa, 28.  
   teeth, 89.  
 Canker sore, 510.  
 Canula in tracheotomy, 547.  
 Cap crowns, 350.  
 Cap for front teeth, 375.  
 Capillary nævi maculæ, 683.  
   erectile tumors, 895.  
   hemorrhage, 513.  
 Capping dental pulps, 245.  
   with clarified quill, 246.  
   with lead, tin, and asbestos, 247.  
   with metal caps, 246.  
   with oiled silk or vellum, 246.  
   with oxychloride of zinc, 245.  
 Caps in dental inflammation, 223.  
 Capsicum and myrrh in affections of the gums, 479.  
   in angina, 109.  
   in hemorrhage, 410.  
 Capsular ligament of lower jaw, 67.  
 Capsule of encephaloid cancer, 950.  
 Carbolic acid and teeth, 233.  
 Carbonate of magnesia as a decolorizer, 249.  
   in phosphor-poisoning, 788.  
   of potash in sensitive dentine, 200.  
 Carbonic acid and temperature, 197.  
   in dental caries, 161, 197.  
 Carbuncle, treatment of, 511.  
 Carcinoma of jaw, 937.  
 Carded cotton in burns, 531.  
 Caries and necrosis of walls of nares, 644.  
 Caries of antral walls, 644.  
   of teeth, 135.  
     cachexia in, 136.  
     causes of, 136.  
     complicated cavities, 185.  
     constitutional relations, 135.  
     differs from caries in bone, 177.  
     general manner of treating, 177.



- Caries of teeth, inflammatory process of, 136.  
     on approximal faces of teeth in general, 184.  
     on buccal face of molars, 283.  
     on grinding face of molars, 282.  
     on labial face of incisors, 285.  
     on neck surface of incisors, 283.  
     on posterior face of incisors, 283.  
     principles of treatment, 183, 187.  
 Caries of the maxilla, 764.  
     common treatment of, 768.  
     diagnosis of, 764.  
     ostitis the cause of, 764.  
     treatment by sulphuric acid, 770.  
     by surgical engine, 769.  
 Carious denture, 284.  
 Carnochan's operation for exposure of second branch, 876.  
     of fifth nerve, 876.  
 Carotid artery, 53, 744.  
     external, 744.  
     primitive, 745.  
     ligation of, 745.  
         in inferior triangle, 745.  
         in superior triangle, 745.  
 Carron oil and burns, 531.  
 Cartilaginous jaw planes, 93.  
     tumors, 937.  
         of tongue, 574.  
 Casserio's ganglion, 77.  
 Cast of mouth, 416.  
 Castile and other soaps as a cause of disease of the gums, 482.  
 Catalan's inclined plane, 376.  
 Catalogues, dental, 365.  
 Catarrh, nasal, 633.  
     Schneiderian membrane, 631.  
 Catechu and kino in dental hemorrhage, 411.  
 Cathartics in neuralgia, 866.  
 Caudate cells, 939.  
 Cauliflower epithelioma, 139.  
 Causes of consumption, 139.  
     of dental abscess, 219.  
     of gum diseases, 475.  
     of neuralgia, 856.  
     of odontalgia, 198.  
     of palatine deficiencies, 613.  
     of salivary calculus, 258.  
     of sensitive dentine, 198.  
     of tooth discoloration, 250.  
 Caustic potash in osseous caries, 770.  
 Caulerization in dental hemorrhage, 411.  
     in salivary fistulæ, 760.  
     in sensibility of dentine, 199.  
 Cavities among imperfect enamel, 283.  
     at neck of incisors, 283.  
     for filling, 282.  
         approximal, 285.  
         crown, 282.  
     in teeth, 282.  
 Cavities of decay opening into pulp-chamber, 245.  
     on buccal face of molars, 283.  
     on posterior face of incisors, 283.  
 Cazenave's neuralgic pomade, 868.  
 Celluloid and vulcanite, 431.  
     gum on metal base, 441.  
 Celsian lip operation, 731.  
 Cement plombe, 318.  
 Cementum, 85.  
     analysis of, 92.  
 Cerebral diseases and chloroform, 971.  
 Cervico-facial nerve, 58.  
 Chalk and dental caries, 164.  
 Chalky teeth, 180.  
 Chambers's mixture for epilepsy, 117.  
 Chancre of nose, 656.  
 Changes in rami of lower jaw, 375.  
     in the tongue, 549.  
 Character of agents in contact with teeth, 160.  
     of epithelioma, 697.  
 Chase's case of secondary cyst of antrum, 935.  
     new amalgam, 305.  
 Chassaignac's écraseur, 579.  
 Cheeks and lips, 726.  
 Cheesy deposits and pyaline, 194.  
 Cheever's ablation of tonsil gland, 543.  
     osteo-plastic exsection of lower jaw, 823.  
 Cheiolooplastic operations, 726.  
     by Blasius, 732.  
     by Celsus, 731.  
     by Chopart, 731.  
     by Dieffenbach, 732.  
     by Dupuytren, 731.  
     by Horn, 731.  
     by Liston, 732.  
     by Morgan, 731.  
     by Mütter, 732.  
     by Roonhuysen, 731.  
     by Roux, P., 731.  
     by Roux, T. W., 731.  
     by Serres, 733.  
 Chemical decomposition of bone, 771.  
     treatment of dental hemorrhage, 411.  
 Chemico-vital relation of dental caries, 135.  
 Chemistry of amalgam, 312.  
 Chimney-sweep's cancer, 697.  
 Chip-blower, 280.  
 Chisels in extraction of teeth, 393.  
     in treatment of osseous caries, 769.  
     used in dentistry, 273.  
 Chloasma, 669.  
 Chloral hydrate in tetanus, 838.  
 Chlorate of potash as a tooth-bleacher, 249.  
     in stomatitis, 106.  
 Chloride of iron in dental hemorrhage, 409.  
     of sodium and the teeth, 194.  
     of zinc as a calcific agent, 177.  
         as a cause of pulpitis, 198, 188-206, 244.  
         as a cleanser of amalgam, 307.  
         as a pain-obtunder, 199.  
         in dental caries, 188.  
 Chlorine gas as a decolorizer, 249.  
     water in cancerous affections, 703.  
     in decolorizing, 249.  
 Chloroform, 962.  
     action on heart, 963-970.  
     age in relation with, 968.  
     and laudanum as a local anæsthetic, 412.  
     apparent death from, 973.  
     appearance of, 963.  
     as a specific in ether-sickness, 961.  
     cerebral disease in relation with, 971.  
     composition of, 963.  
     dangerous character of, 963.  
     degradation of, 963.  
     dilution of by air, 966.  
     disease of the heart in relation with, 970.



- Chloroform, disease of the lungs in relation with, 970.  
 hysteria in relation with, 969.  
 in neuralgia, 867.  
 induction of insensibility, 964.  
 insanity in relation with, 972.  
 minims required for anæsthesia, 964.  
 position for administering, 964.  
 preparatory stimulation, 965.  
 relation of atmosphere with, 964.  
   of fear with, 965.  
 smell of, 963.  
 strength or debility in relation with, 968.  
 subcutaneously used, 979.  
 surgical operations in relation with, 964.  
 taste of, 963.  
 treatment of accidents with, 973.  
 use of in conjunction with brandy or ether, 965, 966.  
 use of in spasms, 119.  
 weight of, 963.
- Cholera infantum in dentition, 112.
- Cholesterine in saliva, 192.
- Chromidrosis, 677.
- Chronic angina, 108.  
 inflammation, 992.  
 periodontitis, 214.  
 phagedæna of tongue, 558.  
 pharyngitis, 603.
- Cicatrices, rules for treatment of, 739.
- Cicatricial tissue, 716.
- Cicatrix from burns, 739.  
 in hare-lip, 716.
- Cider and the teeth, 193.
- Ciliary ganglion, 77.
- Ciliated epithelium, 64.
- Circumvallation in inflammation, 983, 995.
- Clamps used with rubber dam, 298.  
 Buckingham's pattern, 299.  
 Elliot's pattern, 299.  
 Hickman's pattern, 299.
- Clasp teeth, 415.
- Classes of teeth; 180.  
 in relation with the operation of extraction, 384.
- Classification of pulp-nodules, 215.  
 of teeth, 87.  
 of tumors, 884.
- Clean cutting in nerve-sections, 878.
- Cleaning tracheal tubes, 547.
- Cleanliness and the teeth, 174.
- Cleansing of mouth before taking impressions, 418.
- Cleft lip, 712.  
 palate, 613.  
   complete, 613.  
   Fergusson's operation for, 623.  
   incomplete, 613.  
   of hard parts, 617.  
   operation for, 620.  
   preparation of patient for operation, 617.  
   Roux's operation for, 621.  
   surgical anatomy of parts, 618.  
   the author's operation for, 623.  
   uranoplasty, 628.  
   Warren's operation for, 628.  
 velum, 617.
- Clinical histories of nævi, 680.  
 illustrations in tumor diagnosis, 885.
- Clinical illustrations in necrosis, 787.  
 remarks on treatment of epithelial cancer, 708.
- Clinoid process of os sphenoidium, 44.
- Cloquet's ganglion, 80.
- Closure of tear-canal, 27.
- Clot-forming agents, 410.
- Cobweb in hemorrhage, 410.
- Cod-liver oil in angina, 110.  
 in burns, 531.  
 in rickets, 144.
- Codman and Shurtleff's atomizer, 414.
- Coffee in neuralgia, 856.  
 as a specific in ether sickness, 961.
- Coffer dam, 397.
- Coffin's system in orthodontia, 371.
- Cohesive gold, 326.
- Cohnheim and white blood-corpuscles, 998.
- Coin plugs, 333.
- Colchicum in neuralgia, 865.  
 in rheumatic odontalgia, 207.
- Cold a cause of dental caries, 197.  
 in anæsthesia, 411.  
 in the head, 996.  
 the cause of diarrhœa, 114.  
 water in burns, 531.  
 in diagnosis of exposed pulp, 281.  
 in hemorrhage, 513.
- Colic in tetanus, 834.
- Collecting nitrous oxide, 975.
- College operating case, 330, 332.
- Color in calculi, 264.
- Columnar epithelium, 64.
- Coma and polypi, 643.
- Combustibility of ether, 956.
- Comedo, 674.
- Comminuted fractures, 802.
- Common carotid artery, 53, 746.
- Communications of nasal fossa, 633.
- Compatibility with tooth-substance of gutta-percha, 313.
- Complete luxation of jaw, 797.
- Complex apparatus in relation with orthodontia, 378.
- Complexion in phosphor-necrosis, 791.
- Complicated arthritis, 831.  
 fractures, 802.  
 hare-lip, 718.  
 teeth-cavities, 285, 289.  
 wounds of face, 519.
- Complications in nasal fractures, 658.
- Composition of amalgam, 303.  
 of blood, 148.  
 of black vulcanite, 435.  
 of celluloid, 435.  
 of vulcanite, 435.
- Compound jack-screw, 382.
- Compression in dental hemorrhage, 411.  
 in facial hemorrhage, 513.  
 in lingual hypertrophy, 372.  
 of nævi, 685.
- Compressors, 293.  
 used in dentistry for control of saliva, 293.
- Concave surface of scirrhus, 949.
- Concentric fibroma, 938.
- Conclusion concerning vela obturators, 463.
- Condensing instruments, 342.  
 plugs, 345.
- Condition of parts in jaw luxation, 798.



- Conduction in celluloid, 435.  
 Condylod process, 35.  
   condition of in luxation, 797.  
 Congenital fissure of hard palate, 614.  
   luxation of lower jaw, 799.  
   tongue-tie, 584.  
   union of gums, 488.  
 Congestion in spasms, 117.  
   of spleen and tongue, 550.  
   of the lungs, 996.  
 Conical teeth and the rubber dam, 301.  
 Conium in irritation, 869.  
 Conjoined loss of nose and lip, 736.  
 Connective tissue, diseases of, 677.  
   keloid, 677.  
   molluscum fibrosum, 678.  
   rhino-scleroma, 679.  
   tumor, 679.  
   xanthoma, 679.  
 Consistence in calculi, 264.  
 Constipation in tetanus, 835.  
 Constituents of mucus, 161, 194.  
 Constitution of teeth, 91.  
 Constitutional diseases associated with an-  
   tral disorders, 747.  
   relation of dental caries, 160.  
   treatment of dental caries, 136.  
 Construction of obturators, 445.  
 Continuous gum made of celluloid, 439.  
 Contour amalgam, 304.  
   filling, 336.  
   plugs, 338.  
   of lip in denture-making, 424.  
 Contouring in mechanical dentistry, 429.  
 Contracted maxilla, 125.  
   oral orifice, 726.  
   treatment of, by Dieffenbach, 726.  
   by Mütter, 732.  
   modifications of, by author, 727.  
 Contracting exposed pulp, 203.  
 Controlling dental hemorrhage, 409.  
 Conveniences in dentistry, 349.  
 Convex file in separating teeth, 285.  
 Convulsion from irritation in teething, 118.  
 Convulsions and polypi, 643.  
 Cooper Rose's gum tube, 835.  
 Copland on treatment of tetanus, 836.  
 Copper and dental caries, 189.  
   therapeusis, 188.  
   and pulp tonicity, 189.  
   as an excitant of calcification, 189.  
   in amalgam, 305.  
 Coppery taste in mouth, 785.  
 Coral and pumice as a cause of ulitis, 482.  
 Corium, diseases of, 667.  
   dermatolysis, 670.  
   elephantiasis, 671.  
   frambœsia, 672.  
   morphœa, 672.  
   nævus pilosus, 669.  
   scleroderma, 670.  
   unilateral atrophy, 670.  
 Cork, use of in false anchylosis, 850.  
 Corn, analysis of, 156.  
 Cornu cutaneum, 667.  
   treatment of, 668.  
   of dental pulp, 86.  
   of hyoid bone, 48.  
 Coronary arteries, 54.  
 Corpuscles, Purkinjean, 289.  
 Corpuscles, salivary, 179.  
 Corpuscular lymph, 139.  
 Correcting apparatus, 370.  
   Farrar's, 379.  
   Kingsley's, 377.  
   McQuillen's, 372.  
   Westcott's, 370.  
   White's, 370.  
   double hare-lip, 718.  
 Corrosive sublimate in stomatitis, 105.  
   in syphilitic stomatitis, 105.  
 Corrugated powder-disk, 344.  
 Cortex strata, 927.  
 Corundum disks, 278, 344.  
   points, 345.  
   tape, 344.  
 Coryza in infants, 654.  
   and iodide of potassium, 553.  
 Cosmoline in burns, 531.  
 Costiveness in epistaxis, 634.  
 Cotton as an obturator, 443.  
   in root-filling, 243.  
   seton in salivary fistula, 762.  
   twine in hare-lip operation, 725.  
 Counter casts, 445.  
   openings in alveolar abscess, 226.  
 Cow-horn forceps, 393.  
 Cracks and fissures of tongue, 551.  
   in enamel a cause of pulpitis, 174.  
 Crapulous diarrhœa, 113.  
 Cream in angina, 110.  
   in scrofulosis, 144.  
 Creasote as a cause of ulitis, 482.  
   as a disinfectant, 786.  
   as a parasiticide, 189.  
   in dental caries, 182.  
   in ether-sickness, 961.  
   in neuralgia, 867.  
 Cribriform plate of ethmoid bone, 41.  
 Crimson-tinged tumors of jaw, 942.  
 Crista galli of ethmoid bone, 41.  
 Crown cavities, 334.  
 Crucial incisions in cystoma, 41.  
 Crusta dentium adamantina, 927.  
   petrosa, 85.  
 Cryer's plan of repairing celluloid dentures,  
   438.  
 Cupping, 985.  
 Cups for impression purposes, 416.  
   for relief of visceral congestion, 984.  
 Cup-shape dental atrophy, 145.  
 Cure of dental caries by filing, 182.  
   by filling, 177.  
 Curette in lupus erythematosus, 705.  
 Cuspidati teeth, 89.  
 Cutaneous horns, 667, 692.  
   hyperæmia, 120.  
 Cuts of tongue, 551.  
 Cutting bone scissors, 822.  
   forceps, 401.  
   teeth, irritation from, 100.  
 Cylinders in tooth-filling, 320.  
   for nitrous oxide, 975.  
 Cyst, general diagnosis of, 915.  
 Cystic disease of tonsil glands, 544.  
   tumors, 915.  
   non-explainable, 932.  
   self-explainable, 915.  
 Cystiform antra, 933.  
 Cystoma of tongue, 562.



Cystoma, parasitic, of cheek, 691.  
 Cystomata, 915.  
 Cysto-sarcoma, 940.  
     succulent tumors, 945.  
 Cysts of salivary ducts and glands, 530.

## D.

Da Costa's neuralgic ointment, 869.  
 Dam, rubber, 297.  
 Danger of chloroform, 967.  
 Danger to jaw of infantile alveolar abscess, 104.  
 Data concerning dental tumors, 931.  
 Dead or loose teeth as a cause of disease of gums, 481.  
 Deadrick in jaw operations, 825.  
 Deafness in angina, 107.  
 Debility and infantile diarrhoea, 113.  
     in aphthæ, 511.  
     of organization, 139.  
     or strength in relation with use of chloroform, 968.  
 Deciduous teeth, 87.  
     absorption of roots of, 98.  
     decrease of, 98.  
     foramina of, 98.  
 Decomposition of dental pulp, 209.  
 Deep arteries of face, 54.  
     seated ranula, 601.  
 Defects in the hard palate, 627.  
 Definition of dental tumors, 905.  
     of skin diseases, 120, 667.  
     of term tumor, 884.  
 Deformed or anomalous teeth, 405.  
 Deformities of head in rickets, 143.  
     in dentition, 366.  
 Deformity from burns, 739.  
 Delayed dentition in rickets, 143.  
 Delicate infants and dentition, 100.  
 Dennet's pivot tooth, 358.  
 Dens sapientiae, 91.  
 Dental abscess, 225.  
     arches in articular relation, 427.  
     art, 268.  
     carbolic acid soap as an oral parasiticide, 165.  
     caries, 177.  
     chisels, 275.  
     conveniences, 349.  
     cysts, 915.  
     engine, 271.  
         Bonwill's, 272.  
         White's, 272.  
     evolution a cause of febrile manifestations, 102.  
     exostosis, 405, 905.  
     files, 276.  
     fungoid tumors, 892.  
     hemorrhage, 408.  
     irregularities, 368.  
     irritation in association with dental evolution, 102.  
         and skin eruptions, 120.  
     mirror, 281.  
     napkin, 293.  
     necrosis, 776.  
     nerves, 73.  
         inferior maxillary, 75.  
 Dental nerve, superior maxillary, 73.  
     operating chair, 348.  
     periostitis, 219.  
     pits, 87.  
     plates, 421.  
         in œsophagus, 608.  
     pulp, 83.  
         decomposition, 209.  
         exposure of, 203.  
     splint, 814.  
     therapeutics, 187.  
     trays, 416.  
 Dentes sapientiae, 91.  
     forceps, 397.  
 Dentifrices, 74.  
     improper use of, 481.  
     non-soluble, 218.  
 Dentigerous tumors, 918, 921, 922.  
 Dentinal tubules, 84.  
 Dentine, 83.  
     analysis of, 92.  
     formation of, 83.  
     moist, 181.  
     sensitive, 198.  
     soft, 181.  
 Dentinification, 94.  
 Dentinoma, 915.  
 Dentition, 93.  
 Denture, 421.  
     imperfect, 159.  
     perfect, 158.  
 Denudations, 267.  
     treatment of, 268.  
 Depletion, 985.  
     in periodontitis, 222.  
 Deposits of pigment, 669.  
 Depressed rubber dam, 297.  
 Depressing action of heart as an anti-hemorrhagic, 409.  
 Depression of tongue, 534.  
 Depressor muscles, 53.  
 Derangement of bowels in phosphor-necrosis, 791.  
 Dermatitis, 120.  
 Dermatolysis, 670.  
 Descendens noni nerve, 745.  
 Desirabode's palatine obturators, 455.  
 Destiny of milk teeth, 98.  
 Destruction of alveolar process, 93.  
     of teeth, 208.  
 Destructive disease, 136, 137.  
 Detaching teeth from celluloid plates, 439.  
 Details and principles in diagnosis, 1001.  
 Deteriorated antral secretions, 644.  
 Development of teeth, 93.  
 Deviation of nasal septum, 655.  
 Devitalized dentine and dental pulp, 776.  
 Dewar's dressing, 715.  
 Diabetes mellitus and tongue, 549.  
 Diagnosing dead teeth, 130.  
 Diagnosis, general, 999.  
     of dental irritative fever, 111.  
     of polypi, 641.  
     of the aphthæ, 507.  
     of tumors, 884.  
 Diagram of burs, 201.  
     of contour work, 187.  
     of gum lancing, 103.  
     of imprisoned teeth, 131-133.  
     of inflammation, 980.



- Diagram of nerve-canal pluggers, 242.  
 of nodular dentine, 214.  
 of squamous epithelioma, 710.  
 of tooth nutrition, 778.  
 showing secondary dentine, 215.  
 showing teeth, 87, 88.  
 development, 95.
- Diameter of dental tubules, 214.
- Diamond reamers, 186.
- Diamonds in teeth as ornaments, 364.
- Diaphoresis in angina, 107.
- Diarrhoea from atmospheric changes, 114.  
 from dentition, 102-112.  
 from enteritis, 112.  
 from excess of food, 112.  
 from food not easily digested, 113.  
 from hepatic derangement, 112.  
 from infusoria, 114.  
 from malarial influence, 112.  
 from scrofulous diathesis, 113.  
 from unhealthy milk, 114.  
 from worms, 113.  
 mixture, 510.
- Dibble's saliva-pump, 294.
- Dieffenbach's operation for atresia oris, 726.  
 on lip, 735.  
 for staphyloplasty, 627.
- Diet and aphthae, 511.  
 and bad teeth, 148.  
 in angina, 108.  
 in inflammation, 989.
- Difference in vice tumors, 907.  
 of dental and osseous caries, 135, 565, 776.
- Digitalis in neuralgia, 865.
- Diminution of appetite in phosphor-necrosis, 791.  
 of pulp-cavity, 213.
- Diphtheria and nose-bleeding, 634.
- Diphtheritic inflammation, 991.
- Direct drying of dental cavities, 301.
- Directions for making obturators, 445.
- Dis, 999.
- Disappearance of eruptions associated with convulsions, 115.
- Discoloration of teeth caused by amalgam, 310.
- Discolored teeth, 248.
- Disease a generic term, 999.
- Diseased protoplasm, 139.
- Diseases of external nose, 657.  
 fractures, 658.  
 loss of substance, 658.  
 of first dentition, 100.  
 of the face, 667.  
 immediate, 667.  
 mediate, 667.  
 of the floor of mouth, 590.  
 of the gums, 475.  
 of the periosteum, 209.  
 of the pharynx, 603.  
 of the teeth, 135.
- Disinfecting dental pulp-canal, 242.
- Disking incipient caries, 182.
- Disks, corundum, 278.
- Dislocation of the inferior maxilla, 797.  
 cause of luxation, 797.  
 condition of parts in luxation, 797.  
 congenital luxation, 799.  
 diagnosis of luxation, 797.
- Dislocation, forms of displacement, 797.  
 fracture associations, 798.  
 in men and women, 798.  
 subluxations, 799.  
 treatment of luxation, 800.  
 use of anæsthesia in, 801.
- Dispensing nitrous oxide, 975.
- Displacement of nasal septum, 658.
- Dissection of lips and cheeks, 52.  
 of soft palate, 619.  
 of tongue, 60.
- Distention of antral walls, 749.
- Distinction of blood in hemorrhage, 512.
- Distribution of nerves of face, 57.
- Disturbances in tissue metamorphosis, 980.
- Diuretics in inflammation, 990.
- Diversion in angina, 107.
- Division of frænum in tongue-tie, 584.
- Donovan's solution in neuralgia, 866.  
 in syphilis of the tongue, 555.
- Double hare-lip, 719.  
 screw in orthodontia, 378.
- Douche bath, 666.  
 in ozæna, 644.
- Dover's powders, 995.  
 in odontalgia, 205.
- Doyle's oral speculum, 823.
- Drain in necrosis, 793.
- Drainage in treatment of ranula, 592.
- Drain-tubes in replantation of teeth, 254.
- Dressing contour fillings, 98.  
 gutta-percha plugs, 315.  
 jaw fractures, 802.
- Dribbling, treatment of, 763.
- Dried fruits and the teeth, 173.
- Drill, Merry's, 271.
- Drill-holes in orthodontia, 383.
- Drilling engines, 272.  
 roots and necrosis, 780.
- Drills, rose and spear, 271.
- Drip-tube, Herrick's, 280.
- Dropsy of antrum, 751.
- Drop-tubes, 280.
- Dry cupping, 985.
- Dryness and sensitive dentine, 202.  
 and tooth-filling, 301.
- Dubs's screw forceps, 403.
- Duct compressors, 294.  
 Hawes's, 294.  
 Morrison's, 294.  
 Osborn's, 294.  
 Rich's, 296.  
 Smith's, 294.  
 of Bartholin, 66.  
 of Steno, 66.  
 of Wharton, 66.
- Ductus ad nasum, 27.
- Duplay's speculum, 654.
- Dupuytren's lip operation, 731.
- Duration of acute tetanus, 834.  
 of scirrhomata, 948.
- Dyscrasia in relation with orthodontia, 367.
- Dyspepsia and anæmia as causes of dental caries, 160.
- E.
- Earth as a dressing, 531.
- Earthy concretions in duct of Steno, 763.  
 salts and tooth-calcification, 92.



- Ease, 999.  
 Ease or difficulty in extracting teeth, 384.  
 Eau de luce in seborrhœa, 674.  
 Eburnification, 177.  
 Eccentric fibroma, 938.  
 Ecraseur, 579.  
 Efflorescence of mouth, 501.  
 Effusions, character of, 995.  
   in burns, 531.  
   in the tissue of pharynx, 605.  
   in tongue, 570.  
 Egg-shaped nodules in dental pulp, 215.  
 Electric illuminator, 611.  
   state not a fixity, 170.  
 Electrical disturbances in dentistry, 189.  
 Electro-chemical dental experiments, 167.  
   relations with caries, 167.  
   galvanism in tooth-extraction, 412.  
   magnetic mallet, 340.  
 Electrolysis in treatment of vascular nævi, 686.  
   of tumors, 896.  
 Elephantiasis, 671.  
 Elevator muscles, 51.  
 Elevators used in extracting teeth, 398.  
 Elliot's rubber dam clamps, 299.  
 Elongated tongue, 549.  
 Emery in plug-finishing, 345.  
 Emetics in angina, 108.  
   in sore throat, 108.  
 Emotional disease of sweat-glands, 677.  
 Emphysema in tracheotomy, 547.  
 Empyothotonos in tetanus, 835.  
 Enamel, 84, 94, 927, 929.  
   abrasion of, 267.  
   analysis of, 92.  
   denudation of, 267.  
   formation of, 94.  
   membrane, 97.  
   stopping, Oehlecker's, 318.  
 Encephaloma, 950.  
   early ulceration of, 950.  
   illustrations of, 950.  
   malignancy of, 950.  
   microscopic views of, 950.  
   protrusion of fungus from, 952.  
 Enchondroma of tongue, 574.  
 Enchondromatous tumors, 946.  
 Encysted tooth-germs, 124.  
 Encystment of teeth by salivary calculus, 258.  
 Endermic application of morphia in neuralgia, 867.  
 Engine, dental, 271.  
   Bonwill's, 272.  
   White's, 272.  
   drill in extraction of roots, 406.  
 English chalk as a decolorizer, 249.  
   method of rhinoplasty, 659.  
   operation in hare-lip, 718.  
 Engorgement of antrum, 756.  
 Enostosis, 904.  
 Enteric fever and tongue, 550.  
 Enteritis in dentition, 113.  
 Epiderm, diseases of, 667.  
   callositas, 667.  
   chloasma, 669.  
   cornu cutaneum, 667.  
   lentigo, 669.  
   lichen pilaris, 668.  
   nævus pigmentosus, 668.  
 Epiderm, diseases of: vitiligo, 668.  
 Epiderm et corium, diseases of, 667.  
   ichthyosis, 673.  
   verruca, 673.  
 Epiglottis, 64.  
 Epilepsy from dental irritation, 118.  
 Epistaxis, 634.  
   associated with hemorrhagic diathesis, 637.  
   passive, 636.  
   plethoric, 636.  
   traumatic, 635.  
 Epithelioma, 697.  
   general consideration of, 697.  
   illustrations of, 700.  
   microscopic character of, 710.  
   of face, 698.  
   of lingual frænum, 596.  
   of tongue, 560.  
   three forms of, 698.  
   treatment of, 699.  
 Epithelium of mouth, 64.  
 Epitome of myeloid growths, 944.  
 Epsom salts in angina, 107.  
 Epulic tumors, 892.  
 Epulides not self-explaining, 897.  
 Epulo-erectile tumors, 894.  
   definition of, 894.  
   treatment by cauterants, 895.  
   by electrolysis, 896.  
   by injection, 895.  
   by pressure, 896.  
   by the serres-fines, 896.  
   by the seton, 896.  
   varieties of, 895.  
 Epulo-fungoid tumors, 892.  
 Erectile epulides, 894.  
   growths, 680.  
   tumors of tongue, 571.  
 Erigeron canadensis in hemorrhage, 104, 409.  
 Errors of nutrition and tongue, 574.  
 Eruption of temporary teeth, 97.  
   on skin, 120.  
   in dentition, 120.  
 Erysipelas, 120.  
   and burns, 740.  
   as a complication in epithelioma, 704.  
   in burns, 532.  
   of tongue, 570.  
   specific for, 740.  
 Erythema, 120.  
 Eschar and scar, 739.  
 Ether, sulphuric, 956.  
   absorption of, 958.  
   action on nervous system, 959.  
   boiling point, 956.  
   carbonic acid as an antidote for sick stomach, 961.  
   chloroform as an antidote for sick stomach, 961.  
   coffee as an antidote for sick stomach, 961.  
   combustibility of, 956.  
   continuance of patient in anæsthetic condition, 961.  
   creasote as an antidote for sick stomach, 961.  
   criterion for judging effects of, 961.  
   effects of a bad article, 960.  
   essentials of exhibition, 956.



- Ether, evanescence of effect, 958.  
 freezing point of, 956.  
 idiosyncrasies, 962.  
 immediate and obvious effect, 959.  
 indicated in obscure neuralgia, 867.  
 instruments used for administering, 956.  
 Jackson's formula for preparing, 956.  
 physical characteristics of, 956.  
 quantity employed, 960.  
 relation of action with that of common  
 alcoholic beverages, 958.  
 relation of atmosphere with, 961.  
 safety of, 962.  
 sick stomach from use of, 761.  
 specific gravity of, 956.  
 spice plaster in sick stomach from, 961.  
 volatilization of, 956.
- Ethmoid bone, 41.  
 articular relations of, 42.  
 boxes of, 42.  
 cells of, 42.  
 cornua of, 41.  
 cribriform plate of, 42.  
 crista galli of, 41.  
 foramina of, 41.  
 general construction of, 41.  
 nasal slit of, 41.  
 olfactory depressions of, 42.  
 perpendicular plate of, 41.  
 turbinated scrolls of, 42.  
 unciform process of, 42.
- Ethyl bromide, 977.  
 accidents associated with use of, 978.  
 color of, 977.  
 mixture with ether and water, 978.  
 mode of preparing, 977.  
 odor and taste, 977.  
 quantity required for anaesthesia, 978.  
 rapidity of action, 978.
- Ethylate of sodium in treatment of naevi,  
 685.
- Evans's studies in dental prosthetics, 428.
- Examples in alveolar abscess, 227.  
 in tumor diagnosis, 885.
- Exanthemas in alveolar necrosis, 787.
- Exanthemata, 122.  
 and dentition, 701.  
 in antral disease, 758.  
 necrosis associated with, 787.
- Excavating in dental caries, 268.  
 instruments used for, 269.
- Excavation of teeth, 282.
- Excavators, 269.
- Excising forceps, 353.  
 saw, 353.
- Excision of naevi, 683.  
 of tongue, 574.
- Exciting causes of dentigerous cysts, 915.  
 of jaw luxation, 797.
- Excito-motor capacity of fifth nerve, 81.
- Exfoliation of dead tooth, 779.  
 of lamina of bone, 774.
- Exhaustion and dental caries, 173.
- Exostosis and subacute inflammatory tumors,  
 904.  
 of the fangs of teeth, 405.
- Exploring needle in diagnosis of bone dis-  
 eases, 904.  
 of odontocoele, 919.
- Exposed pulp in milk-teeth, 126.
- Exposed pulp in permanent teeth, 203.  
 treatment of, 203, 244.
- Exposing dental cavities, 280.
- Exposure of antral wall, 876.  
 of nerves, 871, 881.  
 auricularis magnus, 883.  
 great occipital, 883.  
 inferior maxillary, 872, 873.  
 infra-orbital, 881.  
 lingual, 883.  
 superior maxillary, 874, 876, 878.
- Expression, muscles of, 51.  
 of primary shock, 514.  
 of tongue in disease, 549.
- Exsection of nerves, 871.  
 Carnochan's operation, 876.  
 Garretson's operation, 872, 874, 878.  
 Langenbeck's operation, 876.  
 Pancoast's operation, 876.  
 of inferior maxilla, 823.  
 of the maxillary bones, 816.  
 author's operation for, 826.  
 history of, 816.  
 Horner's operation for, 817.  
 instruments used for, 819.
- Extension finger, McQuillen's, 295.  
 Taft's, 295.
- External lateral ligament of lower jaw, 68.
- Extirpation of tonsil gland, 543.  
 by use of London paste, 539.  
 Cheever's operation, 543.  
 tonsillotomy, 541.  
 Billing's tonsillotome, 542.  
 Kolbe's tonsillotome, 542.  
 Physick's tonsillotome, 541.  
 use of bistoury for, 542.
- Extra-articular ankylosis, 841.
- Extraction of teeth, 384.  
 forceps used for, 486.  
 indication for operation, 384.  
 of tooth-roots, 400.
- Extractum elateri in inflammation, 989.
- Eye-teeth, 89.  
 and caries, 159.
- F.
- Face, anatomy of, 25.  
 diseases of, 467.  
 angioma of, 680.  
 anidrosis, 677.  
 arterial tumors, 680.  
 callositas, 667.  
 chloasma, 669.  
 chromidrosis, 677.  
 comedo, 674.  
 cornu cutaneum, 667.  
 dermatolysis, 670.  
 elephantiasis, 671.  
 framboesia, 672.  
 hyperidrosis, 676.  
 ichthyosis, 673.  
 keloid, 677.  
 lichen pilaris, 668.  
 lupus erythematosus, 693.  
 vulgaris, 694.  
 maculae, 680.  
 milium, 674.  
 molluscum fibrosum, 678.



- Face, diseases of: mollusum sebaceum, 675.  
     morphœa, 672.  
     nævus pigmentosus, 668.  
         pilosus, 669.  
         vasculosus, 680.  
     parasites, 690.  
     port-wine stain, 683.  
     rhino-scleroma, 679.  
     scleroderma, 670.  
     scrofuloderma, 688.  
     sebaceous tumors, 675.  
     seborrhœa, 674.  
     sudamina, 677.  
     syphiloderma, 689.  
     tinea circinata, 691.  
         sycosis, 691.  
     unilateral atrophy, 671.  
     verruca, 673.  
     vitiligo, 668.  
     xanthoma, 679.  
     diseases of lower jaw, 34.  
         muscles of, 51.  
         nerves of, 57.  
 Faces of molar teeth, 156.  
 Facial artery, 53.  
     hypertrophy, 909.  
     marks, 680.  
     nerves, 57.  
     syphilitic tuberculosis, 689.  
     veins, 55.  
 Facing amalgam, 304.  
 Facings of plastics, 364.  
     of porcelain, 363.  
 False bites, 425.  
     bottomed trays, 461.  
     joint in ankylosis, 856.  
     occlusion a cause of periodontitis, 221.  
 Farrar's correcting apparatus, 379.  
 Fascia of parotid gland, 65.  
 Fat and flour, 155.  
 Fatty tumors of tongue, 511.  
 Febrifuges in angina, 108.  
 Fergusson's incisions in jaw exsections, 821.  
     operation for cleft palate, 623.  
 Ferruling tooth crowns and roots, 362.  
 Fetid discharges depending on tooth abscess, 645.  
 Feter in mercurial disease, 786.  
 Fever in phosphor-necrosis, 788.  
     irritative, 110.  
 Fibro-calcareous stroma of dentine, 83.  
     plastic tumors of Lebert, 938.  
     recurring tumors, 938.  
     serum, 888.  
 Fibromata, 938.  
     diagnosis of, 938.  
 Fibrous polypus, 641.  
 Fifth pair of nerves, 69.  
     function of, 80.  
 Figure-of-8 tie, 725.  
     manner of making, 725.  
 Files, 274.  
     as prophylactic and curative, 182.  
     carriers, 277.  
     finishing, 342.  
     Forbes' carrier, 278.  
     Line's carrier, 278.  
     Miller's carrier, 279.  
     objections to use of, 185.  
 Filiform papillæ of tongue, 62.  
 Filing in dental caries, 183.  
     in pivoting operations, 354.  
 Filling lower teeth, 336.  
     in tooth extraction, 393.  
     over exposed tooth-pulp, 244.  
     pulp-canals, 241.  
     teeth, 320.  
         with amalgam, 303.  
         with gold, 319.  
         with cohesive gold, 326.  
         with non-cohesive gold, 320.  
         with gutta-percha, 312.  
         with oxychloride of zinc, 315.  
         with tin, 318.  
         with plastic, 318.  
         with zinc phosphate, 317.  
 Filth in tetanus, 835.  
 Finishing approximal fillings, 342.  
     files, 342, 343.  
     plugs, 341.  
     stones, 344.  
     vulcanite plates, 434.  
 First teeth, 87.  
 Fish-bones in pharynx, 609.  
 Fish-hook in throat, 609.  
 Fish-skin disease, 673.  
 Fish-tail screw, 382.  
 Fissures and cracks of tongue, 551.  
     of the hard palate, 614.  
 Fistula, salivary, 760.  
     Agnew's operation for, 761.  
     author's operation for, 762.  
     common treatment of, 761.  
     Horner's cure for, 761.  
     illustrative case of, 761.  
 Fixation lines on artificial denture, 424.  
     of masks to face, 473.  
     of plates to mouth, 421.  
 Flagg's method of pivoting teeth, 358.  
     tongue-holder, 293.  
     zinc phosphate, 318.  
 Flaps in plastic operations, 740.  
 Flasking celluloid work, 440.  
     vulcanite work, 431.  
 Flasks for vulcanizing, 432-437.  
 Flat files, 276.  
     pigmentary nævi, 680.  
     warts, 673.  
 Fleischman's bursa, 597.  
 Floor of mouth, diseases of, 590.  
     of calculi in salivary ducts, 595.  
     of epithelioma, 596.  
     of lipoma, 592.  
     of nævi, 596.  
     of ranula, 590.  
 Flour, superfine, 155.  
     unbolted, 155.  
 Fluids, oral, 190.  
 Fly-blisters, 986.  
     in periodontitis, 222.  
 Fly-larvæ in sinuses, 657.  
 Foil carriers, 321.  
 Foils, cohesive, 326.  
     gold, 319.  
     soft, 320.  
     tin, 318.  
 Follicles of mucous membrane, 64.  
 Follicular inflammation, 497.  
     of pharynx, 604.  
 Fontanelle and rickets, 143.



- Food and dental caries, 147.  
 Foot lathe, 356.  
   sprayer, 413.  
 Foramen, mental, 28.  
 Foramina of milk-teeth, 98.  
 Forbes's chisels, 274.  
 Forceps for cutting bone, 822.  
   for excising operculum, 847.  
   for extracting teeth, 386.  
   for removing dead pulps, 239.  
 Foreign bodies in nasal associate sinuses, 653-656.  
   in nose a cause of ozæna, 644.  
   in pharynx, 608.  
   in Steno's duct, 763.  
   particles in face wounds, 512.  
 Forget's unique case of odontoma, 923.  
 Fork screw-driver, 360.  
 Formation of enamel, 94.  
 Forms of gutta-percha, 315.  
   of tongue-tie, 584.  
 Formula for amalgam, 303.  
   for aperient mineral water, 106, 493.  
   for antacid mouth-wash, 164.  
   for dental paste, 208.  
 Fossa, canine, 28.  
 Foul breath, 539.  
 Foundation cement, 317.  
 Fountain drip point, 280.  
 Four stages of staphylophary, 621.  
 Fracture in tooth extraction, 407.  
   in alveolar process, 802.  
   of maxillary bones, 802.  
   bandages used, 807.  
   Barton's bandage, 806.  
   Bean's splint, 809.  
   character of, as influenced by cause, 803.  
   comminuted, 805.  
   complicated, 802.  
   from tooth extraction, 400.  
   Garretson's bandage, 808.  
   Gibson's bandage, 807.  
   simple, 802.  
   Nasmith's splint, 808.  
   splints used, 806.  
   Sudduth's splint, 809.  
   treatment of, 806.  
   nasal bones, 658.  
   displacement of, 658.  
   gutta-percha splint, 658.  
   pasteboard splint, 658.  
 Fractured tooth-roots, 400.  
   extraction of, 400.  
   cutting forceps used for, 400.  
   Dubs's forceps used for, 403.  
   Hullihen's forceps used for, 403.  
   screw used for, 402.  
 Frænum epiglottidis, 58.  
 Frail teeth and oxychloride, 316.  
 Framboesia, 672.  
 Framework of pharynx, 602.  
 Frankel's nasal speculum, 655.  
 Freckles, 669.  
 Freezing the gums, 413.  
 Frog-face, 642.  
 Front tooth amalgam, 304.  
 Fruits and soft teeth, 173.  
 Fulcrum forceps, 399.  
 Fulness at base of forehead, 634.  
 Functional disorder in inflammation, 995.  
   tumors, 889.  
 Functions of dyscrasic children, 100.  
   of nose, 633.  
 Fungi and salivary calculus, 258.  
 Fungiform papillæ of tongue, 574.  
   warts, 673.  
 Fungoid scirrhus, 948.  
   tumors, 892.  
 Fungus hæmatodes in odontocoele, 920.  
 Furnace of vulcanite apparatus, 434.  
 Furred tongue, 549.  
 Furuncular epidemics and antrum, 757.  
 Fused teeth, 131.
- G.
- Gags in mouth operations, 629.  
   Elsberg's, 629.  
   Goodwillie's, 629.  
   Kolbe's, 628.  
   Whitehead's, 628.  
   Wood's, 629.  
 Galvanic cauterization in disease of tongue, 560.  
 Galvanization in scleroderma, 670.  
 Galvano-cauterant in treatment of nævi, 686.  
 Ganglia of fifth pair of nerves, 77.  
   Casserio's, 71-77.  
   lenticular, 77.  
   Meckel's, 79.  
   naso-palatine, 80.  
   ophthalmic, 77, 78.  
   otic, 80.  
   submaxillary, 80.  
 Gangræna oris, 492, 498.  
 Gangrene of gums, 493.  
   of pharynx, 604.  
 Garengeot's key, 399.  
   obturator, 462.  
 Gargle in angina, 107.  
   in chronic angina, 209.  
   in tonsillitis, 534.  
 Garretson's exsection of inferior maxilla, 823.  
   jaw bandage, 808.  
   operation for cleft palate, 623.  
   for exposure of maxillary nerve, 872-874, 875-877.  
   for salivary fistula, 762.  
 Gas and pus in dental pulp-cavities, 209.  
   nitrous oxide, 973.  
 Gates's tooth-crowns, 360.  
 Gauze and collodion in hare-lip, 722.  
 Gelatinoid polypus, 639.  
 Gemischte narkose, 978.  
 General indications in treatment of alveolar abscess, 226.  
   remarks on extraction of teeth, 407.  
   treatment of inflammation, 988.  
 Genial tubercles, 35.  
 Genioplasmic operations, 729.  
 Germ of tooth, 93.  
 German experience in necrosis, 793.  
   method of rhinoplasty, 659.  
 Germs of heterogeneous development, 130.  
 Gibson's jaw bandage, 807.  
 Gingivitis of pregnant women, 493.  
 Giralde on multiple cysts of antrum, 935.  
 Glairy mucus, 161.



- Glanders, 639.  
 Glands, salivary, 65.  
 Glandule buccales, 64.  
   labiales, 64.  
 Glandular salivary calculi, 260.  
 Glenoid cavity of temporal bone, 66.  
 Glistening gum, 102.  
 Glossitis, 563.  
 Glue paste in mask-making, 473.  
 Goa powder ointment, 692.  
 Gold, 319.  
   as a conductor, 244.  
   as a filling material, 319.  
   as a root-filling, 242.  
   as a therapeutic agent, 187.  
   blocks, 319.  
   cohesive, 319.  
   cylinders, 319.  
   in amalgam, 305.  
   in dental therapeutics, 187.  
   in root-filling, 242.  
   mats, 349.  
   pellets, 319.  
   ribbons, 319.  
   soft, 319.  
   twists, 319.  
 Gomphosis, articulation, 26.  
 Gonorrhoea of nares, 656.  
   treatment of, 656.  
 Gooch's capula, 640.  
 Good on aphthæ, 502.  
 Goodwillie's mouth-stretcher, 823.  
 Gout and neuralgia, 856.  
   in pulpitis, 207.  
   in tonsillitis, 539.  
 Grafting tooth-crown, 361.  
 Graham's respirator, 789.  
 Granular character of dental germ, 211.  
   hypertrophy of tongue, 572.  
 Granulations in chronic angina, 107.  
 Granules of dentine in pulp, 211.  
 Grapes and dental caries, 173.  
 Grave's neuralgia plaster, 868.  
 Grayish-white tumors of gum, 892.  
 Grinding face cavities, 282.  
   of pivot tooth, 355.  
 Groove for passage of facial artery, 30.  
   infra-orbital, 28.  
   primitive dental, 93.  
 Group of facial muscles, 51.  
 Growth of bone around tooth-germs, 93.  
   of teeth-roots, 95.  
 Guilford on use of cutting burs, 200.  
 Guillois's cement, 318.  
 Gum arabic in chronic angina, 109.  
   boil, 225.  
   camphor in sensitive dentine, 200.  
 Gumma of forehead, 689.  
   of nose, 651.  
 Gummatous tumors of tongue, 551.  
 Gums, 475.  
   abscess of, 225.  
   anatomical character of, 475.  
   congenital union of, 488.  
   diseases of, 475.  
   effect upon of chloride of zinc, 482.  
     of creasote, 482.  
     of dead or loose teeth, 475.  
     of improperly inserted artificial den-  
     tures, 475.  
 Gums, effect upon of over-crowded dental  
   arch, 481.  
   of periodontitis, 477.  
   of scorbutus, 479.  
   of syphilis, 475.  
   of tartar, 475.  
   of the mercurial impression, 477.  
   of the use of improper dentifrices  
     and brushes, 481.  
   freezing in tooth extraction, 414.  
   gangrene of, 475.  
   healthy state of, 475.  
   inflammation of, 475.  
   lancing, 103.  
   lead-line upon, 490.  
   oidium albicans upon, 494.  
   wedgers, 300.  
 Gunshot wounds in jaw fractures, 806, 812.  
   of pharynx, 607.  
 Gustatory nerve, 76.  
 Gutta-percha, 312.  
   as an impression material, 420.  
   as a tooth-filling material, 312.  
   brittleness of, 313.  
   combinations with, 314.  
   forms of in market, 315.  
   Hill's stopping, 314.  
   in dental therapeutics, 188.  
   in fracture of nasal bones, 658.  
   in jaw fractures, 814.  
   instruments used for working, 314.  
   porosity of, 313.  
   red, 313.  
   stickiness in, 313.  
   test of quality, 313.  
   white, 313.  
 Guy's hospital neuralgic liniment, 869.  
 Gymnastics of the teeth, 173.
- ## H.
- Hæmatin a colorizer of dentine, 250.  
 Hair moles, 669.  
 Half-arches, 59.  
 Half-dentures, 423.  
 Half-erupted wisdom-teeth, 781.  
 Hainsby's compressor, 715.  
 Halitus of tooth sac, 94.  
 Hamilton on jaw fractures, 812.  
 Hamular process of sphenoid bone, 46.  
   and tenotomy of tensor palati muscle, 46.  
 Hand lathes, 355.  
   mallet, 333.  
   pieces used with dental engine, 273.  
   sprayer, 412.  
 Hard palate, 50.  
   necrosis of, 782.  
   stone, 344.  
 Hare-lip, 711.  
   condition of patient, 711.  
   Hainsby's compressor for, 715.  
   illustrative operation, 711.  
   mode of operating, 711.  
   time suited for operation, 711.  
 Harmless dental obtundors, 200.  
 Harris's tooth-forceps, 391.  
 Hatchet excavators, 269.  
 Haversian canals in cementum, 85.  
 Hawes' duct compressor, 294.



- Hawk-bill tooth-forceps, 387.  
 Hay, analysis of, 157.  
 Head, human, 26.  
 Healing wounds, 517.  
     approximating, 517.  
     by first intention, 517.  
     by granulation, 517.  
     by ligature materials, 517.  
     by use of plasters, 518.  
 Health and dental organism, 176.  
     of child in relation with operation for  
         hare-lip, 711.  
     relation of vulcanite, 435.  
 Healthy saliva, 178, 191.  
 Heart-colored tumors of jaw, 942.  
 Heart-diseases and chloroform, 970.  
 Heat in inflammation, 994.  
 Heated needles in treatment of nævi, 687.  
 Heavy foils, 326.  
 Hemorrhage after lancing gums, 103.  
     bayberry powder in, 103.  
     erigeron canadense in, 104, 409.  
     Monsel's solution in, 104.  
     in tooth extraction, 408.  
         alum water in, 410.  
         bayberry powder in, 410.  
     dependent on anæmia, 409.  
         on purpura, 409.  
         on typhoid condition, 409.  
     medicinal agents used for, 410.  
     nitrate of silver in, 411.  
     opium and lead in, 411.  
     packing alveolus, 411.  
     in exsection of jaw, 820.  
     in facial wounds, 512.  
         arterial, 512.  
         capillary, 512.  
         venous, 512.  
     treatment by acupressure, 513.  
         cold water, 514.  
         knotted bandage, 513.  
         ligation, 573, 741.  
         medicaments, 513.  
         pad and bandage, 513.  
     in tonsillotomy, 543.  
     nasal, 634.  
 Herbst's plan for retaining replanted teeth,  
     252.  
 Herd's dental forceps, 400.  
 Hereditary dental caries, 175.  
     predisposition and spasms, 115.  
     syphilis, 146.  
 Herpetic tonsillitis, 537.  
 Herrick's fountain drip-point, 280.  
 Heteroclitic cells, 887.  
 Heterogeneous tooth-germs, 130.  
 Heyfelder's operation for removal of both  
     superior maxillæ, 821.  
 Hey's saw, 828.  
 Hexagonal fibres of enamel, 84.  
 Hickman's rubber dam clamps, 299.  
 Hill's stopping, 314.  
 Hindostan stone, 344.  
 Histogenesis of epithelioma, 699.  
 Histoid mixed tumors, 948.  
 Histological appearance of myeloid growths,  
     942.  
     distinctions in tumors, 889.  
 History in tumor diagnosis, 885.  
     of phosphor-necrosis, 788.  
 History of rachitis, 140.  
 Hoe excavators, 269.  
 Holding jaw-splints in position, 807.  
 Holes in the palate, 627.  
     in the teeth, 135.  
 Holmes on tetanus, 837.  
 Homologous tumors, 885.  
 Horn or Roonhuysen's lip operation, 731.  
 Horne and Thornwaite's refrigerating appa-  
     ratus, 411.  
 Horner on jaw operations, 817.  
     on fistule operations, 761.  
 Horny excrescences of skin, 667.  
 Hospitals and aphtha, 499.  
 Hot and moist applications in neuralgia, 867.  
 Hot foot-baths in periodontitis, 222.  
     in shock, 516.  
 Hot-air syringe, 302.  
 Hullihen's screw forceps, 403.  
 Hulme on calcification of dental tissue, 215.  
 Humoral origin of tetanus, 834.  
 Humphrey on tumor softening, 947.  
 Hunter's transference of teeth, 257.  
 Hutchinson's syphilitic teeth, 145.  
     tooth forceps, 396.  
 Hydatid cysts, 936.  
 Hydrastis canadensis, 703.  
 Hydrate of chloral in periodontitis, 223.  
 Hydrochloric acid in aphthæ, 509.  
     in saliva, 195.  
     in typhoid condition, 161.  
 Hydrops antri, 75.  
 Hygromata of neck, 597.  
 Hygrometric character of gelatinoid polypus,  
     640.  
 Hyoid bone, 48.  
     and tongue, 61.  
     cornuæ of, 48.  
     muscles of, 48.  
 Hyoseyamus in dental irritation, 119.  
 Hyperdrosis, 676.  
 Hyperostosis, 909.  
 Hypertrophic tumors, 889.  
 Hypertrophy caused by specific conditions,  
     911.  
     of gum structure, 484.  
     of maxillary tuberosity, 914.  
     of tongue, 572.  
     of tonsil glands, 538.  
     of uvula, 587.  
 Hypodermatic medication, 978, 995.  
 Hysteria and chloroform, 969.  
  

I.

 Ice-cream in angina, 108.  
     in pulpitis, 206.  
 Ice-water in epistaxis, 635.  
 Ichthyosis, 673.  
 Idiopathic glossitis, 563.  
     trismus, 850.  
 Idiosyncrasies in ether, 962.  
 Idiosyncrasy in accident, 515.  
 Ill odor in necrosis, 786.  
 Illumination in rhinoscopy, 611, 654.  
 Illustration in amalgam, use of, 306.  
     in contouring, 336.  
         after Dorr, 339.  
         after Webb, 337.



- Illustration in contouring, after Weld, 338.  
 in cystoma, 594, 917.  
 in diagnosis of tumors, 885.  
 in encephaloid disease, 951.  
 in epulic operations, 898.  
 in exsection of lower jaw, 826, 827.  
   of upper jaw, 819.  
 in filing, 185.  
 in gum lancing, 103.  
 in hygroma, 597.  
 in inflammation, 980.  
 in jaw fracture, 802.  
 in orthodontia, 368.  
 in phosphor-necrosis, 791-795.  
 in ranula, 594.  
 in rhinoscopy, 612.  
 of alveolar abscess, 227.  
 of cement and dentine, 83.  
 of deciduous teeth, 93.  
 of dental anomalies, 131.  
   nerves, 84.  
   pulp, 84.  
 of dentinal tubules, 84.  
 of diminishing pulp-cavities, 213.  
 of enamel columns, 85.  
 of enlarged tonsil glands, 538.  
 of epulides, 898.  
 of face wounds, 512, 706, 733.  
 of horns of face, 692.  
 of interglobular spaces, 86.  
 of lip-operations, 713.  
 of neuralgic lesions, 860.  
 of obturators, 448.  
 of osseous caries, 771.  
 of permanent teeth, 88.  
 of polypi operations, 642-662.  
 of sarcomata, 948.  
 of scirrhus, 949.  
 of tooth development, 95.  
   pivoting, 350.  
 of tumors, 884.  
 of use of surgical engine, 827, 872, 874, 878.  
 of vascular tumors, 682.  
 of vela, 463.  
 Imitation coral, 318.  
 Immediate bleaching of teeth, 248.  
   disease of facial skin, 667.  
     anidrosis, 677.  
     atrophy, 671.  
     callositas, 667.  
     chloasma, 669.  
     chromidrosis, 677.  
     comedo, 674.  
     cornu cutaneum, 667.  
     dermatolysis, 670.  
     elephantiasis, 671.  
     framboesia, 672.  
     hyperidrosis, 676.  
     ichthyosis, 673.  
     keloid, 677.  
     lentigo, 669.  
     lichen pilaris, 668.  
     miliun, 674.  
     molluscum fibrosum, 678.  
     sebaceum, 675.  
     morphœa, 677.  
     nævus pigmentosus, 668.  
       pilosus, 669.  
       vasculosus, 680.  
 Immediate disease of facial skin: rhino-  
   scleroma, 679.  
   scleroderma, 670.  
   sebaceous tumors, 675.  
   sudamina, 677.  
   telangiectasis, 680.  
   verruca, 673.  
   vitiligo, 668.  
   xanthoma, 679.  
 Immobile tongue, 574.  
 Impaction of wisdom-tooth, 781.  
 Impaired nutrition and purulency, 755.  
 Imperfect denture, 159.  
 Imperfectly treated jaw fractures, 803.  
 Imperforate nostril, 656.  
   use of bougies in, 656.  
   pharynx, 607.  
 Impression materials, 417.  
   gutta-percha, 420.  
   modelling compound, 420.  
   plaster of Paris, 418.  
   wax, 417.  
   trays, 416.  
 Impressions for artificial teeth, 416.  
 Imprisoned teeth and abscess, 234.  
 Improper union of metals as a cause of pul-  
   pitis, 206.  
 Incipient disease on approximal faces of  
   teeth, 184.  
 Incising tooth forceps, 401.  
 Incisions in jaw exsections, 819.  
   in treatment of ulcers, 783.  
   of tongue, 551.  
 Incisive fossa, 29.  
 Incisor forceps, 386.  
   teeth, 87.  
 Inclined planes in dentistry, 184.  
 Incomplete luxation of jaw, 797.  
 Increase of cemental tissue, 904.  
 Incubative state of rickets, 140.  
 Indian corn, analysis of, 156.  
   method of rhinoplasty, 659.  
 India-rubber in tooth separation, 286.  
   ring as an anti-hemorrhagic, 104.  
 Indications for the extraction of teeth, 384.  
   in treatment of dental caries, 135, 177,  
     187, 190.  
   to be met by an artificial denture, 415.  
 Induration of tongue, 551.  
 Infant and adult teeth, 87, 88.  
 Infantile disease and first dentition, 100.  
   eruptions, 120.  
   syphilitic coryza, 633.  
   trismus, 839.  
 Inferior dental artery, 54.  
   nerve, 77.  
   labial artery, 53.  
   maxillary bone, 34.  
   nerve, 75.  
     Garretson's operation for ex-  
       section of, 872, 874, 878.  
   triangle of neck, 745.  
   turbinate bone, 41.  
 Infiltrated epithelioma, 698.  
 Infiltrating lupus, 694.  
 Inflammation, 980.  
   active congestion, 983.  
   and sensitive dentine, 202.  
   definition of, 980.  
   diagrams of expression of, 981, 982, 983.



- Inflammation, functional disorder, 994.  
 heat, 994.  
 of local import, 983.  
 of pulp, 203.  
 of systemic import, 984.  
 of throat, 108.  
 pain, 994.  
 phenomena associated with, 983.  
 redness, 994.  
 relation of irritant with, 980.  
 repair, 997.  
 simple vascular excitement, 983.  
 stagnation, 983.  
 suppuration, 983.  
 treatment of, 984.
- Inflammatory tumefaction of maxilla, 907.  
 tumors, 887.
- Infra-orbital canal, 28.  
 foramen, 28.  
 groove, 28.
- Infusoria and diarrhoea, 112.  
 and tartar, 266.
- Inhaler for ether, 957.  
 for nitrous oxide, 976.
- Injections in salivary fistule, 761.  
 of nævi, 685.
- Inner tracheal tube, 547.
- Innervation in dentition, 113.
- Innutrio-ossium, 140.
- Inosculation of fifth nerve, 81.
- Insanity and chloroform, 972.
- Insect bites of tongue, 570.
- Inside of nose, 631.
- Instruments for extracting teeth, 386.  
 for raising soft tissue from hard palate, 628.  
 for removing tartar, 265.  
 for tooth-plugging, 269.  
 for treatment of cicatrix, 852.  
 for working amalgam, 308.  
 cohesive gold, 327.  
 gutta-percha, 314.  
 used in exsection of upper jaw, 819.
- Interarticular fibro-cartilage of lower jaw, 67.
- Interdental splint, 814.
- Interdigitation in gold filling, 326.
- Interference of hearing in hypertrophy of tonsil, 583.
- Interglobular spaces, 86.
- Internal lateral ligament, 35.  
 maxillary artery, 54.  
 vein, 56.
- Intestinal worms, 113.
- Intestines of infants, 113.
- Intra-cranial disease and polypi, 641.
- Introduction of gutta-percha into teeth, 314.
- Investing celluloid work, 440.  
 vulcanite work, 431.
- Iodide of potassium as an antiplastic, 555.  
 as an arterial sedative, 555.  
 in stomatitis, 105.  
 of zinc in hypertrophy of tonsil, 539.
- Iodine as a local anæsthetic, 412.  
 as a pulp-devitalizer, 126.  
 in antral disease, 754.  
 in lupus, 696.  
 in replantation, 253.
- Iodoform in treatment of epithelial cancer, 709.
- Ipecacuanha in spasms, 116.
- Iron and quinia in angina, 110.  
 in rickets, 144.  
 use of, in epithelioma, 703.
- Irregularities of the teeth, 366.
- Irritability of mouth, 416.
- Irritable systems and dead teeth, 777.  
 tooth-root, 241.
- Irritation and dentition, 100.  
 the cause of inflammation, 980.
- Irritative fever, 101, 110.
- Italian method of rhinoplasty, 659.
- Ivory exostosis, 904.  
 of teeth, 83.
- J.
- Jack's enamel cutters, 274.  
 matrix, 324.
- Jack-screw, 378.
- Jagged bodies in œsophagus, 608.
- Jameson and exsection of jaw, 816.
- Japanese bibulous paper, 301.
- Jarvis's separators, 287.
- Jaw articulation, 66.  
 dilators, 851.  
 Kolbe's instrument, 851.  
 Scultetus's wedge, 852.  
 exsection, 816.  
 upper, 30.
- Jones's fulcrum forceps, 399.
- Jourdain and exsection of jaw, 816.
- Jugular vein pneumogastric nerve, 745.
- Jujubes in chronic angina, 109.
- K.
- Kane on cold as a cause of tetanus, 834.
- Keloid, 677.
- Kentish ointment in burns, 532.
- Keratitis in infants, 147.
- Key instruments in tooth extraction, 397.
- Kinds of dental plates, 421.  
 of tongue-tie, 584.  
 of tumors, 884.
- Kingsley's artificial vela, 464.  
 correction of dental irregularities, 377.
- Kino and catechu in hemorrhage, 411.
- Kirby's neuralgic liniment, 867.
- Knife in the treatment of ranula, 591.
- Knife-edge circular-saw, 829.
- Knotted bandage in facial hemorrhage, 513.
- Kolbe's jaw dilator, 851.  
 powder insufflator, 640.  
 tonsillotome, 541.
- Koster's tubes and cylinders, 699.
- L.
- Labarraque's solution, 249.
- Lacerated foramen, 45.
- Laceration of gum in tooth extraction, 407.
- Lachrymal bone, 48.  
 canal, 48.  
 groove, 27.  
 nerve, 72.  
 tubercle, 48.
- Lactic acid and teeth, 192.  
 and the absence of phosphates, 144.



- Lactucarium in irritation, 119.  
 Laminae exostosis, 904.  
     of bone, exfoliation of, 782.  
     of sarcomatous tumors, 940.  
 Lanceolate cells, 942.  
 Lancets, 986.  
     bistoury, 986.  
     spring, 987.  
     thumb, 987.  
 Lancing gums in periodontitis, 222.  
     infants' gums, 103.  
     preliminary to tooth-extraction, 407.  
 Langenbeck's operation for polypus, 642.  
     osteo-plastic resection, 843.  
     section of maxillary nerve, 876.  
 Lanonier and staphyloraphy, 620.  
 Laryngotomy, 545.  
 Larynx, view of, 545.  
 Late dentitions, 100.  
 Lateral region of skull, 49.  
     view of neres, 632.  
 Lateralis nasi artery, 54.  
 Lathes, foot, 356.  
     hand, 355.  
 Latitude in treatment of epulides, 892.  
 Laying open wounds in tetanus, 834.  
 Laxity of articular connections, 798.  
 Lead and opium in hemorrhage, 409, 514.  
     as a canal-filling, 244.  
     for modelling oral plates, 421.  
     water and laudanum in periodontitis, 223.  
     wire suture, 517.  
 Leeches in angina, 107.  
     periodontitis, 223.  
     phosphor-necrosis, 792.  
 Leeching, 986.  
 Leidillot's lip operation, 736.  
 Lemon juice and the teeth, 173.  
 Lemonade in irritative fever, 111.  
 Lenticular ganglion, 77.  
 Lentigo, 669.  
 Leptothrix filaments, 165.  
 Lesions of first dentition, 100.  
 Levator palati muscle, 618.  
 Lewis's double V in hare-lip, 719.  
 Liabilities of teeth to caries, 158.  
 Lichen pilaris, 121, 668.  
     treatment of, 668.  
 Ligation in arterial hemorrhage, 513.  
     of arteries, 741.  
         carotid, 74.  
             in excision of jaw, 820.  
         facial, 741.  
         lingual, 743.  
         occipital, 743.  
         temporal, 743.  
 Ligatures in orthodontia, 372.  
     in wounds of face, 517.  
 Likeness of teeth with age, 87, 427.  
 Limbosa articulation, 26.  
 Lime and discolored teeth, 249.  
     in rickets, 144.  
 Linear cicatrix in hare-lip, 717.  
 Lingua vitula, 578.  
 Lingual artery, 63.  
     nerve, 76.  
     neuralgia, 568.  
 Lion forceps, 829.  
 Lip and cheeks, 726.  
     Lip and cheeks, operations upon, 726.  
         retractors, 824.  
     Lipoma simulating ranula, 592.  
     Liquefied nitrous oxide, 975.  
     Liquid soap in seborrhœa, 674.  
     Liston's lip operation, 732.  
         museum, fibrous tumors in, 945.  
     Litmus paper, 180.  
     Lobelia in spasms, 115.  
     Lobules of salivary glands, 65.  
     Local anæsthesia in tooth extraction, 411.  
         caries, 177.  
         contamination a cause of necrosis, 782.  
         diseases of tongue, 550.  
         expression of alveolar abscess, 225.  
         features of dental abscess, 225.  
         irritation the chief cause of exostosis, 904.  
         remedies in neuralgia, 867.  
         treatment of dental hemorrhage, 410.  
             of inflammation, 984.  
             of lupus, 696.  
         use of ether in neuralgia, 867.  
     Localized stomatitis, 102.  
     Location of ganglia of fifth nerve, 77.  
         of Casserio's, 71.  
         of Meckel's, 79.  
         of naso-palatine, 80.  
         of ophthalmic, 77, 78.  
         of otic, 80.  
         of spheno-palatine, 79.  
     Lockjaw in adults, 834.  
         in infants, 838.  
     London hospital anodyne liniment, 864.  
         paste, 511.  
         use of in sensitive dentine, 200.  
     Loop matrices, 324.  
     Loops and bands in orthodontia, 380.  
     Loose teeth in relation with gums, 481.  
         tooth-structure and discoloration, 248.  
     Lorenser's statistics in phosphor-necrosis, 788.  
     Loss of substance from nose, 664.  
         of translucency in teeth, 210, 248.  
     Lower bicuspid and canine tooth forceps, 390.  
         cow-horn forceps, 395.  
         incisor and bicuspid tooth forceps, 387.  
         jaw, anatomy of, 34.  
         luxation of, 797.  
         molar tooth forceps, 396.  
     Lung disease and chloroform, 970.  
     Lupus, 693.  
         erythematous, 693.  
         vulgaris, 694.  
     Luxation of inferior maxilla, 411, 797.  
         forms, 797.  
         from tooth-extraction, 411.  
         treatment of, 800.  
     Lymph, 139, 888, 997.  
         and pus, 755.  
         the vis vitæ, 888.  
         tumors, 889.  
     Lymphangitis, 137.

## M.

- Machine-cut burs, 201.  
 Mack's screws in pivoting, 338.  
     in plugging, 336.



- Macula, 680.  
 Maggots in sinuses, 657.  
   salt water in treatment of, 657.  
 Magitot's experiments, 192.  
 Magnet, use of, in dentistry, 244.  
 Magnified dental pulp, 84.  
 Magnifying mouth mirror, 281.  
 Maisonneuve's zinc arrows, 560.  
 Making model of mouth, 420.  
   suction cavities, 422.  
   zinc cast of mouth, 445.  
 Malaise in tetanus, 834.  
 Malar bone, 47.  
   borders of, 47.  
   likened to pads, 47.  
   process of, 47.  
   shape of, 47.  
   surface of, 47.  
 Malarial poisoning and tongue, 550.  
 Malarticulation, 423.  
   a cause of alveolar abscess, 221.  
 Mal-eruption of the wisdom-teeth, 781.  
 Malgaigne's ellipse in hare-lip, 719.  
 Malic acid and the teeth, 173.  
 Malignancy of encephaloma, 950.  
 Malignant epulides, 897.  
 Mallets, plugging, 333.  
   automatic, 339.  
   Bonwill's, 341.  
   Buckingham's, 341.  
   electro-magnetic, 340.  
   Holmes's, 341.  
   lead, 333.  
   lignum-vitæ, 333.  
 Mania-a-potu and chloroform, 972.  
 Manipulation of impression trays, 418.  
   with rhinoscope, 612.  
 Manner of extracting teeth, 384.  
   of operating in hare-lip, 713.  
   of pivoting teeth, 350.  
 Manufacture of amalgam, 303.  
   of artificial denture, 423.  
   of obturators, 442.  
 Margetson's illuminator, 612.  
 Marion Sims on tetanus, 840.  
 Marrow-like tumors, 937.  
 Marshall Webb's pivot-tooth, 360.  
 Masks, facial, 471.  
 Massage, 993.  
   in neuralgia, 870.  
 Masseteric nerve, 76.  
 Match-stick for testing fit of pivot-tooth and root, 350.  
 Materials for dental impressions, 417.  
   for amalgam, 303.  
   for cement plombe, 318.  
   for enamel stopping, 318.  
   for filling teeth, 303.  
   for gold, 319.  
   for gutta-percha, 312.  
   for Hill's stopping, 314.  
   for oxychlorides, 315.  
   for plastic tin, 318.  
   for test plugs, 241.  
   for tin, 318.  
   for zinc phosphates, 318.  
 Matrices in tooth-filling, 324.  
 Mats in tooth-filling, 321.  
 Maxillary bone, inferior, 34.  
   alveolar process of, 34.  
   Maxillary bone, angle at varying ages, 34.  
   caries of, 764.  
   treatment of, 768.  
   condyloid process of, 34.  
   coronoid process of, 34.  
   external oblique line of, 35.  
   luxation of, 35, 411, 797.  
   mental foramen of, 34.  
   mylo-hyoid ridge of, 35.  
   necrosis of, 774.  
   rami of, 35.  
   semi-lunar notch of, 35.  
   shape of, 34.  
   sublingual fossa of, 35.  
   submaxillary fossa of, 35.  
   superior, 29.  
   symphysis of, 35.  
   anterior palatal canal, 33.  
   articulations of, 34.  
   crest for turbinated bones, 33.  
   lachrymal tubercle, 32.  
   muscles associated with, 34.  
   orbital surface of, 32.  
   orifice of antrum, 33.  
   palate process of, 32.  
   posterior dental groove, 32.  
   processes of, 30.  
   shape of, 30.  
   sinus of, 30.  
   tuberosity of, 28.  
   zygomatic surface of, 32.  
 Maxillary sinus, diseases of, 747.  
   tooth-hills in, 30.  
 Maynard's forceps, 393.  
 McGrath's obturator, 448.  
 McLean's button, 715.  
 McQuillen's correcting apparatus, 372.  
   extension finger, 295.  
 Means of dryness in dental operations, 293.  
   clamps, use of, 298.  
   Fisk's saliva ejector, 295.  
   Flagg's tongue holder, 293.  
   hot air syringe, 302.  
   McQuillen's extension finger, 295.  
   Morrison's duct compressor, 294.  
   Rich's duct compressor, 296.  
   rubber dam, 297.  
   saliva pump, 295.  
   Taft's thimble, 295.  
   use of napkins, 293.  
 Measles, necrosis from, 787.  
 Measure of mouth, 416.  
 Meatuses of nose, 40.  
 Mechanical dentistry, 415.  
   destructives and the teeth, 173.  
   disease of antrum, 759.  
   treatment of breaks in hard palate, 784.  
   of dental caries, 202.  
   of hemorrhage, 411.  
 Mechanico-dental lesions in trismus, 841.  
 Mechanism of speech, 467.  
 Meckel's ganglion, 79.  
 Mediate diseases of facial skin, 667.  
   cancer, 667.  
   exanthemata, 667.  
   scrofula, 667.  
   syphilis, 667.  
 Medical relations of vulcanite, 435.  
 Medication in typhoid fever, 162.  
   of sensitive dentine, 198.



- Medicinal agents in hemorrhage, 410.  
 Medicines and articles of food, 172.  
   and dental caries, 160.  
   used in hypodermatic injections, 978.  
 Medulla oblongata in tetanus, 835.  
 Meigs's ether-cure in neuralgia, 867.  
 Meningocele, 936.  
 Mental foramen, 28.  
 Mento-dental splint, 810.  
   occipital sling, 376.  
 Mercurial diathesis and antrum, 758.  
   enlargement of tongue, 556.  
   necrosis, 785.  
   ulcer of tongue, 556.  
   ulitis, 477.  
 Mercurio-syphilis, 137.  
   syphilitic cachexia and dentition, 102.  
 Mercury and dental caries, 172.  
   and the dentitional period, 786.  
   in alloys, 306.  
   in inflammation, 993.  
   in syphilis of tongue, 552.  
 Merry's drill, 271.  
 Metal basis in celluloid gum, 441.  
   forced through tooth foramen a cause of  
   abscess, 243.  
   pivots, 356.  
 Metallic taste in mouth, 785.  
 Metals subject to quicksilver, 312.  
 Metastatic disease of tongue, 571.  
   neuralgia, 855.  
 Metz's nasal reflector, 654.  
 Micrococci, 165.  
 Microscopic analysis of caries, 166.  
   of the odontomata, 923.  
   anatomy of tooth, 83.  
   appearance of myeloid, 942.  
   of encephaloid, 953.  
   cells of hard cancer, 559.  
   character of epithelial cancer, 698, 710.  
 Milium, 674.  
 Milk, analysis of, 150.  
   and infantile diarrhoea, 112.  
   in chronic inflammation, 993.  
   in saliva, 191.  
 Milk-teeth, 87.  
   absorption of roots of, 98.  
   destiny of, 98.  
   foramina of, 98.  
 Miller on caries of bone, 769.  
   on prevention and treatment of osseous  
   caries, 768.  
 Mindererus in angina, 107.  
 Mineral acids in syphilitic ulceration, 783.  
   water, artificial, 106, 493.  
   for costiveness, 106.  
 Mirror of Anagnostakis, 281.  
   used with rubber dam, 297.  
 Misplaced teeth, 234, 889.  
 Mistakes in tooth-extraction, 251.  
 Mixed narcosis, 978.  
 Mixing amalgams, 306.  
 Mode of operating in hare-lip, 711.  
 Modelling compound, 420.  
 Models for teeth, 420.  
 Modification on impression trays, 417.  
 Modified excavators, 288.  
 Moist dentine, 181.  
 Moisture and tooth-filling, 293.  
 Molar forceps, 391.  
 Molar teeth, 90.  
 Molluscum fibrosum, 678.  
   sebaceum, 675.  
 Monsel's salts in hemorrhage, 513.  
   solution of iron as a pulp-devitalizer, 126.  
 Morgan's lip operation, 731.  
 Morning sickness in phosphor-necrosis, 791.  
 Morphia and sensitive dentine, 203.  
   hypodermatic use of, 995.  
 Morphœa, 672.  
 Morrison's compressor, 294.  
 Mother-mark, 680.  
 Motor cord of fifth nerve, 75.  
 Motores-uvulæ muscle, 51.  
 Mouth, anatomy of, 50.  
   as an archway, 50.  
   central pendulum of, 50.  
   commencement of alimentary canal, 50.  
   fluids of, 51.  
   lips as boundaries of, 52.  
   models, 420.  
   offices of, 50.  
   roof of, 50, 58.  
   sectional expression of, 58.  
   stretchers, 823.  
   in atresia oris, 727.  
   veil of, 50.  
   vestibule of, 50.  
   washes, 163.  
 Mucin and diarrhoea, 112.  
 Muciparous cysts in floor of mouth, 593.  
 Mucoid engorgement of antrum, 754.  
 Mucio-musculo-aponeurotic nature of phar-  
 ynx, 602.  
 Mucous deposits, 161.  
   glands, 64.  
   membrane of mouth, 50, 64.  
 Mucus, 52.  
   constituents of, 64.  
 Muguet, 495.  
 Multiple scarification in lupus, 696.  
   screw in orthodontia, 370.  
 Muriate of ammonia in neuralgia, 866.  
 Muscles attached to ethmoid bone, 46.  
   to hyoid bone, 48.  
   to lachrymal bone, 48.  
   to maxillary bone, 34, 35.  
   to palate bone, 39.  
   to sphenoid bone, 46.  
   of expression, 51.  
   of tongue, 50.  
   genio-glossal, 60.  
   genio-hyoid, 60.  
   hyoglossal, 60.  
   lingual, 60.  
   stylo-glossal, 60.  
   stylo-pharyngeal, 60.  
 Muscle-strain in staphyloraphy, 619.  
 Muscular structure of tongue, 60.  
 Mütter's lip operation, 732.  
 Myeloid tumors, 941.  
 Mylo-hyoid groove, 36.  
   muscle, 35.  
 Myomata of Virchow, 939.  
 Myrrh and capsicum in gum affections, 479.
- N.
- Nævus, arterial, 680.  
 maculæ, 680.



- Nævus pigmentosus, 668.  
     pilosus, 669.  
     port-wine stain, 683.  
     vasculosus, 680.  
 Names of teeth, 87.  
 Napheys' sedative, 869.  
 Napkin, dental, 293.  
 Narcotics in inflammation, 990.  
 Nares, 631.  
 Narrow-beak forceps, 389.  
 Nasal abscess, 643.  
     bone, 29, 46.  
     catarrh, 633.  
     chancre, 637.  
     douche applied, 666.  
     fossa, 631.  
     gonorrhœa, 656.  
         treatment of, 656.  
     hemorrhage, 654.  
     mucous membrane, hypertrophy of, 655.  
         treatment of, 655.  
     nerve, 72.  
     reflector of Metz, 654.  
     septum, 631.  
         deviation of, 655.  
 Nasmith's jaw splint, 808.  
 Naso-palatine ganglion, 80.  
     pharyngeal polypi, 642, 643, 662.  
         extirpation of, 642.  
         syringe, 662.  
     pharyngoscopy, 610.  
 Natural cure of dental caries, 177.  
 Nature's removal of dead tooth, 776.  
 Neck cavities and gutta-percha, 312.  
 Necrosis, 774.  
     alveolar, 779.  
     definition of, 774.  
     from alveolar diseases, 776.  
     from dental diseases, 776.  
     from injuries, 786.  
     from lack of room for eruption of wisdom-tooth, 781.  
     from mercury, 785.  
     from syphilis, 782.  
     from the exanthems, 787.  
     from osteal inflammation, 774.  
     from periosteal inflammation, 774.  
     from phosphorus, 788.  
         treatment of, 791.  
 Needle-point pluggers, 327.  
 Negrier's treatment of epistaxis, 635.  
 Nélaton's plan in jaw-luxation, 801.  
 Neoplasms, 937.  
     of nose, 655.  
     of pharynx, 607.  
     of uvula, 587.  
 Nerve, 57-69.  
     anterior dental, 73.  
     auriculo-temporal, 76.  
     author's operation for section of inferior maxillary, 872.  
     author's operation for section of nasal, 874.  
     buccal, 76.  
     canal pluggers, 243.  
     Carnochan's exposure of superior maxillary, 876.  
     character of, 69.  
     ciliary, 72.  
     deep temporal, 76.  
     Nerve extractors, 240.  
         fifth pair, 70.  
         frontal, 71.  
         function of, 80.  
         ganglia, 77.  
         ganglia of Casserio, 77.  
         gustatory, 76.  
         inferior dental, 77.  
         inferior maxillary, 75.  
         labial, nasal, palpebral, 74.  
         lacrimal, 72.  
         lesions proper and their treatment by operation, 871-880.  
         masseteric, 76.  
         Meckel's ganglion, 77.  
         nasal, 72.  
         naso-palatine, 79.  
         of the face, 57.  
         ophthalmic division, 71.  
         orbital, 72.  
         origin, 69.  
         otic ganglion, 78-80.  
         Pancoast's operation for exposure of second branch of fifth, 876.  
         paste, 126.  
         pterygoid, 76.  
         sections, 871.  
         submaxillary, 80.  
         superior maxillary divisions, 73.  
         trifacial, 70.  
     Nervous mania, 859.  
         temperament and dentures, 415.  
         temperament and neuralgia, 856.  
             in relation with orthodontia, 366.  
     Neuralgia, 855.  
         after amputation, 857.  
         Anstie's view of, 856.  
         arising out of pulp-calcification, 215.  
         atmospheric relations to, 856.  
         character of pain, 855.  
         definition of term, 855.  
         derangements in respiration, 858.  
         from gas in pulp-cavity, 209.  
         functional disturbances in, 856.  
         illustrations of condition, 860.  
         improper aëration of blood, 858.  
         malaria as a cause of, 857.  
         neuromata in, 874.  
         not a disease, 856.  
         odontalgic relations, 857.  
         of tongue, 568.  
         predisposing causes of, 856.  
         syphilis as a cause of, 857.  
         treatment of, 864.  
         ulcerating nerve-cords, 857.  
         various medicaments used in, 865.  
         vascular perversion, 858.  
     Neuroma of nasal nerve, 874.  
     Neuro-paralytic ulcers, 639.  
     Neutral mixture, 111.  
     New bone in necrosis, 794.  
     Nicking frænum in tongue-tie, 586.  
     Niemeyer's neuralgic pill, 870.  
     Nitrate of silver in angina, 109.  
         in synovitis, 831.  
         of zinc, 318.  
     Nitrous oxide gas, 973.  
         action of, 977.  
         collecting, 975.  
         condition demanding caution, 977.



- Nitrous oxide gas, discovery of, 974.  
 dispensing, 975.  
 illustration of apparatus, 974.  
 liquefied, 975.  
 manner of preparation, 974.  
 use as a pain-obtunding agent due to, 978.  
 washing, 975.
- Nodular dentine, 214.
- Nodules in scirrhus, 949.
- Non-closure of antral openings, 754.  
 cohesive gold, 320.  
 manner of using, 320.  
 conducting substances in root-filling, 244.  
 explainable tumors, 937.  
 treatment of, 937.  
 explaining epulides, 897.  
 soluble dentifrices a cause of gum recession, 218.  
 specific exostosis, 904.
- Noni-nerve descendens, 745.
- Normal condition of gum covering simple osseous cysts, 915.
- Northrop's corundum points, 344.
- Nose, 631.  
 anatomy of, 631.  
 artificial, 462.  
 surgical, 456, 462.  
 deviation of septum, 655.  
 diseases of, 631.  
 epithelial sores, 657.  
 foreign bodies in, 653-656.  
 fractures of, 658.  
 glanders, 639.  
 hemorrhage from, 634.  
 hypertrophy of mucous membrane, 655.  
 imperforate nostril, 656.  
 loss of substance, 658.  
 nasal abscess, 643.  
 ozaena, 644.  
 polypi, 639.  
 fibrous, 641.  
 gelatiniform, 639.  
 intruding on antrum, 639.  
 sarcomatous, 642.  
 rhinoscopy, anterior, 654.  
 scrofulous ulcers of, 637.  
 sectional expression of, 59.  
 simple nasal catarrh, 633.  
 specific disease of, 638.  
 studies in rhinoplasty, 659.  
 syphilitic coryza, 650.  
 ulcers of, 637.  
 cancerous, 639.  
 neuro-paralytic, 639.  
 scorbutic, 639.  
 scrofulous, 637.  
 syphilitic, 638.  
 traumatic, 637.
- Notch in hare-lip, 717.  
 semi-lunar, 36.
- Notched teeth, 145.
- Nourishment of pulp, 83.
- Number and shape of roots of teeth, 87.  
 in gold, 319.  
 in tin, 318.  
 of human teeth, 87.
- Nunneley on excision of tongue, 582.
- Nutrition of enamel, 84.  
 of teeth, 777.
- Nutritional pabulum exuding from blood-vessels, 998.
- O.
- Objection to file, 185.
- Obscure case of salivary calculus, 261.
- Obstruction of Wharton's duct, 593.
- Obtunding dental agents, 198.
- Obturator, 442.  
 Baker's, 469.  
 Booth's, 468.  
 Buckingham's, 450.  
 casts for, 445.  
 cotton packing, 443.  
 definition of term, 442.  
 Desirabode's, 455.  
 Dieffenbach's rubber stud, 442.  
 Garengot's, 462.  
 impression for, 444.  
 Kingsley's, 464.  
 McGrath's, 448.  
 Models for, 445.  
 Paré's, 462.  
 Stearn's, 464.  
 Suersen's, 467.  
 vela, 463.  
 Wildman's, 456.
- Occipito-mental sling, 376, 809.
- Odontalgia, 198.  
 from confinement of pus and gas in pulp-cavity, 209.  
 from exposure of pulp, 203.  
 from recession and absorption, 217.  
 from sensitive dentine, 198.  
 hysterical, 217.  
 nodular, 214.  
 reflex, 215.  
 rheumatic, 203.  
 sympathetic, 215.
- Odontalgic associations with viscera, 207.
- Odonto-cardialgia, 216.  
 cephalalgia, 116.  
 gastralgia, 216.  
 neuralgia, 215.  
 otalgia, 216.  
 periosteal tumors, 803.  
 sciatica, 217.  
 common treatment of, 216.  
 illustrative cases of, 216.
- Odontocoele, 918.  
 examples of, 918.
- Odontoma, 918, 921, 922.
- Odor in inspissated mucus, 195.
- Oehlecker's enamel stopping, 318.
- Oesophageal bougie, 610.
- Oesophagitis, 609.
- Offensive breath, 163.
- Office of uvula, 51, 589.
- Oidium albicans, 690.
- Oil of eucalyptus in epithelial cancer, 709.  
 of turpentine in neuralgia, 866.
- Oils in tuberculosis, 993.
- Olfactory channel, 633.
- Ollier's osteogenetic experiments, 817.  
 U-incisions, 823.
- On exciting cause of dental tumors, 915.
- Opaque teeth, 248.
- Operating case of Philadelphia Dental College, 330-332.



- Operating chair for dentists, 348.  
 Operation for removal of inferior maxilla, 823.  
   for removal of superior maxilla, 821.  
 Operations practised upon the tongue, 574.  
   upon the lips and cheek, 726.  
     Blasius's, 732.  
     Chopart's, 731.  
     complicated hare-lip, 718.  
     Dieffenbach's, 732.  
     double hare-lip, 718.  
     Dupuytren's, 731.  
     Horn's, 731.  
     Liston's, 732.  
     Morgan's, 731.  
     Mütter's, 732.  
     Roux's, 731.  
     section of lip, 726.  
     Serre's, 731.  
     simple hare-lip, 711.  
 Operative dentistry, 268.  
 Opereulum excising forceps, 846.  
   of gum a cause of dental caries, 846.  
 Ophthalmic ganglion, 77.  
   nerve, 71.  
 Ophthalmoscopic mirror for dental purposes, 281.  
 Opiates in carcinoma, 704.  
 Opisthotonos in tetanus, 835.  
 Opium and ether in neuralgia, 866.  
   and lead as an anti-hemorrhagic, 514.  
   and mania, 459.  
 Optic foramina, 44.  
 Oral æsthetics, 427.  
   cavity, 726.  
   fluids, 178, 190.  
   gangrene, 499.  
   mucous membrane, 50.  
   parasites, 165.  
   surgery, 25.  
     definition of, 25.  
     typh fever, 161.  
 Orbit, composition of, 27.  
 Orbital cavity, 27.  
 Organic and inorganic matter of teeth, 92.  
 Origin of carcinoma, 697.  
   of fifth nerve, 70.  
   of periodontium, 95.  
 Oro-nasal innervation, 81.  
   secretions, 81.  
 Oro-pharyngeal space, 60.  
 Orthodontia, 366.  
 Os dentis, 927.  
 Osborn's porcelain compressor, 294.  
 Osseo-spongy character of alveolar process, 28.  
 Osseous anatomy of skull, 26.  
   corpuscles, 930.  
   repair in disease of upper jaw, 780.  
   tumor of right superior maxilla, 912.  
 Osteo-dental tumors, 915.  
   dentine in tooth-pulp, 214.  
   enchondroma, illustration of, 917.  
   gingivitis, 492.  
   gingivitis gangræna neonatorum, 492.  
   Osteoplasts, 930.  
 Osteophytes in phosphor-necrosis, 790.  
 Ostosis, 904.  
 Otic ganglion, 80.  
 Outlet of antrum, 40.  
 Oval files, 276.  
 Overcrowded condition of dental arch as cause of ulitis, 472.  
 Overfed infants, 113.  
 Overhung lower jaw, 375.  
 Over-stimulation in dental caries, 188.  
 Oxide of tin in dental caries, 188.  
 Oxychlorides, 315.  
   as a filling material, 315.  
   as a foundation material, 317.  
   as a hardener of teeth, 317.  
   as a pulp-capper, 317.  
   as a whitener of teeth, 316.  
   composition of, 316.  
   formula for, 316.  
   introduction of, 317.  
   manner of using, 315.  
   use of in poor teeth, 316.  
 Ozæna, 643.  
   as a dyscrasic disease, 643.  
   as a parasitic disease, 643.  
   from accumulation and degeneration of common antral secretion, 644.  
   from caries and necrosis of osseous boundaries of nares, 644.  
   from caries of walls of antrum, 644.  
   from constitutional causes, 644.  
   from lodgment and retention of foreign bodies, 644.  
   from tooth abscess discharging into antrum, 644.  
   from ulceration of mucous membrane of antrum, 644.  
   of caries, 644.  
   origin of term, 643.  
   treatment of, 643.
- P.
- Packing amalgam, 307.  
   in jaw exsection, 820.  
 Paget on the myeloid growths, 943.  
 Paget's operation on tongue, 582.  
 Pain in angina, 109.  
   in inflammation, 994.  
   in removing dead pulp, 239.  
   in scirrhus, 949.  
   in use of oxychloride of zinc, 246.  
 Paint as a whitener, 250.  
 Palatal defects, 442, 613.  
   cleft palate, 613.  
   treatment by obturators, 442.  
   surgical operation, 613.  
 Palate bone, 36.  
   articular process of, 38.  
   articulation of, 39.  
   attachment of muscles, 39.  
   nasal surface, 37.  
   orbital process of, 38.  
   palatine surface of, 38.  
   pterygo-palatine canal, 38.  
   relation of with inferior meatus, 38.  
   resemblance to letter L, 37.  
   sphenoid process of, 38.  
     hard, 59.  
     soft, 50, 618.  
 Palatine deficiencies, 442.  
 Palato-glossus muscle, 619.  
   pharyngeus muscle, 619.



- Pancoast's operation for exposure of maxillary nerve, 876.  
 Pandora's box, 125.  
 Paper in mask-making, 471.  
   litmus, 180.  
   turmeric, 180.  
 Papillæ, dental, 94.  
   of tongue, 61.  
 Papillary epithelioma, 697.  
 Papilloma of tongue, 514.  
 Paraboloid chisels, 274.  
 Paraffin in celluloid work, 439.  
 Paralysis of cheek, treatment by operation, 738.  
 Parasites, oral, 86, 165.  
   of skin, 690.  
 Parasitic fungi, 496.  
   theory of dental caries, 165.  
 Parasiticides, 165.  
 Paré's obturator, 462.  
 Parotid gland, 65, 190.  
   surgical relations of, 746.  
   secretion, 190.  
 Partial dentures, 423.  
 Partly developed teeth and the rubber dam, 301.  
 Parulis, 225.  
 Passive epistaxis, 636.  
   motion in false ankylosis, 851.  
   pharyngitis, 603.  
 Pasteboard splint in jaw fractures, 806.  
 Pathology of tetanus, 835.  
 Paul, James, M.D., on nutrients, 148.  
 Pearls in epithelioma, 699.  
 Pearly teeth, 181.  
 Peck's cylinders, 319.  
 Peculiarities in articular relations of jaw, 367.  
   in teeth, 424.  
 Pediluvia in angina, 108.  
 Pedunculated polypi, 641.  
 Pemphigus in infants, 120.  
 Perfect denture, 158.  
 Pericementitis, 219.  
 Periodontal hypertrophy, 922.  
 Periodontium, 85, 95.  
   diseases of, 209.  
   formation of, 95.  
 Periodontitis, 219.  
   acute form of, 219.  
   caused by accumulation of tartar, 221.  
   by false occlusion, 221.  
   chronic form of, 219.  
   from rubber ring, 222.  
   from wedging, 222.  
   relation with pulp-cavity, 220.  
   tartar as a cause of, 220.  
   the cause of ulitis, 219.  
   treatment of, 222.  
 Periosteum in phosphor-necrosis, 789.  
 Periostitis, dental, 219.  
 Permanent teeth, 87.  
   of lower jaw, 88, 385.  
   of upper jaw, 88, 385.  
 Permanganate of potash as a disinfectant, 192.  
 Perrine's fulcrum forceps, 399.  
 Perspiration in spasm, 118.  
 Persulphate of iron in hemorrhage, 410.  
 Peruvian bark and snake-root in gangrene of gums, 493.  
   in malarial disturbance, 991.  
 Perversion of circulation, 980.  
 Petroleum in burns, 531.  
 Phagedenic ulcers of mouth, 782.  
 Pharyngitis, 603.  
   sicca, 605.  
 Pharynx, 602.  
   blood-vessels of, 603.  
   communication with, 602.  
   description of, 602.  
   effusions of, 605.  
   foreign bodies in, 608.  
   imperforate, 607.  
   inflammation of, 603.  
   neoplasms, 607.  
   nerves of, 603.  
   post-pharyngeal abscess, 605.  
   sectional expressions of, 59.  
   senile inflammation of, 605.  
   stricture of, 607.  
   syphilitic ulcers of, 606.  
   tubercles of, 606.  
   wounds of, 607.  
 Phenate of soda as a disinfectant, 792.  
 Phénol-sodique in hemorrhage, 514.  
   in phosphor-necrosis, 792.  
 Phenomenon in neuralgia, 856.  
 Phosphor-necrosis, 788.  
   periodontitis, 219.  
 Phosphorostitis secondary to periostitis, 788.  
 Physical condition of infant in dentition, 100.  
   expression of teeth, 87, 428.  
 Physick's tonsillotome, 541.  
   tooth forceps, 397.  
 Physiognomical adaptation of teeth, 426.  
 Physiology of fifth nerve, 80.  
 Pigmental deposits, 668.  
 Pillars of fauces, 59.  
 Pimples, 121, 674.  
 Pins or stitches in face wounds, 517.  
   swallowing, 609.  
 Pits a cause of dental caries, 87.  
   of alveolar process, 36, 87.  
 Pitted teeth, 145.  
 Pittings of tooth-enamels, 145.  
 Pivot files, 354.  
   teeth, 350.  
   and trismus, 849.  
 Pivots, wood and metal, 356.  
 Plans of pivoting teeth, 350.  
   of tooth-filling, 320.  
 Plaster cups, 419.  
   of Paris as an impression material, 418.  
   as a tooth whitener, 250.  
 Plasters in wounds of face, 518.  
 Plastic-caught nerves, 881.  
   enamel, Flagg's, 318.  
   facing, 364.  
   infiltration, 995.  
   surgery in cicatricial wounds, 739.  
   in treatment of epithelial cancer, 705.  
   tin, 318.  
   tumors of Lebert, 938.  
 Plasticity of gutta-percha, 313.  
 Plate for study of tracheotomy, 547.  
 Plates for dental purposes, 421.  
   for teeth, 421.  
 Platina pivots, 358.  
 Plethora and dental hemorrhage, 408.  
   and periodontitis, 219.



- Plethoric epistaxis, 636.  
     temperament and neuralgia, 856.  
 Pleurosthotonos in tetanus, 835.  
 Pluggers for gold, 327.  
     Abbot's pattern, 329.  
     Atkinson's pattern, 327.  
     Butler's pattern, 329.  
     Smith's pattern, 330.  
 Plugging alloy combinations, 306.  
     mallets, 333.  
     nares in epistaxis, 635.  
     teeth, 282.  
 Plumpers, 428.  
 Pneumogastric nerve and jugular vein, 745.  
 Pointed files, 276.  
     tongue, 550.  
 Poison of typhoid fever, 162.  
 Pollock's treatment of caries by sulphuric acid, 770.  
 Polypi, 639.  
     fibrous, 641.  
     gelatinoid, 639.  
     Langenbeck's operation for, 643.  
     Mann's operation for, 643.  
     Nélaton's operation for, 643.  
     origin of, 641.  
     sarcomatous, 642.  
     treatment of by desiccation, 640.  
         by galvanic éraseur, 640.  
         by Gooch's canula, 640.  
         by injection, 640.  
         by polyptrites, 640.  
         by torsion forceps, 641.  
 Polyptrite, 640.  
 Polypus intruding on antrum, 641.  
     nasal, 639.  
 Poor diet and neuralgia, 856.  
 Porcelain facings, 363.  
 Porte polishers, 344.  
 Portio dura nerve, 71.  
 Port-wine stain, 683.  
 Position in filling lower teeth, 336.  
 Positive method in orthodontia, 379.  
 Posterior dental foramen, 36.  
 Post-pharyngeal abscess, 605.  
 Potash baths in tetanus, 836.  
 Potatoes, analysis of, 153.  
 Potential cauterants in sensitive dentine, 200.  
     used in cancer, 700.  
 Powders for the teeth, 164.  
 Predisposing causes of neuralgia, 856.  
 Predisposition to dental caries, 135.  
     to rickets, 141.  
 Prejudice and the file, 185.  
 Premature dentition, 100.  
 Preparation of gutta-percha, 312.  
     of mouth for artificial dentures, 415.  
     of patient for cleft palate operation, 617.  
     of roots for pivoting, 353.  
     of tooth cavities for filling, 282.  
 Prescriptions for neuralgia, 865.  
 Preserving vitality of exposed pulp, 204.  
 Pressure in hemorrhage, 513.  
     in treatment of cleft of hard palate, 616.  
 Preventing separated teeth from falling together, 284.  
 Prevention of osseous caries, 768.  
 Priestley, Dr., and nitrous oxide, 974.  
 Primary expressions of osseous necrosis, 776.  
     shock, 514.  
 Primitive dental groove, 93.  
     carotid artery, 53.  
     ligation of, 745.  
         of inferior triangle, 745.  
         of superior triangle, 745.  
 Principles and details in diagnosis, 1001.  
     related with extracting teeth, 384, 407.  
 Probe, use of, in alveolar abscess, 227.  
 Process, alveolar, 28.  
 Prodroma of rickets, 142.  
     of tetanus, 834.  
 Progress of contour work, 839.  
 Prolonged shock, 516.  
 Pronunciation after amputation of tongue, 575.  
 Proper bite in articulation, 423.  
     odontocoele, 918.  
 Prophylaxis and predisposition to disease, 148.  
     soft teeth, 148.  
     in alveolar abscess, 219.  
     in rickets, 141.  
 Prosthetic dentistry, 415.  
 Protococcus dentalis, 166.  
 Protoplasm, 139.  
 Protruding jaw, 375.  
 Pterygoid branches of fifth pair of nerves, 76.  
     process of os sphenoidium, 46.  
 Ptyaline and cheesy deposits, 194.  
 Puffiness of the gums, 479.  
 Pulp, dental, 83, 94.  
     caps for, when exposed, 246.  
     cavity, diminution of, 213.  
     decomposition of, 209.  
     destruction of, 208.  
     exposure of, 203.  
     filling over, when exposed, 244.  
     granules of osteo-dentine in, 214.  
     inflammation of, 203.  
     of milk-teeth, 98.  
     nodules in, 215.  
     palliative treatment of, 204.  
     paste for destroying, 208.  
     radical treatment of, 204.  
     tumors of, 892.  
 Pulp-chambers and canals, 239.  
     containing dead pulp, 239.  
     cotton plug of, 241.  
     disinfection of, 242.  
     gold plug of, 241.  
     permanent plug of, 241.  
     removal of pulp from, 239.  
     sealing after removal of pulp, 240.  
     temporary plug of, 240.  
 Pulpitis, 203.  
 Pulse in fever, 111.  
 Pumice in plug-finish, 347.  
 Puncture in alveolar abscess, 226.  
 Purkinjean cells of cement, 85.  
 Purpura as a predisposing cause of hemorrhage, 408.  
 Puruloid secretion of antrum, 753.  
 Pus and gas in dental pulp-cavities, 209.  
     and lymph, 755.  
     formation in tonsillitis, 537.  
     in cavity of alveolus, 226.  
     in phosphor-necrosis, 791.  
     meaning of, 994.  
 Pustular inflammation, 121.  
 Pustules, 121.



Putrescence and mercurial necrosis, 786.  
Putrescency of pulp and amalgam, 311.  
Pyogenic membrane, 225.

## Q.

Quality test of gutta-percha, 313.  
Question of tooth-extraction in alveolar abscess, 225.  
Quick narcotism from ether, 95.  
Quicksilver as a solvent of metals, 312.  
Quinine and snuff in neuralgia, 867.  
iron, and cinchona in treatment of erysipelas, 740.

## R.

Rabid animals, wounds received from, 516.  
Rachitis, 140.  
Raisins and the teeth, 173.  
Rambo's porcelain facing, 363.  
Rami of lower jaw, 34.  
Ranula, 590.  
illustrations of, 594.  
treatment of, 591.  
Rare case of salivary calculus, 261.  
meat in epistaxis, 636.  
Rashes, 122.  
Rauque's liniment in neuralgia, 867.  
Rawness after amputation of uvula, 589.  
of throat in chronic angina, 107.  
Reaming dental canal, 239.  
Recalcification of teeth, 188.  
Recession and absorption of gum and alveolus, 217, 486.  
treatment of, 218, 481.  
Recipe for zinc chloride, 316.  
Recurrence of syphilitic ulcers, 638.  
Recurring epulo-fibrous tumors, 901.  
Red gutta-percha, 313.  
hot needles in treatment of *nævi*, 687.  
pimples upon the gums, 484.  
vulcanite, 431.  
Redman's correcting plate, 377.  
pluggers, 322.  
Redness in inflammation, 994.  
Reduction in jaw luxation, 799.  
Reflex irritability, 207.  
odontalgia, 215.  
Reformative effort of dental pulp, 189.  
Regnoli's operation on tongue, 581.  
Relation of fractured roots to alveolar line, 400.  
of moisture with tooth-filling, 293.  
of rickets with scrofulosis, 141.  
of teeth with jaw, 86.  
of tooth-form with caries, 135.  
Relational anatomy of carotid artery, 765.  
Relationship of tumors, 887.  
Remarks on extraction of teeth, 407.  
Remedies used in tetanus, 837.  
Removal of foreign bodies from nose, 633.  
of mouth impressions, 420.  
of plasters, 518.  
of polypus, 662.  
Removing broach from teeth, 244.  
dead tooth-pulp, 239.  
Repair an inflammatory act, 997.  
of broken teeth, 363, 438.

Repairing celluloid dentures, 438.  
living tissues, 160.  
Replantation and transplantation of teeth, 251.  
in restitution, 256.  
Reproduction of bone in necrosis, 794.  
Requirements of dental trays, 416.  
for pronunciation, 467.  
Resecting lower jaw, 826.  
upper jaw, 819.  
Resections in necrosis, 795.  
of nerves, 871.  
Resistance in dental caries, 135.  
Resistiveness in gutta-percha, 313.  
Respiration in angina, 109.  
in ether exhibition, 961.  
Respirator, Graham's, 789.  
Respiratory channel, 633.  
Rest in hemorrhage, 410.  
in inflammation, 988.  
Restitution of tooth, 256.  
Résumé of dental caries, 76.  
of the subject of ankylosis, 854.  
Retaining screws, Mack's, 336.  
points, 339.  
Retention of arsenic in a tooth, 208.  
Retractors in jaw operations, 824.  
use of ligations, 745.  
Retro-pharyngeal abscess, 605.  
Rheumatic neuralgia, 855.  
odontalgia, 203.  
pulpitis, 207.  
tonsillitis, 539.  
Rheumatism a cause of pulpitis, 207.  
Rheumatoid arthritis, 833.  
Rhigolene, 414.  
Rhinoplasty, 658.  
Dieffenbach's operation, 663.  
English method, 659.  
German method, 659.  
Indian method, 659.  
Italian method, 659.  
Syme's operation, 659.  
Tagliacozzi's operation, 659.  
Von Graefe's operation, 659.  
Rhinorrhœa, 638.  
Rhino-scleroma, 679.  
Rhinoscopic view of posterior nares, 610.  
Rhinoscopy, anterior, 654.  
posterior, 610.  
Ribbon-filling, 321.  
Rich's duct-compressor, 296.  
Richardson on oral parasites, 165.  
on salivary corpuscles, 179.  
Richardson's atomizer, 414.  
Richat's treatment of neuralgia, 867.  
Rickets, 137.  
and hereditary syphilis, 137.  
Riggs's calculi instruments, 264.  
Rim-support for obturator, 447.  
Ringworm, 691.  
treatment of, 692.  
Roasted fig in gum-boil, 224.  
Robin microscopically on odontoma, 929.  
Robust infants and dentition, 100.  
Rogers and exsection of maxilla, 816.  
Roller in jaw-fractures, 807.  
Roof of mouth, 50, 58.  
Roonhuysen on Horn's lip operation, 731.  
Root forceps, 388, 404.



- Root growth, 95.  
 Roots of teeth requiring to be extracted, 29.  
 Ropes of gold in tooth-filling, 321.  
 Rose and spear drills, 270.  
 Rosenmüller's fossa, 612.  
 Rotten-stone in plug finishing, 345.  
 Rouge in plug finishing, 345.  
 Round-celled sarcoma, 940.  
 Roux's operation for cleft palate, 62.  
   for lip, 731.  
 Rubber dam, 297.  
   applied, 301.  
   applier, 299.  
   clamps, 598.  
     Buckingham's pattern, 299.  
     Elliot's pattern, 299.  
     Hickman's pattern, 299.  
   mirror, 297.  
   weights, 300.  
   tubing in orthodontia, 372.  
   wedges, 280.  
 Rules for excavating teeth, 291.  
   for insertion of dental plates, 415.  
   for lancing children's gums, 103.  
   for rubber damming, 300.  
 Rumboldt's treatment of hypertrophy of tonsil, 541.  
 Ruppaner's treatment of hypertrophy of tonsil, 539.
- S.
- Safety ligatures in orthodontia, 383.  
 Saliva, 51, 190.  
   abnormal, 192.  
   analysis of, 190.  
   from parotid gland, 190.  
   from sublingual gland, 191.  
   from submaxillary gland, 191.  
   healthy, 191.  
   pump, 294.  
   relation of, with dental operations, 293.  
   tests for accidental substances found in, 196.  
     for acid condition of, 196.  
     for alkaline condition of, 196.  
     for hydrochloric acid, 196.  
     for lactic acid, 196.  
     for nitric acid, 196.  
     for sulphuric acid, 196.  
   - unduly acid, 196.  
     alkaline, 198.  
   unhealthy, 192.  
 Salivary calculus, 258.  
   acids, 258.  
   analysis, 258.  
   anomalous cases of, 261.  
   corpuscles, 179.  
   instruments used in removing, 265.  
   simulating cancer, 259.  
 Salivary fistula, 760.  
   Agnew's operation for, 761.  
   author's operation for, 762.  
   causes of, 760.  
   common treatment of, 761.  
   Horne's operation for, 761.  
   irregular track in, 761.  
 Salivary glands, 65.  
   parotid, 65.  
   sublingual, 65.  
   Salivary glands, submaxillary, 66.  
     secretion, 190.  
   Salivation in mercurial poisoning, 786.  
     in phosphor-necrosis, 791.  
     temporary, 786.  
   Salt sheet-bath, 106.  
     water destructive of leeches, 223.  
   Salter on advent of wisdom-tooth, 781.  
   Sanguineous reaction in burns, 531.  
   Saponis viridis in seborrhœa, 674.  
   Sarcoma, 940.  
     globo-cellulare simplex, 940.  
     round-celled, 940.  
     spindle-celled, 940.  
   Saturnine affections, 490.  
   Saws, dental, 278.  
     surgical, 828.  
   Scalds, 530.  
   Scaly diseases, 121.  
   Sear in burns, 533.  
   Scarification of gums, 102.  
   Schindylesis articulation, 26.  
   Scirrhomia, 891.  
   Scirrhou cancer, 891.  
     of tongue, 558.  
   Scissors for amputation of uvula, 588.  
     for cutting bone, 822.  
   Scleroderma, 670.  
   Scorbutic ulcers of nose, 639.  
   Scorbutus and antrum, 758.  
   Scotch stone, 344.  
   Scraping of apples in burns, 531.  
     of carrots in burns, 531.  
     of potatoes in burns, 531.  
   Screw-driver in pivoting, 360.  
   Screws for extracting teeth, 402.  
     in tooth-filling, 336.  
   Screw-taps, 358.  
   Scrofuloderma, 688.  
   Scrofulosis, 136.  
     a cause of dental caries, 137.  
   Scrofulous and scorbutic tumors, 907.  
   Scrofulous angina, 107.  
     children and dentition, 102.  
     inflammation, 992.  
     tonsil, 544.  
     ulcers of nose, 637.  
   Scrolls, turbinated, 40.  
   Scultetus's jaw-wedge, 852.  
   Scurvy, 479.  
     Turner's antidote for, 479.  
     use of vegetables in, 479.  
   Sebaceous glands, diseases of, 674.  
     comedo, 674.  
     miliun, 674.  
     molluscum sebaceum, 675.  
     seborrhœa, 674.  
     tumors of, 675.  
   Seborrhœa, 674.  
   Secondary cyst in antrum, 934.  
     dentine, example of, 214.  
     indications in dental caries, 182.  
     shock, 514.  
     syphilis of tongue, 553.  
   Secretion of dental pulp, 84.  
   Section of cranial bones, 49.  
     of cutaneous horn, 692.  
     of dental nerve and maxillary canal, 872.  
     of enamel, 85.  
     of maxillary nerve at oval foramen, 874.



- Section of nasal nerve, 875.  
 superior maxillary nerve at foramen rotundum, 878.  
 teeth, 86.  
 temporo-maxillary articulation, 67.
- Sectional expression of mouth, 58.  
 view of new mode heater, 434.
- Seed-like bodies in ranula, 595.
- Selection of pivot teeth, 355.
- Self-explaining cystic tumors, 915.  
 tumors, 884.
- Seltzer-water and teeth, 193.
- Semi-lunar ganglion, 77.  
 notch, 36.
- Sensitive dentine, 198.  
 aconite as an obtunder of, 200.  
 action of cold or hot drinks upon, 199.  
 of sweets upon, 199.  
 actual cautery as an obtunder of, 200.  
 as a cause of odontalgia, 198.  
 camphor and morphia as an obtunder of, 200.  
 carbonate of potassium as an obtunder of, 200.  
 chloride of calcium as an obtunder of, 200.  
 of zinc as an obtunder of, 199.  
 chloroform as an obtunder of, 202.  
 creasote as an obtunder of, 200.  
 definition of term, 198.  
 etherization as an obtunder of, 202.  
 ethylate of sodium as an obtunder of, 200.  
 glycerole of thymol as an obtunder of, 200.  
 hypothesis of cause, 198.  
 in filed teeth, 185.  
 instrumentation in, 200.  
 iodine as an obtunder of, 200.  
 London paste as an obtunder of, 200.  
 morphia as an obtunder of, 203.  
 nitrate of silver as an obtunder of, 200.  
 oil of cloves as an obtunder of, 200.  
 pain in excavating, 200.  
 state of oral fluids in, 200.  
 subcutaneous use of morphia, 203.  
 temporary oxychloride of zinc plugs, 203.
- Sensor portion of fifth nerve, 57.
- Separating files, 276.
- Separation as a prophylactic and curative agent, 182.
- Septicæmia in tongue operation, 584.
- Septum of nose, 655.
- Sequestra in necrosis, 782, 787, 794.  
 removal of, 793.
- Sequestrum after measles, 787.
- Serrated instruments, 327.
- Seton, use of, with nævi, 686.
- Shading oxychlorides, 316.
- Sharp bodies in œsophagus, 608.  
 excavators and sensitive dentine, 200.
- Sheath of carotid artery, contents of, 745.
- Sheet-bath, salt, 106, 993.  
 tin, 318.
- Shock, 514.  
 characteristics of, 514.  
 definition of, 514.  
 idiosyncrasies in connection with, 515.  
 interference with function, 514.  
 intermediate, 515.
- Shock, primary, 514.  
 prolonged, 515.  
 relation with lymphatic temperament, 514.  
 secondary, 515.  
 simple, 514.  
 treatment of, 515.
- Shreddy sac in dental abscess, 225.
- Shrunk tongue, 549.
- Sick stomach in use of ether, 961.
- Silver wire in face wounds, 517.
- Simple angina, 107, 603.  
 bone cysts, 915.  
 cystomata, 915.  
 inflammatory tumors, 887.  
 nasal catarrh, 633.  
 shock, 515.  
 splints in jaw fractures, 815.  
 tooth cavities, 282.
- Sinus, maxillary, diseases of, 747.
- Sinuses in necrosis, 790.
- Skin grafting, 533, 644.  
 parasites, 690.
- Skull and hyperostosis, 911.
- Slavering in dentition, 102.
- Sleep in fever, 111.
- Sling for protruding lower jaw, 376.
- Slop-fed cows, 173.
- Sloughing in burns, 533.
- Sluggish system, 138.
- Smell and taste, 81.
- Smith's amalgam pluggers, 315.  
 duct compressor, 294.
- Snaring of polypi, 642.
- Snuff and quinine in neuralgia, 867.
- Soda, bicarbonate, in burns, 531.
- Soft bodies in œsophagus, 609.  
 dentine, 181.  
 gold, 319.  
 palate, 603.  
 anatomy of, 603.  
 part of mouth, 50.  
 teeth and clasps, 415.  
 filing, 183.
- Softening of antral walls, 749.
- Sordes, 194.
- Sore mouth, 106.  
 throat, 603.
- Spaces, interglobular, 86.
- Spasmodic trismus, 849.
- Spasms, 115.  
 atropia in, 116.  
 belladonna in, 116.  
 bromide of potassium in, 116.  
 cantharides and camphor in, 116.  
 from congestion of nerve centres, 117.  
 hepatic derangement, 117.  
 passive congestion, 117.  
 pure irritation, 116.  
 in dentition, 115.  
 lancing gums for, 116.  
 of glottis in nitrous oxide, 977.  
 steam bath in, 117.  
 valerian and gentian in, 116.
- Spear and rose drills, 270.
- Specific conditions of pharynx, 606.  
 ulcer of necrosis, 783.
- Speech after operation upon tongue, 575.  
 mechanism of, 467.
- Spermaceti in angina, 110.



- Sphenoid bone, 43.  
   articulation, 46.  
   body of, 43.  
   clinoid process of, 44.  
   concave plane of, 44.  
   ethmoidal spine of, 44.  
   greater and lesser wings of, 45.  
   hamular process of, 46.  
   muscles related with, 46.  
   nutritional foramina of, 44.  
   olfactory grooves of, 44.  
     foramina of, 44.  
   olivary process of, 44.  
   pterygoid process of, 46.  
   resemblance to bat, 43.  
   rostrum of, 44.  
   sella turcica of, 44.  
   turbinated lamellæ of, 44.  
 Spheno-palatine ganglion, 79.  
 Spider-web in hemorrhage, 410.  
 Spina ventosa, 915.  
 Spindle-celled sarcoma, 940.  
   jack-screw, 382.  
 Spiral springs in dentistry, 423.  
 Spirits of Mindererus in inflammation, 989.  
 Spiritus nitri dulcis and the teeth, 173.  
 Splitting of teeth from gas in pulp-cavity, 211.  
 Sponging hot skin with alcohol, 112.  
 Spongy exostosis, 904.  
 Spray apparatus, 412.  
   nozzles, 666.  
   of ether or rhigolene as a local anæsthetic, 413.  
 Spring lancet, 987.  
 Squire's cross-cuts in treatment of port-wine stain, 688.  
 Standard alloy, 304.  
 Stannous gold, 318.  
 Staphylophary, 613.  
   and syphilis, 613.  
 Starvation of nævi, 686.  
 Stearn's velum, 464.  
 Stellwagen's cutting forceps, 401.  
 Steno's duct, 65.  
   complication with dental abscess, 231.  
 Stern's illuminator, 612.  
 Sthenic fever, 111.  
 Stickiness in gutta-percha, 313.  
 Stimulation of pulp, 182.  
 Stimulants in dental hemorrhage, 410.  
   in stomatitis, 105.  
 Stippled celluloid gum, 440.  
 Stitches and pins in face wounds, 317.  
 Stomach of infants, 113.  
   teeth, 89.  
 Stomatitis, 102, 489.  
 Stones, Arkansas, 344.  
   hard, 344.  
   Hindustan, 344.  
   Scotch, 344.  
 Stop hinge in artificial vela, 468.  
 Strain in cleft palate operations, 619.  
 Strangulation of nævi, 684.  
   of tongue, 579.  
 Strength or debility in relation with chloroform, 968.  
 Stretching nerves, 880.  
   auricularis magnus, 882.  
   inferior maxillary, 882.  
   lingual, 883.  
   occipital, 882.  
   supra-orbital, 883.  
 Stricture of pharynx, 607.  
 Stroma of dentine, 83.  
 Stromeyer's forceps, 801.  
 Strophulus, 121.  
 Structural consolidation and dental necrosis, 779.  
 Strumous rhinorrhœa, 638.  
 Students' pluggers, 330.  
 Studies in æsthetic dentistry, 427.  
   in gold filling, 320.  
   in hare-lip, 723.  
   in condition of patient, 711.  
   in mode of operating, 713.  
   in time of life best suited to operation, 711.  
   in obturators, 442.  
   in plastic surgery, 726.  
   in teeth articulation, 423.  
 Study of tumors, 884.  
 Stylo-maxillary ligament, 68.  
 Subacute inflammatory tumors, 904.  
   synovitis, 831.  
 Sublingual gland, 66.  
   and ranula, 598.  
   secretion, 191.  
 Subluxations of lower jaw, 797.  
 Submarine amalgam, 304.  
 Submaxillary ganglion, 80.  
   gland, 65.  
   secretion, 191.  
 Substances used for making artificial nose, 448.  
 Substantia vitrea, 927.  
 Substitution in broken teeth, 363.  
 Sucking-bottles and aphthæ, 499.  
 Suction cavities, 422.  
 Sudamina, 677.  
 Sudduth's splint, 809.  
 Suersen's velum, 467.  
 Suffocation, treatment of, 545.  
 Sugar and the teeth, 172.  
 Sulciform dental atrophy, 145.  
 Sulphate of lime as an impression material, 418.  
   of potassa in hypertrophy of tonsil, 538.  
 Sulphuric acid in dental abscess, 232.  
   in maxillary caries, 770.  
   in treatment of salivary calculus, 265.  
   ether, 956.  
 Superficial burns, 531.  
   fascia of face, 52.  
   skin cancer, 698.  
 Superfine flour, 155.  
 Superior dental arch, 158.  
   maxillary bone, 29.  
   nerve, 73.  
     author's operation for exposure of, 875.  
     Carnochan's operation for exposure of, 876.  
     Langenbeck's operation for exposure of, 876.  
     Pancoast's operation for exposure of, 876.  
 Supernumerary teeth, 127.  
 Support of dental tray in mouth, 418.



- Supporting artificial teeth, 421.  
 Suppuration, 994.  
 Supra-hyoid bursa, 599.  
 Surfaces of teeth, 91.  
 Surgical anatomy of facial region, 25, 741.  
   of neck, 745.  
   of nerves of head, 871, 883.  
   of nose, 631.  
   of the teeth, 83.  
     cementum, 85.  
     dental pulp, 83.  
     dentine, 83.  
     enamel, 84.  
   consideration of dental caries, 177.  
   engine in exsection, 828.  
   in maxillary caries, 769.  
   relations of anomalous dentition, 124.  
   of veins of face, 742.  
   triangles of neck, 744, 746.  
 Susceptibility and dentition, 101.  
 Sutures and skull, 26.  
 Swallowing pins, 609.  
   the tongue, 586.  
 Sweat-glands, diseases of, 677.  
   anidrosis, 677.  
   chromidrosis, 677.  
   hyperidrosis, 676.  
   sudamina, 677.  
 Sweating in inflammation, 989.  
 Swedging dental plates, 445.  
 Swedish leeches, 986.  
   in angina, 107.  
 Sweet spirits of nitre and the teeth, 173.  
 Swelling in inflammation, 994.  
   of uvula, 587.  
 Syme's operation on tongue, 581.  
   view of trismus nascentium, 838.  
 Sympathetic odontalgia, 215.  
 Symptoms of jaw-fractures, 803.  
   of tetanus, 834.  
 Synonymes of tumors, 891.  
 Synovial fluid, 67.  
   membrane of lower jaw, 66.  
 Synovitis, 831.  
   acute, 831.  
   suppurative, 832.  
   treatment of, 833.  
 Syphilis, 137.  
   and antrum, 758.  
   of tongue, 551.  
 Syphilitic necrosis, 782.  
   teeth, 144.  
   tuberculosis, 689.  
   ulcers of nose, 638.  
 Syphiloderma, 689.  
 Syringe, hot-air, 280.  
   water, 280.  
 Systemic complications and amalgam, 311.  
   inflammation, 984.
- T.
- Tabes mesenterica and dentition, 113.  
 Taft's thimble, 295.  
 Taking away sequestra, 793.  
   cold, 984.  
   impressions of mouth, 416.  
 Talbot's tooth-crown, 351.  
 Tampon in epistaxis, 636.  
 Tannic acid in hemorrhage, 103.  
 Tartar and fungi, 264.  
   on teeth, 258.  
     analysis of, 258.  
 Tartaric acid and the teeth, 173, 194.  
 Taste and smell, 81.  
 Tearing sac of alveolar abscess, 227.  
   vascular naevi, 687.  
 Teeth, 83.  
   abrasion of, 267.  
   and their diseases, 135.  
   bicuspidati, 89.  
   bleaching, 248.  
   cementum of, 85.  
   chalky, 181.  
   classification of, 87, 180.  
   cuspidati, 89.  
   dark, 248.  
   deciduous, 87.  
   dentine of, 83, 94.  
   denudation of, 267.  
   discolored, 248.  
   enamel of, 84, 94.  
   extraction of, 384.  
   filling, 320.  
   gymnastics of, 173.  
   incisors, 87.  
   molars, 90.  
   of the blue shade, 181.  
   of sanguine and allied temperaments, 180.  
   pearly, 181.  
   periodontum of, 95.  
   surfaces of, 91.  
   transplantation of, 251.  
   tunica propria, 93.  
     reflexa, 94.  
   whitening, 248.  
   with tuberculous disposition, 181.  
 Teeth to be extracted, 384.  
   affording no prospect of usefulness, 384.  
   associated with incurable abscess, 384.  
   congesting and debasing neighboring parts, 384.  
   containing nodules of dentine, 384.  
   lacking antagonists, 384.  
   overcrowded in arch, 384.  
   roots badly putrescing, 384.  
     the source of unendurable pain, 384.  
     with fungoid excrescences, 384.  
 Teething children and the mercurials, 787.  
 Temperature in celluloid work, 437.  
   in gutta-percha, 312.  
   in tonsillitis, 537.  
   in vulcanite work, 434.  
   in relation with ether, 961.  
 Temporary matrix, 324.  
   salivation, 311.  
   teeth, 87.  
 Temporo-maxillary articulation, 26, 66.  
 Tertiary syphilis of tongue, 554.  
 Test for acid secretions, 190.  
   for quality of gutta-percha, 313.  
   bite in articulation, 423.  
   filling in pulp-canals, 241.  
 Testing gutta-percha, 313.  
 Tetanus, 834.  
   acute, 834.  
   causes of, 834.  
   chronic, 834.  
   from replantation of tooth, 257.



- Tetanus, idiopathic, 834.  
     pathology of, 835.  
     symptoms of, 834.  
     traumatic, 834.  
     treatment of, 836.  
 Therapeusis, dental, 187.  
 Therapeutical filling, 316.  
 Third dentition, 128.  
 Thirst in fever, 111.  
 Thrush, 496.  
 Thudichum's douche, 654.  
 Thymus gland in tracheotomy, 546.  
 Thyroid artery in tracheotomy, 547.  
 Time for operation in hare-lip, 711.  
     of retention of pins and stitches, 517.  
 Tin foil, 318.  
 Tin in amalgam, 303.  
     plugs in children's teeth, 318.  
 Tinea circinata, 691.  
     sycosis, 691.  
 Tissue innodulaire, 716.  
 Toad-marks, 669.  
 Tobacco chewing and abrasion, 267.  
     tongue, 561.  
 Tobold's illuminating apparatus, 655.  
 Tongue, the, 60, 549.  
     abscess of, 567.  
     acute inflammation of, 563.  
     arteries of, 63.  
     atrophy of, 573.  
     cartilaginous tumors of, 574.  
     coating of, 549.  
     color of, 549.  
     cystic tumors of, 562.  
     diseases of, 549.  
     dissection of, 60.  
     effusions of, 570.  
     epithelioma of, 560.  
     erectile tumors of, 571.  
     erysipelas of, 570.  
     fatty tumors of, 571.  
     hypertrophy of, 572.  
     immobility of, 574.  
     insect bites of, 570.  
     local injuries of, 550.  
     meaning of, in form, 549.  
     metastatic disease, 571.  
     moisture of, 549.  
     motion of, 549.  
     neuralgia of, 568, 863.  
     operations practised upon, 574.  
     the papillæ of, 61.  
     papilloma of, 574.  
     scirrhus of, 558.  
     syphilitic ulcers of, 551.  
     temperature of, 549.  
     tie of, 584.  
     tubercle of, 562.  
     venous tumors of, 574.  
     views of, 59, 60.  
 Tonic compound, 493.  
 Tonsil glands, 60, 534.  
     abscess of, 544.  
     extirpation of, 541.  
     hypertrophy of, 538.  
     in chronic angina, 109.  
     inflammation of, 534.  
     syphilitic affections of, 551.  
     tonsillotomy for, 541.  
     use of London paste in, 539.  
 Tonsillitis, 535.  
     common treatment of, 534.  
     specific treatment of, 535.  
 Tooth abscess discharging into antrum, 644.  
     ache, 198.  
     bleaching, 248.  
     brushes, improper use of, 481.  
     capping in periodontitis, 223.  
     crowns, Bonwill's, 359.  
         Gates's, 360.  
     cysts, 933.  
     extraction, 384.  
         accidents associated with, 407.  
         hemorrhage associated with, 408.  
     extracting instruments, 386.  
     germs, 93.  
         of heterogeneous development, 130.  
     hills in maxillary sinus, 30.  
     nutrition, 777.  
     picks, 174.  
     powders, 174.  
     tunics, 93.  
 Torsion forceps, 611.  
     in hemorrhage, 513.  
 Townsend formula for amalgam, 304.  
 Trachea, view of, 545.  
 Tracheal tubes, 547.  
 Tracheotomy, 546.  
     atomization of fluids in, 547.  
     complications in, 546.  
     wire brush in, 547.  
 Translucency in teeth, loss of, 210.  
 Transplantation and replantation of teeth,  
     251.  
     of skin, 706.  
 Traumatic epistaxis, 635.  
     trismus, 850.  
     ulcers of nose, 637.  
 Trays for taking impressions, 416.  
 Treating and filling teeth in relation with  
     laws of surgery, 187.  
 Treatment for gum absorption, 487.  
     of dental caries, 174-177.  
     of dental irregularities, 369.  
     of exposed pulp, 204.  
     of nose ulcers, 637.  
     of phosphor-necrosis, 791.  
     of pulp-cavity in replantation, 253.  
     of salivary calculi, 260.  
 Trial plate, 421.  
 Triangle of neck, 745.  
 Trifacial nerve, 70.  
 Trigeminal nerve, 70.  
 Trismus, 833.  
     dentium, 841.  
     from pivot-teeth, 849.  
     nascentium, 838.  
     traumaticus, 850.  
 Trouvé's polyscope, 610.  
 Tubercle of tongue, 582.  
 Tubercles, genial, 35.  
     of pharynx, 606.  
 Tubercula, 123, 138.  
 Tubular consolidation, dental, 177.  
     lupus, 694.  
 Tumefaction of gum, 102.  
 Tumors, 884.  
     arterial, 894.  
     classes of, 884.  
     classification of, 884.



- Tumors, definition of term, 884.  
   dental fungoid, 892.  
   epulo-erectile, 894.  
   exostosis and subacute inflammatory, 904.  
   histological distinctions of, 889.  
   homologous, 887.  
   hyperostosis, 904-909.  
   hypertrophic, 889.  
   illustration of, 955.  
   illustration in diagnosis, 885.  
   local and dyscrasic, 884.  
   microscopic appearance of encephaloma, 953.  
   non self-explaining epulides, 897.  
   odontoma, 918.  
   odonto-periosteal, 922.  
   recurring fibrous, 938.  
   relationship, 887, 938.  
   resultant from interference with function, 889.  
   rules for understanding, 884.  
   scrofulous and scorbutic, 907.  
   simple inflammatory, 887.  
   stand-point of study of, 884.  
   the epulic, 892.  
   ulitic, 892.  
   venereal and tubercular, 907.  
   venous, 681, 895.  
 Tunica propria, 93.  
   reflexa, 94.  
 Turbinate bones, 40.  
   inferior bone, 40.  
   lachrymal and ethmoid process of, 41.  
   maxillary process of, 41.  
   relation of with meatuses, 40.  
   scroll-like character of, 40.  
   susceptibility to inflammation, 41.  
 Turk-island salt bath in scrofula, 993.  
 Turmeric-paper as a test for alkalinity, 180.  
 Turnbull's experiments with ethyl bromide, 978.  
 Twin teeth, 406.  
 Two kinds of tumors only, 884.  
 Type of aphtha, 495.  
 Typh fever, 162.  
 Typhoid condition as a predisposing cause of dental hemorrhage, 408.  
   state and plastic operations, 854.
- U.
- Ulcer in chronic angina, 109.  
   of antrum of Highmore, 647.  
   of necrosis, 782.  
     acid nitrate of mercury in treatment of, 783.  
     corrosive sublimate in treatment of, 783.  
     incision in treatment of, 783.  
     iodide of potassium in treatment of, 783.  
     iodine and creasote in treatment of, 784.  
     syrup of pyrophosphate of iron in treatment of, 783.  
   of nose, 637.  
     cancerous, 637.  
     exanthematous, 639.  
   Ulcer of nose, neuro-paralytic, 639.  
     scorbutic, 639.  
     scrofulous, 637.  
     syphilitic, 639.  
     traumatic, 637.  
 Ulceration of mucous membrane of antrum, 644.  
   of nares, 644.  
 Ulcers, 637.  
 Ulitic tumors, 892.  
 Ulitis, 475.  
   from chloride of zinc, 482.  
   from creasote, 482.  
   from dead or loose teeth, 481.  
   from improperly inserted artificial teeth, 481.  
   from overcrowded dental arch, 475.  
   from periodontitis, 475.  
   from scurvy, 475.  
   from syphilis, 475.  
   from the mercurial impression, 475.  
   from use of improper dentifrices and brushes, 475.  
   from vulcanite, 484.  
 Unbolted flour, 155.  
 Uncovered pulp-chambers, 246.  
 Uncovering upper jaw, 817.  
 Underhung jaw, 375.  
 Unilateral facial atrophy, 671.  
   jaw luxation, 797.  
 Union of wounds by first intention, 716.  
 Unique case of odontoma, 923.  
 Universal root forceps, 388.  
 Unloading capillaries, 992.  
 Upper cow-horn forceps, 393.  
   jaw in necrosis, 794.  
   lip, making, 735.  
 Uranoplasty, 628.  
 Urticaria of tongue, 572.  
 Use of gutta-percha in dentistry, 312.  
   of rhinoscope, 612.  
 Uvula, 51, 587.  
   amputation of, 587.  
   diseases of, 587.  
   engorgement of, 587.  
   hypertrophy of, 587.  
   in angina, 107.  
   neoplasm of, 587.  
   scissors, 588.  
   tumors of, 587.
- V.
- Vallet's mass in epithelioma, 703.  
 Varieties of gutta-percha, 313.  
 Varying angles of jaw rami, 375.  
 Vascular system of external and deep facial region, 741.  
   ligation of external carotid artery, 741.  
     of facial artery, 741.  
     of lingual artery, 743.  
     of occipital artery, 743.  
     of primitive carotid artery, 745.  
     of temporal artery, 742.  
   line of arteries, 743.  
   warts, 698.  
 Vaseline in burns, 531.  
 Vault of nose, 632.  
 Vegetable parasites, 165, 690.



- Veins of facial region, 55.  
 of auricular, 55.  
 of frontal, 55.  
 of labial, 55.  
 of lingual, 55.  
 of internal jugular, 55.  
 of maxillary, 55.  
 of nasal, 55.  
 of temporal, 55.
- Vela, 463.  
 Baker's, 469.  
 Booth's, 468.  
 Kingsley's, 464.  
 Stearn's, 464.  
 Suersen's, 467.
- Velocity of dental engine, 343.
- Velum palati, 59.
- Venereal and tubercular tumors, 907.
- Venesection, 986.  
 in infantile spasms, 117.
- Venous hemorrhage, 513.  
 after tooth-extraction, 408.  
 tumors, 681, 895.  
 of tongue, 574.
- Veratrum viride as a depressant, 410.  
 in erectile growths, 681.  
 in periodontitis, 223.
- Vermifuge medicines in neuralgia, 866.
- Verruca, 673.  
 acuminata, 673.  
 digitata, 673.  
 filiformis, 673.  
 plana, 673.  
 vulgaris, 673.
- Vertical section of face and neck, 59.
- Vesiculæ, 120.
- Vessels of dental papillæ, 94.
- Vestibule of mouth, 50.
- Vicarious dental hemorrhage, 408.  
 disease of sweat-glands, 677.  
 • epistaxis, 637.
- Vice tumors, 887.
- View of air-tubes, 545.  
 of fifth nerve, 69.  
 of inferior maxillary and gustatory nerves, 871.  
 of posterior nares, 612.  
 of right half of base of skull, 49.  
 of teeth, 87, 88, 91.
- Vinegar and dental caries, 173.
- Virchow and cell segmentation, 998.
- Virginia snake-root as a tonic, 493.
- Virus, 516.
- Viscosity in saliva, 191.
- Vitality in ulceration, 783.
- Vitiated nutrition and purulency, 755.
- Vitiligo, 668.
- Vitrification, 177.
- Volta's pile, 605, 993.
- Vomer bone, 39.  
 articulation of, 40.  
 with maxillary and palate bone, 40.  
 association with triangular cartilage, 39.  
 naso-palatine groove, 39.  
 relation of septum of nose, 39.  
 shape of, 39.  
 view of, in position, 39.  
 separated, 39.
- V-shaped cuts, 284.
- Vulcanite and celluloid, 431.
- Vulcanite and celluloid, apparatus for working, 433, 436.  
 as a cause of ulitis, 484.  
 black, 435.  
 blank rim, 440.  
 composition of, 431, 435.  
 continuous gum, 439.  
 dental plates, made of, 431.  
 flasks for moulding, 432, 437.  
 obturators made of, 431.  
 packing for dental plates, 439.  
 repairing, 438.
- Vulcanized splints, 814.  
 tooth pivots, 357.
- W.
- Warm climates, relation of with health of teeth, 197.
- Warren's operation for cleft palate, 622.
- Warts, 673.
- Warty teeth, 905.
- Washes for the teeth, 163.
- Washing nitrous oxide, 975.
- Water syringe, 280.  
 tight tooth dam, 297.
- Watery effusions, 888, 995.
- Watson's chlorine-water, 991.  
 in nasal ulcerations, 637.  
 in pharyngitis, 604.
- Wax for impressions, 417.
- Wearing down of teeth a cause of pulpitis, 205.
- Webb, Marshall, on contour work, 337.  
 on pivoting, 359.
- Wedge in tooth-filling, 320.  
 of Scultetus, 852.
- Wedging in orthodontia, 378.  
 in tooth-extraction, 393.  
 teeth, 286.
- Weld on contour work, 338.
- Wells, Dr. Horace, and nitrous oxide, 974.
- Westcott's correcting apparatus, 370.
- Weston's insoluble cement, 318.  
 pulp-caps, 246.  
 soft cement, 304.
- Wet-cupping, 986.
- Wharton's duct, 66.  
 obstruction of, 593.
- Wheel files, 343.
- Whiskey in rattlesnake-bite, 516.
- White corpuscles, excess of, 996.  
 enamel stopping, 318.  
 fur on tongue, 549.  
 gutta-percha, 313.  
 oak bark in stomatitis, 106.  
 paint in burns, 531.  
 sores of the aphthæ, 509.  
 tongue, 561.
- White's correcting apparatus, 370.  
 dental engine, 272.  
 head-rest, 348.
- Whitehead's operation on tongue, 534.
- Whitening teeth, 248.
- Wildman's artificial nose, 459.  
 obturator, 456.
- Wings of sphenoid bone, 43.
- Wire brush in tracheotomy, 547.  
 seton in salivary fistule, 761.



Wisdom-teeth, 91.  
     forceps, 397.  
     in alveolar abscess, 230.  
     in caries, 159.  
 Withdrawal of pin or ligature in face  
     wounds, 518.  
 Wolverton's tooth-forceps, 396.  
 Wood pivots, 356.  
     polishing points, 344.  
 Wooden spatula in hare-lip, 722.  
 Woorara in treatment of tetanus, 837.  
 Worms in comedo, 674.  
     in dentition, 113.  
 Wounds of mouth and associate parts, 512.  
     burns and scalds, 530.  
     complications, 512.  
     deformities, 531.  
     healing, 517.  
     illustrations, 519.  
     indications in, 512.  
     relation of foreign particles, 512.  
     shock, 512.  
     virus, 516.  
 Wounds of pharynx, 607.  
 Wrist-bathing in fever, 989.

## X.

Xanthoma, 679.

## Y.

Yaws, 672.  
 Yellow fur on tongue, 549.  
     tartar, 264.


## Z.

Zeroderma, 673.  
 Zinc as a decolorizer, 249.  
     as a cause of pulpitis, 199.  
     as a cleanser of amalgam, 306.  
     as a pain obtunder, 199.  
     as a parasiticide, 189.  
     as a pulp-capping material, 244.  
     as a recalcifier, 188.  
     as a filling material, 316.  
     as an ingredient in amalgam, 304.  
     cast of mouth, making, 245.  
     chloride and dental caries, 177.  
         and necrosis, 780.  
     in sensitive dentine, 200.  
     in stomatitis, 105.  
     nitrate of, 318.  
     phosphates, 317.  
         composition of, 317.  
         forms of, 318.  
     plaster in epithelial cancer, 699, 703.  
     sulphate in antral disease, 754.


THE END.























✓







