

On Addison's disease : clinical lectures on Addison's disease and a report on diseases of the supra-renal capsules / by Edward Headlam Greenhow.

Contributors

Greenhow, Edward Headlam, 1814-1888.

Publication/Creation

London : printed by J.W. Roche, 1866.

Persistent URL

<https://wellcomecollection.org/works/dbry7zj6>

License and attribution

This work has been identified as being free of known restrictions under copyright law, including all related and neighbouring rights and is being made available under the Creative Commons, Public Domain Mark.

You can copy, modify, distribute and perform the work, even for commercial purposes, without asking permission.




Wellcome Collection
183 Euston Road
London NW1 2BE UK
T +44 (0)20 7611 8722
E library@wellcomecollection.org
<https://wellcomecollection.org>

WK700
1866
G81o



22101622295





83562
Dr Bristowe
with the Author's Comments

ON


ADDISON'S DISEASE:

CLINICAL LECTURES ON ADDISON'S DISEASE AND
A REPORT ON DISEASES OF THE SUPRA-RENAL
CAPSULES.

BY

EDWARD HEADLAM GREENHOW, M.D.,

FELLOW OF THE ROYAL COLLEGE OF PHYSICIANS,
CONSULTING PHYSICIAN TO THE WESTERN GENERAL DISPENSARY,
ASSISTANT PHYSICIAN TO THE MIDDLESEX HOSPITAL, ETC.



LONDON:

PRINTED BY J. W. ROCHE, 68, PARADISE STREET,
ROTHERHITHE.

1866.

8375

14 84 5623

WELLCOME INSTITUTE LIBRARY

WELLCOME INSTITUTE LIBRARY
11 ELSWORTH ROAD, TRAFALGAR SQUARE, LONDON, W.C.2

WELLCOME INSTITUTE LIBRARY



WELLCOME INSTITUTE LIBRARY	
Coll.	welMOmec
Call	
No.	WK700
	1866
	G810

P R E F A C E.

MY object in undertaking the investigation, of which the result forms the latter part of this little volume, was to shew what is actually known respecting "Addison's Disease;" in order, if possible, to dispel those doubts regarding the reality of its existence which are still entertained by many members of the profession. I may, perhaps, venture to express the hope that no one, who impartially considers the evidence set forth in that paper, can any longer hesitate to recognize a definite relation between a certain train of morbid phenomena, and a particular form of disease in the Supra-Renal Capsules. If this truth be once fully recognized, it will then be no longer necessary to go on accumulating evidence in support of the reality of Dr. Addison's discovery; but future enquiries, starting from the basis of what is already known, may rather be directed towards the elucidation of the true nature and causes of Addison's disease. Towards this further object I have endeavoured also, in however small a degree, to contribute, by suggestions arising out of my own clinical observation and confirmed, as it appears to me, in some measure, by the evidence I have collected.

A paper, of the character of that communicated to the Pathological Society, being necessarily founded so largely on cases recorded by other observers, I resolved, so soon as the Council had decided on its publication in the *Transactions*, to reprint it, in order that I might have the opportunity of sending copies to as many of the Reporters of cases quoted as might not be members of the Society. It was after-

wards suggested to me that the addition of some Clinical Lectures on Addison's Disease, which I had already published in the *Lancet and British Medical Journal*, would increase the interest of the reprint, by presenting the clinical aspects of the subject more fully than could be attempted with propriety in a communication to the Pathological Society. I determined, therefore, to prefix the Lectures to the Report on diseases of the Supra-renal Capsules, supplementing them, however, with some additional information, and omitting, from the second lecture, and also from the report, some passages that were rendered superfluous by their juxtaposition with the first lecture.

77, UPPER BERKELEY STREET,

November, 1866.

CONTENTS.

LECTURES ON ADDISON'S DISEASE.

LECTURE I.

DISCOVERY OF ADDISON'S DISEASE; ONE PARTICULAR AFFECTION OF THE SUPRA-RENAL CAPSULES—CONSTITUTIONAL SYMPTOMS AND EXTERNAL SIGNS—CASE WITH CARIES OF THE SACRO-ILIAC SYNCHONDROSIS; PRESENCE OF CHARACTERISTIC SYMPTOMS AND SIGNS—CASE WITH TUBERCLE IN LUNGS; APPEARANCE OF SYMPTOMS VERY SHORTLY BEFORE DEATH; SLIGHTNESS OF DISCOLORATION—CASE WITH SLIGHT TUBERCLE OF LUNGS AND PERITONEUM; DISEASE ARISING PROBABLY FROM LOCAL INJURY; LONG COURSE OF ILLNESS; INTENSE AND UNIFORM DISCOLORATION—OCCASIONAL LATENCY OF DISEASE; CASE IN ILLUSTRATION—OCCASIONAL INTERMITTENT COURSE OF DISEASE; CASE IN ILLUSTRATION—CASE WITH CARIES OF VERTEBRÆ WITHOUT DISCOLORATION; DEATH AT AN EARLY STAGE OF THE DISEASE—CASE OF SPURIOUS DISCOLORATION; ABSENCE OF CHARACTERISTIC SYMPTOMS AND SIGNS—NATURE OF ADDISON'S DISEASE; RELATION BETWEEN MORBID CHANGE IN CAPSULES AND SYMPTOMS DURING LIFE—TREATMENT PAGE 1

LECTURE II.

TYPICAL CASE NOW IN HOSPITAL; INJURY TO BACK; WELL-MARKED CONSTITUTIONAL SYMPTOMS AND DISCOLORATION OF SKIN; SYMPTOMS OF DISEASE OF VERTEBRÆ; PROBABLE ORIGIN OF DISEASE IN CAPSULES—CASE WITH TUBERCLE OF LUNGS AND PERITONEUM; CHARACTERISTIC CONSTITUTIONAL SYMPTOMS; DISCOLORATION OF SKIN SLIGHT BUT CHARACTERISTIC; BLACK DISCOLORATION ROUND TUBERCLE ON PERITONEUM—DISCOLORATION OF SKIN IN ADDISON'S DISEASE NOT DUE TO TUBERCULOSIS—CASE UNDER OBSERVATION; CHARACTERISTIC SYM-

PTOMS ; VERY SLIGHT DISCOLORATION ; INTERMITTENT COURSE OF DISEASE ; GRADUAL DEEPENING OF COLOUR—CASE UNDER OBSERVATION ; HISTORY OF INJURY TO HIP ; USUAL SYMPTOMS ; WELL-MARKED DISCOLORATION ; IMPROVEMENT TWICE IN HOSPITAL—REMARKS ON TREATMENT	PAGE 24
--	---------

ON DISEASES OF THE SUPRA-RENAL CAPSULES.

CASES.

CASE OF CANCER OF THE SUPRA-RENAL CAPSULES—CASES OF ADDISON'S DISEASE OF THE SUPRA-RENAL CAPSULES	PAGE 38
---	---------

REPORT ON DISEASES OF THE SUPRA-RENAL CAPSULES.

OBJECT OF INVESTIGATION—COLLECTION OF CASES—ANALYSIS OF CASES—BRONZED-SKIN WITHOUT DISEASE OF SUPRA-RENAL CAPSULES—CANCEROUS DISEASE OF SUPRA-RENAL CAPSULES—MISCELLANEOUS DISEASES OF SUPRA-RENAL CAPSULES—IMPERFECTLY DESCRIBED OR DOUBTFUL CASES—ADDISON'S DISEASE OF THE SUPRA-RENAL CAPSULES—QUITE UNCOMPLICATED—ALMOST UNCOMPLICATED—WITHOUT EVIDENCE OF COMPLICATION—WITH VERTEBRAL DISEASE OR LUMBAR ABSCESS—WITH TUBERCULAR DISEASE—WITH NON-TUBERCULAR DISEASES—SUMMARY OF ANALYSIS—NATURE OF MORBID CHANGE IN ADDISON'S DISEASE OF THE SUPRA-RENAL CAPSULES—ONE OR BOTH CAPSULES INVOLVED—CONDITION OF THE SUPRA-RENAL NERVES—SEAT OF DISCOLORATION—STATE OF THE BLOOD—DURATION, PROGRESS, AND CHARACTER OF ILLNESS—INFLUENCE OF SEX, AGE, AND OCCUPATION, ON THE OCCURRENCE OF ADDISON'S DISEASE	PAGE 45
--	---------

TABLES OF CASES.

CLINICAL LECTURES
ON
ADDISON'S DISEASE.

LECTURE I.*

DISCOVERY OF THE DISEASE—CONSTITUTIONAL SYMPTOMS AND EXTERNAL SIGNS
—CASE ASSOCIATED WITH CARIES OF THE SACRO-ILIAC SYNCHONDROSIS—
CASES WITH TUBERCLE IN LUNGS—OCCASIONAL LATENCY OF DISEASE—
OCCASIONAL INTERMITTENT COURSE OF DISEASE—CASE ASSOCIATED WITH
CARIES OF VERTEBRÆ WITHOUT DISCOLORATION—CASE OF SPURIOUS DIS-
COLORATION—NATURE OF ADDISON'S DISEASE—TREATMENT.

GENTLEMEN,—Ten years ago the late Dr. Addison, senior physician to Guy's Hospital, published a monograph "On the Constitutional and Local Effects of Disease of the Supra-Renal Capsules." Beyond the fact, which had been revealed by post-mortem examinations, that these organs were liable to inflammation and suppuration, to effusions of blood into their substance, and to cancerous and tubercular degeneration, nothing whatever was known respecting their diseases, or the influence which these exercised on the general health, until the publication of that work. Dr. Addison had for a long period observed, from time to time, cases evidently belonging to one and the same class, characterized by very remarkable symptoms, and to which, for want of a perfect knowledge of their true nature, he applied the term idiopathic anæmia. It was in the course of his endeavours to obtain some additional light on the nature of these cases, that he discovered the relation between the symptoms he had observed and disease of the supra-renal capsules; which relation he brought for the first time under the notice of the profession in the work I have just mentioned. Dr. Addison briefly stated the symptoms which he had found occurring in connexion with supra-renal disease to be as follows: "Anæmia, general languor and debility,

* Reprinted from the *Lancet*, Vol. 1., 1865.

remarkable feebleness of the heart's action, irritability of the stomach, and a peculiar change of colour in the skin." On account of this discoloration of skin, which Dr. Addison at first conceived always to accompany the disease, it was originally named "melasma supra-renale." At a later period, however, Dr. Addison stated, at a meeting of the Medico-Chirurgical Society, that cases might and did occur without any such discoloration. The newly-discovered malady was nevertheless afterwards called bronzed-skin disease, but has now become generally known by the more appropriate and convenient name of Addison's disease; appropriate because it commemorates the name of the discoverer, in accordance with the custom which has connected the names of Bright and Pott with the diseases which they first recognised, and convenient because it involves no theory as to the ill-understood nature of the disease itself. Dr. Addison's book contains the record of eleven cases, some of which he had not seen during life, and several of which were certainly not true examples of the disease now known by his name. Indeed he appears, at that time, to have thought that any disease involving the structure of the supra-renal capsules would be accompanied by the symptoms he described. Subsequent observation appears to show that the symptoms, peculiar to Addison's disease, only occur in connexion with that form of disease of the supra-renal capsules which has commonly been called tubercular, a term perhaps not precisely accurate, but which, for want of a better, I shall on this occasion continue to employ. I do not, however, mean you to infer that the deposit found in the capsules in these cases is identical with tubercle as we meet with it in other organs, but only that it has such an apparent resemblance to it, and undergoes degenerative changes of so similar a character, that this term is, in the present state of our knowledge, the most convenient for clinical purposes; more particularly as we find it, in a very large proportion of cases, occurring in persons of a tubercular diathesis. Evidences of inflammation, afforded by adhesion to neighbouring organs and by thickening of the connective tissue surrounding the capsules, are, indeed, common in Addison's disease, but are always associated either with abscess or with tubercular affection of the capsules themselves. Abscess—or at least transformation of the capsules into cysts filled with creamy-looking fluid, or with thinner fluid containing flocculi—has been found associated with the symptoms of Addison's disease in a few instances. It appears to me, however, that there are good grounds for believing that in such cases the abscesses have been formed by the softening down of the deposit, and that they

are therefore only examples of one form of the ordinary tubercular affection. With the exception of a case reported by Dr. Duclos, a French physician, as one of cancer of the supra-renal capsules, but which, from the description and symptoms, I am inclined to regard as having been, in reality, a true example of Addison's disease,* no single case of cancer of those organs has to my knowledge been reported, in which either the constitutional or external symptoms of Addison's disease were present. Neither, with the exception of the same case, has cancer of the supra-renal capsules, so far as I can discover, ever been reported, unassociated with, or probably otherwise than secondary to, cancer of other organs.

Addison's disease is therefore due to a much more definite affection of the supra-renal capsules than its discoverer himself supposed; and, as we have seen, the manifestations of its existence during life are clearly divisible under two heads—viz. : 1, constitutional symptoms; and 2, external signs.

Having had under my own care during the last few years at least five genuine cases of the disease, and having had the opportunity of seeing several of those which were under Dr. Addison's care, I shall now sum up the results of my own personal observation as to the constitutional symptoms and external signs of this singular malady.

I. The constitutional symptoms are: gradually progressive asthenia, often originating without any apparent cause, and seldom dating from any definite period; great languor and indisposition for exertion, with, in advanced cases, breathlessness and palpitation, frequent sighing or yawning, and generally faintness on making any muscular effort, sometimes even on being raised up in bed. There is almost invariably great weakness of the heart's action and remarkable feebleness of pulse; loss of appetite; irritability of stomach, with nausea; and, towards the close of the illness, at least occasional, often persistent, vomiting. The mind is generally clear to the last, but so great is the prostration in the latest stage of the disease that the patient often lies in a drowsy, apparently semi-comatose state, from which, however, he can be roused by questions, and to these he generally gives pertinent, though slow and reluctant, answers. The above I should class as the most characteristic symptoms of the disease: but there are in many cases pains in the loins, hypochondria, or epigastrium; and, more rarely, dimness of sight, vertigo, and, near death, a tendency to incoherence or delirium. Death takes place from asthenia, and often rather suddenly. It is a

* See further remarks on this case, at p. 50.

remarkable fact, that, notwithstanding the great debility which is the earliest and most constant symptom of the disease, there is, in uncomplicated cases, comparatively little or no emaciation. The skin also is soft and cool; the tongue usually clean and moist until the last days of life; the bowels seldom disordered, though sometimes confined; and the urine generally normal. It should be observed that the constitutional symptoms of this malady have been sometimes masked, or at least overlooked, in cases in which the patient has been contemporaneously suffering from some other serious wasting disease, such as phthisis or lumbar abscess; though, even in such cases, the languor and prostration are for the most part out of all proportion to the severity of the more obvious complaint: a circumstance well illustrated by a case I shall presently quote, which was under the care of Mr. Hulke some time since in this hospital, and in which—partly no doubt on account of the complication with psoas abscess, partly also from the absence of discoloration of skin—the disease of the capsules was not suspected during life.

II. The external signs of Addison's disease are found in the discoloration of skin, which, when present in a fully developed form, is, I need scarcely say, its most striking feature. It is true that in a recent case in this hospital, in which the discoloration was very slight, I ventured to diagnose the disease from the constitutional symptoms, and that diagnosis, as you well know, was verified by the post-mortem examination; but, as a rule, the external signs have been the main ground on which this disease has been hitherto diagnosed. The discoloration of skin in Addison's disease is very peculiar, and gives to the patients in whom it is well marked the appearance of belonging to one of the darker races of mankind. Most frequently it is of a dusky or yellowish-brown, but sometimes rather of an olive or greenish-brown colour. The shade is not uniform on all parts of the body, but is generally darker on the face, neck, and hands, and in the axillæ and groins. The penis and scrotum and the nipples and areolæ are usually the darkest parts of the natural skin, and the discoloration of these last may be regarded as one of the diagnostic external signs of Addison's disease. If the patient have been blistered, or have sustained any other superficial abrasion of the skin, the injured surfaces are always darker than the surrounding parts, but the cicatrices of deeper injuries usually remain pale. Very often, also, small well-defined specks or patches of darker colour, resembling moles, are found upon the face neck, arms, or trunk; but so far as I have observed, they only appear

on the already discoloured skin. Although the discoloration is generally most marked on certain parts of the body, and may even exist on some parts while the skin of other parts is of the normal hue, there is rarely, or never, any definite line of demarcation between the discoloured and normal portions of the skin; but the former fade insensibly into the latter. The characteristic discoloration is not restricted to the skin, but, in well-marked cases, is also usually found upon the lips in the form of an irregular stain running lengthwise, and upon the gums and buccal mucous membrane in the form of stains or patches; these last may, perhaps, when present, be considered as the most decisive of the external diagnostic signs of Addison's disease. It is, on the other hand, important to remark that the conjunctivæ always remain uncoloured, and in the more deeply discoloured cases their pearly whiteness presents a striking contrast to the dusky hue of the face. I may mention, by the way, that this discoloration of the gums and buccal mucous membrane affords another analogy between the discoloration of Addison's disease and the natural colour of the darker races; two Hindoos who were hospital out-patients of mine having presented dark stains on those parts, exactly resembling the stains found in cases of Addison's disease. Moreover, in one of them I noticed that some superficial cicatrices were of a darker shade than the surrounding integument.*

We have had in the hospital, during the last year, two well-marked

* While these sheets are passing through the press, I have received, from Dr. Balthazar Foster of Birmingham, the notes and photograph of a most remarkable case, in which the irritation of blisters has caused renewed deposits of dark pigment in the skin of a mulatto who has for some years been gradually turning white.

A mulatto aged 43, the child of an escaped negro slave by an English mother, about six years ago began to change colour; his wife first noticed white specks on his back, which gradually coalesced and spread until the whole trunk became white; the upper parts of the legs and arms then became spotted with white patches, and the limbs are at this time in great part white, though less so towards the hands and feet which remain dark. The white colour terminates half-way up the neck and the face remains dark, with ordinary mulatto features and black crispy hair; spots of white are appearing, however, on the right side of the forehead and at the angles of the jaw. The white skin is soft and healthy, not to be distinguished from that of a European. The man had good health up to three or four years back, but has since been ailing, apparently in consequence of intemperate habits. He suffers from bronchitis, and on each occasion that a blister has been applied to the surface, it has sufficed to reproduce, in the white skin, several irregular spots of the original dark colour, which have hitherto

cases of this rare malady; one in April last, and the other quite recently. The first of these well illustrates both the constitutional symptoms and the external signs which I have just described.

W. B., aged twenty-four, an engineer's labourer, first came under my observation on the 12th of April, 1864, when he was admitted into Cambridge ward, under my care. He stated that he had been in good health until about nine months previous to his admission, when an abscess had formed in the left hypochondriac region. A few weeks later, after the healing of the abscess, he had been seized with severe pain in the left hip, shooting downwards along the course of the sciatic nerve; and the pain had continued with varying intensity ever since. About the same time he had begun to lose strength, becoming very rapidly weaker during the last ten days. He had for some weeks lost his appetite, and had been affected with nausea and occasional retching, with, for the last day or two, vomiting of food. He said that he had suffered latterly from sudden attacks of breathlessness and faintness on exertion; and he actually fainted while under examination in the waiting-room. His face had a sunburnt appearance, and his wife and mother, on being questioned, said that they had observed his complexion becoming darker for the last three or four months. From the above symptoms I at once diagnosed the case as a genuine example of Addison's disease.

On the day after admission the patient could with difficulty be raised up in bed on account of tendency to faintness. The pulse was extremely feeble, small, and compressible; the heart's impulse feeble, and the sounds exceedingly faint; the skin cool and soft; the tongue moist and clean; the urine dark-coloured, acid, copious, free from albumen, specific gravity 1022; the bowels costive. General hue of skin dusky; the face somewhat darker, resembling that of a person bronzed by exposure; the back and sides of the neck darker than the face; the hands much darker than the arms, and the knuckles sensibly darker than the surrounding surface, as were likewise the cicatrices of several former injuries. Here and there on the neck were a few well-defined almost black specks. The skin over the spine, for nine inches downwards from the eighth dorsal vertebra, was much darker than the

remained, but have certainly not spread. The heart's action is weak, the heart-sounds and pulse are feeble and the circulation far from vigorous.

Should any post-mortem examination be hereafter obtained in this, I believe, unique case, it will be most interesting to learn whether any abnormal condition of the supra-renal capsules be found to exist.

rest of the back. Over the left hip, where a blister had been applied four months previously for the relief of the sciatic pain, was an oblong surface, four inches by five, much darker than any other part of the body. At some parts near the edges and centre of the patch, where apparently there had been superficial ulceration, the skin was nearly as black as that of a negro. The nipples and areolæ were very dark. The cicatrix of the abscess in the left hypochondrium was itself pale, but was surrounded by a dark-coloured ring. The penis and scrotum were extremely dark; the thighs and legs much less dark than the body. The lips had a dark, almost black, stripe of varying breadth extending along their whole length. The buccal mucous membrane, with the exception of a few paler spots, was also of a dark, almost black, colour, and there were several well-defined dark patches on the gums of the lower jaw. The conjunctivæ were clear and perfectly white. The patient became progressively weaker from day to day; vomiting recurred after almost every meal; the pulse became quicker and nearly imperceptible; the heart-sounds were only audible on very close examination; the sense of faintness was constant and intense; and the surface of the body became cold to the touch two days before death, which took place five days after his admission. His intellect remained unimpaired to the last.

At the post-mortem examination, the body was spare, but not much emaciated, and its general hue dusky, but paler than it had been during life. The muscles were of a normal red colour; the blood thicker and darker than usual, presenting under the microscope an excess of red corpuscles. The lungs were quite free from tubercle. Many of the mesenteric glands were enlarged; their surfaces were pale and yellow, and on section they had a somewhat dry, cheesy texture. The vessels of the small intestine were much congested. Peyer's patches were enlarged, prominent, of yellowish-white colour, and remarkably opaque. The solitary glands scattered throughout the ileum were also enlarged. The supra-renal capsules were closely invested with very dense connective tissue and were both much enlarged; they were of very firm consistence, and on section no distinction was visible between cortical and medullary substance, the whole organs being converted into masses of firm, yellowish-white tissue, in parts semi-transparent. Scattered throughout these masses were numerous opaque yellow deposits, varying in size from a hemp-seed to a small bean, of cheesy consistence mixed with gritty matter. On laying open the pelvic fascia at the upper edge of the true pelvis on the left side, about half

an ounce of thick, creamy-looking pus escaped. The abscess was connected with carious bone at the sacro-iliac synchondrosis.*

You will have noticed, in the case I have just read, the presence of almost every one of the constitutional symptoms which I have enumerated above as being characteristic of Addison's disease; and although the asthenia appears to have supervened contemporaneously with the sciatic pain, the latter could not even during life be considered as its cause, it being altogether insufficient to account for the severity of the symptoms. Again, with reference to the external signs, you will have seen that this case presented all those which I have described as specially diagnostic of the disease: the face, neck, and hands were darker than the general surface; the areolæ, penis, and scrotum were the darkest parts of the natural skin, and the cicatrix of the blister on the hip was almost black, whilst the deeper cicatrix of the abscess remained pale; lastly, the lips and buccal mucous membrane were deeply discoloured with the characteristic stains.

The other case we have had in the hospital during the past year is that to which I have already referred as having been diagnosed independently of the external signs.

On the 20th of January last, E. W., a girl aged twelve years, was brought to me in the out-patient room. She was scarcely able to move, had an extremely languid, listless, exhausted aspect, a pallid countenance, and a remarkably small feeble pulse. Her breathing was frequently interrupted by sighing and yawning, and the slightest attempt at exertion caused her to retch. Her eyes were large and prominent, and the conjunctivæ peculiarly white. Her skin was cool and her tongue clean. There was no cough nor diarrhœa. No other disease being discoverable to account for her extremely asthenic condition, I immediately diagnosed the case as a true example of Addison's disease, though without that marked discoloration of skin which generally accompanies it. On inquiring into her previous history, I learned that she had suffered from bronchitis in July, 1864, on recovering from which

* This case is fully reported in the *Transactions of the Pathological Society*, Vol. xv., pp. 228-30. In addition to the facts related above, it should be added that the heart had much fat upon its outer surface, and that its right cavities were occupied by a large firm yellow clot entangled in the cords of the tricuspid valve and sending a process into the appendix auriculæ. On microscopical examination, the cheesy deposits in the capsules were found to consist of opaque amorphous granular matter, mixed with some granular shrunken cells and nuclei and some oily matter. The intervening semi-transparent portions consisted of similar granular material intermixed with fibrous tissue.

she was sent into the country; and I further elicited the fact that on her return home, after an absence of six weeks, apparently quite well, her parents had remarked that she looked somewhat sunburnt, which they attributed to her having been much in the open air. This slight dinginess of complexion still remained, but was insufficient to afford any decisive confirmation of the diagnosis. She had continued without any definite symptoms of illness until a few days before she was brought to the hospital, although her father had regarded her as "drooping" during the three or four previous weeks. On Sunday, Jan. 15th, she had been sick for the first time, but had continued to attend school until Wednesday, the 18th, on which morning the sickness recurred, and she complained of feeling cold. Her mother had then administered a strong cathartic powder, which was followed by copious purging and vomiting, and from that time intense depression had set in. The patient not wishing to come into the hospital, I attended her at home for several days, during which she slightly rallied, the sickness abated, and she was able to take and retain food. On Jan. 24th she began to cough, and expectorated a small quantity of glairy mucus, sometimes tinged with blood; the vomiting returned in its former severity, and she was admitted into Murray ward on the 26th.

On examination after her admission a slight duskiess was observable, not only on the face, hands and neck, but also on the abdomen and about the knees and axillæ; the nipples also appeared slightly dark. On examining the mouth minutely I detected a single dark stain, of the size of a large pin's head, upon the mucous membrane lining the inside of the right cheek, but no other definite patch or stain was found on any part of the body. There was slight dulness on percussion and bronchial breathing below both clavicles; but she had scarcely any cough, and no expectoration after her admission into the hospital. The asthenia, however, increased; she always vomited soon after taking food; and retching, faintness, and failure of the pulse came on whenever she was moved. She scarcely slept at all, became very restless on the 27th, and died rather suddenly on the evening of Jan. 28th, retaining her consciousness to the last.

At the post-mortem examination, the aspect of the body was that of a person with a naturally dark skin, but with fair chest, feet and legs. There was a moderate amount of fat on the thorax and abdomen, and the muscles were firm and red. The apices of both lungs were puckered on the surface and consolidated by the deposition of tubercle, chiefly of the grey semi-transparent kind. There were no cavities, but the tubercle

was beginning to soften at one or two points in the right lung. There were also two or three small masses of grey tubercle in the lower lobes of both lungs. Nearly colourless clots of moderately firm consistence were found in all the cavities of the heart, adhering to the musculi pectinati and chordæ tendineæ, and extending into the great vessels. There were a few small reddish patches of congestion near the pyloric extremity of the stomach. In the lower part of the ileum Peyer's glands were more prominent than usual, and the mucous membrane was somewhat congested; the solitary glands were also enlarged, and a few of them were opaque and slightly yellow. The supra-renal capsules were both much enlarged and their fibrous envelopes thickened. The right capsule was firmly adherent to the liver, kidney and diaphragm, and the left to the kidney and diaphragm. Both capsules were hard and somewhat nodulated; and, on section, no trace of the normal structure could be discovered, nor any distinction between cortex and medulla. The natural substance of the organs was chiefly replaced by masses of opaque yellow matter, partly of cheesy consistence and partly friable, separated from each other by a greyish semi-transparent tissue of tough consistence. Beneath the thickened fibrous envelope of the right capsule was a small collection of puriform fluid. The disease was apparently less advanced in the left than in the right capsule, there being a larger portion of the greyish semi-transparent tissue, and smaller deposits of the cheesy material, in the former than in the latter.*

* My friend and colleague Dr. Burdon Sanderson made at my request a microscopical examination of the left supra-renal capsule from this patient, of which I append the notes already published in the *Transactions of the Pathological Society*, Vol. xvi., p. 249.

“The capsule, which is still attached to the kidney, is of the size and shape of a walnut. It is closely invested with a covering of dense fibrous tissue, about half an inch in thickness, which is in some parts separable from the external surface of the organ, in others firmly adherent, and, as it were, incorporated with it. In the section of the organ no distinction can be made out between rind and kernel; but it exhibits several varieties of structure and consistence without definite arrangement. Some parts are of a pinkish colour, somewhat translucent, and of firm consistence; others are white, soft, of a consistence approaching to cream-cheese, and occasionally gritty. Between these there are various gradations; thus in many parts the tissue has lost its translucency and colour, but not its consistence. Between the translucent parts and opaque parts there is a great difference in structure, as shown under the microscope. The former exhibit (even without the addition of acetic acid, and much more distinctly after the addition of that re-agent) nuclei which are embedded in a finely granular stroma. The granular appearance is owing partly to albuminous granules (which disappear

In this case you will remark that the constitutional symptoms, although equally severe, if not more so, than in the case previously narrated, had set in suddenly only a very short time before death, instead of coming on gradually during some months. You will observe, moreover, that the discoloration, although strictly characteristic as far as it went, even to the single pin's-head stain on the buccal mucous membrane, was so much less advanced than it was in W. B.'s case, or than it generally is in conjunction with the latest stage of the constitutional symptoms, that it failed to attract my attention until I sought for it in order to confirm the opinion I had already formed. Nevertheless the fact remains, which in the present state of our knowledge of the disease, I cannot pretend satisfactorily to explain, that, in spite of these discrepancies between the two cases during life, the supra-renal capsules were found after death in an almost identical state of degeneration.

In striking contrast to the case of the girl E. W., was that of a woman, Mrs. W., aged thirty-one, who came under my care several years ago as a patient at the Western General Dispensary. In her case the most obvious and striking feature was the intense and characteristic discoloration of skin, which led me at first sight to diagnose Addison's disease, even before inquiring into the constitutional symptoms. She attributed her illness to a strain received in turning a mangle five years before, when she fancied that something gave way in her right side, and she was laid up in bed for some days with severe pain in the right iliac region. From that time she had never been robust, but began to droop more decidedly three years later; became worse in September, 1858, and presented herself at the dispensary in January, 1859. She had suffered from occasional pain in the loins, sickness and vertigo. Her skin was cold and appetite bad. The pulse was under 80, and excessively feeble; the heart's action weak, the lungs apparently healthy, but the respiration feeble. The catamenia had been irregular, and there

with acetic acid), partly to fat-granules. These nuclei are usually oval or round; but in some parts they are elongated, in a definite direction, into spindle-shaped bodies or nuclear fibres. The opaque portions exhibit no nuclei or cell structures, either with or without acetic acid. They exhibit, in fact, only albuminous, fatty granules, the latter being more abundant in proportion to the advance of the process of softening. No structure having any resemblance to tubercle is to be found. It is tolerably evident that the change consists (1) in the development in the organ of the firm tissue, of which the structure is above described, viz., an albuminous exudation undergoing gradual transformation into fibrous tissue, and (2) of the fatty degeneration of this substance."

were signs of extreme anæmia, the lips being livid, the gums blanched, and the tongue pale. The whole uncovered surface of the skin had a dusky hue, as if from greenish pigment; but the discoloration was not of uniform shade, and was most evident upon the forehead, temples, and sides and back of neck. On the sides of the face and neck, and on both arms, were several almost black spots, with well-defined margins, resembling nævi, but which the patient assured me had appeared within the last three months. The discoloration on the body was less deep, and, with the exception of some dark patches in the dorsal region, more uniform in shade than that on the face and neck. There was an ill-defined, dark-brown line along the red portion of the lower lip, near the margin of the skin; the buccal mucous membrane on both sides had a sallow hue, with several distinct light-brown stains; the conjunctivæ were clear and pearly. The hair had a strikingly dull, dusky appearance, and was said to have become much darker during the few preceding months. She complained of smarting in the darker portions of the face and neck when warm. Was very wakeful at night.

From this time she continued to suffer from occasional sickness, vertigo, and pain in the loins; the anæmia and coldness of surface increased; the pulse soon became too feeble to count; palpitation, breathlessness and a tendency to syncope supervened, and she sank in about two months from the time I had first seen her. For several days before death she was unable to sit up, and had palpitation and retchings on the least movement. A disagreeable fetid odour was observed about her person during the last two days of life. She was conscious to the end.

At the post-mortem examination, the whole body was of a dusky mulatto colour, but the hue was darkest on the abdomen, and next to this on the face, neck, insides of the elbows and margins of the axillæ. There was little or no emaciation in any part, and there was a thick layer of fat under the thoracic and abdominal integuments. The muscular tissue was normal in appearance. The lungs were perfectly healthy, with the exception of a very few small yellow tubercles in the apices. The heart contained a large fibrinous clot in the right cavities, extending into the pulmonary artery. The under surface of the omentum, the peritoneal lining of the diaphragm and abdominal parietes, and the peritoneal covering of the liver were studded with small opaque, yellowish, irregularly stellate bodies, which could be readily scraped off the serous surface with the back of a scalpel, leaving the subjacent membrane apparently intact, but slightly opaque. The peritoneal covering

of the small intestines was slightly roughened by the presence of small, perfectly transparent granular bodies, closely aggregated upon the serous surface. There were some patches of congestion on the mucous surface of the cardiac end of the stomach, which was otherwise healthy. Both supra-renal capsules were converted into hard yellowish masses. On section, the left capsule was found to consist entirely of yellow cheesy matter, apparently tuberculous; the right capsule was in a similar state, but softened at the centre, from which oozed a few drops of thick creamy fluid when the capsule was divided. There remained no appearance either of cortical or medullary substance.*

The three cases I have now related not only well illustrate, respectively, though in different degrees of intensity, the constitutional symptoms and external signs of Addison's disease, but also show that on the one hand these symptoms may run through a slow, chronic and progressive course, extending over several months, or even years, and that on the other hand the disease may remain latent until near the close of life. I say "latent," because it would be contrary to all analogy to suppose that any important change could have taken place in the condition of the supra-renal capsules within the last ten days of life, during which only in the case of E. W., any definite symptoms of the disease were visible. It is in these latent cases, especially, that the discoloration of the skin sometimes affords the earliest indication of the impending danger. The records of this hospital contain the notes of a case which illustrates, even more strikingly than that of E. W., the occasional latency of Addison's disease until almost the eve of its fatal termination, and also the occasional appearance of the discoloration of skin some time before the accession of any of the constitutional symptoms. In the case of E. W. some slight indisposition had apparently existed during three or four weeks, and the characteristic symptoms supervened ten days before death; whereas, in the case I am about to relate, the history would appear to show that the patient had continued to feel perfectly well until within four days of death, although his friends had observed the discoloration of skin for several weeks previously.

W. P., aged twenty, was admitted into the Middlesex Hospital on the 11th of July, 1854, under the care of Dr. Seth Thompson. The colour of his skin had been changing for six weeks, and more rapidly

* This case is reported in the *Transactions of the Pathological Society*, Vol. x., p. 269. The fact of the strain in the back so long before the patient's last illness is not, however, mentioned in that report, for at that time experience had not led me to attach the importance I now do to such local injuries, with reference to the causation of the disease.

during the last few days. The patient stated that he had first begun to feel languid and unwell two days before his admission; but the feeling increased so rapidly that he was unable to move about when brought to the hospital. Previously to this attack he had always enjoyed good health, had been of sober habits, and well fed. On admission, his skin and conjunctivæ were of a peculiar dark, dirty-brown colour; the skin was covered with a cold clammy sweat, and his pulse was scarcely perceptible. He was restless, and answered questions with difficulty, though perfectly conscious. He stated that the only pain he had was deep-seated, and in the region of the liver. The cold sweat continued, and he died the following morning.

At the post-mortem examination, the body was extremely muscular and well-formed, the entire surface was of a uniform and peculiar brown colour; there was slight lividity of the lips and back. The pericardium was firmly adherent, and the whole of the solitary glands of the small intestines were enlarged, forming little solid eminences, the size of millet seeds. Otherwise the internal organs were all healthy, with the exception of the supra-renal capsules. These were both much enlarged, forming dense solid tumours, nearly half the size of their respective kidneys but retaining their characteristic form. On section, they were seen to be composed of an opaque yellow substance, of the consistence of soft cheese. Portions of this substance appeared to be tubercle, as it is seen in the brain; whilst other portions were soft and broken down, like the matter of a scrofulous abscess. In one or two places portions of the natural structure of the supra-renal capsules could be detected.

You will find this case published at greater length in the *Medical Gazette** by Mr. Sibley, about the time when the announcement of Dr. Addison's discovery had excited great interest on the subject amongst the profession; and I quote it with the more pleasure because it is an example of the great value of accurate clinical observation. To the details of the case no peculiar significance or importance was attached at the time, for the connexion between the symptoms observed during life and the local disease found after death was then altogether unsuspected; and yet both the appearance and condition of the patient and the state of the supra-renal capsules were so accurately recorded, as to afford strong and impartial corroborative testimony to the existence of that connexion, when discovered. The apparent cause of the fatal seizure in the above case is not stated; but it seems, so far as I can judge, that in

* *Medical Gazette*, Vol. xxxiii. p. 188.

these latent cases, when once the local affection has reached a certain stage, any depressing influence may serve to bring on the characteristic constitutional symptoms of the disease, and lead to a speedily fatal result. I believe that the strong purge which was administered by E. W.'s mother, and which was followed by such extreme depression, did, in fact, materially hasten her death; and I saw several years ago, in private practice, a case in which over-fatigue appeared to have the same effect.

The first attack of depression is, however, by no means necessarily fatal in every case; hence an obvious explanation of the intermissions which occasionally take place in the progress of this disease. A case in point was communicated by me, last year, to the Pathological Society, which occurred in the practice of Mr. Charles L. Hodson of Bishop's Stortford.* The patient, a gentleman aged twenty-one, had suffered in childhood from strumous ophthalmia, and, about two years before death, had an attack, supposed to be enteritis. In the spring of 1863 he was strong and hearty; but, while abroad during the summer, he began to suffer from occasional attacks of prostration, that is to say, after a long day's walk, he would be so exhausted that several days elapsed before he rallied, and each of these failures of strength seemed to be followed by less perfect reaction than its predecessor. He returned to England in November, and was tolerably well until early in February, when, after a so-called bilious attack, he became much weaker, and, in the beginning of March, came under Mr. Hodson's care. The alternating states of extreme weakness and temporary rallyings, during which latter he was able even to ride on horseback, continued until the 4th of April, when, after a short drive, he became faint and took to bed. A few days later, sickness supervened, and persisted in spite of every remedy until the patient died from exhaustion on the 16th of April. At the post-mortem examination, the capsules presented the change characteristic of Addison's disease, and they were invested with firmly adherent connective tissue; the lungs and all other organs were perfectly healthy.

Looking at this case in the light thrown on it by several others which have come under my notice, in which the disease appears to have originated in strumous subjects from some mischief in the textures around the capsules, I cannot but think that the attack of supposed enteritis may have been in reality the starting-point of the disease, which began to manifest itself a year later. The temporary rallyings

* *Transactions of the Pathological Society*, Vol. xv. p. 231.

in this case were probably due, in great part, to the favourable circumstances in which the patient was placed. In the same manner I think it very possible, that, had our last patient E. W. come into hospital at once, the faint attempt at rallying, which she made during the first few days after she came under treatment, might, with the aid of good food and nursing, have been better maintained, and her life might have been prolonged for some time.

One of the points to which I have directed your attention, in the history of this disease, has been that the discoloration of skin occasionally appears some time previous to the accession of any of the characteristic constitutional symptoms. On the other hand, as I have already stated, cases of the real disease sometimes occur in which no discoloration of skin has existed. Such cases are, indeed, rare, and appear only to be met with where life has terminated at a comparatively early stage of the local affection, either in consequence of complication with some other exhausting disease, or else, possibly, from the feeble constitution of the patient. I shall briefly quote, in illustration of this fact, a case to which I have already referred in a former part of my lecture.

A mechanic, aged thirty, was admitted into the hospital, under the care of Mr. Hulke, in September, 1862, for caries of the spine and psoas abscess, accompanied by a degree of feebleness quite out of proportion to the loss of flesh, and by great irritability of stomach and obstinate constipation. On rising from his bed on the morning of Nov. 6th, to go to the neighbouring watercloset, he became faint, grew weaker during the day, and expired at eight o'clock on the following morning. At the post-mortem examination, an abscess was found in the course of the left psoas magnus muscle, containing nearly a pint and a half of pus. It was connected with caries of the bodies of the third and fourth lumbar vertebræ, and also with another abscess on the right side of the spine, which extended upwards from the third lumbar to the twelfth dorsal vertebra. The supra-renal capsules were enlarged, hard, and nodulated. On section they were found to be infiltrated with a nearly homogeneous translucent material, mottled with a few yellowish friable specks; but some traces of the normal structure were discovered on microscopical examination. The apices of the lungs contained a few scattered deposits of tubercle.*

* For further particulars of the above case see the *Transactions of the Pathological Society*, Vol. xiv., p. 254. It is important, in reference to the causation of the disease in the supra-renal capsules, to observe that the capsule which was contiguous to the older spinal abscess was the most disorganised.

Here, therefore, is a case in which, although the constitutional symptoms in the main agreed with those of Addison's disease, there was no discoloration of skin, and in which also it seems certain that the local affection was at the time of death still in a comparatively early stage; for the material, with which the supra-renal capsules were infiltrated, had not yet undergone degeneration into that yellow cheesy matter which was found in all the cases I have previously described. The patient, in fact, doubtless died much sooner from the complication of the supra-renal with the vertebral disease, than he would have done from either of them separately.

If, in cases such as the one last mentioned, Addison's disease is liable to be overlooked, on account of the absence of that discoloration of skin which is its most obvious feature, on the other hand I should warn you against an opposite source of error in diagnosis—namely, that of mistaking other forms of discoloration of skin for the peculiar discoloration of Addison's disease. This is no unnecessary caution; for within the last year I have seen three cases of discoloration of skin which certainly bore a strong general resemblance to that of Addison's disease, and had consequently been mistaken for it; but on careful examination I found the discoloration in all three cases to be wanting in the true diagnostic signs. We had also in the hospital, the year before last, a very remarkable example of the same class, which might readily have been mistaken, by anyone personally unacquainted with the disease, for a genuine case. As the power of distinguishing ailments of secondary importance, from diseases of the gravest character, is no less valuable in practice than the skill to diagnose these last when they are really present, I will read you the notes of this case in some little detail, and shall then direct your attention to the several points of resemblance, and also to the conclusive discrepancies, between the constitutional symptoms and external signs presented by this spurious case, and those which exist in true cases of Addison's disease.

E. A., aged sixty-five, was admitted into the Middlesex Hospital under Dr. Stewart's care in June, 1863. She was very poor, ill-fed, and uncleanly, and had apparently been tramping about the country for months. Stated that she had always been delicate, and had been ailing for about eighteen months, but more especially since the beginning of the year. Her weakness had increased very much during the last eight weeks, and from having been stout she had become much emaciated. Was free from pain, but experienced a sense of sinking at the epigastrium, and a disinclination for the slightest exertion. Her appetite

had never been impaired, and she had suffered neither from nausea, vomiting, nor breathlessness on exertion. Was unable to say when her skin, which had formerly been soft and fair, began to change colour. Her daughter, however, stated that she had observed her mother's face becoming tawny about two years before. About twelve months later the yellow tinge had appeared to deepen, and she subsequently observed a brown colour on the chest and back, which had continued to spread and increase up to the time of her admission. On admission her face was very yellow, and the conjunctivæ slightly so. The skin was deeply bronzed on the chest and back, more lightly on the thighs, but scarcely at all on the legs and feet, which were considerably œdematous. Pulse 108, moderately full; heart-sounds healthy. Her chief complaints were of extreme sinking and prostration, and of craving appetite.

The patient was temporarily transferred to my care in the month of August, when the following notes of her case were taken:—

Aug. 24th.—Pulse 86, of fair volume, not particularly compressible. Face scarcely sallow, but a little dark under the eyes. Anterior surface of chest to umbilicus of a brownish-black hue, interspersed with numerous small, well-defined spaces of normal-coloured skin. Axillæ paler than chest, and, in the lower part of the left axillary region, a space of normal-coloured skin, the size of a hand. Nipples and areolæ of natural colour. Discoloration on abdomen more uniform than that on chest; no increase of darkness round umbilicus. Groins and pubes less bronzed than surrounding surfaces. Thighs paler than body, but presenting, especially on the insides, a number of small, well-defined, dark patches, some corresponding in colour with the bronzing on the body, and others having a reddish hue. On examination under a lens, some of these are rough, or covered with a small crust, as if they were the remains of former eruption. Discoloration on back paler than on chest, but of the same mottled character, the patches of which it consists not being of uniform shade, but some much darker than others and with abrupt margins, interspersed with small spaces of normal-coloured skin. The legs, below the knees, and the arms are almost entirely free from bronzing, but present numerous small, isolated, dark spots similar to those on the thighs. Hands of natural colour; lips and buccal mucous membrane red and normal. Conjunctivæ slightly yellow and muddy-looking. Discoloration appears to be superficial, and, under a lens, the darkened cuticle in some places looks raised and in others a little rough.

A few days later, in order to determine the seat of the discoloration, the cuticle was raised in two small patches on the chest by the use of

liquor vesicans, and for some weeks after the healing of the blistered surfaces, they remained pale, but gradually resumed the dark colour of the surrounding skin. Under tonic treatment, and with the use of alkaline warm baths, the discoloration very considerably diminished, while with good diet and management the woman's health greatly improved. She regained her flesh and strength, and left the hospital apparently in good health.*

You will, no doubt, have perceived, while listening to this case, that there were several strong points of resemblance, especially in the early history, to what I have described as occurring in genuine cases of Addison's disease. Feelings of languor and debility, dating backwards at least as far as eighteen months, rapid increase of weakness during the last few weeks previous to her admission, epigastric discomfort, and disinclination for the slightest exertion,—these were all constitutional symptoms known to be amongst those usually met with in that disease. Again, the appearance of the discoloration first on the face some two years before, and its then gradually spreading over the general surface of the body, and deepening in colour until it assumed a brown, and in parts an almost black hue,—these, I say, were external signs which undeniably, at first sight, bore a strong resemblance to the usual course of the discoloration in Addison's disease. But, on the other hand, all the most characteristic constitutional symptoms—viz., feebleness of pulse and of heart's action, breathlessness and faintness on exertion, nausea, vomiting, and loss of appetite, were altogether absent; and, what appeared to me even more conclusive, was that those symptoms which were present were all easily referable to an apparent and sufficient cause. In fact, the woman had never been strong, she had led a life of hardship and over-exertion, and as she grew old was sinking from want of proper food and rest. Again, the course in which the discoloration made its appearance was, as I have said, very similar to that usually observed in Addison's disease; but the discoloration itself, when closely examined, was in all respects, both as regards its nature and location, totally uncharacteristic. First, as regards its nature, I have already explained that, in cases of the true bronzed skin of Addison's disease, there are rarely or never any definite lines of demarcation between the darker and lighter parts, but the darker fade insensibly into the lighter, and these into the normal-coloured skin; as was well seen in our last case, that of E. W. In this

* This patient was exhibited at one of the meetings of the Pathological Society and her case is published in the *Transactions*, Vol. xv., pp. 266-8.

woman's case, on the contrary, the whole discoloration was formed of dark patches with abrupt margins, everywhere interspersed with small, well-defined spaces of normal-coloured skin. In the true discoloration, small dark spots, like moles, are frequently found, but always, I believe, on the already discoloured parts; whereas in this woman the small, isolated, dark spots were all on the paler or uncoloured skin. In Addison's disease, also, the discoloured skin remains soft and smooth; whereas in this case the darkened cuticle was in some places raised, and in others rough. Secondly, as regards its location, we have seen that the true discoloration is usually darker on the face, neck and hands, in the axillæ and groins, and on the cicatrices of superficial injuries, than it is on the neighbouring surfaces; whereas the spurious discoloration, in this case, was absolutely palest on all these parts. In all the genuine cases of bronzed skin which I have seen, the nipples and areolæ were deeply discoloured; whereas, in this woman, they were of the natural colour, contrasting strongly with the brown hue of the surrounding integument. Lastly, there were no signs whatever of the stains on the lips, gums, and buccal mucous membrane, which, when present, are amongst the strongest characteristic features of the discoloration in Addison's disease. Moreover, as a post-mortem examination affords the only indisputable evidence regarding the existence or non-existence of this disease, I may mention that I have lately read a case recorded by a French physician (Dr. Vernois), which was almost precisely similar to the above, but in which the woman died instead of recovering, and the supra-renal capsules were found to be healthy.*

I have dwelt at considerable length upon the last two cases, because I am convinced that the incredulity, which still lingers in the minds of many members of our profession, as to the reality of Addison's discovery, has been mainly due to the misunderstanding of cases observed by themselves or reported by others, and which have been, in many instances, either cases of the true disease overlooked during life on account of the absence of discoloration, or, on the other hand, cases of spurious discoloration, in which, of course, the true disease was not found after death. I have never met with any professional man who had had the opportunity of watching the course of a genuine, well-marked case, and who still disbelieved in the existence of the disease.

And now, what is the true nature of Addison's disease? and what

* See Report on *Diseases of the Supra-renal Capsules*; Case No. 9 in Table A.

relation does the change in the supra-renal capsules bear to the constitutional symptoms and external signs, which, as we have seen, are associated with it? Neither of these questions can be satisfactorily answered at present, but it will be well, at least, to understand the exact state of our knowledge with respect to both of them. The deposit in the supra-renal capsules, in cases of Addison's disease, has been frequently called tubercular, and I have, with the reservation already explained, retained the term, on account of the difficulty of finding any other which would more accurately express its true character. The term tubercular, indeed, implies a morbid change of a rather lower type than that of the material of which the deposit in the supra-renal capsules consists in its earlier stage, yet the use of the term fibroid or fibro-cellular would, on the contrary, imply a structure of higher type than is really found in the diseased capsules. I am aware that very accomplished microscopists state that the deposit contains no structure resembling tubercle; yet I am still of opinion that, without being identical with tubercle, it is more closely allied to it than to fibro-cellular tissue, to which, in its earlier stages, its microscopical characters no doubt bear a stronger analogy. It is probable, indeed, considering the number of cases in which caries of the vertebræ and lumbar or pelvic abscesses have been found in association with this disease, or in which deep-seated lumbar pain has been recorded amongst its symptoms, that the morbid change in the supra-renal capsules may, sometimes, at any rate, originate in inflammation, and that, in such cases, the deposit is an inflammatory exudation, which at first takes the form of low-organized, fibro-cellular tissue, and, having little stability, tends rapidly towards degeneration. But, even in this view of the case, the similarity of the deposit to tubercle in its proneness to degeneration and also in the degenerative processes which it undergoes, and the frequency with which, as I have said, we find it occurring in strumous subjects, both appear to me to place it, clinically at least, in the group of tubercular affections.

The exact relation between the change in the supra-renal capsules and the constitutional symptoms and external signs of Addison's disease, it is impossible at present to determine, as we really know nothing respecting the functions of those organs; but that there is an intimate relation between them appears to me unquestionable. It is perhaps possible that there may be a common cause, in the form of some constitutional disorder, inducing both the local affection and the outward manifestations; but the fact, that, in a considerable number of cases, in which the symptoms have been strongly marked during

life, no trace whatever of disease has been found after death, except the change in the supra-renal capsules, appears to me to afford very convincing evidence that the local affection and the external symptoms stand to one another in the relation of cause and effect. This opinion derives additional confirmation from the circumstance, that, although, in several recorded cases, the supra-renal disease has been apparently preceded and set up by neighbouring irritation arising from lumbar abscess or caries of the spine, yet in no case have the symptoms of Addison's disease appeared in conjunction with these other complaints, unless the change in the supra-renal capsules had also taken place. As to the manner in which the supra-renal change operates as a cause in producing these symptoms, it may be, as has been supposed, by Drs. Wilks and Habershon, that the symptoms are due to irritation of the nerves connected with the solar plexus and semilunar ganglia; but as yet this theory, although in some respects plausible, appears to me to be unsupported by any adequate proof. It may be supposed, on the other hand, that these symptoms depend upon perversion or destruction of the functions of the capsules themselves; but there are difficulties also in the way of either of these hypotheses. If the symptoms were due to destruction of function, we should expect them equally to follow the destruction consequent on cancer, which we have seen not to be the case; and their being due to perversion is difficult to reconcile with the fact that the morbid change in the supra-renal capsules must, in many instances, have made considerable progress some time before the accession of any of the constitutional symptoms. In truth, this portion of the pathology of Addison's disease remains as little understood as it was at the time of the publication of Addison's discovery.

Lastly, on the subject of treatment I can offer, unfortunately, but few observations. Only two cases have come under my care for more than that short period, immediately before death, when the state of the patient is as hopeless as that of a person sinking in the last stage of phthisis; and of those two, one died prematurely, as I believe, from the effects of over-exertion. Treatment directed toward quieting the gastric irritation and improving the patient's powers of taking and digesting food, together with care in securing the avoidance of fatigue and of all other causes of depression, may, and I believe will, in many cases, if employed early enough, tend to prolong life and to ward off the fatal asthenia, even after the organic disease is confirmed. In Mrs. W.'s case I found that compound mixture of iron and cod-liver oil had for some time an apparently beneficial effect; and, in

another case, nitro-muriatic acid in combination with a vegetable bitter, alternated occasionally with citrate of iron in an effervescent form, no doubt succeeded for a while in relieving the more urgent symptoms. In our last case, that of E. W., the temporary rallying seemed due to the use of effervescing medicine with chloric ether, and to the administration of liberal support in the form of egg and brandy, beef-tea and milk. But with regard to this disease, it is at present the study of its diagnosis and pathology, even more than of its treatment, which is important, for hitherto every well-authenticated, genuine case has sooner or later proved fatal; and this, I fear, must continue to be the case until further researches may enable us to diagnose the disease in those earlier stages in which it may perhaps be possible to arrest its progress, or to avert for an indefinite time the fatal termination.

LECTURE II.*

TYPICAL CASE NOW IN HOSPITAL—SYMPTOMS OF DISEASE OF VERTEBRÆ—
PROBABLE ORIGIN OF DISEASE IN SUPRA-RENAL CAPSULES—CASE WITH
TUBERCLE OF LUNGS AND PERITONEUM—DISCOLORATION OF SKIN NOT
DUE TO TUBERCULOSIS—CASES UNDER OBSERVATION—REMARKS ON
TREATMENT.

GENTLEMEN,—About a year ago I brought under your notice the subject of Addison's disease, of which we had then recently had the opportunity of studying two well-marked cases. In my lecture on that occasion, I endeavoured to give you a brief summary of the present state of our knowledge regarding the nature and symptoms of that remarkable disease. It is not therefore, my purpose, to-day, to attempt the same general survey of the subject; but, rather, to direct your attention, somewhat more in detail, to a few points, on which, I cannot but think, a little more light has been thrown by the cases we have had under observation since that lecture was delivered.

During the last twelve months, it has singularly happened, that we have had, in the wards of the hospital, four well-marked cases of this uncommon disease; namely, two under Dr. Thomson's care, one under the care of Dr. Stewart, and one under my own care. My own case and one of Dr. Thompson's left the hospital much benefited by treatment, and are still under my occasional observation as out-patients; Dr. Thompson's other case proved fatal on the 2nd instant, and the case under Dr. Stewart is at present in Founder ward. The supra-renal disease, in this patient, is, I scarcely doubt, associated with caries of one or more vertebræ, a circumstance by no means unusual in Addison's disease: but the case is none the less, in its history and progress, a typical example of that disease, and the discoloration of skin is, perhaps, the most characteristic of any which has come under my observation. Partly on this account, and partly also because you have still the opportunity of verifying my statements, I proceed, with Dr.

* Reprinted from the *British Medical Journal*, 1866.

Stewart's permission, to read you an abstract of the notes I have taken of the case.

C. S., aged 32, was admitted an in-patient on the 13th of February. In early life, he worked as an agricultural labourer in his native county of Herefordshire, but for the last thirteen years had been employed as a coal-porter at a London wharf. About three years previous to the commencement of his illness, he had strained his back severely in the lower dorsal region while shunting a loaded coal-truck, and had felt as if something gave way at the moment of the accident. For some days he suffered much pain in the part, and more or less ever afterwards, though he was able to continue his work. He did not himself attribute the origin of his illness to this injury, and, indeed, attached so little importance to it, that I only elicited the fact by careful inquiry. He stated his health to have been uniformly good until about eight or nine months before his admission to the hospital, when his illness began with headache, sweating, and debility, followed by loss of appetite, sickness, and breathlessness on exertion, with pain in the lumbar region and right flank. The symptoms of asthenia steadily increased; faintness supervened on his making any muscular effort, and he had been incapacitated from labour for about two months, when he came under our observation a month ago. The gastric disturbance had also continued; he had frequent nausea and retching, and generally vomited after taking food; the pains in the loins increased in severity, and became associated with gastralgia and with pains in both hypochondria: and these symptoms were all much aggravated by any attempt to move about. Three or four months after the accession of the first constitutional symptoms, his wife had noticed a slight duskiness of colour, which, she believed, was at first confined to the face and hands, but which had gradually spread over the whole body and progressively deepened in hue.

On careful examination, a few days after his admission, I found the skin generally of an olive-brown colour, which was especially marked on the face, hands, and neck, the shade being deepest on the more exposed parts, and least dark on that part of the forehead covered by the hair. The chest, down to the fourth rib, was paler than the face and neck, but the nipples and areolæ were very dark. From the fourth rib downwards the colour gradually deepened; the abdomen was very dark, the groins still more so, and the penis and scrotum almost black. The upper parts of the thighs were also dark, but the colour faded away towards the legs, which were very lightly tinted. On the right flank, and also over the lumbar vertebræ, were well-defined oval patches darker than the sur-

rounding skin, corresponding with the sites of blisters which had been applied, some months previously, for the relief of pain in those parts. The knuckles likewise were more deeply coloured than the rest of the hands. But for the thoroughly English cast of the man's features, the peculiar tinge of the discoloration might have easily caused him to be mistaken for a person belonging to one of the darker races of mankind. The white pearly hue of the conjunctivæ contrasted strongly with the dusky complexion; and this is a peculiarity almost invariably noted in genuine cases of this disease. Upon the face were several small black specks, which might have passed for congenital marks had not the patient's wife assured me that they had appeared since the commencement of his illness; a statement corroborated by the fact that they have manifestly darkened and increased in size, if not in number, since he came under observation. Lastly, there was a dark stain upon the right edge of the tongue, near the tip, and the lips and buccal mucous membrane were mottled with brownish discoloration.

In this description, noted nearly a month ago, I have not found it necessary to make any alteration; for the only change that has occurred in the discoloration is the general deepening of hue, characteristic of the later stages of the disease.

The patient has complained more or less, ever since his admission, of pain in the loins and right side, and of occasional pain in one or other hypochondrium, but most frequently in the right. He also complains of difficulty in stretching out his legs, when he has been lying for some time on his back with his feet resting on the bed and his knees raised; and he says that this difficulty is caused by a sense of tightness, as though the extension of the legs were restrained by cords situated between the flanks and the groins. He has, moreover, a feeling of weakness in the back, as if it were broken or had a loose joint, and a sense of constriction round the lower part of the abdomen, which seems to start from the weak and painful portion of the spine. He rarely now attempts to leave his bed, but, when he does so, suffers from vertigo with dimness of sight and sickness, accompanied by such extreme prostration that he is afraid of falling, and when he sits down in a chair can scarcely rise again. He has an anxious, exhausted expression of countenance, which is increased by sitting up in bed; is breathless on the slightest exertion, and has a tendency to yawn, especially at nights; has frequent retchings, and rarely passes a day without vomiting. His appetite is bad; bowels confined, the fæces being dark coloured and dry; urine normal. The pupils of his eyes are large, and act sluggishly

under the stimulus of light. He is slightly deaf, but his intelligence is unimpaired. He sleeps badly, owing to pain in the loins, which he says is more intense by night than by day. There is frequently uneasiness on pressure over the epigastrium and one or other hypochondrium, and always great tenderness on pressure, and severe pain on percussion, over several of the lower dorsal and upper lumbar vertebræ; but he has neither difficulty in micturition, nor yet pain, numbness, nor formication in the lower limbs. The pulse varies from 80 to 100, is exceedingly feeble even when the patient is in a recumbent posture, and becomes almost imperceptible when he is raised up in bed. The percussion resonance over the anterior and upper part of the chest is slightly deficient, and the respiration is tubular below the right clavicle and harsh below the left. There is also increased vocal vibration on the right side. The percussion resonance is somewhat deficient over the base of the right lung posteriorly, and the respiration is somewhat harsh over the back of both lungs, but there are no moist sounds. The patient has slight cough, and is subject to catarrh. The heart's impulse, though feeble, is comparatively stronger than the arterial pulse, and the sounds are healthy.

The history and progress of this case render it, as I have said, a typical example of Addison's disease; for, although it is true that, besides the caries of vertebræ to which I have already alluded, there exists apparently some slight inactive pulmonary affection, I need not tell you that neither of these would account for the peculiar constitutional symptoms and discoloration of skin which I have described, and which present, in an unusually striking and fully developed form, all the features recognised as belonging to this remarkable malady.

As regards the assumed vertebral disease, I am led to diagnose it, both by the local pain and tenderness in the lumbar vertebræ, and also by the sense of constriction round the abdomen and the difficulty in stretching out the legs. Lumbar pain and obscure pain on percussion over the loins are indeed common in this disease; but here the pain is more severe and better defined than in simple cases of Addison's disease, and is accompanied by the other symptoms I have enumerated, which are by no means usual features. I have no doubt that the injury to the back, received now nearly four years ago, produced some mischief which set up slowly progressive inflammation, with, as I have said, probably caries of the bone and the formation of an abscess; and, if we should hereafter have the opportunity of examining the state of these parts, I expect that we shall find the cellular tissue around the

supra-renal capsules thickened, and the capsules themselves infiltrated with tubercular or scrofulous looking deposit. The time that has elapsed since the injury is indeed considerable, but by no means unparalleled, for, in a case of this disease under my own care some years ago, the illness appeared to have originated from a strain in the back received five years before the commencement of definite symptoms of Addison's disease. That there is an intimate relation between the vertebral and supra-renal disease in our present case, I am well assured; and I believe the latter to have been caused by the extension of inflammation, from the cellular tissue in the vicinity of carious bone, to the envelopes of the capsules, and from them, secondarily, to the capsules themselves, which have thus become the seats of inflammatory deposit. My opinion respecting the origin of the supra-renal disease in this case is confirmed by a careful perusal of all the published cases I have been able to meet with; for not only has caries of the spine been found associated with Addison's disease in more cases than any other lesion, excepting always tubercle in the lungs or other organs, but in many other cases in which it was not discovered I am persuaded, by the symptoms recorded during life, that disease of vertebræ might have been found, had it been sought for at the post-mortem examinations. Moreover, even when no disease of the spine exists, the capsules are often found adherent to adjoining organs and surrounded by thickened cellular tissue, showing that inflammation has probably been the primary link in the chain of local mischief.

The pulmonary affection in this case may possibly be of tubercular character; but, whether or not, it is assuredly much too slight to be of any moment in the illness, and far less could it account for the remarkable prostration and other symptoms under which the man is labouring. Seeing, however, that his occupation has been of a very dusty nature, that he has been subject to catarrh, and that there is certainly no marked difference of percussion-note in the two infraclavicular regions, I incline to believe that the slight pulmonary symptoms are due rather to continued mechanical irritation, arising from the inhalation of dust, than to actual tubercular disease. But on this point I can only speak with some doubt and reserve, for the physical signs are slight, and the patient's condition is such as to preclude a thorough examination; and, it is certain, that, in many cases of Addison's disease, tubercular disease of the lungs has been found in so quiescent a form as to have given rise to no prominent symptoms during life. Moreover, as I have myself explained on many occasions, the pulmonary affection caused by

mechanical irritants is apt to develop slow tubercular disease in persons of strumous constitution. Be this as it may, after eliminating all those symptoms which can be referred to the vertebral and pulmonary affections, there still remain, in an unusually complete degree of development, almost all the symptoms which are especially characteristic of Addison's disease of the supra-renal capsules.*

As the case upon which I have hitherto dwelt is still under observation, and I can therefore only speak of it as Addison's disease on the assumption that the diagnosis is correct, I must now, in order to place the subject more fully before you, give you the details of Dr. Thompson's fatal case, which he has kindly placed at my disposal, and of which Dr. Cayley has made a thorough post-mortem examination.

M. D., aged fifty-five, labourer, was admitted into Hertford ward, under Dr. Thompson's care, on the 6th of last month. He had been strong and hearty until about three months before his admission. His illness began without any definite symptoms beyond gradual loss of strength, to such an extent that he could scarcely stand, was compelled to give up work, and about Christmas became unable to go out, even for a short walk in front of his house. Besides the great debility, he by this time suffered also from breathlessness on exertion, nausea, frequent vomiting, and pain at the epigastrium.

On admission, his complexion was dark, but less so than that of the patient whose case I have just described. His body generally had only a faint brownish tinge; but the penis and scrotum were of a very dark blackish-brown hue, as were likewise the cicatrices of some burns, received in early life, upon the left arm and upon the inner aspect of the right elbow. I should mention, however, that the discoloration of these cicatrices was limited to the less deeply injured parts, and that in the midst of the dark patch on the inside of the right elbow, was a small glistening, white spot about the size of a pea, where the burn had

* This lecture was delivered on the 14th of March, and the patient here referred to died on the 28th. In order to complete the case, I may mention that the supra-renal capsules were found in the state anticipated, the disease being evidently furthest advanced in the left capsule. The intervertebral substance had been torn, apparently by violence, from the upper surface of the first lumbar vertebra for about two-thirds of its depth on the left side of the spine, and in front of the spine, extending from the seventh dorsal to the third lumbar vertebra, was an abscess, containing about two ounces of thick curdy pus. The bodies of the vertebræ involved were denuded and rough. Both lungs were extensively adherent to the walls of the thorax, and the apices presented small masses of obsolete cretaceous tubercle, surrounded by consolidated pulmonary tissue. See case at p. 39, reprinted from *Transactions of Pathological Society*, Vol. xvii., p. 307.

destroyed the deeper layers of the skin. On the back, also, were several cicatrices, some of which were discoloured, while the deeper ones remained of normal hue. The cicatrices of buboes in each groin were stained of a deep brown colour. On the upper surface of the tongue, near its edge on both sides, were several brownish-purple stains, with well-defined margins, perfectly smooth, and neither elevated above the surrounding parts nor differing from them in hardness. The lips and buccal mucous membrane also presented distinct brown stains.

As regards constitutional symptoms, the pulse was almost steadily 60, very feeble and compressible, and, for the first week, the heart-sounds were free from roughness. The respiration was feeble, and slight rhonchus and sibilus, with a few moist sounds, were heard on both sides of the chest. The percussion resonance was slightly deficient over the upper part of the chest, particularly below the right clavicle; but there was nothing to indicate active disease in the lungs.

Whilst in the hospital, the patient suffered much from retching and sickness, and complained of pain in the loins and epigastrium, frequently accompanied by tenderness on pressure over the latter region. He had frequent cramps in the muscles of the abdomen and legs, especially when he retched, and found it easier to lie with the knees drawn up, the cramps becoming worse when the legs were stretched out. A few days after his admission, the matter vomited became of a greenish colour and had a bitter taste. On February 14th, for the first time, a faint systolic murmur was heard at the apex of the heart, and the pulse fell to 52, and became extraordinarily weak, but a day or two afterwards rose again to 60. On the 19th, he was so weak that he fell when he attempted to get out of bed; and, on that day, the matter vomited consisted of mucus streaked with blood. He now slept badly, the retching continued; and by the 22nd he had entirely lost his appetite. On being raised up in bed for examination of the chest, he became very faint and sick. On this day, fine crepitation was found below the left clavicle, and rhonchus and sibilus were heard all over the posterior part of the thorax. There was also marked dulness over the upper part of the chest posteriorly. He had raised a few thick dark green sputa, several of them mixed with blood; and when desired to take a deep breath, he complained of sharp pain near the margin of the right ribs. From this time he gradually sank, a distinct cadaverous odour was noticed about his person, and he expired on the 2nd inst; death being preceded by great restlessness, wandering of mind, and groaning as if from pain.

At the post-mortem examination, the lungs were found firmly attached to the ribs by fibrous adhesions. Deposits of yellow cheesy matter were found in the apices of both lungs, and these deposits were surrounded by dark consolidated tissue intersected by fibrous bands; the lungs were everywhere else perfectly crepitant. There was recent pericarditis; and the right cavities of the heart were filled with firm masses of yellow semi-transparent fibrine, adherent to the muscoli pectinati and chordæ tendineæ, and passing into the pulmonary artery as far as the second division. A similar but smaller coagulum was found also in the left ventricle, passing for a short distance into the aorta. The great omentum was firmly adherent to the diaphragm, and the gall-bladder to the small intestine. The under surface of the diaphragm, the surface of the mesentery, and the peritoneum in front of the spine, were studded with patches of grey, tubercular granules, surrounded by deposits of black pigment. Peyer's glands were normal. The kidneys were slightly granular.

Both supra-renal capsules were enlarged and nodulated, the right being much the larger. The fibrous envelopes were much thickened, and that of the right capsule was firmly adherent to the diaphragm. On section, no traces of cortex or medulla were discoverable; the whole of both organs had been converted into a material which, to the naked eye, had precisely the appearance of tubercle.

Under the microscope, a section of one of the discoloured patches from the tongue shewed deposits of brown pigment, arranged in irregular masses in the papillæ, the superficial layers of epithelium covering them being quite free from discoloration. I may here observe that the deposit of pigment, which causes the discoloration of Addison's disease, is situated, as a rule, entirely in the rete mucosum, the epidermis and the true skin remaining unchanged.*

You will have observed that this case presents the same general features as the former one; namely, gradually progressive asthenia and gastric irritability, attended by discoloration of the skin and of the mucous membrane of the mouth. The black discoloration round the patches of tubercle on the peritoneum, I believe to have been in no way connected with the disease in the supra-renal capsules, for the same appearances have often been observed in chronic tubercular affections of the peritoneum, in cases in which the supra-renal capsules have been found quite healthy. Indeed, several foreign writers are of opinion that the discoloration found in Addison's disease is due, not to the

* See Plate at p. 42, reprinted, with Case, from the *Transactions of the Pathological Society*, Vol. xvii., p. 304.

peculiar morbid change in the capsules, but to the general tubercular disease which is frequently associated with it. It is quite true that, in very chronic phthisis, there is occasionally a dusky hue of skin, and I have lately pointed out to many of you two such cases under my care; but this discoloration in phthisis is comparatively rare, and, when it does exist, is wanting in all the characteristic features of the discoloration peculiar to Addison's disease. Moreover, the cases of Addison's disease which are complicated with advanced phthisis are precisely those in which the discoloration of skin is most frequently absent; whereas, if the theory to which I have referred were correct, those are the very cases in which we ought to find it the most invariable and most strongly marked. The adhesion of the right capsule to the diaphragm and the thickening of the connective tissue round both capsules, in Dr. Thompson's case, afford conclusive evidence of there having been inflammation in those parts, although the post-mortem examination has revealed no obvious cause for it, such as the caries of the spine, which I feel assured will be found in the case of the patient now in Founder ward. Doubtless, some of the symptoms presented by Dr. Thompson's patient were due to the other diseases under which he was also labouring; but this in no way invalidates the correctness of the diagnosis as regards Addison's disease, which was made on the day of the patient's admission to the hospital, and was proved to be correct a month afterwards by post-mortem examination. A few days before death an unpleasant cadaverous odour was observed about this patient's person. This peculiar symptom has been noticed before in Addison's disease, both by myself and by other observers. In my experience, it is a sign of the approach of death, which has invariably taken place in the course of a few days after its appearance.

The discoloration is quite characteristic in both the cases I have related, though it is most intense in Dr. Stewart's case, which you can still see for yourselves. Sometimes, however, the discoloration of skin is slight, and insufficient to suggest the nature of the disease from which the patient is suffering. It has happened to me, on two occasions, to be led to diagnose Addison's disease by the constitutional symptoms alone, aided by the circumstance that there was no other discernible disease to account for them; and I have then had to look closely for the slight discoloration of skin in order to confirm my diagnosis. This occurred, in fact, with regard to the case which I mentioned, at the beginning of this lecture, as having been recently in the hospital under my own care; and, as it seems to show the at least temporary efficacy

of treatment in this disease, I shall devote a few minutes to giving you some particulars of it.

J. D., aged 43, park-keeper, became an out-patient under my care on the 17th of last November. He had had ague some years before, but had been otherwise healthy until about five months before coming under observation. He had suffered much during that time from pain in the loins, especially on the right side, and from pain and sense of tightness in the epigastrium, for the relief of which he had applied a small blister to the part three months before his admission. He had also suffered from vertigo, and latterly from nausea, retching, and vomiting. On admission, he had a languid, exhausted aspect; his pulse was extremely feeble; he was short of breath, and manifestly very ill: but there was no emaciation, nor any obvious evidence of local or constitutional disease. He had a troublesome catarrhal cough, but without any physical signs of pulmonary disease; his tongue was clean, his bowels were confined, and the urine was perfectly normal.

From the absence of any apparent cause for his peculiar symptoms, I was at once led to suspect the existence of Addison's disease and to seek for discoloration of skin in corroboration of my suspicion. I then observed that the face and the back of the neck were slightly dusky, as were also the hands and arms as high as the elbows. The part on the epigastrium where the blister had been applied, three months before, was deeply discoloured; and on the left clavicle there was a yellow-brown stain, about an inch in length, evidently corresponding to the cicatrix of some slight wound. These last features of the discoloration decided me in the opinion that the case was one of Addison's disease. With these exceptions, however, the skin was still fair, and free from pigmentary deposits. The buccal mucous membrane presented several brown stains, in places which had apparently been irritated by the teeth, but the margins of the lips were unaffected.

J. D. continued an out-patient until December 29th, when he was admitted into Hertford ward. His cough had abated, and he had lost the sickness for some time; but on December the 20th he had been attacked with severe pain in the epigastrium, together with loss of appetite, nausea, and breathlessness. These all continued at the time of his admission. His hands were cold; his pulse thready and non-compressible; respiration hurried; and he had a constant inclination to yawn and stretch. His face, hands, and nipples were manifestly darker; and several black specks, of the size of freckles, had appeared since he was first examined, but all on the previously discoloured parts

of the skin. Whilst in the hospital, he had slight cough, raising a thick, dark, scanty mucus. His pulse remained feeble, and he still had pain in the left hypochondrium, but was better in both respects while in the recumbent posture. He left the hospital rather suddenly, in consequence of the shock he sustained from the death of the patients on either side of him on two successive days, but he has continued under treatment up to the present time. He is now decidedly stronger, and has been able to resume his occupation; but he still presents, though in a mitigated degree, the same constitutional symptoms, and the discoloration of skin is becoming gradually more general and its characteristic features more strongly marked.

These circumstances leave no doubt whatever on my mind as to the existence of Addison's disease of the supra-renal capsules; and, although the patient may, with great care and suitable treatment, be propped up for an indefinite time, he must always be considered as in imminent danger of a breakdown under any powerful depressing influence. Even an unusually severe day's work, or a slight attack of diarrhœa, might suffice to upset the balance and lead to a speedily fatal issue of the case. Nevertheless, he has unquestionably benefited much from the means used; for, when he came into the hospital, he was becoming so rapidly worse that it seemed probable he would die in a few days, and he not only improved much before he went out, but continued to do so afterwards with rest and proper treatment at home, and has not yet relapsed.*

* J. D. still remains under observation. He has varied greatly from time to time; having at some times rallied so much as to be able to walk to the hospital, a distance of two miles, and even to resume work for a few days, though this latter attempt always brings on a return of depression. At other times he has been confined to bed for several days together, with retching, vomiting and profound exhaustion. Lately he has been in the country for a few weeks, and presented himself at the hospital on the 9th of October, very greatly improved in health by the change. The discoloration of skin, however, which had to be sought for when I first saw him, has now become very striking. The entire face is of a dusky greenish hue, more closely resembling real bronze colour than is usual in this disease. The hands, especially the knuckles, and the cicatrix on the left clavicle are much darker than formerly. The site of the blister on the epigastrium remains as dark as it was, but looks less so, in consequence of the deepening discoloration of the skin around it. The buccal mucous membrane is more extensively mottled, and there is now a patch of discoloration on the tongue. More of the little black specks, resembling freckles, are likewise observable on the face, neck, and hands. There is still some tenderness on pressure over the left hypochondrium, and distinct uneasiness, scarcely amounting to pain, is felt on percussion over the lower dorsal and upper lumbar vertebræ.

The other case which I mentioned as having been in the hospital under Dr. Thompson's care, and which has remained under my own observation ever since, has followed so very similar a course, that I shall read you a brief history of it, before proceeding to point out the mode of management which I have hitherto found to be the most successful in delaying the progress of this malady.

E. B., aged 26, needlewoman, was admitted into Northumberland ward in March, 1865. Dr. Thompson asked me to examine her on the day of admission. Ten years before, she had hurt her hip, and cupping, which was resorted to for her relief, had been followed by ulceration; but she had been in generally good health and had worked hard until November, 1864. She then began to fall asleep over her work, to have frequent attacks of vomiting, and to suffer from gastralgia and from breathlessness and palpitation on exertion. About Christmas, her friends noticed that her complexion was becoming darker. On admission, her pulse was exceedingly small, and she complained much of lassitude and of vertigo when she moved about, or even raised herself suddenly in bed. She had no appetite, but constant thirst and craving for cold water. Her respiration was quick and shallow, with a tendency to yawning. There was slight dulness on percussion immediately below the right clavicle, and considerable tenderness on pressure in the right hypochondrium. Her face was generally dusky, with ill-defined patches of a darker brown on the forehead and cheeks; the conjunctivæ, as usual in this disease, remaining white. The chest was dusky, the nipples and areolæ intensely brown, and the mammæ atrophied; a circumstance I have observed in other females suffering from this disease. The cicatrices of the ulceration on the hip and of a burn on the right elbow were stained brown, and there was a dark line nearly round the abdomen, corresponding to the line of pressure of a string belonging to her dress. Here you will recognise the same train of symptoms and the same characteristic features of discoloration of skin which I have described in the other cases. This patient improved very much in the hospital, and left it, at the end of some weeks, for the Convalescent Institution at Walton-on-Thames. On her return home, she discontinued the treatment and resumed her work, but fell off again in a month or two; and, on being sent to in haste, I found her one night lying exhausted, cold, almost pulseless, sighing and yawning, retching at every movement, and complaining of intense pain in the hypochondrium. In fact, she seemed almost dying, and I brought her at once to the hospital; where, however, she again rallied, and was

again discharged at the end of a few weeks, in a greatly improved condition. Soon after leaving the hospital, she married, and continued tolerably well for some months, but is now once more under my care as an out-patient, suffering, though in a less intense degree, from her former symptoms, and the discoloration of her skin having certainly become deeper during the interval. Her hair, originally of a dark brown colour, has also gradually changed to black and has become very coarse.*

It seems to be unquestionable, from the history especially of this last case, that Addison's disease, although incapable of cure, is yet in some degree amenable to treatment in respect of delaying its progress, unless the illness have already arrived at its later stages. Owing, no doubt, greatly to our still imperfect knowledge of the nature and causes of the disease, the means of treatment at our disposal are as yet, unfortunately, very scanty. The remarkable asthenia, however, by which the disease is characterised, and the distressing retching and vomiting which usually accompany it, clearly demand the use of therapeutic agents calculated to mitigate these exhausting symptoms, and of such tonic treatment and nutritive diet as may tend to invigorate the general health. On the other hand, the strong evidence as to the frequent origin of the disease of the supra-renal capsules in neighbouring local irritation, and the constant tendency of the patients to succumb under any external depressing influence, imperatively indicate the necessity for abstinence from over-fatigue, or, indeed, from much bodily exertion, or mental strain of any kind. Prolonged rest in bed, I have found an essential part of the treatment in the several cases which have improved for a time under my observation. The use of drastic purgatives

* E. B. continues under observation up to the present time. The discoloration of skin has become deeper since the lecture was delivered, especially on the neck, on the cicatrices inside the right elbow, and round the surface on the right hip which ulcerated after cupping. The discoloration in this last situation is the more striking, because of the contrast between the dark parts of the cicatrices and the white spots where the ulceration was deep enough to involve the cutis. The general surface of the abdomen is as dark as that of a mulatto, and the colour in this region is more intense than on the face. At this date (October 20th) the patient is in her best state, but she has had, since March, several attacks of extreme depression, attended by retching and vomiting, and, during the autumn, two attacks of diarrhoea, each of which has exhausted her so much as to leave, at the time, little apparent chance of her rallying again. At her best she is very languid, breathless on exertion, incapable of doing any work, and has an indescribably weary, depressed look. Her pulse is generally about 72, exceedingly small and feeble, and her skin cold.

should be scrupulously avoided in these cases. Constipation is more common than otherwise in Addison's disease; but, unless it be very extreme, I think it better to abstain from interference than to risk the dangerous depression which often follows the administration of aperient medicines. Many of you will recollect the case of E. W., a young girl who died in Murray ward under my care, of Addison's disease, somewhat more than a year ago, and whose fatal seizure appeared to have been brought on by the effects of a dose of calomel and jalap given her by her mother. As regards diet, the only plan is to give nourishing food of whatever kind the patient's stomach can best bear, and this will probably vary more or less in every case; substituting milk, eggs, jellies, oysters, and the like, for the stronger diet of meat or soups, when the stomach cannot tolerate these latter. For the relief of the nausea and vomiting, ice, soda-water and brandy, chloroform or creasote, bismuth, and effervescing medicines with citrate of iron, have each in turn proved useful in my hands; and, again, each at times has failed to effect any good result. After the sickness has abated, decided benefit sometimes attends the administration of chalybeates and of cod-liver oil or glycerine. In the last two cases I have related to you, cod-liver oil disagreed with the patients; but glycerine, in doses of two drachms, combined with fifteen or twenty minims each of spirit of chloroform and of the tincture of sesquichloride of iron, of the *London Pharmacopœia*, has been of great service. I speak positively on this point, because in each case the patients on several occasions have discontinued the medicine as soon as they felt better, have then lost ground again, and, on applying to me and resuming its use, have in a week or ten days once more begun to improve, without any other simultaneous change in their circumstances.

Little as this is, it is yet all that I can tell you from my own practical experience on the subject of treatment; and I shall now only detain you for one concluding remark. You may be surprised that I have chosen to base my lecture on four cases of Addison's disease, of which one only has passed the crucial test of a post-mortem examination; but I have done so purposely, because I have little doubt, that, in one at least of the other three cases, we shall soon have the opportunity of verifying the diagnosis, and of thereby demonstrating the reality of the relation between the symptoms I have described and Addison's disease of the supra-renal capsules—a relation of which I am myself as firmly convinced as I am of the relation between the physical signs of a cavity in the lungs, or of incompetency of the mitral valve, and the diseases which they respectively indicate.

ON DISEASES
OF THE
SUPRA-RENAL CAPSULES.

CASES.*

CASE OF CANCER OF THE SUPRA-RENAL CAPSULES—CASES OF ADDISON'S
DISEASE.

CASE I.—*Cancer of both supra-renal capsules.*

The specimens were kindly sent to me for examination by Dr. Dickinson, with permission to exhibit them to the Society. They were taken from the body of a man, aged 56, who was admitted into St. George's Hospital, on the 27th of September, 1865, and died on the 27th of January, 1866.

He suffered from pain down the course of the right sciatic nerve, and from other symptoms which were attributed to malignant disease of the vertebræ. Subsequently, partial paraplegia came on, and some hard nodules, supposed to be cancerous, appeared on the surface of the chest. The skin was everywhere of natural colour, and there were no symptoms indicative of supra-renal disease.

At the *post-mortem* examination a large mass of malignant matter was found lying around, and replacing, the lumbar vertebræ, and also surrounding, and partly replacing, the pancreas. Similar formations were found in the substance of the heart, in the cellular tissue of the chest, under the pleuræ, in the liver, in both psoas muscles, and in the cellular tissue surrounding the pelves of the kidneys.

The supra-renal capsules were both similarly infiltrated. The two weighed seven drachms; they were nearly of normal shape, but almost

* Reprinted from the *Transactions of the Pathological Society*, Vol. xvii. pp. 303-310.

entirely composed of firm encephaloid matter. Scarcely any of the proper structure remained, but in one or two situations a little brownish matter indicated its former presence.

CASE II.—*Addison's disease of the supra-renal capsules.*

M. D., aged 55, labourer, was admitted into the Middlesex Hospital, under the care of Dr. H. Thompson, on the 6th of February, 1866.

He had had syphilis early in life, followed by buboes in either groin. Twice also he had had severe falls. He was strong and hearty until about three months previous to his admission into the Hospital, but could not fix any precise date for the commencement of his illness. He first of all became weak and unable to work, was breathless on exertion, had nausea and pain in the epigastrium, and frequently vomited after taking food. The debility progressed rapidly, so that by Christmas he was obliged even to give up taking a short walk in front of his house.

On admission, his skin was of a dusky-brown hue, which was most obvious on the face, but more or less pervaded the whole body. The penis and scrotum were almost black, as were likewise the cicatrices of some burns received in early life upon the left arm and the inner aspect of the right elbow. This discoloration, however, was limited to the less deeply injured parts, and inside the left elbow in the midst of the dark surface was a well-defined, glistening, perfectly white cicatrix, where the burn had destroyed the deeper layers of the skin. There were several cicatrices on the back, of which the more superficial were discoloured, while the deeper ones remained of normal hue. The cicatrices of the buboes in both groins were stained dark brown. On the upper surface of the tongue, near its edges, were several bluish-black stains, with well-defined margins, neither harder nor more raised than the surrounding parts. The lips and buccal mucous membrane also presented distinct brown stains. The pulse was 60, very small and compressible, and varied little while he was under observation. The heart-sounds were faint, but free from murmur. The percussion resonance was slightly deficient over the upper and anterior part of the chest, especially below the right clavicle; the respiration was feeble, and accompanied by slight rhonchus and sibilus, and a few moist sounds; but there was nothing to indicate active pulmonary disease.

Whilst in the Hospital the patient suffered much from retching and vomiting, and complained of pain in the loins and epigastrium, frequently accompanied by tenderness on pressure over the latter region.

He often had cramps in the muscles of the abdomen and legs, especially when he retched, and he found it easier to lie with the knees drawn up, the cramps becoming more troublesome when his legs were stretched out. A few days after his admission the matter vomited became of a greenish colour and bitter taste. On the 14th of February, a faint systolic murmur was heard at the apex of the heart, and the pulse fell to 52 and became extraordinarily weak, but a day or two later, it rose again to 60. On the 19th, he was so weak, that he fell down when he attempted to get out of bed, and on that day the matter vomited consisted of mucus streaked with blood. He now slept badly, and by the 22nd, had quite lost his appetite, the retching continued, and there was a distinct cadaverous odour about his person. On this day there was marked dulness on percussion over the upper part of the chest posteriorly; rhonchus and sibilus were heard all over the posterior part of the thorax, with fine crepitation below the left clavicle. He had raised some thick dark green sputa, several of them tinged with blood, and he complained of sharp pain in the region of the diaphragm on the right side. From this time he gradually sank and died on the 2nd of March, death being preceded by retention of urine, great restlessness, wandering of mind, and groaning as if from pain.

Post-mortem examination.—The lungs on both sides were firmly attached to the ribs by old fibrous adhesions; they were very dark coloured, and in the upper lobes of both, were several deposits of yellow cheesy matter, around which the pulmonary tissue was consolidated and intersected by fibrous bands. There were no recent tubercles, and elsewhere the lungs were crepitant. There had been recent pericarditis; the pericardium contained an ounce of turbid fluid, and patches of granular lymph were scattered over the heart. The right cavities of the heart were filled with firm, yellow, semi-transparent clots of fibrine, adherent to the muscoli pectinati and chordæ tendineæ, and extending into the pulmonary artery as far as the second division. The left ventricle also contained a clot, which passed for a short distance into the aorta. The great omentum turned up over the liver, and was firmly attached to the under surface of the diaphragm; there were also fibrous adhesions between the gall-bladder and small intestine. The under surface of the diaphragm was thickly studded with greyish-yellow, semi-transparent, tubercular granules, and scattered over the mesentery and on the peritoneum in front of the spine were likewise several little patches of similar granules, each surrounded by a deposit of black pigment. There were no traces of recent peritonitis. The mucous membrane of

the stomach was somewhat congested. The surfaces of the kidneys were slightly granular.

The right supra-renal capsule was much enlarged and weighed one ounce and a-half; its fibrous envelope was considerably thickened, firmly adherent to the capsule, and attached by fibrous bands to the diaphragm. It was nodulated, and on section no distinction appeared between cortex and medulla. The greater part of the organ was converted into an opaque substance of the consistence of soft cheese, in some parts of a pale yellow, in others of an orange colour. Near the anterior end, and extending inwards from the hilus, was an irregularly shaped semi-transparent, grey-coloured patch, which sent off prolongations partially separating the yellow cheesy substance into circular masses. This semi-transparent portion was itself studded with opaque yellow nodules. At one point in the yellow substance was a small cavity filled with puriform fluid. The left supra-renal capsule weighed about half-an-ounce; its envelope was much thickened, but did not adhere to the surrounding parts; its surface was much nodulated. On section, there appeared no distinction between cortex and medulla, the organ consisting of irregular roundish opaque masses of a yellow colour, separated by semi-transparent, grey, fibrous tissue. These masses were of a crumbling consistence, and in many places broken down into puriform fluid and granular detritus. Portions here and there were less opaque, and of an orange colour similar to that found in parts of the right supra-renal capsule.

Microscopical examination.—Thin sections of various portions of the right capsule were submitted to careful microscopical examination by Dr. Cayley, who has kindly furnished me with the following report:—

The grey semi-transparent substance presented tracts of connective tissue, with numerous fibre-cells and nuclei, interspersed with masses composed almost entirely of nuclei, and of irregular roundish cells, about the size of white blood-corpuscles, and distinctly nucleated. These were mixed up with little irregular roundish or oval corpuscles and much granular matter, and presented the ordinary characters of tubercle. Portions from the yellow substance presented, in parts, the tubular spaces of the cortex filled with cells containing much yellow pigment and oil; these, in many cases, formed islands, surrounded by tracts of connective-tissue. In other parts were tracts of opaque, oily, and granular matter, which sometimes shewed indications of filling the tubular spaces, and sometimes appeared disseminated without any structural arrangement. The fluid from the cavity

consisted almost entirely of oil and granular debris, and did not appear to be true pus. The characters of the left capsule were very similar, but the tubular structure was much more obscured.

Microscopical examination of slices from the discoloured patches on the tongue, shewed deposits of pigment in the form of irregular brown masses deposited in the papillæ, the superficial layers of epithelium covering them being quite free from colouring-matter. (See Plate, Fig. 2.)

CASE III.—*Addison's disease of the supra-renal capsules.*

C. S., aged 32, coal-porter, was admitted into the Middlesex Hospital, under the care of Dr. Stewart, on the 13th of February, 1866.

He stated that his health had been good until it began to fail, about eight or nine months previous to his presenting himself at the Hospital for admission. Upon inquiry, however, it was subsequently elicited that somewhat more than three years before he had sprained his back severely in pushing a loaded coal-truck, and had experienced at the same time a sensation of something giving way. He had ever since suffered more or less constantly from pain in the region of the lower dorsal vertebræ, for the relief of which he had tried various remedies including blisters. Eight or nine months before his admission he had begun to suffer from debility, sweating, headache, loss of appetite, and sickness, with breathlessness on exertion, followed by severe pain in the right lumbar region. Four or five months later, his wife had observed a change of colour, which she thought appeared first upon the face and hands, and which gradually deepened, and spread over the whole body. He had been compelled to give up work for about two months.

On admission, his skin was of a general olive-brown hue, especially on the face and neck. On the face were several almost black specks; there was a stain on the right side of the tongue, and the lips and buccal mucous membrane were mottled with brown. The upper part of the chest and the legs were lighter in colour than the rest of the body; the abdomen was darker than any part except the sites of blisters, which had been applied over the right flank and lumbar vertebræ some months previously. The nipples and areolæ, and the penis and scrotum were very dark; the hands, and especially the knuckles, were much darker than the arms. The hair and beard were said to have become visibly darker during his illness. The white pearly hue of the

conjunctivæ contrasted strongly with the dusky colour of the skin. The pulse was exceedingly feeble; he was breathless on the smallest exertion; had frequent retching and vomiting after food, and complained much of pain in the epigastrium. He was exceedingly weak, and had such a sense of stiffness and weakness in the back that when he sat down he felt almost unable to rise again; in fact, he said that his back felt broken. There was tenderness on pressure, and well-marked pain on percussion, over the lower dorsal and upper lumbar vertebræ, and he complained of a sense of tightness round the abdomen, from the flanks to the groins, and of pain and difficulty in stretching out the legs, when he had been lying for some time on his back with his knees raised. The percussion resonance was somewhat deficient over the front of the thorax, especially below the right clavicle, and the respiration, which was everywhere a little harsh, was distinctly tubular in the apex of the right lung, but no moist sounds nor other evidences of active pulmonary disease were at any time discoverable.

From the time of his admission he very slowly, but steadily, declined. The retching and vomiting continued with brief intermissions. He suffered from vertigo when raised up in bed, became somewhat deaf and dim-sighted, and some days before death fell into a drowsy semi-comatose state, though still perfectly able to answer questions when roused. He sank, and died on the 28th of March.

Post-mortem examination.—Body moderately nourished, colour much as during life. Both lungs were firmly attached by old adhesions to the ribs, and at the base of the right side of the thorax a cyst the size of a walnut, filled with putty-like matter, was found in the adhesions, which contained also in several places calcareous deposits. In the apex of each lung was a dense solid mass, consisting chiefly of fibrous tissue, apparently the cicatrix of a former cavity. Embedded in these masses of consolidated lung were several opaque yellow nodules, partly cheesy and partly calcareous. The lungs were elsewhere crepitant, but dark-coloured and emphysematous around their free borders. The pericardium contained about an ounce of yellow serum, and presented other traces of slight recent pericarditis. The heart was small and flabby, but its muscular tissue was normal. The right auricle and ventricle were filled by a large partially decolorized fibrinous clot. The left cavities contained a little fluid blood.

The right supra-renal capsule was much enlarged, and embedded in thick fibrous tissue which was firmly adherent to the vena cava and diaphragm. The exterior was nodulated, and on section all distinction

between cortex and medulla was lost. The surface of the section presented an intermixture of a greyish, semi-transparent, somewhat fibrous tissue, and of opaque yellow roundish masses of cheesy consistence, some of which shewed little calcareous patches. The left capsule was much smaller than the right, but was like it embedded in thick fibrous tissue and adherent to the diaphragm, and, indeed, closely resembled its fellow in all respects, except that it contained a larger proportion of crumbling calcareous matter.

The other abdominal organs were healthy, excepting that the kidneys were much congested and that the mucous membrane of the duodenum was studded with minute patches of injection.

Extending in front of the vertebræ, from the seventh dorsal to the third lumbar, was an abscess confined by fibrous investments, containing about two ounces of somewhat curdy pus. The bodies of the vertebræ covered by the abscess were bare and somewhat rough. The intervertebral substance between the last dorsal and first lumbar vertebræ, was separated, on the left side, from the upper surface of the latter vertebra for two-thirds of its depth, but the separation did not extend to the spinal canal. The upper surface of this vertebra was bare and rough, but the bone within seemed to be quite healthy. The spinal canal and cord were normal.

Dr. Cayley compared the nerves of the diseased capsules with those of healthy capsules from two other bodies, and found that the nerves passing to the diseased organs from the semi-lunar ganglion, and especially a branch of the great splanchnic, were at least twice the size of the corresponding nerves of the healthy organs. On microscopical examination of these enlarged nerves, however, after they had been for some time in spirit, the only difference discoverable was an increase in the fibrous investment of the nerve-bundles.

Under the microscope, the greyish semi-transparent substance of the diseased capsules presented a fibrous basis, which was more or less obscured by dark granular matter, with irregular shrunken cells and nuclei. In places there were distinct deposits of small granular cells and nuclei resembling tubercle. The opaque yellow portions consisted in parts of granular and oily débris, and in parts presented the tubular spaces of the cortex filled with dark oily and granular matter.

Sections of skin from the right flank, where a blister had been applied, were also examined by Dr. Cayley under the microscope. The deepest layers of the epidermis were found to be of a rich, dark-brown colour, from the deposit of pigment in the form of little granular

masses in the epidermic cells. The upper layers became gradually less coloured, until quite at the surface the colour was altogether absent. In some places similar pigment-granules were found in the true cutis, immediately below the epidermis. (See Plate, Fig. 1.)

—•••••—

REPORT ON DISEASES OF THE SUPRA-RENAL CAPSULES.*

OBJECT OF INVESTIGATION—COLLECTION OF CASES—ANALYSIS OF CASES—BRONZED-SKIN WITHOUT DISEASE OF SUPRA-RENAL CAPSULES—CANCEROUS DISEASE OF CAPSULES—MISCELLANEOUS DISEASES OF CAPSULES—IMPERFECTLY DESCRIBED OR DOUBTFUL CASES—CASES OF ADDISON'S DISEASE OF THE SUPRA-RENAL CAPSULES QUITE UNCOMPLICATED—ALMOST UNCOMPLICATED—WITHOUT EVIDENCE OF COMPLICATION—CASES WITH VERTEBRAL DISEASE OR LUMBAR ABSCESS—WITH TUBERCULAR DISEASE—WITH NON-TUBERCULAR DISEASES—SUMMARY OF ANALYSIS—NATURE OF MORBID CHANGE IN THE CAPSULES IN ADDISON'S DISEASE—ONE OR BOTH CAPSULES INVOLVED—CONDITION OF SUPRA-RENAL NERVES—SEAT OF DISCOLORATION—STATE OF BLOOD—DURATION, PROGRESS AND CHARACTER OF ILLNESS—INFLUENCE OF SEX, AGE AND OCCUPATION ON THE OCCURRENCE OF ADDISON'S DISEASE.

The three cases above described afford good illustrations of the difference in the effects produced on the constitutional health by different kinds of disease of the supra-renal capsules. In the first case, both the constitutional symptoms and the discoloration of skin characteristic of Addison's disease being absent, no disease of the supra-renal capsules was diagnosed during life, and yet these organs were found after death to have been destroyed by cancer. In the two latter cases Addison's disease was at once diagnosed when the patients came under treatment, by the peculiar train of constitutional symptoms with discoloration of skin, and the correctness of the diagnosis was verified after death by examination of the supra-renal capsules. There are now a great many instances on record, in which the same circumstances have occurred as in these two latter cases; but yet it appears, from occasional discussions and publications, that

* Reprinted from the *Transactions of the Pathological Society*, Vol. xvii., p. 310.

there are members of the profession even in England, and apparently a much larger number abroad, who still entertain doubts on the subject, and who regard the occurrence of symptoms leading to the diagnosis, during life, of a certain morbid condition and the discovery of that identical morbid condition after death as mere coincidences, rather than as evidences of any definite relation between the symptoms and the disease. In support of this scepticism two classes of cases have been adduced, viz., first, cases in which there had been discoloration, termed "bronzed skin," during life, and in which, nevertheless, the capsules were found healthy after death; and secondly, cases in which discoloration of skin did not exist during life, and yet the capsules were found diseased after death.

In order to remove the doubts mainly fostered by misapprehension of these two classes of cases, it seemed necessary to investigate the sources of error in both of them, and to determine why, when in so many instances disease of the supra-renal capsules had been correctly diagnosed during life, in others it had been diagnosed and had not been found after death, and in others, again, it had remained unsuspected until revealed by *post-mortem* examination. With the view of endeavouring to answer these questions, I resolved, after a debate on the subject which took place at a meeting of the Pathological Society about two years ago, to collect and examine all the cases I could find of any kind of disease of the supra-renal capsules which had been verified by *post-mortem* examination, and also all the cases of so-called bronzed skin without any disease of the supra-renal capsules. Collections of cases of disease of the supra-renal capsules had indeed been made, shortly after the publication of Dr. Addison's work, by Mr. Hutchinson in the *Medical Times and Gazette*, by Dr. Copland in his *Medical Dictionary*, and by a Committee of this Society; but these, of necessity, contained only a very small proportion of the cases now on record. Dr. Wilks had also published, in the eighth volume of the present series of *Guy's Hospital Reports*, a most interesting and important paper on Addison's disease of the supra-renal capsules, containing a digest of twenty-five true cases in all of which he had himself examined the capsules; but this paper, although of the highest scientific value, did not fulfil the purpose which I had in view. After I had collected and arranged all the cases in the British and Irish medical publications, Dr. Louis Martineau, a French physician, published a monograph containing a collection of eighty-five cases of all the various descriptions I have mentioned, some drawn from foreign and some from English sources, but many of them not verified by *post-mortem* examination. A few months later Dr. Hayden published

DESCRIPTION OF PLATE

This plate contains a series of figures illustrating the structure of the human eye. The figures are arranged in a vertical column and are labeled with letters and numbers. The text is very faint and difficult to read, but it appears to describe the various parts of the eye and their functions. The figures show the eye in different positions and from different angles, highlighting the internal structures such as the lens, retina, and optic nerve.

DESCRIPTION OF PLATE.

- Fig. 1 shews the distribution of brown colouring-matter in the deeper layers of the epidermis, and here and there in the true cutis, as seen under the microscope, in a section taken from the right flank, where a blister had been applied. Case III. p. 45.
- Fig. 2 shews the distribution of pigment in a papilla of the tongue, as seen in a vertical section under the microscope. Case II. p. 42.

Fig. 1.

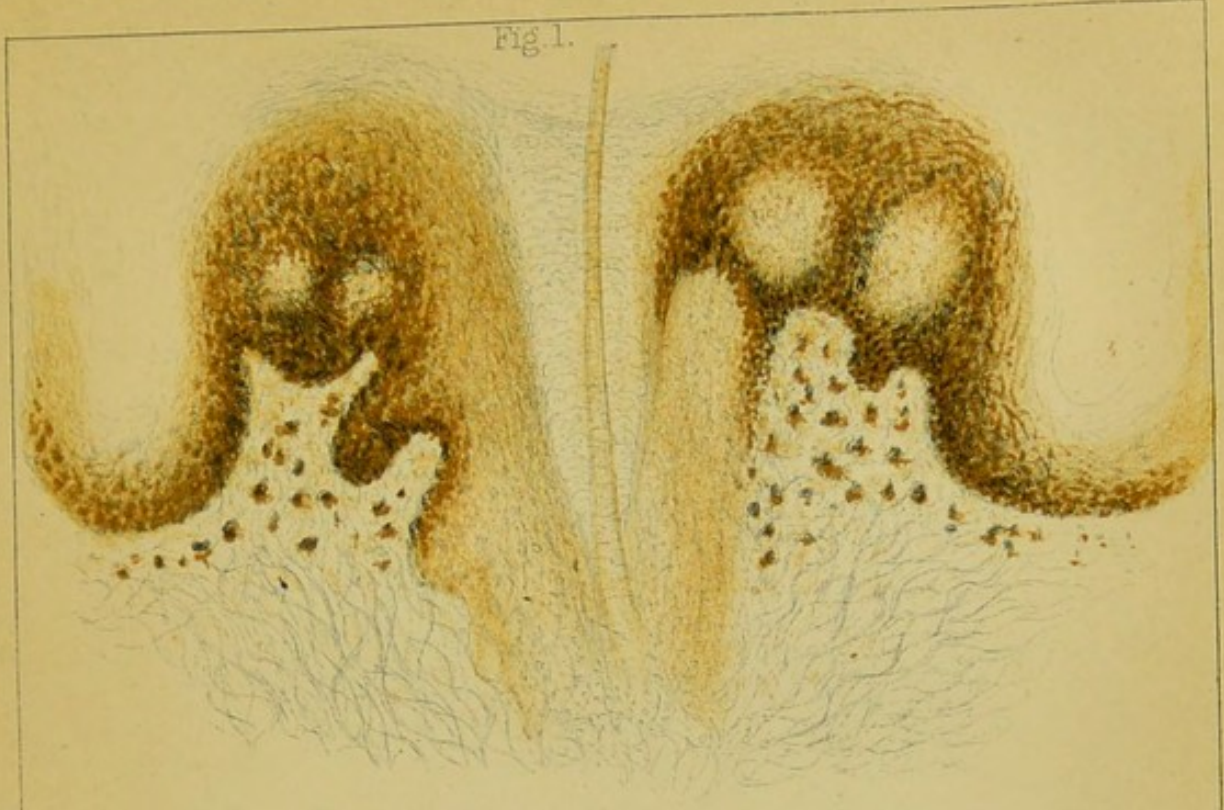
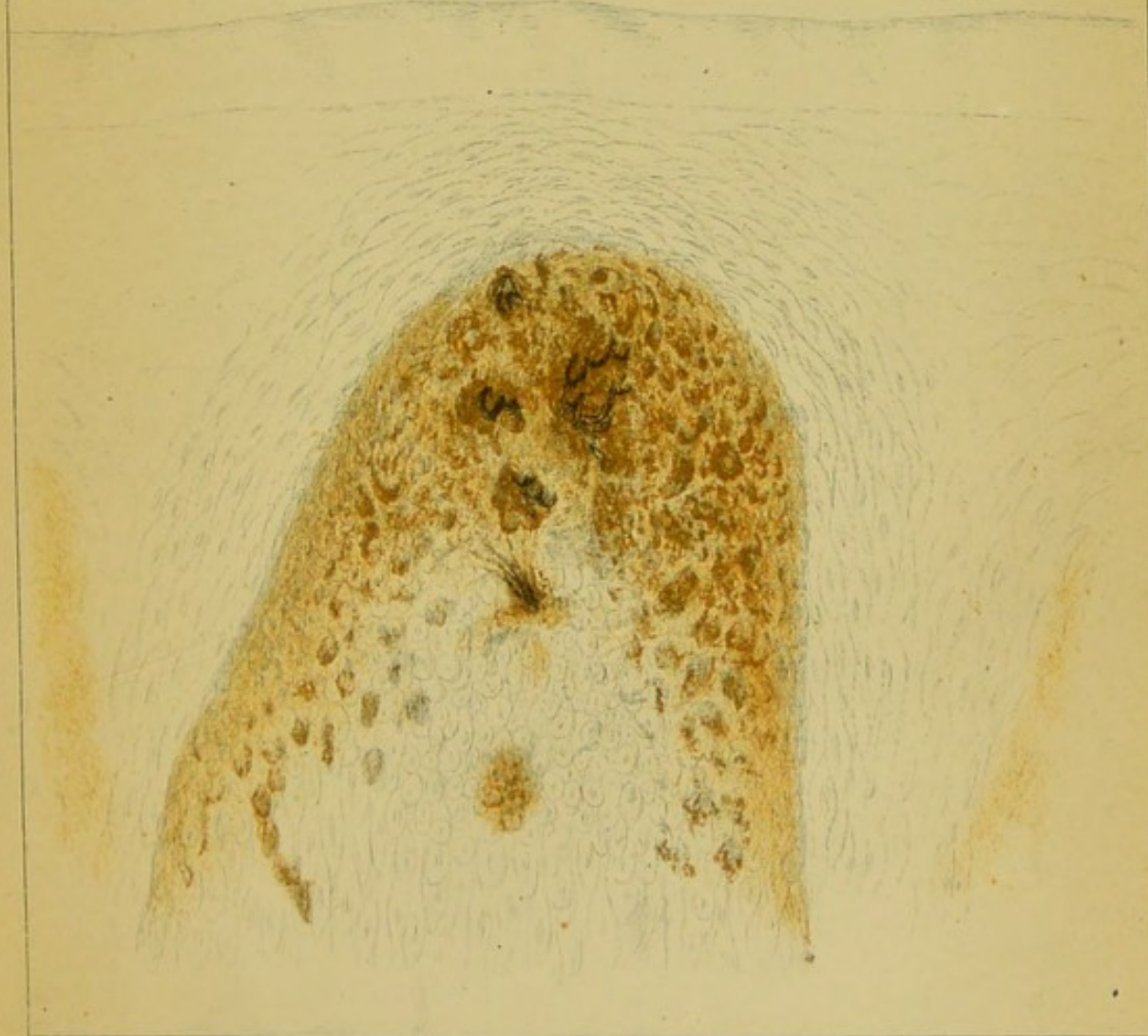



Fig. 2.





a paper on the same subject in the *Dublin Quarterly Journal of Medical Science*, giving a case of his own and a digest of thirty-four already published cases. Finally, my attention was drawn to an important new work by M. Virchow on tumours, containing a dissertation on diseases of the supra-renal capsules, which referred to collections of cases made by him and published in Canstatt's *Jahresbericht* during the years 1856-60, inclusive.

On consideration of all these publications, however, I remained of opinion that a much wider survey of facts than was comprised in any of them, and one made, moreover, from quite a fresh point of view, was required in order to throw more light upon the true character of Addison's disease, and upon the different characters of the diseases which have been confounded with it. If this could be accomplished, there seemed a reasonable prospect of finally setting at rest the doubts regarding the reality of Addison's discovery, which have been mainly kept alive by the confusion between genuine and spurious cases. I, therefore, persevered in my intention, and added to my Tables all the foreign cases, with autopsies, quoted by Dr. Martineau and M. Virchow; but, in order to avoid the inaccuracies and omissions inseparable from second and third-hand reports, I have taken them all direct from the original sources, except a very few published in journals to which I could not obtain access. In many instances the same case has appeared in different publications, with different names attached to it, and sometimes with slight discrepancies of age and other circumstances; but, by a scrutiny which involved great labour, I believe that I have succeeded in excluding all duplicate reports, and at the same time have avoided the appearance of omissions by supplementing the names of the reporters to societies or journals with those of the medical men who had charge of the cases, and who had sometimes published them independently elsewhere. Whenever cases have been brought under the notice of the Pathological Society, I have quoted from the report in the *Transactions* rather than from any which may have appeared in other publications.

I have now collected, so far as I can discover them, all the cases of disease of the supra-renal capsules of whatever kind, and all those of bronzed skin without any supra-renal disease, which have been brought forward from the time of the publication of Addison's discovery up to the end of the year 1865, making, in all, *one hundred and ninety-six* cases, which I have abstracted on a uniform plan and arranged in a tabular form. The first column in the tables shews the number of the case for conveni-

ence of reference, together with the name of the reporter, of the publication from which the report is taken, and also that of the medical attendant on the case, when not himself the reporter. Then follow in order, in the subsequent columns, the sex, age and occupation of the patient, the previous history and duration of the illness, the symptoms, the colour of skin, and lastly, the results of the *post-mortem* examination, both as to the state of the supra-renal capsules and as to the condition of other organs.

Analysis of cases.—At the outset of my examination I found that the cases would naturally fall into two *prima facie* groups; viz., first, those cases which presented a certain train of symptoms briefly described by Dr. Addison, attended almost always by discoloration of skin, and second, those cases in which the said symptoms were absent. These peculiar symptoms, together with the discoloration of skin, are well exemplified in Cases II. and III. prefixed to this paper.* On carefully analyzing all the cases I had collected, it appeared not only that a very large proportion of them belonged to the first of these groups, but also that in all the cases in that group, and, with a very few exceptions, in no others, the supra-renal capsules were reported to have undergone a morbid change entirely analogous to that described in the two cases of Addison's disease at the head of this paper.

This further fact rendered the whole number of cases finally divisible into two categories. The one comprehends all those cases, *one hundred and twenty-eight* in number, in which there had clearly taken place in the supra-renal capsules the morbid change characteristic of Addison's disease, and coincides generally, as I have said and the following analysis will shew, with the presence of the symptoms of Addison's disease during life. The other includes all the remaining cases of morbid change in the supra-renal capsules of whatever description, as well as the cases of bronzed skin without any change in the supra-renal capsules; and from these, as will be seen, with a few explainable exceptions, the symptoms of Addison's disease were altogether absent. Lastly, I have been obliged to place in this second category, a number of cases in which the change in the capsules was so imperfectly described, or appeared from the description to be of so doubtful a character, that it was impossible fairly to class them with the genuine cases. These miscellaneous groups in the second division amount, in the aggregate, to *sixty-eight* cases, and I shall first briefly deal with them, before proceeding

* For a full description of the symptoms and discoloration of Addison's disease, see also "Constitutional symptoms," and "External signs," at pp. 3 and 4.

to the consideration of the true cases of Addison's disease. They are comprised in the four tables A, B, C, and D.

Bronzed-skin without disease of supra-renal capsules.—Table A. comprises *ten* cases in which there was bronzing of skin during life, but in which the supra-renal capsules were found to be healthy after death. *One* only of these (No. 5) presented any resemblance to the train of constitutional symptoms characteristic of Addison's disease. It is remarkable in this case that the *post-mortem* appearances in other organs afford no sufficient explanation of the cause of death, and, moreover, the defective description leaves the real character of the discoloration of skin doubtful, so that no legitimate deduction can be drawn from the case as it stands. Of the other *nine* cases it may suffice to say, what a reference to the Table will shew, that not one presented the constitutional symptoms, without which the discoloration is of small value in diagnosis, and that the discoloration itself appears in no case to have presented the really characteristic features, whilst in several of the cases it was of a totally different character, and in some appears to have arisen from deposits of bile in the skin or from syphilitic eruptions. In one case the discoloration obviously arose from uncleanness and vermin, and strikingly resembled that seen in a living case exhibited by myself to the Pathological Society and recorded in its *Transactions* (Vol. xv., p. 226). The discoloration in this latter case was so deep and extensive that it might readily have been mistaken at first sight for that of Addison's disease; but, from the absence of almost all the constitutional symptoms, and of all the characteristic features of the discoloration, I was able at once to pronounce with certainty as to the case not being a true example of that disease, and, in fact, after a few months, the patient recovered almost entirely from her illness and her skin became much paler. The above being all the cases I have been able to find of bronzed-skin without disease of the supra-renal capsules, in which the discoloration was sufficiently analogous to that characteristic of Addison's disease to have been quoted with reference to it, I think I am justified in concluding that such cases are extremely rare, and that, when they do occur, a careful investigation of their history and symptoms, and a close examination of the discoloration itself, would enable any physician, conversant with Addison's disease, at once to discriminate such spurious cases from genuine cases of that disease.

Cancerous disease of the supra-renal capsules.—Table B. includes *twenty-four* cases reported as cancer of the supra-renal capsules; but,

of these, the *two* last (Nos. 33 and 34), reported by Drs. Mettenheimer of Frankfort and Duclos of Tours were manifestly, from the descriptions, cases of Addison's disease and not of cancer. In neither of these cases does there appear to have been any microscopical examination to determine the character of the morbid product, and Dr. Mettenheimer, at least, was so little clear on this point as to state that there were "either tuberculous or cancerous indurations in the left lung." He merely reports that the places of the supra-renal capsules were occupied by cancerous deposit; but, in the fuller description of Dr. Duclos, the condition of the supra-renal capsules exactly coincides with that characteristic of Addison's disease and by no means with that usual in cancer of those organs. They are said to have been hard and nodulated, to have grated in places against the scalpel, and to have presented precisely the appearance of lardaceous tissue. Moreover, in order to accept as correct the report of cancer in these cases, we must admit that primary cancer had commenced simultaneously, and proceeded, *pari passu*, in the two symmetrical organs, which is certainly a most unusual, if not an absolutely unknown, occurrence in the history of cancer. Finally, these are the only *two* out of the *twenty-four* reported cases of cancer which were accompanied either by the train of constitutional symptoms or by the peculiar discoloration of skin characteristic of Addison's disease, an incredible circumstance, if cancer of the supra-renal capsules could really produce the same effects as Addison's disease of those organs. Of the *twenty-two* other cases of cancer not one presented anything resembling the train of constitutional symptoms of Addison's disease; seven only, including the four reported by Dr. Addison himself, are said to have been more or less discoloured, and, even in these, such discoloration as there was appears to have been quite uncharacteristic. The history of many of these cases is most imperfectly given, and they have, apparently, been published with no other view than that of shewing, that in cases of cancer of the supra-renal capsules there either was, or was not, discoloration of skin supposed to be analogous to that characteristic of Addison's disease. The accumulated evidence of these *twenty-two* cases proves, in my opinion, conclusively, that cancerous disease of the supra-renal capsules does not produce either the aggregate of symptoms or the peculiar discoloration of skin incident to Addison's disease of those organs. That Dr. Addison himself should have been mistaken on this point, and should at first have believed that any morbid change in the structure of the supra-renal capsules would suffice to produce

the symptoms and appearances he had observed in connection with one particular change, can be no matter of surprise, if we reflect that when he published his work, he had seen but five true cases of the disease which bears his name, and had had no opportunity of watching the cancerous cases during life, so as to ascertain, what much additional evidence renders patent to us, that some degree of very different discoloration of skin was all that they had in common with cases of the genuine disease.

Miscellaneous diseases of the supra-renal capsules.—In Table C. are placed all the cases of reported disease of the supra-renal capsules, which are clearly neither cancer nor yet true Addison's disease. These are but *ten* in number, and on reference to the Table it will be seen that only two (Nos. 35 and 39) presented any discoloration of skin, and that the very reverse of characteristic, whilst in a single case only (No. 38) did the symptoms at all resemble those of Addison's disease, accompanied however by extreme pallor instead of by discoloration. I am, however, strongly of opinion that in this latter case the capsules were really healthy—the appearances described in them strongly resembling those produced by *post-mortem* change—and that the real cause of death was not discovered at the autopsy. I think it may fairly be inferred from the small number of cases I have been able to find referable to this Table and from the facts connected with them, that diseases of the supra-renal capsules which are neither cancerous nor yet true Addison's disease are of very rare occurrence, and that none of the few recorded, which appear to be chiefly apoplexy, amyloid disease, or fatty degeneration, are found to be attended either by the constitutional symptoms or external signs of Addison's disease.

Imperfectly described, or doubtful cases.—It was to be expected that among so large a number of cases, reported by observers of such various degrees of experience and with such different opportunities for observation, there would be some so imperfectly described, and others of so doubtful a character, as to render it impossible to determine their true places in such a classification as I have attempted. All such cases, *twenty-four* in number, I have thrown together in Table D. In several of these the characteristic nature either of the symptoms or of the discoloration of skin convinces me that they were really cases of Addison's disease, and that the description of the morbid change in the supra-renal capsules alone was at fault; but I was, nevertheless, compelled to set them aside as unsatisfactory subjects for discussion and unsafe grounds on which to base any conclusions.

These four Tables comprise, as I have said, the sixty-eight cases which, upon a careful analysis of the whole number collected, I was obliged to exclude from the category of genuine and reliable cases of Addison's disease.

ADDISON'S DISEASE OF THE SUPRA-RENAL CAPSULES.—I now proceed to the consideration of the *one hundred and twenty-eight* cases in which there appears to be no doubt, from the description of the condition of the supra-renal capsules, that those organs had undergone the peculiar morbid change characteristic of Addison's disease, and in almost all of which the characteristic constitutional symptoms and external signs were also more or less fully developed. In a very considerable number of these cases the disease in the supra-renal capsules is said to be have been entirely, or almost entirely, uncomplicated, and in a few cases undoubtedly of genuine character, the other organs had not been examined. In a large majority of the remaining cases, the disease in the capsules was found to be complicated only with tubercle in the lungs or other organs, in a considerable number with vertebral or lumbar disease, frequently associated also with tubercle, and, in a small residue of cases, with non-tubercular diseases of a serious nature. These circumstances have afforded data for corresponding subdivisions of the genuine cases, each of which I have formed into a separate Table.

Uncomplicated cases.—Table E. comprises *twenty-four* cases in which the only disease found on *post-mortem* examination was that of the supra-renal capsules, the other organs being reported all healthy. In *twenty* of these cases the constitutional symptoms and discoloration of skin characteristic of Addison's disease coexisted in a well-marked form; in *one* case (No. 72) the constitutional symptoms were well-marked, but there was no discoloration, and in *three* cases (Nos. 70, 86, 91,) there were some of the constitutional symptoms and more or less discoloration of skin, but neither apparently fully developed.

Almost uncomplicated cases.—Table F. contains *seventeen* cases in which the lesions found in other organs were of a very trifling nature. In *four* the mucous membrane of the stomach was congested or otherwise altered, in *seven* the glands of the small intestines were enlarged and prominent, and in *six* the mesenteric glands were enlarged, or contained cheesy deposits. In *eleven* of these cases the constitutional symptoms and the characteristic discoloration of skin coexisted, in *three* cases (Nos. 96, 98, 101,) the constitutional symptoms existed together with more or less discoloration of skin, and in *one* case (No.

102), with no discoloration at all. In *two* cases (Nos. 104, 109,) the distinctive constitutional symptoms appear to have been absent, but there was in both a certain degree of characteristic discoloration of skin.

Cases without evidence of complication.—In Table G. are placed *five* undoubtedly genuine cases which must be classed as uncomplicated, the state of other organs not having been examined. *Four* of these presented both the train of constitutional symptoms and the characteristic discoloration of skin, and although in one case (No. 113), which came under observation only on the day of death, no symptoms are reported, the characteristic discoloration is recorded in general terms.

Subtracting the above forty-six virtually uncomplicated cases in these three Tables from the hundred and twenty-eight cases of Addison's disease, there remain eighty-two cases complicated with some other organic disease.

Cases complicated with vertebral disease or lumbar abscess.—In Table H. are shewn *fifteen* cases complicated with disease of the vertebræ or lumbar abscess, which, in nine out of the fifteen, was associated with tubercle in the lungs or other organs; in three of the remaining six cases the state of other organs is not reported. *Eleven* of these cases presented both the constitutional symptoms and the discoloration of skin characteristic of Addison's disease; in *one* case (No. 128) the constitutional symptoms existed without discoloration; and in *three* cases (Nos. 125, 126, 127) no symptoms but those of the complicating diseases are reported, in one instance associated with discoloration of skin, and in the two others with no discoloration at all. In two of the uncoloured cases there were open lumbar abscesses, which doubtless hastened the termination of the illness; in the third case no details are given of the vertebral disease, except that it was known during life, and therefore was probably severe.

It is almost certain that vertebral disease existed in many more than these fifteen cases in which it was diagnosed during life, or discovered after death. In twenty-two other cases there was severe pain in the vertebræ or loins, associated, in several instances, with tenderness over the vertebræ, or with such symptoms of spinal disease as incontinence of urine, sense of tightness round the abdomen, and numbness, loss of power, or spasmodic twitchings in the lower limbs.

Cases complicated with tubercular disease.—Tables K., L., and M. comprise, in all, fifty-seven cases complicated with tubercular disease only, and classed according to its various degrees of development and severity,

from a little quiescent tubercle in the apices of the lungs, to the most general and advanced tuberculosis.

Table K. contains *twenty-five* cases in which the disease of the supra-renal capsules was complicated only with tubercle in the lungs, except in two cases, in one of which there was slight disease of the mitral valve and in the other disease of the bones of the left foot. In none of these cases was the tubercle in the lungs sufficient to account for death; in two cases only were there cavities in the lungs, but without symptoms of phthisis during life, and, in at least twenty cases, the tubercular complication was too slight to have produced any effect on the course of the illness. Many of the cases in this Table might, in fact, have been classed with the virtually uncomplicated cases, had it not been my object to shew clearly the nature of the complication most frequently associated with Addison's disease. In *fifteen* of the twenty-five cases, the constitutional symptoms and the discoloration of skin were both characteristic. In *three* cases (Nos. 138, 139, 146) the constitutional symptoms were accompanied by more or less discoloration and in *two* cases (Nos. 137, 148) they seem to have existed without any discoloration at all. One of these last, however, occurred before the time of Addison's discovery. In *three* cases (Nos. 131, 132, 150) the constitutional symptoms, though imperfectly described, were probably characteristic and were attended by characteristic discoloration of skin. In *one* case (No. 153) no symptoms could be reported, as the case was seen only after death, but discoloration of skin was noted. In *one* other case (No. 152) neither constitutional symptoms nor discoloration are reported; but this case also occurred before the publication of Addison's work.

Table L. includes *nineteen* cases in which Addison's disease was complicated with more general tuberculosis than in the previous Table. In *eleven* of these cases, the constitutional symptoms and characteristic discoloration of Addison's disease were distinctly marked, and it will be observed on examination of the Table, that these are, generally speaking, the cases in which the tubercular disease was least severe or acute. In *two* cases (Nos. 165, 171) the constitutional symptoms probably existed, though imperfectly described, or perhaps partially masked, for there was characteristic discoloration in the first, and sufficient discoloration for diagnosis in the second, of the two cases. In *six* of the more severe tubercular cases no symptoms are recorded but those of the complicating disease. There was, however, characteristic discoloration in two of these (Nos. 158, 162), more or less dis-

coloration in two others (Nos. 166, 174), and only in one case (No. 160), is it positively said that there was no discoloration at all, though in one other (No. 164) which occurred before Addison's discovery, no discoloration was noticed.

In Table M. I have placed *thirteen* cases in which the disease of the supra-renal capsules was complicated with phthisis, and its constitutional symptoms were apparently masked by those of the predominant disease. In *three* only of these cases (Nos. 179, 181, 183), some of the distinctive constitutional symptoms of Addison's disease are reported to have existed in conjunction with those of phthisis, and in all the three there was more or less characteristic discoloration of skin. In the *ten* other cases no symptoms are mentioned but those of the complicating disease. In six of these, however, some discoloration is reported; in one case (No. 180), of date previous to Addison's discovery, no discoloration was noticed; and, in three only (Nos. 174, 177, 186), is there said to have been no discoloration at all.

Cases complicated with non-tubercular diseases.—There remain only *ten*, of the whole number of cases, to place in Table N. under my last head, viz., that of serious non-tubercular complications, such as disease of the heart, liver, kidneys, or brain. In *six* of these cases some of the constitutional symptoms of Addison's disease were present in conjunction with those of the complicating disease, and in five of this number (Nos. 187, 192, 194, 195, 196), there was characteristic discoloration of skin, in one (No. 191), no discoloration at all. In *two* cases (Nos. 189, 193) the only symptoms recorded are those of the predominant disease, with some discoloration in the first, and none in the second, of the two cases. Lastly, in *two* cases (Nos. 188, 190), no symptoms were known or reported, and no discoloration of skin existed.

Summary of analysis.—The results of the foregoing analysis of the one hundred and twenty-eight cases of Addison's disease are summarized in the following Table. The totals at the bottom of the three columns of the left-hand half-table indicate the division of the 128 cases with reference to the degree of the constitutional symptoms alone; those at the bottom of the right-hand half-table indicate the division of the same cases according to the degree of discoloration alone. The figures in the right-hand half-table shew the number of cases in each group in which there existed characteristic, slight, or no, discoloration. The figures in the left-hand half-table shew the number of cases in each group in which well-marked, slight, or no, constitutional symptoms co-existed with the different degrees of discoloration.

Number of Cases.	Classes of Cases.	Degrees of Discoloration.	No. of Cases with Constitutional Symptoms well-marked.	No. of Cases with some Constitutional Symptoms.	No. of Cases with no Constitutional Symptoms.	No. of Cases with Characteristic Discoloration.	No. of Cases with some Discoloration.	No. of Cases with no Discoloration.
46	Addison's Disease virtually uncomplicated (<i>see</i> Tables E., F., G.).	Characteristic.	35 ^a		1 ^c	36		
		Some.	3 ^b	3 ^d	2 ^d		8	
		None.	2 ^b					2
59	Addison's Disease complicated with Vertebral and Tubercular Disease (<i>see</i> Tables H., K., L.).	Characteristic.	37 ^a	4 ^c	3 ^c	44		
		Some.	3 ^b	1 ^d	3 ^d		7	
		None.	3 ^b		5 ^e			8
23	Addison's Disease complicated with Phthisis and other serious diseases (<i>see</i> Tables M., N.).	Characteristic.		5 ^c		5		
		Some.		3 ^d	7 ^d		10	
		None.		1 ^d	7 ^e			8
128			83	17	28	85	25	18

It will be observed that the constitutional symptoms of Addison's disease existed in a well-marked form in eighty-three cases, and the characteristic discoloration of skin in eighty-five cases. In seventy-two cases ($35^a + 37^a$) the well-marked constitutional symptoms and characteristic discoloration co-existed. There remain eleven cases ($3^b + 2^b + 3^b + 3^b$) in which the constitutional symptoms were well-marked, but which presented only slight discoloration or none at all. On the other hand there remain thirteen cases ($1^c + 4^c + 3^c + 5^c$) which presented the characteristic discoloration, but in which only some or none of the constitutional symptoms are reported. Of this whole number of ninety-six cases, ($72 + 11 + 13$) which presented, in a fully developed form, either the constitutional symptoms or peculiar discoloration of skin characteristic of Addison's disease, or both, although five occur among the cases with serious non-tubercular complications, not one is found among the cases complicated with advanced phthisis. This last fact would seem to be a sufficient refutation of the theory propounded by M.M. Virchow, Bazin and other foreign authorities, that the discoloration of skin characteristic of Addison's disease is the result, not of the morbid change in the supra-renal capsules, but of the general tuberculosis, which is occasionally associated with it.

Subtracting these ninety-six cases, all of which presented character-

istic symptoms, or discoloration, or both, from the total number of one hundred and twenty-eight, there remain thirty-two cases, of which twenty ($3^d + 2^d + 1^d + 3^d + 3^d + 7^d + 1^d$) presented some of the constitutional symptoms, or some discoloration of skin, and, in many instances, both, leaving only twelve cases ($5^e + 7^e$) which presented neither any of the constitutional symptoms nor any discoloration of skin. In two of these latter the case was not observed during life, and the other ten were all complicated with phthisis, open lumbar abscesses, or other predominant diseases, which were apparently the causes of death, rather than the co-existing disease in the supra-renal capsules.

When due allowance has been made for the inexperience of many of the observers with regard to this little-known disease; for the want of opportunities of observation in many of the cases; and for the difficulty, in many others, of recognising the symptoms of this disease in the presence of some more obvious complaint: it must, I think, be admitted, that rarely has a more overwhelming array of facts supported any scientific hypothesis, than is presented, by the results of this analysis, in support of the relation between a certain train of constitutional symptoms, attended by discoloration of skin, and one particular organic lesion of the supra-renal capsules.

Nature of morbid change in the supra-renal capsules in Addison's disease.—By the great majority of reporters this particular organic lesion has been described as tubercular or serofulous; but Dr. Wilks appears to regard it as an idiopathic or peculiar disease, and Dr. Burdon Sanderson, in reporting upon a specimen of this disease in the capsules which he kindly examined for me, says that no structure was to be found having any resemblance to tubercle. Dr. Dickinson also speaks of the disease as something *sui generis*. On the other hand, my friend Dr. Cayley, who has carefully examined specimens from four of the cases I have reported to the Pathological Society, considers the deposit in the capsules to be essentially of a tuberculous nature, as do likewise Dr. Child, of Oxford, and Dr. Hayden, of Dublin. Rokitansky, Virchow, Trousseau, and other foreign authorities also agree in applying the term tubercular to this particular deposit in the supra-renal capsules; and, certainly, its very frequent occurrence in persons affected with tubercle in the lungs or other organs, taken together with the rarity of its association with any other disease, cannot fail to indicate some intimate relation between this particular lesion characteristic of Addison's disease and the tubercular diathesis.

Whatever differences of opinion may exist as regards the nature of the morbid deposit in cases of Addison's disease, none exist as to the general and microscopical appearances of the diseased capsules. These are generally enlarged, hard, and nodulated. On section they scarcely ever present any trace of the distinction between cortex and medulla, or any remains of the natural tissue. It is evident that there has been an exudation which has obliterated the original structure. In a large proportion of the accurately-recorded cases, the appearance of the capsules on section is said not to have been uniform, but marbled by the admixture of two different looking deposits. One of these is semi-transparent, firm, and, when first cut into, of a greyish colour, rapidly assuming a pinkish hue on exposure to the air; the other is generally seen in the form of irregular roundish, opaque, yellow or cream-coloured masses, of more or less friable consistence, embedded in the translucent portion. Often, on careful examination, various gradations will be met with, intermediate between the translucent tissue and the opaque friable nodules, and sometimes there are harder portions of cretaceous character, either in the form of granules or of larger masses. Sometimes, also, collections of thick, creamy fluid, called abscesses by some observers, are found occupying larger or smaller portions of the diseased organs, which, in exceptional, probably older, cases, are shrivelled instead of being enlarged, and contain only this fluid with a little cheesy matter, or else are hardened throughout into cretaceous masses.

Under the microscope the translucent portion is generally found to consist of a more or less fibrous basis, mixed with much granular matter, containing shrunken cells and nuclei, some of the nuclei being occasionally elongated into spindle-shaped bodies. The yellow opaque nodules consist, in differing proportions according to circumstances, of amorphous granular matter mixed with irregular-shaped shrunken cells, nuclei, and oil. When the creamy liquid from cavities, or so-called abscesses, has been examined, it has been found not to be true pus, but to consist mainly of oily débris.

In a large but uncertain proportion of the cases there were evidences of inflammation in the cellular envelopes of the capsules, such as thickening and firm adhesions to neighbouring organs—the diaphragm, liver, pancreas, vena cava, kidneys or stomach—and it is probable that these have existed more frequently than they are reported, but have been overlooked in making the *post-mortem* examinations. In some cases it appears evident that the inflammation has originated in neighbouring tissues, and has spread from thence to the cellular tissue

surrounding the supra-renal capsules; as in a case (No. 117) in which the patient had suffered from right lumbar abscess some years before his last illness, and, after his death from Addison's disease, a white, fibrous-looking, obliterated sinus was found to proceed upwards from the cicatrix of the former wound to the structures in which the right capsule was embedded. In this case, as well as in another (No. 115), in which the illness had originated in right lumbar abscess, the right capsule was obviously in a more advanced stage of disease than the left. Sometimes, at least, the history of the case seems to shew conclusively that the inflammation producing the mischief had arisen from some external injury. In the last of the three cases prefixed to this paper (No. 129), the patient, some three years previous to the apparent accession of Addison's disease, had sustained an injury in the back, from which he had continued to suffer more or less pain during the whole intervening period. In this case, moreover, the injury sustained was on the left side of the spine, and the disease was clearly of oldest standing in the left capsule. In one of my own cases (No. 155) the patient had strained her back while turning a mangle, several years before her death, and dated the failure in her health from that injury. In a third case (No. 119) the patient had hurt his back by a fall eight years before, and caries of several vertebræ was found after death. In these and other similar cases it appears impossible to avoid the conclusion that the supra-renal disease was secondary to the mischief produced by the local injury.

One or both capsules involved.—In all the hundred and twenty-eight cases, with the exception of *eleven*, both capsules are reported to have been found diseased; but the disease was by no means always in the same stage. On careful study of the reports it appears clear that in twelve cases the disease was most advanced in the right, and in thirteen cases in the left, capsule; and it is probable that similar inequalities may have existed in other instances, though unreported. It seems, however, quite unimportant as regards the symptoms and progress of the case, whether the one or the other capsule be in the most advanced state of disease, for the constitutional symptoms and characteristic discoloration were equally present in both sets of cases. This may be verified on examination of the Tables; but I may adduce here, as examples, two cases (Nos. 130 and 117) in which the constitutional symptoms and discoloration of skin were equally characteristic and well-developed, but in one of which the disease was evidently older in the right capsule, and in the other, in

the left. In *eleven* cases, as I have said, it is not definitely reported that both capsules were diseased; but in *two* of these (Nos. 74, 125), one capsule is not mentioned; in *two* more (Nos. 108, 180), one of the capsules was not examined; in *one* (No. 81), the right capsule is said to have been absent, and in *two* (Nos. 172, 179) the second capsule is described as softened in texture, so that there remain only *four* cases in which it is positively reported that one capsule was diseased, while the other remained healthy. In one of these four (No. 86), in which no other disease whatever was found in the body, the constitutional symptoms and discoloration of skin both existed, though not fully developed; in two others (Nos. 164, 175) only the symptoms of the complicating disease were noticed, and there was only slight or no discoloration, and, in the remaining case (No. 188) nothing could be known beyond the absence of discoloration, the person having been found dead. The insignificant number of the exceptional cases proves that, as a rule, both capsules are involved in cases of Addison's disease; and, so far as any inference can be drawn from such scanty data, it seems probable that neither symptoms nor discoloration are fully developed in those rare cases in which only one organ is diseased, and that it is immaterial whether the right or the left capsule be the one involved, for there were two cases of each in the four cases of disease of only one capsule.

Condition of supra-renal nerves.—Dr. Habershon and one or two other observers have drawn special attention to the relations between the vaso-motor and pneumogastric nerves and the supra-renal capsules, and to the condition of the supra-renal branches of these nerves in cases of Addison's disease. In the cases quoted by them, the nerves passing to the diseased capsules from the semi-lunar ganglia were enlarged, and in one case the semi-lunar ganglion itself was embedded in the enlarged capsule. It is, in their opinion, mainly to the implication of these nerves that the chief symptoms of Addison's disease, in their opinion, are due. Little evidence on this point is furnished by the cases I have collected, as the state of the nerves is mentioned only in a very few instances, and in one or two of these there is said to have been no discoverable change. In the two last of the three cases at the head of this paper I witnessed the examination of the supra-renal nerves; in the first case they appeared to be normal, while, in the second, the nerves passing to the capsules from the semi-lunar ganglia, and especially a branch from the great splanchnic, which joined the posterior surface of the capsules, were found to be at least twice the size of the corresponding nerves of healthy capsules. Micro-

scopical examination of these enlarged nerves, however, discovered only an apparent increase in the fibrous investment of the nerve-bundles. That the vomiting and even some of the other symptoms of Addison's disease may be induced by a morbid condition of the supra-renal nerves seems, nevertheless, the most probable supposition; but it must not be forgotten that this is, after all, a secondary question, as the condition of the nerves is a consequence, not a cause, of the disease in the supra-renal capsules.

Seat of discoloration.—Microscopical examination of the discoloured skin of Addison's disease shews the discoloration to be due, as a rule, to deposit of pigment in the rete mucosum, the more superficial layers of the epidermis and the true skin remaining generally uncoloured. This distribution of pigment in certain layers of the skin only is not peculiar to Addison's disease, but resembles that found on examining the skin of the darker races of men, and Mr. Hutchinson found exactly the same distribution of colouring-matter in the skin of a man who had suffered from yellow fever in the Crimea, and who was bronzed, without disease of the supra-renal capsules. In one case, however, the epidermis is reported to have been loaded with pigment, which in many places was collected in greater quantity in its deeper layers, but in others was equally distributed throughout it. In the third case prefixed to this paper, I found, in addition to the usual deposit in the rete mucosum, slight traces of colour in some of the superficial scales of the epidermis, others being perfectly normal; there were also small masses of pigment deposited here and there in the cutis. Whether in the rete mucosum, or in other parts of the skin, the pigment is arranged in granular masses; and the margin between the pigmented layers of skin and the super- and sub-jacent layers is always abrupt and well-defined, and follows the undulations of the rete mucosum, even when, as in the case just referred to, there are scattered deposits in other parts of the skin. In a very small number of cases pigmentary deposits have been found in the peritoneum, or other internal organs, as in the second case prefixed to this paper, but it is very doubtful whether these can be regarded as in any way connected with the disease in the capsules, seeing that precisely similar deposits are found in chronic tubercle of the peritoneum (which was one of the complications in the case referred to), and in some other chronic diseases. In many cases the hair has become visibly darker along with the darkening of the skin, and, on microscopical examination after death, pigment has been found in the hair as well as in the rete mucosum. I

may add that the naturally brown hair of a young woman who is still under my care, suffering from Addison's disease, has become of a raven-black colour and coarser in texture, since she first came under observation more than a year ago.

State of the blood.—The blood seems to have been very rarely examined in cases of Addison's disease. In one case pigment is said to have been found in the blood, and, in the same case, it was found also in the spleen; in a few cases the white corpuscles of the blood are said to have been in excess; in one or two, the blood is reported to have been normal, and in one or two others the red corpuscles were certainly not deficient. Dr. Hayden says that the white corpuscles have been found in excess in all the cases in which the blood has been examined, but in support of the assertion he only adduces two cases, and my experience certainly does not confirm his view. Professor Dr. Buhl, on the other hand, considers that in Addison's disease, there is always great deficiency of fibrine in the blood, but he has evidently founded his opinion on cases in which there was also disease of the spleen, and his experience as to the fluid state of the blood and the entire absence of clots after death is altogether opposed to the general evidence on this point. In every case in which I have witnessed the *post-mortem* examination, firm, discoloured fibrinous clots were found in the right cavities of the heart, attached to the muscoli pectinati and chordæ tendineæ, and passing sometimes for a considerable distance into the pulmonary artery. Similar clots in the right ventricle are reported in a large number of the cases, and less frequently as existing also in the left ventricle, but I regard them, at least in this disease, as mere consequences of the usually slow mode of death. As yet, however, no satisfactory conclusions can be drawn from the hitherto insufficient investigations into the condition of the blood in cases of Addison's disease.

Duration, and course of illness.—The commencement of Addison's disease can but rarely be referred to any particular date, and patients can seldom fix any definite time for the commencement of their symptoms, so that in the present state of our knowledge it is scarcely ever possible to determine, with accuracy, the actual or comparative duration of the local disease and its external manifestations. Moreover, even in those cases in which the duration of the illness is exactly specified, no great reliance can be placed upon the correctness of the reports, for the disease is infinitely most frequent among the labouring classes, who usually date the commencement of an illness

only from the time when it disables them from work; whereas Addison's disease, being essentially a chronic complaint, is often so insidious in its advances, that patients are able to continue their ordinary occupations until some external depressing cause upsets the tottering balance, and they break down altogether only a few weeks, or even days, before death.

It has been supposed that a very considerable length of time is necessary for the development of the discoloration of skin, but the evidence I have collected does not confirm that assumption, although, for the reasons I have stated, it has not sufficient weight to negative it. The characteristic discoloration as well as the constitutional symptoms existed in thirteen cases, in which the illness is stated not to have lasted above four months. On the other hand, the discoloration was absent in two cases (Nos. 102, 148) in which the illness had lasted more than six and twelve months respectively. It is, however, undeniable that the discoloration seems to have been most intense and universal in very slow chronic cases which had been under observation for periods of from one to seven years. The progress of the disease is by no means always that of a steady advance. There have been remarkable remissions in some of the best-marked cases, during which the patient has been able temporarily to resume his ordinary occupations, and these have even occurred two or three times in the same case, and yet the patient has eventually died of the disease. Speaking from my own observation of several cases which I have carefully watched for considerable periods of time, the discoloration has seemed to me to become less deep during the intervals of improvement, but I have never seen it disappear after it had once been distinctly marked. Notwithstanding the extreme debility, breathlessness on exertion, feeble pulse and general exhaustion, neither emaciation nor anæmia, properly speaking, exist in simple cases of Addison's disease. The blood in all the *post-mortem* examinations I have witnessed was dark-coloured and rather thick, and the muscles generally firm, well-nourished, and of a deep-red colour. Emaciation is, indeed, sometimes mentioned as existing during life, but, unless where there was also wasting disease, such as phthisis or lumbar abscess, the *post-mortem* reports do not confirm this statement; on the contrary, in many cases, a large amount of yellow fat has been found under the integuments, especially of the abdomen, and also in the omentum and around the heart and other organs.

The existence of an unpleasant odour about the person in the last stage of Addison's disease has been observed in a certain number of

cases, including three of those recorded by myself, and it has been considered by some to be identical with the peculiar exhalation from the Negro-skin. As far, however, as my own observation goes, the fetid odour in these cases partakes rather of the cadaverous character, and may possibly be the result of commencing decomposition during the very slow death common in this disease. None of the three patients whom I watched survived its appearance many days. Death for the most part takes place slowly from gradual sinking, and in only eleven cases is it reported to have been at all sudden.

Influence of sex, age, and occupation, on the occurrence of Addison's disease.—Males appear to suffer much more frequently than females from Addison's disease; ninety-two of the true cases having belonged to the former, and only thirty-six to the latter sex. The disease seems not to occur in childhood, the earliest age at death having been eleven years in a boy (No. 105) and thirteen in a girl (No. 156), one of my own cases; and it appears to be equally rare in advanced life, only seven males and four females having died above the age of fifty, and of these only two males and one female were beyond the age of sixty years. But whilst among males the mortality is pretty evenly distributed over the hard-working years of life, among females the greater proportion of deaths takes place between the ages of fifteen and twenty-five, and, again, between those of thirty-five and fifty. The occurrence of Addison's disease seems to be in a great measure limited to the classes engaged in active manual labour; only eight males and three females, so far as can be gathered from the reports, having belonged to the middle or higher classes of society. The facts thus brought out are, the almost exclusive occurrence of this disease among the classes most liable to local injuries from accidents or over-exertion; its much greater comparative prevalence among persons of that sex which is most exposed to these causes of injury; and the pretty equal distribution of the mortality caused by it over the active period of life, to which it is almost entirely confined. These facts appear, at least in some measure, confirmatory of the opinion I have already expressed, based on the history of individual cases, that the origin of Addison's disease of the supra-renal capsules is due, in a hitherto quite unsuspected degree, to the extension of inflammation to those organs from diseased or injured adjacent parts in persons of a tubercular diathesis.

TABLE A.

CASES OF BRONZED SKIN, WITHOUT DISEASE OF THE SUPRA-RENAL CAPSULES.

Reporter and Reference.	Sex and Age.	Previous History, and Duration of Illness.	Symptoms.	Colour of Skin.	Post-Mortem Examination.	
					State of Supra-Renal Capsules.	State of other Organs.
1. Mr. HUTCHINSON, Path. Trans., vol. viii., p. 341, 1857, Mr. J. ALLEN, Liverpool.	Male, 25, sailor.	Had had yellow fever in Crimea; never well afterwards; skin much tinged at time of fever, and had latterly got darker. Last illness, fourteen days.	Dyspnoea; pain in left side; dusky, bloated countenance, anxious and disturbed expression.	Entire surface more or less bronzed—face, arms, and hands least; areolæ dark, colour deepest on lower part of trunk, on scrotum and penis, and inside thighs. Under microscope, large deposit of pigment in rete mucosum.	Both quite healthy.	Pneumonic consolidation of both lungs.
2. Dr. HARLEY, Path. Trans., vol. x., p. 264, 1858, Dr. PARKES.	Male, 66, cabman.	Jaundice seven years before, followed by darkening of skin on face, neck, and other parts; for five years, colour remained unaltered, and health good. Illness, six months.	None recorded; patient had ascites.	Face, neck, and arms dark; over trunk, and especially abdomen, colour diversified with irregular white patches; conjunctivæ slightly yellow, with a little dark pigment; a dark patch on mucous membrane of lips.	Healthy.	Hob - nail liver; spleen greatly enlarged.
3. Dr. QUAIN, Path. Trans., vol. ix., p. 412, 1858, Dr. BUCKNILL.	Female, 45, sempstress.	Had been insane five months prior to commencement of discoloration. Discoloration, nine months.	Convulsive movements of body and legs; mind weak and childish, appetite voracious; progressive emaciation. Three attacks of apoplexy; the third fatal.	Discoloration began with sallowness of face; the skin of face, arms, hands, and body, became as dark as a Mulatto's, but with a yellow tinge; conjunctivæ very clear.	Committee of Pathological Society reported that they did not look upon the supra-renal capsules as diseased.	Healthy, excepting brain and skull.

Reporter and Reference.	Sex and Age.	Previous History, and Duration of Illness.	Symptoms.	Colour of Skin.	Post-Mortem Examination.	
					State of Supra-Renal Capsules.	State of other Organs.
4. Dr. SLOANE, Med. Times and Gazette, vol. xxxvi., p. 221, 1857, Dr. BARCLAY.	Female, 21.	Had suffered from liver complaint, with permanent discoloration of skin. Duration uncertain.	Those of phthisis, with pain in left lumbar region, gastrodynia, occasional vomiting, and diarrhoea; progressive weakness and emaciation. Died from sinking.	Whole surface bronzed; abdomen, loins, hips, inner part of thighs, and arm-pits darkest; mammae round nipples much lighter than surrounding skin; many white spots on breast and back; eyeballs pearly white.	Both appeared normal, and free from any morbid deposit.	Lungs, mesenteric glands, and peritoneum tuberculous; left kidney filled with cysts containing whey-like fluid and curdy matter; right kidney contained one walnut-sized mass of tubercle.
5. Mr. G. MAX, Brit. Med. Jour. 1856, p. 819.	Male, 46.	Congenital blindness; slight attacks of gout, but otherwise good health. Duration uncertain.	Pulse feeble, breathing hurried, rest disturbed; debility, cough, vomiting, diarrhoea. Death in a convulsive, comatose state.	Discoloration most marked on face, neck, axillae, arms, and legs; small brown spots scattered over body.	Both perfectly normal.	Lungs emphysematous; left ventricle of heart dilated.
6. M. LURON, Comptes Rendus de la Société de Biologie, 1856, p. 241, M. GUBLER.	Female, 57.	Cough and spitting of blood for many years. Duration uncertain.	Those of the last stage of phthisis, with emaciation and copious diarrhoea.	Bistre patches on forehead and cheeks; backs of hands and wrists dirty brown; over rest of surface, earthy hue common in last stage of phthisis.	Both normal.	Lungs disorganized by tubercular degeneration; cavities filled with pus.
7. M. PUECH, Gaz. Hebdomadaire, 1856, p. 706.	Female, 28.	Several attacks of syphilis. Duration unknown.	Sank under cerebral attacks, which supervened on phthisis.	Earthy colour of face; large brown patches nearly covering breast and abdomen, darkest round umbilicus; no desquamation of cuticle.	Both normal.	Emaciation; tubercle in lungs and intestines; effusion into brain and ventricles; liver enlarged.

Reporter and Reference.	Sex and Age.	Previous History, and Duration of Illness.	Symptoms.	Colour of Skin.	Post-Mortem Examination.	
					State of Supra-Renal Capsules.	State of other Organs.
8. M. PUECH, Gaz. des Hôpitaux, 1857, p. 190.	Male, 54.	Long constitutional syphilis; otherwise tolerable health. Discoloration, eighteen months.	Loss of strength, nausea, pain and tenderness in iliac region, dysentery. Death from peritonitis, following intestinal perforation.	Face brownish; chest, abdomen, and thighs of a sepia tint; crusts of ecchyma on chest, beneath which normal coloured skin contrasted with surrounding parts.	Both healthy.	Liver contained many sharply-defined masses of yellow matter, from size of a walnut downwards; some of them purulent in centre.
9. Dr. MARTINEAU, De la Maladie d'Addison, p. 40, Dr. VERNON.	Female, 77, rag collector.	Had been very poor and uncleanly. Last illness a few weeks.	Edema of one foot, ecchymosis and gangrene of the other; depression, diarrhoea, and gradual sinking.	Skin of a very dark hue; chest and abdomen darkest, face and hands lightest; epidermis covered with small scales.	Both quite normal, and free from adhesions.	Healthy, excepting slight effusion into the pia-mater, pleurae, and pericardium.
10. Dr. FRÉMY, Bulletins de la Société Anatomique, 1863, p. 42	Male, 59.	None given. Duration unknown.	None reported, but cancer of the œsophagus.	Some days before death, the skin assumed in places a very evident bronze hue.	Both quite healthy. Microscopically examined.	Cancer occupying the lower portion of the œsophagus.
11. Dr. ADDISON On Disease of the Supra-Renal Capsules, p. 30.	Female, 60.	Neither known.	None recorded.	Skin of face, arms, and chest of a peculiar light-brown swarthy hue.	Both contained a considerable amount of cancerous deposit invading their whole structure, and almost obliterating their cavities.	Cancer of mamma, left lung, and surface of liver.

TABLE B.

CASES OF CANCEROUS DISEASE OF THE SUPRA-RENAL CAPSULES.

Reporter and Reference.	Sex and Age.	Previous History, and Duration of illness.	Symptoms.	Colour of Skin.	Post-Mortem Examination.	
					State of Supra-Renal Capsules.	State of other Organs.
12. Dr. Addison, loc. citat., p. 32.	Female, 53, servant.	Had enjoyed good health until last illness; duration, four months.	Eruption on body, soon cured, after which, pain in abdomen and back, with vomiting.	Tawny discoloration on sides of neck, with three marked patches, one on sternum, others under axillæ; skin on dark parts somewhat raised and corrugated.	Right capsule healthy; left infiltrated with malignant material, and closely adherent to kidney.	Stomach, and some of the mediastinal glands, cancerous.
13. Dr. Addison, loc. citat., p. 38.	Female, 28.	Neither known.	None recorded.	Skin of peculiar dingy appearance; not very strongly marked.	Right capsule healthy; in left capsule, a malignant tubercle had caused rupture of a vein, and effusion into the capsule, which had not otherwise undergone much deterioration.	Not mentioned, except cancer of the uterus.
14. Dr. Addison, loc. citat., p. 39.	Male.	Neither known.	None recorded.	Patient's face of a dingy hue, though he was naturally of a fair complexion.	One capsule very much enlarged, and converted into a hard mass of apparently cancerous disease.	Cancer of thorax and lungs.
15. Dr. KirkES, Med. Gazette, vol. xxxv., p. 35.	Male, 43, stone-mason.	Had been of intemperate habits. Illness, two years.	Chronic pulmonary symptoms, and hemiplegia. Died in coma, succeeding to a fit.	No bronzing noticed. (N.B.—This case occurred several years before the publication of Addison's work).	Right capsule healthy; left capsule the size of a pear, hard, and nodular, composed of dry, yellowish material, resembling degenerated tubercle.	Cancerous deposits in brain, lungs, and kidney.

Post-Mortem Examination.						
Reporter and Reference.	Sex and Age.	Previous History, and Duration of Illness.	Symptoms.	Colour of Skin.	State of Supra-Renal Capsules.	State of other Organs.
16. MR. SIMLEY, Med. Gazette, vol. xxxiii., p. 189, MR. MOORE.	Female, 58.	None given. Ill- ness, five years.	A fit at beginning of ill- ness; ulceration of tumour in breast last nine months. Died partially hemiplegic.	The sallow hue of can- cer.	Right capsule enlarged, and most of the organ converted into a mass of firm, scirrhous cancer; in left capsule, several small cancerous nodules.	Cancer of skull—sof- tening of left hemi- sphere; cancer of breast, liver, and of lumbar glands.
17. DR. HALDANE, Edin. Med. Jour., vol. vii., p. 586, 1861.	Male, 36.	None given.	None recorded.	No bronzing of skin.	Both cancerous, and much enlarged; a little glandular structure re- mained in right capsule.	Cancer of bronchial glands, of left lung and pericardium, of kidneys, pancreas, omentum, and abdo- minal lymphatic glands.
18. DR. FALCONER, Brit. Med. Jour., 1861, vol. ii., p. 662.	Male, 49, groom.	None given. Ill- ness, four months.	Skin dry and harsh, ap- petite bad, bowels con- fined, occasional vomiting, great debility; pain, on pressure, in left hypo- chondrium. Death sud- den.	General colour pale, and somewhat sallow; con- junctivæ pearly white.	Both enlarged by can- cerous deposits.	Cancer of stomach, kidneys, &c.
19. DRS. PEACOCK and BRISTOWE, Path. Trans., vol. viii., p. 333, 1856.	Female, 18, tent- maker.	Said to have had a fall some time pre- vious to illness. Du- ration, at least six months.	Fever; pain in left knee and thigh; progressive debility and emaciation; latterly, dorsal and first lumbar vertebræ promi- nent—eventually, bron- chitis.	Complexion unusually pale and clear.	Deposit of cancer occu- pied their place,	Cancerous disease of lungs, bronchial glands, liver, kidneys, pelvic peritoneum, lumbar and left in- guinal glands, and shaft of left femur.

Reporter and Reference.	Sex and Age.	Previous History, and Duration of illness.	Symptoms.	Colour of Skin.	Post-Mortem Examination.	
					State of Supra-Renal Capsules.	State of other Organs.
20. DRS. PEACOCK and BRISTOWE, Path. Trans., vol. viii., p. 337, 1856.	Male, 55, copper- smith.	Had enjoyed good health until last illness. Duration, some months.	Gradual loss of flesh and strength; pain in shoulders, back, and limbs; cough and expectoration; finally phthisis.	Skin of normal colour; deep purple line along margin of gums.	Both enlarged, and their original substance replaced by encephaloid deposit.	Cancerous deposits in lungs, heart, ribs, and left kidney.
21. DR. MURCHISON, Path. Trans., vol. ix., p. 400, 1857.	Female, 62.	None given.	None recorded.	Pale and anæmic; no bronzing.	Right capsule four times the normal size, consisting chiefly of a mass of medullary cancer; left capsule healthy.	Extensive cancerous deposits in liver and right lung; tumour size of an orange in right side of neck.
22. MR. SIBLEY, Path. Trans., vol. x., p. 272, 1859.	Male, 66.	None given. Illness, sixteen months.	Small hard lump near base of tongue, which ulcerated; glands under jaw became enlarged. Died of exhaustion.	No discoloration.	Right capsule much enlarged, and converted into a firm, cream-coloured substance, partially broken down; under microscope, showed fibrous structure and fusiform cells, also many cells closely resembling epithelial cancer-cells; left capsule healthy.	Epithelial cancer of tongue and of glands beneath the jaw, verified by microscopical examination; other organs healthy.
23. DR. WILKS and MR. HUTCHINSON, Path. Trans., vol. viii., pp. 255 and 340, DR. GIBB.	Female, 33.	Nine years ago, pain at catamenial period, followed by tumour size of foetal head in left side of abdomen.	Severe pain in loins, vagina, &c., consequent upon the gradual growth of tumour.	Two years before death, distinct brownish discoloration of abdomen, especially below navel; chest also brown, particularly over sternum.	Right capsule converted into a brown tumour the size of a goose's egg, consisting throughout of very vascular medullary cancer; left capsule healthy.	Cancer of abdomen.

Reporter and Reference.	Sex and Age.	Previous History, and Duration of Illness.	Symptoms.	Colour of Skin.	Post-Mortem Examination.	
					State of Supra-Renal Capsules.	State of other Organs.
24. Dr. CAYLEY, Path. Trans., vol. xvi., p. 250.	Female, 45.	None given.	Those of cancer of the uterus.	Skin dusky and sallow, especially on face and neck; areolæ, axillæ, and groins not darker than usual, and no dark patches anywhere.	A pea-sized nodule of medullary cancer projected from the surface of the right capsule, but did not invade the medullary portion of the organ.	Cancer of uterus, with secondary deposits in peritoneum, liver, kidneys, and in lumbar and mesenteric glands.
25. Dr. J. OGLE, Path. Trans., vol. xvi., p. 250.	Female, 3.	Had been in good health until eight months before death.	Last few days of life constant vomiting and extreme exhaustion.	The whole skin of a gipsy, coppery hue, but nowhere at all of that colour termed bronzed.	Left capsule the seat of a large encephaloid cancerous growth, weighing over two pounds.	Body very stout, with abnormal development of hair on face and body; a cancerous mass in liver; other organs healthy.
26. Dr. L. MARTINEAU, De la Maladie d'Addison, p. 67, M. SECOND- FEREOL.	Male.	None given.	Never those of Addison's disease.	No bronzing of skin.	Cancerous.	Cancer of stomach and liver.
27. Dr. L. MARTINEAU, loc. citat., p. 67, Dr. LETENNEUR, Nantes.	Male.	None given.	Cancer of the parotid gland.	No bronze discoloration.	Right capsule replaced by a mass of encephaloid cancer; left capsule contained four small tumours, showing between them a small portion of normal tissue.	Cancer of the pancreas; cancerous nodules in both kidneys.

Reporter and Reference.	Sex and Age.	Previous History, and Duration of Illness.	Symptoms.	Colour of Skin.	Post-Mortem Examination.	
					State of Supra-Renal Capsules.	State of other Organs.
28. Dr. DELPIERRE, Gazette des Hôpitaux, 1856, p. 393.	Female, 81.	None given.	Multiple cancer, which had commenced in clitoris.	No bronzing of skin.	Capsules had become masses of cancer.	Nothing reported.
29. M. VINCOW, Canstatt's Jahresbericht, 1857, Bd. iv, p. 267.	Female.	None given.	None recorded.	No trace of discoloration of skin.	Both entirely cancerous.	Cancer of the uterus, of the lymphatic glands, and kidneys.
30. M. BALL, Bulletins de la Société Anatomique, 1858, p. 423. M. BEQUEREL, Hôp. de la Pitié.	Male, 36.	Twelve years in Africa; failing health since cholera in 1855. Five weeks in hospital.	Jaundice, with fever and enlargement of the liver; cough, hot skin, vomiting, prostration, copious and foetid diarrhoea; sweat, tears, and urine deeply jaundiced.	Face deeply sun-burnt, but a large number of small spots, apparently ecchymotic, visible on forehead, head, and neck; nothing on other parts of the body.	Cancer of the left capsule; right capsule healthy.	Cancer of the smaller curvature of stomach; liver and spleen enlarged.
31. M. BESNIER, Hôp. Beaujon, Bulletins de la Société Anatomique, 1857, p. 85.	Male, 48, carpenter.	Health good until two years before death. Two months in hospital.	Gradual loss of strength, flesh, and appetite; pain in epigastrium and in hepatic region, increased by pressure; numbness, formation, and sensations of cold in lower extremities; lumbar pains extending along the course of sciatic nerves.	Uniform pale sallow colour of the whole surface; discoloration of sclerotics, and of buccal mucous membrane.	In place of capsules, two large tumours of softened encephaloid tissue; left capsule the smaller of the two, size and shape of a hen's egg. No traces of normal structure.	Cancerous nodules in base of right lung, in duodenum, and kidneys; liver and spleen enlarged.

Post-Mortem Examination.						
Reporter and Reference.	Sex and Age.	Previous History, and Duration of Illness.	Symptoms.	Colour of Skin.	State of Supra-Renal Capsules.	State of other Organs.
32. Dr. GREENHOW, Path. Trans., vol. xvii., Dr. DICKINSON.	Male, 56, leather- dresser.	None given. Dura- tion uncertain; four months in hospital.	Pains down course of right sciatic nerve, partial paraplegia, and other symptoms of malignant disease of vertebrae; hard nodules on chest, sup- posed to be cancerous; no symptoms pointing to su- pra-renal disease.	The skin was of natural colour all over the body.	Both nearly of natural shape, but almost entirely composed of firm encephal- oid tissue; in one or two places, a little brownish matter indicated the re- mains of the proper struc- ture.	A mass of malignant matter lying around and replacing the lumbar vertebrae and pancreas; similar for- mations in the adjoin- ing organs, and also in the heart and chest.
33. M. MERTENHEIMER, Frankfort, Deutsche Klinik, 1856, p. 483.	Male, 47.	None given. Ill- ness several years.	Depression, total want of appetite, and continual pain in loins; heart's ac- tion feeble, debility ex- treme. Death almost sud- den.	Face and hands of a Mulatto-like brown co- lour, with a smoky or metallic hue; rest of body coloured more like jaun- dice.	Both capsules had com- pletely disappeared, their places being occupied by cancerous deposits.	Some tuberculous or cancerous indura- tions in the left lung; pulmonary tissue soft- ened, and full of black pigment; nut- meg liver.
34. Dr. DUCLOS, Hôp. St. Gatien, Tours, Bulletin Génér- al de Théra- peutique, p. 98.	Female, 36.	Failure of health dated from a time of heavy work as laun- dress, in the open air. Illness, ten months.	Progressive debility; gra- dual disappearance of ca- tamenia, fixed and con- stant pain in loins. On day of death, sudden pro- stration, followed by vo- mitings, under which the patient sank quite unex- pectedly in a few hours.	Whole surface smoke- coloured like a Mulatto; Negro-black patches on back of neck, elbow, thighs, and instep, also in left axilla and right groin; conjunctivæ normal; buccal mucous membrane marbled with blackish stains, as in some dogs.	Both capsules in a state of complete cancerous de- generation, forming tu- mours of the size and shape of eggs, very hard, and much nodulated; on section, they grated against the scalpel, and presented precisely the appearance of lardaceous tissue; per- fect scirrhus.	Lungs perfectly sound; no trace of tubercle; other or- gans all quite healthy.

T A B L E C.

CASES OF MISCELLANEOUS AFFECTIONS OF THE SUPRA-RENAL CAPSULES.

Reporter and Reference.	Sex and Age.	Previous History, and Duration of Illness.	Symptoms.	Colour of Skin.	Post-Mortem Examination.	
					State of Supra-Renal Capsules.	State of other Organs.
35. Mr. H. THOMPSON, Path. Trans., vol. ix., p. 411.	Female, 81.	None given.	None recorded except chronic bronchitis. Death in a comatose state.	Last year of life, skin bronzed, except on face and hands; colour deepest on lower part of trunk. Under microscope, whole skin permeated by colouring matter.	Right capsule yellow, and, when laid open, scarcely distinguishable from surrounding fat. Under microscope, abundant oil-globules, some granular matter, and a little fibro-cellular substance.	Healthy, excepting congestion of kidneys.
36. Dr. BRINTON, Path. Trans., vol. ix., p. 414.	Male, 51.	None given. Illness many months.	None recorded, excepting dropsy and desquamative nephritis.	Skin not bronzed, but having the pallor of Bright's disease.	Medullary substance of capsules had disappeared, and here and there cortical substance was much thinned; central cavity contained some small fatty and calcareous masses.	Not described.
37. Dr. WILKS, Path. Trans., vol. xi., p. 280.	Male.	None given.	None recorded except general cachexia and syphilitic disease of frontal bone.	Not described.	Both large and remarkably firm, resembling lardaceous liver. Under microscope, seen to be infiltrated with the glistening material peculiar to that disease. This infiltration did not much affect the structure.	Lardaceous disease of liver, spleen, and kidneys.

Reporter and Reference.	Sex and Age.	Previous History, and Duration of Illness.	Symptoms.	Colour of Skin.	Post-Mortem Examination.	
					State of supra-renal Capsules.	State of other Organs.
38. Dr. GOOLDEN, Lancet, 1857, vol. ii., p. 266.	Male, 46, surgeon.	Had twice had rheumatic fever. Last illness about eight months.	Extreme anæmia; pulse quick and compressible; pressure on epigastrium produced distress and vomiting; latterly, breathlessness, palpitation, vomiting, and numbness of hands and feet.	No discoloration, but extreme pallor and bloodlessness.	Right capsule a large flaccid bag; cuticle very thin and grey; centre, a large cavity lined with chocolate-coloured granular matter; left capsule smaller, presenting similar appearances, but containing some medullary substance.	All healthy; brain not examined.
39. M. CHARCOT, Comptes Rendus de la Société de Biologie, 1857, p. 146.	Male, 57.	Habitual ill-health. Acute illness, fourteen days.	Emaciation, coldness of skin, pulse almost imperceptible, loss of appetite, thirst; sero-sanguinolent diarrhoea, albuminuria. Death almost sudden, from exhaustion.	Large brown patches on most parts of body; slight, but almost general lichenoid condition of skin; face, hands, and feet of normal colour.	Normal in size and appearance. Under microscope, an abundance of fat granules.	Tubercle in lungs and intestines; Bright's disease; other organs healthy.
40. Dr. R. BENNETT, Path. Trans., vol. xv., p. 224.	Male.	None given.	Those of broncho-pneumonia.	No discoloration.	Hydatid cyst, size of small orange, occupied the place of left capsule, all trace of which had nearly disappeared; right capsule healthy.	Chronic disorganization of lung.
41. Dr. J. OGLE, Path. Trans., vol. xvi., p. 252.	Male, 61.	Admitted to hospital for injury to back from a fall.	Paralysis of all the limbs, dilatation of one pupil; delirium preceding death.	No unnatural appearance of skin.	A cyst, size of a marble, in left capsule, with almost transparent parietes, and containing turbid serum; both otherwise healthy.	Spinal cord in cervical region softened with ecchymosed spots.

Reporter and Reference.	Sex and Age.	Previous History, and Duration of illness.	Symptoms.	Colour of Skin.	Post-Mortem Examination.	
					State of Supra-Renal Capsules.	State of other Organs.
42. Dr. CAYLEY, Path. Trans., vol. xvi., p. 252.	Female, 72.	None given.	Those of chronic bronchitis.	No discoloration.	A firm, yellow tumour in right capsule, the size of a walnut. Under microscope, seen to consist almost entirely of oil-globules.	Nothing reported.
43. Dr. J. OGLE, Path. Trans., vol. xi., p. 280, Dr. BOYD.	Male, 43.	Had been for some time an idiot, and epileptic. Duration unknown.	Epileptic seizures; death in comatose state.	No discoloration.	Both highly congested, and central parts occupied by extravasated blood, which had completely broken down their proper texture.	Veins of scalp, and cerebral veins, much congested.
44. Dr. DICKINSON, Path. Trans., vol. xiv., p. 256.	Male.	None given.	The usual symptoms of phthisis; end hastened by diarrhoea.	No discoloration.	Right capsule large, distended with black coagulated blood, which could be washed out of sections, leaving the organ healthy; left capsule normal.	Lungs phthisical.

TABLE D.

CASES IMPERFECTLY DESCRIBED, OR OF DOUBTFUL NATURE.

45. Dr. ARDISON, On Disease of the Supra-Renal Capsules, p. 19.	Male, 22 stone- mason.	None given. Illness a few months.	Pain in stomach, vomiting, and tic-douloureux; latterly soreness in hypogastric region, and vomiting of bilious matter. Day	Face of a dingy colour; also the axillæ and hands.	Both atrophied and adherent to surrounding parts by dense areolar tissue; on section, presented a pale homogeneous aspect,	A little iron-grey consolidation and calcareous deposit in apices of both lungs; mucous membrane of
---	---------------------------------	-----------------------------------	---	--	--	---

Reporter and Reference.	Sex and Age.	Previous History, and Duration of illness.	Symptoms.	Colour of Skin.	Post-Mortem Examination.	
					State of Supra-Renal Capsules.	State of other Organs.
46. Dr. ADDISON, On Disease of the Supra-Renal Capsules, p. 35, Dr. BARLOW.	Male, 58, sailor.	General health had been good. Illness about two months.	before death, extremities cold, hands blue, and pulse almost imperceptible.		showing fibrous tissue, fat, and cells about the size of white blood corpuscles.	stomach in parts ul- cerated, in others in- jected; Brunner's glands prominent; Peyer's and solitary glands hypertrophied; spleen enlarged; other organs healthy.
47. Dr. MARKHAM, Path. Trans., vol. x., p. 268.	Male, 36, painter.	None given.	Tightness over epigas- trium, loss of appetite, and feeling of sickness, without actual vomiting; almost blindness of left eye; latterly, increased sickness and debility.	Complexion naturally dark, but was thought to have grown darker.	Tubercular deposit found in one of the capsules.	Considerable soften- ing of the brain; kid- neys enlarged, fatty, and a few tubercles on surface—also on spleen and on part of peritoneum; other organs not examined.
48. Mr. R. HALL, Bakewell, Med. Gazette, vol. xxxiii., p. 62.	Male, 28.	None given.	None recorded except pericarditis.	No bronzing of any part of skin.	One five times the natu- ral size, and infiltrated with low fibrinous mat- ter; the other, smaller than natural, contained several masses of calcare- ous and cheesy matter.	Not described.
			None recorded.	Bronzed, especially about the thighs.	Both atrophied, and had undergone calcareous de- generation; no trace of healthy structure discover- able.	Lungs emphysema- tous; layer of fat, an inch thick, over abdo- men.

Reporter and Reference.	Sex and Age.	Previous History, and Duration of Illness.	Symptoms.	Colour of Skin.	Post-Mortem Examination.	
					State of Supra-Renal Capsules.	State of other Organs.
49. Surgeon-Major WYATT, Med. Gazette, 1865, vol. i., p. 113.	Male, 25.	Previously healthy. Illness, six months.	Extreme depression and debility, loss of appetite, frequent retching and vomiting; dyspnoea on exertion. Death from exhaustion.	Face and whole body dusky brown; colour almost black round nipples and umbilicus.	Both very dark, irregular in form, and quite hard on section.	All healthy; fat deep yellow.
50. Dr. POPHAM, Dublin Quart. Jour. of Med. Science, Aug. 1865, p. 220.	Female, 50.	Jaundice two years before death, when discoloration and illness commenced.	Appetite entirely lost; uncontrollable vomiting towards close of life; depression of spirits, phthisis; before death, delirium, moaning, and screaming.	General olive-coloured hue, darker on back than on front of body; back of neck negro-black; nipples and areolæ dark, as in pregnancy; dark stains inside lips, and on buccal mucous membrane.	Right capsule but little changed; left capsule pulpy and diffuent, wasted, and containing a cavity the size of a pea, filled with unhealthy pus.	Tubercles in lungs; liver fatty.
51. M. BAZIN, Léçons sur la Scrofule, 1861, p. 45.	Male.		Scrofulous.	No peculiar colouring of skin.	Complete change of capsules into masses of tubercle.	Not mentioned.
52. Mr. HARRINSON, Brit. Med. Jour. 1861, vol. ii., p. 578.	Female.	None given. Duration uncertain.	Debility, feebleness of heart's action, nausea, vomiting, hiccough, and anorexia; ten days before death, almost total loss of speech, lasting two days; labour was artificially induced the day before death; last day, diarrhoea and delirium.	Had had a muddy skin for three or four years; whole surface bronzed for some months before death.	Both in an advanced stage of disease. (No description).	Other abdominal organs healthy; rest of body not examined.

Reporter and Reference.	Sex and Age.	Previous History, and Duration of Illness.	Symptoms.	Colour of Skin.	Post-Mortem Examination.	
					State of Supra-Renal Capsules.	State of other Organs.
53. Mr. HARRINSON, Brit. Med. Jour. 1863, vol. ii, p. 605.	Female, 44, lady.	None given. Ill- ness, about five months.	Great and progressive weakness, constant nau- sea, occasional vomiting, variable appetite, frequent lumbar and abdominal pains. Death from as- thenia.	Swarthy discoloration of skin, most marked on forehead and face, and at flexures of elbows and knees.	Interior of left capsule softened and broken up; right capsule in a similar, but less advanced condi- tion.	Other abdominal or- gans healthy. Rest of body not examined.
54. Dr. MARTIN, Brit. Med. Jour. 1858, p. 389.	Female, 50.	Healthy from in- fancy. Illness, about eighteen months.	Pain in loins, breathless- ness and palpitation on exertion, loss of appetite, nausea, vomiting; pulse feeble; consciousness to the last.	Skin generally of a dark, brunze colour, especially over face, shoulders, and hands; conjunctivæ pearly.	Right capsule converted into a cyst, filled with sero-purulent fluid; left shrivelled into a mere membrane, without glan- dular structure.	Nothing reported.
55. Mr. BARTON, Dublin Hospi- tal Gazette, 1859, p. 203.	Female, aged.	Ailing for two years. Last illness, six weeks.	Great enlargement of li- ver; loss of flesh and strength; death from sink- ing.	Face, shoulders, sides, and especially axillæ, deep-brown; colour very deep over abdomen and thighs; breasts of nor- mal colour, looking very pale by contrast.	Both enlarged, deep yel- low, and entirely infil- trated with matter not re- sembling the cancerous matter in the liver or lym- phatic glands, being hard- er and more granular than either.	Lungs healthy; li- ver twice the natural size, and thickly studded with malig- nant tubercle; glands along the aorta filled with cancerous depo- sit.
56. Dr. BELL FLETCHER, Assoc. Med. Jour., 1856, p. 1011.	Male, 43, writer.	Had had good health until about two years before death.	Debility, faintness, and depression; loss of appe- tite and vomiting; dimi- nution of sight, with giddi- ness; urine slightly al- buminous. Died from	From commencement of illness, colour gradually changed to yellow, and then to a dusky-brown hue; darkest in arm-pits; conjunctivæ pearly white.	Right capsule enlarged, hard, and of a deep red colour; left capsule not so large, but in same condi- tion.	Effusion into mem- branes of brain; fatty degeneration of heart; Bright's disease; great excess of white glo- bules in blood.

Reporter and Reference.	Sex and Age.	Previous History, and Duration of Illness.	Symptoms.	Colour of Skin.	Post-Mortem Examination.	
					State of Supra-Renal Capsules.	State of other Organs.
57. Dr. GIBBON, Med. Gazette, vol. xxxiv., p. 62.	Male, 52, cabman.	None given. Illness, six months.	sinking; latterly wandering of mind. Slight cough, general weakness, loss of appetite, pulse soft and weak. During last days of life, low typhoid condition.	Yellowish-brown appearance; conjunctivæ normal.	Both enlarged, and consisting of mere membranous bags, containing shreds of disintegrated tissue; right capsule still showed some healthy cortical structure; normal tissue of left entirely destroyed.	All healthy.
58. Dr. BARCLAY, Lancet, 1863, vol. i., p. 117.	Male, 25, baker.	Had suffered for years from epistaxis. Illness, fifteen months.	Pain in abdomen; slight oedema of legs, and ascites; emaciation and exhaustion.	Slight bronzing of skin over abdomen, chest, and fronts of thighs.	Both enlarged, and of a mottled, red colour.	Small abscesses in right lung; liver, spleen, and kidneys enlarged.
59. Dr. ISAAC TAYLOR, New York, Med. Gazette, vol. xxxv., p. 36, Amer. Jour. of Med. Science.	Male, 42.	Had never had syphilis. Illness, six months.	Progressive feebleness; constipation, slight albuminuria, convulsions. Died in coma.	Sun-burnt appearance over whole face; spots, resembling faded syphilitic eruption, over whole body.	Both atrophied, and broken down into granular masses, of a chestnut colour; in left capsule, a thin portion of healthy tissue.	Miliary tubercles in upper lobe of left lung; in apex of right lung, old cicatrices; liver and kidneys fatty.
60. Dr. CRISP, Path. Trans., vol. xiii., p. 248.	Male, 60.	None given. Illness, eighteen months.	Lassitude, general debility, frequent sickness. Death from gradual sinking.	Skin of a peculiar colour, but not bronzed.	Only a small portion of one appears to have been removed.	Said to be healthy.

Reporter and Reference.	Sex and Age.	Previous History, and Duration of Illness.	Symptoms.	Colour of Skin.	Post-Mortem Examination.	
					State of Supra-Renal Capsules.	State of other Organs.
61. Mr. J. KENT SPENDER, Brit. Med. Jour. 1858, p. 768.	Female, 53.	Health had always been good. Illness a few months.	Lassitude, diarrhoea, and exhaustion.	Had the pallor, with dark earthy tint usually associated with malignant disease; darkness much increased over flexures of joints.	Supra-renal capsules absent.	Black pigment in mesenteric and bronchial glands; also in parenchyma of lungs.
62. Dr. MURNEY, Dublin Hosp. Gazette, 1858, p. 228.	Male, 34.	Good health until two years before death, when he had a sudden fit.	Heart's action feeble; pulse, 50; debility, loss of flesh, and constant nausea. Died from a fit.	Bronzing of face, neck, and hands; areolæ deeply tinged, dark ring round umbilicus, and dark line along linea alba; rest of body of normal colour.	Right capsule chocolate-coloured, of firm, fibrous texture, with a small, yellow, pea-sized tubercle in centre; left capsule absent.	Brain not examined; heart fatty; left kidney small, and full of scrofulous matter; right kidney hypertrophied.
63. M. DAYOT, Bulletins de la Société Anatomique, 1857.	Male, 35.	Nothing reported.	Abscess on upper side of lowest right rib. Death from congestion of lungs.	No bronze colouring.	Both enlarged and hard, reddish in centre, yellow outside. (Professor Robin found an amorphous granular matter deposited between the cells in the yellow layer.)	Nothing reported.
64. Prof. Dr. BUHL, Wiener Med. Wochenschrift, 1860, p. 21.	Male.	None given.	Pulse small and quick, heart sounds weak; pneumonia in right lung, and pleurisy on both sides; later, hoarse voice and laboured breathing. Death rapid.	Bronze colour of face, hands, and genital organs. (After death blood fluid; no trace of fibrine.)	Both hollow, filled with brownish liquid; within cavities, some remains of medullary substance; cortex thickened and tough.	Pleure and liver studded with miliary tubercles; grey hepatization of right lung; croupous membrane in larynx; spleen enlarged; kidneys granular.

Reporter and Reference.	Sex and Age.	Previous History, and Duration of Illness.	Symptoms.	Colour of Skin.	Post-Mortem Examination.	
					State of Supra-Renal Capsules.	State of other Organs.
65. Prof. Dr. BUHL, Wiener Med. Wochenschrift, 1860, p. 22.	Female, 29.	None given.	None reported.	Colour especially strongly marked on the abdomen. (After death, blood thin and fluid.)	Cortex of both in same condition as lymphatic glands.	Emaciation; oedema of lungs and feet; abdominal glands large tough masses which, under microscope, showed thick fibrous bands, and deficiency of cells, but no sign of cheesy degeneration.
66. M. BREHME, Deutsche Klinik, 1857.	Male, aged.	Had been dead two or three days when examined.	Unknown.	Deep bronze hue of skin, some round whitish scars; on abdomen, penis, and inner parts of thighs, colour deepest, and shining like metal.	Both small, with thickened cortex, and presenting cavities with brownish, bloody fluid; in cortex, some yellowish-white, millet-sized deposits.	Emaciation; oedema of feet; emphysema of lungs, and pleuritic effusion; fatty heart and kidneys.
67. Dr. HARDY, Union Médicale, 1858, No. 90.	Male, 45.	Several times intermittent fever; ulceration of glands in neck; frequent pneumonic affections. Three months in hospital.	Prurigo pedicularis; emaciation, with ravenous appetite; phthisis.	Most of body covered with small blackish crusts; skin generally Mulatto-coloured; face, fore-arms, penis, and scrotum scarcely tinged; sclerotics, scars of blisters, and cupping quite white.	Abnormally shaped, and studded with small yellow tuberculous granules, surrounded by a yellow envelope, which contrasted with the reddish tissue beneath.	Tubercle of lungs and intestines; infiltration of mesenteric, portal, and lymphatic glands.
68. M. SECOND FÉRFOL, Gaz. des Hôpi-	Male, 35, floor-polisher.	Intermittent fever and jaundice at various periods; cough and expectoration,	Indigestion, weakness, loss of appetite, vomiting, and giddiness; pains in loins and epigastrium;	Discoloration began on forehead; latterly face and hands sepia-brown; membrane of lips also	Both hard, irregular, and embedded in adipose tissue; on section, merely two masses, of fatty ap-	Lungs studded with small grey tubercles; in apices also many, yellowish and soft-

Reporter and Reference.	Sex and Age.	Previous History, and Duration of Illness.	Symptoms.	Colour of Skin.	Post-Mortem Examination.	
					State of Supra-Renal Capsules.	State of other Organs.
taux, 1856, p. 406, M. CAZENAVE.		and latterly excesses in drinking. Last illness, twenty months.	phthisis; latterly diarrhoea, hicough, and constant vomiting—bile in vomit. Death from exhaustion.	stained; at last, sclerotics and whole integument jaundiced; brown pigment in whole thickness of epidermis.	pearance, traversed by cartilaginous filaments, enclosing yellow lardaceous substance, partly semi-fluid; bile present. Under microscope, only fat-globules and globules of pus.	ened; bronchial and mesenteric glands enlarged, some of latter yellow and fatty; liver enlarged and jaundiced; a diseased hepatic gland had stopped biliary circulation.
69. Dr. ADDISON, Med. Gazette, vol. xxxvi., p. 539, Mr. WILKS.	Female, 18, lady.	Chronic rheumatism two years before; bronzing, one year. Illness, about four months.	Great lassitude, and after a long walk, three months before death, violent sickness, lasting three or four days; pulse very feeble, skin soft, tongue clean, appetite bad; sickness returned in two months, and lasted, with short intervals, till death.	General surface bronzed; face olive-brown, chin shining like bronze; areolæ quite black.	Left capsule size of a hen's egg, and adherent to spleen and kidney; it contained a large quantity of purulent matter; right capsule also adherent, but smaller, and matter contained in it less fluid and gritty.	About an inch of fat on abdomen; body otherwise much emaciated; viscera generally quite healthy.
70. House-Surgeon to Reading Hos-	Male, 26, travelling	Had had good health; bronzing uncertain. Illness, three days.	Three days before death, was attacked with vomiting, and fell into a com-	No medical report of colour, but friends had observed a change within	Both greatly enlarged; no trace of normal structure; mostly converted	All healthy.

TABLE E.

CASES OF ADDISON'S DISEASE OF THE SUPRA-RENAL CAPSULES, QUITE UNCOMPLICATED.

Reporter and Reference.	Sex and Age.	Previous History, and Duration of Illness.	Symptoms.	Colour of Skin.	Post-Mortem Examination.	
					State of Supra-Renal Capsules.	State of other Organs.
pital, Med. Gazette, vol. xxxix. p. 265.	musician.		pletely prostrate condition.	the last few months, so that he was "like a gipsy."	into a greyish, firm tissue, with patches of calcareous degeneration; but some parts in a different state.	
71. Mr. VALENTINE, Med. Gazette, 1861, vol. ii., p. 33; also, Guy's Hosp. Rep., vol. viii., p. 55.	Male, 30, marine store- dealer.	Good health until four months before death.	Gradual loss of flesh, strength, and appetite; acute pain in lower part of back; great irritability of stomach; extreme prostration towards the last.	Skin of face and body of a dusky hue; whole surface very dark after death.	Both wholly disorganized; normal structure replaced by softening serofulous deposit.	All healthy.
72. Dr. GULL, Med. Gazette, 1863, vol. i., p. 83.	Male, 31, publican.	None given. Illness, four months.	Debility, pallor, and emaciation; appetite bad, frequent sickness, pain of back, and also nervous symptoms— <i>e.g.</i> , loss of sensation in one side of face, numbness in legs, and partial incontinence of urine.	No bronzing of skin, but face of a sallow or yellowish cast.	Both converted into large masses of an albuminous, lard-like substance (depositedly formed); semi-lunar ganglia involved; right one actually embedded in capsule, left one merely in contact with capsule, and its nerves only involved.	All healthy; some of the lymphatic glands contiguous to the supra-renal capsules enlarged.
73. Dr. LITTLE, for Dr. MACKENZIE,	Female, 18.	Two years before death, a severe shock to the nervous system. Illness and dis-	Great feebleness, frequent fainting, and distressing vomiting; tongue moist and pale, catamenia	Universal discoloration, with some patches, almost black, colour deepest over flexures of joints and	Right capsule a more diffiuent mass, attached by strong adhesions to liver, diaphragm, and kidney;	So far as examined, healthy.

Post-Mortem Examination.						
Reporter and Reference.	Sex and Age.	Previous History, and Duration of Illness.	Symptoms.	Colour of Skin.	State of Supra-Renal Capsules.	State of other Organs.
Path. Trans., vol. xiii., p. 247, Dr. FRASER.		coloration began from that time.	irregular and scanty; progressive weakness, with, at length, inability to sit up in bed; mind clear until a few minutes before death.	lower half of trunk; labial and buccal mucous membrane brown, with some well-marked darker patches; conjunctivæ pearly—a spot of pigment on right eye.	left capsule in like manner attached to diaphragm, spleen, and kidney; under microscope, no ves-tige of normal structure, but a strong fibrous envelope, containing pus and a little cretaceous matter.	
74. Dr. WILKS, Path. Trans., vol. x., p. 273, Mr. WELFORD, Bishopwear- mouth.	Male, 21.	None given. Ill-ness, some months.	Excessive and progressive debility; rapid pulse, persistent vomiting, thirst; stupor towards close of life, from which he could be roused by loud speaking.	Complexion had been darkening for some months; colour dusky; several olive-coloured patches on shoulders, chest, and umbilical region; penis and scrotum very dark.	Right capsule wholly changed in structure by the deposition of a firm albumino-cretaceous deposit throughout its substance; centre softened. Left capsule not described.	Other organs healthy; liver enlarged from congestion; patches of black exudation, like melæna, in right and left recti-muscles, near umbilicus.
75. Dr. WILKS, Path. Trans., vol. xv., p. 218.	Female, 22.	Had had good health until her confinement about two years before. Discoloration and debility, about two years.	Exceedingly small, weak pulse; extreme debility; latterly retching, and inability to sit up.	Whole body of a greenish-brown hue, darkest on knuckles of hands, in axillæ, and on lower part of abdomen.	Both converted into yellow hard masses, apparently formed of separate masses, embedded in tough fibrous material; some cretaceous matter in parts. Right capsule smaller, left rather larger than normal size.	All healthy.
76. Dr. HARDWICK,	Male, 52.	None given. Ill-ness, two years.	Gradually increasing debility; great prostration.	Of a uniform yellowish-brown colour, with one or	About twice the normal size; on section, shewed	All healthy.

Reporter and Reference.	Sex and Age.	Previous History, and Duration of Illness.	Symptoms.	Colour of Skin.	Post-Mortem Examination.	
					State of Supra-Renal Capsules.	State of other Organs.
Path. Trans., vol. xv., p. 223. 77. Dr. HARDWICK, Path. Trans., vol. xv., p. 224.	Female, 69.	None given.	Great prostration, with some emaciation, and frequent vomiting.	two small white patches on side of neck. Uniform brown tint; lips of a dark-brown colour; conjunctivæ pearly white.	a uniform grey lardaceous deposit; no cheesy material, nor softening. Both somewhat enlarged, and filled with masses of deposit—some grey and firm, others soft and cheesy.	All healthy.
78. Dr. GREENHOW, Path. Trans., vol. xv., p. 231, Mr. C. L. Hodson, Bishop- Stortford.	Male, 21, mer- chant	Had suffered from strumous ophthalmia in infancy, and two years before death from supposed enteritis. Last illness, eight months.	Occasional attacks of prostration; latterly, extreme faintness, feeble action of heart, and distressing sickness.	Skin discoloured, especially on temples, cheeks, and sides of throat; several dark moles on arms and chest; areolæ very dark.	Both nodulated, and invested with firmly adherent connective tissue; on section, some parts semi-transparent, and of fibrous consistence, others opaque and of cheesy material; intermediate portions firm, but opaque.	All healthy; body fairly covered with fat.
79. Dr. WILKS, Guy's Hosp. Reports, vol. viii., p. 47, Dr. PAVY.	Female, 26.	Attributed her illness to overwork. Ailing one year; discoloration, eight months.	Twitchings resembling those of chorea; last few days of life, vomiting set in, which caused great prostration; death rather sudden.	Face, neck, and shoulders of a peculiar dirty olive hue; conjunctivæ pearly white; after death, face very dark, with still darker patches on forehead; skin of neck, axillæ, and flexures of elbow-joints, as brown as bistre.	Right capsule presented, in its interior, masses of a yellow substance in a more or less softened state; left contained a quantity of encysted puriform fluid; each was embedded in a mass of thickened cellular tissue.	All healthy; body in good condition.

Reporter and Reference.	Sex and Age.	Previous History, and Duration of Illness.	Symptoms.	Colour of Skin.	Post-Mortem Examination.	
					State of Supra-Renal Capsules.	State of other Organs.
80. Dr. WILKS, Guy's Hosp. Reports, vol. viii., p. 34, Drs. VINCENT and RANKING, Norwich.	Female, 59.	Married lady, affluent, mother of five children, of active habits, but very stout. Discoloration about one year; illness, eight months.	Complete loss of appetite; constant sickness; irritability of body and mind; feeble pulse; faintness; rallied once, but colour continued to deepen; muttering delirium last day of life.	Face and hands first discoloured—later, general surface, but less markedly under dress; face, neck, and hands of a dirty copper colour; peculiar sickening smell from skin about neck; conjunctivæ clear.	Both enlarged, nodulated, and composed of two substances in about equal quantity—one firm, smooth on section, of a dull-green colour, the other yellow and more friable; under microscope, morbid material appeared to be degenerate lymph.	Lungs and other organs healthy; skin loaded with yellow fat.
81. Dr. WILKS, Guy's Hosp. Reports, vol. viii., p. 59, Mr. STEDMAN, Godalming.	Male, 32, agricul- tural la- bourer.	Had been healthy. Illness, four years.	At first, vomiting and purging; afterwards lassitude, sense of sinking in abdomen, flatulence, and sickness, which became constant, with total prostration two days before death.	Face mulatto-coloured; back and thighs darker; penis and scrotum as dark as those of a negro; conjunctivæ pearly white.	Right capsule absent; left one large, hard, and nodulated, shewing on section a tough albuminofibrous substance, which enclosed opaque friable matter containing some chalky grains.	All healthy; no emaciation; thick layer of fat lining abdominal parietes.
82. Dr. HABERSHON, Guy's Hosp. Reports, vol. x., p. 80, Mr. WEBB.	Female, 19.	None given. Ailing two and a-half years; illness, six months.	Slight pain in stomach; sickness and progressive weakness; amenorrhea six months; pulse feeble and compressible; three days before death, seized with pain in head, followed by drowsiness and insensibility; died comatose.	Skin resembling that of a mulatto, some parts of body being almost as dark as that of a negro; deposit of pigment in gums.	Left capsule consisted only of a small mass of white, low-organized pro-duct, surrounded by dense tissue; fatty and semicretaceous substance replaced the normal structure; under microscope, fibroid tissue, imperfect cell-growth, and highly-refracting granules were	Lungs and other organs normal; body plump.

Reporter and Reference.	Sex and Age.	Previous History, and Duration of Illness.	Symptoms.	Colour of Skin.	Post-Mortem Examination.	
					State of Supra-Renal Capsules.	State of other Organs.
83. Dr. HABERSHON, Guy's Hosp. Reports, vol. x., p. 82.	Male, 18, book- binder.	Abscess in neck from diseased glands nearly two years before death. Health began to fail from that time.	Debility, irritability of stomach, feeble and compressible pulse; abdomen contracted; appetite tolerably good; irritability of stomach, and prostration increased till he sank from exhaustion.	Generally of a deep colour; two narrow, almost black rings, on neck; axillæ also dark.	observed; right capsule smaller, but similarly affected. Left capsule much enlarged and infiltrated with deposit—in some parts cheesy, in others calcareous; enlargement towards semi-lunar ganglion, which, with nerve branches, was surrounded by dense fibroid tissue; right capsule rather less affected, and nerves could be traced to it more easily.	Lungs and other organs normal; very thick layer of fat on abdomen; heart covered with fat; spleen large and soft.
84. Dr. STURGES, Lancet, 1864, vol. ii., p. 569.	Male, 23, engine- cleaner.	None given. Illness, above three years.	Debility, vomiting, frequent diarrhoea, and epistaxis; improved very much at one period, but relapsed; some months before death, choreic spasms for several weeks.	Face and whole body of a copper-coloured hue, approaching to bronzing; Numerous dark-brown specks over whole surface, and some brownish specks on soft palate.	Both infiltrated with cheesy matter.	All healthy.
85. Mr. WALLACE, Assoc. Med. Jour., 1856, p. 1035.	Female, 48, private patient.	None given. Illness, nine months.	Faintness, occasional vomiting, and diarrhoea; listlessness and torpor; once, on being suddenly raised, a slight convulsive fit.	Skin of a deep-brown colour, most marked on face, hands, and arms.	Organs scarcely traceable, presenting a granulated disintegrated mass of a yellowish-grey colour.	All healthy; abundance of yellow fat on chest and abdomen.

Reporter and Reference.	Sex and Age.	Previous History, and Duration of Illness.	Symptoms.	Colour of Skin.	Post-Mortem Examination.	
					State of Supra-Renal Capsules.	State of other Organs.
86. Dr. JEAFFRESON, Brit. Med. Jour., 1857, p. 22.	Male, 40, labourer.	None given. Illness, about one year.	Feebleness of pulse; frequent vomiting, coldness of surface; tenderness on pressure in region of duodenum and two dorsal vertebrae; heavy, depressed manner; on day of death, headache, insensibility, and slight convulsions.	Skin yellow from beginning of illness; a month before death, was noted to be universally of dark leaden hue, but conjunctivæ quite clear.	Left capsule contained an encysted tumour, whose walls were hard and almost gristly, the interior being cheesy matter, in some parts softening down to pus.	All healthy; only structural disease in body was in left capsule; little emaciation; yellow fat on abdomen.
87. Mr. J. KENT SPENDER, Brit. Med. Jour., 1857, p. 274.	Female, 21.	None given. Illness, one year; discoloration, three months.	Progressive debility and emaciation, with feeling of coldness; loss of appetite, and nausea; sense of weight in right hypochondrium; depression, failure of memory; death quiet, from exhaustion.	Skin of face nearly as brown as a Mulatto's; backs of hands, especially knuckles, very dark; all the covered portions of surface were of normal colour.	Right capsule very large, and adherent to liver and kidney; left capsule of normal size; on section, purulent matter exuded from both, and a number of little miliary bodies were visible, which, under microscope, were found to be cheesy masses surrounded by creamy fluid.	All healthy; cranium not examined; body greatly wasted; fibrinous coagula in heart.
88. Mr. J. MOORE, Lancet, 1864, vol. ii., p. 475.	Male, 30, clerk.	Had not been in good health for two years. Discoloration, six months.	Debility and general disposition; sickness almost constant the last few days; pulse 120, thready; great feebleness; died of exhaustion.	Face of a pale olive hue; backs of hands very dark; several patches of black pigment on lips; eyes not discoloured; discoloration on body slight.	Both converted into soft yellow cheesy masses.	Normal.
89. Dr. WILKS, Guy's Hosp.	Male, 13.	None given. Illness, four months.	Pain in back; inability to stand or sit; extremely feeble pulse; drowsiness,	Whole surface of a yellowish-brown hue, excepting palms of hands and	Both enlarged, and converted into a tough yellow amorphous matter,	All healthy; Peyer's patches in small intestine, much raised;

Reporter and Reference.	Sex and Age.	Previous History and Duration of Illness.	Symptoms.	Colour of Skin.	Post-Mortem Examination.	
					State of Supra-Renal Capsules.	State of other Organs.
<p>90. Reports, vol. viii., p. 52, Dr. ADDISON'S last case; Dr. ALDIS.</p>	<p>Male, 16.</p>	<p>None given. Illness, six months; three weeks in hospital.</p>	<p>prostration, loss of appetite, nausea, and vomiting; dribbling of urine; last days of life, delirium and slight convulsions.</p>	<p>soles of feet; colour most intense over joints of hands and feet; no definite patches; a little pigmentation on lips.</p>	<p>interspersed with some grey and translucent substance; no trace of original tissue.</p>	<p>solitary glands very distinct.</p>
<p>90. Dr. HAYDEN, Dublin Quarterly Journal of Science, Feb.-May, 1865.</p>	<p>Male, 16.</p>	<p>None given. Illness, six months; three weeks in hospital.</p>	<p>Headache for several months; severe pain in abdomen; languor and loss of appetite; heart's action feeble, sight dim, and respiration hurried on the slightest movement; frequent sickness last ten days of life; death from exhaustion.</p>	<p>On admission, face deep olive, with a darker patch on forehead, which had appeared when headache commenced; general surface of body less discoloured; minute brown spots visible on abdomen; conjunctivæ pearly white.</p>	<p>Both much enlarged, hard, and nodulated; left capsule much larger than right, and presented the appearance of pale cheese, with about a teaspoonful of thick, white puriform matter in centre; right capsule not divided.</p>	<p>All healthy; body much wasted.</p>
<p>91. Dr. WILKS, Guy's Hosp. Reports, vol. xi., 1865, Dr. STRANGE, Worcester.</p>	<p>Male, 26.</p>	<p>None given. Illness, eighteen months.</p>	<p>Debility; partial loss of appetite; no vomiting; at last delirium, and death from exhaustion.</p>	<p>Eighteen months before death, bronzing slight, in patches; six months later, bronzing well marked all over face and hands, line across forehead very distinct; rest of body clear.</p>	<p>Right capsule described by Dr. Strange as large and distended with pus, the left smaller, and commencing to degenerate; one capsule, examined by Dr. Wilks, was enlarged and converted into a mass of cheesy consistency, with some cretaceous matter, the envelope enclosing it being much thickened.</p>	<p>Every other organ remarkably healthy; no emaciation; half-an-inch of fat on abdomen.</p>

Reporter and Reference.	Sex and Age.	Previous History, and Duration of Illness.	Symptoms.	Colour of Skin.	Post-Mortem Examination.	
					State of Supra-Renal Capsules.	State of other Organs.
92. Dr. R. Holt, Lancet, 1865, vol. ii., p. 454.	Male, 43.	Previously healthy. Illness, eight months.	Gradually increasing lassitude, with shooting pains in lower extremities; loss of appetite, sickness, giddiness, pain in epigastrium; later, aching pain in lumbar region, aggravated by straightening the back; last two days of life, semi-comatose state.	Striking discoloration of face, hands, and scrotum, and of a patch on chest where mustard plaster had been applied; rest of body of normal colour; lips and buccal membrane of same colour as face; black stains on sides of tongue, centre of normal colour.	Left capsule size of a pigeon's egg, converted into a bag containing thick yellowish fluid, and fragments resembling the white of a hard-boiled egg; right capsule adherent to liver, and presenting the appearance of a serofulous lymphatic gland proceeding to suppuration.	Other organs healthy; right side of heart contained a fibrinous clot adherent to tricuspid valve.

T A B L E F.

CASES OF ADDISON'S DISEASE, ALMOST UNCOMPLICATED. (LESIONS OF OTHER ORGANS UNIMPORTANT.)

93. Dr. Addison, On Disease of the Supra-Renal Capsules, p. 12.	Male, 35, customs' tide- waiter.	Much anxiety and exposure in his occupation; had rheumatism eight years before death, with great nervous depression; since then, general good health; occasional bilious vomit-	Headache and vomiting; delirium and unconsciousness lasting twenty-four hours, and then numbness and want of power in extremities; improved and returned to work for a time; last month of life, pulse ex-	Original sallow complexion deepened into olive-brown; change of colour gradual from beginning of illness; face had a dark look like that of miasmatic poisoning; mucous membrane of lips deeply stained.	Both contained compact fibrinous concretions seated in the structure of the organ; superficially examined, they were not unlike some forms of strumous tubercle.	Lining membrane of stomach finely injected, of a bright-red colour, with two or three spots of ecchymosis; membrane thickened, and surface covered with tenacious mucus; in-
---	--	---	--	--	--	--

Reporter and Reference.	Sex and Age.	Previous History, and Duration of Illness.	Symptoms.	Colour of Skin.	Post-Mortem Examination.		
					State of Supra-Renal Capsules.	State of other Organs.	
94. Dr. WILKS, Guy's Hosp. Reports, vol. viii., p. 42, Drs. ADDISON and HABERSHON.	Male, 32, engine- driver.	Had lived freely, and had suffered from gonorrhœa and syphilis; illness and discoloration, nearly three years. Last attack, one month.	Loss of strength and darkening of skin; in hospital two years before death, and left relieved; a month before death, took cold and relapsed; pulse and heart feeble; extreme weakness, dizziness, and failure of vision on attempting to walk; no appetite; death rather sudden, from exhaustion.	Skin dark-brown, and of a deeper tinge in axillæ, and at navel, nipples, and scrotum; mucous membrane of gums and mouth stained with patches of a leaden hue; after death, colour greenish-brown, remarkably uniform, excepting two black specks on face; margin of lips dark.	Right capsule about normal size; left enlarged; structure of both destroyed by a deposit consisting mainly of white brittle cretaceous matter, and of a semi-translucent matter resembling dirty blanch-mange; right capsule was softening in middle, and contained about a drachm of cream-like fluid; both firmly adherent to surrounding parts. Under microscope, semi-transparent parts seen to consist of amorphous substance, mixed with granules; the yellower friable matter consisted of little else than fatty and cretaceous granules.	some parts, irregular superficial abrasions; brain, lungs, and all other organs normal.	Mucous membrane of stomach highly injected, and covered with tenacious mucus, as if a low form of inflammation had existed; Peyer's patches, and solitary glands at lower end of ileum, remarkably prominent; all other organs healthy.

Post-Mortem Examination.						
Reporter and Reference.	Sex and Age.	Previous History, and Duration of Illness.	Symptoms.	Colour of Skin.	State of Supra-Renal Capsules.	State of other Organs.
95. Dr. HABERSHON, Guy's Hosp. Reports, vol. vii., p. 232.	Male, 23, lighter- man.	Good health until a year before death, about which time he was over-worked; some years previously, had had syphilis, and had been on the coast of Africa.	Weakness and inability to work; three weeks before death, after a dose of castor-oil, violent vomiting, which continued, with great prostration; pulse slow, and very compressible; feeling of cold, and faintness; breath short; mind clear until last day, when he became drowsy.	Semi-jaundiced appearance of face, and numerous dusky-red blotches on cheeks and forehead; discoloration much less on other parts of body; after death, face olive-brown colour; genital organs very dark, body and limbs only slightly discoloured.	Both much enlarged, hard, and surfaces uneven; on section, presented dense whitish semi-translucent tissue, with yellowish cheesy matter; also some cretaceous material.	Mucous membrane of stomach covered with tenacious mucus; patches of injection, and some points of ecchymosis, most marked at greater curvature; mucous membrane of duodenum injected; slight white consolidation at apex of right lung; other viscera healthy.
96. Dr. ADDISON On Disease of the Supra-Renal Capsules, p. 25.	Male, middle- aged, barrister.	None given. Illness about one year.	Extreme languor, faintness, and anæmia; heart's impulse feeble, palpitation on exertion; urgent and distressing vomiting of mucous matters, occasionally tinged with blood.	General surface dingy; on face, neck, and arms, various sized deep chestnut-brown patches; here and there also blanched-looking patches.	Both enlarged, hard, irregular, consisting of a firm reddish semi-transparent basis, interspersed with spots of opaque yellow matter, and strongly resembling enlarged mesenteric glands, mottled with tubercular deposit.	Mucous membrane of stomach spotted with small numerous elevations, apparently increased development of natural structure.
97. Dr. WILKS, Guy's Hosp. Reports, vol. viii., p. 56, Mr. TOULMIN, Dr. GULL.	Female, 37.	Health good. Illness, two years.	Gradual decline; prostration of strength; pulse almost imperceptible; circulation very feeble; faint saccharine smell of breath; sickness and inability to take food.	Skin first orange, and then Arab-coloured; face and areolæ of nipples darkest; lips covered with pigment spots; dark line where garters had been	Both hard, and adherent to adjacent parts by tough inflammatory tissue; on section, exteriors of both found to be a yellow, firm material, as in other cases, but interiors softened	Apices of lungs indurated by chronic pneumonia; glands of duodenum enlarged; solitary glands, and Peyer's patches prominent; specks of

Reporter and Reference.	Sex and Age.	Previous History, and Duration of Illness.	Symptoms.	Colour of Skin.	Post-Mortem Examination.	
					State of Supra-Renal Capsules.	State of other Organs.
98. Dr. BRISTOWE, Path. Trans., vol. xi., p. 276.	Male, 18, printer.	Good health until last illness. Dura- tion, four months.	Constant vomiting of glairy mucus, tinged with bile; rapid emaciation, occasional headache, gid- diness, and frequent ri- vors; much thirst, slight fever, and diarrhoea; tongue red, covered with yellow fur; death from exhaustion.	tied; conjunctivæ pearly white. No discoloration; after death, complexion was noted as brownish, but there was nothing like bronzing.	down into creamy matter, like purulent mucus. Both hypertrophied, and consisting of nodules of buff-coloured material, which were largest in left capsule, and mixed with some putty-like material and a little hard earthy deposit, all blended together, and surround- ed by dense greyish fib- rous tissue; no traces of healthy structure.	black pigment on omentum, perito- neum, and other in- ternal surfaces. Cerebellum firmly attached to dura ma- ter by old adhesions; liver dark-brown, firmly attached to diaphragm, and con- gested throughout; viscera healthy, but mostly adherent and congested.
99. Dr. HARE, Brit. Med. Jour., 1865, p. 331.	Male, about 45.	None given. Ailing two years.	Lassitude; day before death, vomiting and con- vulsions, followed by a semi-comatose condition.	Face and hands appeared exceedingly tanned; dis- colored patch on chest, where a blister had been applied; conjunctivæ pearly white.	Right much enlarged, adherent to liver; abscess in lower part; in upper part, tubercular cheesy- looking matter, embedded in firm whitish-bluetissue; left capsule smaller than right, no abscess, but other- wise in similar condition.	Pleuritic adhesions; lungs emphysema- tous; heart fatty.

		Post-Mortem Examination.				
Reporter and Reference.	Sex and Age.	Previous History, and Duration of Illness.	Symptoms.	Colour of Skin.	State of Supra-Renal Capsules.	State of other Organs.
100. Dr. FRESNE, Gazette des Hôpitaux, 1857.	Female, 30, married woman.	Always fairly good health. Illness, about one year.	Illness sudden; severe pains in lumbar region, and vomiting; pulse small and quick; heart's action hurried; progressive emaciation and debility; death rather sudden.	General and marked brown discoloration soon following symptoms of illness; colour extended to buccal mucous membrane.	Both three times the normal size, hard, nodulated, and completely converted into tuberculous matter.	Old peritoneal adhesions; nothing more reported, except no tubercle in lungs.
101. Mr. SIBLEY, Med. Gazette, vol. xxxiii., p. 188, 1854, Dr. S. THOMP- SON.	Male, 20, painter.	Unknown; discoloration, about six weeks. Illness, a few days.	Last days of life, languor, inability to move about, cold sweating, great feebleness of pulse, restlessness, soreness of throat; deep-seated pain in region of liver; perfectly conscious, but slow in answering questions.	Skin of a dark, dirty-brown colour, and conjunctivæ the same.	Both much enlarged, firm, and dense; on section, composed of opaque yellow cheesy substance, in some parts broken down; here and there, portions of the natural structure could be detected.	Pericardium firmly and universally adherent; liver tough and congested; solitary glands of small intestine enlarged, forming eminences the size of millet-seeds.
102. Mr. E. CROSSMAN, Brit. Med. Jour., 1860, p. 359.	Male, 59, gardener	None given. Illness, eight months.	Progressive prostration, emaciation, anorexia, and vomiting, with dull weight and pain at epigastrium, and at one time diarrhæa; death from exhaustion.	No appearance of bronzing; skin of a yellowish-white colour.	Both totally disorganized and converted into empty cavities, the walls of which were coated internally with a thin layer of yellow cheesy matter.	Lungs healthy, except old adhesions; pancreas and mesenteric glands hard, and coloured black externally; parts of liver and kidneys also black externally.
103. M. VIRCHOW, Canstatt's Jahr-	Female, 16, servant.	Always weakly, and troubled with palpitation on exertion;	Lassitude and vertigo; pains in lumbar region, back, and head, and later	Early in illness, face brownish; on face and arms, round, sharply-de-	Both slightly enlarged, and studded throughout with hard tuberculous nodules.	Mesenteric glands all much enlarged, hardened, and glis-

Reporter and Reference.	Sex and Age.	Previous History, and Duration of Illness.	Symptoms.	Colour of Skin.	Post-Mortem Examination.	
					State of Supra-Renal Capsules.	State of other Organs.
esbericht, 1859, part iv., p. 288, M. SCHMIDT, Rotterdam.		five months before death, fright checked catamenia, and health declined from that time.	in epigastrium; loss of appetite, often vomiting after food; progressive anæmia and debility; towards the last, constant drowsiness, extinction of pulse, and death.	fined, almost black specks; on neck and backs of hands, in axillæ, flexures of joints, and on parts compressed by strings, fading into normal skin.	dules, which here and there were softening down; these nodules were massed together towards the centre, and embedded in a grey semi-transparent substance.	tening like lard; follicles of intestines much swollen.
104. M. VIREHOW, Canstatt's Jahresbericht, 1858, part iv., p. 273, M. WAGNER.	Male, 16.	Previously healthy. Three months under treatment.	Perityphlitis and acute stomach catarrh.	Three weeks before death, appearance of bronzing on face.	Both somewhat enlarged, hard, and studded throughout with small masses, varying in size, and resembling tuberculous matter.	Mesenteric and solitary glands, Peyer's patches, and spleen enlarged.
105. Mr. J. HUTCHINSON, Path. Trans., vol. ix., p. 414, Dr. J. R. BENNETT.	Male, 11.	Had been losing flesh for some time; bronzing, about six months. Illness only a few weeks.	Progressive weakness; last week of life, having apparently been overdone by a long walk, slight diarrhoea, sickness, and a series of convulsive seizures.	Whole surface discoloured; face markedly but not uniformly bronzed; a patch on forehead, which shaded off into the less dark skin; backs of hands and sides of knees deeply bronzed; a few faint streaks on lips; conjunctivæ pale.	Both entirely disorganized, containing chalk and cheesy matter, and firm fibrous structure binding together these elements; no softening nor evidence of recent inflammation; no trace of normal tissue.	No disease of other organs except of mesenteric glands, many of which were the size of marbles, and contained cheesy matter encapsuled in very dense or even osseous walls.
106. M. ULRICH, Deutsche Klinik 1862, p. 25.	Male, 24.	Had long suffered from stomach derangements, and previous winter from supuration of glands in	Cachexia, indigestion, loss of appetite, nausea, headaches, vomiting, sleeplessness, prostration of strength; pulse small,	For two or three years, discoloration of skin like that of a Mulatto.	Both thickened and nodulated; on section, found to be entirely changed into grey tubercles and yellow	Peyer's patches prominent, and some of mesenteric glands enlarged, and on section

Reporter and Reference.	Sex and Age.	Previous History, and Duration of Illness.	Symptoms.	Colour of Skin.	Post-Mortem Examination.	
					State of Supra-Renal Capsules.	State of other Organs.
107. Mr. G. MACKENZIE BACON, Med. Gazette, vol. xl., p. 132; also, Guy's Hosp. Reports, vol. viii., p. 48.	Male, 15, plasterer.	neck. Illness, six weeks. Good health till last illness. Illness, about eight months.	skin cool, obstinate constipation; death from exhaustion. Loss of appetite, nausea, and debility, then giddiness and pain in head; intervals of improvement; last week of life, prostration, hiccough, and constant vomiting of food; anaesthesia, with pain in extremities; death from sinking.	Skin began to darken soon after first symptoms of illness; after death, body of a dusky olive hue, except part of chest, with deeper brown patches on face, knees, and along spine; scrotum and penis almost black; conjunctivae pearly white.	low cheesy masses; no trace of normal tissue. Left capsule large; normal structure obliterated; stroma pale, with firm light-yellowish deposits; right capsule of about normal size, studded with smaller deposits of same nature, but evidently older and undergoing degeneration.	Lungs and other organs quite healthy, except fine pleuritic adhesions on right side, and enlargement of mesenteric glands.
108. Dr. HOUSELEY, Lancet, 1860, vol. ii., p. 8; also, Guy's Hosp. Reports, vol. viii., p. 53.	Male, 33, farmlabourer.	Gonorrhoea two years before death. Illness more than a year.	Debility, loss of appetite, nausea, occasional vomiting, pain at epigastrium, constipation; pulse and heart-sounds feeble; last few days of life, incessant sickness.	Face and hands brown; colour nearly natural on chest, but much darker over abdomen and thighs; dark ring round umbilicus; penis and scrotum dingy black; skin on section shewed the colouring matter in the rete-mucosum.	The capsule examined consisted of a smooth hard pinkish mass of fibroalbuminous tissue, degenerating in parts; this tissue was found under the microscope to be composed of nucleated fibre; in the midst were some yellow softer masses, resembling what is called serofulous matter.	Kidneys, liver, and spleen quite healthy; near the surface of liver, some cretaceous masses, probably the remains of old tubercular disease.
109. Dr. WILKS, Guy's Hosp.	Male, 25.	None given. Severe illness two days.	Acute eczema of both arms and hands, for which patient took small doses	No discoloration noticed, but darkness on arms after eruption; after death, face	Right capsule twice the natural size, and converted into firm lardaceous matter.	Lungs congested; other organs all healthy; peritoneal

Reporter and Reference.	Sex and Age.	Previous History, and Duration of Illness.	Symptoms.	Colour of Skin.	Post-Mortem Examination.	
					State of Supra-Renal Capsules.	State of other Organs.
Reports vol. viii., p 44.			of arsenic, with other remedies, and improved greatly; suddenly, vomiting and purging set in, and he sank.	sallow, skin of body pale and natural, that of genital organs and nipples dark; brown spots on thighs, whether these had been seats of eruption was uncertain.	terial; no softening nor cretaceous material in any part; left capsule much smaller, material whiter and more friable, but not cretaceous; organ contracted as if deposit were older than in right capsule.	adhesions between liver and diaphragm; in the abdominal walls a small cyst, apparently an old abscess, containing some putty-like matter.
110. Dr. WILKS, Guy's Hosp. Reports, vol. viii., p. 39. Dr. BARLOW.	Male, 24, carpenter	Robust health until five months before admission, when he over-exerted himself in running to catch a train.	Great debility; irritability of stomach, entire loss of appetite, emaciation; pulse very soft and feeble; day before death, great exhaustion, constant nausea, and vomiting.	Skin of a sallow olive brown; discoloration most marked about the knees; inside of lips mottled with black pigmentary deposit, and surface of lips very dark.	Right capsule much wasted; in its substance, many small round hard fibroid masses; left capsule atrophied; in place of normal structure, several cysts, containing turbid, colourless fluid.	Not examined.
111. Mr. VALENTINE, Med. Gazette,	Male, 35, mason.	Had been healthy until last illness. Duration, several months.	Pain in back, between lower dorsal and upper lumbar vertebrae, with	Sallowness over whole body; face, neck, and arms darkest; discolora-	Both diseased; no trace of healthy structure, but in its place a greyish	Not examined.

TABLE G.

CASES OF ADDISON'S DISEASE, APPARENTLY UNCOMPLICATED. (STATE OF OTHER ORGANS NOT REPORTED.)

Reporter and Reference.	Sex and Age.	Previous History, and Duration of Illness.	Symptoms.	Colour of Skin.	Post-Mortem Examination.	
					State of Supra-Renal Capsules.	State of other Organs.
1861, vol. ii., p. 33; also, Guy's Hosp. Reports, vol. viii., p. 41.			partial loss of power in lower limbs; three months later, debility, loss of appetite, vomiting, depression, and latterly intense pain at epigastrium.	tion more marked after death.	amorphous lardaceous matter of the consistence of wax.	
112. Dr. DUNCAN, Dublin Quarterly Jour. of Med. Science, vol. xxxvi., p. 450, 1863.	Female, 40.	Uniform good health until last illness. Duration, eighteen months.	Debility, loss of appetite, irritability of stomach, mental hebetude; day before death, incoherence and torpidity.	Bronzing on face, on exposed parts of neck and arms, over flexures of joints, fronts of thighs, and round navel; rest of skin natural in colour.	Both in a state of yellow tuberculous degeneration.	Not examined.
113. Dr. WILKS, Guy's Hosp. Reports, vol. xi., p. 33. Dr. INGLIS, Worcester Infirmary.	Male.	None obtained. Died on day of admission.	None reported.	General bronzed hue.	Right capsule converted into a large mass of yellow cheesy substance, enclosed in a thick investing membrane; in left capsule, disease was said to be not so far advanced.	Nothing reported.
114. Dr. WILKS, Guy's Hosp. Reports, vol. xi., p. 36. Dr. GILBERTSON, Preston.	Female, 50.	Had been tolerably well until a few weeks before death. Discoloration, about three months.	Attacks of vomiting and prostration at three successive periods, the third and fatal one lasting eight days; pulse almost imperceptible; consciousness to the last; death from exhaustion.	Colour of face, and especially forehead, dingy brown, and beneath the eyes almost black; whole surface of body dingy, particularly of chest.	Both converted into a firm lardaceous or cheesy substance, in every respect like what has been hitherto observed in Addison's disease.	Not mentioned.

T A B L E H.

CASES OF ADDISON'S DISEASE, COMPLICATED WITH VERTEBRAL DISEASE OR LUMBAR ABSCESS.

Reporter and Reference.	Sex and Age.	Previous History, and Duration of Illness.	Symptoms.	Colour of Skin.	Post-Mortem Examination.				
<p>115. Dr. Addison On Disease of the Supra-Renal Capsules, p. 15.</p>	<p>Male, 26, carpen- ter.</p>	<p>Very good health until about seven months before death. Laid up for two months.</p>	<p>Supposed rheumatic pains in right leg, extend- ing to hips and spine; attacks of giddiness and dimness of sight, with pain at back of head and partial unconsciousness; back tender; great debil- ity, appetite impaired, heart-sounds feeble, faint- ness on rising; vomiting, with hiccough; almost torpid from feebleness, but could be roused by speaking.</p>	<p>Discoloration noticed for three months; face and forehead of a general yel- lowish hue; several patches of darkened skin, and similar black patches on the lips.</p>	<table border="1" style="width: 100%; border-collapse: collapse;"> <tr> <th style="width: 50%; text-align: center;">State of Supra-Renal Capsules.</th> <th style="width: 50%; text-align: center;">State of other Organs.</th> </tr> <tr> <td style="vertical-align: top;"> <p>Both converted into masses of strumous dis- ease, of all degrees of con- sistency; left capsule ad- herent to outer coat of stomach; upper part fluid, pus-colour; lower part firmer, and putty-like; right capsule—lower part fluid, centre putty-like, top quite earthy, angular pieces being readily de- tached.</p> </td> <td style="vertical-align: top;"> <p>Psoas abscess on right side, nearly de- stroying neighbour- ing vertebræ at their centres; lungs con- tained hard masses of grey strumous pneumonic deposit; heart and other or- gans healthy.</p> </td> </tr> </table>	State of Supra-Renal Capsules.	State of other Organs.	<p>Both converted into masses of strumous dis- ease, of all degrees of con- sistency; left capsule ad- herent to outer coat of stomach; upper part fluid, pus-colour; lower part firmer, and putty-like; right capsule—lower part fluid, centre putty-like, top quite earthy, angular pieces being readily de- tached.</p>	<p>Psoas abscess on right side, nearly de- stroying neighbour- ing vertebræ at their centres; lungs con- tained hard masses of grey strumous pneumonic deposit; heart and other or- gans healthy.</p>
State of Supra-Renal Capsules.	State of other Organs.								
<p>Both converted into masses of strumous dis- ease, of all degrees of con- sistency; left capsule ad- herent to outer coat of stomach; upper part fluid, pus-colour; lower part firmer, and putty-like; right capsule—lower part fluid, centre putty-like, top quite earthy, angular pieces being readily de- tached.</p>	<p>Psoas abscess on right side, nearly de- stroying neighbour- ing vertebræ at their centres; lungs con- tained hard masses of grey strumous pneumonic deposit; heart and other or- gans healthy.</p>								
<p>116. Dr. Wilks, Guy's Hospital Reports, vol. viii., p. 61. Dr. McDonogh, of Clapham.</p>	<p>Female, 26.</p>	<p>Had had angular our- vature of spine from infancy, causing de- formity, and compel- ling the use of crutches; discolora- tion, about three years.</p>	<p>Pain in back and side; gradually increasing de- bility, loss of appetite, and frequent sickness; was found dead in bed, after being two days in hospital, during which time she was too prostrate to take food.</p>	<p>After death, skin ob- served to be dark, and face more so than body, but discoloration alto- gether of a slight kind.</p>	<table border="1" style="width: 100%; border-collapse: collapse;"> <tr> <th style="width: 50%; text-align: center;">State of Supra-Renal Capsules.</th> <th style="width: 50%; text-align: center;">State of other Organs.</th> </tr> <tr> <td style="vertical-align: top;"> <p>Left capsule three times the natural size, of larda- ceous consistence, yellow, with a little translucent substance, which was fir- mer and fibrous. Scattered through it, were portions of dead-white soft matter. Right capsule not much enlarged; contained a little cretaceous matter.</p> </td> <td style="vertical-align: top;"> <p>Lungs and heart healthy. Several dor- sal and lumbar ver- tebræ almost destroy- ed; surrounding these, and adjacent to supra-renal capsules, a quantity of creta- ceous and putty-like matter, the remains of an old abscess.</p> </td> </tr> </table>	State of Supra-Renal Capsules.	State of other Organs.	<p>Left capsule three times the natural size, of larda- ceous consistence, yellow, with a little translucent substance, which was fir- mer and fibrous. Scattered through it, were portions of dead-white soft matter. Right capsule not much enlarged; contained a little cretaceous matter.</p>	<p>Lungs and heart healthy. Several dor- sal and lumbar ver- tebræ almost destroy- ed; surrounding these, and adjacent to supra-renal capsules, a quantity of creta- ceous and putty-like matter, the remains of an old abscess.</p>
State of Supra-Renal Capsules.	State of other Organs.								
<p>Left capsule three times the natural size, of larda- ceous consistence, yellow, with a little translucent substance, which was fir- mer and fibrous. Scattered through it, were portions of dead-white soft matter. Right capsule not much enlarged; contained a little cretaceous matter.</p>	<p>Lungs and heart healthy. Several dor- sal and lumbar ver- tebræ almost destroy- ed; surrounding these, and adjacent to supra-renal capsules, a quantity of creta- ceous and putty-like matter, the remains of an old abscess.</p>								

Reporter and Reference.	Sex and Age.	Previous History, and Duration of Illness.	Symptoms.	Colour of Skin.	Post-Mortem Examination.	
					State of Supra-Renal Capsules.	State of other Organs.
117. Dr. COTTON, Med. Gazette, vol. xxxvi., p. 33.	Male, surgeon.	Right lumbar abscess ten years before, which remained open fifteen months; afterwards healed up, and patient became strong and well. Last illness, two years and a-half.	Languor, palpitation, sense of sinking, vomiting, hicough, and numbness of fingers; periods of marked improvement usually following change of air; always made worse by work; last days, extreme prostration, frequent sighing.	General surface of a dusky yellowish bronze colour; face, neck, chest, backs of arms, and hands of a darker hue; several dark freckles, and blackish mole spots; scrotum and areolæ round nipples of a sooty colour.	Both enlarged and adherent—right to liver and to seat of former abscess, and studded with encysted collections of yellow tuberculous cheesy matter, out of some of which pus could be squeezed; left capsule larger than right; appearances similar, but apparently of more recent origin.	A prominent cicatrix in right loin, near spine, from which a whitish, fibrous-looking obliterated sinus proceeded upwards to site of structures in which right capsule was embedded; other organs comparatively healthy.
118. Dr. GREENHOW, Path. Trans., vol. xv., p. 228.	Male, 24, engineers' labourer.	Nine months before death, had had abscess in left hypocondrium, which soon healed. Illness, seven months.	Severe neuralgic pain in left hip, downwards along course of sciatic nerve; rapid decline of strength; constipation, flatulence, and gastralgia; nausea and vomitings; loss of appetite; breathlessness and faintness on exertion; intellect unimpaired to the last.	Body dusky; face and neck darker than general surface; knuckles and cicatrices of former abrasions darker than surroundings; dark mole-like specks on neck; nipples and areolæ almost black; lips, gums, and buccal mucous membrane stained in patches; conjunctivæ clear and white.	Both disorganized, and converted into masses of firm yellowish-white tissue, in parts semi-transparent, interspersed with numerous opaque yellow deposits, of cheesy consistence, mixed with gritty matter.	Small abscess, communicating with carious bone at left sacro-iliac synchondrosis; lungs adherent to ribs, but free from tubercle; mesenteric glands enlarged; Peyer's patches enlarged, prominent, and of yellowish-white colour.
119. Dr. GLOVER, Edin. Med. Journal, 1859; also,	Male, 39, labourer.	Had hurt his back by a fall eight years before death. Discoloration, five years; illness above one year.	Gradual emaciation and debility, with pain and weakness of back and right thigh; pulse feeble, quick; cough and expectoration.	General surface of a dark yellow-brown colour; darkness most intense round nipples, outside knee, on hands, and	Structure of left capsule quite destroyed; some parts consisted of grey, semi-translucent deposit, others of opaque white	Left lung adherent; right indurated at apex, but containing no recent tubercle; caries of two lowest

Reporter and Reference.	Sex and Age.	Previous History, and Duration of Illness.	Symptoms.	Colour of Skin.	Post-Mortem Examination.	
					State of Supra-Renal Capsules.	State of other Organs.
Guy's Hosp. Reports, vol. viii., p. 50.			toration; vomiting, especially in last days of life; acute curvature of spine in upper lumbar region.	on mucous membrane of lips; penis and scrotum almost black.	material, with some pieces of cretaceous matter; right capsule seemed to have been similarly affected.	dorsal and two upper lumbar vertebrae, with psoas abscess.
120. Dr. HARDWICK, Path. Trans., vol. xv., p. 221.	Male, 29, tanner.	Three years before illness, pain in right hip and thigh. Duration, about twenty-one months.	One attack of epilepsy; psoas abscess; great debility, dizziness, breathlessness, occasional sickness.	Skin generally of a dirty olive-brown tint; discoloration a little deeper round eyes and mouth, on neck, axillae, and abdomen; areolae very dark; conjunctivae pearly.	Both hard, nodulated, and hidden in dense fibrous tissue; on section, some parts firm, grey, and lardaceous, others yellow and cheesy; in left capsule, a softened portion forming a cavity.	Psoas abscess on right side of spine; caries in front of third lumbar vertebrae; scattered tubercles in both kidneys; other organs not examined.
121. Mr. SIBLEY, Path. Trans., vol. x., p. 266, 1858. Drs. HANCORN and Buss.	Male, 43, shoemaker.	Ten years before, abscess of right wrist; five years before, disease of spine and paraplegia. Discoloration one year; laid up six weeks.	Angular curvature of lower dorsal vertebrae; extreme emaciation; pulse quick, small, and feeble; progressive debility, and faintness on exertion.	Face and hands dark-brown, like those of a half-caste; arms, legs, and trunk of a similar tint, but much less dark; skin of uniform colour, except some maculae of darker tint on face.	Both small, hard, and knobby; converted into yellowish cheesy substance; no distinction between cortex and medulla; under microscope, this substance found to be composed of shrivelled nuclei, not unlike tubercle corpuscles, with a large amount of amorphous granular matter, supported by fibro-cellular structure.	Complete absence of fat; organs generally healthy; in apices of lungs some small tubercles, breaking down in a few places; disease, however, very limited.

Post-Mortem Examination.						
Reporter and Reference.	Sex and Age.	Previous History, and Duration of Illness.	Symptoms.	Colour of Skin.	State of Supra-Renal Capsules.	State of other Organs.
122. Dr. PEACOCK, Path. Trans., vol. xi., p. 278.	Male, 20, shoe- maker.	Fits during early life, and some years before fatal illness, disease of hip, with abscesses. Discoloration and illness, about six months.	Feebleness of pulse, great debility, hurried breathing on exertion, slight cough; sickness and diarrhoea last two days of life; screaming convulsions, in the third of which he died.	Skin everywhere of a peculiar dark-brown colour, particularly intense on forehead, along spine, and back of each arm; darker portions of skin gradually fading off into lighter-coloured parts.	Right capsule adherent to kidney, left to pancreas; both enlarged, and consisting of dense, tough, glistening fibrous walls, circumscribing an irregular cavity; the left contained much creamy fluid; under microscope, walls consisted of closely and irregularly - arranged fibrous tissue, together with numerous clustered nuclear bodies.	Not examined.
123. Mr. J. HUTCHINSON Medical Gazette, vol. xxxii., p. 593. Dr. BURROWS.	Male, 24, hawker.	Spinal disease in childhood; spinal abscess recurred about two years before death, but healed after some months. Pain in back, eight months; discoloration, four months.	Slight emaciation; pain in lumbar region; pulse quick, small, and soft; tongue moist and clean; bowels relaxed; during last weeks of life, daily vomiting; death sudden, after exhaustion by a purgative.	Generally of a copper-bronze tint; head and neck very deeply stained; on thorax and abdomen, brown marks interspersed with lighter spaces; penis and scrotum almost black; dark patches on legs; conjunctivæ white.	Right capsule somewhat enlarged; on incision, purulent-looking fluid issued from several portions of its centre, with several hardish yellow pea-sized bodies, resembling concrete tubercular matter; left capsule in a similar state, but smaller.	Excess of fat on heart; slight disease of one mitral valve; bodies of fifth and sixth dorsal vertebrae destroyed, but no active disease.
124. Dr. LOUIS MARETINEAU,	Male, 42, hall-	Five years before death, abscess connected with caries,	Much cough; vomiting and colic; obstinate constipation; breathlessness	Skin bronzed over whole body, deepest inside thighs; hair and beard had be-	Right capsule twice the natural size, in two lobes; in the smaller one, no ap-	Some grey and some yellow tubercle in apices of both lungs;

Reporter and Reference.	Sex and Age.	Previous History, and Duration of Illness.	Symptoms.	Colour of Skin.	Post-Mortem Examination.	
					State of Supra-Renal Capsules.	State of other Organs.
"De la Maladie d'Addison," p. 46, Dr. MOISSENET.	porter.	and angular curvature of spine; abscess cured after eighteen months. Last illness, nearly a year.	on exertion; extreme prostration and emaciation; last hours, coma.	come much darker, and buccal mucous membrane coloured like a Negro's; cicatrices of boils darker than surrounding skin.	parent change; the other hard and nodulated, shewed on section two large yellowish tubercles softening down; left capsule atrophied; a small cavity lined with tuberculous matter.	spine, &c., could not be examined.
125. Dr. GUBIAN, Gazette Médicale de Lyon, Canstatt's Jahresbericht, 1858.	Male, 36.	Bilious temperament; exhausted constitution. Duration unknown; eighteen days in hospital.	Typhoid fever; during recovery, he fell into a state of prostration; digestive organs were disturbed, and there was fixed pain in dorso-lumbar region, increased by any endeavour to sit up; patient died from exhaustion, conscious to the last.	Sepia tint of whole skin, dating as far back as patient could remember; hue darkest on nape of neck, on scrotum, and on mucous membrane of lips.	Right capsule five times the normal size, nodulated, and entirely composed of a yellowish, cheesy mass, in process of softening, and having the exact appearance of tuberculous deposit, which was confirmed by the microscope; left capsule not mentioned.	Recent pneumonia; no tubercle in lungs, but some in bronchial glands; disease of lumbar vertebrae; puckered patches on Peyer's glands.
126. Dr. BARY, Path. Trans., vol. viii., p. 330.	Not stated.	None given.	None recorded, except diseased vertebral column.	No trace of bronze discoloration.	Proper structure in great part apparent, but containing nodules of firm substance, grey and semi-transparent externally, yellow and opaque internally, the grey portion predominating; disease evidently at an early stage.	Not described.

Reporter and Reference.	Sex and Age.	Previous History, and Duration of Illness.	Symptoms.	Colour of Skin.	Post-Mortem Examination.	
					State of Supra-Renal Capsules.	State of other Organs.
127. Dr. C. COOTE, Path. Trans., vol. x., p. 271.	Male, 23.	None given.	None recorded, but caries of sacral and lumbar vertebrae, causing lumbar and pelvic abscesses; death from exhaustion.	No discoloration of skin.	Both much enlarged; normal structure almost entirely replaced by firm yellowamorphous deposit; traces of cortical tubes seen only in a few spots.	Kidneys contained deposits of white tubercular matter, softening in parts; several mesenteric glands infiltrated with (probably) scrofulous deposit.
128. Mr. HULKE, Path. Trans., vol. xiv., p. 254.	Male, 30, mechanic.	None given. Duration uncertain.	Pain and tenderness in lumbar region of spine; psoas abscess; some emaciation, extreme feebleness, very irritable stomach, obstinate constipation; last day of life, faintness.	No discoloration of skin.	Both enlarged, hard, and knobby; on section, homogeneous, mottled with a few yellowish friable specks; under microscope, traces of normal structure.	Caries of third and fourth lumbar vertebrae; psoas abscess; scattered tubercles in apices of both lungs.
129. Dr. GREENHOW, Path. Trans., vol. xvii. Dr. STEWART.	Male, 32, coal-porter.	Had sprained his back severely in pushing a coal-truck, upwards of three years before death, and had felt more or less pain ever since. Illness about nine months, discoloration five months.	Debility, sweating, headache, loss of appetite, and sickness; breathlessness on exertion; severe pain in right lumbar region; pulse exceedingly feeble; retching and vomiting after food, pain in epigastrium; tenderness and pain over several vertebrae; vertigo, deafness, and dimness of sight; drowsy, semi-comatose	Whole surface olive-brown, especially face, neck, and hands; several almost black specks on face; tongue, lips, and buccal membrane stained; abdomen darker than rest of body, except sites of blisters; nipples and areolae, penis and scrotum, very dark; hair and beard had darkened; conjunctivae pearly.	Both embedded in thick fibrous tissue, and adherent; right much enlarged, nodulated, and on section shewed no distinction of cortex and medulla, but a mixture of greyish semi-transparent somewhat fibrous tissue, and of roundish yellow cheesy masses, with small calcareous patches; left capsule smaller, and conjunctivae pearly.	Lungs attached by old adhesions to ribs; in adhesions a cyst filled with putty-like matter, and some calcareous deposits; cicatrices and yellow opaque nodules in apices of lungs; abscess in front of vertebrae, from seventh dorsal to third lumbar; inter-vertebral

Reporter and Reference.	Sex and Age.	Previous History, and Duration of Illness.	Symptoms.	Colour of Skin.	Post-Mortem Examination.	
					State of Supra-Renal Capsules.	State of other Organs.
130. Dr. BAILY, Path. Trans., vol. viii., p. 325. Drs. BURROWS and BAILY.	Male, 18, baker.	Skin had long been dark. Illness above a year.	Extreme languor, loss of appetite, pain and tender- ness in lumbar region, and over abdomen; head- ache, delirium, vomiting, yawning, and great de- pression; peculiar odour of Negro skin; two inter- vals of great improve- ment; in last relapse, tor- por, vomiting, coldness, albuminuria; before death, blindness, laboured breathing, jactitation.	Whole surface bronzed; darkest parts front of neck, areolæ, scrotum, and penis, and on abdo- men where blisters had formerly been applied.	Both small, hard, yel- low, and nodulated; right capsule mostly firm, grey, semi-transparent, with a yellow, opaque, brittle substance in centre of nodules; in left capsule but little grey, nearly all opaque yellow substance, which in parts was hard and calcareous, and in one small cavity contained semi-liquid matter.	A tubercular mass, not larger than a grain of pearl-barley, in lower lobe of each lung; left pleura ad- herent throughout; bronchial glands large.
			state some days before death from exhaustion.		tained more of the cal- careous matter.	substance separated on the left side from the upper surface of the first lumbar, for two-thirds of its depth.

T A B L E K.

CASES OF ADDISON'S DISEASE, COMPLICATED WITH TUBERCLE IN LUNGS ONLY.

Reporter and Reference.	Sex and Age.	Previous History, and Duration of illness.	Symptoms.	Colour of Skin.	Post-Mortem Examination.	
					State of Supra-Renal Capsules.	State of other Organs.
131. Dr. VAN CORPUT, Brussels, Gazette Hebdomadaire, 1863, p. 493.	Female, 37, house-keeper.	None given. Illness some months.	Epigastric pains and emaciation; death sudden.	Characteristic brown discoloration, darkest on face, backs of hands, around nipples, in axillæ, and near umbilicus; on gums and palate, small roundish bluish-brown stains.	Both three times the natural size, hard, and nodulated; cortex thickened, and dark-red brown; medullary substance entirely replaced by yellowish tubercular masses from the size of a pea downwards, scattered throughout both lungs; pigment in bronchial glands, liver, and grey substance of brain.	A single hard cretaceous tubercle, the size of a pea, in apex of left lung; numerous small melanotic masses, from the size of a pea downwards, scattered throughout both lungs; pigment in bronchial glands, liver, and grey substance of brain.
132. Prof. Dr. BUHL, Wiener Med. Wochenschrift, 1860, p. 6. Dr. VOGEL.	Male, 20.	None given.	None mentioned, but a striking general decay of strength.	Whole surface bronzed, but colour deepest on fingers; tongue also stained with brown patches.	Both enlarged, tough, and containing yellow cheesy nodules; left capsule almost entirely transformed into a cheesy mass.	Lungs contained scattered military tubercles, and were loaded with pigment; enlarged bronchial glands, and solitary glands of intestine, also dark-coloured; other organs healthy.
133. M. VIRCHOW, Canstatt's Jahresbericht, 1859. M. SCHMIDT, Rotterdam.	Male, 23, sailor.	Intermittent fever previous year. Illness some months, followed by discoloration.	Debility, coldness of skin, loss of appetite, vomiting, pains in loins; progressive emaciation and prostration; death from exhaustion.	Face and hands became of a dusky-brown colour, and sepia-coloured stains were found on the neck, in the axillæ, and lumbar regions, which faded gradually into the normal coloured skin.	Both enlarged and tuberculous, pink softened portions alternating with harder yellow or yellowish-white parts; in left capsule three pea-sized cavities, formed by the softening down of tubercle;	Old tubercle in apices of lungs; follicles of intestines swollen and thickened; other organs healthy.

Reporter and Reference.	Sex and Age.	Previous History, and Duration of Illness.	Symptoms.	Colour of Skin.	Post-Mortem Examination.	
					State of Supra-Renal Capsules.	State of other Organs.
134. Dr. GROMIER, Gazette Médicale de Lyon, 1857.	Female, 51.	None given. Illness, fifteen months.	Loss of appetite and flesh; later, pains in loins, excessive debility, and slight convulsive symptoms before death, which took place from exhaustion.	Intense brown discoloration soon following early symptoms of illness.	adjoining lymphatic glands also enlarged and tuberculous. Both found tuberculous.	Miliary tubercles in apices of lungs.
135. Dr. GIOCOMO MINGONI, Gaz. Med. Ital., Lombardia, 1856, No. 42.	Male.	Hemiplegia at 8 years old, for some months; dysentery at 25, and again at commencement of illness. Duration, twenty months.	Debility, languor, and vomiting of food; loss of flesh, pains in loins, vertigo; body became cold, pulse failed; death from exhaustion.	Face and hands began to darken with first symptoms of illness; discoloration appeared later in axillæ, on scrotum, and in large patches on elbows and knees; also on lips.	Right capsule small, and contained some crude tubercles, shewing normal structure between them; left capsule greatly enlarged; on section, a quantity of pus escaped, and a tuberculous mass was seen partly softening down.	Crude tubercle in apex of left lung; slight appearance of softening in brain.
136. Dr. ISAAC TAYLOR, Med. Gaz., vol. xxxv., p. 36, 1856, from Amer. Journ. of	Male, 22.	Two years before admission to Belle Vue Hospital, New York, had symptoms of phthisis, which had entirely subsided. Duration unknown.	Feebleness and emaciation; nausea and vomiting; pain in right side, and constipation; pulse small and weak; hebetude of mind and body; suppression of urine two	Face and neck of a light sun-burnt hue; backs of hands brown; small darkish spots on each lip, which deepened while under observation; trunk and limbs of normal col-	Right capsule consisted solely of tuberculous material, in part solid and in part fluid; left capsule as large as a hen's egg, and contained, within a thin layer of cortical struc-	Some old cicatrices, and a few scattered tubercles, in apices of both lungs.

Reporter and Reference.	Sex and Age.	Previous History, and Duration of illness.	Symptoms.	Colour of Skin.	Post-Mortem Examination.	
					State of Supra-Renal Capsules.	State of other Organs.
Med. Science.			days before death; died comatose.	our; after death, darker tinge observed in axillae, and on right side of abdomen.	ture, a collection of tubercular matter, partly solid, partly semi-fluid.	
137. Dr. KIRKES, Med. Gaz., vol. xxxv, p. 35.	Male, 25.	Fever two years before, and had been badly off. Duration uncertain.	Great exhaustion, nausea, vomiting, and faintness; no urine secreted for some time before death.	No bronzing of skin noticed. (N.B.—This case occurred some years before the publication of Addison's work.)	Both enlarged, and filled with masses of firm yellowish cheesy-looking matter, in which particles of calcareous matter were embedded.	A little old tubercle in lungs.
138. Mr. F. WORKMAN, Brit. Med. Jour. 1863, vol. ii, p. 605.	Male, 33, labourer, formerly cavalry soldier.	Four years before death, his horse fell on him, and injured his loins; had been ailing ever since.	Lumbar pains, progressive debility, occasional sickness, and at last dyspnoea.	Face and upper extremities slightly bronzed for eighteen months.	Both filled with tubercular deposit.	Lungs contained a few miliary tubercles; no report of other organs.
139. Mr. A. FERNIE, Reading, Brit. Med. Jour. 1857, p. 581. Dr. COWAN.	Female, 14.	Had been ailing for three years; three weeks in hospital.	Emaciation, vomiting, constant pain in right side; pulse small and compressible; last days of life, extreme prostration, coldness of surface, and incessant vomiting.	Complexion muddy; nails black, as if from dirt; a number of small spots, of darker colour, on legs.	Both much enlarged; on section, consisted of yellow cheesy deposit, mottled with narrow streaks of red substance; cheesy deposit, in some parts of creamy consistence, in one part calcareous.	Small deposit of tubercle in apex of each lung; other organs all healthy.

Reporter and Reference.	Sex and Age.	Previous History, and Duration of Illness.	Symptoms.	Colour of Skin.	Post-Mortem Examination.	
					State of Supra-Renal Capsules.	State of other Organs.
140. Dr. ROBERTSON, Med. Gazette, vol. xxxiii., p. 646, 1856.	Male, 26, labourer.	Never any serious illness till the last. Duration, twenty-two months.	Appetite bad; sickness and vomiting at intervals; pain in legs and right hypochondrium; pulse small and feeble; death from exhaustion.	Bronzing commenced about a year before death; face, arms, hands, and chest a dark brown; face and hands deepest; conjunctivæ pearly.	Both much enlarged; left capsule a soft cheesy mass, in a firm glistening yellow envelope; right capsule contained a solid cheesy substance, with a softened portion resembling cream.	Apex of left lung contained two or three small chalky deposits; other organs healthy; blood thicker than usual after death.
141. Dr. E. MONTGOMERY, Path. Trans., vol. xiii., p. 246. Dr. BARKER.	Male, 14.	Had had perfect health until last illness. Duration, five months.	Loss of flesh; extreme weakness, almost inability to move, frequent vomiting, vertigo, feeble voice; no pain.	Skin everywhere distinctly bronzed; deepest on belly and back; forehead and fore-arms paler.	Substance of capsules entirely destroyed; replaced by granular and calcareous matter.	A few calcareous tubercles in apices of lungs.
142. Dr. DICKINSON, Path. Trans., vol. xvi., p. 243. Dr. PITMAN.	Female, 39, straw-plaiter.	None given. Illness about a year.	Debility, wasting, frequent vomiting; pulse small and weak, respiration feeble, manner listless; skin cool, but patient complained of burning heat; breath had a sickly smell; urine abundant and healthy; slight convulsion, followed by semi-coma before death.	Skin generally bronzed to a Mulatto tint; darkest on buttocks, on upper and inner parts of thighs, near groins, and dark patches above each patella.	Left capsule enlarged, adherent to pancreas; on section, hard, elastic, marbled, resembling a fibro-plastic tumour; centre occupied by soft opaque broken-down yellowish matter, not unlike crude tubercle; right capsule much smaller; central part semi-fluid, resembling creamy pus; several greyish nodules, like miliary tubercles.	Small mass of crude tubercle at apex of right lung, besides two or three round masses, rather larger than peas, believed to be tubercle; mitral valve thickened.

Post-Mortem Examination.						
Reporter and Reference.	Sex and Age.	Previous History, and Duration of Illness.	Symptoms.	Colour of Skin.	State of Supra-Renal Capsules.	State of other Organs.
143. Dr. MONRO, Dundee, Assoc. Med. Jour., 1856, p. 48.	Female, 40, clergy- man's wife.	Generally healthy, but never robust; eight or nine months before death, much anxiety and bodily fatigue. Illness dated from that time.	Short dry cough, with scanty expectoration; great debility; pulse small and compressible; sickness and prostration; consciousness to the last.	Dark spot on forehead several years before death, from which discoloration gradually spread over body; latterly, general hue that of a Lascar, dark- est over back of neck, elbow-joints, and knees; stains on mucous mem- brane of lips.	Right capsule much en- larged, and adherent to liver; left capsule much smaller; on section, both organs presented two ma- terials, one dense and of gristly hardness, the other a yellow cheese-like de- posit.	Tuberculous deposit in apices of both lungs; solitary gas- tric glands very pro- minent; tubular glands of mucous membrane nearly gone, their place sup- plied by granular amorphous material.
144. Dr. L. MARTINEAU, "De la Maladie d'Addison," p. 43. Drs. CORNIL and VAST.	Female, 48, labourer.	Discoloration had begun to appear after a time of great grief, six years before death. Illness, about fifteen months.	Pains in limbs and ab- domen, and great debility, with some vomiting; to- wards the last, emaciation and prostration; tendency to faint if raised up; cough and slight hæmop- tysis; no appetite; an- swered questions with dif- ficulty; death quiet, from exhaustion.	Skin discoloured over whole body; most deeply bronzed on forehead, face, and backs of hands; col- our uniform on hands, in patches on forehead.	Both much enlarged; enveloping membranes very thick, and sending processes into the organs; on section, right capsule showed large yellowish masses, of tuberculous ap- pearance, some still hard, others softening down into pus; left capsule in a similar state, but less advanced.	In apex of right lung, some crude tu- bercles; round these, and in the upper part of lung, some rather extensive patches of chronic pneumonia.
145. Dr. L. MARTINEAU, "De la Maladie d'Addison," p. 30. Dr. FREMY.	Male, 27, farrier.	Healthy until eighteen months be- fore death.	Loss of strength and appetite; vomiting; dull pain in hypochondria, in- creased by pressure or by walking; pulse soft, com- pressible; tongue clean; progressive debility, pass-	Fair complexion became brown, and light hair dark; before death, gene- ral greenish-brown hue, deepest on face, insides of arms and legs, on penis, and on scars of burns;	Right capsule adherent, rough, and nodulated; on section, presented a yel- lowish cheese-like appear- ance; no trace of normal structure; left capsule larger and less adherent,	In apex of left lung, a few tubercles, one of which was soften- ing; other organs healthy.

Reporter and Reference.	Sex and Age.	Previous History, and Duration of Illness.	Symptoms.	Colour of Skin.	Post-Mortem Examination.	
					State of Supra-Renal Capsules.	State of other Organs.
146. Dr. CHILD, Oxford, Lancet, 1865, vol. i., p. 176.	Female, 37.	None given. Illness about five months.	ing into torpor last two days of life, but consciousness perfect when roused by questions; death in a convulsion.	blackspecks scattered over face; insides of lips and cheeks, and soft palate, deeply stained; conjunctivæ normal.	with some pus in centre; shewing traces of normal structure. Under microscope, cheesy portions presented precisely the elements of yellow tuberculous masses when softening down.	Small deposits of tubercle in apices of lungs; mesenteric glands enlarged; other viscera healthy.
147. Dr. HUGHES, Dublin Quart. Jour. of Med. Science, November, 1865, p. 363.	Male, 45, herdsman.	Subject to dyspepsia and pyrosis for several years. Last illness a few months.	Progressive debility, sickness, breathlessness on exertion, vertigo on assuming an erect position; severe but intermittent pain from lumbar vertebrae encircling abdomen; pain and tenderness on pressure both of arms and spine; death from sinking.	Face, neck, and hands smoky brown; colour well marked in axillæ, around nipples, in groins, on scrotum, knees, and on epigastrium where croton-oil had been applied; in axillæ, and on arms, a few scattered almost black spots.	Both hard, completely infiltrated with tubercular matter; right capsule the larger, and appeared on section a mass of crude tubercle, with no remains of normal structure.	Miliary tubercles scattered on surface of lungs, beneath the pleure.
148. Dr. WILKS,	Male, 38,	For a twelvemonth past had been failing;	Pains in limbs, debility, and cough; towards the	No discoloration.	Twice their natural size, white, firm, and hard;	Lungs contained a number of yellowish

Reporter and Reference.	Sex and Age.	Previous History, and Duration of illness.	Symptoms.	Colour of Skin.	Post-Mortem Examination.	
					State of Supra-Renal Capsules.	State of other Organs.
Guy's Hospital Reports, vol. viii., p. 38, Dr. OWEN REES.	wheelwright.	much worse the last nine weeks.	last, utter prostration, could scarcely move in bed, and did not care to speak; pulse exceedingly feeble; frequent vomitings.		on section, seen to be composed of two substances, one firm and translucent, the other opaque-yellow, exactly resembling that called scrofulous.	deposits, the size of peas, much resembling the deposit in the capsules; heart and other organs healthy.
149. Dr. SEATON REID, Med. Gazette, 1861, vol. ii., p. 32.	Female, 28.	Always weakly; had suffered for two years from cough and pain in side. Last illness, three or four months.	Extreme languor; failure of appetite; tendency to fainting; pulse rapid and feeble; tongue moist, much thirst; towards close of life, increased listlessness and depression, and disinclination to speak; daily vomiting of yellow or greenish fluid.	Face yellowish-brown, with many dark spots on cheeks; dark streak along centre of lips; buccal mucous membrane discolored; two or three ink-like streaks on tongue; back and sides of neck olive-brown, nipples and arm-pits very dark; trunk and thighs Mulatto-colour, with spots like those on cheeks.	Both entirely disorganized; the right composed of cheesy or scrofulous-looking matter, the left of hard, fatty matter.	Left lung had considerable deposit of tubercle at apex, without any cavities.
150. Mr. T. HOLMES, Path. Trans., vol. ix., p. 405. Dr. PAGE.	Male, 43, clerk.	Abscess connected with sternum for seventeen years. Illness, seven or eight months.	Aching pain across loins; depression, feeble pulse, loss of sleep.	Skin of a dark, dingy colour, especially on face, hands, and legs; more bronzed on parts exposed to light; of a yellowish hue on legs.	Both enlarged; natural tissue quite gone, and replaced by a firm white parenchyma, in which was a copious deposit of crude tubercle, softened in places.	Extensive tubercular deposit in lungs; a vomica in each apex.

Reporter and Reference.	Sex and Age.	Previous History, and Duration of Illness.	Symptoms.	Colour of Skin.	Post-Mortem Examination.	
					State of Supra-Renal Capsules.	State of other Organs.
151. Dr. F. B. GRAY, Med. Gazette, 1860, vol. i., p. 237.	Male, 47, labourer.	None given. Illness some months.	Gradual loss of strength, flesh, and appetite, with frequent vomiting, and pain in belly or loins; extreme prostration of mind and body; offensive odour of breath and skin.	Whole body of a nearly uniform dusky-brown colour.	Both enlarged, and their proper tissue entirely replaced by yellow cheesy tubercle.	Small cavities and calcified tubercles in apices of lungs; other portions of lungs studded with small miliary tubercles.
152. Dr. WILKS, Guy's Hospital Reports, vol. viii., p. 33. Dr. HODGKIN for Dr. BRIGHT.	Female, 38.	None given.	None reported, but pain in chest, and cough.	Not mentioned. (N.B. — Case occurred some years before the publication of Addison's work.)	Both enlarged, and occupied by a yellow adventitious deposit, which in parts was softening down.	Lungs contained tubercles, but quite insufficient to account for death.
153. M. BRÄHME, Deutsche Klinik, 1857.	Male.	Corpse brought to dissecting-room.	Unknown.	Whole surface, except face, of a dark greyish-brown colour, deepest in axillæ and inguinal regions; here and there round whitish scars.	Right capsule enlarged, and filled with yellowish, firm, apparently tuberculous masses, from the size of a bean downwards; left capsule shrivelled, but in similar condition.	Lungs tuberculous.
154. Dr. GULL, Med. Gazette, 1865, vol. ii., p. 441.	Male, 45.	Had had cough, hæmoptysis, and puriform expectoration, but signs of phthisis were not decided. Illness seven years.	Great feebleness, pain of limbs, and at one time daily (morning), sickness; occasional dimness of sight on first rising; disease of left foot.	When last admitted into hospital, hue very brown; nipples especially tinged, and also lower extremities.	Both small and hard; right adherent to liver, and shewing, on section, fine white tissue and calcareous matter; left contained calcareous matter,	Apex of right lung puckered, with chalky grains in its tissue; recent tubercle in lower lobe; left lung healthy, except one

Reporter and Reference.	Sex and Age.	Previous History, and Duration of illness.	Symptoms.	Colour of Skin.	Post-Mortem Examination.		
					State of Supra-Renal Capsules.	State of other Organs.	
155. Dr. GREENHOW, Path. Trans., vol. x., p. 269.	Female, 31, married.	Had strained her back in turning a mangle, several years before. Illness, six months.	Occasional vertigo, pain in loins, sickness, feebleness of pulse, coldness of skin, palpitation, breathlessness and faintness on exertion; smarting in darker portions of skin when warm; foetid odour last two days of life; mind clear to the last; death from exhaustion.	Body of a dusky olive hue; general surface of exposed parts greenish-bronze colour, darkest on forehead, temples, and back of neck; colour not quite uniform, presenting a number of small patches; several dark well-defined spots, like naevi, on arms, face, and neck; lips and buccal membrane stained; conjunctivæ pearly white.	Left capsule consisted entirely of yellow cheesy tubercle; right capsule in a similar state, but softened at centre; no trace either of cortical or medullary substance.	State of Supra-Renal Capsules. mixed with viscid fluid.	State of other Organs. cretaceous nodule; tibia and tarsal bones soft.
156. Dr. GREENHOW, Path. Trans., vol. xvi., p. 247.	Female, 13.	Bronchitis six months before death; soon after, slight duskiness, attributed	Sickness, feeling of cold; listless, exhausted aspect; small feeble pulse; frequent sighing and yawn-	Discoloration scarcely observable till last days of life, when the duskiness of face and hands became	Both much enlarged; envelopes thickened, and adherent to surrounding parts; right capsule hard,	No emaciation; apices of lungs puckered on surface, and consolidated by chief-	

TABLE L.

CASES OF ADDISON'S DISEASE, COMPLICATED WITH TUBERCLE IN LUNGS AND OTHER ORGANS.

Reporter and Reference.	Sex and Age.	Previous History, and Duration of Illness.	Symptoms.	Colour of Skin.	Post-Mortem Examination.	
					State of Supra-Renal Capsules.	State of other Organs.
157. Dr. WILKS, Path. Trans., vol. xiv., p. 253. Dr. TRUMAN.	Male, 26, grocer.	to sun-burning; last illness followed a severe purge. Duration, fourteen days.	ing; retching on the slightest exertion; later, cough, with scanty expectoration of mucus, tinged with blood, and faintness, with vomiting, on being moved; conscious to the last; death rather sudden.	more evident, and the nipples, axillæ, abdomen, and knees shewed a slightly dusky hue; a single small dark stain on buccal mucous membrane.	nodulated, and consisting chiefly of opaque-yellow masses, cheesy or friable, with here and there some gritty matter, bound together by greyish semi-transparent tissue; in upper part, some puriform fluid; no trace of normal structure; left capsule smaller, and disease appeared less advanced.	ly grey semi-transparent tubercular deposit; in right lung, tubercle beginning to soften; a little grey tubercle in lower portions of both lungs; Peyer's patches prominent, mesenteric and solitary glands enlarged, and a few of the latter opaque and yellowish.
158. Dr. MURCHISON Path. Trans., vol. xv., p. 224. Dr. W. T. GAIRDNER.	Male, 15, paper-stainer.	None given. Illness above a year.	Excessive weakness and want of energy; dull, aching pain in region of kidneys; towards the last, vomiting.	At first, slight yellowish tinge on face, which gradually darkened; after death, skin universally of a yellowish-brown hue, more markedly so on abdomen.	Right capsule much enlarged, and infiltrated with masses of yellow tubercle; left capsule smaller, but similarly diseased; under microscope, deposit found to consist of granules, oil-globules, free nuclei, and a few imperfect cells.	Puckered cicatrix at apex of right lung; old pleuritic adhesions; a few masses of tubercle between jejunum and pancreas, which were adherent to each other.
		None given. Illness above a year.	Chilly fits, pains in back, diarrhoea and sickness; typhoid erysipelas of face, and tubercular peritonitis.	General darkening of skin; almost Negro blackness on points of fingers, penis, and scrotum; slight staining of mucous surface of lips.	Both enlarged and indurated; the normal structure, except a little in left capsule, replaced by a yellow cheesy substance, partly infiltrated with cretaceous matter.	A little tubercle in both lungs; peritonium universally tuberculous.

Post-Mortem Examination.		State of other Organs.				
Reporter and Reference.	Sex and Age.	Previous History, and Duration of Illness.	Symptoms.	Colour of Skin.	State of Supra-Renal Capsules.	State of other Organs.
159. Dr. PAGE, St. George's Hospital, Brit. Med. Jour. 1859, p. 717.	Male, 17, saddler.	None given. Ill- ness four months.	Debility, emaciation, vomiting, pain across loins, and burning sensa- tion at lower part of ster- num; pulse very feeble; skin cold; wandering of mind; torpor at the last.	Universal discoloration, of a dirty yellowish hue, approaching to bronze on exposed parts; conjunc- tivæ perfectly white.	Both enlarged, and oc- cupied by a mass of tu- bercular deposit; no por- tion of healthy gland left.	Small collection of crude tubercle in apex of right lung; mesen- teric glands enlarged, and tuberculous.
160. Dr. MURCHISON Path. Trans., vol. x., p. 268. Dr. SCURRAH,	Male, 36.	None given.	None reported, except that there was pericar- ditis.	No bronzing of any part of skin.	Right capsule much en- larged, left rather smaller; interior, and greater part of both, the seat of a mass of yellow scrofulous depo- sit.	Acute tubercle of lungs, pleuræ, peri- toneum, liver, and kidneys.
161. ADDISON "On Disease of Supra-Renal Capsules," p. 22. Dr. BRIGHT, 1829.	Female.	None known. A month in hospital.	Irritability of stomach; bilious vomiting; debility; obscure tumour in left breast; swelling of paro- tid; drowsiness, from which she could be roused; pain over forehead, and a little wandering for a day or two before death.	Complexion very dark. (N. B. — Case occurred many years before the publication of Addison's work.)	Both enlarged, lobulat- ed, and the seat of morbid deposits, apparently of a scrofulous character; they were at least four times their natural thickness, solid, and hard; one part of left capsule had sup- purated, containing two drachms of yellow pus.	Upper lobe of each lung puckered, and containing one or two masses of earthy mat- ter, besides several incipient tubercles; small abscess beneath mammary; brain atro- phied; heart and other organs healthy.
162. Dr. WILKS, Guy's Hospital Reports,	Male, 28, coach- man.	Sudden hemiplegia a year before death, from which he never recovered.	Felt very ill the last few weeks of life, complaining of pain in head; a second paralytic stroke caused death.	Skin of an unusually dark colour; face and hands of an olive tint.	Both disorganized from presence of adventitious material, of a grey, semi- transparent appearance; scattered through this	Scattered tubercles in upper lobes of lungs; arachnoid in- flamed, fluid in ven- tricles; softening at

Reporter and Reference.	Sex and Age.	Previous History, and Duration of Illness.	Symptoms.	Colour of Skin.	Post-Mortem Examination.	
					State of Supra-Renal Capsules.	State of other Organs.
163. Dr. W. H. BROADBENT, Path. Trans., vol. xiii., p. 246.	Female, 23.	Change of disposition, and impaired health, for two years, attributed to a severe mental shock.	Headache and vertigo, followed by chorea; progressive weakness; vomiting after meals; peevishness, and sometimes violence.	Had been observed for some time as becoming discoloured; face and hands tanned, as if by the sun.	were small masses of yellow cheesy material.	junction of left corpus striatum and thalamus opticus. A few firm yellow tubercles in apices of lungs; mesenteric glands enlarged; a small firm white tumour on posterior surface of lumbar enlargement of spinal cord, out of which it sprang.
164. Dr. KIRKES, Med. Gazette, vol. xxxv., p. 35.	Male, 34, hostler.	Of intemperate habits, and subject to epilepsy.	None reported, except general tubercular disease; death in a fit.	Not mentioned; at the autopsy, no spots were visible on the surface. (Case occurred before the publication of Addison's work.)	Right capsule thickened and distorted by the deposition of large masses of firm yellow cheesy tubercle; left capsule healthy.	Tubercle in most of the viscera.
165. Dr. G. HARLEY, Path. Trans., vol. ix., p. 402. Dr. MACKENZIE.	Female, 33.	Had consulted Dr. M. eight years before for general ill health, anæmia, dyspepsia, and slight uterine derangement.	Five months before death, excessive anæmia, weakness, and emaciation; marked pain was caused when positive pole of galvanic battery was placed over seat of supra-renal capsules.	Peculiar sallowness of the skin. General surface of the skin opaque; rather dusky, or freckled brown than bronzed. Several dark patches on the chest; one much larger than the rest at the lower portion	Both much enlarged; right capsule firm, lobulated, and, on section, of a dirty white hue; no trace of normal structure; left capsule presented the yellowish-white colour of crude tubercle, with a	Liver enlarged, with some miliary tubercles on anterior surface; right ovary adherent to uterus, and to a cyst containing material similar to that in capsule;

Reporter and Reference.	Sex and Age.	Previous History, and Duration of Illness.	Symptoms.	Colour of Skin.	Post-Mortem Examination.	
					State of Supra-Renal Capsules.	State of other Organs.
166. Dr. Woodhouse, Brit. Med. Jour., 1863, vol. ii., p. 605.	Male, 63, gentle- man.	Always of sallow complexion and gouty constitution. Illness several months.	Progressive debility and emaciation; œdema and purpura of legs; no nausea or vomiting; enlargement of liver and ascites; death from asthenia.	of sternum. Tawny patches on forehead and left temple.	softer part towards middle, from which milky fluid escaped on pressure. Both enlarged, and infiltrated with tubercular matter.	abdominal organs extensively adherent. Liver enlarged and granular; spleen large and friable, with tubercular concretion size of walnut; lungs healthy.
167. Mons. MALHERBE, Gazette des Hôpitaux, 1856, p. 427.	Female, 48.	Severe mental emotion eighteen months before death, from which time health failed.	Wandering pains in limbs and abdomen; pulse extremely slow and feeble; progressive debility, slight emaciation, constant vomiting, diarrhœa; death from sinking.	Skin, naturally very white, acquired a gradually deepening shade of brown; after death, colour deepest in groins and axillæ, but perceptible everywhere.	Left capsule greatly enlarged, and contained two large masses of tubercle; right capsule of lardaceous consistency, resembling crude tubercle, with a number of encysted tubercular deposits in a cheesy state.	Cervical glands enlarged; lymphatic glands generally almost transformed into masses of tubercle; left kidney full of encysted tuberculous deposits, some cheesy, some suppurated, others hard.
168. Mr. LEEMING, Med. Gazette, 1860, vol. i., p. 87.	Female, 47.	None given. Illness said to have lasted four years.	General debility, loss of appetite, pain in lumbar region extending to right groin; pulse soft and weak; twice improved in general health but relapsed.	Bronzed all over body twenty-two months before death; face and hands darkest. On abdomen and chest many dark spots gradually shaded off.	Both broken up into pul- erulent-like fluid with masses of softened tubercle in centres.	Pleuræe adherent; lungs infiltrated with tubercle; spleen tubercular; pancreas full of tubercular deposit and pus.

Reporter and Reference.	Sex and Age.	Previous History, and Duration of Illness.	Symptoms.	Colour of Skin.	Post-Mortem Examination.	
					State of Supra-Renal Capsules.	State of other Organs.
169. M. TROUSSEAU, Gazette des Hôpitaux, 1856, p. 365.	Male, 30, coach- man.	Had enjoyed good health. Illness five months.	Gradual emaciation, loss of strength, dislike to meat; occasional pain in loins; later a shivering fit followed by copious diar- rhœa; coldness of surface and delirium. Death from rapid sinking.	Bistre discoloration first on face and hands; axillæ, penis and scrotum, especi- ally dark; interior of lips as black as a dog's.	Left capsule much en- larged and almost entirely changed into heteromor- phous product. Numer- ous tuberculous masses in both capsules.	Some old tubercles in apices of lungs; scattered tubercles in kidneys; other or- gans healthy.
170. Dr. L. MARTINEAU, "De la Maladie d'Addison," p. 65. Professor SEITZ, Munich.	Female, 47.	Good health, but given to drinking. Illness nine months.	Loss of flesh, indigestion, vomiting and chronic catarrh of stomach; later debility, profuse sweat- ings, hectic fever and death.	Dark yellow-brown dis- coloration on head and neck, less marked on body.	Both of the size of wal- nuts, hard and homoge- neous, consisting of yellow tuberculous matter in process of degeneration.	Scattered tubercles in lungs; small tu- bercular deposits in spleen and on perito- neum of stomach; liver fatty.
171. Prof. Dr. BUHL, Wiener Med. Wochenschrift, 1860, p. 20.	Male, 28.	None given.	Excessive emaciation and exhaustion. Death from gradual sinking.	Grey-brown discolora- tion on face and neck; well-marked on hands and feet, gradually fading away towards arms and ankles; genital organs dark; sides of tongue stained from root to tip with black-brown patches.	Both enlarged, and con- taining tough yellow cheesy masses, identical in character under the so- microscope with the so- called miliary tubercles in lungs, liver and spleen.	Apices of lungs, liver, and spleen, studded with miliary tubercles; lymphatic glands throughout body enlarged, with yellow cheesy mate- rial towards their centres; lungs infil- trated with black pig- ment; spleen greatly enlarged.

Post-Mortem Examination.						
Reporter and Reference.	Sex and Age.	Previous History, and Duration of illness.	Symptoms.	Colour of Skin.	State of Supra-Renal Capsules.	State of other Organs.
172. Prof. Dr. TRAUBE, Berlin, Wiener Med. Wochenschrift, 1860, p. 699.	Male, 43, labourer.	Always healthy un- til two months before death.	Cough, emaciation, ob- stinate diarrhoea; pulse high, skin hot, tongue dry, thirst, loss of appetite; restlessness, wandering at nights, slight albumi- nuria.	Peculiar dark colour of skin, more striking after death; extensive desqua- mation of cuticle.	Medullary substance of right capsule softened; left capsule studded throughout with large yellow cheesy masses, so that little remained of normal structure.	Acute tubercular in- filtration of paren- chyma of lungs; two apoplectic patches in lower lobe of right lung; tubercle of intestines; spleen en- larged; nutmeg li- ver.
173. Dr. GREENHOW, Path. Trans., vol. xvii. Dr. H. THOMPSON.	Male, 55, labourer.	Strong and hearty until last illness.	First, loss of strength, then breathlessness on exertion and nausea. In hospital, retching and vomiting, pains in loins and epigastrium, cramps in legs and abdomen, loss of appetite, prostration. Signs of pulmonary and heart affections; restless- ness, wandering of mind, death from sinking.	General surface had a faint brownish tinge; penis and scrotum almost black, as were likewise some cic- trices of old injuries, except the deepest parts, which remained pale; purplish stains on tongue; distinct brownish stains on lips and buccal mucous mem- brane.	Both enlarged and nodu- lated; right much the largest; fibrous envelopes thickened and right one adherent to diaphragm; no traces of cortex or me- dulla; the whole of both organs converted into ma- terial, which, to the naked eye, had precisely the ap- pearance of tubercle.	Yellow cheesy de- posits in apices of both lungs, surround- ed by dark consoli- dated tissue; diaph- ragm, mesentery, and peritoneum in front of spine studded with patches of grey tu- bercle; recent peri- carditis; lungs at- tached to ribs by fi- brous adhesions.
174. Dr. J. OGLE,	Female, 14.	None given.	Rapid phthisis, with signs of diseased kidney	Quite natural.	Both much thickened and shewing only a small	Lungs phthisical; left kidney, and inner

T A B L E M.

CASES OF ADDISON'S DISEASE, COMPLICATED WITH PHTHISIS.

Reporter and Reference.	Sex and Age.	Previous History, and Duration of Illness.	Symptoms.	Colour of Skin.	Post-Mortem Examination.	
					State of Supra-Renal Capsules.	State of other Organs.
Path. Trans., vol. viii., p. 330, 1856.			and bladder.		portion of natural tissue, the remaining parts being the seat of a firm yellowish-white deposit, resembling crude scrofulous matter. Under microscope, deposit shewed large numbers of ill-defined non-nucleated cell-structures, interspersed amidst granular and fatty matter.	surface of bladder, near its base, the seats of softened, broken-down scrofulous material.
175. Dr. J. W. OGLE, Path. Trans., vol. viii., p. 332.	Male, 36.	None given.	Those of phthisis.	Case stated as one of "No bronzing," but skin of face described as "dusky," evidently from venous congestion.	Right capsule very large and adherent to kidney and liver; investing membrane much thickened and whole gland seat of scrofulous deposit softened and broken down into pus-like fluid at posterior part; left capsule healthy.	Lungs emphysematous, and the seat of scrofulous deposit.
176. M. VIRCHOW, Canstatt's Jahresbericht, 1859, part iv., p. 288. M. SCHMIDT, Rotterdam.	Male, 48, labourer.	Had been in prison, and sickened there.	Emaciation, dry and scaly skin, fever, diarrhoea. Death with all the symptoms of phthisis.	Face dusky-brown.	Both tuberculous, especially the left, which presented scarcely any healthy tissue.	Extensive tubercle of lungs, bowels, spleen, and mesenteric glands.

Reporter and Reference.	Sex and Age.	Previous History, and Duration of Illness.	Symptoms.	Colour of Skin.	Post-Mortem Examination.	
					State of Supra-Renal Capsules.	State of other Organs.
177. Dr. G. HARLEY, Path. Trans., vol. ix., p. 410.	Male, 35.	None given.	None reported except that there was acute phthisis.	No bronzing of skin.	Both much enlarged, firm, and on section presenting the appearance of crude tubercle; no trace of normal structure. Under microscope, traces of the characteristic colunar cell-masses could be detected.	Miliary tubercularization of lungs.
178. Dr. KIRKES, Med. Gazette, vol. xxxv., p. 35.	Male, 21.	None given. Severe illness ten weeks.	Cough, night-sweats, emaciation, and great irritability of bowels.	A peculiar yellow sallow tint as if sun-burnt. The change in hue of skin was obvious and striking. (N.B.—Case occurred some years before the publication of Addison's work.)	Right capsule enlarged and occupied by firm, cheesy deposit, surrounded by a hard whitish capsule-like tissue. Left capsule in a similar state, but matter softer and in parts quite puriform.	Tubercular disease of both lungs; ulceration of large intestine.
179. Dr. EDWARDS, Med. Gazette, vol. xxxvi., p. 350.	Male, 48, tailor.	Phthisical for the last three years; tumour to right of sternum.	Emaciation and debility; cough and dyspnoea; impaired appetite and occasional vomiting after food.	Bronzing of face, becoming more marked as disease advanced. No discoloration elsewhere.	Both soft in texture; in right capsule three-fourths of normal structure replaced by an opaque-grey fibrinous mass. No deposit in left capsule.	Lungs tubercular; a few old deposits on mitral valve; a few tubercular deposits on surface of left kidney.
180. Dr. KIRKES, Med. Gazette, vol. xxxv., p. 35.	Male, 47.	None given.	The usual symptoms of phthisis with irritable bowels and foetid breath.	No bronzing noticed. (N.B.—Case occurred some years before the publication of Addison's work.)	Left capsule enlarged and containing some masses of opaque-yellow substance resembling tubercle. Right capsule not examined.	Tubercular disease of larynx, trachea, lungs, and intestines.

Reporter and Reference.	Sex and Age.	Previous History, and Duration of Illness.	Symptoms.	Colour of Skin.	Post-Mortem Examination.	
					State of Supra-Renal Capsules.	State of other Organs.
181. Dr. CHRISTIE, Med. Gazette, vol. xxxiv., p. 347.	Female, 36.	Good health until last illness. Duration, six months.	Cough and expectoration followed by pain in head and lumbar region; right side of face semi-paralyzed; pulse feeble. Died comatose. Chronic phthisis. Progressive debility.	A dark mahogany colour all over body and legs.	Both enlarged and containing a series of cysts filled with a thin serous fluid with small floating flocculi. Very little cortical substance remaining. Right capsule nearly one mass of tubercular deposit, weighing 3 drachms; left in same state, weighing 7½ drachms.	Phthisis in both lungs.
182. Mr. HARRINSON, Brit. Med. Jour. 1860, p. 959.	Male, 35, baker.	Never strong; had had pleurisy and glandular affections. Discoloration three years; laid up four months.	Chronic phthisis. Progressive debility.	Discoloration began on forehead and spread over body.	Both enlarged and wholly converted into masses of yellow friable substance, embedded in firmer white albuminous material.	Lungs tubercular; mesenteric glands enlarged; right kidney contained a scrofulous abscess. Lungs studded with tubercles, which were softening in the apices.
183. Dr. WILKS, Guy's Hospital Reports, vol. viii., p. 60. Mr. HARRIS, of Hackney.	Male, 46, painter and glazier.	None given. Discoloration said to have been two years; known illness, six months.	Cough and night-sweats followed by loss of appetite, debility and sickness. A month before death, hæmoptysis. Last days, constant vomiting.	Skin deep bronze colour, hands and face darkest.	Both enlarged and filled with apparently tubercular matter.	Lungs thickly studded with tubercles, and cavities in both apices; liver enlarged, and slightly cirrhotic.
184. Dr. BRITAN, Brit. Med. Jour. 1858, p. 107.	Male, 31, boiler- maker.	None given.	Those of phthisis and disease of liver.	Skin covered with purpurous patches, but no bronze discoloration.	Both contained extensive deposits of crude tubercle, which, however, had not entirely obliterated their natural structure.	Cartilage of knee-joint ulcerated; strumous abscess in left kidney.
185. Mr. T. HOLMES, Path. Trans., vol. ix., p. 414.	Not stated.	None given.	None recorded, except phthisis and pneumonia.	Small roundish blotches of a dark brown hue, affecting epithelium only. (Committee of Pathological Society report that in some parts the lower layers		

Reporter and Reference.	Sex and Age.	Previous History, and Duration of Illness.	Symptoms.	Colour of Skin.	Post-Mortem Examination.	
					State of Supra-Renal Capsules.	State of other Organs.
186. Dr. L. MARTINEAU "De la Maladie d'Addison," p. 70. M. WORMS.	Male.	None given.	Nothing reported, but death from pulmonary consumption.	of epidermis contained brownish pigment.) No bronze discoloration of skin.	Both much enlarged and hard; enveloping tissue thickened; on section seen to be converted into a cheesy substance, divisible into separate masses, which were softened at their centres into yellow and creamy pus.	Nothing reported.
187. Dr. Addison "On Disease of the Supra-Renal Capsules," p. 9.	Male, 32, baker.	Cough for three years. Discoloration nearly three years.	Loss of flesh and excessive weakness; soreness of chest about the scrobiculus cordis; voice puerile and whole demeanour childish.	Whole skin of dark hue resembling coloured races; palms of hands and soles of feet lightest, scrotum and penis darkest; conjunctivæ pearly white.	Both diseased and as hard as stones; left about the size of a hen's egg, with head of pancreas firmly tied down to it by adhesions.	Lungs universally adherent; pneumonia in right lung, but no tubercles; pericardium distended with dark-brown fluid; recent lymph effused over whole serous surface.

T A B L E N.

CASES OF ADDISON'S DISEASE, WITH NON-TUBERCULAR COMPLICATIONS.

Reporter and Reference.	Sex and Age.	Previous History, and Duration of Illness.	Symptoms.	Colour of Skin.	Post-Mortem Examination.	
					State of Supra-Renal Capsules.	State of other Organs.
188. Dr. HALDANE, Edin. Med. Jour., vol. viii., p. 1036.	Male.	Unknown; found dead.	None known. Death from rupture of the aorta.	No discoloration of skin.	Left capsule, enlarged, lobulated, and converted into putty-like material, contained within a firm cyst; no trace of normal structure; right capsule healthy.	Communication be- tween aorta and peri- cardium.
189. Mr. J. HUTCHINSON, Med. Gazette, vol. xxxiii., p. 233. Dr. F. FARRE.	Male, 37, licensed victual- ler.	Had been intempe- rate. Illness at least one year.	Pain in lumbar region; pain and swelling in shoulder-joints; severe rigors; low typhoid state, with muttering delirium; death from delirium tre- mens.	A yellowish-brown tinge.	Both capsules consisted of collections of matter, surrounded by thin layers of healthy structure.	Body well nourish- ed; circumscribed abscess, size of or- ange, in right lobe of liver.
190. Mr. N. F. DAVEY, Med. Gazette, vol. xxxix., p. 30.	Female, 18.	None reported. Du- ration of illness un- known.	None reported. Con- fined two days before death.	No discoloration.	Left capsule large, dark- grey, and containing soft, reddish-brown matter mixed with yellowish cheesy masses; right capsule very small, pink, semi-transparent and ge- latinous.	Fluid in pericar- dium and pleuræ; lungs cedematous; heart, liver, and kid- neys enlarged and fatty.
191. Dr. BARRAN, Brit. Med. Jour. 1858, p. 107.	Male, 19, lath- render.	Hæmaturia in early life; last illness about a year.	Debility, headaches, con- stant vomiting; tender- ness at epigastrium; albu- minuria; day before death, hæmoptysis.	Body of natural colour.	Both enlarged and filled with tubercular-looking deposit.	Effusion of blood under arachnoid; bronchi filled with bloody froth; sto- mach spotted with ex- travasation; Bright's disease.

Reporter and Reference.	Sex and Age.	Previous History, and Duration of Illness.	Symptoms.	Colour of Skin.	Post-Mortem Examination.	
					State of Supra-Renal Capsules.	State of other Organs.
192. Dr. STURGES, St. George's Hosp., Lancet, 1864, vol. ii., p. 569.	Male, 32, coaster- monger.	None given. Ill- ness above three months.	Loss of strength and appetite, thirst. Towards close of life uncontrollable vomiting; consciousness to the last.	Skin generally bronzed; areolæ round nipples dark; scrotum and penis very dark; colour deepened from day to day in Hospi- tal.	Both enlarged and occu- pied by tubercular-look- ing deposit.	Much sub-cutaneous fat; hydatid cyst con- nected with liver.
193. Dr. J. W. OGLE, Path. Trans., vol. ix., p. 407.	Male, 62.	None given.	Fits; hemiplegia of right side; coma alter- nating with delirium.	No discoloration of skin.	Enlarged, hard, nodula- ted, and firmly adherent; no distinction between cortex and medulla; subs- tance of a uniform charac- ter and yellow colour. Under microscope exten- sive fatty deposit, and much opaque fibroid ma- terial, obscuring the natu- ral tissue which existed in a shrunken condition.	Softening of left cerebral hemisphere. Extensive disease of kidneys.
194. Dr. ROWE, Med. Gaz., vol. xxxiii., p. 190, 1855.	Male, 20.	Always delicate. Illness, at least eight months.	Last days of life, frequent epileptic fits; diarrhœa; incessant vomiting; de- lirium; semi-comatose state; disgusting odour from breath and skin.	General brown tint with a few darker patches, and very small dark well-de- fined spots on face. After death, skin darkest over stomach, axillæ, backs of hands and neck; scrotum quite black.	Both atrophied, consist- ing of a cheesy, gritty, semi-purulent deposit.	Body plump, thick layer of fat under in- tegments; brain, pale and soft; large loose fibrinous clot, extending into left pulmonary artery.

Reporter and Reference.	Sex and Age.	Previous History, and Duration of Illness.	Symptoms.	Colour of Skin.	Post-Mortem Examination.	
					State of Supra-Renal Capsules.	State of other Organs.
195. Dr. SYMONDS ROOTES, Med. Gaz., vol. xxxiii., p. 581, 1855.	Male, 54, solicitor.	Diseased hip-joint in early life; concussion of brain a year before death, never well afterwards. Bronzing, six months.	Weariness, languor, debility, vomiting; no loss of appetite. Last month, short fits of unconscious- ness with convulsive move- ments of left side; delirium passing into coma, day before death.	Generally of a dirty yellow hue; face and hands became gradually the colour of stains of walnut-juice; conjunctivæ normal; discoloration equally striking after death.	Both considerably en- larged, of firm consistence, and on section presenting an appearance closely re- sembling a tuberculated gland.	Head, not examined; spleen enlarged and soft; other organs healthy; abundance of deep yellow fat be- neath skin and in omentum; muscles of a peculiar deep red colour.
196. Dr. J. ERICHSEN, St. Petersburg, Brit. Med. Jour., 1864, vol. i., p. 41.	Female, 21.	In good health until thirteen years of age. Severe scarlatina at fourteen. Discolora- tion, seven years; ill- ness, three or four years.	Indefinable malaise; in- creasing bodily and men- tal hebetude; frequent vomiting. Latterly great loss of power and in last hours, syncope, convul- sions, delirium, and wide dilatation of pupils.	Skin of an uniform bronze colour deepest at the joints; pigment deposited in Malpighian network.	Both greatly enlarged, lobulated and surrounded by thick capsules, through which calcareous concre- tions were scattered; in- terior filled with a cheesy yellowish mass, mixed with calcareous granules and crystals of choleste- rine. No trace of normal structure.	Brain, lungs liver, and spleen appear all to have been more or less affected by chronic disease.

DR. GREENHOW.

17th of April, 1866.

37



✓



