with Dr Paterson Compl

(9)

CASE

OF

CONGENITAL LYMPHATIC VARIX.

By ROBERT PATERSON, M.D., F.R.C.P.E., etc., Leith.

(*Reprinted from the Edinburgh Medical Journal for May* 1871.)

The subject of this short notice, and of the annexed woodcut, taken from a photograph, and produced on wood by Mr Williamson of Melbourne Place, gives a faithful representation of this rare and unusual variety of diseased structure.

The child was that of a labouring man, residing in Giles Street, Leith. His wife was attended in her confinement by a midwife, and I was only asked to see the infant the day after birth, in consequence of the peculiar appearance which the right leg exhibited.

I found that the child was a female, not strong, weighing, in all probability, between six and seven pounds, and in every other respect having a healthy appearance, with the exception of the right leg. This limb was at least twice the size of the left one, had a slight purple tint all over, with here and there, on the most prominent parts, a bluish tinge. The whole limb, from Poupart's ligament in front, and round by the crest of the ilium behind, down to the toes of the foot, was one mass of twisted and contorted varices. The general appearance which the limb exhibited may be likened to that of a very bad case of varicose veins of the leg in an adult, only the vermicular prominences rolled, as it were, round and round the leg in a singular manner. This has been well represented in the woodcut. The child had the perfect use of the limb, but did not move it much unless it was handled, which was obviously painful to it; it was surrounded with cotton wadding, and put into an easy position. The child suckled well, and so long as the limb was at rest, the child seemed free from pain. On examining the limb next day, there was little or no change in its appearance externally. The cotton that had been applied the previous day was saturated with moisture; and it may be remarked that this transpiration from the limb continued throughout the life of this little child; indeed,

the quantity of fluid that must have passed out of its system in this way readily accounts for the rapidly-increasing weakness which day after day manifested itself.

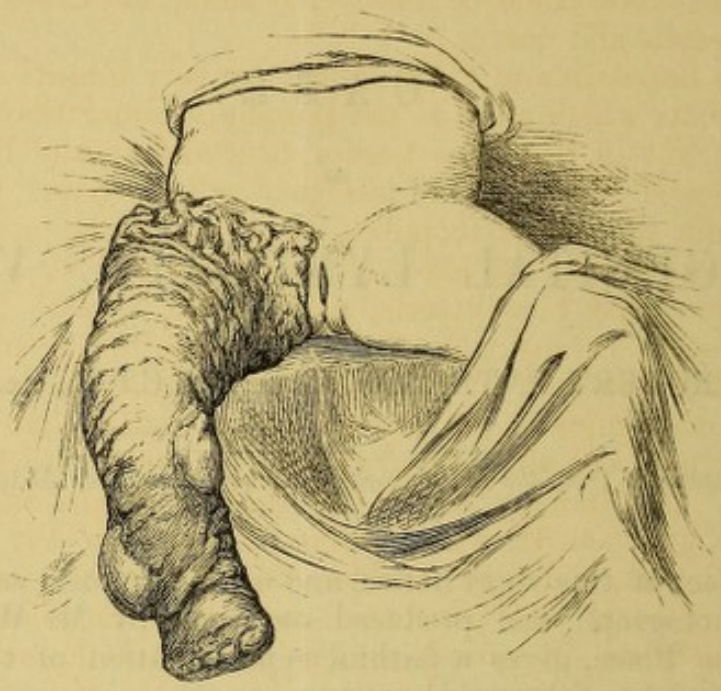

Although suckling well and sleeping calmly, it gradually became weaker; the abundant transpiration from the limb never diminishing. All the other functions were conducted naturally. Little or no change took place in the general appearance of the limb for some days, its colour and general appearance being as I have described it; about the fifth day, however, large blebs made their appearance on each side of the ankle; and next day these increased much in size, especially the one over the outer ankle. The colour, too, of the whole limb became darker, and the child's system was obviously becoming much enfeebled. The photograph was taken next day, being the seventh day of the child's existence; and without any further change worth recording, it gradually became weaker, and died on the morning of the ninth day after its birth.

The limb was carefully examined next day. The varicose prominences all proved to be enlarged lymphatic vessels, filled to distention with a milky serous fluid. From their abrupt beginning in front, exactly on a line with Poupart's ligament, and enclosing the buttock behind, from the crest of the ilium downwards, these twisted and corded lymphatic vessels presented a very peculiar appearance. As the diseased structure passed down the limb, these vessels became, as it were, rolled together, especially at the lower part of thigh and knee-joint, and further down became spread out around the leg and foot, as is well represented in the woodcut. Around the crest of the ilium behind, but especially along the course of Pou-

part's ligament in front, the tissues were all much condensed, reminding one of tight bands stretched across. There was no appearance of glandular or other structures. The muscles, glands, bloodvessels, etc., beneath, all seemed natural, and no distended lymphatic vessel could be discovered along the course of the deep-seated vessels and nerves.

It was impossible to trace, unless by very minute dissection, the impediments which arose to the lymphatic circulation over the right buttock; but in front the tissues, over and around Poupart's ligament, seemed like a mass of hardened cellular tissue, tightly strung across from iliac crest to pubes, and without the appearance of a gland or other vessel to allow circulation of any kind to take place. The deep-seated bloodvessels, nerves, etc., beneath this ligament, did not seem in any way affected; indeed, the peculiarity of this case, which appeared at the time most striking, was the want of anastomotic connexion between the external and internal lymphatics.

I have not been able to find any case on record exactly resembling this one. Rokitansky, in his "Pathological Anatomy," gives the case of a nun, æt. 62, who exhibited œdema of the subcutaneous cellular tissues, and very considerable effusion of a milk-like fluid in both pleural and peritoneal cavities, with dilatations in the lymphatic vessels in various regions and in the thoracic duct.

Dr Grainger Stewart also describes a case of a man, æt. 60, in whom appearances of a somewhat similar kind were found; and probably cases, even more allied than those of Rokitansky and Stewart, may be found in the works of Baillie, Cruveilhier, Hassi, Amussat, and others. They all, however, differ in almost every essential particular from the case we have just recorded, in so far that the dilated lymphatic vessels of this case appeared on the surface of the extremity, and could not be traced in any way as connected with any lesion of the bloodvessels or absorbent system of the deeper-seated organs; in fact, the case seemed to turn upon the point whether or not there was sufficient anastomosis between the external and internal system of absorbents. I now regret much that the thoracic duct and other organs within the abdomen were not examined.

EDINBURGH: PRINTED BY OLIVER AND BOYD.