

Case of aneurysm of the ascending aorta pressing upon the base of the right ventricle and opening into the origin of the pulmonary artery : with remarks on the communications of the sacs of aneurysms with the cardiac cavities and adjacent vessels / by Thomas B. Peacock, M.D.

Contributors

Peacock, Thomas B. 1812-1882.
University of Glasgow. Library

Publication/Creation

London : [Printed by J. Roche], 1868.

Persistent URL

<https://wellcomecollection.org/works/zwnce9fx>

Provider

University of Glasgow

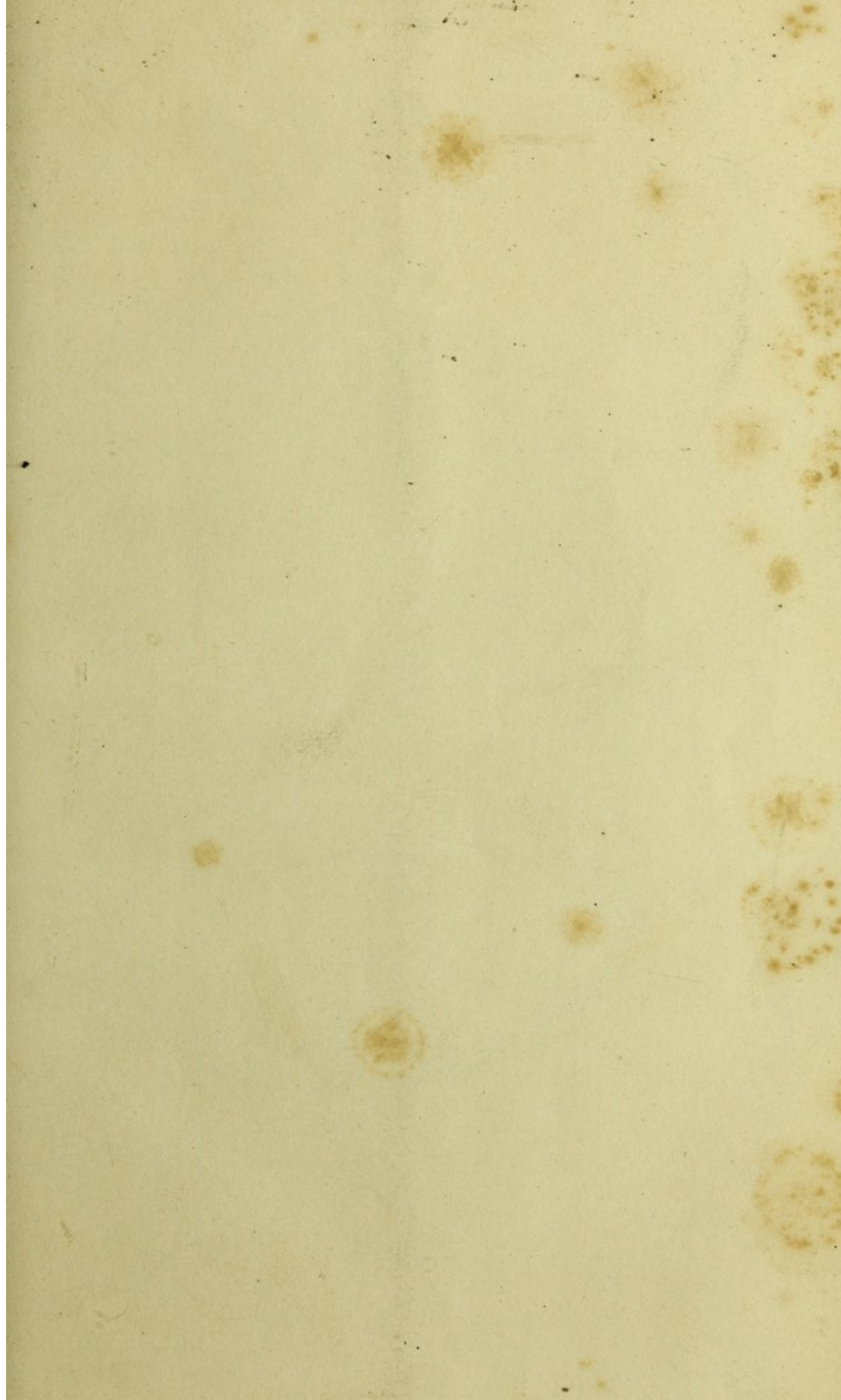
License and attribution

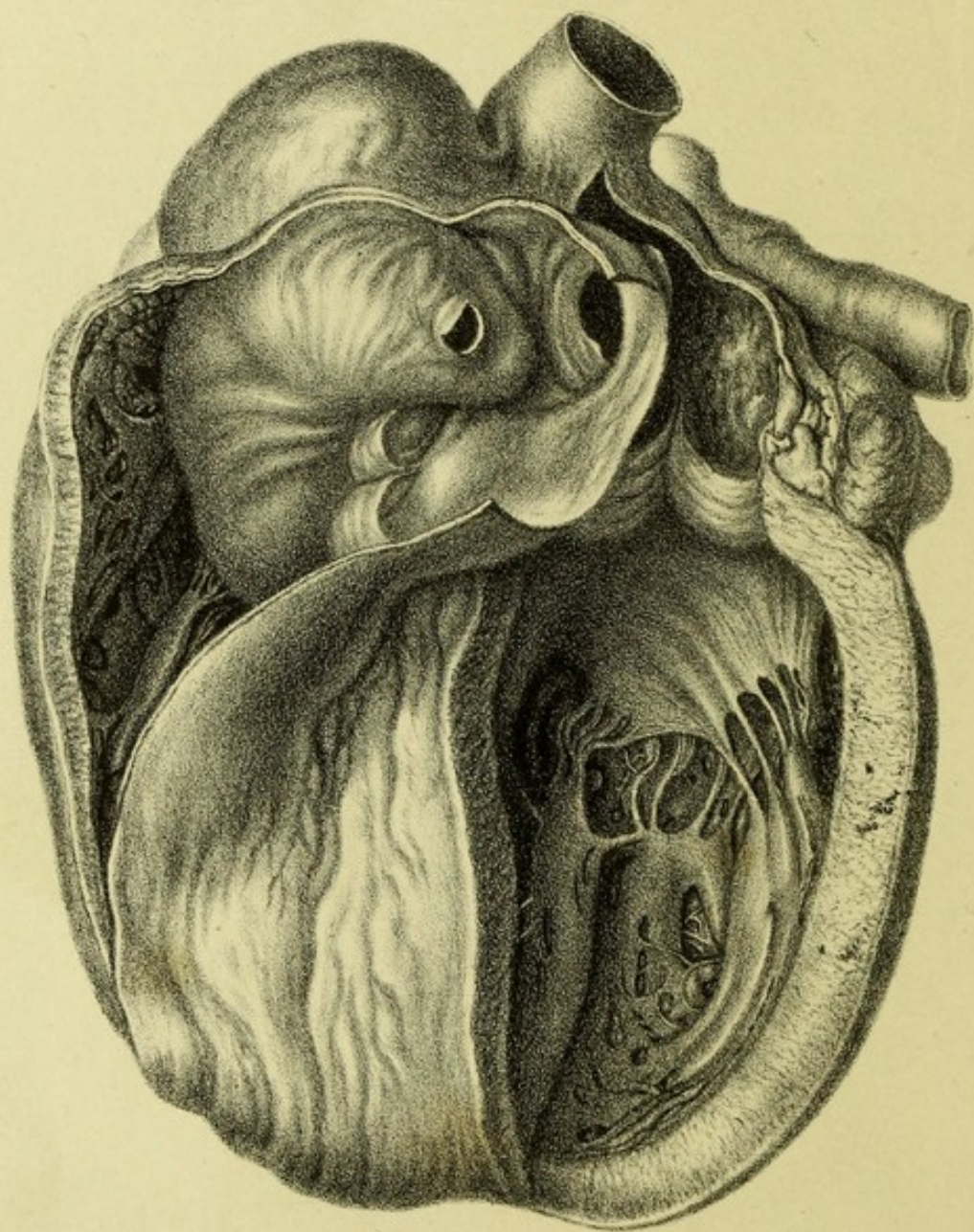
This material has been provided by This material has been provided by The University of Glasgow Library. The original may be consulted at The University of Glasgow Library. where the originals may be consulted. This work has been identified as being free of known restrictions under copyright law, including all related and neighbouring rights and is being made available under the Creative Commons, Public Domain Mark.

You can copy, modify, distribute and perform the work, even for commercial purposes, without asking permission.



Wellcome Collection
183 Euston Road
London NW1 2BE UK
T +44 (0)20 7611 8722
E library@wellcomecollection.org
<https://wellcomecollection.org>





18

CASE OF ANEURYSM

OF THE

ASCENDING AORTA

PRESSING UPON THE BASE OF THE RIGHT VENTRICLE AND OPENING INTO
THE ORIGIN OF THE PULMONARY ARTERY;
WITH REMARKS ON THE COMMUNICATIONS OF THE SACS OF
ANEURYSMS WITH THE CARDIAC CAVITIES
AND ADJACENT VESSELS.

BY THOMAS B. PEACOCK, M.D., F.R.C.P.,

PHYSICIAN TO ST. THOMAS'S HOSPITAL AND THE VICTORIA PARK HOSPITAL FOR
DISEASES OF THE CHEST,

LONDON:

PRINTED BY J. ROCHE, PARADISE STREET, ROTHERHITHE,

1868.

CASE OF ANEURYSM

ASSIGNING AORTA

THE CASE OF ANEURYSM OF THE AORTA, WITH A REPORT OF THE PATHOLOGICAL AND ANATOMICAL FINDINGS, BY THOMAS B. LEITCH, M.D.

BY THOMAS B. LEITCH, M.D.

PHYSICIAN IN CHARGE OF THE DISPENSARY, AND LATELY OF THE HOSPITAL, NEW-YORK.

NEW-YORK: PUBLISHED BY A. LEITCH, 100 NASSAU ST. 1855.

Aneurysm of the ascending aorta pressing upon the base of the right ventricle and opening into the origin of the pulmonary artery; with remarks on the communications of the sacs of aneurysms with the cardiac cavities and adjacent vessels.

CASE.—W. S., aged 26, was admitted into St. Thomas's Hospital on the 11th of October, 1867. He was of a healthy family, and had enjoyed good health till he had an attack of rheumatic fever four years before. He recovered from this, and continued well till within five weeks of his admission. He stated that he first suffered from pain in the abdomen, especially in the epigastrium and right hypochondrium, followed by shortness of breathing and a dry cough; and about a month after his stomach began to swell, and subsequently the lower extremities became oedematous. When admitted, his cheeks were flushed, the lips livid, the tongue clean, but morbidly red, and the pulse sharp and of a somewhat regurgitant character. The respirations were short and abrupt. There was nothing materially amiss with the lungs, except that the respiratory sounds were harsh, and that there was some rather fine crepitation at the lower part of the right side. The præcordial dull space commenced at the level of the second cartilage and became entire at the third, and extended from the right side of the sternum to within a finger's breadth of the line of the left nipple. The apex of the heart apparently beat in the fifth interspace below the nipple. The external jugular vein on the right side was distended, and the carotids pulsated visibly. Over the whole præcordia there was a systolic murmur, which was most distinct at the level of the fourth cartilage, and was there followed by a ringing second sound. To the right of the upper part of the sternum the murmur was distinctly heard, but was not there very loud, and the second sound was followed by a slight murmur. At the lower part of the præcordial region the systolic murmur was heard, but that with the second sound was inaudible; neither murmur could be heard in the left dorsal region. The liver was considerably enlarged and tender to the touch. There was general anasarca and some ascites. The urine was not albuminous. He died on the 28th of November.

The *post-mortem* examination took place on the following morning.

The lungs, especially the right, were much congested. The liver was enlarged and mottled, and weighed four pounds twelve ounces avoirdupois. The kidneys were pale, and apparently healthy. The spleen was healthy, and weighed three ounces and a half. The pericardium was extensively attached by old, but not very firm, adhesions. The heart was greatly enlarged, and weighed twenty-eight ounces. The aortic valves were all somewhat opaque and thick, and the left fold was much thickened and contracted, so as to allow of free regurgitation. Immediately above the angle of attachment of the right and left folds there was an expansion of the coats of the aorta, involving a considerable portion of the front and right side of that vessel, so as to constitute an aneurysmal sac fully the size of a large hen's egg. This protruded into the cavity of the pericardium above, and into the upper part of the infundibular portion of the right ventricle and origin of the pulmonary artery below, so as greatly to obstruct the passage. (See Plate VI.) The portion of the aneurysm which projected into the ventricle involved the pulmonary valves, one of which was completely destroyed and another partially so, the third being entire. At the level of the pulmonic orifice there was an oval opening from the sac of the aneurysm into the ventricle, which had thin and smooth edges as if produced by the gradual expansion and thinning of the coats. It was of small size, about two lines wide and four long. Below this and on the most prominent portion of the aneurysm where projecting into the right ventricle, there was a patch of fibrine, about a line in thickness and of the size of the middle finger-nail, and on the endocardium on the opposite side of the ventricle there was a corresponding patch; it was evident from the smooth and polished surfaces of the two that they had rubbed together during the ventricular systole. The lower edge of the opening from the aorta into the aneurysm formed a distinct projection; the inner surface of the sac was rough and irregular; and the coats were in places atheromatous and very thin, both where projecting into the pericardium and into the ventricle. The cavity contained only recent coagula. The left ventricle was greatly enlarged, and was pointed at the apex; its walls were considerably increased in width, and the muscular substance was firm. The mitral valves were somewhat thick and opaque. The left auricle was large; the right auricle and ventricle were dilated; and the walls of the ventricle were thick and firm and had in places undergone the fibro-cartilaginous transformation. Much coagulum was contained in the cavities on both sides.

The dimensions of the heart were as follows:—

Girth of the right ventricle	-	-	81	Paris lines	=	182.25	m.m.	or	7.18	inches.
„ left	„	-	66	„	=	148.5	„	=	5.86	„
Thickness of walls of right ven. base	3	„			=	6.75	„	=	2.66	„
„ „ midpoint	3.5	„			=	7.87	„	=	.31	„
„ „ apex	-	1.5	„		=	3.37	„	=	1.33	„
„ „ left ven. base	5	„			=	11.25	„	=	4.44	„
„ „ midpoint	7	„			=	15.75	„	=	6.21	„
„ „ apex	-	3.5	„		=	7.87	„	=	3.1	„
Length of right ventricle	-	-	59	„	=	132.75	„	=	5.23	„
„ left	„	-	35	„	=	78.75	„	=	3.1	„
Right aur. vent. ap. ad. ball No. 19	66	„			=	148.5	„	=	5.86	„
Left „ „ „	15	54	„		=	121.5	„	=	4.79	„
Pulmonic „ „ „	10	39	„		=	87.75	„	=	3.46	„
Aortic „ „ „	11	42	„		=	94.5	„	=	3.72	„

This case presents several points of interest in reference both to diagnosis and pathology.

The physical signs which were observed during life indicated the existence of obstructive and regurgitant disease of the aortic valves; but there was more evidence of interference with the circulation on the right side, in the amount of anasarca and the turgescence of the jugular veins, than ordinarily attends simple aortic valvular disease. For this at the time no satisfactory reason could be given, but after death it was fully explained by the presence of the aneurysmal sac which was found to press on the pulmonic orifice. The examination after death proved that the diagnosis was correct so far as the state of the aortic valves was concerned; but that there were other diseased conditions which had not been detected during life and which explain the peculiarities that were then not accounted for. It will be observed that there was a loud diastolic sound heard to the left of the sternum, about the level of the fourth cartilage, and this was supposed to be due to secondary dilatation of the pulmonary artery and consequent more powerful reaction on the valves. The examination after death showed, however, that the pulmonic orifice, so far from being increased in size, was, on the contrary, obstructed; and it must be concluded that the loud sound heard was caused by the sudden tension of the walls of the aneurysm during the ventricular diastole. The murmur which followed the second sound was ascribed, during life, to the aortic valves being only slightly incompetent; it was supposed that they might admit of being properly brought together, but that after approximation one of the segments might permit retroversion and consequent regurgitation. With the results of the *post-mortem*

examination before us, the correctness of this inference may, however, be open to doubt, and it may be supposed that the murmur was rather due to the escape of blood from the aneurysmal sac by the opening into the pulmonic orifice. I am, however, not disposed to adopt that supposition, but rather to maintain my original view. Indeed, it seems most probable that the communication between the aneurysmal sac and pulmonary artery and right ventricle only occurred shortly before death, and was in no degree connected with the auscultatory signs which had been observed during life. Had the opening been of long duration, it could scarcely have retained the thin transparent edges without any thickening or fibrinous deposit upon them.

2. The alteration in the form, size, and weight of the heart were such as generally occur in cases of aortic valvular and aortic disease of some duration, with, however, a greater degree of increase in the right side than generally obtains in such cases. The organ was altogether much enlarged; and the chief stress of the disease having, as usual, fallen on the left ventricle, that cavity was much expanded, and especially was elongated and pointed at the apex; its walls were greatly increased in thickness, and the muscular structure was both firm and resistant. The left auricle and the right cavities were dilated, and the walls of the right ventricle hypertrophied—the hypertrophy of that cavity being doubtless greater from the obstruction to the exit of the blood from the right ventricle, caused by the pressure of the aneurysmal sac. All the apertures, except the pulmonic, were also, as in cases where there is general enlargement, increased in capacity. The heart was nearly three times its natural weight.

REMARKS ON THE COMMUNICATION OF THE SACS OF ANEURYSMS WITH THE CARDIAC CAVITIES, OR ADJACENT VESSELS.

The earliest case, so far as I am aware, in which an aneurysm has been found to open into any of the cavities of the heart, or the vessels entering or passing from the organ, is one related by M. Beauchene in 1811,* the seat of communication being in that instance the left auricle. In 1812, Dr. Wells recorded a case, which had been seen during

* In the *Bulletin de la Fac. de Méd. de Paris*, Tom. II., 1809 to 1812, No. 5, 1812, p. 128, a case of aneurysm of the aorta, which occurred to M. Sue, is related by MM. Payne and Zink. The aneurysm is described as "s'ouvrant" into the pulmonary artery, but it appears only to have projected into the vessel, not to have opened into it.

life by Dr. Baillie, in which an aneurysm burst into the pulmonary artery. In 1832, an instance of rupture of the sac of an aneurysm into the vena cava superior was noticed in the *Lancet*; and in 1838, Mr. Curling related a case of communication with the right auricle. A second instance of opening into the pulmonary artery occurred to Dr. Munro, in 1839; and in 1840, Dr. Reid reported four cases—one in which the aneurysm opened into the right auricle, two which ruptured into the pulmonary artery, and a fourth of communication between the descending aorta and the left pulmonary branch. In the same year, Dr. Thurnam illustrated the pathology of cases of this description in an able and original memoir, published in the *Medico-Chirurgical Transactions*. In this paper he collected the particulars of ten cases, including those before referred to, and one which had occurred at the Westminster Hospital in the practice of Dr. Roe, and which had been under his own observation;* and referred to the existence of six other specimens preserved in different museums. Since that time, various instances of aneurysm opening into the cardiac cavities or adjacent vessels have been placed on record in this country, or on the Continent. I have myself had the opportunity of seeing two recent cases besides that reported in this communication. Of these, one occurred in the practice of Dr. Henderson, at the Royal Infirmary of Edinburgh, in which the aneurysm opened into the right ventricle. In the other, which fell under my own notice at the Chester Infirmary, the sac opened into the appendage of the right auricle. In the appendix to this paper will be found references to, and brief abstracts of, thirty-three cases which I have found recorded in different periodicals; so that, together with the six specimens mentioned by Dr. Thurnam, as contained in the museums of the Royal College of Surgeons, St. Bartholomew's Hospital, and the Faculty of Medicine of Paris; and four cases described by Rokitsansky, in which, though communications had existed, they had become closed, the recorded cases cannot at the present time be less than forty-three in number. It is, indeed, highly probable that with leisure to search the contents of museums and the literature of this and other countries, the number might be considerably increased. Of the cases referred to, three, those related by Dr.

* In the abstract of this case, contained in the table in the appendix, I have supplied from notes kindly furnished to me by Dr. Thurnam, a much fuller report than has hitherto been published.

Ogle, Dr. Lichtenberg, and Dr. Moxon, are published in our own *Transactions*.

The cases collected may be classed in four groups, according to the portion of the aorta from which the aneurysms arose.

1st. Those in which the sac is situated at the origin of the aorta, in the sinuses of Valsalva or immediately above the points of attachment of the valves. This group embraces the largest number of cases, including eighteen of the thirty-two collected.

2ndly. Those in which the sac occupies a part or the whole of the ascending portion of the arch, between the commencement of the aorta and the origin of the arteria innominata. The cases of this description also are not uncommon; they constitute twelve out of the thirty-two cases.

3rdly. Cases in which the whole of the ascending and transverse portions of the arch, with more or less of the descending aorta, are dilated. Two cases only of this kind are included in the collection. And

4thly. A solitary case, to which I shall have again to allude, in which the ascending portion of the arch was dilated, and from the upper part of the descending aorta beneath the orifice of the left subclavian artery, an infundibular shaped sac arose, which opened into the left branch of the pulmonary artery.

The aneurysms arising near the origin and from the ascending portion of the aorta most commonly occupy the right and anterior aspects of the vessel. Dr. Thurnam states, that of eighteen cases, in which there were twenty-two distinct aneurysms, which were more or less decidedly limited to the sinuses of Valsalva, and which had either pressed upon or ruptured into some portion of the heart, twelve were situated in the right, four in the left, and six in the posterior sinus. He also says that the portions of the vessel above the sinuses, and especially above the points of attachment of the valves, are even more frequent seats of aneurysm than the sinuses themselves.

In the more recently reported cases, it is rare that the descriptions are so precise as to enable a similar comparison to be instituted; but of seven cases which are either fully described or in which I have had the opportunity of personally examining the specimens, in five the aneurysm occupied the right, and in two the posterior sinus; and in six cases in which the sac arose above the points of attachment of the valves, in three it was above the angles of the right and left valves, and in three above the right and posterior valves.

The *size of the aneurysmal sacs* varies in some degree according to the

seat which they occupy; those originating from the sinuses and the commencing portion of the aorta being rarely so large as those which arise from a higher part of the vessel. Thus of the cases of the first group the aneurysm is said to have been in

- 1 case the size of a nut, in
- 3 of a walnut,
- 4 of a hen's egg,
- 1 of the fist, and in
- 3 of an orange.

In one case it is said to have been capable of holding an ounce and a half of blood; in one it was eighteen lines in circumference and twelve deep; and in one in which the sac was biloculate, one portion was as large as a hen's egg, the other double that size.

Of the second group of cases, the aneurysm is compared in

- 2 cases to a hen's or duck's egg,
- 2 to the fist,
- 1 to an orange, and in
- 5 cases it occupied nearly the whole, or the whole, of the ascending portion of the aorta.

In one case the sac was biloculate, one portion being as large as a hen's egg, the other as a walnut.

In the two cases of the third series, the dilatation is said to have been considerable; and in the solitary case of the fourth description the sac at its aortic extremity would admit the thumb, and at its termination in the left pulmonary branch was of the size of the carotid or subclavian artery. In several of the cases besides those mentioned, the aneurysms are stated to have been biloculate, or to have had pouches projecting from the larger cavity.

Seat of communication.—The aorta at its origin is in immediate connection with the pulmonary artery, the right ventricle, the right auriculo-ventricular aperture, and the adjacent parts of the right auricle. Higher up, it is in juxta-position with the sinuses and appendages of the auricles, and with the upper portion of the right ventricle, and especially with the pulmonary artery and its branches. At a still higher level, a large portion of the vessel is exposed in the pericardiac cavity, and the descending vena cava lies on its right side. It is, therefore, with these several parts that aneurysms arising from the different portions of the aorta especially tend to form communications. Thus, of the cases of the first group, or those in which the aneurysms were situated at the commencement of the aorta,

- 3 opened into the right auricle,

- 1 into the right auriculo-ventricular aperture,
- 3 into the right ventricle,
- 1 into the right ventricle and pulmonary artery,
- 7 into the pulmonary artery, and
- 3 into the left auricle.

Of the series of cases in which the sacs were situated in the ascending portion of the aorta,

- 6 opened into the vena cava superior,
- 1 into the right auricular appendage,
- 1 into the right ventricle,
- 1 into the right ventricle and pulmonary artery, and
- 3 into the pulmonary artery.

In one of the cases in which the whole arch was dilated, the connection was with the vena cava superior; in the other, with the pulmonary artery. In the single case of the fourth class it has already been mentioned that the supposed sac opened into the left pulmonary branch. Thus, aneurysms at the commencement of the aorta generally open into either auricle, the right ventricle, and especially the pulmonary artery; while those which arise from the ascending aorta, form connections with the vena cava superior, and less frequently with the pulmonary artery. Taking the whole of the cases into consideration, without reference to the precise portion of the aorta from which the aneurysmal sacs arise, and adding to the cases collected in the appendix the six others of which the specimens are stated by Dr. Thurnam to exist in museums, and the four described by Rokitansky, of forty-three cases, in

- 7 the aneurysms opened into the vena cava superior,
- 5 into the right auricle or auriculo-ventricular aperture,
- 4 into the right ventricle,
- 2 into the right ventricle and pulmonary artery,
- 18 into the pulmonary artery,
- 1 into the left pulmonary branch,
- 3 into the right pulmonary branch, and in
- 3 into the left auricle.

Dr. Hope has described and figured a case* in which an aneurysm, at the origin of the aorta, was supposed to have burrowed behind the attachment of the valves, and so to have opened into the cavity of the left ventricle. But, while there can be no doubt that aneurysms of

* Morbid Anatomy, Figs. 6 and 7, p. 20.

the sinuses of Valsalva do sometimes follow this course (though no instance of the kind is included in the collection), it seems more probable that the case referred to was one of aneurysm of the ventricle opening into the aorta, such a result being by no means of uncommon occurrence.*

In one of the cases described by Mr. Beck, in which the sac opened into the right ventricle, there is said to have also been a communication between the ventricles. In this case the nature of the disease is not clear. The communication between the ventricles may have been a congenital defect entirely unconnected with the aneurysm; but it is perhaps more probable that a small sac may have been formed at the base of the ventricle in connection with the diseased valves, and have opened both into the origin of the aorta and into the right ventricle. Cases of this kind frequently occur as the result both of acute and chronic valvular disease. The case in which an aneurysm originated at the upper part of the descending aorta, and opened into the left pulmonary branch, is said by the author, the late Professor Reid, of St. Andrew's, to have followed precisely the course of the ductus arteriosus in the fœtus. While admitting the possibility of its being a diseased condition of a duct which had never become obliterated, he inclined to the idea that it was an aneurysmal sac. I hesitate much to differ from any opinion expressed by Dr. Reid; I cannot however but think it more probable that the disease was of congenital origin. The peculiar infundibular shape of the sac, with its large aperture at the aortic end and its smaller opening at the pulmonic, and the fact that the remains of the duct could nowhere be found, certainly are in favour of the latter view.

In several of the cases collected, and particularly in that now related, the aneurysm projected and threatened to burst into the sac of the pericardium. This occurrence has been familiar to pathologists since the publication of the well-known case of Morgagni; and it is a result readily explained by the thinness of the external coat of the ascending aorta, and the very imperfect support which the vessel receives in that situation from the attached pericardium. I have not thought it worth while to collect cases specially to illustrate this termination. The cases

* In a case by Dr. Hanna (*Dublin Journal*, Vol. VII., p. 80, 1835), an aneurysm at the origin of the aorta projected and threatened to burst into the cavity of the left ventricle. I have also recently met with a case in which an aneurysm of one of the sinuses opened into the left ventricle.

published in the Pathological Reports may, however, be taken as affording a fair indication of the relative frequency with which the aneurysms of the commencement and ascending portion of the aorta rupture into different parts. Thus it will be found that only four cases of aneurysm rupturing into any of the cardiac cavities or vessels are reported; while there are eleven cases in which the aneurysm burst into the pericardium. This calculation does not include the cases of *dissecting aneurysm*, which are in various respects very different from common aneurysmal tumours, and, in a large proportion of cases, rupture into the pericardium. Aneurysmal sacs, which burst into the pericardium, generally originate from the ascending portion of the aorta above the sinuses, and they are usually only of small size and probably of recent origin, so that the layers of pericardium on their surfaces have not become adherent. Indeed, of the cases of aneurysm described in the *Transactions*, which ruptured into the pericardium, in all but two, one related by Dr. Cockle,* in which there was a pulsating tumour externally, the other by Dr. Little,† the sacs were comparatively of small size. On the other hand, aneurysmal tumours which originate from the ascending portion of the aorta, near its origin, do occasionally attain a very large size without rupturing into the pericardium. I may particularly refer to a case of the kind exhibited at the Society by myself, which had been sent up from Hastings by Mr. Penhall,‡ and a case which has quite recently occurred in my practice at St. Thomas's Hospital, in which a sac originating immediately above the point of attachment of the right and posterior semi-lunar valves, was certainly larger than a full-sized orange. In all such cases the layers of pericardium doubtless become adherent at a comparatively early period, and so afford additional protection to the sac, and prevent its rupture.

The mode by which the communications between aneurysmal sacs and the cavities of the heart are formed varies in different cases. In some instances they occur suddenly, and are produced by the laceration of the sac of the aneurysm and the walls of the cavity or vessel which have become intimately united; in others they result from the gradual thinning of the tissues till they ultimately give way. In the former class of cases, if the patient die shortly after the occurrence of the rupture, there is found a longer or shorter fissure, with ragged, irregular edges; in the latter, under similar circumstances, the aperture is round or oval,

* Vol. VIII. 1856-57, p. 132.

† Vol. I. 1846-47 and 47-48, p. 232.

‡ Vol. VIII. 1856-57, p. 130.

and is surrounded by very thin and smooth margins. If, however, as is frequently the case, the patient survive the occurrence for some time, the aperture becomes much altered in appearance, so that it is often impossible to decide in what way it may have been originally formed. It is then usually found to be rounded or more or less oval in shape, and its edges are thick and firm and not unfrequently studded with fibrinous vegetations. The case related by Dr. Wells, of which the preparation is now in the museum of St. Thomas's Hospital, the specimen figured by Rokitansky, two of the cases described by Dr. Reid, and that of Dr. Herapath, in all of which the aneurysm burst into the pulmonary artery; the cases of M. Beau and Dr. Moxon, in which the sacs opened into the left auricle; and those of MM. Goupil and Tripier, in which they ruptured into the vena cava superior, offered very characteristic examples of the formation of openings by laceration. On the other hand, in the case of Dr. Henderson, and that described in this paper, in which the aneurysm communicated with the pulmonary artery, and in the case at the Chester Infirmary, which opened into the appendage of the right auricle, the apertures were the result of gradual thinning and erosion.

The *size of the openings* also varies in different cases; and, in some degree, according to the mode in which they are formed; being considerably larger when due to laceration, and of smaller size when depending on erosion. In the former class of cases they are described as having been in the form of slits or fissures, from a quarter of an inch to an inch and a half long. In the latter they are oval or rounded, and correspond in size to crow or goose-quills, or lead-pencils, or peas, or to large bougies; and in one case the opening is said to have been capable of admitting the little finger. In nine or ten cases there were two or three openings between the sac and the cavity or vessel; and in some instances, as when there were communications both with the pulmonary artery and right ventricle, the openings were a considerable distance apart.

It is not always possible to ascertain the precise *duration of life* after the occurrence of the communications; for in some cases there do not appear to have been any symptoms which conclusively indicated the period at which the opening occurred; and in others the patients were only under observation during the last period of life, while the communications had probably taken place some time previously. Of cases in which the period was well ascertained, and the openings were probably the result of laceration, in

2 instances the patients died almost immediately ; in
 1 case in an hour ;
 1 „ 2 hours ;
 1 „ 4 hours ;
 1 „ 13 days ;
 1 „ 15 days ; and in
 1 „ 5 weeks.

In one case the patient is reported to have survived for a few hours ; and in another, in which there were two openings, one of them is supposed to have been formed immediately before death, the other two months previously.

Of similar cases, but where the openings are supposed to have been caused by gradual thinning and erosion, in

2 death was almost immediate ; in
 1 it occurred in 18 hours ;
 1 in 6 days ;
 1 in 8 days ;
 1 in a month ;
 1 in 7 weeks ;
 2 in 2 months ;
 1 in 4 months ;

and in one in which there were two openings, one opening is supposed to have preceded death by five months.

This shows, as would indeed be supposed, that death is more frequently immediate or rapid in cases in which the openings are the result of a sudden tear, than when it takes place more gradually from erosion.

Not only, however, does the mode in which the connection between the aneurysm and cavity is formed, affect the probable duration of life after the occurrence, but the seat which the opening occupies is also very influential in the result. Thus, of six cases in which the aneurysms communicated with the vena cava descendens, in three death occurred in from six to fifteen days from the occurrence of the openings ; while in the other three the patients survived four, five, and seven weeks. Of four cases which opened into the right auricle or auricular appendix, in one death ensued immediately, and in the others life was prolonged for thirteen days, one month, and four months. Two patients, in whom the communications were with the right ventricle, died,—in one instance probably immediately, in the other in eleven weeks. Of seven cases in which the aneurysms ruptured into

the pulmonary artery, in five the fatal event ensued almost immediately or in the course of a few hours, while two other of the patients survived two and four months. Of two patients in whom there were two openings, one into the pulmonary artery, the other into the right ventricle, the first opening preceded death in one case by two months, in the other by five. Of the two cases of rupture into the left auricle one patient died within an hour, the other within four hours of the event. It thus appears that when the communications interfere only with the venous circulation of a portion of the body, the occurrence is not attended with immediate danger, and the patients may survive for several days. When, on the contrary, the formation of the openings causes derangement of the whole venous circulation, there is great danger of the occurrence of immediate or rapid death, though the first effects may subside and the patient's life may be prolonged for some months. Lastly, when the communication is with the left auricle, there is apparently little chance of the patient's long surviving the occurrence. In the first class of cases the danger is probably chiefly due to the disturbance of the cerebral circulation; in the second to the obstruction of the whole venous system, and the consequent secondary disorder of the viscera; and in the third to the engorgement of the lungs.

History.—Symptoms. The patients who are the subjects of aneurysm of the ascending portion of the aorta, are most commonly of the male sex, and at about the middle or more advanced period of life. Not unfrequently they have been the subjects of rheumatism, and have been addicted to spirit-drinking and habits of intemperance. Most usually they present the common cardiac symptoms—dyspnoea, palpitation and tumultuous action of the heart, dropsical symptoms, and signs of engorgement of the lungs and parenchymatous viscera. These symptoms sometimes commence insidiously and advance gradually; in other cases they occur somewhat suddenly and as the result of some injury or strain. The communications between the aneurysmal sac and cardiac cavities not unfrequently appear to occur under some exertion or emotion which may have quickened and excited the circulation; and their formation is generally indicated by a remarkable aggravation of the previous symptoms, and by the occurrence of syncope. If the communication be with the vena cava superior or the adjacent part of the right ventricle, there is observed a remarkable turgescence of the veins of the chest, upper extremities, head, and neck, and the upper parts of the body and the corresponding limbs become remarkably œdematous, the œdema being, indeed, often limited to these parts. Usually, also,

symptoms of active cerebral disorder rapidly supervene. When, on the other hand, the opening is into the pulmonary artery or right ventricle, the dropsy is more general, and the symptoms are rather those of regurgitant disease of the aortic valves combined with mitral or pulmonic obstruction. In the cases in which the aneurysm opens into the left auricle, the symptoms will probably be those of combined aortic and mitral regurgitation.

In several cases in which marked evidences of venous derangement of the upper parts of the body suddenly occurred, the nature of the affection has been correctly diagnosed during life; but where the openings are into the pulmonary artery, right ventricle, or left auricle, the diagnosis will generally be attended with great difficulty and uncertainty. Any inferences in such cases must necessarily be mainly based on the physical signs, and it is only when the patient has been under observation for a considerable period that the signs can be accurately observed and fully considered. The signs which have been noticed in cases of this kind have generally been a harsh murmur heard most loudly over the pulmonic orifice, of a very superficial character, replacing both sounds and occupying the interval, so as either to be continuous or to consist of two portions immediately connected. Such a murmur is propagated in the course of the aorta and its branches, and is not heard, or only indistinctly, at the apex. A marked purring tremor is also generally felt about the pulmonic orifice with the diastole of the ventricle. The difficulty in correctly estimating the inference to be deduced from the signs is however great, for in a large proportion of cases in which there are aneurysms at the commencement of the aorta, the aortic valves also are incompetent or so diseased as to become sources of obstruction. The signs, therefore, of the one condition blend with and confuse those which are due to the other. Notwithstanding these difficulties, however, conclusions as to the nature of the affection possessing general accuracy have in several cases been arrived at, and in one instance the diagnosis effected was entirely correct. In this case, that of Dr. Wade, two loud murmurs were heard over the fourth cartilage instead of the usual cardiac sounds. The second murmur was of a hissing character, and so prolonged as to continue till the commencement of the systole, and it was accompanied by a marked purring tremor. The first murmur was of a loud bellows character. Both murmurs were heard in the common carotids and over the whole of the upper part of the chest, but were not specially propagated towards the left subclavian region. At the apex a systolic mur-

mur only was heard. From these signs it was inferred that there was regurgitation either from the aorta or pulmonary artery, and most probably from the former; that the regurgitation was not into either ventricle or into the left auricle; and that it was more likely to be into the pulmonary artery than into the right auricle, from the greater frequency of communications of the sacs of aneurysm with the artery than with the auricle.

In the case which is the subject of this paper, though from the evidence of obstruction at the right side of the heart, suspicion was raised that the case was not one of aortic valvular disease alone, the existence of an aneurysm at the commencement of the aorta was not clearly diagnosed; and the communication between the aneurysmal sac and the pulmonary orifice probably only occurred shortly before death. In a case which has more recently occurred in my practice at St. Thomas's Hospital, in which there was a double murmur at the aortic orifice, I was, however, led to infer from the suddenness with which the symptoms were described as having first occurred when the patient was engaged in laborious work, from the engorgement of the jugulars and the pain experienced in the right side of the neck, and from the murmur with the systole being propagated very loudly to the right and upper part of the sternum, that there was probably not only obstructive and regurgitant disease of the aortic valves, but that an aneurysm also existed at the commencement of the aorta. This inference proved, on *post-mortem* examination, to be correct; and the aneurysmal sac, which was of large size, was found to have pressed upon the right auricle and vena cava descendens, and threatened to burst both into the cavity and vein.

TABLE OF CASES OF ANEURYSM OF THE AORTA OPENING INTO THE CAVITIES OF THE HEART OR LARGE VESSELS.

Author and Reference.	Age.	Sex.	History.	Seat of Aneurysm, etc.	Seat of Communication, etc.	State of Heart.	Symptoms, Physical Signs, etc.
1. BEAUCHENE, Bulet. de la Soc. de Méd. t. ii., 1810, No. 3, p. 38. Dr. Thurnam, Med. Chir. Trans., vol. xxiii., 1840, p. 323, case 13.	About 40	M	No history.	Aneurysm the size of a large nut imme- diately above the aortic valves, on the convex side of the vessel between the coronary arteries.	The aneurysm pro- jected between the auricles, and pressed on both; there were four small loculi, one of which opened into the left auricle by an aperture two or three lines in diameter.	The sac projected also into the pericardium. Heart much enlarged.	
2. WELLS, Trans. of a Soc. for the Imp. of Med. and Chir. Know., vol. iii., 1812, p. 85. M. C. T., vol. xxiii., case 8. The preparation of this case is in the Museum of St. Thomas's Hospital, and is marked x 746.	53	M	A merchant; symptoms of cardiac dis- ease of about three years' duration.	Aneurysm the size of an orange, arising above the right and left aortic sinuses.	The aneurysm adhered to the pulmonary ar- tery just below its bi- furcation, and commu- nicated with it by a narrow opening, half an inch long, with jagged edges.	Heart much distended with blood.	After being fatigued by walk- ing and taking a hearty meal, the symptoms suddenly came on while playing with children, and the patient died in eight or nine hours. He was seen by Dr. Baillie.

Author and Reference.	Age.	Sex.	History.	Seat of Aneurysm, etc.	Seat of Communication, etc.	State of Heart.	Symptoms, Physical Signs, etc.
3. Lancet, 1832-33, vol. ii., p. 666, M. C. T., vol. xxiii., case 4. This case is also referred to in the Lancet for 1833, vol. ii., p. 63, as Mr. Beevor's case. The preparation is said by Dr. Thurnam to be at St. Bartholomew's.	41	M	A coachman; intemperate; long subject to dyspnoea, cough, expectoration and palpitation.	Aneurysm of the ascending portion of the aorta, commencing about an inch above the valves, and extending to near the origin of the arteria innominata. It occupied the right side of the vessel, and contained coagulated blood.	An opening less than the size of a sixpence into the vena cava superior, about an inch above the auricle. (The aneurysm pressed upon the vena cava, so as to render its cavity impervious.— <i>Lancet</i> , 1833.)	Heart large and ventricles dilated.	The aperture probably formed seven weeks before death. There was great lividity of the face, and clusters of distended veins about the thorax and neck. Edema at first of face, afterwards of lower extremities. Dulness and impulse under the right clavicle. Loud bruisement opposite the origin of the aorta. Delirium.
4. CURLING, N. S., Med. Gaz., N. S., vol. i., 1838, p. 895, M. C. T., vol. xxiii., case 5.	35	M	Subject to cough and dyspnoea, and anasarous for four months.	Aneurysm the size of a hen's egg immediately above the attachment of right and posterior valves.	Opened, by an aperture the size of a crow-quill, into the right auricle, just behind the appendix.	Left ventricle hypertrophied and dilated, and some ossific deposit in aortic valves.	Pulse weak and resilient; pulsation and murmur to the right of the upper part of sternum; lividity of face. Orthopnoea.
5. REID, Ed. Med. and Sug. Jour., liii., 1840, case 1., p. 96.	35	M	Tin-smith; intemperate; subject to palpitation; result of strain in lift-	Aneurysm at commencement of aorta, the size of the fist, involving the three sinuses of Valsalva.	Projected into the right auricle, and opened into its cavity by two oval openings; projected also into the left auricle.	Heart large and cavities dilated, valves healthy, pericardium uni-	Edema and lividity of upper part of body, and great dyspnoea. Double bellows-murmur at cardiac and sternal regions. Delirium.

Author and Reference.	Age.	Sex.	History.	Seat of Aneurysm, etc.	Seat of Communication, etc.	State of Heart.	Symptoms, Physical Signs, etc.
Dr. Peebles's case. M. C. T., vol. xxiii., case 7.			ing heavy weight a month before death.			versally adherent.	
6. Ibid. Case 2, p. 99. Dr. Alison's case. M. C. T., vol. xxiii., case 10.	36	M	Intemperate; symptoms commenced six months before death, and became exaggerated after admission.	Aneurysm the size of an orange, immediately above the valves.	Pressed upon the left auricle; and opened into the pulmonary artery by a transverse slit with jagged edges one inch and threenths long, one inch and a half above the valves.	Heart large; two aortic valves diseased and incompetent.	The opening probably only commenced a few hours before death. General cardiac symptoms previously, and a sudden fatal accession.
7. Ibid. Case 3, p. 101. Dr. Graham's case. M. C. T., vol. xxiii., case 11.	60	M	No history, except that a month before admission into the Hospital he was seen by a medical man, and found to be suffering from cardiac symptoms.	Ascending aorta dilated, and great dilatation also of descending portion of arch. Small infundibular-shaped aneurysm arose from right side of summit of dilatation of descending aorta, and was about one inch long. The opening from the aorta would admit the thumb,	Opened into left branch of pulmonary artery by a rounded aperture, with fringed edges, one quarter of an inch beyond the bifurcation of the vessel. The canal occupied the situation of the ductus arteriosus in the foetus, but was not thought by Dr. Reid to be a dilatation or reopening of the duct.	Hypertrophy and dilatation of heart, with disease of the aortic and mitral valves.	Death shortly after admission into Hospital.

Author and Reference.	Age.	Sex.	History.	Seat of Aneurysm, etc.	Seat of Communication, etc.	State of Heart.	Symptoms, Physical Signs, etc.
8. Ibid., vol. liv., 1840, p. 114. M. C. T., vol. xxiii., case 12.	53	M	Gentleman; strong bron- chitic sym- ptoms of some months' du- ration.	but that into the pul- monary artery was only as large as the carotid or subclavian. Aneurysm extended from upper part of sinuses of Valsalva to origin of arteria in- nominate and would contain the fist.	Opened into the trunk of the pulmonary artery by a ragged fissure nearly one inch and a half long.	Heart heal- thy.	Sudden accession of dyspnoea, followed by insensibility and death in four minutes.
9. SMITH, Proceedings of Path. Soc. of Dublin, 1839-40. Dublin Journal, vol. xviii., 1841, p. 164; and Stokes on Diseases of Heart and Aorta, 1854, p. 554.	22	M	Porter; heal- thy till three months be- fore death, when he be- came subject to dizziness and faintness followed by palpitation and pain in the region of the heart, and dyspnoea.	Aneurysm at the commencement of the aorta.	Small opening into the pulmonary artery near its origin, with thickened and rounded edges; evidently of old date.	Left ven- tricle dilated but not hy- pertrophied; right ventri- cle some- what thick.	Pale and bloated face, blue lips, orthopnoea, intermittent pulse, intense fremitus over whole præcordia, and bruit with systole. Dulness from 2nd to 8th rib. Epileptiform attacks, and death after one. Opening sup- posed to have formed about four months before death.
10. MUNRO, Hope on Diseases	24	M	Porter; ten years before had rheu-	Whole ascending aorta dilated into a large, irregular sac,	Two openings from the aneurysm into the pulmonary artery, one	Heart more than twice its natural	Great dyspnoea, cough, and expectoration; palpitation; ac- tion of heart tumultuous; pulse

Author and Reference.	Age.	Sex.	History.	Seat of Aneurysm, etc.	Seat of Communication, etc.	State of Heart.	Symptoms, Physical Signs, etc.
of the Heart, &c. 3rd. ed., Lond. 1839, p. 469. Med. Chir. Trans., case vol. xxiii., 9.			matism. Ac. Symptoms commenced with an at- tack of pneumonia ten weeks before death. Afterwards had dys- pnoea, palpi- tation, œde- ma of lower extremities, and swelling of abdomen.	which adhered firmly to the pulmonary artery. Internal coat reddened and rugose, with numerous car- tilaginous plates ad- vancing to ossifica- tion.	inch and a half above the valves; the larger capable of receiving the point of the little finger, and the smaller a crow-quill; and both being regular, round, and cartilaginous; a third opening, with thin and ragged edges, ex- isted near the arch.	size, pale, flabby, and blunt at the apex; cavi- ties dilated; valves heal- thy, except aortic, which were thick- ened.	large and thrilling, afterwards intermittent; countenance tumid and livid; abdomen distended, lower extremities œdematous. Dulness on percussion increased; first sound with soufflet audible over whole front, and at back on both sides of spine, but most distinct at sternum; second sound short, and obscured by first.
11. ROE and THUR- NAM, Med. Chir. Trans., vol. xxiii. (S. S., vol. v.), 1840, p. 323, case 7. In this paper the author refers to four preparations of aneurysms, which had opened into the	33	M	Baker; rheu- matic fever twenty years before death, and pleu- risy of left side three years be- fore. Eleven weeks be- fore, sud- denly felt something	An aneurysm of the right anterior aortic sinus immediately above the valve, which would contain a small orange, and was lined by fibrinous coagula; lining membrane of aneurysm and aorta atheromatous.	The aneurysm pro- jected into the mouth of the right ventricle and pulmonary artery, and involved the valves. Two rounded aper- tures of communica- tion with the ventricle, one the size of a No. 4, the other of a No. 7, bougie.	Hydroperi- cardium. Heart near- ly double its natural size, and weigh- ed sixteen ounces and a half. Hy- pertrophy with dilata- tion; valves incompetent.	Face pale, but lips livid; superficial veins, especially left jugular, very tumid; hurried breathing, cough, and expecto- ration of a brownish colour; pain in præcordia, and extend- ing to spine; extremely jerking pulse; dropsy of extremities; superficial sawing sound sup- planting natural sounds, very intense in second left intercostal space, two inches from sternum; very loud with systole, less

Author and Reference.	Age.	Sex.	History.	Seat of Aneurysm, etc.	Seat of Communication, etc.	State of Heart.	Symptoms, Physical Signs, etc.
13. BECK, Med. Chir. Trans. vol. xxv. (S. S., vol. vii.), 1842, p. 15.	31	M	Surgeon ; always short- breathed ; but enjoyed good health till after suf- fering from mental an- xiety six years before death. Be- came much worse three years before, suffering from dys- pnoea and anasarca.	Dilatation of right sinus of Valsalva.	The dilatation com- municated with the right ventricle by two small apertures. There was also a communica- tion between the ven- tricles below the sac.	The right and left aortic valves were much thickened. Heart two and a half times the natural size.	Dyspnoea, oppression, vomit- ing, and syncope. There was a superficial murmur with the second sound, most distinct at the base, and tremor.
14. HENDERSON, Lond. and Ed. Monthly Journal, vol. iii., 1843, p. 457. Own notes in Pathological Register.	41	F	Symptoms of cardiac disease com- menced after a chill, with pain at the chest, follow- ed by vertigo and palpita- tion. He had had acute	Aneurysm of left side and front of as- cending aorta ; origi- nating about half an inch above valves by aperture size of half a crown. Sac ex- tended from heart to level of arch, and was constricted in the middle at	Bulged into right ventricle and origin of pulmonary artery, and opened into the ven- tricle by an aperture with very thin edges, about the size of a pea, situated immediately below the valves.	Pericardi- um adherent by loose at- tachments. Heart na- tural. Aorta not much dilated, and its coats healthy.	Sudden death about seven months after first accession of symptoms ; pulsating tremor to left of sternum at the upper part, with increased dulness over large space ; systolic murmur at fourth and fifth left cartilages, with loud second sound. Great pain at intervals, extending from re- gion of heart and down left arm.

Author and Reference.	Age.	Sex.	History.	Seat of Aneurysm, etc.	Seat of Communication, etc.	State of Heart.	Symptoms, Physical Signs, etc.
15. TRIPE, Lancet, 1844, vol. ii., p. 221. Case at London Hospital in 1842.	36	M	rheumatism five years be- fore. A seaman; died the day after admis- sion.	point of attachment of pericardium to aorta. An aneurysm capa- ble of containing an ounce and a half of blood, originating by a fissure an inch and a quarter long, behind the posterior aortic valve. The sac con- tained coagulum.	The aneurysm opened into the right auricle by two circular open- ings, the size of peas, situated just above the auriculo - ventricular aperture.	Heart near- ly double its natural size from hyper- trophy and dilatation of left ventri- cle. Aortic valves thick- ened, indur- ated, and os- sified. Great dilatation of right side.	Ailing for some time with cough, dyspnoea, and palpita- tion. Face and surface of body livid; hæmoptysis; regurgitant pulse. Bruit over whole præ- cordia, with the second sound, and continued during the inter- val; loudest at the sternum at the level of the third rib; mur- mur also at the base, and in the course of the vessels with the first sound.
16. PEACOCK, London and Edinburgh Monthly Journal, 1845, vol. v., p. 16.	48	M	A horse- keeper; of very intem- perate ha- bits; attend- ing to his work till oc- currence of fatal sym- ptoms, and previous his-	An aneurysm the size of a duck's egg, com- mencing a quarter of an inch above the at- tachment of the right and posterior semi- lunar valves, involv- ing the anterior and right side of the ves- sel, and terminating a quarter of an inch	The aneurysm pressed upon the descending cava, and opened by two round apertures, each the size of a large bougie, into the right auricular appendage, and threatened also to burst into the peri- cardium.	Pericardi- um univer- sally adher- ent by thick layers of condensed membrane. Heart large; fatty dege- neration of muscle	Face sallow and puffy, œdema of extremities, and effu- sion in abdomen. Suddenly seized with dyspnoea, vomiting, and syncope, and died in eigh- teen hours.

Author and Reference.	Age.	Sex.	History.	Seat of Aneurysm, etc.	Seat of Communication, etc.	State of Heart.	Symptoms, Physical Signs, etc.
17. TURNBULL, Lancet, 1845, vol. ii., p. 91.	41	M	tory not known.	below the arteria innominata; lining membrane of sac and artery with osseous plates and atheromatous.		and much fat on surface. Great hypertrophy and dilatation of left ventricle, and dilatation of right ventricle.	Increased dulness, distinct purring sensation at base, and a loud and harsh double murmur, continuous, but more intense with the systole. At the apex the two sounds heard, but obscured by the murmurs.
18. Cossy,	45	F	A seaman; cardiac symptoms came on after he had fallen down a hatchway and injured his left side, five months before death; seriously ill about two weeks.	Aneurysm originating immediately above the valves, and extending so as to involve the arteria innominata; several smaller pouches from sac; and internal surface congested and showing tendency to ulceration; whole aorta somewhat diseased.	The aneurysm opened, by an aperture in one of the pouches, obliquely into the pulmonary artery, just above the valves; and by another, direct and size of a small quill, into the right ventricle, just below the valves. The aneurysm projected into the pericardium, and the layers were there adherent.	Heart rather larger than natural; considerable hypertrophy of left ventricle, and of columnaræ of right.	Swelling of face and upper extremities, and lividity of lips and

Author and Reference.	Age.	Sex.	History.	Seat of Aneurysm, etc.	Seat of Communication, etc.	State of Heart.	Symptoms, Physical Signs, etc.
Archiv. Gén. de Méd., 4 ^{me} série, t. ix., 1845, p. 33.			pitiation; gradually re-covered, and was then suddenly seized with vertigo, etc.	vian artery, and an aneurysm on the convex side, beneath the arteria innominata, size of hen's egg.	millimètres (.59 E. I.) below the entrance of vena innominata, nine millimètres (.35 E. I.) long and five wide.	valves natural.	face, followed by oedema of lower extremities. First sound replaced by a bruit, which was continued through the interval of silence, heard over the front and behind; second sound natural. Died three or four days after admission into hospital.
19. ROKITANSKY, Krank. der Arterien, Wien, 1852-7, Beob., Taf. x., p. 51. In this work, another case is related in which an aneurysm opened into the pulmonary artery, and three in which the communication was with the right pulmonary branch. In all these the openings had closed.	49	M	Copperplate printer.	Aneurysm originating from right side of aorta, and involving whole ascending portion, with a smaller sac, about the size of a walnut, between the aorta and pulmonary artery.	The smaller sac opened by an irregular-edged and triangular-shaped opening, four lines and a half long, into the trunk of the pulmonary artery, shortly above the attachment of the right and posterior valve.	Heart considerably enlarged, and loaded with fat; both ventricles, and especially the left, dilated.	Sudden death.

Author and Reference.	Age.	Sex.	History.	Seat of Aneurysm, etc.	Seat of Communication, etc.	State of Heart.	Symptoms, Physical Signs, etc.
20. OGLE, Path. Trans., vol. iv., 1852-53, p. 114.	27	F	Had suffered from palpitation and dyspnoea for three or four years, but had been worse for a few weeks.	Aneurysm of aorta at inner and posterior part, immediately above valves, size of small hen's egg. Ascending aorta rough and atheromatous.	Aneurysm opened by an oval, oblique aperture, three-fourths of an inch long, into the pulmonary artery, about a quarter of an inch above the valves, which it involved.	Right and left ventricle dilated.	Died about two months after accession of more urgent symptoms. Dyspnoea, cough, bloody expectoration, palpitation, irregular and jerking pulse, and vomiting; face pale, lips blue, but not marked cyanosis; systolic murmur in præcordia, loudest at left side of sternum, opposite third cartilage; clear diastolic sound on right, but none on left of sternum. Tremor with the systole.
21. HERAPATH, Med. Association Journal for 1853, p. 683.	53	M	Intemperate. Taken with pain in the epigastrium and nausea, shortly after having taken food, followed by vomiting and prostration of strength.	Aorta atheromatous and dilated throughout the arch; a transverse laceration of the coats at commencement of descending portion, three-quarters of an inch long; no distinct aneurysmal pouch.	The coats of the pulmonary artery were adherent to the dilated aorta, and just above the valves there was a laceration an inch long.	Heart large and flabby; valves healthy.	Died about a day after the commencement of illness, and one or two hours after the more severe symptoms indicating the rupture appeared.

Author and Reference.	Age.	Sex.	History.	Seat of Aneurysm etc.	Seat of Communication, etc.	State of Heart.	Symptoms, Physical Signs, etc.
22. MAYNE, Dublin Journal, 1853, vol. xlv. (N. S., vol. xvi.), p. 257.	50	F	Suffering from dyspnoea several years.	Enormous dilatation of the arch of the aorta, and extending two inches down the descending portion. Inner coat atheromatous and diseased. Right and left vena innominata and the descending cava were pressed upon and adherent to the dilated aorta.	Free communication between the dilated aorta and the vena cava superior, at a point about two inches above the origin of the aorta.	Heart healthy.	Suddenly seized, while laboriously occupied, with sense of tightness in throat, followed by dyspnoea, giddiness, and marked cyanosis and swelling of face, neck, and upper extremities, and upper part of trunk, with great venous engorgement and injection of eyes; heaving impulse at second right cartilage, with superficial bruit there and over front of chest; purring tremor in veins; no oedema of lower extremities. Communication apparently occurred eight days before death.
23. BEAU, L'Union Médicale, t. vii., 1853, p. 374.	39	M	Sailor; of intemperate habits; suffering for years from cardiac symptoms.	Dilatation of the commencement of the aorta, with two aneurysms at the right and left side projecting into the right and left auricles; that on the right side as large as a hen's egg, that on the left double that size.	The left aneurysm ruptured into the left auricle by a fissure a centimètre (.39 E. I.) in length.	Heart twice the natural size; no valvular disease.	Committed a debauch, and soon after seized with aggravation of former symptoms, and died in about an hour.

Author and Reference.	Age.	Sex.	History.	Seat of Aneurysm, etc.	Seat of Communication, etc.	State of Heart.	Symptoms, Physical Signs, etc.
24. GOURIL, Arch. Gén. de Méd., Série 5 ^{me} t. v. (1855, t. i.), p. 725.	58	M	Suffered from shortness of breath from birth, but worsened twelve years before death. Oedema of the lower extremities for three or four years.	The inner coat of aorta was diseased from its origin to the abdominal portion; immediately above the valves it became dilated, and on the right side there was an aneurysm the size of a hen's egg, which arose five centimètres (1.9 E. I.) above the origin; it pressed upon the right auricle and venacava superior and the right bronchus and pulmonary artery; it contained adherent clots.	The aneurysm opened into the vena cava superior by an oval opening thirty-five millimètres (1.26 E. I.) in circumference, with unequal and red edges, immediately below the entrance of the vena azygos. Beyond the aneurysm the aorta gradually resumed its natural size. The obstruction to the vena cava was diagnosed during life.	Left ventricle very large; right ventricle small. No valvular disease.	Suddenly seized, when excited by anger, with insensibility, followed by palpitation, injection of conjunctivæ and lividity of face, swelling of neck, and excessive dyspnoea. Great lividity and oedema of upper parts of body, and, except slight cedema of ankles, none of lower extremities. A soft murmur was heard at the base and on the right side of sternum with the systole, and prolonged into the silence; a harsher and stronger bruit with the second sound. Pulse small; action of heart violent. Sudden death after about a month.
25. J. H. BENNETT, Clinical Lectures, 3rd. ed., 1859, case cix., p. 595.	33	M	Symptoms commenced five months before death, with pain, followed by a sense of something having given way below	Aneurysm, the size of a large walnut, between the aorta and pulmonary artery, originating immediately above the root of the aorta.	Transverse communication with the pulmonary artery, four lines long, situated an inch above the valves; superior vena cava also compressed.	Left ventricle somewhat large; right ventricle hypertrophied and dilated. Heart weighed 15 ounces and a half.	Pulse irregular; anasarca; soft, blowing, systolic murmur, and natural second sound at apex; at junction of third left costal cartilage with sternum, first sound loud, prolonged, and blowing; second, short, abrupt, and rasping; over manubrium, rough, continuous, blowing murmur occupying both sounds.

Author and Reference.	Age.	Sex.	History.	Seat of Aneurysm, etc.	Seat of Communication, etc.	State of Heart.	Symptoms, Physical Signs, etc.
26. M. PIERRESON, Bulet. de la Soc. Anat., 2 ^{me} série, t. V., 1860, p. 198.	61	M	the ensi- form carti- lage, hæ- moptysis, and dis- charge of noea and blood from rectum; dys- cedema of lower ex- tremities.	Three centimètres (1.17 E. I.) above aortic valves, on left side, a large bilocu- late aneurysm arose, which contained soft coagula.	The aneurysm com- municated by a small opening with the pul- monary artery.	Recent pe- ricarditis; slight hyper- trophy of left ventri- cle; valves healthy.	Orthopnoea; lividity of lips and face; cedema of lower ex- tremities; powerful impulse of heart; pulsating tremor in second left intercostal space, near sternum; souffle with the first sound, and purring tre- mor; afterwards swelling of ex- ternal jugulars.

Author and Reference.	Age.	Sex.	History.	Seat of Aneurysm, etc.	Seat of Communication, etc.	State of Heart.	Symptoms, Physical Signs, etc.
27. WADE, Med. Chir. Trans., vol. xlv. (S. S., xxvi.), 1861, p. 211.	35	M	Railway- porter; after having lost blood by piles, began to have pul- monary symptoms six months before death. About two months be- fore, strained himself, and after that the symp- toms became aggravated.	An aneurysm, capa- ble of containing small hen's-egg, origi- nated above the right and left semi-lunar valves; a few small patches of atheroma in aorta.	Communicated with the pulmonary artery by a vertical slit about three lines long, with smooth and rounded edges, behind the pos- terior division of the pulmonary artery. There was also a second opening into the right ventricle, im- mediately below the valves, which was about four lines long, and had ragged and thin edges. This is supposed to have oc- curred shortly before death.	Heart large; valves heal- thy.	Increased cardiac dulness, es- pecially in vertical direction; apex beating in sixth interspace; cardiac sounds, as heard over the cartilage of fourth rib, replaced by two murmurs; that with the second sound occupied the whole period of silence; a loud bellows- murmur heard also with the first sound. The murmurs were heard at the upper part of the chest, both before and behind. At the apex, a single systolic murmur was heard, and the second sound was distinct; purring tremor at the fourth car- tilage. Sudden death after dis- charging much blood from the rectum.
28. TRIPIER, Thèse de Paris, 1863. De l'anévrysme artério-veineux spontané de l'aorte et de la veine cave supérieure, p. 36, case	55	M	Travelling merchant; temperate habits, and enjoyed good health, ex- cept suffer- ing occasion- ally from diz- ziness; sud-	On the right and pos- terior side of the aorta above the valves, a large aneurysm arose, which was ovoid in shape, and as large as the fist, and ad- hered to the pulmon- ary artery; it adhered also to the vena cava,	The aneurysm com- municated with the vena cava superior by an aperture in the form of a button-hole, two centimètres (.78 E. I.) long; its edges were slightly broken, and very fine and near to- gether. The opening	Fluid in pericardium; slight hyper- trophy of heart; no valvular dis- ease. Great con- gestion of membranes	When admitted, the swelling and cyanosis of head, neck, and upper part of trunk and upper extremities, and fore-arms, and the distension of the veins, were very marked; the parts beneath the base of the thorax not being at all involved. There was no- thing remarkable as to the respi- ration, and the sounds of the

Author and Reference.	Age.	Sex.	History.	Seat of Aneurysm, etc.	Seat of Communication, etc.	State of Heart.	Symptoms, Physical Signs, etc.
under M. Ram- baud, at the Hôtel Dieu de Lyon.			denly taken at night with vertigo and dyspnoea, followed by swelling and lividity of the face and upper part of trunk; and these symptoms continued, when he was admitted in- to the hos- pital, two days after.	and the vein was flattened on its sur- face. The tumour contained some fibrin- ous and soft clots.	was two centimètres and a half (.97 E. I.) from the commence- ment of the vein. The vein, though flattened and contracted when in contact with the aneurysm, was perme- able throughout, and again expanded below.	and sub- stance of the brain.	heart were natural; but three centimètres (.78 E. I.) from the right side of sternum, be- neath the clavicle, there was dulness, pulsation, and a soft, feeble, systolic murmur; pulse small and frequent; great agita- tion, followed by delirium, and lapsing into coma, with increased evidences of obstruction to the venous circulation. The patient died thirteen days after his ad- mission, and fifteen after the marked occurrence of the symptoms.
29. LICHTENBERG, Path. Trans., vol. xvi., 1864-5, p. 96.	29	M	Enjoyed good health till he met with an ac- cident, for which am- putation of the left arm was per- formed. Went on	Aneurysm originat- ing by an opening eighteen French lines in circumference, from the posterior sinuses of Valsalva. The sac was about an inch long, and pro- jected into the right auriculo-ventricular aperture. It was	The sac opened at its end into the auri- culo-ventricular aper- ture, by an opening capable of admitting the handle of a steel pen, or eight lines in circumference.	Heart hy- pertrophied and dilated, but flabby, and with fatty de- generation; aortic valves somewhat thickened; appearance	Suffered from palpitation, dyspnoea, severe vomiting, and increased temperature; the urine became albuminous, and he had a peculiar "grey, unearthy look," and died collapsed. Fremissement in the lower cardiac region, each sound of heart replaced by a strong bruit, principally heard at the base and at the left of the sternum.

Author and Reference.	Age.	Sex.	History.	Seat of Aneurysm, etc.	Seat of Communication, etc.	State of Heart.	Symptoms, Physical Signs, etc.
30. GULL, Lancet, vol. iv., 1864, p. 410.	34	M	<p>well after the operation till the thirty-seventh day, when he was seized with cardiac symptoms; and he died thirteen days after their accession.</p> <p>Formerly a soldier; suffered from dyspnoea and inability for hard work for several years.</p>	<p>somewhat wider than the opening from the artery, and had a smaller pouch projecting from its side. Atheromatous deposits in aorta.</p> <p>Aneurysm involving front part and side of aorta, extending from an inch above the origin to the arteria innominata, and containing recent clot.</p>	<p>Opened into the vena cava superior, by an aperture the size of an ordinary lead-pencil.</p>	<p>Recent pericarditis; a heart healthy.</p>	<p>Five weeks before death, swelling and venous engorgement of neck and upper extremities and upper part of trunk, so as to form a remarkable contrast to lower part and extremities; no murmur with the heart's sounds, but a vibratile thrill over the whole right side of chest, synchronous with the diastole; soft whizzing murmur at upper part of sternum, above only with the diastole, below also with the systole; pulse small and regular, and the right less than the left; cough and frothy expectoration.</p>

Author and Reference.	Age.	Sex.	History.	Seat of Aneurysm, etc.	Seat of Communication, etc.	State of Heart.	Symptoms, Physical Signs, etc.
31. MOXON, Path. Trans., vol. xvii., 1865-6, p. 80. Mr. G. T. Hawkins's case.	45	M	Seaman, and afterwards gold-digger; subject for five months to occasional pain in the heart at night, and vomiting in the morning; addicted to spirit-drinking.	Ascending aorta dilated and diseased; an opening, the size of a shilling, just above the valves, into an aneurysm as large as a walnut, containing fibrinous clots.	The aneurysm projected into the left auricle, and burst into it by a large rent.	Heart slightly hypertrophied.	After eating a full breakfast, felt sense of distension in the stomach, but walked out and ate his dinner; after that had violent retching and vomiting, and pain in the stomach; followed by restlessness, cold sweats, faintness, and death in four hours.
32. PEACOCK, Paper (<i>Antea</i> , p. 111.).	26	M	Enjoyed good health till an attack of rheumatic fever four years before death; symptoms commenced about two months before with	Aneurysm, the size of a large hen's egg, originating above the point of attachment of the right and left aortic valves.	Aneurysm projected into the pericardium, and was very thin in places; it also pressed upon and obstructed the origin of the pulmonary artery and the base of the right ventricle, and had destroyed two of the left ventricular valves. There was an opening with very thin	Extensive old adhesions of pericardium; great hypertrophy and dilatation of heart, especially of left ventricle; extensive disease	Suffered under aggravated cardiac symptoms; cheeks flushed, lips livid; distension of jugulars; cedema of face and upper extremities, as well as of other parts of body; dulness greatly extended, and especially in vertical direction; apex beat in fifth interspace; at base, systolic murmur, followed by loud, ringing, diastolic sound, and that by a slight murmur; at

Author and Reference.	Age.	Sex.	History.	Seat of Aneurysm, etc.	Seat of Communication, etc.	State of Heart.	Symptoms, Physical Signs, etc.
33. ROBERTS, Brit. Med. Journ., May 2, 1868, No. 383, p. 421.	28	M	pain in right hypochondrium, shortness of breathing, dry cough, and swelling of lower extremities.	Aorta dilated to one-third more than its natural calibre, for an inch and a half from its origin. From this dilated part, and immediately above the right and left sinuses of Valsalva, there sprang a wide-mouthed aneurysmal pouch, resembling in size and shape the half of a large walnut shell.	The aneurysm was funnel-shaped, and projected fully half an inch into the cavity of the pulmonary artery, immediately above the valves. In the centre of this projection there was a round opening, large enough to admit a good-sized pea, with very thin, smooth, membranous edges; and on each side was another small opening. Pulmonary artery not dilated or atheromatous; lining membrane	of two aortic valves. Heart weighed twenty-eight ounces.	apex only the systolic murmur, and second sound without murmur; pulse somewhat regurgitant; liver enlarged.
						Pericardium unadherent throughout by old attachments; heart of very large size, and all its cavities dilated and the ventricles hypertrophied, especially the left. Aortic orifice somewhat large, but valves	Orthopnea; lips livid, face pale; some ascites; considerable oedema of legs and thighs; cough, dyspnea, expectoration with streaks of blood; pulse quick and jerking, and visible in superficial arteries; præcordial bulging; heart beat in fifth interspace, half an inch outside nipple; greatly increased dulness, both vertically and transversely; a superficial, loud, harsh double murmur, or a single murmur consisting of two parts and covering both sounds, heard most intensely at the upper level of cardiac dulness, and between sternum and

Author and Reference.	Age.	Sex.	History.	Seat of Aneurysm, etc.	Seat of Communication, etc.	State of Heart.	Symptoms, Physical Signs, etc.
					of aorta in dilated part rough and atheromatous, and in places calcareous.	closed it nearly, if not perfectly.	nipple; propagated to the vessels in the neck, and heard much less intensely at the apex; the murmur was accompanied with an intense vibratile thrill; voice weak, and cough-sound a little metallic. Incompetency of aortic valves diagnosed, and aneurysm suspected.

Dr. PEACOCK, 21st of January, 1868.

