

**On peculiar appearances exhibited by blood-corpuscles under the influence of solutions of magenta and tannin / by William Roberts, M.D.**

**Contributors**

Roberts, William, Sir, 1830-1899.  
Royal Society (Great Britain)  
University of Glasgow. Library

**Publication/Creation**

[London] : [publisher not identified], [1863]

**Persistent URL**

<https://wellcomecollection.org/works/ecq6ms83>

**Provider**

University of Glasgow

**License and attribution**


This material has been provided by This material has been provided by The University of Glasgow Library. The original may be consulted at The University of Glasgow Library. where the originals may be consulted. This work has been identified as being free of known restrictions under copyright law, including all related and neighbouring rights and is being made available under the Creative Commons, Public Domain Mark.

You can copy, modify, distribute and perform the work, even for commercial purposes, without asking permission.



Wellcome Collection  
183 Euston Road  
London NW1 2BE UK  
T +44 (0)20 7611 8722  
E [library@wellcomecollection.org](mailto:library@wellcomecollection.org)  
<https://wellcomecollection.org>







“On Peculiar Appearances exhibited by Blood-corpuscles  
under the influence of Solutions of Magenta and Tannin.”

By WILLIAM ROBERTS, M.D., Physician to the Manchester  
Royal Infirmary.

THE object of the following paper is to give an account of certain observations which seem to indicate that the cell-wall of the vertebrate blood-disk does not possess the simplicity of structure usually attributed to it.

It is well known that the blood-corpuscles, when floating in their own serum, or after having been treated with acetic acid or water, appear to be furnished with perfectly plain envelopes, composed of a simple homogeneous membrane, without distinction of parts. But, as will appear from the observations here to be related, when the blood is treated with a solution of magenta (nitrate of rosanilin) or with a dilute solution of tannin, the corpuscles present changes which seem irreconcilable with such a supposition.

Attention is first asked to the effects of magenta. When a speck of human blood was placed on a glass slide and mixed with a drop of a watery solution of magenta\*, the following changes were observed. The blood-disks speedily lost their natural opacity and yellow colour; they became perfectly transparent, and assumed a faint rose colour; they also expanded sensibly, and lost their biconcave figure. In addition, a dark-red speck made its appearance on some portion of their periphery. The pale corpuscles took the colour much more strongly than the red; and their nuclei were displayed with great clearness, dyed of a magnificent carbuncle-red. Many of the nuclei were seen in the process of division, more or less advanced; and in some cells the partition had resulted in the production of two, three, or even four distinct secondary nuclei.

These appearances were first observed in freshly-drawn blood from the finger. Subsequently blood from the horse, pig, ox, sheep, deer, camel, cat, rabbit, and kangaroo was examined in like manner. The effect on the red corpuscles (to which all the observations hereinafter recorded are exclusively confined) was in each instance the same as in human blood.

The nucleated blood-disks of the oviparous classes, when treated similarly, yielded analogous results. The coloured contents were forthwith discharged; the central nucleus came fully into view, and assumed a deep-red colour; the corpuscles expanded, they lost

\* The solution I found to answer best in these experiments was a nearly saturated solution of nitrate of rosanilin, made by boiling the salt in water, and filtering after it had stood twenty-four hours, then diluting slightly with water to prevent precipitation.

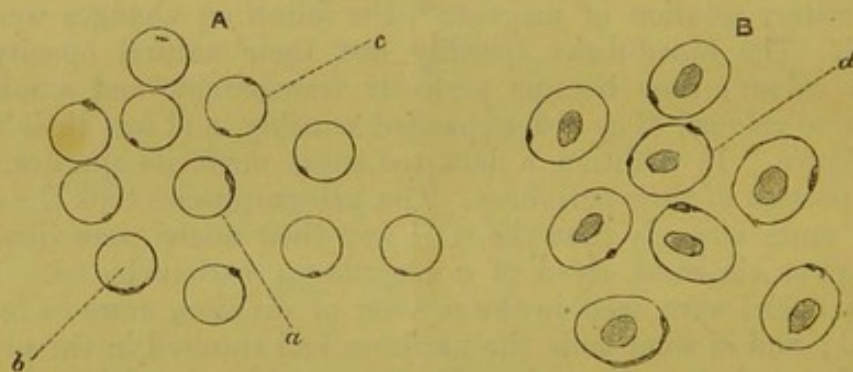


something of their oval form, and approached nearly, or sometimes quite, to a circular outline. Lastly, there appeared on the periphery a dark-red macula, of a character and position resembling that seen on the mammalian blood-disk. Such a macula was detected in the fowl, in the frog, and in the dace and minnow.

Owing, however, to the large quantity of molecular matter floating in the serum, and which was coloured by the magenta, difficulties were found in preparing specimens which carried conviction that the macula in question was not an adhering granule. It was also found that it required a nice adjustment of the relative quantities of the solution and of the blood to bring it out. It was only when the right proportions were hit, and especially when the disks were made to roll over in the field of the microscope, that the existence of a coloured particle organically connected with the cell-wall could be satisfactorily made out. The best specimens were prepared from human blood drawn in the fasting condition, and from the blood of a kitten two days old.

From well-prepared specimens of human blood the following particulars were gathered (see fig. 1):—Nearly every disk possessed the parietal macula; it could be distinctly recognized in nine-tenths of them; and in several of those in which it was not at first visible, it came into view as the corpuscles revolved in the field.

Fig. 1.



A. Human blood. B. Fowl's blood treated with magenta.

The macula was clearly situated in the cell-wall, and not in the interior of the corpuscle. Usually it appeared as if imbedded or set in the rim of the disk, like the jewel in a diamond ring; but sometimes it occupied various positions on the flat surfaces, and when so placed, the spot was difficult or impossible to detect.

It commonly presented a thickly lenticular shape; sometimes it was square, and occasionally in appearance vesicular (fig. 1, A, a). In some instances, and especially in long-kept specimens, the particle was seen to stand out on the outline of the disk like an excrescence. Still more rarely, instead of a spot, a thick red line ran round the circumference for a quarter or a third of its extent (fig. 1, A, b).

As a rule it was extremely minute, covering generally not more



than a twentieth or thirtieth of the circumference ; but there was a considerable variation in its magnitude and distinctness. Very rarely two specks could be seen ; but the occurrence of adhering granules rendered the verification of this point extremely difficult.

This description applies, so far as the inquiry has yet been prosecuted, to the mammalian blood-disk generally, making allowances for differences in size. In the camel the macula occupied indifferently any part of the oval outline.

Among the oviparous classes, the blood of the fowl, frog, dace, and minnow has been most fully examined (see fig. 1, B) ; but the blood of the sparrow, duck, goose, and turkey was also searched, as well as that of the newt and carp.

In all of these a tinted particle appeared, more or less constantly, in the cell-wall, when the corpuscles were treated with magenta\*. The presence of a central nucleus in these classes caused the macula to be invisible more frequently than in mammalia, inasmuch as it suffered eclipse when situated over or under the central nucleus.

In the fowl, dace, and minnow it was found easy to bring out the parietal macula ; in the fish two spots were not unfrequently seen. The macula was situated indifferently on any part of the periphery ; and sometimes it projected from the surface. When happily prepared the specimens were even beautiful. The central nucleus was dyed of the finest red ; and on the delicate outline of the cell-wall hung the red parietal macula, offering a not altogether fanciful resemblance to the astronomical figures representing the moon coursing in its orbit round the earth.

At this stage of the inquiry it was conceived that an improved demonstration might be obtained by fixing the dye with a mordant, and then subjecting the corpuscles to a lavatory process, so as to get rid of the floating granules which so much interfered with the view. For this purpose a solution of tannin (which is one of the mordants for magenta used in the arts) was employed ; and some advantage was found therein. When a solution of tannin, of 3 grains to the ounce of water, was added to blood that had already been dyed with magenta, it was found that the parietal maculæ had their colour intensified, and that they became more conspicuous objects. The investigation was, however, not pushed any further in this direction, for it was found that tannin alone produced an even more remarkable effect than magenta. To this effect I now desire to draw particular attention.

When a solution of tannin, of the strength of 3 grains to the ounce, was applied to human blood, or to that of the horse, ox, sheep, pig, or cat, the blood immediately became turbid ; and when a drop was placed under the microscope the corpuscles were found greatly changed, as represented in fig. 2.

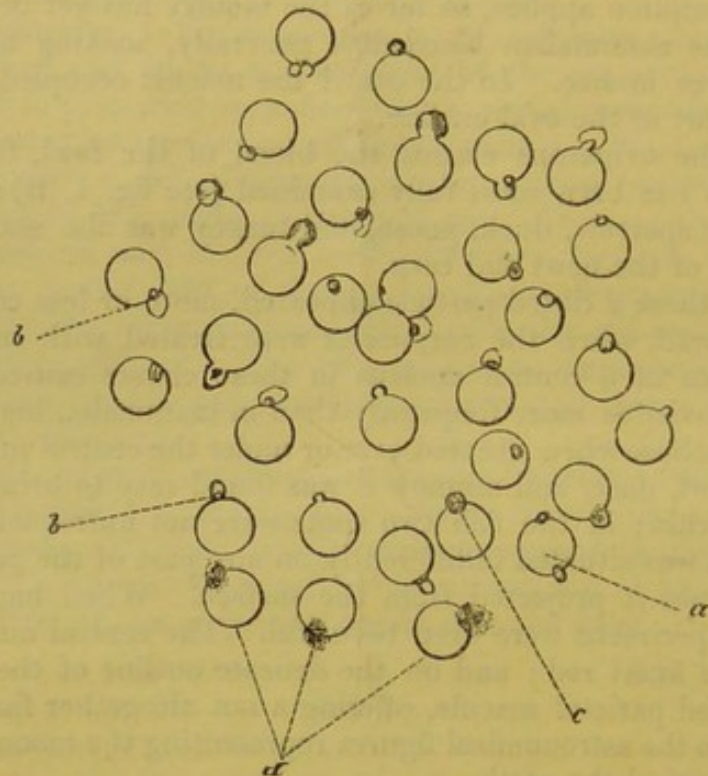
Each corpuscle appeared to have thrown out a bright, highly re-

\* In order to bring out the best results, it was found requisite to modify the strength and quantity of the solution for the different kinds of blood. This doubtless depended upon the varying densities of the liquor sanguinis and cell-contents in different animals.



fractive bud or projection on its surface. The projections were usually about a fourth part of the size of the corpuscle on which

Fig. 2.



Human blood after the action of tannin.

*a.* Double pullulation.

*b, b.* Hooded modification.

*c.* Outline of the cell seen continuously through the pullulation.

*d.* Bursting of the pullulations independently of destruction of the cell.

they were fixed; but they varied considerably. Some were only minute bright specks in the cell-wall; others were half or even two-thirds as large as the corpuscle itself. Very rarely (in mammalian blood) two such projections were seen; and as rarely a corpuscle was devoid of any.

The projections were commonly round or dome-shaped, bordered with a deeply refractive outline. Frequently a minute, apparently vesicular body could be seen within this outline, and then the projection presented a curiously hooded aspect (fig. 2, *b, b*). In a urinary deposit from a lad twelve years of age, containing pus and blood, nearly every blood-disk presented the hooded appearance after the addition of tannin.

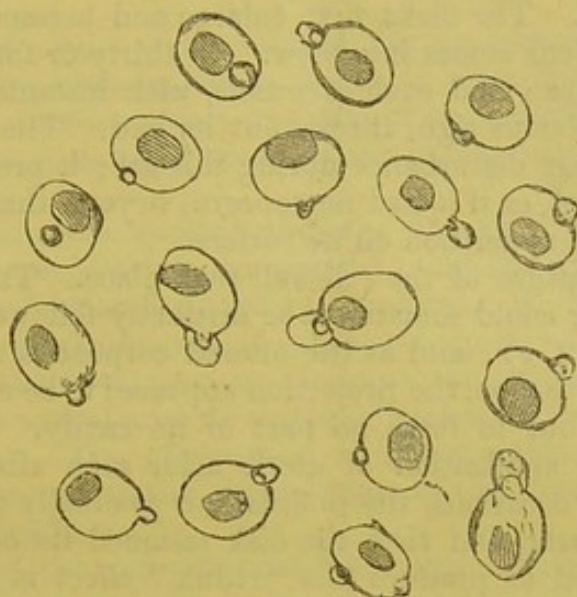
The blood of the fowl, turkey, duck, and goose showed exactly analogous phenomena with the same reagent (see fig. 3).

The projection had sometimes the hooded character with a vesicular body within; sometimes the projection offered no such distinction of parts. It was situated indifferently on any part of the periphery. In all the birds examined a second projection was as rare as in mammalia.



Of fish, the dace, minnow, and carp were examined. The tannin-solution produced a similar effect to that seen in the fowl—with this

Fig. 3.



Blood of fowl after the action of tannin.

difference, that a large number of corpuscles had two projections instead of one. In the carp double and single projections occurred in about equal proportions; in the minnow double projections were all but universal. The second projection was situated sometimes at the opposite pole of the disk, sometimes in near proximity to its fellow, or at any point between. Very rarely, a third projection was seen in the dace.

In the blood of the frog there was a strong tendency to the indefinite multiplication of the projections; two, three, four, and even five would rise in succession on the surface of the disk. It appeared, too, not unfrequently as if the entire outer membrane of the cell was detached from the parts beneath and raised into eight or ten unequal elevations, giving the outline of the disk an irregularly crenate appearance\*.

The formation of these singular projections, or *pullulations*, on the blood-disks could be watched without difficulty by placing a drop of the tannin-solution beneath the covering glass, and permitting a little blood to insinuate itself into the solution under the microscope. As the blood flowed in and mingled with the tannin, the corpuscles were observed gradually to enlarge, and then *suddenly*, without previous warning, to shoot out the projection. As a rule, it does not appear to grow afterwards. The phenomenon was finely seen in the defibrin-

\* There is a certain adjustment of the proportions between the tannin-solution and blood required to bring out the effects described in this paper; but the proper proportions are, practically, very easily found after a few trials for each kind of blood. In mammalian blood, one drop of blood mixed in a conical glass with four or five of the solution generally answered perfectly. Any considerable excess of blood or solution above these proportions caused destruction of the corpuscles.



ated blood of the fowl after it had been allowed to sink through a column of syrup (sp. gr. 1025) in a test-tube. Fowl's blood washed in this way was mixed, in a little glass, with about five times its volume of the tannin-solution, and a drop immediately put under the microscope. The disks first enlarge and become rounded, and the central nucleus comes into view. In thirty or forty seconds the pullulation begins; and each corpuscle, with instantaneous rapidity and without previous sign, throws out its bud. The disk itself suffers not the least disturbance during this act; it preserves its symmetry unchanged, as if it had no concern, beyond that of proximity, with the sudden apparition on its surface.

No visible rupture of the cell-wall took place. The circular outline of the latter could sometimes be distinctly followed through the projection (fig. 2, *c*); and as the altered corpuscles revolved in the field of the microscope, the projection appeared to be organically connected with it, but to form no part of its cavity. In the human blood-disks the application of acetic acid, soon after the tannin, caused, on two occasions, the pullulations gradually to subside, and finally to disappear, and then the disk resumed its original circular outline. I failed to produce this "redux" effect in the fowl; and did not always succeed with human blood, probably because the change produced by the tannin had gone too far.

The modification noted under the term "hooded" appearance depends, I believe, upon secondary conditions of concentration and quantity of the tannin-solution in comparison to the blood. When the hooded condition has been watched in the act of occurrence, it was noticed that the outer hood was shot out *first*, and instantly after this the highly refractive vesicular body made its appearance within. The contents of the hood (excluding the vesicular body) appeared usually to refract the light like the body of the cell, or even less strongly; sometimes, however, more strongly.

The effect of tannin did not cease with the production of the elevations just described. At first the cells and their projections preserved their elasticity; but after a while (a few minutes, or several hours, according to the proportions used) the corpuscles and their projections became solid, and they could be cracked by pressure under the microscope like starch-granules. More slowly the same destruction overtook the corpuscles spontaneously; and this significant fact was observed in the course of it:—sometimes the cell ruptured before the projection, the latter persisting as a bright granule amid or near the débris; sometimes, on the other hand (in the horse), the projection broke up before the disk to which it was attached. In this latter case, the hood (if there were any) broke up first into a scattered nebula of granular appearance, and then the nucleolus-like body within burst into three or four bright fragments (fig. 2, *d*). This train of events seemed to remove all doubt as to the complete isolation of the projection from the cavity of the disk. Last of all, the disk itself began to crack; in a few days all my specimens were thus destroyed.

In addition to magenta and tannin the following substances were



tried, but they did not produce phenomena in the least analogous with the foregoing:—gallic acid, ferrocyanide of potassium, santonine, sulphate of magnesia, alcohol and water, solutions of carbolic acid, of atropine, morphia, iodine, sugar, gum, glycerine, and infusion of coffee.

A solution of picric acid produced the appearance of a parietal particle like that brought out by magenta, except that it was not coloured. An exactly similar appearance was on one occasion observed in blood-corpuscles in the urine of a patient with acute Bright's disease.

When magenta was applied after the process of pullulation had taken place, the projections were found to take the dye strongly, and especially the vesicular body within the hood. By this proceeding beautiful and remarkable objects for microscopical examination were obtained. In the fowl, dace, and minnow the projection was tinted earlier than the central nucleus—probably from its more ready access to the pigment. The explanation of these appearances presents great difficulties, and in the present state of the inquiry can only be offered provisionally.

The effect of the magenta-solution is not merely to tint, and so render visible a very minute body. In watching the effect of magenta, the first thing observed is that the natural yellowish colour of the disk is discharged, and that a faint rose tint is assumed in its stead. The disks at the same time lose their biconcave shape. The parietal macula is rather "brought out" than revealed, and the action of the solution is, to a very great extent, of a simply osmotic character.

The action of the tannin-solution is likewise in the main of a similar nature, but modified in some very peculiar manner. Its first operation is to cause the corpuscle to enlarge by imbibition, and this goes on progressively until at length the cell is destroyed. If the solution be strong, this destruction supervenes at once. The tannin also unites with the cell-contents and coagulates them, imparting to the corpuscle, finally, a solid consistence. The conditions of the imbibition are disturbed by the previous application of magenta; for no pullulation, or at most only traces, occurs when the corpuscles are treated *first* with magenta and *then* with tannin.

The bearing of these observations on the current views respecting the structure of the vertebrate blood-disk is important. They seem to warrant the inferences drawn in the two following paragraphs:—

1. The exact identity of the appearances produced in the blood-disks of the ovipara with those observed in the mammalian corpuscles lends strong support to the view that these corpuscles are homologous as wholes; and that the mammalian blood-disk is not the homologue of the nucleus of the coloured corpuscle of the ovipara, as was conceived by Mr. Wharton Jones.

2. The observations likewise lead to the belief that the envelope of the vertebrate blood-disk is a duplicate membrane; in other words, that within the outer covering there exists an interior vesicle which encloses the coloured contents, and, in the ovipara, the nucleus.



Dr. Hensen\* of Kiel had already in 1861 convinced himself, from wholly different observations, that the blood-corpuscles of the frog possess such a structure. On this view the blood-corpuscle is anatomically analogous to a vegetable cell, and the inner vesicle corresponds to the primordial utricle.

The present observations indicate, by direct proof, a duplication at only one or, at most, two points in the blood-disks of mammals and birds. Nevertheless certain appearances, occasionally observed, favour the notion of a complete duplication (fig. 1, *b*).

The admission of this hypothesis, however, scarcely removes the difficulties sufficiently to permit a tenable explanation to be offered of the appearances described in this paper. Yet, as it may prove suggestive to some other inquirer, I will not suppress what appears to me the explanation least open to objections. It might be conceived that the cells enlarged by imbibition, until at length the less distensible inner membrane gave way, and permitted an extravasation of a portion of the cell-contents between it and the outer membrane, its own continuity being in the meanwhile instantaneously restored by cohesion of the ruptured borders†. In this way a microscopic drop of the cell-contents would be lodged between the outer and inner membrane, and completely severed from the general cell-cavity. The peculiar modification spoken of as the "hooded" appearance might be due to imbibition of fluid between this microscopic drop and the outer envelope.

The chief difficulties in the way of this explanation arise out of the differences of nature which appear to exist between the projection and the general cell-contents of which it is supposed to be a detached portion. The projection refracts light much more highly than the cell-contents; it also is deeply dyed by magenta; whereas the cell-contents are only very feebly so.

In conclusion, it may be added that important advantages may be expected from the use of magenta in histological researches. Its inert chemical character, its prodigious tinting power, and its solubility in water eminently fit it for such a purpose. It will probably prove of especial use in bringing into sight objects which otherwise evade the visual organs from their absolute colourlessness and transparency, and from the equality of their refraction with the medium in which they exist.

\* Zeitschrift für Wissensch., Zoologie, Band xi. p. 263.

† In the same manner as a soap-bubble when bisected, instead of collapsing, forms, in virtue of the adhesiveness and fluidity of its envelope, two new and perfect bubbles. That the cell-wall of the blood-disk possesses some such endowment seems highly probable. I have on several occasions witnessed, after adding magenta, the total extrusion of the nucleus, both in the frog and in the newt, without the least collapse of the corpuscles.





