

On the anatomy, decay and development of the trichina spiralis / by Dr. Bristowe and Mr. Rainey.

Contributors

Bristowe, John Syer, 1827-1895.

Rainey, G. 1801-1884.

Pathological Society of Great Britain and Ireland.

University of Glasgow. Library

Publication/Creation

[London] : [Printed by J.W. Roche], [1854]

Persistent URL

<https://wellcomecollection.org/works/xe58ngu4>

Provider

University of Glasgow

License and attribution

This material has been provided by This material has been provided by The University of Glasgow Library. The original may be consulted at The University of Glasgow Library. where the originals may be consulted. This work has been identified as being free of known restrictions under copyright law, including all related and neighbouring rights and is being made available under the Creative Commons, Public Domain Mark.

You can copy, modify, distribute and perform the work, even for commercial purposes, without asking permission.



Wellcome Collection
183 Euston Road
London NW1 2BE UK
T +44 (0)20 7611 8722
E library@wellcomecollection.org
<https://wellcomecollection.org>





*I, Hughes & Sonnet & Co
the Author kind regards*
(74)

(From the Transactions of the Pathological Society for 1854.)

ON THE
ANATOMY, DECAY AND DEVELOPMENT OF THE
TRICHINA SPIRALIS.

BY DR. BRISTOWE AND MR. RAINEY.

OUR object, in the following paper, is to give a brief, but connected account, of a series of observations which we have made on the anatomy, degeneration, and development of the *Trichina Spiralis*.

The anatomy has already been described minutely, and, in many respects, accurately, by Professor Luschka. We believe, however, that but little attention has been hitherto paid to the subjects discussed in the later part of our communication, and, though we have investigated them somewhat laboriously, we feel that a great deal remains to be done before the whole truth can be looked on as established, or even before our own views can be unhesitatingly admitted.

The patient in whom the parasite was discovered was a man, æt. 56, who died in St. Thomas's Hospital, of associated pulmonary and cardiac affection. His leg had been amputated by Mr. Solly, about five or six years before death, and since that time he had been constantly about the Hospital. There is no record of any unusual appearance in the muscles of the amputated limb, and at no subsequent period had there been reason to suspect the existence of any imperfection in the muscular system. The diseased condition, which consisted in the presence of large numbers of small, white, oval, or fusiform bodies, which were distinctly visible to the eye, and the direction of which corresponded to that of the muscular fibres, was observed, though unequally marked, in all the striped muscles that

were examined, with the exception of the heart, and nothing similar to it was recognized in any other tissue of the body.

On microscopic examination, it was ascertained that, in the situation of nearly every one of these white spots, there was, more or less enveloped in fat, a small ovoid cyst, which frequently contained a well-formed worm, coiled upon itself, but which even more frequently presented an imperfect animal, or no animal whatever, being either apparently empty, or filled with fat, or encroached on by earthy deposit.

Now, quite irrespective of the suggestions which these different appearances give rise to, it might reasonably be inferred that where so large a number of beings, limited as to their term of life, are disseminated throughout the human frame, they would be present in various stages of development; that some would be in course of formation, others would be matured, others, again, in process of decay; and that examinations conducted with even ordinary care, could scarcely fail to recognise many, at least, of the different epochs in their existence. This we have endeavoured to effect, and in order that the account of our investigations may be as complete as possible, we shall arrange our description of the animal under three heads, which we propose to discuss as follows, in the order of convenience, rather than that of nature.

1. The anatomy of the adult worm and of the structures developed in connection with it.
2. The changes which accompany, and indicate its decay.
3. The mode in which it is developed.

1. *Anatomy of the adult worm and of the structures developed in connection with it.*—In all stages of development, and in nearly all cases, the Trichina-cyst is situated in the centre of a fusiform collection of fat, the long axis of which is coincident with that of the cyst (Plate XIV. Fig. 1); or, in other words, connected with each pole of the cyst there is a cone of fat, the base of which is moulded on the cyst, while its apex points in the opposite direction. The magnitude of the cones, and consequently the amount of fat in them, varies considerably; sometimes they are three or four times as long as the cyst to which

THE HISTORY OF THE

REIGN OF THE

EMPEROR

OF THE

OF THE

OF THE

OF THE

OF THE

OF THE

OF THE

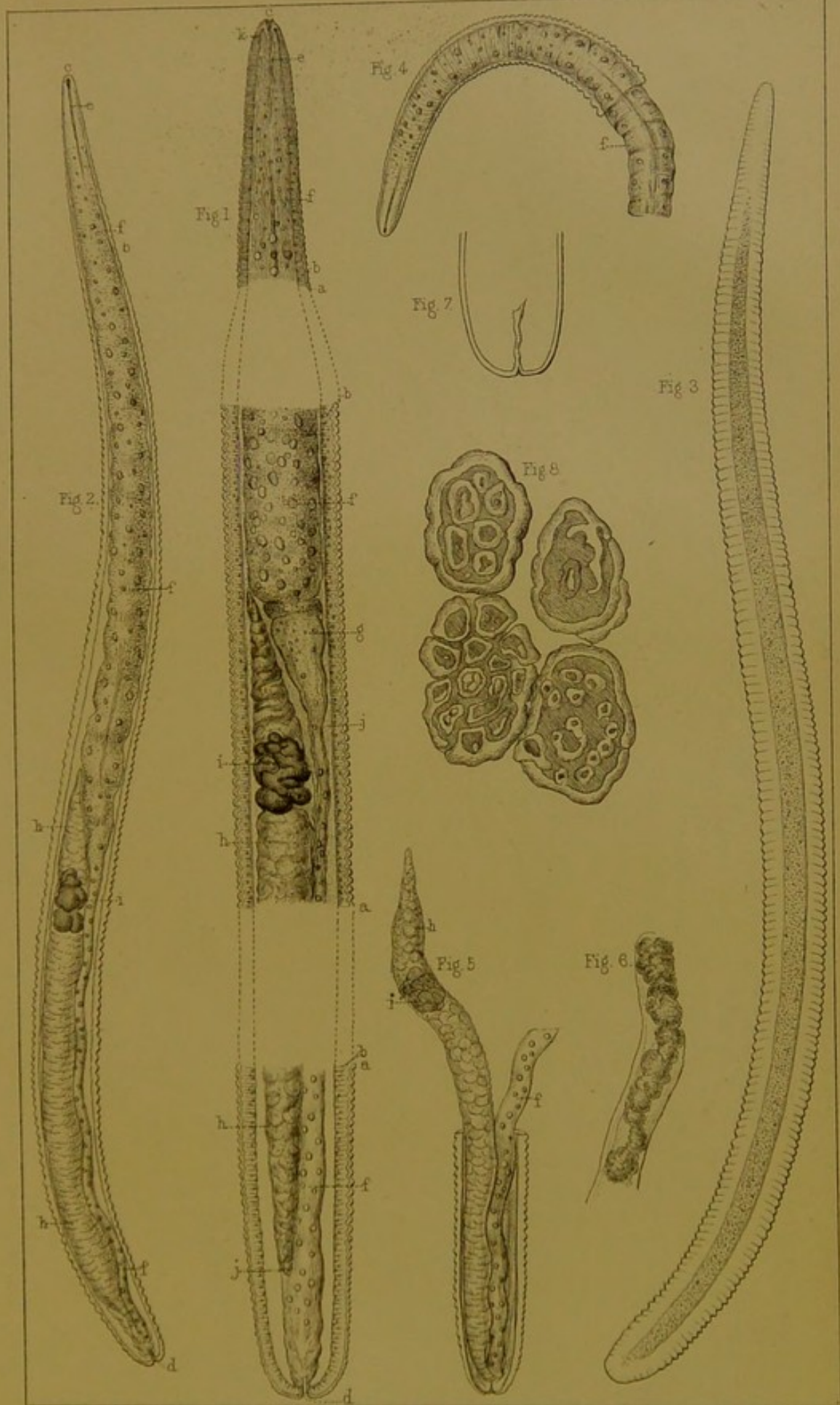
OF THE

OF THE

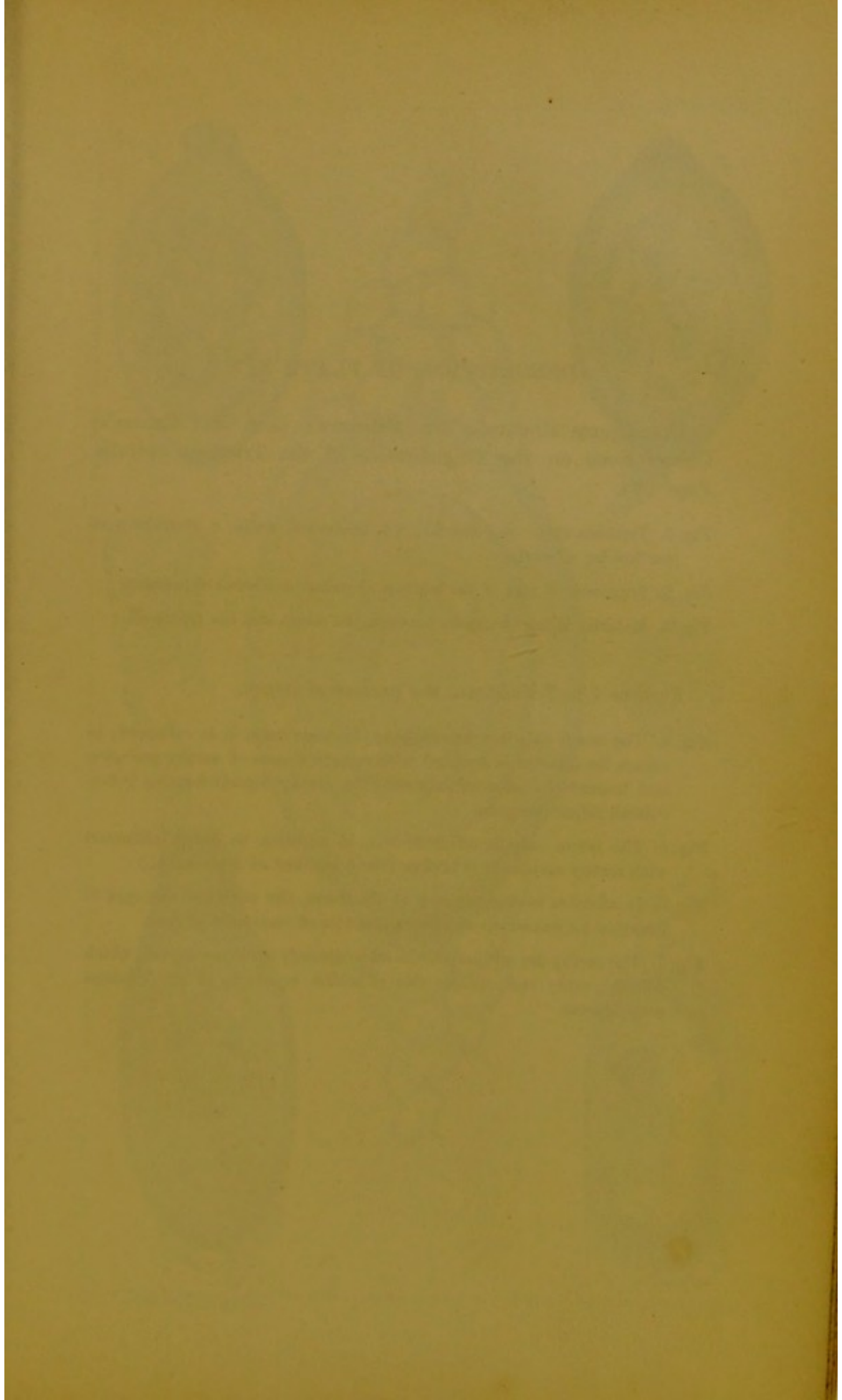
DESCRIPTION OF PLATE XIII.

The figures illustrate Dr. Bristowe's (and Mr. Rainey's) Observations on the Anatomy of the *Trichina Spiralis*. Page 274.


- Fig. 1. *Trichina spiralis*. *a a a*. integument; *b b b*. muscular layer; *c*. mouth; *d*. anus; *e*. cesophagus; *f f*. alimentary canal; *g*. funnel shaped portion, with pyriform bodies at its base; *h*. tube connected with reproductive process; *i*. yellow deposit in it; *j j*. space between muscular layer and parts internal to it. It terminates above in minute points.
- Fig. 2. The same less magnified, intended to show better the relative size and situation of parts. The letters indicate the same structures as in the preceding.
- Fig. 3. The same with its surface in focus, to show one of the longitudinal muscular bands.
- Fig. 4. Fragment of the anterior part of the worm, with the alimentary canal protruding, and apparently exhibiting a central tube.
- Fig. 5. Fragment of posterior part of worm. The generative tube, *h*, protrudes, and its cellular structure is exhibited. A portion of the alimentary canal is likewise exposed. At this part it is contracted, and consists apparently of a structureless membrane studded with refractive globules.
- Fig. 6. Generative tube acted on by acetic acid. The cells are heaped together, and the basement membrane is seen.
- Fig. 7. Integuments of the lower part of the worm from which the entire contents have been separated by endosmose. The crenate appearance lost, and the prolongation into the anus is visible.
- Fig. 8. Appearance frequently presented by fat formed either free among the muscles, or connected with *Trichina* cysts.











DESCRIPTION OF PLATE XIV.

The figures illustrate Dr. Bristowe's (and Mr. Rainey's) Observations on the Degeneration of the *Trichina Spiralis*. Page 274.

Fig. 1. *Trichina* cyst. *a.* polar fat; *b b.* laminated walls; *c.* granular matter inside; *d.* worm.

Fig. 2. Fragment of one of the laminæ, showing its fibrous appearance.

Fig. 3. Material filling the space between the worm and the cyst wall.

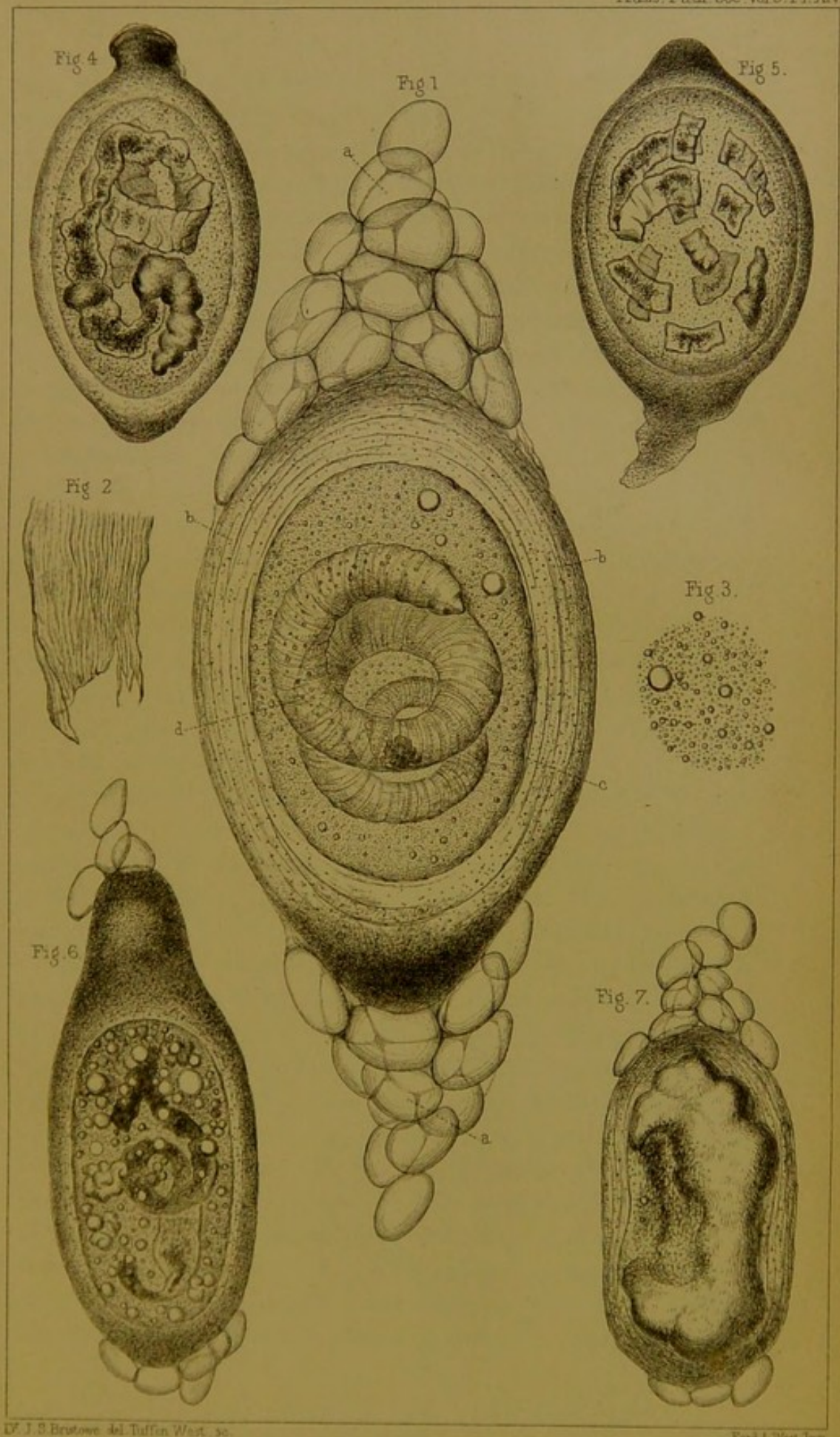
Figures 4 to 7 illustrate the process of decay.


Fig. 4. The worm only is here affected. In some parts it is collapsed; in others its interior is studded with opaque masses of earthy granules; and towards its anterior extremity the earthy deposit forms a tuberculated refractive mass.

Fig. 5. The worm only is affected; but, in addition to being infiltrated with earthy matter, it is broken into a number of fragments.

Fig. 6. In addition to degeneration of the worm, the cavity of the cyst is occupied by numerous refractive globules of carbonate of lime.

Fig. 7. The earthy deposit here forms an irregularly ovoid concretion, which fills the cyst; and on one side of which remnants of the *Trichina* may be seen.





they are appended, sometimes they comprise merely three or four fat cells, usually, however, their size is intermediate between these extremes, and occasionally a cyst is buried in a mass of adipose tissue. Still the amount of fat present in any instance appears to bear no relation whatever to the age of the cyst. It is a somewhat remarkable circumstance that the muscles in this case present numerous collections of fat, which are clearly unnatural, and yet apparently unconnected with the presence of any of the *Trichinæ*, and that these collections, though varying within certain limits, in shape and amount, are usually fusiform, and similar in other respects to those developed in connection with cysts.

The tissue above described is absolutely fat; that is to say, it consists of cells equalling in size those of normal fat, rendered polyhedral by mutual pressure, and filled by a transparent fluid, which is soluble in ether, and which escapes in the form of oil-globules when the cell-walls are ruptured; yet for all this, it presents, in many instances, certain peculiarities which appear to distinguish it from the fat in other parts of the body. In the first place, the interior of the cells is often studded with minute acicular crystals, composed, apparently, of stearine, and, in the second, many of the fat cells manifest a tendency to division and vacuolation (Plate XIII. Fig. 8). In the few cases where the latter process only has taken place, the cells are tuberculated on the surface, and consist of a thick refractive crust circumscribing a central cavity; but in most instances both processes have concurred, under which circumstances the cells are divided into a number of irregular masses of various sizes, each of which is excavated more or less perfectly in the way above described, the margin of the original cell being, however, generally still indicated by a thick, but somewhat uneven refractive frame.

The latter peculiarity is the most important one, but it is by no means constant, and its presence or absence is determined by no evident rule. The best specimen we met with was, certainly, in the neighbourhood of a cyst in process of formation; still it was so often observed connected with perfect cysts, or even with such as were in a state of decay, and on the other hand it was so often absent in

the case of developing cysts, that, though it clearly indicates a peculiar property in the fat, it obviously is in itself an unimportant and accidental modification, and in no way connected with the development, or any other condition of the parasite. It may be added, that almost invariably, in each collection of fat, the character of the component cells is uniform, and also that the fat contained within any cyst always presents the same appearance as that external to it.

The muscular fibres are displaced by the presence of the cysts and their polar fat, and appear connected to these structures by the same means and in the same degree that they are connected to one another, but no further. We are unable to recognize any adventitious formation, or any condensation of tissue analogous to the Hydatid cyst, or to which the term cyst can be applied, independently of that which essentially belongs to the parasite itself. The muscular fibres in the immediate vicinity of the cysts are almost always studded, apparently on the surface, with minute molecules of oleo-albuminous material, but in every other respect they present a healthy appearance. This deposit, which was too frequently met with to allow of its being looked upon as an accidental appearance, resembles the material found in the interior of the perfect *Trichina*-cysts. Its absence was most frequently, if not solely, observed in the neighbourhood of cysts in process of formation.

Structure of the Cyst.—The shape of the cyst (See Plates XIV. and XV., and especially Plate XIV. Fig. 1) is generally ovoid, measuring about $\frac{1}{70}$ th of an inch in the long diameter, and about $\frac{1}{100}$ th of an inch in the short; occasionally it is pyriform, sometimes globular, but very frequently the extremities are more or less elongated or otherwise altered in form. In some cases, the poles are prolonged and attenuated, so that the cyst is rendered fusiform; in some they present nipple-like projections of various sizes, in others they form irregular protuberances, and more than once a cylindrical process was observed about equal in length to the cyst from which it sprung. These modifications of form sometimes exist at one or other extremity only of a cyst, but more usually they occur in both situations at the same time, and, as before hinted at, are frequently altogether wanting.

THE HISTORY OF THE

REIGN OF THE EMPEROR

OF THE

OF THE

OF THE

OF THE

OF THE

OF THE

OF THE

OF THE

OF THE

OF THE

DESCRIPTION OF PLATE XV.

The figures illustrate Dr. Bristowe's (and Mr. Rainey's) Observations on the Development of the *Trichina Spiralis*. Page 274.

Fig. 1. represents a fusiform collection of fat, in which an ovoid central portion is becoming separated from the rest by an indistinct membrane, which, in this instance, is almost solely indicated by the accompanying granular deposit.

Fig. 2. The sides of the cysts are here tolerably perfect, but the ends are incomplete, so that the part within still communicates with that without.

Fig. 3. The cyst is complete. Its cavity is filled with fat, and between the contained fat and the cyst wall several nuclei may be detected.

Fig. 4. A cyst containing the fat cells and large numbers of nuclei. Its inner surface is somewhat irregular, an appearance occasionally present in the young cyst.

Fig. 5. A cyst containing fat and nuclei; but in addition to these there is an imperfect worm.

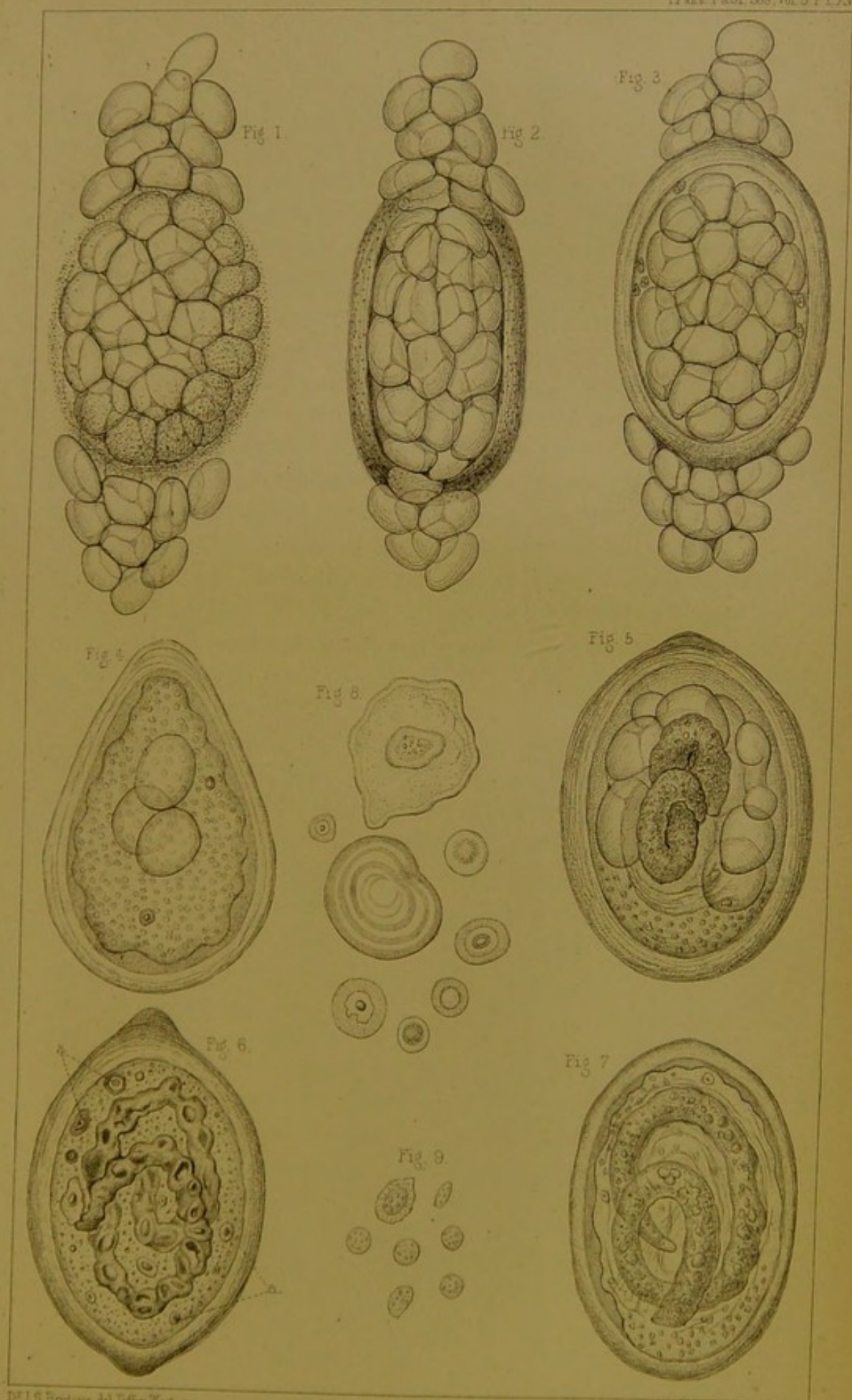
Fig. 6. Cyst presenting an imperfect worm. The latter exhibits no indication of organisation, but consists, apparently in great part, of masses of oily substance, in which there is a tendency to the same process as that represented in the fat found in certain other parts. (Plate XIII. Fig. 8).

a a. Concentric bodies or cells.

Fig. 7. Cyst containing an imperfect worm and large numbers of nuclei. The worm is somewhat irregular in outline, and appears to be made up of an oily-looking material. Around it, occupying the cavity of the cyst, are a number of membranes or fibres, which, most probably, are remnants of the walls of fat cells.

Fig. 8. Concentric bodies or cells magnified 670 diameters.

Fig. 9. Nuclei magnified to the same degree.





The cavity of the cyst is more uniform in shape, being ovoid pyriform, or globular, according to the general form of the exterior, but it never extends into the polar enlargements, or takes any part in their formation. The walls are of considerable thickness, and vary between $\frac{1}{100}$ th and $\frac{1}{150}$ th of an inch at the sides. They are usually a little thicker at the ends than elsewhere, even if the shape of the cyst is regularly ovoid; but when enlargements occur at these points, the thickness of the walls becomes increased in proportion to them. The parietes consist essentially of a transparent, refractive, laminated material, which is often rendered opaque by a deposit of minute granules. This deposit is generally more copious on the outer than on the inner surface, and diminishes through the thickness of the wall from one to the other, but occasionally it is most abundant on the inner aspect, and becomes less so towards the outer. In nearly every instance it is most dense at the poles, and especially so if they present conical or other enlargements, under which circumstances these often appear perfectly opaque and black to transmitted light. In many cases the granular formation is altogether absent, but, in the majority of instances, a greater or less amount is present, and oftentimes it is so abundant, as almost, or even entirely to conceal the cyst-contents. Its absence or presence, or its amount, when present, seems quite a matter of accident, and is perfectly unconnected with the age of the *Trichinæ*; it is quite as abundant in some of the forming and adult cysts as it is in the degenerating ones, and both the degenerating and fully-formed cysts are often totally free from it. It is rapidly dissolved in hydrochloric acid without any appearance of effervescence, and probably, therefore, consists of phosphate of lime.

In cysts which have been rendered transparent by the action of acid, or still better in those which are naturally clear, the structure of the walls is easily recognized. They are distinctly laminated, but the concentric lines indicating this arrangement are not nearly so sharp and well-marked as those characterizing the Hydatid membrane. Now and then, but comparatively rarely, one of these lines can be distinctly traced all round, and the *Trichina* cyst then seems to be divided into two more or less

distinct capsules; this appearance, however, is clearly an accidental one, and cannot be considered to indicate an organic distinction, for it is certainly absent in the great majority, and even when present, the parts external, and those internal to it, present precisely similar anatomical characters. Generally, the laminae are partially separated, here and there, from one another, the resulting spaces being either empty, or filled with granular matter, or containing a few small nuclei, like those afterwards to be described. Such spaces, though not altogether wanting in the sides, are most abundant at the ends, and on their presence, the slight increase of thickness at these points is generally dependant. Further, in all those cases in which enlargements, whatever their form, occur at the poles, they are due to a similar but much more extensive separation. In some of them the enlargements are simply dependant on a series of separations, placed directly one over the other, but in most of them they are wholly or in great measure produced by a single large interval, which contains either one or more fat cells, or a refractive earthy concretion, soluble with effervescence in hydrochloric acid, or a few nuclei enveloped in granular matter. Although, from the account we shall give further on, there is good reason to suppose that the earthy deposit is a later appearance than the fat, and an indication of decay, still, it must be confessed, that it is sometimes present in the poles of cysts which contain perfect animals, or animals in an embryonic condition; while, on the other hand, fat still persists in the extremities of some of those that are in progress of decay.

Fragments of the laminae entering into the formation of the cyst-walls are often accidentally detached, and their structure becomes apparent (Plate XIV. Fig. 2). At first sight they appear to consist of uniform and parallel fibres, but they are really rather to be looked on as portions of a membrane which is marked by parallel lines or depressions, arranged at equal intervals; for they retain, under all circumstances, their membranous character, and never become resolved into simpler anatomical elements. The structure is certainly different from anything we have ever seen in any kind of false membrane, and cannot be confounded with any such formation.

Contents of the Cyst.—The worm is not present in every cyst; and even when present is often in a state of decay, or in process of formation. We have never, under any circumstances, seen more than one in a cyst; and, indeed, from the manner in which the occurrence of two or three in such situations is generally alluded to, we suspect that it has been hastily admitted, and that it is probably an error. In its normal condition the worm generally forms a spiral of two, three, or even four turns, the axis of which corresponds either to the long or to the short diameter of the cavity in which it lies. (Plate XIV. Fig. 1.) The curvature seems always to take place in one direction, so that, except some alteration in this respect has been produced by violence, the different parts always hold the same relative position to the eye of the observer. The material which fills up the space around the worm is often somewhat opaque, and consists of refractive molecules and globules of various sizes suspended in an apparently viscid fluid; at all events the material, after its escape from the cyst, retains, for a time, the form impressed on it at the time of its exit. (Plate XIV. Fig. 3.) We have never detected in it anything that could be called a nucleus or a cell.

The worm (Plate XIII. Fig. 2), measures about $\frac{1}{35}$ th of an inch in length, and $\frac{1}{720}$ th of an inch in thickness; it tapers gradually towards the anterior extremity, which is somewhat sharp; and again, but in a less degree, towards the posterior, which is obtuse and rounded. So far as we have been able to ascertain, it presents a distinct integument, lined throughout by a muscular layer; an oral and an anal orifice, and an alimentary canal passing directly from one to the other; in addition to which, there is in its posterior third another tube, which is probably connected with the reproductive function.

A. The integument (Plate XIII. Figs. 1 and 2) is distinctly visible at every part of the surface; it is transparent and homogeneous, and its thickness, which is about $\frac{1}{16000}$ th of an inch, but which diminishes towards the extremities, is indicated at the apparent margins of the animal by two sharp, parallel, finely-crenated lines, which correspond respectively to its inner and to its outer surface. The crenations are the lateral manifestations of alternate annular constrictions and elevations which

exist throughout the entire length of the worm, but which are less distinct and altogether smaller at the ends than in the intermediate parts. When the body is distended from endosmose (Plate XIII. Fig. 7), the annular markings disappear, and the lines indicating the thickness of the skin become straight and parallel, so that the crenated appearance is not dependant on varying degrees of thickness in the integument. On one occasion when thus distended, all the soft parts in the neighbourhood of the anus were separated in mass from the integumentary covering, and it was clearly seen that the latter was prolonged inwards for a short distance, as a lining to the lower part of the excretory apparatus (Plate XIII. Fig. 7).

B. Immediately within the integument is a layer of variable thickness (Plate XIII. Figs. 1 and 2), generally three or four times that of the former, which consists of a soft, transparent, faintly-yellowish material, the outer part of which is structureless, while the inner is studded with minute refractive granules. Its external surface is pretty firmly adherent to the inner surface of the skin, but its internal aspect, which is somewhat irregular and soft in outline, seems unattached to the structures with which it is in contact. This layer lines every part of the integument, but exists in diminished quantity in the neighbourhood of the head and tail. In the latter situation it is reflected on to the internal prolongation of the skin, but soon becomes undistinguishable; at the opposite extremity, where it loses all traces of granularity, it appears to become continuous with the parietes of the œsophagus. The existence of this layer is tolerably manifest in most of the animals even in their entire state; it becomes clearly evident when, from accidental contraction of the structures internal to it, a vacant interval is formed between them; and when the contents of the worm protrude either in the form of a hernia or from a divided end, its torn extremities are always distinctly visible. Besides this expansion, which seems completely to invest the animal, there are two bands (Plate XIII. Fig. 3.) passing from the neighbourhood of the head to that of the tail, one situated on its upper, one on its under surface. They measure about one-third the breadth of the body; their margins are indicated by distinct parallel lines,

and their substance by a minutely granular appearance, much like that observed in the inner-half of the layer before described. These bands might easily be mistaken for a central cylindrical canal, but by careful adjustment of the focus it may be easily ascertained that such is not the fact; for they are invisible when the axis of the worm is in focus, but become evident when either its upper or under surface is brought into view. The uniformly-diffused layer and the longitudinal bands seem identical in structure, and are both partially dissolved and expanded by acetic acid. There can be little doubt, we think, both from their character and from the position they occupy, that they are to be looked on as a muscular development.

c. The oral aperture (Plate XIII. Figs. 1 and 2, *c.*) occupies the extreme anterior point of the worm, is generally well-marked, and may appear either as a conical depression, a minute papilla, or a circular, or ovoid spot. The anal orifice (Plate XIII. Figs. 1 and 2, *d.*), situated in the centre of the opposite extremity, is equally distinct, and is generally indicated by a slight depression.

The intestine (Plate XIII. Figs. 1 and 2, *fff.*), in the anterior two-thirds of its course, presents a tolerably uniform character, and in its normal state completely fills the cavity of the worm, although it seems to be unconnected with the muscular layer, and often becomes separated to a greater or less extent from it. The commencement of its canal, or the cavity of the œsophagus, may be easily recognised in the transparent anterior extremity of the animal, by the inner surface of its walls, which appears as two parallel, straight or sinuous lines, separated by a slight interval. These can be traced directly from the oral orifice, but after a short course they become indistinct, being concealed by the gradually accumulating granular matter around them. External to this, and about half way between it and the margins of the animal, two other lines may be recognised, one on either side, each of which begins in a minute transparent point (Plate XIII. Fig. 1, *k.*) immediately below the mouth. By tracing the lines backwards it becomes apparent that they represent the anterior portion of that interval which exists between the muscular coat and the intestinal wall, which structures become continuous above the bright spots just mentioned. In the remainder of its course the anterior division of the intestine gradually increases

in size until it attains its full diameter; and its structure, in some respects, is rendered more distinct. Its character may be sometimes discernible while it is still *in situ*, but it is best recognised when a portion projects from a broken end (Plate XIII. Fig. 4). It is distinctly sacculated, transparent, and contains a considerable number of round, or irregularly-shaped refractive, slightly yellowish bodies, of large comparative size, which are clearly within it, but appear to be situated in its periphery. The axis of the sacculated intestine seems to be occupied by a cylindrical canal, which is always more or less indistinct, and which is probably the true intestinal cavity continued directly from that of the œsophagus, while the tissue around it, that is, between it and the surface of the intestine, is most probably the direct continuation of that which forms the walls of the œsophagus. But whether it is to be looked on merely as the intestinal wall, or whether it is developed for the purpose of ministering to any special function, or whether it is the true parenchyma of the animal, may be a matter of doubt. The tissue swells up under the influence of acetic acid, but it is not solid, for, on pressure, the globules which it contains may often be made to move from one part to another, or to escape through an accidental wound.

At the commencement of the posterior third of the worm the intestine becomes abruptly funnel-shaped, and in the rest of its course forms a slender, slightly-meandering canal (Plate XIII. Figs. 1, 2, and 5), which occupies the concavity of the worm, and becomes a little expanded just above the anal aperture, with which it appears to communicate by a short contracted tube. We have never been fortunate enough to obtain the funnel-like portion (Plate XIII. Fig. 1, *g.*) in a free state, yet we have seen it so distinctly in several instances while *in situ*, that we entertain no doubt of its existence; and of the presence, moreover, at its junction with the sacculated portion of the intestine, of two small, lateral, pyriform, yellowish offshoots. We suspect that the funnel-like appearance is due to the gradual diminution of the tissue around the proper intestinal canal, and that the continuation of the latter alone forms the remainder of the intestine. This possesses, we believe, membranous

walls, which are invariably characterised by being studded with numerous globular refractive bodies of uniform size; but we do not recognise in it either nuclei or an epithelium. We believe that it forms a direct communication with the anus, and that we have several times seen that communication, but it is so obscured by the presence of the second canal, and of other tissues, that it may be, perhaps, unsafe to speak positively on the point.

D. Besides the intestinal canal, there extends through the posterior third of the animal, and occupying its convexity, another tube, which is of large size, and often fully half as thick as the body of the animal (Plate XIII. Figs. 1, 2, and 5). It terminates above in a blind conical extremity, the apex of which corresponds in situation to the base of the funnel-shaped portion of the intestine. Its lower extremity is not so distinct; sometimes it has appeared to end in a narrow cæcum, a little anterior to the termination of the intestine; but at other times we have seen it continued directly to the anus, so that there can be little doubt of its communication with that orifice. This tube differs remarkably in structure from every other part in the animal, and presents no trace of the granules and globules so abundant elsewhere. When seen in its normal position, it presents a delicately mottled appearance; when free, and we have sometimes had it with its conical extremity projecting (Plate XIII. Fig 5.), it may be seen distinctly that this mottled appearance is due to the fact of its cavity being occupied by polygonal, non-nucleated cells, of various sizes, which sometimes seem arranged so as to circumscribe a central canal, but which generally appear to fill the entire tube. By the employment of acetic acid we have more than once seen a delicate basement membrane lifted from the mass of cells, so that there can be little doubt that the tube is to be looked on as a true canal lined by a proper epithelium (Plate XIII. Fig. 6). At the upper part of this tube, and at the base of its conical extremity, the yellow mass (Plate XIII. Fig. 1, *i*.) observed by Dr. Farre, is often, though not always seen: it appears to us to be due to a deposit of yellow, oily matter, probably in the interior of the cells. It occupies the entire thickness of the tube, but a variable

portion of its length; when it escapes, it runs into yellow oil-like globules of different sizes.

The above description of the cyst and worm resembles in most particulars that given by Professor Luschka in his valuable paper published in the third volume of Siebold and Kolliker's "*Zeitschrift für Wissenschaftliche Zoologie*;" still, it differs from it in many points, and to the most important of these we will now draw attention.

1st. This gentleman considers the *Trichina*-cyst to be double, the outer part belonging to the human being, the inner to the worm; and he describes a special arrangement of vessels developed in connection with the outer membrane. The existence of blood-vessels around and upon the cysts we do not doubt, but we question the importance which he attaches to their presence, believing them to be merely the proper vessels of the muscle displaced by the cyst, and spread out on its surface; and at the same time, for the reasons before given, we have no hesitation in affirming that the cyst is essentially one, and the property of the parasite itself.

2nd. In describing the anatomy of the worm, he states that the parietes of the posterior third of the alimentary canal are formed of hexagonal cells. This appearance we have not recognised; but with regard to the second tube occupying this portion of the animal, we have observed, beyond a doubt, that it possesses an epithelial lining, a fact which he does not appear to have remarked.

3rd. He states that both the intestine and the tube connected with the generative process end by free extremities in the posterior part of the worm, and that the anal end of the animal presents three flaps. Now we are confident all this is erroneous; the flaps have no existence, the posterior extremity being rounded, as in our drawings, or, at most, slightly indented; and the canals, instead of ending freely, are prolonged directly to the anus itself, or are attached to it through the medium of other structures.

4th. He imagines that the tube in the posterior third of the worm is a testicle, and that the sacculi or some other parts in connection with the intestine form an ovary. This view may

or may not be correct, but certainly we do not think he has brought forward sufficient evidence in support of it. In fact, in our opinion, one of the chief reasons he advances for considering the latter an ovary, namely, that it presents bodies like those occupying the cavity of the cyst, appears opposed to his opinion rather than in favour of it; for, in the first place, in neither situation have the bodies any character that would warrant one in believing them to be eggs; and in the second, it seems very unlikely that the eggs should be so frequently and so numerous deposited in situations so inappropriate for their development.

5th. He describes the *Trichina* as being remarkably tenacious of life, and his description of its movements is so minute and careful that we can scarcely fail to be convinced of the correctness of his conclusions; most of the specimens we have more recently examined have been preserved in glycerine, and often, even up to the time of writing this paper, six or eight weeks after the *post-mortem* examination at which they were discovered, we have distinctly seen them, when removed from their cysts, perform motions that it was difficult to believe were not the manifestations of life. On the whole, however, the conclusion at which we have arrived is, that they probably depended on the absorption of fluid from endosmose into the body of the worm.

Finally. There are other minute differences between us, both in the description of the cyst and in that of the worm, but it seems unnecessary to dwell upon them, for, to the majority of readers, they would probably be uninteresting, while those who take a deeper interest in the subject will scarcely fail to refer to Professor Luschka's own description.

2. *Degeneration of the Trichina.*—The contents of many of the cysts differ materially from the contents of those we have hitherto described, and the appearances are such as can only be the result of their death and degeneration. It is worthy of remark, however, that the walls of such cysts seem almost invariably to present as complete and healthy a structure as those which contain the most perfectly formed animals.

The abnormal appearances alluded to are due to the deposit of earthy matter, at one time confined to the worm itself, at another time, perhaps, to the space around it, but mostly occurring in both situations at the same time, though not always in a proportionate degree.

In those cases where the worm only is affected, it appears, in the first instance, to become irregularly collapsed and flattened, all distinct evidence of internal organisation disappears, and even its annular markings are often altogether obliterated. Its interior becomes studded with opaque irregular masses of granular matter, which are sometimes pretty uniformly diffused through it, but are generally aggregated in certain spots, the intervals between which remain tolerably transparent. In a later stage the opaque deposit is less abundant, and the substance of the worm is infiltrated, more or less, by a refractive, slightly tuberculated material; but as both forms are soluble in hydrochloric acid with effervescence, it seems probable that the different appearance of the deposit in the latter case is due to the coalescence of the juxtaposed and originally distinct earthy granules constituting the opaque masses (Plate XIV. Fig. 4). Even in the earlier stages there is a tendency in the degenerate worm to become broken transversely, but this brittleness is much more marked in the later periods; and frequently cysts can be seen filled with small oblong fragments, partly refractive, partly opaque, which are clearly the remains of their calcified occupants, and which frequently so far retain their relative position as to indicate the course of the original convolutions (Plate XIV. Fig. 5). Associated most frequently with this degeneration of the animal, is observed a deposit in the cavity of the cysts around it, which varies in amount, and is sometimes so abundant as totally to conceal the remains of the worm. This deposit may be described as existing under three forms, which, however, merely represent successive stages in its formation, and not essential differences. In the first and earliest condition, it consists of bright refractive, slightly yellowish, globules, varying from about the $\frac{1}{1000}$ th of an inch in diameter downwards, and looking so exactly like oil, that they can only be distinguished from it by the action of re-agents. Often merely a few

of these are apparent, but sometimes the cyst is so completely filled by them, that the worm, if present, is quite invisible (Plate XIV. Fig. 6). In the second condition the deposit partly exists under the form of distinct globules, but partly, also, consists of tuberculated masses of various, and often considerable size, which appear to originate in the coalescence of the former. In the third and last form, the cyst is filled by an ovoid semitransparent concretion, which generally has a faintly yellowish hue, but sometimes an inky tint, and, in the centre, or at the side of which, the collapsed and opaque remains of the worm are more or less distinctly seen (Plate XIV. Fig. 7). Concretions of this kind readily crack under pressure, and some even appear to have become fractured independently of *post-mortem* violence. All the varieties of deposit above described, whether occurring within the body of the animal, or external to it, dissolve readily with copious effervescence in hydrochloric acid, so that they evidently consist, in part, at least, of carbonate of lime. In every case, without exception, it seems to differ in chemical composition from the granular material deposited in the walls of the cysts, for, as has already been stated, no effervescence accompanies the solution of the latter in acids. Indeed it is curious to watch the action of this re-agent under the microscope. Its passage through the cyst wall is indicated by the gradual disappearance from without inwards of the granules there deposited, without any accompanying evolution of gas, but no sooner has it permeated the walls, and reached the contents, than violent effervescence ensues, which ceases only when all the earthy material occupying the cavity of the cyst is dissolved. After the earthy matter has been removed by this means, the indistinct remains of the worm are nearly always visible, and generally a greater or less amount of albuminous material and oil is left, which have either formed the organic basis of the earthy matter, or are the remnants of the material which originally occupied the cavity of the cyst.

From the above description it follows, that the death of the *Trichina* is characterized by the appearance of earthy matter, both in the substance of the animal and in the space around it; that in the former it is deposited in the shape of amorphous

granules or minute spherules, which ultimately coalesce to form a transparent homogeneous mass; that in the latter it appears in the form of globules of various sizes, which simulate oil in a remarkable manner, and which, after a time, run together, and finally produce a solid cast of the *Trichina*-cyst, which probably remains in the situation in which it was formed as a permanent, innocuous, foreign body. The very nature of the process seems to indicate that it is one of decay, and that it actually is so is abundantly confirmed by the fact, that it is essentially identical with the process of degeneration as it occurs in an analogous parasite, the common hydatid.

Development of the Trichina.—The subject of the development of the *Trichina*, which it may be thought should have formed the first, or, at all events, an earlier part of this paper, we have reserved till now, partly because it has been less completely investigated, and partly because our views with reference to it could only be thoroughly explained after the structure of the animal and its mode of death had been duly appreciated.

Before giving our explanation of the facts observed in relation to this part of our inquiry, we will briefly state the facts themselves, taking no further liberty with them than that of arranging them in what appears, to us, to be their chronological order.

1. In an earlier part of this communication, we have mentioned that not only is nearly every cyst situated in the centre of a certain amount of fat, but that, besides this, the affected muscles are studded with deposits of adipose tissue, which clearly are an abnormal development, associated in some mysterious way with the presence of the parasite, and yet, apparently, not directly connected with any *Trichina*-cyst. Some of these collections consist merely of three or four fat vesicles, variously arranged; others, of a very large number, irregularly clustered; whilst the majority form fusiform masses, equalling in size and shape some of those in which are situated perfect cysts.

2. At the centre of many masses of fat, in other respects resembling those last mentioned, an ovoid portion, exactly similar in size and shape to a perfect *Trichina*-cyst, is marked

off, more or less distinctly, from that around it. Sometimes the separation seems to be merely due to a slight difference in the arrangement of the fat cells; those forming the periphery of the ovoid mass being somewhat flattened on the surface, or in some way or other more definitely arranged than those in their immediate neighbourhood. Sometimes a similar portion is partially surrounded by a transparent homogenous membrane, of varying thickness, sometimes by a deposit of granules, identical in appearance and composition with those occurring in the walls of more perfect cysts. (Plate XV. Fig. 1). The presence of the latter is probably to be looked on as accidental, but it is, to a certain extent, of value, inasmuch as by its opacity it serves to point out the existence of a wall in situations where no membranous formation is visible. These indications of a cyst-wall are generally somewhat unequally distributed, being sometimes more marked at one end than at another, and sometimes more visible at the sides than at either extremity. In every case the fat within them is precisely similar to that without.

3. In other cases may be detected cysts with the sides perfect, of normal thickness, laminated, with or without granular deposit, but with one or both of their apices deficient, so that the fat which invariably fills them is directly continuous through the deficiencies with that external to them. (Plate XV. Fig. 2.)

4. Perfect cysts, occupied by fat, which accurately resembles that on the outside, and yet is perfectly separated from it, are present in tolerable abundance. In many of these, globular or lenticular granular nuclei (Plate XV. Fig. 9.), about the $\frac{1}{4000}$ th of an inch in diameter, are seated between the interior fat and the cyst-wall, and are generally clustered in the small angular intervals formed by the divergence of contiguous fat cells. (Plate XV. Fig. 3.)

5. Others are to be met with which contain large numbers of nuclei, but few or even no fat vesicles. (Plate XV. Fig. 4.)

And lastly, Many cysts may be observed which present imperfect worms, that is, worms in which both internal and external organization are more or less indistinct, yet in which there is no deposit whatever of earthy matter. Such animals are sometimes recognised in cysts, which are still, more or less,

filled with fat, the fat cells appearing larger than usual, and apparently, in some cases, coalescing (Plate XV. Fig. 5); sometimes they are observed in cavities, which are crossed in different directions by membranous bands or fibres, the remnants, probably, of collapsed and empty fat cells (Plate XV. Fig. 7); and frequently they are met with in cysts, in which neither fat nor fibres are apparent. (Plate XV. Fig. 6.) The space around the animal, whether it contains fat or fibres, or neither of them, is generally studded with nuclei, such as are described above. Their number, however, varies considerably, and an absence of them occurs, we believe, only in those cases in which the animal approximates to its perfect condition. Besides nuclei, there exist, frequently in the same situation, peculiar cells (Plate XV. Fig. 8), or rather bodies, varying from about the $\frac{1}{60}$ th of an inch downwards. They are round, or slightly sinuous in outline, and in their most characteristic form consist of concentric rings of refractive material, separated from one another by distinct intervals. The smaller ones are often composed of one such ring only, surrounding a central cavity, but the larger ones present frequently as many as six or seven of them. In what is apparently their earliest condition, these bodies exist as oily-looking spheres, in which, judging from the difference of refractive power in different parts, there is clearly a tendency to a process of vacuolation. These formations, though frequently associated with the nuclei, are not in proportionate numbers to them, and in some instances are present when the nuclei are altogether wanting. What their exact nature is, it is not easy to determine, but their characters, though much more symmetrical, so strongly remind us of those which we have described and figured as occurring occasionally in the fat, that we are inclined to believe that these bodies are to be looked on as peculiar modifications of fat rather than as cells.

The imperfect animals present certain differences among themselves, but the varieties of character are neither so numerous nor so well marked as to require a lengthy description. In some cases they seem to consist of little else than an aggregation, more or less dense, of small oily particles; in other cases they are irregular and tuberculated, and formed of oily matter arranged in masses of various sizes in which that tendency to

become hollowed out and divided before alluded to is distinctly manifest (Plate XV. Fig. 6); and in other instances again, the worm has assumed a more definite shape, its parietes, though still imperfect, are visible, and its substance, though not distinctly organized, presents a more uniform condition than that of the former, and altogether a more characteristic appearance (Plate XV. Fig. 7).

It is at once obvious, that since none of the appearances above-described belong to the perfect condition of the parasite, they must be associated either with its development or with its decay.

Assuming that they are due to the latter process, the sequence of events would be, first, the conversion of the animal into oily matter, and the simultaneous production of cells or nuclei; second, the gradual disappearance of these, accompanied by the development of fat in the interior of the cyst; and, lastly, the absorption of the walls of the cyst, and the coalescence of its fat with that external to it. Now it seems to us that no very strong arguments can be adduced in favour of this view, while several obvious objections to it at once suggest themselves. In the first place the appearance of nuclei in large numbers can scarcely be looked on as an evidence of death, and, indeed, they are totally absent from those cysts that are in a state of earthy degeneration, and are never present, even in the perfect ones, except occasionally, and then indistinctly in the substance of their walls. In the second place, the conversion into cells, even though they be fat cells, is not a recognised method of decay; the deposit of oil-globules in tissues, as an evidence of their degeneration, is frequent enough, it is true, but that is altogether a different thing from the formation of actual adipose tissue; we never found a liver, a kidney, a brain, a muscle, or even a thymus, changed into fat, though the tissues of some of them may be displaced by it, and may ultimately become atrophied; still less are we likely to find any parasitic being thus converted; and, most certainly, such a phenomenon never takes place in the Hydatid. Lastly, we have already described one kind of degeneration totally different from this, resembling the process as it occurs in other parasites, and consisting in a deposit of earthy matter in the

interior of the cysts; the occurrence of this seems to render the existence of any other form of degeneration unnecessary, and therefore, to a certain extent, improbable; and the more so, as the calcified remains are so abundantly met with as to constitute, in themselves, an apparently fair proportion of defunct animals to the number of the living.

But all that has been here adduced against the idea of the appearances we have described being evidences of decay, namely, the fact of the formation of nuclei, the development of cells, and the actual existence of another recognised form of degeneration, are reasons in favour of the opposite view, and in corroboration, it may be added, that in a case in which so vast a number of beings were present, and in which, according to all human probability, they existed in every stage of development, it would be a remarkable fact, if, after some hundreds of observations, many of which were instituted with special reference to this object, no trace should have been discovered of any earlier condition of the animal than its adult state. Yet, if the appearances we have enumerated do not belong to the development of the worm, such is the position in which we shall stand; we shall have examined some hundreds of cysts, we shall have looked earnestly and anxiously for anything that could throw light on their formation, and yet we shall have totally failed in discovering any, the remotest trace of a process which, unquestionably, must have been going on in nearly every part of the muscular system.

The view we have adopted may now be briefly stated. A certain amount of material, apparently fat, is formed between the muscular fibres; a portion of it, equal in size to a *Trichina*-cyst becomes separated from the rest, at first indistinctly, and ultimately by the formation round it of a perfect cyst wall; the adipose tissue thus circumscribed, retains, for a time, its original character, then gradually vanishes, and nuclei make their appearance; finally, traces of a worm become visible, which, in proportion to the disappearance of the fat and nuclei become more and more distinct, till at length they result in a perfect *Trichina*. We believe that in the course of this process the fat cells have a tendency to coalesce and enlarge, and that the nuclei, though their exact function is not easy to determine,

play an important part in those intermediate changes which occur between the appearance of the animal and the disappearance of the fat; but what the signification of the concentric bodies may be, is not very clear; we are inclined to suspect, however, that they are not so much agents in the work of development, as they are peculiar, though accidental, phenomena, making their appearance in the course of that process.

Now, the formation of a worm from the contents of a cyst, by the successive stages we have here indicated, is sufficiently in accordance with the ordinary mode of development in the egg, to render it a not improbable occurrence. The chief difficulty, and seeming anomaly, lies in the original formation of the cyst itself, and to the examination of this subject we now proceed.

A very little consideration of the matter will show that the cyst must have been produced in one of these ways. It must either have been a result of equivocal generation, or it must have been deposited bodily, as an ovum, or it must have been developed *from* an ovum. These alternatives we will discuss separately,—

1st. If we allow the possibility of the occurrence of equivocal generation, there is little difficulty in adapting it to the present case; indeed the facility with which every phenomenon may be explained is remarkably seductive; still, as all evidence goes to disprove the existence in any shape whatever of this mode of development, and as the facts in this case are not so wholly inexplicable on other principles as to render it necessary to have recourse to it, we cannot, consistently with the principles of philosophy, admit its operation in the present instance.

2nd. The characters of the cyst, and the nature of the process that clearly goes on in it, at once suggest a close analogy between it and an egg: yet, it cannot strictly be regarded in that light, except on the supposition that it is deposited as such by a parent worm of proportionate size. This idea may not seem altogether unreasonable, indeed it may seem very probable that if the *Trichina* is an embryonic animal, it should, in some cases, escape from its prison, and become developed in the usual manner into a worm of such dimensions as to be capable of depositing ova as large as a *Trichina*-cyst. Still,

reasonable and probable as all this may appear, it is inconsistent with facts; such a worm has never been met with, though its size would have rendered it tolerably conspicuous; and moreover the appearances we have described are not in accordance with it, for it fails to account for the presence of fat in abnormal situations, it fails to explain the appearances which we suppose to represent the earliest condition of the cyst; and further, as in this case, the deposit of fat around a cyst would be a secondary phenomenon, it ought to be absent from the youngest ones, and to increase in amount according to their age, whereas if we were to venture to state any rule with respect to its presence, it would be that, it is generally most abundant around the youngest cysts; and lastly, the shape of the cysts is very various, and certainly some of them are very un-egg-like in appearance. If, then, we reject this view, as well as the previous one, which it seems obvious we must do, we are reduced to the necessity of adopting the third alternative which is, that the *Trichina*-cyst is developed *from* a germ deposited by a pre-existing animal.

It is self-evident if the previous theories have been satisfactorily disproved, that as the *Trichina*-cysts are themselves stationary, and yet are found in every part of the muscular system, their germs must have been diffused by animals which possessed and used the power of locomotion. Now, though this may have been effected to a certain extent by that being, whatever its nature, which was their original progenitrix, it is indubitable that the chief diffusion must have been brought about by the deposit of ova by *Trichinæ* themselves, which had escaped from the cysts in which they were contained. The existence of empty cysts is favourable to this view, and the non-discovery of free worms in the muscular tissue is not against it, for, from their small size, and from the probable rarity of their escape, they might easily elude detection, and even if found might be supposed to have been squeezed accidentally from neighbouring ruptured cysts.

But what are the changes that go on in an ovum thus laid down? It is clear that it cannot form an embryo in the usual way. It is clear also that the ovum does not grow bodily until it attains the bulk of a perfect *Trichina*-cyst, because we

have seen no indications whatever of those graduations of size which would, under such circumstances, necessarily exist between the original minute ovum and the perfect *Trichina*-cyst; on the contrary, all cysts, whatever their degree of perfection, are, as nearly as possible, of uniform dimensions. Hence it follows, that the germ must have undergone some peculiar mode of development, in virtue of which it must have produced that accumulation of fat which seems invariably to precede the formation of a *Trichina*-cyst, either by itself becoming converted into cells, which, by assimilating fat from the surrounding tissues, ultimately assume the visible character, though not the function of true human fat, or, what is perhaps the same thing, their presence must have provoked a deposit of fat, on which they impressed peculiar and characteristic properties.

We are fully sensible of the difficulties that beset this explanation; it seems strange, if not incredible, that a germ should become developed into tissue resembling human fat, and that a portion of this tissue should become separated from the remainder by a cyst wall; that a body resembling an ovum, in all things except its manner of development, should be thus produced, and that changes in its contents resembling those in an ovum should occur, and result in the formation of a perfect worm. Still, however contrary to analogy it may appear, we cannot but believe that the facts we have collected indicate that this really is the mode in which the parasite is developed.

The analogy that exists between the *Trichina* and *Echinococcus*, suggests a few remarks before finally quitting the subject. They resemble one another in the fact of being parasitic animals enclosed in laminated cysts, and both from the structures of the cyst, from their position with respect to the animals, and from the existence of the former being in each case the constant, the existence of the latter the variable phenomenon, there is great reason to suppose that the *Hydatid* bears the same relation to the *Echinococcus* that the *Trichina*-cyst does to the *Trichina*, and therefore, that the former is neither to be looked on as a modified animal, nor yet as a true egg, but that it is to be regarded as a cyst developed

from a germ, and capable of producing animals — a body, indeed, analogous to an ovum, though not homologous with one.

The mode in which degeneration occurs, we have shown to be identical in both; but there are marked differences in the manner of development and growth. *Trichina*-cysts are always of the same size; contain, according to our observations, but one animal; and never appear to develop cysts or animals in the thickness of their walls. *Hydatids*, on the other hand, vary greatly in dimensions, and possess active powers of growth; we have seen cysts, characterised by their laminated walls, less even than an *Echinococcus*; they frequently contain a large number of *Echinococci* which are developed in connection with the parietes; and in the thickness of the latter, other *Hydatids* often arise. The chief distinctions appear to be that the *Hydatid* has a power of growth and a degree of fecundity altogether superior to those possessed by the *Trichina*-cyst, in virtue of which the local development of the parasite is carried on with extraordinary rapidity; whereas, in the case of the *Trichina*, the chief, if not the entire, reproductive power, lies in the animal itself, which, possibly, may possess the power of moving from spot to spot, and thus of diffusing its germs throughout the body. Or, it is not impossible, that its germs may, in some mysterious manner, be received into the circulation, and afterwards be deposited in a way, equally unknown, between the muscular fibres.

Finally, the now ascertained fact, that the *Hydatid* is merely a modification of the *Tænia* in which development has become interfered with by external circumstances seems strongly to indicate that the *Trichina* also may be the representative of some other parasitic worm, probably of one of the well-known *cœlminths* of the alimentary canal. This is a suggestion for which we claim no credit, it has already been made by others, and is, in the present state of our knowledge, so natural a one that there can be little doubt that it will prove to be substantially correct.



