

**Collection of facts illustrative of the morbid conditions of the pulmonary artery / by Norman Chevers, M.D.**

**Contributors**

Chevers, Norman, 1818-1886.  
University of Glasgow. Library

**Publication/Creation**

London : [Printed by Wilson and Ogilvy], 1851.

**Persistent URL**

<https://wellcomecollection.org/works/ay3fkcg>

**Provider**

University of Glasgow


**License and attribution**

This material has been provided by This material has been provided by The University of Glasgow Library. The original may be consulted at The University of Glasgow Library. where the originals may be consulted. This work has been identified as being free of known restrictions under copyright law, including all related and neighbouring rights and is being made available under the Creative Commons, Public Domain Mark.

You can copy, modify, distribute and perform the work, even for commercial purposes, without asking permission.



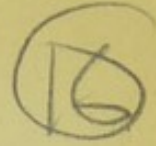Wellcome Collection  
183 Euston Road  
London NW1 2BE UK  
T +44 (0)20 7611 8722  
E [library@wellcomecollection.org](mailto:library@wellcomecollection.org)  
<https://wellcomecollection.org>







COLLECTION OF FACTS



ILLUSTRATIVE OF THE

MORBID CONDITIONS

OF THE

PULMONARY ARTERY.

BY

NORMAN CHEVERS, M.D.

CIVIL ASSISTANT-SURGEON, CHITTAGONG, BENGAL; MEMBER, AND LATE MEMBER OF THE  
COUNCIL, OF THE PATHOLOGICAL SOCIETY OF LONDON.

*(Published in the LONDON MEDICAL GAZETTE, between July 1846 and  
September 1851.)*

LONDON:

PRINTED BY WILSON AND OGILVY,

57, SKINNER STREET, SNOWHILL.

1851.

\* \* \* Several typographical errors will be met with, especially in the latter chapters of this memoir. The manner in which the book is paged has prevented the author from making out a list of corrigenda. It is trusted, however, that the reader will make due allowance for these unavoidable mistakes, some of which, unfortunately, render portions of the text extremely obscure.



ON THE  
MORBID CONDITIONS  
OF THE  
PULMONARY ARTERY,  
*&c. &c.*

---

MANY remarkable and important cases of various forms of disease affecting the structures of the pulmonary artery may be found scattered through the pages of our medical literature; and, recently, there have appeared several valuable memoirs illustrative of particular organic lesions which the tissues of that vessel are liable to undergo. Among these the essays by Mr. Paget in the *Medico-Chirurgical Transactions*, and the papers of Dr. Craigie and Dr. Ormerod in the *Edinburgh Medical and Surgical Journal*, deserve especial mention. Still I am not acquainted with any work in which the student can meet with a general and comprehensive history of the principal diseases that are known to affect this artery, or to which the morbid anatomist who happens to observe remarkable deviations from the natural condition of the vessel can at once refer with the probability of being able to compare his cases with similar recorded instances.

The pulmonary artery appears to be constructed in a manner which renders it far less liable than are the systemic arteries to undergo extensive and conspicuous organic changes: and the manner in which post-mortem examinations of the thoracic viscera are usually conducted—that of removing the heart and lungs separately from the body, and of making vertical incisions through the pulmonary structures—appears to have always led to a want of caution in examining the entire tract of a vessel thus mutilated and divided. From this it has resulted that the diseased conditions of this artery have remained, upon the whole, matters of neglected inquiry: morbid anatomists have very rarely been at the trouble of systematically examining its whole extent in cases of pulmonary and cardiac disease, and hence indolence, rather than demonstration, has led to the establishment of a general but most erroneous belief that the lesions to which this vascular tract is prone are less

frequent and less important than those which are continually observed in the structures of the systemic arteries.

A practical investigation of the diseases of the vascular system, pursued in a large public institution during a period of more than ten years, has enabled me to collect a considerable number of original and, I venture to think, important memoranda of the abnormal conditions to which this artery is liable. Some remarkable instances of rare lesions of this vessel have also occurred in the practice of my friends, who have obliged me with a sight of the diseased structures, and have furnished me with narratives of the cases. In the following pages I have endeavoured to combine my own facts with those which have occurred in the experience of others, in such a manner as to present, in a condensed form, the outline of a history of the principal diseases of the pulmonary artery.

Interesting as I venture to believe the observations thus collected will prove to the scientific investigator, I should still not have felt willing to undertake the task of eliciting and recording them, did I not hope to deduce from their correlation results of greater importance than those which usually accrue from the discussion of any merely anatomical question; and if it did not appear that such an inquiry would, in no small degree, tend to advance that great purpose which must ever be the final object of all pathological research—the treatment and mitigation of disease. In the following pages I shall lose no opportunity of applying the facts adduced to the illustration of certain definite and leading principles which I believe it to be most necessary to establish for the proper therapeutic management of diseases of the heart and lungs.

Before entering upon the main subjects of the present inquiry, it will be necessary to devote a few observations to some leading points in the



*Normal Anatomy of the Pulmonary Artery.*

This is a vessel *sui generis*, partaking almost equally of the structural characteristics of the arteries and the veins; resembling the former in the character and arrangement of its principal tissues, and the latter in its pliability, thinness, and dilatability.

As the distance which the blood has to be propelled through the pulmonary vessels is short compared to that which it traverses in permeating the extended tract of the systemic arteries, and as the entrance of the venous blood to the lungs is greatly aided by the respiratory movements, the distending power which the right ventricle ordinarily exercises upon the pulmonary artery is considerably less than that of the left ventricle upon the aorta. Still, the muscular force of the right ventricle, in a state of health, is by no means inconsiderable, and the shortness of the tract of the pulmonary artery, together with the frequent causes of transient obstruction to which it is almost necessarily liable, render it requisite that it should be constructed in a manner which will at once enable it to escape rupture, to undergo considerable distension, and to return to its natural condition immediately after the cause of over distension shall have ceased to operate.

It is evident that a vessel possessing the comparatively rigid and inelastic structure of the aorta would, if occupying the position of the pulmonary artery, very shortly become inefficient under the frequent causes of temporary and permanent obstruction to which that vessel is exposed—its strong and closely knit fibres would soon become stretched and inelastic, its inner tissues would become thickened and loaded with fibrinous and bony deposits (the necessary concomitants of great dilatation in the systemic arteries), and, in a few years, aneurism, or laceration of its coats, would almost certainly result.

Hence we find that the pulmonary artery is constructed in a manner which renders it capable of long resisting the injurious effects of over-excited cardiac action and pulmonary obstruction. The recurved form of its branches in great measure prevents the impulse of the ventricle from being too powerfully exerted upon the minute vessels of its subdivisions; and the thinness, pliability, and tenacity of its structures, fit it to receive powerful shocks with impunity, and to suffer extraordinary distension without at once becoming permanently dilated.

I have been at some pains to determine the relative dilatability of the aorta and the pulmonary artery, and have found, by accurate measurements, that the ascending portion of the latter is very far more dilatible laterally (or when its tissues are

stretched in the direction of the fibres of its middle coat), than is the latter at the commencement of its arch; while, although the structures of the pulmonary artery are somewhat more extensible in a vertical direction than are those of the main systemic trunk, the difference in this respect between the two vessels is far less considerable. The aorta, on the contrary, although less yielding in every way than the pulmonary artery, is more extensible in the vertical than in the horizontal direction.\* This might be anticipated from our knowledge of the anatomical relations and the functions of the parts. The entrance of the blood to the pulmonary artery being, in great measure, due to the action of the lungs, and the right ventricle possessing, under ordinary circumstances, a very moderate degree of muscular power, the vessel does not require to be possessed of remarkable extensibility in the line of its axis, but the frequent delays to which the circulation through the lungs is liable render it absolutely necessary that it should be capable of great lateral distensibility, so as to perform, during brief periods, the office of a temporary reservoir for the blood, which can neither return to the ventricle, nor gain a ready transit through the lungs. The aorta, on the contrary, is, under ordinary circumstances, far less liable to causes of temporary obstruction. During periods of great muscular effort, &c. the passage of blood through its branches is somewhat delayed, but this retardation occurs to a less degree, and operates within a more extended system of vessels, than is the case in the pulmonary artery; hence remarkable dilatability is not requisite in the aorta;—on the other hand, however, the impulse of the powerful left ventricle acts with great extending force upon the whole aortic tract, and therefore it becomes necessary that the tissues of this vessel should possess great elastic extensibility in the vertical direction.

In a previous essay† I have described the beautiful arrangement of a structure situated between the epithelial lining and the elastic coat of the arteries, and which appears to be in great measure designed to assist them in resisting undue vertical extension. This

\* In one of my experiments, I took a square portion of the aorta of a young adult from the sinus of Valsalva, and another portion, of precisely equal dimensions, from the ascending pulmonary artery (their structures were perfectly free from any morbid change), and I found their relative dilatability and extensibility to be as follows:—Taking the transverse and longitudinal measurements of both portions as 27, the *lateral dilatability* of the *aortic portion* was represented by 41½; that of the *pulmonary* by 47. The *longitudinal extensibility* of the *aortic fragment* was equal to 43; that of the *pulmonary*, to 45.

† Account of the Sub-serous Membrane of the Aorta, Guy's Hospital Reports, No. 10.



structure appears to be far less fully developed in the ascending pulmonary artery than in the aorta, and the latter vessel seems to owe its vertical elasticity principally to the tissues which are disposed upon the exterior of its middle coat. As I shall endeavour to shew, it is probably to the rudimentary development of the sub-epithelial fibrous tissue in the ascending pulmonary artery, that the comparative rarity of semi-cartilaginous and earthy interstitial deposits in this portion of the arterial tract is due.

The question of the *comparative size of the pulmonary and aortic orifices* has occupied the attention of many anatomists, the results of whose researches have been so greatly at variance as to leave the matter altogether in an undecided position; one or two authorities declaring that the pulmonary ostium is decidedly narrower than the aortic; while the majority concur in the opinion that the former is naturally the wider of the two.

To ascertain the true natural relative size of these two vessels is certainly a matter of no slight difficulty. It will be found comparatively easy to discover the dimensions of the aorta, which may be readily measured without producing any extension of its tissues, but it will be seen that to take an accurate measurement of the width of the pulmonary artery, without stretching its thin and yielding coats, is a piece of manipulation which requires considerable tact and caution. It is almost impossible to measure this vessel either by compasses, a rule, or a cylinder, without either allowing it to remain in a partially collapsed state, or producing an amount of dilatation which, of course, does away with the accuracy of the experiment. In measuring the respective width of these vessels in recent subjects a fallacy is also liable to arise, from the fact that, under ordinary circumstances, the right cavities and vessels of the heart are, at the moment of death, in a state of extreme distension, while those on the left side are comparatively empty,—under which conditions the pulmonary artery is, in a great measure, prevented from undergoing that degree of tonic contraction which is known to occur after death in the whole of the systemic arteries. Lastly, it appears to be certain that, in by far the larger number of individuals, the temporary obstructions to which the pulmonary circulation is always liable, produce a certain degree of permanent dilatation of the artery, which slight dilatation, notwithstanding the exceeding frequency of its occurrence, the early age at which it is often established, and the unquestionably healthy condition of adjacent parts with which it is generally accompanied, must, in reality, be

considered as a decidedly abnormal and morbid state.

I have taken exact measurements\* of four pulmonary arteries selected with the greatest caution from young well-formed adults (three males and one female), whose deaths had been produced by causes not directly influencing the cardiac and pulmonary functions: and in whose lungs and circulatory apparatus no disease could be discovered. In these specimens I found the average measurements of the pulmonary orifice to be as follows:—Circumference—immediately above the valves,  $32\frac{1}{2}$  English lines; directly below the valves,  $38\frac{1}{4}$  English lines.

In eight cases, the average measurement of the upper (and narrowest) portion of the aortic orifice was also within a very small fraction of  $32\frac{1}{2}$  lines. The average width of the lower part of the aortic orifice is  $36\frac{1}{2}$  lines—nearly two lines less than that of the corresponding portion of the pulmonary artery; but it is evident that in measurements of this kind, the width of the *narrowest* part of the outlet is the point of most importance, as it alone represents the dimensions of the orifice, by which the blood has exit from the ventricle. The greater width of the lower part of the pulmonary ostium must not be regarded as the effect of dilatation—it is due to the peculiar form of the right ventricle, which is naturally rather broader at its upper part than the left. From the caution which I employed in choosing these specimens with reference to the stature, age, and cause of death of the individuals—rejecting many scores of specimens to which more or less objection might have been made on account of the height of the subjects, the causes of dissolution, or the engorged or otherwise faulty state of the lungs—I have no hesitation in stating my conviction that the size of the two arterial outlets of the heart is naturally the same, and that every departure from this correspondence must be regarded as a diseased condition.

\* The mode in which I have always been in the habit of measuring the orifices of the large arteries, and which I believe to be the least susceptible of error, is to lay the vessel open by a vertical incision, without removing it from the heart, or subjecting it to any rough manipulation, and to place across the part of which it is required to obtain a measurement, a piece of common twine which has been previously sufficiently wetted to enable it to adhere to the whole inner circumference of the artery: when the string has been accurately applied in a direct line across the vessel, its ends are cut off on either side precisely at the spot where they touch the divided edge of the middle coat of the artery, and the measurement of the portion of string thus separated is immediately taken. This, of course, precisely represents the width of the vessel to which it has been applied.



I have made another set of observations of this kind in subjects who have died from chronic disease entirely apart from the heart and lungs, in whom the bulk of the circulating fluids had been long diminishing, and who had been compelled to remain in a state of complete inaction for long periods previously to their dissolution. In subjects of this kind (providing there has been no considerable previous lesion of the heart and its appendages) the measurements of the aortic and pulmonary outlets are found to be either precisely identical or varying in an exceedingly slight degree. Still it is undeniable that, in the larger proportion of adult hearts, the measurement of the pulmonary artery above its valves more or less exceeds that of the aorta in the corresponding situation. But, although this disproportion is so frequent, it is certainly unnatural. The more healthy the entire pulmonary and cardiac apparatus is, the more nearly will the upper ostia of the two great arteries be found to correspond in width; and I have long felt no hesitation in deciding, wherever (independently of morbid thickening, or any other visible structural change) the pulmonary artery, immediately above its valves, is found wider than the aorta in the same situation,—that the former vessel is unduly dilated,—and, on the contrary, when the pulmonary is the narrower of the two (its tissues retaining their elasticity), that the mouth of the aorta has become morbidly stretched. *The relative dilatability* of the upper and lower portions of the pulmonary and aortic ostia is also a matter of some anatomical interest. I have found the former artery, measured above the valves, to be dilatable to  $43\frac{1}{2}$  lines,—directly below to 46, while the greatest dilatability of the upper aortic ostium is 43, that of the lower  $39\frac{1}{2}$  lines. Hence, the upper ostia of the two vessels are nearly equally dilatable; but although, as in the aorta, the lower portion of the pulmonary orifice is the wider, the pulmonary artery differs from the aorta in presenting naturally a greater disparity in its width below and above the valves, and also in having its lower ostium more extensible and more yielding than the upper. This is evidently attributable to the fact that while the lower margins of the aortic valves are attached to a strong and almost unyielding fibrous structure, an exceedingly thin fibrous expansion exists in the right ventricle beneath the pulmonary sigmoids. Under circumstances of long-continued distension, there is, however, occasionally observed considerable thickening and rigidity of the sub-endocardial fibrous tissue at this spot.

These apparently trivial minutæ are, in reality, of considerable importance, and for

this reason—that the size of the heart and its vessels of course varies exceedingly in different subjects, according to the stature, age, sex, and thoracic development of the individuals, and the quantities of their circulating fluids;—hence, although correct averages may be drawn from very accurate measurements of perfectly well-formed hearts, it will rarely happen that the size of any heart will be found to correspond precisely with the standard. And, indeed, it is clear that neither departure from, nor accordance with any fixed standard can alone be regarded as a certain indication either of the healthy or diseased condition of a part. Thus a vessel, which is considerably below or above the average size, may, in reality, be in a perfectly healthy condition; while another, the width of which precisely corresponds with the standard, may have undergone a very considerable amount either of dilatation or contraction. Hence the necessity of observing and comparing the *relative* width and dilatability of the two great arteries, as well as of the upper and lower portions of their orifices. It is scarcely of so much importance, even, to remark whether the bulk of the whole cardiac apparatus be large or small, as to observe how far the relative width and dilatability of its several portions have been preserved. A heart in which this relation persists, can scarcely be in an inefficient state; while, in a diseased organ, the relative proportions of the orifices, and their due elasticity, are rarely if ever maintained.

The researches of Hasse with regard to the relative size of the aorta and pulmonary artery, have led that observer to conclude with Bizot, that the latter is naturally wider than the former; still one or two of his observations are strongly confirmatory of my own views. It has been stated\*, that the relative disproportion between the two arteries is discoverable as early as the seventh year, and it is certainly true that this morbid disproportion may be established at almost any age. M. Hasse, however, observes that, “in children the orifices of the two arteries continue equally capacious until the sixth or even the tenth year,”—a very strong evidence that any consequent disparity must necessarily be the result of unnatural dilatation.

M. Hasse observes, that, as life advances, the progressive enlargement of the two arterial orifices of the heart differs; both increase equally until the meridian of life, but the aortic orifice enlarges more rapidly in advanced life than that of the pulmonary artery, so that, in old persons, the latter is even narrower than the aorta. This varia-

\* Anatomical Description of the Diseases of the Circulation and Respiration. By C. E. Hasse. Translated by W. E. Swaine, M.D. Published by the Sydenham Society, 1846.



tion M. Hasse has met with earlier in males than in females, (in the former from the 50th year upwards, in the latter not till after the 60th). In a still later period of life it no longer applies\*. I have found that, in persons above the age of 60 years, there is always considerable dilatation of both arteries, but that their relative proportions vary in great measure according to the nature of the causes which have occasioned death. Thus, in an extremely enfeebled woman, who died of bronchitis at the age of 65, the circumference of the pulmonary outlet exceeded that of the aortic by three lines. On the contrary, in two men who died of malignant disease at the respective ages of 74 and 77, the circumference of the aortic ostium exceeded that of the pulmonary by one and a half, and two lines. But, in a man who died of gangrene in his 89th year, although (as in the other cases) the tissues of the pulmonary artery and ascending aorta appeared almost entirely free from any other change than loss of elasticity, the lower portion of the orifice of the former measured 45 lines, while that of the latter was only 39 lines in circumference.

I noted it as a remarkable fact, that, in this aged person, the narrowest portions (which were here the lower ostia) of the pulmonary artery and aorta had respectively become dilated very nearly to the utmost extent to which I have shewn that these parts of the vessel are naturally capable of being stretched. It will be found in the pulmonary artery, as in the aorta, that in an exact ratio to the degree in which any part of the vessel has become permanently dilated, is the loss of elasticity in that portion of the tube: thus we have seen that the natural measurement of the lower ostium of the pulmonary artery is  $38\frac{1}{2}$  lines, and that it admits of being stretched about eight lines: hence, in adult males, where this portion of the vessel is 41 lines in circumference, it may be premised that it will probably not admit of being dilated more than four or five lines; and, in cases where it is 44 or 45 lines in circumference, it will be found to have nearly or entirely lost its elastic properties.†

In cases where the upper or lower

portions only of the two great arteries are much dilated, life may be considerably prolonged; but it is probable that, whenever both the upper and lower portions of their cardiac orifices become permanently dilated to the greatest extent which the natural yielding of their structures is capable of admitting—even independently of any very apparent change in their tissues beyond mere loss of elasticity—life begins to be held on an exceedingly frail tenure. It is true that, in a few cases, the widest part of the pulmonary orifice has been found to exceed its natural measurement by an inch or more, but the subjects of this lesion have invariably died from failure of the heart's action. And it can scarcely be doubted that a considerably less degree of dilatation than this is sufficient to occasion sudden death in consequence of any cause which tends to produce over-distension of the ventricles.

This question appears to be by no means undeserving of further investigation, especially as illustrative of the immediate cause of death in extreme old age, and in cases of long-standing disease of the heart and lungs.

The following are the principal subjects which will be considered in the succeeding observations:—Congenital Irregularities in the Mode of Origin and Distribution of the Pulmonary Artery; Unnatural Dilatation and Contraction of its Canal; Inflammation; Pulmonary Apoplexy; The causes which determine the deposition of Clots in the Pulmonary Artery; The Diseases of its Valves; Ulceration and Laceration of its cardiac and pulmonary divisions. The Pathological Condition of the Ventricles, especially of the Right, in cases of Disease of the Pulmonary Artery and Lungs; Symptoms and Diagnosis of the Diseases of this vessel; a Sketch of the General Principles of Treatment which it is necessary to pursue in these and other forms of Organic Obstructive Disease in the Cardiac and Pulmonary Apparatus.

#### CONGENITAL MALFORMATIONS OF THE PULMONARY ARTERY, AND IRREGULARITIES IN ITS FORM AND MODE OF ORIGIN.

As it almost amounts to an invariable rule that each of the severer kinds of congenital malformation of the heart is characterised by more or less departure from the natural condition of the pulmonary artery, a complete description of all the cases where this vessel is found in an abnormal condition must involve an allusion to nearly every one of the congenital malformations to which the cardiac apparatus is liable. I shall therefore endeavour to render this portion of the history as brief as possible consistently with my plan of furnishing reference to all the

\* Cyclopæd. of Anat. and Physiol.; Art. Heart.

† When any vessel is found dilated, if its standard capacity be known, the loss of elasticity in its tissues may generally be taken as an indication of the degree in which its calibre has become increased. But this test does not, of course, hold good after the canal has become permanently widened beyond the extent to which it is naturally dilatible. Whatever slight amount of elasticity varicose and aneurismal vessels may possess, is due to the increased development of their elastic tissues. It is scarcely necessary to add, that a test of this kind only avails to show that every vessel has a naturally fixed amount of elasticity, as well as an average capacity.



most remarkable examples of the several kinds of malformation in which the pulmonary artery is especially implicated; merely stating the leading particulars of each instance, and especially selecting those details which afford the amplest data in illustration of the pathology and symptomatology of this interesting class of diseases.

*Malformations by defect of the Pulmonary Artery.*

*Absence and congenital obliteration.*

In the vertebrate animals, an aorta is an inseparable and essential constituent of the circulating apparatus\*. The absence of a true pulmonary artery, originating by a separate outlet from the heart, is, however, a condition which has been not unfrequently observed. The ascending aorta has been found absent only in acardiac foetuses; where there is a heart there is always a pervious ascending aorta, however narrowed, malformed, or displaced that vessel may be: but imperforation, or entire absence of the ascending pulmonary artery, may coexist with a rather high degree of cardiac development.

*A single ventricle giving off a single artery (aorta), which distributes one branch to the lungs.*

The condition of the heart in its earliest stage of development here becomes permanent: the organ remains in the form of two simple cavities, undivided by septa, and the pulmonary and systemic vessels are distributed from a common trunk. The most singular instance of this species of malformation is one related by Mr. Wilson†. The child lived 7 days, and had merely slight lividity of the lips on the day of its birth and a short period before its death. It seemed weak, and in pain, but otherwise it performed all its functions naturally. Death resulted from inflammation of the heart. The heart was found embedded in a cavity formed on the superior surface of the liver, and consisted of a single auricle, ventricle, and arterial trunk, which latter ascended into the thorax, and soon divided into two large branches, the aorta and the pulmonary artery. The aorta, ascending, formed its arch as usual. The pulmonary artery divided into its two branches. The circumference of the aorta, where it separated from the original trunk, was an inch and a quarter. The circumference of the pulmonary artery was only fifteen-sixteenths of an inch. No bronchial artery was sent to the lungs from the aorta or any of its ramifica-

tions. There were no bronchial veins. The lungs were, however, larger in proportion than in other children of the same age\*.

A second case has been recorded by Mr. Standert†. This child lived only 10 days; it had cyanosis, but it is stated that the respiration, muscular action, and temperature of the body, were not materially affected. The heart consisted of one auricle, into which the pulmonary veins and the venæ cavæ entered, and which presented the rudiment of a septum, in the form of a muscular band, crossing the ostium venosum; and one ventricle, whence arose the aorta, which sent off a small branch in the situation of the ductus arteriosus. This branch divided into two arteries, which were distributed to the lungs. The pulmonary veins were four in number; but neither the area of these veins, nor that of the vessel which acted as the pulmonary artery, exceeded half the common dimensions. It does not appear very certain that the above case strictly belongs to the class in which I have placed it. It may, not improbably, have been one in which the ascending pulmonary artery had become obliterated, the ductus arteriosus only remaining to perform its functions, in which case the condition of parts, although in appearance almost identical with that observed in Wilson's and Tiedemann's cases, must of course have been, physiologically, altogether different.

It has very rarely happened, in the instances of this kind which have been recorded,

\* Mr. Wilson considered that "the pulmonary arteries and veins, in addition to their usual offices, performed those of the bronchial vessels."

There appears to be a tendency to displacement in cases where the heart is single. Ant. de Pozzi relates (in the *Ephemerides Nat. Cur.* Ann. 4 and 5, Obs. 40,) the somewhat marvellous case of a man, ætat. 27, who suffered, during four years, from palpitation, which could only be relieved by venesection, and who died in a sudden attack of syncope. The pulsation of the heart was not felt in the usual place, but low down on the left side, near the diaphragm. The heart was found very large, consisting only of one cavity or ventricle, containing sixteen ounces (!) of very dark blood. The whole substance of the heart was wasted, the arteries elongated and drawn together, so that the arterial blood (*sanguis spirituosus*) could not be fully expelled. In the place of the right ventricle the ascending vena cava was found raised into a large tumor (the single auricle).

In a specimen of *Ectopia cordis*, (preserved in the collection at Guy's Hospital, Prep. 1379<sup>25</sup>,) where the ventricular part of a singularly malformed heart protruded from the central portion of the chest, the ventricle—a large part of which has been sliced off vertically—appears to me to have been single; and an excellent anatomist, who examined the preparation with me, coincides in that opinion. The auricles, which were situated within the thorax, communicate with each other by a very wide aperture. These, however, are not invariably the characters of congenitally displaced hearts, which, in several cases, have been found normally constructed.

† *Philos. Trans.* vol. xcv. p. 228.

\* Except, of course, in those rare cases where a head or limb has been alone produced.

† *Philosophical Transactions*, vol. lxxxviii. p. 346.



that the infants have survived for more than a few days, but I shall hereafter have occasion to quote a case (by Dr. Mauran) in which, although there was merely a single auricle and ventricle, and the pulmonary artery was impervious at its origin, the child lived ten months and a half.

*A single ventricle giving off a single artery (aorta), which distributes two branches to the lungs.*

A malformation of this kind was observed by Dr. Farre\*, in a male infant, which died seventy-nine hours after birth, having suffered for thirty hours from dyspnoea, and some coldness and livor of the surface. The heart was found distended to the utmost with blood: it consisted of an auricle and a ventricle. From the ventricle one artery—the aorta, furnished with semilunar valves—arose; its first two branches were pulmonary, very large, and situated close to each other.†

Otto describes that when there is a single arterial trunk from the heart, the pulmonary branch or branches are usually given off low down. Occasionally, however, higher up in the ascending portion of the aorta, as described by J. F. Meckel (*Descriptio Monstrorum Nonnullor*, p. 11).

*Heart consisting of two auricles and two ventricles, giving off a single artery, which distributes pulmonary branches.*

M. F. Tiedemann observed the following singular malformation in the heart of a male child, which died 9 days after its birth. The superior and inferior vena cava, and the coronary vein, opened into the right auricle. From the arterial part of the heart arose a single but very large trunk. After giving off the coronary arteries, there arose from the right side of this great trunk a large artery, which ascending gave off the left and right carotid, and the right subclavian. From the posterior part of the great arterial trunk the left and right pulmonary arteries originated; these were sub-divided and distributed in the usual manner. A little higher up the main trunk became very much contracted, but immediately afterwards resumed nearly its former calibre, and represented the descending aorta. From the arch of the aorta (beyond the contraction) the left subclavian artery arose. The foramen ovale was pervious. The right

auricle communicated with the right ventricle, and the left auricle with the left ventricle. The ventricular septum was perforated at its upper part, so as to allow a communication between these two cavities. The great arterial trunk took its origin chiefly from the right ventricle, but there was a small communication of its orifice with the left ventricle also.

The child [when born] appeared well nourished, but wasted until the time of its death. It took the breast feebly; the warmth of the body was very sensibly less than that of other children of the same age. Its breathing was always short, but there was not any blueness of the surface. Death was preceded by convulsive attacks, and appears to have been due to inflammation of the spinal chord, and congestion of the meningeal vessels of the brain\*.

Dr. Arrowsmith, who translated the above case, and appended some interesting physiological remarks, justly observes that it appears to be quite unique. The ventricular septum was in great measure formed, although the ventricular arterial trunk remained still undivided at its origin; in fact, nearly in its primitive state. It appears probable that, in all the cases where the cavities of the heart remain single, there exists, from a very early period of intra-uterine life, a certain amount of impediment to the pulmonary circulation, owing either to narrowness of the pulmonary vessels or mechanical obstructions of various other kinds†. The figure which accompanies this case, in the original paper, shows that here the afferent vessels of the lungs were of considerable, though apparently not of full, size; hence, probably, the more advanced formation of the septa.

*The heart consisting either of a single auricle and ventricle, or of two auricles and one ventricle, the pulmonary artery and aorta arising by separate orifices from the ventricle.*

There is another class of cases where, the cavities of the heart remaining single, the pulmonary artery is found to have become completely developed. The instance already quoted from the *Ephemerides* belongs to this class. The following is a nearly parallel example:—

In a case published in Hufeland's *Journal*‡, a man, æt. 24, who from his infancy had been subject to violent beating of the heart, suffered after an attack of pneumonia from great increase of palpitation and frequent paroxysms of suffocation, in which he found no relief, except by pressing the chest

\* Pathological Researches, Essay 1, on Malformations of the Human Heart, p. 2.

† M. T. Weber (*Observatio Anatomico Path. de Corde Univentriculari e quo unus tantum truncus arteriosus surgit*. Bonnæ: 1832) describes and figures a similar malformation which he found in the heart of a calf. There were, however, two auricles in this case, and a large common coronary artery was given off from the ascending aorta.

\* *Zeitschrift für Physiologie*, B. iv. H. ii.; and *LONDON MED. GAZ.* vol. xiv. p. 704.

† See *Cyclop. of Pract. Med.* vol. iii. p. 66.

‡ Quoted in the *Lancet*, 1828-9, p. 137.



strongly against some resisting body. An incipient hæmorrhoidal discharge seemed, for some time, to mitigate the symptoms, but subsequently the results of thoracic obstruction became aggravated, anasarca and ascites supervened, and death ensued, apparently from suffocation. The cavity of the chest was found to be filled with several pints of bloody serum. The pericardium, to its whole extent, adhered to the heart, the cavities of which were filled with black blood. The *septum ventriculorum* was totally wanting; not the slightest trace of it could be found. The origin of the vessels was natural; the apertures of the veins were slightly enlarged, and the aorta was remarkably flaccid. No mention is made of the existence of cyanosis.

A child, æt. eleven days, died apparently of umbilical phlebitis, in the Foundling Hospital of Paris. The heart was found to consist of a single auricle and ventricle, and the aorta and pulmonary artery were given off from the latter by separate orifices. The child suffered from cough and great dyspnoea, but there was *no cyanosis*\*.

Tiedemann† describes the heart of a boy, eleven years of age, who had long suffered from cyanosis. This organ was found to consist of two auricles, but only one ventricle, from which the aorta and pulmonary artery sprung.

Chemineau‡ examined the heart of a foetus consisting of three cavities; the right received the vena cava, the left the pulmonary veins, while from the central, or ventricle, the pulmonary artery and the aorta arose§. Other instances of this kind of malformation have also been recorded.

I have already referred to the probability that the undeveloped state of the septa in these as in many other cases of congenital malformation of the heart, depends, to a certain degree, either upon the narrowness of the pulmonary branches, or upon the existence of some cause of obstruction either in the lungs or systemic vessels; but, independently of this, more or less imperfection of the ventricular, as well as of the auricular septum, is in these cases rendered an arrangement of almost absolute necessity during the entire period of intra-uterine life, owing to a defect by which the whole of the above-described malformations appear to be characterised||; *i. e.* the absence of a ductus arteriosus. In either of these kinds of malformation a ductus arteriosus could answer no useful purpose, but in either the closure of the ventricular septum, could it

possibly occur, would at once produce a fatal alteration in the course of the circulation. It will be borne in mind that, although a great degree of livor may be present, cyanosis is not an essential or even a usual concomitant of the above kinds of malformation.

In cases of this description, as well as in those of the two classes previously alluded to, the abnormal condition of the heart and arteries is purely one of arrested development. Most of the other forms which I shall have to describe are to be considered either as the results of disease occurring during intra-uterine life, or as mal-conformations, in the strict sense of the term, combined to a greater or less degree with arrest of development. In many of these kinds of malformation the arrangements of parts have been regarded as almost identical with those which naturally exist in the circulating systems of several of the lower animals,—such as the ophidians, fishes, batrachians, birds, and inferior mammalia. In some of the cases, where the fault lies merely in arrest of development, or the malposition or excess of parts, these analogies, to a limited extent, hold good; but most anatomists of the present day will agree with Otto that a large proportion of the comparisons of this kind which have been drawn are fanciful and overstrained.

*Obliteration of the ascending pulmonary artery, or congenital occlusion of its orifice.*

The cases of this class are, in reality, instances of obliteration of the pulmonary artery, not of absence or non-development of the vessel. Careful examination will generally show that the ascending pulmonary trunk has existed as a separate, if not as a pervious canal—whether in some of the cases it has ever communicated with the ventricle must remain a matter of doubt. Its obliteration usually appears to be attributable to disease occurring at a very early period of intra-uterine life, probably antecedent to the second month, as shown by the imperfect state of the ventricular septum which is observed in a very large proportion of the cases.

The recorded instances of this remarkable species of congenital lesion are rather numerous; and I have myself had opportunities, within the last two years, of examining three recent specimens of the kind, exclusively of several well-marked examples which are to be found in the various pathological collections of this metropolis. Five cases were quoted by M. Gintrac, and many others have been subsequently observed. I find twenty-one cases of this description on record,

\* Archives Gen. de Méd. Feb. 1843.

† Zoologie, Part I. p. 177.

‡ Vide Sandifort, Obs. Anatom. Path. T. iii. C. i. p. 38.

§ As quoted in the Cyclop. of Pract. Med.

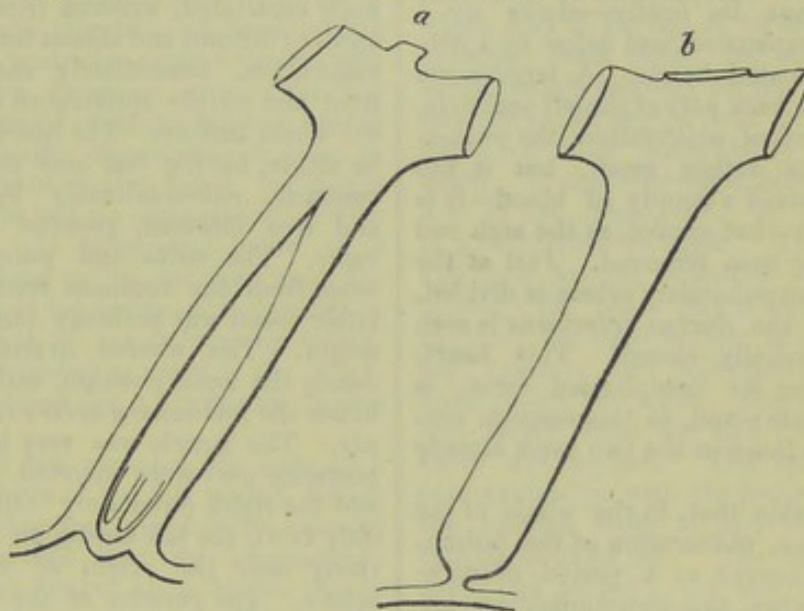
|| See remarks on Mr. Standert's case.



exclusively of the three which I have recently seen.

The pulmonary artery has been found obliterated in several ways. There may be discovered merely an indistinct band of condensed cellular tissue, or a thin impervious cord extending upwards in the usual course of the vessel, and attached to a small transverse arterial canal which sends branches to either lung; or a strong firm membrane may be observed stretched completely across the lower part of a narrow channel

(the rudiment of a pulmonary artery) extending from the base of the right ventricle, and communicating with a branch from the aorta. The upper surface of this membrane may present some slight traces of a valvular structure (Fig. *a*), and it is sometimes dilated into a little shallow pouch which projects downwards into the ventricle. Occasionally the orifice appears suddenly constricted, as if a thread had been drawn tightly around it (as represented in the diagram, fig. *b*). Perforation of the ventricular



septum is a usual, but not invariable, accompaniment of congenital obliteration of the pulmonary orifice. Wherever life has been prolonged beyond a few weeks the ventricles have communicated. The ductus arteriosus is generally, but not always, pervious. The ovalian canal may or may not remain patent. In most of the cases where life has been considerably prolonged, this opening has been found either completely obliterated or greatly contracted.

In the whole of these cases the lungs receive blood either directly or indirectly from the aorta, or from arteries distributed by its primary branches. This supply is furnished in several modes, of which the following are the principal.

*The orifice of the pulmonary artery obliterated, the arterial duct remaining pervious.*

Permanency of the canalis arteriosus is the most frequent as well as the most natural means by which the lungs are supplied with blood in cases where the orifice or ascending trunk of the pulmonary artery is congenitally imperforate. The most remarkable instances of this kind on record are those observed by Dr. W. Hunter, Mr. Hodgson, Mr. Howship, Dr. Mauran, and Dr. Spittal.

In Dr. Hunter's case,\* the infant, which

was born at the eighth month, had cyanosis, dyspnœa, and violent palpitation of the heart, and died on the 13th day; the commencement of the *pulmonary artery* was converted into a solid substance or cord; but, except at its beginning, it was everywhere pervious, though small, and the *canalis arteriosus* had supplied it with a scanty share of blood. The right ventricle had scarcely any cavity left. The *foramen ovale* was very large.

There are two preparations, in the collection at Guy's Hospital, which bear a strong physiological resemblance to the heart described by Dr. Hunter.

In that marked 1383 (which is the heart of a foetus or very young infant), the right ventricle is furnished with a diminutive tricuspid valve, but has become almost obliterated by an extraordinary concentric thickening of its walls. The *pulmonary orifice* is obliterated, the *ductus arteriosus* open. The *ventricular septum* is entire. The aorta, which is large, originates from the left ventricle.

The preparation 1382<sup>64</sup>, is also the heart of a foetus: its *pulmonary orifice* is closed. The auricles are small, communicating freely with each other. A very small chink, about a line in length, represents the right auriculo-ventricular orifice—below this, and rather to the left, is a little

\* Med. Obs. and Inquiries, vol. vi., p. 291.



cavity (the right ventricle), furnished with the diminutive rudiment of a tricuspid valve. The right auricle communicates with the left by a large *foramen ovale*, guarded by a remarkably formed sigmoid valve which opens just above the left auriculo-ventricular orifice. The ovalian valve must have permitted a free passage of blood from right to left, but must have been efficient, or nearly so, in the contrary direction. The left ventricle, which is capacious, and communicates freely with the left auricle, is partially separated about its centre—above by a membranous expansion, and below by a network of pectinated bands. A large aorta arises from the back part of the left ventricle. Above the point of obliteration, the pulmonary artery is rather small, but it has evidently received a supply of blood—it is uncertain from what source, as the arch and its vessels have been removed. Just at the point where the pulmonary artery is divided, the orifice of the *ductus arteriosus* is seen apparently partially closed. This heart, notwithstanding its complicated form, is essentially single; and, in this respect, corresponds with those in the two cases already detailed.

It is probable that, in the whole of the above instances, obliteration of the pulmonary orifice occurred at a period of intra-uterine life, when the communication between the ventricles had been entirely or nearly closed by the septum, under which circumstances the right ventricle, destitute of an outlet, and reduced to the condition of an inefficient cul de sac, became contracted and almost impervious. This is the only class of cases with which I am acquainted where—the pulmonary orifice being congenitally imperforate—a free communication between the ventricles does not exist. This condition of heart appears to be incompatible with a prolonged duration of extra-uterine life.

Mr. Hodgson's case was published in the London Medical Review. The heart has also been described by Dr. Farre. The *foramen ovale* was widely open. Some of the fibres were wanting in the ventricular septum, and the lining membrane of the left ventricle had three foramina, giving it a cribriform appearance. In the place of the *pulmonary artery* there was an impervious filament leading to a very large *ductus arteriosus*, which might be traced from the aorta into two pulmonary branches. The trunk was much larger than an ordinary *ductus arteriosus*, but smaller than a pulmonary artery. The child lived seven days.

Two similar specimens are referred to by Farre, as contained in Mr. Langstaff's museum,—one from a still-born infant, the other from a child who lived 6 months. In this case there was a considerable per-

foration of the *septum of the ventricles*, but it was nearly closed by the fibres which almost filled up the right ventricle. The same author makes slight allusion to two other specimens.

A remarkable case, showing how completely the development of the ventricular and auricular septa may be prevented, when occlusion of the pulmonary orifice occurs at a very early period of intra-uterine life, is related by Dr. J. Mauran.\* A female child, *æt.* 10½ months, of small stature and exceedingly emaciated, suffered from frequent attacks of difficult and almost totally suspended respiration, immediately succeeded by a livid and purple appearance extending over the whole surface. The heart was found to be single, having but one auricle and one ventricle, communicating by a very large and free foramen, guarded by a tricuspid valve. The aorta and pulmonary artery arose from the common ventricle, but the latter vessel was perfectly impervious at its origin. The *ductus arteriosus* occupied nearly the usual position, and was open, and hence the *pulmonary artery* received its supply. The auricle was very large; into its posterior part were inserted the two cavæ and the right pulmonary vein (there were only two), the left having an insertion anteriorly near the origin of the pulmonary artery. The parietes of the ventricle were unusually thick and strong.

Dr. F. Ramsbotham observed a very similar condition of parts in a child 6 months old. The heart was single, consisting of one auricle and one ventricle; it was turned to the right side, and the *ductus arteriosus* seemed to supply the place of the *pulmonary artery*. The pulmonary veins of the left lung terminated in the left subclavian vein—that of the right lung passed through the diaphragm and terminated in the vena portarum. There appeared to be an attempt to form a pulmonary artery and vein†.

The following instances represent the condition of parts which is most frequently observed in cases of this description, viz., the partial division of the heart by an imperfect ventricular septum—the aorta originating either from the right ventricle, or from a point immediately over the septum, mid-way between the two ventricles.

Dr. Farre relates‡ the case of a female infant, *æt.* 4 weeks, where the *ventricular septum* was perforated; the aorta arose from

\* Philadelphia Journ. of Med. and Physical Sciences, vol. xiv., p. 253.

† So stated in the original account; but, as the course of the pulmonary veins is distinctly mentioned, this allusion is obscure: it probably refers to a rudiment of the fourth pulmonary vein, only one being described as passing from the right lung.—Medical and Physical Journ. vol. lxi. p. 548.

‡ Pathological Researches, p. 27.



both ventricles, and was dilated. The *pulmonary artery* was imperforate as far as its bifurcation, and its branches received their blood from the aorta, through the ductus arteriosus. The right auricle and ventricle were larger than the left. The child was cyanosed.

Mr. Howship's case\* was that of a female child, *æt.* 5 months, which had suffered from cyanosis and frequent suffocative attacks. The heart was found much larger than ordinary, the right ventricle was strong, the walls of the left wasted, the left auricle exceedingly small, and almost incapable of transmitting blood. Both ventricles communicated with the aorta, which, however, arose from the right. A rudiment of the *pulmonary artery* was with difficulty discovered—it arose in the usual situation of that vessel, but it was impervious, and had no communication with the ventricle. It terminated below in a small ligamentous cul de sac close upon the membrane lining the cavity of the ventricle. The upper part of the pulmonary artery, which was distributed as usual to the lungs, was freely supplied by a pervious *ductus arteriosus*.

Dr. Spittal† has recorded the case of a female child, born at the full period, which presented nothing anomalous in its external appearance, except that the integuments were observed to be of a bluish-purple colour, especially over the extremities. The colour of the skin varied in intensity, being sometimes darker than at others. The child took its nourishment freely, and, for the first few days of its existence, appeared to be doing well. This state, however, did not continue; the infant began to refuse its food, and became subject to frequent attacks of syncope, in one of which it was reported to have expired, having lived only 23 days. On examination, the heart was found to be nearly of the usual size. The walls of the right ventricle 3-16ths of an inch in thickness, those of the left 1-4th of an inch thick. The cavity of the former was greatly larger than that of the latter. The tricuspid and bicuspid valves were of their natural structure. A slight deficiency existed in the upper part of the *septum of the ventricles*. Immediately above this the aorta arose; it was larger than ordinary as far as the ductus arteriosus, being a quarter of an inch in circumference, but beyond this point the vessel was not examined. The rudiment of the *pulmonary artery* arose from the usual situation at the base of the ventricle close to the aorta, by a very small vessel of the usual structure, but capable of admitting only a very small probe, and quite

impervious at its origin. In passing upwards, the vessel became rather abruptly enlarged in breadth, and, immediately beyond the ductus arteriosus, divided into its right and left pulmonary branches. The *ductus arteriosus* was open, and admitted a large probe freely. The auricles were naturally formed. The *foramen ovale* was capable of admitting a goose-quill. It is stated that auscultation revealed nothing unusual in the action of the heart.

Dr. Houston observed a good example of this kind of malformation in a male child which died at the age of 18 months. It was cyanosed from birth, and about the sixth month, when teething began, it had several convulsive struggles, one of which terminated in total insensibility and apparent death; it was recovered, however, by inflation of the lungs, &c. It finally expired in a convulsive struggle. The *venæ cavæ* and their leading branches were unusually dilated; the heart larger and firmer than natural; the right auricle double the ordinary capacity and thickness; the *foramen ovale* round and wide. The right ventricle was larger than the left. The tricuspid valve was perfect. The ventricle had no communication with the *pulmonary artery*; the passage from it into that vessel was totally blocked up. The left auricle was small and empty; the left ventricle exhibited nothing singular in its size or structure, but communicated with the right by a large round opening in the *ventricular septum*. The aorta at its origin was much dilated; the *ductus arteriosus* was large and pervious, and served as a trunk to the branches of the pulmonary artery. The pulmonary artery, though inconsiderable, was pervious down to its point of attachment at the ventricle.\*

There are two specimens of this kind of malformation in the Museum of Guy's Hospital.

That numbered 1379 is evidently the heart of a very young infant. The aorta arises from both ventricles. The *pulmonary artery* is quite closed at its origin. This artery communicates above with the aorta by the pervious *canalis arteriosus*. There is an aperture in the upper part of the *ventricular septum*.

The preparation marked 1380<sup>50</sup> is also from a young infant. A large aorta springs from both ventricles above the wide aperture in the *ventricular septum*. The orifice of the *pulmonary artery* is quite obliterated. There is a small opening in the *auricular septum*. The *arterial duct* is pervious. The right ventricle is not very powerful, but is stronger than the left. The right auricle greatly dilated; the left very small.

\* Edinburgh Medical and Surgical Journal, vol. ix., p. 399.

† Ibid. vol. xlix. p. 109.

\* Dublin Hospital Reports, vol. v. p. 234.



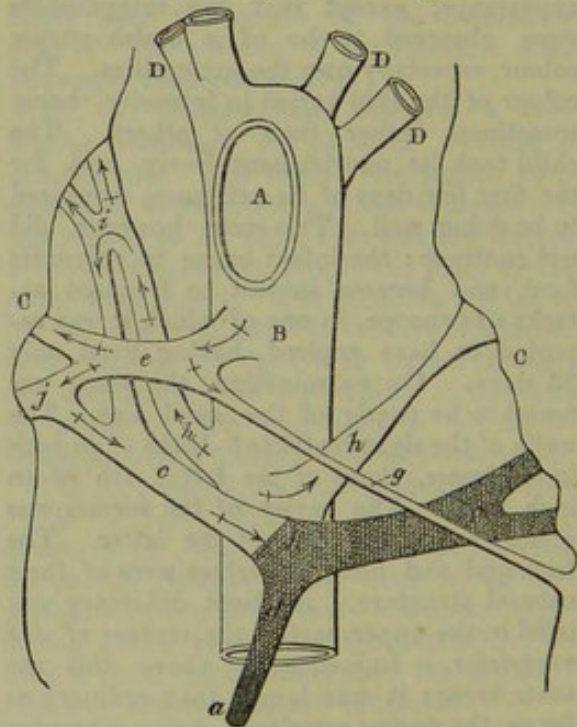
*Pulmonary artery closed, or obliterated.*

*Lungs supplied by the ductus arteriosus and bronchial arteries, or by enlarged bronchial arteries only.*

The following is an excellent example of the latter kind of malformation. In the heart of a girl, *ætat.* 16 years, presented to the Hunterian Society by Dr. F. Ramsbotham, there was no *pulmonary artery*: its deficiency appeared to be supplied by the *bronchial arteries*; the aorta, springing from a point between the two ventricles, ran on the right side of the trachea. There were two right bronchial arteries, and one left, all enlarged. The girl died of tubercular phthisis. The face had been very livid\*.

A remarkable case of the former description occurred within my own observation, in a patient of Dr. Babington's, at Guy's Hospital, in October, 1844. The subject of this malformation was an old-fashioned looking boy, *ætat.* 10 years, born at the full period. His mother stated that she had suffered great mental disturbance during gestation. His intellect was precocious; he was always considerably cyanosed. An intense cardiac bruit was audible between the shoulders. Death resulted from an acute attack of thoracic inflammation. On inspection, some bloody fluid, containing thin shreds of fibrine, was found in the pericardium. The volume of the heart was large; its muscular parietes were dense and strong. The right auriculo-ventricular orifice was considerably narrowed, the tricuspid valve ill-formed, and imperfect. Both ventricles were of full size; the right was rather rounded in form, with strong muscular parietes: the walls of the left were equally powerful. The upper part of the *ventricular septum* was deficient, leaving an oblique, but free, interventricular opening, capable of admitting the first joint of the forefinger. This opening was formed in such a manner that the anterior curtain of the mitral valve on the left side formed the base of the left aortic sigmoid valve on the right. The aorta, perfect in all its parts, and about as large as it usually is in a person fourteen or fifteen years of age, arose from the right ventricle in the usual situation of the pulmonary artery, giving off two coronary arteries behind the sygmoids, and distributing the vessels of the arch in the usual manner. No distinct traces of a *pulmonary orifice* were observable; but, in the position usually occupied by the ascending pulmonary trunk, my friend Dr. Gull, who examined the parts with great care†, found a thin impervious cord (*a*) passing upwards to a vascular

canal, (*c, c,*) transversely placed, which was evidently the upper part of the pulmonary artery, consisting of its right and left branches, passing to the lungs, and a portion of its ascending trunk (*d*), which, however, terminated below in a cul-de-sac. This latter portion of the vessel, as well as the whole of the left branch (*b*), was completely filled with a dense coagulum of some standing. At a short distance below the termination of its arch, the aorta gave off from its under part a large pervious *arterial duct* (*e*), which passed to the right lung, dividing into two branches just before it reached the bronchus; one, (perhaps both) of these branches communicated very freely with the branches of the pulmonary artery at (*j*). A very slender and long vessel (*g*), scarcely more than wide enough to admit a bristle, was also distributed from the arterial duct to the left lung. About half an inch below the duct two large vessels (*hh*), evidently *bronchial arteries*, greatly developed, passed upwards, one from either side of the aorta to the right and left lung. That on the left side appeared to have become narrowed in the middle; on the right very free communications may be observed between the pulmonary artery and the bronchial, as represented at (*i*).



- A, Commencement of the transverse part of the aortic arch, the heart and ascending portion of the arch having been removed.  
 B, Descending thoracic aorta.  
 C, C, Lungs.  
 D, D, D, Vessels of the arch.

The above figure is merely a diagram, and by no means fully represents the extensive communications which existed between the large arterial branches at their entrance to the lungs.

\* *Med. and Physical Journal*, vol. lxi. p. 548.

† And to whose suggestions I am much indebted for several of the details of the diagram.



The narrowing of the bronchial artery and of the branch from the duct on the left side must have greatly diminished the supply of blood to the left lung; but, while the left branch of the pulmonary artery remained pervious, that lung must have been freely supplied from the right, as may be at once seen on referring to the diagram.

The mitral valve was in an extremely diseased state; its orifice was somewhat narrowed, and the whole of the chordæ tendineæ of its anterior curtain were ruptured, their extremities being loaded with fibrinous deposits. Both auricles were large. The *foramen ovale* was closed; but, below it, there was a narrow circular opening through which a common director could be passed from either auricle, although it was furnished with a little imperfect valve. The left auricle presented a line of rough, granulated, fibrinous deposit, just above the origin of the posterior mitral curtain; an appearance frequently observed where there is disease of the left auriculo-ventricular orifice. The lungs were large, and extensively emphysematous on the surface; they contained several extensive recent apoplectic effusions. The liver was extremely congested, and bore traces of having suffered engorgement on previous occasions. The spleen was large and fleshy; its tunic very opaque. The kidneys were much congested, and starred with minute spots of ecchymosis, as were also the mucous linings of their pelves.

The heart and aorta are preserved in the museum at Guy's Hospital. The former is numbered 1383<sup>25</sup>.

It is probable that the life of this child would have been considerably prolonged had not extensive lesion of the mitral valve been superadded to the malformation from which he suffered. The lungs were more freely supplied with blood than is usual in such cases, and that the pulmonary circulation had remained tolerably unimpeded until shortly before the date of the fatal attack is evidenced by the capacity and strength of the left ventricle, which is usually found small and weak in cases where arterial blood is scantily returned from the lungs. An attack of thoracic inflammation, in itself of rather a severe kind, became fatally aggravated by the obstruction offered by the diseased mitral, which also appears to have determined the occurrence of the pulmonary apoplexy and the great engorgement of the abdominal viscera.

The formation of a clot within the left branch of the pulmonary artery most likely tended to hasten the fatal event, the supply of blood to the left lung from the arterial duct and left bronchial artery being extremely scanty. The formation of a coagulum in the artery was in all proba-

bility attendant upon the pulmonary apoplexy, which was very extensive in this lung. The cardiac bruit heard between the shoulders was doubtless produced by the mitral lesions.

*The pulmonary circulation supplied by supernumerary arteries from the aorta or its branches.*

Otto and Andral state that the pulmonary arteries are sometimes given off from the subclavian.\*

Although the preparation of the parts which were removed in the following case is imperfect, and it was not positively ascertained in what manner the pulmonary vessels received their supply, I think there are strong grounds for believing that blood was conveyed to these arteries by a branch from one of the large vessels of the arch, and, most probably, from the left subclavian. In May last, Dr. Thomas Chambers presented to the notice of the West London Medical and Surgical Society the heart of a boy between 9 and 10 years of age, who had laboured from his birth under the usual symptoms of morbus cæruleus, had several times suffered from hæmoptysis, and died rather suddenly with symptoms of pulmonary obstruction. Upon examination after death, the lungs were found extremely congested, and nearly airless throughout. The whole of the pericardial surfaces were inseparably united by old adhesions. By the kindness of Dr. Chambers and Mr. Prescott Hewett, I had an opportunity of carefully examining the heart. The right auricle was rather unusually large, the left (which received five pulmonary veins) was singularly small. I could not discover any opening in the *auricular septum*. The right ventricle was remarkably capacious and strong, and communicated with the left (which was unusually small), by an aperture in the *septum* large enough to admit the passage of the little finger. The aorta arose from the right ventricle; it was large and strong, gave off the two coronary arteries in the usual situation, and was complete in all its parts. The *ductus arteriosus* (which was attached to the ascending portion of the aorta about an inch and a half above its origin) was perfectly closed. A small depression was visible at the upper part of the right ventricle, to the left of the aortic orifice;—this hollow was evidently the rudiment of the *ventriculo-pulmonary opening*, but it was completely

\* Otto quotes instances where this was observed in the lower mammalia. Legallois noticed it in a rabbit. Otto also saw, in a double monster, an artery from the innominata trunk pass to an accessory lung, (Selt. Beob. Part I. p. 16. I shall have to allude to other instances of this kind).



occluded by a dense membrane of fibrous structure. Immediately above this partition a narrow passage (the ascending portion of the pulmonary artery) extended upwards to the back of the aorta, where it divided into two branches; one of these appears to have passed to the right lung, and the other is again subdivided into two. I believe that the lower of these went to the left lung, and that the upper received blood from some aortic branch. The arterial ligament passed directly from the upper and inferior part of the ascending aorta to the point of divergence of the two main pulmonary branches. In the portion of the aorta which remained, there were not any vessels which could have conveyed blood to this rudimentary pulmonary artery, but this must, in all probability, have been supplied by branches arising either from some of the large vessels of the arch, or from some part of the descending thoracic aorta. That the supply was received from the latter source is rendered extremely improbable by the fact that, immediately distal to the left subclavian artery, the tissues of the aorta were considerably thinner and weaker than they were a short distance above this point, rendering it probable that a somewhat diminished current of blood passed through the descending part of the main artery. Two or three of the orifices of the superior aortic intercostal arteries were left attached to the vessel, (which had been divided obliquely immediately anterior to the origin of the left subclavian): these were of the natural size: hence the further improbability that the pulmonary artery received any supply from the aorta below its arch. The origins of the brachiocephalic and left carotid arteries appeared of the ordinary dimensions, and did not seem to have been capable of admitting more than the usual quantity of blood. The left subclavian had been severed, and therefore it was impossible to judge of either its dimensions or its course, but the obliterated state of the arterial duct, the undilated condition of the brachiocephalic, left carotid, and intercostal arteries, and the thinness of the coats of the descending aorta, appear to render it a perfectly fair conjecture that the pulmonary artery could not have received its supply of blood from any other source than the left subclavian.

Whatever uncertainty may attach to the manner in which the pulmonary artery was supplied with blood in this remarkable case, its detail affords one or two extremely interesting facts—as shewing for how long a time an individual may survive, although suffering from so extreme a malformation, and as proving that the natural closure both of the arterial duct and the ovalian foramen may be effected, even in a case where there

is complete occlusion of the pulmonary ostium. The heart is preserved in the Museum of St. George's Hospital.

The following case, by M. Bigger,\* affords a rare example of absence of the pulmonary artery, the lungs being supplied by a supernumerary vessel from the arch of the aorta. An infant which, from the fifth day after birth, had been affected with cyanosis, died at the age of 5½ months, of convulsions and dyspnoea. The left ventricle and auricle of the heart were found to be much smaller than the right. The *foramen ovale* was still patent. The pulmonary veins were much contracted, but no traces of the [true?] *pulmonary arteries* could be detected. The aorta arose from the septum of the two ventricles, and communicated with both. A considerable *arterial branch*, about the size of the *arteria innominata*, was given off from the arch of the aorta, and was distributed to the lungs.

In January 1842, Mr. G. Smith detailed, at the Westminster Medical Society, the case of an infant which attracted attention soon after its birth by the dark colour of its skin. It, however, went on pretty well, and appeared in good health, except that it was subject to attacks of crying, with shortness of breath, at which time the blueness of the surface was very much increased. It died suddenly at the age of eight months. The body was plump and fat. The heart was large, the right auricle and ventricle were of great extent, and composed the greater portion of the organ; the right ventricle was more muscular than natural, and the left had the small proportions proper to the right. The *pulmonary artery* was wanting, with the exception of what appeared to be the small rudiment of one going in a direction towards the ductus arteriosus. The aorta, which was very large, arose from both ventricles, the *ventricular septum* being incomplete. The vessels branched off from the arch of the aorta as usual; but, in addition to these, there was an artery about the size of the subclavian arising from the under surface of the arch. This shortly divided into two branches, which were distributed one to each lung. There were three or four small pulmonary veins, which passed to the left auricle. The *foramen ovale* was open sufficiently to admit a goose-quill in an oblique direction.†

As the precise spot from which the supernumerary branch arose in the two cases just quoted is not mentioned, and as no reference to the arterial duct is made in either, it would be difficult to judge whether the

\* Wochenschrift für die Gesamte Heilkunde, 1839, No. 36; and Edinburgh Med. and Surgical Journal, vol. lv. p. 25.

† Lancet, Jan. 15th, 1842.



lungs were, in reality, supplied by an accessory vessel formed especially for that purpose, by an enlarged bronchial artery, or by the ductus arteriosus, which, owing to the complete obliteration of the ascending pulmonary trunk, would have had the appearance of arising as a distinct branch from the aorta. The latter is most probably the true explanation. At all events, these cases bear the closest physiological relation to those which have been previously quoted.

A few other cases of obliteration of the pulmonary orifice have been recorded, but these are rendered imperfect in their details from the circumstance that the precise manner in which the lungs received their supply of blood was not ascertained, the aorta having been cut through a short distance above its origin. I have recently seen an instance of this kind; but, as I understand that the gentleman in whose practice it occurred intends to publish the case, I shall make no further allusion to it at present.

Dr. Shearman, of Rotherham,\* details the case of a delicate female child, ætat. 8 years, who suffered from slight cough, hæmoptysis, and some lividity about the mouth and eyes. The chest was well formed, except that the left side was more prominent than the right. "There was a flat sound over a much greater extent than natural in the cardiac region; on a level with the superior margin of the third rib on the sternum, a loud bellows sound with the first or systolic beat of the heart, which was heard louder under the right clavicle, and not under the left; another loud rasping bellows sound at the ensiform cartilage, with the first beat, which decreased in intensity as you left that spot; and another systolic bellows sound at the apex, more feeble than the others, which decreased in intensity higher up the ventricle. There was a slightly perceptible purring tremor over the apex, and very great jugular pulsation in the neck." Every three or four weeks she was seized with hæmoptysis to a greater or less extent, accompanied by symptoms of cyanosis; during the intervals she had very little if any cough, but she was not capable of taking any exercise without producing very rapid respiration and a violet colour of the skin, on which occasions the jugular pulsation was very great. She died of hæmoptysis about nineteen months after she was first seen by Dr. Shearman.

Both lungs were found very full of grey tubercle. The heart, with its pericardium attached, weighed ten ounces. The right ventricle was considered by Dr. S. to be on the left side of the heart, and the right side of the heart constituted the apex, instead of

the left. The auricle connected with the tricuspid valve was very large, and had two large venous openings; the other, connected with the mitral valve, was very small and thin, and only one very minute orifice\* could be found. The *foramen ovale* was open. The ventricles communicated by an aperture in the septum, large enough to admit the little finger, just at the root of the aorta. The *pulmonary artery*, like a very small vein, opened into that ventricle which was divided from the auricle by the tricuspid valve. The semilunar valves of the pulmonary artery were quite rudimentary, and the author appears to think that the lungs did not receive blood by that route. As the upper part of the aorta was not preserved, the precise manner in which the circulation through the lungs was carried on could not be ascertained.

Lediberder† (quoted by Hasse) found the pulmonary artery closed by a transverse membranous expansion without any aperture whatever. I have failed to obtain a sight of the original narrative.

Mr. Fearn‡, of Derby, relates the case of an infant which had been affected from the time of its birth with considerable difficulty of breathing, drowsiness, and lividity of the surface. It died at the end of the 7th week. The aorta was nearly twice its ordinary calibre. The *pulmonary artery* was much smaller than natural; it did not cross the root of the aorta, but ran along its right side, giving off its branches to the lungs in the normal way. It contained some fluid blood, and its communication with the ventricle was cut off by a thin membrane stretching across its commencement. The upper part of the *septum ventriculorum* was deficient. The *foramen ovale* was open, and as large as in the foetal state. The right auriculo-ventricular opening would scarcely admit the passage of a probe. The left auriculo-ventricular opening was natural. The ductus arteriosus was closed. This interesting case appears to have been in many respects similar to that observed by Dr. Thomas Chambers. Unfortunately no clue is afforded to the precise manner in which the upper part of the pulmonary artery was supplied with blood—whether from dilated bronchial vessels, or supernumerary branches from the arch or elsewhere.

M. Gintrac§ cites the instance (observed by M. Lordat) of a child, six weeks old,

\* In a subsequent communication Dr. Shearman mentions "that the very small orifice, like a minute vein, connected with the small auricle, had, he feels convinced, never been used as a pulmonary vein."

† Bulletin de la Soc. Anat. t. ii. p. 68.

‡ Lancet, Nov. 22, 1834, p. 312.

§ Observations et Recherches sur la Cyanose, on Maladie Bleu, par E. Gintrac, M.D. p. 201.

\* Provincial Med. and Surg. Journal, July 30th, 1845.



which, while tranquil, performed its functions naturally, there being merely a bluish appearance of the upper eyelids; but when it cried, or was otherwise excited, the surface of the body became blue. It died in a paroxysm. The heart was small, and nearly of a spherical shape; the walls of the right ventricle were extremely thickened, its cavity was exceedingly small; the size of the right auriculo-ventricular orifice corresponded with that of the ventricle. The auricles were well shaped, and the *foramen ovale* was large. The *pulmonary artery* was very small, and entirely obliterated at its commencement. The manner in which the lungs were supplied does not appear to have been observed. The case was probably, in most respects, similar to that by Dr. Hunter, already quoted.

In the whole of the recorded instances of congenital obliteration of the ascending pulmonary artery, where the symptoms have been described, there were, to a greater or less degree, cyanosis and other signs of pulmonary obstruction. In the three cases which have occurred recently in some measure within my own observation, life was, I believe, more prolonged than in any other recorded instances, with the exception of that by Dr. Ramsbotham. In these three cases there was anatomical evidence of the fact that a considerable quantity of blood circulated through the lungs. In two the left cavities of the heart were equal in capacity to the right. In Dr. Thomas Chambers's case they were much smaller, but not extremely contracted. In nearly all the other examples which I have cited there were evidences of a very greatly impeded pulmonary circulation. This obstruction is evidently due less to the indirectness of the course by which the blood reaches the lungs, than to the unnatural narrowness of the pulmonary vessels, which, although greatly varying in dimensions in different individuals, are very rarely, if ever, equal in capacity to the pulmonary branches of a well-formed organ. In all such cases the occurrence of slight pulmonary disease may at once determine the fatal issue; but it is certain that—other things being equal—the duration of life in this, as in most other forms of congenital heart disease, depends mainly upon the degree of freedom with which the blood gains access to, or returns from, the lungs.

To render this part of the subject complete, it will be necessary to devote a few observations to the

#### *Offices of the Bronchial Arteries in health and disease.*

The physiological properties of these vessels are exceedingly curious, and appear, even in the present day, to be in great measure overlooked by anatomical writers. It

has generally been considered that the bronchial arteries are merely intended to convey nutrient material to the pulmonary tissues, and to supply the external and internal secreting surfaces, and the glandular apparatus, of the lungs: and, although cases have been alluded to by authors in which these vessels were absent\*, it cannot be questioned that, under ordinary circumstances, their duties may be almost exclusively of this nature. Still, the capillary anastomoses of the pulmonary artery with the bronchials, as described by Ruysch, Petsche, Haller, and Reisseisen, are so free, and the blood contained in the extreme pulmonary branches is so well fitted for all the purposes of nutrition and secretion, that it is difficult to resist the conviction that the true pulmonary vascular system would be alone sufficient to maintain the organic integrity of the parenchyma and other structures of the lungs, and that the bronchial arteries have been superadded for the purpose of performing certain additional and peculiar functions. Indeed, it cannot be questioned that these vessels are designed to fulfil another very curious and perhaps very important office; they appear to be almost equally calculated either to supply the pulmonary artery, where the entrance of blood to that vessel is mechanically impeded, or to afford, to a limited extent, a means of exit to its branches, when the passage of its contents through the veins is rendered difficult by extreme pulmonary or cardiac obstruction†: thus affording a physiological parallel

\* That the bronchial arteries may be totally absent, and their functions be efficiently supplied by the pulmonary capillaries, is an opinion fully in accordance with my own views; still, in such cases as those related by Wilson and others, where no bronchial arteries can be discovered in their usual situation, it is scarcely admissible to decide that these vessels are certainly wanting. There are so many ways in which the bronchials may be supplied by anastomoses with other branches in their vicinity; and, as will be presently shewn, so many modes in which additional vessels may be given off to compensate for defect either in the bronchial or pulmonary system, that it is almost impossible to prove the total absence of the latter vessels in any given case, unless the whole of the arteries of the chest, neck, and abdomen, have been minutely examined. Several instances of abnormal distribution of the bronchials have been recorded. Christopher Fichel (Haller, *Disputat. Anatom.* vol. iii. p. 6) saw a common bronchial artery given off from the subclavian distal to the origin of the mammary; and Ruysch states that he very frequently met with this arrangement. The latter authority also describes that the termination of the upper intercostal artery may pass to the lungs. Cruveilhier has seen a bronchial artery given off by the inferior thyroid, and various other arrangements of these vessels have been observed.

† Reisseisen always found that injection was conveyed from the pulmonary artery into the bronchials with greater facility than from the bronchials into the pulmonary artery. He also observed that by far the greater number of bronchial arteries end in the pulmonary veins.



to the duties performed by the external epigastric and external thoracic veins, and the internal mammary and epigastric arteries, which, under ordinary circumstances, are merely engaged in conveying blood to and from the integumentary and muscular structures in their vicinity, but which are also subsidiary to the cavæ and the aorta: communicating with the great venous and arterial trunks by free though indirect anastomoses, they are capable of undergoing extraordinary dilatation whenever those important vessels become obstructed, of conveying large quantities of blood in a direction contrary to that of their ordinary current, and, in short, of almost entirely assuming the important functions of the main systemic vessels. Hence we have seen that where the pulmonary artery is congenitally occluded, the bronchials, extremely dilated, may, in great measure, fulfil its office; and, on the other hand, where the aorta is congenitally obliterated at the lower part of its arch, the bronchials, and upper intercostal arteries, into which they frequently open, are found remarkably dilated, having evidently taken an important share in conveying blood to that portion of the aorta which is distal to the stricture. It is, of course, evident that, where obstruction of the pulmonary artery or aorta occurs late in life, functions of this kind cannot be fully assumed by the slenderly developed bronchials. Still, it is probable that, even at the adult period, the supplementary action of these arteries is occasionally, and to a limited extent, called into play; and it appears highly probable that, in many cases of great and long-continued pulmonary obstruction, the relief afforded to the over-distended pulmonary artery by its anastomosing vessels is by no means inconsiderable.

With regard to the general pathological relations of the bronchial vessels little is known; and the subject is one which promises to afford an interesting field for diligent inquiry, especially as regards the conditions of these vessels in various forms of pulmonary and cardiac diseases.

It has been argued that hypertrophy of the left ventricle occasionally produces pulmonary apoplexy by the violence with which the blood is impelled through the bronchial arteries; but this appears to be physically impossible: and, in such cases, the rupture of the vessels within the lung is probably due to very different causes: I have, however, occasionally been inclined to attribute the determination of pulmonary congestion, apoplexy, and œdema, to an obstructed condition of the bronchial orifices consequent upon a diseased state of the internal tissues of the aorta. The smallness of the vessels however, renders it difficult to bring this to absolute proof without injecting the parts

*in situ*, which can rarely be done. Still I think that this suggestion deserves investigation, as it is evident that any cause which tends to promote congestion or inflammation of the lungs must be greatly aggravated where the vessels which anastomose with the pulmonary arteries and veins are in an obstructed condition\*.

In the following case, which I saw in June last, it appeared probable that the great extent of the pulmonary inflammation, and the rapidity with which it involved the whole of both lungs, was to a certain, though probably to a minor, degree, owing to the lesion in question.

A man between 30 and 40 years of age, who appeared to have been previously the subject of tubercular deposit in the lungs, died, after a fortnight's illness, of suppurating pneumonia, involving nearly the whole of the pulmonary tissue, and in some parts assuming almost the characters of gangrene. There was an aneurism of the descending arch of the aorta, which had obliterated the left subclavian artery; and, below this, the sub-epithelial tissue of the vessel was greatly thickened, and otherwise diseased. The orifice of the principal bronchial artery was almost obliterated, scarcely admitting a bristle; externally to the aorta, this vessel was unusually wide.

In a case of remarkable obstructive disease of the aortic valves related by M. Fenema, and quoted by Professor Tiedemann, it is mentioned, that "the first intercostal arteries were narrowed and contractéd, and then unusually dilated. The patient—a soldier, æt. 43—had suffered from asthma, and symptoms of great oppression in the chest."

Otto mentions that we sometimes find these arteries very much enlarged in persons affected with cyanosis. He has seen this once. Tiedemann† and others have made the same observation. Otto also refers to a case of aneurism of the bronchial artery‡—a very rare lesion—but an evidence of the activity of the circulation through those vessels.

#### CONGENITAL NARROWING OF THE PULMONARY ORIFICE.‡

The great frequency of disease of the pulmonary orifice occurring during intra-uterine

\* In cases of pulmonary congestion, where the aortic orifices of the bronchial and upper intercostal arteries were almost obliterated by thickening, &c., I have found the trunks of those arteries externally to the aorta unusually wide: but this is an uncertain condition, as it may probably depend upon delay to the passage of the blood through these vessels consequent upon diminished cardiac impulse.

† Zeitschrift f. Physiol. vol. i. part i. p. 111.

‡ A Leprotus in Comment. Bonon., vol. i. p. 345 and 353.

‡ In quoting a very extended series of cases, a



life, compared with similar lesion of the aortic ostium, cannot fail to be observed.\* The aorta, it is true, is liable to several lesions of congenital origin, among which the fusion of its valves into a funnel-shaped channel is one of the most striking; but, during intra-uterine life, the functions of the aorta are light compared with those performed by the pulmonary artery, upon which mainly devolves the office of transmitting blood to the lower part of the body, and it is not surprising that, during the earlier months of foetal existence, obstruction to the circulation, depending, it may be, either upon malposition of the body of the infant, pressure upon the umbilical cord, &c., or upon faulty conditions of the lungs, should determine the occurrence of imperfection or irreparable lesion in the delicate tissues about the pulmonary orifice, while the aorta, being less influenced by these or any other causes of obstruction, escapes uninjured.

Whenever, in more advanced life, the pulmonary artery is called upon to perform an unusual † or too active function, it is found to be as liable to various forms of structural disease as is the aorta.

Congenital narrowing of the pulmonary ostium has been noticed by a large number of observers; and several writers have, to a certain extent, discussed the pathological relations of this lesion. Among others, Sandiforth, Hein, Louis, Dr. Craigie, and Dr. Stillé, have made it the subject of especial notice. The lesion is not by any means one of very common occurrence, as is proved by the fact that more than two instances of the kind have rarely been noticed by the same observer; relatively, however, it cannot be regarded as by any means rare, for it presents itself more frequently than does any other of the graver kinds of malformation to which the heart is liable. I have

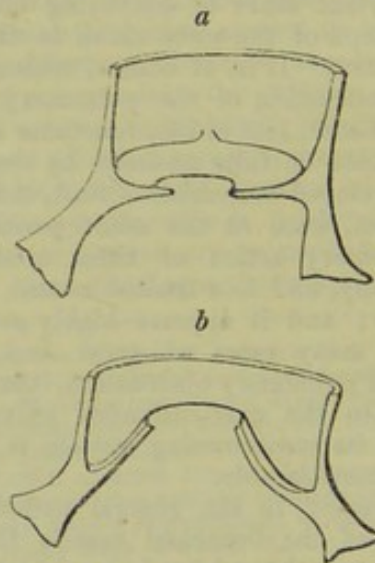
large number of which correspond in many particulars with each other, I have, of course, been compelled to abridge many of the narratives, merely retaining, in each, those details which best illustrate the nature and effects of the lesions observed in the pulmonary artery and remainder of the circulatory system, and omitting many facts which certainly add much to the pathological value of most of the cases as they appear in the original works. The utmost that I have been able to effect, consistently with due brevity, has been to retain the most prominent and essential features of each case in such a manner that the perusal of the whole may furnish the reader with a complete view of all the symptoms which attend cyanosis, and of all the effects which have been noticed to result in the system from congenital malformation of the pulmonary artery. For the entire details of each case I must refer my readers to the original narratives.

\* In nineteen cases of congenital malformation of the heart, described by M. Louis, there was contraction of the pulmonary artery in ten; but of the aorta, only in one.

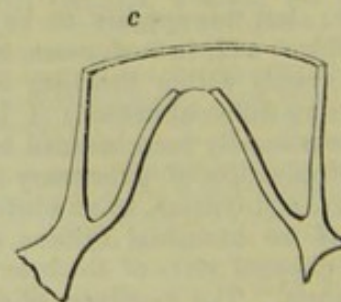
† As in cases where the main arteries communicate freely by the ductus arteriosus.

met with notices of about 60 well-marked instances of the kind, and might, doubtless, have obtained histories of many others, had it appeared necessary to extend my search still further.

Congenital arctation of the pulmonary orifice may occur in an almost infinite variety of forms. Occasionally there is found a very narrow passage, either confined merely to the ostium of the vessel, or involving also a portion of its ascending canal. This strait is generally rendered uneven by warty or ossific elevations. In other cases the orifice is less narrow than in the preceding instances, its sides being furnished with indistinct traces of rudimentary valves. Cruveilhier, Craigie, and many other observers, have described cases where the pulmonary orifice was furnished with an imperfect valvular apparatus, in the form of a transverse or conical partition, having an aperture in its centre, and presenting a smooth surface below; but above, three slightly elevated ridges which are apparently rudiments of the free edges of sygmoid valves (diagrams *a* and *b*). This is the state



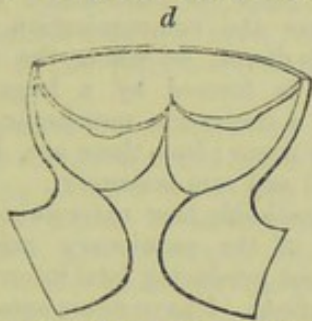
of parts most frequently noticed in cases of congenital narrowing of the pulmonary orifice. A very similar appearance is occasionally seen in the aorta. In some instances the mouth of the artery is occupied by a thimble-shaped membrane, perforated at its apex, and smooth on both surfaces (Fig. *c*). Several cases have occurred in



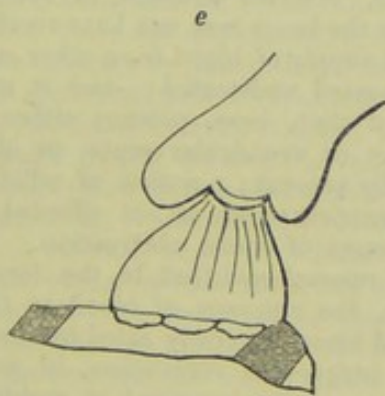
which the obstruction has been due to excrescences adhering to the valves. An in-



stance is noted by Kreysig,\* where the pulmonary artery was narrowed only on one side. In an example by Nasse, quoted by M. Hasse, the pulmonary orifice was blocked up by fleshy columns hardly separable from each other. A similar condition is described by Dr. Elliotson, as occurring in a case where the walls of the ventricle appeared to have grown up around the mouth of the pulmonary artery, forming a short narrow canal, leading to the orifice of the vessel, which was of the usual size (an appearance which may be represented by the diagram *d*).



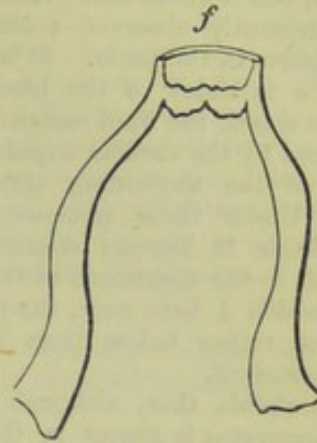
In a case related by Mr. J. Marshall, the valves were found in a contracted and inefficient state, and the vessel above presented a singular contraction. The diagram (*e*) is copied from Mr. Marshall's paper. In some instances, the vessel has been found considerably, but not extremely, narrowed, and either destitute of valves or furnished with only two sygmoid curtains.



In cases where the opening is extremely narrow, and life is prolonged for several years, the constricted part usually has a tendency to be forced upwards by the impulse of the ventricle. We have seen that in some of these instances, where the orifice is closed by a perforated membrane, this becomes extended into a funnel-shaped tube; in others the structures at the base of the vessel become rather elongated, and then the rudimentary valvular ring, which is the seat of obstruction, has an appearance of being situated unusually high up in the canal. In other cases a portion of the muscular tissue of the ventricle immediately at the root of the artery becomes stretched

\* Herzkrankheiten, vol. iii. p. 104, quoted by Otto.

upwards, and may form a little supplementary muscular cavity below the pulmonary orifice, as figured in diagram *f*.



Lastly, the artery may simply be diminutive in size, but complete in all its parts. It is probable, however, that, in the cases of this kind which have been observed, the tissues of the arterial orifice have been rendered contracted and unyielding by previous disease; as it is clear that, providing the whole structures were healthy, the size of the artery would not fail to be proportioned to that of the ventricle.\* Several other forms of contraction of the pulmonary orifice have been observed. These will be noticed in the details of the several cases.

The whole of these morbid conditions are evidently due to lesions of the vessel occurring at a very early period of intra-uterine life; the obstruction thus produced checking the further development of the parts, and frequently preventing also the due formation of the ventricular and auricular septa, and other portions of the cardiac apparatus, which are at that period either wholly undeveloped, or but imperfectly formed.

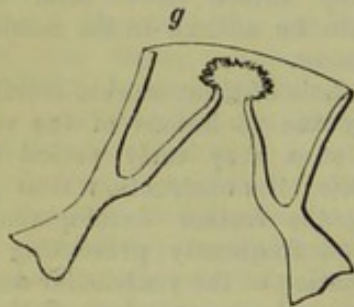
It has been remarked by several authori-

\* It may be supposed that the small size of the pulmonary artery is here the result of the diminished quantity of blood which passes through it to the lungs in consequence of the open state of the ventricular septum; but this view would generally be erroneous—as, in those numerous cases where, the pulmonary artery being contracted, the aorta is given off either from the right ventricle, or midway between the two cavities, there is not the slightest reason to believe that blood ever passes completely through the septum from right to left, however freely it may do so in a contrary direction; in these cases also the ovalian foramen is not unfrequently closed. In hearts which I have seen, where a free opening—apparently the result of ulceration—had long existed between the ventricles, the pulmonary artery was not diminished in size. In a few instances, however, (as for example in that which will presently be quoted from M. Schuller, where contraction of the pulmonary orifice was attended with an open state of the foramen ovale and arterial duct, the ventricular septum being complete), the narrowness of the vessel may be, in part, owing to the diversion of the stream into another course.



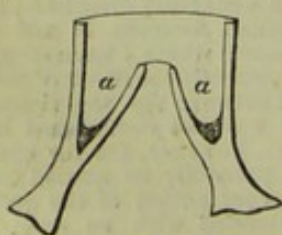
ties, that, where the pulmonary valves are concreted, rendering the orifice of the vessel extremely narrow, the artery above is not contracted, but is occasionally rather dilated. I have frequently observed a similar condition of parts in the aorta. It is evidently attributable to delay of the blood in that part of the vessel, the fluid remaining almost uninfluenced by the cardiac impulse in consequence of the unyielding state of the ostium. Under these circumstances the aorta is liable to become considerably dilated; but, in the specimens of the lesion in question which I have seen, the pulmonary artery was rather below than above the ordinary standard.

It is probable that, although a normal valvular apparatus is absent in these cases, regurgitation of blood into the ventricle occurs in but a very small proportion of instances. The arterial aspects of the contracted orifices are occasionally clothed with small distinct masses of organised vegetations, which freely admit of the passage of blood into the artery, but afterwards close together and prevent reflux. A very curious arrangement of this kind is observable in a heart preserved in the Museum of Guy's Hospital. (fig. *g*.) The details of this case



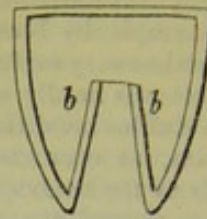
will be mentioned hereafter. In most of the examples where the rudiments of the sygmoid curtains form an elevated cone projecting upwards into the vessel, this apparatus in reality constitutes a very efficient valve. In many of these cases the mechanism of the parts is very similar to that of the small glass ink bottles which are contrived in such a manner as to be carried open in the pocket without escape of the fluid.

The only difference is that the sides of the funnel-shaped valve of the artery (*a, a*), require to be pliable, and capable of



being pressed together; were they wholly inelastic, like those of the conical glass tube,

(*b, b*), they would admit of some degree of



reflux at every ventricular diastole. It, however, rarely, if ever, happens in the pulmonary artery that the malformed valve altogether loses its pliability. In a few cases, where the communication with the ventricle is direct, or where the orifice of the artery is formed by a large circular opening in a transverse membrane, regurgitation may occur; but these are, I believe, exceptional and rare instances.

It is remarkable how extreme a degree of narrowing of the pulmonary orifice may exist without producing fatal interruption to the circulation. I have never seen or heard of any instance where the area of the aortic opening had become reduced to less than the diameter of a common writing-quill, but a considerably greater degree of arctation of the pulmonary orifice has been noticed even in persons above the age of ten years, and this too in cases where it was not observed that any supernumerary arteries communicated with the lungs. There frequently, however, remains a doubt, in such cases, whether the lungs may not have received an indirect supply of blood from other sources, which passed undetected;—and it must be observed that, here, patency either of the auricular or ventricular septa, or of both, is usually present; a means of relief to the right ventricle which is not afforded to the left in cases of aortic obstruction. It will also be remembered that, in the former instances, the entrance of blood to the obstructed vessel is greatly aided by the action of the lungs—the respiration, in many of these cases, being increased in rapidity evidently for the purpose of, in some measure, compensating for the scantiness of the supply of blood to the lungs by the quickness of its transit,—a point which has been very ably argued by my friend Dr. Lloyd. It will be observed that, in cases of this description, the duration of life depends far more upon the strength of the right ventricle, and the expansibility of the lungs, than even upon the size of the vessels by which the pulmonary circulation is carried on—a fact of no small practical moment.

In classifying the cases where the pulmonary orifice has been found congenitally narrowed, reference should especially be had to the relative position which this vessel, the aorta, and the ventricles, are found to occupy in the several instances; as the va-



riations which occur in this respect are extremely marked, rendering the degree of malformation very far indeed more salient in some cases than in others; and especially as it is found that such variations produce considerable difference in the state of the circulation, and distinctly affect the viability of the individuals who suffer from these malformations.

Still it appears preferable to arrange the cases according to the degree of abnormal communication which is observed to exist in the several instances, premising that the modes in which the large vessels are found to be given off from the heart, in cases of arctation of the pulmonary orifice, are as follow:—

1. The aorta arising from the right ventricle, the narrowed orifice of the pulmonary artery being situated to its left, and anteriorly. The septum of the ventricles pierced by a rounded opening, which may either be confined to the upper portion of the partition, or be so extremely wide as to leave the ventricles separated merely by a slightly elevated falx.

2. The aorta, originating behind the pulmonary artery, nearly midway between the ventricles, and above the ventricular septum, which terminates by a crescentic margin below the ostium of the vessel; thus leaving an aperture of greater or less size through which both ventricles communicate alike with the arteries and with each other.

3. The narrowed pulmonary artery and the aorta arising, as usual, from the right and left ventricles, with or without a rounded aperture in the ventricular septum.

Although by far the larger proportion of instances in which these malformations occur are congenital, it occasionally becomes a matter of difficulty to decide whether many, if not the whole, of the abnormal appearances are not the results of comparatively recent disease. In the cases of the first and second orders, just described, such a doubt cannot for an instant be maintained; a single glance will shew that the principal lesions are congenital, although morbid changes of later date may have been superadded; but with regard to the third class, it is often by no means easy to decide;—in such cases an opinion can only be founded upon a minute examination of the structures, and a knowledge of the duration and character of the symptoms during life.

The following arrangements of parts have been observed in cases where the orifice of the pulmonary artery was congenitally narrowed. (1.) The pulmonary circulation supplied by enlarged bronchial arteries. (2.) The auricular and ventricular septa imperfect; the ductus arteriosus remaining permanently open. (3.) The foramen ovale and arterial duct permanently open; the

ventricular septum being complete. (4.) The arterial duct and ventricular septum pervious; the foramen ovale perfectly obliterated. (5.) The arterial duct closed, the ventricular and auricular septa perforated. (6.) The ventricular septum, only, incomplete. (7.) Patency of the foramen ovale only. (8.) Entire absence of any unnatural communication either between the cavities of the heart or its great vessels. A collection of examples of each of these kinds of malformation will furnish some interesting data illustrative of the pathology of the circulation.

(1.) *The pulmonary orifice contracted—the lungs supplied by enlarged bronchial arteries.*

Reference has been already made to a class of cases where—the ostium of the pulmonary artery being congenitally occluded,—the supply of blood to the lungs is in part or wholly furnished by dilated bronchial arteries, arising from the descending thoracic aorta. The following case proves that a similar arrangement may obtain where the entrance of the pulmonary artery is merely extremely narrowed. It is, however, the only well-marked instance of the kind with which I am acquainted.

M. Jacobson describes\* the heart of a boy who died with morbus cæruleus, and in whom the aorta, which was considerably enlarged, was given off from the right ventricle. The *pulmonary artery* was not more than one-fourth the size of the aorta, its ostium being greatly contracted by thickening of its valves. But, to compensate for this, the *bronchial arteries* were very much enlarged; three of these vessels passed off from the right and left sides of the aorta to the lungs, and a branch was distributed to either lung from the pericardial artery. A large opening existed in the *septum of the ventricles*; the *foramen ovale* was almost closed.

II.—*With patency of the auricular and ventricular septa and ductus arteriosus.*

We have observed that, in by far the larger proportion of instances of non-development or congenital occlusion, of the pulmonary orifice, the arterial duct remains permanently open throughout the life of the individual; still, such an arrangement does not invariably obtain, even in those extreme instances; and, in cases where children are born with great narrowing of the pulmonary ostium, it may be stated, as a general rule, that the obstruction to the circulation thus produced (however extreme it may be) is usually not sufficiently great to determine the permanency of the arterial duct. This is pro-

\* Meckel, Archiv. für Physiologie, B. ii. St. i. 13.



bably due to the fact that, to whatever extent the arctation of the pulmonary artery may have gone, the entrance of blood through its narrowed orifice is rendered considerably more free immediately the child is born, and respiration commences. Arctation of the pulmonary orifice is doubtless a source of far greater obstruction to the passage of blood from the right ventricle during intra-uterine life, while the respiratory organs are inactive, than it is subsequently to birth; hence we may probably account for the fact that a degree of obstruction in the pulmonary artery which has been sufficient to determine the persistence of an opening in the ventricular septum, has, in many cases, not been capable of preventing the foramen ovale and the arterial duct from becoming naturally closed. There are, however, several instances on record in which permanence of the arterial duct was attendant upon the form of lesion now under consideration: still, they are few compared with those in which the duct has become obliterated; not amounting, in fact, to more than one case in ten. And it will be observed that in the whole of the following instances, although the canal was pervious, its channel had become, to a certain degree, contracted. And it is probable that in cases of this kind it never retains that width relatively to the pulmonary artery which is observed in the naturally-constructed foetal heart. This last observation also applies to the cases where permanence of the arterial duct is combined with an obliterated state of the pulmonary orifice. I believe that, neither in these nor in any other class of instances where life has been much prolonged, has the arterial duct been found to exceed, if ever it has been seen to equal, one of the main pulmonary branches of a well-formed individual of the same age.

A remarkable instance of this kind of malformation is recorded by Dr. Cheever\*. The patient was a boy, who died at the age of 13½ years. During the first months of infancy his skin began to assume a purple tinge, and his respiration became, at times, laborious. As he grew up, his chest presented an appearance of deformity. Dyspnoea, attended with slight cough and occasional expectoration of blood, continued to increase until Dr. C. saw him: he was then 12 years of age. He was tall and slender, having little flesh on his extremities. The last joints of his fingers and toes were unusually long, broad, and bulbous; the nails hooked, and of a dark purple colour. The surface of the body generally was of a leaden hue; but, on the accession of a paroxysm, some parts, such as the lips, nose, and

ears, acquired a very dark purple tint. He was very sensible to cold, and the temperature of his body, when at rest, was below the natural standard, though easily raised by the slightest exertion. There were no marks of a diminished energy of the brain; his intellectual powers were good. Attempts at active exercise produced very severe paroxysms of palpitation and dyspnoea, blackness of the tongue and fauces, and all the most vascular parts of the surface; a turgidity of the vessels of the neck, an engorgement of the countenance, and great heat of the surface\*. These symptoms also often occurred unexpectedly when he was not using exercise. The paroxysms above described continued to increase in force and frequency, and were latterly complicated with symptoms of hydrocephalus. His cough became incessant, attended with frequent expectoration of black blood, and great difficulty in breathing. His eyes, before prominent and suffused, now seemed starting from his head; he was paralytic on one side, extremities œdematous, bowels torpid. During his last illness the heat of his body was very variable, often great. His pulse was quick and small, but regular. Deglutition was often suspended, and he had frequent hæmorrhages from the mouth and nose. He died reduced to the last degree of emaciation. Upon examination, the thymus gland was found large and distinct, the lungs very small and dark coloured, and adherent to the ribs on either side, and very firmly to the diaphragm. Tubercles were pretty generally diffused throughout their substance. The cavities of the thorax and pericardium appeared black and gangrenous†, but free from serous effusion. The heart, generally, appears to have been smaller than is usual in persons of that age; its apex was obtuse, and there was a collection of fat upon its surface, which was remarkable, considering the emaciation of the subject. The auricles were distended with blood. The parietes of the right ventricle were so much increased in hardness and muscularity as to render it incapable of containing more than half an ounce of blood. The *pulmonary artery* was nearly impervious; its valves were thickened into a triangular form, and so much constricted as to admit with difficulty the eye of a small probe. The *ductus arteriosus*, about half an inch in length, was pervious, and of the size of a crow-quill. The sides of the left ventricle were thin, and its cavity propor-

\* In some other cases of cyanosis the body has been noticed to be liable to intense flushes of heat.

† This was probably an excessive degree of the ecchymosed appearance of the thoracic serous membranes which has been observed in some other instances of cyanosis.



tionally increased. There was a perforation in the *septum of the ventricles*, just below the origin of the aorta, large enough to admit the little finger. Through this communication ligamentous bands, resembling the chordæ tendinæ, passed to either ventricle, proving that the perforation was the effect of malformation, not of disease. The *septum* of the *auricles* was entirely wanting.

M. Obet\*, describes the case of a boy who became affected with cyanosis in his second month, and died at the end of his 3d year. The lungs were found to be sound, the right auricle was greatly larger than the left; the rest of the heart was of usual size. The *foramen ovale* was open; the *pulmonary artery* very small; its tunics were thin, like those of a vein, and its orifice so contracted that it would scarce admit a probe; it arose a little in front of the *septum* of the ventricles. The *canalis arteriosus*, which was very narrow at its origin, opened into the left subclavian. The *septum of the ventricles* was deficient towards the base of the heart. The aorta—larger than natural—arose above the *septum* in such a manner that one of its sigmoid valves corresponded with the right ventricle. The aorta gave off its primary branches in an irregular manner, and passed to the right of the trachea, the pulmonary artery passing to the left.

III.—*The ductus arteriosus and foramen ovale patent; the ventricular septum complete.*

In the following cases the narrowing of the pulmonary orifice must have occurred much later than in the instances just quoted.

M. Bapt. Schuler† mentions a male infant whose nails and lips became blue a few days after birth, and who lived only 7 weeks. Upon examination, the lungs were found of a blackish purple colour. The right auricle was distended with blood, and its walls were thicker than natural. The *venæ cavæ* and coronary veins were also distended. The *foramen ovale* was widely open, and its valve reticular. The walls of the ventricles were very fleshy, especially those of the right, the cavity of which would scarcely admit a small nut. The valves of the *pulmonary artery* coalesced and projected upwards, leaving but a very contracted opening. The orifice of the aorta was much wider than natural, and its valves thickened. The *arterial duct* was narrow. Many of the mesenteric glands were in a state of scrofulous degeneration.

The above case nearly resembles those

already detailed in which closure of the pulmonary orifice was followed by extreme contraction, nearly approaching to obliteration, of the cavity of the right ventricle; the larger proportion of the blood, finding no early exit from that receptacle, passed freely through the wide *foramen ovale* into the left cavities, whilst the pulmonary ventricle became extremely small. If, however, this contracted state of the ventricle was not rather apparent than real, it is probable that the lungs received a supply of blood from accessory vessels which escaped M. Schuler's observation, as the pulmonary circulation could scarcely have been adequately maintained through the narrow ventricle and slender arterial duct.

M. Seiler\* observed the case of a man, æt. 29, in whom the chest was found to be deformed, its cavity being much narrowed. The lungs were small, collapsed, of a livid colour, almost approaching to black, and pressed into the posterior part of the cavity by the enlarged heart. This organ was three times larger than natural; its walls were much thickened, those of the left ventricle were thicker than the thumb, and presented traces of ossification. The cavities were full of blood. The *foramen ovale* and *arterial duct* were pervious, the former very freely. The *pulmonary artery* was very narrow, its valves ossified. The aorta was very large; its tunics were not thinned.

IV.—*The foramen ovale obliterated, the ventricular septum and arterial duct pervious.*

An instance of this description is related by Dr. Houston†. The subject of his case was a boy, æt. 3 years, who died of phthisis and bronchitis. There was violent action of the heart, but the pulse was feeble and the skin cold. The face, hands, and feet, were of a dark livid hue; this colour had not been habitual, and "had only come on when he laboured under pectoral affections." It could not be ascertained whether violent exercise produced the same effect. The right auricle was found to be large, the *foramen ovale* closed. The *pulmonary artery* was about half the usual size, and furnished with two semilunar valves. A smooth defined hole, large enough to admit the little finger, and twice as large as the pulmonary orifice, led through the *septum*, from the right ventricle into the upper part of the left ventricle. The left auricle was small. The left ventricle of the same size and thickness as the right. The aorta was unusually capacious; its valves were perfect. The

\* Bulletin des Scien. Med. réd par Grapenon, t. ii. p. 65, 1808.

† Diss. de Morb. Cœrul. Cœniponte, 1810, quoted by Hein.

\* Horn. Nues. Archiv. Bd. ii. Heft. ii., 1805, quoted also by Corvisart as from "a thesis read at Wittenberg."

† Dublin Hospital Reports, vol. v. p. 322.



*ductus arteriosus* was diminished in size, but not obliterated.

These are the only examples with which I am acquainted where permanence of the *ductus arteriosus* has been observed coincidentally with narrowing of the pulmonary orifice. In the whole of the instances of this lesion which I shall next have to cite the duct was found impervious.

V.—*The pulmonary artery small. An abnormal communication existing between one of its branches and the subclavian.*

It may be considered that, in the following instance, as well as in the case by M. Obet already cited, the arterial duct remained pervious; but it appears certain that, in both of these hearts, the communicating vessel was not in reality the *canalis arteriosus*, but the remains of the communication which, at a very early period of intra-uterine life, while the circulation of the upper portion of the body is carried on through the branchial arches, naturally exists between the vessels which afterwards form

\* Since the appearance of the preceding section of my paper I have met with a report of the following case of extreme narrowing of the pulmonary orifice attended with an unclosed state of the auricular and ventricular septa and arterial duct. The subject of this rare malformation was a boy, who, for the first two years of his life, did not manifest any peculiarity of appearance or disorder of function beyond occasional attacks of bronchitis, during which his face appears to have assumed a congested appearance. When he had entered his fourth year Dr. John Bell, who narrates the case, found him suffering from the usual symptoms of the blue disease, but apparently not in a very extreme degree. The sternum and anterior part of the thorax were unduly prominent. The pulse was frequent, and rather full, but easily compressed. "Impulse and the bellows sound well marked over the sternum. Dulness on percussion was of limited extent." The respiration was hurried and panting, but he usually ran about and amused himself like other children of his age. From this period up to the time of his death, which occurred when he was somewhat under the age of 8 years, he continued to suffer from repeated attacks of "pulmonary oppression and congestion," which, within the last two years of his life, became more violent. The prominence of the sternum and left side of the chest went on increasing; the distension of the jugulars and their pulsations were still more perceptible. Usually, the [heart's] sounds were not strong, although those of regurgitation were quite distinct. During a paroxysm there was, however, a loud bellows and rasping sound, with another less evident, and comparable to a subdued gurgling or churning. The pulse all the while was frequent, but without force. At two different periods, together with great præcordial and pulmonary compression, dyspnoea, &c., there was tympanitis, with obstinate constipation, and anasarca, against which all the usual diuretics and means of indirect reduction were utterly powerless. But the abstraction of a few ounces of blood, either from a vein or locally, exerted an immediate and beneficially controlling influence over the disease. The common purgatives, diuretics, and

the right and left pulmonary and subclavian arteries. The occasional permanence of this communication between the canals in question has been very clearly described by Dr. Paget.\*

M. Holst† relates the case of a girl who enjoyed perfectly good health until she was two years old, when her skin began to assume a blue appearance, especially at the parts most distant from the heart. She then experienced feelings of suffocation, giddiness, and spasms. These attacks were usually followed by sleep, after which the blueness of the skin was less. Violent palpitations of the heart, with difficulty of breathing, coldness, and frequent epistaxis, gradually succeeded; and though the frequency of the seizures diminished, yet their violence and duration gradually increased. During the paroxysms, the left side became colder than the right, and the pulsations of the arteries at the wrist of the left arm could not be felt. She died suffocated in one of these attacks. The heart was found very large; the right side larger than the left. There

expectorants, would then manifest their customary effects. Little or no benefit was derived from digitalis. The appetite was generally good, and the craving for various articles, some of them of an indigestible nature, inconveniently great. He died somewhat unexpectedly, after having in great measure recovered from two very severe attacks, which were relieved by venesection. It was found that each pleural cavity contained five or six ounces of serous fluid, the pericardium a small quantity. The heart was very much enlarged in consequence of the hypertrophy of its right ventricle, the parietes of this cavity being twice their ordinary thickness. Nothing peculiar in the appearance of the right auricle. The left cavities were atrophied, but otherwise natural. An opening about half an inch in diameter existed at the upper part of the *ventricular septum* common to the two ventricles and the aorta. The ascending aorta was nearly twice its natural size. The *ductus arteriosus* was open, and large enough to admit a goose-quill. The pulmonary artery was of its natural size at the entrance of the arterial duct, but gradually tapered towards the right ventricle, with which it communicated *directly* by an opening so small as scarcely to admit the introduction of a common probe. The *foramen ovale* was not closed, but evidently not sufficiently open to allow of any deleterious admixture of venous and arterial blood.

(As quoted in the *Bullet. de Sci. Méd.* August 1845.)

The extreme minuteness of the right ventriculo-arterial opening, and the absence of any valvular appearance at its mouth, led Dr. Bell to consider that, during life, blood passed from the pulmonary artery into the ventricle, and not in the contrary and usual direction. This opinion is certainly favoured by the fact of the existence of a regurgitant sound during the paroxysms.

\* On the Congenital Malformations of the Heart, *Edinburgh Medical and Surgical Journal*, vol. xxxvi. p. 287; an essay to which (in common with most recent writers on malformations of the heart) I am indebted for much valuable information.

† *Hufeland's Journal*, Jan. 1837; quoted in *Amer. Journ. of Med. Science*, vol. xxi. p. 457.



was communication between the two auricles, not only by the *foramen ovale*, but also by an abnormal opening. The aorta and pulmonary artery arose from the right ventricle. These arteries and all the others were smaller than natural. The left subclavian artery arose from the upper angle of a triangular sac, into the two other corners of which opened the left vertebral artery and an abnormal canal, considered by M. Holst to occupy the place of the *ductus arteriosus*. By this last the subclavian artery was in communication with the left branch of the pulmonary; but, as this canal was very small, but little blood could enter into the subclavian artery, which seemed to have received most of its supply from the left vertebral: so that the blood, in getting from the aorta to the left subclavian, must have passed through the carotids and the circle of Willis. This condition of parts was considered to account for the occasional cessation of the pulse, and the diminished temperature of the left arm.

VI.—*The auricular and ventricular septa perforated—The arterial duct closed.*

Many instances of this kind of malformation have been observed; and, in these, although the arrangement of parts has been in all physiologically similar, the degree and form of the congenital lesions have varied in an extremely remarkable manner. Thus, in one case, the arterial duct was pervious at its aortic end, though closed towards the pulmonary artery. In several instances there has not existed the slightest trace of an arterial canal; in others, the septum of the auricles has been found nearly complete, the foramen ovale being furnished with an efficient valve, while the ventricular septum was almost totally absent. In a fourth set, the main imperfection has existed in the auricular partition; and in a fifth, great contraction of the pulmonary orifice has been coincident with a very moderate amount of communication between the right and left cavities. These diversities of structure have clearly depended, in some cases, upon the period of intra-uterine life at which the lesion of the artery has occurred; in others, upon the degree of obstruction established in the vessel.

In the following example, observed by M. Caillot\*, the malformation was only in a small degree removed from that which was found in the instances by Dr. Cheever and Dr. Bell, already cited; there the auricular and ventricular septa were imperfect, and the arterial duct pervious, but greatly contracted: here the heart was similarly malformed, and the canalis arteriosus was barely closed.

A girl, who had been cyanosed from birth, died with hydrocephalic symptoms at the age of 11 years and 7 months. The heart was found obtuse at its apex, and with a considerable deposit of fat on its surface; it was but little larger than natural. The *pulmonary artery* arose rather more to the left than usual; its coats were thin; its valves were cartilaginous, and so contracted together as scarcely to leave an aperture half a line in diameter. The aorta rose above the *ventricular septum*, which was deficient at its upper part; the vessel principally communicated with the right ventricle. This cavity was larger than the left, and its walls were stronger. The free edges of the tricuspid valve were cartilaginous. The *foramen ovale* was widely open. The *ductus arteriosus* was patent as far as the pulmonary artery, where it was closed by a cicatrix. All the veins were distended with blood; one of the cavæ was three times larger than the aorta. The upper part of the chest was contracted. The structures of the lungs were condensed, and were in an advanced condition of phthisical degeneration.

In the next examples which I shall quote there were found traces of a malformation similar to that observed by MM. Obet and Holst; viz. a communication between the pulmonary and left subclavian arteries. In these instances, however, the abnormal channel had become completely obliterated.

M. Caillot observed\* the case of a boy, ætat. 3 years, who began to shew indications of morbus cæruleus at the age of two months. After death, the ends of his fingers only were of a livid colour, approaching to black, but spots like ecchymoses were spread over various parts of the body. The heart was placed transversely, its basis being situated unusually to the right. The right auricle was so distended as to equal the remainder of the heart in volume. The cavity of the right ventricle was small, and its walls of due thickness. The *pulmonary artery* was very narrow. There was a large opening in the *ventricular septum* above which the aorta originated. The *foramen ovale* was closed. The *ductus arteriosus* (branchial canal?), which was closed, extended towards the left subclavian. The aorta took a course above the right bronchus, and behind the trachea, towards the left of the vertebral column. The right carotid and subclavian arteries arose by separate orifices.

M. Duret† narrates the history of a child, 11 years of age, who was cyanosed from his earliest infancy; and, when sixteen months

\* Hasse, Diss. de Morb. Cærul. Lips. 1813; quoted also by Corvisart and M. Hein.

\* Bullet. de l'Ecole de Méd. 1807, p. 24.  
† Quoted by Corvisart.



old, began to suffer from convulsive movements of the body, and fainting, during which attacks the face became completely of a violet hue. These paroxysms were subsequently produced by any unusual effort or mental emotion. Upon examination, the heart was found to be larger than natural; the aorta arose from the *septum of the ventricles*. The commencement of the *pulmonary artery*, which had but two sigmoid valves, was much contracted. Just above the valves the vessel was still more contracted; but, higher up, its diameter was larger: its coats were thinner than natural. The *foramen ovale* was open, and about four lines in diameter. The *canalis arteriosus* (branchial canal?), which was completely obliterated, terminated in the left subclavian artery, from which arose the carotid of the same side, while the right subclavian and carotid originated from the aorta by distinct openings.

Several cases of this kind have occurred in which no trace of an arterial duct could be discovered; a negative fact, it is true, but one of great interest and weight, coming, as it does, from a number of very accurate observers.

Sandifort has given\* the history of a boy who suffered from cyanosis, dyspnoea, pulsations in the neck, a tumid and livid condition of the face, constant shiverings, occasional epistaxis, which relieved his symptoms, a foul state of the tongue, and foetid breath. The urine was red, and the bowels costive. These symptoms commenced at the beginning of the child's second year, and continued to increase until the time of his death, which occurred at the age of 12 years. The lungs are described to have been found compressed by the enlarged heart, which was full of blood. The pericardium contained some serum; the right cavities were greatly enlarged. There was an aperture in the *fossa ovalis* which would admit a probe. The aorta arose from both ventricles over an aperture in the *septum*; the right ventricle was dilated. An excrescence on the valves of the *pulmonary artery* had so far closed the orifice of that vessel that it would only admit a small probe. There was no *ductus arteriosus*. The lungs were small, but not diseased.

Dr. Knox† relates the case of a female child, 4 years of age, who had remained in good health until six months after birth, when a blueness of the surface was remarked, particularly after any exertion, with constant difficulty of breathing. On inspection, the lungs appeared to be sound,

though dark coloured. The *foramen ovale* was pervious and pretty large. The *pulmonary artery* arose from the right ventricle, its coats were thin, and it was about the size of a goose-quill in its diameter: it possessed all the characters of the artery, such as its valves, and its division into two branches. The aorta arose from both ventricles in such a manner that the ventricles communicated with each other, and with the cavity of the vessel. Not the smallest vestige of the *ductus arteriosus* could be discovered; it seemed never to have existed.

Dr. E. Lexis records\* the case of a girl who was born apparently sound and strong, and who presented nothing remarkable for the first year after birth, except, now and then, a difficult asthmatic respiration. Afterwards, severe symptoms of morbus cæruleus presented themselves, the little patient becoming liable to paroxysms of strong suffocation, which she endeavoured to relieve by bending the body forwards. These symptoms were subsequently aggravated by convulsive movements, and painful darting sensations in the limbs. The pulsation of the heart was very strong, but irregular in quality and frequency, and sometimes so small that certain pulsations could not be distinguished. The breath was very foul. The appetite was irregular, and the thirst increased. She died at the age of 5½ years. The left lung was adherent to the costal pleura; the pulmonary tissue contained a few tubercles. The heart was enlarged, the parietes of the right ventricle thicker than those of the left. There was an opening in the *auricular septum* large enough to receive a swan's feather, but closed on the left side by a valve. The aorta, of the usual size, originated above an opening in the *ventricular septum* large enough to admit the tip of the index finger. A probe passed into the *pulmonary artery* entered the ventricle with difficulty. Between the edges of the artery and the semilunar valves there were found a number of blind sacs, into which the probe passed more than half an inch. The communication of the pulmonary artery with the ventricle was about the diameter of a crow-quill. The *arterial duct* was absent.

In a foetus of about 8 months, Otto† found the heart placed perpendicularly in the chest, and rather to the right. It was of the usual size, except that the right auricle was much dilated. The *foramen ovale* was large enough to admit a small pea. The left auricle was about a quarter as large as the right, and had no communication

\* Obs. Anat. Path. cap. i.]

† Edinburgh Medical and Surgical Journal, vol. xi. p. 57.

\* Lancet, 1845-6, vol. ii. p. 433.

† Seltene Beob. z. Anat. Phys. u. pathol. gehör. Bresl. 1816, p. 11. Quoted by Hein.



with the left ventricle. There was no *ventricular septum*; both sides of the heart were of equal strength. The auriculo-ventricular valve was well-formed. The aorta was situated more than usually to the right. The *pulmonary artery* had three semilunar valves, was about one-third as large as the aorta, and arose to the left of that vessel; it gave off two branches to the lungs, but did not form a *ductus arteriosus*.

It will be observed that in at least three of these four cases in which the *ductus arteriosus* was absent, the pulmonary artery appears to have been imperfectly developed and generally diminutive, and not merely contracted at its orifice, as is usual in most of the forms of atresia of this vessel. The same peculiarity will also be noticed in some other instances of absence of the arterial duct, to which reference will be made in the next section.

It can scarcely be doubted that, in these cases, the contraction of the pulmonary artery occurred less as a result of structural lesion in the vessel, than as a consequence of the non-development of the arterial duct; in fact, as a natural provision by which the entrance of an undue quantity of blood to the lungs during intra-uterine life was entirely precluded. In a foetus where the pulmonary artery was extremely narrow, and the auricular and ventricular septa remained pervious, a *ductus arteriosus* would be scarcely at all required, of whatever importance such a communication might prove subsequently to the commencement of respiration. And there can be little doubt, that in the four cases related above, this canal became obliterated and absorbed at a very early period of intra-uterine existence.

I believe that the fact of the duct being absent in these instances, and pervious in those related by Dr. Cheever and Dr. Bell, is explicable upon the grounds which I have already hinted at:—in the class of cases just described, the non-development or early closure of the duct appears to have been the primary lesion, whence resulted the formation of a very narrow pulmonary artery, and the persistence of the auricular and ventricular openings; while, in the other examples, the principal lesion seems to have been disease of the pulmonary ostium occurring at a time when the arterial duct was fully formed, but while the inter-ventricular partition was still imperfect.

The condition of the ventricular portion of the heart in Otto's patient shews that the case was nearly allied to those instances already cited, in which absence or obliteration of the pulmonary orifice determined the non-development of the septum cordis—leaving the efferent portion of the organ essentially in the condition of a single ventricle. In the

four following cases there is every reason to believe that the arterial duct had been open previously to birth, though the obstruction to the pulmonary circulation subsequently to the commencement of respiration was not sufficient to prevent its closure at a later period. In this particular these cases differ from that by Dr. Mauran already noticed. I have before shewn the reasons why patency of the duct should be far more frequently observed in cases of obliteration of the pulmonary orifice, than in others where this opening is much contracted.

Dr. Farre\* narrates the case of a person of the male sex, 22 years of age, whose figure was diminutive, and appearance and mental faculties puerile. The face was of a deep violet colour. In proportion to his height, the size of his abdomen and capacity of his thorax were large. When at rest, his breathing was easy, but rather quicker than natural; he occasionally took a full inspiration with perfect freedom. Whilst capable of taking exercise, slight exertions sufficed to bring on dyspnoea and cough. There was jugular pulsation; the superficial veins were enlarged and varicose. His ankles were oedematous, and there was sometimes vertigo. The pulse was observed, for a few weeks previously to his death, to range from 100 to 120; respirations from 26 to 28. The temperature of the hand was 98°, beneath the tongue 100°; while that of the room was 76°. The bowels were stated to be regular, except during the winter previous to his death, when some blood was discharged without any relief of symptoms. His urine was high coloured, offensive, and scanty. Death occurred rather suddenly (after a gradual failing of the muscular power), subsequently to taking a rather fuller meal than usual. On examination, the extremities were found to be slender: height 4 feet 3 inches. All the characters of puberty were wanting. Gangrene had commenced in one of the great toes. The pleuræ were universally adherent; the lungs were free from tubercles; their cellular tissue was coloured with blood. The veins of the chest were unusually congested, but the inferior cava and coronary veins only were dilated. The auricles were of due size; the valve of the *foramen ovale* was of due size, and efficient. The auriculo-ventricular orifices were narrowed; the right admitted the points of two fingers, the left the point of only one finger. The tricuspid and mitral valves were otherwise malformed. Both auricles opened into a ventricle, which was not only more capacious, but thicker in its walls than natural. The *pulmonary artery* arose from the superior and central part of this ventricle by a very narrow mouth

\* Op. citat. pp. 37-40.



of dense structure; its semilunar valves were concealed by a warty excrescence which grew from them, leaving a passage barely large enough to admit a small probe. The rest of the artery was of its proper size. The *ventricular septum* was wanting, and instead of the left ventricle, a pouch, impervious towards the left auricle, was continued from the right ventricle, and opened anteriorly into the aorta by a free orifice. The *ductus arteriosus* was closed. The left vertebral artery arose from the aorta between the left subclavian and carotid arteries. In the descending aorta no branch remarkable for its size appeared as low as the fifth intercostal. All the abdominal viscera were so greatly congested as to appear of a deep claret colour.

M. Vallete has related\* the case of a female child born at the full period, who, for six months, remained in appearance healthy, when, all at once, the skin presented a blue tint, and the respiration became difficult. When six months old, convulsions took place, and were succeeded by hemiplegia of the right side, which, however, gradually decreased and finally disappeared, still leaving that side somewhat weaker than the opposite. The cyanosis persisted, increasing when the patient ran or walked quickly, and being deeper on the right than on the left side. At the age of 6 years the patient caught cold, which produced bronchitis and fatal pulmonary congestion. It was found that the ventricular parietes were, on both sides, about two lines in thickness. A large communication, through which the thumb could easily be passed, existed between the ventricles—the circumference of this opening was rounded and smooth; the *septum* was only four lines high, the aortic orifice was normal, and situated at the internal and upper part of the circumference of the inter ventricular opening. The orifice of the *pulmonary artery* was separated from that of the aorta by a small eminence which formed the upper part of the circumference of the inter-ventricular opening. The *pulmonary artery* was about half the size of the aorta; neither it nor its orifice presented anything irregular. The auriculo-ventricular orifice was single, common to the auricles and ventricles, situated at the base of the cavity of the ventricles, behind the aorta and pulmonary artery; it was furnished with a large triangular valve, the base of which was inserted into three-fourths of the circumference of the opening, and the summit of which was fixed, by means of small fleshy columns, to the posterior walls of the ventricles. The valve was large enough to close the orifice completely. The auricles communicated freely by two openings.

M. Hein relates\* the case of a lad, æt. 16, who was very severely affected with cyanosis, having been livid from the earliest period. His chest was narrow, and his breathing short and difficult. There was strong palpitation of the heart, the pulse was 100 and hard, becoming weak and still quicker when oppression was greater, and latterly increasing still more in rapidity when the symptoms were alleviated. He had suffered from copious hæmoptysis, but died from accumulation of mucus in the air-passages. The lungs were found extremely congested, flaccid towards their bases, and small compared with the size of the heart. The left contained a vomica. The bronchial glands were hard and enlarged. The heart was unusually large. There was merely a vestige of a *ventricular septum*. The two sides of the organ were of nearly equal thickness. The valves of the *pulmonary artery*, coalescing, formed a little ring, about three lines in diameter, which projected into the artery. There were three openings in the valve of the *foramen ovale*. The *arterial duct* was closed.

The most extreme degree of this kind of malformation was observed in a heart shewn to Dr. Farre by Mr. Lawrence (in the collection at St. Bartholomew's). Here the venæ cavæ and pulmonary veins opened into their respective auricles, but the *auricular septum* was very imperfect, consisting only of a small muscular band, which left a large foramen ovale without a valve. The *septum of the ventricles* was altogether wanting, so that the ventricle communicated with the auricles by a single ostium, around which a valve was attached. The aorta and pulmonary artery, the entrance of the latter being somewhat contracted, arose side by side from the left part of the ventricle. The history of the case was unknown; but, from the size of the heart, it appeared probable that the child had lived some months.†

Cases of this class are found to vary exceedingly with respect to the size and form of the inter auricular communication: in some, the septum has been found either wholly deficient or merely in a rudimentary state, while in many others it was evident that the process which closes the foramen ovale subsequently to birth had been commenced in the natural manner, and had been arrested only at the period when it was just verging upon completion. The two following cases are fair examples of the extreme degrees of this species of malformation.

In a female child whose complexion was always more or less blue, who suffered from difficulty of breathing, and died at the com-

\* De istis Cordis Deformationibus quæ Sanguinem Venosum cum Arterioso Misceri permittunt. Gotting. 1816, p. 37.

† On Malformations of the Heart, pp. 30-1.

\* Gazette Médicale, and Lancet, cir. Feb., 1845.



pletion of her first year, Mr. Ring found that the heart was furnished with two descending venæ cavæ, one of which terminated in the right, the other entering the left side of the auricle (which was single, the *auricular septum* being totally absent), with the ascending cavæ. The *septum of the ventricles* was also remarkably imperfect. The aorta arose from both ventricles. The *pulmonary artery* was much smaller than usual.\*

As a contrast to this case we may take that described by Dr. Nevin.† A boy, æt. 10 months, first began to suffer from symptoms of blue disease about a month subsequently to birth. Death occurred during a violent paroxysm. The heart was found larger than usual; the coronary veins were remarkably turgid; the aorta, at its origin, was considerably enlarged, and arose equally from both ventricles. The *pulmonary artery* was remarkably contracted, and its valves were firmly attached by their apices to the internal coat of the artery, and appeared somewhat ossified as their bases. The *arterial duct* was closed. The right ventricle was considerably enlarged. The *foramen ovale* admitted a large probe. The carotid and subclavian arteries on each side arose by separate trunks.

In other examples narrated in this section, the inter-auricular communication seems to have been as narrow as in the instance by Dr. Nevin, and perhaps even narrower. Indeed, the existence of a very wide communication between the auricles appears in these cases to be a somewhat rare exception to the general rule, and the great width of the aperture may, in some instances, be attributed rather to dilatation occurring subsequently to birth, than to an original arrest of development.

The following are interesting examples of the varieties, both in the anatomical condition of the parts, and in the resulting symptoms, which cases of this description are wont to present.

Dr. John Crampton‡ relates the following instance:—

A boy had, from his birth, been subject to palpitation, attended with pain in the left side. His complexion was livid and sallow; the whole surface of his body was extensively anasarous; his breathing was very laborious, and he could not lie on either side, but was easiest sitting up. The pulse at the wrist was 140, small, and synchronous with the heart's action; but latterly both became irregular and intermittent. The measurement of the right side of the thorax

exceeded that of the left by half an inch. A very loud *bruit de soufflet* was distinctly audible in every part of the thorax, and in the neck. Latterly he suffered from diarrhœa. His symptoms were, on one occasion, temporarily relieved by a profuse perspiration. Death occurred from exhaustion at the age of ten years. Attached to the right ventricle there was found a supernumerary cavity which communicated with the pulmonary artery. This cavity also communicated with the right ventricle by an opening large enough to admit the little finger, and formed under the columnæ carneæ of the ventricle. The *pulmonary artery* was perfectly destitute of valves; its lining membrane, at the usual situation of the valves, appeared a little puckered; at this spot the artery was contracted, but above, it was considerably dilated. The *septum of the ventricles* was imperfect, and the *foramen ovale* patent.

Dr. Todd, who also examined this case, attributed\* the formation of the supernumerary cavity to a partial dilatation of the infundibular portion of the right ventricle in consequence of the obstruction at the pulmonary orifice. I shall presently have to quote other cases which bear a very close resemblance to this.

Mr. A. Napper has related† the case of a boy, æt. 5 years and 7 months, who began to be the subject of cyanosis and its attendant symptoms subsequently to a fall which he suffered at the age of six months. He died with symptoms of acute hydrocephalus. On examination of the brain, extensive ramollissement of the right hemisphere and serous effusion were found to exist. The lungs were extremely small and flaccid, and of a bright crimson colour throughout. The heart was of normal dimensions; both ventricles were contracted; both auricles were extremely distended with blood. In the situation of the *foramen ovale* there was an opening about half an inch in length and a line in breadth; its valvular form rendered it probable that this opening did not ordinarily admit of the passage of the blood. The aorta communicated equally with both ventricles. The ventricular orifice of the *pulmonary artery* was much contracted, scarcely admitting the large end of a common blowpipe. The sigmoid valves were exceedingly small, but otherwise perfect.

Mr. John C. Bloxham describes‡ the case of a girl who died at the age of 3 years, having been the subject of cyanosis almost from birth. The heart was found lying transversely in the chest, and of an enormous size compared with the growth of the child.

\* Medical and Physical Journal, vol. xiii. p. 120.

† Duncan's Medical Commentaries, vol. xix. p. 326.

‡ Trans. of the Dublin College of Physicians, 1830.

\* Cyclopædia of Anatomy and Physiology, vol. ii. p. 634.

† Med. Gaz. vol. xxvii. p. 793.

‡ Ibid. vol. xv. p. 435.



The right auricle was enlarged and hypertrophied; the left appears to have been small; the *foramen ovale* would have admitted a goose-quill, but was furnished with a valve. The thickest portion of the walls of the right ventricle measured a quarter of an inch; of the left nearly half an inch. The aorta took its origin nearly equally from both ventricles, and was unusually large. The *pulmonary artery* communicated with the right ventricle; its parietes were extremely thin, and it was altogether so diminutive that its existence was discovered only by tracing its branches backwards from the lungs. "It was perceived on the posterior surface of the heart collapsed, and bifurcating immediately on its exit, so that the trunk was not, in any part of its circumference, above a line in length." It was only furnished with two valves. The aorta, which was unusually large, arose above the septum, and communicated more freely with the right ventricle than with the left. The tricuspid valve was thickened, and callous at its margin. The pericardial, pleural, and abdominal cavities contained serous effusions. The lungs were tubercular, contracted, and adherent to the ribs and spine. The liver was much enlarged, encroaching on the chest.

Dr. Hope details the case of a girl, æt. 8 years, whose lips, nose, cheeks, palpebræ, hands, and feet, were of a violet colour; the tongue and mouth still darker. There was dyspnoea on the slightest exertion, and cough only when hurried; the sternum was very prominent; great sensibility to cold, headache, vertigo, drowsiness, and sluggishness. Pulse very small and weak; and when the patient was hurried it was irregular, intermittent, and unequal. A very loud, hissing, superficial, bellows murmur was heard in the præcordial region, synchronous with the first sound of the heart; the diastolic sound was healthy, or nearly so. The child died of a chronic abscess in the brain. The heart was one-half larger than natural; the walls of the right ventricle were thickened to half an inch; the cavity was slightly dilated, and the *pulmonary orifice* contracted to the size of a goose-quill, whilst a common opening from the right ventricle, admitting the index finger, existed into the aorta and left ventricle. The left ventricle was one-third of an inch thick, and its cavity about natural. An oblique passage, admitting the handle of a scalpel, existed between the auricles. The lungs were rather flaccid, imperfectly crepitant, and universally gorged with black blood\*.

M. Huet furnishes an instance† where he found the *pulmonary artery* very narrow in

a patient 13 years of age. The aorta arose from both ventricles. The *foramen ovale* was open; the arterial duct closed.

The preparation numbered 1382<sup>48</sup> in the collection at Guy's Hospital affords an interesting type of this kind of malformation. It is the heart apparently of a young adult in which there are evident traces of universal pericardial adhesion and of inflammation (probably of old date) affecting the substance of the organ, the presence of interstitial deposit being very apparent, especially in the walls of the right ventricle. The valves of the *pulmonary artery* are fused into a conical canal, upon the upper surface of which slight traces of the free edges of the curtains are perceptible; the artery above is about the natural size. A singularly free communication exists between the ventricles; the right ventricle is rather larger than the left, and its walls are slightly thicker. The muscular tissue of the imperfect ventricular septum is remarkably developed. The right auricle is very large; the left greatly contracted. The *foramen ovale* appears to be unclosed, but well defended by a strong valve.

It will be observed that, in a considerable proportion of the preceding instances, cyanosis is mentioned to have occurred (as it generally does in cases of congenital imperfection of the heart) at a period of some days or months subsequently to birth\*. Dr. Quain has very justly argued† that, in cases of this description, the accession of cyanosis shortly after birth is immediately determined by the commencement of the process of closure in the arterial duct: it might also have been added, and in the *foramen ovale*. A large proportion of the instances above related, as well as many of those which will be subsequently adduced, afford strong corroboration to this view. In the five cases where permanence of the arterial canal was coincident with arctation of the pulmonary orifice, the passage of the duct had become narrowed: in the two instances where the branchial canal remained pervious, this channel was also remarkably narrow. In 13 out of the 27 cases in which patency of the *foramen ovale* was found to coexist with narrowing of the pulmonary orifice, there were found evidences that a process of con-

\* This happened in twelve of the cases. In most of the other instances the precise time at which cyanosis appeared is not mentioned. In the remaining examples (four) it is reported to have existed from birth; but this statement does not appear to have been, in all those cases, the result of actual observation on the part of the reporters. I believe it to be an extremely rare occurrence for an infant to be born in a condition of true cyanosis, if, indeed, such a circumstance has ever occurred at all; but cases have been observed in which lividity, which afterwards became permanent, appeared very shortly after the commencement of respiration.

† Dublin Medical Press, vol. viii. p. 88.

\* Treatise on Diseases of the Heart, p. 468.

† Bulletin de Sc. Méd. t. ii. p. 72, 1808.



traction in the inter-auricular opening had proceeded to a certain, and, in most of the instances, to a very considerable extent. Besides the instances in which the arterial duct was observed to be extremely contracted, there were also twenty cases where the auricular septum remained to a greater or less degree pervious, in which no direct communication existed between the aorta and pulmonary artery. It is certainly observable, that, in the majority of cases where the foramen ovale and ductus arteriosus remain permanently open in consequence of congenital obstruction to the circulation, an effort is made by nature to close these apertures by the usual vital processes; and, although this effort proves abortive, it is sufficient to produce a certain amount of contraction in the abnormal passages; to which contraction the accession of the symptoms of obstruction to the circulation, and of morbus cæruleus during the earlier months of infancy, is, I believe, in most cases referrible. This proposition will receive still further confirmation when we arrive at the consideration of the facts upon which the now generally recognised doctrine of the causes of cyanosis rests.

In the next class of instances of narrowing of the pulmonary artery to which I shall have to refer, the ventricular septum was perforated, but no communication existed either through the foramen ovale or the arterial duct.

VII.—*The pulmonary orifice narrow—the ventricular septum imperfect—the foramen ovale and arterial duct closed.\**

This species of malformation, like those which have been previously described, pre-

\* The following remarkable instances of contraction of the pulmonary ostium, associated with perforation of the auricular and ventricular septa, were accidentally omitted when describing the several conditions of parts with which that malformation is found to be associated.

The first and second of these correspond with the cases observed by Sandifort, Knox, Lexis, and Otto, in which narrowing of the right ventriculo-pulmonary orifice was attended with complete absence of the arterial duct; and the first case is especially interesting when placed beside the example cited by the latter author. The absence of any trace of an arterial duct at a period of a few years after birth, may not be deemed positive evidence that such communication has never existed, but the fact of its entire absence in two fetuses dissected by different observers, is sufficient proof that the existence of the duct, or of any analogous communication, is not absolutely essential for the continuance of intra-uterine life; providing the supply of blood to the lungs be limited by a narrow condition of the pulmonary artery, and by a free communication between the right and left cavities of the heart.

Nich. Steno observed, in an otherwise monstrous fetus of the female sex, that the pulmonary artery was much narrower than the aorta. The latter vessel, which was situated to the right, arose from both ventricles, the septum

sents several remarkable varieties, the most interesting of which consists in an entire absence of the arterial duct, as observed in the following instances.

Professor Huss, of Stockholm, attended a boy 6 years of age, who had from birth exhibited the usual symptoms of cyanosis. When he entered the Hôpital des Séraphins the colour of his skin was dark blue, that of the mucous membrane of the mouth clear blue;—he had frequent attacks of palpi-

being imperfect. The auricles were in the usual foetal condition. There was no ductus arteriosus. (*Acta Hafniensia*, p. 1. p. 200, as quoted by Hein, Tab. II.)

The following history has been given by Drs. Aran and H. Bennet (*Lancet*, 1844, vol. i. p. 501).—A girl, ætat. 20, who had been the subject of cyanosis of a very aggravated kind, died in the Hôtel Dieu, death being apparently mainly the result of disease of the hip, and erysipelas consequent upon caries of one of the ribs. Her stature was small. She presented no signs of puberty, and her understanding was imperfectly developed. She had no cough, except when hurried, nor dyspnoea; the feet were often œdematous. The superficial venous system was much developed; voluminous veins of a deep blue colour crossed the skin in every direction, and were united by a net-work of anastomosed veinulæ. Latterly, vertigo, and even loss of consciousness, frequently resulted from exertion. A short time previously to her death the cardiac impulsion was found to be smart and short, but considerably stronger and more extensive than natural: it was followed by a diastolic back-stroke. Opposite the apex of heart, the two sounds were perceived, with an appearance of systolic murmur; but the first was a loud prolonged bellows murmur, with a very sensible purring tremor opposite the arterial orifices of the organ; and the second very short and loud. The bellows murmur was very sensible and superficial over the pulmonary artery, from its valves to the top of the sternum, along the left side of that bone. This murmur was limited superiorly by the clavicle, and on the sides by the right edge of the sternum, and by a perpendicular line proceeding from the external extremity of the left clavicle; no murmur in the vessels of the neck, nor upon the course of the aorta; pulse regular, 112, very small, and weak; resonance of the lungs normal, and the vesicular murmur pure in all the extent of the chest.

On dissection, the body was found to be generally œdematous; the heart was one-half larger than natural, right ventricle one-third more voluminous than the left. The walls of the right ventricle were half an inch in thickness; the arterial orifice was seated at the superior part of the ventricle, near the septum: it was contracted to the size of a goose-quill; its circumference was surrounded by cartilaginous patches, and almost obliterated by small yellowish and fibrous vegetations, very little adherent to the edges of the orifice. The pulmonary valves were higher seated, an inch above the contraction, so that between the orifice of the ventricle and the pulmonary valves was a cavity, half an inch high, and one inch in width, covered by the lining membrane of the heart slightly thickened, and containing a polypous concretion; the pulmonary orifice was contracted to a quarter of an inch, and the arterial coats were thinner than natural. There was no vestige of ductus arteriosus. The ventricular septum was perforated at its upper part by a smooth and circular aperture half an inch in extent: aortic orifice and valves perfectly sound. Right auricle dilated, and slightly hypertrophied. The septum of the auri-



tion and hæmoptysis, and at times convulsions. During several months that he continued in the hospital the hæmorrhage from the lungs became more and more frequent, and in one of these attacks he died. The heart was found about three times as large as the patient's fist. The enlargement was principally in the right ventricle, behind which was the left ventricle like an appendix. The *foramen ovale* was closed. At the upper part of the *inter-ventricular septum* there was a semilunar opening of nine lines extent. In the right ventricle the orifice of the *pulmonary artery* formed a circular opening two lines in diameter with a cartilaginous margin; two lines within this opening there existed two folds resembling semilunar valves. The sinus of Valsalva formed a pouch eleven lines in diameter, filled with fibrinous clots, organised and adherent to the parietes, so that the canal was of the same diameter as its orifice; the length of the pouch was six lines. There was *no vestige of an arterial duct*.\*

M. Gintrac relates† the case of an infant who had exhibited in a very marked degree the symptoms of morbus cæruleus, and which died in the second week after birth. The cerebral vessels were found extremely

*cles* was perforated by a valvular slit. Great consolidation of the lungs by tubercles, of which a great many were softened; there were two little caverns at the summit of the left lung. Large tubercular masses were also found in the spleen.

The case alluded to at p. 371, where a diagram is given of the peculiar valvular apparatus with which the pulmonary artery was furnished (fig. *g*), was that of a young lady, a patient of Dr. Iliff's, who died at the age of 12 years, with the usual symptoms of malformation of the heart, which had appeared during her infancy, and gradually increased. The state of the heart, discovered after death, has been described by my friend, Mr. W. T. Iliff, jun. (MED. GAZ. vol. xxxvi. p. 1376). The organ was rather large, the right auricle strong and large, the *foramen ovale* open so as to admit a goose-quill, but valvular on the right side; the ventricles were about equal, communicating at their base by an opening in the *septum* sufficient to admit the little finger; *pulmonary artery* small and thin, with a conical valve truncated above to form an opening, which, being thickly beset with vegetations, would scarcely admit a crow-quill. The cord of the *ductus arteriosus* was complete. There were also vegetations on the aortic and mitral valves. The heart is preserved in the museum at Guy's Hospital (Preparation 1379<sup>75</sup>). I observe that portions of the inner surfaces of the tricuspid valve are also coated with adherent clots. The left auricle and ventricle are of small capacity. An inspection of the preparation, or of the diagram which I have given, will at once shew that the peculiar form of the funnel-shaped valve, and the arrangement around its opening of a little tuft of elastic vegetations which close together over the aperture, must have completely prevented even the slightest reflux of blood into the ventricle during the diastole of that cavity.

\* Gazette Méd. de Paris, Feb. 11th, 1843.

† Archives Générales, as quoted in Med. Chir. Review, Jan. 1839.

gorged with blood; the lungs were also very highly congested, and did not crepitate firmly on pressure. The heart was very large, and shaped somewhat like that of a turtle. The right ventricle was highly muscular; from this cavity the aorta as well as the *pulmonary artery* was found to arise. The latter was, however, nearly closed up; and *no trace of ductus arteriosus* was visible. The left ventricle was atrophied, and exhibited no appearance of arterial aperture or of mitral valve. In the *septum cordis* was a large round aperture which permitted a very free communication between the two ventricles.

In the preceding section a case related by Drs. John Crampton and Todd was cited, in which the contracted pulmonary artery arose from a supernumerary muscular cavity which communicated with the right ventricle. The following is a somewhat similar instance.

Mr. G. Holmsted attended a girl, ætat. 9 years, who, up to the age of 3½ years, was quite healthy, but then began to be affected with shortness of breath, lividity of the surface, and extreme chilliness. She continued in this state till about three months previous to her death, when, in consequence of a severe fright, she went into a kind of fit, which lasted about two hours. After this she became subject to occasional attacks of the kind, which came on with pain in the head and giddiness, a pallor of the face, with extreme difficulty of breathing, and increased palpitation. She died rather suddenly in an attack attended with pain in the head, and the evidences of thoracic obstruction. The heart was more than naturally large and muscular. The right auricle was found much distended, containing four or five ounces of blood. The *foramen ovale* was perfectly closed. The aorta was placed over the *septum of the ventricles*, and about the centre of the right ventricle there was a small opening into a corresponding cavity in the muscular structure of the heart, and from the upper part of this cavity the *pulmonary artery* went off. The left cavities were comparatively small. The *ductus arteriosus* was closed. The lungs were of a dark colour; the vessels of the head were a little fuller than usual.\*

Except in the closed state of the foramen ovale, the condition of parts in the above case did not materially differ from that observed in Dr. Crampton's patient: it is, however, evident from the figure which accompanies Mr. Holmsted's narrative, that here the point of obstruction was formed at the narrow opening which led from the right ventricle to the supernumerary muscular cavity, and not at the entrance of the pulmonary

\* London Medical Repository, vol. xvii. p. 455.



artery, as was the case in Dr. Crampton's instance. The position, in Mr. Holmsted's case, of the supernumerary cavity at a considerable distance below the spot at which the pulmonary artery usually arises, must also be regarded as a proof that this additional ventricle was not formed by a mere dilatation of the infundibular portion of the right ventricle in consequence of an obstruction at the pulmonary orifice.

The following cases present several remarkable varieties of this kind of malformation.

Mr. J. Marshall gives the following account\* of a man who had been cyanosed from birth, and had always suffered from symptoms of suffocation upon the slightest exertion:—The surface was cold; the pulse small and frequent, but regular. A few months before his death, he became dropsical, his breathing grew extremely oppressed, and he was incapable of lying down. Four gallons and a half of effusion were removed from the abdomen, with considerable temporary relief; but re-accumulation of the fluid occurred, and the patient died, at the age of 23 years. The abdomen was found to contain five gallons of fluid. The right auricle of the heart was large; the *foramen ovale* perfectly closed. In the *ventricular septum* there existed an aperture about an inch in diameter. The semilunar valves of the *pulmonary artery* were shrivelled, and appeared useless, but were not ossified. About an inch above the valves the artery was contracted so as to form a stricture, hardened by ossific deposit, and about the diameter of a goose-quill. The coats of the artery above the stricture were very thin, and formed a sort of sac. The ventricles were of equal strength. The pulmonary veins and left auricle were very much diminished in size; the left ventricle also was small. The aorta arose naturally, and its valves were healthy. The lungs were small and black from the blood they contained, but were not diseased.†

The following case is interesting, from the care with which the physical signs were observed:—

Dr. C. F. Gravina relates ‡ the case of a boy, *ætat.* 9 years, who had been cyanosed from his birth, and suffered from a violent and continual palpitation of heart, and short rapid respiration. On the least exertion these symptoms were severely aggravated. The respiration was heard distinctly all over the chest; but in the precordial region two abnormal cardiac sounds were

recognised: one of them resembled the purring of a cat, and was heard during the systole of the heart; the other, which appeared to accompany the contraction of the auricles, was so clear and sonorous that it was heard over the whole of the right side of the chest; over the left side, however, it was scarcely heard. While the boy was in a state of repose his pulse beat from 78 to 84 in the minute; but, on the least excitement, rose to 100 or 105. He died suddenly, in consequence of an attack of convulsions and dyspnoea. The lungs were found of a violet colour, regular in their form, and crepitating on pressure. The right ventricle was nearly twice as large as the left; but its walls were of the ordinary thickness. The left ventricle was smaller than common. The *ventricular septum* was deficient below the point where the aorta arose, leaving a circular communication between the two ventricles. This opening was largest on that side which corresponded with the right ventricle, but was somewhat contracted on that of the left. The aortic orifice was much dilated, as were also the semilunar valves, which appeared proportioned to the increased dimensions of the vessel. The *pulmonary artery* was very much contracted, but its walls were unaltered. The *foramen ovale* was closed.

Dr. Pulteney attended a young gentleman who could not walk across the room without turning almost black in the face and hands, and becoming faint and almost breathless. He sunk under an attack of dysentery, at the age of 13 years and 9 months. The lungs were found to be remarkably small and collapsed, and some parts of them were so flaccid as to suggest the idea of their having been incapable of performing their functions. The heart was of the natural size. The orifice of the *pulmonary artery* was much smaller and more firm than is usual, but there was no fault in its valves. The ventricles communicated by a deficiency in the upper part of the *septum* capable of admitting the end of a finger. The ventricles and right auricle appear to have been of ordinary size; but the left auricle was very small.\*

In this case the imperfect state of the ventricular septum appears to have been due to mere rigidity of the structures at the base of the pulmonary artery, without any imperfection in the vessel itself. It might be judged from this, and one or two other examples in which the pulmonary ostium was not found extremely contracted, that the closure of the *foramen ovale* has been due to the comparatively slight amount of obstruction existing in the vessel. In se-

\* MEDICAL GAZETTE, vol. vi. p. 886.

† I have alluded to this case at the commencement of this paper, and given a copy of Mr. Marshall's sketch of malformed artery (fig. e, p. 370.)

‡ Schmidt's Jahrbucher, July 1839, and Edinburgh Medical and Surgical Journal, vol. xxxv.

\* Medical Transactions of the College of Physicians, vol. iii. p. 334.



veral cases, however, extreme contraction of the artery has been found in conjunction with an impervious state of the auricular septum. The following instance may be taken as a fair example of this condition. It is certainly possible that the narrowness of the orifice may have been gradually increasing up to the time of the individual's death; but the history of the symptoms renders it probable that the vessel had been greatly obstructed from the earliest period:—

The second case recorded by Dr. Pulteney\* is that of a lad whose complexion had always been dark, or inclining to black; he was liable to fits, upon the accession of which he suffered from oppression at his heart, became weak or faint, grew dusky in his colour, and at last almost black, fell down, and seemed insensible. He commonly soon came out of the fit with sobbing and yawning, and a sense of fatigue. He could escape the fit by instantly lying down on the carpet on his left side, and remaining immovably fixed in that posture for about ten minutes. He died at the age of 13 years. The orifice of the *pulmonary artery* was so small that it could barely give passage to a small probe. The *ventricular septum* was perforated so as to allow the thumb to pass. No other cardiac lesion is mentioned either in this or in the preceding case; and, as the instances were recorded at a time when patency of the foramen ovale was regarded as one of the most frequent causes of the blue disease, it is quite improbable that Dr. Pulteney could have overlooked such a deficiency had it existed.

Besides the specimen presented by Dr. Iliff, and already referred to, there are two very interesting examples of this kind of malformation in the collection at Guy's Hospital.

The preparation marked 1379<sup>50</sup> is taken from a lad, æt. 16, who was of rather robust appearance, and who had since his birth been much troubled with palpitation of the heart and great dyspnoea upon the slightest exertion. He had also suffered from frequent attacks of pain in the left side. He entered the hospital on account of an indolent ulcer on the leg, depending on feeble circulation. Both lower extremities were rather œdematous. There was usually lividity of the lips, but it was only on increased exertion that his face became decidedly blue. The pulse was regular, but slow and feeble. He was subsequently attacked with fever, and died after profuse hæmoptysis, from which he had never before suffered. A small quantity of bloody serum was found in the cavity of the right pleura; the substance of the lung was rather œdematous, and contained miliary tubercles. The left lung was enormously en-

gorged with blood, friable, and containing, at its apex, a tubercular excavation, apparently of old standing. The bronchial mucous membrane was highly vascular; the pericardium contained about  $\text{ʒij}$ . of sanguinolent serum.\* The *pulmonary artery* at its commencement was about half its usual size.† The right auricle was enormously dilated, the tricuspid orifice was wide, and its valve doubtless admitted of free regurgitation. The right ventricle was exceedingly large, and bore traces of hypertrophy. The aorta arose from the right ventricle, posteriorly to the pulmonary artery. The *ventricular septum* was deficient above, leaving a communication an inch in diameter between the ventricles. The left cavities were small, and their parietes were much attenuated. The aorta was very large, and its valves were somewhat thickened. The *foramen ovale* was closed. There was a considerable deposit of fat upon the surface of the heart.

The specimen numbered 1382<sup>32</sup> is a heart, which appears to have belonged to a person 15 or 16 years of age; the pulmonary orifice would barely admit a common pencil; the upper portion of the artery is of fair size. The aorta arises above an aperture in the *ventricular septum*, and communicates rather more freely with the right than with the left ventricle. The walls of the left ventricle are thinner than those of the right; the right ventricle is much stronger and more capacious than the left. The right auricle is dilated, the left much contracted. The *foramen ovale* is closed. The preparation does not present any trace of an *arterial duct*, and, as the aorta becomes suddenly smaller at the spot where the arterial ligament is usually attached, there has not improbably existed some irregular communication between one of the vessels of its arch and the pulmonary artery. The aortic, mitral, and tricuspid valves, present numerous vegetations. The upper intercostal branches of the aorta are rather larger than natural.

Several other examples of this species of malformation have been recorded. Of these the following are the principal.

Mr. Abernethy ‡ mentions the case of a child, ætat. 2 years, who died with symptoms which indicated an impediment to the transmission of the blood through the lungs. The aorta arose from the right ventricle, which was of unusual size and thickness. The orifice of the *pulmonary artery* was small, and the remainder of the vessel one-

\* Report by Mr. Dade, MED. GAZETTE, vol. xi. p. 159.

† In the preparation it scarcely appears to be capable of admitting a slender little finger.

‡ Surgical and Physiological Essays; Part Second.



third less than its usual size. The *ventricular septum* was imperfect. The left cavities were considerably smaller than the right.

In the heart of a cyanosed boy, ætat. 6 years, M. Olivry\* found contraction of the *pulmonary artery* associated with an imperfect state of the *ventricular septum*. The *foramen ovale* and *arterial duct* were closed. A similar condition of parts was observed by Meyer†, in a girl who died in her 7th year.

Dr. Farre describes‡ a heart (preserved in Sir A. Cooper's collection), which was taken from a boy in whom, at the time of birth, nothing unusual was observed; but after a few months cyanosis began to appear, which was heightened by passions of the mind, and by cold. Before he was three years old he had lost the use of his lower extremities; but this paralysis subsided in a few weeks under medical treatment. At the earliest period at which he was able to express his feelings, he complained of frequent nausea and severe headache. These symptoms were brought on or increased by the causes above mentioned, and were established at the age of five years. At the age of nine years and five months he was found to have lost the use of his left thumb; and, in two days afterwards, there was paralysis of the arm and leg on the same side, with partial convulsions of short duration. He expired in a few days, with the symptoms of an acute head affection. Upon dissection, an abscess was found in the right hemisphere of the brain, containing about an ounce and a half of a thick, dark-coloured, and extremely unhealthy pus. The ventricles of the heart communicated at the root of the aorta. The semilunar valves of the *pulmonary artery* were contracted into a small circle. The *arterial duct* was closed. The state of the auricular septum is not mentioned, but patency of the *foramen ovale* could scarcely have been overlooked.

Dr. Watson§ makes slight allusion to the case of a lad, æt. 17, in whom the pulmonary orifice would not admit a goose-quill, the *ventricular septum* being imperfect.

A similar instance of malformation in a girl 21 years of age, is recorded by Professor Duglison, in the Philadelphia Medical Examiner for May 1845. Of this patient's early history nothing was known; but during the last year of her life she was unable to perform any work, or take exercise of any kind, as upon the least exertion or excitement she was attacked with palpitation and dyspnoea, accompanied with some blueness of the skin,—all of which gradually disappeared on her remaining at perfect rest. She

was also subject to attacks of the same kind after dinner: these paroxysms during the latter part of her life came on every day, continuing for two or three hours, even though she remained perfectly quiet, being apparently excited by the mere stimulus of food. She had also a constant and strong rasping bruit, accompanying the first sound of the heart, and masking it partially. She suffered much from headache, which, a few days before her death, became greatly increased, accompanied with high febrile excitement, followed by delirium, coma, and death. At the time of her death the patient was menstruating profusely. On examination, the *septum ventriculorum* was found deficient at the orifice of the aorta, giving that vessel an origin from both ventricles; the *pulmonary artery* was contracted, so as barely to admit the little finger; both lungs were studded throughout with crude and miliary tubercles, none of which were softened; the left lateral ventricle of the brain was filled with pus, the lining membrane being inflamed and thickened, and in the posterior lobe of the same hemisphere was found a cyst the size of a robin's egg, also filled with pus, but having no connection with the ventricle. The substance of the brain presented numerous red points, but was not altered in consistence.

A large proportion of the above cases afford ample additional confirmation to the fact which I have already stated, that contraction of the pulmonary artery, which has, at a very early period of intra-uterine life, produced sufficient obstruction to prevent the complete development of the ventricular septum, may still fail to determine the persistence of the ductus arteriosus and foramen of Botal. But, although the inter-ventricular communication was large and free in several of the examples just cited, I am not acquainted with any instance of this class where the septum was in so imperfect a state as to leave the ventricular portion of the heart in the condition of a single cavity, while in not less than six of the instances where the auricular septum remained incomplete, the partition of the ventricles was found in a merely rudimentary state.

In the whole of the remaining instances of congenital arctation of the pulmonary artery with which I am acquainted, the ventricular septum was completely formed.

There appears to be no reason to believe that, in any of the class of cases at present under consideration, closure of the foramen ovale has occurred previously to birth. In the few instances where that remarkable aberration from the natural condition has been observed, there has existed a state of parts altogether different from that noticed in the above examples.

This question may possibly admit of dispute, but it seems to be in the last degree

\* Quoted by M. Gintrac, op. cit. p. 177.

† Meckel, Archiv. B. i. H. 2, Tab. n, 42, p. 284.

‡ Op. cit. p. 24.

§ Medical Lectures, vol. ii. p. 247.



improbable that occlusion of the communication between the auricles should occur at a sufficiently early period in foetal existence to become the means of preventing the full development of the ventricular septum.

VIII. *Contraction of the right arterial ostium, with patency of the foramen ovale, the ventricular septum complete, and the arterial duct obliterated.*

It is evident that, in the cases where this species of malformation occurs, the inflammatory or other morbid condition which has produced the arctation of the pulmonary orifice has become established at a period when the ventricular septum has obtained its full development. The obstruction to the pulmonary circulation determines the permanency of the foramen ovale, but the arterial duct becomes naturally closed. It is difficult to explain the difference in this latter respect between the cases now under consideration, and those of Class III.\*—in which arctation of the pulmonary orifice is attended with a perfect condition of the ventricular septum, but with a pervious state both of the foramen of Botal, and the ductus arteriosus,—otherwise than by the conjecture that, in cases of the eighth class, the impediment in the artery has originally been slighter in than those of the third; or that, in the latter instances, the arterial lesion has been established for some time previously to birth; while, in the former, disease has been set up in the vessels almost immediately after the commencement of respiration, when the arterial duct has begun to close, the foramen ovale still remaining open.†

Whatever may be the true explanation of this point, it is however certain that many causes of obstruction to the circulation which are capable of determining the patency of the septal opening, prove quite insufficient to prevent the closure of the arterial canal: hence the frequency of imperfection of the auricular septum, and the rarity of permanence of the duct. In some of the cases of this class which I shall have to quote, there appears to be reason to believe that the foramen ovale had become closed, but that the progressive increase of obstruction at the pulmonary orifice had given rise to so great distension of the right auricle as to occasion perforation of the membrane of the ovalian fossa.

\* Page 374.

† Berni of Vienna (quoted by Mr. A. Taylor) states, that if a child respire only for a few seconds, the duct becomes contracted at one of its extremities, commonly at the aortal end. I have not satisfied myself of the correctness of this observation, but there appear to be strong grounds for believing that the process of closure usually commences later in the foramen than in the arterial duct.

The two following cases are rendered interesting by the close analogy which they bear to other instances previously detailed. The first is also remarkable from the fact that the lesion of the arterial orifice was obviously attributable to the presence of a morbid deposit, and did not appear to be attended with faulty development of the valvular apparatus.

Dr. Edward Hallowell\* examined the body of a female child, æt. 6 months, who had from birth been more or less affected with difficulty of respiration, and latterly much subject to cough, during the paroxysms of which the face became suffused, and the nails and ends of the fingers cyanosed. On inspection, the body was found to be well formed, with considerable embonpoint, and no œdema; the fingers were curved inwards, and of a purplish colour. The lungs were quite healthy, of a light pink or rosy hue, not engorged in the slightest degree, and perfectly healthy throughout. The mucous membrane of the trachea and bronchial tubes was slightly injected; the pleuræ free from effusion; pericardium healthy. The heart measured from apex to root about 2 inches; its transverse measurement was about 2½ inches. The right ventricle was enormously hypertrophied, there being scarcely any cavity; its walls were about 5 lines in thickness, the septum 6½ or 7 lines: those of the left ventricle were about 2 lines: the cavity of this ventricle was of natural size. The diameter of the aorta nearly double that of the *pulmonary artery*, the orifice of which was almost entirely obliterated by a warty excrescence, arising from the middle semilunar valve upon its under surface, and extending to the others, to which it adhered. The external surface of this vegetation was lobulated, having a warty appearance, resembling a small raspberry, though less regular in its conformation, presenting, when cut into, an almost cartilaginous hardness, and adhering very strongly to the surface of the valve. The obstruction to the artery was so great that a silver probe passed with some difficulty: the coats of the artery appeared to be thinner than natural. The right auricle was greatly dilated, its capacity being double that of the left; the greatest thickness of its parietes, one line, that of the left, half a line. The *foramen ovale* was patulous, its opening being about 3 lines in diameter. The tricuspid, mitral, and aortic valves were healthy. The liver was greatly enlarged and congested, occupying one-third of the abdominal cavity. The other organs were not examined.

\* American Journal of Medical Sciences, vol. xxii. p. 365.



M. Lallemand relates\* the case of a woman who, from her earliest infancy, was liable to become in some measure cyanosed upon unusual exertion. Her respiration was habitually oppressed. At the age of 47 years she ceased to menstruate, and began to suffer from palpitations attended with acute pain in the precordial region, and her lips and general surface became of a livid blue colour. She also became subject to attacks of profuse epistaxis. At the age of about 57 years she was attacked with hemiplegia of the left side of the body, the paralysed limbs being occasionally convulsed: bleeding gave some relief, but she died a short time after the paralytic attack. The heart was found enormously enlarged; the right auricle was greatly dilated, and contained seven ounces of blood. The *auricles communicated* by an opening about 4 lines in diameter. The right auriculo-ventricular orifice was contracted. The right ventricle was not more than large enough to contain a pigeon's egg, its parietes being from 11 to 16 lines in thickness. The *ventriculo-pulmonary orifice* presented a septum which was convex towards the artery and pierced in its centre with a perfectly circular orifice  $2\frac{1}{2}$  lines in diameter. Above this the artery presented nothing material. The left auricle was much larger than natural; the left ventricle was also of very large size, and its walls hypertrophic. The *arterial canal* was entirely obliterated. In the anterior part of the right hemisphere of the brain was found an encysted purulent collection.

It will be remarked, in the above instances, how completely the condition of the right cavities of the heart corresponded with that which was noticed in a set of cases observed by Dr. W. Hunter and others (p. 280), where obliteration of the pulmonary artery was attended with an open state of the foramen ovale and arterial duct, the ventricular septum being complete; as also with that noticed by M. Bapt. Schuler, in a case (Class III. p. 374), where arctation of the pulmonary orifice, (also unaccompanied by perforation of the septum,) had in like manner determined the permanence of the canal and duct. The instances at present under consideration, in which the foramen was open and the duct closed, complete the series. In both of these cases the main current of blood, failing to gain a free passage through the right ventricle and pulmonary artery, was diverted into the left cavities through the open foramen ovale; hence, the right ventricle, being deprived of its due quantity of blood, became greatly diminished in capacity; the occurrence of

this contraction being doubtless considerably aided, in M. Lallemand's case, by the narrowed condition of the right auriculo-ventricular orifice. It is probable that, in each of these individuals, the aggravation of the symptoms, and ultimately the fatal event, were owing to gradually increasing contraction in the right ventricle and pulmonary orifice, and, possibly, also to diminution in the size of the foramen ovale.

It is to be regretted that in the following case no distinct idea is given of the size of the right ventricle. As, however, it is merely stated that the heart was "*somewhat enlarged*," and that the walls of the right ventricle were greatly hypertrophied, it is probable that its cavity was, at least, not very greatly dilated.

Dr. Robert Spitta lately communicated to the Medico-Chirurgical Society\* the case of a lady, ætat. 40, who was of diminutive stature and pigeon-breasted, but without any positive deformity. She had cyanosis from birth, indicated by blueness of the cheeks, lips, and tongue. The heart's action was said to have been regular when at rest, but sudden exertion produced palpitation and dyspnoea. She suffered very much from cold. In March 1845, she was suddenly seized (while at rest) with dyspnoea, and partial syncope, accompanied by convulsions, and afterwards with intense pain referred to the epigastrium, loins, and hypochondria. This condition lasted twenty-four hours, when she died. The patient had previously suffered from serious attacks of a similar nature occurring at long intervals. In November 1843, she had also an anasarca of the abdomen and lower extremities, from which she completely recovered, and never afterwards became dropsical. She had never suffered from rheumatism. The heart was found to be heavy and firm, and somewhat enlarged. The hypertrophy was chiefly on the right side, the right ventricle being as thick as the left, and the right auricle three times as thick as the left auricle. The *foramen ovale* was patulous, the opening about 4 lines in diameter, and valvular. The auriculo-ventricular valves were thickened, but moveable: the aortic valves healthy. Above the semilunar valves of the *pulmonary artery* an adventitious membrane was stretched completely across; it was a line in thickness, and perforated in its centre by a mere slit with margins of a red colour, and fringed with fibrine of the blood, (vegetations?) The three semilunar valves were thrown up, as they are naturally during the systole of the heart, and fixed in that position by the adhesion of (what would have been) their free borders to the adventitious membrane.

\* Recherches Anatom.-Pathol sur l'Encephale, t. ii. p. 7.

\* MEDICAL GAZETTE, vol. xxxvii. p. 305.



The following case is singular, from the existence of a remarkable malformation of the right ventricle which has been noticed in connection with several kinds of congenital lesion of the organ, but which has not, so far as I am aware, been observed in any other instance of narrowing of the pulmonary orifice.

M. Obet narrates\* the case of a female child who began to suffer from the symptoms of blue disease a few days after birth. She was also subject to occasional prolonged attacks of bilious vomiting. She died at the age of 5 years from aggravation of the cardiac disturbance. The right cavities of the heart were found distended with blood and fibrinous concretions. There was very considerable thinning of the walls of the right ventricle, especially at its apex, where they were not more than a quarter of a line in thickness. An unnatural enlargement of the tricuspid valves (*musculi pectinati*?) caused the right ventricle to be partitioned into several cavities. The left cavities of the heart were narrowed, the *foramen ovale* was open, and about 4 lines in diameter; both arterial apertures were narrow, and the width of the *pulmonary* orifice was less than that of the aorta.

In this case, as in most of those which have still to be cited, the obstruction to the pulmonary circulation had produced its ill effects principally by occasioning impediment to the emptying of the right ventricle, there being, in all probability, in the first place, neither sufficient contraction of the pulmonary orifice, nor a sufficiently free communication between the auricles to occasion diversion of the main current of blood through the auricular septum into the left cavities.

One of the earliest recorded instances of contraction of the pulmonary orifice is that related by Morgagni. A young woman, who had always been sickly from the time of her birth, whose breathing was oppressed, and whose skin was of a livid colour, died at the age of 17 years. The heart was found to be small, and rounded at its basis; the right auricle was more fleshy than the left, and twice as large; the *foramen ovale* would admit the little finger. The tricuspid valve was malformed, two of its curtains being unusually small. The valves of the *pulmonary artery* were in a natural state at their base, but their upper edges were cartilaginous, and even partially ossified, and so united together as to leave a passage for the blood not larger than a lentile. This opening was furnished with membranous and fleshy excrescences, so placed as to answer the purpose of valves, by allowing the exit of

blood, from the ventricle and preventing its return.

In the following instances it is by no means clear that obliteration of the *foramen ovale* had not been effected subsequently to birth; on the contrary, it appears to be highly probable that in both cases the membrane of the *fenestra ovalis* suffered perforation in consequence of the gradually increasing obstruction at the entrance of the right *ventriculo-arterial* orifice.

Dr. Craigie has given the following narrative\* :—

A countryman, *æt.* 19, had, from infancy, been always subject to shortness of breath, which was very urgent in cold damp weather; the lips, hands, and nails, had always been of a purple or livid colour. From his earliest recollection he had always been subject to palpitation, aggravated to an extreme degree by exertion. During the last two years there had been occasional swelling of the feet and ankles. Notwithstanding these complaints, he continued to work at agricultural labour of a light nature until about five weeks before his death, when he was suddenly attacked with rather copious hæmorrhage from the lungs while sitting quietly by the fire. In a week after this he came under Dr. Craigie's care. The hæmorrhage had recurred several times during the week. The face, lips, tongue, interior of the mouth, and nails, presented deep purple and leaden tints. The anterior part of the chest was very prominent, the sternum arched, and the shoulders much elevated. Respiration was 28 in a minute, performed by the accessory muscles with much labour. There were physical signs of extensive bronchitis, with scanty secretion. Extensive dulness over the cardiac region. The cardiac beats were from 92 to 96 in the minute, performed with rather strong impulse, and a rough rasping or sawing murmur, considerably prolonged, accompanied the first sound; this was heard most distinctly on the right side of the sternum, immediately between the third and fourth ribs. The more urgent symptoms were greatly relieved by perfect rest and the limited use of anodynes and anti-spasmodics; but, five days before his death, hæmoptysis again occurred, but soon ceased, the heart's action becoming strong and labouring, with a very small pulse at the wrist. The lividity increased; the patient suffered much from coldness of the surface and hurry of respiration, which progressively increased until his death. The pericardium was found to contain  $\frac{3}{4}$ ij. of serum. The heart, which weighed eighteen ounces, was much enlarged,

\* In a valuable and elaborate paper published in the *Edinburgh Medical and Surgical Journal*, vol. ix. p. 268.



especially its right auricle. The membrane of the *fenestra ovalis* was thin and reticulated, and presented many minute holes, and, at its lower limbus, an elliptical hole, one-third of an inch in diameter, communicating directly with the left auricle. The right ventricle was large in capacity, and its walls were much hypertrophied. The origin of the *pulmonary artery* was provided with a firm opaque membrane, concave towards the ventricle, convex towards the artery, and so elevated as to form a truncated cone, with a small aperture in its centre and apex, not more than large enough to admit a common probe. This aperture was surrounded by a fringe of warty prominences. The upper part of this cone presented three membranous slips, indicating the position of the attachment of each valve. The left auricle and ventricle were of the natural size, and otherwise healthy. The state of the left lung only is mentioned; portions of its tissue were solid, firm, and unusually dark-coloured, and it contained several dilations of the bronchial tubes, one of which was as large as a filbert. One of the kidneys was atrophied, and its secreting portion almost lost; the other was large, but in some spots presented traces of the granular change.

M. Cherrier\* attended a man ætat. 34 years, who had been free from any signs of heart affection until the age of 14 years, when he fell into a deep ditch full of water in the winter time. For some days after the accident he suffered from a low fever, and, during a protracted convalescence, blueness of the lips and extremities of the fingers manifested itself; and, from that time up to his death, the cyanosis continued to become aggravated, growing more and more intense during the last two years of his life. The discolouration of the entire body was extreme. During the latter period he suffered from four severe attacks of pneumonia. For the cure of these, bleeding was employed; but this produced such great weakness that it had to be discontinued. At the age of 28 years he married, and had two children, which died of scrofulous affections at the age of 3 years. He suffered from extreme debility, palpitations, coldness of the entire surface, and difficulty of breathing. He became affected with a severe pleurisy of the left side, which was attended with great aggravation of the dyspnoea. This was followed by two attacks of apoplexy; the last of which was followed by hemiplegia, and proved fatal. The left pleura was found to be filled with sanguinolent serum, compressing the lung, and evidently the product of acute inflammation. The heart was enormously large, its vessels and

cavities, and more especially the ventricles, being engorged with blood. The right cavities were singularly large; the auricles exteriorly did not present any very remarkable appearance, but they communicated by an orifice more than an inch in diameter. The walls of the ventricles were diminished in thickness; the interventricular septum was complete; the free edges of the *pulmonary sigmoids* were ossified, rendering the orifice so narrow as scarcely to admit a crow-quil. There was great congestion of the nervous centres and abdominal viscera.

There can be little doubt that, in the whole of the above-cited instances of this class, the narrowing of the pulmonary orifice dated from a period antecedent to, or very shortly after, birth,—although, as generally occurs in every form of congenital contraction, the narrowing appears to have continued to increase as life advanced:—still, in all instances of this class, it will be necessary to ascertain whether the obstructive disease of the pulmonary valves has not been set up at a considerably later period of life, either occurring in coincidence with accidental non-occlusion of the foramen ovale, or becoming in itself the cause of perforation of the interauricular septum, as the occurrence of such a train of lesions is not altogether improbable.

The narrator of the following case believed that the perforation of the auricular septum was due in his patient to accidental causes; but this appears to be questionable, as the precise condition of the structures surrounding the opening are not stated with sufficient accuracy to enable us to judge whether it was due to imperfect development or to ulceration:—

Cajetanus Tacconus relates\* the history of a beggar-girl, about 15 years old, who walked with great difficulty, and was remarkably cyanosed. She suffered from constant palpitation of the heart, and extreme weakness in all her limbs; was able to swallow only very thin or liquid aliment, and even that not without much difficulty. Her complaints were much increased during winter; she had as yet no appearance of the catamenia; her pulse was quiet and weak. She attributed this disorder to a sudden and excessive fright which she experienced, the consequence of a fall from a great height, at the age of 5 years. She remained under the author's observation for three years; and during this period he could never discover that her nostrils, thorax, or abdomen had the least degree of motion in respiration. At the end of this time, during a very severe season, she began to complain of pain in her left side, and to discharge by

\* De Bononiensi Scientiarum et Artium Instituto atque Acad. Commentar. t. vi.; Bonon 1783, and Med. Jour., vol. vi. p. 407.

\* Quoted by M. Gintrac, op. cit. p. 180.



the mouth a black grumous blood. She died on the four-and-twentieth day after the accession of these symptoms. It was found, on inspection, that the contents of the abdomen encroached so much upon the thorax as to render the capacity of the latter cavity extremely small. The lungs were hard, dry, and contracted; the left lobe was of a dark livid colour, and adhered to the pleura at the part where the patient had complained of pain. About three ounces of black grumous blood were found on the surface of the diaphragm and in the trachea. The shape of the heart was cubical rather than conical; the left ventricle, in its shape and structure, appeared as the right ventricle usually does in a natural state, and *vice versa*. The valves of the *pulmonary artery* were adherent to each other in such a manner that water could be pressed into the artery only by a small opening; and this the author supposed to have been made by a probe with which he examined the state of the valves. The pulmonary vein (possibly the veins united in a single trunk) was empty and contracted; the *canalis arteriosus* was closed, but the *foramen ovale* was found open, and larger than it usually is in the foetus. The remainder of the dissection afforded nothing preternatural.

IX.—*Contraction of the pulmonary orifice, the ventricular and auricular septa being complete, and the arterial duct obliterated.*

In certain cases of this description it may also be extremely doubtful whether the abnormal condition of the artery is congenital or of later date, the duration and character of the symptoms being the only means by which a decision can be formed; but, in the examples which I have selected as illustrative of this species of malformation, the appearances discovered after death appear to have rendered the congenital origin of the disease a matter of almost absolute certainty. In the following case by Dr. Blackmore, where the appearances discovered were of the most rare and singular character, it is probable that the foramen ovale had become closed previously to birth, and that a ductus arteriosus had never been developed, as the arrangement of the parts was such that the presence of those communications during the foetal existence of the child was rendered wholly unnecessary:—Here the narrowness of the pulmonary artery does not appear to have been the primary lesion.

A female infant began to suffer from the ordinary symptoms of blue disease at the age of 2 months. All her complaints became aggravated after her inoculation at the age of 16 months. Assimilation was in perfectly performed. She never walked

alone, nor talked intelligibly. The body was extremely puny, and the chest chicken-breasted; the pulse at the wrist was small, very feeble, but regular. Death occurred at the age of 3½ years, after a flow of black blood from the mouth and nose. The heart was found to be so large as to hide and compress the lungs; the right auricle and superior cava were greatly distended with blood; the right ventricle was greatly hypertrophied; the left ventricle was extremely small in comparison with the right. Where the left auricle should have been, only small muscular vestiges were found, without cavity. On attempting to lay open what at first sight appeared to be the tip of the left auricle, the knife entered a large single cavity, between which and the left ventricle no communication existed, except through a small fissure, the natural ventricular opening being occluded by a firm adherent fleshy membrane. From the posterior superior part of the right ventricle arose the aorta, much dilated; immediately below the aorta a small *pulmonary artery* had its origin. The left ventricle held a small coagulum of black blood, which must have entered it by the fissure above described, and which was its sole outlet. Its substance was healthy; no *ductus arteriosus* remained. The right auricle proper received the trunk of the superior cava, around the orifice of which was attached a fine delicate membrane. Two small pulmonary veins entered the inferior part of the left auricle, which was nearly obliterated, and one large vein entered its superior part. The auricular septum presented the *fossa ovalis* in its natural state, without communication with the right auricle. The left auricle had, however, a direct communication with the left ventricle by means of a small fissure through which the blood returning to the lungs must have passed, and thence into the right side of the heart. The lungs were small, particularly the left, and dense, like flesh; but there was no tubercular deposit or confirmed induration.\*

In the remaining instances of this class which have been observed, the lesions were of a far more simple character than in the above example:—

Dr. Elliotson† refers to the case of a very young woman who died in St. Bartholomew's Hospital. A bellows sound was heard in the precordial region, and the patient suffered from venous congestion and dropsy. The walls of the right ventricle appeared to have grown up around the mouth of the pulmonary artery, so that the opening from

\* Edinburgh Med. and Sur. Jour., vol. xxxiii. p. 268.

† The recent Improvements in the Art of Distinguishing the various Diseases of the Heart, p. 21, pl. 1, fig. ii.



the ventricle was no larger than the circumference of a goose-quill; and a short canal of this size had to be traversed before it reached the mouth of the *pulmonary artery*, which was of natural size. Dr. Elliotson believed this malformation to be congenital, as two little supplementary right ventricles existed here: one leading from the pulmonary artery, and the second from the first. The heart is in the Museum of the College of Physicians.

Dr. Craigie details\* the case of a railroad labourer, *ætat.* 44, who became a patient of Dr. Graham, with symptoms which were at first mistaken for those of fever. His history was indistinct. About two weeks previously, after a debauch of ten days' duration, he was seized with severe cough, hoarseness, headache, and thirst, and gradually lost flesh and strength. When admitted to the Infirmary his intellect seemed rather confused; he complained of frontal headache, and denied that he had any other local uneasiness; was very hoarse, and spoke very indistinctly, apparently from a very hurried state of his respiration. He had frequent cough, without expectoration; pulse 120; face rather livid. After his admission, the respiration continued very frequent—about 60 in the minute. He was delirious and restless at night, and died on the third day. Both lungs were found to contain tubercles, and were much consolidated: the apex of the left was occupied by a large tubercular cavity. The heart weighed thirteen ounces. The right auricle was much dilated, and decidedly thicker and firmer than usual. The right ventricle was much hypertrophied, its walls being nearly as thick as those of the left usually are, and its cavity was at the same time smaller [than natural?]. The *pulmonary semilunar valves* were so united as to form a ring, which could only admit the point of the little finger. The artery above was much dilated, and its walls attenuated. The left cavities appeared healthy. The aortic semilunar valves were somewhat thickened, but were adequate. The aorta was also dilated at its arch, but not to the same extent as the pulmonary artery.

Death seems to have been produced in this individual by the sudden aggravation of his pulmonary disease, rather than in consequence of the cardiac obstruction, which does not appear to have been excessive. I have met with several instances of heart disease in which the cavity immediately posterior to the seat of obstruction appeared, when first examined, to be in a state of concentric hypertrophy, but this condition was always, in reality, merely apparent, the cavity becoming expanded so soon as the

cadaveric rigidity of the heart had ceased. This is liable to occur in cases where death is rather suddenly induced by accidental causes which do not immediately influence the heart.

The following case affords an excellent illustration of the effects of extreme obstruction to the circulation through the right cavities of the heart, where the embarrassment of the over-distended auricle and ventricle is not relieved either by an open state of the ventricular septum or by patency of the foramen ovale.

M. Fallot has recorded the case of a woman, *ætat.* 63, who, after the cessation of the menstrual discharge at the age of 47, became subject to dyspnoea. The heart beat tumultuously, but the pulse was regular, although hard and vibrating. Relief appeared to be afforded by bleeding, which was frequently practised. Three months previously to her death she was seized with violent pains in the region of the heart, and with frequent attacks of vertigo. Her respiration became more embarrassed, and she was unable to stand. Two or three weeks before her death she became delirious. She expired in great agony. The heart was found to weigh  $14\frac{1}{2}$  ounces; by its excessive development it had pushed the mediastinum into the right cavity of the thorax. The right auricle and ventricle, and the two *venæ cavæ*, were much enlarged; and, in consequence of the dilatation of the cavities on this side, the tricuspid valve did not nearly close the auriculo-ventricular opening. The walls of the right ventricle were softened, and much thinned, but were covered by a thick lamina of coagulum, composed of different coloured strata, and partially enveloping the *columnæ carneæ*. In place of the semilunar valves of the *pulmonary artery*, a thick membrane, attached to the circumference of the orifice of the artery, was found; its concavity, which was directed towards the ventricle, was pierced at its centre with an opening about the size of a goose-quill. The free and attached borders were thicker than the rest of this membrane. The left cavities of the heart were of the natural size, and were perfectly healthy. The tissues of the lungs were much compressed by the enlarged heart\*; the liver and entire system of abdominal veins were found gorged with blood†.

\* It is probable that in this as well as in other cases where it has been stated that the structures of the lungs have become altered by the pressure of a dilated heart, the pulmonary lesions have not in reality been due to this cause, but have resulted either from imperfect expansion, congestion, pneumonic consolidation of the lungs, pleuritic effusions, or other similar conditions.

† As quoted in the London Medical and Surgical Journal, vol. v. p. 61.



I have now endeavoured to trace out, by means of a classified series of fifty-five detailed cases, the several forms in which congenital narrowing of the pulmonary orifice is wont to occur; detailing the various modifications of the lesion from its most complicated form, in which the arterial impediment, becoming established at a period when the heart is still in the condition of a single auricle and ventricle, prevents the development of the cardiac septa, and determines the permanence of the arterial duct, until we arrive at the simplest condition in which the malformation can possibly occur; *i. e.* as a defect which is confined to the pulmonary ostium, and which has been produced at so late a period as to have no influence whatever in preventing the other portions of the heart and its appendages from attaining their full and normal development. I should have been content with illustrating each species of the lesion by merely one or two examples, had it not been for the singular fact, that nearly every instance of this kind of malformation has been found to present certain marked peculiarities which in a striking degree distinguish it from all the other recorded instances to which it is allied; in fact, it appears that scarcely any two cases of this kind perfectly agree: the history of each appears to develop some new feature in cardiac pathology, and to afford some additional insight into the inexhaustible resources by which nature is prepared to enable the central organ of the circulation to adapt itself to those vicissitudes which are so liable to affect it during the progress of its development.

I shall reserve the discussion of many important points connected with the history of the above lesions until I arrive at the consideration of the morbus cæruleus, and the diagnosis, prognosis, and treatment of diseases originating in the pulmonary artery.

#### *Absence of the sigmoid valves.*

In many of the cases of narrowing of the pulmonary ostium which have been already cited, the valvular apparatus at the origin of the vessel presented scarcely the faintest resemblance to the natural arrangement of the sigmoid curtains, the development of the valves being especially incomplete in those cases where the imperfect state of the ventricular septum, and other extremely defective conditions of the heart and its vessels, proved that the arterial lesion had occurred during the earlier periods of intra-uterine life. In the larger proportion of these instances, however, there existed some form or other of imperfect valvular apparatus, which must have proved more or less efficient in guarding the vessel against reflux; and, in one only—that observed by Dr. Crampton, (p. 457)—was the vessel entirely destitute of

a valvular apparatus: a similar defect was also observed in the following case, which has been recorded by Dr. Favell.\*

The subject of this extraordinary malformation was a boy, ætat. 8 years, who died of cerebral irritation. During his illness his pulse was always slow, not exceeding 70 in the minute: the boy was well developed. On placing the ear below the left nipple there was a loud souffle, and it was stated that, if the boy was much excited, or had taken active exercise, his countenance became blue. On examination after death, the heart was found to be of normal size; but, on opening the right auricle, the *foramen ovale* was seen completely unclosed, and capable of allowing the passage of the little finger. There was no communication between the right auricle and the corresponding ventricle, so that the whole of the blood must have passed through the foramen ovale. In the left ventricle, immediately behind the mitral valve, there was a large aperture through the *septum* which opened into the commencement of the *pulmonary artery*: this vessel had no valves. The right ventricle would scarcely contain a small walnut.

This case is extremely interesting when compared with the example by Dr. Blackmore (cited at p. 749). Here we observe a singular adaptation of parts by which the immediate ill effects of the primary lesion,—complete occlusion of the *right* auriculo-ventricular orifice,—were averted: in Dr. Blackmore's case was displayed a still more extraordinary alteration in the course of the circulation consequent upon non-development or early occlusion of the *left* auriculo-ventricular opening. The faulty condition of the pulmonary artery in either case, although apparently secondary to the other cardiac lesions, was evidently the principal cause of the lividity of surface, and symptoms of cardiac obstruction, from which the patients suffered. It will be noticed that, both in this case and in that related by Dr. Crampton, the valveless pulmonary artery communicated directly with a small muscular cavity which in reality merely formed an appendix to the ventricle from which the vessel received its supply of blood: it is probable that this arrangement of parts in some degree compensated for the absence of a valvular apparatus, by preventing the reflux blood from being immediately thrown back into the ventricle from which it had been propelled. It is to be regretted that it has not been stated whether the bruit which was heard in both of these cases was synchronous with the diastole or the systole of the heart. There can be little

\* Provincial Med. and Surg. Journal, vol. iii. p. 440.



doubt that in cases of this description rupture or inflammation of the valvular apparatus, occurring at a very early period of foetal life, has been followed by its absorption. In another portion of this memoir I shall have to shew that, even in adult life, the valvular apparatus of the pulmonary artery may be almost entirely destroyed and removed by disease.

*The pulmonary artery furnished with two semilunar valves.*

Several cases of this description have been recorded, and I have already cited one by Dr. Houston, and another by M. Duret, in which the valvular defect was attended with a contracted state of the artery. In the following instances this malformation was apparently not accompanied by congenital narrowing of the vessel. It is, however, evident that, in an example of the kind adduced by Sandifort\*, there must have originally existed some serious cause of obstruction at one or other of the cardiac outlets.

The heart of a 7 months male foetus was found to be almost round. The left ventricle, which was very small, communicated with the right by a foramen in the *septum ventriculare*. The aorta communicated with both ventricles, but more freely with the right. The *pulmonary artery* was of the usual size, but was only furnished with two valves. The *arterial canal* was narrow, resembling a little branch of the pulmonary artery. There was only one left pulmonary vein.

The following case is rendered of great interest, by the fact that, in the aorta as well as in the pulmonary artery, two sygmoid curtains only had been developed.

Dr. Taylor attended a bricklayer of intemperate habits, ætat. 38 years, who died of pneumonia, pleurisy, and pericarditis, and in whom the physical signs of hypertrophy of the heart and regurgitant disease of the aortic valves were very apparent. On inspection, the heart was found to present the following lesions. The pericardium bore traces of inflammation, and contained two ounces of turbid serum. The aortic valves admitted of regurgitation; the orifice of the aorta was about half closed by numerous large vegetations adherent to the sygmoid valves; these vegetations were partly soft and of recent formation, and partly firm and calcareous; there were only two sygmoid valves in the aorta. The mitral was slightly thickened; its orifice admitted three fingers. The walls of the right ventricle were a little thickened. There were only two sygmoid valves in the *pulmonary artery*: it was not ascertained whether these valves were efficient, but they presented no disease

whatever, neither thickening nor any other change.\* Dr. Taylor also refers to an example of this malformation related by Briquet.

Dr. Graves details the case of a man, ætat. 66 years, who died with hydro-pericardium and pneumonia, in whose heart the following appearances were discovered. The *pulmonary artery* contained a fibrinous clot, which presented the usual division produced by the branches of that vessel. There were only two valves, and they were both coated with a recent deposition of lymph, which was, in some situations, almost a quarter of an inch thick. A small part of this lymph was accidentally removed while examining the valves, and the latter were seen much thickened and opaque; in this respect contrasting in a very remarkable manner with the valves of the aorta, which were quite free from disease.†

From the duration of the lives of several of those who have been the subjects of this kind of malformation, it is evident that the valvular defect is not necessarily attended with regurgitation, so long as the tissues of the curtains remain in a sound condition, but parts thus malformed appear to be extremely liable to undergo various morbid changes, the occurrence of which usually determines the fatal issue of such cases. This is exceedingly well illustrated in the following case by Mr. Paget:—

A girl, ætat. 20, of irregular habits, and the subject of renal disease, died apparently from the effects of an extensive deposition of coagula upon the valves and in the branches of the *pulmonary artery*. Mr. Paget found that this vessel was furnished with only two sygmoid curtains, which were thickened and opaque, and had on their free borders and adjacent surfaces large growths of brownish-yellow, soft, fibrine-like substance, which firmly adhered to them, and which had in their interior small grains of earthy substance‡.

In commenting upon this case, Mr. Paget directs attention to the fact, which he believes has hitherto passed unnoticed, that in the majority of cases in which only two valves have been found in the aorta or pulmonary artery, those valves have been often extremely diseased. This fact, Mr. Paget adds, is very important; for it affords evidence (which is confirmed by several other observations) that parts which, from defective or erroneous development, are wrongly shaped, are often at the same time imperfect in their tissue, and are therefore very liable to disease

\* Lancet, Dec. 4th, 1841, p. 314.

† A System of Clinical Medicine: Dublin, 1843, p. 905.

‡ On Obstruction of the Branches of the Pulmonary Artery: Medico-Chirurgical Review, vol. xxvii. p. 182 (1844).



(p. 188). Previously to the appearance of the above observation, it occurred to me to remark that, where absence of the septum of two of the aortic sygmoids occurs as a congenital lesion, manifest traces of a more recent disease of the valves are not unfrequently also present, in the form of irregular thickening of the ill-shaped curtains, and deposits of small fibrinous concretions upon portions of their surfaces; as, independently of the great liability of the parts so malformed to suffer from vicissitudes in the circulation, they are also very apt to be implicated in the derangements of the heart and its appendages which frequently coexist in these cases\*.

*Absence and congenital closure of the arterial duct.*

Independently of those cases in which the office of a ductus arteriosus is found to be performed by a distinct vessel passing from the right ventricle to the aorta, and of those in which the place of the duct is supplied by a communication between the pulmonary artery and one of the large vessels of the arch, there are several kinds of cardiac malformation in which there is every reason to believe that closure of the duct exists as a congenital lesion. Although, in the majority of these cases, no vestige of the duct is discoverable subsequently to birth, it does not appear probable that, in any instance, this canal has been originally wanting; unless we presuppose the existence of some primary defect in the branchial vessels. It seems to be more feasible that the communication in question, having been rendered unnecessary by the establishment of certain abnormal conditions in other portions of the cardiac apparatus, has either become closed at the period when the arterial root and branchial vessels assumed the condition of the primitive, systemic, and pulmonary arteries, or has undergone contraction and absorption at a somewhat more advanced stage of foetal existence.

Absence of the arterial duct has been observed in coincidence with the following conditions of cardiac malformation:—where the ventricular portion of the heart is single, giving origin to a single arterial trunk;—where a single artery originates from ventricles which are partially divided by a septum;—where the pulmonary artery is narrow. Absence of the duct has also been observed (by Dr. Blackmore) in the case, already cited, of obliteration of the mitral orifice with narrowing of the pulmonary artery, and has been remarked in a singular case of transposition of the aorta and pulmonary artery which will be detailed in a subsequent part of this memoir. The two latter instances

\* Guy's Hospital Reports, vol. vii. p. 408 (Oct. 1842).

appear to be solitary examples of this kind of lusus; but, in the three former kinds of malformation, it has been more frequently observed. Allusion has been already made to the fact that, in those instances where the ventricular portion of the heart is single, giving origin to a single arterial trunk or to a distinct aorta and pulmonary artery arising by separate orifices, or in which the ventricles, communicating by an opening in the septum, send off an artery which afterwards separates into pulmonary and systemic branches, the ductus arteriosus is absent,—this peculiar arrangement by parts rendering its presence unnecessary. I shall quote the following examples in illustration of this point; as instances of these kinds of malformation are of by no means frequent occurrence.

In a male foetus, of eight months, F. R. Meckel\* found the heart to be nearly equal in length and breadth; its apex was divided into two tubercles. The aorta, which was one-half wider than natural, arose from the middle of the base over the septum, there giving off a very narrow *pulmonary artery* as a branch which passed behind the trachea towards the vertebral column. There was *no canalis arteriosus*. The *septum of the ventricles* was perforated by an opening of the measure of one line vertically, and four lines in width†.

In the following case the malformation was in some degree analogous to that observed by Ant. de Pozzi, Tiedemann, Chemineau, and others (in cases cited at pp. 276—278). But the heart, although essentially single, in reality presented four cavities.

In 1842, a female child, ætat. 4 months, and of whom it was impossible to obtain any precise information, was deposited in the Hôpital des Enfants Trouvés, of Paris. The child was seized with dyspnœa several times in the course of the day, the attacks being accompanied with a bluish tinging of the whole surface of the body; it was accordingly sent to the infirmary. Here, on the ensuing day, it presented general cyanosis, and the tongue, anus, genitals, and adjacent parts, were of a blackish-violet colour. Asphyxia supervened five or six times in the twenty-four hours. The heart beat 136 times per minute, and a marked *bruit de soufflet* replaced the normal sound in the heart during its diastole. About ten days after this, the child died of dyspnœa: nearly all the anterior half of the thorax was found occupied by the pericardium, and, on laying open this, it was seen that the heart consisted of only one

\* Reil's Archiv. Bd. 9, p. 437, quoted by Hein.

† This case almost precisely resembles one related by M. F. Tiedemann, and cited at the commencement of this paper (p. 277). I had not met with this instance when I cited that by M. Tiedemann.



ventricle and one auricle, the deep sulcus between which was filled up with a process of the left lobe of the liver (with, of course, a portion of the diaphragm). The auricle, which was much larger than the ventricle, was nearly spherical, and its sides, which were about one-eighth of an inch in thickness, were furnished internally with strong columnæ carneæ (musculi pectinati?). At its posterior part the two venæ cavæ opened into it by a common mouth, or a sort of sinus, apparently a rudiment of a right auricle. The pulmonary veins terminated in their ordinary manner. The ventricle was of a conical shape; its walls were much thicker on its left than on its right side. Three openings existed in its base. The auriculo-ventricular closed by a true mitral valve, the aortic opening; and on the right side of the latter an opening into a cylindrical sac which seemed to represent the right ventricle, but had no communication with the auricle. The *ductus arteriosus* was wanting. There was no malformation in any of the viscera except the heart, nor in any part of the arterial system\*.

Here the circulation must have pursued exactly the same route as in the case by Dr. Favell, cited at the commencement of this chapter: but, in the present instance, the malformation appears to have been more extreme, especially that of the auricular portion of the heart.

M. Hein (op. citat. p. 29) appears to have been the first author who noticed the coincidence of absence of the arterial duct with great narrowing of the pulmonary artery; citing the cases by Otto, Knox, Meckel, and Steno, in illustration of this fact. To these instances I have added the examples by MM. Lexis, Aran, Huss, Gintrac, and Dr. Blackmore†, which taken together are sufficient evidence of the fact that narrowing of the pulmonary orifice is frequently attended with absence of the arterial duct. It is difficult to account for the occurrence of this coincidence otherwise than by concluding that early obliteration and absorption of the duct has been followed by an imperfect development of the artery; the canal of which has, up to the period of birth, remained merely of sufficient size to

transmit the slender current of blood which circulates through the lungs previously to the commencement of respiration.\*

The question of the *possibility of closure of the arterial duct occurring previously to birth* is one of extreme interest and importance, especially in a medico-legal point of view. That the passage may become closed during the earlier stages of intra-uterine life is rendered certain by the facts already adduced; whether occlusion of the canal and conversion of its tissues into an impervious cord can occur at a later period of foetal existence is a more doubtful question, but one which I believe may, not improbably, be ere long answered in the affirmative.

A case has recently occurred at Ayr, in which there appears to be strong reason to believe that closure of the duct had occurred previously to birth. The medical facts of this case, so far as they have been afforded, are as follow. The body of a female child was discovered buried in a waste ground enveloped in a woollen bag. The body was found to be in a state of putrefaction, with desquamation of the cuticle. It weighed five pounds, and was twenty inches in length. Its mouth and nostrils were stuffed with flax. The umbilicus was in the centre of the body, the cord cut close to the abdomen, and left without ligature. The scalp was covered with hair, and the nails were full-grown; a large portion of the brain, which had been reduced to a pulpy state, had escaped through the openings of the skull. There was an extensive ecchymosis all over the fore part of the neck, and an effusion of blood on the exterior of the trachea. The heart and lungs weighed one ounce; the lungs were collapsed: the right was considerably decomposed, and sunk when put in water. The left was of a red colour, and firm in texture, and floated on the surface when immersed in a vessel filled with water; but on pressure there was no crepitation. The right side of the heart was filled with coagulated blood, the *foramen ovale* partly open, and the *ductus arteriosus* impervious. The liver was large, and of a leaden hue; the *ductus venosus* almost obliterated, and the meconium was found in abundance in the lower bowels.

Strong circumstantial evidence was adduced to prove that this infant came into the world alive shortly before 6 o'clock A.M., and that its body was deposited in the

\* Gaz. des Hôpitaux, Supp. Dec. 1842, and Lancet, 1843.

† While citing examples of narrowing of the pulmonary artery attended with absence of the *ductus arteriosus*, I omitted an example related by M. Deguise, and cited by M. Ollivier, Dict. de Méd., art. Vaisseaux Pulmonaires, of a woman, ætat. 20, who suffered from cyanosis, debility, palpitation, and dyspnoea; a bruit de souffle was prolonged in the course of the *pulmonary artery*. On inspection, this vessel was found to be extremely narrowed. The ventricles and auricles respectively communicated with each other, and the *arterial canal* was absent. The precise meaning of the latter expression is rather doubtful.

\* Otto alludes to other instances observed by Stenson, Bartholini, Kreysig, and Chemineau, in which the duct was entirely absent, and also makes slight reference to the existence of the same defect in a monster, with abdominal cleft and hernia cerebri, but I am not acquainted with the details of these cases, unless the instance by Chemineau be one of non-development of the ventricular septum, to which I have alluded at the commencement of this paper.



spot where it was subsequently discovered between 10 and 11 o'clock, A.M. on the same day. This train of evidence, if confirmed, would lead to the conclusion, either that the duct became closed almost immediately after birth (for it cannot be believed that this infant survived its birth more than four hours and a half, to say nothing of the probability that it did not respire even for so many minutes), or that the child had come into the world with the duct nearly or quite closed. The facts of this case, however, were not proved in a sufficiently demonstrative manner to render it an example upon which it is possible to argue with any degree of certainty; still, it is one, which unquestionably very decidedly suggests the probability that closure of the duct in the ordinary manner may occur previously to birth, and one which strongly shows the necessity for further examination of this most important physiological question. No fact can be more clearly ascertained than that the foramen ovale may become closed previously to birth; and it appears to me that, as the question at present rests, no medical witness is justified in declaring that the existence of a contracted or closed state of the arterial duct is a certain evidence that the infant has respired\*.

We have, at present, no absolutely demonstrative knowledge of the causes which naturally produce the closure of the arterial duct: we are, therefore, not justified in declaring that those causes may not, in certain instances, be brought into operation previously to the birth of the child; many instances of cardiac malformation countenance this idea, and there are numerous facts which, to a certain degree, suggest, although they do not absolutely confirm, an opinion that the commencement of the process of contraction in the ductus venosus, foramen ovale, and arterial duct, may possibly be among the causes which determine the expulsion of the foetus from the uterus at the ninth month.

#### *Low division of the pulmonary artery.*

The pulmonary artery has, not very unfrequently, been found to divide into its two main branches at a very short distance above its origin. In examining the body of a young girl who died of a passive aneurism of the left cavities of the heart, M. Cassan found that the pulmonary trunk did not, in

\* It does not appear to have been stated in evidence in the above case whether the pulmonary orifice and other portions of the heart and its appendages were in a natural condition. In any instance where there exists narrowing of the vessel or any other serious malformation of the heart, or in which those who examined the body have neglected to observe the previous condition of each cavity and outlet of that organ, the fact of obliteration of the arterial duct certainly cannot be received as a proof that the infant has been born alive.

reality, exist at all, but that the vessel divided just above its origin into its two branches. These two branches were of the ordinary width.\*

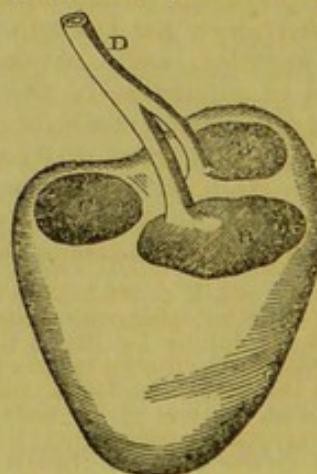
In the case by Mr. Bloxham, already cited, of a child, ætat. 3 years, the pulmonary artery was extremely narrow, and bifurcated immediately on its exit, so that the trunk was not, in any part of its circumference, more than a line in length. Slighter degrees of this kind of malformation are not unfrequently noticed.

#### MALFORMATION BY EXCESS OF THE PULMONARY ARTERY.

##### *The pulmonary artery arising from the heart by a double origin.*

The only instance of this kind with which I am acquainted is that related by Kerckring.† The subject of this malformation was an infant about 3 months old, in whom the heart was divided into three ventricles; *i. e.* the right was double, and from each of its two cavities there arose a pulmonary artery which united above into a common trunk. The heart had been carelessly removed from the body for another purpose, so that the distribution of the cavæ and other vessels which had been cut away was not observed.

Neither the above account, nor the representation of the heart (which is exactly copied from Kerckring's plate in the subjoined cut), render it perfectly clear that the vessel which took its origin from the two ventricles was, in reality, the pulmonary artery. More than one case has been recorded in which the aorta arose by a double origin;‡ and, upon examination of the



B, Two right ventricles of the heart.  
C, Left ventricle.  
D, Pulmonary artery given off from both right ventricles.

\* *Archiv. Générales*, P. S. t. xiii. p. 82.

† *Spicilegium Anatomicum*, Obs. 49, p. 139-40.

‡ Dr. M. E. White, of Carlow, has described the heart of a double-headed foetus in which there were three ventricles, but here a single vessel was placed anteriorly, and gave off a single pulmonary trunk; while, from the two posterior cavities, the systemic vessels arose. (Dublin



figure, it will be observed that the long single vessel formed by the union of the two ventricular branches has rather the appearance of an aorta than of a pulmonary artery.

*Unusual number of valves.*

The instances in which the pulmonary artery is found to be furnished with four sygmoid valves are by no means extremely rare.\* Dr. Todd (Cyclop. of Anatomy and Physiology) speaks of the occurrence of five valves in this vessel; Malcarne (quoted by Dr. Grave-) mentions a case where the aorta divided soon after its origin, and was furnished with five valves, but I have not been able to meet with the details of any example in which a similar arrangement occurred in the pulmonary artery.

Dr. Theophilus Thompson has collected some interesting facts with relation to this species of irregularity in illustration of the following case†:—

The author was requested to visit a woman, æt. 38, suffering from great drowsiness, with lividity of the complexion, a purple and swollen state of the lips, distension of the external jugular veins, and anasarca. The pulse was rapid and feeble; the impulse of the heart rather weak; the first sound shorter, and more flapping, the second less distinct, than natural; both sounds were, however, unattended with roughness, and there was no evidence of any obstacle to the circulation. The debility gradually increased, her legs became more and more œdematous, and at length erysipelatous and gangrenous, when she died. This patient, although never robust, had enjoyed an average share of health until attacked with Asiatic cholera during the prevalence of that disease in this country, after which her strength was permanently impaired, and she occasionally complained of palpitation of the heart on going up stairs. Two years before her death she suffered from an attack of fever. From this time she exhibited a livid complexion, and a peculiar drowsy apathetic appearance, which induced visitors to suppose her idiotic.

Medical Press, vol. i. p. 212.) Dr. Chichester has detailed (Loudon's Magazine of Nat. History, vol. i. p. 135, quoted by Dr. Paget) the appearances observed in the dissection of a monstrous sheep, with one head, one heart, and one stomach, but with the rest of the body generally double: from each ventricle sprang an aorta: of the two vessels one turned to the right, and the other to the left. The one which turned to the left went down in the natural direction, while that which turned to the right crossed the right vertebral column, and passed down on the outer side of it. A transverse canal of somewhat small calibre passed down from the beginning of the turn of the arch on one side to the same part on the other side, thus forming a communication between the two aortas.

\* Dr. Graves refers (in his Clinical Medicine, p. 905) to the specimens in the College of Surgeons of Ireland, which exhibit the aorta with four valves.

† Med. Chir. Trans. vol. xxv. p. 247.

On inspection, there was found some effusion into the peritoneum, pleura, and pericardium, and serous infiltration, with redness of the bronchial tubes. The heart was larger than natural, and exhibited a circumscribed dilatation at the part of the right ventricle more immediately connected with the right ventricle. This ventricle was found to be formed of two cavities, separated from each other by an imperfect septum. This septum was composed, not of a uniform fleshy wall, but of decussating and hypertrophied columnæ carneæ, some of which, separating from each other near the base of the ventricle, left an aperture of communication about an inch long and half an inch broad. The arterial chamber of the right ventricle was rather less spacious than that adjoining the auricle, which corresponded in size and appearance to the right ventricle in its natural condition. The connecting orifice was partially covered by one of the divisions of the tricuspid valve\*. The walls of the left auricle, and of both the ventricles, were of natural thickness; but the right auricle was twice as thick as the left. The *pulmonary artery* was furnished with four valves, which were found, on admeasurement, equal in size. Each of the valves was well-developed, furnished with a corpus sesamoideum, and about nine-tenths of an inch in diameter. As each of the valves was of natural size, an additional valve was rendered necessary by the preternatural width of the pulmonary artery, the circumference of which exceeded that of the aorta by nearly an inch. The author justly observes, that this specimen furnishes an exception to the rule laid down by Meckel,

\* A malformation of the right ventricle in some measure similar to that observed in Dr. Thompson's case, but unaccompanied with an analogous state of the valves, has been described by Dr. Fletcher. The man from whom the specimen was taken was about 63 years of age, an itinerant collector of rags, who, after a walk of five or six miles, was found dead in his bed. It was stated that he had latterly been rather asthmatic. The tricuspid valve was healthy; across the cavity of the right ventricle was a muscular partition, dividing it into two unequal parts, the larger next the auricle, the smaller communicating with the pulmonary artery. The partition seemed made up of carnæ columnæ, and was perforated by an opening capable of admitting the little finger, the edges being semi-cartilaginous; an opening large enough to admit a goose-quill communicated with the left ventricle, and the larger cavity of the right ventricle. The foramen ovale was capable of being opened by a probe. The left auricle and mitral valve were healthy; in the left ventricle the opening from the right ventricle was seen before (below?) the origin of the aortic valves, two of which had ossific deposits in their substance. The aorta was slightly dilated. The veins of the arachnoid were congested, and there was effusion of fibrinous serum between this membrane and the pia mater.

A case by M. Obet, in which a very similar condition of the ventricle was observed in connection with arctation of the pulmonary orifice, has been already detailed.



"Omnes in eo conveniunt valvulæ numero imminutas mote augeri, numero auctas mole minui."

It will be found, however, that the first, third, and fourth of the following examples, corroborate the statement of Meckel, and correspond with two cases observed by Petsche and Bizot\*, in one of which the additional valve was found singularly small, in the other quite rudimentary. The first in some measure corresponds with an instance mentioned by Morgagni, in which one of the valves was larger than the rest. In the fifth instance the condition of the artery closely resembled that described by Dr. Thompson, the whole of the valves being regular and symmetrical in form.

In the Museum at Guy's Hospital there are four preparations (numbered 1435<sup>35</sup> 1413<sup>25-30</sup>) in which various modifications of this condition of the artery are remarkably well displayed.

In one of these, three of the curtains are well formed, but the vessel is also furnished with an additional sygmoid pouch, which is capable of holding a pea.

In a second there are four valves, but the septum between two of these is longer than that which separates either of the others, the free edges of the curtains having apparently been stretched downwards.

In the third specimen there is a very minute imperfectly formed additional valve, formed by a little curtain supported above by slender isolated cords; these cords attach the upper margin of the valve, almost at its central part, to the arterial walls.

The fourth preparation displays a still more minute extra valve, which is not only attached laterally to the artery by tendinous cords, but also presents a thin membranous bridle, which extends upwards from that portion of the free edge at which the corpus arantii is usually situated, and is united with the arterial wall above. This is the only specimen which I have seen in the human subject where a sygmoid curtain was attached to the artery by a tendinous cord occupying the situation of the corpus arantii, but such an arrangement of parts is observed to be permanent in the upper row of valves defending the aorta of the shark; and there is every reason to believe that, in the human heart, the primitive condition of a sygmoid valve is that of a membranous curtain attached to the vessel at its upper part by isolated tendinous cords. I have stated the grounds on which this conclusion is formed in a previous essay†, and I have no doubt that the corpora arantii are the vestiges of

the attachments of the central chordæ tendinæ of the valves.

The same collection also contains another specimen (marked 1413) which presents four perfectly symmetrical valves, which are in every respect healthy and natural in structure, except that here, as in most of the other specimens, some of the lateral attachments of the curtains are formed by isolated cords; a condition of parts which I believe to be in every instance congenital, and not the result of atrophy of the tissues of the valves.

*Origin of extra branches from the pulmonary artery.*

A few instances have been noticed in which one or other of the subclavian arteries took its origin from the pulmonary. Breschet\* mentions a case in which the left subclavian arose from this vessel; and J. F. Meckel† has described the origin of the right subclavian from the division of the pulmonary artery in a calf. Instances in which the descending aorta, left subclavian, &c., apparently arose from the pulmonary artery, and in which the latter vessel communicated with the innominata or left subclavian, belong more properly to another division of this subject.

*The lungs supplied by additional branches from the systemic circulation.*

In the course of the foregoing observations, various instances have been alluded to in which obliteration or contraction of the pulmonary artery was in some measure compensated by the existence of branches passing to this vessel from the subclavians, or arch of the aorta, or by the establishment of a permanently dilated condition of the aortic bronchial arteries. In addition to these, Otto refers to several cases in which, besides the usual pulmonary artery, the lungs were supplied by accessory arterial branches; for example, an instance where a large branch from the aorta, in the region of the sixth dorsal vertebra, passed to the lobes of the right lung‡. Another case, where a single twig passed to the under lobe of the left lung§; and one in which very small pulmonary arteries passed equally to both lungs from the pericardial arteries||.

A very remarkable instance of this kind has been related by M. A. Maugars, of Angers.¶ The subject of this malformation was a child, æt. 7 years, in whom a considerable artery, which arose from the

\* Quoted by Hasse.

† Tabul. Anat. Path. Fas. ii. p. 2, cited by Otto.

‡ Huber, in Anat. Helvet. vol. viii. p. 85.

§ J. F. Meckel, in his Archiv. f. d. Physiol. vol. vi. p. 454.

|| Jacobson, in Meckel, vol. ii. p. 154.

¶ Sidellot, Recueil Period. vol. xiii.; and in Corvisart, Journ. de Méd. An. x. Pluv.

\* Haller, Collect. Anatom. Dis. vol. vi. p. 774;—Mém. de la Société d'Observation, vol. i., quoted by Dr. Thompson.

† Guy's Hospital Reports, vol. vii. p. 414, and plate 1.



superior anterior and right side of the abdominal aorta, and ascended between the aorta and œsophagus, entered the chest through the œsophageal opening of the diaphragm, having given off, at a short distance from its origin, the right sub-diaphragmatic artery. Immediately above the diaphragm, and above the œsophagus, it divided into two branches. Each of these entered the posterior inferior and internal part of either lung, and was distributed throughout the inferior lobes. The trunk of the artery, and its principal divisions, gave off no other branch than the sub-diaphragmatic, and were not accompanied by any corresponding vein. The trunk and right branch of the pulmonary artery itself were of the ordinary dimensions, but the left branch was much smaller than usual, not equalling the right by one-half. This defect was evidently compensated by the accessory branch from below. On injecting the pulmonary arteries, it was found that they inosculated freely with the branch derived from the abdominal trunk. The pulmonary veins were distributed in the usual manner. The lungs were sound, but were rather larger than usual. The heart was also rather enlarged.

This last case appears to afford a type of the whole of the instances in which the lungs are supplied with accessory vessels from the aorta or its branches, an arrangement which seems to have been invariably determined by the existence of some considerable impediment to the circulation through the pulmonary artery during the earlier periods of cardiac development. There are strong reasons for believing that, in many instances of contraction and obliteration of the pulmonary ostium, these lesions have been partially compensated by the distribution of additional arterial branches from the systemic vessels to the lungs, an arrangement which has been overlooked in dissection. It would add greatly to our knowledge of the abnormal anatomy of the blood-vessel system if the plan of injecting the arteries and veins, and then carefully dissecting the parts *in situ*, were adopted in every case where there was reason to believe that death had resulted from congenital malformation of the heart.

#### *Permanence of the arterial duct.*

In a previous essay\* I have endeavoured to trace out the principal causes which occasionally determine the non-closure of the arterial canal subsequently to birth; and have also attempted to afford some elucidation of the means by which the natural obliteration of this vessel is effected in the

healthy infant: it now remains to analyse and classify the great variety of instances of congenital malformation of the heart and its large vessels in which permanence of the arterial duct constitutes the leading feature in the malformation; and it is certainly extremely interesting to observe how many different forms of congenital obstruction are attended with this condition: and to remark the singular diversity of lesions, the ill effects of which are, to a greater or less degree, mitigated by its establishment.

The following are the principal conditions under which non-occlusion of the arterial canal has been found to occur:—(1.) Where the duct occupies an unusual position; (2.) Where the orifice of the pulmonary artery is obliterated or congenitally narrowed; (3.) Where the aorta arises from the right ventricle and the pulmonary artery from the left; (4.) Where the orifice of the aorta is closed; (5.) Where the upper portion of the descending thoracic aorta is contracted or obliterated; (6.) Where the foramen ovale becomes closed previously to birth.

It has been very justly considered that the existence of any permanent cause of embarrassment to the circulation, similar to those which are present in most of the above-mentioned kinds of malformation, is sufficient to determine the non-closure of the arterial canal subsequently to birth; but it is also probable that various other circumstances, such as the existence of some severe, but temporary, cause of obstruction in any portion of the vascular circle of the child either before or after its birth, a diseased condition of the tissues of the canal, or a failure in the operation of those means by which the natural closure of the duct is usually effected, may determine its persistence, as a direct communication between the pulmonary and systemic trunks, throughout the entire life of the individual. To complete the series of instances where non-occlusion of the duct has been observed, we must add those in which it is associated with (7) imperfection of the ventricular septum, and with (8) an unclosed state of the foramen ovale; together with those (9) in which there is not discoverable any other appearance of malformation or defect in the heart or its appendages.

I have already adduced cases in illustration of several of these kinds of congenital aberration: the following interesting examples will assist to complete the series.

#### *I. Cases in which the arterial canal occupies an unusual situation.*

Failure of the process by which the duct becomes materially closed is not by any means invariably determined in cases where this vessel is irregularly distributed, but it is

\* On Permanence of the Ductus Arteriosus; and Constriction of the Thoracic Aorta; and on the means by which the Duct becomes naturally closed, MEDICAL GAZETTE, vol. xxxvi. p. 187.



very remarkable that, in by far the larger number of instances where any deviation from its usual course has been observed, the canal has remained in a pervious condition. The following example is, I believe, unique.

*The arterial duct arising from the right ventricle.*

Wrisberg\* refers to the case of a girl, æt. 7 years, in whom the *ductus arteriosus*, which was as large as it usually is soon after birth, arose from the right ventricle close to the orifice of the pulmonary artery. In this manner the aorta received blood from both ventricles.

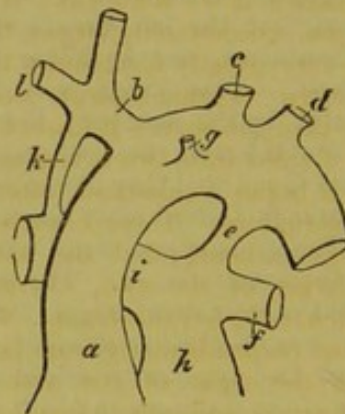
*Communication between the pulmonary and subclavian arteries, associated with other congenital defects in the heart or its appendages, independently of contraction of the pulmonary orifice.*

I have already cited (pp. 283, 374, 452) instances in which an obstructed condition of the arterial outlet of the heart was in some measure compensated by the existence of an abnormal communication between the pulmonary trunk and the left subclavian artery, adopting the view of Dr. Paget, that, in these cases, the irregularly disposed arterial canal is not in reality the *ductus arteriosus*, but the remains of a communication which, during the earlier period of foetal life, naturally exists between those portions of the branchial apparatus which afterwards form the right and left pulmonary and subclavian arteries. The following remarkable case has been cited by Dr. Paget, and appears to afford unquestionable evidence of the correctness of his view.

*The pulmonary artery communicating with the aorta in the usual position of the canalis arteriosus; a vessel at the same time uniting the left branch of the pulmonary with the innominata artery.* M. G. Breschet describes† the case of a male infant which lived 6 weeks, and during the brief period of its existence suffered from difficulty of breathing, attacks of vomiting and convulsion, and an habitual drowsiness, with coldness of the extreme parts of the body. On examination, the heart, which was of ordinary size, was found to be situated in the median line of the thorax, its point being directed to the left. It had but one auricle and one ventricle, which communicated by so large an opening that the organ might be considered to consist only of a single cavity. The aorta (*a*) arose in front and to the right, and gave off from the upper part of its arch (which passed to the left) the brachio-cephalic (*b*)

and left carotid and subclavian arteries (*c, d*), and at its under part received (*e*) a large vessel (the arterial duct), which M. Breschet describes as arising from the left branch (*f*) of the pulmonary artery. A small branch (*g*) was also distributed from the anterior part of the arch to the thymus gland. Further behind the aorta, and to its left, arose (*h*) the pulmonary artery. Between the right branch (*i*) of this vessel and the brachio-cephalic trunk there existed a communicating vessel (*k*), which was larger and narrower than the arterial duct, and which was inserted just at the root of the right subclavian artery (*l*).

FIG. 1.



I am not acquainted with any other instance in which two direct communications existed between the pulmonary artery and systemic vessels in the form of a *ductus arteriosus* and a branchial canal. M. Breschet's case also forms a remarkable exception to the rule which I believe generally obtains—that, where there is total deficiency of the ventricular septum of the heart, the arterial duct is absent.

*A single branchial canal uniting the pulmonary with the left subclavian artery.*

One of the earliest recorded instances of the existence of a branchial duct, is that mentioned by John Christian Reinmann.\* In the body of a beggar, who had died of suffocative catarrh, this author found an arterial canal ascending from the pulmonary artery and uniting with the left subclavian.

Dr. James Jackson has detailed the history of a female child, ætat. 5 years, whose death was principally due to the effects of an acute gastro-enteritic attack of five days' duration. She lay quiet during nearly the whole of her last illness, and was disposed to stupor. The countenance "was not very morbid," and was of a good colour; the respiration was most uncommonly accelerated, and was peculiarly irregular; the action of the heart was rapid, troubled, and confused; the palpitation of the heart, and

\* In *Gottingische Anzeigen*, 1778, Num. 50; and Sandifort, *Obs. Anatom. Pathol.* t. iii. c. i. p. 39.

† *Mémoire sur l'Ectopie du Cœur*, p. 9.

\* *Nova Acta Acad. Nat. Cur.* T. i. Obs. 74, p. 302.

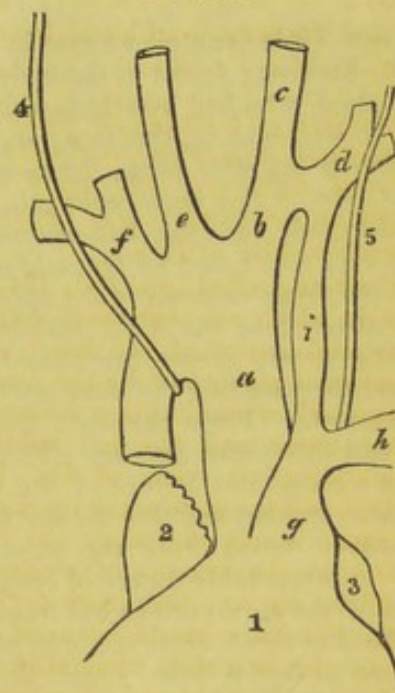


shortness and rapidity of respiration, had long and often been noticed by those about the child. These symptoms had been increased by exercise. The child was always unwilling to go upstairs; she always went up slowly, and often begged to be carried up. She had not, however, been subject to such paroxysms of dyspnoea as seemed to those about her to constitute disease. It was not remembered that her countenance or extremities had ever been livid, or even otherwise than fair and florid. Her death was rather sudden. The mucous membrane of the entire alimentary canal was found to present marked traces of intense inflammation; the lungs were natural; the pericardium contained more fluid than is usual; the heart was uncommonly large; the auricles were very greatly distended; the *pulmonary artery* was much larger and more prominent than the aorta: it formed a small arch, and divided into two branches immediately as it began to descend, after having made its curvature. These branches went to the lungs as usual; but the left, which was the larger of the two, distributed a *small branch to the left subclavian*. The aorta arose almost perpendicularly from the heart, passing to the right of the arch of the pulmonary artery, and, after ascending rather more than two inches, it divided into two branches, which immediately subdivided into the carotids and subclavians.\* The *foramen ovale* had not closed, and there was an *opening between the ventricles* large enough to admit the passage of a finger.†

Otto Bernhard has described the case of an infant which died very shortly after birth, in which the viscera of the chest and abdomen were generally normal, and the body of the heart was naturally formed; but the aorta (*a*) presented a singular aberration: it first ascended perpendicularly to the region of the fourth or third dorsal vertebra, and then turned to the right; so that, above the right bronchus, it formed its arch, which was directed to the right; then, curving behind the right bronchus, it descended on the right side of the spine. The *truncus anonymus* (*b*), which was the first vessel given off on the left side of the arch, separated into the left carotid (*c*) and subclavian (*d*). The right carotid (*e*) and subclavian (*f*) arose by separate orifices from the right portion of the arch. The *pulmonary artery* (*g*) was naturally formed, and divided into its two branches, of which the left (*h*) passed directly to the left lung,

and the right (not represented in Bernhard's figure) entered the right lung, after having curved behind the ascending aorta, and in front of the right bronchus and descending aorta. The *ductus arteriosus* (*branchial canal*) (*i*) arose from the pulmonary artery rather from its left branch: it was still pervious, and longer than common, and entered the left subclavian artery (*d*) at the distance of a few lines beyond the separation of that vessel from the innominate trunk.\*

FIG. 2.



- 1, Upper portion of the heart.  
2, 3, Auricles.  
4, 5, Right and left vagi nerves.

These, with the instances by MM. Obet and Holst, already quoted, are the only cases with which I am acquainted where an abnormal communication existed between the pulmonary and subclavian or innominate arteries; but cases have been related in which the vestige of a communication of this kind was found uniting the vessels in the form of an impervious cord.†

\* De Arteriarum e Corde Prodeuntium Aberrationibus, p. 14. Berolini, 1813.

† In his splendid work on the Surgical Anatomy of the Human Body, Mr. Quain has given representations of a preparation in Guy's Museum, where the closed remains of a *branchial duct* passes upwards to a pouch in the aorta, from which the left subclavian artery takes its origin (p. 20, figs. 8 and 9). In a case related by Fiorati and Sandifort (and figured by Quain, pl. 7, figs. 1 and 1 b), besides other remarkable abnormal arrangements in the arch of the aorta, an *arterial ligament* (*a*) was found attached to a small pouch (*b*) from the descending arch of the aorta. The left subclavian artery (*c*) arose from this pouch in close approximation to the remains of the canal. The remarkable arrangement of the pneumogastric and recurrent nerve (*d d*) around the remains of this obliterated canal, as compared with the distribution of the left vagus

\* The obscure wording of this description, and the absence of any allusion to the descending portion of the aorta, leaves the true nature of the malformation in the systemic trunk a matter of considerable doubt.

† London Med. and Phys. Jour. vol. xxxiv. pp. 100-2.



II.—*The cases in which permanence of the arterial duct attends closure or contraction of the pulmonary orifice* have been discussed in previous sections (pp. 280 and 372), and those in which—

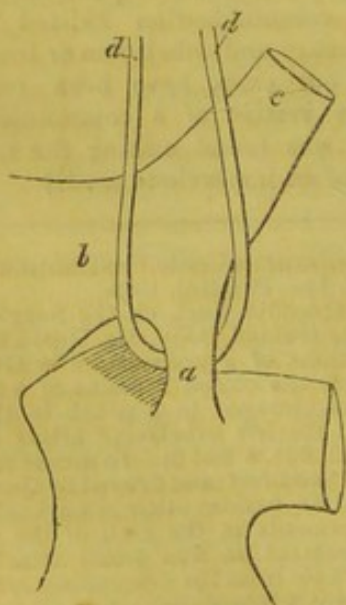
III.—*Transposition of the aorta and pulmonary artery is attended with a similar condition*, will be noticed in a subsequent chapter.

IV.—*Patency of the arterial duct associated with closure of the orifice of the aorta.*

Professor Tiedemann cites a case in which E. L. R. Romberg found in the body of an exposed child, who had breathed with difficulty, who was blue in the face, and died on the fourth day after birth, the cavities of the right side of the heart enlarged, their walls thickened, and the left auricle and ventricle very small, and *no trace of aortic orifice*; the *foramen ovale* wide open, and its valve directed to the right auricle; the *pulmonary artery* giving branches to the lungs, and then sending the *ductus arteriosus* to the aorta. From the arch arose the carotid and subclavian arteries. There was therefore a congenital closure of the origin of the aorta, and beyond this the aorta must have received blood from the pulmonary artery.\* A remarkable degree of congenital arctation of the aortic orifice has frequently been noticed in cases where the arterial duct has become perfectly closed; and, although I have met with two instances in which an open state of the canal was attended with a

in Bernhard's case, where the canal remained pervious, deserves to be noticed as a point of great physiological interest.

FIG. 3.



\* As quoted from F. Tiedemann's "Von der Verengung und Schliessung der Pulsadern in Krankheiten," in Edinburgh Med. and Surg. Journal for July 1846, p. 149.

very diseased condition of the aortic syngoids, I am not acquainted with any example where non-closure of the duct could be satisfactorily traced to this cause; but the possibility of the occurrence of such a result can scarcely be denied.

V. *Patency of the duct, associated with contraction or obliteration of the aorta distal to the left subclavian artery.*

In a previous essay\* I have given notes of most of the recorded instances in which a more or less free communication has existed through the arterial canal where the aorta is (1) *constricted or closed immediately above the orifice of the duct*; (2) *where it is constricted opposite to the opening of the duct*, and (3) *where the artery is contracted both above and below the aortic end of the canal*. In none of these cases with which I am acquainted has the communication between the pulmonary and systemic vessels been more than two or three lines in diameter; and, in the majority of examples, the duct has been found of very inconsiderable size: but there is another class of instances, closely allied to these, in which the aorta having become greatly contracted or obliterated distal to the left subclavian artery, the arterial canal forms so wide a communication between the pulmonary and systemic trunks, that the descending aorta appears to be partially or wholly distributed by the pulmonary artery. The three following cases afford remarkably good illustrations of different modifications of this species of malformation.

*Contraction of the aorta distal to the left subclavian artery.* The arterial duct patent in such a manner as to give the descending thoracic aorta an appearance of being distributed equally by the arch of the aorta and by the pulmonary artery. Dr. Farre relates† the case of a male infant, who, during the first fortnight of his life, appeared like other children; but, after that period, breathed very quickly and began to waste. The skin was always extremely pale, and the extremities cold. Oedematous swelling of the legs, and sometimes of the face, took place. The functions of the stomach and bowels were imperfectly performed. He died suddenly, without convulsion, at the age of 8 months. On examination, Sir A. Cooper (in whose collection the heart was preserved), found that the chest was prominent and rounded; the pericardium and each of the pleural cavities contained serum. The heart was large and square; the *foramen ovale* was dilated; the *pulmonary artery* was larger than the aorta, and arose from both ventricles, but chiefly

\* MEDICAL GAZETTE, vol. xxxvi. p. 188.

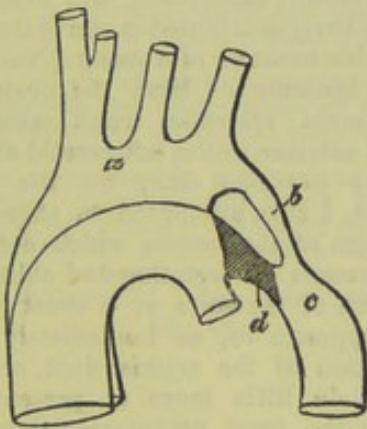
† Op. citat. p. 15.



from the right. It is described that the ascending aorta (*a*) branched into the arteria innominata, left carotid, and left subclavian arteries, and then dwindled into a small vessel (*b*), which terminated in the descending aorta (*c*); the latter arose as a branch of the pulmonary artery in the situation of the *ductus arteriosus* (*d*). Having received the branch from the ascending aorta, it gradually dilated to its proper size.

The subjoined diagram from Dr. Farr's plate (fig. 10) will give a fair idea of the nature of the malformation. In this, as well as in the two following diagrams, I have defined, by a darker shade, that portion of the vessel which appears to me to represent the pervious arterial duct.

FIG. 4.

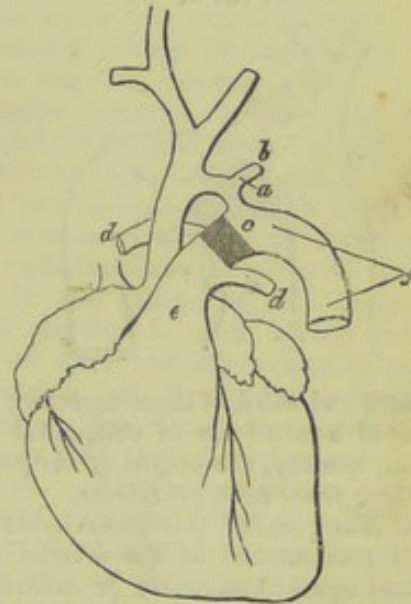


*Great contraction of the aorta above and below the origin of the left subclavian artery; a wide communication by the arterial duct between the pulmonary artery and the descending aorta, giving the latter vessel an appearance of being distributed by the former.* Mr. F. B. Barret, of Stone, Staffordshire, describes the condition of a female infant, which appears to have been born dead. It was the subject of a large ventral hernia, and presented several other remarkable deviations in the form and position of its viscera. The heart lay partly in the chest and partly in the abdomen, and could be seen projecting below the sternum under the abdominal integuments. The cartilaginous margins of the false ribs on the right side were hollowed out, forming a considerable concavity for its reception. Mr. Barret describes the condition of the great vessels as follows:—"The pulmonary artery was very large: it not only divided into its right and left branches, but proceeded upwards, forming a large arch; it then descended, occupied the usual situation of the [descending] aorta, and gave off the arteries to the trunk and lower extremities according to the usual distribution of the aorta. The ductus arteriosus arose from the upper part of this anomalous arch; and from the very centre of the ductus arteriosus

was given off the left subclavian artery. The [ascending] aorta proceeded almost in a straight direction upwards, and, shortly after its junction with the ductus arteriosus, it divided into two branches—the arteria innominata, and the left carotid; and these were all its branches."\* The condition of the ventricular septum of the heart is not mentioned.

After examining Mr. Barrett's very beautiful sketch, from which the subjoined outline is copied, I am inclined to adopt a somewhat different view with regard to the arrangement of the vessels from that advanced by the author. It appears to me that the narrow canal (*a*) is not the arterial duct giving origin to the left subclavian artery (*b*), but the descending portion of the arch of the aorta, much contracted. That portion (*c*) of the pulmonary artery which lies between the origins of the right and left pulmonary branches (*dd*) and the upper part of the descending arch of the aorta (*a*) is evidently the *canalis arteriosus*, the great width of which renders the pulmonary artery (*e*) perfectly continuous with the vertebral portion (*f*) of the descending thoracic aorta.

FIG. 5†.



*Obliteration of the aorta distal to the left subclavian; the arterial duct patent; the pulmonary artery forming a continuous trunk with the descending thoracic aorta.* The following case was communicated to Dr. Farr by Sir Astley Cooper.‡ A male infant, whose mother had previously given birth to children the subjects of cardiac malformation, died in convulsions 2 days

\* Lancet, 1844-5, vol. i. p. 349.

† In the above cut (fig. 5) the letter (*a*) has been accidentally attached to the left subclavian artery instead of the narrowed portion of aorta from which that vessel springs.

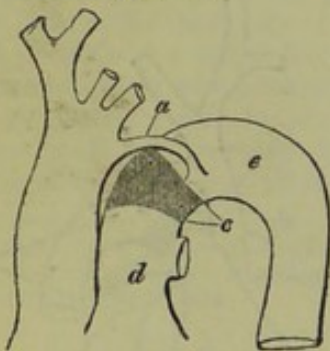‡ Op. cit. p. 13.



subsequently to its birth, having suffered from dyspnoea and cyanosis. The heart was found to be larger and thicker than natural. The *ventricles communicated* by an opening in the septum. The *pulmonary artery* arose from the right ventricle, and formed the aorta descendens, besides giving off its usual branches to the lungs. The ascending aorta arose naturally, but, passing upwards, terminated in forming the innominate, left carotid, and left subclavian arteries, and a very small branch, which was pervious only in a part of its course, to the descending aorta. The air-cells of the lungs did not appear to be completely filled with air.

Upon examining the subjoined diagram (which is taken from Dr. Farre's plate), the small partially-closed vessel (*a*) in which the ascending aorta appears to terminate, resembles, at the first glance, the remains of a ductus arteriosus; but it is in reality the trunk of the aorta, rendered impervious immediately distal to the left subclavian artery, while the continuation of the canal is formed by the wide arterial duct (*c*) which unites the pulmonary artery (*d*) with that portion (*e*) of the descending aorta which is situated immediately below the point of obliteration.

FIG. 6.



The first and third of these cases are good examples of a rare form of congenital malformation, namely, *the origin of the pulmonary artery from both ventricles*.

Other examples of this remarkable condition of permanence of the arterial canal consequent upon obliteration or contraction of the upper part of the descending aortic arch have been recorded.

Steidelle\* has related a case where the aorta and *pulmonary artery* arising as usual, the aorta was entirely distributed to the head and upper extremities; while the pulmonary artery, after giving off two branches to the lungs, continued as the descending aorta without any communication with the ascending aorta. The explanations of the above cases will apply to this, which was evidently also an instance of obliteration of the aorta between the origin of the left sub-

clavian artery and the orifice of the arterial duct.

Otto found the left subclavian artery and descending aorta given off at the separation of the pulmonary branches in a child with phrenic rupture, deficiency of a finger, &c. (Breslau Museum, No. 8025.) In this case the obliteration or contraction of the aorta must have occurred between the origins of the left carotid and subclavian arteries. I have more than once seen the aorta remarkably contracted at this spot. A narrowing of this kind is well displayed in a specimen placed by Mr. W. Muriel in the Museum at Guy's Hospital, and represented in the Guy's Hospital Reports, (Vol. vii. p. 453.) A similar contraction will also be observed in the heart represented by Mr. Barrett (fig. 5 of this chapter). Otto also found the left carotid, subclavian, and descending aorta, similarly distributed in one of the hearts of a double monster of a sheep (No. 8020, Breslau Museum). Here the obstruction in the main systemic trunk must have occurred anterior to the left carotid artery.

In my previous essay on the ductus arteriosus, I have attempted to afford some explanation of the causes which determine the occurrence of arctation and obliteration of the arch of the aorta at a short distance above, opposite to, or immediately below, the insertion of the arterial duct, and shall therefore do little more at present than allude to the great pathological interest of this question\*. I think it cannot be doubted

\* I cannot, however, allow this opportunity to pass without replying to certain objections which have been raised by the author of a very able review of Professor Tiedemann's work on Obliteration and Closure of the Arteries in Diseases, in the Edinburgh Medical and Surgical Journal for January 1846, p. 154, against my conjecture that contraction and obliteration of the aorta may be produced by the loop formed by the pneumogastric and left recurrent laryngeal nerves which encloses the arch of the aorta, at the parts where arrangement which I am also disposed to consider as mainly instrumental in producing the natural closure of the arterial duct. In allusion to this suggestion, the reviewer observes—"But this seems inadequate to account for the occurrence, if we remember that the recurrent nerve winds round the aorta in every case, whereas this accident occurs in a very small proportion of the human species; and if we further remember that the indentation of compression is deepest in the convex part of the aorta, whereas the recurrent nerve in its enclosure of the arch touches only the concave part of the artery." In answer to the first of these objections I must state that I never attempted to maintain that the natural arrangement of the nervous loop around the aorta is liable to produce constriction of this vessel, although it is probable that the arrangement in question is intended to effect the obliteration of the arterial duct. In every case where obliteration of the upper part of the aorta has occurred, that vessel has been found greatly distorted in shape, and more or less changed in position; and it can be only in cases where the nervous loop compresses the aorta in an unusual manner (as in Romer's case, where the nerve was found within the indentation of the con-

\* Quoted by Hein, Paget, and Otto, from Sammlung, Chirur. Beobacht. v. ii. p. 114, 1778.



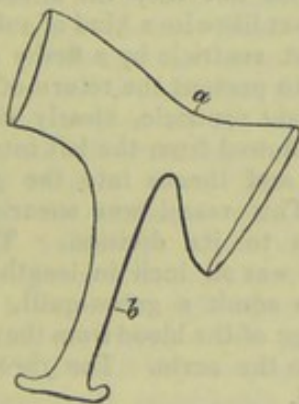
that, in nearly the whole of the above instances, the obliteration or contraction of the aorta, and the consequent alterations in the course of the circulation, must have been established during the period of intra-uterine life.

VI.—*Non-obliteration of the arterial duct in cases where the foramen ovale is closed previously to birth.*

In the few cases where the occurrence of obliteration of the foramen ovale previously to birth has been satisfactorily proved, the children have not, I believe, survived longer than from twenty to thirty hours. Still, in such instances it appears to have been evident, from the peculiar condition of the

stricted vessel) that this singular lesion is produced. I must venture to state that the reviewer's second objection, with regard to the position at which the indentation is deepest, is decidedly erroneous. There are, undoubtedly, instances in which the indentation is principally marked at the convex part of the aorta, but there are also others where the constriction affects nearly equally the entire calibre of the vessel; this is, of course, the case in every instance of complete obliteration of the artery at this spot, and the appearance is well marked in many instances of contraction, as shown in the subjoined cut (*a*), which is accurately copied from the plate attached to Mr. Muriel's case of contraction of the aorta near the insertion of the arterial ligament (*b*). But there is still a third

FIG. 7.



class of instances, in which the constriction is wholly confined to the spot at which the recurrent nerve winds around the concavity of the aorta. This is remarkably well displayed in a specimen preserved in Guy's Museum, and numbered 1450<sup>70</sup>. It may be argued that the nervous loop is immediately in contact with the aorta only at its concave part,—but the nerve so closely surrounds at least two-thirds of the circumference of the vessel as to render it clear that slight alteration in the relative position of the parts would readily bring the nervous loop into too intimate contact with either of those portions of the cylinder at which permanent constriction is liable to occur. I have, however, never ventured to advance my view of this subject otherwise than as an opinion, which, although founded upon a considerable number of remarkably corroborative anatomical facts, is as yet by no means absolutely proved. Still, I believe that its probability is not in any way invalidated by the above objections. I must again draw attention to the remarkable arrangement of the nervous loop around the obliterated branchial canal, represented in Fig. 3 of this chapter, as corroborative of my view respecting the influence of the recurrent nerve in closing the arterial duct.

cavities of the heart, that the open state in which the arterial duct remained was essentially necessary for the due maintenance of the circulation, not only before but subsequently to the commencement of respiration. This was unquestionably the case in a most remarkable specimen of the kind which I have been kindly permitted to examine by my friend Mr. Ebenezer Smith; here the closure, *ante partum*, of the foramen was associated with an extreme degree of contraction, almost amounting to obliteration, of the left cavities of the heart, a condition which rendered the existence of a free communication through the ductus arteriosus absolutely indispensable.

Vieussens relates\* the case of a male child which, at its birth, appeared well nourished, and of good shape, but its respiration was always difficult, its voice hoarse and feeble, and the entire surface of its body constantly of a leaden colour. Its extremities were always cold. It survived its birth only about thirty hours, every means which was adopted to facilitate the circulation having proved ineffectual. The lungs were found to be remarkably swollen and congested, but not inflamed; the pulmonary blood-vessels were much dilated, and the pleural cavities contained a large serous effusion. The right ventricle of the heart was much enlarged, and the pulmonary artery extraordinarily dilated. There was no *foramen ovale*. "Thus," Vieussens remarks, "the blood had not passed with freedom from the right cavities of the heart into the left, and the left ventricle was unable to propel it to the surface and extreme parts in sufficient quantity, or with sufficient force, to maintain the natural warmth and colour of the body." No direct mention is made of the state of the arterial duct and left cavities of the heart in this case, but it appears probable, from the above description, that the former was pervious, and that the latter were deficient both in capacity and muscular power. In a case of this kind alluded to by Dr. Williams†, there existed an unusual communication between the vena cava and pulmonary veins.

Cases of this description are of the highest importance in a medico-legal point of view, as they fully disprove the opinion maintained by many anatomists, that obliteration of the foramen ovale must be received as a certain evidence that respiration has been established. It is assuredly impossible to deny that in the heart of a child which has died within the uterus, and has been expelled in a putrid condition, the foramen ovale may be found completely and permanently closed.

\* *Traité de la Structure du Cœur*, Chap. viii. p. 35.

† *Cyclopædia of Practical Medicine*, vol. iii. p. 67.



In such cases as these, it would, however, probably be always possible to determine, by an examination of the heart and its appendages, that the closure of the foramen had occurred at some period or other antecedent to birth.

The above cases complete the series of instances in which non-obliteration of the arterial duct is found to exist in conjunction with some obvious cause of mechanical obstruction to the circulation either in the pulmonary or systemic vessels. A variety of examples in which an open state of the duct was observed independently of any evident cause of impediment to the circulation, will be adduced in the next section.

The cases of permanence of the *canalis arteriosus* which now claim our attention are less complete, and are therefore, in some degree, less important in a pathological point of view, than those which were discussed in the preceding section\* :—they certainly tend to substantiate the negative statement that the duct may remain unclosed independently of any very distinct cause of obstruction to the circulation ;—still, most of these cases appear to be defective in several leading particulars, and it is highly probable that in the larger proportion of their number, if not in all, the non-closure of the vessel has been due to the existence of a serious impediment in some part of the vascular circle, which impediment may, in some instances, have ceased to act after a permanent communication between the pulmonary and systemic trunks has been established ; while in others it has continued in operation throughout the life of the individual, although its existence has subsequently escaped the scrutiny of the morbid anatomist. This conjecture is rendered probable by the fact, that, in some of the following examples, the patients appeared to be altogether free from the usual symptoms of the blue disease, while in the others the intense lividity of surface, and severe thoracic oppression from which the individuals suffered, rendered it evident that they were the subjects of some kind of permanent cardiac obstruction.

*Permanence of the duct associated with an incomplete state of the ventricular septum.*

In this class of instances it appears to be almost a matter of certainty that the cardiac

\* *Erratum.*—In the last section, note to page 966, last line of first column, and first line of second column, for “the loop formed by the pneumogastric and left recurrent laryngeal nerves which encloses the arch of the aorta, at the parts where arrangement which,” &c., read, “the loop formed by the pneumogastric and left recurrent laryngeal nerves which encloses the arch of the aorta at the parts where the vessel is liable to become constricted, an arrangement which,” &c.

and arterial defects must have been due to the existence both before and after birth of some serious impediment to the circulation, which either ceased to operate as age advanced, or remained undetected after death, by those who observed the cases : the scantiness of the following histories renders the latter idea by no means improbable.

Richerand\* relates the case of a man who presented himself at one of the Parisian hospitals to be operated on for stone in the bladder. His complexion was remarkably livid, his respiration laborious, and his pulse irregular. He could not utter two words in succession without taking breath, was obliged to sleep in a sitting posture, and was particularly remarkable for his indolence. This indolence, joined to the great simplicity of his nature, was such that he had never been able to maintain himself. A small bleeding from the arm relieved his pains, but the difficulty of breathing increased, and he died from suffocation.

The heart was found to be full of blood. The right auricle was principally dilated ; the ventricles were nearly equal in the thickness and capacity of their walls. The *ventricular septum* was perforated by an aperture about half an inch in extent, and directed obliquely from below upwards, from before backwards, and from right to left, so that not only the direction of the opening, but likewise a kind of valve, formed in the right ventricle by a fleshy column so placed as to prevent the return of the blood into the right ventricle, clearly showed that the blood flowed from the left into the right ventricle, and thence into the *pulmonary artery*. This vessel was aneurismally distended up to its division. The *ductus arteriosus* was an inch in length, and large enough to admit a goose-quill, allowing a free passage of the blood from the pulmonary artery into the aorta. The *foramen ovale* was closed.

The long existence of symptoms in the above case renders it evident that the cyanosis and other evidences of delay to the circulation were not due, as frequently happens in cases of congenital heart disease, to the recent superaddition either of pulmonary obstruction or of endocardial or valvular lesions. It is to be regretted that the condition of the lungs and of the ascending aorta was not observed, as there had in all probability always existed some severe cause of impediment in both. There must have been a greater amount of impediment on the left side than on the right, but the small diameter of the arterial duct renders it probable that the aorta was not completely obliterated.

\* *Nouveaux Elémens de Phys.*, Paris, 1811, t. i. p. 295.



Sandifort speaks of a case in which the *arterial duct* was present, but not of so large a size as it naturally is, and the aorta arose equally from both ventricles.\*

In the case (cited by M. Louis) of a man, *ætat.* 40, who had been the subject of a certain degree of cyanosis, the *pulmonary artery* was found to be dilated, and the *arterial duct* was sufficiently wide to admit a large goose-quill. The ventricles communicated by a large opening in the *septum*.

The preparation numbered 1382<sup>16</sup> in Guy's Museum presents a very remarkable modification of this description of congenital fault. It is the heart of a child between 3 or 4 years of age, who was under the care of my friend Dr. Lloyd suffering from hooping-cough. Dr. L. was informed that the child had always been liable to occasional lividity of the face and nails; but, during his attendance, he had never perceived any appearance of cyanosis, until on one occasion, when he found the little patient in a violent paroxysm, with its face extremely blue and congested: the child was placed in a bath, and there expired. The right auricle is of large size, the right ventricle is also large, and its walls are rather hypertrophic. The right auricle presents an abnormal oval aperture, which is situated just above the left margin of the right auriculo-ventricular opening, partially separating the anterior tricuspid curtain from its upper attachment. This aperture extends into the right ventricle, and is continued through the upper and back part of the *ventricular septum* into the left ventricle, where it opens by an oval orifice, about three lines in diameter, in the tendinous spot, which is situated just below the aortic valves. In this manner there exists an abnormal communication between the right auricle and the right and left ventricles. The *pulmonary artery* is wide, its left branch (the right has not been preserved) remarkably so. The pulmonary valves are healthy. The *arterial duct* is open, but is barely capable of admitting a common probe. The *foramen ovale* is perfectly closed. The left auricle is rather contracted. The left ventricle is of fair size, but not apparently either hypertrophied or dilated. The aortic valves are quite healthy; the ascending aorta is rather dilated: portions of its lining membrane are somewhat diseased. As mentioned in the catalogue, *the descending aorta becomes remarkably small immediately distal to the left subclavian artery*, but without presenting any appearance of stricture, or the slightest trace of morbid alteration in its tissues.

It may perhaps be considered that in some of the above cases the permanence of

the arterial duct was owing to the closure of the foramen ovale previously to birth, but it appears to be highly improbable that so unusual a change as the too early occlusion of the foramen could be effected in a case where obstruction to the circulation had already prevented the completion of the ventricular septum.

*Patency of the duct associated with an unclosed state of the foramen ovale.*

It appears that in most of the cases where the foetal condition of the heart has become permanent, the individuals have suffered very severely from all the worst symptoms of cardiac obstruction. The details of the cases unfortunately do not furnish us with any distinct clue either to the causes which determined the non-closure of the passages, or to those which have subsequently given rise to the symptoms of morbus cæruleus. And it is, of course, unnecessary to attempt an hypothetical explanation of a point which appears to admit of being demonstrably elucidated by the careful examination of future cases of this description.\*

M. Jurine observed the case of a child which suffered from the usual symptoms of blue disease, and died at the age of 6 months. The left auricle was very capacious; the *foramen ovale* was still pervious, as was also the *arterial canal*, which was, however, sensibly diminished in calibre.†

Dr. Farre and Mr. English relate the case of a female child which lived 18 days. Nothing remarkable was observed at her birth, but she cried faintly, and seemed rather weak. Her skin and eyes were somewhat yellow. There was an occasional threatening of suffocation when she sucked; unusual quietness and perpetual drowsiness were remarked during the first week; and in the course of the second week she had fits of crying, during which the respiration became affected in a remarkable manner. On the 14th night, the fit of crying was more severe than on any former occasion, and for several moments the breathing was suspended, the lips becoming black, when a strong convulsive effort, with a deep sigh, restored animation. On the 18th day, the child had a violent paroxysm, in which the breathing was frequently suspended for more than a minute; the lips were black, and the eyes fixed. At 8 o'clock she seemed to be dying: the extremities were cold; the coun-

\* In instances of this kind it appears to be absolutely necessary to ascertain not only the precise condition of the cavities and orifices of the heart, and of its immediate appendages, but also of the pulmonary vessels, and of the lungs and thoracic cavities and organs generally, as well as of the entire track of the aorta, the large systemic vessels, and principal abdominal viscera.

† Mém. de la Soc. Royale de Med. t. x. p. 52, and quoted by Gintrac.

\* Observaciones Anatomico-Pathologicae, 1779.



tenance cadaverous; the lips black; the breathing performed by short convulsive inspirations and long groaning expirations, with now and then a sigh. On putting her into a warm bath, it was surprising to see the improved state of the respiration, the expirations being assisted by gentle pressure on the abdomen and ribs. This treatment having been continued for half an hour, she was wrapped in warm flannel, and seemed to sleep for an hour, when the breathing gradually got worse, and all the former train of symptoms returned. The warm bath was again resorted to, with the same benefit as before; but, on taking the child out of the bath, she soon ceased to breathe if left to her own efforts. Mr. English therefore kept his hands constantly on the thorax and abdomen, and, by assisting the expirations, prolonged her life about two hours. For ten minutes together she sometimes lay without the least appearance of life, when a strong convulsive action of all the muscles of the thorax and abdomen, with a deep sigh and several catching sobs, renewed the circulation. Then the colour would return to her lips; she would stretch her limbs and open her eyes. The last struggle of this kind took place a quarter of an hour after he supposed she was dead. He never could feel the pulsations of the heart, although he frequently examined the region of that organ. He once observed that the pulsations of the radial arteries were synchronous. The heart was found to be of proper size and figure, its respective cavities being only proportioned to each other; but the valve of the *foramen ovale* was so very imperfect that a free communication existed between the auricles. The *ductus arteriosus* was open, and larger than natural. The *pulmonary artery* was proportionably larger, but its right and left branches were of their proper size. The liquor pericardii was increased in quantity; the other cavities of the chest were free from serum, and the appearance of the lungs was natural. The liver was overcharged with blood: its gall-bladder and ducts preternaturally contracted. (The skin and eyes continued to be very yellow up to the time of the child's death, and the fæces were deficient in bile).

It is most probable that in this case the symptoms were not by any means due to the open state of the *foramen ovale* and arterial duct, but were owing to some undiscovered impediment either in the pulmonary or systemic vessels which in the first place occasioned the non-closure of the foetal canals, and subsequently gave rise to the extreme embarrassment to the cardiac movements.

Mr. J. Hume Spry details\* the case of

\* Memoirs of the Medical Society of London, Vol. vi. p. 17.

a female, ætat. 17 years, who had never menstruated except once, a short period before her death. She had always from her birth been remarkably dark-coloured, and the discolouration rapidly increased as she advanced to riper years. The colour of her face was said to have been always blue, and her tongue was very blue. She had continually a very acute throbbing pain in her head, confined principally to the forehead and temples. She had always felt a great pain and sense of weight in her left side, attended with constant palpitations of the heart. Respiration was performed with difficulty, and she had sometimes a very slight cough. She was very indolent; and upon any unusual exertion she was in danger of fainting. Some years previously to her decease she had small-pox so severely as to be in immediate danger. The body was found to be greatly emaciated. The venous system was preternaturally loaded with blood; the pericardium adhered very firmly to the pleura costalis, but did not contain any fluid. The heart was remarkable for its great size and weight, and was distended with an enormous quantity of dark fluid blood; the *foramen ovale* was pervious, and nearly two inches in circumference; the *canalis arteriosus* was open, but its size is not mentioned. The lining of the heart was white, and appeared to be rather thickened. The author made a particular examination of the lungs, having understood that in cases where the lungs have been much obstructed the *foramen ovale* has been found pervious; but the lungs of this woman were evidently free from any disease. Mr. Spry considered that the appearance of the heart probably did not depend upon obstructive or other disease of those organs.

Dr. Burns has given the following narrative\*:

J. M. was to appearance, when born, a healthy and robust child. Symptoms of disease commenced at the approach of his third year, and increased until his death. He was at first liable to be seized, after any over-exertion, with spasmodic twitches in his muscles, accompanied with urgent cough and dyspnoea; and occasionally, during these paroxysms, the colour of his skin changed to a faint purple hue. Cessation from exertions usually proved sufficient to restore the functions to their natural state. He passed through the usual infantile diseases without material alteration in his symptoms, which remained with little change for forty or forty-two years. During the whole of this period he had been able to follow his usual employment, which was that of a painter; but latterly he acquired a tor-

\* Observations on some of the most frequent and important Diseases of the Heart, &c. p. 17.



pid and unhealthy appearance. The symptoms increased in urgency; the paroxysms recurred more frequently than formerly, and were excited by the most trivial causes; the countenance was permanently bloated and purplish; the oppression and anxiety in the chest became intolerable; general œdema supervened; the body was almost incessantly bedewed with a cold and clammy sweat; the appetite failed; the pulse became small, feeble, and hardly perceptible; the debility was extreme. The anxiety and depression rapidly increased, until death put an end to his sufferings. On examination, the thorax was found to contain about a pound of aqueous fluid, of a yellowish tinge. The lungs were every where sound, and free from adhesion. The pericardium contained about two ounces of darker fluid than that effused into the chest. The *ductus arteriosus* and *foramen ovale* were open; the former equalling in size a large crow-quill; the latter the circumference of the barrel of a goose-quill. The brain and abdominal viscera were perfectly healthy; but the veins of the testicles and urinary organs were varicose and turgid with blood.

Although no allusion is made to the form and capacity of the chest in either of these cases, it seems to be very evident that, in the three latter examples, the original and principal obstruction to the circulation did not exist in the pulmonary apparatus, but that the chief obstacle lay in some part of the systemic circulation. These cases are almost rendered valueless by the silence of their authors respecting the condition of the aorta, as there appears to be strong reason to believe that there existed some considerable impediment to the flow of blood through that vessel in at least three of the instances. The details of M. Jurine's case are too slight to furnish any clue to the detection of the original cause of obstruction.

The following is an abstract of the case of a person whose body was inspected by Mr. Molloy and myself at Guy's Hospital:—

A female, ætat. 32, died of phthisis in Oct. 1837. She was the mother of eight children, five of whom were still living and healthy. Her constitution had never been robust, but she had not been the subject of any severe illness until the preceding winter, when she had a pulmonary attack, which, however, left her in the following spring. Her phthisical symptoms were of three months' duration. She was not supposed to have been the subject of cyanosis, although her face was rather livid during the last fortnight of her life. On inspection, the lungs were found to present extensive traces of phthisical disease. The heart was small and pale; its right cavities were little distended. The *foramen ovale* was sufficiently wide to admit the little finger. It was partially guarded

by a wide and thin valve, which besides its usual connections on the left side, was also attached to the walls of the right auricle above and below by four or five short and slender cords; it appeared to have allowed the passage of blood from the right to the left auricle. The *pulmonary artery* was not diseased, but the *arterial duct* was sufficiently open to permit a large-sized probe to be passed from the aorta into the pulmonary artery; but on the pulmonary side its orifice was guarded by a small nipple-like process, resembling in form the pointed vegetations sometimes noticed upon the aortic valves; the apex of this was fissured, allowing the passage of blood or of an instrument from the aorta, but apparently acting as a complete valve in the contrary direction. The aortic orifice of the duct was wide, and surrounded by linear specks of white deposit. The left auricle and bicuspid valve were healthy. The walls of the left ventricle were rather hypertrophic and were well contracted. The aorta was perhaps slightly dilated, but it was otherwise healthy. The liver, spleen, and kidneys, were enlarged, and considerably congested. The heart with its appendages is preserved in the museum at Guy's Hospital, numbered 1383<sup>65</sup>.

In this case the condition of the heart was such as to convince me that, although the non-closure of the *foramen ovale* and *arterial duct* was possibly determined by the existence of some cause of obstruction to the circulation subsequently to birth, that cause had long since ceased to operate. The fact that blood could pass through the duct only from the aorta to the pulmonary artery, and not in a contrary direction, was sufficient proof that the permanence of the canal had not been maintained by that diseased condition of the lungs which subsequently proved fatal; and the entire absence of cardiac symptoms, together with the generally healthy appearance which the tissues of the heart and its appendages presented, were convincing evidences that the organ had not been compelled, throughout the life of this individual, to struggle against the resistance of any permanent impediment to the circulation.

*Patency of the arterial duct unassociated with any other defect in the heart or its appendages.*

The appearances presented by a preparation numbered 1383<sup>50</sup> in Guy's Museum appear to me to have been due to causes similar to those which probably determined the permanency of the duct in the case last cited; but, as the preparation merely consists of a portion of the aorta and pulmonary artery, and as no history of the case has been preserved, it is of course uncertain whether it properly belongs to this class at



all. In that specimen the *ductus arteriosus* is merely sufficiently open to admit a very small probe. The tissues of the pulmonary artery, and of the aorta, are entirely free from the slightest appearance of dilatation, or of any other change. The parts are apparently those of a child 8 or 10 years of age. I believe that, in this as well as in the preceding case, the simply open state of the arterial duct was probably due to partial failure in the process by which the canal is naturally closed. The true nature of such cases must, therefore, remain unexplained until the causes which produce the obliteration of the duct have been clearly demonstrated.

The following case, by Professor Huss, of Stockholm, would, at first sight, appear to be one in which patency of the duct existed independently of any other congenital defect in the heart or large vessels; but I am inclined to believe that the lesion was of a far more complicated nature.

The subject of this case, a youth 19 years of age, had generally enjoyed good health: he had, however, been affected with palpitations of the heart after exercise. His skin had never been blue; on the contrary, it was always white and transparent. Five months before his entrance into the hospital, he had been affected with severe articular rheumatism, followed by palpitations, difficulty of respiration, cough, epistaxis, permanent tinnitus aurium, and gradual prostration of strength. After his entrance, he continued to sink, and, at the end of six weeks, expired, without his skin ever having assumed the least blue colour. On examination, the left ventricle was found of an oval shape, enlarged so as to be able to hold a goose's egg; its parietes were an inch in thickness. The aortic valves were corrugated, and studded with osseous concretions; two of these valves had each a perforation as large as a pea. In one of the sinuses of Valsalva there was a small aneurism. The descending aorta was dilated, and formed at the commencement of its arch a sac as large as a pigeon's egg, without there being any lesion of its internal membrane. Two inches three lines from the orifice of the *pulmonary artery* there was a direct communication between its left branch and the aorta, two lines broad and six lines long, so that the ring finger could be passed through it. It terminated in the aorta, just below the origin of the subclavian and carotid arteries\*.

This case bears so remarkably close a resemblance in its leading details to one which occurred within my own observation, some years since, at Guy's Hospital, in which patency of the arterial duct, and the

subsequent formation of an aneurism of the descending portion of the aortic arch, were evidently due to a strictured condition of the aorta distal to the left subclavian artery, that I am disposed to attribute the occurrence of similar lesions in this case to a like cause of impediment to the systemic circulation, which may have escaped the notice of Professor Huss. At all events, a comparison of this instance with my own case, which is given in the subjoined note\*, may not be altogether uninteresting.

The details of most of the above cases are, upon the whole, by no means satisfactory, as there is reason to believe that many of them are deficient in some of their most important particulars; and it is probable that, had we been furnished with the entire histories, several of these examples would have required a different classification from that which I have now given them. Still, none of these cases are deficient in pathological interest, and more than one of them must be received as convincing evidence of the fact, that patency of the arterial duct may be found in cases where there

\* The preparation numbered 1383<sup>80</sup> in the collection at Guy's is taken from a man, *et.* 21, who died of pneumonia, which was attended with some lividity of the face, but not with sufficient discolouration to lead to a suspicion that he was the subject of any cardiac disease. On inspection, the lungs were found to present extensive traces of recent pneumonia. The right ventricle of the heart was strong, and not particularly dilated; there was considerable thickening of the valves of the *pulmonary artery*, and small concretions adhered to their corpora Arantii. The trunk of the pulmonary artery was greatly dilated; its tissues were so much thickened that it no longer presented its usual structural appearance, but more closely resembled the systemic trunk: portions of its interior were raised by interstitial deposit, and, at one spot, its lining membrane was rendered irregular by vegetations. The pulmonary artery was adherent to the aorta at the spot where the arterial ligament usually exists, and there the two vessels communicated by a rather irregular circular opening, about two lines in diameter, (a far smaller aperture than that which existed in M. Hasse's case). Immediately above this opening, the aorta was remarkably contracted by a narrow and defined stricture. An aneurismal dilatation, about the size of a walnut, existed in the most prominent part of the descending arch of the aorta, nearly opposite to the opening of the duct. There were only two aortic valves: these were greatly thickened, and some irregular masses of vegetations adhered to their ventricular surfaces. It is a remarkable fact that the aorta of this man's brother, who died in the hospital some months afterwards, was found to be furnished with only two semilunar valves. The left ventricle was hypertrophied and dilated. An inspection of this interesting preparation will show that, although no distinct remains of an arterial canal exist, the communication between the arteries is not of an aneurismal kind. Some doubts may be entertained upon this point in M. Huss' case; but it appears, from the description, that there also the abnormal opening was distinct from the aneurismal pouch which existed in the descending portion of the arch of the aorta.

\* *Gazette Méd. de Paris*, February 11, 1843; as quoted in the *American Journal of Medical Sciences*.



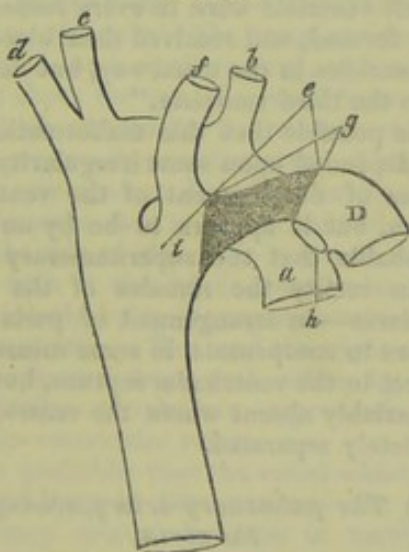
does not exist any discoverable cause of permanent obstruction to the circulation.

*The left subclavian artery originating from the arterial duct.*

A remarkable case in which the malformation was considered to exist, is related by J. T. Klinkosch\*.

A woman, 32 years of age, who had been sterile for ten years, gave birth to her first child, a boy, which was living and well nourished, but it was the subject of great malformation of the head and face, and died in half an hour after its birth. It was found that the arch of the aorta, (*a*) arising from the left ventricle, passed to the right, and gave off three distinct branches, first the left carotid (*b*), then the right carotid (*c*), and afterwards the right subclavian (*d*). The *pulmonary artery* (*e*), arising in the usual manner, passed backwards and to the left, and then separated into its two main branches and the *canalis arteriosus* (*f*). This latter canal joined the descending aorta at the distance of four lines beneath the origin of the right subclavian artery; and, from the duct at about one-third of its length from the aorta, the left subclavian artery (*g*) took its origin.

FIG. 1.



I think that, upon inspection of the subjoined figure, which is a correct diagram from Klinkosch's plate, it will be perceived that this malformation differs in no very material degree from that already alluded to at page 963, note 3 (case by Fiorati and Sandifort), in which the left subclavian artery arises from a kind of pouch, situated at the commencement of the descending aorta, which pouch is joined below by the arterial or branchial canal. The portion of vessel (*g*) which is situated between the

pulmonary branch (*h*) and the left subclavian artery (*f*) appears to me to represent the entire extent of the arterial duct, while the portion of the canal (*i*) from which the left subclavian arises seems to be merely prolonged from the aorta, and not to be in reality a portion of the arterial canal.

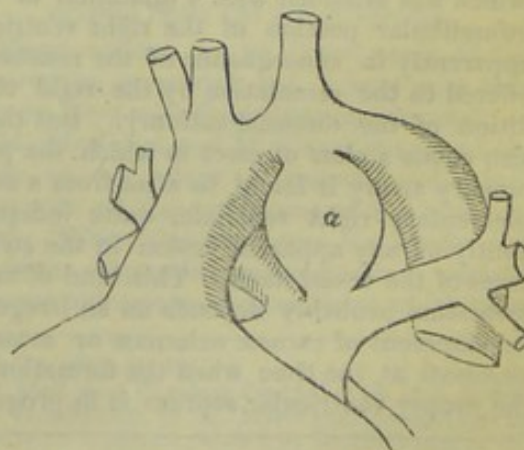
*Aneurism of the arterial duct.*

The only fully detailed instance of this remarkable lesion with which I am acquainted, is that related by M. Billard\*.

In 1826, a male infant, two days old, was brought to the hospital of the Trouves. It was of middle size, its respiration was difficult, its face livid, and its cry stifled. The temperature of its body was natural, the pulse small, frequent, and easily compressed. The child remained two days in this state, and died on the third. On inspection, the stomach and intestinal canal were found remarkably congested, the liver was gorged with blood; both lungs were also engorged. The heart was more voluminous than is usual in infants at birth; the cavities on either side were nearly equally dilated, and were filled with dark blood. The arterial canal (*a*) presented the form of a large cherry-stone; its transverse diameter was about three and a half lines, and its circumference nine lines. Externally it had the appearance of communicating freely with the aorta, but this was not in reality the case, as its interior was filled with organised clots, disposed in layers such as are observed in the aneurismal tumors of adults, merely leaving in the centre a passage which would barely admit a crow-quill. The other organs presented no particular alteration.

M. Billard also makes slight reference to another case of aneurism of the duct which was related to him by M. Baron, and in which the symptoms were less marked than in the above instance.

FIG. 2.



\* In Dissertat. Med. Select. Pragensis, vol. i. Anat. Partus Capite Monstroso, p. 190, et Tab. A, figs. 4 and 5.

\* Traité des Maladies des Enfants Nouveaux-Nés et à la Mamelles, p. 567, Paris 1828, and Atlas, Planche viii. fig. 1.



It is probable that, in M. Billard's case, the symptoms were chiefly due to the dilated and weakened condition of the heart, consequent upon the great obstruction to the circulation which the disease in the arterial canal must have produced during intra-uterine life. Still it cannot be denied, that the too early closure or permanent contraction of the arterial canal would be liable to produce very serious embarrassment to the lungs and right ventricle.

#### MALPOSITION OF THE PULMONARY ARTERY.

There are several species of congenital malformation of the heart in which the principal error is found to consist in an unusual mode of origin of one or both of the great arterial trunks. Thus (1), the pulmonary artery has been found to take its origin from a small supplementary right ventricle. (2), both aorta and pulmonary artery may arise in a similar manner from a kind of third ventricle. (3), the artery which supplies the lungs may arise as a branch from the aorta. (4), the aorta and pulmonary artery occasionally arise from the right ventricle; and (5), in other cases, they proceed from the left ventricle\*. (6), the aorta may be situated over an opening in the *septum ventriculare*, while the pulmonary artery arises from the left ventricle. (7), the position of the ventricles, and of their corresponding vessels, is sometimes found to be transposed; and, lastly (8), the pulmonary artery may originate from the systemic ventricle, while the aorta arises from the pulmonary ventricle. To render the nature of these malformations sufficiently clear it will be necessary to consider each species briefly in detail.

##### (I.) *The pulmonary artery originating from an additional right ventricle.*

A description has already been given of cases in which contraction of the pulmonary orifice was attended with a dilatation of the infundibular portion of the right ventricle, apparently in consequence of the resistance offered to the circulation by the rigid condition of the diseased ostium†. But there also exists a class of cases in which the pulmonary artery is found to arise from a supplementary right ventricle, quite independently of any apparent lesion in the structures of the vessel itself. This kind of malformation probably depends on an irregular development of *carneæ columnæ* or *musculi pectinati* at the time when the formation of the proper ventricular septum is in progress

\* Allusion has already been made to those cases in which the pulmonary artery takes its origin from both ventricles.

† Cases by Dr. Crampton (p. 457), and Drs. Aran and H. Bennett (p. 699).

(as illustrated in cases by Dr. T. Thompson and Dr. Fletcher, p. 833). An instance of this malformation, observed by Mr. Holmsted, has been cited at p. 700, as illustrative of the causes which may prevent the free entrance of blood to the pulmonary artery. The following is an example of a very similar malformation:—

Dr. Farre describes the preparation of a heart in the museum of St. Bartholomew's Hospital, in which the right and left ventricles are equal in muscular substance, and the valves natural. The aorta, which is of its natural size, arises over the *septum of the ventricles*, opening equally into both ventricles. Two apertures in the right ventricle communicate very freely with a very small third ventricle, from which the *pulmonary artery*, correctly formed, and of its usual size, arises. The *auricular septum* is perfect. From the appearance of the heart, Dr. Farre considered that the age of the subject exceeded 14 years.

##### (II.) *The pulmonary artery and aorta originating from a supernumerary ventricle.*

Mr. J. Bell (cited by Dr. Burns) has given an account of a heart in which "both the *pulmonary artery* and the aorta arose from a middle or third ventricle. The right and left ventricle were in every respect correctly formed, and received their blood from their auricles in the usual way, but delivered it into the third ventricle."

It is possible that this malformation may have depended upon some irregularity in the process of development of the ventricular septum, but it appears to be by no means improbable that the supernumerary cavity was in reality the remains of the *bulbus arteriosus*—an arrangement of parts which appears to compensate in some measure for a defect in the ventricular septum, but which is invariably absent where the ventricles are completely separated.

##### (III.) *The pulmonary artery arising from the aorta.*

Instances of several varieties of this species of congenital defect have been cited at the commencement of this paper\*, but, as malposition of the artery which supplies the lungs is one of the most characteristic features of a very rare and interesting kind of cardiac malformation, I cannot omit the following remarkable example:—

Dr. Carson relates† the case of a child which was well developed at its birth, and which, for two or three days afterwards, appeared to be in perfect health, with a

\* Page 276, et seq.

† Edinburgh Medical and Surgical Journal, Vol. lxii. p. 134.



natural colour of the skin. On the third day it was unusually soporose, sighing frequently, and the respiration was more hurried than usual; it also ceased to take the breast, and Dr. C. remarked an unusual dark colour of the skin. On the fourth day it appeared to be in a profound sleep, breathing rather hurriedly, and frequently sighing deeply. There was no fever, nor any remarkable diminution of temperature. On applying the ear to the chest, the heart's sounds were found to be rather hurried, but their succession was regular: the whole body was of a dusky hue, resembling that of a dark-complexioned person. The child died on the fifth day. Slight effusion was found in the pericardium; there was one large artery given off from the heart, and from this the *pulmonary artery* sprung. The thus-united aorta and pulmonary artery was considered to be larger than the aorta of so young a child. It proceeded from a large ventricle, which appeared, at first sight, to constitute the whole of the ventricular portion of the heart. The systemo-pulmonary artery was separated from the ventricle by semilunar valve (valves?), and from a very large auricle by a tricuspid valve. Into this auricle opened, by three orifices, three pulmonary veins. The size of the two *venæ cavæ* led Dr. C. to think that one of these three veins might be systemic. The large auricle communicated, by a small opening, with another auricle about the size of a small horse-bean, into which entered the two *venæ cavæ*, each not above two lines in diameter. This small auricle communicated with a cavity of the size of a swan-shot in a fatty muscular mass upon the side of the large ventricle, constituting with it the whole ventricular mass, and evidently being the representative of the right ventricle. This and the right auricle were separated from each other by small cobweb-like membranes representing the auriculo-ventricular valve.

It is probable that the vessel which supplied the lungs in this case was not a true pulmonary artery, but was in reality the ductus arteriosus. The heart appears to have presented an extreme degree of that kind of malformation in which, obliteration of the ascending pulmonary artery occurring subsequently to the completion of the ventricular septum, the right ventricle, being no longer required to propel blood to the lungs, becomes extremely contracted, and the ductus arteriosus performs the office of the pulmonary artery\*.

(IV.) *The aorta and pulmonary artery arising from the right ventricle.*

In the early part of this essay a description was given of those cases in which the

\* See the case by Dr. W. Hunter, and other instances, cited at p. 280.

pulmonary artery is found occupying its natural position, but is either obliterated or greatly contracted at its origin, and in which the aorta also arises from the right ventricle; in addition to these, there appears to be a class of cases in which, independently of any remarkable contraction of either vessel, the aorta and pulmonary artery originate from the right ventricle.

Dr. Paget\* refers to a case of this kind, and quotes a similar example related in the Arch. Gén. de Médecine, T. xxiii. In a case which has been briefly related by Dr. F. Ramsbotham†, both the aorta and the *pulmonary artery* arose from the right ventricle, there being a communication between the ventricles by an *orifice in the septum*. There was no appearance of lividity in the child, except that the lips were usually pale, and the fingers occasionally appeared of a blueish-grey colour. The child died suddenly at 10 years of age. She was healthy until the age of 2 years, when exertion caused some shortness of breath. She was of a lively, placid disposition; the pulse was rapid and small; the pulsations in the carotids could be distinctly observed. She lay on her back, or on the left side, with her legs drawn up to the body, and the back bent to a semicircle. The appetite and general health were good. The sensation to the hand applied over the heart was that of a sawing, and to the ear that of the purring of a cat. Twelve months before her death she became much emaciated. The appetite was greater than natural; the skin dry; the heart laboured in its action; and the respiration was much hurried, and was attended with a short irritating cough, without expectoration. She was (latterly?) unable to lie down. At length the face and lower extremities became anasarcaous. She expired suddenly, jumping up as if she had been frightened.

(V.) *The pulmonary artery and aorta arising from the left ventricle.*

There appear to be three cases of this description on record, but I have only been able to meet with the following example‡:—

M. Maréchal and M. Carré examined the body of an infant 3 months old which died with all the symptoms of the blue disease. When the child was six weeks old, its lower extremities and abdominal parietes became œdematous—a condition which twice

\* Op. citat. p. 294.

† Med. and Physical Journal, Vol. lxvi. p. 548.

‡ In addition to M. Maréchal's case, Otto refers to an instance related by K. Hoffman, in the New York Medical and Physical Journal; and also to one by M. Mery, in the Mémoires de Paris, 1700; but I have in vain sought for the latter case in the Memoirs of the Academy of that period. Dr. Paget also makes brief allusion (op. citat. p. 294) to an instance of the kind.



yielded to the use of tincture of digitalis. It was found, on examination, that the peritoneum did not contain any fluid; the liver was larger than natural; the pleural and pericardial cavities contained a notable quantity of yellow serosity; the heart, especially its auricles, was, with its vessels, distended with dark blood. The aorta and pulmonary artery appeared to originate from the same cavity. The latter divided into two branches, which supplied the right and left lung; the *ductus arteriosus*, which arose from the left branch, was sufficiently open to admit an ordinary probe. The left ventricle presented at its base the orifice of the aorta, furnished with sigmoid valves; and, to its right, at the distance of three lines, that of the *pulmonary artery*, which was destitute of valves. Below the aorta, an auriculo-ventricular valve, divided into two portions, formed a canal capable of admitting the end of the fore finger, communicating with the left auricle, which formed a common cavity with the right auricle. Below the orifice of the pulmonary artery there was an opening about three lines in diameter, furnished with a kind of valve formed by a fold of endocardium: this opening communicated with the auricular cavity, and, at its upper part, was partially separated by a thick prominence from the orifice of another cavity of small size, which was the rudiment of the right ventricle.\*

(VI.) *The aorta arising from both ventricles, the pulmonary artery from the left.*

The malformation described in the following case appears to form an intermediate link between that in which both arteries arise from the left ventricle, and that in which the aorta arises from the right ventricle and the pulmonary artery from the left:—

Dr. Wilmer Worthington relates the case of a female child which had from birth been liable to almost daily attacks of oppressed breathing, attended with blueness of the skin and nails. Some time before its death, which occurred at the age of 22 months, it began to emaciate, and had occasional cough and diarrhoea. On examination, the right auricle was found to be very small, and it exhibited no appearance of *musculi pectinati*. The pulmonary veins opened into this cavity, and the auricle appeared to be merely a dilatation of these vessels. There was no opening between this part of the heart and the right ventricle. The *foramen ovale* remained open, so that the blood from the lungs passed directly through this opening into the left auricle. This cavity was larger than natural, and presented the usual appearance of *musculi*

*pectinati* usually found in the right auricle. The ostium venosum existed on the left side of the heart, with its usual valves. The ventricles were of the ordinary size and thickness. Their interior structure presented the usual appearance. The aorta arose from the right and left ventricle by a spreading mouth, which formed a communication with both these cavities, the *ventricular septum* being deficient immediately under the mouth of the aorta. The aortic valves were wanting. The *pulmonary artery* arose from the left ventricle, at a short distance from the aorta. No *ductus arteriosus* existed, this passage, as Dr. Worthington remarks, being unnecessary on account of the pulmonary artery and aorta proceeding from the same cavity.\*

It is probable that the primary lesion, in this case, was obliteration of the right auriculo-ventricular opening. In several particulars this instance bears an interesting resemblance to one related by Dr. Favell, and cited in a previous chapter.† In that example, however, the pulmonary artery arose as usual from the right ventricle.

(VII.) *Complete transposition of the cavities and vessels of the heart.*

In many cases of complete or partial transposition of the thoracic and abdominal viscera, the pulmonary cavities of the heart, with the pulmonary artery and cavæ, are found to be situated on the left side of the thorax, while the systemic auricle and ventricle and the aorta are placed on the right side. In these cases the aorta and pulmonary artery arch to the right. The following examples will sufficiently illustrate this species of malformation:—

Meckel (filius) describes and figures‡ a specimen, preserved in his father's museum, in which the base of the heart is situated to the left, and its apex to the right. The cavæ were situated on the left side; the pulmonary auricle and ventricle were also to the left. The aortic ventricle was on the right side. The *pulmonary artery* was situated anteriorly to the aorta, which arched to the right, and descended on the right side of the dorsal vertebræ. The positions of all the other thoracic and abdominal viscera were reversed.

M. Parisot, of Nancy, relates§ the case of a man, ætat. 29, in whom the heart occupied the right side of the thorax, the aortic ventricle lying to the right and the pulmonary ventricle to the left side. All the divisions of the circulating system followed the same transposition. The aorta was placed to the right, and was crossed by the *pul-*

\* American Journal of the Medical Sciences, vol. xxii. p. 131.

† Page 828.

‡ De Cordis Conditionibus Abnormibus, p. 4, Tab. 1, 1802.

§ Archiv. Gén. de Méd. June 1839, as quoted in Edinburgh Medical and Surgical Journal.

\* Journal Gén. de Méd. t. iii. de la 2<sup>e</sup> série, p. 354, Dec. 1819, quoted by Cintrac, p. 173.



*monary artery*, which passed from left to right, and the thoracic and abdominal aorta descended on the right side of the vertebral column. The other viscera of the chest and abdomen were also transposed\*.

It does not appear that this kind of deviation from the natural position of the several parts of the circulatory apparatus has any tendency to shorten the lives of the individuals in whom it occurs†.

This peculiarity has been observed in the bodies of adults of all ages who do not appear to have suffered from any symptoms of thoracic obstruction. Dr. P. A. Jewett relates an instance of this kind‡ in which the individual lived to the age of 65 or 70 years. In fact, the transposed viscera are usually so well-formed, and so symmetrically placed, in these cases, that the peculiarity of their situation can scarcely be regarded as a defect. There also appear to be some instances of malformation in which the cavities of the heart occupy their natural situation, while the main arteries pass over to the right side of the chest instead of to the left.

The cases of the above class are altogether distinct from those in which the pulmonary artery arises from the systemic ventricle, and the aorta from the pulmonary ventricle. The different varieties of that remarkable species of malformation will form the subject of the ensuing chapter.

#### *Transposition of the Aorta and Pulmonary Artery.*

This remarkable and very serious kind of malformation appears to depend upon some error in the process which, at an early stage of intra-uterine life, causes the separation of the arterial bulb into two distinct vessels; the primitive systemic, and pulmonary trunks. That this erroneous division of the vessel occurs previously to the development of the ventricular septum is proved by the details of the following case.§

\* For other cases of this transposition, see Haller, de C. H. Fabrica, T. ii. Lib. iv. § 4, p. 89; and Dr. Darling, in New York Journal of Medicine, p. 378.

† A case is mentioned in the New Orleans Medical Journal, and quoted in the Dublin Medical Press, Vol. 13, p. 202, of a male negro slave, *at*at. 25, in whom the stomach, liver, and spleen, and the thoracic viscera, were found to be respectively transposed; the heart occupied the right side of the chest, but no allusion is made to the manner in which its large vessels were given off. There was extensive adhesion between the heart and pericardium, and death had been caused by rupture of the right auricle, but nothing is said with regard to the condition of the valves and cavities of the heart. It is probable that in this case the cardiac lesions occurred quite independently of the peculiar arrangement of the thoracic viscera.

‡ New York Journ. of Med. May 1844.

§ From the Archiv. Gen. de Med. Feb. 1843, as quoted in the Lancet for 1842-3, vol. ii. p. 224. I have already briefly alluded to this case, at p. 278.

A child, born on the 21st of November, 1842, was deposited on the same day at the Foundling Hospital in Paris. Those who had the care of it remarked that it was often the subject of great distress of breathing, with a quick and dry cough, and especially that when it drank, a state threatening suffocation ensued. The child was large, and externally well formed; but it died in 11 days, apparently of umbilical phlebitis. The heart was found to be bag-shaped, or rather rounded at the place of the apex, and to consist of only one ventricular cavity. Viewed from the front, the *pulmonary artery* was quite hidden by the aorta, which originated from the right and anterior portion of the ventricle, and by the auricular appendices, for of those there were two which were well formed, although there was only one auricle. A line directed obliquely backwards, and from right to left along the base of the ventricle, would have crossed, first, the opening of the aorta; next, that of the pulmonary artery; and, lastly, the auriculo-ventricular opening. The spleen was large, but no other viscus or portion of the circulatory apparatus presented any anomaly. The most remarkable circumstance of this case was, that no cyanosis had been noticed during life.

A variety of appearances have been found in the several instances of this kind of malformation which have been recorded. In cases of transposition of the great arteries, some of those communications which exist, during foetal life, between the pulmonary and the systemic heart and their vessels always remain permanent;—either the ventricular septum, the foramen of Botal, or the arterial duct, is always pervious in examples of this malformation; indeed, it would, at first sight, appear impossible that, in such cases, the circulation could be in any way maintained, even for a few minutes, unless *two* of these channels remained open—one to convey a portion of the venous blood to the left, which is here the pulmonary ventricle, the other to return the arterialized fluid to the right ventricle, or to the aorta, which here arises from that cavity. There are, however, cases of this description upon record in which only *one* abnormal communication, the arterial duct or foramen ovale, was observed to be present, and still the children lived for a considerable period. It is very probable that the histories of these cases are imperfect in some of their details, and that those who have recorded them failed to observe some abnormal communication which existed either between the cavities of the heart or some of the great vessels; as, for example, one or more of the pulmonary veins may have entered the *venæ cavæ*, or the bronchial arteries may have been much enlarged,



and have thus produced an unusually free communication between the aorta and the lungs.

In some instances of this malformation the auricular and ventricular septa have been found imperfect; in others, the foramen ovale only is stated to have remained unclosed; in a third set the arterial duct and the auricular septum have continued permanently open; in a fourth, there does not appear to exist any abnormal communication except through the ductus arteriosus; and, lastly, the ventricular and auricular septa, and the arterial duct, may all remain pervious.

These facts will prove that, although transposition of the two primitive arteries is very liable to determine the establishment of a permanent communication through the ventricular and auricular septa, and the arterial duct, it does not by any means necessarily prevent the natural closure of either these parts. In the majority of these cases the cavities of the heart occupy very nearly their natural position, while the transposed arteries arch as usual to the left. In one instance (Gomage's), however, although the position of the ventricles was partially reversed, the aorta arose from what is usually the pulmonary ventricle, and arched to the right, while the pulmonary artery originated from the systemic ventricle. In another case (Walshe's), the ventricles were transposed, but the aorta appears to have arched to the left.

Dr. Walsh has observed that, in several cases of transposition, the large vessels of the arch have been given off in an irregular manner; in other instances, however, these arteries have been distributed in the usual way.

The following are the most remarkable recorded instances of the several varieties of this species of malformation.

(1.) *Transposition of the pulmonary artery and aorta; the septa of the auricles and ventricles imperfect; the ductus arteriosus closed.*

Mr. S. S. Stedman has narrated\* the case of a female child which was born at the full period of gestation, but which was observed to be small at birth, although nothing unusual was then remarked in her appearance. She seemed to be in good health, and thrived well for a fortnight, at the expiration of which time, without any apparent cause, she was seized with a violent fit of coughing, with convulsions and dyspnoea. The surface of the body became of a deep purple colour, and the lips, tongue, and roof of the mouth, became almost black. These symptoms continued for about six or eight minutes, and

then gradually abated; the child, however, never regained its natural colour, but remained of a dull leaden hue until death. The child was always cold, drowsy, and torpid, and grew very slowly. About three weeks before death the wrists and legs began to be œdematous; and, for the last fortnight of her life, there was evident fluctuation of the abdomen from ascites. Death occurred, during a severe paroxysm, at the age of 7 months and 8 days. On examination, the abdomen was found to contain a considerable quantity of fluid. The liver was dark-coloured and much enlarged, and on its surface were flakes of false membrane, the results of inflammation. The right lung was much larger than the left, and appeared better inflated; the left was compressed by the greatly enlarged heart. The pericardium was thickened, and contained two or three ounces of fluid, which, together with several patches of false membrane on the surface of the heart, indicated the existence during life of intense pericarditis. The heart weighed  $3\frac{3}{4}$  oz. Its position was natural. The right ventricle extended considerably more towards the left side than is usual, and the aorta arose from its base instead of the pulmonary artery. The left ventricle was situated almost entirely on the posterior part of the heart, and gave origin to the *pulmonary artery*. The origin of the aorta was situated in front and to the right side of the pulmonary artery; its arch took the usual direction, and terminated on the left side. Its valves were of the usual number. The branches arising from the arch came off irregularly: the innominate and left carotid arose by a short common trunk, and the next branch was the left vertebral, and the third, the left subclavian. The *pulmonary artery* passed upwards, parallel to and in contact with the aorta, but behind and to its left side. Its orifice was not so wide as that of the aorta; its valves were natural. A little above its origin it was very much dilated; it divided, as usual, into its right and left branches, and the *ductus arteriosus*, which was completely closed, arose from the left branch, and was attached to the aorta in the usual situation. The right auricle was distended with blood, and its walls were remarkably thickened. The *venæ cavæ* opened into it as usual; the parietes of the right ventricle were remarkably thickened, and its cavity was large. The right auriculo-ventricular orifice was much dilated; it was furnished with a tricuspid valve as usual. The left auricle was comparatively small, and had opening into it the pulmonary veins, which also appeared smaller than natural. The walls of the left ventricle were rather thinner than those of the right. The left auriculo-ventricular orifice was about half the size of the right. The mitral valve was

\* Lancet for 1841-2, vol. i. p. 645.



natural. The ventricles communicated by a large opening in the upper part of the *septum*. The *foramen ovale* was closed, with the exception of a small opening of the size of a crow-quill.

Mr. T. W. King has given the particulars of a remarkable instance of this species of malformation.\* The subject of this case was a child 2 years and 9 months old, a patient of Mr. Sanders, of Gravesend. There had been blueness of the lips and nails, and some discolouration of the face and skin generally. The child was tall but emaciated, and it never walked. It died rather suddenly. The right auricle was found to be dilated and hypertrophic. The *fossa ovalis* was large and cribiform, having apertures capable of admitting a black-lead pencil. The tricuspid valve was well formed. The right ventricle was large and strong, and contained a solid clot fully as large as a pigeon's-egg, of irregular shape, and lamellar structure, but softer within than without. The right ventricle was stronger than the left. The arch of the aorta was natural in size and structure, and in the distribution of the coronary and brachio-cephalic vessels. Below the attachment of the *ductus arteriosus* (which was quite closed) the aorta was rather small. The left auricle was of moderate size, and appeared to have received only two veins†. There was an opening between the ventricles larger than a crow-quill. The *pulmonary artery* was very wide; its valves were considered to be efficient, but scanty: its main branches were both of large size, but the right was much larger than the left. The heart is preserved in Guy's Museum, and numbered 1392<sup>45</sup>.

## II. *Transposition of the pulmonary artery and aorta; absence of communication through the ventricular septum and arterial duct: the foramen ovale open.*

Providing the description of the following case be complete and accurate, it affords an instance of a most singular and interesting malformation; but there appears to be great reason to believe that the author either overlooked certain important anatomical details, or in some way misinterpreted the appearances which he observed.

Mr. William Gamage has recorded the history of a female child, which was born at the full time, apparently healthy, but re-

mained of a purplish hue, particularly in the lips and gums, and at the extremities of the fingers and toes. For two months, it showed no further symptoms of deranged organisation except uncommon feebleness and an indisposition to motion. But, in a short time, it became subject to frequent paroxysms of violent struggling; in which respiration was hurried and difficult, the face became black, the whole skin was injected with dark blood, and death seemed inevitable, but the child would recover after a fit, and immediately fall asleep. The paroxysms increased in frequency; it moaned continually, but never cried; the languor increased; it slept, except it awoke to suffer. Every movement was weak, every faculty ill performed. The right arm was paralysed, the eyes had a glassy appearance, aphthæ covered the mouth, and spread extensively on the nates: there was also considerable and distressing cough. Death occurred 15 weeks subsequently to birth. The whole heart was found distended with black and fluid blood to twice its natural size. The situation of its cavities was completely changed. The right auricle and ventricle were superior (anterior?), and to the left side of the chest; the left cavities were towards the right side of the chest: the apex pointed to the right. The aorta descended on the right side of the spine; the vena cava was on the left. The *arteria innominata* distributed blood to the left, while the single carotid and subclavian were sent to the right. The position of the whole of the organs of the thorax and abdomen was in like manner reversed. The aorta was very small, and arose directly from what is commonly the right ventricle, and rode over the root of the pulmonary artery, which had its origin in the opposite ventricle. The veins were connected with the heart in the usual manner; the blood of the *cavæ*, therefore, was received into the same ventricle that gave origin to the aorta, and the pulmonary veins poured their blood into the ventricle from which the pulmonary artery had its origin. No communication existed between the aorta and pulmonary artery; the *ductus arteriosus* seemed never to have existed. The *foramen ovale* was open, and very much enlarged. Mr. Gamage considered that, through this aperture, the blood on each side must have mixed, that being the only way in which the body could have received one drop of arterial blood.\*

It will be observed, that the malformation which is described to have existed in the above case, was very far more complicated than that which is noticed in the generality of instances of complete transposition of the thoracic viscera; for there, although the

\* Monthly Journal of Med. Science, 1844, vol. iv. p. 32. The fact that the main arterial trunks were transposed appears from the title of the case, but it is not expressly stated in the anatomical description of the heart and its appendages.

† The contracted state of the opening in the ventricular septum renders it probable that the other two pulmonary veins communicated with one of the *cavæ* or with the right auricle.

\* New England Journ. of Med. and Surgery, vol. iv. p. 244: Boston, 1815.



position of the cardiac cavities and of their respective arteries is reversed, the cavæ open, as usual, into the pulmonary side of the heart, and the pulmonary veins into the systemic side; but here, on the contrary, the aorta arose from that portion of the heart which was supplied from the cava, and the pulmonary artery was appended to that side of the organ which received its blood from the pulmonary veins. Thus far, Mr. Gamage's case corresponds with many of the other examples of transposition noticed in this chapter; but the most singular feature of the case is, that the only communication stated to have existed between the two sides of the heart was through the dilated foramen of Botal. Had the ductus arteriosus been pervious, or had the septum of the ventricles been incomplete, the case would have been perfectly clear; but, admitting the correctness of the anatomical description, it is difficult to perceive in what manner the circulation was carried on, as it can scarcely be conceived that a portion of the venous blood passed through the foramen ovale on its way to the pulmonary ventricle, and subsequently returned, in an arterialed state, through the same opening to reach the systemic ventricle. It is most probable that either one of the venæ cavæ opened into the systemic auricle (only one vena cava is mentioned in the detail of the case), or that some of the pulmonary veins opened into the systemic auricle, or into the veins which communicated with that auricle, or that there existed an unusually free anastomosis between the descending aorta and the pulmonary vessels.

It appears that another case somewhat similar to that related by Mr. Gamage has been recorded\*, but I have only been able to meet with the following brief particulars, as cited by J. F. Meckel. The aorta arose from the pulmonary ventricle, and the *pulmonary artery* from the systemic ventricle; the *arterial duct* was altogether closed, but the *foramen ovale* was open to the diameter of from eight to nine lines. The child lived  $2\frac{1}{2}$  years.

II. *The primitive arteries transposed; the ductus arteriosus and foramen ovale pervious: the septum of the ventricles perfect.*

The following case was observed by M. Ducrest.† A female child, born at the Hospital of Maternité, never had its respiration perfectly established; it never uttered a single cry, and refused the breast as well as all liquids which were offered to it. The skin was of a rather deep blue colour, and,

notwithstanding extreme weakness, and these unfavourable circumstances, it survived its birth 10 hours. On examination, the body was found to be fully developed, and the limbs well proportioned, and it presented in every respect the appearance of a child born at the full period. Each lung presented a double fissure which divided it into three lobes; the lungs floated, and appeared to be healthy. The aorta took its origin from the right ventricle, and gave off in the usual manner two cardiac coronary arteries. The trunk of the *pulmonary artery* arose from the left ventricle, and, after a short course to the left of the aorta, divided into three branches—two going to the lungs, the third representing the *canalis arteriosus*, uniting with the aorta towards the termination of its curvature. All these vessels were of their usual proportions. The ventricle from which the aorta originated, besides its position on the right side, exhibited all the usual characters which distinguish it from the left ventricle. The two venæ cavæ and the large cardiac veins terminated in the right auricle; the left auricle received the four pulmonary veins. The *foramen ovale* was furnished with a perfect valve which opened from the right to the left auricle. The *septum* between the ventricles was complete. No unusual appearance was met with in any other part of the body.

A case of this description occurred to Dr. Wollaston, of St. Edmundsbury, and has been imperfectly recorded by Dr. Baillie.\* A child, about 2 months old, was observed to have a most unusually livid skin, and the surface of its body felt colder than that of a child properly formed; the respiration was stated to be natural. After death, the heart was found to be of normal size; the aorta arose from the right ventricle, and the *pulmonary artery* from the left. There was no communication between these vessels except through the small remains of the *ductus arteriosus*, which was just large enough to admit a crow-quill. The *foramen ovale* was a little more closed than in a child newly born.

Dr. Farre † describes the case of a male infant (the eleventh child of a female six of whose infants were still-born at the full period) which appeared at his birth to have been well nourished. As soon as he was born, he began to cough violently. He lived 5 months, during which period he suffered from cyanosis, epigastric palpitation, coldness, difficulty of breathing, and cough. At the age of two or three months he had several fits, which were relieved by

\* Winstar, System of Anatomy, vol. i.: Pennsylvania, 1811.

† Archiv. Gén. de Méd., Sept. 1840; and Edinburgh Med. and Surg. Journ. vol. lv.‡

\* Morbid Anatomy (Second Edition), p. 38, Engravings of Morbid Anat. Fas. i. p. 6, figs. 1 and 2.

† Op. cit. p. 29.



the warm bath. He received the infection of small-pox, and expired in a fit when the pustules began to appear. The aorta, with its ventricle, marked by its muscularity and figure, constituted the right portion of the heart; the *pulmonary artery* branched correctly; the origin of the *ductus arteriosus* was preserved, but, unfortunately, its connexion with the aorta was dissevered by the manner in which the latter was truncated. The duct was too small to admit the rounded extremity of a common probe; the right auriculo-ventricular valve was tricuspidal, and the left mitral. The *foramen ovale* was imperfectly closed, the valve being cribriform, but the foramina were very minute. The lungs had a natural appearance.

The preparation in Guy's Museum, numbered 139240, is the heart of a young child in which the aorta arises from the right ventricle, and the *pulmonary artery* from the left; the *arterial duct* is open, the *ventricular septum* is complete, and the *foramen ovale* appears to be rather freely pervious.

A fifth instance of this kind is described by Dr. Walsh.\*

The subject of this case was a decrepit-looking male infant, ætat. 10 months, with extremely flaccid flesh, and slight œdema about the ankles. The skin was of a deep leaden colour, particularly the toes and the extremities of the fingers. The surface felt cool, and the infant appeared to suffer from chilliness: it was restless; its eyes were prominent and staring; the respiration was very frequent, and sometimes gasping; the pulse between 120 and 130. There was no abnormal murmur in the cardiac region, or in the course of the great vessels; the heart's action was tumultuous, and its impulse strong and widely diffused. The child died during a paroxysm (of dyspnoea?), death being in all probability hastened by a slight diarrhoea and pulmonary catarrh under which it suffered at the time. It was found that the aorta arose from the right ventricle, and, at its origin, slightly overlapped the *pulmonary artery* which sprung from the left ventricle. The aorta gave off the two coronary arteries in the usual way, and two subclavian and two carotid arteries arose from the upper border of the arch. The aortic and pulmonary sygmoids were well formed and healthy; the *ductus arteriosus* was pervious, and large enough to admit with ease a good-sized probe. The right auricle contained an enormous quantity of black grumous blood, and an adherent fibrinous mass was found close to its appendix. The walls of the left auricle were

almost membranous: scarcely any muscular fibres were to be seen in them; its cavity appeared to be about one-third as large as that of the right: it received the four pulmonary veins. The *foramen of Botal* was perfectly open, of an oval form: it measured about  $\frac{3}{8}$ ths by  $\frac{2}{8}$ ths of an inch, and was capable of being considerably dilated. The ventricles were transposed, that on the right side being furnished with a mitral valve; that on the left with a tricuspid valve. The *septum ventriculare* was not perforated.

It will be observed that in this, as in many other forms of malformation of the heart not primarily depending upon obstruction to the circulation, the children continued to be perfectly well nourished up to the period of their birth, but that symptoms of cyanosis became very apparent immediately the processes which tend to close the arterial duct and foramen ovale subsequently to the commencement of respiration began to operate. In M. Durest's case, respiration was never fairly established. In Dr. Wollaston's case, death occurred when the arterial duct had become very narrow and the foramen ovale had begun to contract. In the heart described by Mr. Stedman, the duct was closed, and the foramen ovale was barely pervious. A nearly similar condition of parts was found in Dr. Farre's case. The death of Dr. Walsh's patient was in some measure due to acute pulmonary and intestinal irritation; but the immediate cause of dissolution most probably existed in the narrowed condition of the arterial duct. The cause of the cyanosis in these cases has been very clearly explained by Dr. Quain.

#### IV. *Transposition of the aorta and pulmonary artery, the auricular and ventricular septa complete, the arterial duct pervious.*

There appears to exist a class of cases of this description, but, as I have already stated, it is difficult to understand how the circulation can be maintained at all in a case of transposition of the vessels where there is only a *single* communication between the pulmonary and the systemic heart and their vessels. In these instances it must be concluded that some means of communication have escaped detection, unless we suppose that, in such cases as the following, life has been prolonged until the period at which the foramen ovale has become completely closed, when a sudden stop has been put to the circulation. This explanation is, however, not altogether satisfactory, especially as the details of the cases are by no means complete.

Mr. Langstaff mentions the case of a well-proportioned male infant which had cyanosis immediately after birth, and was

\* *Medico-Chirurgical Trans.*, New Series, vol vii. p. 1 (1842). Dr. Walsh's paper contains many interesting particulars relative to this species of cardiac malformation.



much colder than natural. For three weeks it had only a slight difficulty in breathing, except when it sucked; but the impediment to the respiration gradually increased until it amounted to dyspnoea, during which the skin became still darker, and the temperature lower. At the age of 10 weeks it died suddenly in one of those paroxysms. The pulse was remarkably languid and small, sometimes obscure, and the bowels were disordered. The right auricle was found to be so much distended as to be nearly equal in size to the rest of the heart. The right ventricle was natural, except that the aorta arose from it; the left ventricle was as thin in its parietes as the right, and had a smaller cavity; it gave origin to the *pulmonary artery*, which communicated freely with the aorta by the *ductus arteriosus*, the size of which was proportionate to that of the other vessels\*.

I have thought it necessary to state this imperfect case, but it is doubtful whether it does actually represent a distinct species of malformation. A careful examination of the specimen might decide this question, which, it will be perceived, is one of considerable physiological interest.

V. *Transposition of the primitive arteries: the ventricular and auricular septa previous and the arterial duct open.*

In cases where the aorta and pulmonary artery are transposed, and the ventricular septum is incomplete, it may, of course, be expected that the foramen ovale and the arterial duct will be found unclosed if the infant die within a few hours of birth: still, I am not aware that this has ever been observed in the human subject. In the heart of a lamb which had not lived longer than 2 days, J. F. Meckel† found the position of the pulmonary artery and aorta reversed, the aorta arising from the right, the *pulmonary artery* from the left ventricle. The *ductus arteriosus* was widely open; the branches of the pulmonary artery were small; the aorta arched to the left. The *foramen ovale* was open, and the *ventricular septum* was incomplete‡.

\* Lond. Med. Rev. vol. iv. as cited by Farre p. 28.

† Tab. Anat. Path. Fas. 2, p. 1, and Tab. ix. fig. 1.

‡ Meckel also refers to a similar malformation which he found in a bicephalous calf (p. 2). Besides the above instances, several other cases of transposition of the aorta and pulmonary artery have been recorded. Otto gives the following references:—Tiedemann, in his G. R. and L. Ch. Treviranus Zeitschrift für Physiologie, vol. i. p. 1, tab. vii. E. D'Alton, D. de Cyanopathie Specie ex invicem permutata arteriæ pulmonalis atque aortæ origine. 4to. Bonnæ, 1824, with plates. Joseph Burkart, D. de Monstro Humano Notabili, Friburg, 8vo. 1825. Dugès, in Journ. Gén. de Méd. vol. ci. p. 88. Dr.

THE CAUSES OF PERMANENT ABNORMAL COMMUNICATIONS BETWEEN THE CAVITIES OF THE HEART.

Throughout the foregoing observations, it has been assumed, as a well ascertained fact, that, in all cases where the cavities of the heart remain single, or in which the ventricular septum is found incomplete subsequently to the birth of the child, these structural imperfections have depended upon the occurrence, at a very early period of intra-uterine life, of a certain amount of impediment to the pulmonary circulation, the result either of a structural defect in the pulmonary apparatus, or of a distinct cause of mechanical obstruction existing in some other part of the vascular system. It has also been taken for granted that, in a large proportion of cases where the foramen ovale and arterial duct remain permanently open, the persistence of these canals is due to the influence of similar impediment operating either before or very shortly after birth. This view has arisen from observation of the frequent association of imperfection of the auricular and ventricular septa, and patency of the *ductus arteriosus*, with contraction or obliteration of the right auriculo-ventricular orifice or pulmonary artery, with imperfect development of the lungs, or with narrowing or occlusion of the mitral aperture, or of some portion of the aortic arch.

It would now be difficult to ascertain the precise time at which the influence of vascular obstruction in producing non-closure of the foetal passages of the heart first became known to anatomists, but it is certain that the credit of establishing this view cannot be assigned to any writer of the present day. Morgagni was undoubtedly well acquainted with the principle,\* and, in the year 1783, Dr. William Hunter referred† to the existence of an abnormal communication between the ventricles, as an arrangement intended to make up for the defect in a pulmonary artery which was preternaturally too small to give passage to the whole blood of the right ventricle, without which compensation life could not go on. In 1805, Dr. Walker published some remarks on a case in which he very expressly attributed deficiency in the septum of the ventricles to a want of capacity in the pulmonary artery.‡

Subsequently to this, Dr. Burns explained the dependence of an open state of the foramen ovale upon dilatation of the left cavities,

Walshe also refers to a case by Martin in Müller's Archiv. H. iii. S. 22, 1839. The child lived ten weeks.

\* Epist. xvii. § 13.

† Medical Observations and Inquiries, vol. vi. p. 306.—My attention was directed to this passage by a friend.

‡ Med. and Phys. Journal, vol. xiii. p. 431.



or contraction of the right ventricle and pulmonary artery.\* M. Hein has also confirmed this observation, assigning contraction of the pulmonary orifice as one of the causes of permanence of the foramen of Botal.†

More recently, this principle has received strong confirmation from various pathological writers:—among others, MM. Berard and Bouillaud have remarked upon the coincidence of patency of the cardiac septa with causes of obstacle to the emptying of the cavities; and a very clear exposition of the matter has been given by Dr. C. J. B. Williams, in the Cyclopædia of Practical Medicine.‡

Similar opinions have also been adopted and extended by Mr. T. W. King,§ and by Dr. Craigie.||

The establishment of this view has gone far to correct the opinion, which is, even still, entertained in its fullest latitude by a few pathologists, that imperfection of the auricular and ventricular septa, and permanence of the arterial duct, are invariably to be regarded as injurious states, as the primary and essential conditions of the disease, and as the principal, if not the sole causes, upon which the symptoms of morbus cæruleus depend. It is doubtless true that,—in a certain small proportion of cases where the open state of the foetal communications has depended upon *transitory* causes of obstruction occurring very early in life, and has become aggravated by subsequent disease after the impediments which produced the non-closure have ceased to be in operation,—patency of one of these openings must be regarded as a morbid condition; still it must be borne in mind that, in every instance, these communications have originally fulfilled a preservative office, affording the sole means by which nature has been enabled to prevent the circulation from being wholly arrested in consequence of some severe cause of obstruction.¶

\* Op. citat. p. 19.

† Op. citat. (pub. 1816), p. 14.

‡ Dr. Williams observes, that "Openings in the septum of the ventricles, when combined with decided contraction of the arterial tubes, we cannot but view as in most instances the effects of the latter; for it is a simpler idea, and one more consistent with the laws of development, to suppose that an obstruction, which pathologically speaking, is of frequent occurrence, retains the current of blood in the course which it held in the early period of its formation, than to ascribe a perforated septum to some specific and inexplicable arrest of its natural development. Art. Malformations of the Heart, vol. iii. p. 66. 1834.

§ LONDON MED. GAZETTE, vol. xxvii. p. 751. Jan. 1841.

|| Edinburgh Med. and Sur. Journal, vol. lx. p. 274.

¶ Dr. Craigie has illustrated this principle in the following just remark: "In opposition to what has been hitherto taught, the open state of

It is to be remembered, however, that instances of this uncomplicated kind are of by no means frequent occurrence; every anatomist who has practically investigated the subject will agree with Dr. Craigie that "the [permanently] open state of the foramen ovale" [and also of the ventricular septum and arterial duct] "is rarely a primary and solitary lesion." In fact, these defects will generally be found to exist in association with some permanent obstruction to the circulation, either in the right or left heart, or in some portion of the pulmonary or systemic vessels.\* A very simple illustration of this principle may be found in any case where the pulmonary artery is narrowed at its orifice, and either the ventricular septum, the ductus arteriosus, or the foramen ovale, is permanently open:—here the contraction of the artery is the disease,—the abnormal communication is the preservative adaptation, by means of which the circulation is rendered comparatively free, and the life of the individual is prolonged. I have already endeavoured to trace out the influence which progressive narrowing of these communications has in aggravating the symptoms of the disease; and, ultimately, in determining its fatal issue,† and it cannot be doubted that, were it possible to induce closure of the openings in the cardiac septa, and of the abnormal passage of the arterial duct in these cases, severe and ultimately fatal aggravation of the symptoms of obstruction would be produced in the majority of instances; while, in many, the consequence would of necessity be instantaneous death. It is, of course, quite evident that, in a large proportion of cases of ventricular and arterial communication, and in some where the auricular septum only is deficient, the circulation would be at once arrested by any cause which could obliterate the abnormal channel. It therefore can never be a matter of surprise that a patient should have lived for many years with comparatively mild symptoms of heart disease, although the subject of a singularly large communication of the kind in question; as it will be perceived that, had there not been an abnormal aperture between the cavities or great vessels of his heart, to compensate for some permanent obstructive lesion in another part of the circulatory apparatus he probably could not have continued to

the foramen ovale is in a large proportion of cases, the means of prolonging life." Op. citat. p. 274.

\* It is frequently, if not generally, observable that, where free patency of the foramen ovale exists as the sole congenital defect, it is associated with marked dilatation of the pulmonary artery, shewing that impediment has existed either towards the extreme branches of that vessel, in the left side of the heart, or in the systemic circulation.

† See the previous chapter, p. 72.



exist at all; or that, had the communication been less free than it was, the symptoms would have been more aggravated, and the term of life far less prolonged. Hence, in the majority of these cases, we must not be satisfied with discovering a deficiency in one of the septa of the heart, and in attributing death to that imperfection, but it will be necessary to search further for the cause of obstruction to the circulation which has originally produced that defect, and in the subsequent aggravation of which the cause of death may generally be detected.

It has been loosely stated, that permanence of the foramen ovale has less tendency to destroy life than has any other species of congenital malformation of the heart;—but, although it is undeniable that, under unfavourable circumstances, every imperfection in the cardiac apparatus, however slight, has a tendency to turn the balance against the chance of recovery, it must not, we repeat, be usually considered that the ill consequences of this defect at all outweigh its preservative influence. Persons live longer, and are healthier with an open state of the foramen ovale, than with any other prominent form of cardiac malformation, because this deficiency, when it exists alone, usually depends upon slighter causes of obstruction than does either of the others to which the heart is liable; on the contrary, where the ventricular septum is deficient, or the arterial duct remains rather widely open, the symptoms are usually of a more prominent character, and the term of life is considerably shortened: this is, however, traceable to the fact that the defects in question are almost invariably due to the presence of some very considerable source of impediment either in the pulmonary or systemic circulation. It is, therefore, by the amount of obstruction, and not by the extent of the abnormal communication, that our opinion on the severity of these cases must be formed.

M. Louis denies the probability of the opinion that a perforated condition of the ventricular septum depends upon narrowing of the pulmonary artery, but he admits that such constriction of the vessel must, if it be congenital, prevent the foramen ovale from becoming closed, in consequence of the resistance which it affords to the passage of the blood from the ventricle\*. This distinction is evidently not a just one, as the same cause which would prevent the closure of the foramen of Botal subsequently to the birth of the child, would, if occurring sufficiently early, equally tend to arrest the formation of the ventricular septum. M. Louis' opinion was probably due to the

observation of cases in which there was reason to believe that perforation of the septum ventriculare occurred subsequently to birth. It is, however, impossible to believe that the exceedingly frequent coincidence of a distinct mechanical impediment to the circulation through the pulmonary artery, with congenital deficiency of the ventricular septum, can be regarded otherwise than in the relation of cause and effect.

I am not aware, from my own observation, that stricture of the aortic orifice, where that vessel is distributed from [the left ventricle, has ever been found to occasion congenital deficiency of the ventricular septum,\* but various forms of obstructive aortal disease, occurring at a later period of life, are observed to be attended with a tendency to perforation, or aneurismal yielding of the upper and fibrous portion of the septum, which is occasionally found to be extremely thin immediately below the base of the right aortic sygmoid valve,—a condition which has been described by Dr. Spitta, and which I have myself seen. Perforation of the ventricular septum may also occur at various periods of life from several causes, such as abscess, rupture consequent upon fatty degeneration, acute ulceration in rheumatism, &c.

In his recent work on Narrowing and Obliteration of the Arteries in Disease, Professor Tiedemann notices the frequent association of patency of the foramen ovale with arctation of the orifice of the pulmonary artery, whence Morgagni inferred that the narrowing of the vessel had taken place at birth; but the Professor contends that this could not be the case, otherwise the ductus arteriosus must be open also, which it is not. This reasoning is, however, erroneous; the ductus arteriosus has been found open in several instances of contraction of the pulmonary orifice†, and we have seen that, in cases of congenital obliteration of the ascending pulmonary trunk, permanence of the arterial canal is the most frequent compensating provision; on the other hand, a case of congenital narrowing of the pulmonary orifice has been recorded‡, in which the foramen ovale was obliterated, while the ductus arteriosus remained pervious. And, in a very large number of examples, where the congenital origin of arctation of the right ventriculo-arterial orifice was evidenced by its association with an incomplete condition of the ventricular septum, both the foramen of Botal and the arterial duct

\* It has been argued that congenital imperfection of the septum may be determined by a narrowed state of the aortic orifice; but I am not acquainted with any of the cases upon which that conclusion is based.

† Records of six cases are cited at pp. 373-4-5, and 452.

‡ Dr. Houston's case, p. 374.

\* Mémoires ou Recherches Anatomico-Pathologiques, Paris, 1826.



were found perfectly impervious.\* Indeed, a case which I have cited, at the commencement of this paper (Dr. T. Chambers' case, p. 284), proves that the pulmonary orifice may become completely obliterated during intra-uterine life, without preventing the subsequent closure of the duct and foramen. I have already attempted to explain the reason why permanence of these two canals is not determined in all cases of congenital narrowing of the pulmonary orifice (pp. 372, 3). In some instances of contraction of this aperture, in which patency of the foramen ovale is the only other associated lesion, it may possibly not be very easy to decide with absolute certainty whether the morbid appearances are congenital, or whether, as Professor Tiedemann suggests, the foramen may not have been reopened in consequence of the impediment which the blood encountered in moving from the right side of the heart; still, the cases must be of rare occurrence in which a careful examination of the structures will not enable the anatomist to form a tolerably accurate opinion as to whether the lesions in question were of congenital origin or of more recent date. It may perhaps happen that, in some cases of great contraction of the pulmonary orifice, either the ventricular or the auricular septum may become thinned, and perforated by ulceration;† but I am not acquainted with any cases in which the appearances presented by the abnormal apertures rendered it at all certain that this event had occurred‡. It will generally be easy to distinguish an ulcerated opening in any portion of the cardiac apparatus from a

\* For examples, see p. 699.

† It has been considered that in cases of extreme mitral contraction, the fossa ovalis occasionally becomes perforated in this manner — this may doubtless occur; but it is probable that, to say the least, in the majority of these instances, the open state of the foramen is in reality merely an accidental complication, the size of the congenitally patent communication becoming much increased by subsequent distension. This latter opinion has been clearly laid down by Dr. Farre, and it is certain that, in cases where the foramen ovale is perfectly closed, distension of the left auricle may proceed to an enormous degree without giving rise to perforation of the septum. In the Museum of St. George's Hospital there is a specimen of mitral contraction in which a most extraordinary dilatation of the left auricle has occurred, rendering the septum perfectly translucent, but without destroying the continuity of its fibrous tissue. Professor Tiedemann himself refers to a still more remarkable case of this kind in which the auricle was more than large enough to admit three fists within its dilated and thin-walled cavity.

‡ A heart is preserved in Guy's museum (numbered 1380), which presents a large perforation, by some considered to be the result of ulceration, in the upper part of the ventricular septum. Both the aortic and the pulmonary valves are considerably diseased, but there does not exist any remarkable degree of narrowing at the orifice of either vessel.

congenital deficiency of the tissues of the part; and I believe that most persons who have been in the habit of examining malformed hearts, will concur in declaring, without the slightest hesitation, that the smooth and regularly formed circular openings through which the blood is diverted in cases of arctation of the pulmonary artery are indisputably the results of congenital defect. If the opinions of Professor Tiedemann are intended to apply to cases of this kind in general, they are assuredly not valid, and they cannot be regarded as in any degree subversive to the views on this point which had been long previously established.

The only other controvertible opinion on this subject which it is necessary to allude to here, is that of Mr. Thiebault, who has suggested that the blue disease may arise, in the first instance, from a plethoric state of the infant at birth, preventing the changes which should take place in the circulation at that period. It is true that the severity of the first symptoms of cyanosis may occasionally sustain a temporary relief from the employment of that practice which Mr. Thiebault recommended on the strength of his theory, viz. of allowing a certain quantity of blood to flow from the umbilical cord immediately after birth: still, it is of course impossible to believe that a cause of this kind, occurring at so late a period, could have any influence in producing an irregular disposition of the vessels of a malformed heart, or that the treatment in question could avail in modifying the confirmed structural defects which are observed in such cases.

If, however, it be merely argued that engorgement of the heart may become the cause of the first *symptoms* of cyanosis in cases where the organ is congenitally malformed, or that a state of extreme plethora may have a tendency to retard the closure of the foramen ovale and arterial duct, the plausibility of the opinion can scarcely be denied.

#### ON THE CAUSES OF CYANOSIS.

The malformations to which the heart is liable usually consist of lesions, which are not inconsistent with the prolongation of intra-uterine life\*, but which are calculated to produce very serious embarrassment when respiration commences, and when the alterations naturally effected after birth in the circulatory apparatus begin to be established.

The paroxysms of suffocative dyspnoea, the lividity of the surface, and all the other distressing symptoms which constitute the leading features of cyanosis, were formerly

\* There are some exceptions to this rule, but they do not appear to be of frequent occurrence.



attributed solely to the admixture of venous with arterial blood through the abnormal cardiac apertures which are usually discovered in these cases, and to the consequent diffusion of a dark and vitiated fluid through every part of the arterial system; but this opinion has been in great measure abandoned since the facts have been established that the symptoms in question may be present in cases where no abnormal communication whatever exists between the cavities of the heart, as well as in instances where it is utterly impossible that the smallest quantity of venous blood could have entered the arterial system: while, on the other hand, the symptoms of morbus cæruleus are not by any means necessary attendants either of patency of the cardiac septa or of permanence of the arterial duct.

¶ The opinion at present adopted by many pathologists with regard to the cause of the symptoms of morbus cæruleus is, that they depend entirely upon delay to the passage of the blood through the lungs, resulting from the presence of a fixed impediment to the circulation.

Morgagni appears to have been the first writer who attributed the intense lividity of cyanosis to obstruction in the trunk of the pulmonary artery. Louis ascribed this symptom to some obstacle to the circulation of the blood through the veins; and MM. Bertin and Berard coincide in believing that the blue appearance of the surface in those affected with abnormal apertures in the cardiac septa depends on the stasis of the blood in the right cavities of the heart, and upon the consequent difficulty with which the venous blood circulates; and, though it be complicated almost always with the mixture of the two kinds of blood, still it is not produced by this mixture. The opinion that cyanosis is exclusively due to the circulation of venous blood through the arterial system, has been satisfactorily disproved by Dr. Stillé\*, who adduces ample evidence in proof of the conclusions, (1) that cyanosis may exist without admixture of the blood; (2) that there is not always a proportion between cyanosis and the degree in which the blood is mixed; (3) that complete admixture of the blood may take place without cyanosis; and (4) that cyanosis depends upon congestion of the general venous system from obstruction in the right side of the heart or in the pulmonary artery, impeding the return of its blood to the lungs.†

\* In a valuable paper on Cyanosis, in the *American Journal of the Med. Sciences*, vol. viii. p. 25: 1844.

† In 54 out of 62 cases of cyanosis analysed by Dr. Stillé, the pulmonary artery was either contracted, obstructed, or impervious. In the remaining 8, the conditions presented by this vessel were fully capable of producing great venous congestion.

The results of my own investigations are almost entirely confirmatory of Dr. Stillé's inferences. Cases of cyanosis will very rarely occur in which the morbid anatomist will fail to discover some organic cause which acts virtually as an impediment to the pulmonary circulation. Dr. Stillé has, perhaps, referred somewhat too exclusively to the right side of the heart and the pulmonary artery as the seats of the mechanical obstacle to the circulation in these cases, for it will occasionally, though rarely, be found that the physical impediment to the circulation exists in the pulmonary tissue, or is even external to the lungs, as in Dr. Marcet's well-known case\*; and, in some few instances, the cause of obstruction is situated either in the left heart or in the aorta. Still, in every case of cyanosis, there will be found to exist some cause or other which tends essentially to prevent the free and complete circulation of the blood through the lungs, to retard its passage through the venous system, and, consequently, to render the process of its arterialization slow and incomplete.†

Dr. Stillé has also argued that obstruction to the pulmonary artery is never found without the concurrence of cyanosis. This is perfectly true as regards most of the cases of congenital narrowing of this vessel, but it does not hold good in all: for instance, where congenital imperfection of the pulmonary valves does not become seriously obstructive until late in life, the symptoms which it produces are not necessarily those of cyanosis‡; and I shall hereafter have to cite an instance in which extreme narrowing of the pulmonary orifice, the result of endocarditis occurring at the adult period, was not attended with the slightest appearance of lividity of the surface: in fact, it appears that, for the complete establishment of that generally dilated condition of the entire

\* *Edinburgh Med. and Sur. Jour.* vol. i. p. 412.

† As a general rule, the heart's action is greatly accelerated in cases of cyanosis depending upon contraction of the pulmonary orifice, and upon various other kinds of cardiac malformation: an arrangement by which the smallness of the quantity of blood which passes through the lungs, and becomes oxygenised there, is, in some measure, compensated by the rapidity of its transit. Still, in the majority of cases, this adaptation is not sufficiently complete either to prevent great delay to the circulation through the right cavities of the heart, or to produce the oxygenisation of the entire volume of the circulating fluid so rapidly or so effectually as is usual.

‡ In the cases of a man, *ætat.* 44, related by Dr. Craigie, and of a woman, *ætat.* 63, detailed by Dr. Fallot (cited at pp. 749-50 of this paper), the pulmonary valves were found united into a thickened ring: in the one case, capable of admitting the end of the little finger; and in the other, merely allowing the passage of a goose-quill. There were evidences of very considerable impediment to the circulation in both of these cases, but there does not appear to have been any cyanosis in either.



venous system which attends cyanosis, the obstruction to the circulation must have been present either at or before birth, when the capillary vessels are naturally more capacious than they are in the adult, or it must become confirmed previously to the full development of the body, while the entire vascular system is pliant and dilatable, and is still capable of readily adapting itself to permanent changes in the circulation.

It is, of course, well known that various kinds of obstructive disease of the heart and lungs, occurring in adult life, are liable to produce extreme internal venous congestion and considerable lividity of the surface; but I am not acquainted with any instance in which an impediment of this kind, coming into operation subsequently to the age of twenty-five years, has produced that general and intense blueness of the entire surface which forms the characteristic feature of true cyanosis depending upon congenital malformation of the heart.

In extreme cases of original defect of the cardiac apparatus, such as those in which the ascending pulmonary trunk is obliterated or absent, the cyanosis appears to be due less to the circuitousness of the course by which the lungs are supplied with blood, than to the unnatural narrowness of the pulmonary vessels,\* which are almost invariably far less capacious than in the ordinary condition; hence the pulmonary veins and left auricle are usually more or less contracted in these cases, while the lungs are either badly developed and imperfectly expanded, or present the evidences of chronic impediment in the dilated condition of their tubes.

There are still a few pathologists who adhere to the old opinion that cyanosis mainly depends upon the circulation of carbonised blood through the arterial system, insisting upon the fact that, in the great majority of cases of morbus cæruleus, the septa of the heart are more or less deficient. As I have already stated, it is now established that cyanosis may exist quite independently of imperfection of the cardiac partitions or of admixture of the venous and arterial blood: still, I apprehend that M. Berard and Dr. Stillé have argued somewhat too exclusively in maintaining that admixture of the two currents has no influence whatever in producing cyanosis, as it appears by no means unreasonable to conclude that, in extreme cases of this kind, where the impediment to the pulmonary circulation is great, and where

\* Some of the cases in which the heart has been found situated below the diaphragm, prove that, where its canal is free, great deviation in the course of the pulmonary artery is not a necessary cause of dangerous impediment to the circulation, and is not the main cause of dyspnoea and cyanosis in extreme cases of malformation.

a large quantity of venous blood evidently passes into the aorta at every systole of the ventricles, the discolouration of the surface, and especially the lividity of the mucous membranes, which is so frequently observed in these cases, is, in part at least, due to the dark hue and impure condition of the arterial blood. Admitting this, it must be borne in mind that the principal reason why cyanosis is generally present in cases of extensive communication between the cavities of the heart will be found in the fact that a cause of obstruction which is capable of preventing the natural closure of the septa will rarely fail to occasion permanent and severe impediment to the circulation. Where an abnormal opening is discovered in the cardiac apparatus of one who has only lately become cyanosed, or where such an aperture presents traces of recent enlargement, it must not be at once concluded that the presence or augmentation of this communication has occasioned the cyanosis; but the first cause of the disease must be sought for, and this will generally be discovered in the form of some manifest impediment to the circulation which has determined the patency of the opening from birth, and which, having become recently aggravated, has produced the cyanosis at the same time that it has increased the size of the abnormal foramen.

Dr. Meigs adheres to the doctrine that persistence of the foramen ovale is the cause of cyanosis in infants. He observes, that, "as the occlusion of the foramen ovale is prevented by the torrent of blood flowing from the inferior vena cava, raising and keeping raised the interauricular valve, which is thin and floating, it occurred to him to place the cyanosed child on the *right* side, with the head and trunk somewhat raised, so that the interauricular septum should be maintained horizontal, and the blood contained in the left auricle should press with its whole weight on the closed valve. He has frequently seen the blue colour disappear at the very instant the infant was placed in this position, proving that the oxygenating blood only entered the arteries." Dr. Meigs adds, that he has thus saved the lives of fifty or sixty children in a hundred; whereas, as is well known, all the other means hitherto tried have failed.\*

Successful as this application of Dr. Meigs's theory has evidently proved, it is certain that his explanation of the fact is by no means demonstrative. So far from patency of the foramen ovale being an essential concomitant of the blue disease, it is well known that, in a very considerable proportion of instances of cyanosis, the auricular septum is perfectly closed; and two cases

\* Report of the Academy of Sciences, Paris, June 2nd, 1845, and Dublin Med. Press, vol. xiv. p. 18.



are upon record\* in which cyanosis was distinctly attributable to closure *ante partum* of the foramen of Botal. Wherever this communication remains too long open in a child, there must exist some cause, either of obstruction to the circulation, or of over-distension of the heart, to prevent its closure; and it is to that cause, and not simply to the patency of the auricular septum, that the cyanosis is due; otherwise it is clear that every infant would remain cyanosed until the termination of the usual period at which the foramen becomes naturally closed, and every individual whose auricular septum remained imperfect would be the subject of morbus cæruleus,—neither of which circumstances are found to obtain. The position of the body recommended by Dr. Meigs is, however, well calculated to relieve those paroxysms from which the subjects of congenital heart disease suffer, as it places nearly the whole of the voluntary muscles in a state of relaxation, thereby rendering the circulation through the extreme vessels as free as possible, and (what is of still more importance) as it facilitates the supply of arterial blood to the lungs and to the brain.

Much unnecessary discussion has been expended upon the question of whether, in cases of septal deficiency, admixture of the venous with the arterial blood occurs constantly, or only as the result of occasional causes of impediment to the pulmonary or systemic circulation. In by far the larger proportion of instances of extensive congenital malformation of the heart, and certainly in all those cases where direct communication between the cavities or arteries exists as the result of a permanently obstructed state of any of the cardiac orifices or vessels, admixture of the two currents of blood is a matter of necessary occurrence—the sole means by which the circulation is maintained at all; and here the state of the parts shews at a glance in which direction the diverted current has been accustomed to pass. Thus, in cases of transposition of the aorta and pulmonary artery, where the ventricular septum and foramen ovale remain pervious, it is evident that blood must be continually passing directly from the right to the left ventricle, and from the left to the right auricle. In other instances, where the orifice of the pulmonary artery is closed, and the aorta arises from the right ventricle, it is apparent that the contents of the left cavities can only reach the aorta by passing from left to right through the aperture in the septum, which is always provided in these cases. So, also, in the majority of instances where the foramen ovale remains open, but pro-

tected by an efficient valve, it is clear that blood has traversed the aperture only from right to left. But in many cases of congenital malformation of the left cavities of the heart, it is evident that the current through the foramen has always been from left to right. In cases of patency of the ductus arteriosus, associated with contraction of the pulmonary orifice, the lungs, of course, receive some portion of their supply of blood through the duct from the aorta; but, where there exists a contracted or obliterated state of the aorta below the origin of the left subclavian, it not unfrequently happens that a considerable stream of blood is regularly conveyed by the duct from the pulmonary artery into the aorta. In the larger proportion of these cases it is impossible that the direction of the current should be permanently reversed; the foramen ovale is generally defended on one side by a more or less efficient valvular apparatus, and an analogous arrangement has occasionally been developed in patency of the ventricular septum and arterial duct\*.

It has been argued by M. Cloquet and Dr. Willis, that when the right and left cavities of the heart are of equal and proportionate strength, no admixture of the arterial and venous blood will occur during their contractions, even although there may exist free communications between the vessels, or through the septa. A few cases have been observed which go far to substantiate the general correctness of this doctrine; but the instances of extensive malformation of the heart are so few in which the two sets of cavities are exactly proportioned to each other, or in which the whole of the cardiac outlets are perfectly free from obstruction, that the rule is by no means one that admits of being either extensively or frequently applied.

It is now allowed by the majority of pathologists that, in itself, patency of the foramen ovale (where the opening, although free, is guarded by an efficient valve) is by no means necessarily attended with cyanosis; and it is probable that, where this exists as the principal defect in the cardiac apparatus, the passage of blood through the aperture is ordinarily by no means large, and that the transit of a full stream from one auricle to the other may be merely an occasional occurrence for the purpose of relieving distension under circumstances of accidental engorgement or obstruction. Still, it is doubtful whether we can fully admit the opinion of Bichat and Louis, that, "in examples of septal deficiency, or at least in cases of open foramen ovale, no admixture of venous with arterial blood occurs except

\* Cases by Vieussens and Mr. Ebenezer Smith, p. 967.

\* See cases observed by Richerand, p. 1087, and by the author, p. 1090.



under circumstances of obstruction;" for, as we have already seen, these deficiencies are seldom, if ever, present where there is not also discoverable some cause of permanent impediment to the circulation, which probably at all times occasions a certain degree of comminglement of the currents, although that mixture may not be sufficient to produce serious vitiation of the arterial blood. It is generally found that, when the subjects of the minor degrees of septal deficiency become affected either with pulmonary disease, or with any causes of delay to the systemic circulation, the dyspnoea and lividity of the countenance are greater, and the consummation of the fatal issue is usually more rapid than might have been expected from the extent of the recent pulmonary disease, or from the severity of the other superadded causes of obstruction, had these existed alone—facts which go far to corroborate the belief, that in cases of permanence of the septal openings there generally exists some fixed impediment to the circulation, although that impediment may not be sufficient to produce any visible ill consequences while the heart is tranquil, and the lungs remain free from congestion or other superadded lesion.

It is a demonstrable fact, that there may constantly occur considerable commixture of venous with arterial blood, and yet the individuals may be well nourished and active, and may arrive at maturity without ordinarily presenting sufficient blueness of the surface to attract the attention even of a medical man.

In other instances of this kind the patients may continue for many years to enjoy tolerable health, being only occasionally liable to more or less lividity of the surface, either with or without a certain amount of dyspnoea, occurring in consequence of extraordinary exertion, repletion, or transient causes of pulmonary obstruction. Here the intensity of the cyanosis can never be taken as an indication of the degree of abnormal communication which exists between the cavities of the heart. Louis has very justly remarked, that "the change of colour is never found to be in proportion to the freedom of the communication;"—for it is, of course, evident that, wherever obstruction of the outlets exists, the more freely the cavities communicate the less will the circulation be impeded.

In either of the above sets of cases the symptoms of morbus cæruleus may become permanently developed in their greatest intensity whenever additional and permanent obstruction occurs to the passage of the blood through the lungs, or immediately the muscular power of the heart becomes seriously impaired. Instances of considerable malformation of the heart occasionally occur

in which cyanosis does not appear until the age of puberty, and others have been observed where the lividity of the surface, which had occasionally presented itself from birth, did not become permanent until a rather advanced period of life. In the former of this class of instances the increased impediment is probably due to a want of that development of the pulmonary apparatus which usually takes place at the approach of adult age; in the others it may be traced to additional narrowing or other consequences of acquired disease in the malformed structures, causes which are probably further aggravated by plethora, and by a certain amount of deterioration of the lungs.

Allusion has been already made to the influence of contraction of the foramen ovale and arterial duct in producing the first symptoms of morbus cæruleus in children who are the subjects of congenital cardiac defect; it does not usually appear that such defect necessarily interferes with the health of the infant so long as its system is freely supplied with placental blood; but, so soon as respiration and the organic changes which accompany the commencement of that process become established, the malformed heart fails to perform with facility functions for which its structure very imperfectly adapts it, and the evidences of severe obstruction are quickly developed; these are, in all probability, also aggravated by the increased bulk of the fluids, which is produced when the process of assimilation commences. The opinion advanced by M. Billard, that a perfectly oxygenated blood is not necessary to the new-born foetus, taken in conjunction with the fact that the infant's body has usually a slightly livid appearance until the funis is secured and respiration is fully established, has been regarded as a sufficient explanation of the circumstance that several hours or days frequently elapse after birth before the symptoms of the blue disease present themselves in those children whose hearts are structurally imperfect. I am not, however, aware of any fact which proves that the blood supplied to the foetus during intra-uterine life is less completely oxygenised than that which circulates through the arteries of the mother; and it is evident that the slight discolouration of the surface alluded to above is merely the transient result of the embarrassment and delay which the circulation necessarily sustains at the time when the infant is gasping in its first efforts to inspire.

#### ACUTE INFLAMMATION OF THE PULMONARY ARTERY.

Acute inflammation, arising spontaneously in an extensive tract of either of the great thoracic arteries, is a disease of by no means



very frequent occurrence: still, for many years past, acute aortitis has been recognised as a malady of perfectly defined character; and it appears to have fallen to the lot of most recent morbid anatomists to observe cases in which it has been evident that a more or less active form of inflammation of the pulmonary artery was one of the leading morbid appearances discovered after death. Still, even at the present time, some of those pathologists who have observed the larger proportion of the instances in question, deny that the morbid changes discovered in the artery have been, in reality, due to inflammation of its tissues, regarding them as the results of mere passive coagulation of blood within the vessel, either consequent upon impediment to the pulmonary circulation, or produced by a morbid tendency to spontaneous coagulation in the blood itself. Cases have, however, occasionally, though rarely, presented themselves, in which it was evidently a matter of absolute certainty that the lesions discovered in this artery were the results of acute and very active inflammation. In other instances, the leading features of the disease, as well as the morbid appearances presented by the artery, have not assumed so definite a character as to render the inflammatory origin of the lesions perfectly indisputable: still, even in these cases, the probability has been altogether in favour of the belief that the disease was essentially one of inflammation. Apart from these, there occurs a third class of highly important cases, in which the lesions bear a considerable resemblance to those displayed in the previous instances, but in which there is every reason to believe that the adherent coagula and other morbid appearances discovered in the vessel have resulted mainly from obstruction to the pulmonary circulation, attended, doubtless, with a certain amount of inflammation in the over-distended vessels. In a fourth set, it is extremely difficult to ascertain whether any inflammatory action has been at work in the formation of the fibrinous deposits found in the artery: here, if inflammation has existed, it has evidently been of a transient nature, and of a far less distinct type than in those cases alluded to under the first class.

I shall endeavour to present a brief description of each of these classes of cases in succession; commencing with those in which the symptoms during life, and the morbid appearances discovered on examination, were evidently due to acute inflammation of the pulmonary artery: alluding first, for the sake of arrangement, to those instances in which the *branches* of this vessel were the principal seats of disease; reserving those in which the *valves* were seriously affected for a subsequent section.

The comparative immunity from disease of the right cavities of the heart and pulmonary artery, as compared with the cavities on the left side and the aorta, has long formed a matter of speculation to pathologists: and many ingenious conjectures have been advanced in elucidation of this difficult question. Corvisart attributed this difference to the more decidedly fibrous organisation of the valves on the left side. Bertin regarded it as an effect of the more stimulating nature of the arterial blood. A similar view has been adopted by Dr. Furnivall, who conjectures that, as the "fully elaborated arterial blood is the natural stimulus to the heart's action," this fluid, "highly elaborated, and rich as it is in stimulant material, may be rendered by disease more stimulating to the parietes of the cavities and canals through which it circulates than the venous would be to the right ventricle." Dr. Hope believed that a concurrent, if not a principal cause, is to be found in the greater pressure or strain to which the left valves are subject, in consequence of the superior contractile energy of the left ventricle, and the greater weight of the arterial circulation. The correctness of this last opinion is strongly borne out by the fact, abundantly illustrated in the preceding chapters of this memoir, that, during intra-uterine life, while the right ventricle and its artery have a principal share in transmitting the blood through the systemic circulation, these parts are extremely liable to become the seats of disease and mechanical injury; while the left cavities and ascending aorta, to which, at this period, a much less active function pertains, comparatively rarely suffer from any serious lesion until after the direct communication between the right heart and one main systemic artery has been permanently cut off. It is probable, however, that here, as in the generality of nature's provident operations, the result is due not to a single cause, but to a combination of associated influences.

I am disposed to attribute the greater immunity from mechanical injury and disease of the right heart and pulmonary artery, in some measure to the comparatively yielding nature of their structures, the free reflux of which the tricuspid valve admits, whenever the ventricle is over-distended; and the great pliability and extensibility of the muscular, valvular, and arterial tissues,—circumstances which must all have an influence in rendering the parts less liable to mechanical injury upon occasions of obstruction and over-excitement. In a very large proportion of the cases of spontaneous mechanical lesion of the heart, the mischief is found to have occurred on the left side: the right cavities being more accustomed to obstructions, and being natu-



rally more yielding, do not so readily suffer from undue distension. It is also highly probable that the cavities on this side of the heart are naturally more adapted to the reception of irritating fluids than are those on the left: as, in health, the former receive the highly carbonized blood from the veins, while the latter are accustomed to transmit only a perfectly depurated stream, so, in disease, a strongly azotised, or otherwise morbid fluid, may be conveyed with impunity by the right cavities, while it produces the most irritating effects upon the left. All are aware that pungent substances, which may be borne without injury on the mucous membrane of the interior of the lip, produce the most violent inflammation if applied to the conjunctiva of the eye; and yet it would be difficult to assign to this any other reason than that of necessity.

It has been already shewn that, in its structural characteristics, the pulmonary artery holds an intermediate position between the arteries and veins, possessing several of the characteristics of both classes of vessels; it is also observable that the acute diseases to which this artery is liable, present, in many respects, the combined characteristics of phlebitis and arteritis; indeed, upon the whole, the morbid conditions of the pulmonary artery appear to be more nearly allied to those of the venous than to those of the arterial system. The general pathological laws which regulate the deposition of coagula in these vessels, and the circumstances which produce decolouration of their tissues, appear, however, to be nearly the same in both instances.

I believe that the only perfectly unquestionable anatomical evidences of the recent existence of acute arteritis, or phlebitis, are the presence of layers of fibrine, or portions of coagula closely adhering to the lining of tracts of the diseased vessels, together with an infiltration of their subepithelial tissues with a deposit of translucent fibrine, (an appearance which is, however, very rarely indeed observed either in the veins or in the pulmonary artery;) and lastly, a certain degree of reddish discolouration of the interiors of the inflamed vessels.

Morbid anatomists are accustomed to meet with four kinds of coagula in the cavities of the heart, and in the larger arterial and venous trunks: viz. (1.) Loose masses of dark crassamentum, filling the cavity or tube, but not adherent to its parietes: these may either be found in association with an inflamed state of the portions of vascular tissue with which they are in contact, or may be simply the results of the ordinary coagulation which occurs within a few hours after death. (2.) Soft masses or cords of yellow fibrine, of laminated structure, enclosing in their interstices so large a

quantity of serum, that very slight pressure with the fingers is sufficient to reduce them to less than half their original bulk; these are usually attached to layers of dark coagulum, and are evidently formed subsequently to death. (3.) Laminated masses and cords of flesh-coloured fibrine, tough, elastic, free from serum, and compressed into the smallest compass, evidently by a strong condensing force; in fact, these coagula closely resemble portions of fibrine which have been squeezed in a cloth until their serum has been removed. When occupying the ventricles, they are generally found interlaced between the cords of the mitral and tricuspid valves. It is almost impossible to avoid the conclusion that these coagula have formed previously to the complete extinction of life, and that their condensation has been produced by the muscular contraction of the living heart. (4.) Patches, tubes, or masses of more or less decolourized coagula, opaque and friable, and closely adherent to portions of the lining membrane of the diseased cavity or vessel. Wherever deposits of this kind are found in any portion of the vascular apparatus, the previous existence of an amount of inflammation sufficient to produce a complete alteration in the function of the lining membrane in those portions of the vessel to which the morbid deposit is attached, may be taken for granted. Each of these kinds of coagulum is liable to be found in the trunk and branches of the pulmonary artery, and a careful examination of their several distinctive characters will often prove the principal means of ascertaining the condition of the vessel previously to death.

It will here be necessary to offer a few remarks upon the red or purple discolourations so often met with in the pulmonary artery, as well as in other parts of the vascular apparatus; and which have been too exclusively attributed either to acute inflammation of the stained tissues, or to the post-mortem transudation of the colouring matter of the blood quite independently of any previous organic lesion. There are, doubtless, instances where reddening of the arterial and venous tissues occurs as a vital process; but the longer I have investigated the diseases of the blood-vessel system, the more I have become convinced that, in at least the larger proportion of cases, the florid stains which are frequently observed in the interiors of those vessels, whether arteritis or phlebitis has or has not existed, are the results of staining, or imbibition of the blood subsequently to death. It appears that the interiors of the large vessels are capable of receiving a red colour by vascular injection; but I feel assured that the discolourations in question are, in a vast majority of instances, post-mortem changes. Still it is important to observe that the pre-existence of inflam-



mation or softening in the tissues renders them particularly liable to become stained very shortly after death. In fatal cases of typhus, erysipelas, phlebitis, &c. I have occasionally found the heart and entire tract of the arterial system deeply stained, even before the body was totally devoid of heat: this evidently depended upon the low crasis of the blood, and its rapid disintegration, as well as upon the deficient cohesion of the vascular tissues.

In extremely close and sultry weather, and especially where the quantity of fluids in the bodies is large, as well as in certain cases of sudden death, poisoning, death by lightning, &c. it will frequently be found that transudation of the colouring matter of the blood through the vascular tissues commences very shortly after life becomes extinct quite independently of any previous structural fault in the blood-vessels themselves: but I think that, in the generality of cases, where, within two days after death, in cold weather, and under ordinary circumstances, the interiors of the large arteries and veins are found greatly discoloured, it may usually be concluded that, although this appearance may possibly not be associated with any inflammatory lesion, it has resulted either from a highly vitiated state of the circulatory fluid, from impaired vital cohesion of the vascular tissues, or in consequence of both of these causes combined. It is well known that the disease which has been termed erysipelatos arteritis usually proves so extremely rapid in its fatal progress, as not to admit of the gradual deposition of adherent lymph or coagula upon the interiors of the inflamed vessels—whence the only morbid appearances presented by these canals after death, is intense discolouration, with or without a certain degree of thickness and softening of their inner tunics; appearances which it is, at present, scarcely possible to distinguish from the effects of ordinary decomposition. The microscope may hereafter be successfully employed in discriminating between these cases; but we are now capable of forming our opinion respecting their true nature only by connecting the appearances presented in the vessels with the symptoms observed during life.

Acute inflammation of the pulmonary artery has been found to occur under the following circumstances. (1.) As a sequence of phlebitis. (2.) In cases of morbus Brightii; and in persons habituated to intemperance. (3.) As a result of exposure to cold and rheumatism; and (4.) as an attendant of certain forms of pneumonia.

The existence of noxious and irritative matters in the blood of patients suffering from rheumatism, gout, scarlatina, typhus, and renal anasarca, as well as from that worst species of phlebitis in which purulent

matter gains access to the general circulation, is now very generally admitted; and the injurious influence of fluids thus vitiated, upon the tissue of the vessels which convey them, often becomes strikingly displayed in those diseases. I have, in a previous essay\*, discussed at considerable length the influence of humoral changes in determining the occurrence of acute inflammation of the arterial system. I shall therefore, in this place, merely state my conviction that, in a vast majority of instances, the idiopathic forms of phlebitis, endocarditis, and arteritis, are mainly due to vitiated and irritating conditions of the circulating fluid.

Inflammation of the large arteries has been by no means unfrequently observed in association with *phlebitis*, and several cases have been recorded in which inflammation of a distant vein has been followed by the development of a similar morbid condition in the pulmonary vessels, associated with pneumonia, generally of the lobular kind, tending to the formation of circumscribed abscesses in the lungs. Some pathologists have been disposed to regard this train of morbid actions merely as the separate results of a diseased condition of the general system, producing a tendency to the coincident development in various parts of the body of certain destructive forms of inflammatory lesion. The truth of this view has certainly never been satisfactorily disproved: it is now, however, generally considered that, in cases of phlebitis, the arterial inflammation, and the suppurative disease of the lungs, liver, and other organs which usually accompanies it, are due to the entrance of purulent fluid into the blood—an accident which not only produces a most serious vitiation of the vital fluid, but is also believed to occasion an impediment to the circulation, by the lodgment of pus-globules in certain of the visceral capillaries, which are not of sufficient capacity to permit their transit. It is now satisfactorily proved that death may rapidly ensue where purulent matter is introduced into the general circulation, especially where the pus is derived from a foul or gangrenous surface: it has also been demonstrated that, in persons the subjects of phlebitis, who have died with symptoms closely resembling those presented by the animals into whose veins purulent matter was injected by M. Lebert, pus-globules could be detected in the circulating fluid. These facts, however, while they strongly favour the opinion that, here, the inflamed state of the vessels and internal organs results directly from the entrance into the circulation of a poisonous fluid from the diseased veins, do not by any means afford

\* Guy's Hospital Reports, No. 13, "Observations on Acute Aortitis."



absolute confirmation to the ingenious hypothesis that the coincident occurrence of suppuration in the lungs or liver is due to the impaction of the absorbed pus-globules in the capillary vessels of those organs. Still, the idea is so feasible, and has received such strong confirmation from the experiments of the French pathologists, that we are by no means justified in treating it slightly.

In some fatal cases of phlebitis the inflammation is found to have extended, not only to the heart and pulmonary artery, but also to nearly the entire tract of the principal systemic arteries. In other instances, the vessels intervening between the original seat of mischief and the inflamed pulmonary artery do not present any very decided morbid change; and it would appear that there is another set of cases in which the pulmonary veins become intensely affected, while the pulmonary artery remains exempt from inflammatory change\*. In a fourth class of instances, inflammation of portions of the lungs and other organs may be discovered, the pulmonary artery, as well as the veins anterior to the primary seat of inflammation, having the appearance of being entirely free from all traces of acute disease.

Acute inflammation of the pulmonary artery may supervene in cases of *phlebitis* occurring under various circumstances. As, for instance, (1.) where inflammation of a portion of the venous system occurs spontaneously as the result of some grave constitutional defect; (2.) in cases of phlebitis of the uterine veins supervening upon parturition; and (3.) after injuries and surgical operations. I shall quote briefly the principal recorded instances of the disease, as developed under each of these conditions.

It appears that in females who have long been the subjects of derangement of the catamenial function, and in whom that diseased state of the fluids which characterises the worst form of chlorosis has consequently been produced, there occasionally arises a tendency to spontaneous inflammation of the uterine veins, which usually extends merely to the communicating vessels of the pelvis and to the crural vein, producing a variety of phlegmasia dolens. The disease rarely advances beyond this point, but the following case, by M. Lediberder\*, shows that it is occasionally attended with very extensive lesions in various portions of the vascular system, and that acute inflammation of the pulmonary artery may occur at some period of its progress.†

A young woman, æt. 21, of a strong constitution, who had always lived under circumstances favourable to health, and who began to menstruate at the age of 17 years, entered La Pitié, on the 6th of April, 1837, having suffered for two years from the symptoms of gastralgia and chlorosis, which had gradually increased in intensity during the last three months. On the day of her admission she was attacked with vertigo, delirium, excitement, and headache, unattended with any lesion of movement or acceleration of pulse. The cerebral symptoms gained their height in the course of twenty-four hours, remained stationary for about four days, and then diminished gradually, but had not completely disappeared by the 20th, when an attack of hemiplegia, affecting both sensation and motion on the left side, supervened. The paralysis of sensation lasted four days, that of motion six days. On the 5th of May, five days after the disappearance of the last symptom, she was suddenly seized with excruciating pain in the right lower extremity, with swelling, and tension, and dilatation of the superficial veins of the limb, in which arterial pulsation could not be felt. Besides these local symptoms, the countenance appeared sunken, the body generally was cold, and the pulse small. In the course of twenty days these new symptoms had passed off, but on the 20th of June another formidable train of symptoms suddenly made their appearance. After two days she began to suffer from pain in the left hip: in the evening, at about half-past eight, she complained of an acute pain in the loins, and went to bed. Her face was pale, and expressive of suffering. She now complained of a feeling of suffocation; she breathed high, and with great difficulty; the heart's action was very rapid and violent. She shortly fell into a state of syncope, which lasted three minutes: during this faint, there occurred a very abundant alvine evacuation. She came to herself spontaneously, and for a few moments felt relieved: the palpitation was calmed, but

\* Quoted by M. C. Baron, Archives Générales de Médecine, 3d Series, t. ii. p. 18.

† It appears that, in M. Lediberder's case, the state of the uterine veins, and even of the internal iliac on the right side, was not investigated; but there are strong grounds for believing that, in the majority of instances of this species of phlebitis occurring in amenorrhœal subjects, the mischief originates in that set of vessels. It is possible, however, that, in this instance, the inflammation commenced either in the crural vein, or near the bifurcation of the cava. An accident which is of by no means very rare occurrence in various forms of cachectic disease.

\* Dr. R. Lee (Med. Chir. Trans. vol. xix. p. 44), and Mr. Adams (Dublin Journal, vol. xviii. p. 142), each relate a case in which phlebitis—in one instance of the uterine veins of a female recently delivered, and in the other of the basilic vein, which had been opened for the relief of puerperal convulsions—was followed by inflammation of the pulmonary veins. It is unfortunate that, in neither of these cases, is the condition of the pulmonary artery at all alluded to: but it is highly improbable that these very accurate observers could have overlooked inflammation of this vessel had it actually existed.



the dyspnœa continued. In a short time the difficulty of breathing increased; she complained of pains in the abdomen; the body grew pale, and was covered with a cold sweat; then the agitation and suffering became extreme. Sensation ceased in the extremities, she screamed, wept, and exclaimed that she was dying. The breathing became more and more difficult, until at last the patient merely gasped. At about ten o'clock she expired without agony or convulsions. On examination, there was found a very considerable softening of the left cerebral hemisphere. The heart did not present any alteration, with the exception of a marked thickening of a portion of the left auricle just above the mitral orifice. There was a large quantity of soft dark coagulum in each of the auricles; the ventricles contained less blood. The lower part of the left internal jugular vein contained a yellow fibrinous clot, of firm consistence, and adherent to the lining membrane. The coats of this vein were more than twice their natural thickness, and the surrounding cellular tissue was indurated to the extent of a line. The lower part of the vena cava contained a clot which adhered posteriorly to about one-fifth of the circumference of the vessel. This coagulum was prolonged into the veins of the lower extremity, and it was found to be more and more adherent the lower it was traced. It adhered to the entire circumference of the crural vein: it passed but a short distance into the left hypogastric and iliac veins: it was prolonged into the crural vein and its collateral vessels, and extended into the upper part of the veins of the leg. Above, the clot was rather firm, and of a dark-grey colour; lower down, it became of a more sanguine colour, was less firm, and presented here and there small cavities. Near the crural arch, it was so adherent to the vessel as not to admit of separation except by a careful dissection; the walls of the vessel were somewhat thickened, and its investing cellular tissue was rather indurated. Various bulgings appeared here and there at the points of entrance of the large collateral veins; the vessel was converted into a complete cord. The pleural cavities each contained about three ounces of reddish limpid and transparent serosity; the lungs were entirely free from adhesions, they were of a reddish purple colour anteriorly, and purple behind; they contained much air in front, but were dense posteriorly. In this situation they were œdematous. They did not contain any granular matter or tubercles; the bronchial tubes were perfectly healthy. The two principal branches of the *pulmonary artery* contained coagula which were prolonged into the tertiary divisions of the vessel, where they terminated. These clots

almost completely filled the calibre of the arteries. They were of a greyish colour marbled with black, of a cellular appearance, without distinct layers, and of firm consistence; they could not be easily torn; they were unattached except in about one-sixth of their circumference. Their surface was more smooth towards the point of adhesion, and was covered by a fine membrane, which became gradually lost in the lining membrane of the vessel. Upon being stretched, this membrane separated into minute cellular filaments. The adhesions formed by the clots were more extensive on the right than on the left side; beyond their tertiary divisions, the pulmonary arteries were wide; the pulmonary veins did not contain any blood.

It may be questioned whether the train of morbid processes developed in the above case resulted directly from inflammation of the pelvic veins, giving rise, either to the direct extension of the disease along the vascular tract, or to the entrance of purulent matter into the general circulation; or whether the cerebral, venous, and arterial inflammations were not the separate results of a vitiated condition of the circulatory fluid, giving rise to a disposition to acute inflammation in various parts of the blood-vessel system. In the absence of fuller details, I am strongly disposed to adopt the latter view. The deterioration of the fluids which results in ordinary cases of amenorrhœa and chlorosis, may not generally be sufficiently extreme to give rise to organic disease of any portion of the vascular system, but it is evident that, in extreme instances of this condition, where protracted suspension of an important excretory function has given rise to a state of extreme cachexia, attended with a highly morbid state of the vital fluid, there certainly does exist a marked tendency to the spontaneous development of acute and subacute forms of inflammation in various parts of the body, and more especially in the structures of the blood-vessel system. It would, of course, be out of place to enter more fully into the consideration of this subject at present, but the point is one that deserves a most careful investigation.

The two following cases, reported by Cruveilhier,\* afford the most complete examples on record of acute inflammation of the pulmonary artery, as occurring in association with uterine phlebitis following labour.

A woman, ætat. 29, of a highly nervous temperament, was delivered of her first infant, at the Maternité, on the 12th of July, 1830. Considerable hæmorrhage followed the labour. The patient had a very anæmial

\* Anatomie Pathologique, Tome 1, Liv. 2\*, pp. 18 et seq. Pl. 1 and 2.



appearance; her face was pale, her pulse small and frequent, and she complained of great debility. There was severe hypogastric pain in the region of the uterus, augmented by the slightest pressure. Commencing uterine phlebitis was diagnosed. 13th. The hypogastric pain had diminished, the febrile condition continued, but in a less degree. 14th. The secretion of milk was established, (the woman suckled her infant.) On the three following days there were copious sweats, accompanied by various nervous symptoms, headache, and a tendency to syncope. On the 18th, 19th, and 20th, she was more tranquil, but the pulse remained frequent. The hypogastric pains returned, and extended over the whole abdomen. The administration of pills containing calomel and digitalis produced frequent evacuations, which were followed by relief. On the 23d she complained of very severe pain on a level with the left false ribs: she stated that she had been liable to this symptom. Examination of the chest did not give any satisfactory result. The pain was not removed by frictions and cataplasms, but yielded to a blister applied on the 24th. From the 25th of July to the 3d of August the patient appeared to be convalescing; she suckled her infant with more success than on the preceding days. On the 3d new symptoms presented themselves: oppression, cough, difficult expectoration, anxiety, nervous excitement, and extreme frequency of the pulse. There was no tenderness in the hypogastrium. Exploration of the thorax gave no very definite indications of disease; percussion developed a natural sound; auscultation afforded only a slight gurgling at the base and posteriorly. The secretion of milk was suspended. On the two following days her condition remained unimproved: the face was sunken; there was oppression and cough, with great distress; the pulse was very frequent. After vomiting and purging had been produced by an evacuant, the patient ceased to make any complaint. There was now diarrhoea. The pulse became more and more frequent: there was no expectoration. She died on the 9th, twenty-eight days after her accouchement, and six from the occurrence of the last exacerbation of her symptoms.

*Examination.*—In the abdomen there existed no traces of peritonitis, with the exception of slight arborescent injection here and there upon the surface of the large intestines; otherwise, the intestinal canal appeared healthy. The uterine and ovarian, and nearly the whole of the branches of the external iliac veins, resembled hard cords, being filled with dense adherent and decolourised clots. The left external iliac, and the left crural veins, with every one of

their divisions, contained coagula, which were less dense and less adherent, and which were evidently of recent date. At the base of the left lung were found two small purulent cavities, circumscribed and superficial, and distinguishable through the pleura by their yellowish-white colour. In the interior of one was a little adherent slough. Many other points of the surface of the lung presented indurations, with various degrees of redness; one of these resembled a small apoplectic effusion. The posterior halves of the inferior lobes of both lungs were rendered perfectly inadequate to respiration by infiltration of sero-purulent matter. Upon incising the lung in different directions, firm concretions were found filling the branches of the *pulmonary artery*. This vessel, when carefully opened, presented a sanguine concretion, which was decolourised and slightly adherent to the parietes; it branched with the vessel, penetrating into some of the very small ramifications. It was evident that the coagulation of blood had commenced in the arterial trunk, and had subsequently extended into the smaller branches, as the coagula in the latter were red and less firm; while, by their decolourisation and tenacity, the clots in the larger branches presented unequivocal evidence of their ancient date. Upon dividing the clots\*, a collection of purulent matter, which presented all the characters of phlegmonous pus, was found in the centre of the largest coagulum.

In a woman who died fifteen days after her accouchement, and who presented, during the latter days of her life, a train of typhoid symptoms, Cruveilhier found the primitive iliac vein and its divisions filled with adherent sanguine concretions, which presented various degrees of age. They were white in the principal trunks, where they contained pus in their interiors, and became red and gradually less coherent in the extreme divisions. The lower extremities did not present any marked traces of oedema. The liver was of a light yellow colour, softened, and otherwise diseased; the uterus was equally flabby, but without structural alteration. There was pleurisy of the posterior border of the right lung, with ordinary diffused and

\* M. Baron considers that in cases of this description the train of lesions in the artery occurs in a manner the reverse of that described by Cruveilhier; he believes that the coagulation commences in the extremities of the arteries, and extends backwards to the larger branches: this may possibly sometimes occur, but in the generality of cases the appearances of the various portions of coagula favour the opinion of Cruveilhier. It seems that almost any part of the tract of inflamed vessel may be the first to receive a deposit of adherent coagulum. Such deposits are very liable to occur in the large branches; they then form a kind of nuclei, which, so soon as they become sufficiently prominent, are increased by further depositions both on their cardiac and distal extremities.



lobular pneumonia. The pleurisy was evidently consecutive. The lung, when divided, presented divisions of the *pulmonary artery* filled with fibrinous concretions. These deposits were white, and contained pus in their interiors: they divided and subdivided with the branches of the vessel, becoming red and scarcely coagulated in the smaller ramifications. The concretions did not exist in the small vessels in the near vicinity of the portions of lung which were affected with lobular pneumonia. In the part of the lung which was the seat of ordinary inflammation (diffused pneumonia), the tissue of the organ was infiltrated with pus, and was in the condition of grey hepatization. Cruveilhier found in this subject a very rare pathological alteration—a considerable and irregular shred of lung was isolated in the middle of this organ, and was not attached, except by a very narrow pedicle formed by the air and blood-vessels. This portion of lung did not present in other respects any of the characters of gangrene.

Where fatal phlebitis occurs as the result of injuries and surgical operations, it is liable to be associated with all the lesions of the pulmonary tissues alluded to in the above histories: acute pulmonary oedema, purulent infiltration, lobular pneumonia, the characteristic form of circumscribed pneumonic abscess, and pleurisy, have frequently been observed in these cases. In a few instances the association of these lesions with inflammation of the pulmonary artery has been clearly displayed; but, as in the phlebitis which occasionally follows an operation, the patient usually sinks very rapidly under the prostrating severity of the disease, death may occur in these instances before the sensible evidences of inflammation of the vessel—such as the deposition of adherent coagula, &c.—have become established. It is also probable that, in many cases where the morbid appearances in the lung substance have been carefully noted, an extensively diseased state of the pulmonary artery has been entirely overlooked.

The following brief narrative, also by M. Cruveilhier, affords a good example of acute inflammation of the pulmonary artery occurring in association with a peculiar form of traumatic phlebitis.

In a man who died twenty-nine hours after amputation of the thigh, which had been rendered necessary by a recent injury, Cruveilhier found phlebitis of the medullary canal of the femur, capillary phlebitis, and apoplexy of the liver, and commencing phlebotic inflammation of the spleen. The lungs contained purulent cavities, which were principally situated at the base and posterior part of the right: they were generally small, and irregular in shape, projecting from the surface of the lung, and sur-

rounded with a red and indurated areola. The superior lobe was entirely exempt. A section of this lung discovered some abscesses in its interior, and revealed a decolourised concretion, which filled and adhered to a secondary division of the *pulmonary artery*. In this, as well as in other cases which have occurred to him, Cruveilhier found that the veins of the stump, and of all the other parts of the body, although examined with great care in their trunks as well as in their smaller ramifications, did not present any change.\*

It can scarcely, I think, be doubted for an instant, that, in the whole of the above cases, the patients were the subjects of acute inflammation of the pulmonary artery. In Cruveilhier's first case, the progress of the thoracic mischief which immediately led to dissolution occupied six days; and, although it is not improbable that a certain degree of insidious inflammation commenced in the pulmonary artery earlier in the disease, when the patient first complained of pleuritic pain on the 23d of July, the fatal attack of pneumonia and arteritis did not commence until nine days afterwards. It is clear that in M. Lediberder's patient, a deposition of fibrine must have taken place in some of the obstructed portions of the pulmonary artery previously to the occurrence of the fatal attack of dyspnoea. It is probable, however, that the vessel had remained tolerably free until a very short time previously to her woman's death. Cruveilhier's third case (an indisputable example of acute pulmonary arteritis) must be taken as evidence that decolourised clots may form in this vessel within twenty-six hours; and the character of the fatal attack which destroyed Lediberder's patient in an hour and a half, together with the recent character of the changes found in the pulmonary tissues after death, appear to me to prove almost incontestibly, that this woman was destroyed by the acute attack of pneumonia associated with active disease, superadded upon sub-acute inflammation, of the pulmonary artery. In the remaining example, (Cruveilhier's second case) the entire duration of the disease was only fifteen days, but no mention is made of the precise time at which the evidences of thoracic mischief were first presented.

It will be found, then, that, in certain cases of acute phlebitis, the patients fall into a typhoid condition almost immediately after the

\* This observation, although of great value as illustrating the now established principle that fatal results may be produced by inflammation of very minute veins, does not, of course, by any means apply to all cases. The most extensive inflammation of the large veins of the stump occasionally presents itself in persons who die with typhoid symptoms shortly after undergoing amputation.



commencement of the venous inflammation, presenting the collapsed and death-stricken aspect of persons whose systems are mortally contaminated by an animal poison; here, where death occurs, as it occasionally does, within a few hours after the onset of the attack, pus may be discovered in the circulating blood, which is indisposed to coagulate; the principal viscera are found generally softened, and present partial traces of incipient inflammation of the lowest character, such as indistinct ecchymosis, mottling, and irregular vascularity; the lungs appear congested in that defined manner which indicates the earliest commencement of lobular pneumonia, or have various portions of their tissues, and perhaps their entire substance, infiltrated with serous or sero-purulent fluid. This latter condition is not to be confounded with the state which occasionally precedes hepatization in ordinary cases of pneumonia; it is not the precursor of any second stage, but is a disease *sui generis*, and is essentially fatal in its character. In these cases, examination may fail to discover clear evidences of inflammation of the pulmonary artery; still this process may have commenced although the products of inflammation may not have had time to form. Where life is protracted for some hours longer, or when the patient continues to struggle on for a few days, the liver, spleen, and lungs are usually found to be the seats of circumscribed abscesses and purulent infiltrations, and these appearances, when occurring in the lungs, are generally associated with traces of pleuritis of the most asthenic character, principally affecting the surfaces of the lower lobes and diaphragm, and may also be attended with the evidences of acute inflammation of tracts of the pulmonary artery. When the whole, or the majority of these lesions occur in association with each other, the disease is always rapid in its progress, and is probably entirely beyond the aid of human science. It will be observed that inflammation of the vessels and substance of the lungs may be set up at any stage of the progress of low forms of phlebitis;—wherever the surface of a stump remains unadherent, and destitute of healthy discharge, and so long as the tract of an external vein, not previously the seat of varix, retains the slightest traces of inflammatory action, the danger of pulmonary arteritis and of secondary abscess of the principal viscera may be seriously apprehended.

In all such cases, attention to the renal and hepatic functions is most imperatively called for. Purulent infection is commonly regarded as an ultimate pathological condition, which may chance to occur in almost any case, and which is entirely beyond the influence of preventive means. A very long and practical investigation of the subject has, however, convinced me that (except in certain puerperal cases) the extremely

low and unhealthy form of phlebitis which permits the entrance of purulent matter into the general circulation, never occurs, in this country, to any but those whose constitutional powers have long been impaired by various excesses or vicissitudes, and that it is then intimately associated with a more or less diseased condition of the principal seccernent and depurative viscera. Under these circumstances, it may often be impossible to ward off the threatened attack, although its onset may be clearly anticipated, and our efforts will probably be as vainly employed to resist the rapid fatality of the disease when its progress has commenced: still, in the subjects of known or suspected renal and hepatic lesion, it always remains in our power to postpone surgical operations which are not demanded by immediate necessity; or, at least, where such delay is impossible, or where injuries have been accidentally inflicted, we may still be prepared to employ measures to ward off the threatened evil, or to meet it at its earliest approach; and, however feeble our most cautious efforts may eventually prove in the accomplishment of these objects, it still remains with us to guard the patient against many circumstances that may seriously aggravate the peril of his condition. Where an individual, whose kidneys or liver have long been in a condition either of organic disease or of serious functional derangement, becomes the subject of an accidental injury or surgical operation, any circumstance which tends to produce increased vascular action in his impaired organs is fraught with the most imminent peril to his life. In one, especially, whose vital powers have recently been lowered by the shock of a capital operation, the passage of a draught of cold air over the surface of the body, or even the employment of any of those mild diuretic and chologogue medicines, which are usually prescribed in such cases, may prove the means of setting up at once a train of acute internal inflammations of the most rapid and uncontrollably destructive character.

I am fully convinced that, if surgeons would resolve to adopt previously to all operations, and in every case of injury and wound, even in those of the most apparently trivial description, the precautionary measure, which I ventured to urge very strongly some years ago,\*—of carefully examining the condition of the liver and spleen, and more especially of the kidneys, the occurrence of many of those formidable inflammations of the solid viscera and of various serous and vascular structures which so often follow external wounds, might be entirely averted.

The following case, by M. Bouillaud, affords

\* Guy's Hospital Reports, New Series, vol. 1. "Observations on certain of the Causes of Death after Operations and Injuries in London Hospitals, with a view to their prevention."



a very remarkable example of acute inflammation of the pulmonary vessels occurring as a sequence of phlebitis in a distant part. There appears to be every reason to believe that the pulmonary artery of this patient was the seat of morbid inflammatory change. This is stated to have been so in the heading of the report\*; but, by a singular oversight, no allusion whatever is made to the condition of this vessel in the detail of the case. I have thought it right, however, to quote this case, as, even if it be regarded merely as an instance of pulmonary phlebitis, it still tends to illustrate, in a very interesting manner, the pathology of the class of diseases now under consideration.

A vigorous man, *ætat.* 31, suffered from pains in the thighs, which were at first suspected to be neuralgic, but they were attended by strong febrile symptoms, and afterwards gave place to œdema of the lower limbs. He died of an acute pulmonary attack.

*On examination,* the heart was found rather contracted, its cavities containing fibrinous clots, in which no appearance of pus was discoverable. There was redness of the internal membrane of the auricles, particularly of the left; an uneven and tubercular state of the internal membrane of the aorta, without any trace of reddening. Many of the branches of the pulmonary veins were filled and obliterated by coagula of altered blood, which were friable and grumous, resembling the dregs of wine, with an intermixture of pus. In some of the obliterated veins liquid pus was found; in others concrete pus; in a third set a false membrane adhered very intimately to the interiors of the vessels. The venous tissues were evidently thickened. One of the veins which contained the false membranes appeared to extend to a purulent depôt situated in the interior of the lung. On compressing the pulmonary tissue, small drops of pus and little cylinders of altered fibrine were forced from the extremities of the divided veins. The trunks of the pulmonary veins contained fluid blood, and their lining presented a redness similar to that of the left auricle, but without thickening of the venous tissues. In the left pleural cavity was found a large quantity of citrine serum, quite limpid, but the lower part of the cavity contained abundance of shreddy (fibrinous) deposit. The lung on this side was pressed towards the ribs, and, to a certain degree, atrophied by the compression of this effusion, and covered with false membrane, which was in some places adherent, in others loose; in some spots organized, in others amorphous. About a cubic inch of the base of this lung

was occupied by a depôt of matter resembling wine-lees mixed with pus: this cavity did not exhale a gangrenous odour, and all around it there existed very distinct vascular injection. The bronchial tubes and their branches did not present any morbid appearance. There was not any effusion in the right pleura; the corresponding lung was generally distended with blood, but remained crepitant. Towards its anterior edge it was marked with red spots of partial induration, and with perfectly circumscribed purulent deposits—lesions which exactly corresponded with those which it is usual to find in individuals who die after capital surgical operations. Carefully dissected, the portions of lung which were altered in patches, or small indurated masses, offered all the anatomical characters of incipient inflammation. The tissue was easily broken down, as in hepatization, and the smaller vessels contained fibrinous coagula. In every one of the indurated masses infiltration of pus had commenced. Only one of the purulent collections was situated somewhat deeply in the substance of the lung. The bronchial tubes on this side were normal. There was remarkable distension of the inferior vena cava, about the spot where it receives the hepatic vein, where it was filled with coagulated blood. The surface of the concretion which distended it was covered with a material which appeared to consist of blood mingled with pus. Upon the internal surface of the vein there was a false membrane more or less adherent, which, in the spots where it was examined, was white or yellowish, or more or less deeply discoloured by blood: it was of the consistence of the false membranes which were found in the pleura. The presence of this false membrane was the principal cause of the thickening which the walls of the vein presented. Similar lesions extended into the iliac veins, and throughout all the deep veins of the right lower extremity, many of which contained pure pus, but without appreciable reddening of their lining membrane, which was only less transparent than in the natural condition. Many small depôts of pus existed around the obliterated and inflamed veins. A very large abscess was found in the muscles of the calf of the leg. The nerves of the posterior part of the leg appeared to be hypertrophied. The subcutaneous veins were healthy. The veins of the left limb were less affected than those of the right, and were permeable, although the iliac vein on this side participated in the affection of the vena cava and of the veins of the right limb. The vena porta was healthy. Little purulent collections were found in the cellular tissue surrounding the bladder, and could be traced to adjacent divided veins.

\* The words used are, "Fausses membranes dans les divisions de l'artère pulmonaire."



The bladder was contracted, and contained a very small quantity of urine, together with a remarkably elongated calculus developed upon one of the ends of a hair pin, which, in three-fourths of its length, was not covered by any earthy deposit. The lining membrane of the bladder was remarkably thickened, presenting spots of capillary injection, and a roughened and papillated surface. Upon compressing the kidneys urine mixed with pus escaped.\* The liver was healthy; the spleen was softened: its substance, of a reddish-grey colour, broke down under the slightest pressure, appearing to be infiltrated with pus and blood.

Whether purulent absorption had or had not occurred in the above case, it appears evident that a destructive form of inflammation was directly propagated from the inflamed veins to the heart and pulmonary vessels and tissues. It is probable that the phlebitis originated in the veins of the diseased bladder; and the extension of the irritation from that organ to the kidneys may have been the circumstance which determined the occurrence of such extensive asthenic inflammation in a person whose constitution had hitherto been good.

In some observations which I published in 1841 on acute aortitis,† I had occasion to remark upon the tendency which the lining of the aorta has, in common with most of the true serous membranes, to suffer from acute and sub-acute inflammatory changes in persons of shattered constitution and intemperate habits; and especially during certain stages of Bright's disease of the kidney. I then stated, and subsequent inquiry has confirmed the observation, that by far the larger proportion of cases of acute inflammation of the aorta occur in patients of this description, whose principal excretory and secretory organs have long been undergoing insidious morbid change. Acute aortitis is, however, by no means a frequent complication of renal anasarca, although, in cases of this description, the entire tract of the systemic arteries almost invariably presents manifest traces of sub-acute inflammatory lesion. As regards the pulmonary artery, I am not acquainted with any perfectly demonstrative case in which a patient, the subject of any form of Bright's disease, has died from acute and general inflammation of this vessel; although it is by no means unusual to find adherent coagula of recent formation in portions of the artery where death has occurred from renal anasarca and its com-

plications. In the next chapter, however, I shall have to refer to numerous instances where an apparently less active or sub-acute form of inflammation was found to have invaded the pulmonary artery in persons suffering from morbus Brightii. At present, I must be content with stating my belief that the vessel is liable to be attacked with inflammation of the most acute character in cases of this description.\* That such disease of the artery is apt to occur in persons of highly intemperate habits is proved by the following narrative. Nothing remark-

\* The following is an interesting example of inflammation of the trunk of the pulmonary artery occurring in association with a certain amount of renal disease. The opinion that these lesions existed in the relation of cause and effect may perhaps not be generally adopted. It is true that the congenitally faulty state of the right ventricle and its appendages must have rendered those parts in some degree liable to suffer from further impairment in consequence of comparatively slight causes of constitutional or local irritation. Still, I am inclined to believe that the inflammatory mischief which was set up in this vessel almost immediately after the occurrence of an external injury, was very probably determined by the faulty condition of the renal apparatus.

A milk-boy, *ætat.* 15, was admitted into the Royal Free Hospital, Feb. 20th, 1847. On the 12th he had bruised his left knee by a fall, and had since suffered from constant pain in that joint, and also, for two or three days before admission, in the right knee. On the day after the accident, he began to experience pain in the left side of the chest, and difficulty of breathing. When admitted he was much collapsed, and the extremities were cold and livid. The cheeks were of a deep purple colour, and the lips blue. The pulse was 124 in the minute, and extremely feeble. The tongue dry, and covered with a whitish fur. The respiration was peculiarly rapid and panting, and he was compelled to lie on the back, partly inclined to the right side, and with his head low. He complained of pain in the region of the heart, palpitation, and difficulty of breathing. Both knee-joints were swollen and tender, and there existed a red and swollen patch over the left trochanter. The respiration was puerile, and was attended with occasional mucous râles. As I shall have to refer to the state of the heart's actions, as ascertained by Dr. Peacock, in a subsequent part of this memoir, I shall omit them here. He gradually sank and died at eight o'clock on the following morning. The boy was much exhausted, and his intelligence so impaired, that it was impossible to collect from him any satisfactory account of his previous state of health. It was ascertained, however, that he had always been of a livid complexion, but was stout, healthy, and capable of a full amount of exertion, until February 1846, when he was thrown from a cart, and sustained concussion of the brain. He continued under treatment six days: the only peculiarity then observed in his appearance was slight lividity of the lips. Since that time he had been gradually getting thinner and weaker; he was constantly chilly, and very subject to take cold. He complained occasionally of palpitation, difficulty of breathing, and pain in the region of the breast; and his hands and face were always very blue, but especially so in cold weather, or when he was suffering from affection of the chest. His appetite was generally defective, and he occasionally vomited his food. His father is of a livid complexion, and has a "pigeon breast."

On examination, the brain was found healthy,

\* Unfortunately no further particulars are given respecting the true state of these organs; but the fact mentioned above goes far to prove that their pelvis, at least, were in an inflamed constitution.

† Guy's Hospital Reports, vol. vi. pp. 312, 322.



able was observed in this patient's abdominal viscera, but it must be strongly doubted whether, in a man of his advanced age and irregular life, the kidneys and liver could possibly have retained their natural integrity of structure and function. A workman, æt. 65, who had always enjoyed good health, though a great brandy-drinker, had been affected latterly with cough and mucous expectoration, which, however, did not prevent him from following his occupation. After working one day in the water, he was seized with shivering, pain in the side, and dry cough. He tried some remedies at home, and then applied to Dr. Hankel. On the 2d of June, he presented the following symptoms:—His countenance was pale and disturbed; the eyes prominent and brilliant; a short and dry cough; pain, and a sensation of compression about the middle of the chest; there was pain from dyspnoea, particularly at night, preventing him from sleeping; continued thirst; anorexia; white tongue; hot skin; pulse 100; respiration accelerated; gait slow and insecure. He had been eight days affected in this manner.

though much congested. Both lungs were engorged with blood, sparingly crepitant, and contained several masses in the state of pulmonary apoplexy. The heart weighed ten ounces; the foramen ovale was closed; the sinus of the right ventricle was divided from the infundibular portion of that cavity by a thick muscular septum, defective only at its centre, over a space of sufficient size to admit the forefinger. The cavity thus formed communicated with the aorta by an orifice three lines in circumference. The infundibular cavity of the ventricle gave origin, as usual, to the *pulmonary artery*, the orifice of which was very small, and was provided with only two valves, which were extremely thick and opaque. The coats of the artery were much indurated and thickened, and its canal was entirely obstructed by fibrinous coagula. At the sides of the vessel these coagula were of a dirty-white colour, and were laminated and firmly adherent to the valves and diseased lining membrane; but towards its centre they were softer and less discolored. The obstruction occupied the whole trunk of the vessel, and extended a few lines in each direction. The distal branches were free from disease. The ductus arteriosus displayed a conical cavity, extending two or three lines from the bifurcation of the pulmonary artery: beyond this it was impervious. The pulmonary veins were natural. The left cavities of the heart were small. The aorta communicated with the left ventricle by an orifice of about the same size as that by which it arose from the right ventricle. The aorta was large from its origin to the sulcus marking the attachment of the arterial ligament: from that part its calibre greatly decreased. Its valves and tissues were normal. The bronchial and œsophageal branches were somewhat large. One of the kidneys was somewhat rattled. It appears probable that in this case disease was set up in the malformed pulmonary artery shortly after the occurrence of the first accident, but there is every reason to believe that acute mischief again attacked the already faulty and obstructed vessel some days previously to the boy's death.—*Medico-Chirurgical Transactions*, vol 30, p. 132. I regret that I have been compelled to abridge some of the details of this important case, which, with the observations appended by Dr. Peacock, are of great interest.

There was an increase of fever during the night of the 2d. On the evening of the 3d, the agitation of the patient was much increased; he had dyspnoea; frequent cough, without expectoration, and continual desire to pass water; the countenance was more fallen, and the pulse weaker. In the afternoon of the same day his agitation was redoubled, and he got out of bed several times: at five in the evening, his anguish was so extreme that he left his room, complaining in a tremulous voice of his painful state, and wished to move to a room in the upper story for the sake of fresh air; his wife hearing him go hastily up stairs, ran up after him: he had just time to throw himself on a bed, was attacked with a slight rattle, and died on the instant. On examination, the eyes that, during life, had been prominent were now sunken. The lungs (marbled white and blue) did not fill the thoracic cavity completely. They appeared to the touch engorged with blood. On cutting into them, there flowed a moderate quantity of blood not very deep-coloured; the tissue of these organs felt sufficiently elastic; there existed old adhesions at their lateral and posterior parts. The heart was not distended with blood; it contained some concretions resembling polypi, particularly in the right ventricle; the lining membrane of the heart, that of the arch of the aorta, and its valves, were healthy. The *pulmonary artery* contained similar concretions: one of them was remarkably large and firm, but did not adhere in any part. The parietes of this artery were of a uniform intense redness, as if they had been rubbed with black-cherry juice. This redness could not be removed by washing, nor by scraping with the handle of a scalpel; it penetrated the whole thickness of the lining membrane of the vessel: the capillary vessels were not injected. This red tint did not extend to the right ventricle nor to the lungs. The other large vessels presented nothing similar. There was nothing remarkable either in the cranium or abdomen.\* Notwithstanding the fact that, in this case, the coagula which were found in the pulmonary artery remained unadherent to the parietes, the character of the symptoms, and the absence of any very extensive inflammatory or obstructive lesions in the lungs and heart, appear to me to afford convincing evidence that the individual perished from acute inflammation of the vessel producing coagulation of blood in its interior, and consequently fatal obstruction to the pulmonary circulation.

Acute inflammation of the trunk and branches of the pulmonary artery occasionally presents itself as an idiopathic dis-

\* Archives Générales, August 1834; from Rust's Magazin, t. xxxiv. Part II. p. 244.



ease in persons of apparently healthy constitution who have suffered from exposure to cold and wet. It is probable that in such instances the disease partakes of a rheumatic character; it is true that, rare as it is to meet with the evidences of acute inflammation of the pulmonary valves in cases of rheumatic fever, it is still more unusual to observe either pulmonary arteritis, or acute aortitis, during the progress of that malady. It appears, however, that, in common with nearly the whole of the true serous membranes, the lining of the trunk and branches of the pulmonary artery is occasionally liable to become inflamed in persons of rheumatic diathesis. I shall hereafter have to cite a case illustrative of this fact. In the following highly interesting example the almost general inflammation which attacked the vascular system of the unfortunate patient was probably of a rheumatic character; but the details are not sufficiently precise to enable us to decide that such was certainly the case.

M. Meli has recorded\* the case of a mariner, æt. 24, tall, of strong constitution and sanguineous temperament, who had spent three days in a very cold snow-storm in a vessel where he was mostly engaged at the pump. He was violently chilled, and was afterwards attacked with intense fever, attended with much heat, thirst, great headache, sense of constriction in the throat, and great anxiety. The skin was the seat of a sense of burning, which passed into itching. On the 17th of January (the third day of his disease), he applied to M. Meli, who found the face flushed, the eyes suffused, and the pulse hard and tense. The patient complained of pain in the throat, difficulty of swallowing, and rheumatic pains, which were felt sometimes in the chest, and sometimes in the abdomen†. The patient lost some blood, and laxatives and antimonials were prescribed. Though, on the 18th of January, the patient was better, yet, on the 19th all the febrile symptoms were more intense. The skin was in several places red, and in others presented effusions of blood as after beating; the surface was painful, especially in the region of the larger venous trunks; and the slightest touch or pressure aggravated the pain‡. The pulse was very rapid, vibrating, and, in the left arm, diastolic. The patient complained of great

thirst, anxiety, throbbing headache, and strong pulsation over the whole body. The blood drawn on the previous day was covered with a thick buffy coat; the serum was very scanty, and the clot was firm and tough. As M. Meli considered, from the quick and violent beating of the arteries, and the redness and tenderness in the course of the veins, that the disease was inflammation of the vessels, he ordered another blood-letting and the use of foxglove. 20th.—The patient was somewhat better, but his night had been rather restless. The symptoms also continued, and on the 21st the extravasations on the skin were more numerous and larger; pure blood was discharged from the throat, and blood and bloody mucus from the bowels. The symptoms persevered, notwithstanding the use of local and general blood-letting and foxglove, with laxatives, until the night between the 29th and 30th, when the patient had a violent attack of shivering. He became very restless and anxious, and was convinced of the near approach of death. Dr. Meli found him with shrunken features and dark blue complexion; the pulse was intermitting, tremulous, and scarcely perceptible; the abdomen was tense and burning; the extremities cold. The patient soon afterwards expired, with violent and agonizing oppression. The body was examined on the two following days. It was emphysematous, and in different parts of the cellular membrane reddish serum was effused, and there were ecchymoses. The nostrils and rectum contained much blood. All the superficial and deep-seated veins of the lower extremities were filled with blood, and their walls were hard, thickened, and red-coloured internally. The arteries were in the same state. The trunks of the femoral veins and arteries were highly inflamed, thickened, and solid; and their coats were covered with networks of capillaries filled with blood. Their interiors were lined with layers of adherent plastic lymph, which, in different points, presented consistent purulent matter. The abdominal cavity was filled with much reddish serum, containing blood-clots. The peritoneum was much reddened, and covered with numerous fine red vessels. In several parts of the intestines and mesentery were ecchymosed spots. All the arteries and veins of the abdomen were reddened, and felt hard, as if they had been injected with the usual injection matter; and externally and internally plastic lymph was found effused. In several places they were closed, and united by the effusion of lymph; and in few places did they contain blood. In the interior wall of the aorta, two inches above its division into the iliac arteries, there was found an opening smaller than a lentile, but no laceration was seen in the trunk. The arterial walls were swelled

\* Journal of Omodei, and Tiedemann's *Von der Verengung und Schliessung der Lulsadern in Krankheiten*, and *Edinburgh Medical and Surgical Journal*, vol. lxiv. p. 142.

† There is no reason to believe that these thoracic and abdominal pains were in reality rheumatic; they were doubtless attendant upon the acute disease of the great blood-vessels which was then in progress.

‡ A remarkably sensitive condition of the surface of the body has been observed by Dr. Bright in certain cases of acute arteritis.



and much thickened, the calibre of the vessel was diminished, and the inner coat was of a brownish red colour. At the point where the cæliac artery arises from the aorta there was a circular cording of the vessel, which extended into its division into the gastric, hepatic, and splenic arteries. This consisted of effused plastic lymph, which resembled a false membrane, and could be detached by the handle of the scalpel. The inferior vena cava was in like manner inflamed, much contracted in calibre, and to its inner coat were attached patches of false membrane which resembled valves. The part of the vena cava ascending behind the liver contained purulent matter. The arteries and veins of the mesentery were inflamed, hard, and red, and the vessels of the intestinal mucous membrane were much distended with blood. A similar condition of the blood-vessels of the stomach, liver, spleen, pancreas, kidneys, urinary bladder, and sexual organs, was observed. Their inner membrane was covered with thick fine networks of capillary vessels. The arteries and veins of the upper extremities were greatly inflamed, and quite in the same state as those of the lower. The *pulmonary arteries* and veins were also inflamed, especially the trunks, though less than the arteries and veins of the abdomen. The walls of the bronchial and œsophageal arteries were firmer and thicker than usual, and their inner membranes were inflamed. The coronary arteries were inflamed throughout, as also were the coronary veins; these vessels were externally covered with lymph which had exuded from the cellular membrane. The walls of the auricles and ventricles, and also the trunks of the arteries and veins, were covered with numerous capillary vessels. The inner surface of the left ventricle was lined with a coating of lymph which stretched over the columnæ carneæ, and partly hung free into the cavity of the ventricle, and the layer extended into the left auricle, and into the beginning of the aorta. The inner surface of the superior cava was lined with coagulated lymph. The inner surface of the throat was reddened, the velum was swelled, the uvula enlarged, and the whole surface was covered with numerous capillary vessels. Some clots of blood adhered to the mucous membrane. The vessels of the brain and its membranes also presented marks of inflammation.

The above case is probably almost unexampled in the extent and severity of the vascular lesions which it presented. It can scarcely be conceived that such an extraordinary amount of disease in structures which are by no means remarkably liable to be attacked with idiopathic inflammation, could have occurred simply as the effect of

long-continued exposure to cold in a perfectly healthy individual. It is evident that this patient must have been previously the subject of some grave constitutional defect; such as the vitiated condition of the fluids which precedes the development of acuterheumatic disease, or the faulty state of the blood which attends the worst forms of sea-scurvy. Several of the morbid appearances observed in this case were not dissimilar to those usually met with in extreme instances of scorbutus; and it appears to be far from improbable that, in a young and originally vigorous man, who had been previously exposed to the ordinary causes of scurvy, the endurance of extreme cold and fatigue would excite diseased actions similar to those from which this individual perished. It is evident, however, that, whatever may have been the real origin of his disease, the man's death was immediately due to inflammation of the pulmonary artery, and the consequent obstruction to the circulation through the lungs.

Considerable stress has been laid by authors upon the occurrence of inflammation of the pulmonary artery, and fatal obstruction of its branches in cases of *pneumonia*. It is evidently considered that these lesions have occurred in the relation of cause and effect: my own observation has not led me to adopt this view, but, before arguing the question further, it may be as well to adduce the principal facts upon which the opinion usually held is founded.

M. Cruveilhier speaks of having found clots in the pulmonary artery in some cases of diffused pneumonia involving one-half or two-thirds of the lung.\*

The following case has been expressly referred to as an instance of fatal obstruction of the pulmonary artery occurring as a consequence of pneumonia. It was communicated by M. Richelot to the *Société Médico-Pratique of Paris*, and has been briefly quoted by M. Baron in his valuable essay on obstructions of the Pulmonary Artery, already cited (p. 17). Mr. T., solicitor, ætat. 38, general health good; had been affected with a slight cough for the last twenty years; the chest, carefully examined, presented nothing extraordinary; hæmoptysis from time to time; dyspnœa on walking quickly. After a long journey on the 1st November 1837, he was seized with violent pain in the epigastrium, which yielded to the application of leeches, and other general remedies. 8th.—Hæmoptysis of pure red blood, dyspnœa; venesection was proposed but refused, and the patient continued his wonted avocations, though advised to refrain; a day or two after he presented all the symptoms of pleuro-pneu-

\* Anatomie Pathologique, T. i. Liv. xi. p. 20.



monia on the right side. Auscultation and percussion were not performed, from the refusal of the patient. Copious venesection, and the usual remedies, were had recourse to with success: nothing remained but slight dyspnoea. When convalescent, he was all at once attacked with approaching suffocation, and fainted away; having recovered his senses, he indicated the epigastrium as the seat of his suffering. This amelioration did not last long, for the feeling of suffocation returned: about half a pound of blood was drawn with difficulty from the arm; the face became livid; there was violent tenesmus; agitation, followed by prostration and death. *Autopsy, 32 hours after.* The parietes of the thorax presented the dark-red colour peculiar to asphyxia; the pericardium contained about three ounces of a sanguinolent serosity; heart normal, its cavities contained a small quantity of clotted blood; the left lung presented adhesions of old date; about two pounds of reddish serosity in the right pleura; a few fragments of the lung thrown into water floated on the surface; both lungs were of a blackish-red colour posteriorly and inferiorly, but no *engouement* nor hepatization. "The principal branches of the *pulmonary artery* were nearly obliterated by clots of black blood, several of which adhered slightly to the walls of the vessels, were soft in their centre, and surrounded by a portion of a somewhat lighter colour; the blood was perfectly liquid everywhere else." Cranium and abdomen in the normal state\*. Dr. Richelot considered that death was produced by syncope, owing to cessation of the circulation caused by the obliteration of the pulmonary artery by clots of blood. We have therefore reason to conclude that the patient died *suddenly*.

Dr. Graves has recorded† the case of a man, *ætat.* 60, who came under his care with pneumonia and partial solidification of the right lung, with a complete absence of fever. The disease remained stationary for about three weeks, then there occurred a sudden change for the worse, and the patient died in about 26 hours. On examination it was found that, in addition to the solidification of the lower two-thirds of the right lung (the left lung was entirely free from pneumonic lesion), the pericardium was distended with a very abundant straw-coloured fluid. The membrane was in every way healthy. The heart felt very soft, and lay collapsed; its structure was pale, but otherwise normal. The *pulmonary artery*

was occupied by a fibrinous clot, which presented the usual division produced by the branches of that vessel. There were only two valves, and these were coated with a recent deposition of lymph, in some situations almost a quarter of an inch thick. The valves were much thickened and opaque, contrasting in a remarkable manner with those of the aorta, which were quite free from disease. The lining membrane of both the pulmonary artery and the aorta presented its usual appearance, as did also the endocardium. There was some calcareous deposit on the tricuspid and mitral valves, but not more than is frequently observed in subjects of the same age. There was no anasarca or effusion into the pleuræ or abdomen. The hydropericardium and inflammation of the pulmonary valves had not been expected during life. Both had evidently arisen within thirty hours of the patient's death, contemporaneously with the sudden exacerbation of the symptoms.

These cases, together with many of the foregoing instances, certainly prove that acute pulmonary arteritis is likely to occur *in association* with various inflammatory conditions of the lungs and their appendages, but I do not consider that these or any other cases with which I have met, by any means establish the principle that pneumonia, in any of its forms, is liable to produce acute inflammation of the pulmonary artery. It is true that in some cases where very large portions of the lungs become consolidated, producing death from mechanical obstruction to the pulmonary circulation, branched coagula are found traversing the whole of the ramifications of this vessel, but these clots are always unadherent, and unattended with any of the marks of arteritis, and are evidently merely the effects of slow coagulation of blood in the vessel during the protracted agony of death from gradual suffocation. In none of the cases which have been narrated above was there reason to believe either that the pulmonary obstruction had been sufficient to determine the occurrence of coagulation in the affected vessels, or that inflammation had been propagated from the diseased lung substance to the arterial tissues. It was certainly noticed in Bouillaud's case that one of the inflamed veins passed from the near vicinity of a purulent cavity; but it will be recollected that in one of Cruveilhier's cases of lobular pneumonia,\* it was distinctly mentioned that clots did not exist in the small vessels in the near vicinity of consolidated lung. In M. Richelot's case, so far from there being sufficient pulmonary obstruction to account for the extensive coagulation which occurred in the vessels, it

\* As cited in the Medical Times, vol. xii. p. 122, May 17th, 1845.

† Dublin Journal, vol. xxii. p. 388, and Clinical Medicine, p. 904 (a few particulars are given in the former account which are not found in the latter).

\* Second case, p. 838.



does not appear that any portion of the lung was in a state of consolidation, nor is it by any means certain that this patient had ever been the subject of pneumonia at all: in this case the pleuritic effusion was large, but it existed only on the right side, while the vascular obstruction appears to have occurred equally in both lungs. In Dr. Graves' patient, also, the pneumonic consolidation was entirely confined to a part of one of the lungs, while a portion of pulmonary tissue, amply sufficient to admit of a tolerably free circulation, was found in a perfect respirable condition.

It has been argued that pneumonia is essentially dependent upon an inflamed condition of the smaller vessels of the lung. The opinion of Cruveilhier that lobular pneumonia is intimately connected with capillary phlebitis of these organs, may apply in certain instances; and, indeed, in the case of inflammation of any structure, it is, of course, impossible to deny that its capillary vessels are principally involved in the morbid process. Still, I am confident that pulmonary arteritis is by no means a frequent accompaniment of pneumonia, and that it still less frequently exists as a *result* of that lesion. I have examined numerous cases of pneumonia in every stage, and, I believe, in every form of the disease, and have failed to discover either the faintest trace of acute lesion in the wider pulmonary branches, or the slightest appearance of adherent coagula in the smaller ramifications. So generally, indeed, has this been the case, that I am in the habit of suggesting that recent pulmonary apoplexy may be distinguished, at a glance, from circumscribed red hepatization, by observing that, in the former disease, some of the arteries which pass into the consolidated portion of lung, are always obliterated by coagula; while in the latter the vessels are, as far as I have observed, almost invariably pervious. Particular allusion has been made by Mr. Paget\* to the fact, that he has often found the branches of the pulmonary artery blocked up by clots formed during life in those who die of great *œdema of the lungs*.† There can be no doubt that certain of the cases which produce pulmonary œdema, have also a tendency to determine the formation of adherent clots in the pulmonary vessels: thus the two cases‡ which Mr. Paget cites in illustration of his principle, were examples of confirmed morbus Brightii, in which it was probable that the disease in the pulmonary artery and the œdema of the lungs, were merely the asso-

ciated results of the condition of renal anasarca from which both patients suffered, if, indeed, the obstruction to the pulmonary vessels was not the older lesion of the two. I have frequently traced out the course of the pulmonary artery in examples of œdema of the lungs arising from various causes, and have been led to conclude that, as a general rule, the vessels remain perfectly free from all traces either of recent inflammation or of fibinous deposit, as far as they can be traced by ordinary dissection. More or less extensive obstruction of branches of this vessel has been observed as a usual attendant of *gangrene of the lung*:—it may probably occur either as a consequence or as a cause of that lesion. That complete obliteration of the vessels leading to the sphacelated part is not invariably present in these cases, is, however, proved by the fact, that fatal hæmorrhage has been known to occur from extension of the gangrene to a large pulmonary vessel which had remained unclosed.

The details of the following instance of acute pulmonary arteritis are too incomplete to be of any pathological value; but, as the case appears to afford a rather striking example of this disease, I shall quote it for the benefit of those who may have access to the work in which it originally appeared.

M. Tiedemann quotes\* the case of a laundress, in whose body, after death, clots were found to extend from the right ventricle into the *pulmonary artery* and its branches, adhering to their walls, while the inner membrane was rough and flocculent, and presented in various parts small whitish specks, to which the coagulated blood adhered. In various spots, also, could be detected membranous shreds, which resembled coagulable lymph.

Kreysig and Otto have observed the interiors of the heart and blood-vessels bearing traces of acute inflammation in certain cases of children who have died from the exanthemata, scarlet-fever, measles, and small-pox. In many persons destroyed by the last-mentioned disease, Taunton noticed the traces of arterial inflammation in various stages and degrees. The same phenomena are observed in the arteries in some cases of repelled cutaneous eruptions.† My own observation does not furnish me with any case of the above description in which acute inflammation of the pulmonary artery has been discovered after death. Still, it is probably occasionally present, especially where the patients are cut off rapidly by the sudden occurrence of extensive thoracic inflammation.

\* In his highly interesting papers on "Obstructions of the Branches of the Pulmonary Artery." *Medico-Chirurgical Transactions*, vols. 27 and 28.

† *Loc. cit.*, p. 167.

‡ Cases 2 and 3.

\* From *L'Esperance*, Mars 15, 1845.

† Review of Professor Tiedemann's work on "Arctation and Closure of Arteries in Disease." *Loc. cit.*, p. 422.



## SUB-ACUTE INFLAMMATION OF THE PULMONARY ARTERY.

THE pathology of the class of cases which now falls under our notice is involved in considerable obscurity; it must, however, be admitted that the view entertained by more than one able pathologist by whom the subject has been discussed, is opposed to the conclusion which I have arrived at, namely, that in these, as in all other instances where *adherent* coagula are found obstructing the pulmonary artery, or, indeed, any other portion of the blood-vessel system, the formation of such deposits has been attendant upon a certain amount of inflammation in those portions of the vascular tissues.

A highly valuable series of cases of obstruction to the pulmonary artery was published by Mr. Paget in 1844 and 1845\*. In the whole of the instances detailed by that gentleman, the cause of the coagulation of blood which was found to have occurred in branches of this vessel is ascribed either to (1) obstruction to the circulation through the pulmonary capillaries, (2) to extreme languor of the circulation, or (3) to the existence of some morbid state in the constitution of the blood itself, tending to increase "that adhesion of it to the walls of the vessels which constitutes, even in the healthy state, the greatest resistance which the heart's power has to overcome."†

Dr. Dubini, who has also investigated this subject, disallows the supposition that an inflammation (like phlebitis) of the obstructed vessels determines the formation of coagula in the pulmonary artery; and suggests that the cause of the coagulation during life is in the altered crisis of the blood: still, he thinks that there are many facts in opposition to this theory, "which," (he rather *naïvely* adds), "destroys every hope of success in the explanation of the genesis of the clots."‡

It is undeniable that the whole of the causes alluded to by these authors are frequently observed to have had considerable influence in determining the formation of the deposits in question; but that they are, under any circumstances, capable of occasioning the formation of *adherent* clots in the pulmonary vessels, quite independently of a certain amount of inflammation in the vascular tissues, can scarcely be ad-

mitted. Long delay to the pulmonary circulation, resulting from any mechanical obstruction to the access of blood to the systemic arteries, is evidently liable to produce more or less inflammatory lesions in the afferent vessel of the lungs, in consequence of its unnatural distension by an undue quantity of carbonized blood. In cases of fever, and in other diseases of an extremely asthenic character, the heart's action may become so greatly depressed as to favour the deposition of adherent coagula in various portions of the vascular system, but my own observation has not furnished me with any instance of this description where there was not full reason to believe that the vessels so affected had also been the seats of previous inflammatory lesion. It is now generally understood by pathologists that in patients suffering from extremely vitiated states of the circulating fluid, the causes which lead to death are almost invariably attended with inflammatory lesions of various tissues, characterised by the depositions of unhealthy fibrinous deposits in the affected parts. The influence of various humoral changes in determining the occurrence of asthenic inflammation, especially in the serous and vascular tissues, has long been recognized, and in any case where the blood is admitted to have been in a sufficiently diseased state to admit of its spontaneous coagulation in its proper vessels, we are, I think, fully at liberty to assume that the quality of the fluid was also sufficiently depressed and irritating to produce inflammation of the internal tissues of any portion of the vascular circle.

It is highly probable that, under any of the above circumstances, *non-adherent* clots may be formed previously to death in the vessels either of the pulmonary or systemic circulation; but it is certainly altogether opposed to the ordinary principles of pathology to maintain that coagula are capable of becoming adherent to any portion of the interior of the vascular tract, independently of a certain amount of inflammation of the arterial or venous tissues at that spot.

There are various forms of disease in which adherent coagula are liable to form more or less gradually in various parts of the afferent vessel of the lungs. Upon the grounds already stated, I have always attributed the production of these deposits either to the occurrence of acute inflammation in small portions of the vascular tract, or to the establishment of a more gradual or sub-acute inflammatory process in those situations. These circumstances are found to occur (1) in various instances of morbus Brightii; (2) apparently also in some few cases of rheumatism; (3) as well as in a very large proportion of that diversified class of diseases in which the pulmonary tissues

\* Medico-Chirurgical Transactions, vol. 27, p. 162, and vol. 28, p. 253.

† Mr. Paget does not by any means deny the occurrence of coagula in the pulmonary artery in association with inflammation of that vessel; but it is necessary to mention that the case which I shall quote from his paper as an example of sub-acute inflammation of the pulmonary artery, does not appear to be regarded by the author in that light.

‡ As quoted by Mr. Paget from the "Annali Universali di Medicina, di Febbrajo. 1845."



become occupied by spontaneous apoplectic effusions. The whole of these cases are of sufficient pathological importance to call for a separate consideration.

*Sub-acute inflammation of the pulmonary artery in cases of morbus Brightii.*—The tendency to the formation of adherent coagula in the emulgent veins, and in many other portions of the blood-vessel system, in severe forms of Bright's disease of the kidney, has long been observed: these lesions are usually found in association with inflammatory effusions into one or more of the serous cavities, and both sets of organic changes are known to be alike due to a highly diseased and irritating condition of the circulating fluid.\* The influence of this cause in producing cardiac and aortal disease cannot by any means be denied. And wherever adherent coagula are found in any portion of the pulmonary artery of patients who have died from renal disease and its complications (independently of the presence of any very distinct *previously existing* cause of obstruction to the circulation through the lungs),† it may, I submit, be confidently assumed that the affected portions of the artery have participated in the general tendency to inflammatory lesion of the serous and vascular tissues which characterises this disease.

The following case, which occurred within my own observation about ten years since,

\* Mr. Paget has advanced the hypothesis that, in cases of morbus Brightii, "the diseased blood adheres more than healthy blood does to the walls of the vessels; the urea, or some other retained constituent of the urine, acting in the same manner, as experiments have shown that salts of baryta, and some other bases, will act, which, when introduced in even very small quantities into the blood, hinder or altogether prevent its passage through the small vessels, although the heart be acting with full force." This theory by no means satisfactorily supports the doctrine of the spontaneous coagulation of blood in the vessels of these patients. The most prominent and characteristic physical change which the blood undergoes in cases of renal anasarca is an unusual degree of fluidity, and a marked inability to coagulate firmly; hence the great liability of these patients to spontaneous hæmorrhages, and the danger which they experience from uncontrollable bleeding after operations and injuries. It is true that clots are more liable to form in the vessels of patients suffering from disease of the kidneys, and of the other depurative viscera, than in any other class of cases whatever, but this arises, not from a greater tendency in the blood to become coagulated, but from a greater liability in the tissues of the blood-vessel system to become the seat of severe inflammatory lesions.

† In the generality of cases of advanced renal disease, it is evident that the circulation is much interfered with in consequence of capillary obstruction in the various organs of the abdomen; but it is certain that, whatever influence this circumstance may have in *assisting* the deposition of coagula upon diseased portions of the arterial tracts, it alone can never prove sufficient to occasion a positive stagnation in the current through the pulmonary vessels.

affords a striking example of the occurrence of inflammatory disease in the pulmonary artery, and in several other vessels in association with confirmed renal degeneration.

A stout labourer, aged 32 years, was admitted to Guy's Hospital with general anasarca, and slight ascites, of about a month's standing. His whole body was highly œdematous, the heart's action inordinate, and an abnormal sound was very distinctly audible over the region of the aortic valves. He suffered from intense dyspnoea, and frequent cough, with bloody expectoration: the urine contained albumen. The difficulty of respiration continued to become more and more urgent until his death, which occurred seven days after his admission. Upon examination after death, the left pleura was found entirely lined with a firm spongy layer of bloody fibrine, and filled with reddish serum. The lung contained three apoplectic clots of large size; and was compressed and rendered useless by the fluid in the pleura. The right lung was extensively hepatized, but contained air. Many branches of the *pulmonary artery*, in both lungs, were filled with coagula, apparently of several days' standing. The bronchial membrane bore traces throughout of acute inflammation. The heart was considerably enlarged; its right cavities were distended with blood, and a cystiform concretion of pale fibrine, about the size of a filbert, adhered within the right auricular appendix. The left ventricle was dilated, and slightly hypertrophied; the aortic valves were rather thickened and contracted, and one of them was completely filled with a globular pellet of firm coagulum. Portions of the aorta had small granular clots adhering to their surfaces: other parts of this vessel were reddened, and the lining membrane of its great sinus was raised by a few semi-transparent deposits. The structures of the liver and spleen were hard and contracted; the kidneys were enlarged, pale coloured, and easily lacerated: and in one of the emulgent veins I found fibrinous coagula, evidently of long standing.\*

There may exist some doubt with regard to the true cause of the pulmonary apoplexy, and attendant lesions of the pulmonary artery, in this case. My own belief is, that they did not depend upon aortal obstruction, but were the results of inflammation and softening of branches of the artery occurring in coincidence with extensive inflammation in other parts of the vascular system.

\* I have also recorded another case of renal anasarca, in which I observed appearances almost precisely similar to those described above, in both emulgent veins, portions of the *pulmonary artery*, and ascending aorta. Guy's Miscellaneous Inspection-Book, vol. xiv. p. 14.



Dr. Bright has furnished us with a very marked example of renal disease determining the occurrence of fatal obstruction in the pulmonary artery.\*

M. R., a middle-aged woman, was admitted to Guy's Hospital, Nov. 8th, 1826, with anasarca. She had been two or three times in the hospital, during the last two years, with renewed attacks of the same disease, and had gone out relieved. She was now in the most hopeless and advanced state of disease. The effusion somewhat diminished under treatment; but, on the evening of the 21st, she became rather suddenly worse, complaining of great difficulty in drawing her breath; and, although assistance was immediately obtained, she died in a few minutes.

*Sectio cadaveris.*—Lungs tolerably healthy in structure; but it was found that the *pulmonary artery* was completely blocked up by a coagulum of fibrin of firm texture. The hand was not particularly large. The vena portæ, and its large branches going into the liver, were likewise obstructed with coagulum, nearly separated from the red particles, and the saphena vein was in the same condition. The liver was tolerably free from morbid change. The kidneys afforded very fine specimens of the confirmed granulated change. The spleen was healthy.

The following interesting case is abridged from Mr. Paget's report.†

A ruined wine-merchant, 55 years old, and who had drunk hard, had been in St. Bartholomew's Hospital since the 18th of April, suffering from stricture of the urethra and paralysis of the bladder. He was a bloated, unhealthy looking man, and had occasionally slight œdema of the hands and feet; but he was so nearly well that he never complained of more than the disorder of his urinary organs. It was once noticed that he had a cough; and he said that he was often subject to such an one, but thought it trivial. In the last week of his life he had sometimes spoken of having occasional shortness of breath, so that when he wished to sleep in the day, he was "apt to be taken with a panting;" and such an attack came on once or twice while he was walking in the ward; but these attacks were rare, they lasted only a short time, and they never appeared so serious as to elicit more than a passing remark from him. Within two hours of his death he talked in the same good spirits in which he had been all day. On the morning of the 4th of May, he was thought to look unusually well. In the afternoon, after a short sleep, he proposed

to a patient near him to have tea; but first he went to the water-closet, and, on his return, presenting nothing unusual in his appearance, he sat down on his bed-side. A minute after, he fell heavily on his face; and, with a slight distortion of his mouth and of one arm, died before two minutes more had elapsed.

On inspection, it was found that some of the large bronchi contained a frothy mucus slightly tinged with blood. The left pleural cavity was obliterated by general and rather close adhesions, the right was free, and contained a small quantity of fluid. The lungs were large and deep-coloured, but, externally, appeared nearly healthy: their upper lobes were œdematous; the middle and lower lobes partially emphysematous, and containing a moderate amount of blood and serum. There was in no part of either lung a trace of pulmonary apoplexy, or of intense congestion. The right cavities of the heart were larger, their walls were of about the natural thickness. The tricuspid and pulmonary valves were healthy, and so was the *pulmonary artery*, in the size and texture of both its trunk and all its visible branches. But nearly all the branches beyond the primary divisions of the pulmonary artery contained clots of blood, which, from a comparison of them with those found in tied arteries, Mr. Paget judged to be from three to ten days old, those of the least age being in the largest branches. They were firm, cylindroid, and of various colours—black, brownish, pink, and yellow ochre, irregularly mixed. Some of them even much drier than recent clots, and grumous; others appeared invested and intersected by thin layers of white fibrine. Most of them filled the portion of the artery in which they lay, some did so to distension; a few of the driest and most decolorised adhered to the walls of the vessel, and left the surface rough and blood-stained when they were removed. The clots did not commonly extend continuously from any large branches of the pulmonary artery into many of its successively subordinate divisions: some of them were in the shape of thick cylinders from half an inch to an inch in length, which filled a branch of the artery, but were not even in contact with the similar clots which filled adjacent branches; some extended from a larger branch into two or three smaller ones derived from it, filling them all, but ending abruptly; only a few branched many times, and filled a larger series of the branches of the artery. No branch of the pulmonary artery less than half a line in diameter appeared to contain any of these clots, and the pulmonary veins were healthy and empty. The left auricle and ventricle were larger, and the walls were thicker, than in the healthy state: they

\* Reports of Medical Cases, vol. i. p. 19.

† The case is very fully detailed by Mr. Paget (op. cit. vol. 28, p. 353), but for the sake of brevity I have omitted many of the negative statements.



contained a small quantity of black fluid blood. The mitral valves were opaque, but pliant, and probably efficient. The aortic valves were in a similar condition, and of large size, adapted to the aorta itself, which was uniformly slightly dilated and thickly beset with fatty, and a few earthy, deposits in its coats. The large systemic arteries and veins were all healthy and empty, or contained a little fluid blood. The entire digestive canal was healthy, as was also the liver and pancreas. The spleen was of middle size, and soft. In both kidneys the pelvis and infundibula were dilated, the papillæ flattened and expanded, and the texture generally, but not uniformly, indurated and contracted, so that their external surface was lobed, and in parts coarsely granular. The ureters were dilated and tortuous, the bladder very large, and its walls thin and weak.

Mr. Paget also relates two other cases in which similar morbid appearances were observed in the pulmonary artery in association with renal disease; but he very justly suggests that here the state of the heart and lungs may also have had a great share in producing those vascular lesions.\*

In November, 1846, I was present at the inspection of the subjoined case. The details are unfortunately imperfect; but there is reason to believe that the individual's habits had been intemperate, and his liver and kidneys presented manifest traces of chronic disease.

A wine-cooper, ætat. 45, came under treatment at Guy's Hospital, suffering principally from cough with mucous expectoration. Some time previously he had been the subject of empyema of the left side, which had been relieved by tapping, at another hospital. There still remained a fistulous external opening, but this appeared to be confined to the parietes. Previously to his death he suffered from ascites and anasarca, and there were observed to be evidences of a large cavity in the centre of the left lung. On *examination*, the right cavities of the heart were found to be very capacious and thick. The trunk of the *pulmonary artery* was greatly dilated, as were the whole of its branches that remained open. The right lung contained tubercular deposits scattered throughout its substance; its lower parts were remarkably congested, and large portions presented traces of recent pulmonary apoplexy. One of the two primary branches of the artery on this side was completely obstructed by a strongly adherent coagulum, the lower portion of which, which had been exposed to the current of blood in the primary arterial branch, projected in the form of a rounded pellet: it

was of a dusky purple colour, and was about the size of a common marble; but, immediately beyond this part, the vessel became greatly contracted upon the adherent clot, which internally had a semi-transparent horny appearance, like the outer layers of coagulum in very old aneurisms. A small portion only of the lower lobe of the left lung contained air; its remaining portion was compressed, tough, and solid, and reduced to a very small substance by an extremely thickened and cartilaginous state of the adherent pleural surfaces. Its centre was occupied by a large cavity, the surfaces of which appeared to have been placed nearly in apposition by compression. The pulmonary branches on this side were extremely large; two considerable tertiary branches were completely obstructed at their origins by adherent clots, which did not project from the orifices. Where the coagula were torn from their attachments, there merely remained a rough surface tinged with blood. The left ventricle was rather large, but it appeared small when compared with the right. The aorta was healthy. The liver presented an extreme degree of "hob-nail" contraction. The kidneys were large, and coarse in structure.

*Occurrence of clots in the pulmonary branches in association with rheumatism.*

Like the trunks of the systemic arteries, those portions of the afferent vessel of the lungs which are situated above its valves appear usually to enjoy an almost complete immunity from severe inflammatory lesions in cases of rheumatism. I have already, however, had occasion to quote an instance (M. Meli's case) which probably formed an exception to this rule. In the following example, also, there appear to be strong grounds for believing that the arterial lesions were due to that vitiated condition of the blood which is known to attend rheumatic cachexia. In this instance, however, the deposition of clots in the vessels appears to have depended upon a less acute form of inflammation than that which attacked the vascular system of M. Meli's unfortunate patient.

A respectable married woman, 29 years old, was admitted into St. Bartholomew's Hospital, under the care of Dr. Burrows, on the 5th of May, 1843. She had enjoyed good health till the previous October, when she had rheumatism, which affected rather severely all the large joints in succession, and lasted for six weeks. After her recovery, she had occasional wandering pains, and three weeks before her admission she noticed that her eyelids and face began to swell, and her joints, especially her knees and elbows, became swollen and painful, so that on the fourth day of her illness she was

\* Cases II. and III., vol. xxvii. pp. 168-171.



obliged to confine herself to bed. On admission, the swelling of the joints had subsided, but they were stiff and tender; her feet and ankles were slightly œdematous. She was extremely weak and languid, complained of great thirst, and lay on her back, unable to lie on either side. She breathed 32 times in a minute, with some difficulty occasionally. Her pulse was 116, and soft. Her complexion was sallow, with flushed cheeks, dark lines around the eyes, and sharpened features. The lips were dry and pale, the tongue dry and furred, with a red tip. An abundant hot and acid-smelling perspiration was on the skin, and the urine was scantily but naturally secreted. Auscultation of the heart's sounds detected nothing unnatural. For three days after her admission no material change in her condition ensued. Nutritive diet, and gentle purgatives and diaphoretics, were given, and she appeared slightly improved; but the great depression of the system, the anxiety of expression, and the rapid pulse and respiration, persisted. She perspired profusely, and was very thirsty. For two days the abdomen was distended, tympanitic, and rather painful on pressure: on the next day she complained of great tenderness in the right iliac region; and on this day also (May 9th) the præcordial region was found tender, and on auscultation a distinct bellows-sound was heard at the base of the heart, accompanying the systole. The state of the joints varied from day to day. On the 10th, the cheeks and forehead were covered with an erysipelatous blush, and numerous red acuminated papulæ had appeared upon the chest; the urine was very irritating, and smelt offensively; sloughs had begun to form upon the sacrum, and the weakness and depression were increased. On the morning of the 11th, after passing a comfortable night, she was suddenly seized with a sensation of great tightness in the præcordial region, violent palpitation of the heart, and the most urgent dyspnoea. The attack lasted for an hour, and then she returned to nearly the same state as she had been in before it: but from this time she sank more rapidly. Upon auscultation, no respiratory murmur was heard below the right breast, and it was dull on percussion; the habitual dyspnoea became greater, the sloughs on the nates and sacrum extended, the abdomen became again tympanitic and tender, especially about the right iliac region. She vomited several times, and died in the afternoon of the 13th. Dr. Burrows observed that the symptoms were very obscure at the time of the patient's admission; he regarded the case as one of rheumatism occurring in a woman of feeble constitution. Upon the appearance of the remarkable symptoms on the morning of the 11th of

May, he formed the opinion that she was attacked with passive pneumonia of the right lung, and he considered it highly probable that the constitution was suffering under the depressing effects of the typhus poison, for there were several severe cases of typhus fever in the beds adjacent to that of the patient at this time.

At the examination forty hours after death, Mr. Paget found all the blood which appeared in the ordinary course of the dissection, either fluid, or coagulated in soft black masses. The pericardium contained half an ounce of fluid; there were a few slender adhesions between the trunks of the large vesseis, and on the surface of the heart were two white spots. The heart was of ordinary size, and its parts well proportioned, but its tissue was rather weak and pale. The valves on its right side were thin, clear, and healthy; those on the left side were a little thickened and opaque, but quite pliant. In the coats of the aorta were a few scattered fatty deposits; those of the *pulmonary artery* were healthy. Each pleural sac contained a small quantity of clear fluid, and at the apex of each lung there was an adhesion, with a few dry and shrivelled tubercles beneath it. The lower lobes of both lungs were slightly but generally œdematous, and gorged with blood. The upper lobes, with the exception of the small groups of old tubercles, were healthy. The air-passages were also healthy. Nearly half the branches of the *pulmonary artery*, from those of the second order to those of the fifth and sixth, (and probably to yet smaller branches), were blocked up by old coagula of blood. These were cylindrical, soft, and grumous, and in colour were a mixture of pale pink and dirty greyish white, with spots and blotches of deep crimson. They were not more numerous in one lung than in the other, and were irregularly scattered through all parts of each. They did not quite fill the vessels which contained them, but at various parts they adhered closely to the walls. The trunk of the pulmonary artery, and many of the branches, which did not contain coagula of the kind just described, contained fluid and softly clotted black blood. The abdominal and pelvic organs were healthy in their structure, but very pale and weak.\* It appears to be rather uncertain whether the violent aggravation of this patient's symptoms, which occurred suddenly three days before her death, depended, as Dr. Burrows conjectured, upon the supervention of passive pneumonia, or upon the formation of soft coagula in the already greatly obstructed pulmonary branches. Either of these causes would have been sufficient to account for the great præcordial

\* Mr. Paget's first Memoir, loc. cit. p. 174.



distress, palpitation, and dyspnoea, with which the patient was then attacked. It is highly probable that both these influences in some measure concurred to produce the symptoms in question, but the latter doubtless had the greater share in determining the fatal result.

*On the occurrence of adherent coagula in the pulmonary artery in association with apoplexy of the lungs.*

M. Cruveilhier appears to have been one of the first writers who observed the coincidence of coagula of long standing occupying a more or less extended portion of the pulmonary arterial tract with apoplectic extravasations into the tissues of the lungs. He remarks\* that in a case of pulmonary apoplexy accompanying disease of the heart, he found all the arterial divisions which impinged upon the extravasations filled with concretions which ramified with the vessels. The clots which filled the smaller divisions of the artery were solid, and of a reddish colour; those which occupied the larger branches were hollow and decolourised. These clots did not adhere to the arterial parietes, neither did the latter present any appearance of inflammation. In 1838 I brought forward notes of a few cases† in which I had met with a similar train of morbid appearances; but it is to Mr. Paget that pathologists are indebted for an exposition of the frequency with which these lesions occur, and for a description of the anatomical characters which they usually present.‡ This gentleman observes that in all, or in a great majority, of cases of pulmonary apoplexy, especially in that form of it in which the blood collects in a defined and compact dark mass, the branches of the pulmonary artery, leading to the seat of effusion, are blocked up by coagula, which present the distinguishing characters of those formed long previous to death. In most cases (perhaps in all those which depend only on disease of the heart), he has remarked that the coagula are found in those branches alone in which the circulation is obstructed, but, in some instances, they extend further, the apoplectic effusion being inconsiderable in comparison with the size and number of the branches which are filled by coagula. These cases, he considers, make it highly probable that sometimes the formation of coagula in the pulmonary arteries, when found combined with pulmonary apoplexy, has been not consequent on the effusion of blood but coincident with it, or has, in some measure, preceded it.

\* Anatomie Pathologique du Corps Humain, t. i. livraison iii. p. 3.

† Since published in Guy's Hospital Reports, No. 13: Observations on Acute Aortitis.

‡ Medico-Chirurgical Transactions, vol. xxvii. p. 163.

It is almost needless to say that pulmonary apoplexy most frequently results from severe and long-continued causes of mechanical obstruction to the circulation through the lungs—such as chronic bronchitis, contraction of the mitral and aortic ostia, aneurisms of the ascending aorta, &c. It is evident, however, that the structure and arrangement of the pulmonary vessels are admirably adapted to enable those tubes to resist the injurious mechanical effects of inordinate distension during very lengthened periods. The remarkable pliability and tenacity of the branches of the artery, which impart to them a close similarity to the internal veins, have already been alluded to at the commencement of this memoir; and all morbid anatomists must have observed that, in their capability of undergoing extreme distension, the pulmonary veins are scarcely equalled by any other set of vessels in the body. This has evidently been provided for in the peculiar mode in which these veins are distributed throughout the lungs. Dr. Addison has demonstrated that the branches of the pulmonary veins do not accompany those of the pulmonary artery in all their ramifications, as was supposed by the older anatomists, but that they lie separately at the bottom of the pulmonary fissure, surrounded only by a loose cellular membrane, and resting merely upon the surface of the unbroken pulmonary tissue. These vessels are thus, throughout their whole course, found to be situated on the exterior of the aerial cellular structure of the lungs.\* Hence the artery is admirably adapted to endure temporary or long-continued distension consequent upon obstruction to the transit of blood through the pulmonary capillaries; while, under circumstances of impediment to the free emptying of the pulmonary veins, both sets of vessels are capable of assuming the condition of reservoirs, in which the delayed blood is permitted to accumulate.†

\* Observations on the Anatomy of the Lungs, by Thomas Addison, M.D. Medico-Chirurgical Transactions, vol. xxiv. p. 153. 1841.

† The degree in which the pulmonary arteries and veins admit of being dilated, is generally displayed in extreme cases of contraction of the left auriculo-ventricular orifice, where care has not been taken during life to reduce very considerably the volume of the circulating fluid. The extraordinary amount of dilatation which may be produced in the pulmonary veins by causes of direct obstruction, is well illustrated in a case related by Dr. R. Townsend. A man, æt. 62, died asphyxiated, after having long suffered from frightful periodical attacks of suffocative orthopnoea. About twelve months previously to his death he had profuse hæmoptysis, but this did not again recur. On examination, the pulmonary veins were found enormously loaded with blood, being dilated to at least four times their natural size; those vessels, which are naturally no bigger than crow-quills, being as large as the fingers of a glove. This state of the veins was



The question of the source of the extravasations in pulmonary apoplexy has long formed a subject of discussion with pathologists. The opinion formerly entertained that in these, as well as in some other forms of disease attended with hæmoptysis, the blood escaped from unbroken vessels by a process of exhalation, has probably been wholly abandoned, since a more careful investigation of structural anatomy has proved the impossibility of such an occurrence. The practical researches of Mr. Hilton have, I believe, enabled that gentleman to enunciate the principle that hæmorrhages invariably occur from the open mouths of vessels. It still remains, however, to determine from which set of pulmonary vessels these extravasations take place. The extreme frequency of large deposits of coagula in branches of the pulmonary artery would lead to the conclusion that it is from these canals that the hæmorrhage occurs. I am inclined to believe that, in some cases, especially where the extravasations are remarkably large, the blood is effused from arterial branches of considerable size. In one of the first examples of pulmonary apoplexy which I examined minutely, I felt convinced that many of the smaller branches of the artery had suffered rupture, followed by extravasation of blood into the substance of the lungs. Upon opening the vessels which led into the clots, their linings were found softened, and presented other very decided marks of acute inflammation: other portions of the artery also displayed similar changes. This occurred in a patient who died from the effects of long-continued bronchial obstruction. It is evident that in cases of this particular description, as the cause of impediment exists merely in the capillary circulation of the lungs, the extravasations must necessarily occur from some portion of the arterial tract, the venous system of the organs remaining perfectly free from undue distension. In a large proportion of instances, however, (as in Cruveilhier's case already cited,) the structures of the arteries, which are found obliterated, or obstructed by clots, do not pre-

found to arise from the compression which they suffered at their entrance into the left auricle, the parietes of which seemed converted into one solid unyielding mass of tubercular matter, nearly an inch in thickness, developed in the tissues of the auricles; and, by the pressure which it made on the pulmonary veins, diminishing their calibre so much that a probe could with difficulty be passed through them into the auricle. In the narrative of this case no allusion is made to the presence of adherent clots either in the dilated veins or in the pulmonary artery, or right cavities of the heart, nor to the existence of any traces of pulmonary apoplexy, although that lesion was doubtless present at the time when the attack of hæmoptysis occurred. ("Contributions to Pathological Anatomy," and Medical and Physical Journal, vol. lxxviii. p. 520.)

sent any very evident traces of recent inflammatory change: hence it is probable that, either the tissues of the vessels, having been long protected from irritation and over-distension by the attached coagula, have had time to regain their natural condition, or that the effusions have been due to rupture of some of the pulmonary capillaries. In discussing this question, M. Cruveilhier, after alluding to the obstructed condition of the arterial branches, mentions the fact that Laennec discovered coagula in some of the divisions of the pulmonary veins in a case of apoplexy of the lungs. This, however, I believe to be a rare and exceptional occurrence. Mr. Paget, who has evidently examined the lesions which attend this disease with great minuteness, makes no allusion whatever to coagula in the pulmonary veins, nor has such a condition presented itself within my own observation. It is evident that the pulmonary veins are very far more dilatible than the pulmonary artery; and, although they may occasionally suffer rupture\*, this lesion very unfrequently, indeed, takes place, even under circumstances of extraordinary distension. I am very strongly disposed to believe that, in the great majority of instances of apoplexy of the lungs, the pulmonary artery, having long been submitted to inordinate distension, at length becomes irritated and inflamed by the continued presence of highly carbonised blood within its dilated and now inelastic branches, coagula gradually become deposited over tracts of the diseased and yielding vessel, which they alike defend from the contact of the blood and from the occurrence of ulceration or rupture in those situations. Subsequently, however, branches of the vessel give way, and permit the escape of blood into the pulmonary substance: the extravasation continues to extend as far as the elastic tissues of the lung will admit, and then, doubtless, the open vessel becomes compressed by the surrounding coagulum, and is subsequently further defended by the deposition of a solid clot in its interior. This view is not wholly theoretical, as it will be found that the morbid appearances, which have next to be described, afford very strong evidence of its validity. My own observation does not enable me to decide the question of whether pulmonary apoplexy ever

\* M. Portal has recorded a case in which a rupture, nine-tenths of an inch in extent, occurred in one of the left pulmonary veins near the point of its emergence from the lungs. The sigmoid valves of the aorta were greatly diseased, and caused impediment; the entire heart was enormously dilated, the pericardium being inseparably adherent. The left pleural cavity was full of blood. This occurred in a person 21 years of age, who died during a fit of hæmoptysis, having suffered from symptoms of cardiac disease for three years previously, (Memoirs of the Royal Academy of Sciences at Paris, 1784.)



depends upon rupture of the bronchial arteries. It is, however, evident that the opinion which has been held by some pathologists that this lesion may result, in cases of hypertrophy of the left ventricle of the heart, from the violence with which the blood is propelled through these slender vessels, is wholly inadmissible. It is by no means improbable that where, in addition to long combined obstruction to the pulmonary circulation, the orifices of these vessels become, as frequently happens, greatly contracted, owing to the formation of bulky interstitial deposits in the subserous tissue of the descending aorta, their canals, being thus exposed to a very inordinate degree of distension, may become ruptured within the substance of the lungs, and produce appearances closely similar to those which characterise the ordinary forms of diffused pulmonary apoplexy.

The following case, by Mr. Paget, affords an excellent example of the various morbid appearances presented by the pulmonary artery in the severe forms of apoplexy of the lungs depending upon mechanical obstruction to the circulation.

A widow, 70 years old, thin and emaciated, came under treatment with symptoms of severe thoracic obstruction, supervening upon the aggravation of a winter cough. She sunk rapidly on the third day after her admission. Dr. Burrows remarked an extreme hurry of the circulation, with febleness of the pulse, and great prostration of strength.

In the examination 36 hours after death, the lungs were found of ordinary size, but deeply wrinkled when collapsed. There were a few scattered adhesions on their anterior surfaces. Their tissue was generally light and crepitant, and in a few parts slightly oedematous; the air cells were of ordinary size, except about the lower and anterior margins of the lobes, where there was a moderate degree of emphysema. In a few parts the pulmonary tissue was compressed, and at the anterior and lower border of the left lung was a small patch of compact pulmonary apoplexy, with some diffused apoplexy around it. The bronchi were of ordinary size, their mucous membrane thin, pale, and firm; their tubes full of thick, semi-transparent, viscid mucus. In each lung, one of the superior, and one of the inferior main branches of the *pulmonary artery* were blocked up by a large, firm, mottled, clot of blood, which from itself, as a trunk, sent branches into two or more of the next order of branches of the artery. The colours of the clot were black, deep crimson, rusty, pink, and yellowish, in various irregularly mingled shades; they were moderately firm, of nearly uniform consistence throughout, and capable of being rubbed into a thick grumous substance;

they adhered so firmly by parts of their surfaces to the adjacent walls of the vessels, that they could not be smoothly removed. The branches of the largest clots did not extend far into the arteries, but terminated abruptly in the arterial ramifications immediately proceeding from those in which they lay. But beyond their terminations, many smaller branches of the pulmonary arteries in all parts of the lungs contained short, firm, dry, mottled, and adherent clots, variously coloured. None of these were long or much ramified; none were continued through more than two branches, and many of them were not more than half or three quarters of an inch long; some were even shorter, and lay like bits of large clots upon the walls of the vessels; they had all the same characters as those already described, and the portions of lung adjacent to and beyond them were not different from the rest. Moreover, in several of the larger branches of the artery, there were appearances of clots of blood formed like those just described, and having been still further altered and organized. There were pale, semi-transparent, soft, and flattened narrow bands, attached firmly to the walls of the artery, and presenting all the characters of the organized clots which the narrator has sometimes seen adhering to the walls of divided arteries. They were from one quarter of an inch to an inch in length, and about one-tenth of an inch wide; a few were fixed in their whole length to the walls of the artery, but most of them by their ends only, so that a probe could be passed under them. Among the clots there were all gradations, between those last and those first described; and, in one instance, one of the largest of the more recent clots was continuous with a flat, semi-transparent, and adherent portion, like those which had existed for the longest time. (These appearances are well represented in a plate.) The branches of the pulmonary arteries which were thus obstructed were firm and polished internally, but in many places had fine, scattered, and grouped grains of yellow deposits in their coats. They were all of natural size, and the pulmonary veins were healthy. The cavities of the right side of the heart were considerably dilated and hypertrophied. Both of them were distended by soft and uniformly black coagulum, slightly adhering to their walls; and in the appendix of the right auricle the coagulum had become firm, mottled, and closely adherent, somewhat like those in the pulmonary arteries. The left auricle and ventricle were also dilated and hypertrophied, but in a less degree than the right; they contained a smaller quantity of similar soft, black coagulum. The tricuspid valve was healthy; the pulmonary valves were



large, and in small patches, opaque, but thin and pliant; the mitral valve was slightly thickened, and had several spots of soft yellow substance beneath its ventricular surface; the aortic valves were also irregularly thickened and opaque, with enlarged corpora Arantii, bearing small warty growths; but both they and the mitral valves might be deemed able to discharge their functions. The liver was small, tough, and granulated, and a great part of its surface was covered by long adhesions. The gall-bladder was full of calculi. The kidneys were small, and somewhat granulated, with adherent capsules, and numerous cysts full of transparent fluid. The large veins and the systemic arteries, as far as they were examined, were healthy.\*

The morbid appearances described in the above narrative very closely indeed resemble those which I have myself frequently observed in cases of this description. I took the following notes after examining the lungs of a strong middle-aged man, who died, with bronchitis, hydrothorax, and extensive pulmonary apoplexy, at Guy's Hospital, in September 1846:—

A large secondary branch of the *pulmonary* artery was completely blocked up by a firm decolourised coagulum, evidently of long standing, the end of which hung into the cavity of the primary division of the vessel, in the form of a pedunculated, hollow, fibrinous concretion, of oval form, precisely similar to those cystiform fibrinous deposits which have been so accurately described by Dr. Hughes as adhering to the internal parietes of the heart, in many cases of cardiac obstruction.† While tracing out the branches of the vessel, my friend Dr. Gull pointed out to me two small blueish spots, which at first sight appeared to have been produced by effusion of blood beneath the arterial lining. It was impossible to distinguish with the unaided eye the polished surface which covered these thin deposits, from the epithelium of the vessel; still they could be peeled off, leaving a perfectly smooth surface of artery beneath. In examining one of the secondary branches of the vessel, I found that its calibre had become greatly contracted by the presence of a firmly adherent deposit of this kind, which extended to a distance of two or three inches. It occupied about one-half of the periphery of the artery, leaving a free, though greatly diminished, canal for the passage of blood. It appeared to be of considerable standing, being nearly decolourised, and of very dense consistence. It seemed probable that the transit of blood had gradually smoothed down the exterior of this deposit, until it at length presented a level and polished surface, which appeared to

be perfectly continuous with the proper lining membrane of the artery.\* The heart of this patient was hypertrophied, and his aorta rather dilated, but there was no marked degree of valvular disease. These appearances, it will be observed, closely resembled those which were observed by Mr. Paget in the preceding case. It can scarcely be doubted that, in both instances, the deposition of coagula, in the larger branches at least, was due to a certain amount of inflammation set up in the tissues of the over-distended vessels. Both cases are rather extreme examples, but they may be taken as fairly representing the general character of the morbid appearances which more or less extensive tracts of the artery will be found to present in the majority of instances of true pulmonary apoplexy.†

Occasionally some of the larger branches of the pulmonary artery leading to the apoplectic portions of lung are found completely coated with tubular fibrinous deposits, as was the case in a female who died with old obstructive and regurgitant mitral disease at Guy's Hospital in December 1845.

\* I have never observed an appearance precisely similar to this in any of the systemic arteries. In these vessels, where a portion of fibrinous coagulum becomes deposited upon the lining of the tube, its surface usually remains to a certain degree granular and rough, and is always ready to receive fresh deposits from the blood. The only exceptions to this rule are the cystiform clots, which are produced in the cavities, and, occasionally, about the valves of the heart, and which generally present a smooth exterior; and the interiors of old and partially cured aneurismal sacs, the coagulum of which sometimes offers a dense and polished surface to the current of blood. In general anatomical characters the mode of deposition of coagula in the pulmonary artery bears a close similarity to that process as it occurs in the veins. In many cases, large coagula, which either coat or occlude portions of the larger branches, peel off with the greatest readiness from the interior of the vessel, leaving the epithelium smooth and, not unfrequently, free from discolouration. It is evident that here, as in the veins, the deposition of clots is designed as a means of protecting inflamed surfaces of the vascular tract, and of guarding them against distension, and the irritating contact of the blood; the circulation through these vessels is for a time either diminished or suspended until the inflamed surfaces have regained their healthy condition, or have ceased to be acutely diseased, and then the deposit is entirely absorbed or remains permanent, according to the degree in which it has previously become adherent to the vessel. Uneven and granular clots may frequently be observed in the pulmonary artery; indeed, it is probable that all fibrinous deposits in this vessel at first present rough surfaces which, if life be much prolonged, have subsequently a tendency to become smoothed and levelled.

† I have here restricted the term "pulmonary apoplexy" to those cases in which ulceration or rupture of portions of the vessels of the lungs is followed by the extravasation of considerable quantities of blood into the tissues of those organs, excluding those instances in which nearly the whole of the effused blood finds exit by the air-passages.

\* Op. cit., vol. xxvii. p. 178.

† An appearance of this kind is represented in Mr. Paget's engraving already alluded to.



Here I found apoplexies in various portions of the lungs. The ascending trunk of the pulmonary artery was dilated, and coarse in structure, but free from opacity or interstitial deposit. One of its primary branches was coated, but not obliterated, to the distance of about an inch and a half or two inches, by a layer of partially decolourised clot, which closely adhered in some spots, and was merely glued to the interior of the vessel in others. Other fibrinous coagula which adhered to this led into the various ramifications of the vessel, but did not completely fill the larger ones. The lining membrane was discoloured, as if ecchymosed, at the spots where the clot adhered most strongly, and was perfectly clear where it was most loosely attached. The whole of the surrounding lung-tissue was filled with dark and rather softly coagulated blood, but no rupture could be detected in any of the larger vessels.

I have never seen any instance in which lesions of the above description extended throughout the entire tract of the pulmonary artery in cases of apoplexy of the lungs. Neither have I ever, under such circumstances, found the valves, or the first two inches of the vessel, occupied by clots, or bearing any traces of recent inflammation.

It will generally be observed that a more or less adherent clot occupies a considerable tract of the branch from which the hæmorrhage has occurred; but other branches may often be traced through the clot, which remain quite pervious, and present no appearance of having been at all injured in their structures by compression—a fact which appears to prove that the formation of clots within the vessels is not, in this instance, the result of external causes. The vessels which lead to the extravasations are usually most replete with coagula, but their entire tract is not always obstructed by these masses: very frequently the clots are deposited at intervals, leaving portions of the vessel an inch or two in length apparently free from disease.

It would appear that occasionally very large deposits of this kind occur in the vessel, and remaining for months, perhaps for years, as causes of obstruction to the circulation, aggravate considerably the symptoms from which the patient suffers, without tending immediately to hasten the fatal termination of the disease. This appears to have been the case in the following instance.

A woman, aged about 36 years, died at Guy's Hospital in August 1845, having suffered from extreme difficulty of breathing, with marked lividity of the countenance. She was incapable of lying down; there were the evidences of pleuritic effusion on

the left side, and a loud superficial bruit was heard over the right ventricle. The pulse was small, rapid, and feeble.

On inspection, a large quantity of serum was found in both pleural cavities. The larynx was rather narrowed. The bronchi contained a brown viscid secretion; there was intense vascularity of the pulmonary mucous membrane; the lungs were congested, and partially emphysematous, and presented a certain degree of apoplectic mottling at various spots. The pericardium contained a moderate quantity of clear serum. The right auricle was exceedingly capacious, and its walls thick. The tricuspid orifice was contracted by deposit beneath its endocardium, forming a wrinkled edge rather less than two inches in circumference. The right ventricle was somewhat dilated: its walls were remarkably strong and thick. The *pulmonary artery* was rather below than over the average size: its left primary branch was obstructed, at its commencement, by a singular tongue-shaped mass, which projected upwards to the distance of about an inch and a half, having a broad base of attachment below, and gradually diminishing in size, and tapering to a point above. The lower and wider portion of this growth had the appearance of having been deposited between the coats of the vessel, as its polished surface was quite continuous with the lining membrane, but it had evidently been formed upon the interior of the artery in the manner which has been already described. This mass also formed a dark prominence on the exterior of the vessel, and it projected so considerably inwards as greatly to narrow, although it did not altogether occlude, the arterial canal. The most pointed part of this body was evidently formed of decolourised coagula of blood: the interior of the mass had the appearance of blood which had long been enclosed until it had become colourless and friable. No other deposits were discovered in the branches of this vessel. The left auricle was enormously dilated; the auriculo-ventricular orifice was extremely contracted and bony, barely admitting the handle of the scalpel. The lower mitral orifice was also contracted. The left ventricle was small: its walls were about equal in thickness to those of the right. The aortic valves were efficient, but rather thickened. The aorta was nearly of the average size. The liver and kidneys were congested, and rather contracted, but there did not appear to be more disease about these viscera than would inevitably result from the extreme and long-continued cardiac obstruction.

Although, in the majority of cases, pulmonary apoplexy, with its attendant lesions, is due to the influence of some fixed impedi-



ment to the circulation, it may evidently result from any cause which greatly diminishes the cohesion of the pulmonary vascular tissues, whether that cause be inflammation, over-distension, or a highly vitiated condition of the blood. Dr. Byron mentions\* that the lesion in question was very frequently met with in the bodies of those who were carried off by the epidemic yellow fever of Gibraltar in 1828. He also refers to its occurrence in that form of low typhoid fever which was formerly known as "typhoid pneumonia," and narrates cases in which extensive extravasation of blood into the lung occurred, to all appearance, merely as the result of a species of hæmorrhagic diathesis. The occasional association of pulmonary apoplexy with gangrene of the lungs has been remarked by several authors, especially by Dr. Graves and Dr. Thomas Addison. The former gentleman denies that the effused blood is capable of producing inflammation, gangrene, or softening of the affected portions of the lung; the latter considers that the circumscribed gangrene of Laennec is commonly a mere effect or advanced stage of pulmonary apoplexy. It is evident that gangrenous disorganization of the substance of the lung may occur independently of any clear evidences of the previous or concurrent existence of apoplectic effusion: it is also certain that most extensive extravasations of this kind are frequently met with where the vitality of the surrounding lung substance does not appear to have suffered in the least degree from the presence of the adventitious mass of coagulum; still it cannot be denied, that, where the constitutional powers have been previously greatly lowered by asthenic disease, the disintegration and compression which portions of the lung sustain in consequence of these effusions may, not improbably, be followed by sloughing of the parts. Nevertheless, I am inclined to believe, that, in most of the cases where gangrene and apoplexy are found associated with each other, the effusion of blood has been the secondary lesion consequent upon the rapid destruction of vessels which have not become sealed in the ordinary manner previously to their implication in the gangrenous action. In the generality of cases of this kind the hæmorrhage probably arises from small vessels, the larger branches having become closed by coagula, or retaining sufficient vitality to be capable of resisting the destructive process. Death, however, has been known to result from the sloughing of a considerable branch of the artery occurring during the rapid progress of gangrene of the lungs.

\* "Rare Cases," Dublin Journal, vol. xxvii. p. 67.

*Occurrence of adherent coagula in the pulmonary branches in cases of malignant disease.*

Mr. Paget was, I believe, the first author who fully directed the attention of pathologists to the fact that when the matter of medullary cancer or scirrhus passes into the blood, and circulating with it, is stopped in the capillary vessels of the lungs, the branches of the pulmonary artery may be to a great extent filled by it, and by coagulated blood or fibrine mixed with it. He offers the following case as a good example of this fact:—

A woman of drunken habits, 45 years old, had been in St. Bartholomew's Hospital with all the symptoms and appearance of one suffering from cirrhosis. She could assign no distinct date to the commencement

\* *Note on Cases of Pulmonary Apoplexy.*—If, in the present state of pathological knowledge, it were necessary to bring forward a variety of facts in proof of the opinion that large extravasations of blood into the tissue of the lungs result from the active bleeding of open vessels, and not from transudation or exhalation, as was formerly maintained, very strong evidence would be found in those cases where large apoplectic effusions have produced rupture of the pleura pulmonalis, and proved suddenly fatal by hæmorrhage into the thoracic cavity. It is quite evident that such a lesion as this could not result from a gradual oozing of blood into the pulmonary tissue. Almost instantaneous death from the effusion of three quarts of blood into one of the great serous cavities (see case by Dr. Ferguson, in the first vol. of the Dublin Med. Transactions, p. 11) can only occur as the result of rupture of some considerable vessel. It is true that, in the case just alluded to, as well as in several others which have been collected in an interesting memoir by Dr. Paterson, ("Observations on Pulmonary Apoplexy proving fatal by rupture of the periphery of the lung by effusion of blood into the pleura"—Edinburgh Med. and Sur. Journal, Jan. 1846), the vessels from which the hæmorrhage proceeded were not detected. This, however, is not remarkable, when the torn and infiltrated condition of the pulmonary tissues in those cases is taken into account. The plan usually adopted by Mr. Hilton, of slowly injecting water from a large syringe into the vessels of the part or organ from which the bleeding is known to have occurred, is usually most successful in discovering the breach of vascular continuity. But even the failure of this means is by no means sufficient evidence that the hæmorrhage has not occurred from some considerable vessel which has either become closed, from the coagulation, subsequently to death, of the surrounding infiltrated blood, or from the formation of a plug in its canal upon the occurrence of the fatal syncope.

This class of cases also affords an interesting proof of the great influence which the elastic property of the tissue of the lungs has in controlling hæmorrhages which occur within those organs. Pulmonary apoplexy rarely, if ever, proves suddenly fatal when the open vessels lie deeply towards the interior of the lungs; on the contrary, when the lesion occurs near the surface and the pleura becomes ruptured, death from uncontrolled hæmorrhage appears to be the almost necessary result. Good specimens of clots deposited in the pulmonary artery, in association with pulmonary apoplexy, are preserved in the collection at Guy's, Preparations 145055 and 145060.



of her disease, and died very much emaciated, jaundiced, and with considerable ascites and anasarca of the lower extremities. On examination thirteen hours after death, the author found the liver large, hard, yellow, and dry and adherent to a contracted great omentum. It contained several medullary tumors, composed of very soft tissue, out of which could be pressed a large quantity of pulpy matter of golden or king's-yellow colour, mixed with various shades of green and brown. A quantity of the same matter, but more nearly fluid, seemed loosely effused in the substance of the liver, and some more of it was contained in the large hepatic blood-vessels. In each of the lungs, irregularly scattered through every part, there were nearly a hundred small masses of medullary matter, of the same bright yellow colour as those in the liver. They did not form any tissue, but appeared loosely effused, so that, after any one of them was cut through, each part of it could be wiped away without injuring the structure of the lung. A similar yellow substance, but apparently thinner and more nearly fluid, filled a number of the small branches of the *pulmonary artery*, in such a manner, that, on a section of the lung, fine yellow ramified lines were seen, as if the arteries had been injected with chromate of lead and size, or some thick material. There could be no doubt that the cancerous substance had been conveyed with the blood from the liver to the lungs, where, being arrested, and obstructing the minute vessels, it had permitted fresh substance, with blood, to accumulate behind it. Mr. Paget further adds, that there is a preparation from another case of the same kind in the museum of St. Bartholomew's Hospital (Diseases of the Lungs, No. 19); but the characters are less marked, because the cancerous matter is uncoloured. He has notes of a third similar case; and in another preparation in the same collection (Diseases of the Blood-vessels, No. 100) the trunk of the left pulmonary artery is filled by a large firm mass, apparently composed of fibrine mixed with cancerous matter, which extends into all the branches that are preserved. This was taken from a lady, from whom, in the course of eleven years, Mr. Lawrence removed, at different times, both breasts, and three large tumors which formed upon or between the cicatrices left after former operations. In the first breast removed (in May, 1828) there appeared only an enormous enlargement of the mammary gland; in the second (in 1834) a large tumor, resembling most the carcinoma hyalinum of Müller, was removed. In the three following operations, performed in 1835, 1837, and 1839, the tumors removed were distinctly medullary. The patient

died suddenly while she seemed in progress of recovery. In the examination, the left lung was found everywhere adherent, and extremely congested; the right lung was not adherent, but pale, œdematous, and somewhat emphysematous: its vessels were healthy. There were no cancerous deposits in either lung, nor any in the bronchial glands.\*

The well-known appearances which usually so strongly characterize the solid coagula found in vessels which communicate with extensive fungoid deposits, and more especially the detection of cancer cells within them, will prove the best tests of the malignant origin of these clots. It will, however, be borne in mind, that, in advanced stages of cancerous cachexia, inflammation is occasionally liable to attack many of the larger vessels of the body quite independently of any impediment produced in their channels by the lodgment of malignant debris. The subjects of advanced cancer are always liable to the occurrence of insidious inflammation of internal surfaces and organs, in consequence of operations and other vicissitudes; and in those cases the arteries and veins certainly participate in this tendency to acute and subacute asthenic lesion.

I have been favoured with the following case of morbid growth in the pulmonary artery, by my friend, Dr. Edmund L. Birkett, in whose practice it occurred. It presents several interesting features; but it appears difficult to assign the precise cause to which the formation of the polypoid mass was due.

Caroline P., æt. 25, married, but without family, inhabiting an ill-ventilated room in a badly-drained part of Bermondsey, had been seriously ill fourteen days when Dr. Birkett first visited her (Feb. 18th, 1846). She had been frequently subjected to exposure to cold, and had, in consequence, experienced many attacks of inflammatory thoracic disease. When first visited, her aspect was anxious and distressed: there was great dyspnoea, amounting to orthopnoea; slight cough, but without expectoration; pulse quick, sharp, vibrating, and without strength. She complained much of palpitation, and of pain, occasionally very severe, about the præcordial region. The heart's action was tumultuous, its rhythm natural, its impulse stronger than natural. The chest, on percussion, was resonant, and the respiratory sounds loud, with occasional dry bronchitic rhonchi. There was also slight emaciation and irritability of stomach. During the whole period of the illness there was no material change, excepting as re-

\* Op. cit. vol. xxvii. p. 165.



garded the heart; for here, at a subsequent period, was observed a to and fro sound, superficial, and most audible a little to the right of the nipple, and not traceable along the course of the aorta. About the same time, the respiration, though distressed throughout, appeared to become so far relieved as to admit of her lying in the horizontal posture. The pulse retained the same character throughout, though becoming towards the last much weaker. The irritability of stomach was relieved. At one time the micturition was accompanied by pain, owing probably to the action of the nitre contained in the medicine. Her mental faculties continued perfect to the last. The treatment was local depletion, with counter-irritation over the region of the heart, with mercury, salines, and purgatives. She died April 2d.

*Autopsy.*—Head not examined. Chest: a little clear serum on the left side; extensive old pleuritic adhesions; no signs of recent pleurisy; lungs congested posteriorly, of a dark red colour, and exuding, on section, frothy serum, but filled throughout with air; bronchial tubes natural, but containing some mucous secretion. Heart: no fluid in the pericardium, which was smooth, but white and opaque at parts; the heart was large, its nutrient vessels much gorged; the cavities were large, the parietes but little hypertrophied; the mitral valve was slightly thickened, but in other respects healthy, as were also the other valves. Within the *pulmonary artery*, at its point of division, was a circular space as large as a fourpenny-piece, surrounded by a ring of vegetations, to which was slenderly attached a mass of the size of a large walnut, of a yellowish colour, and, in substance, resembling the roe of a mackerel. The liver was slightly congested; so also were the kidneys; the intestines were healthy. The anterior lip of the uterus was swollen and dark-coloured.

Adherent clots may be found in branches of the pulmonary artery in various forms of long-continued direct and indirect obstruction to the pulmonary circulation\*; but in the generality of cases of this kind they will be observed to be associated with evidences of the previous existence of pulmonary apoplexy.

*On the occurrence of non-adherent fibrinous clots in the pulmonary artery.*

Most practical morbid anatomists must have observed that in very severe cases of pneumonia, bronchitis, mitral obstruction, disease of the valves of the systemic artery, and aortic aneurism, where death has been

preceded by a greatly protracted suffocative struggle, a tenacious branched coagulum of pale elastic fibrine is occasionally found to occupy the entire tract of the pulmonary afferent vessel, by no means completely filling it, and not apparently adhering to any part of the arterial parietes, which remain free from all traces of inflammatory lesion. It now appears to be generally admitted that these, as well as the condensed masses of recent fibrine which are so frequently discovered in the cavities of the heart, are probably formed some time previously to death, when the delay to the circulation is becoming extreme, and the contractile power of the heart begins to fail.

Dr. Corrigan has recorded an interesting case in which this appearance was found in the pulmonary vessels of a patient who died in the depressed stage of fever.

M. W., aged 70, admitted into Hardwicke Fever Hospital, 20th of November, 1845. For the last one or two years he had been much exposed to cold, and had suffered greatly from poverty. Fourteen days before admission, he was seized with rigors, headache, and vomiting. He became worse from day to day, lay in a small close room, and received little attendance. Symptoms on admission:—Shivering, and cold extremities; pulse very weak; tongue dry, hard, and dark-brown; all secretions and excretions scanty; countenance vacant; intelligence imperfect: he lies on his back, and makes no complaint. Treatment: ether, ammonia, and brandy. 21st, 22d, and 23d—Sinking continued, notwithstanding that he had freely of wine, brandy, ammonia, &c. He lay in bed on his back, making no complaint, with a pulse hardly perceptible. On the 23rd, the tongue was moist, with slight mucous rattle in the throat. On the 24th, he showed more restlessness, with an inclination to attempt getting out of bed. On that day he died.

*Post-mortem.*—The lungs were healthy in texture, with slight bronchial effusion. The tissue of the heart was healthy. The left ventricle contained grumous dark-coloured blood. A bulbous shaped polypus lay in the right ventricle, not sufficient to fill it. This polypus, narrowing gradually as it passed into the *pulmonary artery*, extended along this vessel, being about the thickness of a quill, then divided at the bifurcation of the artery, and continued its ramifications along the arterial branches. The extensive polypus of fibrine was so firm that, taking it by the root which lay in the right ventricle, it was drawn out with all its attached branches, unbroken from the artery. It was not attached any where to the sides of the vessels, but lay like a cord along their centre. Dr. Corrigan considers that the structure of the polypus shewed that it had probably been

\* Mr. Paget found deposits of this kind in the pulmonary artery in a case where the pulmonary veins were compressed by a medullary tumor. (Op. cit., vol. xxvii. p. 173). Similar appearances are also not unfrequent in various forms of obstructive disease of the left heart.



for some days in process of formation. It was very nearly destitute of the colouring matter of the blood, except in its smaller ramifications. It was not of great size, as is generally the case in polypi of recent formation in the cavities of the heart, but was firm, comparatively hard, and small compared with the size of the cavities in which it lay. Dr. C. considers, however, that the most satisfactory proof of its formation having occupied some time, is probably to be found in its structure. It consisted of distinct layers of fibrine. The outer layer or layers were comparatively soft, and when laid hold of, and pulled on, could be most readily drawn off the fibrinous cord which constituted the middle of this long tree-like polypus. This centre fibrinous cord was very firm and pale-coloured. The distinct layers into which the polypus easily separated, resembled exactly the separate layers which are found in successive deposits of lymph in the trachea in croup. It appeared evident that it had either been the cause or the consequence of the sinking of the powers of circulation. But, whether the cause or the consequence, it is plain that, when once formed, it would be a serious hindrance to the circulation, and would most probably, or even necessarily, cause death by its constantly increasing size, and the proportionately increasing obstruction which it produced. Dr. Corrigan adds a practical hint of the necessity of giving wine early in cases such as this, when the gradually failing power of the circulation is the prominent symptom in typhus fever.\*

The appearances presented by the laminated fibrine in the above case, seem to have so closely resembled those which are very commonly observed in the compressed yellow coagula found in the cavities of the heart, that they can scarcely, I think, be received as evidence that the coagula began to form in the ventricle and artery so early as Dr. Corrigan conjectures. Still the possibility of such an occurrence is not to be denied, and there is certainly very strong reason to believe that coagula of this description are, in all instances, formed previously to the cessation of the heart's action. Similar consistent branched coagula are occasionally found occupying the pulmonary veins in cases of obstructive disease. Two specimens of this kind are preserved in the collection at Guy's (numbered 1520<sup>28</sup> and 1520<sup>32</sup>)\*.

#### OBSTRUCTION TO THE PULMONARY ORIFICE CONSEQUENT UPON ENDOCARDITIS.

It has been shewn, at the commencement of this paper, that, during intra-uterine life, as well as for a certain period after the commencement of respiration, while the

ascending portion of the pulmonary artery forms the principal conduit through which the systemic vessels are supplied with blood, its structures are far more liable to become the seat of extensive inflammatory lesions, than are those of any other artery in the infant's body. I have alluded to the fact that where, in consequence of obstruction to the circulation through the lungs or aorta, the ductus arteriosus remains permanently open, the tissues of the pulmonary artery appear to retain much of their original liability to morbid change, and have been found to present lesions closely similar to those which are usually confined to the aorta and its valves. I have already entered into a consideration of the causes which appear to give to the commencement of the pulmonary artery in youth and adult life, so remarkable a comparative immunity from those diseases which are so frequently developed in the main systemic artery; and it is certainly most interesting to observe, that, while the left side of the heart and its vessels are liable to various morbid conditions, the gradual advance of which does not, in the majority of instances, necessarily tend to the destruction of life, until after the lapse of a somewhat protracted term of years, the corresponding structures on the right side, which, if equally diseased, would necessarily become the seat of very rapidly fatal obstruction to the circulation, are capable of bearing the most severe vicissitudes, with a remarkable degree of freedom from injurious consequences. I have been most strongly impressed with this fact in the examination of the bodies of those who have died from the remote effects of rheumatic endocarditis. During a period of nearly fourteen years in which I have had extensive opportunities of observing cardiac disease in nearly all its forms, I do not recollect to have met with any single instance in which narrowing of the left ostia of the heart, the sequel of rheumatism, was associated with any proportionate amount of lesion at the pulmonary orifice. In common with other parts of the heart, the commencement of this vessel is doubtless liable to participate in the effects of rheumatic endocarditis, but the lesions which the parts sustain appear to be so very rarely of a permanent nature, that neither my reading nor my observation affords me any definite information on the subject.†

The number of fully de-aired and indisputable recorded instances of inflammatory obstruction of the pulmonary orifice, occurring subsequently to the period of infancy, and independently of original defect in the

\* M. Hasse considers that the presence of the opaque coagula often found in the heart is to be regarded as the immediate cause of death.

† Except in those cases where the valves have been originally malformed.



valves, is so extremely small, that I am unable to arrange them in pathological order. In fact, after a very careful review of a considerable number of cases in which it might be presumed that disease of this orifice had been set up after the heart had attained its mature development, I have only been able to select two detached instances; and, even of these, the one which I shall now quote may not be considered as by any means a perfectly unexceptionable example. It is recorded in Dr. Edward L. Ormerod's valuable paper "On a Systolic Murmur in the Pulmonary Artery, and its application to the Diagnosis of Functional and Organic Murmurs."\*

W. C., aged 28, first came under the care of Dr. Bond of Cambridge, (by whom the following notes were taken). He was a waterman, of temperate habits. Subject for the last two years to palpitation, of which he then complained, with a dragging sensation in the epigastrium, and dyspnoea on exertion, but he was able to retain the horizontal position to the last. The surface of the body was of a dusky purple, but he had no notable distension of the superficial vein, nor jugular pulsation. He had anasarca and ascites from time to time, and died gradually with these symptoms in December, 1839. There was dulness on percussion in the region of the heart for a space of two inches square. The heart's impulse was increased and extended. There was a loud harsh murmur nearly synchronous with the systole, loudest and harshest to the left of the sternum in the third intercostal space, but audible all over the cardiac region, and in the epigastrium. The sounds continued audible in the same situation, but not at the same time, till his death; for the murmur after the lapse of a year was found to have become diastolic. After death the heart was found nearly twice its natural size, and the pulmonary valves agglutinated into a thick cartilaginous ring, leaving a permanent orifice just large enough to admit the passage of an ordinary quill. All the other valves were healthy.

It is by no means improbable that the above was a case of congenital malformation of the pulmonary orifice, which, for many years, caused little impediment to the circulation, until it became aggravated by super-added disease. As, however, it is impossible to judge with certainty of the true nature of this particular class of cases from mere description, I have thought it as well to insert it at this place.†

\* Edinburgh Medical and Surgical Journal, June 1846, p. 96.

† A case very similar to this is recorded by Professor Tiedemann, in his work on Arctation and Closure of the Arteries in Disease, as quoted in the Edinburgh Medical and Surgical Journal for June 1846, p. 127.

The following case of obstructive disease of the pulmonary valves, with which I have been kindly favoured by my friend Dr. Edward Lloyd, in whose practice it occurred, is probably the most remarkable instance of the kind on record, in the extent of the disease, as well as in several of the circumstances which attended its progress: it appears to me to afford an almost unique, though most instructive, example of cardiac disease:—

Amelia S., ætat. 38, came under the care of Dr. Lloyd, on the 3rd of February, 1845. She was a dark-complexioned sallow woman, with a very anxious and haggard expression of countenance; she was by occupation a work-woman at a dry-salter's, where she had been chiefly employed in packing galls, in lifting heavy weights, and in having to go up and down flights of stairs. She had always been an active person, and in these habits continued until confined by her last illness. Her habits were intemperate, and of late they had been more so than usual. In the preceding October, she was run over, but it was not certain that she received any material injury; still her head was cut, and her husband maintained that from that time she became less healthy than formerly. She, however, returned to work, and, up to Christmas-day, continued her usual avocations with her accustomed activity, frequently carrying sacks of two hundred-weight up and down stairs throughout the whole day. She had been subject to winter cough, and her husband appeared to think that she used sometimes to have attacks of fainting previously to her last illness, but her employer maintained that she was never short-breathed, and that he had never heard of her being faint: his expression was that "she could do the work of a man." Her attack commenced on Christmas-day, or soon afterwards. On that day she had a quarrel with her husband, when it is stated that he struck her several blows on the side, and she, from that time, complained of pain in that situation. This, however, does not appear to have attracted much attention, except that she was unable to go to work. On the Sunday following, she had another quarrel with her husband, when the neighbours interfered. On Monday she was very unwell, and on Tuesday she took to her bed, complaining of pain in her left side, which she ascribed to a blow from her husband. She now sent for Dr. Jewel: that gentleman observed the presence of a cardiac bruit. On the 3rd of February, when Dr. Lloyd first saw her, she had been ill five weeks; she lay on her left side, with an anxious expression of countenance, and peculiarly harassed though not difficult or laborious respiration, with every now and then a long deep-drawn breath, followed by a number of short inspirations.



Respirations 36-40. Pulse 130, very small, sharp, and slightly irregular. She complained of pains in her limbs, knees, and ankles, but particularly in the right arm, on examining which an abscess was subsequently found over the biceps, but she appeared to suffer chiefly from a severe pinching pain, which sometimes gave the sensation of a knife going through her on her left side. Skin hot; bowels relaxed; sensorium undisturbed. She was extremely irritable. The hurry of respiration increased when she was raised. She complained of cough, with some expectoration of a mucous character, not allowing her any rest from the pain it caused in her left side. She was said to have eaten nothing for a week, had no desire for food, and could not sleep at night. The extreme hurry of respiration was very remarkable indeed. The chest was resonant throughout; the respiration coarse and loud at the apices of the lungs,—there was no abnormal pulmonary sound, with the exception of a slight mucous r le heard over the right scapula. The heart's sounds were indistinct, heard more clearly at the apex than at the base: in the latter situation there was an abnormal sound, (which appeared to Dr. Lloyd to have the characters of a pericardial *frottement*), heard over a space of about two inches in diameter from the right nipple to the sternum, but not at all audible in any portion of the course of the aorta or carotid arteries. This sound was superficial and loud, but soft, with a distinct back stroke. No fremitus could be felt. She was ordered calomel and opium at night: serpentary and ammonia, and sago, beef-tea, and calves'-foot jelly.

On the 4th, she was much in the same condition; had passed a very restless night; her cough was troublesome; she expectorated frothy mucus tinged with blood. The abdominal cardiac sound was unchanged; the respiration was still extraordinarily hurried. Pulse 135, small and sharp. The urine was found to be slightly coagulable. There had been one loose motion during the night. The liver could be felt below the ribs. She now complained of pain in her right side on auscultation: a slight rubbing was heard in this situation. Emplast. Lytt e, lat. sinist.; Hydrarg. Chlor. gr. i.; Opii, gr. i. nocte, et P.

On the 5th, she felt better; her face was less anxious. She had passed a comfortable night, and slept a good deal during the day. The skin was perspiring; she was extremely weak, and when she got out of bed she was obliged to lie on the floor to avoid fainting. She had done this for some time during her illness. The tongue was clean and moist; the blister had risen well. Pulse 130, small, and irregular in the duration of each beat. The cough was relieved, but respiration was

still hurried. After a severe fit of coughing she became very cold and faint, and hot bottles and flannel were necessary to keep her warm. Her appetite was much improved: she had taken calves' foot jelly. The right arm was painful; the pain in the legs was less. P. M. Habt. Vin.  iv.

6th.—Was much agitated on the preceding night; since which she continued to grow worse. The countenance was more sunken; the respiration very hurried; pulse slower, 100, and intermittent; the cough troublesome; the heart's sounds were much more indistinct; and the abnormal murmur feeble. There was some dulness at the base of the left lung, with some  egophony. The tongue was rather brown; lips dry and parched; sordes on the teeth. She had not had the wine ordered, which was prescribed at last visit. Brandy  iv.; Infus. Serpentari e C. et Tr. ejusd. c. Ammon. Sesquicarb. gr. v. quartis horis.

On the 7th, she was much lower; the abnormal cardiac sound was heard over a smaller space; the heart's sound was irregular and indistinct. Respirations, 40. Pulse, 114. Tongue brown; teeth covered with sordes.

On the following day she was much the same; the pulse was slower, about 90, very weak, and hardly to be felt. Respiration was very hurried; there was subsultus, and she was evidently sinking. She died on the morning of the 10th, having sunk gradually.

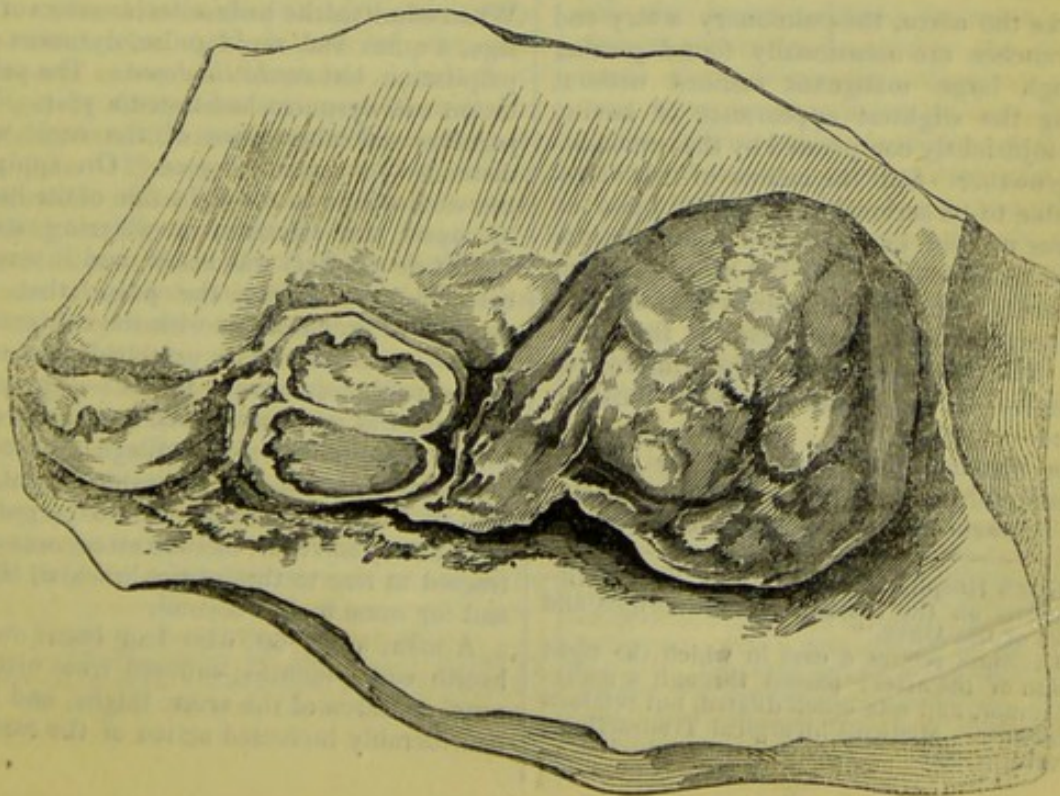
*Autopsy.*—The body was very spare and thin. The abscess on the fore part of the right arm was found to contain about an ounce of sanious pus, with some old coagula of blood. Recent and soft pleuritic adhesions were found on the right side of the chest, with puenmonic consolidation, approaching the stage of grey hepatization, of a small patch in the centre of the lung. The base of this lung presented a somewhat congested appearance, which was probably cadaveric. Both lungs, when cut into, yielded a large quantity of serum, mixed with air-bubbles. On the left side there were a few old pleuritic adhesions, with some fluid in the pleural cavity; the lung itself presented no other morbid change than  edema. The pericardium contained about two drachms and a half of fluid, and was perfectly healthy. The heart was of a normal size, and not at all gorged with blood. The left side was healthy; both aortic and mitral valves were sound. There was no hypertrophy or dilatation. The tricuspid valve was healthy. The right auricle contained a coagulum, but was not distended; the right ventricle also contained a small coagulum. On examining the *pulmonary artery*, a hard body was felt considerably obstructing its canal, but a probe was easily passed, and could be moved from side to side on the anterior wall



of the artery; it could also be passed between two bodies which blocked up the valves. On carefully laying open the artery, its orifice was found to present two tumors and one valve; the tumors corresponding to the posterior valves, and having a crescentic surface on their ventricular margin. One of these masses was about double the size of the other, the smaller being about the size of a large walnut. When placed in situ, it was found that each had smooth corresponding surfaces, evidently produced by friction between the two bodies. They were, externally, of a dark grey or brownish colour, having generally a somewhat warty and roughened surface. On laying them open with a scalpel, they exuded a gelatinous fluid of a very tenacious character. They were hard, and apparently organised, with fibres arranged in small convolutions. They were light-coloured internally: their bases or ventricular margins were apparently in a state of inflammatory softening, breaking down on the slightest touch, and separating from the substance of the artery without difficulty. The gelatinous fluid was examined by the microscope, and found to contain nucleated cells, not of a malignant character. The remaining valve was covered with some shaggy vegetations or fibrinous deposit: it was of normal size, and smooth and healthy on its arterial or inner surface. The coronary arteries were healthy; there were two openings to either artery. The omentum was attached to the abdominal parietes by old adhesions. The liver was much enlarged, stretching down to, and encroaching on, the umbilical region: it was congested and coarse in structure, and adherent to the abdominal parietes. The spleen was also large. The kidneys were

larger than usual, and of coarse structure; their tunics were adherent, and they were very lacerable and pale. The ileum was congested, and presented some spots of ecchymosis: it contained nothing but a small quantity of bilious mucus.

Among other valuable remarks which Dr. Lloyd has appended to his report of the above case, he observes that it proves how great an amount of obstruction may continue to be borne on the right side of the heart, provided the lungs are sound, and in working condition. He considers that the heart itself shewed no evidences of obstruction, as there was neither hypertrophy nor dilatation, nor even engorgement of its cavities: in fact, there was a singular absence of marked evidences of cardiac obstruction both before and after death. There was no impediment to the return of blood from the jugulars, no blueness of the lips, congestion of the countenance, or œdema of any part of the body. Dr. Lloyd very justly accounts for this absence of cardiac engorgement and external congestion in two ways: first, the quantity of the circulating fluid was small, the patient being thin, spare, and at rest, and must have become smaller and smaller as the disease of the valves increased, from the woman's taking no nourishment of any kind, and also from the reducing effects of treatment; and, secondly and principally, he thinks this circumstance accounted for by the remarkably hurried action of the lungs, whereby a small quantity of blood was sucked up by atmospheric pressure from the ventricle at every respiration. This, frequently repeated, he believes, answered the purpose of the natural and slower respiration, and larger supply.





This remarkable specimen is preserved in the collection at Guy's (numbered 1413<sup>53</sup>.) The artery has the appearance of being much dilated. Large portions of the clots have been removed, but the remaining masses are still of extraordinary size. All the valves are ruptured at their lower attachments, but this has occurred subsequently to removal, owing to the extremely softened condition of the parts.

The preparation marked 1413<sup>50</sup> in Guy's museum is the base of a heart in which the valves are more or less generally coated with layers of recent inflammatory product. Those portions of the ventricular surfaces of the *pulmonary* sigmoids which remain free from fibrinous laminæ appear to be pliable, and free from thickening or marked opacity. I have not succeeded in obtaining any history of the case.

Like the aortic sigmoids, the valves of the pulmonary artery occasionally, but rarely, present rows of minute semitransparent wart-like vegetations, which are usually arranged in the form of double festoons at the lowest and most projecting parts of their surfaces of contact. I have elsewhere stated\* my grounds for believing that these little bodies are not mere adventitious deposits from the blood, but organised growths from the endocardial surfaces, and that, under circumstances of disease, they are intended to protect the outlets of the heart from undue attrition, as well as from the deposition of clots, and also to prevent the occurrence of adhesion between opposed surfaces of inflamed valves.

#### OBSTRUCTION TO THE PULMONARY ARTERY CONSEQUENT UPON EXTERNAL COMPRES- SION.

Like the aorta, the pulmonary artery and its branches are occasionally found passing through large malignant tumors without having the slightest appearance of having been injuriously compressed by the surrounding growth.† Still the calibre of this vessel is liable to be seriously encroached upon by various morbid growths, and accumulations in the neighbourhood of the heart—such as pericardial deposits, large fluid effusions into the thoracic cavities, aneurism of the aorta, &c. The following cases afford interesting examples of these rare forms of obstruction:—

An instance is recorded in the Dublin Journal for May, 1841, in which extensive and thoracic effusion, the result of double

pleurisy suddenly supervening upon chronic bronchitis, produced so much compression of the heart as to render it probable that death had resulted from complete flattening of the right ventricle. For eighteen hours previously to the unfortunate patient's death he suffered from frightful dyspnoea. The state of the pulmonary valves is unfortunately not described.

*Compression of the base of the right ventricle and origin of the pulmonary artery by an aneurism of the ascending aorta.*—About eleven years since, I watched the case of a middle-aged man, who was admitted to Guy's Hospital, with a pulsating aneurismal swelling upon the left side of the sternum. He suffered from hæmoptysis and extreme dyspnoea, and died in about a week after his admission. Upon examination, a large aneurismal pouch was found arising from one of the sinuses of Morgagni, and pressing forwards the base of the ventricular septum in such a manner as to place it completely in contact with the outer wall of the right ventricle: in this way the orifice of the *pulmonary artery* had become nearly flattened. Anteriorly this was completely the case; the left pulmonary sygmoid valve had become adherent by a fibrinous clot to the most projecting part of the tumor. At the parts where the compression must have been greatest, and where the surfaces must have been placed completely in contact with each other, the endocardium was deeply reddened, and, in parts, coated with fibrinous coagula. The heart is preserved in the pathological collection at Guy's, (numbered 147825).

The two following interesting parallel instances have been recorded by Dr. Elliotson:—

Owen S., ætat. 39, had been ill five years. When admitted, he had ascites, anasarca of the legs, a quick and rapid pulse, dyspnoea and palpitation, but *could lie down*. The palpitation and dyspnoea had lasted a year. The jugulars and other veins of the neck were distended to a great degree. On applying the stethoscope to the right side of the heart, or upon the sternum, a whizzing sound (*bruit de soufflet*) was heard, and it was ascertained, by feeling the pulse, that this sound was synchronous with the contraction of the ventricles. The principal *post-mortem* appearances were as follow:—The pericardium was adherent to the heart, and contained some portions of cartilage: there was a cartilaginous body in the substance of the wall of the right ventricle, where the pulmonary artery leaves it, and the artery was contracted in size to that of the brachial, there, and for some inches beyond.

A man, ætat. 60, who had been out of health some months, suffered from orthopnoea, anasarca of the arms, thighs, and legs, considerably increased action of the carotids

\* Guy's Hospital Reports, vol. i. N. S., "Observations on the Diseases of the Orifice and Valves of the Aorta."

† Dr. Sims relates a case in which the right division of the artery passed through a malignant tumor, and was much dilated, but retained its texture. Medico-Chirurgical Transactions, vol. xviii. p. 290.



and radials, and distension of the veins of the neck, with tenderness of the epigastrium. A loud and distinct *bruit de soufflet* was heard at the upper part of the sternum, at the moment when the ventricles contracted, proving that the obstruction must be at the outlet of one of those cavities, while the situation in which the noise was heard, and the distension of the veins pointed out the right as the one implicated. The only material differences between these two cases were, the circumstance that in the former the patient could lie down, while in the latter he could not, and the increased action of the carotid and radial arteries in the latter. On examination, the pericardium was found adherent to the surface of the heart in every part; the heart itself was enlarged to twice its natural size, and its substance was very much softened, and so changed in texture as almost to have lost its fibrous appearance. A part of this change might be owing to the decomposed state of the body, but certainly not all of it. The walls of the cavities were thickened, but not in proportion to the increase in size of the whole heart; the cavities themselves, and especially those on the right side, being much dilated. At the origin of the *pulmonary artery*, a fibro-cartilaginous structure, as large as a small egg, was found almost surrounding the artery, which was so much diminished in calibre that it would scarcely admit the little finger; beyond, the artery retained its usual size. There was also found to be a large aneurism of the aorta, which had burst.\*

*Obliteration of the right pulmonary branch by an aortic aneurism.*—The collection at Fort Pitt contains a preparation taken from the body of a corporal, about 33, who died of phthisis pulmonalis, in which the right branch of the *pulmonary artery* is completely closed at its origin by the pressure of a small aneurism arising from the concavity of the aorta, near its base. The closure was permanent from adhesion. The inner coat of the pulmonary artery contiguous, had lost its natural smoothness. This disease of the vessels was never suspected during life, the symptoms being only those of ordinary phthisis†.

*Congenital narrowness of the pulmonary artery.*—Dr. Barlow has described a highly interesting class of cases of young patients who have suffered from birth from an imperfectly developed condition of the respiratory apparatus, the thorax being more or less narrow or deformed, the trachea small, and the lungs ill expanded, who, at or about the

period of puberty, are liable to become the subjects of grave cardiac symptoms; and eventually to die from the effects of obstruction to the circulation. In such cases it is generally found that the left cavities of the heart and aorta are either normal in size or below the natural capacity.\* The right cavities are more or less dilated and hypertrophied, while the pulmonary artery remains small, and, what is very remarkable, has occasionally been found by Dr. Barlow to be really below its usual standard capacity. This obtains so long as the vessel remains healthy.

I have myself observed a few instances in which the right ventricle had become hypertrophied in consequence of the long obstruction, and in which the pulmonary artery remained small, independently of any apparent organic fault in its texture;† but it is, undoubtedly, far more usual to find this vessel more or less dilated, in cases where the circulation through the lungs has been long and severely impeded.

The tissues of the pulmonary artery, being naturally far more extensible than are those of the aorta, probably do not undergo precisely the same changes of dilatation, &c., coincidentally with the occurrence of hypertrophy of the right ventricle, as do the structures of the aorta under parallel circumstances. The right ventricle appears to be capable of becoming hypertrophied before the pulmonary artery has undergone any remarkable or proportionate dilatation; and this may be especially the case in those instances where (as Dr. Barlow argues) the vessel is small from originally faulty development. Should the patient's muscular system be weak (as usually happens in this class of instances), it is probable that the ventricle will also become dilated before a similar change occurs in the artery: the muscular tissue of the former depending more for its tone upon nervous influence than does the elastic fibrous structure of the other. The presence also of a freely acting safety valve on the right side of the heart, and a healthy condition of the abdominal vessels, will, at the commencement of these cases, have considerable influence in relieving the pulmonary artery; while, on the contrary, a close tricuspid, and obstructed abdominal circulation, would tend greatly to hasten its dila-

\* In some cases the left auricle and ventricle are dilated, while the aorta remains small, although free from any traces of organic disease.

† This has not merely occurred in very young individuals; in the case of the middle-aged man, the state of whose lungs I have described in the chapter on pulmonary apoplexy, the orifice of the pulmonary artery was nearly of the ordinary capacity, although some of its branches were greatly obstructed by old coagula. The heart was hypertrophied, and the aorta somewhat dilated.

\* MEDICAL GAZETTE, VOL. X. p. 221.

† Third Fasciculus of Anatomical Drawings selected from the Collection of Morbid Anatomy in the Army Medical Museum at Chatham. Plate vi.



tation. It must also be borne in mind, that in cases of this description death is not generally to be ascribed to the mere obstruction produced by the imperfect development of the pulmonary apparatus, but that it is usually caused by the superaddition of a certain amount of inflammatory or other disease in the originally defective lungs, which hastens on the fatal result long before the heart and its appendages have undergone those changes which they would ultimately have presented had life been considerably prolonged.

It is therefore not to be considered that the instances in question by any means disprove the generally prevailing rule, that obstruction to the pulmonary circulation has uniformly a tendency to produce dilatation of the afferent vessel of the lungs. And it is of course almost unnecessary to add that they do not in the slightest degree prove that pulmonary obstruction can, under any circumstances, have a tendency to produce a diminution in the capacity of this artery.

Dr. Barlow has also shewn that a condition of parts similar to that described in the above class of cases may result from the occurrence of adhesion of the pericardium at a period of life when the development of the thoracic organs is still incomplete.\* I have also brought forward a series of instances which illustrate the fact, that complete adhesion of the pericardium, occurring in adult life, has a tendency to produce diminution in the size of the heart and its vessels in all cases where there is no valvular disease, and the pulmonary and systemic circulations remain tolerably free.†

All morbid anatomists are now acquainted with the fact, that in the majority of cases of pulmonary consumption the cavities of the heart are found considerably below the ordinary standard capacity; and that the pulmonary artery and aorta usually, to a greater or less degree, partake in this change.

Pathologists are indebted to Dr. P. M. Latham for an explanation of the remarkable and important principle upon which this adaptation is effected.‡ It is observable that in the larger proportion of cases of phthisis, even long after nearly the entire structure of both lungs has been rendered irrespirable by solid deposits and purulent excavations, there is usually, while the patient remains unexcited and at rest, an almost entire absence of severe dyspnoea. This often continues even up to the period of dissolution: the patient dying from hæmorrhage, exhaustion, cerebral complication, —or, in fact, from almost any other cause than mere suffocation. This is shewn to

depend upon the very small quantity of blood which is propelled, at each systole of the contracted right ventricle, through the pulmonary vessels, as well as to the rapidity of its transit through the narrowed cavities of the heart. The colliquative sweats and diarrhoea, which are such frequent attendants of the later stages of this disease, are therefore not to be regarded either as processes which are wholly injurious to the system, or as altogether dangerous symptoms which it is absolutely necessary to repel by vigorous treatment: they must, on the contrary, be viewed as the principal means which nature adopts to relieve the heart and lungs from a large proportion of the circulating fluid—a relief which the latter organs require, not only in consequence of the great diminution of their aerating surfaces, but also on account of the impaired action of the bronchial exhalents which is usual in this disease.\*

It is doubtless owing to a similar diminution in the bulk of the circulating fluid that the circulation through the lungs is usually so free in cases of malignant disease of those viscera. Large masses of softening cancerous deposit are occasionally found occupying very extensive portions of the pulmonary structure in the bodies of patients who have scarcely been at all subject to dyspnoea, and even in cases where no symptom has occurred to lead to the recognition of the disease during life. In such cases as these the heart and its vessels have usually been observed to have adapted themselves to the diminished volume of the blood.

*Narrowing of branches of the pulmonary artery in the vicinity of phthisical cavities.*—In extensive tubercular degeneration of the lung, even after softening and suppuration have commenced, it is often singular to observe branches of the pulmonary artery, of various diameters, passing through the apparently disorganised lung, their interiors remaining entirely free from the slightest discolouration or deposit, although the canals

\* It has been observed by one of our leading pathologists that he regards a small heart as a bad coincidence in the case of tuberculous disease, adding, that he would rather have a large heart than a small one in connexion with phthisis. —[Clinical Remarks on a case of *Tabes Mesenterica*, by Dr. C. J. B. Williams: *MED. GAZ.*, vol. xviii., p. 1490.]—I cannot but venture to prefer the doctrine of Latham to that of this high authority. It will, I believe, be usually observed that in cases of phthisis where the heart is large the respiration has been proportionably difficult, the pulse comparatively slow, and the patients to a greater or less degree subject to that depression of spirits from which the rapidity of the circulation in phthisis usually renders the victims of this hopeless malady so providentially free. The condition of the phthisical heart cannot be regarded as one of atrophy: all its cavities are usually small and well contracted; and the muscular tissue of its walls is firm, and well adapted to maintain short and rapid propulsive movements.

\* *Guy's Hospital Reports*, vol. v., New Series.

† *Guy's Hospital Reports*, vol. i., New Series.

‡ See *Lectures on Diseases of the Heart*, *MED. GAZ.*, vol. iii.



have evidently been in some degree encroached upon by the surrounding effused matters. In more advanced stages of disease, however, when phthisical excavations have become completely formed, complete obliteration of the arterial tracts, which are thus left in a state of isolation, generally occurs, while those portions of the closed arteries which intervene between the point of occlusion and the nearest pervious branch undergo a remarkable degree of contraction, which leaves them in the condition of very narrow conical cul-de-sacs. This latter change has been very accurately described by Dr. Ballie, who remarks, that when blood-vessels are traced into abscesses of the lungs, he has found them very much contracted just before they reach the abscess, so that the opening of their extremities has been closed up entirely. On such occasions it will require a probe to be pushed with a good deal of force, in order to open again their extremities. In these contracted vessels, he adds, the blood is coagulated as it is under similar circumstances in other parts of the body. This change of the blood-vessels he regarded as designed to prevent the occurrence of large hæmorrhages, which would certainly prove almost immediately fatal.

My own observation has led me to believe, with Cruveilhier, that the obliterated trunks of pulmonary vessels much more frequently form the principal substance of the bands which traverse the cavities of many phthisical excavations than the statements of Laennec and Andral would lead us to suppose. While the excavations are of moderate size, the obliterated arteries are usually seen passing across the cavities, in the form of greyish cords, covered externally with a coating of pus, fibrine, and particles of tubercular matter, and presenting, on transverse section, a close grained coagulum, having the appearance of soddened glue, perfectly identified with their degenerated tissues, and completely occluding their canals. These obliterated vessels are easily broken across, their structures having lost their tenacity; and, as the cavities increase in size, the isolated portions appear to become removed by sloughing, leaving only rounded extremities, which form slight elevations on the sides of the vomicae.

It appears that in the generality of chronic phthisical excavations, the portions of vessels which pass across the cavities become perfectly obliterated. It is in the last degree improbable that any artery which has long remained in this manner completely isolated should ever remain sufficiently pervious to become either the seat of aneurism or the source of hæmorrhage. So far as I have observed, or can learn, these accidents are only liable to occur in vessels which are

situated upon the walls of cavities, and which are not completely isolated. Still, it is not improbable that, where the excavation is very rapidly formed, a considerable tract of artery may become detached before the process of obliteration has been completed, and may then either suffer perforation or be actually separated during a violent paroxysm of coughing, as is described to have been the case in a somewhat remarkable case described in the *Ephemerides Nat. Cur.*

#### *Dilatation of the Pulmonary Artery.*

The fact that as life advances the pulmonary artery, in common with all other parts of the vascular system, is liable to become gradually and permanently dilated;\* and that the establishment of fixed causes of obstruction, either in the lungs, left heart, or systemic circulation, are at all periods liable to produce a similar result, have already been commented upon in previous chapters of this memoir. It now merely remains to cite a few examples in which remarkable dilatation of this vessel was found to have occurred under somewhat unusual circumstances.†

We have seen that an unnaturally wide condition of this vessel is found in several classes of cases of cardiac malformation. The following instance presented at once the largest amount of simple dilatation of this vessel that has ever fallen within my notice, and one of the most singular congenital irregularities that has been known to occur in the heart of an adult:‡—

\* General dilatation and loss of elasticity are the only visible physical changes to which the tissues of the pulmonary artery appear to be liable in extreme old age, independently of the operation of accidental morbid influences. In most of the hearts of very aged persons which I examined, the structures of this vessel retained, to the eye, a nearly healthy appearance; the valves especially presenting a striking contrast to those of the aorta. Morgagni describes the condition of the heart in a man of 98, in whom all the valves belonging to the orifices of the right ventricle were not only not rigid nor thickened, but even like those which belong to the pulmonary artery, they seemed to be formed of a thinner membrane than usual. The mitral valves, however, were found thicker than they ought to be; and the aortic valves were all bony, inflexible, and protuberating internally, &c. The arch of the aorta and its vessels were free from bony scales, which were however seen in the remaining part of the aorta.—Letter XXI. A. 15. It appears, in fact, that degeneration of the tissues of this vessel is not by any means a necessary attendant of old age, but is most frequently the result of over distension and other accidental morbid influences.

† Cases of too great capacity of the pulmonary artery are described by Cooper (in Farre), Richerand, Corvisart, Testa, J. F. Meckel, Hufeland, Lawrence, Young, &c.

‡ Full details of this case have been published by Mr. Alfred Taylor, in the *MEDICAL GAZETTE*, vol. xxxvi. p. 19.



A woman, 45 years of age, dropped suddenly in the street, near Guy's Hospital, and died, gasping and pallid, without any convulsions, immediately after she had been brought into the house. Some suspicion was entertained that she had swallowed about a drachm of nux vomica powder an hour before her death, but this was not proved to have been the case. I was present at the autopsy, July 12th, 1844. The body was lean, but scarcely had the appearance of being wasted. The extreme parts of the body were remarkably blue. Some of the muscles, especially the internal ones, were very pale. The chest was much deformed, the ribs being compressed laterally below the præcordial region, apparently by the tight lacing. The pericardium contained a considerable quantity of clear fluid. The heart was very large, owing entirely to the dilated condition of its right cavities, which were distended with dark semi-fluid coagula. The pulmonary artery was very conspicuous; there were some white patches, like cicatrices, upon its left side; posteriorly it was adherent to the aorta by strong bands.\* The auricles communicated by an oblique opening capable of admitting the ends of three fingers; in the remains of the septum below this was an oblique passage, closed on the side of the left auricle; this was evidently the vestige of a foramen ovale: therefore there must have been originally two of these communications in this individual—one of which had closed, the other remaining permanently open. Four pulmonary veins were found opening into the right ventricle, as did the common termination of the coronary veins, which was furnished with a well-formed valve. The right auricle was very capacious. The tricuspid valve was not malformed. The right ventricle was capacious and thick. The *pulmonary valves* were bordered with a few vegetations; their tissue was unusually thick, but still retained its pliability. Immediately below its valves the orifice of the artery measured four inches and four lines in circumference; at the upper attachments of the valves it was about one line wider (the normal measurement of these parts being respectively  $38\frac{1}{2}$  and  $32\frac{1}{2}$  lines). Notwithstanding this dilatation of the vessel, there was no reason to doubt that its valves were perfectly efficient. The left auricle was less capacious than the right. The left ventricle appeared remarkably small when compared with the right; its parietes were by no means thin, but their muscular structure was soft. The aortic orifice was structurally healthy, but it was remarkably narrow, measuring some-

\* It is known to all anatomists that in some subjects the pulmonary artery is united to the ascending aorta, and that in others a considerable interval is found between these vessels.

what less than two inches below the valves. The vessel was small throughout its entire course; but, immediately below the left subclavian artery, it was in a marked degree more contracted than elsewhere. Several enlarged bronchial glands were found near this spot; these may have encroached slightly on the aorta, or the dilated pulmonary artery may have somewhat compressed it, but there was no distinct structure here: and the undilated state of the left ventricle and ascending aorta proved that this narrowing of the vessel had not caused much impediment to the circulation. Neither the internal mammary, nor the intercostal arteries were perceptibly dilated. The lungs were in parts highly emphysematous, and were generally much congested. The liver was congested. The spleen small, and surrounded by adhesions. The kidneys were small, and tolerably healthy.

It was ascertained that this person was one of twins born at the eighth month. She had always been liable to shortness of breath, and to become blue upon unusual exertion. Her habits had been irregular and intemperate.\*

It is evident that this female must have always been liable to great pulmonary congestion; and it is certainly most extraordinary, considering the nature of the congenital defect of her heart, and the artificial deformity of her chest, that she should have reached the middle period of life. It will be observed that in this case the orifice of the pulmonary artery had become widened to a degree considerably beyond that to which it is naturally dilatable—a circumstance to which I have alluded at the commencement of this paper, as producing a tendency to sudden death, upon the occurrence of any circumstances which occasion over-distension of the right cavities. It is evident that the degree of mental perturbation which could have urged this unfortunate individual to procure the means of committing suicide, was amply sufficient to produce fatal embarrassment of a heart so weakened and malformed.

\* A case somewhat similar to this occurred to Mr. Harrinson, who, in 1844, presented to the Reading Pathological Society the heart of a child two years and two months old, who had been the subject of cyanosis. The right side of the heart was enormously distended with clots of fibrine; the auricle and ventricle were greatly enlarged. The auriculo-ventricular orifice was so much enlarged or dilated as to annihilate the functions of the valves. The *pulmonary artery* was greatly dilated. The ductus arteriosus was impervious. On the left side the auricle was very small, and the foramen ovale open; its edges rounded, and no valvular apparatus; the auricular appendages absent. No appearance of the entrance of any pulmonary veins; left ventricle very small. Mr. Harrinson conjectured that the pulmonary veins must have terminated either in the vena azygos or in the superior cava.



The average circumference of the pulmonary artery, at its widest part, is about 38 lines. Dr. Hope has described a case in which this vessel measured five inches half way up, and four and a half near the valves. Here the sygmoids were stretched, and were considered to be inefficient.\* In such instances as these, the duration of the patient's life must obviously depend chiefly upon the strength of the right and left ventricles, and the degree of safety-valve action of the tricuspid.

It is usual to find the pulmonary artery with its valves more or less (sometimes extremely) dilated, coarse in structure, and irregularly thickened and opaque, in cases of old bronchitis and extensive emphysema of the lungs, &c., as well as in instances where death results from mitral and aortic obstruction.†

In cases of old bronchitis, mitral and aortic obstruction, &c., it is usual to find the entire tract of the pulmonary artery more or less inordinately dilated. In the generality of examples of this change, the branches of the vessel are observed to have undergone the greatest amount of structural alteration, presenting an almost varicose appearance, their anterior being thickened and opaque, and discoloured by striæ and patches of atheromatous deposit. In more extreme examples, the main trunk and valvular apparatus of the artery are also found to have undergone, in addition to their dilatation, a marked degree of thickening, and to have become the seat of a certain amount of opaque interstitial deposit—appearances which deprive the vessel of its characteristic appearance, and give it an aspect very closely resembling that of the ascending aorta. The following case, with which I have been kindly favoured by my friend Dr. Peacock, affords a very excellent example of the class of lesions now under consideration.

\* I have never myself seen any case in which the pulmonary valves had become inefficient in consequence of retroversion, or from any other effect of dilatation independently of mechanical violence or congenital defect.

† Instances of too great capacity of the pulmonary artery are also described by Cooper (in Farre), Richerand, Corvisart, Testa, J. F. Meckel, Hufeland, Lawrence, Young, and others. Otto has also given the following references to recorded cases of aneurism of this artery.—And. Cæsalpin. *Catoptrices*, Lib. vi. cap. 20; Blancard, *Anat. Pract. Rat. Cent. ii. Obs. 74*; Fabrig. von Hilden, *Observat. et Cur. Chir. Cent. ii. Obs. 89*; Eggerdes, in *Misc. Acad. Nat. Cur. Dec. 11, An. VI. 1687*, p. 415; Morgagni, *Epist. XXIV. Art. 36*; Matani de *Aneurismal. Præcordior. Morbis*, p. 125; Baader, *Observat. Med. Incis. Cadav. Illust. Frib. 1765*; Bach v. Richter's *Chir. Bibliothek*, vol. viii. p. 498; Essen Schmidt, in *Schmucker's Vermischt Schriften*, vol. ii. p. 241; J. C. Stark, in *Abhandlungen der Erlangen Physic zu Alexander*, Trans. vi. 765.

Wm. Cassidy, æt. 72, cooper, admitted into the Royal Free Hospital, July 3d, and died July 5th, 1847. He was dying when I saw him. The face was pale, the cheeks livid, and the jugulars were distended and pulsating. The hands were cold and livid. He was greatly emaciated, and the abdomen and the cellular membrane, of the lower extremities more especially, were distended with fluid. The chest sounded dull on percussion of the level of the nipple on the left side; and on the right, from a somewhat lower point, a loud and rough systolic murmur was audible at the præcordia, and was followed by a flat second sound. This sound was most intense an inch and a half to two inches below the nipple, and external to a vertical line drawn from it. The pulse was unequal in strength, and occasionally intermitted. No history of his previous illness could be obtained.

The brain was below the average weight, or only 42 oz. 4 dwt. avoirdupois. There was some fluid beneath the arachnoid membrane and in the ventricles.

A considerable amount of fluid was contained in each pleural sac. The lungs were partly compressed by the fluid, and partly emphysematous: on section, they yielded much spumous fluid. The bronchi were of large capacity, and the cartilages unusually hard and thick. The dilatation extended throughout the bronchial ramifications, and the mucous membrane was generally reddened, and the tubes filled with a glairy mucous fluid.

There was a large, thick, and opaque patch of old lymph on the anterior surface of the right ventricle, which, when removed, left the pericardium beneath it smooth and glistening. The right auricle was studded with small nodular concretions of old lymph. There was but little fat in the heart. The heart weighed 14 oz. There was great dilatation and hypertrophy of the right ventricle, the cavity being 4 in. and 3 lines in length, and its walls three lines thick at the base; four and a half at the mid-point, and one and a half at the apex. The tricuspid aperture was very large, allowing of the passage of a ball measuring five inches in circumference. The pulmonary orifice was also extremely large, allowing of the passage of a ball measuring three inches and nine lines in circumference. The tricuspid and pulmonic valves were somewhat thickened, but not otherwise diseased. The trunk of the pulmonary artery was very much dilated, and the sinuses at its origin especially so. Its branches were throughout very large, and, though the lining membrane of the trunk was free from appearances of disease, that of the primary and secondary divisions, and the smaller branches, was the seat of extensive atheromatous deposit. In the smaller vessels the coats were



so much thickened that on section they remained wide open, and in some there were small, hard, and partly adherent pinkish-coloured coagula. The left ventricle was also hypertrophied and dilated, measuring three inches in length, and from six lines to two and a half lines in width. The mitral valve displayed some nammillary thickening, and the free fold was somewhat atheromatous. The aortic valves were thickened at their free edges, but not incompetent. The aorta around the angles of the valves was extensively ossified, and the orifice of the right coronary artery was nearly closed by a deposit of this kind. The other coronary artery, and the right throughout the remainder of its course, was not materially diseased.

The lining membrane of the aorta was extensively studded with atheromatous patches. The sinuses of Valsalva were much dilated, and the aorta generally was large, and its ascending portion elongated.

The liver was large, lobulated and coarsely granular. The kidneys large, mottled, irregular in shape, and studded with smaller or larger sized cysts.

The peritoneal cavity contained much fluid.

The occurrence of atheromatous deposit in the pulmonary artery, and especially in the branches of that vessel, is now generally recognised as a by no means unusual pathological appearance: it is usually associated with a greater or less amount of hypertrophy or dilatation of the right ventricle, and with a proportionate degree of congestion of the general venous system. These latter abnormal conditions may exist either as the direct results,\* or as the mere coincidents of the arterial lesions.

#### *Aneurism of the pulmonary artery.*

The occurrence of aneurism in this vessel has rarely been observed: the great dilatability of the ascending portion of the artery appears to be the principal cause of its immunity from this lesion, while its internal branches are still further protected by the elastic support afforded by the pulmonary tissue. Indeed, when we take the true nature of aneurism into consideration, it becomes probable that the morbid appearances which will be described in the following cases were not due to a process strictly analogous to that by which aneurisms of the systemic arteries are produced: in fact, the condition appears to be more nearly allied to

\* In one of his valuable papers on cardiac disease, Dr. G. H. Barlow alludes to a case occurring in his own experience, in which thickening and rigidity of the coats of the *pulmonary arteries*, extending into their smaller ramifications, had produced engorgement of the right ventricle, and its consequences. ["Select Clinical Reports," Guy's Hospital Reports, vol. v. N.S. p. 177.]

a form of varix which occasionally affects the larger veins.\*

The following case occurred in the practice of Dr. Fletcher, of Birmingham†:—

A thin, pale girl, æt. 19, a screw-wormer, was admitted to the Birmingham General Dispensary. She complained of violent pain in the head, and of some pain in the left side of the chest, great dyspnoea, and troublesome cough. Immediately under "(on?)" the left of the sternum, between the second and third ribs, there was dulness on percussion over a space measuring nearly four square inches. Over this spot a very liquid pulsation was felt, accompanied by a purring thrill, so rough and so close to the surface, that it seemed almost to grate on the fingers. At the same place a hollow rasp sound was heard with the systole of the heart, and also for a moment at the commencement of the diastole, as if the blood was receding. The patient lived a year after these symptoms were observed, and, after repeated attacks of bronchitis and pneumonia, died rather suddenly.

*Inspection.*—The *pulmonary artery* was found dilated into a pouch, the interior circumference of which measured nearly six inches, and which pointed principally in the anterior direction, where the internal and

\* The diseased state of the vena cava observed in the following case seems to have approached as nearly to the condition of aneurism as did the lesions of the pulmonary artery in any of the examples which have next to be cited.

Dr. Edward R. Squibb has recorded the history of a mulatto man, aged 37 years, who, for ten months previously to his death, suffered from a violent but remittent pain in the abdomen, with irritability of stomach, a sensation of obstruction after taking food, and occasional vomiting. Shortly before his death, the pain abated, and the patient felt able to sit up in bed. The exertion of rising up caused a feeling of great weakness and tendency to faint. He was immediately laid down, but expired in a few hours.

On examination, the abdominal viscera were found imbedded in and quite hidden by masses of coagulated blood, the viscera themselves appearing to be quite in a healthy condition. A rupture of the ascending cava was discovered just below the lower concave surface of the liver. The veins at this point had been very much dilated, and its coats much diseased and thinned. A semi-organized mass or clot, which was contained in the dilatation, was connected by its surface to the softened coats of the expanded vessel, and the rupture had occurred at the junction of the edge of this mass with the side of the vessel, and not at the projecting point of the dilatation. The tumor was on the anterior portion of the circumference of the vessel, and was overlapped by the lower edge of the liver, and by a portion of the stomach, which latter circumstance may account for the sensation of obstruction so constantly complained of during life.—*Philadelphia Med. Examiner*, Oct., 1846, p. 583.

† This case has been detailed at length by Dr. Fletcher, in the 25th volume of the *Medico-Chirurgical Transactions*; but for the sake of brevity, I have here given the account published by Dr. Blakiston in his recent work on "Certain Diseases of the Chest," p. 98.



middle coats were wanting, and where a fibrinous clot was found. One of the pulmonary valves was contracted. The aorta was first a little dilated, and then contracted, particularly where it was joined by the ductus arteriosus. There was also a permanent communication between the two ventricles.

Ambrose Parè has recorded the somewhat doubtful case of a certain tailor, who, "by an aneurisma of the *arterious vein* [pulmonary artery], suddenly, whilst he was playing at tennis, fell down dead,—the vessel being broken. His body being opened, Parè found a great quantity of blood poured forth into the capacity of the chest; but the body of the artery was dilated to the largeness of a man's fist, and the inner coat thereof was bony. For which cause Parè, within a while after, shewed it to the great admiration of the beholders, in the Physicians' School, whilst he publicly dissected a body there."\*

It is much to be regretted that the details of the following case have not been more satisfactorily given. I quote the account from a periodical†, having failed to procure a sight of the work in which it was originally published.

In September 1814 Dr. Harlan assisted Dr. Parrish in the examination of the body of Captain M——, a middle-aged person of robust constitution. His disease had never confined him to his house; and the day preceding his death he called on Dr. Parrish, and complained of dyspnoea and pain in the back of his neck. His symptoms were referred to stricture of the œsophagus; and Professor Winstar, who was consulted, advised the use of the probang: the patient deferred this operation, and, during the same night, was attacked with increased difficulty of breathing and exacerbation of all his symptoms. A bleeder being sent for, he lost some blood, with temporary relief; but in a short time afterwards he expired in convulsions.

The autopsy very unexpectedly developed an aneurism of the *pulmonary artery*, the sac of which extended so far back as to press upon the œsophagus, and produce symptoms of stricture in that part. There was considerable effusion in the lungs, and a lump of coagulated blood in the trachea, near the glottis, which most probably occasioned his sudden death. The effusion was occasioned by the rupture of the aneurismal sac, which was adherent to the air-cells of the lungs.

Dr. Harlan justly observes that it was fortunate the probang was not employed.\*

Mr. Fearn, of Derby, has recorded† the case of a patient who died from hæmoptysis, in whom an aneurismal sac of the size of a nutmeg was found jutting into a tubular extremity on the upper lobe of the left lung. The parietes of the sac were thin, and did not contain any fibrinous layers; a vessel, the size of a small crow-quill, leading from a considerable trunk of the *pulmonary artery*, was distinctly traceable into the sac.

Dr. Peacock has also met with an instance in which a pulmonary branch of the size of a crow-quill was found so dilated at one spot as to be capable of holding a bean. This dilatation was situated within a cavity hollowed out in the parenchyma of the lung containing blood; the lining membrane of the vessel was continuous. Several other cavities, containing pus, existed at the upper part of the lung. Dr. Peacock attributes this lesion to the loss of support which the vessel must have sustained, owing to the removal of the elastic substance of the lung in its vicinity. He also very justly denies the identity of this lesion with aneurism, as it occurs in the systemic arteries.

The preparation numbered 1450<sup>60</sup> in the collection at Guy's, displays an artery of considerable size, traversing the wall of a pthysical cavity, and presenting two small aneurismal dilatations, one of which has burst into the cavity. The lining of the vomica appears to be unusually thin. Another branch, of equal diameter, occupies another portion of the wall of the excavation; its canal appears to be obliterated.

The lesion which destroyed life in the following case appears to have been closely similar to that form of rupture of the proper tonics of the aorta which usually gives rise to dissecting aneurism:—A Pontonier, twenty-one and a half years of age, who had enjoyed good health excepting slight dyspnoea during three months he had been in the army, after having engaged in carrying wood during the day, was roused in the night by a violent pain at the right of the sternum, with great dyspnoea, which subsided in a few minutes. He afterwards became much relieved. During the afternoon of the following day he asked for drink, became pale and collapsed, and died. On examination, a number of

\* The use of this instrument cannot be too strongly deprecated in doubtful cases of dysphagia. I have met with two instances in which the œsophagus was greatly compressed by aneurisms of the descending aorta; and in each of which—the structures of the œsophagus having become completely removed—there remained a large rounded aperture, which was merely closed by thick layers of coagulum. Had a probang been introduced in either of these cases it must have inevitably caused instantaneous death, by entering the aneurismal sac.

† Lancet, Feb. 6, 1848.

\* Book 1st, De Tumoribus, Cap. XXVIII. London edition, fol. 1649, p. 204.

† Medico-Chirurgical Review, July 1839, from "Medical and Physical Researches, by R. Harlan, M.D. F.R.S. London and Philadelphia, 1835."



calcareous concretions were found on the outer side of the *pulmonary artery*, close to its origin, and extending towards the right ventricle. The inner coat was separated from the elastic for the space of three inches from the point at which it joins the right ventricle, and torn into shreds, which projected into and narrowed the cavity. The whole lining membrane was coated with a thin layer of fibrine. At its origin from the ventricle, exactly in the situation where the concretions terminated, was a hole of the size of a fourpenny-piece, through which the blood had escaped into the pericardium; the neighbourhood of this opening was of a blood-red colour. The lungs were healthy and bloodless.\*

Mr. Curling, of the London Hospital, has most kindly furnished me with the following highly interesting narrative of a case of traumatic diffused aneurism of the right branch of the pulmonary artery. The patient was admitted under the care of Mr. Luke.

"Edmund Taylor, a healthy and muscular young man, aged 23, was brought to the London Hospital about 5 in the morning, Sept. 30, 1838, having been stabbed in the chest with a long clasp-knife a short time previously. The wound was about an inch in extent, and situated at the front and upper part of the right side of the chest, near the junction of the cartilage of the third rib with the sternum. I was informed that instantly after its infliction there was a profuse hæmorrhage, and that the patient coughed up almost immediately a considerable quantity of blood. When admitted he was very faint, and there was a slight oozing of blood from the wound, but this ceased after the edges had been brought together with adhesive plaster. His breathing continued afterwards to be much oppressed, and for two days he coughed up occasionally a small quantity of blood. Pneumonia supervened, but it was checked by general and local blood-letting, and by antimony and mercury exhibited until the mouth became affected. He appeared to be going on tolerably well, when, on the eleventh day after the injury, he was seized with a fit of coughing, and upwards of sixteen ounces of blood suddenly gushed out from the wound. From this period there was a daily hæmorrhage, varying in quantity from one or two ounces to four or five; and he frequently expectorated small clots of blood. The blood which issued from the wound was thin, and sometimes mixed with matter like pus; and air always escaped when the part was dressed. Digitalis, the acetate of lead, and other remedies, were given to check the hæmorrhage, but with no effect. The patient got gradually weaker; and being exhausted by the

daily losses of blood, died on the 29th day after the injury.

"The body was examined the day after death. It was much wasted and exsanguineous. The knife had passed in an oblique direction, dividing the cartilage of the third rib, and entering the chest a little to the right side of the anterior mediastinum. The whole of the front part of the middle lobe of the right lung was converted into a false aneurismal sac. There was a large irregular cavity, filled with coagulated blood, part of which was in layers, and deprived in a great degree of the red particles, and part loose and soft, and of a greyish-red colour. There was also a small quantity of coagulated blood. At the bottom of this cavity, towards the heart, was distinctly perceived an opening in a large vessel, capable of admitting a full-sized goose-quill;—the aperture communicated with the right branch of the pulmonary artery just as it divides into several branches for distribution throughout the lung. The pulmonary tissue surrounding this false aneurism was hepatized; and there were firm pleuritic adhesions on that side of the chest. The pericardium contained about three ounces of turbid serum, and there was a thin layer of loose lymph coating a great part of the heart. The left lung and the abdominal viscera were sound. The mammary artery was untouched, but the small intercostal vessel communicating with it was divided.

"It will perhaps excite some surprise that a considerable wound of one of the two main branches of an artery transmitting the whole of the circulating fluid of the body, should not have been attended with such a loss of blood as to have destroyed life in a short period. A wound of the same extent in the *arteria innominata* or common iliac arteries, less in size than the vessel wounded in this case, would no doubt have proved fatal in a few minutes. The safety of the patient may, however, be ascribed to the inferior power of the right ventricle of the heart as compared with that of the left. In the collapse which resulted from the profuse hæmorrhage consequent upon the wound, we may conclude that coagulation took place,—that the opening in the right branch of the pulmonary artery became closed, and bleeding arrested for a time. The action of the right ventricle, reduced by the hæmorrhage and the treatment afterwards pursued, appears to have been insufficient to disturb the false aneurism which had formed in the substance of the lung; but unfortunately it was subsequently ruptured in a violent fit of coughing. Although the aneurismal sac was of some considerable size it was smaller than might have been expected, considering the magnitude of the vessel wounded,—its near approximation to the heart,—the dura-

\* Foreign Med. Review, Oct. 1842, p. 547: Dr. Helmbrecht, Casper's Wochenschrift.



tion of life after the injury,—and the soft vascular and unresisting nature of the tissue which formed the parietes. But this circumstance may perhaps be explained by the inferior propulsive power of the right ventricle. A false aneurism of the aorta, under similar conditions, if not sooner destructive to life, would, I think, have attained in the same period a very much larger size. At the time that the bleeding recurred, eleven days after the infliction of the wound, the lung had been consolidated by inflammation. It was enabled, therefore, to offer considerable resistance to the effusion of blood and the extension of the aneurism.”

It is singular that, while so much has been written upon the subject of injuries to the lungs, so few facts should have been hitherto elicited with regard to the precise manner in which lacerated and punctured wounds of branches of the pulmonary artery heal. It is probable that their closure is usually effected by the gradual infiltration of blood into the surrounding tissue of the lung, as well as by the collapse of that organ consequent upon the presence of blood or air within the pleura, aided by the depressed state of the circulation which results from the hæmorrhage, and from the depleting plan of treatment which is usually adopted. In gun-shot wounds, the closure of the vessels is doubtless greatly aided by the contused condition of all the tissues.

#### RUPTURE.

Rupture of the main trunk and larger branches of the artery has been known to occur in several instances. This lesion appears usually to result from a diseased condition of the vessel, and is a far less frequent consequence of severe crushing injuries to the chest, than is rupture of the thoracic aorta. In the following case, however, the laceration appears to have been produced by a violence of this description :—

A healthy, robust youth, ætat. 22, was, in a scuffle, wounded in the neck; he fell down on the spot, and died almost directly. Very little blood flowed from the wound. On dissection, the wound was found to have penetrated two inches in depth, passing between the trachea and left subclavian vein, but neither these or any other important parts were injured. Nearly five pounds of black coagulated blood were found in the left bag of the pleura; the cavity of the pericardium also contained a quart of clotted blood. This membrane exhibited an irregular rupture, nearly two inches in length, at the point corresponding to the root of the left lung; the *pulmonary artery* was found to have given way just beneath the point where the pericardium is reflected upon this

vessel: its parietes did not, however, exhibit any traces of morbid change.\*

The following case has been recorded by Mr. Wm. Gunn, R.N. :—†

A seaman, ætat. 46, after suffering from pain in the head, extending down the neck and arm to the hand, which was benumbed, while making some considerable exertion, fell back without speaking, and in a state of exhaustion, from which he never recovered. On opening the chest, the left side was found completely full of blood, the lung being collapsed under the pressure. A rupture existed in the *pulmonary artery* about half an inch from its origin, and large enough to admit the point of the little finger. The artery was diseased at the point where it had given way.

Two highly interesting cases of rupture of the trunk of the pulmonary artery have been fully detailed by M. Ollivier.‡

A remarkable instance of this lesion has also been recorded by Mr. J. Adam, jun.§

The patient was a man of debilitated constitution, 52 years of age, who, for some time previous to his death, had been subject to various uneasy feelings, referred to the region of the stomach and head, with general derangement of the digestive functions, and latterly to irregular action of the heart, accompanied sometimes with a sense of constriction across the chest, increased on using any corporeal exertion, or too frequent indulgence in spirituous liquors. Latterly, when the fluttering action of his heart became distressing, he was obliged to have recourse to the recumbent posture for relief. Death occurred suddenly. On opening the thorax, a large quantity of dark grumous blood gushed out from the right pleural cavity, which was nearly filled with the effusion. Two polypi or coagula of blood were found in the right ventricle. The valves of the *pulmonary artery* were in a state of ossification. This vessel was extremely thin, and enlarged to nearly four times its natural size, being not less than seven inches in circumference. It contained an organized polypus, extending from the semilunar valves about four inches along the artery. A rupture had taken place in the “middle” of the artery, and it appeared that there was an opening in the centre of the polypus, through which the blood seemed to be transmitted from the ventricle to the lungs and aorta, and other large vessels issuing from its arch

\* Medico-Chirurgical Review, July, 1848. From the Archives Générales.

† Edinburgh Med. and Sur. Journal, January, 1829, and LONDON MED. GAZETTE, Vol. iii. p. 545.

‡ Dictionnaire de Med. : art. Vaisseaux Pulmonaires.

§ In the Calcutta Medical Transactions, Vol. ij. p. 115.



were completely ossified. A similar condition of disease also extended throughout the remaining portion of the aorta. There was no apparent disease of the lungs.

Mr. Fearn, of Derby, has published notes of the case of a man, *ætat.* 63, who had been troubled with a cough for a long time, but in whom stethoscopic examination revealed nothing beyond the evidences of general bronchitis. The patient was suddenly seized with a tremendous attack of hæmoptysis. The bleeding, however, was restrained for a while by appropriate remedies, but it again returned, and the patient died from exhaustion, nearly four days after the first attack of hæmorrhage. On examination after death, it was found that the right *pulmonary artery* was ruptured, just at its entrance into the lung, and the pulmonary tissue was broken down by the quantity of blood which had been poured into it. There were no tubercles, nor any other adventitious deposit, in either lung.\*

A case of sudden death from rupture of the pulmonary artery, is alluded to by M. Devergie, (*Médecine Légale*, t. i. p. 66). And another, occurring in a man 54 years of age, is noted in the Sixth Annual Report of the Registrar-General (p. 288.)

#### *Ulceration.*

The coats of the pulmonary artery occasionally become eroded and perforated in cases where aneurismal tumors of the arch of the aorta greatly encroach upon this vessel. A similar lesion is also produced in certain cases of phthisical disease; and sloughing of branches of the artery has occurred, though by no means frequently, in cases of pulmonary gangrene and pneumonic abscess.

In cases of aneurism of the arch of the aorta, especially where the dilatation principally affects the under and back part of the vessel, an ulcerated or ruptured communication is liable to be formed between the pulmonary and systemic arterial trunks. The lesion is, of course, by no means one of frequent occurrence, but several instances of the kind are upon record, of which the following appear to be most characteristic:—

Dr. Wells relates the case of a merchant, 35 years of age, who had suffered from apparent premonitory symptoms of phthisis, and from a slight attack of hemiplegia, which, however, had passed away when he consulted Dr. W. He then suffered from a noise in his ears, flatulence, and pains in his hands and feet, occasionally attended with slight swelling in the same parts. He did not complain of any unusual feelings in his chest. After considerable fatigue in

walking, he was suddenly seized, between 8 and 9 o'clock P.M., while playing with his children, with a sense of great oppression in his chest. He soon after became sick, and vomited a matter streaked with blood. The surface was cold. Soon after midnight he was found labouring under a constant desire to cough, and was continually expectorating mucus tinged with blood. The body was moistened with a cold sweat, and his pulse was extremely feeble: sometimes it was scarcely perceptible. At 5 A.M. his pulse was very feeble and irregular; his breathing difficult; skin pale, cold, and covered with a clammy sweat; and he frequently tossed and writhed his body as if suffering great pain or uneasiness. The faculties of the mind seemed unimpaired. About a quarter of an hour later he became suddenly worse, and in a few minutes expired. Almost immediately before his death, he complained much of heat in his chest.

*Autopsy, two days after death.*—The blood-vessels of the lungs were very much distended, and there was also a considerable quantity of blood in the air-cells. Each cavity of the chest contained about ten ounces of a fluid highly tinged with blood. The pericardium contained about two ounces of a fluid similarly tinged. The tumor adhered to the *pulmonary artery* just before its division into the right and left branches. Within the circumference of this adhesion there was a narrow hole, by means of which a communication was formed between the two arteries. The cavities of the heart and great vessels were very much distended with blood.\*

The following nearly parallel case is related by Dr. J. Reid:—

A gentleman, aged 53 years, who had been for some months complaining of slight bronchitic symptoms, with some precordial uneasiness, was suddenly seized with violent dyspnoea, rapidly followed by insensibility, and in about four minutes from the commencement of the attack he was dead.

On examination 48 hours after death, the heart and all its valves were found healthy. That portion of the arch of the aorta between the upper part of the sinuses of Valsalva and the origin of the *arteria innominata* was dilated into an aneurism capable of holding the fist. The dilatation chiefly projected to the left side, and there the coats of the artery were not only irregularly thickened, but contained numerous yellow patches. The left side of the aneurism adhered firmly to the trunk of the *pulmonary artery*, and a ragged irregular fissure, nearly an inch and a half in length, formed a communication between them. The

\* Provincial Medical Journal, and Med. Times, Nov. 15th, 1845.

\* Trans. of a Society for the Improvement of Med. Chir. Knowledge, vol. iii. p. 85.



aneurism contained only a few small clots of fibrine. The lungs contained a very considerable quantity of blood, and some serum.\*

Although the particulars of the following case are detailed at considerable length, it is difficult to learn, from the description, whether the arterial lesion was primarily due to aneurism of the vessel or to erosion of its tunics. The rupture of so large an artery could scarcely have occurred under the circumstances.

Mr. ———, ætat. 36, of a consumptive family, suffered more or less from symptoms of phthisis from the autumn of 1841 to November, 1842, when he was attacked with active hæmoptysis. The blood was coagulated, and expectorated without effort. At the end of a month he sank from the exhausting effects of the hæmorrhage.

*Examination.*—There were adhesions between the pleura of the left side. The pulmonary pleuræ of both sides presented the peculiar spotted appearance which results from strumous deposit. The upper part of the left lung was entirely occupied by a large cavity containing about half a pint of grumous and coagulated blood. The walls of this cavity were composed of the parenchymatous structure of the lung, condensed and solidified by pressure. Upon careful examination, the left branch of the *pulmonary artery*, at the distance of two inches from its bifurcation, was found to open into this cavity by an aperture as large as a crow-quill. The communication of the artery with the abscess was considered to be the result of the coats of the vessel giving way, rather than the effect of the ulceration of the abscess, as the opening from the artery was funnel-shaped, and terminated in the smallest possible aperture. The trunk of the pulmonary artery was so large as at first to be taken for the aorta, for it had a complete curvature to the right as high up as the left clavicle. It was thought that this dilatation of the vessel was perhaps attributable to pressure of the cyst upon one of its main divisions. The patient had suffered from difficulty of breathing from childhood; but it is not mentioned that marked dyspnoea was one of his later symptoms. Indeed, the narrative does not clearly prove that the left division of the artery had been greatly compressed by the abscess.†

In some cases of congenital defect, where the arterial duct remains permanently open, the aorta and pulmonary artery are found perfectly in apposition, and communicating by a wide opening of somewhat irregular

form. In distinguishing such cases, it will be necessary to observe whether the aorta is dilated at that spot, and especially to remark whether the valves and trunk of the pulmonary artery are thickened and opaque; as, where a communication has long existed between these vessels, the pulmonary artery usually takes upon itself much of the functions of the aorta, while its structures assume an appearance closely resembling those of the systemic artery.

In addition to the cases mentioned above, four preparations (numbered 14, 15, 87, 102) of the lesion under consideration are stated to be preserved in the collection at St. Bartholomew's Hospital; and one (No. 366) in the Hunterian Museum. A case in which an aneurism opened into the pulmonary artery has also been recorded by MM. Payen and Zeinck.\* Another instance has also been contributed by M. Sue.†

Dr. Lee observed that, in a case where a large branch of the pulmonary artery opened into the cavity of a phthisical abscess, the vomica was not lined with that peculiar membranous structure which usually invests the walls of cavities of this class.‡

It is not usual for the arterial branches which pass upon the sides of pulmonary vomicæ to become occluded by coagula. It is probable that in these cases, wherever hæmorrhage occurs from the corrosion of a large vessel which has not previously become aneurismally dilated, the perforation of the artery is due, either to sloughing of the interior of the abscess, a not unfrequent occurrence in phthisis, or to the absence of that solid deposition which usually lies beneath the pyogenic membrane of phthisical cavities.

I was present at the examination of the body of a man, ætat. 58, who died, February 4th, 1845, in the accident ward of Guy's Hospital, from the secondary effects of a fracture of the elbow-joint. He had suffered from bronchitis, with foetid expectoration, for some time previous to his death. The walls of the right ventricle were rather thin. Nearly the whole of the posterior portion of the right lung was in a boggy condition, the result of a low form of pneumonia; the pulmonary tissue being in this situation generally infiltrated with abominably foetid sanies. This portion of the lung contained several cavities, one of which opened into a circumscribed cavity in the pleura; the lung surrounding this opening was in a sloughy condition. The trunk of the *pulmonary artery* was rather wide, and decidedly thin. Its surface was free from stain or deposit, but dull. The tissues of the vessel which traversed the diseased lung were generally

\* Edinburgh Med. and Surgical Journal, vol. liv. p. 114.

† Mr. W. Crowfoot, Jun., of Beccles; Med. Chir. Transactions, 2d Series, vol. viii.

\* Bulletin de la Faculté de Méd., 1819.

† Journ. de Méd. Contin. t. 24, p. 124.

‡ Dublin Medical Journal, vol. xxv. p. 168.



softened, especially in the inflamed parts. Several branches, rather larger than crow-quills, were more or less obstructed by dark adherent clots. In some branches these were evidently old, and nearly absorbed,—the vessels again beginning to be permeable by blood; in others, the clots produced complete obliteration, and were adherent to the entire circumference of the arteries which they occupied. Throughout most of the inflamed parts, however, many branches of the vessel remained perfectly free. A very considerable arterial branch was almost completely obliterated in two places by the pressure of cavities on either side. At each of these spots the vessel scarcely equalled a whipcord in circumference. The contracted portion which was most distant from the heart, was partially obstructed by some whitish fibrine, and the lining membrane of the other strait was vividly and deeply reddened, evidently by an interstitial effusion of blood. This vessel may have been capable of transmitting a very slender current of blood. The lesions which it presented did not appear to be particularly recent, being, in all probability, of several days' standing.

Another branch, of equal size, presented traces of severe inflammatory change, at a spot where it lay in the close vicinity of a sloughy cavity. Here the interior of the vessel bore traces of circumscribed thickening; its lining membrane was blackened, as if from the interstitial effusion of blood which had become partially absorbed. The centre of this discolouration presented a raised whitish defined spot, where the tissues of the vessel had lost their cohesion and appeared to be in a sloughing condition; the diseased tissue was not, however, sufficiently softened and detached to allow of hæmorrhage. This position of the artery was not defended by adherent coagulum: a small band which it gave off appeared to have been obliterated by fibrous deposit; but, although this had become nearly absorbed, the vessel still remained so greatly contracted as to be almost impervious.

It is probable that, had this patient's life been protracted for a day or two, or had the force of his circulation been greater, the separation of the sloughy portion of the artery would have been followed by fatal hæmorrhage.



*Ulceration of the Pulmonary Artery (continued).*

THE lesions presented in the following remarkable case, which occurred within my own observation, were of so singular and so obscure a character, that I am doubtful whether to ascribe them to ulceration, or to softening of the tissues of the valves, the result of acute inflammation superadded to disease of old standing. Whether the destruction of the entire valvular apparatus occurred suddenly, or was the gradual result of chronic changes, must now, I fear, remain unexplained:—

E. C—, aged 19, a servant, of pale aspect and heavy appearance, whose habits had been rather irregular, was admitted to Guy's Hospital, Nov. 9th, 1851, with symptoms of renal anasarca, which had been increasing for the last four months, until five weeks prior to her admission, when the swelling of the body became nearly general. Upon her admission the anasarca extended over the whole of the body and the face. The breathing was 38, not painful, unless when she was on her back; pulse 106. Cough, from which she had suffered for some time, had been more troublesome at night for the last fortnight, but she did not expectorate. The urine was small in quantity, and albuminous. The right side of the chest, below the clavicle, was resonant on percussion; the left, in the same spot, dull, with cooing sibilant rales: posteriorly there was also dulness on both sides. The heart's sounds were regular. She appeared to improve under treatment for a few days, having perspired very freely, and slept better.

On the 13th, the pulse was observed to be irregular. For about three weeks from this date, the œdema, cough, and difficulty of breathing, continued to vary, as the skin and bowels were, or were not, acted upon. During the last two or three days of her life the heart's action was observed to be indistinct, and she became much depressed; the skin was dry; the pulse varying, at different times, from 88 to 100, and very feeble; the countenance swollen, with dark areolæ round the eyes. She complained of nausea, and much pain in the right lumbar region, passing up to the shoulder; but, on the evening of the day before her death, the bowels having acted copiously, she perspired very freely; the breathing still continued laborious, with much wheezing. On the day of her decease (Dec. 3d) the features appeared shrunk, the dark areolæ still surrounding the eyes. She had slept

very little; the pulse 100, and feeble; the tongue rough and furred: the skin dry, the breathing laborious, and there was entire suppression of urine. Her debility was so great as to require a free administration of stimulants. She gradually became weaker towards the close of the day, sinking down in the bed, and, at about five o'clock, P.M., she expired.

*Sectio Cadaveris.*—Each pleural cavity contained a little serum, and the right lung was partially coated with loose fibrine; the lungs were generally œdematous, and there were traces of pneumonia (grey hepatization) at the upper part of the right. The rima glottidis was œdematous; the heart did not appear enlarged; the walls of the right ventricle were rather thick, but its cavity was of very moderate size; it contained a good deal of dark coagulum. The *pulmonary valves* were almost entirely destroyed; no trace of pouches remained, and merely a few thin tattered slips adhered to the lines where the crescents had been attached. A flattened mass of fibrinous coagulum, which had in great measure lost its colour, adhered to the spot where the left and anterior curtains had joined. Between the origins of the right and left pulmonary branches an oval fibrinous mass, as large as a hazel-nut, adhered to the lining membrane of the vessel; it was firm, appeared to have undergone contraction, and contained earthy particles. It evidently interfered with the passage of the right pulmonary branch, which appeared narrow, and corrugated internally, and in a less degree than that of the left. The parts above and below the orifice of the vessel were of a purplish red colour: the lining membrane here was loose and irregular, detached at some spots, and raised by patches of atheromatous deposit in others; but the endocardium of the ventricle generally did not appear diseased. The walls of the left ventricle were rather thick, and its cavity by no means large; the aorta was small and healthy: the liver was enlarged,\* soft, and much congested; the spleen was enlarged; the kidneys were white, large, flabby, and mottled.

It is much to be regretted that, in this case, owing to the very ordinary character of the symptoms, attention was not particularly called to the state of the heart during life. It was considered, by some of

\* The specimen is preserved in Guy's Museum.



those who witnessed the inspection, that the destruction of the valves was the result of acute inflammatory softening; still, the disease seemed to be extremely localized, and it appeared to me that the reddening of the artery and parts adjacent was due rather to the imbibition of blood by the loosened and diseased surface, than to acute inflammatory change. From the circumstance of a mass of coagulum, partially deprived of its colouring matter, adhering to a spot which once must have given attachment to portions of the curtains, it is evident that the patient had survived the destruction of the valvular apparatus for several days at least,—possibly for a far longer period. The presence of atheromatous deposit, and of an earth-infiltrated clot in the ascending portion of the artery, showed that this vessel had long been the seat of extensive disease: this, together with the obstructed condition of the main branches of the artery, with the additional impediment to the pulmonary circulation which resulted from the pneumonic and pleuritic effusions, must have exposed the valves to constant and long-continued violence, under which, it is probable, they at length became ruptured and destroyed. The ill effects of this extensive lesion were, doubtless, in a great degree mitigated by the strength of the right ventricle.

The following is a brief abstract of cases involving remarkable abnormal conditions of the pulmonary artery, which have been recorded, or which have occurred, more or less, within my own observation (these latter are marked "seen") since the publication of the earlier chapters of this memoir:—

*A single ventricle giving off a single artery (aorta), which distributes two branches to the lungs.*—Male child, well developed, but cold and livid. Attacks of dyspnoea, in one of which it died, seventy-eight hours after birth. The father said to labour under heart disease. A single auricle of large size receiving the cavæ, two pulmonary veins, and the coronary vein. Auriculo-ventricular opening of large size, and provided with an imperfect valve. The ventricle well developed. The aorta, guarded by three simular valves, gave off, from its posterior part, two pulmonary branches. Coronary arteries not given off at the aortic sinuses, but a single vessel, which appeared to have originated from the concavity of the arch above the pulmonary branches, passed down in contact with the left side of the aorta, and divided at its root into two branches, which were distributed upon the anterior and posterior aspects of the heart (a very similar arrange-

ment observed in the heart of a calf. M. T. Weber, *Observatio Anatomico Path. de Cord. Univent, e quo unus tantum truncus arteriosus surgit.* Bonnæ 1832). M. Foster, Report of Proceedings of the Pathological Society of London, 1846-7. *Seen.*

An imperfect, but apparently similar, specimen from a cyanosed child, which died at the age of ten weeks, from convulsions of eight or nine days standing. The respiration had been free.—Dr. Crisp, *Ibid.*

*Obliteration of pulmonary orifice.*—The ascending portion of this vessel obliterated. The foramen ovale, ventricular septum, and arterial duct, remaining pervious in a cyanosed male child, eleven months and two weeks old. Dr. Peacock, *LONDON MED. GAZ.*, March 31st, 1848.

Also the following interesting, but imperfect, cases:—

*Obliterated pulmonary artery.*—Foramen ovale and ventricular septum pervious. Heart evidently that of a child at least several weeks old. Author, *LONDON MED. GAZ.*, Dec. 31st, 1847.

A dumb cyanosed female, ætat. 12 years, always delicate; subject to palpitation and dyspnoea on exertion, and to cough and pain in the side: death apparently from bronchitis. Both ventricles slightly hypertrophied, and of nearly equal thickness, opening in ventricular septum. *Ascending pulmonary artery* not discoverable? foramen ovale closed. Lungs of natural size. Unfortunately the arch was not preserved. (Case slightly alluded to in my memoir.)—Dr. Crisp, *Trans. Lond. Path. Soc.*, 1847. *Seen.*

*Pulmonary orifice contracted. Lungs partially supplied by enlarged bronchial arteries.*—Man, ætat. 19, cyanosed. There appears to have been great contraction of the *pulmonary artery*. *Bronchial arteries and arteria comes nervi phrenici* unusually large and tortuous; the latter terminated in the lung. The lungs presented tubercles at different parts. *Foramen ovale open. Arterial duct closed.*—Mr. F. Le Gros Clark, *LOND. MED. GAZ.*, June 4th, 1847.

*Contracted pulmonary orifice. Patency of auricular and ventricular septa and arterial duct.*—A cyanosed child, seventeen months old, which died from cerebral effusion. Entrance of the *pulmonary artery* small, and provided with only two valves. A free aperture in the base of the septum ventriculorum. The *foramen ovale and arterial duct* very nearly closed.—Dr. Peacock, *MED. GAZ.* Feb. 1848.

*Contraction of pulmonary orifice. Auricular and ventricular septa perforated. Arterial duct closed.*—In a dissipated man, about 28, Dr. Marcus found the *pulmonary valves* contracted and inefficient. The *tricuspid valve* might be regarded as want-



ing. Two small openings in the *ventricular septum*. *Foramen ovale* widely open.—Casper's *Wochenschrift*, 1849, and *MED. GAZ.* Dec. 1849.

In the case of a cyanosed boy 13 years of age, who died of pneumonia, the aorta arose entirely from the sinus of the right ventricle. The orifice and trunk of the *pulmonary artery* would scarcely give passage to a goose quill. Left ventricle very small, and had no exit except by an aperture of sufficient size to admit the point of the fore-finger, which opened into the right ventricle beneath the origin of the aorta. A small valvular opening in the *fossa ovalis*. State of the *arterial duct* not ascertained.—Mr. N. Ward for Dr. N. Parker, *Pathological Society's Report*, April, 1847.

*Pulmonary orifice narrow, deficient interventricular septum, closure of arterial duct and foramen ovale*.—Child, about two years and five months; cyanosis commencing three months after birth. Extreme contraction of *pulmonary orifice*; opening in the *septum ventriculare*; left cavity small; *ductus arteriosus* and *foramen of Botal* closed.—Dr. Peacock, *London Pathological Society's Report*, Dec. 7th, 1846.

*Early tendency to closure of arterial duct*.—Fœtus, born at seven months and a half, died in fifteen minutes after birth, in consequence of hæmorrhage from the umbilical cord. *Arterial duct* nearly closed, capable of admitting only the shank of a large pin.—Author, *London Pathological Society's Report*, 18th January, 1847.

*Congenital closure of the aortic orifice, probably compensated by an open state of the arterial duct*.—A female child, born at the full term of pregnancy. It lived two days, and died in convulsions, having been until their occurrence apparently in good health. The heart was natural in size and normal in situation; the cavities of the right auricle and ventricle were much enlarged. The *pulmonary artery* was in the same condition. All the *carneæ columnæ* on the left side were fused together, so as to obliterate the ventricular cavity, and present in lieu of it a solid mass. The only trace of ventricle was at the upper part of the latter, where there was a little hollow space, of a rounded form, just capable of holding a small pea, and presenting within, slight traces of *chordæ tendinæ* and mitral valve. The *ostium aortæ* was perfectly closed; and, on opening the ascending portion of the arch, two small folds of the lining membrane indicated the site of the sigmoid valves. The left auricle was natural, the *foramen ovale* large, and the coronary arteries arose at their usual place, and ramified in the usual manner.—E. Canton, Esq., *MED. GAZ.*, March 1849, p.

561. Mr. Canton was so obliging as to afford me an opportunity of carefully examining this valuable specimen of exceedingly rare and curious malformation.

*Open ductus arteriosus, associated with contraction of the aorta distal to the left subclavian artery*.—Case of this malformation occurring in a male child born at the eighth month, and which died at the age of ten weeks.—Dr. Peacock, *LONDON MED. GAZ.*, Nov. 26th, 1847. *Seen*.

*Case illustrating the earliest stage of the malformation usually known as "distribution of the descending aorta from the pulmonary artery"*.—Author, *Report of Pathological Society of London*, 15th March, 1847.

*Permanence of arterial duct associated with disease of the aortic valve, and narrowing of the aorta opposite the left subclavian artery*.—An interesting example of this malformation, occurring in a woman, æt. 34, is recorded by Dr. B. G. Babington.—*Ibid.* April 19th, 1847. *Seen*.

The case of closure of the *foramen ovale* previously to birth, alluded to in the memoir, is related in detail by Ebenezer Smith, Esq.—*Ibid.* Dec. 7th, 1846, p. 53. This highly important specimen is preserved in the Museum at Guy's. *Seen*.

*Transposition of the pulmonary artery and aorta without transposition of the cavities of the heart. Foramen ovale and ventricular septum open*.—This malformation observed in a cyanosed child which died at the age of three years. By M. Colnies.—*Archives Générales*, vol. v. p. 284, for 1834.

*Rupture of pulmonary artery*.—An interesting case of extensive rupture of this vessel, with laceration of the left auricle, in which the individual survived the injury nearly four hours, is related by Mr. Prescott Hewett.—*LONDON MED. GAZ.*, May 14th, 1847.]

#### *Condition of the Cavities of the Heart in Cases of Malformation associated with error in the Pulmonary Artery.*

*Right auricle*.—In nearly all instances of congenital cardiac defect this cavity is largely developed, being usually much dilated, sometimes enormously so; and generally with more or less thickening of its muscular structure. In some cases the pulmonary veins open into this cavity by uniting and forming two orifices; in others, one or two of those vessels terminate here, while one or more communicate with the superior cava: in one instance the whole of the pulmonary veins were found to enter this cavity. The valved, cribriform, and widely patent states of the *foramen ovale*, are well known to anatomists. Occasionally the auricular septum presents two orifices



quite distinct from each other, and separated by muscular structure. In a case (Dr. Blackmore's) where the tricuspid was unusually imperfect, the orifice of the superior cava was defended by a thin valvular apparatus.

*Right ventricle.*—The tricuspid valve has been found in various ways malformed, in cases of narrowing of the pulmonary artery. Contraction of the right auriculo-ventricular orifice is a not unfrequent concomitant of arctation of the pulmonary ostium.\* It appears to be a rule that, when the pulmonary orifice becomes obliterated, subsequently to the completion of the ventricular septum, the right ventricle undergoes so much contraction as almost to disappear entirely: hence, evidently, one form of single heart. In the larger proportion of cases of malformation of the pulmonary artery, the right ventricle is remarkably developed. In none of the severer cases that I have seen has it presented the tenuity of the anterior wall, and that external flattening which characterise this ventricle in its normal condition, but its cavity usually assumes more or less of a globular form: and (in the cases of obliteration and severe obstruction of the pulmonary artery) its walls are probably never thinner than those of the left ventricle, and are generally far thicker. In most cases of this description it is mechanically a matter of absolute necessity that the right ventricle should be of large capacity; but it is occasionally so large as to render it apparent that its condition is rather one of hypertrophy and dislocation than of merely unusual dimensions and muscular power. In cases of this description the ventricle rarely becomes attenuated and aneurismal: still, this extreme result has been observed.

*Left cavities.*—In all cases of obstruction to the pulmonary artery, the size and strength of the left auricle and ventricle are proportioned to the quantity of blood permeating the lungs. This does not always depend on the manner in which the pulmonary artery is malformed at its orifice: thus, in one case this vessel may be merely contracted, and the lungs receive a very small supply of blood: in another, the ascending pulmonary trunk may be wholly obliterated, and yet the pulmonary circulation may be comparatively freely supplied from aortic branches. In the latter case the left cavities will remain of fair size, perhaps nearly or quite equalling the

right; in the former they will be found contracted in dimensions, and of weak muscular power. In fact, without examining either the lungs or the large vessels, the degree of freedom of the pulmonary circulation may generally be at once resolved, in cases of contraction or obliteration of the pulmonary artery with deficient ventricular septum, by observing the size and strength of the left cavities as compared with the right. In some instances, where the aorta has been disturbed directly over the septum, and the left cavities have been well supplied from the lungs, I have found the left ventricle fully as strong and as large as the right, having evidently taken an active part in propelling the blood into the aorta. Still as, in a very large majority of these cases, the supply of blood to the lungs is unnaturally small, and circulates with difficulty, it is usual to find the left auricle and ventricle remarkably small, and with rather thin parietes. Indeed, in many cases, the left ventricle appears to perform no other function than that of propelling a small supply of oxygenised blood through the open septum into the right ventricle, upon which nearly the whole onus of carrying on both the pulmonary and the systemic circulation devolves. Where the orifice of the aorta is obliterated, the ventricular septum being complete, the cavity of the left ventricle becomes nearly obliterated. I believe that, in several forms of congenital disease of the heart, attended with great pulmonary obstruction, death is hastened by the thinned and weakened condition of the left cavities, which have become so atrophied and powerless as to be incapable of contracting firmly upon any unusual quantity of blood that may be accidentally thrown into them.

A review of the examples of congenital heart disease, and of cardiac lesions occurring at late periods of life, which have been collected in the preceding pages, affords us an extraordinary insight into the many and beautiful resources which nature possesses in adapting the still uninjured portions of a diseased or deficient heart to the necessities of the circulation. There are no truths more important in physiology or pathology, none which convey to the physical student a more direct and striking evidence of the greatness of the Creator's plan in the construction of man's body, than the facts that life and circulation may continue under either of the following conditions:—

When the right auriculo-ventricular orifice, the ascending pulmonary artery, the mitral opening, the aorta ostium, or the descending thoracic aorta, is perfectly obliterated; where the foramen ovale or arterial duct is closed previously to birth; or where, in

\* I believe that great narrowing of the tricuspid orifice rarely, if ever, occurs independently of contraction of other outlets of the heart. I have met with two remarkable instances of this lesion, in each of which the mitral orifice was also extremely narrow. A complication of this kind, of course, gives uncertainty to the diagnosis, and diminishes the prospect of survival.



adult life, the pulmonary valves have become totally destroyed. It is a consciousness of the gift of recognising such beautiful truths as these, and of obtaining, through them, an insight, however partial, into the right means by which nature should be assisted in her efforts to resist disease, that frees the labours of the pathologist from every embarrassment of fear and disgust, and leads him forward in his researches by the power of a resistless and inexhaustible charm.

#### *Diagnosis and Symptoms.*

When I find an accomplished physician and careful auscultator of the present day omitting from his treatise all consideration of the signs which characterise the diseases of the pulmonary artery, as being of little practical value, owing to the extreme rarity of those lesions;\* and when, on looking over the materials which have been brought together in this memoir, I find that, in consequence, probably, of a similar opinion in the profession generally, scarcely more than two or three practical observers have considered the diagnosis of this class of diseases worthy of their attention,—I cannot but feel some degree of apprehension in bringing forward the following imperfect details in illustration of a subject regarding which so little positive information has hitherto been acquired. It is certain, however, that the diseases which affect the pulmonary artery are neither rare nor unimportant, and that, when present, they are generally characterized by certain distinctive rational symptoms and physical signs. The present chapter will merely embody a few scattered facts which I have been able to collect in elucidation of the subject. I trust that their evident imperfection will lead to more careful observation, and to the establishment of more definite results.

It would, of course, be almost impossible, and quite useless, to attempt to lay down any precise rules for diagnosing every one of the various malformations to which the cardiac apparatus is liable; but a few general rules, founded principally upon the relative frequency of the principal forms of congenital lesion, and upon a knowledge of the periods to which life may be extended in each, may lead to the establishment of a series of diagnostic principles, which, although not by any means absolutely certain in their application, will frequently assist us in arriving at correct opinions.

It will probably never lie within the

\* Practical Observations on Certain Diseases of the Chest, and on the Principles of Auscultation, by Peyton Blakiston, M.D., F.R.S., p. 223, 1848.

power of any physician to diagnosticate the particular set of lesions which are present in the vascular system of a cyanosed infant\* within a few days of its birth. Its heart may be the seat of any conceivable kind of malformation: still, if the child has become cyanosed almost immediately upon the establishment of respiration, it is most probable that it suffers from closure of the pulmonary orifice, with imperfection of the ventricular septum.

Where the symptoms of morbus cæruleus are not developed until some days or weeks subsequently to birth, it is probable that the orifice of the pulmonary artery is narrow, the ventricular septum open, and the foramen ovale and arterial duct either closed or distinctly contracted; or the latter of these passages may have become narrowed or closed, while the former is widely pervious.

If the infant be upwards of a year old, it is in the least degree improbable that it suffers from the malformation usually known as "distribution of the descending aorta from the pulmonary artery."

If the child has survived its fourth year, transposition of the great arteries is scarcely to be suspected.†

When cyanosis is present at about the age of three or four years, it is probably due, either to great contraction, or closure of the pulmonary orifice, with ventricular communication. Should a single systolic bruit be heard superficially in the region of the pulmonary orifice, the case will almost certainly prove to be one of the former kind.

At the age of one month, or at any subsequent period, it cannot be judged with any probability that the heart literally consists of only two cavities.

In early infancy there are no means of diagnosing between imperforation of the pulmonary artery and transposition of the two main arteries, except that the former irregularity is of far more frequent occurrence than the latter.

If the patient be above the age of seventeen years, imperforation of the pulmonary orifice can scarcely be suspected.‡

A person above the age of sixteen years, or a young adult, suffering from cyanosis of long standing, a bruit being audible in

\* In these remarks, I have not used the term "cyanosis" as merely characterising the symptom of lividity of the surface, but as comprising that train of phenomena which mark the existence of congenital malformations of the heart.

† In the three recorded cases of this malformation in which the longest survival occurred, the children died respectively at the ages of ten months, two years and nine months, and three years.

‡ Two individuals have presented this malformation at the age of ten years; one at twelve; and one at sixteen.



the region of the pulmonary artery, most probably has contraction of the orifice of that vessel, with perforation of the septum ventriculare.

If the individual has passed the period of early youth before becoming the subject of cyanosis; or if that symptom, formerly scarcely perceptible, has become considerably more apparent of late, it is, at first sight, probable that the disease is congenital narrowing of the pulmonary artery, the impediment having latterly been increased by thickening and further contraction of the parts, consequent upon super-added disease. In this case the ventricles probably do not communicate.

If the patient has passed the age of thirty years, the existence of congenital deficiency of the ventricular septum is highly improbable. Those who suffer from a congenital cause of obstruction which has originally been sufficient to arrest the development of the septum, very rarely, if ever, attain so advanced an age.\*

If, in any given case of cyanosis, the symptoms be ascribed solely to a patent condition of the foramen ovale, the incorrectness of that diagnosis will certainly admit of proof upon examination of the body.†

The larger number of the above diagnostic rules will, doubtless, occasionally fail; but I believe that they afford as near an approximation to the truth as we are at present capable of obtaining when attempting to generalise upon a disease so multi-form in its types, and, at the same time, subject to so few variations in its rational symptoms, as congenital malformation of the heart.

Having given very full details of the more prominent symptoms in most of the cases which I have cited, it appears quite unnecessary to enter into a separate description of the various characteristics of

\* In the four cases of this defect (the lesion being unquestionably congenital) where life was most prolonged, three of the individuals died respectively at the ages of twenty-two, twenty-four, and twenty-five years; and in an example observed by Dr. Fletcher, and already cited, an opening as large as a goose-quill was found in the ventricular septum of a man sixty-three years of age. In one rather questionable case the person is stated to have died at the age of twenty-seven. Richerand relates a case of imperfect septum ventriculare in which the patient attained the age of forty years; and Louis cites the instance of a general officer in whose heart a similar malformation was discovered. However, as Dr. Todd very pertinently remarks, there does not appear to have been any contraction of the pulmonary orifice in either of these two cases. I greatly doubt that an individual in whom a large and free congenital communication exists between the ventricles can reach the period of middle life.

† In the analysis of 180 cases of cyanosis, M. Aberle, of Vienna, found that two-thirds of the individuals were males.

morbus cæruleus. It is almost impossible that any practitioner should fail to distinguish a case of this description. The diagnosis between ordinary cardiac disease and congenital malformation is, however, a matter of some importance, and will be discussed hereafter.

The amount of positive information which has been adduced relative to the auscultatory signs of the various malformations of the heart, is exceedingly small.

Considerable attention has of late years been paid to the physical signs which characterise obstructive disease of the pulmonary orifice. Dr. Ormerod, who has published a highly interesting and suggestive paper on the subject,\* evidently regards as the most distinctive sign the presence of a murmur heard loud at the base of the heart, and which may or may not be also traceable along the aorta, but most clearly audible in a line from the third left intercostal space at the edge of the sternum, towards the middle of the left clavicle, for the distance of from two to two and a half inches. This is unquestionably the situation at which there is reason to expect that a bruit arising from obstructive disease of the pulmonary orifice should be most intense; but where, as is usually the case in these instances, the position of the heart is more or less abnormal, owing to the enlarged condition of the right ventricle, and where the cardiac action is much excited, the bruit is so liable to have its point of greatest intensity altered, and to be diffused over a very large portion of the thoracic cavity, that I apprehend it will, in a considerable proportion of cases, be found extremely difficult to assign to it by any means so definite an anatomical boundary.†

\* "On a Systolic Murmur in the Pulmonary Artery, and its Application to the Diagnosis of Functional and Organic Murmurs." *Edinburgh Med. and Surg. Journal*, 1846, p. 95.

† In a discussion which arose subsequently to the reading of Dr. Ormerod's paper at the Medico-Chirurgical Society, Dr. C. J. B. Williams objected that the rule laid down by Dr. Ormerod did not sufficiently distinguish aortic from pulmonary arterial murmurs. "When an aortic murmur was weak, it might be heard at the mid-sternum, yet not be loud enough to reach the arteries of the neck; but when made louder by anything exciting the actions of the heart, then it was heard in the neck, and showed its aortic origin. This is commonly the case in anæmia, in which the loose, ill-filled state of the arteries, makes them bad conductors of sound; and this, he suspected, would apply to most of the cases" (of "functional disease") "described by Dr. Ormerod as those of pulmonary murmurs" (*LONDON MEDICAL GAZETTE*, June 6th, 1845). Dr. Ormerod's observation has led him to conclude that a murmur may be heard in the pulmonary artery in acute rheumatism, as also in many cases of anæmia and its kindred maladies, which murmur he believes there are good reasons for concluding not to arise from organic disease, as well on account of the variable nature



In chronic cases, and where the bruit is single, the *superficial character* of an abnormal sound heard over the base of the right ventricle, and in the course of the pulmonary artery, becomes very distinctive of its origin in that vessel.\* The *tone* of the bruit, of course, varies greatly in intensity, according to the nature of the lesion which produces it. An abnormal sound originating in this artery is usually systolic, being occasionally so much prolonged as entirely to mask the second sound.†

of the murmur itself, as, most conclusively, on account of the rarity of disease of the pulmonary valves.

\* In cases of phthisis, Dr. P. M. Latham has frequently met with a systolic murmur occupying the space between a line drawn from the left side of the sternum along the upper edge of the second costal cartilage, and continued an inch along the second rib, and another line drawn from the sternum along the lower edge of the third costal cartilage, and continued an inch along the third rib. This sound is a gentle bellows murmur, which cannot be perceived either in the præcordial region, or in the course of the aorta, or in the carotids. Dr. Latham considers that, where, from direct examination of the lungs, a suspicion only of tubercular disease can be entertained, the murmur in the space indicated must always contribute to confirm it. He supposes the pulmonary artery, in its first divisions, to be the seat of the murmur, but doubts whether it becomes such in consequence of its own disease, or by reason of pressure or impediment reaching it from diseased lung. I am not aware that the above observation has been explained by dissection; nor am I acquainted with the existence of any perceptible organic condition in the heart or pulmonary artery in cases of phthisis which could account for the occurrence of this murmur. Whether it depends upon pulmonary or pleural lesions, a want of relation between the size of the ventricle and the capacity of the artery, or upon other causes, has yet to be explained. Loose adhesion of the lung to the pericardium, emphysema of the pulmonary edges, which is common in phthisis, and especially where portions of the edges are occupied by tubercular deposit; recent pleuritic granular exudation, and the presence of an abscess in the anterior margin of either lung, but particularly of the left, may, in phthisis, produce abnormal sounds synchronous with the movements of the heart, almost undistinguishable from those connected with organic disease of that organ: but all these sounds are, as far as I have observed, more or less modified by respiration. I have never discovered any morbid condition of the pulmonary artery, either in these or in any other cases of phthisis, which appeared capable of producing a bruit.

† This was noticed in a patient of Dr. Peacock's, whose case I have already cited in the chapter on Acute Inflammation of the Pulmonary Artery, reserving the physical signs for insertion in this place; as, although the cardiac lesions were somewhat complicated, the auscultatory phenomena appeared to have agreed pretty closely with the rules laid down by Dr. Ormerod. "The chest yielded a clear sound on percussion, except in the præcordial region, where the resonance was impaired over a larger space than natural. The liver could be felt extending a little below the edges of the ribs; the sternum was arched and prominent, more especially towards its base. A loud murmur was heard in the præcordia, accompanying the impulse of the heart. It was of a soft, blowing character, and was most intense at the cartilage of the third left

A diastolic bruit has rarely been observed as marking regurgitant disease of the pulmonary orifice. In one of Dr. Ormerod's cases which I have cited, a loud, harsh systolic murmur became diastolic previously to the patient's death—probably in consequence of a gradual failure in the power of the right ventricle. In Dr. J. Bell's case, already detailed, the sounds of regurgitation were quite distinct, and apparently attended with an abnormal first sound. Here, however, there was reason to believe that the blood passed downward *from* the narrow and valveless pulmonary artery to the right of the ventricle. In the case of aneurism of the pulmonary artery, with contraction of one of its valves, related by Drs. Fletcher and Blakiston, the sound appears to have been double. "Immediately on the left of the sternum, between the second and third ribs, there was dullness on percussion over a space measuring nearly four square inches. Over this spot a very liquid pulsation was felt, accompanied by a purring thrill, so rough and so close to the surface, that it seemed almost to grate on the fingers. At the same place a hollow rasp sound was heard with the systole of the heart, and also, for a moment, at the commencement of the diastole, as if the blood was receding."\*

rib near the sternum, or at a point half an inch above the nipple, and between that body and the sternum. It was here prolonged throughout the whole period, so as to render the second sound inaudible. From this point it continued to be heard very distinctly, though decreasing in intensity, along the upper part of the sternum, in the subclavian and carotid arteries" (this circumstance may have been due to the existence of a very free communication at the base of the ventricles), "and on the left of the spine, in the interscapular and dorsal regions. It was also heard, less distinctly, in a line from between the nipple and sternum, towards the middle of the left clavicle. Below the level of the nipple the murmur became shorter and more feeble; and, at the point of pulsation of the apex, towards the epigastrium, and on the right side of the lower half of the sternum, it was followed by a very clear second sound."

\* The signs observed in the above case agree well with those given by M. Aran (partly, apparently, on Hope's authority, and partly theoretically) as the characteristics of *Aneurism of the Pulmonary Artery*.

"*General symptoms*.—Those of hypertrophy, with dilatation of the heart, which generally accompanies this morbid state. Dilatation of the pulmonary artery can only be confused with dilatation, or with sacciform aneurism of the aorta; but never in either of these" (two latter) "cases do we find pulsation between the second and third ribs. Even if an aneurismal tumor of the arch of the aorta should have destroyed the cartilages of the second and third ribs, it would not be possible to make a mistake in diagnosis, because the aneurisms of the aorta are very large, and the murmur which they produce is grave and distant, instead of being acute and superficial; and, besides, the tremor would be perceived above the clavicles, which is never the case in dilatation of the pulmonary artery."—*Practical Manual of the Diseases of the Heart*, translated by Harris.



Attempts are frequently made to diagnose the presence of those deficiencies in the ventricular and auricular septa which so frequently attend congenital narrowing of the pulmonary orifice. Where, however, as usually happens, these communications are wide, and not associated with a diseased and roughened condition of the adjacent endocardial surfaces, I am not acquainted with any evidence in favour of the belief that their presence occasions the development of abnormal sounds: indeed, it should hardly be expected that, where, owing to the presence of some permanent cause of obstruction, the course of the circulation has been diverted through one of these apertures, any abnormal sound should attend the transit of the fluid, so long as the communications continue to be direct, smooth, and perfectly free. In some cases where deficiency in the ventricular septum exists, independently of any narrowing of the arterial orifices, the abnormal aperture is liable to become greatly contracted, and the surrounding endocardium is then usually found to present more or less irregularity of surface, wrinkling of the membrane, warty vegetations, or raised fibrinous deposits. Here it becomes doubtful whether the systolic bruit which is generally heard at the base of the heart is due to the forcing of a slender stream through the narrow communication, or to the passage of the currents, on their way to the arteries, over its irregular margins.

The rational symptoms which distinguish impediment to the entrance of this vessel are usually more characteristic than the descriptions of Tiedemann,\* and of other authorities, would lead us to believe.

It has been shown that, although, in congenital cases, blueness of the surface usually attends obstructive disease of the pulmonary artery, this is not present unless the impediment is very considerable; and the case observed by Dr. Lloyd, although it can only weigh as a rare and exceptional instance, proves that the utmost amount of impediment may be established in the pulmonary artery of an adult without producing livor of the surface, providing the lungs act freely, and the volume of the circulating fluid is small.

An habitually small and rapid, but *regular*, condition of the pulse, usually associated with a more or less excessive action of the heart, is so generally present in cases of congenital cardiac defect, that it cannot be regarded as pathognomonic of contraction of the pulmonary orifice; still, it becomes an important aid to diagnosis in cases where

\* For Prof. Tiedemann's account of the symptoms of narrowing of the pulmonary orifice see Edinburgh Med. and Surg. Journal for April 1846, p. 442.

narrowing of this vessel occurs in the adult.\*

Diminution in the volume of the pulse, attending aggravation of dyspnoea and palpitation, is, of course, always to be regarded in this, as in every other form of heart disease, as an unfavourable sign, as evidencing superadded pulmonary or cardiac obstruction.

A very characteristic and highly interesting leading pathognomonic sign of obstruction to the pulmonary artery appears to have almost altogether escaped the attention of writers on heart-disease. I allude to the distinctive circumstance that, in a very large proportion of cases, individuals suffering from great narrowing of the pulmonary artery seek the recumbent or horizontal position, either habitually or during paroxysms; while those who are the subjects of any other form of pulmonary obstruction, or of impediment to the circulation through the left heart, breathe most freely when the shoulders are raised, and the body is placed almost vertically. This circumstance has been noticed incidentally by the observers of several of the foregoing cases, but it never appears to have received its true weight, or its pathological explanation.† It is evident that,

\* Dr. Williams observed that the pulse is not affected in cases of obstruction to the pulmonary orifice (as quoted by Copland, Dict. of Pract. Medicine, art. Heart, § 78). It is true that the pulse seldom intermits or is irregular in these cases, except occasionally, where there is regurgitation, or where the power of the heart begins to fail; but the smallness and rapidity of the pulse are too characteristic, in these cases, to allow it to be believed that the above opinion is still entertained by that eminent observer.

† This is abundantly shown in the instances which I have cited. Thus, in Dr. Lexis's case, the girl experienced paroxysms of strong suffocation, which she endeavoured to relieve by bending the body forward.

Dr. Pulteney's patient "could escape the fit by instantly lying down on the carpet on his left side, and remaining immovably fixed in that posture for about ten minutes."

In Dr. Ramsbotham's case, where the pulmonary artery and aorta arose from the right ventricle, with patency of the ventricular septum, the child "lay on her back, or on the left side, with her legs drawn up to the body, and the back bent to a semicircle."

In a patient of Dr. Peacock's "the respiration was peculiarly rapid and panting, and he was compelled to lie on the back, partly inclined to the right side, and with his head low."

In Dr. Birkett's case it is noticed that latterly "the respiration, though distressed throughout, appeared to become so far relieved as to admit of her lying in the horizontal posture."

In the case by Dr. Bond, of Cambridge (cited by Dr. Ormerod) the man "was able to retain the horizontal position to the last."

Dr. Lloyd's patient "lay on her left side;" and, "when she got out of bed, she was obliged to lie on the floor to avoid fainting. She had done this for some time during her illness."

In Dr. Elliotson's case there was dyspnoea, with palpitation, but the man "could lie down."

Mr. Adam noticed that, in a case of dilated



whatever distress of breathing occurs in uncomplicated cases of this description results from impeded and insufficient access of blood to the lungs; and that hence the recumbent position affords the aid of gravitation to the contractile efforts of the heart, and, at the same time, renders the supply of arterial blood to the brain more free than it could otherwise be. This symptom cannot, however, be assigned merely to cases of congenital narrowing of the pulmonary artery: it is characteristic of all circumstances which impede the free access of blood to the pulmonary vessels. Thus it occurs in certain instances of tumors in the anterior mediastinum, and where extensive pericardial deposits and effusions compress the anterior surface of the heart. I have also observed it in two cases of aneurism of the root of the aorta, pressing forward to the sternum, and interfering with the pulmonary artery.\*

It is a matter of great importance to be prepared to distinguish between those cases, so well described by Dr. Barlow, in which narrowness of the chest gives rise to cardiac obstruction, and those in which congenital disease of the heart has occasioned ill-development of the other thoracic organs. Thus, nothing could be less rational than to recommend athletic sports

pulmonary artery, obstructed by an "organised polypus," the patient was latterly obliged to have recourse to the recumbent position for relief "when the fluttering action of the heart became oppressive."

I believe that the only cases on record, of narrowing of the pulmonary artery, in which it is mentioned that the patients were compelled to remain in the erect position, are the two by Dr. J. Crampton and Mr. Marshall. In the latter the exception is accounted for by the fact that latterly the patient suffered from large ascitic effusion. I have not been able to meet with the original report of the former case, and can only find that, in addition to the cardiac defects, the whole surface of the body was extensively anasarcaous, and that the measurement of the right side of the thorax exceeded that of the left by half an inch. It is probable that here also some grave cause of pulmonary embarrassment exterior to the heart was in operation.

\* In some cases of aneurism of the root and arch of the aorta there is considerable obstruction to the circulation (independently of the interference of the tumor with surrounding parts); the patient being consequently liable to suffocative attacks. In others the transit of blood is free, and the breathing little embarrassed, almost up to the time of the patient's death. In these two cases the aneurisms were evidently of the latter kind; while the second of Dr. Elliotson's cases (quoted in the chapter on Obstruction to the Pulmonary Artery consequent upon External Compression) was of the former description. There the pulmonary artery was extremely narrowed by a fibro-cartilaginous deposit, while there was a large aneurism of the aorta. In this instance the obstruction to the systemic circulation counterbalanced the defective pulmonary supply; and, consequently, the individual could not lie down.

for a narrow-chested child, the subject of congenital heart-disease; while almost equally ill results would accrue from denying proper exercise in the case of a person under fourteen or fifteen years of age, whose only discoverable physical fault was an ill-formed chest, attended with shortness of breath, and a liability to occasional palpitations.

Little difficulty attends this diagnosis during childhood; but, where the cases present themselves for the first time towards the age of puberty, rather more discrimination will be required. Here the following facts may be taken into consideration:—In cases of congenital disease of the heart in which the symptoms first become severe at puberty, the chest is not usually extremely ill-formed: the orifice of the pulmonary artery is mainly in fault, and a systolic bruit in this situation is usually present: whereas, in those cases of Dr. Barlow's where a bruit occurs (which by no means always happens), the abnormal sound may usually be traced to the mitral valve. At this period of life, however, the diagnosis is rather a matter of interest than of utility, as the principal mischief in either case is irreparable, and a knowledge of the precise nature of the cause of obstruction cannot materially influence treatment. The remark has been introduced here merely with a wish to enforce very strongly the necessity of distinguishing between the two sets of cases during childhood.

Permanence of the arterial duct is so generally associated with some other grave organic and obstructive lesion, either in the aorta or in the pulmonary artery, that it appears doubtful whether any perfectly distinctive signs of its existence can be obtained. Dr. Williams, however, states, as some ground of diagnosis in cases of this defect where there is no other very serious lesion to obscure it, that the murmur accompanying the first sound of the heart is *prolonged into the second*, so that there is no cessation of this murmur before the second has already commenced. From this sign—taken, of course, in connection with other symptoms—he has been able, in at least two cases, to diagnose this lesion; and post-mortem examination proved the accuracy of this diagnosis.\*

*Prognosis in Cases of Cyanosis, &c. involving a Faulty Condition of the Pulmonary Artery.*

Some leading data for prognosis in cases of congenital cardiac defect may be drawn from the earlier remarks in the chapter on Diagnosis. Thus it will be found that,

\* LONDON MEDICAL GAZETTE, May 7th, 1847, p. 824.



in cases of "*distribution of the descending aorta from the pulmonary artery*," death occurs within the first year. In *transposition of the great arteries* (unattended with general transposition of the viscera), life has not been known to be protracted beyond the fourth year, while death usually occurs much earlier. The highest age which is known to have been attained in *imperforation of the ascending pulmonary artery* is 16 years; but here, also, life is rarely so protracted. I can only discover five cases of this lesion in which the individuals survived the age of a year and a half.\*

The subjoined analysis of 159 cases of congenital organic defect of the heart, or cyanosis (from Dr. Aberle, of Vienna), affords a fair ratio of the probability of survival under these circumstances:—

Death, in the first 24 hours . . .	4 cases.
" in the first fortnight . . .	16 "
" before the end of 1st month . . .	7 "
" second to third month . . .	6 "
" third to sixth . . . . .	8 "
" sixth months to one year . . .	12 "
" one year to two years . . .	7 "
" two years to three . . . . .	9 "
" three years to six . . . . .	11 "
" six to eight . . . . .	11 "
" eight to eleven . . . . .	13 "
" thirteen to sixteen . . . . .	12 "
" sixteen to twenty . . . . .	8 "
" twenty to twenty-five . . . . .	10 "
" twenty-five to thirty . . . . .	6 "
" thirty to thirty-five . . . . .	5 "
" thirty-five to forty-five . . . . .	5 "
" forty-five to sixty . . . . .	4 "
" at eighty . . . . .	1 "

159

We find here, that, previous to the expiration of the first year of existence, 57, or 35 per cent., of the cases proved fatal. Upwards of two-thirds (108) of the individuals died before the age of eleven years; between that age and twenty-five years 30 more had fallen from the list; and, of the remaining 21, five only passed the age of 45 years.

Every epoch of the brief life of an individual suffering from a grave congenital defect is fraught with danger to the patient, and with the deepest anxiety to his physician. The commencement of respiration is attended with imminent danger of fatal

\* In 26 cases of obliteration of the orifice or ascending portion of the pulmonary artery, collected in this memoir, death occurred at the following ages:—Still-born (1); 7 days (1); 13 days (1); 23 days (1); uncertain, but under 1 month (4); 4 weeks (1); 6 weeks (1); 7 weeks (1); 5 months (1); 5½ months (1); under 6 months (1); six months (1); 8 months (1); 10½ months (1); 11½ months (1); 11 months (1); 8 years (1); between 9 and 10 years (1); 10 years (1); unknown (1); 16 years (1).

embarrassment to the circulation, the heart now becoming suddenly burthened with functions which it is destined never to perform with freedom; and, at the period when the closure of the arterial duct and foramen ovale should be effected, the struggle for existence becomes still more protracted, and equally precarious. The third period of danger is proved to attend the first dentition. Hooping-cough, scarlatina, and measles, fall with double weight and fatality upon these unfortunate little patients. Another season of trial is ushered in by the approach of the second period of dentition; while, in any year of childhood, death may occur from hydrocephalus, bronchitis, pneumonia, pulmonary tubercular disease, diarrhoea, or gradual aggravation of those agonising paroxysms which characterise the disease. Thus it will be perceived to be indeed a matter of almost hopeless difficulty for a cyanosed child to struggle on to the age of puberty; but that life should be extended beyond the period at which that change is effected, is an anticipation which can scarcely be entertained, even by the most sanguine.

The unfortunate little subject of these defects is, in almost every instance, unable to take part in those active and clamorous sports which the young child in vigorous health instinctively pursues, for the development of his respiratory organs and muscular system. Hence, as the period of maturity approaches, when the other organs of his body have acquired nearly their due bulk and proportion, and when, as the result of habitual inactivity, a preponderance of fluids almost invariably exists, the narrow and ill-formed chest and deficient pulmonary apparatus present causes of nearly inevitably fatal obstruction to the circulation through the imperfect and relatively feeble heart.\*

The observations of Farre and others lead to the belief that corresponding cardiac defects are liable to occur in several children of the same parents. Several children of one family may be born with

\* Persons with very slight and apparently uninjurious congenital defects in the heart and its appendages, rarely survive the period of greatest muscular strength (25 years). Under such circumstances, the heart is peculiarly susceptible of acquired disease, and the lungs are extremely liable to sudden and extensive inflammations. It is extremely rarely that we meet with any congenital defect of the heart (except valvular foramen ovale and corded sigmoid valves) in a person advanced in life. For particulars regarding the influence of deficient thoracic development in producing dangerous impediment to the circulation through the right side of the heart, in cases where that organ is not malformed, see Dr. Barlow's valuable paper in the 7th volume of the Guy's Hospital Reports, as well as some observations by the author in the same volume.



various cardiac defects; or several children may be born still, and one with cardiac malformation. Our evidence upon this subject, however, is extremely scanty.

Occasionally, malformation of the heart may have caused the death of the fœtus in utero. Dr. Hunter argued that many miscarriages at the earlier or later months may depend upon some undiscovered malformation, perhaps of this kind.

In those females suffering from severe congenital disease of the heart who survive the age of puberty, menstruation usually occurs late. Whether women thus circumstanced have ever become the mothers of healthy children subsequently to the establishment of that function, I have not been able to ascertain: in fact, the marriage of such persons must be an extremely rare occurrence. Great cardiac obstruction appears almost equally to determine the late development of puberty in the male. In all the slighter forms of congenital cardiac defect, occurring in patients of either sex, it is probable that the offspring does not suffer in any evident degree. In a case of great contraction of the pulmonary orifice which I have quoted from M. Cherrier, it is mentioned that the man married at the age of 28 years, and had two children, who died of scrofulous affections at the age of three years. This, however, may have been merely an accidental coincidence. It is to be regretted that our information upon this subject also is so extremely scanty. A few additional facts would be of very high physiological interest.

Persons who are the subjects of congenital obstructive disease of the heart are always liable to suffer from temporary or organic cerebral lesions, consequent either upon deficient supply of blood to the brain, the circulation of an ill-depurated fluid through the vessels of that organ, or mechanical obstacle to the emptying of its veins. Most of the leading symptoms in these cases are cerebral—drowsiness, torpor, giddiness, vertigo, headache, loss of consciousness, syncope, &c. After the first months of infancy a large proportion of deaths in cyanosis result from various kinds of cerebral disease; such as watery softening, hydrocephalus, abscess of the brain, congestion, or other grave lesions of the nervous centres, producing convulsions and convulsive attacks, hemiplegia, and temporary or permanent paraplegia.

The rule, in cases of cyanosis, is that the intellect is deficient, mainly from a faulty condition of the brain, and partly also, no doubt, from the want of mental training which is usually, and almost necessarily, attendant upon prolonged ill health in childhood and early youth. The recorded

instances of ordinary or precocious development of intellect in these subjects are extremely rare, and might, probably, be found to have been placed on record chiefly upon the authority of partial friends. The development of the intellectual faculties, however, is not, as some writers have argued, proportioned in these cases to the degree in which the heart is malformed, but to the degree in which the blood is arterialised, and to the quantity of that fluid which is supplied to the brain.

These patients rarely perish from the gradual symptoms which usually characterise obstructive disease of the heart. They are liable to die suddenly from failure of the heart's action, or to sink rapidly when bronchitis, or pneumonia, or any other cause tending to embarrass the lungs, comes into operation; but they are not affected with dropsy (except in those cases where cyanosis occurs comparatively late in life, as the result of lesions superadded to congenital malformation), and œdema very rarely presents itself as one of the earliest (noticed) symptoms, as is often the case in ordinary heart-disease. In congenital cyanosis, the venous system seems to adapt itself to the overloading, from delay, which it constantly experiences; the right auricle, cavæ, and entire venous system, appear to have been of unusual capacity from the first, and the veins of the liver especially are capable of containing a vast quantity of delayed blood. Hence there is a less tendency to the occurrence of dropsical exudations here than in cases where obstruction to the circulation commences at a later period of life. Although dropsical effusions rarely proceed to extremity in cases of this kind, their development, where they do occur, must be regarded as an evidence of the most excessive and serious degree of obstruction. Œdema of the legs and feet is apt to appear in the advanced stages of morbus cæruleus, and is liable to be attended with gangrene,—less on account of extensive distension, than owing to sluggishness of the circulation in parts remote from the heart.

The lungs, mesenteric glands, and other internal organs of persons suffering from cyanosis, are extremely liable to become the seats of tubercular deposit. This is accounted for by the supposition of an authority, whose name has escaped me, that it depends upon the deficient and imperfect supply of arterial blood to the parts.

It is singular that so able an observer as Rokitansky should have failed to notice this very ancient and well-supported fact. He observes, "All forms of cyanosis, or rather all the diseases of the heart, great vessels, and lungs, adapted to produce cyanosis in a greater or less degree, cannot co-



exist with *tuberculosis*. Cyanosis affords a complete protection against it, &c."\*

Many of the cases of cyanosis adduced in the earlier portions of this memoir wholly negative the opinion of Rokitansky, and prove that, on the contrary, the subjects of congenital malformation of the heart are rather excessively prone to suffer from *tuberculosis* at all ages, but especially where life is somewhat unusually prolonged.†

Hæmorrhages from the nose, mucous membrane of the bowels, and lungs, are liable to occur at all periods of the lives of cyanosed patients, but are most frequent towards the close of existence, when congestion is greatest, and the obstruction to the circulation resulting from the advance of structural impairment of the organs is at its height. The lighter forms of hæmorrhage are usually followed by temporary relief; but hæmoptysis, as it involves an extremely severe lesion, and almost invariably results in these cases either from tubercular or pneumonic degeneration of lung-substance, from bronchitis, or from

some new and serious impediment to the pulmonary circulation having its seat in the pleuræ, left heart, or systemic vessels, must always be viewed with the utmost apprehension.

Hepatic, splenic, gastric, and enteritic congestions, may be regarded almost as the necessary and physiological attendants upon congenital cardiac obstruction, and are constantly liable to be determined into states of more or less active disease. A foul tongue, offensive breath, imperfect digestion, a general tendency to defective nutrition, bad or capricious appetite, a faulty biliary secretion, with constipated or irregular bowels, are the almost inseparable concomitants of the state under investigation; and hence the danger attendant upon diarrhœal and dysenteric attacks in these patients.

Whenever the urine is found to be albuminous in a case of acute exocardial or endocardial disease, the prognosis is bad, as here it rarely fails to happen that the kidneys are the seat of fixed organic lesion, of which the cardiac mischief is not the cause, but the result. Possibly, though not very probably, patients thus affected may recover for a time, but, as far as I have observed, they most frequently sink under the immediate attack, or only survive it for a very brief period, during which the abatement of symptoms is extremely partial. This arises from the fact that, in acute cardiac and arterial diseases of renal origin, the lesions are generally of the most extensive and the gravest character. In all forms of chronic heart-disease where the urine is albuminous, when the patient is first seen the prognosis is invariably bad, especially where the duration of the renal affection is not known; and so long as this symptom resists judiciously-employed treatment, the patient's condition must be regarded as very critical. The sudden appearance of albumen in the urine of an individual suffering from organic heart-disease, is always a most discouraging symptom; but the practitioner should not on that account neglect to employ systematic endeavours to relieve its cause, as it may depend upon little more than excessive congestion of the kidneys, which may, not improbably, be removed, when the bulk of the circulating fluid, or of any ascitic effusion which may be present, has become diminished, or when the renal functions have become lightened by moderate excitation of the cutaneous and intestinal actions.

The secretion of scanty and high-coloured urine, as evidencing renal congestion, is a frequent characteristic of cyanosis; true Bright's disease is, I believe, only noticed in these cases as a very rare and accidental complication. The subjects of cyanosis

\* As quoted by Dr. Stillé, Philadelphia Med. Examiner, April 1849, and Ranking's Retrospect, vol. x., from *Hundbuch der Path. Anat.* Bd. ii. p. 510.

† See Dr. Ramsbotham's case of obliteration of the pulmonary artery: death at the age of sixteen years from tubercular disease. Dr. Shearman, imperforate pulmonary orifice in a girl, ætat. 8 years. Lungs found very full of grey tubercle. Dr. Cheever, marked contraction of the pulmonary orifice in a boy aged 13½ years; cyanosis from the first months of infancy. Tubercles were found pretty generally diffused through the substance of the lungs. M. Schuler, cyanosis: death at seven weeks; scrofulous degeneration of the mesenteric glands. Mr. Houston, contraction of the pulmonary artery, with cyanosis; death from phthisis and bronchitis at the age of 3 years. M. Cuillot, cyanosis from birth; death at 11 years and 7 months. Lungs condensed, and in an advanced state of phthisical degeneration. M. Lexis, extremely contracted state of the pulmonary artery in a girl 5½ years of age. The pulmonary tissue contained a few tubercles. Mr. Napper, contracted pulmonary artery, with cyanosis, in a child aged 5 years and 10 months. Lungs tubercular. Messrs. Aran and Bennett: a female, ætat. 20. Great contraction of the pulmonary artery; very aggravated cyanosis; great consolidation of the lungs by tubercles; death from hip-disease and erysipelas consequent upon caries of one of the ribs. Case occurring at Guy's Hospital: lad, ætat. 16; contraction of the pulmonary artery; cyanosis. The right lung contained miliary tubercles; the left was engorged with blood, and contained at its apex a tubercular excavation, apparently of long standing. Dunghison: a female, ætat. 21; congenital contraction of the pulmonary artery, with cyanosis. Both lungs studded throughout with crude and miliary tubercles, none of which were softened. Dr. Craigie: a man, ætat. 44; pulmonary valves contracted so as to form a ring, which could only admit the point of the little finger. Both lungs contained tubercles, and were much consolidated: the apex of the left was occupied by a large tubercular cavity. Mr. Le Gros Clarke: case of a man, ætat. 19; great contraction of the pulmonary orifice; cyanosis. The lungs presented tubercles at different parts.



could scarcely live through those vicissitudes or excesses which occasion the commoner forms of mottling and granular disease of the kidney. Hence, whenever failure of the renal function, or an albuminous state of the urine, occurs in these cases, it must be viewed with much apprehension, as indicating the superaddition of more or less severe structural alteration in organs which have never performed their functions with healthy freedom. It is here that the most delicate discrimination of the pathologist, and the nicest judgment of the therapist, must combine in an endeavour to relieve the weak and overloaded heart, to remove bronchitis, that the pulmonary transpiration may be rendered as free as possible, to increase the action of the skin, to exclude from the diet and medicine everything that may act directly or indirectly as an excitant to the suffering organs; and, in short, so carefully to free the kidneys from all excessive duty and additional causes of irritation, that the congestion may have a tendency gradually to subside, and to leave the organs capable of performing a moderate function with comparative ease.

In concluding this perhaps unduly lengthened memoir on diseases of the pulmonary artery, I should feel that I owed an apology to those who may have done me the honour to accompany me throughout my investigation, did I not believe that I have rendered some service to medicine in proving that a class of diseases which has hitherto been considered of such unfrequent occurrence, so barren of interest, and so destitute of importance, as scarcely to deserve a separate place, or even more than a passing notice, in systematic works, will, upon being observed with proper attention, reveal a series of physiological and pathological facts of the highest interest, and a set of therapeutic indications of no trivial moment.\*

\* It was originally my intention to have concluded these observations with a concise abstract of views relative to the treatment of cardiac diseases. Finding, however, that my remarks extended themselves beyond the due limits of this already very lengthened paper, I have embodied them in a separate treatise—"On the Management of Diseases of the Heart, and of Aortic Aneurism"—which is now publishing in Calcutta, and which, I trust, will shortly be submitted to the profession at home.

[ Chittagong, Bengal, November 1st, 1850.

THE END.



474  
2



