

On the treatment of certain injuries of the eye, occurring in infants and young persons / by Richard Middlemore.

Contributors

Middlemore, Richard, 1804-1891.
University of Glasgow. Library

Publication/Creation

[London] : [Wilson & Ogilvy], [cbetween 1800 and 1899?]

Persistent URL

<https://wellcomecollection.org/works/ygms7nab>

Provider

University of Glasgow

License and attribution


This material has been provided by This material has been provided by The University of Glasgow Library. The original may be consulted at The University of Glasgow Library. where the originals may be consulted. This work has been identified as being free of known restrictions under copyright law, including all related and neighbouring rights and is being made available under the Creative Commons, Public Domain Mark.

You can copy, modify, distribute and perform the work, even for commercial purposes, without asking permission.



Wellcome Collection
183 Euston Road
London NW1 2BE UK
T +44 (0)20 7611 8722
E library@wellcomecollection.org
<https://wellcomecollection.org>





17

ON THE
TREATMENT
OF
CERTAIN INJURIES OF THE EYE,
OCCURRING IN INFANTS AND YOUNG PERSONS.

BY RICHARD MIDDLEMORE, ESQ.,

SURGEON TO THE BIRMINGHAM EYE INFIRMARY.

[*From the London Medical Gazette.*]

Faint, illegible text at the top of the page, possibly bleed-through from the reverse side.

CERTAIN INFLUENCES OF THE AIR

Faint, illegible text below the title, likely the beginning of the main body of the work.

BY RICHARD W. HARRISON, JR.
Faint, illegible text at the bottom of the page, including the author's name and possibly a publisher's imprint.

I PURPOSE, in my present communication, to place before the readers of the MEDICAL GAZETTE the result of my experience in the treatment of cataract occurring in early life, whether congenital, the result of local injury, or taking place from any circumstance not distinctly ascertained.

If ordinary congenital cataract be allowed to continue until the subject of this defect has arrived at or towards adult age, certain important changes take place; for instance, the lens is absorbed, the anterior and posterior hemispheres of the capsule become thick and opaque, and either fall into apposition, or become united by an organized medium.

Concussion of the eye or head, wound of the lens and its capsule, and a variety of other accidents, may occasion cataract, and, if such an event take place in early life from any of these circumstances, and no attempt be made to relieve it, thick, tough, capsular cataract is likely to remain, and is especially prone to contract adhesions to the iris, and to diminish the pupillary aperture.

It will be perceived from this statement, that if, in early life, the lens and its capsule become opaque from any cause, and no prompt surgical efforts be employed to procure the disappearance of the opaque matter, a secondary, and far more troublesome, and less manageable form of disease will almost certainly occur. Hence, it may be laid down as a rule of practice, admitting of scarcely any exception, that operative proceedings should be employed soon after the distinct establishment of the cataractous malady, *whenever it occurs in early life*. I say *in early life*, because, when the same malady occurs at an after period, the same reasons for removing it by operation do not exist. For instance—1, if, then (at a late period of life), the disease continue for very many years, it is not by any means so liable to be converted into a more unmanageable description of malady, so that a time of choice is, as it were, allowed us; on this account it would be manifestly improper to select, for the purpose of performing an operation, the period of inflammation, just when the eye is very

unfavourably situated for such a proceeding; 2, the eye is perfectly developed, and its growth cannot, therefore, be arrested, as it may be if an operation be too long delayed, as in the case of congenital cataract; 3, the sensibility of the retina *has been* perfect, and *has been* exercised, so that atony of that important part is not likely to take place from the oftentimes temporary, and always partial, discontinuance of its natural stimulus*, as occurs in the instance of cataract (traumatic or otherwise), affecting only one eye, in elderly persons; 4, the question of personal appearance is comparatively of little importance, &c.

Cataract occurring in young persons is now generally treated by the anterior or posterior operation of solution. In performing either of these operations, we are very properly directed to destroy the anterior capsule to an extent at least equal to the size of the natural pupil; but I am convinced this important direction is by no means sufficiently attended to. In the operation of keratonyxis, owing to the difficulty of moving the needle about in a texture like that of the cornea, without causing the escape of the aqueous humour, the capsule is sometimes merely divided; a portion of the cataract escapes into the chambers of the eye, and perhaps a small quantity of the soft flocculent lens is interposed between the lips of the incision in the capsule. So, also, in the posterior operation of solution, the needle, having passed through the lens towards its margin, is, indeed, pushed through the anterior capsule, if that membrane be healthy, but, if unusually thick and tough, it may be *raised upon and pushed before* its point; but in depressing its point, with a view of lacerating the capsule, it will, very often I fear, pass nearly through the same aperture at which it entered, into the substance of the lens, where it may be moved about with much apparent, but little really useful, effect. Now, in

* The reader will be so good as to bear in mind that I am not professing to discuss at all in detail the propriety of operating for cataract, when existing only in one eye, in persons at an advanced period of life.

such cases, what is the result of these proceedings? The wound of the capsule heals very readily, if no portion of the lens be interposed between its edges, and there is scarcely any vestige of the puncture; but if any portion of the lens protrude through the opening, it is gradually absorbed, and there remains an opacity of the capsule of a greater or less extent. The capsule being not at all, or only very slightly, opaque, proceeds to the absorption of the lens, which it generally accomplishes; it then becomes opaque; its two layers meet, or they become united, and constitute a thick, tough, opaque texture, which is, in fact, worse than the original disease. Sometimes, when the posterior operation of solution has been performed, the injury to the capsule may have been more extensive than I have now stated, but still not sufficiently great to permit the discharge of the whole of its contents, nor to destroy its opacity until it has completely absorbed the lens, when, having become, as it oftentimes will do, inflamed, it generally secretes a lymphatic matter, by means of which the capsules, the iris, and an intervening mass of lymph, are united, and remain as a future obstacle to vision. Hence, then, arises the necessity—and the fact cannot be too frequently presented to the notice of junior practitioners—of making a free laceration, and extensive comminution of the anterior hemisphere of the capsule, at a *first operation*, namely, to prevent the occurrence of that form of disease in which the two layers of the capsule meet or become united, form adhesions to the iris, and constitute an obstacle to vision which nothing short of extraction can entirely remove. The importance of preventing the *secondary* disease, by a due attention to the treatment necessary for the perfect cure of the *primary* affection, is manifestly very great; and, on this account, I hope to be excused for referring to the subject in a manner which to some may bear the appearance of needless repetition.

If, however, the disease take place in the eye of a young person, from injury—for example, a slight wound of the cornea and capsule—what are the measures best adapted to secure to the patient the best chance of the restoration of sight?

If the injury be unattended with displacement of the lens, or any material

wound of the cornea, or any severe inflammatory symptoms, the plan of treatment I am about to propose, and which has not been previously stated by any author with whose labours I am acquainted, appears to possess many advantages. On referring to the ophthalmic articles in the *Surgical Dictionary* of Samuel Cooper,* and the Treatise of W. Lawrence,†—works which are characterized by fulness of detail, accuracy of statement, and extent of research—I find the treatment of such injuries is represented to consist in the employment of purgatives, the application of leeches, blisters, &c.; no mention being made of an early operation with a view of preventing the formation of tough capsular cataract. The only allusion to the subject I can find is in a communication by Mr. Barton,‡ in which, sanctioning the recommendation and practice of St. Yves,§ Warren,|| Beer,¶ and others, he advises the early extraction of the lens, in cases where it has been accidentally displaced; ** and likewise, though some-

* A Dictionary of Practical Surgery, p. 1038, London, 1838.

† A Treatise on the Diseases of the Eye, p. 143, London, 1833.

‡ LONDON MEDICAL GAZETTE, vol. v., p. 784.

§ A Treatise on the Diseases of the Eyes, translated from the French, by J. Stockton, M.D. London, 1744.

|| New England Journal.

¶ Lehre von den Augenkrankheiten, b. 2, Wein, 1813—1817.

** The following quotation, from the ingenious Treatise of St. Yves, may not be uninteresting:—"When the eye receives a violent stroke, the crystalline is loosed immediately, and, in two or three days, it becomes opaque, so that the patients can only perceive the light" (p. 228). After having stated that the lens, when so displaced, may have two situations, which he describes, he proceeds as follows:—"The *third* place is when the cataract passes altogether into the anterior chamber, and is placed between the *cornea transparens* and the iris; from whence it must be taken out in the *manner* that shall be described in the sequel of this *Treatise*" (p. 229). The "*manner*" consists in making a section of the cornea, introducing a scoop, and *canting* the lens through the opening. The author's words are: "When you design to perform this operation, to draw out the crystalline which has passed in the foregoing manner (that is, into the anterior chamber), the patient must be seated in a chair, with his eye fronting the light; open both his eye-lids with your thumb and fore-finger, then, with a sharp-edged lancet, divide the *cornea transparens* a little below the middle of the pupil. You must continue your incision transversely, from one side of the cornea to the other, in such a manner that you do not leave unsevered, on each side, above half a line's breadth of the *cornea transparens*. Then introduce a fine small scoop through the orifice, convey it behind the crystalline, and, with it, draw out that humour, through the incision made in the cornea." (P. 262.) I shall still further extend this foot note, for the purpose of introducing the following curious quotations:—"Three sorts of cataracts pass through the hole of the pupil. In

what vaguely, recommends the extraction of the lens when rendered opaque by accidental violence, without being displaced. But I do not know that this advice is intended to apply to young children, as the only examples brought forward, in proof of the utility of the practice suggested, are, the cases of "a country gentleman" and "a mechanic." I apprehend, however, it is *not* intended to apply to very young children, inasmuch as the only operation proposed is that of extraction, an operation, which, although I will not go so far as to assert it is not possible to perform on a child two or three years old, yet I may safely affirm it is so difficult of performance, (the iris being convex, the lens soft, the eye, as it will be under the circumstances in question, inflamed, the patient very young, &c.) in a manner which may justify the expectation of a successful result—successful as regards the appearance of the eye, and the restoration of

the first, the consistence of the crystalline is soft; in the second, it is hard and concrete, like a stone; in the third, it is partly soft and partly petrified. When it is soft, the aqueous humour which lies behind this body thrusts it forwards and fixes it in the pupil; but, when this body is hard, it passes at once through the hole of the pupil, upon the least effort made in bending the head." (p. 262) "Whatever passes during the operation (of couching), through the hole of the pupil, if it be of sufficient solidity, the point of the needle must be pushed through the hole of the pupil, without touching the iris; then pierce the body of the cataract with the point of your needle, and place it where it is usually placed (that is, in the vitreous humour), p. 271." The reader of these extracts will not fail to remark that St. Yves understood the nature of dislocation of the lens into the anterior chamber; was aware of the inconvenience its presence occasioned; and practised and advised its extraction, with a view of relieving them. He was also aware that, when the lens was somewhat soft, it would occasionally press against the iris, (he calls this passing *into*—and who can say this is incorrect—not *through* the pupil) and that the extraction of this soft lens was necessary not only to restore vision but also to relieve pain and inflammation. Mr. Gibson of Manchester, has received much credit for suggesting the removal of soft cataract, by making a small incision of the cornea; and the justly celebrated Dupuytren has been infinitely lauded for recommending the introduction of a needle through the sclerotica into the anterior chamber, with a view of depressing the crystalline when dislocated into the anterior chamber; but I much question if any impartial reader can give either of them much credit for *pure* originality, as far as these questions are concerned, after having perused the work of St. Yves. The subject of dislocation of the lens is somewhat fully discussed by Dr. Warren, of Boston, and its treatment illustrated by the recital of cases; and I am rather astonished his remarks have been so little referred to. [They were re-published in the *Medical and Physical Journal*, vol. xxxvi. p. 386.] He advises the early extraction of the lens when displaced, even although it may not have passed into the anterior chamber, but makes no reference to the disease when occurring in infants and children.

vision—as to be *almost* impossible. Perhaps, however, the question is set at rest by Mr. Hunt, who, in the course of an interesting communication, "On extraction of the lens, in some injuries of the eye," (which appears to be a further development of the views of his able and experienced colleague, Mr. Barton,) makes the following statement: "Before concluding, it may, perhaps, be advisable to mention some restrictions which may be necessary in the employment of the proposed method: as circumstances may occasionally occur which would render the operation inapplicable, attention must be given to the age of the individual; for if the patient be so young as to render the fixing of the eye, without the aid of a speculum, impossible, or of such an advanced age as would contra-indicate the performance of any operation, extraction of the lens would, in both instances, be improper. And as a farther objection to the operation at an early age, it must be considered that absorption of an injured lens, like most other reparative processes, proceeds more rapidly, and with much greater certainty, in children than in adults." (*North of England Medical and Surgical Journal*, p. 495. London, 1831.) The latter part of this statement is perfectly true, but the question is, can we, by omitting an operation, *certainly prevent* the formation of the capsular disease, which is admitted, on all hands, to be so difficult of management? If this cannot be done, then, I apprehend, an operation is far more needful in early life than at any other period of existence: and that a suitable and efficient operation can be performed, and ought to be performed with but little delay, it is the object of my present communication to prove.

I now proceed to explain the operative proceedings it is the main object of this communication to recommend; and it will be understood they are adapted to those cases of traumatic, or other forms of cataract, occurring in infants or young persons. For, if traumatic cataract, not attended with displacement of the lens, occur after the latter age, the necessity for an operation is much less than at an earlier period, chiefly because the lens is less prone to become absorbed, and the capsule to undergo those changes which so generally occur in younger subjects. And here I beg to state that, on one or two important

points, I entirely differ from preceding writers. First, in pointing out that, when the lens is rendered opaque in infants and very young persons by the application of accidental violence, it is *absolutely necessary* to cause its removal by a surgical operation, unless, indeed, it be at the same time displaced, or associated with other injury necessarily destructive to vision; and secondly, in stating that when this accident occurs in early life its cure should be attempted, not by the operation of extraction, which, for ought I know to the contrary, some persons may be injudicious enough to perform, but by that of solution.

Operation.—If a child have sustained an injury of this description—the cornea not being much injured; the inflammation produced by the accident not being severe; the lens opaque, but not displaced;—I prepare the eye for operation, by applying belladonna to the eyelids, and bind up the healthy organ. Having steadied the eye by means of the fingers of an assistant, (I scarcely ever use a speculum) if operating upon the left eye, and by the agency of my own if operating upon the right eye, I introduce the needle through the sclerotica, as for the posterior operation of solution,* and, by continued and varying movements, lacerate the capsule as freely as possible, to an extent equal, at least, to the size of the pupil in its ordinary state of dilatation. Having done this, bearing in mind that the needle is slightly curved, I very gently withdraw it, keep the patient in a darkened apartment, and employ any antiphlogistic or other measures the after course of the case may render necessary. The daily application of belladonna is requisite, with a view of facilitating and rendering more perfect the solution and absorption of the comminuted lens and its capsule.

Let it be remembered that, as the

* I do not advise the performance of keratonyxis, because the cornea has, in many of these cases, already sustained injury; the eye is irritable from the existence of a slight degree of inflammation; and, on these accounts, the necessary manipulations through the cornea would be more than commonly difficult. The needle employed is small and round, being slightly curved at its point. It is introduced with its point downwards (towards the lower part of the cornea), so that neither its concave nor its convex surface is opposed to the iris. As soon as the needle is perceived within the pupil, its point is directed, by a slight rotation of the handle, towards the

object of this operation is to prevent the establishment of a secondary form of disease (tough capsular cataract), which usually occupies in its development several months, it is not imperative to perform it so soon as the opacity of the lens appears; neither is it advisable to do so until all acute inflammation has been subdued; in this respect differing from some cases of dislocation of the lens, which may demand the prompt performance of a surgical operation.

Sometimes it is necessary to perform a second operation, but this seldom happens if the first operation is practised with the necessary care, except in those cases where the lens has become opaque independently of any local injury, which has caused the laceration of the capsule. So that a first and single operation for congenital cataract affecting the whole lenticular substance would not be so likely to be perfectly effective as would the same operation performed upon the eye of an infant suffering from traumatic cataract. In fact, in the case of congenital cataract, a single operation will not, by any means always, effect the entire removal of the disease, however carefully and perfectly performed.

I shall conclude with the following condensed summary of the more material statements contained in the preceding remarks:—

1. *Proposed operation.*—Posterior operation of solution, with very free laceration of the capsule.

2. *State of disease or injury to which the proposed operation is adapted.*—Any injury of the eye, occurring in infants or persons not more than thirty years old, and producing opacity of the lens *in situ*, but not occasioning any extensive wound or injury of the cornea, or other part of the globe, necessarily destructive to vision. Should the soft lens, uncovered by its capsule, (which has been extensively torn by the accident,) be thrown from its natural situation, either into the pupil or the anterior chamber, the operation is not required; first, because the supposed free laceration of the capsule protects the patient from the occurrence of capsular cataract; and, secondly, because the youthfulness of the patient, and the softness of the lens, render almost certain the disappearance of the cataract without the performance of a surgical operation.

3. *Time at which an operation should be performed.*—As soon as acute inflam-

mation has subsided, and any inflammation the globe, or any injury the cornea has sustained, has been either much moderated or altogether subdued. Just as, in other instances, when about to perform a surgical operation, we get the parts, upon which we propose to operate, in as quiet and tranquil a condition as possible beforehand, so here we act on the same principle, and, by freeing the eye from inflammation, place it in the most favourable state we can to sustain the irritation occasioned by the operation we propose to perform. The operation is not suggested with a view of relieving pain or inflammation, or with the intention of preserving the vision of the opposite eye; for it is presumed that a somewhat slight wound of the cornea, and opacity, without displacement of the lens, will neither produce serious inflammation or severe pain of the

affected eye, nor endanger the vision of its fellow. It is performed with a view of restoring the sight of the injured eye, and of preventing the establishment of that form of capsular cataract which, as I have previously explained, is always difficult of management*.

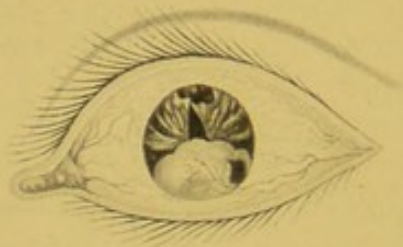
I could readily append to this communication a number—a very large number—of cases which have occurred in my own practice, and which forcibly illustrate the advantages of the plan of treatment now suggested, but am unwilling to lengthen this communication, and apprehend the explanations I have given, which embrace principles rather than details, render this measure in some sort unnecessary.

* I may as well remark that it was for the removal of this capsular disease that I invented the needle-forceps described in the number of this journal for April 7, 1838.

affected eye, and especially the vision of
the fellow. It is performed with a view
of restoring the sight of the injured eye,
and of procuring the relief of the patient
from the pain of the disease which is
the cause of the blindness. It is always
attended with a number of very large
and deep scars which have occurred in the
course of the disease, and which formerly
have been the subject of the plan of treat-
ment now suggested, but the operation
is performed in the same manner, and
gives the same results. I have
never seen a case in which this operation
was not successful.

I have no doubt that it was the
result of the operation, and I have
never seen a case in which this
operation was not successful.

vision has subsided, and the eye is
now the subject of the disease. It is
performed with a view of restoring
the sight of the injured eye, and
of procuring the relief of the patient
from the pain of the disease which
is the cause of the blindness. It is
always attended with a number of
very large and deep scars which
have occurred in the course of the
disease, and which formerly have
been the subject of the plan of
treatment now suggested, but the
operation is performed in the same
manner, and gives the same results.
I have never seen a case in which
this operation was not successful.



The eye of James Sheppard after the operation for Artificial Pupil.
The Pupil is situated just above the opaque part of the cornea.



