

Case of tuberian gestation : with rupture of the cyst containing the embryo, and fatal hemorrhage into the peritoneum / by R.M. Glover.

Contributors

Glover, Robert Mortimer, 1816-1859.
University of Glasgow. Library

Publication/Creation

[Edinburgh?] : Balfour and Jack, [1842?]

Persistent URL

<https://wellcomecollection.org/works/effym8vr>

Provider

University of Glasgow

License and attribution

This material has been provided by This material has been provided by The University of Glasgow Library. The original may be consulted at The University of Glasgow Library. where the originals may be consulted. This work has been identified as being free of known restrictions under copyright law, including all related and neighbouring rights and is being made available under the Creative Commons, Public Domain Mark.


You can copy, modify, distribute and perform the work, even for commercial purposes, without asking permission.



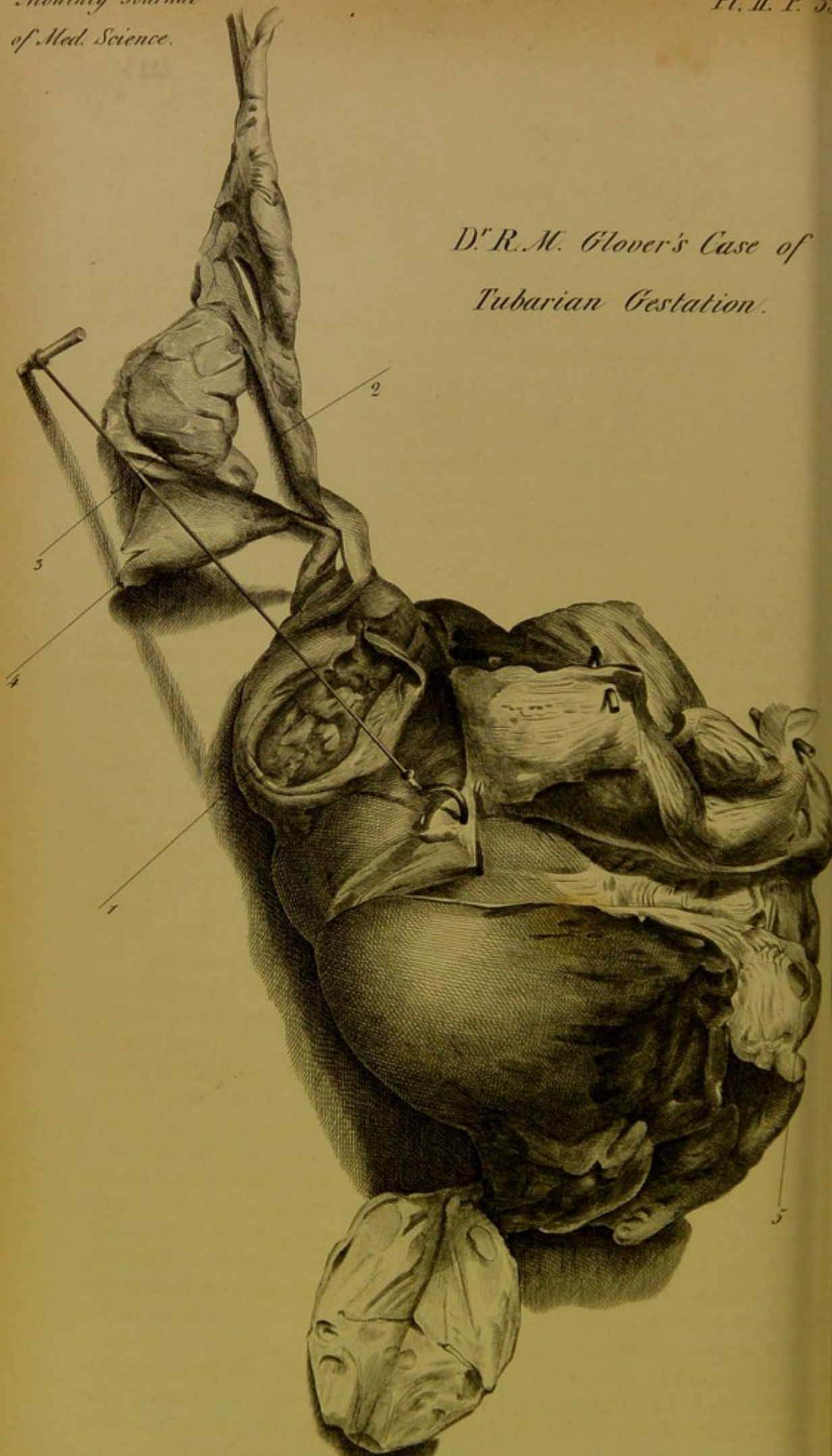
Wellcome Collection
183 Euston Road
London NW1 2BE UK
T +44 (0)20 7611 8722
E library@wellcomecollection.org
<https://wellcomecollection.org>







*D^r R. M. Glover's Case of
Tubarian Gestation.*



J. Bennett.
with the history complete.
(23)

CASE OF TUBARIAN GESTATION,

WITH

RUPTURE OF THE CYST CONTAINING THE EMBRYO, AND FATAL
HEMORRHAGE INTO THE PERITONEUM.

By R. M. GLOVER, M.D. EDIN.,

NEWCASTLE-ON-TYNE.

(Extracted from the Lond. and Edin. Monthly Jour. of Med. Science for April 1842.)

The subject of this case was aged 39, of stout habit of body; she had been married for the second time for three months. Since her marriage she had not menstruated, though previously her menstruation was regular. During her first marriage she had three miscarriages, but never bore a viable child.

On the 30th of November last, she was seen by Mr Dixon of Gateshead; she then complained of bearing-down pains in the back and abdomen, especially in the former seat, with slight bloody discharge from the vagina. On examination per vaginam, the lips of the uterus were found rather tumefied, but close. The pulse was little affected, and the tongue clean. A gentle aperient and an anodyne draught were prescribed. The bowels were in consequence gently opened, and the pains ceased.

Next day about the same time, *i. e.*, in the afternoon, she had a similar attack, when the same treatment was renewed with equal success. This time, a few fibrinous shreds were passed along with the bloody discharge. The bloody discharge was very slight, and the shreds, as described, lightly pressed together, would not make up the size of a small nut.

On the morning of the 2d of December, the patient appeared well, and got up to cook dinner for the household; this was before noon. A sense of uneasiness caused her to go to bed about noon. About 3 P.M. she was suddenly attacked with severe, nay, excruciating pain in the lower part of the abdomen. She was then alone in the house, and her shrieks were unattended to for half an hour, when she succeeded in procuring assistance, and Mr Dixon was again sent for.

At 4 P.M. he found his patient in a state of collapse; her extremities cold; rigors; the pain in the bowels continuing; the lower part of the abdomen excessively painful on pressure. The

pulse was scarcely perceptible, and apparently but little quickened, about 80; the tongue continued clean. An examination per vaginam was again made, and the lips of the uterus were found less tumefied. A draught of laudanum and ether was ordered.

I saw the case in consultation with Mr Dixon shortly before eight o'clock. Previously to this she had severe vomiting, a watery fluid being ejected from the stomach with great force. Her state was generally as has just been described. The abdomen was everywhere painful on pressure, especially inferiorly, where it had a doughy feel. Superiorly, there was some degree of tympanitis. Great pain was especially felt over the iliac fossæ. There was now no discharge from the vagina. The pupils were dilated, and the patient in a state of partial stupor.

Amidst the difficulties with which the case was invested, we determined to treat it as for peritonitis. Turpentine injections were ordered, and sixteen leeches to the abdomen over the seat of pain; a bolus of twelve grains of camphor, and two of opium were directed to be taken immediately.

She continued in the same state during the night. At 12 o'clock she had a draught containing nitrous ether and ammonia; and this was repeated several times during the night. In the night-time she had three turpentine injections, and her bowels were freely moved. Towards morning there was repeated vomiting, and again a watery fluid was ejected with great force.

The symptoms of depression continued to augment, she lay during the next day in a state of insensibility, and died at 6 P.M.

Autopsy.—An inspection of the body was made forty hours after death by Mr Dixon and myself.

No external sign of pregnancy was observed.

On opening the peritoneum, a large clot was perceptible, occupying the space from the umbilicus in front downwards into the pelvis. The transverse colon distended with flatus, exhibited several patches of inflammation on its peritoneal coat; and on opening the intestine, the mucous membrane was observed in some parts reddened opposite these external marks. The same was observed in many parts of the small intestines. The pelvis and iliac regions, and posterior part of the abdomen contained a quantity of dark-coloured fluid blood, which we estimated at two pounds; while the clot we conceived might weigh three-quarters of a pound. The peritoneum lining the inferior and posterior parts of the abdomen, and the pelvis, exhibited an intense redness, which appeared to arise partly from increased vascularity, but chiefly from coloration by contact with the effused blood. A careful examination of the interior of the peritoneum was made by the hand, and with the light of a candle, with the view of detecting some ruptured vessel, the cause of the hemorrhage; but in vain. However, a sac of the size of a walnut was found

where the left Fallopian tube joined the uterus; its interior surface communicated with the peritoneum by an irregular shaggy opening, and by adherent clots, which could be pulled from openings resembling those of veins. The uterus and its appendages were carefully secured; but the further inspection of the body was prevented by the impatience of the relations of the deceased who were present.

The uterus and its appendages were examined by me, with the valuable assistance of Dr Embleton, the lecturer on anatomy in our medical school.

The uterus was somewhat enlarged, and its lips slightly tumefied; and on being opened, was found to be lined by the decidua, apparently of very recent formation, to within three or four lines of its orifice. This membrane was red, of a nearly uniform tinge, soft and spongy, and terminated towards the mouth of the uterus by a somewhat elevated margin, which may be described as composed of striæ. The point of the scalpel pushed through the decidua, and slightly moved, gave the sensation to the hand of a firmly resisting body beneath, at the depth of half a line or less. Air could be injected from the right Fallopian tube into the uterus, but not from that of the left side, nor from the uterus into the cyst already alluded to. The left Fallopian tube was clearly connected with this cyst, although impervious about four lines above it. The cyst has been already sufficiently described.

The left ovary was much shrunk, and a hydatid was observed attached to it. On its outer surface was a recent cicatrix, in which a minute dark clot could be observed. Near this, on section, two corpora lutea could be observed. The ovarian extremity of the left Fallopian tube was very open, and beautifully fimbriated.

The right ovary, laid open, showed two corpora lutea, and several Graafian vesicles. A cell was observable in the neck of the uterus. Notwithstanding that the embryo was not found in this case, being probably in the huge clot described, there cannot be a doubt entertained I think of the nature of the case; and this being granted, the chief remarkable circumstance with regard to it is the *early period* of gestation at which rupture of the sac took place.

In general, rupture of the sac in cases of tubarian pregnancy takes place towards the third month. This is the statement of Baudelocque,¹ and is corroborated by a case related by an old authority, De Graaf,² and by a very modern one, Dr Fairbairn, the narrator of a very recent case of the kind.³ From the size

¹ Art des Accouchements, t. 2, p. 450, -52, fourth edition.

² See his explanation of the Tabula Vigesima Prima, in the work De Mulierum Organis.

³ MONTHLY JOURNAL OF MED. SCIENCE for 1842, p. 197.

of the sac in the present case, and the absence of marked symptoms of pregnancy, together with the recent formation of the decidua and state of the uterus, I should not be inclined to consider the pregnancy as more advanced than three weeks. All the symptoms of such cases, with confirmation of the great effusion of blood that occurs in them, will be found described in these authors, also by Capuron,¹ and doubtless by other writers. It is not my intention to enter into the literature of the subject; but I should be inclined to conjecture that parallel cases are more frequent than is supposed. A practitioner in this neighbourhood described to me a case of the kind which occurred to him four years ago. In his case also the foetus had apparently attained the third or fourth month of gestation.

EXPLANATION OF THE PLATE.

The anterior view of the uterus is represented; a transverse section is made of the left portion, besides the general section, and a portion of uterus reflected and reversed, in order to show the decidua as described. 1. Is the sac; 2. The left Fallopian tube; 3. The recent cicatrix on the left ovary; 4. The hydatid; 5. The cell in the neck of the uterus.—The appearances on section of the right ovary are sufficiently clear.

¹ Cours Théorique et Pratique des Accouchements, t. 2, p. 673, second edition.

