

**A case of arrested development of the cerebellum and the bones of the skull in a child / by Francis Ogston, jun.**

**Contributors**

Ogston, Francis, Jr., 1846-1917.  
University of Glasgow. Library

**Publication/Creation**

Edinburgh : Oliver and Boyd, 1880.

**Persistent URL**

<https://wellcomecollection.org/works/e7m2a9bu>

**Provider**

University of Glasgow

**License and attribution**

This material has been provided by This material has been provided by The University of Glasgow Library. The original may be consulted at The University of Glasgow Library. where the originals may be consulted. This work has been identified as being free of known restrictions under copyright law, including all related and neighbouring rights and is being made available under the Creative Commons, Public Domain Mark.

You can copy, modify, distribute and perform the work, even for commercial purposes, without asking permission.



Wellcome Collection  
183 Euston Road  
London NW1 2BE UK  
T +44 (0)20 7611 8722  
E [library@wellcomecollection.org](mailto:library@wellcomecollection.org)  
<https://wellcomecollection.org>





With compts from <sup>8/3/87</sup> F.O.J.

A

\*948. - 1882

CASE OF ARRESTED DEVELOPMENT  
OF THE  
CEREBELLUM AND THE BONES OF  
THE SKULL IN A CHILD.

BY

FRANCIS OGSTON, JUN., M.D.,


ASSISTANT-PROFESSOR OF MEDICAL JURISPRUDENCE IN THE UNIVERSITY OF  
ABERDEEN.

*(Reprinted from the Edinburgh Medical Journal for September 1880.)*

PRINTED BY OLIVER AND BOYD, EDINBURGH.

MDCCCLXXX.

c





A CASE OF  
ARRESTED DEVELOPMENT OF THE CEREBELLUM  
AND BONES OF THE SKULL.

---

THE following case of defective development of brain and skull, which was met with in a child of sixteen months of age, seems worthy of record, as it is of interest to the physiologist and to the medical jurist—to the latter, since a child which would have been regarded as non-viable should have been reared, and should have survived its birth for so long a period of time.

In comparing the defects found in this case with Breschet's Table of Monstrosities, it might be classed as follows:—

Order I.—Agenèses.

Genus I.—Agénésies.

*History.*—Of the life history nothing could be learned further than that both father and mother, who were healthy, had been farm-servants, and that it was an only child. There was no family history of hereditary defect or syphilitic disease. The child had been born in the country, at some distance from a medical man, and the doctor who attended the birth had never seen it afterwards, and could give no account of its early months. The mother stated that it had never been able to suck, had required constant care and attention, had never made any attempt to speak or walk, and could not even sit up on her knee without support; but that it moved its limbs equally well on both sides. The child had been found by its mother one morning dead in bed beside her; and at the request of the law authorities I was called on to make a post-mortem examination, and to report on the cause of its death, when the following appearances were noted:—

POST-MORTEM EXAMINATION.

*External Appearances.*—The body much emaciated, but not more so on one side than on the other; the extremities well formed; the chest symmetrical; the organs of generation well formed, and both testes in the scrotum. The length of the body  $27\frac{1}{2}$  inches. The circumference of the head at the level of the supra-orbital ridges and the occipital protuberance, 17 inches.

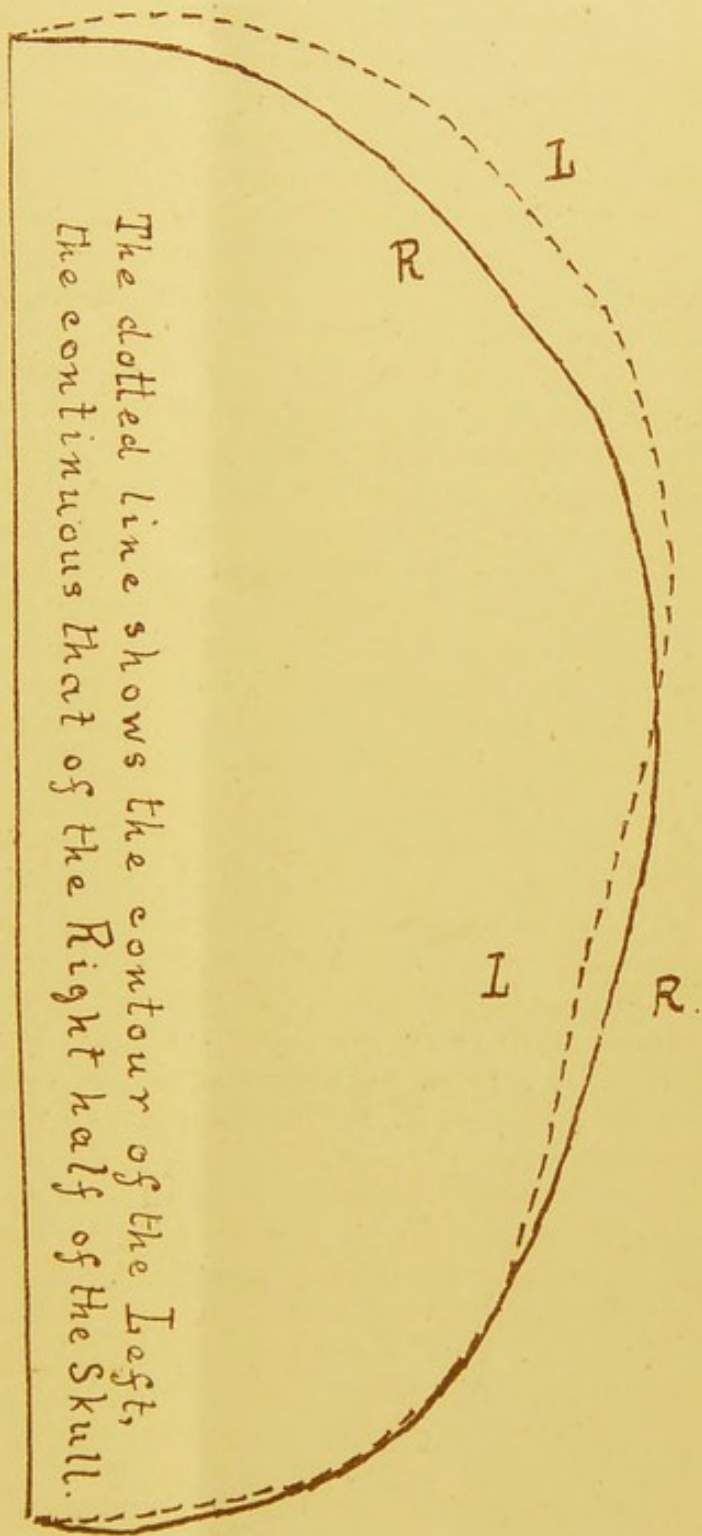


The right side of the head flatter than the left, especially at its posterior fourth (*vide* Plate I.). The left auricle normal in size and position; the right represented by a few scattered tubercles hardly raised above the level of the skin, arranged somewhat in the form of the auricle, the upper part being most distinct. On being cut into, these appeared to be composed of cartilage, and were intimately connected with the skin. There was no trace of the external meatus, nor were the rudiments of the pinna connected with the bones on which they lay by any ring of cartilage. The opening between the eyelids of the right side  $\frac{3}{8}$  of an inch in length; the eyelids and lashes well formed, except for their size. The right eye totally wanting, the stump appearing to consist of mucous membrane, with no trace of pupil, etc. The left eye normal. The nose hooked like a parrot's beak, thickened at the junction of the cartilage and bones, its direction turned to the right, and the right aperture smaller than the left. The mouth well formed, but twisted to the right, so that its left angle fell on a line drawn from the root of the nose to the centre of the sternum. The lips well formed. The right cheek flatter, and the whole of the right side of the face very much smaller than the left. The measurement from the symphysis to the angle (or what appeared to be so) of the lower jaw on the right side, outside the cheek,  $1\frac{5}{8}$  inch, on the left side  $2\frac{5}{8}$  inches; from the root of the nose across the angles of the jaws to the third cervical vertebra, right side 6 inches, left side  $6\frac{1}{2}$  inches. The fontanelles of the skull still unclosed. Very little hair on the head. The joints rigid. The lower part of the belly greenish. The front of the body generally pale, the back parts purplish. A round swelling, the size of a marble, an inch from the outer angle of the right orbit, on a level with it (sebaceous cyst).

*Internal Appearances.*—On reflecting the scalp the fontanelles were found to be still unclosed, and the sutures of the skull were marked by lines of cartilage  $\frac{1}{8}$  of an inch in breadth. The bones of the right side of the head appeared flatter than those of the left, especially at the right half of the occipital and the posterior part of the parietal bone at its inferior angle. On the right side, the temporal, pterygoids, and the masseter muscles seemed wanting; the muscles of the mouth and cheek otherwise appeared normal. The right zygomatic arch was very rudimentary, being represented merely by a short process of cartilage springing from the malar bone, and a similar one from the temporal bone. The hard and soft palate normally developed, the right side, however, and the right side of the upper jaw, being smaller than the left. The right half of the tongue about a third the size of the left, so that the tip was inclined to the right, and appeared to be formed of the left half of the organ. The lower jaw very much deformed on the right side (*vide* Plate II.), which ended in a rounded knob behind the second temporary molar tooth, with a small projecting tubercle; no trace of the coronoid and condyloid process existing (see under).

Plate I.


Posterior



The dotted line shows the contour of the Left,  
The continuous that of the Right half of the Skull.

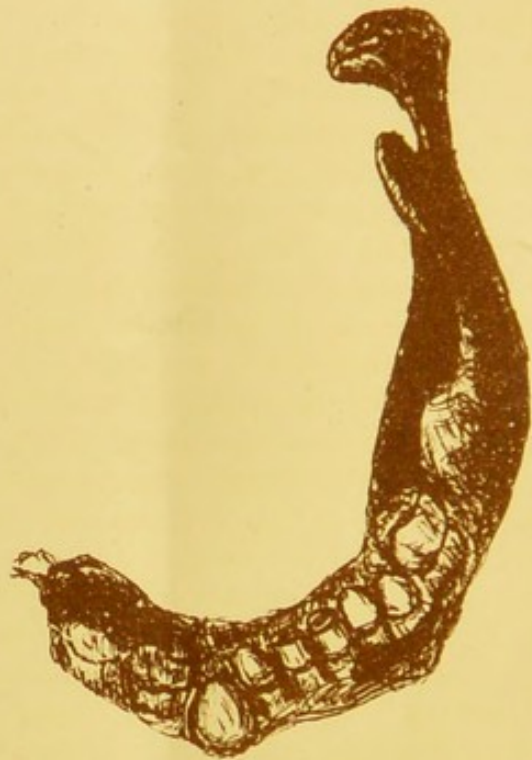Anterior  
F.O. del.








Plate II.



F.O. del

Defective development of the right  
half of the lower jaw, in a child.

Life size.



The right temporal bone was small, showing no trace of glenoid cavity, auditory meatus, or mastoid process. The cavity of the tympanum was also wanting, this part consisting of a transparent lamina of bone, bounded above by a narrow isthmus of bone. The semicircular canals seemed normally developed (see under). On the left side these bones were normal. The cerebral lobes normal, equal in size; but the right one appeared flatter posteriorly than the left. This on further examination was found to be caused by a defect in the cerebellum, the right posterior cerebral lobe falling lower down than the left. The ventricles of the brain and the ganglia at its base seemed normal. The optic nerve was normal on the left side, but the right was much smaller than usual. The olfactory nerves normal. The medulla oblongata and the pons varolii appeared normal, or nearly so. The right half of the cerebellum smaller than the left, and somewhat irregular in shape (see under, Plate III.) The substance of the brain contained considerably more blood than usual. The gullet and air-passages normal. The lungs contained a considerable amount of dark blood and white froth. A few minute spots of effused blood (Tardieu's spots) on the surfaces of the lungs and heart. The right cavities of the heart contained considerably more blood than the left cavities. The blood in both contained firm clots. The valves and walls of the heart healthy. The liver, spleen, and kidneys loaded with blood. The right lobe of the liver smaller than usual. From these appearances I gave it as my opinion that the child had died from suffocation (smothering), judging from the gorged state of the lungs, liver, spleen, and kidneys, from the punctiform ecchymoses (Tardieu's spots) on the lungs and heart, and from the amount of blood in the right cavities of the heart; but stated that the defects in its cerebellum and jaw had rendered it so weakly that its life would be much more easily extinguished than that of a normally-formed child.

I append a more minute description of the defective structures in this case.

I. *The Central Parts of the Brain.*—Measurements of the cerebellum :—

Antero-posterior, .	Left, $2\frac{5}{8}$ inches.	Right, $2\frac{1}{8}$ inches.
Transverse, .	„ $1\frac{3}{4}$ „	„ $1\frac{1}{4}$ „
Vertical, .	„ $1\frac{1}{2}$ „	„ $1\frac{1}{2}$ „

The anterior part of the right lobe of the cerebellum seemed undeveloped (as is shown in Plate III.), the whole measuring about two-fifths the bulk of the left lobe, and being flattened to a considerable degree. The right side of the pons varolii seemed a little less than the left.

*Nerves.*—1. The olfactory nerves were normal. 2. The optic commissure seemed smaller on the right side, and the right



optic nerve was much smaller than the left. 3. The motor oculi appeared to be absent on the right, normal on the left side. 4 and 5. The fourth and fifth nerves were normal. 6. The abducens was absent on the right, and small on the left side. 7. The facial and auditory nerves were very small on the right, normal on the left side. 8. The glossopharyngeal, pneumogastric, and spinal accessory nerves were absent on the right, normal on the left side. 9. The hypoglossal nerve was wanting on the right, normal on the left side.

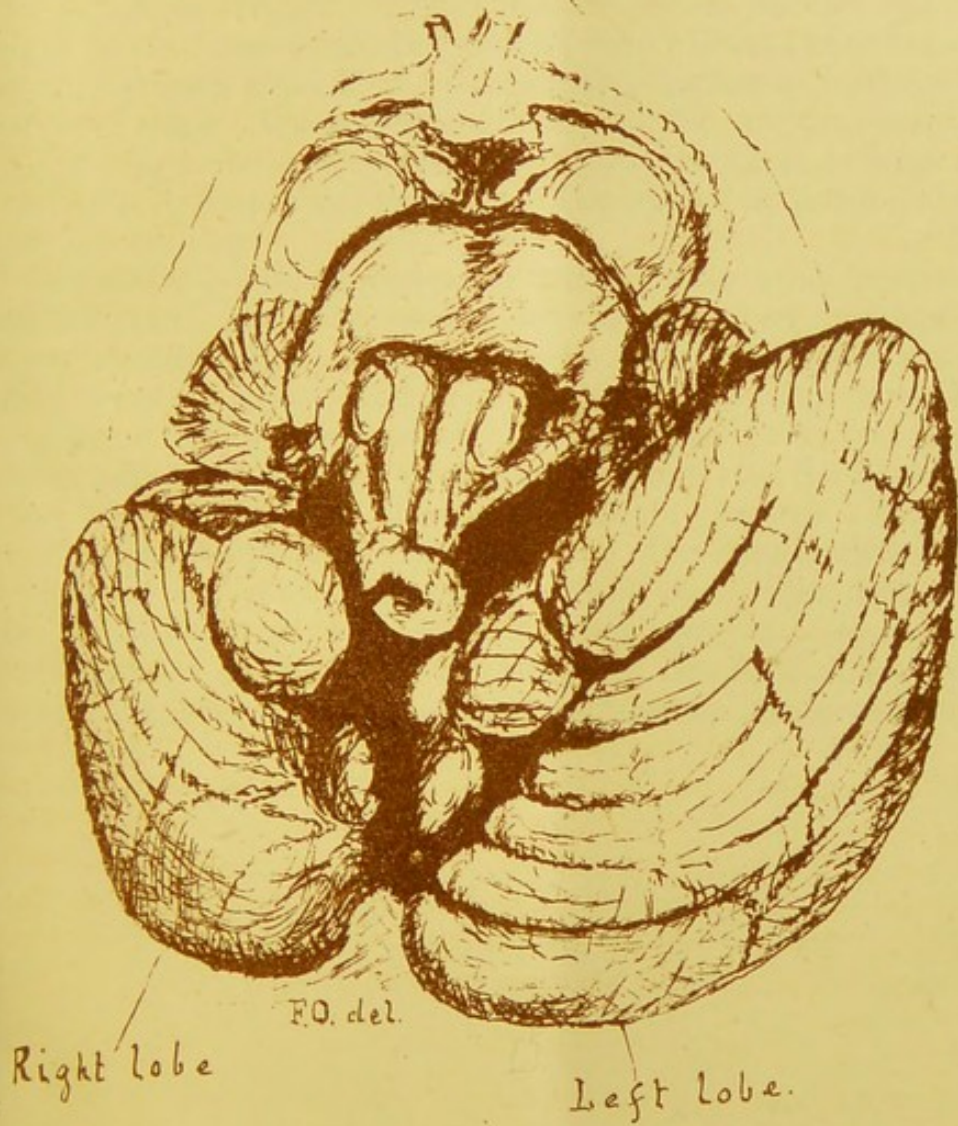
II. *The Lower Jaw.*—The line of the symphysis menti ossified and vertical, internally marked by a distinct groove. Only the left genial tubercles well marked. Beneath the left incisor and canine teeth the margin of the jaw was curled outwards and upwards, producing a deep groove parallel to the margin. The mental foramen was deficient on the left side, extremely minute on the right (deformed) side, but transmitting a minute filament. The inferior dental foramen and nerve were normal, as were all the ridges and fossæ on the left side. On the right side of the jaw the teeth behind the lateral incisor were crowded together, the canine being pushed forward, and the two temporary molars being contained in a stumpy alveolar process, which ended posteriorly in a rounded spine or tubercle. There was no lower border on the side of the jaw, but merely alveolar process. None of these teeth had erupted. The two central incisors and the right lateral incisor were the only teeth seen above the gum. The left lateral and the canines were seen above the bones, but were not through the gum. The central incisors were decayed at their cutting edges. On the left side the first temporary molar was seen underneath the periosteum of the alveolar process, and an expansion of the bone showed the position of the second molar, while another expansion just beneath the anterior edge of the coronoid process seemed to indicate the position of the first permanent molar.

*Measurements of the Lower Jaw.*

Symphysis to canine angle—Right,	$\frac{4}{8}$ inch.	Left,	$\frac{7}{8}$ inch.
Depth of jaw at first molar—	„ $\frac{7}{8}$ „	„	$\frac{9}{8}$ „
Thickness	„ $\frac{6}{8}$ „	„	$\frac{6}{8}$ „
Length of right side in a straight line from the lower edge of the symphysis to the tip of the tubercle,			$\frac{7}{8}$ „
Length of the left side from symphysis to angle in a straight line,			$1\frac{1}{2}$ inches.
Symphysis to condyle in a straight line,			$2\frac{1}{4}$ „
„ anterior edge of coronoid,			$1\frac{5}{8}$ „
Angle to tip of condyle,			$1\frac{3}{8}$ „
„ „ coronoid,			$1\frac{1}{8}$ „
Alveolar process to tip of coronoid,			$\frac{1}{2}$ inch.
Length of the left condyle,			$\frac{1}{8}$ „

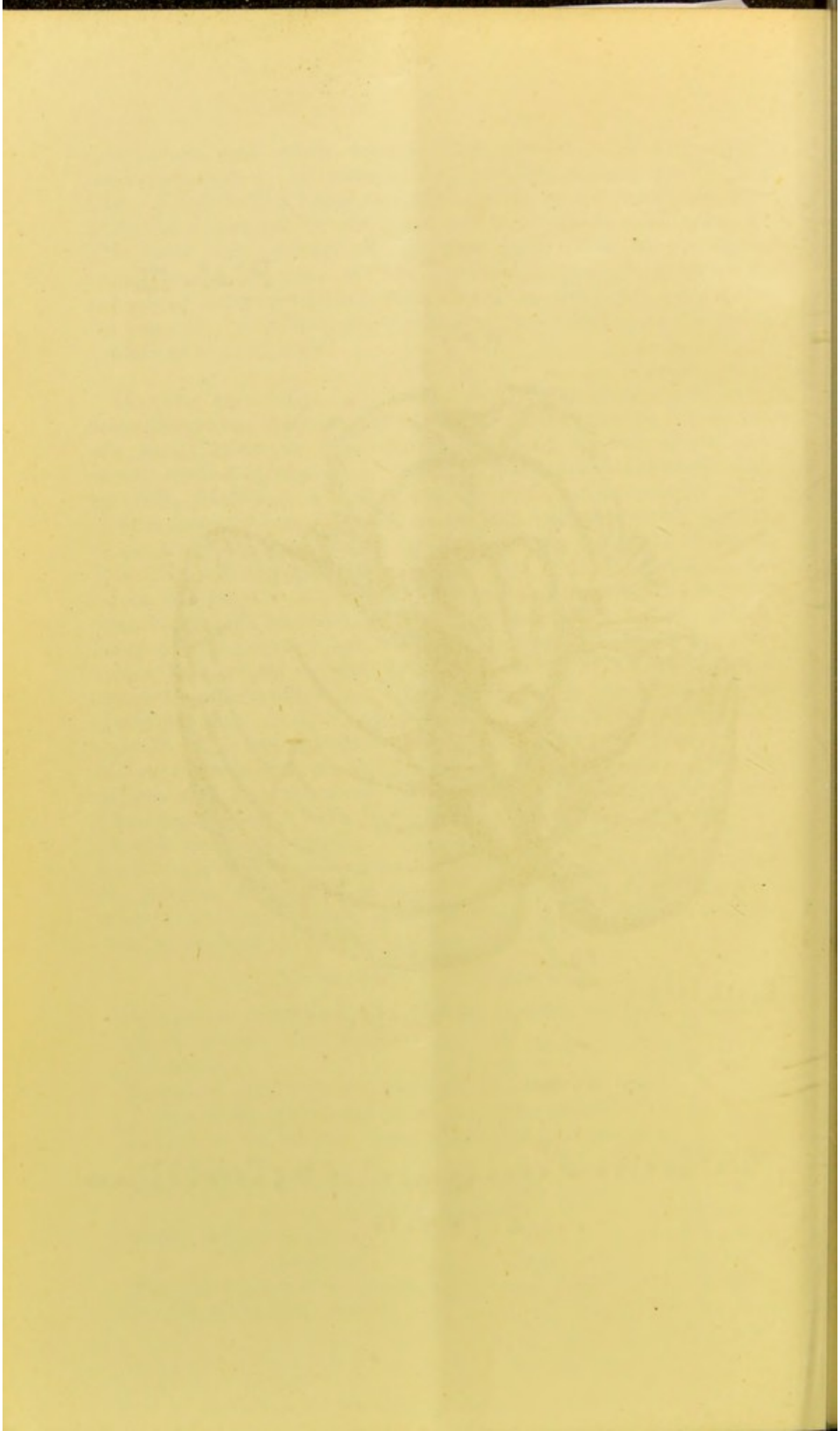


Plate III.



Defective development of the Cerebellum.  
Life size.





Left canine angle,	. . . . .	50°.
Right „ „	. . . . .	60°.
Right body rising at an angle of	. . . . .	20°.
Left ramus at angle of 40° to the lower margin of the body.		

III. *The Right Temporal Bone.*—*Externally*—The zygomatic process directed downwards, outwards, and forwards, cartilaginous and  $\frac{1}{8}$  inch in length. Eminentia articularis absent, and no cartilage in the fossa where the glenoid cavity should have been. The mastoid process absent. A rounded bony eminence in the posterior temporal ridge. The condyloid process of the occipital bone  $\frac{3}{8}$  inch from the zygomatic process. No auditory, styloid, or vaginal process. No stylo-mastoid foramen. The squamous portion about the size of a shilling.

*Internally.*—The eminence for the superior semicircular canals well-marked. A deep hollow over the tegmen tympani. The cassarian depression deeply marked. The groove for the lateral sinus deeply marked, and ending above in a very deep hollow, capable of holding the tip of the forefinger, the bottom of which was so near the depression over the tympanum that the bone between them was diaphanous. The hiatus fallopii present. The groove for the superior petrosal sinus absent. The carotid canal normal, containing the carotid artery of normal size. The internal auditory meatus normal, and containing an apparently normal nerve. The aqueduct of the vestibule normal. No Eustachian tube nor canal. Jugular foramen and foramen lacerum posterius present.

LIBRARY  
COLLEGE  
MAY 19 1892





