

Descriptive catalogue of the teratological series in the Museum of the Royal College of Surgeons of England.

Contributors

Royal College of Surgeons of England. Museum.
University of Glasgow. Library

Publication/Creation

London : [Royal College of Surgeons of England], 1893.

Persistent URL

<https://wellcomecollection.org/works/qenjnnx5>

Provider

University of Glasgow


License and attribution

This material has been provided by This material has been provided by The University of Glasgow Library. The original may be consulted at The University of Glasgow Library. where the originals may be consulted. This work has been identified as being free of known restrictions under copyright law, including all related and neighbouring rights and is being made available under the Creative Commons, Public Domain Mark.

You can copy, modify, distribute and perform the work, even for commercial purposes, without asking permission.



Wellcome Collection
183 Euston Road
London NW1 2BE UK
T +44 (0)20 7611 8722
E library@wellcomecollection.org
<https://wellcomecollection.org>



Glasgow
University Library




Presented
51-1913

H18- b. 23



30114013044733



THE UNIVERSITY OF CHICAGO

LIBRARY OF THE UNIVERSITY OF CHICAGO

PRESENTED BY THE COUNCIL OF
THE ROYAL COLLEGE OF SURGEONS OF ENGLAND

DESCRIPTIVE CATALOGUE
OF THE
TERATOLOGICAL SERIES
IN
THE MUSEUM
OF THE
ROYAL COLLEGE OF SURGEONS OF ENGLAND.

ANIMAL MALFORMATIONS

BY

B. THOMPSON LOWNE, F.R.C.S.,

LECTURER ON PHYSIOLOGY AT THE MIDDLESEX HOSPITAL MEDICAL SCHOOL.

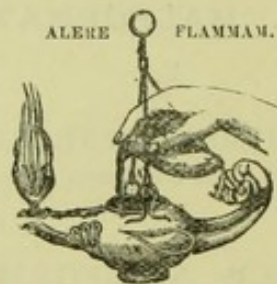
VEGETABLE MALFORMATIONS

BY

Dr. MAXWELL T. MASTERS, F.R.S.



LONDON:
PRINTED FOR THE COLLEGE;
AND SOLD BY
TAYLOR AND FRANCIS, RED LION COURT, FLEET STREET.
1893.



PRINTED BY TAYLOR AND FRANCIS,
RED LION COURT, FLEET STREET.

THE former Catalogue comprised the descriptions of 479 specimens. Since its publication in 1872 this number has been increased to 868, rendering it most necessary that a new Catalogue should be made.

It was found convenient to separate the Vegetable Malformations from the Animal, and they are now placed after that group. The work of cataloguing and describing the Animal Malformations has been intrusted to Mr. B. T. LOWNE, and the Vegetable Malformations to Dr. MAXWELL T. MASTERS.

C. STEWART,
Conservator.

November 18, 1893.



Digitized by the Internet Archive
in 2015

<https://archive.org/details/b21462902>

INTRODUCTION

TO THE

CATALOGUE OF ANIMAL MALFORMATIONS.

By B. THOMPSON LOWNE, F.R.C.S., &c.

ANIMAL Teratology has been defined as a branch of Pathology which deals principally with conditions resulting from some deviation from the normal, occurring at an early stage of development—probably nutritive changes which give rise to hyperplasia or atrophy of individual cells or groups of cells.

Many deviations from the normal type can, however, scarcely be regarded as Pathological: such are reversions, either apparent or real, to a more primitive type, or “varieties” which occur suddenly and which are transmitted more or less certainly until they become racial characters.

Geoffroy St.-Hilaire termed such deviations “Hemiteres,” Malformations, and regarded those here referred to as Pathological as “Monstra,” Monsters. Such a distinction is not always possible, as there is no obvious line of demarcation by which the two conditions can be separated. The most remarkable so-called Monsters are perhaps “Double Monsters,” united Twins; but there is reason to

think that even these result from hyperplasia or doubling by fission of groups of cells in the early stages of the ovum, and may be regarded as due to a reversion to a mode of multiplication normal in many of the lower forms of life. The stony corals normally exhibit double polypites in every possible degree, which originate from imperfect fission; and the ova of some animals normally produce two embryos instead of one.

Modern writers on Teratology have not included most of those slight deviations from the normal which have no pathological significance in their systems of Classification; they are, nevertheless, retained in the present Collection. The number of such deviations in the Museum is small, although they are exceedingly common in nature: such are abnormal distribution of blood-vessels and nerves, the presence of abnormal and the absence of normal muscles, varieties in the process of ossification, &c.

Deviations of this character are frequently of far greater interest to the morphologist than distinct pathological conditions, "Monsters," which are more frequently preserved. When a larger collection of such has been acquired, a revision of the Classification adopted may become advisable.

An ideally perfect arrangement is at present not possible owing to our ignorance of the Etiology of Malformations. It has been found advantageous on this ground to make a primary division of the Collection into several "Series," following as nearly as possible the Classification of the Physiological and Pathological collections.

The first series may be regarded as the principal one to which the remainder are supplementary. It contains all the general malformations of the head and trunk. It has been found necessary to separate malformations of the limbs; these form a second series. The third and following series consist of malformations affecting single organs or

groups of organs. This arrangement is purely artificial and anatomical, but it is the only one with our present knowledge which can be adopted without placing objects in proximity on purely theoretical grounds and separating others the comparison of which is important and is facilitated by their juxtaposition. Such a classification has been adopted by all the leading authorities on the subject.

Each Series is grouped in one or more Classes. Each Class consists of malformations which are similar, and which are probably related in their origin. The first Series contains five Classes as follows :—

- Class I. Situs mutatus.
- II. Secondary Dichotomy.
- III. Double Malformations.
- IV. Malformations with Deficiency.
- V. Malformations with Distortion.

In the second Series the three last Classes only occur, but it appears probable that Secondary Dichotomy, if it could be distinguished from Primary Dichotomy in its final stages, would be found to exist. The third and following Series are for the most part either too small or the malformations are too little understood to need or admit of subdivision ; others are provisionally subdivided on an anatomical basis. Two, however,—Series VII. Malformations of the Heart and Blood-vessels, and Series IX. Malformations of the Urino-generative System,—are well represented and have been divided into Classes.

The minor degrees of deviation from the normal are fairly represented in the first of these, and are included in a single Class, "Hemiteres." The remaining malformations are many of them obvious arrests, that is, they exhibit a permanence of a previous developmental condition. Others are so altered by adaptive modifications and subsequent diseases, that it is not easy or perhaps possible to

discover the original nature of the defect. They have therefore been included with arrests as "defective conditions."

Malformations of the Urino-generative Organs are still more difficult to classify.

True Hermaphroditism has been regarded by all Teratologists as a condition "*sui generis*," mere excess in the size and number of parts is quite distinct.

False Hermaphroditism is far more common than true Hermaphroditism, but it is impossible to separate it by any definite line of demarcation from Hypospadias in the male, nor is it always clearly an arrested condition, more especially in the female. It has been thought safer, therefore, to unite all these forms in a single class as "defective conditions of the Genitalia."

The last Series is a collection of malformed ova from Birds; some preparations of malformation of the oviduct in Birds have been also included in this Series, as they apparently throw some light on the malformed ova, near which they are placed.

CONTENTS.

	No. of Preparations.
SERIES I. ABNORMAL CONDITIONS AFFECT- ING THE HEAD AND TRUNK	1—373
CLASS I. SITUS MUTATUS.....	1—3
CLASS II. SECONDARY DICHOTOMY	4—7
CLASS III. DOUBLE MALFORMATIONS	8—175
Subclass I. HOMOLOGOUS TWINS.	
Subclass II. ACARDIACUS	8—18
1. <i>Microcephalus</i>	8—11
2. <i>Acephalus</i>	12—18
3. <i>Acormus</i> .	
4. <i>Amorphus</i> .	
Subclass III. ANTERIOR DICHOTOMY AND PLEURO- PAGUS	19—66
* IN FISHES	19—23
** IN REPTILES	24—27
*** IN BIRDS	28—37
**** IN MAMMALS	38—66
1. <i>Monocranus Dignathus and Trigna- thus</i>	38—42
2. <i>Diprosopus</i>	43—48
3. <i>Dicephalus conjunctus</i> ...	49—56
4. <i>Dicephalus disjunctus</i>	57—62
5. <i>Pleuropagus</i>	63—66
Subclass IV. EMPROSTHOZYGOSIS	67—80
1. <i>Xyphopagus</i>	67
2. <i>Thoracopagus</i>	68—80

	No. of Preparations.
Subclass V. PARASITIC EMPROSTHOZYGOSIS	81—91
Subclass VI. PROZYGOSIS AND POSTERIOR DICHOTOMY	92—145
* IN BIRDS	92—102A
** IN MAMMALS	103—145
1. <i>Prozygosis</i>	103—110
2. <i>Schizocephalus</i>	111—112
3. <i>Schizocotis</i>	113—120
4. <i>Schizorhachis</i>	121—134
5. <i>Dipygus</i>	135—137
Subclass VII. ANTERO-POSTERIOR DICHOTOMY	138—145
Subclass VIII. OPISTHOZYGOSIS AND PYGOPAGUS ..	146—153
1. <i>Opisthozygosis</i>	146—149
2. <i>Pygopagus</i>	150—153
Subclass IX. PARASITIC HYPOGASTRODIDYMUUS	154—163
* IN BIRDS	154—158
** IN MAMMALS	159—163
Subclass X. MESODIDYMUUS.	
Subclass XI. TRIPLEX MALFORMATIONS.	
Subclass XII. CRANIOPAGUS	164—166
* IN BIRDS	164
** IN MAMMALS	165—166
Subclass XIII. TERATOMES	167—171
1. <i>Sacral teratome</i>	167
2. <i>Epignathus</i>	168—171
Subclass XIV. HETEROLOGOUS UNION.	
Subclass XV. INCLUSIO FŒTALIS	172—175
CLASS IV. MALFORMATIONS WITH DEFICIENCY. 176—360	
Subclass I. CRANIOFACIAL DEFICIENCY	176—287
* IN FISHES	176—180
** IN BIRDS	181—182
*** IN MAMMALS	183—287
Group I. Persistent Branchial Clefts.	
Group II. Arrested Formation of the	
Mandible	183—187
1. <i>Brachygnathus</i>	183—185
2. <i>Unilateral Agnathia</i>	186—187

	No. of Preparations.
Group III. Hare-lip and Cleft Palate ..	188—202
Group IV. Deficiency of the Cranio- facial Axis	203—287
A. MESOFACIAL DEFECT.....	203—209
1. <i>Median Hare-lip</i>	203—209
B. PROSENCEPHALIC AXIAL DEFECT ..	210—241
1. <i>Rhinocephalus</i>	210—230
2. <i>Arhynchus</i>	231—238
3. <i>Anopia</i>	239—241
C. MESENCEPHALIC AXIAL DEFECT ..	242, 242A
D. PROSTHO-MESENCEPHALIC DEFECT..	243
E. EPENCEPHALIC AXIAL DEFECT	244—255
1. <i>Agnathia</i>	244—246
2. <i>Synotia</i>	247—255
F. PROSTHO-EPENCEPHALIC DEFECT ..	256—287
1. <i>Cyclocephalus</i>	256—265
2. <i>Nanocephalus</i>	266—287
Subclass II. POSTERIOR DEFICIENCY OF THE AXIS..	288—302
Group I. Simple Deficiency of the Axis ..	288—289
Group II. Sympodia.....	290—302
Subclass III. DEFECTIVE DEVELOPMENT OF THE SOMATO-PLEURAL LAMINÆ	303—360
Group I. Defective Closure of the Thoracic and Abdominal Cavities	303—313
1. <i>Fissure of the Sternum</i>	303—305
2. <i>With Ectopia of the Abdominal Viscera</i>	306—313
Group II. Defective Closure of the Neural Laminæ.....	314—360
1. <i>Spina bifida</i>	314—338
2. <i>Occipital Deficiency</i>	339—340
3. <i>Epicephalocle</i>	341—344
4. <i>Anencephalus</i>	345—360
CLASS V. MALFORMATIONS BY DISTORTION ..	361—373
Subclass I. SPINAL CURVATURES.	
1. <i>Simple Curvature</i>	361—370
2. <i>With Ectopia of the Viscera</i>	371—373

	No. of Preparations.
SERIES II. ABNORMAL CONDITIONS OF THE LIMBS AND OTHER APPENDAGES	374—485
CLASS I. EXCESS IN THE NUMBER OF PARTS ..	374—418
* IN INVERTEBRATES	374—381
** IN VERTEBRATES	382—418
1. <i>In the Horns of Ruminants</i>	382—383
2. <i>Polydactylus</i>	384—418
CLASS II. MALFORMATIONS WITH DEFECT	419—464
1. <i>Aschistodactylus</i>	419—425
2. <i>Perodactylus</i>	426—429
3. <i>Nanomelus</i>	430—444
4. <i>Micromelia</i>	445—448
5. <i>Amelia</i>	449—459
6. <i>Hemimelia</i>	460—464
CLASS III. MALFORMATIONS BY DISTORTION..	465—485
1. <i>Talipes</i>	465—481
2. <i>Curvature</i>	482—483
3. <i>Congenital Dislocation</i>	484—485
SERIES III. ABNORMAL CONDITIONS OF THE SKIN AND ITS APPENDAGES	486—499
SERIES IV. ABNORMAL CONDITIONS OF THE OSSEOUS AND MUSCULAR SYSTEMS.	500—524
A. Of the Vertebrae	500—504
B. Of the Sternum and Ribs	505—513
C. Of the Limbs	514—518
D. Of the Muscles	519—524
1. <i>Deficiency of the Diaphragm</i>	519—524
SERIES V. ABNORMAL CONDITIONS OF THE SENSORY ORGANS AND PERIPHERAL NERVOUS SYSTEM	525—537
A. Of the Eye	525—529
B. Of the Ear	530—536
C. Of the Peripheral Nervous System.....	537

SERIES VI. ABNORMAL CONDITIONS OF THE
DIGESTIVE ORGANS 538—561

- A. Of the Teeth 538—540
- B. Of the Alimentary Canal 541—561
 - 1. *Atresia of the Pharynx and Œsophagus.* 541—545
 - 2. *Diverticula of the Alimentary Tract* .. 546—548
 - 3. *Imperfect development of the Intestines.* 549—550
 - 4. *Atresia of the Rectum* 551—561

SERIES VII. ABNORMAL CONDITIONS OF
THE HEART AND BLOOD-VESSELS .. 562—625

- CLASS I. HEMITERES 562—580
- 1. *Abnormal arrangements of the Blood-vessels* .. 562—569
 - 2. *Situs mutatus* 570—571
 - 3. *In the number of Arterial Valves* 572—576
 - 4. *Variations in the development of the Columnæ
 Carneæ* 577—578
 - 5. *Fissure of the apex* 579
 - 6. *Division of the cavity of a Ventricle by an
 adventitious septum* 580

- CLASS II. ARRESTS OF DEVELOPMENT; DEFICIENCY 581—625
- 1. *Arrested closure of the Ductus Arteriosus* 581
 - 2. *Of the Foramen Ovale* 582—591
 - 3. *Of the Ventricular Septum* 592—616
 - 4. *Of an Artery (Stenosis)* 617—619
 - 5. *Of a Valve* 620—624
 - 6. *Misplacements of the Heart (see Nos. 303-305).*
 - 7. *Absence of the Pericardium* 625

SERIES VIII. ABNORMAL CONDITIONS OF
THE DUCTLESS GLANDS..... 626—628

- A. Of the Spleen 626—628

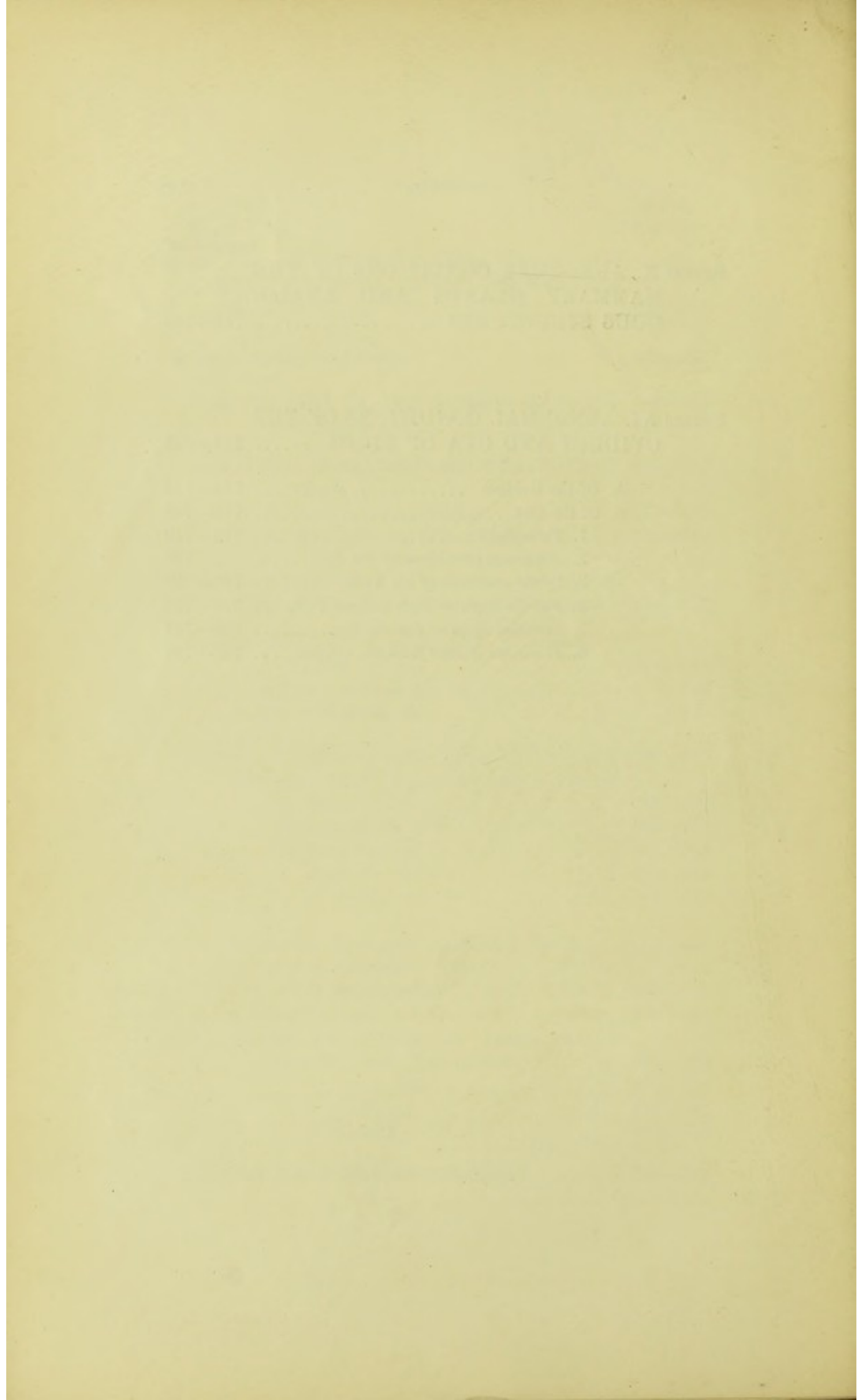
SERIES IX. ABNORMAL CONDITIONS OF THE URINARY AND GENERATIVE ORGANS	629—711
A. <i>Of the Kidneys and Ureters</i>	629—647
CLASS I. EXCESS IN THE NUMBER OF PARTS. 629—642	
1. <i>Dichotomy</i>	629—642
CLASS II. MALFORMATIONS WITH DEFICIENCY. 643—647	
1. <i>Simple Arrest</i>	643
2. <i>Union of the two Kidneys</i>	644—645
3. <i>Total deficiency of the Kidneys</i>	646—647
B. <i>Abnormal Conditions of the Genitalia—including Ab-</i> <i>normal Conditions of the Bladder in Vertebrates..</i>	648—711
CLASS I. EXCESS IN SIZE AND NUMBER OF PARTS	648—649
* IN INVERTEBRATES	648
** IN VERTEBRATES	649
CLASS II. MALFORMATIONS WITH DEFICIENCY. 649—703	
Subclass I. SIMPLE ARREST OF GROWTH AND DE- VELOPMENT	650—660
† IN THE MALE	650—653
†† IN THE FEMALE	654—660
1. <i>Double Uterus</i>	654—658
2. <i>Atresia of the Os</i>	659—660
Subclass II. EPISPADIAS AND ECTOPIA VESICÆ	661—668
1. <i>Epispadias</i>	661
2. <i>Ectopia vesicæ</i>	662—668
Subclass III. CLOACAL FORMATIONS	669—677
Subclass IV. HYPOSPADIAS, ANDROGYNE, AND GYNANDRY (False Hermaphrodism)	678—703
1. <i>Hypospadias</i>	678—684
2. <i>Androgyne</i>	685—697
3. <i>Gynandry</i>	698—703
CLASS III. TRUE HERMAPHRODISM	704—711

No. of
Preparations.

SERIES X. ABNORMAL CONDITIONS OF THE MAMMARY GLANDS AND ANALO- GOUS STRUCTURES	712—713
--	---------

SERIES XI. ABNORMAL CONDITIONS OF THE OVIDUCT AND OVA OF BIRDS	714—749
---	---------

A. Of the Oviduct	714—715
B. Of the Ova	716—749
1. <i>Twin Eggs</i>	716—719
2. <i>Abnormal conditions of the Yolk</i>	720
3. <i>Of the coverings of the Yolk</i>	721—728
4. <i>Pseudo-Eggs, or Eggs without Yelks</i> ..	729—735
5. <i>Included Eggs or Pseudo-Eggs</i>	736—747
6. <i>Fibrinous Masses from the Oviduct</i>	748—749



INTRODUCTION

TO THE

CATALOGUE OF VEGETABLE MALFORMATIONS.

BY DR. MAXWELL T. MASTERS, F.R.S. &c.

IN the following arrangement an attempt has been made to follow as closely as possible the same general principles as those which have been acted on in the Animal series. The classification is artificial, and framed so as to facilitate the search for any particular specimen. Accordingly the several malformations catalogued are arranged primarily according to the organ in which they occur. The classification is thus founded upon results rather than processes.

Vegetable Teratology presents in some measure greater difficulties than Animal Teratology, owing to the greater simplicity of plant organization and to the less perfect division of labour and differentiation of function. A leaf, for instance, fulfils the functions of absorption, of transformation of food-material, of transpiration, of excretion, of secretion, of respiration, to all or most of which separate organs are assigned at least in the higher animals. It may be true that different portions of the leaf's tissue may be set apart for these varied offices, but the function of the various histological elements is still imperfectly known, and even if it were more perfectly determined it would not invalidate the correctness of the general statement just made. The boundaries between deviations of a merely physiological character, or between such as are obviously pathological

and those that are teratological, are less clearly marked out in the vegetable kingdom than in the animal world. This might have been anticipated from what has been said as to the relative simplicity of plant organization and the relative complexity of its functions. Difficulties also arise owing to the simultaneous occurrence of different malformations in the same organ. Very frequently this is the result of compensation, or "*balancement organique*" as St.-Hilaire called it. An arbitrary classification in such cases becomes almost a necessity, owing to the impossibility of accurately assigning the complex of phenomena to any one physiological group. Many malformations retain in advanced life the conformation and arrangement that were proper to them at an earlier period, but which are usually modified as development goes on. Very often, too, an arrangement of parts, which is abnormal in one flower, is the habitual state of affairs in another. Considerations of such nature are important with reference to the course of evolution in plants. Arrests of growth and of development in individuals not only repeat or protract the state of things characteristic of the juvenile condition of the affected plant, but they furnish a more or less probable indication of what may be assumed to have been the course of evolution in the species in the past. Hence such arrests are sometimes spoken of as "reversions," and the condition in general as "atavism." Similarly some cases of exalted development may hypothetically be conjectured to represent the future condition of the plants, or at least to indicate the direction in which the tendency to modification is likely, according to circumstances, to display itself.

Whilst the arrangement of the specimens on the shelves is according to the particular organ principally affected, it may be well to point out here that the malformations met with in plants may also be grouped according as they afford illustrations of deviations from the ordinary course of growth and of development, or of both in combination. By growth is here meant simply the natural increase of substance without material change other than that in bulk. By development is meant the progressive evolution, or development from simple to complex states.

Deviations from the regular course either of growth or development may be classed according as they are the result of arrest, degeneration, exaltation, or perversion (metamorphosis) of the natural processes.

The terms made use of will present no difficulty to the animal teratologist, and they are fully explained in my 'Vegetable Teratology,' published by the Ray Society in 1869, and in the German edition, translated by Dr. Dammer in 1886 under the title 'Pflanzen Teratologie.' Incidental reference is made in the following Catalogue to some of the illustrations and descriptions contained in those volumes.

A. Deviations from the ordinary phenomena of growth involving partial or complete alterations in:—

I. SIZE.

Arrested growth	{ Abortion. Atrophy.
Exalted growth	{ Hypertrophy. Ramification or Polyclady. Chorisis. Enation.

II. PERIODICITY.

Retarded rate of growth	Opsiphory.
Accelerated rate of growth . .	Proioblasty.

III. ARRANGEMENT.

Interrupted	{ Contraction. Concrescence or Inseparation.
Continuous	{ Isolation. Spiral Torsion. Fusion. Dialysis.
Irregular	{ Prolification. Displacement. Heterotaxy.

B. Deviations from the ordinary course of evolution or development, such as continuous or temporary changes involving partial or complete alteration in:—

I. NUMBER.

Arrested development . . .	{	absolute	Suppression.
		relative	{ Oligomery. Oligotaxy.
Increased development . . .	{	absolute	{ Pleiomery. Pleiotaxy.
		relative	{ Isomery. Anisomery.

II. FORM.

Regular (Atavism? Stasimorphy).	{	Reversion.
		Regular Peloria. Homomorphy.
Irregular (progressive)	{	Di- tri-morphy.
		Irregular Peloria.
		Zygomorphy.
		Metamorphy. Heteromorphy.

III. COLOUR.

Defective	{	Albinism.
		Chlorosis.
Excessive		Chromatism.

The specimens are arranged on the shelves on an arbitrary plan to facilitate study and reference. The primary division is into several Series according to the particular organ or member affected. Each Series is divided where requisite into Classes or other subdivisions according to the nature of the malformation.

CONTENTS.

	No. of Preparations.
SERIES I. ABNORMAL CONDITIONS OF THE EPIDERMAL SYSTEM	Not represented.
 SERIES II. ABNORMAL CONDITIONS OF THE ROOT-SYSTEM	750—751
CLASS I. POLYCLADY	750
Subclass I. FASCIATION.....	751
 SERIES III. ABNORMAL CONDITIONS OF THE STEM (AXIS) AND ITS BRANCHES ..	752—756
CLASS I. POLYCLADY	752—756
Subclass I. FASCIATION	754—756
CLASS II. ADHESION	— —
 SERIES IV. ABNORMAL CONDITIONS OF THE FOLIAGE-LEAVES	757—775
CLASS I. ARREST OF GROWTH AND DE- VELOPMENT	757
CLASS II. SPIRAL TORSION	758
CLASS III. SUBDIVISION (DICHOTOMY)	759—765
<i>a. Choris in the Horizontal Plane</i>	759—762
<i>β. Enation in the Vertical Plane</i>	763—765
CLASS IV. PITCHER-FORMATIONS (ASCIDIA)	766—774
CLASS V. ADHESION	775

	No. of Preparations.
SERIES V. ABNORMAL CONDITIONS OF THE INFLORESCENCE	776—789
<i>a. Affecting the Axis of the Inflorescence</i>	776—785
CLASS I. POLYCLADY OR DICHOTOMY	776—781
Subclass I. FASCIATION	782—785
<i>β. Affecting the Bracts or Leaves of the Inflorescence</i>	786—789
 SERIES VI. ABNORMAL CONDITIONS OF THE BUDS	 790—794
 SERIES VII. ABNORMAL CONDITIONS OF THE ASEXUAL OR NON-ESSENTIAL FLORAL LEAVES	 795—815
<i>a. Affecting the Calyx—Sepals</i>	795—799
Phyllody	795—798
Petalody	799
<i>β. Affecting the Corolla—Petals</i>	800—802
Enation	800
Dialysis	801
Pleiotaxy	802
<i>γ. Affecting the Andræcium—Stamens</i>	803—810
Petalody	803—806
Polyphyly	807—808
Pistillody	809—810
<i>δ. Affecting the Gynæcium—Carpels</i>	811—815
Phyllody	811
Dialysis	812
Polyphyly	813—815
 SERIES VIII. ABNORMAL CONDITIONS OF THE SEXUAL OR ESSENTIAL FLORAL LEAVES	 816—819
Monœcious Condition of an ordinarily Diœ- cious Plant	816
Pistillody of Stamen	817
Petalody of the Ovules	818
Staminody of the Ovules	819

	No. of Preparations.
SERIES IX. ABNORMAL CONDITIONS OF THE FLOWER AS A WHOLE, OR OF MANY PARTS OF THE SAME FLOWER CON- CURRENTLY	820—832
Reduction of number of Parts : Meiophylly ..	820
Phyllody and Regular Peloria	821
Prolification of the Flower	822—825
Synanthly	826—831
Peloria	832
 SERIES X. ABNORMAL CONDITIONS AFFECT- ING THE FRUIT AS A WHOLE	 833—863
Prolification of the Fruit	833—842
Syncarpy	843—863
 SERIES XI. ABNORMAL CONDITIONS OF THE EMBRYO-PLANT	 864—868
Polyembryony	864
Synopthy	865—868

CATALOGUE

OF

MALFORMATIONS IN ANIMALS.

SERIES I.

ABNORMAL CONDITIONS AFFECTING THE HEAD AND TRUNK.

Class I. SITUS MUTATUS.

(*Reversal of the Viscera.*)

THIS condition is probably the result of a variation of the developmental process. In Mammals it is perhaps produced by an abnormal turning of the embryo, so that the left instead of the right side comes to lie upon the yolk.

A similar reversal is normal in some species of laterally unsymmetrical Mollusca, such as *Achatina* and *Fusus*.

1. The trunk of a Human foetus with complete transposition of all the viscera. The small intestines have been removed.
Mus. Heaviside.
2. A similar specimen with all the organs *in situ*.
3. An injected and dried preparation of the heart and large vessels, with some of the abdominal viscera of a Human adult, in which all the parts are transposed. The preparation includes the stomach, liver, spleen, and cæcum.

Class II. SECONDARY DICHOTOMY.

The preparations in this series probably arise from Dichotomy resulting from injury ; two growing points are formed in the place of one. Such malformations lead by an easy transition to those in which a true division of the embryo occurs during the process of development (Class III.).

They usually, perhaps always, occur in parts which are capable of being reproduced when lost by injury.

4. An Earthworm with the posterior third of the body symmetrically double. *Presented by W. Clift, Esq., 1810.*
5. An Earthworm with the posterior third of the body unsymmetrically double. *Presented by Prof. J. Bell, 1888.*
6. A Lizard in which a portion of the extremity of the tail is double.

This is probably an acquired condition, associated with the well-known powers of repair possessed by these animals.

Hunterian.

7. A green Lizard with a similar but more perfect double tail.
Presented by F. Hutchinson, Esq., 1881.

Class III. DOUBLE MALFORMATIONS.

Syn. Twin Malformations.

Double Monsters.

Dichotomy of the Axis.

Doppel-Missgeburten.

Monstra duplicia, *Gurlt.*

Diploteria, Verdoppelung, *Ahlfeld.*

Double Malformations are the result of a misdevelopment of Homologous Twins (*Ahlfeld*), Twins produced from a single ovum.

According to *Ahlfeld*, in 506 births of human twins 444 originated from two, and 62 from a single ovum. That is in 444 each fœtus was enclosed in a distinct amnion, and the placentæ were discrete. In 62 the fœtuses were enclosed in a common amnion and the placentæ were more or less completely fused into a single organ.

The evidence on which it may be concluded that the malformations of this class arise from an abnormal development of Homologous Twins is :—

1. Such malformations are commonest in animals which most frequently produce twin-births, sheep, cattle, and man, they are comparatively rare in the multiparous Carnivora and Rodentia.

2. A double or partially double primitive trace or dorsal groove has frequently been observed in the early stages of development in the eggs of Birds and Fishes, the segmentation-spheres of *Amphioxus* have been observed so arranged as to indicate a partially double morula, and two embryos are normally developed from a single ovum in *Lumbricus trapezoides*, Kleinenberg.

3. The three layers of the blastoderm are continuous when the twins are united, and the differentiation of homologous parts is such that they are continuous in the component twins in a large number of cases.

4. When the fusion occurs at a later period, so that homologous parts are not necessarily united, adhesion taking place only between skin and bone, there is always an indication of similarity of position between the component twins; for example, they may be united vertex to vertex, or sacrum to sacrum, or the posterior extremity of one may protrude from the umbilicus of the other. A reversal of this condition has rarely or never been observed; this indicates that the adhesion is not an accidental one of two embryos developed from separate ova.

5. When one embryo is amorphous or but little developed the heart is always absent, and the circulation is maintained by the heart of the more developed foetus. There is always a common amnion, so that even when the less developed embryo becomes a parasitic tumour or cyst enclosed within the other, there is no reason to doubt their origin from a single ovum.

The evidence which exists enables us to do little more than speculate as to the primitive cause of the doubling of the dorsal groove. Perhaps the close resemblance of Homologous Twins indicates that the primary cause of doubling is an abnormal condition of the first segmentation spindle, and that it occurs subsequently to impregnation.

Lereboullet concluded that the veritable germ is always single, like the vitellus, but susceptible of budding, reduplication, like the bodies of the Hydrozoa. The deviations which arise always exhibit a manifest tendency to revert to the primitive type*.

Klaussner, in an illustrated monograph on multiple formations (Mehrfachbildungen), 1890, discusses their etiology, and gives a complete Bibliography of recent work on the subject; the excellent reports of B. C. A. Windle in the Camb. Journ. of Anat. & Phys. 1890-93, should also be consulted.

Subclass I. HOMOLOGOUS TWINS.

Homologous twins are twin-births produced from a single ovum with united membranes and placentæ †.

Such Twins are always of the same sex and are precisely similar, frequently inheriting the same tendencies; many cases are recorded where they have grown up so much alike as to be distinguished from each other with difficulty, and their deaths have occurred at nearly the same time.

Subclass II. ACARDIACUS.

This malformation is always developed from the same ovum, with a well-formed fœtus. In one yelk twins (Homologous Twins) the allantois of each reaches the chorion, and a common placenta is formed with two cords; or more rarely the cords are partially or completely united. When the allantois of one twin grows faster than that of the other, the former may occupy the greater part or the whole of the decidua serotina. The less developed allantois is then inserted upon the larger one and their vessels inosculate. The cord of the less developed twin is ill formed, and the circulation through it is reversed by the heart of the more developed embryo; this leads to atrophy of the heart of the less developed twin, with great œdema, venous congestion, and imperfect development and atrophy of all the organs of the acardiac fœtus. The heart of the more developed twin is always hypertrophied (*Ahlfeld*).

* Comptes Rendus, 1855, pp. 885, 1029.

† Examples of such placentæ are desiderata in the Collection.

In rare instances the cord of the acardiac twin atrophies, and it only receives blood from the other fœtus through vessels inosculating in the membranes. Under these circumstances the head only is developed, or the upper or lower portion of the acardiac twin and the acardiac becomes parasitic by adhesion or inclusion. (*See Craniopagus parasiticus, Sacral teratome epignathus, and Inclusio fœtalis.*)

1. *Microcephalus.*

Syn. Mylacephalus.
Paracephalus.
Perocephalus.
Anceps.

In this form there is a more or less complete cerebro-spinal axis with a membranous but exceedingly ill-formed cranium, which is often reduced to a mere cyst; one or more of the cranial bones is sometimes recognizable; usually an ill-developed occipital bone is present.

8. The right half of a Human acardiac microcephalous fœtus with great hypertrophy of the connective tissue, so that the whole body has an elongated ovate form. There are no traces of limbs on this side, but a small tubercle represents the lower extremity on the other half (see No. 9). The anterior portion is separated from the rest by a slight constriction; it is covered with short soft brown hair. There was also a depression dividing that portion which represents the nates, and corresponding to the normal cleft between them. The spinal column has the usual flexures; but the spines of the vertebræ are represented by a long continuous rod of cartilage, probably the remains of the unsegmented investing mass. Some of the laminæ have been removed to show the spinal canal. There are numerous large cysts in the integument behind the spinal column.

This fœtus was one of twins; the other was well formed.

The skull presents a very large occipital bone of considerable thickness; all the other parts of the cranium and face are so defective that they cannot be recognized. The tympanic cavities are marked by a blue glass rod; a black bristle below this marks the

opening of the pharynx externally. Masses of cancellous bone above and below the opening probably represent the jaws. The thoracic cavity is filled with reticulated areolar tissue. The abdominal cavity is comparatively large. A small stomach is seen at its upper part: this communicates with the pharynx by a narrow pervious œsophagus. There is no pyloric orifice to the stomach, and no duodenum. A quarter of an inch of small intestine, blind at either extremity, lies below the stomach, but is in no way connected with it. The large intestine is blind above, makes a sigmoid curve, and terminates in a straight rectum, which opens externally by an anus. There is a considerable cavity in front of the intestine partially occupied by the kidneys (which are fused together into a single gland), the Wolffian body and its duct, and the urinary bladder. See the account of the other half of the same fœtus, No. 9.

There is a long straight aorta in front of the spine, which terminates below in two umbilical arteries, and above by two carotids and subclavians. The right umbilical artery is marked by a blue glass rod; the right carotid is indicated by a bristle. Behind the aorta several sympathetic ganglia are apparent; and the pneumogastric nerve is seen in the neck lying upon the bodies of the vertebræ.

Presented by John King, Esq., 1868.

9. The other half of the same fœtus, showing the left Wolffian body and its relation to the kidneys, which are seen in section. This is one of the most remarkable instances of the permanence and extraordinary growth of a temporary structure yet observed. A slice has been made through the hypertrophied integuments in the region of the inferior extremity, and the imperfect bones of the extremity are exposed. Three small openings, probably those of the mouth, orbit, and meatus auditorius, are indicated by bristles.

Presented by John King, Esq., 1868.

10. The right half of the head and neck of a microcephalus fœtal Calf. The skull-cavity is excessively irregular and very small, consisting rather of several bony cysts than of the normal series of bones. The vertebræ of the neck constitute an enormous cancellous bony mass, traversed by a very much bent spinal canal and cord. The mouth forms a cavity that does not communicate with the œso-

phagus. There is an ill-shaped external ear. The external form is very irregular, from the great hypertrophy of the subcutaneous fat and connective tissue.

Hunterian.

11. The other half of the same.

Hunterian.

2. *Acephalus.*

Syn. Mylacephalus.

This is the usual form of Acardiacs. Both the head and thorax are absent, and the vertebral axis is only represented by a few ill-formed lumbo-sacral vertebræ; the pelvis is more or less developed, and supports one or both the posterior limbs, which are sometimes united as in Syreniformia.

12. A Human male acardiac acephalous fœtus. Both the heart and head are wanting. The whole trunk is very œdematous, and has been much distorted by the manner in which it was originally mounted. Three extremities are better formed than the remainder of the body; the left anterior extremity is, however, a mere shapeless mass. The spine has been exposed behind, and its laminæ removed on one side to show the cord. It has a single curve, with its convexity backwards, and consists almost entirely of cartilage, but is otherwise normal.

13. The right half of an acardiac acephalous fœtus, which has been divided longitudinally in the median line. The vertebral column is truncated at either extremity, and consists of twenty-two segments, with a large spheroidal bony nucleus in each segment, except the first three.

The neural canal is closed in by laminæ; it contains a cord, and its upper extremity is filled up and closed by a fibrous mass containing a small cyst. A proboscis ending in an ovate knob terminates the axis in front externally. The thoracic and abdominal cavities are not separated from each other. The upper and back part of the body-cavity is filled with a dense mass of connective tissue closely united to the spine, probably representing the lungs, with an empty cavity, probably pericardial, in front bounded anteriorly by a small sternum. The lower part contains one great median kidney, a pair of ureters, and a urinary bladder. The

external sexual organs are too imperfect to denote the sex. There are apparently no internal generative organs. There is no liver. The intestine commences blindly in a sac in the umbilical cord and terminates in a rectum, which is impervious. The integument is much hypertrophied. The arm is very imperfect, and is terminated by a single nail. The posterior extremity is furnished with three toes, and is much more normal in form than the arm. The pelvis is apparently fairly developed.

14. The other half of the same. It exhibits similar characters, except that there is no arm on this side.

15. An acardiac acephalous (*Myelacephalus*, Doran) Human fœtus. Weight in the recent state 13 oz., long diameter $5\frac{1}{2}$ inches.

In the recent condition this acardiac had a dull pink colour, its skin was like that of a newly born infant, and was covered with short fine lanugo.

It exhibits a small kidney and ureter, which terminates on the external surface, and some coils of small intestine, a short large intestine, and a kind of cloaca the orifice of which is indicated by a bristle. The opening is near the umbilicus, and it is evidently not a true cloaca.

The lower limbs are fused as in Syreniformia, so far as their external parts are concerned, but the bones of the right lower limb although represented are very imperfect. Those of the left lower limb and the left half of the pelvis and sacrum are fairly developed. The vertebral axis is only represented by the sacrum and coccyx, and by two ill-formed lumbar vertebræ. No other parts have been recognized.

This preparation was described and figured in the Transactions of the Obstetric Society (Lond.), vol. xxxi. p. 4, by A. Doran, Esq.

Presented by H. E. Testrail, Esq., 1889.

16. An acardiac acephalous Lamb. The left posterior extremity was precisely similar to the right, but has been removed to display the position and character of the internal organs. It is described by the donor as "a twin with a perfect lamb born alive."

The vertebral column is subnormal below the cervical region, where it terminates in a single large rounded cervical vertebra; all

traces of the head are wanting. The dorsal vertebræ are somewhat deformed, each bearing a pair of ribs. The sternum is only represented by a small ossicle, probably a manubrium. The sternal extremities of the costal cartilages are separated by a wide fissure terminating below in an omphalocele. The lumbar vertebræ are somewhat deformed. The innominate bones are subnormal. The sacrum is reduced to a single mass of bone, not divided into vertebræ. The caudal vertebræ are reduced to mere rudiments. The shoulder-girdle is represented by a small nodule of bone attached to the cervical vertebræ by two fasciculi of muscle.

The thoracic cavity is divided into pleural and pericardial cavities by rather thick membranes, but both the pericardium and pleuræ were empty. The diaphragm completely separates the thoracic and abdominal cavities. The latter contained an imperfect intestinal canal, which passes in part into the omphalocele.

The omphalocele contained an imperfect liver and a small coil of small intestine. The large intestine begins in the omphalocele and makes a few curves in the abdomen; it terminates in the remains of the allantoic sac.

The testes and kidneys are subnormal. The ureters are widely dilated, opening with the seminal ducts, vesiculæ seminales, and intestine into an elongated muscular bladder, the allantoic sac, which extends to the umbilicus.

The scrotum is very large, and consists of connective tissue and dartos covered with skin. The gubernaculum of the left testis was traced into this tissue.

A large vein in front of the thoracic cavity was traced to the intestinal coil. The vessels were not, however, further dissected; a red glass rod has been placed in the umbilical artery.

Presented by J. W. Teans, Esq., 1879.

17. The skeleton of an acardiac acephalous foetal Lamb from Trinidad. The foetus consisted of an almost spherical mass about 10 inches in diameter, with a pair of fairly developed posterior extremities growing from it. It was covered with thick black wool. It possessed a considerable body-cavity, which contained a coil of intestine, No. 18.

The bones form two separate masses. The upper one consists of the ribs and vertebræ; it was situated in the wall of the spherical mass. The lower one consists of the innominate bones and the inferior extremities.

The vertebræ are ankylosed by their laminæ, and the spines form a single broad blade. The spinal canal is occluded, and there is considerable contortion of the whole column. The ribs are ankylosed together, and are exceedingly broad.

The innominate bones are united in front, but are widely separated behind; there is no trace of a sacrum. The femora are articulated with the pelvis by imperfect joints. The limbs are fairly developed, but the two outer digits have been arrested in their growth.

Presented by Dr. Huggins, 1866.

18. The intestine of the same. It is blind at either extremity, and forms a large much-convoluted mass.

Presented by Dr. Huggins.

c. *Acormus*.

Acardiacs in which the head only or the head and a very defective trunk are present. This condition is very rare and is unrepresented in the Museum.

d. *Amorphus*, Gurlt.

Syn. Anideus, St.-Hilaire.

Acardiacs reduced to a shapeless mass of connective tissue covered by skin and hair, rarely with rudimentary traces of stomach and spleen. Only known from cows, goats, and sheep; perhaps, as Doran suggests, acardiacs with a rudimentary ill-formed pelvis should be included (Alban Doran, *Obst. Soc. Trans. Lond.* vol. xxxi.). Unrepresented in the Museum.

Subclass III. ANTERIOR DICHOTOMY AND PLEUROPAGUS.

Syn. Cephalodidymi, Gurlt.

Monstres doubles monosomiens, Geoff.

Anadidymi, Klaus.

This group includes all those malformations in which the axis is bifurcate at its anterior extremity (*Anterior Dichotomy*), as well as those in which the axes are completely double, but in which they are placed side by side, and either united behind by the

coalescence or incomplete differentiation of the adjacent lateral parts of the vertebræ, or by a very incomplete extension of the somatopleure (*Pleuropagus*). Without dissection these conditions cannot be separated, hence they have been included in a single group.

* IN FISHES.

19. Two specimens, each consisting of two newly hatched Trout united by the posterior portions of the ventral aspect. The single yolk-sac is attached to the lower specimen, showing their origin from a single yolk.

Presented by the Duke of Wellington, 1870.

20. A similar pair of Trout, hatched at Strathfieldsaye.

Presented by the Marquis of Tweeddale, 1877.

21. Malformed Salmon-fry, showing varying degrees of anterior and posterior dichotomy, from Sutherland.

Presented by Dr. D. Tulloch, 1882.

22. Two small Sharks united by the abdominal walls. The remains of a single yolk-sac (pseudo-placenta) is seen between the pectoral fins.

A female Shark was taken by the donor (mate of a vessel) in the Indian Ocean (34° S. lat., 90° E. long). When brought on deck and cut up, about thirty living young escaped from its abdomen. The specimen presented lived for two days in a bucket of sea-water.

Presented by E. Bestard, Esq., 1866.

23. A foetal Dogfish, exhibiting anterior dichotomy.

Hunterian.

** IN REPTILES.

24. A small English Ringed Snake with two heads. The axis is distinctly double to about half an inch behind the occipital bone only, although there are traces of duplicity in the ventral region more than an inch further back.

Hunterian.

25. A small Snake with two distinct heads and double vertebræ in the anterior portion of the body. One head is slightly lateral and smaller; its neck is shorter than that of the other. *Hunterian.*
26. A small Indian Water-Snake (*Hydrophis*) with two heads.
Presented by J. Shortt, M.D., 1866.
27. A small English Snake with two heads.
Presented by W. White Cooper, Esq., 1872.

*** IN BIRDS.

28. A newly hatched Duck with partial doubling of the face.
(See *Monocranus dignathus*, p. 13.)
Presented by A. T. Ward, Esq., 1882.
29. A foetal Duck with two heads and necks; the dorsal vertebræ, the trunk, and its appendages are single.
Hunterian.
30. A newly hatched Duck, exhibiting anterior dichotomy; there are two bills and a partially double head and neck.
Purchased, 1878.
31. A similar Duck with more pronounced dichotomy. The two heads are distinct.
Presented by Peter Lord Pavitt, Esq., 1881.
32. A similar foetal Turkey, with the skull and vertebral canal open from arrested closure of the neural arches.
Presented by Lady Northampton.
33. A similar foetal Fowl, in which the neural arches of the head are undeveloped. The brain-membranes are exposed, owing to the imperfect development of the skull.
Presented by Sir W. Blizard.
34. A similar foetal Chick with fusion of the heads, so that the approximate eyes have coalesced into a single organ. The neural arches of the head are undeveloped and the brains are exposed. The spinal cord is deficient, the vertebral canal containing its membranes only. *Hunterian.*

35. Twin foetal Pigeons united by the dorsal regions of the spinal column, the median visceral laminae being absent. The right lamina of one bird and the left of the other form the abdominal and thoracic walls. The heads and necks are distinct. The neural arches in the upper part of both vertebral columns are defective.

Purchased, 1858.

36. Twin foetal Guinea-fowls similarly united with fusion of the vertebral columns in their upper part. There is also fusion of the head and necks. The median eyes are fused into a single but abnormally large organ. The mandibles likewise form a single organ. The neural arch of the skull is open, and the brain and spinal cord are deficient. *Presented by E. Belfour, Esq., 1818.*

37. A similar union of twin foetal Ducks. The brain is completely double and exposed.

**** IN MAMMALS.

1. *Monocranus dignathus*, Gurlt.
Monocranus trignathus, Gurlt.

In this malformation only a portion of the face is doubled, or a small ill-developed jaw or part of a jaw appears under one or both ears. Perhaps such instances of malformation do not properly belong to the group in which they are placed, as there is no evidence that they arise from dichotomy of the axis, but it would be impossible to separate them in practice, as transitions exist between the lesser forms of this malformation and true anterior dichotomy.

38. The head of a monocranous dignathous foetal Pig. The anterior part of the face, the mandible, tongue, and the anterior portion of the maxillary bones are double. There is a considerable fissure in the palate, from which a fibrous band extends to the united mesial rami of the mandible. A portion of skin covered with hair, representing the median cheeks, is lodged in the fissure in the palate.

Hunterian.

39. The head of a similar foetal Pig, dissected to show the accessory masseter muscles. The tongue is double; the other parts are single. This specimen before dissection exhibited only what appeared to be a second mouth in the cheek.
40. Part of the skull of a trignathous Foal, with anterior dichotomy extending to the presphenoid region. In the recent state the interval between the two naso-maxillary processes presented the appearance of a median hare-lip with a cleft palate. There were two sets of olfactory nerves. *Presented by J. Bland Sutton, Esq., 1889.*
41. The malformed and very imperfect third mandible and maxillæ removed from the pharyngeal region of the same Foal. The upper mass is believed to represent the additional maxillæ and the lower the mandible. *Presented by J. Bland Sutton, Esq., 1889.*
42. The tongue of the same Foal with a small additional tongue on the right side corresponding with the pharyngeal opening with which the bones preserved in No. 41 were connected. *Presented by J. Bland Sutton, Esq., 1889.*

2. *Diprosopus.*

Syn. Monocranus, Gurlt.

In this malformation the face is more or less completely double, but the cranial cavity is single. The dichotomy of the axis seldom or never extends further back than the presphenoid region.

43. A Kitten with dichotomy of the anterior part of the face; one mouth is very imperfect. There is a single pair of eyes. *Hunterian.*
44. A Kitten with dichotomy of the head extending further back than in the last, so that there are four eyes. The eyelids of the median eyes have no inner commissures, but are united and bound a single fissure. *Hunterian.*

45. A fœtal Kitten with more considerable anterior dichotomy. The laminæ of the vertebræ and spinal cord are deficient in the lumbar region. *Hunterian.*
46. An anencephalous diprosopous fœtal Pig. There is a single median eye. *Purchased.*
47. The head of a diprosopous Calf with anterior dichotomy extending as far back as the presphenoid bone. The muzzles are united by a thick fold of integument almost to their extremities. There is a single median eye situated behind a triangular opening formed by the fusion of two pairs of eyelids. *Hunterian.*
48. A diprosopus Human male fœtus, born at full term.

This fœtus is apparently a case of Diprosopus in the human subject, an exceedingly rare condition. There are several concurrent malformations. The lips and palate are deeply cleft; the digits of the right hand are not separate, and the right foot is turned inward and the left outward. The placenta is adherent to the frontal fontanelle.

Presented by E. W. Alden, Esq., 1883.

3. *Dicephalus conjunctus.*

Syn. Dicephalus, Gurlt.

In *Dicephalus conjunctus* the dichotomy extends backwards into the basioccipital, and all the parts of the skull are completely double except the occipital bone. The latter is very large, and traces of doubling are observable in the cervical vertebræ.

The tongue is double, and in extreme cases there is complete doubling of the cervical vertebræ and of the parts of the neck, as well as incomplete doubling of the thoracic viscera.

49. The skull of a Calf exhibiting anterior dichotomy of the cranio-facial axis. There are two distinct median orbits. The median malar bones are fused into a single bone; they support a small mass of bone, which articulates by a very imperfect joint with the median rami of the mandibles. The median rami of the mandibles are united by suture, and are much thickened and distorted. The

base of the skull exhibits a single enlarged basioccipital and a bifurcated basisphenoid with its two median alisphenoids united. The exoccipitals, supraoccipital, and temporals are single, except that there are traces of median squamosals. The other bones of the head and face are completely double.

50. A similar skull, in which, however, dichotomy extends as far back as the basioccipital. In this skull there are two supraoccipital and a median external auditory meatus; the periotic bones of the median ear are double; both faces are distinct and well formed. *Hunterian.*

51. A similar skull of a Lamb in which the dichotomy has extended somewhat further back.

From the collection of the late J. Merryweather, Esq., 1888.

52. The brain of a Calf with anterior dichotomy. All the parts in front of the pons are double. The pons, medulla, and cerebellum are single. *Hunterian.*

53. A portion of the brain of a Calf double as far back as the foramen magnum. It is stated in Hunter's MS., "Dissections," that all the cerebral nerves were double, that the eighth pair were double at their origin, but that the median eighth pair became fused and terminated in their passage through the skull in connective tissue.

Hunterian.

54. A portion of the skull and the brain of a Sheep with dichotomy extending as far back as the basioccipital bone.

55. The anterior part of a dicephalous Lamb, dissected. The heart presents three auricles and four ventricles. The aortic arches are two in number; the left is normal; the right is inverse in curvature. The left pulmonary artery is normal, the right incomplete and united with the aorta. The branches of the left arch are a common carotid and left subclavian; the carotid bifurcates and forms the right and left carotids of the left head; the vessels from the right arch are similar. The vena cava superior is single and on the right side. There are two

pairs of lungs. The median lungs are displaced; they are seen in the neck and resemble a thymus. The aortic arches are united behind the heart. The pneumogastric nerves are four in number, the median nerves uniting into a single trunk. The median fore limbs are represented by fused rudimentary scapulæ, which are united with the open laminæ of the spinal canal at its angle of bifurcation.

The additional malformations present are the open laminæ of the vertebral canal in the dorsal region; and a median hare-lip in the right head.

Presented by G. Quatremaine, Esq., 1875.

56. The tongues, hyoid bones, larynx, trachea, and œsophagus of a dicephalous Calf, probably from the same animal as No. 52, dissected. The double hyoid arch has its median cornua distinct, close together, and cartilaginous. The median pair of tonsils are seen fused together between the two tongues. It is stated in Hunter's MS., "Dissections," that there was a third median carotid in front of the trachea, which divided in the head into two vessels having the usual branches and distribution.

Hunterian.

4. *Dicephalus disjunctus*.

Syn. Dicephalus, Gurlt.

In *Dicephalus disjunctus* the axis is double in front as far back as the dorsal or even the lumbar vertebræ.

Anatomical characters.—The heart has sometimes only a single extra ventricle; in other cases there are two distinct hearts, with two aortic arches and a single dorsal aorta. The vessels given off by each arch are very variable. The cerebrum is always double, and the cerebellum is usually double. In some instances the lungs are reduced to a single pair, in others a second pair are present, frequently much reduced in size. The alimentary canal is double in front, and single behind. The union takes place in extreme cases in the jejunum.

Additional malformations, such as spina bifida, hare-lip, &c., are frequent in such malformations.

57. The cervical and some of the dorsal vertebræ of a dicephalous Calf, in which dichotomy extends as far back as the anterior dorsal vertebræ. The atlas and axis of the right neck are unfortunately lost. The dorsal spines below the dichotomous region are bifurcated. There are two ossific centres in the bodies of the dorsal vertebræ, a condition seen in almost all malformations of the spine. A number of small ossific centres occur between the bodies of the vertebræ at the point of bifurcation. There is a piece of cartilage in the angle of bifurcation.

Presented by J. B. Stauffer, Esq., 1867.

58. The brains and a portion of the spinal cord of a dicephalous Lamb. Dichotomy extends backwards an inch and a half beyond the foramen magnum.

59. The œsophagus of a dicephalous (?) Lamb bifurcated to within about 4 inches of the stomach.

Presented by R. Partridge, Esq.

60. The spinal columns of a dicephalous male Calf. The cervical vertebræ of both necks are normal, the upper three dorsal vertebræ of the right and the upper four of the left column are deformed. The remaining dorsal and upper lumbar vertebræ are united by the adjacent ribs and transverse processes. The lower lumbar vertebræ are fused by their centra; and the sacral and caudal vertebræ are single. There is an additional vertebra on the left side, and the centra of the vertebræ in the lower dorsal and upper lumbar region are irregular. A median double scapula is represented by a subtriangular plate of bone and cartilage.

Presented by Colonel Burgess, 1891.

61. The heart and respiratory organs of the same animal. The heart is single, but there are four lungs. The adjacent lungs are very small, but are quite distinct. The aortic arch passes backwards to the left over the median lungs. There are four carotids and two subclavians. The carotids to the right head come off by a common trunk from the root of the aorta; those to the left head arise from

the aortic arch. The left subclavian passes behind the left trachea. The remaining vessels are all very irregular.

Presented by Colonel Burgess, 1891.

62. The œsophagi and part of the diaphragm and stomach of the same. The œsophagi are distinct and pass through separate openings in the diaphragm. The rumen is double, the reticulum partly double, but the psalterium is single and normal.

Presented by Colonel Burgess, 1891.

5. *Pleuropagus*, Förster.

Syn. Dicephalus, *Gurtt.*

Monstres doubles sysomiens, *Geoff.*

Dicephalus bispinalis, *Gurtt.*

In *Pleuropagus* two axes are adherent side by side. Such abnormal twins have hitherto been called dicephalus, from their external resemblance to dichotomous conditions of the anterior extremity of the axis. In these forms, however, the whole axis is double. They are transitional between anterior dichotomy and emprosthozygosis. The median limbs are frequently fused together, and are sometimes reduced to mere tubercles.

63. A Human pleuropagous twin-birth, about the end of the third month (length $4\frac{3}{4}$ inches), with the mesial (posterior) arms and legs fused together as far as the carpus and tarsus. It is apparently female, but the organs of generation are very imperfectly formed. This specimen is transitional between thoracopagus and the more marked forms of pleuropagus.

Purchased, 1870.

64. Human male pleuropagous twins. The median (posterior) arms form a mere tubercle upon the back. There are no median legs, although there are two axes even to the extremity of the sacrum. The median innominate bones are absent.

65. The bones and ligaments of the united mesial arms of an exactly similar foetus.

A small portion of the broad sternum, formed by the

union of two sterna, supports a pair of clavicles closely pressed together; distinct and flattened in front, but united behind. These articulate with the two acromia of a very remarkable double scapula, and are also united with the glenoid cavity by ligament, a piece of cartilage intervening. The scapula is symmetrical, and presents two spines and two acromia; one of the latter has been cut through and turned back to show the manner in which the glenoid cavity is articulated with the clavicles. The cartilage already mentioned, situated between the clavicles and glenoid cavity, is the only rudiment representing the anterior median limbs.

66. The viscera of the same; these are double, but those of the right fœtus are considerably smaller than those of the left; the latter are reversed. The hearts were situated in distinct pericardia. The heart of the left is three times the size of that of the right fœtus. The latter gives off a small aorta, which joins the descending aorta of the left fœtus just below its arch. The livers are intimately united; the œsophagi, stomachs, and duodena are distinct as far as the orifice of the bile-duct, where the intestines unite in a sacculate dilatation; below this point the intestine is single but reversed, the cæcum being on the left side.

Subclass IV. EMPROSTHOZYGOSIS*.

Syn. Thoracodidymus, Gurlt.

In Emprosthozygosis the twins are united above the umbilicus face to face, and equally or subequally developed.

Anatomical characters.—Body-wall of thoraces continuous, sterna united by their posterior ends, rib continuous with rib. Hearts distinct, each in a separate pericardium; pericardia united, or hearts replaced by a single tricœlian heart. Intestines distinct or united in the region of the vitelline duct, or by its remains; sometimes also by a common duodenal sac. Livers separate or united in front. Umbilical cord single, with

* Ἐμπρόσθιος, in front; ζυγώω, to unite.

two veins, and four, or rarely five arteries. Viscera usually but not always with situs mutatus in one of the twins.

Extremely rare, probably unknown, except in Man. Gurlt's cases, one in Calf, two in Lambs, and a Hen are not true Emprosthozygosis, as the vertebræ are united in the neck; they are extreme examples of antero-posterior Dichotomy.

1. *Xiphopagus*, Geoff.

The least degree of Emprosthozygosis. The union is by the xiphoid cartilages of the sterna and by the abdominal walls above the umbilicus.

67. A wax model of the band of union of the "Siamese Twins" made in 1830, when they were 19 years of age. In childhood the band was proportionately much larger and shorter, so that the twins were much closer together. The xiphoid cartilages of the sterna pass across the upper edge of the band. The condition of these twins at the age of 19 and their history is given in the Phil. Trans. 1830, p. 117. *Presented by G. B. Bolton, Esq., 1830.*

2. *Thoracopagus*, Förster.

Syn. Sternopagus, Geoff.

In this form the thoracic cavities are united by the visceral laminæ.

68. Female Human thoracopagous twins, 3 inches long (about the third month of gestation).
Presented by Sir E. Home, Bart., 1804.

69. A similar twin-birth, 3 inches long (about the third month of gestation).

The relation of the foetuses was disturbed when this specimen was first put into spirit, so that it does not apparently conform with the above description of thoracopagus. Naturally the foetuses would face each other in this and in the preparations Nos. 70 and 71.

Presented by W. Parry, M.D., 1870.

70. A Human female thoracopagous twin-birth, 8 inches long (probably about the end of the fourth month of gestation). *Presented by Sir W. Blizard, Bart., 1811.*
71. A Human female thoracopagous twin-birth, about $10\frac{1}{2}$ inches long (probably at the end of the fifth month). *Presented by Sir Joseph Banks, Bart., 1819.*
72. A Human female thoracopagous twin-birth, about 12 inches long (about the end of the sixth month of gestation). *Hunterian.*
73. Human female thoracopagous twins about full time of gestation. The deficiency of the anterior abdominal wall above the umbilicus is very considerable, the viscera being covered by membrane only. *Hunterian.*
74. A similar twin-birth, with the visceral cavities laid open to show the disposition of the viscera. The diaphragmata and pericardia are united. The hearts are quite distinct. The livers are completely fused: there are, however, two transverse fissures and two ductæ venosæ. The intestines of the two communicate by a short capacious gut near the lower part of the ileum. The single cord has been laid open, and is seen to contain two distinct umbilical veins (injected) and five umbilical arteries, one fœtus having a small additional one. The fœtus on the left-hand side of the preparation has the disposition of the viscera reversed.

In five labours this woman had malformed births three times,—these twins, a child with the feet growing from the nates, and a child with undeveloped forearms, so that the hands appeared as if growing from the extremity of the humerus; all were still-born. The above particulars are extracted from a letter from Mr. G. W. Friend to the Curator of the Hunterian Museum.

Presented by G. W. Friend, Esq., 1815.

75. Human thoracopagous twins of small size, with the viscera removed to show the union of the thoracic and abdominal parietes from within. The disposition of the ribs is well seen in this preparation.

76. The heart and lungs of the same.

The heart is formed of the united hearts of both foetuses ; it is much elongated in the direction of a line joining the two spinal columns. There are two distinct ventricles, and a single auricle extending the whole length of the upper part of the ventricles. There is a rudimentary auricular septum. There are two auriculo-ventricular openings, each guarded by a bicuspid valve.

The cavities of the heart have been laid open. The ventricle on the right-hand side of the preparation has two arterial openings at its base, an aorta and a pulmonary artery, the latter indicated by a blue glass rod. The ventricle on the left-hand side has a single artery or aorta, which gives off three pulmonary arteries near its origin. This vessel is laid open to show the orifices of the pulmonary vessels. There are four lungs, two on each side of the preparation. Neither set exhibits situs mutatus.

77. The livers, stomachs, and duodena of the same. The livers are united along their whole anterior edges. The stomachs and spleens are seen one on either side of the liver. The gall-bladder and the ducts of each liver are distinct. The duodena open into a common pouch just below the entrance of the gall-ducts. The intestine was single from the confluence of the duodena to the termination of the jejunum.

78. The lower portion of the small and the commencement of the large intestine of the same. The jejunum terminates in a large pouch, on the extreme left of the preparation, from which two ilea arise. There are two caeca, and each has a distinct vermiform appendix. The large intestine was completely double.

79. Human female thoracopagus twins about the end of the sixth month of gestation. One of the foetuses has syreniform fusion of the posterior limbs, and there is complete ectopia of all the abdominal viscera. The thoracic cavities have been opened to show the hearts, which are very abnormal ; one is above the other. The upper heart consists of an auricle and ventricle. The ventricle gives an aorta to either foetus, and is fused with the base of the ventricle

of the lower heart. The lower heart has two auricles. The apices of both ventricles are turned towards the front of the preparation.

80. A similar double foetus.

The mother, a primipara, was delivered without assistance.

Presented by G. W. Furber, Esq., 1878.

Subclass V. PARASITIC EMPROSTHOZYGOSIS.

In all forms of double malformations there is a tendency for one of the twins to become acardiac ; it is then termed a parasite, and the supporting foetus is designated the autosite. In Parasitic Emprosthzygosis the anterior extremity of the parasite is wedged in between the thoracic laminæ of the autosite, and lodged in the middle of a fissured sternum. The parasite is usually very defective ; the axis may be entirely wanting, the limbs only being developed. More frequently there is a rudimentary abdominal cavity in the parasite, communicating with that of the autosite above the umbilicus, as in ordinary thoracopagus. The abdominal cavity of the parasite is sometimes distinct from that of the autosite, and has a separate umbilicus. A perfect series of transitional forms exists between this condition and ordinary thoracopagus ; hence it has been called parasitic, or heterodelphous thoracopagus.

81. A Frog with a small additional anterior extremity, springing from the posterior and lateral part of the sternum.

Hunterian.

82. A similar Frog, in which the additional limb has been dissected.

Presented by J. B. Sutton, Esq., 1889.

83. A Pigeon with a small accessory wing growing from the lower part of the sternum. There is no other trace of a second embryo, and the skin has been reflected to show the union of the limb by muscles and ligament with the sternum.

Hunterian.

These three preparations have been placed in their present position as it appears most probable that the additional limbs are the remains of a second embryo.

84. A female foetal Pig with a headless acardiac parasite united to the thorax and abdomen. The cervical region of the parasite is attached to the sternum of the autosite. The body-cavities of the two are continuous. The parasite has a single large kidney, a urinary bladder, and a pair of hypogastric arteries. There is also a small piece of intestine connected with that of the autosite by a long narrow gut. The abdominal cavities have been laid open to show their continuity. *Hunterian.*

85. A foetal Kitten with a similar parasite. *Hunterian.*

86. A foetal Kitten with a parasite attached to the sternal region. The body-cavity of the parasite is very small and distinct from that of the autosite. There are two distinct cords for a short distance at least from the umbilicus. The parasite appears to have no spinal column ; but the posterior limbs are well developed, and the anterior limbs are small but clearly recognizable.

Presented by E. Belfour, Esq.

87. A similar specimen, in which the anterior extremities of the parasite are fused with the left anterior extremity of the autosite.

88. A similar specimen, except that the anterior extremities of the parasite are wanting.

89. A specimen similar to No. 86, with the body-cavities laid open to show that they are quite distinct. That of the parasite contains a single large kidney and a urinary bladder : it has no alimentary canal. *Hunterian.*

90. The skeleton of a similar Kitten and parasite. The sternum of the autosite is divided by a wide oval fissure, in which the four limbs of the parasite are seen. The parasite has no vestige of an axis, unless a band of ligament in the centre of the sternal fissure represents its remains. The

anterior pair of parasitic limbs are fused as far as the carpus. The Kitten was one of a litter of three, the others were normal.

91. A clay model of the Chinese lad Ake, aged 16, with an acephalous parasite attached to the lower part of the sternum. The model was made from memory by a Chinese artist. The following extracts from a letter from J. Livingstone, Esq., Surgeon to the British factory at Hong Kong in 1804, give the history of the case :—

“Ake was born with another male child of nearly the same size united to the pit of his stomach by the neck, as if his brother had plunged its head into his breast. The mother died from the effects of the labour.

“Since birth the parasite has not increased much in size. The shoulder-bones are remarkably prominent. Here the model is faulty, since it presents the roundness of infancy; but all the plumpness had disappeared from the original, and the bones seem only covered with skin. The manner in which the thighs appear is quite happy; but the feet, particularly the left, are not sufficiently clubbed. In the original the feet and toes are less perfect than in the model; the toes adhere, and one or two are wanting.

“I have the authority of Lieut.-General Wood for stating that the trunk and neck measure 11 inches, and the longest limb 13 inches.

“The attachment of the neck of the parasite admits of a semi-rotatory motion, and Ake shows that his brother's arms can be moved freely. The thighs and legs remain stiffly bent, the femora being ankylosed to the innominate bones and tibia. The genital organs are too perfect in the model, since no vestige of testes and very little scrotum can be seen in the original. The penis is, however, large in proportion, with the glans about half covered by the prepuce; it was subject to occasional erections. The kidneys seem to perform their function perfectly; the anus is wanting. Ake is now about 4 feet 10 inches high, of feeble frame and sickly appearance. Except in the incumbrance above described, he is in all respects perfectly formed. Ake's respiration is commonly laborious; to relieve it, he frequently supports the parasite with his hands; his pulse is commonly quick and small. Mr. Gomez felt the pulsation of the carotids in the neck of the parasite distinctly; he also felt feeble pulsation at the wrists.”

The condition of Ake, as far as can be judged from the model, seems precisely the same as that of the Kittens, Nos. 85 to 89.

Presented by H. L. Thomas, Esq., 1822.

Subclass VI. PROZYGOSIS AND POSTERIOR DICHOTOMY.

Syn. Katadidymus.

Prozygosis differs from Emprosthozygosis in the more complete union of the twins, which are united from the umbilicus to the vertex. It may be either symmetrical or unsymmetrical. The unsymmetrical forms unite prozygosis and pleuropagus on the one hand, and prozygosis and posterior dichotomy in its extreme form (Schizocephalus) on the other, and also form an intermediate link between pleuropagus and antero-posterior dichotomy.

* IN BIRDS.

92. A Chick with the posterior half of the cerebro-spinal axis double. There are four legs, but the wings are two in number. The abdominal parietes are deficient, and the neural laminae are undeveloped in the cervical region. There is a slight notch in the upper mandible, as if a tendency to superior dichotomy had likewise existed.

Hunterian.

93. A Duckling with posterior dichotomy of the greater part of the spinal column. There are four legs and wings. The median wings are united into a single organ. There is considerable deficiency in the coverings of the abdomen.

94. Posterior dichotomy of the spinal column in a Chick, with fusion of the soft parts of the median pairs of legs as far as the knee.

Mus. Brit.

95. A similar Chick.

Hunterian.

96. A Chick with considerable posterior dichotomy of the axis, accompanied with total deficiency of the beak, mandible, and tongue. The posterior nares are completely exposed. The hyoid bone is not deficient. Unfortunately the thoracic and abdominal parietes have been removed, so that it is impossible to discover how far they were defective.

97. Posterior dichotomy in a Duckling extending into the cervical region, and perhaps involving the base of the skull. The neural arch of the skull is open and the brain is exposed. The upper mandible and maxillary bones are entirely deficient, but there is a slight frontal protuberance.
Presented by D. Hanbury, Esq.

98. A Duckling in which there is posterior dichotomy of the axis. The left division of the axis is rudimentary in comparison with the right, and the legs of the left side are fused to the toes. There are two distinct femora and seven digits; the condition of the limb is similar to that seen in No. 135. This specimen has been partially dissected to show the connexion of the redundant limbs with the spine.
Mus. Brit.

99. The posterior part of a Duck affected with slight posterior dichotomy, laid open to show the pelves and their contents. There are four perfect legs, although two only appear to have been functional. The anus is double. That of the right side is imperforate; it forms a small nipple-like projection externally, and is connected with the cloaca by an imperforate band. The intestine has three cæca instead of two.

Presented by Mrs. Robinson, 1819.

100. The oviduct, rectum, and cloaca of a Fowl with two external openings. The cloaca is bifurcated below. A single oviduct opens into its left side. This specimen is probably from a bird affected similarly to the last but to a less degree. Mr. Tegetmeier had a similar Fowl in which both openings were functional.

Presented by Dr. Halford, 1862.

101. A similar preparation. *Presented by E. Cock, Esq., 1873.*

102. The urogenital system and posterior part of the alimentary canal of a similar Cochin-China fowl, dissected. There are two external cloacal openings and three intestinal cæca.
Presented by Mr. J. Ebbs, 1889.

- 102 A. The pelvis of a dipygous male Fowl dissected. There are two united median limbs which present syreniform characters. (See Nos. 290-302.)

The right kidney was entirely absent. The left kidney is abnormally large and has a dichotomous ureter. This preparation, so far as the median limb is concerned, is similar to No. 158, but there is no evidence of their having had a similar origin. It is possible, however, that No. 158, like this, was originally a dipygous condition.

Presented by W. B. Tegetmeier, Esq., 1892.

** IN MAMMALS.

1. *Prozygosis* *.

Syn. Somatodidymus, *Gurlt.*

Monstres syncephaliens, *Geoff.*

Synkephalus symmetros, *Förster.*

Janus-Bildung.

In *Prozygosis* there are two perfectly distinct axes united at their anterior extremities, so that at an early stage there must have been two distinct embryos. The fœtuses arising from such embryos are united by the visceral arches and laminæ above the umbilicus. The right side of one axis unites with the left side of the opposite one.

103. Female Human twins, about the seventh month of gestation, united by *prozygosis*. The faces are opposite to each other, and at right angles to the normal position; they are much flattened, the eyes are closely approximated, and the ears are very low down. The two embryos were probably distinct at first, and became united by the fusion of the anterior extremities of the investing mass of each with that of the other, so that the trabeculæ became united in the same manner as the other facial arches are joined, the right arch of one embryo being fused with the left arch of the other.

The following history is recorded:—"Labour lasted forty-eight hours, delivery followed without instruments. The mother, a negress, had convulsions. The fœtuses lived five minutes, a very

* *Πρὸ*, before; *ζυγίω*, to unite.

unusual occurrence in such cases. There was one funis and one placenta."

Presented by T. Sharp, M.D., 1820.

104. A similar twin-birth about the sixth month of gestation, except that the two faces are not perfectly symmetrical, the mouth of one being a small circular opening.

Mus. Brit.

105. The skulls of a similar foetus. The right facial arches and frontal bone of the one are united with the left of the other and *vice versâ*. The cranial axes are at right angles to the facial; a single hour-glass shaped opening represents the pituitary fossæ. The anterior fontanelles are united. The mandibles, which have not been preserved, were normal.

106. The vertebral columns, ribs, and sterna of the same foetus. The cervical vertebræ are imperfectly formed, and the first ribs are minute. The right somatic arches of one axis are united with the left of the other, enclosing a common thoracic cavity.

107. The thoracic viscera, diaphragm, and livers of the same. There are two pairs of lungs and two hearts, one gives off a pair of aortic arches right and left. The right arch unites with the left arch from the other heart, the left arch is unconnected with the other heart, both end in descending aortæ. The other heart has only one arch, which is a left one.

108. The œsophagus, stomach, and intestines of the same. The stomach is bilaterally symmetrical, and has two spleens attached to it. The first tract of the small intestine is single, but the pancreas is bifurcate. The lower portion of the small intestine is double; it divides dichotomously about midway between its ends. The remainder of the intestine is symmetrically double.

109. Twin foetal Hares united by the anterior extremities of the axes. The anterior portion of each axis has been

arrested in development, so that the faces exhibit cyclopia, agnathia, fusion of the ears, &c.

Presented by Sir W. Blizard, 1811.

110. Twin foetal Hares in a similar condition. There is a frontal proboscis on one face.

2. *Schizocephalus.*

Syn. Iniops, Geoff.

Synkephalus asymmetros, Förster.

Janus-Bildung.

This condition depends, apparently, on an extension of posterior dichotomy into the base of the skull. An accessory face is formed in the angle between the two axes. This face is deficient in its axial parts, and hence it exhibits the phenomena of axial arrest or deficiency, as fusion of the eyes and ears, agnathia, &c. (See Class IV.)

111. A foetal Pig with dichotomy of the axis extending forward into the basisphenoid region. The accessory face has the eyes fused together as far as the edges of their irides. There is a frontal proboscis above, and a pair of closely approximated ears below; conditions precisely similar are seen in deficiency of the cranio-facial axis.

Hunterian.

112. A similar foetal Pig with the eyes of the accessory face distinct, but so obliquely placed that the fissures of the eyelids are almost vertical.

Presented by J. Winterbottom, Esq.

3. *Schizocotis* *.

Syn. Synkephalus asymmetros, Förster.

Janiceps, Geoff.

Janus-Bildung.

Under this term those forms have been classed in which, in addition to complete dichotomy of the trunk, dichotomy of the

* *Koris*, the occiput.

posterior part of the skull is apparent externally. A pair of more or less developed external ears exist between the two axes, exhibiting variable degrees of fusion with one another in a manner analogous to that seen in extreme cases of axial deficiency.

113. A female Human foetus with posterior dichotomy extending into the base of the skull, probably as far forward as the posterior part of the basisphenoid. There is a pair of well-formed external ears behind fused together below, with a single meatus between them. A small circular fossa above these, with a depression in its centre from which a minute tuft of hair is growing, probably represents a rudimentary Cyclops-eye. *Mus. Brit.*

114. A precisely similar but larger foetus.

115. A similar female Human foetus with the dichotomous condition extending a little further forwards, so that a transverse fissure corresponds to the position of a Cyclops-eye. Brought from the East Indies in 1805.

Presented by Sir E. Home, Bart., 1807.

116. A foetal Rabbit with dichotomy extending into the base of the skull. The approximate external ears are of small size ; they are very defective, and are fused together.

Hunterian.

117. A foetal Rabbit with more complete dichotomy of the base of the skull. There are a distinct pair of additional ears. The roof of the skull has been removed to show the extent of the dichotomy. This was one of a litter of six, the remainder were normal.

Presented by C. R. Bree, M.D., 1871.

118. A foetal Cat with dichotomy extending to the base of the skull, and involving only part of the basioccipital bone. The additional external ears are very defective and are fused together.

Hunterian.

119. A similar new-born Lamb. The soft parts have been removed from the anterior parts to show the union of the

skeletal parts of the thoraces and the manner in which the two spinal columns are connected with the single skull. As in the last preparation, the dichotomy has only extended into the basioccipital region.

Presented by C. R. B. Keatley, Esq., 1877.

120. A similar dichotomous foetal Pig.

4. *Schizorhachis*.

Syn. Dipygus, Förster.

Déradelphus, Geoff.

Under this term all cases of complete dichotomy of the spinal column have been included, except those in which the malformation extends to the head and appears externally. Complete dichotomy of the spinal column almost always extends to the occiput, and usually affects the basioccipital bone slightly.

121. A foetal Pig with dichotomy of the whole spinal column and four distinct anterior extremities. The thoracic and abdominal cavities have been opened to show the heart and main arterial trunks. The heart consists of two left hearts united ; there are no pulmonary hearts. Each ventricle gives off an aorta which crosses to the opposite side, so that the heart on the left side supplied the right inferior extremities, and that on the right the left. The carotids, two in number, are given off together from the arch of the right aorta. The trachea is single. The lungs are very small and imperfect ; they probably consist of a single pair. The vessels of the right heart are injected. The palate is deeply cleft. *Hunterian.*

122. A similar foetal Pig with the skull and spinal canals laid open to show the brain and cords. The adjacent lateral tracts terminate by joining each other, the outer ones alone pass to the brain. *Hunterian.*

123. A similar but anencephalous foetal Pig. The base of the skull is exposed ; the cerebral nerves are, however, quite distinct at their point of exit from the skull. *Hunterian.*

124. A foetal Puppy with dichotomy of the spinal column. The median pair of anterior extremities are represented only by a tubercle. It is probable that the dichotomy does not extend into the upper part of the cervical region.

Hunterian.

125. A similar foetal Puppy.

Purchased, 1874.

126. A foetal Kitten with dichotomy of the axis and four complete anterior extremities.

Hunterian.

127. A similar Kitten.

Hunterian.

128. The skeleton of a similar Kitten, in which the occiput is slightly cleft, so that there are two exoccipitals.

This specimen belongs strictly to the subdivision *Schizocotis*; it is probable, however, that some of the preceding specimens are similarly affected. It has therefore been thought expedient to separate those forms only as *Schizocotis* in which the cleft condition of the skull is apparent externally. These divisions are not separated by any distinct lines of demarcation and are purely artificial. The manner in which the median ribs are depressed and united in animals affected with dichotomy is well seen in this preparation.

Presented by J. Burton, Esq.

129. A similar foetal Kitten, with the skull and spinal canal opened to show the brain and the double medulla and cord.

Hunterian.

130. A similar Kitten, with the thorax and abdomen opened to show the viscera. There is slight anterior dichotomy affecting the lower lip, mandible, and tongue, with fissure of the palate. The alimentary canal is double from the lower portion of the ileum downwards.

Hunterian.

131. A similar Kitten, with the thorax and abdomen opened and the viscera raised to show the kidneys, of which there are but two, the urinary bladders, and hypogastric arteries.

Hunterian.

132. A similar Kitten, in which the median pair of anterior extremities are united as far as the carpus. The upper lip and palate are deeply cleft. *Hunterian.*
133. A female Human foetus with complete dichotomy of the spinal column, probably affecting the basioccipital region. although there is no external indication of dichotomy extending to the skull. There are two perfect trunks united by the thorax. One of the right arms is distorted at the wrist. *Hunterian.*
134. The posterior portion of a foetal Pig, with posterior dichotomy of the spinal column commencing in the lumbar region. The right half of the double axis and its limbs are much smaller than the left. This preparation has been dissected to show the viscera.

The intestine and stomach are drawn up. There are two urinary bladders; that belonging to the accessory axis has two ureters and two minute kidneys. There is a large suprarenal capsule on the right side. The left axis has only a single, much elongated kidney on its left side. The aorta bifurcates to supply the second axis.

5. *Dipygus.*

(Imperfect posterior dichotomy of the cerebro-spinal axis.)

In this condition the dichotomy does not involve the cerebro-spinal axis of the neck or anterior part of the dorsal region. It is usually confined to the sacro-lumbar vertebræ.

135. The skeleton of a dipygous Kitten.

The axis deviates to the right side, and the laminæ of the vertebræ are deficient in the lumbar region. The right innominate bone of the right axis and the left innominate bone of the left axis are united by the pubic symphysis; each bears a perfect limb. The other innominate bones are rudimentary, and their ilia and acetabula are fused together. The tuberosities of the ischia of these median imperfect bones are ankylosed with those of the more developed fellow bones. The left femur of the right axis and the right femur of the left axis are fused into a single broad bone with two heads; this articulates with a single median tibia and two fibulæ. There are two perfect feet to this median limb.

136. A dipygous bitch Pup with the abdomen laid open to show the viscera.

The innominate bones and additional posterior extremities are precisely like those of No. 135. The rectum bifurcates about an inch and a half from its extremity; the right portion is blind. The external sexual organs are double. There are two vaginae and two bladders. The right bladder is smaller than the left. The right kidney is very small; its ureter becomes impervious about a line from its inferior extremity, where it is connected with the left vagina. The left kidney is very large; its ureter opens into the left bladder. A bristle points to the right kidney. The vaginae and anus are also marked with bristles.

Hunterian.

137. The external and internal generative organs and a portion of the double pelvis of a large Dog, dissected.

There is no history of the preparation; but it is probably from a dipygous animal very similar to the last, except that the posterior innominate bones are less developed, so that the median leg was probably either rudimentary or wanting.

The accessory innominate bones consist chiefly of the tuberosities and posterior rami of the ischia; these are united below by ossified fascia, which extends to the arch of the pubis. There are two penes, urethrae, and bladders, and but two testes. Each bladder has a single ureter opening into its outer side. The right kidney is reduced to a hard fibrous button-shaped mass, about three quarters of an inch in diameter; the right bladder is much thinner than the left, and its cavity is occupied by a fungous mass of granulations. The muscles of the bulbs of the urethrae arise partly from the additional and partly from the normal pelvic bones. The right prostate is very small, and the urethra of this side is impervious where it passes between the pelvic bones.

Subclass VII. ANTERO-POSTERIOR DICHOTOMY.

Syn. Hemipagus, Geoff.

Anterior and posterior dichotomy sometimes coexist in the same embryo. The forms included in this group certainly differ from pleuropagus in the marked predominance of posterior dichotomy and the very intimate union of the two axes in the cervical region. When the anterior dichotomy only affects the

face they may be considered as instances of posterior dichotomy complicated with slight doubling of the facial rudiments; but when the anterior dichotomy involves the cranio-facial axis it is by no means easy, without dissection of the axis in the cranio-cervical region, to be certain that the malformation is not extreme asymmetrical prozygosis. As, however, forms exist uniting these malformations in a single series, No. 145, a Human foetus which apparently belongs to it, has been placed in this group.

138. A foetal Kitten with complete dichotomy of the trunk, and a slightly double condition of the tongue and mandible.

Hunterian.

139. A similar foetal Kitten with more considerable dichotomy of the mandible and tongue, accompanied by cleft palate.

140. A similar Kitten.

141. A similar Kitten with the united anterior extremities dissected to show the union of the scapulæ and the fusion of bones of the limb.

Purchased, 1893.

142. A similar Kitten with the median anterior limbs fused as far as the carpus.

143. A foetal Pig with posterior dichotomy (Schizorhachis) combined with anterior dichotomy of the lower jaw and tongue. There is a considerable cleft in the palate connected with the median rami of the jaw by a fold of mucous membrane. (No. 38 exhibits a similar condition.)

Hunterian.

144. A similar foetal Pig. The additional mandible is attached by a pedicle to the base of the sphenoid; it is reduced to a mass beset with teeth and hair. The tongue is double. There is also a pedunculated teratome attached to the palate; its nature is doubtful. The palate is cleft; there are three anterior nares. The malformation is further complicated by a meningocœle.

Presented by J. Bland Sutton, Esq., 1889.

145. A female Human fœtus with antero-posterior dichotomy (Schizorhachis combined with anterior dichotomy), producing considerable doubling of the face. There are four eyes, but the inner ones are contained in a single orbit. The axes diverge, both in front and behind, from a point in the basisphenoid bone. *Hunterian.*

Subclass VIII. OPISTHOZYGOSIS AND PYGOPAGUS.

Syn. Hypogastrodidymus, *Gurlt.*

Ischiopagus, *Geoff.*

Pygodidymus, *Gurlt.*

In Opisthozygosis two distinct embryos are united by the posterior extremities of the vertebral columns, and the right and left halves of the two pelves (Opisthozygosis); or by the union of the right with the left halves of the pelves only (Ischiopagus). The former is unknown except in the Human subject, and the latter is only recorded in Man and in a single case in Calves (*Gurlt*); it is certainly very rare in quadrupeds. Parasitic opisthozygosis (Hypogastrodidymus) is, however, far from uncommon. Pygopagus is the least degree of Opisthozygosis, characterized by union of the pelvic vertebræ. The fœtuses are turned back to back. In several cases the twins have lived to adult age. They are usually, perhaps always, female.

1. *Opisthozygosis.*

146. Human female twins united by opisthozygosis, about the sixth month of gestation. The viscera had been removed and the spinal columns and pelvis much damaged by a hasty examination. The viscera were fortunately preserved, and are seen in No. 147.

The sacrum of one side only has been developed. It is situated at right angles to the two spinal columns, which are placed end to end, the bodies of the vertebræ being united without any perceptible break. The sacrum is entirely cartilaginous, no traces of the second sacrum exist. The pelves are otherwise perfect; but the right innominate bone of one fœtus is united with the left in-

nominate bone of the other, and *vice versâ*. The ilia are united to the lumbar vertebræ by elongated transverse processes. The upper pair of limbs (in the present position of the preparation) belong to the upper and the lower pair to the lower fœtus. Each fœtus may be considered as having its pubic symphysis open and its pubic bones united with those of the other. The axial parts posterior to the point of union in the upper fœtus turn to the right, those of the lower to the left side of the preparation.

The upper fœtus is well formed, except in the pelvic region. The lower fœtus is very imperfect. Its face is misshapen, and the upper cranial bones are altogether wanting. The superior extremities are thick and defective, and the fingers are very short, owing to the imperfect condition of the terminal phalanges. The nails are scarcely perceptible. No history has been preserved.

147. The viscera and generative organs of the same. The viscera of the upper fœtus are seen upon the right hand, those of the lower upon the left-hand side of the preparation.

The heart, liver, and lungs of the upper fœtus are normal: the development of the intestines seems to have been somewhat arrested; they terminate in a very capacious thin-walled rectum, which was much stained with meconium. There is a small anal opening marked by a white bristle.

The heart, lungs, and liver of the lower fœtus are much smaller; the intestines are however about equal to those of the upper one; but there is much less enlargement of the lower part of the bowel, which opens into the enlarged intestine of the upper fœtus near the anal opening. The most remarkable character in these viscera is that they do not exhibit "*situs mutatus*." The kidneys in both fœtuses exhibit the condition known as horseshoe kidneys; united below. The four ureters open into a single large urinary bladder, which is laid open; the orifices of the ureters are marked by black bristles. The urethra is likewise laid open. The uteri are both equally developed; both vaginæ are well formed, but they both open with the urethra on the right (above in the prepa-

ration); their openings are marked with black bristles. The labia majora, minora, and clitoris are well formed on this side.

The external generative organs of the left side are very ill-formed, and are only connected with the internal organs by the right round ligament of the uterus of the lower foetus. There is no indication of either urethra, vagina, or anus on this side. There is a small swelling, about as large as a pea, at the anterior extremity of the left labium.

148. Human female twins, about the sixth month of gestation, united by opisthozygosis. The second foetus is excessively malformed, and possesses neither heart nor brain.

The axes are united near the lower part of the dorsal vertebræ by ordinary intervertebral cartilage and ligaments, exactly like those between the consecutive vertebræ. The remainder of both vertebral columns is wanting as far as the sacral vertebræ. There is a large sacrum on the left side, placed at right angles to and behind the united vertebral columns. The sacrum on the right side is very defective, consisting of a mere ring of bone articulated with the base of the left sacrum by cartilage and ligament.

The neural arches of the vertebræ are open behind at the point of union between the sacra and vertebral columns. The laminæ of both columns form a continuous series with those on the adjacent sides of the sacrum on the left side, and of the rudimentary sacrum on the right; a large lozenge-shaped opening is thus left in the neural canal.

The neural canal of the sacrum is continuous with that of the vertebræ, and this makes a sharp bend backwards from either axis to meet the sacral neural canal.

The following facts were recorded by Drs. Marcet, Roget, and Mr. Lawrence from an examination made when the foetus first arrived in England:—"The interval between the lamina of the vertebræ was occupied by a strong membrane; on the division of this, the medulla spinalis was seen running across from one spine to the

other, and distributing its nerves laterally to the two lateral pelves."

From a careful consideration of the above conditions, it appears that the axes of two embryos came into contact at a very early period of development, so that the neural cords and the proto-vertebræ in the dorsal regions were developed in a continuous series; and the caudal extremities of the axes became displaced and partially absorbed, so that the axial portion of the sacrum has been developed from the remains of one of these displaced axes. The neural arches appear to have followed the same law of development as the visceral arches at the point of union between the fœtuses, those of the one axis tending to unite with those of the other instead of with their fellows.

A comparison with other specimens of a similar malformation renders it probable that the upper pair of legs and the corresponding pelvic bones were developed from the visceral laminae of the upper, and the lower pair from those of the lower fœtus.

The thoracic viscera of the upper fœtus are normal. The aorta in the abdomen turns off to the left pelvis and gives off a pair of large hypogastric arteries, of which the upper is the larger. At the point where the aorta turns off to the left it gives origin to two large vessels: one runs straight into the thorax of the lower fœtus and terminates in two innominate arteries, the other supplies the right pelvis and lower limbs.

The whole of the anterior walls of both fœtuses are extremely defective. The ribs of the lower fœtus are developed behind only. A slip of muscle crosses its body-cavity from the left axilla to the right pubis. Its thorax was chiefly occupied by a large sac, the greater part of which has been removed with the viscera, and is seen in the next preparation. This sac communicated with the intestines above and with the mouth below. It is referred to in M. Maunoir's original description of this monster (*Med.-Chir. Trans.* vol. vii. p. 257) as a "kind of cloaca," of which he says, "On opening the cloaca it was found to contain the rudiments of a lower jaw and of a tongue, which were immersed in meconium, with which the cavity was filled." The cranial and facial bones are only represented, in the inferior head, by irregular masses of cartilage. There is a very rudimentary and misshapen external ear. The brain was represented by a large cyst filled with blood, a condition usual in anencephalic conditions: this was removed before the fœtus was sent to England.

The following history is recorded (*Med.-Chir. Trans.* *l. c.*):—
"A girl of 16 or 17 gave birth to this fœtus in Geneva; it lived

a few minutes. There was no difficulty in the labour; the perfect head was born last."

Presented by the Medico-Chirurgical Society, 1816.

149. The abdominal viscera of the same, except the liver, and the kidneys which were contained in the left pelvic portion of the twin-birth; these parts had been removed.

The following viscera are seen in this preparation:—The stomach of the superior fœtus is displayed at the upper part of the mica, with the duodenum, the remains of the liver, the jejunum, and ileum. Near the middle of the latter, and connected with it by about three quarters of an inch of intestine, is a portion of the large cloacal sac from the inferior fœtus.

The accompanying description of the liver occurs in M. Maunoir's paper (*l. c.*):—"An enormous liver covers the whole intestinal mass, and appears through the transparent membranous abdominal wall, between the laminae of which a single umbilical cord [probably the umbilical vein only is here alluded to] passes in a serpentine course and enters the liver." The liver, anterior abdominal wall, and cord have unfortunately not been preserved.

The ileum bifurcates about an inch from its inferior extremity and opens into two distinct cæca, each having a short vermiform appendix. The large intestines are double: that on the right side of the preparation belongs to the right side of the monster; it is opened to show its blind termination above the uterus. The left large intestine belonged to the left inferior portion; it terminates in an anus.

The kidneys of the right side are preserved; they are adherent throughout their entire length. The left kidneys are wanting, but are stated to have had but one ureter between them. The bladders, urethras, and external sexual organs on both sides are normal. There is a uterus on each side, the right one being considerably larger than the normal fœtal uterus.

Presented by the Medico-Chirurgical Society.

2. *Pygopagus*.

Syn. Pygodidymus, Gurlt.

Ischiopagus, Förster.

Pygopagus is occasionally met with in the Human subject; it differs from extreme anterior dichotomy in the equal development of the four posterior extremities, and in the two vertebral axes being separate as far as the extremity of the sacrum. The

twins are united back to back. It is the least degree of Opisthozygosis.

Judith and Helena, "The Hungarian Sisters" (Phil. Trans. vol. 50, p. 311), and Millie-Christine, the "Two Headed Nightingale," exhibited in London in 1871 (Lancet, 1871, i. p. 725), are examples.

150. A wooden model representing two pygopagous infants. Probably the model of "united twins from the Philippine Islands."

The anus is represented as single, and the vaginae are united at their posterior commissures,—the usual disposition of these parts in such malformations.

Presented by the Rev. Wm. Livingstone, Nov. 1, 1842.

151. Pygopagous Human foetal twins, at term. The extremities of the sacra are united; there is one coccyx. In all other respects the bony pelvis are normal and quite separate.

Presented by Dr. Holt.

152. The placenta of the preceding. There are two amniotic sacs, the smaller contained a normal foetus, and its funis is inserted into the margin of the placenta. The larger contained the malformation; its funis is single for two inches and then bifurcates; it is inserted into the middle of the placenta.

Presented by Dr. Holt.

The question arises whether the three foetuses with a common placenta originated from one or two ova. The double amnion renders the latter hypothesis probable, whilst the complete fusion of the placenta indicates a community of origin for the three. (See Triplex Malformations.)

It appears possible that placenta may unite although developed from separate ova.

153. Pygopagous female twins, said to be united by the soft parts only. The right labium of one foetus is fused with the left labium of the other. The remaining parts are all double.

The malformation is complicated with double spina bifida in the lumbar regions.

1887.

Subclass IX. PARASITIC HYPOGASTRODIDYMUS.

The malformations included in this group apparently bear the same relation to Opisthozygotic Malformations that Parasitic Emprosthozygosis bears to Emprosthozygosis. The axis is apparently absent or very defective in the parasite.

* IN BIRDS.

154. A Chick with the rudiments of a second Chick occupying the pubic symphysis. The rudimentary Chick consists of a pelvis, with total deficiency of an axis, and of two posterior limbs fused together above as far as the middle of the femora by the skin and soft parts.

Hunterian.

155. A similar specimen.

Presented by Dr. F. R. Fairbank, 1876.

156. A similar specimen. It is said to have lived three weeks.

Presented by J. Farmer Hall, Esq., 1881.

157. A Chick with the imperfect wings and legs of a second Chick attached to the abdominal integuments.

Hunterian.

158. The pelvis of a Hen, which had two cloacal openings leading out of a common cloaca. On the right were the remains of an imperfect hypogastrodidymus parasite.

The parasite consists of a small imperfect pelvis formed by the union of two additional ilia and of a single bone, probably representing two united femora, the distal extremity of which bears a pair of tibiae which terminate below in rounded stumps.

Presented by W. E. de Winton, Esq., 1893.

** IN MAMMALS.

159. The skeleton of a half-grown female Cat, with an imperfect accessory pair of innominate bones occupying the pubic symphysis; an accessory pair of limbs is attached to them.

Although the axial parts of this pelvis and the remainder of

a second animal are absent, there can be little doubt that these bones were developed from a second embryo. If the axis had been developed, an opisthozygous twin monster would have resulted.

The second pair of limbs are short, distorted, and ankylosed to the pelvis, probably from disuse. Their patellæ are absent.

The Cat was caught in a trap in a wood, where it had been living in a wild state.

Presented by W. B. Tegetmeier, Esq., 1867.

160. The bones of the pelvis and inferior extremities of a Sheep, with the pelvic bones and posterior extremities of an imperfect twin similarly attached. In this preparation the parasitic limbs are fused as far as the metatarsus. A comparison of these limbs with the dichotomous limb of a monkey, No 410, shows the difference between malformation from fission and fusion in a marked manner.

Hunterian.

161. A Human female foetus at full term, with an acephalous parasite below the umbilicus. The legs of the parasite are more perfect than the arms.

A diverticulum of the ilium, convoluted, and several inches in length, apparently represented the intestine of the parasite, but this was not preserved.

The genito-urinary organs were partially reduplicated.

This malformation closely resembles parasitic emprothozygosis, from which it is, however, undoubtedly distinct.

Presented by John Gay, Esq., 1887.

162. The genito-urinary organs from the same foetus. There are two perfect female external genitals, and each is connected with a vagina and uterus having only one Fallopian tube and ovary. There are two urinary bladders, each with only one kidney. The bladder on the observer's right is much dilated and sacculated as the result of atresia of the urethra. The corresponding kidney and ureter are also dilated. The opposite kidney has two ureters, one of which is attached to the wall of the vagina on the left side. A single rectum lies between the two vaginæ. *Presented by John Gay, Esq., 1887.*

163. The skeleton of a Calf, with an additional pair of innominate bones and of posterior limbs.

This skeleton at first sight appears to belong to a dipygous calf, but there are no sufficient indications of dichotomy of the vertebral column. It differs from parasitic hypogastrodidymus in the fact that the pelves are not united. It is possibly an example of pygopagus in which the second embryo, except its posterior limbs and pelvic girdle, have undergone complete atrophy.

Subclass X. MESODIDYMUS.

The cerebro-spinal axis has been found double, in young embryos, in the dorso-lumbar region and single at each extremity. It is perhaps doubtful if such embryos attain any but the earliest stages of development. No specimen occurs in the Museum.

Subclass XI. TRIPLEX MALFORMATIONS.

The so-called triplex human foetus described in the 'Atti dell' Accadem. Gioen.' t. viii. p. 203, is undoubtedly an example of pleuropagus combined with anterior dichotomy of one axis. Several cases are recorded by Gurlt as having occurred in animals. Triplex and even quadruplex malformations (in one instance) are described in fishes by Klaussner ('Mehrfachbildungen,' 4to, Munich, 1890).

Such malformations are exceedingly rare. The nearest approach to such a condition in the Museum is No. 151. It is very doubtful, however, whether the three foetuses were the product of a single ovum.

Subclass XII. CRANIOPAGUS.

These malformations arise from the adhesion of two embryos by the skulls. The second embryo is usually greatly aborted, and is often a mere atheromatous tumour.

* IN BIRDS.

164. A Duckling with the remains of a second embryo adhering in the superior fontanelle, which has not been closed. It consists of a kind of atheromatous tumour, partially occupied by a hernia of the Duckling's brain, with a small but well-developed leg and foot growing from it.

Hunterian.

** IN MAMMALS.

165. Craniopagous twins, unequally developed.

This malformation is complicated by ectopia of the abdominal viscera in both, and nanomelus in the larger twin. The bladder of the larger twin was also abnormally distended, contained half a pint of urine-like fluid, and occupied the greater part of the abdominal cavity.

The birth is described in the 'Lancet,' Aug. 26, 1876.

Presented by Dr. W. Playfair.

166. The skull of a Bengalee child, with a second imperfect skull attached to the anterior fontanelle, which is widely extended. The base of the second skull is much contracted, the foramen magnum being almost closed. All the bones of the face are much smaller than those of the supporting skull. The faces are turned in almost opposite directions, so that the left frontal bones of one skull articulate by suture with the right parietals of the other, and *vice versa*.

The history of this skull and an account of the child are given in the Phil. Trans. vol. lxxx. p. 296, from which the following particulars are extracted:—

The child was a male, it was more than four years old at the time of its death, which was caused by the bite of a cobra. It was very emaciated, a fact attributed to the parents having used it as a show, always keeping it covered up, except when payment was made for its exhibition. The woman who acted as midwife was terrified at the appearance of the additional head, and tried to destroy the child by throwing it on the fire: it was rescued after one eye and ear were considerably burnt.

There was no trunk to the second head ; but it was surmounted by a short neck terminating in a rounded tumour, which is stated by one observer to have been quite soft at the age of two, and by another to have been quite hard and cartilaginous at the age of four. Its external ears were represented by mere folds of skin, and there was no auditory meatus. The normal face and head were not malformed. The brains were distinct, each invested in its own membranes ; the dura mater of each adhered to that of the other at the point of contact. The chief supply of blood to the upper head was by a number of vessels passing from the membranes of one brain to that of the other. The movements of the features of the upper head appear to have been purely reflex, and by no means to have been controlled by the feelings or desires of the child. The movements of the eyes of the accessory head did not correspond with those of the child, and the eyelids were usually open, even during sleep.

Hunterian.

Subclass XIII. TERATOMES.

Amorphous tumours, consisting of connective tissue containing bones, cartilage, and hair, are frequently found adherent to the gluteal region (Sacral teratome), or impacted between the facial arches (Epignathus). These are probably the remains of a second embryo. Similar tumours also occur in the substance of the ovary and testis. It is possible that many anomalous tumours originate from minute fragments of a degenerating twin similarly included or overgrown by the twin embryo. This possibility has originated the theory of foetal infection as a cause of tumours which first become apparent in after life. (*Ahlfield.*)

1. *Sacral teratome.*

167. A sacral teratome of somewhat conical form, composed of fibrous tissue, fat, and cartilage, which was removed from the nates of a child about 14 months old. A papilla at its extremity appears to represent very obscure indications of a limb. The remains of a portion of intestine, originally blind at each extremity, and about 3 inches long, is seen at its base. It originally contained a fluid

resembling meconium. The child recovered quickly from the operation. The tumour has been cut through vertically to show its structure.

Presented by T. Blizard, Esq.

2. *Epignathus.*

(Impaction between the facial arches.)

In such cases the palate is most frequently the seat of impaction, and the parasite is modified excessively.

168. The injected head of a Human foetus with a large lobulated vascular tumour, the remains of a second foetus, growing from the median fissure of the palate, which has been kept open by it. The tumour projects from the mouth, which it dilates considerably. It is adherent to the right commissure of the lips, and entirely invested the superior maxillary bone of the foetus, which has been removed and is seen in No. 170.

The lobulated tumour presents a widely extended mouth in front. A piece of purple glass rod is placed in its cavity, extending between the commissures of its lips. A long tongue-shaped projection is seen in the mouth-cavity; but it is covered with lanugo, so that it does not probably represent the tongue. The lips and alveoli are very distinct; they are divided into two lateral portions by large lobules of a fatty tumour. A single nostril, marked by a blue glass rod, appears above the left half of the upper lip; at the inner side of the nostril is a deep fissure, probably the remains of the nasal cavity; this fissure is marked by a purple glass rod. The left upper alveolus has been exposed by the removal of the gum, and is very distinct.

One of the largest of the fatty lobes, which make up the bulk of the tumour, has been cut through to show its structure. It consists of firm vascular fat with an atheromatous centre. A small cyst appears at its upper part. On the right side there is a piece of adherent placenta, and just below it is a loose, pendent, lobulated mass about an inch and a half in diameter. As one of its lobes felt very hard it was opened, and was found to contain a compact mass of bones, fifty-nine in number (see No. 169). The skin of the tumour is soft, vascular, and covered with lanugo. The lobe which contained the bones presents three indistinctly separate hard white papillæ, something like aborted digits.

The most remarkable point in this specimen is that lips and alveoli of the tumour only are recognizable, as if its position had determined the nature of the parts formed. There can be no reasonable doubt that the tumour consists of the remains of a second embryo.

169. Fifty-nine ossicles from the tumour in the last preparation. They are most complex in form, and were closely packed together. There is but one which resembles any normal bone, the first of the series; it appears like the lamina of one of the cervical vertebræ.
170. The superior maxillary bone and a portion of the malar bone from the same, taken from the right side of the tumour. These belonged to the foetus and not to the parasitic growth. It is normal, although it supported a portion of the tumour.
171. An ill-formed tooth removed from the petrosal bone of a Horse. A congenital sinus, representing the persistent second branchial cleft, was connected with the tooth. (See Trans. Path. Soc. vol. xlii.)

Presented by J. B. Sutton, Esq., 1891.

Subclass XIV. HETEROLOGOUS UNION.

Instances of heterologous union of parts of a second embryo and a well-formed foetus are recorded. See Tsortis, "Organe Génitale Externe de la Femme sur le Dos d'un Homme," Journ. Méd. de l'Armée, Athènes, 1892; and Windle, Report on Teratological Literature," Journ. Anat. & Phys. Camb. vol. xxvii.

There are no instances in the Museum, and some doubt may, perhaps, be permitted as to their actual existence.

Subclass XV. INCLUSIO FŒTALIS.

Syn. Cryptodidymus, Gurlt.

Fœtus in Fœtu.

Sometimes instead of a second embryo becoming impacted in the visceral arches of another, it becomes enclosed within its abdominal cavity. The included embryo in these cases is contained in a cyst, and connected with it by an imperfect funis. Under

these circumstances it may live and grow for many years. It is always excessively defective and much deformed. Both the including subject and foetus are usually male.

It is probable that such included foetuses owe their origin to very nearly the same conditions as those which give rise to other forms of doubling. It is not easy to understand how a second ovum could enter the body-cavity of an embryo, whilst there is no difficulty in understanding how a second embryo on a common yolk could be so included. The cyst under such circumstances would owe its origin to a portion of the common amniotic sac, which the included embryo must necessarily carry before it. It is true no connection has been observed between the cyst and the umbilicus; but, all things considered, the above seems the least improbable means of accounting for the phenomenon. The disappearance of a portion of the amnion in several years is by no means inexplicable, especially when it is remembered that the membrane must have been extremely thin at the time of its induplication.

172. A portion of a cyst (which contained the foetus No. 173) from the abdomen of a well-formed male child aged between 9 and 10 months. The preparation includes a portion of large and small intestine of the child.

The case is described by Mr. G. W. Young in the 'Med.-Chir. Trans.' vol. i. p. 234. The cyst is recorded to have contained 78 ounces of fluid, and to have discharged a portion of its contents several times into the peritoneal cavity; it is further stated to have been placed between the layers of the transverse mesocolon. The same thing was also believed in M. Dupuytren's case*; but much difficulty arises in the explanation of the phenomenon if such really be the fact. In the present instance it will be seen that the mesentery is likewise adherent to the cyst, and the whole mass is so matted together that it would be impossible to determine whether the cyst is between the layers of the mesocolon or not; it is much more probable that the cyst was originally placed between the mesocolon and mesentery. The portion of the cyst which has been preserved consists of a number of layers, a fact quite in

* Bulletin de la Soc. de la Faculté de Méd. Paris, an 13, no. 1, p. 4. Himly, Foetus in Foetu, p. 18.

consonance with the opinion that it was originally formed by an induplication of the amniotic sac. It is very thick, and presents a villous surface within. The upper part of the cyst, which was covered by the omentum, has not been preserved. It is stated to have been very thin and transparent.

Presented by G. W. Young, Esq.

173. The imperfect fœtus from the same, divided vertically to show its internal structure. It has no head, its trunk is very much curved, and possesses four misshapen limbs. It was connected with the cyst by a large funnel-shaped umbilical cord, which contains a coil of intestine.

Mr. Young states that "when the fœtus was taken from the cyst it was covered with sebaceous matter, and when this was removed, it appeared as rosy and healthy as if it were alive." At the upper extremity of the trunk a fibrous mass is seen with a portion of the cyst adherent to it; this is said by Mr. Young to have been "of a dark red colour when first taken from the cyst, and abundantly supplied with blood." It is exactly similar to the mass usually representing the brain in anencephalous fœtuses. That part of the fœtus which corresponds to the frontal region bears a narrow line of fine hair upon it; this forms a long lock on either side. The vertebral column consists of eleven blocks of bone, representing as many vertebral centres. The posterior aspect of these is covered by a membrane; there are no remains of the spinal cord, and no traces of laminae. The skin on either side of the vertebrae is covered with short fine black hairs. The sacrum is rudimentary, and entirely formed of cartilage. One of the vertebral bodies in the dorsal region seems also to be entirely formed of cartilage. The vertebral column is surmounted by several masses of bone and cartilage, which probably represent the base of the skull and facial bones. The axis is bent almost at right angles in the dorsal and lumbar regions. A small opening, in which a bristle is inserted, is seen in the mesial line at the most anterior part of the fœtus; it is apparently a vessel, probably a median carotid.

In front of the hair, at the anterior part of the fœtus, is a frontal proboscis, considerably enlarged and perforated at its free extremity: it is extremely similar to the same structure in cases of cranial arrest. (See Nos. 212 *et seq.*)

The body-cavity is not divided by any diaphragm, and is almost filled by a saccular dilatation of the intestine, which forms a blind

sac in front of the sacrum ; there is no anus. A blind coil of intestine fills the cavity of the umbilical cord and communicates with the main intestinal cavity at the umbilicus. The whole was filled, according to Mr. Young, with a dark fluid resembling meconium, although there is apparently no vestige of a liver. In the upper part of the trunk the lungs may be distinctly seen, compressed against the vertebral column. No other internal organs have been developed. The external generative organs are probably those of an imperfect male. The penis is rudimentary, perforated at its extremity only, and having a blind urethral pouch immediately beneath its root. There is no bladder.

Presented by G. W. Young, Esq.

174. A cyst with a portion of the stomach and jejunum from a lad between 15 and 16 years of age. The cyst contained the imperfect male fœtus preserved in the next preparation, No. 175. The case was described in a pamphlet by N. Highmore, Esq., in 1814.

The cyst in this case is intimately and extensively connected with the duodenum and jejunum. A portion of the stomach, which is excessively elongated, is seen on the left of the preparation ; it has been filled with horsehair. The duodenum is seen opening on the left into the upper part of the cyst ; from this point the intestine forms part of the wall of the cyst as far as the right extremity of the preparation, where the opening of the jejunum is seen ; a piece of glass tube has been inserted into this opening. The intestine was below and not above the cyst when it was *in situ*. The interior of the wall of the cyst, except that portion of it which was formed by the intestine, is covered with ragged processes of membrane, so that it has a villous appearance. The funis arose from the posterior and upper part of the cyst (the lower part in the preparation). The whole was very vascular, and the lad died of hæmorrhage into its interior.

Presented by N. Highmore, Esq.

175. The fœtus from the same. There is no head, but some slips of membrane unite the upper part of the vertebral column with the funis ; they represent the membranes of the brain. A quantity of long, thick, matted hair is seen growing from near the same point, probably from what should have been the frontal region. The limbs are very

ill proportioned and are strongly flexed. The hands are at right angles to the arms. The whole of the left leg has apparently been absorbed, a large denuded surface on the side of the pelvis being the only indication of its ever having existed. The right foot is bent inward as in talipes varus. The sharp angles of the joints have undergone absorption, the bones being denuded and partially removed at these points. The upper part of the body has a long fleshy papilla growing from it, enlarged and hollow at its extremity; it is undoubtedly a frontal proboscis. In Mr. Highmore's original description it has been mistaken for a nipple, and hence the fœtus was erroneously described as a female. The generative organs are those of an imperfect male, consisting of a rudimentary penis invested by a very voluminous circular prepuce.

The funis is short and thick, and when recent the fœtus was covered with sebaceous secretion.

Presented by N. Highmore, Esq.

Class IV. MALFORMATIONS WITH DEFICIENCY.

(Arrests.)

The great majority of malformations with deficiency are indubitably arrested conditions of growth or development. It is extremely difficult to separate malformations which result from atrophy from those which are true arrests, and it is hardly ever possible to determine the precise stage in which arrest first took place.

Subclass I. CRANIOFACIAL DEFICIENCIES.

Sometimes the facial arches are imperfectly developed, or there is failure in the closure of the branchial clefts. These malformations are very usually, although not necessarily, accompanied by imperfect development of the axis. On the other hand, when the anterior part of the axis is imperfect, there are generally, but not always, defects in the face of a similar character. If a dissection is made of the whole head, it is always possible to separate the two classes, but without dissection it is impossible to assert that the craniofacial axis is either arrested or properly

developed when the face is imperfect. Thus it will be seen, by a comparison of Nos. 196 and 204, that the more marked forms of hare-lip and cleft palate pass by insensible degrees into marked axial arrest ; whilst other forms of cleft palate, not distinguished by any well-defined characters, exhibit no such defect.

* IN FISHES.

176. The anterior portion of an Eel with complete deficiency of the face in front of the eyes. The mandible extends beyond the anterior extremity of the truncated skull. The cranium and part of the spinal canal have been laid open. The four anterior ganglia are much compressed from before backwards. The anterior pair of ganglia (olfactory) have displaced the second pair, and lie partially between instead of entirely in front of them.

177. The head of a young Salmon with a similar truncated face; the maxillæ are placed almost at right angles to their normal position, and overlap the mandible on either side.

Presented by Mr. Shepherd, 1871.

178. A vertical longitudinal section of the anterior part of a Carp, with complete deficiency of the face in front of the eyes. The development of the mandible is likewise defective ; the defect does not extend beyond the truncated face.

Hunterian.

179. A small Trout with a similar truncated face, from Ballymena, Ireland.

Presented by W. B. Tegetmeier, Esq., 1889.

180. The head of a Trout, with imperfectly developed gill-covers, from Assynt, Sutherland.

Presented by E. N. Alston, Esq.

** IN BIRDS.

181. A Sparrow with a deep cleft dividing lower beak in the mesial line.

Hunterian.

182. A foetal Chick in which the anterior portion of the cranio-facial axis is absent. The eyes are fused into a single organ. The upper beak and the maxillary and frontal arches are entirely wanting. *Purchased.*

*** IN MAMMALS.

Group I. *Persistent Branchial Clefts.*

Fistulous openings sometimes occur in the neck and face, which have been ascribed to persistence of the Branchial Clefts. See Nos. 531 to 536.

Group II. *Arrested formation of the Mandible.*

(*Brachygnathus*, *Gurlt.*)

1. *Brachygnathus.*

Shortening or general defect in the size of the mandible occurs occasionally in Mammals; it is usually an accompaniment of defective development of the face.

183. The skull of a new-born Calf with a cleft between the maxillary bones, and defect of the palate-bones and pterygoid processes. The whole skull is shorter and broader than the normal type. There is considerable shortening and deformity of the mandible. *Hunterian.*

184. The skull of a Calf with considerable shortening of the whole craniofacial axis and extreme curvature and shortening of the rami of the mandible.

Presented by T. Wormald, Esq.

185. Anterior part of the head of a South Down Sheep with considerable shortening of the lower jaw. This deformity is not uncommon on the Downs near Brighton, the subjects of it being known to the shepherds as "Hog-jawed Sheep." *Presented by Dr. E. L. Ormerod, 1872.*

2. *Unilateral Agnathia.*

186. The skin and soft parts of a Lamb's head exhibiting a malformation due to the absence of the right half of the inferior maxilla, the right superior maxillary, palate, and

malar bones. The cavity of the mouth is completely open on this side, and is continuous with the persistent first visceral cleft, the posterior boundary of which is formed by a smooth groove of mucous membrane sloping outwards, backwards, and upwards to the pinna of the ear; this probably represents the inner walls of the Eustachian canal and external auditory meatus. The tongue is well developed, but divided into three lobules from before backwards by depressions of its surface; and on the right side it is tightly tied down to the floor of the mouth. A wide median cleft extends through the posterior half of the palate. The lower eyelid is undeveloped, and the eye is only separated by a thin band of mucous membrane from the floor of the mouth.

Presented by B. J. Vernon, Esq., 1882.

187. The dried skull of the same Lamb from which the preceding specimen was taken. All the bones developed in connection with the first visceral arch are completely absent; the malar bone and the pterygoid process are also wanting. The right premaxillary bone is well-formed, and continued somewhat further backwards than the same bone on the opposite side. All the different portions of the right temporal bone are represented, but are not well developed; the tympanic bone is especially small, and the bulla rudimentary. The external auditory meatus is seen as a small foramen; there was no trace of a tympanic membrane, nor of the bones of the internal ear. The zygomatic process of the squamosal and the posterior orbital process of the frontal bones are absent. The right parietal bone is divided by a horizontal suture into two nearly equal portions, and at its anterior inferior angle is a small quadrate plate of bone, probably a Wormian bone. The left half of the inferior maxilla is very short and curved inwards at its anterior extremity. The right half of the hyoid arch was well developed, but the bones forming it were somewhat smaller than those on the left side. The brain was normal, but the 5th and 9th nerves on the right side were small.

The Lamb was otherwise well formed, and was observed

sucking; it was killed on the day following that on which it was born. See account in 'Journal of Anatomy and Physiology,' July 1883, by S. F. Eve, Esq.

Presented by B. J. Vernon, Esq., 1882.

Group III. *Hare-lip and Cleft Palate.*

Facial arrest in its slightest degree consists in defective development of the premaxillaries and maxillary bones, so that a cleft is left between them, constituting Cleft Palate or Hare-lip. The nasal septum is defective in the more severe forms, or the whole anterior part of the axis, including the ethmoid bone, may be deficient. All the facial bones may be very defective, with shortening of the bones of the base of the skull. Very frequently this shortening appears to be accompanied by an increase of breadth in the axial bones, giving rise to considerable clefts between the arrested parts of the face.

188. A Dog's head, showing a median cleft in the nose and upper lip.

A race of Pug-dogs existed in Paris in 1886 in which this malformation was established. See Sutton, "Congenital Fissures of the Mouth," Trans. Odont. Soc. 1887.

Presented by J. B. Sutton, Esq., 1888.

189. A vertical longitudinal section of a Dog's head, in which there was a median cleft of the nose and lip. The lower edge of the vomer has a free edge more than a quarter of an inch above the floor of the nasal fossæ.

Presented by J. B. Sutton, Esq., 1888.

190. A dry specimen of a skull showing the cleft between the premaxillary bones, from a similarly malformed Dog.

Presented by J. B. Sutton, Esq., 1888.

191. The head of a new-born Bulldog, with double hare-lip and cleft palate.

Presented by J. Ashburn, Esq., 1874.

192. Skull of a "Toy Terrier" two days' old with cleft palate.

Presented by Mr. Palmer, 1874.

193. The head of a young Lion born in the Zoological Gardens, March 1862, with cleft palate and arrested growth of the

septum narium. The litter consisted of two, this and another in the same condition. The alveoli of both jaws are arrested also. Several other Lion-cubs born in the Gardens have been similarly affected. *Purchased.*

194. A portion of the skull of a six-months' fœtus with considerable deficiency of the maxillæ and palate-bones, giving rise to a wide cleft in the palate. The vomer supports the premaxillaries, which are separated by a fissure on either side from the maxillæ.

Presented by Sir W. Fergusson, Bart., 1865.

195. A portion of the skull of a new-born child, with considerable divergence of the pterygoid process and palate-bones. There is entire deficiency of the bony palate, and the maxillæ are widely separated from each other and from the premaxillaries. *Presented by Sir W. Fergusson, Bart.*

196. A portion of an adult skull in which there is a cleft nearly an inch wide between the lateral halves of the bony palate. The vomer is bent over to the left side, and is united to the left half of the palate. The alveoli are very defective. There are only two teeth on the left side.

Presented by Sir W. Fergusson, Bart.

197. The premaxillary bones from eight cases of cleft palate in infants. *Presented by Sir W. Fergusson, Bart.*

198. The premaxillary bones from two cases of cleft palate in children. *Presented by Sir W. Fergusson, Bart.*

199. The premaxillary bones from a case of cleft palate in an adult. *Presented by Sir W. Fergusson, Bart.*

200. A premaxillary bone from a case of hare-lip. *Presented by C. Heath, Esq., 1888.*

201. The cranium of a Native of one of the islands of the South Pacific. There is complete fissure of the palate. The right half of the alveolar arch is more developed than the left, and part of the left premaxilla is adherent to it.

The fissure is thus shown to be a lateral fissure between the left premaxilla and the left maxilla.

The lower margin of the vomer is free. There is a persistent frontal suture and want of symmetry in the foramen magnum.

Presented by Sir W. Fergusson, Bart., 1873.

202. A dissection of the tensor and levator palati muscles and the neighbouring parts in a case of cleft palate in the adult.

The soft palate only is apparently cleft in this case, but the bones are implicated slightly, although to a much less extent than in the foregoing preparations. The preparation is of special interest because it shows the manner in which the levator palati and palato-pharyngei muscles keep the edges of the soft palate apart. The upper fibres of the superior constrictor, which act as their antagonist, are unusually well developed. This is the original dissection on which Sir W. Fergusson founded his operation of Staphylorophy, which consists in dividing the fibres of the levator palati, palato-pharyngei, and palato-glossi. The preparation is minutely described in his original description of the operation, published in 1845, 'Trans. Med.-Chir. Soc.' vol. xviii. pp. 273-301.

Presented by Sir W. Fergusson, Bart.

Group IV. *Deficiency in the Craniofacial Axis.*

When the craniofacial axis fails or undergoes atrophy or absorption, the lateral arches unite prematurely, so that fusion of the lateral organs results. The axis becomes narrowed, or is absent in parts of the skull, and the corresponding nervous and facial structures fail to be developed. The presence of lateral parts corresponding to the several portions of the axial region affords a strong indication that the axial parts are not absent from the commencement of development, but that they fail and become atrophied at an early stage. The most common form originates in the absence or failure of the parts developed from the investing mass in front of the notochord, the olfactory lobes and nasal capsules are then deficient. When the investing mass fails more posteriorly the eyes and mesencephalon are found wanting. When the investing mass fails in front of the

ear-capsules, so that the basi-occipital ends in a point between them, the mandible is usually absent; and in extreme cases, when the structures normally developed in the investing mass in front of the ear-capsules all fail, the tympanic cavities are fused in front. It frequently happens that the mesencephalic or epencephalic region is deficient, whilst the anterior and posterior portions of the craniofacial axis are developed. The changes which produce these abnormal conditions probably commence in the investing mass, and not in the subsequently formed bones, since failure as frequently occurs between the basioccipital and basiphenoid as in either of these bones. In this case the anterior part of the basioccipital and the posterior part of the basisphenoid are equally arrested. The nerve-centres appear to be always arrested at points corresponding to the deficient portions of the axis, so that it appears improbable that the malformation originates in deficiency of the facial arches. Rarely one lateral half only of a portion of the cranium is arrested, the other being normally developed.

A. Mesofacial defect.

The malformations included under this head are characterized by failure in the development of the ethmo-vomerine plate.

1. *Median Hare-lip.*

203. A portion of the head of a Human infant, with arrested development of the ethmoid bone, absence of foramina in the cribriform plate, of the nasal septum and premaxillaries. There is a single median nostril and a deep cleft between the lateral halves of the upper lip. In this case the foramen ovale of the heart was patent, the testes had not descended, and there were six digits on each hand and one foot. (See Nos. 411-413.)

Presented by R. Partridge, Esq.

204. The head of a female Human fœtus, with a broad cleft in the upper lip continuous with the nostrils, arrest of the septum narium, and entire deficiency of the bony palate. There is also apparently considerable deficiency of the skull in the occipital region, similar to that exhibited in No. 340.

Hunterian.

205. The head of a Human foetus with arrest of the ethmoid bone and nasal septum. The eyes are approximated. There is no palate. The nostrils are absent, and the upper lip is deeply cleft in the mesial line. A section has been made through the mandible and tongue to exhibit the condition of the roof of the mouth and the nasal cavity.

Presented by Sir W. Blizard.

206. A portion of the head of a Human foetus with shortening of the whole craniofacial axis. The right eye is abnormally small, and the left is absent; its eyelids are wanting, and a mere depression marks the position of the orbit. The palate and the upper lip are entirely wanting. The maxillary and naso-frontal processes remain distinct. The external ears present numerous abnormal lobules. The base of the skull has been dissected to show the imperfect condition of the middle ear and tympanic bones. The right Eustachian tube is marked by a black bristle; it is a mere groove open below.

207. A Child's head showing a median hare-lip. The premaxillary bones and the ethmo-vomerine plate are absent. (See Trans. Odont. Soc., Dec. 1887.)

Presented by J. B. Sutton, Esq., 1888.

208. The facial bones with a portion of the frontal and sphenoid bones from the same. The hard palate is absent, the premaxillary bones are united in the middle line, and the nasals are completely wanting. The orbits are very shallow and abnormally large.

Presented by J. B. Sutton, Esq., 1888.

209. A vertical section of the head of a Human foetus in which the palate is entirely deficient. A groove above the mouth, marked by a bristle, represents the nasal cavity. The cribriform plate of the ethmoid is very small, its vertical plate is absent. The palato-pterygoid and maxillary process (suborbital arch) are absent. The eye is abnormally small. The external ear is represented by a small lobule; there is no meatus. The cavity of the skull occupied by the middle cerebral lobe is much enlarged; the remainder of the cranial cavity is correspondingly contracted.

B. Prosencephalic axial defect.

Syn. Rhinocephalus, Cyclocephalus, Ethmocephalus, *Geoff.*
Cyclops, Gurlt.

W. Vrolik * first ascribed the origin of the following forms to arrest of development of the anterior portion of the investing cartilage of the notochord ; and there can be little doubt that this is the most satisfactory explanation yet arrived at. The trabecular arch and the structures arising from it are always absent or defective. The nasal septum is either entirely absent or is represented by a defective vomer. The whole ethmoid bone is usually wanting. There are traces of inferior spongy bones in the frontal proboscis, a process arising from the union of the naso-frontal processes. There is sometimes a single nostril, sometimes a pair beneath the eyes, between the united sub-ocular arches, when a defective nasal cavity exists between the maxillæ. More frequently the proboscis is perforated by a nostril, and contains a cavity extending back to the skull, in which a pair of cartilaginous spongy bones are situated. In such cases the maxillary bones are very massive and are fused in the median line. The orbits are united into a single cavity, and the eyes are more or less perfectly fused, sometimes forming a single globe. The brain exhibits unmistakable signs of arrest. The corpus callosum is almost always absent, the fornix is absent or rudimentary, the cerebral lobes are usually very defective and are fused in front with each other ; the third and lateral ventricles, in most cases, are opened out into a large cyst, which occupies the greater part of the cranial cavity, a condition which may well induce the belief that the cause of the phenomenon is probably internal hydrocephalus at a very early period of embryonic life. It is certain that hydrocephalus oftens accompanies this condition : examples are seen in specimens Nos. 237 and 238.

* Over den Aard en Oorsprong der Cyclopie ; Amsterd. 1834.
Müller's Arch. 1836.

1. *Rhinocephalus*.

Syn. *Rhinocephalus* and *Cyclocephalus*, *Geoff.*
Cyclops, *Gurlt.*

In *Rhinocephalus* the naso-frontal processes form a frontal proboscis.

210. A foetal Lamb's head with entire deficiency of the axis in the facial region, a solid frontal proboscis, partially fused eyes, and a pair of imperfect nostrils between the maxillæ. The roof of the skull has been removed to show the complete absence of the ethmoid bone and fusion of the optic foramina. *Hunterian.*
211. The brain of the same showing the fusion of the hemispheres in front, the absence of the corpus callosum, the open condition of the large third ventricle, and the complete absence of the olfactory nerves. *Hunterian.*
212. The head of a foetal Boar, with complete deficiency of the facial axis. The eyes are partially fused. An orifice corresponding to the nostrils is situated at the extremity of the proboscis. *Hunterian.*
213. A similar preparation with the eyes more closely united. *Hunterian.*
214. The head of a foetal Sow, similar to the last two, but with the eyes still more closely united. *Hunterian.*
215. The head of a foetal Sow, in which the frontal proboscis is turned back over the forehead. The eyes are fused as far as the edges of the corneæ.
216. The head of a foetal Pig with the eyes fused into a single globe. The roof of the skull has been removed to show the brain. The cerebrum is very small; its anterior lobes are completely fused. The middle lobe of the cerebellum and the corpora quadrigemina are proportionately very large; the latter are not covered by the cerebrum. *Hunterian.*

217. The head of a similar foetal Pig. The roof of the skull has been removed. The cerebral lobes are completely fused in front. The whole brain scarcely fills a quarter of the cranial cavity. *Hunterian.*
218. A similar preparation, but the eye is apparently very defective. The cornea and lens seem to have been arrested in their growth. The cornea is conical. *Hunterian.*
219. A similar specimen with the side of the face dissected to show the form of the skull, the superior maxillary bone, and pterygoid processes. The zygoma and the ascending ramus of the mandible have been removed. The prolongation of the frontal bones into the proboscis is well seen in this preparation. *Mus. Brit.*
220. The head of a foetal Pig with cyclopia, dissected, to show the condition of the brain and nerves. The distribution of the ophthalmic branch of the fifth to the proboscis, and of the superior maxillary nerves to the maxillæ, is well seen on the right side of the head. The brain is exposed on the left side. The small hemispheres are fused together. The corpora quadrigemina and the cerebellum are not covered by the cerebrum.
221. A dissection of the head of an Indian wild Boar with similar deficiencies.
- The upper preparation consists of a section of the head. The cavity of the proboscis extends back to the cranial bones and contains a cartilaginous fold, probably the inferior spongy bones. The lower preparation shows the maxilla and teeth, the pterygoid and styloid process, the middle ear and its ossicles, together with the gustatory and hypoglossal nerves.
222. A foetal Boar with similar deficiencies. There is considerable inequality of development on the two sides, with consequent dislocation of the eye. *Hunterian.*
223. A foetal Hare with similar deficiency. The frontal proboscis is comparatively small.

Presented by A. Newton, Esq.

224. A foetal Kitten with partial fusion of the eyes and a small frontal proboscis. *Hunterian.*
225. A male Human foetus, about the seventh month of gestation, with deficiency of the facial axis and a frontal proboscis. The eyes are contained in a single median orbit and fused as far as the corneæ. The right external ear and the thumb of the same side are very defective. *Mus. Brit.*
226. The head of a Human foetus similarly affected. A transverse vertical section has been made through the posterior part of the head to show the condition of the brain. The section passes through the corpora quadrigemina, the fourth ventricle, and the cerebellum. The corpus callosum is absent, the fornix is rudimentary. The corpora quadrigemina are very large, the cerebrum is small, and entirely contained in the anterior portion of the skull. The third ventricle together with the lateral ventricles form an enormously dilated cyst, occupying the whole of the back and upper part of the cranial cavity. *Presented by C. H. Welch, Esq., 1868.*
227. The posterior part of the brain of the same foetus. *Presented by C. H. Welch, Esq., 1868.*
228. A longitudinal vertical section of the head of a similar foetus. The cerebral lobes are very small, and exhibit an unmistakable condition of arrest. The corpus callosum is absent, and the fornix is rudimentary. The condition of the ventricles as well as the rest of the brain is similar to that seen in the last preparation. The cavity of the proboscis extends back to the dura mater.
229. A section of the head of a Human foetus showing a similar malformation. In this specimen, however, the eye is absent, and the usual situation is marked by a fissure beneath the proboscis; the development of the brain has been arrested, the corpus callosum and the fornix are undeveloped, and the lateral and the third ventricles are united into a large cavity, which is not covered behind

by the posterior cerebral lobes. In this foetus the anus was imperforate, the testicles were undescended, and there was a supernumerary digit on each hand. (See Nos. 414 and 415.)

Presented by F. T. Gramshaw, Esq., 1880.

230. A skull from a similar Human foetus showing defective development in the presphenoidal and ethmoidal regions.

Presented by J. D. Cooke, Esq., 1881.

2. *Arhynchus.*

Syn. Cyclops Arynchus, Gurlt.

In the following preparations the frontal proboscis is absent, indicating a still higher degree of anterior facial arrest.

231. The head of a foetal Lamb with the eyes partially fused together. The upper part of the skull has been removed to show the small size of the basisphenoid, the persistence of the trabeculae cranii, and the absence of the presphenoid and ethmoid bones. The optic foramina are fused into a single foramen. The mandible projects considerably in front of the united maxillae.

Presented by W. R. Gilbert, Esq.

232. The brain of the same. The anterior cerebral lobes are completely fused together. Behind the cerebrum is a large triangular space, corresponding to the third and lateral ventricles; the fornix is seen crossing this space. The corpus callosum is completely absent.

Presented by W. R. Gilbert, Esq.

233. The skull of a similar foetal Lamb. The mandible projects more than in No. 231.

234. The skull of a foetal Horse, with a large median orbit. The axis is entirely wanting in front of the basioccipital. There are traces of a vomer between the solid pterygoid, palatine, and maxillary bones, but there is no trace of a nasal cavity. The mandible projects an inch and a half beyond the maxillae. The cranial cavity is much contracted, and probably only contained a cerebellum.

235. A foetal Kitten with complete fusion of the eyes.
Hunterian.
236. A similar Kitten, with the thoracic and abdominal cavities laid open, to show the perfect condition of the internal organs.
Hunterian.
237. The head of an hydrocephalic foetal Pig, with deficiency of the facial axis and fusion of the eyes into a single globe. The vertex is occupied by a very large cyst.
Hunterian.
238. A Human foetus with similar deficiency of the cranio-facial axis and complete fusion of the eyes. The cerebro-spinal canal has been laid open. The whole cavity has evidently been occupied by a large water-cyst. The head is doubled back on the contorted spinal column, so that its axis is almost parallel with that of the vertebral column. There is complete deficiency of the occipital region and extreme spina bifida. The preparation should be compared with Nos. 339, 340.

3. *Anopia.*

In the following preparations the deficiency extends still further back ; the trabecular arch is entirely wanting ; and the eyes are rudimentary or absent, although the orbit remains.

239. The head of a foetal Pig with entire deficiency of the facial axis, naso-frontal processes, and eyes. There is a V-shaped fissure in the position of the eyelids, which has been enlarged on the right side to show the complete deficiency of the eye. The skull has been opened above, and the cerebellum is seen to be the only portion of the brain it contains.
Mus. Brit.
240. A portion of the occipital and parietal bones of the same.
Mus. Brit.
241. The head of a foetal Pig with anterior deficiency of the facial axis and absence of the eyes. The maxillary processes are separated by a deep wide fissure, so that the two halves of the snout are turned outwards and upwards.
Hunterian.

C. Mesencephalic defect.

Syn. Anopia.

It sometimes happens that the middle of the cranial axis and cavity are greatly reduced in size and otherwise defective, with an imperfect development or atrophy of the mid-brain, whilst the anterior cerebral lobes and the anterior facial region are normal. In this condition the eyes are rudimentary or absent. The tentorium divides the cranial cavity, sometimes to such an extent as entirely to separate the cerebral hemispheres from the cerebellum.

242. A vertical longitudinal section of the head of a Lamb, in which the cerebellum is cut off from the cerebrum by the tentorium. The axial parts between the cerebrum and cerebellum are entirely wanting. The eye is very small and rudimentary. There is atresia of the œsophagus, the upper part of which is apparently entirely wanting. The pharynx is wanting and the mouth ends in a pouch behind the tongue.

242 A. Half the skull of the same. The bones are all present except the orbito-sphenoids, which are represented by membrane only. The frontals are much elevated in front and defective behind; the parietals and all the bones behind the frontals are very small. The eye on this side was exactly like that on the other.

D. Protho-mesencephalic defect.

Very rarely the maxillary and mandibular arches are developed when the whole axis and central nervous system are defective in front of the basioccipital and corpora quadrigemina respectively.

243. A median vertical section through the head of a Pig in which the basisphenoid and presphenoid segments are entirely wanting. The mesethmoid is present. There is a well-marked cerebellum and pons, and the corpora quadrigemina are apparently normal. The rest of the brain is represented by a cyst which projects from the skull. A thick-walled tube extends from the cyst to the

region of the pituitary fossa. This tube does not apparently communicate with the pharynx.

The pharynx is enormously dilated. A Eustachian tube opens on the upper anterior wall. There is no communication between the mouth and pharynx. The openings of the larynx and œsophagus into it are indicated by glass rods. There are no nostrils, but the upper lip is fairly developed. The tongue, mandible, and ears are normal.

Presented by J. B. Shattock, Esq., 1885.

E. Epencephalic axial defect.

The axis of the skull immediately in front of or between the ear-capsules is sometimes defective. In the less marked forms (*agnathia*) only the mandibular arch fails, but the posterior portion of the cranial cavity is contracted. In the more marked forms (*synotia*) the tympanic cavities coalesce, the hyoid arch is constantly present, and the mandibular is usually wanting.

1. *Agnathia*.

The brain-case is slightly contracted behind, especially immediately in front of the ear-capsules, the mandible is absent. The eyes and ears are approximated below, but the mouth and pharyngeal cavities are continuous.

244. The head of a fœtal Pig with total deficiency of the mandible. The eyes and ears are slightly approximated below.

Presented by R. Semple, Esq., 1820.

245. A similar specimen. The roof of the skull has been removed to show the reduced size of the brain-case and cranial axis behind.

246. The skull of a Pig with a similar malformation. The tympanic bullæ are partially fused with each other.

College Stores.

2. *Synotia*.

Syn. Monstres Otocéphaliens, Geoff.

The tympanic cavities are united below, the tympanic and squamosal bones being fused together, although the periotic capsules retain their normal position. This condition is explained by the

view that the tympanic and squamosal bones are integumental ossifications, as has been pointed out by Mr. W. K. Parker. Their position is most variable in malformations, whilst the primitive ear always retains its normal relations with the axis. The external ears are more or less fused together a little above the hyoid bone; there is usually only a single meatus externus, and this frequently communicates with the pharynx by an open tube, or spiracle as it has been termed. There are sometimes two, one on either side, when the meatus does not coalesce with its fellow. This spiracle is not the Eustachian tube, which may coexist with it, but apparently that part of the first visceral cleft which lies in front of and externally to the tympanum. It does not usually communicate with the tympanic cavity. In some forms of Synotia the spiracle or spiracles are absent and the united tympanic membranes form the roof of the pharynx (see No. 252). The mouth and nasal cavity, which are continuous, are usually completely separated from the pharynx by the downward growth of the suborbital (maxillary) arches, and less frequently by the united tympanic membranes when the suborbital arches are absent. The lungs are commonly well formed, and are inflated at birth by the passage of air through the spiracle or spiracles when present. Sometimes the cranial and facial axes remain in their normal relation with each other; but sometimes the relation between the facial and cranial axes is abnormal, and the cribriform plate, in those Mammals in which it is normally vertical, forms part of the floor of the brain-case, the whole brain being pressed forward by the contraction of the posterior portion of the skull.

In cases of this character the ethmoid bone and nasal capsule are also often deficient. These form a connecting link between epencephalic and protho-epencephalic arrest.

247. A longitudinal vertical section of the head of a foetal Lamb, with deficiency of the lower jaw and mouth. The bullæ of the ears and malar bones are fused below. The facial and cranial axes are in the same line. The median structures of the brain are all more or less defective behind,

and the lateral halves are fused in the median line. The cerebral hemispheres, corpus callosum, and fornix are normal. The eyes were approximated and directed downwards. The pharynx has not been preserved, but was probably similar to that in the following preparations.

Presented by Sir E. Home, Bart.

248. The skeleton of the other half of the same head. The fusion of the squamosal bones, zygoma, malar, and superior maxillary bones across the mesial line below is well seen. The basisphenoid and presphenoid bones are absent, and the basioccipital is narrowed in front.

Presented by Sir E. Home, Bart.

249. The head and neck of a foetal Lamb, with deficiency of the mandible and fusion of the ears. The facial is at right angles to the cranial axis, so that the ethmoid forms part of the floor of the skull-case.

The side of the skull has been partially removed to show the base from within. A section has been made through the nasal cavity, and the pharynx has been laid open. A purple glass rod marks each of the following, the optic foramina, foramina rotunda, and the tongue, a hollow organ situated above the anterior part of the pharynx. The only external opening of the pharynx is by the Eustachian tubes and external auditory meatuses. The membrana tympani were absent. Blue glass rods mark the sphenoidal fissure, the foramen ovale, the external auditory meatus, and the anterior condyloid foramen. A white rod has been placed in the jugular foramen.

Hunterian.

250. The anterior portion of the brain of the same, showing the entire absence of the corpus callosum and fornix. The remainder of the brain had decomposed before it was removed from the cranial cavity.

Hunterian.

251. A median longitudinal section of the head of a Human foetus. The lower jaw is exceedingly small and, perhaps, entirely absent. The nasal cavity is shut off from the pharynx by a membranous septum; the tongue is very small, only half an inch in length, and may be observed lying above the epiglottis. Immediately in

front of the tongue is a mass of muscle and connective tissue, which represents the structures of the floor of the mouth. The posterior portion of this mass has the appearance of nævoid tissue, which is indicated by a group of large vessels. The pinna is well developed, but a groove extends downwards from the auditory meatus to the front of the neck. The lateral ventricles of the brain are much dilated.

252. The skull, larynx, and pharynx of a synotic foetal Lamb.

The maxillæ are closely approximated, and the tympanic bones are fused into a single horseshoe-shaped plate, which was closed by a double tympanic membrane. This membrane was found ruptured; its edges contain imperfect auditory ossicles. The tympanic and pharyngeal cavities are united. The mandible is entirely absent, and the pterygo-palatine arches are represented by a mere spicule of bone.

Presented by W. B. Tegetmeier, Esq., 1893.

253. The skin of the head of the same Lamb.

Presented by W. B. Tegetmeier, Esq., 1893.

254. The head of a synotic foetal Lamb with the eyes fused into a single median globe, the whole ethmoid region is absent. The maxillæ are large, and are placed at right angles to the cranial axis. All the internal parts have been removed, so that no accurate description can be given.

Hunterian.

255. A vertical longitudinal section of the head and neck of a synotic foetal Lamb, with deficiency of the facial axis and presphenoid, and complete fusion of the eyes. The brain is very defective in front.

The maxillæ are at right angles to the cranial axis; they form large cancellous masses of bone, which are fused together in the mesial line. There is no vestige of a mandible. The ears are fused together, so that there is a slight auditory meatus communicating with the pharynx by a spiracle. The other characters are precisely similar to those seen in synotia generally.

Presented by Dr. E. L. Ormerod, 1864.

F. Prostho-epencephalic defect.

Syn. Stomacéphalie, Geoff.

The defect of the craniofacial axis commences between the ear-capsules and becomes gradually more marked in front of this region; the basisphenoid may be partially developed, but the axis is entirely absent anteriorly to it. No arches are developed in front of the hyoid arch. The tympanic cavities and external ears are more or less fused together. The cranial cavity is small and rounded. The face, when present, consists of a frontal proboscis and a pair of more or less united eyes. Sometimes the maxillæ are represented by a small papilla. These parts are placed immediately beneath the skull. The term *cyclocephalus* has been applied to this form.

In the most defective conditions the face is completely wanting, but a pair of external ears, sometimes fused together in the median line, exist. An atrophied median eye sometimes exists, but is more commonly absent. In such cases the frontal and maxillary probosces are either very rudimentary or wanting. When the ears only are present, the squamosal bones form a shield in front of the skull-case. The term *nanocephalus* has been applied to this form.

The periotic bones always retain their normal position with regard to the axis, and the tympanic bones are usually removed from them. The pharynx always ends blindly above, but often communicates with the exterior by tympanic spiracles.

The brain is either arrested in its development or, in *nanocephalus*, is completely absent, the skull-cavity being occupied by a cyst surrounded by the anterior termination of the medulla. In *cyclocephalus* in the human subject the axis of the skull remains in the same line as that of the vertebral column.

The most extreme form of cranial deficiency is entire absence of the skull, or a mere cyst between the external ears terminates the axial canal in front. The term *acephalus* has been used to designate this malformation.

This form differs from *acardia* in having an independent heart.

1. *Cyclocephalus.*

256. The head of a male foetal Pig with a frontal proboscis and a pair of eyes fused as far as the cornea. The maxillæ are represented by a papilla beneath the eyes. The mandible is absent. The tympanic cavities are united. The external auditory meatuses are not fused together; a black bristle is passed through that on the left side into the pharynx. The pharynx has been laid open. The animal was otherwise normal.

257. A similar preparation in which the eyes are fused into a single globe. The ear, pharynx, and larynx are dissected. The hyoid arch is perfect.

On the right side the anterior wall of the external meatus only has been removed, on the left side the tympanum has also been laid open. There was an external opening beneath the bullæ into two distinct passages which lead into the pharynx; these auditory spiracles are marked by two bristles. The median Eustachian tube is also marked by a bristle. The tympanic membranes were both perfect.

258. The head of a foetal Sow with similar deficiency. In this specimen the median eye appears as if it had been much damaged by inflammatory action.

259. A section through the head of a similar foetal Pig, showing the total absence of the craniofacial axis in front of the basisphenoid bone. A bristle marks the external opening of the pharynx. *Presented by Sir E. Home, Bart.*

260. The tympanic bulla and the labyrinth of the left ear from the same.

261. The head of a Human foetus about the end of the sixth month, with a single eye in the mesial line and conjoined tympanic bones. There is no vestige of the mandible or facial axis.

A dissection from behind shows the cavity of the skull and pharynx. The eye and ears are in front of the axis of the skull,

which is perpendicular instead of horizontal. The craniofacial axis is entirely deficient in front of the basisphenoid. The tongue is well formed, and occupies the upper part of the pharynx. The pharynx opens externally by spiracles communicating with the external auditory meatus.

262. The posterior portion of the skull and brain of the same. The section passes through the cerebellum, pons, corpora quadrigemina, and a portion of the medulla and the fourth ventricle.
263. The lateral half of the head of a Human female foetus with entire deficiency of the facial axis, fusion of the eyes, absence of the mandible, and approximation of the ears. The pharynx opens by the aural passage, through which a black bristle has been passed. A mass of cartilage and several small masses of bone are seen beneath the eye, representing in some degree the deficient facial bones; there is also slight curvature of the cranial axis forward. *Presented by W. Squire Ward, Esq., 1863.*
264. A longitudinal vertical section of the head and neck of a foetal Lamb with complete fusion of the eyes and ears and absence of all the other parts of the face. The cerebral lobes are hollow, and all the axial structures of the brain are wanting, the lateral parts were fused in the median line. The pharynx opens by the median external auditory meatus, which is entirely removed from the auditory capsule. The tympani are absent. A bent purple glass rod indicates the passage between the auditory meatus and the pharynx. *Hunterian.*
265. The opposite half of the same. *Hunterian.*

2. *Nanocephalus.*

266. The skull of a foetal Lamb with deficiency of the entire axis in front of the basisphenoid region. The mandible and all the facial structures, except a shallow orbit, are absent. The squamosal bones are united beneath the skull. The bullæ of the ears are not fused in this preparation. *Presented by C. B. Rose, Esq., 1869.*

267. The skin of the head of a similar foetal Lamb.
268. The skull and hyoid bone of the same.
269. A foetal Puppy with a nanocephalous skull. There is a very imperfect Cyclops-eye, a soft imperforate frontal proboscis, and a similar structure representing the maxillæ. The pharynx opens through the aural tract. The roof of the skull has been removed to show its base from within. The axis terminates in the basisphenoid region, immediately in front of the foramen magnum. All the bones of the skull except those of the ear-capsule are very small; these are of their normal magnitude, and occupy a very large part of the base of the skull. *Mus. Brit.*
270. A nanocephalous foetal Puppy with no eye or orbit; it is otherwise similar to the last. *Hunterian.*
271. A similar foetal Hare, but without any maxillary proboscis.
272. A similar nanocephalous foetal Kitten, but without any proboscis. There is a cæcal foramen representing the orbit. The tympanic bullæ are united. The single meatus externus has been laid open to show the tympana; beneath these is a passage, marked by a bristle, leading into the pharynx. The thoracic cavity has been opened and the thymus removed to show the normal condition of the heart and lungs. *Hunterian.*
273. A similar foetal Kitten.
Presented by Dr. H. J. Holt, 1876.
274. A microcephalous foetal Pig with fusion of the tympanic cavities. A small bifid tubercle on the face is the only remnant of the united and atrophied eyes. There are no other facial organs except a pair of external ears that are united by their bases. The neck and thorax have been laid open to show the perfect condition of the hyoid arch, larynx, trachea, and lungs. The calvarium has been removed to show the base of the skull. *Hunterian.*
275. The nanocephalous skull of a similar foetal Pig. The squamosal bones are fused together and form a square

projecting plate above the united tympanic bullæ. The frontal bones are very defective. The basioccipital is the only bone in the cranial axis, and it ends in a point in front.

276. The anterior half of a nanocephalous foetal Kitten. The external ears were united at the base; but the left lateral half of the head has been removed to show the head in section. A bristle marks the external opening of the alimentary and respiratory tracts.
277. A microcephalous Human foetus, in which the face is entirely wanting, its position being occupied by a pair of ill-formed ears fused together above and below, with a small rounded tubercle between them in the place of a meatus. The skull and spinal canal have been laid open from behind.
278. A longitudinal vertical section of the anterior part of a nanocephalous foetal Lamb. The brain in front of the medulla is represented by a cyst only. The pharynx opens externally through the united tympanic bullæ and external meatus. *Presented by Sir W. Blizard.*
279. The atlas and bones of the skull from the other lateral half of the same. The anterior part of the skull is seen to be extremely defective. The bones of the ear-capsule retain their normal position, but the tympanic and squamous elements were united across the mesial line in front of the defective cranial axis. *Presented by Sir W. Blizard.*
280. The left half of a longitudinal section of the anterior part of a nanocephalous foetal Pig. The cranial bones are very thick. The specimen is in other respects similar to the last. *Hunterian.*
281. The right half of the same. *Hunterian.*
282. A portion of the spinal column and cord of a foetal Lamb. The medulla ends in a rounded extremity. It is surrounded by a case, partly of membrane and partly of carti-

lage, which represents the cranium: a pair of imperfect periotic capsules are imbedded in its walls. *Hunterian.*

283. The anterior extremity of a nanocephalous foetal Lamb. The head is represented by a pair of ears and an elongated bladder-like cyst, which projects between and above them. The pharynx is laid open from the side, and a quill is passed into it through each external auditory meatus.

Presented by the Prince de Condé.

284. The anterior portion of a foetal Lamb, in which the head is represented by a pair of ears only at the anterior extremity of the axis. The skin has been reflected to show the tympanic bullæ, and the auditory meatus has been opened on one side to show the membrana tympani. The pharyngeal cavity has also been laid open.

Presented by Sir W. Blizard.

285. The skin of the anterior region (corresponding to the head), and the anterior region of the spinal column, including the first two dorsal vertebræ and their ribs, of a female foetal Hare. The pinnæ of the ears are well developed, but the median meatus is absent. A portion of the skin in front is devoid of hairs; from this a process extends dorsally in the mid-line, giving the part the ordinary appearance of hare-lip. Although there were one or two depressions of the smooth skin they were all blind, and there were no indications of mouth, nose, or eyes.

A bristle has been passed between the atlas and the rudimentary occipital bone, which alone represented the skull. The exoccipitals are well developed; the left shows a small piece of cartilage near its dorsal extremity, which may represent the supraoccipital. The basioccipital presents two centres of ossification. In front of the left exoccipital is a small scale-like piece of bone indicated by a bristle. This is apparently the mastoid. A similar piece has probably been removed from the right side. The alimentary canal terminated blindly in front immediately beneath the skin; the larynx and all other parts were normal.

286. An injected foetal Pig, in which the axis terminates in the same manner. The pharynx is laid open, and bristles

are passed on each side from the external meatus of the ear into its cavity.

A circular fold of mucous membrane divides the cavity of the pharynx into two portions. The upper probably represents that portion which is normally above the soft palate. The ring seems to represent the soft palate; it has been slit up in front. The right lung and the liver were removed, it is stated, to show more clearly the position of the remaining viscera. The intestine terminates in a blind sac in the umbilical cord. There is no anus, and the kidneys have coalesced in the median line. The lateral toes of the hind feet are abnormally large.

287. A male foetal Pig with a pair of ill-developed external ears, and a long thin proboscis with an irregular mass of cartilage in its extremity, as the only representatives of the head and face.

The right side of the back has been dissected to show that the spinal column is truncated above. A minute fistula nearly an inch below the ears communicated with the pharynx, but it has been laid open in front with that cavity. The thoracic and abdominal cavities have been exposed to show the viscera.

Hunterian.

Subclass II. POSTERIOR DEFICIENCY OF THE AXIS.

Group I. *Simple Deficiency of the Axis.*

The caudal and even the sacral vertebræ are defective or even entirely absent.

288. A Mouse with a rudimentary tail, caught in a barn at Acton, Middlesex, in 1878, with several hundreds of others, all with the tails in a more or less rudimentary condition, a breed having been established.

Presented by Dr. Edward Hamilton, 1878.

289. The pelvis of a Cat with arrested sacral and caudal region. It was one of a litter of four, which all had truncated tails; the mother presented the same condition.

Presented by Mr. J. Marle, 1880.

Group II. *Sympodia*.

Syn. Monstra Syreniformia, Monopodia, et Syméliens, *Geoff.*

Just as fusion of the lateral organs of the face results from arrest of the facial axis, so arrest of the posterior extremity of the spine gives rise to fusion of the posterior limbs, unless their growth is likewise arrested (see No. 431). In posterior axial arrest the development of the viscera of the lower part of the abdomen is very defective; the rectum is usually absent, and the colon is greatly enlarged and terminates in a blind extremity. The posterior extremity of the axis is curved back, and has marked indications of arrested growth. The innominate bones are fused below as far as the acetabula, and the femora, when present, are rotated outwards until the knees look backwards; hence the limbs are fused by their external aspect. The lower extremities of the femora may be united into a single symmetrical bone; the tibiæ are usually fused into a single bone, which may either terminate in a blunt stump or support a compound foot, consisting of more or less of the normal pair united by their outer sides, with the heels turned forward. The united limbs are usually curved, so that they are concave in front. The term *sympodia* has been used to designate this condition; fœtuses so malformed are said to be sireniform. Sometimes one limb is entirely or partially wanting. When it is wanting or inconspicuous, the term *monopodia* has been used; the developed limb is usually rotated as in *sympodia*.

290. A sireniform Human fœtus. The rectum ends in a *cul-de-sac* above the pelvis; there are no traces of external generative organs, but the ovaries and Fallopian tubes are well developed, although the body of the uterus is wanting.

Presented by Lawson Tait, Esq., 1878.

291. A sireniform Human fœtus. The soft parts of the lower extremities are fused, but the osseous structures remain separate. The toes of the imperfectly united feet are ill-formed and unsymmetrical in size and number. The anal *cul-de-sac* is absent, and a small tubercle of integument in the gluteal region is the only representative of the external generative organs.

Presented by Dr. Edmund Walter, 1883.

292. A Human male fœtus at about the seventh month of gestation, with defective development of the posterior extremity of the axis, with rotation and fusion of the lower limbs. The foot is formed of the inner portion of both feet, and presents four toes, the two inner toes of each foot. The external sexual organs are extremely defective. The abdominal cavity has been laid open to show the dilated condition of the colon.
293. A similar fœtus in which the fused posterior extremities terminate in a two-lobed stump. One lobe is turned back laterally ; it is considerably longer than the other.
Presented by J. Stringfield, Esq.
294. A similar fœtus in which the fused limbs ended in a single rounded stump. The limb has been dissected to show the arrangement of the muscles. The external vasti form a single muscle behind ; the sartorii are straight, and run down the outer sides of the stump. The two long adductors are close together in front. The tibia terminates in a long blunt cartilaginous point.
295. The viscera of the same. The lungs are very small, and both are of nearly equal size ; each has only two lobes. The intestine terminates in an enormously dilated colon.
296. The external integument of the united limbs of the same fœtus.
297. A similar fœtus, with the skeleton of the stump and lower portion of the body exposed. This specimen shows the peculiar flexure of the spine well, the fusion of the bones of the limb, and their excessive rotation. There are two patellæ.
Presented by Dr. W. G. Sheppard, 1867.
298. A similar fœtus, with the muscles of the lower half removed to show the skeleton. The pubes and ischia are fused. There is but one limb, as far as the skeleton is concerned. The tibia terminates in a point.
Presented by J. F. Steedman, 1864.

299. The skin of the conical stump-like limb of the same. A small nipple-like prominence only represents the right limb. *Presented by J. F. Steedman, 1864.*
300. The thoracic viscera of the same, exhibiting situs mutatus or transposition. *Presented by J. F. Steedman, 1864.*
301. A small Human foetus with monopodia, about the sixth month of gestation. A section has been made through the head and trunk as well as through the single stump, which represents the lower limb. The spine is contorted, the pelvis cannot be recognized. The limb terminates in a rounded stump, like that of an amputated limb. The patella is turned backward, and a small square piece of cartilage only represents the distal extremity of the limb.
302. A sireniform Human foetus at about the fourth month of intra-uterine life. *Presented by Dr. G. Rugg, 1876.*

Subclass III. DEFECTIVE DEVELOPMENT OF THE SOMATO-PLEURAL LAMINÆ.

Syn. Cleft Formation.
Spaltbildung.

Group I. *Defective Closure of the Thoracic and Abdominal Cavities.*

This condition sometimes arises from simple arrest of development; the abdominal cavity, however, remains open more often as a result of some other malformation, especially curvature of the spine, the union of twins, or displacement of the abdominal viscera. A portion of the diaphragm is occasionally wanting.

1. *Fissure of the sternum (ectopia of the heart).*

Slight fissure of the sternum may exist without displacement of the heart; in the gravest forms there is complete ectopia of that organ.

303. The sternum of a Goose with deficiency of the median ossification. The carina is completely absent, its place being occupied by a fissure.

304. The sternum of an adult Wood-Owl (*Syrnium aluco*) with median deficiency. The lateral parts are very divergent below. *Presented by W. B. Tegetmeier, Esq., 1877.*
305. Part of a well-nourished Blue-rock Pigeon, with ectopia of the crop, which is widely open anteriorly, its free edges being blended with the integuments. The food apparently passed along a grooved recess at the back of the crop. No appearances indicative of injury were observed. *Presented by W. B. Tegetmeier, Esq., 1885.*

2. *With ectopia of the abdominal viscera.*

Syn. Schistocomus, Gurlt.

Cases of ectopia are most usually accompanied by other malformations; hence several are arranged in other parts of the Collection. See Nos. 357-360, 371-373, 519-524.

306. A fœtal Pig with deficiency of the anterior thoracic and abdominal walls. The heart and peritoneal sac protrude from the cleft. The anterior membranous investment has been removed. *Hunterian.*
307. A female Human fœtus at about the seventh month, with the greater part of the intestine protruding above the umbilicus. The walls of the sac which contained this intestine have been removed. *Presented by W. Harris, Esq.*
308. A female Human fœtus, probably at about the seventh month, with deficiency of the abdominal parietes. There is a large visceral tumour covered by transparent membranous walls. The tumour contains the liver and the greater part of the intestinal canal. There is also arrested development of the forearms. The hands are placed at right angles to the limb. There are but three fingers on the left and four on the right hand. The left leg is shortened. There is curvature of the spine and spina bifida in the lumbar region. *Hunterian.*
309. A female fœtus with ectopia of abdominal viscera. *Presented by J. A. Hedges, Esq., 1881.*

310. The lower part of the trunk and lower limbs of a female Infant which lived five days. There is but one kidney, that of the right side. The suprarenal capsule only is present on the left side. The hypogastric region was imperfectly closed, and the rectum protrudes as a hernia. The anus is imperforate.

The uterus is divided into two parts, of which the right is the more perfect. The external generative organs are on the right of the ruptured hernial sac. The dilated ureter opens into the urachus. The left foot is very imperfect. *Presented by F. Treves, Esq., 1883.*

311. A portion of the trunk of a female Human fœtus, with displacement of the viscera and deficiency of the anterior abdominal wall. The liver and kidneys are disproportionately large. The abdominal parietes immediately above the umbilicus are very thick and loaded with fat, but over the liver they are thin and membranous.

Presented by Dr. C. H. Bennett, 1868.

312. A Human fœtus with ectopia of the abdominal viscera and deficiency of one half of the pelvis and corresponding limb.

Presented by J. Gay, Esq., 1873.

313. The body of an Infant with ectopia of the abdominal viscera. There is an opening an inch and a half in diameter, situated in the abdominal wall to the right of the umbilicus, through which the stomach and the whole of the intestine, except the last three inches, have protruded. At the lower margin of the opening the eiongated fundus of the urinary bladder, together with the testes and their mesorchia, are seen lying outside the abdomen. The right hypogastric artery (marked with a bristle) crosses the front of the bladder to reach the umbilical cord. In the recent state the peritoneal surface of the exposed viscera was inflamed.

The infant was born at full term and lived twenty-six and a half hours. His mother, aged 38, had previously given birth to seven healthy children. (See Trans. Medical Soc. vol. xiv. p. 396.)

Presented by Dr. T. Elliott, 1891.

Group II. *Defective Closure of the Neural Laminae.*

Dropsy of the axial canal of the brain and spinal cord is by far the most frequent disease of intra-uterine life. When confined to the cord it gives rise to the condition known as spina bifida; the neural arches are open behind, although they are usually well developed. In extreme forms a lamina and spinous process is formed on each side of each defective vertebra and lies parallel to the transverse process, the canal being completely opened out by the pressure of the tumour. The tumour consists of the membrana reuniens superior of Remak, or of skin, connective tissue, and the substance of the spinal cord spread out into a cyst, and almost converted into fibrous tissue by hypertrophy of its connective elements. Sometimes the tumour becomes pedunculated by pressure, which the perfect laminae above and below exert upon it during its rapid increase. Spina bifida is common in the lumbo-sacral region, but extremely rare in the back and neck, except when accompanied by internal hydrocephalus and considerable malformation of the skull. In the latter case the occipital bone exhibits considerable deficiency. When dropsy occurs at a later period of development it gives rise to the formation of an enormous cyst on the occiput or vertex, *epicephalocele*; and when it occurs towards the close of intra-uterine life it produces distention of the skull and great enlargement of its neural arch, *hydrocephalus*.

1. *Spina bifida.*

314. A Kitten with spina bifida. The neural arches of the lumbar vertebrae are defective. There is a small sinus through which a glass rod has been passed. During life cerebro-spinal fluid escaped freely from the sinus.

Presented by Lawson Tait, Esq., 1876.

315. A portion of the lumbar and sacral region of a new-born Child affected with spina bifida. The surface of the tumour is ulcerated. *From Sir A. Cooper's Museum.*

316. A vertical section of the lower part of the back and sacrum of a new-born Child with spina bifida. In this specimen the chorda equina is incorporated with the walls of the tumour. *From Sir A. Cooper's Museum.*

317. A similar specimen with the spinal canal opened from behind. *Hunterian.*
318. A vertical section of the lumbar and sacral region of a Child affected with spina bifida. The lower extremity of the cord is incorporated with the walls of the tumour, from which the lumbar nerves appear to arise. This preparation and the last, No. 317, were taken from children born of the same parents. *Hunterian.*
319. A sacral spina bifida opened from behind; the sacral nerves have been cut through at their junction with the wall of the cyst.
320. The lumbar vertebræ and sacrum of a new-born Child with spina bifida, showing the defective condition of the neural arches. *Hunterian.*
321. A dried preparation, consisting of the bones and ligaments of the lower portions of the vertebral column of a Child with spina bifida. There is a thin membranous cyst corresponding to the intervertebral ligaments and membrane. The neck of the cyst is very narrow; but this appearance is much increased by the mode of preparation.
Presented by Dr. Thurnam, 1871.
322. The lower part of the spinal column of a Child aged 12, with a spina bifida involving the three lower lumbar and all the sacral vertebræ. The left half of the body of the fifth lumbar vertebra is undeveloped, and this gives the sacrum a considerable inclination to the left side. (See Trans. Clin. Soc. 1885.)
Presented by R. W. Parker, Esq., 1884.
323. The spinal cord and soft parts from the same case. The walls of the sac are much thickened, and it is partially filled by newly formed fibrous tissue. These changes probably resulted from the repeated injection of iodine. The termination of the spinal cord where it enters the sac and the nerves passing from it into the intervertebral foramina have been dissected out. (See Trans. Clin. Soc. 1885.) *Presented by R. W. Parker, Esq., 1884.*

324. Part of the vertebral column from an Infant with extensive spina bifida in the dorso-lumbar and sacral regions. The laminae are widely open. (See Trans. Clin. Soc. 1885.)
Presented by R. W. Parker, Esq.
325. Part of the vertebral column of an Infant with lumbo-sacral spina bifida. (See Trans. Clin. Soc. 1885.)
Presented by R. W. Parker, Esq.
326. A sacral spina bifida in which the termination of the spinal cord enters the sac and is attached to its posterior wall; the attachment is marked by an umbilicated depression. (See Trans. Clin. Soc. 1885.)
Presented by R. W. Parker, Esq., 1884.
327. A vertical section of a large lumbar spina bifida from a Child. The tumour is divided by a vertical septum, which is perforated by a large oval opening. The integument has been removed, but the tumour is covered by subcutaneous fat. *Presented by R. Partridge, Esq., 1869.*
328. A sacral spina bifida from a Child. The tumour is covered with thickened integument; it has been opened at the side. Its cavity is seen to be divided into loculi by imperfect septa.
329. A spina bifida from the sacral region of an Infant. The cauda equina passes directly backwards from the spinal canal, and is attached to the posterior surface of the cyst. The membranes form a median partition within it. (See Trans. Clin. Soc. 1885.)
Presented by R. W. Parker, Esq., 1883.
330. A sacral spina bifida dissected. The continuation of the dura mater and arachnoid entering into the formation of the walls of the sac are displayed. The spinal cord passes directly backwards from the upper part of the sac, and is continued down its posterior surface; in its course the nerves are given off in a double vertical series. The nerves pass horizontally forwards from the back of the sac, the anterior and posterior roots are distinct. The ganglia on the posterior roots occupy the usual position. (See Trans. Clin. Soc. 1885.)
Presented by R. W. Parker, Esq.

331. The six lower dorsal, the lumbar and sacral vertebræ of a new-born Child with spina bifida. The laminæ of the four lower dorsal, lumbar, and sacral vertebræ have been widely separated by dropsy of the cord. The laminæ are well formed and are abnormal only in having been opened out by the tumour. This specimen indicates very clearly that spina bifida does not arise from arrest of development, but from pressure from within.

Presented by F. Kiernan, Esq., 1871.

332. A section of the sacrum of an Adult with spina bifida.

Presented by Sir W. Blizard.

333. A Human female fœtus with spina bifida, cleft palate, talipes, and arrested development of the vagina and vulva.

Presented by S. Saunders, Esq., 1874.

334. A portion of the head and neck of a Child which died three days after birth from the effects of a ligature applied to a cervical spina bifida. The peduncle of the tumour is marked by a bristle; it passes between the laminæ of the sixth and seventh cervical vertebræ, the spines of these bones are deficient. The laminæ of the perfect vertebræ have unfortunately been removed to show the cord.

Presented by A. White, Esq., 1827.

335. A section of a spina bifida in the lower lumbar and sacral regions. The skin over the tumour is drawn in, and the cyst-cavity is obliterated by newly formed fibrous tissue. The cure resulted from the repeated injection of iodine into the sac. (See Trans. Clin. Soc. 1885.)

Presented by R. W. Parker, Esq., 1885.

336. A similar specimen. (See Trans. Clin. Soc. 1885.)

Presented by S. G. Shattock, Esq., 1885.

337. A spina bifida with a process of bone projecting from the junction of the bodies of two vertebræ backwards across the neural canal to the laminæ, perforating the spinal cord. (See Trans. Clin. Soc. 1886.)

Presented by R. W. Parker, Esq., 1886.

338. The skeleton of a hydrocephalic Human foetus with a spina bifida involving the dorsal, lumbar, and sacral regions. In this specimen the bodies of the vertebræ are also deficient, so that the spine is completely cleft as high as the cervical region.

2. *Occipital Deficiency.*

339. The skull and vertebral column, with a portion of the ribs and the pelvis, of a hydrocephalic Human male foetus, with distortion of the vertebral column, defective development of the occipital bone, and defective closure of the vertebral canal behind.

The laminae of the cervical and first six dorsal vertebræ are widely separated behind; those of the right side are absent. There are apparently but five cervical vertebræ, and their laminae are fused together. The head was pressed back so that the edges of the enormously dilated foramen magnum rested on the edges of the laminae of the dorsal and cervical vertebræ, to which they were attached by ligament. The supraoccipital cartilage bones are very small. There are, however, two scale-like bones representing the upper part of the supraoccipital bounding the foramen magnum above. The frontals and parietals are very large. There is spina bifida in the lumbar and sacral region. The pedicles and laminae of the lower dorsal and lumbar vertebræ are well developed, but they are spread out on either side, so that the spinal canal is open behind. There was talipes of both feet.

Presented by J. Hutchinson, Esq., 1870.

340. An occipital bone with similar deficiency, from a Human foetus.

3. *Epicephalocoele.*

Syn. Monstres Exencéphaliens.

Meningocele.

Encephalocoele.

In these malformations the brain and membranes form a large cyst, only partially enclosed in the cranial cavity.

341. The skull of a Calf, with a large rounded opening in the supraoccipital bone through which a very large epicephalocoele protruded. The opening corresponds to the interval between the four centres of ossification of the occipital bone.

Presented by J. B. Sutton, Esq., 1886.

342. A Human female foetus with a large cyst-like tumour in the occipital region. The frontal bones are much depressed. The cyst has been opened behind ; the posterior part of the cerebrum protrudes into it.
343. The head of a Human foetus with a large epicephalocele on the vertex. *Hunterian.*
344. The head of a Human foetus with a pedunculated cyst eight inches in diameter on the occipital region. This cyst is supported and attached to the head by a minute pedicle. The cutaneous cyst contains a smaller cyst which is apparently an encephalocele in its interior. It is stated that the cavity of the inner cyst communicates with the cavity of the ventricles of the brain.

Presented by F. S. Palmer, Esq., 1884.

4. *Anencephalus.*

Syn. Monstres Pseudencéphaliens et Acéphaliens, Geoff.

In anencephalus the roof of the skull is absent or consists of the membrane-bones pushed forward upon the forehead, where they form a narrow band or crest ; the cartilaginous supraoccipital is always absent, and the whole base of the skull is widely exposed. The neural arches of the cervical vertebræ are usually more or less open, they are rarely closed. The brain is frequently absent ; it is sometimes represented by a cyst filled with fluid or blood, or by a cerebroid tumour, which protrudes from the open cranial cavity. The condition arises, probably, sometimes at least, from ulceration of the vertex in the embryo.

345. A vertical section of the head of a female anencephalous Human foetus. The roof of the skull and the laminæ of the cervical vertebræ are entirely wanting. The brain-membranes, containing some brain-substance and a large clot, form a tumour which projects behind the head.

Presented by W. Copeland, Esq.

346. A vertical section of the head of a female anencephalous Human foetus, injected. The roof of the skull is wanting ; the laminæ of the first three cervical vertebræ are open. There is no trace of brain, but the base of the skull is covered by a thin vascular membrane. *Hunterian.*

347. The other half of the same. *Hunterian.*

348. The abdomen of the same foetus opened in front, with the principal viscera removed, to show the much lobulated kidneys, a condition of arrested development. *Hunterian.*

349. A preparation similar to No. 347.

Presented by Sir W. Blizard.

350. A section of the head and trunk of an anencephalous Human foetus with extreme inflected curvature of the upper part of the spinal column, absence of the laminae of the vertebrae and of the whole axial nervous system. The peripheral nervous system is well developed, the nerves terminating (centrally) in the fibrous tissue behind the bodies of the vertebrae.

Presented by John Gay, Esq., 1872.

351. The skeleton of the head and trunk of an anencephalous Human foetus. The vertebral canal is open and exhibits an inflection in the cervical region.

This skeleton is apparently from a foetus precisely similar to No. 350.

Presented by D. Alton, Esq., 1885.

352. The skull and vertebral column of an anencephalous Human foetus. The frontals, parietals, and the upper part of the squama occipitalis are very narrow from before backwards, and these bones are much depressed, so that they lie upon the anterior part of the base of the skull. The supraoccipital is absent, so that the opening is an immensely enlarged posterior fontanelle. The exoccipitals are very large and perforated by a considerable foramen. The spinal canal is open, the laminae and spines being spread out on either side; several are ankylosed together, as are also the three upper ribs of the right side. The bodies of the cervical vertebrae exhibit two lateral centres of ossification, a condition very constantly met with in conjunction with other forms of abnormal development.

Mr. Langstaff's Museum.

353. The skull of an anencephalous Human foetus.

Presented by J. Messiter Lang, Esq., 1874.

354. The skeleton of the head and trunk of an anencephalous Human foetus. *Presented by Alex. McKellar, Esq., 1879.*

355. A male anencephalous Human foetus.
Presented by John Abbey, Esq., 1826.

356. A male anencephalous Human foetus with the placenta adherent to the membranes of the brain.
Presented by T. M. Donohoo, Esq., 1862.

357. A female anencephalous Human foetus with ectopia of the viscera. The sac containing the protruded intestine has been laid open; a large portion of the placenta is seen adhering to the sac.

These two preparations are interesting, as they show an extremely frequent complication of these conditions. On *à priori* grounds it would appear extremely likely that the placenta would become adherent to an open membranous surface like the peritoneum, arachnoid, or pia mater, or to the edge of an ulcerating surface. It is not a little remarkable that so many have considered such adhesion as the cause of the malformation, as it is far more probably an effect, or an accidental complication extremely prone to occur.

Hunterian.

358. A female anencephalous Human foetus with a large cerebroid tumour occupying the open skull-cavity. There is also ectopia of the viscera on the left side of the umbilicus. The whole left flank of the abdomen is absent as far back as the edge of the quadratus lumborum.

The cerebroid tumour, which was adherent to the amnion, was observed pulsating. This malformation is said "to have lived twenty minutes and to have cried when the tumour was manipulated."

Presented by W. A. Duncan, Esq., 1873.

359. An anencephalous Human foetus with ectopia of the viscera.
Presented by Dr. A. Forsyth, 1875.

360. A Human foetus with ectopia of the abdominal viscera, encephalocele, and adhesion of the placenta to the head.
Presented by E. T. Aydon Smith, Esq., 1884.

Class V. MALFORMATIONS BY DISTORTION.

Subclass I. SPINAL CURVATURES.

The causes producing congenital curvature of the spine are unknown ; it may nevertheless be looked upon as the effect of disease, and may occur at any time during foetal life from the earliest period. Except that the resulting malformations are more grave, it often differs in no way from ordinary lateral curvature.

1. *Simple curvature.*

361. A Perch with congenital curvature of the spine.
Hunterian.
362. A similar specimen, with the integuments and muscles of the left side dissected off.
Hunterian.
363. A Trout with congenital curvature of the spine.
Presented by Sir A. Carlisle.
364. The skeleton of a Sole with congenital curvature of the anterior part of the spine.
Presented by F. E. Manby, Esq., 1880.
365. The embryo of a Goose about the fourth day of incubation, with curvature of the axis.
Hunterian.
366. A portion of the skeleton of a Fowl, showing lateral curvature of the lower dorsal region of the spine, probably congenital.
Presented by Mr. John Marle, 1877.
367. A precisely similar specimen. The egg was hatched in an incubator.
Presented by Mr. John Marle, 1889.
368. The skeleton of the trunk of a hybrid Duck, bred in St. James's Park, with a very remarkable antero-posterior flexure of the sacral region, giving rise to considerable shortening of the trunk.
Presented by H. J. B. Hancock, Esq., 1868.

369. A foetal Calf removed from one of the lateral halves of a divided uterus, No. 654, with considerable curvature of the spine. *Hunterian.*

370. A model of a specimen of congenital malformation of the spinal column, thorax, and left scapula, from a female, aged 31 years. Instead of the normal posterior dorsal curvature of the spine, there is a slight anterior curve, also a sharp lateral curve with the convexity to the left, apparently due to the absence of the right half of the third dorsal vertebra. In the lower dorsal region is a longer and slighter compensatory curve. There are only seven ribs on each side, but the upper rib of the left side evidently consists of three ribs united, and it articulates with three vertebræ. The intercostal spaces are abnormally wide. The sternum is directed obliquely from above downwards and to the left. The left clavicle is much deformed. The cavity of the thorax is much diminished in all its diameters, especially in the antero-posterior, and its capacity is distinctly less on the right than on the left side. The left scapula is rotated forwards and fixed to the spine by a flat bridge of bone extending from the middle third of its posterior border to the lamina and spinous process of the sixth cervical vertebra.

The woman from whom the above model was made was of average height, and until uncovered did not present any noticeable deformity, owing to the extreme width of the costal spaces.

The impulse of the heart's apex was widely diffused. She died of morbus cordis. See an account of the specimen by Mr. Willett and Mr. Walsham in the 'Med.-Chir. Trans.' vol. lxiii. p. 257, 1880.

Presented by Alfred Willett, Esq., 1881.

2. *With ectopia of the viscera.*

Syn. Monstres Célosomiens, Geoff.

371. A Human female full-time foetus with curvature of the spine and considerable contortion of the inferior extremities. The anterior thoracic and abdominal wall has been removed, with the viscera; it forms the next preparation.

The abdominal cavity is so small that all the viscera protruded into a large sac situated in front of the abdomen.

372. The anterior thoracic and abdominal wall of the same, showing the opening through which the viscera protruded.

The anterior wall of the hernial sac has been removed. The posterior aspect of the abdominal wall has a transverse ridge below the neck of the exomphalos; this corresponds to the pubic symphysis; below the ridge the external abdominal wall looks backward and presents a mucous surface of a triangular form. This surface may be looked upon as a kind of cloaca. The intestine opens at the apex of the triangle, where it is marked by a green glass rod; it has probably been cut at this point, as it entered the umbilical cord to form an umbilical hernia, a condition commonly seen in such malformations when the bowel ends in a blind extremity in the cord. The ureters open by two minute openings marked by bristles at the base of the triangle. The vagina is situated in the centre of the space; it is marked by a purple rod: a papilla, with a blind foramen between it and the vagina, is seen above the latter and between it and the ureters; its nature is uncertain, but it probably represents the blind rectum; it is marked by a pale blue glass rod. The liver and intestine are voluminous. The kidneys have coalesced in the median line, one ureter only is pervious; the other is impervious except at its ends. A purple rod is passed under both ureters. There is a body on the left side which is not paired on the right, it appears to be a suprarenal capsule. The uterus is very large, and its cornua are widely separated. The diaphragm is imperfect, and the heart is much drawn down by the displacement of the abdominal viscera.

373. The bones of a foetal Calf with strong backward curvature of the spine and doubling back of the ribs. The pelvic bones are closely approximated, and several of the ribs are fused together. There has evidently been complete ectopia of the viscera. No anterior extremities existed. This condition is nearly identical with that described by Gurlt under the term *Schistozomus reflexus*, except in the absence of the anterior extremities. *Hunterian.*

SERIES II.

ABNORMAL CONDITIONS OF THE LIMBS AND
OTHER APPENDAGES.

Class I. EXCESS IN THE NUMBER OF PARTS.

* IN INVERTEBRATES.

374. A specimen of *Amblypneustes griseus* with a sixth ambulacrum, which is placed in the middle of the ambulacrum that lies to the left of the madreporic plate.

Presented by C. Stewart, Esq.

375. A specimen of *Echinus acutus*, in which each of the five genital pores is replaced by a group of pores from two to five in number. The shell (corona) has grown irregularly from ankylosis having taken place between certain of its plates.

Presented by C. Stewart, Esq.

376. A specimen of *Antedon rosacea*, showing abnormal divisions of two of its arms.

Presented by W. Bateson, Esq.

377. A male Common Shore-Crab (*Carcinus mænas*), in which the dactylopodite of the left chela is trifold. *Purchased.*

378. A female Crab (*Cancer pagurus*), with the dactylopodite of the right chela trifold; the additional parts resemble an entire left chela without joints.

Presented by W. Bateson, Esq.

379. Female Crab (*Cancer pagurus*). The normal flattened endopodite of the third maxilliped on the right side is replaced by a small chela.

Presented by W. Bateson, Esq.

380. A female Cockchafer (*Melolontha vulgaris*), with a trifold left antenna. There are three foliaceous terminal organs. The relations of the laminated fans of the antenna to

the scape are indicated by a drawing. The upper fan is apparently the normal one.

Taken at Bearstead, Essex.

Presented by W. Bateson, Esq.

381. Brimstone Butterfly (*Gonepteryx rhamni*). A second right posterior wing is developed close to the normal wing, probably a case of fission of the imaginal wing-disc. In the Lepidoptera and Diptera and probably in all the Metabola the wings are developed from embryonic sacs (wing-discs, *Weismann*); the division of such a sac into two is similar to the division of a limb in its early stage in the Vertebrata. *Purchased.*

** IN VERTEBRATES.

1. In the Horns of Ruminants.

As the horns of Ruminants often exhibit conditions of dichotomy and excess in the number of parts similar to those which affect the limbs, they have been placed in the present series, as it appeared the most convenient position in the collection.

382. Part of the skull of an Axis Deer (*Cervus axis*), with an additional pair of tines growing out below the burr of the right horn; probably the result of dichotomous division of the horn at its base.

Presented by P. L. Selater, Esq.

383. The skull of a Sheep with four horns. The breed is now established in the Isle of Arran. *Purchased.*

2. Polydactylus.

Syn. Perissodactylus; Megalomelus perissodactylus, *Gurlt.*

Several distinct conditions have been arranged under this head. It has, however, been thought wiser to attempt no division until a much larger collection of specimens can be obtained. Most of these malformations apparently result from fission or dichotomy, either of a single digit, or of several, or

even of the entire limb. Sometimes the accessory digits resemble adventitious buds, and the supernumerary parts not unfrequently simulate to those of the opposite limb. Some are admitted to be varieties; such are the accessory toes of the St. Bernard dog and Dorking fowl: but these are also probably the effect of fission or dichotomy.

384. A Newt (*Lissotriton punctatus*) with a double hind foot, caught at Dorking.

Presented by H. Newton, Esq., 1875.

385. The foot of a Fowl with the inner toe bearing an accessory digit of three phalanges, nearly resembling the second toe of the other foot, on its inner side. The middle toe has also a minute supernumerary nail growing from its last phalanx on the same side.

The existence of a supernumerary toe on the inner side of the foot is characteristic of the Dorking breed, and is transmitted very truly. *Vide* a paper by G. B. Howes, "On the Pedal Skeleton of the Dorking Fowl," in the *Journal of Anatomy and Physiology*, vol. xxvi.

Hunterian.

386. The skeleton of the other foot of the same bird.

Hunterian.

387. Bones of right foot of a Dorking Fowl, showing an extra digit attached to the hallux.

Presented by Mr. W. Pearson.

388. The foot of a Fowl with numerous adventitious digits growing from it and from each other. From China.

Presented by J. W. Clark, Esq., 1875.

389. A similar foot.

1892.

390. Six feet of young Pigs, from three animals of one litter. They present various degrees of polydactylism. The feet of the other pigs of the same litter were normal, and no history could be obtained of deformities in related pigs. *Presented by Lawson Tait, Esq., 1877.*

391. A right manus of a Pig, with a supernumerary digit on the inner or radial side, articulated to the trapezoid bone. The other manus was similarly malformed, but the hinder extremities were normal. From an animal bred at Colebrooke, Fermanagh.

Presented by Sir Victor Brooke, Bart., 1873.

392. A left manus of a Pig, with a supernumerary digit on the radial side ; it has the full number of phalanges, and is not the pollex, but a reduplication of the second digit.

Presented by Mr. R. E. Holding, 1881.

393. The left manus of a Pig with five toes—the four normal digits and an extra digit on the inner side. The other fore foot is said to have been exactly similar ; but the hind feet were normal. No history could be obtained, as the pig was bought at a market in North Germany. Sent to the donor by Dr. Otto Zacharias Geestemunde.

Presented by Charles Darwin, Esq., 1877.

394. The right manus of a Pig, with a small accessory inner toe behind the normal one.

This toe is probably a supernumerary digit added to the normal second digit, and not a thumb.

Hunterian.

395. The left manus of a Pig, with considerable enlargement of the second metacarpal bone, which bears a large accessory toe inside its normal digit. The accessory toe simulates the inner digits of the right manus. It cannot be identified with any normal digit.

Presented by Mr. E. Horniblow, 1872.

396. The skeleton of the manus of a Pig which is almost completely double, consisting of a normal left and an accessory right manus.

The condition of this manus, as well as the succeeding, is apparently identical with that of a human hand described by Jardine Murray (*Med.-Chir. Trans.* vol. xlv. p. 29), a photograph of which is preserved in the Museum of the Middlesex Hospital.

Hunterian.

397. The skeleton of a double manus of a Calf with separate epiphyses to the canon-bones and phalanges. *Hunterian.*
398. Part of the skeleton of the left manus of a Calf with a supernumerary toe on its inner side. The epiphysis of the third metacarpal bone is very broad, and is partially divided into two portions, the shaft is correspondingly broad below.
399. The right manus of a small Horse, with an accessory hoof and imperfect digit growing from the inner side of the distal extremity of the middle metacarpal bone. The splint-bones are normal, and there is no evidence to show that the hoof and digit represent the second. As in the above and some of the following cases, it has apparently the characters of a digit from the other manus. The epiphysis of the metacarpal bone is also partly doubled.
Purchased.
400. The left second and third metatarsal bones of a Horse, with excessive development of the second, which ends below in a trochlear extremity for articulation with a digit*.
401. The right metacarpal (canon) bone of the same Horse, with a supernumerary second metacarpal of large size. The accessory bone has an inferior trochlear surface for a digit. An internal splint-bone, however, existed as usual, a fact which can readily be made out from the articular surfaces and general form of the bone, although it has been unfortunately lost.
402. The left metacarpal (canon) bone of the same, similarly malformed.
403. The skeleton of the right manus of a Horse, with an additional largely developed digit intercalated between the inner splint-bone and middle toe. The second row of carpal bones is fortunately preserved, and exhibits an additional bone, probably an os magnum. A great deal of irregularly

* A similar case of development of a splint-bone in the manus is figured and described by Wood-Mason in the *Proc. Asiat. Soc. Bengal*, 1871, p. 24.

ossified tissue surrounds both digits. The horse was shod on both toes. *Presented by Lawson Tait, Esq., 1872.*

404. The skeleton of a double supernumerary limb said to have grown from the "shoulder" of a Horse. The real nature of this specimen is doubtful. *Hunterian.*

405. The skeleton of the left manus and right pes of a half-grown Cat. The manus possesses seven digits; there are also two trapezoid bones in the carpus. The pes has five digits.

In the manus the digits are arranged in the following order, beginning from the inner side of the hand:—A preternaturally slender thumb and a second digit (index), having its ungual and median phalanges like those of a right digit, are articulated with the trapezium and inner trapezoid respectively; an accessory digit, consisting of three phalanges, is attached to the outer side of the first index by ligament; a second index with normal left characters follows; its metacarpal bone does not reach the second trapezoid, but ends in a point above, and is joined to the head of a third abnormal metacarpal bone, so intimately, that it appears at first sight to be a portion of that bone; this is perhaps a third accessory digit; the remaining digits are the normal third, fourth, and fifth. It appears as if the inner side of this manus has been doubled, with the accessory toes reversed.

In the pes the second digit is supplemented by an additional reversed second digit. The middle cuneiform is also double. The inner cuneiform exists, but the normal rudiment of a hallux is absent.

Presented by B. T. Lowne, Esq.

406. The right manus and left pes of the same animal, exhibiting the same malformation, dissected to show the muscles.

In the manus a distinct extensor muscle, proprius pollicis, goes to the accessory or inner pollex, and a second similar muscle goes to the phalanges of the accessory index. It has probably been detached from its proper pollex, which is extremely minute and has become united with the finger which bears it. There is a flexor brevis pollicis (?) to the same digit.

The pes has an additional extensor with a single tendon for the supernumerary toe. There is also an additional flexor profundus and a large abductor. It also receives a slip from the superficial flexor.

The cat from which these specimens were taken was one of a litter of five. All had five or six digits on the pes and six or seven on the manus, with one exception, where the hand was normal. The female parent was also the mother of the probable male parent; both had six or seven digits on the pes and manus respectively. The same peculiarity has been noticed in others of the breed. The mother is since said to have produced a perfectly normal litter. These animals were born at Kingswood, near Bath.

Presented by B. T. Lowne, Esq., 1872.

407. The four feet of a white male Cat. The right fore foot has seven toes. All the other feet have six toes each.

Presented by Lawson Tait, Esq., 1883.

408. The right hind foot of an adult Cat dissected. There are two supernumerary digits on the inner side united in the following manner:—The metatarsals are fused at each end. There is a single broad basal phalanx supporting two toes, each terminating in a claw; a third imperfect toe is represented by a styliform bone attached to the outer side of the phalanx. There are three additional tarsal bones articulated with a very broad astragalus; one of these is undoubtedly a scaphoid, the other two are interposed between the scaphoid and metatarsal. Their nature is doubtful.

Presented by Lawson Tait, Esq., 1876.

409. The hands of a Silvery Gibbon (*Hylobates leuciscus*), each with a supernumerary digit attached to the inner side of the fifth metacarpal bone.

Presented by J. B. Sutton, Esq., 1886.

410. The pelvis and posterior extremities of a small Monkey with doubling (dichotomy) of the whole inner side of the left limb.

The obturator foramen is double, and there are two ischial protuberances. The femur is abnormally thick and has a double trochanter major. There are two tibiæ; the outer one, being very thin, resembles a fibula closely, but an examination of the tarsus at once reveals its true nature. All the bones of the tarsus except the os calcis and astragalus are double. The astragalus is very broad

and exhibits unmistakable marks of partial doubling; it articulates with two scaphoids, and each of these has its three cuneiforms. An additional cuboid is seen between the two sets of cuneiform bones. All the toes are doubled, except the hallux, and occur in the following order, from within outwards,—1st, 2nd, 3rd, 4th, 5th, 2nd, 3rd, 4th, 5th. The median thumb is evidently crowded out, as its cuneiform bone exists. The inner set of cuneiform bones are very much crowded together. All the toes are unmistakably left digits, none are reversed.

Hunterian.

411. The right hand of a new-born Infant, with a supernumerary fifth finger springing from the fifth metacarpal bone. The specimen has been dissected to show the arrangement of the tendons. The accessory finger receives the tendon of the extensor minimi digiti, a slip from it going to the normal digit. The accessory finger also receives a slip from the adductor. The infant from which this, together with the two following preparations, was made exhibited several other malformations. See No. 155.

Presented by R. Partridge, Esq., 1864.

412. The left hand of the same Infant, dissected. It presents a very rudimentary accessory fifth finger, attached by ligament only to the metacarpal bone, which has neither tendons nor muscles.

Presented by R. Partridge, Esq., 1864.

413. The right foot of the same Infant, with a supernumerary outer toe. The specimen is dissected. The fifth and supernumerary toe are equal in size; both are articulated with a very broad metatarsal bone. The fourth tendon of the flexor longus digitorum splits into two equal parts; one portion is inserted into the accessory toe. The additional toe also receives a distinct slip from the tendon of the peroneus tertius. The other foot was normal.

Presented by R. Partridge, Esq., 1864.

414. The right hand of a new-born Infant, with a papilla, which represents a supernumerary digit, attached to the outer side of the little finger.

Presented by F. S. Gramshaw, Esq., 1880.

415. The left hand of the same Infant with a similar growth containing a small mass of bone.

Presented by F. S. Gramshaw, Esq., 1880.

416. The bones of a Human thumb with dichotomy of the terminal phalanges. The accessory and normal bones are symmetrically developed, apparently right and left.

Presented by Dr. Thurnam, Esq., 1872.

417. The skeleton of the left foot of an adult Human female, with a supernumerary fourth toe, resembling that of the right foot, between the outer and fourth digits. The additional toe has a distinct but imperfect metatarsal bone, which is attached to the outer side of the fourth, and wedged between it and the fifth metatarsal bone. There is a cup-shaped cavity at the base of the fifth metatarsal bone, which lodges the base of the accessory bone.

Presented by Erasmus Wilson, Esq., 1869.

418. A portion of a Human foot which had six toes. The great toe has been removed. The three outer toes are enclosed in a common integument to their extremities.

Hunterian.

Class II. MALFORMATIONS WITH DEFECT.

1. *Aschistodactylus*, Gurlt.

Syn. Syndactylus, Geoff.

Arrest of development is occasionally uncomplicated, as in *aschistodactylus*, or webbing of the digits. It is more commonly accompanied by atrophy, which is sometimes so complete that no trace of the part remains. So-called intra-uterine amputations apparently always arise from atrophy. Sometimes a single bone is undeveloped, probably from early arrest and atrophy.

419. The skeleton of the manus of a Pig, with the second phalanges of the functional digits adherent, and their third phalanges fused into a single bone. This condition probably arises from imperfect differentiation of the digits and persistence of the primitive connecting web in which they are formed.

Presented by Sir W. Blizard.

420. The other manus of the same animal ; the functional digits are included in a single hoof.

Presented by Sir W. Blizard.

421. A precisely similar specimen.

Presented by Sir E. Home, Bart.

422. The right fore and hind feet of a new-born Pig, with the hoofs united. Born at the Zoological Gardens of parents imported from Cuba similarly malformed.

Presented by A. D. Bartlett, Esq., 1877.

423. A similar specimen in which the digits are included in a single narrow pointed hoof.

Hunterian.

424. The right hand of a Monkey (*Pithecia satanas*), in which the third and fourth fingers are united to their ends by integument. The left hand was in a similar condition.

See Proc. Zool. Soc., May 1882.

Presented by the Zoological Society, 1882.

425. A dissection of the second and third toes of the right foot united by a web of skin (*aschistodactylus*), from an old man, aged 83, who died in the Wilts County Lunatic Asylum.

Presented by Dr. J. Thurnam, 1873.

2. *Perodactylus*.

(Defective development of one or more digits.)

Syn. Ectrodactylie, Geoff.

426. The left hind foot of a Pig, in which the third digit is shortened by arrest of growth. It is worthy of remark that in the *Solidungula* this is the only functional digit.

Hunterian.

427. The other hind foot of the same animal with more considerable defect of the corresponding toe.

Hunterian.

428. The left hand of a Human infant at birth with considerable shortening of the finger. The ungual phalanges and the nails are much smaller than is normal. The thumb is short and thick, but its terminal phalanx is not abnormally defective. The mother had a similar malformation.

Presented by R. Partridge, Esq., 1868.

429. The hands of a full-time Human foetus. The right is prepared as a skeleton. The thumb of the left hand is represented by an imperfect terminal joint only ; this adheres to the hand by a narrow pedicle of integument. In the right hand the thumb is entirely wanting, and the fifth digit is adherent to the metacarpal bone of the fourth. The union is ligamentous, and the base of the fifth metacarpal bone has been entirely absorbed. The process of atrophy seen in progress in these digits is precisely similar to that which affects supernumerary digits. In these the phenomenon is observed far more commonly than in the normal parts.

Presented by R. Partridge, Esq.

3. *Nanomelus.*

Syn. Brachymelia.

Phocomèle, *Geoff.*

Peromelia, *Gurlt.*

Ischnomelia, *Gurlt.*

Although arrest of growth and arrest of development affecting the limbs very frequently occur together, and one is either the result or cause of the other, yet there are certain forms of arrest of growth giving rise to a great shortening of the limbs, *brachymelia*, which are not accompanied by any obvious arrest of development. In brachymelia the bones are usually exceedingly well ossified, but there is frequently deformity from irregular contraction of the muscles, as well as great hypertrophy of the subcutaneous tissue. Arrested growth is sometimes confined to the digits, and is more frequent in the forearm and leg than in the arm and thigh. When the whole of the lower limbs is affected, the pelvic girdle is also usually of small size. Arrest of the forearm or leg gives rise to considerable modification in the arrangements of the muscles ; the flexors and extensors of the digits in these cases usually arise from the shaft of the humerus or femur.

When the development of a limb, or a portion of a limb, is arrested and the arrested portion undergoes atrophy a stump is frequently left like that of an amputated limb. The process

is apparently the same as that which is seen in a less complete stage in Nos. 412, 429, and 441. The remains of the atrophied limb are usually apparent as a papilla upon the stump, showing that the ordinary view, that such conditions arise from intra-uterine amputation, is fallacious. Those who suppose the amputation arises from ligature by the umbilical cord seem to forget that the cord is a growing structure, and that it is so often wound around the neck and body that amputations not only of the limbs but of the head would be frequent, and slighter effects of such constriction would occur in numerous cases. No definite line can be drawn between the conditions classed under the terms *ischnomelia*, *peromelia*, and *amelia*. Transitional conditions are of frequent occurrence.

430. A foetal bitch Puppy with extreme shortening of all four extremities and arrest of growth in the posterior portion of the trunk. *Hunterian.*

431. A foetal Pig, in which the development of the posterior limbs and pelvic girdle has been considerably arrested. The femora are deficient from atrophy, so that the limbs are only attached to the trunk by skin and ligamentous tissue. The abdomen has been opened below to show the extremely diminutive condition of the pelvis and pelvic viscera. The hind legs terminate in blunt points, and each has a very imperfect hoof. *Hunterian.*

432. A foetal Puppy, in which the development of all four limbs has been arrested. The specimen has been much altered by having been dried previously to being placed in spirit, but is of extreme interest, as it exhibits a very rare condition, a patagium extending from the flank to the elbow on either side. *Mus. Brit.*

433. A female Human foetus with shortening of all four extremities. There is a considerable abnormal deposit of subcutaneous fat. The child was still-born at the eighth month of pregnancy.

Presented by William Lyon, Esq., 1825.

434. A male Human foetus with very defective forearms and four malformed fingers on each hand. This foetus also

exhibits agnathia and malformation of the ears. It is said to have lived about twenty minutes.

Presented by F. G. Coates, Esq., 1876.

435. A female Human foetus with arrest of growth in the pelvic girdle and all four extremities. The left inferior extremity has been dissected. The muscles of the toes and the gastrocnemius arise from the femur immediately below the insertion of the psoas and gluteus maximus. A constriction may be seen around the right thumb, which is obviously in the first stage of so-called intra-uterine amputation.

Presented by Sir S. Hammick.

436. The skeleton of a full-time hydrocephalic Human foetus, with extreme shortening of the limbs. All the bones are well ossified except the sternum ; its cartilaginous condition is an indication of arrested development. The shrivelling of the cartilaginous epiphyses has much increased the deformity.

Presented by R. Liston, Esq.

437. The skeleton of a similar foetus with the great arteries injected and preserved. The urinary bladder is also attached to the pelvis.

438. The skeleton of a Human female foetus at full-time with extreme shortening of the limbs, accompanied by considerable deformity from the curvature of the tibia and fibula, arrest of growth in the pelvic region, and rotation of the lower limbs so that the feet project almost backwards as in sireniform deformity.

Presented by W. Adams, Esq., 1872.

439. The right leg of an Infant with congenital absence of the tibia. The foot is turned inwards. The astragalus articulated with the fibula and the upper end of the latter bone articulated with the femur. Most of the muscles of the leg are represented and are all attached to the fibula.

Presented by Thomas Bryant, Esq., 1883.

440. The bones of a right leg and foot, from which the fibula and several bones of the feet are congenitally absent.

Removed by amputation from a boy, aged 3 years. He walked

on the bent lower end of the tibia and the dorsum of the foot, with the sole directed upwards. The specimen is fully described in *Trans. Path. Soc.* vol. xliii.

Presented by J. H. Targett, Esq., 1892.

441. The bones of a left leg and foot, from which the tibia is congenitally absent. Some of the tarsal bones, especially the astragalus, are much malformed.

Removed by amputation from a girl, aged 18 years. The left leg was very short, and the foot was in the position of extreme talipes equino-varus. Walking was performed with the aid of a single crutch which was held in the grasp of the deformed limb and advanced by it. The specimen is fully described in *Trans. Path. Soc.* vol. xliii.

Presented by J. B. Sutton, Esq., 1892.

442. The skeleton of a Human foetus, at about the sixth month of gestation, with the radii and thumbs wanting. The head is slightly hydrocephalic. All the bones are abnormally slender, especially the clavicles, which are considerably bent. The ossification of the sternum is very irregular and imperfect, as is also that of the pubic symphysis. *Presented by Erasmus Wilson, Esq., 1869.*

443. The two anterior extremities of a Human foetus at about the sixth month with complete absence of the radius on both sides. There are but three fingers. A dissection has been made by the donor of the muscles and nerves of one side. *Presented by S. G. Shattock, Esq., 1882.*

444. The upper extremities of a foetus with congenital absence of the radii. *College Stores, 1884.*

4. *Micromelia.*

This term has been applied to minute undeveloped limbs. Examples are exceedingly rare.

445. A part of the lower extremity of a Child said to have been amputated at the knee-joint, dissected. The foot is reduced to a single toe and the leg is represented by two large masses of cartilage. The common flexor and

extensor tendons are attached to the phalanges in the usual way. The tarsus is apparently not differentiated from the cartilages representing the tibia and fibula.

Presented by W. Adams, Esq., 1886.

446. A portion of the left hip of a Wild Boar, with a small process representing the left posterior extremity. The following particulars are extracted from Hunter's Manuscript 'Cases and Dissections,' vol. iii. p. 70:—The animal had no kidney on the left side, the left testicle had not descended, its epididymis, vas deferens, and vesiculum, as well as the gubernaculum, were entirely absent. The gland itself was rudimentary. The right testicle was normal and situated in the scrotum. *Hunterian.*

447. A Human full-time fœtus, with the inferior extremities represented by button-shaped processes, and the position of the superior extremities indicated by minute depressions only. The left inferior extremity has been dissected; it is seen to consist of ligamentous tissue, into which numerous irregular muscles arising from the pelvis are inserted. The testes are abdominal, and there is an excessive development of subcutaneous fat.

Presented by C. J. White, Esq., 1870.

448. A Human male fœtus, 7 inches in length, about the fifth month of gestation, with the left arm arrested and atrophied. The arm consists entirely of soft tissues, and has a three-lobed extremity; one of the lobes terminates in a slender thread-like process. The remains of the limb are attached to the glenoid cavity by connective tissue. The great pectoral muscle ends in the connective tissue of the limb. A portion of the integument has been removed to show the conditions described above.

Mus. Brookes.

5. *Amelia.*

Where the limbs are totally deficient. In such cases it is impossible to determine whether the condition arises from primitive deficiency of the limb, or from subsequent arrest followed by atrophy.

449. Two specimens of *Abramis blicca*. The lower fish is normal, the upper shows absence of the ventral fins.

Presented by W. Bateson, Esq.

450. A Frog with entire deficiency of the right anterior extremity. A portion of the integument has been removed to show the complete absence of all traces of a limb.

Hunterian.

451. Skeleton of a Gull shot in the neighbourhood of Wigtown with complete absence of the left lower extremity. The bird was sent in the flesh and no trace of a femur could be discovered, although the skin was intact. The acetabulum appears equally developed on both sides. See 'Field' newspaper, Oct. 4, 1879.

Presented by W. B. Tegetmeier, Esq., 1879.

452. A Chick, with total deficiency of the right inferior extremity. The inner toe of the left foot is double.

Hunterian.

453. The anterior part of an adult Wild Rabbit (shot in Essex), without any trace of the right fore limb. The animal ran fairly well, the left limb was apparently nearer the middle line than usual. It was sent entire to the Museum and carefully examined. The skin is put up as a separate preparation (No. 454). No vestige of scapula or limb-bones could be found. The muscles are dissected.

Presented by H. J. Barrett, Esq., 1883.

454. A part of the skin of the same animal showing complete absence of the right fore limb.

455. A skeleton of an adult female Cat, without a trace of fore limbs below the scapulæ. The animal was born at the residence of the late Mr. Henry Doubleday, the well-known entomologist of Epping, about the year 1830, who kept it until it died and prepared the skeleton. See 'Mechanic's Magazine,' Feb. 27th, 1830, and Mr. Mant's letter, Museum letters, June 27th, 1879, also 'Field' newspaper, Nov. 8th, 1879 (woodcut).

Presented by Julius A. Marsh, Esq., 1879.

456. A foetal bitch Puppy, with total deficiency of the anterior extremities. There is slight arrest of development of the face. *Mus. Brit.*
457. A foetal Puppy, in which the right fore limb is completely absent. *Presented by the Brown Institution, 1887.*
458. The skeleton of a Human seven-months' foetus, with total deficiency of the right arm. The scapula and clavicle are, however, present. The left arm is represented by a cartilaginous humerus, a slender ulnar, and a single digit, which consists of a metacarpal bone and three phalanges united by cartilage and ligament. *Presented by Sir W. Blizard, 1811.*
459. The skeleton of a male Infant (three weeks old), in which both arms are entirely wanting and there is arrest of development of both legs, especially the right. *Presented by Bernard E. Broadhurst, Esq., 1872.*

6. Hemimelia.

The preparations classed under this term are usually regarded as intra-uterine amputations ; there is, perhaps, no reason for so regarding them except their superficial similarity to the stumps of amputated limbs.

460. A female Human foetus, about the fifth month of gestation. The left leg is deficient from the knee ; it presents the appearance of the stump of an amputation. There is also defective development of the face and left anterior extremity. The left hand at first sight appears to have but three digits, but on closer inspection two of these are seen to be double. The manner in which these fingers are flexed and adhere together throws considerable light upon the condition exhibited by Nos. 484 and 485.
461. The right leg of a foetus, of which the other three extremities exhibit the condition known as intra-uterine amputation (see Nos. 462, 463, 464). Only a single toe is developed. The tibia is represented by a large mass of

cartilage, and a small cartilaginous nodule represents the bones of the foot. The leg is much shortened and bent. A section has been made to show the cartilages.

Arrest of differentiation of the same kind, affecting only a portion of a segment in the limb, would give rise to fusion of the upper part of the bones in the forearm or leg, either above or below. A very interesting specimen of fusion of the upper part of the radius and ulnar of both arms in an adult is preserved in the museum of St. Thomas's Hospital.

462. The right arm of the same foetus. The limb terminates just below the elbow in a stump like that of an amputation.

The arm has been divided vertically to show the condition of the internal parts. The humerus is perfect and articulates with a piece of cartilage, which represents the upper extremity of the ulna. The direction of this rudimentary olecranon is such that the forearm, if developed, would be flexed at right angles to the arm. The triceps and brachialis anticus are both seen in section. The skin is stretched tightly over this olecranal cartilage, but it forms a tubercle at its anterior extremity, an exceedingly rudimentary representative of the forearm and hand.

463. The left arm of the same foetus, in which the upper arm ends in a conical stump at the junction of the middle and lower thirds of the humerus. A longitudinal section has been made through it, to show the rounded termination of the humerus and its relation to the integument. A minute cutaneous knot represents the more anterior parts of the limb.

464. The left inferior extremity of the same foetus. All the parts below the condyles of the femur are represented by a minute tubercle only on the outer side of a rounded stump; and this is formed by the skin, which is stretched tightly over the inferior articular extremity of the femur. The limb has been divided vertically.

Class III. MALFORMATIONS BY DISTORTION.

The malformations included in this division are probably due to some form of cerebro-spinal irritation or defect. They frequently accompany other abnormal conditions.

1. *Talipes*.

Talipes varus, valgus, calcaneus, calcaneo-varus and -valgus occur as congenital conditions. The question of their origin from irregular muscular contraction is still an open one; but the arguments in favour of this view are exceedingly strong. The subject is discussed at length in Mr. W. Adams's Jacksonian Prize Essay on Club-foot, chapter xii. p. 195.

465. The right leg and foot of a Human infant at birth, with *talipes* varus, dissected to show the muscles.

Presented by W. Adams, Esq., 1864.

466. A similar preparation.

Presented by W. Adams, Esq., 1864.

467. A similar preparation.

Presented by W. Adams, Esq., 1864.

468. Two Human foetal left astragali. The upper specimen is deformed, and was taken from the foot of a new-born infant with *talipes* varus. The other specimen is normal.

Presented by W. Adams, Esq., 1864.

469. The tendo Achillis, tibialis posticus, flexor longus, and tibialis anticus tendons of a Child, a year old, that had been operated on successfully for club-foot at six weeks.

The line of junction between the old and new tendon could only be traced with difficulty, especially in the tibialis anticus and posticus tendons. In the former there seemed to be about half an inch, and in the latter three eighths of an inch of new tendon. In the tendo Achillis rather more than half an inch of new tendon could be recognized. The flexor longus does not appear to have been divided.

Presented by W. Adams, Esq., 1864.

470. The right leg and foot of an adult Human subject, with extreme talipes varus, injected and dissected to show the muscles, vessels, and nerves. The contracted condition of the plantar fascia is well seen.

471. The right leg and foot of a Human adult with congenital talipes varus, dissected.

Presented by R. Partridge, Esq., 1866.

472. The left leg and foot of the same subject, dissected, to show the bones and ligaments.

Presented by R. Partridge, Esq., 1866.

473. The right leg and foot of a Woman, aged 30, with talipes varus, dissected and dried.

This specimen is minutely described in Mr. W. Adams's Prize Essay, p. 163. It is of extreme interest, because there is no doubt about its having been congenital in its origin.

The oblique position of the os calcis, the vertical deviation of the astragalus, the lateral position of the navicular bone in respect to the astragalus, the displacement inwards and backwards of the cuboid bone, and the angle of flexion of the anterior portion of the foot from the transverse tarsal joint are well exhibited.

Presented by W. Adams, Esq., 1864.

474. The bones of a left foot illustrating the deformity of congenital talipes equino-varus. The weight of the limb borne on the outer border of the foot has led to an arrest of development of the fifth metatarsal bone. The dorsal surface of the cuboid is marked with irregular deposits of new bone, resulting from inflammation and thickening of the soft tissues over it.

From a man, aged 24, who was admitted to a hospital for severe talipes equino-varus with cavus. The tendo Achillis and the tendons of the tibiales had been divided without benefit two years previously. Amputation was performed at the patient's request, as the repeated ulceration of the skin thickened by pressure was the cause of much pain.

Presented by F. S. Eve, Esq., 1892.

475. A right leg and foot showing congenital talipes equino-varus, from a Child aged 18 months. The inverted and extended position of the foot and the contraction of the soleus and gastrocnemius and of the tibialis anticus and posticus are well shown. The opposite limb was similarly deformed. A careful microscopical examination of each muscle and of the popliteal nerve and its main divisions from the left limb was made, but no changes were observed. The spinal cord was examined in many places, but no abnormality was found. (See Trans. Path. Soc. vol. xxxv. p. 423.)

Presented by R. W. Parker, Esq., 1884.

476. The bones concerned in talipes equino-varus from an anencephalous foetus of about seven months. The neck of the astragalus is lengthened, and directed inwards with an unnatural obliquity. The os calcis is rotated inwards. Various changes in the articular facets of both bones may also be observed.

477. Three astragali and ossa calces, of which that placed in a median position is normal for comparison. The bones placed uppermost are from the left limb of the same foetus as No. 475; they show the changes in the astragalus and os calcis alluded to in the preceding specimen. The bones placed below are also from a case of talipes equino-varus, but are little altered. (See Trans. Path. Soc. vol. xxxv. p. 423.)

*Presented by R. W. Parker, Esq., and
S. G. Shattock, Esq., 1884.*

478. Right foot of an Infant affected with congenital talipes calcaneus.

Presented by J. Hutchinson, Junr., Esq.

479. A leg and foot of a foetus, showing slight exaggeration of the position of flexion natural during the latter periods of gestation.

*Presented by R. W. Parker, Esq., and
S. G. Shattock, Esq., 1884.*

480. Four astragali from cases of talipes calcaneus of different degrees, showing prolongation forwards of the superior

articular facet and of the facets for the malleoli. (See Trans. Path. Soc. vol. xxxv. p. 427.)

*Presented by R. W. Parker, Esq., and
S. G. Shattock, Esq., 1884.*

481. The right foot of an Infant, affected with talipes calcaneus.

Presented by Stanley Boyd, Esq., 1881.

2. *Curvature.*

482. The skeleton of the hind leg of a Rabbit, in which the femur is much shortened and curved. During life the animal was unable to use the limb; it was turned up over its back.

Presented by B. T. Lowne, Esq., 1871.

483. The bones of the arms of a Human subject, with extreme contortion of the radius and ulna in both limbs. The carpal extremity of the right ulna is dislocated.

3. *Congenital dislocation.*

484. The phalanges of a distorted Human hand, dislocated and adherent to each other, probably by abnormal muscular contractions at an early period. The specimen is imperfect.

Hunterian.

485. Two of the metacarpal bones and some of the phalanges of a similar distorted hand. The specimen is imperfect.

Hunterian.

SERIES III.

ABNORMAL CONDITIONS OF THE SKIN AND ITS APPENDAGES.

The specimens classed under this Series are probably all due to variation or congenital diseases. As there are but few of them, and nothing is known of their origin, they have not been further subdivided.

486. Two specimens of Pilchard (*Clupea pilchardus*), showing increased number of scales on one side.

Presented by W. Bateson, Esq.

487. A Flounder with deep pigmentation on its under surface, which is normally white; the condition is said to be always associated with a notch behind the eye, which is well seen in the present specimen.

Presented by Mathias Dunn, Esq., 1892.

488. A Fowl which is almost entirely without feathers. It came from the egg in this condition and lived seven months.

Purchased.

489. A full-grown Mouse without hair on its skin from birth. The vibrissæ and scales on the tail are normal, and the integument is considerably wrinkled as if from hypertrophy*.

Presented by W. Clift, Esq., 1820.

490. A similar hairless Rat, killed with a similar Rat in a barn near Colchester, Feb. 1, 1872.

Presented by Dr. Bree, 1872.

491. The feet of a Golden Poland Cock, five years old, with two spurs, one of very large size, on each foot.

Presented by T. B. Curling, Esq., 1872.

492. A large horn which grew from the groin of a Ram.

Hunterian.

493. The core of the same.

Hunterian.

494. The head of a Cow with a very large horn-like appendage growing from the forehead immediately between the eyes.

Hunterian.

495. A portion of the core of the same hollowed into numerous cysts.

Hunterian.

496. Another portion of the same.

Hunterian.

* A similar condition is described by J. S. Gaskoin as a zoological variety, Zool. Soc. Proc. 1856, p. 38.

497. Another portion of the same. *Hunterian.*
 498. Another portion of the same. *Hunterian.*
 499. The dried head of a Sheep with a similar appendage.
From Mr. Swan's Coll., 1875.

SERIES IV.

ABNORMAL CONDITIONS OF THE OSSEOUS AND MUSCULAR SYSTEMS.

This Class is intended to include all variations from the ordinary type in the disposition and arrangement of muscles and of individual bones.

A. Of the Vertebræ.

500. The spinal column of a Sole (*Solea vulgaris*) with arrest of development of twelve postanal vertebræ. The bodies of these vertebræ are only about one half the usual length, and have the appearance of being pressed together. *Presented by C. Stewart, Esq., 1886.*
501. A portion of the spine of a Rabbit, consisting of the lower four lumbar and the upper three sacral vertebræ. A wedge-shaped half-centrum is ankylosed to the anterior extremity of one of the lumbar vertebræ. It bears a costal process, an anterior articular process, and a half-spine, which have been painted black. There is a lateral curvature of the spine in the lumbar region, the convexity of which is directed to the left. In consequence of a compensatory curvature the first sacral vertebra did not articulate with the ilium on the right side, and the right pleuropophysis of that vertebra has developed into a long process (painted red) which is in series with the lumbar costal processes. (See Trans. Path. Soc. vol. xli. p. 341.) *Presented by J. B. Sutton, Esq., 1891.*
502. An atlas with incomplete closure of the laminæ, which are slender and tapering.

503. The cervical vertebræ of a Human adult in which the atlas, axis, and third vertebræ are united into a single bone. The laminæ and bodies are completely fused, the odontoid process is rudimentary. There are two transverse processes on the left side and but one on the right. The left side has two and the right only one intervertebral foramen. The superior articular surfaces for the occipital condyles are flat. There is one irregular spinous process. The inferior articular processes are abnormally large, especially that on the right side. The fourth and fifth vertebræ are small and have abnormal outgrowths of bone on the left side, which articulate with the vertebræ above and below. The exostosis on the fourth vertebra is perforated by a large foramen.

The malformation in this instance probably originated in imperfect development of the vertebræ, but it has clearly been greatly modified subsequently to birth. It is evident from the great absorption and compression of the bones on the right side that the head must have been carried over the right shoulder during life. The condition may possibly have originated from injury even at or after birth. There is no history.

Presented by L. A. Dunn, Esq., 1889.

504. A Human dorsal vertebra of which the laminæ have not united. The neural canal is completely closed by the approximation of the two laminæ, and the two well-developed halves of the bifid spinous process run parallel to each other, but on a slightly different level.

Presented by S. G. Shattock, Esq.

B. Of the Sternum and Ribs.

505. The sixth and seventh cervical and three upper dorsal vertebræ of a Human adult with a normal first rib and a well-developed cervical rib on each side.

No history; found in Stores, 1873.

506. The sternum and rib-cartilages of a Human adult, in which the cartilages of the eighth ribs are united directly with the sternum, and those of the first and second, on the left side, are fused together.

Hunterian.

507. The sternum of a Human adult in which the body is divided into five pieces by the persistence of sutures between the several segments, which are only partially ankylosed. This sternum is abnormally large, and the eighth costal cartilages join the xyphoid process directly.
508. The cleft sternal extremity of a Human rib.
509. Two of the left lower ribs of a Human subject, with dichotomy of their anterior extremities, probably from the same subject as No. 508.
510. The first and second right ribs, probably from the same subject, united by bone throughout the greater part of their length.
511. The first and second right ribs united by bone. From a male skeleton received from Vienna. The corresponding ribs of the opposite side and all the other bones were normal. *Purchased, 1878.*
512. Two specimens of united ribs from a Human subject, one from the right and the other from the left side. *Presented by F. Kiernan, Esq., 1872.*
513. Two similar specimens from a Sheep.

C. Of the Limbs.

514. A humerus with a small supra-condyloid process. *Presented by Dr. Seymour Taylor, 1887.*
515. A left Human humerus with a supra-condyloid process. The radial artery and median nerve pass beneath it; there is also an inter-condyloid foramen. From a woman, aged 95. 1888.
516. The external condyle of a femur showing a sesamoid bone in the head of the gastrocnemius. 1888.

Instances are recorded in which the number of tarsal bones is reduced by congenital synostosis of the os calcis and navicular, of the os calcis, astragalus, and navicular; or an increase in number may arise from the separation of the external tubercle

from the back of the astragalus (os trigonum, *Bardeleben*), or of the tuberosity of the navicular; division of the internal cuneiform bone into a dorsal and a plantar ossicle; or by the presence of a supernumerary ossicle at the fore and inner part of the os calcis.

517. A pair of Human astragali, exhibiting *Bardeleben's* os trigonum.

518. The skeleton of a left Human foot, showing an extra facet on the astragalus and a corresponding facet on the cuboid.

Presented by J. B. Sutton, Esq.

D. Of the Muscles.

1. *Deficiency of the diaphragm.*

519. The trunk of a full-time male Human foetus with deficiency of the left half of the diaphragm. The anterior wall of the thorax and abdomen has been removed. The thoracic viscera have been pushed over to the right side by the intrusion of the abdominal viscera into the thorax.

520. A male Human foetus with deficiency of the left side of the diaphragm and hernia of the intestines into the thorax, with consequent displacement of the thoracic viscera. The thoracic and abdominal cavities are laid open. The abdominal wall was deficient in front.

Presented by T. Blizard, Esq.

521. The thorax and viscera of a full-time Human foetus exhibiting a similar condition.

522. The trunk of a full-time male Infant, with *Situs mutatus* and deficiency of the right half of the diaphragm. The right pleural cavity contained the greater part of the large and small intestine. This has been removed to show the opening in the diaphragm, which is now occupied by the mesentery of the intestine and a recurved portion of the right lobe of the liver. The right testis has not descended.

The infant lived twenty-four hours and cried vigorously, but was somewhat cyanosed. It was the offspring of a girl, aged 17. The labour was normal.

Presented by W. Sturrock, Esq., 1892.

523. A male Human foetus at about the fourth month of gestation, with deficiency of the diaphragm and anterior abdominal wall, and considerable arrest of growth of the left lower extremity. The thoracic viscera are depressed on the left side, and there is lateral curvature of the spine. The case is described in the 'London Medical and Physical Journal,' vol. lii. p. 367.

Presented by J. C. Yeatman, Esq.

524. The trunk of a female Infant in which the whole of the intestinal canal has passed into the thorax, through a deficiency in the left side of the diaphragm; the intestines occupy the left side of the thoracic cavity, the heart is pushed over to the right side of the middle line, while the right lung, which is collapsed, is just seen. The left lung is entirely hidden by coils of intestine; the commencement of the jejunum passes through the diaphragmatic aperture; the descending colon descends through the same and courses down the left loin to the rectum; the liver, kidneys, and stomach are normal.

The spleen is entirely surrounded by peritoneum. The genito-urinary organs are normal. The deficiency is in the left side of the diaphragm, and is sufficiently large to admit of the tips of two fingers.

The child was twenty inches long and above the average weight. It lived 6 hours.

The symptoms of dyspnœa increased gradually as the result of the respiratory movements, which undoubtedly forced the intestine into the thorax. The cardiac impulse was observed on the right side before death occurred.

Presented by A. K. Willis, Esq., 1889.

SERIES V.

ABNORMAL CONDITIONS OF THE SENSORY ORGANS AND PERIPHERAL NERVOUS SYSTEM.

A. Of the Eye.

525. The head of a large Carp, with entire deficiency of the eye on the left side.

Hunterian.

526. The head of a Barbel with absence of the right eye.
Presented by W. B. Tegetmeier, Esq., 1884.
527. A Chick at about the tenth day of incubation, in which the left eye has suffered arrest at a very early period. The right eye is abnormally large, and the upper beak deviates to the left, so that it crosses the lower one.
Presented by B. T. Lowne, Esq., 1872.
528. A Chick about the beginning of the third week, similarly malformed.
529. The right eye of a Sheep, with a dark brown tumour from which a lock of wool has grown on the outer edge of the cornea.
Presented by J. C. Chaylor, Esq., 1870.

B. Of the Ear.

530. An ear-like appendage from near the angle of the jaw of a Goat (*Capra hircus*). The appendage has been slit up to show a rod of cartilage which it contained ; above is a lymphatic gland.

Such appendages are not infrequent in some breeds of goat, and sometimes contain a muscular bundle. It has been suggested that they are supernumerary auricles.

Purchased.

531. The right ear of a Sheep showing a hair-clad flap of skin, representing a cervical auricle, situated an inch below the external auditory meatus. The surface of this flap which looks towards the concavity of the ear is covered with skin, bearing coarse papillæ and a well-developed supernumerary tooth. This tooth projects from the margin of the flap near its attachment to the neck, and its extremity is sharply pointed and somewhat hooked. In shape it resembles the incisor tooth of a sheep. The *cul-de-sac* immediately behind the cervical auricle, and indicated by a blue rod, is considered to be a persistent portion of the second branchial cleft. (See Trans. Path. Soc. vol. xlii.)

Presented by J. B. Sutton, Esq., 1891.

532. A Pig's head with similar appendages.

533. A rudimentary and malformed ear-lobe removed from a Child, 2 years 11 months old, on Feb. 18th, 1876.

It was on the right side, and about one inch below and anterior to the normal position of the ear ; this situation presented a deep depression having an appearance indicative of an imperfect development of the mastoid part of the temporal bone. The left ear-conch was also imperfectly developed, though in a far less degree, and in its natural position. The orifice of the meatus was closed by integument. In the present specimen a bristle is placed in the minute aperture of the meatus. The child could only hear very loud sounds and (in Dec. 1877) not sufficiently to enable it to acquire speech.

Presented by W. D. Dalby, Esq., 1877.

534. A malformed Human ear with absence of the external auditory meatus. 1885.

535. A supernumerary auricle from the side of the neck, with the portion of skin which covered it. At the upper part of the specimen is a plate-like expansion of bone, which terminates in a fork on the side towards the observer's left. On the other side it is continuous with a curved bar also of bone. Below this is a pointed rod of fibro-cartilage, which in the recent state was covered with skin. This formed a nipple-like projection at the middle of the anterior margin of the sterno-mastoid. The bar lay in the subcutaneous tissue, while the plate was deeply situated and firmly attached to muscle, apparently the sterno-mastoid.

From a healthy boy, aged 6 months. See *Lancet*, vol. ii. 1889, p. 1003. A drawing of this child is preserved in the collection.

Presented by Frederick S. Eve, Esq.

536. The right half of the head of a foetus, with two small pyriform tubercles attached to the cheek, half an inch from the angle of the mouth. Immediately in front of the pinna of the ear there is also a small pedunculated tumour. Histological examination of the buccal tubercle shows that it consists of dense connective tissue covered by skin bearing soft hairs and richly supplied with sebaceous and sweat-glands of large size. Such tubercles

are said to correspond with the line of closure of the mandibular cleft, and are frequently termed mandibular tubercles. *Presented by J. Bland Sutton, Esq., 1892.*

C. Of the Peripheral Nervous System.

537. The last cervical and three upper dorsal vertebræ of a Human adult, together with a portion of the brachial plexus. The second dorsal nerve on both sides joins the first dorsal and with the eighth cervical forms the lower trunk of the plexus.

SERIES VI.

ABNORMAL CONDITIONS OF THE DIGESTIVE ORGANS.

A. Of the Teeth.

538. Three specimens of Human incisor teeth adherent in pairs. The lower specimens are the upper and lower milk median incisors; the upper specimen apparently consists of the two median upper incisors intimately united. They are probably all from the same subject.

Presented by J. Swan, Esq., 1838.

539. A Human second molar tooth with an inverted tooth wedged in between its roots. (The inverted tooth is probably the wisdom-tooth, which has been developed on the ascending ramus of the mandible, and which has grown downwards, displacing the roots of the second molar with its crown, which is impacted between them.)

540. The double tusk of an Elephant.

B. Of the Alimentary Canal.

1. *Atresia of the pharynx and œsophagus.*

The pharynx may terminate in a blind pouch, which is either entirely separated from the œsophagus or connected with it by a fibrous or muscular cord only; in such cases the œsophagus often opens into the trachea, near its bifurcation.

541. The tongue, pharynx, trachea, and œsophagus of a Human foetus, with a small portion of the diaphragm and stomach. The œsophagus opens into the trachea just above its bifurcation; it is not connected with the pharynx. The trachea has been opened in front, and a green glass rod has been inserted into the œsophagus.

542. The pharynx, œsophagus, and trachea of an Infant. The upper end of the œsophagus forms a blind pouch an inch and a quarter long, continuous with the pharynx, but not with the remainder of the gullet. The opening of the latter is into the trachea half an inch above its bifurcation. This is marked by a green glass rod.

From an infant that died a few days after birth. It always became blue when it attempted to swallow, and for this reason the existence of the malformation was suspected during life.

Presented by J. Bland Sutton, Esq., 1892.

543. A similar preparation. *Presented by J. B. Sutton, Esq.*

544. A similar preparation from a new-born Child, in which the lungs and stomach are also preserved. The œsophagus is united with the pharynx by a muscular band.

Presented by Dr. Ayres.

545. A similar preparation from a Human foetus; the lungs are abnormal in form, and have not been inflated with air.

2. Diverticula of the alimentary tract.

546. A portion of the intestine of a young Emu. Attached to its convex surface by a narrow diverticulum is a spherical cyst two inches in diameter. The cyst may be considered a persistent yolk-sac, and its peduncle as the remains of the vitelline duct.

Presented by Sir Edmund Giles Loder, Bart.

547. Part of the intestine of a Duck (*Anas boschas*) with three cæca. They are of equal length and all arise from the bowel at the same level. *Purchased, 1887.*

548. A diverticulum ilei from a Man, aged 46, who died of cancer of sigmoid flexure and intestinal obstruction.

Presented by Dr. J. F. Goodhart, 1875.

3. *Imperfect development of the intestines.*

549. Part of the ileum and cæcum of a Human fœtus in which the appendix is absent and the cæcum is very short.

Presented by J. B. Sutton, Esq.

550. The malformed alimentary canal of an Infant otherwise apparently well developed ; the stomach is normal. The upper part of the small intestine dilates from above downwards and then terminates in a very narrow ileum. The large intestine is very narrow and short. The child died on the fifth day after birth with fæcal vomiting. The rectum was also apparently obstructed two inches above the anus.

Presented by F. Fawson, Esq., 1883.

4. *Atresia of the rectum.*

Syn. Atreto cornus, Gurlt.

One of the most frequent malformations which come under the notice of the surgeon is atresia ani, or arrest of development of the lower extremity of the rectum.

551. The rectum of a female Child nearly two months old born with an imperforate anus, for which no operation was performed ; it is much distended, and its muscular coats are hypertrophied. The following note is extracted from Hunter's Manuscript 'Cases and Dissections : '—“ Upon examination of the body the large intestines were found very much enlarged and distended, particularly towards the rectum. The jejunum and ileum were slightly inflamed ; the viscera in other respects appeared natural. The colon and rectum contained fluid fæces.”

Hunterian.

552. The rectum of a Child with imperforate anus ; the last inch of the bowel is represented by a fibrous cord only ; it is much distended above, and its coats are thickened.
553. The rectum of a female Child which was born with imperforate anus, in which an operation was performed ; death took place a few hours later.

Hunterian.

554. The rectum of a female Child born with an imperforate anus. An operation was performed more than a month before death. *Presented by A. C. Hutchinson, Esq., 1828.*

555. The rectum of a male Child upon whom an operation for imperforate anus was performed with some success. In this instance the trochar had to be introduced three inches before it reached the intestine. The child survived more than ten months. The parts around the artificial opening are much contracted by the action of the spirit in which it is preserved, so that its length is reduced to little more than an inch. The child suffered much from constipation, sometimes for three weeks at a time, and also from a small fistulous opening between the intestine and the urethra; the urine first became tinged with fæces at the end of three months. The intestine above the stricture is greatly dilated and hypertrophied.

Presented by A. C. Hutchinson, Esq., 1823.

556. A portion of the rectum of a Child born with an imperforate anus. It has been considerably distended by the meconium. *Presented by Sir W. Blizard.*

557. A similar preparation. *Presented by Sir W. Blizard.*

558. A portion of the rectum of a female Child with a complete septum nearly four inches from the anus. This preparation had been dried before it was put into spirit.

Presented by T. B. Curling, Esq., 1871.

559. The imperforate rectum of a foetal Pig. *Hunterian.*

560. A vertical section of the pelvis of a male foetal Pig, showing the viscera *in situ*. The rectum terminates in a blind pouch; there is no anus. *Hunterian.*

561. A similar preparation from a female foetal Pig, in which the vagina is also imperforate, and the uterus is largely dilated with fluid. *Hunterian.*

SERIES VII.

ABNORMAL CONDITIONS OF THE HEART AND BLOOD-VESSELS.

Class I. HEMITERES.

(Minor irregularities in the position and form of the heart and vessels.)

1. *Abnormal arrangements of the Blood-vessels.*

In most cases the vessels only are misplaced or have an abnormal distribution, but malformation of the vessels is sometimes accompanied by graver malformations or faulty positions of the heart itself.

562. The thorax of a Human foetus laid open in front, with the arteries injected. The two carotids are given off from a common trunk in the situation of the innominate artery. The left subclavian arises separately, and the right springs from the posterior part of the arch of the aorta, and passes behind the oesophagus to its destination.

From the Museum of Sir A. Cooper, Bart.

563. A portion of the arch of a Human aorta. The vertebral arteries are given off between the innominate and left carotid arteries. The right vertebral is considerably larger than the left.

564. The arch of a Human aorta with abnormal distribution of the vessels arising from it, the left vertebral coming off from the arch.

Presented by Francis Hutchinson, Esq., 1878.

565. A similar preparation.

Presented by F. Hutchinson, Esq., 1878.

566. An abnormal Human aortic arch. The aorta passes upwards and to the right instead of the left, and the arch has its concavity forwards behind the trachea and oesophagus.

On the left of the œsophagus the vessel ends in a diverticulum, from which the left subclavian artery arises above ; the ductus arteriosus enters it below. The descending aorta originates from the transverse part of the arch behind the diverticulum. The right subclavian arises in front of the left, and the two carotids come from the ascending portion of the arch close together.

Presented by C. B. Lockwood, Esq., 1889.

567. The bifurcation of a Human abdominal aorta. The right common iliac artery forms a long single trunk, which, instead of dividing into the external and internal iliacs, dipped down deeply into the pelvis and then, making a sharp bend, turned upwards again to be continued as the common femoral. *Presented by C. Gross, Esq.*

568. An abnormal arrangement of the vertebral arteries, the right exceedingly small. From a man, aged 52, who was accidentally killed by being run over ; all his viscera were healthy. *Presented by Dr. J. F. Goodhart, 1875.*

569. An adult Human heart with a persistent left superior cava. The two venæ cavæ are united by a slender transverse vessel which receives the inferior thyroid vein. *College Stores, 1886.*

2. *Situs mutatus.*

570. A large Human heart with all its parts reversed ; there was also reversion of all the viscera. The systemic auricle and ventricle are enormously enlarged and hypertrophied. The coronary sinus is largely dilated and receives two large veins. There is no evidence that the hypertrophy and dilatation are due to the malformation. These changes are the results of disease. The spleen in this case was divided into nine separate glands (see No. 627). The specimen is described and figured in the Path. Soc. Trans. vol. xx. p. 93, pl. v.

Presented by Dr. Hickman, 1871.

571. A Pig's heart with the position of the ventricles and auricles reversed, and a very free communication between the right and left auricles. The blue rod is placed in the

pulmonary vein and in the auricle functionally corresponding to the normal left auricle ; the red rod is in the left ventricle and aorta.

Presented by Roger Prosser, Esq., 1873.

3. *In the number of Arterial Valves.*

Sometimes two or four valves exist at the mouth of the aorta or pulmonary artery. With our present knowledge it is perhaps best to consider these deviations as variations. There is no evidence of dichotomy in cases of supernumerary valves. The condition is not very rare, and it is not believed to interfere materially with the functions of the heart.

572. The heart of a Child, aged $4\frac{1}{2}$ years, with a small extra semilunar fold at the orifice of the pulmonary artery. (B. 12.*) *Presented by Dr. Peacock, 1876.*

573. A similar specimen from an adult heart. There is also old disease of the aortic valves. (B. 34.) *Presented by Dr. Peacock, 1876.*

574. A portion of the pulmonary artery with four semilunar valves, which are very irregular in size. (B. 23.) *Presented by Dr. Peacock, 1876.*

575. A similar preparation in which the four valve-flaps are equal in size. (B. 22.) *Presented by Dr. Peacock, 1876.*

576. A portion of the right ventricle and pulmonary artery of a female, aged 75 years, with five semilunar flaps. The two extra ones are very small. (B. 13.) *Presented by Dr. Peacock, 1876.*

4. *Variations in the development of the Columnæ Carneæ.*

577. The heart of a Girl, aged 5 years, with a strongly developed transverse bundle of fibres (a moderator band?)

* The Nos. in brackets placed after the specimens presented by Dr. Peacock were upon them formerly, when they were in the museum of the Victoria Park Hospital. These numbers are referred to by Dr. Peacock in his work on Malformations of the Heart, &c.

forming an incomplete septum in the right ventricle. (B. 2.) (See Med.-Chir. Trans. vol. xxxi. p. 61; Dr. Peacock, Malf. of the Heart, 2nd edition, p. 86 & pl. vi. fig. 1.) *Presented by Dr. Peacock, 1876.*

578. The heart of a Boy, aged 15, with a strongly marked muscular band crossing the cavity of the right ventricle. There is also hypertrophy of the right ventricle, deficiency of the upper part of the ventricular septum, and open foramen ovale. The pulmonary artery is obstructed by coagula. There were symptoms of cyanosis during life. (B. 5.) (See Med.-Chir. Trans. vol. xxx. p. 131; Malf. of Heart, p. 79 & pl. vi. fig. 2.) *Presented by Dr. Peacock, 1876.*

5. *Fissure of the apex.*

579. A Human heart with a bifid condition of the apex. The indentation corresponds to the position of the interventricular septum, and from it a slight groove extends upwards along the anterior surface of the septum. *Presented by S. G. Shattock, Esq., 1887.*

6. *Division of the cavity of a ventricle by an adventitious septum.*

This condition is perhaps a very near approach to excess of development. In the following preparation, however, it is apparently due to a variation in the development and position of the columnæ carneæ.

580. An adult Human heart with a strong muscular septum dividing the apex of the right ventricle into two cavities. The septum terminates in a concave margin between the pulmonary artery and the tricuspid valve; it apparently consists of united columnæ carneæ. It is perforated by numerous small openings, between the muscular bundles of which it is composed. *Hunterian.*

Class II. ARRESTS OF DEVELOPMENT; DEFICIENCY.

1. *Arrested closure of the Ductus Arteriosus.*

581. The heart of a male Infant, which died with symptoms of cyanosis five days after birth. The ductus arteriosus is

quite patent. The foramen ovale remains as a slight opening. The heart is abnormally large and weighed $1\frac{1}{4}$ oz. *Presented by Dr. Thurnam.*

2. *Of the Foramen Ovale.*

582. The heart of a Child, 3 years old, with a large valvular opening in the fossa ovalis. A quill is passed through the opening. *Presented by Sir W. Blizard, 1811.*
583. The heart of a Child with an open foramen ovale; the branches of the pulmonary artery are disproportionately small. The right cavities of the heart are dilated. The child was slightly cyanosed during life. (B. 1.) (Path. Trans. vol. i. p. 61.) *Presented by Dr. Peacock, 1876.*
584. An open foramen ovale from the heart of a Child, aged 8 years. Slight cyanosis first commenced after an attack of measles at the age of 6 and continued until death. The aortic orifice is somewhat contracted. (B. 16.) (See Malf. of Heart, p. 115 & pl. vii. fig. 4.) *Presented by Dr. Peacock, 1876.*
585. The heart of a Girl, aged 16, with a largely open foramen ovale. The patient had no symptoms of cyanosis. (B. 20.) (Path. Trans. xi. p. 68; Malf. of Heart, p. 116.) *Presented by Dr. Peacock, 1876.*
586. The heart of a Man, aged 20 (who died of phthisis), with a completely open foramen ovale. The right ventricle is dilated and hypertrophied. (B. 3.) (Path. Trans. i. p. 200; Malf. of Heart, p. 112 & pl. iii. figs. 1, 2, 3.) *Presented by Dr. Peacock, 1876.*
587. The heart of an Adult with a valvular opening in the fossa ovalis. A glass rod has been passed through the opening. *Presented by Sir W. Blizard, 1811.*
588. A similar preparation. *Presented by Sir W. Blizard.*
589. The auricular septum of an adult Human heart, with a similar opening in the fossa ovalis. *Hunterian.*

590. The auricular septum of an Adult of sixty years of age, with a double valvular opening in the fossa ovalis.

Hunterian.

591. A large foramen ovale closed by a sacculated membrane with several apertures in its margin.

Presented by Dr. Peacock, 1876.

3. *Of the Ventricular Septum.*

592. The heart of a lad of thirteen, with both ventricles laid open. The septum is deficient above, so that a semilunar opening exists between them.

Mus. Heaviside.

593. A portion of the heart of a Horse with deficiency of the ventricular septum and dilatation of one of the cusps of the aortic valve which served to fill the deficiency in the ventricular septum.

Presented by J. B. Sutton, Esq., 1889.

594. The heart of a Boy, aged 12, with a defective ventricular septum and an arrested pulmonary artery which communicates with the aorta. The foramen ovale is also imperfectly closed. The boy was cyanosed during life.

Presented by M. D. Makura, Esq., 1882.

595. A part of the hypertrophied heart of a Human adult with precisely similar malformations. A blue rod has been placed in the pulmonary artery.

Presented by J. C. T. Jennings, Esq., 1876.

596. An adult Human heart with a semilunar opening in the upper part of the ventricular septum, protected by a pouch-like valve of endocardium. The upper edge of this valve is strengthened by a thickened margin, above which there is a semilunar opening between the ventricles. The pouch projects considerably into the right ventricle; it is perforated by several small openings. The outer flap of the tricuspid valve is converted into a similar pouch, which probably covered the septal pouch during the ventricular systole, and partially closed the abnormal opening.

Purchased.

597. A small Human heart, with a semilunar opening at the upper part of the ventricular septum. The pulmonary artery has not half its normal calibre. The left auricle and the left auriculo-ventricular opening are much contracted. The mitral valves are very imperfect. The right auricle is enormously dilated, its walls being entirely membranous in places.

The condition of the pulmonary artery and the dilated right auricle point to an imperfect condition of the lungs, with corresponding venous congestion. Unfortunately no history has been preserved.

598. The heart of a female Child aged 6 months. The interventricular septum is imperfect in its upper part. The orifice of the pulmonary artery is slightly contracted, and its trunk is much enlarged. (B. 10.) (See Trans. Path. Soc. v. p. 64 ; Malf. of Heart, 2nd edit. p. 91.)

Presented by Dr. Peacock, 1876.

599. The interventricular septum of the heart of a Child that died cyanosed, aged 17 months ; the upper part of the ventricular septum is deficient. (B. 11.) (See Path. Trans. ii. p. 37 ; Malf. of Heart, p. 56 & pl. i. fig. 2.)

Presented by Dr. Peacock, 1876.

600. The heart of a Boy, aged 12 months, with an incomplete septum. The ductus arteriosus is closed, the orifice of the pulmonary artery is contracted, and both ventricles are of equal thickness. (B. 9.) (See Path. Trans. vii. p. 83 ; Malf. of Heart, p. 100.)

Presented by Dr. Peacock, 1876.

601. The heart of a Boy, aged two years, with an imperfect septum. The aorta arises from both ventricles, chiefly from the right. The walls of the right ventricle are greatly hypertrophied. The foramen ovale is closed. The ductus arteriosus is not preserved. (B. 19.) (See Path. Trans. vol. xi. p. 40 ; Malf. of Heart, p. 102 & pl. iv. fig. 3.)

Presented by Dr. Peacock, 1876.

602. The heart of a Boy aged $6\frac{1}{2}$ years who exhibited characteristic symptoms of cyanosis. The pulmonary artery

is greatly contracted, and the whole upper part of the septum is absent. The foramen ovale is widely open. The ductus arteriosus is closed. (B. 6.) (See Path. Trans. vol. v. p. 67 ; Malf. of Heart, p. 51 & pl. iii. figs. 4 & 5.) *Presented by Dr. Peacock, 1876.*

603. The heart of a Boy, aged 7 years, with the pulmonary artery somewhat contracted. The septum of the ventricles is deficient in its upper part and the foramen ovale is closed. The ductus arteriosus was not preserved. (B. 26.) (See Path. Trans. xvii. p. 45 ; Malf. of Heart, p. 84.) *Presented by Dr. Peacock, 1876.*

604. The heart of a Boy aged 9 years who had cyanosis. The interventricular septum is imperfect. The pulmonary artery is very small and its orifice is contracted. The ductus arteriosus and the foramen ovale are both closed. The walls of the right cavity are greatly hypertrophied. (B. 21.) (See Path. Trans. vol. xiii. p. 57 ; Malf. of Heart, p. 50.) *Presented by Dr. Peacock, 1876.*

605. Atresia of the orifice and trunk of the pulmonary artery. The ventricular septum is deficient above, the ductus arteriosus is enlarged to the size of the normal pulmonary trunk. The aorta arises from both ventricles, especially from the right : the walls of this cavity are as thick as those of the left ventricle, and its cavity is the larger. The foramen ovale is closed. From a cyanotic boy aged 9 months. (B. 8.) (See Path. Trans. vol. ii. p. 205 ; Malf. of Heart, p. 68 & pl. v. fig. 1.)

Presented by Dr. Peacock, 1876.

606. A Human heart, the cavities of which have been laid open to show an imperfect septum ventriculorum and arrested development of the pulmonary artery. The communication between the ventricles is situated at the upper border of the septum, and is one-third of an inch in diameter. The large aorta arises equally from both sides of the heart. The pulmonary artery is represented by a small vessel, the course of which is indicated by a blue rod. It cannot be traced further than the groove between the

ventricle and the aorta, in front of the latter. The right and left pulmonary branches are chiefly derived from a patent ductus arteriosus. The blue rod projects from the cut end of the left branch. From an infant, aged 22 months, who died of whooping-cough.

Presented by W. Sturrock, Esq., 1892.

607. The heart of an Adult with a very narrow orifice to the pulmonary artery and an imperfect ventricular septum. The foramen ovale is open, the ductus arteriosus is not preserved. (B. 31.) (See Path. Trans. vol. xxi. p. 78.)

Presented by Dr. Peacock, 1876.

608. The heart of a Girl aged 19 years. The heart is greatly hypertrophied and exhibits an incomplete interventricular septum, stenosis of the pulmonary artery which will just admit a no. 9 catheter, below the valve; there are only two valve flaps. The foramen ovale and ductus arteriosus are open, the latter is as large as a crow-quill. (B. 7.) (See Path. Trans. vol. vii. p. 80; Malf. of Heart, p. 53 & pl. iv. fig. 2.)

Presented by Dr. Peacock, 1876.

609. The heart from a Boy, aged 2 years, with an imperfect septum, and the aorta arising from both ventricles. The pulmonary artery is almost completely occluded at its orifice. The right ventricle is very thick. The ductus arteriosus and foramen ovale are closed, both ventricles are dilated. The boy was cyanotic. (B. 4.) (See Path. Trans. i. p. 52; Malf. of Heart, p. 45; Edin. Jour. Med. Sc. 1847, p. 644.)

Presented by Dr. Peacock, 1876.

610. Stenosis of the pulmonary artery which would admit a No. 12 catheter, with defect of the septum. The foramen ovale is closed. The ductus arteriosus was not preserved. (B. 32.) (See Path. Trans. vol. xxi. p. 79.) From a patient aged 18 years. *Presented by Dr. Peacock, 1876.*

611. The heart of a Boy aged $8\frac{1}{2}$ who was cyanotic from birth. The pulmonary artery is nearly obliterated; the aorta is very large and has five semilunar valves, two are almost fused into one, and one is very imperfect. The septum

is largely deficient above. The foramen ovale was closed. The ductus arteriosus has not been preserved. The walls of both ventricles are of equal thickness. (B. 28.) (See Path. Trans. vol. xx. p. 87.)

Presented by Dr. Peacock, 1876.

612. The heart of a cyanotic Girl aged 13 years. The pulmonary artery of small size and entirely closed by a diaphragm (formed by the union of its thickened and rudimentary valves?) (B. 30.) (See Path. Trans. vol. xx. p. 61.) *Presented by Dr. Peacock, 1876.*

613. The heart of an Infant, aged 4 days, with two auricles and one large thin-walled ventricle, from which the aorta and pulmonary artery have distinct origins. The child was cyanotic and otherwise malformed. (B. 27.) (See Path. Trans. vol. xviii. p. 251.)

Presented by Dr. Peacock, 1876.

614. The heart of a Boy, aged 11 months, with complete absence of the septum. There is atresia of the pulmonary artery and a patent ductus arteriosus. (B. 33.)

Presented by Dr. Peacock, 1876.

615. The heart of a Child, aged 10 weeks, with deficiency of upper part of interventricular septum, contraction of the pulmonary orifice and an abnormal muscular pouch in the upper and outer aspect of the right ventricle. (See MS. Path. vol. iii. p. 20.)

Presented by Dr. Goodhart, 1876.

616. A Human foetal heart, with the position of its great vessels reversed (*situs mutatus*). There is no trace of a ventricular septum. There is but one auriculo-ventricular opening, with five valves around its margin. There is one large auricle with a small pouch on its right side; this pouch has an auricular appendix, and obviously represents the systemic auricle.

4. *Of an Artery (Stenosis).*

Is usually accompanied by other abnormal conditions. See No. 597, where there is stenosis of the pulmonary artery.

617. The heart of a Man aged 23 who had never been cyanosed.

The *right* heart is hypertrophied. The pulmonary artery is contracted at its orifice by thickening and fusion of the valves. It admitted a ball measuring 15 French lines. The septum is complete. (B. 18.) (See Malf. of Heart, p. 122.) *Presented by Dr. Peacock, 1876.*

618. The heart of an Infant aged 9 days. There is complete closure of pulmonary artery. The ventricular septum is perfect, and the walls of its cavity are very thick. The foramen ovale and ductus arteriosus are open, the right ventricle is very small. (B. 25.) (See Malf. of Heart, p. 72 & pl. v. fig. 2.)

Presented by Dr. Peacock, 1876.

619. The heart of a Child with a contraction of the infundibulum of the right ventricle which would admit a No. 2 catheter. There are two pulmonary valves above the stricture, and the vessel is dilated above the valves. The ductus arteriosus is closed. (B. 35.)

Presented by Dr. Peacock, 1876.

5. *Of a Valve.*

Occasionally one of the flaps of an arterial or of an auriculo-ventricular valve is arrested and remains rudimentary. This condition is usually accompanied by disease of the valves and by warty growths on the endocardium. It is probably the result of congenital disease.

620. A portion of the heart of a Boy, 10 years of age, with two of the aortic valve-flaps united into a single flap. The valves are thickened. There are several wart-like fibrinous growths on the endocardium, and the remains of numerous old pericardial adhesions are apparent. *Hunterian.*

621. The commencement of the aorta from a Boy aged 15 years, with two of the semilunar valves united into a single valve. (B. 14.) (See Malf. of Heart, pl. viii. fig. 2.)

Presented by Dr. Peacock, 1876.

622. A similar preparation in which the union is less complete. (B. 15.)

Presented by Dr. Peacock, 1876.

623. The heart of a Child 6 weeks old. The aortic opening is somewhat contracted, and two of the valves are slightly united by their contiguous borders. The valves when recent had minute fibrinous deposits on their edges. The foramen ovale is only imperfectly closed. (B. 24.)

Presented by Dr. Peacock, 1876.

624. A preparation of the aorta and pulmonary artery of a Child aged 10 weeks. Two of the aortic valves are united into a single valve. There is contraction of the aorta distal to the left subclavian, with a much enlarged ductus arteriosus. (B. 17.) (See Malf. of Heart, p. 152 & pl. viii. fig. 1.)

Presented by Dr. Peacock, 1876.

6. *Misplacements of the Heart.*

Such are Mesocardia, where the heart is situated in the median line; Ectocardia pectoralis or ectopia of the heart (see page 88); Ectocardia abdominalis, in which the heart is situated in the abdomen; and Ectocardia cervicalis, in which the heart lies in front of the neck. Examples are a desideratum in the Museum. (See Dr. T. B. Peacock, 'On Malformations of the Human Heart,' 2nd edit., London, 1866.)

7. *Absence of the Pericardium.*

The heart very rarely occupies a portion of the pleural cavity, usually the left pleural sac, and has no distinct pericardial sac. Four cases are recorded by Dr. Peacock, *l. c.* page 10.

625. Part of the thoracic viscera of a Human adult, showing the heart and left lung enclosed in a common pleuro-pericardial sac. *Presented by C. B. Lockwood, Esq., 1892.*

SERIES VIII.

ABNORMAL CONDITIONS OF DUCTLESS GLANDS.

A. Of the Spleen.

The Human spleen normally exhibits a tendency to become lobulated; occasionally the lobules are separated and form

accessory spleens, and in some cases numerous small separate glands occur in the place of a single spleen ; division of the spleen is probably a mere variety.

626. A Human spleen with a small detached lobule on its concave surface. *Hunterian.*

627. Seven, out of nine, small spleens from the same subject as the malformed heart, No. 570. The case exhibited complete transposition of the viscera ; it is described in the Path. Soc. Trans. vol. xx. p. 93.

Presented by Dr. Hickman.

628. A portion of the thorax of a Human foetus, with a small lobulated body, possibly a spleen, attached to the upper surface of the diaphragm and lodged in a cavity behind the base of the left lung. The body is very vascular, and exhibits one large and several small cysts.

From the Stores, 1891.

SERIES IX.

ABNORMAL CONDITIONS OF THE URINARY AND GENERATIVE ORGANS.

A. Of the Kidneys and Ureters.

Class I. WITH EXCESS IN THE NUMBER OF PARTS.

1. *Dichotomy.*

Dichotomy affecting the kidney to a greater or less extent occurs comparatively frequently. In the slightest forms the gland only exhibits indications of doubling, which extend in the more marked forms to the pelvis and then to the ureter. Sometimes there are two pelves and ureters. The most marked condition of dichotomy exhibits two distinct ureters opening separately into the bladder ; the kidney has then the appearance of two kidneys fused together. The opposite sides of the body are commonly affected symmetrically, and sometimes the double kidneys of opposite sides extend across the mesial line and are fused together by their lower edges.

629. A small injected double Human kidney with a double pelvis and ureter ; the ureter becomes single about three inches from the gland. *Presented by Sir W. Blizard.*
630. The fellow kidney to the last. The ureters are united closer to the gland than in the preceding preparation. *Presented by Sir W. Blizard.*
631. The urinary organs of a Child. The ureters are double on each side. Those on the right side are united before opening into the bladder, whilst those on the left side enter the bladder by two separate orifices. *Presented by Leonard A. Bidwell, Esq.*
632. A double Human kidney and a portion of the urinary bladder. There are four ureters, two to each kidney. The left kidney has not been preserved.
633. A section of a very large Human kidney. The pelvis and ureter are double ; they are injected. *Hunterian.*
634. A section of a similar kidney. *Hunterian.*
635. The lower part of a Human urinary bladder with four perfectly distinct ureters. The orifices of the ureters and seminal ducts are marked by bristles. *Mus. Heaviside.*
636. A similar preparation from the same subject as Nos. 633 and 634. *Hunterian.*
637. A similar preparation, in which only one lateral half of the bladder has been preserved. *Hunterian.*
638. A pair of kidneys from a Human adult, with partial doubling of both glands and of their pelves. The glands are united by their lower margins. A portion of the aorta is preserved, and a second set of renal arteries are seen about $2\frac{1}{2}$ inches below the normal vessels.
639. The kidneys of an adult Human subject with partial doubling of both glands, including their pelves. The lower edges of the glands have coalesced across the mesial line.

640. The lower half of the trunk of a Human foetus with large partially double kidneys united by their lower edges across the mesial line. There is an additional renal artery on the right side only.

Presented by Sir W. Blizard.

641. Urinary organs of a Girl $3\frac{1}{2}$ years old who had spina bifida in the sacral region, incontinence and turbid condition of urine since birth. There is pyelitis of both kidneys, and the left ureter is double at the commencement and greater part of its length, but becomes single at about an inch from the bladder. Both ureters are much dilated.

Presented by W. H. Day and A. Doran, Esqs., 1880.

642. The kidney of a Pig with a double ureter. The additional ureter is enormously dilated and connected with cysts in the upper part of the kidney.

Presented by S. Wilkinson, Esq., 1873.

Class II. MALFORMATIONS WITH DEFICIENCY.

1. *Simple arrest.*

643. The kidneys of an anencephalous full-time (?) foetus slightly arrested in their development. The lobuli are somewhat more distinct than in the normal kidneys of a seven months' foetus.

2. *Union of the two Kidneys.*

644. The kidneys of a Child 10 months old, enlarged, lobulated and united by their lower borders ("Horse-shoe Kidney").

Presented by Dr. Goodhart, 1876.

645. A horse-shoe Kidney removed from a lunatic. It was situated entirely on the left side with the concavity towards the spine, its lower end rested in the left iliac fossa. The ureters ran side by side to within an inch of the bladder, at which point they coalesced, the common duct opening at the usual spot. All the other

organs were normal except the skull, which showed peculiarities in its conformation. See MS. Notes, vol. iii. p. 261. *Presented by S. G. Shattock, Esq., 1888.*

3. *Total deficiency of the Kidneys.*

646. The pelvis of a common Fowl with only one kidney, the left, which is much enlarged. The right kidney is undeveloped, but the ureter was detected leading from the right side of the cloaca, and ending in a small mass of tissue. The specimen is figured in the Proc. Zool. Soc., May 1885, in a paper entitled "Hypertrophy and its Value in Evolution." *Presented by J. Bland Sutton, Esq., 1886.*

647. A portion of the trunk of a Fœtus with total absence of the kidneys, abnormal union of the rectum and urachus, and failure in the development of the external sexual organs. The remains of the Wolffian bodies are seen one on either side connected with the allantois, which still retains a connexion with the rectum, although there is apparently no continuity between the cavities of the two organs. There is a band of fibrous tissue, a round ligament or gubernaculum on either side, united with the remains of the Wolffian body. The adrenals are large and ovoid in form. The feet were also malformed.

The case is described in the 'Transactions of the Obstetric Society,' vol. xxxiv.

Presented by A. E. Giles, Esq., M.B., 1893.

B. *Abnormal Conditions of the Genitalia—including Abnormal Conditions of the Bladder in Vertebrates.*

Class I. *EXCESS IN SIZE AND NUMBER OF PARTS.*

* *IN INVERTEBRATES.*

648. Portions of a Tapeworm (*Tænia mediocanellata*), showing increase in the number of genital systems in many of the proglottides. One proglottis is 356 millim. in length. *Purchased.*

** IN VERTEBRATES.

649. The testicles of a common Fowl. Those of the opposite sides are equal in size. A spherical mass, having the same structure as a normal testicle and measuring $\frac{5}{8}$ of an inch in diameter, is attached to the mesorchium of the right testicle.

Class II. MALFORMATIONS WITH DEFICIENCY.

Subclass I. SIMPLE ARREST OF GROWTH AND DEVELOPMENT.

† IN THE MALE.

650. The pelvis of a Human foetus with a retained testis on the right side. There is no protrusion of peritoneum into the inguinal canal. The gubernaculum is dissected out.
1887.

651. A left testis with a portion of its tunica vaginalis. The small globular body of the testis is suspended by a narrow peduncle from the epididymis, which projects as a rounded cord, three inches in length, from the tunica vaginalis. The vas deferens, which is separated from the spermatic vessels, forms a convoluted loop (globus minor) beneath the serous membrane, and then joins the vessels to form the body and globus major of the epididymis. There is no hydatid of Morgagni, but in its place there is a cystic projection from the free end of the epididymis.

From a man, aged 30, who died of heart-disease. The left testis was normally situated, and the corresponding internal abdominal ring was closed by peritoneum. The right testis, the vasa deferentia, and the vesiculæ seminales were normal.

Presented by J. H. Targett, Esq., 1892.

652. The base of a urinary bladder, with the prostate gland. The left ureter, vas deferens, and vesicula seminalis are normal. The ureter and vas deferens on the right side are absent, and the vesicula seminalis is only represented by a small mass of tissue (showing the usual structure of

that organ), which has been coloured with carmine. The orifice of the left ureter is normally placed.

From a labourer, aged 42, who died with a ruptured axillary aneurysm. There was only one kidney, the left, and no trace of a right kidney nor of the right renal artery and vein could be found. Both the adrenals were normal in size, structure, and situation. The absence of the right vas deferens was discovered accidentally on dissecting the specimen, and no note had been made as to the presence or absence of the right testicle.

653. The pelvis and ill-developed genito-urinary organs of a male, aged 48 years. The external organs of generation would best be characterized as early puerile. The testes are small shapeless masses of yellow fat; they were found on dissection lying just outside the external abdominal ring. Long and slender vasa deferentia connect them with the single common ejaculatory duct. The vesiculæ seminales and prostate gland are in a condition of most imperfect development. A rudiment of the epididymis can be detected. The penis is long but extremely slender, and the bladder is natural.

The parts were taken from a well-developed muscular male. His face was large and feminine and almost destitute of hair. His limbs and trunk were thickly covered with fat. On careful examination no testes could be detected either in the scrotum or the inguinal regions. The pubic hair was scanty and thready. He had not been married. A fuller account of the case is published in the Clinical Society's Transactions, vol. ix. 1876-7, p. 192.

Presented by Edmund Owen, Esq.

†† IN THE FEMALE.

1. *Double uterus.*

The Müllerian ducts in some animals (the Didelphia) remain distinct, in others partially distinct, forming the uterine cornua; or they unite to form the cavity of the uterus, their distinct ends forming the tubes, as in Man. Sometimes in the latter the union either fails partially or entirely, giving rise to a corniculate or double uterus. The vagina is also divided by a septum in extreme cases.

654. The uterus of a Cow, in which there is a partial septum below the cornua. The body of the uterus contains a single cavity, from which the deformed immature fœtus No. 369 was taken. There are two cervices and a double os.
Hunterian.

655. The vagina and internal generative organs of a Human adult female. The vagina is completely divided by a strong muscular septum. The uterus is double, and each lateral half is quite separate from the other; they have been bent over laterally in making the preparation. There is a single tube and ovary to each uterus. The cavities of the vagina and uteri are laid open.

Presented by T. Wormald, Esq.

656. The orifice of the vagina of a Human adult female; it is divided by a strong muscular septum, commencing immediately above the urethra. The right nymphæ forms a free process posteriorly, as if it had been dissected from its attachment.

657. A double Human uterus and vagina. One of the lateral uteri contains a full-time fœtus; the other cavity is considerably developed, measuring 4 inches in diameter. The vagina is completely divided by a septum. The bladder, the right side of the vagina, and both uterine cavities are laid open. There is but a single Fallopian tube to each uterus.
Hunterian.

§ Sometimes one lateral half of the uterus is undeveloped, *uterus unicornis*; sometimes the os or the vagina is occluded. It is uncertain whether such malformations should properly be included in the present Class.

658. A pregnant bicornuate uterus from a woman, aged about 30, who had been killed by a crane accident.

The uterus is divided into two distinct cornua of about the same size. The left cornu contained a fœtus between the second and third months of gestation. The right ovary exhibits a true corpus luteum. The left has none, so that either the corpus luteum is not the remains

of the follicle which yielded the ovum from which the fœtus was developed, or the fertilized ovum passed over from the right cornu to the left through the undivided cervix.

The specimen is described in the Transactions of the Obstetrical Society, vol. xxxiv. 1892.

Presented by J. R. Ratcliffe, Esq., M.B., 1892.

2. *Atresia of the os.*

659. A section of a Human adult female pelvis, with the internal generative organs *in situ*. The uterus is very much enlarged ; it is prolapsed, and lies in the curve of the sacrum. The os was occluded, and an operation was performed, but the patient died. The uterus contained a quantity of offensive fluid. The right ovary is diseased and contains large cysts filling the right iliac fossa. There are traces of blood-clot in the peritoneal cavity.

Presented by T. Wormald, Esq.

660. Imperfect development of the uterus, with atresia of the os externum. From an insane woman. (See Trans. Obst. Soc. 1880.)

Presented by Dr. G. H. Savage, 1878.

Subclass II. EPISPADIAS AND ECTOPIA VESICÆ.

Malformations in which there is arrested closure of the abdominal parietes below the umbilicus, with the deficient space occupied by the urinary bladder. When the closure is almost complete, *epispadias* results : in the more severe forms of this malformation the anterior wall of the bladder is absent, and the posterior portion of that viscus forms a part of the abdominal wall, and projects as a soft rounded tumour, upon the surface of which the ureters open. The symphysis pubis is either deficient or ligamentous, and the penis usually consists of little more than a glans.

1. *Epispadias.*

661. The bladder and generative organs of a Man, aged 22, with extreme epispadias ; the bladder is of small size,

and opens by an infundibuliform passage above the root of the penis. The penis is shorter than is normal; it consists of a pair of cavernous bodies surmounted by a rudimentary glans; its upper surface is grooved and covered with mucous membrane. The symphysis pubis is imperfect and ligamentous.

Presented by R. Partridge, Esq., 1865.

2. *Ectopia vesicæ.*

662. The lower part of the trunk of a Human foetus at about the sixth month of gestation, with complete ectopia of the bladder, so that its posterior wall forms a soft rounded tumour, extending from the umbilicus to the root of the penis, which is rudimentary. The ureters open immediately above the root of the penis; their orifices are marked by bristles. The mother was a negress, aged 16 years. The foetus was one of twin-birth and was still-born.

Presented by Dr. R. Sweeting, 1869.

663. The lower part of the trunk of a small Human foetus with complete ectopia of the bladder. The penis is represented by a slight rounded eminence, apparently the glans, with a fold of skin beneath it united to it by a well-marked frenum. There is a slight vertical line immediately above the glans, on each side of which are the openings of the prostatic and seminal ducts. The ureters are marked by bristles. The scrotum is well formed; but the testes have not descended. One kidney is preserved; it is much lobulated from arrest of development.

Presented by L. J. Beale, Esq., 1829.

664. The lower part of the trunk of a Human foetus at about the sixth month of gestation; with complete ectopia of the bladder. The penis is similar to that of the last preparation. The kidneys and ureters are preserved; they are much atrophied. The orifices of the latter are marked by bristles.

665. A Human female pelvis from an adult, aged 39 years. The pubic bones are separated from each other to the extent of five inches, and the interval is occupied by a

ligamentous band. The woman from which this pelvis was taken was the subject of complete ectopia of the bladder (see next preparation). The pelvis has evidently been much modified by the manner in which the weight of the body is thrown upon the sacrum, the pubic bones being reduced by atrophy and their symphysis widely separated.

Presented by C. Mayo, Esq.

666. A plaster cast of the bladder and external generative organs of the same individual.

This cast is in the cast-room.

Presented by C. Mayo, Esq.

667. Ectopia vesicæ from a female foetus with deficiency of the abdominal wall from the labia to the umbilicus. The ureters are marked by dark blue rods. The small intestine communicates with the bladder, and its course is indicated by a pale green and by a yellow rod. The uterus is represented by the two Müllerian ducts, which have remained separate. The Fallopian tubes will be readily recognized by their proximity to the ovaries. Two portions of the small intestine, adherent to the abdominal wall, have been left *in situ*.

The malformation is described in vol. xv. of the Obstetrical Society's Transactions.

Presented by the Obstetrical Society, 1888.

668. The lower part of the trunk of a female foetus with a widely open allantois. The cloaca is marked by a red rod. The intestine opens into the bladder.

The right and left ducts of Müller are distinct. The right is less developed than the left, and there is only one ovary on the left side.

This specimen is described at length by Mr. A. Doran in the "Journal of Anatomy and Physiology," vol. xv. p. 226.

Presented by Ritchie Norton, Esq., 1880.

Subclass III. CLOACAL FORMATIONS.

The union of the rectum with the bladder or external genital opening is not infrequently a complication of genito-urinary malformation.

669. The pelvic organs of a Girl, aged 11, with the rectum and vagina opening into a common cloaca. The rectum is much hypertrophied.

The case is described in the *Trans. Obstet. Soc.* vol. xxii.

Presented by Dr. Wynn Williams, 1880.

670. Genito-urinary organs with the anus of a female foetus. The rectum is distended, but its termination suddenly narrows and opens by a narrow channel upon the floor of the urethra. 1889.

671. The rectum and bladder of a male Child, 10 days old. The dilated rectum communicates with the membranous portion of the urethra by a narrow orifice through which a bristle has been passed. The anus is imperforate.

The case is described by the donor in the '*Medical Times and Gazette*' for July 24th, 1875.

Presented by W. D. Wilkes, Esq., 1877.

672. Part of the rectum and bladder of a male Child, presenting a condition similar to the last.

Presented by Dr. Arthur Farre, 1877.

673. A similar specimen.

Presented by Walter Rivington, Esq., 1877.

674. The pelvic viscera of a male Infant, aged 6 months, with the rectum opening into the urethra. (See *Trans. Obstet. Soc.* 1880.) *Presented by John E. Boyton, Esq., 1880.*

675. A similar preparation.

676. The rectum and bladder of a new-born Child with imperforate anus. At the anal end of the rectum a narrow channel of communication with the bladder exists. A

portion of the skin attached to the middle of the rectum marks the point where Littre's operation was performed. Fæces were passed in the urine. The child died on the third day after the operation. (See 'Lancet,' 1886.)

Presented by R. H. Barkwell, Esq., 1886.

677. The rectum, generative organs, and bladder of a female Child, two weeks old. The vagina, the urethra, marked by a dark blue rod, and the rectum, marked by a pale green rod, open into a common cloaca. The uterus is bicornuate and the vagina is divided by a septum; its two lateral halves contain a yellow and a red rod respectively. The left half of the vagina and the rectum open by a common orifice.

Presented by F. S. Eve, Esq., 1893.

Subclass IV. HYPOSPADIAS, ANDROGYNE, AND GYNANDRY.

(False Hermaphroditism.)

The conditions commonly known as hermaphroditism are chiefly dependent on various forms of arrested development of the urino-generative tract. Those which affect the male are classified in the following pages under the terms *hypospadias* and *androgyny*, and those which affect the female under the term *gynandry*.

Hypospadias is the slightest form of arrest in the urino-generative tract in the male, but no definite line can be drawn anywhere between the slightest degree of hypospadias and the most highly abnormal form of androgyny; a perfect series of transitional malformations exists between these extremes. Simple hypospadias consists in the defective closure of the anterior part of the urethral canal below, so that the urethra opens at a distance from the extremity of the penis, although it is continued as an open groove to its normal termination. In those animals in which the penis is contained in a sheath the abdominal integument is united to the penis along the edges of this groove, and the usual retractor muscles are absent. In the most marked forms the scrotum is completely divided into two lateral organs, which in the human subject exactly simulate the labia of the female. The urethra opens at the base of the penis between the lateral halves of the scrotum.

In Androgyny the penis is very rudimentary or absent, and the scrotum is cleft. The urethra and sexual orifice are distinct in the human subject; but in animals this is not usually the case. The sinus pocularis, or male homologue of the uterus, is largely developed and generally has two more or less developed cornua. The vasa deferentia are commonly impervious throughout a considerable portion of their length. The testes are generally abdominal or lie in the inguinal canal; they are usually much atrophied, and probably never exhibit their normal structure. The subjects of this malformation so closely resemble the female externally that it is impossible to determine the sex without dissection. Many forms of gynandrous females resemble normal males far more closely than even slightly androgynous males do.

In most animals the penis is present, but permanently retracted in lateral sigmoid curves, and remains very diminutive; it is usually entirely concealed in a fold of integument, and strongly resembles a clitoris. In Bulls, where the bulb of the urethra is normally a capacious pouch, it forms the termination of the urino-generative tract, and closely resembles the vagina of the female. Such animals are called "Free Martins" when, as is usually the case, they are twins with perfect males; they frequently have well-developed teats and much larger mammary glands than are normal in the male. The urethral bulb terminates in a solid sexual cord of enormous dimensions; this cord is always surmounted by a pair of cornua; sometimes it is perforated by the Müllerian ducts, which run through its entire length and terminate blindly in the cornua. It will be remembered that the Müllerian ducts normally disappear in the human male at an early period, but that they persist in the female and form the uterus and Fallopian tubes. This structure is therefore the homologue of the female uterus largely developed. The whole structure of the generative organs of these "Free Martins" is such that, even after dissection, Hunter believed them to be Cows with testes instead of ovaries*. This is not the case; but cysts (cysts of Morgagni) frequently occur in the

* See 'The Works of John Hunter,' by J. F. Palmer, vol. iv. p. 34; and Hunter's 'Animal Economy.'

peritoneal fold which embraces the upper extremity of the cornua of the hypertrophied Müllerian ducts, and the epididymis is sometimes separated from the extremely atrophied testis; this probably led Hunter to regard them as female. The occurrence of these imperfect twin males has given rise to the belief that all female cattle born as twins with males are imperfect: this, however, is not so, as a perfect female is sometimes produced with a male at a birth. There is not, however, any evidence of the existence of androgynous Bulls which are not "Free Martins;" but attention has probably not been paid to this subject.

Gynandry includes those cases in which the female organs appear like those of the male; it frequently occurs in the human female, and the extent of the malformation is considerably less than in Androgyny. The vagina almost always remains as a narrow canal; but the uterus is commonly well developed. The clitoris attains a very large size and strongly resembles the male penis. In infants it is impossible to distinguish between a hypospadiac male in which the malformation is extreme and a gynandrous female without examining the internal organs. Atresia of the anus sometimes accompanies this malformation, and occasionally the rectum opens into the urino-genital sac, giving rise to a cloaca.

1. *Hypospadias*.

678. The generative organs of a male Sheep with extreme hypospadias. The urethra opens immediately in front of the anus; but a groove passes forward from this point to the extremity of the penis. The glans penis is small, but is situated in the normal position. The retractor muscles of the penis are absent, and the abdominal integument is united with the edges of the groove on the underside of the penis, as far forward as the glans. The scrotum is cleft into two distinct sacs; these are filled with hypertrophied connective tissue. The testes are abdominal. The vesiculæ seminales and vasa deferentia open into the urethra. *Hunterian.*

679. A similar preparation. The upper part of the bladder, vasa deferentia, and all the parts beyond have been removed. *Hunterian.*

680. A longitudinal section of the extremity of the penis of a similar Sheep. *Hunterian.*
681. A portion of the hypospadiac penis of a young Ass. *Hunterian.*
682. The generative organs of a Dog with extreme hypospadias. The scrotum is bifurcated. There is a large hood-like pouch in front of the imperforate penis, and a median furrow in front of the urethra. The urethra opens close to the anus. The testes are contained in the scrotum. *Hunterian.*
683. A vertical median section of a pelvis of a Human male six months' fœtus with extreme hypospadias. The urethra opens at the root of the penis; it is marked by a bristle. The scrotum is deeply cleft; the left testis is seen in the inguinal canal; the right gland is entirely within the internal abdominal ring, and lies in the right iliac fossa.
684. A portion of a Human fœtus with slight hypospadias. The right testis is abdominal. The omphalo-mesenteric vessels persist as a delicate filament. *Presented by Sir Erasmus Wilson, 1884.*

2. Androgynæ.

Syn. Pseudo-hermaphroditus, *Gurlt.*

Androgynus, *Gurlt.*

Hermaphrodismes masculins, *Geoff.*

Hermaphrodismes neutres, *Geoff.*

685. The generative organs of a small androgynous Dog. The testes are abdominal and atrophied. The vasa deferentia are impervious and like fine threads. The penis is imperforate and very rudimentary. The urinary and sexual outlets are immediately in front of the anus; they are close together, but distinct. The vasa deferentia are united into a single cord, nearly two inches behind the external orifice*.

Presented by Sir E. Home, Bart., 1802.

* Described in *Phil. Trans.* vol. lxxxix. p. 157, tab. iv. figs. 1 & 2.

686. The generative organs of an androgynous Sheep. The penis is imperforate and of small size; it is retracted in lateral sigmoid curves, so that its extremity lies in front of the urethral outlet. The retractor muscles are well developed; the glans is covered by a hood-like sheath. The extremity of the urethra is marked by a blue glass rod. There are four well-marked teats, each with a single gland-duct. The testes are abdominal. *Hunterian.*

687. The generative organs of a young androgynous Bull. The penis is permanently retracted, so that its extremity lies in a sac-like pouch in front of the anus. *Hunterian.*

688. The testes of the same animal, imbedded in a mass of subcutaneous fat above four well-formed abdominal teats. *Hunterian.*

689. A section of the pelvis of an androgynous Calf, showing the generative organs.

There is a narrow urino-genital pouch, about 4 inches in length; it is marked by a blue rod. The urethra, marked by a purple rod, opens into this sinus near its outlet. The upper (anterior) extremity of the sinus ends in two cornua, into which the vasa deferentia open. Two small cysts, probably the remains of the upper part of the Müllerian ducts, lie near the extremity of the cornua. The left cornu and part of the corresponding vas has been accidentally destroyed. The right testis is seen under the pubic arch: a section has been made through it to show its structure. The left testis is elongated and atrophied considerably. The vas deferens of the right side is impervious throughout a great portion of its length. A clitoris-like fold at the orifice of the sinus encloses a very diminutive folded penis in a small cyst-like cavity.

Hunterian.

690. A section of the pelvis of a Sheep, from the West Indies, in which the generative organs closely resemble those in the last preparation, except that the testes are both much elongated and the uterus masculinus (or upper part of the genital pouch) is perforated by two tubes, Müllerian ducts. There are no cysts of Morgagni, or at least they are not apparent*. *Hunterian.*

* See Hunter's 'Animal Economy,' p. 60.

691. The generative organs of a very young Calf, described as "Palmer's Free Martin." They exhibit a highly androgynous condition. The large urethral bulb is laid open from above to show the orifices of the urethra and sexual ducts.

Just within the orifice of the bulb which forms the external opening, and closely resembling the vagina of the female, a slight depression is seen, and immediately beneath this, in the anterior wall of the bulb, is an exceedingly diminutive penis; it is retracted permanently in sigmoid curves. The neck of the bladder opens into the sinus of the bulb near its upper extremity, and just above it are the openings of the vasa deferentia; the bulb is prolonged slightly above these, and ends in a thick solid cord, the sexual cord of the embryo. This terminates above in two solid cornua, an inch and a half in length; a pair of rudimentary testes are suspended in a peritoneal fold at their extremities. The epididymis is much larger than the gland, and this has given rise to the opinion that both ovaries and testes exist: sections have been made through these parts. The microscope shows that the testes consist of dense fibrous tissue with cells; the character is not that of an ovary, but closely resembles the testes usually found in these cases. The vasa deferentia are incorporated with the sexual cord above, but are well formed below, as are also the vesiculae seminales*.

Hunterian.

692. The generative organs of an androgynous Bull. The animal was described as "Mr. Arbuthnot's Free Martin"†.

This preparation is essentially similar to the preceding, except that it is much larger, and the genital cord is perforated by Müller's ducts; these have been laid open through their entire length; they are seen to terminate blindly near the extremity of the cornua. The vesiculæ seminales are normal, and the vasa deferentia are developed; they pass up in front of the genital cord for a short distance, and then extend as convoluted tubes along its outer borders, to the extremity of the cornua; they terminate in the epididymis.

* Museum Drawings.

† Hunter's 'Animal Economy,' 1st edit. p. 57, pl. i., 2nd edit. p. 71, pl. ix.; and Museum Drawings. The descriptions of plates ix. and x. in the second edition of the 'Animal Economy' are transposed and wrongly numbered.

The testes lie close to the extremity of the cornua; they are very small in proportion to the epididymis, and hence they might easily be mistaken for ovaries. The openings of Cowper's ducts and of the vasa deferentia are marked with purple, and the urethra with a green glass rod.

Hunterian.

693. A similar but much larger preparation, from "Mr. Wright's Free Martin," which was 5 years old *.

In this preparation a portion of the bladder has been removed and the spermatic arteries injected. The orifice of the bladder is marked by a blue glass rod; the openings of the vasa deferentia and Cowper's glands are marked with green rods. The sexual cord in this preparation is quite solid. The testes are situated at the extremity of its cornua; one is seen in section. Hunter said of them:—"I call these bodies testicles, first, because they are twenty times the size of the ovaries of the cow, and nearly the size of the testicles of the bull, or rather those of the 'ridgil,' the bull in which testicles never come down; secondly, the spermatic arteries are similar to those of the bull, especially of the 'ridgil'; thirdly, the cremaster muscle passed up from the rings of the abdominal muscles as it does in the 'ridgil.' Although I call these bodies testes, for the reasons given, yet when cut into they had nothing of the structure of the testicle, not being similar to any thing in nature; they had more the appearance of disease." On microscopic examination they are found to abound in fibrous tissue enclosing cells, with here and there what appear to be seminal tubes. Hunter adds: "The animal had four teats, but the glandular part of the udder was small."

Hunterian.

694. A similar but much smaller preparation, described as "Mr. Wells's Free Martin" †.

The vesiculæ and their ducts, as well as the terminal portions of the vasa deferentia, are normal. Cowper's glands are present, and there is a rudimentary penis retracted in sigmoid curves. The sexual cord is solid, as are likewise its cornua. There is only a trace of an epididymis on the left side; but the cornua of the sexual

* Hunter's 'Animal Economy,' 1st edit. p. 59, pl. ii., 2nd edit. pp. 64 & 71, pls. viii. & x.; and Museum Drawings.

† 'Animal Economy,' 2nd edit. p. 64, pl. xi.

cord end in a large thick-walled cyst: the vas deferens on this side is deficient in several places. On the right side there is no trace of a vas or epididymis, and a small oval body, more like an ovary than a testis, exists in the place of a testis; it consists of tissue, however, which, on microscopic examination, appears identical with that of which the imperfect testes of these malformations usually consists; there is no reason to regard it as otherwise than an imperfect testicle. There is much fat in the neighbourhood of these rudimentary sexual bodies. The animal from which this preparation was taken was a "Free Martin." The following history is given by Hunter in his 'Animal Economy':—"It was between three and four years old, and had never been observed to show any signs of desire for the male, although it went constantly with one. It looked more like a heifer than Free Martins usually do. The teats and udder were small, compared to those of a heifer."

Hunterian.

695. The generative organs of an androgynous Calf dissected. The uterus masculinus is much smaller than in the last preparation, and the bladder communicates with a thick-walled persistent allantois which opens at the umbilicus.

Presented by J. T. Davy, Esq., 1892.

696. The lower portion of the trunk of a male Child in which the external generative organs so closely resemble those of a female that the child was called "Ellen." The scrotum is very large, completely divided into two halves, so that it forms two labium-like folds of skin; these are thickened by hypertrophied connective and adipose tissue. The penis is absent; but a fold of skin strongly resembling the nymphæ and clitoris exists in its place: it is probably the prepuce. The urethra and sinus pocularis open by distinct orifices between the lobes of the scrotum. A blue glass rod marks the orifice of the sinus. The urethra is laid open laterally, as is also the lower part of the sinus. The upper part of the sinus is surrounded by prostatic tissue, and it terminates in a pair of cornua, to which the vasa deferentia are attached; these are probably impervious. The testes are abdominal. The bladder and one kidney have been preserved.

Presented by R. Partridge, Esq., 1865.

697. A portion of a Human fœtus exhibiting a similar malformation, dissected. The uterus masculinus is well marked.
Presented by Sir Erasmus Wilson, 1884.

3. Gynandry.

Syn. Hermaphroditismes femines, Geoff.

698. A section of the pelvis of a Puppy, with a cloaca common to the rectum and urino-generative pouch. The sex is uncertain; but the appearance of the glands is more like that of ovaries than of testes.

There is a large sinus with two cornua beyond the opening of the bladder, but no trace of vas deferens, vesiculæ, or penis. There is no uterus, properly so called, and no vagina. The microscopic structure of the genital glands is more like that of an ovary than of an abnormal androgynous testis. In their immature state and extremely fibrous condition, however, it would be impossible to assert with any degree of certainty that the animal was either a modified male or female.

699. The ill-developed generative organs of a Ewe. The clitoris is large, and beneath it (as the specimen is placed) is a narrow channel representing the vaginal orifice. The lower half of the vagina is very narrow and its walls are thickened; the upper half is dilated into an oval cyst. The ovaries appear well developed.

Presented by Frederick T. Eve, Esq., 1885.

700. The external and internal generative organs of a Human female fœtus. The clitoris is greatly enlarged, and the opening of the vagina is reduced to the diameter of the urethra for more than an inch from its outlet; beyond the neck of the bladder it dilates to its normal size. The uterus and ovaries are normal. The posterior wall of the vagina has been laid open, and a bristle marks the orifice externally.

701. The generative organs of a Human female infant. The clitoris is very large; a fold of skin above it represents the prepuce. The labia are close together below the

urethra-like external generative opening : they resemble a scrotum. Externally this foetus could not have been distinguished from a hypospadiac male. The inch and a half of the genital tract common to the vagina and urethra is very narrow. Above the neck of the bladder the vagina is normal ; it has been laid open to show the os and cervix uteri. The Fallopian tubes and ovaries are normal. The left round ligament has been preserved ; it ends in the cellular tissue of the labium.

702. The external organs of generation of a Human female infant. The vaginal opening is contracted as in the last two preparations. There is a very large clitoris almost embraced by the labia and nymphæ, the latter forming a prepuce above the clitoris.

There appears to have been an imperforate anus accompanying the malformation, for which an operation has been performed ; this is not, however, recorded.

Hunterian.

703. The bladder and generative organs of a female Child, aged 7, exhibiting well-marked gynandry. The child died of retention of urine. The bladder is greatly hypertrophied, and has a lateral sacculus on each side, into which a ureter opens. These sacculi appear to represent the trigone, and the central large cavity has perhaps resulted from great hypertrophy of the detrusor. The urethra opens at the end of the clitoris. The uterus is very imperfect and bicornuate ; there is only one ovary, that of the left side. A minute blind sinus or recess between the root of the clitoris and the narrow opening of the vagina possibly represents the normal orifice of the urethra. (See Trans. Path. Soc. 1893.)

Presented by H. W. Page, Esq., 1893.

Class III. TRUE HERMAPHRODISM.

Syn. Hermaphrodisme bisexuel, *Geoff.*

True Hermaphrodisism cannot be regarded as either the result of excess or defect in the normal developmental process ; but these malformations appear to be due to excess and arrest combined. They naturally follow those remarkable conditions known as Androgyny and Gynandry, with which they appear to have some connection.

True Hermaphrodisism is not uncommon as a malformation amongst unisexual Invertebrates. Sometimes one side of the body is male and the other female ; this is the usual form amongst insects. Another form of true hermaphrodisism has been frequently observed amongst fish, in which a portion of one or both ovaries is differentiated into a testis. Certain Fishes are normally hermaphrodite, and *Myxine glutinosa* is said to be male in the character of its sexual organs when young, and to become female at a later period.

704. An hermaphrodite example of *Polyommatis alexis*. The right side has the characters of the female and the left those of the male. Lateral hermaphrodisism in insects is well known to occur not infrequently. The internal organs in these cases are stated to be male on one side and female on the other, corresponding with the external characters. *Purchased.*

705. The genital glands of an hermaphrodite Codfish (*Gadus morrhua*). The centre of the specimen is occupied by two well-developed ovaries. Attached to the outer and posterior part of one ovary is a large mass composed of foliated and papillary processes of fat. This body represents an ill-developed testicle. Nothing corresponding to it was observed on the other side.

Presented by W. B. Tegetmeier, Esq.

706. The ovaries and external generative aperture of a Codfish injected. A large piece of convoluted testicle is intimately connected with the wall of the right ovisac, in the

middle of its outer margin. It is uncertain whether the seminal ducts in this case open into the ovisac ; but in a precisely similar case described by Dr. J. A. Smith there were five distinct ducts perforating the ovisac and opening into the cavity of the ovarium (see Journal of Anatomy and Physiol. 1870, p. 256).

Presented by W. Lynn, Esq., 1825.

707. A similar preparation, in which the posterior end of the left ovary is united with a convoluted mass of testicle almost equalling the ovary in size.

Presented by Sir A. Carlisle, 1821.

708. A similar preparation, but not injected, in which a portion of convoluted testicle is attached to the anterior end of the left ovary. The testis is about half as large as the ovary. The right ovisac has been opened to show the tufts of ova.

Presented by Sir E. Home, Bart., 1802.

709. The ovaries of a Fish, probably a small Cod, with a very small convoluted mass of testis attached to the anterior extremity of the right ovary.

Mus. Brit.

710. The hermaphrodite genital organs of a Mackerel (*Scomber scomber*). The ovaries lie ventrally to the testes. The male and female organs are of about equal size. Ova and spermatozoa were well developed. (See Journal of Linn. Soc., Zool. vol. xxiv.)

Presented by W. B. Tegetmeier, Esq.

711. An hermaphrodite Trout (*Salmo fario*). The right genital gland is ovarian in structure. The left, which is larger, consists chiefly of ovary, but a portion, 26 mm. from its anterior end, 16 mm. long and 5 mm. wide, has the structure of a testicle. The genital ducts lead from the posterior end of the glands to the urogenital chambers. This may be regarded as a case of a fundamentally male fish having partly acquired a female character. From the self-fertilized ova healthy and normal young were reared. (See Journal of Linn. Soc., Zool. vol. xxiv.)

Presented by T. Andrews, Esq.

SERIES X.

ABNORMAL CONDITIONS OF THE MAMMARY GLAND
AND ANALOGOUS STRUCTURES.

712. Supernumerary nipples and mammæ from a female Monkey. *Presented by J. B. Sutton, Esq., 1889.*

713. A similar preparation from a male Monkey. *Presented by J. B. Sutton, Esq., 1889.*

SERIES XI.

ABNORMAL CONDITIONS OF THE OVIDUCT AND OVA OF
BIRDS.

A. Of the Oviduct.

714. The sacrum of a young Fowl with the right oviduct persistent. It forms a large thin-walled cyst, which was distended with air. The left oviduct was normal; it has been removed, but its orifice is indicated by a bristle. *Presented by W. B. Tegetmeier, Esq.*

715. The oviduct and ovary of a small Hen, which during life laid pseudo-eggs about the size of a Pigeon's, consisting exclusively of albumen, covered by a very perfect shell. One of the eggs is seen in the abdominal opening of the oviduct. The oviduct is so small that it could not grasp and transmit the yolks. The ovary is loaded with well-developed ova. When the abdomen was opened the peritoneal cavity was found to be full of the yellow fluid contents of the yolks, which had escaped. The egg which is now in the open extremity of the oviduct was found in the abdominal cavity; another was situated in the cloaca.

As the egg found in the abdominal cavity had undergone no change, it appears probable that it passed back into the abdominal cavity when the Fowl was killed; it was therefore replaced in the extremity of the oviduct, to show how it must have passed into the peritoneal cavity. It appears that as each yolk was matured it fell into the abdomen, and was ultimately absorbed, whilst the oviduct poured out albumen and formed a shell, as it would if the yolk had passed into its tube. The Hen, when killed, was apparently perfectly healthy. Specimens of the eggs are preserved in No. 729.

Purchased, 1871.

B. Of the Ova.

1. *Twin Eggs.*

In these two yolks or two perfect Chicks are enclosed in a single shell. Double-yelked eggs seldom produce two Chicks. Twin Chicks are probably produced from single-yelked eggs.

716. The egg of a domestic Fowl with two yolks. The shell is well formed, and the egg is larger than the normal size. A portion has been cut away to show the interior.

Hunterian.

717. A similar specimen.

Hunterian.

718. The egg of a domestic Fowl containing one Chick. A twin Chick escaped from the egg; both birds were then alive. The one now in the egg, however, died immediately.

Presented by W. D. Oliver, Esq.

719. The egg of a Fowl containing two distinct and perfect Chicks. The allantois and yolk appear to have been single.

2. *Abnormal conditions of the Yolk.*

720. Portions of a Duck's egg which had been hard-boiled. On opening the egg the yolk, although of normal size and clearly defined, was as white as the coagulated albumen.

Presented by W. B. Tegetmeier, Esq.

3. *Of the coverings of the Yellk.*

Inflammation of the oviduct gives rise to deficiency of the calcareous covering of the egg and to a fibrinous condition of the albumen. In some cases, from causes at present unknown, the membrana putaminis is the seat of calcareous deposit.

721. The shells of three eggs, in which the shell-membrane is the seat of calcareous deposit.

722. The shell of a Hen's egg, in which the small pole of the albumen was prolonged into a short spiral and covered with shell. It is probable that this specimen is due to disease in a minor degree, similar to that which produced the following abnormal eggs.

Presented by Dr. F. R. Fairbank.

723. A Hen's egg, invested in a strong fibrous shell-membrane, but without any shell. The albumen is drawn out into a long twisted process at one pole of the egg. A section has been made through the albumen to show its fibrinous condition.

Presented by Sir A. Carlisle, 1818.

724. A similar specimen, in which both poles of the egg are prolonged.

Presented by W. Clift, Esq., 1811.

725. Two Hen's eggs without shells united by a narrow pedicle, but with a thick shell-membrane, exhibiting small spots of calcareous deposit on the surface. *Hunterian.*

726. A similar specimen.

Presented by W. B. Tegetmeier, Esq., 1867.

727. A similar specimen. Found in a farm-yard frequented by Fowls.

Presented by J. Prankerd, Esq., 1879.

728. Two eggs united by a bar-like prolongation.

Presented by 'Land and Water,' 1888.

4. *Pseudo-Eggs, or Eggs without yolks.*

729. Pseudo-eggs laid by the Hen the oviduct and ovaries of which are preserved in preparation No. 715. The eggs consist of normal albumen enclosed in a small but well-formed shell.
730. A small, elongated, curved, pseudo-egg from a Fowl.
Presented by W. S. Pocklington, Esq., 1860.
731. A similar egg. *Presented by G. L. Rugg, Esq., 1881.*
732. The shell of a similar pseudo-egg.
733. The imperfectly calcified egg-shell of a similar egg.
734. Two small pseudo-eggs, formed of concentric masses of fibrinous albumen and united by a long pedicle; they are without shells. Sections have been made through them to show their structure.
735. The egg of a Bantam Hen, with two small masses of albumen, which have descended upon it in succession, covered with shell, and united by calcific deposit to its upper extremity.

5. *Included Eggs or Pseudo-Eggs.*

Sometimes a small egg, or pseudo-egg, remains in the oviduct or, according to Mr. Tegetmeier, is carried back from the shell-secreting into the albumen-secreting portion of the oviduct, and becomes invested with a second layer of albumen and a second shell; or it is met by and invested in a second ovum; in this way one egg becomes included in another. Very frequently the included egg is cracked or broken; in such cases impaction is probably the cause of the phenomenon.

736. The shell of a normal Hen's egg, enclosed in a larger very thin shell. The inner shell is cracked, and appears to have been cracked within the oviduct. The space between the outer and inner shells probably contained albumen only, poured out under the irritation of the cracked and impacted egg.

737. A similar specimen.
738. A smaller egg-shell included within a larger one ; both shells are perfect. An opening has been made in the outer one. *Presented by Dr. Birch, 1857.*
739. The shell of a Goose's egg, containing that of a second egg ; both shells were perfect : the outer shell has been fractured. *Presented by Dr. Leach.*
740. A small well-formed pseudo-egg, which was found within another egg. *Hunterian.*
741. A small Hen's egg found enclosed within one of normal size. *Presented by C. J. Lambe Esq., 1877.*
742. A similar specimen. *Presented by George Collette, Esq., 1880.*
743. A similar specimen. *Presented by H. C. Harmsworth, 1875.*
744. A Duck's egg enclosing within it a second egg, with a calcified shell. Only albumen filled the space between the two shells. *Purchased, 1880.*
745. A Duck's egg enclosing a second egg with a calcified shell. *Presented by S. W. Sibley, Esq., 1883.*
746. A similar specimen. *Presented by W. B. Tegetmeier, Esq., 1884.*
747. An included egg. *Presented by W. R. Swain, Esq., 1889.*

6. *Fibrinous masses from the Oviduct.*

748. An immense fibrinous mass, containing a broken egg, from the oviduct of a Hen. A section has been made to show the composition of the tumour. *Presented by W. B. Tegetmeier, Esq., 1871.*
749. A section of a similar fibrinous mass, containing a broken egg. *Presented by W. B. Tegetmeier, Esq., 1871.*

CATALOGUE

OF

MALFORMATIONS IN PLANTS.

SERIES I.

ABNORMAL CONDITIONS OF THE EPIDERMAL SYSTEM.

Malformations of the epidermal system as distinct from pathological states are very uncommon. They comprise such cases as excessive or defective villosity, glaucescence, and the like, which are more fittingly represented in the physiological and pathological departments.

SERIES II.

ABNORMAL CONDITIONS OF THE ROOT-SYSTEM.

Class I. POLYCLADY, excessive degree of branching.

These cases are due to increase in the number of growing points, but it is for the most part impossible to determine whether the multiplicity is absolute, or whether it arises from the repeated subdivision of one original growing point (dichotomy). Of very few vegetable malformations are the course of development and minute anatomy known.

750. Root of Carrot dividing into four fleshy branches, one of which is twisted spirally around the others, probably in

consequence of some obstruction to direct downward growth.

Presented by Dr. Masters.

Subclass I. FASCIATION.

FASCIATION—Polyclady associated with conrescence or arrest of development, so that the numerous branches do not separate one from another, but remain congenitally united or inseparate.

751. Fasciated root of *Spiræa canescens*. The branches of the root, instead of becoming separate, remain in union one with another, producing a banded or flattened appearance.

Hort. Kew.

A fasciated condition, though extremely common in the stem and branches, is rarely met with in the root. A summary of the principal cases recorded is given in 'Pflanzen Teratologie' von M. T. Masters, p. 35.

SERIES III.

ABNORMAL CONDITIONS OF THE STEM (AXIS) AND ITS BRANCHES.

Class I. POLYCLADY, excessive subdivision.

752. Branch of *Dodonæa viscosa* the slender branchlets of which form fan-shaped tufts of radiating subdivisions, the whole forming a dense head. The ultimate branchlets expand at the tips into small fleshy expansions covered with glandular hairs.

There is no history of the specimen, which, however, has the appearance as if it might have been the result of the puncture of an insect, or possibly of the attack of a fungus.

753. Branches of common Ling (*Calluna vulgaris*) in which the branchlets are much increased in number, shortened, and arranged in dense tufted masses.

Presented by S. J. A. Salter, Esq.

Subclass I.

Fasciation or Polyclady associated with concrescence, so that the branches do not separate one from another or from the axis, but remain more or less inseparate.

Simple Polyclady, a condition which corresponds very closely with "Dichotomy" in the animal series, is due to an excessive development of the growing points and consequent increased subdivision, but the concrescence, or imperfect separation, which is so marked a feature of Fasciation, can only be considered as the result of an arrest of development. Over-formative activity in one direction is thus by compensation associated with arrest of growth in another. Another very common condition associated with fasciation is spiral torsion of the stem, the result of a check to growth on one side, as contrasted with rapid development on the other. Fasciation is usually the result of over-rapid growth, and is not confined to any one class of plants, being as common, or nearly so, in shoots that become ultimately woody, *e.g.* the Ash, as in those that remain herbaceous, as in the Asparagus. A list of the plants most usually affected is to be found in 'Vegetable Teratology,' p. 20, where also several illustrations will be found.

754. Stem of a species of *Daphne* showing abnormal production of shoots, which remain in union instead of forming separate branches. *Presented by J. Wilson, Esq.*

755. Branch of a species of *Casuarina* showing the flattened or banded condition of the stem arising from fasciation, as well as the contorted state so often associated with it.

Presented by Baron Sir Ferd. von Mueller.

756. Fasciation and spiral torsion in the upper part of the stem of *Valeriana officinalis*. As a result of the torsion the branches are all given off on one edge.

Presented by Rev. T. A. Preston.

Class II. ADHESION.

Botanists designate under the head of Cohesion the union (or more frequently the want of separation) between the parts of one organ, or between different members of the same whorl. Adhesion, on the other hand, is applied to the real or apparent union of one organ to another of a different character, or to a member of a different whorl. In illustration of this matter attention may be called to 350 A, Part I., of the Catalogue of this Museum, which well shows the adhesion of primarily distinct branches one to the other, thus constituting a case of natural grafting.

SERIES IV.

ABNORMAL CONDITIONS OF THE FOLIAGE-LEAVES.

Class I. ARREST OF GROWTH AND OF DEVELOPMENT.

757. Leaves of *Croton Veitchii*, two normal; the detached one is nearly destitute of stalk, and is arrested in its growth and developed in a shell-like form.

Royal Gardens, Kew.

Class II. SPIRAL TORSION.

Instances of spiral torsion from side to side are common in leaves as in stems. It is relatively much less common to meet with leaves rolled from the apex towards the base (circinate) as may be seen in the following preparation.

758. Leaves of *Banksia* sp., spirally coiled from the apex towards the base. A similar malformation occasionally occurs in the Weeping Willow, *Salix babylonica*. All the leaves on a tree may be thus affected, such trees being grown in the gardens of the curious. Occasionally the origin of the malformation is evidenced by the sudden reversion of one particular branch to the normal condition.

Presented by Dr. Masters.

Class III. SUBDIVISION (DICHOTOMY).

Such growths occurring as primary developments are included under the head of "Chorisis," but if they occur at a relatively late period of development on, or from, an organ already advanced in development, they are comprised under the general category of "Enation." ('Vegetable Teratology,' p. 445, with illustrations.)

a. Chorisis in the Horizontal Plane.

759. A frond of the common Hart's-tongue Fern (*Scolopendrium*), dichotomous in its upper part from fission, or from the development of supernumerary growing points.
Presented by Mr. Clift, 1808.

760. A dichotomous Fuchsia leaf.
Presented by S. G. Shattock, Esq., 1880.

761. Leaf of *Begonia argyrostigma* in which the apex divides into two distinct lobes.

762. *Gardenia florida*, showing one of the leaves branched at the base so as to form a two-lobed leaf.
Royal Gardens, Kew.

β. Enation in the Vertical Plane.

763. Leaf of *Cyrtodeira fulgida* in which a leafy outgrowth from the base of the midrib on the under surface has taken place. The outgrowth is continuous with the true margin of the leaf at the base.—Enation.
Royal Gardens, Kew.

764. Leaf of Kail (*Brassica oleracea*) showing leafy outgrowths projecting vertically from the nerves on the upper surface of the leaf and illustrating the fact that leaves may become branched in a manner similar to that of the branches themselves.—Enation.
Presented by Dr. Masters.

765. Cabbage-leaf (*Brassica oleracea*) showing leafy outgrowths from the midrib, which is thus branched in place of remaining undivided as usual. Such productions are common in the leaves of Kail.—Enation.
Presented by Mr. N. Brown.

Class IV. PITCHER-FORMATIONS (ASCIDIA).

The formation of pitcher-like or cup-like growths in plants arises from various causes, such as the infolding and union of the margins of a single leaf, but much more commonly from the circumstance that development and growth, instead of taking place principally and equally in one plane, are manifested in a circular direction, so that a cup-like dilatation at the end of the leaf-stalk or from one of the lateral veins of the leaves takes place, and a cup- or pitcher-like form results. In other cases the margins of two adjacent leaves remain in union to form a cup. Pitcher-formation is not restricted to the leaves, as similar dilatations occur at the ends of the branches, owing to the disproportionate growth of the peripheral layers of tissue as compared with that of the central portions. (See 'Vegetable Teratology,' pp. 30 and 312, with figures.)

766. Leaves of *Yucca* in which one margin is sharply infolded, whilst in other cases the apex of the leaf is bent downwards, forming a hood. The cause of the production is not ascertained. *Presented by G. E. Frere, Esq.*

767. Imperfectly-developed pitcher of *Nepenthes*. The tendril at the apex of the leaf expands not into a cup furnished with a lid, as it does normally, but into an oblong leafy expansion, the inner surface of which is studded with numerous glands. *Royal Gardens, Kew.*

768. Pitcher-like leaf or ascidium of Cabbage (*Brassica oleracea*), the stalk dilated at its apex into a leafy cup, owing to the development of the leaf on all sides instead of in one plane. *Presented by Dr. Masters.*

769. Cup-like outgrowth from leaf of Cabbage from cupular dilatation as in the preceding specimen. *Presented by Martyn Roberts, Esq.*

770. "Pitcher" or funnel-shaped outgrowth from the leaf of the Cabbage. The lamina, instead of forming a horizontal plane, is here developed as a sheath or tube expanding

later on into a foliaceous cup. There is no true union of the edges, for they were never separate.

Royal Gardens, Kew.

771. Leaflet of *Camoensia maxima* provided with a long slender stalk dilating at the extremity into a cup-like formation. The other leaflet is normal. *Royal Gardens, Kew.*

772. Shoot of *Higginsia*. From the axil of a normal sessile leaf is produced a small leaf on a long slender stalk. The blade is cup-shaped owing to the concrescence of the margins near the base. *Royal Gardens, Kew.*

773. Pitcher-like growth of *Kalanchoe crenata*, arising from the union and concrescence of the margins of two adjacent leaves. *Royal Gardens, Kew.*

774. Leaves of *Guatteria caffra* apparently partially united at the base back to back. The condition is more likely to have arisen from enation or from branching of the leaf. *Royal Gardens, Kew.*

Class V. ADHESION.

775. A specimen showing the adhesion of the blades of two leaves of Rhubarb (*Rheum*) whilst the leaf-stalks or petioles remain free. The leaves were given off from opposite sides of the root-stock, so that the two leaf-blades formed a cap over the apex of the stock, and were raised above it by the subsequent lengthening of the leaf-stalks. Union must therefore have taken place between the two blades at a very early stage of development, owing to pressure probably, and before the formation of the petioles. *Presented by Dr. Masters.*

SERIES V.

ABNORMAL CONDITIONS OF THE INFLORESCENCE.

a. Affecting the Axis of the Inflorescence.

Class I. POLYCLADY OR DICHOTOMY.

776. A dichotomous ear of Wheat, in which the culm is single but the inflorescence branched.

Presented by Mr. Searson, 1871.

777. A triple head of Teasel, produced by the branching of the axis of the inflorescence.

778. Branched spike of the Common Barley (*Hordeum vulgare*). The supernumerary branches are produced towards the base and the middle of the spike, not at the apex, showing that the direction of growth is mainly centripetal.

Presented by H. C. Watson.

779. Plant of the Buckthorn Plantain (*Plantago Coronopus*), showing in place of the usual simple spike a much-branched cluster. In such instances it often happens that the parts of the flower are not perfectly constructed, but are represented by scales, as if overgrowth in one direction were attended by defective organization in another. Such cases of excessive branching of the inflorescence are occasionally classed under the head of lateral proliferation of the inflorescence.

Presented by Dr. Masters.

780. Flower-heads of *Trifolium resupinatum*, showing supernumerary branches and secondary flower-heads proceeding from the primary ones as a result of over-luxuriant development or proliferation of the inflorescence.

781. Flower-head of Marigold (*Calendula officinalis*) in which the central axis is prolonged beyond the first flower-head and bears a second capitulum at its apex. The specimen affords an illustration of median proliferation of the inflorescence.

Presented by Dr. Masters.

In connexion with proliferation of the Inflorescence, reference should

be made to No. 245 (see Part I. p. 54, of the Catalogue), and which shows a greatly increased number of cones in the Pinaster (*Pinus Pinaster*), the result of excessive development.

See also No. 247 *a* of the same Part, which is a cone of a Larch, *Larix europæa*, in which the axis of the cone has been prolonged beyond the apex in the form of a leafy shoot. See also 'Vegetable Teratology,' p. 100.

Subclass I. FASCIATION.—POLYCLADY ASSOCIATED WITH
CONCRESCENCE.

782. A double head of Cowslip-flowers with the flower-stalks slightly adherent through their entire length.

Presented by Mrs. Scott, 1872.

783. Plant of Daisy (*Bellis perennis*) showing a fasciated flower-spike arising from the multiplication of the growing points and the inseparation or concrecence of the resultant shoots.

Presented by Mr. Hillier.

784. Flower-stem of *Pyrethrum uliginosum*, flattened and distorted owing to the production of numerous shoots which are concrecent—that is, remain in union one with another instead of separating.

Royal Gardens, Kew.

785. Pineapple (*Ananassa sativa*), showing a branched condition of the inflorescence, forming a fasciated, cock's-comb-like mass. The Pineapple consists of a large number of flowers, each arising from the axil of a bract. As the fruit ripens the bracts and flowers become fleshy by increase of the cellular tissue, so that all the flowers of one inflorescence become blended into one fleshy mass. By compensation the seeds are usually abortive.—Azores.

Presented by A. Raith, Esq.

β. Affecting the Bracts or Leaves of the Inflorescence.

786. "Green Dahlia," *Dahlia variabilis*, in the condition known as Phyllody. The bracts and scales of the involucre being developed as small leaves, the true flowers are abortive or entirely suppressed. (See 'Vegetable Teratology,' p. 244, fig. 128.)

787. Flower-heads of *Cineraria* in which the bracts of the inflorescence are developed in the form of miniature leaves, whilst the true flowers are either abortive or entirely suppressed.
788. So-called Double Lily, *Lilium candidum*, in which no true flowers are produced, but in which numerous petaloid segments are arranged in a spiral manner along the stem, from petalody of the bracts. ('Vegetable Teratology,' p. 376, fig. 190.)
789. Flower-spikes of Cocksfoot grass (*Dactylis glomerata*) in which the spikelets are replaced by tufts of leaf-scales. (Phyllody.) *Presented by Mr. Nicholson.*

SERIES VI.

ABNORMAL CONDITIONS OF THE BUDS.

790. Portion of the stem of a garden Tulip, with bulbs in the axil of the leaf, showing the homology of subterranean bulbs and aerial buds. *Presented by Dr. Masters.*
791. Stem or haulm of Potato (*Solanum esculentum*) showing tuber-like buds produced in the axils of the leaves. *Presented by Miss Ormerod.*
792. Fruit of Pineapple (*Ananassa sativa*) showing a tuft of young shoots or "gills" produced at the top of the fruit, owing to the production of supernumerary buds in that situation. This specimen might equally well be included under proliferation of the Inflorescence. (See 'Gardeners' Chronicle,' March 18, 1882.) *Presented by Dr. Masters.*
793. Pineapple (*Ananassa sativa*) in which the flowers have not been formed, but in their place tufts of leaves have been produced, by means of which the plant might have been reproduced. Sexual reproduction here is supplanted by vegetative bud-production. (Figured in 'Gardeners' Chronicle,' March 18, 1882.) *Presented by Dr. Masters.*

794. Tuber of Potato (*Solanum esculentum*) showing the presence within the original tuber of numerous secondary tubers, which are liberated by the bursting of the rind of the old tuber. Probably the result of some injury during growth. (See Rendle in 'Journal of Botany,' July 1893.)
Presented by Mr. Binder.

SERIES VII.

ABNORMAL CONDITIONS OF THE ASEXUAL OR NON-ESSENTIAL FLORAL LEAVES.

a. Affecting the Calyx—Sepals.

795. The fruit of a Cucumber in which the sepals are developed in the form of leaves. This excessive development is classed under the head Phyllody.
796. Flower of *Primula sinensis*, in which, by excess of development, the calyx is represented by large leafy sepals. ('Vegetable Teratology,' p. 248, fig. 131.)—Phyllody of the sepals.
Presented by Dr. Masters.
797. Flower of the Chinese Primrose (*Primula sinensis*) in which one of the sepals has, by excess of development, assumed the guise of an ordinary leaf.—Phyllody of the sepals.
Royal Horticultural Society.
798. Flowers of garden Nasturtium (*Tropæolum majus*) in which the usually irregular spurred calyx is replaced by a regular spurless condition, and in which the petals and stamens are represented by stalked green leaves.—Phyllody and Regular Peloria.
Presented by Dr. Masters.
799. Flower of *Philesia buxifolia* in which one of the sepals is developed in the form of a curved horn-like petal.—Petalody of the sepal.

β. Affecting the Corolla—Petals.

800. Flower of *Gloxinia* from the outer surface of the corolla of which protrude five petaloid segments forming an imperfect second corolla outside the first. ('Vegetable Teratology,' p. 451, fig. 213.)—Enation.

801, 801 *a*. Flower of *Rhododendron jasminiflorum* showing isolation of usually coherent petals.—Dialysis.

Presented by Rev. T. Preston.

802. Flower-heads of a garden Dahlia (*Dahlia variabilis*) in which the constituent florets have a second corolla within the first, thus constituting a true double flower.—Pleiotaxy. The ordinary Dahlia, though commonly called a double flower, is not so, the appearance being due to the development of the central or disk florets in the same form as those of the ray.

Presented by Dr. Masters.

γ. Affecting the Andræcium—Stamens.

803. Flowers of a garden *Anemone* in which the petals are increased in number and the stamens are replaced by petals.—Petalody of the stamens.

Presented by Dr. Masters.

804. "Double" flowers of a Cyclamen, *C. persicum*. The flowers are doubled by the production of supernumerary petals in the place of stamens.—Petalody of the stamens.

Presented by Messrs. Page and Sons.

805. Flower of garden Fuchsia showing the anthers replaced by petaloid expansions.—Petalody of the stamens.

Presented by Dr. Masters.

806. Flowers of a Polyanthus (*Primula veris*, var.) with additional petals, and stamens supplanted by petals.—Petalody of the stamens.

807. Flowers of *Yucca gloriosa* showing increased number of stamens.—Polyphyly of the andræcium. (See 'Gardeners' Chronicle, 1876, vol. vi. p. 337.)

Presented by Mr. Nicholson.

808. Semidouble flower of *Oncidium leucochilum* with three additional petals and a "column" with two additional anthers, the central one of which represents the normal anther, while the two lateral ones correspond to two of the inner series of three which are usually abortive.—Polyphyly of the andrœcium.—Atavism.

809. Flowers of Wallflower (*Cheiranthus Cheiri*, var. *gynantherus*) in which the petals are abortive or suppressed, and the stamens more or less converted into carpels.—Pistillody of the stamens.

Presented by Royal Horticultural Society.

810. Flowers of Wallflower (*Cheiranthus Cheiri gynantherus*) from which the petals are absent, and the stamens more or less completely replaced by carpels.—Pistillody of the stamens. ('Vegetable Teratology,' p. 306, fig. 163.)

Presented by Dr. Masters.

δ. *Affecting the Gynœcium—Carpels.*

811. Flowers of "Plymouth" Strawberry (*Fragaria vesca*, var. *muricata*) in which the carpels are developed in the shape of small folded leaves.—Phyllody of the carpels.

Presented by Rev. Canon Ellacombe.

812. Flower of Poppy (*Papaver orientale*) showing dialysis or isolation of the carpels, which are usually confluent at the edges.—Dialysis of the carpels.

Presented by G. E. Frere, Esq.

813. A Walnut with three carpels instead of two, the normal number.

"This is a true case of [numerical] variation. The additional carpel has precisely similar relations to each of the normal carpels, and bears no evidence of having arisen from the fission of either of these. In many cases an additional part arises in plants from the development of one which exists at an early stage, but which usually fails by abortion. No third carpel, however, exists normally at any period of development in the fruit of the Walnut."—Polyphyly of the gynœcium.

Presented by J. Quekett, Esq., 1859.

814. The fruit of a Bean with three carpels instead of one. The third carpel is very small. There is but a single seed, and this is borne by the largest carpel.

"This case differs from the former in several particulars. The two additional carpels are by no means equally developed with the normal one; many of the allies of the Pea (*Leguminosæ*) normally possess three carpels, whilst the Walnut-tribe (*Juglandæ*) either have two or four. The first case is probably one of simple variation: this is possibly one of reversion to an ancestral condition."—Polyphyly of the gynæcium.

815. Drawing of a fruit of Cucumber in which a portion of the fruit has become "superior" by the growth of the carpels beyond the floral envelopes, the withered remnants of which are shown in the left end of the fruit. The greater portion of the carpels are conerescent with the axis or flower-stalk, *i. e.* "inferior," but the portion beyond the flower-segments is free from all attachment to the axis.

Presented by James Salter, Esq.

SERIES VIII.

ABNORMAL CONDITIONS OF THE SEXUAL OR ESSENTIAL FLORAL LEAVES.

The essential parts of the flower are the male sporangia in the form of anthers with their contents the male spores or pollen-grains; and female sporangium or embryo-sac embedded in the nucellus of the ovule, and containing the female spore, which ultimately develops into the embryo. The male sporangia are sometimes borne on different plants from the female, in which case the plant is technically called "diœcious;" in other cases male and female sporanges are borne on the same plant, but in different flowers, when the term "monœcious" is applied, the flowers in both the preceding instances being unisexual. When male and female sporanges occur in the same flower, the flower is structurally bisexual, though by no means necessarily functionally hermaphrodite. Teratological deviations in these

ERRATUM.

Page 185, 10 lines from bottom, *for* Stamens *read* Ovaries.

particulars, though very meagrely represented in the Museum, are very common. A monœcious plant becomes dioecious or *vice versâ*; an hermaphrodite flower becomes unisexual, or a unisexual flower becomes hermaphrodite. The male sporanges may assume the characteristics of the female organs and *vice versâ*; and the female sporange may be so modified as to produce pollen-grains (microspores) in its interior.

816. Monœcious Hop in which a female catkin is borne on the extremity of the male inflorescence instead of on a separate plant. ('Vegetable Teratology,' p. 193, fig. 101.)

817. Catkins of a Willow (*Salix*) in which some of the stamens and anthers or male sporanges have assumed the appearance and structure of carpels.—Pistillody of stamen.

Willows are usually "dioecious" trees, sometimes "monœcious," and sometimes "androgynous," when male and female flowers occur on the same catkin. True structural hermaphroditism has not been recorded in Willows.

818. Pods or "Siliques" of a Cruciferous plant showing a dilatation or pouch in the centre, containing, in place of the ovules, imperfectly constructed flowers, thus showing that flowers may be formed upon leaves as well as upon axes. (See 'Vegetable Teratology,' p. 180, figs. 94, 94a, 95.)—Petalody of the ovules &c.

Presented by Dr. Masters.

819. Stamens of *Passiflora* in which the ovules contain pollen. The megasporange here produces microspores, a complete inversion of the natural order of things. This specimen is noteworthy as being the first of its kind on record. It is described in the 'Transactions of the Linnean Society,' vol. xxiv. p. 143, tab. xxiv., by S. J. A. Salter, Esq., F.R.S.—Staminody of the ovules.

A similar phenomenon was afterwards observed in the flowers of *Rosa canina*. (See Masters, in 'Journal of Botany,' 1867, p. 319, tab. lxxii. fig. B, 1-9.)

SERIES IX.

ABNORMAL CONDITIONS OF THE FLOWER AS A WHOLE, OR OF MANY PARTS OF THE SAME FLOWER CON- CURRENTLY.

In very many cases changes in one organ or part of the flower are associated with changes in other parts. Sometimes all these diversities are of the same nature and apparently dependent on the operation of the same cause ; at other times they are of an opposite or compensatory character, excess in one direction being balanced by defect in another, and so on.

Synanthy, or union of two or more flowers, and Prolification of the flower (see 'Vegetable Teratology,' p. 115 *et seq.*) (not of the inflorescence, see Series V.) are included under this heading.

Reduction of number of parts—Meiophylly.

820. Flower of *Rosa sericea* with four instead of five sepals and petals. This is an instance analogous to those included under Simple Variation in other Departments of the Museum, but it is impossible to dissociate it from teratological deviation. *Royal Gardens, Kew.*

821. Flowers of *Tropæolum majus*, showing the petals, the stamens, and, to some extent, the carpels, developed in the shape of stalked leaves. The usual irregular spurred conformation is replaced by a regular symmetrical form. —Phyllody and Regular Peloria.

Presented by Dr. Masters.

Prolification of the Flower.

822. Strawberry showing branching of the axis within the calyx, in the form of a 5-pointed star. It is a common thing for the axis of the flower of the Strawberry, that is to say, the succulent receptacle, to become fasciated and cock's-

comb-shaped from dichotomy ; the resultant subdivisions do not, as a rule, separate fully, but remain as a flattened expansion. In the present instance, however, there is partial separation of the branches.

Presented by Prof. Ed. Morren.

823. Flower of a Rose (*Rosa rubiginosa*). The flower-tube or haw is not developed, the sepals are leafy, and the central axis of the flower is prolonged into a short branch bearing leaves and terminated by a flower-bud.

Presented by Mr. Nicholson.

824. A section through the flower of a Rose, in which the central axis bears supplementary lateral flowers, the central axis being prolonged into a leafy shoot bearing a small flower-bud at the apex.

Presented by Dr. Masters.

825. Section of flower of double Tulip. The outer perianth-segments have been removed to show the carpels detached one from another and surrounding a central axis with supernumerary petals.—Proliferation.

Synanthy.

Union of one or more flowers is of very common occurrence. Sometimes it is the result of excessive branching, arising from inordinate development of the growing points, in which case it is homologous with the condition known as Fasciation, but more often it is due to actual union of two or more originally distinct flowers at a very early period of their growth from pressure or some other accidental circumstance.

826. Complete union of two flowers of Fuchsia, arising probably from pressure at an early stage of growth.

Presented by Dr. Masters.

827. Specimen showing union of two flowers of Fuchsia and abortion of some of the floral organs in consequence of pressure.

Presented by Mr. Wild.

828. Normal and abnormal flowers of *Gloxinia*, the abnormality arising from the confluence of two flowers into one composite flower with an additional number of parts.

Kew.

829. Flower-cluster of Foxglove (*Digitalis purpurea*) in which some of the uppermost corollas have become blended into one composite, bell-shaped flower, through the centre of which passes the axis of the cluster with other more or less abortive flowers. (See also 'Vegetable Teratology,' p. 40, fig. 17.)

830. *Ixora crocata*, showing union of two flowers into a composite flower.

831. Union of two flowers of *Fritillaria pyrenaica*. The union takes place at an early stage of growth and some of the parts of the flower at the line of junction are obliterated by the reciprocal pressure.

Royal Gardens, Kew.

Peloria.

The development of an habitually irregular zygomorphic flower in a regular actinomorphic form is known as *Peloria*. The regularity arises from two different causes,—one in which the flower is regular owing to the non-development of its irregular parts (Regular *Peloria*); the other in which the irregular parts are increased in number so that the flower becomes symmetrical (Irregular *Peloria*). Regular *Peloria* exemplifies an arrest of development and probably a repetition of an ancestral condition, *i. e.* Atavism. Irregular *Peloria*, on the other hand, indicates an advanced degree of development. This was the earliest form recognized, in *Linaria vulgaris*, by Linnæus. (See Masters, "On the Existence of two Forms of *Peloria*," *Natural History Review*, April 1863. 'Vegetable Teratology,' pp. 219, 228.)

832. Flowers of Orchid (*Phaius Wallichii*), one normal, the other with supernumerary spurred petals (labella).—Irregular *Peloria*.

Kew.

SERIES X.

ABNORMAL CONDITIONS AFFECTING THE FRUIT AS A WHOLE.

A mixed group to which the same observations apply as those made under Series IX.

Proliferation or "pseudo-doubling" of Fruit.

It sometimes happens that a fruit appears to be double, though the doubling is more apparent than real. It usually results from hypertrophy of the axis or from its prolongation between and beyond the carpels, in which case it is known as "proliferation of the fruit." Several illustrations are given in 'Vegetable Teratology,' p. 423 *et seq.*

833. Pear:—The carpels or true fruits are not developed, but in their place the central axis of the flower is prolonged into a long leafy branch. The edible portion of the Pear is, in reality, a dilatation of the upper end of the flower-stalk, enclosing within it, under ordinary circumstances, the true carpels or core. *Presented by Dr. Masters.*

834. "Fruits" of Pear, with secondary fruits growing from their summits. The so-called fruit of the pear or apple is, in reality, the dilated end of the flower-stalk, in which are embedded the carpels constituting the true fruit, and which are commonly known as the "core." In these specimens the carpels are not developed, but in their place the axis dilates in the resemblance of a second fruit on the top of the first. The presence of leaves on the "fruit" shows its really axial nature. *Presented by Dr. Masters.*

835. Is a similar specimen to the preceding, and with the top of the flower-stalk or the flower-tube of an Apple dilated, bearing sepals on its border, one of which is developed into a leaf (phyllody of the sepal), while in the centre is a normal fruit.

836. A similar specimen in the Pear.

837. A similar specimen.

838. Two Pears showing a thickened hypertrophied axis arising from the top of a fruit-stalk, and bearing leaves, the lower portions or stalks of which are conerescent with the axis, so that they do not separate from it, and are, moreover, greatly thickened or hypertrophied.

839. The fruit of a Pear exhibiting "pseudo-doubling."

840. The fruit of an Orange exhibiting "pseudo-doubling."

From St. Thomas's Hospital.

841. Abnormal development of the rind of a Lemon in the form of an excrescence from the summit and representing the rudiments of a second whorl of carpels. The preparation has been accidentally reversed in mounting, the apex being directed downwards.

842. Fruit of Citrus containing a second fruit in the interior, arising from the development of a second whorl of carpels above the first.—Pleiotaxy of gynæcium or intra-carpellary proliferation.

Presented by Rev. Lansdown Guilding.

Union of Fruit (Syncarpy). See 'Vegetable Teratology,' p. 46.
(See also *ante*, Synanthly, p. 187.)

843. Two Quinces on a single peduncle united by fusion of their sarcocarps. *Presented by W. J. B. Smith, Esq., 1858.*

844. Two Cherries united in the same manner.

Presented by T. H. Stewart, Esq.

845. A similar specimen.

Presented by Prescott G. Hewett, Esq., 1871.

846. Two Plums united in the same manner.

Presented by Mr. J. Geoghan.

847. Two Apples united in the same manner. *Hunterian.*

848. Two Apples similarly united, divided vertically to show the divergence of the axes of the two fruits. The tree from which this fruit was obtained produced a crop of similar fruit every year. *Presented by Sir A. Carlisle, 1829.*

849. Twin Apples united at the base in consequence of the union of the pedicels in an early stage of growth. The tree pro-

ducing them was stated to bear them in large numbers year after year. *Presented by Mrs. Ringer.*

850. Syncarpic fruits of Apple arising from the union of two fruits. *Presented by Prof. Oliver.*

851. Section of syncarpic Apples.

852. A similar section.

853. A similar section.

854. Union of two fruits of Cucumber along one side of their entire length. *Presented by Mr. Bisley Roberts.*

855. Fasciated Vegetable Marrow. *Presented by J. Gay, Esq., 1877.*

856. Two Gourds on a single peduncle united by fusion of their sarcocarps. *Presented by W. J. B. Smith, 1858.*

857. Fasciation and synanthly of a Cucumber ; five fruits are closely united.

858. Two small Cucumbers on a single peduncle, adherent through their entire length and cut through transversely to show the manner in which they are united. *Presented by W. J. B. Smith, Esq.*

859. Two Cucumbers similarly united throughout two thirds of their length. *Presented by W. Clift, Esq., 1829.*

860. Two Cucumbers similarly united ; the growth of one has, however, been arrested at a very early stage. *Hunterian.*

861. A section of three Cucumbers similarly united. *Presented by Mr. E. Horniblow, 1875.*

862. Three Grapes united by fusion of their sarcocarps. *Presented by Mr. J. Geoghan, 1885.*

863. "Three Spanish Nuts (*Corylus*) united by their pericarps : union seems to have taken place during the later stages of development, as it is not complete, and the adjacent portions of the pericarps are flattened. A section has been made through the nuts." [The condition may have arisen from the development of the two carpels usually suppressed.] *Presented by Prof. Flower, 1871.*

SERIES XI.

ABNORMAL CONDITIONS AFFECTING THE EMBRYO-PLANT.

"It occurs, not unfrequently, in the Orange and Hazel that more than one embryo is developed in a single testa ; and this condition is very common in the Coniferae, Cycas, the Onion, and the Misseltoe. Now and then a union of these embryos takes place." (Lindley's 'Introduction to Botany.')

Polyembryony.

864. Twin seedling Chestnuts from one seed. Six ovules are formed originally, but usually five of them, or (as in this preparation) four, become abortive.

Presented by S. G. Shattock, Esq., 1880.

Synophthy. ('Vegetable Teratology,' p. 57.)

865. "Two Bean-seeds united by their cotyledons near their hila, which are distinct. The testa is continuous over the two seeds."

Hunterian.

866. Two seedling Orange plants attached by their cotyledons ; they were produced from a single seed. There are four cotyledons, but the two between the embryos are smaller and are closely adherent to one another.—Synophthy.

Presented by B. T. Lowne, Esq., 1871.

867. Three seedling Orange plants growing from a single seed. The cotyledons are united between the embryos. The third embryo is very much smaller than the other two.

Presented by B. T. Lowne, Esq., 1871.

868. Seedling of *Carthamus tinctorius* showing union of two leaves and deflexion to one side. The union is at the base, only the apices diverging one from the other.

Kew.



H 12 - 6 23

✓

