

Engravings of the skeleton of the human body / by John Gordon.

Contributors

Gordon, John, 1786-1818.
University of Glasgow. Library

Publication/Creation

Edinburgh : Blackwood, 1818.

Persistent URL

<https://wellcomecollection.org/works/jvqpj8xv>

Provider

University of Glasgow

License and attribution

This material has been provided by This material has been provided by The University of Glasgow Library. The original may be consulted at The University of Glasgow Library. where the originals may be consulted. This work has been identified as being free of known restrictions under copyright law, including all related and neighbouring rights and is being made available under the Creative Commons, Public Domain Mark.

You can copy, modify, distribute and perform the work, even for commercial purposes, without asking permission.



Wellcome Collection
183 Euston Road
London NW1 2BE UK
T +44 (0)20 7611 8722
E library@wellcomecollection.org
<https://wellcomecollection.org>



Glasgow
University Library



G2-b. 8


D. F. 1. 27.

Glasgow University Library

661 878 9
CANCELLED

ALL ITEMS ARE ISSUED SUBJECT TO RECALL

GUL 96.18




ENGRAVINGS

THE SKELETON

HUMAN BODY.

JOHN GUTHRIE, M.D. F.R.S.E.

EDINBURGH



ENGRAVINGS
OF
THE SKELETON
OF THE
HUMAN BODY.

BY
JOHN GORDON, M.D. F.R.S.E.

LECTURER ON ANATOMY AND SURGERY, AND ON THE INSTITUTIONS
OF MEDICINE, EDINBURGH.

EDINBURGH :

PRINTED FOR WILLIAM BLACKWOOD, PRINCE'S STREET ;
AND T. & G. UNDERWOOD, FLEET STREET,
LONDON.

1818.

ENGRAVINGS

THE SKELETON

OF THE

HUMAN BODY

BY
JOHN GORDON, M.D. F.R.S.E.

LECTURE ON ANATOMY AND SURGERY, AND ON THE TESTICULAR
OF MINING, EDINBURGH.

EDINBURGH:

PRINTED FOR WILLIAM BLACKWOOD, PRINCE STREET,

AND T. & C. BARNARD, FLEET STREET,

LONDON.

1815.

PREFACE.

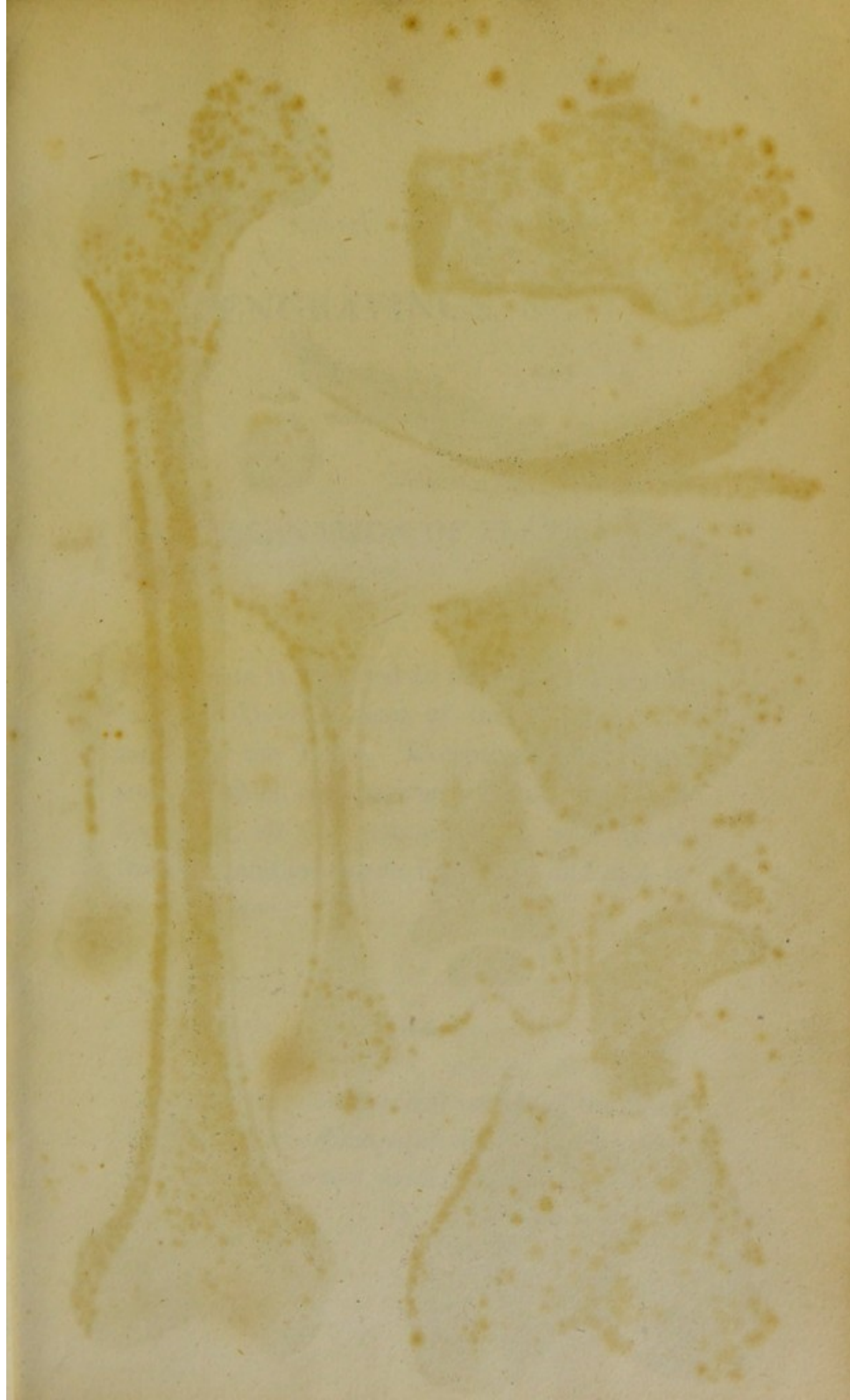IN the following Fasciculus of Plates, the Author has endeavoured to exhibit, in a convenient form, a series of representations of those parts of the Human Skeleton, with which it is of most importance for the physiologist and the medical practitioner, to be accurately acquainted. If the publication shall in any degree answer the purpose for which it was meant, it is the intention of the Author to illustrate the Anatomy of the other parts of the Human Body, in a similar manner, and on the same principle of selection.

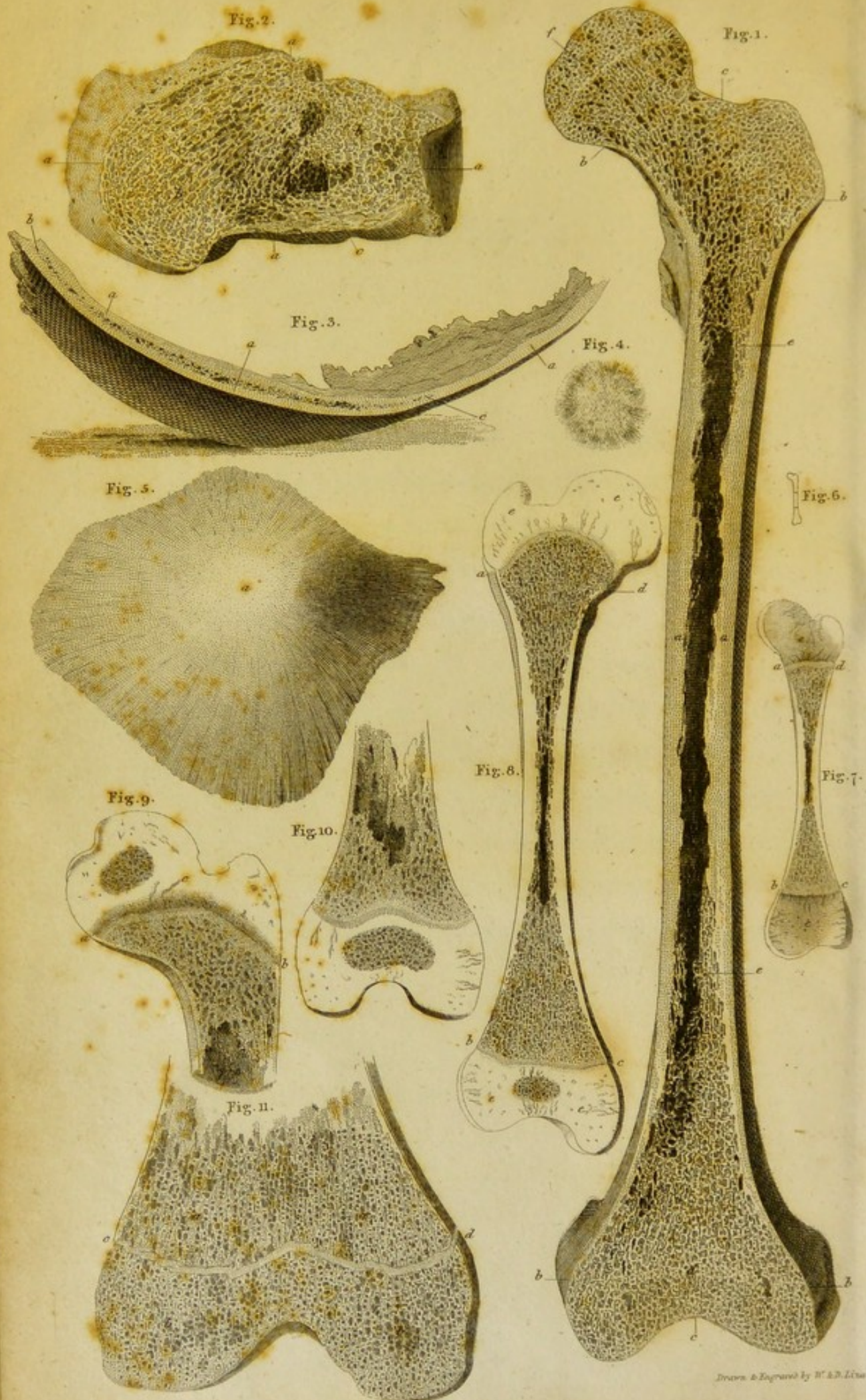
EDINBURGH, 26th December, 1817.

PREFACE.

In the following Fasciculus of Plates, the Author has endeavoured to exhibit, in a convenient form, a series of representations of those parts of the Human Skeleton, with which it is of most importance for the physiologist and the medical practitioner, to be accurately acquainted. If the publication shall in any degree answer the purpose for which it was meant, it is the intention of the Author to illustrate the Anatomy of the other parts of the Human Body, in a similar manner, and on the same principle of selection.

Edinburgh, 20th December, 1817.





ENGRAVINGS, &c.

EXPLANATION OF PLATE I.

THIS Plate is intended to illustrate the Structure and Developement of the Osseous Substance of the Bones. Excepting Figures 4th and 6th, which have been copied from NESBITT'S *Osteogeny*, all the representations were taken from Preparations made by myself, and still in my possession.

FIGURE 1.

Represents a longitudinal section of the dried Thigh Bone of a Man aged thirty years; which measured from *c* to *c* sixteen inches and a half.

- a, b, c,* The Compact Osseous Substance ; forming a continuous Wall, or Shell, tapering from *a* to *b*, and then preserving the same thickness along *b, c, b*.
- d, e,* The Spongy or Reticular Osseous Substance, or Cancelli ; passing gradually into a Medullary Cavity at *e*. The Medullary Cavity extends from *e* to *e*.
- f,* A Faint Line of more Compact Substance, in the site of the layer of Cartilage, which separated the Epiphysis from the Body of the Bone.

FIGURE 2.

Represents a longitudinal section of the dried Heel Bone of the same Subject ; which measured from *a* to *a* two inches and a quarter.

- a,* The Compact Osseous Substance ; forming a Wall, or Shell, of uniform Thickness.
- b, c,* The Spongy Substance ; occupying the whole interior ; except at *c*, where there is a slight Cavity, which, however, is accidental.

FIGURE 3.

Represents a longitudinal section of the dried Parietal Bone of the same Subject; which measured, longitudinally, along its surface, five inches and a half.

- a*, The Compact Osseous Substance.
- b*, *c*, The Spongy Substance, or Diploe; which occupies only a part of this Bone, gradually terminating at *c*.

FIGURE 4.

Is a copy of a representation by NESBITT,* of the Ossifying Part of a Parietal Bone, in a Fœtus only two months after conception. The Osseous Fibres have the appearance of an irregular net-work.

FIGURE 5.

Represents the dried Parietal Bone of a Fœtus

* Human Osteogeny, Pl. 1. Fig. 7.

about five months, viewed externally, and nearly of its natural size.

a, The Point of Ossification.

FIGURE 6.

Is a copy of a representation, by NESBITT,* of the recent Thigh Bone of a Fœtus under two months. The space included in the middle, between the two small lines, is the only part ossified. The Figure is of the size of nature.

FIGURE 7

Represents a section of the Thigh Bone of a Fœtus about the fifth month, of the natural size. The Preparation was recent, and the Periosteum alone removed.

a, b, c, d, The Ossified Part of the Bone.

e, The Epiphyses, which are still entirely Cartilaginous; and are perforated by a number of *Ramifying Canals*, which are here

* Human Osteogeny, Pl. VI. Fig. 7.

visible, in consequence of their being more opaque than the substance which they penetrate. These Canals extend inwards from the Bone already formed, and from such parts of the Epiphyses, externally, as are covered with Periosteum; but never from an Articulating Surface.*

FIGURE 8.

Represents a section of a recent Thigh Bone at the period of Birth, of its natural size. The Preparation was minutely injected with glue and vermilion, and the Periosteum removed.

a, b, c, d, The Body of the Bone Ossified.

e, The Epiphyses, penetrated by Ramifying Canals; and in the lower of which, a point of Ossification has made considerable progress. A thin layer of the Cartilage, close to the Body of the Bone at each end, *a d*, and *b c*, is softer than the rest.

* Until the late investigations of Mr. HOWSHIP, these *Ramifying Canals*, as I have called them, were considered by Anatomists as large Blood Vessels. Since reading his excellent Essay, (*Medico-Chir. Transact. Vol. VI.*) I have examined them in the Human Body with more attention. The results will be found in my *System of Anatomy*, Part III.

FIGURE 9.

Represents a section of the upper end of the recent Thigh Bone of a Child about a year old, of its natural size. The Preparation was minutely injected with glue and vermilion.

a, b, The Line of Separation between the Ossified Body of the Bone, and the Epiphysis.

c, The Epiphysis, with its Ramifying Canals, and a Point of Ossification at its upper part, considerably developed.

FIGURE 10.

Represents a section of the lower end of the same Bone, in which the appearances are similar

FIGURE 11.


Represents a vertical section, from side to side, of the lower extremity of the Thigh Bone of a male aged twenty, which measured from *c*

to *d* three inches. The Preparation was recent, but the Periosteum was removed.

a, The lower end of the Body of the Bone ossified.

b, The Epiphysis, ossified also.

c, d, A layer or septum of Cartilage, still separating the Body from the Epiphysis.



to 4 three inches. The Preparation was recent, but the Periosteum was removed.

a. The lower end of the body of the bone ossified.
 b. The Epiphysis, ossified also.
 c. A layer of septum of Cartilage, still separating the body from the Epiphysis.

NO other ossification was seen in this bone.
 The bone was taken from a young animal.
 The bone was taken from a young animal.
 The bone was taken from a young animal.

IN ANIMALS

It is the most common form of ossification.
 It is the most common form of ossification.
 It is the most common form of ossification.

IN HUMANS

It is the most common form of ossification.
 It is the most common form of ossification.
 It is the most common form of ossification.

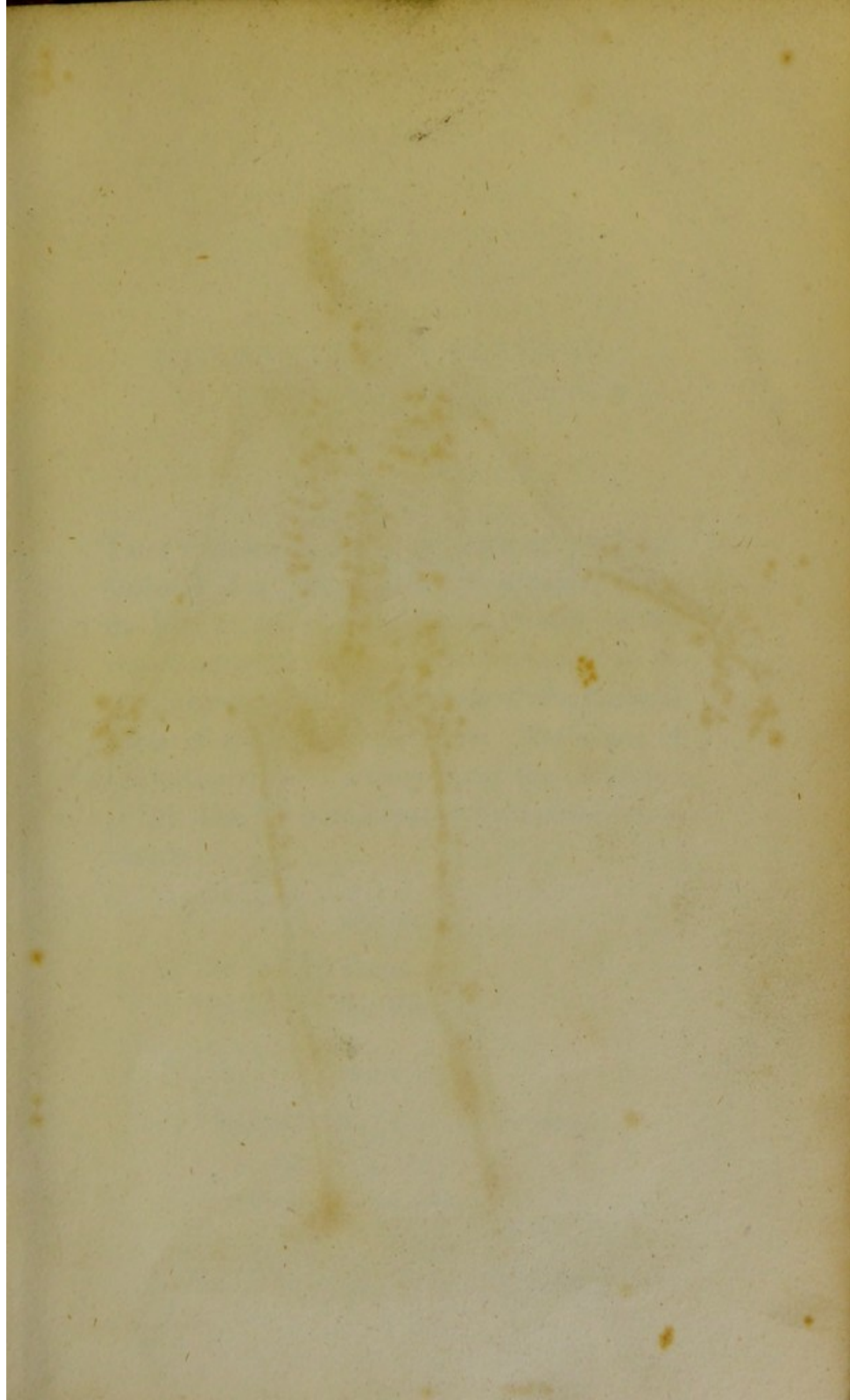
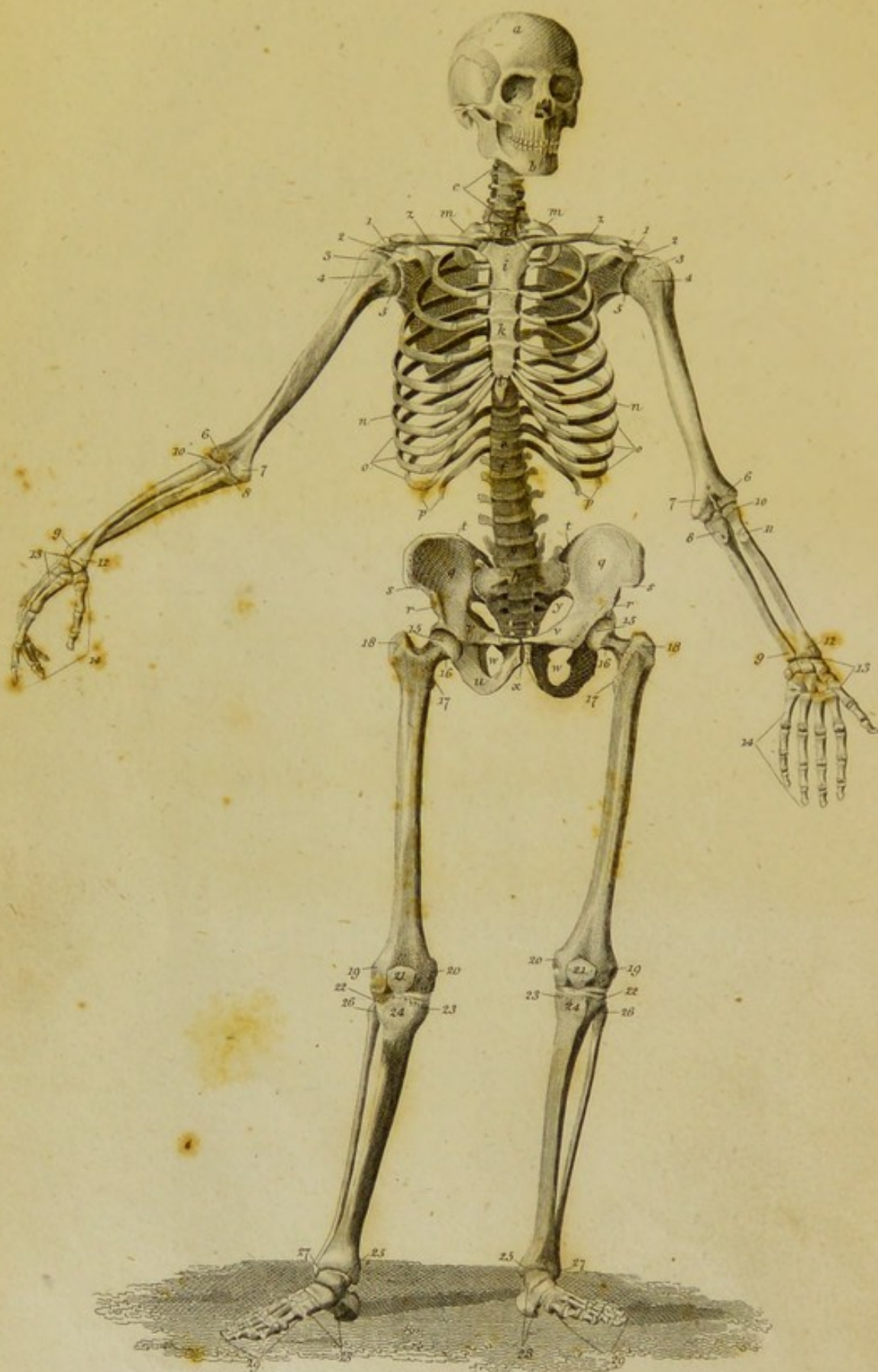


PLATE II.



Drawn & Engraved by W. & D. Linn

EXPLANATION OF PLATE II.

THIS Plate exhibits a Front View of the dried Skeleton of a Male Adult. It is copied from the *Tabulæ Anatomicae* of LODER;* and is sufficiently accurate for the purpose intended to be served by it, viz. the illustration of the General Form of the Human Skeleton. The place of the Interarticular Cartilages, and the Cartilages of the Ribs, has been supplied by Artificial Substances.

THE HEAD.

a, The Frontal Bone.

b, The Lower Jaw Bone.

THE TRUNK.

c, The five lower Cervical Vertebrae.

* *Tabulæ Anatomicae*, 2 vols. folio, 1797.

- d*, The first Dorsal Vertebra.
- e*, The last or twelfth Dorsal Vertebra.
- f*, The first Lumbar Vertebra.
- g*, The last Lumbar Vertebra.
- h*, The Sacrum.
- i*, The Head of the Sternum.
- k*, The Middle Part or Body of the Sternum.
- l*, The Extremity or Point of the Sternum,
sometimes called the Ensiform or Xiphoid
Cartilage.
- m*, The first Sternal Rib.
- n*, The seventh Sternal Rib.
- o*, The eighth, ninth, and tenth Ribs.
- p*, The eleventh and twelfth, or two Floating
Ribs.
- q*, The Fossa or Venter of the Ilium.
- r*, The Anterior and Inferior Spinous Process
of the Ilium.
- s*, The Anterior and Superior Spinous Process
of the Ilium.
- t*, The Posterior Spinous Process of the Ilium.
- u*, Part of the Ischium.
- v*, The Ascending Ramus of the Pubes.
- w*, The Obturator or Thyroid Hole of the Os
Innominatum.
- x*, The Symphysis of the Pubes.
- y*, The Sciatic Notch.

THE UPPER EXTREMITIES.

- z, The Clavicle.
- 1, The Acromion Process of the Scapula.
- 2, The Coracoid Process of the Scapula.
- 3, The Larger Tuberosity or Tubercle of the Os Bracchii, or Arm Bone.
- 4, The Lesser Tuberosity of the Arm Bone.
- 5, The Head of the Arm Bone.
- 6, The External Condyle of the Arm Bone.
- 7, The Internal Condyle of the Arm Bone.
- 8, Rough Surface on the Ulna, for the attachment of the Bracchialis Flexor Muscle.
- 9, Lower extremity of the Ulna.
- 10, The Head of the Radius.
- 11, Tubercle of the Radius.
- 12, Lower extremity of the Radius.
- 13, Bones of the Carpus, or Wrist.
- 14, Bones of the Metacarpus and Fingers.

THE LOWER EXTREMITIES.

- 15, The Head of the Thigh Bone.
- 16, The Neck of the Thigh Bone.
- 17, The Trochanter Minor.
- 18, The Trochanter Major.
- 19, The External Condyle of the Thigh Bone.
- 20, The Internal Condyle of the Thigh Bone.

- 21, The Patella.
- 22, The External Condyle of the Tibia.
- 23, The Internal Condyle of the Tibia.
- 24, The Tuberosity of the Tibia.
- 25, The Internal Malleolar Process of the Tibia.
- 26, The Head of the Fibula.
- 27, The Extremity or External Malleolar Process of the Fibula.
- 28, The Bones of the Tarsus, or Instep.
- 29, The Bones of the Metatarsus and Toes.

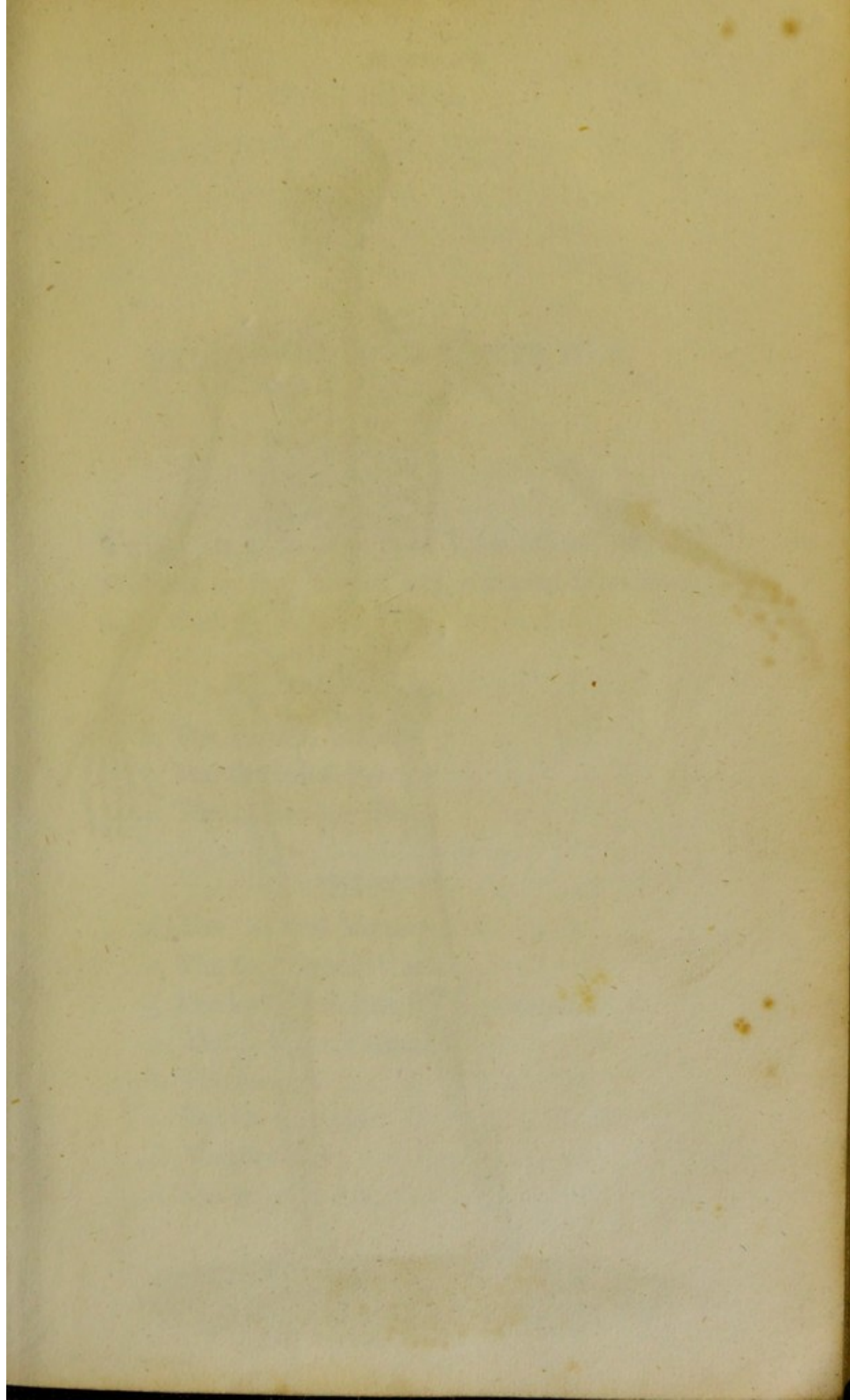
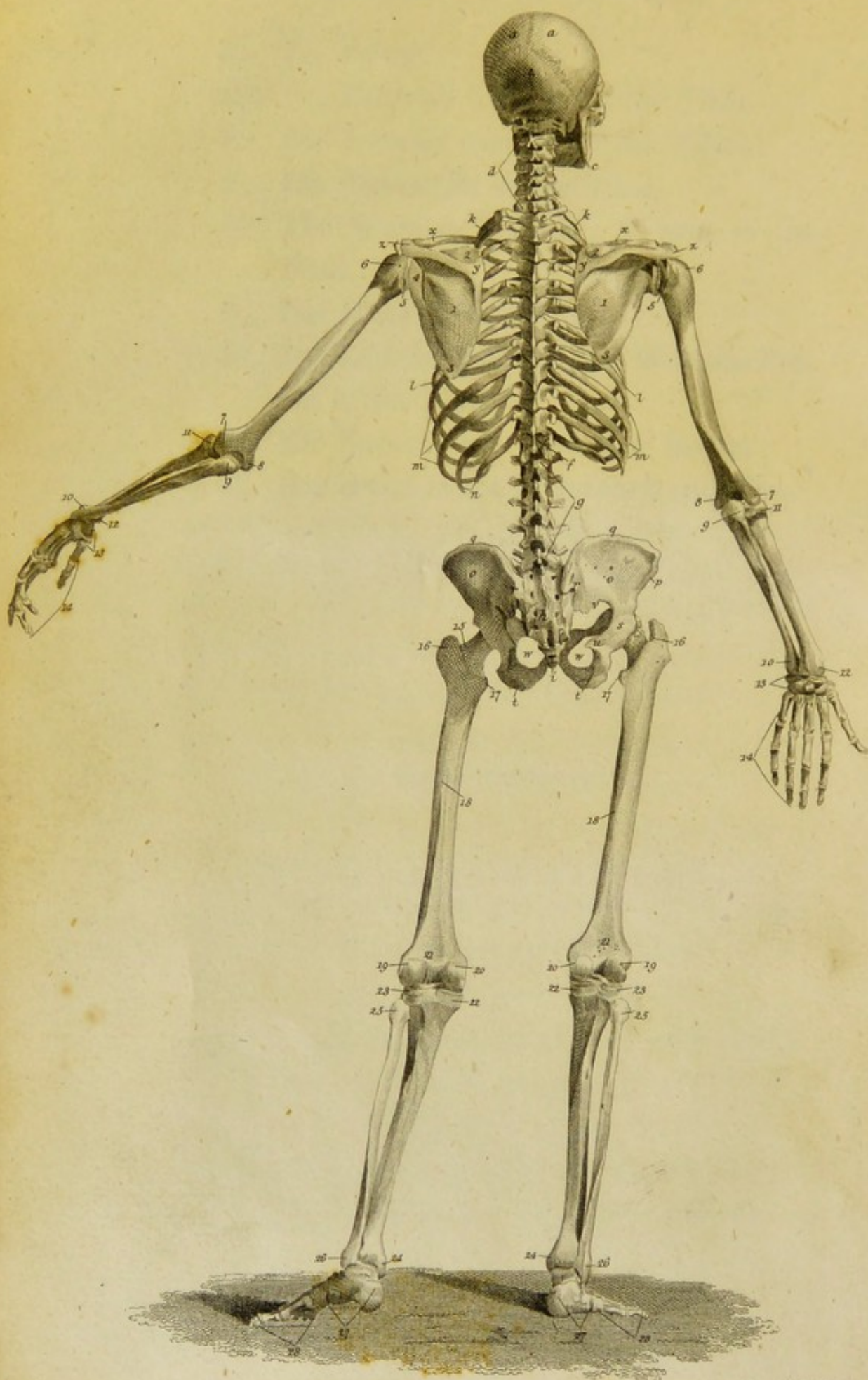


PLATE III.



EXPLANATION OF PLATE III.

THIS Plate exhibits a Back View of the same Skeleton as the former, and is copied from the same Work by LODER.

THE HEAD.

- a*, The Parietal Bone.
- b*, The Occipital Bone.
- c*, The Lower Jaw Bone.

THE TRUNK.

- d*, The Cervical Vertebrae.
- e*, The first Dorsal Vertebra.
- f*, The last or twelfth Dorsal Vertebra.
- g*, The Lumbar Vertebrae.
- h*, The Sacrum.
- i*, The Os Coccygis.
- k*, The first Rib.
- l*, The seventh Rib.

- m*, The eighth, ninth, and tenth Ribs.
- n*, The eleventh and twelfth Ribs.
- o*, The Dorsum of the Ilium.
- p*, The Anterior and Superior Spinous Process of the Ilium.
- q*, The middle of the Crest of the Ilium.
- r*, The Posterior Spinous Process of the Ilium.
- s*, The Dorsum of the Acetabulum.
- t*, The Tuberosity of the Ischium.
- u*, The Spine, or Spinous Process of the Ischium.
- v*, The Sciatic Notch.
- w*, The Obturator or Thyroid Hole.

THE UPPER EXTREMITIES.

- x*, The Clavicle.
- y*, Posterior extremity of the Spine of the Scapula.
- z*, The Acromion Process of the Scapula.
- 1, The Fossa Infraspinata of the Scapula.
- 2, The Fossa Supraspinata of the Scapula.
- 3, The Lower Angle of the Scapula.
- 4, The Posterior Margin of the Glenoid Cavity of the Scapula.
- 5, The Head of the Os Bracchii, or Arm Bone.
- 6, The Large Tubercle of the Arm Bone.
- 7, The External Condyle of the Arm Bone.

- 8, The Internal Condyle of the Arm Bone.
- 9, The Olecranon.
- 10, The Styloid Process of the Ulna.
- 11, The Head of the Radius.
- 12, The Styloid Process of the Radius.
- 13, The Bones of the Carpus, or Wrist.
- 14, The Bones of the Metacarpus and Fingers.

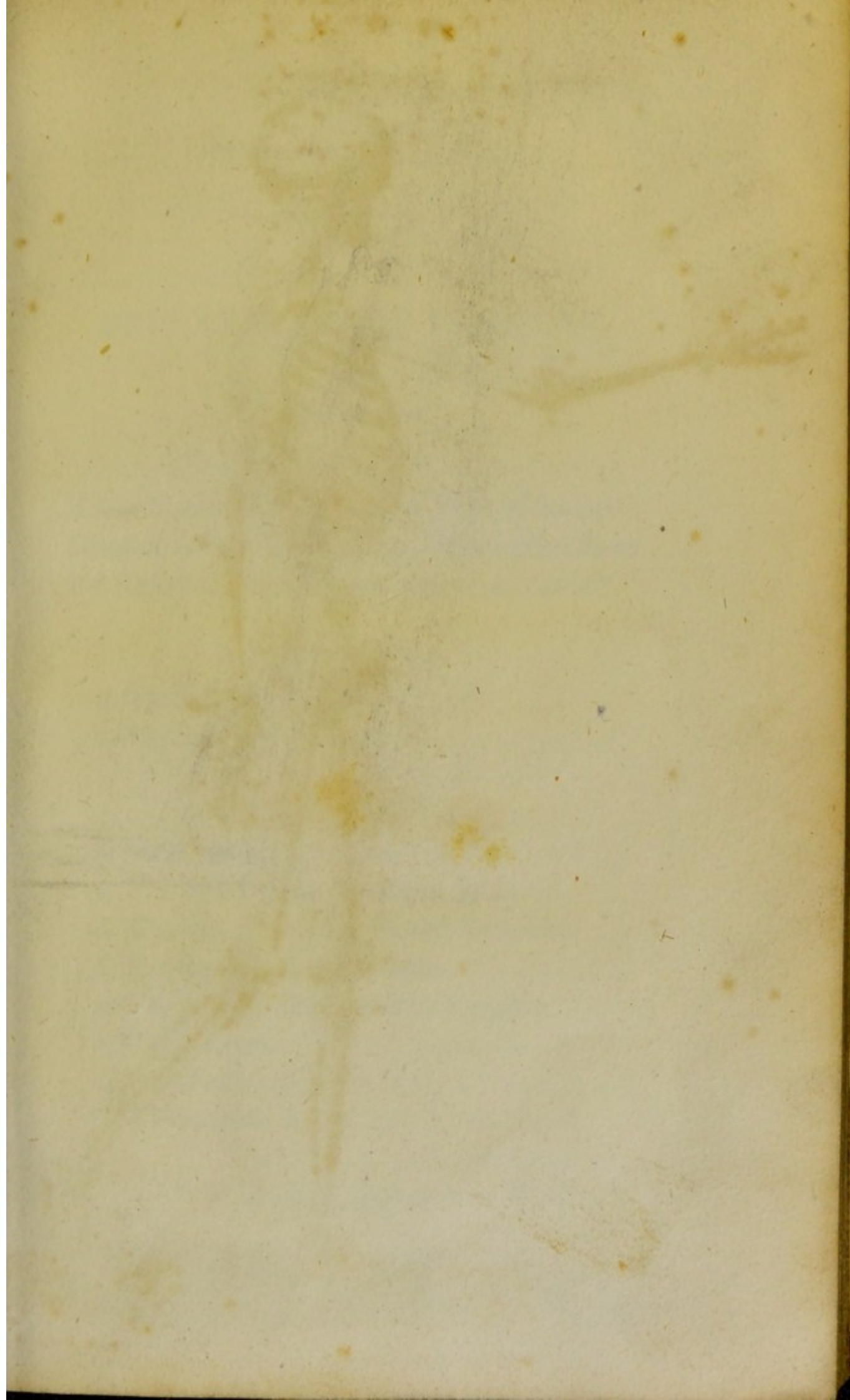
THE LOWER EXTREMITIES.

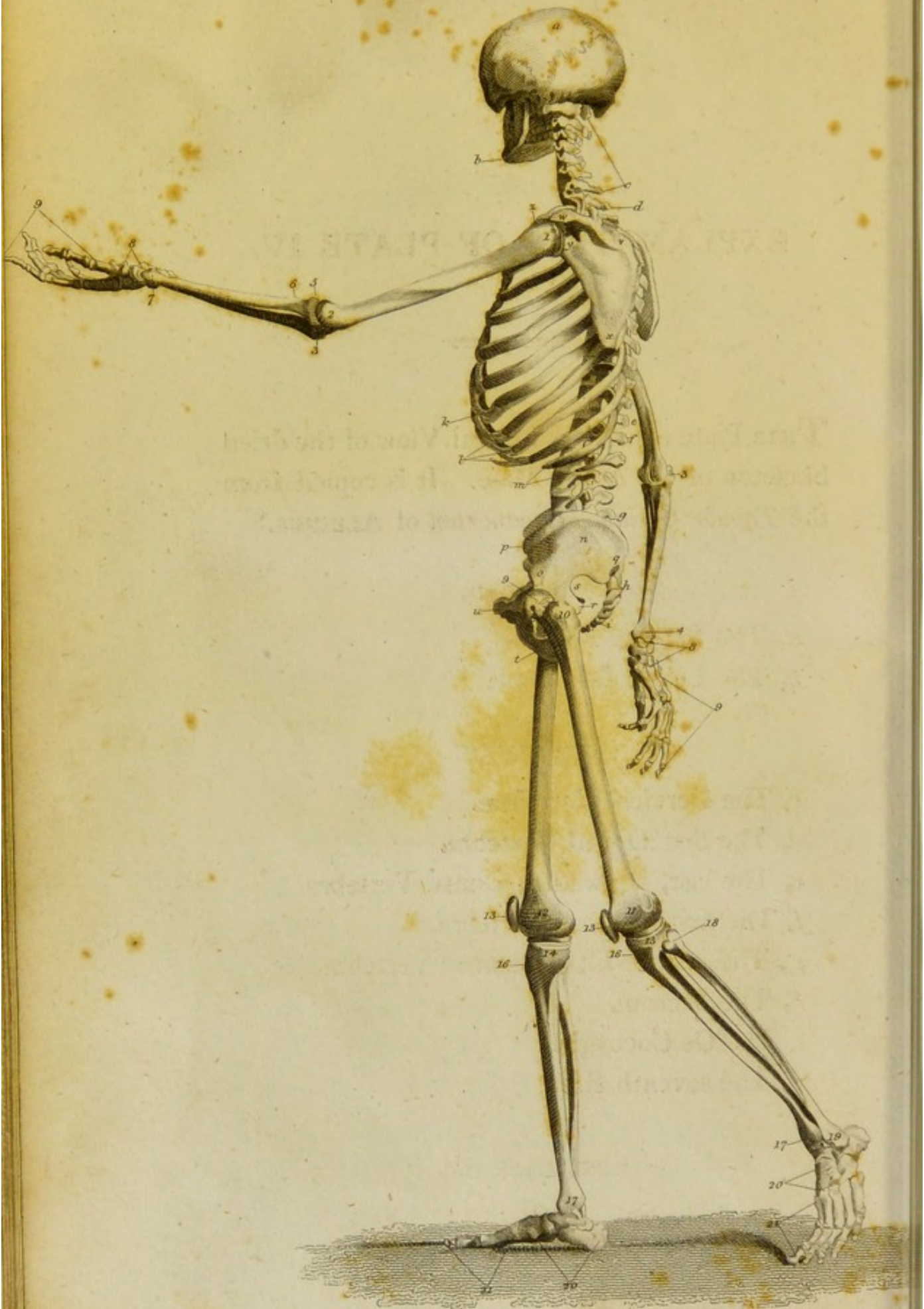- 15, The Neck of the Thigh Bone.
 - 16, The Trochanter Major.
 - 17, The Trochanter Minor.
 - 18, The Linea Aspera.
 - 19, The External Condyle of the Thigh Bone.
 - 20, The Internal Condyle of the Thigh Bone.
 - 21, The Popliteal Fossa of the Thigh Bone.
 - 22, The Internal Condyle of the Tibia.
 - 23, The External Condyle of the Tibia.
 - 24, The Internal Malleolar Process of the Tibia.
 - 25, The Head of the Fibula.
 - 26, The Extremity or External Malleolar Process of the Fibula.
 - 27, The Bones of the Tarsus, or Instep.
 - 28, The Bones of the Metatarsus and Toes.
-

8. The Internal Condyle of the Arm Bone.
9. The Olecranon.
10. The Styloid Process of the Ulna.
11. The Head of the Radius.
12. The Styloid Process of the Radius.
13. The Bones of the Carpus or Wrist.
14. The Bones of the Metacarpus and Fin.

Fig. 1.

15. The Neck of the Thigh Bone.
16. The Trochanter Major.
17. The Trochanter Minor.
18. The Linea Aspera.
19. The External Condyle of the Thigh Bone.
20. The Internal Condyle of the Thigh Bone.
21. The Popliteal Fossa of the Thigh Bone.
22. The Internal Condyle of the Tibia.
23. The External Condyle of the Tibia.
24. The Internal Malleolar Process of the Tibia.
25. The Head of the Fibula.
26. The Extremity or External Malleolar Process of the Fibula.
27. The Bones of the Tarsus or Instep.
28. The Bones of the Metatarsus and Toes.





EXPLANATION OF PLATE IV.

THIS Plate exhibits a Lateral View of the dried Skeleton of an Adult Male. It is copied from the *Tabulæ Ossium Humanorum* of ALBINUS.*

THE HEAD.

a, The Parietal Bone.

b, The Lower Jaw Bone.

THE TRUNK.

c, The Cervical Vertebrae.

d, The first Dorsal Vertebra.

e, The last, or twelfth, Dorsal Vertebra.

f, The first Lumbar Vertebra.

g, The last, or fifth, Lumbar Vertebra.

h, The Sacrum.

i, The Os Coccygis.

k, The seventh Rib.

* Folio, Leyden, 1753.

- l*, The eighth, ninth, and tenth Ribs.
- m*, The eleventh and twelfth Ribs.
- n*, The Dorsum of the Ilium.
- o*, The Anterior and Inferior Spinous Process of the Ilium.
- p*, The Anterior and Superior Spinous Process of the Ilium.
- q*, The Posterior Spinous Process of the Ilium.
- r*, The Spine, or Spinous Process of the Ischium.
- s*, The Sciatic Notch.
- t*, The Ascending Ramus of the Ischium.
- u*, The Symphysis of the Pubes.

THE UPPER EXTREMITIES.

- v*, The Extremity of the Spine of the Scapula.
- w*, The Acromion Process.
- x*, The Inferior Angle of the Scapula.
- y*, The Posterior Border of the Glenoid Cavity of the Scapula.
- z*, The Lesser Tubercle of the Arm Bone.
- 1, The Larger Tubercle of the Arm Bone.
- 2, The External Condyle of the Arm Bone.
- 3, The Olecranon.
- 4, The Styloid Process of the Ulna.
- 5, The Head of the Radius.
- 6, The Tubercle of the Radius.
- 7, The Styloid Process of the Radius.

- 8, The Bones of the Carpus, or Wrist.
- 9, The Bones of the Metacarpus and Fingers.

THE LOWER EXTREMITIES.

- 10, The Trochanter Major of the Thigh Bone.
 - 11, The External Condyle of the Thigh Bone.
 - 12, The Internal Condyle of the Thigh Bone.
 - 13, The Patella.
 - 14, The Internal Condyle of the Tibia.
 - 15, The External Condyle of the Tibia.
 - 16, The Tuberosity of the Tibia.
 - 17, The Extremity, or Internal Malleolar Process of the Tibia.
 - 18, The Head of the Fibula.
 - 19, The Extremity, or External Malleolar Process of the Fibula.
 - 20, The Bones of the Tarsus or Instep.
 - 21, The Bones of the Metatarsus and Toes.
-

8. The Ligament of the Capsule of the Hip Joint.
9. The Bones of the Pelvis and Thighs.
10. The Trochanter Major of the Thigh Bone.
11. The External Condyle of the Thigh Bone.
12. The Internal Condyle of the Thigh Bone.
13. The Femur.
14. The Femoral Condyle of the Thigh Bone.
15. The External Condyle of the Thigh Bone.
16. The Tibia.
17. The Extremity of the Tibia.
18. The Head of the Tibia.
19. The Extremity of the Tibia.
20. The Bone of the Thigh and Hip.
21. The Bone of the Thigh and Hip.
22. The Bone of the Thigh and Hip.
23. The Bone of the Thigh and Hip.
24. The Bone of the Thigh and Hip.
25. The Bone of the Thigh and Hip.
26. The Bone of the Thigh and Hip.
27. The Bone of the Thigh and Hip.
28. The Bone of the Thigh and Hip.
29. The Bone of the Thigh and Hip.
30. The Bone of the Thigh and Hip.
31. The Bone of the Thigh and Hip.
32. The Bone of the Thigh and Hip.
33. The Bone of the Thigh and Hip.
34. The Bone of the Thigh and Hip.
35. The Bone of the Thigh and Hip.
36. The Bone of the Thigh and Hip.
37. The Bone of the Thigh and Hip.
38. The Bone of the Thigh and Hip.
39. The Bone of the Thigh and Hip.
40. The Bone of the Thigh and Hip.
41. The Bone of the Thigh and Hip.
42. The Bone of the Thigh and Hip.
43. The Bone of the Thigh and Hip.
44. The Bone of the Thigh and Hip.
45. The Bone of the Thigh and Hip.
46. The Bone of the Thigh and Hip.
47. The Bone of the Thigh and Hip.
48. The Bone of the Thigh and Hip.
49. The Bone of the Thigh and Hip.
50. The Bone of the Thigh and Hip.
51. The Bone of the Thigh and Hip.
52. The Bone of the Thigh and Hip.
53. The Bone of the Thigh and Hip.
54. The Bone of the Thigh and Hip.
55. The Bone of the Thigh and Hip.
56. The Bone of the Thigh and Hip.
57. The Bone of the Thigh and Hip.
58. The Bone of the Thigh and Hip.
59. The Bone of the Thigh and Hip.
60. The Bone of the Thigh and Hip.
61. The Bone of the Thigh and Hip.
62. The Bone of the Thigh and Hip.
63. The Bone of the Thigh and Hip.
64. The Bone of the Thigh and Hip.
65. The Bone of the Thigh and Hip.
66. The Bone of the Thigh and Hip.
67. The Bone of the Thigh and Hip.
68. The Bone of the Thigh and Hip.
69. The Bone of the Thigh and Hip.
70. The Bone of the Thigh and Hip.
71. The Bone of the Thigh and Hip.
72. The Bone of the Thigh and Hip.
73. The Bone of the Thigh and Hip.
74. The Bone of the Thigh and Hip.
75. The Bone of the Thigh and Hip.
76. The Bone of the Thigh and Hip.
77. The Bone of the Thigh and Hip.
78. The Bone of the Thigh and Hip.
79. The Bone of the Thigh and Hip.
80. The Bone of the Thigh and Hip.
81. The Bone of the Thigh and Hip.
82. The Bone of the Thigh and Hip.
83. The Bone of the Thigh and Hip.
84. The Bone of the Thigh and Hip.
85. The Bone of the Thigh and Hip.
86. The Bone of the Thigh and Hip.
87. The Bone of the Thigh and Hip.
88. The Bone of the Thigh and Hip.
89. The Bone of the Thigh and Hip.
90. The Bone of the Thigh and Hip.
91. The Bone of the Thigh and Hip.
92. The Bone of the Thigh and Hip.
93. The Bone of the Thigh and Hip.
94. The Bone of the Thigh and Hip.
95. The Bone of the Thigh and Hip.
96. The Bone of the Thigh and Hip.
97. The Bone of the Thigh and Hip.
98. The Bone of the Thigh and Hip.
99. The Bone of the Thigh and Hip.
100. The Bone of the Thigh and Hip.




PLATE V.

Fig. 1.

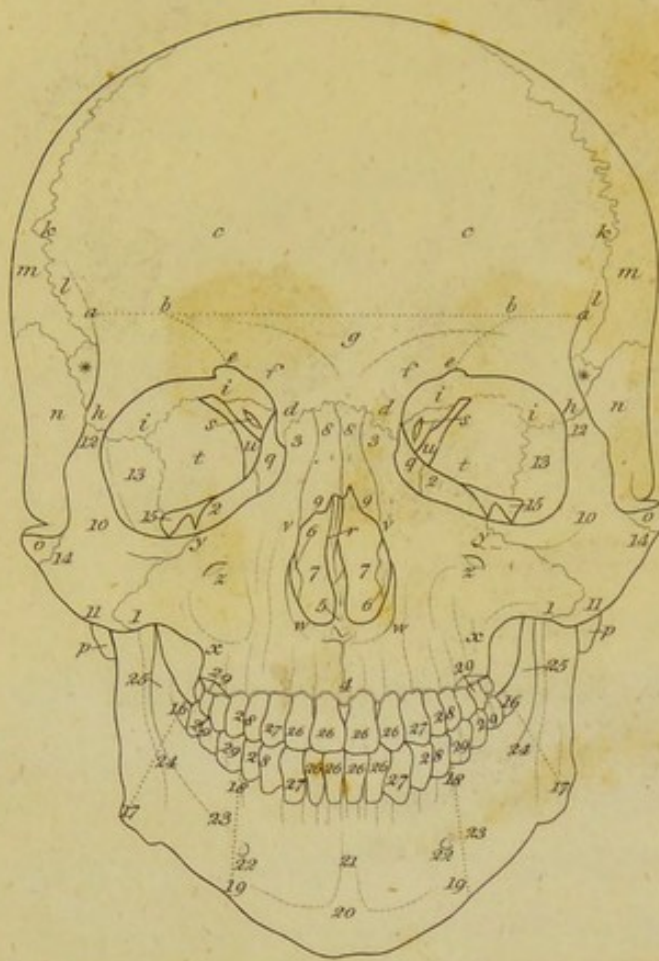


Fig. 2.

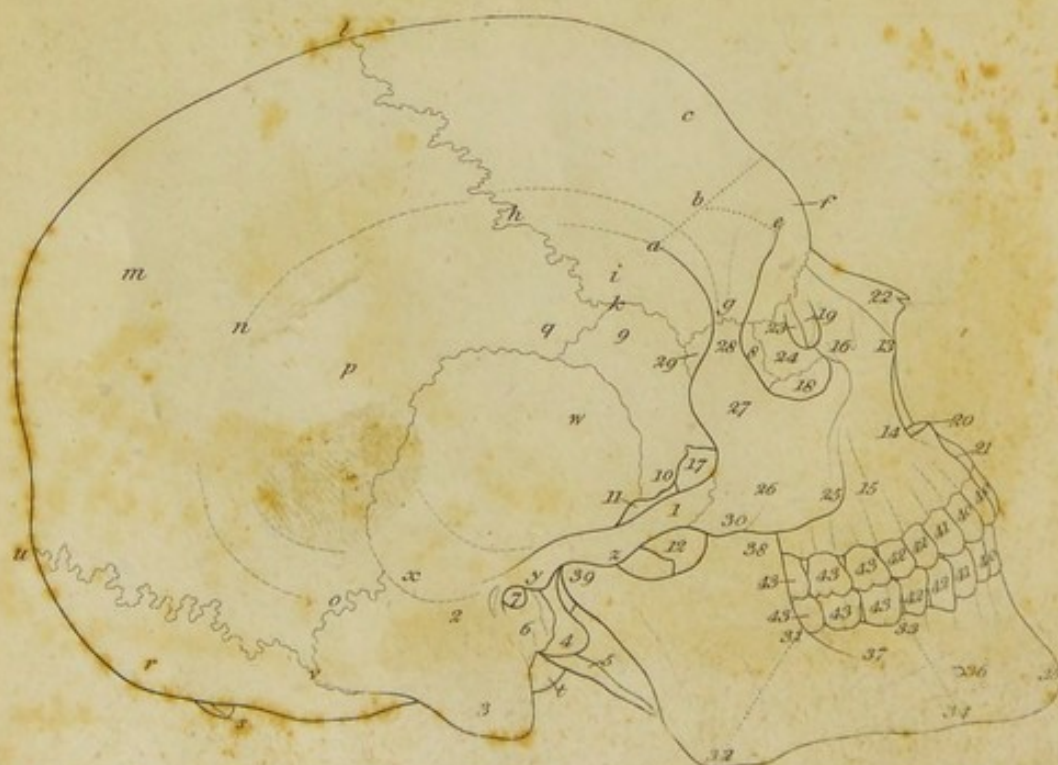

Fig. 1.

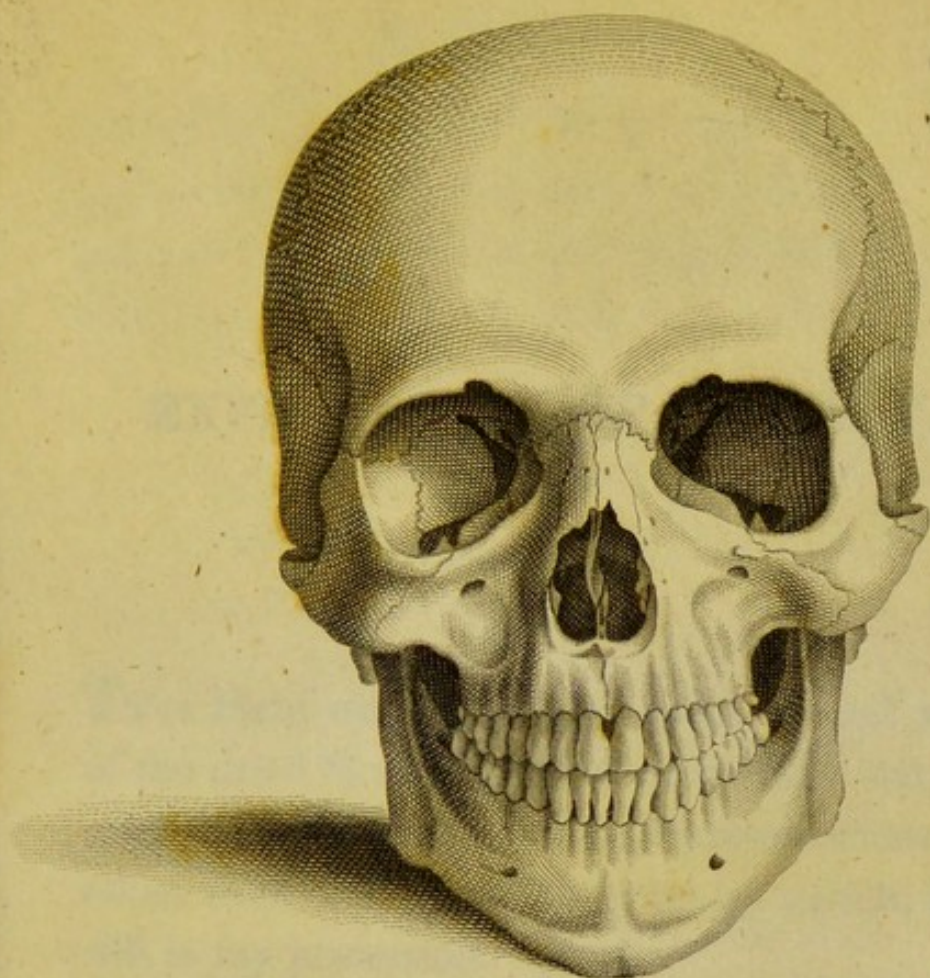
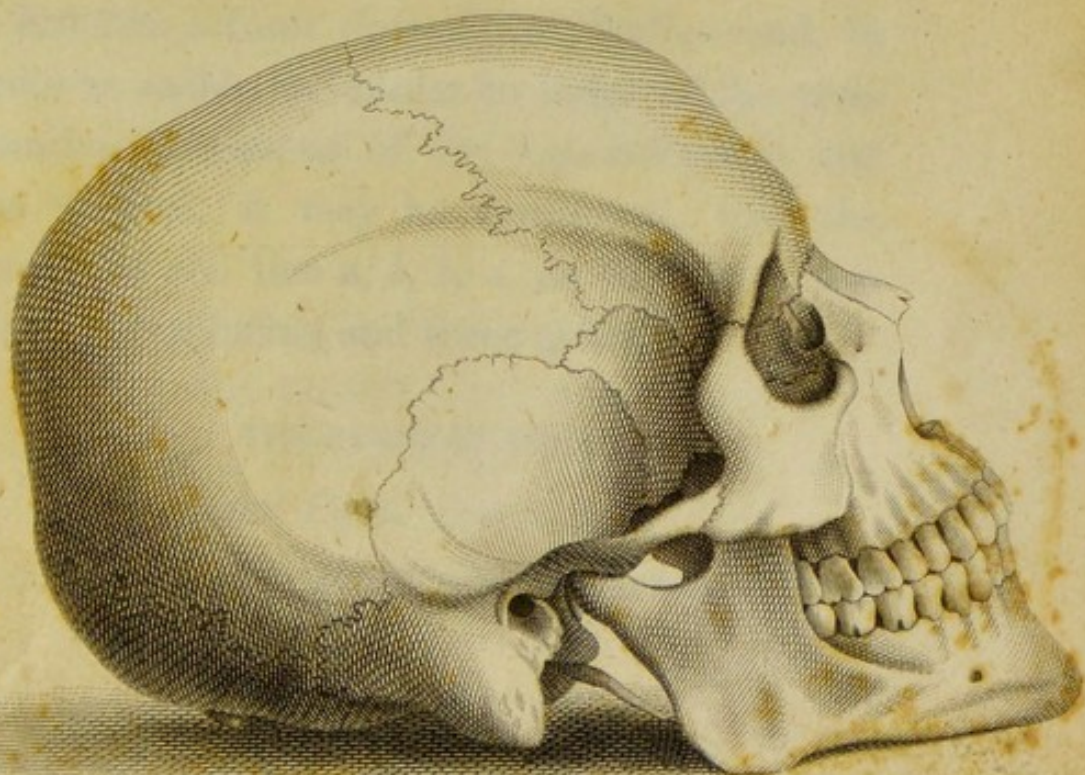
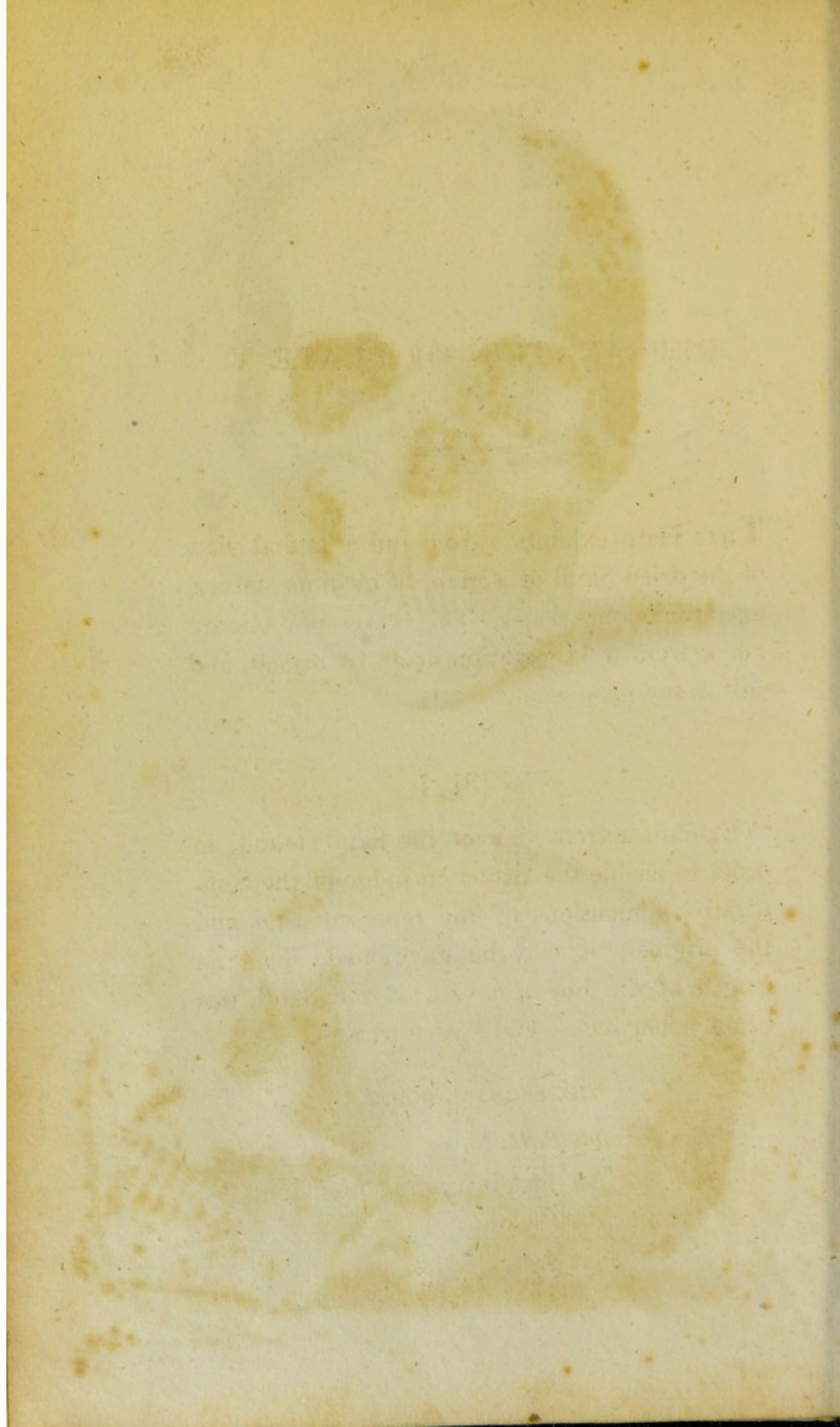


Fig. 2.



Drawn & Engraved by R. Miller.



EXPLANATION OF PLATE V.

THIS Plate exhibits a front and a lateral view of the dried Skull of a Man, of medium stature, aged thirty-one years. The representations are taken from a Preparation made by myself, and still in my possession.

FIGURE 1.

Exhibits a front view of the Skull;—and, in order to enable the reader to judge of the comparative dimensions of the representation and the original, it may be mentioned, that the length of the line *a, b, b, a*, on the Skull, was exactly four inches and three quarters.

THE FRONTAL BONE.

The Frontal Part.

a, b, b, a, An imaginary line bounding the Frontal Part below.

- b, a*, The portion of this line separating the Frontal Part from the Malar Process.
- b, b*, The portion of this line separating the Frontal Part from the Lower and Middle Part.
- c*, The Frontal Protuberance.

The Lower and Middle Part.

- d, d*, The Nasal Process.
- d, e*, Margin of this Process, often called the Internal Angular Process, which runs upwards and outwards, to unite with the edge of the Malar Process at *e*, and to form with it the Orbital Arch.
- e*, The Supra-orbital Hole, through which the Frontal Nerve, and a Twig of the Ophthalmic Artery pass.
- e, b*, Imaginary line separating the Lower and Middle Part from the Malar Process.
- f*, The Superciliary Protuberance.
- g*, The Glabella.

The Malar or External Angular Processes.

- h*, The Apex of these Processes.
- h, e*, Margin of these Processes, uniting with the Nasal Process at *e*, to form the Orbital Arch, on each side.
- h, e, d*, The Orbital Arch, on each side.

The Orbital Processes.

i, i, The Lower Surface of these Processes, forming a part of the Orbit on each side.

The Temporal Parts.

k, a, Arched Ridge, separating the Anterior Surface of these Parts from the Frontal Part, and continuous with the Margin, *a, k*, of the Malar Processes.

l, Outer Surface of these Parts, to which a portion of the Temporal Muscle is attached.

THE PARIETAL BONES.

m, The Anterior Inferior Angle of these Bones.

THE TEMPORAL BONES.

The Squamous Portion.

n, The External Surface of this Portion.

o, The Anterior Extremity of the Zygomatic Process.

The Mastoid Portion.

p, Tip of the Mastoid Process.

THE ETHMOID BONE.

The Cellular or Lateral Parts.

q, The Orbital Plate, forming a part of the Orbit.

The Perpendicular Plate.

- r*, The Anterior and Lower Margin of this Plate, united with Cartilage in the recent Subject.

THE SPHENOID BONE.

The Lesser Wings.

- s*, The Optic Hole, or Foramen Opticum, through which the Optic Nerve and Ophthalmic Artery pass from the Cranium into the Orbit.

The Large Wings.

- t*, The Orbital Plane of these Wings, forming a part of the Orbit.
- * Outer Surface of the Tip of these Wings, forming a part of the Temporal Fossa.

The Anterior Foramina Lacera of the Cranium, or Superior Orbital Fissures.

- u*, Front View of these Fissures, uniting with the Inferior Orbital Fissures below. Through these Fissures, on each side, pass the Motor Oculi, or Common Oculo-Muscular Nerve; the Patheticus, or Internal Oculo-Muscular Nerve; the Abductor Oculi, or External Oculo-Muscular Nerve;

and the First Branch of the Trigeminal Nerve, together with the Ophthalmic Vein.

THE SUPERIOR MAXILLARY BONES.

The Body.

v, w, x, y, The Anterior Surface of the Body of these Bones.

z, The Infraorbital Hole, through which the Infraorbital Nerve passes.

1, *x, y*, The Anterior Surface of the Malar Process of these Bones.

2, The Superior Surface of the Orbital Plate.

The Nasal Process.

3, The Upper Extremity of this Process.

The Alveolar Arch.

4, *x*, The Anterior Surface of this Arch.

5, The Anterior Extremity of the Nasal Crest, and the Root of the Anterior Nasal Spine.

5, *w, v*, The Incisura Nasalis.

THE SPONGY BONES.

6, The Inner Surface of these Bones.

THE CAVITIES OF THE NOSE.

7, The Cavities of the Nose, viewed directly in front.

THE NASAL BONES.

8, 9, The Anterior Surface of these Bones.

THE MALAR BONES.

The Body.

10, 11, *y*, The Anterior Surface of the Body of these Bones.

10, *y*, The Upper and Inner Margin of this Part, forming, with the Frontal Process, the Orbital Arch.

The Frontal Process.

12, Its Upper Extremity joined to the Malar Process of the Frontal Bone.

12, 10, Its External Surface.

12, *y*, The Orbital Arch, formed partly by this Process, partly by the Body of the Bone.

The Orbital Process.

13, Its Upper and Inner Surface, forming part of the Orbit.

The Zygomatic Process.

14, Its Outer Surface.

*The Spheno-Maxillary, or Inferior Orbital
Fissure.*

- 15, The Anterior and Outer Extremity of
this Fissure.

THE LOWER JAW BONE.

The Body.

- 16, 17, Imaginary Line separating the Body
from the Ramus on each side.

- 17, The Angles of the Bone.

- 18, 19, Imaginary line separating the Mental
Portion of the Body from the Lateral Por-
tions.

- 20, 21, The External Mental Protuberance.

- 22, The Mental Holes, or Anterior Openings
of the Subdental or Inferior Maxillary Ca-
nals, through which come the extremities
of the Inferior Maxillary Nerves.

- 23, 24, The External Oblique Ridges.

The Rami.

- 25, Groove in the Anterior Border of the Co-
ronoid Processes.

THE TEETH.

- 26, The Incisor, or Cutting Teeth.

27, The Eye Teeth, Canine Teeth, or Dentes Cuspidati.

28, Small Grinders, or Bicuspid Teeth, or Dentes Bicuspidati.

29, The Grinding Teeth, Large Grinders, or Molares.

FIGURE 2.

Is a Lateral View of the Skull ; and, to afford a scale for judging of dimension, it may be observed, that the surface from *k* to *l* in the Preparation, measured exactly four inches and three-fourths.

THE FRONTAL BONE.

The Frontal Part.

a, b, Imaginary line separating this Part from the Malar Process below.

c, The Frontal Protuberance.

The Lower and Middle Part.

d, Surface of the Nasal Process looking towards the Orbit.

e, The Supraorbital Hole.

e, b, Imaginary line separating this Part of the Bone from the Malar Process.

f, The Superciliary Protuberance.

The Malar Process.

g, Its Apex, united to the Frontal Process of the Malar Bone.

g, d, Margin of it, uniting with the Margin of the Nasal Process to form the Orbital Arch.

g, a, Its Outer Margin.

The Temporal Part.

h, a, Arched Ridge, separating this Part from the Frontal Part.

i, Outer Surface of this Part, forming a portion of the Temporal Fossa of the Skull.

The Coronal Suture.

k, l, The Right Half of this Suture.

THE PARIETAL BONE.

m, The Parietal Protuberance.

n, Middle of the Arched Ridge.

o, Posterior Inferior Angle of the Bone.

o, n, h, The whole Extent of the Arched Ridge.

o, p, q, The Temporal Surface.

q, The Anterior Inferior Angle.

THE OCCIPITAL BONE.

The Occipital Part.

r, The Occipital Protuberance.

s, The Occipital Spine.

The Condyles.

t, Part of the Right Condyle.

The Lambdoid Suture.

u, *v*, The Right Half of this Suture.

THE TEMPORAL BONE.

The Squamous Portion.

w, *x*, Outer Surface of this Portion, forming part of the Temporal Fossa of the Skull, and giving attachment to fibres of the Temporal Muscle.

y, 2, 1, The Zygomatic Process.

y, The Root of this Process.

z, The Tubercle of this Process.

1, Its Anterior Extremity, united by Suture to the Malar Bone.

The Mastoid Portion.

2, 3, *v*, *x*, The Outer Surface of this Portion.

3, The Mastoid Process.

The Petrous Portion.

4, The Vaginal Process.

5, The Styloid Process.

The External Auditory Canal.

6, 7, View of this Canal to within a fourth-part of its termination in the Tympanum.

THE ETHMOID BONE.

8, Part of the Orbital Plate of this Bone.

THE SPHENOID BONE.

The Large Wing.

9, 10, Outer Surface of this Wing, forming part of the Temporal Fossa of the Skull.

10, Sharp Ridge, separating this Surface from

11, The Zygomatic Surface or Fossa, of this Wing.

The Pterygoid Process.

12, Outer or Zygomatic Surface of its External Plate.

THE SUPERIOR MAXILLARY BONE.

The Body.

13, 14, 15, 16, The Anterior Surface of the Body.

17, The Tuberosity of the Body.

18, The Superior Surface of its Orbital Plate.

The Nasal Process.

19, Upper Part of the Lachrymal Fossa of this Process.

The Alveolar Arch.

20, The Anterior Nasal Spine.

20, 21, Suture joining the Alveolar Arches of the two Superior Maxillary Bones.

THE NASAL BONE.

22, Lower Part of the Outer Surface of this Bone.

THE LACHRYMAL BONE.

The Lachrymal Plate.

23, The Lachrymal Fossa of this Plate.

The Orbital Plate.

24, The External or Orbital Surface.

THE MALAR BONE.

The Body.

25, 26, 27, Outer Surface of this Part.

The Frontal Process.

27, 28, The Outer Surface of this Process.

The Orbital Process.

- 29, The Outer or Temporal Surface of this Process.

The Zygomatic Process.

- 30, Outer Surface of this Process.

THE LOWER JAW BONE.

The Body.

- 31, 32, Imaginary Line separating it from the Ramus.
32, The Angle of the Bone.
33, 34, Imaginary Line separating the Mental from the Lateral Portion of the Body of the Bone.
35, The Mental Process.
36, The Mental Hole.
37, The External Oblique Ridge.

The Ramus.

- 38, the Outer Surface of the Coronoid Process.
39, Outer Extremity and Surface of the Condyle.

THE TEETH.

- 40, The Incisor, or Cutting Teeth.

- 41, The Eye Teeth, Canine Teeth, or Dentes
Cuspidati.
42, The Small Grinders, or Bicuspid Teeth,
or Dentes Bicuspidati.
43, The Grinding Teeth, Large Grinders, or
Molares.




PLATE VI.

Fig 1.

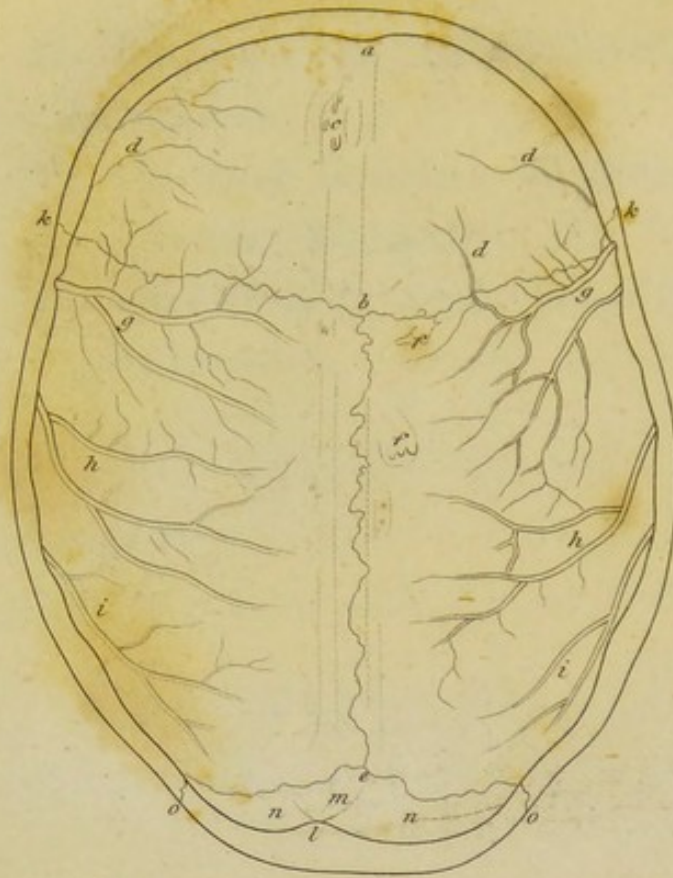
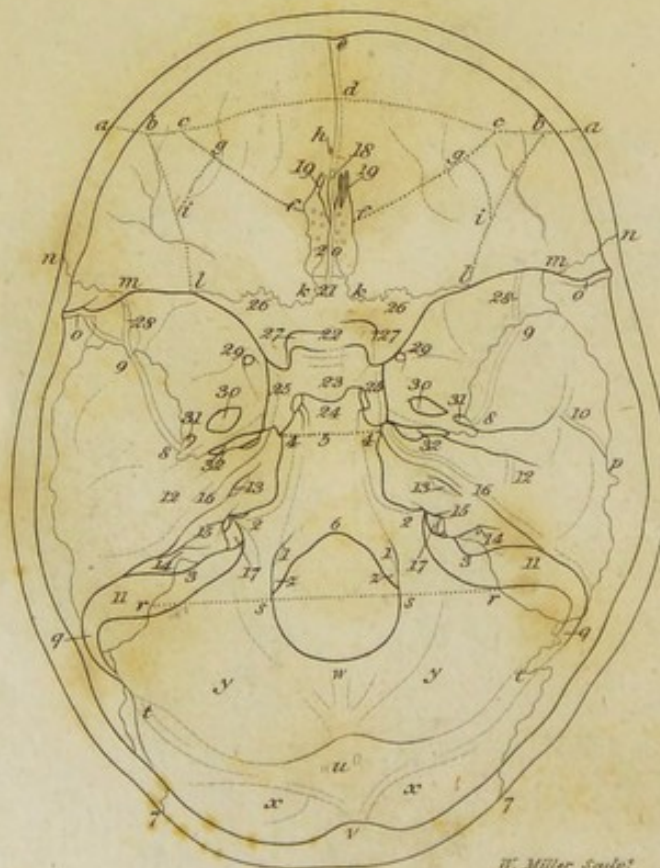


Fig: 2.



W. Müller Sculp.

Fig. 1.

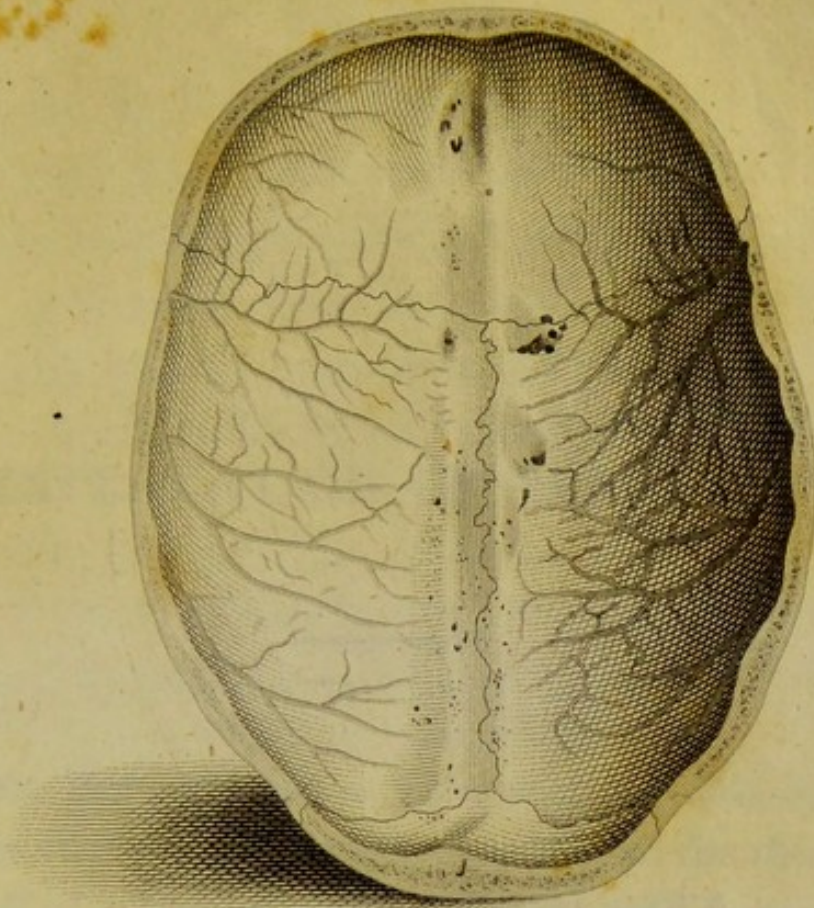
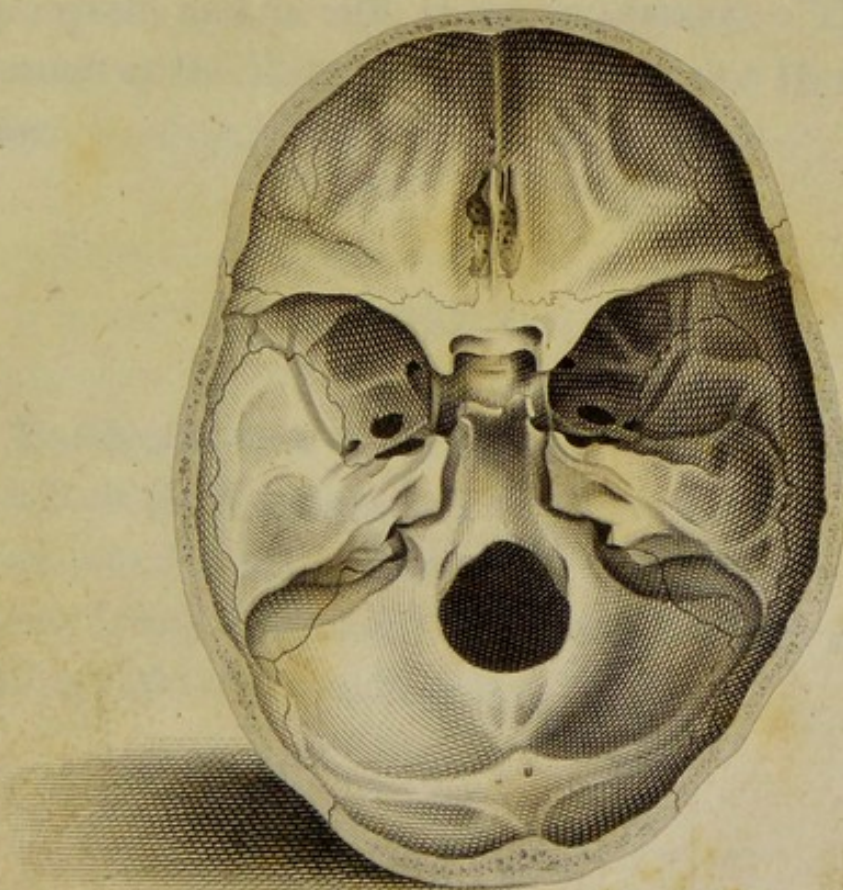
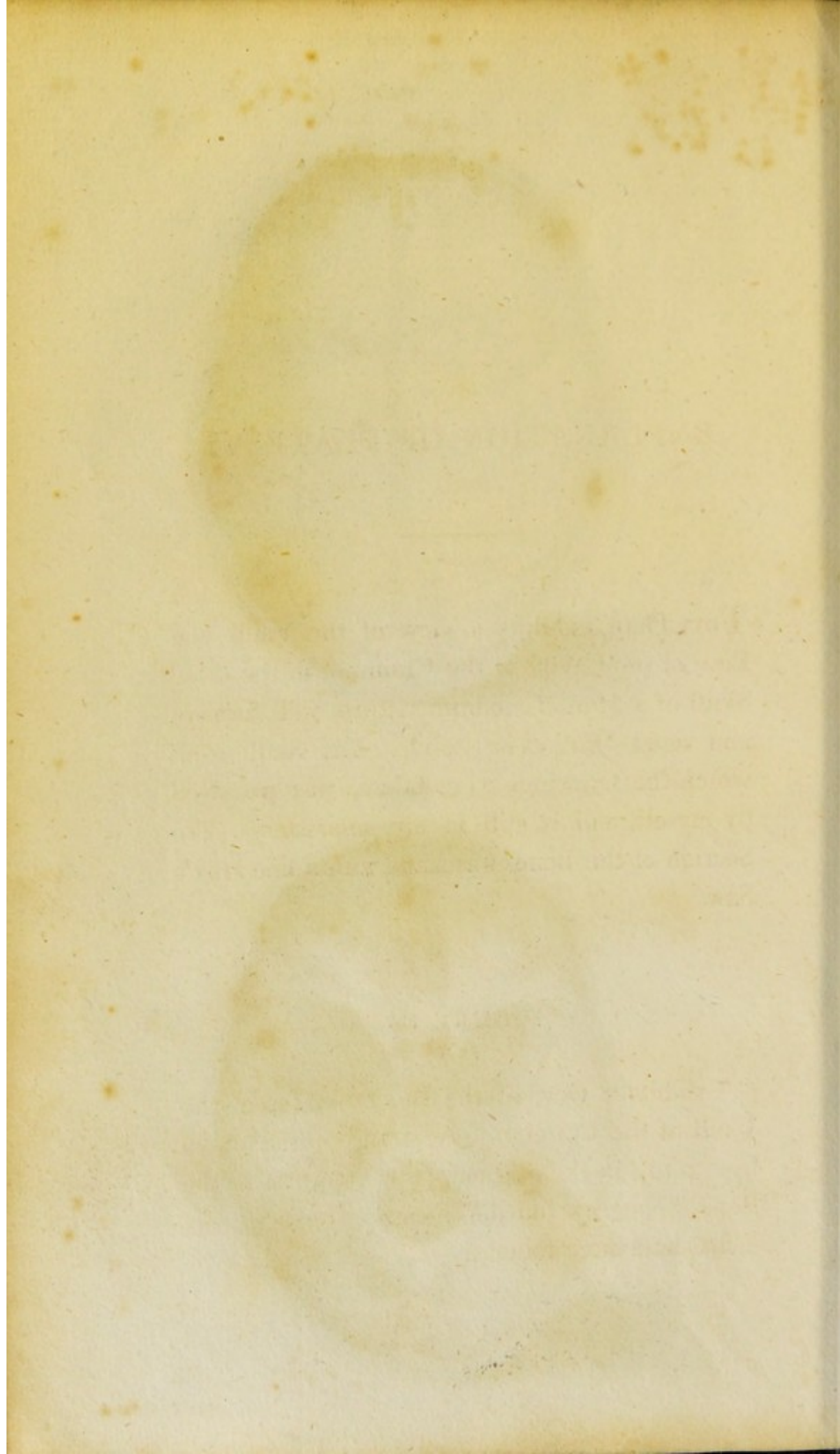


Fig. 2.





EXPLANATION OF PLATE VI.

THIS Plate exhibits a view of the Vault and Base of the Cavity of the Cranium, in the dried Skull of a Man of medium stature, well formed, and aged thirty-four years. The Skull from which the Drawings were taken, was prepared by myself, and is still in my possession. The Section of the Bones was made with a fine HEY'S Saw.

FIGURE 1.

Exhibits a view of the Inner Surface of the Vault of the Cranium. A straight line drawn from *a* to *l* in the original, (the thickness of the Bone being excluded,) measured exactly six inches and three fourths.

d, e, Upper Part of the Frontal Spine, to which the anterior extremity of the Falx of the Dura Mater is attached.

e, Section of this Spine.

The Lower and Middle Part.

f, g, c, d, c, g, f, Imaginary Line separating the Inner Surface of this Part from the Inner Surface of the Frontal Part, and of the Malar and Orbital Processes. The Plate of Bone included within this Line, constitutes the Inner Wall of the Frontal Sinuses.

h, The Foramen Cœcum, at which the Superior Longitudinal Sinus begins.

h, d, The Root of the Frontal Spine.

The Malar Processes.

i, b, c, g, i, Imaginary Line circumscribing the Basis of these Processes, which is turned towards the Cranium.

The Orbital Processes.

k, l, i, g, f, k, Imaginary Line marking the Boundary of the Inner or Cranial Surface of these Processes.

The Temporal Parts.

l, m, n, a, b, i, l, Imaginary Line marking the Boundary of the Inner or Cranial Surface of these Parts.

m, n, Lower Extremity of the Coronal Suture.

THE PARIETAL BONES.

o, Depression for the Middle Meningeal Artery and Veins, which afterwards ramifies into the Depressions marked *g, h*, in Fig. 1.

p, Vascular Depression afterwards ramifying into those marked *i*, Fig. 1.

q, The Lower Parietal Furrow; lodging a part of the Lateral Sinus of the Dura Mater.

THE OCCIPITAL BONE.

The Occipital Part.

r, s, s, r, Imaginary Line bounding this Part below.

t, w, t, The Internal Transverse Ridge, with the Transverse Occipital Furrow on its top. Part of the Tentorium Cerebelli is attached to the Ridge, and part of the Lateral Sinus of the Dura Mater is lodged in the Furrow.

u, Point at which the Transverse and Perpen-

dicular Ridges and Furrows intersect each other.

v, u, w, The Internal Perpendicular Ridge, with the Perpendicular Occipital Furrow on its top. The upper half of the Ridge gives attachment to the posterior end of the Falx Cerebri, and the lower half to the Falx Cerebelli. The Perpendicular Furrow lodges the posterior extremity of the Superior Longitudinal Sinus.

x, Lower Half of the Upper Occipital Fossa.

y, The Lower Occipital Fossa, corresponding to the Hemisphere of the Cerebellum.

The Condyles.

z, The Inner Surface of each Condyle.

1, The Anterior Condylloid Hole, through which the Hypoglossal Nerve passes out.

*The Anonymous Processes.**

2, Upper Surface of these Processes.

* These have been called by some writers, *Processus pro Medulla Oblongata*. HILDEBRANDT describes them under the name of *Processus Anonymi*; and SOEMMERING calls them, *Tubera quibus canalis nervi lingualis medii subjicitur*. Most other modern anatomists have passed them over altogether, although no parts of the Bone are more constant or better marked.

The Jugular Processes.

- 3, Upper Surface of these Processes, with the Jugular Furrow deeply impressed on it, which ends in the Posterior Foramen Lacerum of the Cranium at 17.

The Basilar or Cuneiform Process.

- 4, 5, 4, Imaginary Line separating this Process from the Body of the Sphenoid Bone, with which at Maturity it is always completely united. Hence the Occipital and Sphenoid Bones have, with propriety, been described by some Anatomists as one.
- 4, 2, The Inferior Petrosal Furrow on each side, which terminates behind in the Posterior Foramen Lacerum, and Lodges the Sinus of the same name.
- 5, 6, The Upper Surface of this Process called the Basilar Furrow, on which the Annular Protuberance and Medulla Oblongata rest.
- 6, s, w, s, 6, The Foramen Magnum, through which the Spinal Cord with its Membranes passes; together with the Accessory Nerves, the Vertebral Arteries, the Dura Mater; and certain Ligaments attaching the Occipital Bone to the two Upper Cervical Vertebræ.

7, *t*, The Lower Half of the Lambdoid Suture.

THE TEMPORAL BONES.

The Squamous Portion.

8, 9, Depression for the Middle Meningeal Artery and Veins, beginning at 8 at the Foramen Spinosum of the Sphenoid Bone, and passing again into the Large Wing of this Bone at 9.

10, Depression for a Branch of the same Vessel, which passes into the Parietal Bone at *p*, and afterwards ramifies into the Depressions, marked *i* in Figure 1.

The Mastoid Portion.

11, The Sigmoid Furrow, which is continuous with the Inferior Parietal Furrow at *q*, and runs into the Jugular Furrow of the Occipital Bone 3, lodging part of the Lateral Sinus.

The Petrous Portion.

12, Eminence corresponding to the Superior Semicircular Canal of the Labyrinth of the Ear.

13, Orifice of the Internal Auditory Canal, by

which the Facial and Auditory Nerves enter.

14, Outer or Cranial Orifice of the Aqueduct of the Vestibule.

15, Inferior or Cranial Orifice of the Aqueduct of the Cochlea.

16, The Superior Petrosal Furrow, lodging a Sinus of the same name.

17, The Posterior Foramen Lacerum of the Cranium on each side, in which the Jugular Furrow of the Occipital Bone terminates; and through which the Nervus Glosso-pharyngæus, the Nervus Vagus, and the Nervus Accessorius pass out of the Cranium; and where the Lateral Sinus ends in the Internal Jugular Vein.

THE ETHMOID BONE.

Its Perpendicular Plate.

18, The Crista Galli.

Its Cribriform Plate.

19, 20, Upper Surface of this Plate.

19, Slit close to the Root of the Crista Galli, through which the Nasal Branch of the Ophthalmic Nerve passes into the Nose.

THE SPHENOID BONE.

Its Body.

- 21, Triangular Peak projecting forwards, to be joined to the Cribriform Plate of the Ethmoid Bone.
- 22, The Tubercle, or Processus Olivaris.
- 23, The Sella Turcica, or Ephippium, which contains the Pituitary Gland.
- 24, The Perpendicular Plate, of which the projecting corners are called the Posterior Clinoid Processes.
- 25, The Fossa Carotica, along which the Internal Carotid Artery runs.

Its Lesser Wings.

- 26, Upper Surface of these Wings, of which the corners projecting over the Sella Turcica are called the Anterior Clinoid Processes.
- 27, Foramen Opticum, or Optic Hole, perforating the Basis of each Wing.

Its Large Wings.

- 28, Depression on the Inner or Cranial Surface of the Large Wing, for the Middle Meningeal Artery, after it leaves the Temporal Bone at 9.

- 29, The Foramen Rotundum, or Round Hole, through which the second Branch of the Trigeminal Nerve passes.
- 30, The Foramen Ovale, through which the third Branch of the Trigeminal Nerve passes.

The Spinous Processes.

- 31, The Foramen Spinosum, through which the Middle Meningeal Artery with its accompanying Veins passes.

The Middle Foramen Lacerum of the Cranium.

- 32, View of this Hole on each side. It is formed by the Sphenoid Bone, and the Apex or the Petrous Portion of the Temporal. In the recent Subject, it is entirely filled up with Tendinous Substance. It is visible only in the dried Skull.
-

29, The Foramen Rotundum, or Round Hole, through which the second branch of the Trigeminal Nerve passes.

30, The Foramen Ovale, through which the third branch of the Trigeminal Nerve passes.

The Foramen Proterum.

31, The Foramen Spinosum, through which the Middle Meningeal Artery, with its accompanying Vein, passes.

The Middle Foramen of the Cranium.

32, View of this Hole on each side. It is formed by the Sphenoid Bone, and the Apex or the Petrous Portion of the Temporal. In the recent Subject, it is entirely filled up with Laminae Substance. It is visible only in the dried Skull.

33, Foramen Opticum, or Optic Hole.

34, Foramen Acousticum, or Acoustic Hole.




PLATE VII.

Fig: 1.

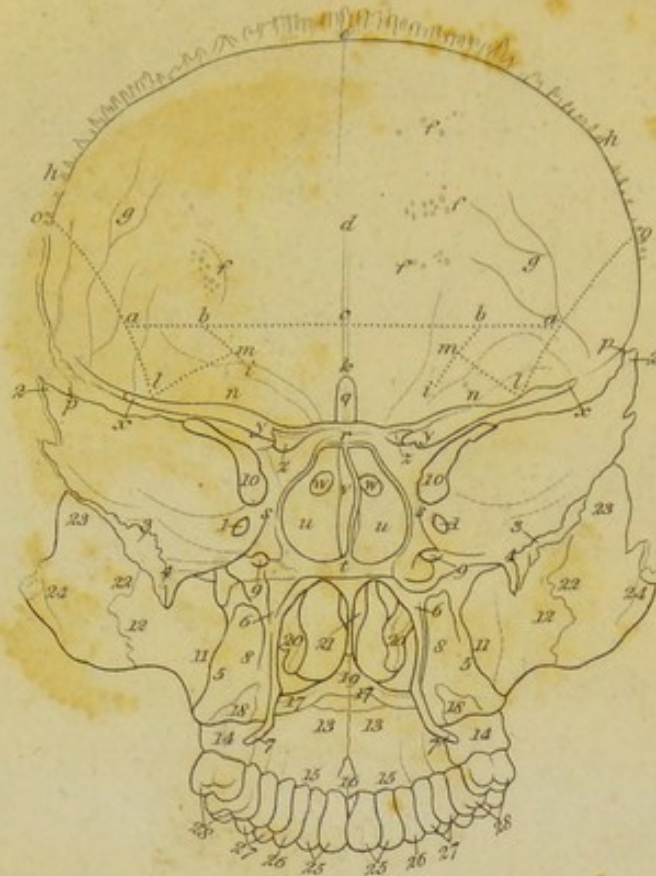
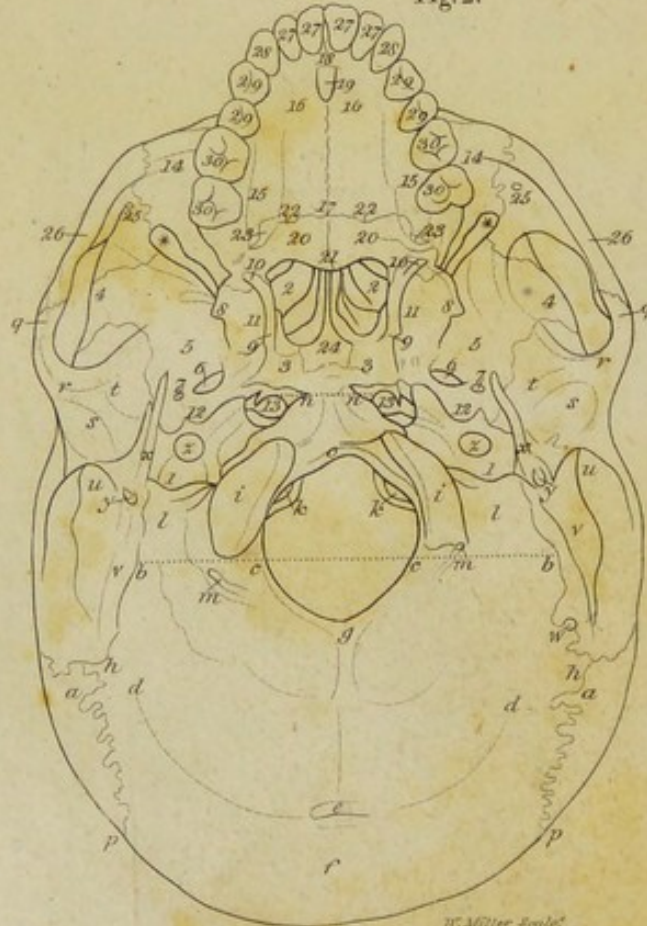


Fig: 2.



W. Miller Sculp.

Fig. 1.

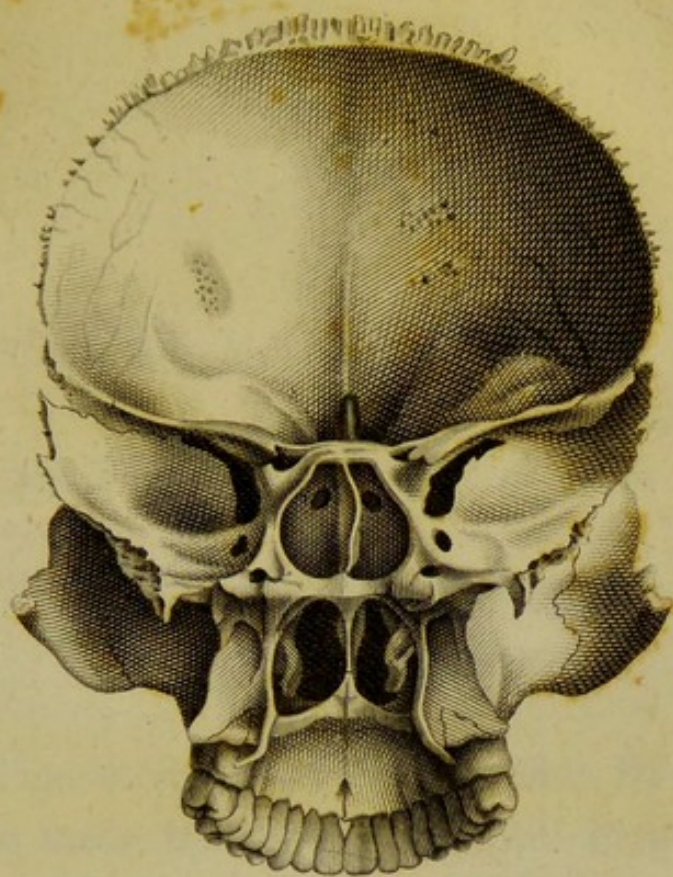
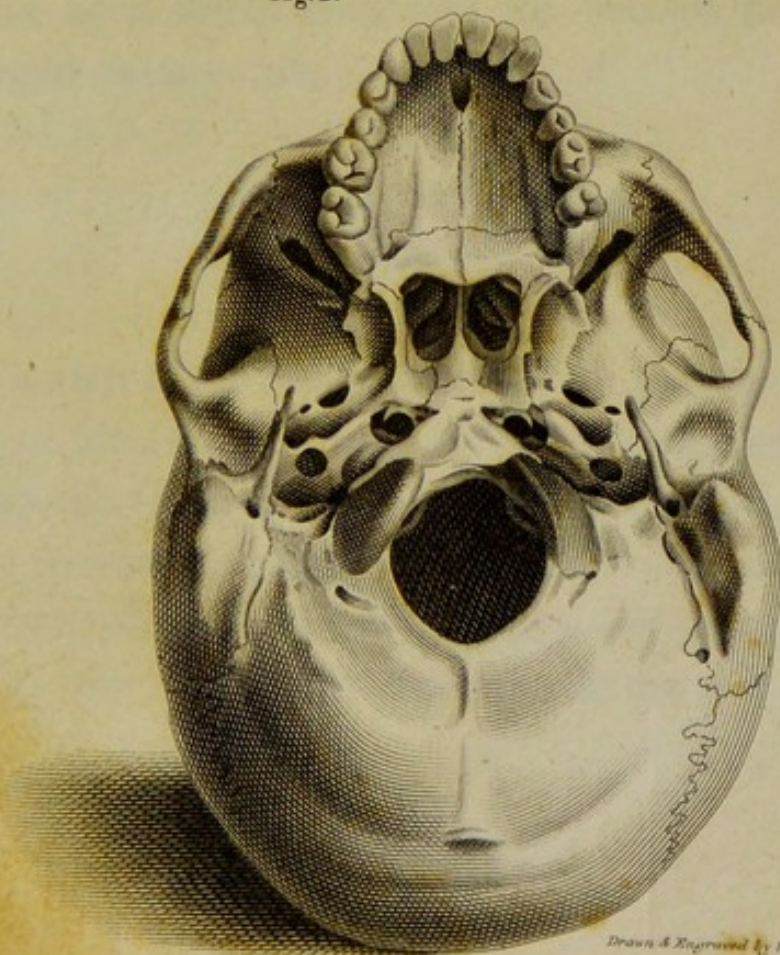
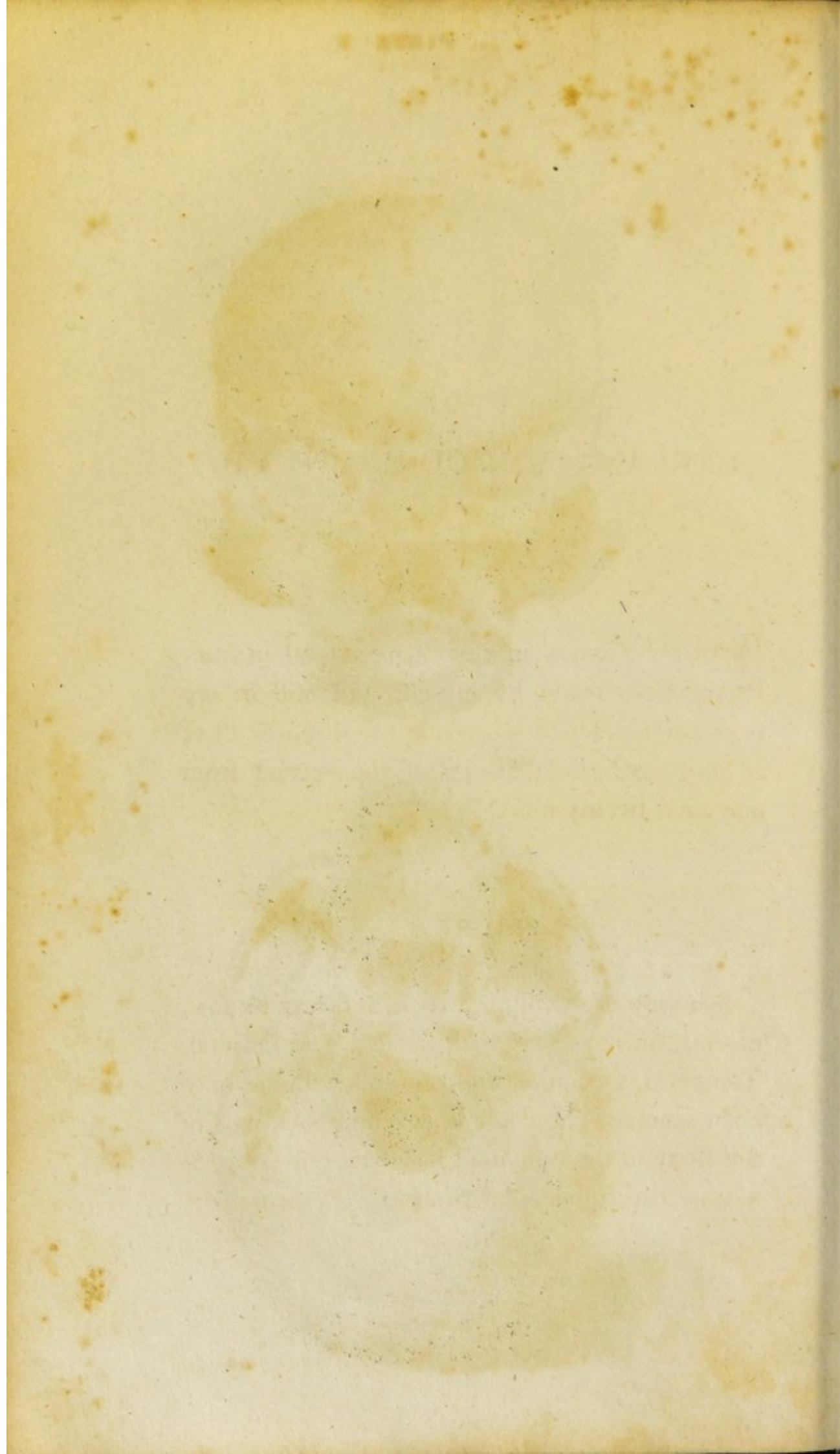


Fig. 2.





EXPLANATION OF PLATE VII.

BOTH the Figures in this Plate are taken from Preparations made by myself, and still in my possession. The first is from the dried Skull of a Man aged thirty-five; and the second from one aged twenty-nine.

FIGURE 1.

Is a view of the Skull, which, as far as I know, has not hitherto been exhibited. The Parietal, Temporal, Occipital, and Lower Jaw Bones have been removed; and the upper and back part of the Body of the Sphenoid has been cut away, to expose the Sphenoidal Sinuses. From *o* to *o*,

measured in the Preparation exactly four inches and three-fourths.

THE FRONTAL BONE.

The Frontal Part.

a, b, c, b, a, Imaginary Line bounding this part below.

b, a, Part of this line separating it from the Malar Process on each side.

b, c, b, Part of this line separating it from the Lower and Middle Part.

c, d, Upper part of the Frontal Spine.

d, e, The Frontal Furrow.

f, Depressions for the Granulations of the Pia Mater.

g, Depressions for the Meningeal Vessels.

h, e, h, Part of the Margin of the Frontal Bone, which is joined to the Parietal Bones; along the whole of which it may be observed, that the Serræ formed by the Outer Table of the Bone, project beyond the level of the Inner Table, especially towards the point *e*.

The Lower and Middle Part.

i, b, c, b, i, Imaginary line bounding this Part above and at the sides.

k, c, The root of the Frontal Spine.

The Malar Processes.

l, m, b, a, l, Imaginary line circumscribing the Surface of the Base of these Processes, which forms a part of the Wall of the Cranium.

The Orbital Processes.

n, The Superior or Cranial Surface of these Processes.

The Temporal Parts.

o, p, l, o, The Inner or Cranial Surface of these Parts.

p, The Point which receives the Anterior Inferior Angle of the Parietal Bone.

p, o, Margin which is joined to the Parietal Bone, and where the Inner Table projects beyond the level of the Serræ on the Outer Table.

THE ETHMOID BONE.

q, The Top of the Crista Galli.

THE SPHENOID BONE.

The Body.

r, The Tubercle, or Processus Olivaris.

r, s, t, s, r, Section of the upper and back part.

of the Body of the Bone, exposing the Sphenoidal Sinuses.

t, r, Section of the Septum of the Sphenoidal Sinuses.

u, u, The Sphenoidal Sinuses.

v, The Left Surface of the Septum, which is here seen in consequence of a bending of the Septum to one Side, which is very common.

w, w, The Orifices by which these Sinuses open into the Upper Meatus of the Nose.

The Lesser Wings.

x, y, The Posterior Margin of these Wings.

y, The Anterior Clinoid Process on each side.

z, The Optic Hole on each Side, perforating the Basis of these Wings.

The Large Wings.

1, The Round Hole on each Side.

2, 3, The Margin of these Wings, which is joined to the Squamous Plate of the Temporal Bones.

The Spinous Processes.

4, The Upper Surface of these Processes.

The Pterygoid Processes.

- 5, Inner Surface of the External Plate of these Processes.
- 6, 7, Posterior Margin of the Inner Plate of these Processes.
- 7, Hamulus, or Hook-like Process at the extremity of this Plate, over which the Tendon of the Circumflexus Palati Muscle plays.
- 8, The Pterygoid Fossa.
- 9, The Posterior Orifice of the Vidian Canal, through which the Vidian Branch of the Superior Maxillary Nerve passes. It is rather larger than usual in this case.

The Anterior Foramina Lacera of the Cranium, or Superior Orbital Fissures.

- 10, View of these Holes from behind.

THE UPPER JAW BONES.

The Body.

- 11, The Tuberosity.
- 12, The Posterior Surface of the Malar Process.

The Palatine Process.

- 13, Inferior Surface of this Process.

The Alveolar Arch.

- 14, 15, 16, The Inner Surface of this Arch.
- 14, The Posterior Extremity of this Arch.
- 16, The Foramen Incisivum, or Anterior Palatine Hole.

THE PALATE BONES.

The Palatine Process.

- 17, Inferior Surface of this Process.

The Pterygoid Process.

- 18, The Posterior Surface of this Process, looking towards the Pterygoid Fossa of the Pterygoid Process of the Sphenoid Bone.

Longitudinal Palatine Suture.

- 19, 16, The whole length of this Suture, formed by the Palatine Processes of the Palate Bones behind, and of the Upper Jaw Bones before.
- 19, The Posterior Nasal Spine.

THE SPONGY BONES.

- 20, The Inner Convex Surface of these Bones, looking towards the Lower Meatus of the Nose on each Side.

THE VOMER.

- 21, The Right Surface of this Bone, it being bent a little to one Side, as it commonly is.

THE MALAR BONES.

The Body.

- 22, Posterior Surface of this part, on which a portion of the Temporal Muscle plays.

The Frontal Process.

- 23, The Posterior Surface of this Process.

The Zygomatic Process.

- 24, The Posterior Surface of this Process.

THE TEETH.

- 25, The Two Incisors on each Side.
26, The Canine Tooth, or Dens Cuspidatus, on each Side.
27, The Two Bicuspid Teeth on each Side.
28, The Two Molares, or Grinders, on each Side. The Third Molaris, or Dens Sapien-tiæ, was wanting in this Skull.

FIGURE 2.

Exhibits a view of the Skull from below, the Lower Jaw being removed. In the Preparation, a straight line drawn from *q* to *q* measured within an eighth of five inches.

THE PARIETAL BONES.

a, The Posterior Inferior Angle of these Bones.

THE OCCIPITAL BONE.

The Occipital Part.

b, c, c, b, Imaginary line bounding this Part below.

d, e, d, The External Transverse Ridge.

e, The Occipital Spine.

f, The Occipital Protuberance.

g, e, The External Perpendicular Ridge.

h, The Lateral Angle of the Occipital Bone on each side.

The Condyles.

i, The Inferior Surface of these Processes, covered with Cartilage in the recent Subject.

k, The Posterior or Inner Openings of the Anterior Condylloid Holes.

The Jugular Processes.

- l*, The Inferior Surface of these Processes.
m, The Posterior Condylod Hole, situated farther forward on the left than on the right Side. It transmits a Vein from the soft parts without, into the Lateral Sinus of the Dura Mater.

The Basilar or Cuneiform Process.

- n, n*, Imaginary line separating this Process from the Body of the Sphenoid Bone.
o, n, n, Lower Surface of this Process, to which the Anterior Recti Muscles of the Head are attached.
o, c, g, c, o, The Foramen Magnum.

The Lambdoid Suture.

- p, h*, Lower extremity of this Suture.

THE TEMPORAL BONES.

The Squamous Portion.

- q, r*, The Zygomatic Process.
r, The Tubercle of this Process.
s, The Articular or Glenoid Cavity.
t, r, The Articular Eminence.

The Mastoid Portion.

- u*, The Mastoid Process.
- v*, The Digastric Fissure, to which the Posterior Belly of the Digastric Muscle is attached.
- w*, The Mastoid Hole, which is wanting on the Right Side. It opens into the Sigmoid Furrow within, and usually transmits a Vein from the soft parts to the Lateral Sinus of the Dura Mater.

The Petrous Portion.

- x*, The Styloid Process.
- y*, The Stylo-Mastoid Hole, through which the Facial Nerve comes, to be distributed on the Face.
- z*, The Lower Orifice of the Carotid Canal, by which the Internal Carotid Artery enters the Cranium.

The Posterior Foramina Lacera of the Cranium.

- 1, The Sinuosity leading to these Holes, which cannot be directly seen, unless they be viewed a little from before,

THE ETHMOID BONE.

- 2, The Inner Convex Surface of the Turbinated Plate on each Side of this Bone, projecting into the Upper Meatus of the Nose.

THE SPHENOID BONE.

The Body.

- 3, The Vaginal Process on each Side, overlapping the edge of the Base of the Vomer.

The Large Wings.

- 4, Part of the external Surface of these Wings, forming a portion of the Temporal Fossa of the Cranium.
- 5, Part of the external Surface of these Wings forming a portion of the Zygomatic Fossa of the Cranium.
- 6, The Foramen Ovale.

The Spinous Processes.

- 7, The Foramen Spinosum.

The Pterygoid Processes.

- 8, Inner Surface of the External Plate of these Processes,

9, 10, Posterior Margin of the Inner Plate of these Processes.

10, Hamulus of the Inner Plate.

11, The Pterygoid Fossa.

Groove leading to the Eustachian Canal.

12, This Groove is formed by the Spinous Process of the Sphenoid Bone before, and by the Petrous Portion of the Temporal Bone behind. It leads outwards and backwards into the Eustachian Canal of the Temporal Bone.

The Middle Foramina Lacera of the Cranium.

13, A view of these Holes from below. They exist only in the dried Skull, being filled up with Membrane in the recent Subject.

THE UPPER JAW BONES.

The Body.

14, Lower Surface of the Malar Process.

The Palatine Process.

15, 16, 17, The Inferior Surface of this Process.

The Alveolar Arch.

- 18, 15, Inner Surface of this Arch.
19, The Foramen Incisivum, or Anterior Palatine Hole.

THE PALATE BONES.

The Palatine Process.

- 20, The Inferior Surface of this Process.

The Longitudinal Palatine Suture.

- 21, 18, The whole length of this Suture; formed from 21 to 17 by the Palate Bones, and from 17 to 18 by the Upper Jaw Bones.

The Transverse Palatine Suture.

- 22, 22, This Suture disappears at each extremity in the Posterior Palatine Hole.

The Posterior Palatine Hole.

- 23, This Hole is the lower Orifice of a Canal, called the Anterior or Large Pterygo-Palatine Canal, which transmits the Anterior Palatine Nerve.

THE VOMER.

- 24, The posterior part of the Basis of this Bone.

THE MALAR BONES.

The Body.

- 25, Posterior Surface of this part of these Bones, forming a portion of the Temporal Fossa of the Cranium.

The Zygomatic Process.

- 26, The Lower Margin of this Part.

The Spheno-Maxillary, or Inferior Orbital Fissures.

- * View of the outer four-fifths of these Fissures, the remaining fifth being concealed by the Outer Plate of the Pterygoid Processes of the Sphenoid Bone.

THE TEETH.

- 27, The Two Incisor Teeth on each Side.
28, The Canine Tooth, or Dens Cuspidatus, on each Side.

- 29, The Two Bicuspid Teeth on each Side.
30, The Two Molares or Grinders on each Side, the Third Molaris, or Dens Sapien-
tiæ, being wanting.
-

99. The Two Incisor Teeth on each Side.
99. The Two Molars on each Side.
Side, the Third Molar, or Third Molar,
the being wanting.

THE VULGAR

THE VULGAR

THE VULGAR
THE VULGAR
THE VULGAR

THE VULGAR

THE VULGAR

THE VULGAR

THE VULGAR

THE VULGAR
THE VULGAR
THE VULGAR
THE VULGAR
THE VULGAR

THE VULGAR

THE VULGAR
THE VULGAR
THE VULGAR
THE VULGAR




Fig: 1.

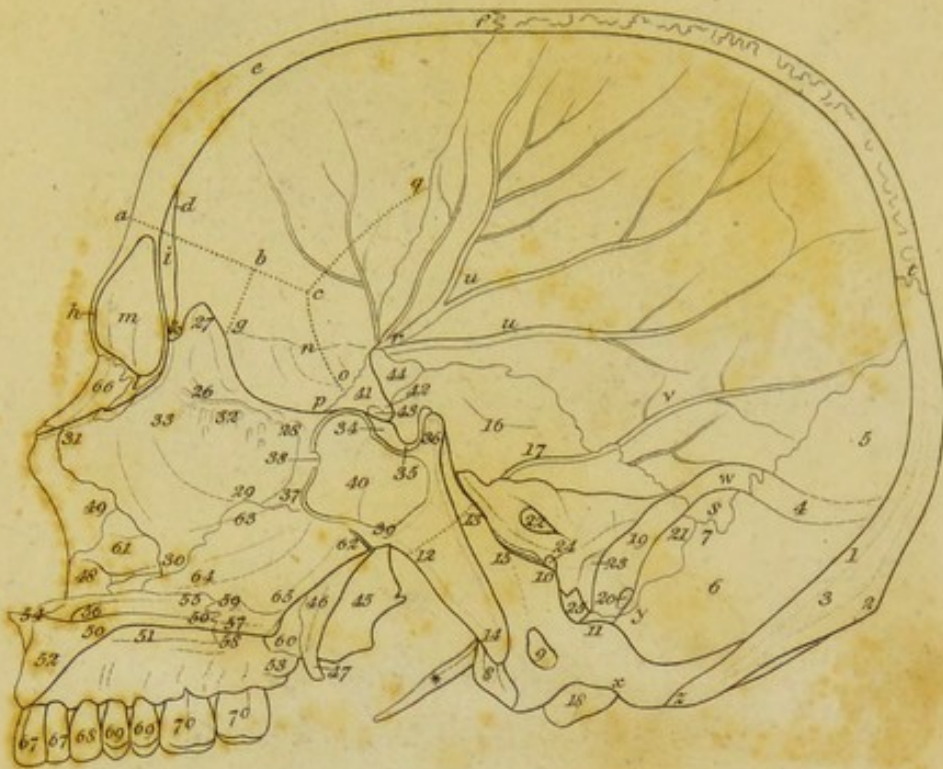


Fig: 2.

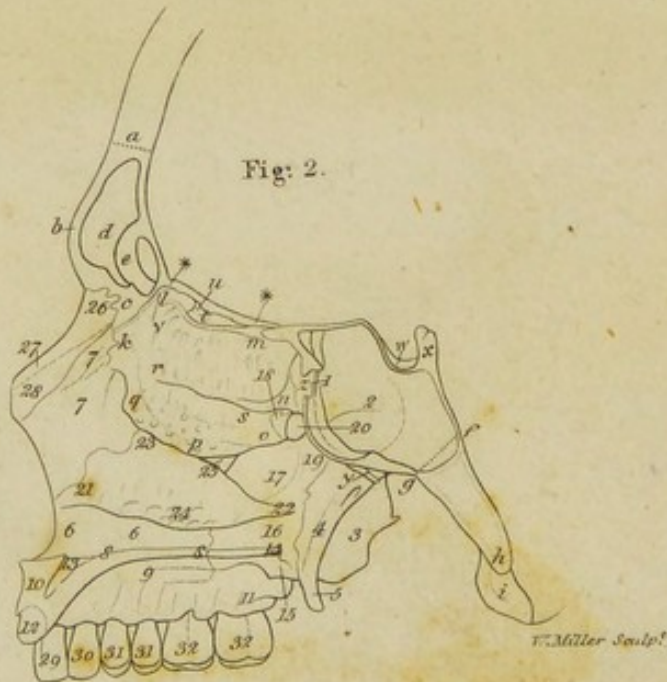
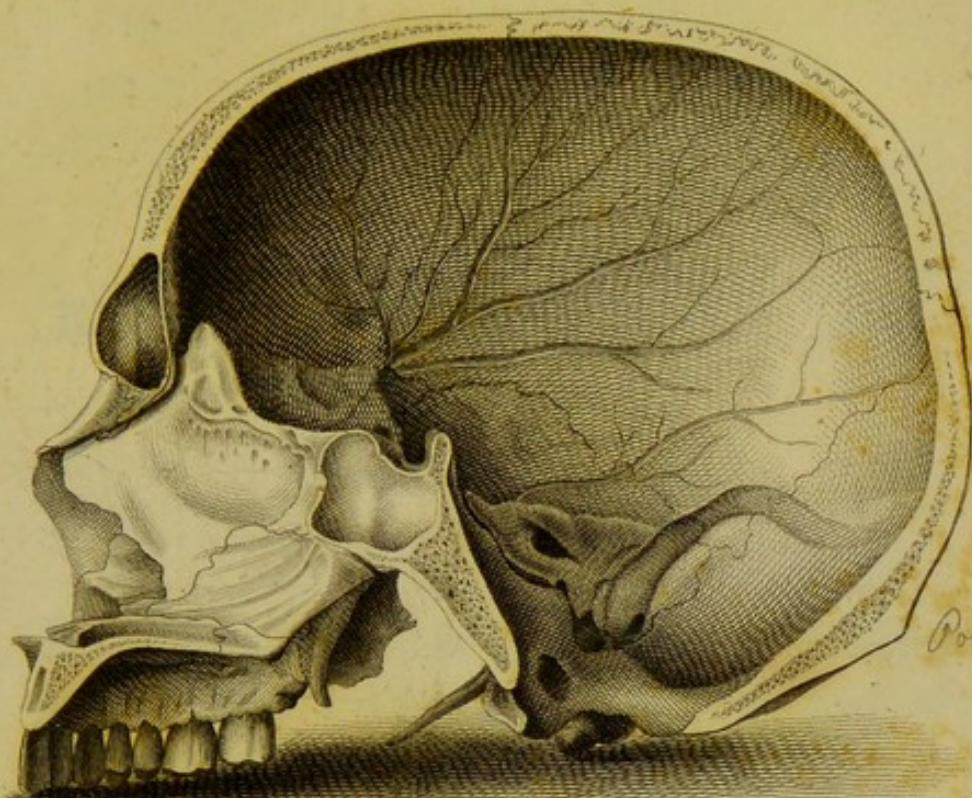
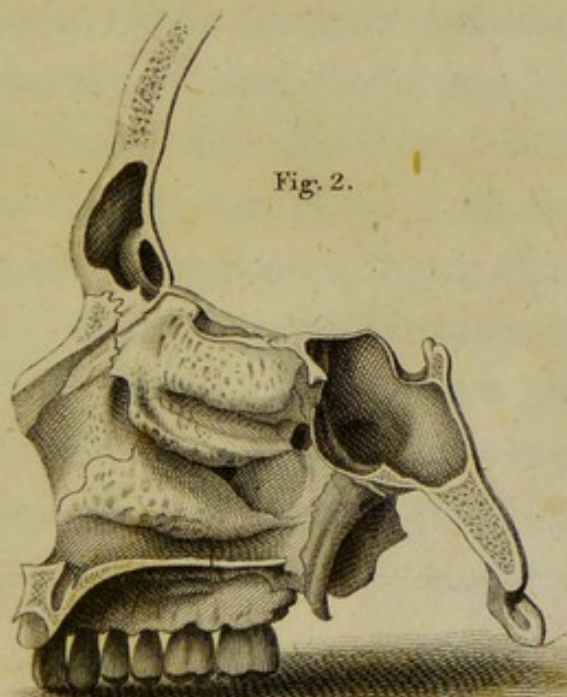


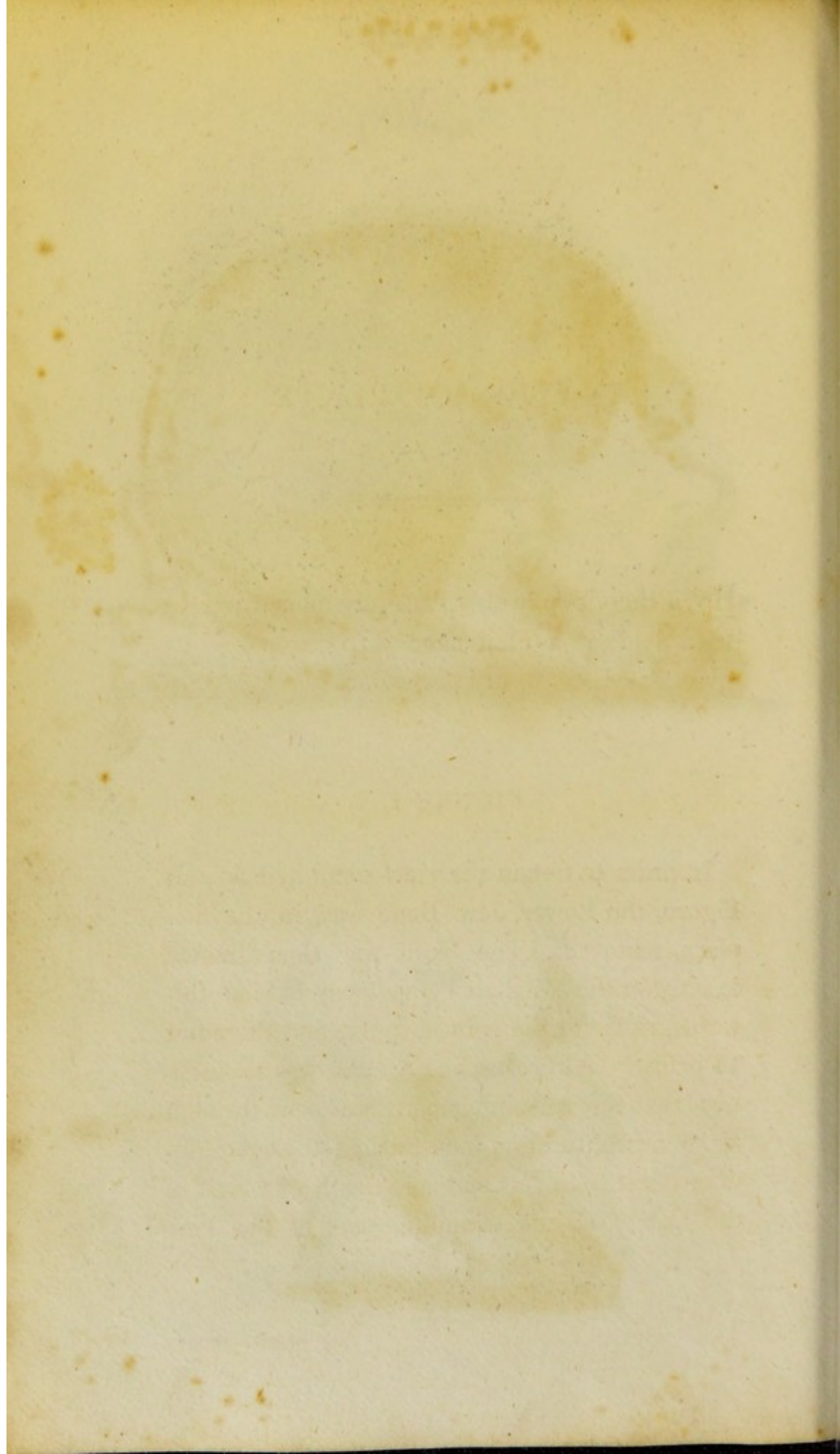
Fig. 1.



Posterior for Aurum

Fig. 2.





EXPLANATION OF PLATE VIII.

BOTH the views in this Plate, are taken from the dried Skull of a Man aged forty, prepared by myself, and still in my possession.

FIGURE 1.

In order to obtain the view exhibited in this Figure, the Lower Jaw Bone was, in the first place, removed. The Skull was then divided exactly in the Median Plane from behind forwards, as far as the point *e* above, and the point 14 below. After this, the Section was so inclined, that the remaining parts were cut through about a twelfth of an inch to the left of the Median Plane. In this manner, the Right Half of the Cavity of the Cranium, part of the Left

Frontal and Sphenoidal Sinuses, and the whole Left Surface of the Osseous Septum of the Nose, have been exposed. A straight line drawn from the point *f* to the point 14, measured in the Preparation five inches and a half.

THE FRONTAL BONE.

The Frontal Part.

a, b, c, Imaginary line bounding this Part below.

d, Top of the Frontal Spine.

e, f, Section in the Median Plane.

e, a, Section to the Left of the Median Plane.

In both parts, the Diploe *e* is very distinct.

The Lower and Middle Part.

g, b, Imaginary line separating this Part from the Inner Surface of the Base of the Malar Process.

h, Section of the Left Superciliary Protuberance.

i, Lower part or root of the Frontal Spine.

k, The Foramen Cœcum.

l, Section of the Nasal Spine, lying betwixt the Nasal Bones before, and the Perpendicular Plate of the Ethmoid Bone behind.

m, Inner or Median Part of the Left Frontal

Sinus. The letter *m* is placed on the middle of the Septum, which separates it from the Right Sinus.

The Malar Process.

n, c, b, g, n, Imaginary line circumscribing the Base of this Process, which forms a part of the Cavity of the Cranium.

The Orbital Process.

o, p, g, n, o, Part of the Superior or Cranial Surface of this Process.

The Temporal Part.

q, c, o, Imaginary line bounding this part before.

THE RIGHT PARIETAL BONE.

r, Anterior Inferior Angle of this Bone.

s, Its Posterior Inferior Angle.

t, Its Posterior Superior Angle.

t, s, Left Limb of the Lambdoid Suture.

t, f, Section of the Sagittal, or Parietal Suture.

u, Depressions corresponding to the larger anterior branch of the Middle Meningeal Blood Vessels.

v, Depressions corresponding to the smaller posterior branches of these Vessels.

w, Inferior Parietal Furrow, lodging a part of the Right Lateral Sinus of the Dura Mater.

THE OCCIPITAL BONE.

The Occipital Part.

x, y, Imaginary line bounding this Part before.

z, t, Section of this Part along the Median Plane.

z, 1, Section of the lower part of the Internal Perpendicular Ridge.

1, t, Section of the upper part of the same Ridge.

2, z, Section of the External Perpendicular Ridge.

2, t, Section of the Occipital Protuberance.

3, Diploe between the two Tables of Compact Substance.

4, Right Half of the Transverse Occipital Furrow.

5, Right Superior Occipital Fossa.

6, Right Inferior Occipital Fossa.

7, Lateral Angle of the Occipital Bone.

The Condyle.

8, Inner Surface of the Right Condyle.

9, Right Anterior Condylloid Hole, which in

this Preparation was a good deal larger than usual.

The Anonymous Process.

- 10, Top of the Right Process of this name.

The Jugular Process.

- 11, Upper and Inner Portion of the Right Process of this name.

The Basilar, or Cuneiform Process.

- 12, 13, Imaginary line separating this Process from the Body of the Sphenoid Bone.

- 14, 12, Section of this Process, made a little to the left of the Median Plane, and exhibiting the Diploe, of which it is chiefly composed.

- 15, Right Half of the Basilar Fossa.

THE RIGHT TEMPORAL BONE.

The Squamous Portion.

- 16, Cerebral Depressions on the Inner Surface of this Portion.

- 17, Depression corresponding to a posterior branch of the Middle Meningeal Artery.

The Mastoid Portion.

- 18, The Right Mastoid Process.

- 19, The Sigmoid Furrow, receiving the Lateral Sinus of the Dura Mater, after it has left the Inferior Parietal Furrow *w*.
20, The Posterior Condylod Hole opening into the lower part of this Furrow.
21, *y*, Suture joining this portion of the Temporal to the Occipital Bone, called the Additamentum of the Lambdoid Suture.

The Petrous Portion.

- 22, Orifice of the Internal Auditory Canal ; in this Preparation rather larger than usual.
23, Outer or Cranial Orifice of the Aqueduct of the Vestibule.
24, Outer or Cranial Orifice of the Aqueduct of the Cochlea.
25, Posterior Foramen Lacerum of the Cranium.
* Styloid Process.

THE ETHMOID BONE.

The Perpendicular Plate.

- 26, 27, 28, 29, 30, 31, 26, View of the Left Surface of this Plate.
27, Left Surface of the Crista Galli.
28, 26, Section of the Left Half of the Cribiform Plate, which is attached to the Perpendicular Plate along this line.

- 29, 28, Border of the Perpendicular Plate, which is joined to the Rostrum 37 of the Sphenoid Bone.
- 30, 29, Border of the Perpendicular Plate, which is joined to the Upper and Anterior Margin of the Vomer.
- 31, 30, Edge of the Perpendicular Plate, which is united to a Plate of Cartilage in the recent Subject.
- 31, 27, Border of the Perpendicular Plate, which is joined to the Nasal Bones below, and to the Nasal Spine 1 of the Frontal Bone above.
- 32, Canaliculated Structure on the Surface of the Perpendicular Plate, through which Twigs of the Olfactory Nerve pass.
- 33, Inner Half of that Opening or Slit formerly pointed out, (Plate VI. Fig. 2. 19,) through which the Nasal Branch of the Ophthalmic Nerve passes from the Cavity of the Cranium into the Cavity of the Nose.

THE SPHENOID BONE.

Its Body.

- 34, The Tubercle, or Processus Olivaris.
- 35, The Sella Turcica,

36, Section of the Left Side of the Perpendicular Plate.

37, The Left Surface of the Rostrum.

38, Inner Half of the Orifice, by which the Left Sphenoidal Sinus communicates with the Upper Meatus of the Nose.

39, Angular Ridge to which the Base of the Vomer is affixed.

40, Perpendicular Section of the Left Sphenoidal Sinus, within a twelfth of an inch of the Septum. The Figure 40 is placed on the middle of this Septum.

The Lesser Wing.

41, Upper Surface of the Right Lesser Wing.

42, Its Corner, called Anterior Clinoid Process.

43, The Foramen Opticum perforating its Basis.

The Large Wing.

44, Inner Surface of the Top of the Right Large Wing.

The Pterygoid Process.

45, External Plate of the Right Pterygoid Process.

46, Internal Plate of this Process.

47, Hamulus of this Plate.

THE UPPER JAW BONES.

The Body.

48, Part of its Inner Surface forming a portion of the Lower Meatus of the Nose.

The Nasal Process.

49, Inner Surface of this Process forming part of the Middle Meatus of the Nose.

The Palatine Process.

50, 50, Section of the Palatine Process of the Left Upper Jaw Bone.

51, Lower Surface of the Palatine Process of the Right Upper Jaw Bone.

The Alveolar Arch.

52, Section of the Left Alveolar Arch, a little to the left of the Median Plane.

53, Posterior extremity of the Right Alveolar Arch.

54, 55, The anterior part of the Nasal Crest.

54, The Anterior Nasal Spine.

56, The Upper Orifice of the Left Ductus Incisivus, or Steno's Duct, or Anterior Palatine Canal.

THE PALATE BONES.

The Palatine Process.

57, 50, Section of this Process in the Left Palate Bone.

58, Lower Surface of this Process in the Right Palate Bone.

59, Posterior part of the Nasal Crest.

The Pterygoid Process.

60, Part of the Inner Surface of this Process of the Right Palate Bone.

THE RIGHT SPONGY BONE.

61, The Inner Surface of the anterior extremity of the Right Spongy Bone.

THE VOMER.

62, 63, 64, 65, Left Surface of this Bone.

63, 62, Its Basis attached to the Sphenoid Bone.

64, 65, Its Lower Margin resting on the Nasal Crest.

65, 62, Its free posterior Margin.

THE LEFT NASAL BONE.

66, Section of the Left Nasal Bone.

THE TEETH.

67, The Two Right Incisors.

68, The Right Dens Cuspidatus.

69, The Two Right Bicuspid Teeth.

70, The Two Right Molares. There was no Dens Sapiientiæ in this Preparation.

FIGURE 2.

After the view in the preceding Figure had been taken, a new Section was made of the same Preparation, beginning at a straight line drawn from *e* to 14, (Fig. 1.) and carried downwards and forwards as much to the right of the Median Plane, as the former Section was to the left. By this means, portions of the Right Sphenoidal and Frontal Sinuses have been exposed, together with the Outer Wall of the Right Cavity of the Nose. The other parts of the Skull, not having been affected by this Section, are left out in the representation.

THE FRONTAL BONE.

The Lower and Middle Part.

a, Imaginary line bounding this Part above.

b, Section of the Right Superciliary Protuberance.

c, Section of the Nasal Spine.

d, Section of the Right Frontal Sinus.

e, *ε*, A large Cell arising from the Inner Wall of the Sinus, and stretching down towards its Orifice. The Section has removed a small part of its Inner Side, so as to open up its Cavity at *ε*. It communicates with the general Cavity of the Sinus below, by a contracted Orifice. These incomplete Cells are very common in the Frontal Sinuses. A front view of one exactly similar to this, may be seen in Plate IX. Fig. 5. i.

The Orbital Process.

***, ***, Edge of this Process on the Right Side, which is joined to the Ethmoid Bone.

THE OCCIPITAL BONE.

f, *g*, Imaginary line separating the Basilar Process from the Body of the Sphenoid Bone.

h, *g*, *f*, Section of the Basilar Process a little to the right of the Median Plane, shewing the Diploe of which it is composed, and also the posterior part of the Sphenoidal

Sinus, which, in this Preparation, extended a short way into it.

i, Inner Surface of the Right Condyle.

THE ETHMOID BONE.

The Right Cellular or Lateral Part.

k, l, m, n, o, p, q, k, The Surface of the Turbinated Plate, which looks towards the Septum of the Nose.

l, m, n, k, l, The upper part of this Plate, on the Surface of which a Canaliculated Structure for receiving the Twigs of the Olfactory Nerve is very distinct.

m, l, Section of the Right Half of the Cribri-form Plate, which joins the Lateral Part to the Perpendicular Plate.

o, p, q, Lower part of the Turbinated Plate.

r, Surface where the upper and lower parts of the Turbinated Plate are united together.

s, r, Fossa or opening leading into the Posterior Cells of the Ethmoid Bone, and separating the upper and lower parts of the Turbinated Plate from each other.

The Cribriform Plate.

t, Small part of the Upper Surface of the Right Half of this Plate.

u, The Inner or Cranial Orifice of a Hole or

Canal leading from the Orbit, and called the Anterior Internal Orbital Hole. It is formed by the junction of the Ethmoid Bone with the Orbital Process of the Frontal. It transmits from the Orbit the Nasal Branch of the Ophthalmic Nerve.

- v, The Outer Side of the Slit or Opening, by which the Nasal Branch of the Ophthalmic Nerve descends into the Cavity of the Nose. The Inner Wall of this Slit, on the Left Side, was seen in Fig. 1, No. 33.

THE SPHENOID BONE.

Its Body.

- w, Right Side of the Sella Turcica.
- x, Section of the Right Side of the Perpendicular Plate.
- y, The Right Vaginal Process.
- z, Portion joined to the Ethmoid Cells.
- 1, Section of the Orifice of the Right Sphenoidal Sinus.
- 2, Section of the Right Sphenoidal Sinus.

The Right Pterygoid Process.

- 3, Its External Plate.
- 4, Its Internal Plate.
- 5, The Hamulus of this Plate.

THE RIGHT UPPER JAW BONE.

Its Body.

- 6, 6, Surface forming part of the Lower Meatus of the Nose.

The Nasal Process.

- 7, 7, Inner Surface of this Process.

The Palatine Process.

- 8, 8, Section of this Process.
9, Lower Surface of this Process.

The Alveolar Arch.

- 10, Section of this Arch, between the Two Incisor Teeth.
11, Posterior extremity of this Arch.
12, Section of the Socket of the Middle Incisor Tooth.
13, Outer Side of the Right Ductus Incisivus.

THE RIGHT PALATE BONE.

The Palatine Process.

- 14, 8, Section of this Process.
15, Little Crest on its Lower Surface, to which the Circumflex Muscle of the Palate is affixed,

The Nasal or Perpendicular Process.

- 16, Part of the Inner Surface of this Process, looking towards the Lower Meatus of the Nose.
- 17, Part of the Inner Surface of this Process, looking towards the Middle Meatus of the Nose.
- 18, Small part of the Orbital Process arising from the Top of the Nasal Process.
- 19, Inner Surface of the Sphenoidal Process also arising from the Nasal Process, and separated from the Orbital Process by the Spheno-Palatine Hole.

The Spheno-Palatine Hole.

- 20, A view of this Hole from the Cavity of the Nose. It is formed by the Orbital and Sphenoidal Processes of the Palate Bone, and by the Body of the Sphenoid. It leads from the Pterygo-Palatine Fossa without, into the Cavity of the Nose, and transmits into that Cavity the Nasal Branches of the Superior Maxillary Nerve, together with Twigs of the Internal Maxillary Artery and Vein.

THE RIGHT SPONGY BONE.

- 21, 22, 23, Convex Surface of this Bone, turned towards the Septum of the Nose.
24, Its Lower, Rough, Cellular Border.

Orifice of the Maxillary Antrum.

- 25, Small part of this Orifice seen between the Spongy Bone below, the Turbinated Plate of the Ethmoid above, and the Nasal Plate of the Palate Bone behind.

THE RIGHT NASAL BONE.

- 26, 27, Section of this Bone.
28, Part of its Inner Surface.

THE TEETH.

- 29, Lateral Incisor.
30, Dens Cuspidatus.
31, The Two Bicuspid Teeth.
32, The Two Molares.
-




Fig. 1.

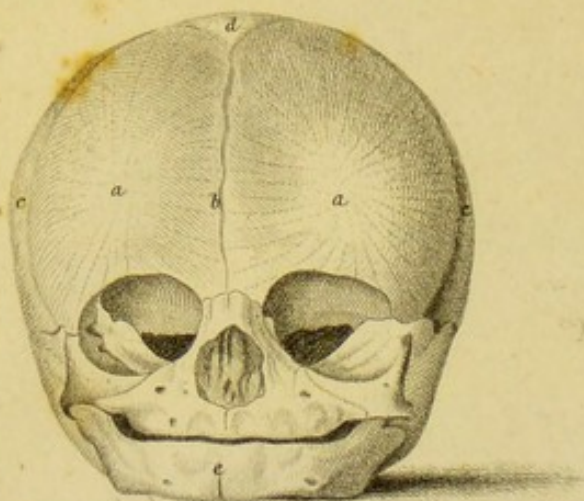


Fig. 2.

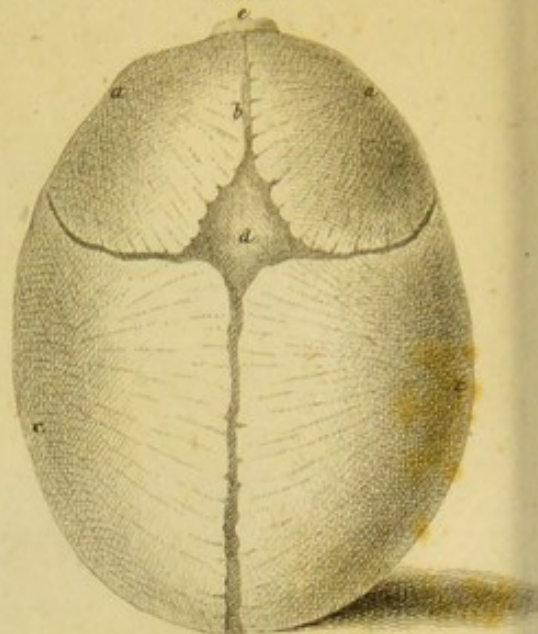


Fig. 3.

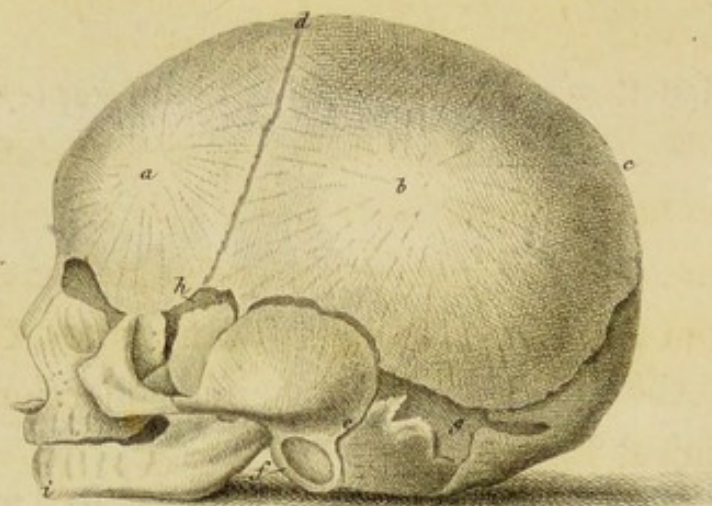
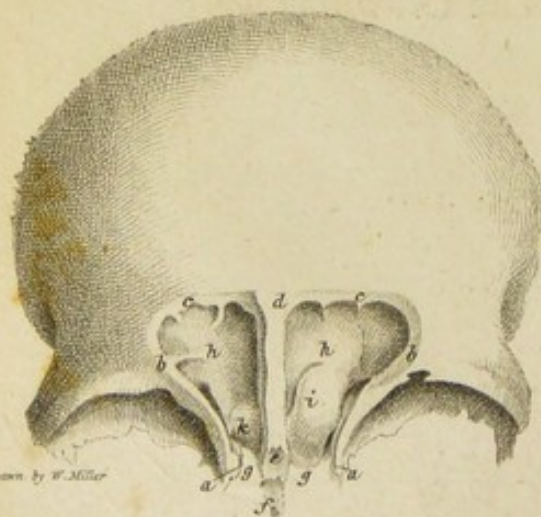
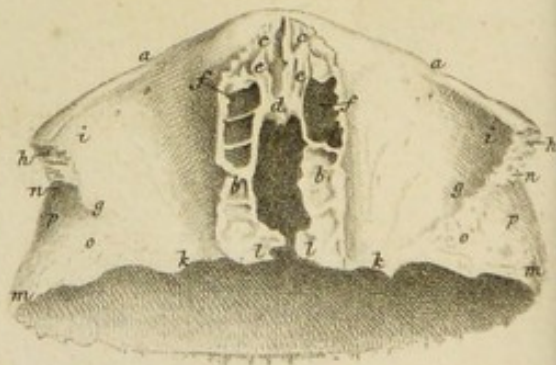


Fig. 4.



Drawn by W. Miller

Fig. 5.



Drawn & Engraved by W. & A. Lister.

EXPLANATION OF PLATE IX.

THE first three Figures of this Plate, represent the Skull of a Foetus at the period of Birth, viewed from before, from above, and from the side. They are reduced copies of Representations taken from nature by MARCUS and FLORIAN CALDANI, to be found in their splendid collection of Anatomical Engravings.*

The two other Figures are intended to illustrate the Anatomy of the Frontal Sinuses. They are taken from Preparations made by myself, and still in my possession. The Drawings were executed by MR. MILLER.

* Icones Anatomicæ, folio, Venice, 1801.

FIGURE 1.

Is a front view of the dried Foetal Skull at Birth. A straight line drawn from *c* to *c*, measures on an average, from three and a quarter to three and a half inches.

a, The Point of Ossification, or Frontal Protuberance, in each Half of the Frontal Bone.

b, Unossified line separating the Two Halves of the Frontal Bone from each other, and ending above in the Anterior Superior Fontanelle. The Edges of the Two Halves are in close contact below, but they are separated by a line of Membrane above.

c, The Parietal Protuberance on each Side.

d, The Unossified Space occupied by Membrane in the recent Subject, denominated the Anterior Superior Fontanelle.

e, Unossified Line, called the Symphysis of the Chin, separating the Two Halves of the Lower Jaw Bone from each other.

FIGURE 2.

Is a view of the same Skull from above.

a, b, c, and d, Refer to the same parts as in the last Figure.

e, The Nasal Bones.

FIGURE 3.

Is a view of the same Skull from the left Side. A straight line drawn from *c* to *i* measures on an average five inches.

a, The Frontal Protuberance.

b, The Parietal Protuberance.

c, Upper extremity of the longest diameter of the Skull *c, i*, which measures on an average five inches.

d, The Anterior Superior Fontanelle.

e, Unossified line separating the Squamous and Mastoid Portions of the Temporal Bone from each other.

f, Annulus Tympani, occupying the place of the External Auditory Canal.

g, Unossified Space, partly Cartilaginous, partly Membranous, denominated the Posterior Lateral Fontanelle.

h, Unossified Membranous Space, called the Anterior Lateral Fontanelle.

i, The Chin; from which, to the point *c*, is the longest diameter of the Skull,

FIGURE 4.

Is a view from before of the dried Frontal Bone of a Man aged thirty, with part of the Anterior Wall of the Frontal Sinuses removed, in order to display these Cavities.

a, b, c, d, The cut edge of the portion of the Anterior or Outer Wall of the Sinuses which has been removed,

d, e, The Septum between the Sinuses, no part of which has been removed.

f, The Nasal Spine.

g, The Opening leading into the Sinuses on each Side.

h, The Inner Wall of each of the Sinuses.

i, Incomplete Cell, arising from the Inner

Wall of the Left Sinus, and having an Opening below, which is not seen.
k, Lesser Cell of this kind in the Right Sinus.

FIGURE 5.

Is a view from below of the dried Frontal Bone of a Man aged thirty, shewing the Openings leading into the Frontal Sinuses. From *h* to *h* in the Preparation measured four inches.

Lower and Middle Part of the Bone.

a, b, Boundary between this Part and the Orbital Processes.

c, c, Serrated Semilunar Surface of the Nasal Process, to which the Nasal Bones are joined.

d, Process called the Nasal Spine projecting from this Surface.

e, Narrow Groove on each Side of this Spine,

forming part of the Roof of the Cavity of the Nose.

f, Opening into the Frontal Sinus on each side.

The Malar Processes.

g, a, Boundary between the Lower Surface of the Malar Processes and the Orbital Processes.

h, The Apex of the Malar Processes.

i, The Lachrymal Fossa on the Lower Surface of these Processes, for lodging the Lachrymal Gland.

The Orbital Processes.

k, l, b, a, g, k, Lower Surface of these Processes.

k, g, Boundary between them and the Temporal Parts of the Bone.

l, b, d, b, l, The Ethmoidal Opening.

The Temporal Parts.

m, n, g, k, m, Part of the Outer Surface of these Parts.

o, Triangular Rough Surface, by which they are joined to the Large Wings of the Sphenoid Bone.

p, Portion of these Parts giving attachment to the Temporal Muscle, and forming part of the Temporal Fossa of the Cranium.

a. Triangular Rough Surface, by which they are joined to the Large Wings of the Sphenoid Bone.
 b. Portion of these Parts giving attachment to the Temporal Muscle, and forming part of the Temporal Fossa of the Cranium.

The Malar Process.

- a. Boundary between the Lower Surface of the Malar Process and the Orbital Process.
- b. The Apex of the Malar Process.
- c. The Lacrymal Fossa on the Lower Surface of these Processes, for lodging the Lacrymal Gland.

The Orbital Process.

- a, b, c, d, e, f, g, h. Lower Surface of these Processes.
- i, j, k. Boundary between them and the Temporal Part of the Bone.
- l, m, n, o, p. The Orbital Opening.

The Temporal Part.

- q, r, s, t, u, v, w, x. Part of the Outer Surface of these Parts.




Fig. 1.

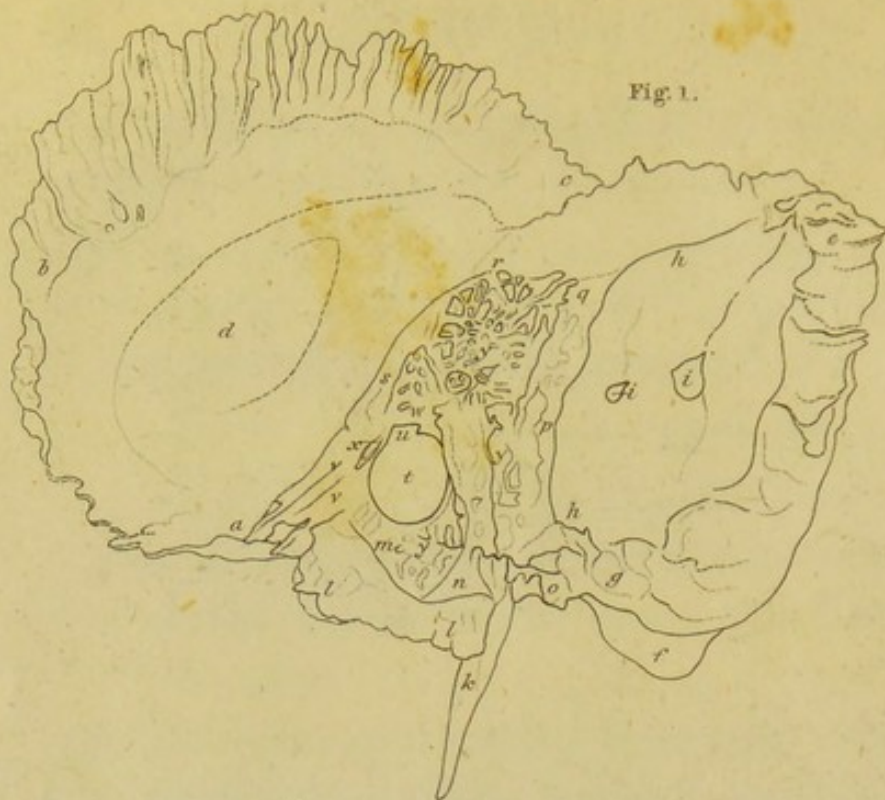

Fig. 2.

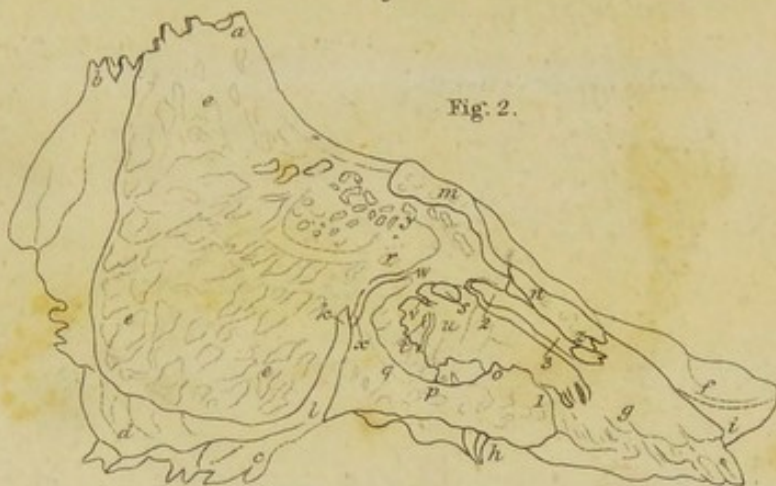
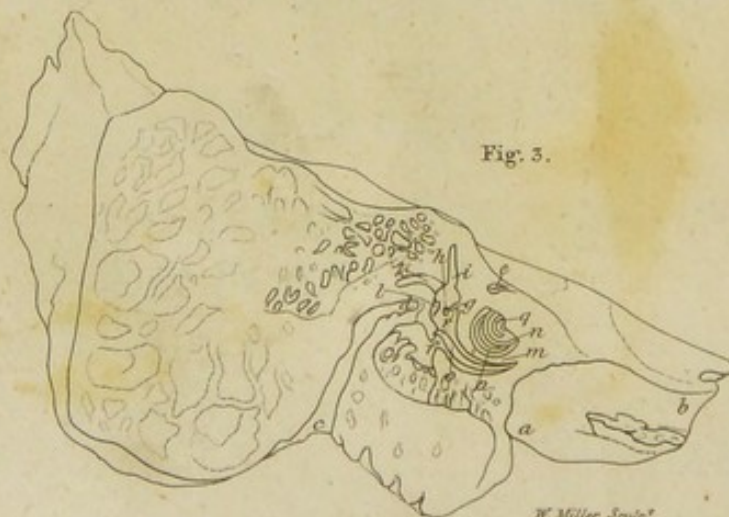
Fig. 3.



W. Miller Sculp.

Fig. 1.

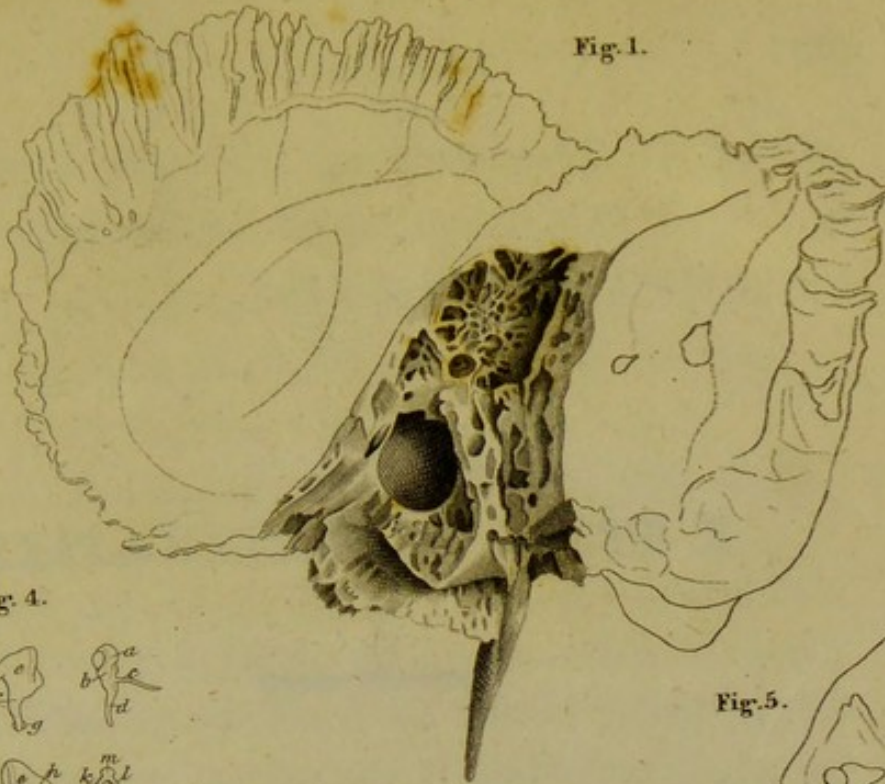


Fig. 4.

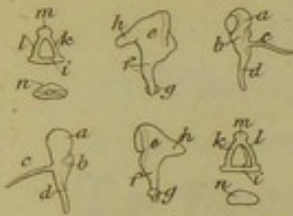


Fig. 5.

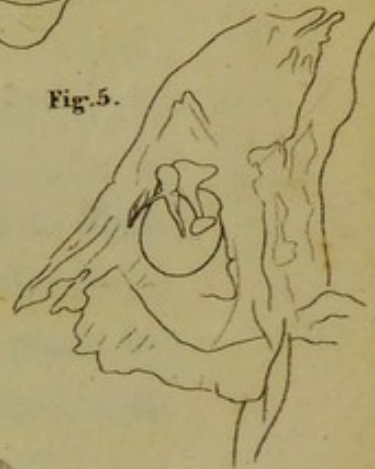

Fig. 2.

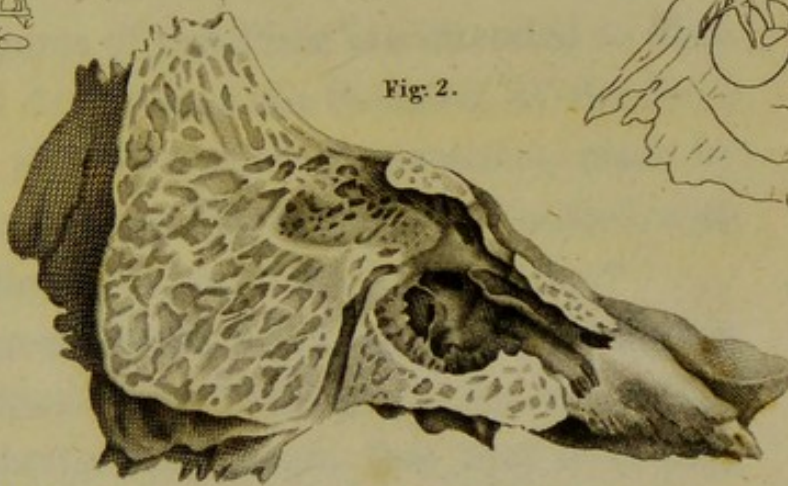


Fig. 6.

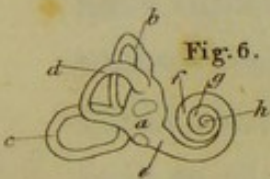


Fig. 3.

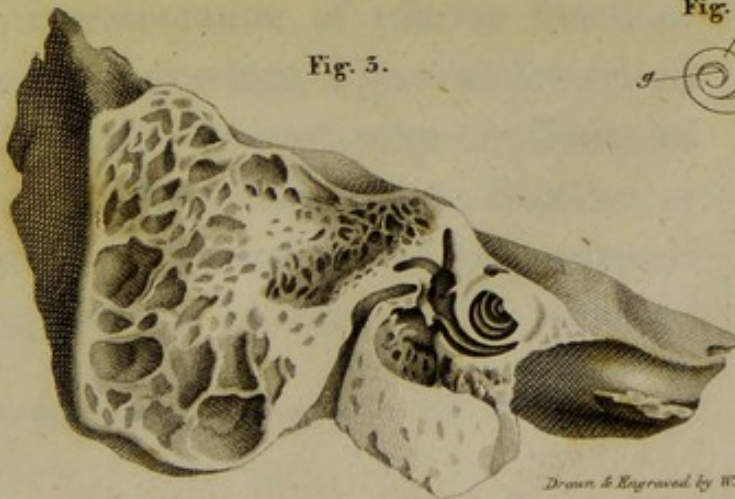
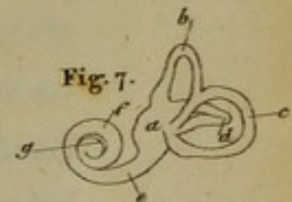
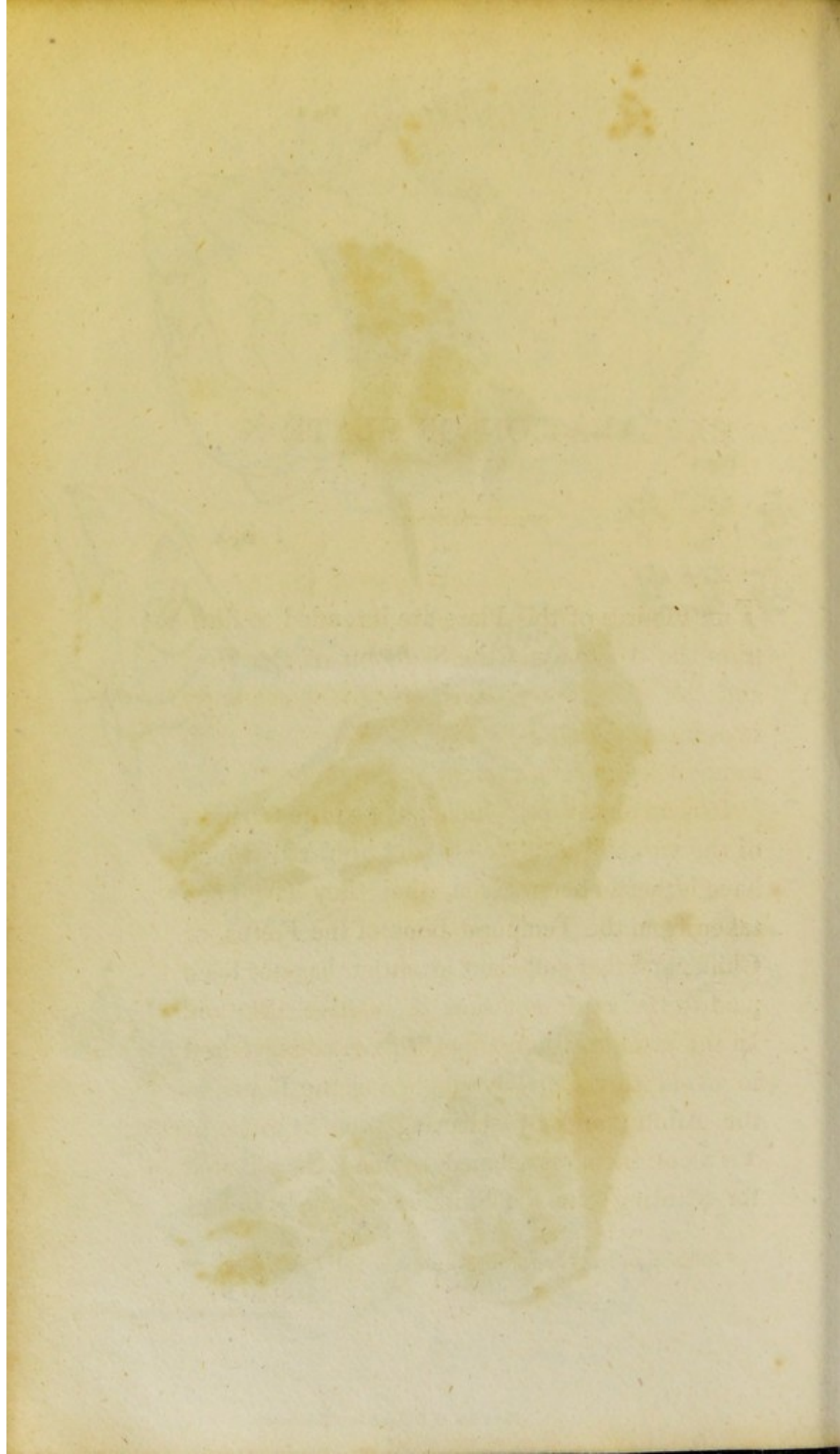


Fig. 7.



Drawn & Engraved by W. Miller.



EXPLANATION OF PLATE X.

THE Figures of this Plate are intended to illustrate the Anatomy of the Skeleton of the Ear; and are all taken from Preparations made by myself, excepting Figure 4, which is copied, with some little alteration, from SOEMMERING.*

It is an objection, which may be urged to most of the views of the Skeleton of the Ear which have hitherto been given, that they have been taken from the Temporal Bone of the Foetus, or Child; and that sufficient attention has not been paid to the representation of relative Position. In the present Engravings, I have endeavoured to avoid this fault, by employing the Bones of the Adult; and by selecting such Sections or Views of them, as seemed to me best adapted for pointing out the Situation of the different

* Abbildungen des Menschlichen Hoerorganes. Fol. Franc. 1806.

parts of the Tympanum and Labyrinth, as well as their Form and Structure. All the parts are represented of their natural size.

FIGURE 1.

Exhibits a view from within, of the Right Temporal Bone of a Man aged 30; the Petrous Portion having been cut away from the Squamous and Mastoid Parts, by a Section passing through its Basis from before backwards. Its object is to display the parts which form the Outer Wall of the Tympanum.

The Squamous Portion.

a, b, Part of the Margin of this Portion, which is joined to the Large Wing of the Sphenoid Bone.

b, c, Part of the Margin of this Portion, which is joined to the Lower Border of the Parietal Bone.

d, Internal or Cranial Surface of this Portion, corresponding to the Outer Surface of the Middle Lobe of the Great Brain, or Brain Proper.

The Mastoid Portion.

e, g, Margin of this Portion, which is joined to the Occipital Bone.

f, Inner Surface of the Mastoid Process.

h, h, Sigmoid Furrow, lodging a part of the Lateral Sinus of the Dura Mater.

i, i, Inner Orifice of two Mastoid Foramina.

The Petrous Portion.

k, The Styloid Process.

l, l, The Vaginal Process.

m, n, o, p, q, r, s, a, m, Outline of the Section, by which this Portion was separated from the Squamous and Mastoid Portions. All parts of this Section lie in the same plane.

Parts relating to the Ear.

t, The Inner Orifice of the External Auditory Canal viewed from the Tympanum, through which is seen part of the Inner and Lower Surface of the Canal itself.

u, Notch in this Orifice, opposite to which is placed the Neck of the Tympanal Bone called Malleus. This Notch, which appears to have escaped the notice of Anatomists, is sometimes curved, sometimes

angular; but most commonly it has the Form represented in the Figure.

v, v, The Outer Wall or Side of the Eustachian Canal, which extends from the Tympanum forwards, and a little downwards and inwards towards *a*.

w, A smooth flat Surface, to which the Head of the Malleus, and the Body, and Short Leg of the Incus, are affixed. (See Figure 5.)

x, A Small Hole, or Short Oblique Canal, called the Glaserian Fissure, which leads from the Tympanum downwards and forwards, and opens externally in the middle of a Groove behind the Glenoid Cavity. Through this Fissure, the Nerve called Chorda Tympani passes.

y, y, y, Cells which communicate with each other, and with the Tympanum. These vary in their number and their size very much. Sometimes the Bone is quite solid below the Inner Orifice of the External Auditory Canal.

FIGURE 2.

Represents the appearance of the Inner Wall of the Tympanum, and the parts connected with it. In order to obtain this view, the Right Temporal Bone was divided from behind forwards, in a plane passing through the Inner Orifice of the External Auditory Canal.

The Mastoid Portion.

- a, b, c*, Margin of this Portion, joined to the Parietal Bone from *a* to *b*, and to the Occipital from *b* to *c*.
- d*, Inner Side of the Digastric Fissure.
- e, e, e*, Section of the Mastoid Cells, which all communicate with each other, and with the Tympanum at *y*, by a large Opening.

The Petrous Portion.

- f*, Semilunar Depression on the Upper Surface of this Portion near the Apex, on which the Trigeminal Nerve rests, just before it expands into the Glaserian Ganglion.
- g*, Part of the Anterior Surface of this Portion, which forms with the Lower Margin of the Squamous Portion, the Angular Notch

of the Temporal Bone, which receives the Spinous Process of the Sphenoid.

h, The Lower Orifice of the Carotid Canal.

i, The Upper Orifice of the Carotid Canal.

k, l, The Inner Side of the Lower End of the Fallopiian Aqueduct, through which the Facial Nerve passes. At *k*, it is seen coming out from the parts of the Bone placed more interiorly; and at *l*, it opens externally by the Stylo-Mastoid Hole.

Parts relating to the Ear.

m, n, o, p, q, r, m, The Outline of the Tympanum.

s, The Fenestra Ovalis, or Oval Hole, leading from the Tympanum to the Vestibule of the Labyrinth, and in which the Basis of the Stapes is lodged.

t, The Fenestra Rotunda, or Round Hole, leading from the Tympanum into the Tympanal Scala of the Cochlea.

u, Rounded Eminence called the Promontory, which corresponds to a recess in the Labyrinth, and of which a Ridge running backwards, separates the Oval and Round Fenestræ from each other.

v, Fine Spicula of Bone, which often stretches across the Hollow which is seen behind the

Promontory, and is affixed to the Posterior Wall of the Tympanum.

w, x, Section of a small Canal, communicating at *w* with the Tympanum, and at *x* with the Fallopian Aqueduct. It lodges the little Nerve, called Chorda Tympani, during part of its course.

y, Section of the Opening of the Mastoid Cells into the Tympanum.

z, 1, o, n, Section of the Eustachian Canal; *z, 1*, being its anterior end, and *o, n*, its posterior, or that by which it communicates with the Tympanum.

2, 3, A Shelf of Bone, attached to the Upper Part of the Inner Wall of the Eustachian Canal, which lodges the small Muscle called Tensor Tympani. The posterior extremity of this Shelf extends backwards into the Tympanum, to above the anterior end of the Oval Fenestra.

FIGURE 3.

Is a view of the Labyrinth laid open on the fore part, and is obtained by filing down the parts represented in the former Figure to a level with the Oval Fenestra; excepting at the space

m, q, where the Section has been made to follow the natural elevation of the Cochlea.

The Petrous Portion.

a, b, Inner side of the Carotid Canal.

c, d, e, Section of the Fallopian Aqueduct :

c being its Opening externally at the Stylo-Mastoid Hole ; *d* the Point at which the Section has cut it off, as it was coming from above the Oval Fenestra ; and *e* a Section of it, just where extending from the bottom of the Internal Auditory Canal in a direction forwards and a little inwards, it makes a sudden turn outwards and backwards over the Fenestra Ovalis. It is at this point *e*, that it is joined by the Vidian Canal on the fore part.

Parts relating to the Ear.

f, A Section of the Fenestra Rotunda, or Round Hole, shewing its communication with the Lower or Tympanal Scala of the Cochlea.

g, A little Conical Spine of Bone projecting backwards into the Vestibule, called the Cribriform Spine, Spina Eminens, Pyramis Ossea, or Pyramis. It is perforated over

its whole Surface, with very minute Holes, which transmit delicate Twigs of the Auditory Nerve.

h, Inner Orifice of the Canal, called Aqueduct of the Vestibule, situated about the middle of the Inner Wall of the Vestibule, and immediately anterior to the common Opening of the Superior and Posterior Semicircular Canals. The Outer or Cranial Orifice of this Canal has already been represented in Plate VI. Fig. 2, 14; and in Plate VIII. Fig. 1, 23.

i, Anterior Extremity of the Superior or Vertical Semicircular Canal.

k, Anterior Extremity of the External or Horizontal Semicircular Canal.

l, The common Opening, or Termination of the Superior and Posterior Semicircular Canals, in the middle of the inner and back part of the Vestibule.

m, n, The Osseous Septum intervening between the Turns or Gyri of the Cochlea; *m* being the Portion which separates the first from the second; and *n* the second from the third Turn or Gyrus.

o, p, q, The Lamina Spiralis, or Spiral Plate of the Cochlea, separating the whole Canal of the Cochlea into two Compartments

or Scalæ, of which the lower is called the Scala Tympani, and the upper the Scala Vestibuli. It begins immediately above the Fenestra Rotunda of the Tympanum *f*, over which it extends like a Roof. It enters the Canal of the Cochlea at *o*; at *p* it is seen in the Second Gyrus; and at *q* it terminates in the last Gyrus, in a little pointed Process called its Hamulus, or Rostrum.

1, The Lower and Anterior Part of the Vestibule, from which the Vestibular Scala, or Compartment of the Cochlea, may be considered as taking its origin; while the Tympanal Scala arises from the Fenestra Rotunda of the Tympanum at *f*.

FIGURE 4.

Exhibits two outline views of the Tympanal Bones of the right Ear in their unconnected state. In the first line, the Malleus and Incus are represented as seen from without, and the Stapes as seen from below in the upper outline, and fore-shortened from its head to its base in the lower. In the second line, the representations are just the reverse. The Malleus and In-

cus are seen from within, and the Stapes from above in the upper outline, while the lower exhibits a view of its base.

THE MALLEUS.

- a*, Its Head.
- b*, Its Neck.
- c*, Its Slender Process.
- d*, Its Manubrium, or Handle.

THE INCUS.

- e*, Its Body.
- f*, Its Long Leg.
- g*, The Orbicular Process.
- h*, The Short Leg.

THE STAPES.

- i*, The edge of its Base.
- k*, Its Anterior Leg.
- l*, Its Posterior Leg.
- m*, Its Head.
- n*, Its Base.*

* In the fore-shortened view of the Stapes in the upper line, the Head of the Bone is represented a good deal too small.

FIGURE 5.

Is a view, in outline, of the Tympanal Bones of the right Ear from within, shewing them in their relative position with respect to each other, and in their connection with the outer wall of the Tympanum. The portion of the outer wall of the Tympanum represented in this Figure, corresponds exactly to that in Figure 1.; and does not, therefore, require any additional explanation. The Slender Process of the Malleus will be observed running forwards into the Glaserian Fissure.

FIGURES 6. and 7.

By pouring a quantity of fusible metal, or of melted lead, into the Labyrinth, and, after it has cooled, filing away the Bone, a cast is obtained of the Cavities of the Vestibule, Semicircular Canals, and Cochlea, which is of no inconsiderable use in the study of the relative position of these parts. From such a cast of the Labyrinth of the right Ear, which is still in my possession, these outline views were taken. In Figure 6.

the Labyrinth is represented as seen from without; and in Figure 7. as seen from within. It may be useful to compare Figure 6. with the view given in Figure 3.

a, The Vestibule.

b, The Superior, or Vertical Semicircular Canal.

c, The Posterior or Oblique Semicircular Canal.

d, The External or Horizontal Canal.

e, f, The first Gyrus or Turn of the Cochlea.

f, g, The second Gyrus.

g, h, The third Gyrus. The wide space intervening between the first part of the second Turn before, and the Vestibule and commencement of the first Turn behind, does not seem to me to have been hitherto represented by Anatomists. It is occupied by solid bone, which gradually passes into the Osseous Septum *m*, Fig. 3.

the Labyrinth is represented as seen from within; out; and in Figure 7, as seen from within. It may be useful to compare Figure 6, with the view given in Figure 3.

a. The Vestibule.

b. The Superior or Vertical Semicircular Canal.

c. The Posterior or Oblique Semicircular Canal.

d. The External or Horizontal Canal.

e. The first Gyrus or Turn of the Cochlea.

f. The second Gyrus.

g. The third Gyrus. The wide space intervening between the first part of the second Turn before, and the Vestibule and commencement of the first Turn behind, does not seem to me to have been hitherto represented by Anatomists. It is occupied by solid bone, which gradually passes into the Ossicle Septum at Fig. 3. joined by

and it will be observed that the first Turn behind

between the first and second Turns, and the

between the first and second Turns, and the

between the first and second Turns, and the

between the first and second Turns, and the

between the first and second Turns, and the

between the first and second Turns, and the

between the first and second Turns, and the

between the first and second Turns, and the

between the first and second Turns, and the

between the first and second Turns, and the

between the first and second Turns, and the


between the first and second Turns, and the

between the first and second Turns, and the

between the first and second Turns, and the

between the first and second Turns, and the

between the first and second Turns, and the



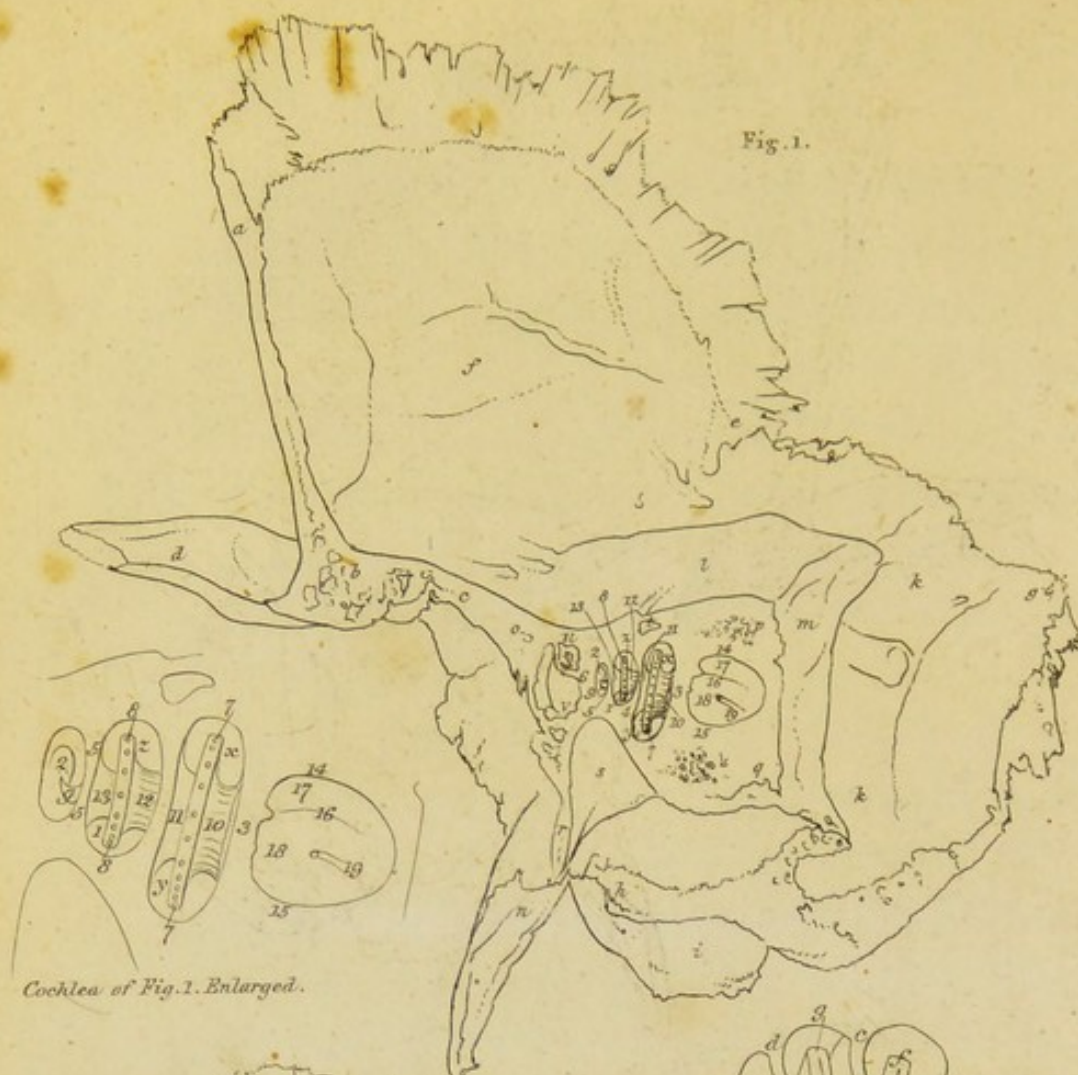
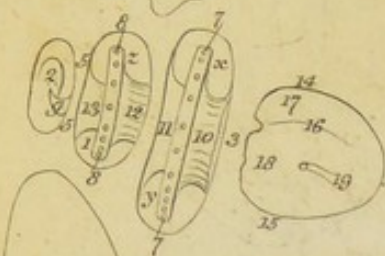


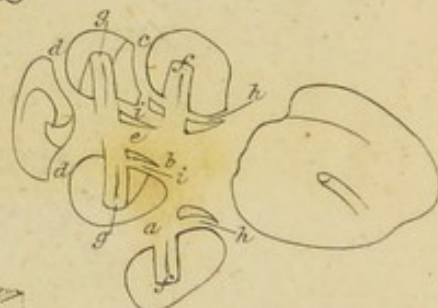
Fig. 1.



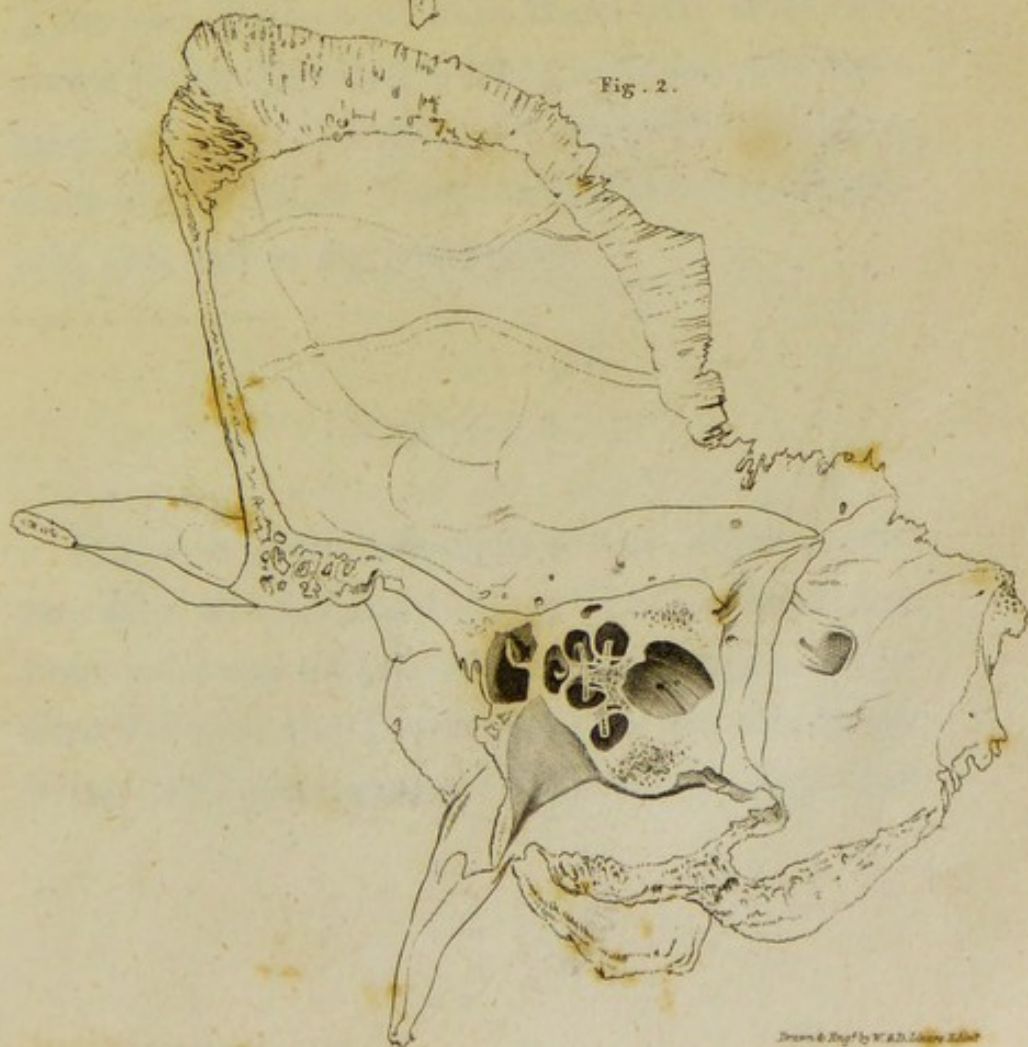
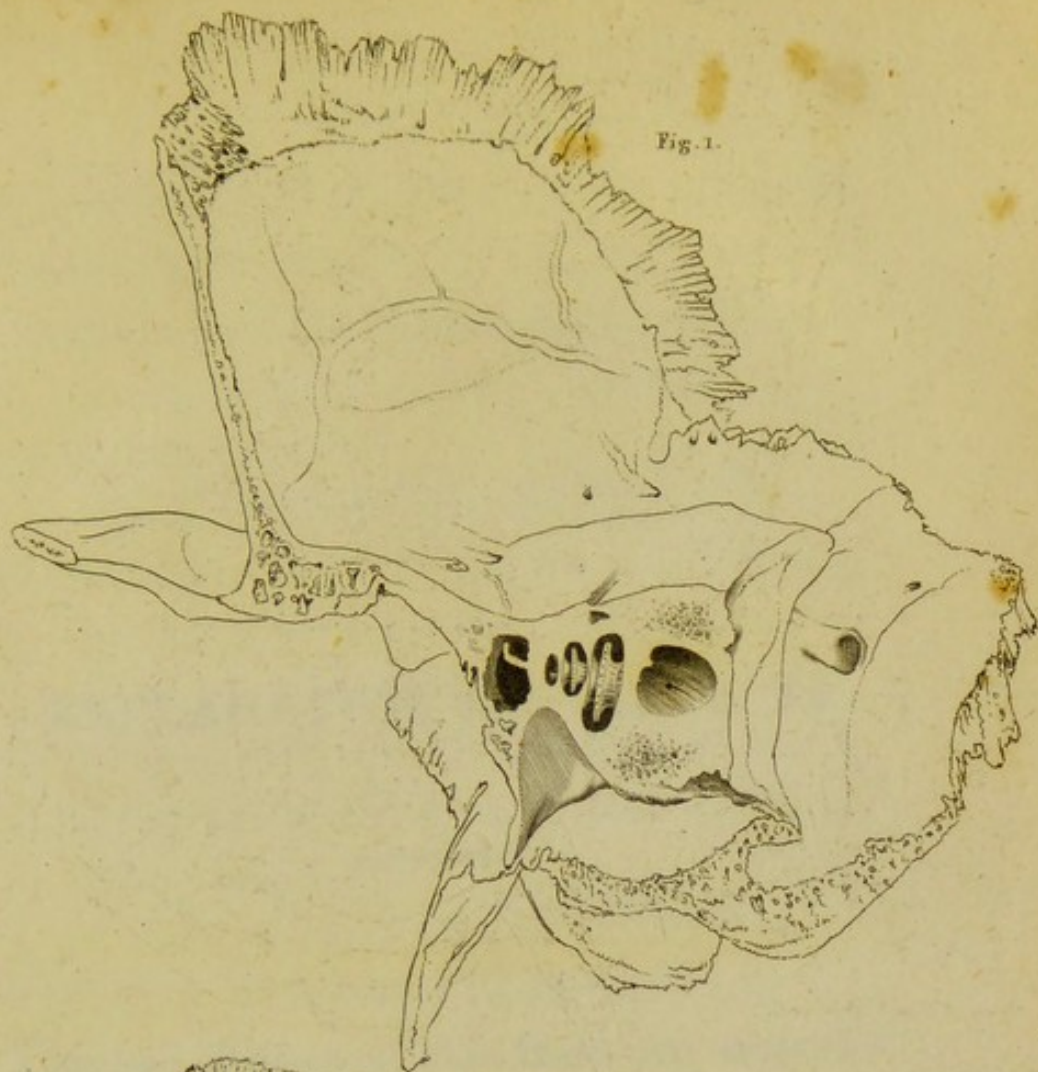
Cochlea of Fig. 1. Enlarged.

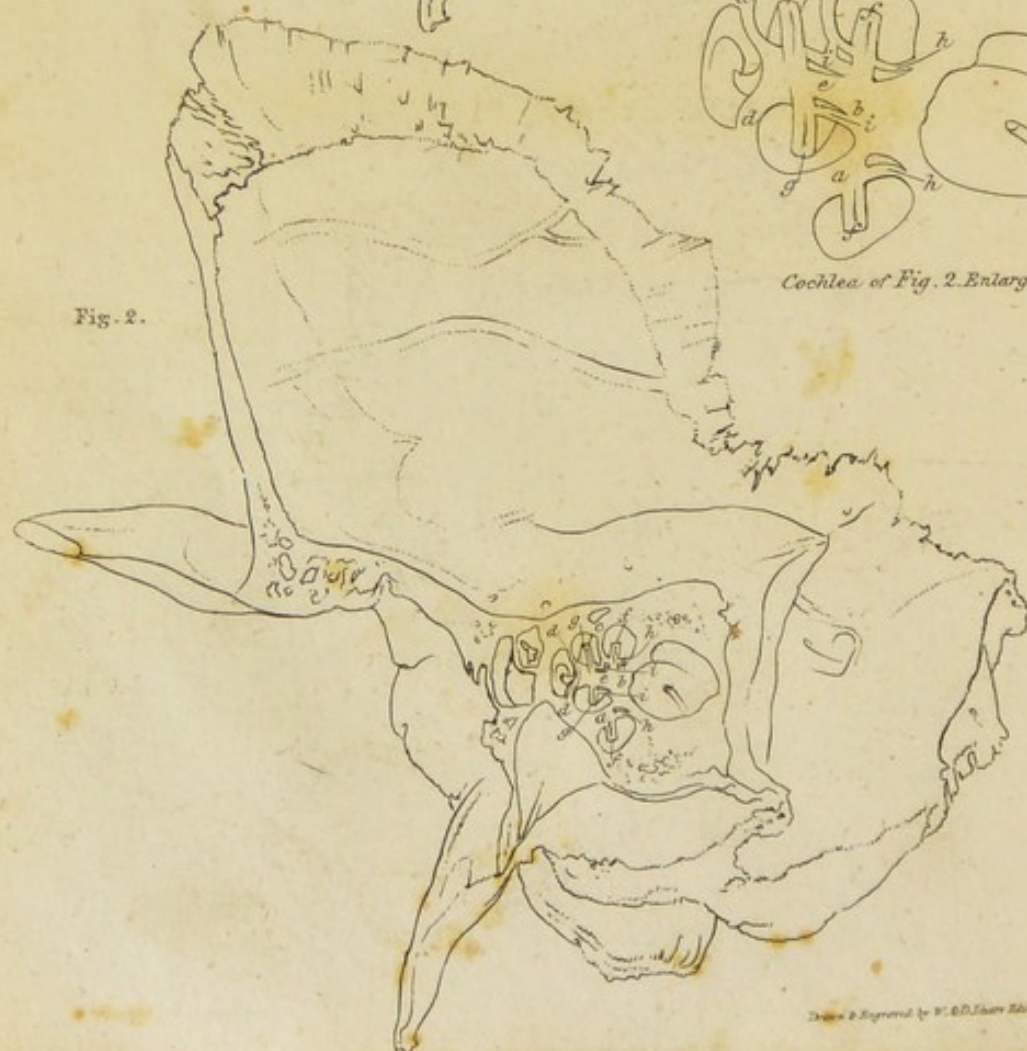


Fig. 2.



Cochlea of Fig. 2. Enlarged.



Drawn & Engr'd by W. A. D. Lillie Esq.



EXPLANATION OF PLATE XI.

THE two Figures of this Plate are magnified views of the Skeleton of the Cochlea; and have been executed with great accuracy from Preparations of the Adult Temporal Bone made by myself, and still in my possession.

FIGURE 1.

Is a view of the Skeleton of the Right Cochlea, after about a third of its Wall or Shell has been cut away on the side next the Apex of the Pars Petrosa; the Lamina Spiralis and Modiolus being left quite entire. The whole Temporal

Bone has been cut across in the Plane of this Section of the Cochlea. In the Preparation, the space from *q* to *r* measured three-fourths of an inch.

The Squamous Portion.

- a, b, c*, Section of this Portion, *b* being a Section of the Tuber Articulare.
- d*, The Zygomatic Process.
- e, a*, Margin joined to the Parietal Bone.
- f*, Inner Surface of this Portion.

The Mastoid Portion.

- g, e*, Margin of this Portion joined to the Parietal Bone.
- h, g*, Margin joined to the Occipital Bone.
- i*, The Mastoid Process.
- k*, The Sigmoid Furrow.

The Petrous Portion.

- l*, Upper Surface of this Portion.
- m*, Posterior Surface of this Portion.
- n*, The Styloid Process.
- o, p, q, r*, Section of the Petrous Portion.
- s*, Section of the Lower Part of the Carotid Canal.
- t*, Section of the Vidian Canal in its progress towards the Fallopian Aqueduct.

Parts relating to the Ear.

u, v, Section of the Eustachian Canal, close to its Termination in the Tympanum.

w, Section of the Shelf in that Canal, for the Tensor Tympani Muscle.

x, y, Section of the First Gyrus or Turn of the Cochlea; *x* being the Tympanal or Lower Scala of this Turn, and *y* the Vestibular Scala.

z, 1, Section of the Second Gyrus or Turn of the Cochlea; *z*, the Tympanal Scala, 1 the Vestibular Scala.

2, Section of the Third Gyrus or Turn of the Cochlea, in which the Scalæ communicate with each other.

3, Section of the Piece of Bone separating the Cochlea from the Internal Auditory Canal.

4, 5, Section of the Osseous Septum of the Cochlea; 4 being the portion of it which separates the First from the Second Gyrus; and 5 the Portion separating the Second from the Third.

6, Section of the Portion of Bone, which separates the Apex of the Cochlea from the Tympanum.

7, 8, 9, The Lamina Spīralis, forming the In-

ner Half of a Septum, which, in the recent Subject, completely separates the Scalæ of the Cochlea from each other. In the dried Bone it is seen, as in this Figure, stretching only one half across the Canal of the Cochlea. The remaining half of the Septum is made up of Membrane in the recent Subject. Along the whole edge of this delicate Osseous Plate, a series of very minute Holes may be seen, which transmit fine Fibrils of the Auditory Nerve.

- 7, 7, Portion of the Lamina Spiralis in the First Gyrus of the Cochlea.
- 8, Portion of the Lamina Spiralis in the Second Gyrus of the Cochlea.
- 9, The Termination, called Rostrum, or Hamulus, of the Lamina Spiralis, in the Third Gyrus of the Cochlea.
- 10, The Inner Surface of the Scala Tympani, in the First Turn of the Cochlea; formed by a Cribriform Plate of Bone which surrounds the Osseous Septum, and is connected with the Root of the Lamina Spiralis.
- 11, The Inner Surface of the Scala Vestibuli in the First Turn of the Cochlea, formed

by the Lower Side of the Osseous Septum between the First and Second Turns.

12, The Inner Surface of the Scala Tympani in the Second Turn of the Cochlea, which is formed by a Cribriform Plate of Bone, surrounding the Modiolus, similar to that surrounding the Osseous Septum in the First Turn.

13, The Inner Surface of the Scala Vestibuli in the Second Turn of the Cochlea; formed by the under Side of the Osseous Septum, between the Second and Third Turns.

14, 15, Section of the Internal Auditory Canal near its bottom.

16, Section of the Ridge of Bone in the bottom of this Canal, called the Falciform Spine, which divides the bottom into two Regions, an Upper and a Lower.

17, The Upper Region of the Bottom of the Internal Auditory Canal; at the extremity of which is found the Inner Orifice of the Fallopian Aqueduct; and a little below that, a small Cribriform Spot, which transmits delicate Twigs of the Auditory Nerve to the Cribriform Spine and Semioval Depression of the Vestibule.

18, The Lower Region of the Bottom of the Internal Auditory Canal. At the extre-

mity of this Region, there is found, *first*, a delicate Cribriform Spot, which conducts Fibrils of the Auditory Nerve to the Hemispherical Depression of the Vestibule; *secondly*, a small Hole (seen in this Figure, 19,) leading to a narrow Canal, which opens by a Cribriform Plate into the commencement of the Posterior Semicircular Canal, and transmits a Twig of the Auditory Nerve; and *lastly*, anterior to both these, a Depression, corresponding to the Base of the Cochlea, exhibiting a winding Cribriform Track, called, by COTUNNIUS, Tractus Spiralis Foraminosus.

19, Small Hole in the Bottom of the Internal Auditory Canal, described above.

FIGURE 2.

Represents the appearances which present themselves when the Temporal Bone is cut across, in a Plane about one-fifteenth of an inch deeper than the Section in Figure 1.

a, b, c, A Section of the Osseous Septum, between the First and Second Gyri of the Cochlea. At *b*, this Septum is seen to consist of a number of delicate Canalicu-

li, which begin in the Cribriform Spiral Track, at the bottom of the Internal Auditory Canal, and communicate with the Scala Tympani in the First Gyrus at *h*, and with the Modiolus at *e*. They transmit Twigs of the Auditory Nerve.

d, d, Section of the Osseous Septum, between the Second and Third Turn of the Cochlea.

e, Section of the Modiolus, exhibiting the Canaliculi in it, through which delicate Fibrils of the Auditory Nerve are conducted to the Lamina Spiralis, in the Second and Third Gyri.

f, f, Section of the Lamina Spiralis in the First Gyrus; shewing that it is composed of two very delicate Plates attached to the Osseous Septum, and between which the Twigs of the Auditory Nerve run on, to escape by the little Orifices represented in the former Figure.

g, g, Section of the Lamina Spiralis in the Second Gyrus, exhibiting a similar Structure, but attached to the Modiolus.

h, h, i, i, Section of a thin Cribriform Plate of Bone, forming the Inner Surface of the Scala Tympani in the First and Second Gyri. It surrounds the Osseous Septum

at *h*, and the Modiolus at *i*, but is separated from both by a small space, in which Fibrils of the Auditory Nerve run towards the Lamina Spiralis, with the Root of which it is connected.

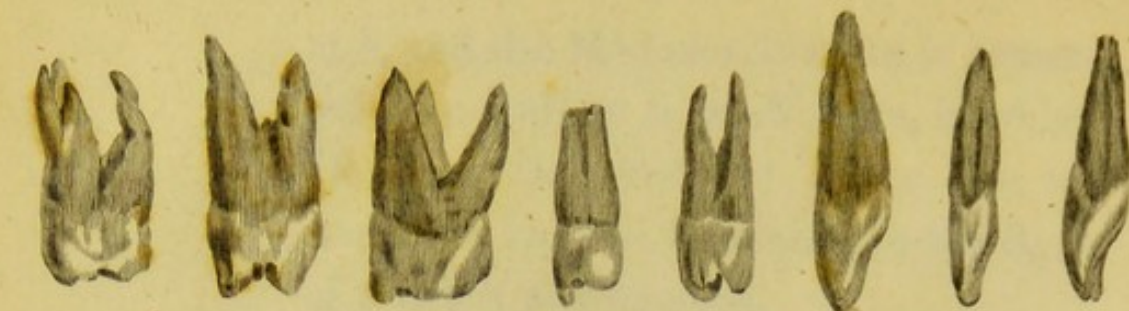

Fig. 1.

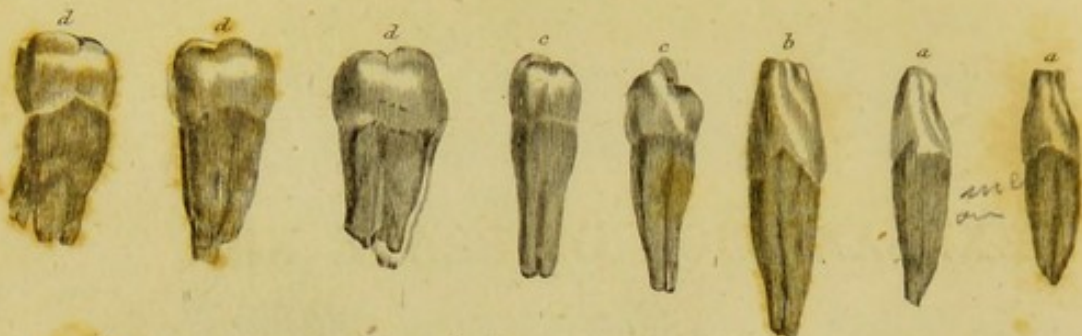


Fig. 2.

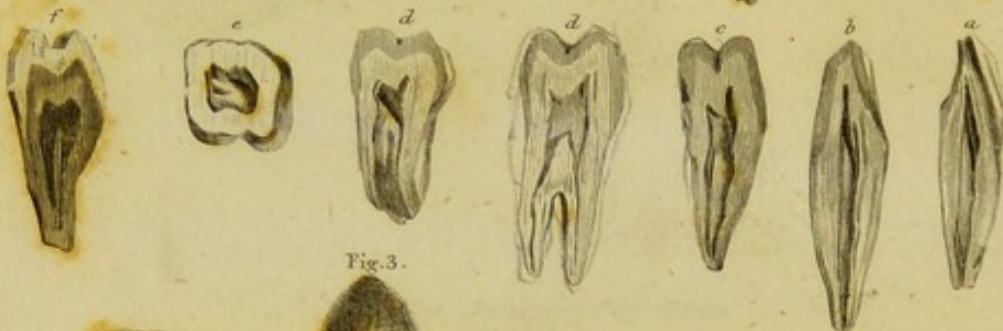

Fig. 3.

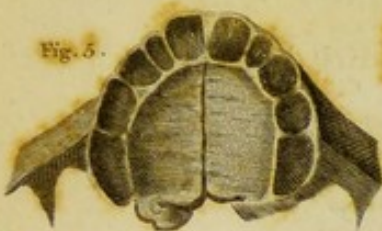

Fig. 5.



Fig. 4.

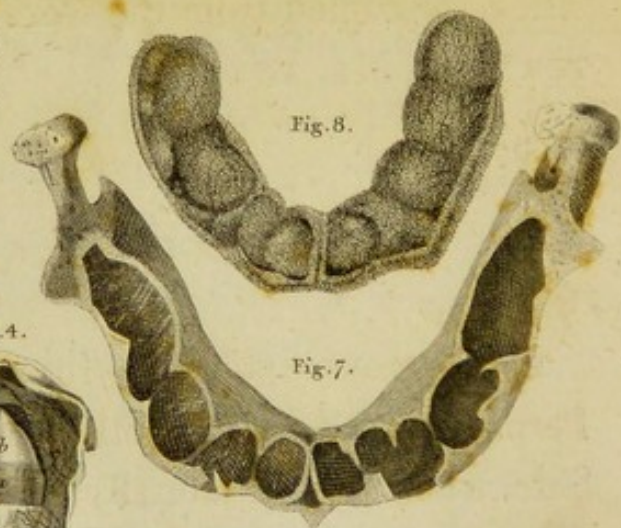

Fig. 8.

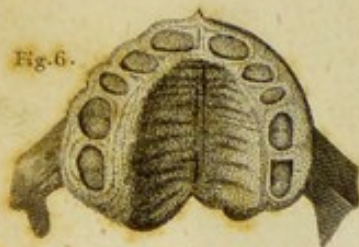

Fig. 6.

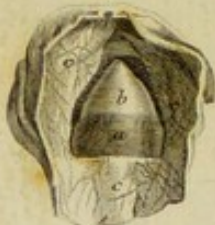

Fig. 7.

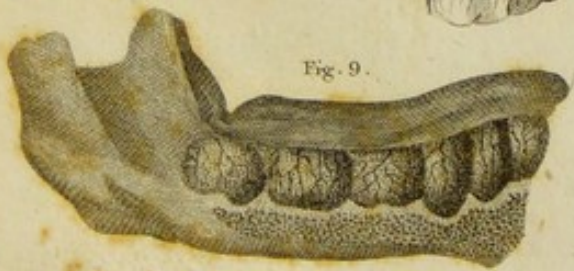

Fig. 9.

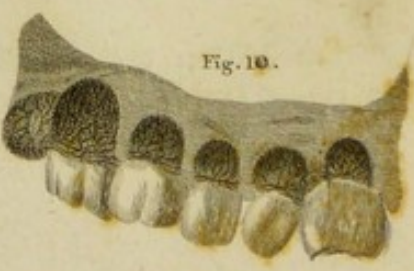

Fig. 10.

Engraved by W. & D. Lister

EXPLANATION OF PLATE XII.

THE Figures of this Plate are intended to illustrate the Structure and Growth of the Teeth. They are copied from the works of JOHN HUNTER* and Mr. Fox.†

FIGURE 1.

Is a Representation, by JOHN HUNTER, of the Permanent Teeth of both Jaws on the Right Side, when viewed laterally.

* Natural History of the Human Teeth. Lond. 1771. 4to.

† Natural History of the Human Teeth. Lond. 1803. 4to.

- a, a*, The Incisors.
- b*, The Cuspidati.
- c, c*, The Bicuspides.
- d, d, d*, The Molares.

FIGURE II.

Is a Representation, by the same Author, of Sections of the four classes of Teeth, to shew their internal Cavities.

- a*, Section of an Incisor.
- b*, Section of a Cuspidatus.
- c*, Section of a Bicuspidatus.
- d, d*, Section of a Middle and Posterior Molaris.
- e*, Transverse Section of the Crown of one of the Molares.
- f*, Longitudinal Section of one of the Bicuspides, to shew the extent and form of the Enamel.

FIGURE 3.

Is a magnified Representation, by the same Author, of the Pulp of one of the Cuspidati.

a, Is the Pulp itself; its more vascular part towards the Apex having been covered with a Cap of Bone, which has been removed.

b, Part of the Sac, which contained the Pulp, turned down.

FIGURE 4.

Is a magnified Representation, by the same Author, of the Pulp of one of the Cuspidati, with the Portion which had been Ossified left adhering to it.

a, The Unossified Part of the Pulp.

b, The Cap of Bone, covering its Apex.

c, Inner Surface of the Sac, reflected back.

FIGURE 5.

Is a Representation, by Mr. Fox, of the Upper Jaw Bones of a Foetus, at three or four Months; viewed from below, so as to exhibit the Sockets of the Temporary Teeth.

FIGURE 6.

Represents the same Bones, with the soft parts still adhering to them. The hard Gum has been cut away, to bring into view the Pulps of the ten Temporary Teeth, each lodged in its proper Socket.

FIGURE 7.

Represents the Lower Jaw Bone of a Foetus of six Months; viewed from above, so as to exhibit the state of the Alveolar Arch.

FIGURE 8.

Is the appearance of the under Surface of the Sacs of the ten Temporary Teeth, pulled out of the same Bone, without laying them open.

FIGURE 9.

Represents the right half of the Lower Jaw Bone of a Child at the period of Birth, with the Anterior Table cut away, to bring into view the Sacs of the ten Temporary Teeth, and of the first or Anterior Permanent Grinder. The Sacs are unopened; and the parts having been previously injected, the Blood-vessels on their Outer Surface are very distinct.

FIGURE 10.

Represents the same Sacs opened, with the newly formed Crowns of the Teeth which they contained turned down, so as to shew the Inner Surface of the Sacs, which is also very vascular.

FIGURE 8.

A BUNNIF

Is the appearance of the under surface of the
Sacs of the ten Temporary Teeth, pulled out of
the same Bone, without laying them open.
The surface of the Sacs is very distinct and
the blood-vessels on their outer surface are very distinct.

FIGURE 9.

Represents the right half of the Lower Jaw
Bone of a Child at the period of Birth, with the
Anterior Table cut away, to bring into view the
Sacs of the ten Temporary Teeth, and of the
first or Anterior Permanent Grinder. The Sacs
are unopened; and the parts having been pre-
viously injected, the blood-vessels on their Outer
surface are very distinct.

FIGURE 10.

Represents the same Sacs opened, with the
newly formed Crowns of the Teeth which they
contained turned down, so as to show the inner
surface of the Sacs, which is also very vascular.

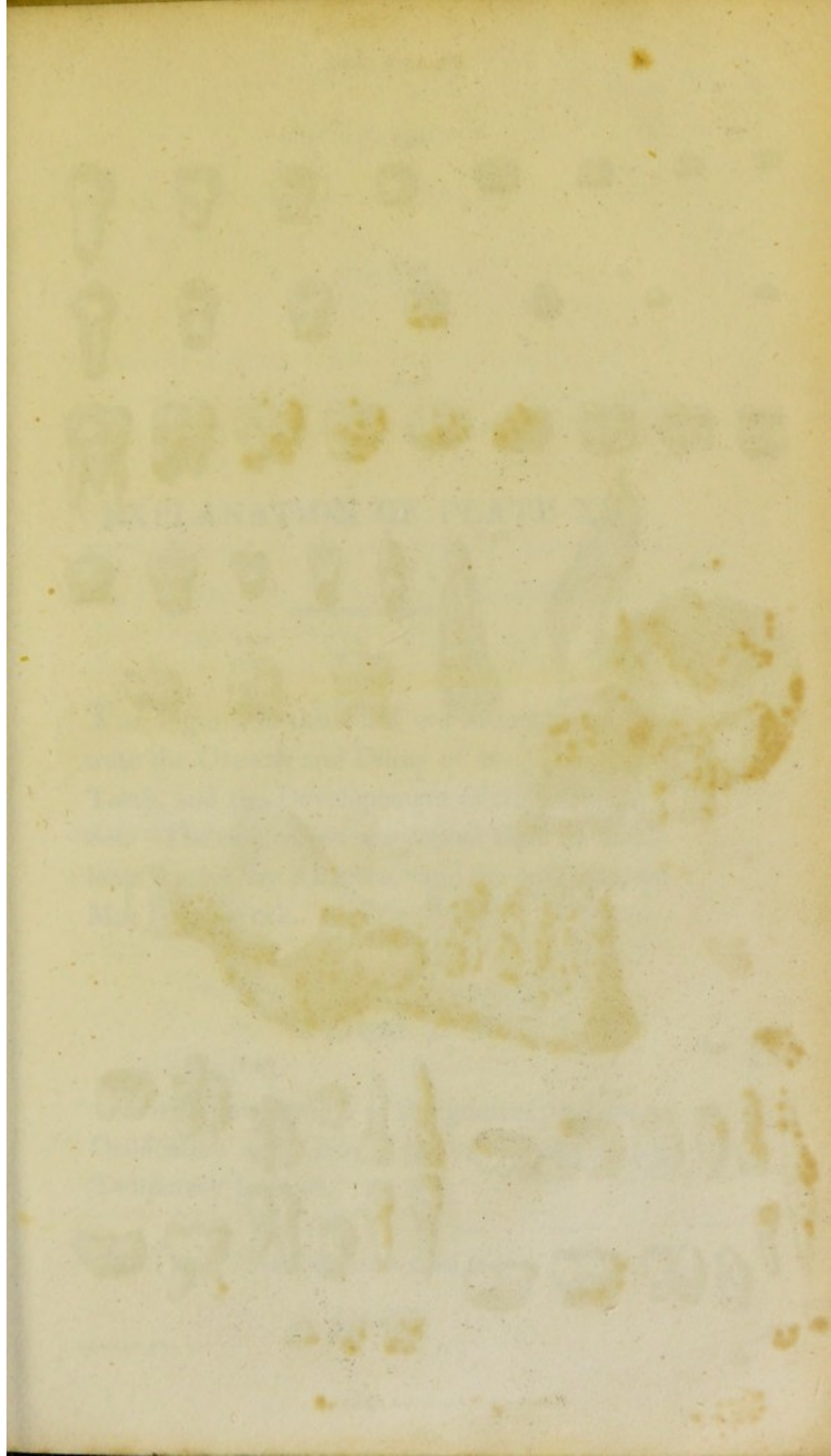


Fig. 1.

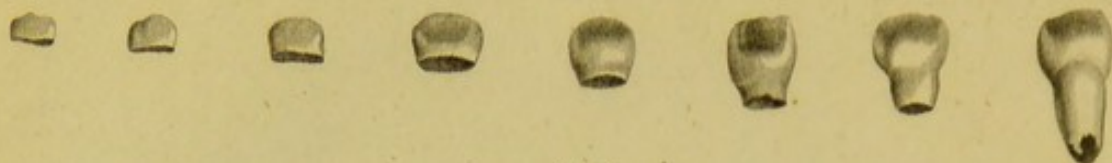


Fig. 2.



Fig. 3.



Fig. 6.

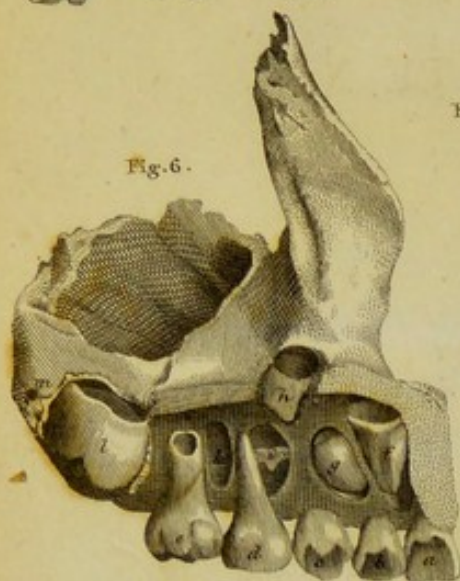


Fig. 5.

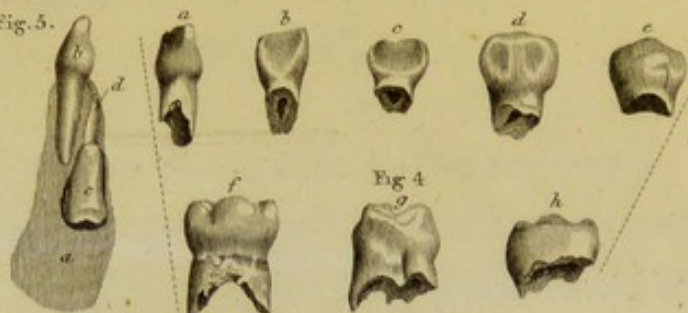


Fig. 4.



Fig. 7.

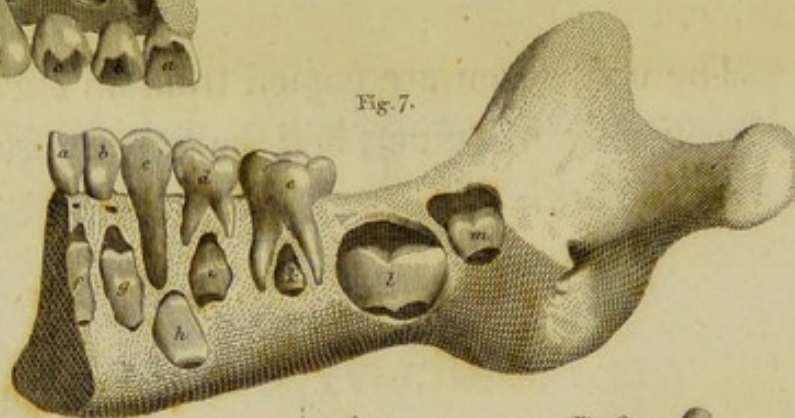


Fig. 8.

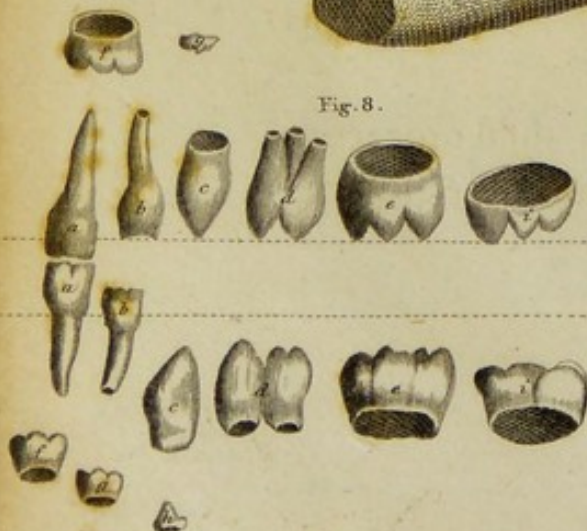
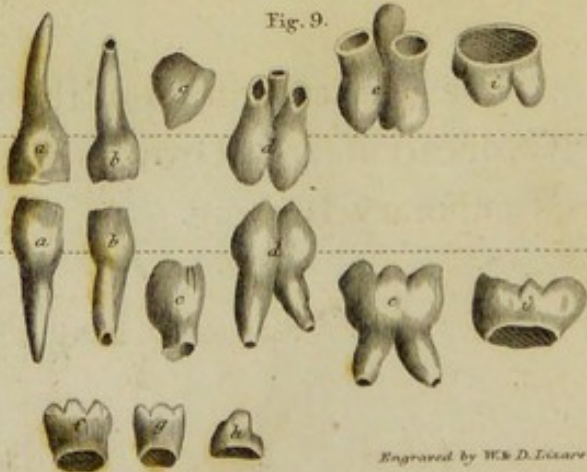


Fig. 9.



Engraved by W. & D. Lillie

FIGURE 2.

EXPLANATION OF PLATE XIII.

THE Figures of this Plate are intended to illustrate the Growth and Decay of the Temporary Teeth, and the Developement of the Permanent Set. The first seven are copied from an excellent Treatise by ALBINUS,* and the two last from Mr. Fox's Work.

FIGURE 1.

Is a Representation of the gradual progress of Ossification and Growth in one of the Upper Temporary Incisors.

* Acad. Annot. Lib. ii. 4to, 1755.

FIGURE 2.

Is a Representation of the gradual Development of one of the Temporary Canine Teeth.

FIGURE 3.

Is a Representation of the progress of Ossification in the Posterior Upper Grinder.

FIGURE 4.

Represents the manner in which the Fangs of the Temporary Teeth disappear, when the process of Shedding begins.

a, A Lateral Incisor, extracted when it had become a little loose in the Jaw.

b, c, Incisors that had been shed.

d, e, Canine Teeth, which had been shed.

f, An Upper Posterior Grinder, extracted when it had become loose.

g, An Upper Anterior Grinder, extracted before it had become loose.

h, A Lower Anterior Grinder, which had been shed.

FIGURE 5.

Represents a vertical Section of the Lower Jaw Bone of a Boy, in whom all the Temporary Teeth had appeared. The Section has been made between the Middle and the Lateral Incisor Tooth on the right Side ; and the object of the Representation, is to shew the relative position of the Temporary Tooth, and the Permanent Tooth which is to succeed it.

a, Section of the Substance of the Jaw Bone.

b, The Right Lateral Temporary Incisor.

c, The Crown of the corresponding Permanent Incisor, lodged in a Cell behind and below the former.

d, Canal leading from that Cell up to the Surface of the Jaw.

FIGURE 6.

Is a view, from within, of the Left Upper Jaw Bone of a Boy of the same age. The Palatine Process, and Inner Table of the Alveolar Arch,

have been cut away, to expose the Cells containing the rudiments of the Permanent Teeth.

a, b, The Temporary Incisors.

c, The Temporary Cuspidatus.

d, e, The Temporary Molares.

f, g, Crowns of the two Permanent Incisors, lodged in Cells above and behind the corresponding Temporary Teeth.

h, Crown of the Permanent Canine Tooth, lodged in a Cell as high up as the Palatine Process.

i, Tip of the Crown of the Anterior Permanent Bicuspis.

k, Cell for the Crown of the Posterior Bicuspis, which has been removed.

l, Crown of the Anterior Permanent Molaris.

m, Eminence, corresponding to a Cell, in which the Middle Permanent Grinder is developed.

FIGURE 7.

Is a view from within, of the Right Side of the Lower Jaw of the same Subject. As much of the Inner Table of the Bone has been removed, as was necessary to bring into view the Cells

containing the rudiments of the Permanent Teeth.

a, b, c, d, e, The Temporary Teeth.

f, g, The Crowns of the Permanent Incisors lodged in their Cells. The Orifices by which these Cells communicate with the Surface of the Jaw, are seen immediately behind the Temporary Incisors.

h, The Crown of the Permanent Canine Tooth.

i, The Crown of the Anterior Permanent Bicuspid.

k, The Crown of the Posterior Permanent Bicuspid.

l, The Crown of the Anterior Permanent Grinder.

m, The Crown of the Middle Permanent Grinder.

FIGURE 8.

The state of the Teeth on the Left Side of both Jaws, in a Child about six or eight Months old. The dotted line is intended to represent the Gum.

a, b, c, d, e, Are the Osseous Parts of the Temporary Teeth; of which the two

Lower Incisors, and the Central Upper Incisor, alone have cut the Gum.

f, g, Ossified Parts of the Crowns of the Permanent Incisors.

h, Ossified Tip of the Crown of the Lower Permanent Canine Tooth.

i, i, Ossified Crowns of the Anterior Permanent Grinders.

FIGURE 9.

The state of the Teeth on the Left Side of both Jaws, in a Child sixteen Months old. The reference is the same as for the last Figure. The Ossified Crowns of the Upper Permanent Incisors and Canine Tooth, similar to *f, g*, and *h*, in the Lower Jaw, have been omitted for want of room.

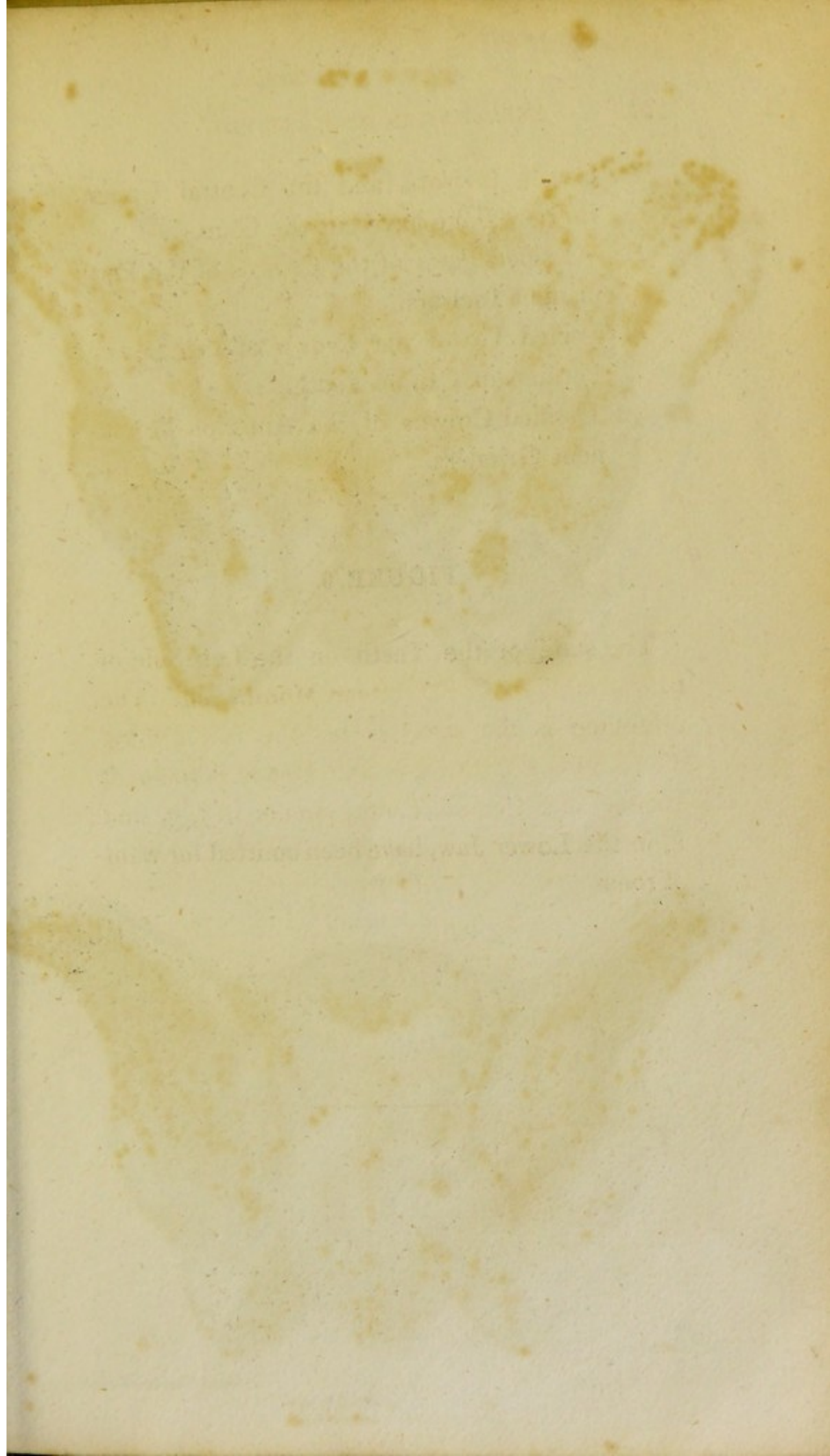

PLATE XIV.

Fig. 1.

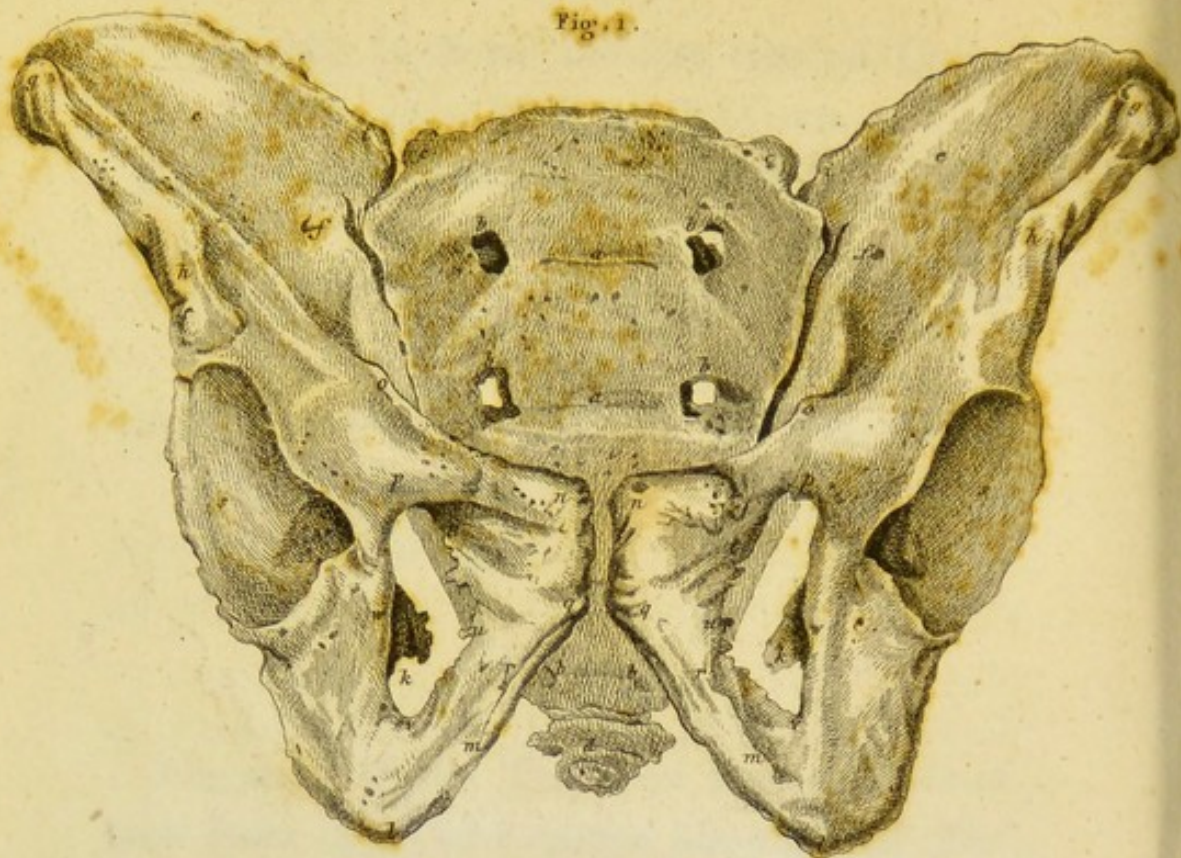
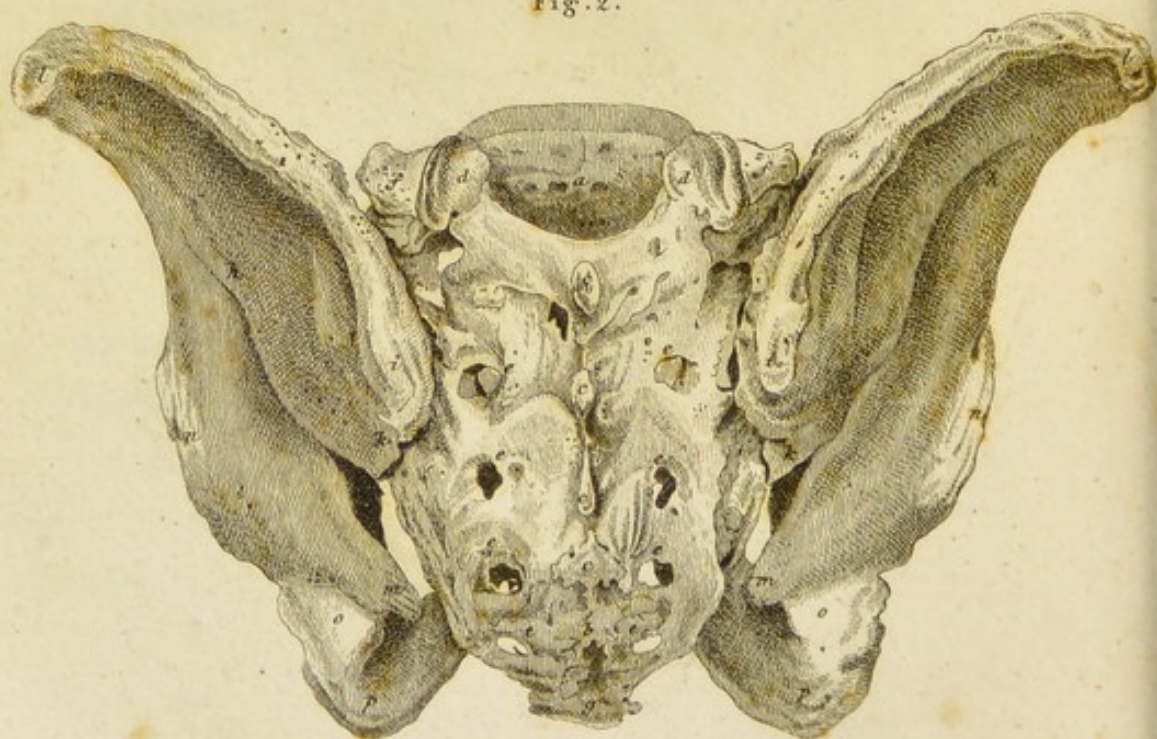

Fig. 2.



Drawn & Engraved by W. R. D. Lister.

PLATE XV.

Fig. 1.

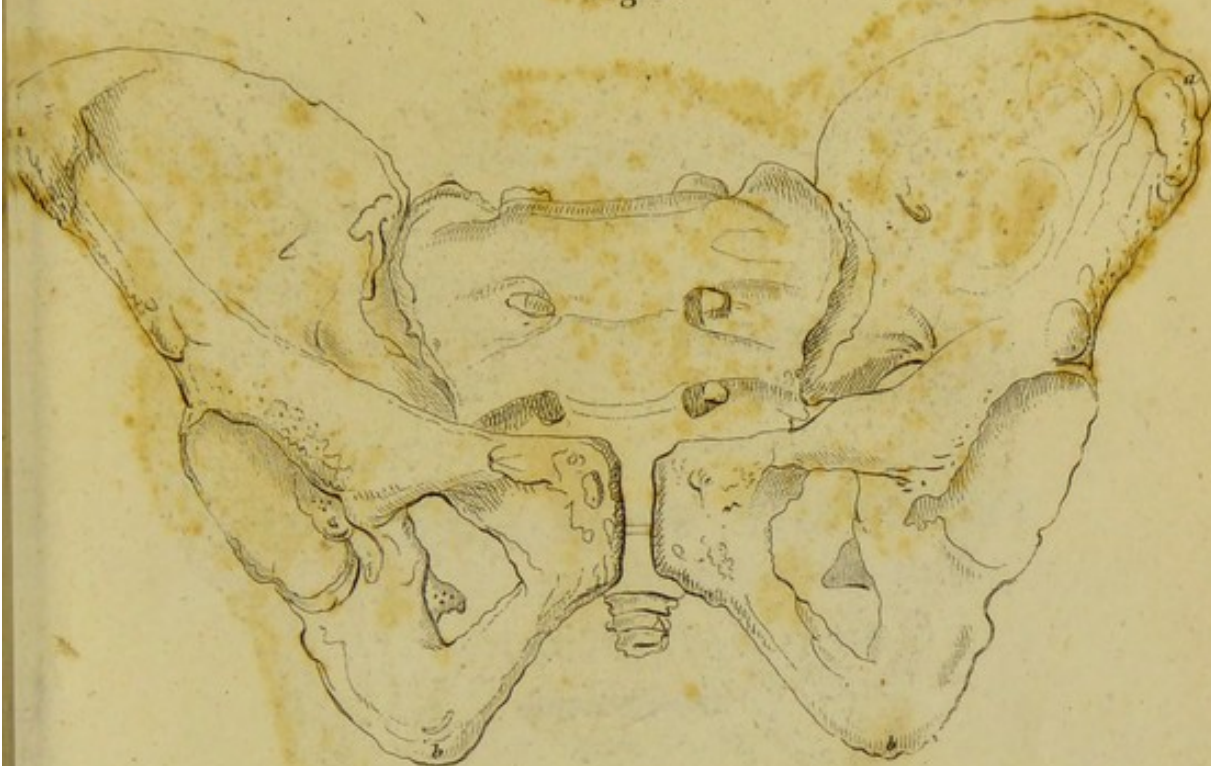
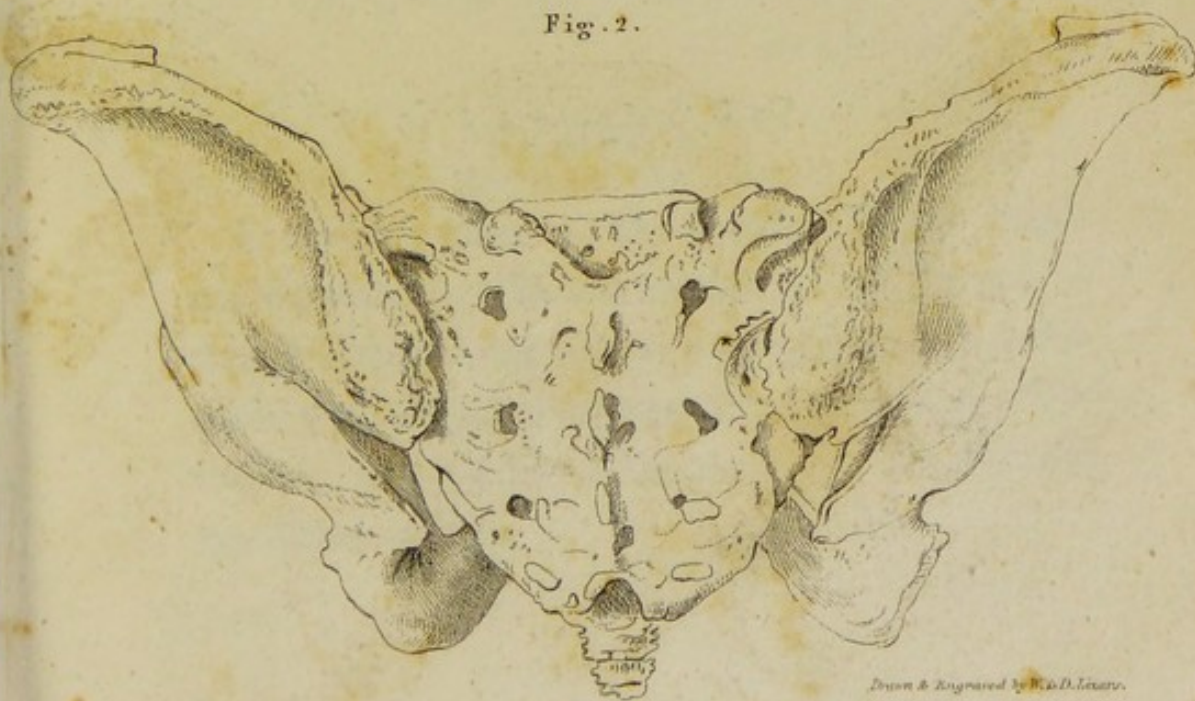



Fig. 2.



Drawn & Engraved by W. D. Lewis.



EXPLANATION OF PLATE XIV.

BOTH the Figures in this Plate, are reduced copies of those composing the thirtieth Table of the splendid work of the CALDANIS, already referred to. They represent front and back views of the dried Pelvis, of a Man aged thirty.

FIGURE 1.

Is a Front View of the Pelvis. In the original Engraving, which is of the size of Nature, a straight line drawn between the points *g, g*, measures ten inches; between the points *p, p*, four inches; and between the points *g, l*, seven and one-third inches.

THE OS SACRUM.

- a, a*, The two uppermost Transverse Lines on its Anterior Surface.
- b*, The Anterior Sacral Foramina. The third pair of these are concealed by the Ossa Pubis.
- c*, Tips of the Articulating Processes.

THE OS COCCYGIS.

- d*, Fore-shortened view of this Bone from before.

THE OSSA INNOMINATA, OR OSSA COXARUM.

The Ilium.

- e*, The Concave Inner Surface of the Ilium, or Venter Ilii.
- f*, Hole for the Transmission of the Vessels and Nerves supplying the Cancelli and Medulla.
- g*, The Anterior Superior Spinous Process.
- h*, The Anterior Inferior Spinous Process.
- i, h*, The Crest of the Ilium.

The Ischium.

k, The Spinous Process of the Ischium.

l, The Tuberosity of the Ischium.

m, The Ramus of the Ischium.

The Pubes.

n, The Crest or Angle of the Pubes.

n, o, p, Anterior Surface of the Ascending Ramus of the Pubes.

n, o, Upper Margin of this Surface.

n, p, Lower Margin of the Anterior Surface of the Ascending Ramus of the Pubes.

q, n, Space united by Cartilage and Ligament to the corresponding part of the opposite Bone, forming the Symphysis Pubis.

q, r, Descending Ramus of the Pubes.

The Acetabulum.

s, Oblique view of this Cavity.

The Obturator Hole.

t, u, v, w, p, t, Front view of this Hole.

t, A Depression called the Obturator Notch.

FIGURE 2.

Is a back view of the Pelvis.

THE OS SACRUM.

- a*, The Upper Orifice of the Spinal Canal.
- b*, The Lower Orifice of this Canal.
- c*, The Spinous Processes.
- d*, The Articulating Processes.
- e*, The Posterior Sacral Foramina.
- f*, The Transverse Processes.

THE OS COCCYGIS.

- g*, View of the Upper and Posterior Part of this Bone.

THE OSSA INNOMINATA, OR OSSA COXARUM.

The Ilium.

- h*, The Dorsum of the Ilium.
- i*, The Superior Posterior Spinous Process of the Ilium.
- k*, The Inferior Posterior Spinous Process of the Ilium.
- l, i*, The Crest of the Ilium.

The Ischium.

- m*, The Spinous Process of the Ischium.
m, k, Opposite Extremities of the Sciatic Notch.
n, The Dorsum of the Acetabulum.
o, Smooth Hollow Surface, over which the Tendon of the Obturator Internus Muscle plays.
p, The Tuberosity of the Ischium.

The Isthmus.

m, The Spinous Process of the Isthmus.
 n, A, Opposite Extremities of the Sciatic
 Notch.

a, The Dorsum of the Acetabulum.
 b, Smooth Hollow Surface over which the
 Tendon of the Obturator Internus Mus-

cle plays.
 c, The Tuberosity of the Isthmus.
 d, The Anterior Process.
 e, The Posterior Sacral Foramen.
 f, The Transverse Process.

g, The Isthmus of the Sacrum.

h, The Upper and Posterior Part of
 the Sacrum.

i, The Lower and Anterior Part of
 the Sacrum.

j, The Isthmus of the Sacrum.

k, The Dorsum of the Sacrum.

l, The Superior Anterior Process of
 the Sacrum.

m, The Inferior Anterior Process of
 the Sacrum.

n, The Isthmus of the Sacrum.

EXPLANATION OF PLATE XV.

THE Figures of this Plate, are reduced outline copies of those composing the thirty-first Table of the Collection by the CALDANIS. They represent front and back views of the dried Pelvis, of a Female aged thirty. These Representations have been placed opposite to those in the former Plate, in order that the differences in the Form and Dimensions of the Male and Female Pelvis might be more easily perceived.

FIGURE 1.

Is a front view of the Pelvis. In the original Engraving, which is of the size of Nature, a straight line drawn between the points *a, a*,

measured eleven inches and a half; between the points *b, b*, four inches and a half; and between the points *a, b*, seven inches and a quarter.

FIGURE 2.

Is a back view of the same Pelvis.

The Figures of this Plate, are reduced outline copies of those composing the thirty-first Table of the Collection by the CALANCA. They represent front and back views of the dried Pelvis of a Female aged thirty. These Representations have been placed opposite to those in the former Plate, in order that the differences in the Form and Dimensions of the Male and Female Pelvis might be more easily perceived.

FIGURE 1.

Is a front view of the Pelvis. In the original Engraving, which is of the size of Nature, a straight line drawn between the points *a, a*

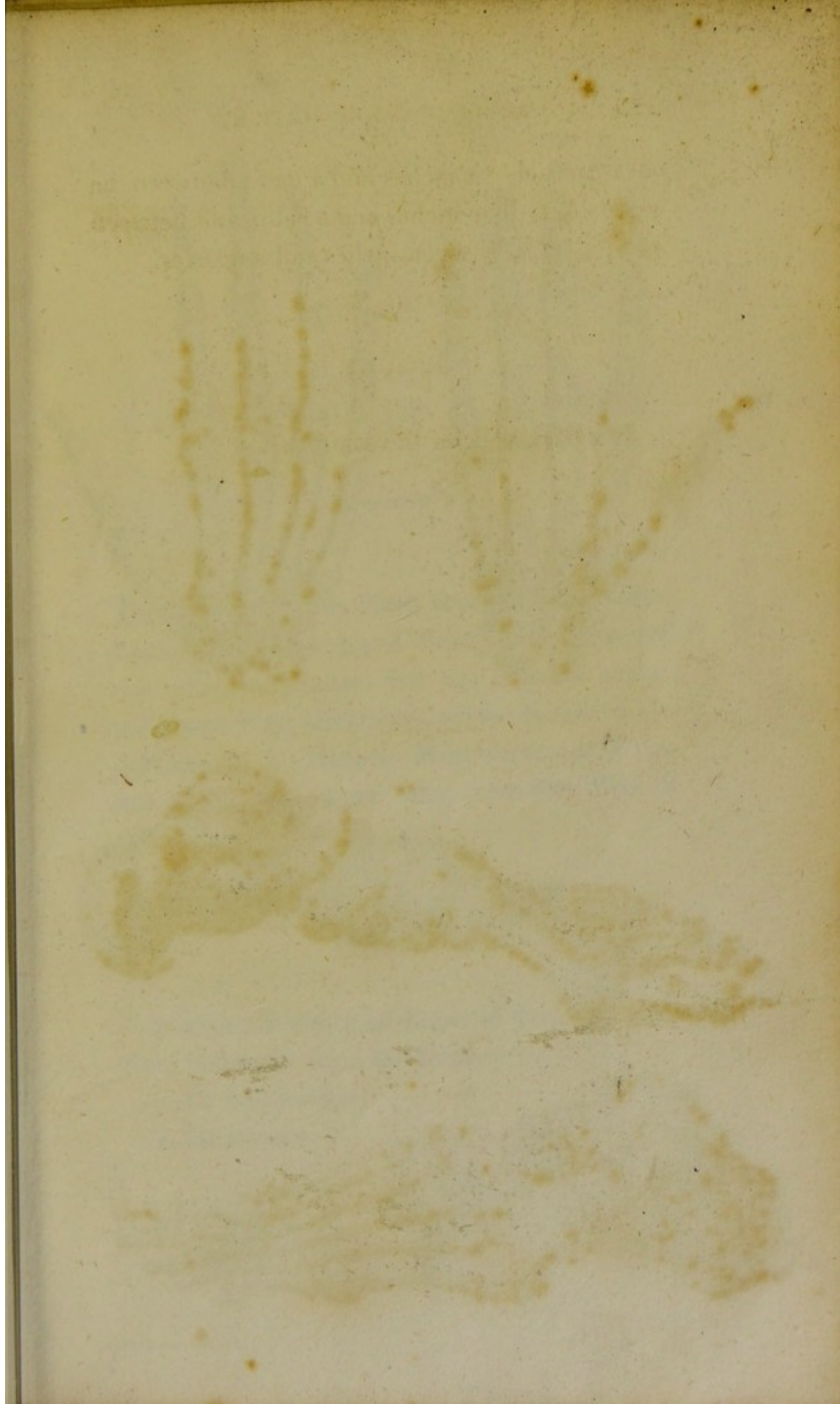


Fig. 1.

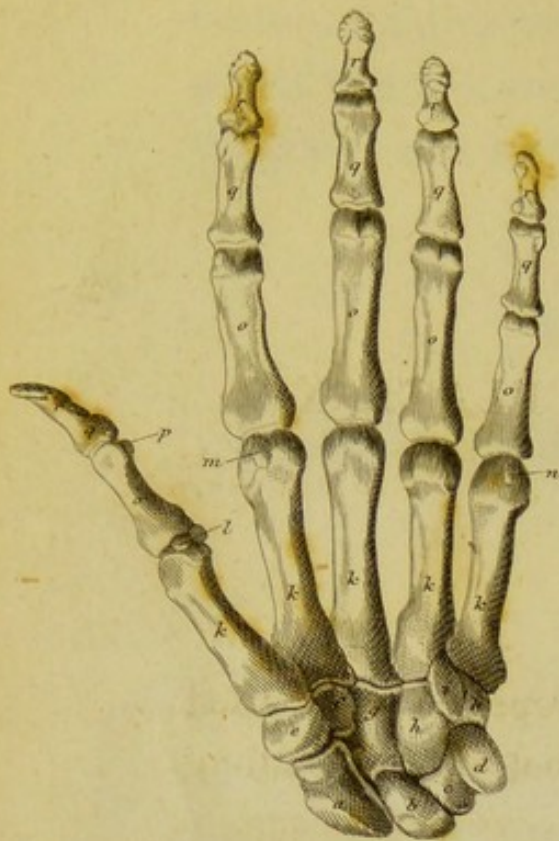

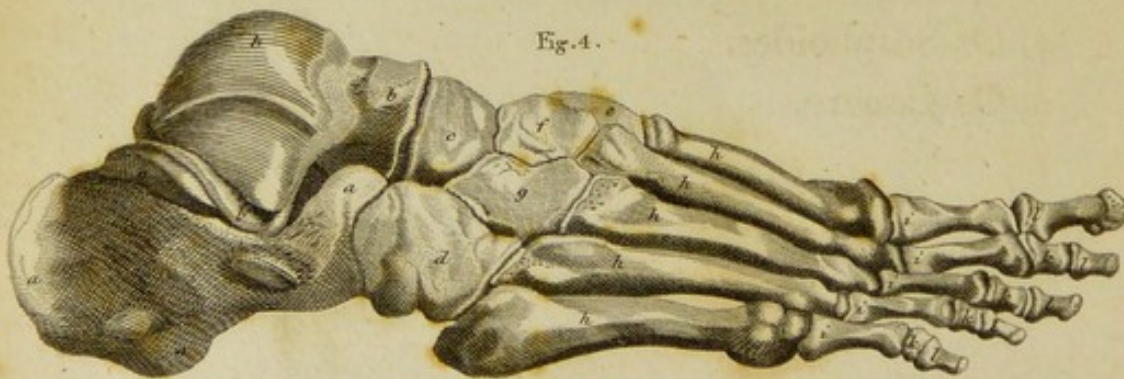
Fig. 2.

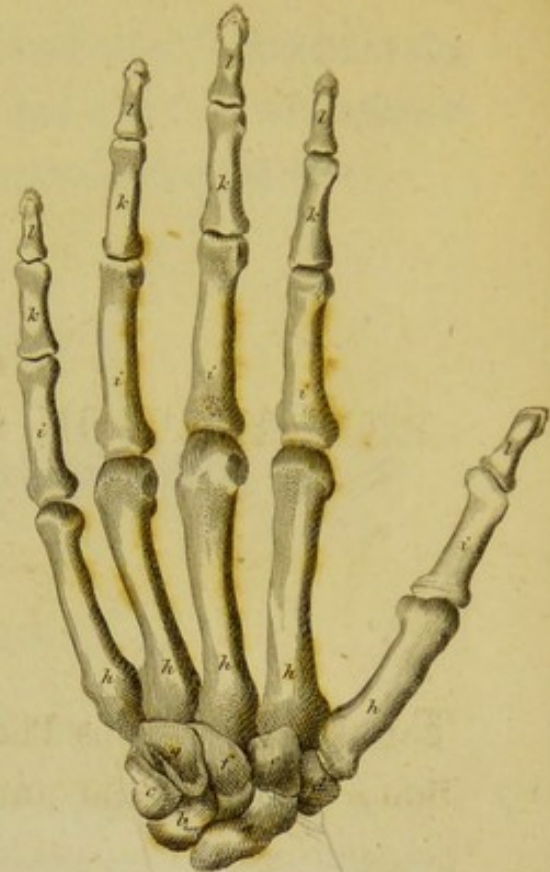

Fig. 3.

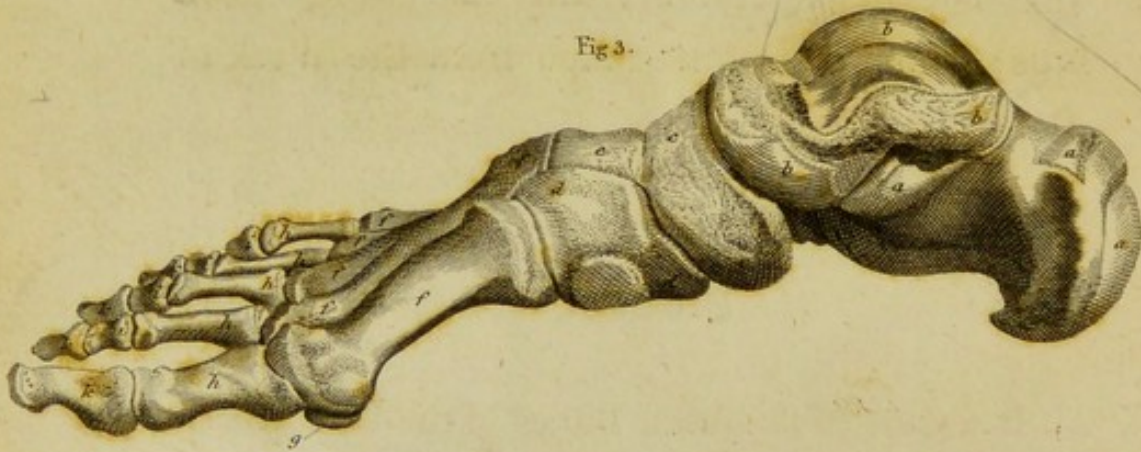

Fig. 4.



EXPLANATION OF PLATE XVI.

THE Figures of this Plate, represent the dried Bones of the Hand and Foot in their natural connection. The two first are reduced copies, with some little alterations, of two beautiful Engravings, in the *Historia Musculorum* of ALBINUS;* the two last are taken from the Work of the CALDANIS.

FIGURE 1.

Is a view of the dried Bones of the Left Hand, from before, or from the Palm.

a, Os Scaphoides.

b, Os Lunare.

* 4to, 1734.

- c*, Os Cuneiforme.
- d*, Os Pisiforme.
- e*, Os Trapezium.
- f*, Os Trapezoides.
- g*, Os Magnum.
- h, h, i*, Os Unciforme, *i*, being its Unciform Process.
- k*, The Metacarpal Bones.
- l*, The Two Sesamoid Bones, at the Joint between the Metacarpal Bone of the Thumb and its First Phalanx.
- m*, Sesamoid Bone, between the Metacarpal Bone of the Fore Finger and its First Phalanx.
- n*, Sesamoid Bone, between the Metacarpal Bone of the Little Finger and its First Phalanx.
- o*, The First Phalanges of the Thumb and Fingers.
- p*, Sesamoid Bone, between the First and Last Phalanx of the Thumb.
- q*, The Second Phalanges of the Fingers.
- r*, The Last, or Unguinal Phalanges of the Thumb and Fingers.

FIGURE 2.

Is a view of the dried Bones of the Left Hand,
from behind.

- a*, Os Scaphoides.
- b*, Os Lunare.
- c*, Os Cuneiforme.
- d*, Os Trapezium.
- e*, Os Trapezoides.
- f*, Os Magnum.
- g*, Os Unciforme.
- h*, The Metacarpal Bones.
- i*, The First Phalanges of the Thumb and
Fingers.
- k*, The Second Phalanges of the Fingers.
- l*, The Last, or Unguinal Phalanges of the
Thumb and Fingers.

FIGURE 3.

Is a view of the dried Bones of the Right
Foot, from the inside.

- a*, Os Calcis.

- b*, The Astragalus.
- c*, Os Naviculare.
- d*, Os Cuneiforme Internum.
- e*, Os Cuneiforme Medium.
- f*, Metatarsal Bones.
- g*, Inner Sesamoid Bone, at the Ball of the Great Toe.
- h*, First Phalanges of the Toes.
- i*, Second Phalanges of the Four Lesser Toes.
- k*, Last, or Unguinal Phalanges of the Toes.

FIGURE 4.

Is a view of the same Preparation from without.

- a*, Os Calcis.
- b*, Astragalus.
- c*, Os Naviculare.
- d*, Os Cuboides.
- e*, Os Cuneiforme Internum.
- f*, Os Cuneiforme Medium.
- g*, Os Cuneiforme Externum.
- h*, Metatarsal Bones.

i, First Phalanges of the Toes. *T* *a* *e*

k, Second Phalanges of the Four Lesser Toes.

l, Last, or Unguinal Phalanges of the Toes. — — — — —

THE END.

EDINBURGH :

Printed by Balfour & Clarke.

A First Phalange of the Toes.
 A Second Phalange of the Four Lesser Toes.
 A Last, or Unguinal Phalange of the Toes.

A Middle Phalanx of the

A Middle Phalanx of the

A Middle Phalanx of the

A Middle Phalanx of the

A Middle Phalanx of the

A Middle Phalanx of the

A Middle Phalanx of the

THE END.

A Middle Phalanx of the

A Middle Phalanx of the

A Middle Phalanx of the

A Middle Phalanx of the

A Middle Phalanx of the

A Middle Phalanx of the


A Middle Phalanx of the


A Middle Phalanx of the


A Middle Phalanx of the

PLATE VII.

PLATE VII.







Feb 19th

Nov 25

