

A case of simple stenosis of the oesophagus, followed by epithelioma / by C. Hilton Fagge.

Contributors

Fagge, Charles Hilton, 1838-1883.
University of Glasgow. Library

Publication/Creation

[London] : [publisher not identified], [1892]

Persistent URL

<https://wellcomecollection.org/works/gdj9bbsg>

Provider

University of Glasgow


License and attribution

This material has been provided by This material has been provided by The University of Glasgow Library. The original may be consulted at The University of Glasgow Library. where the originals may be consulted. This work has been identified as being free of known restrictions under copyright law, including all related and neighbouring rights and is being made available under the Creative Commons, Public Domain Mark.

You can copy, modify, distribute and perform the work, even for commercial purposes, without asking permission.



Wellcome Collection
183 Euston Road
London NW1 2BE UK
T +44 (0)20 7611 8722
E library@wellcomecollection.org
<https://wellcomecollection.org>





D. Faircler

With D. Fagge's kind regards

A CASE
OF
SIMPLE STENOSIS OF THE ŒSOPHAGUS,
FOLLOWED BY
EPITHELIOMA.

BY C. HILTON FAGGE, M.D.

*Reprinted from the Lancet's Hospital Reports. Series III
Vol. XVI*

SOME weeks since, my father, Mr. Fagge, of Hythe, in Kent, placed in my hands for examination a specimen that had been taken from the body of one of his patients who had shortly before died, after suffering from dysphagia for more than forty years.

The history of the case appears to me to be of unusual interest; and I have, therefore, gladly availed myself of Mr. Fagge's permission to publish it in these Reports. The specimen itself displays epithelioma of the Œsophagus, with ulceration and affection of a lymphatic gland. But below the part which is the seat of cancer the Œsophagus is greatly narrowed, and here there is no indication of any change beyond a simple stenosis. It has, therefore, appeared to me, and to others to whom I have shown the preparation, that the epithelioma has probably been of comparatively recent development, and that the long-standing dysphagia was caused by the narrowing of the cardiac end of the Œsophagus. And although this opinion is, perhaps, not entirely beyond the reach of criticism, I have wished to place it prominently before the reader, and I have, therefore, given expression to it in the title which I have chosen for the case, and as a heading to this short communication.

Mr. J. L—, æt. 84 at the time of his death, had for upwards of forty years had a difficulty in swallowing food. He thought it originated in the habit of eating fast. When it first came on it seemed to him as if, when he swallowed anything, the wind met it and forced it back. In consequence of this difficulty of deglutition, all the solid food he took was divided into very small portions. In the last twenty years of his life, whenever he happened to eat a morsel exceeding a certain size (and that very minute), it lodged in the œsophagus, and for several days, or even more than a week, he would take neither food nor drink.

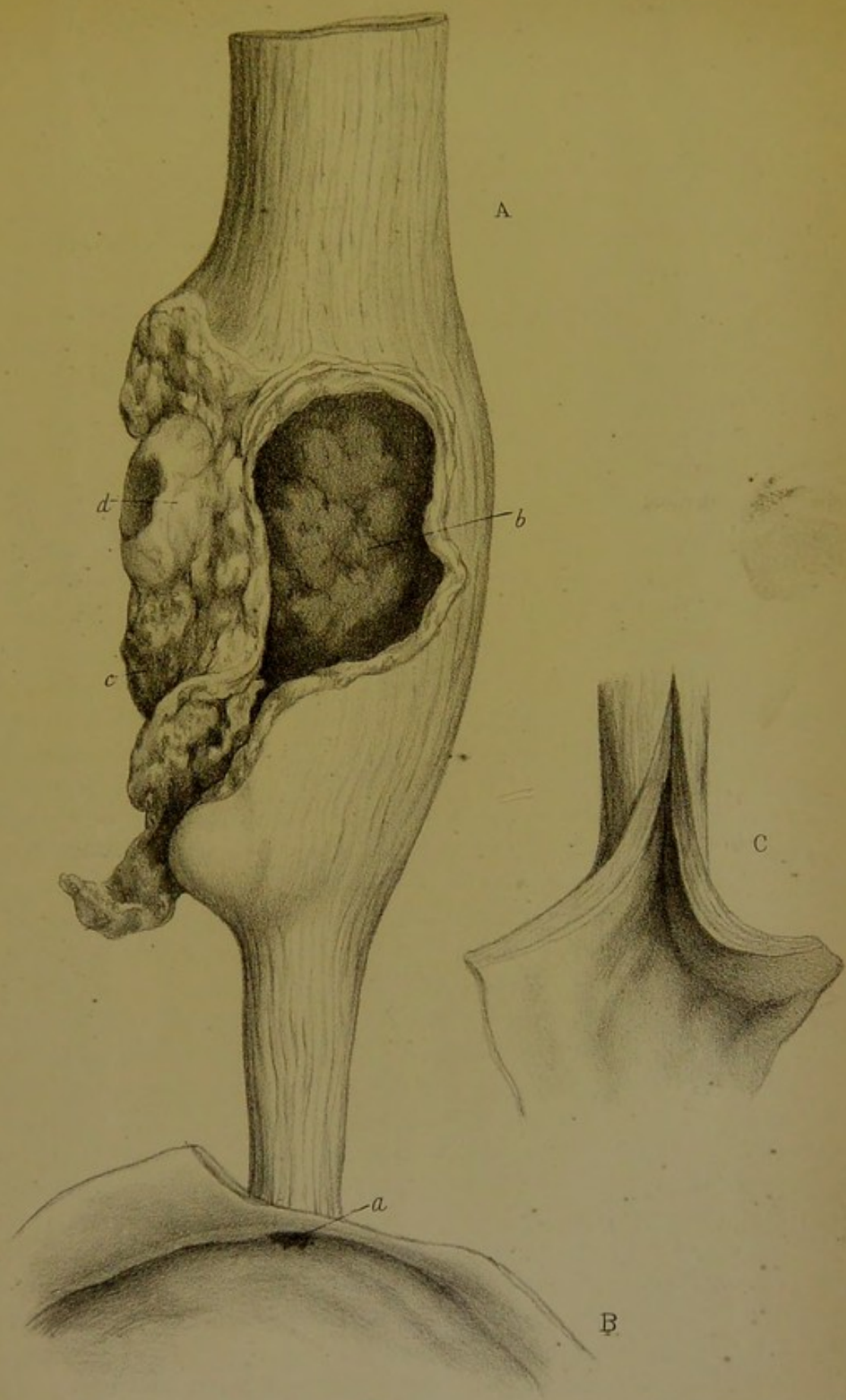
He used to wash down solid food with liquids, and often drank before taking food. He was not known to suffer from sickness, nor did he ruminate nor bring up his food in pellets. He never had a bougie passed down his throat.


For some time before he died he was extremely weak, being only just able to walk from room to room. He indulged to excess in the use of spirits.

About three weeks from the day of his death, on rising one morning, he fell back exhausted, and from that time he lay in a semi-lethargic state, speaking very little, and taking only small quantities of fluids. He was, however, able to swallow fluids to the very last. He brought off a little blood occasionally, but there were no other symptoms pointing to the occurrence of ulceration in the affected part. His pulse was very feeble, and latterly scarcely perceptible, so that his death was expected from one day to another for a fortnight before it occurred. During this time the extremities were cold and livid, and the circulation seemed to cease in them successively; first in one lower limb, then in an upper, and in the other limbs in the same order. As has been already stated, he was eighty-four years old at the time of his death.

On post-mortem examination it was found that the body was by no means emaciated; there was a rather thick layer of fat over the abdominal muscles, and a good deal in the omentum.

The autopsy was conducted in Mr. L—'s private house, and, therefore, without the advantages that are a matter of course in a hospital. The only parts in which any disease was found were the œsophagus and certain structures in its immediate neighbourhood. These were preserved, and have been placed





in the museum of Guy's Hospital. The following description is the result of a careful examination, but this was made after the parts had been macerated for some time in spirit.

The upper part of the œsophagus is rather less than an inch in diameter. This calibre is maintained as the gullet descends, until a point about four and a half inches from the cardia. Here it becomes slightly dilated, its diameter reaching one and a half inch. About two inches lower it again becomes narrower, at first rapidly, afterwards more gradually, so that the shape of a funnel is pretty closely imitated. The narrowest part of all is at the termination of the œsophagus in the stomach. Here the calibre is so small that an ordinary lead pencil is firmly grasped by the gullet.

At its widest part the walls of the œsophagus present a large irregular opening, two inches in length, which is evidently in part the result of ulceration, but which may also in part have been caused by injury during removal from the body. On one side the lung is adherent; there is also close to the outside of the gullet a lymphatic gland, which is the seat of epithelioma.

The coats of the œsophagus are greatly thickened; the longitudinal fibres are very distinct, and within these the transverse fibres are greatly hypertrophied. In the upper part of the tube the thickness of the coats is one fifteenth of an inch, just where the œsophagus opens into the stomach it reaches one fifth of an inch.

In addition to my own somewhat cursory microscopical examination, I have had the advantage of having the specimen carefully examined by my friend Mr. Howse, who has kindly supplied me with the following notes of the observations he made:

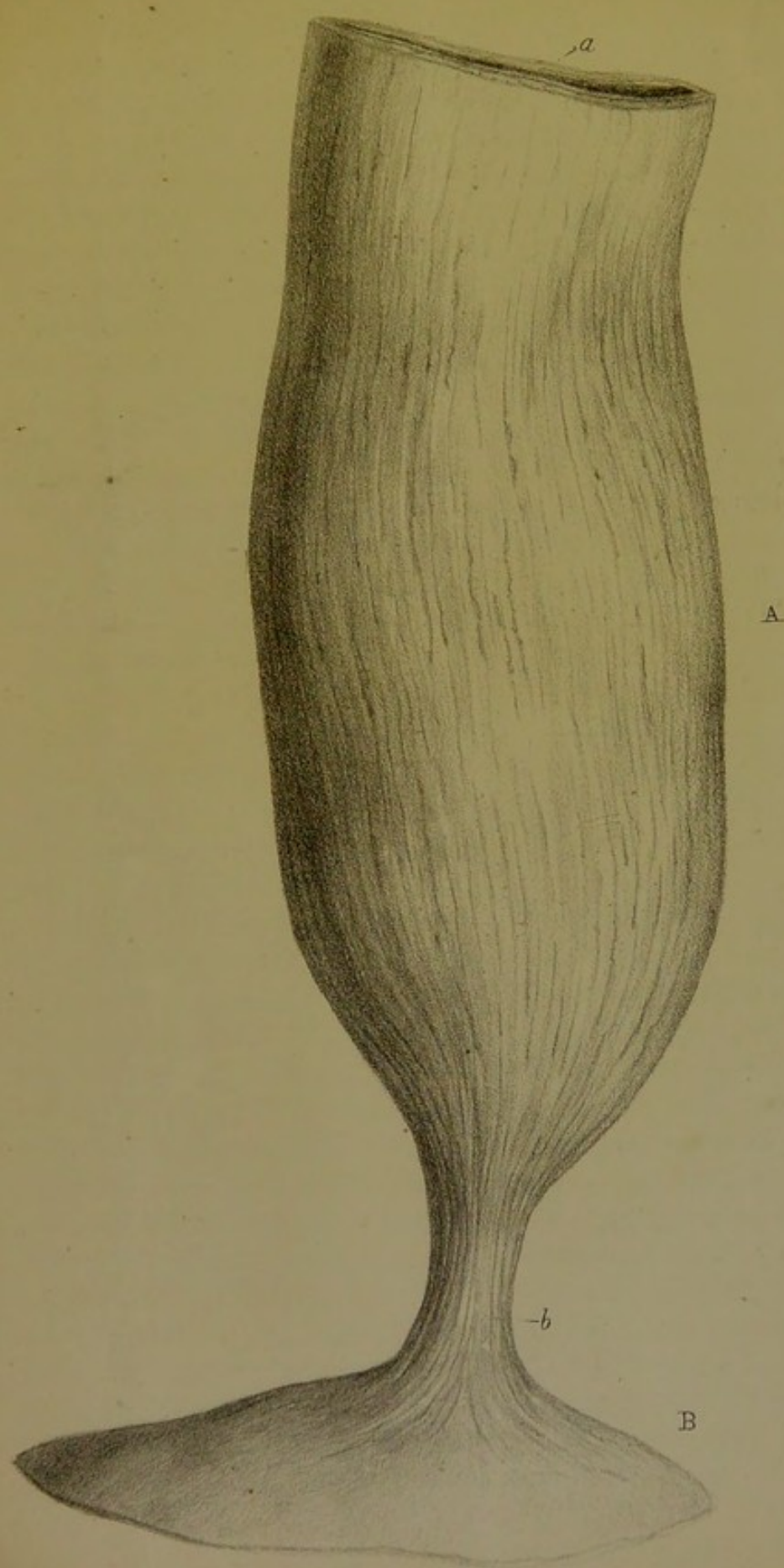“A section taken near the ragged opening previously described showed that the layers corresponding with the mucous membrane and muscular coats were very much thickened. Examined under the microscope, there was a great increase of flattened epithelial elements in the former layer, and of short spindle-shaped cells in the latter. No very definite arrangement of the cells in the epithelial layer at this part could be made out. Indeed, many of them were considerably degenerated, thus leading to the inference that they had been there for some time. A section, however, taken rather farther from the ragged orifice, where the thickening was not so great, showed

the young cells growing inwards in the form of solid processes, representing an imperfect form of gland formation, a mode of growth which I have very generally observed in cases of epithelioma.

"A small bean-like substance was attached to the surface of the œsophagus below the ragged orifice, but above the constriction. It was not very closely adherent to the tube, and appeared to be one of the mediastinal lymphatic glands. A section showed that it was infiltrated with exceedingly well-developed epitheliomatous structures, several beautiful birds' nest capsules being present."

In the year 1866 Dr. Wilks exhibited at a meeting of the Pathological Society a specimen which resembled that above described in some important particulars. The specimen is preserved in the museum of Guy's Hospital, and I have obtained Dr. Wilks' permission to have a drawing made of it, which has been copied in the accompanying plate (see Pl. II). The patient from whose body it was taken had been during life under the care of the late Dr. Rootes, of Ross, and he forwarded to Dr. Wilks the following notes of the case, which (with Dr. Wilks' sanction) I extract from the seventeenth volume of the 'Pathological Transactions,' where they have already been published.

"Mr. J. K—, a farmer, died on the 4th of April, 1866, of pneumonia, being then in the seventy-fourth year of his age. He had always enjoyed good health, and came of a sound and long-lived family. He became a patient of my father's in 1812, and I have known him professionally since 1831, when I first began practice. During the whole of this period he has never had a serious illness which confined him to his bed, but he might have been regarded as a ruminating animal. According to his own account, he never appears to have been free from this ruminating tendency, which I think, therefore, must have been congenital, although he used to say that he thought he might have brought it on by straining at heavy weights when a boy. He never could take any meal without eating very slowly and masticating very carefully, and at the same time taking a draught of fluid to wash down every bolus of food as soon as it entered the gullet. To this end he found cider the most con-





ducive, so that a pint of this liquor always formed a constituent of his breakfast. He never partook of any meal of which he did not bring back some portion, and this he always persisted in saying was done by the act of coughing, and that, in fact, he never was sick, and never had been sick. About forty years ago his father took him to Sir Astley Cooper, who passed a bougie, the only result of which was that he deposited a hearty breakfast he had recently swallowed on the floor of Sir Astley's consulting room. I have often passed a bougie for him, and it has always been followed by his coughing up more or less of the solid or liquid food taken within the last few hours. I have told him many times that I believed he had a pouched or sacculated gullet, although this was a mere-guess. You will not fail to notice the small cardiac orifice of the stomach; but a very careful examination of the diaphragm failed to reveal any trace of injury or disease around the stomach or elsewhere. The complaint produced no inanition, for the body contained a considerable amount of fat."

Dr. Wilks' description of the specimen is as follows :

"The œsophagus is enormous, being as large as an ordinary sized colon, but very different from this in other respects, its walls being of great thickness, from the increased muscular development of its coats. Lying in the dish, in its undistended state, it measures six inches and a half in circumference; it is of nearly uniform size throughout, although slightly bulging in two parts. Towards the stomach it suddenly contracts, and here the tube is as much below the natural size, as in other parts it is above it. It is, indeed, here constricted to half its usual diameter. On placing the little finger inside the stomach, it may be just squeezed through into the œsophagus, and at the same time no thickening and no trace of cicatrisation can be discovered. It appears, however, as if some original narrowing had existed here, and in consequence the œsophagus above had become distended, just as a bladder hypertrophies in a case of stricture of the urethra."

The stomach in this case is stated by Dr. Wilks to be healthy and of natural size and form. But since it has been stuffed with hair for the purpose of preserving its form in the bottle in which it is preserved, one can see that it is really considerably larger than a healthy stomach. I find that its length

from the cardia to the pylorus is fourteen inches. The pyloric ring is more distinct than usual, but quite free from disease.

Mr. Howse has kindly examined the different coats of the œsophagus for me, and reports that he can discover no morbid change beyond hypertrophy of the muscular coat in both its layers. The mucous membrane is of normal thickness.

I have been the more desirous of associating this case of Dr. Wilks' with mine, because such an affection would appear to be extremely rare, so far as I have been able to ascertain in the course of a somewhat careful search into the literature of this subject. Indeed, I have not discovered a single recorded instance in which a similar narrowing of the cardiac end of the œsophagus has been observed on post-mortem examination. This, however, is, perhaps, not in itself very remarkable, for the disease appears hardly to have the power of destroying life; and, therefore, opportunities of tracing such cases to a fatal termination are less likely to fall to the lot of professed pathologists than to be the privilege of practising surgeons.

More just ground for surprise appears to be afforded by the fact that scarcely any writer on medicine has described cases presenting a clinical history similar to that belonging to the two cases which form the subject of this paper. The ordinary forms of organic stricture of the œsophagus generally destroy the patient within no very long period. Cases such as mine must rather be looked for under the head of "spasmodic stricture," and I think it is probable that their protracted course would have led many observers to class as "spasmodic" the cases above recorded. Thus Dr. Graves, in his well-known clinical lectures,¹ mentions the case of a gentleman in whom attacks of sudden dysphagia had become so habitual, that he never ventured to eat unless a glass of water were within his reach; for in him the stopping of the bolus of food was attended with an urgent sense of suffocation. He adds that this gentleman, an excellent anatomist, thought that the sense of suffocation was entirely nervous, or at least that it had nothing to do with any mechanical obstruction in the glottis arising from the neighbourhood of the descending food. On the same page he mentions a somewhat similar instance, that of a nervous young

¹ Second edition, 1848, vol. ii, p. 206.

clergyman. This patient complained of various symptoms indicating debility and dyspepsia, but was chiefly annoyed by a painful and convulsive struggle, which sometimes took place between the bit he had swallowed, just before it entered the stomach, and a something that seemed to resist its further passage downwards. Viewed by the light of our present knowledge, these cases certainly seem not unlikely to have been examples of stenosis of the cardiac end of the œsophagus.

My friend and colleague Mr. Durham has also pointed out to me that Sir Everard Home has alluded to more than one instance in which dysphagia existed for a great many years. Thus he mentions¹ the case of "a lady who had had a narrow swallow from her infancy, which gradually increased upon her, till in an advanced period of life she could scarcely swallow at all . . . A surgeon gave her relief by passing a bougie. This operation it was found by experience was required to be performed once a week." When Sir E. Home saw this patient she was fifty-nine years of age, and extremely irritable and emaciated. Some months afterwards she was taken suddenly with a total want of power of swallowing and died. It does not appear that an autopsy was made.

Another of Sir E. Home's cases is somewhat analogous to mine.² "A lady, forty-six years of age, had from her earliest remembrance had a narrow swallow, but for the last two years had perceived it to be gradually getting worse, till she was unable to swallow anything but liquids, without the danger of being choked. Occasionally she could take some bread soaked in tea. In the night, after sleeping some time, she awoke with a sense of suffocation, and it was an hour before she recovered. At these times she lost her voice till she swallowed some water. She brought up, at all times, a great deal of mucus, particularly after speaking, but still more so after taking food."

She died in a fit of suffocation. "The œsophagus, immediately behind the cricoid cartilage, was contracted, forming a stricture; this was unattended with thickening, and consisted of a fold of the internal membrane only. The orifice through which the nourishment passed was only large enough to admit

¹ 'Practical Observations on the Treatment of Stricture in the Urethra and in the Œsophagus.' Second edition, 1821, vol. ii, p. 398.

² *Op. cit.*, p. 414 (Case VI).

the blunt end of a probe. A plate is appended which shows admirably the "membranous partition across the canal" of the œsophagus, which had caused the long-standing dysphagia in this case.

It is therefore clear that stenosis of the cardia is not the only affection which may produce difficulty of swallowing, lasting from infancy to an advanced age. But in a future case there would probably be but little difficulty in determining whether the seat of obstruction was opposite the cricoid cartilage, or at the extremity of the œsophagus.

There is, indeed, another affection in which dysphagia, from an organic cause, has likewise lasted for a great many years, if we may rely on the accuracy of certain observers of a former generation. I refer to the so-called *Dysphagia lusoria*, a complaint first described by Bayford, of Lewes, in the second volume of 'Memoirs of the Medical Society of London.' According to Bayford this form of dysphagia is due to an abnormal course of the right subclavian artery, arising from the left side of the aortic arch, and passing to the right across the œsophagus so as to compress that tube. The case described by him is briefly as follows :—A woman, Jane Fordham, had from her infancy been observed to have some difficulty of swallowing, but it was not much attended to until she entered into her thirteenth year, when she first experienced those symptoms which commonly precede the eruption of the menses. Nothing did her good but repeated bleedings. Every month she lost blood once or oftener, for without it she could not swallow without extreme difficulty, and a dread of actual suffocation. Violent exercise, and "everything that heated the blood," increased the dysphagia, which went on for many years continually augmenting. In the last twenty years of her life this poor creature could scarcely from day to day muster up resolution to force down food to prevent her starving. The difficulty she described as arising from an obstruction in that part of the œsophagus which is opposite the first bone of the sternum. The food did not return when it came to that place, but seemed to make a momentary stop; and at this instant she felt an inexpressible something approaching to strangulation or suffocation, which she could only compare to what she conceived of the agonies of

death. Upon these occasions she experienced violent palpitations of the heart. Solids gave her less uneasiness than fluids, for which reason she took very sparingly of the latter. She fancied she nourished within her a voracious animal, and attributed all her uneasiness to the fury with which this half-starved monster fell upon each morsel in its passage to the stomach. She died at the age of sixty-two. At the post-mortem examination the œsophagus and stomach are stated to have been perfectly healthy. The only condition found in the dead body to which the dysphagia could be referred was an abnormal course of the right subclavian artery, passing from left to right between the œsophagus and the trachea.

The name *Dysphagia lusoria* was given by Bayford to this affection from the *lusus naturæ* which causes it. His case has been quoted by many later writers, and among others by Mr. Quain.¹

But so far as I can learn, no further observations have since been made, confirmatory of the view that dysphagia may be produced by this peculiarity in the course of the right subclavian artery. It would appear, however, that a much more common abnormality is that in which the artery, after arising from the aorta, runs behind the œsophagus. Its passage between the trachea and the œsophagus seems to be of extremely rare occurrence. The recent literature of dysphagia lusoria is chiefly German; and most writers are, I think, now agreed that an abnormal course of the right subclavian artery is not likely to interfere with the functions of the œsophagus unless the blood-vessel be dilated or aneurismal.

However this may be, it is not probable that such a case as that which forms the subject of this paper could be mistaken for one of dysphagia lusoria, as the obstruction would be referred by the patient to a different seat; and the same may perhaps be said of those cases of œsophageal pouches in which dysphagia seems sometimes to exist for years. Such pouches appear usually to be situated either opposite the bifurcation of the trachea, or in the root of the neck. In the latter case a distinct tumour has sometimes been felt behind the larynx, when the sac has become filled with food during a meal.

¹ 'The Anatomy of the Arteries of the Human Body,' 1844, p. 154.



