On the development and homology of the mammalian cerebellar fissures / by O. Charnock Bradley.

Contributors

Bradley, O. Charnock 1871-1937.
University of Glasgow. Library

Publication/Creation

[London] : [publisher not identified], [1903?]

Persistent URL

https://wellcomecollection.org/works/pvt6uym9

Provider

University of Glasgow

License and attribution

This material has been provided by This material has been provided by The University of Glasgow Library. The original may be consulted at The University of Glasgow Library. where the originals may be consulted. Conditions of use: it is possible this item is protected by copyright and/or related rights. You are free to use this item in any way that is permitted by the copyright and related rights legislation that applies to your use. For other uses you need to obtain permission from the rights-holder(s).

Wellcome Collection
183 Euston Road
London NW1 2BE UK
T +44 (0)20 7611 8722
E library@wellcomecollection.org
https://wellcomecollection.org

ON THE DEVELOPMENT AND HOMOLOGY OF THE MAMMALIAN CEREBELLAR FISSURES.[1]

By O. Charnock Bradley, M.B., *Professor of Anatomy, Royal Veterinary College, Edinburgh.* (Plates XII.–XVI.)

Part I.

Very few serious attempts have been made to discover if there is any regular plan of arrangement of the fissures and lobes of the mammalian cerebellum. If we leave out of account those scattered descriptions of the cerebellum of a single animal, or of one or two animals—such, for instance, as Ganser's (1) classic and oft-quoted investigation into the anatomy of the brain of the mole, Krause's (2) monograph on the rabbit, and Miss Ärnbäck-Christie-Linde's (3) paper on the brain of the shrew and bat; not to mention more of a like nature—we find that the literature on the comparative anatomy of the cerebellum can only be described as meagre. Undoubtedly the best work that has been done in the way of attempting to clear away morphological difficulties is that which has appeared from the pen of Stroud (4). Another paper worthy of mention in this connection is that of Kuithan (5), which appeared almost contemporaneously with Stroud's. These two writers stand practically alone, inasmuch as they did not rest satisfied with an examination of the adult brain, but demanded to know what embryology had to say. Stroud traced the development of the cerebellar fissures in the cat and in man; and Kuithan examined embryos of the sheep and man.

The latest attempt—as far as is known by the present writer—which has been made to establish the homology of the lobes of the cerebellum of mammals appears in the large work by Flatau and Jacobsohn (6) on the central nervous system. The value, great though it still remains, of this last piece of work is impaired by the fact that only adult material was used, and in many cases apparently second-hand descriptions were accepted.

[1] The work, of which the present paper is the outcome, was done by the writer as a Research Student of the University of Edinburgh.

The ideal method, in a question of this kind, appears to be a combination of the embryological and the comparative anatomical. Stroud recognised this, and suggested that it would be necessary to examine into the intrauterine history of every mammal—a colossal task, verily. This being beyond the compass of the powers of one man, he examined two animals embryologically, and gave a long list of adult animals which he stated he had compared with each other. Unfortunately his description of the adult cerebella, seemingly promised in his first paper, is not as yet forthcoming.

Kuithan did not attempt the examination of a series of adult cerebella, but contented himself with the consideration of the development of the fissures in sheep and in man.

In the case of Stroud, Kuithan, and Flatau and Jacobsohn the investigation was apparently begun with the determination to find, if possible, homologies to the lobes of the cerebellum of man. To the mind of the present writer this was a mistake. In questions of this sort the brain of man should be lost sight of as far as possible, since it is admitted to be an organ which has far outdistanced, in its evolution, the brain of the average mammal. It is only after many (if possible, all) mammals have been passed under review that man may be brought in to complete the list as the highest and most richly endowed.

Acting upon the conviction that the brain of man should not be taken as the standard, but that the simplest cerebella should form the starting-point, the present investigation was commenced with a search for the smoothest and least complicated mammalian cerebellum. This was discovered—thanks in part to the paper of Miss Ärnbäck-Christie-Linde—in the shrew and some of the bats. The shrew's was therefore taken as the initial cerebellum; and had it been possible, shrew embryos would have been examined with a view to noting the time and order of appearance of the various fissures. Owing to the difficulty of obtaining a sufficiency of shrews at all periods of intrauterine life, and because of the comparative ease with which rabbit embryos of all ages could be obtained, it was decided to start the embryological part of the investigation with the latter; and indeed the rabbit possibly served the purpose better than the shrew would have done, since the

cerebellum of the adult is built on simple lines, and yet there are parts in it in miniature which attain considerable magnitude in the larger mammals.

Seeing that the rabbit has a cerebellum so very much more simple than, say, that of the carnivora or the ungulates, it seemed well that the development of the fissures in one of the larger animals should also be watched. For this purpose, because of the little difficulty in getting material, the pig was chosen. As it happened, I was able to command material at practically any stage of development, and therefore the ages of both the rabbit and the pig embryos were, with one or two exceptions, absolutely known.

In addition to the examination of the developmental history of the fissures in two mammals, as many kinds of adult cerebella as could be obtained have also been compared.

In this paper are stated the results of the investigation, starting with an account of the appearance of the fissures in the rabbit. Until the time arrives when it is necessary to summarise results, the fissures and lobes will be known by the simplest designations, viz., figures and letters, to the end that the mind may not be influenced by the use of terms which have acquired a certain fixed significance.

Rabbit.

20 *days embryo*, 37 *mm. long* (fig. 3).—When the entire brain of the rabbit is examined at this stage, the cerebellum appears as two fairly prominent lateral projections jutting out on each side just below the mid-brain. A narrow connecting band is also seen running transversely between the mid-brain and the medulla. No fissures are visible to the naked eye; and on making a sagittal microscopic section in the mesial plane, the contour is even except at the posterior lower part of the cerebellar lamina, where a curved hem-like portion is marked off by a shallow fissure (fig. 3, IV.). This fissure makes its first appearance about the 18th day (fig. 1). The hem-like edge of the lamina is continued laterally over the lateral recess of the ventricle, to become continuous with a similar lip belonging to the medulla (fig. 2). It is apparently the Rautenlippe (His).

21 *days embryo*, 42 *mm. long* (fig. 4).—At this stage the cerebellum is very similar in appearance, to the naked eye, to that of the preceding day. The middle portion is somewhat more obvious, but no other visible change has occurred. A mesial sagittal section presents an outline which may be roughly described as triangular, the base of the triangle looking towards the medulla and pons. The two other sides of the triangle constitute what it will be convenient to call the anterior and posterior slopes of the cerebellum. Such a section again shows the fissure mentioned in the description of the 20 days embryo, but it is now farther removed from the extreme edge of the lamina (fig. 4, IV.). There is also a faint indication of another fissure at the upper part of the anterior slope (fig. 4, II.). It may be noted also that the future anterior medullary velum is better marked, as a result of a slight forward growth of the anterior part of the cerebellar lamina.

22 *days embryo*, 50 *mm. long* (figs. 5, 6 and 7).—A distinct advance has been made in development. The cerebellum is still very obviously made up of two prominent lateral masses, connected by a slighter intermediate portion, but the disparity in volume of these three parts is not so evident (fig. 5). In addition to a mere growth in size, other important changes have taken place. On an examination with the naked eye, it is clear that a portion of each lateral projection is about to be differentiated from the main bulk of the mass. This is shown by faint fissures, or rather grooves, slightly indenting the surface (figs. 5 and 6). Moreover, on sagittal section, the fissure, faintly foreshadowed in the 21 days embryo at the upper part of the anterior slope, is unmistakably a definite entity, and cuts the anterior slope into two almost equal parts (fig. 7, II.). The fissure which was the first to appear is still farther from the edge of the lamina (fig. 7, IV.). Further, there is the promise of a third fissure, this being indicated at this stage by a depression on the posterior slope (fig. 7, III.).

At this stage there are therefore evidences of three transverse fissures cutting at least the mesial part of the cerebellum into four portions; and in addition, indication of a subsequent complication of the lateral part.

23 *days embryo*, 50 *mm. long* (figs. 8, 9 and 10).—There is

now undoubted evidence of the rudiments of the three parts of the adult cerebellum. The central portion has increased considerably in volume, and there are shallow antero-posterior grooves marking off the future vermis and hemispheres.

The fissure on the posterior slope, which was not more than hinted at in the 22 days embryo, is now sufficiently deep to be visible by means of an ordinary pocket lens (fig. 8, III.). By the same means two transverse fissures are distinguishable on the anterior slope (fig. 9). The more superior corresponds to that already noticed in the previous stage. The lower one of the two is very shallow, and it is necessary to examine sections in order to be definitely certain that it is in reality the rudiment of a fissure.

Sagittal sections show three fissures, with the commencement of a fourth. The deepest corresponds to the one on the anterior slope of the 22 days cerebellum (fig. 10, II.).

In an embryo of 55 mm. in length, apparently some hours older than the one now under consideration, four fissures can be distinguished without any difficulty (fig. 11). It is desired to call especial attention to this stage, for it is believed that here we have the same number of fissures and lobes in the vermis as belong to the simplest form of mammalian cerebellum. Without applying any special names to these fissures and lobes, and without anticipating the attempt, which will be made later, to homologise them with similar features in the cerebella of other mammals, let it suffice for the present to designate the fissures as I., II., III. and IV., and the lobes as A, B, C, D and E, in each case commencing the enumeration anteriorly. Of the four fissures we may consider II. to stand in the first place of morphologic importance. It appears at an early date in all animals of which we have any embryological account. Moreover, it maintains its supremacy of depth throughout the whole of embryonic life, and on into the adult state. As has been pointed out by previous writers, it is the deepest and most constant fissure of the cerebellum.

In the hemisphere of the 23 days embryo a fissure is growing inwards towards fissure III. of the vermis, and is consequently dividing the most lateral part of the hemisphere into two some-

what unequal parts, the more posterior of which projects the more laterally.

24 *days embryo*, 59 *mm. long* (fig. 12).—To the naked eye the only change is one of increased size and greater distinctness of the fissures. In microscopic sections the fissures are obviously deeper than they were in the preceding stage, and there are indications of a future fissure in lobe A (fig. 12, *c*).

25 *days embryo*, 64 *mm. long* (figs. 13, 14 and 15).—The distinction of vermis and hemispheres is now very clear, and the fissures are more definite. Fissure I. is now of considerable depth and extends completely across the vermis. Fissures II. and III. have invaded the groove marking vermis from hemisphere. The fissures indenting the lateral part of the hemispheres are deeper and approach fissure III. a little more closely. Two pairs of additional fissures can be distinguished in lobe C, these being in the groove between vermis and hemisphere; one pair on the anterior slope, the other on the posterior (fig. 13, *a*, fig. 14, *b*).

In sections, the fissure whose beginning was seen in lobe A of the 24 days cerebellum has attained some depth, and another fissure is forming below it. The former may be called, for the present, fissure *c* (fig. 15).

27 *days embryo*, 67 *mm. long* (figs. 16, 17 and 18).—All the fissures are deeper and much more lateral in extent. The outstanding projection of the hemisphere is now very sharply marked off from the rest of the hemisphere, and when the cerebellum is viewed from the front, is becoming separated from a smaller eminence which has developed in connection with the roof of the lateral recess of the ventricle. The upper and larger projection we shall henceforth speak of as the *paraflocculus*, and the lower as the *flocculus* (fig. 17). These terms were suggested by Stroud, and are useful as indicating that the two structures are not equivalent to the flocculus of man. They arise each in its own particular way. The paraflocculus is a part of the hemisphere proper. The flocculus, on the other hand, has developed in the same manner as lobe E, *i.e.* in close relationship to the Rautenlippe.

The two lateral fissures on the posterior slope of lobe C have now run together in the middle line, and constitute a single

transverse fissure cutting the lobe into two parts (fig. 16, *a*, fig. 18, *a*).

28 *days* (?) *embryo*, 67 *mm. long* (figs. 19, 20 and 21).—On the posterior slope the only change is one of depth and distinctness of the fissures, there being no additions. But when the cerebellum is viewed from the front, it is evident that development has here gone on more rapidly. Fissure II. is now in the form of a crescent, extending almost to the borders of the hemisphere. The fissures in the lateral parts of lobe C are also longer and deeper than in the stage described above. An additional fissure has made its appearance in lobe B. The paraflocculus and flocculus are separated by a still deeper depression, and the paraflocculus is more sharply separated from the rest of the hemisphere (fig. 20).

For the sake of subsequent description, we may indicate the fissure on the posterior slope which divides lobe C into two parts by the letter *a* (fig. 19, *a*, fig. 21, *a*). That this fissure, shallow though it is even in the adult rabbit, is of considerable morphologic importance, is brought out in the section of this paper which deals with the various adult cerebella.

At birth.—At the time when the rabbit is born, the cerebellum is not a replica in miniature of the adult organ, since development progresses rapidly for some days after birth.

The cerebellum at birth has its principal fissures of considerable depth, and some of its accessory fissures have begun to form (figs. 22 and 23). The paraflocculus is now completely surrounded by a fissure, with the exception of its posterior part, where there is no fissure, but merely a shallow depression. The flocculus is also completely bounded by a fissure, but as yet its surface is not sculptured by any lines. Fissure III. fades away in the groove or depression behind the paraflocculus, as also does fissure *a* (fig. 22). Even in the adult the lateral parts of these fissures are not deep.

2 *days after birth.*—After birth, as has been said, there is a fairly rapid change for a few days, until the cerebellum comes to resemble the adult organ.

At the end of the second day the exact connection of the paraflocculus with the vermis is more precisely indicated. Fissure III. has grown more laterally, and it is now evident

that the paraflocculus really belongs to lobe D. Lobe E can hardly be said to extend into the hemisphere at all, fissure IV. disappearing in the groove between vermis and hemisphere. In the earlier stages this lobe was continuous, without any fissure of demarcation with the posterior medullary velum; but from the 22nd day onwards it projects backwards more and more, and consequently a limiting fissure is formed.

Adult cerebellum (figs. 24, 25, 26 and 28).—In giving a description of the adult cerebellum of any animal, it is both convenient and rational to take fissure II. as the dividing line between an interior and a posterior portion. In the cerebellum of the rabbit this fissure lies wholly in the anterior surface, a surface presenting a concavity into which the mid-brain fits. Fissure II. occupies a comparatively high position in the vermis, but slopes rapidly downwards and outwards across the hemisphere to its border. Its great depth is brought out best by making a sagittal section of the vermis (fig. 28, II.). Below this fissure lie some seven folia, the two uppermost of which are separated from the rest by a fairly deep fissure, which we have seen makes its appearance about the 23rd day of intrauterine life, and which has been referred to in the previous paragraphs as fissure I. This is the deepest fissure in that part of the vermis which lies anterior to fissure II. When traced outwards it is found to fail to reach the extreme lateral border of the hemisphere (fig. 24, I.). At a distance of two folia below fissure I. is fissure *c* (as referred to in the embryonic cerebella), not quite so deep as the former, but reaching the lateral border. From the presence of fissure *c* lobe A is divided into two portions, which may be called lobule A_1 below the fissure, and lobule A_2 above it. In lobule A_1 the folia do not extend farther in a lateral direction than to a line corresponding to the lateral limits of the vermis, *i.e.* no hemisphere can be distinguished in this part of the cerebellum. The question of whether there is a lingula in the rabbit corresponding exactly to that of man is one which seems best answered in the negative. There are certainly no folia adherent to the anterior medullary velum.

The vermis and hemispheres behind fissure II. are divided into three lobes (C, D and E), corresponding to those first in-

dicated in the 22 days embryo. Lobe C of the vermis usually carries eight folia, the majority of which are not carried directly into the hemisphere. The fissures between these folia are for the most part shallow, but two of them go to a greater depth than the rest, and are held to be of greater importance. Not only are they deeper than the others, but they appear at an earlier period. A reference to the 25 days embryo shows the forerunners of these fissures as two pairs of depressions; one on the anterior, the other on the posterior slope. In the adult brain the more anterior of the two occurs between folia 2 and 3 (counting from fissure II.), and on being traced into the hemisphere is seen to run for some distance parallel to fissure II., into which it ultimately opens. For more immediate purposes we shall speak of this fissure as fissure *b* (fig. 24, *b*, fig. 28, *b*). An offshoot leaves it in the groove between vermis and hemisphere, and curves outwards and backwards to the border of the hemisphere.

The other deep fissure of lobe C separates folium 6 from folium 7, and corresponds to the fissure resulting from the union of the pair of grooves on the posterior slope which first appeared on the 25th day, and which met in the vermis two days later. This has already been referred to as fissure *a*. In the adult it can be traced to the outermost limits of lobe C. If we recognise the fissures just mentioned as being of importance, it follows that lobe C must be looked upon as consisting of three portions or lobules. These, for the present, will be called lobules C_1, C_2 and C_3, starting the enumeration anteriorly.

The fissure between lobes C and D (fissure III.) is of moderate depth in the middle of the vermis (fig. 28, III.), but becomes very shallow at its lateral borders. In some specimens, however, there is not much difficulty in tracing its curved course outwards and upwards until it is lost in the deep fissure which separates the paraflocculus from the rest of the hemisphere. Lobe D is confined to the vermis, but in most specimens there is a low white ridge connecting it with the paraflocculus. Its surface is formed by three folia (sometimes a shallow fissure divides the lowest folium into two). Of the two fissures between these folia the lower is slightly the deeper, and the lower folium extends rather farther towards the hemisphere

than the other two. These facts are mentioned because of the belief that lobe D of the rabbit corresponds to two lobules in more complicated cerebella.

Lobe E is entirely confined to the inferior aspect of the cerebellum, and, like lobe D, has no direct continuation into the hemisphere.

The paraflocculus projects markedly from the lateral part of the hemisphere, from which it is separated by a deep fissure in front and above, and by a depression behind. It is entirely enclosed in a special fossa formed by the temporal bone (lobulus petrosus). As has been seen in tracing its development, it is really a piece of the hemisphere which has been cut off from the rest. Its developmental connection with lobe D is a point upon which it is desired to lay emphasis.

The flocculus consists of two or three folia, seen best when the cerebellum is viewed from the front, and lying anterior to the paraflocculus (fig. 25). It is in contact with the lateral extremity of lobe B, from which it is separated by a fissure which contains the middle cerebellar peduncle (fig. 24).

Lepus timidus (fig. 27).—The differences between the cerebellum of the rabbit and that of the hare are not perhaps very great, but they seem sufficiently important to merit mention. Lobes A, B and C are practically identical with those of the rabbit. Lobe C has again eight folia in the vermis, and a fissure, *a*, deeper than the rest, separates folia 6 and 7. This fissure is much more definite in hemisphere of the hare than it is in the rabbit.

The most important differences exist in lobe D. Here the number of folia is at least four, as against three in the rabbit; and the uppermost of the four is more definitely joined to the paraflocculus by a ridge which is slightly foliated along its upper border as it approaches the paraflocculus. This fact is mentioned as being the ground upon which the statement, that in the adult rabbit lobe D is connected with the paraflocculus, is based. In many specimens of the rabbit's cerebellum the adult connection is obscure; therefore the evidence afforded by the brain of the hare is welcome.

Before passing to the consideration of the development of the much more complicated cerebellum of the pig, it is perhaps

well to describe those adult cerebella which are built on the same or similar lines as obtain in the rabbit.

Sorex vulgaris (fig. 29).—As previously stated, apparently the simplest form of mammalian cerebellum is found in the shrew and some of the bats. An examination of sagittal sections of the shrew's cerebellum shows that the vermis is divided into fine lobes by four fissures, *i.e.* that the numerical condition as found in the brain of a rabbit embryo of about 24 days is maintained into adult life. Fissure I. is of moderate depth, but does not extend much, if at all, beyond the vermis. Fissure II., on the other hand, is very deep, and passes far out into the hemisphere. Its importance as a morphologic entity probably stands out more plainly in the shrew, and some few animals with a similar simple cerebellum, than it does in many of those in which the fissures are more numerous.

Fissure III. is the shallowest of the fissures of the vermis, and does not invade the hemisphere, or at any rate only slightly. There is a fissure in the hemisphere occupying a corresponding position, but microscopic sections show that there is no union of the two. Fissure IV. very early disappears in a series of sections. There is a projection, from the lateral part of the hemisphere, enclosed in a cell in the temporal bone, and doubtless corresponding to the paraflocculus of the rabbit. It seems very doubtful if a flocculus proper is developed.

Erinaceus Europæus (figs. 30, 31, 32, 33 and 34).—The hedgehog has a cerebellum which, in degree of complexity, may be considered to stand between that of the shrew and that of the rabbit. The vermis is divided into five lobes by four fissures, of which the second (fissure II.) is by far the deepest. This is visible in the vermis when the cerebellum is examined from above, but it leaves the dorsal to gain the anterior surface in the shallow groove which marks vermis from hemisphere. In the hemisphere it slopes rapidly downwards and outwards, in much the same manner as in the rabbit. Fissure I. is second in point of depth. Unlike the corresponding fissure in the rabbit, it reaches the borders of the hemispheres. Fissures III. and IV. are of moderate depth, and run into one another at the lateral boundary of the vermis.

Lobe A is, as a rule, beset by three folia, and, unlike the

corresponding lobe in the rabbit, is not divided by a fissure, *c*. Lobe B has never more than two folia, so far as can be gathered from an examination of some ten brains. Lobe C has five folia in the vermis, the four anterior of which are separated from the fifth by a fissure which corresponds to *a* in the brain of the rabbit, and which is continued into the hemisphere in a like manner. Lobe C, anterior to fissure *a*, becomes much expanded in the hemisphere, and its folia are increased in number. The folium behind fissure *a* retains its single character after its prolongation into the hemisphere (lobule C_3). Lobes D and E have each two folia, and are confined to the vermis.

The paraflocculus is fairly well marked, but does not produce the projection (lobulus petrosus) which is so prominent in the rabbit. The flocculus is rather smaller in the hedgehog than in the rabbit, but has approximately the same position and shape as in the latter animal. Sagittal sections show very clearly the close relationship of this lobule with the posterior medullary velum. As successive sections are examined in a direction away from the vermis, the velum is seen to become thickened by grey matter, which is directly continuous with the grey matter of the flocculus.

Talpa Europæa (figs. 35, 36 and 37).—In the vermis of the cerebellum of the mole, the four fundamental fissures are easily distinguished. Fissure I. is relatively a slightly greater depth than in either the rabbit or the shrew. It is, as usual, limited to the anterior surface, and runs almost vertically downwards in the line of boundary between vermis and hemisphere. Fissure II. is of very considerable depth. Its course is very sinuous, beginning on the anterior surface of the vermis, then taking a sharp bend backwards over the anterior superior border of the cerebellum to gain the dorsal surface, where it again turns sharply forwards and outwards to once more become included in the anterior surface, down which it runs almost vertically. Fissure III. is more distinct than in the shrew. Fissure IV. is of about the same depth as in Sorex.

Lobe A is almost entirely in the vermis, though it expands a little in the lower part of the anterior surface. Its surface possesses two fissures, the lower of which is more pronounced,

and may possibly be comparable to fissure *c* of the rabbit; a fissure not represented in the shrew. Lobe B is constricted in the vermis, where it is constituted by a single folium; but, owing to the erratic course taken by fissure II., it expands considerably in the hemisphere. That part of lobe C which is included in the vermis is comparatively extensive. This lobe is constricted at the junction of vermis and hemisphere, to become again extensive in the hemisphere itself. There are a few shallow fissures in the vermis, but one of them is of slightly greater depth than the rest, and corresponds to fissure *a*. Lobule C_3 consists of a narrow folium in the vermis, but expands in the hemisphere (fig. 35). This is a point of some moment, because in the more complicated cerebella, to be hereafter described, the expansion of this particular lobule in the hemisphere is a prominent feature. Lobes D and E are simple and call for no remark, except that a very thin and narrow band runs outwards and forwards from D, but is entirely hidden by the bulk of the hemisphere. This band extends as far forwards as the base of the paraflocculus.

The paraflocculus is in the form of a rounded lobule, with fissured surface, connected with the hemisphere by a narrow neck, and enclosed in a fossa of the temporal bone. No flocculus can be made out with certainty.

Mus decumanus (figs. 38, 39, 40 and 41).—The cerebellum of the rat is decidedly more complicated than that organ in the mole or hedgehog, and approaches more nearly that of the rabbit. Fissures I. and II. resemble those of the rabbit, except that I. always reaches the margin of the hemisphere, and the central part of II. is visible of the dorsal surface. Fissures III. and IV. are also very similar to those of the rabbit's cerebellum.

Lobe A is divided into two parts by a fissure, *c*, which is almost as deep as I. The upper part of this lobe (lobule A_2) has two folia; the lower part (lobule A_1) a variable number, separated by shallow fissures (fig. 41). Lobe B has two folia, and resembles the like lobe in the rabbit both in position and size. In lobe C there is a deep fissure, *a*, cutting the vermis to almost the same depth as fissure III., and separating a single folium, which is continued into the hemisphere. The rest of lobe C, which is contained in the vermis, has about three folia,

of which the most anterior is the largest. A definite fissure, *b*, cannot be made out. The hemisphere part of lobe C, anterior to fissure *a*, is of considerable size. Lobes D and E are confined to the vermis, the former having three folia, the latter two.

The paraflocculus projects from the hemisphere by a narrow neck, and is received into a fossa in the temporal bone, the investment of bone being less close than in the rabbit. There is a small, simple flocculus lying anterior to the paraflocculus, and touching the lateral borders of lobes A and B.

In the mouse (*Mus musculus*) the cerebellum very closely resembles that of the rat. The paraflocculus has possibly a slightly narrower neck and is more closely invested by bone.

Arvicola amphibius (figs. 42, 43 and 44).—The water-vole has a cerebellum which differs from that of the brown rat in minor points only. Its fissures are the same in number. As a rule, fissure I. does not quite reach the border of the hemisphere. Lobe A is divided by a fairly deep fissure, *c*. Lobule A_2 has two folia, lobule A_1 only one. Lobe B is narrow (as in the rat), and possesses two folia in the vermis. The vermis portion of lobe C has six folia, fissure *a* separating the sixth from the rest. The sixth folium (constituting the central part of lobule C_3) is continued into the hemisphere without either increase in size or accession of fissures. There is possibly a fissure, *b*, placed between the 2nd and 3rd folia, and continued outwards and forwards into the anterior surface of the hemisphere.

Lobes D and E are limited to the vermis, D having two folia, E only one. The paraflocculus and flocculus are almost identical with those in the rat.

The cerebellum of the field-vole (*Arvicola agrestis*, fig. 45) only differs from that of the water-vole inasmuch as its folia are fewer in number.

Pteropus poliocephalus (figs. 46, 47, 48 and 49).—A sagittal section through the middle of the vermis of this large bat discloses an arrangement of lobes not very unlike that of the hedgehog. The number of lobes and fissures is the same, but the folia are somewhat more numerous. Fissure I. is rather shallow, but fissure II. is of great depth; of fissures III. and IV. there is nothing remarkable to note. Lobe A is small and carries about three folia. There is apparently no fissure *c*. Lobe B, on the

other hand, is large, and is provided with five or six folia. There are seven folia in the vermis in lobe C, the seventh of which is separated from those anterior to it by an unmistakable fissure *a*. This single folium of the vermis is connected with two folia in the hemisphere. In Talpa, lobule C_3 increased in size in the hemisphere, but did not acquire any intrinsic fissures. In Pteropus it also expands, and in addition is sculptured by a fissure. It seems good to call attention to this point, in the light of other facts presently to be set forth. Lobes D and E belong exclusively to the vermis; the former has three folia, the latter two.

A noteworthy development appears in the paraflocculus. It consists of two parts, an upper and a lower. In the cerebella to be described in the following pages, the morphologic importance of this feature of the paraflocculus will become evident. The lower portion of the paraflocculus of Pteropus consists of a lobulus petrosus; *i.e.* it projects into a bony fossa and has a narrow neck. Both portions of the paraflocculus are foliated (figs. 46 and 47). The flocculus is small, and divided into two by an almost vertical fissure, only seen when the cerebellum is viewed from the side.

It is interesting to notice the great difference in the cerebellum of the Megachiroptera as shown in Pteropus, and that of the Microchiroptera as exemplified in *Vesperugo pipestrellus*, described and figured by Miss Ärnbäch-Christie-Linde (3). Vesperugo has a cerebellum not more complex than that of the shrew, whereas the cerebellum of Pteropus is as complex as that of the rabbit, or possibly more so.

Sciurus vulgaris (figs. 50, 51, 52 and 53).—The squirrel offers a most instructive degree of complexity in the fissures and lobes of its cerebellum, inasmuch as it exhibits a condition intermediate between the simpler forms, which have already been described, and those of a more complicated nature, still to be considered. For this reason the squirrel's cerebellum is peculiarly serviceable to anyone desiring to establish homologies in the lobes and fissures of mammals in general.

Fissure I. in the squirrel, as in the rabbit, stands second in point of depth. Also, as in the rabbit, it fails to reach the margin of the hemisphere. Fissure II. is far and away the

deepest of all the fissures. It is visible in the vermis, on the dorsal surface; but turning forwards abruptly, it runs down the anterior surface of the hemisphere, with only a slight degree of obliquity. Fissure III. is of considerable depth, and on reaching the border of the vermis, turns at almost a right angle, and runs nearly vertically downwards for some distance. Then, curving outwards and afterwards forwards, it is traceable into the deep fissure separating the paraflocculus from the hemisphere (figs. 51 and 52, III.). Fissure IV. resembles the same fissure in the rabbit, and offers no noteworthy feature.

The greatest interest centres itself in the lobes. Lobe A is of considerable size, consists of five folia, and is indented by a fissure, *c*, between the 2nd and 3rd folia. Another fissure, of a depth almost equal to that of *c*, occurs at a distance of two folia below the latter. Lobe B consists of three or four folia and is not very noteworthy. Lobe C has five folia in the vermis. The anterior four expand in the hemisphere, in the customary manner, and are separated from the fifth by a fissure, *a*. The fifth folium, instead of remaining as a single folium when traced into the hemisphere, as in the rabbit, suddenly expands and forms a not inconsiderable lobule, clearly differentiated from the rest of lobe C by a continuation of fissure *a* (fig. 52). Lobe D is relatively large and carries six folia. It is divided into two approximately equal parts by a fissure of a depth only slightly, if at all, inferior to that of fissure III. We shall refer to this latest fissure as *d* in future descriptions, as its value as a division between parts of the vermis is unquestionable (figs. 51, 52 and 53, *d*). That part of lobe D which lies above fissure *d* (and which we may call lobule D_1) consists of two folia, which becoming one, curves round the inferior border of lobule C_3, and losing its grey cortex, gives place to a white ridge passing directly to the upper part of the paraflocculus. That part of lobe D inferior to fissure *d* (known in the succeeding descriptions as lobule D_2) is not continued into the hemisphere. Lobe E is comparatively small, and consists of only one definite folium.

The paraflocculus is large when compared with the similar lobule of the cerebella already described, and presents the appearance of a rounded foliated band which has been doubled upon itself and placed with its long axis approximately in the

direction of the long axis of the head. The bend is in front (figs. 51 and 52). The flocculus is small and compressed. It lies below the paraflocculus, and can only be seen from the side or front of the cerebellum.

The points in the foregoing description to which it is desired to draw especial attention are as follows:—(1) The increasing complexity of lobe A as compared with the same lobe of all the other animals so far discussed. (2) The considerable expansion in the hemisphere of lobule C_3. (3) The division of lobe D into two parts by the fissure *d*, and the lateral continuation of the upper part (lobule D_1) of this lobe. (4) The arrangement of the paraflocculus in the form of two parallel portions, continuous with each other in front, and the connection of lobule D_1 with the upper portion of the paraflocculus.

The cerebella which remain to be described are all built on much more complicated lines than are those which have been passed under view in the foregoing sections. This being so the examination of the development of the fissures in an animal possessing a richly fissured and foliated cerebellum in adult life will greatly aid in the task of recognising homologies. Therefore pig embryos will be examined, with a view to noting the time and order of appearance of the various fissures.

(*To be continued.*)

REFERENCES.

(1) Ganser, S., "Vergleichend-anatomische Studien über das Gehirn des Maulwurfs," *Morpholog. Jahrbuch.*, Bd. 7, 1882, p. 591.

(2) Krause, *Die Anatomie des Kaninchens*, 1884.

(3) Ärnbäck-Christie-Linde, Augusta, "Zur Anatomie des Gehirnes niederer Säugetiere," *Anat. Ang.*, Bd. xviii., 1900, p. 8.

(4) Stroud, B. B., "The Mammalian Cerebellum," *Journ. Comp. Neurology*, vol. v., 1895, p. 71.

Ibid., "A Preliminary Account of the Comparative Anatomy of the Cerebellum," *Proc. Assoc. American Anatomists*, May 1897.

Ibid., "Morphology of the Ape Cerebellum," *Proc. Assoc. American Anatomists*, Dec. 1897.

(5) Kuithan, W., "Die Entwicklung des Kleinhirns bei Säugetieren," *S. B. Ges. Morph. Physiol.*, München, 1894, and *Münchener Medicinische Abhandlungen*, vii. Reihe, 6 Heft, 1895.

(6) Flatau, E., und Jacobsohn, L., "Handbuch der Anatomie und vergleichenden Anatomie des Centralnervensystems der Säugetiere," Berlin, 1899.

PLATES XII.–XVI.

EXPLANATION OF FIGURES.

In all the figures the same letters and figures are used for corresponding fissures or lobes. The application of the letters and figures is explained in the text.

p.m.v. (in figs. 1 and 3) = posterior medullary velum.
a.m.v. (in figs. 4 and 7) = anterior medullary velum.
ch.pl. (in figs. 1, 2 and 3) = choroid plexus.

All the sections (with the exception of that shown in fig. 2) are in the median plane and sagittal in direction.

Fig. 1. Rabbit embryo, 18 days, 21 mm. Mesial sagittal section through the cerebellar lamina.
Fig. 2. Same embryo. Sagittal section where the cerebellar lamina and the medulla are joining. *lat. rec.* = lateral recess.
Fig. 3. Rabbit embryo, 20 days, 37 mm. Mesial sagittal section through the cerebellar lamina.
Fig. 4. Rabbit embryo, 21 days, 42 mm. Mesial sagittal section.
Fig. 5. ,, 22 days, 50 mm. Posterior view. × 2.
Fig. 6. ,, 22 days, 50 mm. Left lateral view. × 2.
Fig. 7. ,, 22 days, 50 mm. Mesial sagittal section.
Fig. 8. ,, 23 days, 50 mm. Posterior view. × 2.
Fig. 9. ,, 23 days, 50 mm. Anterior view. × 2.
Fig. 10. ,, 23 days, 50 mm. Mesial sagittal section.
Fig. 11. ,, 55 mm. Mesial sagittal section.
Fig. 12. ,, 24 days, 59 mm. Mesial sagittal section.
Fig. 13. ,, 25 days, 64 mm. Posterior view × 2.
Fig. 14. ,, 25 days, 64 mm. Anterior view. × 2.
Fig. 15. ,, 25 days, 64 mm. Mesial sagittal section.
Fig. 16. ,, 27 days, 67 mm. Posterior view. × 2.
Fig. 17. ,, 27 days, 67 mm. Anterior view. × 2.
Fig. 18. ,, 27 days, 67 mm. Mesial sagittal section.
Fig. 19. ,, 28 days (?) 67 mm. Posterior view. × 2.
Fig. 20. ,, 28 days (?) 67 mm. Anterior view. × 2.
Fig. 21. ,, 28 days (?) 67 mm. Mesial sagittal section.
Fig. 22. Rabbit, 30 hours after birth. Posterior view. × 2.
Fig. 23. ,, 30 hours after birth. Anterior view. × 2.
Fig. 24. ,, adult. Anterior surface. × 2.
Fig. 25. ,, ,, Left lateral surface. × 2.
Fig. 26. ,, ,, Posterior surface. × 2.
Fig. 27. Lepus timidus. Posterior view. × 2.
Fig. 28. Rabbit, adult. Mesial sagittal section.
Fig. 29. Sorex vulgaris. Mesial sagittal section.
Fig. 30. Erinaceus Europæus. Mesial sagittal section.
Fig. 31. ,, ,, Anterior surface. × 2.
Fig. 32. ,, ,, Left lateral view. × 2.

Fig. 33. Erinaceus Europæus. Superior view. × 2.
Fig. 34. ,, ,, Posterior view. × 2.
Fig. 35. Talpa Europæa. Superior-posterior view. × 2.
Fig. 36. ,, Anterior surface. × 2.
Fig. 37. ,, Mesial sagittal section.
Fig. 38. Mus decumanus. Posterior view. × 2.
Fig. 39. ,, Superior view. × 2.
Fig. 40. ,, Anterior surface. × 2
Fig. 41. ,, Mesial sagittal section.
Fig. 42. Arvicola amphibius. Superior surface. × 2.
Fig. 43. ,, ,, Anterior surface. × 2.
Fig. 44. ,, ,, Mesial sagittal section.
Fig. 45. Arvicola agrestis. Mesial sagittal section.
Fig. 46. Pteropus poliocephalus. Superior view. × 2.
Fig. 47. ,, ,, Posterior view. × 2.
Fig. 48. ,, ,, Anterior surface. × 2.
Fig. 49. ,, ,, Mesial sagittal section.
Fig. 50. Sciurus vulgaris. Anterior surface. × 2.
Fig. 51. ,, Superior view. × 2.
Fig. 52. ,, Posterior view. × 2.
Fig. 53. ,, Mesial sagittal section.

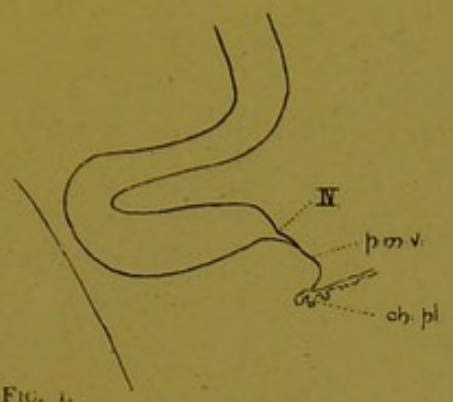

FIG. 1.

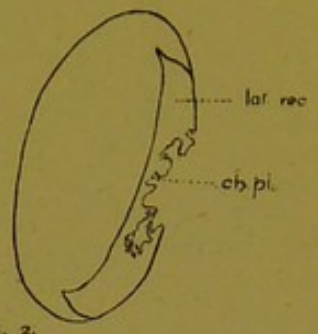

FIG. 2.

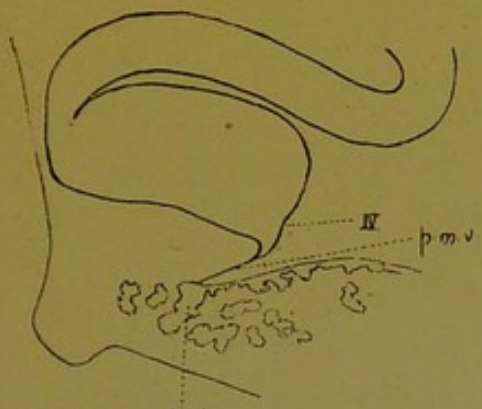

FIG. 3.

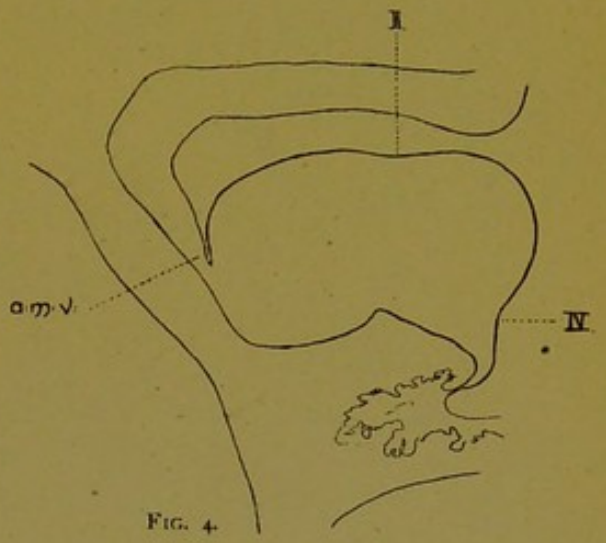

FIG. 4.

FIG. 5.

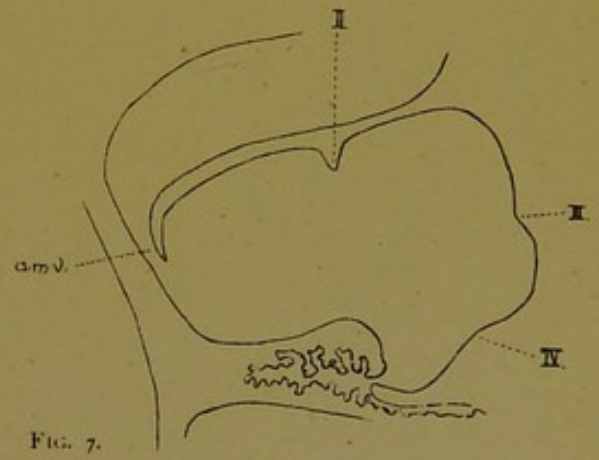

FIG. 7.

FIG. 6.

FIG. 8.

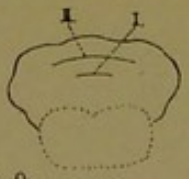

FIG. 9.

Professor O. CHARNOCK BRADLEY on the Development and Homology of the Mammalian Cerebellar Fissures.

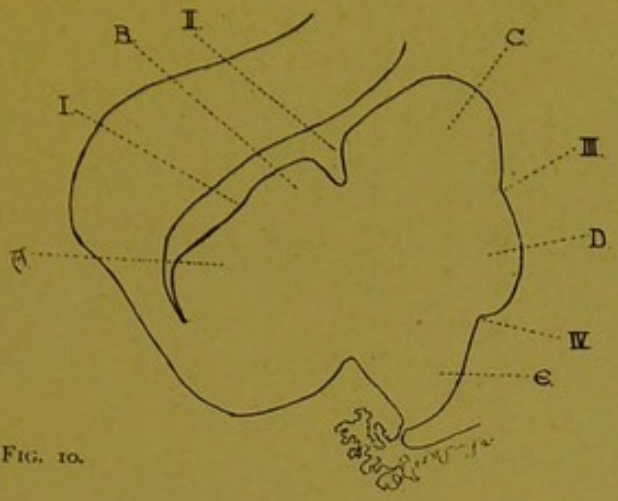

FIG. 10.

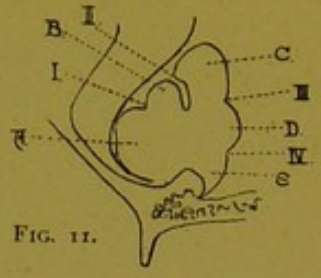

FIG. 11.

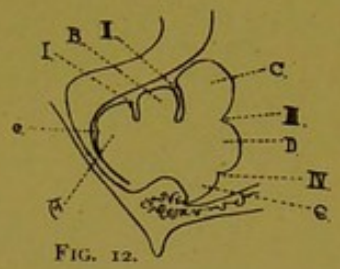

FIG. 12.

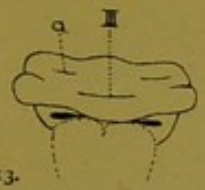

FIG. 13.

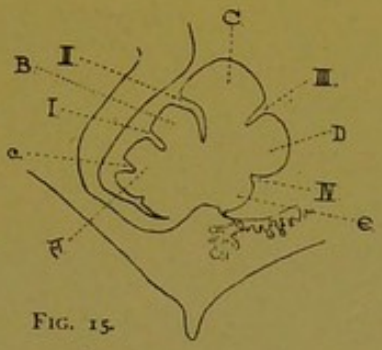

FIG. 15.

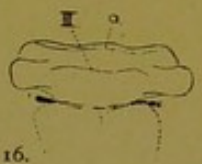

FIG. 16.

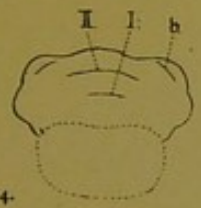

FIG. 14.

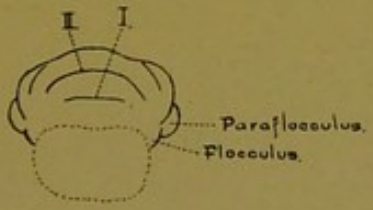

FIG. 17.

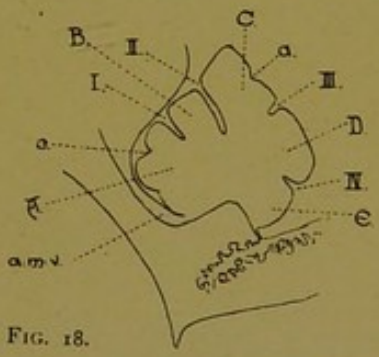

FIG. 18.

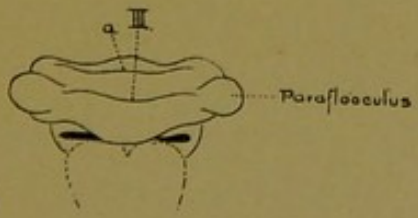

FIG. 19.

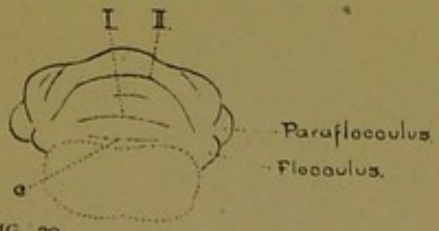

FIG. 20.

Professor O. CHARNOCK BRADLEY on the Development and Homology of the Mammalian Cerebellar Fissures.

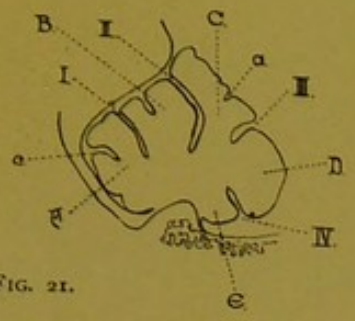

FIG. 21.

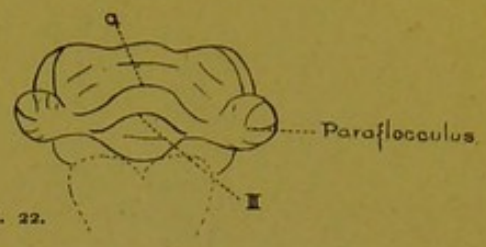

FIG. 22.

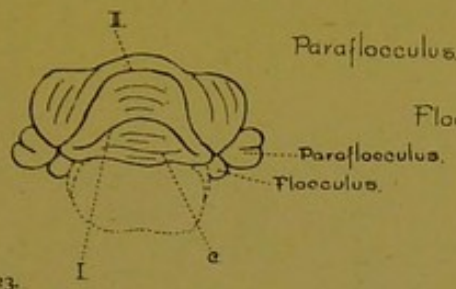

FIG. 23.

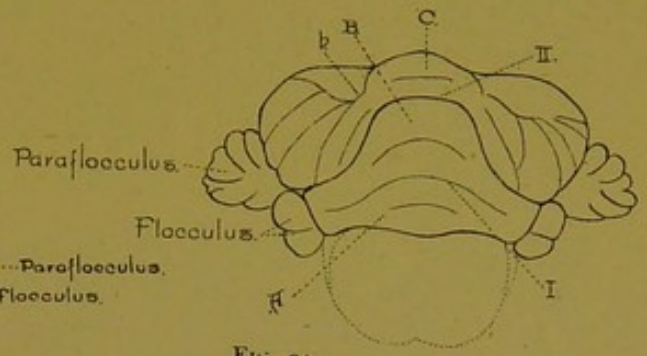

FIG. 24.

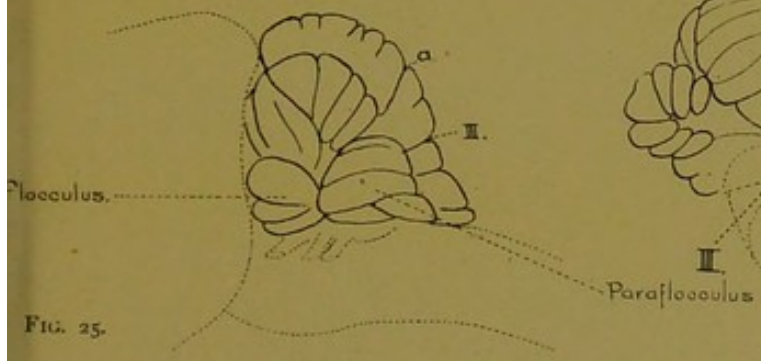

FIG. 25.

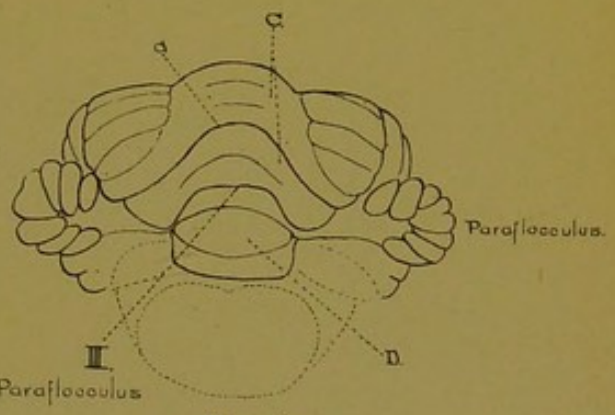

FIG. 26.

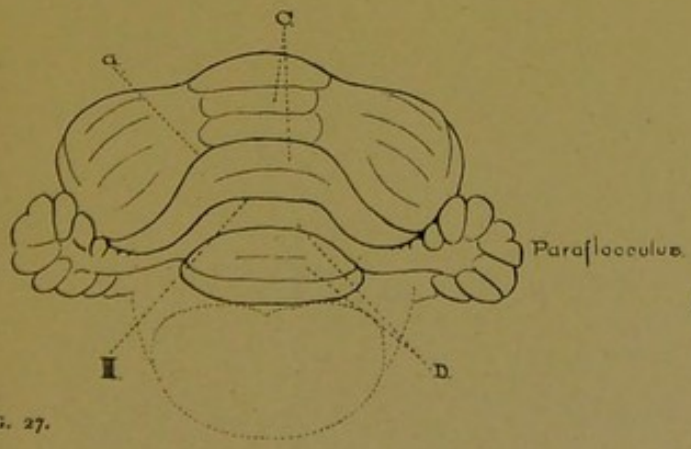

FIG. 27.

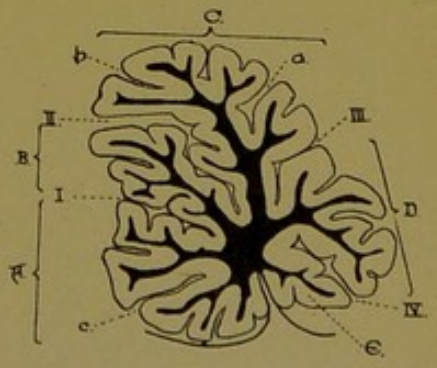

FIG. 28.

Professor O. CHARNOCK BRADLEY on the Development and Homology of the Mammalian Cerebellar Fissures.

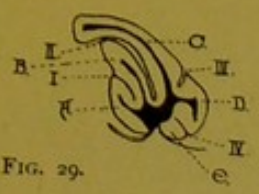

FIG. 29.

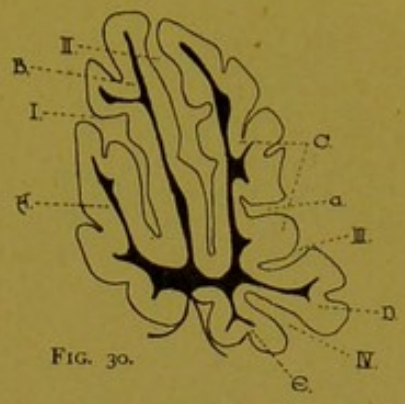

FIG. 30.

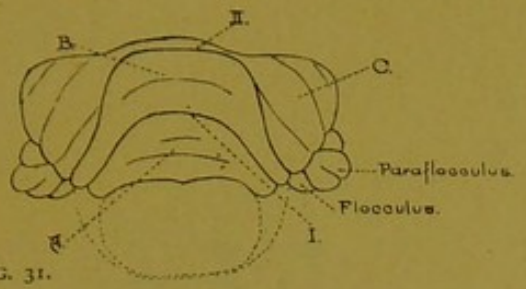

FIG. 31.

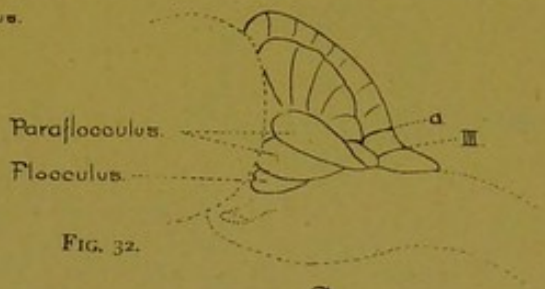

FIG. 32.

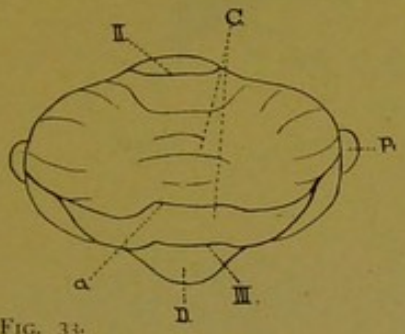

FIG. 33.

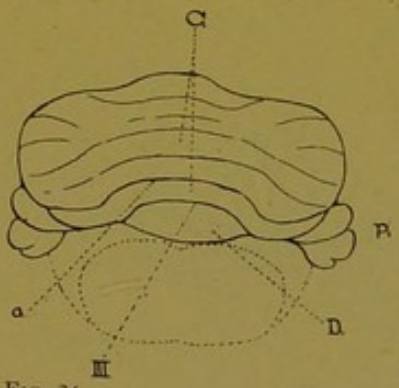

FIG. 34.

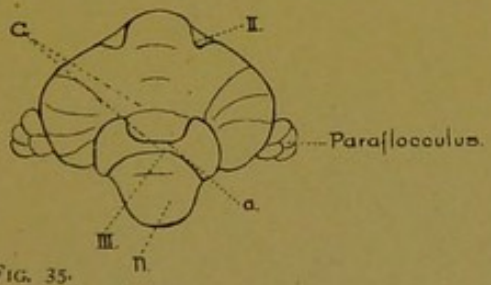

FIG. 35.

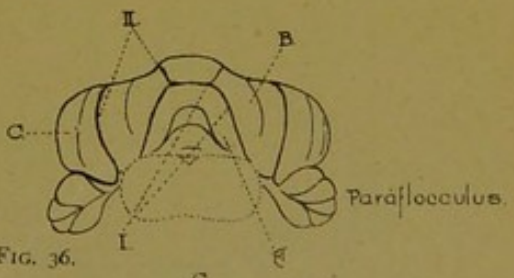

FIG. 36.

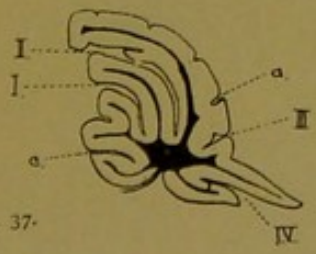

FIG. 37.

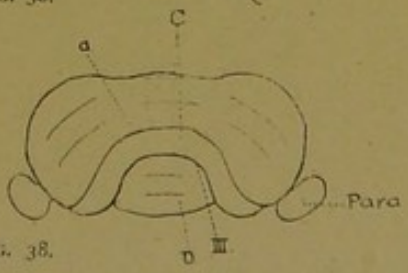

FIG. 38.

Professor O. CHARNOCK BRADLEY on the Development and Homology of the Mammalian Cerebellar Fissures.

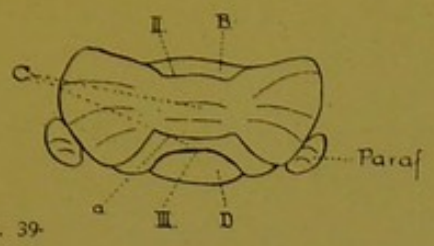

FIG. 39.

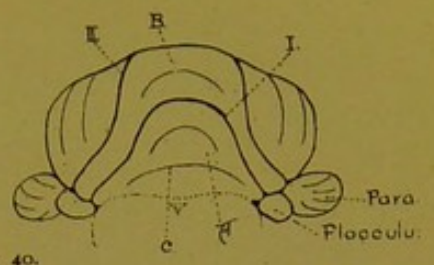

FIG. 40.

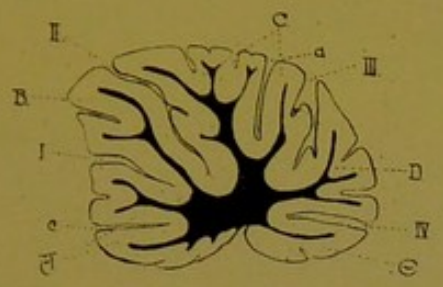

FIG. 41.

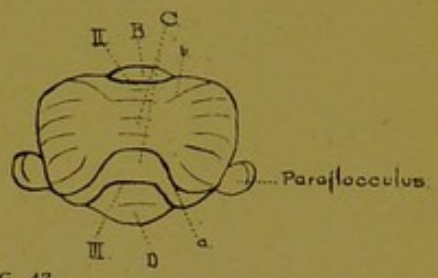

FIG. 42.

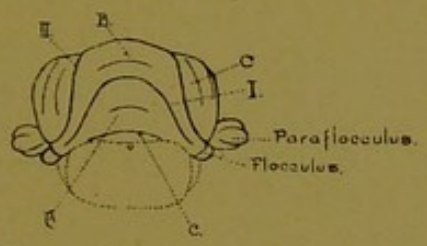

FIG. 43.

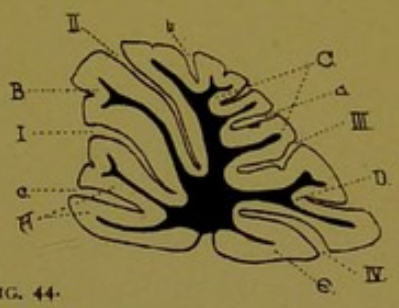

FIG. 44.

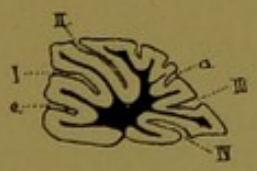

FIG. 45.

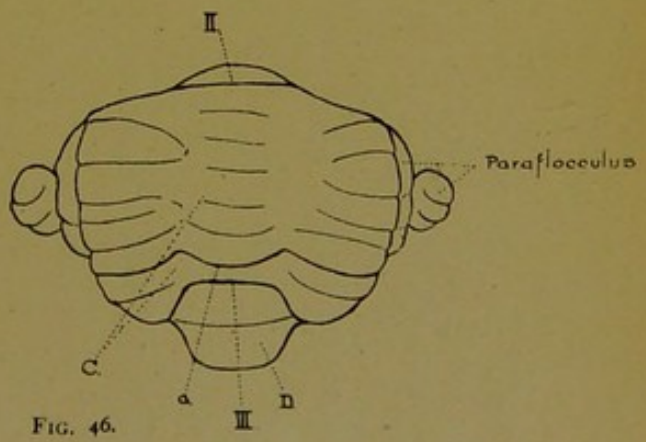

FIG. 46.

Professor O. CHARNOCK BRADLEY on the Development and Homology of the Mammalian Cerebellar Fissures.