

The determination of the influence of the eyeball on the growth of the orbit, by experimental enucleation of one eye in young animals / by W. Ernest Thomson.

Contributors

Thomson, William Ernest Francis.
Ophthalmological Society of the United Kingdom.
University of Glasgow. Library

Publication/Creation

London : [publisher not identified], [1898]

Persistent URL

<https://wellcomecollection.org/works/xtebak7d>

Provider

University of Glasgow

License and attribution

This material has been provided by This material has been provided by The University of Glasgow Library. The original may be consulted at The University of Glasgow Library. where the originals may be consulted. This work has been identified as being free of known restrictions under copyright law, including all related and neighbouring rights and is being made available under the Creative Commons, Public Domain Mark.

You can copy, modify, distribute and perform the work, even for commercial purposes, without asking permission.


**wellcome
collection**

Wellcome Collection
183 Euston Road
London NW1 2BE UK
T +44 (0)20 7611 8722
E library@wellcomecollection.org
<https://wellcomecollection.org>

1903

Professors to Kendrick
With Author's Compliments

GLASGOW
UNIVERSITY
LIBRARY.



The determination of the influence of the eyeball on the growth of the orbit, by experimental enucleation of one eye in young animals.

By W. ERNEST THOMSON, M.D.

(With Plates XVII and XVIII.)

WHEN visiting Moorfields in 1898, I observed that in suitable cases Mules's operation was preferred to enucleation. I had heard and read that enucleation in the young subject resulted in faulty development of the orbit, and it occurred to me that such introduction of a glass globe into the sclerotic ought to minimise failure of growth.

But on making inquiries I found that opinion was divided among surgeons as to whether such failure of development really occurred or not. There seemed, however, to be a feeling that although often stated, it was probably mythical.

There appeared to be little doubt that the subject was one which would be most profitably attacked from the experimental standpoint.

Shortly afterwards there appeared the Report of the Committee of this Society on the relative value of excision and the operations which have been substituted for it. This report* enumerated as one of the disadvantages which have been alleged against simple excision, "the faulty development of the orbit and face on the side from which the eye has been removed when the operation has been performed in

* *Trans. Ophthalmological Society*, vol. xviii (1898), page 256.

early life." The report goes on to say, "Though often referred to in ophthalmic literature, we have been unable to find any definite evidence in support of this suggestion." Then follows the statement that Mr. Gordon Byers (at that time Junior House Surgeon at Moorfields) had carefully measured, in adult life, the orbits in ten cases in which the eyeball was removed in childhood, and had found no appreciable arrest of development, at any rate of the external orifices of the bony walls of the orbit.

Further, in answer to a letter which I addressed to a well-known member of this Society, with reference to my proposed experiments, he replied as follows:—"I fancied the growth of the orbit question after removal of an eye early in human life had been practically settled, *viz.*, that supposing no artificial eye be used, the growth of the conjunctival and palpebral space would be more or less arrested, but the bones would do as they would if the eye were present."

Mr. Treacher Collins, who was a member of the Committee mentioned above, informed me that he knew of no experimental work done to settle this point, and remarked that although the Committee had been unable to find any evidence of faulty development of the orbital margins, there might still be failure of growth in parts of the orbit inaccessible to clinical examination.

Unable myself to find any literature on the subject of experimental enucleation, and convinced that it was quite reasonable to suppose that the eyeball should influence the growth of the orbit, I set about determining the point by experiments upon animals.

The animals chosen were rabbits, because they are the easiest to obtain and to maintain in the limited accommodation at my disposal. It would have been impossible to keep half a dozen dogs or cats for several months, although admittedly they would have been better for the purpose. Even the rabbits were most uncomfortably quarrelsome.

It was rather late in the year before work could be commenced, and there was considerable difficulty in obtaining the animals young enough. Eventually eleven rabbits were obtained, none of which were probably much over twenty days old. Their eyes were open, and they were just able to nibble, and to maintain themselves.

One eye in each of these animals was removed under ether. Antiseptic treatment was carried out. The orbits were plugged with wool soaked in perchloride of mercury solution.

Of the eleven rabbits six survived. It is worth noting that the six survivors were of the common grey wild species, while the five which died came of a domesticated stock, and were of varied colours. The operations were carried on between the 6th and 20th September, 1898.

The six survivors maintained a rapid growth and remained in perfect health during the time they were kept alive. They were eventually killed with chloroform, one in March, at the age of six months, two in April, and three in June, 1899.

It is to be regretted that I did not make an attempt to photograph them during life, as the asymmetry was exceedingly striking. Indeed, it early became obvious that the result would be a positive one, for the animals presented a markedly lop-sided appearance, which seemed to be largely due to loss of prominence of the supra-orbital ridge. After death, when the remaining eye was excised, it became clear that the whole orbital border was contracted on the anophthalmic side. During life several of the orbits were noticed to be occupied by a tumour-like growth, and this was afterwards found to present a modified glandular structure, presumably representing lacrymal gland.

Of the six heads, three were macerated for me by Mr. Eggleton, of the Kelvingrove Museum staff. The other three were kept in preserving fluids, and one was sawn through lengthwise.

It was originally my intention, in conjunction with my

friend Dr. Leslie Buchanan, who has helped me greatly at the operations and otherwise, to have removed the brains from these skulls in order to trace the atrophied fibres. But so much damage was done to the skull in the only case in which the experiment was tried, that this idea was abandoned.

I will now show you the skulls, both wet and dry, and also the skulls of two control* rabbits about the age at which these others were operated on (see Plates).

The anophthalmic orbit is smaller than its fellow in nearly all, if not in quite all, directions. I have made measurements (in millimetres) of both the wet and dry skulls as carefully as I could, but, of course, such measurements cannot be looked upon as absolutely accurate. Some of them are not even attempts at absolute measurement, but these are, relatively speaking, fairly correct as regards the comparison of the two sides. These measurements have all been put into tabular form (see Tables I, II, and III).

It was especially difficult to estimate the depth of the orbit, because the lower orbital margin on the anophthalmic side seems to be slightly nearer the middle line than that of the normal side (Fig. 7), and cannot therefore be taken as an accurate fixed point relatively to the orbital depth. You will, however, probably agree with me that, apart from actual measurements, the curve of the orbital floor is encroached upon all round, forming as it were the surface of a smaller sphere than that of the normal side (Figs. 10 and 11).

Regarding the tabulated figures as a whole, one is struck by the frequent occurrence of the figure 2 and a fraction as expressing the difference between the chief normal and anophthalmic measurements of the bones in the dry state.

Look at Table II, where the three heads 3, 4, and 5 have been measured *after maceration*. In the antero-posterior direction the differences between the two sides are 3, 1·2, and 2·8, average 2·3. In the vertical, 2·9, 2·2, and 2·9,

* The control skulls are not included amongst the plates.

average 2·6. From the top of the orbit to the last molar tooth, 3·7, 2·3, and 2·3, average 2·7. In three other columns there are averages of 2·5, 2·3, and 2·3.

I do not intend to spend time over the figures in detail, but to deal rather with the averages. Full particulars will be found in the tables of measurement. The orbital margins were measured in their greatest antero-posterior and vertical dimensions.* What I may call control measurements were from the top of the orbital margin to the last molar tooth, and from the junction of the zygomatic process and malar bone to the bottom of the supra-orbital notch and post-orbital fissure respectively. The letter N stands for normal, A for anophthalmic, and D for difference between the normal and anophthalmic sides.

The mean of the average differences between the direct antero-posterior and vertical measurements of the two sides is 2·495, and in the case of the control measurements 2·585.†

In order to ascertain if the lower or zygomatic-malar portions were affected, the distance was taken from a point in the middle line of the head between the orbits to the last molar tooth on each side. The average difference here is only ·70 for three skulls. I think this is what one would expect, for the lower portion of the orbit will be largely influenced by the growth of the teeth and muscles of mastication, especially of the temporal muscle, which in the rabbit occupies a considerable portion of the combined orbito-temporal fossa.

It seems clear that the length and height of the bony margins of the orbit are almost uniformly diminished, and that facial deformity has resulted.

Regarding the depth of the orbit, apart altogether from the bony ridges forming its margins, I have found, as before mentioned, no satisfactory way of getting fixed points.

* The antero-posterior measurement is from the orbital angle anteriorly to the tubercle, giving attachment to a slip of the temporal muscle posteriorly. The vertical measurement is the greatest inside measurement.

† It is a curious coincidence that in Table II the mean of the average differences in columns 1 and 2 only is the same as that in columns 1, 2, 3, 6, 7, 8, viz. 2·495.

But even allowing for the deformity caused by the droop of the ill-developed and distorted supra-orbital ridge (figs. 6, 7, 8, 9), it appears to me that the whole cavity is diminished in capacity (figs. 10 and 11).

Turning to the question of the share borne by the *soft structures* of the orbital margin in this diminution (see Table I); the measurements of the heads with soft parts were more difficult, and are thus less accurate than the others, but it may be assumed that the figures for the two sides are relatively not far from the truth. I need only refer to the averages. The average difference in the antero-posterior direction is 4, in the vertical 3.35. The mean of these two is 3.67. Regarding only heads 3, 4, and 5, so as to have a strict comparison between wet and dry, the figure is 3.540 *wet*, and 2.495 *dry*. Difference 1.045. This figure 1.045 represents the average deficiency in the anophthalmic orbit due to the soft parts (see Table III).

It thus turns out that the greater share of the faulty development (2.495 mm.) rests with the bone, and the lesser (1.045 mm.) with the soft parts, which is contrary to expectation.

Taking it as definitely proved that in the rabbit removal of an eye in youth results in deficient and irregular growth of certain bones of the skull and face, what is to be said regarding the probability of similar changes in the human subject?

In the rabbit the supra-orbital ridge is a more or less isolated thin plate of bone overhanging the orbit, not likely to be influenced by parts other than the eye, although indeed, the post-orbital process gives attachment to the strong *attrahens aurem* muscle. In the human subject it forms a more solid portion of the frontal bone, which is itself in relation with the cranial contents, and likely to be influenced as much by the growth of the cerebrum as by that of the eye.

We might expect, therefore, that in the rabbit, as compared with man, the diminution of the vertical diameter would be excessive.

Table II (columns 1 and 2) on the whole confirms this expectation, for 2.66 is a greater proportion of the average total height on the normal side (20.63) than is 2.33 of the average total length on the normal side (25.10).

I cannot think of any such difference between rabbit and man to account for the loss in the antero-posterior direction, and I should suppose that since the antero-posterior orbital length is diminished in the rabbit, the corresponding measurement is likely to be diminished in man, a remark that applies also to the orbital depth.

Lastly, as to the comparative age of operation. The rabbit's average life may be taken as seven years, or 2555 days. Taking sixty years or 21,900 days as the average life of human beings who reach maturity, we find that, by simple proportion, 171 days or about six months corresponds to twenty days in the rabbit. That is, an operation at the twentieth day corresponds to an operation on a child of six months.

But calculation by simple proportion does not take account of the fact that the rabbit matures relatively sooner than the human being. The former is sexually mature at six months, or one fourteenth of its life; the latter at, say, twenty years, or one third of his life.

Looking at it in this light, a rabbit operated on at twenty days corresponds to a child operated on at between two and two and a half years.

The conclusion, then, is that in certain animals the growth of the orbit is influenced by the presence of the eye. Whether the same holds good in man and animals, such as dogs and cats, and the apes, is at present a matter of inference. Personally, I can hardly conceive that such a markedly positive result in rabbits is compatible with a negative result in the others.

TABLE I.—Heads 1, 2, 3, 4, and 5 (*Wet*, i. e. *with Soft Parts, except Skin*).

	1. Antero-posterior measurement, from anterior angle of orbit to tubercle posteriorly. Inside measure.			2. Greatest vertical measurement. Inside measure.			3. From top of orbit to posterior cusp of last molar tooth.			4. From mid-line of head between the orbit to posterior cusp of last molar tooth.		
	N.	A.	D.	N.	A.	D.	N.	A.	D.	N.	A.	D.
	Head 1	21.5	16.5	5	20.5	16.5	4	32.5	29.5	3	31	31
Head 2	20.5	17	3.5	19.5	16.5	3	32	29.5	2.5	30	30	0
Head 3	20	16	4	19.5	16	3.5	Lower jaw present.	Lower jaw present.	Lower jaw present.	Lower jaw present.	Lower jaw present.	Lower jaw present.
Head 4	19.5	16	3.5	19.5	16.5	3	33	30.5	2.5	31.5	31	0.5
Head 5	20.5	16.5	4	20.25	17	3.25	32.5	30.5	2	31	30.5	0.5
Average	20.4	16.4	4	19.85	16.5	3.35	32.5	30	2.5	30.87	30.62	0.25

Note.—N. = Normal orbit. A. = Anophthalmic orbit. D. = Difference between N. and A. All measurements are in millimetres.

TABLE II.—Heads 3, 4 and 5 (Dry, viz. Soft Parts removed by Maceration).

	1. Antero-posterior measurement, from anterior angle of orbit to tubercle, posteriorly. Inside measure.			2. Greatest vertical measurement. Inside measure.			3. From top of orbit to posterior cusp of last molar tooth.			4. From mid-line of head between the orbits to posterior cusp of last molar tooth.		
	N.	A.	D.	N.	A.	D.	N.	A.	D.	N.	A.	D.
	Head 3 . . .	25.2	22.2	3	20.6	17.7	2.9	30.5	26.8	3.7	29.6	28.6
Head 4 . . .	24	22.8	1.2	20.5	18.3	2.2	31.6	29.3	2.3	30	29.4	0.6
Head 5 . . .	26.1	23.3	2.8	20.8	17.9	2.9	32	29.7	2.3	30.6	30.1	0.5
Average . . .	25.10	22.76	2.33	20.43	17.96	2.66	31.36	28.6	2.76	30.06	29.36	0.70

	5. From mid-line of head between orbits, at right angles to it, to the superior orbital margin.			6. From anterior junction of zygoma with temporal process of malar bone, to bottom of post-orbital fissure.			7. From the same point to the bottom of the supra-orbital notch.			8. Approximate orbital depth.		
	N.	A.	D.	N.	A.	D.	N.	A.	D.	N.	A.	D.
	Head 3 . . .	11.3	11.3	0	18.0	15.4	2.6	20.5	18	2.5	17.5	15
Head 4 . . .	10.1	11.3	+1.2	19.2	17	2.2	21.8	19.3	2.0	18.1	15.8	2.3
Head 5 . . .	11.1	11.1	0	20.7	17.8	2.9	20.9	18.3	2.6	18.5	16.4	2.1
Average . . .	10.83	11.23	+ .4	19.30	16.73	2.55	21.06	18.7	2.36	18.03	15.73	2.30

Mean of average differences in Columns 1, 2, 3 and 6, 7, 8 = 2.495.
 " " " " " " 1 and 2 only = 2.495.

Note.—N. = Normal orbit. A. = Anophthalmic orbit. " D. = Difference between N. and A. All the measurements are in millimetres.

TABLE III.—*Comparison of Heads 3, 4, and 5 in the Wet and Dry States to show the Relative Failure of Development of Bone and Soft Parts (Vertical and Antero-posterior Measurements only).*

Mean of the average antero-posterior and vertical differences, in millimetres	WET =	{ 3.540, which is the average difference in length and height due to BONE + SOFT PARTS.
Ditto, ditto	DRY =	{ 2.495, which is the average difference in length and height due to BONE only.
Subtract DRY from WET.	=	{ 1.045, which is the average difference in length and height due to SOFT PARTS only.

Postscript.—I have refrained from speculation as to the cause of the failure of growth, and have left this question entirely open. It is interesting to remember, however, that the post-orbital process is malformed *and drawn towards the orbital cavity* on the anophthalmic side (Figs. 6, 7, and 11), in spite of the strong pull of the *attrahens aurem* muscle in the opposite direction.

Dr. Thomas H. Bryce has pointed out, after an anatomical examination of the skulls, that the uniformity of the developmental failure in all the bones entering into the formation of the orbit is very marked. (*November 8th, 1900.*)

THE UNIVERSITY OF CHICAGO

PHYSICS DEPARTMENT

PHYSICS 351

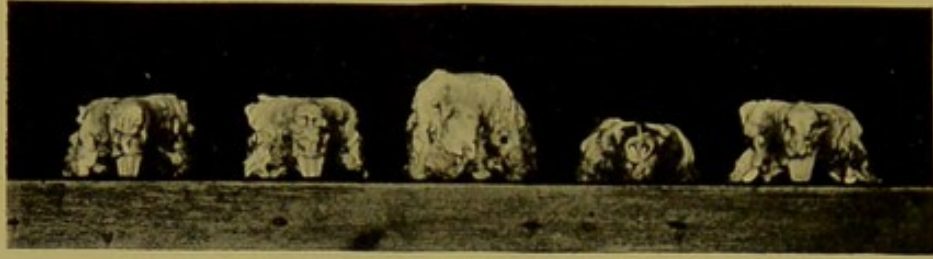

Fig. 1.

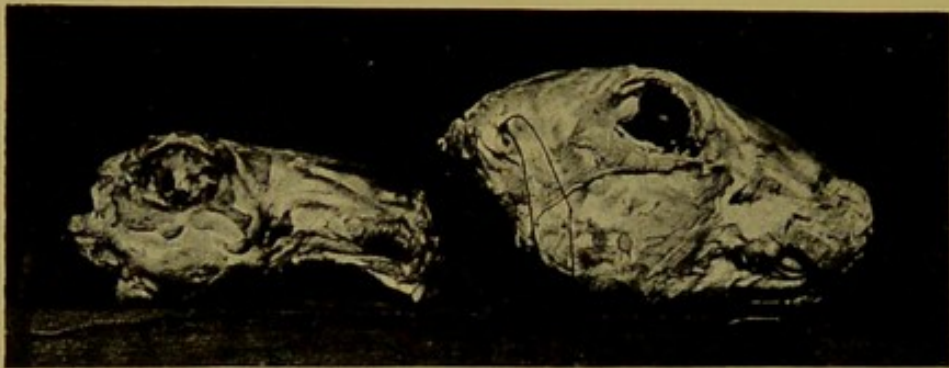


Fig. 2.

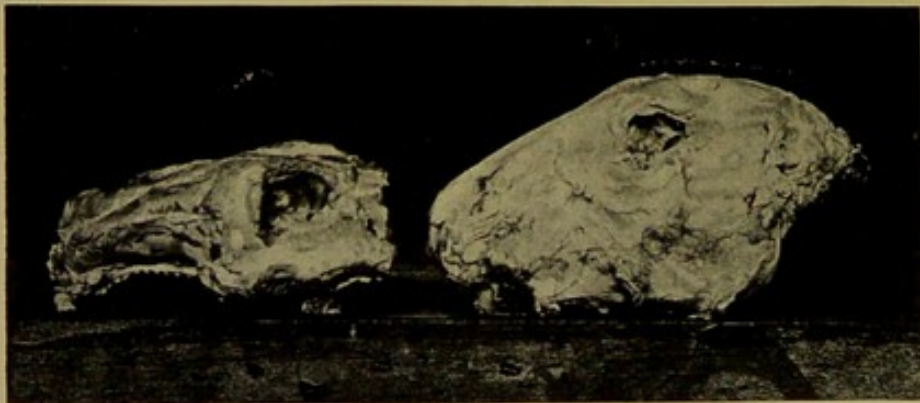

Fig. 3.

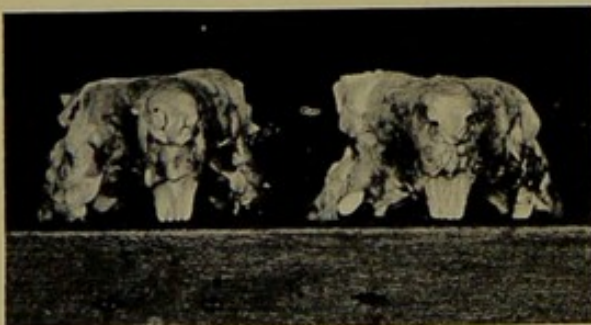


Fig. 4.




Fig. 5.

PLATE XVII.

Illustrates Dr. Ernest Thomson's paper on The Determination of the Influence of the Eyeball on the Growth of the Orbit, by Experimental Enucleation of one Eye in Young Animals (p. 258).

FIG. 1.—Five heads with the soft parts (skin excepted). Seen from before. The central head has the lower jaw attached. All the heads show deformity.

FIG. 2.—Two heads with soft parts, normal side. One head has lower jaw attached.

FIG. 3.—The same, anophthalmic side. The difference between the orbits in this and Fig. 2 is well marked.

FIG. 4.—Two heads with soft parts. Seen from before.

FIG. 5.—The same; from behind. In this and the previous figure the droop of the supra-orbital ridge is most marked.

1872

...

...

...

PLATE XVIII.

Illustrates Dr. Ernest Thomson's paper on The Determination of the Influence of the Eyeball on the Growth of the Orbit by Experimental Enucleation of one Eye in Young Animals (p. 258).

FIG. 6.—Dry skull. Seen from above. This photograph very truly represents the deformity of the frontal bone. Notice the extreme deformity of the supra-orbital portion, and especially of the post-orbital process.

FIG. 7.—Dry skull. Seen from below. The left is the anophthalmic side. The supra-orbital ridge is visible on this side, because of its drooping. The photograph, however, in this case exaggerates: on the normal side some of the supra-orbital ridge can be seen from below, although the photograph fails to show it.

FIG. 8.—Dry skull. Seen from before.

FIG. 9.—Dry skull. Seen from behind. Notice in this and previous figure the great alteration in the position of the supra-orbital ridge.

FIG. 10.—Dry skull, normal side.

FIG. 11.—Dry skull, anophthalmic side. Great care was taken to photograph these two sides from the same point of view. Notice that practically every portion of the anophthalmic orbit is deformed.

NOTE.—Figures 6—11 are all of the same skull.

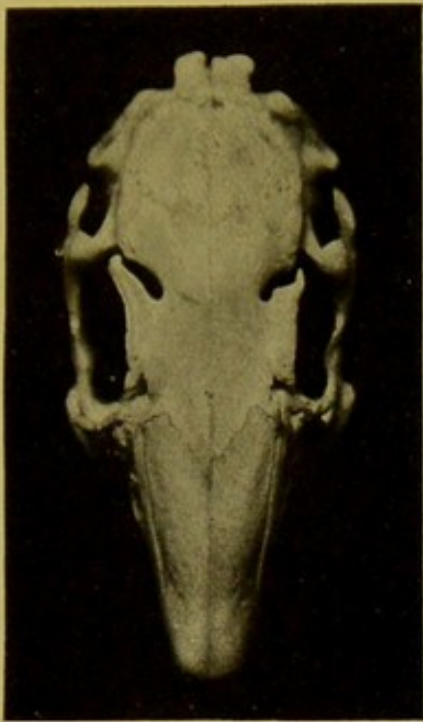


Fig. 6.

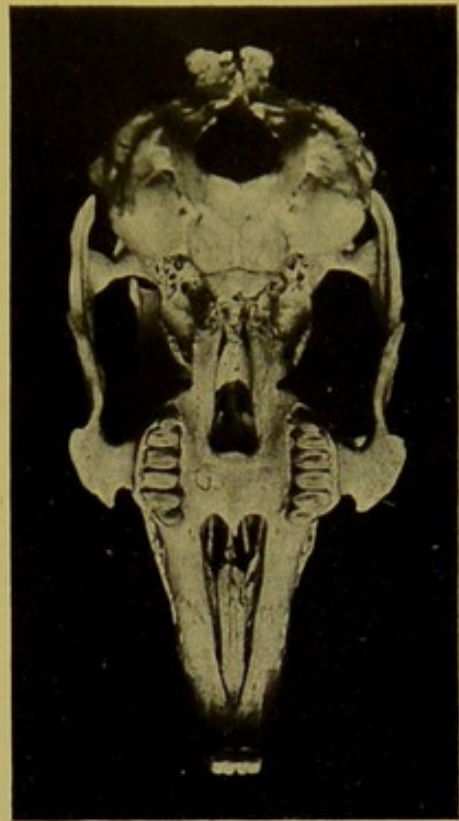


Fig. 7.

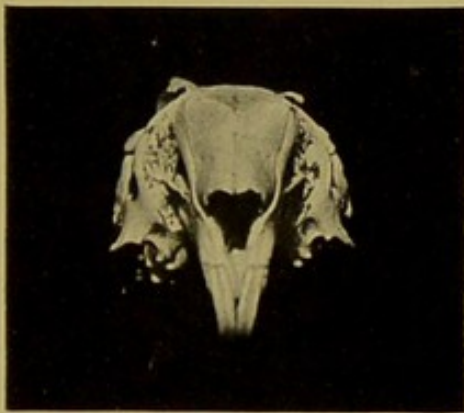


Fig. 8.

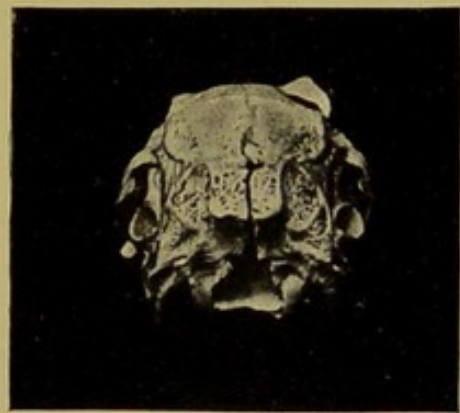


Fig. 9.

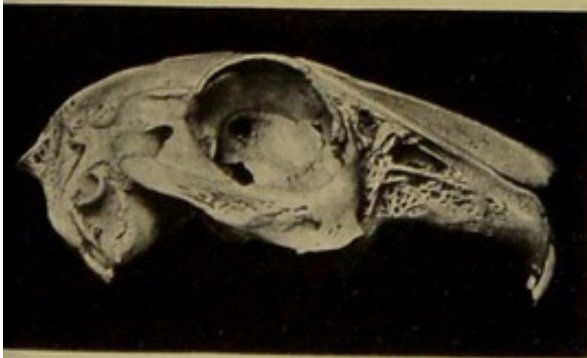


Fig 10.

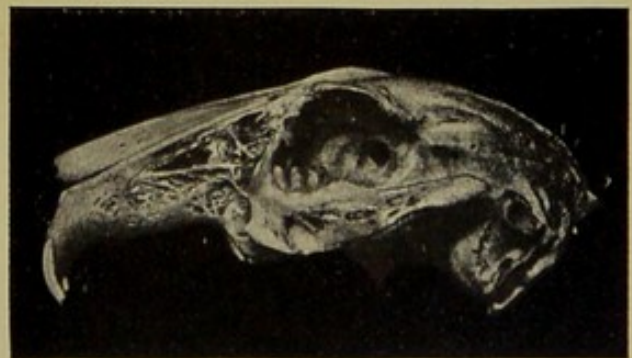


Fig. 11.

