

The catarrhal and suppurative diseases of the accessory sinuses of the nose / by Ross Hall Skillern.

Contributors

Skillern, Ross Hall, 1875-
University of Glasgow. Library

Publication/Creation

Philadelphia, PA ; London : J.B. Lippencott, [1913]

Persistent URL

<https://wellcomecollection.org/works/mcznfdqa>

Provider


University of Glasgow

License and attribution

This material has been provided by This material has been provided by The University of Glasgow Library. The original may be consulted at The University of Glasgow Library. where the originals may be consulted. Conditions of use: it is possible this item is protected by copyright and/or related rights. You are free to use this item in any way that is permitted by the copyright and related rights legislation that applies to your use. For other uses you need to obtain permission from the rights-holder(s).

**wellcome
collection**

Wellcome Collection
183 Euston Road
London NW1 2BE UK
T +44 (0)20 7611 8722
E library@wellcomecollection.org
<https://wellcomecollection.org>



189



John Donald, M.D.

Glasgow
University Library





Presented

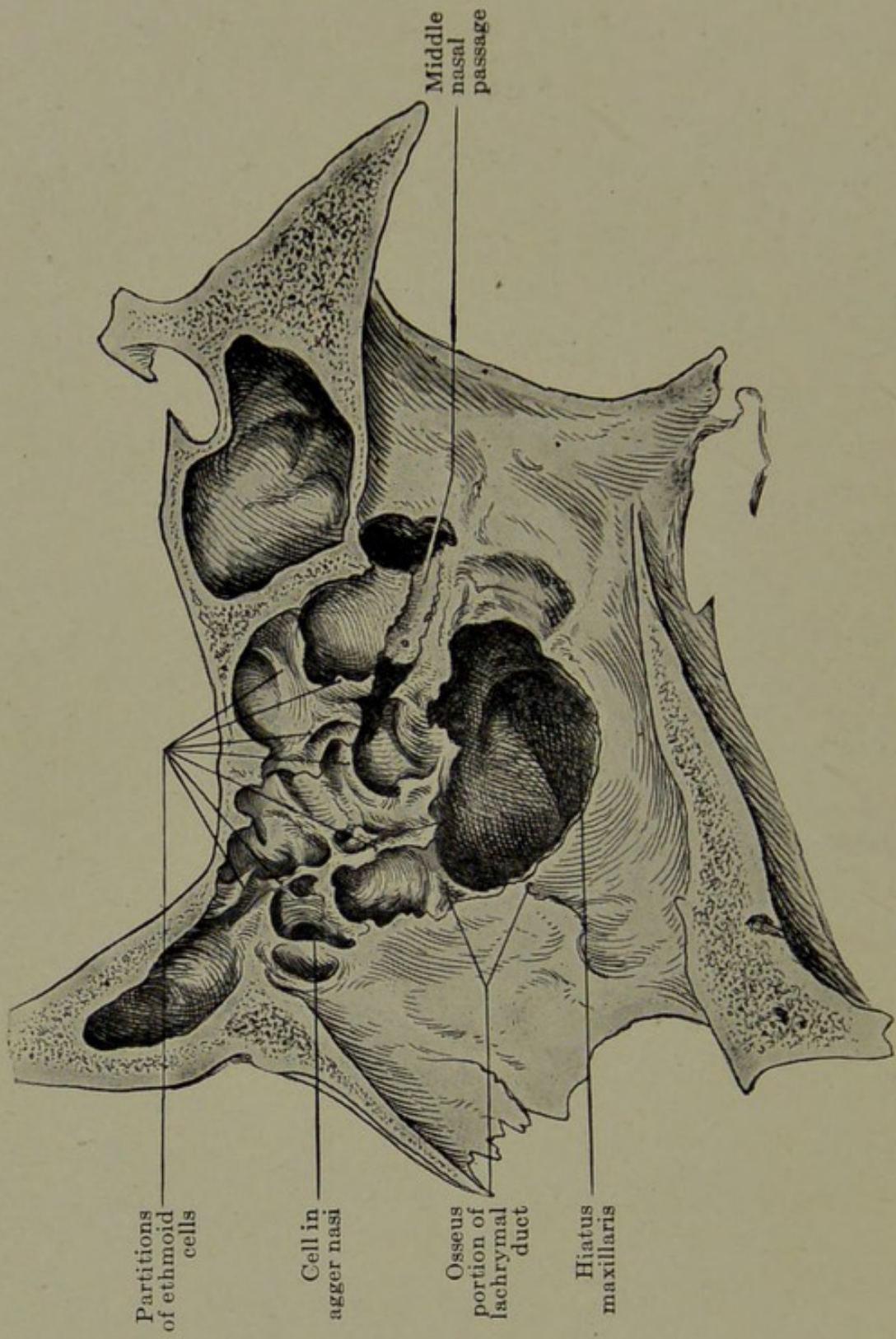
435-1942

912-8.21

Store

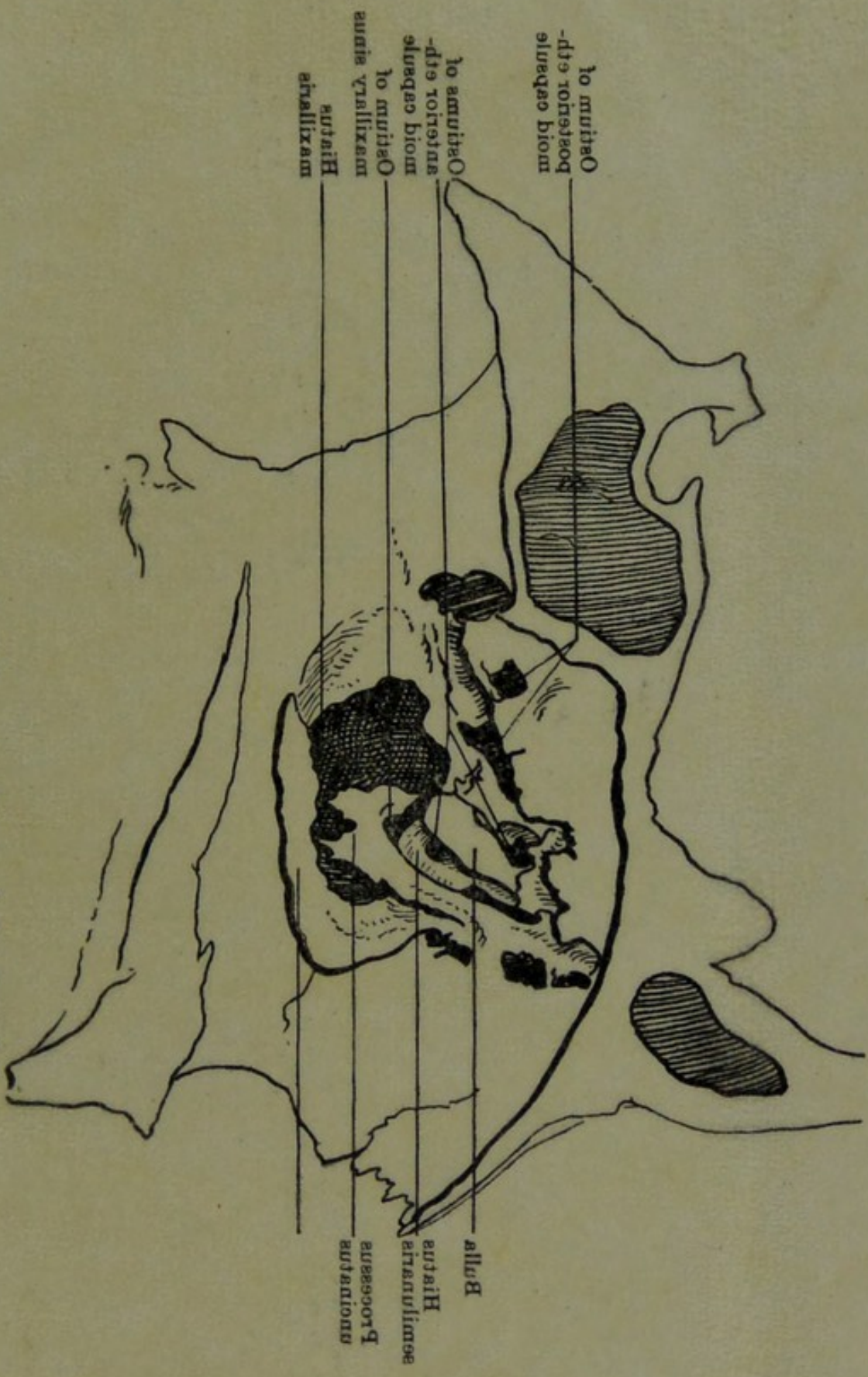

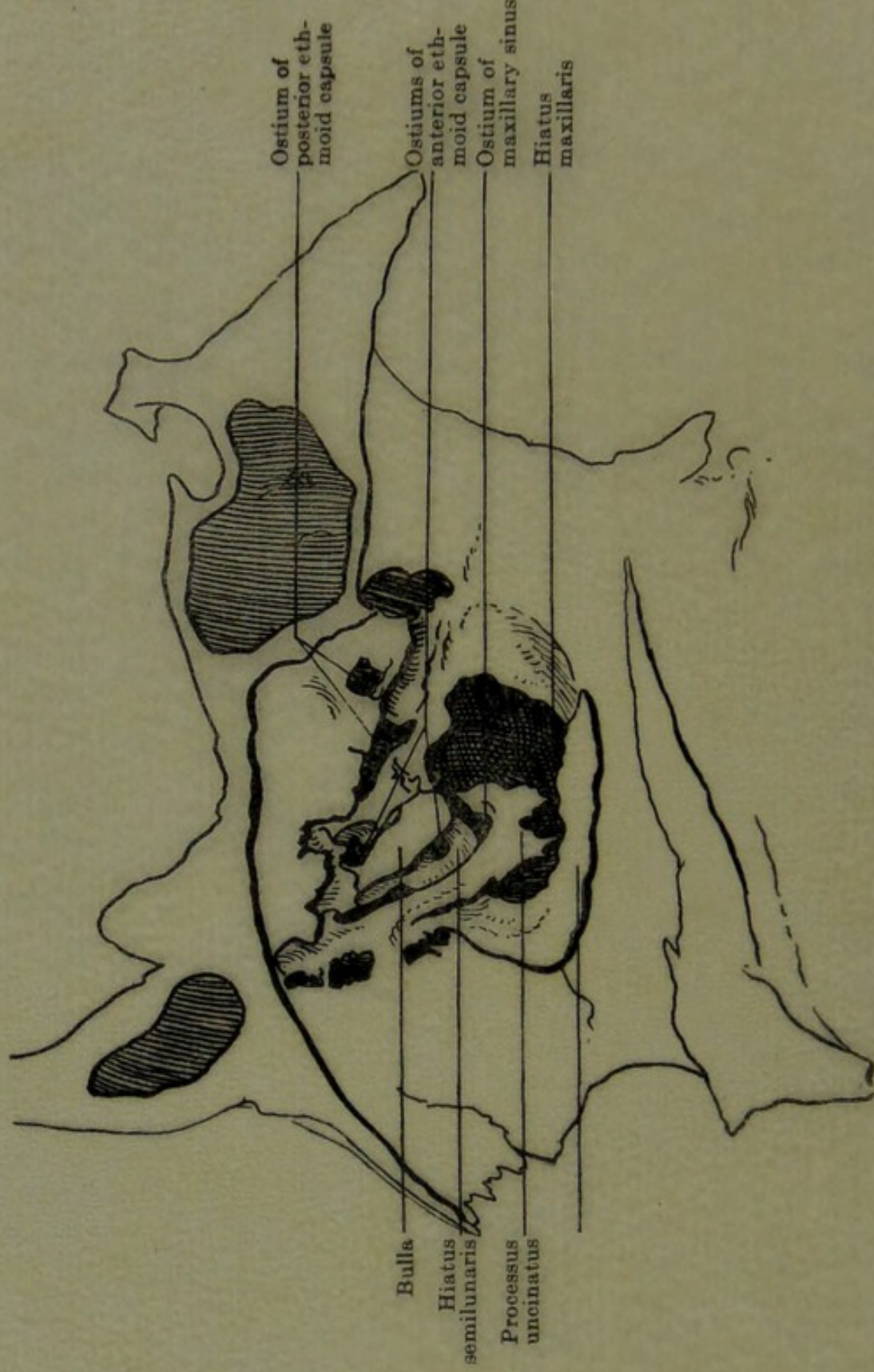




D, Lateral wall of nose. All structures being removed to orbital plate.

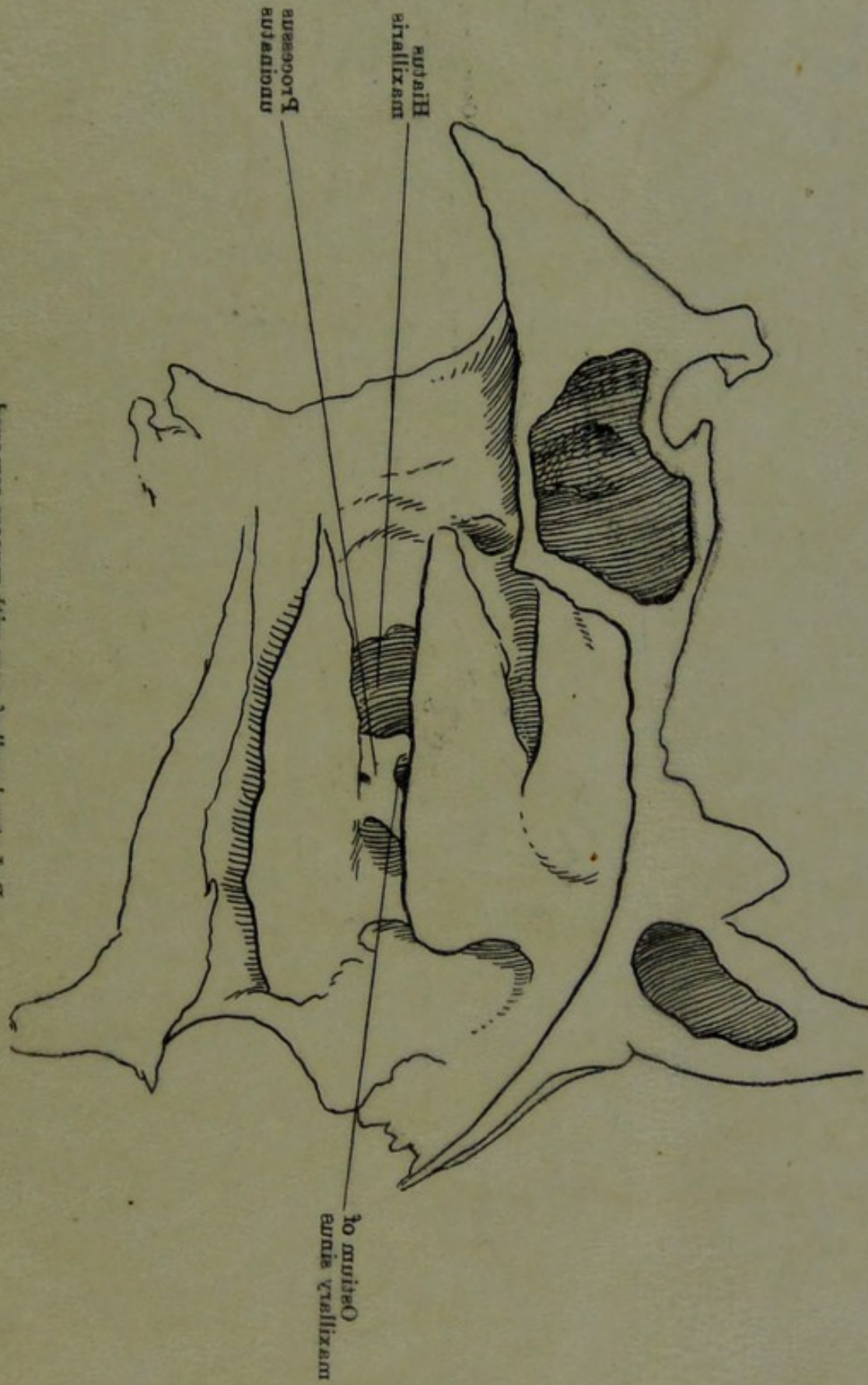
C. Lateral wall of nose with inner wall of ethmoid capsule removed.

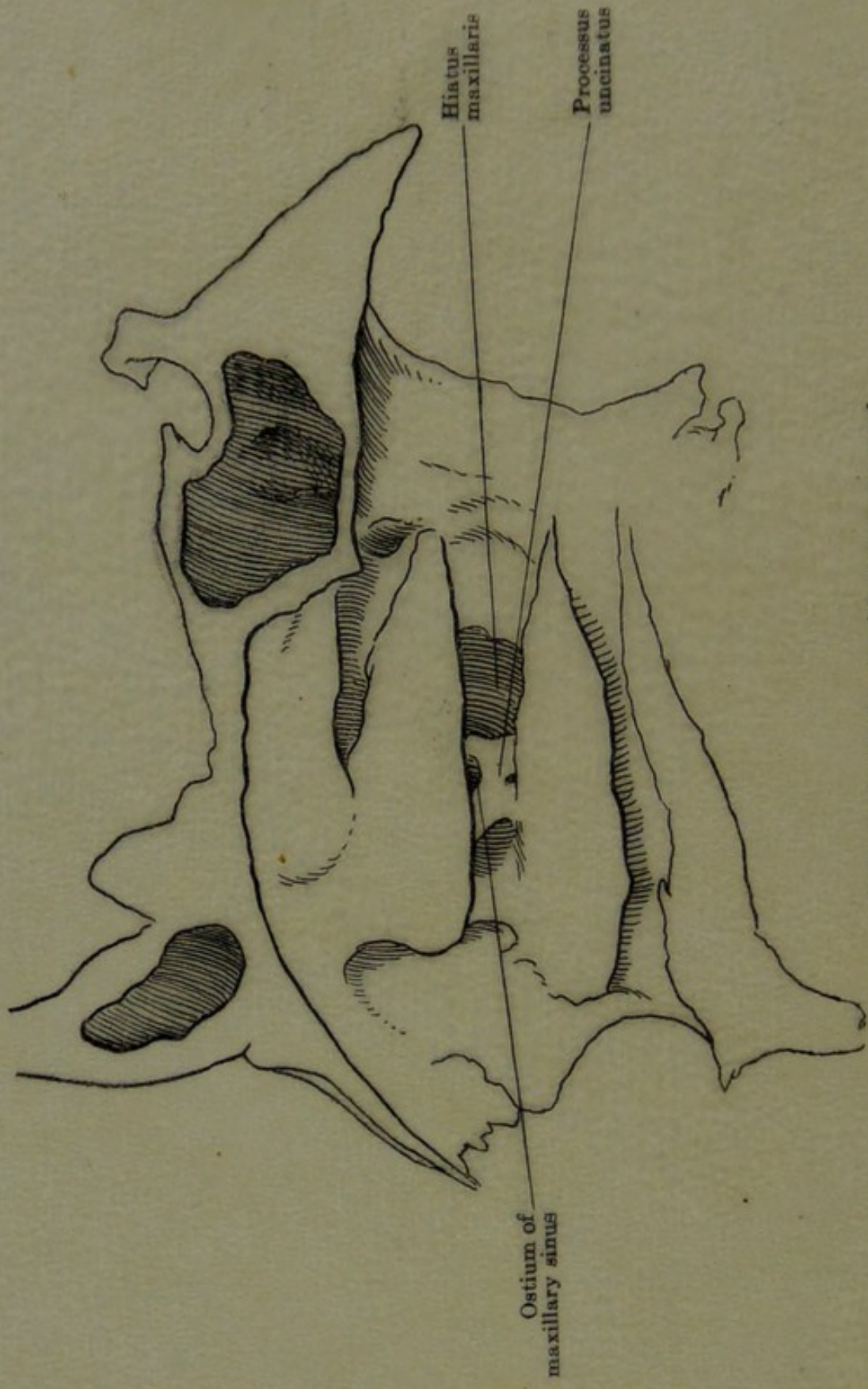




C, Lateral wall of nose with inner wall of ethmoid capsule removed.

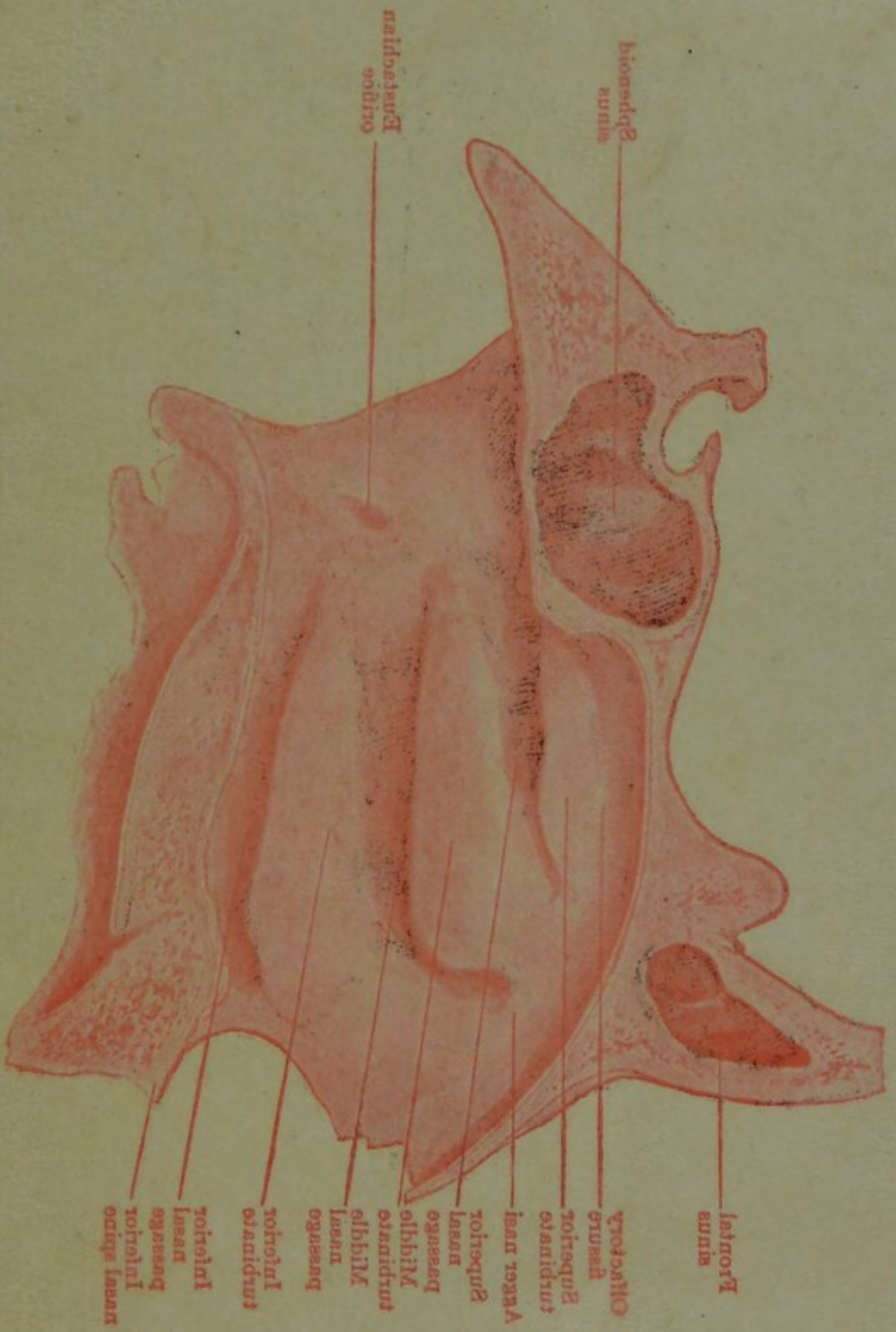
В' Губчатая часть носа с носовыми раковинами.

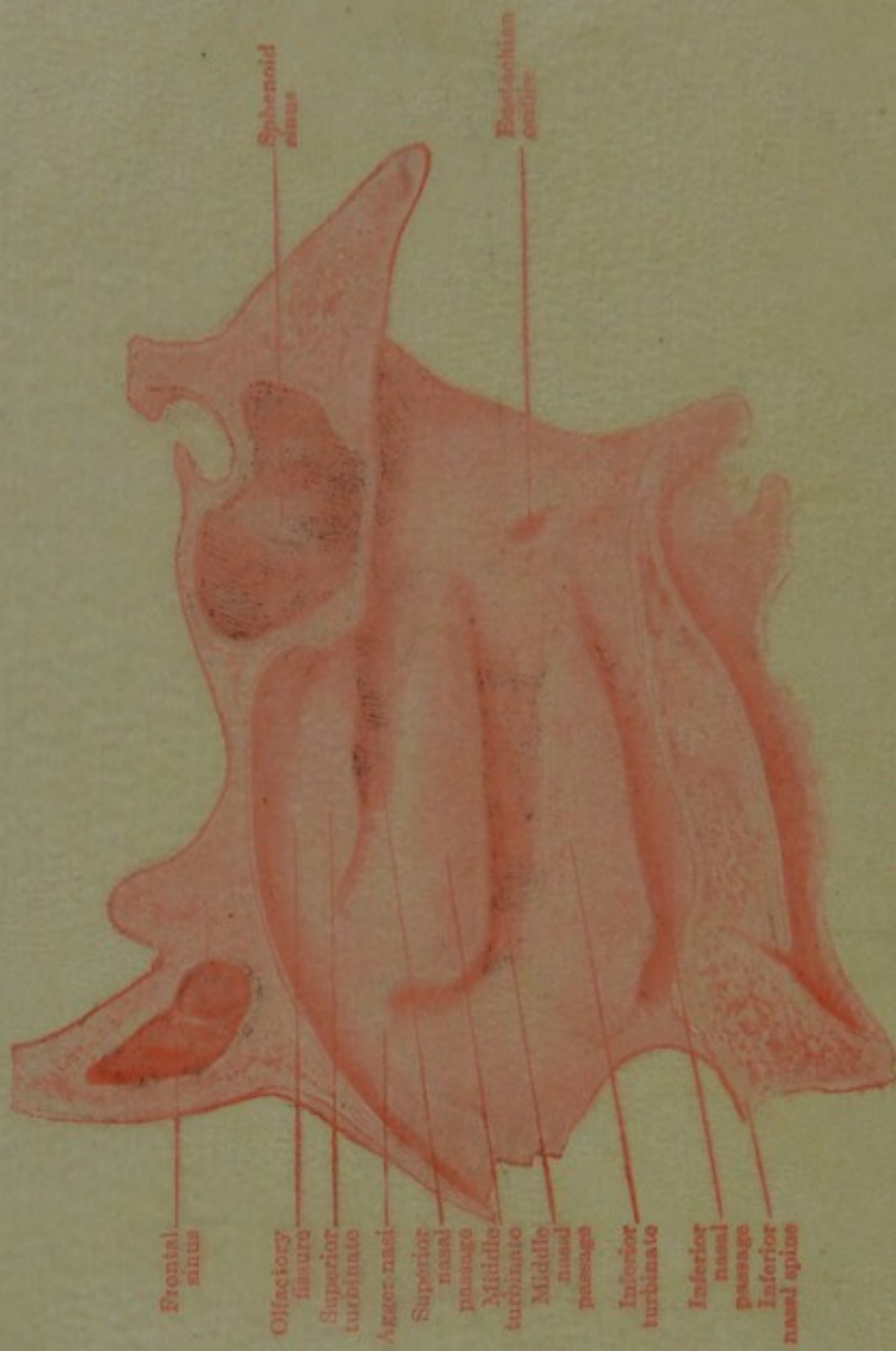




B, Lateral wall of nose with mucosa removed.

A. *Testis ovarium dextrae uterique ovarii, A.*





A. Lateral wall of nose with mucous infold.

THE CATARRHAL AND
SUPPURATIVE DISEASES

OF

THE ACCESSORY SINUSES
OF THE NOSE

By

ROSS HALL SKILLERN, M.D.

*Professor of Laryngology, Medico-Chirurgical College; Laryngologist to the Rush Hospital;
Fellow of the American Laryngological, Rhinological and Otological Society;
Fellow of the New York Academy of Medicine; Member of the
Society of German Laryngologists, etc., etc.*



PHILADELPHIA & LONDON
J. B. LIPPINCOTT COMPANY

COPYRIGHT, 1913
By J. B. LIPPINCOTT COMPANY

*Electrotyped and Printed by J. B. Lippincott Company
The Washington Square Press, Philadelphia, U. S. A.*



PREFACE

DURING courses of teaching the treatment of accessory sinus diseases very frequently students have made inquiry regarding the proper handbook to aid their studies in this direction.

In the German language Hajek and Zarnico would instantly rise to the minds of the well-equipped teacher as admirable works, both from the viewpoint of scientific accuracy and that of practical application.


In the French language Luc, and Sieur and Jacob, have contributed works of decided merit.

In the English language Logan Turner has displayed a commendable spirit of research and has collected much valuable information of a general character, but it cannot be claimed that his work is adaptable as a general text book.

Several excellent works of American and English authors, embracing the Nose, Throat and Ear as a whole, have appeared, but their general scope has not permitted the consideration in minute detail of nasal accessory sinus disease.

To set forth in the English language a thorough and exclusive treatment of this subject has been the inspiration of this work. It will be noted that repetitions occur in several places. These have been intentional, not only to thoroughly impress these parts on the mind of the student, but to obviate the necessity of continually referring to other portions.

Extensive references have been made and every effort has been exerted to give credit where it belongs, nevertheless errors of omission and commission must necessarily have crept into a book of this description. I trust that my American colleagues will apprise me of any such that may come under their notice. In collaboration of this work I have been ably assisted by Messrs. E. F. and Ludwig Faber, Erwin Faber making the anatomical illustrations and Ludwig Faber the operations. Several of the rarer anomalies have been drawn from specimens prepared by Dr. M. H. Cryer and kindly loaned to me for this purpose. I am also greatly indebted to George F. Martin, M.A., for his painstaking and thorough correction and in many instances revision of the manuscript.



CONTENTS

PART I.

GENERAL CONSIDERATIONS.

	PAGE
EXAMINATION OF THE NOSE FOR SINUS DISEASE.....	1
ANATOMY OF THE LATERAL WALL OF THE NOSE.....	3
Basic Structure of the Lateral Nasal Wall.....	4
Anatomy of the Nose in Frontal Section.....*	13
Topographical Anatomy of the Hiatus Semilunaris.....	17
* Mucosa of the Lateral Nasal Wall.....	21
THE DEVELOPMENT OF THE ACCESSORY SINUSES (POST-EMBRYONIC).....	22
RATIONALE OF THE PHYSIOLOGICAL DEVELOPMENT OF THE ACCESSORY SINUSES....	24
PHYSIOLOGY OF THE ACCESSORY SINUSES.....	25
Rôle of the Sinuses During Respiration.....	26
NORMAL MECHANISM OF DRAINAGE.....	26
BACTERIOLOGY OF THE ACCESSORY SINUSES.....	28
Conclusions.....	32
GENERAL ÆTIOLGY.....	34
Through Direct Invasion of the Healthy Sinus by Pathogenic Bacteria.....	34
Through Extension of Inflammation from Neighboring Parts.....	38
Tuberculosis, Syphilis, Neoplasms, and Latent Empyema.....	39
Through the Blood- and Lymph-channels.....	41
Through Traumatism.....	41
Through Foreign Bodies.....	41
Through Contamination by the Pus from an Overlying Sinus. Sinusitis and Sinuitide.....	42
CAUSE OF CHRONICITY.....	43
Interference with Normal Drainage.....	43
Especial Virulence of the Infecting Micro-organism.....	44
Inflammatory Changes in the Mucous Membrane of the Sinus.....	44
Recurrence of the Attacks.....	44
Continuation of the Irritation.....	45
The Consistency of the Secretion.....	45
The Individual Susceptibility of the Patient.....	45
Secretion Flowing in from Another Sinus.....	45
Statistics.....	46
PATHOLOGICAL CHANGES IN THE MUCOUS MEMBRANE OF THE SINUSES.....	47
The Microscopic Appearance of the Mucous Membrane in Acute Conditions....	48
Hyperplastic Type.....	49
Differential Diagnosis.....	50
Ulcerative Type.....	50
UNUSUAL PATHOLOGICAL COMPLICATIONS OR SEQUELÆ OF CHRONIC INFLAMMATION:	
NEW FORMATION AND ULCERATION OF BONE, CARIES, AND NECROSIS.....	50
New Bone Formation.....	50
Ulceration of the Bone.....	51
Caries and Necrosis.....	51

DILATATION OF SINUS WALL BY INTERNAL PRESSURE OF SECRETION (MUCCOCELE, PYOCELE AND LATENT EMPYEMA).....	51
Mucoccele.....	51
METAMORPHOSIS OF THE SECRETION INTO A CHEESY MASS (VERKASUNG).....	52
CHOLESTEATOMA FORMATION.....	52
CALCAREOUS FORMATION.....	52
CARCINOMA.....	53
RELATIVE IMPORTANCE OF THE SECRETION IN CHRONIC EMPYEMA.....	53
LATENT EMPYEMA.....	53
SYMPTOMS OF SINUS INFLAMMATION.....	54
Local Headache.....	54
Cause.....	54
Lack of Constancy.....	55
Character.....	56
Periodicity.....	57
Variations in Intensity.....	57
Localization.....	57
Tenderness over the Sinuses.....	59
Purulent Secretion in the Nose.....	60
Cacosmia.....	62
Changes in the Nasal Mucosa Depending upon Sinus Disease.....	62
THE RELATION OF POLYP FORMATION TO NASAL SUPPURATION.....	63
Other Changes in the Nasal Mucosa Depending upon Sinus Disease.....	66
Erysipelas.....	67
Changes in the Mucosa of the Upper Respiratory Tract.....	67
The Nasopharynx and Pharynx.....	67
Pharyngitis Sicca.....	67
Pharyngitis Lateralis.....	68
LARYNGEAL AFFECTIONS.....	68
PHARYNGEAL AFFECTIONS.....	69
Remote Local Symptoms.....	70
Dizziness and Vertigo.....	70
Psychical and Intellectual Disturbances.....	70
GENERAL SYMPTOMS.....	71
Fever.....	71
Circulatory Disturbances.....	71
Nervous Disturbances.....	72
Sexual Apparatus.....	72
DIAGNOSIS:	
First Series.....	72
Second Series.....	75
DIAGNOSIS BY MEANS OF (1) TRANSILLUMINATION, (2) RÖNTGEN RAY, AND (3) SUCTION:	
Transillumination.....	77
Maxillary Sinus.....	77
Frontal Sinus.....	78
Ethmoid Cells.....	79
The Röntgen Ray.....	79
Frontal Sinus.....	80
Anterior Ethmoid Cells.....	81
Maxillary Sinus.....	81
Posterior Ethmoid and Sphenoid.....	82
Bier's Hyperæmia as Applied to the Nasal Sinuses.....	82
TREATMENT.....	83
Acute.....	83

General Treatment.....	85
Local Treatment.....	86
Chronic Inflammation.....	86
Vaccine Therapy.....	87
COMPLICATIONS.....	87
Relation to the Orbital Cavity.....	88
Relation to the Optic Nerve.....	88
Relation to the Brain.....	89
Vessels and Nerves.....	89
Causes of Complications.....	89
Anatomical.....	89
Pathological.....	91
Manner of Occurrence.....	91
By Continuity—Dehiscence.....	91
By Contiguity.....	91
Mechanical Pressure.....	93
Pathological Conditions.....	93
Orbital Complications.....	94
Disturbances in Circulation.....	94
Intoxication.....	94
Purulent Inflammation.....	94
Orbital Symptoms.....	95
Those Caused by Inflammation.....	95
Those Caused by Pressure (Mechanical).....	96
Those Caused by Toxins.....	97
Cerebral Symptoms.....	97
Empyema of the Accessory Sinuses in Children.....	97

PART II.

MAXILLARY SINUS.

ANATOMY.....	99
Relative Importance of the Walls.....	100
Congenital Defects or Dehiscences.....	102
The Alveolar Boundary.....	103
Normal Position of Ostium.....	107
Accessory Ostia.....	107
ABNORMALITIES AND ANOMALIES OF THE MAXILLARY SINUS.....	107
Formation of Partitions in the Maxillary Sinus.....	114
Blood Supply.....	116
SURGICAL ANATOMY OF THE LATERAL WALL OF NOSE IN REFERENCE TO THE MAXILLARY SINUS.....	116
Sounding the Maxillary Ostium.....	117
ÆTIOLOGY.....	118
Idiopathic.....	119
Direct Extension from the Nasal Mucosa.....	119
Infectious Disease.....	119
From the Alveolus.....	120
Through Contamination from Overlying Sinuses.....	123
Foreign Bodies.....	123
Traumatism—Direct and Indirect.....	124
Osteomyelitis, Syphilis, Tuberculosis, and Malignant Tumors.....	124
Chronic or Latent Empyema.....	125

SEQUELÆ AND UNUSUAL CONDITIONS FOUND IN THE MAXILLARY SINUS:	
Cysts.....	126
The Mucoïd Cyst.....	126
Dentigerous Cysts.....	127
Caseous Metamorphosis (Verkasung).....	129
Stone Formation in the Maxillary Sinus.....	130
Mucocele of Maxillary Sinus.....	131
Cholesteatoma Formation.....	131
DIAGNOSIS.....	132
Closed Empyema of Maxillary Sinus.....	134
ADJUNCTS TO DIAGNOSIS:	
Transillumination.....	134
Mechanism of Transillumination.....	135
Actual Cause of Shadow Formation.....	135
Value as to Reliability.....	135
Röntgen Ray.....	136
Suction or Negative Pressure.....	136
Symptoms.....	137
Nasal Symptoms.....	138
General Disturbances.....	139
Complications.....	140
SYMPTOMS.....	140
Chronic Empyema.....	140
Pain.....	141
Secretion.....	142
Consistency of the Flow of Pus.....	143
Periodicity of Emptying.....	143
Nasopharynx and Larynx.....	144
Disturbances in Olfaction.....	145
Nervous Manifestations.....	145
COMPLICATIONS:	
Caries of the Osseous Walls of the Antrum, with Rupture into the Neighboring Parts, with Abscess Formation.....	146
Dilatation of the Antrum.....	146
Empyema Complicated or Caused by Cyst Formation.....	147
Differential Diagnosis.....	148
Prognosis and Indications for Treatment.....	148
Technique of Sounding and Catheterizing the Maxillary Sinus.....	150
Relation of the Ostium to the Internal Wall of the Maxillary Sinus.....	151
Technique of Needle Puncture with Lavage.....	152
Conservative Treatment.....	156
After-treatment.....	164
Dahmer's Method.....	167
After-treatment.....	170
Pre-turbinal Method: Canfield's Operation.....	172
After-treatment.....	174
MAXILLARY SINUS: OPERATIVE TREATMENT.....	175
Caldwell-Luc Method.....	175
Technique of the Operation.....	175
Operation under Local Anæsthesia.....	181
After-treatment.....	182
Denker's Method.....	183
Modification of the Caldwell-Luc Method.....	185
Results and Untoward Sequelæ of the Radical Operation.....	186

PART III.

FRONTAL SINUS.

ANATOMY.....	187
Thickness of Walls.....	191
Dehiscence of the Walls.....	192
Interior of Sinus.....	192
Relation of the Hiatus Semilunaris to the Frontal Sinus.....	196
Relation of the Frontal Sinus to the Ethmoid Labyrinth.....	197
Bulla Frontalis.....	200
Mucosa of Sinus, Blood Supply.....	200
SOUNDING THE FRONTAL SINUS.....	200
Technique of Sounding the Frontal Sinus.....	201
Natural Difficulties Encountered in Sounding the Frontal Sinus.....	202
Acute Inflammation: <i>Ætiology</i>	204
Pathology.....	206
Acute Catarrhal.....	206
Microscopical.....	206
Acute Purulent.....	207
Microscopical.....	207
Diagnosis.....	207
Symptoms—Acute:	
Pain and Headache.....	209
Tenderness on Pressure and Percussion.....	211
Secretion.....	212
Locality of Secretion.....	212
Appearances of the Nose.....	212
Internal.....	212
External.....	213
External Appearance of the Sinus.....	213
Disturbances in Olfaction.....	213
General Disturbances.....	214
PROGNOSIS.....	214
COMPLICATIONS.....	215
Periostitis and Otitis.....	215
Caries and Necrosis.....	215
Osteomyelitis.....	216
Circumscribed.....	216
Diffuse.....	216
Pathology.....	216
Symptoms.....	217
ORBITAL COMPLICATIONS.....	218
INTRACRANIAL COMPLICATIONS.....	218
TREATMENT.....	218
Technique of Infraction of the Middle Turbinate.....	221
Technique of Resection of Anterior Third of Middle Turbinate.....	223
Complications.....	224
CHRONIC INFLAMMATION: <i>ÆTIOLOGY</i>	225
Retention of Secretion within the Sinus.....	226
PATHOLOGY.....	227
Catarrhal or Fibrous.....	227
Purulent.....	227
Microscopical.....	228

SYMPTOMS.....	228
Pain.....	228
Constancy.....	230
Tenderness on Pressure.....	230
Edema of Upper Eyelid.....	231
Secretion.....	231
Place of Appearance of Secretion.....	232
Disturbances in Olfaction.....	232
Appearance of the Nose.....	233
Rhinoscopy.....	233
Appearances of the Throat.....	234
Dizziness and Vertigo.....	234
DIAGNOSIS.....	235
EXTERNAL SYMPTOMS.....	239
Dilatation of Anterior Wall and Fistula Formation.....	239
ADJUNCTS TO DIAGNOSIS:	
Transillumination.....	240
Röntgen Ray.....	240
DIFFERENTIAL DIAGNOSIS.....	241
PROGNOSIS.....	242
CHRONIC COMPLICATIONS.....	243
Possible Paths of Infection.....	244
Oculo-orbital Complications.....	247
Intracranial Complications.....	248
TREATMENT.....	250
Resection of the Anterior Portion of the Middle Turbinate.....	252
Resection of the Uncinate Process.....	254
Ingals's Intranasal Operation.....	255
Halle's Intranasal Operation.....	257
Good's Intranasal Operation.....	259
Thomson's Modification of Good's Method.....	260
Comparative Value of the Intranasal Operations.....	260
Indications for External Radical Operation.....	261
Evolution of the External Operation on Frontal Sinus.....	262
Knapp's Operation.....	268
Radical or Modified Killian Operation.....	269
Osteoplastic Resection.....	276
Beck's Method of Osteoplastic Resection.....	278
Watson Williams Osteoplastic Method.....	278
Citelli's Method.....	279
Comparison of Methods.....	280
The Ogston-Luc Operation.....	280
Kuhnt's Method for Obliterating the Sinus.....	280
Killian's Method.....	281
Untoward Results Following the Killian Radical Operation.....	282

PART IV.

ETHMOID LABYRINTH.

ANATOMY.....	286
Lateral Nasal Aspect.....	286
Lamella of Uncinate Process.....	288
Lamella of the Bulla.....	288

Lamella of Middle Turbinate.....	289
Lamella of Superior Turbinate.....	290
Relation of Anterior Ethmoid Labyrinth to Frontal Sinus.....	294
Anomalies of Ethmoid Labyrinth.....	294
Blood Supply.....	303
Venous Anastomoses.....	303
Relation of Posterior Ethmoidal Cells to Optic Nerve.....	304
PHYSIOLOGY OF THE ETHMOID.....	305
ÆTIOLOGY AND PATHOLOGY.....	306
Acute Catarrhal Inflammation.....	307
Acute Purulent Inflammation.....	307
Symptoms.....	307
Diagnosis and Prognosis.....	308
Treatment.....	308
Acute Suppurative Ethmoiditis.....	309
CHRONIC INFLAMMATION OF THE ETHMOID LABYRINTH.....	309
Ætiology.....	309
Pathology.....	309
Microscopic Examination.....	310
Symptoms.....	311
Diagnosis.....	312
Treatment.....	313
CHRONIC SUPPURATIVE INFLAMMATION (EMPHYEMA).....	316
Ætiology.....	316
Pathology.....	317
Symptoms.....	318
Secretion.....	318
Olfactory Disturbances.....	318
Rhinoscopic Examination.....	319
Diagnosis.....	319
Transillumination.....	320
Differential Diagnosis.....	321
CLOSED-IN OR LATENT EMPHYEMA.....	321
CHRONIC HYPERPLASTIC INFLAMMATION WITH SUPPURATION.....	325
Complications.....	326
Orbital: Acute and Chronic Rupture into the Bulbar Cavity.....	326
Inflammation of the Lachrymal Duct.....	328
Cerebral: Intracranial Complications.....	328
Prognosis.....	329
Conservative Treatment.....	329
Treatment by Auto-Vaccination.....	330
Intranasal Method.....	330
Method of Luc.....	333
Hajek's Method for Removing Posterior Ethmoid Cells.....	334
Slight Complications Sometimes Following Intranasal Operation.....	335
Emphysema of the Upper Eyelids on Blowing the Nose.....	336

PART V.

SPHENOID SINUS.

ANATOMY.....	340
Peculiar Anomalies and Formations.....	346
Mucosa of Sphenoid.....	348

ACUTE INFLAMMATION:

Ætiology.....	349
Pathology.....	350
Microscopic Histo-pathology.....	350
Symptoms.....	350
Diagnosis.....	350
Treatment.....	351

CHRONIC INFLAMMATION:

Ætiology.....	351
Pathology.....	351
Microscopic Histo-pathology.....	352
Symptoms.....	352
Headache.....	354
Mental Symptoms.....	355
Secretion.....	355
Ocular Symptoms.....	356
Objective Symptoms.....	357
Diagnosis.....	358

SOUNDING THE SPHENOID SINUS.....	361
Technique of Sounding.....	361
Jacob's Method.....	363
Differential Diagnosis.....	363
Empyema of a Sphenoid-ethmoidal Cell.....	366
Empyema of the Posterior Half of a Double Maxillary Sinus.....	366
Prognosis.....	366
Complications.....	368
Process of Infection-mechanism.....	368
Symptoms.....	368
Ophthalmic Manifestations.....	369
Treatment.....	369
Technique of Catheterization.....	370
Technique of Enlarging the Normal Ostium.....	371
Indications for the Radical Operation.....	373
Radical Operation of Sphenoid.....	375
After-treatment.....	379
Maxillary Route.....	380
Jansen's Method.....	380

LIST OF ILLUSTRATIONS

FIG.	PAGE
1. Lateral wall of nose showing relation of pendulous portion of intercranial	* 1
2. Direction and extent of light rays in examination of the anterior portion of the nares	1
3. Killian's nasal speculum	2
4. Lateral wall of nose with mucosa intact.	3
5. Ethmoid, superior maxilla, and palate bone and bones <i>in situ</i>	4
6. Scheme showing articulation of inferior turbinate.	5
7. (a, b) Right inferior turbinate.	5
8. Superior maxilla lachrymal, inferior turbinate, and palate bone in normal position.	6
9. Ethmoid, superior maxilla, and palate bone in normal position.	7
10. Lateral wall of nose with portion of middle and inferior turbinates removed.	8
11. Lateral wall of nose showing processus uncinatus and pars membranacea.	9
12. Lateral wall of nose showing accessory ostium.	10
13. Ethmoid, superior maxilla, and palate bone in normal position.	11
14. Relation of ethmoid capsule to surrounding structures.	13
15. Cross section behind uncinuate process.	14
16. Diagrammatic illustration of the ethmoid capsule.	14
17. Section through ethmoid capsule posterior to the hiatus semilunaris.	15
18. Frontal, ethmoid, and superior maxilla disarticulated.	15
19. Frontal, lachrymal, ethmoidal, and superior maxillary, in normal position	16
20. Lateral wall of the nose with ethmoid labyrinth opened.	18
21. Relation of sinuses and hiatus semilunaris to lateral wall of the nose.	18
22. Transverse section through the middle of the uncinuate process and bulla.	19
23-24. Schematic illustrations of the two formations of the hiatus semilunaris	20
25. Direct connection between the frontal and maxillary sinuses.	20
26. Lateral wall of the nose with anterior half of the middle turbinate removed.	21
27. Section through head of fœtus at birth.	22
28-29. Superior maxilla of fœtus at birth	23
30. Distribution of the three branches of the trigeminus nerve.	56
31. Schematic illustration of pain areas due to sinus disease.	58
32. Method of holding the lamp against the inferior wall of the frontal sinus for trans-illuminating.	78
33. Relation of the optic nerves to the posterior ethmoid cells.	88
34. Relations of frontal, sphenoidal and ethmoidal sinuses to the brain.	89
35. The veins of the orbital, ethmoidal and sphenoidal regions from above downward.	90
36-37. Showing extent and shape of maxillary sinus in the superior maxillary.	99
38. Various structures entering into the base of the maxillary sinus.	100
39. Section through anterior portion of the antrum looking forward.	101
40. Section through the anterior third of the antrum.	102
41. Nasal packing forceps.	103
42. Relation of the roots of the teeth to the floor of the maxillary sinus.	104
43. Thick cancellated bone intervening between the teeth and the antral floor.	105
44. Thick cancellated bone between the apex of the tooth root and the sinus floor.	105
45. Roots of teeth projecting into the maxillary sinus cavity.	105
46. Lateral views of tooth root projecting into the maxillary sinus.	106
47. View of maxillary sinus from without.	106
48. Ostium divided by ridge of mucous membrane.	106
49. Showing situation of accessory ostium in relation to that of the normal ostium.	108

50. Several accessory ostiums.....	108
51. Excessive overdevelopment of maxillary sinus on left with formation of orbital fossa.....	109
52. Excessive development of sinus due to over-reabsorption of cancellous tissue.....	110
53. Marked asymmetry of maxillary sinuses.....	110
54. Reabsorption of bone into the hard palate.....	111
55. Underdevelopment of maxillary sinuses with compact alveolar processes.....	111
56. Narrowing of the antrum due to sinking in of the anterior wall.....	112
57. Narrowing of the antrum due to bulging outward of lateral nasal wall.....	113
58. Sinking in of lateral nasal wall.....	113
59. Complete septum dividing antrum into an anterior and posterior compartment.....	114
60. Ostiums of a double maxillary sinus.....	115
61. Maxillary ethmoid cell at posterior superior angle of antrum.....	116
62. Unusually large ethmoidalis.....	117
63. Upward displacement of bulla with enlargement of the hiatus semilunaris.....	118
64. Cross section through both maxillary sinuses.....	126
65. Large glandular mucoid cyst almost filling antrum of left side.....	127
66. Dentigerous or true bone cyst of an antrum on right side.....	127
67. (a, b, c, d) Section through a tooth and root cysts.....	128
68. Position and bending of sound necessary in attempting to sound the maxillary sinus.....	151
69. Lichtwitz needle for puncture of the maxillary sinus.....	153
70. Position of needle in puncture of the maxillary antrum.....	154
71. Position of the hands in introducing the Lichtwitz needle into the right maxillary sinus.....	155
72. Antral trocar with cannula.....	155
73. Fletcher's needle for puncture of the maxillary sinus.....	158
74. Guarded Hartmann borer.....	161
75. Enlarging the opening in the Cowper operation through the alveolar process.....	162
76. Prothese for closing opening in the alveolus after the Cowper operation.....	162
77. Welhemski's antral trocar.....	164
78. Wagener's antrum punch.....	165
79. Freeman's syringe.....	165
80. Privat's subperiosteal syringe for local anæsthesia.....	167
81. Dahmer's method. First step.....	168
82. Dahmer's method. Second step.....	169
83. Dahmer's method. Third step.....	169
84. Right-angle knife.....	168
85. Dahmer's method. Fourth step.....	169
86. Dahmer's method. Fifth step.....	169
87. Dahmer's method. Sixth step.....	170
88. Dahmer's method. Seventh step.....	170
89. The pre-turbinal method. First step.....	171
90. The pre-turbinal method. Second step.....	171
91. The pre-turbinal method. Third step.....	172
92. Pre-turbinal method. Fourth step.....	172
93. Pre-turbinal method. Fifth step.....	173
94. Pre-turbinal method. Sixth step.....	173
95. Right-angle curette.....	174
96. Hajek's retractor for holding up the lip in the external operation on the maxillary sinus.....	175
97. The mouth in position for the Caldwell-Luc operation on the maxillary sinus.....	176
98. Incision made through soft parts and periosteum elevated, exposing underlying bone of the anterior wall.....	177
99. Anterior wall removed.....	177
100. Mucosa of maxillary sinus removed.....	179

101. The bony wall separating the sinus from the nose removed.	179
102. The mucosa is incised and the flap turned into the antrum.	180
103. Caldwell-Luc operation completed.	183
104. Denker operation complete.	184
105. Completed Denker and Caldwell-Luc operations on skull.	185
106. Hajek-Claus bone forceps.	186
107. Lateral view of a medium-sized frontal sinus.	187
108. Diagrammatic representation of the form and extent of the frontal sinus.	188
109. Extreme lateral extension of the frontal sinus into the malar bone.	188
110. Extreme superior extension of the right frontal sinus.	189
111. Extension of frontal sinus posterior into lesser wings of sphenoid.	189
112. Right and left frontal sinuses of the same size and conformation.	190
113. Asymmetry of frontal sinuses.	190
114. Absence of left frontal sinus.	191
115. Irregularity of frontal sinuses.	191
116. Extreme lateral extension of frontal sinus.	193
117. Frontal sinus sending projections high up into the frontal bone.	193
118. Left frontal sinus opened from above.	194
119. Direct communication of the frontal sinus with an anterior ethmoid cell.	195
120. Formation of ductus nasofrontalis.	195
121. Lateral wall of nose with marked nasofrontal duct.	196
122. Lateral view of a medium-sized frontal sinus.	197
123. Lateral wall of nose with anterior portion of middle turbinate removed.	198
124. Frontal bone and ethmoid capsule disarticulated.	198
125. Frontal bone and ethmoid capsule in place.	199
125a. Prolongation of frontal sinus into crista galli.	199
126. Sound bent for frontal sinus.	201
127. Sounding the frontal sinus after removal of the anterior portion of the middle tur- binate.	202
128. Measuring the distance the sound has penetrated against the side of the patient's nose.	203
129. Anterior ethmoid cell situated beneath the unciniate process.	204
130. Extension of entire ethmoidal labyrinth.	204
131. Lateral wall of nose with middle turbinate removed.	205
132. External table of skull removed, showing the canals of Breschet.	217
133. Thompson's nasal scissors.	221
134. Severing the middle turbinate at its anterior attachment of the lateral nasal wall.	222
135. InfRACTING the middle turbinate with a blunt elevator.	222
136. Position of snare in removing the anterior portion of the middle turbinate.	223
137. Hartmann's cutting forceps.	224
138. Cannula for irrigation of the frontal sinus.	236
139. Position of the hands in irrigating the frontal sinus.	237
140. Venous anastomoses of the nose and orbit.	245
141. Enormous mucocele of the frontal sinus.	247
142. Burrell's nasal shave.	254
143. Removing the unciniate process with the nasal shave.	255
144. Using Lange's forceps to enlarge the nasofrontal passages.	255
145. Operation completed.	256
146. Ingals operation.	256
147. Ingals gold tube for intranasal insertion into the frontal sinus.	257
148. Halle's operation.	258
149. Halle's operation completed.	258
150. Rasp in place for enlarging the frontal ostium.	259
151. Line and extent of incision in the Killian operation on the frontal sinus.	265

152. Two periosteal incisions.	265
153. Killian's V-shaped chisel.	266
154. Illustrating grooves made in the ascending process of the superior maxillary and below lachrymal bone in order to resect this portion.	267
155. Killian operation completed.	267
156. Knapp's incision.	268
157. First step.	270
158. Second step.	270
159. Third step.	271
160. Fourth step.	271
161. Alexander's hollow chisel.	272
162. Bone-cutting forceps for removing the anterior wall of the frontal sinus.	272
163. Fifth step.	273
164. Sixth step.	273
165. Seventh step.	273
166. Eighth step.	273
167. Ninth step.	274
168. Tenth step.	274
169a. Eleventh step.	275
169b. Twelfth step.	275
170. Osteoplastic resection of the anterior wall of the frontal sinus.	277
171. Beck's method of osteoplastic resection of the frontal sinus.	279
172. Schematic reproduction of the construction of the ethmoid capsule.	287
173. Small bulla ethmoidalis.	288
174. Unusually large ethmoidalis.	288
175. Formation of ductus nasofrontalis.	289
176. Cross section through the ethmoid close to the cribriform plate.	290
177. Entire ethmoid capsule is composed of three cells.	291
178. Extension of entire ethmoidal labyrinth.	291
179. Ethmoid labyrinth opened from the orbit.	292
180. Another labyrinth opened from the orbit.	292
181. Diagrammatic representation of infundibular cells.	293
182. Section through ethmoid labyrinth.	293
183. Frontal sinus and hiatus semilunaris forming a straight passage.	294
184. Frontal bulla formed by the upward and forward displacement of the lamella of bulla ethmoidalis onto the posterior wall of the frontal sinus.	295
185. Anomalous situation of the uncinatè process.	295
186. Anterior ethmoid cell situated beneath the uncinatè process.	296
187. Frontal bulla formed by encroaching of an infundibular cell into the frontal sinus.	296
188. Downward displacement of bulla with obliteration of the hiatus semilunaris.	297
189. Upward displacement bulla with enlargement of the hiatus semilunaris.	297
190. Formation of a frontal bulla through the upward extension of the lamella of the uncinatè process.	298
191. Backward displacement of the ethmoidal bulla with the formation of a pre-ethmoidal recess.	298
192. Lamella of middle turbinate displaced forward.	299
193. Showing reduced size of ethmoid labyrinth in the absence of the frontal and sphenoidal sinuses.	299
194. Fronto-ethmoidal cell extending almost the width of the orbital cell in crista galli.	300
195. Fronto- or orbito-ethmoid cell.	301
196. Anomalously situated ethmoid.	302
197. Lateral wall of nose with sphenoid-ethmoidal cell showing intimate relation of optic nerve.	304
198. Normal relation of optic nerves to sphenoid sinus and posterior ethmoid cells.	305

199. Direction of air currents through the nose.	306
200. Lange's frontal sinus and ethmoid punch.	313
201. Ballenger's ethmoid knives.	315
202. Exenterating ethmoid capsule en masse with the Ballenger right-angle knife.	316
203. All in middle turbinate filled with pus.	323
204. Middle turbinate and superior lying cells filled with pus.	323
205. Bulla filled with pus.	323
206. Marked exophthalmos due to rupture of an ethmoidal empyema through the lamina papyracea into the orbit.	327
207. Hajek's instruments for removing the ethmoid cells.	330
208. Opening the ethmoidal bulla with Hajek's hook.	331
209. Removal of the bulla with the Grünwald conchotome.	331
210. Seizing and twisting the middle turbinate from its anterior attachment.	334
211. The hook behind the posterior portion of the middle turbinate in position for severing the turbinate from its attachment.	334
212. The ethmoid hook in position for reducing the superior turbinate to fragments.	335
213. Finishing the stroke.	335
214. Removing the fragments and shreds.	336
215. Position and length of incision for external radical exenteration of the anterior and posterior ethmoid cells.	337
216. Periosteum retracted and bone bared.	337
217. Point of election for opening the ethmoid labyrinth.	338
218. The operation completed.	338
219. Sphenoid bone and ethmoid capsule disarticulated.	340
220. Sphenoid bone and ethmoid capsule in position.	341
221. Section through both sphenoid sinuses.	341
222. Sphenoid sinus enlarged anteriorly.	342
223. Section behind the uncinate processes.	343
224. Position of sphenoidal ostium.	343
225. Varied conformations of superior walls of the sphenoid sinus.	344
226. Entire sphenoid sinus surrounded by cancellated bone tissue.	345
227. Regulation of internal carotid arteries to posterior sphenoidal wall.	346
228. Reabsorption of sphenoid sinus into the lesser wings of sphenoid bone.	346
229. Reabsorption into palatine fossa.	347
230. Reabsorption into pterygoid process.	348
231. Spheno-ethmoidal cell formation.	348
232. Sounding the sphenoid sinus.	362
233. Jacob's method of sounding and catheterizing the sphenoid sinus.	363
234. Position of the hands of patient and surgeon in irrigating the sphenoid sinus.	370
235. Faraci's bone-cutting forceps for enlarging the sphenoidal ostium.	372
236. Enlarging the natural ostium of the sphenoid sinus without removal of middle or superior turbinate.	373
237. Severing the middle turbinate in the centre prior to the removal of the posterior half.	373
238. Radical intranasal operation on sphenoid.	376
239. Radical intranasal operation on sphenoid.	376
240. Radical intranasal operation on sphenoid.	377
241. Radical intranasal operation on sphenoid.	377
242. Radical intranasal operation on sphenoid.	378
243. Evulsor for sphenoid.	378
244. Hajek's modified sphenoid forceps.	379
245. Radical intranasal operation on sphenoid.	380
246. Relation of an unusually large sphenoid sinus to the maxillary antrum.	381
247. Relation of a small sphenoid sinus to the maxillary antrum.	381

LIST OF ILLUSTRATIONS.

COLORED PLATES.

- A. Lateral wall of nose with mucosa intact. B. Lateral wall of nose with mucosa removed. C. Lateral wall of nose with inner wall of ethmoid capsule removed. D. Lateral wall of nose. All structures being removed to orbital plate..... Frontispiece
1. A. Blood supply of lateral nasal wall. B. Nerve supply of lateral nasal wall..... 22
2. A. Normal mucosa of ethmoid. B. Acute inflammation. C. Chronic inflammation..... 50
3. Transillumination of maxillary sinus. Right side normal. Left side diseased..... 78
4. Röntgen ray photograph showing position of sphenoid sinuses..... 82
5. Röntgen ray photograph showing lateral position of sphenoid sinus..... 362

THE ACCESSORY SINUSES OF THE NOSE

PART I.

GENERAL CONSIDERATIONS.

EXAMINATION OF THE NOSE FOR SINUS DISEASE.

THE nose may be likened unto a square box opened behind by a large aperture in the posterior wall but practically closed in front except for a small opening at the inferior margin. This anterior opening is not really in the nose itself but rather in a triangular addition which closes it in from the front. (Fig. 1.)

It will be noted that every structure of importance as far as the sinuses are concerned lies behind the line a-b. Therefore, the

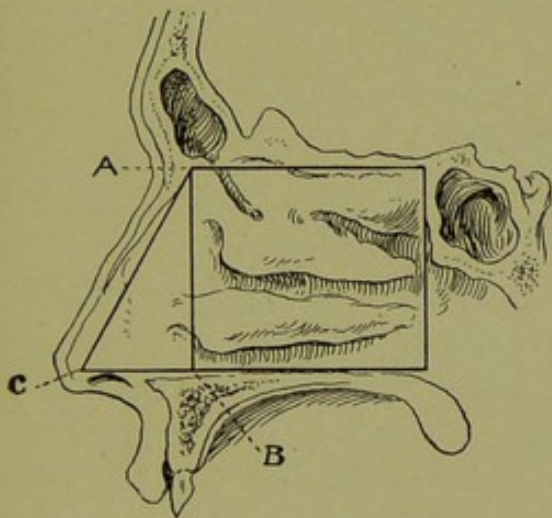


FIG. 1.—Lateral wall of nose showing relation of pendulous portion to intercranial.

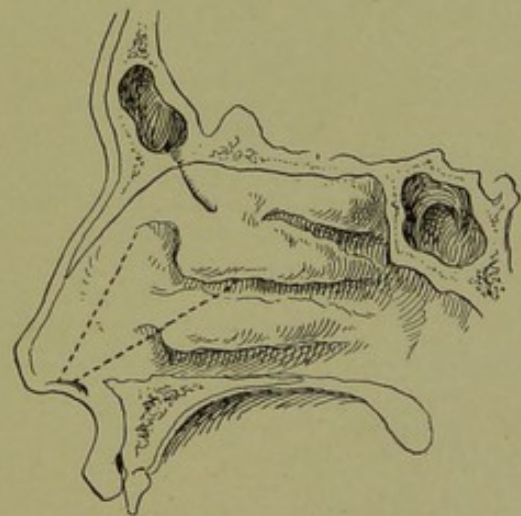


FIG. 2.—Direction and extent of light rays in examination of the anterior portion of the nares.

triangular portion a-b, b-c, c-a, corresponding to the external nose must be eliminated when studying the accessory cavities. We must also bear in mind that the rays of light thrown in by the mirror will illuminate but a small portion of the entire area lying posterior to line a-b on account of the narrow aperture (nares) through which they must pass; therefore, it will be necessary to turn the head of the patient in a number of positions before every part can be seen by anterior rhinoscopy. Examination of the nose with the light directed in this position will bring out clearly

the anterior end and inferior surface of the middle turbinate. (Fig. 2.)

The relative position of this structure is misleading, as it appears as though the cribriform plate must be but a very short distance above. As a matter of fact, the inferior margin of the middle turbinate corresponds approximately to the half-way line between the cribriform plate and floor of the nose (see Frontispiece). In other words, the distance between the cribriform plate and the inferior margin of the middle turbinate is as far as the distance between the floor of the nose and the inferior margin of the middle turbinate. The middle turbinate usually lies so close to the nasal wall that the uncinatè process and bulla ethmoidalis are entirely hidden from view. As it is absolutely necessary to obtain some knowledge of the underlying conditions when a sinus

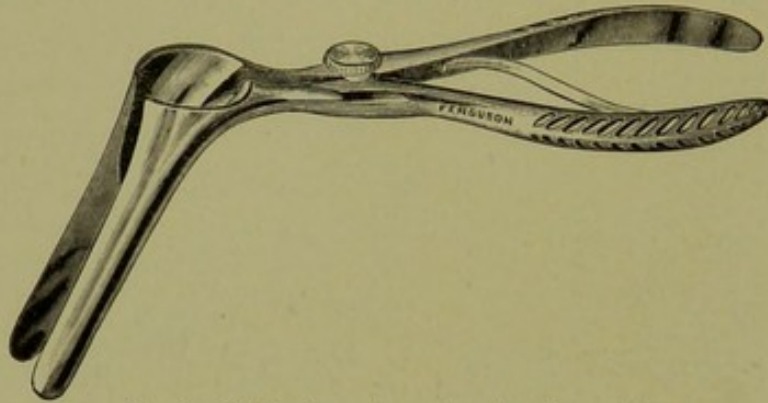


FIG. 3.—Killian's nasal speculum (medium size).

disease is suspected, we must employ some means whereby these parts may be inspected. This is best accomplished by the Killian method of median rhinoscopy.¹ A Killian speculum (Fig. 3) is introduced so that the blades come between the bulla and the middle turbinate. By gently but firmly springing the branches apart, the underlying parts (processus uncinatus, hiatus semilunaris and bulla) are brought into view. If pus is present in any of the sinuses of the first series (those emptying into the hiatus) it will be disclosed by this procedure.

It frequently occurs while performing median rhinoscopy, a sudden snap is heard and the middle turbinate is fractured at its base or juncture with the ethmoid capsule. Absolutely no harm can result from this, and indeed it is rather an advantage, especially if sinus trouble is present, as it allows a much better drainage from the hiatus. Kirstein,² Uffenorde³ and the author frequently perform this intentionally as a therapeutic measure in acute sinusitis.

1. Killian: Ueber rhinoscopia media. Münch med. Wochenschrift, S. 768, 1896.
2. Kirstein: Rhinoscopia nach Killian. Berl. lary. Ges., Bd. 7, S. 13; Bd. 8, S. 9. 3. Uffenorde; Erkrankungen des Siebbeins, S. 150, 1907, Jena.

The range of vision by anterior rhinoscopy as far as the depth of the nose is concerned can hardly be more than two-thirds of the inferior margin of the middle turbinate, except in atrophic noses, when the anterior wall of the sphenoid and occasionally the ostium may be observed. The long Killian speculum placed with the branches between the middle turbinate and septum gives one a slit-like view in the depths, but for general purposes is unsatisfactory, at least as far as the author is concerned. It is better to rely upon posterior rhinoscopy for information regarding the condition of the sinuses of the second series (posterior ethmoid and sphenoid).

ANATOMY OF THE LATERAL WALL OF THE NOSE.

For rhinological purposes this wall may be divided into three portions. 1. The inferior turbinal portion. 2. The middle nasal passage. 3. The ethmoidal portion. (Fig. 4.)

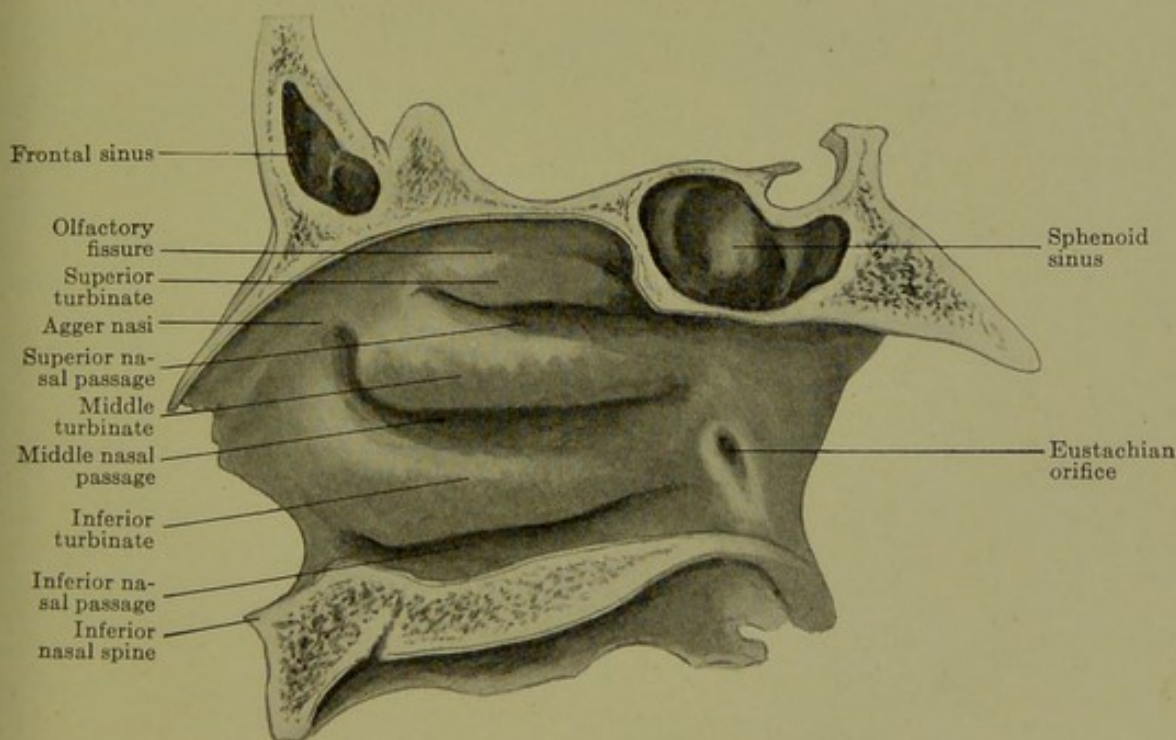


FIG. 4.—Lateral wall of nose with mucosa intact.

1. The inferior turbinal portion extends from the superior insertion of the inferior turbinate in the maxillary bone to the floor of the nose, thereby including the turbinate in its boundaries.

2. The middle nasal passage includes that portion of the lateral nasal wall lying above the inferior turbinate and below the ethmoidal bulla and posterior attachment of the middle turbinate.

It is, therefore, bounded above, anteriorly, by the bulla, above posteriorly by the attachment of the middle turbinate, externally by the uncinatè process, hiatus semilunaris and pars membranacea, below by attachment of inferior turbinate, and internally, partially by the middle turbinate and partially by the septum. The ostiums of the sinuses of the first series empty into this passage (Frontispiece).

3. The ethmoidal portion of the lateral wall of the nose includes all of those structures situated above the inferior margin of the middle turbinate, *i.e.*, bulla ethmoidalis, middle turbinate, ethmoid capsule including superior turbinate (Frontispiece).

BASIC STRUCTURE OF THE LATERAL NASAL WALL.

Two structures form the principal component parts: 1. Superior maxillary bone (inferior portion). 2. Ethmoidal capsule (superior portion). (Fig. 5.)

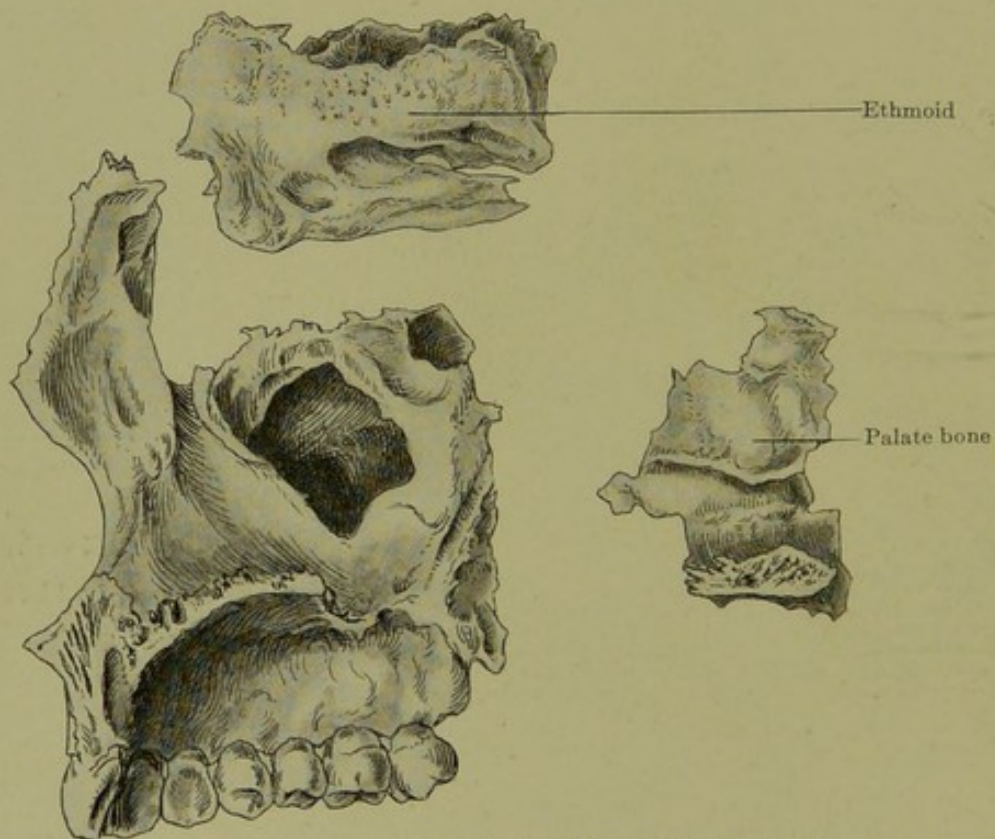


FIG. 5.—Ethmoid, superior maxilla and palate bone and bones *in situ*.

The entire structure is completed by the addition of the palate and inferior turbinate and lachrymal bones. The internal aspect of the superior maxillary bone or inferior portion presents conspicuously a large opening (hiatus maxillaris) leading into a

crater-like cavity which is partially closed in by the overlapping edges of bone (maxillary sinus). In the recent state this sinus is entirely closed in, with the exception of one (rarely more) small ostium, hidden by the lip-like projection of the uncinete process. How, then, is this hiatus maxillaris walled up and what structures enter into the formation of this partition between the maxillary sinus and the nasal cavity?




FIG. 6.—Scheme showing articulation of inferior turbinate.

We note that the opening is not round but rather takes on the character of a broad ∇ at its inferior margin (see Fig. 5). This portion is closed in by serving as a place of articulation for the maxillary process of the inferior turbinate in the following manner. The inferior turbinate does not articulate with the lateral nasal wall as a pendulous body (Fig. 6a), but by a comparatively broad base which forms a distinct portion of that wall (Fig. 6b, 7b.)




FIG. 7, a, b.—Right inferior turbinate. a, internal surface. b, external surface showing maxillary process which contributes toward formation of internal antral wall.

This base fits snugly into the ∇ shaped edge of the maxillary hiatus and with the latter completely encloses the lower fourth of the maxillary antrum. (Fig. 8.) The wall of bone at the floor of the nose is comparatively thick, gradually becoming thinner until it articulates with the maxillary process. The maxillary process, however, is much thinner, forming the thinnest portion of the lateral wall below the inferior turbinate; therefore,

it is plain to see why this part is chosen as the point of election for exploratory needle puncture of the maxillary sinus.

Here we have the lower fourth of the partition completed, but no more. What structures then enter into the formation of the remaining three quarters? A glance at Fig. 9 and Fig. 10 will at once show how largely the ethmoid enters into formation of the lateral wall of the nose. If one draws a straight line from the floor of the nose to the cribriform plate it will be seen that the ethmoid capsule occupies practically one-half of the entire distance. In spite of this fact, even with the ethmoid in position on the superior maxillary we note that a large portion of the max-

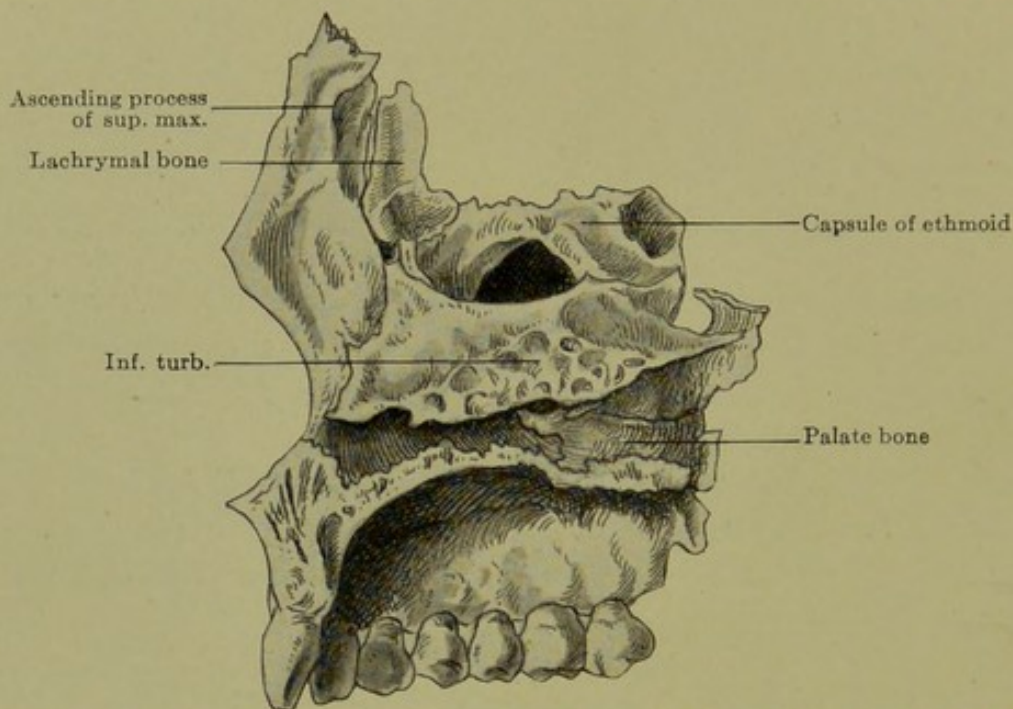


FIG. 8.—Superior maxilla, lachrymal, inferior turbinate and palate bone in normal position.

illaris hiatus remains, only the superior part of the ∇ being completely closed; however, as the middle turbinate more or less screens the underlying structures which enter into the formation of the partition between the nose and antrum, it will be necessary to partially remove this structure in order to intimately study the relations of those parts (Fig. 11).

After the middle turbinate has been removed we immediately note that the orifice leading into the antrum is considerably smaller, being for the most part closed in by a long flat curved strip of bone coming from above and extending downward and backward, practically dividing the space (Frontispiece). The shape of this process of bone is similar to the blade of a scimitar. This

process, however, does not hang free in the cavity, but is held in position by several projections articulating from the adjacent bones. On tracing it to its origin in front we note that it arises from the ethmoidal capsule; therefore, it is a portion of the ethmoid, being known as the uncinatè process (*processus uncinatus*) (Figs. 10, 11).

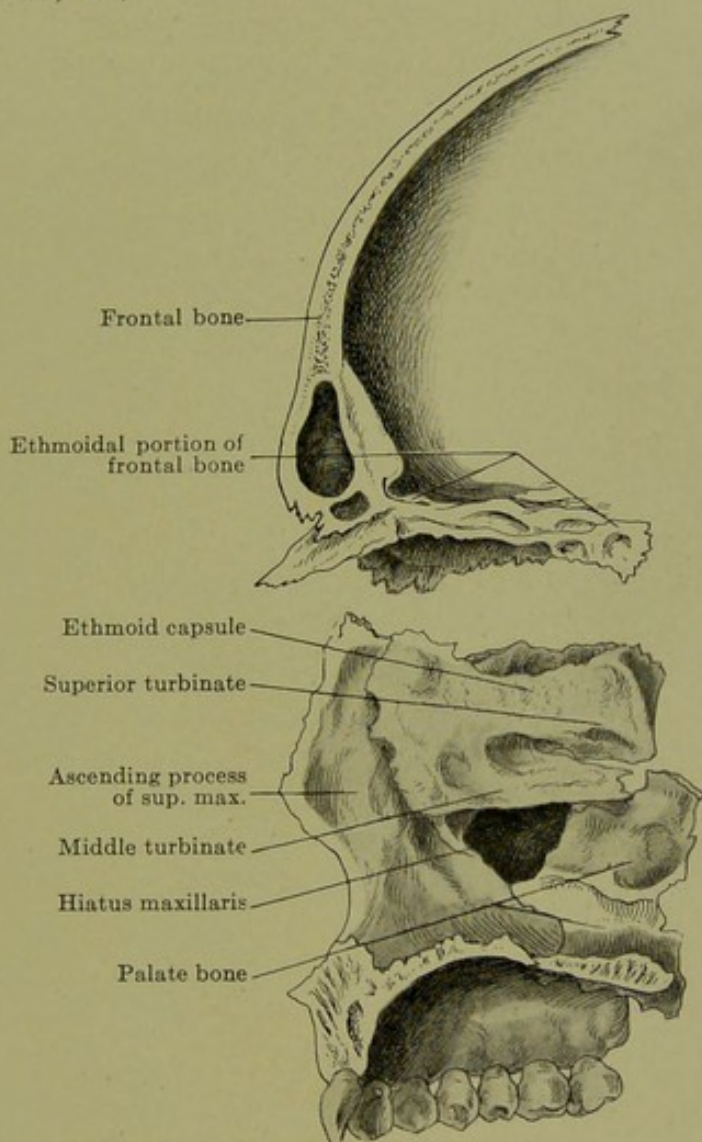


FIG. 9.—Ethmoid, superior maxilla and palate bone in normal position. Frontal in section disarticulated.

Immediately above, the uncinatè process covering the superior margin of the maxillary hiatus in a similar manner as the maxillary process of the inferior turbinate covers the inferior, is situated a smooth, hollow, semispherical bony projection, which is the bulla of the ethmoid (*bulla ethmoidalis*). (Fig. 10.) The entire slit or aperture between the uncinatè process and bulla appears to lead into the maxillary sinus, but such is not the case, as it is completely enclosed by thin bone with the exception of a small

hidden ostium at its posterior third. On account of the shape of this channel it is described as the hiatus semilunaris, and is of interest and importance from the fact that all the sinuses of the first series (frontal, anterior, ethmoidal and maxillary) have their ostiums associated with or draining into it.

The orifice between the lateral wall of the nose and the antrum is now greatly reduced in size, the remaining opening having the shape of a fish-hook, but broken up into smaller segments by the various processes of the bone emanating from the uncinatè process (Frontispiece).

The communication between the (1) uncinatè process and inferior turbinate and the (2) uncinatè process and bulla appears to be constant, while that between the (3) uncinatè process and palate bone is frequently lacking, due to rudimentary development.

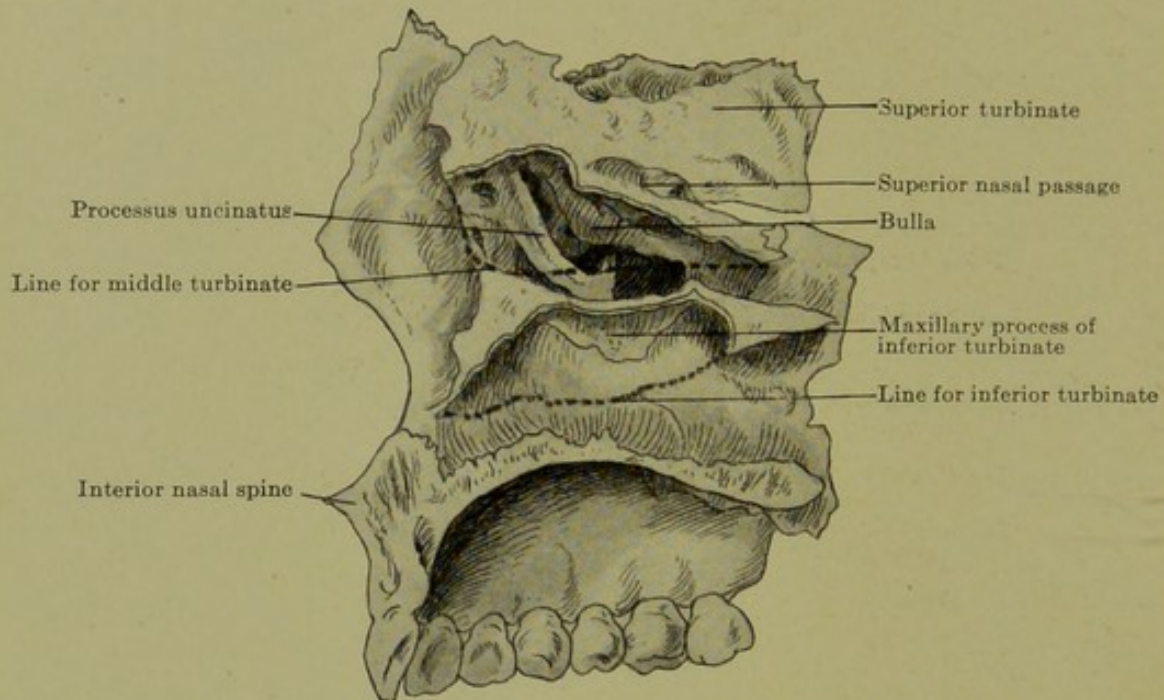


FIG. 10.—Lateral wall of nose with a portion of the middle and inferior turbinates removed.

This still leaves rather a considerable opening even though it is interspersed by several bony bridges. In the skeleton this opening is always present, because no more bony tissue enters into the foundation of this wall. In the recent state, however, this defect in the body structural development is replaced by the mucoperiosteum of both the nose and the maxillary sinus in the following manner: The mucous membrane and periosteum of the nose are so intimately interwoven that it is almost impossible to separate them, consequently they form a continuous covering for the osseous structure beneath. This membrane in the region of the

uncinate process does not dip down into the empty spaces but bridges them over, thereby forming an unbroken wall except in one small space between the posterior third of the uncinatè process and bulla, where an aperture is constant (ostium of the maxillary sinus*). Precisely the same condition prevails in the lining membrane of the antrum, and, as a consequence, we have the spaces around the uncinatè process covered in by two layers of muco-periosteum, thereby completing the partition between the nose and the maxillary sinus. This part of the nasal wall is known as the membranous portion (*pars membranacea*) and is of surgical im-

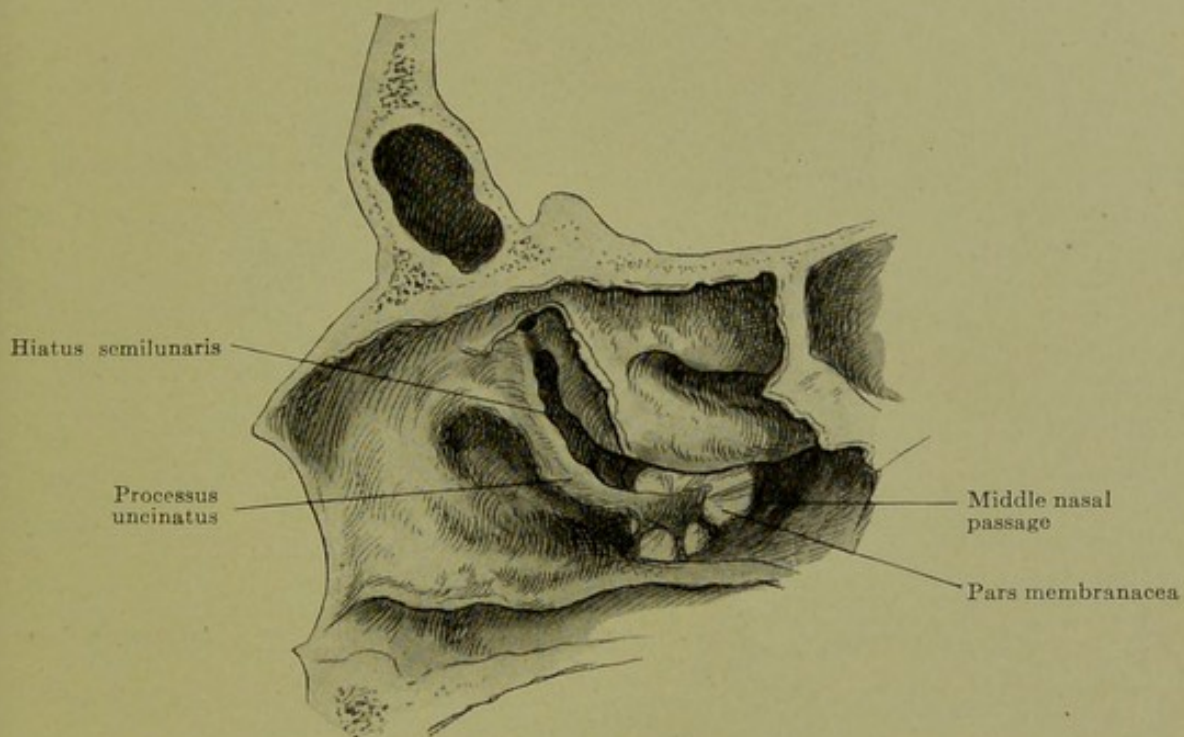


FIG. 11.—Lateral wall of nose showing processus uncinatus and pars membranacea.

portance on account of its being the thinnest and most resilient part of the wall.

The *pars membranacea* is bounded above by the bulla, behind by the palate bone, below by the insertion of the inferior turbinate and in part by the uncinatè process, and thereby enclosing the posterior portion of the uncinatè process in its boundaries (Fig. 11). When accessory ostia are present they are situated between the processes of the uncinatè, usually between that body and the inferior turbinate. In this position they are quite accessible to sounding and the introduction of a catheter, as they lie at or below the inferior margin of the middle turbinate (Fig. 12).

* In making this statement accessory ostia are not considered.

These portions of membrane which lie between the projections of the uncinat process are known as nasal fontanelles, and, when the continuity of the membrane is broken, form accessory ostia. The structural configuration of the uncinat process is quite inconstant, particularly regarding its prolongations (any or all of them may partially fail), and on this account the fontanelles assume irregular shapes in different individuals. The posterior, or that portion lying behind the end of the uncinat process, appears always to be constant.⁴

The completion of the lateral wall of the nose is accomplished by the addition of the palate and lachrymal bones. The palate bone (Figs. 5 and 8) forms the posterior portion of the lateral

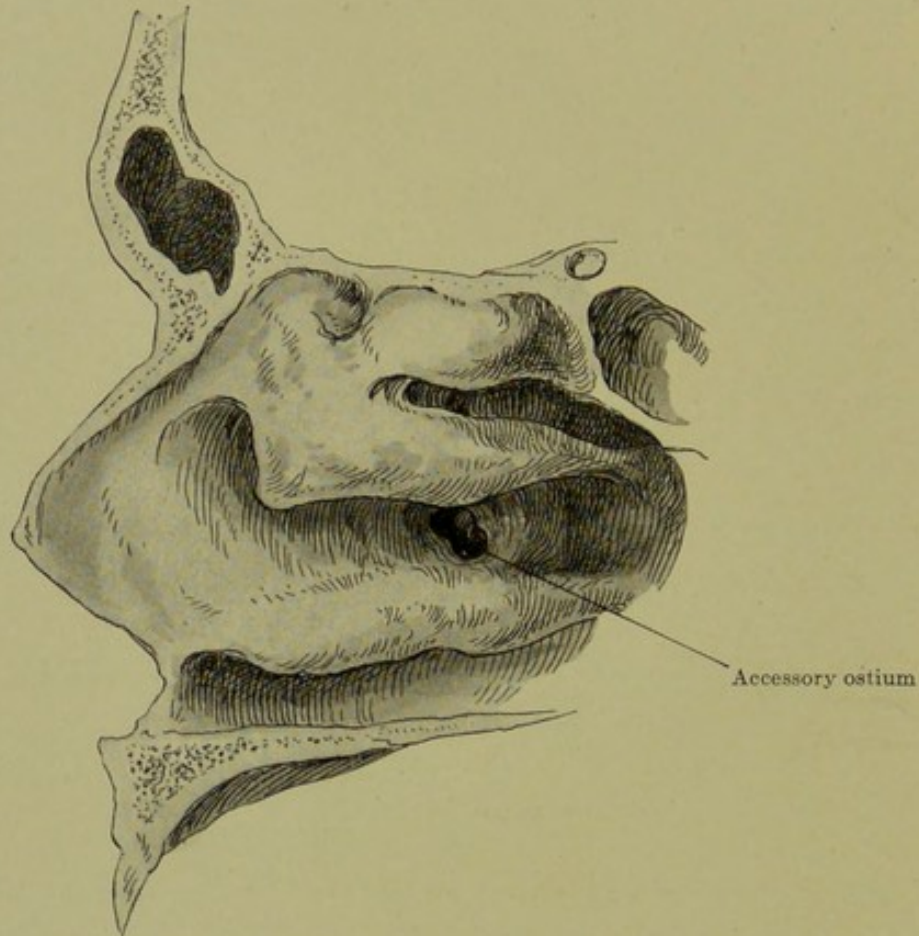


FIG. 12.—Lateral wall of nose showing accessory ostium.

nasal wall as well as the hard palate. It presents crests for the attachment of the inferior and middle turbinates, but is of little importance as far as the accessory sinuses are concerned. The purpose of this bone seems to be that of further strengthening the posterior chambers of the nares.

The lachrymal bone occupies a space between the (Fig. 19) frontal process of the superior maxillary and the lamina papyracea of the ethmoid. This bone is of great surgical importance

4. Onodi: Fontanelle des mittleren Nasenganges. Arch. f. Lary., Bd. 18, S. 488, 1906.

chiefly as a landmark in the operation on the ethmoidal cells by the orbital route, as the posterior ridge corresponds approximately to the anterior boundary of the ethmoidal capsule.

The posterior portion of the lateral nasal wall, that part lying behind the extremities of the middle and inferior turbinates and below the sphenoid sinus, is formed by the articulation of the palate bone with the pterygoid process of the sphenoid (Fig. 13).

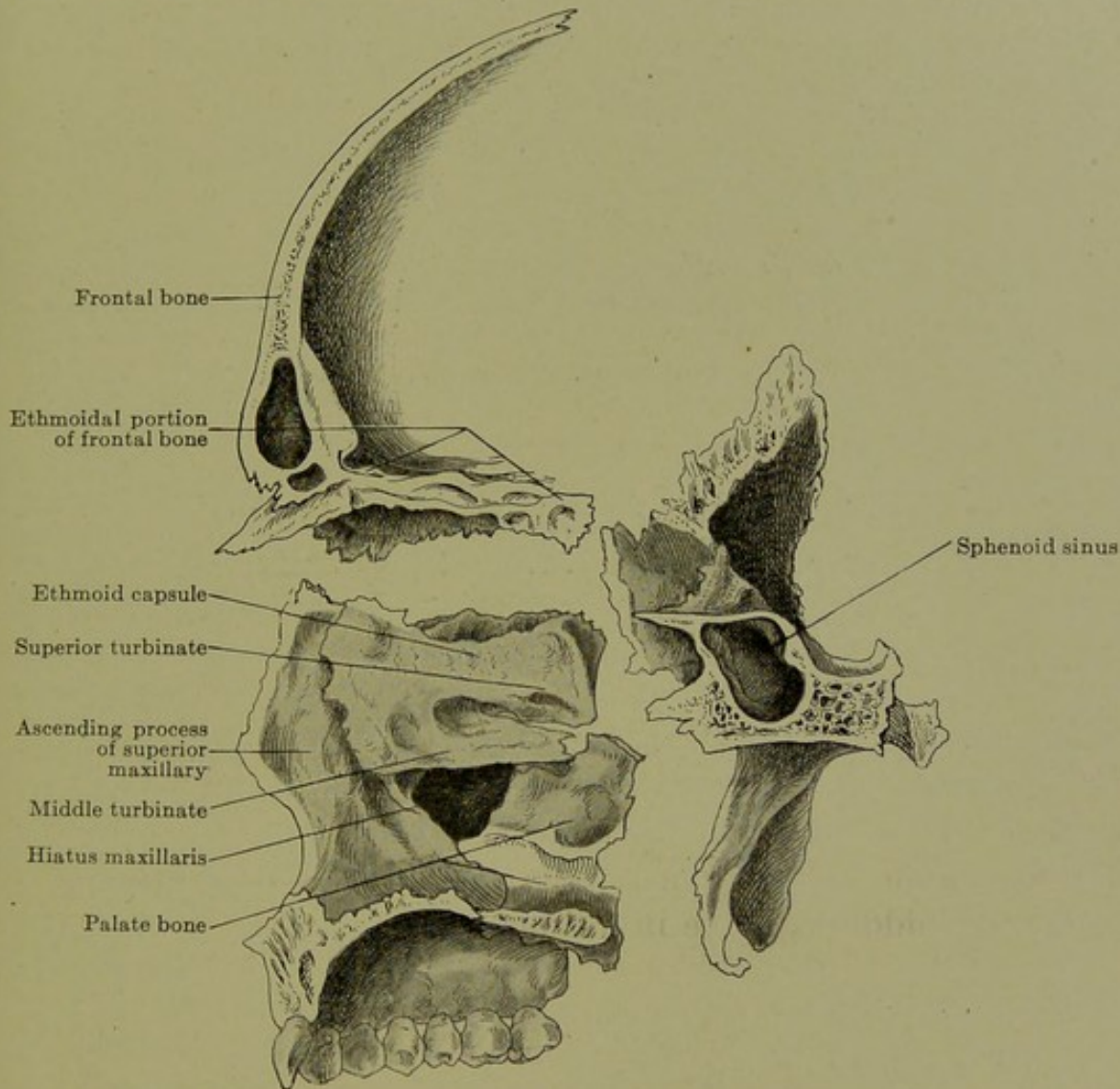


FIG. 13.—Ethmoid, superior maxilla and palate bone in normal position. Frontal and sphenoid in section disarticulated.

The lateral nasal wall as now built up, together with the mucous membrane, represents three nasal passages and three turbinates (inferior, middle and superior).

1. The inferior nasal passage is limited above by the insertion of the inferior turbinate and below by the floor of the nose.

2. The middle nasal passage lies between the junction of the middle turbinate with the ethmoid capsule and the insertion of

the inferior turbinate and containing the bulla, hiatus and unciniate process. Secretion in this passage indicates disease of the sinuses of the first series.

3. Superior nasal passage: In the strictest sense of the term this is really not a true passage, as it is blind in front, being formed by an indenture practically dividing the ethmoidal capsule in half at its posterior aspect, thus forming two turbinates. Neither the middle nor the superior turbinates are separate bones or true turbinates, but are dependences of the ethmoid capsule. The middle turbinate often takes the form of a semi-solid bone, but the superior is but the internal wall of the ethmoid capsule containing the posterior ethmoid cells.

Frequently in the middle turbinate there exist cells which formerly were supposed to be connected with some pathological process, but the authorities of to-day have disapproved of this theory, demonstrating that they are merely misplaced normal ethmoid cells. Under certain conditions they are subject to disease and dilatation or enlargement in precisely the same manner as any other normal ethmoid cell under similar conditions.

This passage is then but a slit in the ethmoid capsule directly over the insertion of the middle turbinate, being from one-eighth to three-eighths of an inch in height, gradually becoming wider as it approaches the choana. It is approximately three-quarters the length of the middle turbinate, consequently but half that of the middle and inferior nasal passages. The inferior nasal passage is of importance, as it contains the ostia of the sinuses of the posterior ethmoid cells and is so formed that any secretion issuing from these ostia must find its way over the posterior end of the middle turbinate in the choana.

The olfactory fissure extends from the anterior superior insertion of the middle turbinate to the anterior wall of the sphenoid sinus, embracing the internal wall of the superior turbinate in its boundaries. It is of surgical importance from the facts that its superior boundary is formed by the cribriform plate (*lamina cribrosa*), and the ostium of the sphenoid sinus is constant in its posterior superior boundary.

It has constantly been the custom to consider the ostium of the sphenoid sinus as belonging to, and emptying into, the superior nasal passage. This is anatomically incorrect, as the examination of several thousand specimens shows that it is the exception rather than the rule to find direct communication between these two structures. This direct communication can only occur when the recessus sphenoidal is excessively deep and the superior turbinate poorly developed.

It should be borne in mind that the cribriform plate is thinnest at its anterior portion, where it is pierced by the olfactory nerves, but becomes gradually thicker as it extends backward, as it joins the sphenoid it is composed of hard cancellated bone which would require considerable force to injure with the ordinary nasal instruments. The olfactory nerves during their passage through the cribriform plate are enveloped in a prolongation of dura mater, which connects more or less intimately with the nasal mucosa. This anatomic formation favors the ready transmission of infection from the nasal cavities to the meninges.

The supreme turbinate (*concha suprema*) has been described by various anatomists, but further than for descriptive purposes it is of little importance, being formed by a very shallow furrow in the posterior part of the superior turbinate. (Fig. 4.)

ANATOMY OF THE NOSE IN FRONTAL SECTION.

It will be remembered that the superior maxillary and ethmoid capsule formed the chief structures of the lateral nasal wall. What is now their precise relation to the formation of the nose in sagittal section? This question can be more easily explained by taking

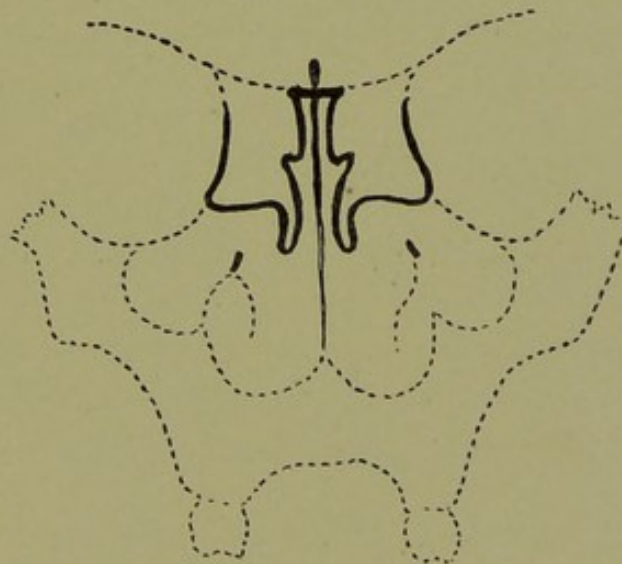


FIG. 14.—Relation of ethmoid capsule to surrounding structures. (After Hajek.)

the accompanying schematic drawing as an illustration (Fig. 14), and comparing it with a specimen taken from life (Fig. 15).

We recall that the structures of the lateral nasal wall lying above the inferior margin of the middle turbinate on the one hand and the uncinat process on the other, belonged to the ethmoid capsule. The boundaries of the entire capsule are empha-

sized by heavy lines in the schematic drawing. Noting this well it will be observed that the right and left capsules hang down on

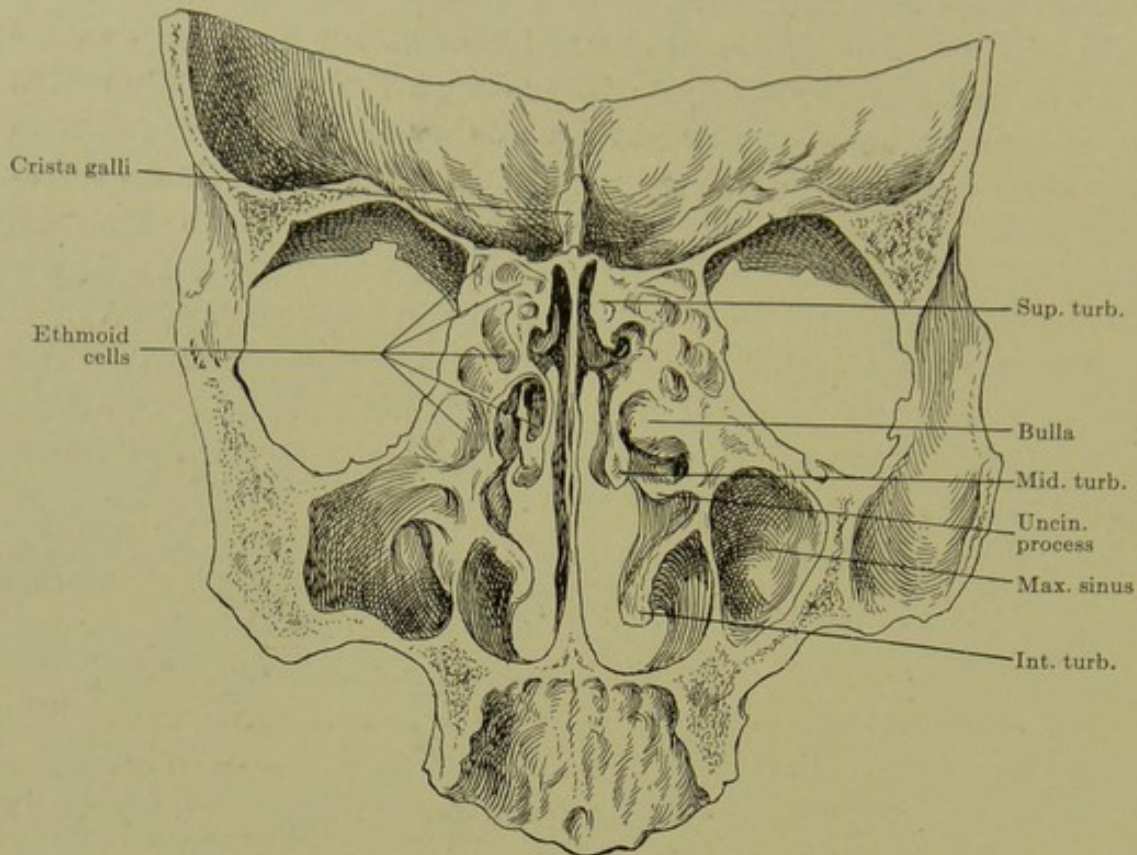


FIG. 15.—Cross section behind uncinat process showing relation of ethmoid capsule to surrounding parts.

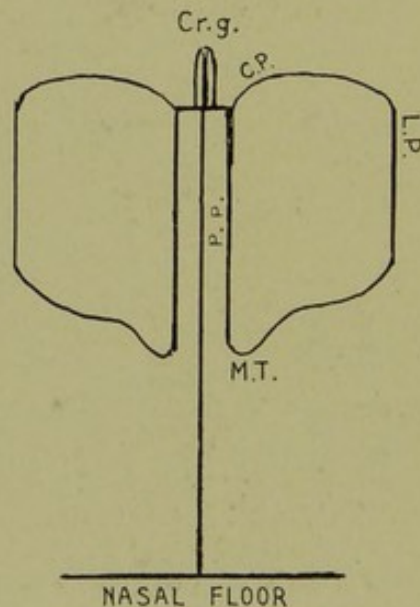


FIG. 16.—Diagrammatic illustration of the ethmoid capsule. Cr. g., crista galli; C. P., cribriform plate; P. P., perpendicular plate; L. P., lamina papyracea; M. T., middle turbinate.

each side of the nasal septum similar to bags, the lower corner projecting downward like a slender process. The entire structure occupies at least half the entire distance between the floor of the

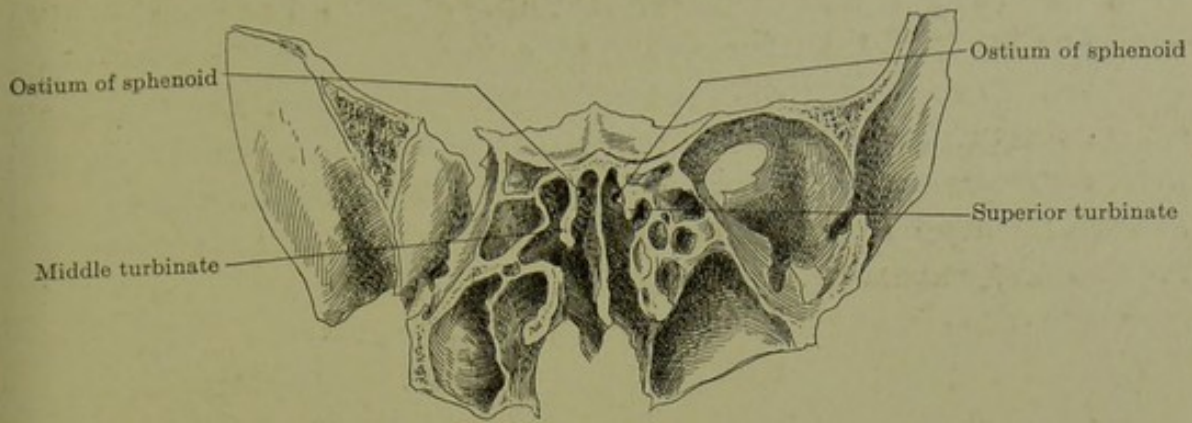


FIG. 17.—Section through ethmoid capsule posterior to the hiatus semilunaris.

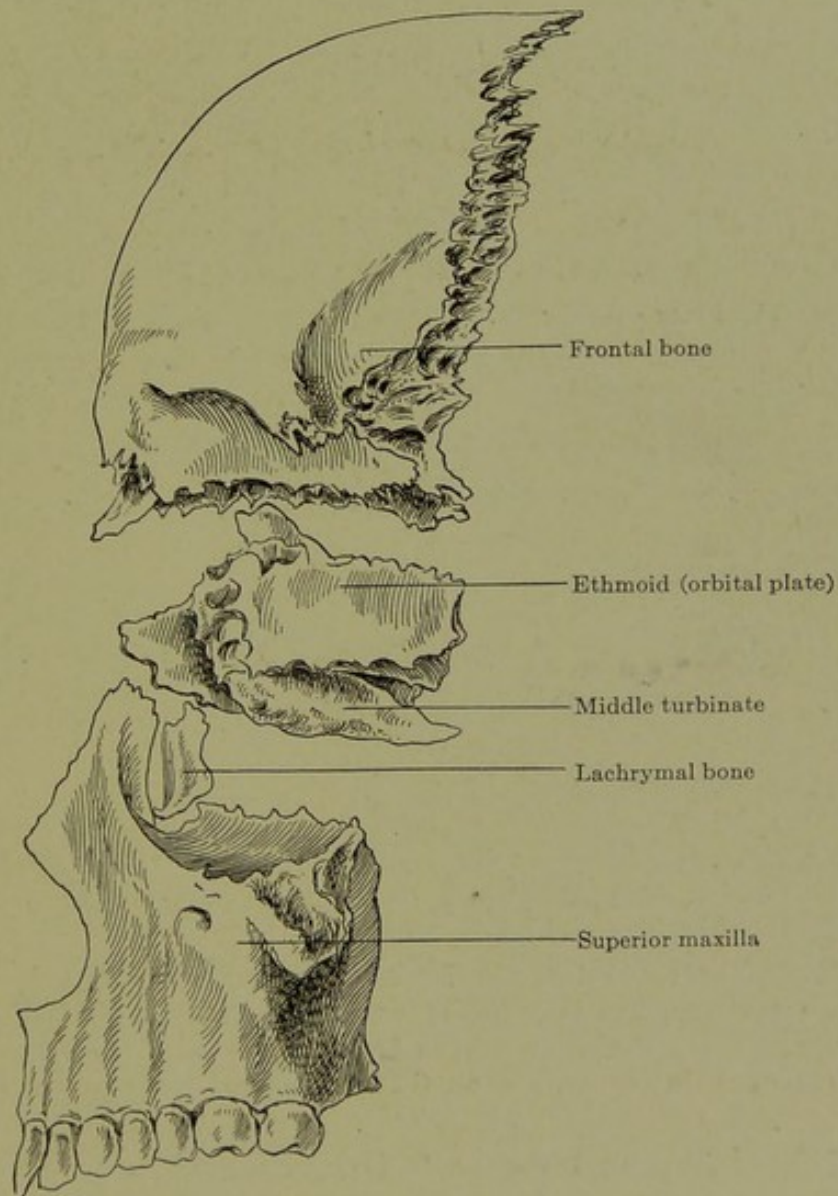


FIG. 18.—Frontal, ethmoidal and superior maxilla disarticulated.

nose and the cribriform plate. On analyzing and comparing this drawing we find that the superior boundary *c. p.* (Fig. 16) corresponds to the cribriform plate, the projection dividing this plate *cr. g.*, the crista galli, the continuation of this process downward; *p. p.* corresponds to the perpendicular plate of the ethmoid (nasal septum). The external orbital boundary, *l. p.*, represents the lamina papyracea.

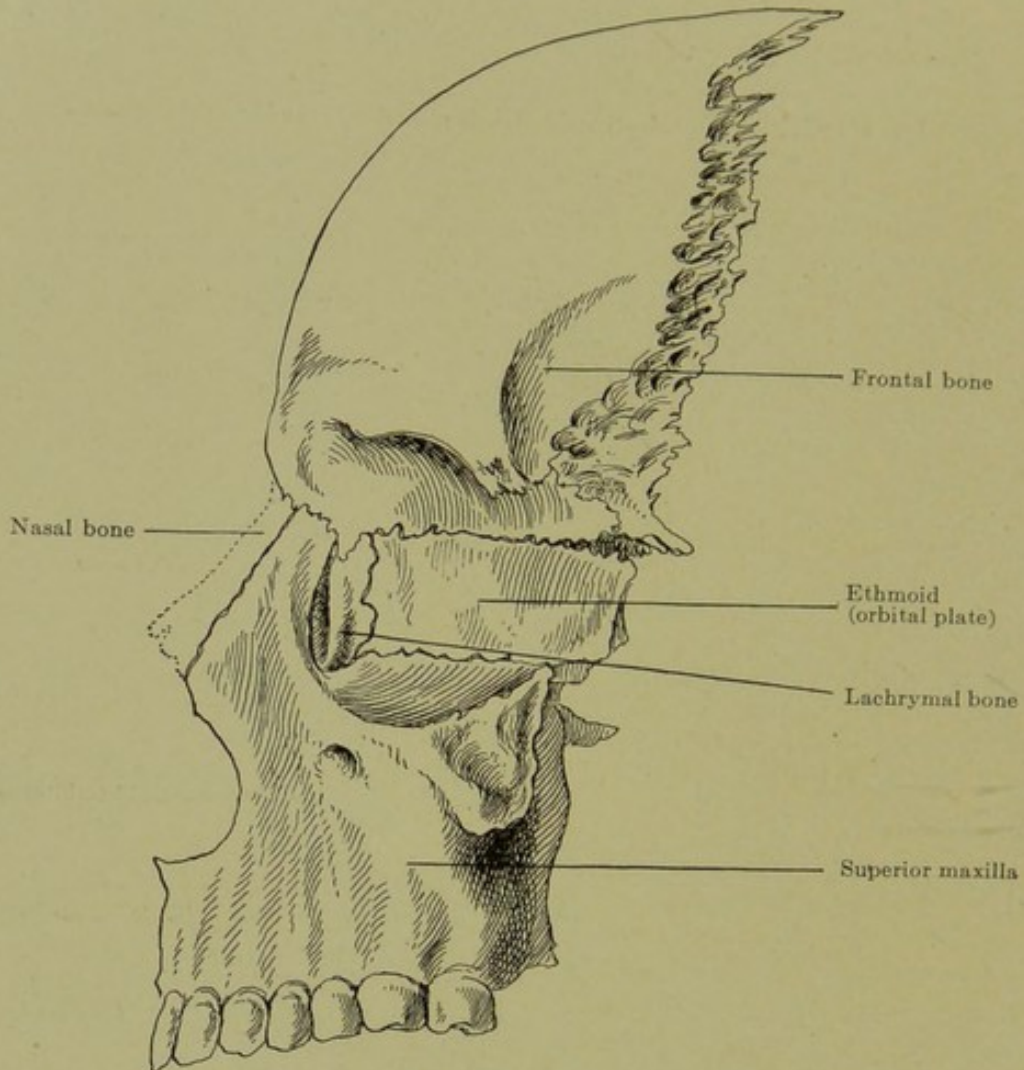


FIG. 19.—Frontal, lachrymal, ethmoidal and superior maxillary, in normal position.

It will be noted that the lamina papyracea does not meet with or touch the lamina cribrosa, but they are separated by cone-shaped dotted lines. These lines represent the articulation of the frontal bone with the ethmoid and will be fully treated upon in the section on the anatomy of the ethmoid labyrinth.

The inferior boundary (*b*) corresponds to the bulla and the long and short projections on the inner side, the middle turbinate and superior turbinate respectively. The short heavy line below the bulla (*p. u.*) represents the posterior extremity of the unciniate

process. When one recalls that this process issued from the anterior portion of the ethmoid capsule in the form of a blade running backward beneath the bulla and having no connection with it, the seeming peculiar position of this line will be apparent. The boundaries of the ethmoid capsule are then the following:

Above by the frontal bone and sphenoid.

The lamina cribrosa has hitherto shared the superior boundary with the frontal in the anatomy of this region. As a matter of fact the roof of the superior anterior ethmoidal cells is formed by the orbital portion of the frontal bone (fovea ethmoidalis), the posterior superior by the sphenoid (lesser wing). The lamina cribrosa leads directly into the olfactory fissure and if a fine wire is passed downward through one of the foramina it will always emerge in the nasal fossa and never into an ethmoidal cell unless dehiscence of the bone is present. This statement is borne out by the examination of hundreds of specimens.

Externally by the lamina papyracea (orbital plate).

Below by the bulla ethmoidalis.

Internally by the inner wall of the middle and superior turbinates.

A cross section further back, behind the end of the uncinate process, shows little change in the configuration of the parts. (Fig. 17.)

We note that the superior turbinate is more conspicuous, the middle turbinate shorter, the bulla and uncinate process absent, but the size and shape of the ethmoid capsule proper remain about the same.

The ethmoid capsule then occupies all that space lying between the inner wall of the orbit and the inner wall of the middle and superior turbinate. Its exact relationship to the orbital wall is shown in Figs. 18, 19.

TOPOGRAPHICAL ANATOMY OF THE HIATUS SEMILUNARIS.

It has been previously shown that the hiatus semilunaris is a more or less shallow curved duct situated in the middle nasal passage between the processus uncinatus and bulla and in normal cases is always covered by the anterior third of the middle turbinate. (Figs. 20, 21.) The hiatus is not of constant width, but has a larger diameter in the depth than superficially, *i.e.*, on cross section it is pear-shaped. (Fig. 22.) It also gradually becomes wider as it extends downward, as its widest part is in direct relation to the maxillary ostium. From this fact the depth of the

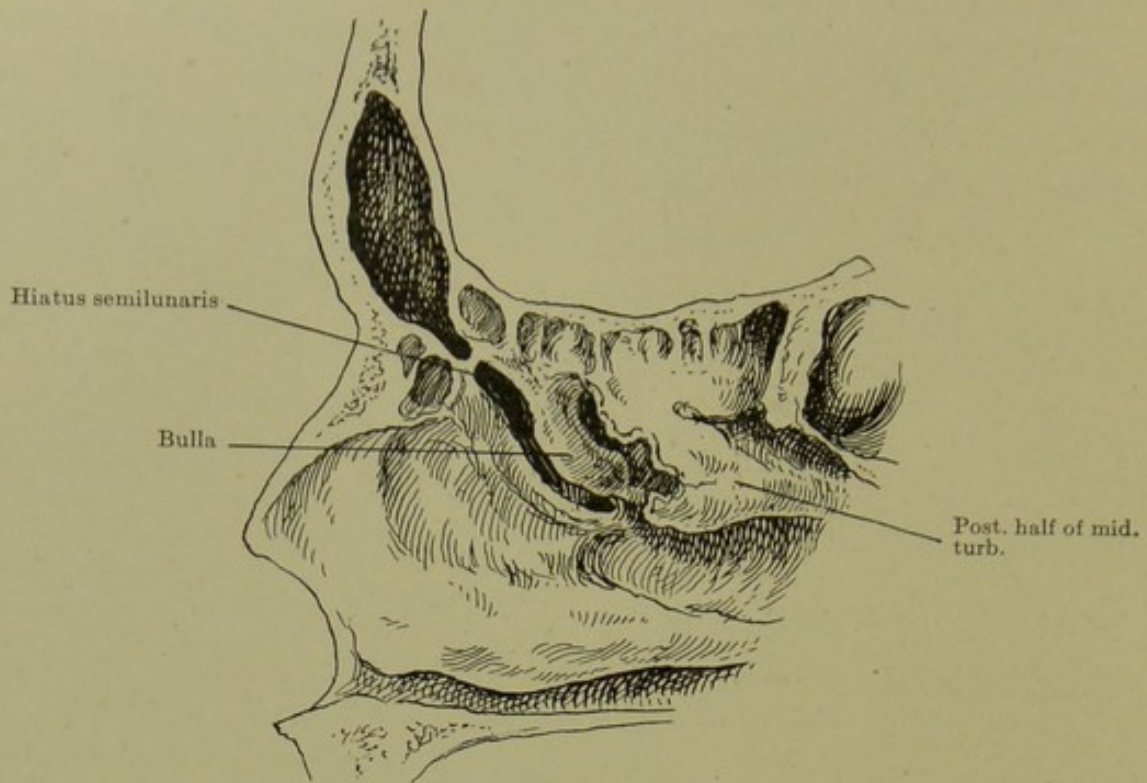


FIG. 20.—Lateral wall of the nose with ethmoid labyrinth opened.

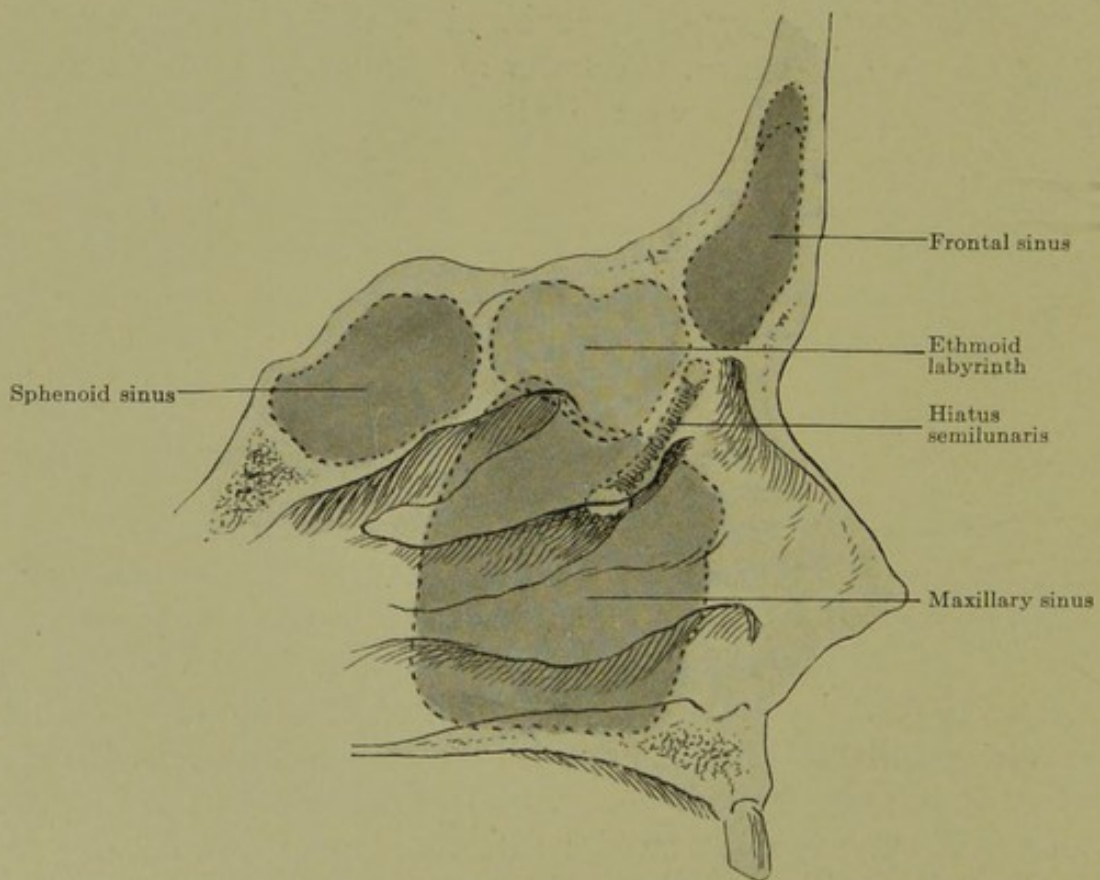


FIG. 21.—Relation of sinuses and hiatus semilunaris to lateral wall of the nose. (Modified after Hajek.)

structure has been termed the infundibulum, while the whole structure, including the depth, the hiatus semilunaris.

This division of the nomenclature has been the source of endless confusion. Heymann and Ritter⁵ but recently have attempted to elucidate the entire subject by applying the term infundibulum to that portion of the hiatus which directly communicates with the frontal sinus. Hajek⁶ has taken exception to this classification and clings to the old accepted meaning of the term.

The anterior and superior ends of the hiatus lead into the frontal sinus in two ways, which Hajek terms the typical and atypical. (Figs. 23 and 24.)

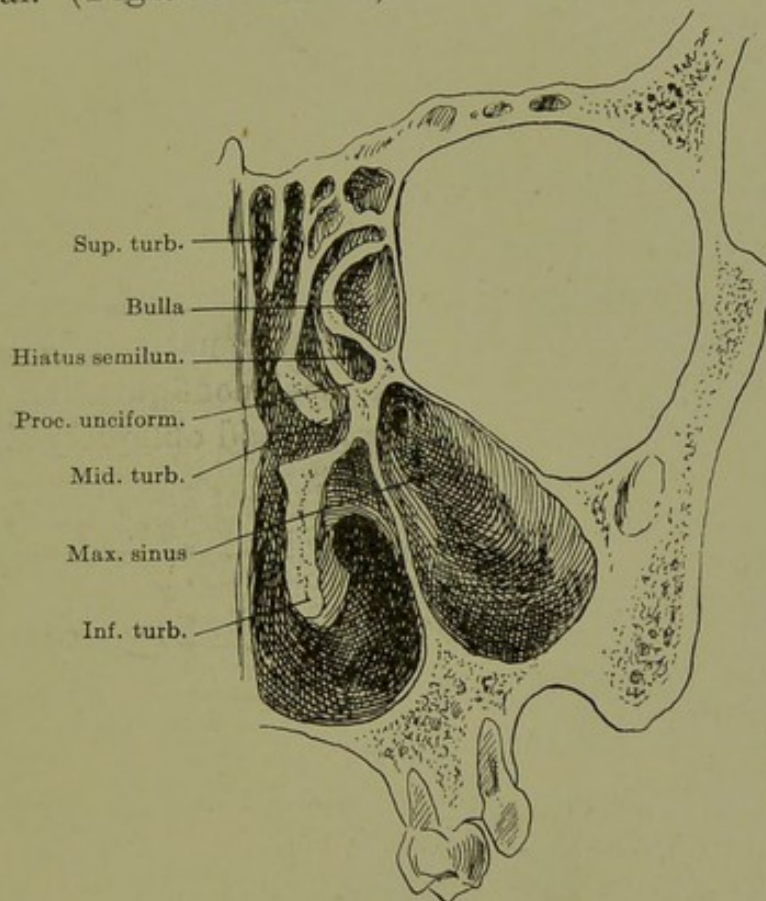


FIG. 22.—Transverse section through the middle of the uncinat process and bulla, showing pear shape of hiatus semilunaris.


1. By direct continuation without the intervention of any hindering structure. (Fig. 23.)

2. By the hiatus ending blind but the continuation of the canal occurring immediately to the inside. (Fig. 24.)

The author would be inclined to refer to the latter as the typical, as the vast majority of specimens show this blind ending of the hiatus. Uffenorde⁷ has demonstrated two further ways by which the hiatus may end anteriorly, but as they are distinct anomalies they will be referred to later (see Anatomy of ethmoid labyrinth).

5. Heyman & Ritter: Zur Morphologie und Terminologie des mittleren Nasenganges. Zeitschr. f. Laryngologie, Bd. 1, S. 1, 1909. 6. Hajek: Die Nebenhöhlen der Nase., S. 39, Note, 1909. 7. Uffenorde (3), S. 4.

The posterior end of the hiatus usually ends in a deep furrow, the maxillary ostium coming in, as it were, from the side and usually an appreciable distance from the posterior extremity. Much has been said regarding the direct passage of purulent



Figs. 23 and 24.—Schematic illustration of the two formations of the hiatus semilunaris. *s.f.*, frontal sinus; *o.e.*, ethmoid ostium; *o.f.*, frontal ostium; *h.s.*, hiatus semilunaris. (After Hajek.)

materials from the frontal sinus into the maxillary. That this can and does occur under certain circumstances must not be denied, but it depends entirely upon the anatomical configuration of the uncinate process. If this structure is broad and obliquely situated

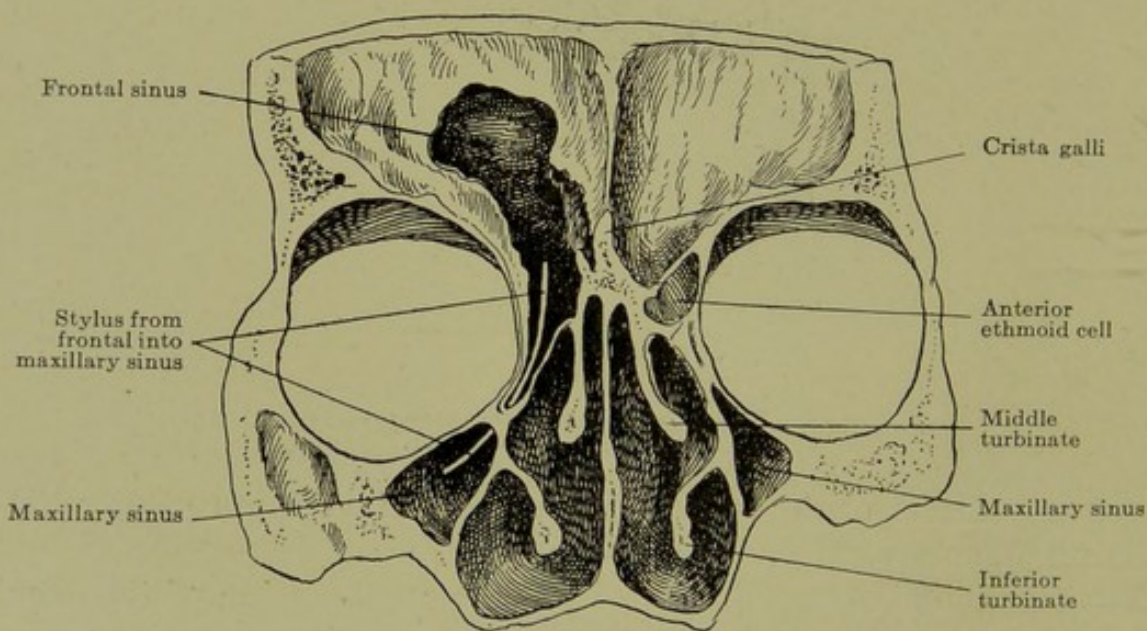


FIG. 25.—Direct connection between the frontal and maxillary sinuses through an abnormally deep hiatus semilunaris.

so that it forms a trough with the lateral wall, the maxillary ostium being at the end of this passage, naturally any fluid coming from above must be directed along the line of least resistance and find its way to this ostium. The size of the ostium also exerts no little influence in allowing the passage of liquids. (Fig. 25.) The ostia

of the anterior ethmoid cells are variously situated. One, however, is practically constant, being situated directly between the bulla and middle turbinate. (Fig. 26.) The length of the hiatus is variable, depending upon the configuration of the parts in the frontal region.

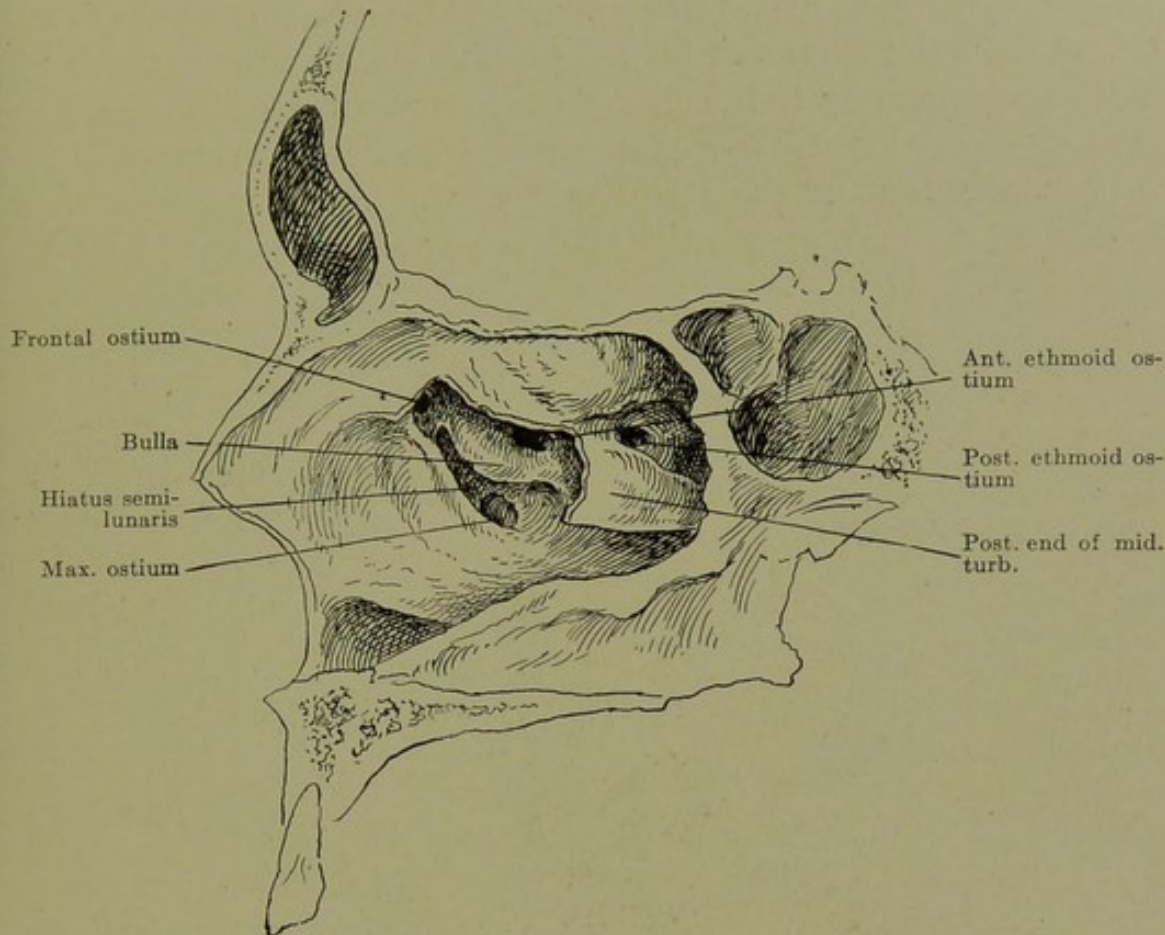


FIG. 26.—Lateral wall of the nose with anterior half of the middle turbinate removed.

MUCOSA OF THE LATERAL NASAL WALL.

The mucous covering of the ethmoidal capsule and inferior turbinate is continuous and similar in appearance, but presents different characteristics. Over the inferior turbinate it is tough and may be several mm. thick, owing to the presence of numerous muciparous glands, swell bodies and connective tissue, while that portion that covers the ethmoid capsule and middle turbinate is tender and quite thin. The blood supply is derived from the sphenopalatine branch of the internal maxillary artery and the anterior and posterior ethmoidal arteries. (Plate 1a.) The sphenopalatine artery supplies the floor of the sphenoid sinus. The ethmoidal arteries supply the ethmoid capsule and the anterior portion of the lateral nasal wall.

THE DEVELOPMENT OF THE ACCESSORY SINUSES (POST-EMBRYONIC).*

Maxillary Sinus.—In the new-born the antrum is present, although in miniature proportions, occupying a space internally to and not below the orbit.⁸ (Fig. 27.) Its actual shape and size devoid of membrane are approximately those of a small bean. (Figs. 28, 29.) In the recent state, however, the lining membrane is very thick in proportion to the size of the cavity, almost filling its lumen and giving it a slit-like appearance. The floor is relatively high, as it barely reaches the attachment of the inferior turbinate.

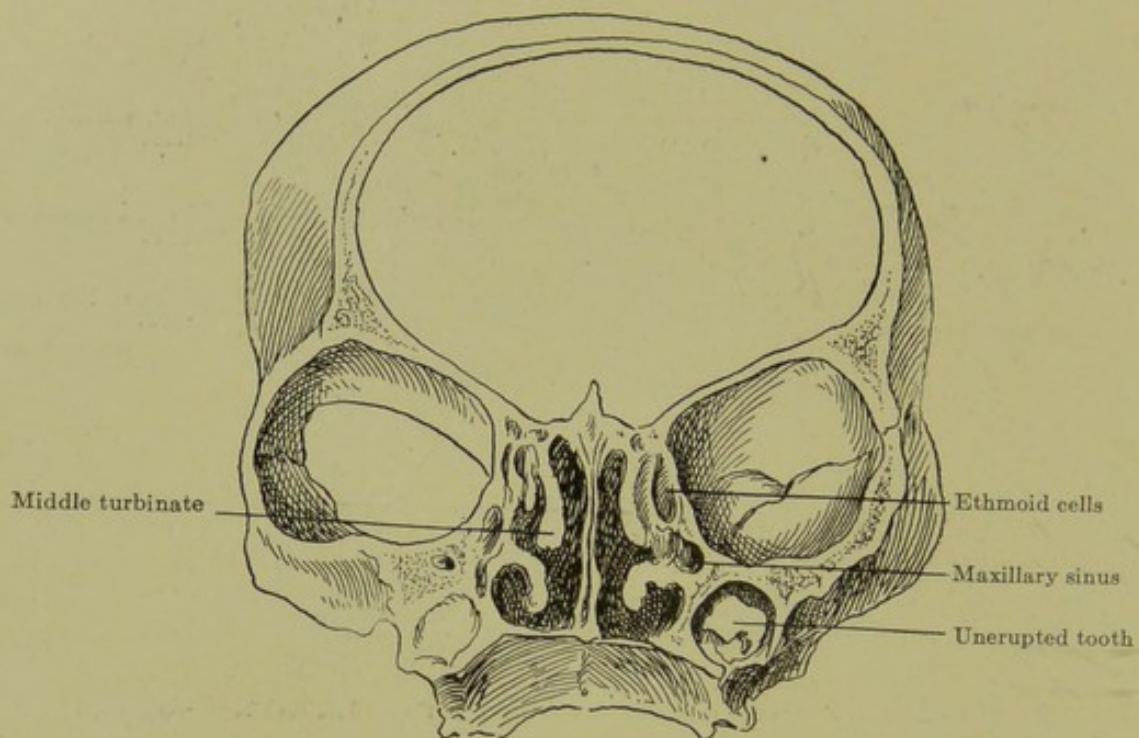


FIG. 27.—Section through head of foetus at birth, showing relation of maxillary sinus to orbit and alveolus, also development of ethmoid.

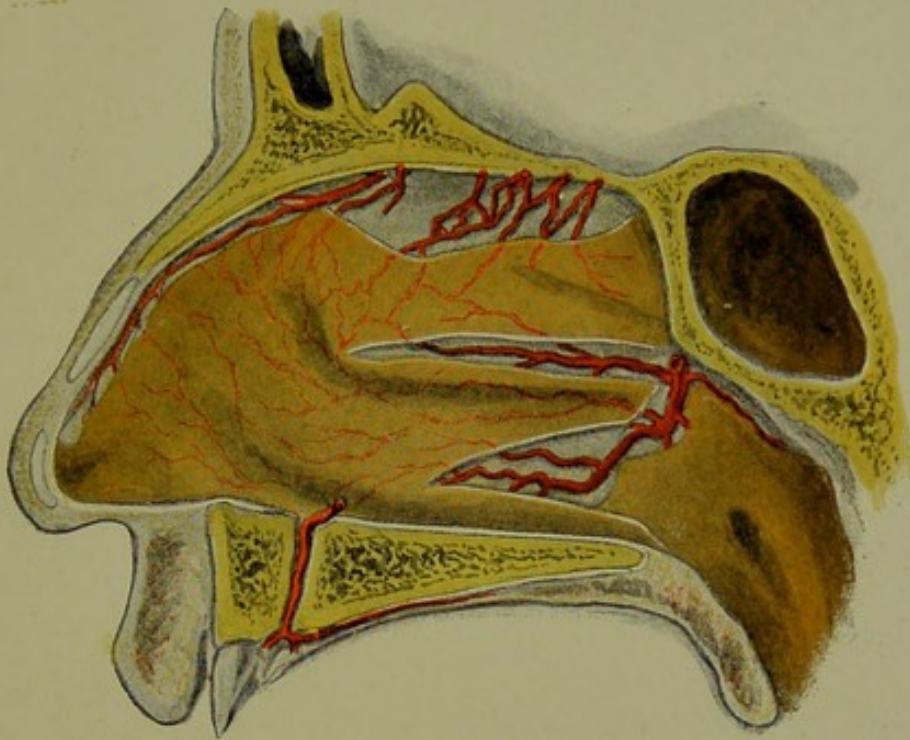
It would appear that the sinus lies in closer relation to the orbit than to the nose. Such is not the case. Even in the nine-month embryo a needle can be passed through the inferior nasal passage into the sinus if the point be sufficiently elevated. The alveolus occupies the same relation inferiorly as does the orbit superiorly.

The subsequent growth of the antrum occurs through the downward development of the alveolar process, and lateral infra-orbital absorption of cancellous bone through the walls of the cavity, and does not assume its permanent shape until after the eruption of

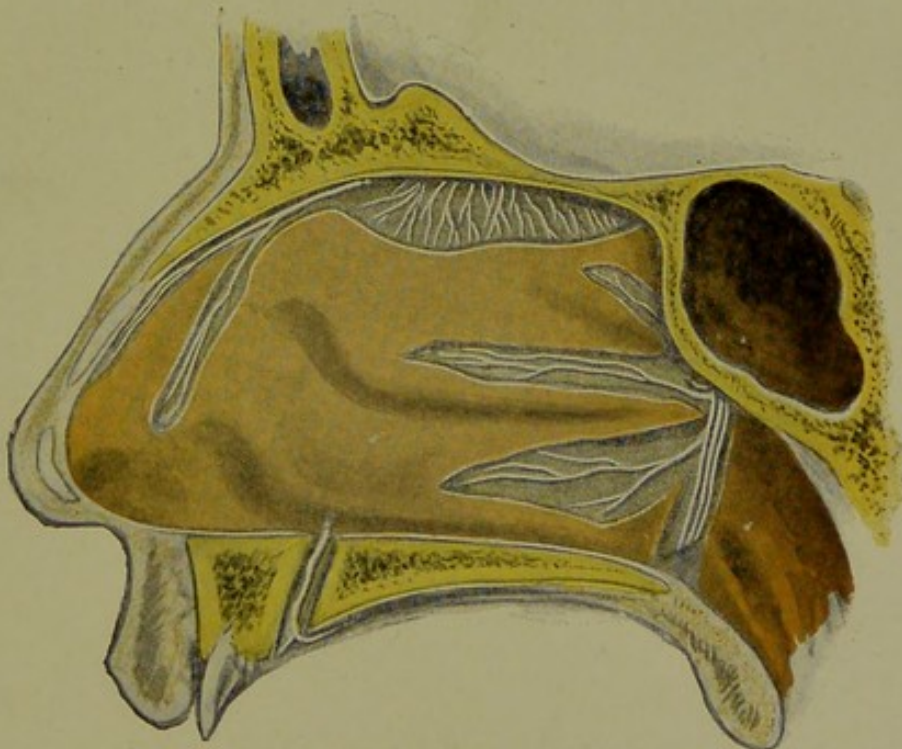
* For an exhaustive treatise on this subject see Onodi: Die Nebenhöhlen der Nase beim Kinde. Würzburg, 1911. In this work the successive stages of sinus development from the six and a half months' foetus to adult life are depicted in 102 plates.

8. Reschreiter: Zur Morphologie des Sinus Maxillaris. Stuttgart, 1878.


PLATE 1.



A, Blood supply of lateral nasal wall. Spheno-palatine artery posteriorly. Anterior nasal and ethmoidal arteries above. (After Sobotta.)

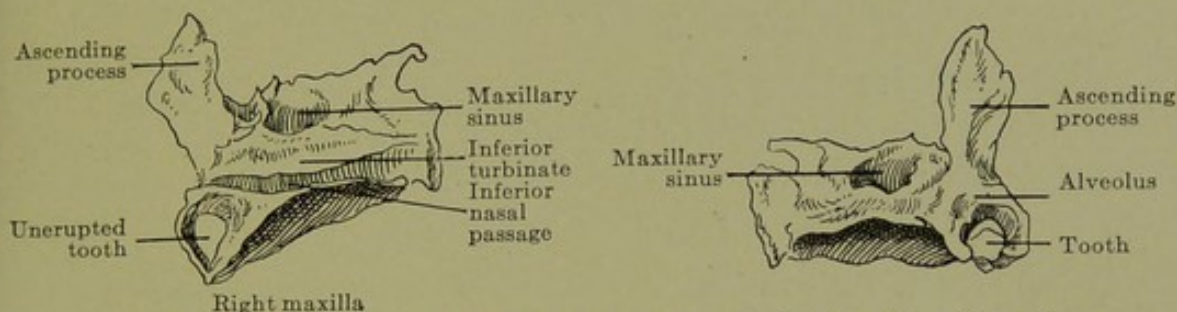


B, Nerve supply of lateral nasal wall. (After Sobotta.)



the permanent teeth, with complete development of the upper jaw. It, therefore, reaches its full size between the fifteenth and eighteenth years.

Frontal Sinus.—This cavity is not present in the newly born, but makes its appearance in the orbital plate between the end of the first and beginning of the third year,⁹ and up to the sixth or seventh year reaches only the size of a pea.¹⁰ It does not commence by direct reabsorption of the frontal bone, but by an upward expansion of an air passage from the anterior ethmoidal labyrinth, which gradually forces its way into the diploe of the squamous portion of this bone. At the end of the seventh to ninth years this sinus may be recognized as a distinct separate cavity above the root of the nose internal to the supra-orbital ridge.



FIGS. 28 and 29.—Superior maxilla of fœtus at birth, showing size of maxillary sinus.

Ethmoid Labyrinth.—These cells are also present at birth (Fig. 27), being hollowed out in the fœtus at the third embryonal month and develop simultaneously with the frontal sinus. The latter is but an offshoot from the ethmoid, which forces its way into the diploe of the nasal portion of the frontal bone.¹¹ Curran¹² has shown that all of the cells are present at birth as well as those which afterward go to form the sphenoid and ethmoid. He dissected fœtuses from three and one-half months until birth, was able to form a continuous picture, thereby drawing reliable conclusions. In fourteen heads about the same number of cells were present that are found in the adult (nine to fourteen). According to Braislin¹³ only four ethmoid cells are present at birth, two anterior and two posterior.

9. Coffin: The Development of Acc. Sin. of Nose. Am. Jr. of Med. Sciences, Feb., 1905.
 10. Steiner: Ueber d. Entwickl. d. Stirnhöhle. Langenbeck's Arch. f. klin. Chir., Bd. 13, S. 144, 1872. 11. Spiess: Die Untersuchungsmethoden der Nase und ihrer Nebenhöhlen. Heymann's Handbuch, S. 238, 1900. 12. Curran: The Ethmoid Cells at Birth and their Development during Fetal Life. Boston Med. and Surg. Journ., vol. 59, p. 565, 1908.
 13. Braislin: The Accessory Cavities in the Nose of a Five-year-old Child. Transactions Am. Otological Society, 1910.

Sphenoid.—At birth this structure is but a faint depression in the cancellated tissue of the body of the sphenoid. It begins to develop about the fourth month, and is fully formed about the sixteenth year.

Coffin⁹ says it is a distinct cavity at the end of the first year. Braislin,¹³ however, found the sinus absent in a five-year-old child. The examination and size of this sinus vary in different children. In some specimens between four and six months of age there is a distinct depression in the body of the sphenoid, while in others of even greater age, no such depression is present, the size of the sinus is no criterion of its age, as two heads of like age may show gross differences in the stage of development of their sinuses.

RATIONALE OF THE PHYSIOLOGICAL DEVELOPMENT OF THE ACCESSORY SINUSES.

Many theories have from time to time been advanced to explain this process. Among others the following appear to be the more feasible: 1. Reabsorption of the bone due to variations in air pressure, particularly that of expiration.

Coffin⁹ appears to have been the first one to advance this theory when he stated that the development of the sinuses may be due to expansion under pneumatic pressure causing resorption of the cancellous tissue, as this development manifests itself at the age at which children begin blowing the nose. Frers,¹⁴ apparently independent of Coffin, comes to the same conclusion, basing his assertion on the following reasons:

1. The principal growth of the sinuses occurs after respiration sets in.
2. According to the law of nature, organs which cease to functionate, atrophy.
3. The sinuses show similarity to the other cavities which are influenced by air pressure (alveoli of lungs).
4. The constant presence of changing pressure in the sinuses. (Ins. neg., ex. pos.)¹⁵
5. The direction of the inspiratory and expiratory streams in relation to the anatomical formation of the nose.

Both Coffin and Frers refer to the fact that the sinuses are poorly developed in children with adenoids; they consider this due to the lack of normal air pressure in the nose during expiration.

Killian¹⁶ does not agree with Frers in any of his points, and says the secondary enlargement of the sinuses must result from some deeper lying phylogenetic influence.

14. Frers: Studien über die postembryonale Entwicklung der Nebenhöhlen der Nase. Vehr. d. Vereins. deutscher Laryn., S. 191, 1909. 15. Neumayer: Ueber den Luftwechsel in den Nebenhöhlen. Mon. f. Ohrenhk., S. 504, 1901. 16. Killian: Discussion zu Frers (14).

PHYSIOLOGY OF THE ACCESSORY SINUSES.

Numerous theories have been advanced regarding the precise function of these cavities, and even at the present moment many authorities will hold almost directly opposite views as to their significance. The theories which have been advanced from time to time and have the most semblance of probability are:

1. Remains of certain rudimentary structures which in lower animals serve as important adjuncts to the sense of olfaction.¹⁷

Certain of the lower animals possess an exceedingly keen sense of smell. This has been shown to be due to accessory olfactory ridges (*Reichwulste*) situated in the frontal, sphenoid, and maxillary sinuses.¹⁷ The ethmoid labyrinth cannot enter into the question, as it is found only in man and the anthropoid apes.

2. An adjunct to olfactory function by evenly distributing the inspired air in the olfactory region.

This theory was advanced by Braune and Clasen.¹⁸ Paulson (1882) and Hartz¹⁹ do not accept this theory, stating that those animals which do not possess any power of olfaction often have the large sinuses. Preyer (1884) also combats this theory with the argument that small children and the lower apes have practically no sinuses, yet possess the keenest sense of smell.

3. To lighten the bones of the skull in order that proper balance may be maintained—Vesalino (1542), Schneider (1655), Bartholinus (1658), Highmore (1681), Muller (1840).*

Braune and Clasen¹⁸ object to this theory, on the ground that, if the sinuses were filled with spongy bone, the total weight would only be raised one per cent. Schwalbe (1887) answers this argument by stating that the head is so evenly balanced that this slight increase would tend to interfere with the proper equipoise. Zarnico (p. 82) rejects the theory as unsound, by pointing out that children have no sinuses but still are perfectly able to balance their heads.

Braune and Clasen¹⁸ have computed the loss of weight which the skull would undergo by substituting air cavities for solid bone and found that the total weight loss was one per cent. Schwalbe (1887) claims however that this small loss of weight considerably influences the poise and counterpoise of the head, as it was entirely limited to the anterior portion (mostly in the bones of the face).

The older theories that they imparted resonance to the voice (Speigel, 1645; Voltini, 1888) or secreted mucus for the purpose of keeping the nasal chambers moist (Haller, 1763; Walter, 1778; Blumenback, 1824; Bidder, 1845) have been disapproved, as in the first instance the ostiums are too small to exert any influence on the sound waves, and in the second not only is the sinus mucous membrane practically devoid of glandular tissue so that sufficient quantity of mucus cannot

17. Ingersoll: The Function of the Accessory Cavities of the Nose. *Ann. Otol. Rhin. & Laryng.*, p. 757, 1906. 18. Braune & Clasen: *Die Nebenhöhlen der Menschlichen Nase in ihre Bedeutung für den Mechanismus des Riechens.* *Zeit. f. Anat.*, Bd. 2, S. 1, 1877. 19. Hartz: *Physiology of Nose and Sinuses.* *Laryngoscope*, p. 958, 1909.

* For the complete literature of the ancients and older writers see J. Wright's *History of the Nose and Throat*, p. 165.

possibly be secreted, but the unfavorable situation of the ostia (except the frontal) for the outflow of the secretion precludes the possibility of their having this function. (Luschka, 1867.)

4. Adjunct to respiration. Moistening the inspired air.*

RÔLE OF THE SINUSES DURING RESPIRATION.

The extensive experiments of Braune and Clasen¹⁸ have definitely shown that a certain amount of air change takes place in the sinuses during respiration. The volumetric changes are not in ratio to the amount of inspired air passing through the nasal chambers, but depend more upon the degree of one inspiration, thus, for example, in the maxillary sinus during ordinary respiration the air change is relatively small, while in forced inspiration, particularly as the alæ of the nose are more or less sucked in, the rarefaction of the air in this sinus will equal that occurring in the nasal passages. Polyps, polypoid hypertrophies and swellings around the ostia naturally exert considerable influence on this physiological exchange of air.²⁰

INTRA-NASAL AIR PRESSURE DURING INSPIRATION AND EXPIRATION.

1. Ordinary inspiration	— 6 mm. to — 8 mm. H ₂ O
2. Ordinary expiration	+ 4 mm. to + 6 mm. H ₂ O
3. Forced inspiration	—50 mm. to —65 mm. H ₂ O
4. Forced expiration	+30 mm. to +35 mm. H ₂ O

NORMAL MECHANISM OF DRAINAGE.²¹

Under normal conditions the accessory sinuses of the nose are capable of self drainage for the following reasons.

1. The lining mucous membrane is composed of ciliated epithelium, the motion wave of the cilia being always directed toward the ostium of the sinus.

2. At every position of the body certain of the ostia are at the lowest portion of the sinus, thus in standing or sitting the ostium of the frontal sinus is low, on lying down the maxillary sinus.

This accounts for the dissimilarity of the subjective symptoms often noted in affections of individual sinuses thus, a frequent symptom of chronic frontal sinusitis is neuralgia over the orbital

*Tunis (Laryngoscope, p. 931, 1910) believes the maxillary sinus serves more for this purpose than any other.

20. Eckley: On the Accessory Sinuses. Chicago Med. Recorder, vol. 26, p. 245, 1904. 21. Yankhauer: The Drainage Mechanism of the Normal Accessory Sinuses. Laryngoscope, p. 518, 1908.

region regularly appearing at a certain time in the morning, continuing several hours, then ceasing as suddenly as it appeared. The explanation of this phenomenon is as follows: During the night while the patient is in the recumbent position the frontal ostium lies in an unfavorable position to allow the continually forming secretion to escape, therefore, it accumulates *in situ*. In the morning, when the erect position is assumed, the mucous membrane around the ostium is more or less swollen and congested from the irritation of the secretion as well as the equalization of blood pressure, consequently stagnation and engorgement result in the sinus. As soon as actual pressure occurs, neuralgia appears and continues until the ostium, either through pressure of the secretion or amelioration of the congestion, becomes sufficiently patulous to allow the partial or full escape of the secretion. Drainage is thus established with instant cessation of the neuralgia. The size of the sinus, profuseness of secretion and virulence of the infection can exercise great influence on the severity or duration of the neuralgic attack.

The maxillary sinus under the same circumstances may exhibit totally different characteristics. Thus, a patient presents himself on a morning for examination with the classical symptoms of maxillary sinusitis except no secretion is seen by rhinoscopy; however, the history of a profuse discharge in the nasopharynx is obtained. This must usually be drawn backward and expectorated. The explanation of this peculiarity lies in the drainage mechanism. During the day the sinus secretes an amount which fills the cavity, and, as the ostium is situated at the superior portion, the secretion only escapes drop by drop, while the patient is in the upright position. As the patient lies on the sound side during the night, the ostium lies in the most favorable situation for drainage, and this, together with the action of the cilia, in a greater or lesser period of time depending upon the consistency of the secretion, enables the sinus to rid itself of its pathological contents, frequently by a system of siphonage, especially if the secretion be viscid. On awakening in the morning, this mass, being free in the nasal passages, is either blown or hawked out en masse, and by the examination, a few hours later, no trace of secretion is to be found in the nose, as in the mean time the mucous membrane of the antrum has not had the opportunity to secrete a sufficient amount to fill and overflow.

The drainage of the sphenoid is similar to that of the antrum,

but on a much smaller scale. The drainage mechanism of the ethmoid cells may be either the simplest or the most complicated of the accessory cavities of the nose,—the simplest when the ostium is situated in the lowest portion of the cell and empties directly into one of the nasal passages; the most complicated when one cell empties into another and into a second or third and, finally, empties into the nose.

BACTERIOLOGY OF THE ACCESSORY SINUSES.

Before considering this phase of the subject it is necessary to ascertain whether the sinuses under normal circumstances act as a habitat for micro-organisms. It was formerly considered that such was the case, but later investigations have proved this assumption false.^{22 23}

Törne²⁴ demonstrated that the healthy sinuses of cadavers which had not been dead over two hours were without exception sterile, as the following table shows:

EXAMINATION OF THE MAXILLARY AND FRONTAL SINUSES AT VARIOUS TIMES AFTER DEATH.

Time of examination after death.	No. of cases.	Bacteriological findings.
45 minutes	1	None
50 minutes	1	None
1 hour	5	None
1 hour 10 minutes	3	None
1 hour 15 minutes	4	None
1 hour 30 minutes	2	None
1 hour 40 minutes	1	None
1 hour 45 minutes	2	None
1 hour 50 minutes	2	None
2 hours 20 minutes	1	None
3 hours 5 minutes	1	Bacteria in left maxillary
4 hours 15 minutes	1	Bacteria in left maxillary
4 hours 30 minutes	1	Bacteria in right and left frontals
6 hours 20 minutes	1	Bacteria in right maxillary
9 hours 10 minutes	1	Bacteria in right and left maxillary
25 hours	1	Bacteria in right and left maxillary and frontals

In consideration of these findings one must naturally infer that bacteria do not find their way into healthy sinuses during life.

22. Törne: Das Vorkommen von Bakterien und die Flimmer-bewegung in den Nebenhöhlen der Nase. *Central. f. Bakteriologie, etc.*, Bd. 33, No. 4, 1903. 23. Lewis and Logan Turner: Suppuration in the Accessory Sinuses of the Nose. *A Bacteriological and Clinical Research. Edinburgh Med. Journ.*, Nov., 1905. 24. Törne: Die Bakteriellen Verhältnisse der Nebenhöhlen und über ihre Schutzmittel gegen Bakterien. *Nord. Med. Arkiv.*, H. 1, No. 2, 1904.

Such, however, is not the case, as the further experiments of the same author confirm.²²

The heads of freshly-slaughtered calves were opened in such a manner that the nasal wall of the maxillary sinus with the ostium was exposed. Small portions of finely-powdered lampblack were strewn over the mucosa of the sinus and results noted by means of a strong reading-glass. The lampblack particles were seen to slowly move toward the ostium (at the speed of 1 cm. per minute) and finally disappear into the nose. This was found to be due to the motion of the ciliated epithelium lining the sinus, as after a short time the motion became more and more feeble and finally ceased altogether.

It has been proved by physiologists that the sinuses are aërated during every nasal respiration. It stands to reason that during these respirations some micro-organisms must find their way into and become lodged upon the mucosa of the sinuses. As soon as this occurs the cilia of the healthy sinus immediately begins its expulsion, as the presence of this minute foreign body stimulates it into great activity.

Törne carried his investigations further by experiments with the normal secretion of the maxillary sinus as to its germicidal action. This was accomplished by opening the antra of cadavers immediately after death under antiseptic precautions and gently scraping the antral mucosa with a dull, spoon-shaped curette, thus obtaining a small portion of mucoid secretion. A freshly-prepared growth of anthrax bacilli was added to this and results noted. After some eighteen experiments it was conclusively proved that if the secretion did not possess strong bactericidal power it was distinctly inhibitory to the further growth of the micro-organisms.

We must then accept that the normal sinuses are protected against the invasion of bacteria in two distinct ways: 1. By the action of the cilia of the mucosa, which continually wave toward the sinus ostium. 2. By the secretion of the glands situated in the mucosa, which possesses a decided inhibitory power to the further growth of the invading germ. Both of these conditions must be overcome before infection of the sinuses can occur.

Suppurative inflammations of the sinuses are the direct result of bacterial invasion, but whether these micro-organisms act primarily directly on the healthy mucous membrane or whether they require that the vitality of the mucous membrane first be lowered by some general systemic disease appears to be more or less of a mooted question.

Both of these theories appear to be tenable. The first seems to have been proven correct by the investigations of Weichselbaum,²⁵ E. Frankel,²⁶ and

25. Weichselbaum: Ueber seltene Localization des pneumonischen Virus. Wien. klin. Woch., S. 573, 659, 1888. 26. E. Frankel: Beitr. z. Path. u. Ätiol. d. Nasennebenhöhlen-Erkrankungen. Virchow's Arch., Bd. 143, S. 92, 1896.

Dmochowsky,²⁷ who demonstrated the presence of true diphtheritic membrane on the mucous membrane of the maxillary sinus in cases of diphtheria. The second theory is substantiated by the numerous cases occurring after certain infections to which one can assign no definite cause. The findings of E. Frankel²⁸ and Wertheim²⁹ of evidences of non-tubercular sinus disease in every third phthisical corpse would also add to the probability of this theory.* E. Frankel²⁸ also found the diplococcus pneumoniae as the predominating organism in pus from the sinuses of individuals who had died of influenza. Zarnico²⁹ lays particular stress on secondary infection occurring in the accessory sinuses, and states that one can readily conceive how a sinus affection may occur even in the course of influenza without being dependent upon the specific organism of the disease (influenza).

The point of infection seems to play an important rôle in this condition, as the bacillus of influenza has long been considered a frequent causative factor from purely a local point of view. This theory of local infection in all cases was generally accepted until Killian³⁰ conclusively demonstrated that in scarlet fever infection resulted through the blood or lymph-channels. Since that time other observers have confirmed his findings. Since Weichselbaum first began his investigations, in 1888, up to the present time, it seems to have been the general endeavor to associate one particular micro-organism with all sinus suppuration. Thus the pneumococcus of Frankel and the influenza bacillus for a long time held sway; other micro-organisms, as the diplococcus pneumoniae, were soon added to these, until now practically all those of suppuration have been found and described as causative factors of this disease.

According to Hajek³¹ and Zarnico,²⁹ they appear as follows in their relative frequency to the causation of disease:

Hajek.	Zarnico.
1. Influenza bacillus.	1. Diplococcus lanceolatus (pneumococcus).
2. Diplococcus pneumoniae.	2. Staphylococcus and streptococcus.
3. Staphylococcus pyogenes aureus and albus.	3. Influenza bacillus.
4. Streptococcus pyogenes.	4. Pseudo-diphtheria bacillus.
5. Bacterium coli.	5. Friedländer's capsule bacillus.
6. Pseudo-diphtheria bacillus.	6. Meningococcus intracellularis.
7. Bacillus pyocyaneus.	7. Bacterium coli.
8. Bacillus Friedländer.	8. Bacillus pyocyaneus.
9. Meningococcus intracellularis.	9. Bacillus pyogenes foetidus.

27. Dmochowski: Beitrag z. path. Anat. u. Ätiol. d. entz. Processes im Antrum Highmori. Arch. f. Laryng., Bd. 3, S. 255, 1895. 28. Wertheim: Tuberculosis. Beiträge z. Path. u. klin. d. Erkrank. d. Nasennebenhöhlen. Arch. f. Laryng., Bd. 11, S. 169, 1901. 29. Zarnico: Die Krank. der Nase und des Nasenrachens, S. 605, 1910. 30. Killian: Die Erkrankung der Nebenhöhlen bei Scharlach. Zeit. f. Ohrenhk., Bd. 56, S. 189, 1908. 31. Hajek (6), S. 3, 1909.

*This is not substantiated by investigations upon the living. See R. H. Skillern: Exploratory Needle Puncture of the Maxillary Sinus upon One Hundred Tubercular Individuals. Journ. A. M. A., Sept. 21, 1912, Part 2.

Lewis,³² in a much later investigation, gives the following, but not especially in their order of occurrence:

- | | |
|---|--------------------------|
| 1. Staphylococci pyogenes, aureus,
citreus, and albus. | 6. Diphtheroid bacilli. |
| 2. Streptococci. | 7. Mesenteric group. |
| 3. Pneumococci. | 8. Dental organisms. |
| 4. Micrococcus catarrhalis. | 9. Obligate anaerobes. |
| 5. Coliform bacilli. | 10. Miscellaneous group. |

According to the investigations of the author, these micro-organisms do not continue the course of the disease uncontaminated, as it is the exception rather than the rule to obtain pure cultures from the pus secreted by the sinuses in subacute and chronic cases, as the following table will show. Lewis and Logan Turner³³ state that in recent cases virulent organisms are met with twice as often as in cases of chronic suppuration.

The reason that one so rarely obtains pure cultures is that most of the chronic cases are the result of mixed or secondary infection. In this class of cases it is difficult, and often impossible, to definitely state which particular organism has been the primary cause of the suppuration, granted that the infection has been one of purely local origin. Another difficulty lies in the fact that certain organisms grow well on one medium, while others require a different kind; thus to cultivate the influenza bacillus, a culture of agar smeared with fresh blood is necessary. Neither the meningococcus nor the pseudo-diphtheria bacillus will thrive well on this substance, therefore different media are required. As the various inoculations should be made with the fresh material, and as the technique is so tedious and varied, one can readily appreciate the difficulties of making accurate observations, much more of obtaining reliable conclusions.

As before mentioned, only in isolated instances were pure cultures obtainable. This fact would raise the following question: If the disease was primarily caused by one specific micro-organism, when and why did secondary infection take place, and what effect has the secondary infection had on the growth and toxicity of the primary or infective germ and subsequently the process of the disease? This seems to be the key-note of the course of sinus affections, and one must revert to the ætiological pathology of the disease in order to elucidate this complex problem.

As influenza (la grippe) is one of the commonest of the infectious diseases which predispose to sinus affections, let us suppose that the patient has recently recovered from an acute attack of this malady. The mucous membrane of the upper respiratory tract is swollen, congested, and lowered in vitality. The swelling interferes with the action of the cilia by mechanical obstruction, and the congestion prevents the glands from properly secreting, thus leaving the mucosa in a condition favorable for micro-organismal invasion.

The invading bacillus of influenza has found suitable soil for growth in one or more of the sinuses, depending upon the virulence of the attacking germ, and causes an acute inflammation, with all its attending phenomena. The sinus mucous membrane being already swollen and œdematous, there is an outpouring of leucocytes and formation of pus, which may or may not drain out, depending upon the position and patency of the drainage canals (ostia). This attack may end in one of two ways. 1. The drainage mechanism (ciliated epithelium) of the sinus may continually functionate, thus draining off the accumulating secretion, inhibiting secondary infection until the natural opsonins of the body conquer the invading bacillus and result in a cure of the disease; or 2. Either through swelling

32. Lewis: The Micro-organisms Present in Suppuration of the Accessory Sinuses of the Nose. *Journ. of Path. and Bacteriol.*, vol. 16, p. 29, 1911.

of the mucous membrane, or unfavorable situations of the ostiums, some interference with the drainage occurs. The accumulating secretions can only find intermittent or insufficient escape; thus partial or complete stagnation results. Through the action of the invading bacillus or its toxins, more or less permanent changes result in the deeper layers of the mucous membrane. At this point the primary infective germ may diminish in virulence and disappear, either through the natural resistance of the individual (opsonins having been formed) or from some loss of substance in the sinus which is necessary for the growth of that particular bacillus. The sinus now offers a suitable soil for secondary infection, which immediately occurs; the secondary infective organism overpowers the already enfeebled initial micro-organism, re-attacking the tissue and causing the disease to become chronic. This same phenomenon is observed in sinus disease following an acute coryza by substituting the coryza for the influenza and the ordinary micro-organisms of suppuration for the influenza bacillus.

It would be of decided advantage, so far as treatment is concerned, if one could draw reliable conclusions from the clinical appearances as to the particular species of the infecting micro-organism present. Unfortunately, this is not the case, for, as E. Frankel²⁶ has pointed out, the clinical picture depends less upon the particular species of the organism causing the disease than upon its virulence, the resisting powers of the tissues, and the presence of other forms of bacteria. The table (page 33) of our own compilation would also endorse this view.

CONCLUSIONS.

1. Pathogenic micro-organisms are never present in normal sinuses, the mucous membrane, under ordinary normal conditions, being able to render inert and expel the germs.
2. The primary or infective germ may disappear, allowing the germ of secondary infection to continue the disease.
3. Pure cultures of one variety of micro-organism are rarely found in chronic cases of sinus suppuration.
4. The commonest organisms found are the staphylococcus and streptococcus.
5. Three to five separate and distinct micro-organisms can usually be isolated from the same culture.
6. The culture is nearly always contaminated by one or more of the so-called nonpathogenic micro-organisms.
7. In these cases where several pus-producing germs are found it is obviously impossible to definitely state which one has been the primary cause of the suppuration.
8. The type of the micro-organism will often change in the course of the disease. During the author's observations it was frequently observed, particularly in the maxillary sinus, that as

GENERAL CONSIDERATIONS.

Name.	Sinus.	Chronicity.	Objective Symptoms.	Subjective Symptoms.	Culture.	Micro-organisms.	Predominating Pathological Organism.
Matlack . . .	Frontal	Years	Always present, but only marked in acute exacerbations	Intermittent. Severe in acute exacerbations	Sterilized cotton in frontal	Staphylococcus pyogenes aureus pure culture	Staphylococcus pyogenes aureus
Freeman . . .	Sphenoid	2 years	Intermittent	Intermittent	Sterilized cotton	{ Bacillus alkaligenus Micrococcus lactineus Staphylococcus pyogenes aureus	Staphylococcus pyogenes aureus
Bliss	Ethmoidal	Several	Constant	Constant	Sterilized cotton	{ Micrococcus dissimilis Staphylococcus pyogenes albus Micrococcus	Staphylococcus pyogenes albus
Ross	Maxillary	1 year	Constant	Not marked	Sterilized cotton	{ Bacillus cereus Staphylococcus pyogenes aureus Bacterium striatum Bacillus	Staphylococcus pyogenes aureus Bacterium striatum
Powell	Maxillary	1½ years	Not marked; odor present	Cacosmia and postnasal discharge	Through canine fossa	Staphylococcus pyogenes aureus pure culture	Staphylococcus pyogenes aureus
Kelly	Maxillary	3 years	None	Postnasal discharge	Inferior nasal passage	Staphylococcus pyogenes aureus pure culture	Staphylococcus pyogenes aureus
Willet	Ethmoid	13 years	Discharge	Discharge	Ethmoid region	{ Bacillus lactis aërogenes Staphylococcus pyogenes aureus	Bacillus lactis aërogenes
Schoenthaler	Ethmoid	Several	Discharge	Postnasal discharge, Cacosmia	Ethmoid region	{ Staphylococcus pyogenes aureus Staphylococcus pyogenes albus	Staphylococcus pyogenes aureus
Gallagher . .	Frontal	Profuse discharge	Sterile platinum loop	Streptococcus pyogenes	Streptococcus pyogenes
Gill	Sphenoid	20 years	Not marked	Cacosmia, ocular	Sterilized cotton	Staphylococcus pyogenes aureus pure culture	Staphylococcus pyogenes aureus
Paul	Ethmoid	Many	Discharge	Discharge	Sterilized cotton	Bacillus lactis aërogenes pure culture	Bacillus lactis aërogenes

the disease gradually diminished the character of the organisms would also change; thus, in the beginning, when the sinus was first opened and drainage established, the fetid, cheesy pus contained saphrophytic germs and even individual species (*Bacterium coli*, etc.). These disappeared in the course of a few weeks, leaving the more common organisms of suppuration (*staphylococcus* and *streptococcus*). In acute exacerbations of chronic sinus affection it is extremely probable that a fresh infection has occurred, possibly from a different species.

GENERAL ÆTIOLOGY.

There exist several distinct processes by which the mucous membrane of the accessory sinuses may become diseased.

1. Through direct invasion of the healthy sinus by pathogenic bacteria.
 2. Through extension of inflammation from neighboring parts.
 3. As a result of tuberculosis, syphilis, malignant tumors, and latent empyema.
 4. Through the blood- and lymph-channels.
 5. Through traumatism—exposure to cold, sea bathing, automobile riding, etc.
 6. Through foreign bodies.
 7. Through contamination from the pus of overlying sinuses.
- Sinusitis.

1. THROUGH DIRECT INVASION OF THE HEALTHY SINUS BY PATHOGENIC BACTERIA.

Under this heading we understand that the mucous membrane of the sinus is primarily affected by micro-organisms which find their entrance either through the ostiums or through the circulatory system, the mucous membrane of the nasal cavity being apparently unaffected.

When considering this theory of entrance through the ostiums it is well to bear in mind that the number of pathogenic micro-organisms momentarily present in the nasal cavities and sinuses depends upon the environment of the individual; thus, in dusty places large numbers may be present, while in great altitudes and on the sea the nares are comparatively free. As sinus diseases do not appear to be more frequent with individuals who follow occupations necessitating the more or less uniform presence of dust-laden air, one must of a necessity give little credence to the theory that sudden introduction of pathogenic bacteria into a healthy sinus will usually create disease in that sinus.

D. B. Kyle³³ states that primary involvement of the nasal accessory cavities is a very rare condition, although he considers the subjugation of the individual to irritating dust vapors or fumes to be an important predisposing factor. He undoubtedly refers to the action of these irritants upon the nasal mucosa.

There are but four diseases to which this condition can be attributed.

In describing sinus affections complicating or resulting from these four diseases we must also consider that it has not been definitely proved that the sinuses are affected through them only in the manner delineated above. There is no reason to believe that infection has not resulted through the inflamed mucous membrane of the upper respiration tract, the circulatory system not being taken into consideration.

(1) Influenza; (2) croupous pneumonia; (3) diphtheria, and possibly (4) erysipelas.

1. *Influenza*.—Since the investigations of Lindenthal³⁴ this disease has generally been considered the most potent factor in the causation of sinus affections. The precise rationale why the bacillus shows especial predilection for the mucous membrane of these structures has not yet definitely been explained. Whether the infecting organisms gain entrance through the air passages or through the blood appears also to be an undetermined question. Weichselbaum³⁵ states that the sinuses are always diseased at some time during the course of influenza. Hajek is of the opinion that the sinus disease is rather a sequela than a complication of influenza.

2. *Croupous Pneumonia*.^{36 37 38}—There is no longer any question that acute inflammatory diseases of the inferior air passages (with the possible exception of tuberculosis) strongly predispose to inflammations within the nasal sinuses. This connection has been observed too often to admit any doubt of their association. Bacteriological examinations of the diseased sinuses in patients succumbing to this affection practically always showed cultures of the diplococcus pneumoniae.³⁶

3. *Diphtheria*.^{39 40}—Judging from the examinations of these authors, it is certain that the accessory sinuses, particularly the maxillary, are commonly infected during the course of diphtheria. Pearce⁴⁰ demonstrated the presence of inflammatory changes in 25 out of 39 cases examined post mortem, the bacillus of diphtheria being present on both sides in all but three instances. The inflammation usually presents the same characteristics as that following infection from other varieties of micro-organisms, *i.e.*, serous, muco-purulent, and purulent, and only in rare instances does it present evidences of the formation of a false membrane. There is every reason to suppose that all these cases were secondary to nasal or pharyngeal lesions, as no sufficient proof has yet been brought forward that primary sinus disease resulting from the invasion of the Klebs-Loeffler bacillus has ever existed.

33. Kyle: Acute Inflammations of the Accessory Sinuses, etc. Journ. Am. Med. Ass'n, vol. 53, p. 1020, 1909. 34. Lindenthal: Ueber die sporadische Influenza. Wien. klin. Wochenschr., April 15, S. 353, 1897. 35. Weichselbaum: Influenza. Wien. med. Wochenschr., S. 222, 1890. 36. Darling: The Accessory Nasal Sinuses and Pneumococcus Infections. Journ. Am. Med. Ass'n, Nov. 10, 1906. 37. Winckler: Bakteriologische Befunde bei Erkrankungen der oberen Luftwege, etc. Ver. Süddeutsch. Lary., S. 109, 1906. 38. Weichselbaum: Ueber seltener Localisationen des Pneumonischen Virus. Wien. klin. Wochenschr., S. 573, 659, 1888. 39. Wolff: Die Nebenhöhlen der Nase bei Diphtherie, Masern und Scarlatina. Zeitschr. f. Hygiene, Bd. 19, S. 225, 1895. 40. Pearce: Bacteriology of the Accessory Sinuses of the Nose in Diphtheria and Scarlet Fever. Journ. of Boston Soc. of Med. Sciences, p. 215, 1898-99.

4. *Erysipelas*.^{41 42 43}—That sinus disease is often associated with erysipelas has been well shown by numerous observers. Some doubt still exists as to the precedence of one over the other, but clinical investigations seem to indicate erysipelas as the primary lesion. Several cases of erysipelas around the alæ of the nose have been reported which permanently healed as soon as the previously-overlooked maxillary sinus disease was operated upon. Unfortunately, the bacteriological examinations do not give sufficient data to enable one to arrive at reliable conclusions. However, Weichselbaum⁴⁴ believed he was able to conclusively demonstrate, at several autopsies, the initial lesion in the sinus.

In these four diseases the sinus affection takes the character of the primary disease, while the sinus affections following the other infectious diseases are principally due to other micro-organisms than those responsible for the primary affection (secondary infection).

It is extremely doubtful that a sinus affection is set up by the direct invasion of pathogenic micro-organisms into a healthy sinus, other things being equal, except in very rare instances. The mucous membrane of the sinus is normally able to withstand the presence of such germs and expel them through the action of the cilia, and infection results only when this power has become enfeebled or lost, through extrinsic causes (swelling of the mucous membrane in infectious diseases, occlusion of drainage channels, traumatic injury, etc.).

Killian⁴⁴ has compared the ætiology of sinus disease to that of the middle ear, where the secretion is driven, under pressure, through the eustachian tube to the middle ear. This comparison does not appear to be entirely apropos, because a medium in the form of a long canal (eustachian tube) exists between the nasopharynx and the middle ear. The sinus ostium, a formation corresponding to an aperture, can hardly be compared with such a structure. Killian states that the sinuses are not so sensitive to the introduction of foreign material as the middle ear, and, consequently, do not react as markedly.

It appears to be a mooted question whether the sinus mucosa is concomitantly affected with the Schneiderian membrane in, for example, an attack of acute coryza, or whether the inflammation secondarily follows, being transmitted through the ostium. All things being equal, it would seem that the former condition prevails, and that the nasal mucosa, together with its offshoots into the accessory cavities, are affected at one and the same time. The sinus mucosa, however, need not necessarily be affected to the same degree as that of the nasal chambers.

41. Weichselbaum: Die Phlegmonöse Entzündung der Nebenhöhlen der Nase. Wiener med. Jahrbücher, 1881. 42. Luc: Ein Fall von Empyeme durch Erysipelas streptococcus verursacht. Deutsch. med. Woch., No. 8, S. 167, 1892. 43. Holmes: Erysipelas and its Relation to Purulent Inflammations of the Nasal and Oral Cavities. Trans. Am. Lary. Ass'n, p. 48, 1907. 44. Killian: Die Erkrank. der Nebenhöhlen der Nase. Heymann's Handbuch, "Die Nase," S. 992, 1900.

The mucous membrane, being already inflamed through extrinsic causes, furnishes a suitable soil for micro-organisms which would otherwise prove harmless.²⁸ This ætiological factor may result from two distinct conditions: (1) infectious diseases (including those enumerated above); (2) certain non-bacteriological diseases of the nasal mucosa which cause swelling and intermittently occlude the sinus ostiums.

(1) Scarlet fever, measles, smallpox, tuberculosis, typhoid fever, and cerebrospinal meningitis are frequently complicated, or more often followed, by accessory sinus empyema.

The direct connection between these diseases and local sinus affection is not at all clear, but probabilities seem to point to some devitalization of the sinus mucous membrane, thereby causing it to be unable to resist the attacks of pathogenic pus-producing micro-organisms.

Singularly enough, in those cases reported the bacteria found in the sinus did not necessarily correspond to those causing the general infection, and thus the meningococcus has been found in individuals with sinus empyema who never had cerebrospinal meningitis. Secondary infection was undoubtedly responsible for these apparently anomalous conditions. This is further illustrated by the fact that the course and severity of the sinus disease in no way depend upon the general condition of the individual nor the particular species of the infecting micro-organisms. The irreparable missing link in these cases is that a bacteriological examination of the purulent secretion from the sinuses was not made during the acute period of the attack.

It is perfectly clear that any condition which would cause general inflammation of the nasal mucosa must of a necessity affect the sinuses, for, as Zuckerkandl⁴⁵ first pointed out, the nasal mucosa communicates directly with that of the sinuses, and the mucous membranes of the nose and sinuses receive their blood supply from the same source. This being true, it necessarily follows that any disease causing general acute rhinitis must cause acute general sinusitis. This, however, does not explain the fact that all the sinuses are not purulently affected after a certain acute infectious disease causing sinusitis, instead of one or two being purulently involved, as is, one can almost say, invariably the case.

Scarlet fever seems to work some particularly malignant influence on the sinuses, especially in children, as has been referred to by Hajek,⁴⁶ Nager,⁴⁷ Herzfeld,⁴⁸ and Killian.⁴⁹ In this disease a great tendency has been observed to affect the bone, which often ulcerates entirely through. Kyle⁴⁹ states that infection due to the pneumococcus, streptococcus, or bacillus of influenza shows a marked tendency to bony necrosis.

(2) Under the heading of non-bacteriological diseases may be considered various chronic hyperplasias and hypertrophies of the nasal mucosa. These are frequently responsible for disease, par-

45. Zuckerkandl: Normale und pathologische Anatomie der Nasenhöhle, Band 1, S. 128, 1893. 46. Hajek (6), S. 2, Note. 47. Nager: Ueber die Mitbetheiligung der Nasennebenhöhlen im Verlauf des Scharlachfiebers. Medic. Klinik No. 25, S. 938, 1909. 48. Herzfeld and Herrmann: Bakteriolog. Befund. in 10 Fällen von Kieferhöhleneiterung. Arch. f. Lary., Bd. 3, S. 143, 1895. 49. Kyle: General Pathologic Processes Associated with or Following Infections of the Accessory Sinuses. Ann. Otol., Rhin. and Lary., p. 775, 1906.

ticularly in the frontal and maxillary sinuses. The rationale of this is as follows: From repeated attacks of colds or other causes, certain portions of the nasal mucosa in the neighborhood of the sinus ostium are left œdematous and hyperplastic. At various times, particularly when the patient is reclining, the blood-pressure is higher in this locality, with consequent swelling and temporary occlusion of that particular ostium. The sinus mucosa, in the meantime, is absorbing the oxygen which is contained in the sinus, but, as no more can enter, there results within a condition of negative pressure, with swelling of and transudation through the mucous membrane. Let us accept that, in a longer or shorter period of time, the ostium again becomes patulous with resolution of the swollen sinus mucosa. The membrane, however, does not have time to fully regenerate before the ostium again becomes occluded through the same causes. This constant swelling and irritation of the mucosa produces inflammatory tissue changes which deprive it of a certain amount of vitality, thus causing it to offer a suitable culture medium for pyogenic bacteria the first time the individual contracts a severe acute coryza.

The same condition probably accounts for sinus disease following the infectious fevers, except that the general disease affects the entire nasal mucosa instead of a local focus in the nasal cavities. Why all the sinuses are not affected in toto, under these circumstances, is a question which must be deferred, acute sinusitis not being considered. (See Infection Through Blood and Lymph Circulation.)

Killian⁴⁴ does not believe that sinus affections can result through occlusion of the ostium, and states that if it does occur the process must be reckoned as a non-inflammatory affection. He does not mention that this condition strongly predisposes to primary infection. Chiari,⁵⁰ on the contrary, firmly believes that this is one of the most frequent causes of chronic sinus disease, and says, when this occlusion continues for some length of time with no infection, the mucous membrane swells and becomes hypertrophic with the formation of polypoid tissues. Kyle⁴⁹ also says the mucous membrane of a sinus is less capable of reproduction than the nasal, which accounts for the disease often following rhinitis.

2. THROUGH EXTENSION OF INFLAMMATION FROM NEIGHBORING PARTS.

This can occur in two ways: *a.* By direct extension of inflammation from the nasal mucosa to the sinus. (Continuity.) *b.* By extension of inflammation from the bone to the same mucosa. (Contiguity.)

Extension by Continuity.—Hajek considers this the greatest

50. Chiari: Die Krankheiten der Nase, S. 215, 1902.

causative factor of sinus disease,⁵¹ and states, even in those cases where no trace of inflammation is visible in the nose, it is probable that the nasal mucosa primarily was affected.

The so-called grippal cold (which may or may not be associated with the influenza bacillus) is undoubtedly the most potent factor in the causation of sinus disease, at least in our country. The ethmoid cells seem particularly susceptible to this disease, and many cases of ordinary acute rhinitis are in reality acute exacerbations of chronic ethmoid cellulitis which the individual suffers every winter. The presumption of the primary affection of the mucosa is assumed.

Killian⁴⁴ believed that in the majority of cases associated with acute coryza the sinuses are primarily diseased, as in influenza. This opinion is endorsed by Zarnico.⁵² It seems to me this matter may be elucidated if one accepts that the nasal mucosa is primarily affected, the inflammation of the sinus mucosa closely following. The nasal mucous membrane finally throws off the disease while the inflammation continues in the sinus because of its unfavorable anatomical configuration.

Extension by Contiguity.—This form is principally observed in the maxillary sinus, and results from carious roots of the teeth causing periosteal and subperiosteal abscesses, particularly those which come into nearest contact with the floor of the sinus (second premolar and first molar). Formerly this condition was considered a most prolific cause of maxillary sinus empyema, but later years have shown that only a small percentage of cases (about twenty-five per cent.) are due to this origin.

3. TUBERCULOSIS, SYPHILIS, MALIGNANT NEOPLASMS, AND LATENT EMPYEMA.

Tuberculosis.^{53 54 55}—Although suppurative sinusitis occurs quite frequently in individuals suffering with pulmonary tuberculosis, yet only in isolated instances has it been possible to attribute the sinus condition to the tubercle bacillus.* Primary infection of the sinus mucosa was apparently an unheard-of condition until Keckwick reported a case in the maxillary sinus, in which, however, the element of doubt was not entirely removed. When

51. Hajek (6), S. 6. 52. Zarnico (29), S. 609. 53. Gleitsmann: Tuberculosis of the Accessory Sinuses. *Laryn.*, p. 445, 1907. 54. Neufeld: Tuberculose, Syphilis und Kieferhöhlenerkrankung. *Arch. f. Lary.*, Bd. 17, S. 215, 1905. 55. Keckwick: Antral Empyema of Tuberculous Origin. *Brit. Journ. of Dental Science*, p. 433, 1895.

* In 51 phthisical corpses examined on the section table no tubercular inflammation or ulceration of the nasal or sinus mucosa was present, although (25) 49 per cent. showed accessory sinus disease. (Oppikofer, *A. f. L.*, Bd. xix, 1907.)

tuberculosis attacks the sinuses it is through the medium of the bone and extends by contiguity to the mucosa of the neighboring sinus. Infection through the ostium seems almost never to occur. All of the sinuses have been reported affected, the frontal, ethmoid, sphenoid, and maxillary.

Empyema of any of the sinuses purely and solely the result of infection from the tubercle bacillus must be an extremely rare affection, for to my knowledge no case has occurred in the Rush Hospital for Consumptives since its foundation (1895).

Osteomyelitis, syphilis, and breaking-down of malignant neoplasms have also been reported as producing sinus disease.^{56 57} With these diseases the sinus affection is nearly always secondary, being due to the caries and necrosis of the osseous walls. The primary disease usually occurs outside of the cavity, working its way inward; therefore, attention must have been called to it before affection of the accessory cavity existed.

Gerber⁵⁸ believes syphilitic infections of the sinuses can occur in the following manner: *a.* Through continuity. *b.* Through entrance of syphilitic secretions; and *c.* Through the blood and lymph. As a matter of practical importance, specific infections of the sinuses must be rare, despite this author's statement that ten to fifteen per cent. of all syphilitics have specific sinusitis.

In any event, the symptoms and operative treatment differ little, if any, from the ordinary type of the disease. Should doubt exist as to the diagnosis, the Wassermann test is to be applied.

Syphilis in the third stage shows a marked predilection to attack the nose, particularly the osseous septum. If prompt treatment is not instituted the disease will often embrace the ethmoid capsule and encroach upon the lateral nasal wall, causing extensive necrosis of these structures.

The following case will illustrate the point:

—, male, 40 years. Complained of constant purulent discharge from nose, which was accompanied by fragments of tissue and large crusts. Examination showed both nostrils completely filled with hard and soft crusts, which bled on disturbing. History of syphilis.

Patient was placed upon 30 gtt. KI, t.i.d. Some days later nose was again washed out. Large perforation in septum from anterior extremity to posterior attachment on sphenoid being held in place by a mere strip of osseous tissue posteriorly. Ethmoid labyrinth practically absent, having almost completely

56. Kuttner: Die Syphilis der Nebenhöhlen der Nase. Arch. f. Lary., Bd. 24, S. 266, 1911. 57. Harke: Beitrag. z. Pathol. u. Therap. d. Oberen Athmungswege, 1895, S. 44. 58. Gerber: Die Syphilis d. Nase u. d. Halses, 1895.

necrosed. After one month's treatment with KI and intranasal applications of iodine, iodide of potassium, and glycerine, the nose healed, leaving an enormous defect in septum, with almost total ablation of ethmoid cells. The inferior lateral wall of nose was not affected by the process.

4. THROUGH THE BLOOD- AND LYMPH-CHANNELS.

This mode of infection is not entirely proved beyond all objection. While several observers have noted purulent sinusitis associated with systemic diseases such as typhoid fever,⁵⁷ chronic nephritis,²⁶ cirrhosis of liver,³⁷ etc., there is nothing to prove that it was in any way dependent upon the primary general affection. As a matter of fact, under the same circumstances, any severe constitutional disease would have produced like results.

5. THROUGH TRAUMATISM.⁵⁹

Direct injuries usually affect the more superficial sinuses (frontal and maxillary), but numerous cases have been reported in which the ethmoid has suffered injury, either by the way of the nose or orbit, which resulted in secondary empyema. The sphenoid sinus, in spite of its depth of situation and protection, has also been the recipient of traumatic empyema in several reported cases. In milder cases without actual penetration, blood exudes into the sinus from the injured mucous membrane. The resisting powers of the sinus being now greatly lowered, a secondary infection is the result of the attacks of the inspired germs, with the ultimate production of true inflammatory changes, formation of pus, and, finally, empyema.

6. THROUGH FOREIGN BODIES.

Empyema of the sinuses through the introduction of foreign bodies is not so rare as is generally supposed. This may occur by the hand of the physician, *i.e.*, tampons, broken sounds, pledget of cotton, etc.⁶⁰

The latter accident occurred in the practice of the author. After a Cooper operation on the maxillary sinus, the patient had been treated a number of times and all suppuration had ceased. One day, while cleansing the wound with a cotton pledget, it slipped off the carrier and was lost in the sinus. The following day the patient had a profuse purulent discharge from the antrum, which con-

59. Röpke: Die Verletzungen der Nase und deren Nebenhöhlen. Wiesbaden, 1905.

60. Krebs (Foreign Bodies in the Nasal Cavity as a Cause of Empyema, Archives of Otolaryngology, p. 226, 1908) reports two cases of maxillary empyema caused by foreign bodies in the nasal cavity.

tinued for several days. I had about decided upon a radical operation, when, fortunately, during irrigation, the cotton was expelled through the ostium with the outflowing solution. Betz⁶¹ reports a case of sphenoid empyema in an officer which was caused by a short piece of straw penetrating the sinus during a cavalry charge. Foreign bodies may, however, remain for years innocuous in a sinus, as has been mentioned by Röpke,⁶² who gives as an example a case of a bullet in an ethmoid labyrinth.

Chiari⁶³ reports a most remarkable case of a man who, in attempting suicide, shot himself through the right temple with a revolver. The wound was situated at a level with the eye and about one inch posterior to the external orbital rim. Examination by the X-ray showed the location of the ball to be in the right sphenoidal sinus. Twenty-five days after the reception of the wound the ball was removed from the sinus by the intranasal operation, with complete recovery to the patient.

Gastric contents forced into the sinuses through vomiting, and causing sinusitis, must be classed under foreign bodies.²⁸ That such a condition can occur has been shown by Harke⁶⁴ and Wertheim²⁸ in the report of several cases, although their cases were only discovered on the autopsy table. Lack,⁶⁵ however, reports a patient who was subject to attacks of acute antral sinusitis, which were always due to pieces of food that had found their way into the sinus.

Oppikofer,⁶⁶ in a postmortem examination of two hundred sinuses, was able to demonstrate the presence of gastric contents in sixteen cases, or eight per cent. The total number of sinuses, however, which contained this matter was forty-four, and in only nineteen was the mucous membrane in any way irritated. This would seem to show that the condition occurred post mortem.

7. THROUGH CONTAMINATION BY THE PUS FROM AN OVERLYING SINUS.⁶⁷ SINUSITIS AND SINUITIDE (KILLIAN⁶⁹).

That the maxillary sinus often acts as a reservoir for purulent secretion which comes from the frontal is a well-established fact, and its occurrence depends upon the anatomic configuration of the uncinate process and semilunaris hiatus.⁶⁸ (See Anatomy.) Hajek⁶ is also of the opinion that in certain positions of the head the sphenoid can receive pus which has been secreted by the poste-

61. Betz: Ein Fall von Fremdkörper in der Keilbeinhöhle. Verh. d. Ver. Süddeutsch. Lary., S. 13, 1894. 62. Röpke (59), S. 61. 63. Chiari: Extraction d'Une Balle du Sinus Sphenoidal par voie Endonasale. Arch. Internat. de Laryng., T. 31, No. 2, 1911. 64. Harke (57), S. 15. 65. Lambert Lack: Diseases of the Nose and Its Accessory Sinuses, p. 285, 1906, London. 66. Oppikofer: Beiträge zur Normalen und pathologischen Anatomie der Nase und ihrer Nebenhöhlen. Arch. f. Lary., Bd. 19, S. 28, 1907. 67. Grünwald: Beitr. z. Chirurgie der oberen Luftwege und Adnexa. Munch. med. Wochenschr., S. 699, 1891. 68. Grünwald (Die klinische Bedeutung der Derivate des Hiatus Semilunaris, Arch. f. Laryng., Bd. 23, S. 183, 1910) has taken up this subject in detail, and shows how, under different anatomical formations, this sinus may or may not receive secretion from overlying structures. 69. Killian: Meine Erfahrungen über des Kieferhöhleneiterungen. Munch. med. Wochenschr., No. 4, 1892.

rior ethmoid cells, and *vice versa*. The experience of the author, together with that of many others, has substantiated this in the first instance. That this pus will ultimately set up an inflammation in the receiving sinus is also possible, but in the majority of cases the induced inflammation is so slight that one or two lavages will effect a cure. This fact I have been able to demonstrate to my own satisfaction time and time again; therefore, it would seem that the secondary or receiving sinus possesses more or less power to retain the inflammatory products which have been secreted by other membranes without itself becoming seriously affected.

In reviewing the ætiological factors it is difficult, and even impossible, to state definitely thus and so has been the cause of a certain sinus affection. We do know that all these circumstances can contribute toward the existence of the disease either singly or combined, but how great a rôle a certain condition played, and how small another, must be, for the present at least, largely a matter of conjecture.

CAUSE OF CHRONICITY.

As before mentioned, the sinuses exhibit a marked tendency toward resolution after having become infected; however, in a certain number of cases the infection overcomes this tendency and the disease becomes chronic. This may be due to a number of conditions, the following of which are the most important:

1. Interference with normal drainage (congenital or acquired).
2. Especial virulence of the infecting micro-organisms.
3. Inflammatory changes occurring in the mucous membrane.
4. Recurrence of the attacks.
5. Continuation of the irritation.
6. Consistency of the secretion.
7. Individual susceptibility of the patient.
8. Secretion flowing in from another sinus.

1. INTERFERENCE WITH NORMAL DRAINAGE.⁷⁰

Congenital.—Under this heading may be placed variations in situation and size of ostia, high deviations of the septum, close approximation of the middle turbinate to the lateral nasal wall, enlarged ethmoidal bulla, or, in fact, any anatomical condition which predisposes to interference with drainage.

⁷⁰. These conditions have been thoroughly discussed in a most satisfactory article by Ballenger, "Ætiology of Inflammatory Diseases of Nose and Accessory Sinuses." *Laryngoscope*, p. 181, 1907.

Acquired.—The acquired conditions (except traumatic) are usually confined to the mucous membrane. Among these may be classed active and passive hyperamias, polypoid swellings, hypertrophies, etc. In the majority of these cases, both the congenital and acquired predispositions are associated in the causation of the disease. How often have we found unilateral sinus disease associated with a case of extreme septal deviation which was not on that side of the deflection!

When empyema is present in these conditions, there results, naturally, more or less obstruction to the outflow of the secretion. This pressure of the pent-back secretion, according to Dmochowski,²⁷ is the exciting cause of the permanent tissue changes in the mucous membrane, with the resulting chronicity.

2. ESPECIAL VIRULENCE OF THE INFECTING MICRO-ORGANISM.

Why individuals exposed to precisely the same contamination will exhibit totally different reactions is a matter that will yet bear considerable explanation. So far as the sinuses are concerned, the idiosyncrasy of the individual probably depends largely upon the favorable or unfavorable drainage possibilities of the sinus, as well as upon the virulence of the attacking germ or the personal susceptibility of the patient.

3. INFLAMMATORY CHANGES IN THE MUCOUS MEMBRANE OF THE SINUS.

Killian⁴⁴ is especially favorable to this cause, giving, however, no definite grounds for his belief except that œdematous swellings show but slight tendencies to spontaneous regeneration.

Killian also rather discredits the theory that the unfavorable situation and size of the sinus ostium have any particular influence on the course of the disease, and says if this were true it would be impossible to understand the spontaneous healing of an acute sinusitis.

4. RECURRENCE OF THE ATTACKS.

Under this heading we understand that the patient has been subject to recurring attacks with intervening periods of health, but, as a consequence of these repeated attacks, permanent inflammatory changes resulted in the mucous membrane. In these cases complete regeneration of the mucous membrane after a given attack did not occur. Certain inflammatory changes followed each recurrence until chronicity was established.

5. CONTINUATION OF THE IRRITATION.

An empyema may be entirely healed and yet an inflammation of the sinus mucous membrane still exist, as it is possible for a sinus to be inflamed without any trace of exudate being thrown off. Chiari⁵⁰ believes that a certain amount of the secretion may remain in the sinus after inflammation has subsided and continue to irritate the mucosa, thus giving rise to hypertrophic and cystic degeneration, with permanent glandular changes. In this manner the sinus inflammation may continue long after the nasal inflammation has disappeared and finally take on the form of chronic purulent catarrh.

6. THE CONSISTENCY OF THE SECRETION.

The consistency of the secretion can also play an important part in the chronicity of the disease. It follows reason that the thicker the secretion, the more difficult is the establishment of drainage.

7. THE INDIVIDUAL SUSCEPTIBILITY OF THE PATIENT.

8. SECRETION FLOWING IN FROM ANOTHER SINUS.

As has been elsewhere mentioned, this condition is noted particularly in the maxillary sinus, but can possibly occur also in the posterior ethmoid and sphenoid. It does not always follow, though, that the receiving sinus itself becomes affected, as it is possible for it to act merely in the capacity of a reservoir for an undetermined length of time. Whether or not infection ultimately occurs depends upon the above-mentioned factors.

Zarnico⁷¹ differentiates two conditions when dealing with this subject: 1. When the underlying sinus acts as a reservoir and does not become affected—pyosinus. 2. When the underlying sinus acts as a reservoir and ultimately becomes infected—sinusitis e sinuitide.

When reviewing these various conditions which predispose to chronicity it would seem to be impossible to state with certainty in each individual case that particular factor which has been the cause of the disease becoming chronic. When one takes into consideration that the line of demarcation between the acute and chronic stadia is exceedingly variable (the time being variously

71. Zarnico (29), S. 610.

given at from four to ten weeks), it must necessarily follow that the pathogenic processes operating within the sinuses must vary in manner, degree and intensity; therefore the occurrence of chronicity would depend more upon certain combinations of the above conditions than upon one individual tendency.

STATISTICS.

The postmortem observations from various clinics would seem to show that sinus disease is much more prevalent than formerly supposed. Examinations made in the autopsy room of all cases, regardless of the cause of death, give varying percentages in which the sinuses were found affected. Thus Gradenigo⁷² found sinus suppuration present in forty-five out of two hundred and three examinations, or 22 per cent.; Harke,⁷³ one hundred and thirty-eight out of four hundred, or 34.5 per cent.; Frankel,⁷⁴ sixty-three out of one hundred and forty-six, or 43.1 per cent.; Lapalle,⁷⁵ fifty-five out of one hundred and sixty-nine, or 32 per cent.; Wertheim,⁷⁶ ninety-five out of three hundred and sixty, or 26 per cent.; Minder,⁷⁴ fourteen out of fifty, or 28 per cent.; Kirkland,⁷⁵ thirty-five out of one hundred, or 35 per cent.; Törne,⁷⁶ fourteen out of seventy-three, or 17 per cent.; and Oppikofer,⁷⁶ ninety-four out of two hundred, or 47 per cent. It was found in those cases of pneumonia and influenza the percentage rate ran high above these figures. Generally speaking, sinus disease was most prevalent in conditions associated with inflammation of the respiratory system.

Comparing these statistics with those of clinical experience, it will be noted that there exists a marked discrepancy—Chiari, for example, gives two per cent. as the total proportion of sinus disease occurring in his clinic in five years, which, in view of the refined technique of the present, is probably a trifle low. Under the best circumstances, however, it is impossible to reconcile the wide disproportion in the figures without an adequate explanation. Törne,⁷⁶ by his observations and experiments on the living ciliary epithelium of animal sinuses, has gone far to elucidate this problem.

Having shown that the cilia not only are capable of but actually do remove extrinsic substances from the sinuses by way of the ostium, it stands to reason that anything interfering with ciliary motion would predispose to the accumulation of material within the cavity. The sinuses contain mucoid glands which continually secrete, the secretion being taken up both by the nose and by evaporation in the sinus. During the last hours of the individual the cilia may become enfeebled and cease to perform their function. In this manner we can readily have a postmortem accumulation of secretion in the sinuses. Lack⁷⁶ has also accepted this theory, and calls attention to the fact that the only true criteria of sinus inflammation are definite pathological changes in the sinus mucosa. The mere presence of serous or mucoid fluid may be the result of a slight catarrh or even postmortem seepages from the nose through the ostium. That body fluids can readily find their way into the sinuses after death is a matter too well recognized to deserve further comment.

72. Gradenigo: Sur l'Empyeme Latent du Sinus Maxillaire. *Ann. d. Mal. de l'oreille*, No. 20, p. 451, 1894. 73. Lapalle: Tableau statistique de 169 autopsies de sinus de la face. *Arch. internat. de Laryn.*, T. 12, p. 225, 1899. 74. Minder: 50 Sections befund d. Nase und deren Nebenhöhlen, etc. *Arch. f. Laryn.*, Bd. 12, S. 328, 1902. 75. Kirkland: The Pathological Conditions of the Cranial Sinuses. *Journ. of Laryn.*, vol. 17, Nov., 1902. 76. Lack (65), p. 268.

PATHOLOGICAL CHANGES IN THE MUCOUS MEMBRANE OF THE SINUSES.

Before taking these changes up in detail it might be well to briefly review the normal histology. The normal histology of the lining membrane of the sinuses is, to all intents and purposes, one and the same; *i.e.*, the microscopic appearance of the antral mucous membrane is practically identical with that of the sphenoid or frontal sinus; the ethmoid cells present some slight difference, chiefly on account of their structural peculiarities. (See Pathology of Ethmoid Labyrinth.)

A cross-section of the mucous membrane of the maxillary sinus, together with the bone, will show, under the low power of the microscope, the following structures (Plate 2a): The epithelium is composed of the ciliated variety similar to that found in the respiratory portion of the nose (basement layer). Sub-epithelial layer contains the blood-vessels and the glands, the latter occurring as isolated clusters scattered here and there. This layer is so intimately associated with the periosteum that it is not possible to distinguish a dividing line. These tracts resemble those of the respiratory surface, but may be distinguished by the scarcity of glandular tissue and the marked reduction in the thickness of the mucous membrane, which in these spaces is seldom more than .02 mm.

The pathological changes which take place in the course of the purulent inflammation depend upon several conditions:

1. The length of time the disease has progressed.
2. Virulence of the attacking germ or germs.
3. Resistance the sinus has shown toward the disease.
4. Favorable or unfavorable drainage conditions.

The maxillary sinus usually shows the greatest pathological changes. This is due to the unfavorable situation of the ostium for drainage; as a consequence, the mucous membrane at the inferior portion is constantly bathed in the purulent secretion. This, I think, accounts for the fact that cheesy, fetid pus is so frequently observed in old chronic empyemas of this sinus, regardless of their primary origin.

These conditions are so intimately associated and intermingled that it is impossible to differentiate them, at least so far as the microscope is concerned; therefore, they had best be considered under the more general heading: Acute and Chronic.

When the mucous membrane becomes first infected, there result an intense hyperæmia and swelling, due to the outpouring of serum into the submucous connective tissue layer, which may be so great as to occlude the lumen of the sinus. The swelling encroaches more and more on the cilia, causing them to wave more and more slowly until, if the pressure is sufficient, they cease altogether. During this stage no secretion is formed, because the lining membrane has not been penetrated by the exudate. This stadium is followed by œdema, caused by the pressure on the blood-vessels.

Blood-vessels: The vessels which supply the sinuses enter through the ostia and return by the same route, with the exception of small, unimportant branches which pierce the bony walls. On this account pressure in a given portion of the sinus will cause circumscribed œdema directly back of that particular portion. This fact accounts for the circumscribed swellings and cyst formation often found in the maxillary sinus.

As the cilia have become motionless, the mucosa is no longer able to throw off the secretion which is continually forming within glands and, by osmosis, through the epithelium, in the event of inflammation. This inflammatory exudate is composed of serum, mucus, leucocytes, and exfoliated epithelium. Micro-organisms may or may not be present. The exudation in the beginning is scanty, becoming serous or serous-bloody, depending upon the infection.

Resolution may now set in with gradual reduction of the hyperæmic and œdematous swellings, the cilia again being set in motion, and the secretion either ceases entirely or assumes a mucoid, or serous muco-purulent and finally a watery character with *restitutio ad integrum*. If, however, the inflammation continues and micro-organisms find their way into the cavity, the cilia being overpowered by the swelling and secretion, they may find suitable soil for their propagation in the areas where punctiform hemorrhages and areas of desquamation of the epithelium have occurred.

The formation of a false or diphtheritic membrane in the acute stadium has been observed.

THE MICROSCOPIC APPEARANCE OF THE MUCOUS MEMBRANE IN ACUTE CONDITIONS.

The epithelium is unchanged; mucous membrane, œdematous; intracellular spaces filled with lymph; more or less round-cell infiltration, depending upon the degree of irritation; punctiform

hemorrhage through connective tissue; blood-vessels engorged; glands unchanged.

If, however, from any cause, the pathological process continues with damming back of the secretion, the inflammatory symptoms become more marked. Greater changes, such as round-cell inflammation, petechial hemorrhages and desquamation, occur in the mucosa. The round-cell infiltration penetrates the deeper layers until the bone is reached, causing pressure, with subsequent tendency toward ulceration caries. Complete resolution cannot occur after this stage of inflammation, for the destruction has been so extensive as to preclude the possibility of Nature overcoming these pathological changes. The mucosa is thickened from the overgrowth of fibrous connective tissue. The lining epithelium, having lost its cilia, is metamorphosed into the squamous or pavement variety. The glands are, for the most part, destroyed and the blood-supply greatly diminished by the obliteration of the finer arterioles and veinlets. If restitution does not occur in a given length of time (four to ten weeks), the disease may be said to have become chronic.

No given length of time can be arbitrarily stated in which an acute disease will become chronic. It depends entirely upon the numerous causes and combinations of causes which have given origin to the disease, together with the favorable or unfavorable anatomic configurations, not to mention the virulence of the attacking micro-organisms or the susceptibility of the individual. There exists no sharp line of deviation, either clinically or pathologically, between the acute and chronic stadiums. Oppikofer calls attention to the fact that even in autopsy findings it is difficult to determine whether the diseased sinus was acutely or chronically affected.

Chronic sinus inflammation exhibits two distinct types: (1) hyperplastic; (2) ulcerative. These forms are not entirely disassociated, as transitional stages are found in the same sinus.

1. **HYPERPLASTIC TYPE.**—The mucous membrane is of a grayish color, often wrinkled and papillomatous and more or less loose from the underlying bone. Hyperæmia, while present, is not so marked as in the acute inflammation. Œdematous changes occur in the mucous membrane which are similar to the ordinary nasal polyp. The connective tissue is thickened. (New formation.) Retention cysts often occur from constriction of the neck of the glands, due not only to the pressure from the round-cell infiltration but to the formation of connective tissue, as the glands and vessels may be atrophied or vessels may be numerous and more or less

dilated. (These two conditions frequently occur in the same specimen.) (Plate 2.)

Small areas of metamorphosis of ciliated into pavement epithelium. Round-cell infiltration usually marked, but may fail entirely. Pavement layer hypertrophied and prominent, taking well eosine stain. Connective tissue thickened, vessels numerous and more or less dilated.⁷⁷ Osteoblasts frequently found, osteoclasts seldom. This is due to the positive disturbance of nutrition (venous stasis). No micro-organisms have as yet been found in the sinus mucosa.

DIFFERENTIAL DIAGNOSIS.

Acute.	Chronic.
Epithelium unchanged.	Epithelium higher.
Never found.	Pavement epithelium frequently found.
Not visible.	Base membrane thickened.
Connective tissue spaces widened.	Connective tissue thickened.
Lymphocytes few.	Lymphocytes many.
Not common.	Fold formation common.
Punctiform hemorrhages large.	Punctiform hemorrhages small.
Bone seldom affected.	Bone often affected.

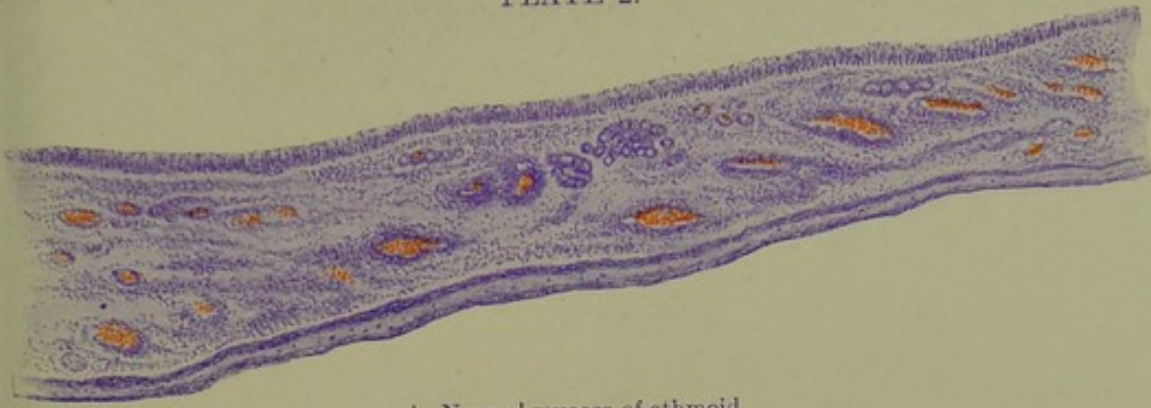2. **ULCERATIVE TYPE.**—No specimen has come under the author's observation where the ulceration was the predominating feature. The true ulcerative type is probably not found as such, but is rather a hyperplastic condition associated with ulcerosus. The relative extent of this pathologic process (ulcerosus) depends as much upon the pressure upon the mucosa as upon the action of excessively virulent micro-organisms.

1. **UNUSUAL PATHOLOGICAL COMPLICATIONS OR SEQUELÆ OF CHRONIC INFLAMMATION: NEW FORMATION AND ULCERATION OF BONE, CARIES AND NECROSIS.**—Recollecting that the third layer of the mucosa and the periosteum are intimately blended, it is easy to see why the bone so often becomes affected during the course of a severe sinus inflammation. Were it not for the collateral circulation through the sinus walls this would happen with much greater frequency.

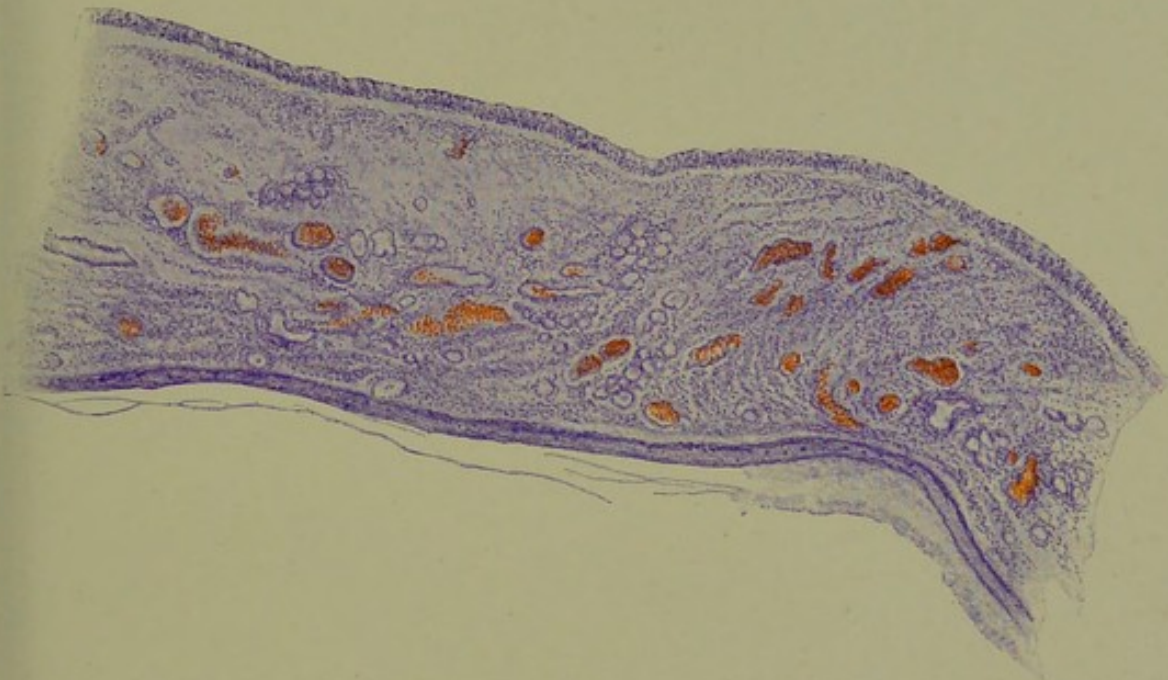New Bone Formation.—When the inflammation first meets the periosteum the blood-vessels supplying the osteoblasts become dilated. If the irritation does not progress beyond this point, on

⁷⁷ Oppikofer (Arch. f. Lary., Bd. 21, S. 422) found this condition in about 40 per cent. of cases examined. It was never found in the acute type, therefore where found is indicative of chronic disease.

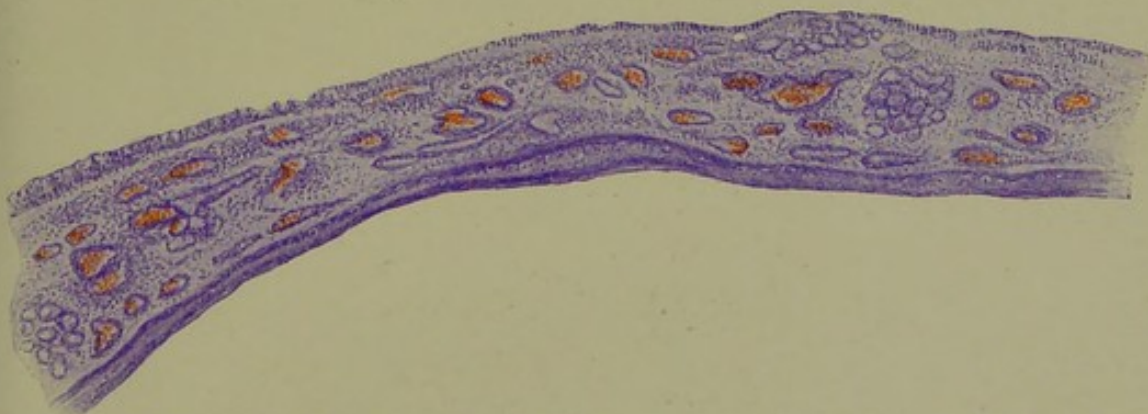
PLATE 2.




A, Normal mucosa of ethmoid.



B, Acute inflammation. Thickening of mucosa. Intense round-cell infiltration. Blood-vessels dilated.



C, Chronic inflammation. Metamorphosis of ciliated epithelium into columnar. New formation of fibrous tissue.



account of the excessive nutrition brought to the part, new bone is deposited in an irregular fashion on the internal walls of the sinus, giving it a roughened appearance. This has no pathological significance.

Ulceration of the Bone.—This condition seems to be dependent upon an especially virulent infection, being always accompanied by ulceration of the superimposed mucosa. It is observed particularly in those cases where partial or complete stagnation has been present; therefore, it would also seem that the pressure of the secretion contributed largely in the ætiology of the ulceration.

Caries and Necrosis.—Actual destruction of a portion of the osseous wall is relatively rare. Gerber⁷⁸ has collected three hundred and nineteen cases, and asserts that this complication is always due to infection through the circulatory system.

2. DILATATION OF SINUS WALL BY INTERNAL PRESSURE OF SECRETION (MUCOCELE, PYOCELE, AND LATENT EMPYEMA).—That a simple empyema, either acute or chronic, would cause actual displacement of the sinus walls has, until recent years, been a controvertible theory. Hajek formerly championed the negative view⁷⁹ in no uncertain manner, until he was able to prove to his own satisfaction the existence of such a condition in the ethmoid labyrinth of one of his own patients.⁸⁰

It is conceivable how pressure from the contained secretion could cause bulging of the wall of the ethmoid and maxillary (nasal wall), as these are exceedingly thin, but that the anterior wall of the frontal sinus should give way under these conditions seems almost incredible, at least from an anatomical point of view. (See Anatomy of Frontal Sinus.) Gerber,⁷⁸ however, insists that such is the case, and claims to have observed the condition on many occasions.

Mucocele.^{81, 82}—This condition is due to a collection of mucous secretion within a sinus, resulting from obstruction to its outlet, with ultimate distention of the walls of the cavity. The sinuses most frequently affected are the frontal and anterior ethmoid cells. Mucocele of the sphenoid sinus does not seem to occur.

The ætiology of these mucoid accumulations is not entirely clear, but it suffices to say that the ostium of the affected sinus has been gradually occluded by chronic catarrhal inflammation;

78. Gerber: *Komplikationen der Stirnhöhlenentzündungen*. S. 32, Berlin, 1909.

79. Hajek: *Discussion zu Gerbers Vortrag. Die Komplikationen der Stirnhöhlenentzündungen*. Deutsch. Lary. Gesell. zu Dresden, 1907. 80. Hajek: *Acute empyem d. Siebbeinlabyrinth, etc.* Zeitschr. f. Lary., Bd. 1, p. 629, 1909. 81. Logan Turner: *Mucocele of the Accessory Nasal Sinuses*. Edinburgh Med. Journ., Nov. and Dec., 1907. 82. Hastings: *Mucocele of the Nasal Accessory Sinuses, etc.* Ann. Otol., Rhin. and Lary., Sept., 1911.

the glands of the sinus mucosa continuing to secrete, the end result must be a gradual dilatation of the walls, with ultimate rupture.

On account of the very slow course taken, pain is rarely felt in the early stages of the disease, and it is not until distinct bulging* of the external walls is noted that the patient comes under medical aid.

If the mass is allowed to accumulate, considerable deformity, particularly from the stand-point of the orbit, will occur, and irreparable damage will be done to the eye on the affected side. (See Frontal Sinus and Ethmoid Labyrinth.) If by any chance a mucocele becomes infected, a pyocele immediately results, changing the process from an ultrachronic one to one of acuteness, depending upon the virulence of the infective micro-organism.

3. METAMORPHOSIS OF THE SECRETION INTO A CHEESY MASS (VERKASUNG⁸³).—A condition occurring during the course of a sinusitis, being due to the regenerative ability of the sinus mucosa, as well as the worn-out virulence of the infecting micro-organism. The inflamed mucous membrane recovers little by little until it is able to successfully withstand the attacks of the micro-organism. The contained secretion, not being able to escape, becomes stagnated, loses its moisture, and a fatty degeneration of the pus corpuscles results. After a time this mass becomes more or less solid, with certain characteristics of soft cheese. As the only irritation present is from the action of the mass itself upon the sinus mucosa, no pus is present; only a thin, sourish secretion is found. (See Maxillary Sinus.)

4. CHOLESTEATOMA FORMATION.⁸⁴—This may be due to two independent causes. 1. The disturbance in evolution during embryonic life (true cholesteatoma). 2. Encroachment of the epithelium from without into the sinus cavity (false cholesteatoma). The true cholesteatoma exists from birth and is probably a factor in the causation of the subsequent empyema. The false cholesteatoma is always dependent upon, and the product of, the existing sinus suppuration. (See Maxillary Sinus.)

5. CALCAREOUS FORMATION.—Stone formation in the sinus is very rare, barely a dozen cases being reported. It shows prefer-

* These dilatations have been known to accumulate for ten to twenty years.

83. Avellis: Der Ausgang des acuten Kieferhöhlenempyems in Verkasung, etc. Arch. f. Lary., Bd. x, S. 271, 1900. 84. Heimendinger: Beiträge z. Path. Anatomie der Kieferhöhle. Arch. f. Lary., Bd. xix, S. 382, 1907.

ence for the maxillary sinus, as the majority of examples have been found in this cavity. (See Maxillary Sinus.) No especial cause has been attributed to their formation.

6. CARCINOMA.—Malignant tumors of the sinuses are not as common as is generally supposed, the one most frequently met with being carcinoma.⁸⁵ Any of these may excite a true purulent sinusitis through breaking down and ulceration of the mucosa.⁸⁶ The tumor itself remains usually unrecognized until tumefaction sets in.

RELATIVE IMPORTANCE OF THE SECRETION IN CHRONIC EMPYEMA.

Absolutely no reliance can be placed upon the character of the secretion as an indication of the pathological condition of the sinus mucosa. It may be profuse, fetid, and of a greenish color, yet the mucosa shows but few, and even insignificant, pathological changes, and, again, it can be thin, serous, and scanty, yet the entire sinus will be filled with hyperplastic and cystic degenerated mucous membrane.⁸⁷ These apparently anomalous conditions are explained by the kind and virulence of the infection, for it appears that the infecting organisms act principally on the epithelium and do not penetrate into the depths of the mucosa.

Hajek says the secretion in acute and chronic inflammation can be differentiated by the fact that the pus in acute inflammation appears to mix with the injected fluid, while in chronic empyema the secretion shows a great tendency to segregate into masses.

As a rule, when the drainage is not good, saphrophytic organisms find entrance into the sinus and cause the secretion to become malodorous. If no apparent interference with drainage is present and the secretion becomes fetid, it is usually significant of some deep-seated tissue involvement.

LATENT EMPYEMA.⁸⁸

By this term is understood the presence of a well-defined sup-puration process within a sinus which continues without giving rise to appreciable symptoms, and being probably due to infection

85. Citelli: Tumeurs Primitives des Sinus du Nez. *Archiv. Internat. de Laryn.*, T xxv, p. 1, 1908. 86. Manasse: Zur Pathol. Anatomie und Klinik der Malignen Nebenhöhlengeschwülste. *Zeitschr. f. Laryn.*, Bd. 1, S. 517, 1909. 87. V. Eicken: Dis. to Tilley. A case in which no pus was to be seen in the nose at repeated examinations, yet on operation both the anterior and posterior walls of the frontal sinus were carious, the dura being exposed and covered with granulations. *Verh. 1st Internat. Laryng.-Rhin. Congress*, S. 222, 1908, Wien. 88. Shambaugh: The Diagnosis of Latent Frontal Sinusitis. *Am. Journ. of Med. Sciences*, vol. 123, p. 416, 1902.

from micro-organisms of slight virulence. This condition is in reality a mild catarrhal process, which nevertheless may become virulent, and even fatal⁸⁹ under the influence of certain forms of irritation, by quickening the dormant bacteria or reducing the resisting powers of the sinus mucosa. The diagnosis is difficult, but not more so than the mild catarrhal inflammation; care must be exercised to differentiate from purulent rhinitis, ulcerating neoplasms, and small foreign bodies. Pus formed in the choana (adenoids) can appear in the superior nasal passage and olfactory fissure and simulate disease of the posterior ethmoid and sphenoid.

SYMPTOMS OF SINUS INFLAMMATION.

The symptomatology of this affection is by no means solely confined to the head, therefore it must be divided into local and general.

LOCAL HEADACHE.

Headache resulting from sinus affections is one of the commonest and at the same time least understood of all the symptoms associated with the disease. As an individual symptom indicative of disease of a particular sinus it is thoroughly unreliable, but its presence or absence in the entire symptom-complex is most important. Its mere absence proves nothing, while its presence may be of inestimable value in making a correct diagnosis. That many such cases have often gone unrecognized is well shown in the following statement by Hajek.⁹⁰ When speaking of this subject, he says: "Many cases of sinus disease with slight nasal symptoms go through their entire life with the diagnosis of chronic headache, taking all manner of cures, such as electro- and hydrotherapy, sea baths, general and special (body) massage, without it ever occurring to anyone that the headache might be caused by a structural disease in the immediate neighborhood (accessory sinuses of the nose)." It is, of course, presupposed that these individuals have never been subject to a thorough rhinoscopic examination. The explanation why this symptom is so little understood will be better appreciated when one studies the following individual peculiarities.

Cause.—The cause of the headache depends upon one or more of several conditions. *a.* Swelling of the mucosa with pressure

^{89.} Cott: Four Deaths in Latent Sinusitis. *Am. Journ. of Surgery*, vol. 26, p. 116, 1912. ^{90.} Hajek (6), S. 13, 1909.

or irritation of the nerves. *b.* Direct contact of the swollen mucosa. *c.* Negative pressure in the sinus. *d.* Stasis following obstruction of the drainage passages. *e.* Ulceration of mucosa with involvement of the nerves. *f.* Reabsorption of toxins formed within the sinus. *g.* Any condition which causes active congestion of the cranial circulation (acute exacerbation of a chronic inflammation, overindulgence in alcohol and tobacco, etc.). *h.* Disturbances in the blood and lymph circulation at the base of the skull.⁹¹

The experience of the author would indicate that pressure on the septum from hypertrophies which so often coexist with sinus inflammations is one of the main causes of persistent headache associated with this disease. That many of the reported cases in which the pain was instantly relieved by the application of cocaine and adrenalin to the drainage passages were in reality relieved by removing the pressure from the septum seems to be beyond all reasonable doubt, as the following case will show:

E. B., 40 years, consulted me for persistent headache, which had troubled him for the past two years. Examination and subsequent treatments showed ethmoid hyperplasia on the left side which corresponded with the headaches. The mucous membrane of the inferior turbinate of the same side was polypoid degenerated posteriorly, encroaching upon the septum. I promised him complete relief after an operation which would consist of removal of the diseased ethmoidal cells. He consented, and this operation was performed. After several days he reported for examination, still complaining of the pain, which apparently had not been influenced by the surgical procedure. This, however, I attributed to postoperative swelling. The ethmoid wound healed in a few weeks with no recurrence of the polypi, the headaches, however, persisting. I suggested that the hypertrophied mucosa of the inferior turbinate be excised. The patient was desperate and readily consented to anything in order to obtain relief. The mucous membrane was accordingly excised with a spoke-shave, with, much to my delight, immediate relief from this pain. The headache had not recurred several months after the operation. This case demonstrates only too well how, when certain sinus conditions are present which should be accompanied by headaches, we are apt to take too much for granted and promise results which, much to our embarrassment, fail to materialize.

Lack of Constancy.—In the chronic form of the disease headache is one of the most inconstant symptoms, the violence of the pain having apparently no relation to the severity of the disease. In certain cases the pain will be almost unbearable, yet the actual symptoms are insignificant; in others the headache is mild, yet enormous tissue changes have taken place in the sinus. Holmes⁹²

91. Grünwald: Die Lehre von der Naseneiterung, S. 114, 1896. 92. C. R. Holmes: Head Pains Caused by Inflammation of the Accessory Sinuses of the Nose. Ohio State Med. Journ., Feb., 1906.

says we may have purulent inflammation of all the sinuses on both sides without the patient ever having suffered from pain at any time. The author has never observed such a case. Regarding the frequency of pain in sinus inflammation, Grünwald puts it at one hundred per cent. in the acute forms, and fifty per cent. in the chronic.

Character.—Under this heading it must be borne in mind that we have mostly to deal with referred pain through the various branches of the trigeminus nerve. Fig. 30 will illustrate how this nerve supplies the various sinuses and the numberless ramifications of its branches.

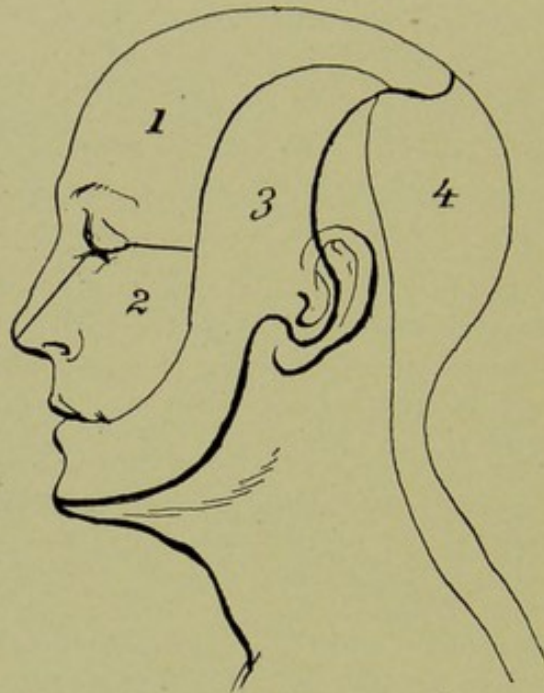


FIG. 30.—Distribution of the three branches of the trigeminus nerve. 1. Ophthalmic division. 2. Superior maxillary division. 3. Inferior maxillary division. 4. Occipital nerves.

The character of the headache varies between the sharp twinging of neuralgia and a heavy, full, benumbed sensation (benommensein); often the pain is almost indistinguishable from ordinary trigeminal neuralgia. These conditions are frequently associated, the acute neuralgia being followed by a diffuse headache or, more often, by a sense of weight and fulness.

As a general rule, acute inflammation of a sinus is characterized by neuralgic pain in the affected cavity (frontal and maxillary); there may accompany this referred pain through the other nerve branches.

In chronic sinusitis the headache may take on any form, as has been noted above; however, one staple characteristic is always

observed,—*i.e.*, diffuse headaches from accessory sinus disease, during recurrent attacks, cause pain in the same portion of the head. Treatment will, of course, influence the character and often the localization of this pain.

Snow⁹³ has observed the occurrence of *tic douloureux* associated with sinus disease. This has not occurred in any of the cases seen by the author.

Periodicity.—In certain cases intervals of complete rest are observed between the attacks of pain. Not infrequently headache manifests itself at a certain time of the day, lasting a few hours, then vanishing as quickly as it appeared, only to return at the same time the following day. The pain in these cases usually appears in the forenoon and lasts several hours. The term “sun pains” has often been falsely applied to this condition. In certain other cases of chronic sinus disease the patient may be relatively free from discomfort for days and even weeks at a time.

Variations in Intensity.—The head pain is intensified by constipation, straining at stool, stooping, sudden jarring, as jumping and lighting upon the heels, also by severe mental work and loss of sleep. As before mentioned, the indulgence in indigestible foods as well as in alcohol and tobacco will greatly contribute toward this cause.

Occasionally the pain and general feeling of distress in the head will become so great as to excite suicidal tendencies in the patient,^{94 95} as the following case will illustrate.

M. R., 45 years, conductor, presented himself for examination with the history of considerable discharge from right side of nose, particularly in the morning, paroxysmal headaches, which sometimes became unbearable; constant feeling of fulness on right side of face and head. This condition had been present for several months and gradually becoming worse, so that he could no longer sleep. He said that he had often been tempted to throw himself from the train, as the constant pressure in his head was beginning to affect his mind. Examination showed symptoms pointing to maxillary sinus involvement, and on exploratory needle puncture great quantities of greenish, lumpy, and extremely fetid secretion were washed out, with complete and instant relief. The lavages were continued for several weeks and ultimately resulted in a cure.

Localization.—The general impression still seems to prevail that inflammations in certain sinuses will invariably cause pain in definite localized areas of the head. This is really not the case, the exceptions far outnumbering the rule. However, individual

93. Snow: *Tic Douloureux and other Neuralgias from Intranasal and Accessory Sinus Pressures*. N. Y. and Phila. Med. Journ., vol. 81, p. 68, 1905. 94. Grünwald (91), S. 112. 95. Kopetsky: *The Relation of Headache, etc.* N. Y. and Phila. Med. Journ., Dec. 2, 1905.

sinuses seem to show some predilection for causing pain, or, at least, some sensory disturbances in certain defined regions. The general idea of this phase of the subject can be obtained from Fig. 30, which shows the distribution of the trigeminus and the possibilities of referred pain from the sinuses to all parts of the face and head. Fig. 31 shows the regions which are more frequently affected from the individual sinuses. Thus, a dull pain between the eyes should be significant of ethmoidal disease. This is usually accompanied by a sense of weight over the vertex.

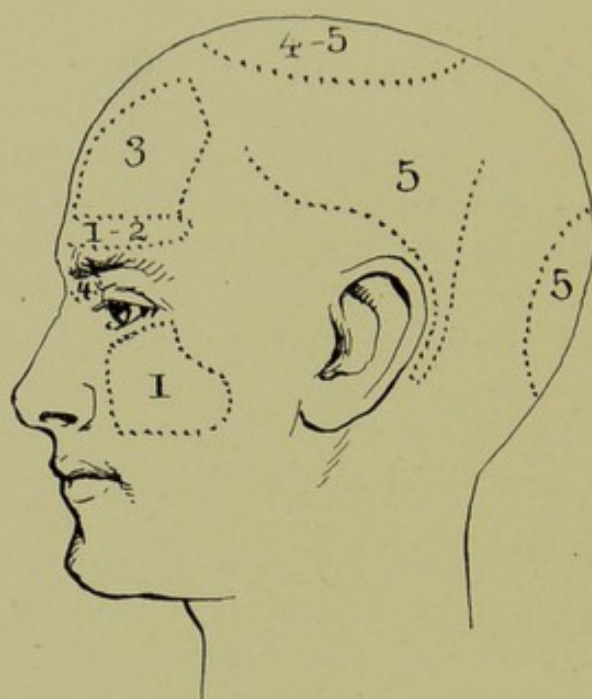


FIG. 31.—Schematic illustration of pain areas due to sinus disease. 1. Acute maxillary sinusitis. 2. Acute frontal sinusitis. 3. Chronic frontal sinusitis. 4. Chronic ethmoidal inflammation. 5. Chronic sphenoidal sinusitis.

Acute maxillary sinusitis, during some stage of its course, will often show neuralgic pain directly in the sinus. In chronic antral suppuration, curiously enough, the pain is often limited to the distribution of the supra-orbital nerve.⁹⁶ Chronic frontal sinus inflammation is looked upon as the one sinus affection which invariably shows some form of pain as one of the necessary symptoms. While in the main this is true, nevertheless, cases have been reported in which severe inflammatory changes in the sinus mucosa had occurred, yet the patient had never experienced the slightest discomfort. The pain, when present in this form of the disease, is apt to be limited to the supra-orbital region, and in typical cases

96. Hajek: Kopfschmerz bei Erkrank. der Nase und der Nebenhöhlen. Wien. med. Presse, No. 11, 1899.

is remittent in type, sometimes almost indistinguishable from idiopathic supra-orbital neuralgia. During the remissions of pain a dull, heavy sensation frequently intervenes.

Inflammations of the sphenoid sinus can give rise to the most excruciating pain through the temples, extending into the mastoid process and even the middle ear and over the vertex, which, in the latter region, changes its character to a sense of heavy weight and oppression. This sinus, with the posterior ethmoid cells, also causes varying degrees of pain in the occipital region.

It must not be inferred that the above symptoms are invariable, for such is, unfortunately, not the case. An uncomplicated frontal sinus disease has been known to give rise to occipital pain, and a sphenoidal sinusitis to supra-orbital neuralgia. Generally speaking, however, the above can be considered as a close criterion of the various head pains lending themselves to differentiation which occur in accessory sinus inflammations. (For further details see Special Sinuses.) Yankhauer⁹⁷ calls attention to a point in diagnosis, in headaches of suspected sinus origin, which has been found valuable. Inhalations of steam will shrink the nasal mucosa, stimulate ciliary motion, and favor drainage from the sinuses by enlarging the passages; therefore, if a patient suffering from a chronic recurrent headache makes use of steam inhalations with even partial or temporary relief, it can definitely be stated that the cause of the headache lies in the nose or one of the nasal accessory sinuses.

TENDERNESS OVER THE SINUSES.

This is of value as a diagnostic symptom when present only over the frontal sinus, very rarely the maxillary. The point of tenderness is not unlimited over the anterior wall, but confined to a small area on the floor of the sinus directly above the inner canthus of the eye.⁹⁸ This is the point where swelling usually occurs, being the thinnest bony portion of the wall, and is often the seat of exquisite tenderness. This symptom, when present, is pathognomonic of frontal sinus inflammation, but comparison should always be made with the sound side to elicit the distinction, as in neurotic individuals false impressions may often be obtained.

Grünwald⁹¹ has attempted to demonstrate that pressure between the eyes will often elicit points of tenderness in ethmoidal

97. Yankhauer: The Drainage Mechanism of the Accessory Sinuses. Laryngoscope, p. 518, 1908. 98. Kuhnt: Über die Entzündliche Erkrankung der Stirnhöhle. Wiesbaden, 1895.

diseases. So far as the author is aware, this has not only remained unsubstantiated but has been denied by other authorities.⁶ Personally I have never been able to observe it in a single case.

PURULENT SECRETION IN THE NOSE.

The mere presence of purulent secretion in the nose is no more indicative of sinus disease than its absence is a proof that no sinus involvement is at hand. If, however, secretion reappears in the same spot shortly after being removed, the evidence is positive that a reservoir of purulent material is underlying, it being impossible for a circumscribed inflammation of the mucous membrane to secrete pus so rapidly in such an interval of time.

The classical symptom of sinus empyema is the presence and continued reappearance of pus in a particular locality of the nose (beneath the anterior third of the middle turbinate for anterior sinus disease, in the olfactory fissure and above the posterior end of the middle turbinate for posterior disease). This symptom, when actually present, is pathognomonic; unfortunately, however, it is often conspicuous by its absence, particularly so at the time of the morning examination. The repeated absence of purulent secretion in the nose, especially if there exists an authentic history of nasal discharge, should, therefore, not be taken as proof positive that sinus disease is not present, as the following case will illustrate:

H. K., 38 years, fireman, referred to me on account of nasal trouble. Patient complained of postnasal discharge, particularly in the morning; unpleasant subjective odor in the nose, which sometimes affected the taste and interfered with the appetite. Never had headaches or, in fact, pain of any kind in the head.

Examination: Slight hypertrophy of the anterior end of the middle turbinate on right. No sign of secretion even after the application of cocaine and adrenalin between turbinate and bulla. Left nares normal. The patient was treated expectantly for some time, but continued to complain of the old trouble. Finally an exploratory needle puncture of the antrum was made and, much to my surprise and relief, a large quantity of thick, creamy pus was evacuated, showing that this had been the seat of the trouble.

The particular point in this case is that at no time was the slightest objective symptom of sinus disease present. We had but two rather vague symptoms upon which to base a diagnosis: the postnasal discharge, which always occurred during the absence of the patient, and the cacostmia, which was, of course, purely subjective. Had it not been for the latter I doubt if the needle puncture would have been made, taking into consideration that the history of the amount of postnasal discharge depends largely upon the imagination of the patient. Under these circumstances, the disease would have remained undiscovered until chronicity had developed.

The explanation of the alternate presence and absence of secretion in the nose depends upon the position of the head, and principally upon the character of the secretion. It is an established fact that when the inflammatory exudate is thick and the ostium large, it is impossible for the sinus to drain by siphonage so that the entire cavity will be emptied at one drainage. These phenomena undoubtedly occurred in the above case, so that when the patient was examined the sinus was undergoing the process of refilling, no traces of the old secretion remaining in the nose.

It has long been recognized by the older writers that diseased sinuses, particularly the maxillary and sphenoid, periodically empty themselves of the inflammatory exudate. Owing to the unfavorable situation of their ostia while the upright position is maintained, this usually occurs during the sleeping hours of the patient. The opposite is the case with the frontal sinus, for here the secretion accumulates during the night and may not escape until some time during the following afternoon. These conditions are undoubtedly closely linked with the exacerbations and sudden remissions of the headache which so frequently are associated with this disease.

The absence of secretion is also observed in the so-called closed empyema (pyocele). (See Pathology.) The amount of exudate secreted is variable, depending largely upon the stage and intensity of the inflammation. The quantity which escapes through the anterior nares is no criterion of the amount actually secreted, for only a small portion of the original may find its exit through these channels. In these cases the greater portion escapes through the choana and is either swallowed or hawked up and expectorated. In acute cases and acute exacerbation of chronic inflammations the secretion is more profuse.

Diminution of the secretion during the course of the disease is usually a sign of remission of the inflammation, but sometimes it is due to partial occlusion of the drainage passages with exacerbation of the disease; however, under the latter circumstances, the subjective symptoms are always intensified to such a degree that the diagnosis is unmistakable.

The consistency of the secretion may change from time to time, depending upon attacks of acute coryza, the state of the weather, etc. So far as the inconvenience of the patient from the secretion is concerned, it is seldom great unless the exudation be profuse. In the latter instance the constant discharge from the nose,

together with the superinduced eczema on the lip and around the angles of the nose, proves a source of extreme annoyance and discomfort.

Cacosmia.—One symptom indirectly caused by the secretion, and when present is almost pathognomonic of sinus disease, is this subjective appreciation of an offensive odor in the nose. This is usually intensified by sudden sharp inspiration through the nostrils (sniffing). The cause of the condition is either the presence of some gas-producing bacteria (when the secretion is odorless) or from putrefaction of the secretion by saprophytic micro-organisms. Complete anosmia is not an uncommon symptom, especially if the olfactory fissure is closed by hypertrophies, purulent secretion, etc. The location of the secretion in the nose is due primarily to the position of the sinus ostium, secondarily to the position of the head, anatomical configuration of the nose as influencing the respiratory portion, pressure of hypertrophies and deviations of the septum.

Adhesion, capillary attraction, and siphonage play an important rôle in influencing the permanent location of the secretion after it has issued from the sinus ostium.* The action of these forces causing the secretion to lodge in atypical positions may lead one into drawing false inferences. Thus pus in the olfactory fissure is symptomatic of sphenoid suppuration. When the middle turbinate lies close to the septum, capillary attraction may draw the secretion from the hiatus around the turbinate into the olfactory fissure, presenting a symptom of posterior disease, when the pus, in reality, was secreted in one of the anterior sinuses. We should be, therefore, particular to always exclude anterior sinus inflammation in these cases before arriving at a final diagnosis.

CHANGES IN THE NASAL MUCOSA DEPENDING UPON SINUS DISEASE.

These may conveniently be divided into acute and chronic.

Acute.—In the first stages the mucous membrane presents the ordinary symptoms of acute inflammation, namely, hyperæmia and swelling, more or less general, depending upon the virulence of the attack. During this stadium the naris on the affected side is often bathed in thick, creamy pus.

* Yankhauer's article (97) gives a detailed description of the mechanism of these forces.

The bilateral appearance of purulent secretion has been noted by some observers, even though the disease was confined to one side. In these cases the secretion came around by way of the nasopharynx, or a perforation existed in the septum.

As the acuteness subsides the inflammation tends to localize itself more and more in the regions of the affected sinus ostia—thus around the uncinata process and the anterior third of the middle turbinate for diseases of the sinuses, first series, and in the neighborhood of the sphenoidal recess and olfactory fissure for the second series. The mucous membrane, at this stage, assumes locally a more or less pale, semi-gelatinous consistency, often showing punctiform dots (sub-epithelial hemorrhages), which are particularly noticeable on the anterior end and lateral surface of the middle turbinate and the hiatus semilunaris.

Chronic.—In this form of the disease the inflammatory changes are localized to the regions where the secretion from the diseased cavities comes in direct contact with the nasal mucosa. These changes take the form of hypertrophies and atrophies. Curiously enough, at that point where the inflammatory exudate first makes its appearance in the nose, hypertrophies (polypoid and fibrous) are usually present, while farther below atrophy is often the rule. A common example of this is seen in hypertrophy of the middle turbinate and atrophy of the inferior, in conjunction with sinus suppuration.

THE RELATION OF POLYP FORMATION TO NASAL SUPPURATION.

Under certain conditions purulent sinus inflammation will give rise to the formation of mucous polyps in the nose. As a proof of this assertion I quote Zarnico,⁹⁹ who emphasizes the following facts: 1. Polyps are often situated around the ostiums of inflamed sinuses. 2. They recur after extirpation. 3. The recurrence is not prevented until the purulent process is cured. Lewis and Turner²³ write that nasal polyps occur more frequently in cases of associated sinus suppuration than in simple cases, particularly in ethmoidal disease.

Jacques¹⁰⁰ does not incline toward this theory, but believes there are numerous conditions which can give rise to the formation of these structures.

99. Zarnico (29), S. 476, 1910. 100. Jacques: Nature, Causes et Traitement des Polypes. Rev. hebdomadaire de Laryngologie, vol. 2, p. 525, 1903.

However, the exact status of this question remains to-day one of the most disputed points of rhinology.

Since Grünwald's⁹¹ contention that all nasal polyps were practically pathognomonic of accessory sinus disease, to Uffenorde's¹⁰¹ assertion that they have absolutely no relation *per se* to it, many opinions have intervened.

Although Grünwald has generally been given credit for the priority of associating polyps with sinus disease, in reality several authors had previously commented on this connection. Wepferi¹⁰² probably first advanced this theory, based on his findings at the autopsy table. Bayer¹⁰³ also associated these two conditions in no uncertain terms.

Kaufmann,¹⁰⁴ one of the first modern writers on this subject, said that in many cases empyema of the maxillary sinus was the only cause for the polyp formation. Several years later Pröbsting¹⁰⁵ stated that polyps on the processus uncinatus were pathognomonic for sinus suppuration.

So far as the actual pathological findings are concerned, in 86 per cent. of the inflammatory sinus disease Grünwald¹⁰⁶ found polypoid hypertrophy, Kronenberg¹⁰⁷ in 60 per cent., and Lewis and Turner²³ 30 per cent.

Before endeavoring to show the actual relation between these connections it might be wise to briefly consider the theories of their pathogenesis as advanced by various authors.¹⁰⁸

Chiari¹⁰⁹ states they are due to chronic irritation of the mucosa from chronic catarrh or purulent inflammation of the sinuses. Grünwald⁹¹ is of the opinion that they are the sequelæ of purulent inflammation of the sinus mucosa. Bosworth¹¹⁰ advanced the theory that the starting point of the polyp was in an accessory sinus; an inflammatory process occurs which takes on something of a myxomatous character. The membrane becomes thick and of a soft, gelatinous consistency, and, on account of intracellular pressure, makes its appearance in the nose.

Alexander¹¹¹ says the actual cause of polyp formation is the inflammatory swelling with disturbances in the circulation.

101. Uffenorde (7), S. 86. 102. Wepferi: Joh. Observ. de Affection Capitis Schapusii, p. 903, 1727. 103. Bayer: Beitrag zum Studium u. zur Behandl., etc. Deutsch. med. Woch., No. 10, 1889. 104. Kaufmann: Ueber eine typische Form von Schleim, etc. Monat. f. Ohrenhk., p. 13, 1890. 105. Pröbsting: Ueber die Entwicklung von Nase, infolge von Nebenhöhleneiterung. Verh. d. Vereins Süddeutsch. Laryng., S. 8, 1894. 106. Grünwald (91), S. 87. 107. Kronenberg: Schleimpol. d. Nase u. Naseneiterungen, S. 259, 316. London Ther. Monatsh., 1897. 108. Yonge: Polypus of the Nose, p. 25, 1906. 109. Chiari: Krankheiten der Nase. S. 195, 1902, Wien. 110. Bosworth: Various Forms of Disease of the Ethmoid Cells. N. Y. Med. Journ., p. 505, vol. 2, 1891. 111. Alexander: Nasenp. in Beziehungen zu der Empyemen d. Nebenhöhlen. Arch. f. Lary., S. 324, Bd. 5, 1896.

Hajek¹¹² writes that a continuing cause of polyp formation is purulent inflammation of a sinus.

It will be noted that all these authors give no pathological reasons for their deductions, but content themselves with making the mere statement that polyp formation can result from sinus disease. The actual pathological change occurring when the purulent secretion is brought into contact with the nasal mucous membrane has been described as follows: An inflammatory exudate occurs beneath the mucous membrane, stasis takes place in the vessels with transudation into the tissues and the formation of a polyp.¹¹³ Heymann¹¹⁴ is of a somewhat different opinion, and writes that the secretion causes an irritation to the smooth mucosa which results in the formation of inflammatory papules. Hyperplasia now occurs, which affects only certain of the granulations, and the resulting œdema causes the formation of small polyps. Yonge¹¹⁵ lays great stress upon the mechanical changes in the glands and says they undergo cystic degeneration by obstruction of the ducts, thereby forming the polyp.

The consecutive changes are as follows:

1. Chronic inflammation of the mucous membrane.
2. Dilatation of the glands.
3. Formation of projections on the infiltrated mucosa.
4. Increase of the œdema.
5. Formation of flat œdematous structures which become relatively constricted at the base and stretched until they constitute a pedicle.

The investigations of the author do not entirely coincide with the above findings, particularly those of Yonge in reference to the occlusion of the glands. While many cases show cystic gland formation, there is no reason to believe that this has been the sole cause of the hyperplasia.

The various stages of polyp formation from accessory sinus disease would seem to be:

1. Round-cell infiltration through the mucosa, resulting from the irritation produced by the secretion.
2. Arrangement of these leucocytes around the blood-vessels and glands, causing partial stasis and predisposing to the transu-

112. Hajek: Warum recediviren Nasenpolypen. Wiener Med. Presse, No. 10, 1902.

113. Zuckerkandl: Anat. der Nasenhöhle. Wien, Bd. 2, S. 115, 1892. 114. Heymann: Handbuch der Laryngologie und Rhinologie. Die Nase, S. 788, 1900. 115. Yonge (108), p. 59.

dition of serum through the vessels into the surrounding tissues and occlusion of the glandular ostii.

3. Dilatation of the interstitial spaces of the connective tissue from the pressure of the exudate with polypoid hypertrophy.

4. Continued stasis of the blood and consequent outpouring of serum with gradual relaxation of the mucous membrane and true polyp formation.

These pathological observations may be true as far as they go, but they do not explain the fact that many cases of empyema run their course without the slightest vestige of polyp formation. Alexander¹¹¹ does not believe the outflow of pus over the mucous membrane is the single cause, but thinks the direct continuity of inflammation from the mucosa of the sinuses to that of the nose the most important causative factor. We must, however, remember that this causative factor cannot, in every case, be definitely determined, yet it is certain that the continued irritation from the inflammatory secretion at least exerts some predisposing influence for the formation of these structures.

Certain authorities^{116 117} hold the opinion that nasal polyps may be the primary cause of a sinus empyema by occlusion of their ostii. This genetic relation, however, has not been sufficiently proven.

If one makes a brief retrospection of this subject it will be seen that polypi occur in a certain percentage of accessory sinus suppurations. It apparently does not depend upon which sinus is affected, although they occur more often with ethmoidal disease. (See Pathology of Ethmoid Labyrinth.) They often occur entirely disassociated with sinus suppuration, and *vice versa*. Why they occur in certain cases of sinus suppuration and not in others is as yet unexplained.

OTHER CHANGES IN THE NASAL MUCOSA DEPENDING UPON SINUS DISEASE.

Eczema of the nasal vestibule, particularly where confined to one side, is an indication of an increased unilateral discharge, and should immediately call attention to the sinuses of that side. Eczema of this character often persists for years until the concomitant sinus empyema is discovered and cured, the presence of which had hitherto not even been suspected.

116. Litchwitz: Bresgen'sche Sammlung Zwangloser Abhandlungen aus dem Gebiet der Nasen, Ohren, Mund und Halskrankheiten. Halle, 1896. 117. Fischenitz: Discussion. Verh. Süddeutsch. Lary., S. 14, 1894.

ERYSIPELAS.

The precise relation of this disease to sinus affections seems to be a mooted question. Some authorities consider erysipelas as the primary lesion; others believe that it is secondary, being due to subsequent infection following the irritation from the secretion. Both theories appear, under certain circumstances, to be correct, as proven by the observations of Weichselbaum (erysipelas primary) and Hajek (empyema primary), but it is probable, at least in the majority of instances, that the empyema is responsible for the erysipelalous outbreak. (See *Ætiology*.)

Partial and complete anosmia are due to two causes: (1) mechanical (from occlusion of the olfactory fissure by hypertrophies, secretion, etc.), or (2) peripheral (from pathologic degeneration of the olfactory cells in the mucous membrane due to the constant irritation from the secretion). The latter condition results from posterior ethmoid or sphenoid disease.

CHANGES IN THE MUCOSA OF THE UPPER RESPIRATORY TRACT.

THE NASOPHARYNX AND PHARYNX.

In acute forms of sinus affection these structures usually remain unchanged. Only in those cases of extreme virulence is a hyperæmia and swelling of the pharyngeal mucosa present. The chronic forms of sinus empyema are frequently associated with pharyngeal disturbances. These are of two varieties: 1. Pharyngitis sicca. 2. Pharyngitis lateralis (granular or hyperplastic).

Pharyngitis Sicca.—This form of the disease does not differ essentially from the ordinary variety of sclerosed pharynx. One symptom, however, when present is very suggestive of sinus involvement (particularly posterior); that is, accumulation of thick, tenacious secretion on the postpharyngeal wall, which is particularly difficult to dislodge, even with a cotton mop.

The form of dry pharynx which accompanies sinus disease is differentiated by the fact that it seems to assume its greatest intensity high up in the nasopharynx and gradually disappears in the depths below the pharyngeal pillars; however, no sharp line of demarcation is to be noted. True atrophy of the mucous membrane occurs in this form of the affection. The epithelial changes are due to the drying of the secretion on the mucosa.

Pharyngitis lateralis is characterized by a definite area of inflammation on the lateral wall of the pharynx behind the posterior pillar of the tonsil. The breadth of the inflammatory tract may vary from the mere streak to the size of an ordinary lead-pencil. This form is frequently seen in posterior ethmoidal and sphenoid suppuration, although the backward flow of pus from any of the sinuses can give rise to the condition. It is caused by the constant flow of purulent secretion over the certain tract at the juncture of the posterior and lateral pharyngeal walls. Uffenorde¹¹⁸ lays particular stress upon the importance of this form of pharyngitis in relation to accessory sinus empyema.

LARYNGEAL AFFECTIONS.

These are not an infrequent accompaniment of sinus suppuration and are probably caused by the constant bathing of the parts with the secretion which has flowed backward into the pharynx. The inflammatory changes in the mucosa are always found on the posterior laryngeal wall and evidence themselves by hyperæmic swellings of the aryepiglottic folds and arytenoid cartilages. In severe cases the posterior third of the vocal cords is affected, with more or less œdema of the ventricular bands. This œdemic infiltration is often so great as to seriously interfere with the mobility of the structures of vocalization.

Various degrees of hoarseness seem to be the predominant laryngeal symptoms. This disturbance of vocalization is due to two causes. 1. The swelling and œdema of the arytenoidal region, causing mechanical interference with the motions of the vocal cords. 2. Tiring of the extrinsic muscles by the constant hawking and attempts to clear the throat of the inspissated secretion. Some form of pain, or, at least, of irritation, is also usually located in the larynx.

It occasionally happens that the sore throat and laryngeal symptoms (hoarseness, etc.) are the only subjective symptoms present, and on this account alone has the patient sought medical advice, never having the slightest intuition that the exciting cause of his discomfort lay in one of the accessory sinuses. The following case will illustrate the point:

F. D., physician, consulted me for a sore throat which had been annoying him for several months. He also complained of recurrent attacks of hoarseness

118. Uffenorde: *Pharyngitis Lateralis*. Arch. f. Lary., Bd. 19, S. 10, 1906.

which always occurred toward evening, and particularly after exceptional vocal usage or sudden changes in the weather. No other history was obtainable except that of a moderate coryza.

Examination of the larynx showed a mild type of subacute laryngitis, arytenoids somewhat swollen and engorged, vocal cords moderately hyperæmic, otherwise normal. Nose apparently normal in spite of the history of coryza. The usual treatment for laryngitis was instituted and continued for some time, with no appreciable change in the condition. One morning he chanced to speak of the cold in his head which he could not rid himself of, and I suggested that perhaps he had some sinus trouble, although none of the usual symptoms were present. An exploratory needle puncture of the maxillary sinus was proposed, to which he readily acquiesced. The right antrum was first punctured and lavaged with negative results; however, as soon as the needle was introduced into the left sinus and air injected, a bubbling sound told the presence of secretion.

On washing out the sinus a large quantity of heavy, ropy pus was expelled from the cavity. This treatment was continued until the cavity discontinued to secrete, which only required a few lavages. The pharyngeal and laryngeal symptoms showed immediate improvement and gradually disappeared without further treatment.

Grünwald¹¹⁹ lays particular stress on this point and says: "An examination of a patient with chronic laryngeal affection must be considered incomplete until the exact condition of the nose and nasopharynx has been thoroughly investigated."

PHARYNGEAL AFFECTIONS.

The symptoms resulting from pharyngeal disturbances depending upon sinus disease are either those of attacks of angina, often occurring as a result of infection of the tonsillar lacuna from the secretion, or those caused by the chronic pharyngitis. In the latter instance the symptoms are occasioned by the continual irritation of the drying secretion, causing constant hawking and rasping and resulting in the exquisitely irritable pharynx which is so often encountered in patients suffering with accessory sinus disease.

Bronchial symptoms, asthma, bronchitis (Lichtwitz,¹²⁰ Hartmann,¹²¹ Hajek⁶), bronchiectasis (Lichtwitz,¹²⁰ Krauss,¹²² Uffenorde,⁷), and emphysema (Uffenorde⁷) have been from time to time reported as complicating accessory sinus empyema.

Gastric disturbances^{123 124} are not infrequent accompaniments of sinus suppuration. These range from slight eructations of gas

119. Grünwald (91), S. 97. 120. Lichtwitz: Die Eiterungen der Nebenhöhlen der Nase und ihre Folgezustände in anderen Körpertheilen. Bresgens Sammlung, Bd. 1, No. 7, 1895. 121. Hartmann: Zur Casuistik der Highmorshöhlenempyeme. Deutsch. med. Woch., No. 50, S. 1026, 1889. 122. Krauss: Arch. f. Lary., Bd. 13, S. 45, 1902. 123. Storck: Gastric Disturbance due to Diseases of the Frontal Sinus. New Orleans Med. and Surg. Journ., vol. 59, p. 547, 1907. 124. Zabel: Eiterüberschwemmung des Magendarmcanals aus Nasennebenhöhlenempyem, etc. Deutsch. med. Wochenschr., Bd. 36, S. 797, 1910.

to active nausea and vomiting, and undoubtedly result from the constant swallowing of the purulent secretion, with reabsorption of ptomaines. Vomiting may also occur from the irritation produced by continued efforts to dislodge the dried secretions in the nasopharynx.

Constipation seems to be quite prevalent with patients suffering with sinus disease, but whether this is more apparent than real, on account of the exacerbations of headache which it produces, is a matter of conjecture.

REMOTE LOCAL SYMPTOMS.

Dizziness and Vertigo.—These manifestations are a frequent accompaniment of sinus suppuration. Dizziness is often more marked on stooping over to pick up something from the ground or on sudden motions of the head. In severe cases it may occur whenever the patient makes any attempt at locomotion.¹²⁷ Vertigo may suddenly manifest itself while the patient is at rest, sitting and reading. It is usually but of momentary duration, although it may be so severe as to excite nausea and even vomiting. Reclining at full length will usually terminate these attacks.

PSYCHICAL AND INTELLECTUAL DISTURBANCES.¹²⁸

These occur more particularly in the chronic form of the disease and manifest themselves as all kinds and conditions of symptoms referable to disturbed mental equilibrium. They begin in a mild and insidious manner, the patient usually having occasional lapses of memory and slight mental wanderings while the mind is concentrated on business affairs. As time elapses and the disease wears on, these symptoms become more and more pronounced, until a decided effort to concentrate the mind is required, which naturally results in disinclination to any form of work requiring mental effort. Unless the disease is checked at this point, the condition will steadily progress until a state of neurasthenia prevails, the patient exhibiting alternate periods of excitability and moroseness, a peculiar antipathy toward friends, especially immediate relations, variable temper, marked indolence and carelessness in dress and general appearance, great mental

125. Scherer: Salzsäuremangel bei Nebenhöhleneiterungen. Verh. deutsch. Laryngologen, S. 147, 1907, Dresden. 126. Uffenorde: Behandlung u. diagnostischen Symptomen. Zeitschr. f. Artzliche Fortbildung, No. 12, 1909. 127. Skillern: Ein Fall von Geschlossenen Empyemen u. s. w. Zeitsch. f. Lary., S. 337, Bd. 1, 1909. 128. Ziem: Ueber Beziehung d. Nasenkrankheiten z. Psychiatrie. Mon. f. Ohren, S. 482, 1897.

depression, melancholia, and even suicidal tendencies.¹²⁹ The relative severity of these symptoms appears to depend upon the condition of drainage, as they are always relieved by permanent ventilation of the sinuses. They are also accentuated by the exacerbations of the headache, and many authors consider that these are directly responsible for their appearance.

Grünwald¹³⁰ believes that the chronic sinus suppuration influences the brain by disturbing the lymph circulation at the base of the cranium. Robertson¹³¹ considers the reflex vasomotor stasis of blood in the meninges to be the exciting cause. One would be inclined to place the blame on the reabsorption of toxins through the sinus walls into the cerebral circulation; however, as Hajek¹³² well puts it, "One cannot definitely explain the exact nature of the disturbances of the brain function in these conditions." It is, however, certain that no tangible anatomical changes occur, as the psychological alterations, for the most part, quickly vanish after thorough drainage is established.

Personally the author is of the opinion that certain of these mental disturbances (psychologic) bear no more relation to the sinus affections than a corresponding disease in any other part of the human economy. That they occur with greater frequency in sinus inflammations cannot be gainsaid, but how often does the gynecologist, for example, encounter precisely the same condition among females afflicted with ovarian and uterine affections! It is the corporeal condition, not the specific disease, that provokes these manifestations.

GENERAL SYMPTOMS.

FEVER.

Fever is always present with acute inflammation and acute exacerbations of chronic affections, but exhibits no especial noteworthy characteristics. The sudden rise of temperature in chronic inflammations is indicative of toxic reabsorption through the sinus walls or of a pending and severe complication, such as rupture, into the neighboring parts.

CIRCULATORY DISTURBANCES.

These range from slight acceleration of the pulse, disassociated with any increase in temperature, to an actual condition of general congestion. The former condition, though there may

129. Stucky: Some Mental Symptoms due to Disease of the Nasal Accessory Sinuses. *Lancet-Clinic*, Jan. 19, 1907. 130. Grünwald: *Lehrbuch*, S. 115, 1896. 131. Robertson: Headache from Non-Suppurative Inflammation of the Accessory Sinuses. *Journ. Am. Med. Assn.*, March 5, 1904. 132. Hajek (6), S. 24.

be no increase in the blood-pressure, seems to affect the veins of the head as well as the arteries, and I have often noted the unwonted prominence of the superficial temporal veins in patients during this period of congestion. The symptoms of this condition consist in flushing of the face, acceleration of the pulse, occlusion of the affected, and often both, nares, prominence of the superficial veins of the temple and forehead, visual disturbances and general irritability of the individual. They may occur at any time, but are usually synchronous with the occlusion of drainage.

Hajek¹³³ says that this condition does not usually appear spontaneously in accessory sinus disease, more often there being a causative factor in the form of ingestion of heavy foods or alcohol.

A marked predisposition to sleeplessness is often coincident with the period of congestion. Actual insomnia, while often present, does not seem to play as important a rôle as the restless, dreamy sleep, which seems to possess no refreshing qualities, consequently the sufferer finds himself in no condition to attend to his ordinary business affairs on arising in the morning. Diminution in the frequency of the pulse, although reported by several authors as occurring with sinus affections, I have never been able to verify to my own satisfaction.

NERVOUS DISTURBANCES.

General nervousness in connection with sinus disease is only to be expected with the symptoms described above, and should be viewed merely as one of the constituents of the general symptom-complex. One of the commonest of these is a feeling of great weakness which suddenly appears and totally incapacitates the individual while present.

SEXUAL APPARATUS.

Inflammation of the sinuses often exercises a marked influence over the sexual function. In ordinary cases there is a marked deterioration, while in the severe cases it may be totally abolished.

DIAGNOSIS.

FIRST SERIES.

When a patient presents himself for examination, and a sinus disease is suspected, our first thought will be to examine for free

133. Hajek (6), S. 20.

pus in the nose. We will suppose, then, in the middle nasal passage pus is seen coming down between the bulla and middle turbinate. Now the all-important point is to ascertain whether this secretion is the overflowing of a reservoir or merely due to circumscribed inflammation of the mucous membrane. This is readily distinguished by merely wiping it away with a cotton mop. If it reappears within a few moments a larger quantity is somewhere concealed, as it is manifestly impossible for the nasal mucosa to secrete such a quantity in so short a time. This is, therefore, one of the principal steps in the diagnosis, namely: not the mere presence of pus in the nose, but its continued reappearance after wiping away is a positive symptom of sinus disease.

We must bear in mind that purulent secretion in the nose can be caused by several conditions, such as foreign bodies, mucous surfaces in apposition (polyps, hypertrophies, etc.), adenoids, atrophic rhinitis, tuberculosis, syphilis, and malignant tumors. Of these the only condition that is liable to be confounded with sinus disease is polyp and hypertrophic formation associated with secretion. As these are often dependent upon one another, they require particular mention. (See Relation of Polyps to Empyema.)

We have thus far demonstrated to our own satisfaction that purulent secretion is present in the middle nasal passage which reappears shortly after removal. Our next step is now to ascertain which particular sinus or sinuses of the first series are secreting the pus. For this purpose we first turn our attention to the maxillary sinus, and for the following reasons: *a.* It is more frequently affected than the others. *b.* It is situated at the lowest portion. *c.* It is reasonably easy of access. A cannula is bent, corresponding to the side affected, and an attempt is made to find an accessory ostium, which occurs in about ten per cent. of all cases. This will probably fail. The normal ostium should then be sought for, but this also usually miscarries. There remains but one method of ascertaining whether pus is present in the maxillary sinus, and that is by needle puncture. (See Maxillary Sinus.) This being accomplished, we will suppose that a quantity of purulent secretion appeared in the basin. We are now sure of one point, *i.e.*, pus was present in this sinus. Our next thought is to learn whether the inflammatory product has been secreted by the maxillary mucosa, or whether the antrum had merely acted in the capacity of a receptacle for pus which had been secreted in one of the overlying sinuses. As it is impossible to determine this offhand, the patient is requested either to wait or return in

an hour or two for further examination. If at the end of that time distinct traces of pus are noted beneath the middle turbinate, we can definitely say that one of the sinuses higher up (frontal or anterior ethmoid) is affected.

We have thus far learned that the maxillary sinus contained pus and that either the frontal or ethmoidal, or both, may be secreting. To further facilitate our diagnosis, it is wise to refract the middle turbinate toward the septum by means of the long Killian speculum. (See Frontal Sinus.) In this way we procure much more room and are better able to judge the conditions existing between the uncinate process and the bulla. An attempt should now be made to introduce a sound into the frontal sinus, and, if this succeeds, to bend a cannula after the curve of the sound and blow air into the cavity, keeping the eye on the highest visible portion of the cannula for the appearance of pus.

If the introduction of the catheter fails, it will be necessary to resect the anterior end of the middle turbinate. (See Frontal Sinus.) The frontal sinus is now washed out, and if pus in an appreciable quantity is expelled we can state with certainty that this cavity is diseased and has secreted the purulent material, for it cannot act as a reservoir for another sinus on account of its high situation. Our findings are now as follows: Frontal sinus diseased; maxillary sinus contained pus, and ethmoid unexplored.

It is now an easy matter to differentiate whether the maxillary sinus is actually diseased or not, for after the drainage passages of the frontal have been cleared by resection of the middle turbinate the secretion finds its way into the nose instead of being directed backward into the ostium of the maxillary sinus, consequently after a few days of treatment to the frontal sinus, on making a needle puncture of the maxillary, it will be found empty. If, however, secretion is continually found in the latter, we can definitely determine the condition confronting us by the following experiment: After thorough lavage of the maxillary as well as the frontal, a pledget of cotton is inserted into the superior portion of the hiatus in such a manner as to exclude all secretion coming down from above. After a period extending from several hours to one day, depending upon the profuseness of the secretion, the nose is again examined. If no pus is to be found beneath the pledget of cotton, it is probable that the maxillary is healthy. Needle puncture will positively determine the correctness of this supposition. If, however, pus is seen below, the maxillary is either

diseased or the secretion has leaked through the cotton. On removal of the plug the secretion from the frontal immediately descends into the nose.

Differentiation between frontal sinus empyema and suppuration of the anterior ethmoidal cells is more or less of a rhinological nicety. When, however, the bulla alone is affected, the secretion appears farther back in the hiatus, because the ostium is situated in the angle where the middle turbinate joins the bulla and not at the lowest portion of the latter. As a matter of fact, it is now generally conceded that when frontal sinus disease exists the anterior ethmoid cells are similarly affected. As the therapy in both instances is practically the same, further consideration of this subject would seem superfluous.

SECOND SERIES.

Recalling the positions of the sphenoidal and posterior ethmoidal ostia, we shall at once see that any secretion from these sinuses must appear in either one of two places: *a.* The olfactory fissure. *b.* In the choana above the posterior end of the middle turbinate. Supposing, then, pus was seen in the olfactory fissure between the middle turbinate and septum, which returned immediately after removal, what would be our first step in ascertaining its source? We know that normally the anterior wall of the sphenoid is hidden from our view by the middle turbinate, and is only visible under certain conditions. (See Anatomy of Sphenoid.) As it is essential that we first learn whether the sphenoid is secreting, an unobstructed view of the ostium is required. For this purpose one makes use of the long Killian speculum, endeavoring to push aside the middle turbinate, thus widening the olfactory fissure. In the majority of instances this will not give us a satisfactory view of the speno-ethmoidal region.

We must now attempt to introduce a sound into the ostium, not only for the purpose of ascertaining its position but to facilitate the subsequent introduction of a cannula. Suppose our attempt has been successful and we have washed out the cavity and brought away a considerable quantity of pus: are we in a position to make an accurate diagnosis? Absolutely, no. We have merely demonstrated that the sphenoid sinus contained pus, but we cannot state with certainty whether the purulent material was

secreted by the mucosa of the sinus or whether it is afterwards infiltrated into the cavity. We are not even certain that the sphenoid contained pus, for, the ostium being invisible, none was seen issuing therefrom, and it is possible that the accumulation was washed from the region of the sphenoidal fissure.

Following the lines already established, *i.e.*, when in doubt to follow the secretion to its source, nothing remains but to remove all structures interfering with this procedure, *viz.*, posterior half of the middle turbinate. This being accomplished, the nasal portion of the sphenoidal wall, with the ostium, is usually visible. We are now in a position to make the following observations. Bearing in mind that it is possible to have the following conditions in this locality: (1) sphenoidal empyema, (2) posterior ethmoid empyema, (3) combined empyema, (4) pyosinus in the sphenoid—how will we proceed to differentiate?

We will assume that pus is seen exuding from the ostium of the sphenoid; a cannula is introduced and the cavity thoroughly cleansed. The patient is allowed to remain near by, either reclining on his back or in a sitting posture with the head bent backward, for twenty to thirty minutes.

In this position the ostium of the sphenoid is at the top of the sinus so that no escape of the secretion can take place.

After this time an examination is made, and if no purulent secretion is found on the anterior sphenoidal wall we can be reasonably sure that the posterior ethmoid cells are not affected. Sometimes, however, this experiment fails, the time being too short to allow the secretion to form. If this proves to be the case, we make use of the following procedure: The sphenoid cavity being cleansed, the ostium is firmly plugged with a pledget of cotton, not hesitating to widen it with a curette if found to be necessary. If, on examination the following day, no secretion is seen outside of the cotton, and, on removing the plug, pus spurts out of the ostium, a positive diagnosis of uncomplicated sphenoidal empyema is apparent. If the purulent material is seen on the outside and, on removal and lavage, no more is obtained from the sphenoid sinus, we can be sure that the posterior ethmoid cells are affected and the pus found earlier in the sphenoid had oozed in from these cells. Suppose, however, pus was present on both sides of the cotton plug: then we are either dealing with a case of combined empyema, or our plug of cotton has leaked. It is

always wise, under these circumstances, to make consecutive pluggings until it is settled beyond all doubt that secretion comes from both cavities.

Pyosinus in the ethmoid as a result of suppuration in the sphenoid is not possible, except to a very limited degree, on account of the anatomical configuration of the parts. A sphenoidal cell situated above the sphenoidal wall may become infected and render more difficult the diagnosis. In such a case the purulent material would appear continually on the sphenoidal wall, yet the sinus itself would be free. This is merely another instance of following the secretion to its source in order to clear up the diagnosis. Hajek (S. 336) reports such a case. In conclusion, it is only necessary to emphasize that the secretion must be followed to its source before a correct diagnosis can be reached. This is often a matter of days and even weeks, and speaks very forcibly against the possibility of making reliable diagnosis by a single, superficial examination.

DIAGNOSIS BY MEANS OF (1) TRANSILLUMINATION, (2) RÖNTGEN RAY, AND (3) SUCTION.

TRANSILLUMINATION. ^{134, 135, 136, 137, 139, 140}

The rationale of this method is to place a small electric lamp in such a position that the rays of light will penetrate the sinus, thus permitting one to obtain an idea of the internal conditions. For this purpose an absolutely dark room is required; where this is not feasible, a dark cloth covering the head of the patient and operator, such as used by photographers, may be substituted.

Maxillary Sinus.—A small electric lamp is placed in the patient's mouth and the current applied until the face is luminous. (Plate 3.) This will also illuminate the maxillary sinuses. If one sinus remains decidedly dark and the other light, we assume that some affection is present in the dark sinus which excludes, to a greater or lesser degree, the light. The dark shadow is, of

134. Heryng: Die Elektr. Durchleuchtung der Highmorshöhleshohle beim Empyema. Berlin klinische Wochenschr., Nos. 35, 36, 1889. 135. Ziem: Durchleuchtung oder Probespülung der Kiefer und Stirnhöhle. Berlin klinische Wochenschr., No. 24, 1891. 136. Vohsen: Zur Elektr. Beleuchtung und Durchleuchtung, etc. Berlin klinische Wochenschr., Nos. 12, 46, 1890. 137. Davidsohn: Die Elektr. Durchleuchtung der Gesichts-Knochen. Berlin klinische Wochenschr., Nos. 27, 28, 1892. 138. Kelly: Suppuration in the Antrum of Highmore. Glasgow Medical Journ., Feb., 1892. 139. Cobb: Transillumination of the Nasal Accessory Sinuses during Acute Coryza. Sec. on Larynx. Trans. A. M. Assn., p. 172, 1902. 140. Caldwell: Transillumination of the Accessory Sinuses of the Nose. New York Med. Journ., Nov. 4, p. 528, 1893.


course, in direct ratio to the density of the affection. In addition to direct transillumination of the anterior sinus wall, light in the pupil,¹³⁷ translucency of the infra-orbital region,¹³⁴ and susceptibility of the patient toward the light of the lamp on the sound side,¹³⁸ have been advanced as particularly diagnostic for empyema of the maxillary sinus. Unfortunately, however, one can place but little reliance on these findings.

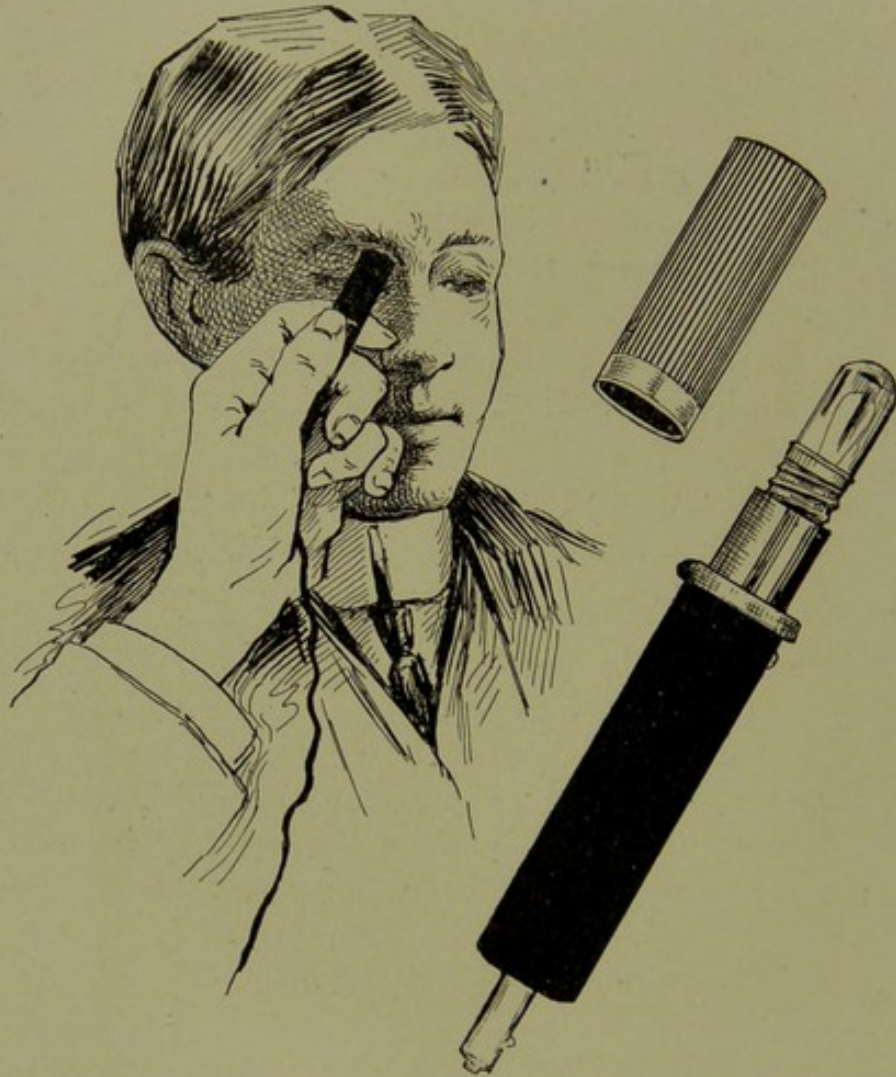


FIG. 32.—Method of holding the lamp against the inferior wall of the frontal sinus for transillumination.

Frontal Sinus.—A metal cover is placed over the lamp so that the rays will only escape at the tip. The end of this is applied firmly against the floor of the frontal sinus at the inner angle of the eye, care being taken to exclude all light from escaping. (Fig. 32.) The best instrument to use is the double lamp, so that comparison can be made without changing. The current is now applied and the two sides compared. If one appears considerably lighter than the other, it is presumed that the side remaining dark is diseased.

PLATE 3.



Transillumination of maxillary sinus. Right side normal. Left side diseased.



Ethmoid Cells.—It has been contended that the anterior ethmoidal cells are subject to transillumination so that reliable conclusions may be deduced.^{141 142} I have never been able to satisfactorily obtain this result although attempted on every possible occasion. It would seem that this has been now more or less generally abandoned.

The early writers considered transillumination a most important and reliable adjunct to our means of diagnosis, which, however, later results have failed to justify. It has now been shown that irregularity in the thickness of the bony walls will lead to all sorts of errors in diagnosis.¹⁴³ Purulent secretion, moreover, is frequently of unlike consistency, some being perfectly opaque, some throwing a well-defined shadow. The value of transillumination from the author's personal stand-point may be briefly stated as follows. It should only be used as an adjunct to the diagnosis; thus, if maxillary sinusitis is suspected, we will say, on the left side, and on transillumination a distinct shadow is cast over this portion of the face, we can assume that the disease is probably present. I would, however, not perform a radical operation on this assumption alone before substantiating the diagnosis by needle puncture.

With the frontal sinus the circumstances are somewhat different. It is impossible to make a needle puncture in this cavity, so that more reliance must, of a necessity, be placed on the transillumination. Even here an external operation is not justified on the results of this test alone, and not until it has been corroborated by all other means of diagnosis at our command should we attempt any radical operative procedure.

THE RÖNTGEN RAY.*

The Röntgen ray has, of later years, become a considerable factor in rhinology, especially in the accessory sinuses. It has gradually developed from merely an agent to ascertain the size and contour of these cavities to one of considerable worth in determining their internal pathological conditions.

141. Robertson: Electric Light in Antral Disease. Journ. of Laryngology, p. 64, 1892.
142. Ruault: Note sur un signe de la suppuration des cellules ethmoidales ant. Arch. de Lary., p. 41, 1893. 143. Onodi transilluminated and applied the X-ray to 1200 frontal sinuses and traced the outlines on the external surface. Many of these were afterward chiselled open. It was most interesting to note the differences in the findings by transillumination and the actual sizes of the cavities. Die Stirnhöhle, S. 22, 1909.

*See the symposium on the use of the Roentgen ray in rhinology. Burger, Gradenigo, Killian, Scheier. Trans. 1st Int. Lary.-Rhin. Cong., p. 229-277, Vienna, 1908.

At the Freiburg clinic (Killian's) patients with suspected sinus disease are routinely subjected to examination by the X-ray and transillumination tests before any intranasal diagnostic procedure is attempted.

The best results thus far obtained have been with the superficial sinuses (frontal, anterior ethmoid, and maxillary). The posterior ethmoid and sphenoid are not always successfully skia-graphed, but there is every reason to believe that these will also be accessible as our technique becomes more and more perfected. It has been supposed that the pus contained in the sinus was responsible for the shadow appearing on the plate. This has been refuted by Chisholm¹⁴⁴ in a number of interesting experiments with gelatine capsules filled with pus, blood, water, etc.

He reaches the conclusion that the swollen mucosa exercises a greater influence in causing the shadows than the character of free secretion in sinus. This has been substantiated by Albrecht,¹⁴⁵ who found no change in the skiagraph after syringing out an antrum which was full of pus. This, however, is subject to qualification, as the same author was able to produce a distinct shadow by injecting purulent secretion into an antrum which previously had shown perfectly clear. It would then seem that, while extensive tissue changes are more amenable to skiagraphy than free secretion, nevertheless, both exercise a given amount of influence on the plates.

Coakley¹⁴⁶ thinks skiagraphy may prove a valuable aid in determining our method of treatment, as in a small sinus we may expect good results from the intranasal method, while in a large sinus with recesses, partial septa, etc., an external operation will probably be indicated.

Frontal Sinus.—In this cavity the X-ray is of inestimable value in determining its height and depth before operating. Not only is the exact size obtained, but also the presence of recesses, partial septa, projections, etc. We can also note if an orbital ethmoid cell lies posteriorly or laterally, thus minimizing the possibility of confusing one of these with the posterior or meningeal wall of the sinus. In this way foci of suppuration may be disclosed and promptly eradicated which otherwise might escape unobserved, to the subsequent detriment of the cure.¹⁴⁷

144. Chisholm: Skiagraphy in the Diagnosis of Frontal Sinusitis. *Annals of Otolaryngology and Rhinology*, p. 979, 1906. 145. Albrecht: Die Bedeutung der Röntgenographie für die Diagnose der Nebenhöhlenerkrankungen. *Arch. f. Lary.*, S. 179, Bd. 20, 1908. 146. Coakley: Skiagraphy as an Aid in the Diagnosis and Treatment of Diseases of the Accessory Sinuses of the Nose. *Ann. Otol., Rhin. and Laryn.*, March, p. 16, 1905. 147. Goldman and Killian: Beitrag zur klinischen Chirurgie, Bd. 54, 1907.

As a means of ascertaining whether disease exists in the frontal sinus, the skiagraph has become almost indispensable. It is absolutely reliable only when the disease is unilateral, as when both sinuses are affected comparison cannot readily be made. Every case is a rule unto itself, therefore a standard of comparison cannot be resorted to. As a rule, unilateral shadows are diagnostics for disease. Coakley¹⁴⁶ and Killian¹⁴⁷ place the greatest reliability in them, and claimed that subsequent operations have always substantiated the presence of disease whenever these shadows were distinctly outlined on the plates. Albrecht,¹⁴⁵ however, reports a case and publishes the skiagraph where the negative shows a distinct shadow over the frontal sinus which, on being opened, was found to be quite healthy. These negative results are the exception, and we must expect them to occasionally appear in the natural course of events.

In ascertaining the exact pathological condition of the sinus, the results have not been so successful. At the commencement of a sinus disease where the mucosa is but slightly engorged the results may be absolutely negative, but where extensive tissue changes have occurred, particularly granulation and polyp formation, the shadows may be so marked that these inflammatory hypertrophies are often outlined in their entirety. It is often difficult, and even impossible, to state with certainty whether the shadow is due to purulent secretion or to hyperplasia of the mucosa. The intranasal findings should guide one in determining this question. It is of importance to remember that not only the anteroposterior, but the sagittal aspect as well, should be taken when the frontal sinus is examined.

Anterior Ethmoid Cells.—It seems to be the general consensus of opinion that the skiagraphical findings, so far as these cells are concerned, are of absolute reliability. Coakley¹⁴⁶ lays especial stress upon this point, and Killian¹⁴⁷ goes so far as to differentiate whether the severity of the disease is greater in the ethmoid or the frontal, from the comparison on the shadows. Albrecht¹⁴⁵ says that, while the results are not to be exclusively trusted with the frontal, nevertheless, with the ethmoid every dependence can be placed upon them. The assertions of these three authorities have invariably been borne out by their operations.

Maxillary Sinus.—The same holds true here as for the frontal sinus; however, it is of much less importance, owing to the other means of diagnosis, which requires less delay or inconvenience

(needle punctures). There are two points, however, which are of the utmost importance: 1. Its ability to discover the precise relation of the roots of the teeth to the floor of the antrum.¹⁴⁸ 2. The presence as well as the size and shape of neoplasms (cysts, sarcoma, etc.). Under the first heading we may be able to discover the cause of the antral suppuration and shape our treatment accordingly, and under the second it is often possible to ascertain, by the configuration and extent of the tumor, whether it is operable, and, if so, how much tissue it will be necessary to remove.

Posterior Ethmoid and Sphenoid.—These cavities for a long time were considered outside the limits of the X-ray, so far as diagnostic purposes were concerned, and it was not until Spiess,¹⁴⁹ and later Pfeiffer,¹⁵⁰ by utilizing a new photographic position, were able to obtain satisfactory negatives of these deep-lying sinuses. By placing the plate under the chin and the light on the vertex they were able to distinguish with considerable certainty the pathological condition of the mucosa of these cavities. Dr. G. E. Pfahler and the author have experimented along these lines with very satisfactory results, as the condition¹⁵¹ of the sinus mucosa both before and after operation was clearly discernible. The position and relations of the sinus are clearly shown in Plates IV and V.

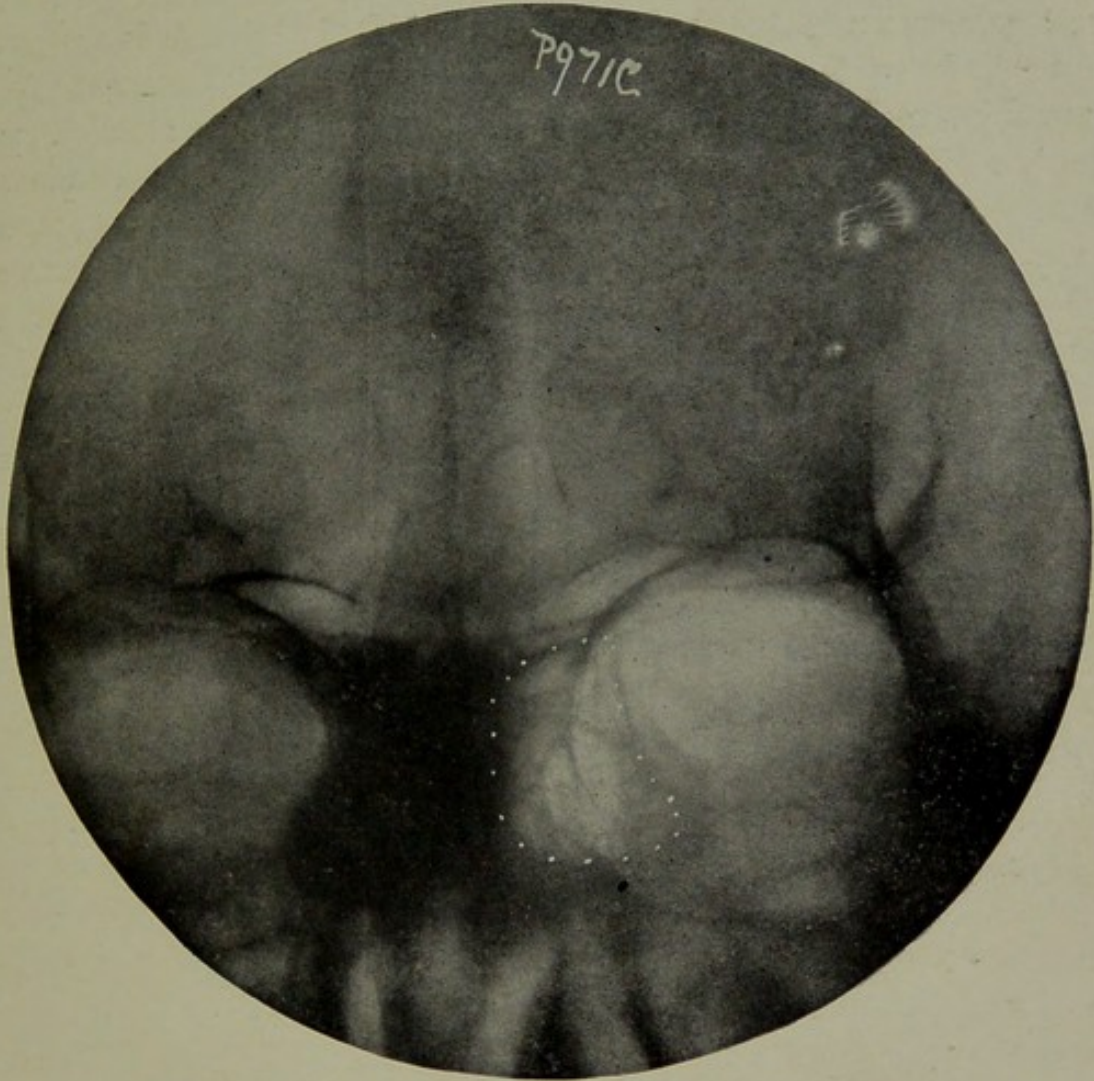
BIER'S HYPEREMIA AS APPLIED TO THE NASAL SINUSES.

This form of treatment has been applied to the nose for diagnostic as well as therapeutic purposes.¹⁵²⁻¹⁵³ In order to diagnose sinus disease the nose is first thoroughly lavaged in order to remove all free secretion. The bulb is then placed in one nostril and, while the patient continuously articulates the letter K, suction is applied. The rationale of this procedure is to form a negative pressure, thus drawing any existing secretion from the ostia of the sinuses.

If a large quantity of free pus is now found in the nose, the diagnosis of sinus disease is made. To corroborate this finding,

148. Mosher: The Use of the X-ray in Sinus Disease. Laryngoscope, p. 114, 1906.
 149. Spiess: Röntgenuntersuchungen der oberen Luftwege in Atlas, etc. München, 1909.
 150. Pfeiffer: Eine neue röntgenographische Darstellung Methode der Keilbeinhöhlen. Arch. f. Laryn., Bd. 23, S. 420, 1910. 151. Skillern and Pfahler: The Roentgen Ray as an Aid to the Diagnosis of Disease of the Sphenoid Sinus. Trans. Am. Lary., Rhin. and Otol. Soc., 1912. 152. Sondermann: Eine neue Methode zur Diagnose und Therapie der Nasenerkrankungen. Münch. med. Wochenschrift, Jan. 3, 1905. 153. Lewis: Negative Pressure as a Therapeutic Agent in Disease of the Nasal Accessory Sinuses. Trans. Am. Acad. Oto-Laryngology, p. 346, 1908.

PLATE 4.



Röntgen ray photograph showing position of sphenoid sinuses. Right sinus filled with bismuth paste shows dark. Left sinus light, extent shown by dotted line.

THE UNIVERSITY OF CHICAGO

PHYSICS DEPARTMENT

PHYSICS 435

LECTURE NOTES

BY

JOHN H. COOPER

1984

1

the suction should be reapplied on the following day, and, if the result is identical, our diagnosis is assured.¹⁵⁴

With posterior ethmoid and sphenoid disease the secretion appears in the choana. While this method seems to be based on sound theoretical grounds, nevertheless, practically, it often leads to disappointment. Not only has this been the experience of the author, but of others^{155, 156} as well. The difficulties appear to be the inability of certain patients to completely close off the choana, and, even when this is successful, the period of time of actual suction seems to be too short to draw much of the secretion out of the sinuses.

TREATMENT.*

The treatment of a given case of sinus disease depends upon a great many conditions. Not only the precise stadium of the disease, but the individual symptoms present are the keynote upon which to base our therapeutic or operative efforts. Take, for example, two cases of acute sinusitis, one pursuing a mild course, the other presenting every evidence of impending cerebral or orbital complications. The first may be treated expectantly, but with the latter prompt and energetic means must be applied. This will also hold good for chronic cases. On the other hand, suppose two individuals suffered from a sinus disease of like intensity. One, being of neurotic temperament, suffered more than the other, who was of phlegmatic disposition. Here, too, different treatments are clearly indicated, therefore the entire question of the treatment of sinus disease resolves itself according to the symptoms presented by that particular case. In order to more clearly define our position, it is necessary to divide sinusitis into acute and chronic.

*Acute.*¹⁵⁷—When a patient presents himself for treatment with the mucous membranes of the nasal tract hyperæmic and engorged, headache, fever, and all the symptoms of an acute inflammation, we must necessarily accept that the mucosa of the sinuses are

154. Sondermann: Weiterer Erfahrungen mit meinem Nasensauger. Arch. f. Lary., S. 425, 155. Uffenorde: Kritische Bemerkungen über die Sondermannsche Saugmethode, etc. Münch. med. Wochenschrift, June 12, 1906. 156. Tilley: Trans. 1st Internat. Laryngo-Rhinological Congress, p. 221, Vienna, 1908. 157. See Symposium on Treatment of Acute Inflammation of the Nasal Accessory Sinuses with Discussion. Hubbard et al. Trans. A. L. A., p. 290, 1905.

* Under this heading we shall not consider sinus disease complicating or accompanying any of the acute exanthemata, but rather a disease, *per se*, which is independent of any constitutional disturbance, and is present either by surviving the causative factor or by spontaneously originating in its present form.

sympathetically affected, for such is, indeed, the case. We must endeavor to ascertain if this affection of the sinuses is causing more symptoms than would naturally be attributed to it. How shall we obtain this knowledge? Mere inspection by anterior rhinoscopy is useless, because the parts are so engorged that little inference can be drawn, though we find quantities of pus in the nasal chambers. We must put the nose in the best possible condition to examine the drainage passages of the sinuses. A hot normal salt solution should be used and the nose thoroughly lavaged, after which a twenty per cent. solution of cocaine with 1/1000 solution of adrenalin applied with a cotton mop until the parts have been shrunk as much as possible. This will often not be very much, on account of the extreme turgescency of the mucosa; however, a certain amount of shrinkage always occurs, and this in itself will frequently occasion the greatest relief to the patient, even though the sinuses are not seriously affected.

Our next step is to ascertain whether the sinuses are secreting pus. In the first stage of acute sinusitis this will not occur, as the mucosa, though hot and turgid, is dry and almost glazed. The secretory stage is the next step in the process of inflammation. We will now accept that the primary inflammatory stage has passed and the residue of inflammation has settled in one or more of the sinuses. We note thick, creamy pus in the middle turbinate passage and perhaps in the olfactory fissure, which immediately reappears on wiping away. What is our first step in the treatment? Shall we confine the patient to bed? Certainly, if it is possible, which in all probability will not be the case. If, however, the headache and general disturbances are severe, this will in itself usually suffice to influence the patient to obey our instructions. We now have two main objects to attain: (a) to keep the patient comfortable, and (b) to allay the inflammation. The first part is carried out by keeping the drainage passages as clear as possible. This may be accomplished in several ways.

First, by applying a strong solution of cocaine and adrenalin at least twice daily, and, after the parts are thoroughly contracted, to douche the nose with a hot saline solution—as hot as can be conveniently borne. This latter has two principal actions: the first to wash away any superfluity of cocaine, thus preventing its being absorbed into the general system, and, secondly, to relieve the engorgement of the sinus mucosa. Between treatments deep inhalations through the nose every two hours of menthol

dr. 1, tr. benz. comp. oz. 4, two tablespoonfuls to half a pint of boiling water, will usually suffice to keep the nose clear. The nares may be lightly plugged with cotton impregnated with menthol. Headache is best controlled by appropriate doses of one of the coal-tar derivatives.

Direct irrigation of the sinus should not be attempted, as it is of very doubtful benefit, and the irritation to the tissues around the ostium caused by the introduction of the catheter far counterbalances any good effect which might accrue from the lavage. The second object is to allay the inflammation. This is accomplished both by local and general treatment. When practicable, the electric-light head bath,¹⁵⁸ consisting of several incandescent lights, which are made to shine directly upon the face of the patient, the eyes being protected, may be used to considerable advantage. The rationale of this method is to produce an active hyperæmia, which acts in the same manner as heat applied to any acute inflammation. Sweating is promoted to enforce the action of the hyperæmia by the administration of 7½–15 grs. aspirin half hour before the electric bath.

GENERAL TREATMENT.

Calomel, one-quarter grain every hour until the bowels move freely. Sweating is of value, provided it is profuse and carried out immediately.

The usual custom of administering hot alcoholic drinks to cause diaphoresis is strongly to be condemned in patients suffering from sinus disease. Alcohol invariably adds fuel to the fire by causing congestion of the cranial circulation. Coffee and tobacco act in a similar manner but in a milder degree.

After the calomel has acted, spts. ammonia arom., gtt. 30 every hour, is given for ten hours, after which the following is prescribed:

Sodii Salicyl.,
 Quinia Bisulph. āā Gr. 30
 Pulv. Doveris Gr. 15
 Misce et Fiat in Capsulem No. 15.
 Sig. One capsule every two or three hours.

This formula is not a new one, and has been used for years with excellent results.

158. Killian: Die Behandlung der entzündlichen Erkrankungen der Nasennebenhöhlen. Deutsch. med. Wochenschrift, p. 721, April 20, 1911.

LOCAL TREATMENT.

Ice-cold compresses over the forehead, eyes, and temples. Hot fomentations, as advocated by some authors, may be substituted if the cold proves disagreeable, but better results are invariably secured, so far as we are concerned, with the former, and they are more acceptable to the patient. In this way it is usually possible to cure the acute attack in from 48 to 72 hours. If, in spite of our treatment, the inflammation progresses and the symptoms become dangerous, it will be necessary to resort to a surgical procedure, the severity of which will depend upon the virulence of the disease.

Acute exacerbations of chronic inflammation are to be treated precisely as though acute, otherwise the indications are somewhat different.

Chronic Inflammation.—The treatment of chronic suppuration, in the absence of urgent symptoms, will depend largely upon the individual. Teachers, selling clerks, governesses and the like, who depend more or less upon their employers, will find it to their disadvantage to be continually treating and blowing the noses, as many people are not only prejudiced but actually fear contagion from them.

In these cases something radical is demanded. On the other hand, individuals who are not dependent upon æsthetic niceties may, in the absence of subjective discomforts, allow a pus-producing sinus to remain neglected for years until the advancement of the disease forces them to seek medical attention. These, however, are only generalities, and, to be precise, we must again make use of a hypothetical case.

Suppose an individual applied for treatment with a mild case of chronic sinusitis, moderate headache, purulent discharge, etc., with occasional acute exacerbations. We are here dealing with a new condition from the acute variety, namely, permanent pathological tissue changes in the sinus mucosa, with occasional obstruction to drainage. Our indications here are to (1) facilitate drainage, and (2) to restore the mucosa to its normal condition. It would be absurd to confine the patient to bed with the same medication as applied to the acute condition unless, of course, an acute exacerbation was present. Our first thought would be to enlarge the drainage passages to their fullest extent by clearing them from all hypertrophies, polypi, etc., and, if necessary, to even resect the septum should a marked deviation occur toward the diseased side. After this has been accomplished, we must direct our attention to the sinus itself by frequent lavages, thus cleans-

ing the mucosa from all detritus. If the symptoms show improvement under this procedure, it should be continued *ad infinitum*. If, however, no improvement is noted, the indications for operation lie with the patient himself. If he considers that he is but slightly inconvenienced with his affliction, and fears no complication, there is nothing more to be said. If, however, he demands to be freed from his complaint, it is our duty to perform the least severe operation that we deem, to the best of our knowledge, will suffice to bring about a cure. If any form of complication threatens, or we note that the disease is beginning to prey on the patient's mind, an operation more or less radical in its effect is absolutely indicated.

VACCINE THERAPY.^{159, 160, 161}

The rationale of this form of treatment is to raise the general resisting power of the body against the particular organism that is causing the local suppuration. This is accomplished as follows: Under the strictest precautions to prevent contamination, a sterile sound is introduced into the diseased sinus and a culture made on blood-smear agar. A definite solution of a pure culture of the dead micro-organism is made and a certain amount of this injected into the patient. The frequency of the injections are guided largely by the symptoms.

The value of this method in sinus disease is questionable for the following reasons: Acute inflammations exhibit a marked tendency toward spontaneous recovery and if proper treatment is instituted a cure will almost certainly result. The majority of chronic cases are associated with mixed infection, therefore, when the culture is plated, how can one decide which particular organism is causing the suppuration? To make a vaccine of the mixed culture is unscientific and will lead to no satisfactory result. It will be seen then that treatment along these lines is largely a matter of conjecture.

The indications for this treatment are not many but still there are cases in which it should be tried. 1. In any case of chronic sinusitis that resists the ordinary treatment and in which a pure culture of the infecting micro-organism is obtained. 2. In old chronic frontal sinusitis which did not improve under intranasal treatment yet was not of sufficient severity to warrant an external operation. 3. In cases of chronic ethmoidal suppuration which did not entirely heal after a more or less complete exenteration. In the latter class I have obtained success after all local means had failed.

COMPLICATIONS.

The great importance attached to complications resulting from accessory sinus disease, as shown by the investigations of recent years, makes it desirable to briefly review the topographical anatomy of these structures. (For minute relations see Anatomy of the Individual Sinuses.)

¹⁵⁹. Levy: Vaccine Therapy in Rhinology and Oto-Laryngology. *Ann. Otol., Rhin. and Lary.*, March, p. 187, 1909. ¹⁶⁰. Birkett and Meakins: The Value of Vaccine Treatment of Chronic Inflammatory Disease of the Accessory Sinuses of the Nose. *Laryngoscope*, p. 851, 1910. ¹⁶¹. Brawley: Auto-vaccines in Nasal Accessory Sinus Infection. *Laryngoscope*, p. 877, 1910.

This consists in: 1. The relation of the sinuses to the orbital cavity. 2. Their relation to the optic nerve. 3. Their relation to the brain and adnexa.

1. RELATION TO THE ORBITAL CAVITY.—The frontal sinus adjoins at the junction of the superior and internal orbital walls. (Figs. 18, 19.) The ethmoid cells form a large portion of the internal lateral wall (Fig. 15), and the maxillary sinus is in direct relation with the inferior wall (Fig. 19), the roof of the sinus forming the floor of the orbital fossa. One can easily presuppose how read-

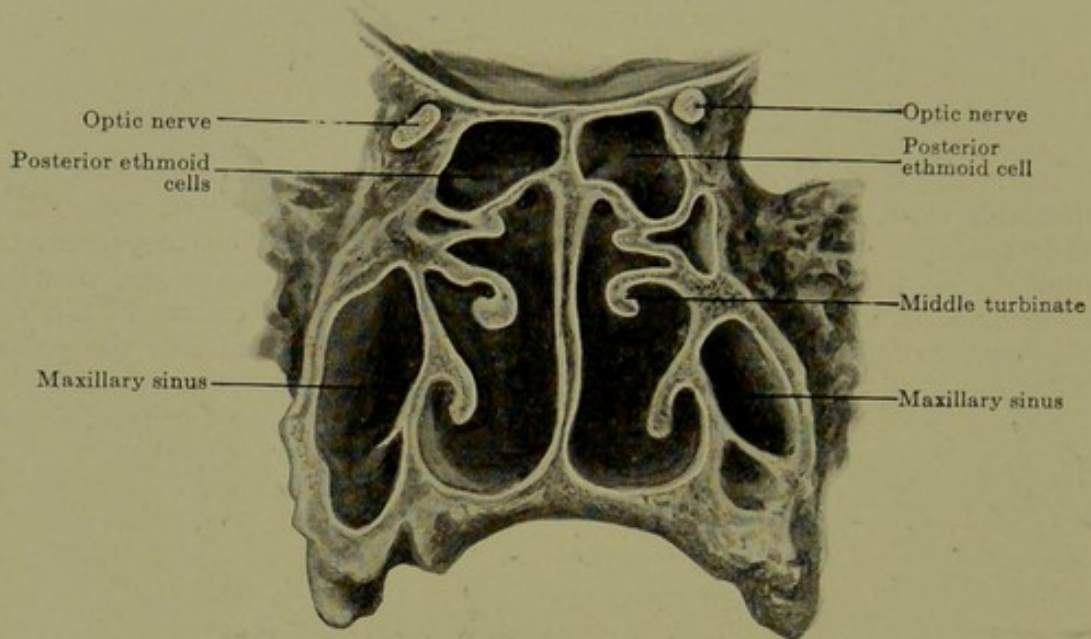


FIG. 33.—Relation of the optic nerves to the posterior ethmoid cells. (After Onodi.)

ily purulent material from the sinuses transgressing these boundaries would penetrate into the various areas of the orbit.

2. RELATION TO THE OPTIC NERVE.—It will be noted that the optic nerve is in close relation to the sphenoid sinus and posterior ethmoidal cells, only a thin layer of bone often separating the two structures. (Fig. 33.)

Unfortunately no constant relation exists between these structures. Sometimes the optic nerve lies in close proximity to the sphenoid and one or two cells of the posterior ethmoid labyrinth and in other specimens several mm. of dense bone separate them. Onodi¹⁶² and Loeb¹⁶³ have made extensive researches in this connection. When the frontal sinus extends backwards into the lesser wing of the sphenoid empyema of this sinus can also affect the optic nerve.

162. Onodi: The Optic Nerve and the Accessory Cavities of the Nose. *Ann. Otol., Rhin. and Lary.*, March, 1908. 163. H. W. Loeb: A Study of the Anatomic Relations of the Optic Nerve to the Accessory Cavities of the Nose. *Ann. Otol., Rhin. and Lary.*, June, 1909.

3. **RELATION TO THE BRAIN.**—The posterior wall of the frontal sinus covers a considerable portion of the anterior lobe of the brain. The ethmoid cells lie directly beneath the olfactory bulbs and the anterior hemispheres, while the sphenoid sinus borders on the optic chiasm, pituitary body, internal carotid and cavernous sinus. (Fig. 34.)

4. **Vessels and Nerves.**—The ethmoid veins and arteries course intracranially for a short distance. A direct communication also exists between the veins and lymphatics of the nasal mucosa and dura. It has also been shown that a considerable portion of the

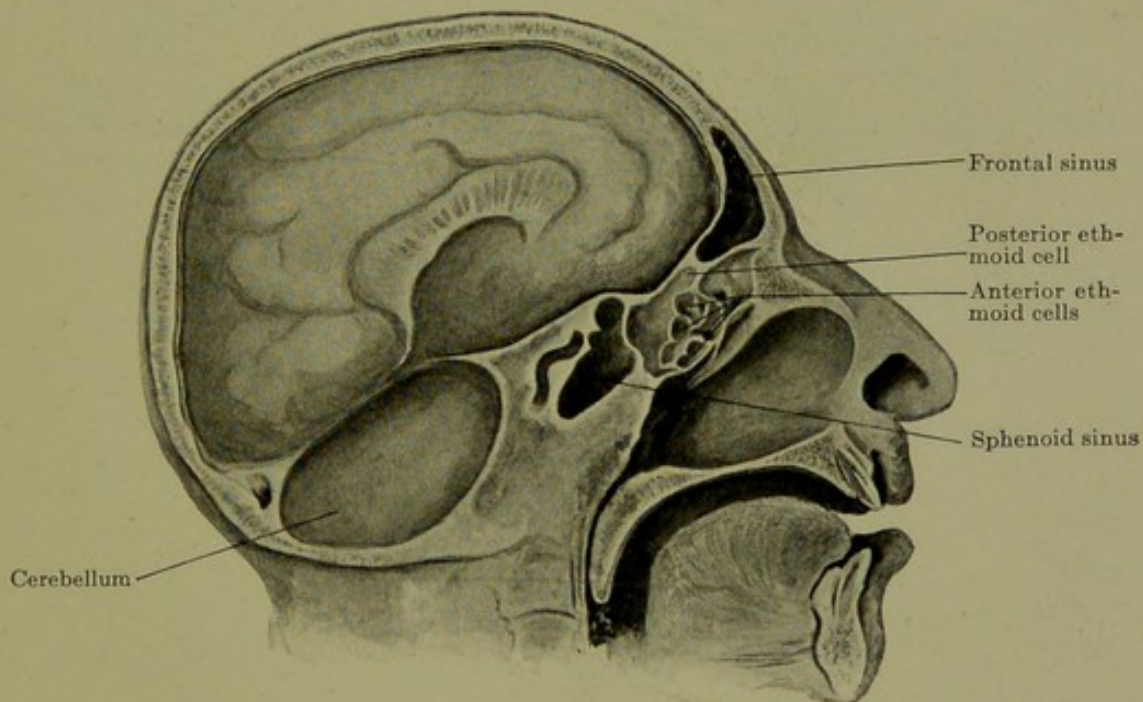


FIG. 34.—Relations of frontal, sphenoidal and ethmoidal sinuses to the brain.

venous blood from the anterior sinuses finds its way into the ophthalmic vein through the supra-orbital, frontal and ethmoid veins. (Fig. 35.)

CAUSES OF COMPLICATIONS.

These may be divided into: (1) anatomical; (2) pathological.

1. *Anatomical.*—*a.* The intimate connection between sinuses and neighboring organs (eye and brain) through the medium of the emissary veins.

Veins of the frontal sinus anastomose with the longitudinal sinus.

Veins of the ethmoid empty into the superior, sometimes inferior ophthalmic veins.

Veins from the ethmoid anastomose with veins of the dura.

Veins of the sphenoid anastomose with the cavernous sinus.* Killian¹⁶⁴ demonstrated connection between the vessels of the sphenoid sinus and the sheath of the optic nerve by means of injections of silver.

b. By the presence of defects in the bony walls separating these structures.

Maxillary: Defects occur in the superior or orbital wall, but rarely cause complications.

Frontal: Dehiscence is not infrequently noted in the orbital process. When this occurs the mucosa of the sinus is in actual contact with the dura; when the defect is in the orbital plate the

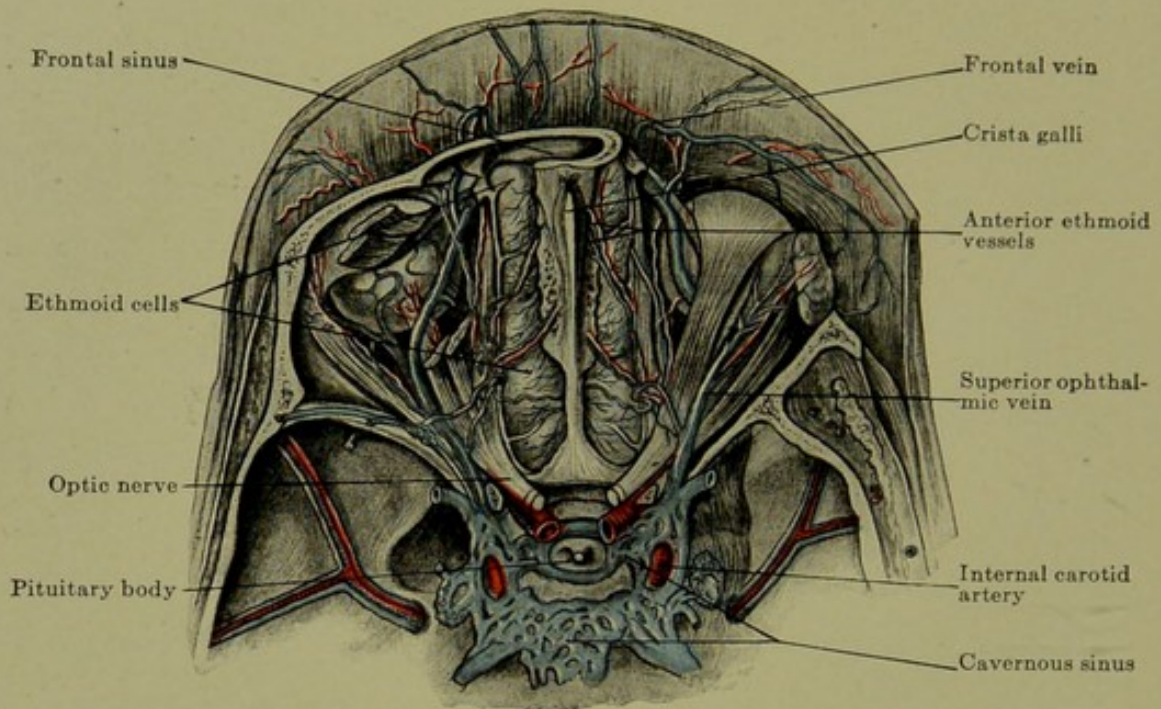


FIG. 35.—The veins of the orbital, ethmoidal and sphenoidal regions from above downward (after Toldt).

periorbital tissues impinge directly on the sinus mucous membrane. The posterior wall may also be defective.

Ethmoid: Defective formation is most frequently noted in the lamina papyracea, thereby favoring the formation of orbital abscess.

Sphenoid: Defects always occur in the superior or lateral walls and seem to appear more frequently than defects in any of the other sinuses, as shown by the numerous cases reported. (See Sphenoid Sinus.)

* The minute anatomy of the circulatory system of this region is well presented by Holmes, *Diseases of the Nasal Accessory Sinuses and their Relation to Pathological Changes of the Eye and Orbit*. Trans. Am. Lary., Rhin. and Otol. Soc., p. 227, 1908.

164. Killian: *Die Thrombophlebitis des oberen Längsblutleiters nach Entzündung der Stirnhöhhlenschleimhaut*. Zeitschr. f. Ohrenhk., No. 37, S. 343, 1900.

2. *Pathological*.—*a*. Stagnation of secretion in the sinuses through obstruction to free drainage.^{165, 166, 167}

Hajek¹⁶⁸ lays considerable stress upon this causative factor and says the obstruction to the free outflow need only be relative to cause threatening symptoms, especially if it is of long duration.

b. Infection by an especially virulent micro-organism (strep-tococcus pyogenes). While certain micro-organisms would appear to play an important rôle in the ætiology of complications following sinus disease, it must not be overlooked that other pre-disposing factors favorable to the growth and increasing virulence of the infecting germ are usually present; therefore, the complication often results from a combination of circumstances rather than any one given condition, for this reason: complications occur much more frequently in chronic than in acute inflammations.

MANNER OF OCCURRENCE.

1. *By Continuity—Dehiscence*.—Gerber¹⁶⁹ says the purulent inflammation of the mucous membrane, under favorable circumstances, is able to cause breaking down and ulceration of bone.

2. *By Contiguity*.—*a*. Direct extension. *b*. Phlebitis. *c*. Lymph-channels. *d*. Metastases. *e*. Nerves.

3. *Mechanical (pressure)*.—Mucocele, pyocele, and hyper-plasias.

1. *By Continuity—Dehiscence*.—When an actual defect in the bone is present the sinus mucosa lies in direct apposition to the covering of the adjoining organ (eye and brain), thus presenting the best possible medium for the transmission of the infection.

2. *By Contiguity*.—*a*. Direct extension of the inflammation occurs in the following manner: The mucosa of the sinus breaks down under the purulent process with the formation of a sub-periosteal abscess and osseous necrosis. The necrotic bone allowing the passage of the pyogenic bacteria causes an extradural abscess on the cerebral side which results either in meningitis, cerebral abscess, or sinus thrombosis.

Extension by contiguity may also occur with no apparent inflammatory bone changes in the osseous walls separating the two

165. Bryan: Chronic Empyema of the Frontal, Ethmoidal, and Sphenoidal Regions. Am. Journ. of Med. Sciences, p. 416, vol. 124, 1902. 166. Sicard: Complications endocraniennes des Sinusitis Frontales. These de Toulouse, 1905. 167. Martin: Ueber die Bedeutung des Verschlusses der Ostien bei entzündlichen Erkrankungen der Kieferhöhle. Mon. f. Ohrenhk., S. 62, 1905. 168. Hajek (6), S. 396. 169. Gerber (78), S. 158.

cavities, except some slight discoloration. The microscopic investigations of Ortmann,¹⁷⁰ Hinsberg,¹⁷¹ and Hajek¹⁷² show, however, that the bone in these instances was not only hemorrhagic, but infiltrated with numerous diplococci from the infected sinus. As these cases all ended fatally, the investigators were able to demonstrate the actual connection between the diseased sinus and the cerebral affection.

b. Phlebitis: Infection spreading through the veins is not an uncommon mode of transmission of a sinus inflammation. The infection of the larger blood-vessels (longitudinal, transverse, sigmoid, cavernous, and petrosal sinuses) is brought about indirectly through a phlebitis of the veins of the diseased sinus mucosa. These veins perforate the bony sinus walls and empty into a tributary vein which goes to form one of the great cerebral venous sinuses. During their course from the sinus they are in intimate connection with the veins of the dura, and consequently are in a position to transmit infection to them, which would then spread to the meningeal structures. The sphenoid sinus is most commonly the source of thrombophlebitis complications. This, of course, is due to its proximity and intimate connection with the cavernous sinus. The ethmoid cells would seem to follow the sphenoid in point of frequency of transmission of infection through venous channels. This is brought by the anterior and posterior ethmoidal veins. The frontal sinus does not furnish so many cases, which is perhaps due to its being situated at some distance from the longitudinal sinus. The maxillary sinus alone does not seem to have been responsible for any case of septic thrombophlebitis following inflammation of its mucous membrane.

c. Lymph-channels: Regarding infection through these channels, Gerber¹⁷³ says: "In those cases in which neither a direct continuation through the bone nor an infection through the blood-vessels can be proved, we must consider that the infection has been propagated through the lymph-channels."

The most convincing proof of this assertion seems to have been presented by Andre¹⁷⁴ when he demonstrated, by means of injections of Prussian blue, the connection between the lymphatics of the nose and those of the perimeninges.

170. Ortmann: Der Diplokokkus pneumoniae bei eitriger Meningitis. Virchow's Archiv, Bd. 120, S. 117, 1890. 171. Hinsberg: Ueber den Infec. Mechanismus. Verh. d. deutsch. Otol. Gesel., S. 191, 1901. 172. Hajek: Ein Beitrag zum Studium des Infections Weges bei der rhinogenen Gehirn Komplikation. Arch. f. Lary., Bd. 18, S. 290, 1906. 173. Gerber: Die Complicationen der Stirnhöhlen. S. 187, 1909. 174. Andre: Contribution a l'etude des Lymphatiques du Nez et des Fosses Nasales, p. 48, 1905, Paris.

d. Metastases: Kuhnt¹⁷⁵ first called attention to the connection between the veins in the sinus mucosa and those of the dura. According to this author, these veins may carry the infectious material from the sinuses to the brain with the formation of a metastatic abscess without the bone showing either macroscopic or microscopic inflammatory changes.

e. Along the nerves: Kay and Retzius¹⁷⁶ deduced from their experiments the possibility of infection travelling through the perineural sheaths of the olfactory filaments, thus causing cerebral complications. Most,¹⁷⁷ on the other hand, failed to demonstrate satisfactorily the connection between the lymph-vessels of the nose and brain.

3. *Mechanical Pressure.*—This form of complication is limited to the eye and results from diseases in the ethmoid cells and occasionally the frontal sinus. It may persist for years without causing permanent damage to the eye.¹⁷⁸ Mucocele, pyocele, hyperplastic ethmoiditis, and empyema with dilatation can contribute toward the causation of this complication.

Both Black¹⁷⁹ and Stucky¹⁸⁰ consider that closed-in empyema is capable of giving rise to the most severe eye symptoms. In these cases the severity depends upon the combination of inflammation with the mechanical pressure.

PATHOLOGICAL CONDITIONS.

Abscess and Fistula Formations Appearing on the Face.—Formerly these conditions were not infrequently met with. Now, on account of the widened scope of our knowledge of the usual course of accessory sinus suppurations, these conditions are practically always anticipated with appropriate measures for their prompt suppression. The most common of these, abscess and fistula formation, are those making their appearance above the internal angle of the eye, and are due to fronto-ethmoidal suppuration. Infra-orbital abscess has not infrequently been reported

175. Kuhnt (98), S. 559. 176. Kay and Retzius: Studien in der Anatomie des Nervensystems. S. 217, Stockholm, 1875. 177. Most: Topograph d. Lymphgefäss. d. Kopfes. S. 91, 1906, Berlin. 178. Risley: Displacements of the Eyeball by Disease of the Frontal and Ethmoidal Sinuses. Internat. Med. Magazine, vol. 9, p. 732, 1900. 179. Black: Frontal Sinusitis as an Ætiological Factor in Acute Retrobulbar Neuritis. New York Med. Journ., June 2, p. 1126, 1906. 180. Stucky: The Relation of the Pathological Condition of the Nose and Accessory Sinuses to the Visual Apparatus. Laryngoscope, p. 49, 1907.

due to maxillary empyema.^{181, 182} Orbital abscess resulting from sinus disease is usually the result of ethmoidal suppuration.

ORBITAL COMPLICATIONS.¹⁸⁴⁻¹⁸⁶—1. Disturbances in the circulation. 2. Intoxication. 3. Purulent inflammation. 4. Pressure symptoms.

1. Disturbances in the circulation consist in: *a.* Hyperæmia. *b.* Thrombosis of the vena centralis retinis (blindness). *c.* Thrombosis of the cavernous sinus.

2. Intoxication: This form affects the optic nerve and is particularly associated with sphenoidal empyema, in which there always exists more or less obstruction.

3. Purulent inflammation: The extension of abscess formation without the mediary of micro-organismal activity is accomplished in the following manner: The continual apposition of the purulent secretion results in maceration of the epithelium, which gradually pervades the entire mucosa until it becomes, in certain areas, loose on the underlying bone. The purulent material, thus coming in direct contact with the bone, slowly infiltrates through the canaliculæ and Haversian canals (possibly with the aid of the blood- and lymph-vessels) and eventually reaches the periosteum of the opposite side. From here on but little resistance is opposed to the spread of the infection.

The course of the infection from the sinuses is sometimes effectually barred from entering the eye by the orbital periosteum in the following manner: The periosteum becomes thickened from repeated irritation, thus preventing further entry of the infection. The purulent material finding its passage barred forms a periosteal abscess and is evacuated at the corner of the eye.¹⁸³

It will be noted that Kuhnt mentions particularly "repeated inflammation." This can only result from long and continued irritation. Therefore, should a severe attack primarily occur it is more than probable that the inflammation would penetrate the orbital periosteum with the formation of an orbital phlegmon.

Kuhnt divides the orbital complications into the following category:

1. Inflammatory: *a.* Affections of the conjunctiva and cornea. *b.* Affections of the uveal tract. *c.* Affections of the retina and optic nerve.

181. Harlan: Exophthalmos due to Disease of the Maxillary Antrum. Ophthal. Record, p. 92, 1898. 182. Ogchu: Orbitalphlegmon following Empyema of the Maxillary Sinus. Annals. of Ophthal., p. 713, 1903. 183. Kuhnt (98), S. 109. See especially—184. Kuhnt: Beziehungen zwischen Nasen und Augenleiden. Verh. 1st Internat. Laryng. Kongress, Wien, S. 109, 1908. 185. Germann: Mitteilung au der St. Petersburg. Augeneheilanstalt. Heft 5, 1899. 186. Eversbusch: Graefe-Saemisch Handbuch, II Teil, IX Band, Kap. 16, 1903.

2. Functional: *a.* Muscular asthenopia. *b.* Loss of accommodation.

3. Mechanical: *a.* Disturbance of the bulbar mobility. *b.* Irritation of the optic nerve through pressure.

Disturbances of vision practically always result from posterior ethmoid and sphenoid disease. Only in rare and isolated cases does this occur from disease of the frontal or maxillary sinuses.

Cerebral Complications: 1. Various forms of meningitis. 2. Extradural, intradural, and cerebral abscess. 3. Thrombophlebitis of the venous sinuses.

Orbital and cerebral complications are often more or less dependent upon one another, being frequently present in the same case; thus, an orbital abscess can cause meningitis either by direct transmission of the inflammation through the optic foramen or by thrombosis of the ophthalmic vein. On the other hand, a low-grade form of meningitis from the sphenoid sinus can cause primary phlebitis of the cavernous sinus, which in turn causes secondary thrombosis of the orbital veins.

SYMPTOMS.—*Orbital:* ¹⁸⁷⁻¹⁹⁰ 1. Those caused by inflammation. 2. Those caused by pressure. 3. Those caused by toxins.

1. *Those Caused by Inflammation.*—The first intimation that the orbital contents have become infected through the sinus disease is often a slight, persistent œdema of the upper lid which is unaccompanied with any of the usual signs of inflammation (hyperæmia, pain, etc.). If the sinus affection is recognized and properly treated at this stage, resolution is practically always effected, as this inflammation is confined to the periosteum. Should, on the other hand, the infection continue, an orbital abscess will result, the severity of the symptoms depending upon the degree and virulency of the infection.

If the periosteum offers sufficient resistance the pus will burrow beneath it, forming a fistulous tract either forward, extending to the inner angle of the eye, or backward as far as the optic nerve.¹⁹¹

187. Ziem: Beziehungen zwischen Augen und Nasenerkrankungen. Mon. f. Ohrenhk., S. 231, 261, 1893. 188. Posey: The Ocular Symptoms of Affections of the Accessory Sinuses of the Nose. Journ. Am. Med. Assn., Sept. 9, 1905. 189. Fish: On the Frequency of Blindness Due to an Affection of the Accessory Sinuses. Am. Journ. of Surgery, Sept., p. 257, 1906. 190. Cohen and Reinking: Beiträge zur Klinik der orbitalen Komplikationen bei Erkrankungen der Nebenhöhlen der Nase. Beiträge zur Augenheilkunde, 78 Heft., 1911. 191. Hoffman: Die Beziehungen der Entzündlichen Orbital Erkrankungen zu den Erkrankungen der Nebenhöhlen der Nase. Verh. d. Vereins. deutsch. Lary. Gesell., S. 91, 1907.

Sometimes the abscess formation, particularly in chronic cases, is very gradual. Under these circumstances the subjective symptoms may be trivial, perhaps at first only a diplopia being present.¹⁹² In making the diagnosis of orbital abscess resulting from sinus affection one must not only be convinced that sinus disease exists, but must consider carefully the seat of the purulent accumulation. With frontal sinus empyema one would expect to find the abscess in the anterior portion of the orbit; with posterior ethmoid or sphenoid suppuration the abscess would be situated posteriorly. The direction of the dislocation of the bulb will often be of service in differentiating these conditions.

2. *Those Caused by Pressure (Mechanical).*¹⁹³—Closed empyema (pyocele) and mucocele, by reason of their slow and gradual growth, will frequently dislocate the bulb without causing inflammatory symptoms. The direction of this dislocation is downward and outward from the frontal sinus; if the accumulation is in the ethmoid, the direction is forward, downward, and outward. When the pressure attacks the optic nerve, disturbances in sight occur, such as decrease in the extent of the field of vision, amblyopia, and even optic nerve atrophy.¹⁹⁴

I have often been impressed with the constant occurrence of one symptom in patients suffering from optic atrophy associated with sinus disease. This is the intermittent paroxysms of excruciating headache. The type of this pain seems to be different from that ordinarily met with in sinus affections in that it is deep-seated and often comes on during the night. As the atrophy progresses and the patient becomes blind the headache undergoes great amelioration.

Changes in the cornea¹⁹⁵ and uveal tract,¹⁹⁶⁻¹⁹⁸ as well as the choroid,¹⁹⁹ retina,²⁰¹ and iris,²⁰⁰ have been reported by the ophthalmologists.

Retrobular neuritis,²⁰² which may result in atrophy and loss of vision,²⁰³ also occurs as a complication of accessory sinus dis-

192. Brown: Empyema of Maxillary Sinus, etc. New York Med. Record, April 1, 1893. 193. Birsch Hirschfeld: Exophthalmus bei Ektasie der Nebenhöhlen der Orbita. Graefe Saemisch, 2nd Teil, 9th Band, 13th Kap., 1907. 194. Chiari u. Marschik: Zusammenhang der Erkrankungen der Orbita und der Nebenhöhlen der Nase. Medizin. klinik, No. 16, 1908. 195. Gradle: On Intra-ocular Disease Brought on by Disease of the Nasal Sinuses. Ophthalmology, vol. 5, p. 400, April, 1909. 196. Ziem (187). 197. Posey: Some Ophthalmological Phases of Diseases of the Accessory Sinuses of the Nose. Journ. of Eye, Ear, Nose and Throat Dis., March and April, 1905. 198. Fish (189). 199. Broeckaert: Opacities des corps vitre, etc. Revue hebdomadaire de larynx, Jan. 5, 1901. 200. Mason: Iritis Due to Diseases of the Sinuses. Iowa Med. Journ., Dec. 15, 1907. 201. Rosenberg u. Baum: Erkrank. der Nasennebenhöhlen u. d. Auges. Zeitschr. f. Lary., Bd. 1, S. 441, 1909. 202. Fish: A Study of 36 Successive Cases of Optic Neuritis. Nasal Accessory Disease Present 26 Times. Journ. Lary., Rhin. and Otol., vol. 22, p. 442, 1907. 203. Piffil: Ueber retrobulbare Neuritis infolge von Nebenhöhlenerkrankungen. Zeit. f. Ohrenhk., Bd. 63, S. 231, 1911.

ease. One of the most notable early signs of posterior sinus disease is an enlargement of the blind spot.²⁰⁴ The presence of this symptom is almost pathognomonic of posterior ethmoid or sphenoid empyema.

3. *Those Caused by Toxins.*—Muscular Anæsthopia and Loss of Accommodation: The optic nerve seems to be particularly susceptible to the action of toxins, and limitation of the visual field is often the first symptom of a sinusitis. That this action was toxic is proved by the rapid return to normal of the visual disturbances after a radical operation. Dull pain and eye-ache is a frequent symptom of early involvement, and can be due to any of these causes.²⁰⁵

Cerebral: The symptoms of these complications differ in no way from those of similar pathological changes due to other causes. They are the usual symptomatology of cerebral affections, depending upon the particular lesion, as intense headache, fever, slowing of the pulse, dizziness, vomiting, delirium, and convulsions. Psychical manifestations are present in the milder cases and during the periods of remission of consciousness.

When either a cerebral or an orbital complication is about to take place in an individual suffering from sinus disease, a change occurs in the general condition.* This change is usually ushered in with a fever and its attending phenomena. The height of the fever is in direct ratio to the violence of the complication. The local sinus inflammation seems to be particularly accentuated, headache and neuralgic pain being conspicuous. After a period lasting from several hours to days, the complication will manifest itself in the adjoining organ suddenly or slowly, as the case may be.

A peculiar forerunner of an impending cerebral complication is that condition which C. Jackson²⁰⁶ calls meningismus. I have in a number of instances been able to demonstrate this to my entire satisfaction. In several cases the cerebral complication was aborted by a timely operation; in others it followed despite my most earnest endeavors to the contrary.

Empyema of the Accessory Sinuses in Children.—Children seem to be particularly susceptible to colds, especially that form

204. Van der Hoeve: Vergrößerung des blinden Fleckes ein Frühsymptom für die Erkennung der Sehnervenerkrankung bei Erkrankung der hinteren Nebenhöhlen der Nase. Arch. f. Augenheilk., vol. 67, S. 101, 1910. 205. Hastings: Ocular Symptoms of Nasal Origin. Report of a Case of Retrobulbar Neuritis and Other Illustrative Cases. Ann. Otol., Rhin. and Laryn., Sept., p. 420, 1906. 206. Chev. Jackson: Meningism as Distinguished from Meningitis. Journ. Am. Med. Assn., March 3d, p. 1265, 1907.

* The non-inflammatory conditions are not here considered.

known as rhinitis; why, then, do not their sinuses more often become affected? * The answer to this question will be apparent if one recalls that the sinuses, with the exception of the ethmoid, are hardly more than indentations in the cancellous bone during the early years of childhood.

Cases of maxillary sinus empyema in children ranging from three weeks of age upward have from time to time been reported.^{207 208 209 210} In many of these the disease manifested itself through abscess and fistula formation in the infra-orbital region. A number of investigators have^{210 211 212} called attention to the simulation of acute idiopathic osteo-myelitis to empyema in children and warn against the confusion of these separate and distinct affections. Avellis²¹³ denies that this condition is a true maxillary empyema, but rather a tubercular disease of the superior maxillary bone. I rather agree with this author in that some local bone infection (not necessarily tubercular) was responsible for the abscess formation; however, some previous illness may have contributed to this local infection, for it is a well established fact that the exanthemata³⁹ in children particularly predispose to osseous necrosis and fistula formation. In several of the above-cited cases, a previous history of scarlet fever was obtained. Coffin²⁰⁸ reports three cases of suppurative ethmoiditis in children nine and ten years of age.

* Panzer, in a material of 15,000 subjects in the Vienna Hospital, found only seven cases. Buffalo Med. Journ., Vol. 44, p. 444, 1905.

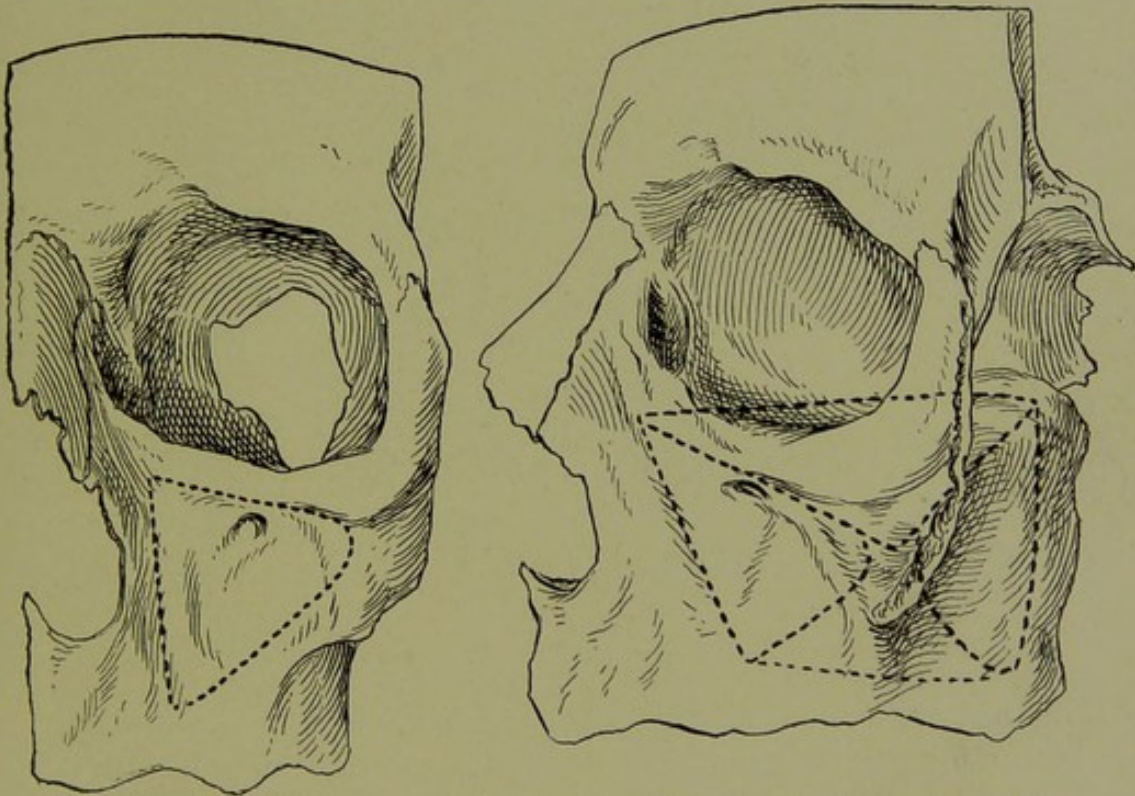
207. Canestro: Entzündung der Highmoreshöhle bei Neugeborenen. Arch. f. Lary., Bd. 25, S. 492, 1911. 208. Coffin (6 months) Sinusitis in Children. Laryngoscope, p. 884, 1904. 209. Mayer (30 months) Empyema of the Antrum of Highmore in Young Infants. Trans. Am. Lary. Assn., p. 54, 1901. 210. Schmiegelow: Ueber akute Osteomyelitis des Oberkiefers. Arch. f. Lary., Bd. 5, S. 115, 1896. 211. Rudaux: Empyeme du sinus maxillaire chez un enfant de trois semaines. Ann. d. Mal. du Larynx, Tome xxi, vol. 2, p. 229, 1895. 212. Lichtwitz: Akute Osteomyelitis des Oberkiefers ein sogenanntes klassisches Empyem der Highmorshöhle simulierend. Arch. f. Lary., Bd. 7, S. 439, 1898. 213. Avellis: Ueber die bei kleinen Kindern ein Kieferhöhlenempyem vortäuschende Tuberculose des Oberkiefers. Munch. med. Woch., No. 45, p. 1433, 1898.

PART II.

MAXILLARY SINUS.

ANATOMY.

The maxillary sinus may be likened unto a pyramid, with the lateral wall of the nose forming the base, the apex being at the junction of the molar with the superior maxillary. (Figs. 36, 37.) This would give us three sides, *i.e.*, a superior, an anterior, and a posterior, and a base. These sides or walls constitute the limitations of the sinus proper, so that the boundaries of the maxillary sinus would be: above, by the orbital plate of the superior max-



FIGS. 36 and 37.—Showing extent and shape of maxillary sinus in the superior maxillary.

illary; anteriorly, by the canine fossa, and, posteriorly, by the pterygomaxillary fossa. The base, as has already been stated, is formed by those constituents which enter into the formation of the lateral nasal wall, *viz.*, maxillary process of inferior turbinate, portion of palate bone, uncinatè process, lamella of ethmoidal bulla, and the pars membranacea. (Fig. 38.)

The alveolar process cannot be considered a wall, as it only forms the inferior border of the fossa which is formed by the junction of the anterior wall and base (lateral nasal wall).

The size and capacity of the sinus depend, as in other accessory sinuses, largely on the amount of bone reabsorption which has occurred, although the sex and age of the individual of course exercise no little influence; thus one would naturally find larger sinuses in the male than in the female, or in the aged rather than in the young.

The dimensions of an average maxillary sinus would be: Height 3.5 cm. (about 1½ inches), breadth 2.5 cm. (1 inch), and depth 3.2 cm. (1¼ inches). These relations are seldom constant. The normal capacity may be put at about 10.12 c.c. in woman and 16.18 in man.

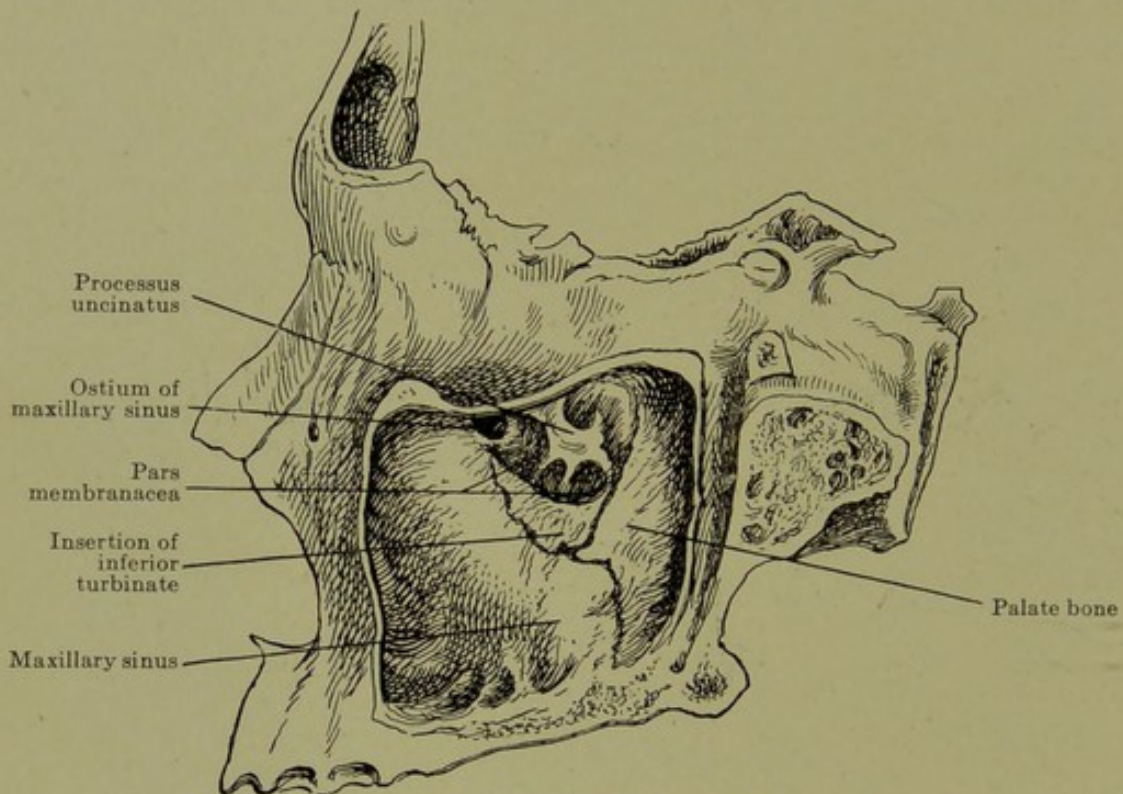


FIG. 38.—Various structures entering into the base of the maxillary sinus.

The shape, relation, and position of the sinus depend more particularly upon the peculiar construction of the individual than upon reabsorption. This phase of the subject will, however, be deferred until the anomalies of the maxillary sinus are considered.

RELATIVE IMPORTANCE OF THE WALLS.

The most important wall, from the point of view of the rhinologist, is the nasal, and for two reasons: 1. Because it contains the sole opening into the sinus and is the first to show pathological changes when the sinus is affected. 2. It is the thinnest and presents the easiest mode of attacking the cavity, either for diagnostic or therapeutic (conservative or radical) purposes.

The anterior or wall of the canine fossa is next in importance, as radical operative procedures are usually made through this structure. It can range from the thinness of ordinary writing paper to several millimeters in thickness, depending upon the age and the construction of the facial bones. Reabsorption can become so extensive in the aged that a portion of this wall may entirely lose its osseous tissue and be formed by the periosteum and mucous membrane of sinus, as a specimen of the author's has demonstrated. The thinnest portion of this wall is directly in the centre of the canine fossa, and is the point of election for opening with the chisel in the external radical operation.

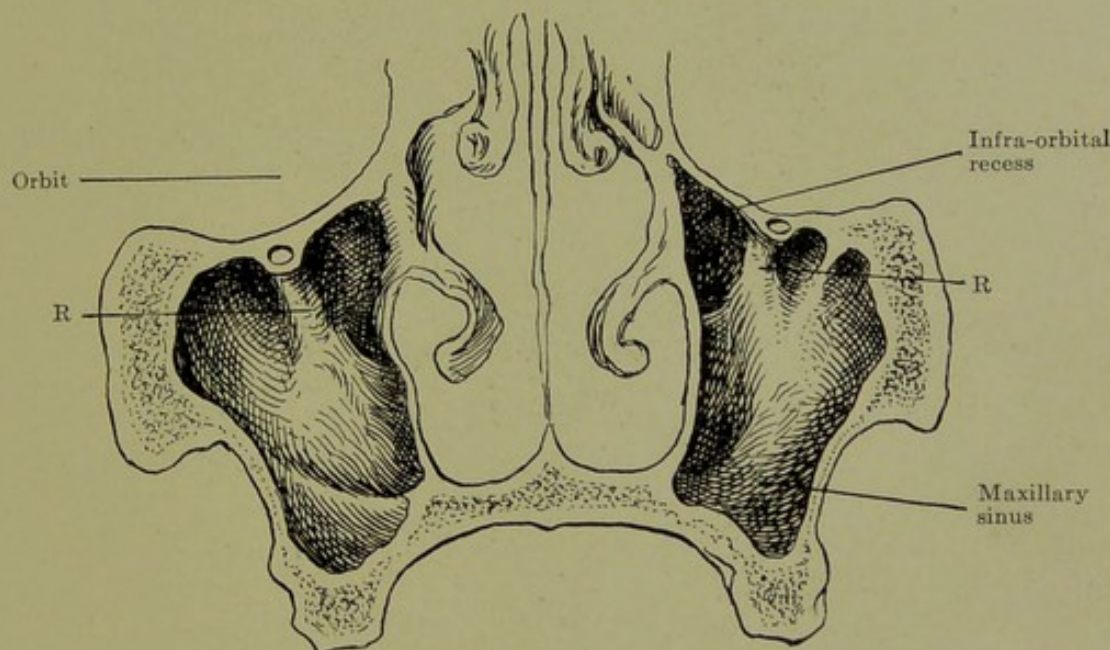


FIG. 39.—Section through anterior portion of the antrum looking forward. R. Ridge for transmission of infra-orbital vessels and nerve.

The infra-orbital foramen lies in this wall close to its upper margin directly over the canine fossa. This fact must always be borne in mind when performing extensive resections, as in the external radical operation.

The posterior or sphenomaxillary wall is usually of even and constant thickness, and presents little of importance to the rhinologist. The superior or orbital plate is of interest on account of the dehiscences which it frequently presents,²¹⁴⁻²¹⁵ and because of its close proximity to the orbit, as well as the fact that the infra-orbital vessels and nerves are practically enclosed in its walls.

214. Zuckerkandl (45), S. 286. 215. Onodi: Die Dehiscenzen der Nebenhöhlen der Nase. Arch. f. Lary., Bd. 15, S. 62, 1903.

The infra-orbital canal which transmits these structures begins on the superior surface, about half way back, and ends in the infra-orbital foramen. Not infrequently it presents a well-marked ridge in the roof of the sinus, causing a more or less marked infra-orbital recess within the cavity.²¹⁶ (Fig. 39.) A separate cell is sometimes present directly below the orbital wall at its anterosuperior angle. (Fig. 40.) This structure is an anomalously-situated ethmoid cell, first described by Logan Turner,²¹⁷ who termed it a maxillo-ethmoid cell. This cell can only exist when the antral roof is situated higher than the ethmoidal bulla. Next to the nasal, the orbital is the thinnest of the boundary walls, particularly in that portion which is occupied by the infra-orbital canal.

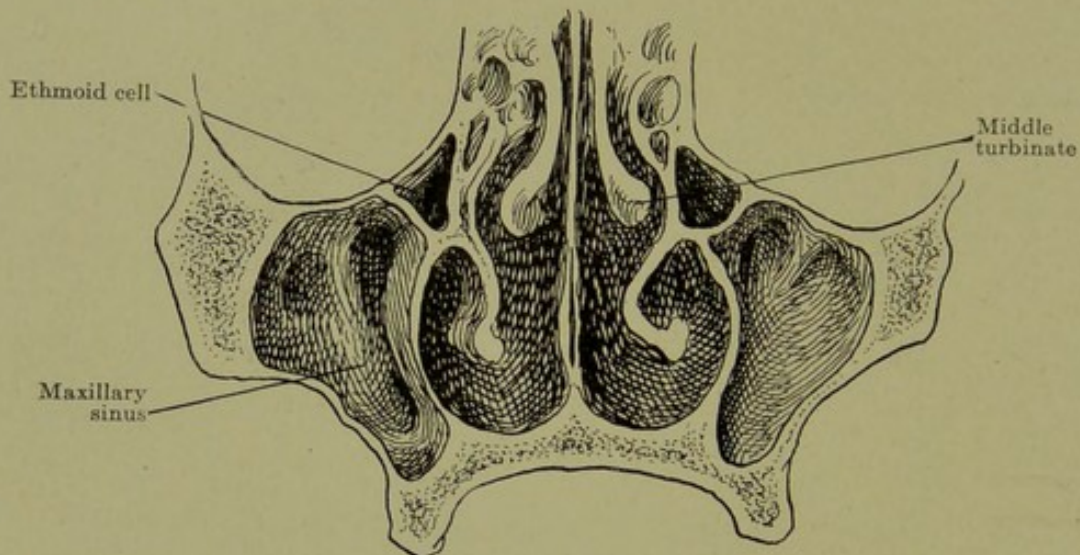


FIG. 40.—Section through the anterior third of the antrum. Small ethmoidal cell situated in the superior angle.

CONGENITAL DEFECTS OR DEHISCENCES.

Dehiscences in the walls of the maxillary sinus are rare, although several instances have been reported.²¹⁴⁻²¹⁸ The principal cause appears to be atrophy from old age, and occurs by continual reabsorption of the walls until the osseous structure entirely disappears from one or more places. Congenital dehiscence is prone to occur along the line of the infra-orbital canal. When defects occur in the lamina papyracea, the orbital plate of the superior maxilla is very apt to share in the defective formation.

216. Cryer: *Internal Anatomy of Face*, p. 63, 1901. 217. Logan Turner: *Accessory Sinuses of the Nose*, p. 7, 1901. 218. Kanasugi: *Ueber die Dehiscenzen der Kieferhöhle*. *Berl. klin. Woch.*, Bd. 45, S. 1405, 1908.

Zuckerkindl²¹⁴ says dehiscence in the sinus walls occurs in three ways: 1. Reabsorption due to old age (most frequent). 2. From deep lying channels for blood-vessels. 3. Defect in the formation of the bone (anomalous). The most frequent situation in the maxillary sinus for these defects is anteriorly in the region of the canine fossa.

THE ALVEOLAR BOUNDARY.

Much greater importance has been given to the ætiological relation of the alveolus to the maxillary sinus than it really deserves, as recent years have shown that carious roots of teeth are responsible only for a small percentage of maxillary sinus empyemas, much smaller than was formerly supposed. Statistics now prove that not more than 25 per cent. of cases result from this cause, while in former years this source would seem to supply

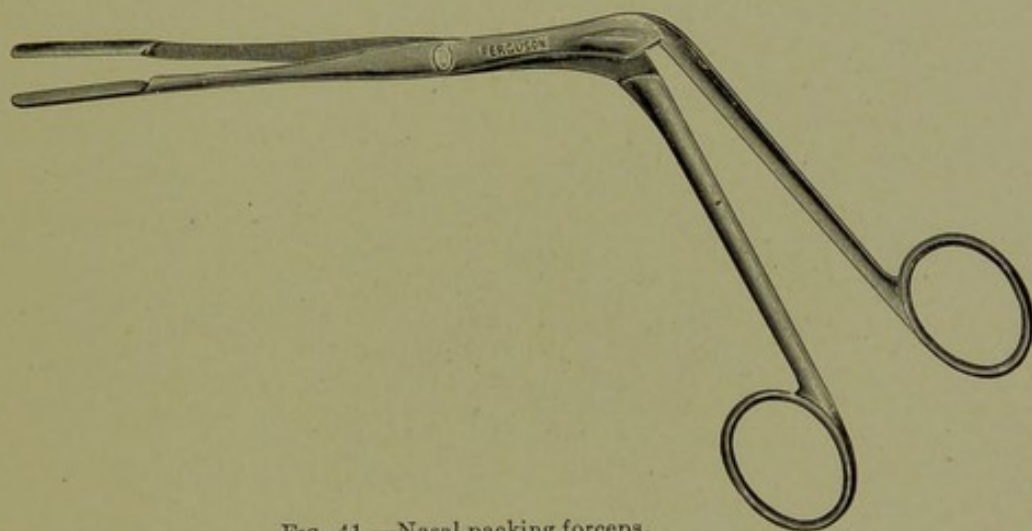


FIG. 41.—Nasal packing forceps.

from 90 to 100 per cent. of all reported cases. However, that they do occur in a given number is undisputed, so that no course of treatment should be instituted in a case of empyema of the maxillary sinus until all upper teeth in relation to the antrum of the corresponding side have been thoroughly examined.

The relation of the roots of the teeth to the antrum has been carefully studied by Zuckerkindl, Cryer,²¹⁶ and Underwood,²¹⁹ with the following results: The floor of the normal maxillary sinus extends from the first premolar to the third molar. (Fig. 42.) As the floor of the sinus does not run parallel with the alveolar process, but is strongly curved above, it naturally follows that the roots of one or two teeth must come in closer proximity

²¹⁹. Underwood: Maxillary Sinus in Relation to the Teeth. Jour. of Lary., p. 620, 1908.

to the floor than those situated at the extremities of the sinus. These two teeth, it will be observed in the illustration, are the second premolar and the first molar, therefore, those to which attention should be first directed, not only for diagnostic but also therapeutic purposes, in empyema of this sinus.

The distances between the apical portions of the roots of the teeth and the floor of the sinus are inconstant in different individuals, depending upon the amount of cancellated bone structure

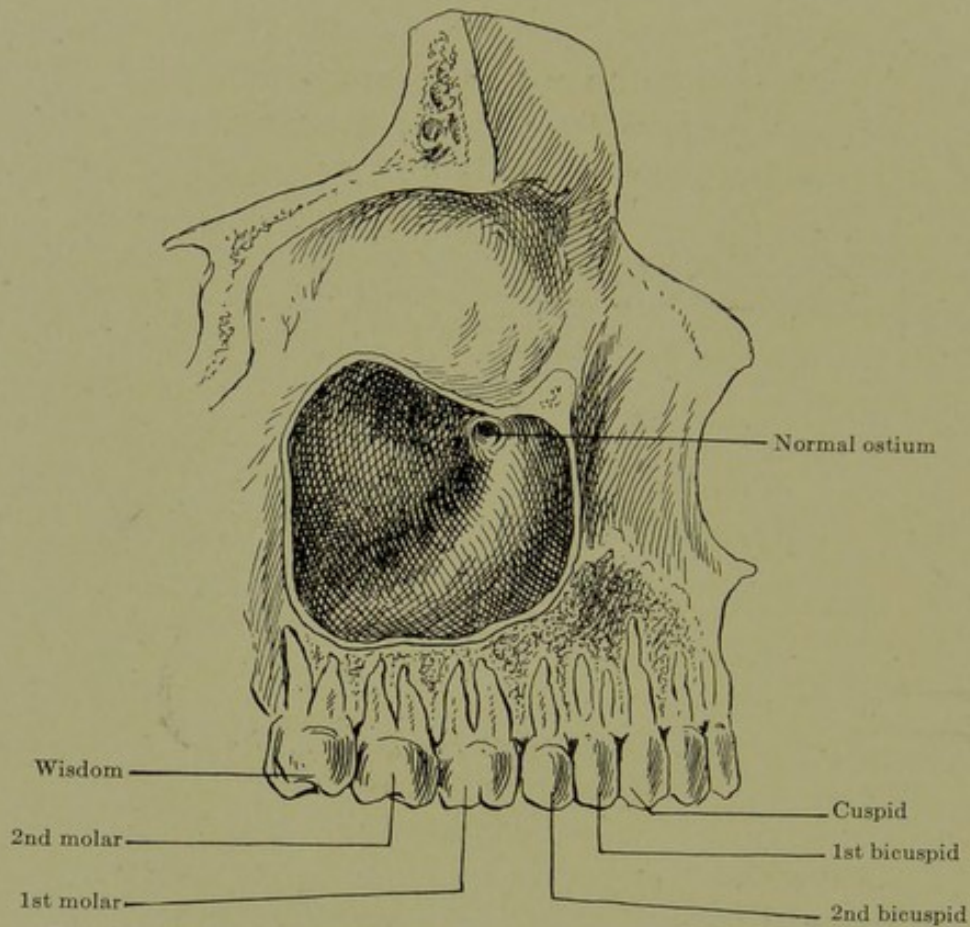


FIG. 42.—Relation of the roots of the teeth to the floor of the maxillary sinus.

which intervenes. Certain specimens show the distance separating these structures to be several millimeters (Figs. 43, 44), while in others the roots project distinctly into the sinus. (Figs. 45, 46.) In the latter instance the sinus mucosa alone separates the root from the cavity proper.

The interior of the maxillary sinus is not always smooth, but quite often presents partial septa, which are usually situated on the floor and in the superior internal angle. (Fig. 39.)

The normal maxillary sinus would then extend from the first premolar to the end of the second molar (on the inside to about

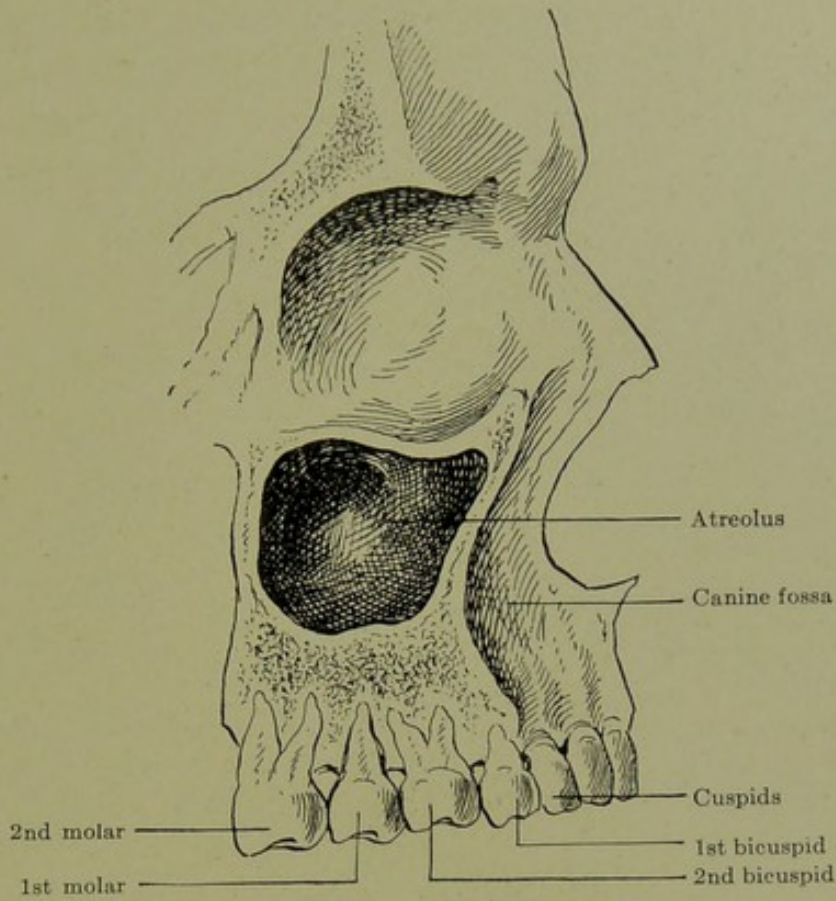


FIG. 43.—Thick cancellated bone intervening between the teeth and the antral floor.

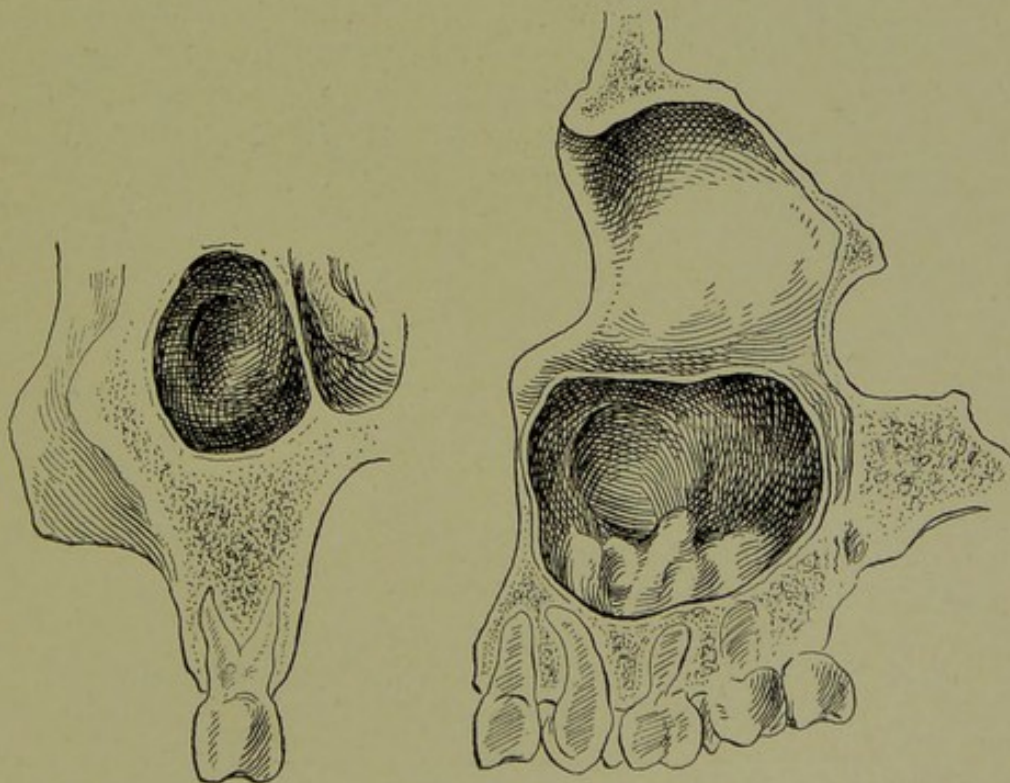


FIG. 44.—Thick cancellated bone between the apex of the tooth root and the sinus floor. (Lateral view.)

FIG. 45.—Roots of teeth projecting into the maxillary sinus cavity.

the posterior osseous tip of the inferior turbinate); in front, from the inferior edge of the orbital ring to a point slightly below the roof of the mouth (floor of the nose),* and from a perpendicular line drawn from the canine tooth to the insertion of the last molar with the superior maxilla. (Fig. 42.)

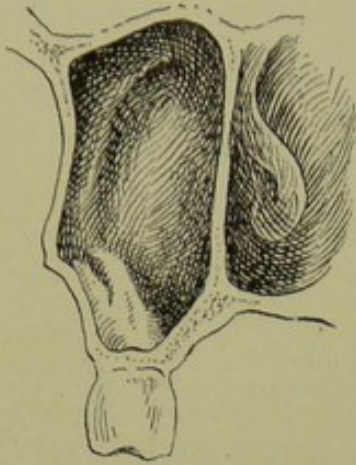


FIG. 46.—Lateral views of tooth root projecting into the maxillary sinus.

The relation of the structures forming the lateral wall of the nose to the base of the sinus from without inward: The nasal wall of the sinus shows a marked tendency to bulge outward, thereby forming an acute angle at its junction with the orbital wall. The insertion of the inferior turbinate is considerably higher up than one would suspect, almost dividing the partition into equal portions. (Fig. 47.) Below the turbinal insertion the structure is entirely osseous, while, above, the pars membranacea, divided by

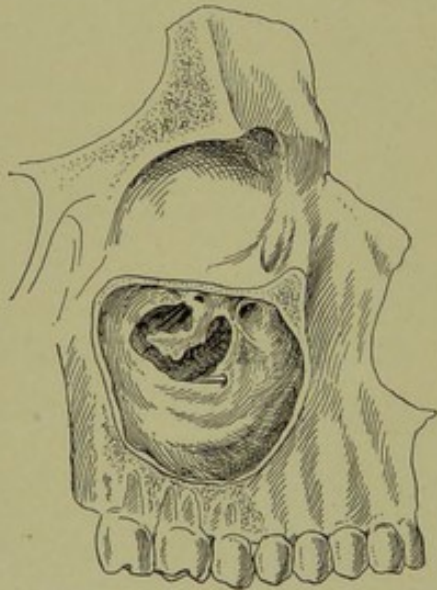


FIG. 47.—View of maxillary sinus from without, showing place of exit of point of needle when introduced intranasally beneath the inferior turbinate at the usual position for exploratory needle puncture.

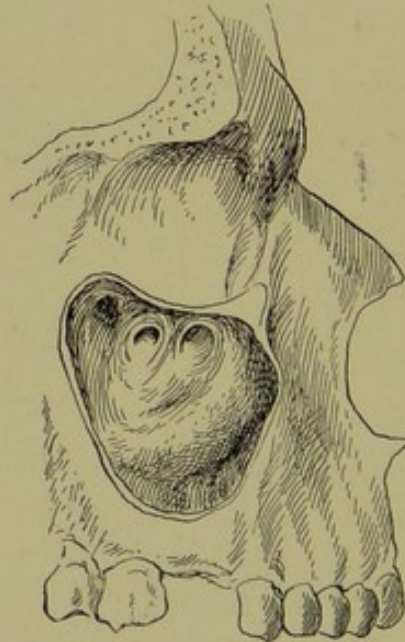


FIG. 48.—Ostium divided by ridge of mucous membrane.

the uncinata process, occupies much of the superior portion. (Figs. 38, 47.)

* Hajek teaches the floor of a normal antrum should equal the line of the nasal floor. This is only true in children before the second dentition, as after this time it becomes deeper through reabsorption of bone.

NORMAL POSITION OF OSTIUM.

The ostium of the maxillary sinus lies in the anterosuperior portion of the sinus, at the junction of the superior and internal walls. Its position is almost constant within a certain limitation, rarely being situated behind the median line. (Figs. 38, 42, 47.) It may assume one of several forms: round, oval, kidney shaped, or in the nature of a long slit; the oval form, however, predominates. The size varies from 2 mm. to 1.7 cm. by 1.1 cm., the average ranging from the size of a buckshot to that of a pea.²²⁰ This opening is not situated as a window in a wall communicating directly from within outward, but takes a distinct direction upward, backward, and inward. From the nasal aspect the direction is naturally downward, forward, and outward. Occasionally, from the antral side, one notes that two ostia situated side by side are present in the space normally occupied by one. This is only apparent and is caused by a reduplication of mucous membrane or a ridge of bone dividing the normal ostium, thereby giving it a bilateral appearance. (Fig. 48.)

ACCESSORY OSTIA.

When an accessory ostium is present (about 10 per cent. of cases), it is situated posteriorly and often inferiorly to the normal opening in some portion of the pars membranacea. It lies either above or below the uncinat process, between its bony prolongations, and is usually round, often being considerably larger than the normal ostium. (Fig. 49.) Unlike the latter, it assumes no direction, but communicates directly with the nasal cavity in the middle nasal passages. They do not necessarily occur singly, but may number two, three, or even four. (Fig. 50.)

Accessory ostia are seldom seen in children,^{220 221 222} being a product of later life, therefore, are undoubtedly connected with the bony reabsorption.*

ABNORMALITIES AND ANOMALIES OF THE MAXILLARY SINUS.

These may consist of several varieties: 1. Overdeveloped or enlarged sinus. 2. Abnormally small sinus. 3. Peculiarly-shaped

220. Oppikofer: Beiträge zur Normalen und pathologischen Anatomie der Nase und ihrer Nebenhöhlen. Arch. f. Lary., Bd. 19, S. 32, 1907. 221. Giralde: Ueber die Schleim-Cysten der Oberkieferhöhle. Virchow's Arch., Bd. 9, S. 463, 1856. 222. Schaeffer. The Sinus Maxillaris in Man. Ann. Otol., Rhin. and Lary., p. 815, 1910.

*Oppikofer (220) found accessory ostia in two instances in children, 7 and 11 years, respectively.

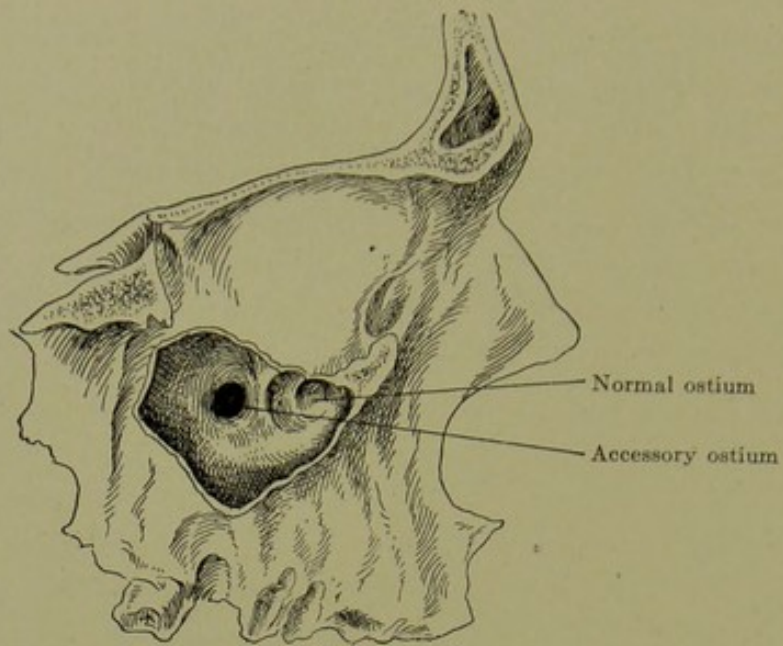


FIG. 49.—Showing situation of accessory ostium in relation to that of the normal ostium.

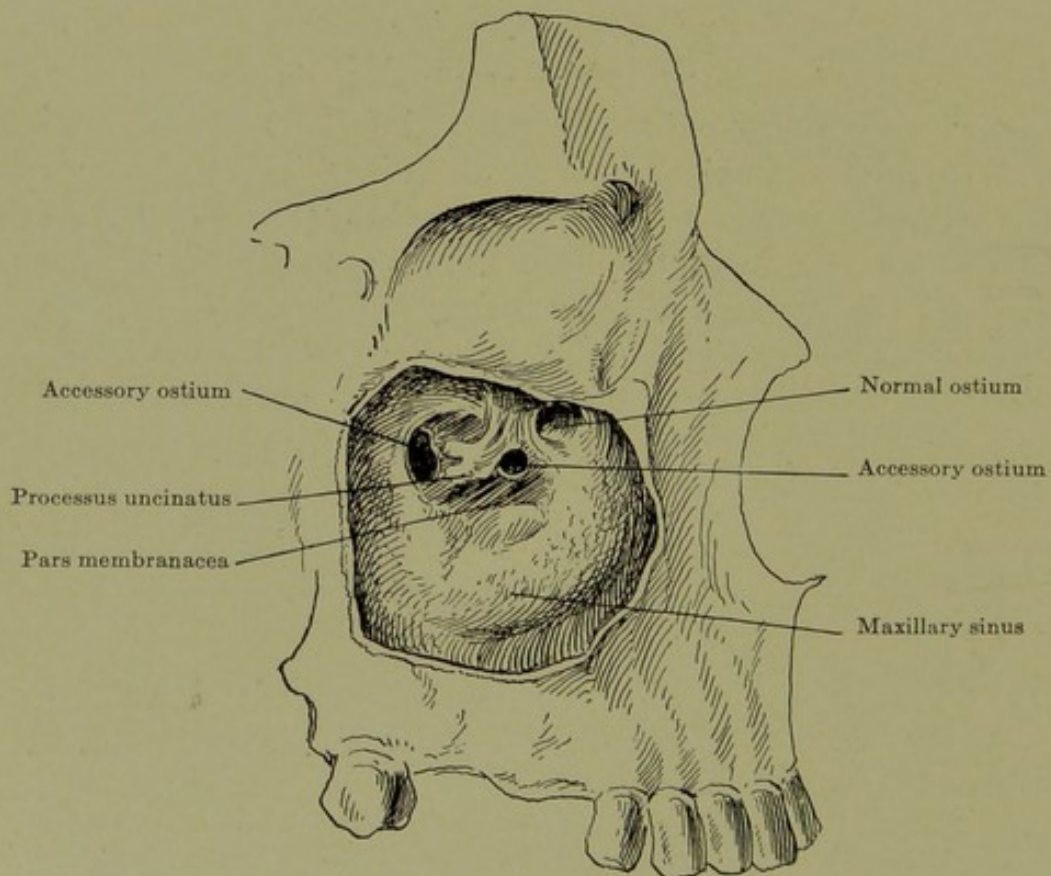


FIG. 50.—Several accessory ostia.

sinus. 4. Misplaced sinus. 5. Combined of two or more of these conditions.

The principal cause of these conditions is hyper-reabsorption of the bone during the formation of the cavities. The opposite condition frequently prevails in number two, although the position of the walls also plays an important rôle in the causation of this form of anomaly.

Misplaced sinus may be due to: (1) Irregularity in the formation of the facial bones, (2) malposition of one or more of the sinus walls, and (3) insufficient or partial reabsorption of the bone.

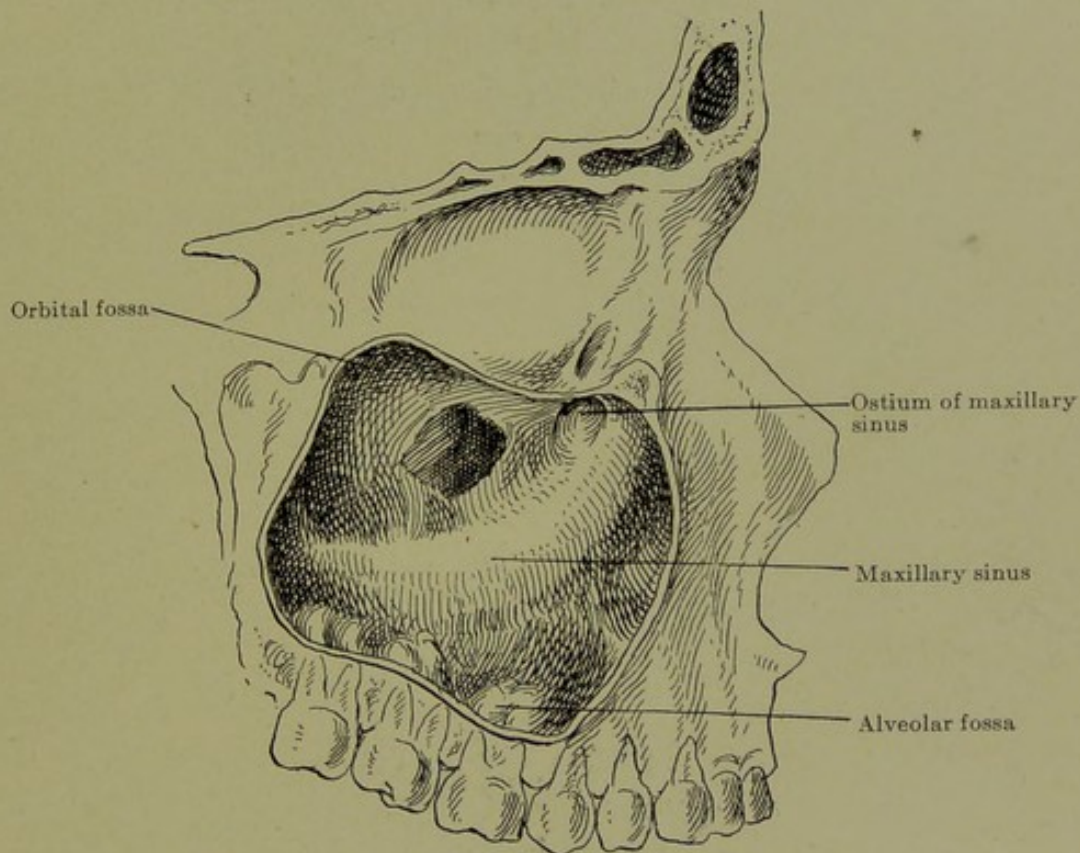


FIG. 51.—Excessive overdevelopment of maxillary sinus on left with formation of orbital fossa. Roots of teeth projecting into floor of antrum.

1. An overdeveloped sinus may be enlarged in several directions, due to the above-mentioned hyper-reabsorption of the bone, including all portions of the sinus. (Figs. 51, 52.)

- a. Reabsorption toward the orbit. (Fig. 51.)
- b. Reabsorption into the palate bone. (Fig. 53.)
- c. Reabsorption into the hard palate. (Fig. 54.)
- d. Reabsorption into the malar bone.

These are of little practical importance, with the exception of that into the hard palate, in which case Hajek says a bulging of

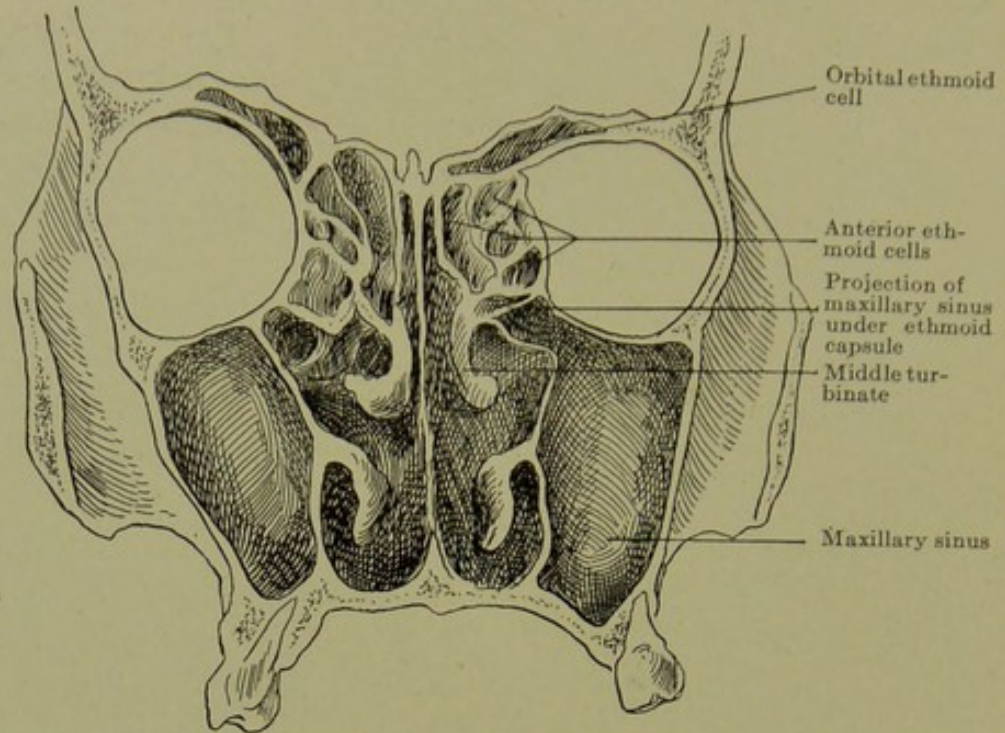


FIG. 52.—Excessive development of sinus due to over-reabsorption of cancellous tissue.

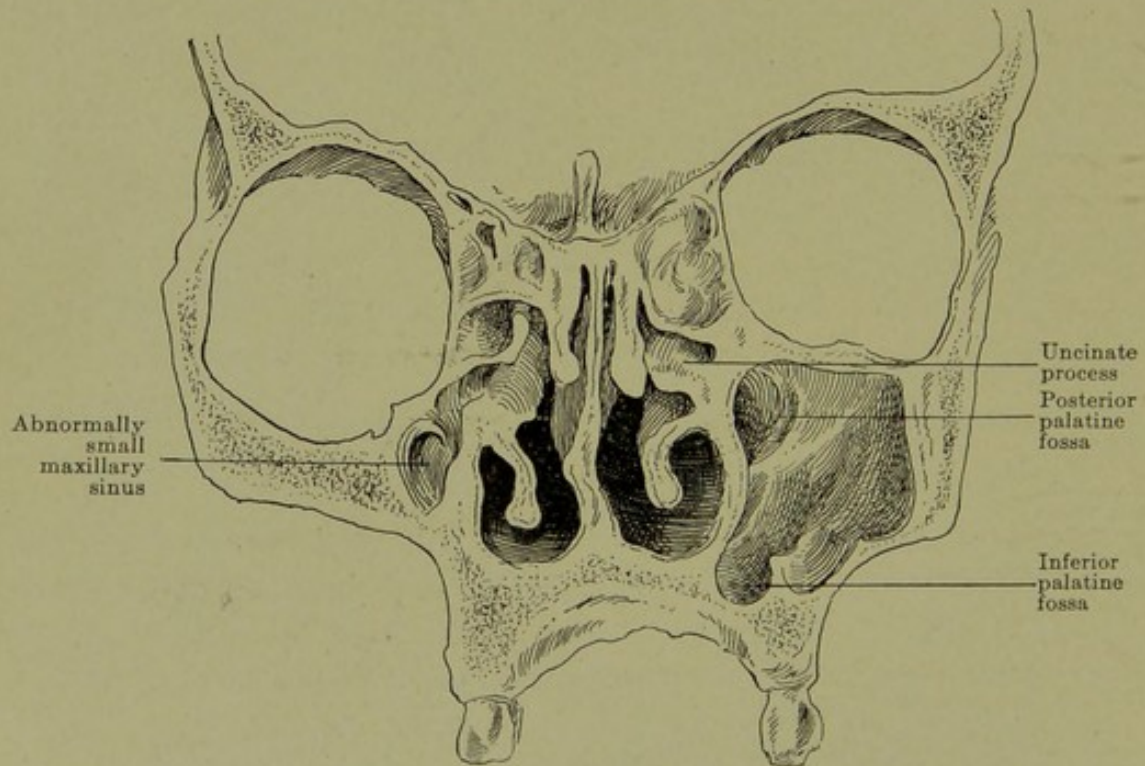


FIG. 53.—Marked asymmetry of maxillary sinuses. Excessive enlargement on the left due to outward expansion of anterior and lateral walls. Right sinus underdeveloped.

the hard palate may take place when empyema with pressure occurs. The anomaly consisting of reabsorption toward the orbit

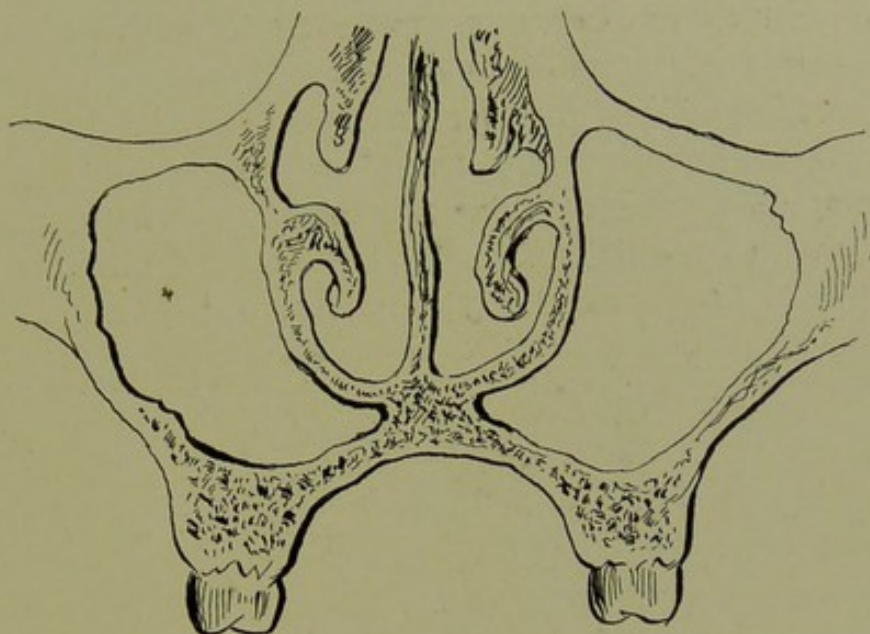


FIG. 54.—Reabsorption of bone into the hard palate, bringing the maxillary sinuses into direct relation with the roof of the mouth.

is of theoretical importance when one considers the possibilities of ophthalmic complications, as well as of transmitting inflammation through the infra-orbital nerve.

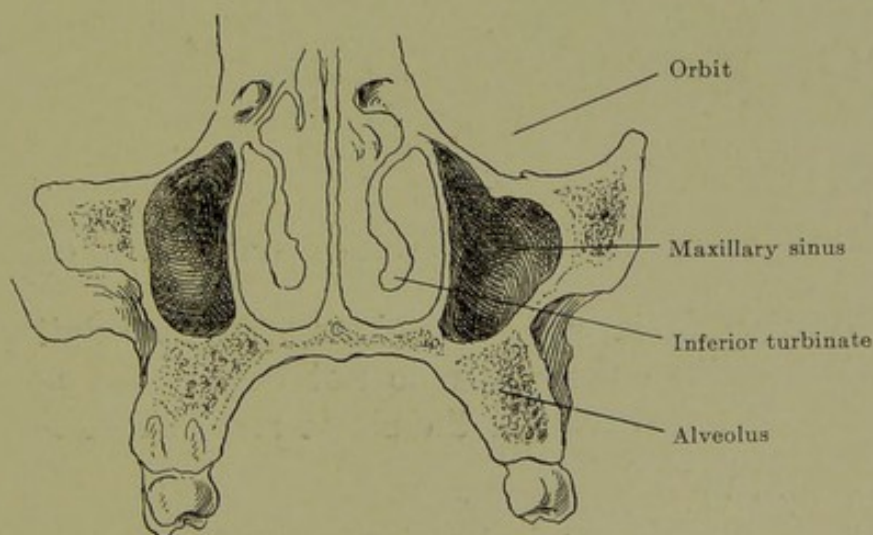


FIG. 55.—Underdevelopment of maxillary sinuses with compact alveolar processes.

1. A rather uncommon source of enlargement of this sinus is the bulging outward of the anterior and lateral walls, as shown in Fig. 53. This protrusion of the walls is more apparent than real when one takes into consideration the asymmetrical formation of

these specimens. It will also be noted that reabsorption has occurred more markedly in all of the enlarged sides than in the other walls.

2. The occurrence of an abnormally small sinus may be due to the two causes mentioned above, *i.e.*, insufficient reabsorption and malposition of the sinus walls.

When the reabsorption has ceased before the sinus has become fully developed, we merely have a small sinus with greatly thick-

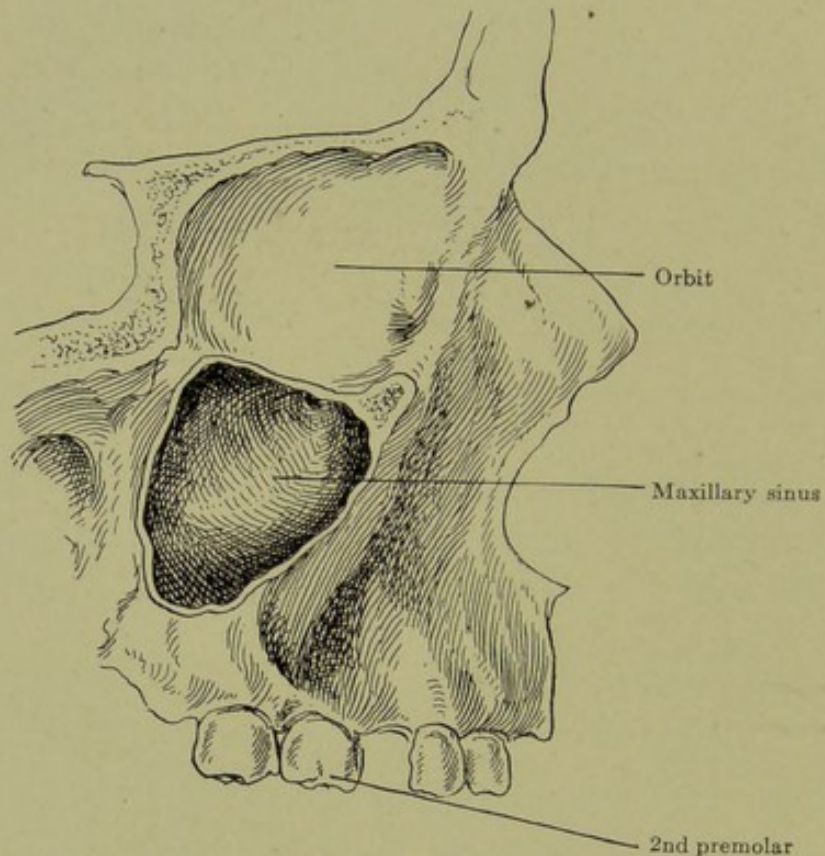


FIG. 56.—Narrowing of the antrum due to sinking in of the anterior wall.

ened walls. (Fig. 55.) The sinus occupies relatively the normal position. When the walls do not occupy the normal positions, not only the position but the shape and size of the cavity will be greatly changed.

In the course of examination of perhaps a thousand or more specimens the author has never seen one case of extensive protrusion outward of the maxillary sinus wall which could not be clearly attributed to some pathological process. In the anatomical museum at Vienna (Zuckermandl's collection) there are a number of specimens showing this peculiarity, all of them due to bone cysts of dentigerous origin. In the opinion of the author dilatation of this sinus outward due to pressure from an empyema cannot occur. (See Anatomy of the Lateral Wall of the Nose.)

This deformity can take place in several ways:

1. Sinking in of the canine fossa.
2. Bulging outward of the lateral nasal wall.
3. Combination of these two.

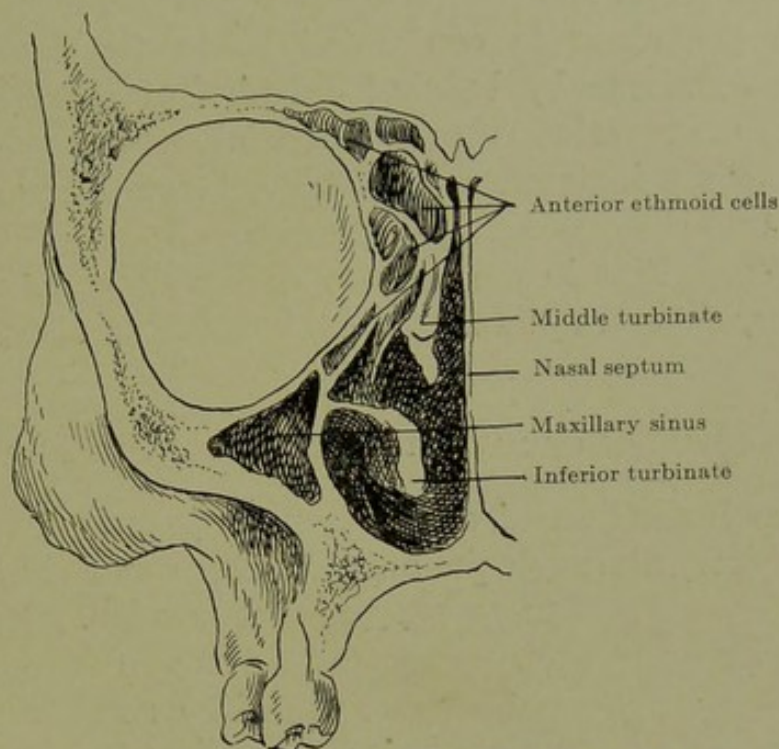


FIG. 57.—Narrowing of the antrum due to bulging outward of lateral nasal wall.

1. Sinking in of the canine fossa: This naturally narrows the anterior posterior diameter of the cavity, and its recognition is of surgical importance, as the operation through the alveolus of the

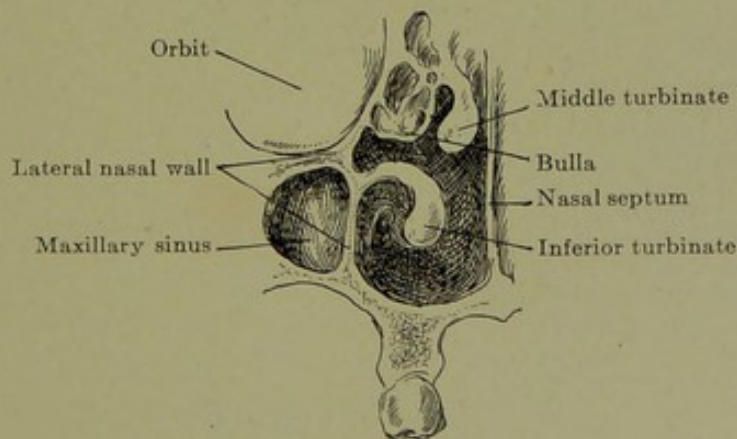


FIG. 58.—Sinking in of lateral nasal wall.

second premolar and first molar would miscarry, the drill penetrating into the canine fossa in front of the antrum. (Fig. 56.)

2. Bulging outward of the inferior portion of the lateral nasal wall occurs at the expense of the superior portion of the sinus,

narrowing the antrum from above downward and placing the pars membranacea in intimate connection with the orbit. This anomaly would make the needle puncture for diagnostic purposes through the middle nasal passage a most dangerous undertaking and absolutely preclude the possibility of operating through it. (Fig. 57.) When the sinus is contracted below the insertion of the inferior turbinate by bulging outward of the lateral wall, an attempted operation through the alveolus would result in the point of the instrument appearing through the floor of the nose. (Fig. 58.)

Peculiarities in the contour of the sinus, as well as misplaced sinuses, depend upon a combination of the above conditions.

FORMATION OF PARTITIONS IN THE MAXILLARY SINUS.^{223, 224}

The formation of complete partitions is, fortunately, of rare occurrence, although partial partitions and ridges are commonly

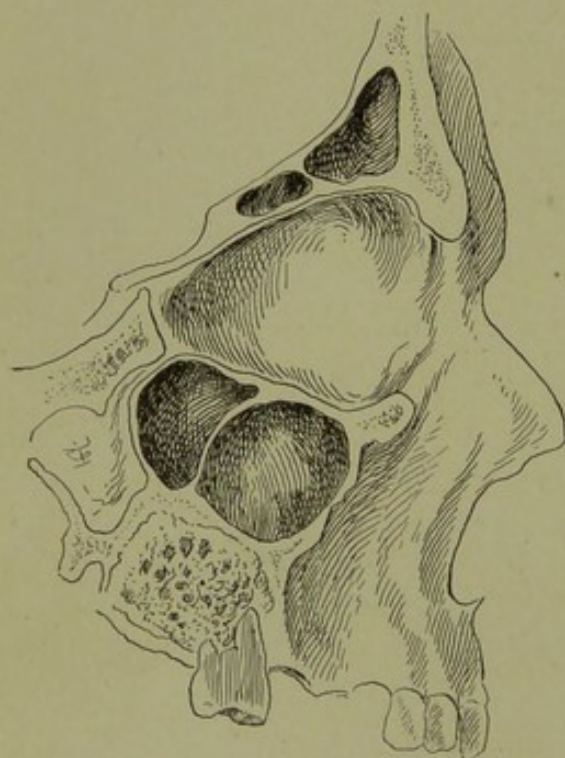


FIG. 59.—Complete septum dividing antrum into an anterior and posterior compartment.

met with. Perhaps the most common form of complete partitions is the perpendicular dividing the antrum into an anterior and posterior division. (Fig. 59.) In this case the two ostia are to be found, one situated in the hiatus in the normal position, and the other, for the posterior portion, in the superior nasal passage, immediately above the middle turbinate. (Fig. 60.)

The morphology of this anomaly can be readily grasped when one considers the posterior division as a misplaced ethmoid cell. That this is really the case is proved by the comparatively large number occurring in which the size of the posterior compartment varies from a small space to half the antral cavity.

223. Zuckerkandl (45), S. 284. 224. Underwood: An Inquiry into the Anatomy and Pathology of the Maxillary Sinus. Journ. of Anat. and Physiol., vol. 44, p. 354, 1910.

(Fig. 61.) The constant position of the ostium into the superior nasal passage is another point in favor of this theory.

One can readily appreciate how confusing this would be if the posterior portion was affected with all the symptoms of an ordinary maxillary sinusitis and a needle-puncture made in the usual place under the inferior turbinate which would only enter the anterior unaffected part with negative result.²²⁶

The mucous lining of the maxillary sinus consists of three layers: ciliated epithelial, tunica propria, and periosteal; the two latter, however, are so intimately connected that to all intents and

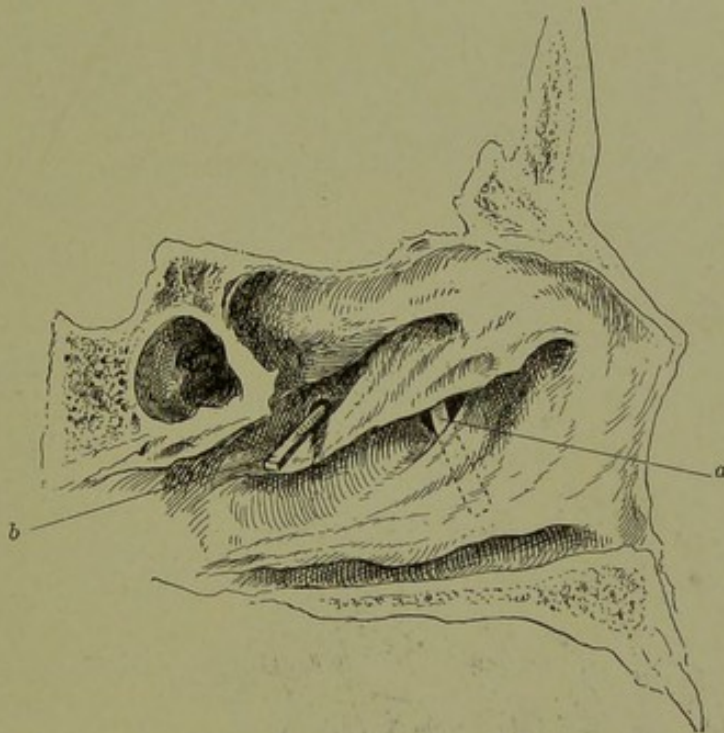


FIG. 60.—Ostiums of a double maxillary sinus. *a*, stylus into anterior compartment; *b*, stylus into posterior compartment.

purposes they form one. The glandular supply is very meagre, being confined, for the most part, in the region of the ostium.²²⁵ The entire thickness of the combined layers is rarely more than .02 millimeter. It is especially loose around the ostium, and prone to œdematous swelling on slight irritation. It is curious to note with what facility this thin, delicate layer assumes a thick, myxomatous mass of tissue under the influence of suppurative processes of comparatively recent origin.

225. Tunis: Inflammation of the Sinus Maxillaris, with Special Reference to Empyema, etc. *Laryngoscope*, p. 939, 1910. 226. Boulay (Sinusitis Maxillaires, Diverticulaires et cloisonnées, *Arch. internat. de laryng.*, vol. 11, p. 375, 1898) has reported such a case.

Blood Supply.—The mucosa receives its blood supply from a branch of the nasal artery which penetrates the ostium, as well as through the pars membranacea. The antral walls receive a double supply, as both sides are covered with periosteum, through which they receive double nutrition. This possibly explains why severe ulceration of the mucosa is often unaccompanied by any manifestations of disease in the underlying bone.

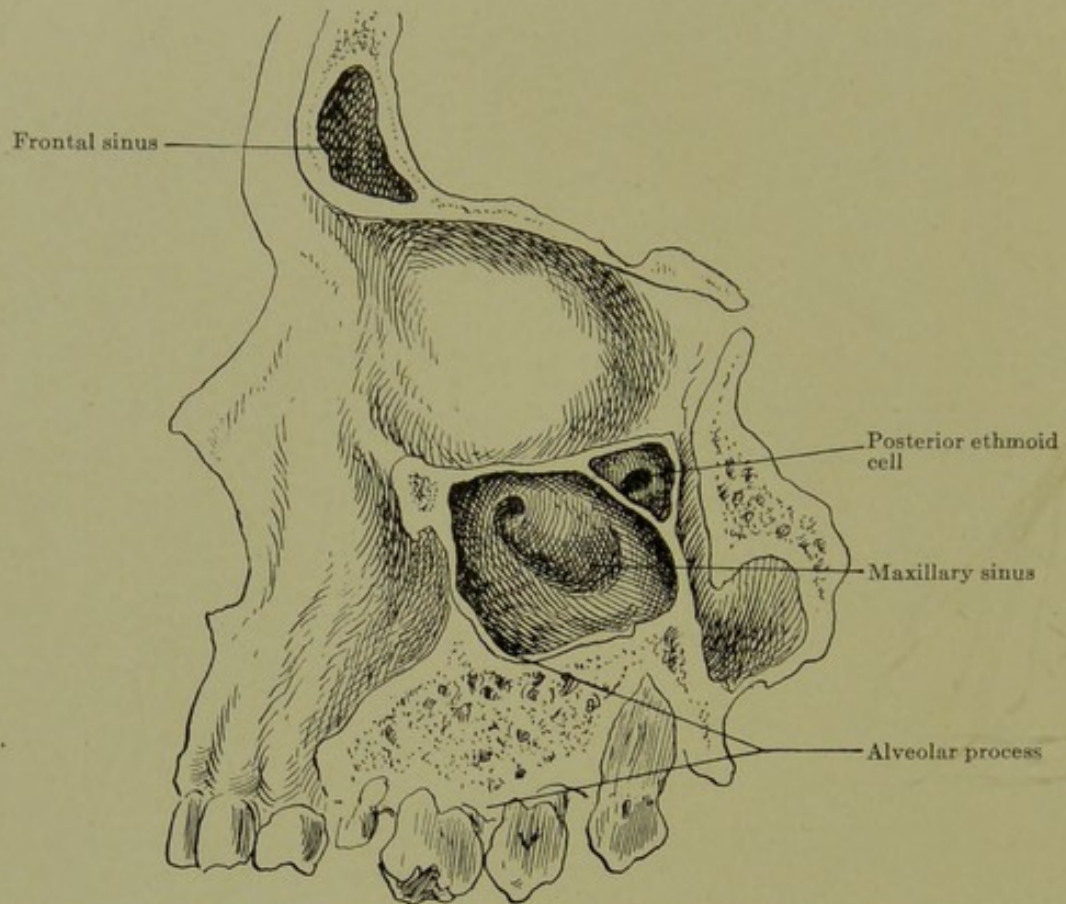


FIG. 61.—Maxillary ethmoid cell at posterior superior angle of antrum.

SURGICAL ANATOMY OF THE LATERAL WALL OF NOSE IN REFERENCE TO THE MAXILLARY SINUS.

Three separate portions of the lateral nasal wall are of interest in this respect: 1. Posterior third of hiatus semilunaris (infundibulum). 2. Pars membranacea. 3. That portion directly beneath the centre of the inferior turbinate (maxillary process of inferior turbinate). The maxillary ostium, as has been stated in the chapter on the anatomy of the lateral wall of the nose, is situated in the posterior third of the hiatus semilunaris. (Fig. 26.)

SOUNDING THE MAXILLARY OSTIUM.²²⁷

Contrary to the opinions of some rhinologists, the author is inclined to believe that the normal ostium of the maxillary sinus, even after removal of the anterior portion of the middle turbinate, can only be sounded and catheterized in a very small percentage of cases.²²⁸ The natural barriers to sounding are: 1. The processus uncinatus. 2. The bulla ethmoidalis. 3. The depth of the hiatus and infundibulum. 4. The position of the ostium in the infundibulum.

1. The processus uncinatus does not protrude from the lateral wall of the nose like an ordinary shelf, but rather like the slit of an oblique pocket. On account of this, the deepest part (infun-

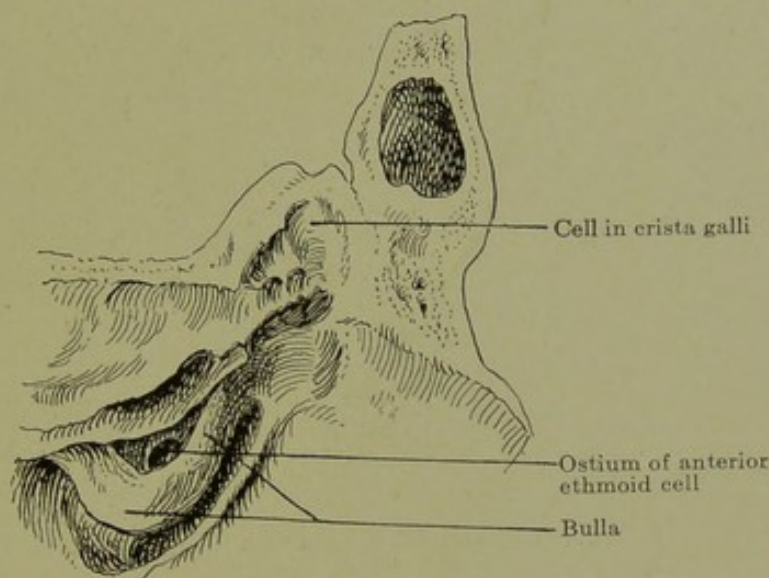


FIG. 62.—Unusually large ethmoidalis.

dibulum) is not directly outward, but rather downward and forward, and it is at the very lowest depth of the infundibulum that the ostium is situated. The depth of the hiatus with infundibulum varies between 3 mm. and 9 mm., the mean depth being 6 mm.

2. The ethmoidal bulla, while always constant, is one of the most variable structures in the lateral wall of the nose. It may be so large as to protrude beyond the inferior border of the middle turbinate, following the middle nasal passage (Fig. 62), or be so small as to form merely the straight floor of the ethmoidal capsule. (Fig. 63.)

227. Siebenmann: Verhand. deutscher Naturforsch. Halle, 1891. 228. Cryer (Trans. Section on Lary. A. M. A., p. 160, 1902) says it is impossible to sound the antrum through the nose.

On the position of the bulla depends largely the possibility of introducing the tip of the sound into the maxillary ostium. If slightly enlarged, it adds to the natural difficulties by not only deepening the infundibulum, but also narrowing the slit-like hiatus semilunaris. (Fig. 20.)

3. The depth of the hiatus and infundibulum depends upon the width of the processus uncinatus and the development of the bulla.

4. The position of the ostium in the infundibulum presents the last natural difficulty to sound this sinus. It is not, as one would suppose, set in the lateral wall of the nose, flat as a window in the wall of a house, but in such a manner that its direction from within out is forwards, downwards, and outwards, which very

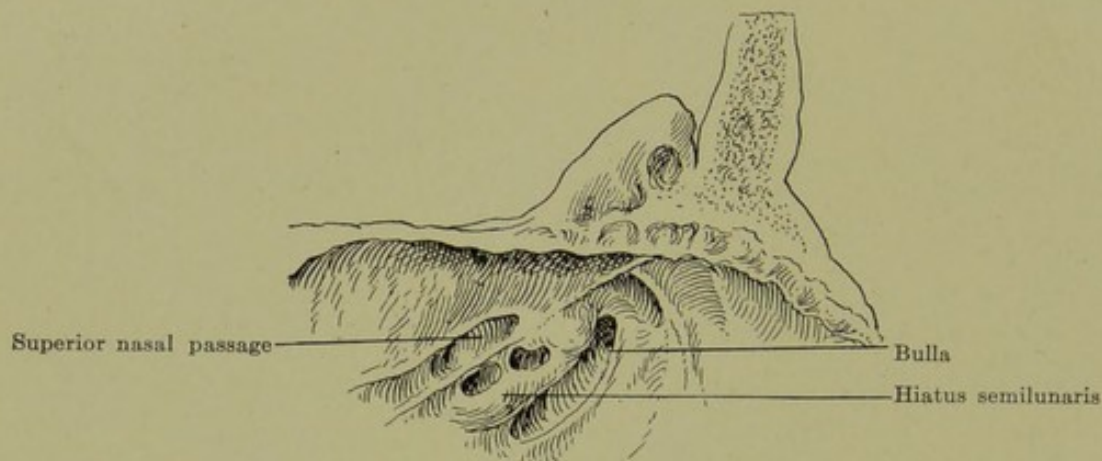


FIG. 63.—Upward displacement of bulla with enlargement of the hiatus semilunaris.

materially adds to the difficulty of sounding, as the tip of the instrument must be bent in a corresponding position.

ÆTIOLOGY.

The antrum is more often diseased than its fellow sinuses, because it has one more ætiological factor, *i.e.*, the intimate relation of its floor to the roots of the teeth. It will be remembered that the sinuses are usually affected through their ostia, occasionally through the circulatory system. The maxillary sinus not only presents this to a marked degree on account of the extremely unfavorable situation of the ostium, but, in addition, certain affections of the alveolus are prone to, in turn, affect this cavity.

The relation of the teeth to the floor of the sinus has already been discussed (see anatomy); however, it is well to repeat that

the teeth from the canine to the wisdom bear more or less relation to the floor, the second premolar and the first molar being the closest in proximity; therefore, any inflammation around the roots of these could easily be transmitted to the sinus mucosa. We then have the following ætiological factors:

1. Idiopathic (arising in the sinus itself), rare.
2. Direct extension from the nasal mucosa (coryza).
3. Infectious diseases (circulatory system).
4. From alveolus (contiguity—blood) (continuity—bone).
5. Through contamination from overlying sinuses.
6. Foreign bodies.
7. Traumatism (galvano-cautery and tamponade), direct or indirect.
8. Osteomyelitis, tuberculosis, syphilis, and malignant tumors.
9. Chronic or latent empyema.

1. **IDIOPATHIC.**—Disease of the maxillary sinus arising from the direct invasion of bacteria, without other appreciable causes, although reported by various authors, we have never observed.

2. **DIRECT EXTENSION FROM THE NASAL MUCOSA.**—This is the most frequent cause of maxillary sinusitis. Whenever general inflammation of the Schneiderian membrane occurs, the mucosa of the sinuses is affected. In all cases of acute coryza there is bound to be more or less inflammation of the maxillary sinus. When general resolution sets in, the sinus membrane also regenerates, and it is only in those cases where the drainage is seriously interfered with that the disease becomes chronic. We can readily see how easily this can occur, especially in the maxillary sinus, where the ostium is situated so high, and the middle turbinate, when swollen, may occlude it. It is not the presence of the secretion so much as the pathological changes in the mucosa occasioned by the pressure and insufficient aëration that causes the disease to become chronic. This will explain the fact that acute maxillary sinusitis is so often observed after the primary nasal affection has disappeared. In repeated attacks of coryza the sinus mucosa which has been the seat of previous attacks will always show an especial predilection for renewed inflammation; in this way the disease may also become chronic.

3. **INFECTIOUS DISEASE.**—The most important of this group is influenza, but the precise reason why this disease shows such a

marked predisposition to affect the sinuses, as well as the working, must for the present remain unanswered.

In Germany and Austria Hungary, influenza plays the great rôle in the causation of sinus diseases. In America it is different. The explanation of this lies in the fact that Russia, being the original starting point for this disease, the epidemics are not only much more severe in that portion of the world, but return every winter with great regularity. Another cause which is not to be underestimated is the negligence of the poorer folk, especially the peasants, in seeking immediate treatment as soon as the disease is acquired. On this account such pathological changes have often occurred when medical attention is first sought, that serious and often subsequently fatal complications have intervened. In the cities of the United States where dispensaries are to be found on almost every fourth corner, these conditions are practically unknown. These are the main reasons why sinus disease, particularly the severer cases, are more prevalent in Europe than with us.

4. FROM THE ALVEOLUS.—It was formerly thought that every case of antral empyema was directly due to dental infection. This opinion has gradually changed, until now the relation is placed at approximately 20 per cent.

Certain authorities cling more or less tenaciously to the dental origin, thus Tilley²²⁹ would seem to place it at 100 per cent., Lermoyez²³⁰ more than 50 per cent., Luc²³¹ at 50 per cent. Among those who hold the opposite opinion may be mentioned Cryer²³² (29 per cent.), L. Turner²³³ (30 per cent.), Richards²³⁴ (25 to 30 per cent.), Piffel²³⁵ (26 per cent.), and Hajek²³⁶ (8 per cent.).

As far as we have been able to ascertain by a careful review of our own cases we would place the proportion at from 20 to 30 per cent. It is impossible to fix on a definite figure, as in certain instances where the teeth were affected, it was evident that the dental disturbances were secondary to the sinus affection. This was proven by the skiagraphic pictures which clearly showed the osteitis extending downward from the floor of the diseased antrum toward the apices of the roots of the healthy teeth (first and second molars).

The supposition previously existed that a carious tooth caused the infection simply by direct extension into the sinus by continuity, being practically always limited to the second bicuspid or first two molars. We have now discovered that this is but one of several ways whereby antral infection results from dental origin.

229. Tilley: Suppuration of the Maxillary Antrum, with Special Reference to Diagnosis and Treatment. *Laryngoscope*, p. 97, 1904. 230. Lermoyez: A Discussion on the Ultimate Results of Surgical Operation, etc. *Journ. of Lary.*, p. 576, 1902. 231. Luc: *Leçons sur le suppuration*, etc., p. 274, 1910. 232. Cryer: *Anatomy of the Face*, p. (64), 1901. 233. L. Turner and Lewis: A Further Study of the Bacteriology of Suppuration in the Accessory Sinuses of the Nose. *Edinburgh Med. Journ.*, Apr., p. 293, 1910. 234. Richards: Origin of Antral Empyemata. *Ann. Otol. Rhin. and Lary.* p. 76, 1905. 235. Piffel: Zur Operation u. Casuistik der Chron. Oberkieferhöhleneiterungen. *Prager med. Wochen.*, No. 17, 18, 1906. 236. Hajek: Ein Beitrag zur Kenntniss des dentalen Empyems der Kieferhöhlen, etc. *Wiener klin. Woch.*, No. 16, 1908.

- a. By direct continuity (carious tooth).
- b. Through periostitis.
- c. Through the circulatory system.
- d. Circumscribed or diffuse ostitis of the alveolar process.
- e. Rupture of an infected dentigerous cyst.

a. By direct continuity. Three forms are observed: 1. Manifest caries. 2. Hidden caries. 3. Dead teeth.

a. *Direct Continuity*.—(1) Manifest caries: After the caries has attacked the enamel, dentin, and pulp successively, the higher toward the root of the process it reaches, just that much more difficult the drainage. The dental canal finally becomes obstructed, the carious process breaks through the apex of the root, with the formation of an abscess. The constantly-accumulating pus seeks an outward passage, which occurs either into the gum or into the maxillary sinus, with the formation of an acute antral empyema.

(2) Hidden caries: Infection from this source usually occurs beneath a filling or crown. The process may be so insidious as to entirely escape the notice of the patient; however, on close questioning, the history of trouble with that tooth is usually elicited. The pathological process is precisely the same as that with manifest caries.

(3) Dead teeth: Teeth in which the nerve has been killed exhibit little reaction against bacterial invasion, consequently infection easily gains entrance to the root without any subjective symptoms. The pulp becomes easily infected through the dentin, as the latter does not react as a sound tooth.

b. *Through Periostitis*.—Periostitis of the alveolar process is usually dependent upon an earlier periosteal abscess, yet may result from constant irritation by grinding, especially when a neighboring tooth has been extracted. The careless extraction of a tooth seems also to be the predisposing moment in many of these cases, although the simple opening of the antrum by drawing a tooth is not in itself sufficient ground to cause an infection.* If several millimeters of spongy bone lie between the root apex and the antral cavity, the periostitis may cause a circumscribed ostitis of this cancellated bony partition. Under these circumstances, after extracting the tooth, the drill will easily penetrate the intervening osseous structure which has become

* Hajek (p. 68, note) lays particular stress upon this fact.

softened by the disease and penetrate the antrum. It must, however, be mentioned that the thicker the layer of bone between the teeth and the floor of the antrum, the less the liability of the individual to contract maxillary sinusitis from dental caries.

*c. Through the Circulation.*²³⁷—The intimate anastomosis of the antral and dental veins explains how readily infection can extend from one to another. While this hypothesis has not definitely been proved, nevertheless, those cases where a tooth has been extracted preparatory to the Cooper operation, and a considerable layer of apparently normal bone must be pierced before the sinus is reached, we can assure ourselves that the circulatory system has acted in a large capacity as a medium of transmission for the infecting micro-organisms. Microscopical examination of these cases would show a healthy area of bone between the foci of infection at the root of the tooth and the secondary area on the nasal mucosa of sinus.

d. Circumscribed or Diffuse Ostitis of the Alveolar Process.—Especially easy to diagnose, for here we have a purulent inflammation of the alveolus. With circumscribed ostitis frequently a portion of bone is necrosed; the empyema does not heal until this sequestrum has either been removed or sloughed off. The pathognomonic symptom of these cases is the exquisitely fetid odor to the purulent secretion, which is always of extreme disgust to the patient. In these cases, even after extraction of the tooth in the diseased area, there is usually no direct communication with the sinus, in contradistinction to the root abscess. The abscess also exhibits a tendency to rupture outward, thus forming a fistula from the maxillary sinus through the alveolus into the mouth.

e. Rupture of an Infected Dentigerous Cyst into the Antrum.—This possibility has been mentioned, and, on account of the extreme rarity, deserves no further consideration.

Finally, it must not be forgotten that dental trouble may be secondary to the sinus disease. A glance at the preparations will show us that roots of previously healthy teeth may become diseased through inflammation due to their close proximity to infectious material. That this does occur will be illustrated in the following case:

237. Strübell: Ueber die Beziehungen der Gefäße der Kieferhöhle zu denen der Zähne. Monatschr. f. Ohrenheilkunde, No. 6, S. 249, 1904.

H. K., 40 years. Acute maxillary sinusitis. No history of dental trouble on that side. Sinusitis cured by intranasal puncture and frequent lavages. Several weeks afterwards noted pain in second bicuspid on diseased side, sensitive to percussion. On lavage no pus or secretion in the antrum. Tooth extracted, root inflamed with beginning abscess formation. Body of tooth perfectly sound. Patient experienced no further trouble either from site of jaw or of sinus.

5. THROUGH CONTAMINATION FROM OVERLYING SINUSES.—This can only occur from the frontal and possibly anterior ethmoidal under certain anatomical and pathological conditions. The anatomical conditions are that the unciniate process must be of sufficient width to carry and guide the purulent secretion to its posterior extremity, and the maxillary ostium must be of sufficient size to allow the secretion to percolate into the sinus. The pathological conditions are that the sinus mucosa must be in a condition to become infected from the secretion.

The mucosa of the sinuses exhibits great tolerance toward purulent secretion before becoming infected, as the following case will illustrate: A. A., 40 years, frontal sinus trouble for several years. No maxillary trouble. After several weeks' treatment the secretion became thin and watery but did not entirely cease. Before discharging her, an exploratory needle puncture of maxillary sinus was made, which brought out a considerable quantity of thick purulent material. In forty-eight hours another puncture was made and the injected fluid returned perfectly clear. This was substituted a few days later showing that the antrum had merely acted in the capacity of a reservoir and was not itself affected.*

6. FOREIGN BODIES.^{238, 239}—Sinus suppuration can be occasioned by the action of foreign bodies which have found their way into the antrum. The mode of ingress may occur in three ways:

(1) Through the natural ostium or an accessory ostium without injury to the sinus walls or mucosa. In this manner many varied substances may find lodgment in the antrum, as blood, vomited matter, snuff, parasites, and even worms. Chloride of iron, which has been used to control epistaxis, has been known to enter the maxillary sinus and set up a purulent discharge.

(2) Through the osseous walls, with injury to the mucosa. This may occur either through the nasal or maxillary wall.

(3) Through an artificial opening in the alveolus. When a foreign body enters into the antrum without external force (through the ostium) it must either be infected or irritating to the lining mucosa in order to cause an immediate empyema. In

* Foreign bodies of an aseptic nature have been known to lie dormant in the antrum for years until an acute infection caused their presence to become manifest.

238. Killian: Fremdkörper in der Kieferhöhle. Heymann's Handbuch Die Nase, S. 1008, 1900. 239. Newcomb: Foreign Bodies in the Antrum. Trans. Am. Lary. Assn., p. 106, 1911.

the course of time the irritation produced will ultimately lead on to infection, although it will depend largely upon the nature of the penetrating substance as to the exact pathological condition evoked. We must always bear in mind the tolerance of the lining mucosa to extrinsic bodies without itself becoming greatly affected, as we see in those cases in which the maxillary sinus acts as a reservoir for the sinuses lying superiorly.

Supernumerary and inverted teeth,²⁴⁰ by their growth upward into the floor of the antrum, may produce sufficient irritation to lower the vitality of the mucosa and become the foci of a spreading infection which subsequently involves the entire cavity of the sinus.

7. TRAUMATISM—DIRECT AND INDIRECT.—*Direct.*—Under this heading we understand an empyema set up directly as the result of an injury either to the external or nasal walls. Through the external walls: This is usually the result of an accident from a fall, blows of a blunt instrument, unskilled extraction of teeth (Tilley), etc. The empyema is occasioned by the wounding of the mucous membrane, which subsequently becomes infected either from the putrefaction of the free blood which has accumulated in the cavity, or from the lack of resistance of the mucosa, due to the injury causing a favorable soil for the growing of the micro-organism of suppuration.

The antral mucosa possesses decided resisting powers toward secondary infection after an injury. As a rule, healing with primary intention will take place under simple antiseptic dressings, even though the injury be extensive.²⁴¹

Indirect.—Through the nasal wall: This probably occurs through wounding the pars membranacea, followed by subsequent infection. This may be caused by galvanocautery of the ethmoid region,²⁴² tamponing the nose,²⁴³ and intranasal surgical procedures.²⁴⁴

8. OSTEOMYELITIS, SYPHILIS, TUBERCULOSIS, AND MALIGNANT TUMORS.—*Osteomyelitis.*—While this affection as an ætiological factor in sinus disease is not uncommon during the first years

240. George Mackenzie: Two Cases of Maxillary Sinus Involvement. *Homeo. Eye, Ear and Throat Journ.*, Jan., 1910. 241. Haga: *Kreig chirurgische Erf. aus dem Chin.-Jap. Kriege, '94-'97.* Berlin, 1897. 242. Tilley (229), p. 102. 243. Avellis: *Einige kurze klin. Bermerk. z. Lehre vom Kieferhöhlenempyem.* *Arch. f. Lary.*, Bd. 2, 1895. 244. Wertheim: *Beitr. z. Path. u. klin. der Erkrank. d. Nasennebenhöhlen.* *Arch. f. Lary.*, Bd. 11, S. 80, 1901.

of infant life, after that time it is extremely rare, especially after puberty. Cases of sinusitis, however, have been reported²⁴⁵ which were clearly the result of a pre-existing osteomyelitis.

Syphilis.—Maxillary sinus empyema as a result of syphilitic infection can only occur through necrosis of some portion of the bony wall through the dissolution of a tertiary lesion. The nasal wall beneath the inferior turbinate and the anterior wall have been reported thus affected,²⁴⁶ but the process is rare enough, as the extreme paucity of the reported cases will admit.

Tuberculosis.—Tubercular disease of the antrum occurs more frequently than with the neighboring sinuses, yet is of itself of great rarity. Koschier²⁴⁷ reported two cases in which he believed the disease was quite primary, and shortly afterward Coakley²⁴⁸ published a similar case. A permanent cure followed the radical operation in both instances. The disease is usually dependent upon a focus of infection in some removed portion of the body which secondarily attacks the bone in the immediate vicinity of the sinus cavity. The seats of predilection for this process seem to be the alveolus of the superior maxillary and the lateral nasal wall. In true tubercular infection the bacillus will always be found on microscopical examination.

Malignant Tumors.—Sarcomas, and particularly rapidly-proliferating epitheliomas, on account of their poor blood supply, can break down and ulcerate, thus producing, by continuity, a purulent process within the sinus cavity. The maxillary sinus is the seat of malignant disease more often than the remaining sinuses together.

9. CHRONIC OR LATENT EMPYEMA.—Under certain circumstances maxillary sinus empyema may take its inception in a chronic form, particularly when the disease occurs from the alveolus. This is due to the primary irritation being mild and continued for some length of time, allowing the mucous membrane to react and fortify itself against the infection. The mucosa, however, finally succumbs to the progressive inflammation, and a well-marked case of chronic empyema results.

245. Menzel: Ueber primäre akute Osteomyelitis des Oberkiefers. Arch. f. Lary., Bd. 21, S. 100, 1909. 246. Neufeld: Tuberculose, Syphilis und Kieferhöhleneiterungen. Arch. f. Lary., Bd. 17, S. 215, 1905. 247. Koschier: Wiener Laryng. Gesellsch, Monat. f. Ohrenhk., S. 43, 1901. 248. Coakley: A Case of Tuberculosis of the Antrum of Highmore. N. Y. Univ. Bulletin of Med. Sciences, p. 121, 1902.

SEQUELÆ AND UNUSUAL CONDITIONS FOUND IN THE MAXILLARY SINUS.

CYSTS.²⁴⁹

Two distinct varieties of cyst formation are found in the maxillary sinus: 1. Mucoid or retention cysts. 2. Dentigerous cysts.

1. The *mucoid cyst* is characterized by single or multiple, semi-spherical, yellow or whitish protuberances on the floor of the nasal wall of the antrum, ranging in size from a millet seed to that of a walnut. (Fig. 64.) Occasionally they may grow to such an extent as to completely fill the antral cavity. (Fig. 65.) As the

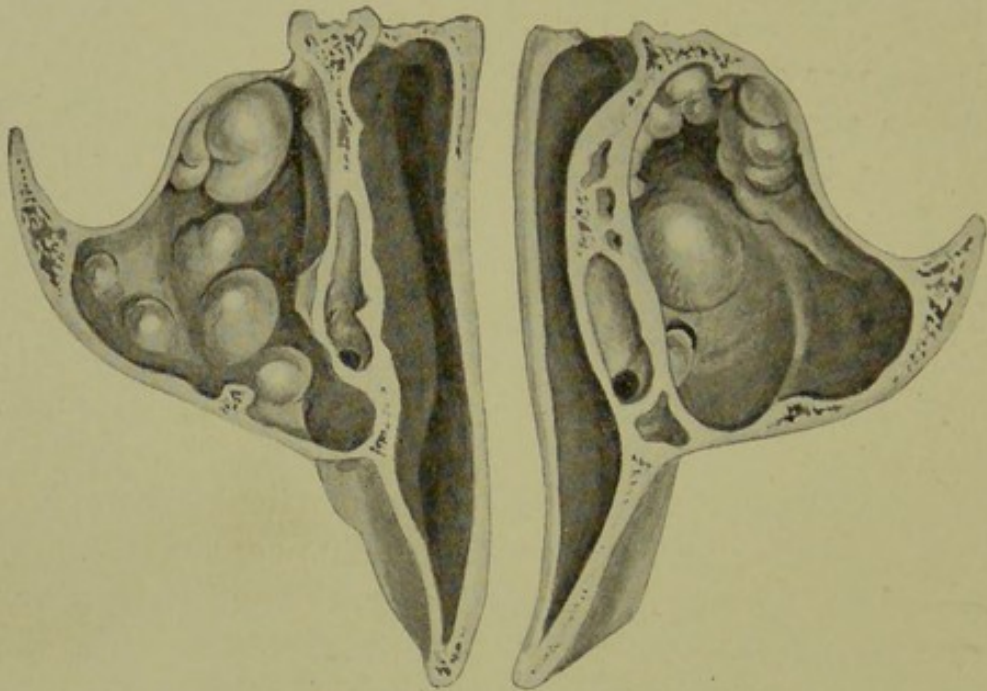


FIG. 64.—Cross section through both maxillary sinuses showing many small mucoid cysts. (After Giraldes.)

name implies, they are occasioned by obstruction to the glandular outlets, due to some form of inflammation in the immediate neighborhood. This inflammation may be in a localized area of the mucosa,²⁵⁰ as they do not necessarily depend upon any previous sinusitis.

The primary contents of these cysts consist of a watery, albuminous liquid containing leucocytes and degenerated epithelium, which later becomes solid through a caseous degeneration. No symptoms are occasioned by the presence of these new growths in their original state, as most examples have been found at the

249. Alexander: Die Schleimhautcysten der Oberkieferhöhle. Arch. f. Lary., Bd. 6, S. 116, 1897. 250. Tunis (225), p. 931.

autopsy which were never suspected during the life of the individual.

2. *Dentigerous Cysts (Cyst of Dental Origin).*—These are

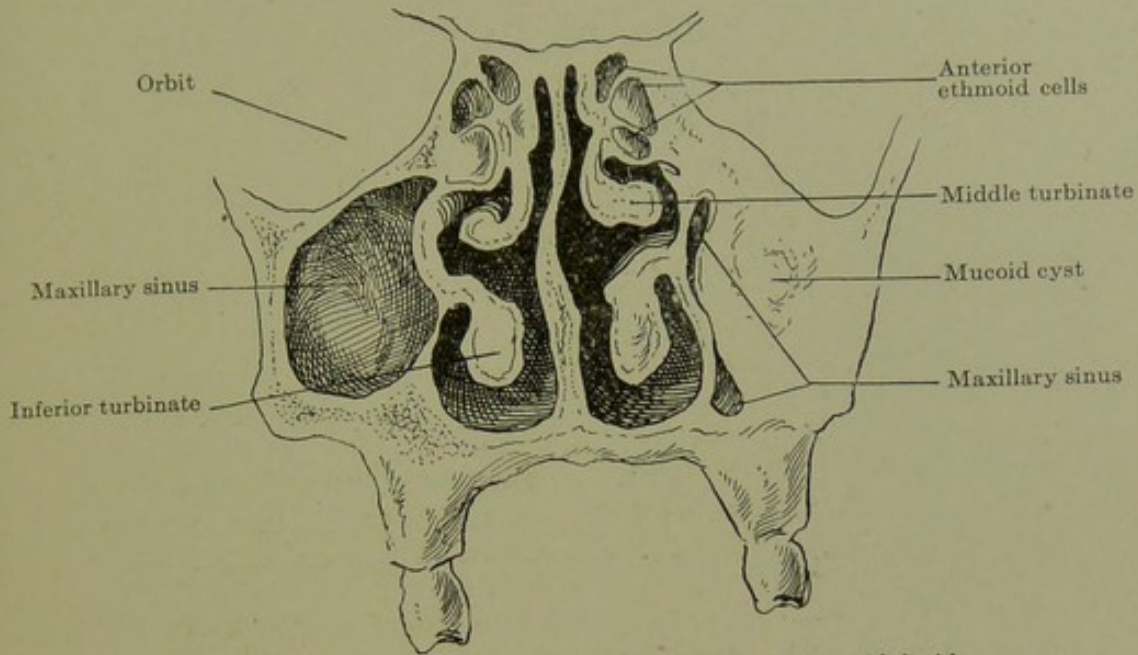


FIG. 65.—Large glandular mucoid cyst almost filling antrum of left side.

caused by disturbances in dentition. Two varieties may be distinguished:²⁵¹ 1. Those due to retention of unerupted teeth

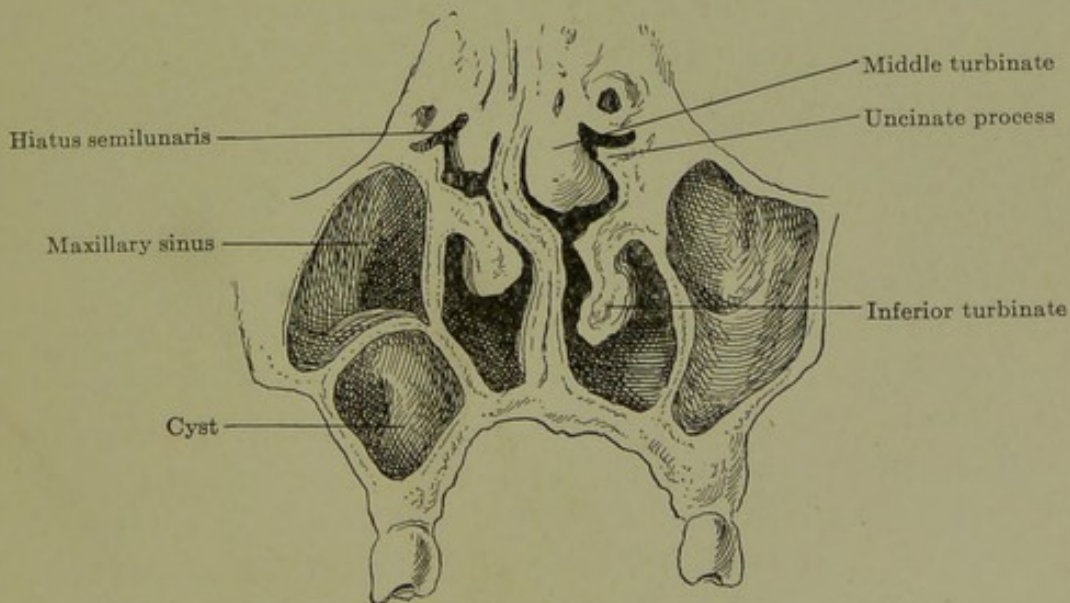


FIG. 66.—Dentigerous or true bone cyst of an antrum on right side.

(improper development)—rare. 2. Those due to inflammatory changes in the root membrane of an infected tooth (periodontal).

The dental cyst is formed by a sac of tough connective tissue,

251. Heath: *Injuries and Diseases of the Jaws*, p. 367, 1867, London.

which enlarges in an upward direction both into the spongy bone and into the maxillary sinus. (Fig. 66.) It does not cease growing until an opening is found which allows the escape of the continually-forming secretion either into the nose or into the mouth. The normal contents consist of a straw-colored, watery liquid, often containing cholesterin, but when infected becomes thick, brownish or chocolate-colored, sometimes degenerating into a cheesy mass. Hydrops antri is a name often falsely given to these cysts which contain thin, watery fluid.

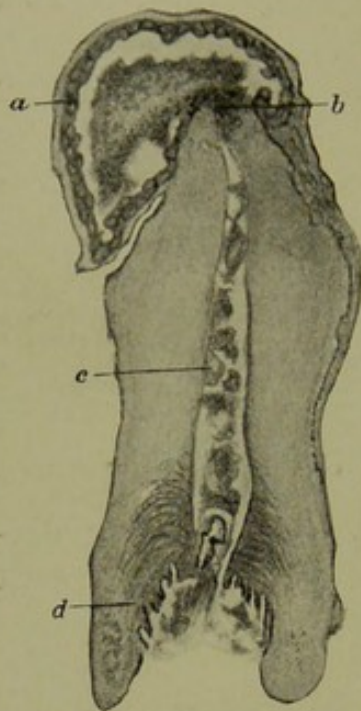


FIG. 67.—Section through a tooth and root cysts (after Hoffmann). *a*, cyst wall; *b*, granulation tissue; *c*, necrotic pulp; *d*, carious portion of tooth.

ÆTIOLOGY AND PATHOLOGY.—Inflammatory changes in the root membrane.²⁵² After a tooth has become carious, micro-organisms find their way into the canal causing a peridontitis at the extremity of the root. This inflammation results in the formation of a minute cyst on the tip of the root (Fig. 67). If the tooth is drawn at this stage, the cyst will frequently be simultaneously extracted. If, however, the irritation continues, and the canal becomes closed, retention of the inflammatory products will take place with subsequent dilatation and cyst formation.

SYMPTOMS.—In the earlier stages all symptoms may be lacking, as the growth takes place painlessly, and not until marked swelling occurs does the patient pay any particular note to the condition. During the later stages a hard, bony distention may be felt directly over the antrum in the region of the ala of the nose.

In the alveolar region this swelling may yield slightly to pressure, emitting a parchment-like crackling, this being due to the partial absorption of bone from the ever-increasing pressure of the cyst.

Occasionally the lateral nasal wall is pushed inward toward the septum, and even the roof of the mouth may show swelling over a considerable area. The cyst continues to enlarge until rupture either into the maxillary sinus, nose, or mouth occurs. If rupture takes place into the antrum, all the symptoms of a true maxillary sinusitis will supervene.

DIAGNOSIS.²⁵³—Dilatation of the anterior sinus wall, in itself, is

252. Hoffmann: Zur Path. der Kiefercysten. Zeitschr. f. Lary., Bd. 3, S. 467, 1911.

253. Kunert: Ueber die Differential Diagnose zwischen Cysten und Antrum-Empyem. Arch. f. Lary., Bd. 16, S. 502, 1904.

enough to clear the diagnosis, as this condition is unknown in sinusitis. The parchment-like feeling, as well as inward distention, of the lateral nasal wall will aid in arriving at a true perception of the condition. If a fistulous communication is present in the mouth, insert cannula and wash out, and, in the event of a cyst being at hand, the injected liquid will return from the same opening and not through the nose. If any doubt remains, a sound may be introduced until the superior wall is reached. The instrument is then withdrawn and measured on the face, and the point will not reach to the inferior orbital plate. A trocar can now be introduced and pierce the roof of the cyst. Water injected through the cannula will return by way of the nose.²⁵⁴ For differential diagnosis between cyst and sinusitis, see page 148.

TREATMENT.^{255, 256}—Nothing but a radical operation will prove of the slightest benefit in these cases. The entire anterior wall must be resected from the canine fossa, and, as the inner lining of the cyst is similar to mucosa of the mouth, no curettage is practised, but these structures allowed to unite, thereby forming one continuous cavity. After a longer or shorter lapse of time the cyst cavity becomes more or less obliterated and a perfect cure results.

CASEOUS METAMORPHOSIS (VERKASUNG).^{83, 257, 258}

This consists of a fatty degeneration of the pus-corpuscles of the exudate with the formation of detritus from broken-down cells and a degenerated epithelium, the entire cavity of the antrum being filled with a solid or semi-solid mass of material having the consistency of "cottage" cheese.

This condition occurs in both acute and chronic empyema, but seems to be associated more particularly with the latter. The actual circumstances which lead on to this metamorphosis have never been satisfactorily explained, although it would seem the explanation would lie in the fact that the mucous membrane has regenerated sufficiently to throw off the disease. In any case the mucosa is no longer affected and the caseous mass occupies only

254. Cobb: Dentigerous Cysts. *Laryngoscope*, vol. 9, p. 397, 1900. 255. Andereya: Zur diagnose und Behandlung der Oberkiefercysten. *Arch. f. Laryn.*, Bd. 20, S. 287, 1908. 256. Bautze: Beitrag zur Lehre von den Kieferzysten. *Zeitschr. f. Laryn.*, Bd. 4, S. 99, 1911. 257. Fischenich: Zur Frage der Verkäsung des Kieferhöhlenempyems. *Verh. süd-deut. Lary.*, S. 526, 1902. 258. Bouvier: Käsiges Kieferhöhlenempyem mit hochgradiger Verdrängung der Nasenscheidewand. *Verh. d. ver deutsch Lary.*, S. 203, 1911.

the position of a foreign body. This is proved by the circumstance that it is only necessary to expel the mass by one or two lavages in order to bring about a permanent cure.

Several conditions may be confused with, or result in, cheesy degeneration:

1. The so-called cases of rhinitis caseosa are undoubtedly identical with the above, except, in the former, cheesy masses force their way through the ostium into the nose.

2. Purulent material which has been secreted above the frontal or ethmoidal sinuses may flow into the antrum and, losing its moisture, assume inspissated and cheesy characteristics without in any way infecting the antral mucosa.

3. A large mucoid cyst situated in the maxillary antrum may become solidified and by its growth cause certain pressure symptoms which lead to its discovery. (Fig. 65.) As only the contents would be brought to light, their similarity to the genuine caseous degenerated pus would warrant a diagnosis of "verkäsung." The symptoms of this condition are those of a very mild case of maxillary sinusitis without free pus being visible in the nose on account of obstruction of the outlet. If the ostium is free, only a thin, serous discharge is frequently observed. On needle puncture it will at first be difficult to force through irrigating liquid, but, once started, cheesy masses with fetid odor will be expelled. It often requires several irrigations before the entire cavity is rid of this material, but after thorough evacuation no return of the condition need be feared.

STONE FORMATION IN THE MAXILLARY SINUS.

Six cases in all have been published of this rare occurrence.^{259, 260} The stones have all been similar in composition to ordinary rhinolith found under the tongue. In all instances they cause symptoms of an acute maxillary empyema associated with considerable pain. The concretions varied in size from a pea to that of a walnut, were of reddish, brownish, or brownish-yellow color, and those that were sawed had no foreign body as a nucleus. No pathognomonic symptoms were present, nor any theories advanced as to their probable genesis.

259. Oppikoffer: Ueber Steinbildung in der Kieferhöhle. Arch. f. Lary., Bd. 20, S. 31, 1908. 260. Mühlen: Ein Fall von Steinbildung in der Kiefer und Keilbeinhöhle, Arch. f. Lary., Bd. 21, S. 371, 1908.

MUCOCELE OF MAXILLARY SINUS.

Although isolated cases have been reported from time to time,^{261, 262} it is doubtful if these were true mucoceles. In every instance the contents were of decidedly fluid nature, while it is well known that those of the frontal sinus and ethmoid labyrinth contain a semi-solid, gelatinous substance. Under these circumstances we would be justified in considering the former as a species of cystic enlargement, especially when the tendency of the maxillary sinus mucosa toward cyst formation is taken into consideration.

CHOLESTEATOMA FORMATION.²⁶³

This is characterized by the formation of a whitish or grayish mass within the sinus, distinctly lamellated, having an extremely fetid odor and showing the presence of cholesterine crystals. According to their origin they are divided into: (1) primary or true cholesteatoma; (2) secondary or false.

1. The true cholesteatoma is undoubtedly of fetal origin, being due to some disturbance in the normal embryonal growth of the epidermis causing an untoward proliferation into the bones of the sinus, which acts as the nidus for the subsequent formation of the tumor. Deep-seated, involving underlying bone.

2. The secondary or false cholesteatoma is caused by a metaplasia of the normal cylinder epithelium of the sinus which takes place either direct from the diseased atrophic nasal mucosa or through a fistulous passage into the mouth. Superficial, only affecting mucosa.

The squamous epithelium grows through the opening until it meets with the inflamed ciliated lining of the sinus. Being unable to unite with it, the epidermis grows in layer form which soon finds insufficient nourishment and dies, another layer taking its place. In this way we can account for the laminated structure which has very aptly been likened unto the layers of an onion. An external or fistulous opening is necessary in order for this to form.

SYMPTOMS.—The subjective disturbances occasioned by these bodies depend upon their size and the pressure exerted upon the sinus walls. When the cholesteatomatous mass fills the antrum bulging of the walls is noted accompanied by intense pain. Tenderness is marked over the entire area, with swelling of the lower

261. Hastings: Mucoccele of the Nasal Accessory Sinuses. *Ann. Otol., Rhin. and Laryn.*, p. 641, Sep., 1911. 262. Lack (65). 263. Winckler: Zur Kasuistik des Kieferhöhlencholesteatoma. *Zeit. f. Laryn.*, Bd. 2, S. 251, 1910.

lid. The naris on the affected side is filled with fetid pus and the inferior turbinate markedly congested.

Operation will disclose a desquamative inflammatory mass of moist caseous lamellated epithelium and putrefying detritus with extremely fetid odor, which, if a true cholesteatoma, will be intimately adherent to the underlying bone; if secondary, will allow itself to be shelled out *en masse*. In the embryonal form unless all of the membrane is removed at the time of operation a recurrence will certainly take place.

The secondary form in contradistinction to the former, being caused by the sinusitis, will respond readily to operative treatment.

DIAGNOSIS.

When a patient presents himself for examination and empyema of the maxillary sinus is suspected, there is but one method which will give definite information: exploratory needle puncture. If pus appears either by aspiration* or by lavage, one is absolutely certain that the antrum contained the purulent secretion. Whether the sinus itself secreted the product or whether it acted in the capacity of a reservoir for material which had been secreted in one or more of the overlying sinuses is a matter to be subsequently determined. Having ascertained that the maxillary sinus contained a pathological secretion our next step is to find the cause and source of the pus.

1. *Examination of the Mouth.*—A certain proportion of cases, twenty to thirty per cent., take their origin from caries of a tooth. This fact can almost always be elicited by the history and by visual and tactile examinations, and if this should prove to be the case, further delay is unnecessary, as our plan of treatment is clearly indicated. If any doubt remains, an X-ray picture will speedily disclose the exact condition of the alveolus and roots of teeth.

Cooper method of treatment: Extract the diseased tooth or root and bore an opening through the alveolus. If, on the other hand, in spite of our endeavors to find some past or present alveolar trouble, no signs or symptoms indicate that such was or had ever been the case; what is the next procedure to be adopted? The simple needle puncture with thorough lavage is merely con-

* Needle puncture with aspiration may fail to bring out the secretion, especially if the pus has become inspissated or degenerated into caseous masses. For bacteriological examinations, however, it is most useful to obtain pure cultures of the infecting micro-organisms.

tinued for perhaps a week, as this procedure alone often brings about a complete cure; under which circumstances, no more pus being visible in the nose by rhinoscopy, the diagnosis is positively established that the maxillary sinus was not only primarily at fault, but that its lining mucous membrane was in a condition to quickly regenerate as soon as it had been relieved of its irritating pathological contents.

It must be borne in mind that one or more of the overlying sinuses may have been primarily affected and later healed spontaneously, a certain amount of secretion having found its way into the antrum and there remaining. Under such circumstances either one of two things must necessarily happen. Either 1. The secretion remains dormant, gradually draining from the action of the cilia and the recumbent position of the patient, or 2. The secretion contains micro-organisms of a virulent form which quickly infect the mucous membrane of the antrum causing a typical case of acute maxillary sinus empyema. The author is of the opinion that the first condition frequently occurs, the second, but rarely, as it has been pointed out that the mucous membrane of the antrum may tolerate the presence of purulent secretion for a long period of time without itself becoming infected. Whether infection occurs, depends more upon the virulence of the contained micro-organisms than upon the quantity of pus involved.

Should the continued lavage through the needle produce no change in the quality or quantity of the secretion, it is imperative that the anterior half of the middle turbinate be removed: (1) to enable one to ascertain whether the ethmoidal cells, or the frontal sinus, are secreting; (2) to lay bare the ostium of the maxillary sinus.

During the interval while the wound is healing, nothing can be done except to continue the conservative treatment, because the bleeding which results from the lightest manipulations in the frontal region would so obscure the field as to make observations practically valueless.

After the part has sufficiently healed (four or five days) make the needle puncture and lavage as usual, then wash the nares with normal salt solution and allow the patient to wait in an adjoining room for one-half to three-quarters of an hour.

If an examination is now made and no pus is seen in the middle nasal passage, it is *prima facie* evidence that only the maxillary sinus has been affected. If, on the other hand, an appreciable quantity of purulent secretion is seen oozing out from the region of the hiatus semilunaris, it is definitely established that one or both of the overlying sinuses is also diseased, as it is manifestly impossible for the mucous membrane of the maxillary sinus to

secrete so freely that the entire cavity fills up and overflows in the short space of time that the patient remains in the waiting room.

Our next problem is to determine whether both the maxillary and the fronto-ethmoidal* sinuses are affected or whether the fronto-ethmoidal alone, the maxillary merely acting as a reservoir for a portion of the purulent material which has been secreted by the mucous membrane of the former. This may be easily and quickly ascertained by the following procedure: Wash out the maxillary sinus as usual (preferably in the morning) after the nasal cavities have been cleaned, pack selvaged strips of gauze lightly but sufficient to exclude immediate penetration in the region of the ductus naso-frontalis, requesting the patient to return the same afternoon for further inspection. Remove the gauze and wash out the nares. The needle puncture is now made, and if the sinus has been the receptacle for pus secreted above, the injected solution will return unchanged.

CLOSED EMPYEMA OF MAXILLARY SINUS.

This condition is caused by partial or complete occlusion of the ostium, causing stagnation of the secretion. An infallible sign of this condition during an attack of maxillary sinusitis is bulging of the pars membranacea in the middle nasal passage, without any trace of secretion being visible in the nose.

ADJUNCTS TO DIAGNOSIS.

TRANSILLUMINATION.—This method is applied in the following manner: The room must be as dark as possible. After the eyes have become accustomed to the darkness, a small electric globe is placed in the patient's mouth (care being taken to remove false teeth if present), and the current applied after the lips are compressed. With a rheostat the illumination should be gradually brightened to the full capacity of the lamp. Bright spots should appear in the canine fossa (Plate 2) and in the infra-orbital regions; the pupils are also dimly lighted.²⁶⁴ Any differences in the illuminations of the sides must be quickly noted; also the subjective symptoms of the patient. This procedure should be repeated several times by turning on the light in

* The term, fronto-ethmoidal, is used because the frontal sinus is rarely if ever alone affected, some of the anterior ethmoidal cells invariably are sympathetically diseased. (See Anatomy of Frontal Sinus.)

264. Brown, Kelly: Transillumination of the Antrum of Highmore. *Brit. Med. Journ.*, vol. 1, p. 650, 1905.

order to confirm as far as possible the first impressions. If strongly marked unilateral shadows occur, it is understood that empyema is present on that side.

*Mechanism of Transillumination.*²⁶⁵—When the current is applied, the lamp being in the mouth, some of the rays enter the maxillary sinus through the alveolus, but the majority first enter the nasal chambers and are reflected through the lateral nasal wall into the antrum (chiefly through the inferior meatus). If sufficient illumination is present the rays will then penetrate the superior or orbital wall and impinge upon the retina, thus giving the subjective sensation of light to the patient.

Actual Cause of Shadow Formation.—Unilateral shadows unfortunately do not always mean that a disease exists on that side. Inequalities in the anatomical formation of the bone are among the chief causes of error. It is now a matter of common knowledge that equalized transillumination of the maxillary sinus is the exception rather than the rule.

Purulent secretion *en masse* is supposed to arrest the rays of light, thereby causing more or less defined shadows on the affected side, depending upon the thickness of the secretion. As a matter of fact, this cannot be depended upon, as it has been demonstrated that an antrum filled with pus may be as translucent as the opposite unaffected side. What, then, causes the area of darkness in diseased sinuses? This question is best answered by the following hypothetical case: A patient shows maxillary sinus empyema on transillumination. A needle puncture is made and a large quantity of purulent secretion is expelled. Again the transillumination test is applied, and the shadow remains as well defined as before the pus was evacuated. After a period of appropriate treatment the affection is cured. Another test is made and the sinus appears as light as the fellow on the opposite side. Our conclusions are now obvious. The shadow must have been caused by the diseased mucosa, for, after resolution occurred, the opacity at once disappeared. This has been the experience of every rhinologist who has made extensive use of this adjunct to diagnosis.²⁶⁵⁻²⁶⁸

Value as to Reliability.—From what has been said, the de-

265. Logan Turner: *The Accessory Sinuses of the Nose*, p. 110, Edinburgh, 1901.
 266. Schwartz: *Ueber d. diagnost. wert der elekt. Durchleuchtung*. *Beit. z. Klin. Chir.*, Bd. 14, 1895. 267. Ziem: *Nochmals die Überschätzung d. Durchl. d. Kieferhöhle*. *Mon. f. Ohren.*, S. 155, 1895. 268. Lambert Lack (65), p. 303.

duction is clear that we must exercise the greatest circumspection in making a positive diagnosis from the findings of transillumination alone. As a matter of fact, it should never be done. We have always at our command a simple harmless procedure which requires but a moment to carry out and is absolutely reliable: the needle puncture. This is particularly applicable when the only symptom of antrum disease is unilateral darkness.

The transillumination test may then be said to be, as far as the antrum is concerned, an important adjunct to corroborate the diagnosis after all other examinations have been made. If the symptoms point toward maxillary sinus disease and the test is positive, well and good; if negative, it is no proof of the non-existence of the affection.

RÖNTGEN RAY.—While not so valuable as in the frontal sinus, the X-ray gives usually reliable information as to the condition of the sinus mucosa. In those cases where disease is present the contour of the sinus is not so distinctly marked as in the healthy cavity. The plate shows a shadow on the diseased side as well as a blurring above the sinus borders. It must be borne in mind that when a copy is printed from the negative, the diseased portion will show lighter instead of darker than the healthy side.

SUCTION OR NEGATIVE PRESSURE.—The rationale of this method is to close the choanæ by allowing the patient to articulate a continuous K, then applying suction to the external nares, thus causing a condition of negative pressure in the nose and forcing any secretion out of the ostia which may be contained in the sinus. This has been of but little value in our hands. Even after the nose had been thoroughly irrigated there always seemed to be a certain amount of secretion drawn into the nose where this method was successfully applied.

It was, however, by no means certain that this secretion was drawn from the sinuses, as the probabilities are that it was hidden in the deeper interstices of the ethmoid capsule. In the vast majority of instances it was impossible to obtain complete closure of the posterior nares, and when this did occur there nearly always appeared to be some hitch in the technique. It would seem for diagnostic purposes that the same result could be obtained by allowing the patient to close the nares between the thumb and finger and forcibly sucking through the nose. In this way one procures a much greater degree of negative pressure than is pos-

sible by the use of the instruments which are at present at our disposal.

SYMPTOMS.—*Acute*.—1. Feeling of distention and pressure: These symptoms are practically always present in the first stages of the acute form. They are due more to swelling and hyperæmia of the maxillary mucosa than to the internal pressure of the pent-up secretion. When present, the naris of the corresponding side is occluded and intensely congested, so that even needle puncture, followed by lavage, has little influence upon it. Walls often sensitive to pressure. 2. Pain may be present or absent, depending largely upon the degree of inflammation present in the sinus.²⁶⁹ It may assume the character of distention, or, what is more often the case, that of neuralgia.

Pain is particularly noticeable when stagnation of secretion with pressure occurs. That this is often the true cause of the pain in contradistinction to swelling of the mucosa is proved by the immediate relief experienced on irrigation of the sinus with expulsion of its contents.

Curiously enough, the neuralgia is not confined over the superior maxillary area, but its seat of predilection is over the orbit of the affected side.²⁷⁰ Supra-orbital pain may be the only symptom, and of such persistence as to simulate frontal sinus disease. Indeed, such cases have by their persistency been mistaken for this affection, with the result that the frontal sinus was needlessly opened. This is an object lesson which requires no comment. Pain in the teeth of the upper jaw on the diseased side is occasionally present, particularly if the empyema was of dental origin. Sometimes only a peculiar uncomfortable feeling is noted in the teeth, as though one particular tooth was loose or longer than its fellows. The headache, whatever its character may be, intensified by stooping, coughing, sneezing, etc., and, in fact, by any condition which produces a sudden jarring of the head or body. The indulgence in alcohol and tobacco also increases the discomfort.

After the disease has lasted several days and become semi-acute the pain, if a prominent symptom, becomes remittent, the exacerbations depending upon the quantity of purulent material secreted. Regarding pain located directly in the sinus, this only occurs when severe local changes are present, such as inflamma-

269. Menzel: Zur Symptomatologie der Kieferhöhlen-empyem. Monat. f. Ohrenhk., No. 6, 1905. 270. Killian (44), p. 1024.

tion of the underlying bone (peri-ostitis) or ulcerations of the soft parts.

Secretion.—*a.* The secretion in acute maxillary sinusitis is not formed at the inception of the disease, but makes its appearance after the first day or two. Its profuseness depends largely upon the causative factor as well as its constituency; thus, empyemas of infectious origin do not, as a rule, secrete so freely as those of dental origin. The character of the secretion may range from serous to purulent and even sanguino-purulent, depending upon the character of the disease. The pus from acute sinusitis of dental origin is apt to be fetid and contain caseous masses.

b. Place of appearance: This is usually in the middle nasal passage, over the uncinatè process beneath the middle turbinate and appearing on the anterior third of the inferior turbinate and often on the septum directly. It is much more likely to appear in this place in acute inflammation than in the chronic form, for in the former there is little likelihood of pathological changes having taken place to dam off and guide the purulent material to other places. However, in seeking for this symptom due consideration should be made for the position of the head, anatomical formation of the nose, and consistency of the secretion. The appearance of the secretion is not always constant, as at certain times during the day the nose may be entirely free from any trace of pus. This is explained by the fact that for some reasons not well understood the ostium and drainage passages suddenly become patulous, allowing the full escape of the sinus contents into the nose. In these cases this often occurs in the form of a siphonage, thus emptying in a short space of time. The usual time for this to occur is immediately after arising, so that when the patient comes under observation during the morning office hours little secretion can be seen. A history of this can always be obtained, as the patient complains of the enormous quantity which he is obliged to expel from the nose every morning.

NASAL SYMPTOMS.—The naris on the affected side is in a continued state of hyperæmia with more or less occlusion. The nasal mucosa is hypertrophied, partially on and around the uncinatè process. The hyperplasia in this locality is occasioned by the continual irritation from the overflowing secretion as well as by continuity through the ostium from the antral mucosa.

The sense of smell is diminished or entirely obliterated, due to either the hyperplasia preventing the odorous substances from

reaching the olfactory space, or to the secretion covering the terminal filaments of the olfactory nerve. In severe cases where the hyperæmia is marked, passive œdema of the eyelids and cheeks is often observed (caused by inflammation of the collateral venous circulation).

It will depend largely upon the general configuration of the middle nasal passage, particularly upon the position of the middle turbinate, as to what may be noted by anterior rhinoscopy.

The classical symptoms are pus appearing from beneath the anterior end of the middle turbinate, flowing down over the inferior turbinate, which immediately reappears on wiping away with a pledget of cotton. When the middle turbinate lies against the septum, it frequently occurs that no trace of pus is to be seen in the middle nasal passage, but in the superior nasal passage a marked quantity is in evidence. This is caused by capillary attraction, the purulent secretion flowing slowly down on the antral side of the middle turbinate reaches the inferior edge and is attracted upward by the mucous membrane of the septum. On first sight this is apt to be confusing and lead the examiners to suspect empyema of one or more of the sinuses of the second series; however, when this secretion is removed it will not immediately return, thus proving that it is not the end stream from a reservoir. If the middle turbinate lies somewhat removed from the lateral nasal wall and the processus uncinatus is not very broad, this symptom will always be present. Unfortunately, this is but seldom the case. The mucous membrane of the processus uncinatus, bulla ethmoidalis and middle turbinate is almost always swollen and œdematous, and these parts usually impinge upon one another, thus closing the anterior outlet. As a consequence the continually forming secretion in the maxillary sinus must find an outlet, which it does, backward into the choanæ, through a passage between the middle turbinate and lateral wall of the nose.

GENERAL DISTURBANCES.—These usually take the form of those which accompany any acute local disturbance and correspond proportionately in severity. Fever and chills are, perhaps, in the beginning the most prominent symptom. In mild infections these may be so slight as to pass almost unnoticed, while in the severer types they are so marked as to confine the patient to bed.

Generally speaking, the individual suffering with acute maxillary sinusitis, even though able to be about, has the appearance

of a sick man. Generally restlessness during the day and sleeplessness during the night are prominent symptoms. Gastric and intestinal disturbances, especially when the secretion has a tendency to flow into the choana and be swallowed, which assumes the form of nausea and eructations of gas, are prone to occur. Peritonitis is not an uncommon incident; in fact, the prevailing symptoms often direct one to believe some throat affection is the cause of the sickness.

COMPLICATIONS.²⁷¹—These are exceedingly rare, but for the sake of completion the following, which have from time to time been reported, must be mentioned.

Orbital.—Œdema of the eyelids: This has been previously mentioned and is due to inflammatory products finding their way into the ethmoidal veins. Œdema of the retro-bulbar cellular tissues causing exophthalmos²⁷² without the formation of a purulent collection.

Exophthalmos due to the formation of an orbital phlegmon.²⁷⁵ Cases of partial or total temporary blindness, which disappeared after varying intervals, have been reported.²⁷³ These, according to Killian, were due to pressure of the œdematous tissues on the optic nerve and central artery of the retina.

Meningitis and brain abscess: Intracranial complications are rare owing to the removed anatomical situation of the maxillary sinus from the cerebral structures. That such complications, however, are possible has been shown by several investigators.^{274, 275} Pyæmia may also result from the products of suppuration occurring in the general circulation.²⁷⁶

SYMPTOMS.

Chronic Empyema.—The symptomatology of this affection is peculiar in the wide range of degree from mild to severe which it may assume. As an example, the symptoms can be so slight as even to fail entirely, the patient being unconscious of any sinus trouble until accidentally discovered. This is, fortunately, the exception rather than the rule, as careful examination in these cases

271. Villemonte-Laclergerie: Complications oculo-orbitaires des sinusites maxillaires. These de Bordeaux, 1906. 272. Pagenstecker: Beiträge z. Aetiologie u. Therapie der retro-bulbären Zellgewebsentzündung. Arch. f. Augenhk., Bd. 13, S. 138, 1884. 273. Halstead: Empyema of Right Maxillary, Ethmoidal and Sphenoidal Sinuses, with Sudden Blindness of the Left Eye. Operation. Recovery of Sight. Archives of Otolaryngology, June, p. 223, 1901. 274. Dmochowski: Entzündliche Prozesse des Antrum Highmori. Arch. f. Laryng., Bd. 3, S. 255, 1895. 275. Manasse: Ueber orbitale und cerebrale Komplikationen bei akuten Nebenhöhlenerkrankungen. (Fall 2) 1 Ver. d. ver. deutsch. Laryng., S. 189, 1911. 276. Zange: Ueber Pyæmie nach Kieferhöhlenerkrankung. Zeit. f. Ohrenh., Bd. 60, 1910.

will usually elicit some symptoms which will ultimately lead to the correct diagnosis. On the other hand, the transmission from the acute to the chronic stadium may take place without perceptible abatement in the subjective sensations, the course of the disease being, as far as the symptoms are concerned, to all intents and purposes, acute.

Pain.—Actual pain in the sinus is usually absent, neither do we find the sensation of fullness nor sensitiveness to pressure as in the acute form. (When the sinus is filled with dilated cysts or mucous polyps the sensation of distention is sometimes present.) Headache in some form is a common symptom, the most frequent being supra-orbital neuralgia, although in severe cases, particularly when partial stagnation occurs, the pain is apt to embrace the corresponding half of the head. (Killian believes the pain is due, not only to the irritation of the trigeminal nerve endings in the mucosa, but to the direct irritation of the main trunks.)

The pain, however, is variable, and for a thorough description the cases must be divided into (1) mild; (2) moderate; (3) severe.

1. In mild cases the pain is absent or at most takes on the character of a full tense feeling in the superior maxillary region of the affected side. Often enough there are absolutely no subjective symptoms from which one could draw an inference that the maxillary sinus was affected. No tenderness, no swelling, teeth on both sides apparently sound, and it is not until exploratory needle puncture has been made that the diagnosis is established.

2. Moderate cases: The pain is similar to attacks of neuralgia, occurring at intervals, and is characterized by its indefinite localization, being but rarely confined to the superior maxillary region. In conjunction with the full tense feeling, sharp shooting pains occur in the infra-orbital nerve and frequently in the supra-orbital region, and, indeed, may be entirely localized to the latter.²⁶⁹ The patient usually complains of a dull indefinite feeling of tenseness in the diseased side of the head, with intermittent twinges of neuralgia over the entire side of the face and forehead. This pain is usually worse late in the morning and towards evening gradually remits. This is due to the fact that partial drainage of the cavity takes place as in the other sinuses. The pain and discomfort of the patient is markedly increased by indulgence in alcohol or tobacco.

3. Severe cases: One would suppose that when the mucous

membrane of the sinus had undergone great degeneration with perhaps underlying caries of the bone, the acute local pain would be well marked.

While this is true in the main, nevertheless exceptions can and do occur as is exemplified in the following cases:

CASE 1.—Mrs. B. Chronic maxillary sinusitis, severe pain on corresponding side of head, almost continuous, little discharge, general symptoms of debility. Radical operation, areas of polypoid degenerated mucosa, little non-fetid secretion.

CASE 2.—Mrs. P. Chronic maxillary sinusitis. Never any pain, profuse discharge, principal complaint of patient subjective fetid odor in nose.

Radical operation, sinus filled with extremely fetid pus, mucosa acutely inflamed and degenerated.

On comparing these cases, one is at once struck with the dissimilarity of the pain in ratio to the inflammatory condition of the mucosa.

The indefinite character of the pain is still marked, but the feeling of tenseness, with sudden, lightning-like paroxysms of neuralgia, is so intensified as to become almost unbearable. These neuralgic attacks are not confined to the diseased side, but are often complained of on the opposite side, particularly over the course of the infra-orbital nerve and in the parietal region. The tense feeling is constant, the patient seldom being entirely free from some discomfort, as in the preceding conditions. Even after a thorough lavage the pain is not relieved.²⁷⁷ Alcohol and tobacco are absolutely intolerated. Any sudden jarring, stooping over, straining at stool—in fact, any conditions which cause congestion of the head—will cause insupportable anguish.

The feeling of anguish so completely covers the affected side that one is often at a loss to state definitely whether several and not one particular sinus is affected; this tension, in other words, is so wide in its scope as to be not at all pathognomonic of maxillary sinusitis.

Secretion.—The character may be serous, mucoid, mucopurulent, or purulent, depending upon the virulence and intensity of the disease. Fetid discharge has usually been considered to be pathognomonic of dental origin. This is not always the case, as any condition which will predispose to putrefaction (stagnation) will accomplish this end. When occlusion of the ostium with stagnation occurs, the white blood-corpuscles sink to the bottom and putrefaction sets in.

The classical place of appearance of the secretion is, naturally, where the ostium empties into the nasal chamber—the middle

277. Hajek: Der Kopfschmerz bei Erkrankungen der Nase und deren Nebenhöhlen, No. 11, S. 418, 1899.

nasal fossa beneath the anterior end of the middle turbinate. The various irregularities in the nose, deviations of the septum, polyp foundations, hypertrophies of the uncinata process and middle turbinate all tend to direct the course of the secretion out of the ordinary channels; therefore, it is not an uncommon occurrence to see pus in untoward and unexpected places.

Consistency of the Flow of Pus.—While in the majority of instances signs of pus are always to be found in the nose, nevertheless, it sometimes occurs, particularly early in the morning, that absolutely no traces of a pathological secretion are to be seen by anterior rhinoscopy. This can be accounted for, as follows: While the patient is reclining during the night on the unaffected side, the ostium of the sinus is naturally in its lowest position. The secretion begins gradually to filter out and by morning a considerable quantity of it lies in the nasal cavities. If it is thickened and inspissated, a mechanism of siphonage now occurs whereby the free secretion already in the nose will flow back into the choanæ, drawing with it a certain quantity out of the sinus. The patient by rasping and hawking, finally dislodges this, expectorating the mass, and on presenting himself for examination will show no traces of secretion.

Periodicity of Emptying.—It has been shown, under the general heading of symptomatology, that the purulent secretion formed in the sinuses is not continually flowing into the nose like a leaking faucet, but intermittently appears drop by drop. This is but a natural condition when we consider that the sinus contains but one ostium,* and for every drop of secretion which is expelled a corresponding volume of air must take its place. As the air must enter by the same passage from which the fluid escapes, atmospheric pressure must exert no inconsiderable influence on the regular outflow of the sinus contents. The viscosity of the purulent material is another factor in this condition, and it not infrequently happens, particularly in maxillary sinus disease, that when the sinus cavity becomes filled and overflowing occurs, most of the contents is siphoned out, leaving the sinus practically empty. (It must be remembered that the ostium of the maxillary sinus lies at the superior extremity of the cavity; therefore, in the worst possible position for favorable drainage.) This siphonage takes place while the patient's head is not in the upright position; therefore, usually at night, and accounts for the hawking and clearing the throat which is such a frequent symptom and so often complained of.

* The accessory ostium appearing in only ten per cent. is not reckoned. Should, however, one be present, the entire physical law of drainage is changed, as the second opening acts as a vent to the normal one, thereby allowing the free and continued outflow of the secretion.

Changes in Consistency.—It is not an unfrequent occurrence in chronic maxillary sinusitis to note the secretion becoming thick and viscid. This is noted particularly in acute colds, during which time it is very profuse, while in the intervals no especial trouble is experienced. These changes are due to an acute exacerbation of the chronic condition, which runs its course, leaving the old affection in its original condition.

The structures of the lateral nasal wall may, in recent cases, show congestion, but, as a rule, hypertrophic and polyp formations are found in the more chronic forms. Unilateral hyperæmia, when present, is due to the congestion of the veins from the pressure of the exudate in the antrum. The seat of the polyp formation is along the free border of the processus uncinatus, around the maxillary ostium, and on the external border of the middle turbinate; in other words, along the course of the escaping secretion. (See section on Relation of Polyps to Empyema.) Hypertrophy occurs particularly on the uncinated process* and anterior extremity of the middle turbinate. Unilateral hypertrophy in these positions is a certain sign of underlying sinus affection. Unilateral occlusion from hyperæmia is always relieved by ridding the sinus of its pathological contents.

NASOPHARYNX AND LARYNX.

Symptoms affecting these parts are so common in maxillary sinusitis that they are practically always concomitant. Sometimes they are the principal symptoms, and patients not infrequently present themselves for treatment for some fancied throat affection when the entire trouble is in the antrum. The symptoms take the form of dryness, particularly accentuated in the morning, hawking and clearing the throat immediately on arising to rid themselves of the accumulated masses of half-dried secretion which has formed during the night. Granular pharyngitis is a sequela of these formations, and it is often confined to one side of the posterior pharyngeal wall (pharyngitis laterales). That form of scleroid pharynx due to the constant drying of secretion may be easily identified, as it gradually loses itself toward the larynx, while toward the choana it is more intensified.

* The lateral nasal swelling of Kaufman (Mon. f. Ohren., S. 13, 1890) is the swollen lip of the hiatus semilunaris, the middle turbinate being rolled above. This swelling often gives one the impression of its being the middle turbinate.

Laryngeal disturbances, such as hoarseness, partial aphonia, and even complete loss of voice, have from time to time been noted.

DISTURBANCES IN OLFACTION.

Neurotic disturbances of this character may take the form of total or partial anosmia, due to the passive or active occlusion of the olfactory fissure through swelling of the mucous membrane, polyps, or collections of purulent material.

A much commoner disturbance is that of subjective perception of fetid odors (*cacosmia*). This is usually paroxysmal, and particularly noticeable when the patient suddenly sniffs. Contrary to the general opinion, I do not believe this factor results from the escape of the purulent secretion into the nose, but rather to the putrefactive gases which continually form, but only intermittently, and, after a certain volume collects, force their way through the ostium into the nose. I have often observed, while forcing air through after needle puncture, that the odor exudes from the nose so as to be noted at some distance from the patient. This has taken place without the slightest trace of any secretion appearing in the middle nasal passage.

While this *cacosmia* is particularly associated with empyema of dental origin, it is by no means pathognomonic of this affection, as it often appears with maxillary sinusitis of nasal origin as well as ethmoidal suppuration.

Indirectly, *cacosmia* may be far-reaching in its effects, as it turns the patient against food or nourishment of any kind.

NERVOUS MANIFESTATIONS.

Neurotic disturbances are sometimes present. They do not depend so much on the actual severity of the disease as upon the temperament of the individual, although, of course, the more virulent the disease, just so much more liability for the predominance of mental disturbances. Certain neurotic individuals note with great exactness the slightest abnormality from their usual condition; others, on the other hand, are not conscious of even considerable unwonted discharge. Various psychological alterations may occur during the course of the disease, as have been enumerated in the general chapter on symptoms, but with the maxillary antrum they are by no means so prevalent as with the other sinuses which lie in closer juxtaposition to the brain.

COMPLICATIONS.

1. **CARIES OF THE OSSEOUS WALLS OF THE ANTRUM, WITH RUPTURE INTO THE NEIGHBORING PARTS, WITH ABSCESS FORMATION.**²⁷⁸—This may occur in the anterior wall,²⁷⁹ posterior wall,²⁶⁹ ²⁸⁰ hard palate,^{281, 282} nasal wall,²⁸³ and orbital wall.²⁸⁴

It is not necessary that caries occur to have a phlegmonous inflammation in the region outside of the antrum, as the inflammation can travel through the foramen in the bone along the nerves and vessels. This is particularly true of the openings for the accessory veins which pierce the antral wall in various places.

Orbital abscess is, of course, the most dangerous of these, for it can easily lead on to intracranial infection. This can occur either through the optic foramen or through the orbital roof.²⁸⁵ Orbital complications through the maxillary antrum run precisely the same course as those from the other sinuses. If exophthalmos occurs, the direction of the protrusion, at least in the beginning, may be directed upward and forward, in contradistinction to that from the anterior ethmoidal and frontal sinuses. Meningeal complications without previous orbital infection rarely occur, owing to the fact that no anatomical connection exists between the maxillary sinus and the cranial cavity. Certain isolated cases, however, have been reported, the one from Claoue²⁸⁶ being of especial interest.

2. **DILATATION OF THE ANTRUM.**—This condition, occurring as a complication of chronic empyema, is dependent upon an absolute occlusion of the ostium, with free secretion from the mucosa.²⁸⁷ Naturally, the nasal wall (pars membranacea) will be the first to yield to the internal pressure, the other walls following in various degrees, as the case might be.

Killian²⁸⁸ and Gerber²⁸⁹ insist upon the comparatively frequent occurrence of this condition. My experience coincides with that of Hajek in that it does not occur; Hajek, however, speaks of dilatation of hard palate.

278. Noltenius: 37 Falle von seröser Erkrank. d. Oberkieferhöhle. *Mon. f. Ohrenhk.*, S. 114, 1895. 279. Paunz: Ueber die Komplikationen des dentalen Kieferhöhlenempyems. *Arch. f. Laryng.*, Bd. 25, S. 449, 1911. 280. Dmochowski (27), Fall 25. 281. Grünwald (91), S. 120. 282. Panzer: *Wien. klin. Wochenschr.*, S. 361, 1896. 283. Killian: *Die Krankheiten der Kieferhöhle. Heymann's Handbuch. Die Nase*, S. 1044, 1900. 284. Cohen and Reinking: *Beitr. z. Augenhk.*, H. 78, Fall 16, 1911. 285. Panas: *Empyeme du Sinus Maxillaire Compliqué d'osteo-periostite orbitaire avec perforation de la voute; abces du lobe frontal et atrophie de nerf optique. Mort.* *Arch. d'Ophthal.*, T. 15, p. 129, 1895. 286. Claoue: *Empyeme du Sinus max. gauche Infection aigue secondaire des sinus sus-naseaux gauches. Accidents meningitiques. Mort.* *Revue de laryng.*, T. 15, p. 805, 1895. 287. Yankhauer: *An Unusual Case of Empyema of the Antrum of Highmore.* *Medical Record*, Aug., p. 256, 1903. 288. Killian (283), S. 1047. 289. Gerber (78), S. 65.

The bulging of the pars membranacea* in the middle nasal passage is a frequent occurrence, even though the ostium is not absolutely occluded. This structure, being composed of two layers of mucous membrane, is quite elastic and returns to its normal position as soon as the internal pressure is relieved. Dilatation from internal pressure of polyps, though a rare condition, is occasionally met with. The polypoid mucosa filling the cavity continues to enlarge, thus actually forcing the healthy osseous walls to yield. The pars membranacea is the first to give way; therefore, occlusion of the naris on the affected side is always present.

3. EMPYEMA COMPLICATED OR CAUSED BY CYST FORMATION.—A tooth cyst may rupture into the antrum, causing or simulating true empyema. Under these circumstances, dilatation of the bony walls is the rule, and it is possible that many cases of supposed dilatation from empyema have been confounded with this condition.

Differential Diagnosis.—It is a rare occurrence that one is obliged to distinguish between certain local conditions in the superior maxilla and antral empyema. There are two other conditions, however, which might cause, at first glance, some confusion, *i.e.*, dental cysts and malignant neoplasms (breaking down and ulceration of a sarcoma). The following differential tables will show wherein they differ:

DIFFERENTIAL DIAGNOSIS.

MALIGNANT NEOPLASMS.	EMPYEMA OF MAXILLARY SINUS.
Bulging of walls.	No bulging.
Softening of walls.	No softening.
Spontaneous loss of teeth.	None.
Secretion most fetid.	May not be fetid.
Blood-stained fibres of tissue in the secretion.	None.
New growth appears in nares.	No new growth.
Glands of neck involved.	No involvement.

* My personal stand in the entire subject of dilatation of the sinus walls from the internal pressure of an empyema is that the healthy osseous walls do not yield. In all the cases of so-called dilatation it could be shown that the disease had infected the bone, thereby impairing its resisting powers. Spongification due to reabsorption of the trabeculae seemed to be the principal pathological change.

DIFFERENTIAL DIAGNOSIS BETWEEN DENTAL CYSTS IN THE SUPERIOR MAXILLA AND CHRONIC EMPYEMA OF THE MAXILLARY SINUS.

DENTAL CYSTS.

Bulging of anterior sinus walls.
 Springy consistency of anterior wall with parchment like crackling under pressure.
 Fistula into lower edge of canine fossa.
 No trace of pus in middle nasal fossa.
 No nasal polyps.
 General symptoms more often absent.
 Squamous epithelium.

EMPHYEMA OF MAXILLARY SINUS.

No bulging.
 Anterior wall firm and solid.
 No fistula.
 Pus present.
 Polyps frequently present.
 General symptoms more often present.
 Ciliated epithelium.

Prognosis and Indications for Treatment.—The prognosis for maxillary sinus empyema is good, so far as life is concerned, with one rare exception—where cerebral complications occur. The prognosis as to cure depends upon many contingencies.

In the ordinary acute form the disease shows a marked tendency toward self-ablation, even without treatment, either local or general. Whether a chronic empyema* will heal under local treatment depends, first, upon whether the exciting cause still persists; second, upon the pathological changes which have taken place in the sinus. If the original cause still remains, naturally we cannot expect a cure to result until it is removed. This is particularly apropos for a diseased tooth, foreign body, or an occluded ostium. The condition which is apt to prove more perplexing is to judge the pathological changes which have occurred within the antrum and to apply appropriate treatment thereto. Unless threatening symptoms prevailed, we would always begin our treatments with the needle puncture, followed by copious lavage, at the same time seeing that the natural drainage was thoroughly established, removing, if necessary, hypertrophied tissues and bodies to accomplish this end.

After this treatment has been applied for two or three weeks with no improvement, the prognosis is certainly not good, for a cure under this method, although at the commencement of the treatment, taking the usual run of cases for a comparison, the prognosis had been favorable, we now have a different proposition to deal with, namely, an operation of greater or less severity.

* By chronic empyema it is understood that the disease has lasted and resisted treatment for at least eight weeks. In those cases which have never been treated, this time may be lengthened to perhaps twelve weeks, as these will usually behave under treatment precisely as the acute cases. Hajek has seen numbers of cases in which the disease had lasted six months and more, yet have yielded without operative interference. A change in the consistency of the secretion is always the first symptom of beginning resolution of the sinus mucosa.

What can we now promise our patient? This again depends upon our old condition of pathological changes. Shall a radical operation be advised, or will we operate intranasally in a conservative manner? This question cannot be answered in an offhand manner, as every case is a law unto itself. All things being considered, the indication lies with the patient himself.

If the affliction seems to prey upon his mind, affecting the general health, even though the local symptoms be not marked, it would seem that the only mode of procedure offering the quickest and most permanent result would be justified. On the other hand, should no such disturbances be present, even though the local symptoms were urgent, an intranasal opening anterior to the inferior turbinate large enough for proper drainage would suffice. One can place absolutely no dependence upon the fetor or consistency of the secretion by the first few needle punctures as an indication for the choice of operation, for I have seen the foulest antrum heal in a few weeks under this mode of treatment. This would seem to be another proof that all fetid maxillary empyemas were not of dental origin.²⁹⁰

If the disease does not heal after the conservative operation, the indications are still more difficult to determine, although the prognosis for ultimate recovery is not materially affected, because we still have recourse to the radical operation, which in 95 per cent. of all uncomplicated cases effects a cure.

When shall the radical operation be advised? In the vast majority of instances this is a personal equation with the patient. Supposing a Krause-Mikulicz operation had been performed, with no appreciable diminution in the suppuration, the patient being a young woman about to be married. Under such circumstances it is only natural to consider the advisability of a radical procedure. Patients who show the ill effects of the disease constitutionally should also come under this heading, precisely as though suffering with a chronic abscess in any other portion of the body. The prognosis in these cases is distinctly good, not only for the local, but for the general effect of the operation as well. On the other hand, we must remember that after good drainage has been established cures have been noted from one to two years after the intranasal opening was made. Timid patients, too, are not only willing but actually insist upon a long course of

290. According to Turner and Lewis (*Edinburgh Med. Journ.*, p. 293, 1910), the fetor is often due to the interaction of microbes, which in pure culture give off no smell.

treatment before submitting to any operation under general anæsthesia.

In treating these individuals it is of great comfort to remember that so long as the purulent secretion collecting in the antrum is continually expelled any further considerable injury to the patient is out of the question. In conclusion, we may say that in the absence of complications an absolute indication for the radical operation exists only in those cases where the bone is diseased or new growths, such as polyps and cysts, are present in the antrum.

The prognosis in cases where complications occur will depend largely upon the nature of the secondary disease. So far as the sinus itself is concerned, it will probably be as amenable to treatment as a similarly uncomplicated condition. This holds good only where extensive disease of the bony walls has not occurred. In the latter instance the extent of the necrosis will serve as a guide as to the ultimate outcome of the affection.

TECHNIQUE OF SOUNDING AND CATHETERIZING THE MAXILLARY SINUS.

Bearing in mind the natural difficulties enumerated above, it is at once evident that lack of space is the chief cause of our inability to successfully carry out this procedure. To obtain as much room as possible and at the same time anæsthetize the parts so that they will be insusceptible to the manipulations of the sound, a twenty per cent. solution of cocaine with a few drops of adrenalin chloride is applied over the middle turbinate, inferior turbinate, and septum, and as much of the middle nasal passage as possible.

After the parts have been contracted and anæsthetized (about 10 minutes) the nose is washed out with a warm normal salt solution to clear the nasal passages of pus and general débris. A sound is now bent about one-half inch from the tip in an outward, downward, and forward direction toward the affected side (Fig. 68) and introduced beneath the middle turbinate, endeavoring to engage the point into the hiatus semilunaris. In the vast majority of instances this will absolutely fail. Infraction of the middle turbinate may now be tried, but usually with the same result, so far as sounding is concerned. The anterior end of the middle turbinate must now be removed, and, as the parts are already anæs-

thetized, this may be immediately accomplished. The tip of the sound will now readily engage in the hiatus and pull forward until the elbow touches on the edge of the processus uncinatus. The sound is then again gently pulled forward; often a rocking motion is necessary to overcome the hypertrophies which are always present in the infundibulum until it slips into the maxillary ostium. We can safely say the tip of the sound is through the ostium when the curved portion has entirely disappeared

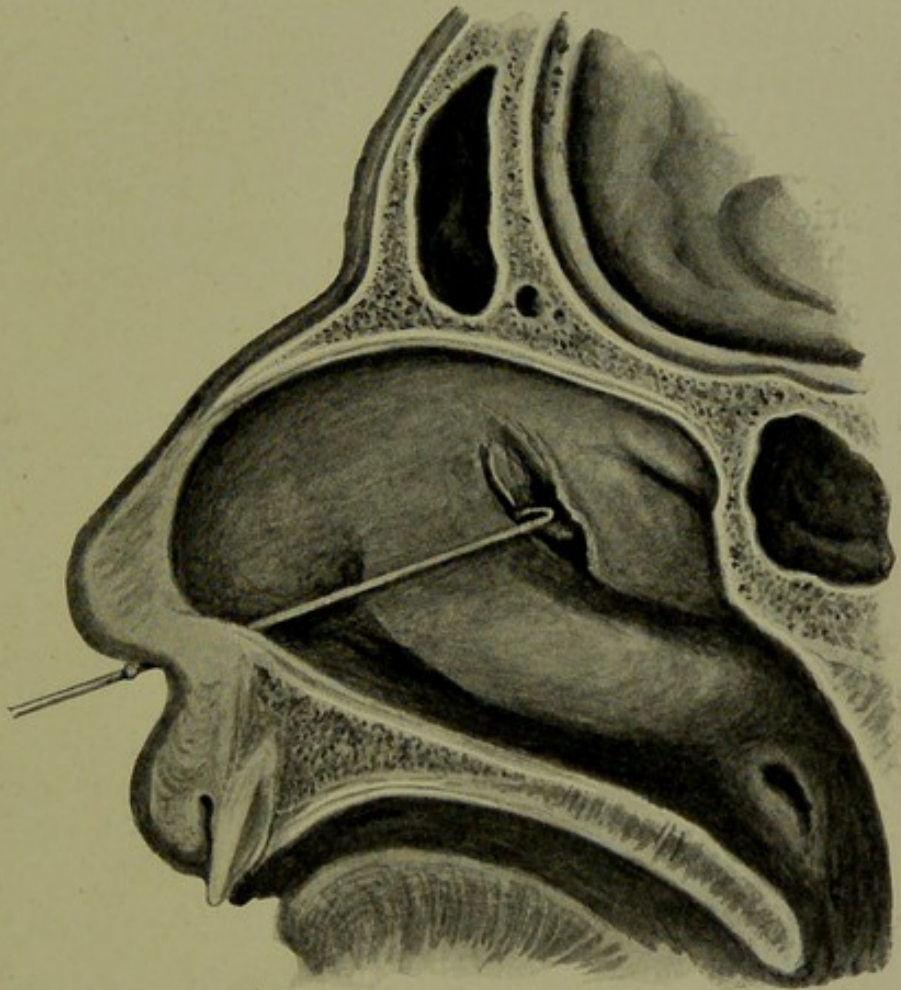


FIG. 68.—Position and bending of sound necessary in attempting to sound the maxillary sinus.

behind the projecting lip of the processus uncinatus if the sound be bent in the manner described. If the introduction of the sound has been successful, a slender silver catheter is bent, corresponding to the curve of the sound, introduced through the same passages, and the sinus irrigated. The introduction of the catheter, even though it be as small as, or even smaller than, the sound, is often more difficult, on account of the end engaging with the irregularities of the hiatus.

Relation of the Ostium to the Internal Wall of the Maxillary Sinus.—The normal position varies but little, being situated at the juncture of the maxillary and ethmoidal portion of the orbital plate, with the lateral nasal wall immediately below and posterior to the lachrymal bone; therefore, at the extreme top of the sinus cavity (Fig. 42) the size of the sinus apparently exercises but little influence on its position.

The pars membranacea occupies a considerable portion of the middle nasal passage and is of surgical importance, because it is composed of but two layers of mucous membrane (antral and nasal), separating the nasal cavity from the maxillary sinus; therefore, the thinnest portion of the lateral nasal wall. (Fig. 38.) It may be bounded above by the lamella of the bulla, below by the superior margin of the inferior turbinate, in front by anterior attachment of processus uncinatus, and behind by ascending ramus of palate bone. It is divided into two parts by the processus uncinatus, and is the second point of election for exploratory puncture of the antrum. (See below.) A number of laryngologists prefer this portion of the antral wall for radical procedures through the nose.*

Accessory ostia, when present,† are always situated in the pars membranacea, either above or posterior (rarely below) the uncinatus process. (Fig. 49.) They may be either single or multiple (the author has seen as many as three), and range from the size of a pin head to that of a pea. On account of their favorable position for sounding, it should always be ascertained whether one is present before any attempt is made to sound the natural ostium.

As previously stated (see Anatomy of Lateral Nasal Wall), the maxillary process of the inferior turbinate forms the thinnest osseous portion of the lateral wall of the nose. For this reason, and because of its accessibility, it is the point of election for the needle puncture of the maxillary sinus.

*Technique of Needle Puncture with Lavage.*²⁹¹—The anterior end of inferior turbinate and especially that portion of the lateral nasal wall beneath are painted with a twenty per cent. solution of cocaine, the cotton carrier being bent to more easily reach the

* See surgical treatment of empyema of maxillary sinus.

† According to Zuckerkandl, in ten per cent. of all cases.

291. Heindl: Die Probepunction der Kieferhöhle vom unteren Nasengang aus, ihre Technik und ihre Resultate. Wien. klin. Wochenschr., No. 16, 1908.

roof of the inferior nasal passage. In ten minutes the parts are sufficiently anæsthetized. Introduce a Lichtwitz needle (Fig. 69), working the point beneath the inferior turbinate until it is about half way back, then elevate the point by depressing the hand until it reaches the attachment of the turbinate with the lateral wall of the nose. Press the shank of the needle firmly against the

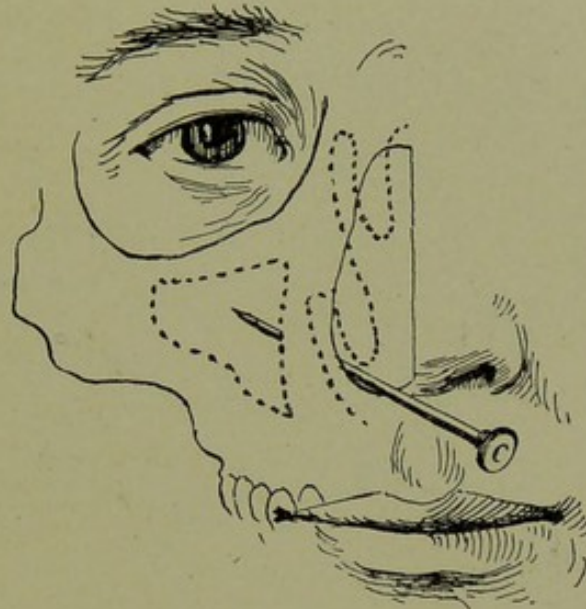


FIG. 69.—Position of needle when introduced in relation to inferior turbinate, maxillary sinus and nasal septum.

septum and push firmly upward and outward (Fig. 70). A common source of failure is to direct the point of the needle too far downward, thus encountering the thick part of the wall.

The needle point should be directed toward the posterior part of the eyeball. A sudden penetration with the crackling of bone and the fixation of the needle against the septum will show that



FIG. 69a.—Lichtwitz needle for puncture of the maxillary sinus through the inferior nasal passage.

the procedure has been successfully accomplished. The needle should now be slightly withdrawn to disengage the point from the swollen mucosa of the opposite side and air injected into the cavity by means of the syringe. This injection of air may fail for several reasons: 1. There may be a spicule of bone caught in the aperture of the needle in which case it must be taken out, cleansed and again introduced. 2. The needle-point may be imbedded in hypertrophied tissue or even a polypoid mass, under which cir-

cumstances it must be further withdrawn and more pressure applied to syringe. 3. The middle turbinate may be so swollen and the ostium so occluded with polypoid tissue that the fluid does not easily return. In these cases a constant increasing pressure on the syringe usually brings the fluid out often with a decided spurt. 4. The needle may have penetrated only the mucous membrane of the lateral nasal wall and glided along the bone. 5. The needle

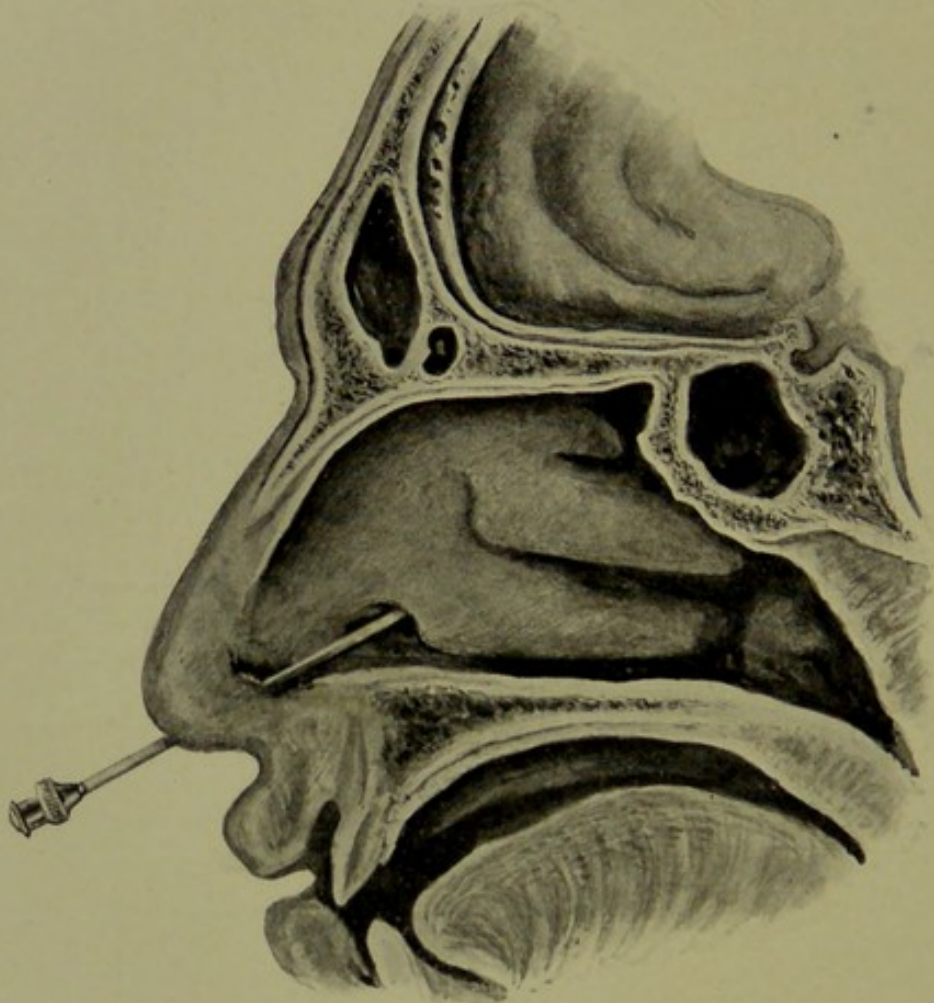


FIG. 70.—Position of needle in puncture of the maxillary antrum.

may have penetrated both walls of the antrum and appeared beneath the skin of the canine fossa. 6. The presence of intranasal polyps, which by valve-like action blocked the ostium from within.²⁹²

Occasionally, even though the needle be properly introduced, it is most difficult to push it through the bone, in which case it must be reintroduced and the attempt again made in another place. If

²⁹² Tilley: Some Considerations in the Diagnosis and Treatment, etc. Brit. Med. Journ., Vol. 2, p. 1370, 1906.

the laryngologist steadies the head of the patient with the opposite hand (Fig. 71) the procedure can practically always be accomplished, except in those cases where the bone is anomalously thickened, when it will be necessary to use a heavier instrument (Fig.




FIG. 71.—Position of the hands in introducing the Lichtwitz needle into the right maxillary sinus.

72). (The author has never met with such a case in actual practice.) It is important to first inject air into the cavity to make sure the needle is in the maxillary sinus. If a liquid was first



FIG. 72.—Antral trocar with cannula.

injected, the needle being, for example, in the tissue of the canine fossa, an abscess would almost surely result. In empyema of this sinus a positive diagnosis can always be made by the peculiar bubbling sound emitted when air is injected. In chronic cases this is often accompanied by the sudden appearance of a marked fetor.

It sometimes occurs, particularly in acute cases, that at first the injected liquid returns perfectly clear, giving one the impression that the cavity is empty. On continued injection a large mass of thick pus which does not mix but is agglutinated suddenly appears in the solution; therefore it is always wise to inject at least several ounces (8-10) before final conclusions are reached.

CONSERVATIVE TREATMENT.—This form of treatment should always be tried first (except in cases as enumerated above), as it is often astonishing to note how frequently even severe forms of the disease recover under a few simple procedures, as the following case well demonstrates:

H. K., male, thirty-eight years old. History of nasal trouble for nearly two years. Considerable discharge from the throat, particularly in the morning on arising. Some discharge of thick mucus and crusts through the right naris. Neuralgic headache confined more or less to right side. Complained particularly of inability to fix the attention and disinclination to any brain work, complaining of a foul, decaying odor in nose, which had been under treatment at various hospitals with little relief.

Examination: Right naris—mucous membrane hyperæmic, slight hypertrophy of middle turbinate, no sign of secretion although particular attention was paid to this point. No objective odor could be noticed. Left naris normal. Throat—pharyngitis lateralis on right side. On general principles a needle puncture was made, and on injecting the antiseptic solution a large quantity of crumbly, cheesy pus was evacuated which mixed with the water and disseminated a most fetid odor over the entire room. The sinus was washed out with about one quart of warm sterile normal salt solution, the residue of which was in turn blown out and the patient told to report the next day.

The patient presented himself as instructed and the needle was again introduced. This time, while the quantity of pus appearing in the solution was quite as large as before, yet it appeared to be what the older surgeons termed "laudable pus," seeming to be organized and did not mix with the water, neither was the slightest odor appreciable. The patient had also remarked that since the first washing out he had not noticed any odor, although he had constantly been on the watch for it. The next irrigation brought a large mass of jelly-like mucus, but no pus. The fourth and last lavage occurred a week later and the solution returned perfectly clear. The patient was discharged with instructions to return immediately should the slightest suspicion of trouble manifest itself, but up to the present writing, although now over two years, he has not put in a reappearance.

The forms of conservative treatment are as follows, in order of their severity: (1) irrigation through the natural ostium or, when present, the accessory ostium; (2) needle puncture through the middle nasal passage; (3) needle puncture through the inferior nasal passage; (4) introducing trocar through inferior nasal passage (Krause method); (5) boring through the alveolus after extraction of a tooth (first molar or second premolar) (Cowper method) (semi-radical treatment); (6) creating a large opening

in the middle nasal passage (Onodi method); (7) creating a large opening in the anterior nasal passage (Mikulicz-Krause method); (8) various modifications of No. 6 and No. 7 (Dahmer method); (9) pre-turbinal method with preservation of the inferior turbinate.

1. Washing out through the natural ostium is a procedure which can be accomplished but rarely, on account of the anatomical configuration of the parts. When, however, the middle turbinate hangs at some distance from the lateral nasal wall, other conditions being favorable, it can sometimes be accomplished after applying a ten per cent. cocaine solution with 1/2000 adrenalin chloride to shrink as well as anæsthetize the surrounding parts.

A probe suitably bent should first be introduced to ascertain the proper angle which the cannula must be curved. Introduction should then be accomplished as has already been described (see technique of sounding), the nozzle fitted to the cannula, and gentle pressure on the syringe applied until free return of the liquid occurs.

There are two drawbacks to this method:

a. The mucous membrane of the ostium is often so swollen that the introduction of the cannula closes the lumen to such an extent that the injected solution only returns with difficulty; therefore, inspissated pus or cheesy clots cannot possibly escape, and the lavage only partially accomplishes its purpose.

b. Often when the earlier introductions of the cannula have been accomplished with little difficulty, the mucous membrane, after several catheterizations, reacts from the constant irritation produced by the introduction, with consequent tenderness and swelling, making subsequent attempts at washing out more and more difficult and finally abortive.

2. Needle puncture through the middle meatus is a method employed by a few specialists, notably of the Killian school of German laryngologists.²⁹³ It has the advantage of penetrating the thinnest portion of the lateral nasal wall, namely, the pars membranacea. The danger of this procedure is injury to the orbit from the point of the needle (see Figs. 57, 58), but this has been done away with by Fletcher²⁹⁴ by using a curved needle

293. Killian: Die Probepunktion der Nasennebenhöhlen. Verh. d. Ver. Süddeutsch Lary., S. 93, 1896. 294. See Reiner's Catalogue, Wien, 1908, p. 98.

(Fig. 73), which is hooked through the pars membranacea, thereby working from behind forward and away from the orbital contents.

Occasionally one experiences difficulties in forcing the point of the needle through the lateral nasal wall, as it is impossible to obtain much leverage for this purpose. This method may be held as an alternate for the puncture beneath the inferior turbinate and applied only when, for any reason, it is inadvisable to use the latter.

3. The needle puncture through the inferior nasal passage offers the safest, surest, and easiest method of ascertaining the contents of the maxillary sinus.²⁹⁵ It can be accomplished almost without pain, and after sufficient cocainization requires but a moment to introduce the needle. Immediately after a positive diagnosis by needle puncture is established it is always indicated, before commencing active treatment, to ascertain if possible the cause of the maxillary sinusitis, as frequently this will entirely




FIG. 73.—Fletcher's needle for puncture of the maxillary sinus through the middle nasal passage.

change our mode of treatment. The upper teeth of the affected side should be carefully examined by tapping to see whether they are abnormally sensitive.

Cavities between the teeth should be sought for, and old crowns on the affected side are to be viewed with suspicion. It must be remembered that the teeth are only the starting point of a dental empyema, and the real cause lies in the ostitis of the bone between the roots and the antrum floor. It is indeed rare to find a direct communication between a tooth cavity and the maxillary sinus without periostitis around the root socket.

The frontal and ethmoidal sinuses on that side must also be

295. Certain authorities have experienced more or less unpleasant consequences following this procedure, and Claus has reported two deaths. In our experience of perhaps 1000 needle punctures we have never seen a single untoward symptom. See Hajek. Ueble Zufälle bei der Kieferhöhlenpunktion. *Verh. deutsch Laryng. Gesellsch.*, S. 163, 1907. Claus. Vier üble Zufälle, darunter zwei mit todlichem Ausgange, bei der Punktion der Oberkieferhöhle. *Beitg. z. Anat. Phys. Path. u. Ther. des Ohres, der Nase u. d. Halses*, Bd. 4, S. 88, 1911. Kronenberg. Über üble Zufälle bei der Anbohrung der Oberkieferhöhle und deren Verhütung. *Zeitschr. f. Laryng.*, Bd. 4, S. 285, 1911. Culbert. Report of a Case of Chronic Suppuration of the Antrum of Highmore. Puncture Followed by Septic Pemphigus and Death. *Laryngoscope*, p. 824, 1910.

examined, as it is possible that the maxillary sinus is acquiring some or all of its pus from these sinuses. Naturally, if either of these possibilities were the case, the form of treatment would be influenced accordingly; *i.e.*, when the root of a tooth caused the empyema, the treatment through the alveolus after the tooth or root had been drawn should be instituted. If any one of these forms of treatment has been decided upon, what solution shall we use and how often shall the treatment be applied? Sterilized warm normal salt solution seems to be the best medication to use, especially for the first few days, the cavity being irrigated daily with at least one quart. This should be continued daily for perhaps one week, then every other day, or, finally, semi-weekly, until a cure results.

How long should we continue to use the normal salt solution before changing the treatment? That depends entirely upon the condition of the secretion.* If the primary character of the pus is crumbly, cheesy, fetid, and mixed with the injected solution, forming a milky mass, which at the end of one week had not changed in character or quantity, a change of treatment is clearly indicated. This change should consist in the addition of either some antiseptic (carbolic acid) or counterirritant (iodine) to the solution (5 per cent. carbolic acid is about as strong as is safe, and iodine in petrolatum 10 per cent.); both substances, after several applications, will cause more or less reaction. If, after a few irrigations with these medicaments, the purulent material shows no change either in quantity, quality, or consistency, one of the following methods must be resorted to:

At this point I should like to call attention to those forms of fronto-ethmoidal sinusitis which Lermoyez²⁹⁶ describes as following lavage of the maxillary sinus. He attributes the case to the fact that purulent material being forced out of the ostium some naturally finds its way into the ethmoidal and frontal ostiums, thereby setting up an acquired sinusitis in these cavities.

This point, to my mind, is not well taken, because, 1. It is well known how the maxillary sinus may act as a reservoir to the frontal, remaining filled with purulent material for months without reaction and then cleared by a single irrigation, demonstrating that no infection of the mucous membrane had taken place. 2. The experiments of Menzel²⁹⁷ have demonstrated that it is impossible to force liquid from the antrum into the frontal sinus via the infundibulum. My

* If, on succeeding injections, the fluid seems to meet with some obstruction in the sinus, it is likely that polypoid degeneration of the mucosa or polyps are present in the cavity. The point of the needle becomes imbedded in this mass, causing the fluid to emerge from the lumen only with difficulty.

296. Lermoyez. Indications et Resultats du Traitement des Sinusitis max. et Frontales. Annales des mal. de l'Orielle, etc., Nov., 1902. 297. Menzel. Experimentelle Kieferhöhlenspülungen. Arch. f. Lary., Bd. 17, S. 371, 1905.

own experience tends to show that while a large number of patients complain of a dull pain extending over the frontal and maxillary sinuses of the affected side for some hours after lavage, nevertheless this pain always disappears over night. This would seem to show that the pain was neuralgic and incidental to the mechanical irritation of the lavage and not to any infection.

4. Introducing a trocar through the inferior nasal passage: This procedure is similar to the needle puncture, except a larger instrument is used, thereby permitting a heavier and more forcible stream to be thrown into the sinus, as well as allowing the insufflation of powder through the cannula.

Technique: Cocainize as in ordinary needle puncture, adding a few drops of adrenalin chloride to the cocaine solution. Introduce the point of the trocar under the middle of the inferior turbinate and endeavor to penetrate the antral wall.

Frequently this is found to be impossible on account of the inferior turbinate preventing the point of the trocar from reaching the thin portion of the lateral wall. Under these circumstances it will be necessary to either luxate the turbinate toward the septum or to resect the anterior portion in order to acquire room. Either of these procedures require but a moment's time to perform, so will hardly cause delay.

Now the point of the trocar will easily penetrate into the antrum. After the cavity has been thoroughly lavaged with a quart or more of warm saline solution, all excess of fluid is expelled by forcible insufflation of air, with the head inclined toward the opposite side.

After the cavity is made as dry as possible, the mucosa is covered with a suitable antiseptic powder and the cannula withdrawn. This treatment should be continued daily until a decided change takes place in the character of the secretion, after which it may gradually be discontinued until entire recovery occurs.

If subsequent introductions of the cannula are attended with a certain amount of difficulty on account of inability to find the original puncture, it is wise to make a mark on the cannula showing the depth of the puncture from the entrance of the naris.

Suppose we had continued this treatment for several weeks with no more improvement that was originally shown at its inception, what course must we take in order to obtain more permanent results? The answer would naturally be, something more radical must be done. However, before any other form of operation is decided upon we must determine absolutely whether there exists, directly or indirectly, any dental complication; in other words, whether any of the teeth on the affected side which are

in relation to the antral floor are affected. The importance of this cannot be over-estimated, for it might prove a source of no little embarrassment to operate intranasally and find subsequently that a diseased root was prolonging the affection. If any dental symptoms can be elicited, the patient should be referred to a dentist skilled in these matters, and at the same time have an X-ray picture taken.

It is not always necessary to sacrifice a sound tooth, the root of which is the seat of an abscess which has caused maxillary sinusitis. It is a common practice for dental surgeons to bore through such a tooth and drain off such purulent accumulations, afterward filling the cavity precisely as in ordinary conditions.

If such is found to have been the case and the cause removed, our irrigations will probably bring about a favorable ending. If, on the other hand, nothing points toward any dental complication, our choice lies between the intranasal method (pre-turbinal) and the radical operation through the canine fossa (Denker).



FIG. 74.—Guarded Hartmann borer.

5. Boring through the alveolus after extraction of a tooth (Cowper method)*: This method is not to be applied unless a carious tooth or root is causing the empyema. After extraction of the offending tooth (usually the second premolar or the first molar), a pledget of cotton saturated with a 20 per cent. solution of cocaine is firmly packed in the cavity for ten minutes. A large dental drill or a guarded Hartmann borer (Fig. 74) is now used to make an opening into the sinus.

This is often reported to be a painless procedure because the bone is free from nerve endings. While this is true, nevertheless, the lining mucous membrane of the sinus is usually swollen and exquisitely tender so that when the sharp point of the instrument commences to penetrate into the cavity the pain is often considerable. As the mucous membrane of the sinus has not been anæsthetized by the first application, it is well at this point to withdraw the instrument and make a fresh application of cocaine directly in the sinus cavity.

The opening is now enlarged either by a curette (somewhat difficult) or, better, by reaming out the opening with the borer. This is accomplished by introducing as in the first instance, then pulling the handle slightly at right angles and revolving so that

* This operation was really performed nearly a century before Cowper's time by Meibom (1650).

the ridges cut the walls in an oblique manner. (Fig. 75.) When the opening is sufficiently enlarged, the cavity is washed out with normal salt solution, powder insufflated, and the obturator inserted.

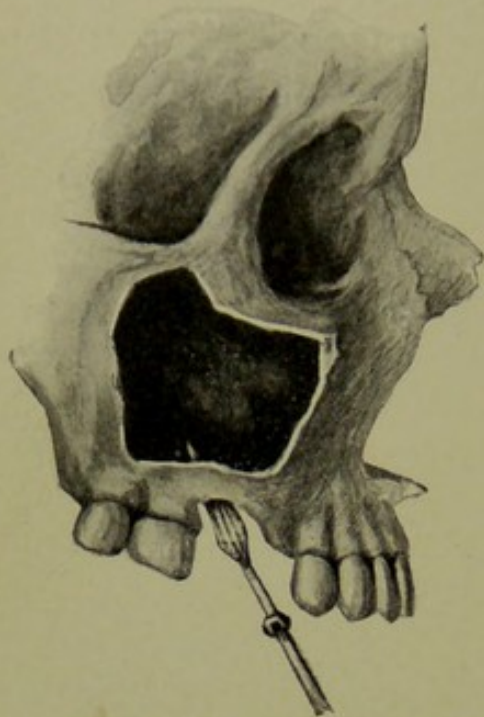


FIG. 75.—Enlarging the opening in the Cowper operation through the alveolar process by reaming out the sides with the burr.

This obturator or plug should have been already made by the dentist, consisting of a medium soft rubber peg held together by two bands, which fit around the two neighboring teeth (Fig. 76). Hollow tubes are hardly to be recommended, as they not only become occluded by granulation tissue and secretion, but also allow the passage of particles of food into the sinus, causing re-infection and prolonging the course of the disease.

The patient should be instructed to syringe out the sinus morning and evening with the salt solution, reporting from time to time for control treatment. He should also be cautioned to allow the cavity to thoroughly drain (which they often themselves facilitate by sucking it

out) before reinserting the plug, but not to permit it to remain out for too long a time, as it is surprising how quickly granulations form at this place, making its replacement difficult and often impossible. After healing is established the plug is permanently removed and closure of the wound occurs in a few hours.

6. Creating a large opening in the middle nasal passage:²⁹⁸⁻³⁰⁰ This method consists in perforating the pars membranacea of the lateral nasal wall and enlarging the opening as much as possible in all directions. Onodi³⁰⁰ has constructed a dilating trocar which appears to be particularly adapted to this work.

Method: The entire procedure is very simple. After cocaine-ization of the middle nasal passage the trocar is introduced directly below the centre of the middle turbinate and, after being sprung apart, is withdrawn, leaving a long laceration in the pars



FIG. 76.—Prothese for closing opening in the alveolus after the Cowper operation.

298. Rethi: Die Behandlung der Nebenhöhleneiterungen der Nase. Wien. med. Presse., Bd. 37, S. 536, 575, 1896. 299. Siebenmann: Die Behandl. der chron. Eiter. der Highmorshöhle durch Resektion der oberen Hälfte ihrer nasalen Wand. Verh. d. südd. Lary., S. 342, 1899. 300. Onodi: Die Eröffnung der Kieferhöhle im mittleren Nasengange. Arch. f. Lary., Bd. 14, S. 154, 1903.

membranacea. The loose and hanging fragments of bone and mucosa are removed with the forceps, and the operation is finished.

In spite of the simplicity with which this procedure is carried out, the disadvantages are many:

- (1) The opening is at the highest point of the antral cavity.
- (2) There is danger of wounding the orbit.
- (3) The middle turbinate must often be resected.
- (4) Granulations form quickly around the wound, thus making subsequent manipulations very painful.

7. Creating a large opening in the inferior nasal passage (Krause,³⁰¹ Mikulicz³⁰²).^{*} Method: The anterior half of the inferior turbinate, middle and inferior nasal passages are anæsthetized with 20 per cent. solution of cocaine until tactile sensibility is absolutely destroyed. Equal parts of adrenalin 1/1000 and of cocaine 20 per cent. are applied several times to control hemorrhage.

Many authors are now opposed to the use of adrenalin on the ground that the tendency to secondary hemorrhage is greatly augmented by its use, due to the vascular relaxation which always follows from two to ten hours after the operation. The author, however, is of the opinion that the enormous advantage derived from the almost bloodless operating field more than compensates for any tendency toward secondary hemorrhage, which in any case is readily controlled by a fresh tamponade.

A suitable pair of nasal scissors is used at this stage to sever the anterior third of the inferior turbinate, which should be done as close to the lateral nasal wall as possible. Some difficulty will often be encountered in this step where the turbinate lies close to the external wall. Bleeding is controlled as much as possible with adrenalin.

Now the free end of the turbinate is removed, preferably with a snare. Needle puncture is made, which at this particular

^{*} The so-called Krause-Mikulicz operation does not really represent the original procedure as carried out by these operations. Mikulicz, working in the dark, used a right-angle stylet to open the antrum through the inferior nasal passage, and Krause merely modified the instrument into his well-known trocar and cannula for the same purpose. Lothrop, of Boston,³⁰³ however, was the first to publish complete reports of this method of operating, and to him naturally belong the honors of being the discoverer. A refinement of this operation which presents somewhat greater technical difficulties but more than compensates for one's pains by the brilliant results obtained is offered by a procedure recently suggested by Dahmer. (See page 167.)

301. Friedländer: Zur Therapie des Empyema Antra Highmori. Berl. klin. Woch., Bd. 26, S. 815, 1889. 302. Mikulicz: Zur Operation Behandlung des Empyems der Highmorshöhle. Arch. f. klin. Chirurgie., Bd. 34, S. 626, 1886. 303. Lothrop: Empyema of the Antrum of Highmore. A New Operation for the Cure of Obstinate Cases. Boston Med. and Surg. Journ., vol. 136, p. 455, 1897.

stage of the operation is of great service for two reasons: (1) it orientates the operator as to the precise position of the infra-turbinal process; (2) it irrigates and cleanses the operating field.

The needle is allowed to remain, acting as a director for the point of the instrument used to open up the sinus, the best instrument for this purpose being that of Welhelski (Fig. 77.) After the point has been forced through the wall below the inferior turbinate the instrument is withdrawn, pulling strongly forward to engage as much of the bony partition as possible, which draws the splinters of bone outward into the nasal passage. An antrum punch is now introduced and the opening enlarged forward and backward until the forceps cease to engage the wall. (Fig. 78.) The posterior edges of the opening can be enlarged also with the Grünwald or any straight bone forceps. After the opening has been made as large as necessary (usually as large as possible), the antrum and nose are packed with selvaged iodoform gauze.




FIG. 77.—Welhelski's antral trocar.

Various medicated gauzes have been recommended as a substitute for iodoform gauze as a dressing after the operation, but it is questionable whether they answer the purpose as well as the latter, certainly not as far as the author is concerned.

If the anæsthetization has been sufficiently intense, the operation can usually be carried out with but a slight amount of discomfort to the patient. The most painful step is when the posterior edge of the opening near the insertion of the turbinate is being enlarged. This is, of course, due to the nerve-trunk lying in this position. (Plate I.)

After-treatment.—As the packing of the sinus and nose will cause intense discomfort, if not actual suffering, it is wise to administer either a hypodermic of morphine or a 30-grain sulphonal powder at bed-time on the day of operation. The patient should observe the rules laid down following an operation. Packing removed following day, slowly and gently, using a large quantity of peroxide and warm water to loosen dried blood and secretion, so as to prevent hemorrhage, which would greatly interfere with treatment. The patient is always relieved by this procedure.

Either of the following methods of treatment may be used:
 (1) Wet method: Cleanse thoroughly the antrum by means of a suitable syringe with a curved nozzle (Fig. 79) and warm nor-

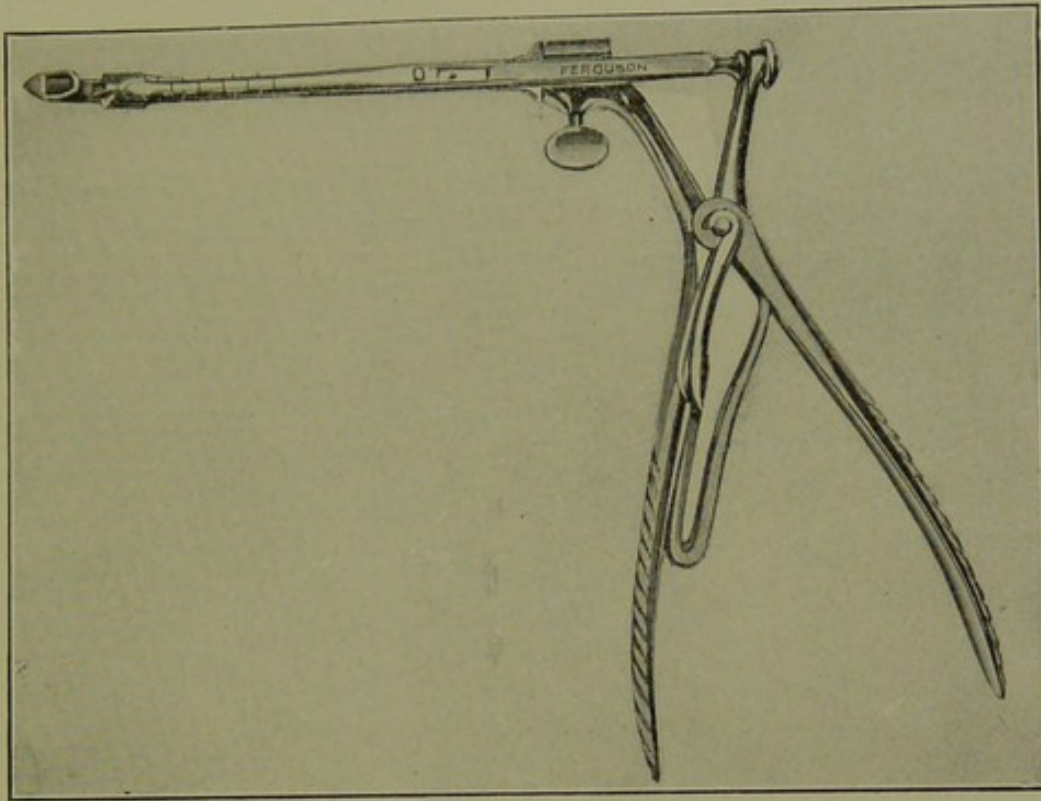


FIG. 78.—Wagener's antrum punch.

mal salt solution until the returning fluid is free from pus. Cause the patient to bend the head toward the sound side to facilitate the escape of the liquid from the sinus. Pack the cavity moderately full with iodoform gauze strips in such a manner that the




FIG. 79.—Freeman's syringe.

floor of the sinus is well covered, not allowing any gauze to protrude into the nasal cavity that would interfere with the passage of air through the nose. The dressing should be changed daily so long as any foul odor persists or the secretion of pus is copious. When the discharge begins to show distinct diminution, the dress-

ing may be applied every other day, gradually increasing the intervals of packing until the mucous membrane no longer secretes.

(2) Dry method: After the first packing is removed, the maxillary sinus is thoroughly wiped out by means of absorbent cotton wound around a cotton carrier and suitably bent to allow easy introduction through the wound into the antrum. Care must be taken to see that the cotton is secure, otherwise it may readily become fastened to a spicule of bone and, on withdrawing the probe, remain in the sinus, thus continuing the suppuration. The mucous membrane on the floor of the sinus should be made as dry as possible. Iodoform or any suitable antiseptic dusting powder³⁰⁴ is now blown into the cavity until the floor and walls are covered. This treatment is continued every day or second day until all pathological secretion from the sinus has been checked.

(3) Combination method: Same as the dry method, with the exception that the patient is taught to wash out the sinus between treatment with a suitable syringe. This should be done at first, night and morning, gradually diminishing the lavages in ratio to the formation of the secretion.

The dry method of treatment is indicated in neurotic and sensitive individuals in whom the removal and application of the packing are a constant source of dread. It is also applicable to those patients who for one cause or another find it impossible to present themselves regularly for treatment.

Advantages of this method: (1) Operation can be done most satisfactorily under local anæsthesia, and the patient is not necessarily incapacitated from his work.

(2) Opening is in the lowest portion of the sinuses that it is possible to obtain through the nose; therefore, moderately good drainage is established.

(3) If a radical operation is subsequently found to be necessary, an important and difficult step in the operation will have already been performed (opening into the nose).

Disadvantages: (1) Only the merest glimpse into the sinus cavity can be obtained; therefore, the actual pathological condition of the mucous membrane must be largely surmised.

(2) The wound shows a great tendency to contraction by granulation before healing has been fully established.

304. Menge: Clinical Notes on the Action of a New Iodine Preparation in Nose and Throat Work. Laryngoscope, p. 491, 1907.

(3) After-treatment always more or less painful. Regarding the dryness of the nares following this operation, it has been our experience never to have seen this complained of in a single case, although sought for. This can possibly be explained by the fact that only a small portion of the inferior turbinate was resected (probably one-fifth), merely sufficient to allow one room to introduce the stylet.

8. Numerous modifications of the Krause-Mikulicz operation have from time to time been advanced, all aiming at some advantageous purpose. One of the best of these, and one which has proved of considerable worth in the hands of the author, is that suggested by Dahmer.

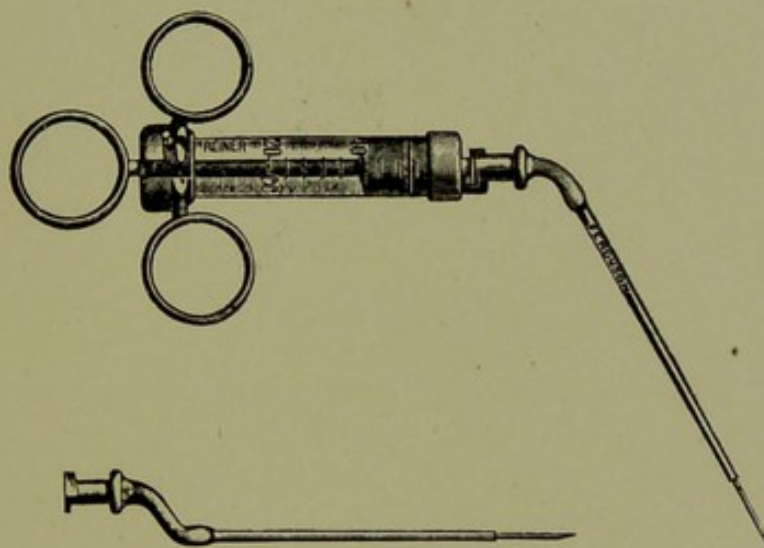


FIG. 80.—Privat's subperiosteal syringe for local anæsthesia.

*Dahmer's Method:*³⁰⁵ The purpose of this method is to create a large opening beneath the inferior turbinate and turn a flap of mucosa from the nose into the antrum along the floor, thus preventing granulations springing up from the edges and insuring a permanent patulous communication between the nose and maxillary sinus.

Method: (1) Prepare the nose by irrigation and application of the 20 per cent. cocaine-adrenalin solution on lateral nasal wall above and below the inferior turbinate and corresponding portion of nasal septum.

(2) Inject subperiosteally from 1 to 3 syringefuls (20-60 Cc.) of a 1 per cent. cocaine-adrenalin solution directly in front of

305. Dahmer: Die breite Eröffnung der Oberkieferhöhle von der Nase aus mit Schleimhautplastik und persistierender Oeffnung. Arch. f. Lary., Bd. 21, S. 325, 1909.

the anterior attachment of the inferior turbinate and in the inferior nasal passage. (Figs. 80, 81.) Wait fifteen minutes.

(3) Irrigate antrum by means of the needle puncture.

(4) Introduce the nasal scissors above and below the inferior

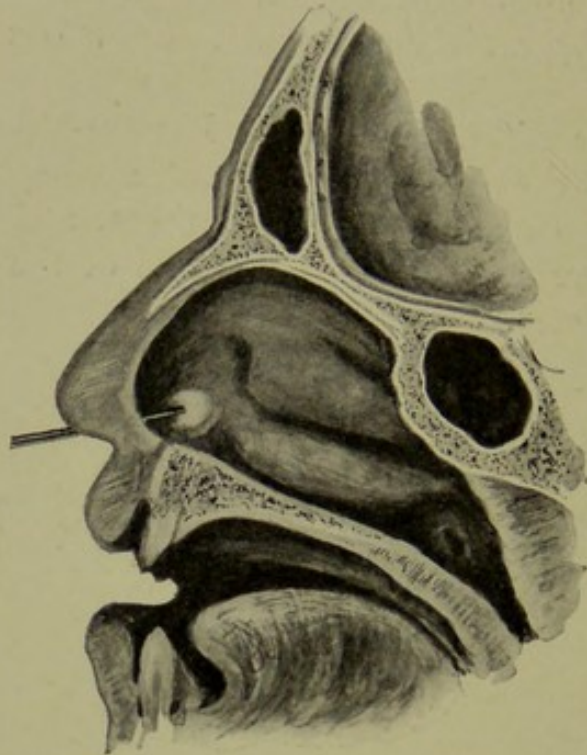


FIG. 81.—Dahmer's method. 1st step. Injection in front of and beneath anterior end of inferior turbinate.

turbinate, and, keeping close to the lateral wall, cut through the anterior third. (Fig. 82.)

(5) Introduce the snare into the incision made by the scissors and after pressing back the shank as far as possible remove the detached portion of turbinate. (Fig. 83.)



FIG. 84.—Right-angle knife.

(6) After thorough sponging with adrenalin 1/1000, a right-angle knife (Fig. 84) is used and the mucosa incised in three directions, making a flap which has for its attachment and base the floor of the nose. (Fig. 85.)

(7) The flap is now submucously resected with a small, sharp elevation down to the middle of the floor of the nose and turned back against the septum. This is the most difficult step in the

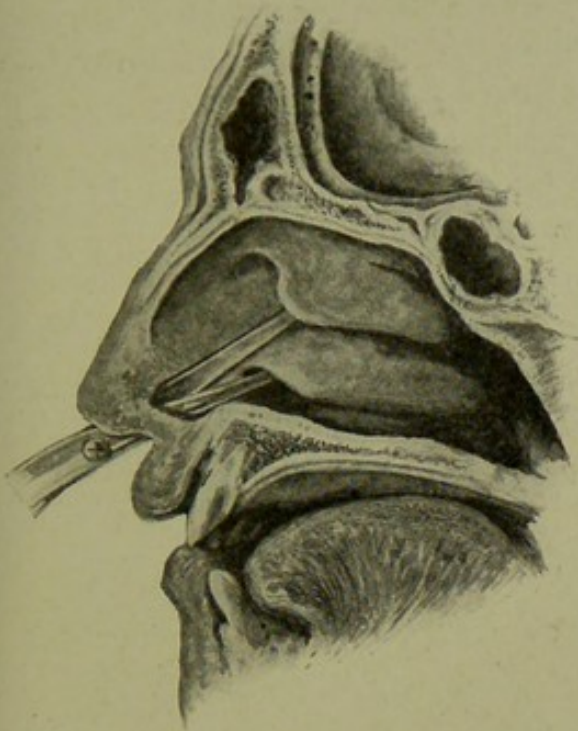


FIG. 82.—Dahmer's method. 2d step. Cutting the anterior third of the inferior turbinate close to the lateral nasal wall.

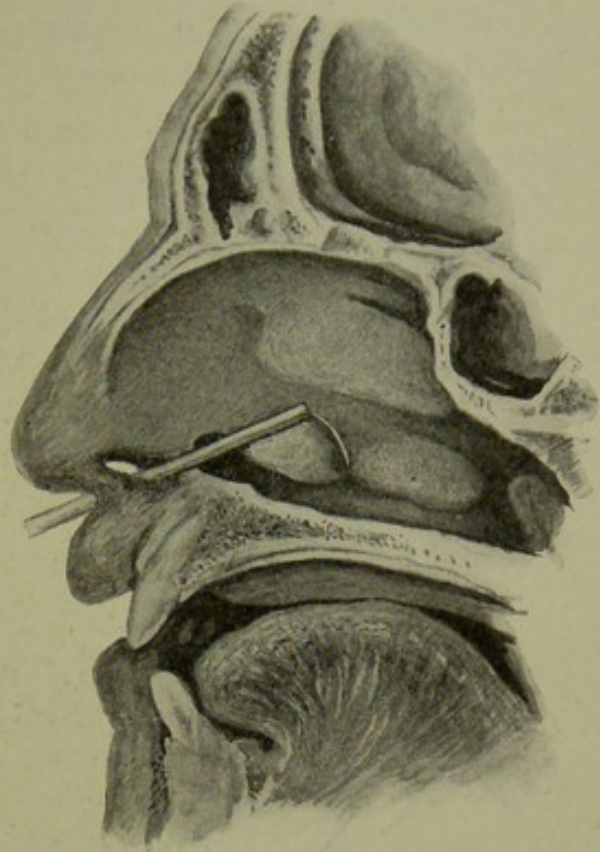


FIG. 83.—Dahmer's method. 3d step. Removing the incised portion of the inferior turbinate with the snare.

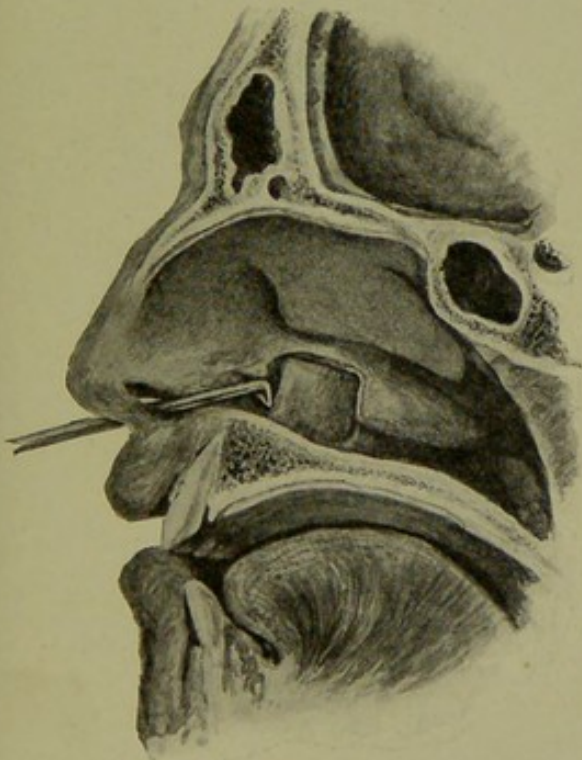


FIG. 85.—Dahmer's method. 4th step. Making the flap of mucosa with the right-angle knife, leaving the base toward the nasal floor.

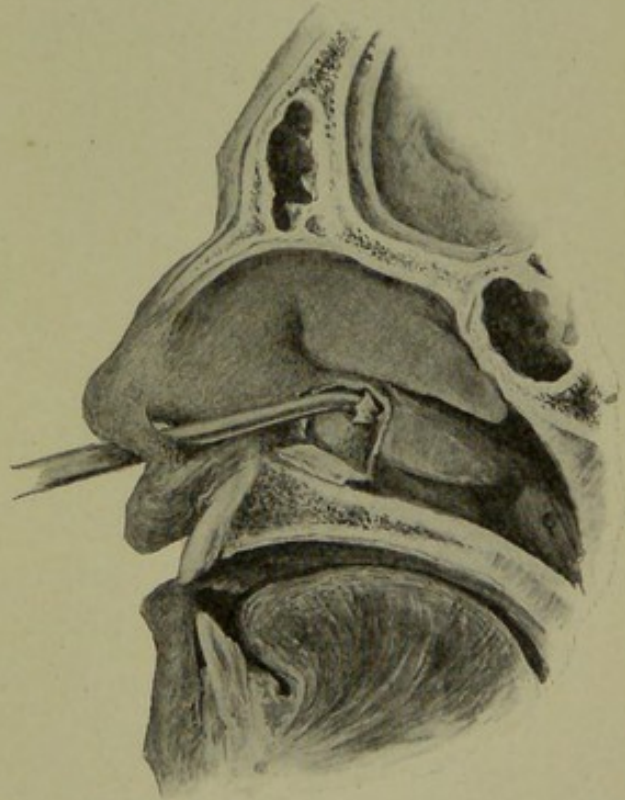


FIG. 86.—Dahmer's method. 5th step. Introducing the Welhemski trocar and penetrating the antrum at the superior posterior angle of the wound.

entire procedure, and the result of the operation depends largely upon its successful accomplishment.

(8) A Welhemienski trocar is introduced in the posterior-superior angle of the wound and pushed into the antrum, and on withdrawal forcibly pulled forward in order to make the opening as large as possible. (Fig. 86.)

(9) The opening is enlarged in all directions by means of the modified double-cutting Wagener punch until it represents approximately the size of the original flap. (Fig. 87.)

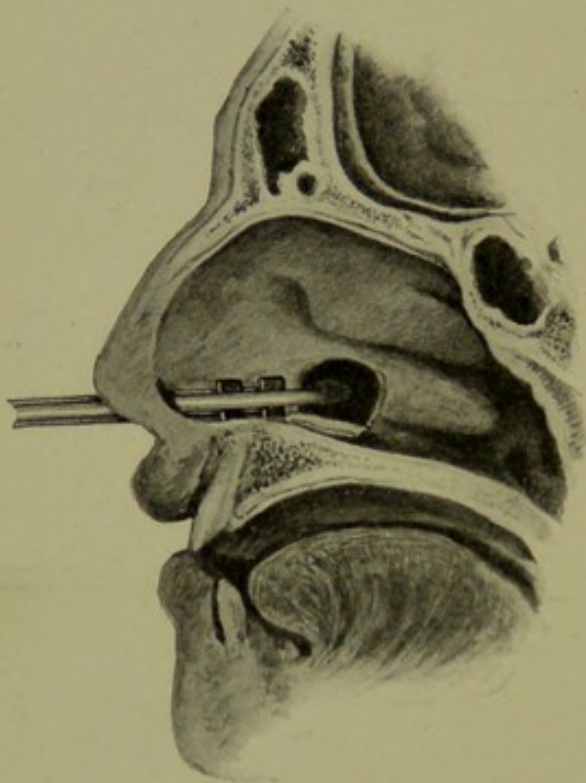


FIG. 87.—Dahmer's method. 6th step. Using the Wagener punch to bite forward and complete the opening into the antrum.

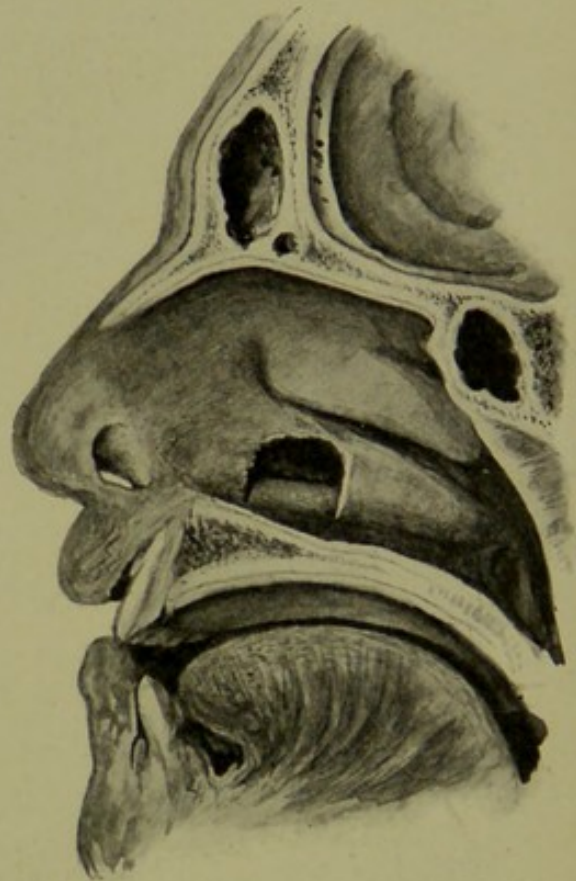


FIG. 88.—Dahmer's method. 7th step. The operation completed, showing the flap of mucosa turned into the antrum.

(10) The antrum is curetted as far as possible, particularly the medial floor, the cavity irrigated, and the flap of mucous membrane turned in, thus forming a continuous unbroken passage between the nose and maxillary sinus. (Fig. 88.)

(11) Strips of iodoform gauze are introduced, the first one covering and pressing on the flap, thus holding it in position against the underlying bone. Subsequent strips are placed over this until the antrum is loosely filled.

After-treatment.—After twenty-four hours, the upper layers of

tampons are removed and, if the cavity appears fetid, irrigation is practised, holding the lower tampon firmly in place with an elevator so as to prevent the flap from becoming dislocated. After forty-eight hours the lower tampon is carefully removed, again holding the flap in place. If, in spite of our endeavors, the flap is rolled out, it must be replaced with a new tampon, otherwise granulations will spring from the underlying bone and gradually occlude the opening.

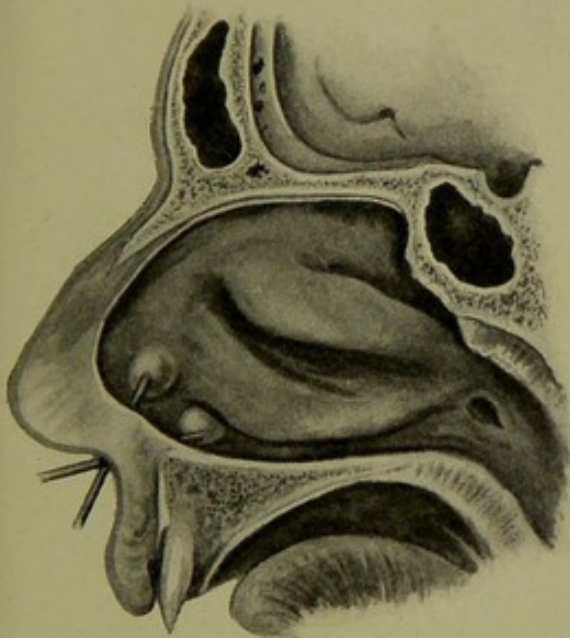


FIG. 89.—The pre-turbinal method. 1st step. Injection of Schleich's solution immediately anterior to the crista pyriformis.

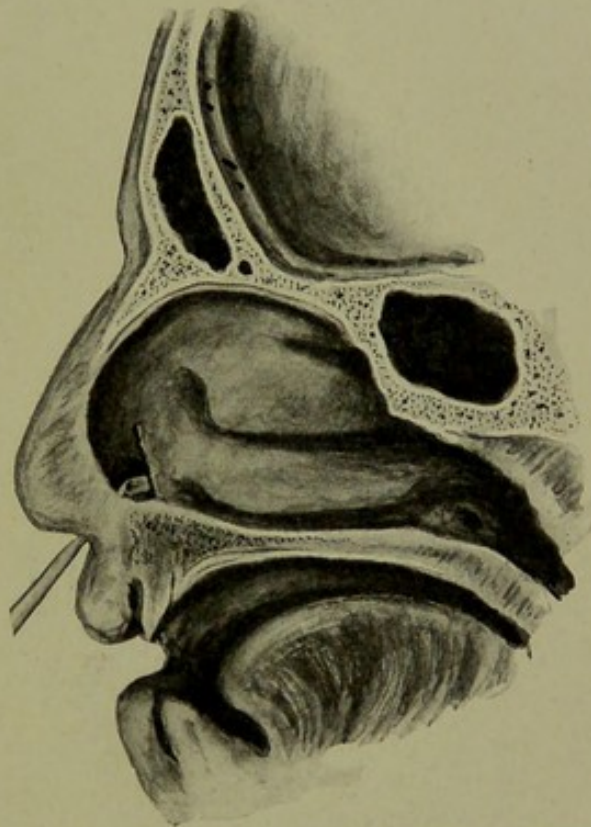


FIG. 90.—The pre-turbinal method. 2d step. Incision extending from above the anterior attachment of the inferior turbinate well into the floor of the nose.

The subsequent treatment will depend upon the amount of secretion present; if copious, two or three irrigations daily, while if moderate, once during the twenty-four hours will suffice. The patient can easily be taught to carry out this procedure himself. Complete healing usually occurs in from two to six weeks. If, after six to eight weeks, the secretion has not greatly diminished, a radical operation is indicated.

Advantages: (1) A permanent opening is installed which permits the patient to practise irrigation without pain, as well as guards against recurrence during a subsequent attack of coryza or influenza.

9. *Pre-turbinal Method: Canfield's Operation.*³⁰⁶—The rationale of the operation is to create an opening in the anterior inferior angle of the antrum, making it possible to inspect the greater portion of the cavity on anterior rhinoscopy and at the same time preserve the inferior turbinate. This is accomplished by resecting the inferior portion of the bony wall which is formed by the junction of the nasal and facial.

Method: (1) Anæsthetize the anterior portion of the inferior

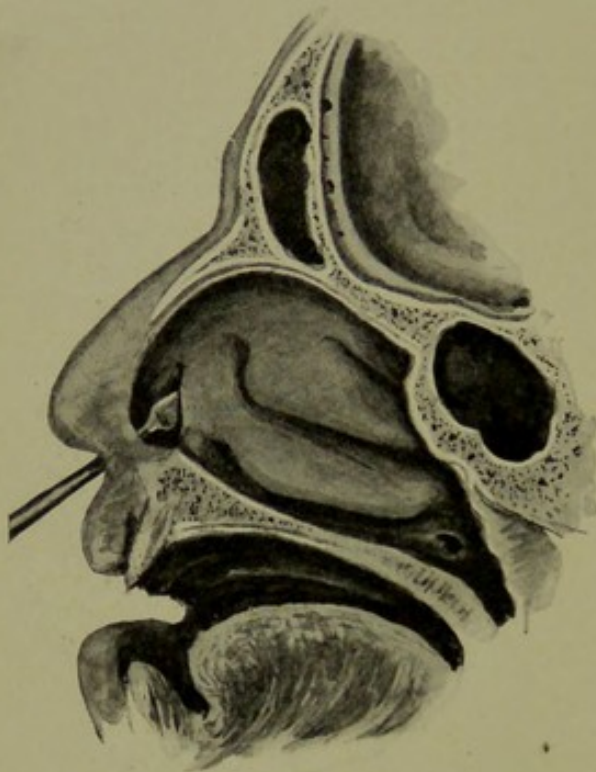


Fig. 91.—The pre-turbinal method. 3d step. Elevating the soft parts from the underlying bone.

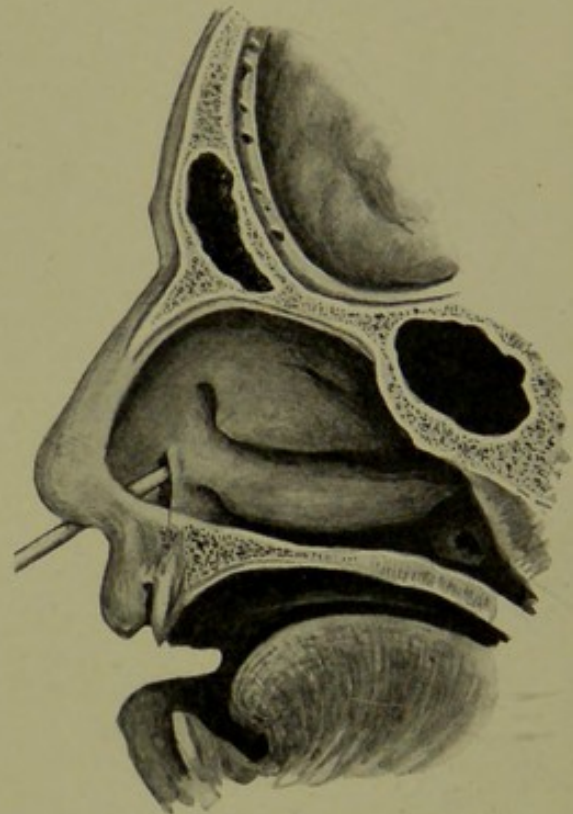


Fig. 92.—Pre-turbinal method. 4th step. Using the hollow chisel to penetrate the crista pyramidalis into the antrum. Superior penetration.

turbinate, inferior and middle nasal passage, and septum with the 20 per cent. cocaine-adrenalin solution.

(2) After thoroughly cocainizing, inject 20 Cc. of 1 per cent. solution of cocaine and adrenalin through the nose directly in front of the anterior attachment of the inferior turbinate subperiosteally into the canine fossa. (Fig. 89.)

(3) Make needle puncture and irrigate antrum.

(4) Make an incision from the middle of the anterior attach-

306. Canfield: The Submucous Resection of the Lateral Nasal Wall in Chronic Empyema of the Antrum. Journ. Am. Med. Assn., p. 1136, 1908.

ment of the inferior turbinate extending well down into the floor of the nose. This incision should sever all tissues down to the bone. (Fig. 90.)

(5) After controlling hemorrhage with adrenalin tampons, a small Freer elevator is used to elevate the periosteum from the crista pyriformis both externally toward the canine fossa and internally toward the nose until a sufficient portion of the bone is exposed. (Fig. 91.)

(6) The antrum may now be opened either with a bayonet chisel having a concave cutting surface (Fig. 92), by applying it first

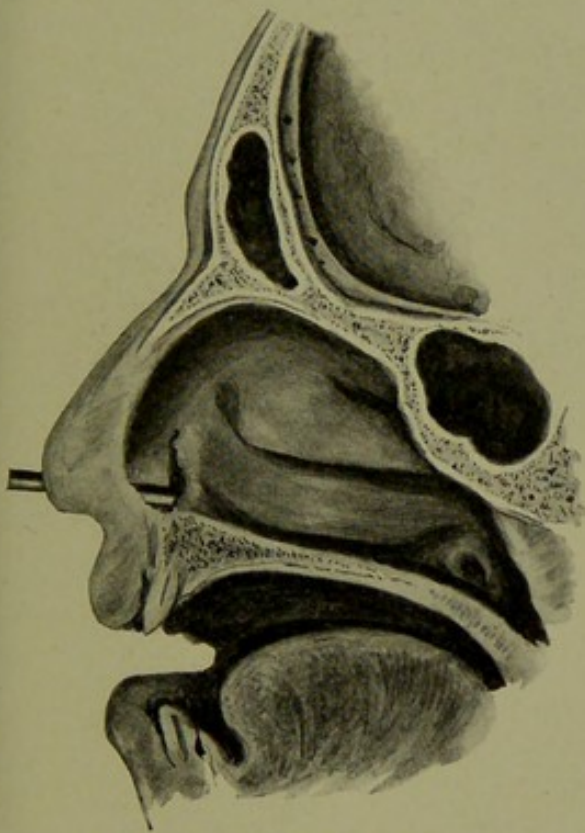


FIG. 93.—Pre-turbinal method. 5th step. Using the hollow chisel to penetrate the crista pyriformis into the antrum. Inferior penetration.

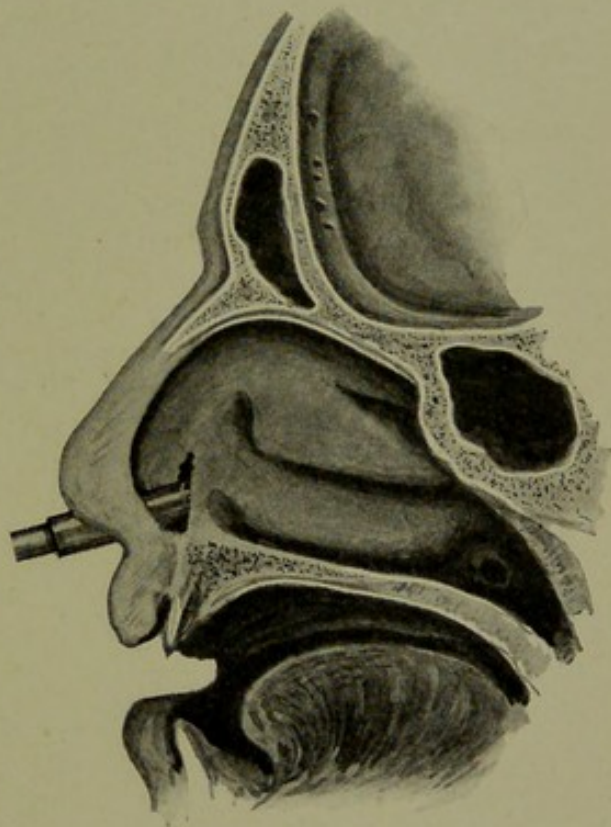


FIG. 94.—Pre-turbinal method. 6th step. Penetrating into the maxillary sinus with the electric trephine.

above and then below (Fig. 93), and removing the loosened bone with strong forceps, or, better, with an electric trephine especially adapted for the purpose (Fig. 94). If the trephine is used, it may be necessary to make several drillings in order to obtain an opening of sufficient size.

(7) Pack a thin strip of gauze saturated in the strong cocaine-adrenalin solution into the antrum and allow it to remain ten minutes. This not only anæsthetizes the mucosa, but also by its

hemostatic qualities clears the cavity of blood and permits a much more satisfactory inspection of the interior.

(8) Introduce an ordinary hard-rubber ear speculum into the opening and thoroughly inspect the antrum for polypoid membrane, necrosed spaces, etc. This procedure can readily be accomplished if sufficient bone has been removed.

(9) Introduce a curette and remove all portions of diseased mucosa, not overlooking the anterior-superior angle, which can be reached by a right-angle curette. (Fig. 95.)

(10) Again inspect the interior of the sinus, using cotton pledgets dipped in adrenalin whenever necessary, and, if it appears clean, irrigate and pack loosely with iodoform tape. The entire procedure can usually be accomplished in thirty minutes with very little inconvenience to the patient, especially if the electric drill is used. Occasionally some œdema over that portion of the



FIG. 95.—Right-angle curette.

face follows, but it is painless and disappears within twenty-four hours.

After-treatment.—The gauze is removed in forty-eight hours; the cavity irrigated and half the original quantity of iodoform tape reintroduced. In two days this is permanently removed, subsequent treatments consisting of irrigation, drying, and insufflation of iodoform or any other suitable antiseptic powder.

Advantages: (1) The sinus can always be inspected and the progress of healing noted.

(2) The drainage is at the lowest possible point reached through the nose.

(3) Local applications can be made to diseased areas resisting treatment.

(4) The inferior turbinate is preserved in its entirety.

(5) The patient can easily carry on self-treatment in the absence of the physician.

MAXILLARY SINUS: OPERATIVE TREATMENT.

CALDWELL-LUC METHOD.^{307, 308}

The rationale of this operation is to make a large opening in the anterior wall of the sinus through the canine fossa for the purpose of inspecting and, if necessary, curetting the diseased mucosa. After this has been accomplished, a large opening in the lateral nasal wall beneath the inferior turbinate is created in order to allow permanent drainage of the cavity into the nose.

TECHNIQUE OF THE OPERATION.—Instruments required: 1. Two retractors (Fig. 96). 2. Scalpels. 3. Several hæmostats. 4. Periosteal elevator. 5. Large and small chisels. 6. Nasal sound. 7. Anatomical forceps. 8. Bone-cutting forceps (Hajek's and Jansen's). 9. Curettes, sharp and dull. 10. Long nasal forceps for packing. 11. Hammer. 12. Scissors. 13. Silkworm gut. 14.

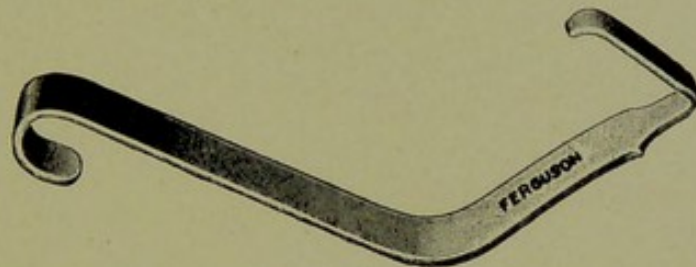


FIG. 96.—Hajek's retractor for holding up the lip in the external operation on the maxillary sinus.

Needles. 15. Iodoform gauze. 16. Plain gauze strips. 17. Solution adrenalin chloride 1-1000. 18. Peroxide of hydrogen.

1. Etherization of the patient as for any major operation.

While certain of our European confreres^{309 310} in recent years practise and strongly advocate this operation under local anæsthesia, it would seem that as far as the American public is concerned, this is for the most part inadvisable. I prefer the local method, whenever possible, on account of the greater facilities offered to the surgeon in the control of the blood and secretion by the patient, as well as his general co-operation. The whole secret lies in the preliminary anæsthetization, as if this is applied according to rule, the surgical manipulations will be painless or practically so. Absolute indications prevail when, for any reason, the administration of a general anæsthetic is inadvisable.

2. Pack the nostril on the affected side with sterile gauze so as to prevent the blood from flowing backward into the choanæ and being inspired.

307. Caldwell: Diseases of the Accessory Sinuses of the Nose, etc. N. Y. Med. Journ., p. 526, Nov., 1893. 308. Luc: Une nouvelle methode operatoire pour la cure radicale et rapid de l'empyeme chronique du sinus Maxillaire. Arch. internat. de Lary., May-June, p. 273, 1897. 309. Nager: Die Anwendung der Lokalanæsthesie bei der Radikaloperation der Kieferhöhleneiterungen. Arch. f. Lary., Bd. 19, S. 98, 1907. 310. Denker: Zur Radikaloperation des chronischen Kieferhöhlenempyems in Lokalanæsthesie. Verh. ver. Deut. Lary., S. 27, 1910.

This is not absolutely necessary, as is seen in the tonsil operations, and may be dispensed with if difficult or for any reason not deemed advisable.

Turn the head toward the healthy side and place retractor in position so that the lip is drawn well upward, exposing the alveolar process, and place gauze sponge between lip and molar teeth. (Fig. 97.)

3. Make an incision from the canine tooth to the second premolar, care being taken to begin well above the gums so as to allow for retraction of the mucosa. (Fig. 98.) This is important

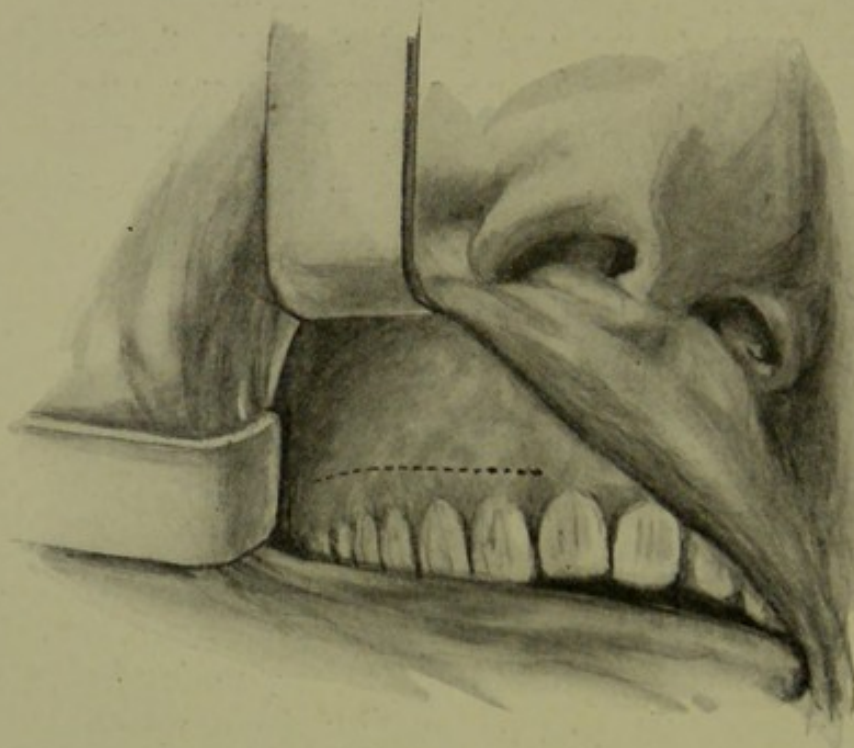


FIG. 97.—The mouth in position for the Caldwell-Luc operation on the maxillary sinus. Dotted line shows position and length of incision.

on account of the difficulty experienced in finally stitching these two surfaces together. The wound is now enlarged by incising the periosteum well under the edges of the external incision.

Hemorrhage thus far is usually not profuse and is best controlled by gauze compress saturated in the adrenalin solution. Occasionally a small artery situated in the posterior extremity of the incision will spurt, but is readily seized by the hæmostatic forceps and torsion applied, thereby controlling bleeding from that source.

4. The periosteum is now thoroughly loosened from the underlying bone and held by a suitable retractor.

5. An opening is made in the anterior wall of the sinus with a small chisel.

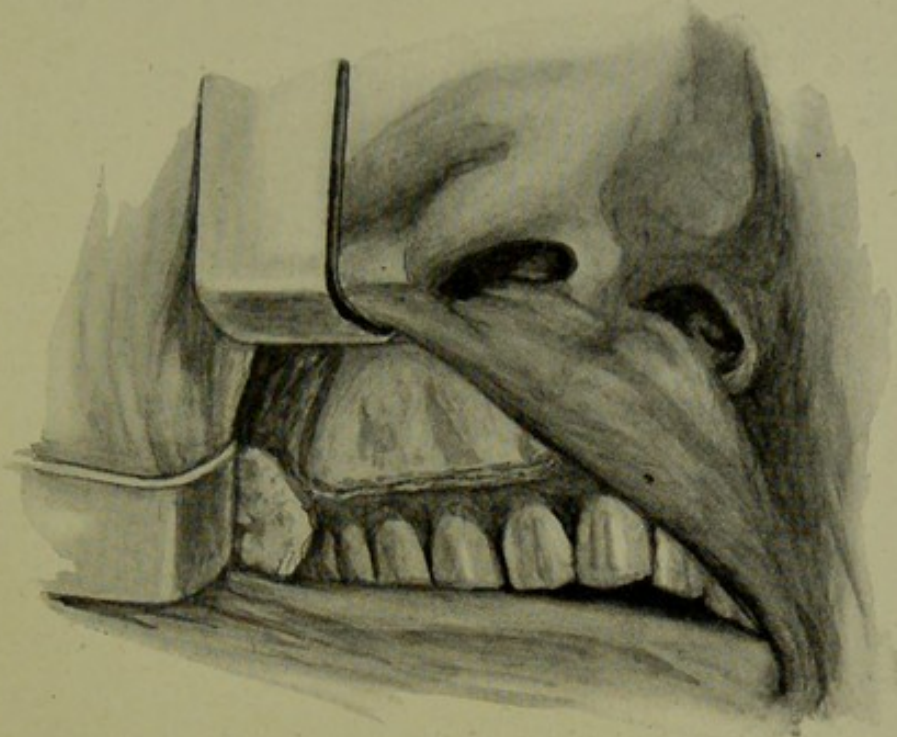


FIG. 98.—Incision made through soft parts and periosteum elevated, exposing underlying bone of the anterior wall. Pad of gauze at the lower extremity of wound to prevent blood from flowing into the pharynx.

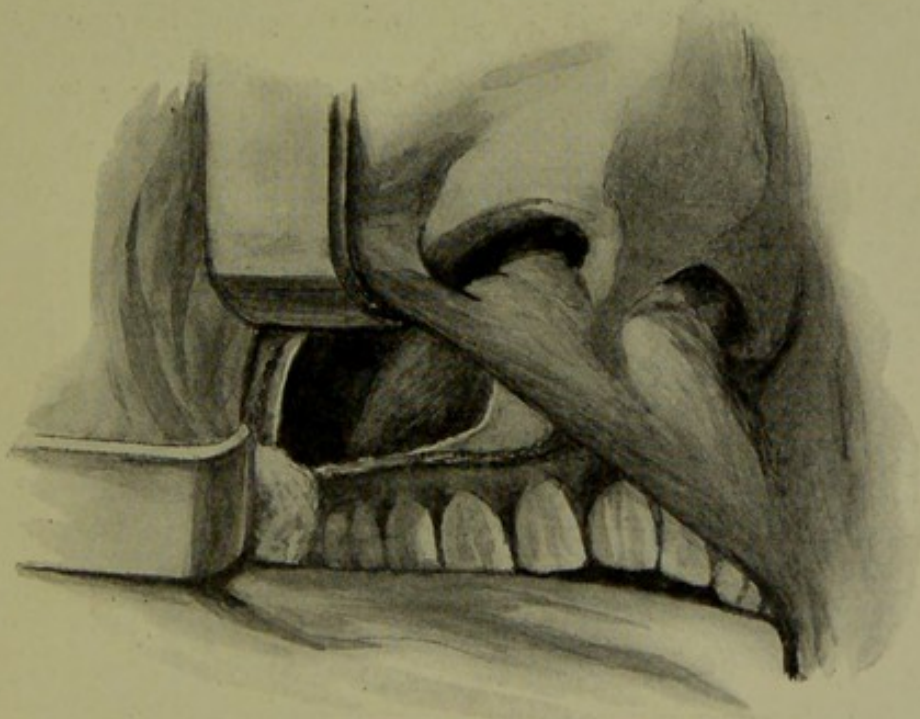


FIG. 99.—Anterior wall removed, showing mucosa of the nasal wall of the maxillary sinus.


It is particularly important that all bleeding be controlled at this stage of the operation in order that one can judge accurately the condition of the cavity on opening.

6. The opening beneath the periosteum is gradually enlarged with a chisel or bone forceps until the greater portion of the anterior wall is removed, care being taken to disclose the anterior recesses of the sinus. (Fig. 99.) The mucous lining of the antrum is usually lacerated by this procedure; if, however, it remains intact, the operator must incise that portion corresponding to the opening in the anterior bony wall. The interior of the cavity is now inspected by means of a reflected light.

It will be necessary to tampon a number of times with long strips of gauze before the blood and pus are sufficiently removed to allow inspection. The addition of adrenalin or hydrogen peroxide to the gauze will greatly facilitate this measure.

7. Curette these portions which show great degeneration, polypoid or otherwise.

This is a most important phase of the operation, for upon this depends the ultimate result and the duration of time required for healing. Seldom is it necessary to rob the sinus of all its mucosa, it being far better to curette only those portions which show great pathological changes, care being taken to search all recesses—particularly the alveolar and palatal—for degenerated mucosa and possibly caries of the bone. If too much of the mucosa is removed, the process of healing will be greatly delayed; if too little, the result of the operation will end in disappointment. However, when one is in doubt regarding the possible regeneration of an area, it is better to be on the safe side and remove it.

8. The next step is to resect that portion of the lateral nasal wall lying beneath the inferior turbinate, as well as a portion of the turbinate itself, so as to procure drainage into the nose.* This is accomplished as follows: Remove the thin layer of bone in such a manner as to leave the nasal mucosa intact. (Fig. 100.) Pass a probe into the nose beneath the inferior turbinate and note where it appears on the lateral wall through the sinus. (Fig. 101.) Make a  shaped flap from the mucosa by two longitudinal incisions with the scalpel, joining them by one cut of the scissors. The superior incision should be immediately below the attachment of the inferior turbinate. Turn the flap of membrane into the sinus and note that it lies smoothly into the nose. (Fig. 102.)

* Some question exists as to the necessity of invariably resecting the anterior portion of the inferior turbinate. When hypertrophied, presenting the possibility of acting as a barrier to free drainage, our course is apparent, but under normal circumstances we find it unnecessary to sacrifice any portion of this structure.³¹¹

311. See Lang, Kuttner, Wagener. Ver. Berl. lary. Gesell., Mar. 22, 1907.

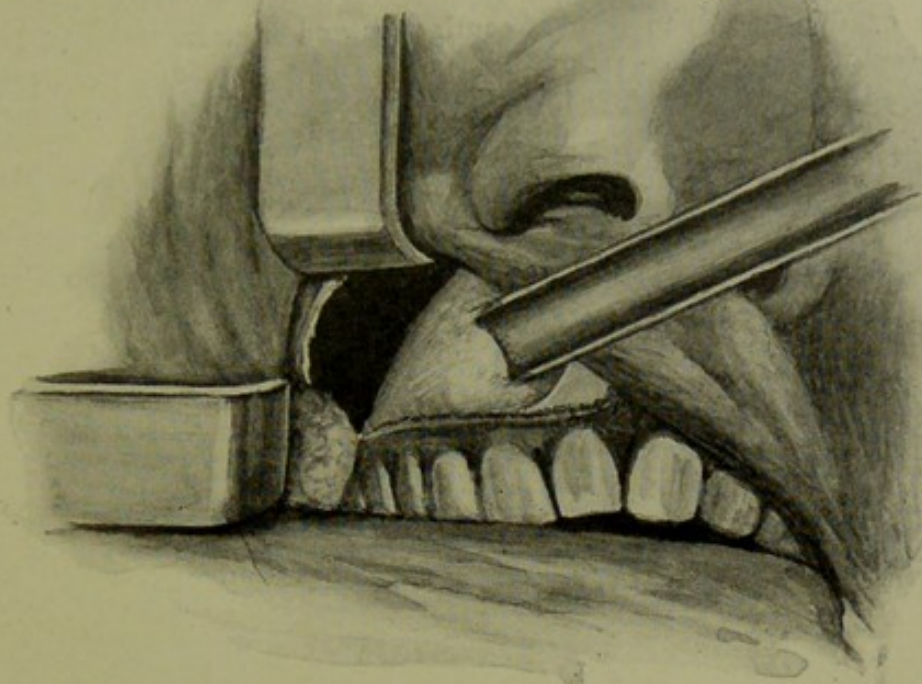


FIG. 100.—Mucosa of maxillary sinus removed, exposing the bare bone of the lateral nasal wall. The chisel in position to remove the bony wall without injuring the nasal mucosa.

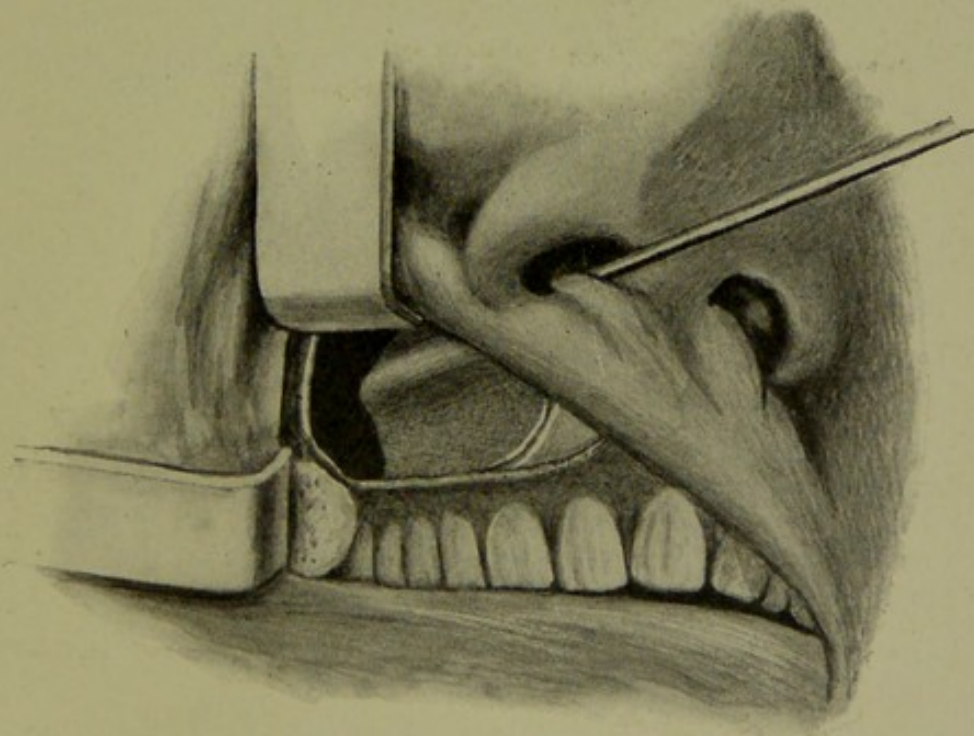


FIG. 101.—The bony wall separating the sinus from the nose removed, leaving the nasal mucosa *in situ* intact. Probe passed into the nose to show the line of incision to make the flap of mucous membrane from the nasal floor to the floor of the antrum.

If necessary, chisel the remaining base of the bony partition until this is possible.

The idea of this flap is to form a continuous and permanent outlet into the nose by preventing granulations as well as forming a base for the growth of epithelium into the sinus to replace that which was removed by the curette.

9. Flush out the sinus thoroughly with lukewarm saline solution, dry and pack with iodoform gauze.

The packing should be done in such a manner that one end protrudes from the nares, the other being in the depths of the sinus. Care must be taken that the flap of mucosa lies smooth and well pressed down, otherwise, in removing the

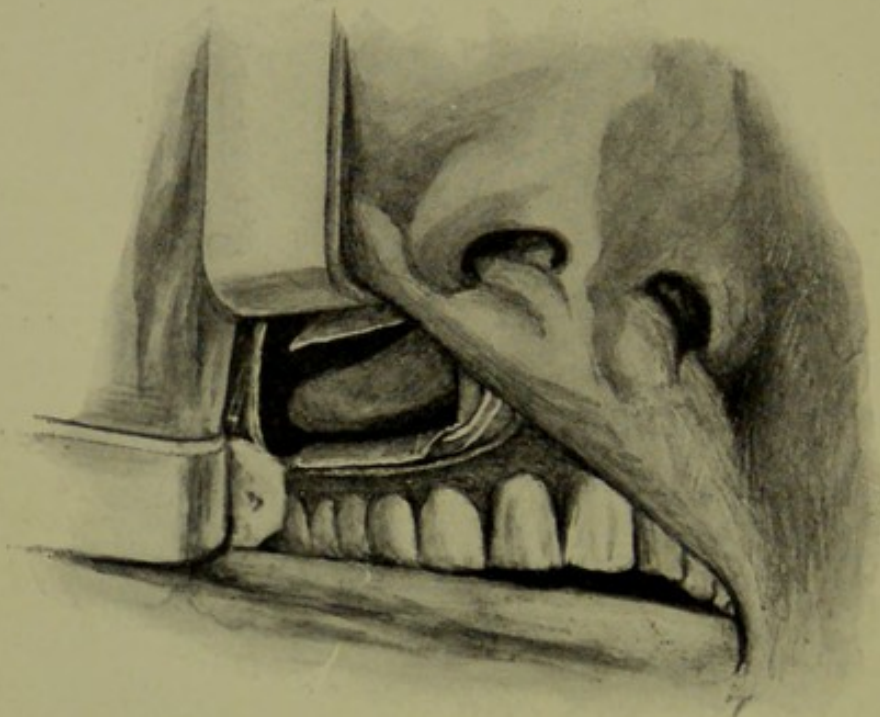


FIG. 102.—The mucosa is incised and the flap turned into the antrum. The position of the inferior turbinate is seen through the opening.

gauze, it will be found crumpled up and an actual hindrance to drainage. Holding this flap in place is best accomplished by taking one yard of seamed gauze, drawing the end through the nose from the sinus. This is gradually packed (not too firmly as this would increase the subsequent œdema) into the sinus until the cavity is filled, the end is packed in the anterior nares.

10. Close the oral wound with two or three silkworm gut sutures.

It is optional whether one applies these sutures or not, as perfect coaptation and healing usually results in either case. We have for the most part discarded them as unnecessary except where there is a possibility of the mucosa turning in and forming a permanent fistula from the removal of too much bone from the alveolar ridge. No dressing is necessary.

OPERATION UNDER LOCAL ANÆSTHESIA.³¹²

Under certain circumstances, such as pulmonary tuberculosis, severe heart and kidney lesions, etc., it may be inadvisable to use general anæsthesia. The operation may then be carried out as follows:

Have two solutions prepared, a stronger one of cocaine and a weaker one of novocaine. Solution No. 1: Water 5, adrenalin 5, cocaine 2. Solution No. 2: Water 20, adrenalin 5, novocaine 0.25.

1. Place patient on operating table. Introduce strip of gauze saturated in strong solution under and above inferior turbinate.

2. Anæsthetize between the lip and gum with solution one, inject into mucosa above the gums in the site of the incision 1 cm. of No. 2. Inject deeply under the periosteum of canine fossa 1 cm. of solution No. 2 and wait five minutes.

3. Place gauze behind line of incision in mouth and incise the mucosa to the bone, extending the cut from the first molar to the canine tooth. Retract periosteum of the anterior wall of the sinus.

4. Make an opening with a gouge large enough to admit a gauze strip, so that the cavity may be freed from purulent secretion.

5. Anæsthetize the interior of the sinus by introducing several strips of gauze impregnated by soaking with solution No. 1. Wait ten minutes. Remove gauze and inspect cavity with reflected light.

6. Enlarge opening in the anterior wall to a sufficient size that all the cavity may be inspected. Curette cavity, taking great care to remove all degenerated mucosa, particularly in the lachrymal region and posterior portion of the floor.

7. Control hemorrhage by frequent tampons of gauze saturated with adrenalin. Hemorrhage from the bone may be controlled by pressure or by applying a cone-shaped instrument and tapping sharply with a hammer. In the event of persistent bleeding, apply a tampon of iodoform gauze and defer suturing for forty-eight hours.

8. Insert a trocar through the wall of the inferior meatus and introduce scissors into the antrum through the canine fossa, resecting the wall for 3 cm. in length and 1 cm. in height. The bony portion is removed with the forceps. The completion of the re-

312. Luc (231), p. 292, 1910.

section of the mucosa is made with a bistoury, thus bringing into view the concave surface of the inferior turbinate.

This may be accomplished even better with Hajek's swallow-tailed chisel. The nasal mucosa is pushed aside and usually remains intact; therefore, a pair of forceps is introduced into the nose and the mucosa pushed toward the antrum, where it may be easily incised with a sharp scalpel.

9. The turbinate is not interfered with unless markedly hypertrophied, as patients will frequently be tormented with crusts after removal of a portion of this body. Cleanse the antrum thoroughly with gauze saturated in a 50 per cent. solution of peroxide of hydrogen. All packing is dispensed with, the cavity being thoroughly insufflated with iodoform and the wall closed with two or three stitches of catgut. During the first few days no other treatment except mentholated vaseline is applied. After eight days, when one need have no further fear as to the cicatrization of the wound, wash out the cavity through the nose. Lavage is then practised twice weekly, and a cure results in about four weeks.

After-treatment.—Rest in bed for twenty-four hours is necessary, the patient being given $\frac{1}{4}$ gr. morphine, $\frac{1}{200}$ atropine, $\frac{1}{4}$ cocaine hypodermically. Unilateral swelling of the face usually occurs, which is due to the traumatism, but subsides in twenty-four to forty-eight hours. This œdema requires no treatment other than hot or cold applications. The gauze is removed through the nose after three or four days, the removal being facilitated by frequent injections of hot water into the nostril.

Zarnico³³³ allows the oral wound to remain open and through it removes the gauze on the second day. He is thus able to apply a hard rubber speculum and inspect the interior of the sinus to ascertain whether the flap of mucosa occupies an improper position or other irregularities are present, which may be corrected under cocaine anæsthesia. No new packing is applied and the oral wound is allowed to close.

A few small, fresh strips are replaced to hold the flap firmly in place and the nostril lightly packed. After the fifth or sixth day, when the inflammation has considerably subsided, a rhinoscopic examination should be made to note whether the opening is patulous, etc. The cavity may be syringed out at this time.

Subsequent treatments consist in gentle lavage, drying, and insufflation of iodoform or pulverized bismuth formic iodide.

313. Zarnico: Lehrbuch, 3 Auflage, S. 649, 1910.

Healing will occur in a few weeks to several months, depending upon the amount of mucosa removed from the sinus. If caries or necrosis are present, the length of time required for healing will be greatly augmented.

DENKER'S METHOD.³¹⁴

Observing a number of failures following the Caldwell-Luc method, this author found, on investigation, that they were due to overlooked areas of disease situated in the anterior-superior angle of the sinus. As these are almost inaccessible with the old operation, he conceived the idea of removing the lower portion

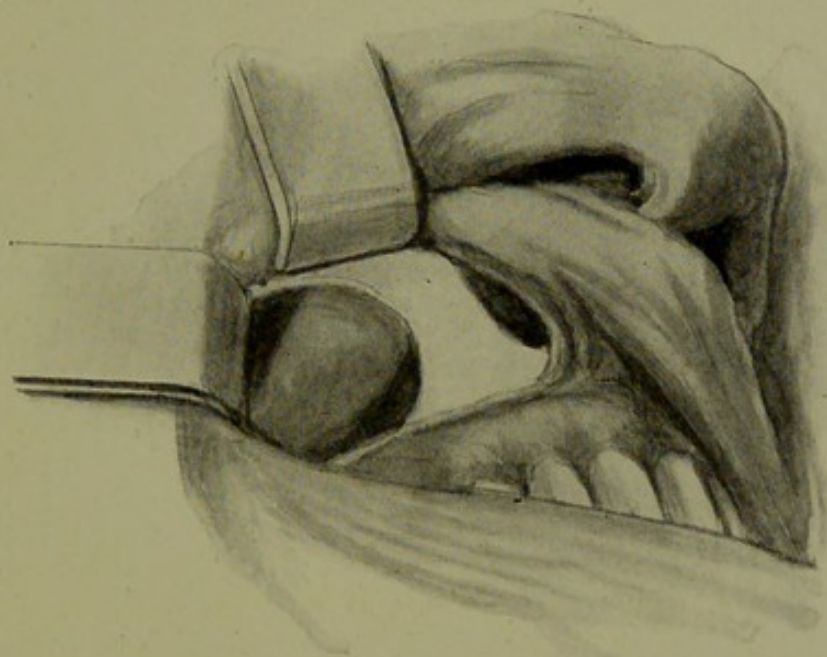


FIG. 103.—Caldwell-Luc operation completed, showing a portion of the facial wall lying intact between the pyriform aperture and the artificial opening.

of the angle formed by the junction of the anterior and nasal walls, thus making a common opening between the nose and the sinus anteriorly. (Figs. 103, 104.) After this was accomplished it was an easy matter to reach all portions of the sinus mucosa with the curette.

Prepare as for Caldwell-Luc.

1. Make incision from wisdom tooth to within $\frac{1}{2}$ cm. of the superior labial frenum.

2. Elevate the soft parts until the pyriform aperture is exposed to the height of the anterior attachment of the inferior turbinate.

314. Denker: Zur Radikal-operation des Chronschen Kieferhöhlenempyems. Arch. f. Lary., Bd. 17, S. 221, 1905.

3. Elevate the mucosa of the inferior nasal passage and nasal floor for about 4 cm. in depth, keeping the parts separated with a strip of gauze.

4. Open the sinus in the canine fossa and enlarge opening in all directions, particularly the anterior inferior angle, until all parts of the interior are brought into view.

5. Curette thoroughly and finish as with the Caldwell-Luc.

This method possesses the following advantages:

1. Practically all of the sinus mucosa is under direct inspection. (The anterior-superior angle may be examined with the aid of a small postnasal mirror.)

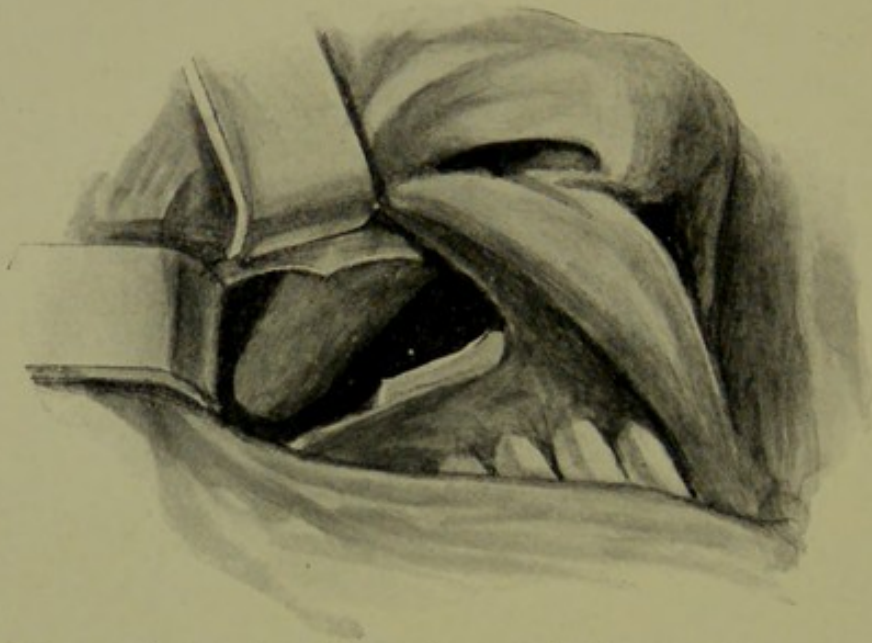


FIG. 104.—Denker operation complete, with complete removal of the osseous bridge, thus obliterating the pyriform aperture.

2. It is less difficult, though more extensive, than the Caldwell-Luc

3. Inspection can be carried out through the nose after the oral wound has entirely healed.

Causes of failure of the radical maxillary operation are:

1. Insufficient inspection during the operation, with overlooking of diseased areas of mucosa.

2. Installing too small a communication with the nose.

3. When of dental origin, in overlooking necrotic bone in the alveolar process.

4. Subsequent reinfection from the nose.

5. Making the oral opening too large, with the formation of a permanent fistula into the mouth.

MODIFICATION OF THE CALDWELL-LUC METHOD.

It is interesting to note the various transformation stages undergone until this operation was finally perfected. While it has been given the Caldwell-Luc appellation, nevertheless in reality it is the product of consecutive modifiers. It originally sprung from the old Desault³¹⁵ operation, which consisted in making a simple opening into the sinus through the canine fossa. Kuster,³¹⁶ nearly a century later, again brought it into prominence, improving the method by modern aseptic surgery and rational after-treatment.

Jansen³¹⁷ modified this by curetting away the entire antral mucosa and making a flap from the mucous membrane of the cheek which was packed into the floor of the cavity. The wound was held patulous by means of an obturator. Boenninghaus³¹⁸ made further changes by resecting this flap of membrane from the nasal wall, thereby being the first one to create a larger communication between the sinus and the nasal cavity.³¹⁹ This method consisted in resecting the anterior sinus wall,

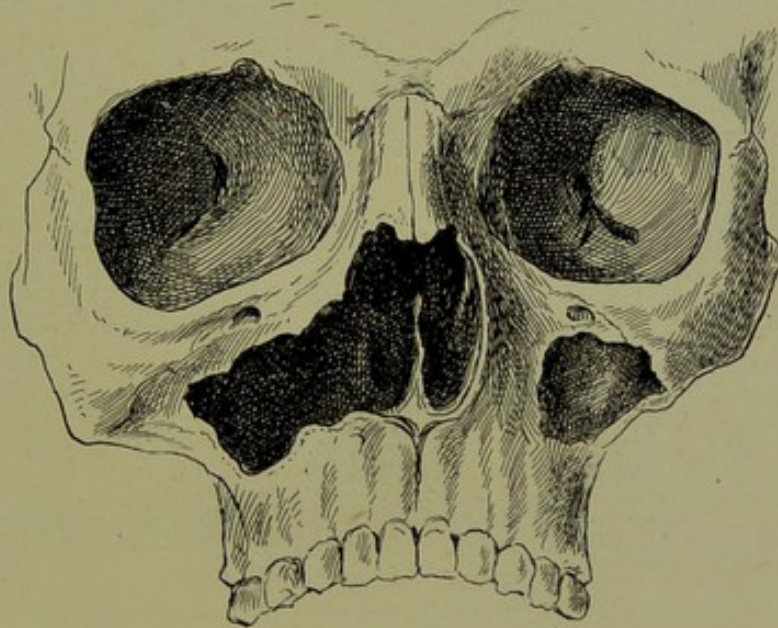


FIG. 105.—Completed Denker and Caldwell-Luc operations on skull. Denker on right. Caldwell-Luc on left.

then the osseous nasal wall. The cavity was then entirely curetted and an incision made through the anterior and posterior third of the inferior turbinate which, together with the mucosa, was turned back into the sinus. The anterior wound was allowed to remain open through which the dressings were made. Caldwell³⁰⁷ and, later, Luc³⁰⁸ made use of this method, but made the flap from the membrane lying below the attachment of the inferior turbinate. The oral wound was also primarily closed after the anterior third of the inferior turbinate had been resected to acquire proper drainage. Hajek³²⁰ curetted only those areas of the sinus mucosa which appeared pathological. Killian³²¹ allowed the oral wound to close without sutures. Finally, Denker³⁰⁵ resects entirely the anterior wall into the pyriform aperture (Fig. 104).

315. Desault: *Œuvres Chirurg.*, p. 156, vol. 2, 1802. 316. Kuster: *Ueber die Grundsätze der Behandl. von Eiterung in starrwandigen Höhlen*, etc. *Deutsch med. Woch.*, S. 235, 1889. 317. Jansen: *Zur Eröffnung der Nebenhöhlen der Nase bei chronischer Eiterung*. *Arch. f. Lary.*, Bd. 1, S. 135, 1894. 318. Boenninghaus: *Die Resection d. facialem u. d. nasalem Wand d. Kieferhöhle mit Einstülpung von Nasenschleimhaut*, etc. *Arch. f. Lary.*, Bd. 6, S. 213, 1897. 319. Lothrop (303) apparently made but a small opening into the nose. 320. Hajek: *Über die Radikaloper. u. ihre Indikationen bei chron. Empyem. d. Kieferhöhle*. *Wiener klin. Rundschau*, No. 4, 1902. 321. Killian: *Bemerkungen zur Radikaloperation chronischer Kiefer und Stirnhöhleenerungen*. *Verh. d. Ver. südd. Lary.*, S. 22, 1904.

*Results and Untoward Sequelæ of the Radical Operation.*³²²—The statistics of twelve operators show that in 297 cases 268 were completely and permanently healed. Several had recurrences, owing to insufficient curettage or to diseased areas which had been overlooked. On the whole, the Denker modification gave better results than the Caldwell-Luc.

Untoward Sequelæ: Very few cases have been reported in which the convalescence has not been rapid and uneventful. Phlegmonous swelling of the cheek due to the stitches may occur, and demands removal of the sutures. Neuralgia in the infra-orbital region has been reported,³²³ which can be caused by injury to the nerve during the operation or postoperative involvements of the nerve in the scar tissue. Anæsthesia of the cheek is frequently observed, and usually disappears in a few weeks. Stenosis of the tear-duct with epiphora should theoretically happen

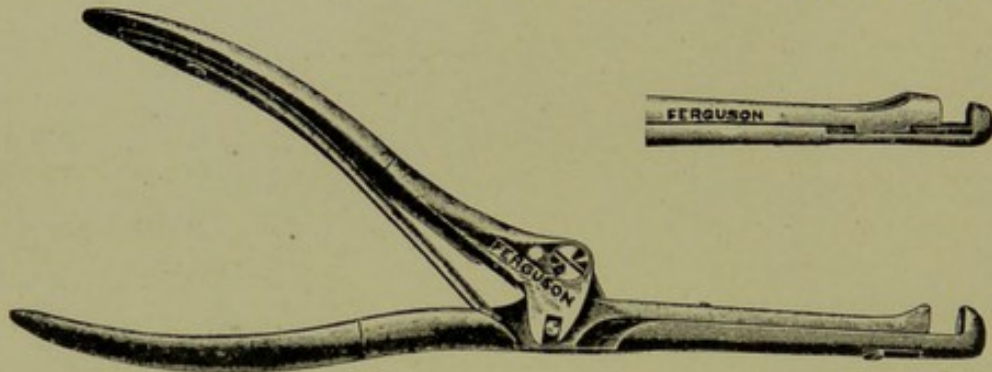


FIG. 106.—Hajek-Claus bone forceps for creating an opening between the nose and maxillary sinus.

with great frequency, although but two cases have been reported, to which the author can add another.³²⁴

Permanent fistulas into the mouth have been noted, but are usually so small that food cannot penetrate into the sinus. These can be prevented by procuring good apposition of the wound edges and not removing too much bone toward the alveolar process. Osteomyelitis of the superior maxillary has followed three times. One case recovered,³²⁵ while two died, as the process spread^{326, 327} by continuity until the entire skull was involved.

322. Boenninghaus: *Handbuch des spec. chirurg. des Ohres.*, etc., Bd. 3, Lief 1-2, S. 128, 1911. 323. Killian: *Schlussatz zu "Bemerkungen zur Radikaloperation chronischer Kiefer und Stirnhöhleenerungen."* *Verh. Süddeutsch Lary.*, S. 33, 1904. 324. Koffler: *Dakryocystitis chron. purulenta.* *Mon. f. Ohrenhk.*, S. 356, 1910. 325. Lubet-Barbon u. Furet: *Osteomyelite du Maxillaire superieur avec ethmoidite et Empyeme du Sinus.* *Ann. d. Mal. de l'Orielle*, Bd. 2, p. 209, 1905. 326. Thomson: *Sinusite Frontale deux cas de Mort post operatoire.* *Ann. d. mal. de l'Orielle*, Bd. 2, p. 409, 1905. 327. Claoue: *Osteomyelite Cranienne envahissante consecutive a une sinusite Fronto-maxillaire.* *Ann. d. mal. de l'oreille*,—Bd. 1, p. 381, 1906.

PART III. FRONTAL SINUS.

ANATOMY.^{328 329}

The frontal sinus, lying in the ascending ramus of the frontal bone, takes the shape of a pyramid, with the base lying inferiorly. (Fig. 107.) It possesses three walls: an inferior, a posterior, and an anterior. As this sinus assumes such a variety of sizes and shapes, for the purpose of comparison we will accept the arbitrarily-chosen normal frontal sinus as suggested by Hajek. (Fig. 108.) We will thus assume that the normal sinus extends from the median line to the supra-orbital notch, and from this point by a concave line back to the median line.*

This may vary from complete absence of the sinus³³⁰ to its spreading to extensive proportions; thus it may extend laterally to the superior orbital process of the malar bone (Fig. 109), or superiorly to a point high up on the vertex (Fig. 110)³³¹ or posteriorly to the lesser wings of the sphenoid (Fig. 111). The shape may be regular (Fig. 112), but it is usually extremely inclined to the opposite (Fig. 113), assuming all sorts of fantastic forms and directions, depending upon the amount of reabsorption the bone has undergone. It apparently is quite independent of its fellow on the opposite side, as one side may be fully developed, while the opposite side practically fails

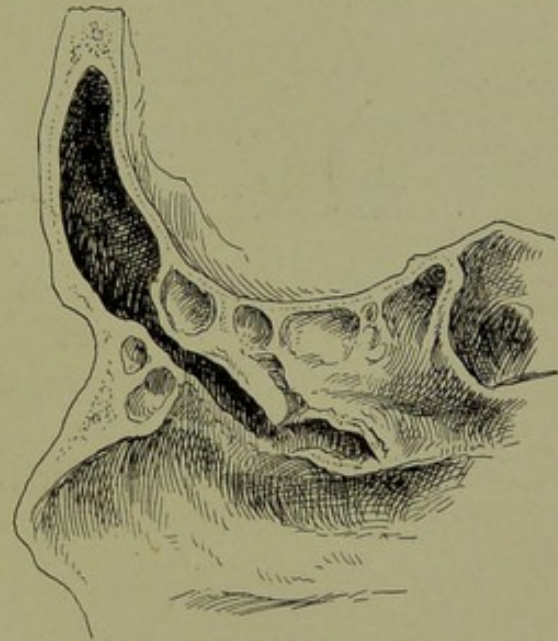


FIG. 107.—Lateral view of a medium-sized frontal sinus with direct passage into the hiatus semilunaris.

328. Lothrop: Anatomy and Surgery of the Frontal Sinus. *Ann. of Surg.*, vol. 28, p. 611, 1898. 329. Mosher: Anatomy of Frontal Sinus. *Laryngoscope*, p. 830, 1904. 330. Total absence of the sinus on both sides occurred in 3.7 per cent. of 200 specimens (Oppikofer, *Arch. f. Lary.*, Bd. 19, 1907), and in 5 per cent. of 1200 (Onodi, *Die Stirnhöhle*). The frontal sinus is considered absent when no cavity is present at the junction of the orbital and squamous portions of the frontal bone. 331. For various measurements of the frontal sinus, see Onodi, *Archives f. Laryn.*, Bd. 14, S. 375, 1903.

* Morphologically, this cavity is but a prolongation from the anterior ethmoid labyrinth which has hollowed out the diploic structure of the ascending ramus of the frontal bone. (For substantiation of this statement see anomalies of ethmoid.)

(Fig. 114); indeed, the two sides are never exactly similar. The left side is usually larger than the right.

It has been stated that reliable conclusions of the extent of this sinus can be drawn from the prominence of the superciliary ridges.³³² This, however, has been shown to be unreliable by the investigations of recent years.^{333, 334}

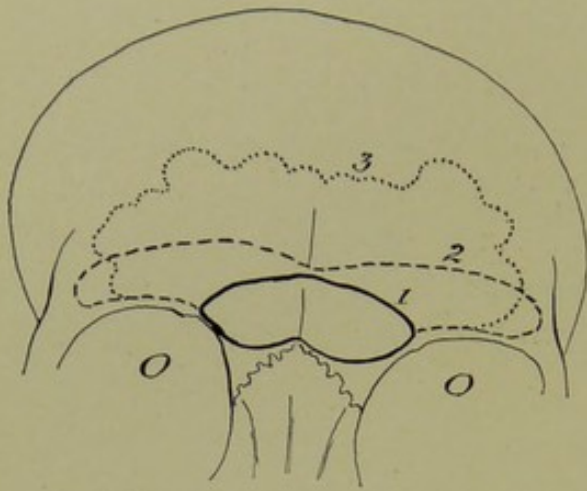


FIG. 108.—Diagrammatic representation of the form and extent of the frontal sinus. (After Hajek.) 1. Moderate size. 2. Large sinus reaching laterally to the malar attachment. 3. Large sinus reaching high up in the frontal bone.

deviations at the expense of the cavity toward which the deviation occurs (Fig. 115). Complete absence of the septum never occurs, although one sinus may occupy the entire frontal region. In these cases but one opening into the nose is present.

Tilley³³⁴ has shown the extremes of deviation which this septum may assume. This is sometimes so marked that one sinus overlaps the other (Fig. 110). The importance of this formation, from a surgical stand-point, cannot be over-estimated, for should one open the anterior wall above the superciliary ridges, this condition being present, he would penetrate into the opposite sinus.

The septum, however, is practically always constant in one position, namely, at its origin directly behind the articulation of the nasal bones. At this point it is straight and situated in the median line, and, should a deviation occur, it takes place above this point.

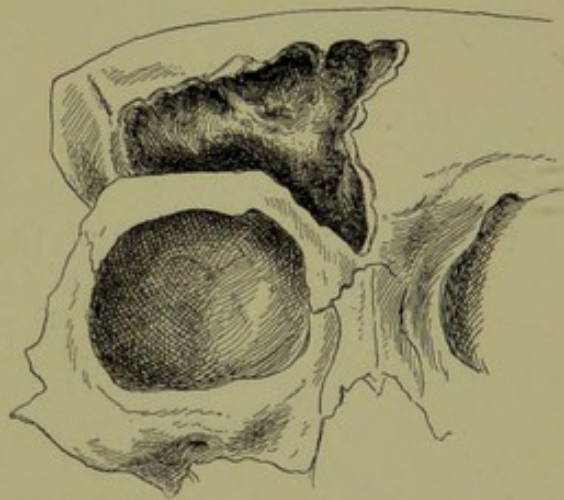


FIG. 109.—Extreme lateral extension of the frontal sinus into the malar bone.

332. Dalla Rosa: Physiologische Anatomie des Menschen, 1898. 333. Zuckerkandl: Anatomie der Nase, Bd. 1, S. 325, 1893. 334. Tilley: An Investigation of the Frontal Sinus in 120 Skulls. Lancet, Vol. 2, p. 866, 1896.

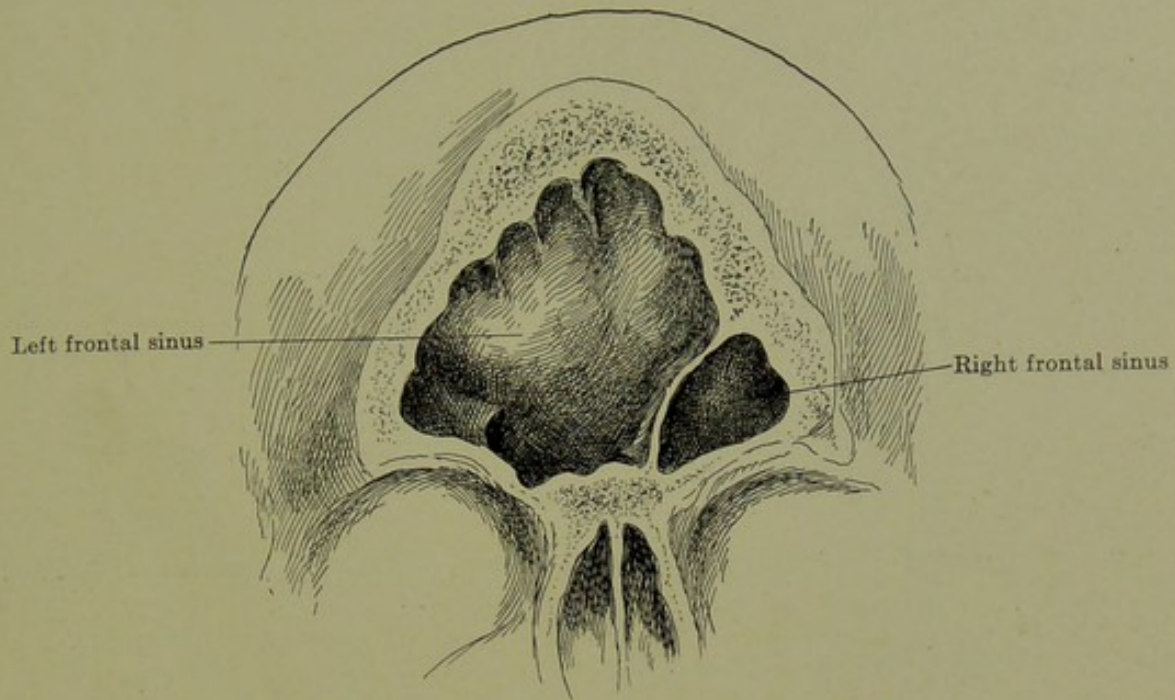


FIG. 110.—Extreme superior extension of the right frontal sinus.

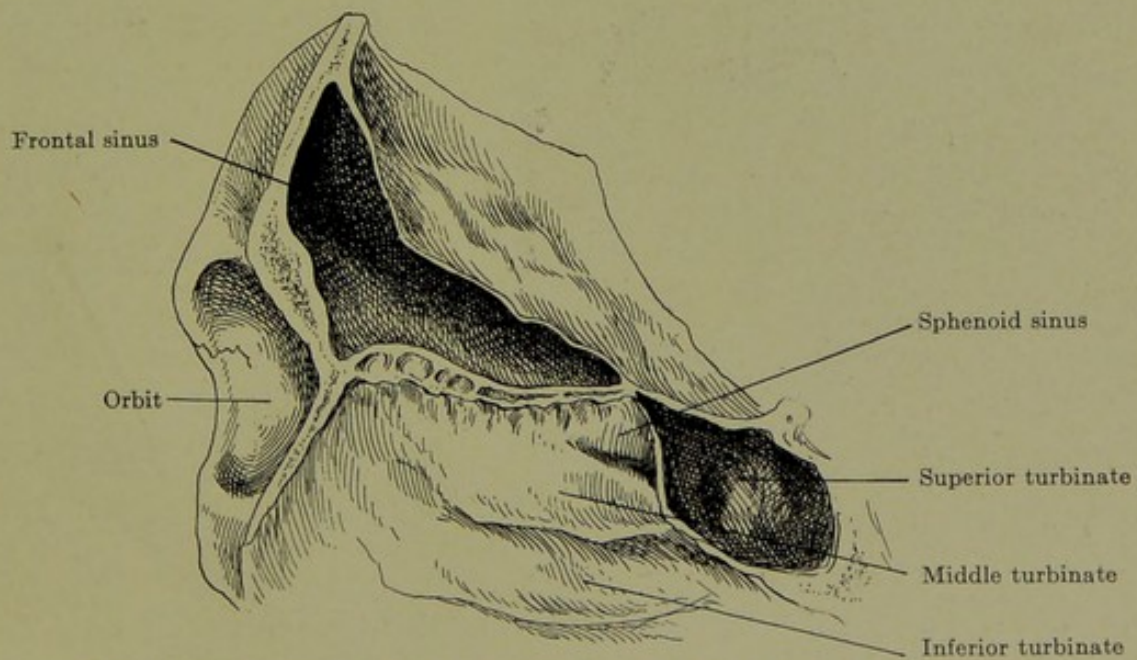


FIG. 111.—Extension of frontal sinus posterior into lesser wings of sphenoid.

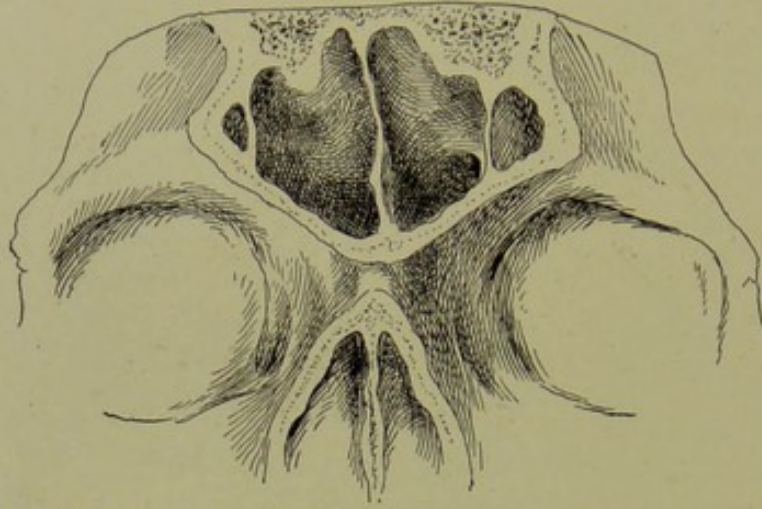


FIG. 112.—Right and left frontal sinuses of the same size and conformation. Septum in median line.

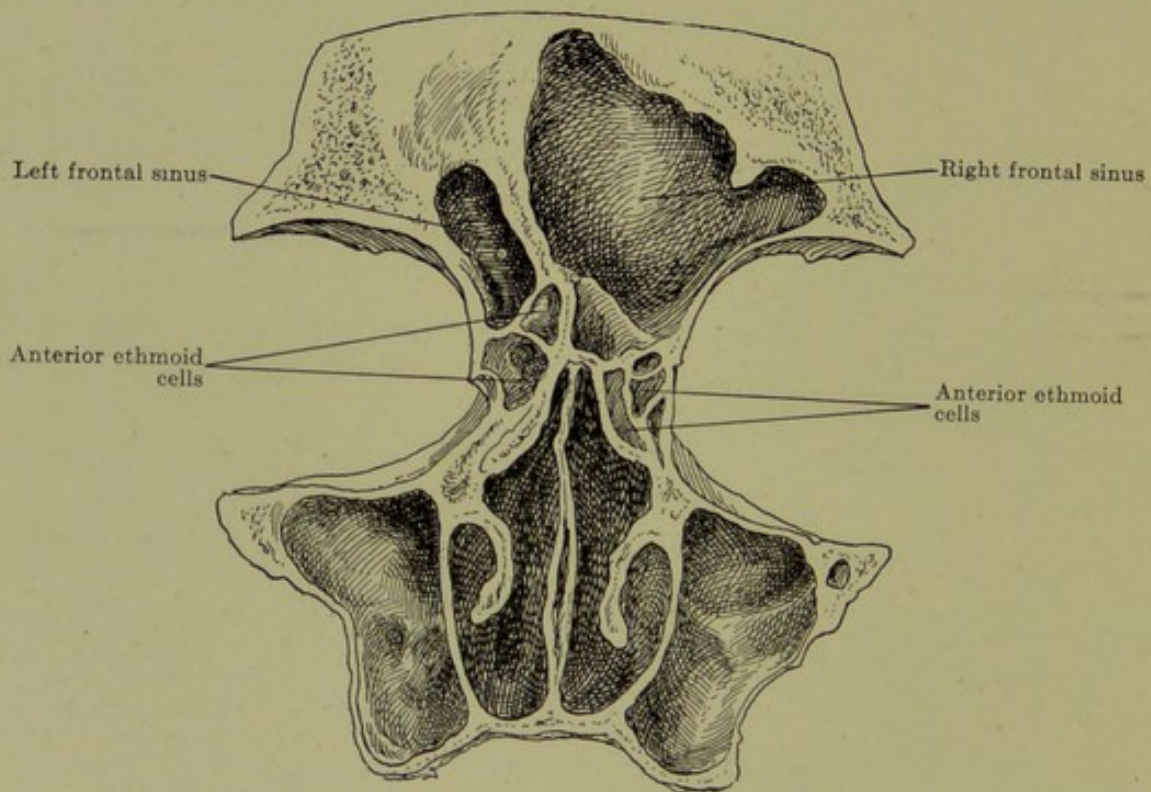


FIG. 113.—Asymmetry of frontal sinuses

The boundaries of the normal sinus would then be: in front by the supra-orbital portion of the frontal bone, behind by the cerebral wall, and below by the orbital plate of the same bone.

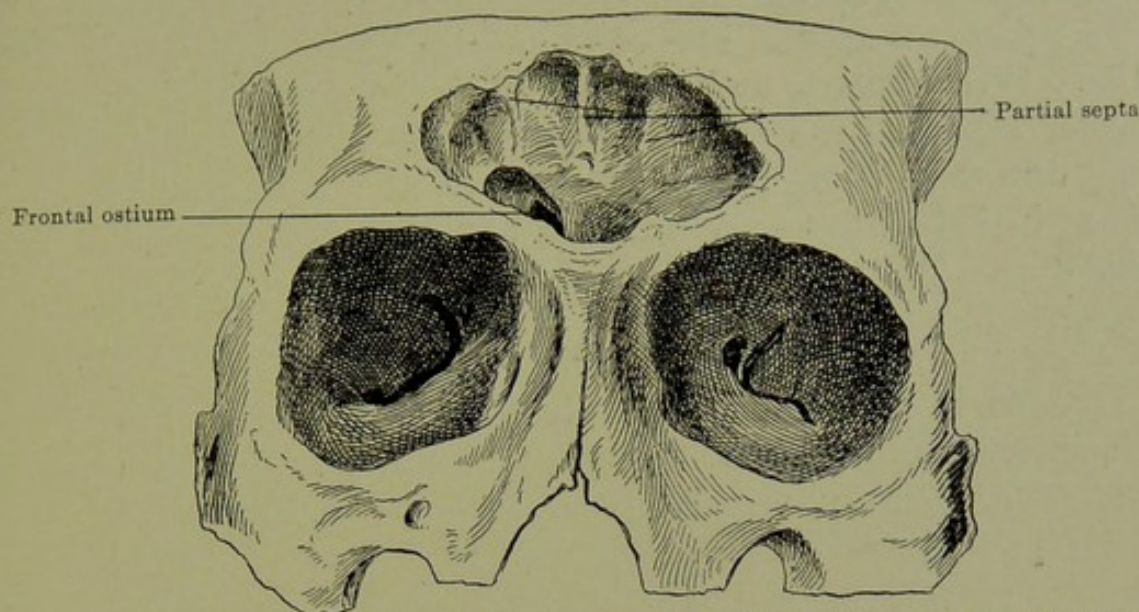


FIG. 114.—Absence of left frontal sinus. Right sinus occupies entire frontal region. One frontal ostium on right.

The inferior wall or base is not flat, but is the shape of a small inverted pyramid, with an ostium at the apex (Fig. 107). This aperture is known as the frontal ostium of the frontal sinus.

THICKNESS OF WALLS.

Such a degree of difference as was seen in the maxillary sinus is not present in this cavity; however, a slight inequality in their

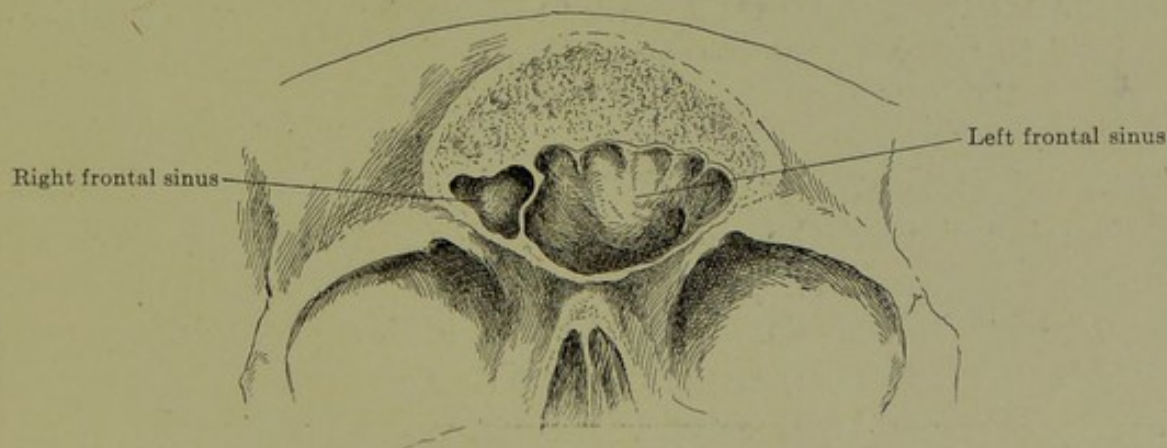


FIG. 115.—Irregularity of frontal sinuses due to extreme deflection of the septum towards the right.

structure exists. The anterior wall is composed of cancellated bone tissue and varies in thickness from $\frac{1}{16}$ to $\frac{5}{8}$ of an inch, the heaviest portion being directly over the superciliary ridges.

The posterior wall is much thinner, rarely exceeding 1/16 of an inch; however, it is composed entirely of compact bone tissue, which somewhat compensates for its lack of bulk. This structure forms part of the wall of the anterior cranial fossa and is in contact with the frontal lobe of the brain. The inferior or orbital wall is the thinnest, and at its anterior and internal junction, directly inside of the orbital ridge, seems to show a decided tendency towards thinness,* for at this point swelling and bulging outward of the bone occur in some cases of chronic frontal sinusitis.³³⁵

DEHISCENCE OF THE WALLS.

Defects in the osseous structure have been found in every wall, including that of the septum, and may be congenital or due to trauma,³³⁵ pathological changes, or senile atrophy.³³⁶ The most frequent part affected appears to be the orbital. Zuckerkandl³³⁷ reports several cases of dehiscence in the orbital plate; these were covered with mucous membrane and periosteum, the defect being only apparent in the bone; and Gerber³³⁸ and Onodi have made similar observations. The anterior wall directly above the centre of the eyebrow seems to be a point of predilection, as defect in the bone at this place has also been reported by the above-mentioned authorities.

Congenital defects in the osseous formation of the posterior or cerebral wall have been reported by numerous observers.³³⁹ Dehiscence in the septum so that the two sinuses communicate has been demonstrated by Killian,³⁴⁰ and Menzel.³⁴¹ Hajek is inclined to believe that these perforations are pathological.

INTERIOR OF SINUS.

The interior of the cavity is usually not smooth, but shows various irregularities, particularly at the junction of the posterior and inferior walls. Partial septa hiding great recesses are often seen (Fig. 116), sometimes making the sinus appear to be

* This was shown to be more apparent than real, the swelling often being due to the infection of the emissary veins, which are particularly numerous at this point.

335. Gerber: Die Komplikationen der Stirnhöhlenentzündung, S. 65, 1909. 336. Onodi: Die Dehiscenzen der Nebenhöhlen der Nase. Arch. f. Lary., Bd. 15, S. 62, 1903. 337. Zuckerkandl: Anatomie der Nase, Bd. 1, S. 354, 1893. 338. Gerber (335), S. 152. 339. Cisneros, Jacques, Mouret, Castex: Cited by Gerber. S. 151, 1909. 340. Killian: Ueber communicierende Stirnhöhlen. Munch. med. Woch., Bd. 44, S. 962, 1897. 341. Menzel: Nebenhöhlenanamolien. Mon. f. Ohrenhk., S. 415, 1905.

double.³⁴² According to Sieur and Jacob,³⁴³ these partial septa have two seats of predilection: (1) the junction of the anterior and posterior walls (commonest); (2) the beginning of the orbital prolongation. Long, finger-like projections, reaching high

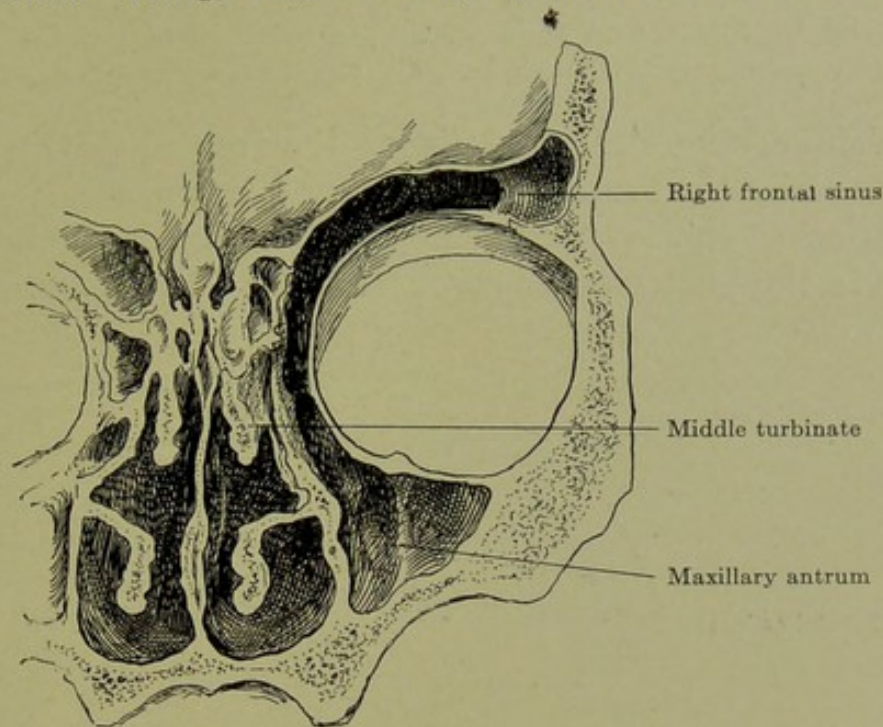


FIG. 116.—Extreme lateral extension of frontal sinus. Direct connection with antrum.

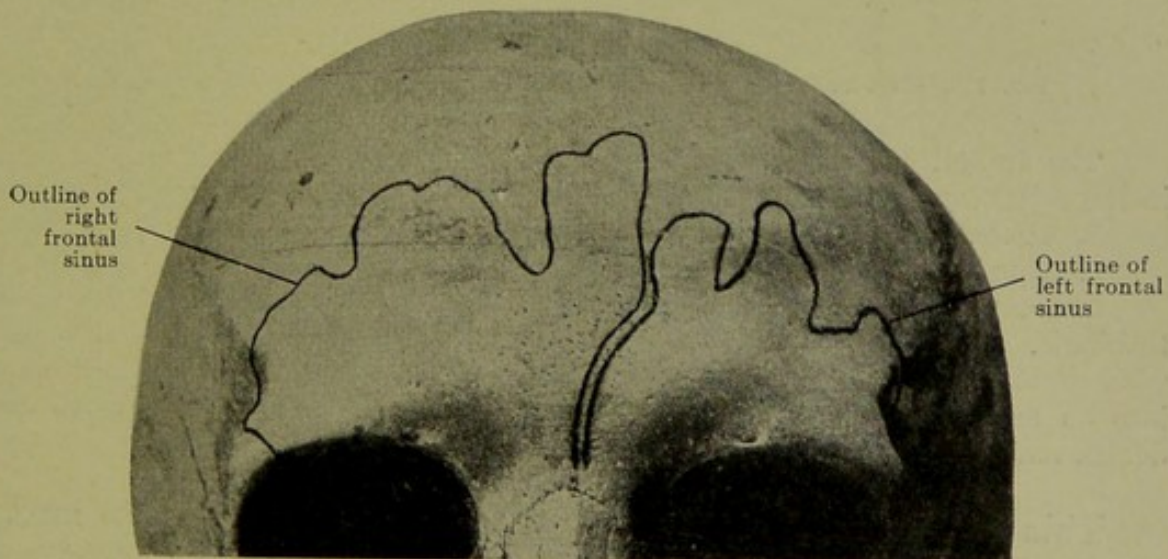


FIG. 117.—Frontal sinus sending projections high up into the frontal bone. (After Onodi.)

up on the forehead or laterally toward the temple, are by no means uncommon. (Fig. 117.) It is the residue in these recesses that often cause recurrence after a radical operation. (See Operation.)

342. M. H. Cryer: Some Variations of the Frontal Sinus. Journ. Am. Med. Assn., p. 284, 1907. 343. Sieur and Jacob: Fosses Nasales et leur Sinus, Paris, p. 409, 1901.

Cases have been reported from time to time in which these septa have been complete, thereby forming an enclosed cell within the frontal sinus which was isolated.³⁴⁴

Hartmann,³⁴⁵ on the other hand, claims that, embryologically, it is impossible for any isolated cell to form within the nasal sinuses, which would seem to be entirely correct, even though Boege³⁴⁶ and Gerber³⁴⁷ combat this assertion.

The communication between the frontal sinus and the nose is formed by the frontal ostium, which lies at the posterior inferior portion of the inferior triangle, in a position almost corresponding to the posterior or cerebral wall of the sinus. (Fig. 118.)

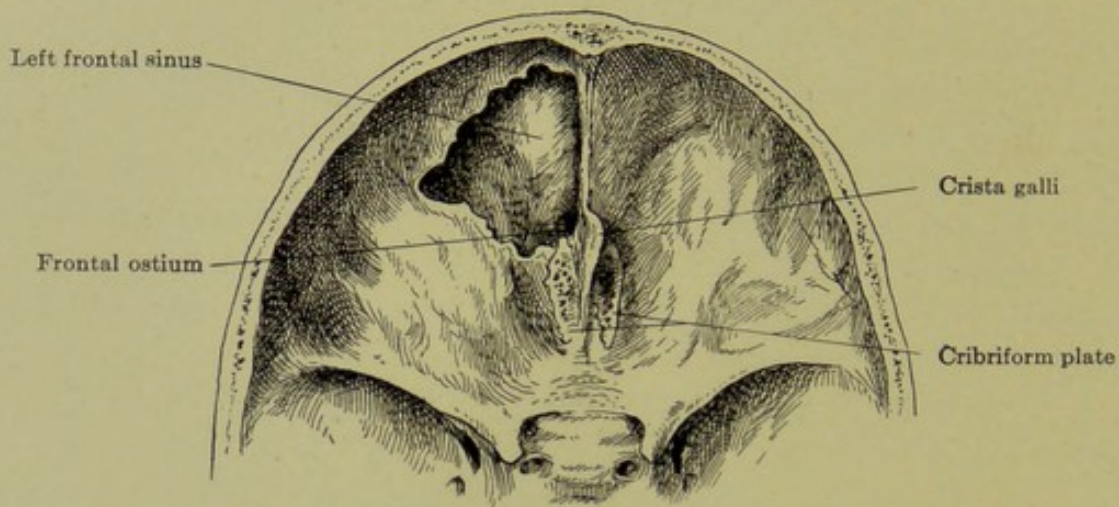


FIG. 118.—Left frontal sinus opened from above, showing relative position of ostium.

The frontal ostium is not constant as regards position, for it may be found in the following localities:^{348 349}

1. At the superior extremity of the infundibulum.
2. Anterior and superior to the hiatus semilunaris.

3. On the roof of the middle nasal passage, at the insertion of the middle turbinate. These are only the usual situations of this structure. Anomalies occur with great frequency, as it is even not uncommon to see the frontal sinus empty into an anterior ethmoid cell (Fig. 119). Onodi³⁵⁰ reports the occurrence of a double nasofrontal duct.

This ostium may empty directly into the nose or into an enclosed duct which leads into the nose (ductus nasofrontalis). In the latter instance we must pass through two ostia before entering the sinus, first the nasal ostium, then the frontal. The ductus

344. Vacher: *Bul. et mem. de la Societe Francaise d'otologie*, 1906. 345. Hartmann: *Anatomie der Stirnhöhle*. Taf. iv, Wiesbaden, 1900. 346. Boege: *Anatomie der Stirnhöhle*, S. 23, 1902. *Dissert. Königsberg*. 347. Gerber: *Komplikationen der Stirnhöhlen*, S. 158, 1909. 348. Heyman and Ritter: *Zeit. f. Rhin.*, Bd. 1, 1909, for an exhaustive treatise on the ostium frontale. 349. Wilson: *Variations of the Ostium Frontale*. *Trans. Am. Laryn. Assn.*, p. 178, 1908. 350. Onodi: *Die Stirnhöhle*, S. 13-71, 1909.

nasofrontalis is not present in every instance, but is formed as follows:

The anterior inferior extremity of the frontal sinus is constructed by the impingement of the anterior superior nasal spine

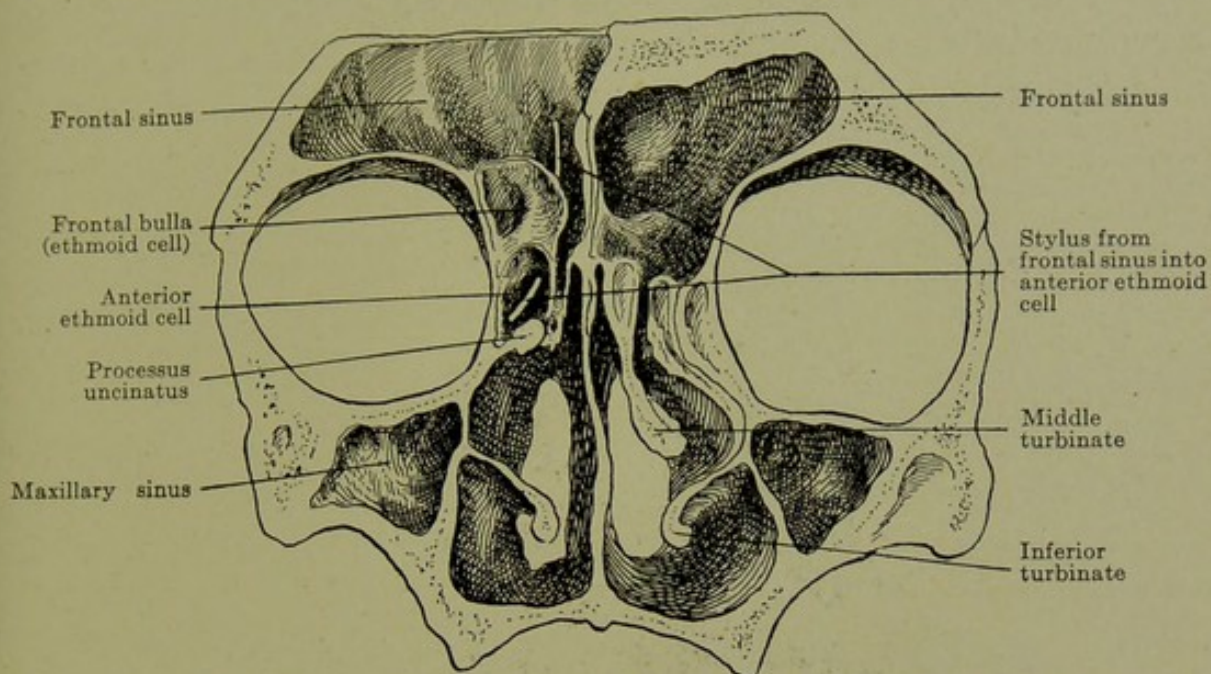


FIG. 119.—Direct communication of the frontal sinus with an anterior ethmoid cell.

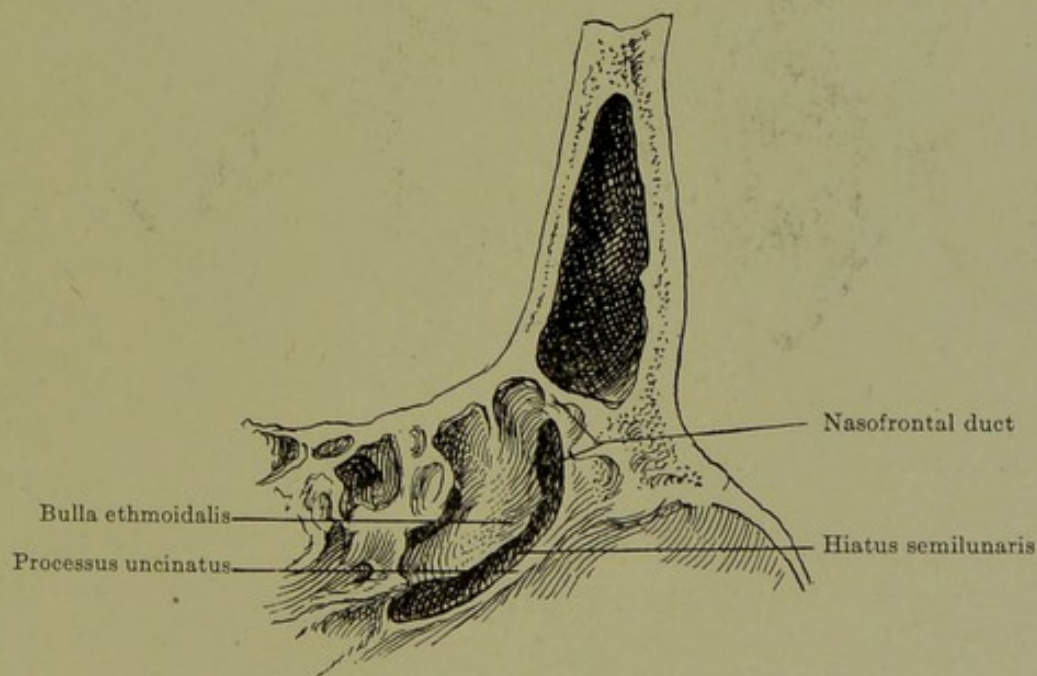


FIG. 120.—Formation of ductus nasofrontalis.

which helps form the frontal ostium (Fig. 20). The ethmoidal bulla is usually situated several millimetres posterior to this structure, thereby allowing the infundibulum to expand; however, when the bulla ethmoidalis lies anterior to its normal position,

instead of the infundibulum being wide it is narrowed into a duct which is closed laterally by the anterior attachment of the middle turbinate. (Fig. 120.) This duct (nasofrontal), therefore, has two ostia, a nasal and a frontal, and is situated at the superior end of the hiatus semilunaris—in fact, is a continuation of this structure into the frontal sinus. (Fig. 121.) Its length is variable ($\frac{1}{8}$ to $\frac{1}{2}$ inch), depending upon the encroachment of the eth-

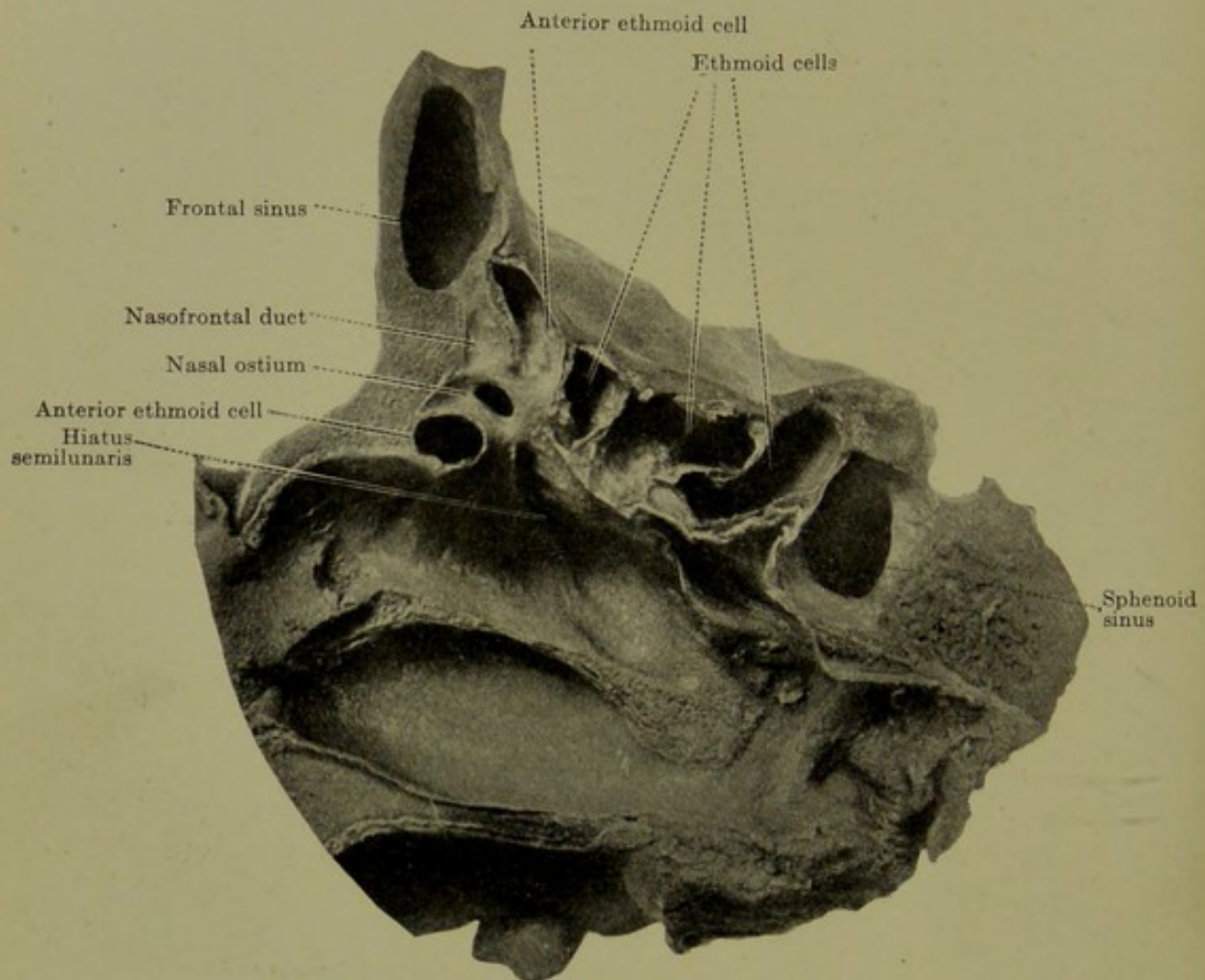


FIG. 121.—Lateral wall of nose with marked nasofrontal duct. (After Hartmann.)

moidal bulla. The boundaries of this structure would then be: anteriorly, uncinatè process, agger nasi, and superior nasal spine; posteriorly, lamella of bulla ethmoidalis; internally, anterior attachment of middle turbinate; externally, lamina papyracea.

RELATION OF THE HIATUS SEMILUNARIS TO THE FRONTAL SINUS.

This structure usually lies directly below the frontal ostium and forms a direct continuation of the sinus duct into the middle

nasal passage. The hiatus assumes two different anatomical formations: (1) direct method of emptying; (2) indirect method.³⁵¹

1. By direct method is meant that the hiatus leads directly into the ostium of the frontal sinus without the intervention of any anatomical hindrance. (Fig. 122.) 2. The indirect method presupposes the presence of an infundibular cell situated in the hiatus, so that it forms a blind ending to this structure, the frontal ostium being situated farther above. (Fig. 123.)

The indirect method is by far the commonest, and is not, as Hajek³⁵² says, the atypical formation. In 176 specimens (including the Cryer collection) examined by the author the indirect method or the presence of an infundibular cell was found in 174 cases.

RELATION OF THE FRONTAL SINUS TO THE ETHMOID LABYRINTH.

As embryologically the frontal sinus is merely an offshoot from the ethmoid labyrinth, it naturally follows that this relation must be a most intimate one.

In the disarticulated frontal bone the frontal sinus appears merely as a cavity divided by a septum. (Fig. 124.)

The ethmoid closes in these apertures from below, thereby forming the floor of the frontal sinus. (Fig. 125.)

It will thus be seen that the floor of the sinus is in reality a portion of the ethmoid capsule. Considering these formations, it readily will be observed that any anomalous formation in the anterior ethmoid labyrinth will exercise no little influence in the configuration of the normal drainage passages of the frontal sinus. At that place

where the frontal ostium leads into the nose one of two conditions is usually present: (1) an ethmoid cell lies between the ostium and the lamella of the bulla; or (2) a second ostium is present which leads into an orbital ethmoidal cell.

where the frontal ostium leads into the nose one of two conditions is usually present: (1) an ethmoid cell lies between the ostium and the lamella of the bulla; or (2) a second ostium is present which leads into an orbital ethmoidal cell.

This cell has frequently been described as a double frontal sinus,²¹⁰ but in reality it is only a prolongation of the ethmoid proper, in spite of its being

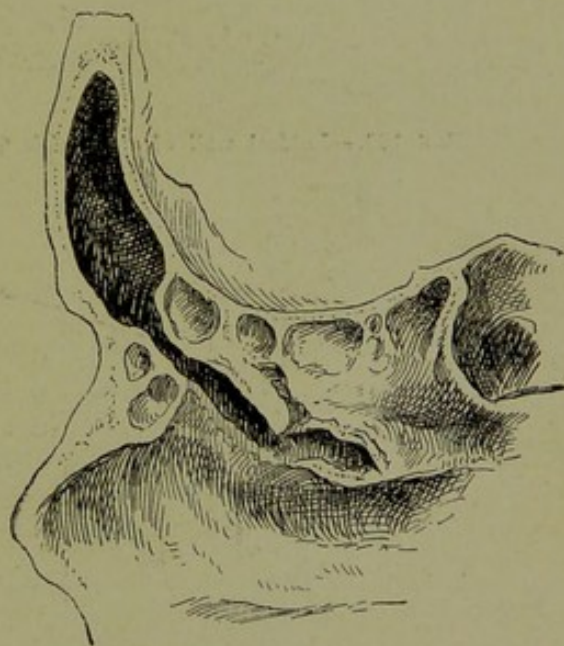


FIG. 122.—Lateral view of a medium-sized frontal sinus with direct passage into the hiatus semilunaris.

351. Killian: Die Stirnhöhle. Heymann's Handbuch, vol. 2, S. 1106, 1900. 352. Hajek: Lehrbuch, S. 163, 1909.

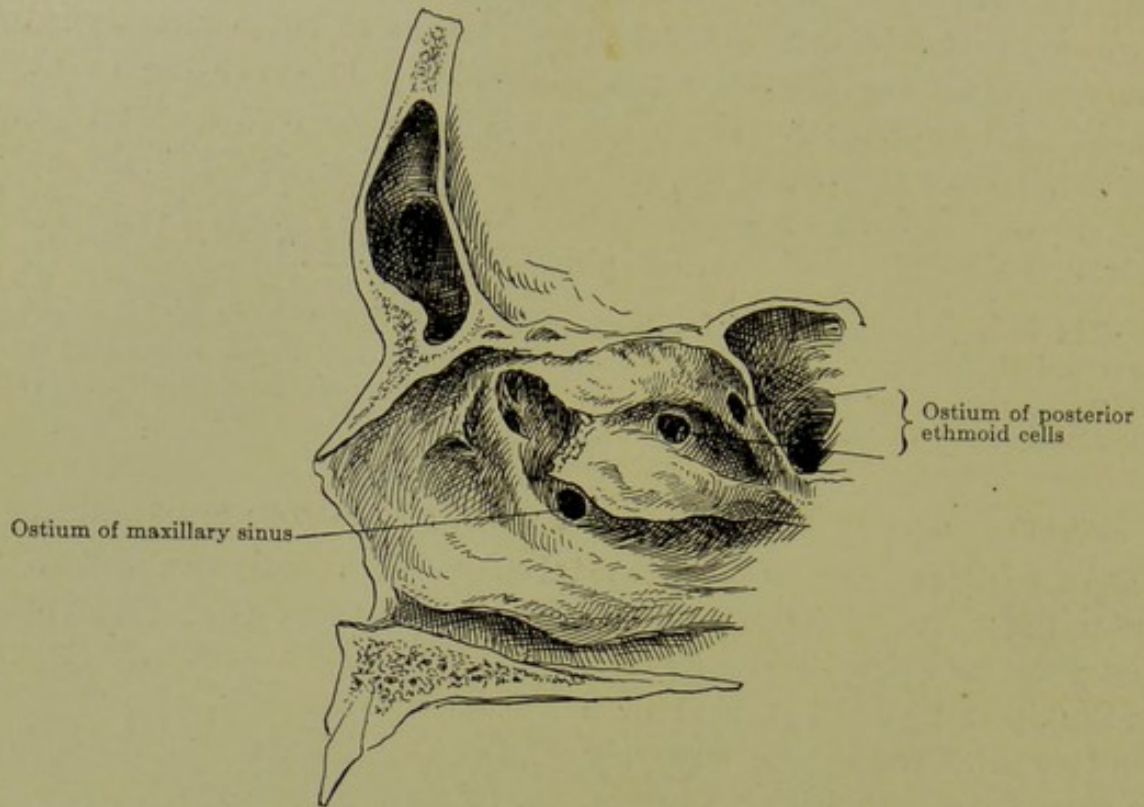


FIG. 123.—Lateral wall of nose with anterior portion of middle turbinate removed.

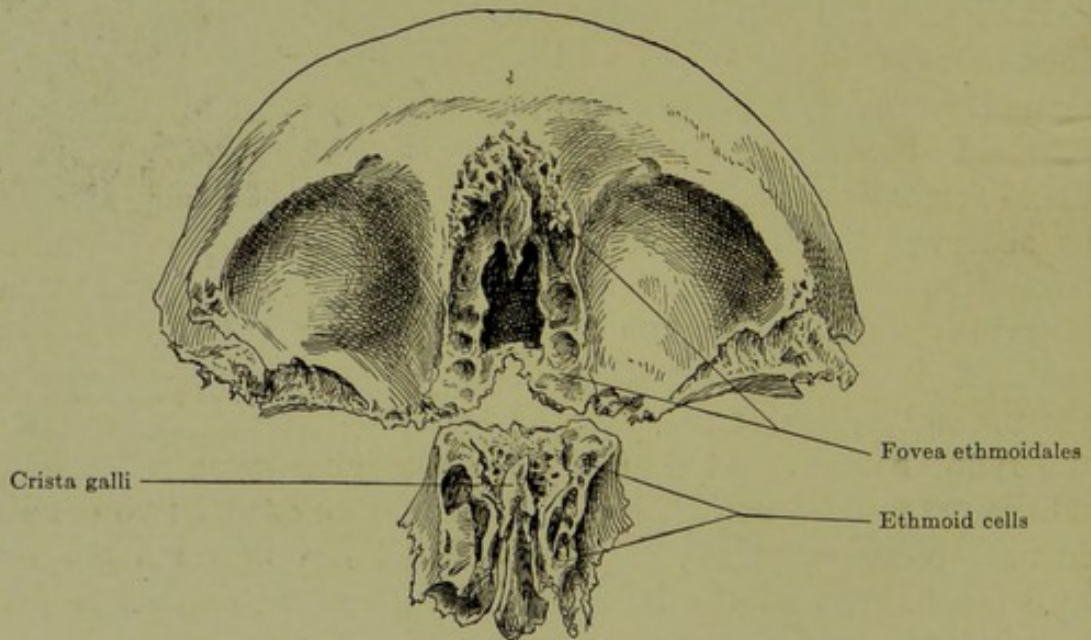


FIG. 124.—Frontal bone and ethmoid capsule disarticulated.

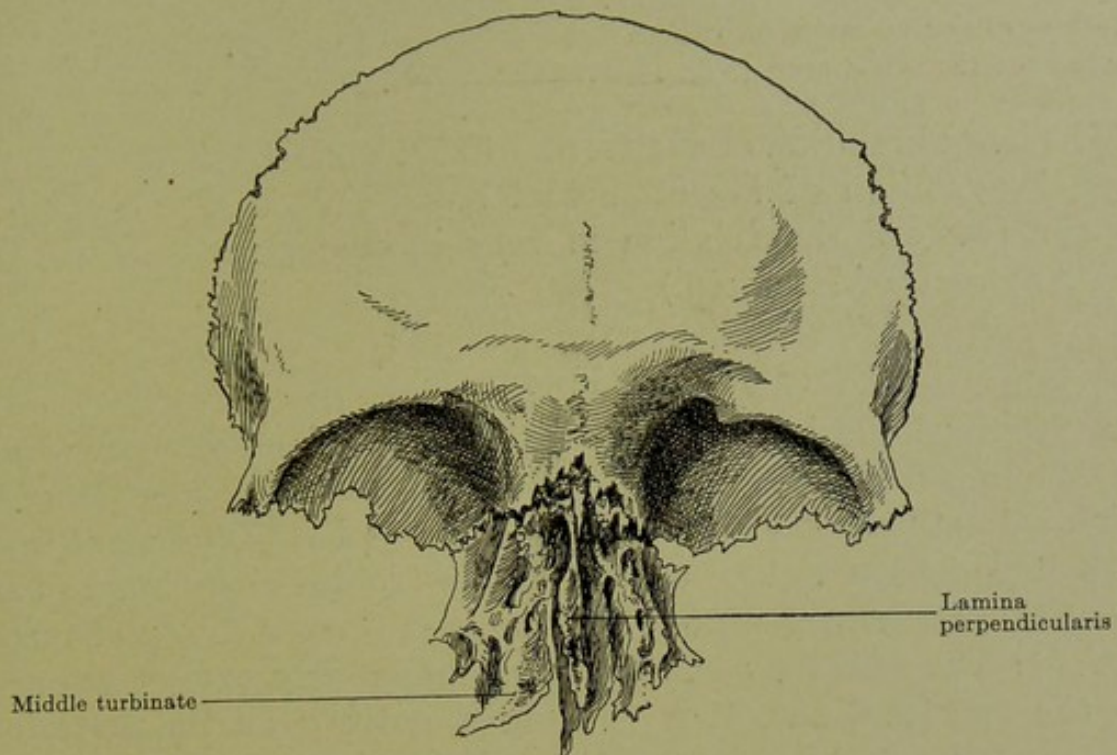


FIG. 125.—Frontal bone and ethmoid capsule in place.

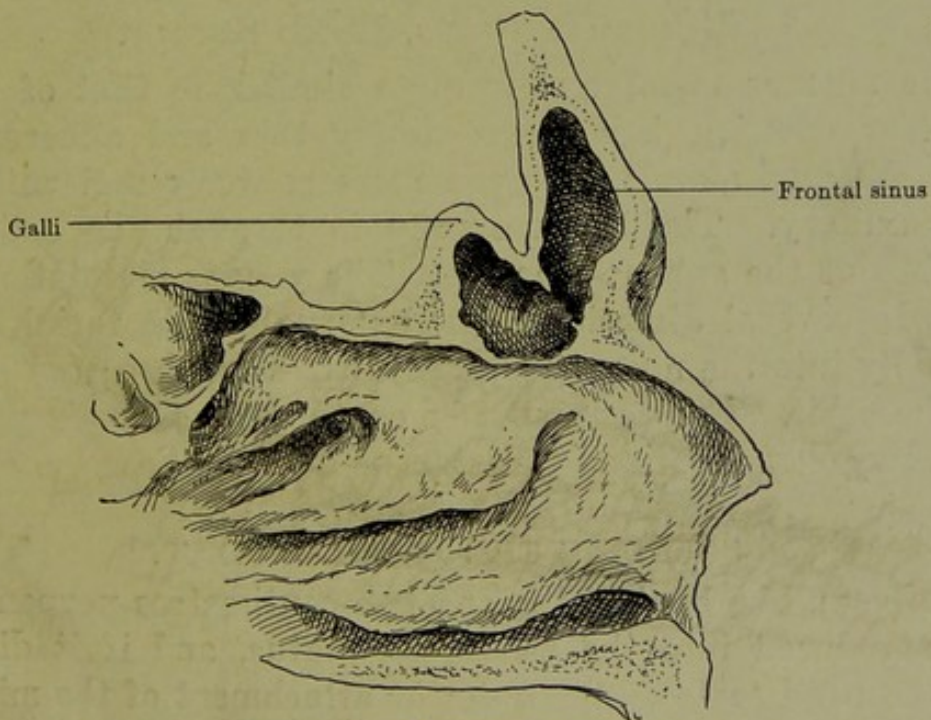


FIG. 125a.—Prolongation of frontal sinus into crista galli.

situated in the frontal bone. Certain authors^{353 354} have reported or demonstrated cases where cells existed over the orbit but had no ostiums into the nose. All these communicated with the frontal sinus and must be considered merely prolongations of, or adjuncts to, this cavity. A backward prolongation may occupy a portion of the crista galli (Fig. 125a).

The actual relation of the frontal to the ethmoid sinus depends upon the position of the ethmoidal bulla. When this structure lies far forward the relation is very intimate, and *vice versa*. (See Anatomy of Ethmoid.)

BULLA FRONTALIS.

A frontal bulla is nothing more than a ballooning upward of an ethmoid cell into the floor of the frontal sinus. It possesses an individual ostium, and is in no way connected with the sinus into which it penetrates. The ostium of the frontal sinus lies to one side of this structure. The frontal bulla is formed in one of three ways: 1. The lamella of the ethmoid bulla may extend upward into the frontal sinus, thus causing a bulging on its posterior inferior wall. 2. An infundibular cell may push its way upward into the frontal sinus. 3. Lamella of uncinatè process may continue upward and insert on posterior sinus wall. (See Ethmoid.)

MUCOSA OF SINUS, BLOOD SUPPLY.

The mucous membrane is quite similar to that of the other accessory cavities, being exceedingly thin and adherent to the bone. Mucous glands are even more sparsely met with than in the maxillary. The blood supply is through the ostium from branches of the sphenopalatine. The venous circulation anastomoses in several directions: (*a*) externally into facial vein; (*b*) internally into the nose; (*c*) posteriorly into dura; (*d*) internally into the orbit. This fact must be continually borne in mind when impending complications threaten.

SOUNDING THE FRONTAL SINUS.³⁵⁵

If a sound be bent at the end two centimetres perpendicularly and introduced into the semilunar hiatus, and if it disappears until the bend rests on the anterior attachment of the middle tur-

353. Mouret: Rapports de l'apophyse unciforme avec les cellules ethmoidales, etc. Revue hebdomadaire de Laryngologie, T. 22, p. 481, 1902. 354. Freudenthal: Nouvelle contribution à l'opération radicale de la sinusite frontale. Arch. Intern. de Laryngologie, T. 20, p. 761, 1905. 355. Jurasz (Ueber die Sondierung der Stirnhöhle, Berlin klin. Wochenschrift, Bd. 24, S. 32, 1887) was the first rhinologist to scientifically probe the frontal sinus on the living.

binate, the end of the sound is in one of three places: (1) frontal sinus; (2) orbital ethmoid cell; (3) frontal bulla.

A fourth place might be added—the cranial cavity. We will, however, leave this out of all consideration, as to penetrate into the brain the probe must be on the inside of the middle turbinate in order to strike the cribriform plate. As we have seen, the fovea ethmoidalis of the frontal bone completely covers the ethmoid capsule, and it would require an unwarranted degree of force to make any impression on the comparatively solid bone of these structures, especially if one uses the very flexible sound designated for sounding the sinuses.

TECHNIQUE OF SOUNDING THE FRONTAL SINUS.³⁵⁶

The sound is bent in the manner described above (Fig. 126), and, after thorough cocainization, is introduced under the anterior third of the middle turbinate.




FIG. 126.—Sound bent for frontal sinus.

In the vast majority of instances this portion of the turbinate must be removed on account of the various anatomical difficulties which are encountered. After this structure has been removed, the sinus may be reached in over 95 per cent. of all cases, due allowance being made for pathological conditions (polyps, hypertrophies, etc.).

At the first attempt the entrance of the sound will probably be arrested by the end becoming caught in the infundibular cell, which is almost always present. Under these circumstances it will be necessary to slightly withdraw the instrument and endeavor to guide the point in a more median direction, thereby gliding over the obstruction. If this does not succeed, the sound must be entirely withdrawn, the point bent toward the septum, and the sounding again attempted. This will usually suffice. If, however, success is still unattained, we must either again remove the sound and make a different bending or postpone the effort until further resolution of the inflamed parts occurs.*

356. Wells: On Sounding and Irrigating the Frontal Sinus through the Natural Opening. *Laryngoscope*, Vol. 10, p. 262, 1901.

* The hemorrhage directly following the removal of the middle turbinate, while not severe, is often sufficient to obliterate the landmarks so as often to make sounding impossible. Under these circumstances further attempts must be postponed until bleeding has ceased.

When the sounding has miscarried with the instrument bent in the usual manner success is often attained by bending the sound more in the arc of a circle. In the first instance the sound should be lifted into the cavity; in the latter, slid in, as it were.

Under no circumstances should the slightest force be used—at least, no more than is necessary to introduce a like instrument into an ordinary unobstructed cavity.³⁵⁷

It has previously been mentioned that when the sound disappears up to the curve the point is either in the frontal sinus, an

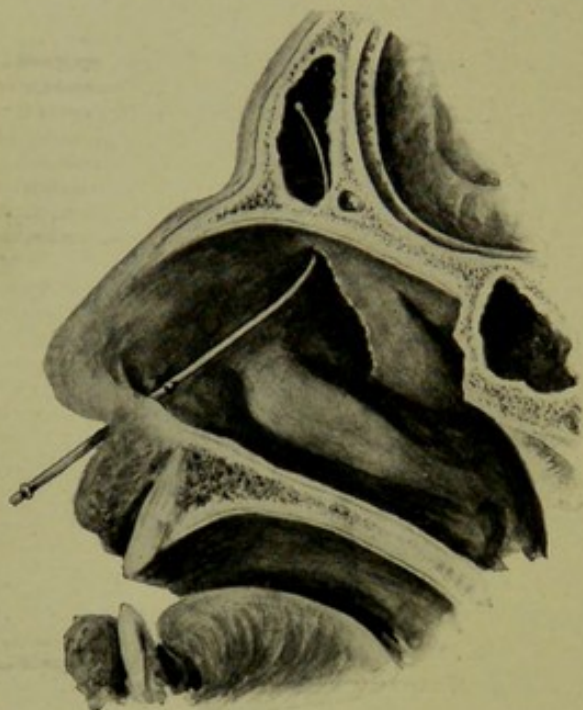


FIG. 127.—Sounding the frontal sinus after removal of the anterior portion of the middle turbinate.

orbital cell, or into a frontal bulla. How, then, can we judge into which of these structures the sound has penetrated? If it is in the frontal sinus the handle will be resting perfectly flat on the lips (Fig. 127). A turning of this handle, causing free external rotation of the tip, denotes that it has penetrated into a cavity not in the median line, therefore an orbital cell. If a frontal bulla is present, the penetration will not be so deep as in the other cavities, as these structures rarely attain any great size. A reliable indication for the

depth to which the sound has penetrated is to measure with the thumb and index-finger on the staff of the instrument, then withdraw it and compare the distance by placing it against the external side of the nose of the patient. (Fig. 128.) In this way one can note precisely where the point of the instrument has penetrated.

NATURAL DIFFICULTIES ENCOUNTERED IN SOUNDING THE FRONTAL SINUS.

These will be considered in their order of occurrence.

1. Position of the middle turbinate: When this structure lies close to the lateral wall of the nose, or is rolled in or swollen, the removal of the anterior third is indicated.

³⁵⁷. Perforations of the posterior wall and the lamina cribrosa (Mermod, *Ann. des mal. de l'oreille*, Tome 22, 1896) have occurred with fatal results.

Uffenorde³⁵⁸ has recently advocated the infraction of this turbinate (first suggested by Killian) in suspected cases, thus avoiding any surgical procedure which ultimately might prove to have been unnecessary. He claims to have been able to introduce a sound into the frontal sinus after this manipulation as readily as when the turbinate was absent. The author has also found this to be extremely practicable.

2. Approximation of the bulla toward the uncinate process: A glance at Fig. 174 will show at once that with such conformation a sound could not be made to penetrate the natural passages into the frontal sinus.

3. Abnormally wide uncinate process (Fig. 129): When the lip of the uncinate process is very prominent, the infundibulum must lie that much deeper in the hiatus semilunaris. Under these circumstances the end of the sound will find difficulty in properly engaging itself in the right direction to penetrate the frontal ostium.

4. Presence of supernumerary infundibular cells (Fig. 130): The tip of the sound often catches in these cavities, thus adding to the normal difficulties of sounding.

5. Presence of a nasofrontal duct (Fig. 121): While the contour of the sound may be proper for ordinary cases, in the presence of such a duct the tip may impinge on the sides and prohibit further ingress.

6. Presence of a frontal bulla (Fig. 131): If the end of the sound catches in one of these structures further introduction is, of course, impossible.

7. Deflection of nasal septum: In the event of a deflected septum so marked that it is impossible to introduce the sound even in the frontal region it will be necessary, particularly in urgent cases, to perform a preliminary submucous resection.

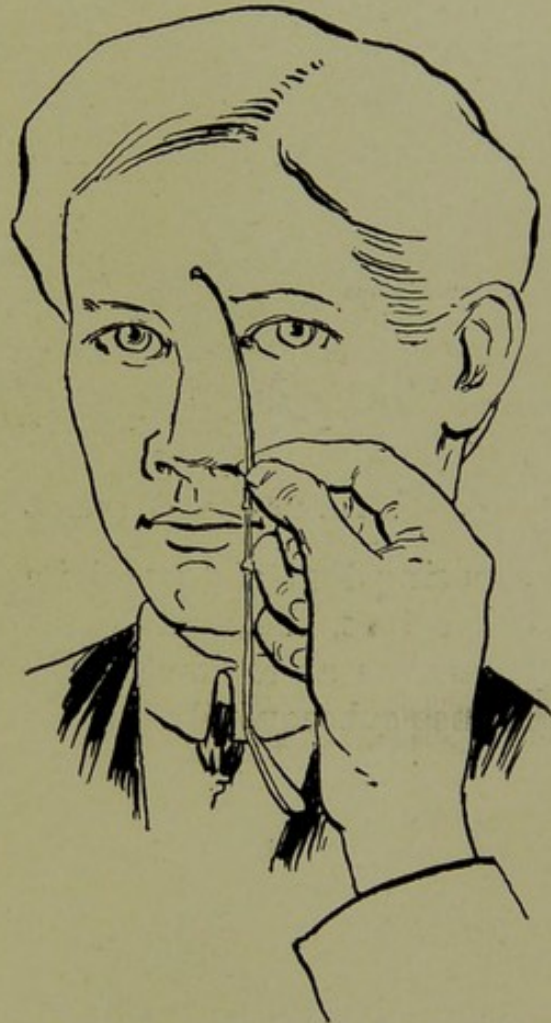

FIG. 128.—Measuring the distance the sound has penetrated against the side of the patient's nose.

ACUTE INFLAMMATION: ÆTIOLGY.

Generally speaking, what applies to one sinus is equally applicable to another, so far as the ætiology is concerned. Regarding the frontal, however, individual points may be emphasized. Pre-

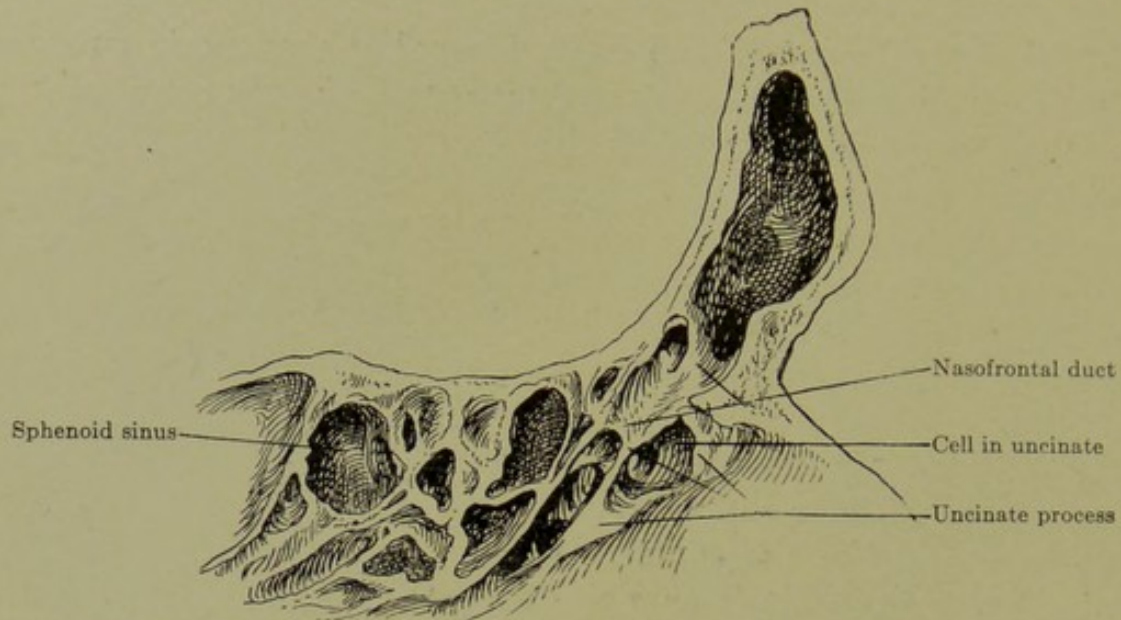


FIG. 129.—Anterior ethmoid cell situated beneath the uncinat process.

supposing that a general inflammation of the sinus mucosa had gone before, the anatomical configuration of the nose is largely responsible as to whether the mucous lining of the frontal sinus becomes subsequently infected rather than that of the other acces-

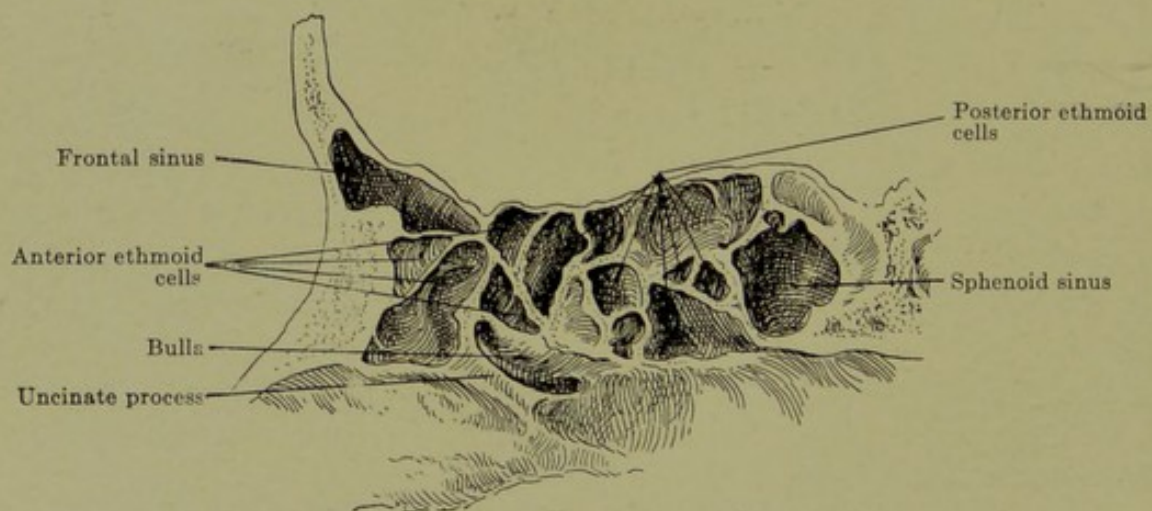


FIG. 130.—Extension of entire ethmoidal labyrinth.

sory cavities. If the structures entering into its drainage passages are favorably situated to insure a patulous opening of sufficient size, even though swelling incidental to inflammation occurred, we should naturally expect this sinus to react physio-

logically, at least, in the same manner and degree as its fellows. Many factors, however, influence this cavity which do not affect the others. We must recollect that the frontal ostium often empties into a narrow tube (ductus nasofrontalis), while the others have their outlets situated directly in one of the nasal passages. The nasofrontal duct is susceptible to occlusion by swelling of the anterior portion of the middle turbinate, thus offering a more or less impermeable barrier to the outflow of exudate.

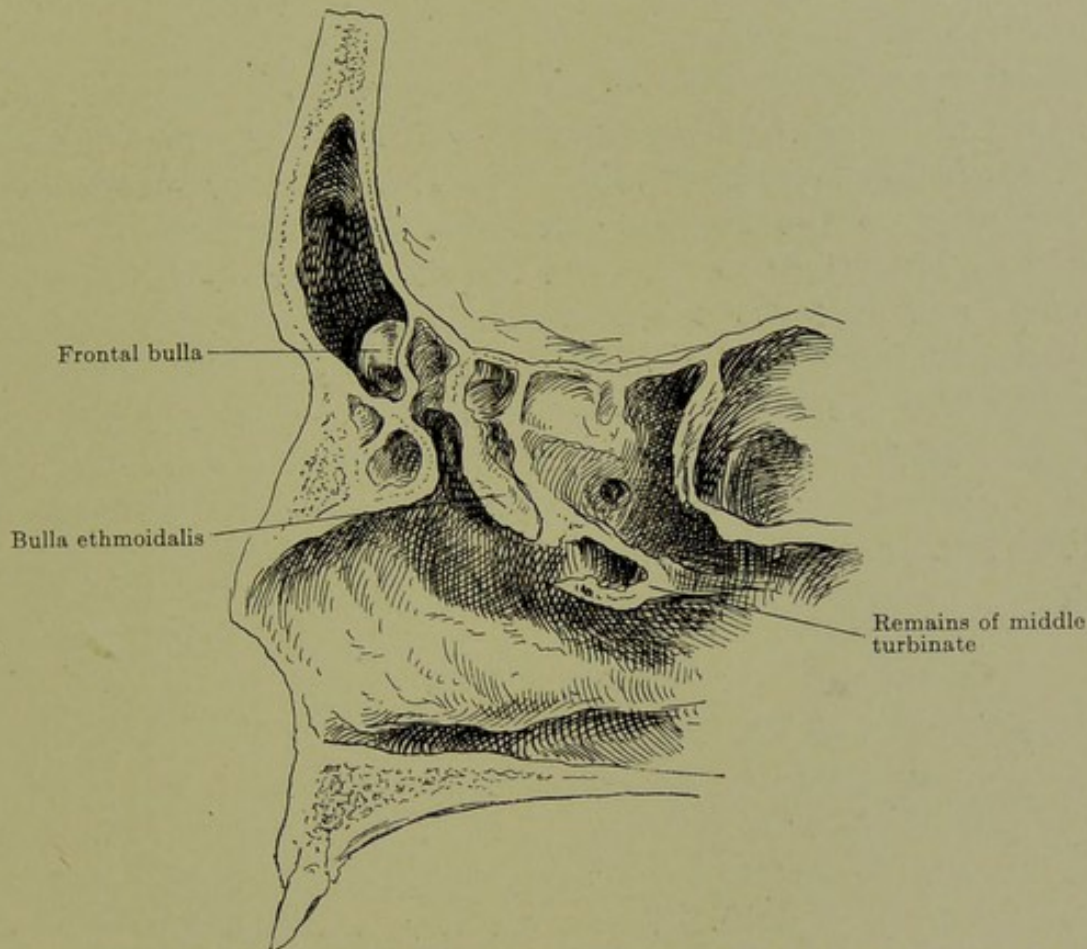


FIG. 131.—Lateral wall of nose with middle turbinate removed. Frontal bulla in floor of frontal sinus.

Deviation of the septum exercises no little secondary influence in this respect from the mere mechanical obstruction of the middle nasal passage, which is doubly emphasized when inflammation sets in on that side.

It would seem that in almost every case of frontal sinusitis deviation of the septum toward the affected side is observed. This is particularly noticeable when an attempt to sound the sinus is made. One cannot attribute this solely to chance, therefore this condition must be an important ætiological factor in the causation of frontal sinusitis. The maxillary sinus cannot be affected to such a degree, because the secretion, after its exit from the ostium, has the chance to flow in any direction, forward, backward, and downward; with the frontal the purulent material must find its way downward until it emerges from the nasofrontal duct.

It must also be remembered that direct primary infection of the sinus mucosa is not necessary to set up inflammation within the sinus. This can be accomplished by inflammatory approximation of the mucosa outside of the sinus leading to the ostium, thereby preventing the ingress and egress of air. The negative pressure thus occasioned, by its sucking action causes the mucous lining to react in no uncertain manner, giving rise to serous inflammation (if no infection occurs) and to purulent inflammation should pathogenic organisms be present. (See Pathology of Acute Frontal Sinusitis.)

Regarding infection from other sinuses, it is, of course, impossible for secretion to flow upward, and the theory of Luc that in lavage of the maxillary sinus the inflammatory products are forced up into the frontal sinus has been successfully controverted by Menzel;²⁸⁹ yet another possibility for the infection of a higher sinus by lower lying cavities remains, *i.e.*, by contiguity. In purulent inflammation of the maxillary sinus the continually-forming pus constantly exudes from the normal ostium. As a result of this continual irritation the mucosa around the orifice becomes affected. The infection creeps along the infundibulum to the ethmoidal cells and thence to the frontal sinus.

PATHOLOGY.

The mucosa of the frontal sinus differs but little from that of its fellows, and may be regarded as a continuation of the mucous membrane of the nose. During the severer forms of acute coryza it is always co-affected with the latter, regeneration occurring simultaneously in both. When for any reason the inflammation persists in the sinus it may take on one of several characters.

ACUTE CATARRHAL.—The sinus mucosa enlarges many times through œdema, and, if the irritation be continued, may so seriously encroach upon the lumen of the sinus as to practically obliterate the cavity. The surface is sometimes smooth, sometimes uneven from localized polypoid swellings. Small punctiform hemorrhages are often seen in localized areas. These latter may be the initial spots of osseous involvement, and are particularly common directly above the frontal ostium. The general color of the mucosa is pale, slightly hyperæmic, or a yellowish-brown. Occasionally an area of marked hyperæmia is present.

Microscopical.—The cilia appear absent in parts, but upon the

whole are fairly well retained. The superficial glands are enlarged. The mucosa is enormously thickened, owing to the extensive œdematous infiltration. Some round-cell infiltration is present in the stroma, but particularly around the blood-vessels. The deeper layers appear but little involved. (Plate 3.)

ACUTE PURULENT.—The acute purulent inflammation principally affects the superficial layer of the mucosa, while in chronic disease all of the layers of the mucosa undergo pathological changes.³⁵⁹ The mucosa is diffusely hyperæmic, swollen, and covered with a greater or lesser amount of purulent secretion. If the secretion is thin, no exudate may be present, owing to the drainage which has occurred through the ostium.

Microscopical.—The epithelial surface shows marked papular irregularities, occasionally presenting areas of true granulation tissue. Large surfaces are present in which the cilia have become entirely lost. Round-cell infiltration is particularly marked directly below the surface, gradually shading off as the deeper layers are approached, except around the blood-vessels and glands. The secretion does not consist entirely of leucocytes, but also contains the *débris* of exfoliated epithelium. (Plate 3.)

Kuhnt (Fall 3) describes a case of acute gangrenous inflammation in which the mucosa was of a grayish-black discoloration, of normal thickness, loose from the underlying bone, and covered with a most putrid secretion.

DIAGNOSIS.

The accurate diagnosis of this affection usually offers no difficulties. The most prominent symptom being pain in the supra- and infra-orbital region, attention is naturally drawn to this locality. The pain does not assume the character of an acute neuralgia over definite areas, but is rather indefinite and embraces, more or less, the entire frontal region, with a culminating point in and around the sinus. The character is dull, with a sense of expansion during the intervals, which quickly assumes a throbbing character that affects the whole system during the super-acute stadium.³⁶⁰ There is always a history of an acute cold, which rhinoscopic examination will substantiate by the character of the secretion which is exuding from beneath the middle turbinate. Unless there exist anatomical malformations in the

359. Froning: Beiträge zur pathologischen Anatomie der Stirnhöhlenschleimhaut im Zustande der Sinusitis frontalis Purulenta. Zeit. f. Laryng., Bd. 4, H. 5, 1911. 360. Compare Coakley: Frontal Sinusitis. Ann. Otol., Rhin. and Laryng., p. 431, 1905.

lateral nasal wall or septum this symptom, viz., secretion in the middle nasal passage, is invariably present.

Deviation of the septum towards the diseased side seems to be present in many cases. As this contributes not a little towards narrowing the nasal passages, it may well be considered an ætiological factor of no little importance in predisposing to frontal sinus affection on that side. In itself it may not have been able to cause the disease, but with a concomitant infection, the drainage passages being so much encroached upon by the septal deformity, the disease may easily become stable, whereas, under normal conditions, it would have succumbed to the regenerative powers of the sinus mucosa.

Tenderness on pressure, particularly at the junction of the inferior and lateral walls, is an almost pathognomonic symptom. It is at this point that the bone is most often affected, and rupture occurs. Careful comparison with this point on the healthy side should be made, as some individuals are more sensitive than others in this locality. Redness and swelling of soft parts sometimes occur, particularly if the infection is virulent. This is the symptom described by the older writers as bulging of the anterior sinus wall, a condition which we know does not occur unless the bone has become badly affected, which, of course, necessitates the presence of a disease of some duration.

Hyperæmia of the middle nasal passage, with more or less swelling, is a constant symptom. Partial or complete occlusion of the nares is common. General disturbances are present in direct ratio to the severity of the disease, although the majority of patients do not consider them of sufficient importance to necessitate confinement to bed.

The general symptoms, unlike those associated with the chronic form, are more continuous, although super-acute exacerbations, particularly in the morning, are not uncommon. In all events, when in doubt, it is our duty to ascertain, so far as possible, the exact source of the secretion, which may be done with the cannula, followed by lavage. If the catheterization is successful and a certain quantity of inflammatory secretion is washed out, we are at least sure of our condition, *i.e.*, the frontal sinus is diseased. Sounding and catheterization should not be employed as a therapeutic measure unless absolutely necessary. (See Treatment.)

Transillumination has proved of little benefit as an adjunct to the diagnosis in acute frontal sinusitis.

Suction by means of negative pressure, when possible to ac-

complish, seems to offer considerable aid, as has been shown by some observers.^{361, 362}

Only in isolated instances have I been able to substantiate these findings with the suction apparatus. Whether this has been due to my inability to properly apply the instrument, or is the general experience of those who have made use of this method, time alone will tell.

SYMPTOMS—ACUTE.

PAIN AND HEADACHE.^{363 364}

It is now generally agreed that these are the most prominent symptoms of acute frontal sinusitis. They are present from the very inception of the disease, and continue, with greater or less severity, until resolution has set in thoroughly, or until the affection has become chronic. (See Pain in Chronic Form.) The seat of the pain is primarily situated in the region of the affected sinus, and later radiates over the area supplied by the supra-orbital branch of the trigeminus. Should the disease continue unchecked, other collateral branches of this nerve become sympathetically affected, with the result that pain is experienced in the vertex, temporal region, or even the occiput and posterior muscles of the neck, although the latter is rare, being more a symptom of posterior sinus affections.

The character of the pain in the beginning is more a feeling of pressure and heaviness; as augmentation of the inflammation occurs, this gradually assumes the character of a true neuralgia, not only being sharp, burning, and lancinating, but dull and throbbing as well. It does not run an even course, but is subject to the utmost vagaries without any apparent reason. These remissions and exacerbations are influenced by almost every act of the individual; thus, if the patient was in a state of comparative quiet and suddenly stooped or quickly turned the head, a severe headache lasting several hours might readily occur. No matter what intensity the pain assumes, it is invariably augmented by blowing the nose, coughing, and straining at stool, or, in fact, any condition which tends to cause congestion of the head.

This explains why alcohol in any form is always followed by acute exacerbations of the headache in sinus disease. This holds good for all the accessory sinuses, but particularly the sphenoid.

361. Sonderman (152): Münch. med. Woch., No. 1, 1905. 362. Mosher: Chronic Suppuration of the Frontal Sinus. Laryngoscope, p. 347, 1907. 363. Kopetzky: The Diagnostic Significance of Headache in Diseases of Nose, etc. N. Y. and Phila. Med. Journ., Dec. 2, p. 1159, 1905. 364. C. R. Holmes: Head Pains Caused by Inflammation of the Accessory Sinuses. Ohio State Med. Journ., Feb., 1906.

Sometimes the pain reaches such an intensity that the sufferer paces up and down the room holding the head between his hands, fearing that he will lose his reason. Fortunately, these acute exacerbations remit with the same celerity with which they appear, and without any apparent cause. The usual history of these cases is that, while headache is a constant symptom, the intense pain is always felt shortly after arising in the morning, and continues for one to three or four hours, remitting as suddenly as it appeared. This phenomenon may be explained in three ways.

1. On account of the recumbent position during the night the blood-pressure is equalized, the blood having freer access to the head. As a consequence, the already inflamed sinus mucosa becomes turgid almost to the point of bursting, the two surfaces from the anterior and posterior walls coming in close apposition, so as to fairly encroach upon one another. The lumen of the sinus is obliterated, so that little or no secretion can be present. This can only occur in the early stages of the affection, before mucopurulent or purulent secretion is established.

2. While the patient is in bed the ostium of the sinus is in an unfavorable position to allow the accumulating secretion to escape. This purulent collection, by its presence, irritates the mucosa, so that when the patient arises the sinus is not only full of pus but the hyperæmia, if possible, is even greater, at least around the ostium. The weight of the pent-up secretion causes more venous stasis, consequently the pain is intense until relief is afforded by natural or artificial evacuation of the sinus contents.

3. In this condition the fault lies primarily with the drainage passages, the sinus mucosa being secondarily affected. It is met with more often in the chronic forms where permanent tissue changes have taken place, although the acute are by no means exempt. The changes are as follows: During the night the various structures comprising the drainage passages become hyperæmic and swollen to such an extent that the air changes in the frontal sinus are entirely suspended. As a consequence the blood absorbs the oxygen therein contained, the volume of CO_2 given off being in disproportion; a condition of negative pressure in the sinus results, which causes intense pain until the sinus is again aërated.³⁶⁵

365. Robertson (131), p. 645.

I have been able often to produce this pain artificially in the maxillary sinus by needle puncture and by fitting on a large syringe and applying negative pressure. This will not succeed if there is free ventilation through the ostium.

A differential diagnosis of these conditions can be made as in No. 1. Lavage or ventilation will not relieve the pain. Reduction of the mucosa must be accomplished by means of ice-bags before an amelioration will set in. In No. 2 lavage, or even aëration which allows the secretion to escape, will speedily cause a reaction for the better; while in No. 3 aëration alone will bring instant relief. This condition will be recognized at once by the complete absence of all secretion.

Headache from negative pressure seems to exhibit some individual peculiarities, in that it follows the course of distribution of the anterior nasal nerve, producing a headache in the orbit, frontal sinuses, and anterior portions of the nose.³⁶⁶

The eye on the diseased side seems to be peculiarly affected by the pain, particularly in the acute form. This is especially observed in the internal muscles when the patient rolls the eyeball upward and inward. Continued reading or attendance on the theatre will always intensify the prominence of this symptom, as well as cause the eye to feel larger and heavier than on the unaffected side. Mental exertion even during the quiescence of the disease will markedly aggravate the tendency toward an acute exacerbation of the headache.

TENDERNESS ON PRESSURE AND PERCUSSION.

These signs rarely fail. Pressure on the pathognomonic point (the inferior wall near the inner canthus of the eye) is always present, and occasionally one is able to elicit marked tenderness over the entire anterior wall. Percussion will also bring out an area of soreness which is considerably greater than on the opposite unaffected side.

The temperament of the individual must be largely taken into account when applying these tests, as neurotic individuals have a decided tendency to exaggerate the symptoms brought out by these methods. Coakley³⁶⁷ cites a case in which pain on percussion over the frontal surface of frontal bone and intense pain on pressure over the orbital plate of the frontal were present, yet on operation he found that the patient did not have any frontal sinus.

366. Brawley: The Headache of Non-Suppurative Frontal Sinusitis. *Laryngoscope*, p. 716, 1908. 367. Coakley: Frontal Sinusitis. *Ann. Otol., Rhin. and Lary.*, p. 431, Sept., 1905.

SECRETION.

At the commencement of the acute attack no secretion is formed. The circumstances are precisely analogous to those of an acute coryza: at first dryness, then hyperæmia, and, finally, formation of secretion. The character of the latter is at the onset thin, serous, and watery, and, of course, cannot be distinguished from that of the nasal mucosa. Mucoid, mucopurulent, and, finally, purulent secretion (sometimes streaked with blood) quickly follow in their successive stages, depending upon the intensity of the disease. As the nasal mucosa regenerates, the secretion from the frontal sinus is more and more apparent. If the disease runs its course, the secretion will retrograde in its manner of appearing; thus the final stage will terminate in the serous character of the onset. This usually requires between ten and fourteen days.

LOCALITY OF SECRETION.

In the acute form of this affection the secretion appears in the typical place, *i.e.*, between the middle turbinate and the lateral wall of the nose. This applies only when the patient is in the upright position, for while reclining it would naturally follow the law of gravity and flow in the channels of least resistance or into the nasopharynx.

The reason why the secretion appears in the typical place so much more frequently in this form than is seen in the chronic form is that hypertrophies and polyps have not as yet had time to form, consequently, with the exception of the hyperæmia, we have no obstruction to divert the flow from the natural channels.

The discharge during the acute stadium is fairly constant, and does not always show the remissions and intermissions that are so common with the chronic. If, however, it tends to diminish and the pain becomes more apparent, we can be sure that some obstruction to the outflow has occurred with no real diminution in the secretion. If, on the other hand, the pain diminishes simultaneously with the discharge, regeneration of the mucous membrane is taking place.

APPEARANCES OF THE NOSE.

Internal.—Rhinoscopic examination will show more or less swelling and hyperæmia of the general nasal mucosa, depending

upon the degree of regeneration which has occurred. If the Schneiderian membrane presents little evidences of the preceding coryza, the hyperæmia will be limited to the structures forming and contained in the middle nasal passage (uncinate process, ethmoidal bulla, and middle turbinate). Changes in the anterior extremity of the middle turbinate are constant, ranging from a hyperæmia to beginning polypoid hypertrophies. The uncinæ process is also involved in this swelling, which was formerly attributed of pathologic importance for frontal sinus empyema.³⁶⁸ Generally speaking, the naris of the affected side is partially or completely occluded, so far as respiration is concerned, this being one of the chief complaints of the patient.

Post-rhinoscopic examination reveals nothing abnormal, unless the purulent discharge meets with some obstruction to the outflow from the anterior middle nasal passage. Under such circumstances it will be seen issuing into the choana over the posterior extremity of the inferior turbinate.

External.—Redness and eczema of the external nares are observed when the secretion is profuse, but, as these occur quite as frequently with a bad cold from the constant use of the handkerchief, no especial import can be attributed to them.

EXTERNAL APPEARANCE OF THE SINUS.

Usually no difference can be distinguished from that of the opposite side. In rare instances, however, a condition arises at that portion of the floor of the sinus above the inner canthus of the eye. This has been described as bulging of the wall. As a matter of fact, this bulging is often more apparent than real, being due to a periostitis swelling over this region.

Kuhnt has shown that this portion of the sinus wall contains many perforating veins which lead from the sinus mucosa to the external periosteum. During infection of the sinus cavity these vessels may carry the inflammatory products outward, depositing them at their point of exit from the cranium. I have grave doubt that actual dilatation in this locality ever occurs with acute frontal sinusitis.

DISTURBANCES IN OLFACTION.

Anosmia occurs on the affected side, which is but a natural consequence, being purely mechanical, due to the swelling of the middle turbinate against the septum, thereby occluding that por-

368. Kaufman: Ueber eine typische Form von Schleimhautgeschwulst, etc. Mon. f. Ohrenhk., S. 13, 1890.

tion of the olfactory fissure which contains the sensory endings of the olfactory nerve. If sufficient space between the aforesaid structures remains, the secretion finds its way upward by capillary attraction, thereby augmenting the difficulties of the odors in finding their way to this region. Other disturbances, such as subjective cacosmia, in contradistinction to the chronic form, are rare.

GENERAL DISTURBANCES.

These are those which accompany an acute infection and do not differ materially for the frontal sinus than for a similar condition in any of the others. I cannot recollect any one symptom which is pre-eminently associated with this cavity, and what has been said under the general symptoms (p. 54) will apply here equally as well.

PROGNOSIS.

The prognosis of acute frontal sinusitis is good, if sufficient drainage be established early in the disease. The ætiological factor of complications depends far more on the interference with drainage than upon the virulence of the infection.* The position of the ostium, situated at the lowest extremity of the sinus, is an important factor in this respect, not only to allow the escape of any fluid which might be secreted but also to permit the passage of air and thorough aëration of the sinus. This is proved by the immediate relief experienced when the ostium and drainage passages are freed with evacuation and ventilation of the cavity.

The vast majority of cases of acute frontal sinusitis heal spontaneously, and practically all (95 per cent.) after free drainage has artificially been established, either through infraction of the middle turbinate or resection of its anterior third.

We must remember that the frontal sinus shows even greater tendency toward spontaneous healing than the maxillary. The resolution which occurs without artificial aid may be slower and be followed by slight permanent changes (catarrh) of the mucosa, so that during the subsequent exposures to cold and wet the patient comes to note that the "cold in the head" shows a marked predisposition to settle over the eye.

In, one might say, all of those cases in which complications occurred or which become chronic neither of these intranasal procedures had been applied, or, if so, their application had been

* This does not apply to sinus disease from internal causes, such as scarlet fever.

delayed until too late for therapeutic benefit. The more frequently acute attacks of frontal sinusitis occur, just that much more liability predominates for the disease to become chronic.

COMPLICATIONS.*

Complications occur less frequently in this form of a frontal sinusitis than in the chronic, being due more to a direct extension of the inflammatory process than to mechanical causes. The mode of transmission to neighboring parts is through phlebitis of the perforating veins. Spontaneous rupture is rare, for the reason that such an occurrence does not have time to formulate, owing to the rapidity with which the acute complications mature.

PERIOSTITIS AND OSTITIS.³⁶⁹⁻³⁷¹

These appear to be among the most frequent types of complications occurring in acute frontal sinusitis. Gerber found them to occur as often in acute as in chronic; that is, in fifty-two cases of ostitis and periostitis complicating frontal sinus disease twenty-six occurred during the primary or acute stadium. The walls most frequently affected were the orbital or inferior.

CARIES AND NECROSIS.³⁷²⁻³⁷⁵

These affections can only be considered an advanced stage of the preceding, as ostitis and periostitis must naturally be primary to them. Gerber considers it not an uncommon occurrence to find them appearing in the course of acute frontal sinus empyema, although not so frequent as the milder affections of the bone. Such has not been the experience of the American³⁷⁶ and English³⁷⁷ rhinologists, as well as some of his own German colleagues.^{378 379}

* For an elaborate treatise on this subject consult Gerber. *Die Komplikationen der Stirnhöhlenentzündungen*, 1909.

369. Axenfeld: Ein Beitrag z. Path. u. Therap. der Frontalen, etc. *Deutsch. med. Woch.*, No. 40, S. 714, 1902. 370. Schmiegelow: Einige seltener klinische beobachtungen die Nebenhöhlen, etc. *Zeit. f. Ohrenheilk.*, S. 293, 1903. 371. Wilson: Abscess of Frontal Sinus, with Perforations of Outer and Inner Tables. *Australian Med. Gaz.*, Oct. 20, 1898. 372. Ingals: Empyema of Frontal Sinus. *Journ. Am. Med. Assn.*, p. 233, July, 1901. 373. Tilley: Two Cases of Chronic Frontal Sinus Empyema, etc. *Brit. Med. Journ.*, p. 648, Sept., 1900. 374. Castex: Sinusite frontale infectieuse, sequestres, etc. *Arch. Internat. de Lary.*, T. 2, p. 1055, 1906. 375. Winckler: Weitere Beiträge zur Chirurgie der Nebenhöhlen, etc. *Zeit. f. Ohrenhk.*, Bd. 40, S. 295, 1902. 376. Richards: Personal Experiences with Frontal Sinus Empyema. *Am. Journl. of Med. Sciences.*, p. 841, 1905. 377. St. Clair Thomson: Frontal Sinusitis—Two Cases of Death after Operation. *Lancet*, Aug. 12th, p. 431, 1905. 378. Jansen: Zur Eröffnung der Nebenhöhlen der Nase bei chronischen Eiterung. *Arch. f. Laryn.*, Bd. 1, S. 142, 1904. 379. Maljutin: Zur Kasuistik der Stirnhöhlenentzündung. *Arch. f. Laryn.*, Bd. 19, S. 363, 1907.

OSTEOMYELITIS.³⁸⁰⁻³⁸²

Infection of the diploë of the bone is caused by retention of an especially virulent secretion and traumatism (operative or otherwise), and occurs in two forms: circumscribed and diffuse.

Circumscribed.—This begins with œdema, pain, especially on pressure over a circumscribed portion of the sinus wall, and general systemic manifestations (fever, prostration, etc.). The pathological process gradually spreads by continuity until the boundaries of the ethmoidal capsule are reached, where it ceases. Thorough resection of the diseased bone will usually result in a cure.

Diffuse.—This form knows no boundaries, but continues unabated until the entire osseous covering of the brain is affected, unless cerebral infection and death halt the progress of the disease. Operations, even though extensive, offer no bar to the progress of the infection.³⁸³

The mechanism of this infection will be better understood if one studies Fig. 132. It will be noted that these canals through the diploë of the bone serve for the transmission of large veins which carry the blood from the surrounding parts. The veins occupying these canals find their endings both externally on the dura mater to communicate with the venous sinuses of the brain. Therefore, infection may cause not only inflammation of the bone along their tract but also a subperiosteal or extradural abscess, or both. The various sutures do not necessitate a break in the continuity of these canals, as the veins penetrate from one bone to another at the point of articulation.

When the diploë of the bone in a circumscribed portion becomes infected, sooner or later one of these canals is reached by the purulent process and the infecting micro-organisms are carried to distant points of the cranium through the blood current. If the infection is so virulent that it overcomes the natural resisting powers, a general osteomyelitis of the cranium results; otherwise, the disease manifests itself locally at the point of the original infection.

PATHOLOGY.—In an advanced case spongification of the osse-

380. Lack: Treatment of Chronic Suppuration in the Frontal Sinus. *Edinburgh Med. Journ.*, Bd. 53, p. 544, 1902. 381. Röpke: Ueber die Osteomyelitis des Stirnbeins, etc. *Verh. s. Deutsch. Otolog. Gesell.*, S. 162, 1907. 382. Luc: Complications crâniennes et intracrâniennes des antrites frontales sup., *Ann. d. Mal. de l'oreille*, etc., No. 35, p. 265, 1909. 383. Tilley: Fatal Case of Chronic Frontal Sinus Empyema. *Lancet*, Aug. 19, p. 534, 1899.

ous tissue along the line of infection is prominent. The bone is bathed in pus not only on its external but internal surface as well. The canals are filled with purulent secretion, and certain portions may have become melted together, forming interdiploic abscesses. At the external points of suppuration the veins are thrombotic.

SYMPTOMS.—Clinical manifestations appear at the very onset of the disease. The part overlying the inflammatory process becomes œdematous and is exquisitely painful on the slightest pres-

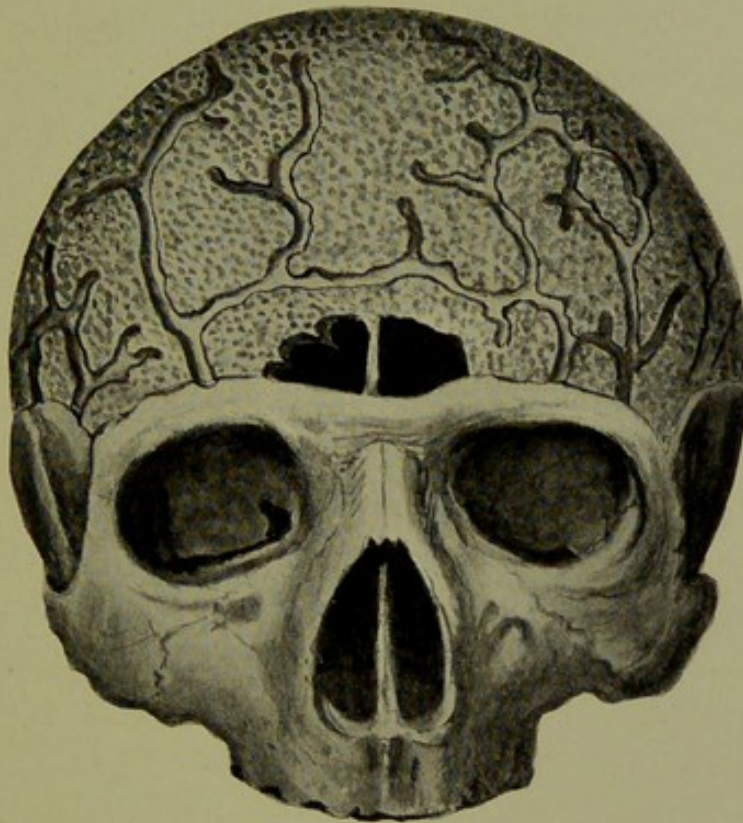


FIG. 132.—External table of skull removed, showing the canals of Breschet. (After Breschet.)

sure. The abscess soon points and ruptures, the underlying bone appearing spongy and infiltrated with pus, sometimes throwing off sequestrars. Unless the process is immediately arrested new foci of infection appear above, which also suppurate until the entire cranium is involved. (Fig. 132.)

Another form has been described in which the original focus of suppuration appears to heal and is followed by secondary foci, which occur consecutively on different portions of the vertex.

These severe infections practically always terminate mortally in general septicæmia, thrombo-phlebitis of one of the large intracranial veins, or meningitis.

ORBITAL COMPLICATIONS.³⁸⁴⁻³⁸⁵

When orbital complications associated with acute frontal sinusitis occur, the symptoms usually set in with violent manifestations, due to the diffuse inflammation of one or more walls. As a result of the rapidity of this process, perforation of the walls occurs and the infectious material is quickly transported to the neighboring tissues, especially those of the eye. All sorts of orbital and ocular conditions have from time to time been reported following acute frontal empyema.

INTRACRANIAL COMPLICATIONS.

Intracranial complications coincident with acute frontal sinusitis rarely result from an actual breaking down of the bony walls with perforation, but rather from the infection being carried to the meningeal structures through the *venæ perforantes*.³⁸⁶ The actual cause of the complication appears to be an especial virulence of the infecting micro-organism rather than a stagnation of the secretion in the sinus under pressure. The following conditions appear to be the most common: Subdural abscess,³⁸⁷ extradural abscess,³⁸⁹ lepto-meningitis,³⁸⁸ thrombo-phlebitis,³⁹⁰ and brain abscess.³⁹¹

TREATMENT.

The treatment to be instituted when a patient presents himself with acute frontal sinusitis will depend upon what phase the affection has assumed. If threatening symptoms of stagnation prevail, naturally a much more energetic course of treatment must be applied than under ordinary conditions. We shall, however, consider the affection from the usual case which is met with in private practice.

Patients seldom individualize the frontal sinus as the seat of the disease, but rather complain of a severe cold with prominent symptoms referable to this region. As a matter of fact, this is

384. Paunz: Durch Nasenkrankheiten verursachte Augenleiden. Knapp: Arch. f. Augenheilk., S. 380, 1905. 385. Lafon Cellulite orbitaire consecutive a un empyeme aigu du sinus frontal. La Clinique ophthal., p. 71, 1906. 386. Schulze: Rapid verlaufende Erkrankungen der Nasennebenhöhlen mit cerebralen complication (Fall 2). Beit. z. Anat., Phys., Path. u. Ther. d. Ohres, etc., Bd. 4, S. 48, 1911. 387. Hinsberg: Ueber d. Infectious mechanismus bei Meningitis nach Stirnhöhleneiterung. Ver. d. Deutsch Otol. Ges., S. 191, 1901. 388. Hopfgarten: Akutes Empyem beide Stirnhöhlen nach Influenza. Fall 3. Deutsch Zeit. f. Chirurg., S. 498, 1896. 389. Freudenthal: Endocranial Complications of Nasal Origin. (Case 1.) Laryngoscope, p. 60, 1910. 390. Denker: Rhinogener Frontallappen Abscess in der Stirngend, etc. Arch. f. Lary., Bd. 10, S. 410, 1900. 391. Gerber: Rhinogener Hirnabszess. Arch. f. Lary., Bd. 16, S. 208, 1905.

precisely the condition we have to deal with. The nasal mucosa is swollen and inflamed with that of the sinus on the affected side. To successfully combat this condition our indications are twofold: (1) to procure drainage; (2) to reduce the swelling and inflammation, thereby producing resolution. General treatment should take far precedence over any local manipulations at this stage of the affection.

From my experience, sounding and attempts at catheterization at this particular time do more harm than good, and are distinctly contra-indicated. If we remember that the tissues are engorged with blood, the condition being one of acute diffuse inflammation, and that the sparse secretion is merely an inflammatory product, for the time being having nothing in common, *pro* or *con*, with the ultimate course of the affection, we can readily see how little the evacuation of this secretion would influence the result. These things being considered, the certain amount of traumatism from the attempts at passing a catheter which inevitably results even in the most skilled hands will but aggravate the inflammation and prove detrimental to immediate resolution.

Two courses are open to accomplish this end. If the patient is a woman, she should be ordered to bed. With males this advice will usually be rejected, particularly if the headache be not marked; however, complete rest may be obtained in another way, *i.e.*, through the Turkish bath. By this means we can obtain a double benefit—by the sudorific action of the bath, as well as the rest in bed incidental to it. The patient then should be sent to an Oriental bathing establishment, with orders to remain in the caldarium (hot room) as long as possible, or until the heart-beat becomes distinctly rapid or symptoms of weakness appear. Neither a massage nor cold plunge should follow, but the body wrapped in a blanket, with immediate retirement to bed, remaining there until morning. He should be given two prescriptions, one for calomel gr. iv, with the same quantity of bicarb. of soda and sugar of milk made into one powder, to be taken immediately on retiring, the other for aspirin ʒii, put up in twenty-grain powders. One of these should be taken before the bath, another shortly afterward, and the remaining two hours apart when awake. On the following morning the congestion is, for the most part, relieved. The aspirin is continued every two hours, care being taken to withdraw it at the first symptoms of gastric irritation.

This statement cannot be ignored, as we have frequently seen cases of indigestion (eructations of gas and epigastric pain) persist for months, despite all treatment, following the continued ingestion of both aspirin and novaspirin.

The patient is cautioned not to overexert himself, either mentally or physically, and, above all, to avoid all alcohol, tobacco, or draughts wherein there is a possibility of reinfection.

A similar course of home treatment may be established for the gentler sex, the above being, for the most part, inapplicable. She must be confined to bed, with ice-bags to the forehead and hot water bags to the feet.* Aspirin gr. xx every two hours as before. General sweating may be induced, but this is rarely necessary. Calomel at bedtime must also not be overlooked. Twenty-four hours is approximately the time in which we may expect the hyperacute symptoms to disappear.

So far as local treatment is concerned, generally speaking, we look upon it rather with disfavor at this time. Cocaine and adrenalin are the only two substances which will contract the tissues. The cocaine acts feebly in this stage, even in stronger solutions, and the adrenalin, while producing temporary ischæmia, causes reactionary swelling after the first effects have worn off, leaving the patient even more uncomfortable, if possible. Not only that, but often individuals show a decided idiosyncrasy toward this drug, it causing the most miserable symptoms, simulating an acute coryza. If some local application is demanded, a nasal douche of normal salt solution as hot as can be conveniently borne should be tried. Steam inhalations may be substituted for the warm saline douches, particularly if the latter do not appear to be effective. These should be repeated every hour and applied for at least five minutes at a time. As some little effort on the part of the patient is required to successfully carry out this treatment, it is usually effectively accomplished after several inhalations have been taken. This will often allay the inflammation, and has the advantage of being more or less permanent.

These treatments will usually suffice to break up the acute condition. The after-treatment will consist in the daily application of cocaine to the region of the middle nasal passage, with subsequent lavage, the rationale being to maintain as free ventilation of the accessory sinuses as possible. The acute sinusitis will heal in from ten to fourteen days.

Suppose, in spite of these measures, while the general nasal inflammation subsided, the condition in the sinus showed no signs of abatement. General treatment is now no longer of avail; something more radical is clearly indicated. The pathological condition is as follows: Nasal mucosa normal, with the exception of those portions bordering on the hiatus semilunaris; the frontal sinus mucosa acutely inflamed. This condition will rarely

* Hot fomentations by means of wash rags wrung out in hot water are occasionally more comfortably borne by the patients than the ice-bags. The action of heat is similar to that of cold in acute inflammations; therefore, theoretically, either would seem to answer the purpose. Our preference, however, lies with the cold applications, particularly if there is a tendency toward febrile manifestations.

occur unless some interference with the drainage has taken place; therefore, it is clearly indicated that these passages be made more patulous with the prompt re-establishment of free drainage.

We now have the choice of two courses: (1) infraction of the middle turbinate; (2) high resection of the anterior end of the middle turbinate. In making this choice we must at first consider the anatomical configuration of the nose, for, should the space between the septum and the middle turbinate be narrow, sufficient room cannot be obtained by infraction. The urgency of the symptoms must also be taken into account, for it may not be well to consider a probability (sufficient drainage after infraction) when a certainty (sufficient drainage after resection occurs

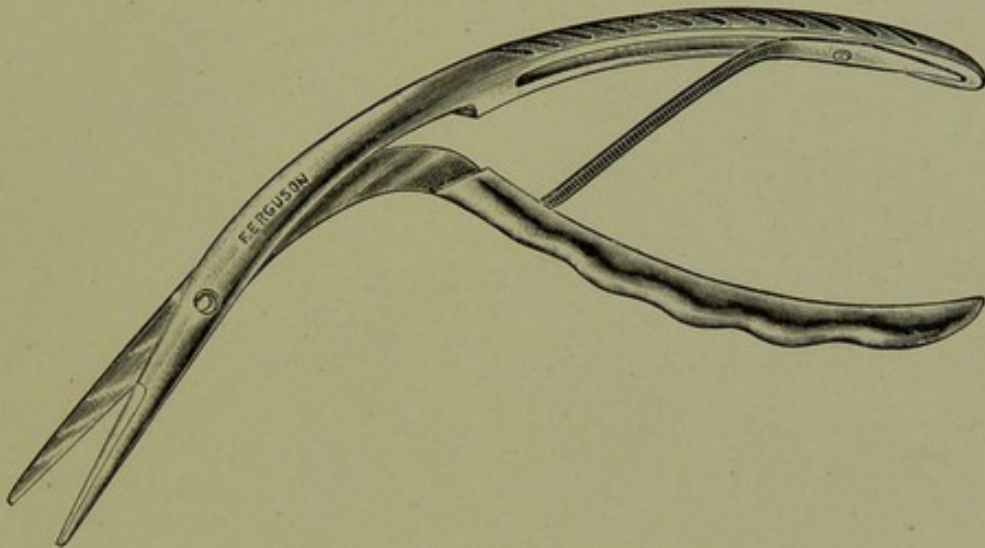


FIG. 133.—Thompson's nasal scissors.

in about 95 per cent.) can be employed. Supposing, however, everything appeared favorable for healing after infraction. How should this procedure be accomplished?

TECHNIQUE OF INFRACTION OF THE MIDDLE TURBINATE.—1. With twenty per cent. cocaine-adrenalin solution shrink thoroughly the anterior end of the inferior turbinate and anæsthetize anterior portion of the middle turbinate and septum, introducing the pledget of cotton between the processus uncinatus and the middle turbinate as far as possible without using force. Wait five minutes, then bend the applicator and cocainize thoroughly as much of the processus uncinatus and hiatus semilunaris as possible.

2. When anæsthesia is complete (ten minutes), introduce the Thompson scissors (Fig. 133), one blade directly beneath the anterior attachment of the middle turbinate as far as they can be pushed without meeting firm obstruction, and, holding them

in as vertical a position as possible, sever the turbinate from its attachment. (Fig. 134.) (In wide nares this step may be omitted.)

No bleeding follows this procedure, and unless one uses great force it is impossible to wound the lamina cribrosa, because one must penetrate the entire anterior ethmoidal labyrinth from below upward with the external blade before the internal can reach this structure.

3. Introduce a blunt mucous elevator between the processus uncinatus and middle turbinate and press the latter forcibly toward the septum (Fig. 135); a slight cracking noise will indicate that the turbinate has been fractured at its attachment.

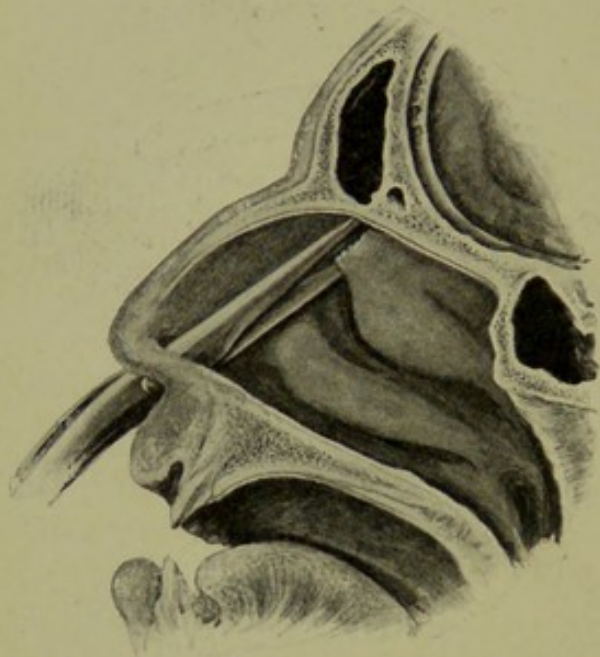


FIG. 134.—Severing the middle turbinate at its anterior attachment to the lateral nasal wall.

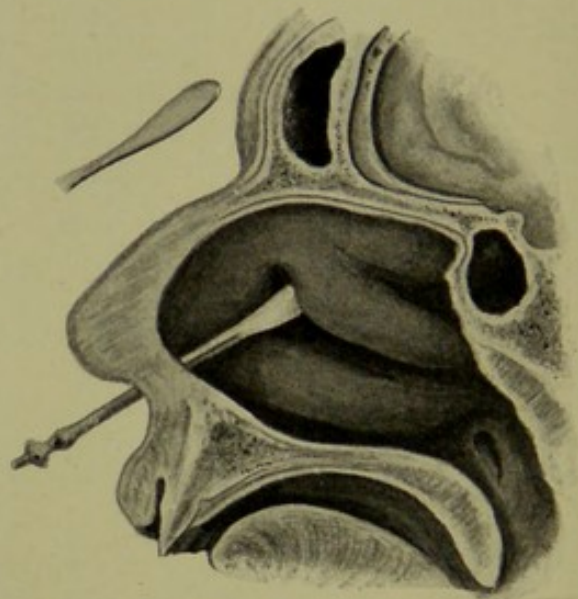


FIG. 135.—InfRACTING the middle turbinate with a blunt elevator.

4. Ascertain if frontal sinus is accessible to the sound, and, if so, in what position the sound must be bent.

5. Introduce cannula bent in a corresponding manner to the sound, and wash out sinus with a warm boric acid solution.

The advantages of this method over resection of the anterior end are:

- a. Lessened danger of infection.
- b. Requires much less time.
- c. The ethmoid cells are not opened.
- d. Little or no postoperative swelling, with its attending dangers.

Contra-indicated when great polypoid changes have occurred in the region of the ductus nasofrontalis and hiatus semilunaris.

In the majority of cases this will suffice to allow sufficient ventilation of the sinus cavity to insure resolution. If, on account of the viscosity of the secretion, none has escaped, the expulsion may be facilitated by applying politzeration, as suggested by Hartmann,³⁹² thereby driving it, by the sudden compression of air, from the cavity.

Healing may be accelerated by shrinking and lavage at first daily, gradually reducing the treatments until entire recovery has taken place. If for any reason this procedure is contra-indicated, or good results have not followed its application, resection of the middle turbinate is required.

TECHNIQUE OF RESECTION OF ANTERIOR THIRD OF MIDDLE TURBINATE.—1. Cocaine as before.

2. Use scissors as in infraction.

3. Introduce snare, the loop bent slightly downward, and work the end of the instrument well upward until it is firmly in position at the superior extremity of the cut in the middle turbinate. (Fig. 136.)

Firm pressure is now applied to the handle of the loop, gradually contracting it until very firm resistance is felt, when it will be necessary to use both hands in order to obtain sufficient pressure. If the sliding arm meets the base and the loop is still entangled in the nose, it will be necessary to unscrew the catch on the shank, make it shorter, and again apply pressure.

Care should be taken, in preparing the snare, to see that the loop disappears well into the barrel, when the sliding arm reaches the base. If this has been done, we shall experience no difficulties in severing the turbinate at the first attempt.

A sudden jerk will announce that the turbinate has been severed. Examination with the speculum shows the severed por-

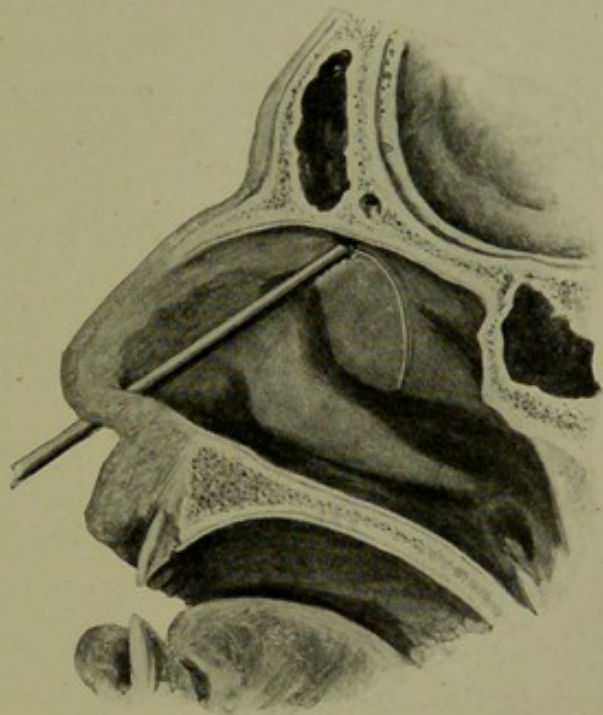


FIG. 136.—Position of snare in removing the anterior portion of the middle turbinate. Note the proximity of the shank of the instrument to the cribriform plate.

392. Hartmann: Ueber das Empyem der Stirnhöhlen. Deutsch. Arch. f. klin. Med., Bd. 20, S. 531, 1871.

tion lying loose in the nose. This is removed with the fine-tooth forceps, otherwise it might be pushed far back into the nasal chambers, necessitating a search, which causes more or less delay. The nasal cavity is gently washed out with a sterilized nasal normal salt solution in order to clear away the blood. Any shreds are removed with cutting forceps, such as those of Hartmann. (Fig. 137.) After a flexible nasal sound has been passed into the sinus the cannula is introduced, a syringe fitted into place, and the cavity irrigated.

This form of treatment practically never fails in acute frontal sinus inflammation. A conservative estimate of the cases cured by this method may be placed at ninety-five per cent., it being

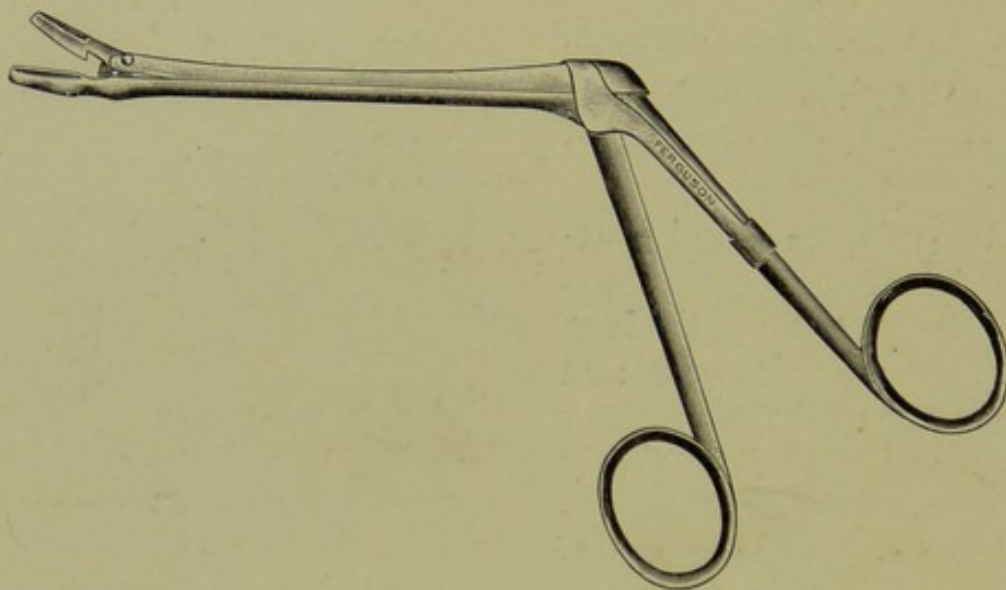


FIG. 137.—Hartmann's cutting forceps.

understood that the disease has been taken in its early stages before pathological changes have occurred in the mucosa or bone.

Cases have been reported in which it was necessary to make a small external opening in the anterior sinus wall in order to relieve the symptoms, but this was in the days before the intranasal methods had reached that stage of perfection to which they have at present attained. Any form of radical operation, however, is strongly contra-indicated as osteomyelitis and meningitis are especially prone to follow.

COMPLICATIONS.

This treatment of complications ensuing during the course of acute frontal sinusitis will depend largely upon the particular nature of the complication. They may be occasioned by two separate pathological conditions or a combination of both, namely: 1. From obstruction to drainage, with consequent stagnation

(rare). 2. From an especial virulence of the infecting germ. The first condition, unless neglected, will be relieved by simple evacuation of the purulent secretion, either through the nose or externally by means of a small trephination in the anterior wall of the sinus. The second, however, will demand prompt and energetic means of the nature of a more or less radical operation, depending upon the amount of tissue involved. As it is often impossible to differentiate these conditions, it is wise, under such circumstances, to make a simple opening in the anterior wall and thoroughly flush out the sinus cavity. If improvement does not follow in a few hours, the entire wall, with as much neighboring tissue as is deemed proper, should be immediately removed so as to eliminate the original focus of infection, and the parts treated as an open wound.

CHRONIC INFLAMMATION: ÆTIOLOGY.

Chronic disease of this sinus does not arise idiopathically, as is sometimes the case with the maxillary, but results always as a sequela of an acute inflammation.

The one great causative factor of the chronicity is disturbance of the normal mechanism of drainage. This is not usually dependent upon one certain individual condition, but rather upon a variety of causes, such as deviation of the septum toward an affected side, thereby causing the middle turbinate to lie close to the lateral nasal wall; inflammatory swellings in the middle nasal passage, hypertrophies of the middle turbinate, polyp formations—in short, any condition, pathological or otherwise, which tends to obstruct or arrest the free flow of secretion from the acutely or subacutely inflamed sinus.

When we recall to mind the long, narrow osseous passage (*hiatus semilunaris*) which forms the sole outlet from the frontal sinus, and how readily any of the above conditions might cause partial or complete obstruction to the outflow of secretion from this cavity, it is small wonder that the ultimate results are those of permanent tissue changes in the mucosa of the sinus.

It is not necessary that this occlusion be either complete or continuous, as is well shown by the cases of chronic sinusitis following repeated attacks of acute inflammation.

This is not due to the severity of the inflammation so much as to the irritation. After the first attack the sinus mucosa does not fully regenerate before another acute attack supervenes. The

reaction is now greater than in the original attack; regeneration occurs more slowly. The repetition of this process over and over again will eventually cause pathological changes (hyperplastic degenerations, cyst formations, etc.) to take place not only in the mucous membrane of the sinus but in the drainage passages as well; while these conditions, moreover, in turn tend to further aggravate the disease. This process is well exemplified by those patients who are habitually subject to attacks of acute coryza.

RETENTION OF SECRETION WITHIN THE SINUS.

Too much stress has perhaps been laid upon this alone being a dominant causative factor of the chronicity. Retention of the secretion alone certainly cannot be responsible for the disease becoming chronic, as is proved by the maxillary sinus acting as a reservoir for pus from the frontal for months and even years, and, after one irrigation, remaining subsequently free from any pathological secretion.

Killian's³⁹³ assumption that individuals suffering from maxillary empyema whose occupations compel them to work with head low, acquire frontal sinusitis from the secretion flowing from the maxillary into the frontal, seems to require corroboration. While the retention of the secretion alone may not result in chronicity, this condition, coupled with pressure within the sinus cavity, is a most potent factor for the formation of severe pathological disturbances.

This pressure may be brought about in two ways: (1) positive; (2) negative.

1. Positive pressure is caused by the complete contact of the pathological secretion on the mucous lining of the sinus. For this to occur some obstruction to its free outflow is necessary. The inflammatory products, being continually secreted, soon fill the sinus cavity, and when the cavity is filled secretion does not cease, but continues with even greater vigor, because of the added irritation.

This is the condition which gives us such stormy symptoms and leads quickly to orbital and cerebral complications.

Fortunately, complete permanent occlusion rarely occurs, as in the event of stagnation under pressure the drainage passages

393. Killian (351), S. 1120.

seem to act in the capacity of a safety valve, allowing the secretion to escape in jets and spurts.

2. Negative pressure results from the absorption by the blood of the air normally contained in the sinus after the closure of the ostium. (See General *Ætiology*.) If the sinus mucosa were in the secretory stage of acute inflammation, and this condition supervened, both positive and negative pressure would befall simultaneously: positive, from the pressure of the contained secretion; negative, from the vacuous suction. The outcome of this double inflammatory condition, if continued for any length of time, must result in acute and severe complications of the neighboring organs. In any event, the injurious effects to the sinus mucosa will be severe and lasting.

PATHOLOGY.

Catarrhal or Fibrous.—This condition is the result of numerous inflammatory attacks which may or may not have been associated with a purulent discharge. It is a condition rather than an actual process, and represents an effort of the mucosa to check the advancement of the inflammation. While the mucous membrane lining of the sinus is thickened to 2–4 mm., it is not uniform, as the surface shows numerous irregularities. The epithelium is but slightly changed, and round-cell infiltration is sparse except in certain areas. The greatest change appears in the sub-epithelial layers, which have become the seat of fibrous connective-tissue formation. This is particularly noticeable around the vessels and over the periosteum. The vessels themselves are dilated and walls thickened. (Plate 3.)

Purulent.—The mucosa does not present a uniform typical appearance, owing to the various degrees of inflammation in different portions of the sinus. The region of the ostium may show all the signs of an acute inflammatory process, while farther away the pathological changes may be fibrous in character, and at the extremities the mucosa can appear perfectly normal. As a rule, the purulent condition is intimately associated with fibrous changes which have occurred during the quiescence of the numerous attacks. In an ordinary case the mucosa is thickened, the surface being irregular, certain areas having the appearance of

velvet, while others are unevenly swollen from regional polypoid hypertrophies.

The color varies from deep red to a grayish translucency. The consistency is extremely friable, as it tears easily under the forceps, although loosened from the bone. Erosions and ulcerations are not frequently seen, even in those areas which have been subjected to pressure. Masses of granulation tissue are common, particularly in the neighborhood of the ostium. Although polypoid hypertrophies are common, true polyps are rare.³⁹⁴ In old cases pigmentation of the mucosa and osteophytic formations are encountered.

The character of the secretion depends largely upon the external influences, as well as upon the species of the infecting microorganisms, and gives us indication of the pathological condition of the sinus mucosa.

Microscopical.—As various stages of inflammation are present it will depend upon the portion of membrane examined as to the findings. In a well-marked case certain changes are constant. The mucosa is thickened, all layers being affected in contradistinction to the acute form. The ciliated columnar epithelium in many places shows metaplasia into the squamous type, a manifestation of the chronicity of the affection.³⁹⁵

Round-cell infiltration is marked immediately below the basal membrane and around the vessels and glands. The laminae of the vessels are dilated and the number of the glands apparently increased. The periosteum is decidedly thickened, and the bone in many places shows evidence of rarefaction and new formation, giving the surface a roughened appearance.

SYMPTOMS.

The symptoms of chronic inflammation of this sinus may vary from their total absence to those quite as marked as in the acute stadium. Therefore, they had best be considered as of two periods—those of quiescence and those of excitation.

PAIN.—In contradistinction to the acute process, all phases of pain may be absent. Cases have been reported in which great inflammatory changes take place in the sinus mucosa without the

394. Knapp: Polypen und Eitersammlung in der rechten Stirnhöhle. Arch. f. Augenhk., Bd. 9, S. 452, 1880. 395. Oppikofer: Mikroskopische Untersuchung der Schleimhaut von 165 chronisch Eiternden Nebenhöhlen der Nase. Arch. f. Lary., Bd. 21, S. 422, 1909.

patient having ever complained of the slightest symptom of headache.³⁹⁶⁻³⁹⁹

Truly these examples are greatly in the minority. It must, however, always be borne in mind that the degree of pain experienced by an individual is entirely a personal equation, and the temperament of the patient plays no uncertain rôle in this connection.

The character of the headache may assume any of the innumerable phases characteristic of pain, ranging from a slight sense of numbness on the affected side to a sickening, splitting cephalalgia, the greatest paroxysms being synchronous with the heart-beat such as observed in cerebrospinal meningitis. The latter phase is only met with in acute exacerbations during periods of congestion from overindulgence of food and drink, especially alcohol, and after unwonted mental exertion or during the prodromes of a pending complication.

The headache seldom assumes any definite form, but is subject to the greatest vagaries, depending even upon the most trivial occurrences; therefore, the sufferer must exercise certain prudences which are unknown to the healthy individual. Constipation, indigestible foods, alcohol in every form, tobacco, mental and physical exertion, stooping, jarring—in fact, any condition which tends toward circulatory congestion of the head—is prone to give rise to distressing symptoms and must be, therefore, strictly tabooed.

Perhaps the form of pain most frequently observed in the average case is a sense of fullness located approximately in the region of the frontal sinus. This form of pain may endure for weeks or months, and if any change is experienced it is always for the worse. When this exacerbation subsides, the same old condition prevails, so far as the intensity of the ache is concerned. Neuralgic pain in the chronic form is rarely observed, except in acute exacerbations of the inflammation from taking cold.

Unquestionably, the character of the pain depends largely upon the drainage. If all conditions are favorable, little discomfort is experienced; if certain obstructions supervene, the opposite will necessarily hold good. This statement is borne out by

396. Hajek (6), S. 180. 397. Luc: Empyeme latent du Sinus Frontale Operation, Guérison incomplete. Arch. internat. de Lary., No. 4, p. 216, 1893. 398. 399. Schech: Zur Diagnose u. Therapie der Chronischen Stirnhöhleneiterung, Arch. f. Lary., Bd. 3, S. 165, 1895. 399. Coffin: The Diagnosis of Frontal Sinus Disease. Trans. Am. Lary., Rhin. and Otol. Soc., p. 158, 1902.

the instant relief often brought about by reinstating the patulousness of the drainage passages in these patients.

Location.—The affected area is above the orbit in the general region of the frontal sinus. (See Fig. 31.) The precise locality often changes with the character; thus during the relative quiescence the cephalalgia is apt to be indefinitely distributed over a larger region than when severe exacerbations occur. In the latter event the pain frequently concentrates in a definite area, manifesting dissimilar characteristics.

Diffuse headache in this affection is decidedly uncommon in chronic frontal sinusitis. According to our experiences, the appearance of this form during the course of this disease is an indication of the coaffection of one or more of the other sinuses.

Typical pain located in the frontal sinus may finally be elicited during some stage of the affection. While this may not always be confined to the limits of the affected cavity, nevertheless, the approximation is sufficient to warrant the appellation; the patients complain that the pain always takes its origin in the sinus. The prominence of this symptom is in direct ratio to the pressure within the cavity (both positive and negative). Occasionally the pain is greater in the healthy sinus. No other explanation than that of reflex phenomena can be given to this curious phase.

Constancy.—As mentioned before, the pain shows a decided tendency toward instability. In a long and chronic case there is a well-defined tendency toward periodical exacerbation at certain hours of the day, followed by an equal regularity of remissions. This exacerbation usually occurs during one of the morning hours, lasting a variable length of time and remitting as quickly as it appeared. The regularity with which this occurs day after day and week after week is quite inexplicable.

TENDERNESS ON PRESSURE.—As observed above, this symptom is prominent during the acute stage of frontal sinusitis. As the disease becomes chronic the tenderness subsides and not infrequently disappears. Above the inner angle of the eye, however, at that spot of greatest intensity in the quiescent stage, a certain amount may be elicited. One is often obliged to examine both sinuses simultaneously to obtain this result, and even under these conditions the test is rather uncertain. Only in those cases where severe inflammatory changes have occurred in the mucus

on the sinus floor, or where the osseous wall is abnormally thin, does one procure signs which are unmistakable in their evidence.

The anterior wall of the sinus is, as a rule, insensible to pressure. During an acute exacerbation, or when the osseous structure is affected, tenderness is sometimes observed, but, on the whole, this wall responds more quickly to percussion than to a steady pressure.

ŒDEMA OF UPPER EYELID.

An evanescent œdema frequently occurs in this locality, especially soon after arising in the morning, and disappears during the day. It is caused by pressure within the sinus on the veins of the mucosa, which freely anastomose with the eye and eyelid.

SECRETION.

The discharge in chronic frontal sinusitis varies in consistency from a thin, serous, watery secretion⁴⁰⁰ to a thick, inspissated, purulent outflow. It is not distinguished by one characteristic during the entire course of the disease, but changes under different conditions; thus, during the quiescent stage it may remain mucoid; if for any reason an acute exacerbation occurs it will become profuse, mucopurulent, or purulent, and remain so until the temporary acute symptoms abate, when it will again re-assume its original mucoid consistency. In contradistinction to that emanating from the maxillary sinus, it is usually inodorous and almost never reaches the extreme fetidity of the latter. This thin, watery secretion between the outflows of the purulent material is due to hypersecretion of the mucoid glands from approximation of the mucous surfaces occasioned by the swelling.

The explanation of this lies in the fact that the frontal sinus during the erect posture lies in the most favorable situation for drainage, the opposite being the case with the maxillary. In the latter decomposition takes place in the lowest depths of the secretion, which is the last to drain through the ostium. Unless artificially removed there remains always a residual stratum of purulent material which, teeming with saprophytes, occasions the marked fetidity. This cannot occur with the frontal sinus, because the ostium is situated at the lowest portion, and, should stagnation with saprophytic infection occur, the fetid pus will be the first to drain out as soon as patulosity of the drainage channels is again established. A certain amount of putrefaction may occur in the depths of the finger-like projections or behind partial septa which occur in large sinuses. One thorough lavage, however, is usually sufficient to remedy this defect unless caries or necrosis has set in.

400. Wertheim: Beiträg z. Pathol. u. Klinik der Erkrank. d. Nasennebenhöhlen. Arch. f. Laryn., Bd. 11, S. 169, 1901.

The amount secreted during the day depends upon the size of the sinus, as well as upon the severity of the disease. The discharge is not usually constant, but shows a tendency to periodically empty itself. It should not be inferred, however, that during certain portions of the day large amounts of secretion are thrown off, the remaining time being free from any traces. On the contrary, a continual ooze is always present so long as the ostium remains sufficiently patulous to transmit the purulent products.

When the secretion is scanty it shows a decided tendency toward crusting. These crusts are small and light in color and do not resemble those found associated with atrophic rhinitis.

The hours of the forenoon seem to be the usual time for the bulk of the discharge to exude, on account of the amount which had collected during the night; this is best judged by the quantity of handkerchiefs used by the patients at this time. Naturally, if other sinuses are coaffected, the amount of the discharge will be increased. The greater the area of diseased mucosa, the larger the amount of purulent products secreted.

PLACE OF APPEARANCE OF SECRETION.

Normally, one would expect to find the secretion exuding from beneath the anterior end of the middle turbinate. In favorable cases this will occur, but many changes have usually taken place in the nasal mucosa, so that we often find it directed elsewhere. A swollen middle turbinate may guide it to the olfactory fissure by capillary attraction. If the uncinatè process is swollen (which is usually the case), the secretion is directed backward over the posterior portion of the inferior turbinate. Polyps in the middle nasal passage may also divert its flow from the natural channels. All of these contingencies must be considered, and, so far as possible, eliminated, before one is able to follow the flow to its natural origin.

DISTURBANCES IN OLFACTION.

Anosmia and occasionally cacosmia seem to be prevailing features in this form of nervous disturbance. Similar to the anosmia occurring during the acute form, it may find its origin in the occlusion of the olfactory space by the swollen middle turbinate. In this condition the sense of smell is present, but is prevented

from performing its function by the inability of odorous substances to reach the terminal filaments.

The second form is caused by purulent secretion being drawn into the olfactory fissure by capillary attraction and being disseminated over the area of olfaction. Power of olfaction is also present in this condition, but is subjugated by the thin layer of secretion, which prevents odorous particles from coming into actual contact with nerve-endings.

It is probable that the constant contact of purulent secretion with the cells of olfaction eventually causes them to undergo some form of degeneration and ultimately lose their function. To bear out this hypothesis one need but cite the numerous cases which, after complete recovery from their sinus affection, never regain the power of olfaction on the affected side.

The subjective appreciation of offensive odors is occasionally complained of by patients suffering from chronic inflammation of the frontal sinus. It would seem that no perversion of function is present with these individuals, as they really perceived something that existed, namely, an actual fetid odor within the nose. Naturally, changes of putrefaction must exist before this symptom can occur, although the secretion itself may be perfectly free from odor.

APPEARANCE OF THE NOSE.

Externally little is seen, with the possible exception of eczematous eruptions around the alæ.

RHINOSCOPY.—1. Secretion: In addition to what has been said, it might be well to add that during the quiescent period the discharge is thin and glairy, giving a varnished appearance to the structures over which it flows. During the active purulent stage it is not unlike that seen in the acute stadium.

2. While changes in the mucosa are to be observed, they are not, at first glance, as apparent as those occurring in the acute stadium. In the former, the changes are more of a fibrous nature, with permanent tissue changes; in the latter, active hyperæmia forms the bulk of the hyperplasia. Unilateral obstruction of the nares is generally present to a greater or lesser degree. When we consider that partial stenosis was, in all probability, originally present, only a slight accentuation of this condition would be sufficient to make a marked contraction on that side.

The obstruction is occasioned by a number of causes.

1. Hypertrophy of the (*a*) uncinata process; (*b*) middle turbinate; (*c*) tuberculum septi.
2. Formation of true polypoid growths (mucous polyps).

It will be noted that the hypertrophies and polyp formations always occur in the tract of the exudate. The irritation produced by being constantly saturated with this purulent material undoubtedly predisposes to, if not actually causes, these structural changes.

(*a*) Hypertrophy of the uncinata process occurs so frequently in cases which have run a chronic course that it has been described as typical for this affection.⁴⁰¹ By anterior rhinoscopy this structure is unduly prominent and takes on a grayish-white, œdematous color. In later stages true polyp formation takes its origin at this point.

(*b*) The anterior extremity of the middle turbinate is also frequently hyperplastically enlarged. In the beginning it is dotted, having a sort of salt-and-pepper effect. Later, as œdematous infiltration occurs, the appearances are more of the inferior surface of a mucous polyp.

(*c*) Hypertrophy of the tuberculum septi:⁴⁰² This occurs directly opposite the anterior end of the middle turbinate, and appears to follow sinus empyema, in which the inflammatory products flow over that portion of the septum. It is not typical for frontal sinus disease, but may occur with any purulent inflammation of the sinuses of the first series.

APPEARANCES OF THE THROAT.

Sclerotic changes are always present, sometimes being atrophic, sometimes assuming the granular form. Unilateral pharyngitis on the affected side is pathognomonic of chronic sinus disease.

DIZZINESS AND VERTIGO.

These are associated, preferably, with the frontal and sphenoid sinuses. No especial reason can be attributed to their appearance, unless it is due to some circulatory phenomena. They are, however, not necessarily significant of cerebral involvement.

General disturbances (see General Symptoms).

401. Kaufmann (104), *Mon. f. Ohrenhk.*, No. 24, S. 13, 1890. 402. Schäffer: *Zur Diagnose u. Therapie d. Nebenhöhlen d. Nase*, etc. *Deutsch. med. Woch.*, Bd. 16, S. 905, 1890.

DIAGNOSIS.^{399 403}

The diagnosis of chronic frontal sinusitis is often one of the most difficult problems facing the rhinologist. During the quiescent stage of disease (latent empyema) it is often impossible to discover any symptom of pathologic import which points directly to this sinus. A diagnostic needle puncture is out of the question, and one often hesitates to sacrifice a portion of the middle turbinate for diagnostic purposes alone. Absolutely no reliance can be placed on the value of the patient's statements regarding the origin of the secretion, as he may state it forms in the nasopharynx. Our first duty in problematical cases is to make repeated examinations until all doubt as to the actual existence of sinus disease is dispelled. For this purpose, if needs be, all diagnostic agents at our hand should be employed (suction, transillumination and X-ray). When convinced that a sinus disease is actually present, even though the symptoms point toward the frontal sinus, the maxillary should be punctured and irrigated.

This may seem a needless procedure, but I have frequently found pus in the antrum and even a true inflammation of the mucosa by this method, whose existence had never been suspected.

If the antrum is found healthy, no harm has been done, and we have eliminated one source of the suppuration. Attention must now be directed towards introducing a sound and subsequently a cannula into the frontal sinus. Presupposing that an attempt had already been made and had failed, we must either infract or excise a portion of the middle turbinate.

Too much emphasis cannot be placed upon the maxim that the absence of secretion proves nothing. Only the actual presence of pus is of positive diagnostic worth.

Supposing, however, we have discovered secretion oozing from the anterior superior portion of the hiatus semilunaris after infraction, our first thought is to ascertain as far as possible its exact source. To definitely state that the frontal sinus is diseased without coaffection of one or more of the anterior group of ethmoidal cells is out of the question, particularly when one takes the so-called orbital ethmoidal cells into reckoning.*

403. V. Eicken: Zur Diagnose der Stirnhöhlenerkrankungen. Verh. süddeut. Lary., S. 56, 1906.

* Coakley says he has never seen a case of frontal sinusitis in which some of the ethmoid cells did not share in the disease.

Should polyps and hypertrophies further obstruct the view it is indicated that all structures that offer any bar to the free access to the sinus be removed. This is particularly applicable when they obstruct the passage of the sound.

Unilateral hyperæmia of the uncinæ process and operculum of the middle turbinate, even in the complete absence of pus, is very suggestive of inflammation of the frontal and anterior ethmoidal cells. If pus is seen, we must follow it to its source in order to make a positive diagnosis. So far as the frontal sinus is concerned, this can only be done by means of the sound and cannula, because the ostium lies so far front in the hiatus semilunaris that to judge without using these instruments whether the secretion comes from the frontal ostium or from the ethmoid cells is almost impossible.

Fortunately this is often of little moment, as the connection between the anterior ethmoid labyrinth and frontal sinus is so intimate that these structures are usually coaffected.

Our next step is to introduce a sound, followed by a catheter, and forcibly inject air into the sinus in order to expel the con-




FIG. 138.—Cannula for irrigation of the frontal sinus.

tained secretion. After the sound has been introduced (see Introduction of Sound) we note carefully if a flow of secretion immediately follows its removal. In any case, the cannula (Fig. 138) is bent corresponding to the curve of the sound and introduced in like manner.

Although the cannula is but slightly larger than the sound, considerable difficulty is often encountered before it finally is brought into the sinus. This is due in great measure to the sharp extremity catching in the swollen mucosa. The only remedy for this is to exercise the greatest patience with the least possible degree of force, for the slightest traumatism will often defeat our purpose.

After the introduction of the cannula has been accomplished the nib is forced in the end and locked by turning. The syringe is now filled with air and forcibly injected into the sinus cavity.

This procedure, while apparently harmless, has given rise to most alarming symptoms. Brühl⁴⁰⁴ reports a case of temporary blindness lasting twenty-four hours, immediately following this manœuvre.

404. Brühl: Zur Kasuistik der Stirnhöhleenerungen. Zeitschrift f. Laryngologie, Bd. 1, S. 637, 1909.

Should secretion be blown out of the ostium, our diagnosis, so far as the frontal sinus is concerned, is made; the question now arises, what is the extent and severity of the inflammation? The possibility of several conditions must be borne in mind. 1. The sinus mucosa may be actively inflamed and constantly secreting and exuding thick pus. 2. Fibrous degeneration may have occurred in portions of the mucosa and, as a consequence, the secretion is thin and serous. 3. The mucosa may be so swollen




FIG. 139.—Position of the hands in irrigating the frontal sinus.

as to almost obliterate the lumen of the sinus with little or no secretion. 4. The inflammation may have disappeared, leaving only a residue in the recesses.

As only a certain amount of the contained pus will be expelled by this method, it will be necessary to irrigate the cavity with a mild sterile fluid, preferably a warm, normal salt solution. The pressure in the beginning must be very light, otherwise considerable distress may be occasioned the patient. The rubber tube connecting the syringe with the cannula must also be held in a certain position (Fig. 139) to avoid soiling not only the garments of the patient but the operator as well. If the mucosa of

the sinus is diseased, some trace will invariably present itself in the returning liquid.

One is in a position to judge, with an approximate degree of accuracy, the quantity and quality of the inflammatory exudate, an important point when taken into consideration with the symptoms. If the secretion is always scanty, yet the symptoms remain severe and apparently little influenced by the irrigation, we can be sure permanent pathological changes have occurred in the cavity. If, on the other hand, a considerable amount of fresh purulent material is invariably brought to light with the escape of the injected fluid, with immediate alleviation of the symptoms, the disease has probably not affected the deeper layers of the sinus mucosa. This does not invariably hold good, but in our experience is the rule rather than the exception.

Some little criterion of the severity of the disease can be formed by the character of the secretion. If it is thick, inodorous and of like consistency (what the older writers termed laudable pus), the mucosa alone is affected, without stagnation, for no disintegration of the secretion has taken place. This form is generally indicative of a general catarrhal inflammation of the sinus mucosa.

A curdy secretion which separates into broken-down masses in the irrigation liquid signifies an old chronic condition with deep-seated inflammation coupled with considerable tissue changes. Foul-smelling pus is the result of saprophytic infection, and is of greater significance in the frontal than in the maxillary sinus, as in the former the sympathetic affection of the bony walls is to be suspected.

A small amount of secretion appearing after lavage does not necessarily imply that the disease is not extensive, for the mucosa may be so swollen as to almost obliterate the sinus cavity. Partial septa may also be present, dividing the sinus into a number of fossa which communicate with one another by such narrow orifices that the fluid cannot reach the various interstices. If the injected liquid partially returns from the opposite nostril, a perforation has occurred in the partition between the two frontal sinuses, with a communication of the disease to the opposite side.⁴⁰⁵

This, however, is also true if the anterior ethmoid cells are diseased. How, then, shall we differentiate these two conditions? This is often impossible, at least for the moment. If the discharge is profuse, by allowing the patient to wait for thirty to sixty minutes after the lavage and again making an examination, if the secretion is again seen, even in a small quantity, it must have issued from the ethmoid cells, for it is not at all reasonable to suppose that the mucosa of the frontal sinus could secrete an appreciable quantity of pus in such a short interval of time.

405. Killian (340), S. 962. Ueber communicirende Stirnhöhlen. Münch. med. Woch., Bd. 44, S. 962, 1897.

I do not look with particular favor on this procedure, by reason of the inconvenience, not to say discomfort, suffered by the patient, due to the damming back with stagnation under pressure of the secretion. This in itself is a dangerous condition, and in the presence of dehiscences may readily lead to severe ocular or cerebral complications. The pledget of cotton, moreover, may leak, thus furthering the difficulties of diagnosis.

If, despite our best efforts, catheterization, for any reason, is impossible to accomplish, and the symptoms are such that it is imperative an accurate diagnosis be made, there remains but one procedure—an external exploratory opening in the supra-orbital region.

EXTERNAL SYMPTOMS.

Tenderness on pressure at the junction of the inferior and lateral walls is not nearly so common as in the acute form; however, when distinctly present, it is a symptom of great diagnostic importance.

DILATATION OF ANTERIOR WALL AND FISTULA FORMATION.

Bulging of the sinus walls occurs usually in connection with a mucocele or tumor; when associated with chronic empyema it must be of years' duration. The following are the pathological changes.⁴⁰⁶ The osseous substance of the inner surface of the sinus wall gives way to the constant pressure and atrophies. The physiological formation of new bone on the external surface continues undisturbed, owing to the external periosteum being unaffected by the pressure. In this manner there occurs an excentric dilatation. As the condition progresses, the atrophic process gains the upper hand; the new bone formation ceases entirely, and the sinus wall becomes as thin as paper. During this stage the parchment-like crackling is elicited on pressure. Finally the wall loses all its bony substance, leaving a membranous fluctuating tumor. Fistula formation occurs also in tuberculosis and syphilis of the frontal plate. Whether connection with the sinus proper exists may be learned in the following ways: 1. Should communication exist, when the fistula is irrigated water will appear in the middle nasal passage. 2. If a sound be passed into the frontal sinus through the nose and another directly into the fistulous opening, they will meet one another.

406. Karbowski. Ein kasuistischer Beitrag zur doppelseitigen Stirnhöhlenerweiterung. Zeit. f. Laryn., Bd. 4, S. 553, 1911.

In all doubtful cases it is necessary to have the opinion of the oculist regarding the ophthalmic conditions. Very often impending complications may be anticipated and thwarted through these examinations.

ADJUNCTS TO DIAGNOSIS.

*Transillumination.*⁴⁰⁷⁻⁴⁰⁹—This method was greatly in vogue in the early part of 1900. The rationale is to place double hooded electric lamps⁴¹⁰ beneath the inferior floor of the sinus in a darkened room and, after applying the current, note the difference of light intensity over the anterior sinus walls (Plate 4). This was formerly considered of great value in diagnosing the comparative differences in the pathological condition of the two sinuses. Unfortunately, subsequent observers⁴¹¹⁻⁴¹³ have demonstrated the fallacy of this opinion.

It is supposed that either a collection of purulent material or swollen mucosa would act as a barrier to the passage of the rays of light. As a matter of fact, large transilluminatory areas in the supra-orbital region have been observed, yet on subsequent operation the frontal sinus has been found to be the seat of a severe inflammation. This condition has also been noted where the margo-supra-orbitalis was thick and diploic and no sinus whatever existed. Under these circumstances it is evident that very little dependence can be placed upon this as a valuable consideration in diagnosing frontal sinus affections; however, it is of some value as a corroboratory evidence.

Even in the best hands errors are liable to creep into the diagnosis, as is well exemplified in the case of Hajek's⁴¹⁴ when the sinus wall was sensitive to pressure, excruciating frontal pain with transillumination showing a large sinus. On operating no frontal sinus could be found.

*Röntgen Ray.*⁴¹⁵⁻⁴¹⁸—After much experimentation it was found that the X-ray offered considerable assistance in ascertaining not only the shape and size of the frontal sinus, but whether

407. Vohsen: Berlin. klin. Woch., Bd. 27, S. 274, 1890. 408. Claus: Zur Durchleuchtung der Stirnhöhlen. Arch. f. Lary., Bd. 13, S. 103, 1903. 409. Logan Turner: Accessory Sinuses of the Nose, p. 120, 1901. 410. (Double Lamp) Furet: Ann. d. mal. de l'oreille, etc., T. 25, p. 692, 1899. 411. Ziem: On the Transillumination of the Maxillary Antrum, Journ. of Laryng., p. 284, 1903. 412. Zarnico: Lehrbuch, S. 178, 1910. 413. Onodi: Die Stirnhöhle (1200 skulls), S. 57-67, 1909. 414. Hajek (6), S. 200. 415. Coakley: Frontal Sinusitis: Diagnosis, Treatment and Results. Annals of Otol., Lary. and Rhin., Sept., p. 452, 1905. 416. Mosher: The Use of the X-ray in Sinus Disease. Laryngoscope, p. 114, 1906. 417. Goldman and Killian: Beiträge zur klinischen Chirurgie, 1907. 418. Chisholm: Skiagraphy in the Diagnosis of Frontal Sinusitis. Annals of Otol., Lary. and Rhin., p. 979, Dec., 1906.

disease existed either in the shape of purulent collections or in pathological changes in the lining mucosa. It was found that the best results were obtained by placing the forehead of the patient upon the photographic plate and taking the picture in the posterior-anterior direction.⁴¹⁹ On examining the plate it was shown that the contour of the diseased side appeared less sharp than that of the sound and cast a shadow corresponding to the intensity of the disease. The X-ray is particularly of value for diagnostic purposes where great deviation of the nasal septum is present, thereby prohibiting any nasal examination.

DIFFERENTIAL DIAGNOSIS.⁴²⁰

Certain conditions may simulate frontal sinus disease, among them being certain forms of neuralgia and headache from Bright's disease.

FRONTAL SINUS DISEASE.

IDIOPATHIC NEURALGIA.

History of acute coryza.	No such history.
Pain at first mild, gradually becoming severe.	Pain sharp at onset.
Little change in intensity.	Pain paroxysmal with free intervals.
Pain intensified by pressure.	Pain relieved by pressure.
Coughing and stooping intensify pain.	Muscular movements or jar intensify pain.
Alcohol and tobacco intensify pain.	Not so.

In all doubtful cases the urine should be examined at least several times to make perfectly sure that no kidney lesion exists.

CHRONIC FRONTAL SINUSITIS.

MUCOCELE.⁴²¹

MALIGNANT TUMOR.

Any age after twenty years.	Any age after 20.	Past forty years of age.
History of an acute attack.		No history of acute stages.
Subjective symptoms intermittent.	No subjective symptoms.	Subjective symptoms progressive.
Nasal discharge intermittent.	No nasal discharge.	May be constant or absent.
Dilatation of sinus very rare.	Always present.	May or may not be present.

Examination of the nose shows:

Changes in mucosa.	No changes.	No changes.
Sounding of frontal sinus produces purulent secretion.	Sinus cannot be sounded.	Sinus impossible to sound when disease is located around ostium.

419. Beck's Atlas of Radiography, 1910. 420. Tilley: Some Points in the Differential Diagnosis of Chronic Suppurative Pansinusitis, with Discussion. Trans. 1st Internat. Lary.-Rhin. Congress, p. 214, 1908. 421. Valude: De la mucocèle du sinus frontal. Annales d'oculistique, Dec., 1899.

PROGNOSIS.

In the strictest sense of the word the ultimate prognosis for chronic frontal sinusitis is good. It must not, however, be inferred that absolute healing, *i.e.*, a return of the normal, invariably occurs; on the contrary, despite all therapy and operative procedures, frequently enough a more or less constant leakage often remains. The immediate prognosis after any form of treatment (the radical methods excepted) is, however, an exceedingly uncertain proposition.

A patient presents himself suffering with an old case of chronic frontal sinusitis which has never been treated. We find hypertrophies occluding the drainage passages, with certain stagnation of the secretion. Can we promise him a cure by intranasal procedures? Absolutely, no. Although every indication points toward favorable results following such measures, nevertheless, certain tissue changes may have taken place in the mucosa of the sinus which preclude *restitutio ad integrum*. Improvement will undoubtedly take place up to a certain point, then the course of the disease will remain unchanged. Free drainage, while essential in such cases, is not a panacea, as many disappointing experiences have taught us.

During the long course of the disease, areas of degeneration of the mucosa from long-continued suppuration have occurred. No amount of ventilation or drainage will remedy this defect, as those diseased portions of the mucous membrane will continue to secrete so long as they are present. This fact explains the cause of failure in those intranasal operations which depend upon the installation of free drainage by enlarging the drainage passages.

For this reason we must exercise the greatest circumspection in making prophecies after any form of conservative treatment in this disease. So far as the subjective symptoms are concerned (and, after all, these are the source of the patient's complaints), much more can be promised. These depend largely upon the condition of ventilation and drainage. In those uncomplicated cases where absolutely unhindered drainage has been installed the most distressing symptoms have invariably disappeared.

The pain is always mitigated, discharge is greatly lessened, and, above all, those nervous and mental manifestations which are infinitely the *bête noire* of the entire symptom-complex rapidly disappear. The discharge resolves itself into thin, serous oozing,

which may even cease entirely and the patient, to all intents and purposes, be cured. The first acute coryza, however, will cause the mucosa to again throw off a purulent exudate, which, during the natural course of the disease, again gradually diminishes and finally ceases. This cycle will continue *ad infinitum*, unless more radical measures are instituted.* Coakley³⁶⁷ reports 14 per cent. cured by intranasal treatment, 51 per cent. improved, and 35 per cent. result unknown.

As far as the patient is concerned it is a personal equation under the circumstances whether he considers himself cured. Some individuals are but little annoyed by a more or less constant discharge from the nose with occasional headaches. Others, on the contrary, brood over such a condition, and by magnifying in their imagination their symptoms, remain dissatisfied until radical procedures have been adopted.

When the bone has become affected or complications have supervened, the installation of drainage has little influence upon the course of the disease. The prognosis after a radical operation is exceedingly good, provided complications, particularly intracranial, have not occurred, for by this means it is possible to inspect all parts of the sinus cavity and remove those portions which appear diseased and would protract the period of healing.

CHRONIC COMPLICATIONS.†

That the frontal sinus more often is the seat of complications than its fellow-cavities is due to the following anatomical facts:

1. It communicates with both the brain and the orbit in a much larger area.
2. Intimate connection exists between the veins and lymphatics of the sinus mucosa and those of the dura mater and meninges.
3. The walls are frequently very thin and, indeed, often show dehiscences.
4. It often contains numerous projections and fossæ which allow the infecting micro-organisms to remain undisturbed, thus favoring their virulence and toxicity.
5. The cerebral wall contains numerous small foramina for the transmission of veinlets through which micro-organisms can find entrance into the cranial cavity.

* As a matter of fact, simple, uncomplicated cases of chronic frontal sinusitis rarely go on to radical operation.

† Owing to the paucity of material and lack of sufficient American data, this section is largely based on Gerber's recent work: *Die Komplikationen der Stirnhöhlenentzündungen*. Berlin, 1909.

The frequency with which complications follow chronic frontal sinusitis is uncertain, as precise statistics are practically unavailable. However, Gerber puts it at 5 per cent., though admitting that his percentage is somewhat higher than other rhinologists.

Complications occur much oftener in (a) older individuals, (b) in males, and (c) on the left side. The larger the sinus the more predisposition toward this eventuality.

POSSIBLE PATHS OF INFECTION.

1. By direct continuity: Ulceration occurs in a given area on the sinus mucosa which communicates to the immediate underlying bone and results in the formation of a carious or necrotic spot. The inflammation continues through the bone, eventually causing some lesion in the neighboring part, depending upon the wall affected: if the orbital wall be diseased, subperiosteal abscess, periorbitis, periorbital abscess, or orbital phlegmon; if the posterior or meningeal wall, carious forms of meningitis, sub- or intradural abscess.

2. Through congenital or acquired dehiscences: When a dehiscence is present, the sinus mucosa lies in direct contact with the dura and perimeningeal structures; therefore, deep infection of the mucosa is practically equivalent to inflammation of the dura.

3. Through the venous anastomosis (Fig. 140): The investigations of Kuhnt⁹⁸ have shown that the veins of the frontal sinus communicate freely with both those of the orbit and of the brain. According to Zuckerkandl,⁴²² a direct communication also exists to the superior longitudinal sinus.

4. Through the passages for the optic nerve and ophthalmic vein.

5. Through the lymph-channels: Andre,⁴²³ having made a special study of this subject, has conclusively demonstrated the lymphatic connection between the free meningeal spaces and the mucosa of the nose and frontal sinuses. Falcone⁴²⁴ has also found a direct connection between the lymphatics of the mucosa of the frontal sinus and those of the subdural and subarachnoidal spaces. This was accomplished by injecting substances

422. Zuckerkandl (45), S. 356. 423. Andre: Recherches sur les lymphatiques du Nez et des Fosses Nasionales. Ann. des mal. de l'oreille, etc., T. 31, p. 425, 1905. 424. Falcone, quoted by Sieur and Rouvillois: Traitement chirurgical des antritis Frontales. Arch. inter. de Laryn., T. 32, p. 398, 1911. (Original in Il Tommasi, No. 24, 1907.)

from the meninges which filled the lymphatic channels in the frontal sinus without entering those of the nasal mucous membrane. Of all these possibilities, the first—*i.e.*, by direct continuity—is by far the most important.

The actual complications may be divided into:

1. Those affecting the sinus itself.
2. The oculo-orbital.
3. The intracranial.

THOSE AFFECTING THE SINUS ITSELF; CHANGES IN THE BONES.—

(a) Periostitis and subperiosteal abscess. These changes may affect any of the sinus walls, although the spot of predilection

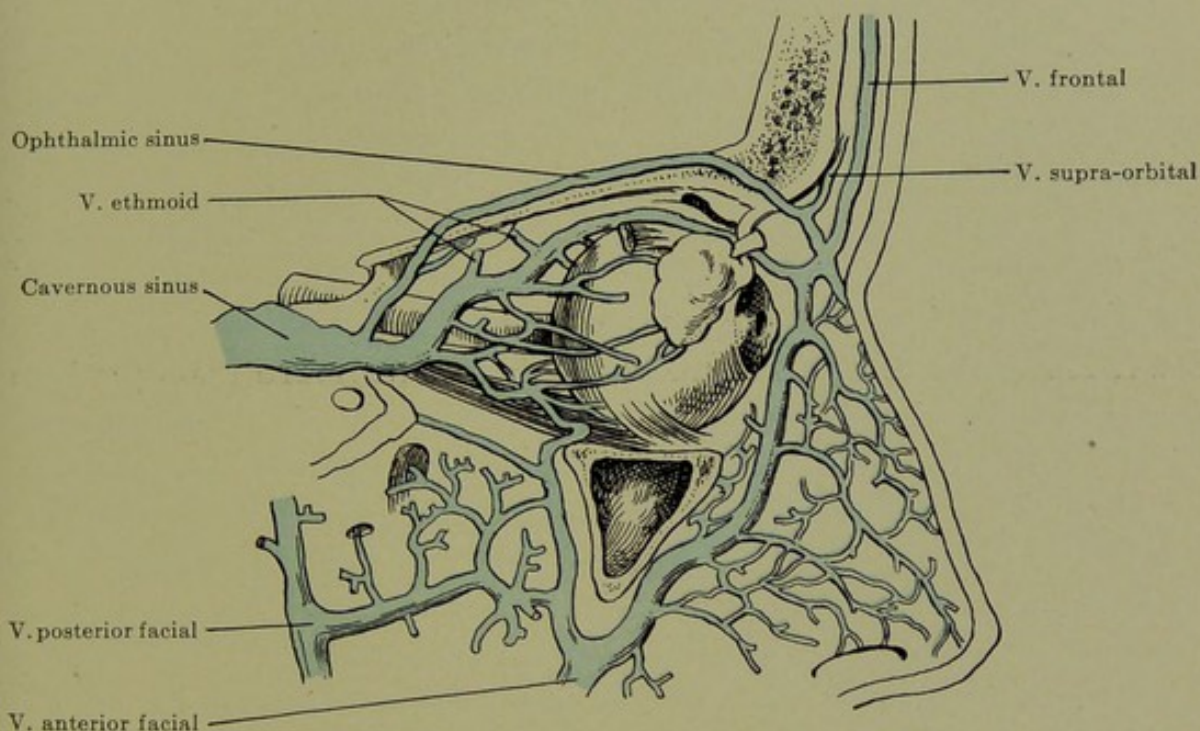


FIG. 140.—Venous anastomoses of the nose and orbit, showing intimate relation. (After Quain.)

appears to be on the orbital partition. They are characterized by a point of exquisite tenderness appearing on the inferior wall near the inner angle of the eye. The upper lid is swollen and cedematous, sometimes so inflamed as to completely close the eye. The pathological changes in the periosteum consist of a thickening, agglutination, and discoloration, punctiform hemorrhages, with thinning and softening of the underlying bone. These forms of complications appear more frequently associated with the acute form of frontal sinusitis.

(b) Caries and necrosis. These osseous affections appear mostly on the inferior and anterior walls and may range from the size of a needle puncture to ulceration of the entire wall. They

are usually due to occlusion of the drainage passages either through an acute coryza or polypoid changes. Influenza and the infectious diseases (scarlet fever, diphtheria, measles, and erysipelas) also appear to play an important causative rôle. In contradistinction to periostitis and otitis, caries and necrosis appear most frequently associated with chronic frontal sinusitis. The symptoms of these affections are similar to those of otitis, except greatly intensified, particularly the headache. Occasionally this is so severe as to simulate a true cerebral complication. General symptoms, as chills and fever, nausea, vomiting, sleeplessness, dizziness, and vertigo, and general lassitude, have been observed and described by numerous authors.

(c) Dilatation of walls. This results chiefly from cysts, mucoceles, and hydrops of the sinus, although Gerber⁷⁸ insists that it may also be dependent upon a pure empyema which has become encysted through occlusion of drainage. We do not propose to dispute this assertion with such eminent authorities (Killian⁴²⁵ and Gerber), yet from a purely physiological standpoint it would seem curious why a stronger wall (anterior) would yield before a weaker (posterior) to a uniform internal pressure from pent-up secretion. That the condition is a great rarity even these authorities freely admit.

MUCOCELE.—Several theories have been advanced for the formation of these mucoid collections: 1. From a previously-existing sinusitis which had never become infected or had lost its virulence, absolute occlusion of the ostium being presupposed.⁴²⁶ 2. From a cyst in the sinus mucosa which had retained its secretion.^{427,428} 3. From an enlarged anterior ethmoid cell.⁴²⁹ Traumatism is usually the immediate existing factor. These swellings progress slowly and, as a rule, without much pain, and are capable of reaching an enormous size, as is well illustrated by the classical case of Barthausen (Fig. 141), in which the eyeball was dislocated almost below the nasal apertures. Their contents are quite characteristic, being composed of a mucoid substance of grayish, brownish, and even a chocolate color, being inodorous and usually sterile. They are, however, capable of infection, in which event

425. Killian: Heymann's Handbuch. Die Nase, S. 1124, 1900. 426. Logan Turner: Mucocele of the Nasal Accessory Sinuses. Edin. Med. Journ., Nov. and Dec., p. 396, 481, 1907. 427. Onodi: Die Mucocele des Siebbeinlabyrinths. Arch. f. Lary., Bd. 17, S. 415, 1905. 428. Sprenger: Ein Fall von Schleimhautcyste der Stirnhöhle. Arch. f. Lary., Bd. 19, S. 136, 1907. 429. Avellis: Die Entstehung der Nichttraumatischen Stirnhöhlenmucocele. Arch. f. Lary., Bd. 11, S. 64, 1901.

a true empyema is formed. The dilatation affects all of the walls of the sinus, and takes on the character of a continual reabsorption and thinning of the osseous structure rather than an actual dilatation. In old cases the walls may have lost entirely the bony consistency, which has been replaced by a tough membrane of connective tissue. Dislocation of the eyeball occurs sooner or later and from mucocele of the frontal sinus, and is always in the direction of downward and outward, in contradistinction to outward from the ethmoid and forward from the sphenoid.

The differential diagnosis between mucocele of the frontal sinus and orbital tumors occasionally offers some difficulties; however, needle puncture with aspiration will acquaint one with the character of the contents. Fluctuation is another important sign which malignant tumors of the orbit do not present.

Hydrops⁴³⁰ of the frontal sinus is, to all intents and purposes, a mucocele with clear watery contents. It is probably due to a serous outpouring into the sinus with closure of the ostium—a condition which has continued for years.

Pyocele is either an infected mucocele or a closed-in empyema in which the virulence of the infecting organism gradually became less effective until it reached a condition of innocuousness, the volume of the collection of purulent material remaining as before. All of these conditions are extremely chronic and require years before they attain any considerable growth.

OCULO-ORBITAL COMPLICATIONS (see General Complications).—These complications rarely occur, *per se*, but are usually antedated by some of the bone affections enumerated above, particularly caries and necrosis.



FIG. 141.—Enormous mucocele of the frontal sinus dislocating the eye downward and outward. (After Barthausen.)

430. Lichtwitz: Ueber die Erkrank. d. Sinus oder Nebenhöhlen der Nase. Prager med. Woch., S. 311, 1894.

They may be divided into the following:

1. Affections of the orbit and cellular tissue.
2. Affections of the adnexa.
3. Affections of the bulb.
4. Functional disturbances.

1. The beginning stage of an orbital complication is an inflammatory swelling of the orbital cellular tissue. This is always associated with a more or less persistent œdema of the upper eyelid. The inflammation may be arrested at this point and gradually recede, only to appear again with greater severity on the next occasion of acute exacerbation of the frontal sinusitis. More often, however, it progresses in ratio to the virulence of the infection, with the formation of an orbital abscess, or, in favorable cases, with a subperiosteal abscess and fistula. Diplopia is one of the most important symptoms in the earlier stages of this affection, as well as interference with the mobility of the bulb. Central scotomas are rare, being associated almost exclusively with affections of the posterior ethmoidal and sphenoidal sinuses.⁴²³

2. Affections of the adnexa.⁴³¹ The lids, tear-sac and duct, and external muscles are also subject to various affections through compression, infection, and toxic influences.

3. Affections of the bulb. Dislocation of the bulb depends upon dilatation of the sinus walls, particularly the orbital from mucocele, pyocele, etc., and may take place without inflammatory appearances. Subperiosteal abscess causes forward and outward dislocation of the bulb, usually accompanied with inflammatory symptoms in the latter. The bulb may also become directly infected through the invasion of micro-organisms from the diseased sinuses.

4. Functional disturbances. Disturbances of function sometimes occur without the slightest sign of any inflammation outside of the sinus. Various causes have been attributed to this condition, as nervous reflex disturbances of circulation and reabsorption of toxins out of the affected cavities.

INTRACRANIAL COMPLICATIONS.*³⁸²—The cerebral complications, like the orbital, are usually dependent upon the primary occur-

* For a detailed and minute treatise on this subject, with extensive references, the reader is referred to the above-cited monograph of Gerber's (also 382).

431. Hoffman: Die Beziehung der entzünd. Orbitalerkrankungen zu den Erkrank. der Nebenhöhlen der Nase. Verh. deutsch Lary., S. 91, 1907.

rence of some osseous lesion in the sinus walls. Occasionally, however, the bone has been found to be macroscopically intact. Under these circumstances the perforating veins must have transmitted the infection. The various routes by which the infection can find its way into the cranial cavity have been already enumerated (see General Complications). Intracranial lesions dependent upon chronic frontal sinusitis may be classified as follows:

1. Circumscribed plastic inflammation of the dura mater, corresponding to the adjoining area of diseased bone. After the disease has penetrated the bone, that portion of the dura lying in apposition loses its shining aspect and appears hyperæmic, thickened, and occasionally discolored. If the process continues, granulations and plastic exudate begin to form, which soon results in agglutination of the dura with the underlying bone.

2. Circumscribed purulent inflammation of the dura mater (extradural abscess). The above process (circumscribed plastic) may become purulently affected, thus constituting either a circumscribed ulceration or an extradural abscess. The formation of the latter occurs between the bone and the dura, and is dependent upon the formation of a plastic exudate at the line of demarcation between the healthy and diseased tissue, thus forming a barrier between the purulent collection and the general subdural space.

3. Pachymeningitis interna, intra- and sub-dural abscess. When the inflammation reaches such intensity that the dura is unable to withstand its attack, the infection penetrates it, reaches the pia mater, and causes inflammation of this structure. If the purulent process becomes encysted, an intra- or sub-dural abscess results, otherwise the infection spreads over a considerable portion of the surface of the pia, resulting in diffuse purulent internal pachymeningitis.

4. Brain abscess. If the infection penetrate the dura and is directed into the brain substance, an abscess of the frontal lobe results.

5. Thrombophlebitis results when the purulent material is carried directly into the longitudinal sinus and finds a place of lodgement along the walls. Pyæmia is usually the ultimate sequel of this condition.

Although individual mention has been made of these conditions, yet they rarely occur singly, one being a forerunner of the other, depending upon the virulence of the infection and the

powers of endurance of the patient, for death claims practically all of the sufferers—certainly, if the disease has acquired any considerable headway. As rhinologists our one and only chance lies in the immediate recognition of these cerebral complications at their very onset and the institution of appropriate radical treatment. That this is most difficult, often impossible, will be shown under the following heading.

Diagnosis.—The symptoms of beginning meningeal complications and those of a severe attack of uncomplicated frontal sinusitis may be, to all intents and purposes, identical. The course of a severe frontal sinusitis may continue for days unchanged, when suddenly threatening symptoms intervene and on operation a meningeal complication of considerable extent is discovered. This is peculiarly applicable to those cases of following frontal sinus disease. Usually, however, certain symptoms manifest themselves at the onset of the complication.

In the first place, there is a decided but indefinite change in the general condition of the patient. This may take the form of an intensity in the headache, which also changes in location. If the pain had been previously limited to the frontal region, the entire cranium becomes involved. Sudden heat flashes frequently appear. The patient at first seems disquieted, sleepless and restless, although no definite cause can be attributed to these symptoms. As the complication develops the physiological changes give way to actual meningeal manifestations, such as vertigo and dizziness, nausea and vomiting, and photophobia. Neither the pulse nor the temperature is characteristic, as sometimes there is fever, sometimes subnormal temperature. The pulse may be fast or slow, but the former is usually the case. When the complication has actually taken place, symptoms of stupor, delirium, etc., with all the appearances of cerebral irritation or compression, appear.

Thrombophlebitis following frontal sinus empyema is such a rarity that it will be described under the sinus from which it most commonly originates (sphenoid).

TREATMENT.

When an ordinary uncomplicated case of chronic frontal sinusitis presents itself for treatment, we are confronted by one of the two following possibilities: either that (*a*) the installation of free drainage and ventilation will bring about a cure, or, at least,

an amelioration of all symptoms, so that only a thin serous discharge persists; or that (*b*) the sinus mucosa has undergone such changes as to preclude the possibility of a cure except through radical operative measures.

A certain amount of information regarding these probabilities may be obtained by rhinoscopy. If the middle passage seems occluded by any of the conditions previously mentioned (see page 234), we would naturally infer that these stand in direct relation to the subjective symptoms. If, on the contrary, the drainage passages seem patulous, the prospect of a successful issue following continued irrigation is considerably diminished. In doubtful cases the radiograph may throw considerable light upon the condition, especially upon the presence of finger-like projections with foci of disease at their extremities, as well as partial septa and fossæ-hiding areas of hypertrophied and granular patches of mucosa.

Let us then consider that we are called upon to treat an ordinary case which has never before been under special treatment. What procedure shall we primarily adopt? Our first thought will be to ascertain whether the continually-forming secretion in the frontal sinus finds an unhindered passage into the nose. This is the first principle in the treatment of any sinus affection and applies particularly to the frontal, as the ostium lies in the most favorable position for constant drainage. Presuming that no polypoid formations are present, we note that the middle turbinate is either swollen at its anterior extremity so that it encroaches on the middle nasal passage, or it lies sufficiently close to the lateral nasal wall to effectually prevent the passage of a sound into the sinus.

As it is absolutely essential that this structure should be removed from its position, two courses are open: 1. Infraction of the middle turbinate. 2. Resection of the anterior third of the middle turbinate. Infraction of this structure is contraindicated when the nasal septum is deviated toward the affected side or the turbinate is so enlarged as to prevent its dislocation. Let us suppose, however, that all conditions were favorable for this procedure and it was successfully accomplished. (For technique see page 221.) As no bleeding to obstruct our vision has occurred, we proceed immediately to the introduction of a suitable sound, which is followed by a catheter and irrigation.

This procedure often temporarily relieves the patient, but a permanent cure rarely results, for the following reasons: The inflected turbinate shows a marked tendency to resume its original position, and, the permanent ventilation being thus interfered with at the next attack of acute rhinitis, the sinus will start anew to suppurate with return of the original symptoms.

Suppose, despite the room acquired by breaking the turbinate against the septum, it does not suffice for proper irrigation, what is the next step to pursue? We can now procure more room only by sacrificing a certain amount of tissue, and that best adapted for our purpose is the anterior third of the middle turbinate.

RESECTION OF THE ANTERIOR PORTION OF THE MIDDLE TURBINATE.

Technique: 1. Cleanse the nares with douches of warm saline solution.

2. Cocainize middle turbinate with 20 per cent. solution of cocaine with few drops of adrenalin chloride, care being taken to introduce the cotton pledgets as high up as possible in the middle nasal passage between the bulla and turbinate, as well as between the turbinate and septum. Repeat this several times and wait at least fifteen minutes.

3. Pry out the turbinate from the lateral nasal wall if necessary and introduce scissors on each side of the turbinate at its anterior attachment, pushing them well up until firm resistance is encountered. (Fig. 134.)

The cribriform plate cannot be injured by this procedure, as the outer blade will meet with firm resistance before the inner is near this structure. As the shank of the snare must occupy this incision it is important that it be made correctly and as high as possible.

4. The turbinate is severed by one firm cut of the scissors and the shank of the snare worked gently upward until it reaches the highest extremity of the cut, the loop encircling the turbinate about at its middle. (Fig. 136.)

It sometimes requires considerable patience to successfully carry out this manœuvre as the loop often catches on various obstacles before finally reaching its position. No end of trouble, however, should be spared, as the successful application of this step has much to do with the ultimate result of the operation.

5. The snare is slowly but firmly contracted until the end of the wire cuts through the turbinate and disappears into the shank of the instrument.

In preparing the snare it should always be tested to ascertain that the end of the loop will completely sink into the shaft, otherwise it may be necessary to readjust it in the midst of the operation.

Little or no bleeding will occur if the parts have been sufficiently adrenalized.

6. Remove the severed piece with a pair of serrated alligator forceps; otherwise it may be pushed farther into the nasal cavity and ultimately lost.

7. Remove any irregular portions of loose bone or membrane with the cutting forceps. An attempt should now be made to sound the sinus, which will succeed in 95 per cent. of all cases. After the successful introduction of the instrument the patient should be allowed to remain away for several days until healing sets in. Lavage should now be regularly instituted and continued for an indefinite time, depending upon the condition of the patient.

The question as to how long lavage should be continued depends upon a great number of eventualities, including the personal views of the rhinologist as to the indications for radical procedures. This perhaps explains why certain operators report many more operations than their colleagues of equal experience in number of patients treated. If the subjective symptoms are greatly ameliorated and the patient is fairly comfortable, the indication for further operative treatment lies entirely with him, as no complications are to be feared as long as free drainage continues. That this conservative course is the proper policy to pursue is shown by the scores of patients who have recovered after months of treatment. Hajek very tersely brings out this point by reporting a case which refused operation although it was apparently indicated. He chanced to meet the patient about a year afterwards, and on noting his perfect health, inquired who had performed the operation. He was surprised to receive the answer that it had completely healed of its own accord.

Should the disease apparently succumb with the exception of a slight discharge, it is well to inject a medicated liquid after the lavage. A 2-5 per cent. solution of nitrate of silver frequently reaches the chronically diseased areas and brings about entire cessation of the secretion. The head of the patient should be inclined strongly forward immediately after the injection, so as to allow the fluid to remain in contact with the diseased mucosa as long as possible. It must, however, always be borne in mind that this sinus once diseased constitutes a weak spot in the human economy which is always liable to become reinfected.

Suppose, in spite of frequent irrigations, the condition of the patient showed very little improvement, should we advise an external operation? When we consider that the probabilities why improvement has not taken place are that sufficient drainage has not been established and that intranasal measures are still open to us, this question should be answered in the negative. It is yet possible to obtain considerably more room by resecting the

uncinate process and curetting the anterior ethmoid cells lying in apposition to the semilunar hiatus. The fact that the ethmoid cells are practically always involved strengthens considerably the indications for this form of operative procedure.

RESECTION OF THE UNCINATE PROCESS.

Technique: 1. Cocainize the parts as before.

2. Introduce a modified hook (Fig. 142) over the uncinatè process and by a quick jerk tear it loose from its attachment. (Fig. 143.)

3. Curette the hiatus from behind forward and above downward until the opening is considerably widened.⁴³² (The ethmoidal bulla must be removed if it interferes in any way with this procedure.)

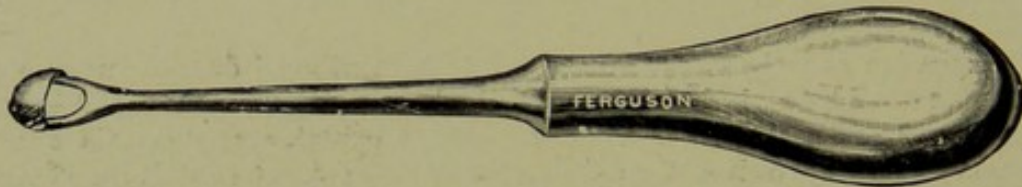

FIG. 142.—Burrell's nasal shave.

Great care must be exercised not to forcibly push the end of the curette too far upward, lest the cribriform plate be injured. The direction of the curette must never be outward for fear of traumatism to the orbital plate, particularly through the lachrymal fossa.

4. Remove all hanging débris and projecting bony spicules with a Lange forceps (Fig. 144), sounding the opening from time to time until it appears quite patulous and as large as possible under the existing circumstances. (Fig. 145.)

Bleeding may prove a source of serious inconvenience to the operator at this point, and if it cannot be controlled by the application of gauze soaked in adrenalin 1-1000, the completion of the operation had best be postponed for two or three days.

After this procedure it is often possible to introduce a fairly large hard-rubber Eustachian catheter and irrigate the sinus with a stream of considerable size. The pressure at the beginning, however, must be moderate, otherwise disagreeable results, such as syncope or severe pain, might ensue. This treatment, followed

⁴³² Worthington: The Intranasal Frontal Sinus Operation; the Accessibility of the Sinus and the Prognosis of the Operation. *Laryngoscope*, p. 940, 1909.

by regular lavage and the occasional removal of exuberant granulations, offers the best possibilities for cure by intranasal treatment.

INGALS'S INTRANASAL OPERATION.⁴³³⁻⁴³⁵

The rationale of this operation is to enlarge the fronto-ethmoidal passages with an electric burr to such an extent that good drainage is insured. A self-retaining gold tube is then inserted to prevent narrowing from granulation tissue formation.

Technique: 1. Cannula introduced into sinus and cavity washed out with a warm saturated solution of boric acid.

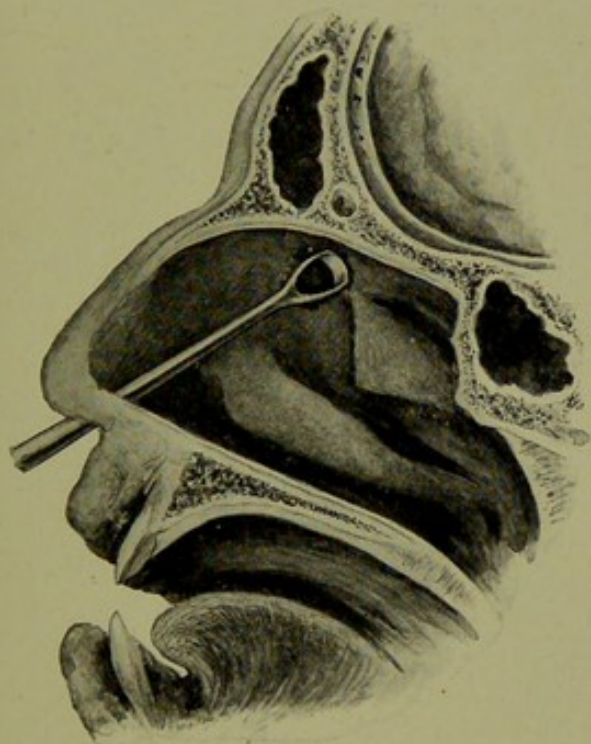


Fig. 143.—Removing the unciniate process with the nasal shave.

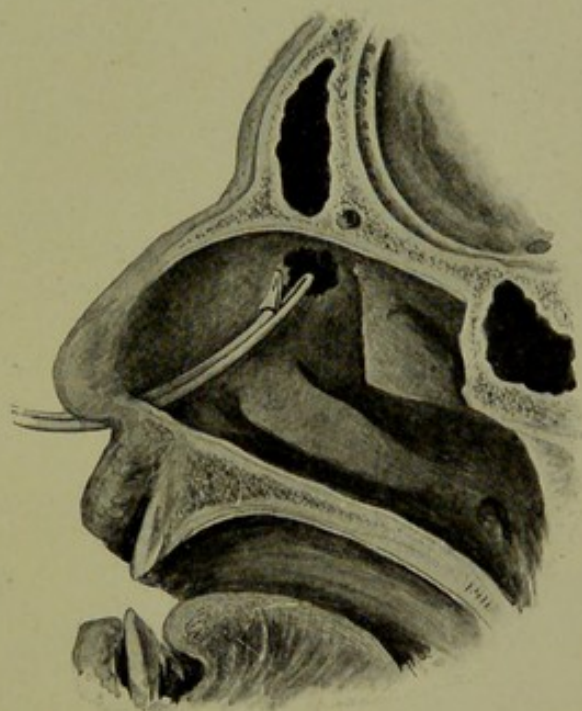


Fig. 144.—Using Lange's forceps to enlarge the naso frontal passages.

2. Anæsthetize with 20 per cent. cocaine hydrochloride in a solution 1-1000 suprarenalin, applying it to the frontal sinus through the long silver nozzle of a syringe; about one-third minim every ninety seconds, five or six times. A weaker solution is used in the nares before the manipulations are begun.

3. Introduce steel pilot and, with the patient in a sitting position, administer ethyl chloride for a minute or two.

4. Remove handle from pilot, slipping on the hollow burr, and attach to dental engine.

433. Ingals. New Operation and Instruments for Draining the Frontal Sinus. Laryngoscope, p. 644, 1905. 434. Ingals: Intranasal Drainage of the Frontal Sinus. Laryngoscope, p. 113, 1910. 435. Ingals: Intranasal Drainage of the Frontal Sinus. Journ. Am. Med. Assoc., p. 1502, May 9, 1908.

5. Push burr up into the nares until it engages in the lower end of the nasofrontal canal. (Fig. 146.)

6. The electric current is now applied and the burr gently pressed upwards, so that in two or three seconds it cuts its way into the frontal sinus.

7. Introduce packer into the enlarged canal and pack sinus with gauze saturated in 20 per cent. solution chloride of zinc, allowing it to remain five minutes.

8. A gold tube (Fig. 147), the upper end of which has been sprung together and covered with a gelatine capsule, is slipped

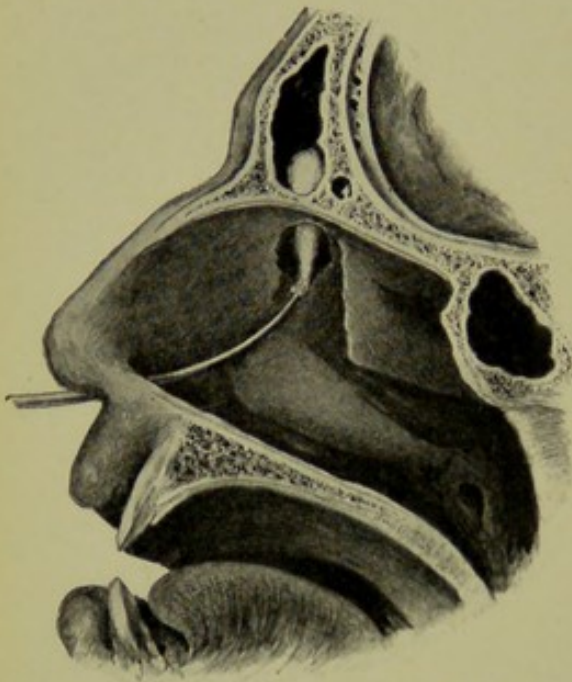


FIG. 145.—Operation completed. Cotton carrier armed with a large wad of cotton easily penetrating the opening into the frontal sinus.

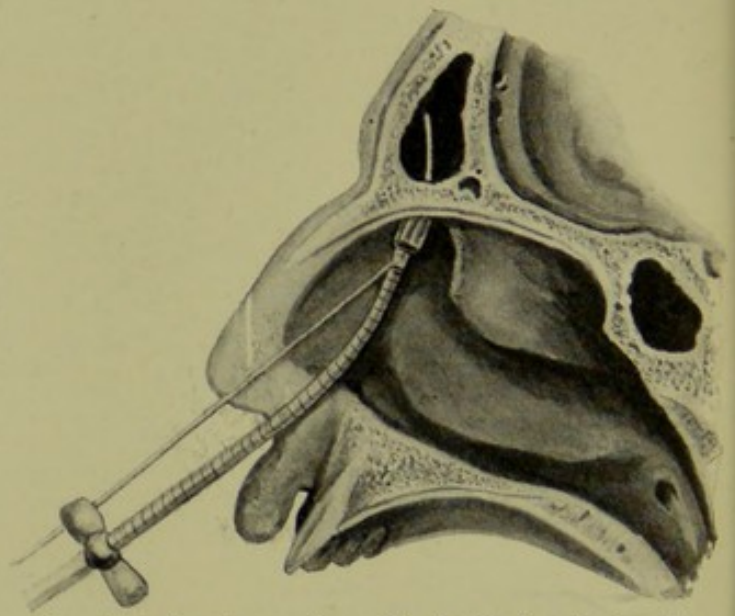


FIG. 146.—Ingals operation. The flexible burr boring into the frontal sinus.

on an applicator and passed up the canal as far as possible into the frontal sinus.

Leaving the tube *in situ* concludes the operation.

The gelatine capsule melts in the course of a few minutes, allowing the end to expand. After-treatment consists of regular lavage with a strong boric acid solution: the patient may be taught to do this himself. The gold tube should remain in place about four months, but may remain even longer if deemed necessary. Ingals has treated about fifty cases by this method and reports 95 per cent. of cures.

I have had no experience with this method, therefore, any endorsements or objections here must naturally be of a theoretical nature. The following points, however, may be mentioned:

1. Any rapidly revolving instrument, particularly when hidden in such proximity to the lamina cribrosa, is dangerous, even in skilled hands.

2. When a suppurating orbital cell is present, the body of the tube could easily occlude the ostium with damming back of the secretion.

3. Where great pathological changes have taken place in the sinus mucosa the operation will probably be unavailing.

Even considering these objections, it must be admitted that in the hands of Ingals, this operation has proved to be of decided worth.

HALLE'S INTRANASAL OPERATION.^{436, 437}

This author removes the anterior-superior spine which forms the anterior portion of the floor of the frontal sinus, thereby creating a large and permanent opening into the nose.

Technique: After having a Roentgen photograph taken for the purpose of orientation,

1. Remove anterior end of middle turbinate.

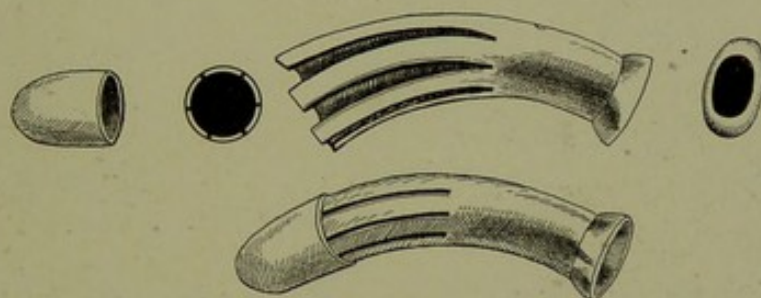


FIG. 147.—Ingals gold tube for intranasal insertion into the frontal sinus. The lower cut shows the tube with the gelatin capsule over the end.

2. Cocainize with 10–20 per cent. cocaine and adrenalin solution, and inject into sinus 0.5 per cent. novocaine and adrenalin solution.

3. Introduce sound as high as possible into the frontal sinus, over which is slid a soft, flexible metal protector which adjusts itself to the tabula interna posteriorly and to the orbit laterally.

4. Remove the sound and introduce drill alongside the protector. Press instrument firmly to the front and apply current, taking care to keep always close to the protector. (Fig. 148.) Any lateral deviation of the instrument must not be permitted.

During the boring it is wise to make a number of interruptions in order to inspect the parts and to allow the burr to cool. It is of the utmost importance to keep the operation under the control of the vision.

436. Halle: External or Internal Operation for Suppuration of the Nasal Accessory Sinuses. Laryngoscope, p. 115, 376, 1907. 437. Halle: Arch. f. Laryng., Bd. 24, S. 249, 1911.

5. After the drill has entered the sinus, it is removed and a pear-shaped one substituted, which is rounded off and polished so that it cannot cut in an upward direction. With this instrument the sides of the wound are reamed off until a large, smooth opening is made into the sinus. (Fig. 149.)

6. Remove polyps and degenerated mucosa with a double curette.

After-treatment: Cavity is packed with iodoform gauze, which is allowed to remain in place three to four days. A silver tube similar to Ingals's is now introduced and may remain indefinitely *in situ* (several months to one year). The patient is not permitted

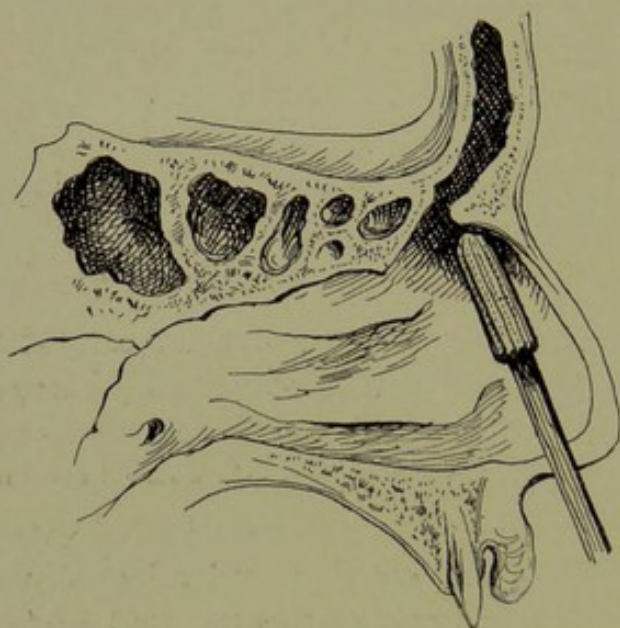


FIG. 148.—Halle's operation. Removing the anterior superior nasal spine with the drill.

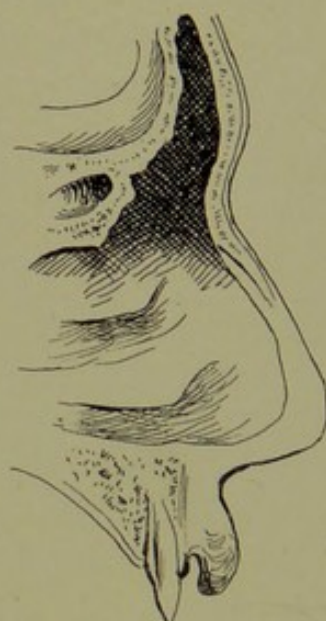

FIG. 149.—Halle's operation completed, showing the large communication between the nose and the frontal sinus.

to practise irrigation on himself, but reports once or twice weekly for this purpose. Nitrate of silver is used to control granulations.

Halle has treated nineteen cases by this method, with eighteen cures. One later required an external radical operation, and even then was not benefited. The entire procedure requires 5 to 15 minutes, and is followed by little or no postoperative shock.

Contra-indications: 1. In those cases in which it is impossible to sound the frontal sinus.

2. When the sinus is inordinately large and contains numerous ramifications.

3. When complications have set in.

GOOD'S INTRANASAL OPERATION.⁴³⁸

The principle of this procedure depends upon the removal of the sinus floor with a rasp after a portion of the frontal process of the superior maxilla has been chiselled away to gain room for its entrance.

Technique: Under local anæsthesia:

1. Removal of middle turbinate.
2. Removal of ethmoidal cells and unciform process.

The ethmoidal cells are removed with Ballenger's knife and the unciniate process with a chisel and biting forceps.

3. A small portion of the frontal process of the superior maxilla is now chiselled away and the anterior medial wall of the ethmoid labyrinth separated from its attachment to the frontal spine.

4. The rasp is introduced and the lateral aspect of the frontal spine gradually filed away, thus enlarging the space between the spine and the orbital wall of the sinus. (Fig. 150.)

The rasp is introduced into the sinus externally to the frontal spine, and by rasping forward and towards the septum the space between the spine and the orbital wall is enlarged. The rasp is so constructed that neither the internal table nor the orbital wall of the sinus can be injured.

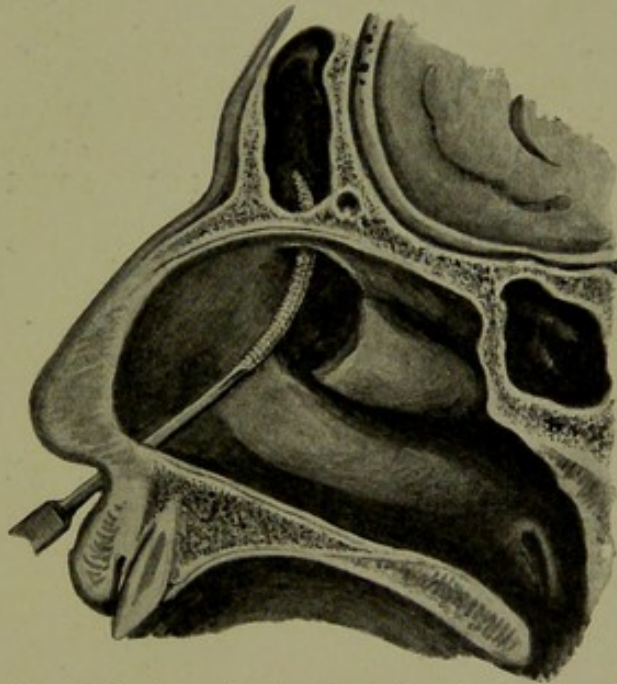


FIG. 150.—Rasp in place for enlarging the frontal ostium.

5. The anterior of the sinus is now curetted, if pathological changes have taken place in the mucosa, after which the cavity is packed with gauze.

After-treatment: The gauze is removed on the following day. In very chronic cases with profuse discharge a gold-plated tube made of coarse wire-cloth is inserted to keep the ostium from closing with granulations. Good states that the operation can be performed under local anæsthesia, but during the rasping it is better to have complete narcosis.

438. Good: An Intranasal Method for Opening the Frontal Sinus, Establishing the Largest Possible Drainage. *Laryngoscope*, p. 266, 1908.

THOMSON'S MODIFICATION OF GOOD'S METHOD.⁴³⁹

This author, instead of chiselling away the bone in front of the probe, introduces a pointed rasp with a groove in the back so that it fits over the probe, and, passing it up as far as possible under reasonable pressure, withdraws it, thus cutting away the bone downward and forward. By repeating this movement, inserting the rasp higher into the duct each time, it is possible to work through into the frontal within a very few minutes and with practically no pain to the patient. As soon as the frontal is opened, different-sized rasps, curettes, or forceps can be used to cut away all of the diseased bone in the anterior ethmoid cells without destroying the mucous membrane on the posterior wall of the nasofrontal duct. No drainage tube is necessary, as the mucosa left in its natural position without impairment to its nutrition will grow over the bone bared by the rasp. Healing thus occurs more quickly.

COMPARATIVE VALUE OF THE INTRANASAL OPERATIONS.

Experience teaches us that the vast majority of cases of frontal sinusitis, both acute and chronic, respond favorably to intranasal measures. The entire subject is dependent upon the condition of sufficient drainage to allow free exit of the inflammatory secretion, thus permitting resolution of the infected mucosa. So long as this drainage is free it is of little moment whether the drainage passages are excessively large or only of sufficient size to permit the escape of all the secretion. Either condition will usually result in a cure.

Experience also has taught us that the high removal of the anterior half of the middle turbinate with curettage of the ethmoid cells in the immediate neighborhood of the nasofrontal passages will in most cases suffice to accomplish the desired result.

The various intranasal operations described above require a skill and proficiency that are only obtainable after the sacrifice of a considerable amount of time and trouble by numerous experimental operations on the cadaver. To our mind, they are only indicated after the ordinary intranasal method has been tried and found wanting; even then there is no guarantee that they will prove efficacious.

439. Thomson: A Safe Intranasal Method of Opening the Frontal Sinus. *Laryngoscope*, p. 810, 1910.

The average of cures by removal of middle turbinate and curettage is about 95 per cent. The other 5 per cent. go on to some form of external radical operation. Certain of this latter 5 per cent. are undoubtedly amenable to the more radical intranasal procedures, but even the authors of these measures state that not all cases are amenable to this treatment. The whole matter then resolves itself into the proposition of drainage. In the 5 per cent. of cases which do not respond to betterment of drainage, pathological changes have occurred within the sinus which demand their removal before resolution will set in. If the sinus is large, with ramifications and partial septa, not to mention the presence of infected orbital ethmoidal cells, any intranasal effort will prove unavailing.

It would, therefore, seem that these methods are only indicated in those cases in which the ordinary, conservative intranasal method had been tried without result, yet were not severe enough to demand an external operation.

INDICATIONS FOR EXTERNAL RADICAL OPERATION.^{440 441}

Let us suppose we had operated by the intranasal route and, although a certain amount of relief was experienced by the patient, nevertheless the disease persisted, how long should we wait before advising an external operation? This question cannot be answered offhand, as every case is almost a law unto itself. Before contemplating any external procedure we should ascertain so far as possible the internal condition of the sinus. The size and shape can be learned by means of the X-ray. Bacteriological examinations must be made to determine the nature of the infection, for should pure cultures be obtained the vaccine treatment by autovaccination is at once indicated.

The temperament, social position, age, and sex of the individual must also, naturally, be considered; as, for example, a woman with chronic frontal sinusitis might easily develop into a confirmed neurotic individual unless measures were taken for the prompt suppression of the symptoms. On the other hand, a patient may experience so much relief from the intranasal opening that he would under no circumstances consider an external

440. Hajek (with discussion): Ueber Indikationen zur Operative Behandlung bei der chronischen Stirnhöhlenentzündungen. *Verh. d. Deutsch. Laryng. Gesell.*, S. 123, 1907.
441. Coakley, Kyle, Loeb: Symposium on Accessory Sinuses. *Trans. A. M. A., Sec. on Laryngology*, p. 193, 1909.

cutting operation in order to be freed from the discharge and occasional pain. In general, the best plan to follow is to wait as long as no urgent symptoms prevail and the patient does not experience too much discomfort from the discharge and occasional headache, as such cases generally slowly improve. The indications for an external operation then may be divided into: relative and absolute.

1. Relative indications: (*a*) when the X-ray shows a large sinus with many ramifications; (*b*) when, despite frequent irrigations, the pus continues fetid; (*c*) when headache continues with no apparent change in the secretion.

2. Absolute indications: (*a*) when the subjective symptoms are severe enough to interfere with the business pursuits of the patient; (*b*) when severe exacerbations occur; (*c*) in abscess and fistula formations; (*d*) in threatened cerebral and orbital complications; (*e*) actual appearance of complications.

Finally, in advising a radical operation we must remember that it is by no means a minor procedure, as many deaths have been reported, and every patient radically operated upon does not always mean every patient radically cured.

EVOLUTION OF THE EXTERNAL OPERATION ON FRONTAL SINUS.

Before the days of rhinoscopy the operation universally practised was simple trephining, followed by external drainage. A refinement in this technique occurred when drainage into the nose was also made by enlarging the nasofrontal passages⁴⁴² through the small opening in the anterior wall. Resection of the entire anterior wall, with an attempt to bring about an obliteration of the sinus, seems to have been in vogue around the year 1882.⁴⁴³ The sinus was thoroughly curetted and allowed to heal by granulation, keeping the external wound open—a long and tedious process. Ogston⁴⁴⁴ appears to have been the first operator to suggest and practise removing the anterior ethmoid cells bordering on the uncinatè process through the break in the anterior frontal sinus wall. Luc⁴⁴⁵ further modified this procedure by introducing a rubber drainage tube, bringing it out through the nose and closing the original wound.

442. Steiner: Arch. f. klin. Chirurg., Bd. 13, S. 144, 1872. 443. Kocher: Empyem und Hydrops der Stirnhöhle. Bern, 1882. 444. Ogston: Trephining the Frontal Sinus, etc. Med. Chronicle, vol. 1, p. 235, 1884. 445. Luc: Leçons sur l' suppuration, etc., p. 291. Paris, 1900.

Kuhnt⁴⁴⁶ went a step farther in removing the entire anterior wall of sinus, curetted thoroughly the mucous membrane, and applied external drainage with the object of obliterating the cavity by granulation.

Technique.—A horizontal incision is made from inner end of eyebrow to outer third of supra-orbital ridge, a perpendicular incision made from internal end of brow reaching above, thus forming an L-shaped wound. The periosteum with overlying soft parts is elevated and the entire anterior sinus wall removed. The cavity is freed from all ridges and partial septa and the mucous membrane thoroughly removed with the curette. A rubber drainage tube is sewed into the sinus at the junction of the two incisions. After-treatment consists of daily irrigation of the cavity with bichloride solution, and, if granulations are not free, with nitrate of silver or chloride of zinc solution.

While Kuhnt brought out two important facts necessary in the healing of a frontal sinusitis, namely, that the partial removal of sinus wall did not reach all diseased hollows, and that very free drainage was indispensable, nevertheless his method has several disadvantages. Chief among these are (a) the length of time the fistula remains open; (b) the postoperative deformity; (c) the complete failure when deep orbital processes are present, and (d) the diseased ethmoid cells are left undisturbed. Coakley⁴⁴⁷ modified this method by packing the frontal sinus and nasofrontal duct so that granulations would spring up and first occlude the narrowest part of the cavity, the bottom of the nasofrontal duct, then the remaining portion of the sinus. This author states the degree of deformity depends upon the size of the sinus. Ropke⁴⁴⁸ further modified the operation by including the exenteration of the anterior ethmoidal cells in widely opening the floor of the frontal sinus. Drainage was made through the nose and the external wound usually closed. The cosmetic result of this operation was somewhat better than that of Kuhnt's, as external drainage was abandoned.

Jansen,¹⁷⁸ leaving the anterior wall intact, resected the inferior wall and exenterated the ethmoid labyrinth through this opening. The cosmetic result was not only not particularly satisfying, but, on account of the spaces left in the cavity from the inability to reach all portions, recurrences were not uncommon. This author later modified the method by making medial and lateral cuts through the anterior wall, breaking it off high up and

446. Kuhnt: Über die entzündliche Erkrankungen d. Stirnhöhlen, etc., S. 207, 1895.
447. Coakley: The Frontal Sinus. Trans. Am. Lary. Assn., p. 226, 1905. 448. Ropke: Die Radikaloperation bei chronischen Eiterungen, etc. Arch. f. Laryng., Bd. 8, 1898.

applying the bone-flap, together with the soft parts, to the posterior sinus wall. Healing was reported to occur in six weeks to six months.⁴⁴⁹

Riedel⁴⁵⁰ removed not only the anterior but the inferior wall as well, thereby performing the most radical operation, from a surgical point of view, possible on the frontal sinus. As the soft parts of the forehead closed the cavity by coming into apposition with the cerebral wall, the entire sinus was thus obliterated. The operation, however, has one unsurmountable disadvantage—that of subsequent deformity, which can reach such proportions as to be hideously repulsive.⁴⁵¹

Hartmann⁴⁵² removed not only the anterior wall of the sinus, but speaks of making an opening in the orbital wall through the ascending process of the superior maxilla. In this manner a partial bridge must have been made.

Taptas,⁴⁵³ of Constantinople, appears to have been the first one to suggest the advisability of making a bridge of bone across the supra-orbital ridge for the purpose of preventing the depression and deformity following the operation. Whether he had actually performed this operation on the living is not recorded.

Killian,⁴⁵⁴⁻⁴⁵⁶ however, was the first operator to develop and popularize this operation, which now bears his name. The purpose of the operation is to obliterate the sinus by allowing the peri-orbital tissues to ascend from below and to apply the skin and subcutaneous tissue originally in front to the posterior wall. In this manner one avoids a distinct disfiguration and at the same time is permitted to exenterate the ethmoid and sphenoid cells without danger of penetrating the cranial cavity.

Technique: After all polyps and hypertrophies dependent upon the sinus suppuration have been removed from the nose and the size of the sinus ascertained by skiagraphy, anæsthesia is induced by chloroform.

The nasal cavity of the affected side is plugged with four cotton tampons, about the size of a cigar, attached to threads.

449. Jansen: Neue Erfahrungen über chronische Nebenhöhlenerkrankungen der Nase. Arch. f. Ohrenhk., Bd. 56, S. 110, 1902. 450. Riedel: Schenke Inaugural Dissertation. Jena, 1898. 451. Winckler: Beitrag zur osteoplastischen Freilegung des sinus Frontalis. Verh. deutsch Otol. Gesellsch., S. 128, 1904. 452. Hartmann: Atlas der Anatomie der Stirnhöhle, S. 25, 1900. 453. Taptas: Trans. Internatl. Med. Congress, Sec. on Larynx, 1900. 454. Killian and Krauss: Die Killiansche Operation chronischer Stirnhöhlenerkrankungen. Arch. f. Lary., Bd. 13, S. 28, 1902. 455. Killian: Bemerkungen zur Radicaloperation, etc. Verh. d. Vereins süddeut. Lary., S. 21, 1904. 456. For complete description in English, see Foster: Killian's Frontal Sinus Operation. Detroit Med. Journ., Oct.-Nov., 1907.

The first one is placed on the nasal floor, the second in the middle nasal fossa, the third in the olfactory fissure, while the fourth is packed firmly along the internal bridge of the nose between the ascending process of the maxillary bone and the septum. This tampon supports the mucosa and pus, preventing injury during the resection of the bone. After the usual cleaning, the head being steadied, an incision, beginning at the temporal end of the eyebrow, is made inward through its middle to the nasal end, where it passes downward in a graceful curve along the side of the nose to the base of the nasal bone. (Fig. 151.) A gauze pad covers

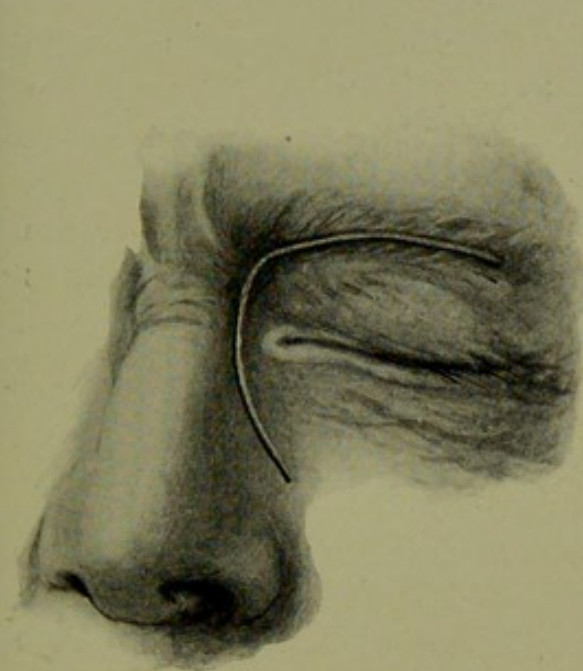

FIG. 151.—Line and extent of incision in the Killian operation on the frontal sinus.

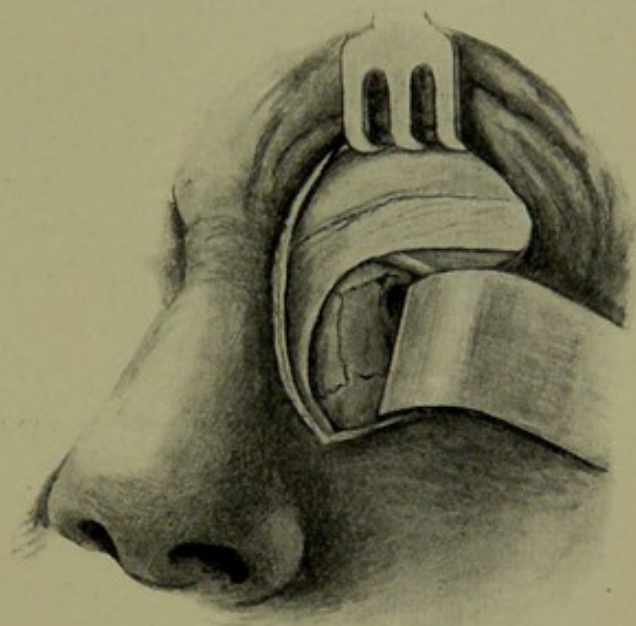

FIG. 152.—Two periosteal incisions. 1st, above the superior orbital rim with periosteum in place on the ridge. 2d, along internal orbital rim with periosteum retracted, thus exposing the lachrymal bone, lamina papyracea, and attachment of trochlea.

the eye. Several cross incisions are made in order to be able to approximate the wound accurately.

Hemorrhage is arrested by hæmostats, which are allowed to remain in place. Edges of wound retracted. The first periosteal incision at temporal end of original incision 6–8 mm. above and parallel to the supra-orbital margin. The second slightly internal to supra-orbital notch, extending downward through the centre of the ascending process of the superior maxillary. (Fig. 152.) The periosteum covering the frontal sinus above the bridge is elevated and retracted. A groove is made in the bone with hammer and V-shaped chisel (Fig. 153), following the curve of the orbital margin until the sinus is penetrated. The lower surface

of this groove forms the upper edge of the supra-orbital bridge.

All of the anterior wall lying above the bridge is removed with bone forceps or chisel and mallet. After complete removal of the anterior wall, the mucous membrane, together with partial septa, is thoroughly curetted, especial care being given to all recesses and hollows; the bridge is smoothed off and the sinus loosely packed with gauze. The resection of the ascending process of the maxillary bone is now undertaken, first elevating the periosteum from the frontal process, lachrymal fossa and orbital portion of frontal bone almost to supra-orbital notch.

A groove is cut through the suture formed by the nasal bone and frontal process in an upward direction by means of the curved V-shaped chisel. Another groove is made through the frontal process at right angles to the preceding, care being taken not to injure the lachrymal sac or the underlying nasal mucosa. (Fig. 154.) When necessary, a third groove is made through the nasofrontal suture, forming the lower edge of the bridge. This is




FIG. 153.—Killian's V-shaped chisel.

important, as otherwise the bridge could easily be destroyed in prying out the resected portion of the ascending maxillary process.

A small opening is made at the junction of these grooves and the bone removed piecemeal so as not to lacerate the nasal mucosa, which is to form the flap leading into the frontal sinus. The extent of bone removed is governed by the size of the sinus, as it should extend well into the floor. The limits for the resection and elevation are: Below, lower part of lachrymal groove; behind, anterior ethmoidal vessels; above, trochlear attachment, supra-orbital notch. After the orbital tissues are retracted the ethmoid cells may be exenterated to the anterior wall of sphenoid.

Reflected light will be necessary for this purpose. The resection of the nasal mucosa beneath the resected frontal process, turning it into the sinus, completes the operation. (Fig. 155.) The wound is flushed out with normal salt solution, iodoform insufflated, and the edges are approximated with aluminum-bronze sutures. A gauze strip in the nose which extends upward holds

the flap of mucosa in position. This strip is removed on the second day and the sutures on the fifth.

This operation was immediately taken up by international operators with invariably good results, both from a curative and a cosmetic standpoint.⁴⁵⁷⁻⁴⁶⁰ It was, however, subject to one great drawback—that of the difficulty in technique (resecting maxillary process without injuring mucosa and holding the trochlea in position, yet reaching the outermost recesses of the sinus). The time consumed (1½ to 3 hours) in performing was also an important factor. Subsequent experience,⁴⁶¹⁻⁴⁶³ curiously enough, has taught us that the very eventualities which Killian so studiously

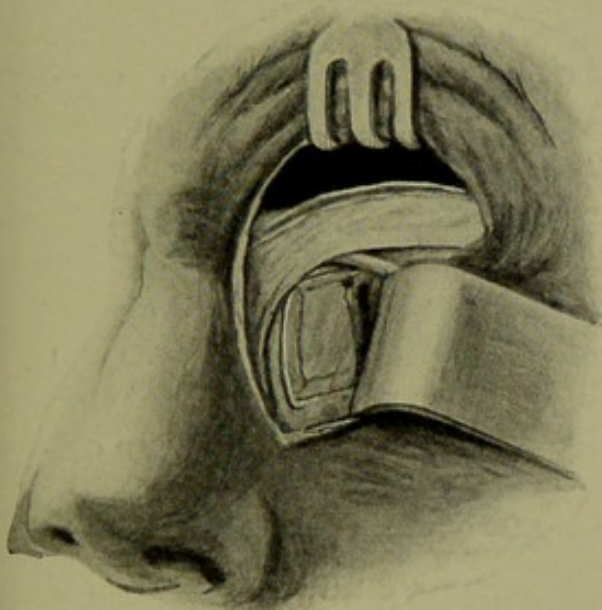


FIG. 154.—Illustrating the grooves made in the ascending process of the superior maxillary and below lacrimal bone in order to resect this portion.

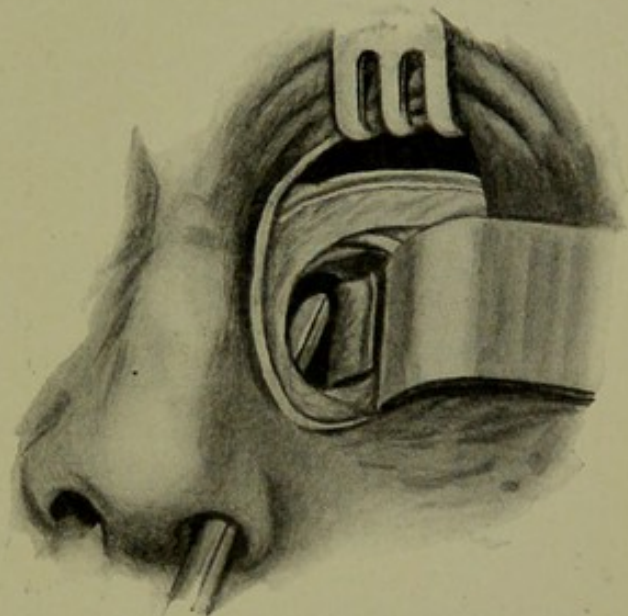


FIG. 155.—Killian operation completed by turning flap of nasal mucosa outward. Forceps in nares shows the wide communication between the nose and the frontal sinus.

endeavored to avoid did not occur, though, intentionally or otherwise, his technique was utterly disregarded. Thus it was found that the trochlea could be loosened from its position and retracted with impunity without the slightest fear of permanent diplopia.⁴⁶⁴ It was also noted that the careful resection of the ascending max-

457. Von Eicken: Unsere Erfahrungen mit der Killianschen Stirnhöhlenoperation. Verh. d. 1st Internat. Lary. Congress, Wien, S. 322, 1908. 458. F. L. Jack: Report of Four Cases Showing Result of Killian's Operation. Journ. Am. Med. Assn., July 21, 1906. 459. Logan Turner: The Operative Treatment of Chronic Suppuration in the Frontal Sinus. Edinburgh. Med. Journ., March, p. 239, 1905. 460. Luc (231), p. 333. 461. Hajek: Lehrbuch, S. 224, 1909. 462. Mader: Beitrag. zur Killiansche Radicaloperation, etc. Arch. f. Lary., Bd. 20, S. 56, 1907. 463. Reichel: Bericht über 60 nach Killian's Methode ausgef. Stirnhöhlenep. Ver. deutsch Otol. Gesellsch., S. 115, 1907. 464. Eshweiler: On the Radical Operation for Chronic Empyema of the Frontal Sinus according to Killian. Arch. f. Otology, Oct., 1904.

illary process to conserve the mucous flap was entirely superfluous, as the cases did quite as well when the flap was either destroyed or lacking as when carefully packed in place. The omission of these steps very materially reduced the time of the procedure, and, together with other minor changes, the operation generally in use at the present time might well be termed the radical or modified Killian operation.

KNAPP'S OPERATION.⁴⁶⁵—The technique of this procedure differs somewhat from that of Killian, in the line of primary incision, as well as the extent of resection of the anterior wall. The intent is to procure better cosmetic results so far as the depression is concerned.

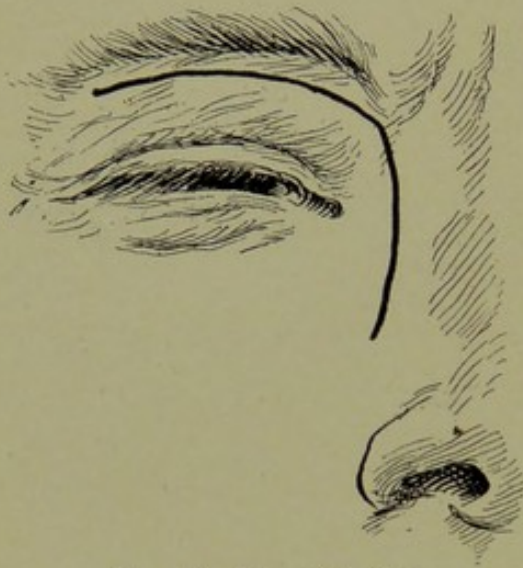


FIG. 156.—Knapp's incision.

Technique: An external incision is made along the upper orbital border midway between the eyebrow and the bony margin of the orbit, extending down along the inner wall and the side of the nose to the floor of the orbit. (Fig. 156.) The periosteum is incised at the orbital margin and with a sharp elevator retracted toward the orbit, gently detaching and pushing aside the soft parts and the lachrymal

sac, thus exposing the internal wall and roof of the orbit. The pulley of the superior oblique is slowly detached from the trochlear fossa, care being taken not to disturb the relation between the tendonous ring and the periosteum to which it is adherent, so that during the process of healing it will assume its normal position. The floor of the frontal sinus is now removed and the diseased mucosa curetted. The nasal process of the superior maxilla, the lachrymal bone and a portion of the orbital plate of ethmoid are resected in order to gain access to the ethmoidal labyrinth and middle meatus. The removal of the ethmoidal cells is now accomplished with suitable forceps.

If the frontal sinus extends unusually high up, a window is cut in the anterior bony wall, leaving a broad supra-orbital margin of bone covered with periosteum. This should be only of sufficient

465. Knapp: The Surgical Treatment of Orbital Complications in Diseases of the Nasal Accessory Sinuses. *Journ. Am. Med. Association*, July 25, 1908.

size to allow proper treatment of the superior margins of the sinus, thus avoiding subsequent deformity. Suture of the cutaneous wound is not practised, and external drainage is made by a gauze strip into the sinus at the internal angle of the wound. The ethmoidal region is lightly packed through the nose.

RADICAL OR MODIFIED KILLIAN OPERATION.—Technique: Preliminary steps before anæsthetization:

Bind up hair securely with sterile towel. Wash out nasal cavity thoroughly with warm normal salt solution. Cleanse forehead, eyebrows and lids with bichloride of mercury 1-5000, followed by alcohol, and cover with wet compress of alcohol and water. Give hypodermic of morphia sulph. gr. $\frac{1}{8}$, atropina gr. $\frac{1}{150}$. Shave eyebrow.

The question of shaving the eyebrow on the side to be operated upon depends upon the operator. It seems, however, to be the general experience that when the eyebrow is shaven it is by no means certain whether it will again grow in or whether it will come in so heavy as to be out of all proportion to its fellow. Under these circumstances, it is better to thoroughly disinfect and leave *in situ*.

Anæsthesia with ether. Pack nose with long strip of sterile gauze, seeing that the end is introduced well within the choana to absorb the blood from anterior sphenoidal wall.

Killian⁴⁶⁶ uses four tampons about the size of small cigars, which are introduced, first between inferior turbinate and septum, the second high into middle nasal passage, the third into the olfactory fissure and the fourth along the anterior angle of the nose. These are fastened to threads which hang out of the nose. This is not necessary to use all these tampons, as one long strip of gauze, inserted posteriorly, completely closing the nares will answer the purpose quite as well.

Make curved incision through the eyebrow around side of nose ending at a point on the middle of the ascending process of superior maxilla opposite the inferior portion of the lachrymal bone. On the right side the incision should be started at the eyebrow and carried downward and on the left side from the cheek upward. (Fig. 157.) This incision is carried down to, but not through, the periosteum. A half dozen or more hæmostats must be in readiness, as the bleeding will be profuse. Nothing further should be attempted until the hemorrhage is completely controlled, a procedure which will require a delay of one or two minutes. No ligatures are to be used, as they may later superinduce secondary infection. The eye is covered with a pad of gauze, to prevent undue pressure from the hæmostats.

466. Killian (455), S. 24.

The overlying soft parts are now dissected away from the periosteum both above and below the attachment of the lachrymal bone with the ascending process of the superior maxilla. The periosteum is now incised along the orbital edge and elevated for a space of one or two centimetres. (Fig. 158.)

A small, half-round chisel is used to open the frontal sinus, there being two points of predilection.

1. Below the supra-orbital ridge immediately above the lachrymal bone, and 2. Above the supra-orbital ridge immediately above the frontal insertion of the superior maxillary.

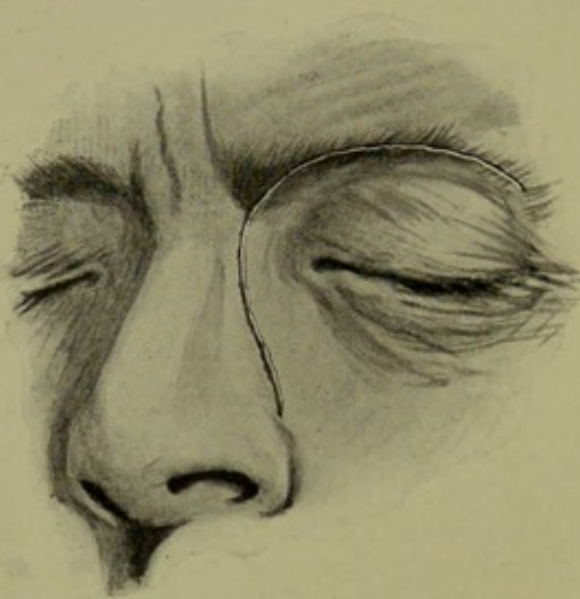

FIG. 157.—1st step. Skin incision for the modified Killian operation on the frontal sinus.

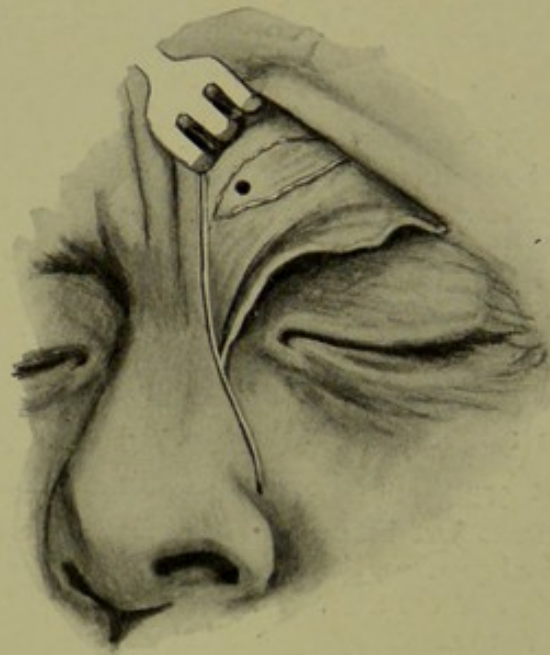

FIG. 158.—2d step. Incision in the periosteum above the supra-orbital rim showing point of election for entering the sinus.

Both positions are practically certain to strike the sinus, but the second is easier and should perhaps be preferred, especially when one has ascertained the exact size of the cavity by means of an X-ray photograph,—a preliminary procedure which should always be applied. After the chisel has penetrated into the sinus, a bent probe is introduced and carried in all directions so that its various dimensions may be ascertained. The periosteum is now incised about a half inch above the superior edge of the orbital ring and carried outward slightly further than the external confines of the sinus and inward and downward the length of the original external incision, but sufficiently internal to allow the formation of the bony ridge. (Fig. 159.)

This periosteal incision is somewhat important, as one must allow for a certain amount of laceration during the course of the operation, therefore it is better to allow too much in the first place. The redundancy can be used to cover the superior surface of the bony ridge, thus further insuring good blood supply to this structure.

Again using the elevator, the periosteum is raised in all directions slightly beyond the sinus borders, leaving untouched that portion which covers the part of the wall which will ultimately form the supra-orbital bone bridge except to loosen it slightly at

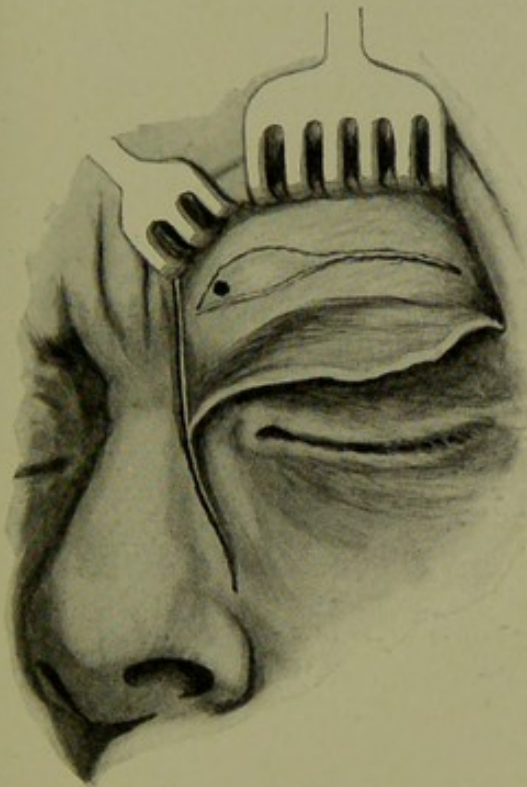

FIG. 159.—3d step. Upper periosteal incision.

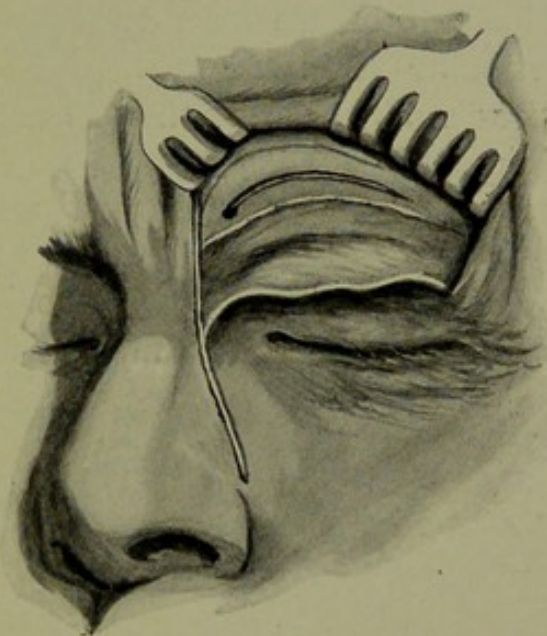

FIG. 160.—4th step. Periosteum elevated above and groove made in bone for the superior edge of the bony bridge.

the superior edge in order to avoid wounding when the preliminary groove for the ridge is made. The soft parts, including periosteum, being retracted and held by an assistant, the curved chisel is now used to make a furrow along the line which will form the superior border of the bridge. This is accomplished by placing the point of the instrument at the external limit of the sinus about one-half inch above the orbital rim, and, by carefully tapping with the hammer, cutting a shallow furrow reaching down to the superior articulation of the nasal bone, always following and keeping a like distance from the curve of the orbital rim. (Fig. 160.)

It is well in the beginning to preserve more bone than will actually be needed for the bridge, as the infra-orbital notch may encroach considerably on the superior cut, making that portion exceedingly weak and liable to fracture on application of the slightest force. If an insufficient amount of osseous structure is left the bridge will be liable to any future traumatism, while if one finds that too much bone remains, it can easily be reduced at the conclusion of the operation. The width of the completed bridge should be at least 5 mm.

This furrow is gradually enlarged until a long slit is made into the sinus. The entire anterior wall above this cut is now removed




FIG. 161.—Alexander's hollow chisel.

piecemeal with larger chisels (Fig. 161), rongeurs (Fig. 162), or other suitable instruments until the sinus is completely bared, particular attention being paid to open all ramifications in their fullest extent, as, when a residue occurs, these are the points of origin. (Fig. 163.)

The diseased portion of the sinus mucosa is now removed with the curette, care being taken to minutely inspect the underlying bone for any traces of necrosis. After controlling hemorrhage the inferior wall is removed in the following manner: The per-

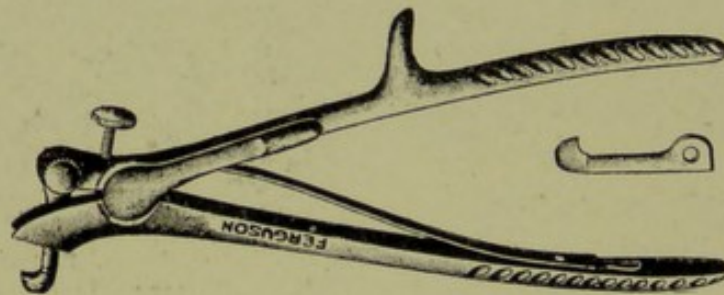


FIG. 162.—Bone cutting forceps for removing the anterior wall of the frontal sinus.

osteum is incised at the internal angular edge of the orbital ridge, the cut being carried downward to the lower part of the attachment of the lachrymal bone with the ascending process of the superior maxillary. (Fig. 164.) An elevator is then introduced and the periosteum, together with the attachment of the superior oblique and trochlear nerve, is raised and pushed over the orbital fat. Below, the lachrymal duct is raised from its fossa with the periosteum lying over the anterior third of the lamina papyracea. The internal and superior part of the orbital socket is thus laid bare at least in its anterior portion. (Fig. 165.) Considerable hemorrhage often follows this procedure, as the ethmoidal vessels

are usually injured. Packings of iodoform gauze, which are allowed to remain some moments in place, will control the bleeding. After this has been accomplished the sharp angle chisel is

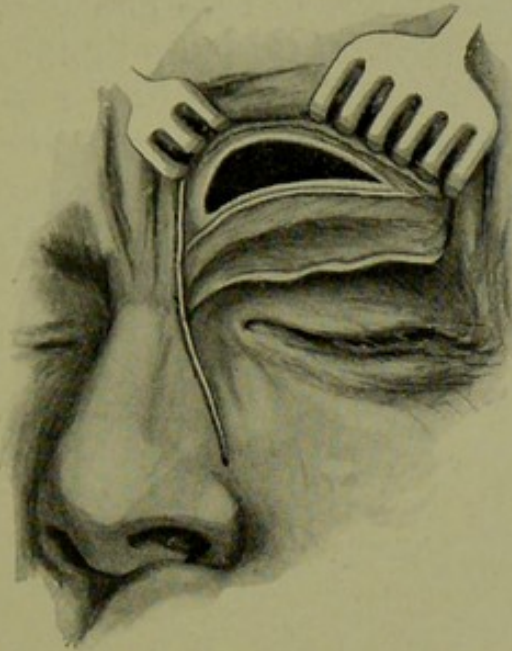

FIG. 163.—5th step. The entire anterior wall of the sinus removed.

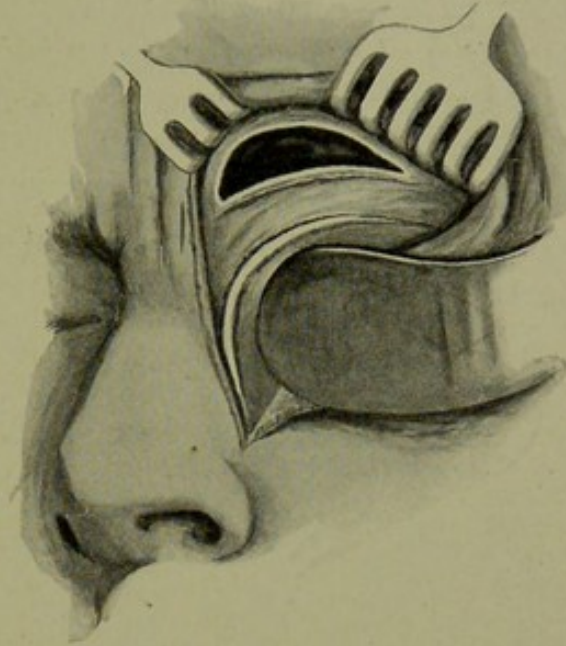


FIG. 164.—6th step. Lower periosteal incision extending along the supra-orbital rim.

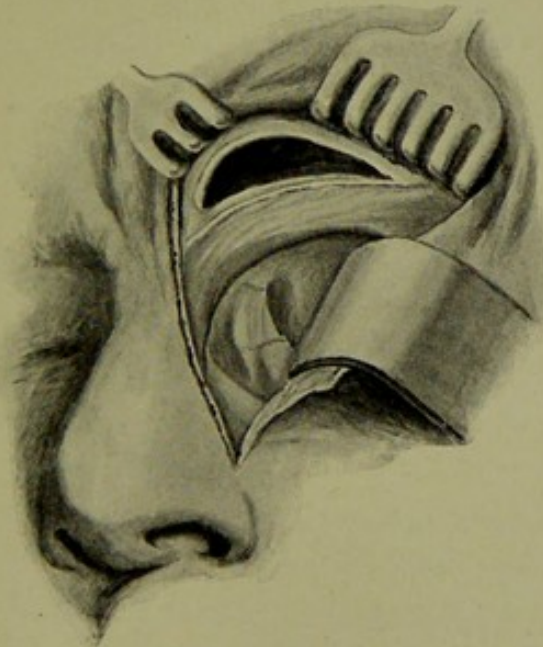


FIG. 165.—7th step. The soft tissues elevated, exposing the floor of the sinus, ascending process of superior maxillary, lachrymal bone, and lamina papyracea.

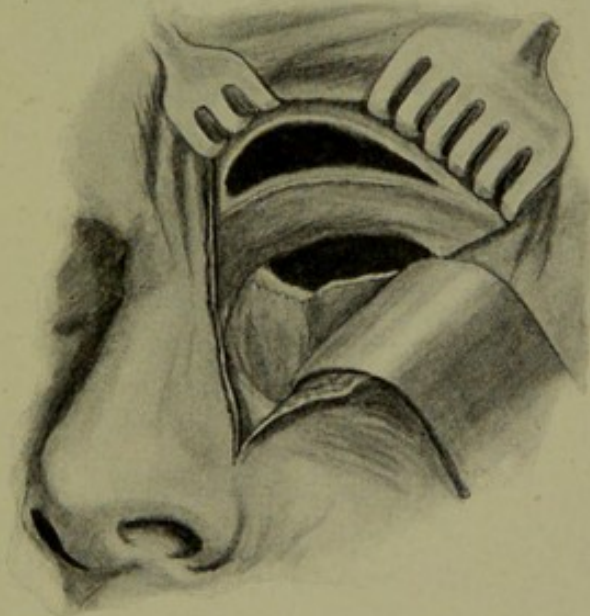

FIG. 166.—8th step. The entire floor of the sinus removed.

placed at the superior internal angle of the sinus floor, and an opening made sufficiently large to permit the introduction of a pair of bone forceps (Jansen's model). The floor is carefully

removed, using a straight chisel when nearing the osseous bridge in order to incur no danger of breaking it, until the cavity is absolutely without an inferior wall. (Fig. 166.)

It is now necessary to remove a portion of the ascending maxillary process in order to reach the infundibular cells and have free access to the bulla and middle turbinate. After elevating the periosteum, taking care not to denude the bridge, two horizontal furrows are made in the ascending process opposite and anterior to the lachrymal bone. (Fig. 167.) A large concave chisel is now taken and the bone removed between the furrows, thus laying bare the anterior ethmoidal structures.

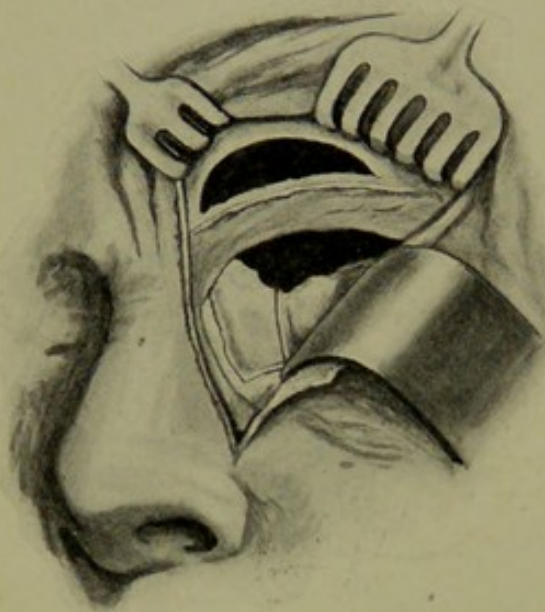

FIG. 167.—9th step. Rectangular groove cut in the ascending process of superior maxillary.

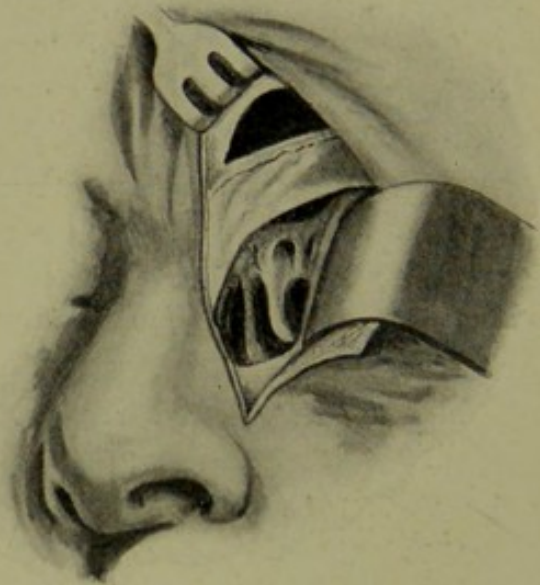


FIG. 168.—10th step. Bony flap resected together with anterior (infundibular) ethmoid cells, exposing the middle turbinate and bulla.

It is not necessary to preserve the underlying nasal mucosa in order to make the flap as formerly advocated by Killian, as results have proved to be quite as good when this plastic formation was omitted.

The superior portion of the lachrymal bone is now removed with the forceps, and the bulla and entire anterior ethmoidal labyrinth exenterated back to the lamella of the middle turbinate.

If the posterior ethmoid cells and sphenoid sinus be diseased it is a simple matter to continue removing the ethmoid cells until the anterior wall of sphenoid is reached. To open this sinus it will only be necessary to remove its wall.

At this point it may be necessary to enlarge the opening anteriorly in order to procure sufficient drainage from the frontal. For this purpose the anterior superior nasal spine may be re-

moved with the bayonet chisel. (Fig. 168.) The gauze packing is removed from the nose and a pair of forceps introduced in the direction of the frontal sinus in order to ascertain whether the communication is sufficiently extensive. Such being the case, the entire wound is thoroughly flushed out with sterile saline solution, a strip of seamed iodoform gauze introduced into the sinus through the nose (Fig. 169*a*), and the external wound closed with silkworm-gut sutures, except at a small portion corresponding to

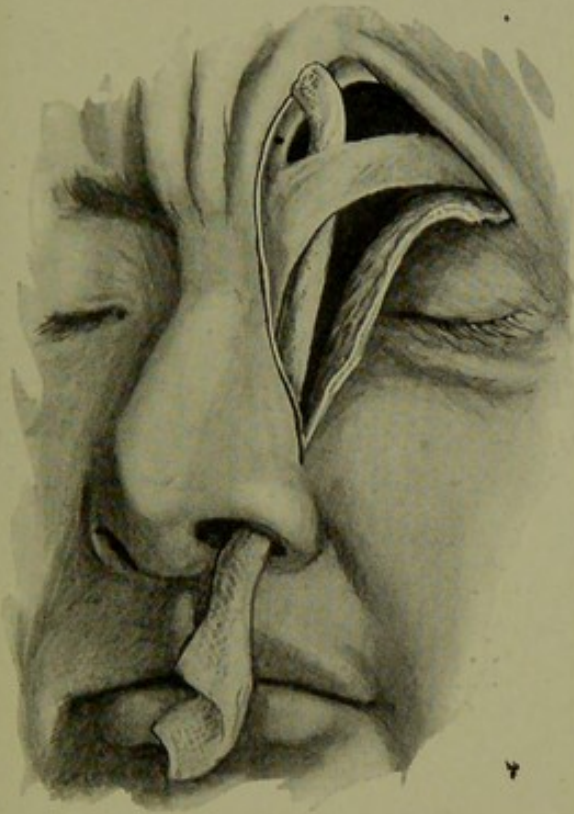

FIG. 169*a*.—11th step. Seamed iodoform gauze carried through the nose into the sinus.

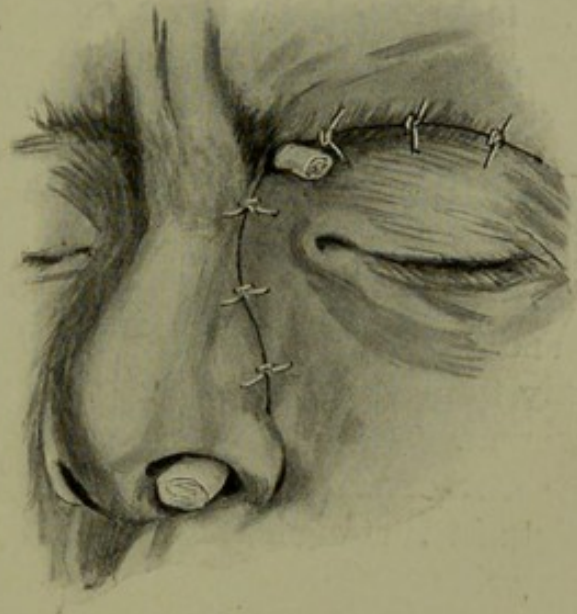

FIG. 169*b*.—12th step. A gauze drain is placed in the internal angle of the incision and the wound closed with silkworm-gut sutures, thus completing the operation.

the internal angle of the eye, in which a small drain is placed. (Fig. 169*b*.)

Primary closure of the entire wound should only be made when the sinus is very small. Under ordinary circumstances a small drainage is allowed to remain in place for two days. If the sinus extends considerably toward the temporal bone, a drain should be placed at the external end of the wound. The presence of acute inflammatory processes, meningeal or ophthalmic complications demand that the wound remain open and secondary sutures only applied after these symptoms have entirely disappeared. Under the latter circumstances daily dressings of humid bichloride gauze should be applied.

The face is dried and iodoform dusted on the wound. Rolled gauze compresses are placed above the bony bridge and inter-

nally along the eye, several thicknesses of loose gauze over these and a firm bandage embracing the eye on the opposite side being applied.

Killian applies moist boric acid gauze dressings.

After-treatment:⁴⁶⁷ The patient should lie on the sound side and not be permitted to blow the nose, as it might prevent the walls from adhering and cause a permanent pneumocele of the frontal sinus. Secretion which forms in the nose must be drawn into the choana and expectorated. The drain through the nose into the sinus may be removed after twenty-four hours or forty-eight hours.

Unless untoward symptoms develop (fever over 100°, severe headache, etc.), the dressing should not be changed until the third day, when it is necessary to remove gauze under antiseptic precautions, sponge wound with bichloride 1-5000 and remove drain from internal angle of wound. A few drops of thin pus can usually be pressed out, after which the opening is gently irrigated so as not to force apart the anterior wall, and a new iodoform drain reintroduced. This is continued every second day until healing is thoroughly established. The stitches can be removed any time after the fourth day, according to the appearance of the wound.

OSTEOPLASTIC RESECTION.^{468 469}—This form of operation consists in turning back a flap of bone with the soft parts from the anterior wall of the frontal sinus, curetting the interior, enlarging the nasofrontal duct, closing the wound by bringing the flap again in apposition.

For cosmetic purposes this method is unexcelled, but is very unreliable on account of the many recurrences of the disease after its application, due to the dead spaces within the sinus. It is only indicated when the sinus is perfectly formed without projections, where the anterior wall may be completely turned back. Involvement of the osseous walls as well as the presence of cerebral or orbital complications are strong contra-indications.

Technique: An incision is made from the inner to the outer end of the eyebrow along its inferior border to obviate any deformity from an irregular position of the brow in the scar formation. The

467. Luc: Treatment after Radical Operation for Chronic Suppurative Frontal Antritis. *Ann. Otol., Rhin. and Lary.*, Dec., p. 963, 1906. 468. Winckler (451). 469. Hoffman: Osteoplastic Operations on the Frontal Sinuses for Chronic Suppuration. *Ann. O., R. and L.*, p. 598, 1904.

incision is carried through the soft parts and periosteum at least 0.5 cm. from the orbital border. A perpendicular incision beginning at the nasal end of the previous cut is now made, reaching above to the superior limits of the sinus (the extent of the cavity must have been ascertained by an X-ray photograph). This incision should not extend straight upwards, but conform to the position of the intersinus septum and lie slightly outside the sinus boundary, where the bone will be chiselled, thus preventing depression of the scar. The periosteum is elevated away from the sinus, *i.e.*, downward over the supra-orbital ridges and medialward, thus avoiding any interference with the soft parts immediately overlying the anterior sinus wall. A small opening is now made at the deepest portion of the anterior sinus wall by means of a small concave chisel. After the limits of the sinus have been verified by the sound the bone is chiselled through in a horizontal and vertical direction, keeping as close as possible to the sinus borders. A stout elevator is forced into the sinus through the original opening, and the flap pried strongly upward until it fractures at its base. (Fig. 170.) If this does not readily occur owing to the thickness of the bone, some of the basal edges may be removed. The flap of bone and soft tissues is now turned back and the interior of the sinus curetted of all diseased tissue, including ridges and partial septa. The nasofrontal duct being scraped is enlarged by removing the anterior superior nasal spine by means of a chisel. A large drainage tube is introduced which is allowed to remain *in situ* from six to twelve weeks. It is held in position by a suture through the skin. The flap is brought into position and the wound closed by primary sutures, the bandage being allowed to remain undisturbed for a week to ten days, unless untoward symptoms supervene. No after-treatment is required, except to keep the nasal end of the tube free from crusts. Irrigation in any form is not used.

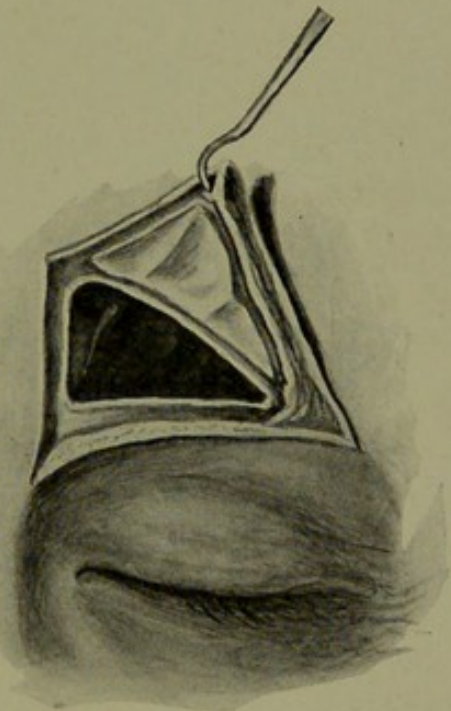


FIG. 170.—Osteoplastic resection of the anterior wall of the frontal sinus. (After Hajek.)

In order that this operation succeed, the following conditions are imperative:

1. The bone-flap must rest everywhere on the surrounding bone.
2. All recesses and granular tissue in the sinus must have been obliterated.
3. The flap must be well supplied with periosteum.
4. A wide connection between the nose and sinus must be established.

BECK'S METHOD OF OSTEOPLASTIC RESECTION.⁴⁷⁰—The exact size of the sinus is ascertained by means of the radiogram and traced on a celluloid film. At the time of the operation this is used as a model and both sinuses opened by sawing off their anterior walls with a Gigli saw. The flap is sawn through at the base and turned downward. Removal of the diseased mucosa, enlarging the natural opening into the nose with the introduction of a large trephine and final replacement of the osseous flap completes the operation.

1. An incision is made through both eyebrows, which is carried across the bridge of the nose at a point lower down.

2. The skin and subcutaneous tissue are now dissected upwards until the upper limits of the frontal sinuses are reached.

3. The celluloid tracing is placed over the sinuses and the periosteum incised around the upper and lateral margins, but not below over the supra-orbital borders or base.

4. The external table of the sinus is penetrated along the entire course of the periosteal incision by means of a flat chisel.

5. The flap is slightly pried open and a Gigli saw drawn from within outward so as to sever the bone but not the periosteum. The skin flap is reflected upward and the periosteal bone flap downward, thus exposing both frontal sinuses (Fig. 171).

6. The diseased mucosa is thoroughly eradicated and the natural opening into the nose enlarged with trephine or rasp. The infundibular cells are also exterminated.

7. A rubber tube containing a wick is passed through into the nose and one end of the wicking loosely folded within the cavity of the sinus, the other end protrudes into the nose.

8. Replace osteoplastic flap, bring down skin flap, and suture with silkworm gut. The gauze is removed in the next day, and on the third to fifth days the rubber tube is replaced by one of silver or gold. The use of douches is to be avoided.

WATSON WILLIAMS OSTEOPLASTIC METHOD.⁴⁷¹—An incision is made through the eyebrow to the root of the nose, then downwards along the side of the nose, just outside the median line. The soft tissues with the periosteum are elevated over the anterior wall of the sinus, and the bone removed to within 3 or 4 mm. of the

470. Beck: A New Method of External Frontal Sinus Operation without Deformity. Journ. Am. Med. Assoc., Aug. 8, 1908. 471. Williams: Discus. to V. Eichen. Trans. 1st Int. Laryng.-Rhinol. Congress, Vienna, p. 333, 1908.

floor. A second incision, about three-quarters of an inch in length, is now made along the inferior and internal margin of the orbit, exposing the lachrymal groove. The lachrymal duct is elevated and retracted, and by means of a chisel, entrance is made into the nose. A fine saw is passed into the nose and divides the nasal process of superior maxillary through this opening. A second saw-cut is now made from the frontal sinus to the lachrymal fossa from behind forwards so as to leave the soft tissues intact. The saw is now placed at the inner portion of the frontal sinus and the bone divided along the bridge of the nose until the nasal bones are cut through. The osteoplastic flap is now turned out, allowing free access to the frontonasal passage. The anterior ethmoid cells can now be removed, and, if necessary, the sphenoid sinus penetrated. The mucosa of the frontal sinus is curetted, ridges removed, and the flap replaced and sutured.

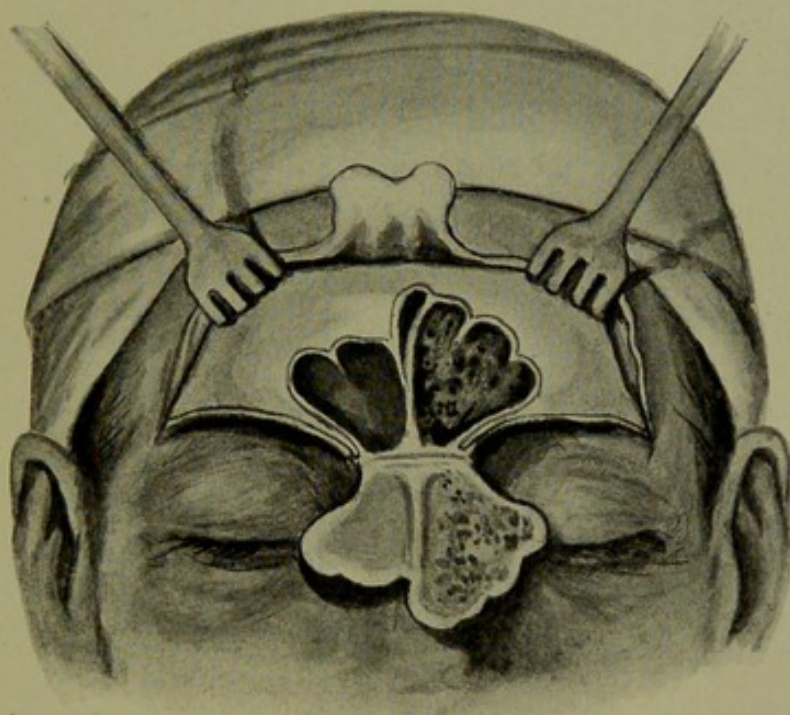


FIG. 171.—Beck's method of osteoplastic resection of the frontal sinus. The skin and underlying tissues have been retracted upwards. The bone flap resected and luxated downwards, exposing the diseased sinus on the left. The right frontal sinus is healthy.

CITELLI'S METHOD.⁴⁷²—This is really a modification of Coakley's open method⁴⁷³ and consists in removal of the anterior wall of the sinus, with thorough curettage of the mucosa, followed by secondary obliteration by means of Mosetig's paste mixture.

The entire anterior wall of the frontal sinus is removed so that all recesses and hollows, together with the anterior ethmoidal cells, can be reached. The sinus and nasofrontal duct are curetted and thoroughly disinfected. The cavity is allowed to remain open, and is daily irrigated with 1/3000 formalin solution and cauterized, especially in the neighborhood of the nasofrontal duct, with chloride of zinc. The cavity is then packed with iodoform gauze. This treatment is continued for two to four weeks until the communication between the nose and frontal sinus is completely occluded with connective tissue and the walls of the sinus are covered with extensive healthy granulations.

472. Citelli: Ueber meine methode, etc. *Zeit. f. Lary.*, Bd. 2, S. 339, 1910. 473. Coakley (360), p. 457.

When these granulations have formed the sinus is thoroughly disinfected with the formalin solution, followed by peroxide of hydrogen. The walls are now dried with sterile gauze and cotton, and finally with very hot air from a specially constructed apparatus.

Sterilized Mosetig's mixture (sesame oil and spermaceti, of each 40, iodoform 60) is slowly poured into the sinus until full, and the wound closed with stitches.

According to Citelli, this method is particularly to be recommended in small sinuses and in young people, and is preferable to Coakley's, as the duration of healing is greatly shortened. Little or no deformity remains, as the infused material is quickly replaced by newly formed connective tissue.

COMPARISON OF METHODS.⁴⁷⁴

The simple trephination through the anterior wall is seldom practised for a curative procedure, but under certain conditions may be of great value, especially when an extensive operation is not advisable. Perhaps the strongest indication for a small external opening is in symptoms of retention during an acute attack, when all intranasal attempts at drainage have failed. Cure in these cases follows almost immediately. For purposes of diagnosis in chronic conditions trephination is also of value; and, indeed, it is always the first step in any radical procedure on the frontal sinus.

THE OGSTON-LUC OPERATION.—During the later 80's and early 90's probably no operation was more generally accepted and performed on the frontal sinus than this one. The results, however, were far from ideal either in a curative or cosmetic sense.⁴⁷⁵⁻⁴⁷⁷ The reason for these failures lay in the fact that all portions of the sinus could not be reached by the operation, and on this account the procedure has been superseded by the newer methods.⁴⁷⁸ The dangers of this operation are also not inconsiderable, as Boenninghaus⁴⁷⁹ has collected fifteen deaths from intracranial complications which were the direct result of this procedure.

KUHNT'S METHOD FOR OBLITERATING THE SINUS.—The results obtained from a curative viewpoint by this method were excellent,⁴⁸⁰ the great drawback, however, was the deformity and the

474. Cobb: Empyema of the Frontal Sinus. (Comparison of Methods.) Boston Med. and Surg. Journal, Aug. 24, 1905. 475. Lermoyez: 17 cases—9 cured—8 relapsed. *Indicat. et Resultat du Traitement des sin. max. et frontales.* Ann. des Mal., etc., Nov., p. 436, 1902. 476. Lack: 11 cases—11 relapses. Treatment of Chronic Suppuration in the Frontal Sinus. Edinburgh Med. Journ., vol. 11, p. 542, 1902. 477. Turner: 10 cases—6 cured—4 relapsed. The Operative Treatment of Chronic Suppuration of the Frontal Sinus. Trans. Am. Med. Assn., Sec. on Lary., p. 303, 1904. 478. Mermod (Arch. Inter. de Lary., vol. 20, p. 51, 1905), however, gives the astonishing number of 165 cured in 165 cases. 479. Boenninghaus: Handbuch der speciellen chirurgie des ohres, etc. Katz, Preysing and Blumenfeld, Bd. 3, S. 171, 1911. 480. Boenninghaus (479), S. 177, collected 101 cases from various operators, with 90 cures.

length of time of post-operative treatment required for healing. Jansen's method of resecting only the inferior wall proved a failure from every point of view, even the author finally admitting its limitations. Ritter⁴⁸¹ practised a modification of this method by resecting also the frontal process of the superior maxillary, and in large sinuses placing a counteropening in the anterior wall. The cosmetic results have been uniformly excellent, and the mortality one death from meningitis in twelve operations. This method, to all intents and purposes, is identical with that of Knapp,⁴⁶⁵ and can be well applied in those cases where the sinus runs backward over the orbit, but not high anteriorly.

Riedel's operation in which complete obliteration of the sinus is obtained by resecting everything except the posterior wall is the most radical and at the same time the most disfiguring of all the external operations. At first sight it would seem to be never indicated, but under certain circumstances it is distinctly the operation of choice. In old people whose constitutions would not stand the shock of a prolonged surgical intervention, the ensuing deformity makes little difference and the rapidity with which the operation can be completed doubly predisposes in its favor. Necrosis and caries of the walls sometimes makes the formation of a bridge impossible; this method is then demanded. When both sinuses are diseased and a double intervention is required, the Riedel operation has been applied with the best cosmetic results.⁴⁸²

Coakley's method of obliterating the sinus secures permanent cures with a very low mortality.* The great disadvantage is the long period of after-treatment while the sinus is being filled with granulations.

KILLIAN'S METHOD.—This form of operation, with minor modifications, is the one generally in use at the present time. The original procedure, which avoids disturbing the trochlea or pulley of internal oblique, has now been abandoned by Killian, as it required an immense sacrifice of time and was found to be unnecessary, as the functions of the eye underwent no permanent disturbances.

This author gives the following indications for his method:⁴⁸³

481. Ritter: Die Erhaltung der vorderen Stirnhöhlenwand bei der radikal Operation. *Verh. d. ver. deutsch. Lary.*, S. 196, 1911. 482. Kuile: Ueber doppelseitige Stirnhöhlenoperation und deren aesthetischen Effekt. *Zeitschr. f. Laryn.*, Bd. 1, S. 645, 1909. 483. Killian (455), S. 23.

* Coakley (355) reports 101 absolute cures in 104 cases.

1. When other forms of operation have failed.
2. The appearance of a fistula, abscess, or necrosis.
3. When symptoms of intracranial complications appear.
4. When, during the course of a chronic frontal sinusitis, pain and fever suddenly appear and the discharge becomes fetid.
5. When the headache referred to the eye is not influenced by intranasal procedures.
6. When the discharge remains fetid despite frequent irrigations.
7. When the sinus inflammation gives rise to recurrent polypoid hypertrophies and polyp formations.
8. When a simple purulent discharge is not relieved by intranasal measures and the patient is anxious to procure permanent relief from his annoying symptoms.

The osteoplastic resection as practised by Hoffman may be used in carefully-selected cases in which the sinus is regular. It is particularly indicated in actors, preachers, lecturers, and school teachers, whose profession requires them to be constantly before the public, as the cosmetic results far surpass those of any other method. The danger of recurrence does not lie so much with the headache and symptoms of occlusion and retention as those of a constant seepage from the nose, due to the formation of granulations within the sinus which do not become covered with epithelium. External fistula formation is of the greatest rarity.

Beck's method has not only the disadvantage of opening a sound sinus, but requires great technical skill and has the same chance for recurrence as the ordinary resection.

Watson Williams's operation is perhaps the most extensive and difficult of all the osteoplastic measures. As it seems to be directly intended to maintain the position of the tendon of the internal oblique, and as this is now known to be unnecessary, the main procedure would seem to have lost its purpose, and the same results can be obtained with much more facility by using the ordinary radical method.

Untoward Results Following the Killian Radical Operation.—Occasionally, in spite of every precaution in technique and asepsis, untoward sequelæ appear, which may only be evanescent or may lead on to fatal consequences.

(a) **ŒDEMA OF THE UPPER EYELID:** This swelling practically always appears on the second or third day following this opera-

tion, often being so marked as to tightly close the eye. As a rule, absorption will take place slowly under moist boric acid dressings, but it frequently requires several weeks before the lid resumes its normal appearance and function. If the œdema is due to an accumulation in the sinus it will be necessary to insert a probe through the wound, thus permitting its escape, otherwise general suppuration of the tissue may supervene. To avoid these œdematous swellings, the eye should receive the greatest care during the operation by keeping it covered with a gauze pad to prevent pressure from hæmostats, and especially not to apply unnecessary force during retraction.

(b) Diplopia due to the dislocation of the tendon of the internal oblique is not an infrequent symptom immediately after the operation.⁴⁸⁴ The condition gradually disappears after a few days, unless permanent injury has been done. Permanent diplopia following the modified Killian operation appears to be of great rarity, judging from available statistics.

Hajek,⁴⁸⁵ in 10 cases in which the trochlea was resected, did not have permanent diplopia in a single instance.

Killian,⁴⁸⁶ in 106 cases, observed diplopia in only five cases, four after four weeks, and one after ten months.

Kahler,⁴⁸⁶ in 30 cases, observed one case of permanent diplopia.

Siebenmann⁴⁸⁷—none in 34 cases.

Ritter,⁴⁸⁸ however, reports three cases of persistent diplopia and recommends stitching the trochlea to the periosteum of the supra-orbital ridge at the conclusion of the operation. The author has one case which has persisted for more than a year, and is only noticeable when the patient looks downward. The condition is relieved by appropriate glasses and appears to be gradually disappearing. The trouble here is undoubtedly due to the tendon of the internal oblique becoming involved in the scar tissue.

(c) Pneumatocele⁴⁸⁹ over the sinus: This occurs when the anterior flap has not adhered to the posterior sinus wall, and is due to the patient forcibly blowing the nose, thus loosening the tissues by inflation. The best means of preventing this is to apply a roll of gauze over this portion at each dressing and hold it firmly in place by the bandage until adhesion has taken place.

(d) Anæsthesia of forehead over area supplied by the supra-orbital nerve. It is, of course, impossible to avoid this occurrence,

484. Bousseau: De la paralysie de grand oblique dans les operations sur le sinus par voie frontale. Arch. Internat. de Laryng., T. 31, p. 640, 1911. 485. Hajek: Ueber Indikationen zur operat. Behandl. bei der chron. Stirnhöhlenentzündung. Wien. med. Wochenschr., June 27, S. 1466, 1908. 486. Killian, Kahler, Ritter: Verh. 1st internat. Lary. Kongress, S. 332, 336, 1909. 487. Siebenmann: Zeitschr. f. Ohrenhk., Bd. 61, S. 353, 1910. 488. Ritter: Kosmetische Stirnhöhlenoperationen. Zeit. f. Lary., Bd. 5, S. 30, 1912. 489. Levinger: Pneumocèle des Sinus Frontalis. Arch. f. Lary., Bd. 19, S. 528, 1907.

as the nerve must be divided. As time gradually wears on, sensation slowly appears, until the parts become supplied by collateral branches or the main trunk reunites.

(e) Supra-orbital neuralgia sometimes appears, due to the involvement of the end of the nerve in the fibrous tissue formation of the scar. Under such circumstances a resection of the nerve is required; therefore, to avoid a second intervention, many operators resect a large portion of the nerve at the time of the original operation.⁴⁹⁰

(f) Stitch abscess: Undoubtedly, many cases which have terminated fatally have originated from one of these abscesses. The parts, being completely closed by sutures, are in favorable condition for secondary infection, which goes on to meningitis and death. On this account most operators abstain from complete closure of the wound without external drainage, and allow the internal inferior margin of the incision to remain open for forty-eight hours. In cerebral or orbital complications of any sort the entire cavity is packed with iodoform gauze; no sutures are applied until after the fourth or fifth day.

In case of a stitch abscess occurring, the suture must be removed and the wound thoroughly irrigated with 50 per cent. solution of euthymol (P. D. & Co.) in water and a small gauze drain inserted.

Blindness on the operated side has been reported,^{491 492} being due either to injury to the optic nerve or to the lengthy pressure of the blood-soaked and hardened dressing.

(g) Osteomyelitis: Postoperative osteomyelitis emanating from the frontal sinus is undoubtedly due to infection in the canaliculi of the bone to the canals of Bresget at the time of, or immediately following, the surgical intervention.

This complication does not appear to be unfrequent, judging from numerous reports of cases from all sides,^{493, 494} but, fortunately, every case does not go to fatal termination, as the disease may become localized in a portion of the frontal bone. On the other hand, the entire table of the cranium can become necrosed, as is illustrated in the well-known case reported by Tilley.⁴⁹⁵

490. Laurens: Chirurgie du Sinus Frontal. Ann. des mal. de l'oreille, T. 1, p. 521, 1904. 491. Knapp: Cecite consecutive a l'operation d'une Emphyseme du sinus frontal. Annal d'ocul., T. 126, p. 67, 1901. 492. Freudenthal (354). 493. Sieur et Rouvillois: Traitement chirurgical des Antrites Frontales Etude critique des accidents consecutifs (osteomyelite). Arch. Internat. de Laryng., T. 31, p. 733, 1911. 494. Luc (42). 495. Tilley: Reported at the meeting of the Brit. Med. Assn., in Portsmouth, 1899.

The only precaution possible against this occurrence while operating is to keep the raw edge of the bone as sterile as possible by frequent applications of gauze moistened with bichloride of mercury, and, in curetting the sinus, avoid opening up the lymph-channels in the bone.

(h) Meningitis: Suppurative inflammation of the meninges appears to have resulted from operations on the frontal sinus more frequently than any other fatal complication.

The Ogston-Luc method would seem to bear the brunt of most of these cases,⁴⁹⁶ the exciting factor being the incomplete removal of all the suppurating ethmoid cells.⁴⁹⁷ Injury to the lamina cribrosa also plays an important rôle.

After the Killian operation a number of deaths from meningitis have been reported, although the path of infection has not always been made clear.⁴⁹⁸⁻⁵⁰³ Tearing out of the olfactory filaments in exenterating the ethmoid cells is undoubtedly a prolific source of this postoperative complication, as the autopsy on many of these cases proved that no injury had been inflicted on the lamina cribrosa, yet the path of infection had occurred through that structure. The osteoplastic resection has also been followed by unpleasant sequelæ, and in one case by death from meningitis.⁵⁰⁴

496. Coffin: Intracranial Complications of Diseases of the Accessory Sinuses. *Med. Record*, vol. 72, p. 767, 1907. 497. Luc. (*Soc. Franc. d'otol.*, T. 20, p. 18, 1904) himself advances this opinion, and has abandoned the operation bearing his name for the proceeding of Killian. 498. Mermod: Lepto-meningite apres une operation de Killian. *Arch. inter. de Lary.*, T. 20, p. 51, 1905. 499. Oppikofer: Sinusite Frontale purulente chron. avec abces orbitaire. *Arch. inter. de Lary.*, T. 24, p. 811, 1907. 500. Von Eicken (457), S. 328. In one of these cases the infection occurred through a tampon saturated with pus from a suppurating maxillary sinus. The path lay through the lymph-channels around the olfactory fibres through the cribriform plate to the olfactory bulb and thence to the pia mater. 501. Reinking: Dis. zu Hajek's Vortrag. *Verh. d. deutsch. Lary. Gesell.*, S. 131, 1907. 502. Hajek: *Wien. Lary. Gesell. Mon. f. Ohrenkh.*, S. 118, 1909. 503. Boeninghaus (479), S. 190, has collected the number of deaths in relation to the number of operations following the Killian method from seventeen operations: 375 operations, with ten, or 2.6 per cent., deaths. 504. Hoffman: Ueber Osteoplastische Operationen der Stirnhöhle. *Verh. d. deutsch. Lary. Gesell.*, S. 132, 1907.

PART IV.

ETHMOID LABYRINTH.

ANATOMY.

The ethmoid labyrinth embraces all that portion lying between the two lateral plates of the orbit. (Fig. 14.) It is composed of two capsules, with a partition (*lamina perpendicularis*) between. The capsules have a prolongation at their internal inferior angle which corresponds to the middle turbinate. The external inferior angle or body of the capsule represents the ethmoidal bulla, and is the most dependent portion of the cellular structures. Immediately beneath the bulla may be observed the cross section of the uncinat process, which at its curve is the lowest portion of the ethmoid bone.* It will be noted that the ethmoid occupies approximately one-half of the entire space between the floor of the nose and the cribriform plate. The *lamina cribrosa* and *lamina papyracea* do not meet, but allow a vacant space, which is covered in by the *fovea ethmoidalis* of the frontal bone. (See page 13.) Along the internal lateral wall of the capsule a projection occurs which represents the superior turbinate. It will be at once apparent that this is not a true turbinate bone, but rather formed by an indentation in the body of the ethmoid. If the section is made through the anterior ethmoidal cells this structure will not be visible. The ostia of the anterior ethmoidal cells lie beneath the middle turbinate in the middle passage, while those of the posterior labyrinth empty into the superior nasal passage below the superior turbinates.

LATERAL NASAL ASPECT.

The relation of the ethmoid capsule to the lateral wall of the nose will be observed in Fig. 9. The anterior boundary is apparently formed by the anterior border of the middle turbinate, although the actual boundary is represented by the uncinat process. The posterior border corresponds to the anterior sphenoidal wall, or, when present, to the sphenoid-ethmoidal fissure. The pendulous portion of the middle turbinate enters so slightly into the formation of the capsule proper that it should be removed

*The pendulous middle turbinate not being considered.

in order to minutely study the lateral wall. (Fig. 10.) It will be observed that the capsule is composed of several furrows running in an oblique direction from behind forward and below upward. As these represent the fundamental ground-work of the entire structure it would be well to apply the scheme of Seydel⁵⁰⁵ for our further consideration of this labyrinth.

For the purpose of understanding the construction of this capsule let us suppose that a box was fitted up with four curved

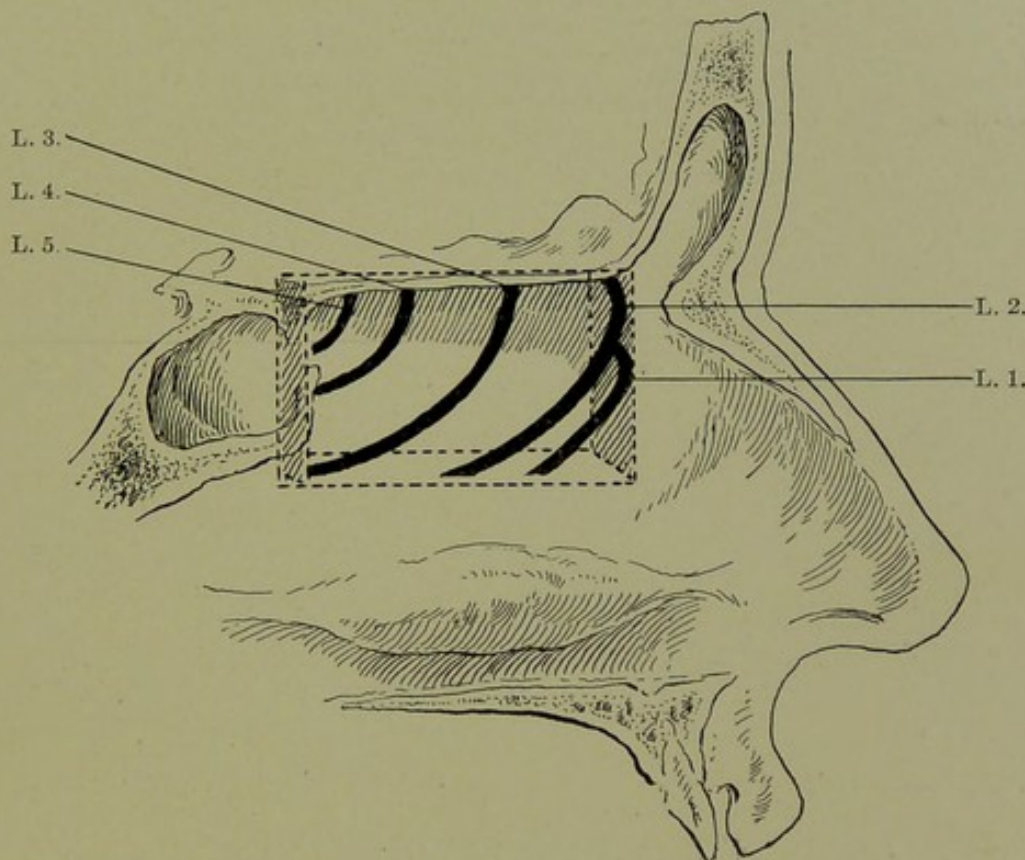


FIG. 172.—Schematic reproduction of the construction of the ethmoid capsule. L. 1. Partition of unciniate process. L. 2. Partition of the ethmoidal bulla. L. 3. Partition of the middle turbinate. L. 4. Partition of the superior turbinate. L. 5. Partition of the supreme turbinate.

partitions, three complete and one partial. (Fig. 172.) The three posterior partitions extend completely from the top to the bottom, making these closed spaces, while the anterior incomplete one reaches from the bottom but halfway to the top. The box is now covered by a lid which extends some distance below the lower edge. The ethmoid capsule may be compared with this structure. The lid which corresponds to the middle and superior turbinate is raised, bringing into view the partitions which correspond to the lamellæ of the various structures which enter into the forma-

505. Seydel: Ueber die Nasenhöhle der höheren Säugethiere u. d. Menschen. Morpholog. Jahrbücher. Leipzig, 1891.

tion of the labyrinth. (Fig. 172.) Partition or lamella No. 1 represents the uncinatè process, lamella No. 2 the bulla ethmoidalis, lamella No. 3 the middle turbinate, and lamella No. 4 the superior turbinal passages. Above these grooves lie the network of cross lamellæ which form and constitute the ethmoid cells. The number and size of these cells depend upon the position of the lamellæ.

LAMELLA OF UNCINATE PROCESS.

Unlike the remaining, this structure does not reach the frontal bone (fovea ethmoidalis), but takes its origin from its fellow (lamella of bulla). By curving downward below and at equal

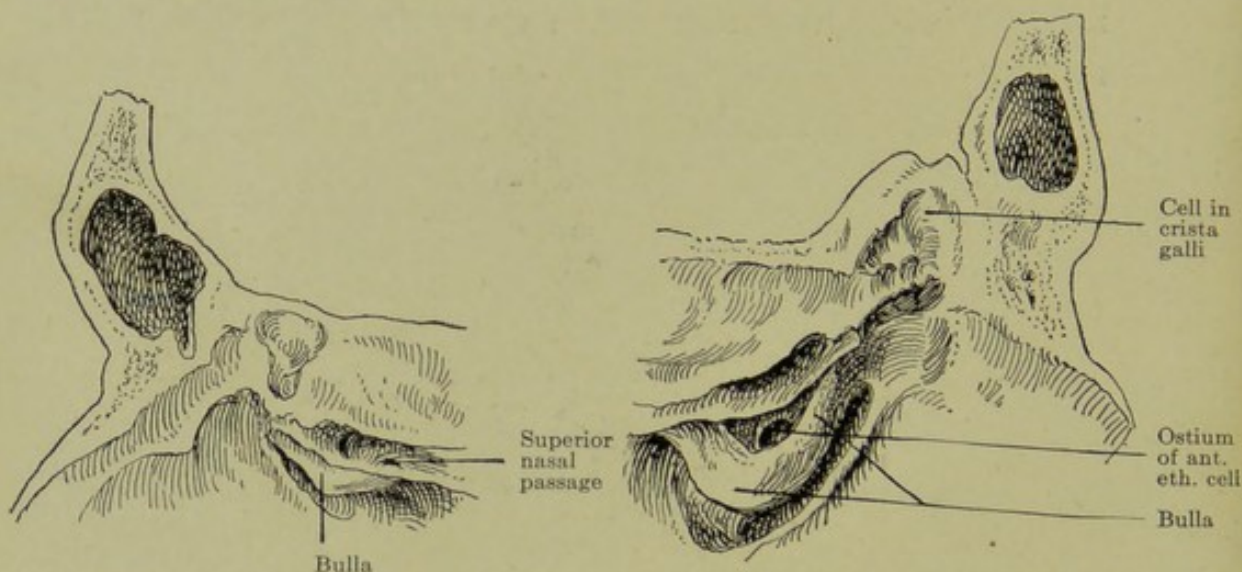


FIG. 173.—Small bulla ethmoidalis.

FIG. 174.—Unusually large ethmoidalis.

distance from the bulla it forms the passage known as the semi-lunar hiatus. Its partial failure above allows the frontal sinus to empty into the hiatus semilunaris, otherwise this sinus would be occluded. At that point where this lamella joins with that of a bulla a pocket is formed, causing the hiatus to end blind. This to a greater or lesser degree may be found on nearly every specimen. Occasionally an ethmoid cell buries itself under the lamella of the uncinatè process, a condition which adds to the difficulty of sounding the frontal sinus.

LAMELLA OF THE BULLA.

This represents the first complete partition of the ethmoid capsule and reaches from the pars orbitalis of the frontal bone to the capsular base as well as from the lateral nasal surface to

*ethmoidalis is genuine singular,
if only one word, the bulla should
have been used. - American illiterati*

the lamina papyracea. When the inferior portion of this lamella is opened, the lowest part of the ethmoid capsule is penetrated. The shape of this structure varies greatly in the normal individual, sometimes it is quite flat and inconspicuous (Fig. 173), sometimes considerably enlarged and very prominent (Fig. 174). The largest and most constant ostium of the anterior ethmoid cells lies in the passage between this structure and the middle turbinate about in the centre of the bulla. (Fig. 174.)

The presence or absence of a nasofrontal duct is due to the position of this lamella. If the lamella of the bulla is situated far forward at its superior extremity it encroaches upon the

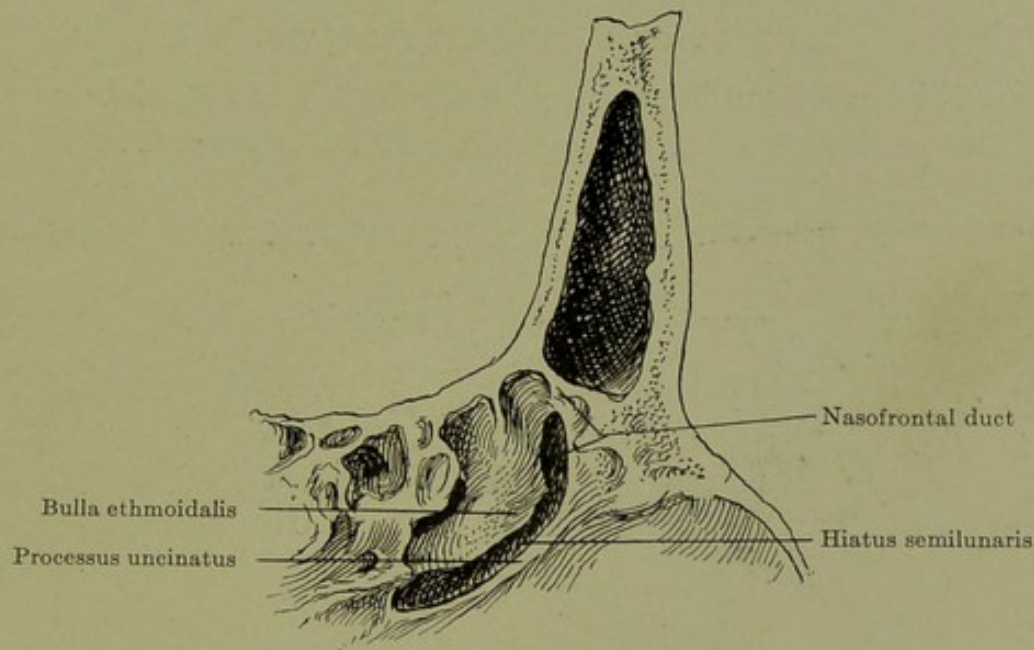


FIG. 175.—Formation of ductus nasofrontalis.

floor of the frontal sinus, causing the latter to become foreshortened. Under these circumstances a narrow passage is formed before the ostium of the sinus is reached. (Fig. 175.) The length and breadth of this duct depend entirely upon the position of the bulla lamella. It is formed by the following structures: In front by the superior nasal spine, externally by the lamina papyracea, behind by the bulla lamella and internally by the external surface of the middle turbinate.

LAMELLA OF MIDDLE TURBINATE.

This also represents a complete partition, being the longest of all the lamella, and is of particular importance because it represents the dividing line between the anterior and posterior eth-

Lamella should be lamellae -
nominative plural

moidal labyrinth. If this lamella lies in front of its normal position, the posterior labyrinth is correspondingly enlarged, and *vice versa*. All of the ostia of the posterior cells empty above and behind this structure.

It is not possible to judge from mere position whether a certain cell belongs to the anterior or posterior labyrinth, as it is possible for one lying directly over the bulla to empty into the superior nasal passage. As the lamella of the middle turbinate separates the middle from the superior nasal passage, this structure is necessarily the partition which separates the anterior and posterior labyrinths; therefore, it would be more correct, from an anatomical point of view, to designate the cells according to their drainage, *i.e.*, cells of middle nasal passage and cells of superior nasal passage.

LAMELLA OF SUPERIOR TURBINATE.

While this partition is short, nevertheless it is complete, reaching to the posterior base of capsule. It assists in forming the

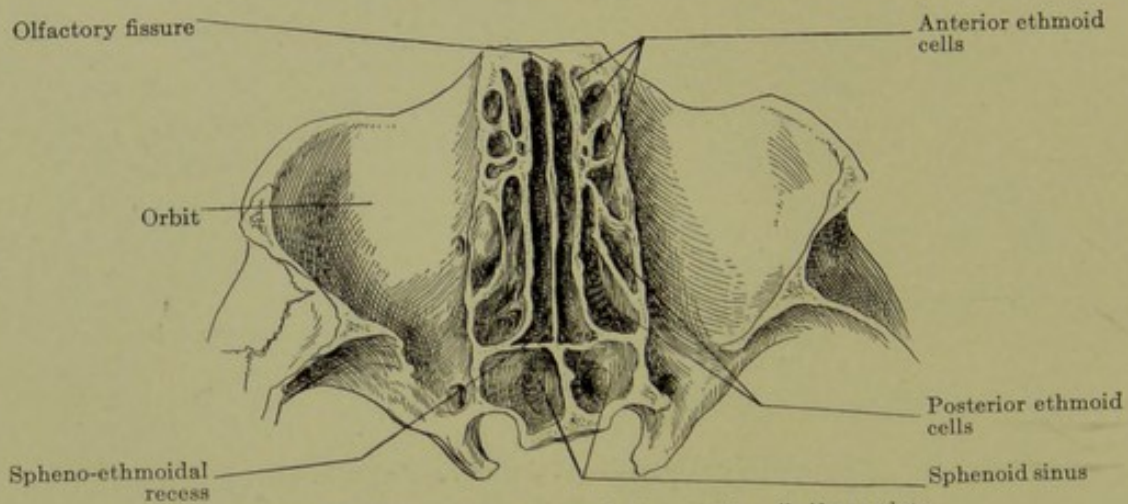


FIG. 176.—Cross section through the ethmoid close to the cribriform plate.

superior nasal passage, and contains the ostia of the posterior ethmoid cells. This plate of bone holds an intimate relation with the anterior wall of the sphenoid and enters largely into the formation of the sphenoidal fissure. If it inserts near the median line, this fissure is not well marked, while if it curve backward and outward, a considerable recess between the posterior body of the capsule and the anterior wall of the sphenoid results. (Fig. 176.)

The number of cells in each labyrinth varies in the normal subject, the lowest number being two or three (Fig. 177), the highest about ten or twelve (Fig. 178). They appear to bear no especial relation to one another, and their form and size vary to

Lamella cannot be both singular and plural. No. It is not.

such an extent that two ethmoidal labyrinths rarely present the same formation, although from the orbital aspect it is usually possible to trace out the different lamellæ. (Figs. 179, 180.) On this account the ostia must vary in number. Each cell has its

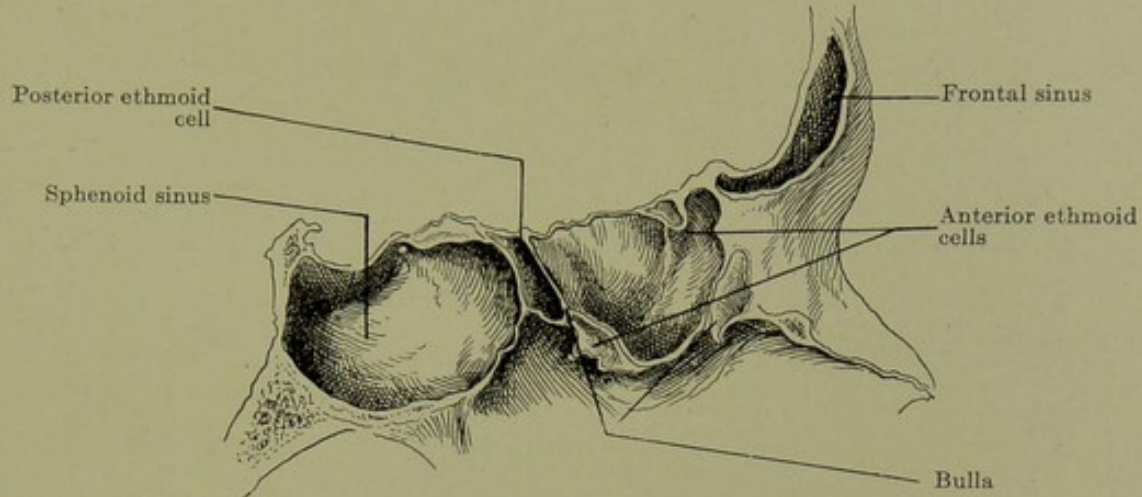


FIG. 177.—Entire ethmoid capsule is composed of three cells: two anterior and one posterior. Enormous ethmoidal bulla.

separate outlet, although some may empty into others before finally appearing in the nasal cavity. The total capacity of the entire labyrinth approximates 8 to 10 cubic centimetres.⁵⁰⁶ The

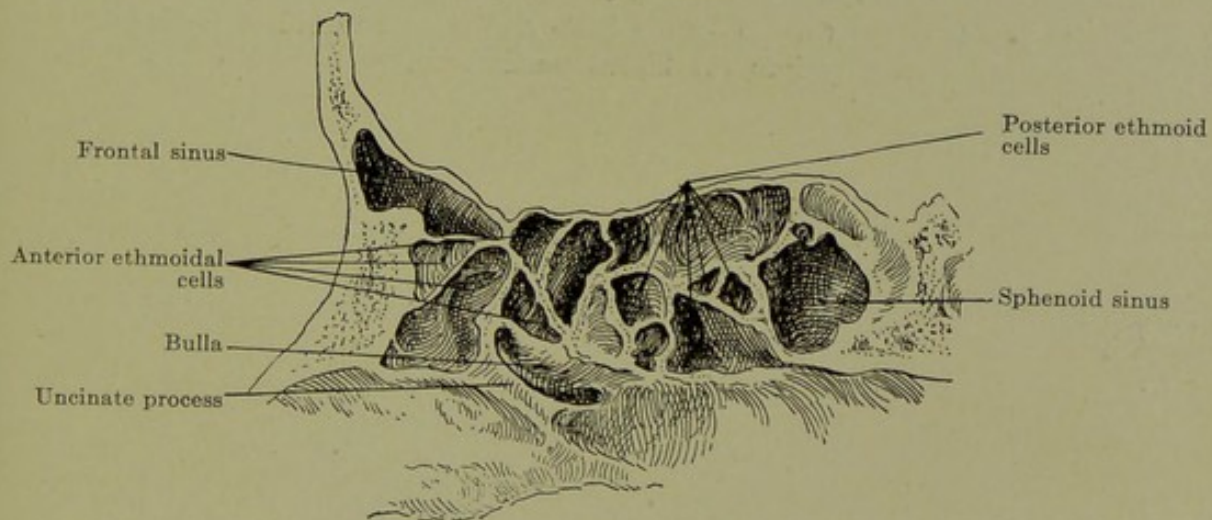


FIG. 178.—Extension of entire ethmoidal labyrinth.

anterior cells empty into the hiatus semilunaris and into the middle nasal passage, and are not confined to any given number.

Anterior cells consist of those of the infundibulum (infundibular cells), those of the pre-ethmoidal recess, and those of the bulla.

Infundibular cells can occur in three places: Anterior, superior and posterior

506. Sieur and Jacob: *Les Fosses Nasales et leurs Sinus*, p. 231, Paris, 1901.

(Fig. 181). The usual positions are anterior under the uncinata process, and superior under the attachment of the ground lamella of the bulla to that of the uncinata process.

Pre-ethmoidal recess. Cells which empty into this space are those lying between the lamella of the middle turbinate, lamella of the bulla and orbital plate of frontal (Fig. 182). The fronto-ethmoidal cells may be included in this category.

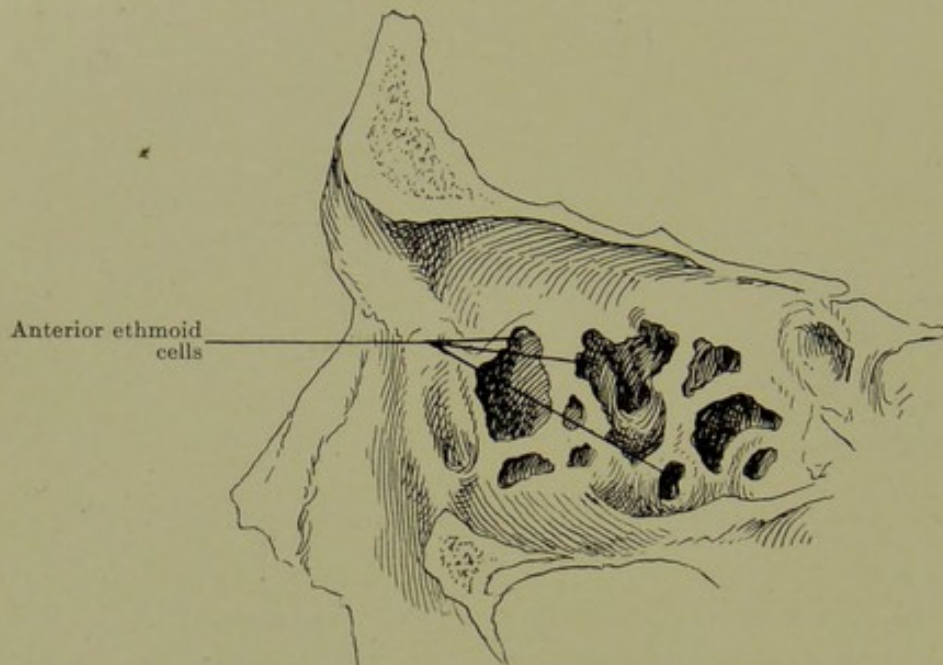


FIG. 179.—Ethmoid labyrinth opened from the orbit, showing the size and number of component cells.

Bulla cells. The ostia of the cells entering into the formation of the bulla are situated in the recess formed by the bulla and middle turbinate and sometimes in front emptying directly into the hiatus semilunaris.

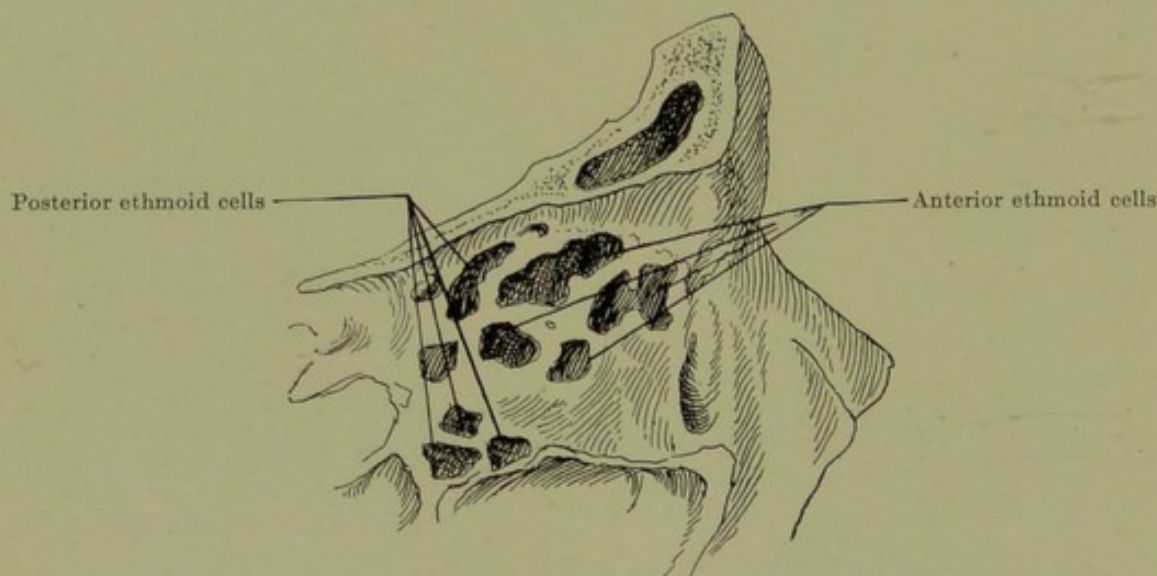


FIG. 180.—Another labyrinth opened from the orbit. Mark dissimilarity in structure from Fig. 179.

The posterior cells are somewhat more regularly placed, one being forward at the junction of the middle and superior turbinate, one lying laterally and one posterior and superior.

The anterior of these lies immediately behind the bulla, so that the posterior wall of the bulla represents the anterior wall of the posterior ethmoidal cell. This cell may occupy a large portion of the inner wall of the orbit or may be prolonged into the orbital vault or even the frontal bone.

Lateral cell. Sometimes this cell pushes itself into the lesser wing of the sphenoid, under which circumstances it lies beneath the optic nerve and ophthalmic artery.

Posterior cell. This cell forms the posterior boundary of ethmoid labyrinth and at the same time the anterior wall of the sphenoid.

Strictly speaking, cells of the anterior and posterior labyrinth are misnomers, as frequently a cell will be found situated in the anterior portion of the capsule which empties into the superior nasal passage. Under these circumstances it would be better to divide the labyrinth into cells of the middle nasal passage and cells of the superior nasal passage. The gross relation of the ethmoidal labyrinth to the true sinuses may be seen in the schematic drawing taken from Hajek. (Fig. 21.)

A horizontal section of the entire ethmoid labyrinth shows that it is broader behind at its junction with the sphenoid than in front where it is in relation to the frontal sinus. (Fig. 176.) The posterior measurement between the nasal wall and lamina

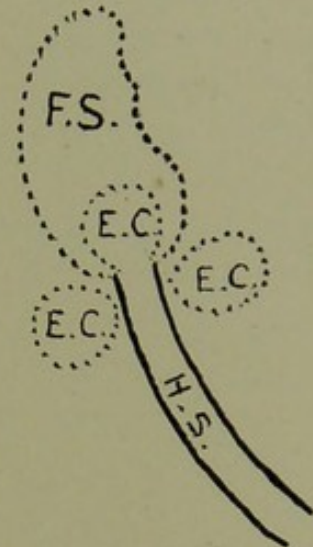


FIG. 181.—Diagrammatic representation of infundibular cells. F. S., frontal sinus. E. C., ethmoid cell. H. S., hiatus semilunaris.

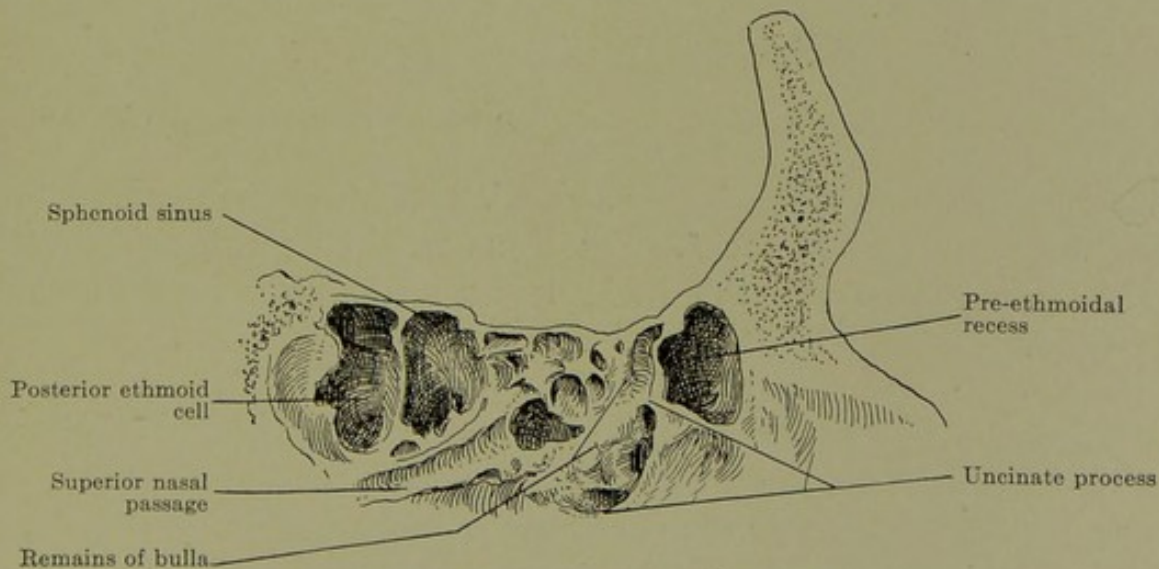


FIG. 182.—Section through ethmoid labyrinth. Frontal sinus absent.

papyracea is about 1.5 cm., while anteriorly in the region of the lachrymal bone it may only measure 0.5 to 0.8 cm. This is of great importance to remember while using a hook or Ballenger

knife, as a much deeper incision can be made posteriorly without fear of injuring the os-planum, but if the instrument is drawn straight forward the lachrymal bone is sure to be encountered.

RELATION OF ANTERIOR ETHMOID LABYRINTH TO FRONTAL SINUS.⁵⁰⁷

One can hardly speak of a strict normal relation between these two structures, as deviations and irregularities are found in almost every skull examined, yet for purposes of comparison a certain standard must be accepted. If the lamella of the uncinatè process and bulla are normal in every respect (size, shape and position), the frontal sinus coming down in the shape of a funnel, we can

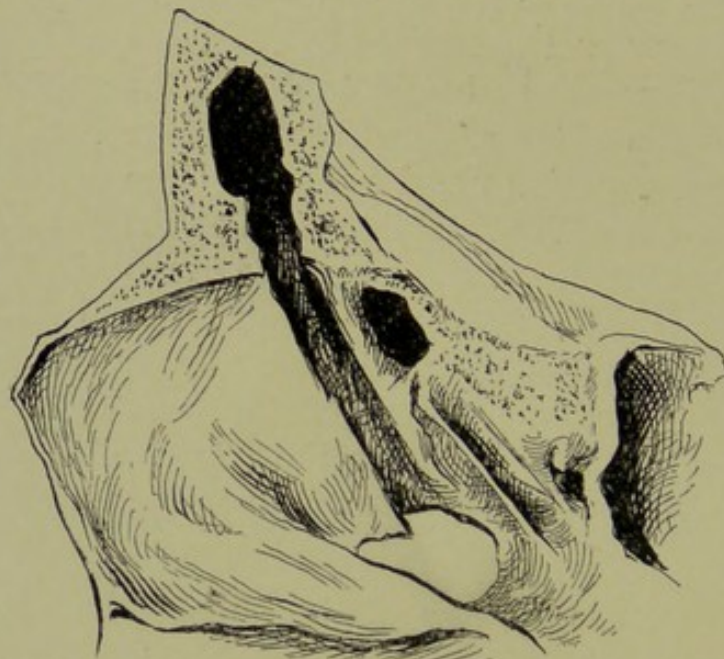


FIG. 183.—Frontal sinus and hiatus semilunaris forming a straight passage.

consider this the normal type. Under these circumstances the semilunar hiatus and the frontal sinus would form a continuous and straight passage, the bulla lying posterior and somewhat superior. (Fig. 183.)

ANOMALIES OF ETHMOID LABYRINTH.

Deviations from the normal may occur in several ways:

1. By malposition or displacement of the lamellæ.
2. By partial or complete absence of lamella.
3. By projections of the air spaces beyond the borders of the ethmoid capsule into other structures.

507. Heyman and Ritter: Zur Morphologie und Terminologie des mittleren Nasenganges. Zeitschr. f. Laryngologie, Bd. 1, S. 1, 1909.

*lamellæ - it should be.
nom. plural.*

4. By dehiscences.

1-2. As these anomalies are dependent upon irregularities in the lamella, they will be considered under one head.

(a) In the lamella of unciniate process: The principal anoma-

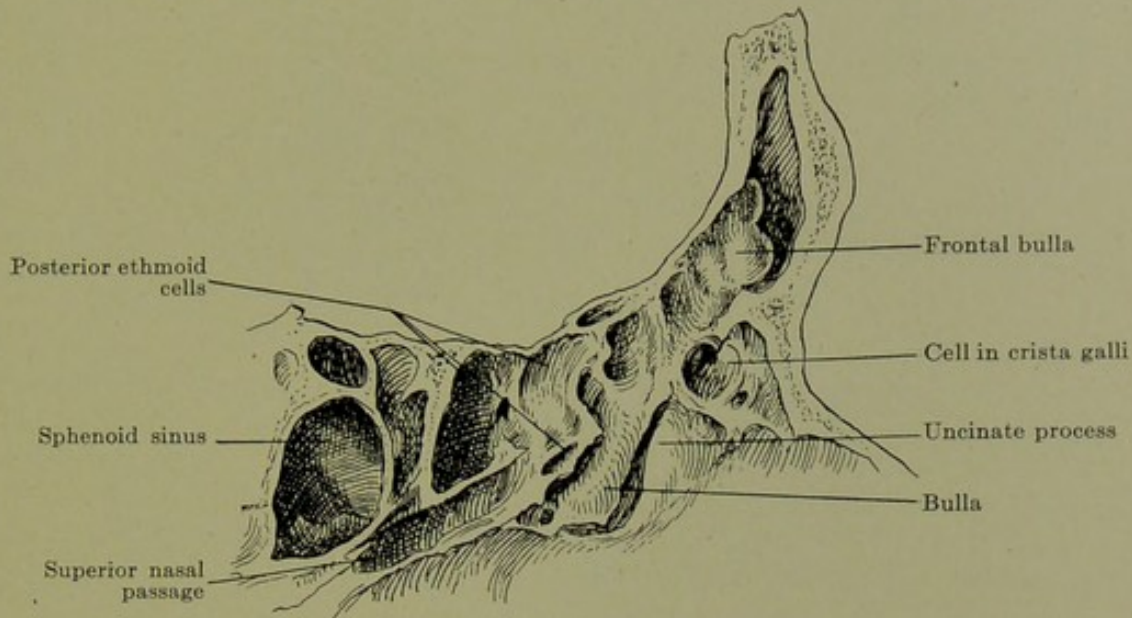


FIG. 184.—Frontal bulla formed by the upward and forward displacement of the lamella of bulla ethmoidalis onto the posterior wall of the frontal sinus.

ous formations of the structure occur in the following ways: (1) upward extension of lamella; (2) partial failure of lamella; (3) cell dividing lamella.

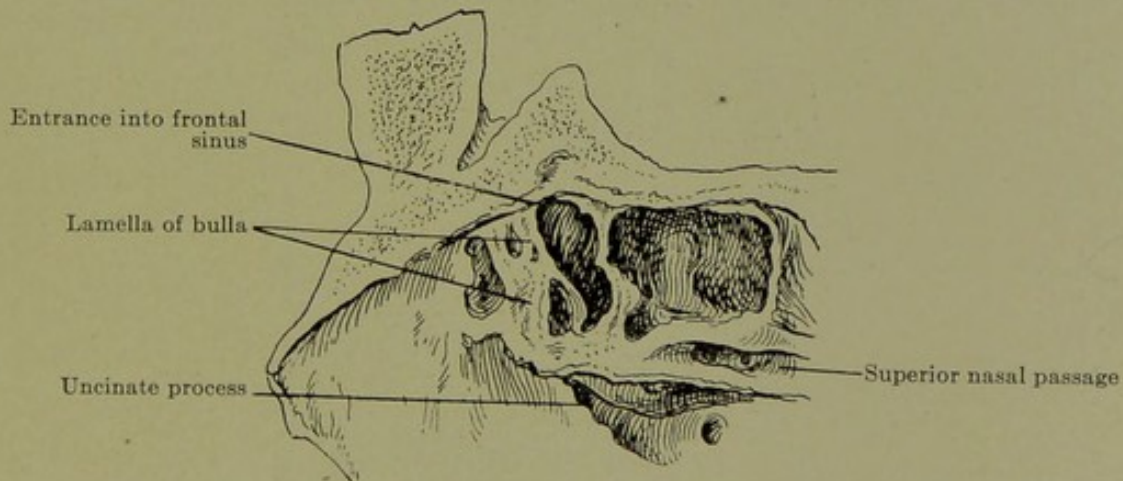


FIG. 185.—Anomalous situation of the unciniate process. Frontal sinus emptying into an anterior ethmoid cell.

(1) Upward extension of lamella (Fig. 184). This plate, instead of taking its origin from the bulla, rises upward into the frontal sinus, forming a cell at the base of this cavity. This is one of the forms of the so-called frontal bulla.⁵⁰⁸ It would be

508. Shambaugh: Construction of Ethmoidal Labyrinth. *Ann. Otol., Rhin. and Lary.*, Dec., p. 771, 1907.

difficult to sound the frontal sinus in the presence of this anomaly, as the point of the instrument would find lodgment in the frontal bulla unless the sound closely followed the mesial side of the middle turbinate.

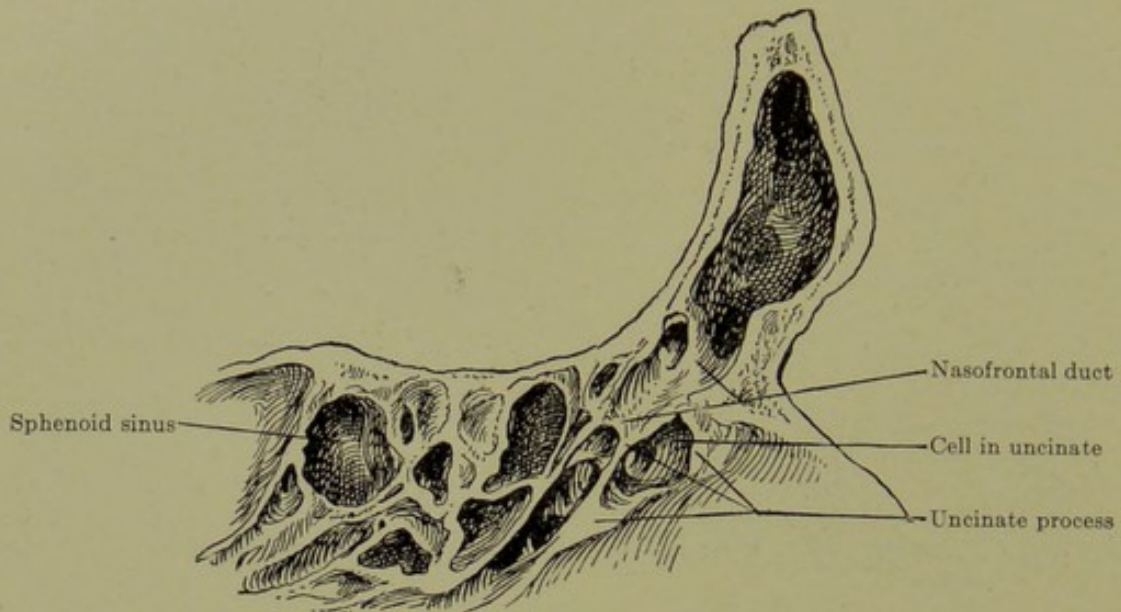


FIG. 186.—Anterior ethmoid cell situated beneath the uncinat process.

(2) Partial failure of lamella (Fig. 185). The uncinat process takes its origin from the base of the ethmoidal bulla, thereby obliterating the anterior portion of the hiatus semilunaris. The

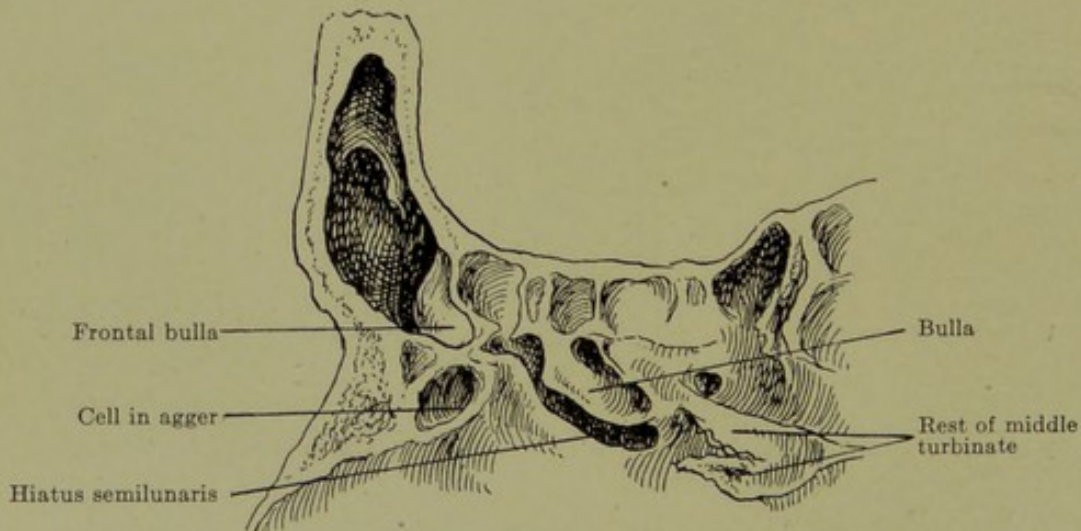


FIG. 187.—Frontal bulla formed by encroachment of an infundibular cell into the frontal sinus.

frontal sinus opens into an anterior ethmoid cell (bulla), which in turn communicates with the middle nasal passage through its normal ostium. This formation absolutely precludes the possibility of introducing a sound into the frontal sinus.

(3) Cell dividing lamella of uncinata process (Fig. 186). When an air space is formed in this process it is always situated at the base or at that portion of the lateral nasal wall which is known as the agger nasi. The ostia of these cells always empty

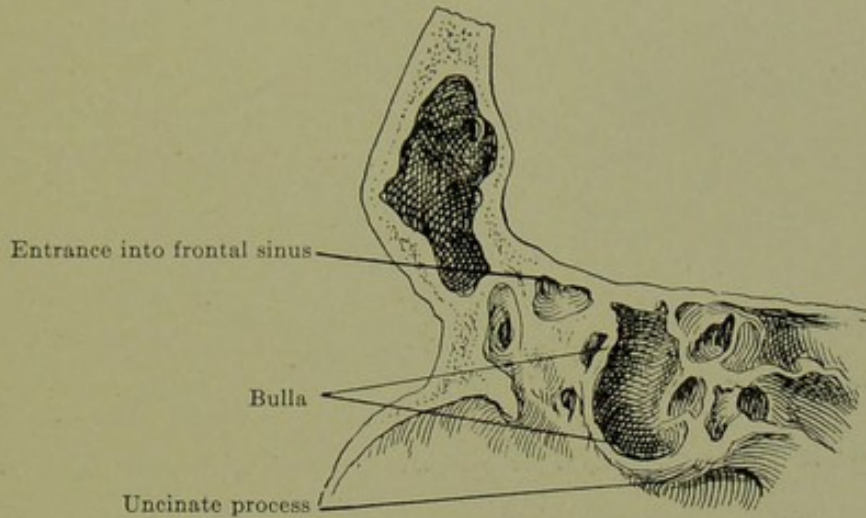


FIG. 188.—Downward displacement of bulla with obliteration of the hiatus semilunaris.

into the infundibulum and are known as infundibular cells. (Fig. 186.) An infundibular cell at the anterior extremity of the hiatus may bulge into the frontal sinus, forming another variety of a bulla frontalis. (Fig. 187.)

(b) In the lamella of the bulla ethmoidalis: The bulla is prac-

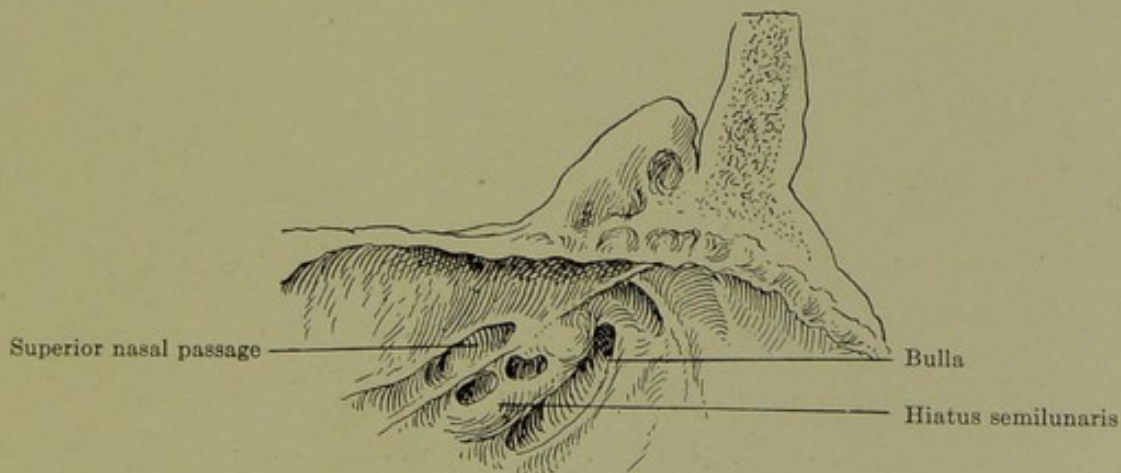


FIG. 189.—Upward displacement of bulla with enlargement of the hiatus semilunaris.

tically always constant, but is subject to various deviations from the normal. These irregularities are seldom due to an absence of portions of the ground lamella, but rather to some malposition or displacement. These displacements may be (1) downward, (2) upward, (3) forward, and (4) backward.

(1) Downward displacement of ethmoidal bulla (Fig. 188). Comparing this with the normal, it will be seen that the bulla is situated further downward and backward, causing a considerable space to be formed between the connecting lamella of the

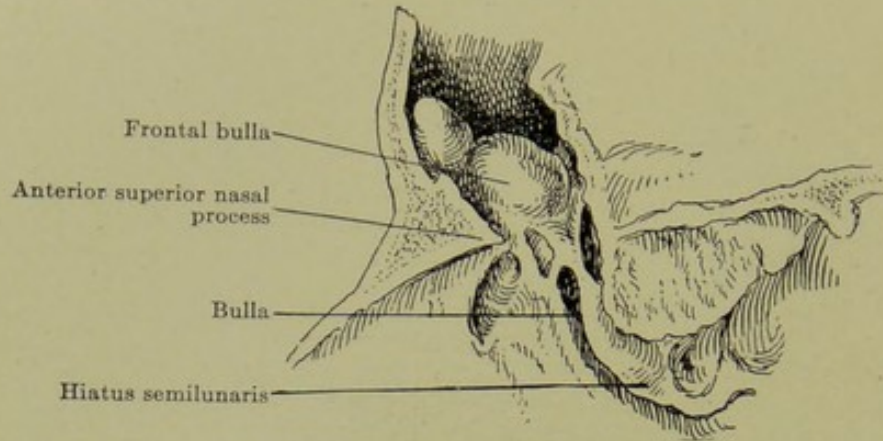


FIG. 190.—Formation of a frontal bulla through the upward extension of the lamella of the uncinatè process.

uncinatè process and bulla and the frontal ostium. Under these circumstances the hiatus has absolutely no relation with the frontal sinus. In order to sound this cavity the instrument must be introduced far above the bulla.

(2) Upward displacement of the bulla (Fig. 189). This

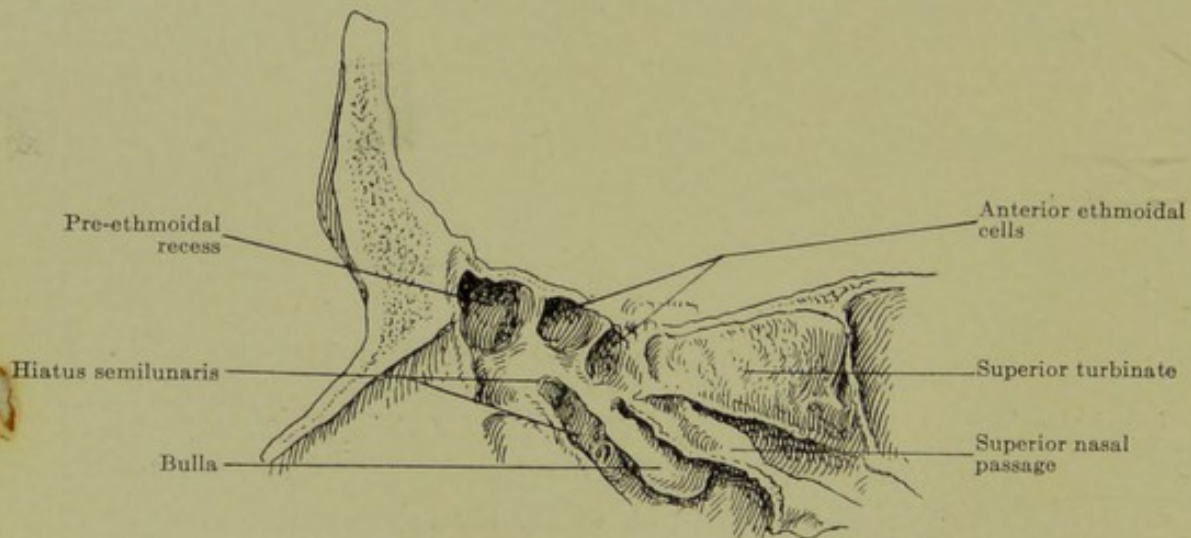


FIG. 191.—Backward displacement of the ethmoidal bulla with the formation of a pre-ethmoidal recess.

formation is, in reality, due to lack of development in the bulla. The ground lamella does not project into the middle nasal passage in any marked degree, but leaves a large free passage into the frontal sinus. This is one of the most favorable formations for introducing a catheter into the frontal sinus.

(3) Forward displacement of bulla (Fig. 185). The bulla lamella is pushed forward against the uncinat process, thereby obliterating the hiatus. In our specimen the only apparent outlet to the frontal sinus is situated close to the cerebral wall. In

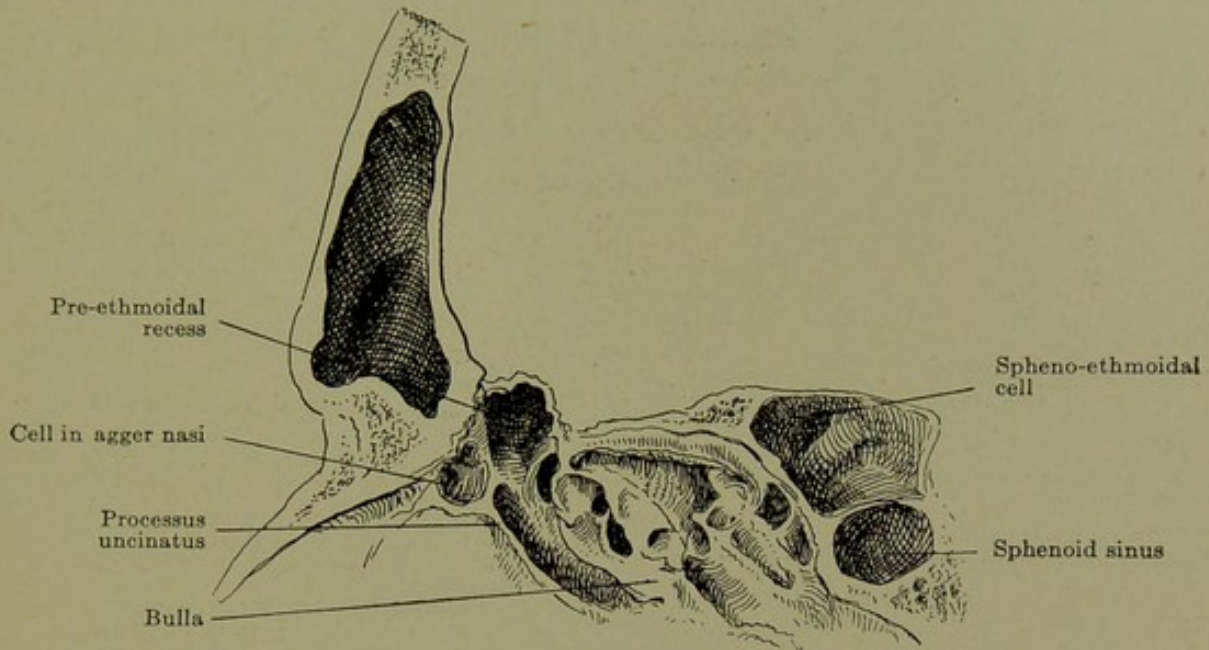


FIG. 192.—Lamella of middle turbinate displaced forward. Large spheno-ethmoidal cell.

order that the frontal sinus may have an outlet, an opening is formed in the lamella of the bulla. When the lamella runs up into the frontal sinus another variety of frontal bulla is formed. (Fig. 190.)

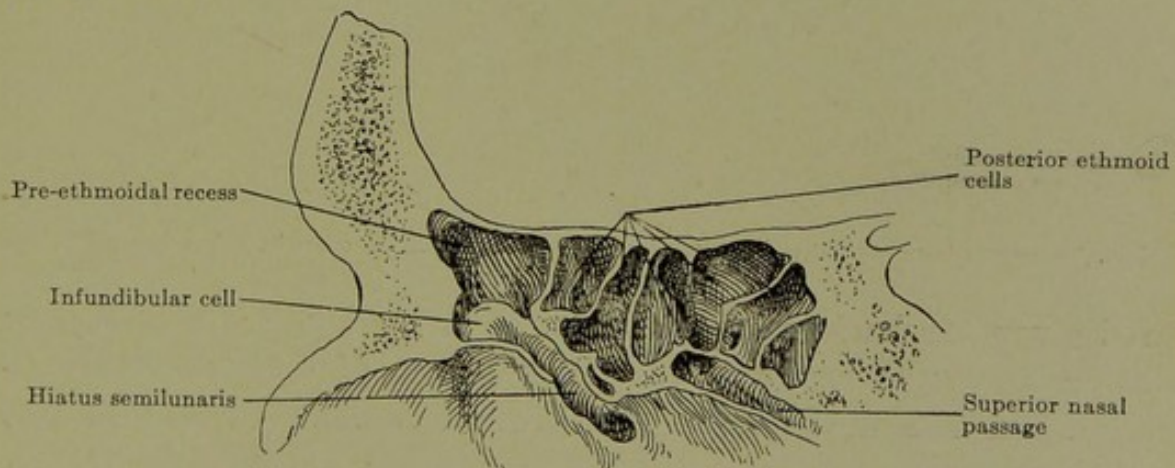


FIG. 193.—Showing reduced size of ethmoid labyrinth in the absence of the frontal and sphenoidal sinuses. Well-marked infundibular cells.

(4) Backward displacement of bulla (Fig. 191). When this structure is displaced backwards a vacant space occurs above the end of the hiatus and in front of the lamella of the bulla. As this space lies in front of the ethmoid capsule proper, yet com-

municates with the nose inside of the semilunar hiatus, it might be well to designate it as the pre-ethmoidal recess. When this anomaly is present the frontal sinus finds its outlet at this point.

(c) In the lamella of the middle turbinate: The only change of note observed in this lamella is that of malposition forward or backward. In the first instance, if the ground lamella lies too far forward, it naturally, being the boundary between (Fig. 192) the anterior and posterior labyrinth, reduces the size of the space occupied by the anterior cells and enlarges that for the posterior.

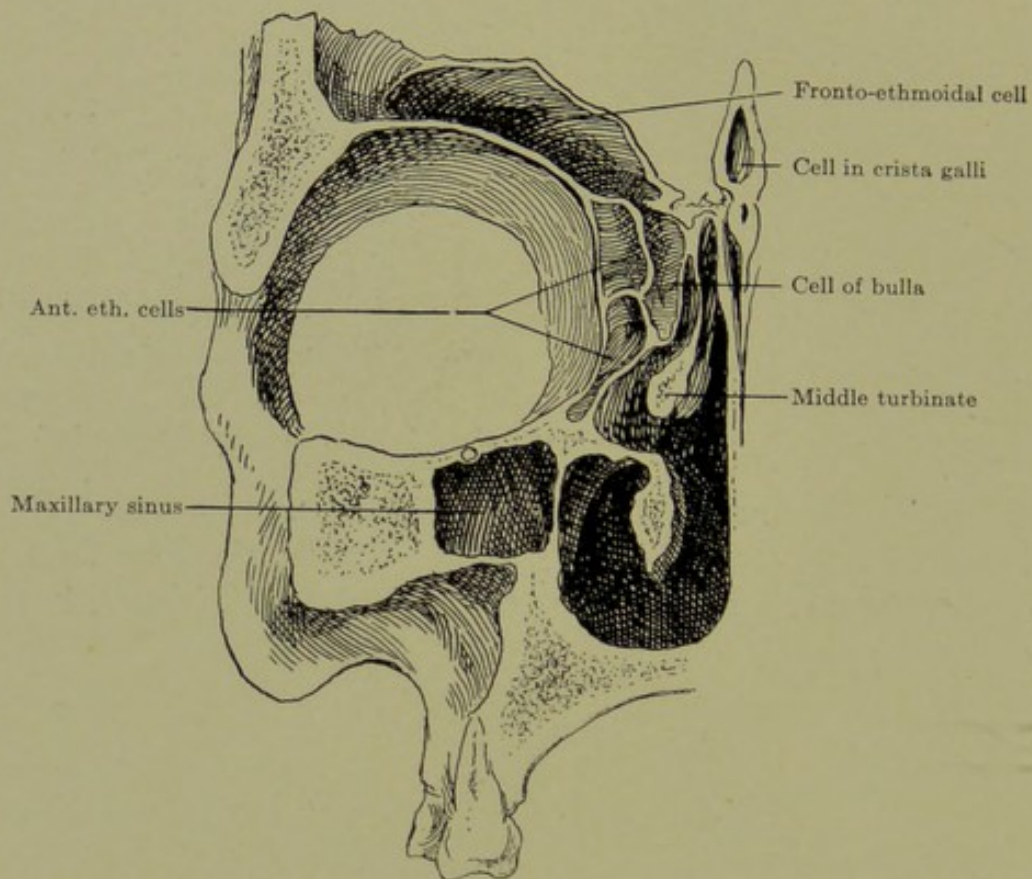


FIG. 194.—Fronto-ethmoidal cell extending almost the width of the orbital cell in crista galli.

If it lie too far backward, the opposite is the case; therefore, the relation of the anterior to posterior group of cells depends entirely upon the position of the ground lamella of the middle turbinate.

(d) In the lamella of the superior turbinate: When the lamella of the superior turbinate assumes a horizontal direction the posterior ethmoidal cell will occasionally override the sphenoid sinus, giving the appearance on section as though the sphenoid sinus was divided by a partition. (Fig. 192.)

(e) Extension of entire labyrinth (Fig. 178): The anterior

cells extend over the hiatus almost into the nasal bones, while the posterior occupy some of the space normally held by the sphenoid sinus. The number of cells in both labyrinths is fourteen—six in the anterior and eight in the posterior.

(f) Contraction of the entire labyrinth (Fig. 193): The cells are pushed together antero-posteriorly, occupying much less space than normally. The entire labyrinth is composed of but six cells, all of them having the appearance as though compressed from behind, forward. Neither sphenoid nor frontal sinus is present.

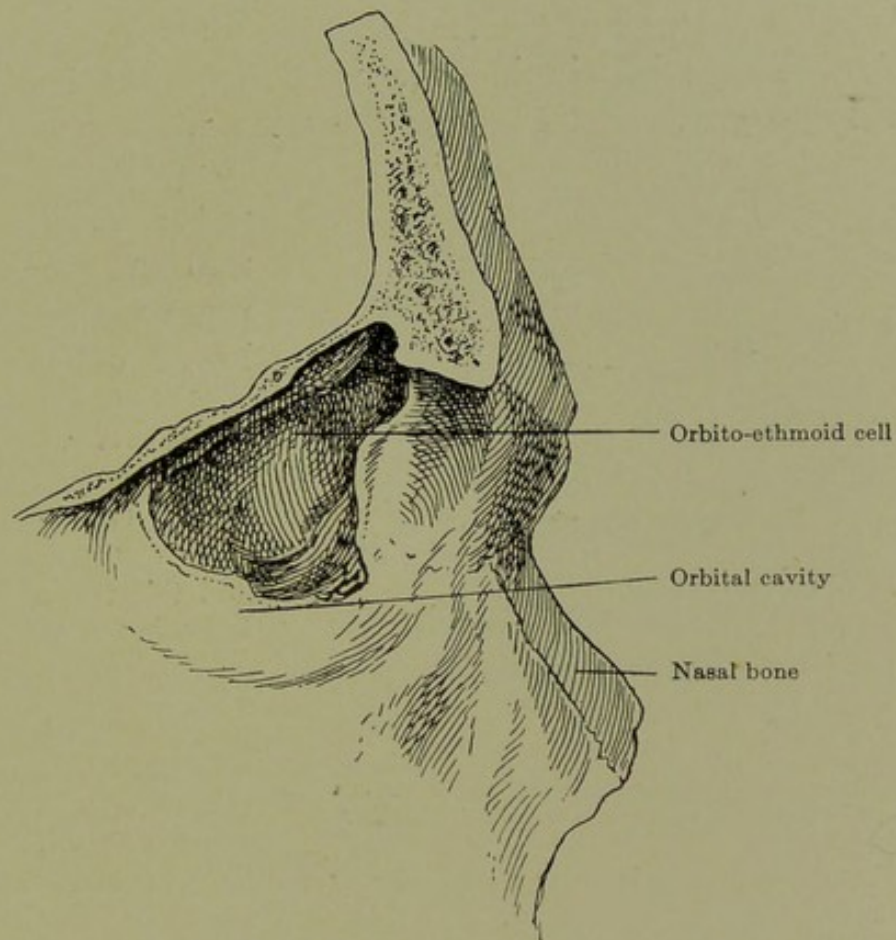


FIG. 195.—Fronto- or orbito-ethmoid cell. Frontal sinus lies directly in front and does not communicate.

3. *By Projections of the Air Spaces.*—Normally, the cells of the ethmoid labyrinth are contained within the limits of the ethmoidal capsule. Under certain circumstances they may extend far beyond these boundaries into the (a) frontal, (b) maxillary, and (c) sphenoid bone, and occasionally into the (d) middle turbinate.

(a) *Fronto-ethmoidal cells:* These are formed by burrowing their way between the orbital plate of the frontal bone, and may, in extreme cases, extend almost the entire width of the orbit.

(Fig. 194.) They frequently present themselves in the supra-orbital ridge outside of the frontal sinus, from which they are always separated by a thin partition. (Fig. 195.) The ostium of these cells is usually situated in the superior portion of the middle nasal passage, directly posterior to that of the frontal sinus, so that in case of their presence, in sounding it would be impossible to judge into which the instrument had penetrated.

(b) Maxillo-orbital cells: These are caused by the bulla occupying a lower position than normal, whereby the outer wall of the lowest cells is formed by the orbital wall of the superior maxillary instead of the lamina papyracea of the ethmoid. (Fig. 40.) No especial significance need be attached to these, as they are readily reached through the nose when necessary.

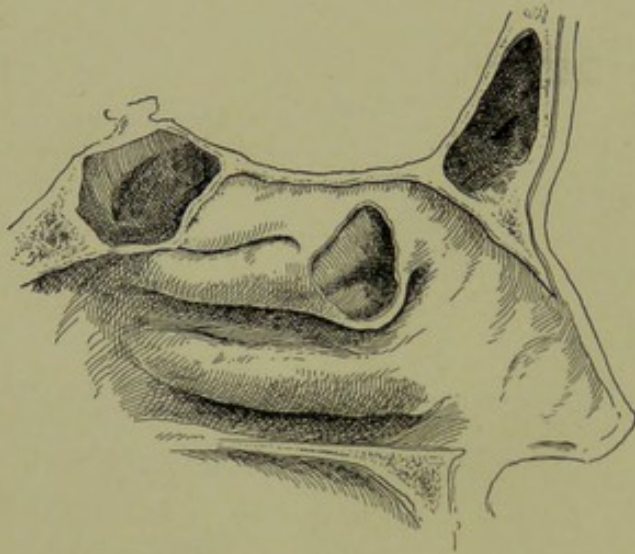


FIG. 196.—Anomalously situated ethmoid cell occupying the anterior extremity of the middle turbinate.

(d) Cell in middle turbinate: This anomalous formation consists of one or more cells which have hollowed out the body of the middle turbinate. (Fig. 196.)

It was formerly supposed that these cells were bone cysts and of pathologic origin. Investigation,^{509 510 511} however, has shown that this theory was false, for the following reasons:

1. They contain ostia as any other ethmoidal cell.

2. The whole structure from a microscopical point of view is similar to a corresponding healthy portion of the ethmoid capsule.

3. No evidence is presented that any pathological process has contributed to the formation of the structure.

These cells may be of any size, from a mere indentation in the base of the middle turbinate to an enormous distention of the entire structure, completely occluding the naris on that side. They undoubtedly grow during adult life under normal circumstances.⁵⁰⁵ The ostia of these cells are usually situated in the superior nasal passage at the angle of junction of the middle and superior turbinates, but occasionally empty into the middle nasal

509. Kikuchi: Der histologische Bau der Knochenblasen in der Nase, etc. Arch. f. Laryn., Bd. 14, S. 308, 1903. 510. Lothrop: The Anatomy of the Inferior Ethmoidal Turbinate Bone, etc. Annals of Surgery, vol. 38, p. 233, 1903. 511. R. H. Skillern: Beitrag zur Kenntnis der Sogenannten Knochenblasen der mittleren Muschel. Arch. f. Laryn., S. 254, Bd. 23, 1910.

passage, the ostia there being situated on the external aspect of the middle turbinate opposite the ethmoidal bulla.

4. *Dehiscences*.⁵¹²—Congenital defects have been noted in certain portions of the ethmoid capsule, particularly the lamina papyracea. In the recent state the break in the continuity of the bony structure is covered in by fibrous tissue. The significance which these anomalies bear is in direct relation to the facility with which infection may travel from the diseased ethmoid cells to the orbital structures. Emphysema of the orbit has been observed on forcibly blowing the nose or sneezing, a circumstance which must be attributed to the pressure of dehiscences in the bony partition between the nose and the eye (lamina papyracea). Defects have also been noted in the superior wall of the posterior cells.⁵¹³

The mucosa lining the cells of the ethmoid labyrinth is similar to that of the sinuses, except somewhat thinner. It contains some few glands—sufficient to keep the surface moist. The olfactory filaments are situated on the superior turbinate, about in its centre.

BLOOD SUPPLY.

The ethmoid obtains its blood supply from the superior nasal branch of the sphenopalatine, as well as the anterior and posterior ethmoidalis, which spring from the ophthalmic artery. (Plate Ia.) None of these arteries is of any considerable size.

VENOUS ANASTOMOSES.

Veins are divided into two groups: 1. Ethmoidal veins returning along the course of their respective arteries, penetrating the anterior and posterior ethmoidal foramina into the orbit, finally emptying into the ophthalmic vein which empties into the cavernous sinus. (Plate Ib.)

2. The ethmoidal veins on the cribriform plate anastomose freely with the veins of the dura mater and the superior longitudinal sinus. These explain why thrombosis of the longitudinal and cavernous sinus can occur from purulent ethmoiditis. They also explain why cases of meningitis following ethmoiditis have occurred without the intervening bone being affected.

512. Onodi: Die Dehiscenzen der Nebenhöhlen der Nase. Arch. f. Lary., Bd. 15, S. 62, 1903. 513. Sieur and Jacob (506), p. 253.

Is this word correct?

RELATION OF POSTERIOR ETHMOIDAL CELLS TO OPTIC NERVE.⁵¹⁴

The normal relation of this nerve to the posterior ethmoidal cell of moderate size is only at the posterior, superior and external angle, and is separated by several millimetres. (Fig. 197.) As the optic nerve leaves the chiasm it courses through the optic groove toward the centre of the eyeball, taking, of necessity, an outward and forward course. The normal ethmoid labyrinth being directed solely forward, it stands to reason that these two structures diverge as they run anteriorly. In certain anomalous

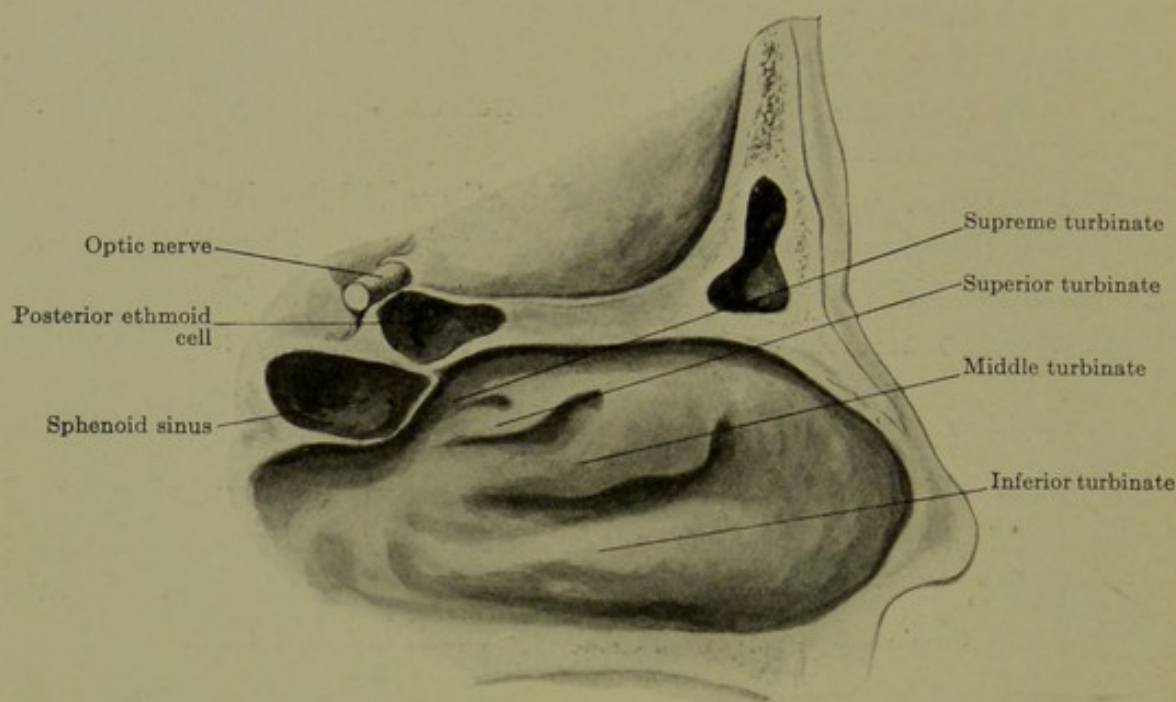


FIG. 197.—Lateral wall of nose with spheno-ethmoidal cell showing intimate relation of optic nerve. (After Onodi.)

formations the posterior ethmoid cells may extend into the lesser wings of the sphenoid. Under these circumstances the optic nerve lies for several millimetres of its course almost within the cavities of these cells, being separated from them by a thin layer of mucosa, or, at best, by an incomplete bony canal. (Fig. 198.) It depends entirely upon the amount of reabsorption that has occurred as to the proximity of the nerve. The importance of being cognizant of this anomalous possibility is obvious, particularly when considering blindness of nasal origin.⁵¹⁵

⁵¹⁴. Onodi: Das Verhältniss des Nervus opticus zu der Keilbeinhöhle u. d. hintersten Siebbeinzellen. Arch. f. Lary., S. 360, Bd. 14, 1903. ⁵¹⁵. Loeb: The Optic Nerve and the Accessory Cavities of the Nose. Ann. Otol., Rhin. and Lary., p. 243, 1909.

PHYSIOLOGY OF THE ETHMOID.

A different function must be attributed to the ethmoid cells than to the sinuses proper however great our ignorance of the physiological significance of the latter may be. In the first place the anatomical configuration of the two structures is totally dissimilar. The sinuses (frontal, maxillary and sphenoid) are true cavities enclosed by bony walls and outside of, or adjunct to, the nasal cavity proper. The ethmoid labyrinth, on the other hand, may be likened unto a sponge and is contained within the boundaries of the respiratory portion of the nose.

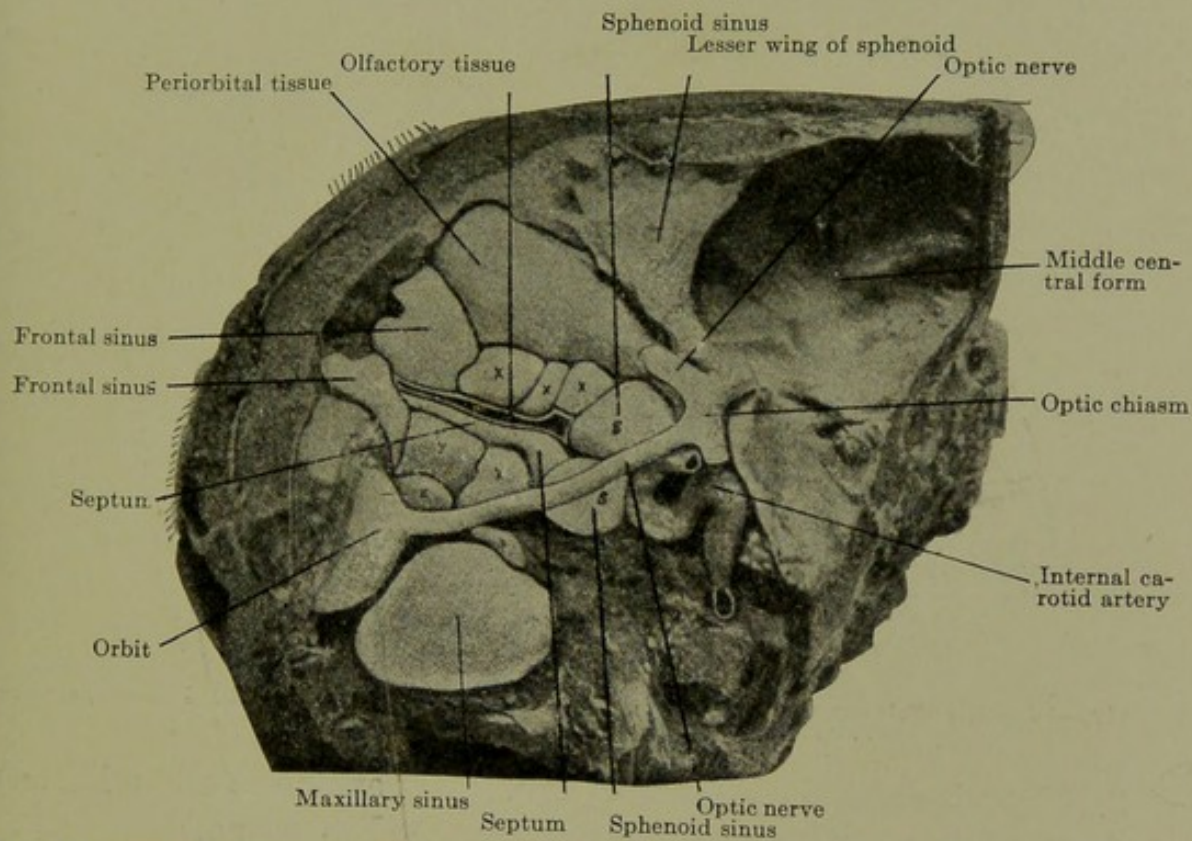


FIG. 198.—Normal relation of optic nerves to sphenoid sinus and posterior ethmoid cells. xx Ethmoid cells. S. Sphenoid sinus. (After Onodi.)

From these anatomical facts and from the experiments of Paulsen,⁵¹⁶ Zwaardemacher,⁵¹⁷ and others on the air currents passing through the nose during inspiration and expiration (Fig. 199), we can state definitely that this structure exercises great influence on the warming and moistening of the inspired air.

The air, on inspiration, describes a half-circle on passing through the nose from the entrance of the nares to the choana. It first impinges on the anterior end of the middle turbinate and is divided into two streams, one passing through the

516. Paulsen: Mitth. d. Vereins Schleswig-holst. Ärzte. Heft 10, 1885. 517. Zwaardemacher: Die Physiologie des Geruchs. S. 50, 1895.

olfactory fissure, the other, which is smaller, beneath and through the middle nasal passage. On expiration the posterior extremity of the middle turbinate acts as a shield and diverts the main stream outward through the middle meatus. The devious passage thus taken by the air currents insures the greatest possible absorption of heat and moisture before entering the larynx.

ÆTIOLOGY AND PATHOLOGY.

Before discussing the cause of ethmoidal disease we must consider the various pathological conditions to which it is susceptible.⁵¹⁸ These may be divided into:

1. Acute catarrhal inflammation.
2. Acute suppurative inflammation.

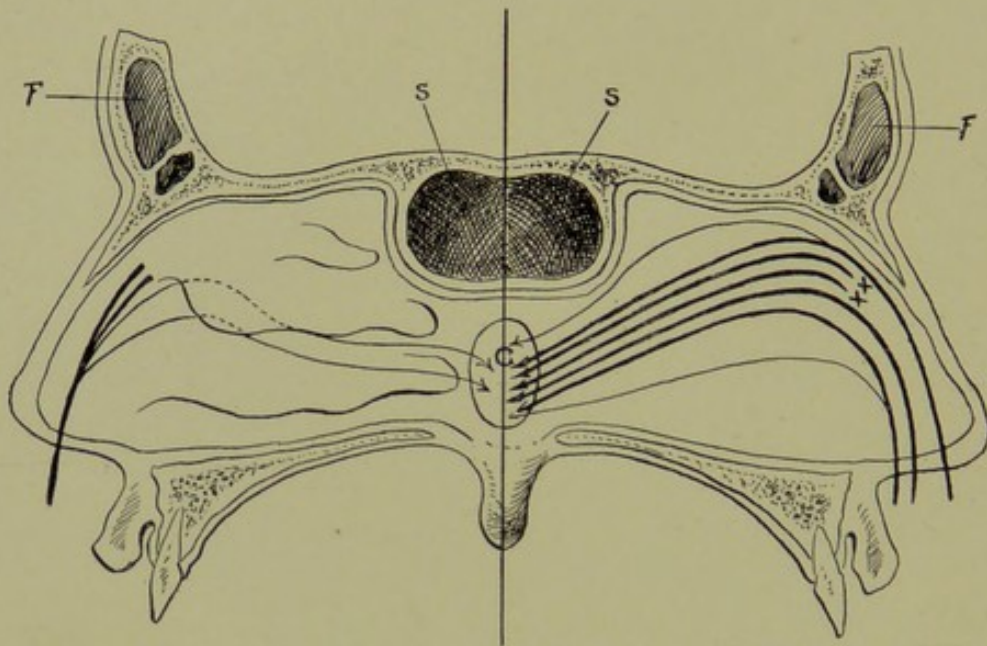


FIG. 199.—Direction of air currents through the nose. Right side, lateral nasal wall. Left side, septum. S. Sphenoid sinus. F. Frontal sinus. C. Choanae.

3. Chronic catarrhal inflammation. (Hyperplastic ethmoiditis.)
4. Chronic suppurative inflammation. (Empyema.)
5. Chronic catarrhal inflammation with suppuration.*

518. Uffenorde: Die Erkrankungen des Siebbeins. Jena. 1907.

*To Bosworth (Various Forms of Disease of the Ethmoid Cells, New York Med. Journ., Nov. 7, 1891) belongs the priority of first recognizing and describing the different affections of the ethmoid cells, as he anticipated Uffenorde by some sixteen years. This classification was the following:

1. Myxomatous degeneration without purulent discharge.
2. Extracellular myxomatous degeneration with purulent discharge.
3. Purulent ethmoidities with polypi.
4. Intracellular polyp without pus discharge.
5. Intracellular polyp with pus discharge.

This was later endorsed by Rice (Relations of Pathologic Conditions of the Ethmoid Region to Asthma. Trans. Am. Laryn. Assn., p. 91, 1899). It will be noted in Bosworth's classification that several of the divisions are in reality the same affection, thus number four and number one are practically identical, the former being an advanced condition of the latter, and, again, number two and number five represent different stages of the same pathological condition.

1. ACUTE CATARRHAL INFLAMMATION.

This condition occurs to a greater or lesser degree with every acute coryza, depending upon the length and severity of the attack. The mucosa of the uncinata process, bulla and external surface of middle turbinate become swollen, having the appearance of a myxomatous degeneration with punctiform hemorrhages on various parts of the surface. The interior of the cells shares in these pathological changes. Resolution occurs more slowly than in the general nasal mucosa. That this condition may result from irritation alone is shown by the results seen in the mucosa following resection of a portion of the middle turbinate.

2. ACUTE PURULENT INFLAMMATION.

Acute empyema of the ethmoid cells *per se* is, generally speaking, an uncommon affection, at least in our country. It is usually associated with acute frontal sinus empyema (anterior cells) or if arising idiopathically may be traced to one of the infectious diseases (influenza, diphtheria, scarlet fever, measles, etc.). Resolution occurs more readily than in the sinuses proper on account of the relatively good drainage of each cell, together with the action of the cilia, which, on account of the small mass of secretion to be expelled, are not so taxed as in the larger cavities.

During the later stages of a fresh coryza it is frequently observed that large masses of purulent secretion are continually blown from the nose with immediate relief of the "stuffiness." Much of this secretion has been thrown off from the ethmoid cells.

In this form of disease the mucous membrane is deep red and covered with a thick purulent secretion. In contradistinction to the catarrhal type this form is directly due to micro-organismal invasion.

Symptoms.—It is difficult to enumerate the precise symptomatology of acute ethmoiditis, for the reason that the disease is rarely met with dissociated from other conditions. In general, it may be compared to a particularly severe cold in the head. Absolute occlusion of nares, particularly in the superior portion between the eyes. (The inferior turbinates are sympathetically engorged.) Headache is, of course, constant, taking on a tense character with occasional neuralgic outshoots towards the deeper structures of the eyes; ocular symptoms are prominent as tender-

ness of the bulb, pain on rotating, epiphora, orbital neuralgia on reading or otherwise concentrating the gaze. Anosmia is marked as long as the nasal obstruction exists. The general disturbances are analogous to those occurring during the course of a severe coryza.

Diagnosis and Prognosis.—The diagnosis of these acute forms of ethmoiditis must be largely conjectural, for the reason that any satisfactory rhinoscopic examination owing to the enormous swelling is out of the question. Adrenalin and cocaine do not act well in these affections; therefore, our means of ascertaining the precise conditions are greatly limited. As a matter of fact, the differential diagnosis between an acute ethmoidal disturbance and an acute cold in the head is an impossibility, as the two conditions are to all intents and purposes inseparable. For practical purposes we might say that the condition is one of acute ethmoiditis when the cold in the general nasal cavity has abated, while the ethmoid appears yet to continue unduly inflamed.

The prognosis is precisely the same as that of an acute coryza. One point, however, must be emphasized. Each attack predisposes toward another, leaving the disintegration of the mucosa more and more marked, until a condition of chronicity develops, together with a marked tendency toward catching cold; therefore, it is wise during the interim between attacks to make a comprehensive examination of this region with the view of ascertaining and suppressing the cause of their discomfort.

Treatment.—Acute catarrhal inflammation: The indications for the treatment of this affection are similar to those of acute catarrh, frontal or maxillary sinusitis, except in this instance we have to combat inflammation in the interstices of numerous cells instead of one continuous cavity. For this purpose we observe the following rules:

- (1) The patient should be ordered to bed.
- (2) The blood should be depleted from the head by opening the bowels with $\frac{1}{10}$ calomel and soda every hour until free purgation is established.
- (3) This may be assisted with a Dover's powder, followed by a hot mustard foot-bath.
- (4) Ice-bags should be applied to the head, covering the eyes and bridge of the nose.
- (5) Inhalations of vapor arising from hot water with tr. benzoïn. comp., teaspoonful to quart.

$\frac{1}{10}$ grain.

This treatment, if instituted early and energetically carried out, will usually cut short the attack. Local treatment, such as applications of adrenalin, cocaine, etc., are badly tolerated, as the after-effect only supplements the discomfort of the original condition and undoubtedly protracts resolution.

Acute Suppurative Ethmoiditis.—A similar treatment to that outlined above is indicated. As the secretion is usually loosened by the vapor inhalations, operative measures are rarely if ever required. If, however, such a contingency arises, resection of the uncinata process with ablation of the ethmoidal bulla may be demanded (see page 330).

3. CHRONIC INFLAMMATION OF THE ETHMOID LABYRINTH.

The ethmoid cells are subject to three different chronic inflammatory processes, two being entirely separate and distinct, and the third a combination of these. They are:

1. Chronic catarrhal inflammation (hyperplastic ethmoiditis).
2. Chronic suppurative inflammation (empyema).
3. Chronic catarrhal inflammation with suppuration.

ÆTIOLOGY.—In contradistinction to empyema, the causative factor for hyperplastic ethmoiditis depends rather upon a protracted and more or less continual disturbance in the nutrition (*circulus vitiosus*) of the ethmoidal capsule than upon inflammatory changes with bacterial invasion. Mechanical causes would seem to be pre-eminent. Repeated attacks of coryza, each one leaving greater changes in the mucosa, certainly contribute to the ultimate formation of polypoid tissue. Particularly wide nares, allowing the inspired air to act as a distinct irritant, are often found associated with polypoid degeneration of the operculum of the middle turbinate.

It is a well-known fact that once polypoid tissue is formed in the nose, just that much greater tendency the mucosa exhibits to transmit this hyperplasia to neighboring cells; therefore, the longer the process has been standing, the greater in all probability the polypoid infiltration.

*PATHOLOGY.*⁵¹⁹—The continual slight irritation of a certain portion of the mucosa causes at first hyperæmia with subsequent outflowing of serum into the interstitial spaces of the connective tissue. If the irritation be mild the hypertrophy will tend to spread itself

519. Skillern: The Comparative Pathology of Hypertrophic and Suppurative Ethmoiditis. *Journ. Am. Med. Assn.*, Dec. 17, 1910.

over a broad area, gradually losing its polypoid character into the surrounding tissues. If, however, it be great, the continual collection of serous elements, assisted by the force of gravity, will soon cause the appearance of a true mucous polyp. These changes occur principally upon the anterior end of the middle turbinate, along the uncinatè process or in the region of the ethmoidal bulla (floor of ethmoid capsule). When the changes occur in the cells proper, some interference has taken place in the collateral circulation from partial occlusion of their ostia or direct continuation of the process from one cell to another.

To E. Woakes, of London, belongs the distinction of first calling attention to the relation between nasal polyps and ethmoid disease.⁵²⁰ This author considered the polyp as symptom and result of a necrosing condition of the underlying ethmoid bone and attempted to prove his assertion by microscopic observations. He was unfortunately assailed on all sides by his colleagues,⁵²¹ so that no further elucidation of the subject was accomplished until Hajek⁵²² made systematic microscopical examinations of not only the polypoid tissue, but also the place of their attachment to the bone. The findings of this investigator were totally dissimilar to those of Woakes, at least as far as their translation was concerned. Hajek found the polyp took its inception in the external layer (columnar) of the epithelium and worked its way inward, finally attacking the bone. The osseous changes were those of apposition and reabsorption, but not the slightest trace of carious or necrotic process was anywhere to be observed. This proved that the name, necrosing ethmoiditis, as given by Woakes to the pathological process, was decidedly a misnomer, as what Woakes considered necrotic bone, from examination with the sound, was in reality a condition of osteo-porosis. Hajek's findings were later substantiated by Cordes⁵²³ and Uffenorde,⁵²⁴ so that it is established that polyps and polypoid hypertrophies are due to external causes and that the many changes in the underlying bony structures are the result and not the cause of these pathological conditions.

Microscopic Examination.—The external lining membrane before polypoid changes occur shows considerable round cell and leucocytic infiltration. No metaplasie of the ciliated epithelium into squamous occurs until the tissues assume a marked polypoid character except over the area which has been subjected to irritation. There is marked connective-tissue formation beneath the basement membrane, the meshes of which become dilated and filled with exudate. The mucous glands are primarily hypertrophied, not infrequently showing enormous cystic dilatation of their acini. The

520. Woakes: Necrosing Ethmoiditis. Brit. Med. Journ., April 14, 1885. Lancet, July 18-25, 1885. 521. Pathology of Necrosing Ethmoiditis. Brit. Med. Journ., March 12, 1892, June 10, 1893. Heath, Martin, Watson, Browne, and Taylor: Brit. Med. Journ., Dec. 10, 19, 22, 1892, and Jan. 3, 16, 1893. 522. Hajek: Ueber Die path. Veränd. d. Siebbeinknochen, etc. Arch. f. Lary., Bd. 4, S. 277, 1896. 523. Cordes: Ueber die Hyperplasie, die Polypöse Degeneration der Mittleren Muschel, etc. Arch. f. Lary., Bd. 11, S. 280, 1900. 524. Uffenorde (518), S. 35.

blood-vessels are surrounded by leucocytes and soon begin to atrophy. The periosteum is hypertrophied and shows fibrous degeneration along the bone, numerous bone-cells range themselves, some forming new osseous tissue (osteoblasts), others causing reabsorption (osteoclasts). In well-marked cases the osteoclasts appear to predominate. These pathological changes are transmitted directly through the bone to the periosteum and subjacent tissues.

SYMPTOMS.—In the earlier stages of hyperplastic ethmoiditis a condition resembling chronic coryza predominates. Every exposure to cold, draughts, damp feet, etc., brings on attacks of sneezing, increased watery secretion from the nose, ocular manifestations, etc. When the disease has become outspoken one of the principal symptoms is the headache, which is marked in the region of the nasal base above and below the eyes and often radiating toward the temples. It is not constant, but seems to depend largely upon the state of congestion of the head. Occasionally the pain is so intense as to simulate an idiopathic neuralgia and lead to resection of a nerve.⁵²⁵ Unlike pain from the sinuses, it is not so markedly affected by indulgence in tobacco or alcohol or by stooping or sudden jarring. A marked feeling of fulness is present in the upper portion of the nose, and not infrequently the patient complains of intra-ocular pressure.

Secretion: The exudate may, on account of its abundance, be one of the most prominent and annoying symptoms. It is of thin watery consistency, straw colored, leaving no perceptible stain upon the handkerchief. During attacks of acute coryza it often assumes a purulent consistency, but after the disappearance of the cold resumes its former appearance.

Olfactory Function: Disturbances in the sense of smell are common on account of the occlusion of the olfactory space by the encroachment of polypoid tissue. Anosmia is naturally most frequently met with, although occasionally a subjective unpleasant musty odor is now and then perceived by the patient. This is undoubtedly due to stagnation of the secretion in some of the interstices behind the polypoid swellings, with invasion of saprophytic micro-organisms. An unpleasant taste in the mouth is often present in the morning, due to stagnation and fermentation of the secretion, which has collected in the choanæ during the night.

525. Marquis: Non-suppurative Ethmoiditis. *Laryngoscope*, p. 12, 1911.

Pharyngeal and Bronchial Symptoms: Certain disturbances met with in the pharynx are often associated with this disease. Granular hyperplastic pharyngitis, particularly behind the posterior tonsillar pillars, is common. Hypertrophy of the tonsils, as well as Eustachian catarrh, may be classed as concomitant affections.

By far the most common bronchial affection occurring with hyperplastic ethmoiditis is asthma, a condition which has long been recognized by laryngologists. How far this may have a bearing upon the ethmoidal disease is well shown by the numerous cures reported after removal of the diseased ethmoidal structures. The precise relation between nasal polyps and asthma has, as far as I am able to learn, not been clearly explained. Bronchitis in various degrees also accompanies this disease, and in Uffenorde's statistics occurs in about 30 per cent. of all cases.

Orbital Symptoms: In contradistinction to sinus empyema the eye symptoms connected with the hyperplastic form of ethmoiditis are usually of mechanical origin. In the former the reabsorption of pus plays a prominent rôle, while in the latter the pressure exerted by the new tissue formation, together with the consequent disturbances in circulation, are the exciting cause.

The subjective symptoms consist of scotoma, neuralgic pains in the bulb, ciliary neuralgia and photophobia. In severe cases vasomotor disturbances, such as hyperæmia of conjunctiva and œdema of eyelids and periorbital tissues, may occur. The appearance of these reflex neuroses is but to be expected, when one recalls that the orbital and nasal cavities are supplied by the same sensory nerves.

DIAGNOSIS.—When the general symptoms point to ethmoidal diseases our first thought would be to examine the middle turbinate and as much of the capsule as possible. For this purpose a long Killian speculum is necessary. The blades should be introduced between the uncinatè process and middle turbinate, and forced apart, thereby giving us a good view of the bulla and surrounding tissues. A sound must now be employed to ascertain the condition of the mucosa. Frequently the base of the bulla will be lined with pearl-like polyp buds, which assume considerable size after the turbinate has been refracted. It is impossible to estimate the degree of polypoid changes that have taken place within the capsule until the cells are laid bare. Posterior rhinoscopy is now

applied to determine the condition of the cells of the superior nasal passage. The maxillary sinus should be punctured to exclude empyema of that cavity. If no signs of purulent secretion or crusts be present, yet polypoid degeneration of the ethmoid mucosa apparent, we can safely make a diagnosis of chronic hyperplastic ethmoiditis.

TREATMENT.—No conservative treatment will suffice after the development of this disease. A certain amount of tissue must be removed, according to the extent of the inflammation. Two forms of the disease are recognized: 1. Large polyp formations, few in number, with circumscribed areas of inflammation. 2. General polypoid inflammation of more or less of the entire ethmoid capsule.

1. Let us suppose we have a patient with several large polyps hanging from beneath the middle turbinate and have satisfied ourselves that no purulent process is present. Naturally our first thought is to remove the polyps. To introduce a snare and remove them without further investigation is bad surgery, for in this way the subsequent hemorrhage will make it impossible to learn their exact source or to ascertain the extent of the polypoid degeneration. We should endeavor to follow up the polyps to their attachment by examining the ethmoidal capsule after resection of the middle turbinate. If the polyps be so large or numerous that this is impossible, it is almost certain that the greater portion of the ethmoid is diseased; however, in any case an attempt should be made to learn their origin. Suppose it has been found that they spring from the region of the uncinata process and bulla. We can choose between two lines of operating: (1) simple ablation of the polyps; (2) ablation of polyps and removal of all polypoid tissue.

(1) Simple Ablation of Actual Polyps: The parts must be thoroughly cocainized and made bloodless with the cocaine-adrenalin solution. The loop of the snare should be made to encircle the polyp, and the end of the tube carried up around

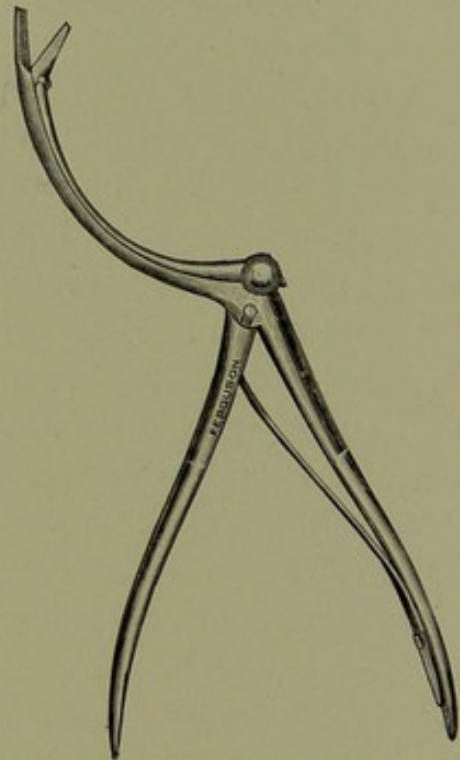


FIG. 200.—Lange's frontal sinus and ethmoid punch.

the base as high as possible by working the wire with a wabbling motion, gradually constricting the loop until firm resistance is encountered. The wire is now slowly tightened until it is felt that any further constriction will cut through the neck of the polyp. After making certain that it has firm hold on the tissue, the entire instrument is suddenly jerked out of the nose. This procedure causes no particular pain, and at the same time, instead of merely severing the polyp from its attachment, leaving a portion of the neck behind, it often removes a considerable part of its bony attachment, thereby obtaining tissue which, if left behind, would serve as a means of the recurrence of the hyperplasia. This manœuvre is repeated until all the visible polyps have been removed.

(2) Ablation of Polyps with the Removal of all Polypoid Tissue: The secret of the successful performance of this operation depends upon the thoroughness of the ischemia produced; therefore, in addition to the cocainization, pure adrenalin chloride should be sprayed up into the ethmoid region after the parts have been cocainized. Twenty minutes should elapse from the time of the first application of adrenalin to the inception of the operation. The polyps are removed with the snare as before by ablation. If any bleeding occur, it can be controlled by the application of cotton pledgets saturated with pure adrenalin chloride. The double Grünwald forceps, which seize but do not bite, are now used, and, always working beneath the middle turbinate, the osseous tissue forming the base of the polyps is removed piecemeal until healthy tissue is reached. This is easily recognized by the whitish, tense, thin membrane which lines the normal ethmoid cells. Several cells may be resected as described on page 330. In this manner, by slow and careful work, incipient hyperplastic ethmoiditis is often effectually combated with preservation of the middle turbinate.

2. *General Polypoid Inflammation of the Ethmoid Capsule.*—This form of the disease is merely an advanced stage of the former, although it often occurs without the primary formation of polyps of any considerable size. During the advanced stadium the polyps may be so numerous as not only to occlude the nares but to cause a widening of the nasal arch. The only effective treatment available for this condition is complete exenteration of the ethmoid capsule. This may be accomplished by the method

described above, but is better accomplished by the method recently described by Ballenger.⁵²⁶

Ballenger's Method: The rationale of this procedure is to exenterate the ethmoid labyrinth *in toto* with the least possible incisions and in the shortest possible time. The author does it as follows:

(1) Cocainization and adrenalization as before.

(2) A Ballenger knife is introduced beneath the bulla at the posterior attachment of the middle turbinate and pulled forward, cutting along the lamina papyracea and as far up as possible. This incision is repeated until the capsule is free from the orbital plate. Care must be taken not to injure this plate at the end of the incision near the inner angle of the eye.

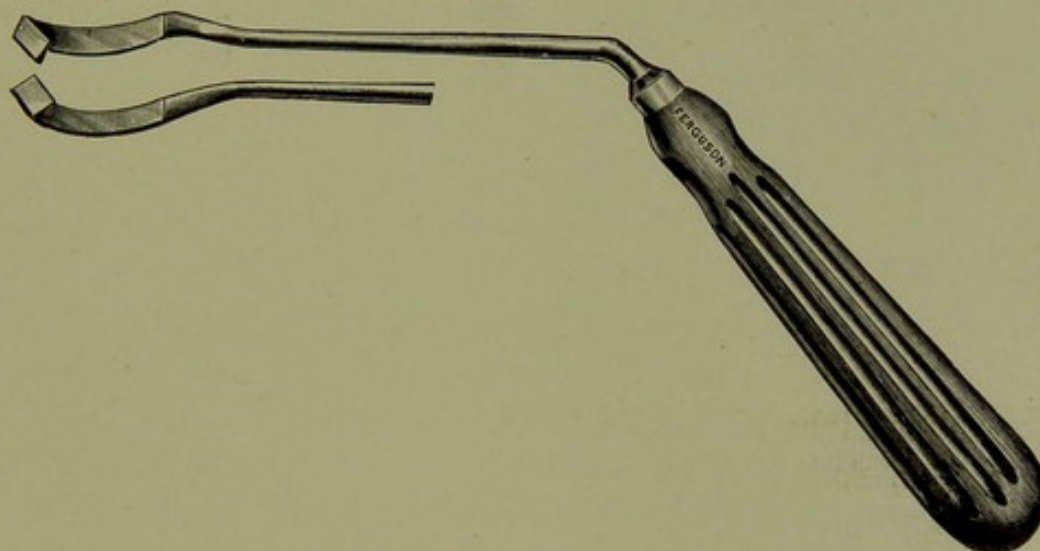


FIG. 201.—Ballenger's ethmoid knives.

(3) The angular knife (Fig. 201) is now introduced until the short blade rests against the anterior wall of the sphenoid, the long blade occupying the cut previously made. The handle is now depressed and the short blade forced through the ethmoid cells slightly below their attachment to the frontal bone.

On performing these cuts the knife must be brought forward with a wabbling motion, thereby fracturing the thin plates of the ethmoid cells in its progress forward.

The knife is drawn completely forward until it emerges from the nose, leaving the severed portion of the capsule lying free in the nares. (Fig. 202.)

526. Ballenger: Diseases of Nose, Throat and Ear, p. 233, 1909.

(4) Remove fragment with stout pair of forceps. In this manner polyps, hypertrophied tissue, *et al.*, are removed in one piece, the capsule being entirely ablated. Bleeding is rather smart for a few moments, but ceases shortly of its own accord. The attending pain is not great and the entire operation requires but a few moments.

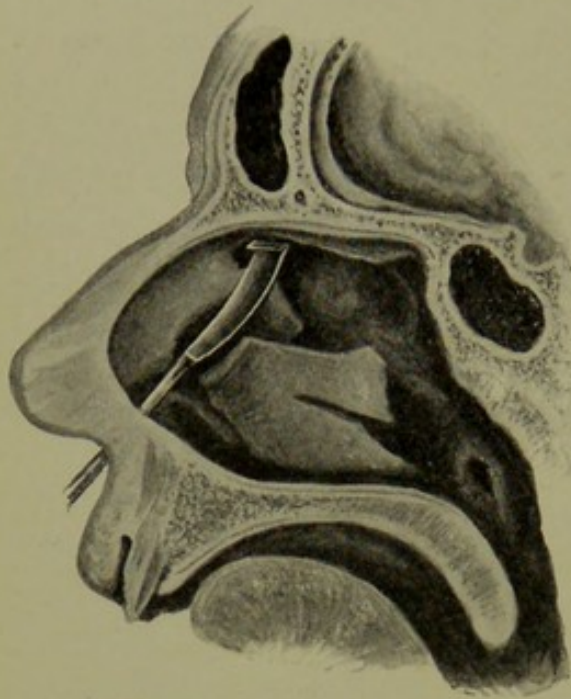


FIG. 202.—Exenterating ethmoid capsule en masse with the Ballenger right-angle knife. The ethmoid capsule with the middle and superior turbinate has been severed from its attachment and has dropped on to the floor of the nose.

When this method was introduced, considerable opposition was encountered from all sides, many rhinologists considering it entirely unjustifiable.⁵²⁷ I am free to admit that I also shared in this opinion, but after the many excellent results obtained without even an untoward symptom the operation has now become a routine practice with me. It should not be particularly painful to the patient, and any tendency toward dryness in the nose after healing seems to be successfully prevented by compensatory swelling of the inferior turbinate.

After-treatment consists merely in keeping the parts free from crusts and débris, which

can be accomplished by daily irrigation with warm sterile normal salt solution, followed by insufflation with bismuth-formic-iodide powder. Tampons of any sort to control hemorrhage are usually superfluous, and only add to the discomfort of the patient.

4. CHRONIC SUPPURATIVE INFLAMMATION. (EMPYEMA.)

Suppurative processes in the ethmoid cells may occur in two forms: (1) open or manifest empyema; (2) closed-in or latent empyema. In the first instance the purulent secretion forming the cells escapes through the ostia and appears in the nose, while in the latent variety some occlusion prevents the pus from escaping, so that it gradually is secreted under pressure until it bursts or is evacuated by artificial means.

ÆTIOLOGY.—Suppuration in the ethmoid cells usually is but an accompaniment of empyema in one of the larger cavities; however, it may occur as a separate process. Acute infectious diseases

527. Ballenger: The Exenteration of the Middle Turbinate Body and Ethmoid Cells en masse. Trans. Am. Lary., Rhin. and Otol. Soc., p. 497, 1909.

seem to exert a peculiar influence toward ethmoidal suppuration, in all probability by lowering the vitality of the lining mucosa.

When one considers that at least half of the respiratory mucosa belongs to the ethmoid capsule it is rather a wonder why more cases of suppuration in these cells are not more frequently encountered.

Another ætiological factor of no little importance is the forcible blowing of the nose during a coryza, thus forcing pus and inflammation into cells that would otherwise remain normal. (Roe.)

Suppuration in the ethmoid cells not infrequently follows packing the nose after an intranasal operation. Cauterization with the actual cautery after the removal of polyps often causes purulent infection, being the direct result of the intense inflammatory reaction.

As the maxillary antrum or the frontal sinus or both are often coaffected, it is frequently a question which has been the primary seat of the disease. Luc believes the ethmoidal cells are always secondarily affected either from the frontal or maxillary sinus.

It is also possible for infection of the ethmoid cells to occur through the lamina papyracea following orbital abscess of idiopathic origin. If we revert a moment to the anatomy and consider the delicacy of the orbital plate separating the ethmoid cells from the orbital structures, it is small wonder that such an infection readily occurs.

PATHOLOGY.—Chronic suppuration in the ethmoid cells is invariably due to bacterial infection. The changes in the mucosa are similar to those in empyema of the large sinuses, being thickened with a marked formation of fibrous tissue. There is a marked tendency toward occlusion of the ostia through swelling of the mucosa, particularly in the smaller cells—a condition due to the especial tenderness and looseness of the ethmoid mucosa. Round-cell infiltration is prominent; gradual proliferation of the epithelium occurs, and in severe cases is often absent in spots, being replaced by granulation tissue.

HYPERPLASTIC TYPE.

Metaplasia of ciliated epithelium into squamous only where parts have come into contact with other structures.
 Meshes of subepithelial connective tissue dilated.
 Round cell infiltration scanty.
 Glands hypertrophied primarily.
 Reabsorption changes in bone predominate.

SUPPURATIVE TYPE.

General metaplasia where secretion comes into contact with mucosa.
 Subepithelial connective tissue shows fibrous formation.
 Round cell infiltration well marked.
 Glands primarily atrophied.
 Apposition of bone predominates.

SYMPTOMS.—It is impossible to enumerate a given set of symptoms that will apply equally well to all cases of suppurative ethmoiditis, as, perhaps, no one affection will exhibit such a variegated clinical picture. It not only depends upon the virulence of the infection and the extent of the process, but upon the disposition of the individual as well. The suppuration usually shows a marked tendency to run its course without causing a great deal of subjective discomfort, and, as Hajek well says, the patient often comes to us complaining rather of pharyngeal or laryngeal disturbances than of trouble located in the nose. Another point to be remembered is that ethmoidal suppuration is usually combined with frontal or maxillary sinus empyema, and in such cases it is difficult to differentiate the symptoms caused by these from those of ethmoidal derivation.

The headache present in these cases shows a marked difference from that caused by the hyperplastic variety unless associated with polyposis. In the uncomplicated form, where free drainage exists, there is often no history of headache whatsoever, while in the closed-in variety, where stagnation has occurred, the head pains are sometimes unendurable. During an acute exacerbation of a chronic ethmoidal suppuration the headache is often diffuse. The typical region for the localization of the pain in ethmoidal disease appears to be over the root of the nose and directly on the vertex, occasionally radiating downward into the mastoid processes. Deep-seated pain in the eyes or tension on the bulb is not present unless stagnation and pressure occur.

Secretion.—The exudate in contradistinction to that emanating from hyperplastic ethmoiditis is distinctly purulent, invariably exhibiting the greatest tendency toward drying and forming crusts not only in the nares, but in the pharynx and even the larynx. The quantity secreted depends, as before, upon the extent and degree of the inflammation; sometimes in the same case it may continue profuse for days, then suddenly reduce itself to a minimum, only to break forth violently at the first acute exacerbation. Pus cells, however, may always be discerned with the microscope—a condition which is not often present in the exudate from the hyperplastic form.

Olfactory Disturbances.—Anosmia is frequent, being due to two conditions: 1. Swelling of the middle turbinate, thus occluding the olfactory fissure. 2. Anatomical changes due to degeneration of the terminal olfactory filaments from the constant bathing in

Take a slide specimen

purulent secretion and cacosmia is the rule rather than the exception, and differs from the sourish or musty smell observed associated with hyperplasias, in that the odor is distinctly fetid. This is undoubtedly caused by putrefactive changes in the various foci of pus, which have become isolated in the numerous interstices of the ethmoid capsular wall. No secretion is observed in the closed type.

The pharynx is hypersensitive, due to the constant rasping and hawking, particularly in the morning, in order to clear the throat of the crusts and particles of dried secretion which have formed during the night. Nausea and vomiting can easily ensue from this cause, giving the appearance of a gastric affection.

Rhinoscopic Examination.—It will be apparent that secretion is present by the signs of crust formation, particularly around the external nares. The middle turbinate is hypertrophic, and traces of pus are visible between it and the lateral nasal wall. If this turbinal be infracted a quantity of secretion often wells out from the middle nasal passage, and if the uncinatè process appears swollen it is almost pathognomonic of the disease.

Polyyps in the recent cases are not present, and, when due to the irritation from the constant bathing with the purulent secretion, are large and spring from those portions of the ethmoid which are low down and prominent (uncinatè process, bulla and middle turbinate). In hyperplastic ethmoiditis without suppuration they are small and numerous, and occupy the various ethmoidal cells. The inferior turbinate is often distinctly atrophic.

Pharyngitis sicca is always present in advanced cases, being due to the evaporation and irritation of the secretion which continually finds its way into the pharynx during sleeping hours. Laryngeal affections, as with the true sinuses, may also occur as a result of the irritation from the down flowing secretion. Chronic dyspepsia has also been reported as a sequela of this condition.

Orbital symptoms are uncommon with suppurating ethmoiditis when the drainage is not interfered with. In long-standing cases symptoms of auto-intoxication from reabsorption of toxins or transmission through the venous system may occur, but as yet such cases have not come under my observation.

DIAGNOSIS.—The diagnosis of free purulent suppuration in the anterior ethmoid cells is not usually a matter of great difficulty, provided the proper examinations are made. The first examina-

tion may not suffice to attain this object, but repeated endeavors will surely bring to light the source of the secretion. Every attention must be paid to the lesser symptoms, such as crusts in the middle nasal passage, unnatural hypertrophies in the region of the unciniate process, etc. Let us, however, take up the diagnosis in a systematic manner. Suppose on examination we discovered an enlarged middle turbinate and traces of pus in the middle nasal passage, both symptoms of disease of any or all of the anterior sinuses. Our first thought is to insert the long-bladed Killian speculum and obtain a view of the middle nasal passage and contained structures. On the application of this instrument more pus is seen to issue from the depths of this fossa. We now thoroughly wash out the nose with the saline solution so as to cleanse the cavity from all free pus, crusts and detritus, and observe carefully whether the secretion immediately reappears. This symptom being positive, we make the customary puncture of the antrum beneath the inferior turbinate with a negative result. Turning next to the frontal sinus, we sound and catheterize this cavity, ultimately washing it out with our salt solution. If no pus appears in the returning fluid a tentative diagnosis of ethmoidal suppuration can be made. It is necessary, however, to go still further and ascertain the exact source of the secretion. Resection of a portion of the middle turbinate will probably be demanded not only for diagnostic purposes, but to create sufficient drainage as well. After healing of the wound has occurred it may be possible to directly observe the purulent matter exuding from the middle nasal passage. This with the reappearance of crusts in this locality which conceal foci of pus, together with the exclusion of maxillary or frontal disease, will substantiate the diagnosis.

Transillumination.—Although this method of diagnosis has its devotees, ⁵²⁸ ⁵²⁹ we have found it thoroughly unreliable in ethmoidal suppuration. This is probably due to the fact that it is impossible to place the light in such a position as to send the rays through the bulla and surrounding structures. At best the shadows in the normal individual are indefinite, and in disease one is obliged to call on the imagination in order to perceive a definite picture. We have long since abandoned this procedure in examination of the ethmoidal region. The X-ray, however,

528. Rault (142). 529. Luc: Leçons sur le suppuration de l'oreille, etc., p. 347, 1910.

not only acquaints one with the condition of the ethmoid cells, but the exact location of the purulent collection as well.

Abnormal difficulties in the diagnosis, such as the maxillary sinus acting as a reservoir for pus from the ethmoid cells, suppurating orbital cells and pansinusitis, have been discussed under the frontal sinus.

DIFFERENTIAL DIAGNOSIS.

CHRONIC HYPERPLASTIC ETHMOIDITIS.	CHRONIC PURULENT ETHMOIDITIS.
Often bilateral. Secretion clear and watery.	Usually unilateral. Secretion purulent
Never crust formation.	Always crust formation.
Headache most prominent symptom.	Headache often light or absent.
Ophthalmic manifestations due to pressure of hypertrophic mucous membrane on vessels.	Ophthalmic manifestations due to infection from purulent secretion.
Gastric disturbances absent.	Gastric disturbances frequent.
Neurasthenic symptoms predominate.	Neurasthenic symptoms not marked if flow of secretion be free.

CLOSED-IN OR LATENT EMPYEMA.

This affection is caused by the primary infection of a cell, whose ostium during the course of the disease has either by swelling of its own mucosa or the coaptation of a neighboring structure become closed, the suppuration within the cell continuing.

Under these circumstances one of four things must occur: 1. The inflammation subsides with subsequent absorption of the secretion. 2. The secretion continues up to a certain stage then remains dormant. 3. The inflammatory products continue to be secreted with dilatation and ultimate rupture of the cell. 4. The formation of a mucocele.

1. Resolution with absorption of inflammatory secretion: This can occur only in the presence of germs which by successive growth gradually lose their virulence. The frequency with which this occurs is a matter of surmise, as after a length of time it would be impossible to ascertain on the autopsy table whether any pathological changes had taken place in a given cell which had thus undergone resolution.

2. Secretion forming and then becoming latent: This form of purulent ethmoiditis results from repeated attacks which finally produce a semi-permanent closure of the ostium. The inflammation does not appear severe enough to cause dilatation or necroses of the walls, neither is it absorbed, but remains in a

dormant state. A certain amount of drainage occurs, for at long intervals the affected cells empty themselves into the nose. Usually but few cells are affected, the most frequent being those of the bulla. The diagnosis of this variety, particularly from an empyema of the frontal sinus, is very difficult, and only by repeated examinations with the free use of the sound is one able to determine definitely the source of the secretion.

3. Empyema with dilatation (pyocele): This is but an advanced form of the latent variety in which the closure is absolute, the dilatation resulting from the pressure of the continued secretion of the purulent products. The disease often is confined to one cell, which, in dilating, encroaches upon the walls of the neighboring cells, absorbing them in its progress until a considerable portion of the ethmoid capsule is hollowed out into one large cavity. Four seats of predilection occur: (1) the free end of the middle turbinate; (2) the middle turbinate in its entirety; (3) the bulla ethmoidalis; (4) the posterior ethmoid cells situated beneath the superior turbinate.

(1) A congenital middle turbinate cell must be present for this pathological process to take place. On rhinoscopic examination the middle turbinate appears to balloon downward, occupying much of the middle nasal fossa. (Fig. 203.) When pressed on with the sound it gives one a parchment-like impression. The contents are purulent, sometimes containing cheesy flakes.

It is difficult to determine—unless the case has been followed up—whether dilatation has occurred through the internal pressure of the secretion or whether simple infection has taken place in physiologically enlarged cells in the middle turbinate. It is, however, only of theoretical interest, as the therapy is precisely the same in either instance, *i.e.*, opening at the lowest extremity with complete evacuation of the contents.

On opening this enlargement with the hook and Grünwald forceps it will be noted that the cavity only extends upward as far as the attachment of the turbinate to the body of the ethmoid capsule. Information as to the true condition which confronts us will be at once obtained by the character of the contents. The lining mucosa of the cavity exhibits the characteristics of any purulently inflamed ethmoid cell.

(2) When the entire middle turbinate is the seat of a pyocele the superimposed ethmoid cells are continuous with that of the turbinate, forming a large cavity which extends from its tip to the frontal wall of the cribriform plate. (Fig. 204.) Rhinoscopic

inspection will only show the enlarged extremity of the turbinate, but on opening with a hook and using a sound the condition will at once become clear.

(3) Purulent dilatation of the ethmoidal bulla. This form consists of a purulent collection in the cells of the bulla which extends to the orbital plate. The bulla projects outward into the middle nasal passage, often reaching the septum, forcing the middle turbinate inward and upward in its progress. (Fig. 205.) Rhinoscopic examination reveals a picture which is often difficult to solve correctly. The dilated bulla occupies the position of a swollen turbinate, the latter structure being often completely hidden from view. A differential diagnosis is for the most part

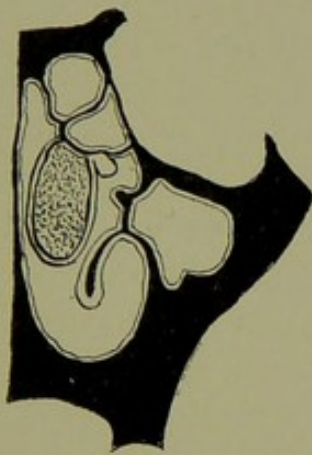


FIG. 203.—All in middle turbinate filled with pus. Remaining portion of the ethmoid capsule unaffected. (After Hajek.)

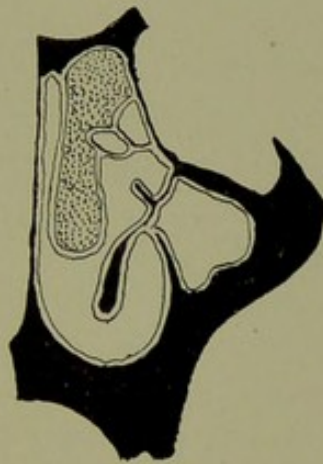


FIG. 204.—Middle turbinate and superior lying cells filled with pus. (After Hajek.)

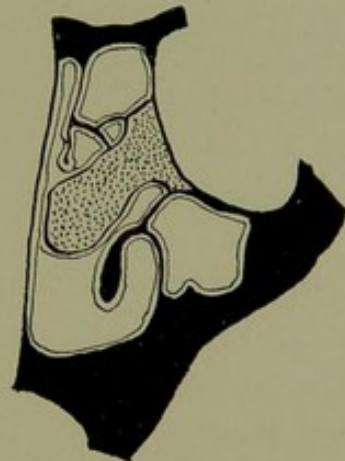


FIG. 205.—Bulla filled with pus. Remaining portion of ethmoid unaffected. (After Hajek.)

impossible until the dilatation has been completely removed, when the turbinate will appear *in situ*. Confusion of this pathological condition with a normally enlarged ethmoidal bulla will hardly occur, as in the former instance some pathological changes are always present in the affected nares.

It must be remembered, when considering these forms of dilatation, that in no instance are they arbitrarily confined to the boundaries mentioned. In perhaps the majority of cases the process embraces a large portion of the ethmoid labyrinth, regardless of the individual structures. The process of dilatation continues until rupture occurs; therefore, it depends entirely upon the resistance of the walls as to the size and extent of the cavity.

4. Mucocoele of ethmoid labyrinth: A mucocoele may occur in

X either the anterior or posterior cells, although the former variety is by far the most common. They are characterized by a swelling at the superior internal portion of the orbital cavity, which progresses slowly without any symptoms of inflammation. The difference in the situation of the frontal and ethmoidal swelling may be too slight to be of any real differential diagnostic value. The protrusion is rounded, even, and, in the beginning, of bony hardness. The overlying cutaneous tissues show no changes from that of the surrounding skin.

As the swelling progresses (sometimes requiring months and even years) the osseous walls become very thin from reabsorption until at the most prominent part a distinct fluctuation is observed. The permanent œdema of the eyelid assumes greater proportions, and the eyeball becomes very gradually dislocated downward and outward until in very old cases it is forced far out of the socket. Spontaneous rupture can now occur. Within the nose a bulging of the ethmoid capsule toward the septum, with the formation of a smooth, rounded tumor, occurs, which shows decided elasticity when pressed upon by the sound. Pain in the eye is sometimes noted after the swelling has encroached upon the orbital structures, although it assumes more the sensation of a feeling of pressure and tension.

The contents of these cystic structures is usually of a thick, mucoid consistency, variable as to color, quite sterile, and sometimes difficult to remove on account of its cohesive qualities.

As regards sterility micro-organisms have occasionally been found, but upon culture were shown to be devoid of virulency. Microscopical examination shows the contents to be composed of fatty degenerated epithelial cells, detritus, a few red and white blood-cells, and cholesterin crystals.

As with the frontal sinus, it is not necessary that the ostium be occluded in order that a mucocele should form, as the contents are often too thick to escape. This would account for the not infrequent history of occasional discharge into the nose.

The middle turbinate may be the seat of a mucocele. Under such circumstances the symptoms will be similar to those associated with an ordinary cystic enlargement in this locality. An opening at the most dependent portion will give immediate information as to the character of its contents.

The posterior ethmoidal cells have been reported as the seat of a mucocele. When this takes place the swelling occludes the posterior nasal passages and may extend into the choana. This

X More common - American
Wentham

condition, unassociated with a similar affection of the anterior cells, must be one of extreme rarity. The simultaneous occurrence of a mucocele on both sides of the ethmoid has also been observed.⁵³⁰

MUCOCELE.	PYOCELE.
Growth extremely slow.	Growth rapid.
No inflammatory symptoms.	Inflammatory symptoms predominate
Tenderness absent.	Tenderness marked.
Firmness on palpation.	Fluctuation.
Mild orbital complications.	Severe orbital complications.
Puncture shows mucoid substance.	Puncture shows pus.
Secretion sterile.	Secretion infected.

When infection of a mucocele occurs a pyocele results.

5. CHRONIC HYPERPLASTIC INFLAMMATION WITH SUPPURATION.

This classification has found considerable opposition,⁵³¹⁻⁵³² most observers contending that the suppuration precedes, and does not follow, the polypoid hypertrophies.

It has been an old and accepted view that the constant drainage of a purulent secretion over a given area of nasal mucosa will sooner or later give rise to polyposis; therefore, these hyperplastic structures are the result of secondary irritation due to the outflow of secretion. This statement was accepted in its literal sense, no modification being observed, and, indeed, some authorities even considered the mere presence of polyps in the nose as pathognomonic of sinus suppuration. While occasional dissent was made,⁵³³ it was not until Uffenorde put himself on record by stating that the suppuration was more often secondary to the polyposis,⁵³⁴ and endeavored to prove the same, that interest was given to this thought. He reasoned as follows: From repeated attacks of simple catarrh, numerous polyps made their appearance from the ethmoid region until a greater portion of the nasal chamber was occluded. Ventilation, as well as the possibility of cleansing by blowing, so seriously interfered with that the continually-forming secretion became stagnated between the polyps. Putrefaction followed and infection resulted, particularly during an attack of acute coryza. As the ostia of the sinuses are more

530. Flath: Ein Fall von doppelseitiger Mucocele. Dissertation Giessen, 1902.
 531. Ballenger: Discussion to Various Infections of Ethmoid. Trans. Am. Acad. Ophthal. and Oto-laryngology, p. 126, 1909. 532. Casselberry, Freer, Ballenger: Pathology of Ethmoiditis, Sec. on Lary. Am. Med. Assn., p. 200, 1910. 533. Sieur and Jacobs: Les Fosses Nasales et leurs Sinus, p. 268, 1901 (note). 534. Uffenorde (518), S. 64.

or less occluded, the infection spreads along their mucosa and results in its permanent involvement. This theory took its inception from the reports of Alexander⁵³⁵ and Skrodski,⁵³⁶ who found, on the section table, absolutely no relation between the occurrence of polypi and the existence of sinus empyema.

Our views on this subject have already been advanced (see Relation of Polyps to Empyema), so that no further comment is necessary. It might, however, be added that we do not accept Uffenorde's views in their entirety, but believe nasal polyps, under certain circumstances, result entirely from the irritation of the purulent secretion exuded from diseased sinuses.

COMPLICATIONS.—*External Rupture with Fistula Formation.*—This seems to be the most frequent form of any complication resulting from purulent sinus affections. This is not at all unnatural when we consider the anatomical configuration of these parts in which the orbital structures are separated from the ethmoid labyrinth by only the thinnest possible plate of bone (lamina papyracea), which frequently shows defects throughout its entire formation.

The point of predilection for perforation to occur is in the region of the ethmo-lachrymal suture. In a large number of instances the lachrymal bone is the seat of numerous pin-point perforations, or if the process has well advanced, an entire melting down of this thin bony structure is observed.

The frequency of abscess and fistula formation, and not in severe orbital affections, is in a very large measure due to the orbital periosteum of the lamina papyracea. The infection penetrates this bony plate and reaches the orbital periosteum. Here considerable resistance is encountered, which may result merely in a slight plastic form of periostitis, or, if the infection is persistent, the new-forming purulent secretion, not being able to penetrate the periosteum, will burrow beneath in the line of least resistance, finally emerging at the superior internal angle of the eye.

Orbital: Acute and Chronic Rupture into the Bulbar Cavity.—Acute: Acute rupture into the eye is characterized by sudden outward dislocation of bulb, swelling and infiltration of eyelids, intense pain in the eye which radiates over that side of the forehead, high fever, and general prostration. Fluctuation may be felt above the inner canthus if the purulent mass be forward.

535. Alexander (111). 536. Skrodski: Zur Aetiology der Nebenhöhlenempyem. Intern. Zentralblatt für Laryng., S. 332, 1897.

The following case, seen in consultation with Dr. John A. Brophy, well illustrates this condition:

Henry A., 16 years old. History of previous nasal occlusion. Awoke on the morning of August 13, 1911, with right eye enormously swollen, exophthalmos, lids tightly closed with total blindness on affected side. Pulsating pain in parietal and temporal regions on right. No pain in eye. Total occlusion of right nares. Temperature 102°. On August 17, operation. Usual curved incision. On exposing lachrymal bone it was found to be so necrosed that the tip of the little finger was easily passed through into the anterior ethmoidal labyrinth. The entire ethmoid capsule was found to be polypoid, degenerated and bathed in pus and was therefore completely exenterated. Sphenoid sinus empty. Wound partially closed, drainage into nose and externally. Following day, temperature 100°. Pulse 100. Entirely free from pain, but no change in appearance of eye (Fig. 206). August 19, exophthalmos much reduced. Patient begins to distinguish light. August 30, patient discharged from hospital.

Unless prompt measures are taken to evacuate the pus, it will quickly find its way backward along the sheath of the optic nerve and penetrate into the cranium, causing lethal intracranial complications.

Chronic: Chronic rupture occurs in a totally different manner from the acute, having none of the stormy symptoms found in the former. It usually begins gradually, becomes larger without pain or any inflammatory symptoms. The eyeball is, little by little, dislocated in the usual direction. Chronic œdema of the

lids makes its appearance early in the process. Rupture may occur without symptoms, or, if an acute exacerbation has set in, with all the appearance of an acute process.

Orbital abscess formation can occur without any perforation of the lamina papyracea through the ethmoidal veins. In such case there are two distinct foci of purulent material—one in the ethmoid cells, the other in the orbital tissues. It is often difficult to differentiate these conditions; however, two manipulations may be tried, which, if successful, will clear the diagnosis. By

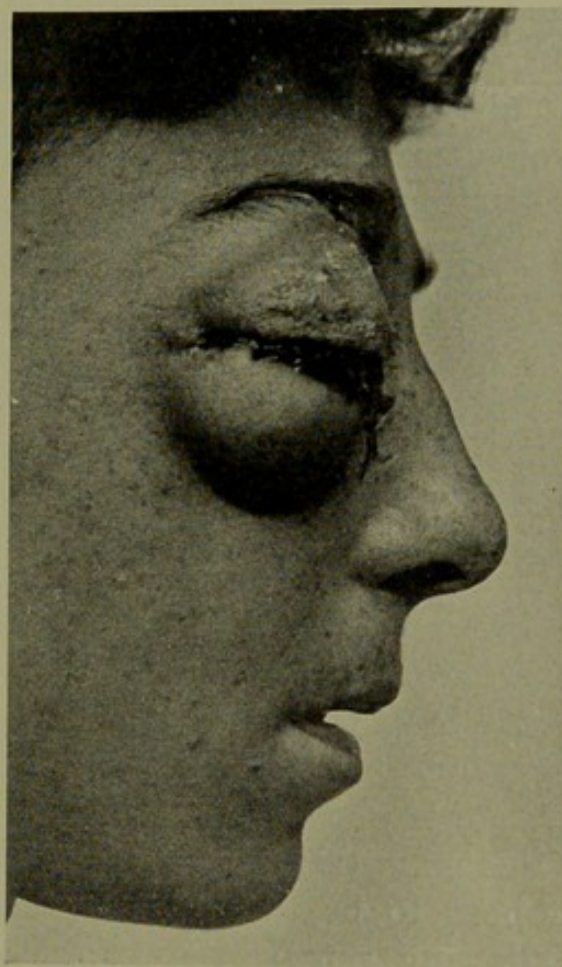


FIG. 206.—Marked exophthalmos due to rupture of an ethmoidal empyema through the lamina papyracea into the orbit.

pressing on the swelling or by allowing the patient to hold the nostrils and forcibly blow, as in the Valsalva method, pus may be made to exude into the nasal cavity. In the latter instance the swelling will become larger, but returns to its original size as soon as the pressure is relieved. If the abscess has already ruptured, blood mixed with pus will be forced out.

Inflammation of the Lachrymal Duct.—This affection is not rarely associated with purulent conditions in the anterior ethmoid cells, largely due to the arrangement of the circulation. The lachrymal sac is surrounded by a network of arteries, a number of which pierce the lachrymal bone, penetrating into the infundibular cells and those of the uncinata process. The returning veins can carry infection from the cells to the lachrymal sac, thus setting up inflammation.⁵³⁷

Functional disturbances are largely due to the hyperæmia and pressure from circulatory disturbances. As most of the ethmoidal veins empty into the ophthalmic, engorgement of these vessels causes a damming back of blood into the veins of the orbit, and particularly in the ciliary network, producing an exaggerated tension in the interior of the eye, which in turn causes disturbances in the circulation of the retina and a baneful influence upon the nervous tissues.⁵³⁸

Cerebral: Intracranial Complications.—These usually occur through the cribriform plate, either by direct extension or through the ethmoidal veins, which richly anastomose with those of the dura in this region. In the latter instance the bone may be absolutely intact.

Meningitis:⁵³⁹ Phlebitis of cavernous sinus and brain abscess appear to be the most common forms of intracranial infection following purulent ethmoiditis. The infection seems, for the most part, to have penetrated the lamina cribrosa either through the natural channels or by caries and necrosis. In contradistinction to the frontal sinus, these meningeal complications occur more frequently with the acute than the chronic ethmoiditis.

Cavernous sinus thrombosis results from the direct infection of the ethmoidal veins which empty into the ophthalmic and thence into the cavernous sinus.

537. Antonelli: Sinusite ethmoido-frontale suite de cellulite orbitaire provoquee par une dacryocystide. Soc. d'ophtalmol. de Paris, Feb. 6, 1900. 538. Ziem: Apropos des Rapports des maladies du nez avec les maladies des yeux. Ann. des mal. de l'oreille, etc., p. 491, 1892. 539. Krauss: Two Cases of Acute Suppurative Ethmoiditis in Children, Resulting in Death. N. Y. Med. Journ., vol. 89, p. 839, 1909.

PROGNOSIS.—Chronic purulent ethmoiditis always requires a certain degree of operative interference before a cure can be obtained. If the pus is limited to a few isolated cells, and these are freely opened, a speedy cure will always result. If the entire labyrinth is suppurating, we face a totally different proposition, as one or two cells are almost sure to escape any intranasal intervention. The presence of necrotic tissue very materially adds to the length of time required for complete resolution, and if extensive necrosis has occurred, subsequent healing may be indefinitely postponed, particularly if the process has invaded the cells of the fovea ethmoidalis.

Certain authors lay stress upon the species of infecting micro-organism being in direct relation to the ultimate prognosis;⁵⁴⁰ thus, a pure staphylococcic infection may be considered good; streptococcic, pneumococcic, and that resulting from the bacillus of Friedlaender are unfavorable. An infection due to the pneumococcus exhibits a decided predisposition towards meningeal infection (some form of meningitis).

After all has been said, the entire prognosis hangs upon the question of free drainage. If this has been installed it is good; otherwise it is bad in direct proportion to the number of foci of suppuration which have been left undisturbed by the operation.

CONSERVATIVE TREATMENT.—Presupposed that the frontal and maxillary sinuses have been excluded and that the ethmoid is purulently affected, the indications are to remove crusts and purulent secretion and at the same time place the nose in such a condition as to cause free drainage from the ostia of the affected cells.

In ordinary cases, where no retention symptoms are present, this may be attempted by systematic lavage after the middle turbinate has been refracted or partially removed as indicated. Any alkaline non-irritating liquid may be used. The patient should be instructed to syringe the nares morning and evening, care being taken not to forcibly blow the nose immediately afterwards on account of the danger of driving the fluid into the middle ear.

If the case is not so chronic that ordinary drainage will suffice to bring about resolution, this form of treatment under regular rhinoscopic supervision will often bring about a complete cure.

540. Sobernheim: Bakt. Untersuchung z. Prognos. u. Behandlungswahl, etc. Arch. f. Laryng., Bd. 23, S. 159, 1910.

Should polyps and polypoid hypertrophies be present before instituting any form of treatment, either at the office or at home, it will be necessary to completely remove these hyperplasias, for the rationale of this treatment depends absolutely upon the installation and continuance of free drainage.

of,
Necessary. The length of time this treatment should be continued depends upon many contingencies. If all subjective symptoms are alleviated, only the annoyance from the discharge remaining, the choice of an operation or of continuing along the same lines lies entirely with the patient. If, on the other hand, the disease recurs with increasing severity with each fresh attack of coryza, the indications are as with the vermiform appendix, to remove the diseased structure.




FIG. 207.—Hajek's instruments for removing the ethmoid cells.

Treatment by Auto-Vaccination.—In old and persistent cases this method has been found of service, particularly when the cells are inoperable from an intranasal standpoint. A culture is made from the discharge. After isolating the infecting germs a vaccine is made from subcultures of them. This is given hypodermatically in increasing doses until a positive reaction occurs. A prompt subsidence of the secretion will follow in those cases which respond favorably to this form of treatment.

Intranasal Method.—This procedure may be termed the semi-radical method through the nose, as it consists in removing intranasally all cells which show signs of suppuration. It is indicated in all cases of uncomplicated suppurating ethmoiditis which require an operation.

Method: (1) Cocainize with cocaine adrenalin as before.

(2) Remove all polyps.

(3) Remove anterior extremity of middle turbinate high up.

It is important to control all hemorrhage before proceeding further, as an unobstructed view of the base of the ethmoid capsule is absolutely necessary, else it would be impossible to judge the extent of the suppuration. To accomplish this cotton mops saturated with adrenalin chloride and held firmly against the bleeding structures will generally in a few moments control the oozing. The naris on that side should be washed out.

(4) The bulla is opened with Hajek's hook (Fig. 207) by inserting the point at the posterior portion and drawing sharply forward. (Fig. 208.)

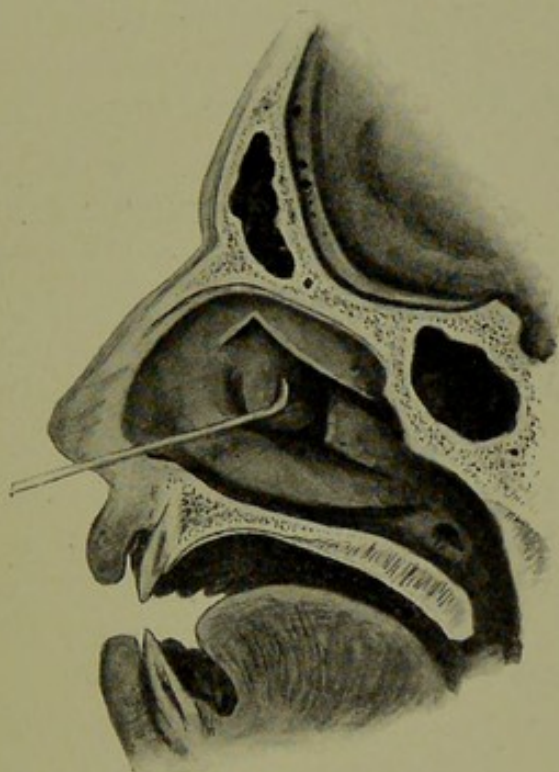


FIG. 208.—Opening the ethmoidal bulla with Hajek's hook after resection of the anterior portion of the middle turbinate.

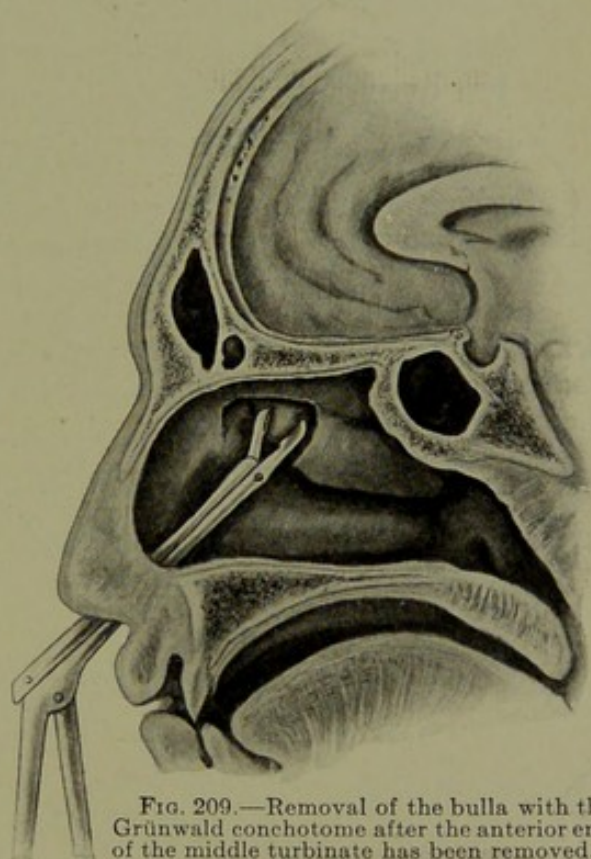


FIG. 209.—Removal of the bulla with the Grünwald conchotome after the anterior end of the middle turbinate has been removed.

This is easily accomplished, as the diseased bone gives way quite easily before the hook. By this manipulation the lowest cell of the ethmoid is opened so that drainage is at least insured at that particular locality. Little bleeding occurs at this point.

(5) Enlarge opening by biting away walls of the cells together with the mucosa by means of the Grünwald forceps until all diseased structure has been removed. (Fig. 209.)

The operation may end at this point, or, if necessary, may be carried further by resecting the uncinata process, thus reaching the infundibular cells. Curetting is very dangerous, and should be applied, if at all, with the greatest caution. While using the forceps it is well to remember that the lower edge of the middle

turbinate is approximately the half-way line between the nasal floor and the lamina cribrosa. It must always be borne in mind that it is better to do too little than too much, for if a focus of suppuration is overlooked, it can be reached at a subsequent operation. Unless undoubted signs point to posterior cellular involvement the lamella of the middle turbinate should be our posterior boundary for the operation, and never broken through, as an infection of the cells of the superior nasal passage will result.

After finishing the operation the nose is again flushed out with the warm saline solution, and bismuth-formic-iodide powder insufflated over the operated areas. A plug of cotton in the opening of the nares closes the procedure.

Packing the nostril with gauze is distinctly contra-indicated in purulent conditions of the ethmoid. The danger of complications from damming back the pus far exceeds the benefits derived toward the prevention of post-operative hemorrhage. As a matter of fact this bleeding is little to be feared. While a certain amount of oozing is sure to occur, coagulation will follow if the patient remains quiet and does not assume a reclining position. We have never been called upon to tampon the nose after this operation.

The immediate result of the operation is a distinct increase in the amount of the discharge due to the free drainage established as well as to the postoperative irritation. This secretion usually diminishes little by little until it either ceases entirely or continues to a minimum degree. After healing is established (about two weeks) if the secretion continues profuse it is wise to gently syringe about 1 dram of a 3-5 per cent. solution of silver nitrate directly into the wounded parts. This will often bring about a great amelioration in the amount and purulent character of the discharge.

The ultimate results of this operation are good as regards alleviation of the distressing symptoms and uncertain as to the future course of the suppuration. Sometimes the discharge is entirely checked, other times it is continuous as before as far as the profuseness is concerned. The cause of continued secretion lies either in a diseased cell which has been overlooked, or, what is more frequently the case, in an infected cell which is situated beyond the reach of an endo-nasal procedure. Such cells are the fronto-orbital and orbital. The advantages of the operation, however, far overshadow any discomforts attending the more or less constant discharge, for free drainage has been established, thus

doing away with the subjective symptoms (headache, mental disturbances, etc.) as well as preventing as far as possible the occurrence of cerebral and orbital complications.⁵⁴¹

This operation will often, particularly in the acute stage, suffice when actual complications have occurred, and, indeed, Farlow⁵⁴² says he has found no cases where other than persistent intranasal treatment has been advisable.

*Method of Luc.*⁵⁴³—Anæsthetize by packing three strips of gauze soaked in cocaine 20 per cent. adrenalin solution in the following places: (1) in middle nasal fossa between middle turbinate and lateral wall of nose; (2) between middle turbinate and septum as high as possible; (3) along the free edge of the middle turbinate. Allow these to remain in place fifteen minutes, after which time the parts will be thoroughly ischæmic and insensible to the touch.

(1) Seize the anterior end of the middle turbinate, using the author's forceps (Fig. 210), and by a twisting motion tear as large a portion as possible loose from its attachments. Repeat this manœuvre until all of the structures are removed.

(2) The bulla now being exposed is grasped in like manner and torn out from its attachment.

(3) The remaining ethmoid cells are removed piecemeal without regard for the lamella until the entire ethmoidal capsule is exenterated to the anterior wall of the sphenoid.

After the nose is washed free of the fragments, tampons saturated with peroxide of hydrogen are applied and allowed to remain in place for several minutes. He warns particularly against the application of permanent tampons.

If despite every intranasal effort the suppuration and general symptoms continue, an external operation is indicated.⁵⁴⁴ Threatened rupture, abscess and fistula formation, beginning cerebral complications also call for external interference.

If perforation has already occurred before operating, it is wise to introduce the sound into the fistula and endeavor to ascertain whether the perforation extends through the orbital plate and if present the size and situation of the opening.

Technique: Under general narcosis a curved incision is made from the eyebrow to a point about one-third of an inch below the inner canthus of the eye. The incision is continued down to the

541. Hajek: Akutes Empyem des Siebbeinlabyrinthes, etc. Zeitschr. f. Lary., S. 629, 1909. 542. Farlow: The Ethmoid Sinus. Trans. Am. Laryn. Assocn., p. 238, 1905. 543. Luc (231), p. 355. 544. Coffin: External Operation for Relief of Ethmoiditis. Ann. Otol., Rhin. and Laryn., p. 491, 1905.

bone. The periosteum and soft parts are elevated, pushing aside the trochlea until the lachrymal fossa is reached. The lachrymal sac is pushed out of its bed and the entrance to the anterior ethmoid labyrinth lies before us.

A hollow chisel is used to open the cells, removing a portion of the frontal process of the superior maxillary if found necessary to gain room. The cells are removed, piece by piece, with the Grünwald or similar forceps until the lamella of the middle turbinate is reached. Orbital and even frontal cells can easily be followed up to their endings. After all the diseased parts have

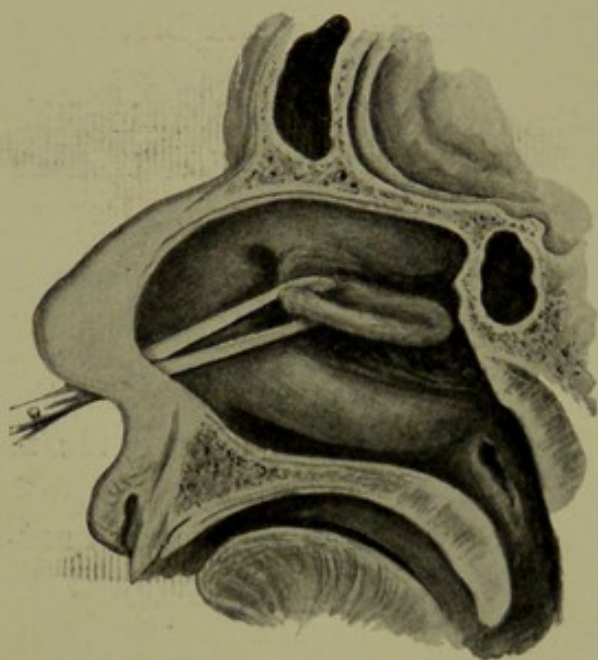


FIG. 210.—Seizing and twisting the middle turbinate from its anterior attachment.

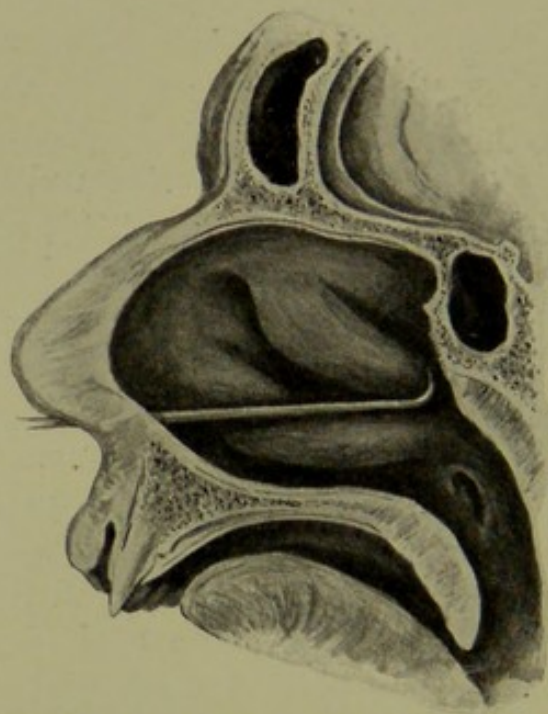


FIG. 211.—The hook behind the posterior portion of the middle turbinate in position for severing the turbinate from its attachment.

been removed a large counter opening is made through the bulla into the nose, and the external wound permanently closed.

If for any reason drainage is deemed necessary a wick of iodoform gauze is inserted into the depths of the cavity and the external wound only closed at its extremities. If the symptoms of the threatening meningeal complications disappear, the gauze is removed after three days and the incision allowed to heal.

Hajek's Method for Removing Posterior Ethmoid Cells.—(1) Anæsthetize in usual manner.

(2) Pass hook behind attachment of middle turbinate and cut forward, thereby severing it completely from its attachment. (Fig. 211.)

(3) Pass hook backward point downward until it reaches the highest point attainable on the anterior sphenoidal wall (Fig. 212), then turn point outward, burying it as deeply as possible into the superior turbinate.

No fear need be entertained regarding injury to the orbital plate, as the length of the hook is not so great as the depth of the ethmoid capsule at this point.

(4) Freely open cells by withdrawing hook forcibly toward the nasal outlet, and repeat procedure until that part of the capsule is reduced to shreds. (Fig. 213.)

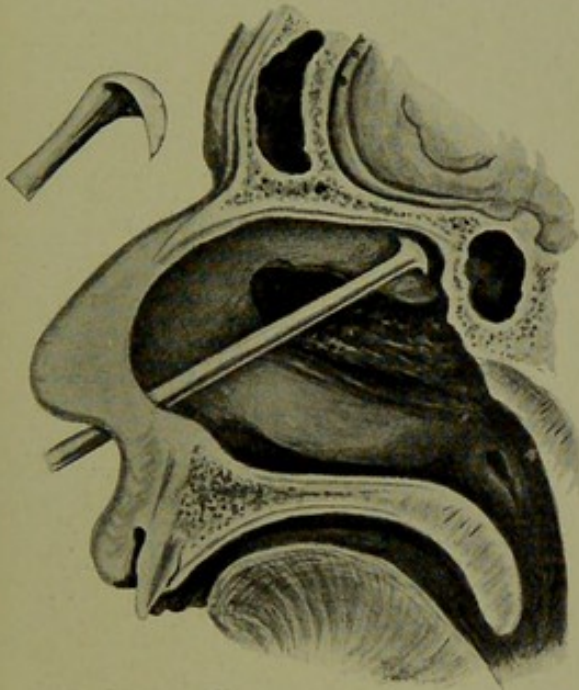


FIG. 212.—The ethmoid hook in position for reducing the superior turbinate to fragments.

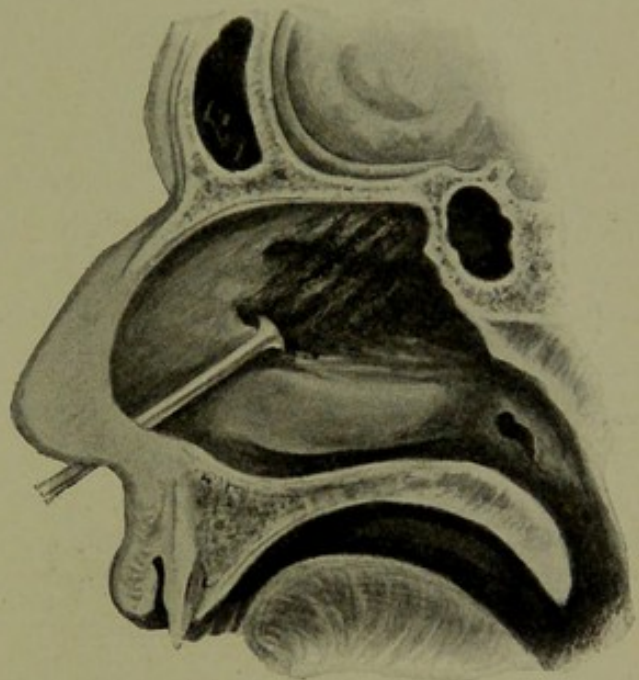


FIG. 213.—Finishing the stroke with the hook in complete exenteration of the ethmoid capsule.

(5) Remove fragments with suitable forceps (Luc or Grünwald), and see that no recesses or partitions remain. (Fig. 214.)

(6) After thoroughly washing, press a tampon saturated in peroxide into the cavity, allow to remain a few minutes, and then remove and powder thoroughly with bismuth-formic-iodide powder.

By this method the anterior cells are for the most part spared, the advantage of which is often great, especially when any tendency to dryness of the nose ensues.

Slight Complications Sometimes Following Intranasal Operation.—Hyperæmia of conjunctiva. This is a not infrequent sequela. The discoloration is often intense, being due to the traumatic stagnation in the ethmoidal veins leading to that portion of the

eye. No fear need be felt for the outcome, as wet compresses of hamamelis virginiana will always reduce the hyperæmia and swelling in a few hours.

Emphysema of the Upper Eyelids on Blowing the Nose.—When this condition makes its appearance we can be sure that either a dehiscence exists in the orbital plate or we have broken through with our instrument. It is characterized by a sudden swelling of the lid accompanied by a sharp lancinating pain. On examination distinct crepitus may be felt. In treating this condi-

tion we must, as far as possible, guard against purulent infection of the orbital structures. For this purpose absolute rest at home with cold compresses of equal parts of euthymol (P. D. & Co.) and water will cause the emphysema to disappear in the course of several days without the development of further complications.

*Method of Guisez.*⁵⁴⁵—(1) Eyebrow shaved and region thoroughly disinfected, nose lavaged with hydrogen peroxide.

(2) Under general narcosis an incision through the inner fourth of the eyebrow is made, descending towards the inner angle of the eye, but passes around it several millimetres below the lachrymal fossa. (Fig. 215.)

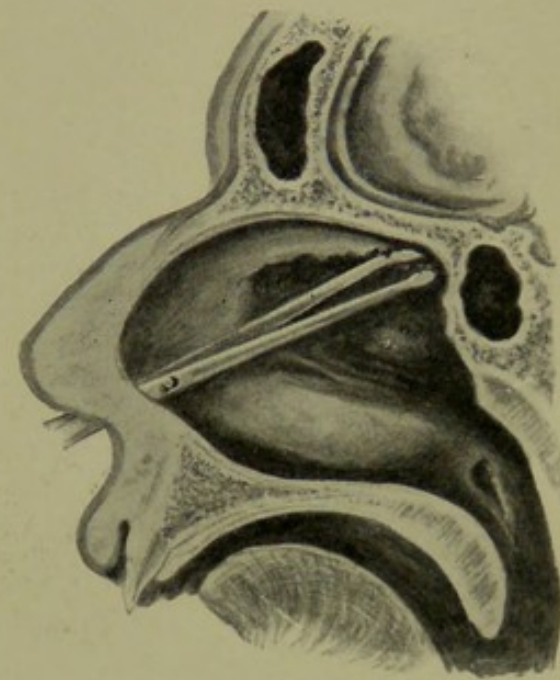


FIG. 214.—Removing the fragments and shreds left by the hook, thus completing the operation.

At the internal and terminal portions the incision will penetrate to the bone, but in the middle, in the region of the caruncula, it must be superficial to allow very delicate dissection.

Bleeding will be free at this point and must be controlled by hæmostats before proceeding further. The supra-orbital nerve must also be entirely severed, so as not to become bound up with the cicatrix.

(3) Dissect carefully layer by layer, cutting successively the tendons of the orbicularis and muscle of Horner, until the lachry-

545. Guisez: Du Traitement chirurgical de l'ethmoidite purulente. Ann. des Mal. de l'oreille, etc., Août, p. 116, 1902.

mal sac is seen in the depths of the incision. This structure is now carefully lifted out of its fossa and pushed as far as possible to one side, in order to avoid wounding it during the later stages of the operation. (Fig. 216.)

(4) Denude the surface of the lachrymal bone and os planum from the periosteum as far as possible. The ocular globe with the capsule of Tenon is entirely separated from the internal orbital surface, avoiding the tendon of the superior oblique. (Fig. 216.)

During this stage of the operation one must avoid injuring the anterior ethmoidal artery, as hemorrhage from this source is not only difficult to arrest, but also entirely masks the field of operation.

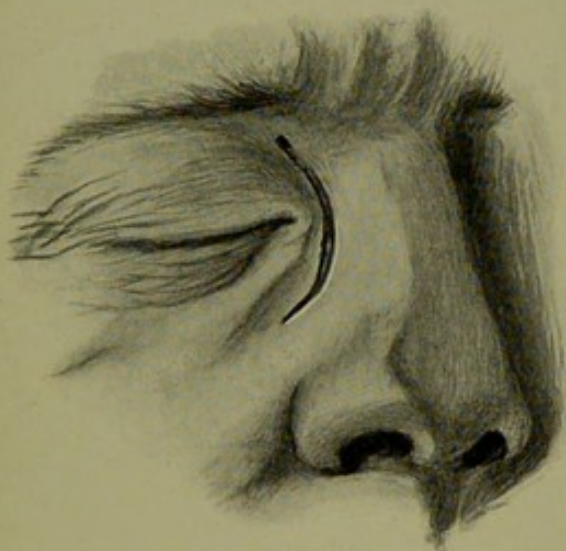

FIG. 215.—Position and length of incision for external radical exenteration of the anterior and posterior ethmoid cells.

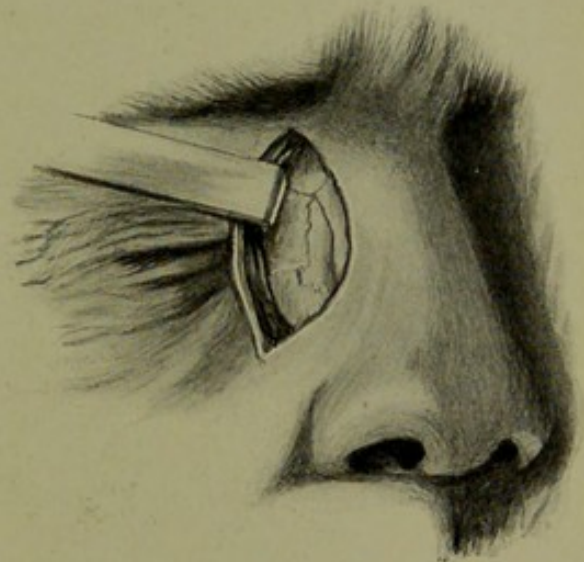


FIG. 216.—Periosteum retracted and bone bared, bringing out the various relations, including the landmark (lachrymal groove).

(5) The internal wall of the orbit being bared, one of two conditions may be present: (*a*) the bone may be intact, or (*b*) a spontaneous rupture may have taken place.

(*a*) If the bone is intact, make a small opening with the chisel behind the lachrymal suture. (Fig. 217). Enlarge this orifice with the forceps and curette, resecting completely the lachrymal bone as well as a portion of the frontal process of the superior maxilla. This is necessary in order to lay bare the lachrymal-ethmoidal cells. Posteriorly the orbit is separated from the os planum with a blunt retractor, or, better, with the index-finger, thus avoiding injury to the ophthalmic artery and optic nerve. The superior boundary of the operation will be the fronto-ethmoidal suture. The entire opening in the os planum should

measure about 2.5 cm. in height by 4 cm. in depth (anteroposteriorly). (Fig. 218.)

(b) If spontaneous rupture has already occurred, the sound should be used to ascertain the direction of the perforation, after which the bone will be resected in the direction of the fistula.

(6) The ethmoid cells are now curetted with the greatest care, never using undue force, avoiding particularly the region of the olfactory fissure. The ethmoid labyrinth can thus be completely exenterated to the anterior wall of the sphenoid.

This step of the operation must be quickly accomplished, as the hemorrhage will be rather profuse. To control this, sterile gauze is saturated with adrenalin chloride and packed in and allowed to remain for a few minutes. After gauze

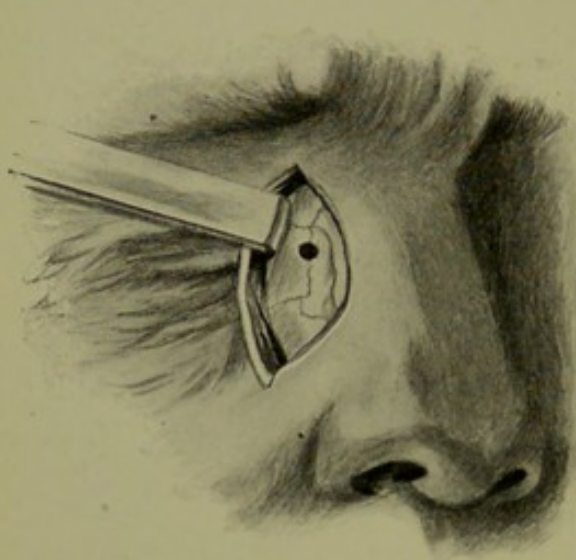


FIG. 217.—Point of election for opening the ethmoid labyrinth. The ridge between the lachrymal groove and the lamina papyracea.

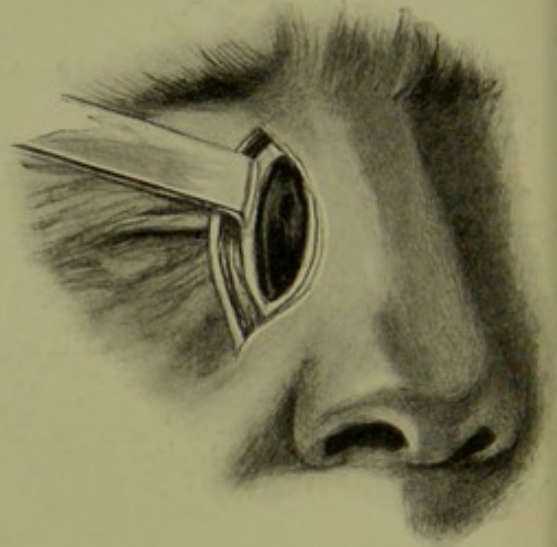


FIG. 218.—The operation completed. All of the ethmoid cells have been removed to the anterior sphenoidal wall. The sphenoidal ostium is visible in the depths of the wound.

has been quickly removed, by means of reflected light it is possible to inspect and remove any fragments of bone and mucosa which remain in the depths of the wound.

(7) After complete exenteration of the cells has been made, shall the subsequent treatment be orbital or intranasal? If pus is present in the nasal fossa the treatment should be both orbital and nasal. All fungosities and polyps must be removed, the middle turbinate resected and a large counter opening made into the nose. The cavity is lightly tamponed through the orbital wound with iodoform or sterile gauze, one end of which is brought out through the nose. The nasal fossa is tamponed by a separate strip. The orbital wound is sutured except at the inferior extremity, where a small drain is allowed to remain for 24 to 48 hours. One

thus avoids retention of blood which would favor infection or the production of a hæmatoma. After-treatment: The tampon is removed on the third day, after which daily cleansing of the nasal fossa is made by means of tampons saturated with hydrogen peroxide. Crusts, *débris* from the cells and portions of mucosa which have escaped the orbital operation are removed as they appear. A mild discharge often persists for several weeks, but is easily controlled by the antiseptic treatments and applications of tincture of iodine. The mucosa of the remaining cells resumes little by little its normal aspect. At the end of several weeks of patient and regular treatment a cure is obtained. Even in those cases in which no communication with the nose is present it is well to install one, as the better drainage thus procured will facilitate recovery much more quickly than when it is attempted solely through the orbital wound.

PART V. SPHENOID SINUS.

ANATOMY.

The sphenoid sinus occupies the body of the sphenoid bone, being situated directly behind the ethmoid capsule at the posterior and superior portion of the nasal cavities. (Fig. 13.) In the fully developed stage it represents a cavity which may be regular, irregular, large or small, depending upon the amount of reabsorption of spongy bone which has occurred. The average capacity of the sphenoid sinus from 180 specimens taken at random may be placed at 5-6 cm.⁵⁴⁶

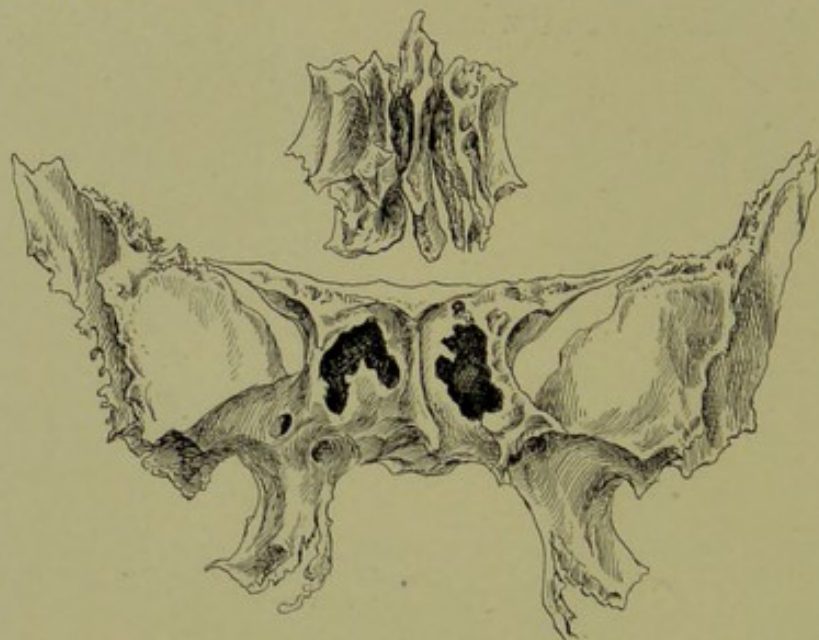


FIG. 219.—Sphenoid bone and ethmoid capsule disarticulated.

If we take a disarticulated specimen and view it from the anterior aspect, it will be noted that the anterior walls of both sinuses seem to be entirely lacking. (Fig. 219.) These are completed by the articulation of the ethmoid capsule (Fig. 220), the apposition of which entirely closes the opening except for a small aperture towards the median line, the ostium sphenoidale (Fig. 223). The sinuses are separated from one another by a partition (septum), which, like that of the frontal sinus, may be considered as a continuation of the nasal septum. Along the anterior attachment this septum is usually in the median line

546. Sieur and Jacobs (506), p. 290.

(Fig. 221), but as it extends backward it frequently deviates to one side, thus making one sinus much larger than its fellow (Fig. 221). Complete absence of this partition, throwing both sinuses into one large cavity with a single ostium, has also been observed.

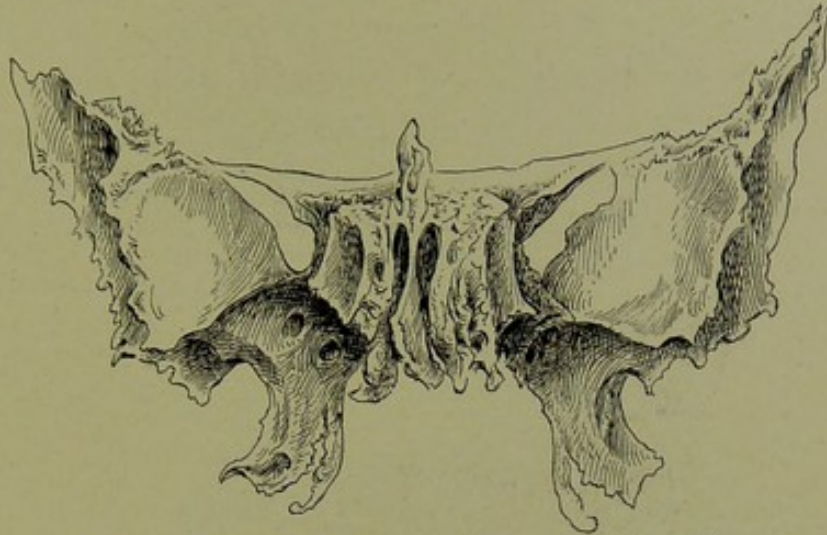


FIG. 220.—Sphenoid bone and ethmoid capsule in position.

The normal sphenoid sinus may be compared to a cube with six sides (walls): (1) the anterior or naso-ethmoidalis; (2) posterior or basilar; (3) superior or cerebro-pituitary; (4) inferior or choanal; (5) external or cavernous; (6) internal or septal.

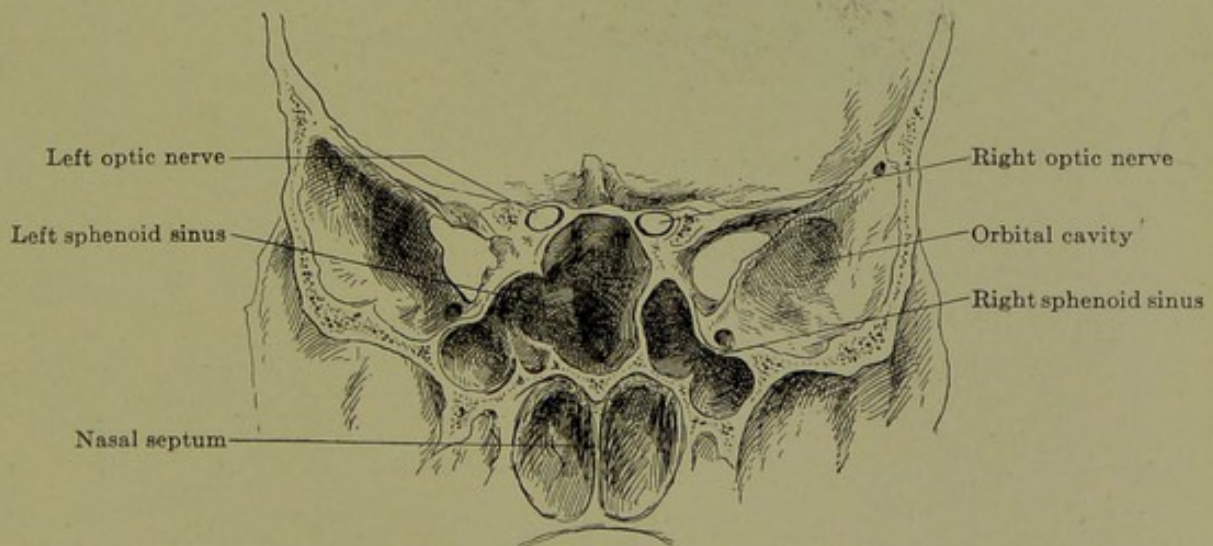


FIG. 221.—Section through both sphenoid sinuses.

1. The anterior wall is the most important rhinologically, because it contains the ostium and is the point of attack in operations on the sinus. It does not assume a true perpendicular position, but points backward and downward, thus forming an obtuse

angle at its junction with the cribriform plate (Fig. 222), and gradually becomes thinner and thinner as it nears this articulation. As the ethmoid enters largely into the formation of this structure, it is divided into two portions: ethmoid (*pars ethmoidalis*) and nasal (*pars nasalis*). The proportion of these two parts depends largely upon the depth of the recess separating the internal portion of the posterior ethmoidal wall from the internal portion of the anterior wall of sphenoid. This groove is known as the *recessus spheno-ethmoidalis* (Fig. 176). It will thus be noted that the deeper this recess the larger becomes the *pars*

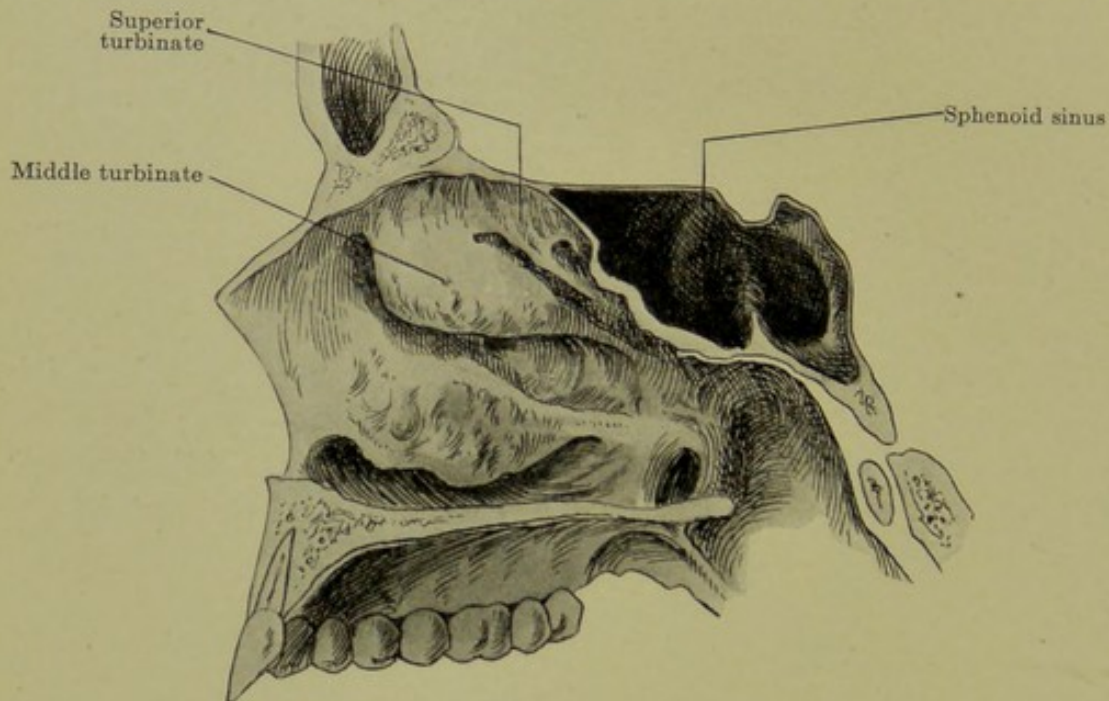


FIG. 222.—Sphenoid sinus enlarged anteriorly, encroaching upon the space occupied normally by the posterior ethmoidal labyrinth.

nasalis of the anterior sphenoidal wall and *vice versa*. The average depth of this structure may be placed at 3-4 mm.

The ostium of the sinus is situated in the nasal portion of the wall, usually in the upper third and seldom below the median line (Fig. 223). Whether it lies close to the nasal septum appears to depend largely upon the depth of the spheno-ethmoidal recess, as the deeper the recess the further away from the median line it seems to find its location. This is of great importance to bear in mind when attempting to pass the sound into this sinus. The position of the ostium in relation to the sinus floor is similar to that found with the maxillary, *i.e.*, in a very unfavorable position for drainage. Its shape is oval in the long axis or round,

and measures approximately 1-3 mm. in diameter.⁵⁴⁷ The size of the opening in the recent state is usually smaller than in the bone itself, for the mucosa of the nasal cavity and sinus meet and

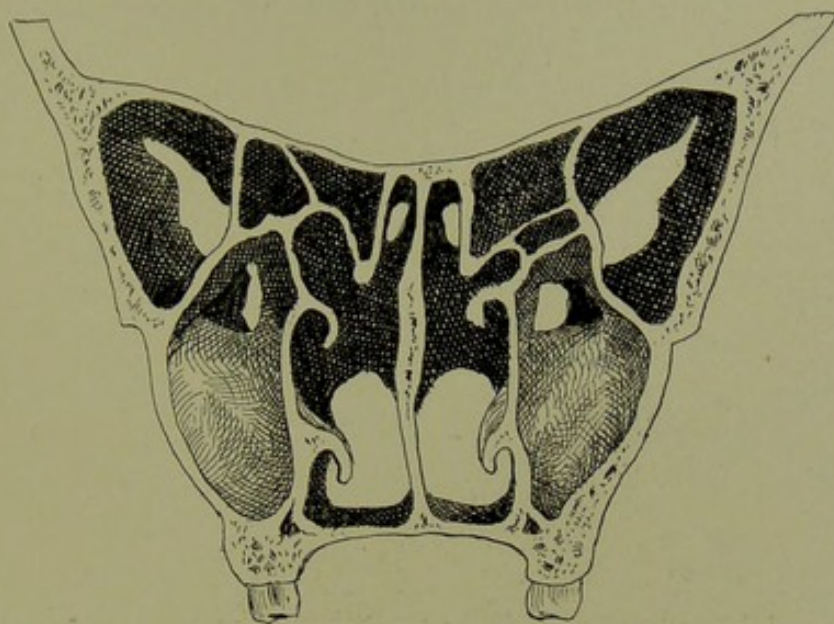


FIG. 223.—Section behind the uncinate processes, showing superior turbinates and position of sphenoid ostiums. (After Sieur and Jacobs.)

form a partial diaphragm over this bone, thus considerably narrowing the lumen of the ostium. (Fig. 224.) The size of the anterior wall depends largely upon the shape of the sinus, as is shown in Fig. 222.

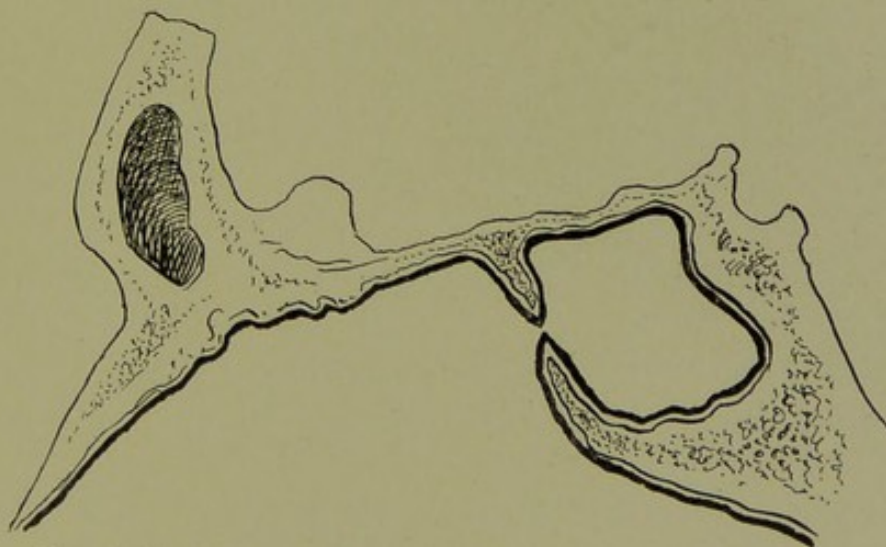


FIG. 224.—Position of sphenoidal ostium. Black line represents mucous membrane.

2. The posterior wall is not subject to such variations as its fellows, as it is composed of thick cancellated bone tissue which

⁵⁴⁷. Hansberg: Die Sondirung der Nebenhöhlen der Nase. Mon. f. Ohrenhk., No. 2, S. 48, 1890.

does not usually yield to instruments of the calibre which are used in operating endo-nasally on the sphenoid sinus. When, however, the sinus is of excessive size from over-reabsorption, all of the walls may suffer from the hyperdistention, and the posterior be reduced to such a thinness that careless or clumsy handling of instruments can cause a fracture or even perforation. Fortunately, this anomaly is of rare occurrence.

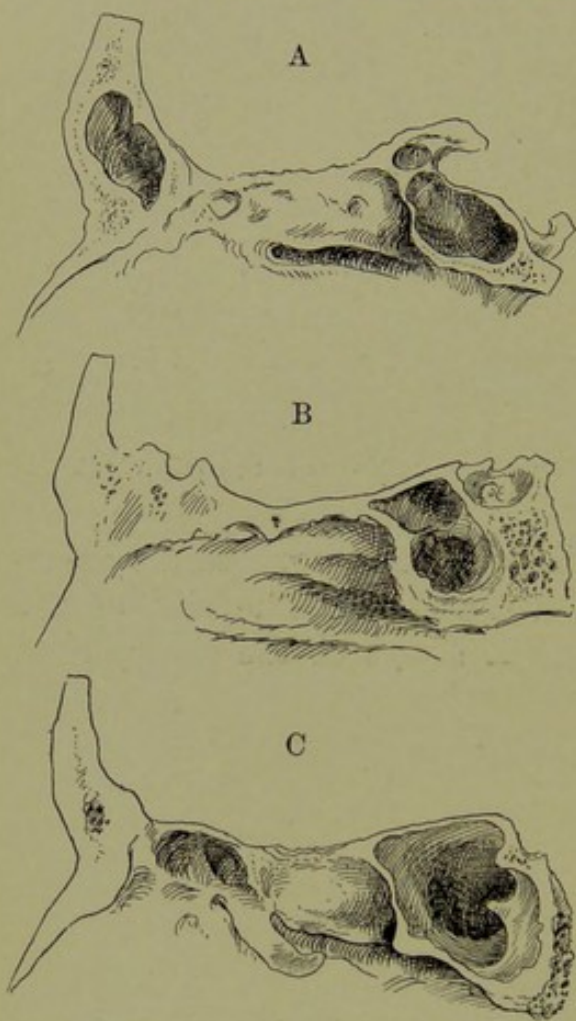


FIG. 225.—Varied conformations of superior walls of the sphenoid sinus.

sinus is variable, depending upon the size and shape of the latter. Sometimes it lies directly superior and other times posterior. (Fig. 225.)

The intimate relation with the optic nerve (Fig. 221) is a predisposing factor to retrobulbar neuritis following purulent sphenoidal sinusitis, particularly if dehiscence not unknown in this region is present.

3. The superior wall is subject to many vagaries not only in shape and position but also in extent and thickness. (Fig. 225.) It is usually composed of thin but very compact bone, yet may be quite thick, containing a considerable amount of cancellated structure. (Fig. 226.) Dehiscences have been reported in this structure in which the sinus mucosa lay in direct contact with the dura.⁵⁴⁸ According to the size and shape of the underlying sinus this wall is in direct contact with most important intracranial structures, —anteriorly the right and left optic nerves and optic chiasm,^{549 550} above or slightly posterior the coronary sinus and pituitary body in the sella turcica. The relation of the sella turcica to the cavity of the

548. Zuckerkandl: Anatomie der Nase, S. 339, 1893. 549. Onodi: Der Sehnerv und die Nebenhöhlen der Nase. 1907. 550. Loeb: Relation of Optic Nerve to Accessory Sinuses. Ann. Oto., Rhin. and Lary., June, 1909.

No regularity exists as to the thickness of bone separating the sinus from the nerve. Investigations^{551 552} have shown that these measurements undergo great variations in different heads and even on different sides of the same head, as in one instance the nerve may lie almost in direct apposition with the mucosa of the sinus, while on the opposite side several mm. of spongy bone will intervene.

4. The inferior wall lies half within the nose, half within the choana (Fig. 4), forming a portion of the vault of the nasopharynx. It is formed of compact bone seldom less than 3 mm. in thickness and may reach even up to 10 mm. It furnishes but one point of interest to the rhinologist, which is that the pharyngopalatine artery traverses the outer angle of its inferior surface, which if wounded gives rise to severe and even fatal hemorrhage. This fact must be borne in mind when operating in this vicinity.⁵⁵³

Through the inferior wall was formerly the operation of choice of several operators.^{554 555} The opening was accomplished through the mouth with the aid of a laryngeal mirror. The method has been entirely abandoned, as it was difficult to accomplish and by no means certain that the sinus would be found.

5. External wall. This structure helps to form a portion of the middle cerebral fossa, and is in direct communication with the cavernous sinus and internal carotid artery (Fig. 227). It is one of the thinnest walls, being often of the thickness of ordinary writing paper, and if the sinus is large may show points of dehiscence, as have been frequently noted. On this account any manipulations in this vicinity with a curette are strongly contra-indicated. Numerous minute openings are visible in the bone for the passage of veins which anastomose with the cavernous sinus.

6. Septal wall presents nothing of importance unless marked deviation occurs. (See Anomalies.) Dehiscence in this struc-

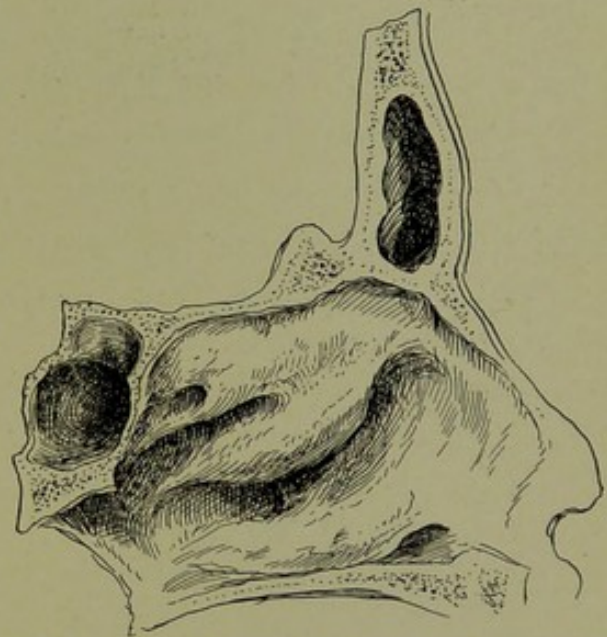


FIG. 226.—Entire sphenoid sinus surrounded by cancellated bone tissue.

551. Berger and Tyrmann: Die Krankheiten der Keilbeinhöhle und des Siebbeinlabyrinthes. Wiesbaden, 1886. 552. Onodi: The Optic Nerve and the Accessory Cavities of the Nose. *Ann. Otol., Rhin. and Lary.*, March, 1908. 553. Myles: Trephining and Curettage of Sphenoid Sinus, profuse secondary hemorrhage requiring ligation of carotid. *Laryngoscope*, p. 293, 1903. 554. Ingals: Discussion on Accessory Sinuses. *Trans. Am. Lary. Assn.*, p. 91, 1895. 555. Rolland: *Montreal Med. Gaz.*, Aug., 1889. *

ture has, as far as we know, not been reported except as a result of inflammatory processes.

PECULIAR ANOMALIES AND FORMATIONS.

These are of three causes: (1) over-reabsorption, causing unnatural enlargement of cavity and prolongations; (2) deviations of inter-sinus septum; (3) over-extension of posterior ethmoidal cells.

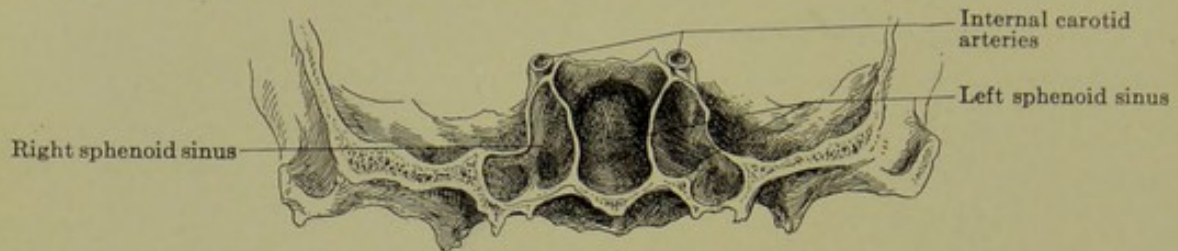


FIG. 227.—Relation of internal carotid arteries to posterior sphenoidal wall.

1. Over-reabsorption often causes the sinus to be prolonged in various directions: (*a*) into the lesser wings and clinoid processes; (*b*) into the antero-inferior angle (palatine); (*c*) into the pterygoid processes.

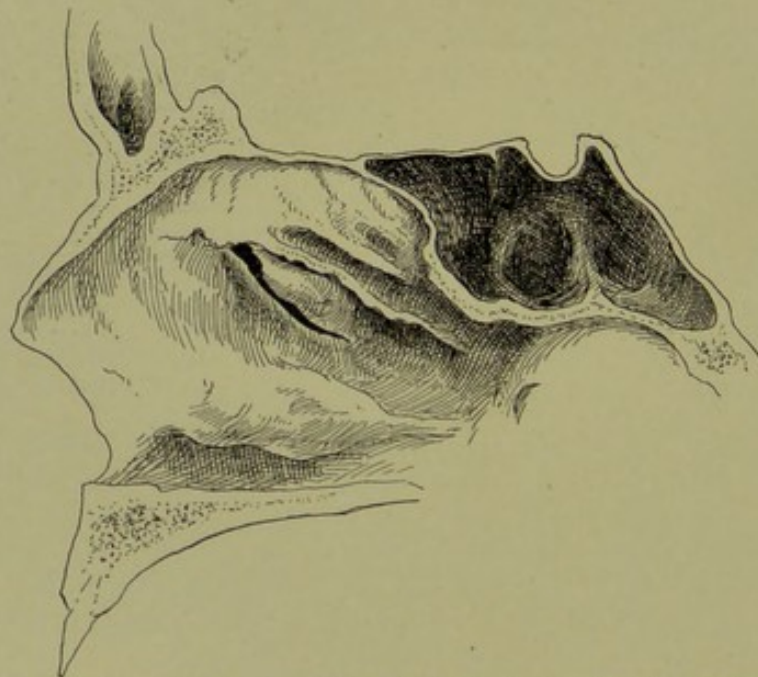


FIG. 228.—Reabsorption of sphenoid sinus into the lesser wings of sphenoid bone.

(*a*) Into lesser wings. (Fig. 228.) When reabsorption occurs in this direction the sinus encroaches upon the optic nerve, often to such an extent that the nerve comes to lie almost within the sinus cavity. The importance of this anatomical configuration cannot be overestimated, especially in connection with ophthalmic

complications resulting from infection of the nerve through inflammation of the sinus mucosa.

(b) Palatine. (Fig. 229.) When this recess occurs the maxillary sinus is in direct relation with the sphenoid, only a thin partition of bone separating the two cavities. This formation is rare, but when present is particularly favorable for operation on the sphenoid *via* the maxillary sinus route.

(c) Pterygoid. (Fig. 230.) Reabsorption into these processes causes circumscribed depressions to be formed in the floor of the sinus. There are of importance in that they favor stagnation of secretion and lavage cannot be thorough.

2. Deviations of Septum: Inequalities in the size and shape of the two sinuses are usually due to a deviation in the septum. This deviation may be slight and confined to the posterior portion or be so great as to practically show both sinuses into one large cavity with a small cell (representing the other sinus) in the anterior external portion. (Fig. 221.) Ordinarily the curvature is in the anteroposterior direction, but it sometimes also takes on a lateral deviation, thus placing one sinus in relation to the sella turcica, both the cavernous sinuses and both the optic

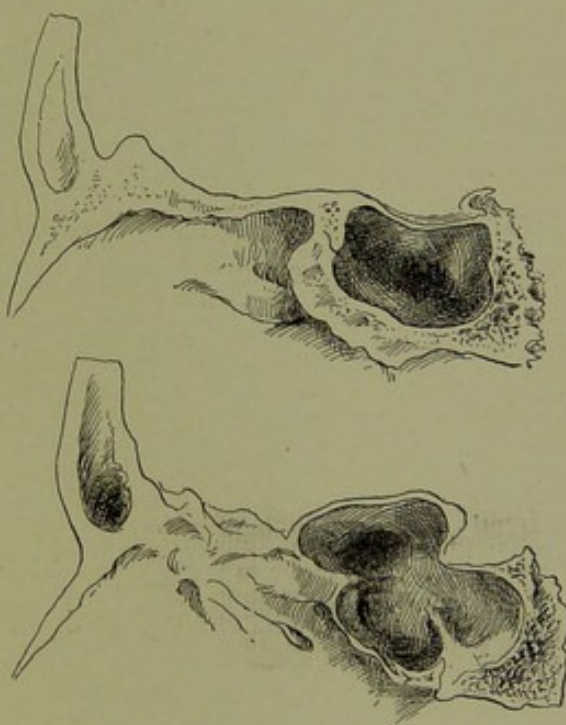


FIG. 229.—Reabsorption into palatine fossa.

nerves. Incomplete septa are frequently formed on the posterior sinus wall. These sometimes reach such a dimension as on section to give one the idea of the presence of a triple sinus. (Fig. 227.)

3. Over-extension of Posterior Ethmoidal Cell: Occasionally one sphenoid sinus is poorly developed; a posterior ethmoidal cell pushing it downward and backward and occupying the place where the sphenoid is normally situated, forming a spheno-ethmoidal cell. (Fig. 231.) Under these circumstances the posterior ethmoid cell is then in relation to the superior structures (optic chiasm and pituitary body). Not infrequently this cell is in relation to the sphenoid sinus of the opposite side, so that if diseased, it could easily communicate the infection to this cavity.

MUCOSA OF SPHENOID.

The mucous lining of the sphenoid sinus is of a dull grayish color and extremely thin, denoting a lack of superficial vascu-

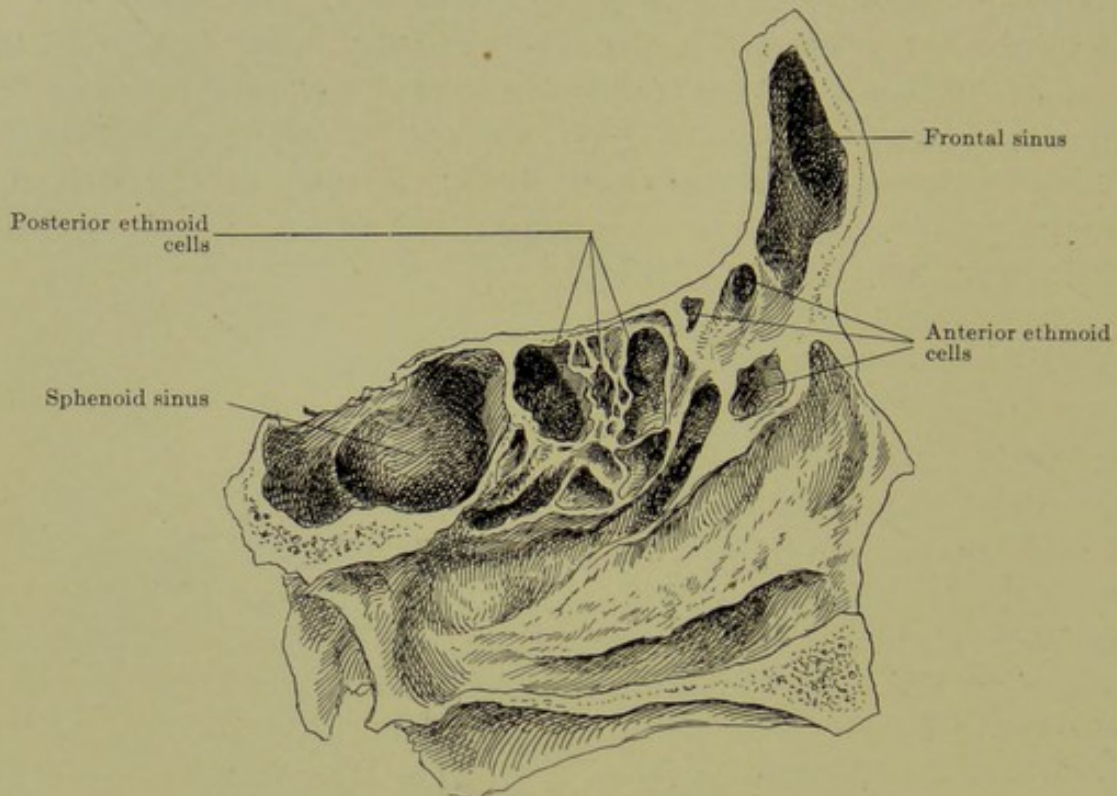


FIG. 230.—Reabsorption into pterygoid process.

larity. It does not adhere strongly to the underlying bone, but may readily be removed with the forceps. As with the other

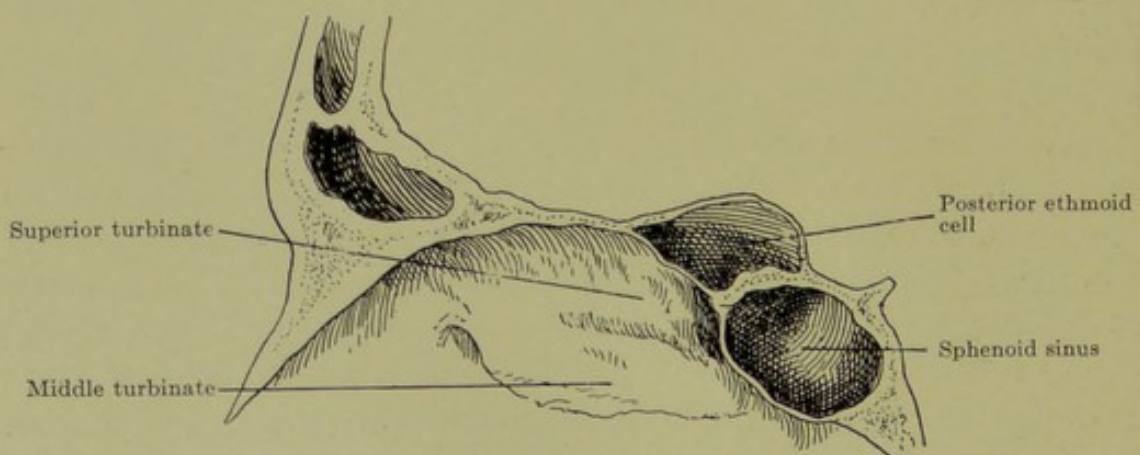


FIG. 231.—Spheno-ethmoidal cell formation.

sinus three layers may be separated: mucous, submucous and periosteal. Glands are sparsely supplied except in the region of the ostium.

The veins of the anterior wall empty into the nose through the ostium and into the ophthalmic and those of the sides and roof into the coronary and cavernous sinuses. These form an important factor in cerebral complications, for in the periosteal layer a network is present which penetrates the bony wall in numerous places and empties directly into the cavernous and coronary sinuses. The arterial supply is obtained from the sphenopalatine, pterygo-palatine and vidian arteries, the sphenopalatine through the ostium of the sinus and the sphenopalatine through the floor.

ACUTE INFLAMMATION.

ÆTIOLOGY. — The deep-lying position of the sphenoid sinus prevents the observation of primary changes in its mucosa; therefore, little is known of the initial pathology of incipient sinusitis affecting this cavity. One factor, however, plays an important rôle, and that is the anatomical situation and peculiarities of the ostium. Being situated comparatively high upon the anterior wall in an unfavorable position for drainage, it resembles in some respects that of the maxillary sinus. The extreme narrowness of the sphenoidal fissures also predisposes to occlusion, particularly during the engorgement coincident to an attack of acute coryza. This would react in a double sense, for the inflammation from the nasal mucosa would spread to that of the sinus as well as causing occlusion of the ostium with subsequent rarefaction. Under these circumstances we can state with a certain amount of assurance that the sphenoid is more or less affected during the course of every acute coryza. In the vast majority of these cases resolution of the sinus mucosa sets in as soon as the primary factor (the coryza) abates; whether the sinus disease becomes chronic, depends largely upon the condition of the passages for sufficient drainage and aëration of the diseased cavity.

It is rare that the sphenoid becomes acutely infected *per se* without some of the other accessory sinuses, particularly the posterior ethmoid cells, sharing the infection. The latter, however, by reason of their better drainage may entirely recover, leaving the disease isolated in the mucosa of the sphenoid. This is particularly true in those cases which follow the infectious diseases, notably influenza.

PATHOLOGY.—The pathological changes found in the mucosa of the sphenoid sinus differ but little from those in its fellows. During the acute stage the entire mucosa in conjunction with that of the nose is involved, being intensely hyperæmic and swollen. As resolution in the former sets in, the sinus involvement generally continues, only returning to normal at a later period, thus giving rise to the impression that the sinus was primarily affected.

Microscopic Histo-pathology.—But little difference is observed from similar conditions in the other sinuses, the mucosa, markedly œdematous, being 1–2 mm. thick. Round-cell infiltration of lymphocytes is particularly marked beneath the epithelial layer, gradually shading off as the centre of the connective tissue layer is reached. The vessels are dilated and full. Occasional hemorrhagic infarcts are to be found.

SYMPTOMS.—When the mucous lining of the sphenoid becomes greatly affected from the general inflammation of the nasal mucosa, certain symptoms ordinarily not present even with a severe cold in the head manifest themselves.

The headache is more severe and becomes vaguely localized in the parietal and temporal regions, often radiating to one or both ears. The ears themselves have a peculiar feeling which is something more than the discomfort resulting from the occlusion of the Eustachian canals. Ocular symptoms, particularly tenderness of the eyeball, are often marked. Fever higher than usual with an ordinary coryza, sleeplessness, more or less dizziness and general malaise complete the chain of symptoms. The diagnosis is comparatively certain if these symptoms continue after the time one would reasonably expect those of an ordinary cold in the head to show signs of subsiding.

DIAGNOSIS.—From a rhinological point of view, the diagnosis of acute empyema is seldom made, for the following reasons: The general nasal mucosa is in a state of acute inflammatory hypertrophy and the nasal cavities filled with secretion. Cleansing and shrinking with cocaine or adrenalin is only to be partially accomplished, owing to the extreme tenderness of the parts, as well as to the lowered efficiency of these medicaments reducing the swelling in acute processes sufficiently to obtain views of the sphenoidal region.* Even should the sinus be sounded and cath-

* Coakley states, "We have never been able in acute cases, even after the most thorough contraction of the nasal mucosa, to get a view through the nose of pus issuing from the normal opening of the sphenoid sinus." *The Sphenoid Sinus*. Trans. Am. L., R. and O. Soc., p. 151, 1902.

eterized, it would be impossible to state with certainty whether pus was or was not present. The only reliable sign we have is the relief experienced by the patient after the catheterization and cleaning of the cavity.

The general symptoms, at least at the commencement of the attack, furnish no clue pointing toward any particular sinus, as they are identical with, or perhaps only a slight exaggeration of, those commonly associated with the ordinary acute coryza. It is only where the head pains and general manifestations are unduly prolonged that attention is drawn to the possibility of a sphenoidal sinusitis.

TREATMENT.—If after the acute stadium of a coryza the sphenoid is still found to be secreting purulent material with symptoms of retention, it will be necessary to further the out-flow by keeping the drainage passages as patulous as possible. This is best accomplished by daily opening the space between the middle turbinate and septum with cocaine-adrenalin solution, and, if necessary, introducing a cannula and washing out the sinus. As a rule, the first procedure will suffice to bring out a cure in ten days to two weeks. Aspirin in xx grain doses every three hours will greatly facilitate resolution. Only in rare cases of threatened complications is an operative enlargement of the ostium necessary.

CHRONIC INFLAMMATION.

ÆTIOLOGY.—The vast majority of acute inflammations within the sphenoid sinus recover either with or without direct treatment, but it must be remembered that following every attack there remains a greater predisposition for the sinus to become again involved at every fresh attack of coryza. Under these circumstances we must consider that successive attacks of acute inflammation play no inconsiderable rôle in the ætiology of the chronic form. Any anatomical irregularities, such as deviated septum or pathological products, as polyps or hypertrophies, which contribute towards partial occlusion of the sphenoidal fissure, must also be classed as predisposing factors.

PATHOLOGY.—The changes seen in the mucosa during chronic inflammation depend upon the intensity of the pre-existing acute process. As a rule, regeneration has occurred in some parts, leaving islands of inflamed or degenerated mucous membrane. The areas of predilection for these polypoid swellings would seem

to be in the region of the ostium and on the floor of the sinus. A peculiarity almost indigenous to this sinus is the tendency of the lining mucosa of the floor to become detached from the underlying bone, thereby predisposing to osseous involvement from the inflammatory products lying in direct apposition to the bony floor.

Microscopic Histo-pathology.—Unless the entire lining of the sinus is chronically affected, two conditions are usually found: (a) œdematous and (b) sclerotic. The first represents a condition where the mucosa has but recently become infected or it has possessed sufficient regenerative power to partially combat the inflammatory process. The second, or sclerotic condition, represents an advanced stage of pathological degeneration of the mucous membrane. In certain cases the mucosa is enormously thickened and has a velvety consistency. This inflammatory hyperplasia is, for the most part, uniform, as it is extremely rare that one finds true pedunculated polyps springing from the mucosa of the sphenoid sinus, although occasionally they have been encountered.⁵⁵⁶⁻⁵⁵⁷

SYMPTOMS.—Perhaps no other sinus presents such a wide deviation in the subjective and objective symptoms as the chronically-diseased sphenoid. A chronic empyema of this cavity frequently exists without especial manifestations which would direct the attention of either the patient or examining physician to this portion of the cranium. On the other hand, sufferers from this disease have been so seriously affected as to seek relief from their misery with such extremes as suicide.⁵⁵⁸ The subjective symptoms, therefore, would depend upon certain conditions, and these conditions are at once referable to, and largely dependent upon, the drainage of the sinus. We can, therefore, roughly divide the cases into: (1) those with free drainage and insignificant symptoms, and (2) those with intermittent or deficient drainage and striking symptoms.*

1. Those with Free Drainage: These are the cases which occupy not an inconsiderable proportion of those diagnosed in our dispensaries as rhinitis sicca, chronic rhinopharyngitis, post-nasal catarrh, etc. The actual condition present is a low-grade form of inflammation in the mucosa of the sphenoid sinus, dis-

⁵⁵⁶. Zuckerkandl: Anatomie der Nase, Taf. 6, Fig. 1, 1892. ⁵⁵⁷. Hajek: Lehrbuch, p. 319, 1909. ⁵⁵⁸. Schaeffer: Die Krankheiten der Keilbeinhöhlen. Heymann's Handbuch, S. 1186, 1900.

* Both of these conditions can, of course, occur in the same case during the natural course of the disease.

charging a thin, mucopurulent secretion which, by reason of sufficient drainage, is never confined under pressure within the sinus.

The most prominent symptoms in these cases are referred to the nasopharynx. The patients often complain of an almost constant postnasal discharge, which has a tendency to dry in the pharynx and is so difficult to dislodge that they are often required to use the finger for this purpose. The secretion has the consistency of pasty glue, and during the night forms into crusts. Discharge through the anterior nasal passages is scanty and often entirely absent, but occasionally, on violent blowing, some particles may be observed in the handkerchief.

Little occlusion or other sensations in the naris of the affected side are complained of by the patient; however, intermittent subjective cacosmia, which takes the form of either putrid or burned flesh, is often the cause of much discomfort. Headache, in the common meaning of the term, is absent; only occasionally is there a vague fulness behind the eyes, which tends to dull the faculty and create a condition of apathy. If, however, anything occurs which would cause partial obstruction to the outflow of the secretion, headache immediately manifests itself.

Examination of the nose anteriorly gives but little data upon which to base, or even to surmise, a diagnosis. On posterior rhinoscopy the choana is usually unnaturally moist, and there may be traces of crust formation, but it is in the pharynx that we obtain a key to the situation.

The mucosa of the posterior wall is either smooth and covered with a thin layer of dried secretion which gives to the parts a varnished aspect, or shows numerous crossed furrows between which the papilla are prominent. In either event, the condition is one that denotes inflammation due to the constant irritation from overflowing and drying secretion. The treatment of this condition is to thoroughly flush out the sinus and keep the ostium as patulous as possible. This may be accomplished by the use of the long-bladed Killian speculum, if no deviation of the septum towards the affected side is present. After thorough cocainization, particularly between the middle turbinate and septum, by means of pledgets of cotton gradually increased in size, the long blades of the speculum are passed between these two structures in the direction of the anterior sphenoidal wall until they meet with firm obstruction. The blades are gently but firmly sprung

apart, thus crowding the middle turbinate against the lateral wall of the nose and bringing into view a portion of the anterior wall of the sphenoid.

It requires considerable proficiency before much can be distinguished through the blades of this speculum, for the reason that only a very small slit at best is present and the reflected light must be carefully focused before it penetrates to the spheno-ethmoidal recess.

The nasal sound is now introduced, and, by gently feeling the sphenoidal wall, the point is made to penetrate the ostium into the sinus. A long cotton carrier saturated with the strong adrenalin-cocaine solution is introduced into the ostium and allowed to remain several minutes until the mucosa around the opening is shrunken, thereby enlarging the ostium. At this point it is an easy matter to introduce a cannula and flush out the sinus. This treatment should at first be continued daily, later less frequently until the diseased sinus mucosa no longer secretes.

The main difficulty with this treatment is the initial sounding of the ostium; however, once the anterior sphenoidal wall comes under our vision, the introduction of the sound into the sinus is only a matter of time and patience.

2. Those with Intermittent or Deficient Drainage: These are the cases in which both the subjective and objective symptoms are conspicuous.

Headache.—This is one of the most prominent, at the same time one of the most unreliable, symptoms connected with the disease. Its presence depends upon the pressure of the secretion or of swollen mucosa within the cavity, in contradistinction to the sense of fulness behind the eye which is due to mechanical pressure from the actual œdema of the parts from venous stasis. As the internal sinus pressure, except in extreme instances, is not constant, it naturally follows that the headache must occur in periodical attacks, the severity of which is dependent upon the degree and prolongation of the pressure of the contained secretion.

These attacks occur, as a rule, daily and last a varying length of time, from one to several hours, the patient being usually prostrated for the time being. When remission occurs it is seldom complete, as a dull, indefinable ache continues until the next paroxysm; in the severe cases it is this ache that reacts so upon the patient's nerves as to make every succeeding paroxysm of pain anticipated with the greatest dread.

The exact location of the head pains is impossible to determine, as it varies with different degrees of inflammation as with different individuals, and even in similar cases is not localized to any definite spot.⁵⁵⁹

Generally speaking, it begins on the vertex and radiates downward to the temples and sometimes into the mastoid region. Again, it may centre in the occipital region, extending into the muscles at the nape of the neck. The deep-seated pain is located behind the eyeballs, and, when severe, even embraces these structures. During the paroxysms or stage of retention the cephalalgia changes its character to an intense sickening throbbing, synchronous with the heart-beat. During the stage of quiescence it assumes more the character of a heavy pressure upon the top of the head.⁵⁶⁰ Indulgence in alcohol or tobacco, constipation, or any slight irregularity which would tend to cerebral congestion, exercises a marked influence on the severity of the pain. Dizziness and vertigo are often prominent, and manifest themselves on any sudden change of the position of the head, such as stooping, sudden turning or jarring.

Mental Symptoms.—As the sphenoid sinus lies in the closest relation to the base of the brain, certain cerebral manifestations appear as soon as pressure is established within the sinus. Inability to concentrate the mind, with extreme aversion to mental work, commonly ushers in this train of symptoms. As the disease progresses these manifestations become more and more marked.⁵⁶¹ (See General Symptoms, page 70.)

Cacosmia is a frequent symptom, owing to the stagnation and putrefaction of secretion in the immediate proximity of the olfactory fissure. This symptom is more strongly marked during exhalation through the nose than on inspiration. When the olfactory fissure is occluded through the hypertrophy of the middle turbinate, or polypoid excrescences, partial or complete anosmia sets in.

Secretion.—A postnasal discharge can always be elicited from the patient, and, indeed, this symptom, or some symptom directly connected with this cause, is not infrequently the principal source of the patient's complaint. The amount of the discharge is not

559. Hinkel: Symptoms and Treatment of Chronic Empyema of the Sphenoid Sinus. Trans. Am. Lary. Assn., p. 93, 1902. 560. Skillern: Ein Fall von geschlossen Empyem, etc. Zeit. f. Lary., Bd. 1, S. 337, 1909. 561. Jonathan Wright: A Case of Isolated, Unilateral, Latent Empyema of the Sphenoid Sinus, with Delirium and Mental Symptoms. Operation and Recovery. Ann. Otol., Rhin. and Lary., Feb., p. 17, 1902.

so troublesome as its continuation, particularly during the morning hours. Its consistency may vary from a mucoid to a fetid purulent, but, as a rule, it is thickly mucopurulent, with a decided tendency to dry on the surface and cohere to the nasopharynx, lateral walls of pharynx, and sometimes the fornices of the larynx. If this occurs in a given case it will always be seen in the morning on arising.

Anteriorly little discharge escapes from the nose, as it would be obliged to pass through the narrow olfactory fissure in order to find its exit in this direction. Even violent blowing of the nose will not force it out anteriorly, though it succeed in dislodging the secretion from the sphenoid-ethmoidal region.

Sore throat is practically always present, being one of the cardinal symptoms, and, indeed, is often the first thing that calls the attention of the rhinologist to some postnasal disturbance. This pharyngitis is often unilateral, manifesting itself on the diseased side.

Hoarseness, and, in rare cases, intermittent aphonia, is occasionally met with, particularly in those cases in which the postnasal discharge is so profuse as to collect around the laryngeal structures. There the arytenoids become irritated, and, finally, chronically œdematous, causing interference with the function of the inter-arytenoidal muscles and, consequently, with the mobility of the cords. In all cases of vocal disturbances associated with nasal catarrh the sphenoid sinus and posterior ethmoidal cells should be thoroughly investigated.

Bronchial and gastric disturbances, also occurring concomitantly with this affection, have already been referred to. (See General Symptoms, page 69.) Tinnitus aurium, without perceptible diminution of hearing or changes in the aspect of the eardrum, associated with this disease are due to the reabsorption of toxins, causing incipient neuritis of the auditory nerve.

*Ocular Symptoms.*⁵⁶²—Scintillating scotoma is most frequently observed. Enlargement of the blind spot is almost pathognomonic for some disturbances in the posterior ethmoid or sphenoid sinuses. Exophthalmos, when present, is due to either (*a*) œdema of the orbital tissue from some obstruction to the returning venous circulation; (*b*) paralysis of the external ocular muscles from

562. Schroeder: Ocular and Orbital Symptoms in Diseases of the Sphenoidal Cavity. Archives of Otology, p. 277, 1907.

toxæmia, or (c) retrobulbar swelling due to extension of the purulent process. These may also occur in combination.

Objective Symptoms.—Anterior Rhinoscopy: The nose presents a totally different picture from that encountered with acute inflammation. On superficial inspection no striking changes are for the moment visible, but on careful examination several pathological conditions will be brought to light. On directing the attention to the olfactory fissure, it will be noted the mucosa in this region is distinctly hyperplastic. The classical symptom of purulent secretion exuding between the middle turbinate and septum, thus occluding the olfactory fissure, is not always present, but is sometimes represented by a small crust in this locality. On removing this crust with a cotton mop a more or less purulent secretion will be seen beneath, which will reappear on wiping away. If the turbinate is so hypertrophied that it presses tightly against the septum, this symptom will be entirely lacking, for under these circumstances the secretion, finding no anterior outlet, will be directed backward into the choana with the main body. Only in exceptional cases, where the olfactory fissure is abnormally wide, do we meet with free pus flowing out and down along the side of the septum to the floor of the nose.

Hyperplasia of the septal and middle turbinate mucosa is always marked when the secretion finds its way in this direction. Sometimes the hyperplasia follows a direct course towards the anterior sphenoidal wall. Occasionally the mucosa of the septum opposite the anterior end of the middle turbinate is so swollen as to give one the impression that a localized abscess existed.⁵⁶³ This hyperplasia is due to the fact that the secretion from the sinus dries on this portion of the septum, causing continued irritation to the underlying mucosa.

Posterior Rhinoscopy: Examination of the nasopharynx usually furnishes definite information of the condition of the sphenoid sinus. As the secretion must escape through the choana, we would naturally seek, in this locality, for some trace of its existence. At this point I must state that in my experience I have rarely seen the nasopharynx filled with free pus and crusts, as has been so often described in text-books. Only in rare instances has this been noted, and never in the profusion so commonly believed. The average case at the time of examination

563. Tilley: The Symptoms, Diagnosis and Treatment of Chronic Suppuration in the Sphenoidal Sinus. Brit. Med. Journ., vol. 2, p. 1198, 1905.

shows a slight mucopurulent or purulent line coming down over the posterior end of the middle turbinate. As for the vault being filled with crusts, this has never come under my notice. Occasionally pus will accumulate in such a manner as to give one the impression that suppurative inflammation has occurred in the pharyngeal tonsil.

The greatest accumulation is present in the morning, directly on arising, as during the night the secretion has a better chance to leave the sinus on account of the lowered position of the ostium.

Changes are invariably present on the posterior and often the lateral pharyngeal walls. Pharyngitis sicca is perhaps the most common, the following variety being pathognomonic of sinus disease. The posterior wall of the pharynx is dry and smooth, having an appearance as though covered with a thin coat of shellac. The condition seems to be intensified as it disappears upward behind the uvula, while there is a gradual shading off into comparatively healthy mucous membrane as it descends toward the larynx. This is readily explained when we consider that the secretion comes from above and, being hawked out, but a comparatively small quantity descends below the pharyngeal orifice.

Another form of pharyngeal inflammation, which is also pathognomonic, is known as pharyngitis lateralis. In this variety the mucosa at the junction of the posterior and lateral walls shows a marked hypertrophy, being hyperæmic and swollen so that it has the appearance of a raised tract about half the size of an ordinary lead-pencil, situated on the diseased side. It is along this tract that the secretion finds its way into the throat. Free purulent secretion in the choana and throat is more often missed than met with; therefore, its absence proves nothing, so far as chronic sinusitis is concerned. A symptom which is sometimes of import is a foul smell to the breath. This is most perceptible to the examining physician and does not resemble any other nasal condition. It is a sweetish, fetid odor, and when present is pathognomonic for purulent sinus affection.

DIAGNOSIS.—Let us suppose we had a case that presented certain symptoms (excessive postnasal discharge, parietal and occipital headaches, and purulent secretion in olfactory fissure) which led us to suspect disease of the sphenoid sinus. What course do we pursue in order to arrive at a positive diagnosis? For this purpose one and only one condition confronts us,

namely, we must prove that the purulent discharge not only issues from, but is secreted by, the mucosa of the sphenoid sinus. As the pus makes its appearance anteriorly between the middle turbinate and septum, let us apply our investigations to this region. Before attempting any manipulations we must thoroughly apply the strong cocaine-adrenalin solution, not only for its anæsthetic qualities, but also in order to gain as much room as possible. After anæsthetization is complete the naris is thoroughly cleansed with a warm salt solution. Remembering now the cardinal principle that pus must shortly reappear after being removed if coming from a reservoir or sinus, we take a cotton mop and gently cleanse the olfactory fissure. If the secretion has formed from a localized inflammation of the mucosa it will not reappear.

During the waning of an acute cold, pus is often seen in the olfactory fissure.

Let us suppose that it reappeared in the same position, our next step is to follow the flow to its origin. The extreme narrowness of the olfactory fissure prevents this; therefore, we must endeavor to artificially dilate the parts until the sphenoidal ostium is brought into view. The mucosa of the middle turbinate and septum is exquisitely sensitive; therefore, much care and patience will be expended before this is finally accomplished. We begin by introducing a small cotton mop saturated with cocaine-adrenalin between the middle turbinate and septum, forcing it back until some resistance is felt. This is allowed to remain a few moments *in situ*, then removed and a large one inserted, the procedure being continued until the mop passes back and rests against the anterior sphenoidal wall.

Thus we not only anæsthetize the parts, but cause a slight dilation as well. The long-bladed Killian speculum is now introduced until the ends are in approximation with the sphenoidal fissure and the blades gently sprung apart. If this manipulation has been properly accomplished, no blood will be seen between the blades; if, however, the tips have lacerated the mucosa of the anterior sphenoidal wall, the entire field will be swimming in blood, making further examination difficult, not to say unavailing. Supposing the introduction of the speculum has been successfully accomplished, we are enabled to see a very small portion of the anterior wall of the sphenoid under reflected light. Only in exceptional cases does the ostium come under our vision, on account of its anatomical situation in the sphenoidal

moidal recess; however, an attempt should be made to find it by first cleansing the anterior wall with cotton mop and, if still invisible, by resorting to the sound.

In very favorable instances the ostium can lie directly at the end of the speculum and when disease of the sinus exists, pus may be seen pulsating in the ostium. If pulsation is present we are certain the mucosa of the sphenoid is affected.

The sound having been introduced in the usual manner (for technique see page 361), on withdrawing it we should note whether pus follows or any trace is present on the tip of the instrument. As a negative finding proves nothing, in order to ascertain whether pathological secretion is actually within the sinus it is necessary to introduce a catheter and, if the ostium be visible, forcibly blow air into the cavity, otherwise flush out the interior with normal salt solution. If pus appears on either of these procedures our diagnosis is made. (See Differential Diagnosis, page 363.)

It should always be borne in mind that there is a possibility of the sinus being empty at the moment of examination, from its having just previously drained. This is particularly true in the morning hours, and in suspected cases a positive diagnosis should not be made until repeated examinations at different periods in the day have been instituted.

Cases in which it is impossible to obtain a view of the anterior sphenoidal wall.—In more than 50 per cent. of the cases anatomical peculiarities, such as deviated septum, abnormally narrow nose, and enlarged middle turbinate, are present which absolutely prevent the application of the long-bladed Killian speculum. Sounding followed by lavage, depending upon the sense of touch, is seldom successful, and when effectively accomplished is most unsatisfactory, for the following reasons: We do not know that purulent secretion is in the sinus, but depend upon the returning flow from the syringe to contain particles of pus. As a matter of fact, unless there is a considerable quantity of thick, purulent secretion present, little evidence will be seen with the returning fluid, as the sinus lies at such a distance from the nasal orifice that most of the pus will be arrested in the various interstices of the posterior ethmoidal region and in the nasopharynx. Under such circumstances, but one course lies open to us, and that is to lay bare the anterior sphenoidal wall—a procedure which will necessitate the removal of some of the intranasal structures. In the majority of instances this will mean resection of the posterior

half of the middle turbinate or resection of a deviated septum, or both, as the case may be. In order to arrive at a definite diagnosis we are perfectly justified in these procedures, as in the event of disease being present a step in the therapy has already been applied, while, should the parts be found healthy, no particular damage has been done.

SOUNDING THE SPHENOID SINUS.

In the normal nose it is difficult to sound this sinus, for the following reasons: 1. The posterior half of the middle turbinate completely hides the anterior sphenoidal wall from view. 2. The sphenoidal recess being a variable structure, the ostium has no constant place of situation. 3. The parts are exquisitely sensitive and do not bear well the various manipulations of the sound. Under certain conditions, however, this manoeuvre may be accomplished even though the ostium is not visible. Naturally, the most favorable conditions for sounding are: (1) when the middle turbinate lies closely inrolled against the lateral nasal wall; (2) when a deviation of the septum occurs toward the opposite side.

TECHNIQUE OF SOUNDING.

Before attempting to introduce the sound in the sphenoidal region it is always advisable to cocaine the parts. If there is sufficient space between the middle turbinate and septum this can be accomplished by means of a cotton carrier saturated with a 4 per cent. cocaine solution; if not, a 2 per cent. spray may be used. A fine, flexible, graduated sound with measurements at 7, 9 and 11 cm. from the tip is now introduced into the nose between the septum and middle turbinate, crossing the latter structure exactly at its middle, and carried backward until it is arrested by coming in contact with the anterior sphenoidal wall.

The most important step of this manipulation is to cross the middle turbinate at a point corresponding to its centre. If the sound is carried too far forward the lamina cribrosa will be touched, while if it is directed too far backward the point will come out into the choana.

The ostium of the sinus is now sought for by gently probing in all places accessible to the point of the sound, using as little force as possible, as the anterior wall is extremely thin in this locality and may easily be broken into—an accident to be carefully avoided unless it is unmistakable that the sinus is diseased.

Much has been said regarding the danger of perforating the cribriform plate during this manœuvre. This is more apparent than real, for that structure lies too far forward and the posterior portion of the roof of the olfactory fissure is quite thick at its junction with the sphenoid sinus and does not readily yield to an instrument as delicate as a probe. Indeed, I have intentionally endeavored to puncture this plate on numerous cadavers, but have failed in every instance, the sound bending before infraction of the bone was accomplished.

In the majority of instances this will fail to find the opening, as the sound, being straight, cannot penetrate into the depths of the sphenoid sinus where the ostium is probably situated. Under these circumstances it will be necessary to entirely withdraw the instrument from the nose and bend the tip slightly

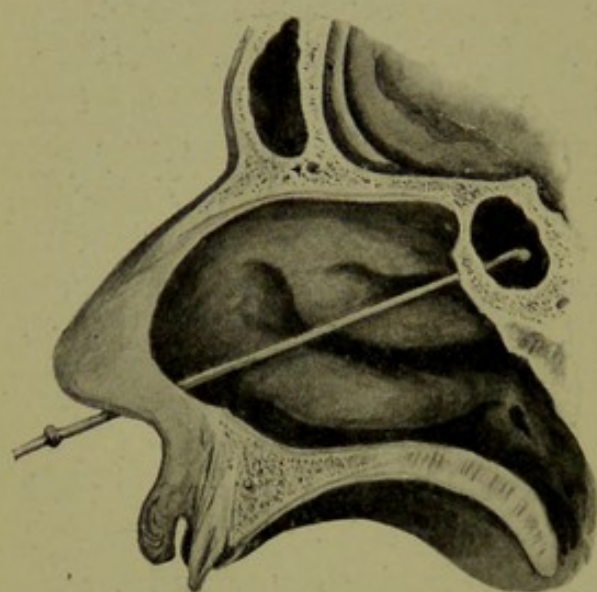


FIG. 232.—Sounding the sphenoid sinus. In this instance the ostium is situated much lower on the anterior wall than is usually the case.

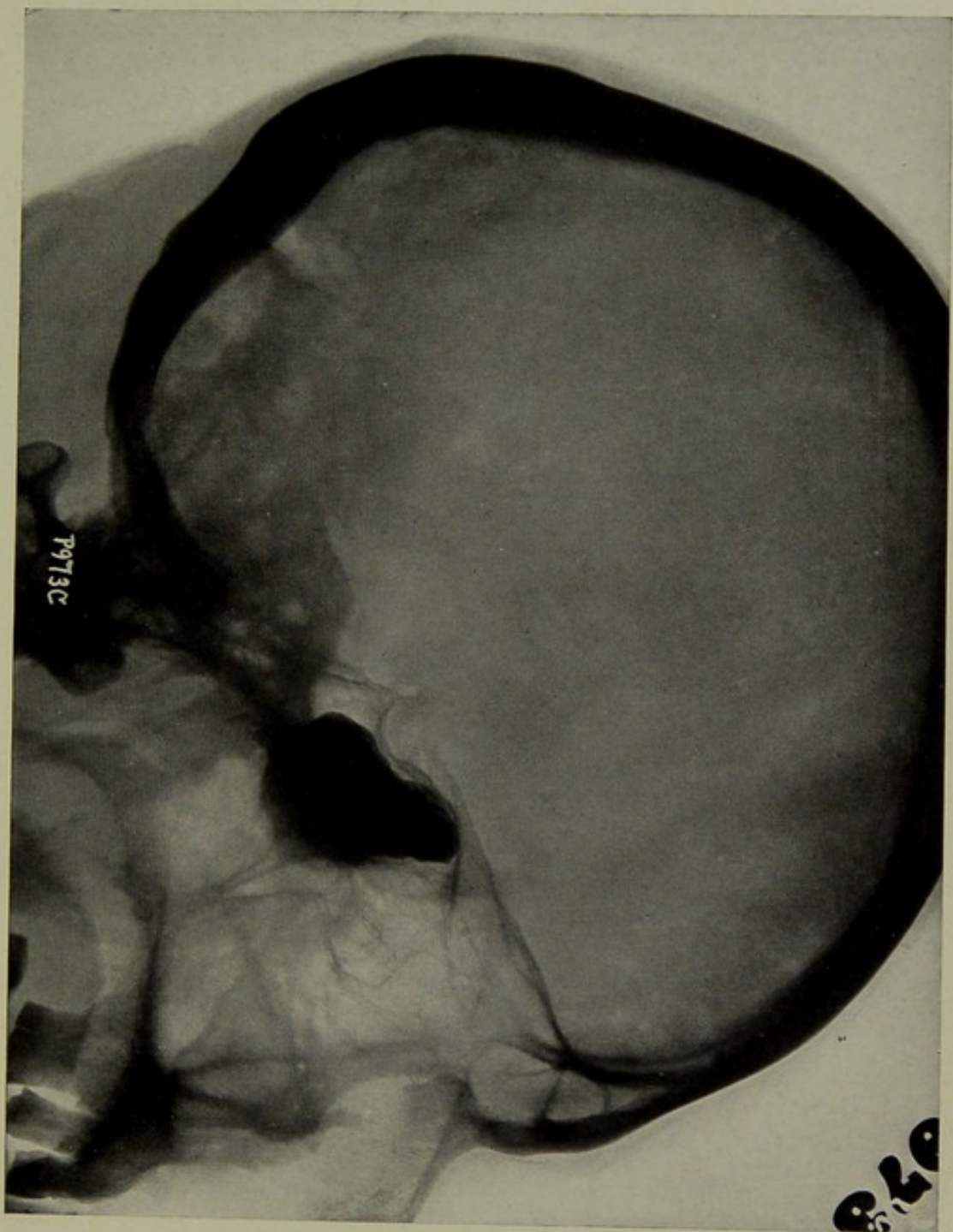
outward and downward: outward in order to penetrate the recess, downward as the ostium is usually situated below the junction of the roof and anterior sinus wall. The sound is again introduced and the ostium sought for by probing with the new curved tip. Sometimes this will succeed, sometimes fail. How do we then know that the point of the sound is actually within the sinus? There is where the measurements on the sound have their importance. The

distance from the anterior inferior nasal spine to the anterior wall of the sphenoid is 7–8 cm. (Fig. 232).⁵⁶⁴⁻⁵⁶⁵ Even in the largest heads these measurements are rarely exceeded.* The first notch on the sound represents 7 cm. If the sound does not enter beyond this mark it is doubtful if one is beyond the anterior sinus wall. If, however, this mark is exceeded, the sound disappearing to the second notch, we are either in the sphenoid sinus or a sphenoid-ethmoidal cell, provided the direction across the cavity has been true.


564. Schaffer (402), S. 906. 565. Hansberg: Die Sondierung der Nebenhöhlen der Nase (Kielbeinhöhle). *Monat. f. Ohrenhk.*, S. 50, 1890.

* The distance between these two points rarely exceeds 8 cm.; indeed, if one has passed a sound in this direction 8 cm. in small heads and 9 cm. in large heads, measuring from the anterior inferior nasal spine, the ostium of the sphenoid sinus is almost certain to have been penetrated.

PLATE 5.



Röntgen ray photograph showing lateral position of sphenoid sinus.



It sometimes occurs that the sound penetrates up to and even past the 11 cm. notch after the tip has passed through the ostium. Under these circumstances we at once know that the sinus extends far backward on that side.

Unfortunately, in the majority of cases our attempts at sounding will prove futile under the usual conditions, for not only have we the normal difficulties to contend with, but also those resulting from inflammation (hypertrophies, polyps, and crusts). The Killian speculum may be used to partially overcome these difficulties, but, as with the frontal sinus, it will probably be indicated to remove a portion of the middle turbinate; but with the sphenoid it will be the posterior half of this body. The object of sounding this sinus is to ascertain the location of the ostium and be able to introduce a catheter, aspirate, or wash out as desired.

*Jacob's Method.*⁵⁶⁶—A catheter similarly curved as one used for the Eustachian tube is passed between the middle turbinate and septum until the cribriform plate is encountered. The instrument is then glided gently along this structure until it reaches the anterior sphenoidal wall. By gently probing, the ostium of the sinus is found and the instrument is passed into the sinus. (Fig. 233.)

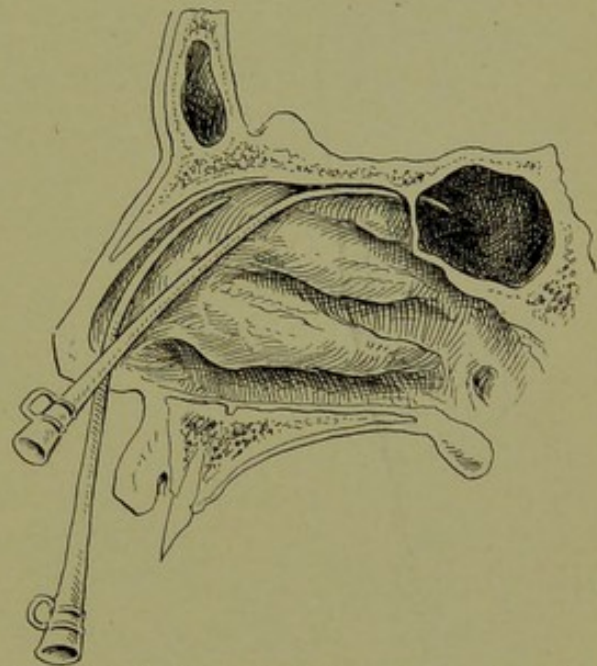


FIG. 233.—Jacob's method of sounding and catheterizing the sphenoid sinus.

DIFFERENTIAL DIAGNOSIS.—Owing to the manifold and curious symptoms that occur during the course of a chronic purulent inflammation of the sphenoid sinus this disease often remains undiagnosed, being confused with some condition associated with the throat, bronchi, or even the general system (anæmia, neurasthenia, etc.). In these doubtful cases one local symptom, when elicited, is the keynote to the situation, *i.e.*, the postnasal discharge. Unfortunately, one is obliged to rely largely upon the description of the patient as to the amount and character of the discharge, but, should this symptom be complained of, it must be followed up to the end in order to determine the exact source.

⁵⁶⁶. Jacob: Catheterisme du sinus sphenoidal. Bull. d. l. Soc. Anat. de Paris, T. 74, p. 893, 1899.

A chronic postnasal discharge, other things being equal,* results usually from: 1. Inflammation of the sphenoidal mucosa. 2. Inflammation of the posterior ethmoidal labyrinth. 3. Combined inflammation of both sphenoid and ethmoid. 4. Purulent inflammation of the nasopharynx (adenoids, lues, tuberculosis, etc.). Let us suppose a patient presented himself with subjective symptoms of posterior ethmoidal or sphenoidal suppuration with a postnasal discharge which we are able to trace to the sphenoidal region. Posterior rhinoscopy shows us that the source is not in the nasopharynx, but somewhere above, as the purulent secretion appears to be coming down over the posterior end of the middle turbinate. Anterior rhinoscopy, even after the removal of a portion or all of the middle turbinate, only shows us that pus is present in the sphenoidal region, but not particularly located in any individual sinus. As with the maxillary in the anterior sinuses, in this instance we first turn our attention to the sphenoid. Our first thought is, of course, to find the ostium or, in certain cases where this is impossible, to break in the anterior wall with a dull curette. If, however, the ostium is seen, the anterior wall is wiped off with a cotton pledget and the parts again inspected. Suppose we are still unable to find any pus around the sinus orifice.

This may be either due to the thick consistency of the pus, the small size of the ostium, or that no secretion is present within the sinus. Under any circumstances our next procedure is to introduce a small cotton pledget saturated with cocaine-adrenalin solution within the ostium and allow it to remain several minutes.

We now cause the patient to bend the head over so that the chin rests upon the chest and remain a few moments in that position. After a varying length of time (two to five minutes) the sphenoidal space is again examined, and if any pathological secretion is in the sinus it will be seen exuding from the enlarged ostium. Does this finding warrant the diagnosis of sphenoidal empyema? No, as we are not certain that the pus did not trickle in from the posterior ethmoidal cells.

As a matter of fact this possibility is largely exaggerated, for in the vast majority of instances where pus is seen exuding from the sphenoidal ostium, particularly under pulsation, the mucosa of the sphenoid is responsible for the secretion.

* Empyema of the sinuses of the first series, in which the purulent discharge finds its way backward into the choana, is, of course, not taken into consideration.

Accepting, then, the possibility of a sphenoidal sinusitis, how can one differentiate from which region the purulent secretion occurs?⁵⁶⁷ In order to accomplish this with a more or less degree of certainty, it is necessary to cleanse the sphenoid as well as the entire postnasal space, so that no secretion is visible in either anterior or posterior rhinoscopy. After this has been done, the patient should either lie on the back or in a sitting position, leaning the head backward until the eyes point toward the ceiling, and keep the position for some minutes.

The rationale of this manoeuvre is to place the parts in such a position as to favor the drainage of secretion from the posterior ethmoidal cells into the sphenoidal fissure. A glance at Fig. 26 will at once make this apparent.

The patient is again examined, using the long Killian speculum if necessary, and if secretion is seen in the vicinity of the sphenoidal wall where it was absent immediately before, we can safely assume that it has its origin in the posterior ethmoidal cells, as it would have been impossible for the mucosa of the sphenoid to have secreted such a quantity in so short a space of time. A negative result is not necessarily of value, as the cells may be empty at the time of examination.

Let us suppose, then, that we found purulent secretion not only in the sphenoid sinus, but externally to it as well. What are the possible conditions that can confront us? 1. An empyema of the posterior ethmoidal labyrinth and sphenoid sinus. 2. An empyema of the posterior ethmoidal labyrinth in which there has been a seepage of pus into a healthy sphenoid sinus.

What means have we at hand to differentiate between these two conditions? To accomplish this successfully it is absolutely necessary that we have a free view into the sphenoidal space; at least, that the sphenoidal ostium is freely visible. This being the case, after thorough lavage and cleansing of this region, including the sphenoid cavity, a pledget of cotton or gauze is introduced into the ostium of the sphenoid, making it impervious to the passage of secretion, and further examination deferred until the following day. On the return of the patient he is closely questioned whether any unnatural or severe headache or other cranial symptoms have developed in the interim.

The structures lying anteriorly to the sphenoid are thoroughly

567. In the experience of Rhese (*Entzündungen der Siebb. und der Keilbeinhöhle*, Arch. f. Lary., Bd. 24, S. 426, 1911) empyema of ethmoid coexisted with sphenoid empyema in 66 $\frac{2}{3}$ per cent. of all cases.

contracted with cocaine and adrenalin in order to obtain the best possible view of the deeper regions, care being taken not to disturb in any way the plug introduced the previous day. Close examination of the sphenoidal region will now show one of two things: either pus is absent or it is present, covering the external surface of the plug. A positive diagnosis is now possible. If pus is present, the posterior ethmoid cells are diseased and have thrown off the secretion which covers the anterior wall of the sphenoid.* To discover whether the sphenoid shares in the inflammation with the posterior ethmoid cells is now a simple matter. After cleansing the posterior nares of all crusts and purulent secretion, the utmost care being taken not to disturb the location of the plug, under direct vision the cotton is seized with the forceps and quickly removed, noting instantly whether secretion of any kind escapes with its withdrawal.

If the ostium appears clean and the sinus cavity is found to be dry and empty, we can exclude the sphenoid from any participation in the affection. If, however, pus appears welling from the ostium, we are certain that it was secreted within the cavity, and, consequently, disease is present in the sinus. Under these circumstances the diagnosis would be combined posterior ethmoidal and sphenoidal sinusitis.

EMPHYEMA OF A SPHENO-ETHMOIDAL CELL.

The occurrence of such a condition would be most confusing, for one would encounter pus coming from above the normal ostium of the sphenoid. Such a case would probably remain unrecognized as such until operation disclosed an apparently horizontal partition dividing the sphenoidal sinus into a superior and an inferior compartment.

EMPHYEMA OF THE POSTERIOR HALF OF A DOUBLE MAXILLARY SINUS.

Recollecting that the ostium of the posterior half of a double maxillary sinus finds itself in the superior nasal passage, an empyema affecting such a cavity could early be confused with sphenoidal disease. Hajek (p. 336) mentions such a case, and was only after many days, with the greatest difficulty, able to make a correct diagnosis. This was accomplished by tamponing the sphenoid and sounding the posterior ethmoid cells, thereby assuring himself of their healthy condition. The sound was then passed into the ostium of the posterior half of maxillary sinus. This cavity was later opened through the socket of the second molar tooth.

PROGNOSIS.—If once the mucosa of the sphenoid sinus becomes chronically diseased it is very doubtful if spontaneous regenera-

* If any doubt exists as to whether leakage occurred through the cotton plug, this manipulation may be repeated.

tion ever occurs, even though naturally favorable conditions supervene. There is no doubt, however, that it may at times become so latent as to give even the patient the impression that a cure has resulted. This period of latency may last until some unfavorable condition arises (exposure to wet feet, change in the weather, etc.), when the inflammation again breaks forth with renewed vigor. So long as there is free drainage existing little danger to life, or even of complications, exists, but as soon as any interference to the free outflow of the secretion manifests itself, at that moment we have an aetiological factor for serious consequences.

The formation of these obstructions can almost be designated as autogenetic, for, while the anterior sphenoidal wall exhibits a marked tendency to osteoporosis with enlargement of the natural ostium during the course of a chronic infection, the mucous membrane of the sinus and sphenoidal fissure, by reason of the constant irritation of the escaping pus, becomes distinctly hypertrophic. On account of the narrowness of the sphenoidal fissure these hypertrophies can present a serious obstacle to the escape of the continually-forming secretion within the sinus. Stagnation of the secretion, even though only partial, seems to heighten the virulence of the infection. Whether this is due to an actual increase in the virulence of the organism or to a decrease in the resisting power of the sinus mucosa is a debatable matter. In all probability, both of these factors act in common.

If the ostium be of sufficient calibre to insure the free outflow of any secretion which may form, the patient may go for months, and even years, without any other disturbance than that which naturally follows the escape of more or less purulent or mucopurulent discharge into the nasopharynx. This is well illustrated in those cases which have undergone operation. It is notable to remark the frequency with which operated patients become reinfected without exhibiting the primary subjective symptoms (headache and mental disturbances) incident to the disease. Reviewing these facts, we can state that the prognosis of chronic sphenoidal suppuration is good, so far as life is concerned, provided that the drainage passages be kept patulous. The prognosis for cure is good if an opening of sufficient size is made in the anterior wall of the sinus that will enable one to reach all portions of the diseased mucosa, but the proneness of the lining

mucosa to constant reinfection is a probability which must not be overlooked.

COMPLICATIONS.—Owing to the deep lying situation of the sphenoid sinuses and their intimate relation to the base of the brain, cavernous sinus, and the optic chiasm and nerve-trunk (Fig. 35), complications embracing these structures as a result of prolonged or virulent inflammation of the sinus mucosa are more frequently observed than with the other sinuses.

Several causes may be ascribed as responsible for their occurrence, as: *a.* intimate anatomical relation of the walls of the sinus to these structures. *b.* The hidden position of the sinus causing the disease to be unrecognized. *c.* The defects and dehiscences in the bony walls, thus bringing the sinus mucosa in direct contact with intracranial structures.

Chief among these, and, indeed, almost peculiar to this cavity, are thrombosis of the cavernous sinus and affections directly implicating the optic nerve (retrobulbar).

1. Thrombosis of the Cavernous Sinus. On account of the normal anatomical position of this venous sinus against the lateral walls of the sphenoid cavities, the latter may readily become infected through the bony walls, either by direct extension of the pathological process through the canaliculi (lymph) or by means of the perforating veinlets.

PROCESS OF INFECTION-MECHANISM.⁵⁶⁸

After the inflammatory process has penetrated the sphenoidal walls, septic infiltration of the venous walls occurs with the production of an endophlebitis, which predisposes to coagulation of the blood along the line of inflammation. The clot formed by this coagulation accumulates layer by layer until the lumen of the vein at this point is partially or completely obliterated with a corresponding stagnation of the circulation. Pathological changes now take place in the thrombus. At first fibrous degeneration sets in with adherence to the walls of the vessel. If the infection is virulent the clot soon breaks down in a semi-purulent mass, at first in the centre, gradually spreading to the extremities. The thrombus being now soft and pliable, small portions are being continually thrown off into the circulation at the distal end of the vein, which cause thrombi in other veins. Various forms of meningitis, including brain abscess, metastatic abscess and infarcts in the lungs, appear to be common sequelæ of this affection when the patient's life is prolonged.

SYMPTOMS.⁵⁶⁹—The onset is similar to that of meningitis: rapid pulse, profuse perspiration and pyæmic temperature. Pain

^{568.} St. Clair Thomson: Cerebral and Ophthalmic Complications in Sphenoidal Sinusitis. *Brit. Med. Journ.*, vol. 2, p. 768, 1906. ^{569.} St. Clair Thomson: The Causes and Symptoms of Thrombosis of the Cavernous Sinus. *The Ophthalmic Review*, p. 293, 1908.

is usually present, referable to the affected side of the head and behind the ear. Any form of cerebral symptoms may be present, from delirium to coma, although a condition of stupor from which the patient may be aroused seems to be the rule.

Ophthalmic Manifestations.—These are always prominent, and by their early appearance (six to sixteen days after the onset) are almost characteristic of the affection. The first symptom to be noted is œdema of the lids and the lower part of the frontal region on the affected side, which gradually spreads until the opposite side is also involved.

Exophthalmos gradually begins to make its appearance with impairment of the ocular movements. The visual changes do not appear to be characteristic, as there may be little or no impairment of sight,⁵⁷⁰ or, on the other hand, intermediate stages to total blindness;⁵⁷¹ however, little reliance can be placed on these tests, as the mental condition of the patient is such as to preclude the possibility of obtaining satisfactory answers.

The pupillary reactions become sluggish, and, if the patient continues to live, purulent infection with ulceration of the conjunctiva results. During these local changes aggravation of the general condition is occurring, which finally results in delirium, coma, and death.

TREATMENT.—It depends considerably upon what intranasal measures have been adopted to make the diagnosis as to what form of treatment will be instituted; thus, if it has been necessary to resect a portion of the middle turbinate and enlarge the sphenoidal ostium before disease in this sinus was discovered, already the surgical end of the treatment will have been accomplished, and nothing remains, at least for the time being, but simple irrigation and perhaps the insufflation of some antiseptic powder. If, on the other hand, but a tentative diagnosis had been made, during which time the augmentation of the symptoms became alarming, it is not only justifiable but absolutely indicated to institute at once such surgical procedures as will disclose the precise condition of the mucosa of the suspected cavities.⁵⁷²

Let us, however, take a case which by reason of sufficient width of the olfactory fissure we have been able to diagnose without

570. Jessop: Infective Thrombosis Involving Cavernous Sinus. Trans. Ophth. Soc. United Kingdom, vol. 23, p. 184, 1903. 571. Reber: Differential Diagnosis of the Orbital Conditions Caused by Sinusitis, Including the Report of a Case of Thrombosis of the Cavernous Sinus. Penna. Med. Journ., p. 790, 1910. 572. Curtis: The Sphenoidal Sinus and its Surgical Relations. Laryn., p. 860, 1904.

removal of any portion of the nasal structures. We see the pus exuding from the sphenoidal ostium. Our first thought is to introduce a catheter and irrigate the sinus, applying this principle daily until amelioration and subsequent cure results.

Technique of Catheterization and Irrigation.—When the middle turbinate has not been disturbed and the sphenoidal ostium remains invisible, it is absolutely essential, before attempting this manipulation, that the sound shall have, beyond doubt, penetrated

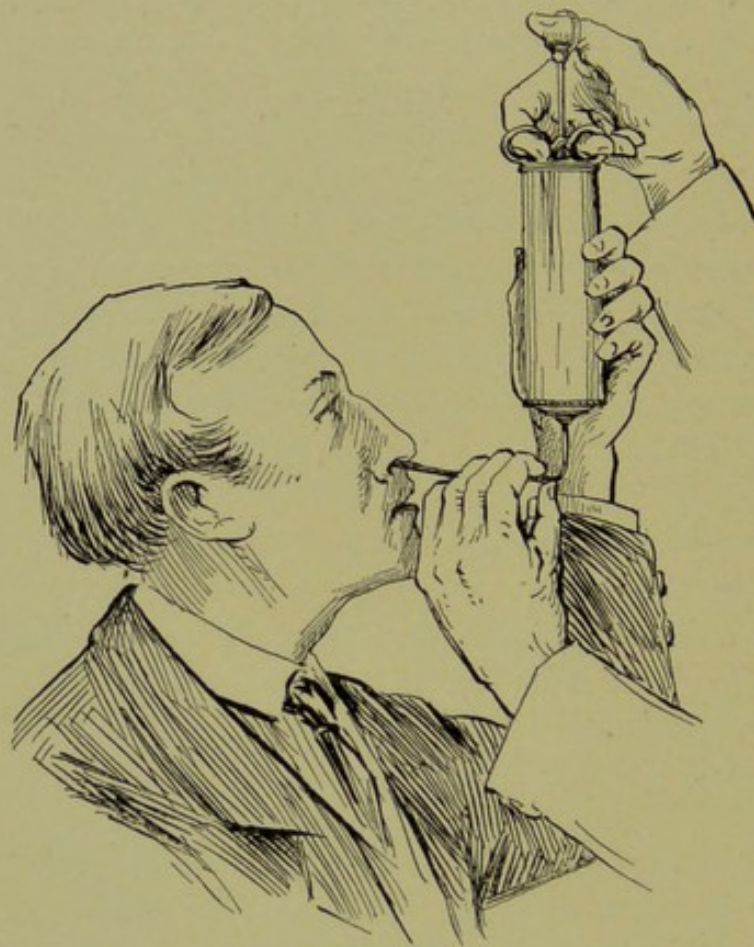

FIG. 234.—Position of the hands of patient and surgeon in irrigating the sphenoid sinus.

into the sinus, in order that one may have exact knowledge as to the direction, proper curve to the catheter, etc. The catheter is now bent in a corresponding curve to the sound and introduced in the same manner until it penetrates the ostium. Holding it in place with the left hand, the syringe is filled with the right and given to the patient to hold while the nib on the end of the rubber tube is fitted into catheter. (Fig. 234.) These are then held together by the left hand, the syringe being taken into the right, and the patient lowers the head and gentle pressure is made upon the piston until the injected fluid issues from the nose. Pus does

not usually escape at the first few drops, but appears after several drachms have escaped, depending upon the consistency of the secretion. It may even occasionally happen that none is observed, particularly when freely miscible with water, as it may lodge in the various interstices of the posterior ethmoid capsule; therefore, this procedure cannot be considered as reliable a one as lavage of the maxillary sinus. Several ounces (8-12) of fluid should be injected, and preferably caught in a black hard-rubber pus basin, in order to more thoroughly differentiate the color of the returned liquid.

This manipulation is not always unattended by danger, as syncope and unconsciousness⁵⁷³ have been reported following simple irrigation; therefore, one must exercise great care to use slight pressure, at least at the beginning.* The therapeutic value of simple irrigation is doubtful except in acute cases, which, however, are rarely recognized. The unfavorable situation of the ostium tends to allow the accumulation of a certain amount of residual pus which cannot be removed entirely without opening the drainage passages. This can be accomplished only by enlarging the sinus ostium.

According to our experience, amelioration usually occurs, but the cure remains unaccomplished. This is undoubtedly due to the permanent changes which have taken place in the sinus mucosa. It is now clear that we cannot expect regeneration to follow the mere mechanical cleansing of the sinus. Something further must be done to facilitate better drainage and aëration of the cavity. This can be accomplished only by enlarging the normal ostium, a procedure which occupies but a few moments and is entirely free from pain.

Technique of Enlarging the Normal Ostium. — Cocainize thoroughly the septum and septal side of middle turbinate, forcing back the cotton mop until the anterior sphenoidal wall is encountered, using, if necessary, the long-bladed Killian speculum as an aid in reaching the deeper-lying portions. When these parts have lost their sensation, introduce the cotton well within the spheno-ethmoidal fissure and allow it to remain therein, thus anæsthetizing the anterior wall, especially around the ostium.

573. Schech: Zur Pathologie der Keilbeincaries. Verh. d. ver. Sudd. Lary., S. 198, 1898.

* Undoubtedly debiscence of the walls was present in these cases, as we have never met with such symptoms in several hundred irrigations.

During this manœuvre it is wise to cause the patient to hold the head with the chin resting on the chest to prevent the cocaine solution from escaping backward into the nasopharynx and being swallowed. It is rather the systemic effect of the cocaine than the shock of the operating which causes syncope in patients while operating in this locality.

After several minutes the cotton carrier is removed and another smaller one, wrapped tightly around the extremity, is dipped into adrenalin 1/1000 and gently forced within the ostium, using a screwing motion to facilitate its entrance. This is in a few moments again removed, and it will be noted that the calibre of the ostium is considerably enlarged. At this stage it is a comparatively simple matter to introduce the spear-shaped point of the cutting forceps (Fig. 235) and resect piecemeal the anterior

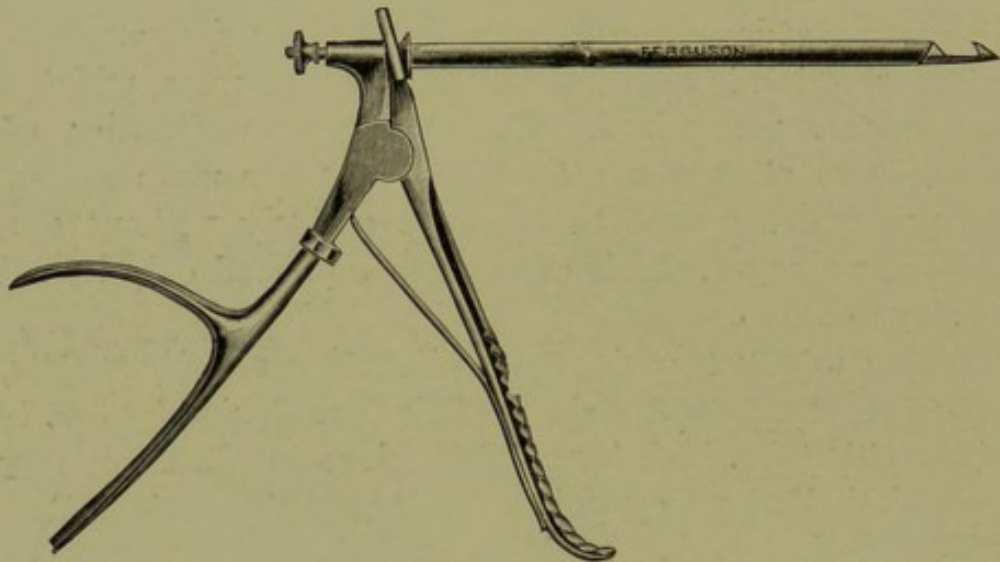


FIG. 235.—Faraci's bone-cutting forceps for enlarging the sphenoidal ostium.

wall in a downward (Fig. 236) direction until the opening is flush with the sinus floor. To guard against too early closure of the wound it is also advisable to remove a portion in the lateral direction.

Some little practice will be necessary until one becomes entirely accustomed to these forceps, as the spring is so strong that during closure of the jaws, the shank has a tendency to jump, thereby disengaging itself from that portion to be removed. This can be overcome by holding the cutting portion firmly in place and pressing the handles together with a slow, steady motion.

This entire procedure should be accomplished without pain and with very little hemorrhage. The anterior of the sinus is now cleansed by flushing and wiping with cotton, and the operation terminated by insuffusing iodoform or a like dressing powder. The after-treatment consists of daily irrigation, followed by dry-

ing and insufflation of powder until the discharge abates and finally ceases. In moderate cases this will usually suffice to bring about a cure, but occasionally this procedure will not give the desired space for complete drainage, when the radical operation with removal of all structures encroaching upon the anterior sphenoidal wall (posterior end of middle turbinate and superior turbinate) is indicated.

It is the rule rather than the exception to find the olfactory space so narrow that it is impossible to reach all parts of the anterior sphenoidal wall even with a fine sound. This is due not only to the natural configuration of the parts, but, in the event

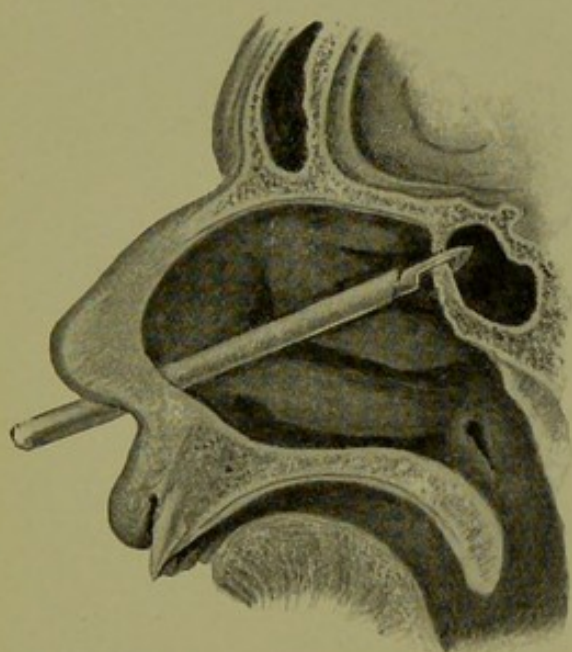


FIG. 236.—Enlarging the natural ostium of the sphenoid sinus without removal of middle or superior turbinate.

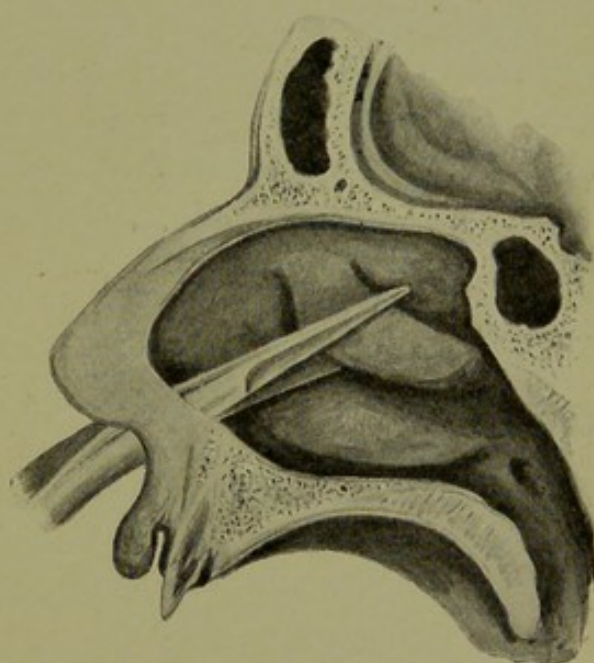


FIG. 237.—Severing the middle turbinate in the centre prior to the removal of the posterior half.

of inflammation, to the various hyperplasias of the mucosa incident thereto. Under such circumstances it is impossible to conserve all of these anterior structures even in making a proper diagnosis, to say nothing of the conservative operation (removal of a portion of the sphenoidal wall). These conditions being present, we can only resort to the more extensive operative measure, *i.e.*, the radical operation.

Indications for the Radical Operation.—It must not be considered that the conservative operation has failed when a certain amount of discharge continues to be secreted. The main indication was to relieve the symptoms and dangers incident to the obstruction to free drainage, and when this has been accom-

plished the serious portion of our ends has been met. On the other hand, the annoyance, and even harm, incident to the continual postnasal discharge must not be minimized, but, with the distressing subjective symptoms a thing of the past behind us and with a free opening in the sinus wall, we are in a much better position to deal with the secreting mucosa than under the former conditions. The instillation of a few drops of 5 per cent. solution of nitrate of silver or a weak solution of zinc chloride will often yield brilliant results in these cases.

1. In all cases of threatened complications.

In acute, and particularly in chronic, cases with insufficient drainage cerebral or orbital complications are liable to occur at a moment's notice. At the first warning of these the radical operation should be performed without a moment's delay, as many cases can be saved where procrastination would cause permanent injuries, and even death.^{574, 575}

That this applies also to orbital and ophthalmic complications has been well shown by Holmes⁵⁷⁶ and Coppez,⁵⁷⁷ who, by curettage of the ethmoid and sphenoid, was able to restore sight in two cases in which blindness had resulted from the sinusitis.

2. When acute exacerbations frequently occur.

There is no question that the sphenoid mucosa, after once being the seat of an inflammatory process, even after complete recovery, exhibits a marked tendency toward renewed inflammation with every slight change in the nasal mucosa. When these exacerbations become so frequent as to be the source of almost constant annoyance to the patient, and, considering the rapid tendency of the opening to close through excessive granulation, an enlargement of the opening by means of the radical operation is indicated.

3. Upon the occurrence of ocular manifestations.

One of the most important symptoms associated with chronic sphenoidal empyema is a gradual diminution in the field of vision. While this is often dependent upon stagnation or special virulence of the secretion, such is not always the case, as the inflammation

574. Snellen, Quix: Bericht. d. Niederl. phys. u. mediz. Kongress, Utrecht, 1909.
 575. Kander: (Meningitis beim Kielbeinhöhlenempyem mit Ausgang in Heilung Verh. sudeutsch. Lary., S. 109, 1907.) This case, which has been reported *in extenso*, illustrates well the value of early surgical intervention. See also R. H. Skillern: The Importance of Rhinological Examination in all Cases of Meningitis of Doubtful Origin. Penna. Med. Journ., Aug., 1909. 576. Holmes: The Sphenoidal Cavity and its Relation to the Eye. (Case 1.) Archives of Ophthal., vol. 25, p. 460, 1896. 577. Coppez: Deux cas de cécité par sinusite sphenoidale. La Presse Med. Belge., No. 11, p. 528, 1906.

in the sphenoid need not necessarily be purulent in order that orbital complications occur; a rarefying ostitis can also cause infection of the optic nerve.

*Radical Operation of Sphenoid.*⁵⁷⁸⁻⁵⁸⁰—1. Cocainize the entire side of the nose to be operated on with 20 per cent. cocaine solution until tactile sensation is entirely lost.

2. Endeavor to sound sinus and get general bearings with probe. (Fig. 232.) (a) See how much of anterior wall of sphenoid can be reached with point of probe. (b) Approximate the depth of the sphenoidal recess. (c) Whether posterior deviation or thickening of the septum exists which might interfere with operation. (d) Whether polypi or polypoid tissue is present. (This is important on account of the bleeding, which will tend to obscure the field, once the operation is started.)

3. Introduce scissors over the centre of the middle turbinate and press firmly into place so that the entire dependent portion will be severed in one cut. (Fig. 237.)

4. Sever turbinate with one firm cut. (The bleeding after this is usually light and can be completely controlled by the application of adrenalin chloride 1/1000 on cotton pledgets.)

5. Pass snare around posterior fragment, working the end of the instrument well up into the cut, and remove that portion. (Fig. 238.) (The hemorrhage here will be more profuse, owing to the sphenopalatine artery being severed close to its entrance into the nose. The patient should have experienced no pain thus far; the only annoyance is purely psychological, due to the sound of crunching which is caused by the breaking down of the ethmoidal cells.)

6. Pass Hajek's hook, point downward, along the olfactory fissure until it meets the anterior superior wall of the sphenoid sinus, and turn point forward and outward toward eye, thus burying it into the posterior ethmoidal labyrinth (Fig. 239), and draw firmly toward the nasal outlet, thereby opening these cells in their entirety from above downward.

One need have no apprehension of injuring the orbit by this procedure, for the posterior ethmoid labyrinth is always thicker than the length of the hook, and if by chance dehiscence of the lamina papyracea be present, the orbital fat, being one-half inch thick, will protect the orbit from injury.

578. Hajek: Zur diagnose u. intra-nasalen chirurg. Behandl. d. Eiterung d. Keilbeinhöhle, etc. Arch. f. Lary., Bd. 16, S. 105, 1904. 579. Laurens: Chirurgie du Sphenoid. Archiv. Internat. de Laryn., T. 17, p. 81, 1904. 580. Skillern: The Present Status of the Radical Operation on the Sphenoid Sinus. Journ. Am. Med. Assn., Dec., 1908.

The posterior portion of the nasal roof behind the lamina cribrosa varies from 1 mm. to 2.5 mm. in thickness, which precludes the possibility of injury by the back of the hook in this direction.

7. This procedure should be repeated several times until the entire posterior labyrinth is reduced to shreds.

8. The fragments are now removed by grasping and pulling out with a Grünwald forceps not fenestrated. (Fig. 240.) The object of this is twofold: 1. By grasping and pulling out, much larger pieces are removed than by cutting. 2. The length of the operation is materially shortened.

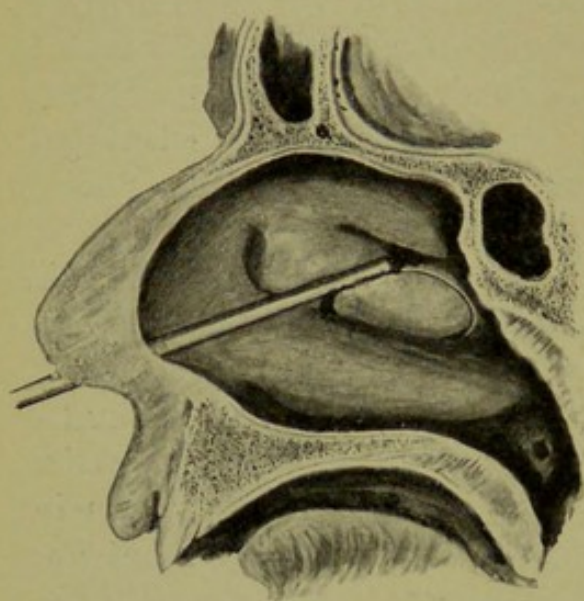


FIG. 238.—Radical intranasal operation on sphenoid. Removing posterior half of middle turbinate with the snare.

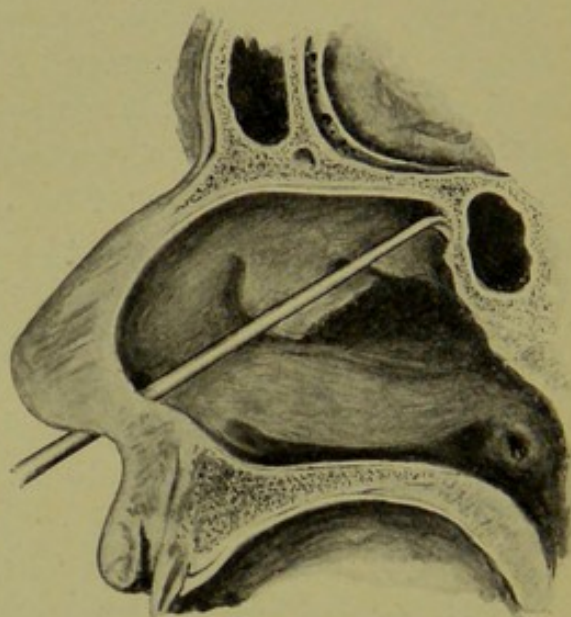


FIG. 239.—Radical intranasal operation on sphenoid. Removing posterior half of middle turbinate with the snare. Hajek's hook in position for breaking down the superior turbinate.

Bleeding is now more or less profuse, but is usually controlled with the adrenalin tampons. In rare cases, however, the operation must be suspended at this point to be finished at a later date. The pain may also be severe, especially when the fragments which contain the naso-palatine nerve are grasped and torn out.

The anterior wall of the sphenoid is now in plain view, although so covered with blood that the ostium, unless large or exuding pus, cannot readily be found. This must be sought for by the probe.

An anatomical condition which is frequently present may now be the source of much confusion, causing one to believe that the sphenoid sinus has already been opened and is now presenting its posterior white shining wall, *i.e.*, when the posterior cell of the posterior ethmoid labyrinth forms the greater part of the anterior sphenoidal wall (see Fig. 182). Sometimes the pars nasalis is so narrow

that this cell seems to occupy the entire posterior inferior portion of the nasal cavity, the sound only penetrating to its posterior wall. This error may be discovered in two ways: 1. By careful palpation with the sound one feels that there is a ridge between the septum and the sinus cavity, in other words, the sound does not glide off gently from the septum into the sinus, but meets with a narrow cleft. 2. By measuring the greatest depth of the supposed sinus one will find it only reaches as far as the normal measurement to the anterior sphenoidal wall.

9. The sphenoidal ostium is now penetrated with the double evulsor (Fig. 241), the blades opening apart (Fig. 242) and the instrument withdrawn (Fig. 243), this being done several times, but cutting in different directions until the hole is made as large as possible with these instruments.

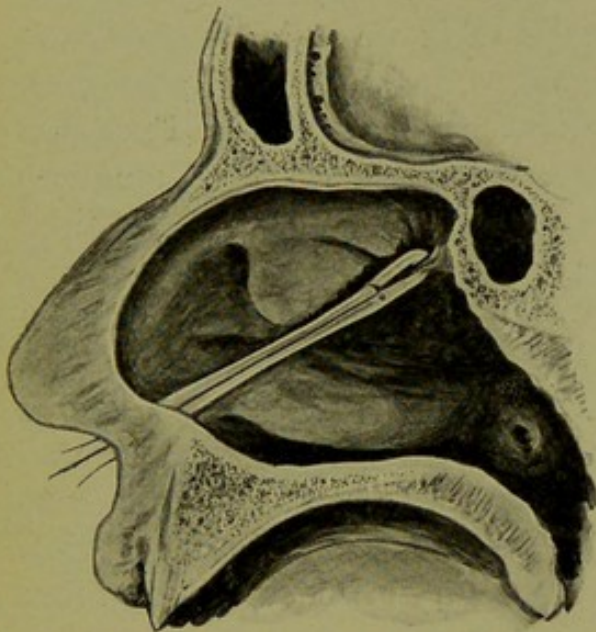


FIG. 240.—Radical intranasal operation on sphenoid. Removing posterior half of middle turbinate with the snare. Removing the debris with the Grünwald forceps.

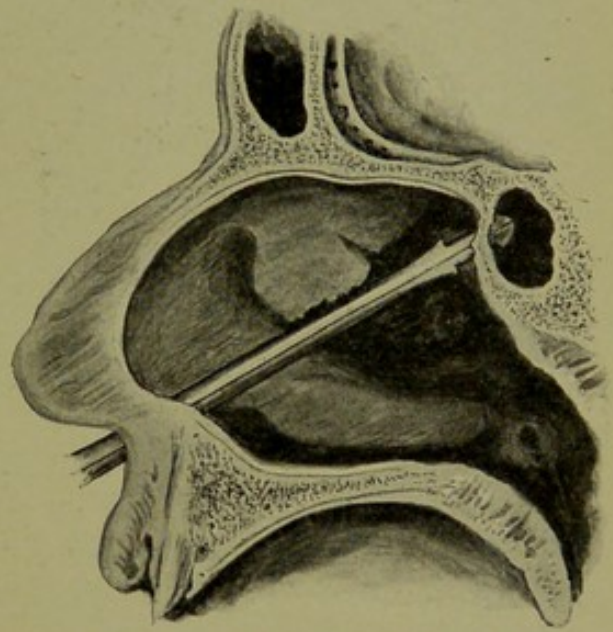


FIG. 241.—Radical intranasal operation on sphenoid. Removing posterior half of middle turbinate with the snare. The evulsor introduced closed into the sinus.

The size of the opening obtained depends upon the thickness, shape and condition of the anterior wall. Naturally one could not expect to obtain as large an opening in Fig. 225*a* as in Fig. 225*c*.

If the ostium is not visible and cannot be found with the probe, several procedures are at the command of the operator:

(1) Breaking through with Shaeffer's or Hajek's curette or Andrew's knife.

(2) Boring a small opening with a hand drill.

(3) Using an electric trephine (not recommended).

(4) Using Gmeinder's chisel (not recommended).

10. Enlarge the opening as far as possible in all directions with the sphenoid forceps. (Fig. 244.) This is, perhaps, the most important and most difficult step in the operation, so far as

a permanent cure is concerned—most important because the larger the hole the better the drainage, and most difficult because the more one bites away, the thicker the bone becomes. (Fig. 245.) If possible, the entire floor should be removed, thus obliterating

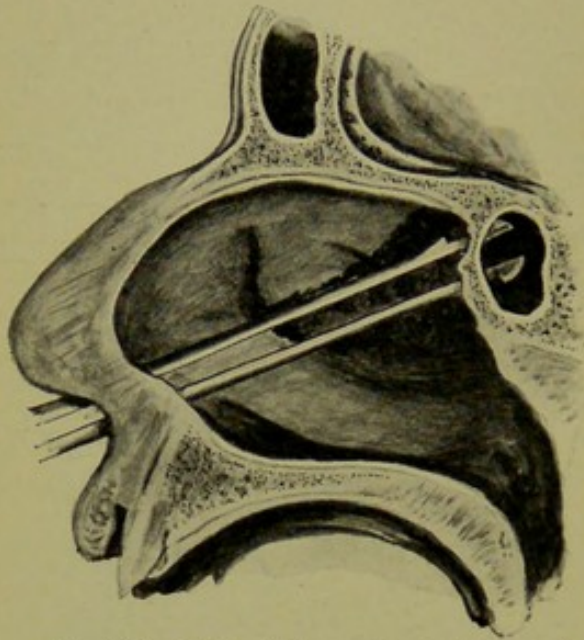


FIG. 242.—Radical intranasal operation on the sphenoid. Removing posterior half of middle turbinate with the snare. The blades of the evulsor sprung apart ready to be withdrawn.

the sinus, as it is almost incredible the celerity with which a hole as large as the end of one's thumb after a few weeks will close up to the size of a small pea. One need have but little fear of extraordinary hemorrhage here, as there is no artery of importance to be injured; in fact, Zuckerkandl states that the sphenoidal is the smallest branch of all the turbinal arteries. (Plate I.)

This stage of the operation is the most trying for the patient, as there is always more or less pain connected with the bone-biting process. If the patient shows a tendency to syncope, he should be allowed to lie down for several minutes, after which the operation can be finished without applying more cocaine.

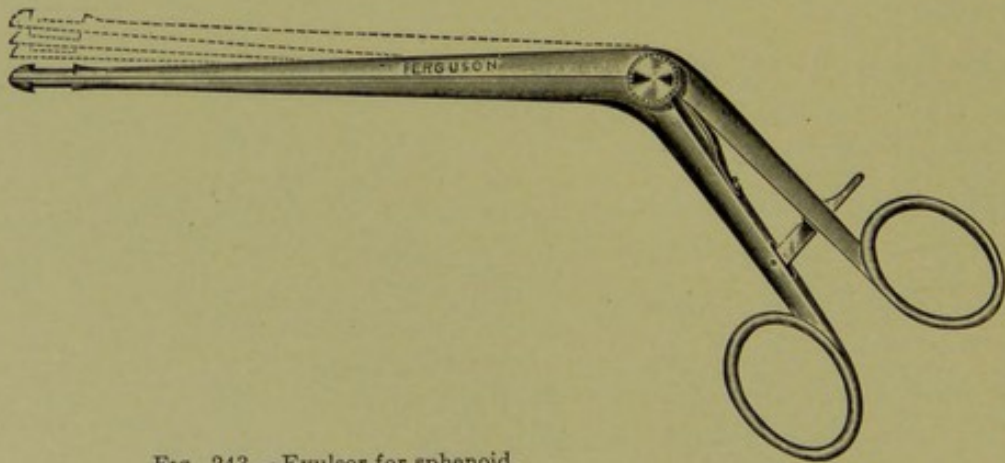


FIG. 243.—Evulsor for sphenoid.

11. Insufflate powder and pack lightly with seamed iodoform gauze.

Shall we curette the sinus? Personally, I am opposed to this, for several reasons: 1. The danger of wounding neigh-

boring structures with fatal consequences.⁵⁸¹ The cavernous sinus is most to be feared, as it lies against the lateral walls of the sphenoid sinus. (Fig. 33.) Dehiscence frequently occurs here, so that the operator may have only the thickness of the mucous membrane and venous wall between him and practically instant death. 2. The mucous membrane of the sinus is rarely so diseased

and degenerated as to even require partial removal. Even though it be so œdematous as to fill the entire cavity like a boggy mass, it is confusing how quickly regeneration occurs after opening the sinus. Scarification or the application of a 20 per cent. zinc chloride or 1-5 per cent. AgNO₃ solution will often hasten this resolution. Polyps of this sinus resulting from empyema seem to me so rarely met with that they demand little consideration.

AFTER-TREATMENT.—Do not remove gauze for four or five days, unless one or more of the following symptoms occur: (1) post-operative bleeding; (2) chills, fever, and symptoms of pus retention; (3) inordinate headache over vertex and in occiput.

After removal of the gauze on the fourth or fifth day, in the vast majority of cases, one will note that the swelling of the mucous membrane has subsided; our most important step now is to prevent the opening in the anterior wall from gradually growing smaller.

The reason this wall shows such a tendency to renew itself is easily explained when one takes into consideration the method nature adopts to bring about healing. In regeneration of the mucous membrane the deeper layer of epithelium is formed from the periosteum and bone, the superficial layer from the mucous membrane of sinuses and nasal cavity. When the bone is wounded, the granulations springing up from the bone are so luxurious that the lateral growths from the mucous membrane of the sinus and nose cannot grow fast enough to form a covering for the former (bone), and complete healing only occurs when this

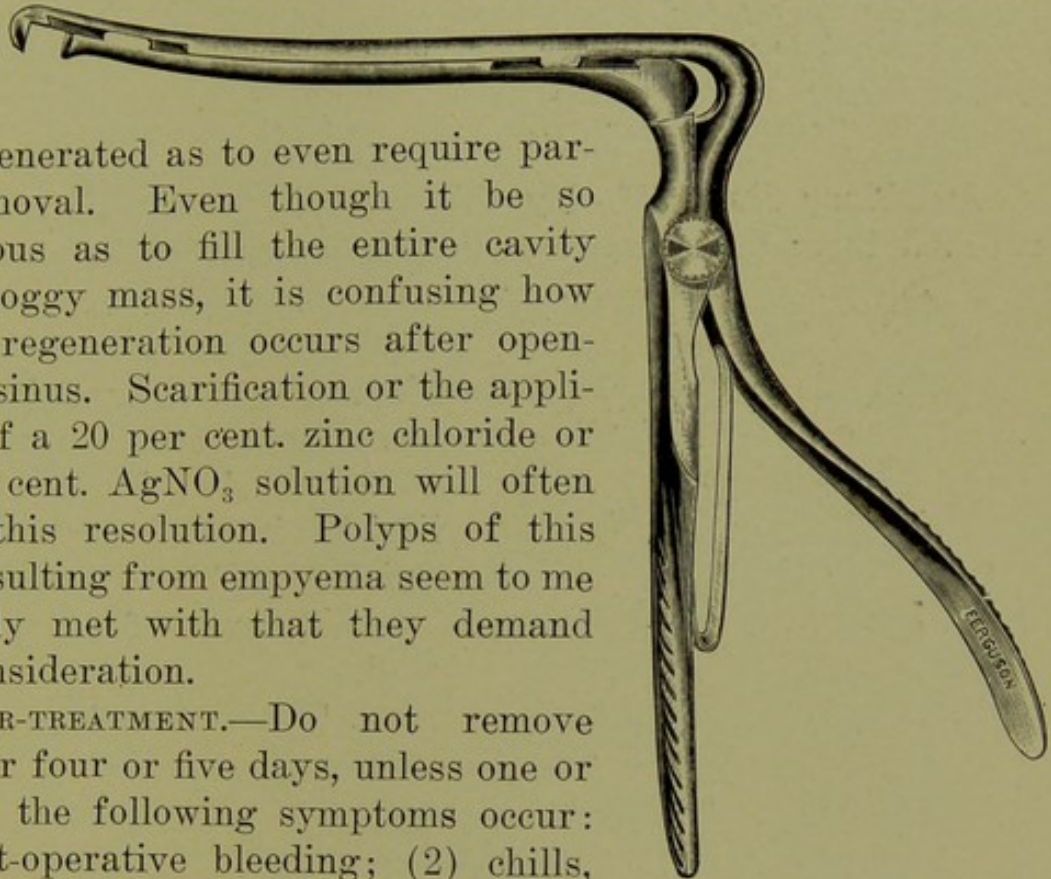


FIG. 244.—Hajek's modified sphenoid forceps.

581. Emerson: Report of a Fatal Operative Case Showing Absence of the Outer Sphenoidal Wall, etc. Laryngoscope, p. 43, 1909.

continuity of membrane takes place. This condition we attempt to further by periodic cauterization of the edges with chromic acid or nitrate of silver. About ten days after the operation when the parts have recovered from the post-operative swelling, a bead of chromic acid, fused on the end of a long probe, is carried back to the opening in the sinus and the edges thoroughly cauterized. This should be continued every week until the edges are covered with scar tissue, which prevents further closure of the sinus.

In applying either chromic acid or nitrate of silver, care must be taken that the part is thoroughly dry so that the substance will not run. It is also of importance not to touch any part of the nose with the acid while the probe is being introduced, as sometimes severe reaction follows which materially interferes with the resolution of the part.

*Maxillary Route.*⁵⁸²—By this method the sphenoid sinus is reached through a large opening made in the anterior wall of the maxillary sinus. This is Jansen's method, although Furet⁵⁸³ has so modified it that the ethmoid cells are spared.

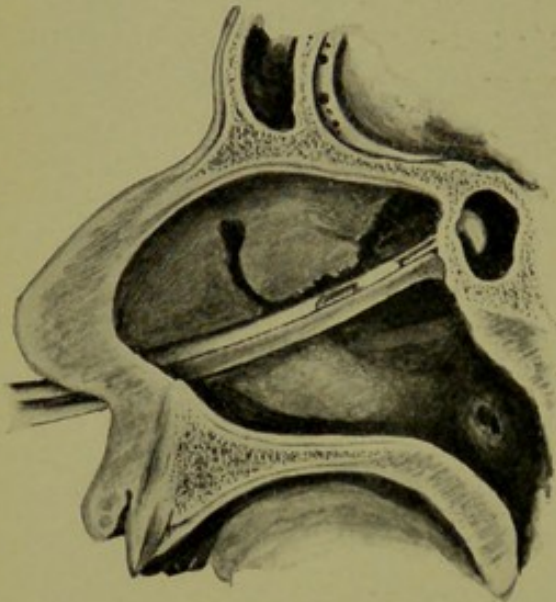


FIG. 245.—Radical intranasal operation on sphenoid. Removing posterior half of middle turbinate with the snare. Hajek's modified forceps introduced and ready to remove the thick osseous base of the anterior wall.

*Jansen's Method.*⁵⁸⁴⁻⁵⁸⁵—1. Incision in gingivo-buccal fold as for Caldwell-Luc operation.

2. Removal of entire anterior wall.

3. The posterior wall is broken into at its superior portion, thereby exposing the posterior ethmoidal cells.

4. The posterior ethmoidal cells are removed, thus bringing into view the anterior wall of sphenoid.

5. Removal of the entire anterior sphenoidal wall.

The indications for this operation, as given by Laurens, are:

1. When the nasal route is difficult or impossible, even though the maxillary sinus is not diseased.

2. When maxillary sinusitis complicates the sphenoidal affection.

3. When cerebral complications of sphenoidal origin appear.

582. Jansen: Zur Eröffnung der Nebenhöhlen der Nase bei chronischer Eiterung. Arch. f. Lary., Bd. 1, 1894. 583. Furet: Trepanation des deux sinus sphenoidaux a bravers un sinus maxillaire sain. Presse Medicale, p. 61, 1901. 584. Mosher: The Anatomy of the Sphenoidal Sinus and the Method of Approaching it from the Antrum. Laryngoscope, p. 177, 1903. 585. Berens: Fourteen Cases of Chronic Multiple Sinusitis Operated upon by Way of Maxillary Route. Trans. Am. Lary., Rhin. and Otol. Soc., p. 89, 1904.

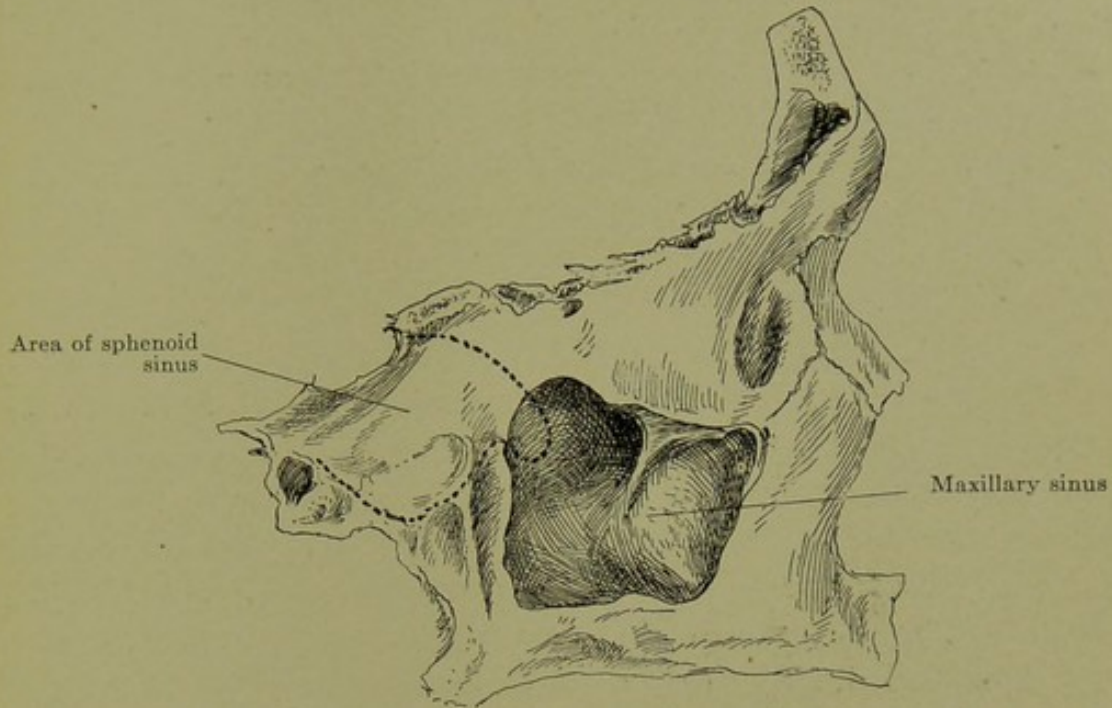


FIG. 246.—Relation of an unusually large sphenoid sinus to the maxillary antrum. Dotted line shows extent of sphenoid sinus.

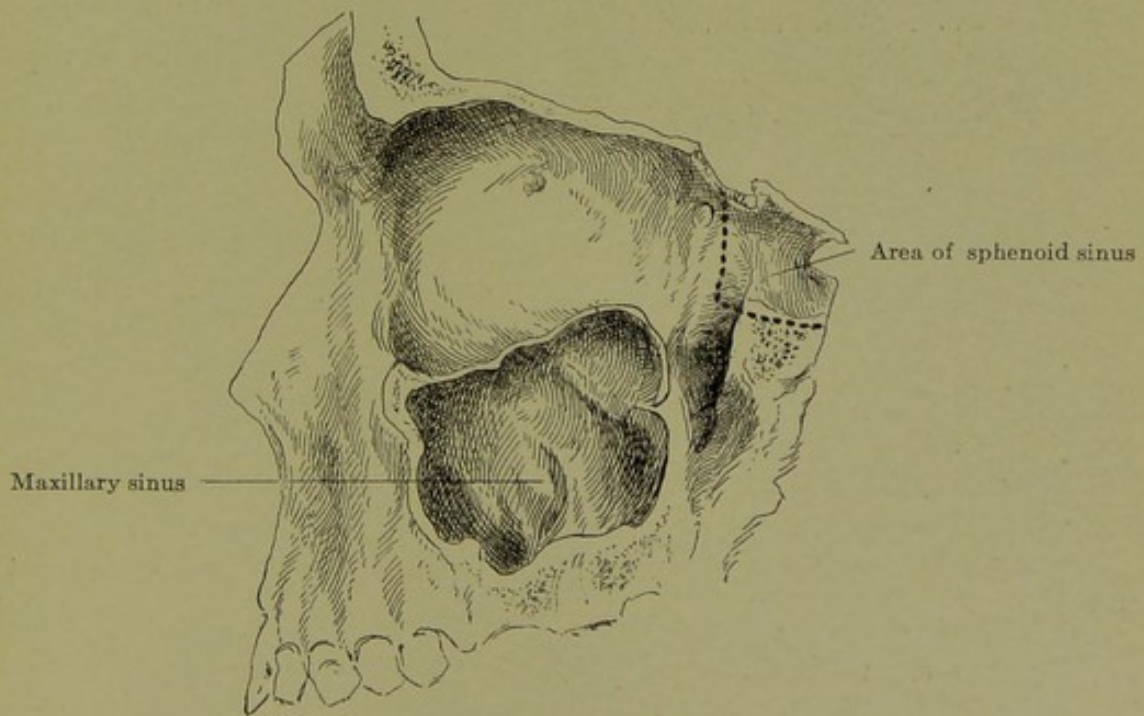


FIG. 247.—Relation of a small sphenoid sinus to the maxillary antrum. Dotted line shows the extent of the sphenoid sinus.

This method has certain well-defined disadvantages:⁵⁸⁶

1. A healthy sinus is needlessly opened and exposed to infection.

2. In spite of the utmost care, there is danger of wounding structures situated in the pterygo-palatine fossa and causing profuse hemorrhage and subsequent disturbance of the sensibility of the face, to say nothing of fatal consequences.

3. Danger of wounding the optic nerve.

Sieur and Jacobs, while practising this operation on the cadaver, perforated the internal wall of the orbit immediately below the groove of the optic nerve, which was dangerously near the nerve and accompanying vessels. In other instances perforation of the sella turcica immediately behind the optic groove and fracture of the external nasal wall in the superior meatus occurred. The favorable anatomical formation for this operation is shown in Fig. 246, while unfavorably in Fig. 247. Weighing the advantages and disadvantages, it would appear that, in the main, the operation is not advisable. The only indication that is debatable is when disease coexists in the maxillary and sphenoid sinuses.

586. Onodi: Das Verhältniss der Kieferhöhle zur Keilbeinhöhle und zu der vorderen Siebbeinzellen. Arch. f. Laryn., Bd. 11, S. 391, 1901.

INDEX

A

- Abscess of brain, 218, 249
- Abscess and fistula formation on face, 93
- Absence of frontal sinus, 187
 - of sphenoidal sinus, 299
- Accessory ostium of maxillary sinus, 10, 107
- Acute inflammation of ethmoid sinus, 307
 - of frontal sinus, 204
 - of maxillary sinus, 137
 - of sphenoid sinus, 349
- Ætiology of accessory sinus disease, 34
- Agger nasi, 3
- Alexander's chisel, 272
- Alveolus, 103
 - relation of, to roots of teeth, 103
- Anatomy of the lateral wall of the nose, 3
 - of the nose in frontal section, 13
- Anosmia as a symptom, 62
- Antrum of Highmore (see maxillary sinus)
- Articulation of inferior turbinate, 5
- Asthma in sinus disease, 69

B

- Bacillus of influenza, 30, 31
- Bacteria in sinus disease, 30
- Bacteriology of the accessory sinuses, 28, 29
- Basic structure of the lateral nasal wall, 4
- Beck's osteoplastic resection of frontal sinus, 278
- Blood- and lymph-channels, extension of inflammation through, 41
- Blood supply of lateral nasal wall, 20
- Bronchial symptoms, 69
- Bulla ethmoidalis, 7, 117
 - cells of, 292
 - circumscribed empyema of, 323
 - displacement of, 298
 - excessive size, 289
 - under-development, 289
- frontalis, 200
 - formation of, 200
- lamella, 288
 - anomalies of, 297

C

- Cacosmia as a symptom, 62
- Calcareous formation, 52
- Caldwell-Luc operation, 175
- Canine fossa, 99
 - operation through, 175
- Cannula bent for frontal sinus, 236
 - for maxillary sinus, 150
 - for sphenoid sinus, 370
- Carcinoma, 53
- Caries of sinus walls, 215
- Catheterization of frontal sinus, 236
 - of maxillary sinus, 150
 - of sphenoid sinus, 370
- Children, empyema in, 97

- Cholesteatoma formation, 52, 131
- Chronic inflammation of the ethmoid sinus, 309
 - of the frontal sinus, 225
 - of the maxillary sinus, 140
 - of the sphenoid sinus, 351
- Chronicity, cause of, 43
- Circulatory disturbances, 71
- Citelli's method of operating on frontal sinus, 279
- Closed empyema, 134
- Complications of sinus disease, 87
 - causes of, 89
 - manner of occurrence, 91
- Contamination from an overlying sinus, 42
- Cowper's method of opening the maxillary sinus, 161
- Cribriform plate, 13, 16
- Crista galli, 14
 - lachrymalis, 10
- Czerney's osteoplastic resection on the frontal sinus, 276

D

- Dahmer's intranasal method of opening the maxillary sinus, 167
- Dehiscence in the sinus walls, 90
- Denker's external method of opening the maxillary sinus, 183
- Depression in sinus affections, 70
- Dental caries as a cause of inflammation, 120
- Dentigerous cysts, 127
- Development of the sinus, 22
 - rationale of, 24
 - of the frontal sinus, 23
 - of the maxillary sinus, 22
 - of the sphenoidal sinus, 24
 - of the ethmoid labyrinth, 23
- Diagnosis of sinus inflammation, 1st series, 72
 - 2nd series, 75
 - by suction, 77
 - by transillumination, 77
 - by X-ray, 77
- Dilatation of sinus walls by internal pressure, 51
- Diphtheria as an ætiological factor, 31, 35
- Diplopia or double vision, 283
- Displacement of eyeball, 326
 - photograph of, 247, 327
- Distribution of trigeminus nerve, 56
- Dizziness, 70
- Ductus nasofrontalis, 194, 196, 289

E

- Eczema of face in sinus suppuration, 66, 213
- Empyema of ethmoid cells, 307, 316, 322
 - of frontal sinus, 207, 226
 - of maxillary sinus, 137, 140

- Empyema of sphenoid sinus, 349, 351
 of middle turbinate, 322
 of bulla ethmoidalis, 323
 combined, 1st series, 72
 2nd series, 75
- Enlargement of the blind spot, 97
- Erysipelas as a cause of inflammation, 35, 67
- Ethmoid bone, 13
 boundaries, 16
 bulla of, 7, 117
 cribriform plate of, 17
 cells, 290
 labyrinth, 286
 anomalies of, 294
 anatomy of, 286
 anterior group of cells, 291
 Ballenger's operation on, 315
 blood supply of, 303
 capacity of, 291
 compared to a box, 287
 complications following operation on, 335
 contraction of, 301
 dehiscences in, 303
 exenteration of, 336
 extension of, 300
 general polypoid inflammation of, 314
 Guisez's operation on, 336
 Hajek's method for removing posterior, 334
 infundibular cells, 291
 intranasal method of operating on, 330
 lamella of, 287
 of bulla, 288
 of middle turbinate, 289
 of superior turbinate, 290
 of uncinatè process, 288
 latent empyema of, 321
 Luc's method of operating on, 333
 mucocele of, 323
 mucosa of, 303
 number of cells in, 290
 ostium, 21, 286
 physiology of, 305
 posterior group of cells, 292
 projection of, 301
 pyocele of, 322
 differential diagnosis from mucocele, 325
 relation of, to frontal sinus, 294
 to lateral nasal wall, 286
 of posterior cells to optic nerve, 304
 venous anastomoses, 303
- Ethmoiditis, acute catarrhal, 307
 purulent, 307, 309
 ætiology of, 306
 chronic, 309, 316
 auto-vaccine in, 330
 Ballenger's intranasal method for, 315
 cerebral complications of, 328
 chronic inflammation, 309
 suppurative, 316
 classification of, 306
 complications of, 326
 diagnosis of acute, 308
 of chronic, 312, 319
- Ethmoiditis, differential diagnosis, 317, 321
 Guisez's external operation for, 336
 hyperplastic, 309
 with suppuration, 325
 intracranial complications of, 328
 Luc's operation in, 333
 olfactory disturbances in, 318
 orbital complications of, 326
 pathology of chronic, 309, 317
 prognosis of acute, 308
 of chronic, 329
 rhinoscopic examination in, 319
 symptoms of chronic, 311, 318
 transillumination in, 320
 treatment of acute, 308
 of chronic, 313
 suppurative, 329
 by auto-vaccination, 330
 by operation, 330
 X-ray in, 320
- Evolution of the external radical operation on the frontal sinus, 262
- Examination of the maxillary and frontal sinuses at various times after death, 28
 of the nose for sinus disease, 1
- Exophthalmos, 96, 327
- Exploratory needle puncture of the maxillary sinus, 152
- Extension by contiguity cause of sinus disease, 39
 by continuity cause of sinus disease, 39
- External operation on the ethmoid cells, 336
 on the frontal sinus, 262
 on the maxillary sinus, 175
 on the sphenoid sinus, 380
- Eye symptoms in accessory sinus disease, 95
- F
- Faraci's bone-cutting forceps for sphenoid, 372
- Fever in sinus disease, 71
- Foreign bodies in the sinuses, 41
- Fossa, canine, 99
 opening maxillary sinus through, 175
- Fovea ethmoidalis, 17, 286
- Freeman's syringe, 165
- Frontal bone, 15
 orbital plate of, 16
 sinus, 187
 absence of, 187
 anatomy of, 187
 anterior wall of, 191
 Beck's osteoplastic resection of, 278
 blood supply, 200
 boundaries of, 191
 catheterization of, 236
 Citelli's method of operating on, 279
 communication with nose, 194
 comparison of methods of operating, 280
 dehiscence in walls of, 192
 development of, 23
 dilatation of the walls of, 246
 enclosed cell within, 194
 extent of normal, 187

- Frontal sinus, failure of one side, 187
 Good's intranasal operation on, 259
 Halle's intranasal operation on, 257
 hydrops of, 247
 indications for radical operation on, 261
 inferior wall of, 191
 Ingals's intranasal operation on, 255
 irrigation of, 236
 Killian's operation on, 264
 Knapp's operation on, 268
 mucocele of, 246
 mucosa of, 200
 osteoplastic resection of, 276
 ostium of, 20, 194, 197
 posterior wall of, 191
 pyocele of, 247
 radical or modified Killian on, 269
 recesses in, 192
 relation to ethmoid labyrinth, 197
 relation to hiatus semilunaris, 196
 relative size and shape of, 188
 septa in, 192, 193
 septum of, 188
 deviations in, 188
 sounding, 200
 technique of, 201
 difficulties encountered, 202
 superciliary ridges as clue to size, 188
 thickness of walls, 191
 transillumination of, 208, 240
 sinusitis, acute, 204
 etiology of, 204
 of chronic, 225
 Beck's osteoplastic resection for, 278
 caries and necrosis in, 215
 caused by disease in neighboring sinuses, 206
 chronic, 225
 Citelli's method for, 279
 complications in acute, 215
 in chronic, 243
 paths of infection, 244
 deviation of the nasal septum in, 205
 diagnosis of acute, 207
 of chronic, 235
 differential diagnosis, 211, 241
 dilatation of anterior wall, 239
 dizziness and vertigo, 234
 external appearance of sinus in acute, 213
 external symptoms of, 239
 eye in acute, 211
 fistula formation in, 239
 general disturbances in, 214
 Good's intranasal operation for, 259
 Halle's intranasal operation for, 257
 headache in acute, 209
 in chronic, 230
 indications for external radical operation, 261
 Ingals's intranasal operation for, 255
 intracranial complications in acute, 218
 treatment of, 224
 in chronic, 249
 diagnosis of, 250
- Frontal sinusitis, operations, comparative value, 260
 Killian's operation for, 264
 Knapp's operation for, 268
 nasal symptoms in acute, 212
 in chronic, 232, 233
 edema of upper eyelid in chronic, 231
 olfactory disturbances, 213, 232
 orbital complications in acute, 218
 in chronic, 247
 osteomyelitis in, 216
 pathology, 216
 symptoms, 217
 osteoplastic resection for, 276
 pain in acute, 209
 in chronic, 229
 pathology of acute, 206, 207
 of chronic, 227
 periostitis and ostitis in, 215
 pressure in sinus in positive, 226
 in sinus in negative, 226
 prognosis of acute, 214
 of chronic, 242
 radical operation or modified Killian for, 269
 or modified Killian after-treatment, 276
 secretion in acute, 212
 in chronic, 231
 suction as a means of diagnosis, 209
 symptoms, acute, 209
 chronic, 228
 tenderness in acute, 211
 in chronic, 230
 Thompson's modification of Good's operation for, 260
 transillumination in, 240
 treatment of acute, 218
 operative, 221
 of chronic, 250
 X-rays in, 240
- Fronto-ethmoidal cells, 301
 Function of accessory sinuses, 25
- G
- Gastric disturbances due to sinus suppuration, 69
 General symptoms of sinus disease, 71
 Good's operation on the frontal sinus, 259
 Grünwald's forceps, 331
 Guisez's external operation on the ethmoid labyrinth, 336
- H
- Hajek-Claus bone forceps, 186
 operation on posterior sphenoidal labyrinth, 334
 Hajek's instruments for ethmoid, 330
 modified sphenoid punch, 379
 sphenoidal forceps, 379
 operation on ethmoid, 330
 Halle's operation on the frontal sinus, 257
 Hartmann's cutting forceps, 224
 operation on the frontal sinus, 264
 Headache in sinus disease, 54
 cause of, 54

- Headache in sinus disease, character, 56
 lack of constancy, 55
 localization, 57
 periodicity, 57
 variations in intensity, 57
- Hiatus maxillaris, 5
 semilunaris, 8
 atypical ending, 19
 topographical anatomy of, 17
 typical ending, 19
- Hoarseness, 68
- Huskinness of voice, 68
- Hyperplasias and hypertrophies of the nasal mucosa as an ætiological factor in causation, 38
- Hyperplastic ethmoiditis, 309
- I
- Indigestion due to sinus disease, 69
- Inferior meatus of nose, 3, 11
 turbinate, 5
- Influenza as an ætiological factor, 31, 35
- Infraction of middle turbinate, 2
- Infra-orbital canal, 102
 foramen, 100
 recess, 102
- Infundibular cells, 197, 291
- Infundibulum, 19, 118
- Ingals's operation on the frontal sinus, 255
- Intellectual disturbances, 70
- Intracranial complications of sinus disease, 95
 ethmoid, 328
 frontal, 218, 249
 maxillary, 140
 sphenoid, 368
- Iris, changes in, 96
- Irrigation of sinuses, frontal, 236
 maxillary, 152
 sphenoid, 370
- J
- Jansen's operation on the frontal sinus, 263
 on the sphenoid sinus, 380
- K
- Killian nasal speculum, 2
- Killian's operation on the frontal sinus, 264, 281
 untoward results following, 282
- Knapp's operation on the frontal sinus, 268
- Krause-Mikulicz operation on the maxillary sinus, 163
- Krause's operation on the maxillary sinus, 157
- Kuhnt's operation on the frontal sinus, 263, 280
- L
- Lachrymal bone, 10
- Lamina cribrosa, 17
 papyracea, 17
 perpendicularis, 17
- Laryngeal affections as a symptom, 68
- Latent empyema, 53
- Lichtwitz's needle for puncture of maxillary sinus, 153
- Lining membrane of sinuses, 47
- Luc's operation on the ethmoid labyrinth, 333
 on the frontal sinus, 262
- M
- Maxilla, superior, 4
- Maxillary sinus, 99
 accessory ostium of, 9, 107
 ætiology of, disease of, 118, 119
 teeth in, 120
 alveolar boundary of, 103
 anatomy of, 99
 anomalies of, 107
 anterior wall of, 101
 blood supply, 116
 Caldwell-Luc method of operating on, 175
 capacity of, 100
 caseous degeneration, 129
 catheterization of, 150
 cholesteatoma formation, 131
 closed empyema, 134
 contamination of, from overlying sinuses, 123
 cysts, 126
 Dahmer's method of operating, 167
 dehiscences in walls of, 102
 Denker's method of operating on, 183
 dentigerous cysts, 127
 development of, 22
 dimensions of, 100
 double, 114
 empyema in posterior half of, 366
 fistula in mouth following operation, 186
 floor of, 103
 foreign bodies, 123
 interior of, 104
 irrigation of, 152
 Krause-Mikulicz method of operating on, 163
 Krause's method of operating on, 157
 latent empyema, 125
 likened unto a pyramid, 99
 malignant tumors of, 124
 mucocele of, 131
 mucoid cysts of, 126
 nasal wall of, 106
 relation to nasal structures, 106
 needle puncture with lavage, 152
 through inferior meatus, 158
 through middle meatus, 157
 osteomyelitis of, 124, 186
 ostium of, 9, 20, 107, 118
 relation of to internal wall, 151
 overdevelopment, 107
 partial septa in, 104, 114
 posterior wall of, 101
 pre-turbinal method of operating on, 173
 relation of floor to teeth, 103
 relative importance of walls, 100
 Röntgen ray, 136

- Maxillary sinus, roof of, 101
 sounding, 117, 150
 stone formation in, 130
 suction or negative pressure, 136
 superior wall, 101
 surgical anatomy of lateral wall, 116
 symptoms of disease in, 137
 syphilis, 125
 transillumination of, 134
 value of, 135
 traumatism of, 124
 tuberculosis, 125
 underdevelopment of, 112
 X-ray in diagnosis, 136
 sinusitis, acute inflammation of, 137
 aetiology of, 118, 119
 Caldwell-Luc method, 175
 after-treatment, 182
 modification of, 185
 under local anaesthesia, 181
 Canfield's operation for, 172
 chronic, 140
 complications of, 140, 146
 of by cyst formation, 147
 of meningeal, 140
 of orbital, 140, 146
 conservative treatment in, 153
 Cowper's method in, 161
 Dahmer's method, 167
 after-treatment, 170
 Denker's method, 183
 diagnosis of, 72, 147, 150, 152
 differential diagnosis, 147, 148
 dilatation of antrum, 146
 general disturbances, 139
 indications for treatment, 148
 inferior nasal passage opening through,
 163
 irrigation in, 153, 157
 Krause-Mikulicz operation, 163
 advantages of, 166
 after-treatment, 174
 middle nasal passage opening through,
 162
 mild case of, 141
 moderate case of, 141
 nasal symptoms of acute, 138
 of chronic, 142
 nasopharynx in, 144
 nervous manifestations in, 145
 olfactory disturbances, 145
 operative treatment for, 175
 orbital complications, 140, 146
 pre-turbinal method, 172
 after-treatment, 174
 prognosis, 148
 radical operation, results of, 186
 secretion in, 138, 142
 severe case of, 141
 symptoms of, 137
 of acute, 137
 of chronic, 140
 syndring through ostium, 157
 teeth in, rôle of, 120
 treatment of, 156
 trocar through inferior nasal passage,
 160
- Maxillary sinusitis, untoward sequelæ fol-
 lowing the radical operation, 186
 Maxillo-orbital cells, 302
 Meatus of nose, 3
 Meningitis, 95, 249, 285
 Middle nasal passage, 3, 11
 turbinate, 2
 cell in, 12, 302
 in empyema of, 322
 infraction of, 221
 lamella of, 289
 removal of, 223, 252
 Mucocele of sinuses, 51
 ethmoidal, 323
 frontal, 246
 maxillary, 131
 Mucous membrane of nose, 21
 changes in, 62, 66
 of sinuses, 47
- N
- Nasal discharge in sinus suppuration, 60
 floor, 3
 fontanelles, 10
 mucosa, 21
 polyps, 63
 roof, 12
 speculum of Killian, 2
 spine, superior, 195
 wall, lateral, 4
 Nasofrontal duct, 194, 196, 289
 boundaries of, 196
 formation of, 195
 ostia of, 196
 Necrosing ethmoiditis, 310
 Necrosis of sinus walls, 245
 Needle puncture of maxillary sinus, 152
 Negative pressure as a means of diagnosis,
 82
 Nervous disturbances, 72
 Neuralgia in sinus disease, 56
 Normal mechanism of drainage, 26
 of frontal sinus, 26
 of maxillary sinus, 27
 of sphenoid sinus, 27
- O
- Obturator for maxillary sinus, 162
 Oedema of upper eyelid, 248
 Ogston-Luc operation on the frontal sinus,
 280
 Ogston's operation on the frontal sinus, 262
 Olfactory fissure, 12
 Optic nerve, relation of posterior ethmoid
 cells to, 304
 of sphenoid sinus to, 344
 Orbital complications of sinus disease, 94
 symptoms of, 95
 those caused by pressure, 96
 by toxins, 97
 of ethmoid sinus, 326
 of frontal sinus, 218, 247
 of maxillary sinus, 140, 146
 of sphenoid sinus, 356
 plate of maxillary sinus, 101

Osteomyelitis of frontal bone, 216, 284
 Ostium in middle nasal passage, 12
 in olfactory fissure, 12
 in superior nasal passage, 12
 of accessory of maxillary sinus, 9, 152
 of anterior ethmoid cells, 21, 286
 of frontal sinus, 20, 194
 of maxillary sinus, 9, 20, 107, 118, 152
 of posterior ethmoid cells, 12, 286
 of sphenoid, 12

P

Pain in sinus affections, 54
 Palate bone, 10
 Pars membranacea, 9, 152
 Pathological changes in the mucous membrane of the sinuses, 47
 Pathology of acute sinus disease, 48
 of chronic sinus disease, 49
 of differential diagnosis, 50
 of ethmoiditis, hyperplastic, 309
 of suppurative, 317
 of frontal, 206, 227
 of maxillary cysts, 128
 of sphenoidal, 350, 351
 Pharyngeal affections as a symptom, 69
 Pharyngitis sicca, 67
 lateralis, 68
 Physiology of the accessory sinuses, 25
 of the ethmoid cells, 305
 Pneumonia as an ætiological factor, 31, 35
 Polyps, relation of to sinus disease, 63
 formation of, 65
 Posterior group of ethmoid cells, 292
 of sinuses, 12
 Postmortem examination of the accessory sinuses, 46
 Pre-ethmoidal recess, 292
 Pre-turbinal method of operating on the maxillary sinus, 172
 Privat's syringe for subperiosteal injections, 167
 Processus uncinatus of ethmoid bone, 7, 117
 Psychological disturbances, 70
 Pterygoid process, 11
 Pus as a symptom of sinus disease, 60
 in middle nasal passage, 73
 in nasopharynx, 353
 in olfactory fissure, 75
 in superior nasal passage, 75
 Pyocele, 61

R


Radical operation on the ethmoid cells, 336
 on the frontal sinus, 264
 on the maxillary sinus, 175
 on the sphenoid sinus, 375
 Recessus spheno-ethmoidalis, 290, 342
 Relation of floor of maxillary sinus to the teeth, 103
 of frontal sinus to anterior ethmoid cells, 197
 of sinuses to optic nerve, 88
 to brain, 89
 to orbital cavity, 88
 Retrobulbar, neuritis, 96, 344


Riedel's method of operation on the frontal sinus, 264
 Rôle of the sinuses during respiration, 26
 Röntgen rays as a means of diagnosis, 79
 ethmoid sinus, 81
 frontal sinus, 80
 maxillary sinus, 81
 sphenoid sinus, 82


S

Scarlet fever as an ætiological factor, 37
 Schleich's anæsthesia in intranasal operations on the maxillary sinus, 181
 Secretion in sinus disease, importance of, 53
 purulent in the nose, 60
 Septa in the frontal sinus, 192, 193
 in the maxillary sinus, 104, 114
 in the sphenoid sinus, 347
 Septum between frontal sinuses, 188
 between sphenoid sinuses, 341
 Sexual apparatus, 72
 Sinuses, anterior (1st series), 2
 posterior (2nd series), 3
 Sinusitis and sinuitide, 42
 Sore throat as a symptom, 68
 Sphenoid sinus, 340
 absence of, 299
 anatomy of, 340
 anomalies of, 346
 anterior wall of, 341
 arterial supply of, 349
 capacity of, 340
 catheterization of, 363, 370
 Jacob's method, 333
 compared to cube, 341
 enlarging ostium of, 371
 external wall, 345
 indications for radical operation on, 373
 inferior wall, 345
 irrigation of, 370
 Jansen's method, 380
 mucosa of, 348
 operation on, through maxillary route, 380
 ostium of, 3, 12, 342
 diaphragmatic, 343
 over-reabsorption of, 346
 pars ethmoidalis, 342
 pars nasalis of, 342
 posterior wall of, 343
 radical operation on, 375
 on, after-treatment, 379
 relation to ethmoid capsule, 340, 342
 to optic nerve, 344
 to pituitary body, 344
 septum of, 340, 345
 absence of, 341
 deviation of, 347
 sounding the, 361
 superior wall, 344
 veins of, 349
 sinusitis, 349
 acute, 349
 ætiology, acute, 349
 chronic, 351

- Sphenoid sinusitis, *cacosmia* as a symptom of, 355
 chronic, 351
 complications of, 368
 diagnosis of acute, 350
 of chronic, 358
 differential diagnosis, 363
 headache in chronic, 354
 histo-pathology of acute, 350
 of chronic, 352
 intracranial complications, 368
 mental symptoms in chronic, 355
 nasal symptoms of chronic, 353
 objective symptoms of, 357
 ocular symptoms, 356
 pathology of acute, 350
 of chronic, 351
 prognosis of chronic, 366
 secretion in chronic, 355
 symptoms of acute, 350
 of chronic, 352
 throat symptoms of chronic, 356
 treatment of acute, 351
 of chronic, 369
 use of Killian speculum in, 353
- Spheno-ethmoidal cell, 347
 empyema of, 366
 recess, 290, 342
- Spheno-palatine artery, 21
- Stone formation in maxillary sinus, 130
- Streptococci and staphylococci, 31
- Suction or negative pressure in sinus disease, 82
- Superior nasal passage, 12
 turbinate, 286
 lamella of, 290
- Suppuration in sinuses, *ætiology* of, 34
 bacteriology of, 28
 diagnosis of anterior group, 72
 of posterior group, 75
 pathology of, 47
- Supreme turbinate, 13
- Surgical anatomy of the lateral wall of the nose, 116
- Symptoms of sinus inflammation, 54
- Syphilis as a causative factor, 40
- T
- Taptas's operation on the frontal sinus, 264
- Teeth in relation to floor of maxillary sinus, 103
- Tenderness over sinus as a symptom, 59
- Thompson's nasal scissors, 221
 modification of Good's operation on the frontal sinus, 262
- Thrombosis of cavernous sinus, 368
 mechanism of infection, 368
 treatment, 369
- Tic douloureux, 57
- Transillumination as a means of diagnosis, 77
 in ethmoid cells, 79, 320
 in frontal sinus, 78, 208, 240
 in maxillary sinus, 77, 134
- Traumatism as an *ætiological* factor, 41
- Treatment of sinus disease, 83
 acute, 83
 by vaccine therapy, 87
 chronic, 86
 ethmoidal, 308, 313, 329, 330
 frontal, 218, 250
 maxillary, 156
 sphenoidal, 351, 369
- Trochlea, resection of in operation on frontal sinus, 267
- Tuberculosis, 39
- Turbinates, inferior, 3, 5
 middle, 2, 12
 superior, 12
- U
- Uncinate process, 7, 117
 cell in, 297
 lamella of, 288
 resection of, 254
- V
- Vaccine treatment of sinus disease, 87
- Verkasung (*metamorphosis* of secretion into cheesy mass), 52, 129
- Vertigo as a symptom, 70
- W
- Wagener's antrum punch, 165
- Welhelmenski's trocar, 164
- X
- X-rays as a means of diagnosis, 79
 maxillary sinus, 136







(52)

G 12 - f

Medicine

SN 42

1913 - S

