

## **Treatment of malocclusion of the teeth : Angle's system.**

### **Contributors**

Angle, Edward H. 1855-1930.  
University of Glasgow. Library

### **Publication/Creation**

Philadelphia : S.S. White Dental Manufacturing Company, 1907.

### **Persistent URL**

<https://wellcomecollection.org/works/brpcqyv9>

### **Provider**

University of Glasgow


### **License and attribution**

This material has been provided by This material has been provided by The University of Glasgow Library. The original may be consulted at The University of Glasgow Library. where the originals may be consulted. Conditions of use: it is possible this item is protected by copyright and/or related rights. You are free to use this item in any way that is permitted by the copyright and related rights legislation that applies to your use. For other uses you need to obtain permission from the rights-holder(s).



Wellcome Collection  
183 Euston Road  
London NW1 2BE UK  
T +44 (0)20 7611 8722  
E [library@wellcomecollection.org](mailto:library@wellcomecollection.org)  
<https://wellcomecollection.org>







Incor

School

Glasgow  
University Library



GLASG

LIBRARY

1.

2.

Incorpo  
for stu  
extra terms.

Dental  
Branch  
Library

tending the  
free, except  
are taking

3. Extra term students who have finished their curriculum at the Hospital shall deposit one guinea for the use of the Library. Provided all books have been returned free from damage, the deposit shall be refunded.

4. Books on loan shall be returned within two weeks, but may be re-issued for a further similar period provided no other student has applied for them.

5. Only two books may be issued at one time.

6. The Library will be open on Thursdays between 3 o'clock and 7 o'clock for lending or exchanging books. The title of the book required should be handed in to the office, but books will only be given out on Thursdays.

7. All books lost or damaged must be replaced by the borrower.

CASE  
Medicine  
UH 50  
I907-A



30114005002285



Glasgow University Library

~~1 - OCT 1980~~

~~GK 83.6A~~

~~24 OCT 1981~~

~~GK 86.238~~


NOT TO BE SENT ON  
ILL

~~CANCELLED~~  
~~10 OCT 1980~~

~~- 8 NOV 1990~~

~~CANCELLED~~  
~~APR 2009~~







~~A. 2~~  
OR 2.1

TREATMENT OF

MALOCCLUSION OF THE TEETH

ANGLE'S SYSTEM.

Seventh Edition, Greatly Enlarged and Entirely Rewritten,  
With Six Hundred and Forty-one Illustrations.

BY

EDWARD H. ANGLE, M.D., D.D.S.,

President of the Angle School of Orthodontia, St. Louis, Mo.; Founder and First President of the American Society of Orthodontists; Surgeon to the Wabash Railroad for Treatment of Fractures of the Maxillæ; Member of the American Society for the Advancement of Science; Member of the American Anthropological Association; Member of the Academy of Science, St. Louis; Charter Member of the St. Louis Society of Dental Science; Member of the New York Institute of Stomatology.  
Honorary Member of the American Dental Society of Europe; Honorary Member Verein Wiener Zahnärzte; Honorary Member Sociedad Dental Mexicana; Member of the American Forestry Association, etc.

PHILADELPHIA:

THE S. S. WHITE DENTAL MANUFACTURING COMPANY.

1907.



---

COPYRIGHT, 1898, BY EDWARD H. ANGLE.

COPYRIGHT, 1900, BY EDWARD H. ANGLE.

COPYRIGHT, 1907, BY EDWARD H. ANGLE.


---

QE 3555(21



To all those who have been perplexed by cases of malocclusion of the teeth and have not become discouraged thereby, but rather stimulated to a keener interest in, and a broader study of, this most beneficent, fascinating, and progressive branch of dental science, this book is respectfully dedicated.





## PREFACE TO THE SIXTH EDITION.

---

THE issuance of the sixth edition of this work in its enlarged form, intended by the author as a culmination of his labor in this line, is inspired by various considerations. The system of appliances and methods of treatment introduced in the former editions have been well received, as is evidenced by the number of editions issued and by their translation into the French, German, Dutch, Scandinavian, and Spanish languages by writers in the countries in which these languages prevail. As a result of busy years devoted to teaching and the exclusive practice of orthodontia, during which the science has been an absorbing study and the subject of most painstaking investigation, the author has been more and more impressed with its far-reaching importance and possibilities. He is actuated in the present instance not alone by the earnest solicitation of teachers, students, and practitioners, but also by an appreciation of the necessities of this science and the hope that the principles herein recorded may be instrumental in promoting its advancement.

The subject is treated far more comprehensively in this edition than in those which have preceded it, they having been limited to the mechanical phases of the subject. Much of this early matter has been re-written, some of it being eliminated—superseded by better methods, the object always being to keep simplicity and efficiency foremost. There has been a studied effort for condensation and systematic arrangement. It is believed that lumbering volumes, like multiplicity of appliances and methods, serve



rather to leave the student in hazy bewilderment than to equip him for useful practice. On the other hand, a mere recital of the achievements of others, by divers means, without system or detail, presupposes a knowledge on the part of the student which if possessed would render the slight information imparted but a possible matter of interest, instead of a necessity for study. That this work will be found radically different in many particulars from the usual work on orthodontia is certain, especially in that many devices for regulating the teeth, which have been familiar pictures from the earliest remembrance of the subject by our oldest practitioners, will be absent; not that they are eliminated on account of their antiquity, but because, analyzed never so carefully, they fall so far short of the present requirements of a regulating appliance. It is believed that such crudities instead of longer handicapping the student are entitled to only such respect as by right awaits them in history.

It has long been the effort of the author to perfect a system which should be complete within itself—a system which should include the simplest and best methods, not only for the treatment of all forms of malocclusion, but for the study and diagnosis of cases, as well as for the teaching of the subject in its entirety. The degree of his success must be determined somewhat by time and the intelligent, unbiased judgment of others.

In the illustrations, which are all original, the art of the photographer and the skill of the engraver have been severely taxed to accurately represent cases from actual practice, with the appliances and methods of treatment employed. No fanciful pen-sketches of imaginary and improbable cases, created to illuminate theoretical, complicated and impractical devices, will be here found. The ideas expressed and the lines of practice laid down are also, except as otherwise stated, original with the author, and he accepts full responsibility for them. A conscien-



tious effort has been made to give proper credit for all inventions of acknowledged merit. To fair minds recorded dates are usually sufficient evidence of priority.

This work is designed primarily for the instruction of students in colleges, and secondarily as a guide and ready-reference book for practicing dentists who have not devoted special study to the subject of which it treats.

It has been said that "order is heaven's first law." Order implies exactness, thoroughness. Not only is an effort made to impress these principles throughout the following pages, but they have prompted the manner of doing it. Literary style has been subordinated to clearness of expression and precision of detail. This may explain a frequent repetition of terms and methods which would be inadmissible in a narrative, but which is here indulged for the convenience of the student, that the necessity for back-reference may be reduced to the minimum.

A poverty of terminology has long been felt in the science of orthodontia, but it has been deemed better to expand the meanings of terms employed, in many instances, to meet requirements than to increase the vocabulary by introduction of new words. Thus, the term "malocclusion" is often used for convenience to express the condition of malposition of a tooth which has no occlusion at all with other teeth. "Elevating" is a term employed with similar license. We may speak of elevating a tooth in the upper arch when we really pull it down, and so with other usage the meaning of which should be clear.

The author expresses obligations to Professor Black for some suggestions in regard to the arrangement of the subject-matter, and to Professor Noyes for the use of selections from his valuable collection of microscopical slides of the peridental membrane, and also for actual work in the preparation of the new and excellent engravings prepared especially for this work to illustrate the



chapter on the Peridental Membrane; also to The S. S. White Dental Mfg. Co., for the excellent illustrations which they have cheerfully prepared and for the painstaking thoroughness of their work as publishers.

EDWARD H. ANGLE, M.D., D.D.S.

St. Louis, October 20, 1900.

## PREFACE TO THE SEVENTH EDITION.

---

SINCE the publication of the sixth edition of this work six years have elapsed—years in which very important steps in the progress of orthodontia have been taken. Much that was therein enunciated and at that time regarded as extreme has become accepted teaching. Much that was foreshadowed has been verified. The recognition of occlusion as the basis of orthodontia, therein first made prominent, seems to the author to mark its real beginning as a science. In these years there has grown a broader and deeper conception of the basic principles of occlusion and their practical application has become of greater importance. At that time the demands in art and occlusion were still supposed to be distinct and independent, but we have since learned their intimate relations and entire interdependence,—in other words, that the best balance and best harmony of the mouth with the rest of the face are only possible with normal occlusion—the full complement of teeth in normal relations.\*

The author has also aimed to point out a simple, yet efficient, as well as logical, method of diagnosis of mal-occlusion, and also of its treatment in from the simplest to the most complex cases, also from the basis of normal occlusion.

---

\* New York Institute of Stomatology, October 7, 1902; *International Dental Journal*, October, 1903. "Art in its Relation to Orthodontia," Angle, read before The American Society of Othodontists, October, 1902; published in *Items of Interest*, September, 1903.



A greater perfection of the regulating appliances, together with a better comprehension of intermaxillary force and anchorage have made the fulfilment of the demands of occlusion and art far easier and almost universally possible, revolutionizing the practice in the treatment of the second and third classes of malocclusion, as well as greatly lessening the difficulties of establishing normal occlusion in many cases of the first great class. A broader experience and closer study of the alveolar process and peridental membrane have given a clearer comprehension of the important changes in these tissues subsequent to tooth movement. We have learned that at best our efforts are only to assist Nature and that if we correctly interpret her wishes and intelligently assist her she will complete the growth and development of these tissues normally in accordance with the type of the individual, so that the resort to mutilation, as dominated by the individual judgment of the practitioner, is no longer a proper plan of treatment, but that it must give place to the logical—the normal—in treatment.

So orthodontia has passed from the empirical of the "old school" and has become, we believe, more nearly an exact science than any other branch of dentistry, or possibly of medicine.

Very naturally such pronounced changes have been marked by strenuous opposition from a few, but we are pleased to note that they have been promptly accepted by the best element in dentistry. In this case, as is usual in all reforms, the opposition has come from those who should naturally be first to recognize the soundness and value of the principles enunciated—the foremost writers of the "old school."\* Their opposition has taken the usual form of opposition to progress in religion, science, and

---

\* See articles by Guilford, Case and others of the old school in *Items of Interest*, August, 1905.



politics, namely, to first ignore; then, "it is not true;" and finally, "we have always believed."

These progressive stages have necessitated many changes in the new edition, such as the entire reconstruction of the chapter on Facial Art, from the basis of occlusion, as well as of the chapters on Treatment, of cases belonging to the second and third Classes of malocclusion. Many devices that were formerly in favor with the author, and still valued by many practitioners, have been placed in the Appendix in order to avoid confusion, and for the reason that in the author's opinion they are not so efficient in meeting most of the demands of treatment as the expansion arch in its present perfected state. Yet for certain uses many of them are invaluable.

Many minor improvements in methods of treatment have been added. In fact, practically the entire book has been re-written in order to make clear the basic principles of the science as well as their practical application. As the practical is naturally and justly expected by the student of orthodontia, many additional cases are carefully described and illustrated and carried through the various stages of treatment, which, we believe, will be appreciated as compared with the time-honored custom followed in other works of merely suggesting innumerable appliances without showing the practical results of their use. Indeed we have not been content with giving the manner of treatment and establishment of normal occlusion, but have shown the condition of many cases years after treatment,—something that will henceforth be demanded in works on orthodontia.

In former editions a portion of the work was devoted to the treatment of Fractures of the Maxillæ. As such practice should not be classified with that of orthodontia it has been deemed advisable to publish a revision of that portion of the work separately.

In the preparation of this edition the author has en-



deavored to express his own views, gleaned from his own extensive experience and observation, and whenever the thoughts of others have been made use of due credit has been given in accordance with the true ethics of literature.

He wishes here to express his obligation to Dr. F. B. Noyes for his assistance in the revision of the chapter on The Peridental Membrane, and to his former student, Dr. Norman G. Reoch, for several drawings, and especially to The S. S. White Dental Mfg. Co., for generously according him every assistance in the publication of the book.

EDWARD H. ANGLE, M.D., D.D.S.

St. Louis, Mo., November 10, 1906.

# CONTENTS.

INTRODUCTION .....	PAGE 1
CHAPTER I.	
OCCCLUSION .....	5
Key to Occlusion—Line of Occlusion—Nomenclature—Forces Governing Normal Occlusion.	
CHAPTER II.	
MALOCCLUSION .....	28
Forces Governing Malocclusion—Classification of Malocclusion—Class I—Class II, its Divisions and Subdivisions—Class III, its Division and Subdivision.	
CHAPTER III.	
FACIAL ART .....	60
CHAPTER IV.	
ETIOLOGY OF MALOCCLUSION .....	88
Premature Loss of Deciduous Teeth—Loss of Permanent Teeth—Imperfect Fillings, Crowns, etc.—Prolonged Retention of Deciduous Teeth—Tardy Eruption of Permanent Teeth—Supernumerary Teeth—Transposed Teeth—Disuse—Abnormal Frenum Labium—Habits—Nasal Obstructions.	
CHAPTER V.	
ALVEOLAR PROCESS AND PERIDONTAL MEMBRANE .....	118
CHAPTER VI.	
TISSUE CHANGES INCIDENT TO TOOTH MOVEMENT .....	132
Alveolar Process—Peridental Membrane—The Pulp.	



## CHAPTER VII.

PHYSIOLOGICAL CHANGES SUBSEQUENT TO TOOTH MOVEMENT.....	PAGE 140
---	-------------

## CHAPTER VIII.

MODELS .....	144
Materials for Impressions—Method of Taking Impressions—The Trays—Taking and Removing the Upper Impression—Taking and Removing the Lower Impression—Removing Impressions from Arches with Spaces, due to Loss of Teeth—Uniting and Varnishing the Impression—Pouring and Separating the Model—Trimming the Model—Value of Good Models—Photographs—Skiagraphs.	

## CHAPTER IX.

REGULATING APPLIANCES .....	163
The Old and the New Methods—Epochs in the History—Requisite Qualifications—Stability of Attachments—Materials for Construction.	

## CHAPTER X.

THE AUTHOR'S APPLIANCES .....	182
General Description of—Instruments.	

## CHAPTER XI.

SOLDERING .....	209
Plain Bands and their Attachments—Technique—Soft-Soldering.	

## CHAPTER XII.

ANCHORAGE .....	224
Simple—Stationary—Reciprocal—Intermaxillary—Occipital.	

## CHAPTER XIII.

ADJUSTMENT AND OPERATION OF APPLIANCES .....	236
Clamp Bands—Plain Bands—Expansion Arches—Wire Ligatures—Combination Adjusted—Combination for Baker Anchorage—Combination Reinforced.	

## CHAPTER XIV.

RETENTION .....	263
Time Required—Principles—Temporary and Permanent Devices—Application of Principles—New Method—Intermaxillary.	

# CONTENTS.

XV

## CHAPTER XV.

TREATMENT.—PRELIMINARY CONSIDERATIONS .....	PAGE 305
Time for Beginning—Time Required—Frequency of Seeing Patients.	

## CHAPTER XVI.

TREATMENT OF CASES.—CLASS I.....	319
----------------------------------	-----

## CHAPTER XVII.

TREATMENT OF CASES.—CLASS II, DIVISION 1.....	448
Class II, Division 1, Subdivision.	

## CHAPTER XVIII.

TREATMENT OF CASES.—CLASS II, DIVISION 2.....	514
Class II, Division 2, Subdivision.	

## CHAPTER XIX.

TREATMENT OF CASES.—CLASS III.....	550
Class III, Division, Subdivision.	

## CHAPTER XX.


OPERATIVE SURGERY .....	566
Immediate Movement—Alveolar Sections—Resection of Peridental Fibers—Section of Frenum Labium—Double Resection of Man- dible.	

## APPENDIX.

Jack-screw—Traction-screw—Lever—Miscellaneous Combinations....	579
--	-----

FINAL SUGGESTIONS .....	610
-------------------------	-----





## INTRODUCTION.

---

MALOCCLUSION of the teeth is found in all races and even occasionally among the lower animals, and has been one of man's afflictions from time immemorial, but that it is becoming more common as civilization progresses is very generally conceded. Indeed, it has become so common that it is now almost the rule, rather than the exception. Go where we will, wander down the village street or the crowded avenues of great cities, or wherever humanity congregates, and we will be confronted by these deformities in such numbers that we are amazed at their prevalence. And in proportion as malocclusion exists the functions of the teeth and speech are impaired, and the facial lines marred.

The opportunities and possibilities of improvement of the features by proper treatment of malocclusion are so great, and the appreciation of the patients and their friends so genuine when the work has been quickly and intelligently performed, we wonder that a closer study and keener interest in the subject by practitioners was not long ago awakened, and are surprised that so few have a proper conception of the possibilities of orthodontia for the improvement of the individual in speech, health and beauty.

It is not enough to simply move into correct alignment irregular teeth. We should have a proper conception of



the denture as a whole and the art requirements of the individual type; of the influence of the malocclusion in arresting or modifying the development of the alveolar process, jaws, and muscles, and in disturbing the normal balance of the face. We must consider the numerous changes which may follow the movement of teeth into correct positions, with the restoration of the natural functions of the occlusal planes, and the assistance the changes will lend to Nature as they stimulate her to efforts for the continuation of normal growth and development of all the related parts, that they may be in best harmony with each other in their new relations—in best harmony with Nature's plan. In many cases there can be no intelligent diagnosis or plan of treatment unless the probable changes through subsequent growth be fully considered.

The real growth of dentistry is of comparatively recent years, and along branches having little in common with orthodontia, so that this branch received little attention until within the last half-century, and it is probable that more real interest has been awakened and more real advancement made in the last twenty years, and especially in the last six, than in its entire previous history.

Much has been written upon the subject of orthodontia, but mostly from the mechanical standpoint, and only very recently has it begun to receive that broad and thorough study which a science of such great importance demands, for its basic principles are grounded in the mysteries of embryology, histology and comparative anatomy, linked with art and physics.

It has rapidly passed through marked evolutionary stages until it is now recognized as a distinct science, the



broad possibilities of which are even yet but dimly comprehended by those who have not given it careful study. In the light of our present knowledge most of the theory, as well as of the practice, of even a few years ago seems strikingly crude.

Of such theory and practice was the common advice to young patients to "let the teeth alone and trust to Nature to straighten them," or to wait until the permanent dentition should be complete before making any effort toward their correction. Of such was the unfortunate sacrifice of teeth with a mistaken view of relieving the crowded condition of the arches, but with the result often of aggravating the malocclusion and giving rise to a serious train of evils, as shown in the chapter on etiology. So, also, the use of huge plates combined with springs taken from clocks and various strange mechanisms as a means of tooth movement, now seems more in accord with many of the teachings of medicine during the period of history known as the "dark ages."

Until within a very few years the teachings of orthodontia in dental colleges was very superficial, even oftentimes being wholly omitted from the curriculum. Now, however, in all of our best colleges separate chairs have been established and the subject is more comprehensively taught. Yet this branch of the science is still made subservient to all others in dentistry, notwithstanding the fact that its exactions in teaching and practice are greater than in any of the other branches of dentistry. There should be still further radical improvements in its teaching, for it is an historical fact that no student has yet acquired at a dental college proficiency in this branch sufficient to enable



him to succeed in its practice as a specialty. In fact, so exacting are its requirements, that, unlike the general practice of dentistry, the mere smatterer can never hope for even moderate success, for often apparently very simple cases of malocclusion are in reality only symptoms of conditions whose management requires the broadest knowledge and mature judgment.

Orthodontia is a subject so great, so important, with such possibilities and rewards, that it is ample in itself for the life work of the best minds. For years it has been the author's firm conviction that it should be classed as a distinct specialty—taught and practiced as such; that it should be freed from the handicapping influences of general dentistry and given an opportunity to develop normally along lines which are so distinctively its own,—lines which define it as a specialty as clearly as do those that define the specialty of ophthalmology, and more clearly than those that define the specialty of rhinology.\* And it is gratifying to note that it is at last rapidly taking its place among the great specialties of medicine as its importance demands.


At the time of the publication of the last edition of this work there were but two or three at most who could be regarded as specialists in orthodontia. At this writing there are over sixty giving their exclusive attention to this branch and limiting their practice to it. One school has been established for its exclusive teaching, and two societies formed for the promotion of its interests, with an unusual number of articles appearing in the literature in

---

\* Angle. *Dental Review*, March, 1896.

which has been reported more and better work than is probably to be found in all preceding literature. Orthodontia when mastered, and practiced as a specialty, becomes one of the most fascinating of the professions and gratifying in its practice, having, as it does, a *clientèle* far more nearly ideal than is to be found in any other branch of medicine, composed of patients in health and in the flower of youth—and that, too, of the cultured and affluent. Yet its exactions on the student and practitioner are so great that only those highly qualified in the science can ever hope to truly succeed; but for such there awaits a field almost limitless in extent and in which they will receive prompt recognition.





## CHAPTER I.

### OCCLUSION.

"SUBSTANTIAL progress in any science is impossible in the absence of a working hypothesis which is universal in its application to the phenomena pertaining to the subject-matter. Indeed, until such a hypothesis is discovered and formulated, no subject of human investigation can properly be said to be within the domain of the exact sciences. . . . It enables one skilled in that science to practice it with a certainty of results in exact proportion to his knowledge of its principles and his skill in applying them to the work in hand."—HUDSON.

ORTHODONTIA\* is that science which has for its object the correction of malocclusion of the teeth.

*Occlusion* is the basis of the science of orthodontia. The shapes of the cusps, crowns, and roots, and even the very structural material of the teeth and their attachments are all designed for the purpose of making occlusion the one grand object, in order that they may best serve the chief purpose for which they were intended, namely, the cutting and grinding of food. We will define occlusion as being *the normal relations of the occlusal inclined planes of the teeth when the jaws are closed*.

*Malocclusion* of the teeth is but the perversion of their normal relations. It can be studied intelligently only from the basis of the normal, and to begin its study without first being familiar therewith would be as unfruitful as the study of the pathology of any other of the

---

\* From the Greek, *opthós*, straight; *odóds*, tooth.



structures of the body without first mastering their anatomy and physiology.

There must be, then, clearly fixed in the mind of the student of orthodontia not only Nature's plan of the normal denture when complete, but also its beginnings,—the growth and development of parts, which is a most intricate and beautiful process, and their co-relations.

The normal human denture in its completeness includes not only the jaws, alveolar process, dental arches, and especially the teeth and peridental membrane, which to us are of prime importance, since on them chiefly our operations are performed, but also the muscles of lips, cheeks, tongue, and mouth, the nasal passages, palate, and throat, as these assist the teeth in performing their functions. They are also powerful factors in establishing and maintaining either harmony or inharmony in the development and arrangement of the teeth, and this just in proportion as they are, singly or collectively, normal or abnormal in their own development and functions.

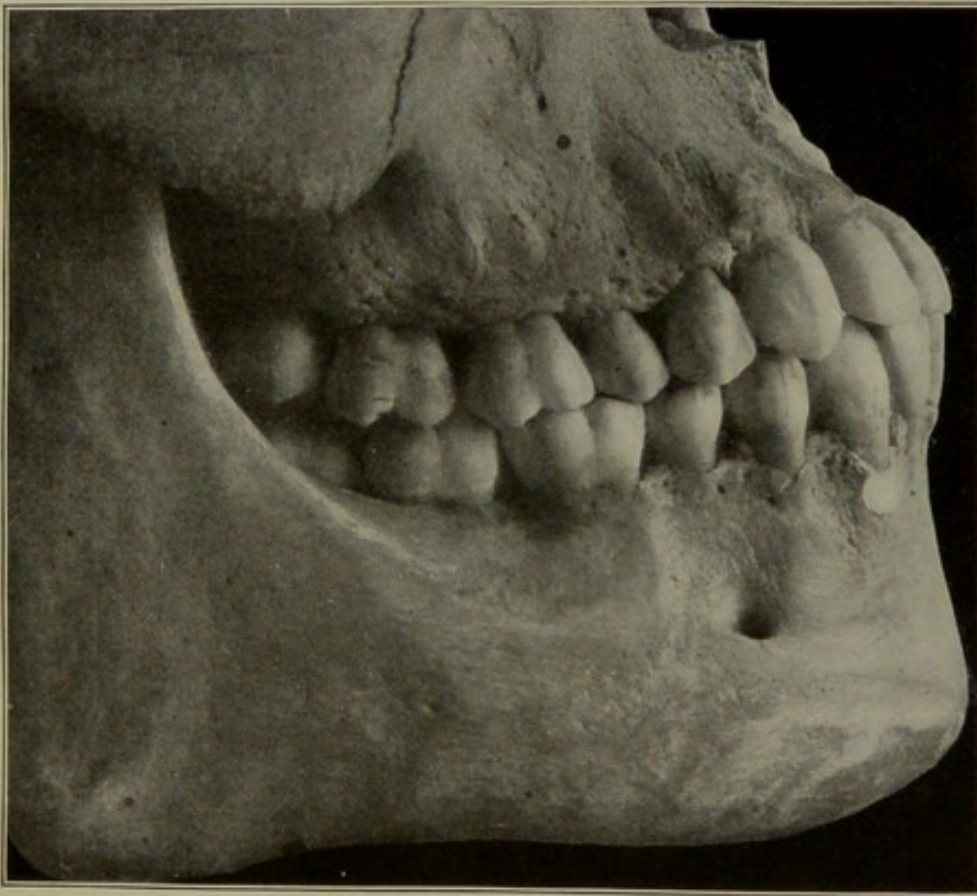It is, of course, not within the province of a work on orthodontia to teach as minutely and thoroughly as is necessary to a complete understanding thereof, the embryology, histology, and anatomy of the human denture. The reader is therefore strongly recommended to their study elsewhere, and especially to the works of Drs. Noyes, Black, Broomell, and Cryer. A thorough knowledge of the individual teeth is of such inestimable value to the orthodontist that the student is urged to carve, or model in clay, the different tooth forms, as in no other way will there be such a vivid impression stamped upon his mind of the correct outlines of their crowns and the positions and relative proportions of their cusps, together with their marginal, triangular, and oblique ridges, their grooves and sulci, and their relations to their antagonists.

Nature, in building the dental apparatus, requires a long period of time—twenty years or more—and from the be-



ginning of the formation of the first dental follicle and the tissues that support and precede it to the eruption of the last third molar, she works in accordance with a definite plan toward a definite end, viz., the production of a type that has been the type of man's denture as long as man has been man.

FIG. 1.



Normal occlusion. (Broomell.)

By referring to Fig. 1, which represents the teeth in normal occlusion, it will be seen that each dental arch describes a graceful curve, and that the teeth in these arches are so arranged as to be in greatest harmony with their fellows in the same arch, as well as with those in the opposite arch.

In their normal relations the external curve of the lower arch is slightly smaller than that of the upper, so that in



occlusion the labial and buccal surfaces of the teeth of the upper jaw slightly overhang those of the lower. The mesio-buccal cusp of the upper first molar is received in the buccal groove of the lower first molar. The teeth posterior to the first molars engage with their antagonists in a precisely similar way; those anterior interlock with one another in the interspaces until the incisors are reached; of these the upper usually overhang the lower about one-third the length of their crowns, though the length of overbite varies, being greater in the teeth indicating the bilious and nervous temperaments, and less in the sanguineous and lymphatic types.

The upper central incisor being broader than the lower, it necessarily extends beyond it distally, overlapping in addition about one-half of the lower lateral incisor; the upper lateral occludes with the remaining portion of this tooth and with the mesial incline of the lower canine; the mesial incline of the upper canine occludes with the distal incline of the lower, the distal incline of the upper occluding with the mesial incline of the buccal cusp of the lower first premolar. In the same order the series of buccal cusps of the premolars occlude—the mesial incline of each upper occluding with the distal incline of the corresponding lower tooth.

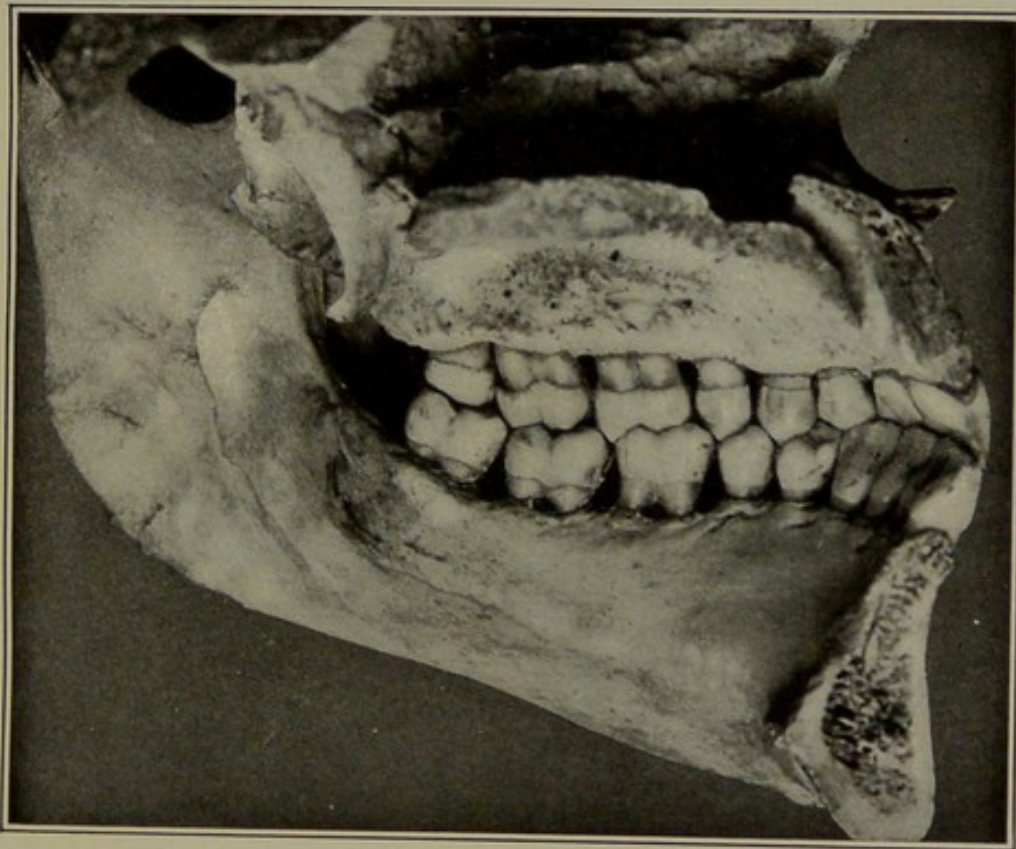
The distal incline of the second upper premolar occludes with the mesial incline of the mesio-buccal cusp of the lower first molar. The mesial incline of the mesio-buccal cusp of the upper first molar occludes with the distal incline of the mesio-buccal cusp of the lower first molar; the distal incline of the mesio-buccal cusp of the upper first molar occludes with the mesial incline of the disto-buccal cusp of the lower first molar; the mesial incline of the disto-buccal cusp of the upper first molar occludes with the distal incline of the disto-buccal cusp of the lower first molar, and the distal incline of the disto-buccal cusp of the upper first molar occludes with the mesial incline of



the mesio-buccal cusp of the lower second molar. The same order is continued with the buccal cusps of the second and third molars, the distal incline of the disto-buccal cusp of the upper third molar having no occlusion.

It will thus be seen that each of the teeth of both jaws has two antagonists or supports in the opposite jaw except the lower central incisors and upper third molars.

FIG. 2.



Normal occlusion, lingual aspect. (Turner.)

As the inclined planes match and harmonize most perfectly in the bucco-occlusal relations of the teeth, so there is a similar arrangement in their linguo-occlusal relations, except that the lingual cusps of the lower buccal teeth project beyond those of the upper into the oral space, as shown in Fig. 2.

Likewise in the transverse arrangement, the buccal cusps of the lower molars and premolars rest between the

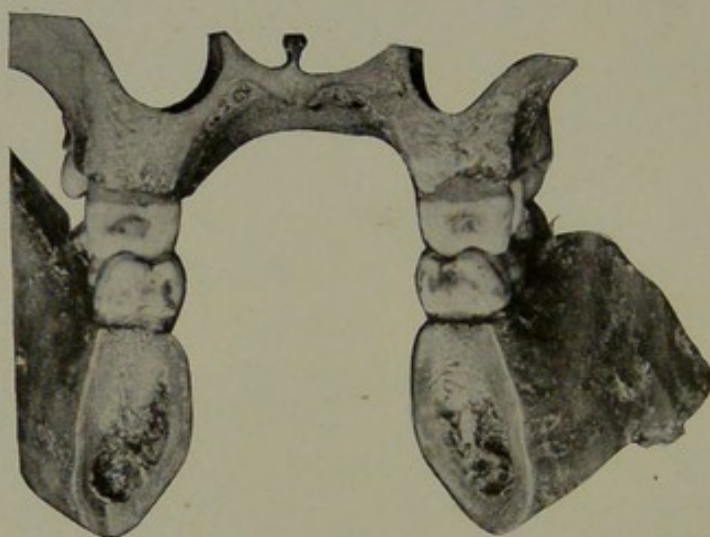


buccal and lingual cusps of the uppers, and the lingual cusps of the upper molars and premolars rest between the buccal and lingual cusps of the lowers, as in Fig. 3.

The grinding surfaces are thus enormously increased in extent and efficiency over what would be possible if they consisted of a single row of cusps or of plane surfaces.

But increase of masticating surface is not the only reason for this complex interdigitation of the cusps and inclined planes of the teeth, but it is of equal importance

FIG. 3.



Normal occlusion of molars, transverse view. (Cryer.)

in providing for the teeth a mutual support. *The sizes, forms, interdigitating surfaces, and positions of the teeth in the arches are such as to give to one another, singly and collectively, the greatest possible support in all directions.*

This is the pattern, the form, the type of the normal in occlusion,—the normal denture.

In building the human denture, Nature has worked toward a definite end to produce the most efficient parts with the most efficient arrangement of these parts that they may in function be most efficient. Each tooth is not only in harmonious relation with every other tooth, but helps to maintain every other tooth in these harmonious rela-



tions, *for the cusps interlock and each inclined occlusal plane serves to prevent each tooth from sliding out of position, and further, to wedge it into position if slightly malposed*, that is if not beyond the normal influence of the inclined planes.

A careful study of the relations of the inclined occlusal planes and the marginal, triangular, and oblique ridges, in connection with the movements of the jaw, cannot fail to impress thoughtful persons not only with the influence which these exert in maintaining each individual tooth in correct position, but as well their wonderful efficiency for incising and triturating the food required by omnivorous man, and with their marvelous forms and arrangement for self-cleansing and consequent self-preservation. So perfect is the plan in the relations of the teeth as a whole that each cusp or part of a cusp contributes perfectly to the balance, harmony and efficiency of all, and consequently the mesio-distal diameter of a tooth, or any portion of it cannot be sacrificed without proportionately disturbing the delicate balance and integrity of form and function of the whole. To one versed in occlusion no argument is needed to impress the importance of the complete and perfect restoration to contour of missing portions of teeth, or of the adjustment to harmony of those teeth that have become inharmonious during their eruption.

Not only are the individual tooth-patterns and the relation of the teeth most perfectly designed for performing their functions, but probably no other forms or relations could produce so beautiful and artistic an effect as an individual feature, or give so much of beauty in lines and expression to the face. The denture, with the teeth in normal occlusion, is a marked element of beauty to any face, however imperfect in other respects.

There is great harmony in the lines of the teeth, though all vary, the result being most pleasing. How the beauty of the central incisor would be impaired if its mesial lines



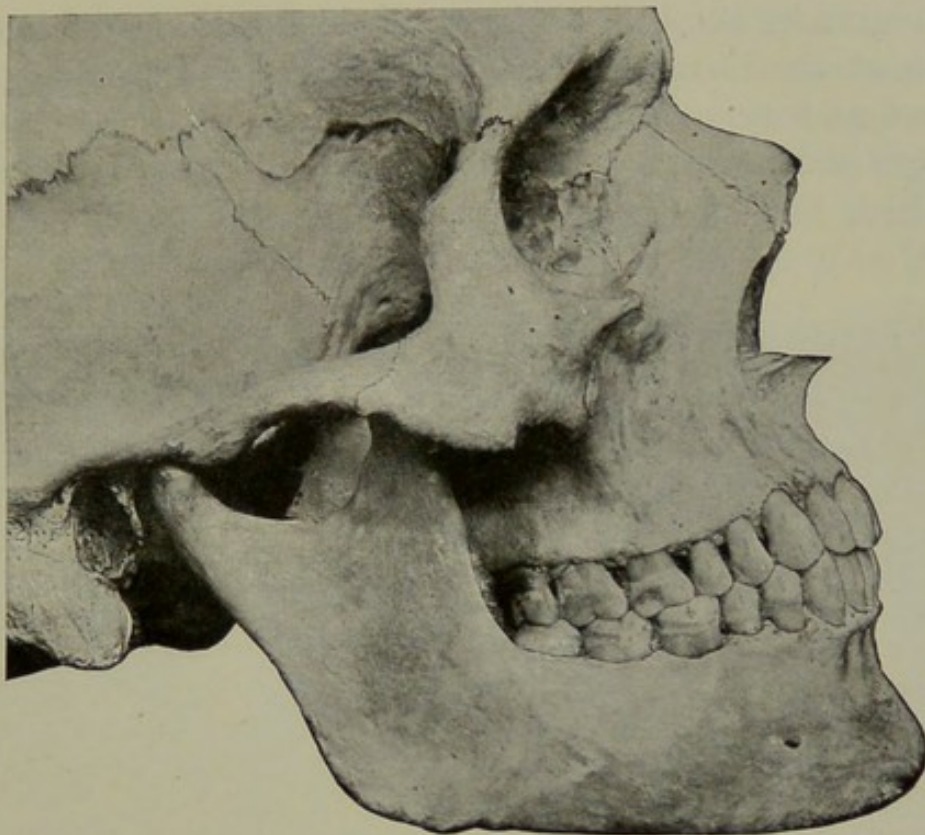
were the same as its distal lines. How much less pleasing would be the result if the lateral incisor were of the same size as the central, or even of the same pattern, instead of possessing the majesty of a pattern and relative size all its own. It is like the central, yet how beautiful in its difference. The canine, though resembling both central and lateral, adds much beauty to the whole in the lines peculiar to its own pattern, and how much the general effect is enhanced by the lateral incisor being shorter and slightly less prominent in the line of occlusion than either the central or canine. As in architecture, the columns of the corners must not be smaller than the intervening columns, so in orthodontic operations, or in unanatomically fashioned dentures, when the lateral is made prominent or of the same length as the other teeth the result is pronouncedly unpleasing. Again, how unpleasing is the effect when these beautiful lines are impaired by grinding any of the marginal surfaces—a fact that should lend caution to the hand of the orthodontist.

The same artistic harmony of the remainder of the teeth, both upper and lower, might be pointed out. We would call further attention here, however, only to that most noticeable unbalancing effect of the mouth in its relation to the other features resulting from the loss of a premolar and retraction of the canine, or, equally bad, the loss of a lateral incisor, and how the great beauty of harmony of the whole is impaired by a space in the premolar region resulting from extraction.

That no two normal human dentures have ever been created that were exactly alike it is reasonable to suppose, since it has never yet been demonstrated that Nature ever duplicates her forms. Three beautiful types or patterns of the teeth in normal occlusion are illustrated in Figs. 4, 5, and 6. None is absolutely perfect. Probably Nature never makes the truly ideally perfect type in *every particular*. It will be seen that each of these dentures slightly

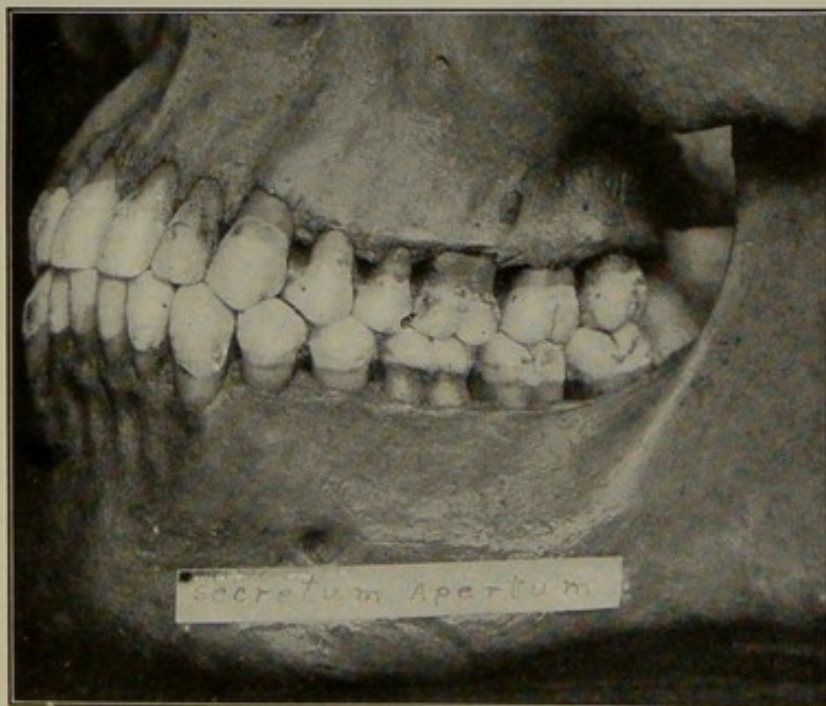


FIG. 4.



(Cryer.)

FIG. 5.



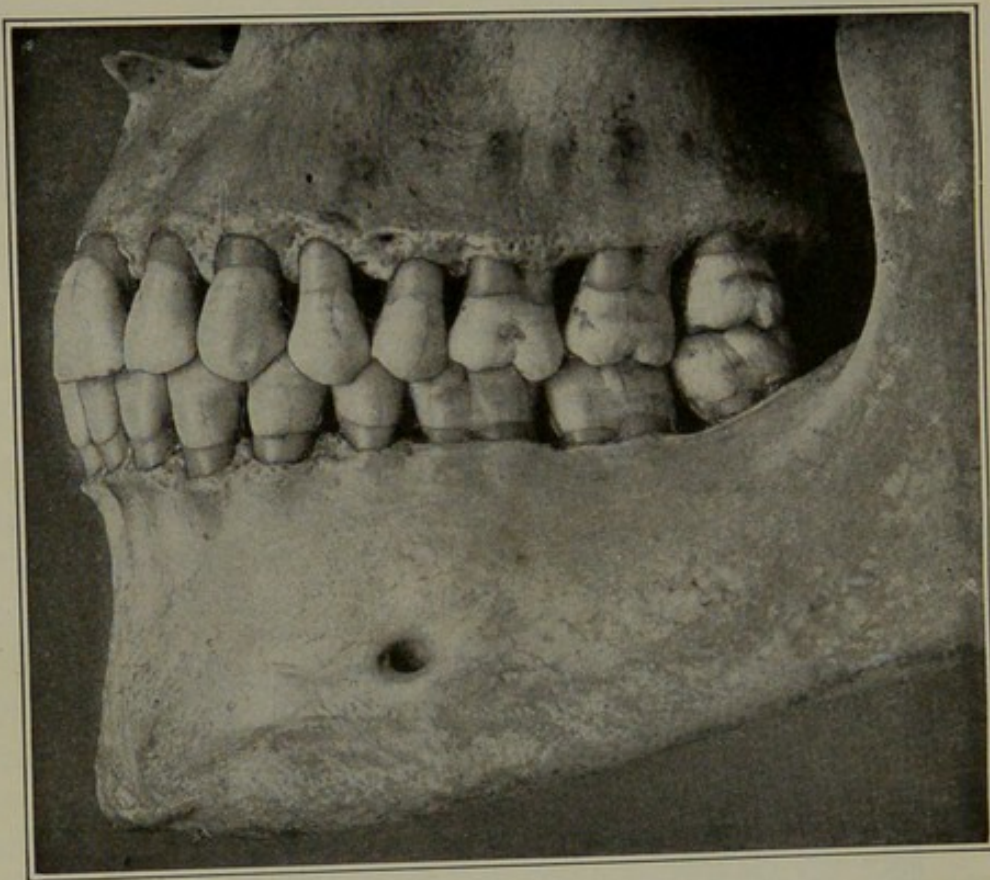
secretum Apertum

(Summa.)



differs from the others: in the position of the denture as a whole in its relation to the skull, in the angles of inclination of the incisors as well as of the other teeth, in the sizes and typical patterns of the teeth, in the length of cusps and consequent overbite of the incisors, in the sizes, widths, and curves of the arches, as well as in the com-

FIG. 6.



(Turner.)

pensating curve of the plane of occlusion. Yet these variations are but natural and doubtless in perfect keeping with the distinctive individual type, and we insist that in the main the dentures are exactly alike in Nature's plan of the normal in human dentures. If all were alike in every particular it would necessitate that the three individuals represented by them also be essentially alike in every other particular.

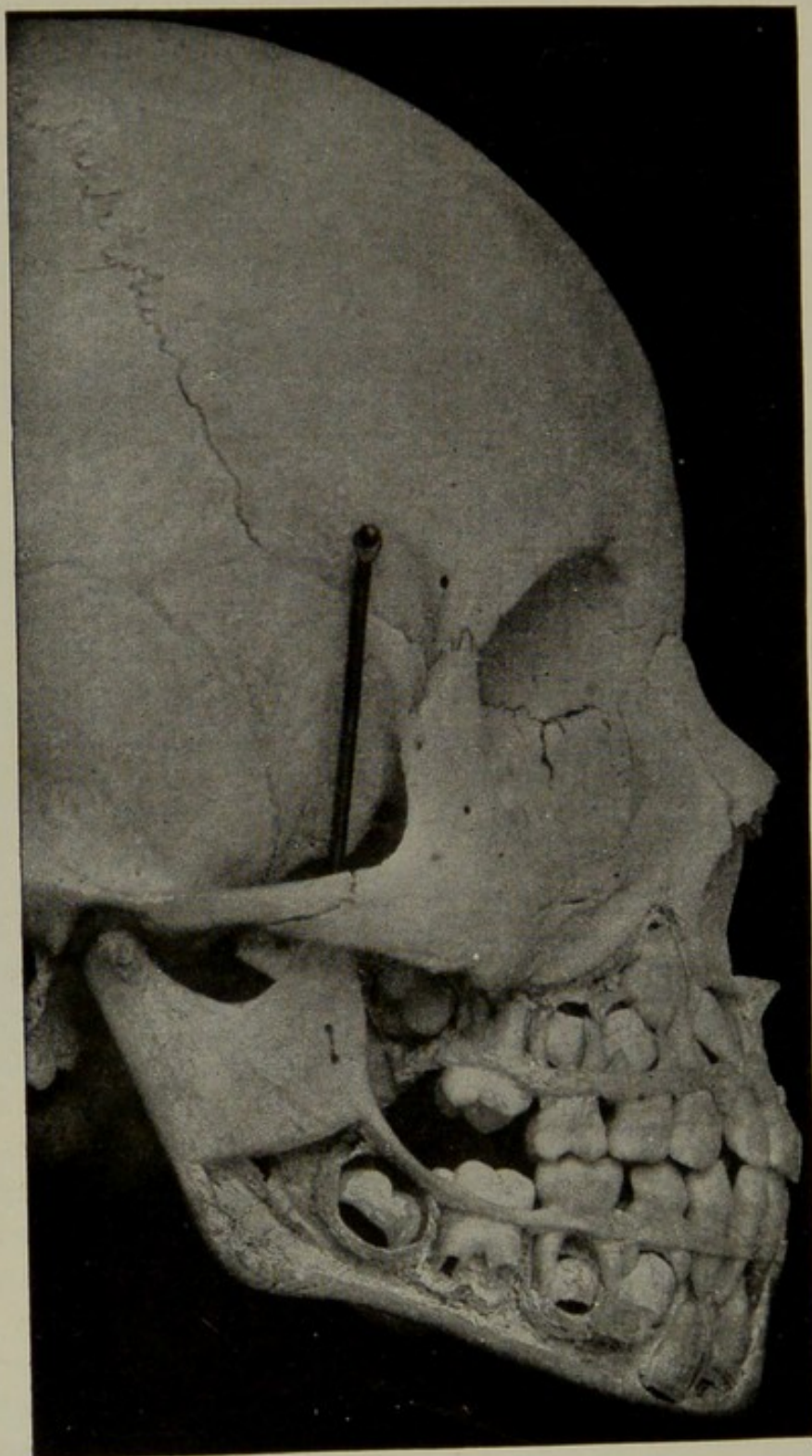


**Key to Occlusion.**—According to Nature's plan of the human denture all of the teeth are essential, yet in function and influence some are of greater importance than others, the most important of all being the first permanent molars. They are the largest of the teeth and the firmest in their attachment, which, together with their location in the arches, makes them the most important of the teeth in the function of mastication. By the lengths of their crowns they also determine the extent of separation of the jaws and length of bite, and in this, as well as in many other ways, are factors in the artistic proportions of the face. Being the first of the permanent teeth to take their positions in the arches, they exercise great control over the positions which the other teeth anterior and posterior to them shall occupy as they erupt at their respective periods and take their respective positions in the arches. As they are already developed and firmly attached in the alveolar process when the other teeth appear, the latter are built into the dental apparatus around them, as it were. They are not only the most constant in the time of taking their positions, but by far the most constant in taking their *normal* positions.

A better understanding of the reason why these teeth take correct positions is gained if we will but remember that theirs are the first permanent tooth germs formed, and also that they are the first of the permanent teeth to develop and erupt, which they do unhampered immediately posterior to the twenty teeth comprising the deciduous set, and that the deciduous teeth are free to erupt normally according to Nature's plan, under the most favorable conditions, and do so nearly always in normal occlusion and in perfect accordance with the requirements for harmony and beauty of the developing child's face. So the first permanent molars in erupting are not only unhampered in taking their positions, but on the contrary they are, as it were, guided into and guarded in correct positions by the usually



FIG. 7.



normal child denture anterior to them, Fig. 7, and by their normal locking on eruption is made possible the normal eruption and locking of all the other teeth both anterior and posterior to them in both lateral halves of each arch.

So important is the influence of these teeth in the building of the dental apparatus that we believe Nature exercises the greatest care in locating them, especially the upper first molars,\*—which we call the keys to occlusion,—and so places them that the rest of the dental apparatus may be completed normally; and if so completed it will, we are convinced, be in best harmony not only with these teeth, but with the physical type of each individual, just as the ears, eyes, the brain, the sphenoid bone, etc., are located to make, when complete, one harmonious whole, distinctive from all other individuals, with a face, a dental apparatus, and all other anatomical characteristics in harmony,—not necessarily perfect as a whole or in any particular part, but with the best harmony of parts.

The fact that the upper first permanent molar varies considerably mesially or distally as to its location in different individuals, which is always noted in anything like an extensive study of the subject, has led superficial students to regard these positions as abnormal, taken by chance, and out of harmony with other principles in the anatomy of individuals, but in reality these variations are to be expected, and are necessary in the creation of different types and different individuals. As, for example, this molar is found to be located farther anterior in its relation to the skull in some of the lower orders of man and the primates, than in the highly developed civilized man, which is necessary in the typical requirements.

Theoretically the first upper molars may differ in posi-

---

\* Angle, "The Upper First Permanent Molar as a Basis of Diagnosis." *Items of Interest*, June, 1906.



tion slightly, even in each lateral half of the dental arches of an apparently normal individual, just as the eyes or ears slightly differ as to height or location in the same person. Probably they are never exactly constant as to the two sides, but we insist that this is but natural and in keeping with the rest of the anatomy, and should no more be regarded as an abnormality when slight than the almost universal slight difference in the positions of the eyes or the ears.

And, finally, that Nature may err in the locating of these molars is doubtless possible, for we know, the unfortunates classified as "freaks" are the result of her anatomical errors, but we must remember that freaks are very rare, and we believe that Nature so very rarely errs in the locating of the first upper molars—the very cornerstones, as it were, in the foundation of the structure of an organ so essential to the whole physical economy as the dental apparatus, as to make it a matter of little or no concern to us except, possibly, in research work. The author has been unable to find, after much study, a single case in an un mutilated denture where it would seem to him that Nature had erred in not locating these most important teeth so as to be in best keeping with the remaining typical anatomical factors.

So it will be seen that we have the most logical and conclusive of reasons for regarding these teeth as the keys to occlusion, and on their positions and the relations of their antagonists with them, to base the classification and diagnosis of malocclusion.

The author is well aware of the criticisms to the acceptance of the first permanent molars as a basis for diagnosis of cases of malocclusion, in contra-distinction to the only heretofore known plan, which is entirely empirical and depends upon the judgment of the operator,\* but he feels sure that an unbiased and more thorough study of the subject

---

\* Cryer, *Dental Cosmos*, September, 1904; Case, *Items of Interest*, July, 1905.



will demonstrate that the first permanent upper molar furnishes more nearly than any other tooth or point in the anatomy an exact scientific basis from which to reason on malocclusion.

It is to be understood that the sense in which we here speak of the upper first permanent molar is its mesio-distal relations, and independently of slight migrations mesially or distally which may have resulted from mutilation, the extent of which migrations, if occurring, can be easily detected and allowances made therefor.

The author has lately become convinced of the wonderful constancy also as to the correct location linguo-buccally of these molars when they have succeeded in locking normally with their antagonists. He believes that when they are found lingually or buccally to their normal positions it is practically always due to mechanical influences resulting from their mal-relation with the opposing molars. Naturally the arch is narrower between these teeth when they first erupt than at the time the denture is completed, as must follow the normal growth of the jaws and other bones. Lack of recognition of these facts has led to the erroneous belief by many that the upper arch should usually be widened in the region of the first molars, even in the cases of young children.

**Line of Occlusion.**—Writers on orthodontia have long been in the habit of making use of an imaginary line, known as “the teeth in alignment,” and the “line of the arch,” from which to note regular or irregular alignment of the crowns of the teeth. It has most often referred to the general line of each individual arch, as outlined by the crowns of the teeth regardless of their number or position, or of the relations of such lines to the skull. In this way two lines of occlusion are often inferred,—one for each arch, which may or may not have direct relation one to the other. In reality, as used, it has been vague and indefinite. So far as the author is aware, none has comprehended its full meaning or importance.



That we should have a line from which to note variations from the normal in the positions of the teeth is important, but that its meaning is deeper and that it has a far greater significance to the student of orthodontia than above indicated, the writer is fully convinced. In the sixth edition of this work he used the term "the line of occlusion" which he defined as being "the line of greatest normal occlusal contact." Yet after a much greater consideration of the subject he believes that this definition, though more nearly expressing the true condition than the terms previously employed, is still inadequate, and he would now define it *as being the line with which, in form and position according to type, the teeth must be in harmony if in normal occlusion.*

There can be, then, but one true line of occlusion, and it must be the same as the architectural line on which the dental apparatus was constructed. This ideal line was intended to govern not only the length, breadth, and peculiar curve of the dental arches, but the size and pattern of each tooth, cusp, and inclined plane composing these arches. And more than this: that as the dental apparatus is only a part of the great structure—the human body—each part and organ of which was fashioned according to lines of design, it must have been intended that the line of occlusion should be in harmony in form and position with, and in proper relation to, all other parts of the great structure, according to the inherited type of the individual. Hence its majesty, and according to our conception of it must be our ability to comprehend not only the art requirements in each case we treat, but as well must it govern our conception of the requirements of the position of the teeth in occlusion and the various operations in treatment. The line of occlusion then, is more than the tangible or material. It may be regarded as the basic ideal of the dental apparatus, the comprehension and appreciation of which will grow in proportion as our knowledge of the science of occlusion unfolds.



We may speak of moving a tooth of the lower arch into the line of occlusion, or of moving a tooth of the upper arch into the line of occlusion, but it must always be remembered that there can be but one *true line of occlusion*, or the line with which each tooth must be in perfect harmony if in normal occlusion.

This line describes more or less of a parabolic curve, and varies within the limits of the normal, according to the race, type, temperament, etc., of the individual. It is difficult to determine exactly what the form of this line should be in each given case. We have already seen with what great care Nature locates the first permanent molars in this line, and by taking advantage of the positions of these teeth, and of the diameters of the incisors and canines, Dr. C. A. Hawley\* has ingeniously made use of the Bonwill law in order to determine the proper form of the line of occlusion. Doubtless this method of approximating the true line of occlusion may be valuable, yet that the line may thus be accurately located the author does not believe, for the reason that the form of the line must be modified according to type, while following this plan its form is governed by the diameter of the six anterior teeth, which may accurately determine its length, but cannot determine its curve. It seems to the author that the best the orthodontist can do is to secure normal relations of the teeth and correct general form of the arch, leaving the finer adjustment to individual typical form to be worked out by Nature through her forces which must, in any event, finally triumph.

All teeth found out of harmony with the line of occlusion may be said to occupy positions of malocclusion, and each tooth may occupy any of seven malpositions or their various deviations and possible combinations.

The malpositions of teeth consist principally in the variation of the positions of their crowns from the normal,

---

\* See *Dental Cosmos*, May, 1905.



with usually little displacement of the apices of their roots, so that they incline at an angle more or less oblique from the normal. In some instances, however, there is some displacement of the apices as well as of the crowns, they having either developed in malpositions, or, as in most instances, having been forced from their normal positions by the eruption of more powerful teeth in juxtaposition, as for example, the crowding linguallly of the lateral incisors by the development and eruption of the canines, as in Fig. 320. Yet even in such cases the displacement is not so great as appears, the malpositions of the crowns magnifying this appearance.

**Nomenclature.**—A definite nomenclature is as necessary in orthodontia as in anatomy. The vagueness of descriptive terms often used renders them very inadequate. The terms for describing the various malpositions should be so precise as to convey at once a clear idea of the nature of the malocclusion to be corrected. The author therefore suggests the following, which, while perhaps not perfect, still seems to be a great improvement on common usage.

For example, a tooth outside the line of occlusion may be said to be in buccal or labial occlusion; when inside this line, in lingual occlusion; if farther forward, or mesial, than normal, in mesial occlusion; if in the opposite direction, in distal occlusion; if turned on its axis it would be in torso-occlusion. Teeth not sufficiently elevated in their sockets would be in infra-occlusion, and those that occupy positions of too great elevation, in supra-occlusion.

These different malpositions in their modifications and combinations comprise the variations of all cases of malocclusion, from the simplest to the most complex, in which may be involved not only all of the teeth, but even the jaws as well. These terms used in connection with the author's classification make possible the conveying of a very complete picture of any given case of malocclusion in very few words.



**Forces Governing Normal Occlusion.**—The inclined planes of the cusps of the teeth already in normal position play an important part by directing the teeth that are erupting to take their normal positions in the arch, but if their influence be perverted they may become mischievous factors in the production of malocclusion.

When the teeth first emerge from the gums their considerable displacement is often noticeable, but this need occasion no uneasiness provided, as eruption progresses, their cusps pass under the influence of normally placed opposing cusps. But if they pass beyond this influence into abnormal relations, they will not only be deflected from their own proper positions, but may displace the opposing teeth and those subsequently to erupt, as well, even to the extent of the disarrangement of the entire thirty-two teeth, as is possible from the mal-locking of the first permanent molars. So there may be times when the dividing line between harmony and inharmony is very slight, hence the importance of careful attention during the important period covering the eruption of the permanent teeth, especially the beginnings.

Harmony between the complete upper and lower arches is also powerfully promoted by their normal action and reaction upon each other through the teeth. As the teeth of the lower arch erupt before their antagonists of the upper arch and are consequently to an extent fixed in their positions before the latter appear, it follows that the lower arch is the form over which the upper is molded. In other words, the lower arch exerts a modifying influence on the form of the upper. Of course, the upper reacts upon the lower, but it is unquestionable, in the author's opinion, that the lower arch is the more important factor in determining the form of the dental arches than the upper, as has hitherto been taught.

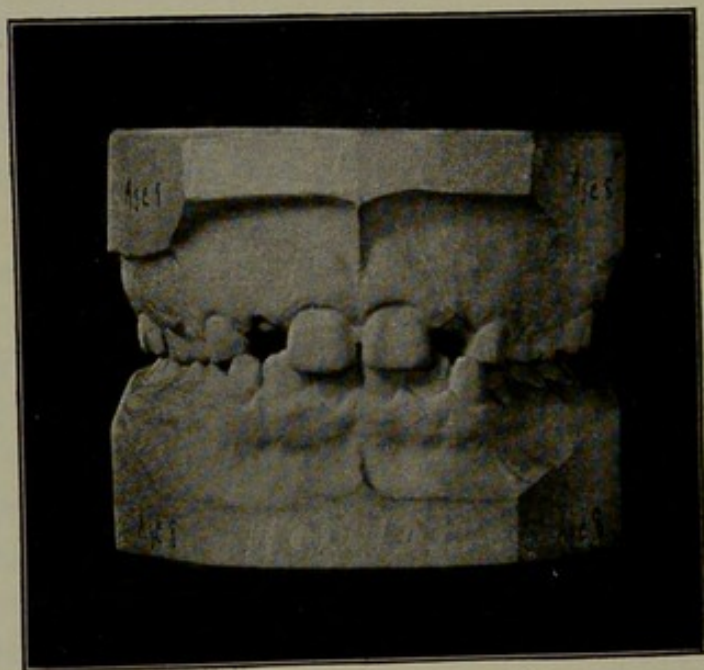
From what has been said it may be readily seen how greatly each arch contributes to the other in maintaining its



form and size when the teeth are in normal occlusion, and how pressure abnormally exerted on any tooth or teeth would be resisted by all the other teeth. For example, pressure exerted on the labial surfaces of the upper incisors would be resisted not only by all the upper teeth acting as blocks of stone do in an arch of masonry, but also by the teeth of the lower arch acting through occlusion.

Inversely, then, one arch cannot be altered in shape without modifying that of the other, nor can it be altered

FIG. 8.



in size without soon exercising a marked effect on the other.

Harmony in the positions of the teeth and in the sizes and relations of the arches is further assisted by another force—namely, muscular pressure—the tongue acting upon the inside, and the lips and cheeks upon the outside, of the arches. The latter, if normal in development and function, serve to keep the arches from spreading, as do hoops upon the staves of a cask; the former prevent too great encroachment upon the oral space, and each, if normal in

function, contributes in like proportion to the harmony of balance. This muscular pressure is far more important than is generally recognized.

Fig. 8 represents the teeth of a child aged eight years, where the jaws and teeth are developing normally. It will be noted that all of the permanent lower incisors have erupted and occupy their normal space in the arch, compelling the lower canines to occupy positions the requisite distance apart. Of special importance is the influence that these teeth exercise on the opposing deciduous canines through their inclined planes, each blow that the upper canines receive from the lower tending to widen the arch, or at least to prevent it from becoming narrower through the pressure of the lips.

So it will be seen that normal occlusion of the teeth is maintained, first, by harmony in the sizes and relations of the dental arches through the interdependence and mutual support of the occlusal inclined planes of the teeth; and second, by the influence of the muscles labially, buccally, and lingually.



## CHAPTER II.

### MALOCCLUSION.

**Forces Governing Malocclusion.**—In beginning the consideration of malocclusion let us remember that it is but the perversion of the normal in the growth and development of the denture—the side-tracking, as it were, of Nature in some of her normal processes of building, and we repeat, that as a basis from which to determine its extent and complexity we must have firmly fixed in our minds a thorough knowledge of the normal denture complete and its co-related parts.

We know that every case has a simple beginning in its variation from the normal, and that very often a single tooth, from slight cause, being deflected from the normal may and usually does involve others. The dividing line, then, between the normal and the abnormal in the beginning is very slight, but always clearly defined, so the normal in occlusion is the only logical basis for determining the variation therefrom and the extent of the abnormal—malocclusion—and, as we shall see, the same forces that contribute to maintaining the teeth in their normal positions and harmony in the sizes of the arches, are equally powerful in maintaining inharmony in the sizes and relations of the arches and malocclusion of the teeth when once established.

In a large percentage of cases of malocclusion the arches are more or less contracted, and as a result we find the teeth crowded and overlapping. In these cases the lips serve as constant and powerful factors in maintaining this condition, usually acting with equal effect on both arches, and effectually combating any influence of the



tongue or any inherent tendency on the part of Nature toward self-correction. In other words, the arches, narrowed and diminished in size, are so maintained by force from the lips, equal in power to that exerted for their normal maintenance when of normal size and relation, with the teeth in normal occlusion. Likewise each inclined plane of the cusps, once out of harmony serves not only to maintain the inharmony, but to increase it, upon each closure of the jaw. It is interesting and instructive to note the result of these forces even in very early indications of malocclusion.

FIG. 9.

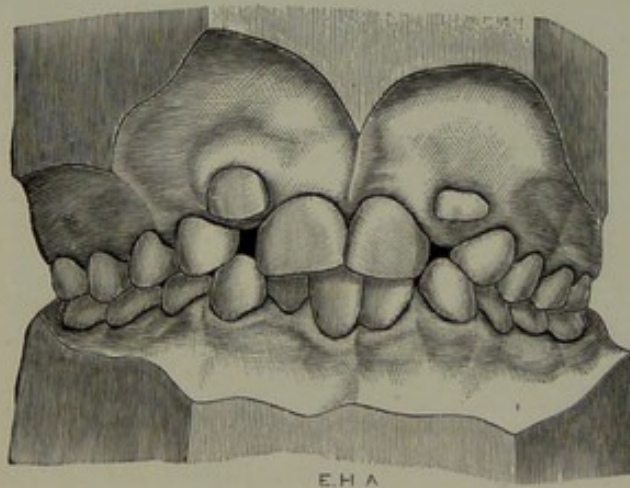


Fig. 9 illustrates a very common and familiar form of developing malocclusion. The case is that of a child where the four lower permanent incisors are fully erupted, but one of them (the left lateral) has been deflected lingually, Fig. 10. The arches being thus deprived of the wedging and retaining influence of this tooth, the external pressure of the lips has closed the space and diminished the size of the arch. At the same time pressure, principally from the lips and cheeks, aided by the occlusal planes of the lower deciduous molars, is gradually molding the upper arch to conform to the diminished size of the lower.

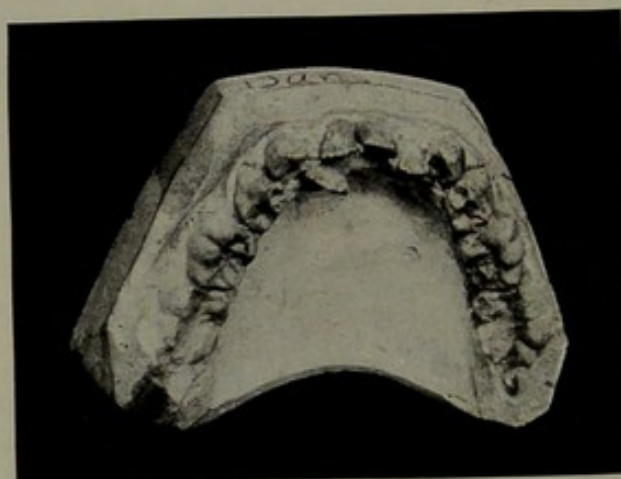
It will thus be seen how effectually the malocclusion will



be maintained and how hopeless it is to expect Nature to correct this deformity unaided. These same influences may be traced in a similar manner in any case of malocclusion.

Recognizing the potency of these influences, it must be apparent that cases of this kind, instead of being self-corrective, will become more and more complicated as time goes on and as each succeeding permanent tooth is erupted. How absurd and unfortunate, then, is the common daily

FIG. 10.



advice from dentists to anxious parents to "let the teeth alone and Nature will correct them unaided."

In all such cases the positions of the erupting permanent lower incisors should be guarded with zealous care, and should be forced to take correct positions and be maintained therein, and thus assist in directing the teeth of the opposing arch into correct relations and be compelled to fulfill their important part in the full normal development of the alveolar process. This is the golden opportunity for beginning intelligent interference for the prevention of what might otherwise become complicated cases of malocclusion. This also applies with equal force to any other lower tooth that may erupt into abnormal position, especially the lower first molars. Then, unless there be



unusual tendencies toward malocclusion, the positions of the teeth of the upper arch will be directed normally.

For the reason previously stated, if the teeth of the lower arch be permitted to remain in malposition even to the slightest overlapping of one or more of the incisors or canines, the arch will be diminished in size just to that extent, and as a result of pressure of the lips there will be a corresponding contraction in the upper arch and some form of bunching of the teeth.

The influence of the lips in modifying the form of the dental arches is an interesting study, and almost every case of malocclusion offers some noticeable and varying manifestation of it. In those cases where there is normal occlusion of the teeth it will be noticed that the lips and cheeks are also normal and perform their functions normally. The upper lip will be found to rest evenly in contact with the gums and upper three-fourths of the labial surfaces of the upper incisors, leaving, however, about one-fourth of the occlusal ends of the central incisors and laterals, and the points of the canines, to be covered by the edge of the lower lip, so that normally there is a restraining force exerted upon the upper incisors and canines by both upper and lower lips. This force is exerted automatically in response to almost every emotion, and results in maintaining the teeth in harmony with the graceful and beautiful curve of the normal individual arch.

In cases of malocclusion strikingly characteristic abnormalities in lip function are often noticeable, leading to the suspicion that more often than is recognized the peculiarities of lip function may have been the cause of forcing the teeth into the malpositions they occupy. The lack of the requisite amount of pressure from the lip is strikingly noticeable in the positions the incisors assume in cases belonging to Division 1 of Class II, in which the upper lip but partially performs its function, exercising little restraining influence upon the labial surfaces of the upper



incisors, the result being that these teeth move forward and protrude in a more or less pronounced manner. In these cases the over activity of the lower lip assists in augmenting the protrusion, for in closing the lips the inner edge of the lower is forced against the lingual surfaces of the upper incisors instead of their labial surfaces. In cases belonging to Division 2 of Class II the upper lip is found to be well-developed, exerting its full force upon the upper incisors, and as we shall see, causing their bunching and the lingual position of their crowns, and thus establishing and maintaining a comparative harmony as to the sizes of the two arches, though in abnormal relations.

The abnormally frequent contraction of the upper lip, manifest in the cases of patients suffering from snuffles, forces the upper incisors more or less inwardly, producing an end-to-end bite and an abnormal wearing of the cutting edges of the upper incisors. Doubtless, also, peculiarities of disposition, and their manifestations in the movements of the lips, in many instances so modify the force exerted upon the teeth as to influence the form of the dental arches.

Another striking instance of the lack of the requisite amount of force exerted by the lips and cheeks upon the external surface of the arch is presented in certain cases of patients suffering from cleft palate which involves the intermaxillary bones and upper lip. The lateral halves of the arch spread abnormally to a greater or less degree, in some instances the teeth of the upper jaw closing completely outside those of the lower, as in Fig. 11.

Dr. Black reports a case in which a portion of the cheek was lost from carcinoma. The normal external force being thus released from the molars, they were forced outward as a result of normal pressure of the tongue.

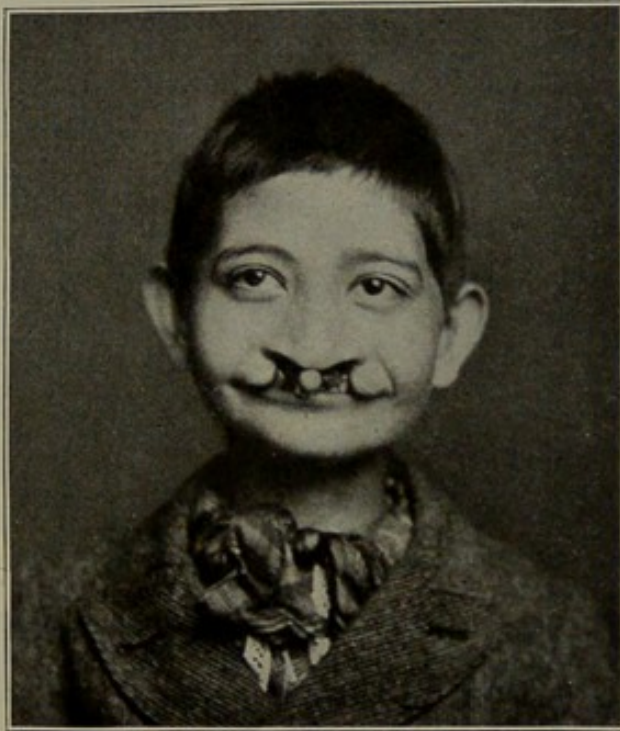The result of pressure from the tongue in exerting force upon the inside of the arch is also a factor, we are con-



vinced, of great importance in determining the form of the arches and the positions of the individual teeth.

That when normal in size, tone, and function, it exercises a gentle force upon the inside of the arch, which is in per-

FIG. 11.



fect harmony with the force exerted by the muscles upon the outside in maintaining the correct balance in muscular influence upon the teeth, cannot be doubted; and so, it is reasonable to suppose that when abnormal in size and function, it may and does exert a modifying influence on the size of the arches and positions of the teeth. As yet we know very little as to the extent of this influence, but we have many proofs of its existence.

That tongues vary considerably in size in different individuals is well known, yet owing to their peculiar muscular arrangement and their variability in size and form when being examined, it is difficult to study them accurately. The author has seen instances of the arch being so



FIG. 13.

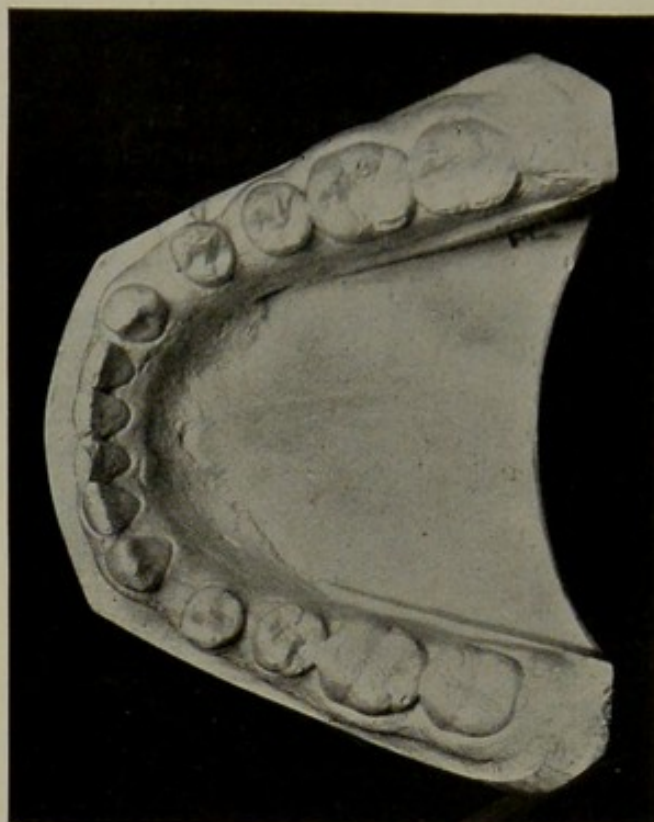
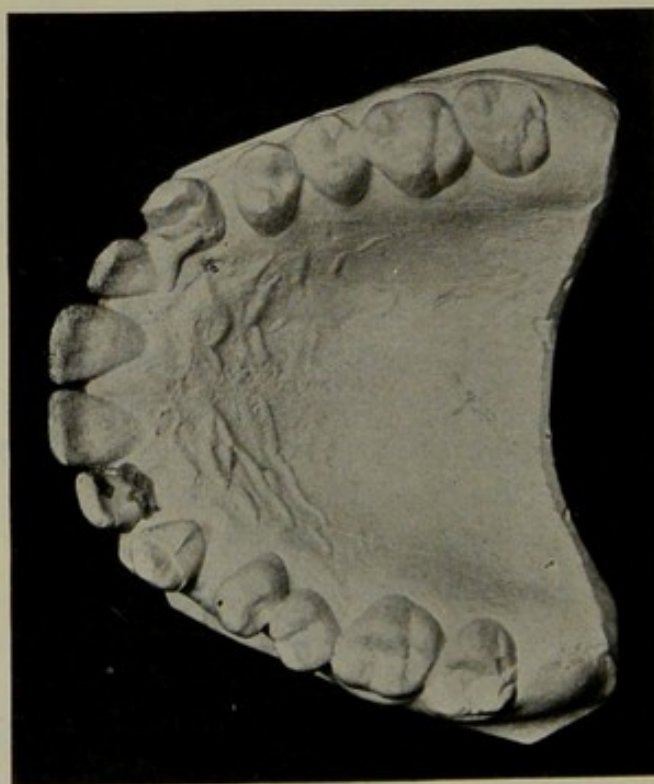


FIG. 12.



enlarged by the influence of the tongue as to create a space between many of the teeth, as in the case shown in Figs. 12 and 13. He has also seen instances where the abnormally narrow form of the arch seemed to him to be due to the lack of proper size and activity of the tongue. It would be interesting to know how the arches have been modified in those rare cases where the tongue has been lost.

**Classification of Malocclusion.**—As we have seen, there are seven distinct positions which teeth in malocclusion may occupy, indicated by their deviation from the line of occlusion. These different malpositions form combinations in cases of malocclusion which are practically limitless in their variations.

The same rule that holds good in the dissimilarity of normal dentures is equally true of cases of malocclusion, for not only do we find the same typical differences in forms, sizes, color, etc., of the teeth, and in form and size of dental arches, but we further find that, although the number of cases is legion, in no two is the arrangement of teeth in malocclusion just alike, even in those strikingly similar cases of Division 1, Class II.

Yet notwithstanding this endless variation which has led to endless confusion in diagnosis and treatment among the old-school writers and practitioners, as we shall see all cases of malocclusion fall naturally into a very few distinct and easily recognized groups, or three great Classes, with their Divisions and Subdivisions, and when so classified the extent of the variation from the normal in each case is easily comprehended and the requirements of treatment made manifest.

These classes are based on the mesio-distal relations of the teeth, dental arches, and jaws, which depend primarily upon the positions mesio-distally assumed by the first permanent molars on their erupting and locking. Hence in diagnosing cases of malocclusion we must consider, first, the mesio-distal relations of the jaws and dental arches,



as indicated by the relation of the lower first molars with the upper first molars—the keys to occlusion; and second, the positions of the individual teeth, carefully noting their relations to the line of occlusion.

**Class I** is characterized by normal mesio-distal relations of the jaws and dental arches, as indicated by the normal locking on eruption of the first permanent molars, at least in their mesio-distal relations, though one or more may be in buccal or lingual occlusion. When the first permanent molars erupt and lock in normal mesio-distal relations it makes *possible*, as we have seen in our study of the normal, the normal locking of each subsequent tooth that erupts, and only under such conditions is this possible. But, as we have also seen, even with a normal beginning, that is, with normally occluded deciduous teeth, normally locked first permanent molars, and jaws and dental arches normal in their mesio-distal relations at the time of this locking, some one or more of the anterior permanent teeth, from a great variety of causes, may be deflected from their normal course, carrying with them to varying degrees both approximating and antagonizing teeth until possibly they may all be involved in malocclusion, yet without disturbing the mesio-distal relations of the first molars, arches, or jaws.

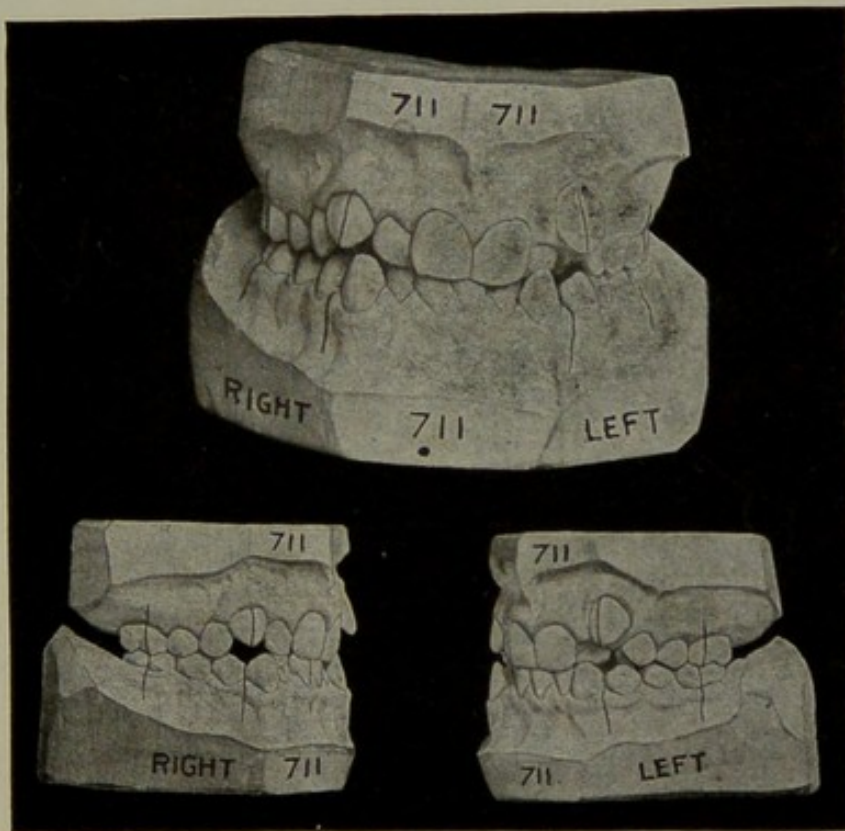
In the average case the arches are more or less shortened and reduced in size, with a corresponding crowding of the incisors, as shown in Fig. 14.

It will be seen that the complicated malocclusion, illustrated in Figs. 15 and 16, also naturally belongs to this large class. The first permanent molars have erupted and locked in normal relations, the malocclusion being confined principally to deviations from the line of occlusion of the incisors and canines, the two arches being much shortened from their full normal contour in front, especially the upper, which is complicated by the procumbent lingual impaction of the right upper canine.



Fig. 17 represents a less complicated and very common form of malocclusion belonging to this class—the result of the premature loss of the right upper deciduous canine which has disturbed the normal process of development of the denture. The upper incisors on the right side have been forced by the lip to occupy positions lingual to the line

FIG. 14.



of occlusion, thereby compelling the right permanent canine, upon its eruption, to occupy a position of much labial prominence, but as the jaws and the molars are normal as to their mesio-distal relations, the case is easily diagnosed as belonging to this great class.

Fig. 18 illustrates what at this age of the patient is a simple case belonging to this class, but which, if not treated, must develop into one of complexity similar to the one shown in Fig. 14.



FIG. 15.

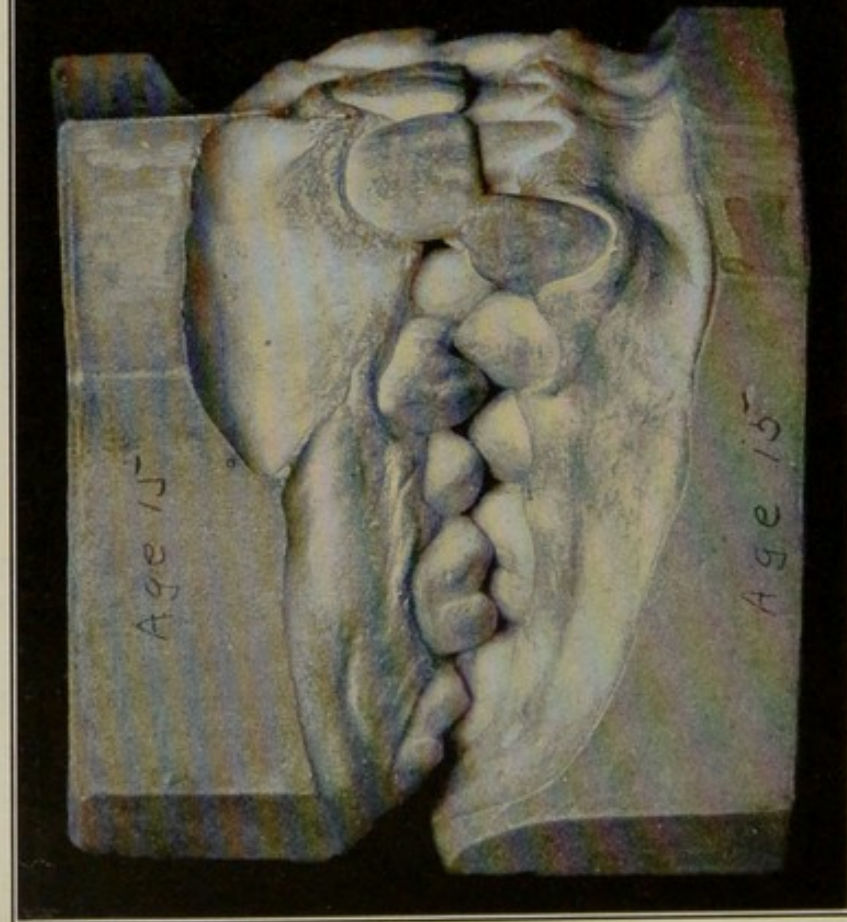

FIG. 16.

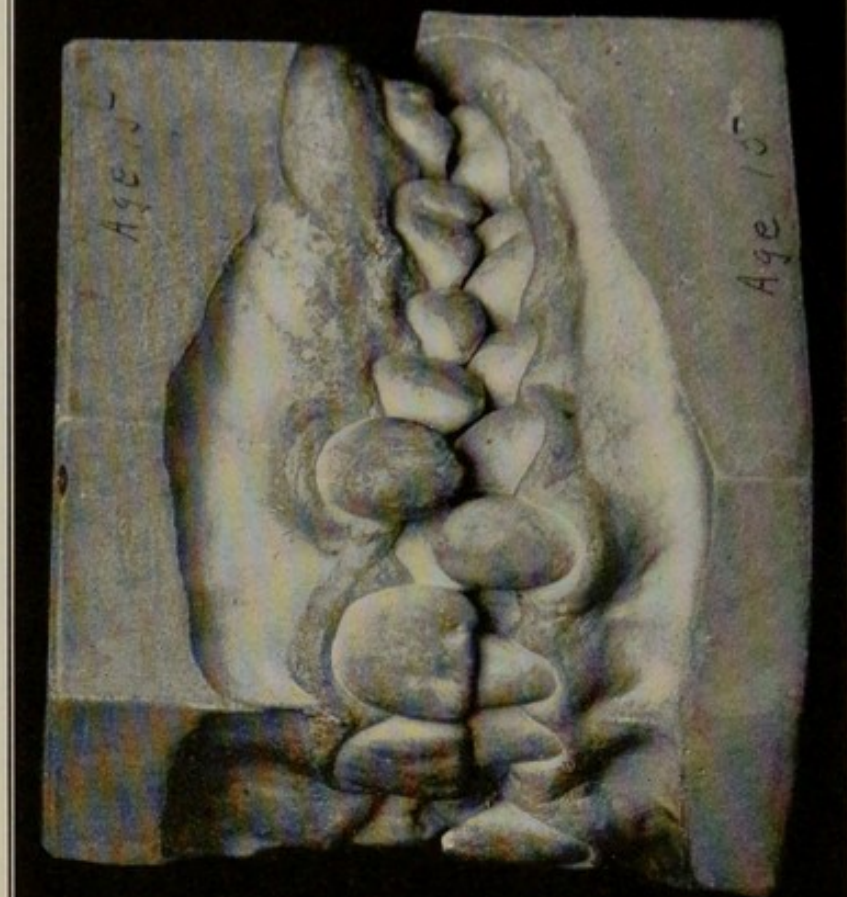
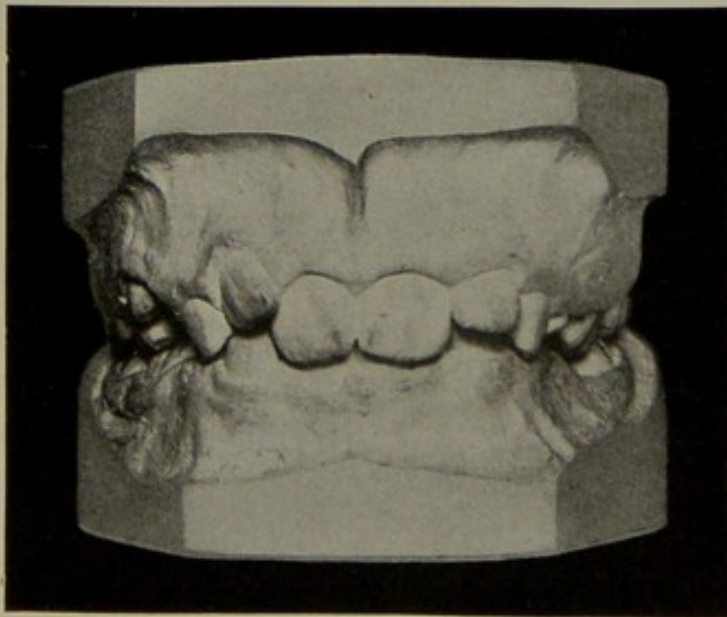


FIG. 17.

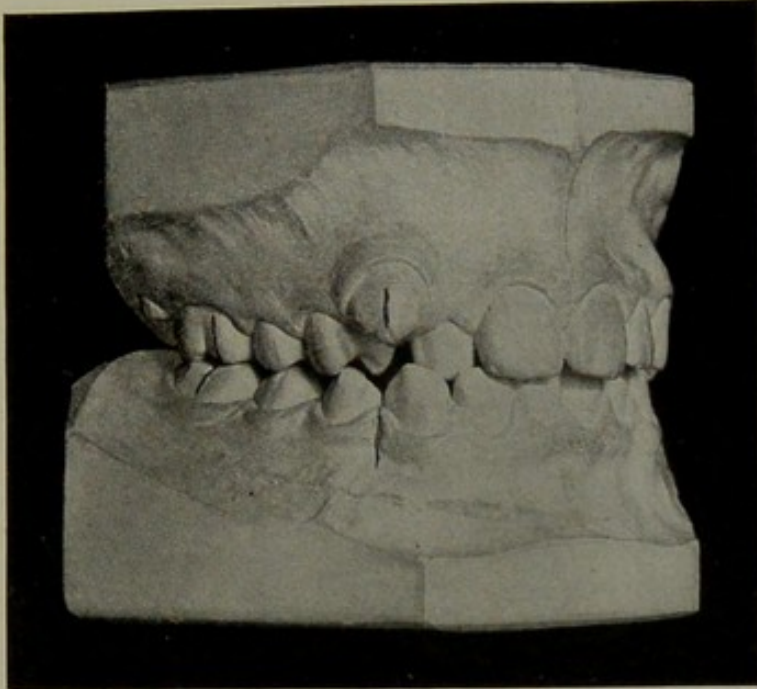

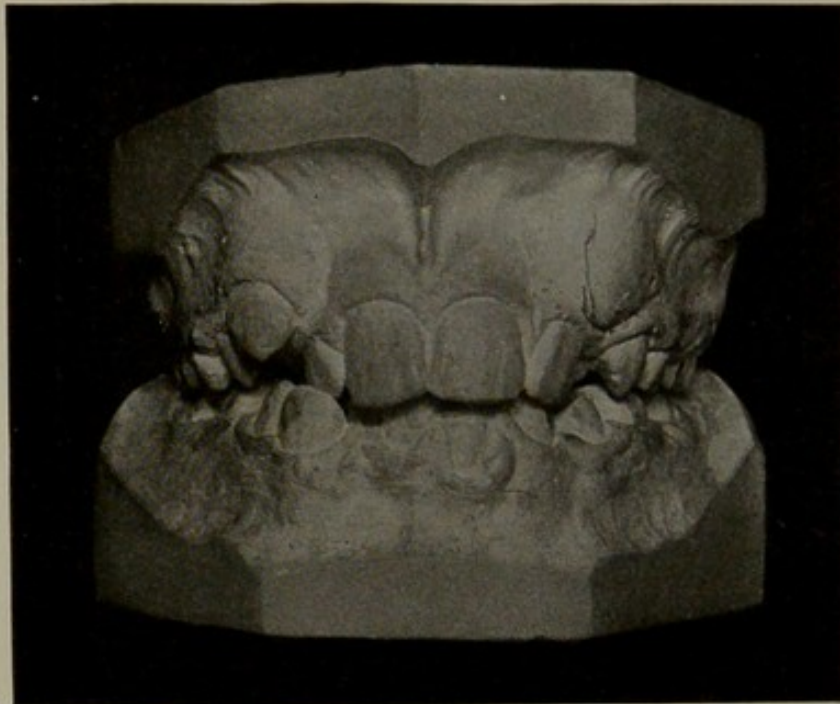
FIG. 18.





Figs. 19, 20, and 21 illustrate another case of pronounced malocclusion in which the incisors, already in positions of marked lingual and torsal occlusion, are being carried still farther out of harmony with the line of occlusion by the eruption of the canines. By noting the relations of the

FIG. 19.



first molars the case is easily distinguished as belonging to this class.

Fig. 22 illustrates a rarer type of malocclusion belonging to this class. Although the mesio-distal relations of the jaws and first molars are normal, yet the lower first permanent molar, as well as the deciduous lower molars and the canine on the right side, have locked in buccal occlusion, and thus is established the beginning of that pronounced and complex type of deformities which, when fully developed, are characterized by the lateral displacement of the mandible and twisting of the mouth, as illustrated in Figs. 408 and 406.

It must be borne in mind, however, that the condition of buccal occlusion of the lower teeth is only an incident in

FIG. 21.

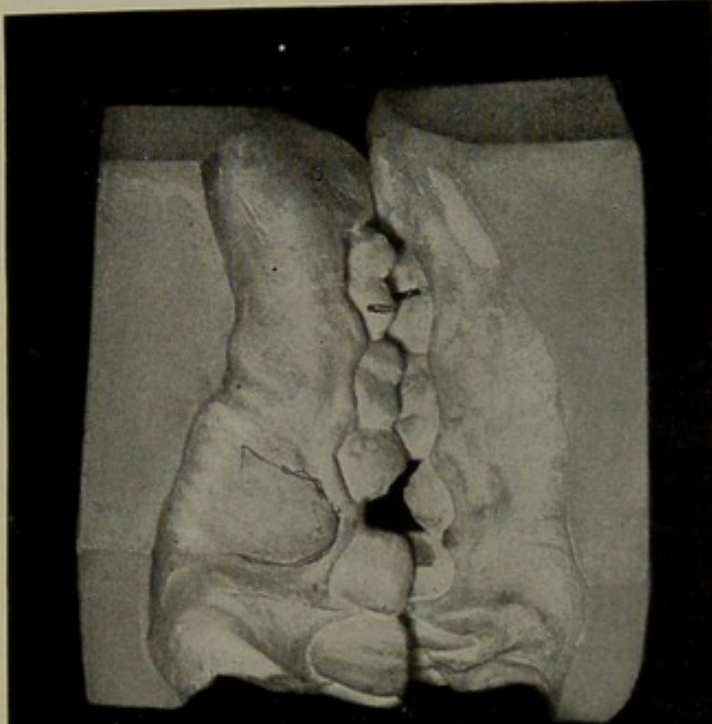
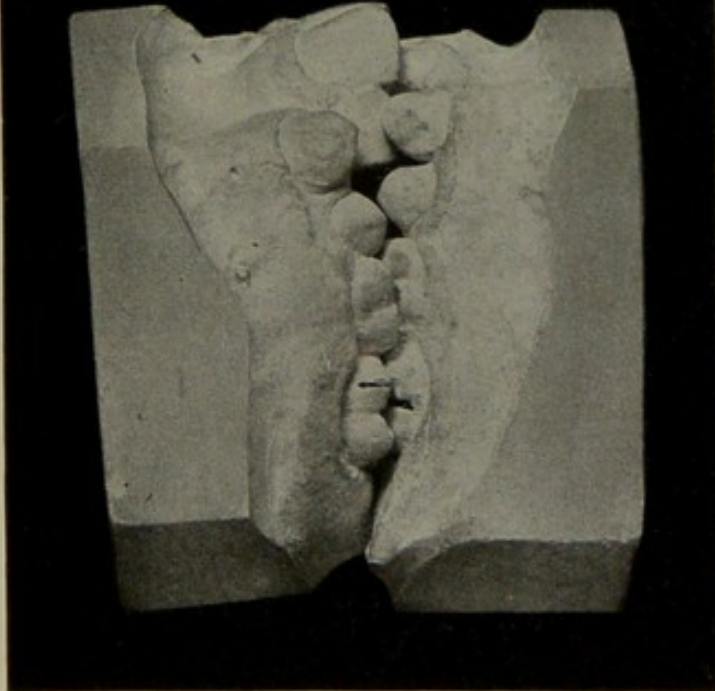


FIG. 20.

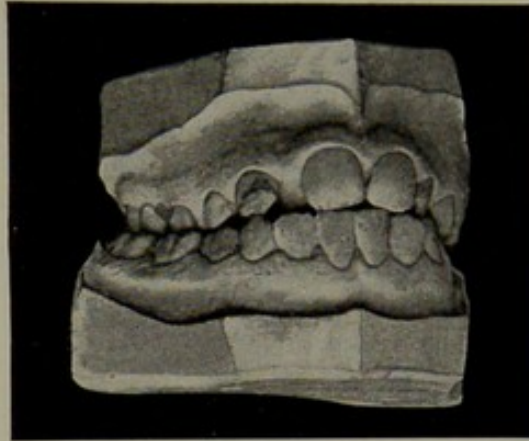


malocclusion and may also be found in cases belonging to any other class.



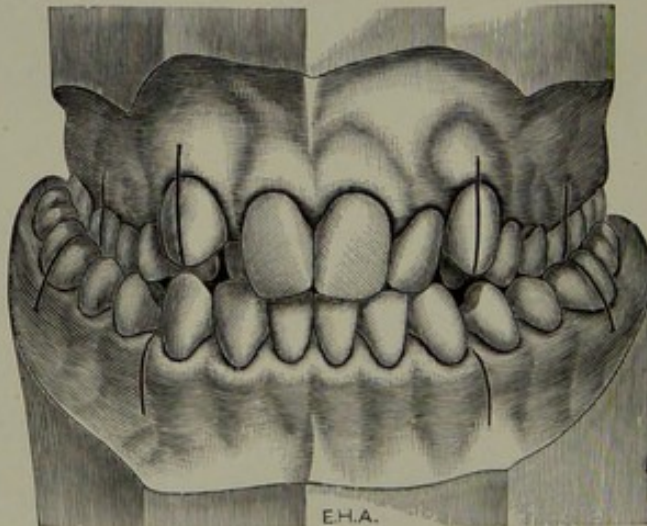
Fig. 23 shows another case in which all the teeth are locked in malocclusion. The mesio-distal relations of the

FIG. 22.



jaws and first molars are normal (indicating the class to which the case belongs), but the molars of both lateral halves of the lower arch, together with the premolars and

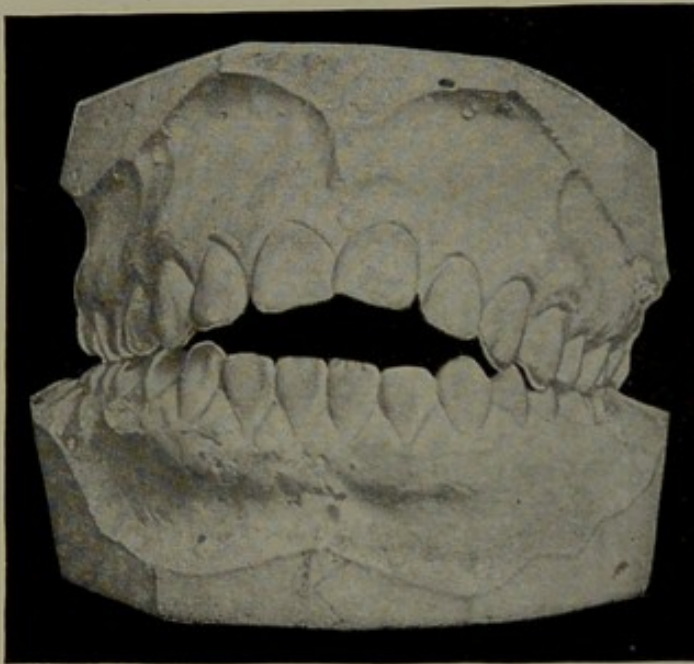
FIG. 23.



canines, are locked in buccal occlusion, with much lingual displacement of the upper molars, premolars, and canines. All of the incisors are also involved.

Fig. 24 shows a case where there is infra-occlusion of both upper and lower incisors, with probably slight supra-occlusion of the molars. Although these conditions may be found in cases belonging to any class, yet the normal

FIG. 24.



mesio-distal relations of the molars place this case in this class.

Fig. 25 shows still another variation in malocclusion which also obviously belongs to Class I, as the first molars and jaws are in normal mesio-distal relations. As the upper incisors are in marked labial positions, the case, if but superficially examined, might easily be wrongly diagnosed, as is often done with similar cases, as belonging to that distinctive and pronounced type of malocclusion, Division 1 of Class II, the distinguishing characteristics and plan of treatment of which are radically different.

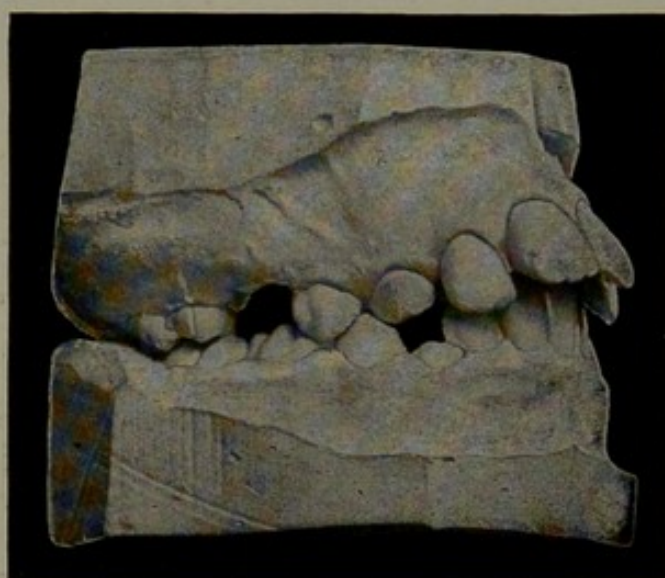We might give almost without number illustrations of the various forms which teeth in malposition may assume in cases belonging to this great class, for the variations are limitless; yet they would all agree in the essential



characteristics, namely, normal mesio-distal relations of the jaws and first permanent molars.

The effect of malocclusion upon the facial lines is always to disturb their balance and harmony, and this in direct proportion to the extent of the malocclusion. This phase of the subject will be discussed at length in the chapter on Facial Art, as well as in the chapters on Treatment.

FIG. 25.

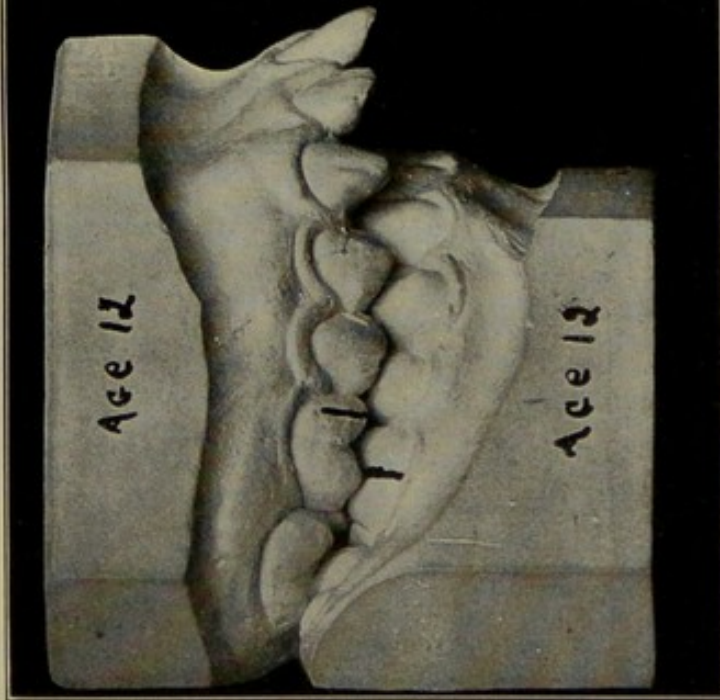


**Class II.**—When from any cause the lower first molars lock distally to normal with the upper first molars on their eruption to the extent of more than one-half the width of one cusp on each side, it must necessarily follow that every succeeding permanent tooth to erupt must also occlude abnormally, all the lower teeth being forced into positions of distal occlusion, thereby causing more or less retrusion, or lack of development, or both, of the entire lower jaw. This condition of distal occlusion is the determining characteristic of this great Class, of which there are two *Divisions*, each having a *subdivision*. The great difference in the occlusion of the teeth in these two Divisions is manifest in the positions of the incisors, the one being protrud-

FIG. 27.

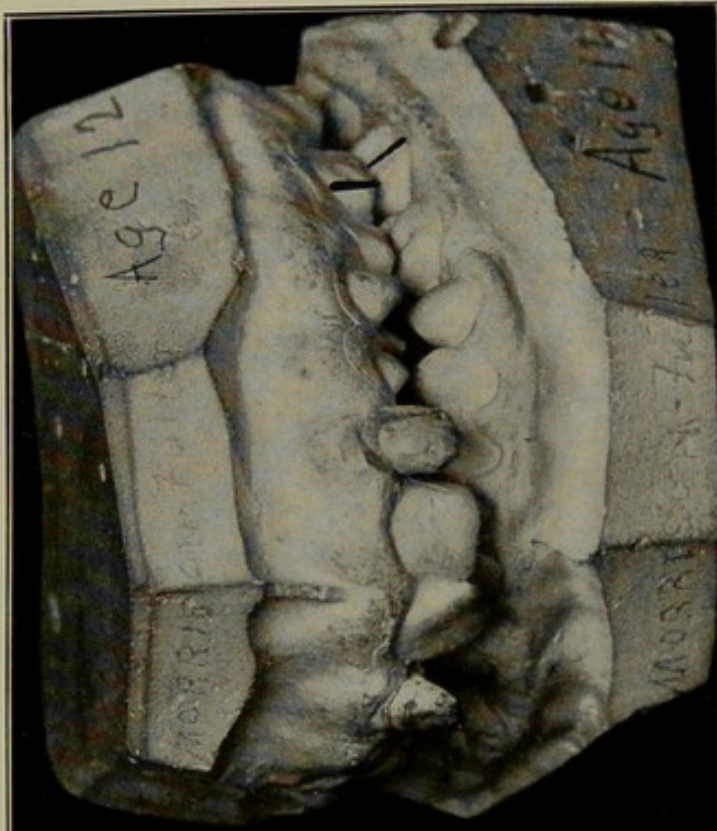

FIG. 26.



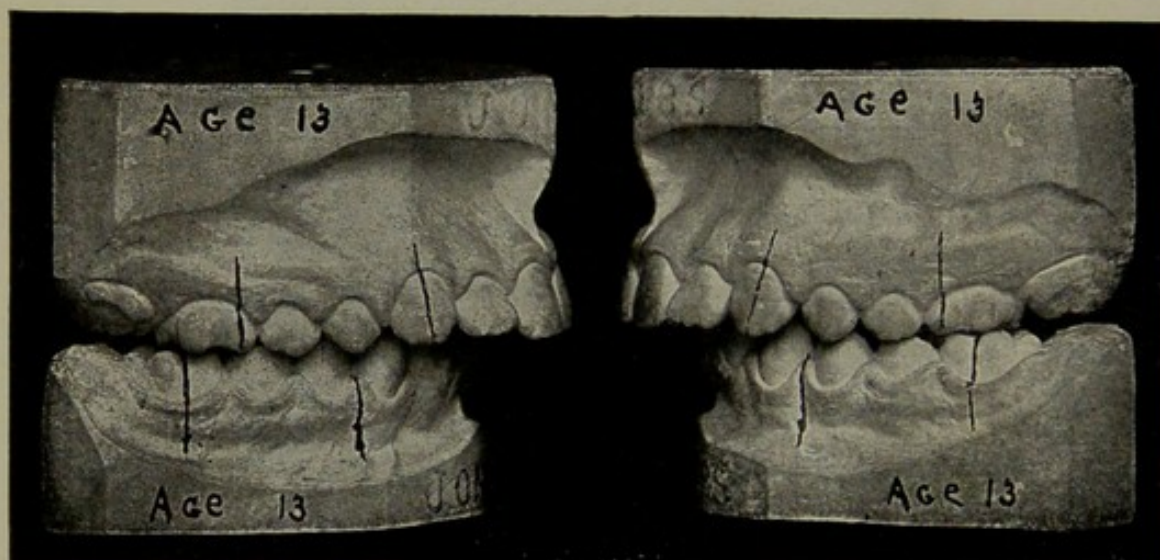

ing and the other retruding, as shown in Figs. 26 and 27. Each of these Divisions has a Subdivision.

Division 1 is characterized by distal occlusion of the teeth of both lateral halves of the lower dental arches, the lower molars having taken this position on their eruption and locking; a narrowed upper arch, lengthened and protruding upper incisors, short and practically functionless upper lip, lengthened lower incisors, and thickened lower lip which rests cushion-like between the upper and lower incisors, increasing the protrusion of the former and the

FIG. 28.

FIG. 29.



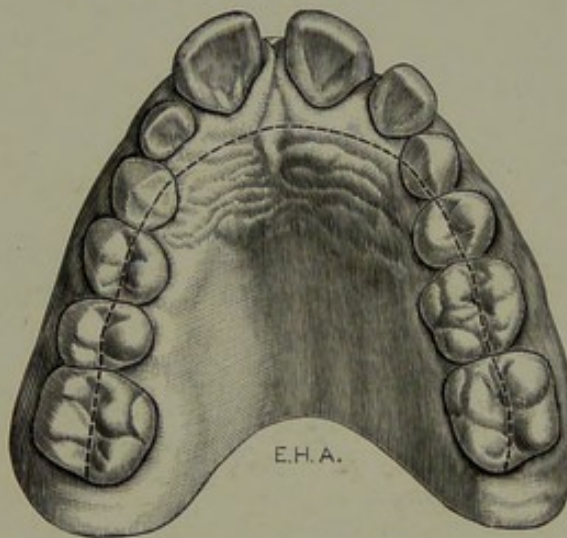
retrusion of the latter. This form of malocclusion is always accompanied and, at least in its early stages, aggravated, if indeed not caused, by mouth-breathing due to some form of nasal obstruction.

The occlusion of a typical, fully-developed case is shown from the right and left sides in Figs. 28 and 29, where it will be seen, by examining both lateral halves of the dental arches, that all of the occlusal characteristics are manifest. Not only are all of the lower teeth effectually locked in distal occlusion in these cases, but the mandible is also



distal in its relation to the maxilla and usually smaller than normal. It is quite normal in form, although the compensating curve of occlusion is greater than normal, due principally to the elevation of the lower incisors from lack of function, while in some instances the lower molars occupy a plane lower than normal in the line of occlusion. The upper arch is always abnormally lengthened and narrowed, as shown in Fig. 30.

FIG. 30.



It seems unnecessary to add illustrations of other cases belonging to this Division, as there is such remarkable similarity between them, the malocclusion differing principally in the degree of the prominence of the upper incisors, and this depending largely upon the age of the patient, all cases being progressive from the time of the eruption and abnormal locking (into distal occlusion) of the points of the cusps of the lower first permanent molars, as shown in Figs. 31 and 32.

The marring effect on the facial lines of cases belonging to this Class are as constant, noticeable, and pronounced as the degree and peculiarities of the malocclusion. Fig. 33 shows two faces typical of the inharmony of the facial lines caused by this form of malocclusion. We shall, how-



FIG. 31.

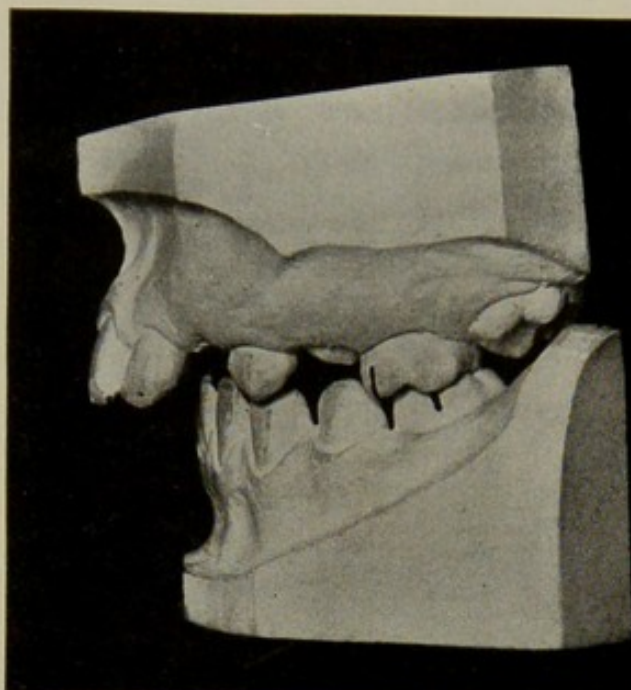


FIG. 32.

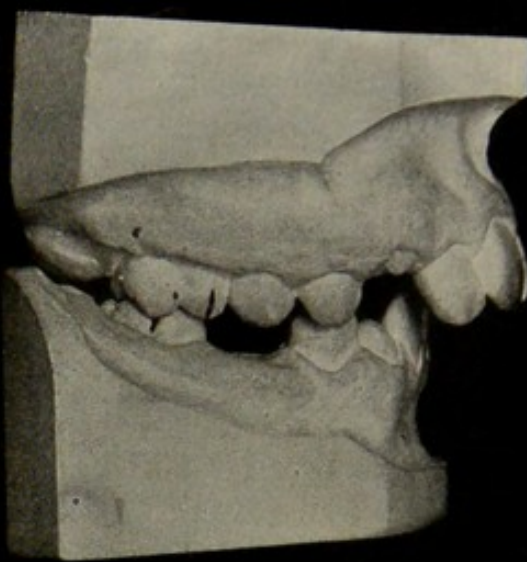


FIG. 33.

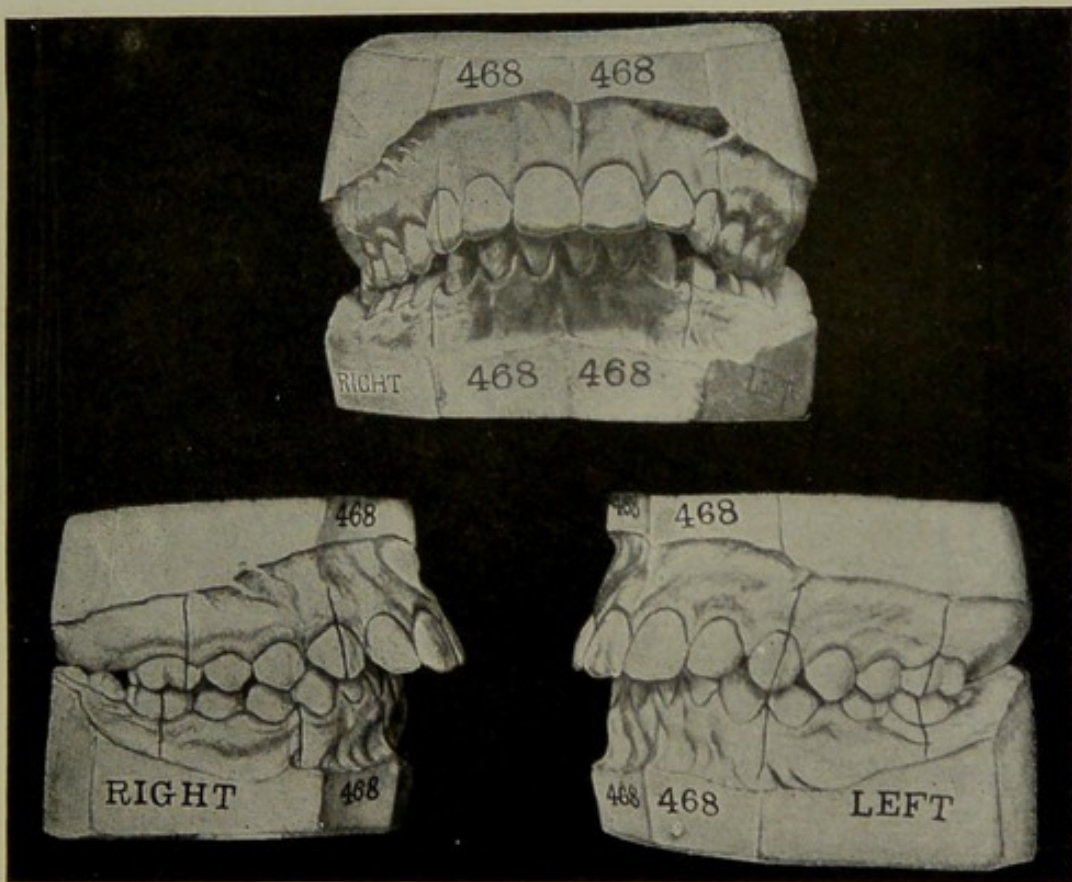




ever, discuss this phase of the subject more at length in the chapters on Facial Art and Treatment.

Subdivision, Division 1 has the same characteristics as the main division, except that the distal occlusion is unilateral, as shown in Fig. 34. The lower left first permanent molar on erupting has locked in normal mesio-distal relations, per-

FIG. 34.



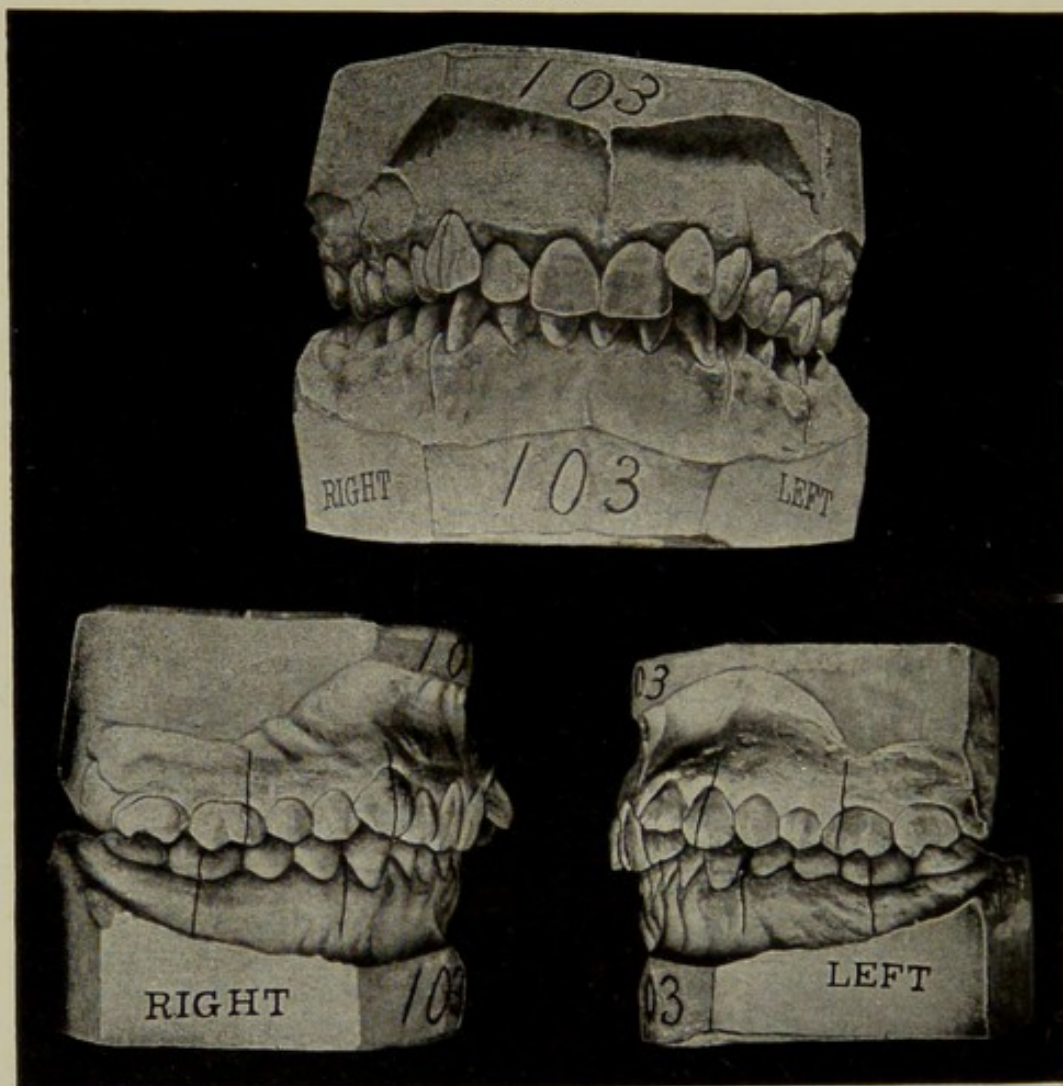
mitting the premolars and canines on this side also to assume normal relations on taking their positions in the arches, while on the right side the lower first permanent molar has erupted and locked in distal occlusion, thereby compelling the lower premolars, canines and incisors also to lock in distal occlusion, and necessitating the distal locking of the lower second and third molars on this side when they erupt. The result of this malocclusion is inharmony



in the relations of the dental arches to the extent of the width of one premolar tooth.

The lines of the face are of course marred correspondingly to the extent of the malocclusion, and in a manner similar to the cases of the main division.

FIG. 35.



Division 2 is characterized specifically also by distal occlusion of the teeth in both lateral halves of the lower dental arch, indicated by the mesio-distal relations of the first permanent molars, but with retrusion instead of protrusion of the upper incisors. In this division there are no complications from pathological conditions of the nasal



passages, hence the mouth is kept closed the normal amount of time, and the lips perform their functions normally, which causes the retrusion of the upper incisors during their eruption until they come in contact with the already retruded lower incisors, resulting in the crowding of the upper teeth in the canine region. Such a case is illustrated in Fig. 35.

In cases belonging to this division there is much similarity, although more variation than in the first division of this class. The width of the arches is more nearly normal and there is less abnormal elevation of the lower incisors, probably on account of their better opportunity for performing their function. There is usually an abnormal overbite of the upper incisors, naturally resulting from their being tipped downward and inward from their normal outward incline, with the teeth of the lower arch usually quite even and regular as to arrangement.

In the harmonizing of the anterior part of the upper arch with that of the lower through lip pressure the malarrangement of the incisors varies considerably, which, not infrequently, however, assumes one of two different and more or less constant types, as well illustrated in Figs. 27 and 35.

Naturally the marring effect on the facial lines, due to malocclusion, in cases coming under this division is noticeable and characteristic, as illustrated in Fig. 68, the retreating jaw and compressed upper lip alone often making diagnosis easy.

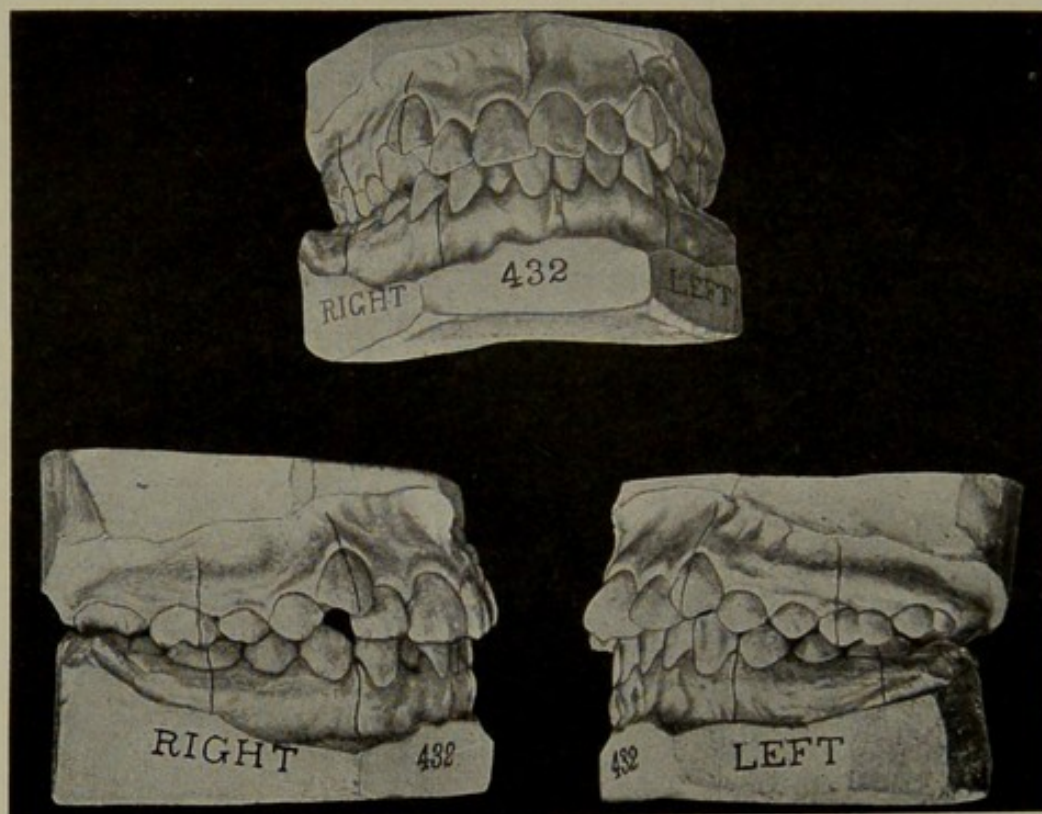
**Subdivision, Division 2** has the same characteristics as the main Division except that one of the lateral halves of the dental arches only is in distal occlusion, the other being normal, as in the Subdivision of Division 1. A fully developed typical case of this kind is shown in Fig. 36. It will be seen that the molars on the left side have, on erupting, locked distally to normal, compelling a distal locking of all the other lower molars and the premolars



on this side, and the crowding and bunching of the incisors and canines of the upper arch, thereby approximately harmonizing the sizes of the two arches.

The effect of this form of malocclusion on the facial lines is shown in Fig. 70.

FIG. 36.

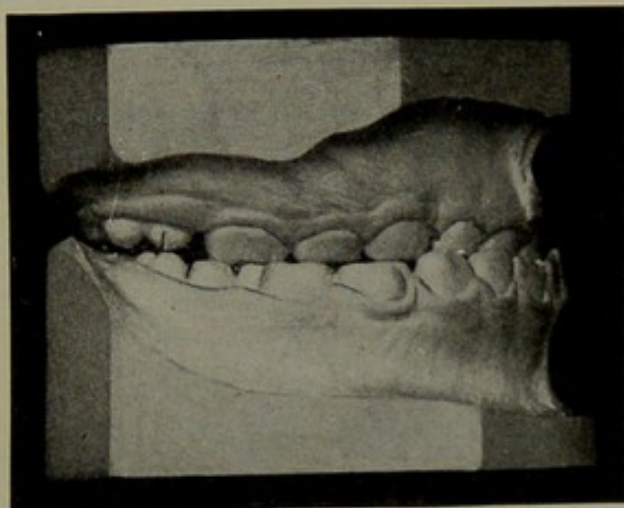


Class III, Division 1 is characterized by mesial occlusion in both lateral halves of the dental arches. The extent to which the mesial occlusion must exist in order to place the case in the division of this class is slightly more than one-half the width of a single cusp on each side, as in Figs. 37 and 38, but in cases that have been allowed to develop—and these cases are always progressive—the mesial occlusion becomes greater, even to the full width of a molar, or more, as in Figs. 39 and 40.

In cases belonging to this class the teeth in their respective arches vary from quite regular arrangement to con-

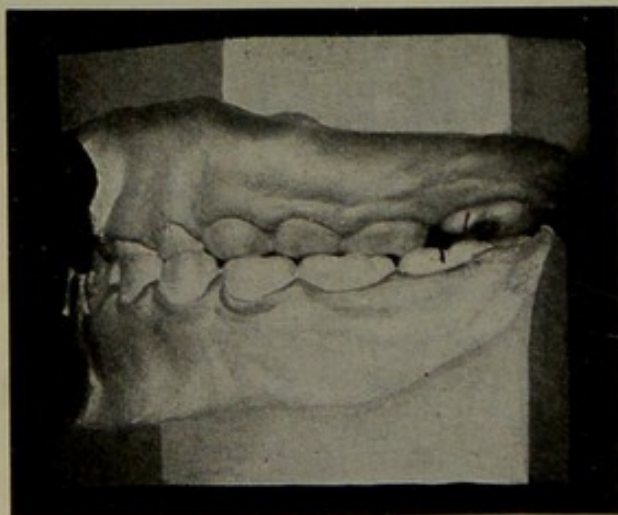
siderable crowding, especially in the upper arch. There is usually a lingual inclination of the lower incisors and

FIG. 37.



canines, which becomes more pronounced as the case progresses, and which is due to the pressure of the lower lip in the effort to close the mouth and disguise the deformity.

FIG. 38.



Other characteristics are considered in the chapters on Treatment.

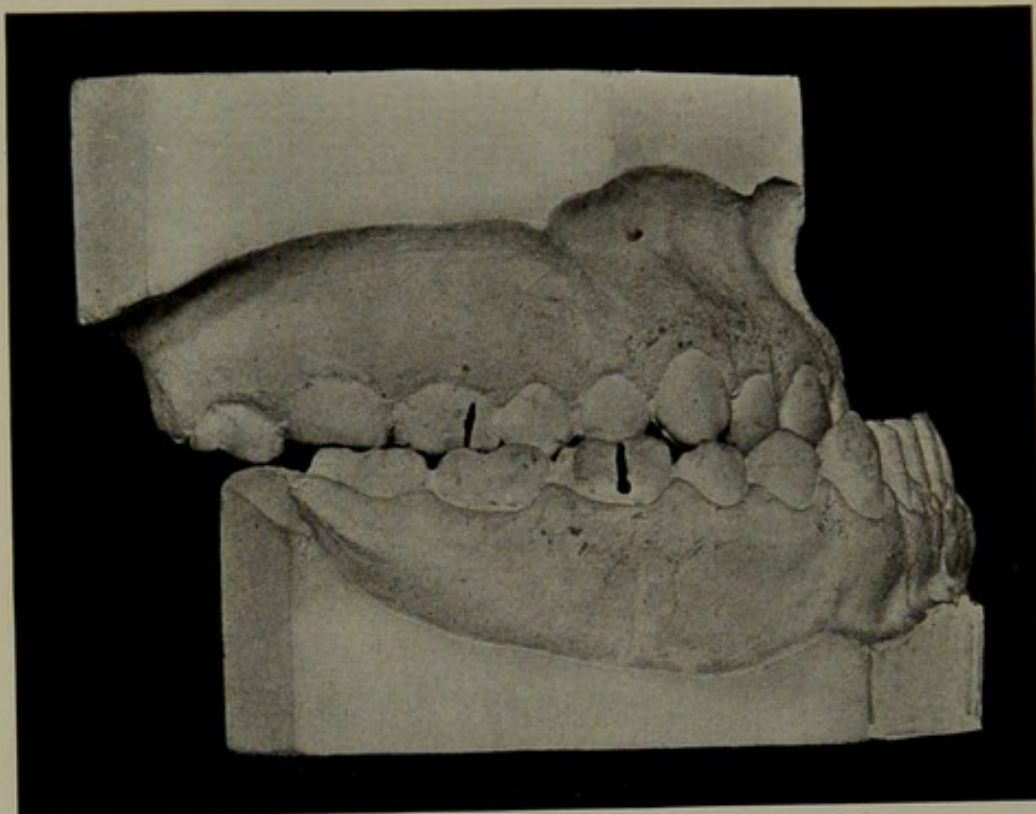
In this class the marring of the facial lines is more noticeable and unpleasing than in either of the other



classes, in advanced cases amounting to a striking deformity, as shown in Figs. 608 and 609.

Subdivision, Division 1 differs from the principal Division only in degree, one of the lateral halves of the arch only

FIG. 39.



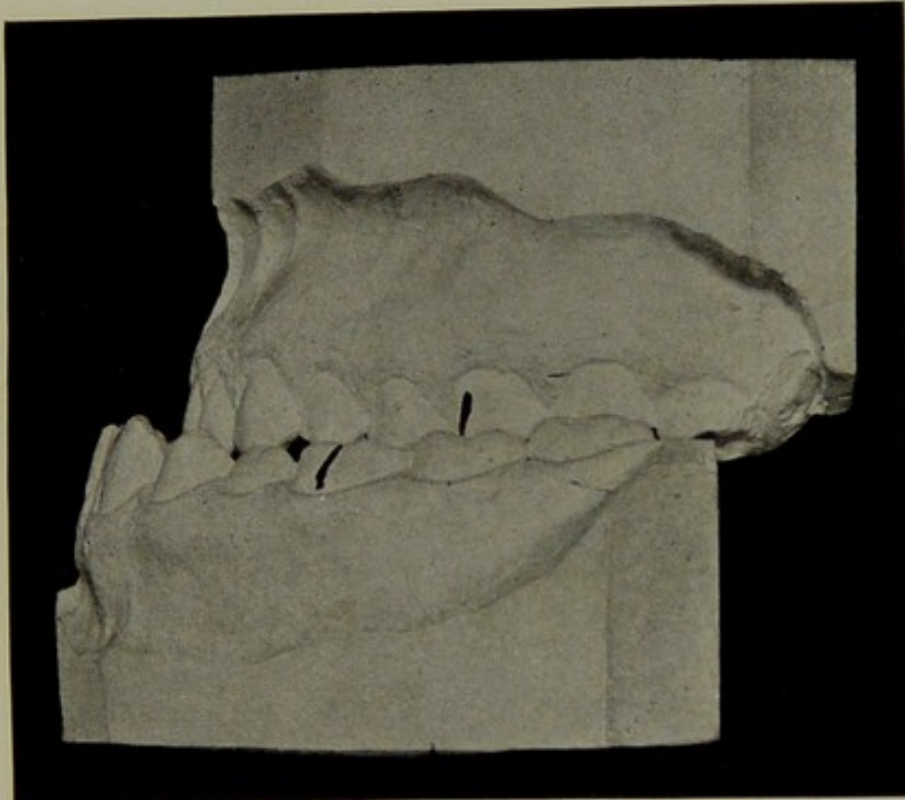
being in mesial occlusion, the other being normal, as shown in Fig. 41, the arches crossing in the region of the incisors, which often occasions much loss of their tissue by abrasion.

That this classification will be found to embrace all cases met with is more than probable. There still remains, however, one possible class, viz., where one of the lateral halves of the lower arch is in mesial occlusion while the other is in distal occlusion, but cases having these characteristics are so very rare that further reference to them seems unnecessary, the writer having seen but two or three cases.

In diagnosing cases according to the above classification

it will be seen that the occlusion of each of the lateral halves of the arches is important, and must be considered separately and with equally careful attention, always beginning with the first permanent molars and assuming, for

FIG. 40.



the reasons previously given, that the uppers are in correct position mesio-distally.

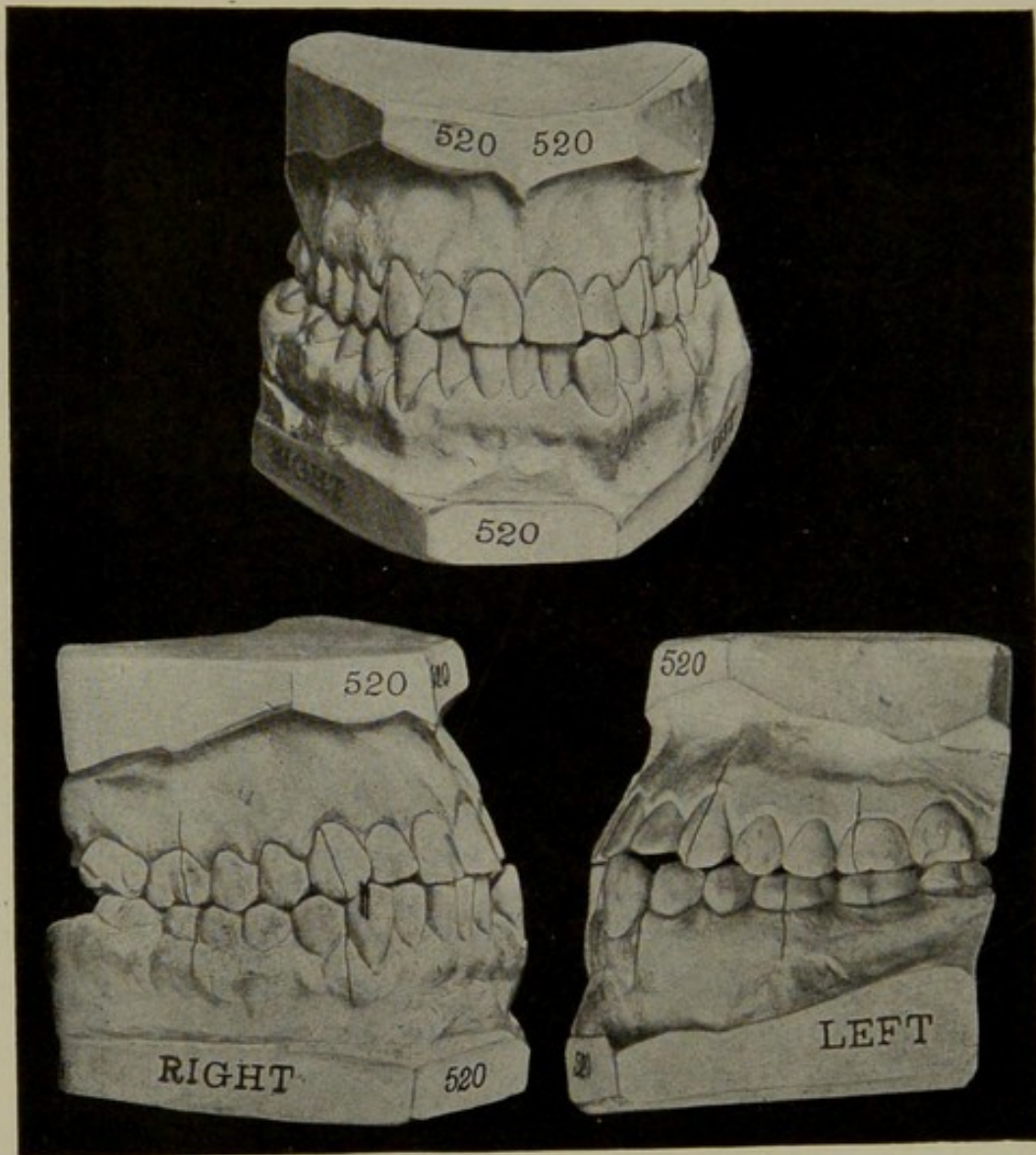
In developing cases of the second and third classes when the teeth of the lower jaw have not locked into distal or mesial occlusion the full width of a cusp on one or both sides, the beginner may be a little puzzled as to the proper classification, but upon careful inspection a majority of the inclined planes will be found to favor one particular Class, Division, or Subdivision, the co-relation of the first molars being, of course, the most important factor, but the other characteristics receiving due consideration.

The loss of a tooth or teeth by extraction is shortly



followed by such marked changes in the positions of the crowns of the remaining teeth as to sometimes render diagnosis more difficult. By the determination of the extent of

FIG. 41.



the tipping of teeth, due to this loss, the case is resolved into its original condition, from which it can be easily diagnosed.

It would be easy to imagine other groups into which cases having similar characteristics in appearance might



be assembled, which has been done recently to a confusing number by some writers of the old school, who, basing classification upon superficial symptoms instead of fundamental principles, have arranged cases in classes variously named for one or other conspicuous symptoms, such as "open bite," "saddle-shaped arch," "V-shaped arch," "narrowed upper arch on one side," "narrowed upper arch on both sides," "prominent canines," "inlocked laterals," "protruding upper incisors," "retruding lower incisors," etc., etc. But such classifications are erroneous and doubtless arose from a superficial study of one or the other of the dental arches, without due consideration of their relations, or of the dental apparatus as a whole from the basis of normal occlusion, for these are not true classes but usually only symptoms of causes and may be an accompaniment of cases found in any of the true classes.

A brief recapitulation of the classification is here given for convenience of study and for ready reference:

**Class I.**—Arches in normal mesio-distal relations.

**Class II.**—Lower arch distal to normal in its relation to the upper arch.

**DIVISION 1.**—Bilaterally distal, protruding upper incisors. Primarily, at least, associated with mouth-breathing.

*Subdivision.*—Unilaterally distal, protruding upper incisors. Primarily, at least, associated with mouth-breathing.

**DIVISION 2.**—Bilaterally distal, retruding upper incisors. Normal breathers.

*Subdivision.*—Unilaterally distal, retruding upper incisors. Normal breathers.

**Class III.**—Lower arch mesial to normal in its relation to upper arch.

**DIVISION.**—Bilaterally mesial.

*Subdivision.*—Unilaterally mesial.



Out of several thousand cases of malocclusion examined, the proportion per thousand belonging to each class was as follows:

Class I.....	692
Class II.	
Division 1.....	90
Subdivision .....	34
Division 2.....	42
Subdivision .....	100
Class III.	
Division .....	34
Subdivision .....	8
	<hr/>
	1000

A writer of a recent text-book, in making use of the author's classification, has abridged it by omitting to name the Classes, Divisions, and Subdivisions, using only the terms "unilaterally mesial or distal," "bilaterally mesial or distal," etc. A moment's reflection should convince any thoughtful person of the grave error of such an incomplete classification in treating of a subject involving such great variations and complexities as malocclusion of the teeth, for if a case is spoken of as simply in unilateral or bilateral distal occlusion it would convey only a very imperfect description of its true condition, as under such a classification it might belong to one or the other of a great group of deformities whose general characteristics differ greatly in other respects and call for widely differing plans of treatment. In other words, it would not classify with any definiteness and would necessitate a lengthy description in order to convey to the listener's mind its true condition; while under the author's classification if a case be spoken of as belonging to a certain Class, Division, or Subdivision,

there is at once created in the mind a quite perfect understanding of the case—not only the peculiarities of the occlusion, and the relations of the jaws, but also the art relations, condition of the throat and nose, habits of the patient, etc., and nothing further is needed to complete the picture except minor individual peculiarities.



## CHAPTER III.

### FACIAL ART.

THE study of orthodontia is indissolubly connected with that of art as related to the human face. The mouth is a most potent factor in making or marring the beauty and character of the face, and the form and beauty of the mouth largely depend on the occlusal relations of the teeth.

Our duties as orthodontists force upon us great responsibilities, and there is nothing in which the student of orthodontia should be more keenly interested than in art generally, and especially in its relations to the human face, for each of his efforts, whether he realizes it or not, makes for beauty or ugliness; for harmony or inharmony; for perfection or deformity of the face. Hence it should be one of his life studies.

As orthodontists we must ever place foremost in importance the normal occlusion of the teeth, for only in normal occlusion is their greatest usefulness possible. But many of our patients would never reach us were it not for the inharmony of their facial lines resulting from mal-occlusion, and if our efforts are intelligently directed we can do far more to render plain or even distorted facial lines pleasingly symmetrical, or even beautiful, than anyone else who has to do with the human face. Indeed the improvement in the proportion and artistic effect which may often be wrought by intelligent effort on the part of the orthodontist is marvelous and almost incredible, but his efforts may also result in producing or enhancing ugliness and deformity if unintelligently directed.

But that our efforts may be intelligently directed toward the ideal, some rule, some principle, must guide us. If



there be not some grand principle as a basis from which to reason we must be but gropers in the dark—experimenters, guessers, with results which may cause embarrassment or even bitter regret.

We know that while all human faces are greatly alike, yet that all differ. Lines and rules for their measurement have ever been sought by artists, and many have been the plans for determining some basic line or principle from which to detect variations from the normal, but no line, no measurement, admits of anything nearly like universal application.

The beautiful face of the Apollo Belvidere has been very largely used as a guide toward the ideal and from which to judge variations, but this is impracticable and misleading, for, notwithstanding the beautiful harmony of proportions of that face, with its straight line touching the frontal and mental eminences and the middle of the wing of the nose, its range of application has been found to be very limited in gaging the harmony or inharmony of other faces.

And this is not surprising when we realize that the Apollo face represents the ideal of the Greek type and the Greek type only, and that we today see not only very few faces of a purely Grecian type, but for that matter, very few of any pure type, unless it be an occasional Roman.

In the early days artists dealt wholly with pure types, as is unmistakably shown in their works that have come down to us. In Grecian art, both painting and sculpture, the faces all conform to the Apollo type, and the type was constant because the blood of the people was pure, that is, comparatively free from admixture with races of different types.

“The ideal of the Roman type, though markedly different from the Grecian, was also closely followed by their painters and sculptors, and where types and religious ideals were so distinctive and so closely adhered to there



could be certain standards and laws to govern them, especially in creative art; but to use the Grecian or the Roman standard as a gage for the types of the present day, especially in America, is impracticable, for our inheritance, our occupations, our mental activities, our habits of thought, our social and climatic conditions, etc., etc., differ so radically, and all these play such vital part in the molding of the mental, moral and physical, as expressed in our whole bodies and especially in our faces, that a standard type is an impossibility. The tendency of modern civilization seems to be to create a law for each individual, and in the face of complex and constantly changing conditions a fixed type as a basis or standard to govern the molding of the human face cannot be established."—(Wuerpel.)

This may all seem discouraging to the orthodontist, but there is a principle, which if intelligently applied brings us the nearest to an ideal result possible with each given patient—that of balance, of symmetry. We should be able to detect not whether the lines of the face conform to some certain standard, but whether the features of each individual—that is, the forehead, the nose, the chin, the lips, etc.—balance, harmonize, or whether they are out of balance, out of harmony, and what concerns us most as orthodontists: whether the mouth is in harmonious relations with the other features, and if not, what is necessary to establish its proper balance.

Now, the ability to determine the proper balance of the features is rare. One of our foremost teachers of art, Mr. E. H. Wuerpel, says that only one in two or three hundred of even art students ever succeed in mastering it, and these only after much observation and practice in sketching and modeling the human face. Yet discouraging even as this seems we believe there is a law for determining the best balance of the features, or at least the best balance of the mouth with the rest of the features, which artists probably know nothing of, and one which for our work is far more



unvarying and more reliable than even the judgment of the favored few. It is, furthermore, a law so plain and so simple that all can understand and apply it. It is that the best balance, the best harmony, the best proportions of the mouth in its relations to the other features require that there shall be *the full complement of teeth, and that each tooth shall be made to occupy its normal position—normal occlusion.*\*

The correctness of this rule will be better appreciated if we will but remember that in those cases where Nature has succeeded in building a normal denture—teeth in normal occlusion—she has also succeeded in building it so as to be in best harmony with the lines of the face, or, conversely, the lines of the face to best harmonize with this denture, and that the teeth in these cases are noticeable marks of beauty. And as malocclusion is but the perversion of normal occlusion, it invariably will be noticed that inharmony in the balance of the mouth with the rest of the lines of the face exists just in proportion to the extent of the malocclusion.

This law may be regarded as one of the corner-stones of the new school of orthodontia in contradistinction to the teaching that has always dominated the practice of the old school—that of leaving to the individual judgment of the operator, without any standard or law, the determination of the requirements in orthodontic operations in each given case.

To satisfy this individual judgment extraction was often, and in complex cases always, resorted to. Its unfortunate and inartistic results may be seen in every community. It is gratifying to note, however, that this fallacious teaching and pernicious practice are rapidly passing and will doubtless soon become mere matters of history.

---

\*Angle, *Items of Interest*, September, 1903.



Fig. 42 shows the face of the Apollo. The face is a study of symmetry and beauty of proportion in the fully developed nose and nostril, the full rounded, finely curved lips, squarely chiseled chin, etc. Every feature is in balance with every other feature and all the lines are wholly incompatible with mutilation or malocclusion.

FIG. 42.



Fig. 43 shows another face which is also one of much beauty and fine proportions. It somewhat resembles the Greek type and the lower half of the face shows lines which could only have been molded over teeth normal in size, type, number and position, and accompanied by normal conditions of development, and normal nasal function. Had but slight malocclusion existed, or had one tooth only been sacrificed during the development of this face the effect

inevitably and unmistakably, to the experienced eye, would have been felt in the marring of these beautiful lines.

When we thoughtfully consider all that enters into the final production of a face beautiful in balance and proportion, that is, how there must have been the normal growth and development of the different peculiar bones and muscles, the normal growth and functioning of nose and throat, palate, tongue, lips, cheeks, and especially of

FIG. 43.



the teeth, upon which the lines of the mouth so largely depend and which by slight deviation from the normal in eruption of a single tooth, the whole system of occlusion may be impaired, the wonder is not that they are so few, but that they are not still more rare. Such perfect proportions and such fine lines as are shown in this face are rare indeed, but be the lines fine or otherwise the principle will hold good, that the full complement of teeth in normal occlusion is essential to the proper typical proportions of any face.



Fig. 44 shows a face greatly in contrast to those shown before. It is neither purely Greek nor purely Roman in type, but is a blending of the two, and yet it also is in fine balance. The features are large and prominent and the head is large, but there is harmony of size, relation and proportion of features that makes a most pleasing whole. The face, while in fine balance, is perhaps not beautiful from a physical standpoint, but it is more. It is beautiful from an intellectual standpoint, possessing strength, no-

FIG. 44.



bility, majesty, that in the author's opinion, are lamentably lacking in the Apollo face. Such fine contour and balance are incompatible with malocclusion, either through malposition or loss of teeth.

Figs. 45 and 46 show the faces of two North American Indians, vastly different in type, and yet how perfectly the law of balance applies to these faces. It will be noted that the mouths are in perfect balance with the rest of their features, making certain that their dentures must have been normal.



FIG. 45.





FIG. 46.



29. GATO, SUN CHIEF OF APACHES.  
COPYRIGHT 1900 H.B. HODGKINS

FIG. 47.




FIG. 48.





FIG. 49.

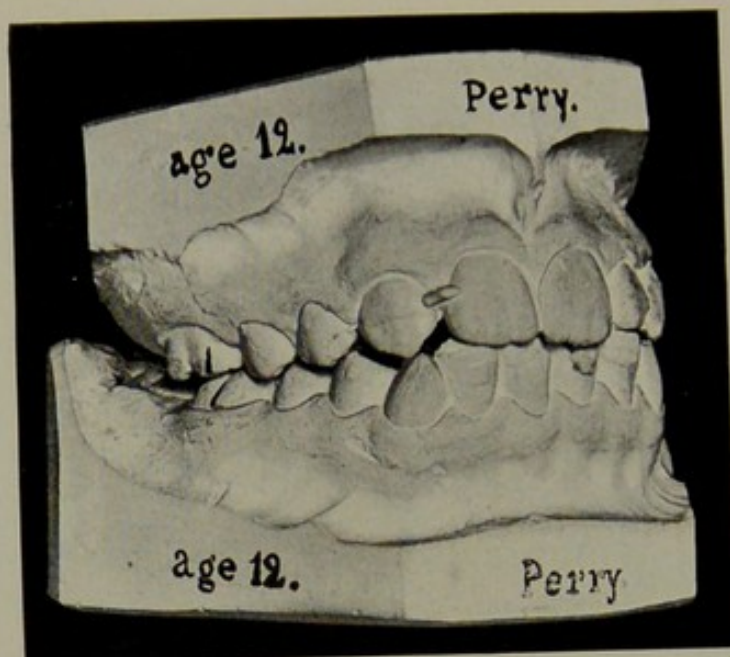


FIG. 50.



The same law of occlusal relations applies to all races and tribes. Where teeth are missing how promptly it is reflected in the contour of the mouth. How noticeable is this in the intelligent, kindly, and well-known face shown in Fig. 47.

It will be noticed in the case shown in Fig. 48 that there is a depression below the wing of the nose which is due to

FIG. 51.



the lack of development of one lateral incisor, Fig. 49, and if the reader will study the proportion of the lines of the mouth with the other facial lines it will be very easy for him to detect how marked is the inharmony resulting from the loss of but this one diminutive tooth, and how greatly the balance of the face would be improved by the restoration of this tooth, its alveolus, etc. And this case is not exceptional, but we insist that the violation of the law we have laid down will in all cases, unless possibly in those of



freaks, be promptly reflected in the disturbed balance of the features.

Figs. 50 and 51, and 52 show the faces of two normally developing children, though it will be observed that they are of strikingly different types. The proportions of the faces, the balance of the features, and the harmonious lines of the mouths tell as truthfully that the teeth are develop-

FIG. 52.



ing into normal occlusion as do the models of the teeth themselves, shown in Figs. 53 and 54.

In these cases Nature has been able to work unhampered by detrimental pathological conditions, as is apparent in the results.

Of course it must be understood that changes in the contour of these young faces must take place with further development. The noses and chins will develop and become more pronounced, and after the eruption of the permanent canines there will be more of an acute angle between the

nose and the upper lip, especially in the face shown in Fig. 52. But the point we would emphasize is the normal

FIG. 53.

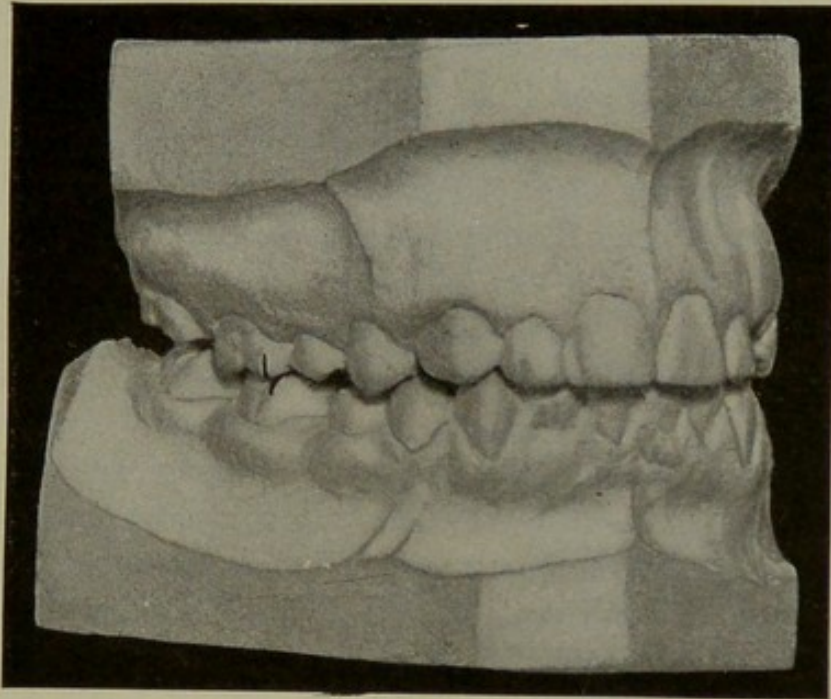
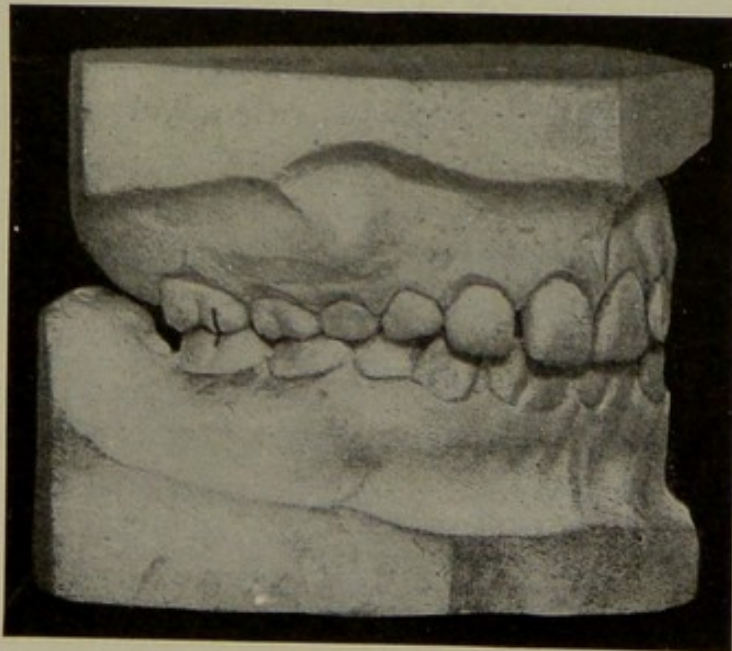


FIG. 54.



development of the mouths of these children, due to the normal development of their dentures, and the consequent



normal balance of the mouths in their relations to the other features. And if we will notice any child so developing, or any person who has reached maturity with the teeth in normal occlusion, we will find an equal harmony of balance of the mouth with the other features, irrespective of their individual types. Dr. Anema has well said that the uniformity of harmony in the facial lines of young children is probably due to the fact that their teeth (the deciduous) are practically free from malocclusion.

The author would not be understood as intending to imply that every face with lines and features in harmony of balance must necessarily be beautiful, nor even that placing maloccluded teeth in normal occlusion will establish harmony of balance of every face in its entirety. There may be other defects such as the lack of development of the nose or chin, or unequal development of the two malar bones, or of any of the bones of the face, etc. These defects of course could not be remedied by the correction of malocclusion, but the best harmony of such faces or of any face is only possible when the teeth are in normal occlusion. It is also the belief of the author that malocclusion, and the loss of teeth by extraction or non-eruption, or a combination of these two causes are responsible for the lack of balance and inharmony in a far greater number of faces than any other cause or combination of causes, and that this inharmony and lack of balance of the mouth must exist just in proportion to the degree of malocclusion.

For a true understanding of what is meant by harmony of proportion and balance of faces, a careful study must be made of faces that are out of balance, as well as of those that are in balance.

An interesting fact, which the author also believes to be convincing proof of what has already been said relative to harmony of facial lines depending upon harmony of occlusion, is the wonderful harmony of facial types with the



types or patterns of the teeth: how the broad and squarish type of tooth harmonizes with a similar type of face; how the long and narrow type of tooth is found to accompany a similar type of face; and our own belief is that the sharpness of definition of the cusps and developmental lines is in direct keeping with that of the facial lines, and *vice versa*. The proof of Nature's wonderful harmony of the tooth patterns with the type of the individual may be strikingly impressed upon anyone who will try to match a tooth lost from a skull with teeth of other skulls.

Notwithstanding that the effect on the facial lines of the varying forms of malocclusion found in the three different classes varies not only with the degree of malocclusion, but somewhat with the individual type of face, yet the facial deformity produced by the malocclusion in each class is so distinctive and constant that after some practice the orthodontist may even classify with considerable accuracy the malocclusion of the people he meets without an actual examination of their teeth. So, also, the loss of teeth produces such distinctive disturbance of the facial lines as to make diagnosis from them alone often easy. One interested soon finds himself making mental diagnoses of malocclusion and classifying facial deformities whenever and wherever he sees new faces.

In Class I, the jaws being normal as to mesio-distal relations, the chin and nose will usually be found in relatively normal balance with the forehead and general contour of the face, with the lines of abnormality principally confined to the mouth itself.


Figs. 55 and 56 show such a case in the profile and front face of a boy fourteen years of age, and the lack of balance in the flat and sunken lines of the mouth clearly indicate diminished sizes of the dental arches. This lack of normal contour of the mouth will be more impressive when it is remembered that at this age a boy's mouth should be relatively more prominent than that of a man, for the reason



that his face has not yet reached its full growth, while the teeth are full sized at eruption. Upon reference, in Figs. 307, 308, and 309, to the excessive malocclusion, the reason for this lack of normal contour becomes apparent. There is very pronounced crowding of the teeth both upper and lower, and as must naturally follow, lack in the development of the alveolar process which is developed only to accord with the positions of the teeth.

FIG. 55.

FIG. 56.




How beautifully our rule applies—that is, the full complement of teeth retained and each made to occupy its normal position—is shown in Figs. 57 and 58, which represent the face of the same boy three years later. The greatly improved contour of the face and restored balance of the features will be observed. Even greater prominence of the lips would improve the face still more, and this will probably follow with further development of the alveolar process which has been so long arrested. The corrected occlusion is shown in Fig. 315.

Fig. 59 shows the profile of another boy, aged eleven, whose facial lines were also thrown out of balance by malocclusion (Class I). Again it will be noticed that the chin and nose are in good harmony with the general contour of the face and that the lack of balance is confined to the mouth, and that in this case the lips, both upper and

FIG. 58.



FIG. 57.





lower, instead of being flat and sunken, as in the last case, are too prominent. By referring to the malocclusion, shown in Figs. 275 and 276, we see at once the reason. The teeth instead of being bunched in the canine region and flattened in front, are bunched, rotated, and prominent in the incisor region. Another point will be noted in this

FIG. 59.



connection—that it is the unnatural position and prominence of the upper teeth that causes the lower lip to protrude. When the lips are closed naturally over teeth in normal occlusion the lower lip rests against the labial surface of the upper incisors (approximately the first third), as has before been stated, and *it is the upper teeth, not the lower, that establish the curve of the lower lip.* In this case, however, there is also another reason why the lips are so prominent, namely, that owing to the excessive overbite the space for the lips is too short for their

natural closure, and when brought together they are protruded unnaturally giving an expression as of pouting to the mouth.

Figs. 282 and 283 show the occlusion after each tooth had been normally placed, which also resulted in the lengthening of the bite and the placing of the features in fine balance, as shown in Fig. 60.

FIG. 60.



The disagreeable fulness and overprominence of the lips has been reduced and instead we now have beautiful and artistic curves in the lines of the mouth.

It seems unnecessary to give in this connection further evidence of the trustworthiness and universal application of our law, or rather, Nature's law, as we believe, in cases belonging to this great class, as other instances will be noted in the chapters on Treatment.

Figs. 61 and 62 show the profile and front views of the face of a young girl whose malocclusion belongs to Division 1, Class II, shown in Figs. 462 and 463, and the lines of



in harmony shown in this face are characteristic of all cases

FIG. 61.



FIG. 62.



FIG. 63.



of this division, and also of its subdivision, except that in the latter they are usually less in degree.



In cases belonging to the first Class, as we have seen, the mouth is the only feature greatly out of harmony, but since in the cases under consideration the mandible and lower dental arches are distal to normal in their relations with the upper, with consequent malocclusion of all of the teeth, the mouth as well as all the lower part of the face is involved and greatly out of harmony with the general contour of the face. There are also other noticeable characteristic points in the lack of balance or harmony in the facial lines of patients belonging to this Division. As they are mouth-breathers the face has usually a dull and listless expression, as illustrated in the face on the left in Fig. 67, and the nose is usually undeveloped, with more or less flattened alæ. As the upper arch is narrower than normal and the incisors protruding, a corresponding inharmony in the contour of the upper lip is noticeable, intensified by its shortness and lack of function, and in connection with the weak and receding chin is noticed the abnormal curve and thickness of the lower lip.

These characteristics are quite constant and vary principally in degree, but upon the whole, create lack of balance of the features, and, in accordance with the rule laid down, in direct proportion to the deviation from the normal in the development of the dental apparatus.

The attempt to restore balance and harmony of proportion to this face by placing all the teeth in normal occlusion, as shown in Figs. 466 and 467, seemingly puts the rule to a severe test, but the result on the facial lines is shown in Fig. 63, and while the face may still not be beautiful, or perhaps even in perfect balance, that it is wonderfully improved cannot be denied, and we believe that by no other means could so perfect a balance have been established to be in accordance with the demands of this pronounced Semitic type.

Since we now have established normal relations of the muscles and of the inclined planes of the teeth, and normal



FIG. 64.



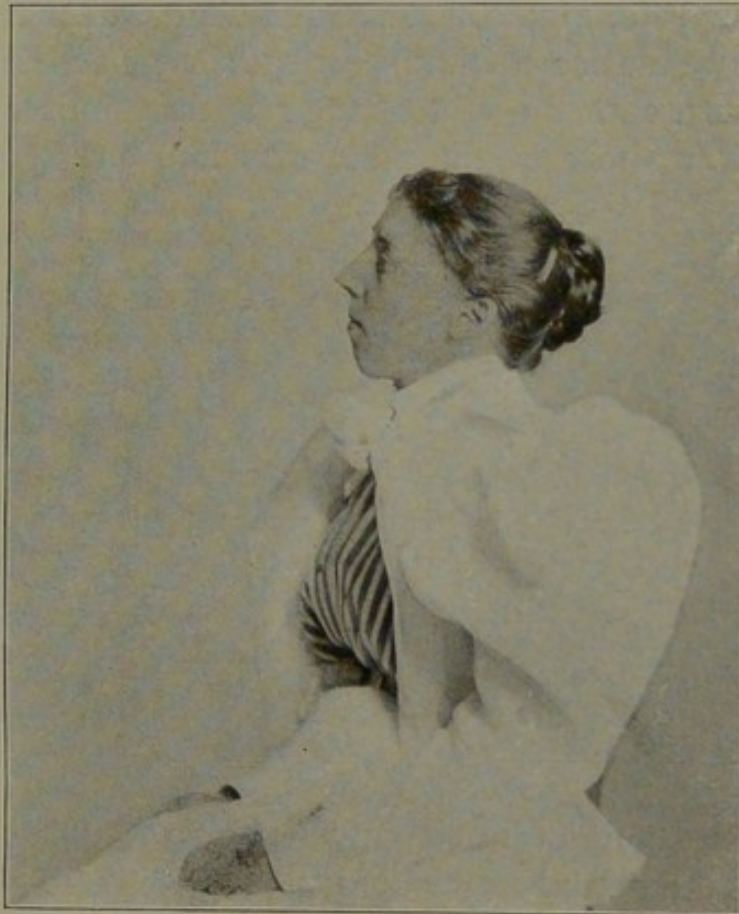FIG. 65.



nasal respiration, the further development of this face must be toward the normal—toward harmony of balance.

That such has occurred is shown in Figs. 64 and 65, from photographs taken two years later than the picture last shown.

FIG. 66.



In this connection let us note the great contrast between the type of this face and that of the Apollo, in which the profile line is straight. To have attempted to straighten the profile line of this patient by sacrificing some of the teeth and reducing the sizes of the dental arches would have been to irreparably deform the face and to produce lines of the mouth inartistic as incongruous and out of keeping with the typical demands.

In this class of deformities there is occasionally noticed a type of chin characterized by pronounced lack in the



development of the mental eminence, which, since the chin is already greatly receded on account of the diminished size and distal position of the mandible, greatly augments the inharmony of the facial lines, as will be seen in the pronounced case illustrated in Fig. 66. Fortunately this accompaniment is somewhat rare.

In cases belonging to the Subdivision of Division 1, Class II, we notice a disturbance of the normal balance of the mouth with the rest of the features similar in characteristics to those of the main division, but usually less

FIG. 67.



in degree, as might be expected, since one of the lateral halves of the dental arches only is in distal occlusion, the other being normal. In these cases the chin is more nearly in correct mesio-distal relation with the rest of the face, and the author has yet to see a case belonging to this subdivision accompanied by the type of chin illustrated in Fig. 66.

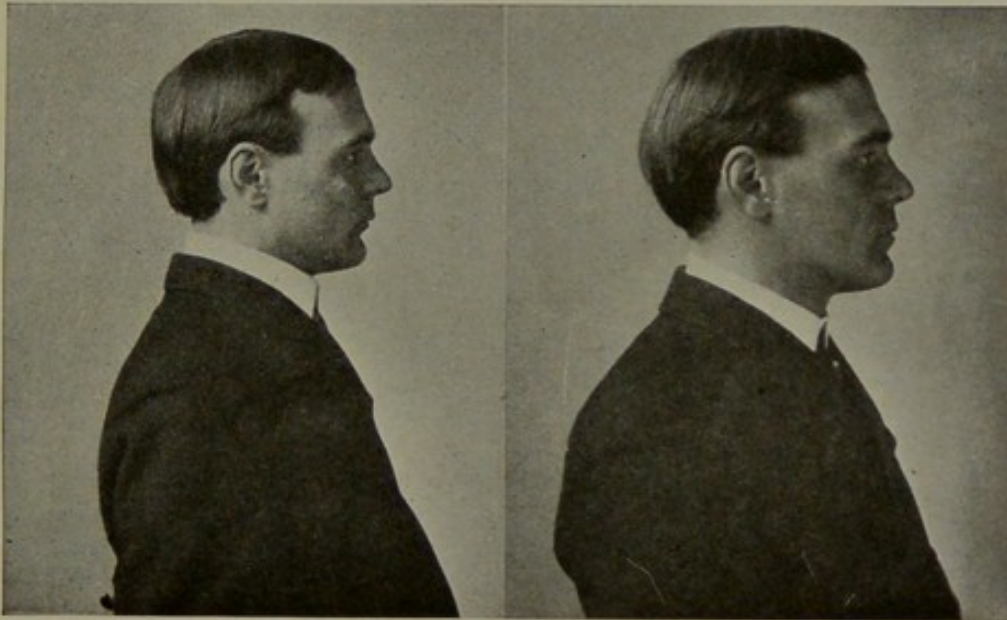
The disturbance of the normal balance of facial lines from malocclusion belonging to Division 2, Class II is characteristic and quite uniform, and naturally follows the receding mandible, distal occlusion, crowded and retruding upper incisors, with normal development of lips, normal breathing, etc. It is illustrated on the right of Fig. 67.



and made more noticeable by contrasting with a typical case belonging to Division 1, Class II, as shown on the left of the same figure. Fig. 68 shows the profile of a young man's face which is fairly typical of these cases. The malocclusion is shown in Figs. 534 and 535. It will be seen that while the head is large and well-shaped, and the forehead and nose strong and in good balance, there is a weakness about the mouth and chin that is greatly out of keeping with the general contour.

FIG. 68.

FIG. 69.



In treatment the rule was again applied and each tooth made to occupy its normal position, with the most gratifying result on the facial lines shown in Fig. 69. The weak inharmonious lines have been changed to those of strength and harmony of balance, in great contrast to what must have resulted from extraction had it been resorted to according to the old plan of treatment. The restored normal occlusion is shown in Figs. 536 and 537.

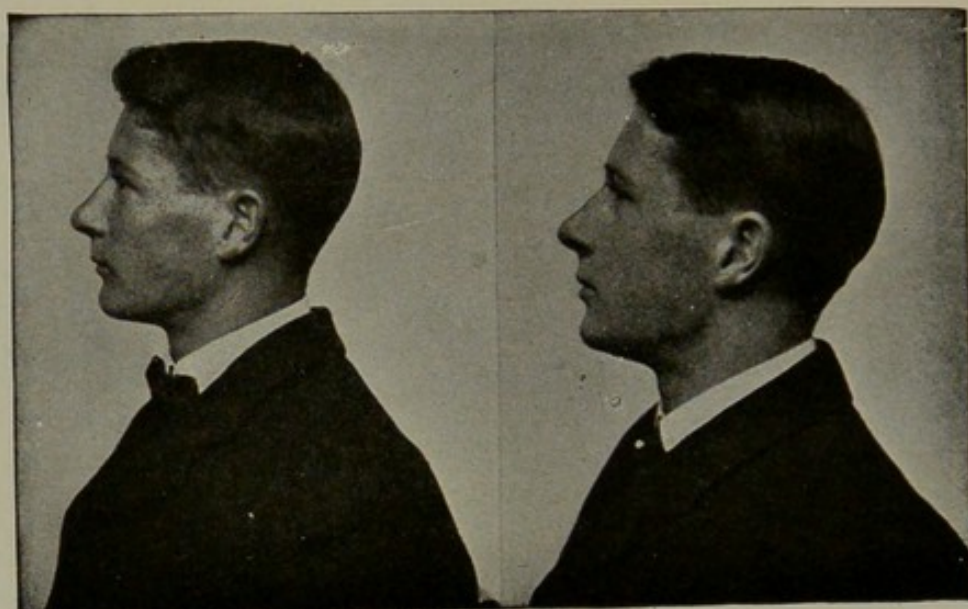
The disfiguring effects on the face caused by malocclusion in cases belonging to the Subdivision of Division 2 are similar to those just shown in the main division, but



usually less in degree, as the teeth are in distal occlusion only on one side, those on the opposite side being normal, yet so marked is the lack of balance of the mouth with the rest of the face in all of these cases that they are easily recognizable in the weakness of the chin and pronounced abnormal curve of the lower lip, as will be noticed in a typical case shown in Fig. 70. In marked contrast are these lines of inharmony with the same lines after treatment, as shown in Fig. 71, the change resulting from the

FIG. 70.

FIG. 71.



application of the law enunciated—the establishment of normal occlusion.

Fig. 72 shows the profile of a girl, aged thirteen, whose facial lines were thrown out of balance by reason of malocclusion peculiar to Class III, as shown in Figs. 600 and 601. A very superficial study is sufficient to show the reason for the flat upper lip and unnatural prominence and heaviness of the chin and lower lip.

The correctness of the law is again proven by the result produced on the facial lines, Fig. 73, through the establishment of normal occlusion.

Although the inharmony in facial lines reaches its max-



imum in cases of malocclusion of this class, it will be unnecessary to give more illustrations of it at this time since they are always just alike in general characteristics, varying only in the degree of the malocclusion, or the mesial inharmony in the relation of the lower dental arch to the upper, and of the mandible to the maxilla, and this usually in proportion to the time which has elapsed in its development from the beginning.

FIG. 72.



FIG. 73.



Thus far we have considered the marring effect on the facial lines from malocclusion of the teeth only; but the loss of teeth through extraction or non-development is another potent and all too common factor in disturbance of the normal balance of the face, and it is a matter greatly to be deplored that mutilation is still such common practice, even among some of the better class of dentists, and it can be accounted for only by the lack of appreciation of the laws of occlusion and their relation to facial art. So satisfied is the author that the law herein enunciated is correct, that before closing this chapter he wishes to make a prophecy concerning it, namely, that its truthfulness will soon be so well recognized that in the report of cases in works like this, pictures of the faces of patients will not be required, it being well understood that if normal occlusion be established the best possible balance will have been given to the facial lines.



## CHAPTER IV.

### ETIOLOGY OF MALOCCLUSION.

A LONG period of time—twenty years or more—is required by Nature to complete the building of the human denture, and during this time not only are all of the beautiful and wonderful structures of the teeth and the rest of the tissues of which the dental apparatus is composed being unfolded in development, but all the other organs and structures of the body are likewise passing through the mysteries and marvels of growth, all, under normal conditions, proceeding continuously and harmoniously toward the final complete development of a normal, if not a perfect, whole, that when completed each may best perform its function—its allotted part in the work of the whole.

Unfortunately these years during which Nature is thus so greatly taxed in her normal processes of growth are years prone to accident and especially to certain forms of disease which interfere with her delicate work. It is indeed very exceptional that she is permitted to complete the growth of any human being without interferences more or less serious. That she may and does frequently overcome most or all obstacles is manifest in the many fine specimens of young manhood and womanhood we see all about us, but that she often in a greater or less degree fails to react from the handicapping effect of disease or accident is also apparent.

All parts of the anatomy are liable to abnormalities in development, as medical literature bears abundant witness, but that no one part is more frequently at variance with the normal in its development than the dental apparatus



is evinced by the fact that malocclusion of the teeth in some form is almost the rule rather than the exception.

We are able to better understand the reason of this when we remember that the dental apparatus is not an organ with but a single function, like the eye or the ear, but that it is a very complex structure, with many functions, into which enter not only the jaws, dental arches, and teeth, but the muscles of mastication, the lips, tongue, nasal passages, palate, and throat, and that in addition to the function of mastication these are also concerned in the vital function of respiration, and also in speaking, singing, whistling, laughing, crying,—in short, in the expression of all the various emotions. The different parts and combinations of parts entering into the performance of these various functions and acts are so intimately associated that even slight inharmony in the growth and development of any one may ultimately involve the whole apparatus, interfering with the normal functions of all, and even producing repulsive deformities, for the influence of these parts on each other is always continuous and progressive,—toward the maintenance of harmony and the normal if normal, and toward the increase of inharmony and the abnormal if abnormal.

The causes of malocclusion, then, to be intelligently comprehended must be studied from the basis of the normal growth of the denture and its co-related parts. Most of the immediate causes are mechanical, yet whatever acts as a hindrance to Nature in performing her delicate offices in the unfolding of the various tissues composing the dental apparatus during its growth, will be operative as a cause in producing malocclusion.

In deciduous dentures we rarely find malocclusion, but this is easily accounted for from the fact that the foods and habits of the child are quite normal and very simple during the eruption of the deciduous teeth. Neither do these teeth meet with interference during their eruption from any



remnants of a previous dentition, which are often such disturbing factors to the placing of the permanent teeth. Their cusps on eruption are well defined and their locking such as to maintain themselves in normal occlusion and the jaws in their harmonious relations, very important as the development of the bones of the head and face progresses. But as the teeth become comparatively flat from the wearing away of their cusps as they approach the last period of their existence, this restraining influence becomes lessened, permitting such freedom in the relations of the jaws to each other as may and doubtless does in many instances lead to the beginning of abnormal locking of the first permanent molars.

Occasionally there is found malocclusion in the deciduous teeth themselves, usually slight, however, and confined to the incisors, but sometimes extensive even to involving the entire denture, and may be caused by forces acting previously or subsequently to their eruption. These we shall discuss later. Usually the irregularities are so slight that it is rarely advisable to interfere for their correction, yet the deciduous teeth exercise such a marked influence on the further growth and development of the jaws and dental arches and the placing of their permanent successors, and through these on the molding of the facial lines, that they should always be objects of the keenest interest to the orthodontist. The shedding of the deciduous teeth through the absorption of their roots being physiological, it should take place normally and without interference with the incoming of their successors, but if the process is abnormal, as is often the case, they may become fruitful causes of malocclusion of their successors.

**Premature Loss of Deciduous Teeth.**—Nature has designed for the deciduous teeth not only the important function of incising and masticating the food required by the child up to the normal period of their loss and replacement by the succeeding permanent teeth, but also that of assisting in a



mechanical way in the development of the alveolar process, and probably, the development of the jaw.

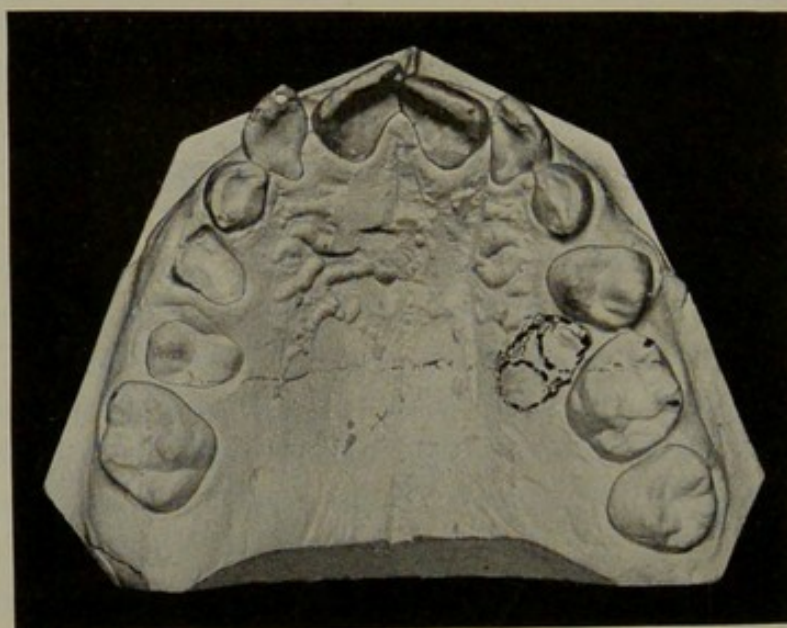
The permanent teeth being larger and more numerous than the deciduous, the greater space required by them is provided by the broadening of the dental arches in the region between the canines, and the lengthening of their lateral halves posterior to the deciduous molars. This is influenced largely by the development and eruption of the permanent molars posterior to the deciduous molars. If the mesio-distal diameters of the deciduous teeth be not impaired by caries and the teeth remain the normal period, the first permanent molar in taking its position in the arch must force its way between the second deciduous molar and the ramus of the jaw, if below, or the maxillary tuberosity, if above.

Coincident with the growth of the jaws the deciduous teeth are carried forward, and the normal mesio-distal lengthening of the alveolar process takes place. If, however, one of the buccal deciduous teeth be prematurely lost, as for example the lower first molar, the wedging influence of the erupting first permanent molar will be felt only distally to the lost tooth, and instead of the normal lengthening of the lateral half of this arch through the pushing forward of all the teeth, the second deciduous molar only will be pushed forward to occupy a portion of the space left vacant by the first deciduous molar. Thus this lateral half of the dental arch will be shorter than normal and if, meanwhile, no teeth have been lost on the same side of the opposing arch the wedging force from the erupting upper permanent molar will have carried forward the deciduous teeth and lengthened the arch normally, whereupon there will be inequality in the length of the lateral halves of the arches on the affected side, with the establishment of malocclusion. And this is not the only evil, for the space occupied by the lost tooth having been greatly diminished, or even closed, the eruption of the succeeding permanent



tooth (first premolar) will be prevented entirely, or the tooth will be forced into buccal or possibly lingual occlusion, as in Fig. 74. The shortened lateral half will not develop and the lower arch will as a consequence be smaller than normal, which must result either in protrusion of the upper incisors, or in their irregular arrangement through the effort of Nature by lip pressure to restore harmony in the sizes of the two arches. Cases belonging to both

FIG. 74.



divisions and subdivisions of Class II are undoubtedly often produced in this way, as will be hereinafter shown.

Results of the premature loss of the deciduous canines may be seen in Figs. 352 and 367. While probably the greatest harm results from the premature loss of the second deciduous molar or canine in either arch, yet the principle applies to the loss of any of the deciduous teeth, the difference being only in degree.

The mechanical influence of the deciduous teeth in the development of the dental arches is so important that they should by all means not only be retained their full normal period, but, if they become affected by caries, their full



mesio-distal diameters should be restored by suitable fillings after sufficient separation.

Likewise, if a deciduous tooth be lost through the premature absorption of its root, the full space occupied by it should be maintained by some suitable retaining device. This may be easily and quickly effected by making small pits in the approximal surfaces of the teeth mesial and distal to the space and inserting the ends of a section of the wire G therein, after which the wire may be lengthened by a few pinches of the regulating pliers to gain tension, and, if necessary, needed space, as in Fig. 224.

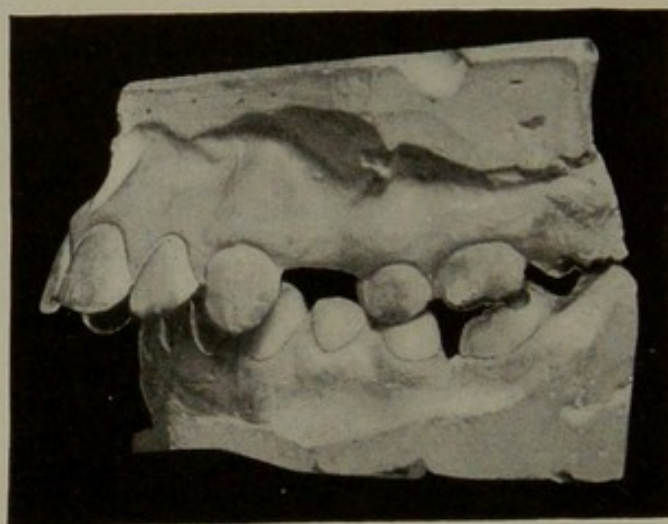
**Loss of Permanent Teeth.**—What we have already said in regard to the mechanical influence of the deciduous teeth in assisting the normal development of the dental arches and promotion of harmony of the facial lines is equally applicable to the teeth of the permanent set up to the period of their full eruption, or until the last of the molars have taken their positions. This is a point of such importance that it should be carefully considered by all teachers and students. If one or more of the permanent teeth anterior to erupting molars be extracted, the wedging process, so necessary in developing the arch, serves only to close the space thus made, and there will be no carrying forward of the teeth and alveolar process anterior to the space, nor the consequent proper contouring of the face. The evil effects already enumerated as arising from unequal development of the two arches will follow.

It should also be borne in mind that the interdependence of the teeth is so great at all times that the loss of one or more at any period of their history must have a marked influence upon the remaining teeth. Each tooth is such an important part of occlusion that its loss should be seriously considered before deciding upon its removal. Occasionally we hear of someone advocating the sacrifice of the first permanent molar (one or more), as a prevention of or cure for malocclusion. The author has yet to see a single case



where the loss of this tooth has not been followed by malocclusion, or aggravations of it if formerly existent, often of a far-reaching and serious nature. The loss of no other tooth is followed by so many and so marked evil effects. Its size, position in the arch, and relations to the other teeth are such as should entitle it to the greatest care with a view to its longest possible preservation. If unavoidably lost it should be immediately replaced by some form of artificial substitute.

FIG. 75.



The author has seen several cases where all of the first permanent molars had been extracted at about the age of nine years, with a view of preventing development of malocclusion of the incisors. The result was the shortening of both of the arches anterior to the spaces, thus robbing the faces of their normal contours and producing an undeveloped, sunken appearance about the mouths similar to that of edentulous persons, while apparently giving no relief to the crowded incisors. Such a case is reported in the first chapter on Treatment.

Fig. 75 shows a case of malocclusion, the cause of which was directly traceable to the unwarranted extraction of several of the permanent teeth. The two lower first molars were extracted at about the age of nine with the inevitable



result. The wedging influence for continuing the normal lengthening of the mandible being lost, the second and third molars were tipped forward as they erupted, without exerting any force in carrying forward the premolars, incisors and canines, so there rapidly followed inharmony as to the sizes of the two arches and the relations of the remaining teeth. The removal of the main support of the jaws caused the shortening of the bite and arrested the normal lengthening of the face, and also forced the cutting edges of the lower incisors against the disto-lingual inclines of the upper incisors, thus rapidly pushing them into marked labial prominence, which, in turn, also tended to force the mandible distally and further assisted in arresting its normal development. This condition was further intensified by pressure of the lower lip, which, owing to the establishment of conditions favoring its malposition and relation, rested habitually between the upper and lower incisors.


Later followed the loss of other teeth by extraction, which only augmented the untoward conditions already enumerated, the result being the establishment of such marked malocclusion as to make the dental apparatus almost useless, as well as causing a marked deformity of the face, and this, too, with facial lines originally in fine harmony, and form and structure of teeth naturally much above the average. Similar cases with like results are, alas, only too common.

The evil effects arising from extraction of the upper lateral incisors in order to provide space in the crowded arch for the canines are so apparent that arguments against the practice seem out of place in a modern textbook. The abnormal appearance given the face in the region of the nose consequent upon the diminished size of the upper arch, together with the carnivorous appearance of the mouth by the resultant prominence of the canines is as repulsive as it is inexcusable.



Still greater deformities are caused by the more inexcusable practice of sacrificing the permanent canines. The face of a patient so deformed is shown in Fig. 76.

FIG. 76.

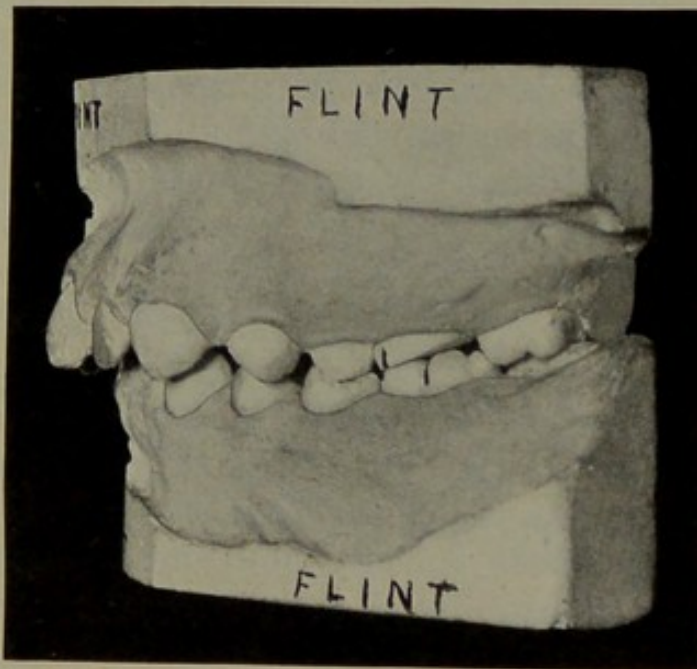


Indeed the enormous prevalence of the practice of extraction of teeth by dentists of this and other countries is a reflection upon the degree of their comprehension of the science of dentistry. Radical reform in this respect ought to be instituted. The trivial excuses often given by men of high standing in dentistry for extraction of teeth are amazing.

We have elsewhere pointed out the interdependence of all the teeth, and the author would strongly insist that the responsibility should not and does not end with the simple extraction of a tooth for any cause, but that unless the space of the sacrificed tooth be immediately supplied with some suitable artificial substitute, malocclusion of the remaining teeth will follow.

**Imperfect Fillings, Crowns, etc.**—The laws of occlusion are not less binding on the dentist than on the orthodontist. We have already noted that teeth are largely maintained in their correct relations by reason of the forms of their crowns, and, especially, the occlusal planes of the cusps, and if in the restoration of lost portions of teeth by means of fillings or crowns the demands of occlusion are ignored, malocclusion must in some form follow. The author daily

FIG. 77.



From the collection of Dr. D. Willard Flint.

sees cases where imperfectly shaped fillings or crowns are exercising a marked influence in causing or maintaining malocclusion. Fig. 77 shows a case where complete distal occlusion in one of the lateral halves of the arches has resulted from a large filling in the first molar that was left in the form of a flat inclined plane; and many illustrations might be given where diminutive and very badly shaped crowns have produced an equally disastrous effect. Some of these are shown in the chapters on Treatment.



**Prolonged Retention of Deciduous Teeth.**—For reasons not yet understood the normal process of absorption of the roots of the deciduous teeth is sometimes delayed. In this event the succeeding tooth will either be prevented from erupting, or it will be deflected into malocclusion. Deflection may also be caused by even a small portion of the root. Many cases of malocclusion belonging to Class I have their beginnings in this way. Cases are occasionally met with where the permanent canine has erupted between the lateral incisor and deciduous canine. It is, however, more commonly held in impaction, or deflected lingually as a result of the non-absorption of the root of the deciduous canine. In rare instances a permanent successor is not developed, for reasons as yet unknown. In such cases the deciduous teeth usually remain much longer than the normal period before being lost through the absorption of their roots, which is of course desirable. They rarely, however, last longer than the twenty-fifth year, the canine being the most enduring. When the indications are clear, however, that a deciduous tooth is actually interfering with the eruption of its successor, it should be removed regardless of the time, as the correct placing of its successor is of great importance. Usually, however, the absorption of the one and the eruption of the other goes on simultaneously, though oftentimes considerably before or after the time prescribed in our text-books. We would strongly caution against interference with the normal process by premature extraction in the desire to expedite matters.

**Tardy Eruption of Permanent Teeth.**—Occasionally a tooth, with or without apparent cause, fails to erupt and remains imbedded in the alveolar process for months, or even years. Usually the space is partially or wholly closed by the adjoining teeth. The impaction of the canine is the most common of that of any of the teeth, since its eruption is subsequent to that of both its mesial and distal associates, so that in all cases it must meet more or less

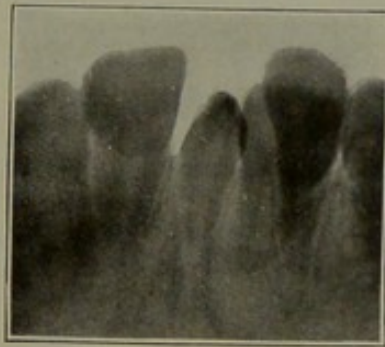


resistance from them. Later, if efforts toward eruption occur and the space be closed the tooth must necessarily be itself deflected or force other teeth into malposition.

It is quite probable that so-called "third dentitions" are only instances of tardy eruption of some one or more of the permanent teeth.

**Supernumerary Teeth.**—Supernumerary teeth, as their name implies, are anomalies, or extra teeth above the normal number of thirty-two. In outline they rarely resemble any of the typical tooth forms, being most commonly peg-shaped or conical. Although they may occur in any part of the dental arches, or even nearly cover the

FIG. 78.



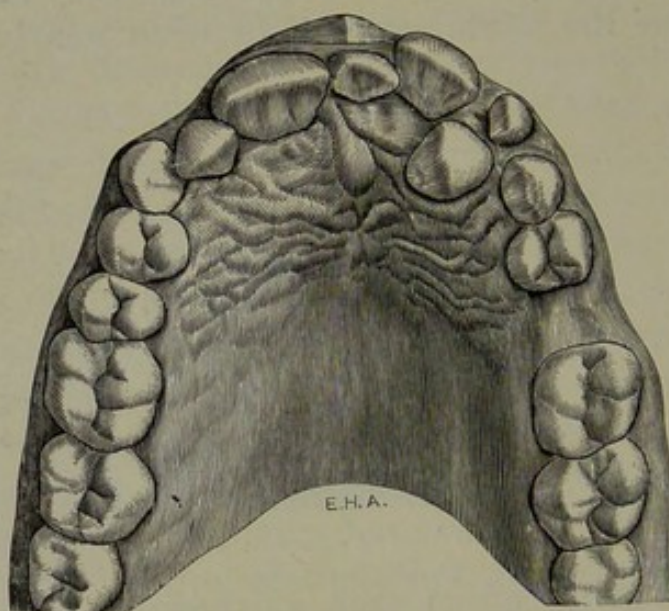
entire vault of the upper arch, as shown in a model in the author's collection and also in two or three other well-known cases, their favorite location is between the central incisors, as shown in Fig. 78 (from Dr. Ketcham's collection), in the region of the laterals, or in the bucco-embrasial spaces between the molars. The reason for their appearance is not clearly established. It is now, however, quite commonly attributed to atavism, or Nature's effort to re-establish original conditions. The typical number of mammalian teeth is forty-four, man in his evolution having lost four incisors and eight premolars. It is supposed that these supernumeraries are some of these suppressed teeth re-appearing in a rudimentary form.



These teeth frequently take their positions, especially in the incisive region, just before the eruption of the permanent teeth, resulting in the deflection of erupting permanent teeth from their normal course.

Fig. 79 represents a model in the author's collection in which two supernumeraries are shown, one between the centrals and the other distal to the canine and somewhat resembling it. Another irregularity is also here shown in that the right central is greatly oversized.

FIG. 79.

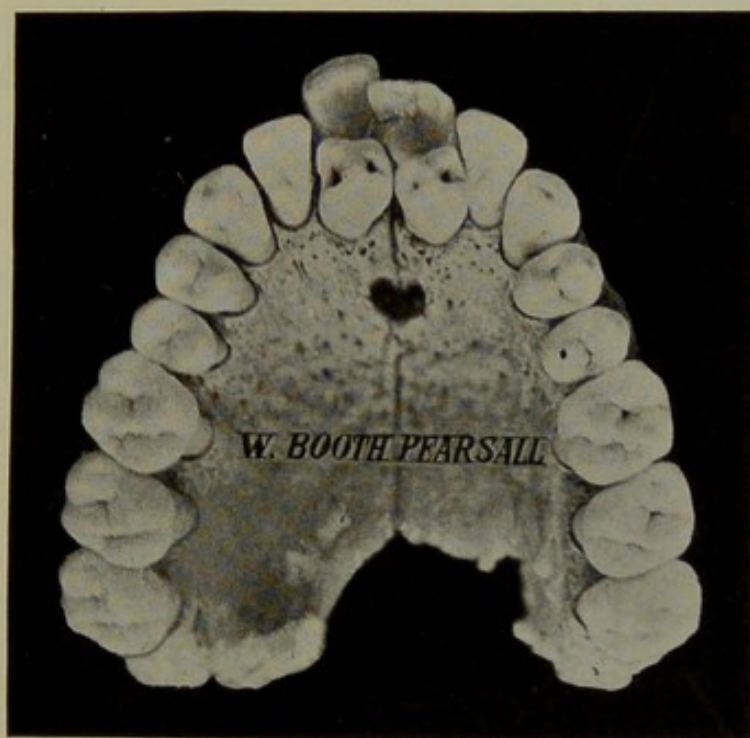


These anomalies seem not to be uncommon as they appear in almost every collection of models of the teeth. Sometimes they remain imbedded in the alveolar process and are revealed only by the probe or skiagraph. Fig. 80 shows a fine specimen of supernumeraries in a skull from the collection of Dr. W. Booth Pearsall of London.

**Transposed Teeth.**—Though far more rare than supernumeraries transposed teeth are also occasionally found, and when occurring often offer perplexing problems in treatment which cannot be dealt with according to rule, but must be solved according to the exigencies of the case.

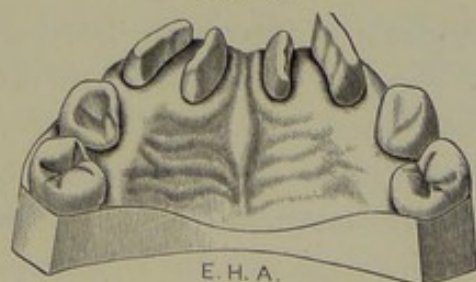
Fig. 81 shows a case, from a model in the collection of Dr. Bosart, where the upper centrals and laterals are transposed, and the author has had one case in which the lower

FIG. 80.



left canine and lateral incisor were almost completely transposed. In treatment it seemed best to effect their complete transposition. This was decided upon, however,

FIG. 81.

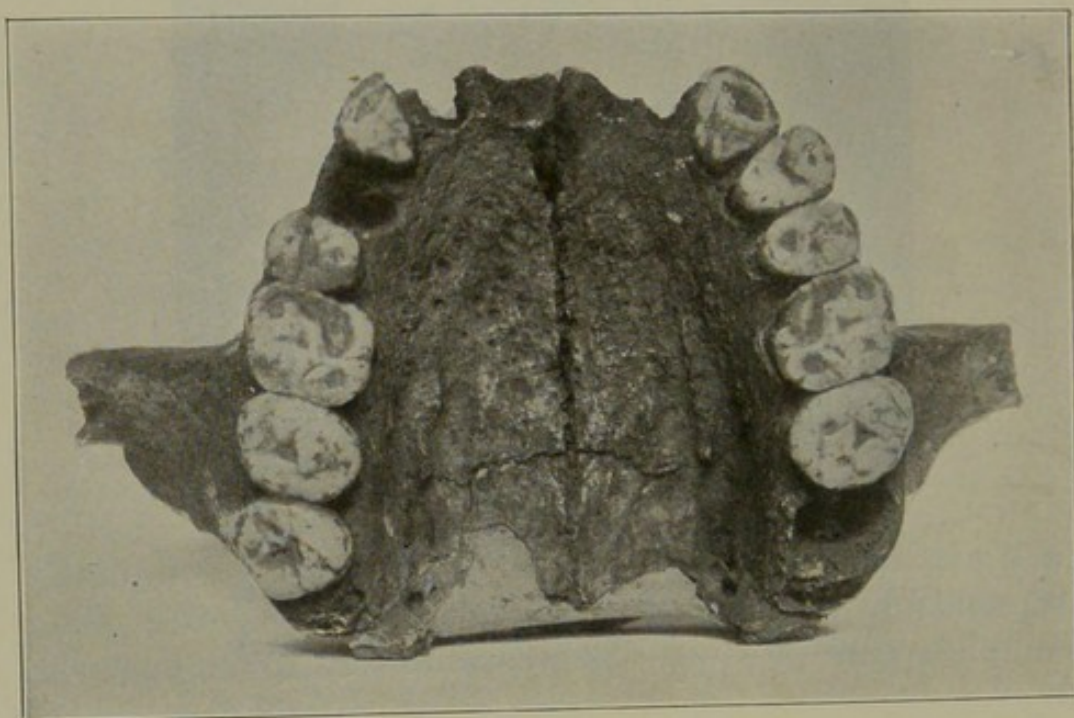


only after full consideration of the difficulties and dangers attendant upon such extensive disturbance of the tissues as would follow their normal placing.



**Disuse.**—According to a well-known physiological law, the use of an organ or muscle tends to stimulate its growth and development, as illustrated in the well-known example of the blacksmith's arm, while disuse tends toward lack of development, or even atrophy, as illustrated in the wings of domestic fowls when contrasted with those of wild fowls. The structure and history of the jaws and teeth show that they were intended for much use. There can be little

FIG. 82.



doubt that the modern methods of food preparation tend to such disuse of the jaws and teeth as to have a marked general effect in causing malocclusion.

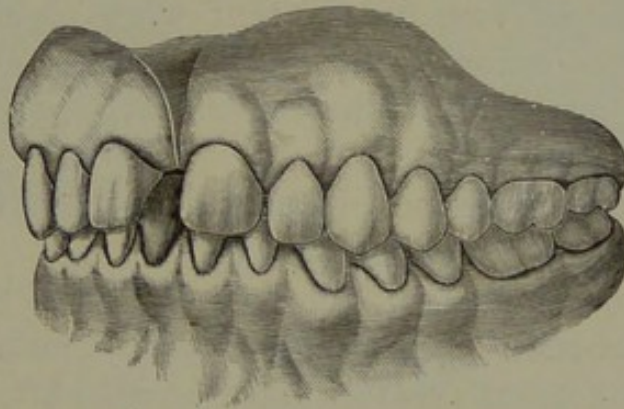
Fig. 82 shows an upper dental arch and teeth beautiful in form and structure, with the vault of the arch also most perfect. It is that of one of the ancient Hawaiians, and it tells its own story of heredity and use. Let the reader compare with this beautiful specimen, which illustrates the harmony of growth and function, the cases of child dentures, so common in this country, where the deciduous teeth



and the probably already erupted four first permanent molars, together with the gums, are greatly diseased, rendering normal use impossible, and this, too, at the important period when the denture should receive the stimulus of full normal use, and he will have no difficulty in understanding at least one of the important reasons why modern dentures are so defective in size and in arrangement of teeth.

**Abnormal Frenum Labium.**—A somewhat common form of malocclusion is distinguished by a space between the upper central incisors, Fig. 83, and occasionally, though very

FIG. 83.



rarely, between the lower centrals. This space varies in width, the distance being from one to four, and even five millimeters, always presenting an unpleasing appearance and interfering with speech in proportion to its width.

The cause of the deformity is abnormal development and attachment of the *frenum labium*, which, instead of being normal in size and ending in its attachment to the gum about five millimeters above the gingiva, not only reaches the gingiva, but passes directly between the teeth and is attached to the likewise overdeveloped mesio-lingual tuft. This strong fibrous ligament keeps the teeth separated, not only by its passive presence, but as well by its action mechanically, as may be easily proven by gently grasping



the lip between the thumb and finger and moving it from side to side in imitation of its normal movements.

At the time the author first described this cause of malocclusion\* it seemed to him probable that the abnormal frenum might be due to an abnormal suture. This question, however, has now, he thinks, been quite definitely settled by Dr. Ketcham, of Denver, who has, during the past two years, conducted an extensive and systematic study of this subject by means of the X-ray and the examination of skulls in museums. He has made skiagraphs of both normal and abnormal frena, and of twenty-six that were normal, eight showed normal sutures and eighteen more or less separation between the intermaxillary bones at the median line. Of twenty-two that were abnormal, eight showed perfect union of the alveolar process between the central incisors, while fourteen showed greater or less separation.

In the skulls examined he found about the same proportion of normal and abnormal sutures.

Fig. 84 shows a normal frenum and normal suture. Fig. 85 shows a normal frenum and abnormal suture. Fig. 86 shows an abnormal frenum and normal suture, and Fig. 87 shows an abnormal frenum and abnormal suture.

Fig. 88 shows the skull of a primate in which there had been an abnormal attachment of the frenum. The suture was normal, but accompanied by a pronounced depression, probably for the better attachment of the frenum.

The conclusion of Dr. Ketcham is that the attachment of the frenum, whether normal or abnormal, is in no wise governed by the normality or abnormality of the suture.†

**Habits.**—The habits of sucking the thumb, lip, or tongue, so frequently formed by young children, while rarely caus-

---

\* *Dental Cosmos*, November 1899.

† See the excellent paper by Dr. Ketcham published in the transactions of the First Annual Meeting of the Alumni Society of the Angle School of Orthodontia.



FIG. 84.

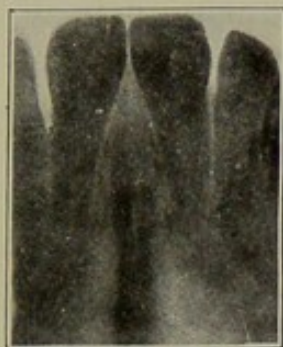

FIG. 85.

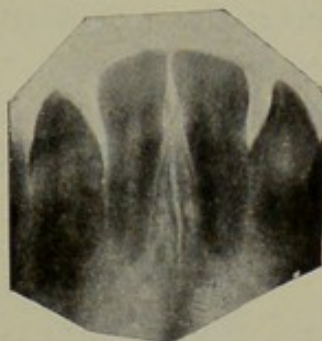

FIG. 86.

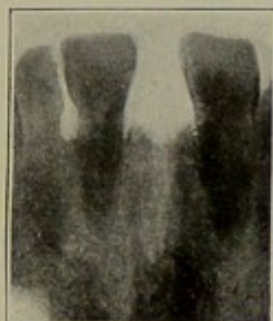

FIG. 87.

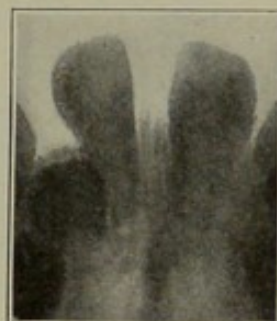
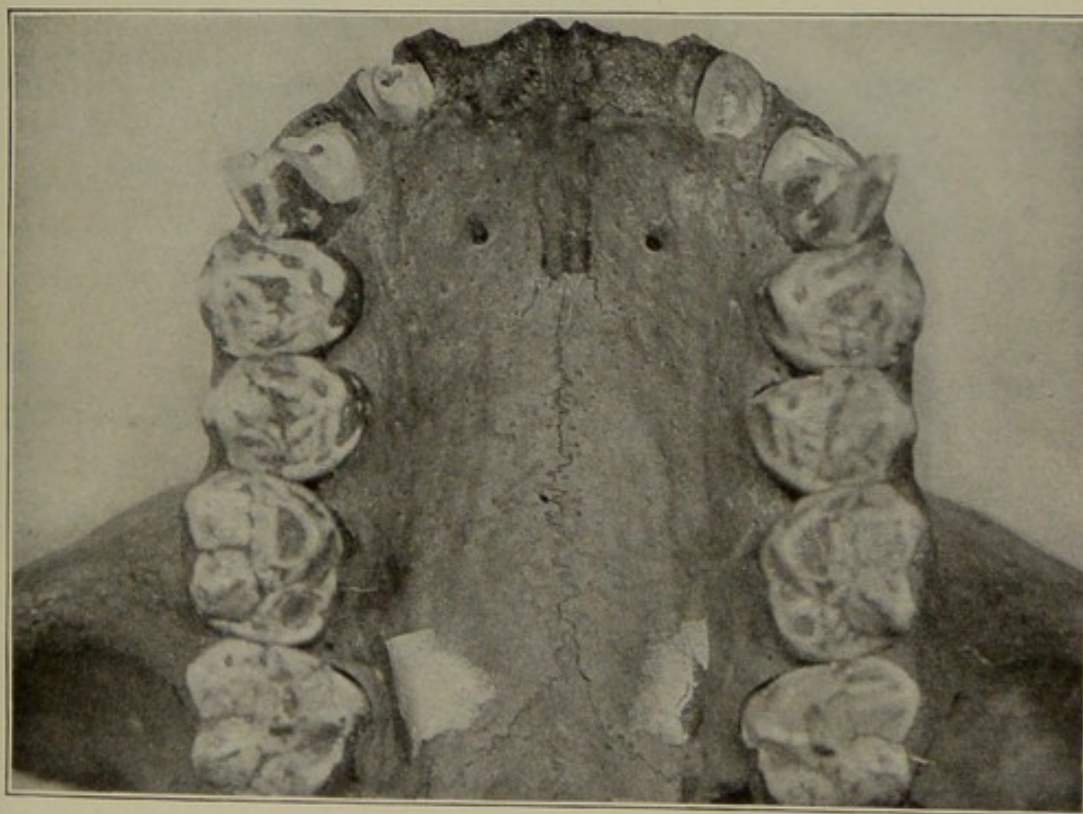


FIG. 88.

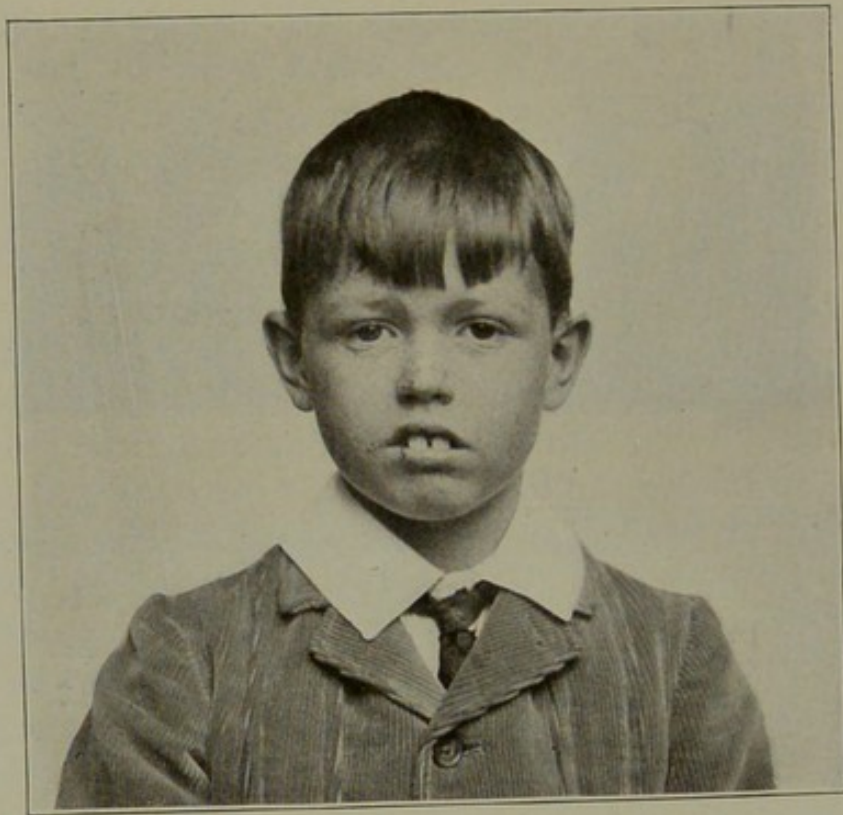




ing displacement of the deciduous teeth, will, if persisted in during the eruption of the permanent incisors, cause marked malocclusion.

Fortunately the habit of thumb-sucking is usually broken before any marked evil effects result, so that cases where malocclusion has really resulted therefrom are rare and easily recognized. The upper incisors and canines are

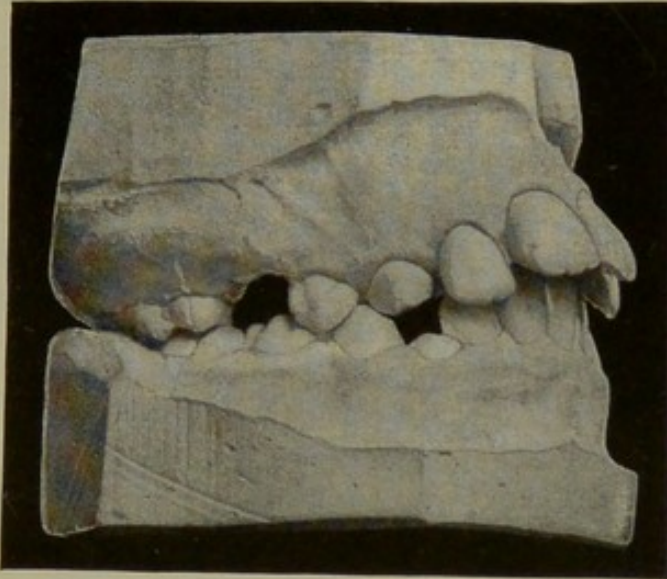
FIG. 89.



drawn forward and to one side, according as the thumb of the right or left hand has been used, while pressure from the back of the thumb upon the lower incisors causes their displacement lingually. These cases are frequently confounded with those of protrusion belonging to Division 1 of Class II. The conditions and results, however, are very different, the latter being mouth-breathers, the former never, as such action would be a physical impossibility. This is illustrated in the difficulty which infants experience

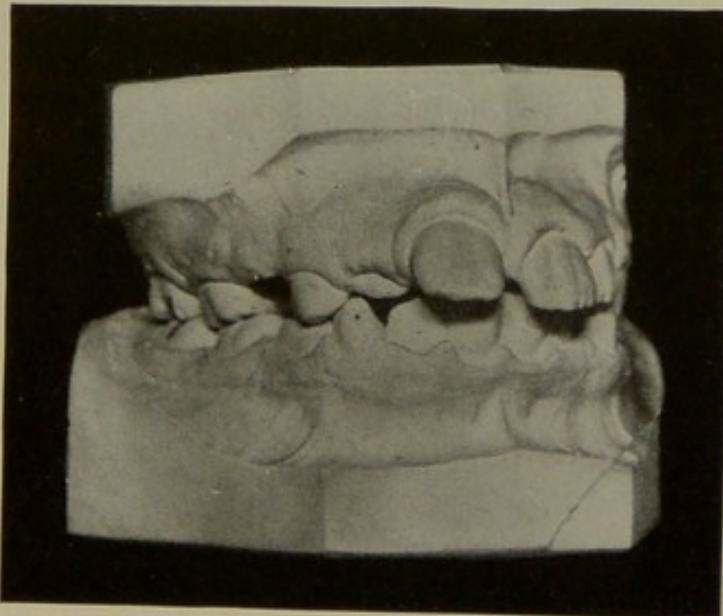
in nursing while suffering from temporary obstruction of the nasal passages resulting from colds.

FIG. 90.



The pernicious habit of biting the lower lip, or pressing the occlusal edges of the upper incisors against its outer

FIG. 91.



surface, as in Fig. 89, will always, however slightly persisted in, move the upper central incisors forward thus



lessening their natural resistance to the narrowing of the lateral halves of the arch. The effect of this habit on the occlusion is shown in the typical cases, Figs. 90 and 91. This habit is more common than seems to be generally supposed, is often extremely difficult to overcome, and probably accounts for many ultimate failures in orthodontic treatment. We know of nothing in orthodontia that causes more annoyance and discouragement to the practitioner. Often after long retention when he believes his work satisfactorily completed, he finds the habit has never been broken and that a few weeks have been sufficient to re-establish the old conditions, or conditions even worse.

The habit is almost invariably a marked accompaniment of cases belonging to Division 1 of Class II and its Subdivision, and unless it be overcome and the normal functions of the lips regained the incisors can never be kept in their normal positions.

The habit of sucking the lower lip, though quite rare, must, if persisted in, produce marked malocclusion. The most repulsive deformity due to malocclusion that the author has yet seen is that shown in Figs. 92 and 93, which was caused by this habit. The upper lip was short and contracted, the gums highly colored, and the lower lip was larger than normal. The lower incisors inclined lingually more than normal and rested in depressions they had formed in the mucous membrane high in the vault of the arch, as shown on the left in Fig. 94. The nose was amply developed, with no indications of nasal obstructions.

Another habit, though more rare—that of resting the tongue between the upper and lower incisors, or frequently protruding it more or less—produces the effect shown in Fig. 95. The pressure upon the incisal edge prevents full eruption and holds the teeth in infra-occlusion, while the molars, being held apart much of the time, lengthen into positions of supra-occlusion from lack of resistance.

It will be found, however, that there are as many vari-

FIG. 93.

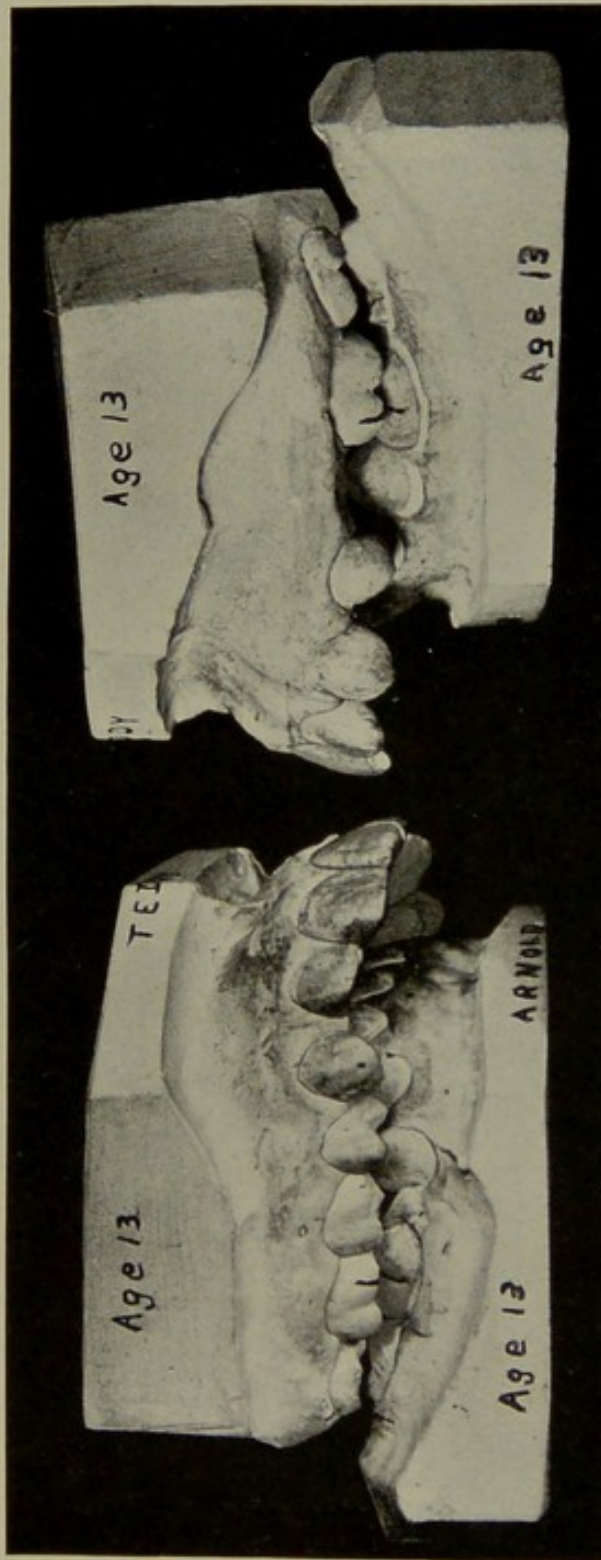
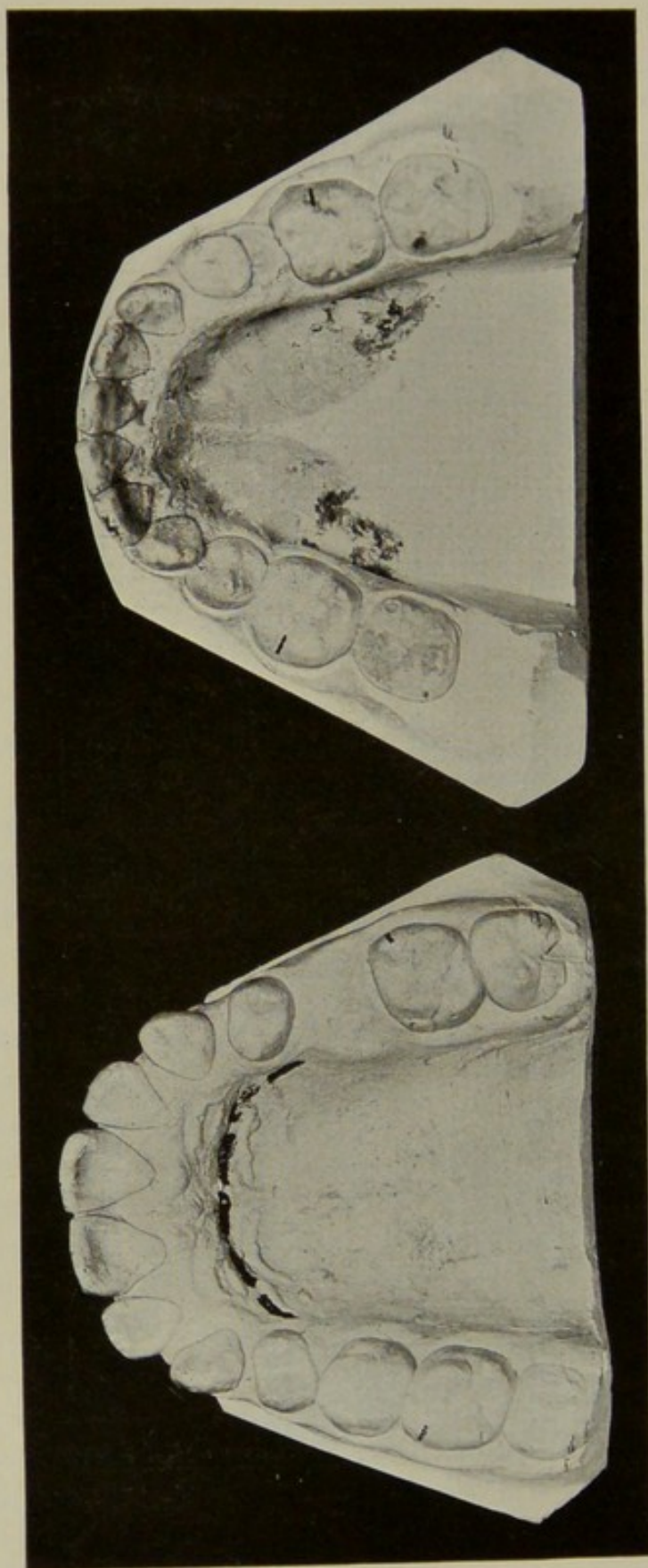


FIG. 92.



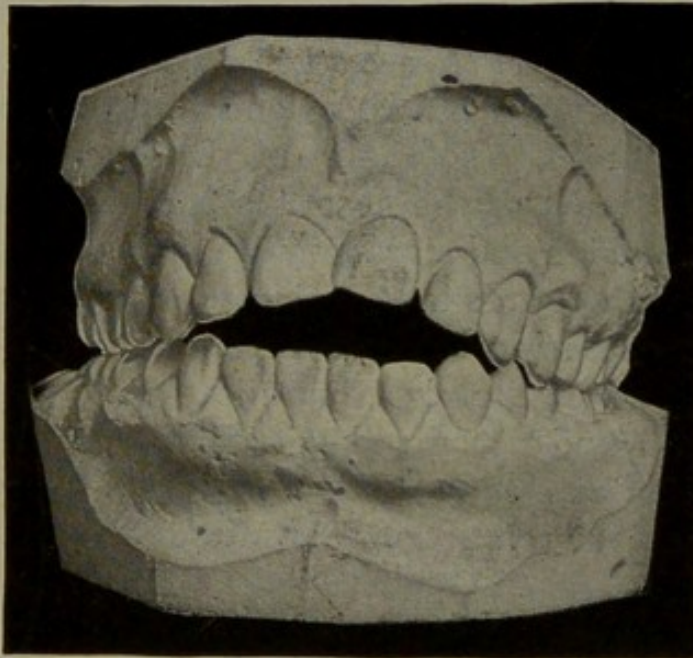FIG. 94.



ations in the habit as there are cases met with, with resultant corresponding variations in the malocclusion. The difficulty of breaking the habit is even greater than that of overcoming the pernicious lip habits, resting, as it does, almost wholly with the patient and very few having sufficient character and persistence to overcome it.

With our present knowledge of orthodontia these cases are the most difficult to treat successfully. The orthodontist should be thoroughly conversant with their peculiarities, and with the obstacles to be overcome in their treat-

FIG. 95.



ment, before beginning which he should have a complete understanding with the patient and his parents as to the responsibilities of both.

**Nasal Obstructions.\***—Of all the various causes of malocclusion mouth-breathing is the most potent, constant, and varied in its results. It is most prevalent between the ages

---

\* See the excellent article by Dr. W. J. Brady in the Transactions of the American Society of Orthodontists, 1902, from which we have here freely drawn, with Dr. Brady's permission.



of three and fourteen years, or during the most important period in the growth of the dental apparatus, and is operative indirectly upon the teeth by causing asymmetrical development of the muscles, as well as of the bones of the nose and jaws, and derangement in the functions of the lips, cheeks, and tongue, while the extent of the general derangement is manifest in proportion to the degree of mouth-breathing and the time it has been practiced. Although it may be lessened or discontinued at the age of puberty, its evil effects may last through life.

In normal breathing an ample amount of air for the needs of the child enters the nasal passages to be warmed, moistened, and strained of impurities on its way to the lungs, where it must give oxygen to the blood. The air while passing through the nose contributes by its presence and temperature to the health of the mucous membrane covering the walls of the nose, the turbinated bones, and frontal, ethmoidal, and maxillary sinuses. Yet it in no way interferes with the delicate balance of pressure between the tongue on the inside and the lips and cheeks on the outside of the dental arches, but allows the normal closure of the mouth and permits the jaws and inclined occlusal planes of the teeth to act for their mutual maintenance in their harmonious relations. Thus function and growth are undisturbed.

If, however, the necessity for mouth-breathing becomes established, all of the beautiful harmony of balance in growth and functions of parts is seriously disturbed, with derangement certain. The air is received directly into the lungs without being cleansed, warmed and moistened. As a result of this imperfect preparation the lungs receive it in insufficient quantities to fully oxygenate the blood, the child becomes pale, anemic, listless, and deficient in size and weight. The lungs lack normal expansion, and the child often becomes flat-chested. Thus weakened, a predisposition to pulmonary and other diseases is established.



The baneful effects of mouth-breathing are always manifest in the face. The nose is small, short, with wings flattened; the cheeks pale and more or less sunken; the mouth is held open almost constantly; the upper lip is short and drawn up in the effort to breathe and fails to develop; the mandible is drawn back and also fails to develop, being almost always smaller than normal, although usually regular in form; the upper arch becomes narrower than normal, and is usually lengthened, probably largely the result of unequal pressure from the muscles. Normally, with the mouth closed, the tongue rests in contact with the vault of the upper arch and the upper teeth, exercising no inconsiderable influence in molding the vault of the arch and maintaining its width.\*

As we have seen, the balance of pressure between it and the external muscles is equal, while with the mouth held open, as is necessary in mouth-breathing, this balance is disturbed, more than the normal amount of pressure being exerted on the outside from the muscles of the cheeks which are on slight tension, and little or none being given by the tongue on the inside, it being made to rest between the lateral halves of the lower arch, which probably accounts for the fact that in these cases the lower arch is rarely narrower than normal.

The causes of mouth-breathing are many, but are always pathological, and are manifest in the posterior, middle, or anterior nares, or in all at the same time. A thorough discussion of the etiology and pathology is clearly not within the scope of this work, but more properly belongs to works on the science of rhinology, to which we would refer the reader, and especially to that by Kyle. Yet it will not be amiss to here consider briefly and in a general way some of the more common causes of mouth-breathing.

---

\*J. Sim Wallace, D.Sc., M.D., L.D.S., in his "Essay on the Irregularities of the Teeth" has given this subject much thought. The work is worthy of most careful reading.



The mucous membrane which lines the nasal cavity is very extensive, covering as it does, all of the cartilage and surfaces of the bones forming the nasal tract, as well as extending into and forming the lining of the frontal, ethmoidal, and maxillary sinuses. Now anything that will act as an irritant to this membrane sufficient to produce engorgement of the bloodvessels with which it is very richly supplied, and consequent thickening of the membrane, will restrict the normal size of the nasal passages, thereby obstructing nasal breathing and necessitating in a corresponding degree a resort to mouth-breathing. This congestion of the membrane may be but temporary, as when caused by slight coryza necessitating partial or complete mouth-breathing for a few days only, and then pass entirely away; or the congestion may take on a chronic form, more or less continuously obstructing the nasal passages and causing chronic mouth-breathing, as in chronic hypertrophic rhinitis, or atrophic rhinitis with polypi, which growths may completely close the nasal passages.

Whatever form the inflammation of the mucous membrane assumes, if protracted in youth, it will seriously interfere with normal growth and development of the bones over which this membrane extends, and indirectly interfere with the growth of other bones causing asymmetrical development, so it is common to find more or less malformation of the septum, with deflections, depressions, bony or cartilaginous enlargements. From like cause we will commonly find great variations from the normal in the turbinated bones, characterized by atrophic conditions, prolongations and enlargements. The floor of the nose may become modified from the same cause, resulting in abnormal shape and probably height of the palatine arch, as well as abnormal form of the dental arch. The arrest in the development of the bones in the intermaxillary region, causing crowding of the incisors, so common in Class I, is in many instances directly



traceable to pathological conditions of the middle or anterior nares. From the same cause the normal form and size of any of the sinuses tributary to the nasal cavity may be and doubtless are often modified and contribute to the impairment of the voice.

But a result far more common is hypertrophy of the pharyngeal tonsil, usually called adenoid vegetation or simply adenoids. This especially interests the orthodontist on account of the marked and certain malocclusion resulting therefrom. It is distinctively a trouble of childhood and is most active during the growth and development of the denture, beginning at about the age of three years, or even earlier, and, for reasons not known, usually terminating in atrophy at about the age of puberty, although in some instances continuing much later in life.

Malocclusion when resulting from adenoids alone is usually distinctive in that the upper arch is narrowed and lengthened, with little or no crowding of the teeth, but with bilateral or unilateral distal occlusion.

As the evil effects of mouth-breathing are so pronounced, how important it becomes that it should have thorough and prompt attention from the most skilful rhinologist only, and that normal nasal respiration be established, otherwise the work of the orthodontist must be futile. On the other hand, how utterly useless is it for the rhinologist to treat the nasal air passages without the co-operation of the competent orthodontist, so that the teeth, jaws, and lips may functionate normally, making possible the normal closure of the mouth the requisite amount of time. The work of the rhinologist and the orthodontist should, then, go hand in hand, for each is equally dependent upon the other.

It is easy to understand the beginning of malocclusion of the teeth in this class of cases, and the various stages are readily followed. At the time of the eruption and locking of the first permanent molars which marks the



true beginning, the conditions for the mal-locking of these teeth is most favorable. The occlusal surfaces of the crowns of the deciduous teeth are comparatively flat, their cusps having largely disappeared through natural wear so that they can no longer exercise much control over the proper relations of the jaws when closed. The mandible, instead of being held forward by the cusps in their locking, is allowed to close more or less distally to normal. This distal movement of the mandible is further made easy by the as yet shallow and imperfectly developed glenoid fossa, permitting the condyle of the mandible much freedom of movement.\* So, as the first permanent molars erupt and the cusps feel their way into occlusion, the lower molars may easily lock in distal occlusion,—not always in full distal occlusion at once, for very often only the minute points of the cusps touch for some time as if hesitating as to which side of the planes of the cusps they will follow.† Probably only a few hours in many cases decides the position they will ultimately assume, whether it shall be normal or abnormal, but when once established their course is progressive until their full normal or distal occlusion ultimately takes place.

In some instances the molars in only one of the lateral halves succeed in locking in normal occlusion, while those of the other lock in distal occlusion. This is easily understood when we remember that the eruption of the teeth in the two lateral halves of the dental arches rarely proceeds simultaneously, those on the side of the greatest functional activity being in advance of the others weeks or even months.

---

\* Angle, "The Upper First Permanent Molar As The Basis of Diagnosis." Read before the American Society of Orthodontists, Sept. 28, 1905. Published in the *Items of Interest*, June 1906.

† Angle, "Some Basic Principles in Orthodontia." New York Institute of Stomatology, Oct. 7, 1902. Published in the *International Dental Journal*, Oct. 1903.



Asymmetrical locking of the molars is further explained by the fact that climatic changes and systemic conditions favor mouth-breathing at different periods of their eruption. The fact that mouth-breathing is but temporary in many cases and can therefore exert a pernicious influence in the locking of the molars but a part of the time, may, it is believed, account for the beginnings of malocclusion in some cases of the second division of Class II, as well as its subdivision. Mouth-breathing may continue only long enough to wrongly divert the points of the cusps of the molars, thus establishing their ultimate complete distal occlusion, when normal breathing may be resumed as the result of treatment, change of climate, or be overcome by more normal systemic changes; and as normal breathing and normal lip functions become re-established all of the characteristics peculiar to this division would naturally follow in development. The majority of such cases are, however, in the author's opinion directly traceable to the premature loss of the upper first or second deciduous molars, or even of the teeth anterior, as may be often noted.

Although many cases of mouth-breathing are found in Class I, some of them may be accounted for, as Dr. McKay has suggested, by the fact that mouth-breathing may have developed in them subsequently to the eruption and normal locking of the first permanent molars.

In conclusion, the author would not be understood as implying that he believes he has exhausted this subject. On the contrary, he feels as all students of the subject must feel—that there is much concerning the etiology of malocclusion that is as yet unknown.



## CHAPTER V.

### ALVEOLAR PROCESS AND PERIDONTAL MEMBRANE.

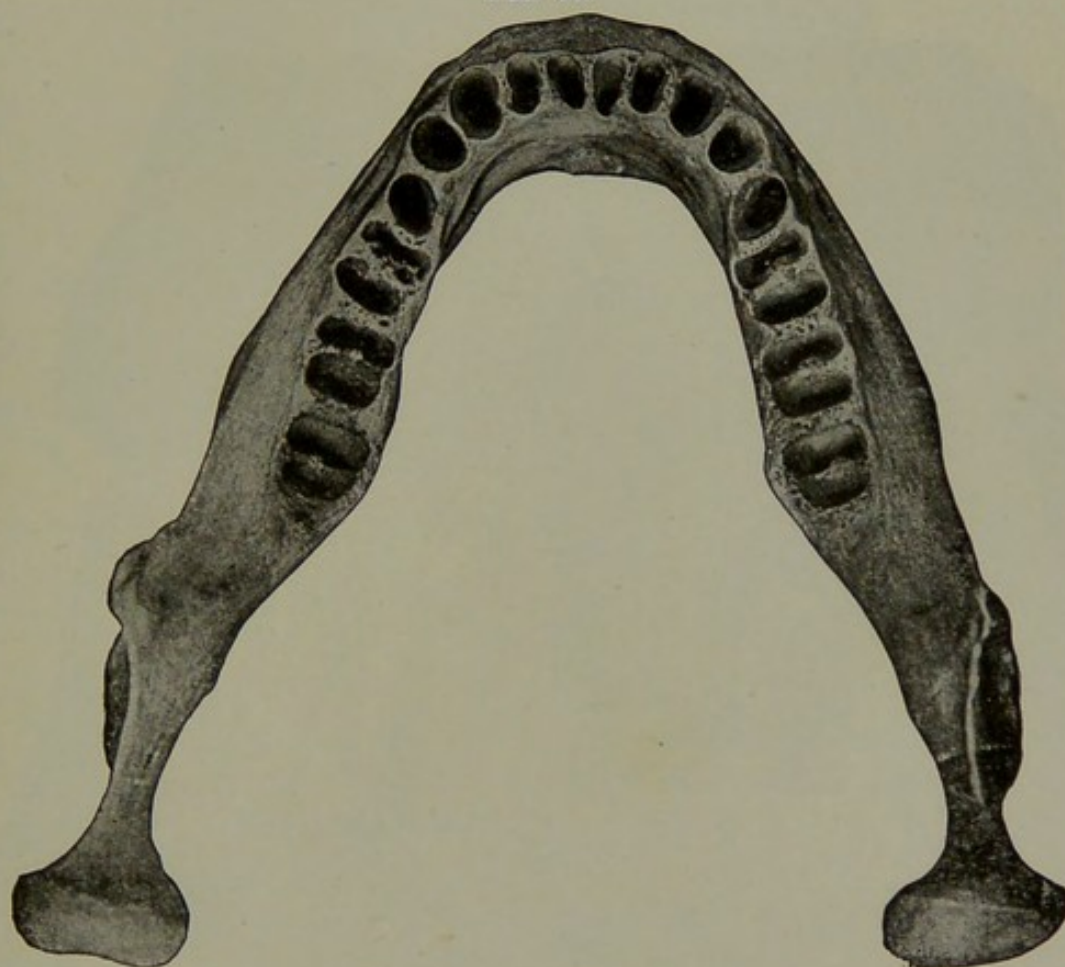
BEFORE entering upon a consideration of tooth movements in the correction of malocclusion it will be necessary to consider in a general way the alveolar process and peridental membrane, as their comprehension is more essential in orthodontia than in any other branch of dentistry, in fact, it is only secondary in importance to the teeth themselves, and it is through our intelligent management of these tissues that we are enabled to successfully correct inharmonious positions of the teeth.

The alveolar process, Fig. 96 is that portion of the maxillary bones formed for the reception and support of the roots of the teeth. It seems to be wholly subservient to the uses of the teeth, as it does not appear before their eruption, and slowly disappears by absorption after their removal. It conforms to whatever position the teeth arrange themselves in, regardless of regularity, so that if tooth movement be undertaken at the proper age an arch greatly diminished in size through crowding of the teeth may be much enlarged and the alveolar process will become rearranged to conform to the requirements of the roots of the teeth in their new positions. The peculiarities of the tissues involved and the richness of their vascular supply admit of their considerable disturbance with a very reasonable assurance that Nature will completely restore them, provided tooth movements be properly conducted.

The alveolar process has an external and an internal plate. The outer plate forms the external surface of the bone. The inner plate forms the alveoli or sockets of the teeth, and though quite loosely formed about the teeth during their eruption and for some time thereafter thus

permitting their considerable movement, gradually with advancing age it becomes diminished in size and fits the roots and necks of the teeth more closely thereby greatly limiting tooth movement without displacement of the process.

FIG. 96.



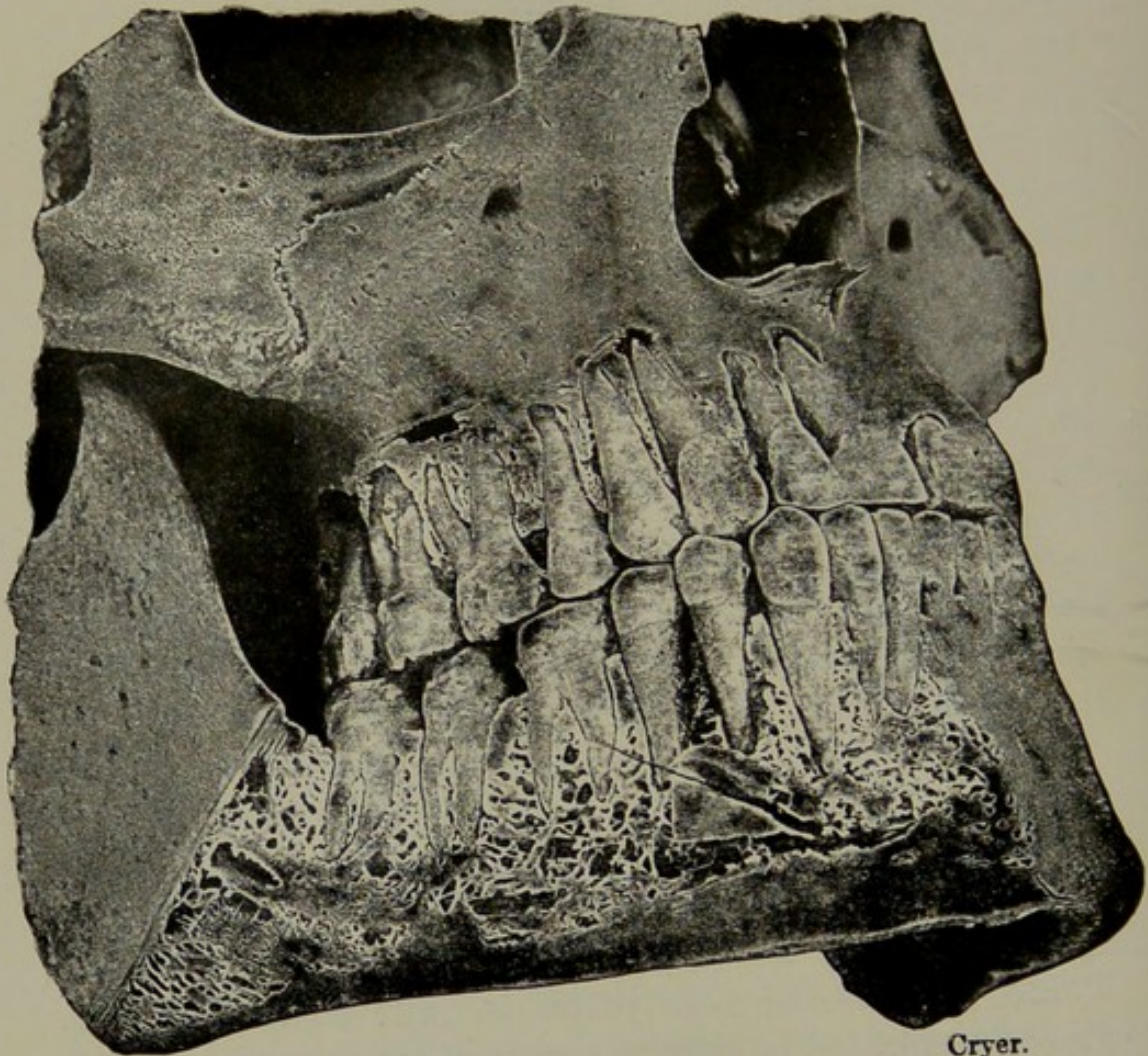
Cryer.

The structure of both plates is quite compact, but is freely perforated by minute openings for the transmission of nutrient vessels. Between the external and internal plates the bone is far less compact, being very cancellous and similar to the internal structure of the larger bones. This cancellated structure, Fig. 97, admits of considerable bending of the process without breaking, especially in the case of young patients. But as age advances the bone becomes more dense and unyielding.



In health the alveolar process surrounds the roots of the teeth to nearly the height of the gingival line. The thickness of the process on both the labial and lingual surfaces varies greatly over different portions of the roots and in different individuals, but in each case the distribution is

FIG. 97.



Cryer.

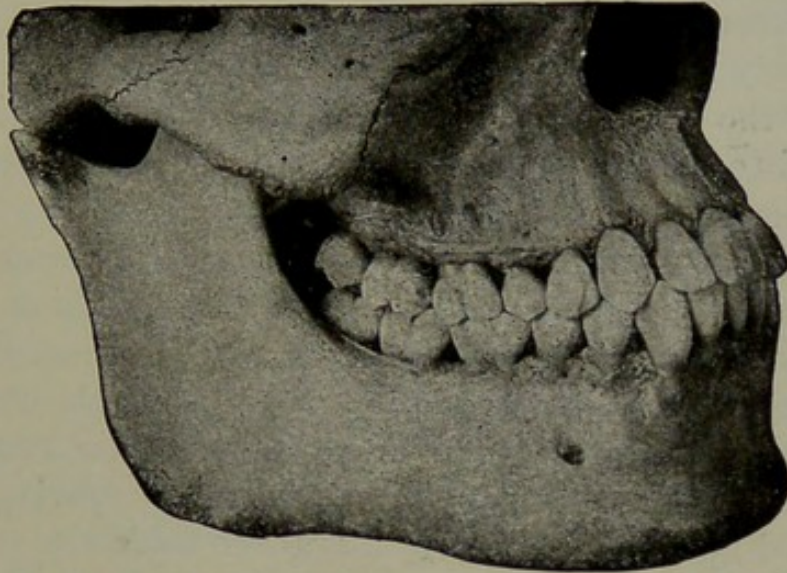
such as to best resist the strain upon the teeth incident to mastication.

It is usually very thinly distributed over the labial surfaces of the roots of the upper incisors and canines and upper third of the premolars and molars, always presenting more or less of a fluted appearance (very noticeable in carefully made models) which is readily detected by pres-



sure of the finger, enabling us to trace quite accurately the exact positions of the roots of these teeth, as shown in Fig. 98.

FIG. 98.



Broomell.

The process at its immediate margin is thin, but abruptly thickens on the buccal surfaces of the upper molars and premolars amounting to a well-defined ridge fully one-eighth of an inch in thickness in some instances, then growing very thin as the apical third of the root is approached, portions of the roots being sometimes wholly uncovered.

On the lingual surface of the upper teeth it is also very thin at the margin, gradually and evenly thickening toward the ends of the roots, and forming the curve of the vault of the arch. That portion, however, covering the roots of the second and third molars assumes quite a uniform thickness in order to form the groove and fossa for the posterior palatine artery.

That portion covering the buccal roots of the lower teeth is thin at the margin, gradually and evenly becoming thicker toward the center of the body of the jaw to form the external oblique ridge, while the labial plate covering the roots of the incisors and canines is thickest near the margin, the remainder being very thin and sometimes



even missing in portions especially if the root be markedly prominent.

Its distribution over the lingual surface of the roots of the lower teeth is thin at the margin, gradually thickening toward the mylo-hyoidian ridge.

Strongly adherent to, and closely covering, the external plate of the alveolar process is the periosteum, which in a modified form dips down into the alveoli to form the peridental membrane.

**Peridental Membrane.**—The peridental membrane is a strong, fibrous membrane forming a close, cushion-like investment of the roots of the teeth, and is the medium of attachment between the alveolar process and cementum. It is composed largely of fibers of inelastic connective tissue, and is richly supplied with nutrient vessels, nerves, cells, and glands. Its function is three-fold:

First, vital, for the formation of the alveolar process on one side and the cementum on the other.

Second, sensory, through which the most delicate touch of the tooth is felt.

Third, physical, holding the tooth in position in the alveolar socket and resisting the movements of the teeth in the various directions. It also supports the soft tissues about the teeth.

**Cells.**—There are five kinds of cells found in the peridental membrane:

First, the fibroblasts, for formation of fibers of the membrane. These are spindle-shaped cells lying between the fibers.

Second, osteoblasts. These are cuboidal cells for formation of the alveolar process, and are found close to the layer of bone or imbedded therein.

Third, cementoblasts, or formative cells of the cementum. These flattened and irregular cells are in close contact with the surface of, and imbedded in, the cementum.

Fourth, osteoclasts, or cells whose function it is to dis-



integrate calcified tissue, and which vary greatly in numbers and location.

Fifth, glands, the function of which is as yet imperfectly understood.

**Arrangement of Fibers.**—The arrangement of the fibers of the peridental membrane is very complex. More than a general description is here impossible. The course which the fibers take varies greatly in different portions of the root. Figs. 99 and 100 show a longitudinal section of the tooth, membrane, alveolar process, and gum, which will give a general idea of the arrangement of these fibers.

It will be seen that those about the neck of the tooth pass outward more or less at right angles, some blending with the gum, other branches curving up to support the gingiva, while others blend with those at the beginning of the alveolar process. Still others anastomose with those from the gingival portion of the adjoining teeth, forming a tough ligament known as the dental ligament.

The manner of attachment of the fibers to the alveolar process at its beginning is noteworthy. Not only are they united to it at points nearest the cementum, but some are attached at the top of the bone, while others pass over to form a union with the alveolar process on its outer surface (well shown in the microscopical section illustrated in Fig. 100), thus making the strongest possible attachment for the resistance of strain.

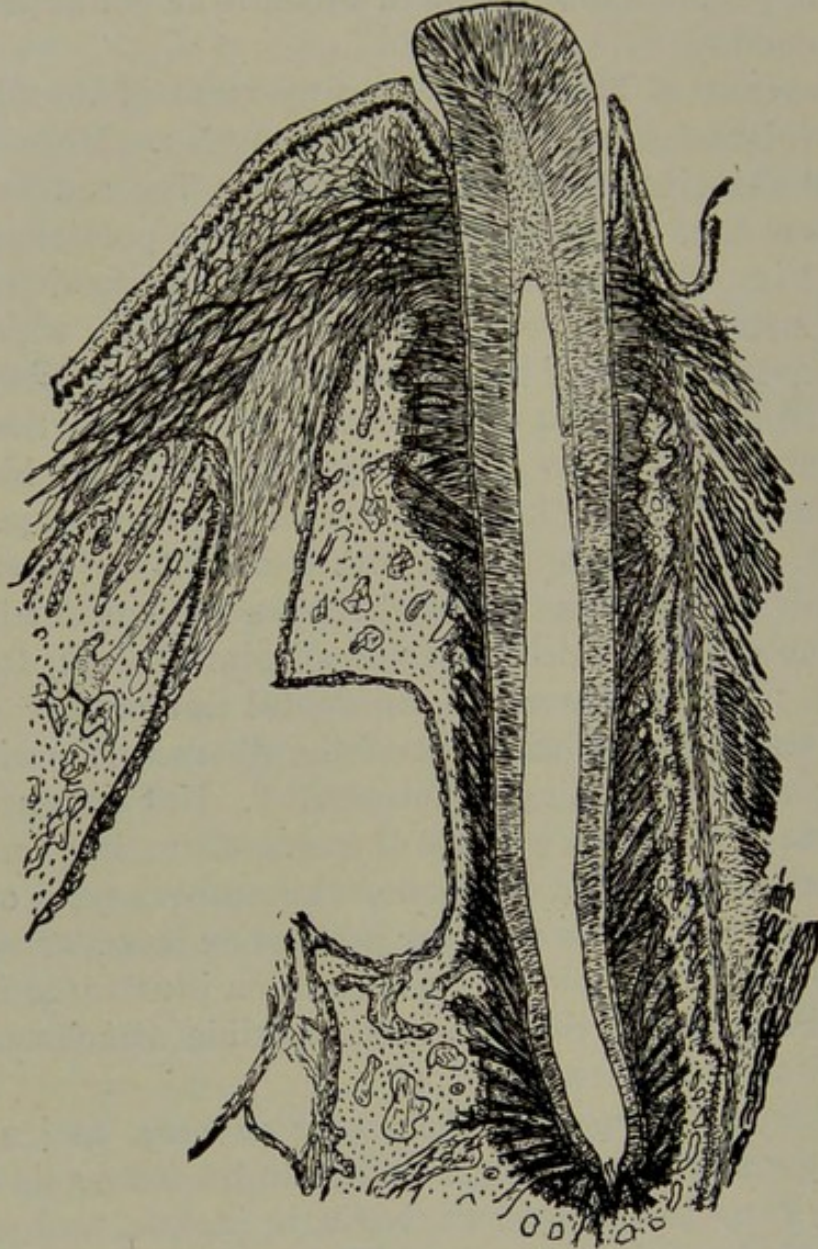
At the beginning of the alveolar process, and a little below, the fibers are at right angles to the long axis of the tooth. They soon, however, begin to incline, and a little farther down their course is oblique until near the apex of the root. These serve to suspend the tooth in its socket. We will call them the suspensory fibers. As we near the apex of the root the fibers again assume a direction more or less horizontal, while at the apex their course is at right angles with the surface.

Fig. 101 shows a transverse section of the alveolar por-



tion, in which the general arrangement of the fibers from

FIG. 99.

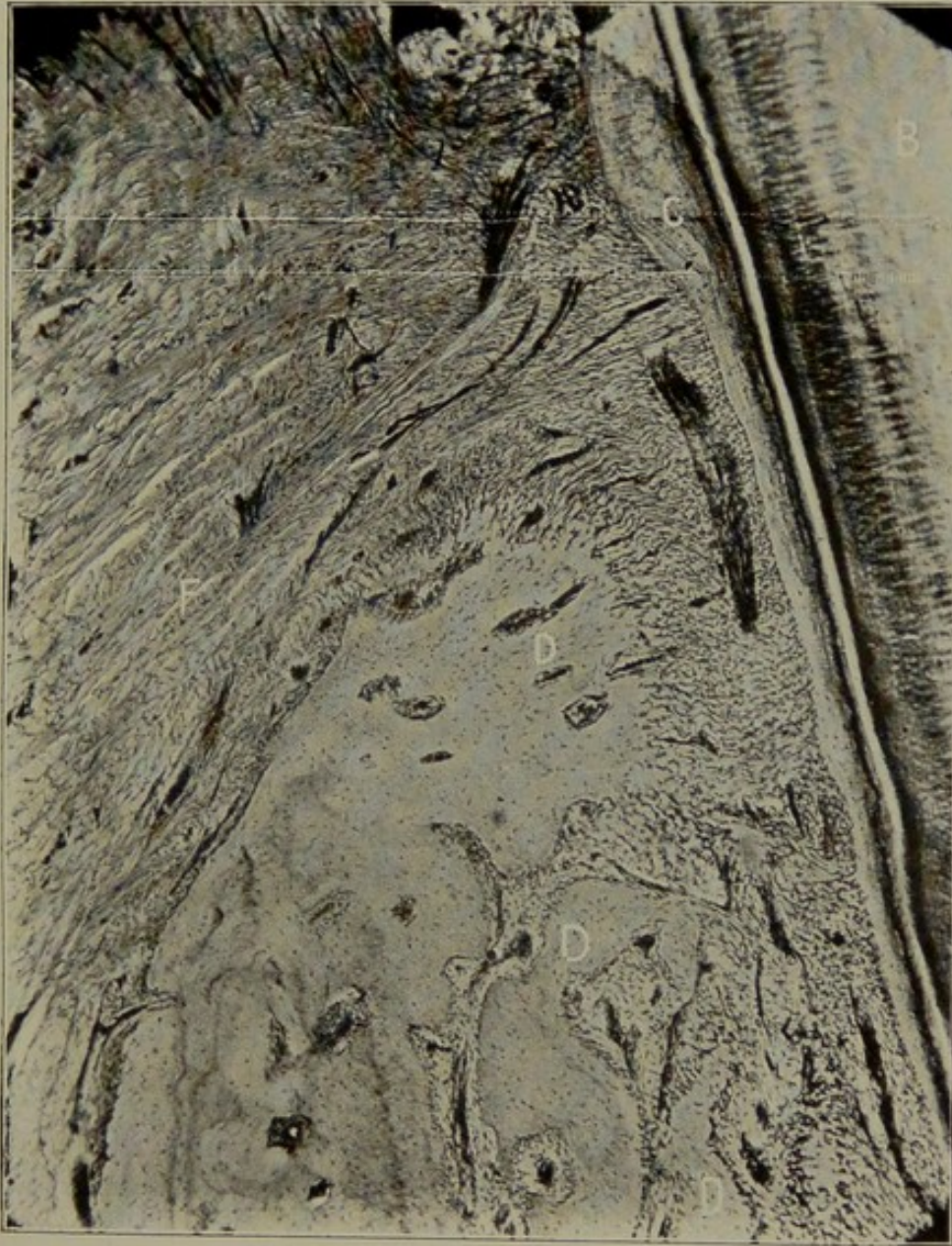


A drawing of a longitudinal section of an incisor of a kitten with crypt of permanent tooth. The labial is to the right and the lingual to the left. The bone is represented in the light stippling. The thinness of the labial plate of the process is shown, with the periosteum and the muscle attached. The lingual plate of the bone is much thicker. (Noyes.)

this aspect is well shown, and it will be seen that some of the bundles of fibers pass out from the cementum at right



FIG. 100.

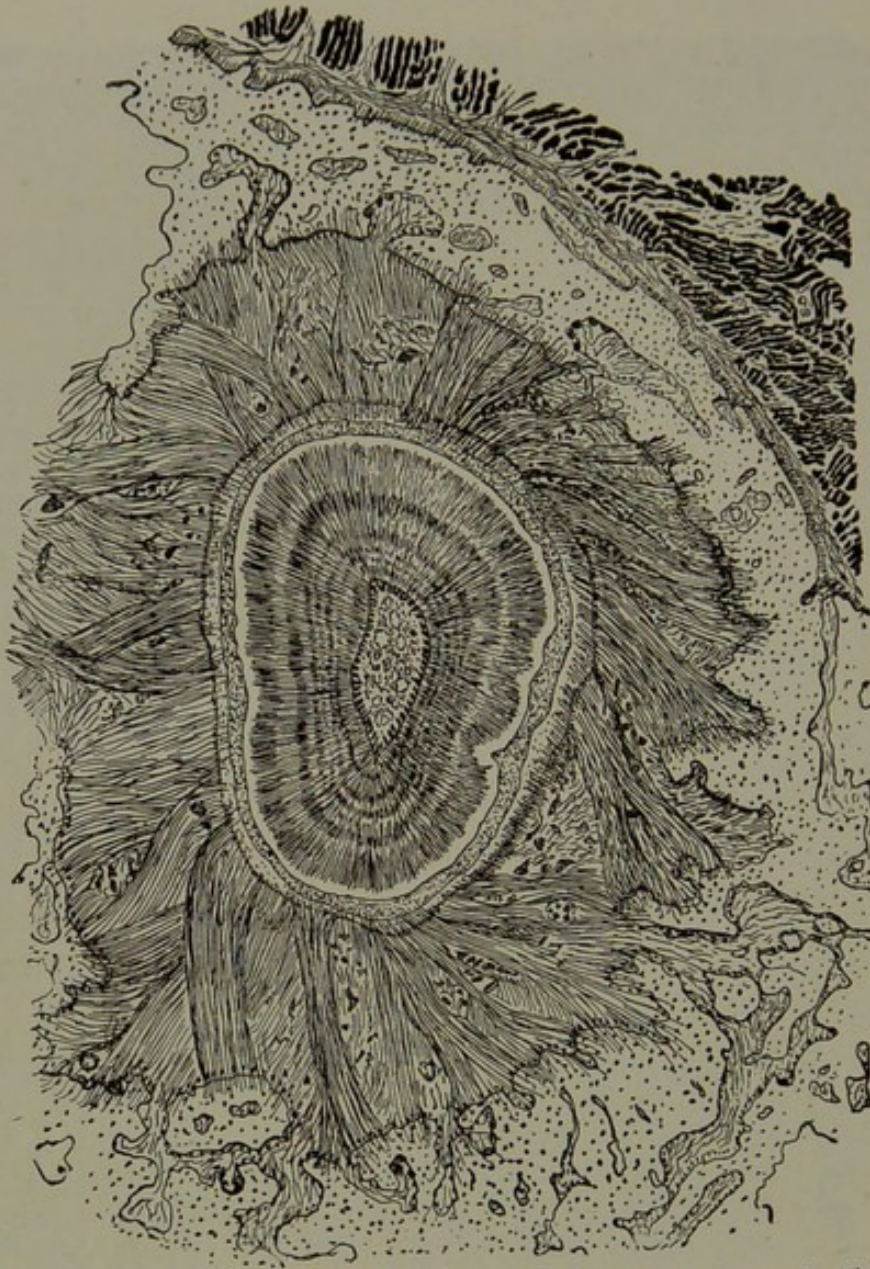

Longitudinal section of the peridental membrane, showing the gingival and upper third of the alveolar portion.

B, dentin, showing the light band at the outer border. C, cementum, showing at the occlusal extremity a thickening where the fibers which pass up to support the gingivæ are attached. D, bone of the alveolar process. The short, strong fibers which support the tooth against lateral strain are seen stretching from the cementum to the bone. A bloodvessel cut longitudinally is seen crossing these fibers. (Noyes.)



FIG. 101.



Drawing of a transverse section of the periodontal membrane in the upper third of the alveolar portion, showing the thickness of the labial plate, with periosteum and muscle attached, and the fibers resisting rotation.

The tooth shows two layers of cementum. The bone is represented by the lighter stippled part, which shows its spongy character. On the mesial side (to the left) the septum is not complete and the fibers pass to the distal of the incisor, which is not shown. The labial plate of bone (above) is very thin, and shows the periosteum with its two layers and the muscle attached to it. (Noyes.)



angles to its surface and pursue the shortest course to the alveolar process, while other bundles are sent out at different angles and cross on their way to the alveolar process. Others still curve laterally, this course being more pronounced at the angles of the root, especially the labial angles, to prevent the turning of the tooth in its socket. The course of these fibers is especially well shown in the reproduction of the microscopical section in Fig. 102.

The fibers soon after arising from the cementum break up into smaller fibers which pursue a more or less parallel course, or in some instances pass around the numerous nerves and bloodvessels in their course outward. These again unite into larger and coarser fibers as they approach the alveolar process. In young subjects a large portion of the alveolar process is often missing between the teeth, as in Fig. 102, in which case the fibers pass directly across to unite with those of the adjoining teeth.

The attachment of the fibers to the cementum and bone is most secure, the ends being literally built into the bony substance, actually penetrating the cementum to its union with the dentin, while the alveolar portions, in addition to the strong attachments gained by the numerous bay-like excavations in its surface, also penetrate the very substance. In reality the bone has been deposited about the fibers, or the fibers built into the bone.

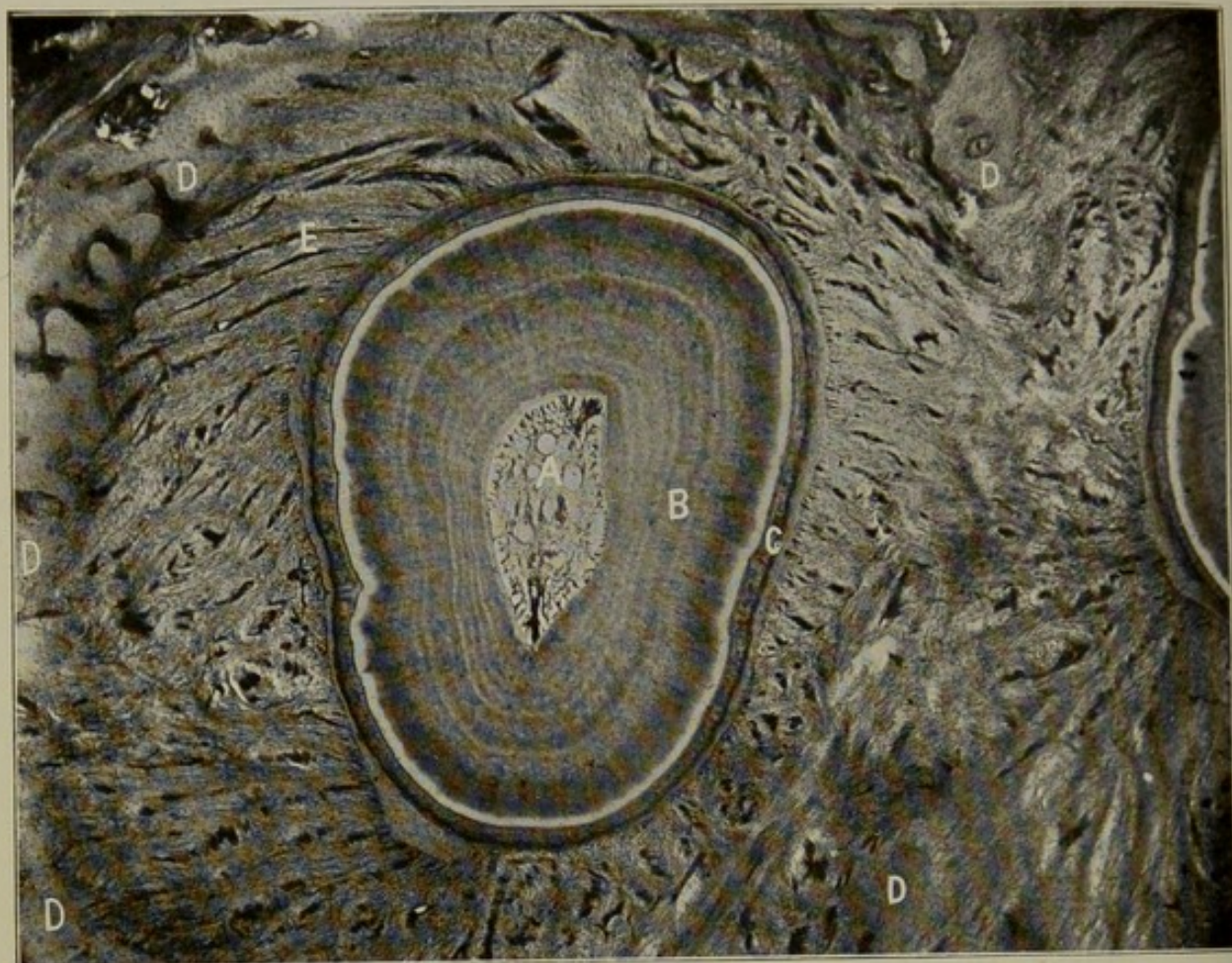
Although the fibers are composed of inelastic tissue and their attachment is most secure, yet it is known that the teeth admit of a slight movement normally. This wise provision doubtless often prevents shock or fracture, and permits a better adaptation of their occlusal planes in masticating food, thus rendering them more efficient. This slight movement is probably due to the bundles of fibers pursuing different directions in their course, so that none is on actual tension until the slack, so to speak, is taken up.

No thoughtful person can study the arrangement of the fibers of the peridental membrane without being impressed



with their wonderful perfection for resisting the displace-

FIG. 102.



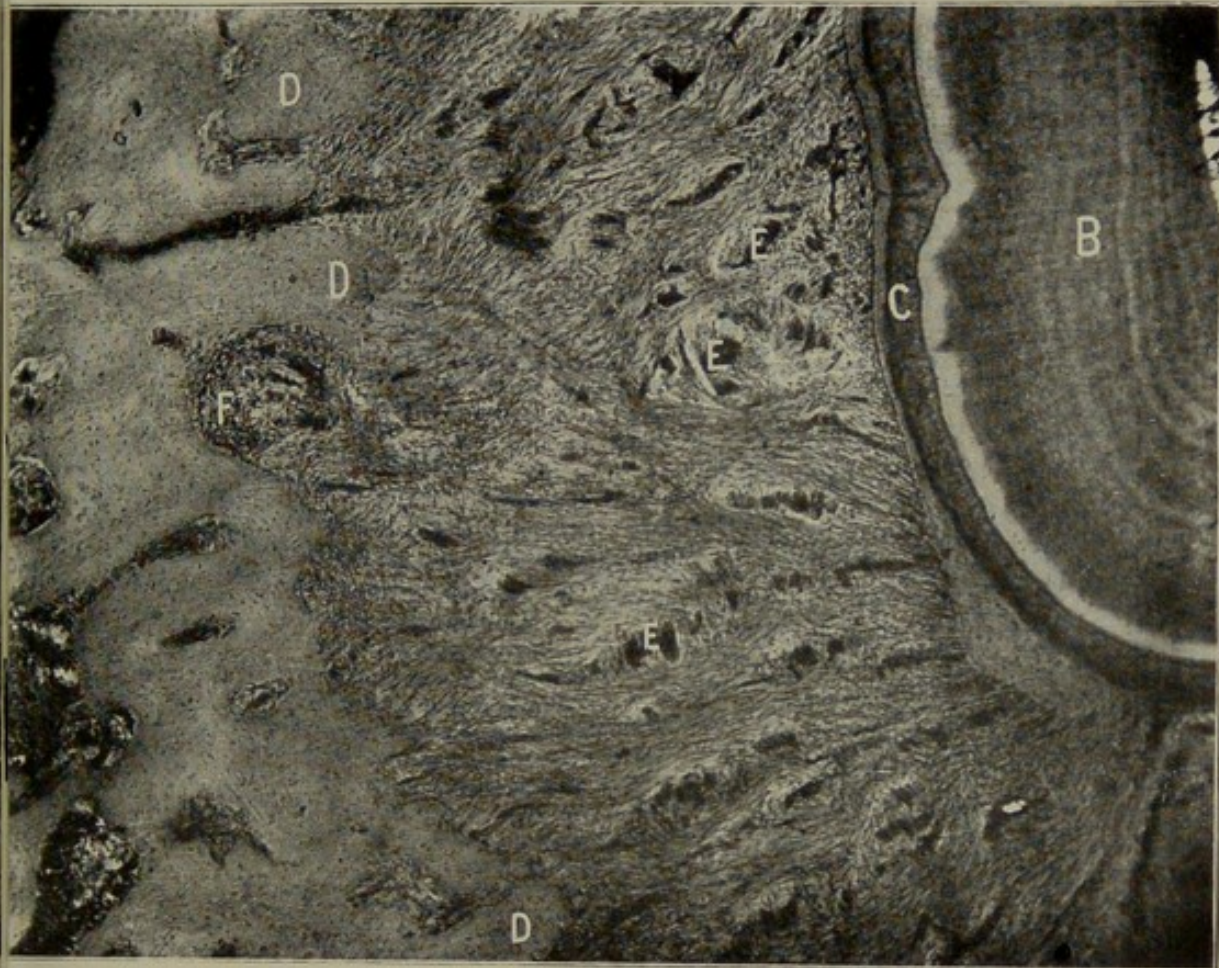
Transverse section of a lateral incisor and its membrane from the occlusal third of the alveolar portion. A, the pulp, showing bloodvessels and nerves. B, dentin. C, cementum, showing two layers. The outer of the two layers of cementum shows at several points greater thickness, where cementum has been built up around the fibers to attach the strong bands that resist rotation. D, bone of the alveolar process. E, dark spots representing indifferent fibrous tissue surrounding and accompanying the bloodvessels and nerves, or fibers which run in a plane at right angles to the section. On the right side the fibers are seen passing from the mesial of the lateral to the distal of the central, the septum of bone not coming between at this point. At the left the fibers are seen passing from the cementum to the bone of the alveolar process. (Noyes.)

ment of the teeth incident to occlusion and mastication, and it is of special interest to the orthodontist, enabling



him to better comprehend not only the proportionate value

FIG. 103.



Transverse section of the peridental membrane, showing the fibers passing from the cementum to the bone, taken from the disto-lingual corner of Fig. 102.

B, dentin. The light band next the cementum shows the first formed layer, or granular layer of Tomes. C, cementum, showing two layers, the inner, or first formed, darker and more even in thickness; the outer, or newer, lighter, and showing a hypertrophy at the disto-lingual corner, where the cementum is being built up around the fibers to attach the strong bands which resist rotation and which are seen stretching across to the bone of the alveolar process, D. D, bone of alveolar process. F, marks a spot where absorption is going on in the bone. The small dark spots next to the surface of the bone are osteoclast cells. (Noyes.)

of the fibers for giving resistance in anchorage, but as



well, to overcome the difficulties from their resistance in the teeth to be moved.

Of the seven possible tooth movements it is well known that depressing a tooth in its socket is the most difficult. This is readily explained from the fact that by far the larger number of fibers—the suspensory fibers—directly resist this movement of the teeth as is required in mastication.

The next most difficult movement is that of rotation. While probably most of the fibers indirectly tend to prevent the tooth from turning in its socket, there are an unusual number at the four angles so arranged as to directly resist such movement.

The lingual and labial movements, less difficult to perform, have less resistance from the fibers, while to the movement of elevation direct resistance is offered only by the fibers at the extreme apex of the root and at the border of the alveolar process, and experience proves that this is by far the easiest movement to accomplish.

**Thickness.**—The thickness of the periodontal membrane varies in different periods of life, being much greater in childhood and becoming gradually less with age. This is brought about largely by the deposition of bone around the entire internal plate of the alveolar process, similar to the lamellar arrangement in the large bones. The membrane is sometimes further encroached upon by increase in the thickness of cementum through deposits by the cementoblasts around the fibers. This becomes especially marked in that pathological condition, hypercementosis, and is well shown in Fig. 103.

**Blood Supply.**—The periodontal membrane is freely supplied with blood which is derived from three sources:

First, from branches given off from the gums.

Second, from numerous branches from the alveolar process.

Third, from one or two large branches entering through

the apical space, which immediately divide and subdivide, some being given off to the pulp and others to the membrane, forming a rich plexus throughout these structures.

The advantage of these various supplies of blood is apparent, for if from disease or pressure the supply be interfered with from one source, that derived from the remaining sources may still be ample.

The question is often asked, "In the rapid movement of teeth is the blood supply to the pulp shut off?" As minute branches of vessels are supplied to the pulp, from the peridental membrane, through the foramen, as well as from the large branch entering the apical space, it is not probable that strangulation could result unless preceded by inflammation.

The vessels supplying the peridental membrane are, for the most part, found midway between the bone and cementum. In old age, however, they are found nearer to the bone, even partially embedded in it, so that their course may often be traced on the surface of the inner plate.



## CHAPTER VI.

### TISSUE CHANGES INCIDENT TO TOOTH MOVEMENT.

WHEN force is exerted upon the teeth to be moved two principal changes take place in the alveolar process. First, a bending of the process; second, absorption of the process in advance of the moving tooth and deposition of bone behind it. These changes vary greatly: according to the age of the patient, in different patients of the same age, in the direction of movement, and also in the rapidity of movement.

In youth, or before the bone has become dense by a preponderance of inorganic substance, it permits of much bending, so that incisors may be moved out of inlock in a few hours, or the lateral halves of the arch widened in a few days, or before much absorption could have taken place in advance of the moving tooth. In further proof of this the process will be found upon examination to be intact about the roots, not only on the labial side, or in front of the moving tooth, but on the lingual or opposite side, as well, it having been carried with the moving tooth. This is easily explained when we remember the cancellous structure of the bone, the inelasticity of the fibers of the periodontal membrane, and their very strong attachment to it.

Another striking illustration of the bending of the bone is in the distal movement of the canine into the space made vacant by the removal of a first premolar. The author has frequently noted that not only the septum of bone just mesial to the canine closely follows the moving tooth, but in some instances even the lateral incisor is dragged in the same direction to quite an extent, owing probably, in the main, to the strength of the fibers composing the dental ligament.



While more or less springing of the bone is probably always an accompaniment of tooth movement, yet in proportion as the bone becomes dense with age so the modification of the process attendant upon tooth movement probably changes from springing to the slower action of absorption and the still slower deposition of bone.

Coincident with the changes in the bone there are also pronounced changes taking place in the peridental membrane. As force is exerted on the moving tooth the membrane is compressed in front of it, between it and the alveolar process, while a greater tension of the fibers of the membrane takes place on the opposite side. As a result of this tension and compression the nerves of the membrane are impinged upon, causing more or less discomfort, which, however, as a result of the slight movement of the tooth and temporary paralysis of the nerves from pressure, subsides more or less quickly according to the amount of inflammation present.

As a result of this pressure the absorbent cells, or osteoclasts, are stimulated to increase in number and in activity. They immediately engage in the absorption of the portion of the bone most involved in the movement, as well as of the bone attachments of the fibers on greatest tension.

While these changes are taking place, the osteoblasts have become active and have begun filling up the depression and reattaching the fibers by the redeposition of bone; but as this is a much slower process than that of absorption the tooth is found to be more or less loose in its socket at the completion of its movement, as well as long after, necessitating its being supported by means of the retaining devices until the deposition of bone shall be complete, the fibers modified, and a normal socket formed for its support in its new position.

Rarely is the movement of only a single tooth in one direction all that is required—as the movement labially, or the rotation of an incisor. More often the movement in



various directions of a number of teeth in both arches is necessary, and frequently the combination of several movements of a number of teeth in both arches is required as, for example, the combined labial and rotary movement of single incisors, or the elevation, rotation, lingual and possibly distal movements of a prominent canine.

With a suitable appliance and the proper regard for the physiological laws governing tooth movement all necessary movements of all teeth may be carried on simultaneously and with but little discomfort to the patient, if undertaken at the proper age.

If a tooth be mechanically elevated in its socket the change chiefly involves the peridental membrane. The fibers at the end directly resisting this movement are severed, and the oblique or suspensory fibers are stretched and recurved upon themselves. The result of the partial withdrawal of the conical root is increased space, not only at the end but also on the sides of the root, so that there is considerable freedom of movement of the tooth, necessitating the deposition of bone over the entire surface of its socket, as well as increase of height of margin. Not only this, but there must be entire reconstruction of all the fibers, and especially of the suspensory, which experience proves requires much time, especially when the movement of elevation is performed after Nature has ceased her efforts at further eruption.

In the movement of depression the bone must be absorbed by the osteoclasts over the entire surface of the alveolus to allow for the advance of the root of conical form. The fibers of lateral support are stretched, while the suspensory fibers are also stretched and severed at their points of attachment to the bone, thereby necessitating more disturbance of tissues and requiring more force and time than any other of the seven movements.

In the rotation of a tooth in its socket little change by springing or bending is probable, the principal change



being absorption of the bone and of those fibers along the entire length of the root that directly resist this movement. Thus is made plain the necessity for so great an amount of force in performing this movement.

In all cases of tooth movement a large number of the fibers of the membrane remain on tension long after its completion (due principally to the recurrent spring of the bone), their force tending to draw the tooth back to its original position, and necessitating considerable support from the retaining devices until the tissues have become thoroughly re-established in harmony with the tooth in its new position.

In accomplishing the movement of teeth lingually, labially (or buccally), mesially, or distally, the principal change is in the position of the crown of the tooth, it being tipped into its correct position. The usual supposition is that the tooth in the alveolar process acts as a lever, the crown, or long end of the lever, moving in one direction, and the apex of the root in the opposite direction. To make clear these supposed changes, and especially the extent of the movement of the apex, writers have frequently used the illustration of a post driven into the earth about one-third of its length. If force be exerted at right angles to the post near its top the post will act as a lever in the displacement of the soil, the two ends of the lever moving in opposite directions and the pivotal point being somewhere near the beginning of the last third of the embedded portion.

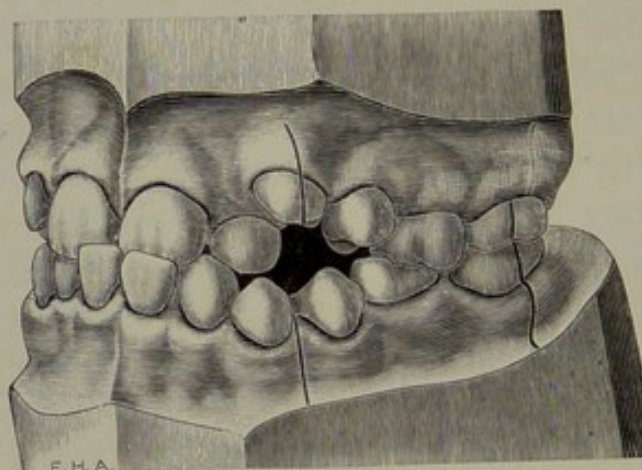
The illustration is a poor one and very misleading, as the mechanical conditions are very different. Doubtless this would be the result if the tooth, like the post, had but one resistant substance and that equally distributed in all directions about its root, but as we have already seen in the study of the alveolar process, the bone varies greatly in thickness over different portions of the root and in different teeth, so the amount of displacement of the apex



depends, oftentimes, upon the location and movement of the tooth and whether one tooth or a number in the same region are being moved in the same direction. In reality there may be little or no displacement of the apex, or there may be considerable.

In the first place, the alveolar process is not a level plane, like that in which the post is implanted, but a projection or high ridge, of elastic structure, admitting of much bending, its susceptibility to this action increasing proportionately as we approach the top. The labial movement of the incisors, as necessary in Fig. 104, especially

FIG. 104.



favours this bending, which is also a matter of common observation in efforts at extraction.

Again, the mechanical difference between the attachment of the post to the soil and the tooth to the alveolar process is such as to produce still further difference in the results of their movements. As the apex of the root is implanted deep in the bone, which is greatly thickened in its lingual direction and reinforced by the strong cortical layer of the alveolar process, its movement lingually could not well take place as a result of springing. This movement is further strongly resisted by the innumerable inelastic fibers that encapsule the apex, radiating in all directions



to effect the firmest attachment possible to the bone, their ends being enclosed in its structure.

So in the labial movement of the crown, the lingual movement of the apex of the root is not only resisted by the bone in front, but also behind and on each side, by reason of its attachment, while in the case of the end of the post little, if any, resistance is offered by the soil behind or on either side, but only by that in front.

Another difference. The force for the movement of the post is applied remotely from the fulcrum, while the force exerted on the tooth by the ligature is applied closely to the fulcrum, or at a point best calculated to facilitate the bending of the alveolar process in the labial direction.

Again, unlike the single post, several teeth may be associated in the movement, which adds still further to the possibilities of the labial, and correspondingly to the impossibilities of the lingual, movement of their apices.

In the lingual movement of incisors there are much greater possibilities for the movement of the apices of the roots in the opposite direction, owing to the lesser resistance offered by their thin covering of bone labially and its much greater thickness on the lingual surfaces of the roots. The result is often noticed following the reduction of protruding incisors, as in those cases belonging to Division 1 of Class II.

In the similar movements of the upper canines and premolars practically the same changes in the positions of the roots follow.

In the movement buccally of the upper molars there is bending or absorption of the outer plate, and the palatine roots are elevated in their sockets to make easier the tipping of the crown, with probably no movement at the apices of the buccal roots, unless it be that they are forced more deeply in their sockets. In the opposite or lingual movement of these teeth these movements are reversed.

In the buccal movement of the lower molars there is



greater displacement of the apices of the roots in the opposite direction from which the crowns are moved, owing to the great thickness of the buccal plate of the alveolar process.

In the movement of teeth mesially or distally there can be little or no bending of the labial and lingual plates, the chief resistance now being offered by the septa and the periodontal attachments, and the movement of the teeth more nearly resembles the movement of the post, the apex moving considerably in the opposite direction from the crown, which is always noticed in the unpleasing angle of the canine after the retraction of its crown.

**The Pulp.**—While the pulp of the tooth is a tissue more or less involved in tooth movement, yet when the operation is properly performed this tissue is practically undisturbed and should suffer no real injury. On the other hand, its normal function may be so interfered with as to cause it to suffer marked disturbance and even complete devitalization, especially if the movement be conducted too rapidly or the force too abruptly applied. The principal danger, however, arises from congestion and inflammation of the tissues of the apical space, causing the partial or complete strangulation of the vascular supply to the pulp. In view of these facts it should be our aim to prevent, as far as possible, all tendency toward inflammation. If the pulp becomes partially congested, as is usually evinced by much sensitiveness to pressure and to thermal changes, and a slight change in color which shows through the enamel, the tooth should be allowed to remain passive for several days, when, usually, these symptoms will subside. The author has noticed several instances where these symptoms have been markedly manifest and have wholly subsided under palliative treatment. Sometimes, however, complete devitalization will follow, and while the death of the pulp under these conditions is to be regretted, the consequences



are not of sufficient importance to occasion any more regret than when it occurs in the treatment of teeth for caries.

The principal evil following the death of the pulp in these cases is the possible permanent discoloration of the crown, which is more liable to follow the speedy death from strangulation than the slow devitalization from the encroachment of caries. For this reason, whenever complete devitalization of the pulp shall be apparent it should be immediately removed and the tooth treated, and the canal filled after the best prescribed methods, when the further movement of the tooth may be conducted without greater fear of inflammation than if the pulp were intact.

In like manner, if it be desirable to change the position of a tooth having an already devitalized pulp, it may be undertaken without hesitancy, provided the surrounding tissues be healthy and the pulp canal first properly cleansed and filled.

It is often desirable to perform tooth movement soon after the eruption of the teeth, or before the root is fully formed, its end then having a broad, funnel-shaped opening. If the movement be properly performed the pulp should suffer no greater disturbance than when the root is fully calcified. In fact there is less probability of strangulation and death than later when the foramen is greatly diminished in size.



## CHAPTER VII.

### PHYSIOLOGICAL CHANGES SUBSEQUENT TO TOOTH MOVEMENT.

So far we have considered the physiological changes which take place in tissues during tooth movement, but we must remember that certain very important changes which were practically unrecognized prior to the publication of the last edition of this work, also occur subsequently to tooth movement.

To better understand these changes we must keep in mind the conditions previously existent. The development of malocclusion is gradual, and in proportion as the functions and positions of the teeth deviate from the normal there is necessitated a corresponding deviation in the development of the alveolar process, and, to a greater or less degree, in the bones of the jaws, vault of the arch, the nasal tract, and the muscles of the face. All being out of harmony, the tendency, as we have seen, is usually to favor still greater inharmony, or departure from the normal, as growth and development progress.

After the crowns of the teeth have been moved into correct positions in the line of occlusion, and harmony of the occlusal planes established, the direction of force has been so changed as to exert a different and more normal influence upon the tissues of the alveolar process and bones of the face. The result of this stimulus is to awaken Nature to continue the building of the denture in accordance with her original plan and the type of the individual.

Evidences are common throughout surgery of Nature's wonderful inherent power to remedy her defects, and of her prompt response as soon as favorable conditions are established. The natural changes following the intelligent



correction of malocclusion are always pronounced and gratifying, and often even surprising.

The cognizance of these changes reveal greater possibilities in art and in establishing the normal in occlusion, and should, in many instances, modify our plan of treatment by obviating the apparent necessity for extraction; and it should also lend greater importance to the question as to the proper time for treatment.

Very frequently where there has been change of position of a number of teeth, especially in both arches, some may occupy planes of greater elevation than others, or the cusps of some may not occupy exactly normal mesio-distal relations, but if we have succeeded in placing the teeth so that their inclined occlusal surfaces sufficiently favor their normal positions, their proper heights and relations will become established through use and the growth of the alveolar process. In some cases the incisors may apparently be too short, but after a few weeks or months of growth, when the buccal teeth shall have become settled in their new positions, the length of overbite will gradually become normal, especially in young patients.

FIG. 105.

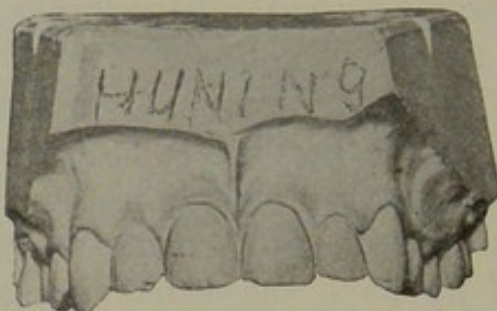

Another noticeable and important change is that following the labial movement of the crowns of a number of incisors, as in Fig. 105. The crowded and bunched positions of the incisors have caused marked arrest in the development of the alveolar process in the region of their apices,



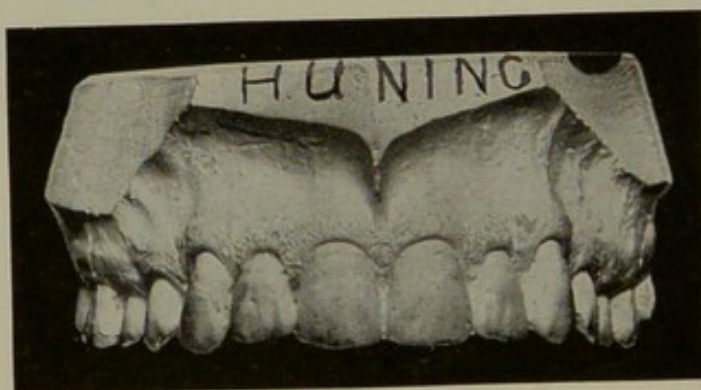
so that after correction these teeth are found to stand at a very pronounced angle, with a very abnormal depression in the region of the apices of their roots, Fig. 106, and an apparent overprominence of the lip, often suggesting the impossibility of their being maintained in such

FIG. 106.



positions, but the crowns of the teeth now being in normal occlusion, Nature is stimulated to continue the development of the alveolar process, and to shift the apices of the roots labially to normal positions, so that in due time there will be the full normal contour of the alveolar process and the teeth will stand at a normal angle, the result being a cor-

FIG. 107.



responding improvement in the contour of the face in the region of the base of the nose—a normal result—which could not have taken place had extraction been resorted to.

The changes here outlined are shown to have taken place in Fig. 107, which represents a model of the corrected case made three years later than that shown in Fig. 106.



The growth of the alveolar process and the shifting of the roots of the teeth toward normal positions as a result of the stimulus following the establishment of normal occlusion seems to vary in different individuals and at different ages of the patients.

As there are no records of other cases outside of the author's practice, this being the first case reported,\* the author is as yet uncertain as to whether there is an age limit in this growth. He is certain, however, that up to the time of the eruption of the canines the response in growth will be most noticeable and gratifying. Probably there is no age at which Nature would not make an effort to complete the development of the alveolar process thus arrested, and succeed to a certain extent. This is an important point which awaits complete investigation, as, if there be an age limit, a need for extraction may thus be furnished, constituting practically the only case to be conceived of by the author outside of deciduous teeth too long retained, supernumerary teeth, or abnormal conditions so extensive as not to be amenable to general laws, but which must be indeed very rare.

It seems to the author that the rules which govern the growth of the alveolar process subsequently to tooth movement are in accord with its normal growth under normal conditions, being most rapid during the period covering the eruption of the incisors and growing noticeably slower after the eruption of the canines.

There are many pronounced changes following tooth movement and the establishment of normal occlusion, in the growth of the alveolar process, in the size and form of the vault of the arch and in the nasal passages and jaws, and also changes in lips and tissues about the mouth—all of which is exhaustively discussed in the chapters on Treatment.

---

\* Angle, MALOCCLUSION, sixth edition. See also the further discussion of this case—page 340.



## CHAPTER VIII.

### MODELS.

**Materials for Impressions.**—In deciding upon a proper course of treatment in any given case it is of first importance to obtain very accurate models of both dental arches. Such models assist in determining not only the variation from the normal and the class to which the case belongs, but also the proper plan of treatment, and are exceedingly valuable as references during its continuance. From such models accurate measurements may be made from time to time for comparison with the natural teeth. In this way may be judged not only the exact movements of the malposed teeth, but any unfavorable movements of the anchor teeth may be detected. These models are valuable only in proportion to their accuracy, and those most nearly approaching accuracy are made from plaster impressions. They must show not only both arches and the relative positions of the teeth and cusps, as well as the vault of the arch, rugæ and gums, but also as much of the roots and positions of the same as are indicated by the gums and alveolar process up to the point where the attachment of the muscles renders obscure the further shape of the jaw.

It is frequently stated by the writers of the "old school" that models sufficiently perfect can be made from impressions taken in modeling compound or other of the plastics. There is no fact better known in dentistry, however, than that an impression of the teeth made with such materials can only remotely approach accuracy even where the teeth are in normal position. The shape of the jaw, together with the shapes and inclination of the teeth, make the removal of a plastic impression, without change of form, impossible. Of the degree to which arrest of development



of the alveolar process has taken place, especially in the region of the roots of the incisors, so important to accurately record in the model, only the merest supposition can be gained from a model made from a plastic impression. From the large number of models of this kind which the author receives each year from dentists, few of which even approach accuracy, it is evident that the value of correct models is not sufficiently appreciated. It is quite probable that those who object to plaster impressions have never learned the correct method of taking them, otherwise they would find but little, if any more, trouble to themselves, or objection from the patient, than in using the plastics.

**Method of Taking Impressions.**—If the student will carefully observe the following simple plan for taking impressions and making models he will find, after a little experience, that the method is not difficult and that the most perfect results are possible. He must, however, observe extreme care and accuracy in each stage of the operation. We may as well remark here that a careless operator could never hope to be successful, and had better remain content with the unreliable results from plastics.

First, the teeth should be thoroughly cleansed from all tartar or soft deposits. For this the little soft-rubber cup disk used with pumice is excellent. Care should be taken not to wound the gums, as any bleeding prevents sharpness in the outline of the gingivæ in the impression.

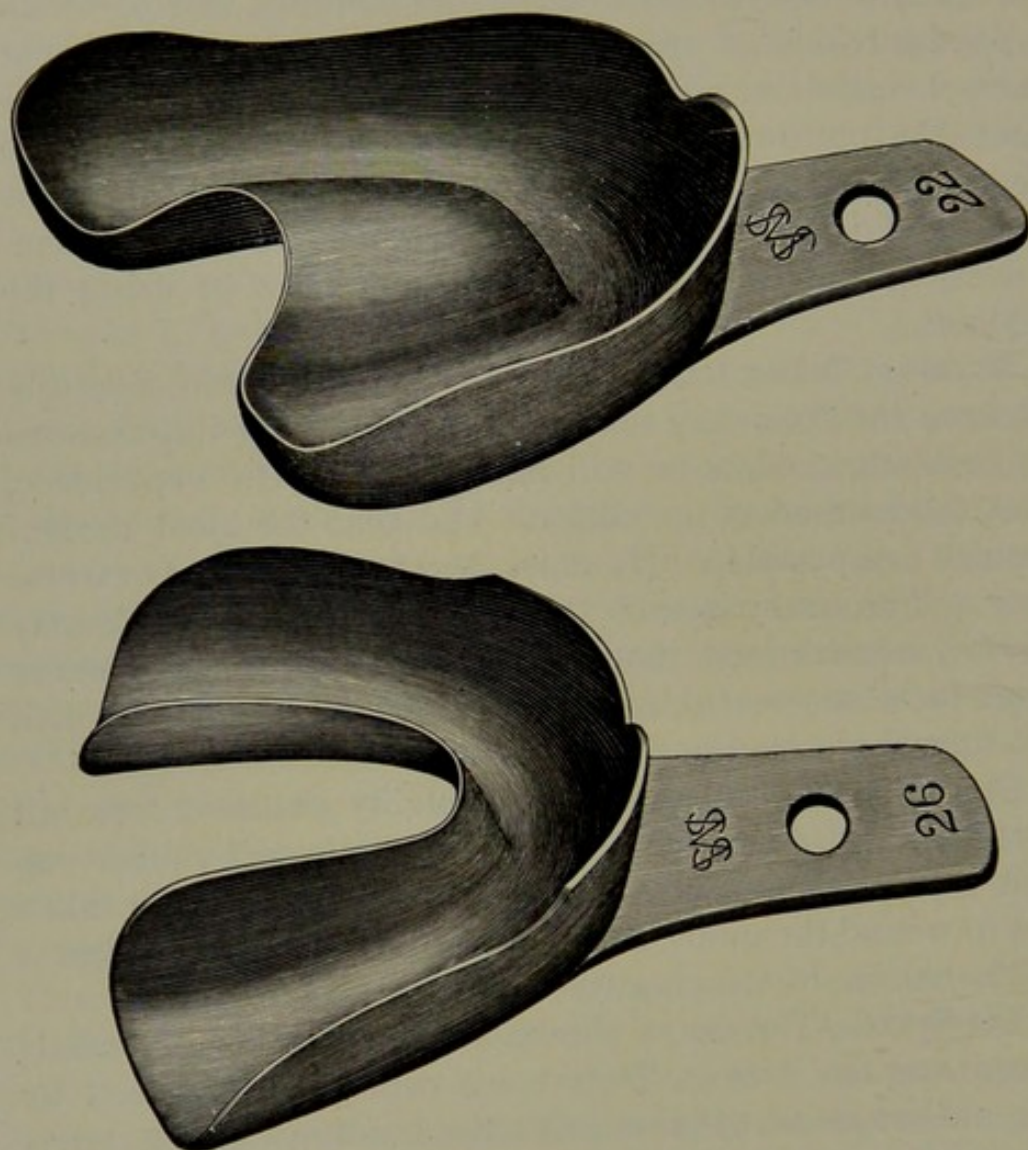
**The Trays.**—The trays shown at Fig. 108 are essential; there are five sizes. They were especially designed by the author in accordance with the anatomy of the parts for taking impressions of complete or partial dentures, the rims and vaults being much higher than in the ordinary trays which were all designed for taking impressions of edentulous jaws. It is very important that they should always be kept thoroughly smooth, bright, and clean. When not in use they should be wrapped in clean



cotton-flannel to prevent marring by contact with each other.

In taking an impression care should be observed to select a sufficiently large tray, which should be bent to conform

FIG. 108.



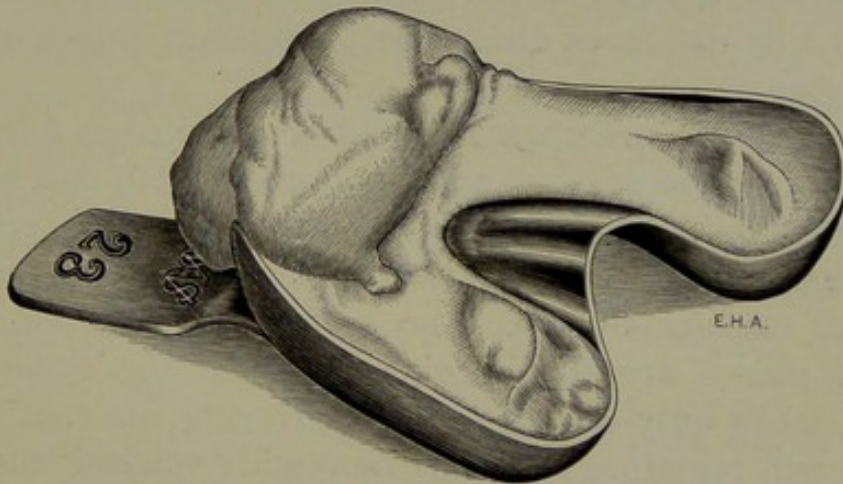
more perfectly to any peculiarity in the shape of the jaw. This will not injure the tray. The proper size and shape will be best determined by trials in the mouth.

**Taking the Upper Impression.**—Good impression plaster is mixed in the usual way to quite a stiff consistency and

carefully distributed, as shown in Fig. 109, the shape and height of the trays making but little impression material necessary. It will be observed that the greater amount is placed in the anterior part of the tray, and heaped up and extended over the outer edge of the rim, none being allowed in the vault of the tray.

It is now placed squarely in position and the plaster allowed to rest evenly in contact with the occlusal edges of all the teeth, *but not yet forced up into position*. The lip is then raised and the plaster extending outside of the rim is carried high up underneath the lip with the finger;

FIG. 109.



this is to insure expulsion of air, as well as a high impression. The patient is now instructed to allow complete flaccidity of the lips. The tray is then forced up evenly until the points of the teeth touch the bottom of the tray, and is steadily supported upon the end of the *index finger only*. To expel the air from the cheeks they are now gently manipulated, but *not drawn down*, as this would expel a considerable portion of the plaster and prevent one of the important objects, namely, a very high and accurate impression.

There being no surplus plaster in the vault of the tray, little, if any, can be forced in contact with the soft palate,



to cause nausea. The patient will therefore not be inconvenienced and the impression may be allowed to remain until it has become thoroughly set, which is very important, as the harder the plaster becomes the more perfect will be the impression. If removed too quickly a film of the plaster will be found adhering to the surfaces of the teeth.

The tray must now be loosened and taken away, leaving the impression in the mouth. It is essential that the tray should loosen easily from the impression, hence the importance of its being kept clean, bright and smooth.

**Removing the Upper Impression.**—All superfluous pieces of plaster should be carefully removed with a pair of pliers, and the saliva and soft portions of the plaster thoroughly removed by means of numerous pledgets of cotton of generous size.

Two grooves are then scraped or cut in the hardened plaster on a line parallel with the canine teeth, but not cut quite through. Then with a quick pry with the point of a pen-knife the anterior plate is loosened and laid, together with all subsequent pieces, on a clean blotting pad. The lateral pieces are then broken off with the thumb and finger, when only the large piece covering the roof of the mouth will remain. This may be readily worked loose and if the operation has been carefully performed the impression will consist of four pieces, although a much greater number would in no way injure it. Great care should be observed to save all small pieces, and to immediately place them near their original positions in the large pieces. The edges of the pieces to be united must be kept free from all fragments of plaster, which may necessitate the washing of each piece separately under the faucet.

**Taking the Lower Impression.**—In like manner the impression of the lower arch is secured, being careful to observe the essential points, namely, carrying the impression material, which has been built up and outside of the anterior part of the rim of the tray, well down beneath the lip *with*



*the finger* before forcing the tray home, then expelling the air by gradually working the cheeks while the tray is steadily held by the ends of two fingers of the left hand, one resting on the top of each lateral half. The handles of the trays are only used for their insertion and removal.

While thus supported the folding in of the cheeks between the gums and distal portion of the tray should be guarded against by gently forcing them outward and backward with the finger.

To guard against the infolding of the tongue it should be raised and gently drawn forward, then allowed to settle back into an easy position.

**Removing the Lower Impression.**—In removing the lower impression, in addition to the labial grooves parallel with the long axes of the canines, it is often desirable to make two similar grooves in the lingual portion of the impression. Sometimes a single groove between the central incisors will be sufficient. The exact number and location of grooves in both impressions should vary according to the positions of the teeth, and should be carefully planned before inserting the impression material.

**Removing Impressions from Arches with Spaces, due to Loss of Teeth.**—In the case of an impression where one or more of the teeth are missing, the difficulty of removing it by ordinary methods is greatly increased. There are two plans, however, by which this difficulty can be easily overcome and accurate impressions of the most difficult partial dentures secured.

The first is by cutting a deep additional groove in the impression mesio-distally in the space of the missing tooth. The lateral halves of the segments are then readily sprung apart and the pieces dislodged. The peculiarities of these spaces should be carefully studied before inserting the impression in the mouth.

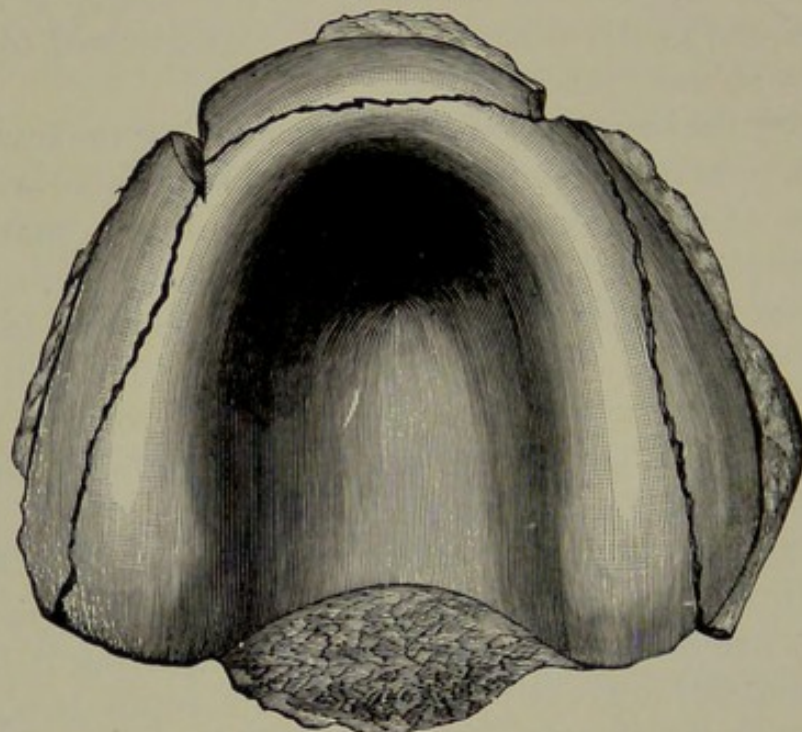
Another excellent plan for weakening the impression at exactly the same points is to insert a piece of thin metal



or tough cardboard in the space of the missing teeth, the pieces being held by the approximal surfaces of the teeth at either end, the lower edge resting upon the gum, while the upper edge should be on a line parallel with the occlusal surfaces of the teeth. By this method grooving will be unnecessary.

**Uniting the Impression.**—After removing the pieces of the impression, they should be dried somewhat before uniting,

FIG. 110.



never, however, allowing them to become thoroughly dry, as when drying ununited they seem to warp somewhat, and when put together after so drying do not form a perfect whole. If allowed to stand a couple of hours they will probably be in best condition to unite, which requires patience and care. If skilfully done the line of fracture can hardly be detected. The pieces are best held together by means of wax made quite hot on the spatula and flowed over the outside, the clean, united ends being held so perfectly in contact that none will flow into the fracture. They



should never be united in the tray, as accuracy by this means is impossible.

In uniting the impression the smaller pieces should be first joined to the larger, instead of attempting to force them into correct position after union of the large pieces. The minute pieces are best held in position with liquid celluloid.

In uniting the pieces should be placed in actual contact *only once*, and immediately secured. The habit of frequently trying pieces together should be avoided, as the fine serrations are thus destroyed.

This method of taking impressions preserves the fine points of the interdental spaces. We believe it to be the only practicable way of making a plaster impression.

After the impression is united it should present the appearance illustrated in Fig 110.

**Varnishing the Impression.\***—The impressions being united, they should be coated very evenly with shellac varnish. At the expiration of half an hour, or when the varnish has become hard, a second coat should be applied over the occlusal surfaces of the teeth and rough points, but not over the smooth surfaces, especially the labial gum surfaces. After drying again the depressions for the cusps

---

\* It is important that only the best quality of varnishes of the proper consistency be used, as only from such can we gain that most beautiful, accurate and artistic surface for our models, so much prized by all skilful orthodontists. If too thin, the hard glossy surface will be wanting and it will be difficult to separate the impression without injury to the model. If too thick all fine tracings of the impression, especially the stipples of the gum, so important to preserve, will be obliterated.

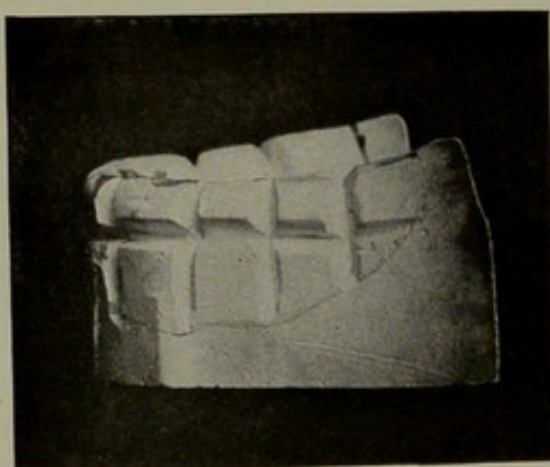
The ordinary gum shellac procurable at drug stores should never be used in making this varnish as it is so greatly adulterated as to make it wholly unfit for this use. A fine grade of the gum may be procured through The S. S. White Dental Mfg. Co. It should be used in the proportions of one ounce of gum shellac to three and one-third ounces of the best commercial alcohol. The sandarac varnish is made by combining the clear, selected tears of sandarac with the best commercial alcohol in the proportion of one ounce of sandarac tears to two and one-half ounces of alcohol.



of the teeth should be carefully examined and all rough portions again varnished so that when dry they will be very smooth, otherwise much trouble will be given by the breaking of the delicate cusps during separation. After again drying apply over the entire impression a very thin, even coat of sandarac varnish of fine quality.

**Pouring the Models.**—After the varnish has dried for half an hour the impression will be ready for filling, which, in order to secure expulsion of air bubbles may best be accomplished by quickly and carefully painting the plaster into the tooth cavities with a small camel's-hair brush, then rapidly filling the remainder of the impression and building it up to generous proportions with a spatula, gently shaking the while, never jarring, after which it should be turned bottom upward on a glass slab.

FIG. 111.



Rogers.

**Separating the Model.**—After the plaster shall have thoroughly set, say over night, and the impression shall have been thoroughly grooved, as in Fig. 111, the pieces may very readily be separated. Should any air cavities be found in the model they may be filled by packing in white oxyphosphate of zinc and pressing it home by replacing the corresponding piece of the impression, which should be allowed to remain until the cement is thoroughly hardened.



when it will readily separate, leaving a very perfect surface. A cusp or broken tooth may in like manner be repaired, or its contour artistically restored with a delicate brush in the application of plaster of a creamy consistence as suggested by Dr. Pullen. None of this plaster, however, should ever be allowed to touch any other portion of the model proper, as the dainty lines of the enamel and stipples of the gum will thus not only be obliterated but an unpleasing, "white-washed" appearance will be given to these surfaces.

**Trimming the Models.**—The models may now be trimmed, and not only will there be a surface as smooth as polished marble, but each cusp, all the interdental spaces, and the rugæ, as well as the inclinations of the roots, and even the minute stipples of the gum and the developmental lines of the enamel, will all be accurately and beautifully shown. The *frenum* and attachment of the muscles, as well as all of the tuberosity and as much of the gum posterior to the last lower molar as possible should also be fully and perfectly shown in the model, as this not only reflects skill in the making of the model, but adds greatly to its beauty and truthfulness. Any coating of suet, paint, varnish, etc., only detracts from the beauty of such models.

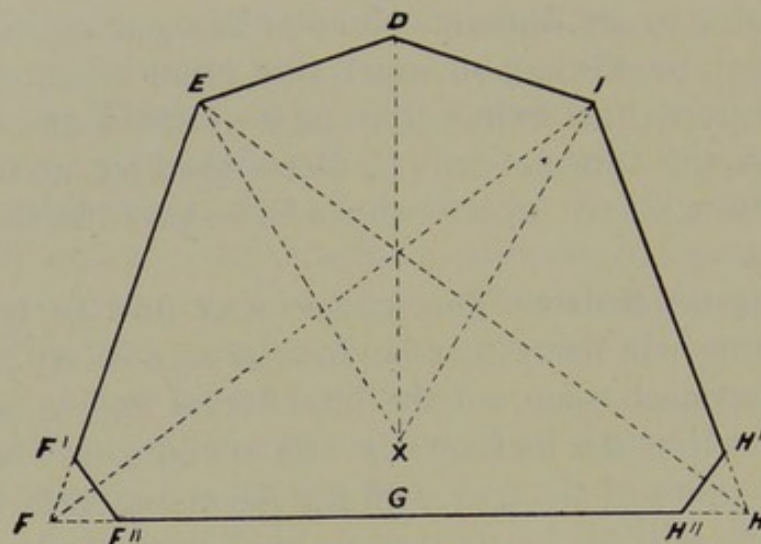
The trimming of the models to graceful proportions, while requiring a little extra time and some considerable skill which can be developed only by experience and attention to details, is well worth while, for a collection of models so trimmed presents a most attractive appearance and cannot fail to reflect much credit on its possessor, especially when taken in comparison with the usual collection of slovenly made models, with practically no attention given to trimming. It may be put down as quite a general rule that the degree of perfection of the models he makes is indicative of the knowledge, skill, and success of the orthodontist in the treatment of his patients.

There is a principle governing the proportions of the



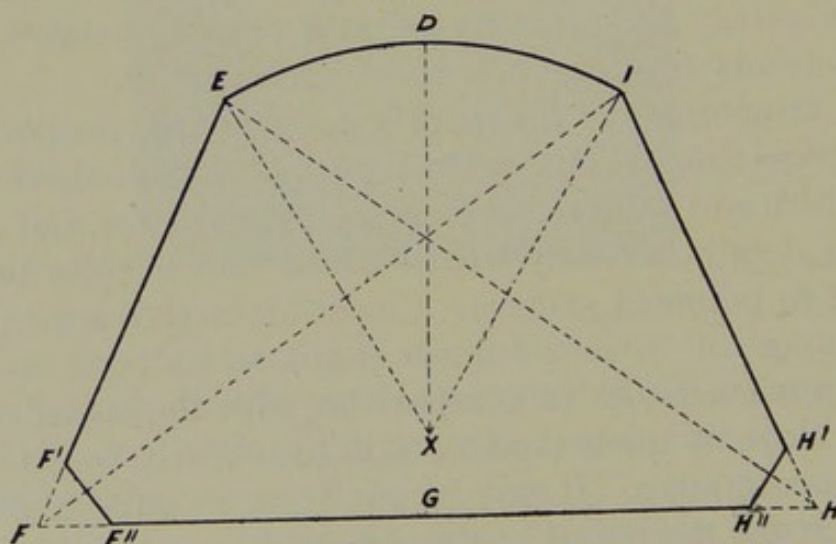
trimmed portions of the model that is very simple and natural and gives fine balance and artistic effect.

FIG. 112.



For convenience we will call the trimmed portion of the model the "art," portion and the untrimmed, or gum and tooth surfaces, the "anatomical" portion. The following

FIG. 113.

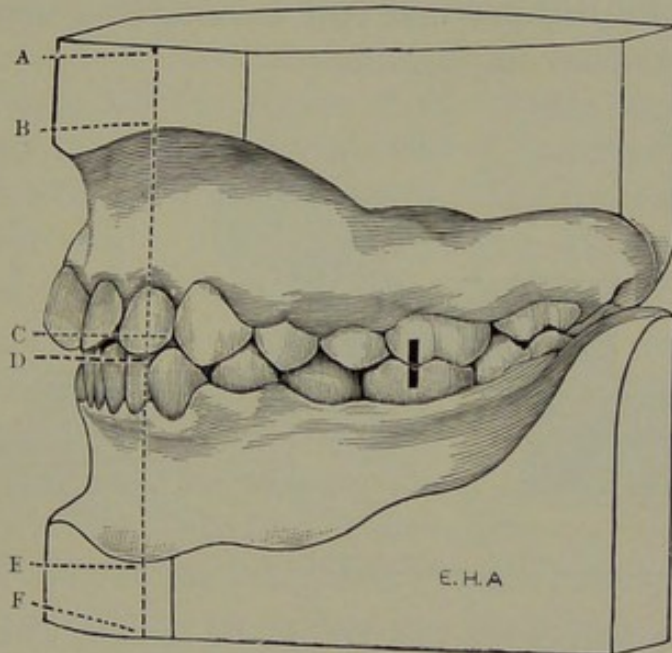


rules for gaining the proper proportions, together with the diagrams indicated in Figs. 112 and 113 were worked out by Dr. Martin Dewey.



In the finished, occluded model, Fig. 114, the base and top should be parallel. In order to determine the proper height of the finished model let the art portion at its thinnest point in both upper and lower that is, A B and E F, equal one-third the width of the anatomical portion at its widest point, that is, measuring from the cutting edge of say the lateral incisor to the highest point of muscle attachment, B D and C E.

FIG. 114.



Trim the line F H, in Figs. 112 and 113, at right angles to the base lines, or top and bottom of the model, and in such a manner as to preserve all anatomical parts.

Trim the lines E F and I H parallel with the line of occlusion as indicated by the first molar and canine.

Establish points E and I over center of normal positions of the crowns of the canines. Let the distance E I equal the distance E X and I X, and with the center X describe the arc E D I. In the lower model trim to this arc, and in the upper trim to plane surfaces, letting D E equal D I regardless of whether or not D comes between the cen-

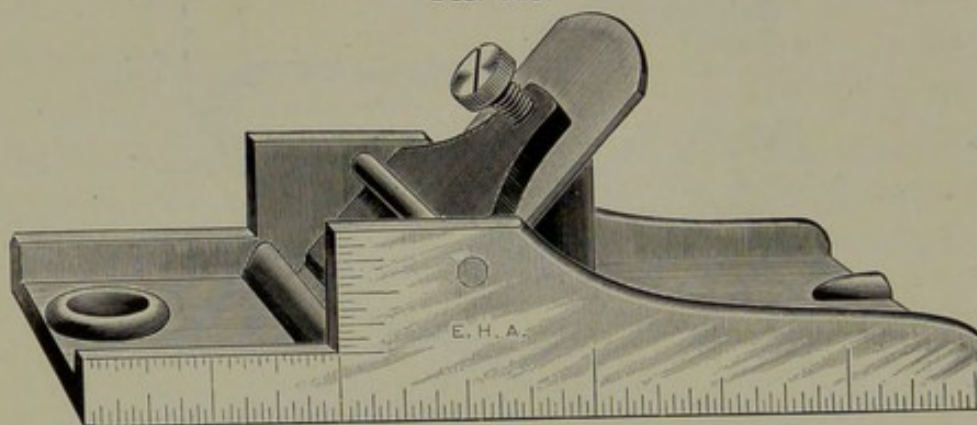


tral incisors. Following this plan any variation from the median line is shown.

The lines  $F' F''$  and  $H' H''$ , Figs. 112 and 113, are run at right angles to  $I F$  and  $E H$  respectively, and each is one-third the length of the line  $E D$  or  $D I$ .

The more truly mechanically these proportions are carried out the more beautiful will be the model. Each surface should be smooth and exactly at right angles to the base line. This is now easily accomplished after a little experience with the author's plaster plane, which is a great convenience, the square and rule making the correct proportions easy of accomplishment.

FIG. 115.



The author is indebted to Dr. F. S. McKay for the suggestion of using a plane for trimming the models, which led to much experimenting, resulting in the style of plane combined with square and rule shown in Fig. 115. It is composed of brass, with bronze blade to avoid corrosion and discoloration of models, and in connection with a strong sharp knife for roughly trimming the model, it is the only instrument necessary. Use of the plane soon develops skill in planing to fine accurate measurements.

There are two important points in the care and use of the plane which are highly essential and without which no one can succeed in its use. First, the blade must be kept exceedingly sharp, a good clean oil-stone being always at



hand for the purpose and frequently made use of. Second, the blade must be set to cut the very *thinnest possible shavings* as the desired line is neared. Coarse shavings are permissible and desirable only in the general shaping of the model.

The models should now be carefully occluded after comparison with the natural teeth, and the occlusion indicated by two or more very delicate pencil markings at convenient places—usually on the lingual surfaces of the molars—so that the proper points of contact may afterward be readily found. It is also well to mark in India ink what we might term the “landmarks,” viz., a point on the mesio-buccal cusps of the upper first molars and the buccal grooves of the lower first molars. The practice of placing models in articulators is obsolete. The lines serve the purpose much better than an articulator of any form. The models should also be neatly labeled and placed in a suitable cabinet for protection from dust and injury, to serve for study and reference, and, on occasion, be valuable as legal evidence. Fig. 116 shows a very convenient form of mahogany case for this purpose.

As soon as the teeth have been completely moved another impression should be taken and models made. This is done after all appliances have been removed and the teeth thoroughly cleansed, and immediately prior to adjusting the retaining devices. These models are valuable for comparison with the natural teeth during the period of retention, as well as for future reference.

Another style of model is also occasionally necessary. It is made from an impression taken of the labial and buccal surfaces of the teeth when the jaws are closed by pressing plaster, mixed to the usual consistency, on these surfaces of the teeth and allowing it to harden, after which it is treated as already described for the making of models.


Such models are shown in Figs. 416 and 480.

It is also of advantage to have “study models” occa-



sionally made during treatment and retention, by pressing a piece of softened wax about one-fourth of an inch thick on the occlusal edges of the teeth, to show only their occlusal surfaces and the appliances *in situ*.

FIG. 116.



**Value of Good Models.**—A collection of fine, accurate models is not only an incentive to keener interest and better work, but is a most valuable form of “library” in itself, in which many valuable phases of the subject are recorded that can never be reduced to writing.

Models should never be mutilated by the fitting of bands and appliances. While they may serve as a basis for gen-



eral measurements for the appliances, the fitting should always be done to the natural teeth.

**Photographs.**—Very important, also, are good photographs of each patient at the beginning of treatment. While such pictures are not so valuable as the face itself for determining the true condition as to harmony and inharmony of the facial lines, they are essential to note by comparison the changes that follow as the result of treatment. Photographs should also be taken at the close of treatment; and also, whenever possible, two or three years after completion of treatment.

Pictures, also, of dental models, though not so valuable as the models themselves as a means of study, make, if artistically mounted in connection with the pictures of the face in a suitably made album, a volume highly interesting to patients and of inestimable value to the true student of orthodontia. Even the simplest cases should not be omitted, for each case teaches some lesson and it is often from the apparently unimportant cases that valuable lessons may be learned both in art and occlusion.

Our requirements in facial photography are very different from those usual in portrait photography, and it is extremely difficult to find photographers of sufficient skill who can comprehend and will fulfill our needs. The modern photographer aims to idealize his work—to bring out the poetical of the face as much as possible. He aims through the possibilities of pose, focus, high lights and deep shadows to obscure all blemishes and inharmonies of balance and proportion, and intensify that which is most beautiful in the features.

Again the term "profile" means to the photographer a quartering view of the face; a "front view" means more or less variation from full front. A smile is also usually insisted upon. Such treatment for their purpose is doubtless proper and such pictures may be very beautiful and reflect the great skill of the photographer, but they are of



little or no scientific value in orthodontia. What is required by the orthodontist is absolute truth and accuracy, both as to inharmony and harmony in the contour and balance of the features, as well as the greatest possible detail as to all fine lines, with no deep shadows or high lights. On the contrary the lights and shadows must be just as evenly distributed as possible, the pose must be natural and not for effect, and the teeth lightly closed in their habitual positions. Two pictures of cabinet size or larger are required, a *full front* and a *full profile*, that is, for the latter the line of focus must be parallel with a line which touches equally the crest of each supra-orbital ridge. This only can give a full normal view of the profile outline. If turned a little from this position, as photographers will usually insist upon, the opposite eye-brow, or portion of the forehead above it, if it be prominent, will show, and overbalance the lower part of the face and consequently make the picture useless as a likeness of the real proportions.

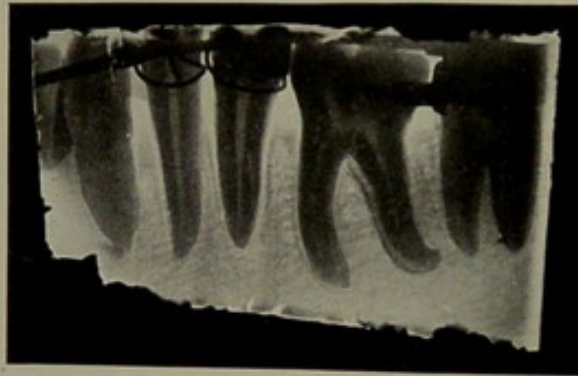
The difficulties in photographing the colorless models are much greater than in photographing the face, for the same reasons we have given relative to gaining detail and avoiding high lights and deep shadows. In the author's collection, numbering several thousand photographs—the work of thirty or more photographers—there are but few truly fine results. He is glad to say, however, that Mr. P. J. Knapp of Buffalo, N. Y., has, after much experimenting, succeeded in producing the best results of anyone in his experience.

**Skiagraphs.**—Skiagraphs, now so easily and quickly made, are often of great value in settling doubts as to whether teeth be missing, or as to their location if merely imbedded. These points may be determined in the majority of cases by careful observation of the contour of the alveolar process and digital pressure, together with the use of the exploring needle, yet where there is any doubt as to the existence or location of a tooth in the alveolar pro-



cess no careful orthodontist would omit for a moment availing himself of the skiagraph for determining these points, though it is greatly to be regretted that on the points on

FIG. 117.

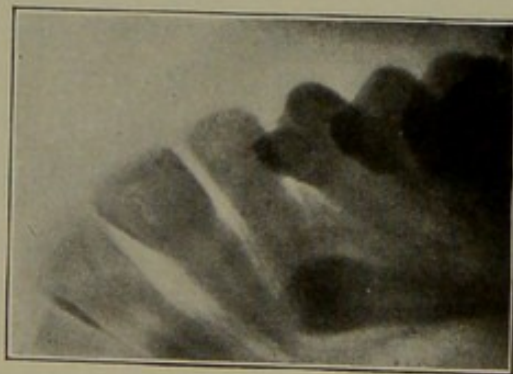

Ketcham.

which we need the most light the skiagraph is often unreliable, for it leaves the shape, length, and exact position of the root often a mere conjecture, yet that the perfect form and outline of the teeth can be shown by it if proper skill be employed is seen in Fig. 117.

Skiagraphs having become a necessity to the specialist in orthodontia it becomes a question whether he should

FIG. 118.



undergo the necessary discipline and expense for doing the work himself or intrust it to others.

Fig. 118 illustrates a case as revealed by the skiagraph



where the canine is so deeply imbedded in the alveolar process as to baffle the ordinary methods of diagnosis.

Fig. 119 shows the rare case of a missing permanent canine. The deciduous canine is shown with its root almost wholly absorbed. The first premolar is about to erupt. The skiagraph showed that in the opposite side of

FIG. 119.



FIG. 120.



the arch the permanent canine and first premolar had failed to develop, and that the deciduous canine, like its fellow on the opposite side, was also about to be lost through absorption of its root.

Fig. 120 shows another case, that of a young lady aged sixteen, where the left lateral incisor is missing. Additional interest is given to this case in the fact that in a cousin of this patient on the father's side the left upper lateral also failed to develop, while a sister and the paternal grandfather of the patient have diminutive, malformed laterals, the father's teeth being normal in development.



## CHAPTER IX.

### REGULATING APPLIANCES.

REGULATING appliances are devices for exerting pressure upon malposed teeth in order to move them into harmony with the line of occlusion.

Two plans are now followed in the designing and constructing of regulating appliances. The first is based upon the belief that each case so radically differs from all other cases that an appliance must be invented and constructed from raw material to meet its special requirements. The second plan recognizes the division of malocclusion into a few clearly-defined classes, with requirements of treatment clearly indicated by each class, and having fixed standard forms of ready-made regulating appliances acting upon definite principles, which amply provide for all requirements of all cases belonging to each class.

The first plan is the one that has been most universally employed, and has come down to us from the earliest history of orthodontia; indeed the greater part of the literature of the science consists of descriptions of appliances which have been invented to accomplish tooth-movements in special cases, until some thousands are recorded, one author alone boasting of many hundred. Although much may be accomplished in skilful hands following this plan, it should require no argument to prove that for many reasons it is most defective and unscientific.

First, it necessitates that each dentist shall be an inventor, and it is well known that the inventive faculty is rather a natural gift than an acquirement, and that it is possessed by only a very few. Then, as all inventions, if perfected, must be experimented with, it must follow that



the treatment of each case must be largely in the nature of an experiment, often necessitating many changes in the plan of treatment, and the invention and construction of new appliances. Hence all treatment upon such theory must be and in fact has ever been, tedious and costly and often resulting in failure.

Second, another objection to following this plan is that the appliances so constructed must necessarily be more or less crude and lacking in requisite proportions, for any instrument reaches perfection as to size, proportion, temper, strength, and finish only after much experimentation and repeated efforts toward perfection in manufacture.

Finally, another objection more serious than all is that as the plan is empirical, with only a vague and indefinite basis from which to reason, the difficulties in teaching and practice become very great and the resultant good very limited. After a life of practice the dentist following this plan must still be in a maze of experiments and unable to impart much information that could be of assistance to his successors. This, we think, is abundantly proven by all the works which have been written on the subject based on this plan.

Such teachings may be said to "begin nowhere and end nowhere," and the attempted correction of malocclusion with such appliances has been most appropriately termed "tinker regulating."

The second plan, as we have stated, recognizes the practicability of fixed, standard forms of devices for performing the different tooth movements necessary in all the various classes of malocclusion, the proper forms having been arrived at as a result of careful experimentation and close observation in a very large number of cases, embracing the greatest variety of malocclusion. Instead of handmade productions by the dentist, which, with his limited experience and meager facilities must always fall far short



of the ideal in delicacy of proportion, temper, accuracy of fit and interchangeability of parts and in finish, they are made upon elaborate machinery, like fine watches or high-class dental or surgical instruments, by the most skilled workmen who have become experts, not only through natural ability but from close study and long experience, insuring the most perfect product at the minimum of expense.

Dr. Farrar long ago predicted the possibility of this plan, for he says in Vol. XX, page 20, of the *Dental Cosmos*:

"It has for some time been evident to me (though by most people thought to be impracticable) that the time will come when the regulating process and the necessary apparatus will be so systematized and simplified that the latter will actually be kept in stock in parts and wholes, at dental depots in readiness for the profession at large, so that it may be ordered by catalogued numbers to suit the needs of the case; so that by a few moment's work at the blow-pipe in the laboratory the dentist may be able, by uniting the parts, to produce any apparatus, of any size desired, at minimum cost of time and money."

If such appliances are practicable, it must become apparent to all thoughtful minds that the advantages from their use over the first plan must be very great, for, instead of being confronted by a confusing and almost limitless number of devices which can at best serve only as general, vague, and often delusive patterns for him, the dentist has but to thoroughly familiarize himself with a few standard devices and their combinations, which he may ever keep in stock in readiness for immediate demands, and which may be quickly and easily applied, thus obviating the great disadvantage of delays, so often necessary in the former plan.

Again, familiarity with the standard appliances adds greatly to the possibilities of development of skill and



judgment in their use, as in the case of the frequent use of favorite patterns of pluggers or excavators.

Finally, instead of being compelled to experiment with inventions until a suitable and efficient instrument has been devised for the case in question, he has the advantage of being able to thoroughly rely upon standard forms of devices as he does for other operations in dentistry. He is thus enabled to direct his energies to a more thorough and intelligent study of the case in hand, such as the problems of occlusion, art relations, anchorage, retention, physiology, etiology, etc., the consideration of which has in the past been almost wholly sacrificed to the devising and constructing of appliances. And whether or not ideal standard regulating appliances have yet been reached, the possibilities and positive advantages of the principle over the first plan are so marked that we think all progressive dentists interested in this branch should make efforts toward developing orthodontia along these lines, rather than to perpetuate a plan that is so obviously wrong and a positive hindrance to the real progress of orthodontia. In no other branch of medicine, nor in any other science so far as known to us, is there such inclination to perpetuate a principle so antiquated, defective and antipodal to progress. Even machinists, finding it impractical, long ago abandoned the practice of making their own tools. Then imagine a modern surgeon teaching his students to invent, forge, and construct from raw material instruments for each operation, or an up-to-date dentist grinding the clays and pigments for the artificial teeth he shall use, or "designing and forging a special instrument for each case or operation." Such was once the practice, but it is now well known that most of the real progress in dentistry and surgery has been made since the dentist and surgeon were relieved of this impractical task by experts, who have produced instruments so perfect in design, construction and finish as even to be often far in advance of the comprehen-



sion and skill of those who are to use them; and the author feels sure that orthodontia has made its greatest progress since the introduction of fixed, standard forms of ready-made regulating appliances. A few of the writers and teachers, it is true, are still linking the present with the past in commending to dental students the acquirement of skill in the construction of regulating appliances, which can only be very crude at best. The custom is archaic and illogical, and the long, tedious hours which students are usually compelled to devote to their making, should by a more advanced standard of teaching be directed to purposes more in keeping with the requirements of true orthodontia. The successful, up-to-date orthodontist classes himself on a different plane from that of a mechanic.

The author's regulating appliances, the description, plan of application, and operation of which will be given later are in direct keeping with the second plan, just described. In fact, the second plan practically originated in the introduction of this system some twenty years ago. They are now standard in all countries where dentistry is practiced, and their efficiency and universal application are recognized. Like most valuable and popular pieces of mechanism, they have numerous imitations, but if intelligent comparison be made with all others from the basis of *efficiency*, *simplicity*, and *delicacy*, their superiority is at once apparent. The differences will be found to be steps backward instead of in advance, and usually necessary for legal reasons.

Naturally it is gratifying to the author to know that all of the few standard forms of appliances introduced by him have been accepted by the profession and are in popular use wherever dentistry is practiced, yet recognizing the great advantages of simplicity, he has found that some of even these few in many instances with advantage give place to the expansion arch, the practicality of which is increased by reason of the recent improve-



ments in the latter appliance. The jack-screw, once a favorite with the author and still an almost universal favorite with dentists generally, has been entirely eliminated from the author's practice. In fact he has found that it is practicable to perform all orthodontic operations with the expansion arch, although other appliances may occasionally be used to advantage.

**Epochs in the History.**—To the real student of orthodontia the history of regulating appliances is a most interesting and instructive study. It shows that their beginnings, as in most sciences, were crude; the unfolding slow, and oftentimes marked by retrogression as well as advance, with the perpetuation of much even to the present time that should have been discarded.

Of necessity, the history of appliances is closely connected with the history of orthodontia and largely measures its progress. One surprising feature of the history is the frequency of rediscovery of identical principles, their materialization differing only in minutiae of manufacture. While the study is of much interest to the student of orthodontia, the limits of this work will not permit of more than the brief mention of such steps in the history as may be regarded as epochs in the evolution of appliances. This will involve the consideration of principles only, and of those whose value is attested by their survival. Mere improvements in methods of applying these principles, however ingenious and valuable, cannot here be noted. The actual principles embodied are few.

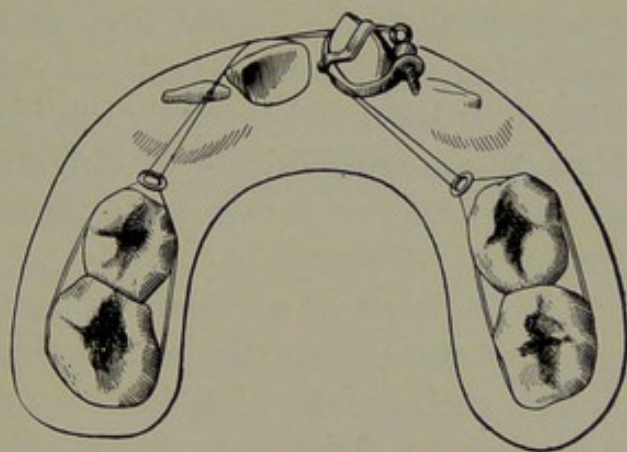
The form of the first regulating appliances, or by whom they were employed, is not known. It may have been, like the substitution of the natural by artificial teeth, far back in the history of man, but the first appliance that was destined to mark a distinct step in the written history of orthodontia was that given to us by Fauchard, of France, in 1726, and which we will call the expansion arch, for its chief function is to expand the dental arch. Its



form in the main is that of the ideal dental arch, and it has been variously named as bandeau, bow, long band, bandelette, etc. Unquestionably the conception of this device, which, in its greatly improved form we rely on so largely in modern practice, was the one greatest step in the invention of appliances.

That which may easily take rank as second in importance was the invention of the tooth band, or the medium for the attachment of appliances to the teeth. Of bands there are two kinds; first, the adjustable clamp band, or one that is held in position by means of a screw with which it is firmly

FIG. 121.



clamped about the crown of the tooth, and second, the plain or brazed band, always made to fit each tooth in question and held in place upon it by means of cement. The first was the invention of J. M. A. Schangé, also a Frenchman. We find it illustrated, as in Fig. 121, in a book of one hundred and eighty pages published in Paris in 1841.\* He seems to have used it chiefly upon the malposed teeth, rather than for anchorage. It is only fair, however, that the honor of the invention should be accorded to him,

\* "Précis sur le Redressement des Dents." Par J. M. A. Schangé, Médecin-Dentiste, membre de plusieurs sociétés savantes. Troisième édition. Paris, 1841.



as its inception has been claimed by others at a much later date.\* It consisted of a ribbon of metal in length sufficient to nearly encircle the crown of the tooth, each end bent outward sharply at right angles, and both thickened and perforated, one threaded, the other smooth. A threaded shaft with perforated head was made to engage these perforations in the band. By turning the shaft the band was diminished in circumference and securely clamped upon the crown to prevent displacement, as shown in the engraving, in principle identical with Farrar's of 1876.

To all students of orthodontia another very important epoch in the history of regulating appliances should be mentioned in connection with Schangé's clamp band, for it is in this connection that the screw first makes its appearance in regulating appliances, the honor of the introduction of which has been erroneously divided between Dwinelle, of New York, and Gaines, of England.\* Their recorded dates of using the screw were, however, eight years later than that of Schangé's.

The plain band consisted of a ribbon of metal fitted to the circumference of the crown, the ends being united by brazing. Although such bands, of gold, were used by the ancients for securing artificial crowns and bridges, it is not clear by whom they were first used for regulating purposes. Desirabode (1726) speaks of them as "bracelets" or "little rings." Thomas Evans, of Paris, mentions them in 1854, and Dr. A. H. Fuller, in the *Missouri Dental Journal*, January, 1872, describes a novel form of plain band. It was constructed by closely wrapping a plaster model of the tooth to be banded with fine platinum wire, over which was flowed 20-carat gold, to which the desired attachments were made.

The real value of the plain band, however, dates from its attachment to the tooth crown by means of oxychlorid of

---

\* Farrar, "Irregularities of the Teeth," first volume.



zinc cement, which was accomplished at about this time by Dr. Magill,\* of Erie, Pa. This effectually prevented its displacement under the ordinary strain necessary in tooth movement. Magill's method of making the band was to encircle the crown with a thin ribbon of platinum, slightly overlapping the ends and uniting by brazing. He was probably not at this time aware of previous use of either plain or clamp bands. By the use of bands the direct, firm attachment of appliances to the teeth was effected, so that loss of power by slipping was reduced to the minimum and an important step in the progress of orthodontia gained.

The regulating jack-screw was invented in 1848 by Dr. Dwinelle, of New York.† It is shown in Fig. 122. This

FIG. 122.



invention marks two important steps. First, the introduction into orthodontia of one of the most compact, yet powerful forms of mechanism for exerting force known to mechanics; second, the beginning of fixed, standard forms of regulating appliances with interchangeable parts kept in stock at the dental supply houses. It consists of a threaded steel shaft with conical head, perforated for the reception of a turning tool, and a rounded nut, also of steel, with long, parallel flanges joined at their extremities in the form of a fish-tail. Although difficult to keep

\* At the meeting of the Western Pennsylvania Dental Society, Pittsburg, March, 1896, in a conversation with the author, Dr. Magill said he could not remember the exact date at which he first began attaching the bands by means of cement, but believed it was in 1871, or 1872.

† Some attempt has recently been made to change the name of this appliance to screw-jack, but as it has been known since 1849 as jack-screw, and is so named in Webster's and the Standard dictionaries, being illustrated in the latter in position against the teeth, and as the term seems more appropriate, this innovation is not regarded with favor.



in position and somewhat expensive, three sizes being required, it was at the time regarded as a boon to the profession, and is still in favor with many dentists.

Lee and Bennett, some time in the 80's attached a washer of elliptical form with perforated ends below the head of the jack-screw, and, attaching ligatures to this and the fish-tail, used the appliance for pulling instead of pushing. The author's traction screw was suggested by this adaptation of the jack-screw, as were probably various other devices that have been used for traction. The traction screw\* may, in any event, be regarded merely as a modification of the jack-screw, and not as the application of a distinct principle.

The force derived from the elasticity of rubber has been extensively used in tooth movement. Rubber for this purpose was introduced by Dr. E. A. Tucker, of Boston, in 1846. Although an immense amount of harm has resulted from its improper application, and it is now far less commonly used than formerly, it is, and doubtless will long remain, a valuable adjunct to regulating appliances under suitable conditions.

Occipital anchorage, gained through the use of the head-gear, for the reduction of the mandible, as well as protruding upper anterior teeth, was introduced by Dr. Norman W. Kingsley, of New York, in 1866. It was of much value, but since the introduction of the Baker Anchorage is far less commonly employed than formerly.

The introduction of piano wire for use in orthodontia by Mr. Walter Coffin, of England, some forty-five years ago, marks another step of considerable importance. On account of its great elasticity, it has been extensively used, but far less now than formerly, as it has been largely supplanted by nickel silver.

---

\* This has been denominated "drag-screw," but the name seems neither so appropriate nor euphonious as the other, and has not been adopted.



The introduction of vulcanite for the construction of regulating plates is, in the author's opinion, of questionable importance, for the reason that the same results by means of far more delicate forms in metal were previously accomplished.

The introduction of delicate metal tubes\* by the author, in 1886, may, we hope, not immodestly, be said to have been another step in the evolution of appliances, as they provide a simple, compact, and ready means of attachment between bands and working appliances. Their value is attested by the fact that since their introduction they have entered into the formation of all appliances of note.

The advent of a complete system is of such great importance, in comparison with the fragmentary methods previously employed, that it is believed to be worthy the distinction of being classed among the epochs in the history of regulating appliances. After a careful consideration of the countless number of appliances that appear in the literature, the author, in 1886, recognized the fact that they must all exert force on moving teeth in one of three ways, namely, by pushing, pulling, or twisting, and it occurred to him that a very few simple forms would admit, through proper interchangeable attachments, of almost universal application, and that thus we might with great advantage dispense with the confusing mass of recorded appliances, many of them extremely crude, complex, bulky, and unhygienic. His system was first described in a paper before the Ninth International Medical Congress, in 1887.

The introduction of nickel silver† (the valuable properties of which are more fully discussed elsewhere) by the author in 1887 for the manufacture of regulating appliances has to such a large extent revolutionized their

---

\* Transactions of the Minneapolis Dental Society, December, 1886; of the Minnesota State Dental Society, May, 1887; and of the International Medical Congress, September, 1887. Also *Ohio Dental Journal*, October, 1887. Angle.

† Archives of Dentistry, September, 1888.



manufacture that it must take rank as an important step in their history.

The introduction of soft brass wire for ligatures by the author is of such great practical value that he believes it should here have honorable mention.

#### REQUISITE QUALIFICATIONS OF APPLIANCES.

**Efficiency.**—As the object of the regulating appliance is to perform tooth movement, efficiency should take precedence over all other qualities. The reason for this is obvious, for at best the correction of malocclusion is to a greater or less degree an unpleasant and protracted operation, and unless the appliance be efficient so that the various tooth movements may be accomplished as rapidly as is consistent with the physiology of tooth movement, the operation will be unnecessarily long and tedious, sacrificing valuable time of both patient and operator, and frequently leading to discouragement and failure.

A very large number of the appliances recorded in the literature are so obviously defective in the plan of construction and operation—distribution of force, manner of gaining anchorage, and manner of attachment—as to greatly lessen their efficiency and to necessitate their being worn far longer than would be necessary with efficient appliances. Indeed we know that many of them could not possibly have accomplished what is claimed for them.

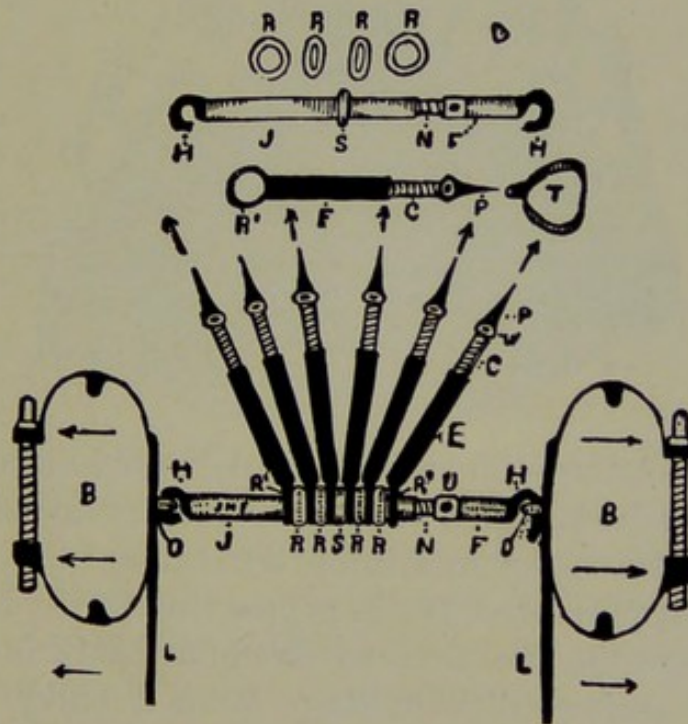
**Simplicity.**—Next in importance to efficiency is simplicity. The regulating appliance should be simple in principle and plan of operation. It is well known that the best forms of mechanism are those freest from complication, simplest in design, and most direct in application of force.

It is also known that some of the most valuable machines possessed limited utility until they had passed through certain evolutionary stages in which the original plans of great complexity gradually gave place to those of simplicity. For example, the electro-magnetic mallet and the sewing-



machine. In fact, many modern inventions are but the discovery of simpler methods in the application of long-known principles; and where complexity may be admissible in some machines, as for example, the printing-press, we must remember that it performs numerous functions, and the limits of space and weight are very broad, with the freest scope for application of mechanical principles. But in the regulating appliances the restrictions of the lips, cheeks, tongue, gums, and occlusion make simplicity and freedom from bulk of the highest importance.

FIG. 123.

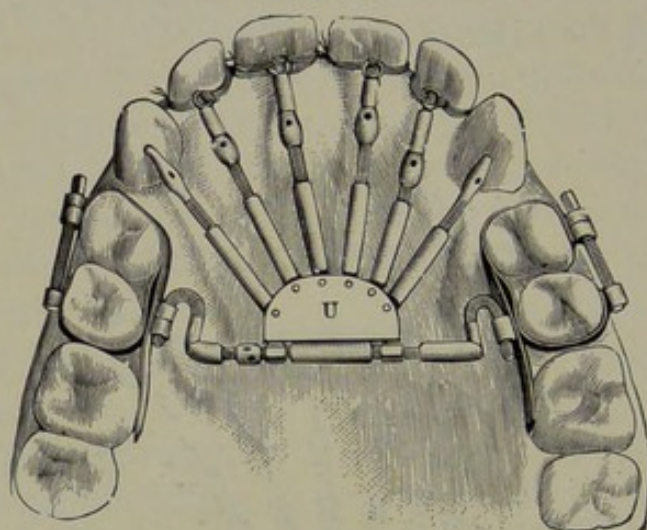


The invention of a simple yet efficient machine is a more difficult achievement than the invention of a complex one. It should be remembered that each additional piece composing a regulating appliance usually augments in a more than proportionate ratio its liability to derangement, as well as the care and time required in its operation, the expense of its construction, and the inconvenience to the patient. And yet the complexity of design and number



of parts of many of the regulating appliances that have come down to us through the literature are such as to create the impression that their originators must have believed this quality to be of the first importance. Many of these appliances are mechanical curiosities, and doubtless in the future will be pointed out as such. Two such are shown in Figs. 123 and 124.\*

FIG. 124.



**Delicacy.**—An appliance which is delicate in size and proportion, and from which all unnecessary material has been eliminated, possesses such important advantages as should be readily appreciated, for in proportion to the bulk of the appliance are the functions of the mouth interfered with.

Another serious disadvantage from a bulky appliance is the difficulty of cleansing it. It affords ready lodgment for particles of food, which, at the temperature of the mouth, soon undergo fermentation rendering the breath most offensive and necessitating the frequent removal of the appliance (either by the patient or dentist, according to its plan of construction) for the purpose of cleansing.

---


\* Transactions Ninth International Medical Congress, Vol. V, p. 577, Washington, D. C., 1887.



Thus the operation is prolonged, but worse than all, the alternate forward and backward movements from the relinquishment and reapplication of pressure so interferes with the tissues involved as to act as an incitant to inflammation—the *principal cause of pain in moving teeth*.

For these reasons a skeleton form of appliance, with direct, stable attachments to the teeth by means of plain or clamp bands, should invariably be used in preference to devices in combination with plates, a remarkable illustration of which is shown in Fig. 125.

FIG. 125.



The use of such crude, bulky, inefficient, and most uncleanly appliances during the evolutionary stages through which orthodontia has passed does not create so much wonder, but why they should still form such an important part of the latest works on orthodontia it is difficult to comprehend. We are glad to note, however, that they are rapidly passing and that they are entirely obsolete in the practice of all members of the new school of orthodontia.

**Inconspicuousness.**—As any devices upon the teeth attracting attention are, to patients of sensitive nature, a source of more or less annoyance, it is important that the regulating appliance shall be made as inconspicuous as possible; and yet we insist that efficiency in an appliance is of so much greater importance that it should be kept fore-



most in view even though the form of appliance best suited to the case be conspicuous.

The wearing of appliances, however, has become so common as to no longer attract much attention.

The degree of unsightliness depends largely upon the manner in which a given appliance is constructed and fitted to the teeth. If gracefully proportioned, with skilfully made attachments and the most perfect finish of parts, the appliance, although noticeable, may not be really objectionable in appearance. But if, as is too often the case, an appliance, though constructed on the same principle, be unnecessarily bulky, badly proportioned, unskilfully attached, with little attention given to finish of parts, its appearance will be repulsive.

**Stability of Attachments.**—No matter how perfect the design and construction of an appliance, if the attachments to the anchor and moving teeth be not such as to insure its stability it becomes worthless, for if it slip or give at the point of anchorage or deliverance it will become either entirely inoperative or the force will be wrongly directed according as the power is derived from a screw or spring, thus prolonging the operation and sacrificing the time of both operator and patient, with the added pain, annoyance, and expense necessitated by the removal and repair of the appliance.

Owing to the irregular and slippery surfaces of the teeth, the gaining of firm attachment to them has always been one of the problems in tooth regulation. Since the introduction of properly made plain and clamp bands firmly cemented or clamped upon the teeth, and of the wire ligatures, the certainty of firm, immovable attachments is assured, with consequent perfect control of the appliances, and direction and intensity of force, making it possible to compute with considerable accuracy the time necessary for tooth movement in each given case. The great advantages of this form of attachment have rendered practically ob-



solete attachments by means of cribs, plates, clasps, etc., and it again becomes difficult to understand why such forms of appliances, with their crude and necessarily unstable attachments, should still find advocates.

**Materials for Construction.**—Gold, silver, platinum, platinous gold, platinous silver, iridio-platinum, platinoid (so-called), aluminum, and several of the baser metals and alloys, as brass, copper, aluminum bronze, steel, and iron, and also vulcanized rubber, may all be used in the construction of regulating appliances, and each possesses properties of more or less value; yet, after experimenting with all of these, the author is thoroughly convinced that the material most nearly filling all requirements is nickel silver.\*

Since its introduction for the manufacture of regulating appliances by the author some twenty years ago, it has largely supplanted all other metals for this purpose. Its great practical value becomes more and more apparent to the unprejudiced practitioner as the peculiar working properties and possibilities of this nearly ideal material are revealed by familiarity of use. In its manufacture great strength and rigidity may be developed, as demanded by the jack and traction screws. Again, it may be given great elasticity, as required by the expansion arches. When properly annealed, it is very malleable, yet sufficiently rigid to give it the excellent qualities so necessary in retention and reinforcing anchorage, as exemplified in the wire G. But its excellent qualities are perhaps best shown in its adaptation to the making of plain bands to be placed upon the teeth for securing the attachments of the appliances. Rolled into a flat ribbon, if it be of the proper quality and properly treated in manufacture, it may be drawn by the band-forming pliers so tightly about the tooth as to conform to its surface with great accuracy,

---

\* Nickel silver, or "German silver," is an alloy of copper, nickel, and zinc, prepared in varying proportions according to the use for which it is intended.



even though it be but three-thousandths of an inch in thickness (C), and yet it will be sufficiently rigid to withstand being driven into place upon the tooth without crimping or changing form if care be used—in striking contrast to gold, silver, platinum, or other metals of the same thickness used for this purpose.

Dr. C. A. Hawley in conducting some experiments in order to determine the comparative strength and stretch of nickel silver, iridio-platinum, and some other metals, found that nickel silver, while possessing great tensile strength, yet admitted of considerable stretching before breaking, which accounts for its beautiful adaptability in banding teeth, making it superior for this purpose to platinum or gold, which while possessing valuable qualities, the most important of which being freedom from oxidation, are yet inferior in this respect.

The surfaces of nickel silver may be readily united with solder, and its fusing point is so high that any of the various grades of gold or silver solder may be employed, if the proper flame be used and care be taken, without fear of injuring the band by overheating.

So slow a conductor of heat is it that the excellent method of soldering\* by holding many of the pieces with the fingers may be employed, again in sharp contrast to any of the other metals we have enumerated.

It is susceptible to a high degree of polish, which should always be given the band after setting, and which in most mouths will remain durable, often assuming a delicate bronze-like color pleasing in appearance. The wearing of bands of this metal for three consecutive years without detrimental change has been noted by the author. In a small percentage of mouths, however, it is true that it does become discolored, even to unsightliness. This fact has given rise to the only prejudice against the use of this

---

\* Introduced by the author in the second edition of this work.



metal that we know of, but this objection seems trivial in view of its many points of superiority. If the orthodontist will insist upon a reasonable degree of cleanliness on the part of the patient while wearing the appliances, or will occasionally devote a moment or two of attention to them himself with the soft rubber disk and pumice, followed by a burnisher, there need be no occasion for complaint.

And lastly, its inexpensiveness brings it again in sharp contrast with gold and platinum; yet we insist that it is its excellent qualities more than its inexpensiveness that makes it so preferable a metal for orthodontic purposes.

The oft-repeated fallacy that gold is the one suitable metal for the construction of regulating appliances is rapidly passing, as it ought, for undoubtedly it has been a real hindrance to progress.



## CHAPTER X.

### THE AUTHOR'S APPLIANCES.

"In art—in all things, the supreme excellence is simplicity."

WHILE giving a course of lectures on the subject of orthodontia to a class of dental students in 1884 the author for the first time made an extensive research into the history and literature of the science and he was amazed to find such a vast number of appliances recorded therein. Indeed most of the literature then consisted of descriptions of regulating appliances which had been constructed for special cases, and the plan being still in vogue several hundred more were recorded in the next few years. Most appliances being invented to meet the requirements of individual cases (and often only hypothetical cases), and usually a special appliance being designed for each malposed tooth, their range of application to other cases was very limited. With the exception of the Dwinelle jack-screw all were constructed by hand from raw material. In connection with them there was simply no system or order, and the difficulties and discouragements in teaching orthodontia at that time can at this date hardly be comprehended.

As already noted, the author, after much consideration, became convinced that notwithstanding this vast number of appliances, each one must act, if at all, by exerting force upon malposed teeth in one of three ways, namely, by pushing, pulling, or twisting. It then occurred to him that it might be possible to construct a few instruments of simple form and standard pattern which would meet the requirements of all cases. More study convinced him that the plan was practicable, and, that if so, the difficulties in teaching and practice would be greatly lessened.



The problem, then, was to devise three instruments, one for pushing, one for pulling, and one for twisting, each of form to admit of almost universal application, and all to be of standard pattern; delicate yet efficient, with interchangeable parts, to be attached to teeth used as anchorage as well as to the teeth to be moved, by means of plain bands made from ribbons of band material, these ribbons or coils of band material also to be of standard width and diameter.

It seemed to the author that the requirements of the instrument for pushing could be best met in some form of jack-screw. The well-known Dwinelle jack-screw, shown in Fig. 122, was, as we have said, then in use, it being composed of steel and three different sizes being required. It soon became apparent that, owing to its peculiar form, difficulties of attachment, and the metal from which it was made, its range of application was far too limited to bring it within the proposed requirements. As a result the author's jack-screw was invented and its construction by any dentist was at that time thought to be practicable. At first it was somewhat crude and consisted of a threaded shaft with a needle-like point. On this shaft was fitted a nut to be turned with a wrench in order to exert force. The shaft of the screw was made to telescope within a base consisting of a square bar of silver which was usually forged from about one-half of a silver twenty-five-cent piece.

The advantages of this jack-screw over the old form lay in the fact that it was far more delicate and admitted of great range in length—from one-fourth of an inch to any desired length—gained by varying the length of the base or sheath. Furthermore, as the threaded shaft was not required to turn, as in the Dwinelle form, the whole screw could be bent to crescent form if desired, as might be of advantage when placed across the vault of the arch. Still another great advantage, the base could be securely held to



the anchor attachments by solder as well as by a variety of other means, as shown in Fig. 623.

While possessing these advantages it still had certain defects which had to be overcome before it would completely meet the great diversity of requirement. It being difficult to bore a hole of uniform diameter in the square base, it was thought a round tube would possess advantages, and after much inquiry a crude form of tubing known as "joint wire" was found in use among jewelers. This was an improvement, though still defective, as the shell was of far greater thickness than necessary and the bore much too small, still requiring boring for its necessary enlargement. Moreover, the tubing not being seamless would spread under strain, and being a crude alloy of silver, it lacked rigidity, so that more metal was required than was consistent with the desired delicacy. Furthermore, the threaded shaft being steel, it gave much trouble from corrosion. So it became necessary to find a more suitable metal from which to make not only this, but if possible, all regulating appliances.

Gold or platinum had previously been almost wholly relied upon, but it seemed to the author that their great expense as well as their malleability was a serious handicap. After tedious experimentation he was delighted to find that a fine quality of nickel silver, or "German silver," as it was then generally called, met the requirements for the construction of not only the regulating but the retaining appliances. We have discussed the desirable qualities of this metal elsewhere.


The trouble of getting manufacturers of tubing to experiment until an ideal seamless tube of nickel silver was produced need not here be dwelt upon. Much credit, however, is due to the Ellwood Ivins Tube Co. for carrying to completion the solution of the difficult problem.

The first improvements of the jack-screw over its original form, then, were in the change of metal, and making



the sheath of tubing and that seamless and of the minimum thickness consistent with strength. Next, it was found that two lengths of tubing would give the screw sufficient range of application, and by making its delivery end flat so that it could be pointed or notched at the will of the operator, its range of attachments was extended. Later another valuable improvement was added in the friction sleeve nut which effectually prevents its displacement by the tongue. As perfected it is shown in Fig. 126.

FIG. 126.



Illustrations of a few of the many uses to which it is applicable are shown in the Appendix.

**Traction Screw.**—To devise an instrument that would be universal in its application for exerting a pulling force was not an easy problem, and after experimenting much with a spring it was abandoned for the power derived from the screw. After much thought it became apparent that a screw for pulling that would have quite as wide a range of application as the jack-screw for pushing could be made by simply modifying the latter. Metal tubing being now at our command, this was made much easier. So a section of wire that had been bent sharply at right angles near one end was threaded and made to telescope a long sheath (similar to the jack-screw), and a nut engaging the threads worked against the end of the sheath opposite to the angle. The short, bent end of the shaft engaged a short section of tubing, all as shown in Figs. 127, 128, 129, and 130. The tubes, being soldered to bands on the anchor teeth and those to be moved, furnished a medium of attachment for the screw and a means for the distribution of the force. By



using two or more of the screws, combinations could be formed whereby a number of teeth might be moved by pulling, so that with it practically all of the requisite movements could be accomplished, while as in the use of the jack-screw, simple, stationary and reciprocal anchorage could be gained.

FIG. 127.



FIG. 128.



FIG. 129.

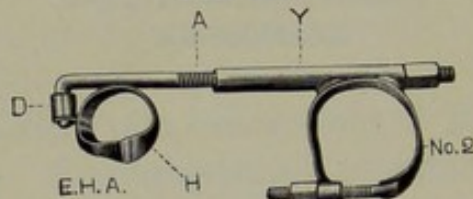
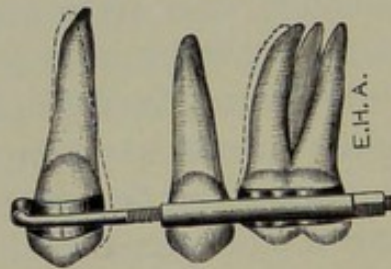


FIG. 130.



At first it was thought that two sizes of this screw were necessary. Later it was found that the larger size only was sufficient and the smaller size was abandoned. A few of its many possible combinations are shown in the Appendix.

**Lever.**—An instrument for exerting a rotary force upon a tooth, which could be applicable in all cases, was next considered, a lever being the only instrument that could meet this requirement. Already we were making



use of this principle in a crude way, namely, by a rigid lever in the form of a finger of metal soldered to a band cemented on a tooth, the long end of the lever being tied to some suitable anchor tooth (see Guilford, American System of Dentistry, 1885); but the range of force thus to be gained was very limited, requiring frequent removals and reapplications of the band in order to bend the lever and continue the force. But the author's device consisted of a very short section of tubing soldered to a band on the tooth

FIG. 131.

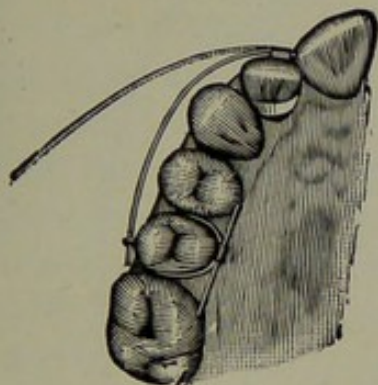
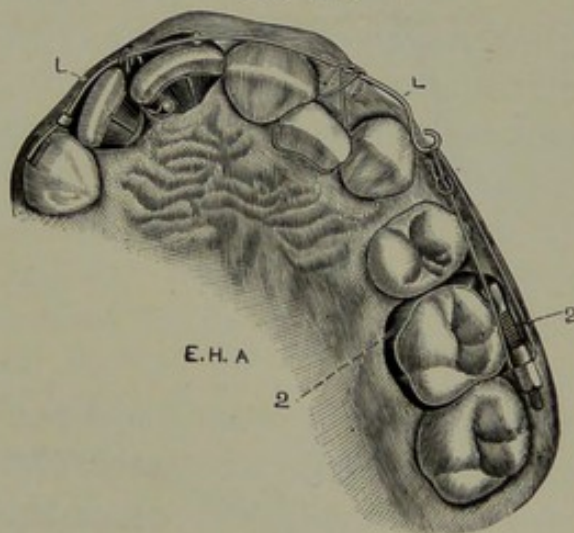


FIG. 132.



to be rotated, into which one end of the lever was inserted, the other end being sprung around and attached by a ligature to some suitable anchor tooth, as in Figs. 131 and 132. Sections of the very elastic form of steel known as piano wire were used as levers, L, Fig. 135, so that a great range of movement could be given to the tooth and any degree of force exerted simply by substituting a lever of greater or less diameter, four different sizes meeting all requirements. By this means any single tooth, or a number of teeth, could be given continuous rotatory force. A few of the almost limitless possible combinations are shown in the Appendix.

As auxiliaries to these three devices were added a



number of short sections of small tubing, R, Fig. 133, and a section of smooth, soft wire, G, Fig. 134, which accurately

FIG. 133.



FIG. 134.

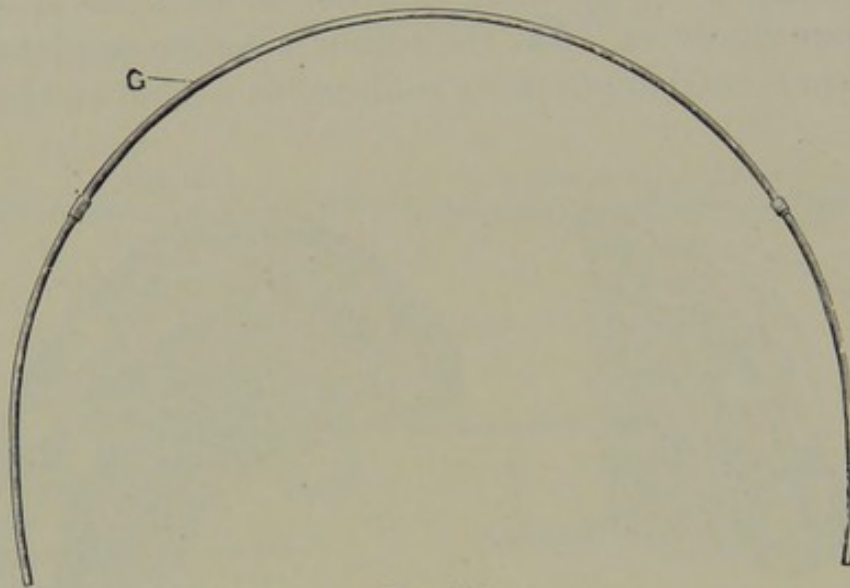
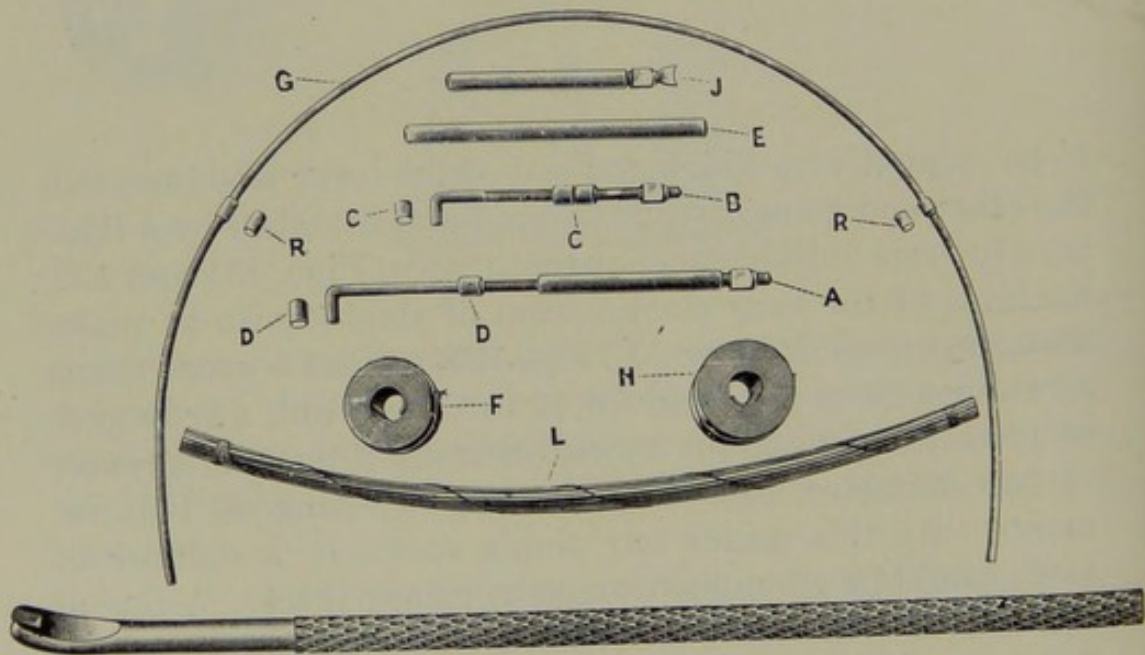


FIG. 135.



telescoped these small tubes, the principal uses of these auxiliaries being the reinforcement of anchorage and the



final retention of the teeth, for which we have since found no substitutes. They are very useful.

The jack-screw E and J, the traction screws A and D, and B and C, and the levers L, together with their auxiliaries, wire G, tubes R, band material F and H, and the wrench, are shown in Fig. 135.

After much difficulty in the manufacture of these devices they were finally made on fine machinery by skilful machinists with great accuracy in the fit, and beauty in the finish of parts, as well as the greatest strength possible consistent with delicacy.

The simplicity, efficiency and range of ready adaptability of these three devices and their auxiliaries were quickly recognized, and they soon largely superseded the limitless number of old, made-to-suit-the-case forms of appliances, and they had and are still having an extensive use by dentists in all countries, but for reasons that we shall note later they are far less used by the author than formerly.

Another special type of appliance seemed necessary to meet the requirements of treatment of a distinctive type of cases which has always given the dentist much trouble. They were formerly loosely designated as "protrusion cases," or "cases of protruding upper incisors," but are now classified as belonging to Division 1 of Class II.

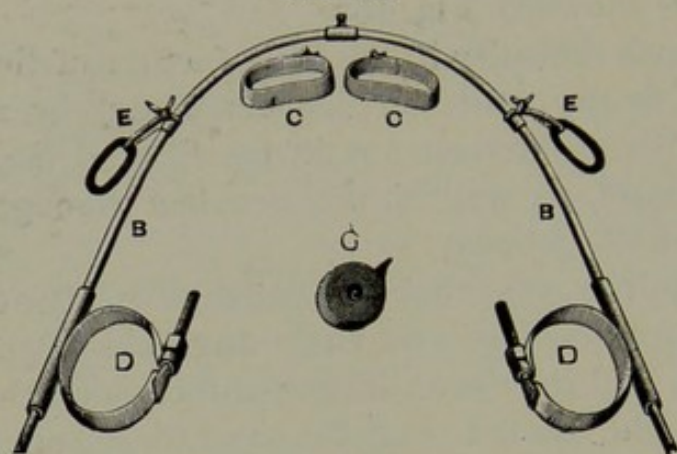
Until recently the plan of treatment of these cases, after extracting the upper first premolars, was to reduce the prominence of the incisors and canines by retracting them (using the molars for anchorage) to close the spaces thus made, and great force being necessary to accomplish this, much unfortunate displacement of the teeth used as anchorage often resulted. In order to avoid this and gain more stable anchorage Dr. Kingsley had made use of occipital anchorage by covering the back and top of the head with some form of cloth or leather cap, and a pulling force was given to the protruding teeth by heavy elastics at



tached to this cap on both sides and distributed to the teeth through various contrivances.

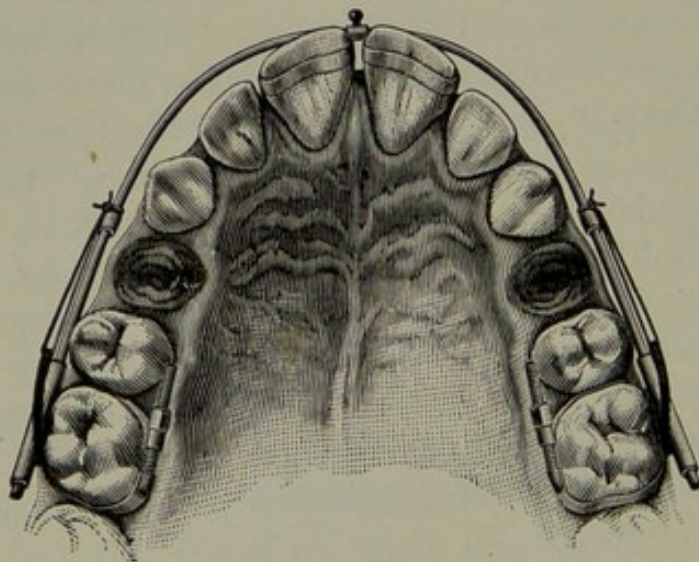
This very original plan was variously modified by Farrar, Goddard and others. Most of the modifications,

FIG. 136.



however, were very bulky, clumsy, and some of them absurdly complicated. In 1888 the author devised an appliance for this special class of cases,\* also making

FIG. 137.



use of this form of anchorage. It consisted of a delicate round bar of metal bent to conform to the shape of the

\* Angle, *International Dental Journal*, June, 1889.



ideal dental arch. It was made to encircle the dental arch, its ends being supported by loosely telescoping tubes

FIG. 138.


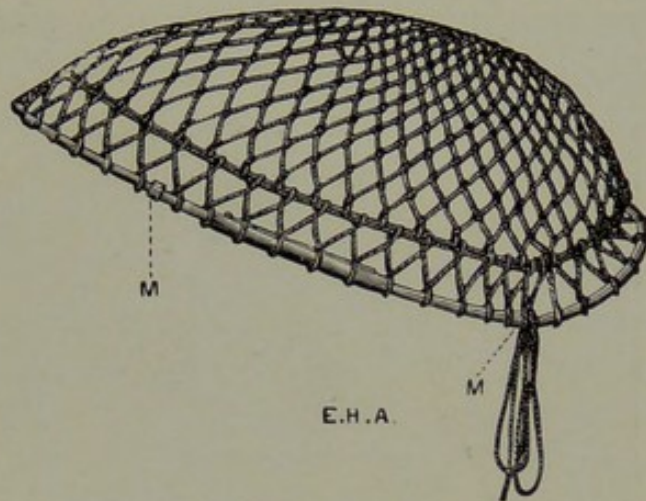


FIG. 139.



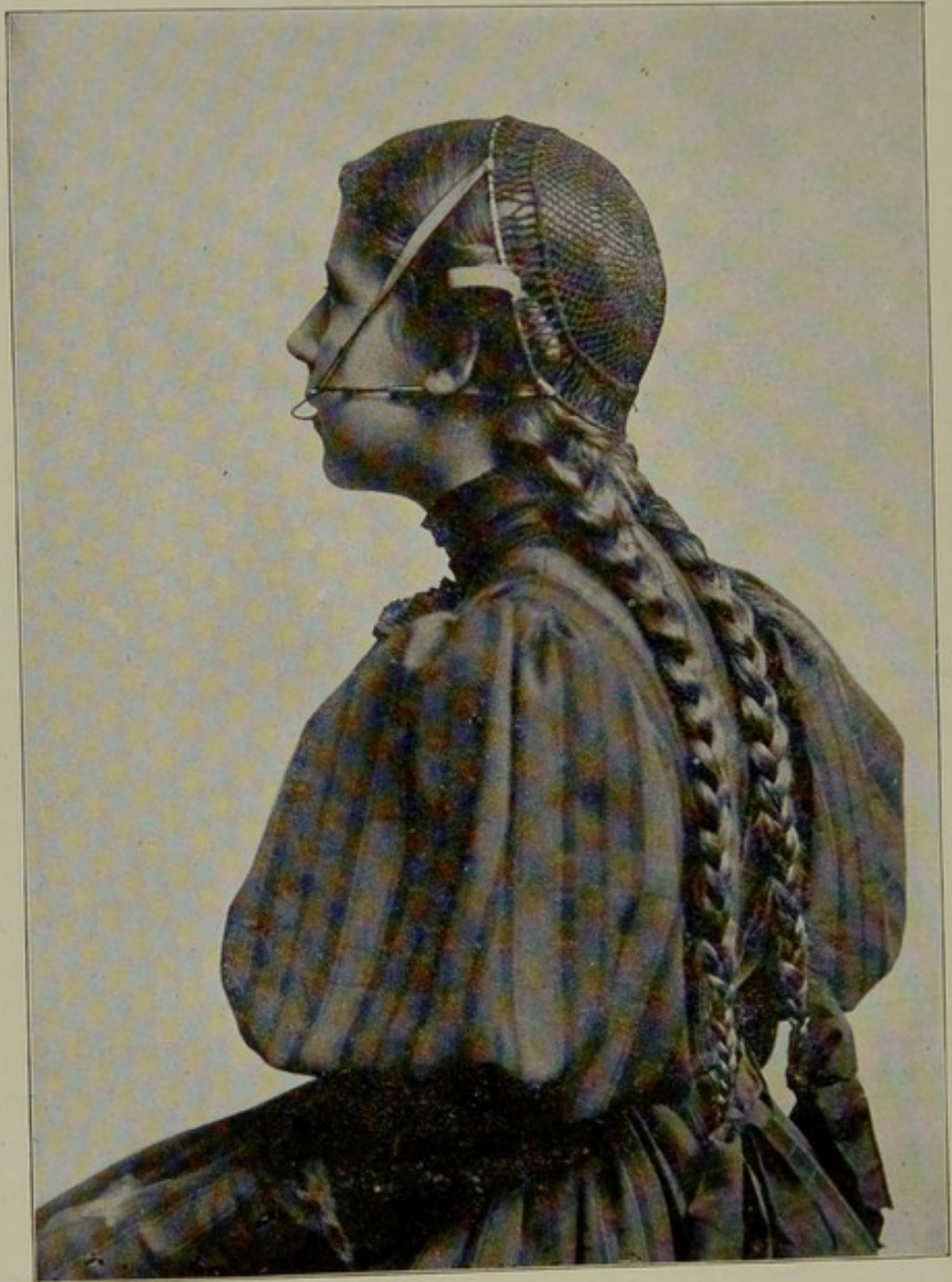
soldered to bands on the upper first molars. The center of this curved bar rested in contact with the labial surfaces of the prominent central incisors and was held in place by notches formed in plain bands cemented upon these teeth, all as shown in Figs. 136 and 137. Force was received upon the center of this spring arch through a traction bar, A, Fig. 138, having a standard in its center with a socket in the end of the standard, which socket engaged a ball soldered to a delicate sheath that in turn was soft soldered to the center of the spring arch, thus forming a ball and socket joint.

The author's headgear for securing occipital anchorage in connection with the above device, is shown in Fig. 139. It is an improvement over the ordinary form in that it consists of an adjustable,



non-collapsible rim, to which is attached by a silk lacing-cord a silk net which fits the back of the head, the rim

FIG. 140.



being large enough not to come quite in contact with the head. By attaching elastic bands, one above and one below



the ear on each side, which engage the hooked ends of the traction bar, any desired degree of force can be directed against the protruding teeth. The device in position upon the head is shown in Fig. 140. The non-collapsible rim distributes the force equally over the patient's head, so that a much greater amount of force can be borne without inconvenience than with the caps formerly employed, which localized the pressure thereby restricting the circulation and causing headache.

By studying this device in its entirety it will be seen how nearly ideal the plan is for the distribution of force for the reduction of the prominent teeth; how as the spring arch receives pressure from the ball and socket joint it is moved distally, not only carrying the protruding teeth with it, but compelling their regular arrangement, all being retracted until the spaces made vacant by the extraction of the first premolars are closed, without any displacement of the posterior teeth.

The headgear and traction bar of course cannot be worn constantly but they are easily removed and replaced by the patient. While the teeth are thus released from heavy pressure they are prevented from springing back by means of delicate rubber ligatures, as shown in Fig. 137, which are made to act constantly. It will be seen that they engage the distal ends of the tubes on the anchor bands, are stretched forward and tied in front of delicate metal collars, thus automatically holding all that is gained in tooth movement by the greater force from the heavy elastics. Later hooks were attached to these collars (sheath-hooks) which directly engage the delicate rubber ligatures. The arch by its own elasticity also constantly exerts considerable force in the desired direction upon the moving teeth. This is effected by giving the arch considerable lateral spring before slipping its ends into the sheaths of the anchor bands, whereby the spring arch in its effort to assume its normal pose manifests a strong tendency to



slide distally through the tubes, giving a corresponding pressure to the incisors. Too great lateral pressure, however, should not be exerted upon the anchor teeth, as in time they would be displaced. Various modifications of this method are shown in the Appendix.

Notwithstanding the great efficiency of this appliance, the present demands of orthodontia are best fulfilled in these cases by the Baker form of intermaxillary anchorage,

FIG. 141.



later to be considered, by means of which extraction is avoided and normal occlusion established instead of merely "improved" occlusion as in the former plan of treatment. For this reason this appliance has been superseded in the author's practice, and though it may occasionally be used as auxiliary to intermaxillary anchorage, yet the necessity for its use will become lessened as greater skill in the employment of intermaxillary anchorage is developed.

Fig. 141 shows the use of the headgear in connection with the chin retractor—a combination principally relied on for reduction of prominence of the mandible in cases belonging to Class III until the advent of the intermaxillary anchor-



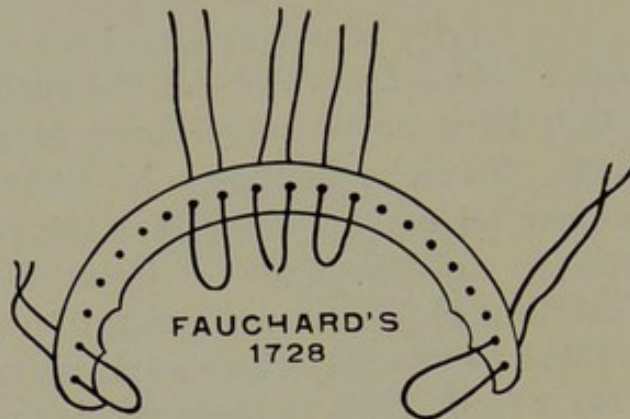
age, which has almost entirely superseded it, although it is still regarded with favor as an auxiliary to intermaxillary anchorage by a few practitioners.

Although, as we have said, these appliances with their auxiliaries are no longer relied upon by the author to the extent formerly, yet many of their simple combinations are still in daily use, chiefly in performing very simple movements of teeth or in certain cases for the readjustment of some teeth that have partially relapsed from their corrected positions. To make the reason for their general discontinuance clear let us remember that the requirements in orthodontia as we understand it today differ greatly from those existing at the time of invention of these devices. Then there was no classification of malocclusion, no standard or basis from which to correctly determine the exact direction or extent of tooth movement other than the one fixed, in each case, by the individual judgment of the operator, which often decreed that where the teeth were crowded room should be provided by the sacrifice of one or more and the pushing, pulling, or twisting of the remainder simply into alignment, and usually limiting this to the upper jaw regardless of the higher requirements of facial art and of the functions of the teeth through occlusion, that according to modern standards completely govern the direction and extent of all tooth movements in each given case. In other words, normal occlusion and facial balance now being the basis from which to reason, consideration of the entire denture instead of only the mere symptoms or the "crooked" teeth, as formerly, is necessitated and often calls for the movement of all of the teeth in one or both arches. This being true, a device to meet the requirements should be able to exert the desired amount of pressure, not only on a single tooth to accomplish any of its required movements, but as well on any or all of the other teeth of the same arch or of both arches in any necessary direction simultaneously.



To compass these exactions would at first thought seem impossible, even with a large number of devices, but it has been found not only possible, but possible with only a single appliance. That appliance in its perfected condition has

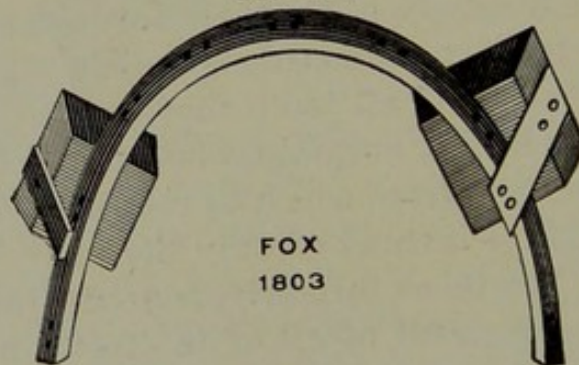
FIG. 142.



been named by the author the expansion arch, from its chief function, although no name can adequately describe it.

For the inception of this valuable device, as we have said, we are indebted to the great French dentist, Fau-

FIG. 143.



chard. Without doubt its introduction marks by far the most important step in the history of regulating appliances. Originally the appliance was very crude, clumsy, unsightly, and its uses greatly limited. It was composed of a flat ribbon of metal, perforated for the reception of



fibrous ligatures by means of which attachments were made to the teeth used as anchorage as well as to the teeth to be moved. The principle has been made use of in many

FIG. 144.

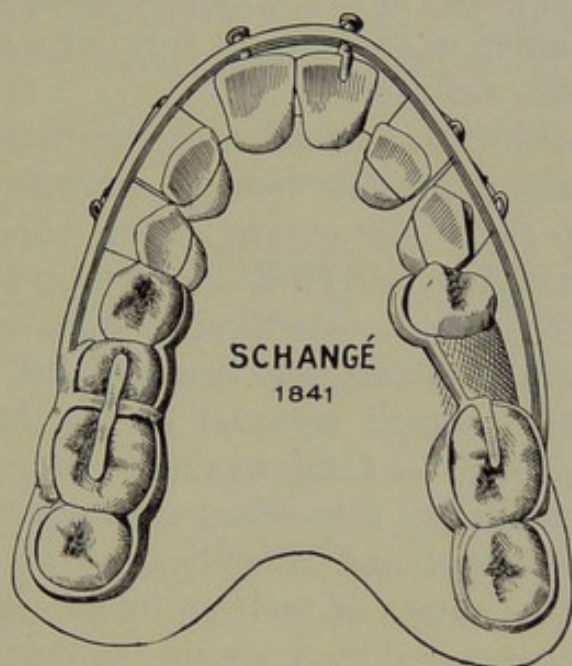
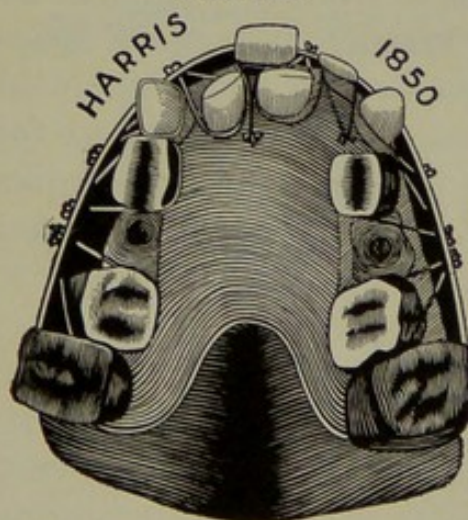


FIG. 145.



modified forms by many practitioners since Fauchard's time, only a few of which have we here space to consider.

Four of the chief of these are represented in Figs. 142, 143, 144, and 145. It is doubtful whether Fox's plan of nearly a century later was any improvement over



Fauchard's. It differed from his principally in the addition of that most useless absurdity, the gag, in the form of blocks of ivory, to prevent the closure of the jaws and interference with the moving teeth.

A marked improvement in the anchorage of the arch was given us by Schangé in 1841, in the form of a skeleton crib attachment to the molars.

Harris's modification consisted in improvement of the manner of attachment for securing anchorage. Metal caps were swaged to cover the crowns of the molars, to which the arch was soldered, and in order to keep these caps in position upon the anchor teeth they, in turn, were soldered to a metal plate covering the vault of the arch. This necessitated the frequent removal of the device for the purpose of cleansing—a fatal weakness in any appliance, as the moving teeth are thus often sprung back and forth by the relinquishment and reapplication of force, which action is a certain means of inciting inflammation. Desirabode's modification was very similar to that of Harris.

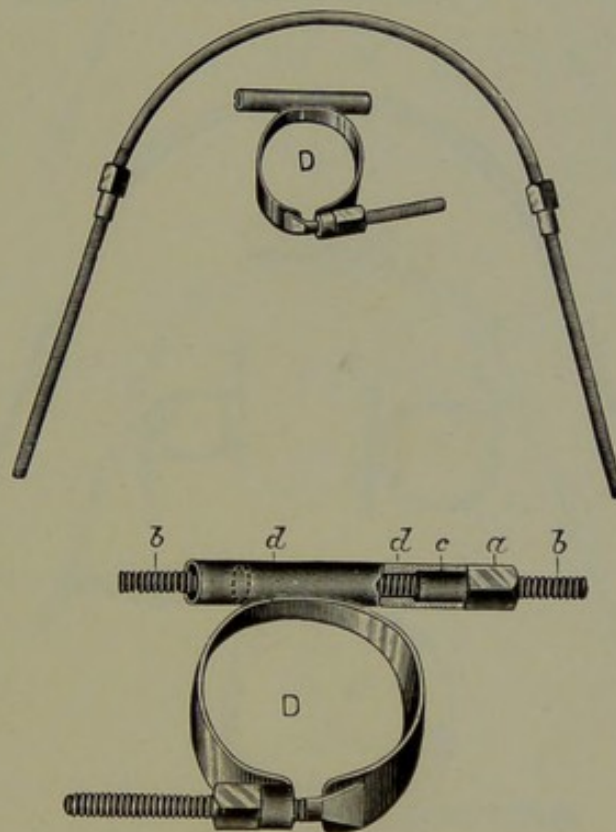
To describe any considerable number of the later modifications would require too much space. They differ chiefly in their proportions and in their manner of attachment, being combined usually with some form of plate.

The author's improvements of this appliance may briefly be said to consist in change of metal (nickel silver), modification of form and proportions, greater length of threading of sides for universal adjustment of size, in the material, style, and proportions of the parts entering into the anchor clamp bands, and in the various attachments, some of which are modified and others newly devised. Important among these is the addition to the clamp band of the long tubular sheath for the reception of the ends of the arch, which not only protects the cheeks from abrasion by the threaded portion of the arch, but gives greater stability to the anchorage. Still others deemed very important are the friction sleeve of the sheath of the clamp



bands, and extension flange of the arch nuts, as shown (enlarged) in Figs. 146 and 147, the extension rib on the ribbed arch E, as in Fig. 147, the sheath hooks, Fig. 151, for use in the Baker anchorage, and last and very important, the brass wire ligatures, Fig. 154, descriptions of all of which follow in connection with instructions for their use.

FIG. 146.



For convenience there are three styles of the expansion arch. Fig. 146 represents the plain arch E which is a very elastic round bar bent to conform approximately to the shape of an ideal dental arch. The sides of this arch are threaded and provided with nuts. One end of these nuts is elongated to form an extension flange, which accurately telescopes the friction sleeve of the sheaths of the D and X bands, as shown in the engraving.

This form of nut adds another truly valuable improvement to the expansion arch, as it enables us to make the



exposed part of the nut very short and compact, at the same time giving greater length of thread and consequently greater strength. Its greatest value, however, lies in the fact that this extension flange prevents the loosening of the nut by unscrewing through friction with the tongue or cheek—a common annoyance since screw devices have been used in the mouth. This improvement is also made use of in the author's jack and traction screws.

FIG. 147.

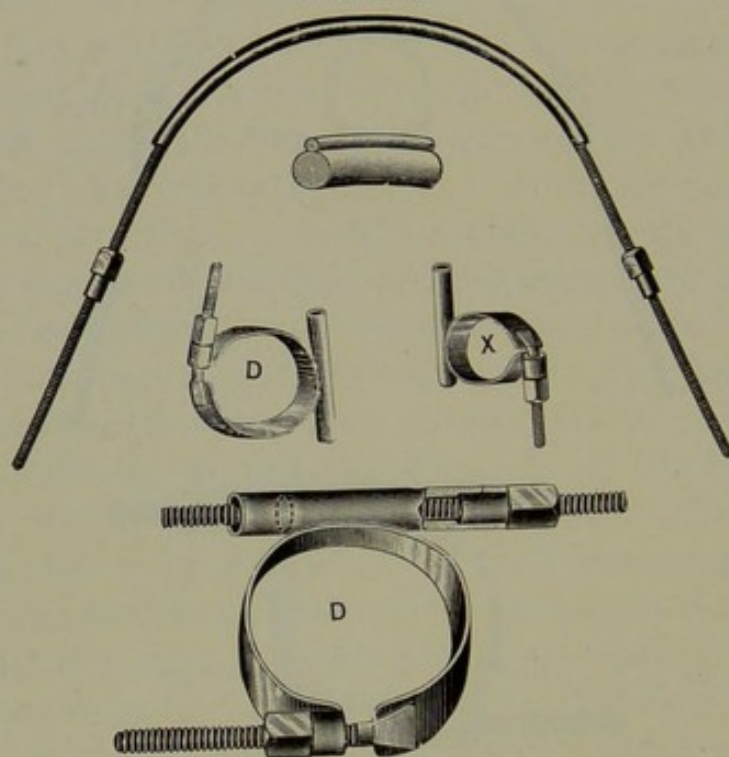
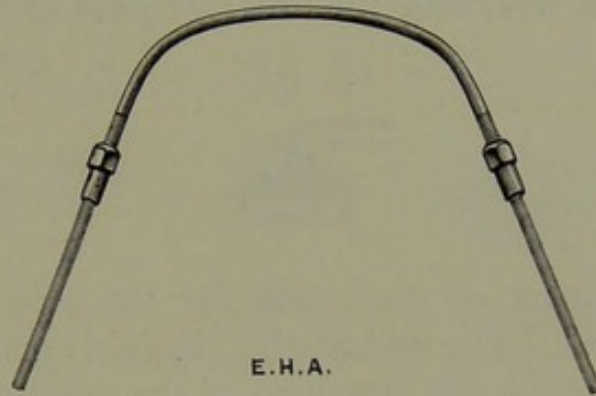


Fig. 147 shows the ribbed expansion arch E, a later modification of the arch last shown and differing from it only in being provided with a delicate rib on the periphery of the unthreaded portion, in which hook-like notches are to be made at desired points to prevent slipping of the wire ligatures. By this means the direction of force on the moving teeth is accurately controlled. It is further valuable in that it greatly increases the strength and lateral spring of the arch, thus adding measurably to its efficiency in widening the dental arches.



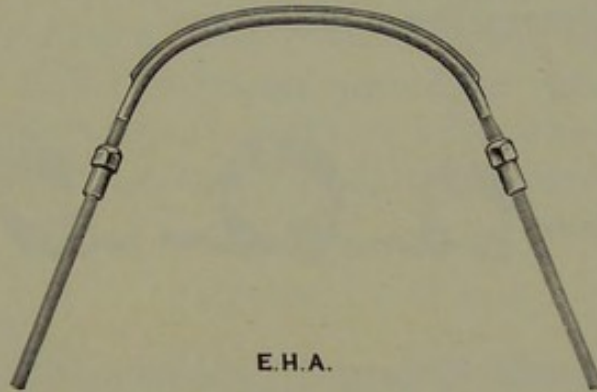
The author has recently added a smaller size of each of these arches, which are especially advantageous in treating

FIG. 148.



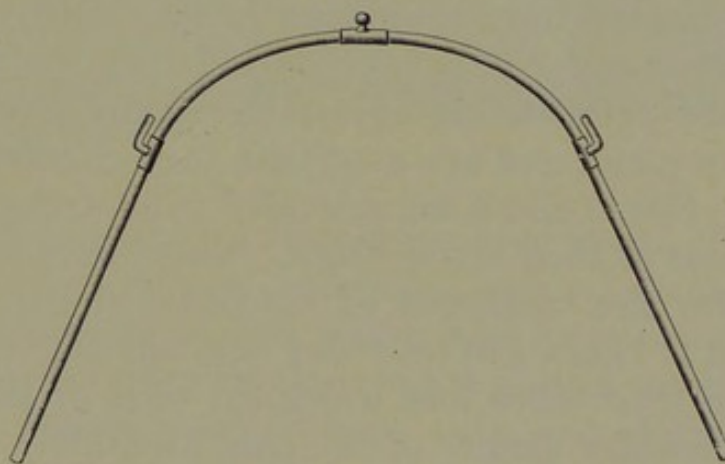
E.H.A.

FIG. 149.



E.H.A.

FIG. 150.




the cases of very young children. They are shown in Figs. 148 and 149.

Fig. 150 shows the third form of the arch as used by the



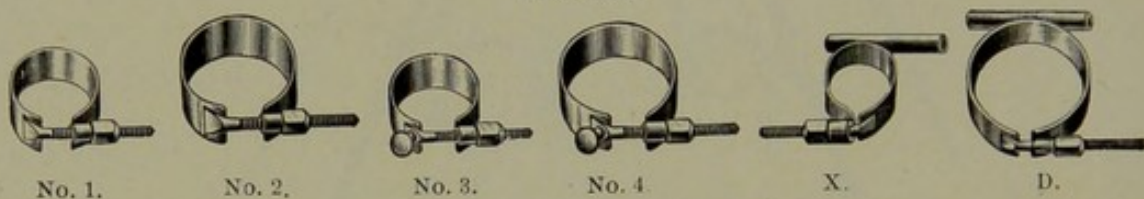
author, known as the arch B. It is smooth and threadless, similar in form and temper to the plain expansion arch E, though more limited in use. It is especially designed for shortening and widening the anterior part of the arch and

FIG. 151.



has a sheath-hook on each side for the reception of the rubber ligatures. The delicate ball in front makes it applicable for attaching the standard of the traction bar when it is desired to use occipital anchorage singly, or as auxiliary to the intermaxillary anchorage.

FIG. 152.



The sheath-hooks (enlarged), shown separately in Fig. 151, are to be attached to either of the other arches whenever it is desired to employ them in connection with the Baker anchorage.

Fig. 152 represents six adjustable clamp bands. Nos. 1 and 2 are plain, and are used both in regulation and in retention. Nos. 3 and 4 are provided with strong, headed pins soldered to their screw-heads. These were especially designed for the treatment of fractures of the maxillæ. The X and D bands are provided with smooth-bore tubes soldered to their sides into which the ends of the arches and the extension flanges of the nuts accurately fit. The X bands are for premolars and the D bands for molars.\*

\* For the varying sizes of molar teeth there are three sizes of D bands, although in the author's practice the medium size alone meets all require-



Fig. 153 shows three coils of band material, already referred to, from which plain brazed bands for incisors, canines, or even premolars may be made, that serve as mediums of attachment to the arch through wire ligatures.

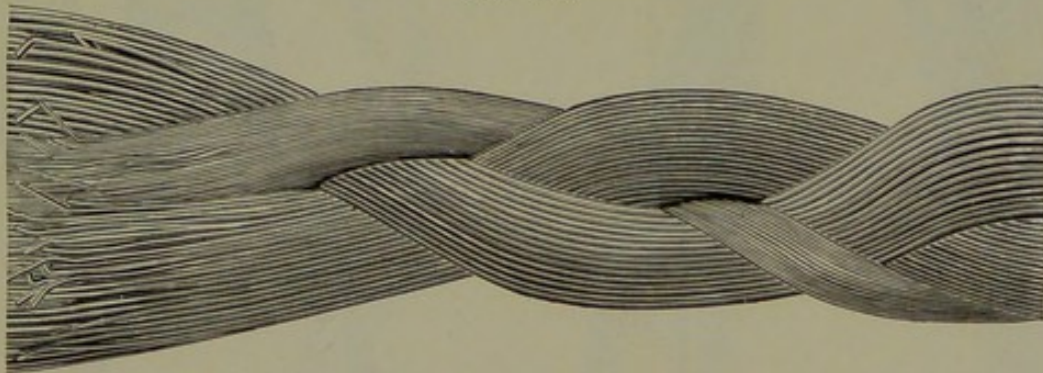
FIG. 153.



They are also very largely used in retaining devices. C and F are of the same width, being narrower than H, and F and H are of the same diameter, being thicker than C. C is used only where a very thin, delicate band is required; F where a stronger band is needed, and has much more universal use; H is principally used for canine bands.

Fig. 154 represents the ligature wire, which is very soft, smooth, and strong, and especially prepared for the use

FIG. 154.




of the orthodontist. It comes in three sizes. The largest size is preferable for performing most tooth movements. The medium size is used where less force is required, or where the teeth are so close together that the larger wire could be passed between them only with difficulty. The smallest size is principally used to hold teeth passively to

ments of the permanent molars. The smaller size, however, is occasionally found to be an advantage when the deciduous molars are used as anchor teeth.



FIG. 155.



$\frac{1}{8}$  IN. WIDE  
1 2 3 4

$\frac{3}{16}$  IN. WIDE  
5 6 7 8

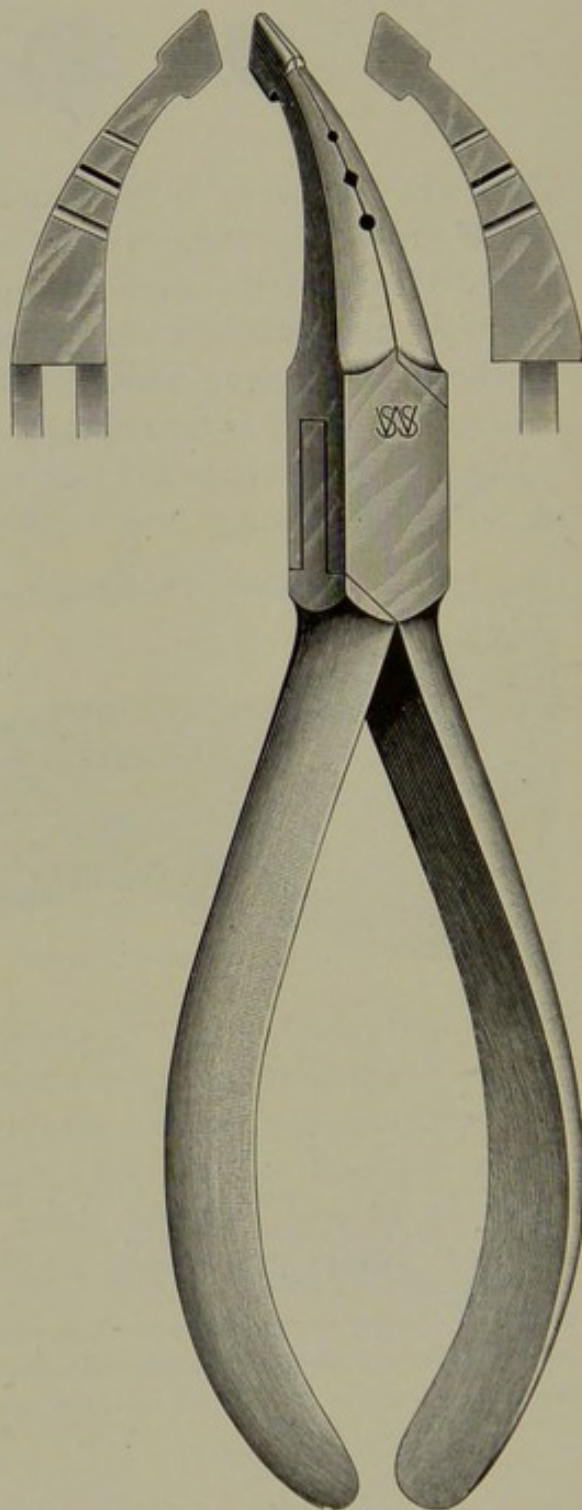
FIG. 156.



FIG. 157.



FIG. 158.





the arch after their movement is completed and while the

FIG. 159.

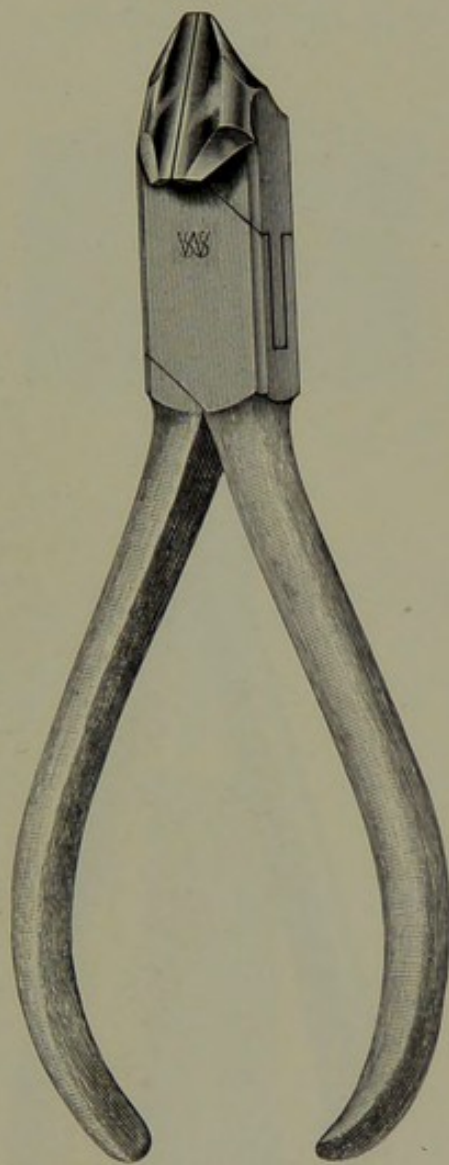
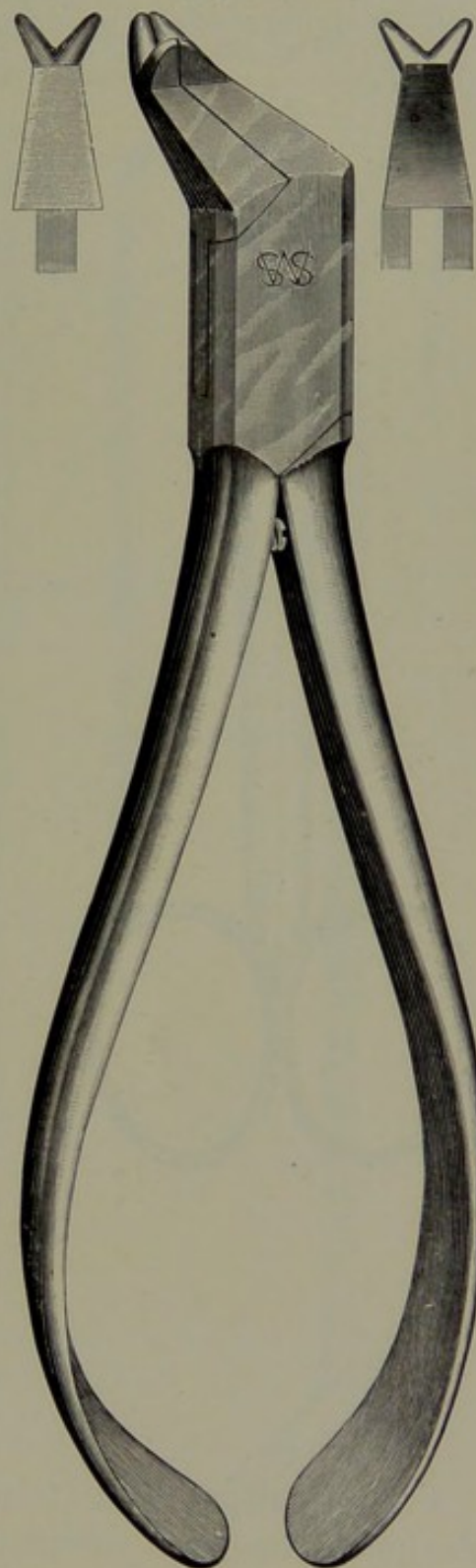


FIG. 160.



movements of other teeth are being completed by means of



the heavier ligatures. It is also sometimes used in connection with the retaining devices.

FIG. 161.




FIG. 162.

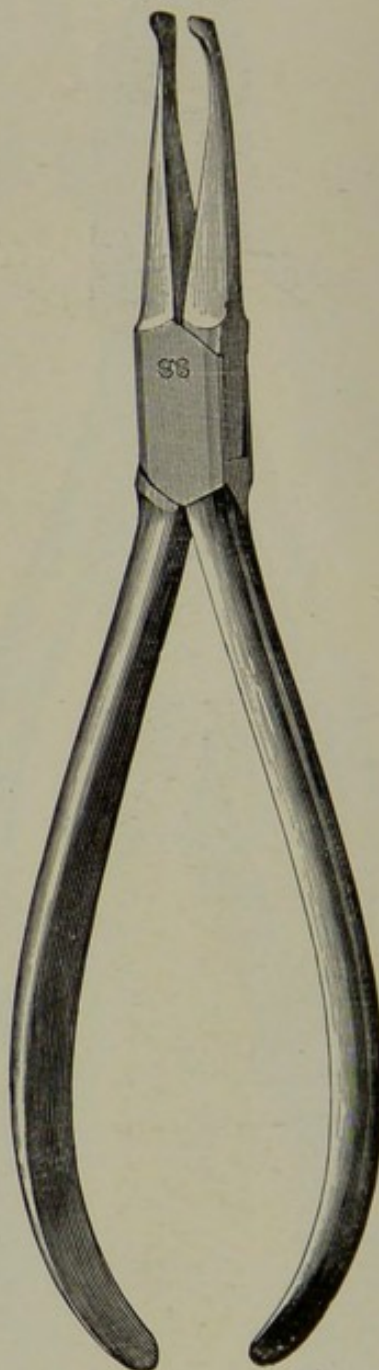


Fig. 155 represents strips of rubber from which wedges are made to exert pressure on some tooth of overprominence, or to assist in rotation.



Instruments.—For uniting the different parts of the appliances to form the various combinations, and for placing them in position upon the teeth, only a few instruments

FIG. 163.

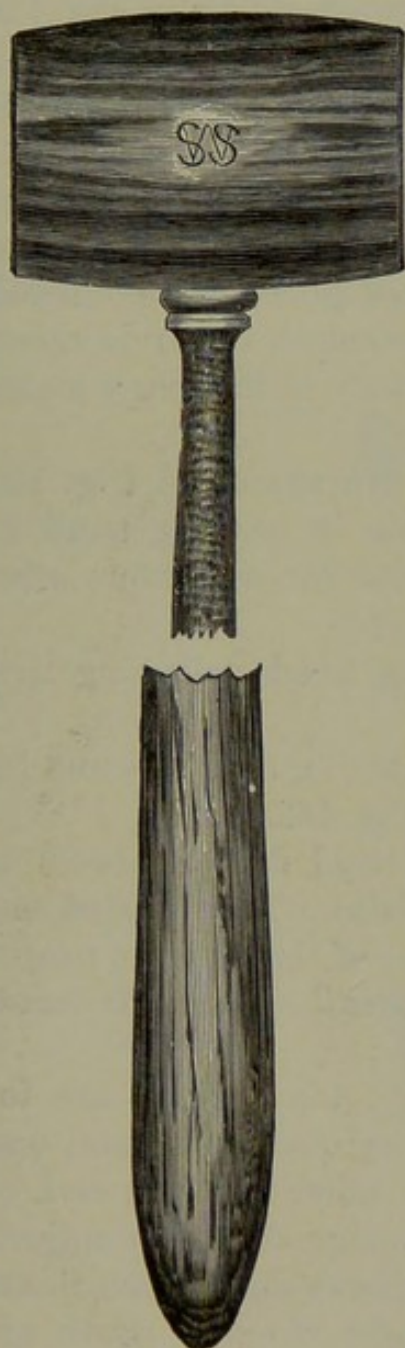



FIG. 164.



FIG. 165.



FIG. 166.



are necessary, but it is important that they should be of the best selection and some of them of special design.

Fig. 156 shows the author's soldering pliers. Their del-



icate proportions and peculiar form making them especially suited for holding bands and small pieces.

Fig. 157 shows another pair of pliers for placing pieces of solder in position, picking up small pieces, etc.

The author's band-forming pliers are shown in Fig. 158. These were designed especially for making bands, their plurality of operating edges making them equally applicable to any surface of any tooth. They are provided with grooves for holding the small square nuts and round wire, and are also very useful for most other orthodontic purposes for which the usual flat-beaked pliers are employed.

A good pair of wire cutters is essential, the style shown in Fig. 159 being the most satisfactory of the many makes the author has tried.

The author's regulating pliers are shown in Fig. 160. These are used for exerting force in moving teeth by lengthening or shortening wire, and for numerous other purposes—a very valuable instrument.

A pair of scissors for trimming bands, clipping ligatures, etc., is shown in Fig. 161.

The How pliers are best for tightening ligatures and for general uses. They are shown in Fig. 162.

An ordinary hand mallet and band driver, shown in Figs. 163 and 164, are also requisite. The beveled end of the band driver is for the purpose of restoring to proper form the friction sleeves of the sheaths of the D bands when by accident they become bent.

The two wrenches shown in Figs. 165 and 166 are for use in turning all the nuts of the various appliances; one, a short single-end wrench, and the other a double-end, or right and left, wrench especially designed for the adjustment of nuts of the clamp bands on lower molars, which are practically inaccessible to a straight wrench. Both are made of steel, nickel-plated and finely finished.

And last, and very important, a suitable lamp for soldering. The author prefers the Lane blowpipe, shown in Fig. 167.



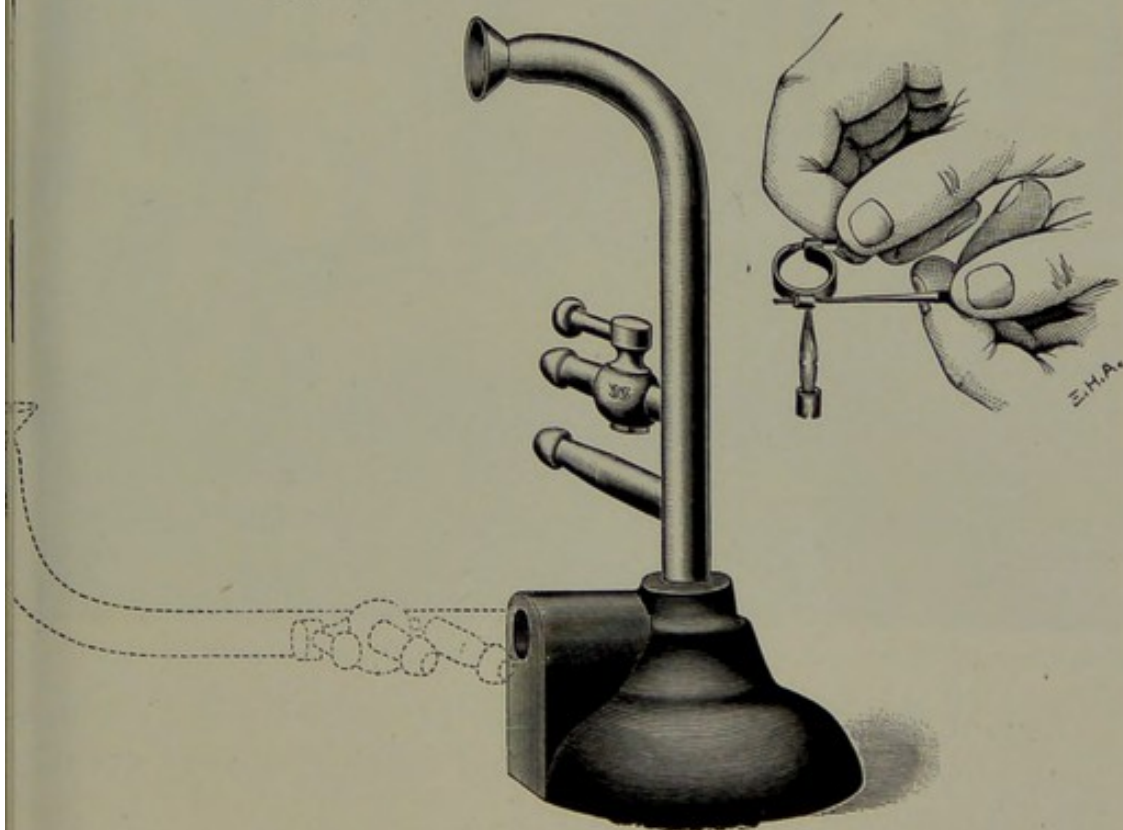
## CHAPTER XI.

### SOLDERING.

It is safe to say that no one will ever acquire much skill in orthodontia unless he attains proficiency in soldering. Efforts have been made by some to construct regulating and retaining appliances so that all unions of parts shall be effected by mechanical attachments, as screw-, hook-, or

FIG. 167.

FIG. 168.



clamp-joints. In principle this is commendable, but in fact, carried beyond certain narrow limits, is impractical, for it necessitates needless bulk, useless complexities, and unnecessary expense, a brazed joint being far stronger, far more compact, cleanly, and inexpensive.



The soldering required in orthodontia may be accomplished easily, and almost instantly, by the operator who will devote a little time to mastering the method here described.

FIG. 169.



One of the first essentials to correct soldering is a clean, neat, convenient place to work; and another of very great importance is a proper blowpipe.

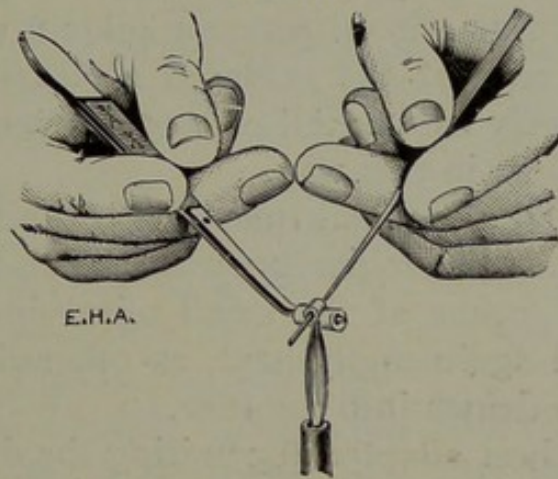
As many of the parts of these appliances are very delicate, it is important that a very fine, sharp, steady flame be used in effecting their union by solder. A large or uneven flame would injure and might ruin them. The Lane blowpipe, Fig. 167, operated with the ordinary foot-bellows is especially well suited, as it produces the requisite flame,



Fig. 168, of most intense heat, yet under the most perfect control, while both hands of the operator are left free.

Fig. 169 shows the bracket table used by the author as a convenience in this work. On this table, three feet long by fourteen inches wide, ample convenience is offered for all the necessary operations preliminary to the adjustment of the appliances upon the teeth. It is covered by a glass slab and holds the blowpipe, connected by tubing with the foot-bellows. The drawers are receptacles for tools and appliances.

FIG. 170.



Notwithstanding the many ingenious spring clamps and other devices that have been invented for holding such small work, the plan introduced by the author in the second edition of this book, if once mastered is far preferable in most cases. It consists in holding the two pieces in contact while soldering by means of the fingers or pliers. The metal of which these appliances are made is most favorable for soldering in this way, it being so poor a conductor of heat that most of the attachments can be made while held with the fingers without any perceptible communication of heat to them, provided the flame be suitable.

Where union of a small tube with a band is desirable, as in Fig. 168, the tube is best held in contact with the band and flame by means of some delicate instrument that



will absorb but little heat. One of Gates' nerve-drills with the point broken off is nearly ideal for this purpose.

Where two small tubes are to be united, as in Fig. 170, the pliers may be used to support one of them.

This method of soldering is not difficult, most students learning it readily. The only point that may seem at all difficult to the beginner is the holding of the pieces in fixed position just at the time the solder is congealing. This is accomplished by touching one or more of the fingers of one hand with those of the opposite hand, as in Figs. 168 and 170, to steady them, holding the pieces gently, not rigidly, just as a good penman holds a pen. After a little practice any of the soldered attachments may be easily and quickly made. All of those shown in Figs. 623 and 624 are made in this way.

Where the end of a small tube is to be united to a band, it is best to fuse the solder upon the band, then hold the small tube by means of the small pliers in contact with the solder and again apply heat, as otherwise the solder will usually be drawn into the tube.

The solder\* best adapted for uniting the different parts of these appliances is silver, although any of the various carats of gold solder may be used, with cream of borax for a flux. No more solder than is necessary should be used, especially in all small attachments—just enough to make a firm union.

Always avoid injuring the metal by overheating, or bringing it to more than a bright red color. Apply only sufficient heat at the right point to thoroughly fuse the solder. In every instance avoid overheating the screws and nuts. This is to be especially observed with the jack and traction screws. Great care is observed in the manufacture of the arches E and B to preserve their stiffness

---

\* The author recommends a silver solder prepared for the use of orthodontists by The S. S. White Dental Mfg. Co.



and strength, and we would impress the fact that heating them would ruin their fine temper and render them worthless.

**Plain Bands.**—As the plain bands form such an important part of the regulating appliances, and especially in this system, it is important that proper methods be employed, not only in their making, but in their setting as well. So erroneous are many of the directions given by authors, and so crude are some of the different methods of making these bands that it may be instructive to here point them out.

First, it is the plan of some to adjust the appliance to the plaster model, forming the bands over the plaster teeth, and then to transfer it to the mouth. A more crude or inaccurate method could hardly be devised, as it is impossible to pinch or burnish band material about a plaster tooth so that its final fit to the natural tooth will be at all accurate, and so made it must soon loosen under the necessary strain of tooth movement.

Another but slightly less crude method in which much unnecessary time is consumed is to cast the form of the tooth in metal, around which the band is hammered and molded to the desired form. The fit of such a band can be but little more accurate than when made after the method last described.

Another method is to make a band in a similar way and then to cover it, forming an entire crown for the tooth. This of all methods is the most absurd, for unless the tooth be mutilated such a band must be imperfect of fit, bulky, and occupy valuable space, and also often directly interfere with occlusion, while the firmness of attachment is no greater, but probably less, than with a plain or clamp band correctly made and properly set with suitable cement.

One author directs that the band shall be made larger than the tooth in order to provide space for the cement—another error, for with a band larger than the tooth its



attachment will be far less firm than if the fit were accurate and it will be almost sure to loosen under the strain necessary in tooth movement. The most accurately fitted band admits of the requisite amount of cement if the latter be properly mixed, which may be due in part to the slight stretching of the band when it is driven into place.

Another author recommends that the band on its inner surface be corrugated or roughened by scratching in order to make the cement adhere more firmly. The folly of such practice ought to be apparent when we remember how firmly cement adheres even to the polished surface of agate or glass. Again, note the inconsistency of roughening the band and not the enamel. Such practice is wholly unnecessary, besides being injurious to the band.

Another method is the use of a strip of metal in length not quite sufficient to encircle the crown of the tooth, and having soldered upon its outer surface, near the ends and at right angles to them, two small buttons around which ligature wire is wound in the form of the figure 8, thus completing the union of the ends of the band by tying. This form of band possesses no advantages over the brazed band, but on the contrary has many disadvantages. It is bulky and uncleanly and under the strain of tooth movement will loosen far more easily, besides being more expensive and requiring more time in tying than is needed in brazing.

We have already stated our reasons for preferring nickel silver for the making of regulating appliances, and especially for the making of bands, in Chapter IX, yet this metal varies greatly in quality, not only on account of differences in the formulæ, but also on account of the manner of manipulation in manufacture.

It is important that it be of the proper fineness, diameter, and temper, or it will be harsh and unyielding and difficult or impossible of proper adaptation to the form of the tooth, in which case it will loosen more readily under the



strain of tooth movement, will occupy unnecessary space between the teeth, and present a less pleasing appearance.

The method of making plain bands employed by Dr. Magill, who must always be regarded as the father of this most valuable adjunct to orthodontia, was to burnish a short piece of band material (platinum) about the tooth, overlap the ends and solder. This method, though much better than those already described, falls far short of the possibilities in band making.

By the author's method\* a ribbon of band material of sufficient length to firmly grasp with thumb and fingers is slipped around the tooth to the desired point, and pinched with the band-forming pliers to conform to the shape of the tooth.

By this means there is sufficient pressure brought to bear to stretch the metal and make it adapt itself with the greatest accuracy to the surface of the tooth around which it is drawn. The author wishes to make clear the necessity of having not only a firm grasp of the band material, but exerting a strong pulling force on it with the fingers, to be counterbalanced by a pushing force from the pliers. If these two forces are properly balanced, although they may be considerable, even to the extent of breaking the band material, they may be employed so skilfully as not to cause pain even to a tooth that is already tender on pressure from tooth movement.

A band so formed and ready for soldering is shown at Fig. 171.

Simply pinching a short piece of band material about the tooth, as has been recommended by some authors, makes a loose fit and an imperfect band. Fig. 172†, taken from one of the modern works on orthodontia, shows a fair sample of such bands.

---

\* Notes on orthodontia. "A New System of Appliances," Transactions Ninth International Medical Congress, 1887. Angle.

† Essig's "American Text-book of Prosthetic Dentistry."



No one should expect other than a very crude band if rough and loose-fitting pliers be used for pinching, for the

FIG. 171.

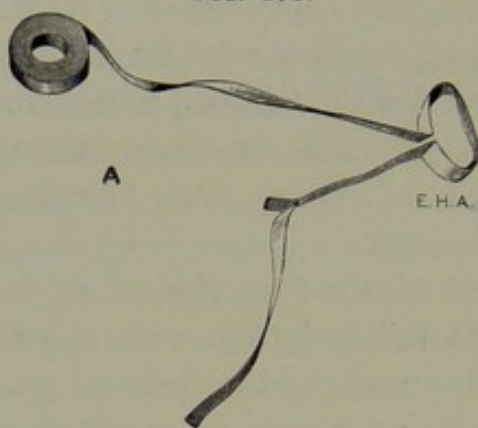
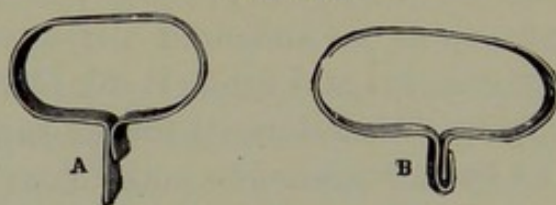
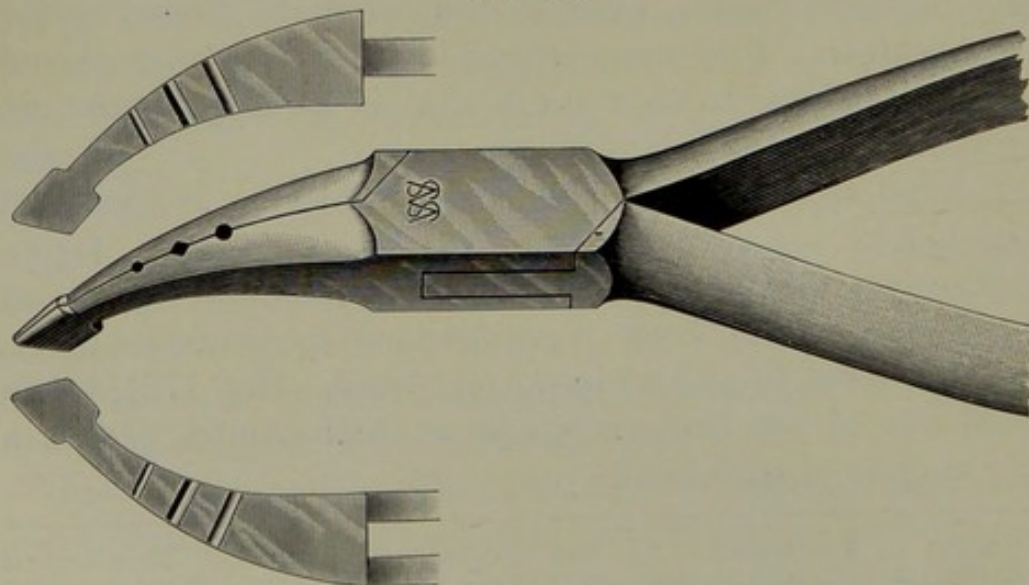


FIG. 172.



junction of the pinched portion will then be rounded, as in Fig. 172, instead of sharp and at right angles, as in Fig. 171.

FIG. 173.



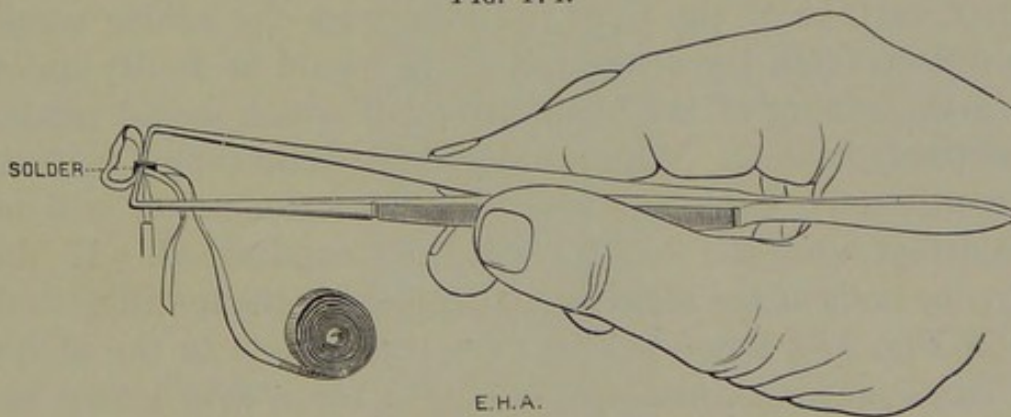
Many advantages will be found in the use of the author's band-forming pliers, Fig. 173. The peculiar shape of the



instrument and form of the jaws make it equally adaptable to all of the various surfaces on any of the teeth where the union of a band is desirable.

In banding the centrals, laterals, or canines the union may be made either on the labial or lingual portion of the tooth. If made on the labial surface that portion of the band crossing the lingual surface of the tooth should be properly burnished to a fine adaptation just before the final strain with the pliers. The canine is the most difficult of any of the teeth to band, but by forming the seam on the lingual incline and firmly burnishing the outer surface while it is being pinched, an accurate fit can in most instances be made. Another plan is to pinch a fold in the band on the lingual incline, while it is being firmly pinched and drawn with the fingers on the opposite side. The band is then removed and a little solder flowed into the fold. It is then replaced and the seam made upon the labial surface by pinching, burnishing, etc., in the usual way.

FIG. 174.

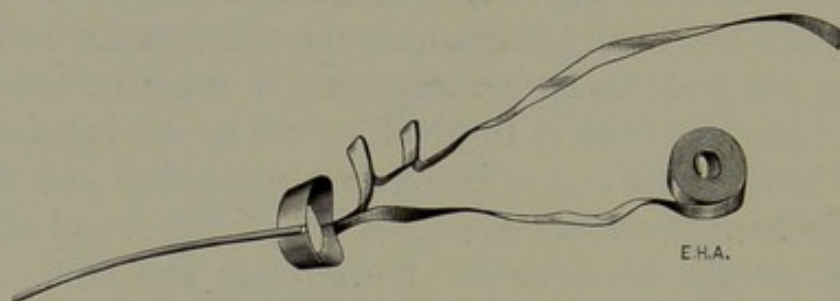


In soldering a band either gold or silver solder may be used. A portion about one-eighth of an inch square wet with borax cream is placed between the angles of the band and held by the band-soldering pliers, Fig. 174, over the sharp flame of the Lane blowpipe. With these pliers uniform pressure is exerted at the exact points necessary to insure a smooth unbroken joint when soldered, Fig. 175.



And as only the minimum amount of heat is absorbed by the pliers no change of form or injury to them is possible. A further advantage is that their points rest in contact with the band material in such position as to be shielded from the solder, so that none will be fused upon the points, thus avoiding an annoyance of no small moment that is often encountered in the use of ordinary pliers, their contact with the solder being almost a necessity.

FIG. 175.



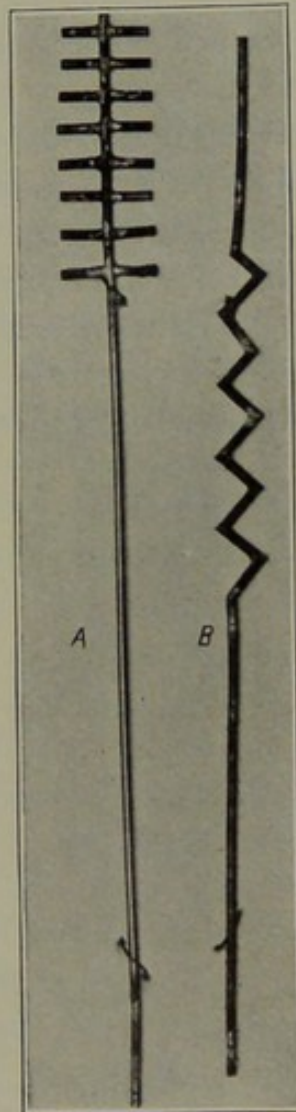
To insure the flowing of the solder in the seam only, plenty of borax should be placed there, but none on the inner surface of the band, as otherwise the solder would be drawn from the seam and there would be faulty union or a thickening of the band, either of which would render it entirely useless. When soldered the band should present a continuous, even surface, otherwise the union will be imperfect and the band should be condemned. If the surplus ends of the band be cut off leaving them still united, as in Fig. 175, there will be very little waste to the strips of band material, and ample length for a firm grasp between the thumb and finger, while pinching, will always be insured. The band being properly fitted, it is ready for any attachments that may be required.

Let us again insist upon the importance of a very hot, fine, sharp-pointed flame in the making of all these attachments, as neatness in such delicate soldering is impossible with a coarse flame. With the proper flame such attachments may be made almost instantly without injury to



the delicate pieces of the appliances, and before the heat can be transmitted to those portions held by the fingers. The flame from the ordinary blowpipe, such as dentists generally use in the various processes in crown and bridge work, is wholly unsuited.

FIG. 176.



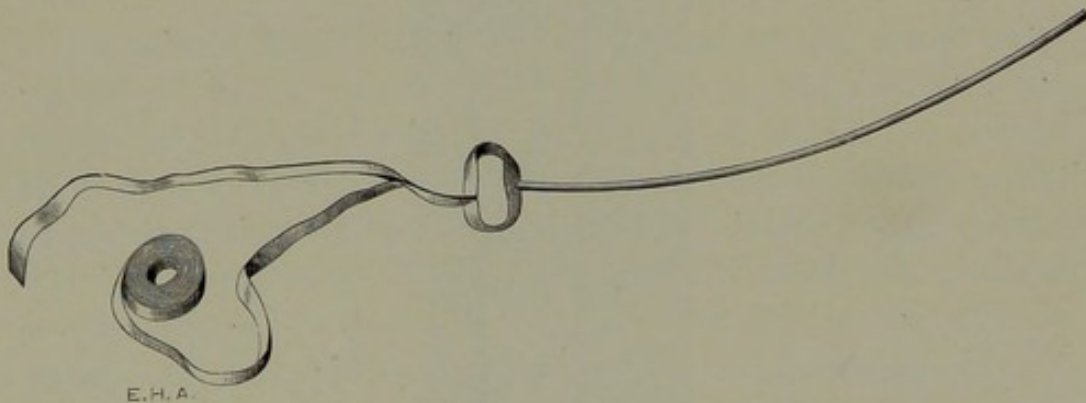
The principal soldered attachments to the plain bands are spurs, staples, etc., from the G wire; tubes, planes of metal, etc., etc. Not a large variety of soldered attachments is necessary, yet the beginner should so discipline himself in the technique of soldering as to be able to make all attachments with great skill and accuracy.



It is often necessary to solder a tube or spur close to the union of a band or other attachment, which must be done without unsoldering the first joint. Fig. 176, shows some delicate soldering, one of the requirements in the course of technique in the Angle School of orthodontia. In A short sections of G wire are placed in pairs at regular intervals opposite each other and at right angles to a longer section of the same wire, each attached by silver solder and independently of all the others. Any student may soon acquire this proficiency in soldering which, although evincing skill, is still crude compared with the soldering in what is known as "filigree work."

B, shows short sections carefully mitered with a file and joined, also by silver solder, using the smallest amount of solder consistent with perfect union.

FIG. 177.



The attachment of a spur to a band is best accomplished by heating the smoothened end of the wire G, touching it to a large piece of borax, holding it in contact with a small piece of solder in the flame until the solder is partially fused, then bringing it in contact with the band at the desired point and again holding in the flame which should be so applied that the heat will be distributed equally between band and spur up to the point of fusion of the solder. After it is fused, Fig. 177 or K, Fig. 623, it is clipped off with the wire cutters to the desired length,



which should not be greater than one thirty-second of an inch, and the roughened end made smooth with file. But little solder should be used, as a large amount would form an incline that would not so well hold the ligature. This spur should always be attached at such an angle as will best prevent the ligature from slipping off, and usually, for reasons which we will note later, close to the gingival margin of the band.

It is desirable that all attachments, both for moving the tooth and in anticipation of retention, be made, if possible, before setting the band, in order that the pain and trouble of removal and substitution of a new band, after the teeth have become tender, may be avoided.

The untrimmed ends of the band serve the useful purpose of a handle for holding it in the flame and in contact with the piece to be attached, as in Fig. 177. After the attachments have been made the ends of the band are trimmed, leaving them long or short as desired.

If a notch\* is to be formed, as in C C, Fig. 136, into which the arch is to rest for its better support, the ends should be left about one-sixteenth of an inch long, but, if not, they may be trimmed still shorter, though it is never desirable to trim them even with the surface of the band. The sharp corners should be rounded by means of a fine flat file.

The band is now deoxidized by boiling in a few drops of dilute sulfuric acid in a small test-tube or other suitable vessel, or it is dipped in phosphoric acid and held in contact with the flame until the fluid is partially evaporated by boiling, then washed and dried.

The band is then ready to be cemented upon the tooth,

---

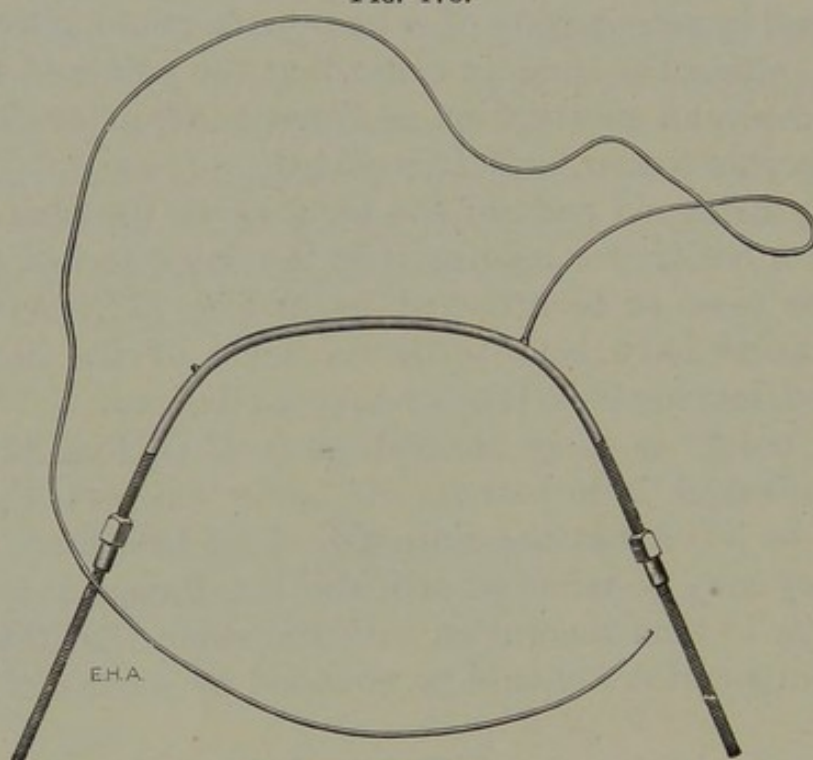
\* Forming a notch in a band, formerly thought to be so necessary, is now rarely deemed advisable by the author, the band and spur being placed at such a point on the tooth that the ligature alone will hold the arch in the desired position.



which will be considered in the chapter on Adjustment and Operation of Appliances.

**Soft-Soldering.**—It is frequently necessary to attach sheath-hooks, and occasionally to make other attachments, to the arches E which are manufactured in such a way as to give them the greatest possible amount of spring. If the sheath-hooks are attached by means of the ordinary soft solder with which they come provided, the temper of

FIG. 178.



the arches need not be injured. We would, however, impress the importance of using the very smallest possible flame procurable with the Lane blowpipe, and slowly raising the temperature to the melting point of this low-fusing soft solder.

It is sometimes desirable to attach spurs to the plain arches E or the arches B. They also should be attached by means of soft solder in order not to injure the spring of the arches.

The best plan for making these spurs is to fuse a very



small piece of this solder upon a section of ligature wire, then hold it in contact with the arch in the flame. This gives a fine conical spur with brass center, which is very strong, yet inconspicuous. Fig. 178 shows the arch with spurs both before and after the surplus wire has been cut off. The spur should be no higher than the diameter of the ligature it is intended to support, as, if higher it will be unsightly and will abrade the lips or interfere with their movements. Dr. Lourie has invented an ingenious form of forceps for raising a barb or spur from the metal of the arch which may obviate the necessity for soldered spurs. Since the introduction of the ribbed arch in which notches may be made to prevent the slipping of the ligatures, without removing the arch from the mouth, the use of spurs is rarely necessary.

Jewelers' soldering fluid (nitro-muriate of zinc) is used as a flux in making these attachments.



## CHAPTER XII.

### ANCHORAGE.

THE movement of one or more teeth in any of their several directions is possible only by the exercise of force and its intelligent application in accordance with the laws of mechanics and dynamics.

According to the well-known law of physics, action and reaction are equal and opposite, hence it must follow that the resistance of the anchorage must be greater than that offered by the tooth to be moved, otherwise there will be displacement of the anchorage and failure in the movement of the teeth to the extent, or, possibly, in the direction desired.

The sources at our disposal for securing anchorage or resistance are, first, the teeth themselves, and second, sources external to the teeth, and anchorages may be classified as simple, stationary, reciprocal, intermaxillary and occipital.

An accurate knowledge of the forms and surfaces of the teeth and their occlusion, the surfaces, lengths, and inclinations of their roots, and the structure, density, and distribution of the alveolar process and peridental membrane, is essential to an intelligent application of the principles of anchorage. The degree of resistance offered by different teeth varies greatly, according to their position, size, length and number of roots, the direction from which force is exerted, and in the manner of mechanical attachment to them.

Of the many improvements in the methods of tooth regulation perhaps none has been greater than the modern devices for gaining and applying anchorage. The former bulky and insecure devices for this purpose in the form



of vulcanite or metal plates or cribs, have become practically obsolete since the introduction of the method of cementing and clamping bands upon the teeth, by which far greater stability and control of anchorage is gained.

The force should be as direct and positive as may be possible with the conditions at our disposal. The ideal anchorage would of course be an immovable base. This, however, it is probably never fully possible to obtain in the mouth owing to the elasticity of the alveolar process and cushion-like function of the peridental membrane. Some displacement of anchor teeth is admissible and sometimes even desirable, provided these teeth be kept within the limits of final restoration by means of the inclined planes of the occluding teeth; but if greater displacement than this occur, malocclusion of the anchor teeth, most difficult or even impossible to overcome, may be established. Hence they should be closely watched and careful measurements and comparisons with the original models be frequently made. Any unfavorable movement perceived should be promptly combated. The embarrassment following any considerable displacement of the anchor teeth is so serious that ample anchorage should always be secured in the beginning.

**Simple Anchorage\*** is that form in which, first, the resistance is overcome by means of an anchor tooth or teeth of larger size or more favorable location, as in Fig. 179; and second, the form of attachment to both anchor tooth and teeth to be moved is hinged or pivotal, admitting of the tipping of both in their sockets, as in Fig. 180.

In Fig. 179 the central incisor is being moved labially by means of a section of the G wire made to rest in a socketed band encircling its crown, the opposite end of the wire engaging a pit in the anchor tooth. As force is exerted by

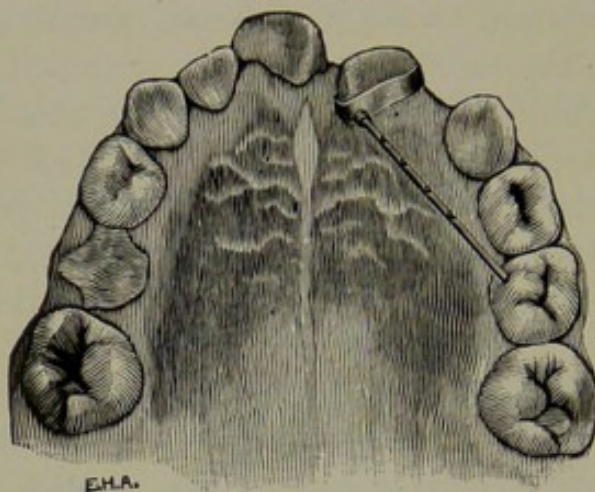
---

\* It is impossible to trace the origin of simple anchorage. It was the first and until recent years the only form employed in orthodontia.



lengthening the wire by means of the regulating pliers, the central incisor, offering less resistance than the larger and more favorably placed molar, is moved outward.

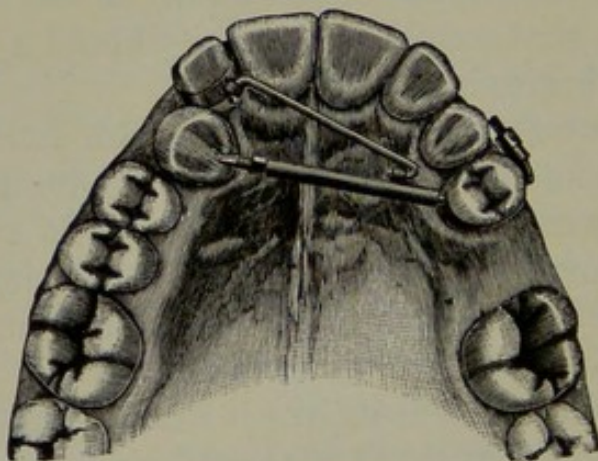
FIG. 179.



*although the form of attachment admits of the tipping of both.*

Fig. 180 illustrates an example of simple anchorage where a firmly implanted canine is being moved labially by

FIG. 180.



means of a jack-screw, the base of which loosely engages a spur attached to the anchor band upon the first premolar. This anchorage by itself would be insufficient, but, as illustrated, all of the incisors are made to assist in overcoming the resistance of the moving canine. It will be

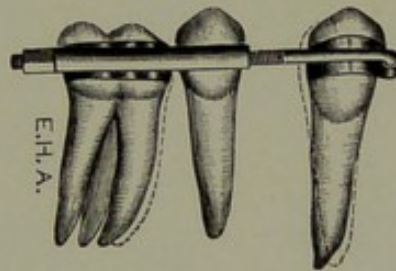


observed that the mechanical attachment to both is practically a hinge.

Of course this principle of anchorage, with its hinge-like attachments, admits of application in exerting a pulling force equally as well as in those cases just illustrated where a pushing force is exerted.

**Stationary Anchorage\*** is that form in which the attachment to the anchor tooth is essentially rigid so that its tipping is impossible, and if moved at all it must be dragged bodily through the alveolar process in an upright position. Fig. 181 shows an illustration of stationary anchorage for the

FIG. 181.



retraction of a canine. The long sheath of the screw is soldered to a clamp band rigidly cemented and clamped upon the molar, while the angle of the screw engages a tube soldered horizontally to a plain band on the canine. The attachment to the canine is hinged and designed to facilitate tipping, while that to the molar is rigid to prevent tipping. Should any displacement of the molar occur, both root and crown would be moved equally and in the same direction. It will thus be seen that the resistance in this form of anchorage is many times greater than in simple anchorage. So efficient is it that the retraction of a canine has been accomplished by anchorage to a premolar alone, with

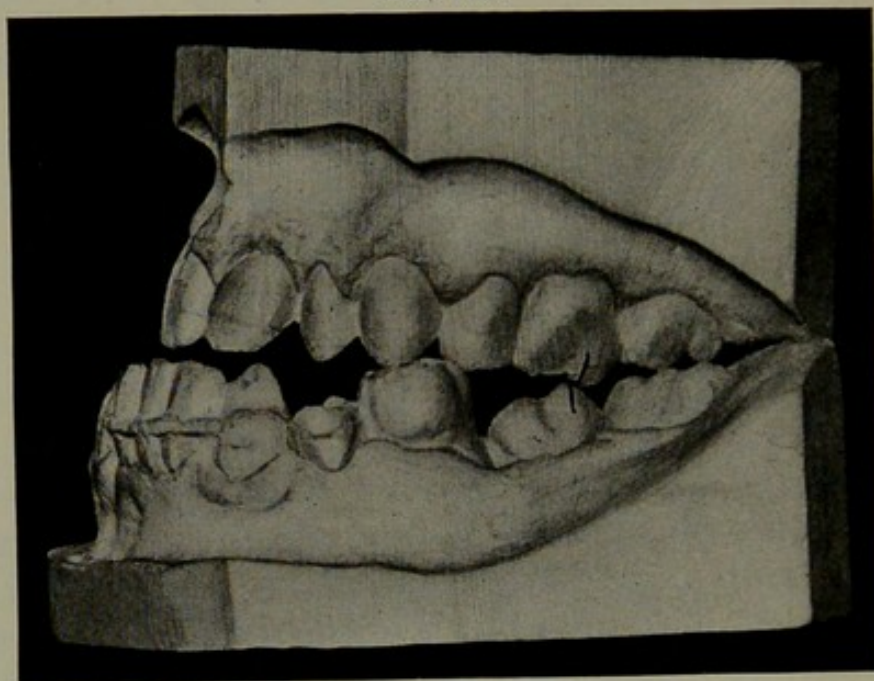
\* This form of anchorage was introduced in its perfect form by the author in the second edition of this work. See, also, *Items of Interest*, December 1887. Full credit must, however, be given Dr. Barrett who first made use of this form of anchorage, though in an imperfect manner, by means of a vulcanite plate entirely covering the vault of the arch and molars, but this, of course, did not admit of strict rigidity of attachment.



but little displacement of the latter, while in the effort to accomplish the same thing by simple anchorage all three molars and one premolar have been displaced.

In making use of stationary anchorage skill and judgment are necessary, for its efficiency depends on the absolute rigidity of the appliance and its attachment to the anchor tooth. Care must be exercised that the amount of force exerted shall at no time be so great as to strain or

FIG. 182.



injure the attachment. This is of vital importance, for any loosening or straining of the attachment would immediately greatly weaken its resistance, or even transform it into ordinary simple anchorage, with possibly embarrassing results. The effect of continuing force after the anchorage has become defective is forcibly illustrated in Fig. 182, which represents the condition of the teeth of a young lady who called on the author for consultation after the irreparable injury shown had been accomplished. In the effort to retract the lower incisors and canines to close the space of the extracted first premolars, the first molars and second premolars were drawn forward and the molars



nearly out of their sockets, and apparently without in the least effecting the desired distal movement of the anterior teeth. Yet the movement of these teeth could easily have been accomplished without displacement of the molars by the proper application of the principles of stationary anchorage.

This valuable form of anchorage in its range of usefulness is more limited than simple anchorage because it is not always possible to secure complete rigidity of both appliance and attachment. It has, however, great use in modern orthodontia and we shall illustrate its application in its partial or complete form many times in the pages that are to follow, and we would call special attention to the directions for adjusting the attachments on page 587.

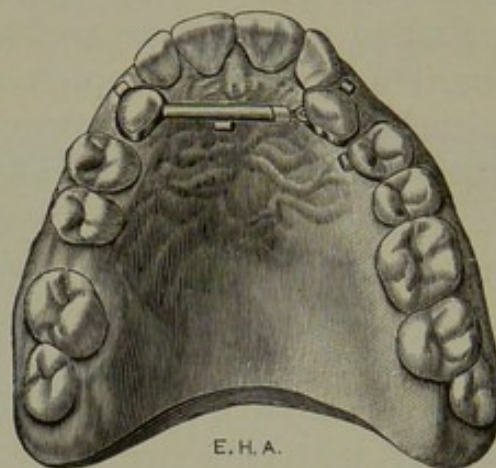
**Reciprocal Anchorage**, strictly speaking, is not a distinct form of anchorage, yet its value, and possibilities in application are such that it may with propriety be so regarded. It is that form in which one malposed tooth is pitted against another, the force, if correctly applied, being reciprocated from one to the other, moving both into normal occlusion. It admits of the widest range of application and is the most valuable form of anchorage. Each case should be studied carefully with a view to its use whenever possible, either in its simplest forms, as in Figs. 183 and 184, or when a greater number of teeth are to be moved, as in widening the arch, Fig. 199, or in combination with other forms of anchorage, or in its most extensive application, in the reciprocal movement of the teeth of opposite jaws, as in Fig. 190. It will be found applicable in a very large percentage of cases and is an important principle made use of in the treatment of many of the cases that will be shown later.

Fig. 183 illustrates the use of reciprocal anchorage in its simplest form where two inlocked canines are being moved in opposite directions into the line of occlusion by means of a jack-screw, the attachment at each end being



such as to admit of tipping of both teeth. The force exerted by tightening the nut upon the screw is reciprocated to both of the teeth, the result being, as both teeth are of the same size and offer equal resistance, that both are moved with equal rapidity into harmony with the line of occlusion.

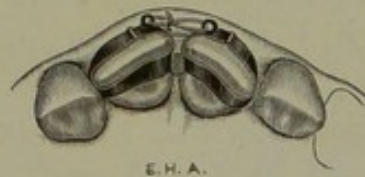
FIG. 183.



The extra tubes shown upon the bands are in anticipation of reinforcing the anchorage and for retention.

Fig. 184 shows where two central incisors are being rotated in opposite directions, force being exerted by the occasional tightening of a wire ligature engaging tubes or spurs on their mesio-labial angles, while an intervening

FIG. 184.



wedge of rubber exerts force on these teeth in the opposite direction, thus the force is reciprocated from one to the other, the effect being to rotate both into harmony with the line of occlusion.

**Intermaxillary Anchorage** is that form in which anchorage is secured by attachments to teeth in the opposite arch. It is the newest form of anchorage, having been introduced by



the author in 1890.\* (See *Dental Cosmos*, September 1891, page 743, from which Figs. 185, 186, and 187 are taken.)

FIG. 185.

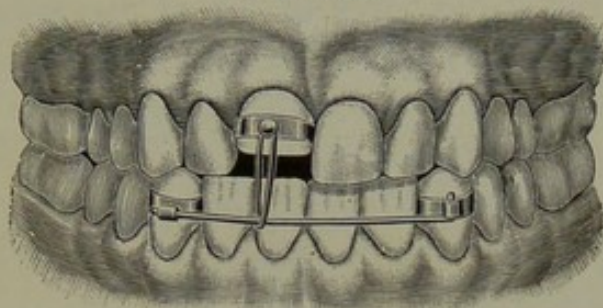


FIG. 186.

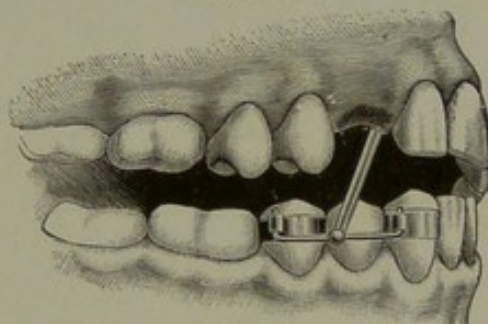
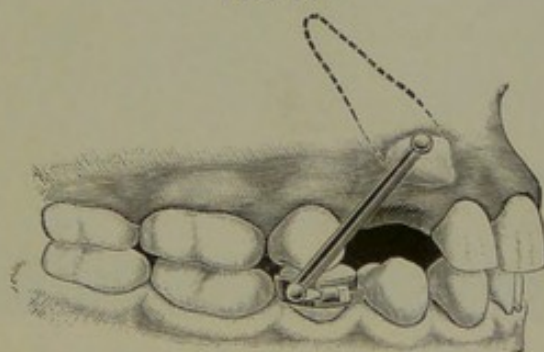


FIG. 187.



It may or may not be used reciprocally. As here illustrated it is not used reciprocally, the elevation of the up-

\* These three pictures, in the form of lantern slides, were first shown before the Illinois State Dental Association at Bloomington, Ill., May 1891, to illustrate a paper given by the author, entitled 'Efficiency and Simplicity in Regulating Appliances.' The paper was discussed by Drs. Case, Matteson, Black, A. O. Hunt, Garrett Newkirk and others.

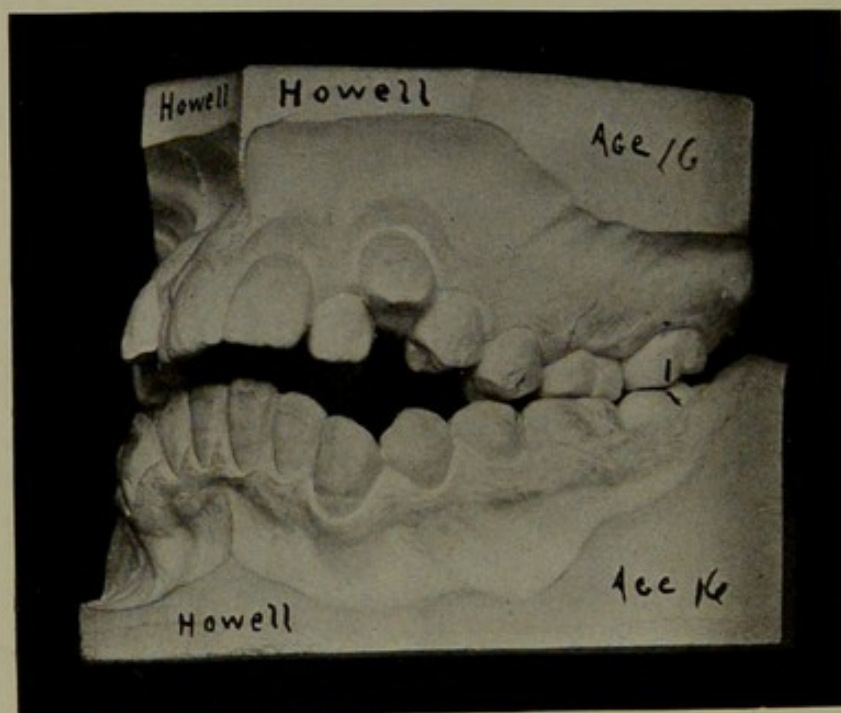
There were about forty additional slides used, and it may be worthy of mention that these were the first lantern slides ever used to illustrate plaster models of cases of malocclusion. They were made by Dr. W. J. Brady and are still in the possession of the author.



per canines in Figs. 186 and 187 being accomplished by means of rubber ligatures attached to anchorage devices on the lower teeth, and the lower teeth prevented from elevating by the irresistible force of direct occlusion.

The principle of intermaxillary anchorage has often been further extended by the author to those cases where elevation of a number of teeth is desired, either in one or both of opposing arches, as in Fig. 188, by first securing the teeth by means of ligatures or bands to the expansion arch

FIG. 188.



from which hook-like spurs project at desired points, over which are engaged rubber ligatures of various strengths.

One of the most valuable modifications of this anchorage is what is now known as the Baker Anchorage, by means of which the teeth of opposite arches may be reciprocally moved collectively—the uppers distally and the lowers mesially, or *vice versa*. This marks an important step in the progress of orthodontia, for with this anchorage the entire plan of treatment of cases belonging to both Classes II and III has been revolutionized, making their treatment



simple and easy with patients of proper age. This form of anchorage, as used by Dr. Baker,\* is shown at Fig. 189,

FIG. 189.†

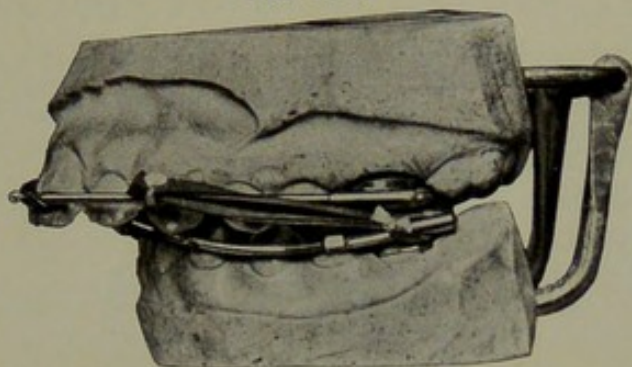
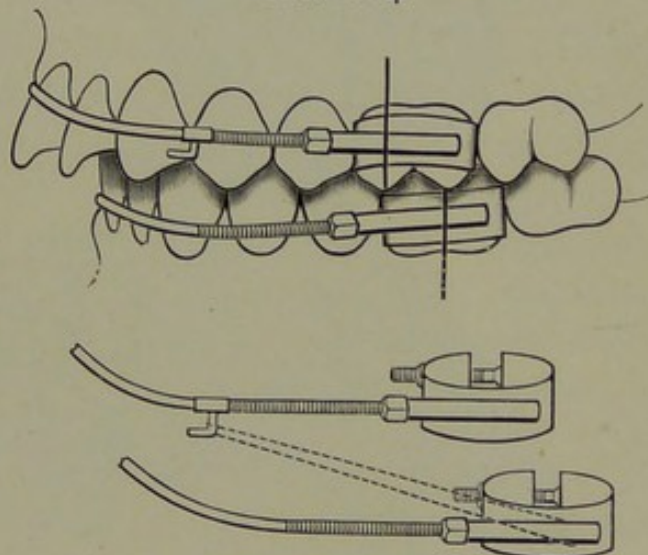


FIG. 190.‡



and the author's modification of it is shown in Fig. 190.

---

\* To the best of my knowledge and belief we are indebted to Dr. H. A. Baker of Boston, for this idea, he having used it in the retraction of the protruding incisors of his son a number of years ago, and it was from him I received the idea. I have hence called it the "Baker anchorage." Dr. C. S. Case of Chicago, also employed this form of anchorage, probably at about the same time as Dr. Baker, not, however, as anchorage complete in itself, as did Dr. Baker, but only as auxiliary to occipital anchorage in a case belonging to the third Class. It is reported in the *Transactions of the Columbian Dental Congress*.

†Angle. Sixth edition.

‡Angle. *Dental Cosmos*, March, 1903.



For a more thorough understanding of intermaxillary anchorage we would refer the reader to the chapters on

FIG. 191.



Treatment of practical cases of malocclusion belonging to Classes II and III, and their Divisions and Subdivisions.



**Occipital Anchorage** is that form in which the resistance is borne by the top and back of the head and force transmitted to the teeth by means of the headgear and heavy elastics connected with attachments upon the teeth, as in Fig. 191. This well-known form of anchorage, heretofore principally applied to the treatment of cases belonging to Division 1 and its Subdivision of Class II, and to Class III, has in the author's practice been largely superseded by the Baker anchorage, just described. Although it is still highly prized by many and will undoubtedly long hold a place in orthodontia, probably chiefly as an auxiliary to other forms of anchorage, the author feels sure that in proportion as skill in the use of the Baker anchorage is developed occipital anchorage will be less and less relied upon.

Finally, the variations in the application of the various forms of anchorage are so many and important that they should be constantly considered in the treatment of each and every case. To the thoughtful orthodontist the possibilities in the delicate shadings of force and anchorage, like that of harmony to the artist in music, are ever widening. With the novice much of importance in anchorage might be lost sight of altogether, or possibly recognized only too late, but as his skill develops he will learn to weigh the problems of anchorage in each case most carefully, seeking to utilize every possible advantage which he will anticipate far in advance of his immediate needs, and in proportion as he is capable of comprehending and skillfully taking advantage of the possibilities of anchorage, so, to a very large extent will ease of treatment and certainty of success be developed. The strings of the violin are but four, but their possibilities in music are immeasurable.



## CHAPTER XIII.

### ADJUSTMENT AND OPERATION OF APPLIANCES.

**Adjustment of Clamp Bands.**—In adjusting the expansion arch with its auxiliaries, all of which have been previously described, the first step is the fitting of the anchor clamp bands, either D or X. The use of the D bands on the first molars is usually preferable, as these are the largest and firmest of the teeth, thereby affording the firmest anchorage. Occasions may arise, however, in which it may be desirable to adjust these bands to the second or third molars, or it may sometimes be desirable to use the X bands on the premolars, either on one or both sides, but their use is only occasionally demanded.

In adjusting a clamp-band the nut should first be loosened sufficiently to allow *ample* size for the crown over which it is to slip. The band should then be shaped between the flat beaks of the band-forming pliers until it conforms approximately to the shape of the crown of the tooth, the shaft of the screw, which should always point forward unless for some special reason, being bent also if necessary. The band should then be worked carefully over the crown with the fingers and made to slide between gum and enamel to the desired point, and then alternately clamped and burnished until made to conform accurately to the shape of the crown.

One of the greatest blunders made in adjusting these bands is to trim or file the band on its edge to prevent supposed interference with the gums. Such procedure only ruins the band. Besides, it is essential that this portion of the band shall pass beyond the swell of the crown and be clamped and burnished to the neck of the tooth



to prevent its slipping off. This is the most valuable part of the band.

Another blunder frequently made is to begin the clamping or burnishing before the band is well over the crown. In this case part of the band must bear the entire strain and will be stretched or torn, or the band will loosen and come off.

It is a mistake to allow the screw to stand out at too great an angle. The band should be turned before clamping until the screw is in close contact with the adjoining teeth. It is then not only out of the way and will give no annoyance to the tongue or lips, but on occasion the projecting end may be of great value for the attachment of auxiliary devices. If the screw should be drawn away from the tooth while tightening the nut it should afterwards be bent back by a burnisher or piece of wood.

The bands are made to endure the greatest strain consistent with their nearly ideal proportions, and far more than ever actually required in tooth movement. They will, therefore, bear considerable tightening of the nut, yet if this be carried too far they will be broken. It is usually best not to clamp the band tightly at first, but to wait until the second or third sitting for the final clamping and burnishing, when there will be more room between the approximating teeth for its better adaptation.

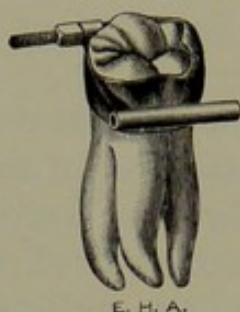The clamping of the bands is ample to secure them in position without cement except in effecting stationary anchorage, as in the use of the traction screw, shown in Fig. 181. We have elsewhere pointed out that no injury to the tooth will result by not cementing the clamp bands in position.

Fig. 192 shows a D band that has been properly adjusted to the crown of a molar. It will be noted that it accurately conforms to the swell of the crown. A small portion of the upper edge has been burnished over the distal marginal ridge. This is important to prevent the possibility of the



band working too far over the crown. A band so adjusted offers the firmest anchorage, and cannot be loosened without breaking, or unturning the nut.

FIG. 192.



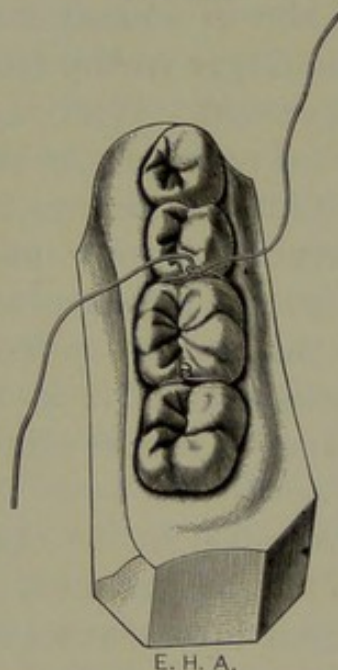
If the teeth to be banded are crowded, care and patience are necessary to work the band into position. This is usually easy with young patients, as their teeth admit of considerable movement. The band is worked between the teeth on one side and allowed to remain for a few minutes, then the other side is gently rocked and pressed with the finger, or better, with a flat piece of wood, until started into place between the teeth. It is then well to allow it to rest for a few minutes, beginning the same operation with the band for the tooth on the opposite side of the mouth, after which, sufficient separation will usually have taken place to readily permit of the further adjustment of the first band.

An excellent method of providing space is shown in Fig. 193, in which a ligature of wire is made to engage the approximal surfaces of the teeth to be separated and tightly twisted. Such a ligature will not give annoyance from displacement, so liable in the use of wedges, and if worn a few hours it will be found that ample space has been gained for the accommodation of the band. This method of separation is equally valuable in gaining space between incisors, or incisors and canines for the plain bands.



Sometimes after adjustment of the anchor band it is found that the mesially adjoining tooth inclines buccally to such a degree as to prevent the passing of the end of the arch into the sheath. This is readily remedied by unsoldering the sheath from the band and resoldering it, with a piece of metal of sufficient thickness intervening. Usually a portion of a ten-cent piece is ample. By this

FIG. 193.



means the sheath is sufficiently projected buccally for the ready insertion of the end of the arch.

Occasionally a case may be found where the tooth which it is desired to use as anchorage inclines forward at such an angle that the sheath of the D band will not properly line with the expansion arch (see Figs. 421 and 422). In this case the band should be removed and the sheath detached and resoldered at the proper angle. This may be readily effected by placing a small piece of solder and borax at the union of the band and sheath, applying heat, and turning the band as desired. It is, however, rarely necessary, as by slightly bending the arch and shifting the position of the band it can in most instances be



properly adjusted without changing the position of the tube.

What has been said regarding the adjustment of the D bands will, of course, also apply to the adjustment of the X, plain adjustable, and fracture bands.

**Adjustment of Plain Brazed Bands.**—In adjusting the plain brazed bands the tooth to be banded is first cleansed, then dried and protected from moisture. The band is filled with oxyphosphate of zinc of creamy consistence, then carried on the end of the finger to the tooth, upon which cement and band are pressed. With the fingers alone the band is carefully worked nearly to its desired position, and then driven down by a few gentle taps from the mallet and band driver. The burnisher is now quickly applied to the edges of the band *only*, and the surplus cement wiped off. When the cement has thoroughly hardened the band should be polished and burnished, as it is well known that a smooth, polished surface is far less liable to discoloration than a rough one.

A band made as described in the chapter on Soldering, and set as above, will fit with the most glove-like accuracy, will present a very neat appearance, and will not loosen under necessary strain. If it is defective in any particular, as too large, weakened by crimping, or slightly torn when driven into position, it should be condemned immediately and a perfect one substituted, for sooner or later it will surely fail and cause annoyance.

In banding a tooth where there is much crowding it may be necessary to provide space in advance. Usually, however, by exercising a little care and patience the banding may be done at one sitting.

**Adjustment of Expansion Arches.**—In adjusting the expansion arch to a given case of malocclusion it can rarely at once be given the form of an ideal dental arch, or as we wish the teeth to be arranged when completed, especially if the malocclusion be extensive, as in Fig. 201, for the



reason that much unnecessary space would thus be occupied by it, with consequently much inconvenience to the patient. For this reason it should first be given a form roughly approximating the form of the dental arch, and after the form of the latter has been improved somewhat through the elasticity of the expansion arch, and the ligatures, it should be removed and bent to more nearly resemble the ideal form, and in this way gradually approximate the ideal in both expansion and dental arches.

If adjusted correctly the expansion arches become guides and patterns for the proper alignment of the teeth and finally temporary retainers.

In changing the form of the arch by bending, *much* care should be exercised not to break it. Let it be remembered that the arch is made from the best obtainable metal and is necessarily quite hard in temper in order to give it the proper strength and spring, and that if carelessly handled it may be easily broken in the threaded portion, and especially at the point where the threaded and unthreaded portions join. But by holding it in the groove of the band-forming pliers and bending it but slightly at any given point, extending the area, if need be, to a number of points in near relation, any desired form may be given it without injury. Whenever broken it reflects carelessness.

The adjustment of the size of the expansion arches for the requirements of the teeth to be moved into proper alignment is controlled by the nuts in front of the anchor tubes. The tendency of beginners is to depend principally on the tightening of the nuts for applying pressure on the moving teeth. This, however, is a mistake, as the principal force should be derived from the ligatures and the elasticity of the arch.

**Adjustment of Wire Ligatures.**—Unquestionably the greatest modern improvement in connection with the use of the arch is the substitution of brass wire ligatures\* for the fibrous

---

\* Fourth edition of this work.



ligatures, on account of their great strength, cleanliness, and freedom from stretching or slipping, making their force direct and positive. With them the possibilities in the use of the arch are greatly extended, shortening the time of treatment, and making easy much that was impracticable or even impossible with the fibrous ligatures, owing to the giving of the knot, stretching of the fiber, and its great tendency to slip. The wire not only entirely overcomes these defects, but, in addition, it has a great advantage in that it may be tightened by additional twists without removal, possessing thereby, in addition to its primary usefulness, the ideal power of the screw, and obviating the necessity for the frequent relinquishment and reapplication of pressure on the moving teeth necessary with other ligatures—the principal source of pain and inflammation in moving teeth. It is very important, however, that only a very fine quality of brass wire, of the proper temper, size, and finish be used. Wire of spring temper is entirely useless.

When applying a wire ligature a piece of ample length, at least a foot long, should be used, so that it may be firmly grasped by both hands and strong tension exerted when twisting it. This should never be more than three-fourths of a turn at first. The surplus ends are then clipped off, leaving projections one-sixteenth of an inch long. These ends are then curled under the arch, usually one on each side, as correctly shown in Figs. 195 and 199, the tension on both strands of the ligature being thus equally distributed, as well as providing a smooth surface to the lips. This is the author's favorite way of disposing of the ends, although Drs. Lourie and Brady prefer to bend both ends of the wire either above or below the arch, as shown in Fig. 194.\*

It is a mistake to suppose that greater stability is given

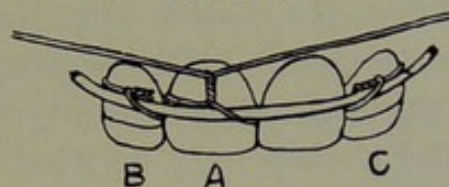
---

\* Brady, *Western Dental Journal*, May 1906.



to the union of the wire by a number of twists. In reality all over three-fourths of a turn is superfluous bulk, as any one may easily verify by exerting pressure with the two

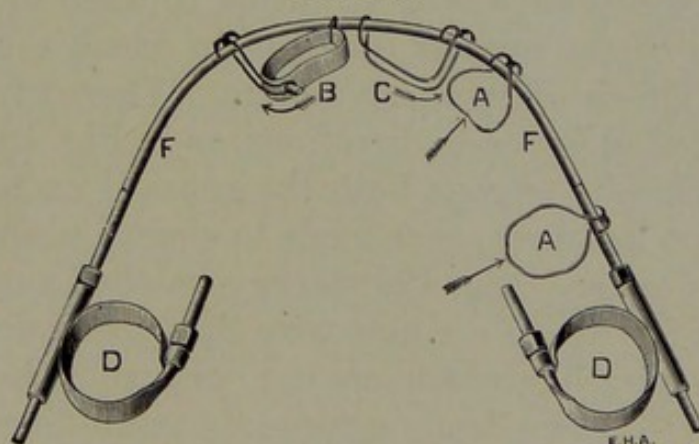
FIG. 194.



hands on a large loop of wire the ends of which have been united by twisting. The twisted portion will simply revolve in the untwisting if sufficient force be used, all of the strain being borne by the primary portion of the twist.

In tightening the ligature, firmly press the tooth and arch between the thumb and finger of one hand while giving it another half-turn with suitable pliers. It should be remembered that the spring of the expansion arch, when used in connection with the wire ligature, is constantly acting, so that, as a rule, a ligature need only be tightened occasionally.

FIG. 195.



Although the uses of the wire ligature in orthodontia are limitless, there are three principal ways of applying it in ligature form: First, the simple ligature, as in AA, Fig. 195, where it is made to engage a single tooth and the



expansion arch, when direct labial or buccal movement is required; second, where rotation and possibly labial movement is required the ligature is made to engage the expansion arch and a spur upon a band cemented to the tooth, as in B; third, the double-loop ligature, as in C, to effect the same movement. The ligature applied in this manner is more uncertain in its results than when applied as last shown, and should only be used occasionally. Its greatest use will be found in the temporary retention of an incisor to the arch after rotation, while the movements of other teeth are being completed.

If the molars or premolars are to be rotated, Fig. 196, the movement is effected in the same manner as in B, Fig.

FIG. 196.

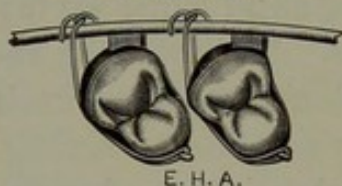


FIG. 197.

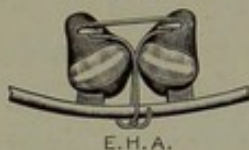
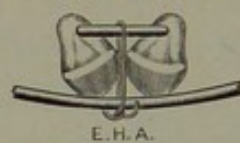
FIG. 198.



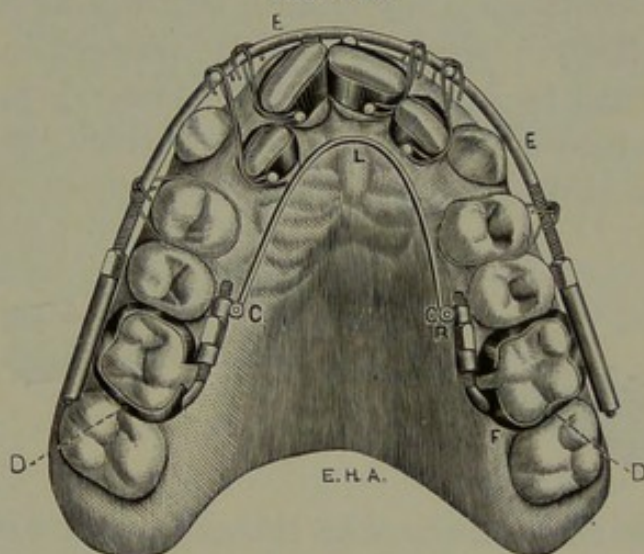
195, by means of spurred bands, ligatures, etc. As here shown the wire ligatures are intensified by means of strips of rubber which have been stretched between the arch and the angles of the crowns opposite to which the ligatures operate. This is often an advantage. Where two teeth are to be rotated in opposite directions, as in Fig. 197, a single ligature made to engage both the spurs is quite as efficacious as two ligatures, each made to engage a spur, and occupies less space. Fig. 198 shows a method suggested by Dr. Reoch for use of a single wire ligature in double rotation. The wire ligature is made to engage a short section of the wire G drawn firmly against the mesio-lingual angles of the teeth. This plan is rarely efficacious on account of the shapes of the teeth and the liability of the toggle to displacement, yet where the shapes of the teeth are favorable it may be used with advantage. The author would suggest, however, that if a small bit of soft solder be used



in uniting the ligature and toggle, the liability of the appliance to loosen would be greatly lessened.

**Combination Adjusted.**—That the reader may better comprehend the uses and great possibilities of the expansion arch let us now carefully consider it in combination with its auxiliaries adjusted to the teeth of the upper arch, Fig. 199, in the very complicated case shown in Fig. 398,

FIG. 199.



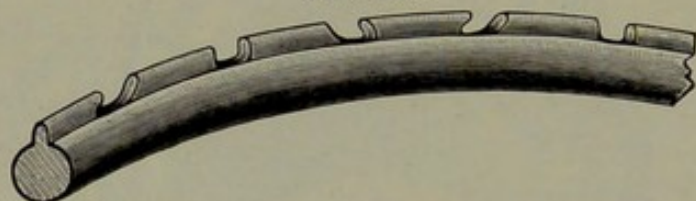requiring the movement of all the teeth in both arches and offering the severest test to a regulating appliance, and at the same time offering us the best of opportunities for its study with a view to its proper adjustment and operation, not only in this case, but for all general uses. Its more extended uses in special cases will be noted later in the treatment of individual cases. In this case the upper dental arch requires much widening, while both centrals and both laterals are to be carried forward and outward and rotated, and the canines are to be elevated in their sockets.

Plain spurred bands and ligatures are adjusted to all the incisors for their combined labial movement and rotation, the spurs on the plain bands having been so placed that pressure exerted by reason of the elasticity of the



arch through the wire ligatures will bear most heavily on the angles of those teeth that are turned lingually, and as they are rotated they will also be drawn labially. By using the ribbed expansion arch and notching the rib for the more stable attachment of the ligatures, the degree and direction of force for moving these teeth is absolutely controlled. A knife-edge file is best suited for making these notches, and much care should be exercised in order to make them effective. They should be fully as deep as the diameter of the rib or even slightly deeper, and slanting so that they will be in the form of a hook to prevent any waste of force by slipping of the ligatures. An enlarged section of the ribbed arch so notched is shown in Fig. 200.

FIG. 200.



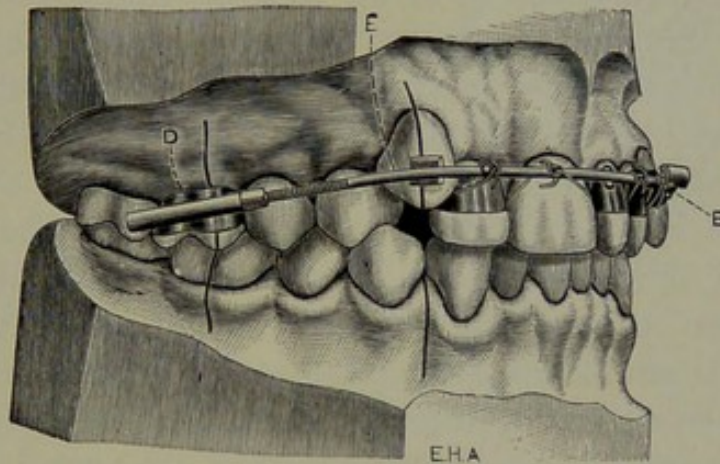
The first molars, attached to the expansion arch through the clamp-bands, are moved buccally by reason of the lateral spring of the expansion arch. The first premolars are moved in the same direction through their attachment to the arch by plain wire ligatures, and the second premolars through contact with the screws of the D bands. Pressure on the canines to move them lingually may be intensified by rubber wedges stretched between teeth and arch and the superfluous ends cut off, as shown in Fig. 201.

By carefully studying the picture (Fig. 199) it will be seen how perfectly force is distributed to accomplish the various necessary tooth movements, and how, as in all perfect mechanisms, each part not only performs its function, but assists, and is in harmony with, all other parts. For example, note how perfectly the force is reciprocated from one moving tooth to another; from one lateral half of the dental arch to the other, and how this is intensified



by the pressure on the center of the expansion arch in front, the tendency being when pressure is exerted at this point, as in all arches, to spring the ends farther apart. As the central incisors are rotated much force is exerted

FIG. 201.



upon them at their diagonally opposite corners, in reality the arch operating on each as two levers combined, the power ends acting in different directions. No tooth can resist this force. At the same time, by tightening the nuts all four incisors are carried forward by the irresistible force equal to that exerted by what is practically two jack-screws combined.

In the anterior teeth one lateral incisor reciprocates its force to the other, one central to the other, all in perfect harmony. Note, also, what complete control we have over the movements of the teeth both singly and collectively through the ligatures, with the anchorage practically derived from all of the teeth in the arch, and representing simple, reciprocal, and, to a considerable degree, stationary anchorages.

With this appliance we may not only expand the arch in all directions, as required in this case and here shown, but as we shall see in the chapters on Treatment, we may widen or narrow either or both of the dental arches on one or both sides, or we may lengthen or shorten one or



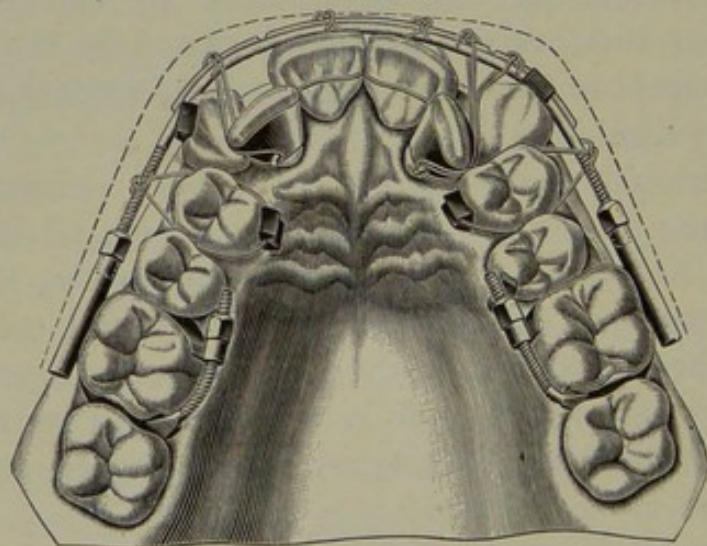
both of the lateral halves. We may move teeth singly in any direction, or we may elevate the teeth, and to a limited extent depress them.

In adjusting the arch as here shown (Fig. 201), it will be seen that it is placed high up toward the gum, as is necessary in all cases in order to keep intense, rigid tension upon the moving teeth, for if the arch be allowed to work towards the points of the teeth, its natural tendency, it will lose much or all of its force, and become a wobbly, inefficient encumbrance.

The tendency of amateurs is often to bend the arch so that it will be too narrow in the anterior part and bind on the canines, preventing the proper adjustment of the incisors. It should be bent so as to afford ample room.

Another common failing of the inexperienced is to give the arch so much lateral spring as to cause buccal displacement of the anchor teeth in cases where no buccal movement of these teeth is necessary.

FIG. 202.



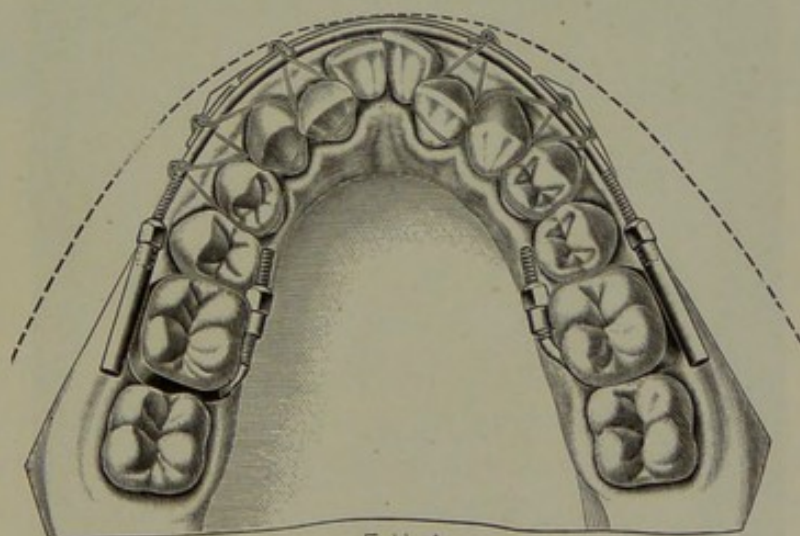
E. H. A.

Fig. 202 shows the combination adjusted to perform tooth movements in a case similar to the one just described and affords another study of the arch in operation. The



premolars are being moved outward by plain wire ligatures occasionally tightened by twisting. The tension on these teeth is made more continuous by blocks of rubber which are enclosed between ligatures and the lingual surfaces of the teeth—a plan which may often be employed with advantage. Force in the opposite direction is being exerted upon the canines also by a block of rubber drawn tightly between arch and tooth. Two ligatures are shown in operation upon the left lateral incisor—one for effecting its lateral and the other its forward movement. This will later become more effective as the tooth is carried forward by tightening the nut in front of the sheaths of the anchor bands. It is often useful. Ligatures are shown on both central incisors, bands being unnecessary on these teeth unless their rotation is desired, especially if the appliance is firmly adjusted and made to lie well up toward the gingiva.

FIG. 203.



In cases where much widening of the arch in the region of the canines is necessary, as in Fig. 203, care should be exercised to give the expansion arch plenty of lateral spring, and so shape it as to allow for the movements of the teeth, and what is also very important is to so locate the



notches for the reception of these ligatures as to exert full force in a lateral direction.

FIG. 205.

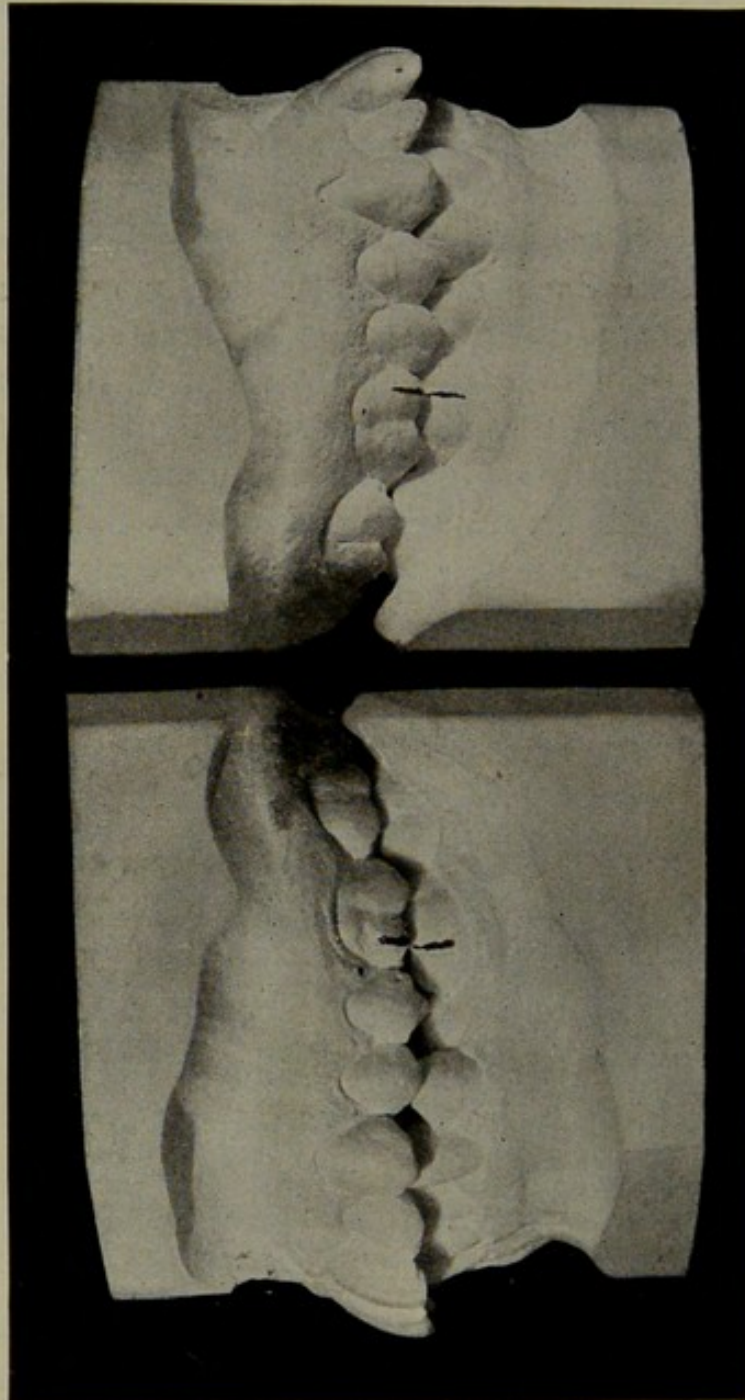


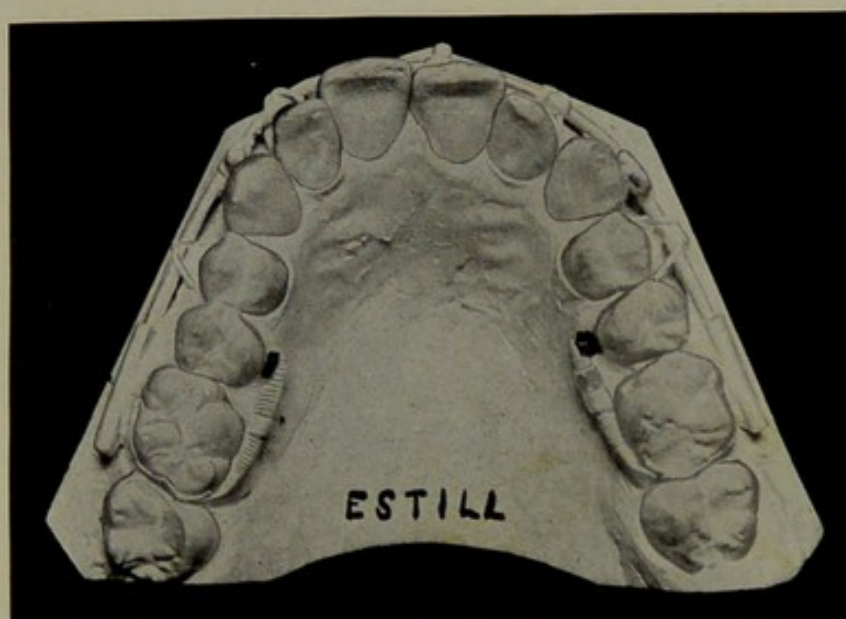
FIG. 204.

Very often when the incisors are protruded it becomes necessary to shorten the dental arch in front and to widen



it in the region of the premolars and canines. Such a case is shown in Figs. 204 and 205. A favorite plan with the author for accomplishing this is to exert force reciprocally from the front of the dental arch to the two lateral halves by means of the threadless arch B, as shown in Fig. 206.

FIG. 206.



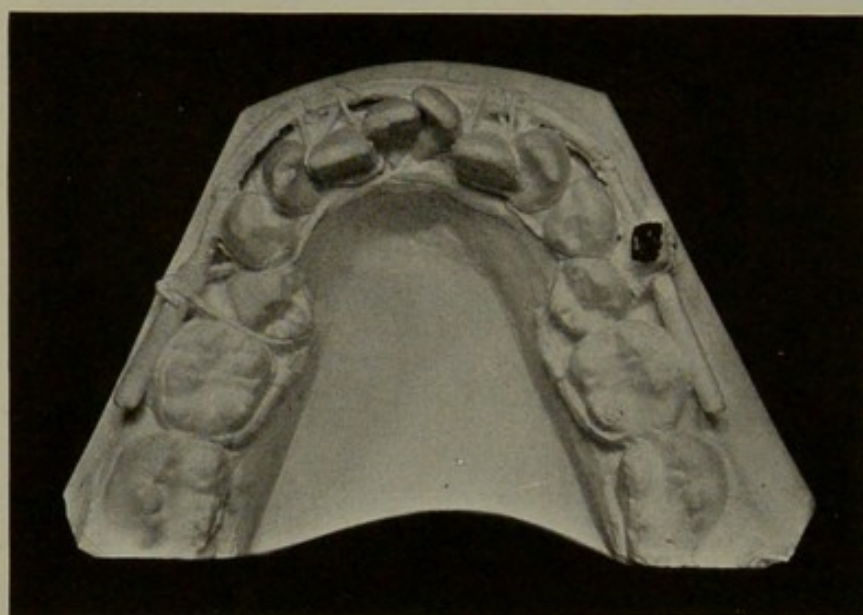
Before slipping the arch into the sheaths of the anchor bands seen upon the molars, much lateral spring was gained by flattening the arch considerably in the middle. Now, by carefully springing it into position in the sheaths, in its efforts to straighten it will move distally, exerting much force in a lingual direction upon the central incisors. By lacing the first premolars to this arch, as shown in the engraving, this force is at once reciprocated from the incisors to them. The second premolars may also be moved outward by ligatures in the same manner, or, by means of strips of rubber drawn between their lingual surfaces and the screw of the anchor bands, as shown in the engraving. The arch must not bind upon the canines but allow ample room for their outward movement, which will usually follow the lateral, wedgelike force received



from the incisors as they move lingually. If this is not sufficient their movement may also be accelerated by ligatures. It will be seen that a ligature is made to encircle each lateral incisor and the arch. This is to prevent their displacement by the moving centrals.

Another instructive lesson in the use of the expansion arch and ligatures may be gained by a careful study of Fig. 207.

FIG. 207.



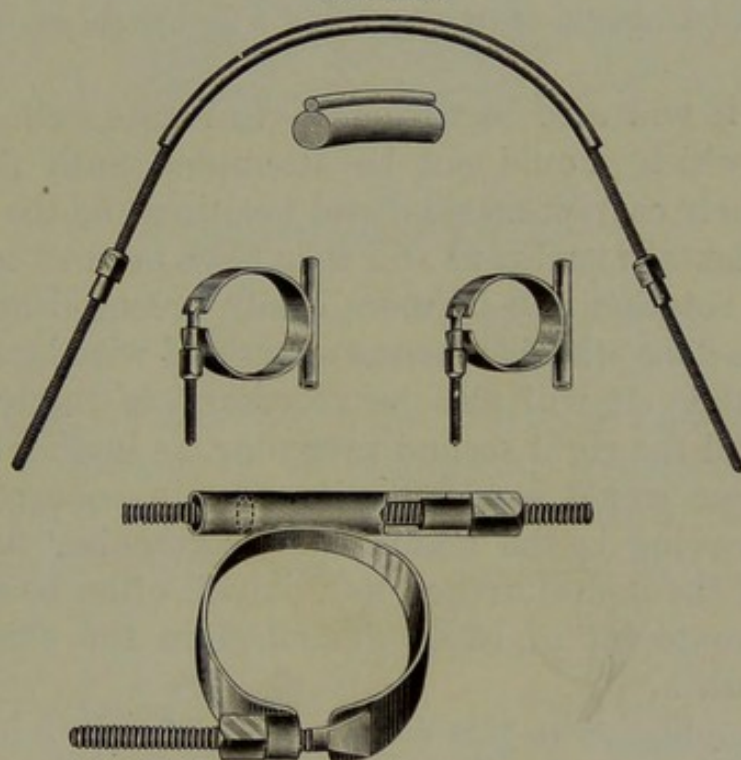
It will be seen how completely we may control the degree and direction of force necessary to effect the various movements. The anchor bands have been carefully clamped and burnished upon the first molars, with the ribbed expansion arch placed in position and bent to correct form so as to give considerable lateral spring and yet not bind upon the canines.

In order to move all of these malposed teeth into harmony with the line of occlusion it will be necessary to move all of the teeth anterior to the second premolars forward, and it will be noted how directly force is applied toward this end. Hook-like notches have been made in the rib of the arch directly anterior to the canines. The ends of



ligatures united are shown at this point resting in these notches. These plain ligatures extend back on each side and firmly embrace the first premolars and canines. By tightening the nuts of the expansion arch anterior to the sheaths on the anchor teeth the arch is moved forward and a powerful force exerted on the canines and first pre-

FIG. 208.



molars for their forward movement. Each lateral incisor is also embraced by a similar ligature and its labial movement effected by an occasional additional twist or renewal of the ligatures, the twists for renewing force always being made before the nuts are tightened.

As the teeth anterior to the second premolars are moved forward and each lateral half of the arch thus lengthened the second premolars are moved outward by the occasional twisting of the ligatures shown in position.

On the right side is shown a small block of rubber which was inserted in the form of a rubber strip between arch and ligature before the latter was twisted. This, although slightly bulky, insures more constant force and is often



taken advantage of. Another plan is to include the rubber wedge between the tooth on its lingual surface and the ligature.

Gradually by this means the teeth are moved into correct alignment. Later it may be necessary to modify the form of the ribbed arch to prevent binding upon the canines. It will also be necessary to rotate the central incisor by means of band and spur engaging a ligature, as in B, Fig. 195.

Later it will also be necessary to rotate both left premolars, which should not be attempted until they have gained their correct mesio-distal positions, as the fibers of the peridental membrane will then have been so broken up that the rotation will be more easily accomplished. This should be done with bands and spurs and wire ligatures, as in Fig. 196. It will also be necessary to rotate the left canine and the right second premolar, as in Fig. 321.

What we would especially impress in connection with this engraving is the manner of lengthening the lateral halves of the dental arches, as this will often be employed in the treatment of cases described in the chapters on Treatment.

By the addition to this combination of sheath-hooks and rubber ligatures we may enlist the Baker anchorage, when all of the upper teeth may be moved distally and all of the lower teeth mesially, as illustrated in Fig. 209, or these movements may be reversed, as shown in Fig. 210, and all this simultaneously, with any other tooth movements that may be required in either or both arches.\*

The modification of form and directions of spring, plus the modifications in ligature attachments, make it possible to meet all the requirements of tooth movement, and in its use it is possible to cultivate a very high degree of skill.

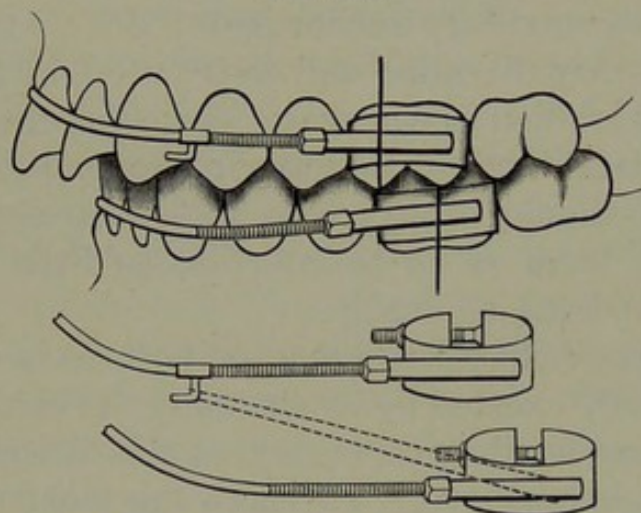
---

\* Angle, "The Importance of the First Molars in Their Relation to Orthodontia." *Dental Cosmos*, March 1903.



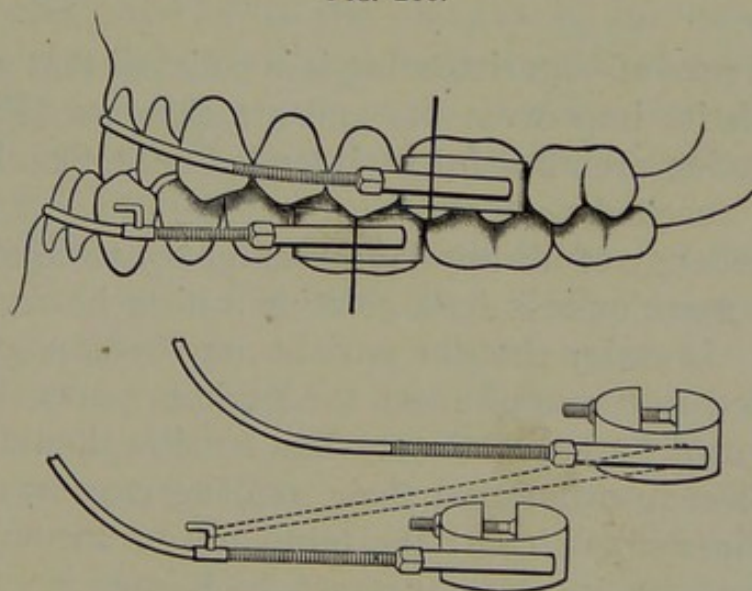
It typifies efficiency and simplicity. It is easily applied and is so stable in its attachments that there need be no slipping or loss of power. It is cleanly and occupies a posi-

FIG. 209.



tion in the mouth that causes the least inconvenience to the patient. If this device be intelligently managed it need interfere but little with the normal functions of the mouth.

FIG. 210.



On the contrary, however, if improperly managed it becomes a constant annoyance, as has been said, and one of the most useless of devices.

In its proper use the widest range for reciprocal anchor-



age is possible. We may also gain simple and a considerable degree of stationary anchorage with it by reason of the tubes and firm attachment of the anchor bands to the teeth used as anchorage, and also, as we have seen, the very valuable intermaxillary anchorage.

The necessary direction and distribution of force should be carefully studied in each case, as well as the effect upon the anchor teeth and all that are in proper position.

The arch should always be made to lie approximately close to the teeth so as to interfere as little as possible with the functions of the lips.

It should be remembered that as its force in tooth movement is usually exerted by its elasticity, its careful bending in order to secure the proper degree and direction of force is of much importance. To make the most of this possibility and at the same time avoid interference with desired movements by binding, or with teeth already in correct position, is the most difficult problem in its management, and yet it is easily solved if intelligently studied in each case.

After years of experimenting it is believed that as shown here, with its improvements and attachments (Fig. 208), the expansion arch has for its intended uses, like the violin in music, reached perfection.

The tendency of all appliances upon the teeth at first is to excite more or less inflammation which, however, soon subsides. In order that the patient may become gradually accustomed to the appliances the various parts should be adjusted at different sittings. The tension should be very light at first in order that their wearing may be attended by no pain and with but the minimum of inconvenience. Later, much greater pressure can be borne.

Although in cases met with for treatment the malocclusion always differs, the adjustment of the expansion arch and its auxiliaries, as shown, is practically always the same, the principal difference being in the form given it by



bending in order to exert force in the desired direction, and in the manner of manipulating the ligatures used in connection with it for the movement of the teeth.

**Adjustment of Combination for Baker Anchorage.**—Fig. 209 shows a very important combination of the expansion arches in which the Baker anchorage is used in the movement distally of the teeth of the upper, and mesially those of the lower, arch in the correction of the malocclusion of cases belonging to Class II.

The arches are adjusted as above described and sheath-hooks are attached to the upper at points opposite the lateral incisors. Either the plain or ribbed arches may be used, the ribbed being preferable in this combination only where deflection of force through the ligatures is necessary in the lateral movement of incisors and canines. The force is exerted by means of one or more small rubber ligatures which engage the sheath-hooks on the upper expansion arch and the distal end of the sheaths of the anchor bands on the lower molars.

The nuts anterior to the sheaths of the bands on the upper first molars are occasionally tightened, as the molars are moved distally, so as to exert all of the force upon them, instead of expending any of it upon the prominent incisors for the time being.

After the upper molars have been moved distally into full normal occlusion with the mesially moved lower molars, it will be found that a space exists between them and the second premolars. The D bands on the upper first molars are then removed, and X bands are placed on the second premolars. The nuts on the expansion arch are moved forward and the arch again adjusted, and the force from the rubber ligature again exerted in order to move the upper premolars distally. A wire ligature is made to engage the upper first and second premolars in order to effect the movement of the first premolars at the same time. As previously in moving the molars, the nuts are kept tight



against the sheaths of the X bands so as to exert all of the force on the premolars and none on the incisors. When these teeth are well back in correct mesio-distal relations with the lower, the nuts are gradually loosened to allow force to be received by the incisors and canines, which, in turn, are soon moved into correct relation with their antagonists.

If care and judgment be exercised the operator will often be surprised by the ease and rapidity with which teeth in these pronounced deformities are adjusted.

It is well known to those experienced that teeth move mesially more readily than distally. Hence the tendency is for the lower teeth to move more rapidly than the upper. This is easily controlled by lacing the lower incisors to the lower expansion arch with wire ligatures, having previously given the arch a downward bend so that when it is lifted by the ligatures it is made to bind in the sheaths of the bands on the first molars, or to exert the same strain upon the apex of their roots as upon their crowns, thus enormously increasing their resistance by establishing stationary anchorage. Thus the degree of movement *en masse* of the teeth of each arch may be completely controlled.

Plain bands are not required on any of the incisors unless their rotation is necessary, the wire ligatures alone being sufficient.

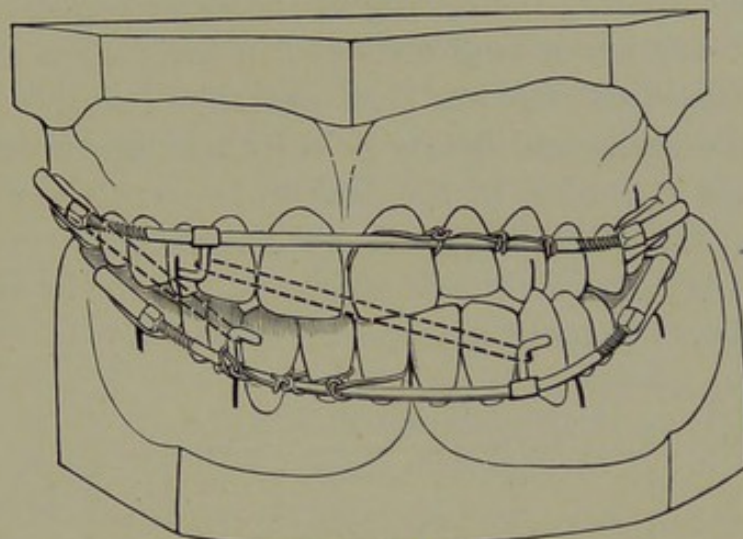
As the upper molars move distally the tendency of the anterior part of the upper expansion arch is to move downward toward the cutting edges of the incisors. It is, therefore, necessary to occasionally loosen the bands on the upper molars (or premolars) and adjust them to proper alignment of the sheaths so that the anterior part of the expansion arch will be kept well up toward the gum.

In the treatment of cases belonging to Class III the same combination of appliances is used, but the plan of operation is reversed, as shown in the diagram, Fig. 210. The sheath-



hooks are attached to the lower expansion arch, well forward, and rubber ligatures stretched between them and the distal ends of the sheaths of the anchor bands on the upper molars.

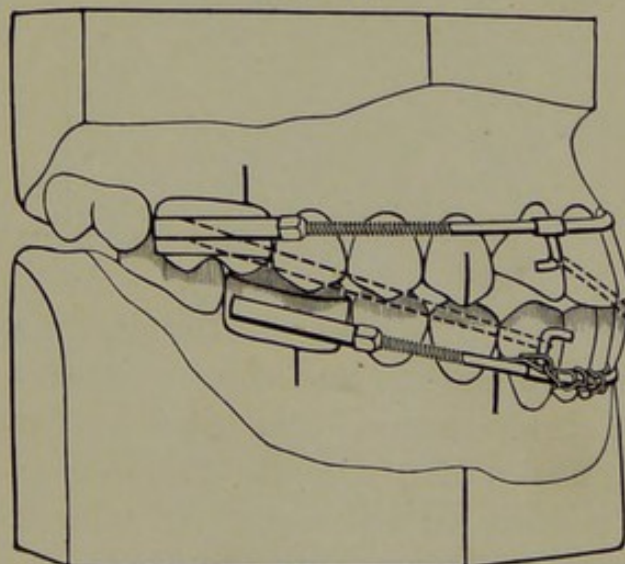
FIG. 211.



E.H.A.

Figs. 211 and 212 show a modification of this anchorage which may occasionally be used to much advantage in those

FIG. 212.



E.H.A.

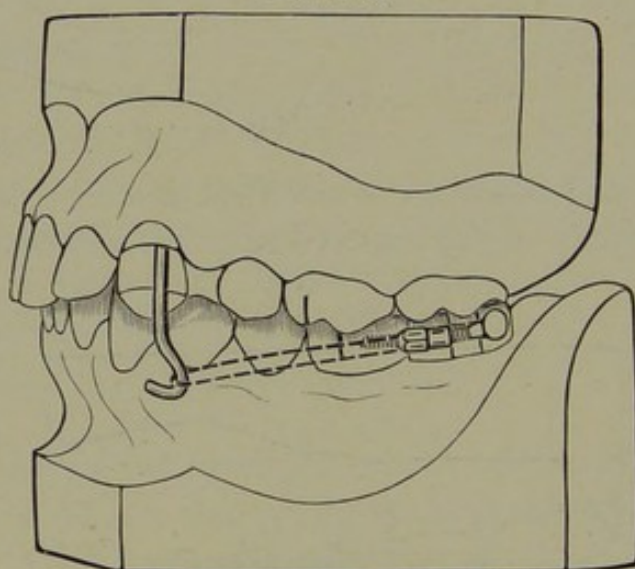
cases, fortunately rare, where the teeth of the lower arch have moved laterally in front and mesially on one side.



While the intermaxillary ligature is carrying the molars and premolars into correct mesio-distal relations on the right side, this is assisted by one acting in like manner in the region of the incisors. These movements are further assisted by the spring of the two expansion arches, the upper one being bent outward in the region of the left lateral incisor, canine, and first premolar, then forced back against the teeth and firmly held by the ligatures, notches being made in the rib of the arch to prevent their slipping.

In like manner the lower expansion arch is used on the opposite side. In the few cases so treated by the author the result was prompt and most satisfactory.

FIG. 213.



E.H.A.

Fig. 213 shows another modification in the application of intermaxillary anchorage and rubber ligatures for the retraction of a single canine. The tooth has been most carefully banded and a bar of metal soldered at right angles to its labial surface on a line parallel with the axis of the tooth, its lower end being shaped in the form of a hook and engaging the rubber ligature. It will be seen how greatly the leverage on the crown of the tooth is thus increased. This combination is very valuable for effecting the re-

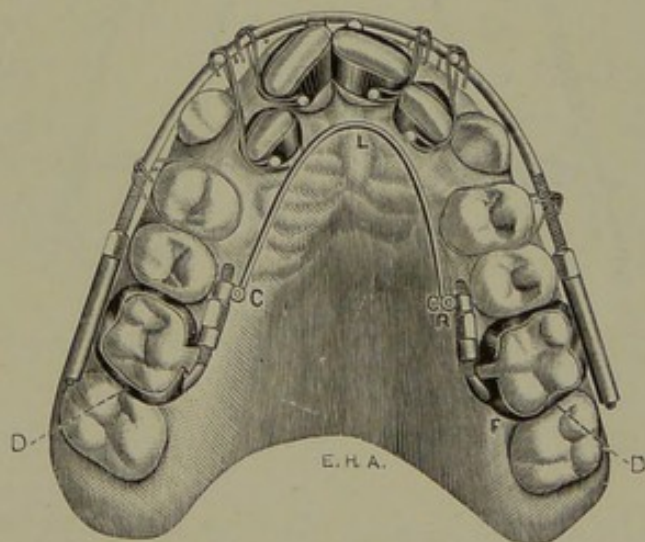


traction of individual teeth and may be used separately or with expansion arches, but of course acting independently of them.

From the foregoing it will be seen that cases of all classes may be treated with the expansion arch. It most naturally meets the demands of occlusion, for with it we can have control of the entire dental apparatus—something impossible in the use of the innumerable appliances that have been devised for the correction of symptoms chiefly, regardless of the laws of occlusion. He who will study its possibilities will be more and more impressed with its wonderful efficiency. In the chapters on Treatment we shall show further modifications in its use in the great range of malocclusion treated.

**Combination Reinforced.**—The elasticity of the arch, especially of the ribbed arch, is sufficient to exert ample force

FIG. 214.



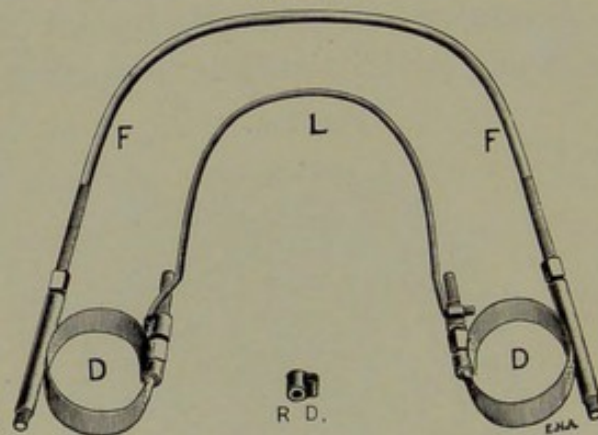
for widening either of the dental arches; yet in very rare instances, where the patient has reached maturity, the force may not be sufficient to accomplish the desired movements as rapidly as may be wished. To meet this limitation the arch may be reinforced by one of the levers *L* which should be adjusted to exert pressure upon the lingual surfaces of the anchor bands, as in Figs. 214 and 215, and attached



on each side by uniting two short tubes, R and D, at right angles, the longer one slipped over the end of the screw of the D band, and the ends of the lever bent sharply at right angles and made to engage the short tubes. Any desired degree of force may easily be gained with this simple method of reinforcement.

A simpler way of securing the reinforcement spring is to insert its finely pointed ends, bent sharply outwards at right angles, into very delicate perforations made in the anchor bands at their mesio-lingual angles, as in Fig. 404, the ends passing through the band and extending between enamel and band. See also Dr. Edmond's method of securing the ends of the reinforcement spring, Fig. 661.

FIG. 215.



In Fig. 215 the threaded ends of the arch are seen to project through the distal ends of the sheath. These ends should be clipped off, otherwise abrasions of the cheeks will follow.

It seems almost useless to caution dentists against their persistent habit of making the nuts of the expansion arch operate against the distal ends of the sheaths of the anchor bands in the effort to reduce prominence of the incisors. This should never be done, as complication from the displacement of the anchor teeth are usually the only results. For this movement the Baker anchorage with force derived from the opposite jaw should be relied upon.



## CHAPTER XIV.

### RETENTION.

AFTER malposed teeth have been moved into the desired position they must be mechanically supported until all of the tissues involved in their support and maintenance in their new positions shall have become thoroughly modified, both in structure and in function to meet the new requirements. It cannot be too strongly insisted upon that the permanency of the teeth in their new positions cannot be hoped for, regardless of the length of time the retaining devices have been worn, unless such occlusion has been established as will enable the inclined planes of the cusps to ultimately act in perfect harmony for mutual support, which also means perfect harmony as to sizes and relations of dental arches.

Dr. Dewey has well said,\* "The normal interproximal contact is of equally great importance as those (forces) before mentioned (inclined planes). It has scarcely been spoken of in the past because writers have failed to recognize its independence from the force of the inclined planes. By the force of interproximal contact is meant the force one tooth in an arch exerts upon those approximating it. This force is passive to a certain extent. It may be illustrated by the blocks of stone in an arch of masonry. The contact point, being only a point on a nearly round surface, is to a great extent like the point of contact between two spheres. If force is brought to bear from one to the other directly parallel in line with their diameters they will remain stationary, but if applied at different angles they will roll. If once the interproximal contact points of the teeth are moved out of line, the teeth tend to move further.

---

\* Dewey, Transactions American Society of Orthodontists, 1904.



The tendency of the lower cuspids to return to old positions of torsal occlusion can be explained in this way."

Retention is too often lightly considered. The problems involved are often so great as to tax to the utmost the skill of the most competent orthodontist, often being greater than the difficulties encountered in the treatment of the case up to this point. It is far easier to lay down rules for the governing of tooth movements than for retention. In this field great patience is required, and ample opportunity is offered for originality and skill in technique.

**Time Required for Retention.**—The time required for mechanical retention varies, according to the age of the patient, occlusion gained, causes overcome, tooth movements accomplished, length of cusps, health of tissues, etc., from a few days to a year, or two years, or often longer, while in the case of unconquered lip or tongue habits, retention may be required for an indefinite period. Upper incisors that have been moved from lingual to normal occlusion, as in Fig. 274, require mechanical retention for a few days only, after which their permanent retention is effectively maintained through normal occlusion or the favorable action upon them through the lower incisors upon each closure of the jaws.

Again, teeth that have been directed into correct positions during the period of eruption need support for a few months only, while much longer retention (for at least two years) would be required for the same teeth if moved after the full development of their alveoli.

Again, the rotation of a tooth causes such great disturbance of the fibers of its peridental membrane that it must be retained far longer than in case of its labial or lingual movement.

As a general rule, with the same tooth movements, the period of retention in the case of a patient aged twenty-one would be about three times as great as in the case of a patient but nine years of age.



Yielding to the temptation to remove the appliances before the teeth have become thoroughly established in occlusion is the cause of many failures in cases probably otherwise well conducted. As so much depends upon this part of the operation, the wearing of the appliances possibly longer than necessary is far better than their too early removal. It must also be borne in mind that unless the causes which have been operative in producing or maintaining malocclusion be removed or modified, the establishing of permanent normal occlusion can rarely be hoped for; for example, if the malocclusion has been caused by pathological conditions of the throat or nose it is very improbable that the teeth will remain in correct occlusion after the removal of the retaining device unless normal breathing be established so that the mouth may be closed the requisite amount of time and the inclined occlusal planes of the teeth may act in harmony for their mutual support. (See chapter on Normal Occlusion.)

Or, if the malpositions of the teeth be due to pathological conditions of the peridental membrane, unless restoration to normal conditions be effected by proper treatment (the possibilities for which are very doubtful in most cases) permanent normal occlusion without mechanical retention cannot be hoped for. Yet in these cases the wearing of delicate and efficient retaining devices indefinitely may be far less objectionable than the malocclusion. These points should be thoroughly understood by the patient before treatment is commenced.

Or, if by the loss of some one or more teeth, as for example the first molars, faulty occlusion result from the tipping of the remaining teeth, the further unfavorable movement of these teeth must be permanently arrested by crowns or bridges, or other methods of replacing missing teeth by artificial substitutes.

We have elsewhere pointed out the forces that maintain the teeth in normal occlusion, hence it seems needless to



say here that to defy these forces and correct and retain the teeth of one arch only without equal attention to the opposite arch, as is still frequently done by the novice, is to court certain failure upon the removal of the retaining devices.

**Principles of Retention.**—As the tendency of teeth that have been moved into occlusion is to return to their former malpositions, the main principle to be considered by the designer of a retaining device is to *antagonize the movement of the teeth only in the direction of their tendencies*.

Very slight antagonism is required, but its exercise must be constant. If the reader will keep these facts in view he will realize that only delicate devices are necessary, and will be impressed with the utter uselessness of much of the bulk and material composing so many of the retaining devices shown in our literature.

To determine the necessities in retention each corrected case should be carefully studied in connection with the original models, noting the various directions in which the teeth are inclined to move, the difference in their sizes, and the proportionate force they will exert.

To secure retention we have at our disposal support or anchorage from the following sources: first, reciprocal, or the pitting of one tooth against another, their tendencies being to move in opposite or different directions; second, teeth already firm in the arch; third, occipital, as shown in Fig. 191; and fourth, intermaxillary retention, or where teeth in the opposite arches are made to act reciprocally for their mutual support through mechanical devices; and finally, the normal occlusion of the teeth which is of course the ultimate retainer in all cases.

We must remember that the patient is already wearied with the inconvenience of the regulating appliances, so it should be the aim to make the retaining devices as delicate, compact, and inconspicuous as possible, always, however, consistent with the main object—perfect support. The



more securely the teeth are held, the more rapidly will they become firm in their new positions. For this reason, and that they may be as little as possible under the control of the patient, whenever practicable the appliances should be made stationary by the attachment of accurately fitted and cemented bands. They should also be readily cleansible by the patient with the brush, that they may in no way injure the teeth. The devices necessary for retaining the teeth need never be bulky nor complicated, nor comprise a large number of pieces. It is remarkable how compact, simple and yet efficient they may be made, and still meet all requirements of the most complicated cases.

With accurately fitting bands properly cemented upon the teeth no possible injury can come to the tooth underneath but on the contrary the band is a protection to the tooth. Yet those attachments which bear against the teeth, such as spurs, and bars connecting bands, should, of course, have as minute a point of contact as possible. For this reason the round wire is decidedly preferable to flat surfaces in the form of bars or clasps—the usual devices in the past.

As the retaining device is to be worn for a considerable time, some prefer its construction from gold or iridio-platinum instead of nickel silver on account of the tendency of the latter to discolor in some mouths, which may be advisable, but it is a fact that may be verified by experiment that if the bands be made of nickel silver there will be far less danger of their loosening.

**Devices for Temporary Mechanical Retention.**—Before adjusting the retaining device it is often best to allow the regulating appliances to remain passively in position upon the teeth for several days or even weeks, in order that the tenderness of the teeth may subside. Yet upon the removal of the regulating appliances there is usually found to be more or less soreness, as well as mobility, in the teeth. It is, therefore, difficult to form and fit bands with any



considerable degree of accuracy without occasioning pain, and yet pain may and should be avoided. So it is best to adjust a temporary device on exactly the same principles as if it were to be permanent, with looser fit of bands, which may be gently worked into position with the fingers alone. If a good quality of cement be used the device will be held firmly in position for a few weeks, until all soreness has subsided and the teeth have become more firm, when a device with bands and all other parts of the most perfect fit and finish may be substituted.

Another simple plan for temporary retention may, when the conditions are favorable, be employed with much satisfaction. It is to make use of the bands and spurs already upon the teeth, having removed the expansion arches, engaging the spurs with strands of the wire ligatures and lacing them about the teeth in such a way as to exert a reciprocal force and antagonize their movements in the directions of their tendencies. In this way the pain caused by removal of old bands and fitting of new ones to the tender teeth is avoided. With experience, judgment and skill in the use of this plan are developed, and the opportunities for its successful employment increased proportionately.

FIG. 216.

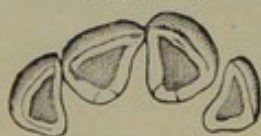

FIG. 217.

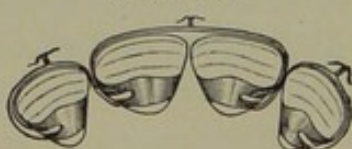
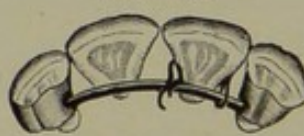
FIG. 218.



Figs. 216, 217, and 218 show a case retained after this method.\* In moving the teeth from their torso-mesial positions bands were made to encircle their crowns, with spurs placed at the gingival edges of the bands at their disto-lingual angles to operate in connection with the expansion

---

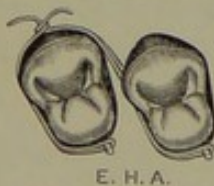
\* Angle, "American Text-book of Operative Dentistry," third edition, page 775.



arch, wire ligatures, etc. In the temporary retention three ligatures were employed. First, one ligature was made to engage the spurs on the central incisors, both ends brought forward and tightly twisted at the mesio-labial angles of the centrals. Thus it will be seen that reciprocal force is exerted that will effectually resist the movement of these teeth in the direction of their tendencies. Second, another ligature was made to engage the spur on the disto-lingual angle of the left lateral incisor, the ends brought forward across its labial surface, one end being passed between the left central and lateral and made to engage the spur upon the central, brought back between these teeth and firmly twisted with the other strand of the ligature at a point on the labial surface of the lateral incisor, as indicated. In precisely the same manner a ligature was made to engage the spurs upon the right lateral and central, all as shown in Fig. 217. By studying the original positions of the teeth in Fig. 216, it will be seen how direct and positive is the reciprocal force exerted by these ligatures in resisting the movement of the teeth.

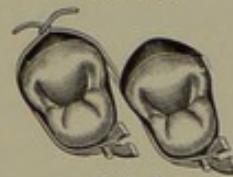
After a few weeks of temporary retention the teeth were permanently retained, as shown in Fig. 218, by other bands placed upon the laterals and connected by a section of the G wire in the usual way, as described elsewhere.

FIG. 219.



E. H. A.

FIG. 220.



E. H. A.

Molars or pre-molars which may have been rotated with the arch, spurred bands and ligatures as in Fig. 196, but which may have partially relapsed, as in Fig. 219, may be readjusted and retained by means of a ligature made to engage the spurs and tightly twisted upon the buccal surface. By engaging strips of rubber between spur and



ligature before tightening the latter by twisting, as in Fig. 220, the readjustment may be effected more speedily, after which a fresh ligature, without the rubber wedges, may be used as a retainer.

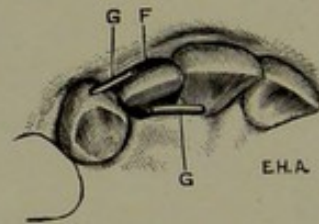
**Devices for Permanent Mechanical Retention.**—The simple band and the short projecting wire, which for convenience we call a spur, embody a principle which may be made applicable to nearly all the requirements of permanent retention in all the various classes. It is surprising to find in what number of combinations they may be employed.

If a single tooth has been rotated its movement in the direction of its tendency may be antagonized by the band and spur, the spur being so placed as to bear against an adjoining tooth, as in Fig. 221, the spur being attached to the

FIG. 221.

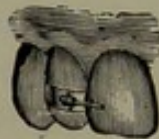

FIG. 222.



band by means of a small tube\* and key pin. However, as the utmost simplicity in all devices worn in the mouth is so desirable, it is usually better to have the spur soldered directly to the band. Greater efficiency resulting therefrom, it is usually preferable to use a band having two spurs, as in Fig. 222. Unnecessarily long spurs should never be used, as they are cumbersome and unsightly. Even shorter spurs than those shown in the engraving may be employed.

Much care should be exercised in placing the points of the spurs which bear against the adjoining teeth so that they will not cause displacement of the tooth retained. As represented in the engraving they are wrongly placed.

\* Transactions Ninth International Medical Congress, September, 1887 and *Ohio Dental Journal*, October, 1887, Angle.



The spurs being made to rest on inclined planes down which they will slide through the force exerted by the tooth in its effort to regain its former position, it would be forced partially out of its socket resulting in its partial relapse. This point may be taken advantage of, however, in some cases where it is desirable to force the eruption of a tooth slightly, for example, a canine after its rotation. The points of the spurs in the case shown should bear upon the gingival ridge of the central, and above the swell of the crown of the canine. The fine adjustment of the spurs should be left until the cement has hardened after setting the band, when they may be bent until their ends touch at the exact points required.

In some instances where the period of retention is to be protracted, or where bands would be unpleasantly conspicuous, spurs may be set in fillings, as in Fig. 223, drilled for the purpose, or newly placed if any convenient cavities exist. In rare instances it may even be desirable to form minute cavities in the enamel, to be properly filled upon the removal of the spur. In the case of deciduous teeth, soon to pass away, the drilling may be considered merely a matter of convenience, and is in many instances preferable to the setting of bands.

FIG. 223.

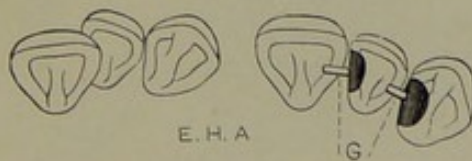
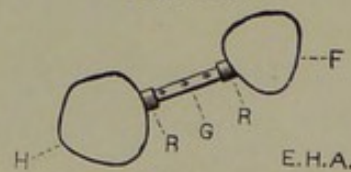


FIG. 224.



A method often desirable when the space of a lost tooth is to be preserved is to connect two bands by a short section of wire G, the ends being engaged in tubes R soldered to the bands, as in Fig. 224.

Another excellent modification of this plan is shown in Fig. 225,\* in which one band is dispensed with, one end of

---

\* Angle. Sixth edition.



the section of wire G being bent in the form of a goose-neck to engage the mesial surface and sulcus of the first pre-molar, the other end being soldered directly to a plain band on the lateral incisor.

FIG. 225.

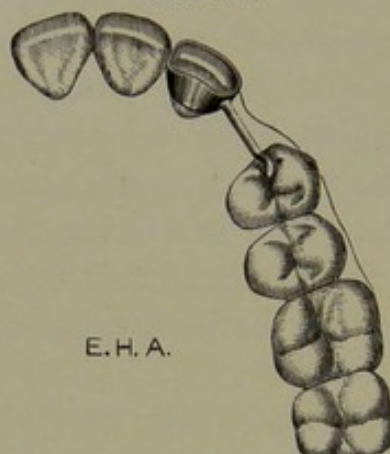
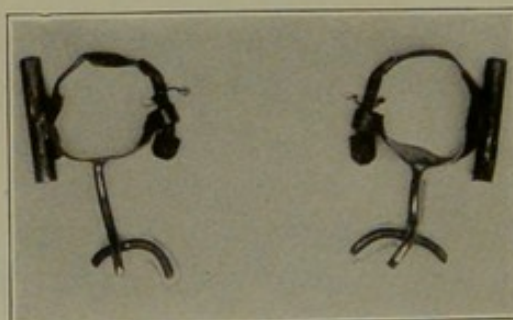


Fig. 226 shows a modification of this plan in which the D bands are made use of for holding the spurs which are to span the regained spaces of lost first molars. Lateral displacement of the spurs is prevented by short sections

FIG. 226.



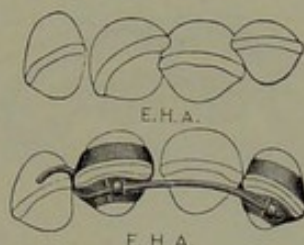
of the wire G bent to crescent form and soldered to the spurs and made to bear against the lingual and labial angles of the second premolars. The bands in this case had been used in effecting the tooth movements.

If two approximating teeth were rotated the firmest support would be given them by uniting a spur to the lingual surfaces of both bands by solder, in which case the device becomes two bands and two spurs united. The



spring of this spur makes possible greater precision in the adjustment of the bands, with less liability of subsequent loosening, than when the bands are directly united by solder.

FIG. 227.



The tendency to rotation of the right central and lateral incisors, plus the lingual tendency of the left central and the mesial tendency of all, are effectually resisted by two bands connected by a spur, with an additional spur made to bear upon the mesio-labial angle of the lateral, as in Fig. 227. The engraving shows the ends of the wire G secured by engaging tubes soldered to the lingual surfaces of the bands. Direct attachment of the ends of the wire to the bands by solder may, of course, also be used, and is usually preferable.

It will be seen that the amount of metal forming the device is reduced to the minimum, and is distributed so as to resist the movements of the teeth only in the direction of their tendencies.

FIG. 228.

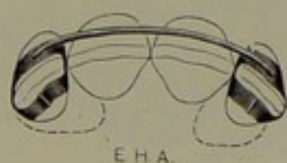

FIG. 229.

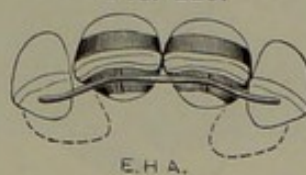
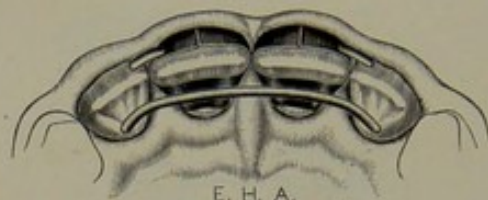
Fig. 228 shows the union of two bands by a section of wire G, employed to antagonize the lingual tendencies of two lateral incisors that have been rotated and moved labially into the line of occlusion—another instance of two bands and spurs united. Another combination of bands and spurs, Fig. 229, attached to the centrals would have accomplished the same result.



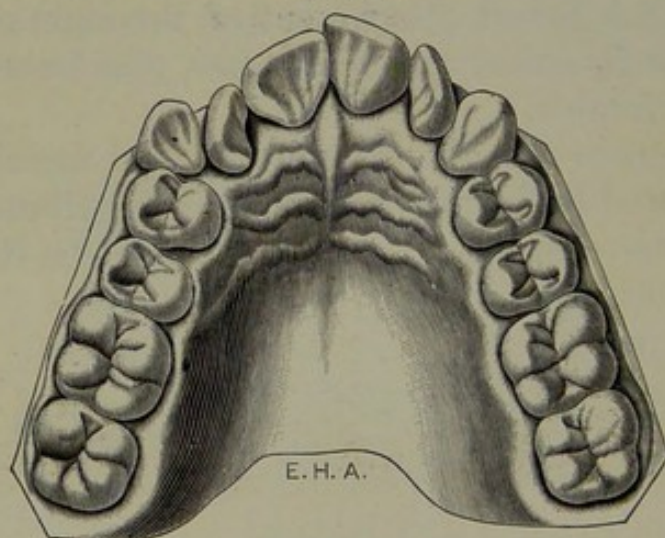
Fig. 230 shows a combination of bands and spurs of great simplicity used to resist the tendency of the incisors to return to their original positions as shown in Fig. 231.

FIG. 230.



Neatly fitting bands upon the central incisors are connected on their lingual surfaces by a section of the wire G, the ends of which project and bear against the disto-lingual surfaces of the laterals, while two spurs are soldered to the disto-labial angles of the bands on the central incisors and bear against the mesio-labial angles of the lateral incisors.

FIG. 231.

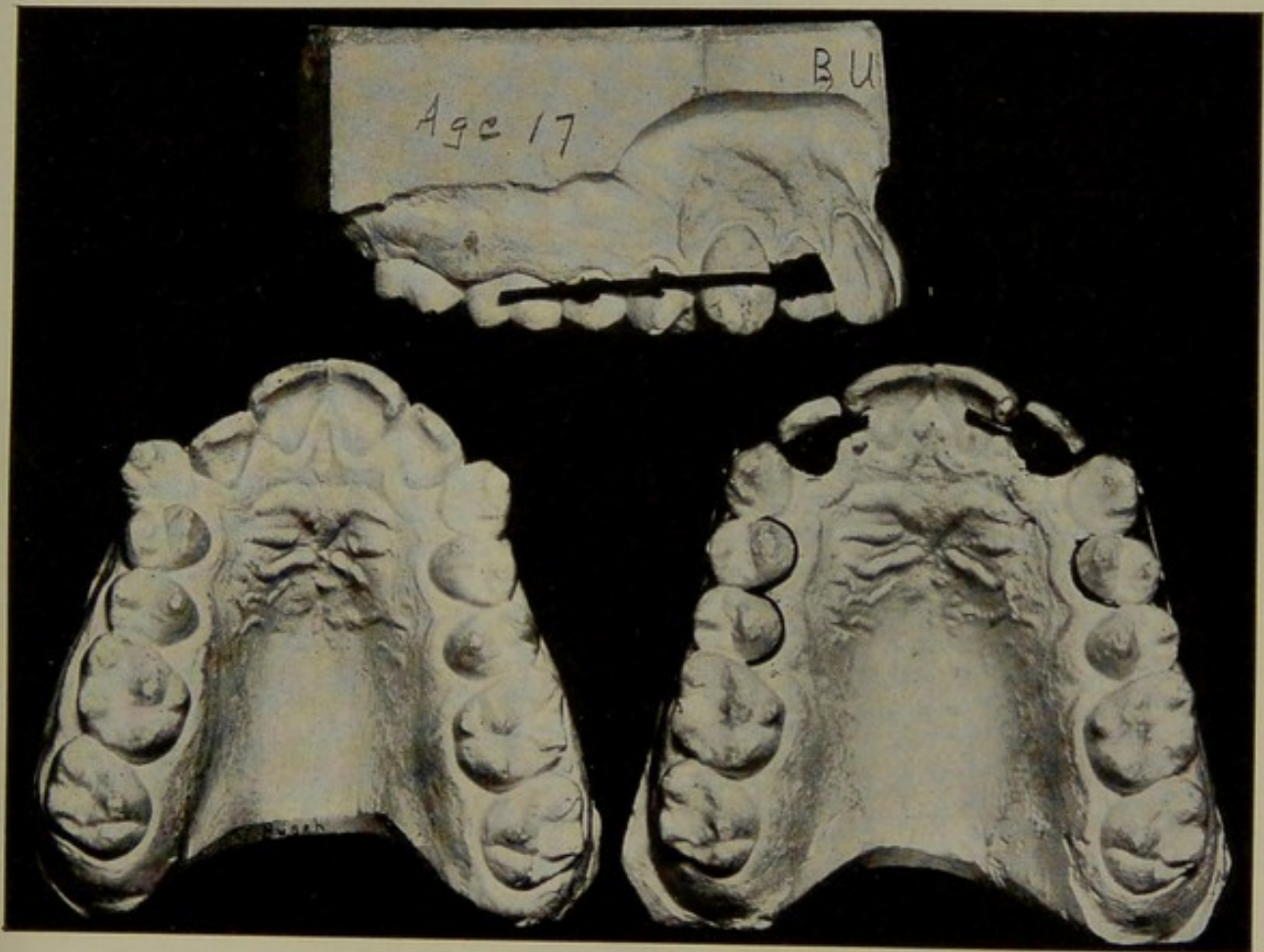


By studying the device carefully it will be seen how effectually all of the various movements are resisted and especially the lingual and torsal movements of the laterals. It is probably the simplest and most compact device that could be constructed for resisting the various movements in question, and is a favorite with the author. It is important that it be adjusted with accuracy, and also



that the ends of the wire be carefully placed, for reasons given in connection with the description of Fig. 222. In some instances it may be an advantage to provide a suitable resting place for the lingual spurs by slightly grooving the marginal ridge of the laterals.

FIG. 232.



Still another plan, one of the author's latest in the retention of this type of cases, is to employ bands on the lateral incisors only, these bands being provided with spurs which bear upon the disto-lingual angles of the centrals, and also having two longer spurs soldered to the disto-labial angles of the bands which cross the labial surface of the canines and first premolars, and are ligated to the latter by means of neatly twisted wire ligatures. Thus are not



only the lingual and rotatory movements of the lateral effectually antagonized, but also the labial movement of the canine and lingual movement of the first premolar, as in Fig. 232.

FIG. 233.

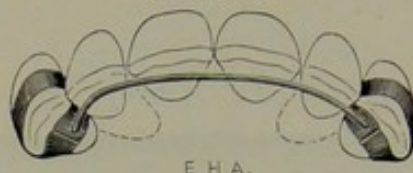



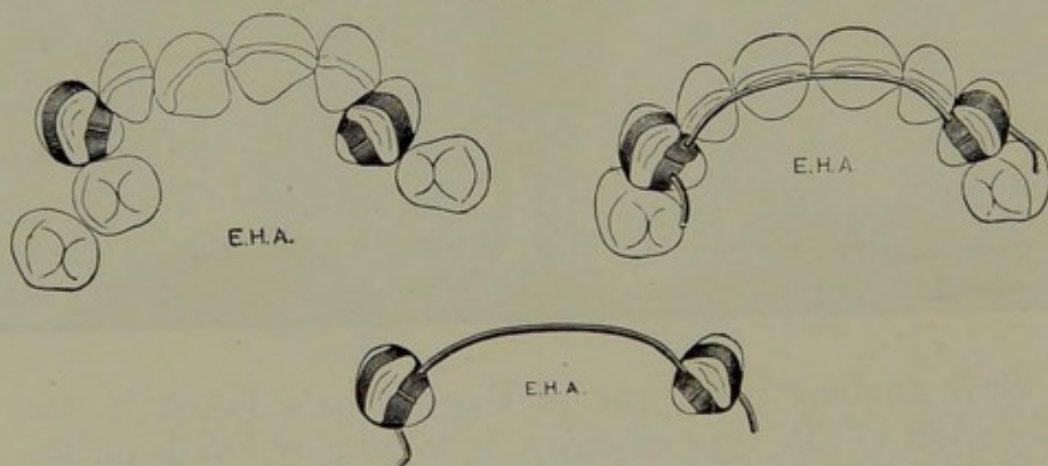
Fig. 233 shows the union of two bands by a section of G wire, which would also resist the lingual movements of

FIG. 234.



the lateral incisors, and the torsal and lingual movements of the canines—the conditions most frequently met with in

FIG. 235.



retention. An additional spur soldered to the long spur, as in Fig. 234, forms another combination for antagonizing the various tendencies of the incisors and canines.

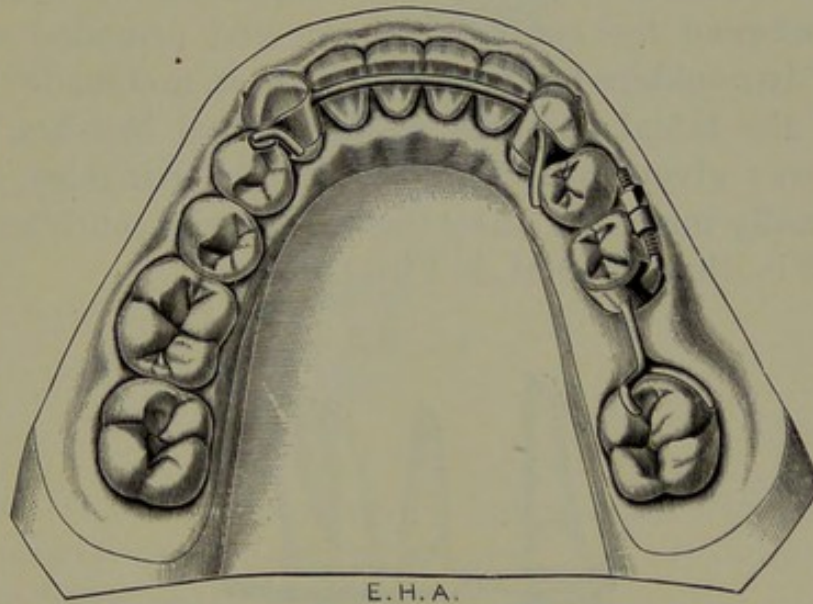
By the addition of two spurs to this combination, as in Fig. 235, the lingual and buccal movements of the first



premolars are also resisted in a complicated case of malocclusion.

Fig. 236 shows where this principle has been employed in resisting the torso-lingual movement of the canines, as well as the lingual movement of the incisors; also the lingual movement of the first premolar on the right. The left

FIG. 236.



canine has been elevated and to prevent its depression a spur has been soldered to the disto-lingual angle of the band, which extends upward and engages the mesio-lingual sulcus of the first premolar. An intervening wedge of rubber is also shown, used to regain the full normal height of the canine which had slightly relapsed. As soon as this is accomplished the rubber is to be removed and the spur bent to rest firmly in contact with the sulcus of the tooth. Space has been regained for the missing right first molar, and is effectually retained by the claw, spur, and band device, as illustrated, also shown in Fig. 226.

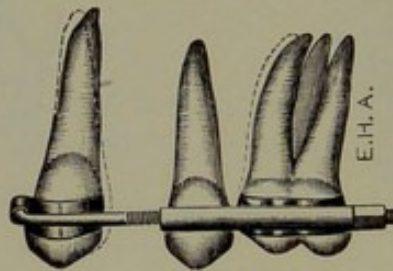
So it will be seen that any or all of the incisors and canines may be firmly supported by combinations of the band and spur, and that the premolars and molars may be included by extending the principle.



Retention of upper incisors that have been reduced from protrusion, as in Division 1 and its Subdivision of Class II, may be successfully effected by the plan shown in Fig. 228, made to extend to bands that have been placed upon the canines or first premolars.

Another plan is to make use of a vulcanite plate covering the vault of the arch, cut short in front and thickened, and perforated for a screw and nut, the screw being flattened between the central incisors and provided with a small T-bar soldered at right angles to it, and made to bear against the labial surfaces of the central incisors. This device was given to us long ago by Dr. Kingsley, and is occasionally made use of by the author with much satisfaction. It is illustrated at A, Fig. 251.

FIG. 237.

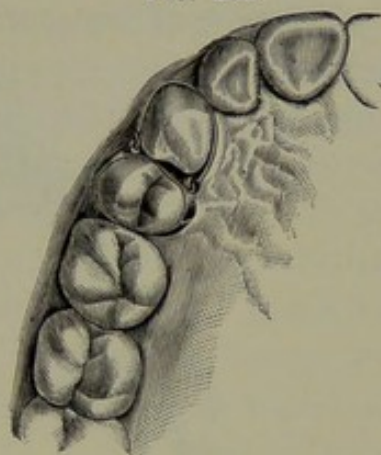


The demands of treatment according to the modern plan, or from the basis of normal occlusion, have rendered the practice of retracting the canine, once so common, now rarely necessary. For the retention of canines that have been so retracted, of course nothing could be more efficient than to allow the traction-screws to remain in position as retainers, as shown in Fig. 237, which should usually be done for at least two months. This, however, is only another form of the principle of two bands and spurs united. As the device is more bulky than necessary it may be removed after the time stated, and the following plan for protracted retention of these teeth be employed. A delicate plain band is made to encircle the second premolar, having two tubes R soldered to the band, one to the mesio-lingual



and one to the mesio-buccal angle of the band. Ends of the largest-sized wire ligature are passed through these tubes, and the wire drawn tightly against the mesial surface of the canine, when the ends are bent sharply around and clipped off. Twisting is unnecessary. The device is correctly shown in the engraving, Fig. 238.

FIG. 238.



E.H.A.

By its use ample support is gained and the bulk and conspicuousness reduced to the minimum. It is important that the tubes shall be close to the gum so the wire loop cannot slide off the canine crown.

A simpler modification of this plan, though very efficient if properly applied, is to dispense with the band on the premolar, extending the wire ligature to enclose both premolar and canine. To prevent this ligature from working beneath the gum a cross ligature passing between the canine and premolar is made to embrace the labial and lingual strands of the first ligature and twisted tightly on either the buccal or lingual side.

Retention of a number of teeth may be effected by a union of bands encircling them, as in Figs. 239 and 240, and this was formerly common practice. The method, however, is crude and inadvisable, as by applying our rule of simplicity and the reduction of the retaining device to the minimum bulk consistent with efficiency, it will be seen



that much unnecessary space between the teeth is monopolized, and that superfluous material is required. It has also other disadvantages. First, it is very difficult to perfectly set all of the bands at once; and second, as a slight springiness is required by all healthy teeth and this attachment is rigid, it will be found that one or more of the teeth will soon break their attachment with the cement, thus lessening the efficiency of the retainer and possibly

FIG. 239.

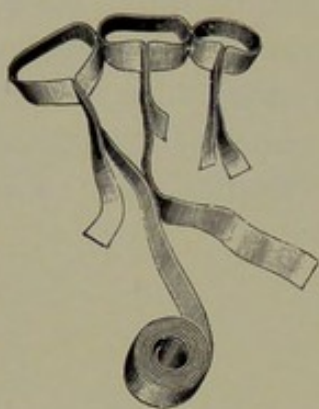
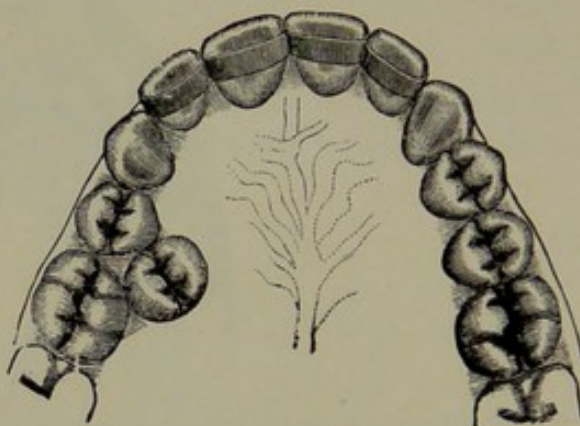


FIG. 240.



endangering the enamel underneath the band through salivary fermentation.

In the use of all bands in retention we would caution that they be inspected at least once in two months, for if they should become loosened they would act as receptacles for food particles, the fermentation of which might in time injure the enamel.

And this may be a good time to discuss the risks or possible injuries to teeth through banding.

Ever since the introduction of this system which marked the beginning of anything like an extensive use of cemented bands upon the teeth, there has been considerable prejudice and criticism by dentists through fear of injury to the teeth therefrom, and as a result many fears and misgivings have been fostered in the minds of the laity. Fortunately as to intelligent dentists these prejudices have been almost completely overcome, for experience in



numberless cases has proved, what ought to have been apparent on reflection,—that the tooth is positively protected from injury so long as the band remains properly cemented upon it. This truth is further exemplified in the daily practice of dentists in cementing crowns. The only danger to the enamel that can possibly arise is through wearing an uncemented band for a long period of time. But unless there is a strong tendency toward caries, this danger is in reality slight, for the flow of saliva between band and tooth reduces to the minimum the dangers of disintegration, and no injury occurs even though uncemented bands be worn for many months. In the past twenty years the author has employed upon the teeth of his patients many thousands of bands, both plain and clamp, the former always cemented, the latter never, except in those occasional cases where stationary anchorage was required, or where they were to be worn as retainers for a protracted period, etc., and yet he can recall only one instance where injury resulted to the enamel through wearing the bands. This was from a treatment band upon a central incisor, which through an oversight on account of its fine fit was allowed to remain on the tooth without cementing for a number of months. Great was his surprise and chagrin upon removal of the band to find a whitened disintegration of the enamel marking the location of the band upon the tooth. In this case the teeth of the patient were strongly predisposed to caries.

In one instance in the author's practice a band was worn continuously for four years and at the expiration of this time the cement attachment was found to be perfect and so strong that cutting of the band was necessary to effect its removal. It is needless to say that the tooth was entirely uninjured. Had it been necessary to wear the band for ten years, or even longer, the author believes no injury to the tooth could have resulted.

As the different periods of regulating the teeth should



not exceed more than a few weeks or months, at most, no injury to the teeth during the process need ever be apprehended. The only danger lies in the long periods necessary for the wearing of the retaining devices, and if these be made with the least possible bulk and contact with the teeth according to the plans we are here outlining, with the bands carefully fitted and thoroughly cemented, and occasionally inspected, there is not the least possibility of injury. Of course that the teeth will be kept properly cleansed by the patient is understood.

For the retention of one or two teeth, for example the second lower premolars that have been elevated in their sockets, a very simple and efficient plan is to encircle the tooth with a band and project a spur so as to engage the sulci of the adjoining teeth.

This may be also applied to the canines, molars, or, in the very rare instances in which it is necessary, to the incisors, the form of the spur being modified to gain the proper bearing, according to the form of the teeth used as supports.

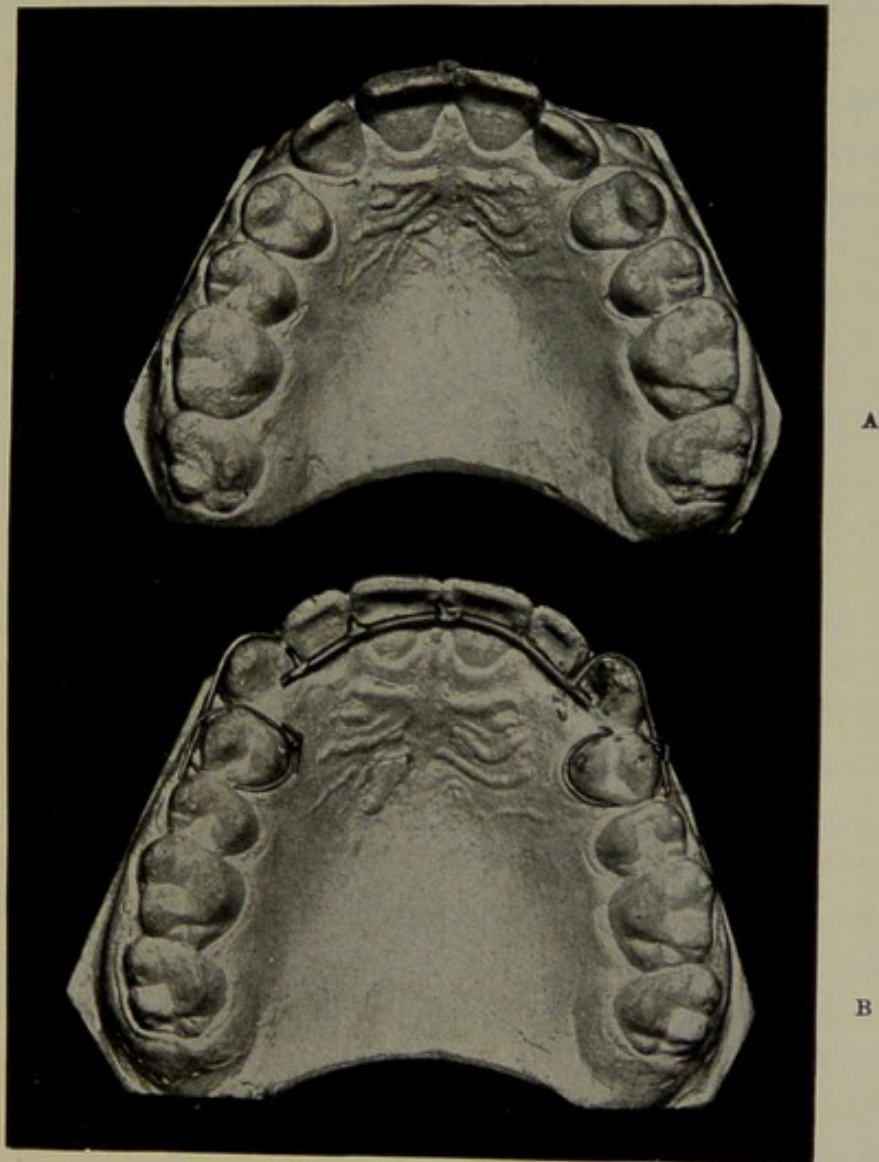
With nearly all of these various forms of retaining devices we may effect the finer adjustment of the teeth, especially those that have slightly relapsed after the device has been worn for some time, by stretching a strip of rubber between the spur and tooth to be moved. After the force from the rubber has moved the tooth the desired distance, the rubber is removed and the spur bent to give firm support to the tooth in its corrected position. The bending is best effected by the strong beaks of the regulating pliers.

There is a new and novel method—the author's latest—which may be made use of in retaining teeth, and which in competent hands will prove to be of great value and to have wide range of application, in which both plain and clamp bands play but a minor part at best, and are often entirely dispensed with.



In the application of this principle advantage is taken of the interproximal spaces between the teeth, these spaces being occupied by very delicate spurs made to project from

FIG. 241.

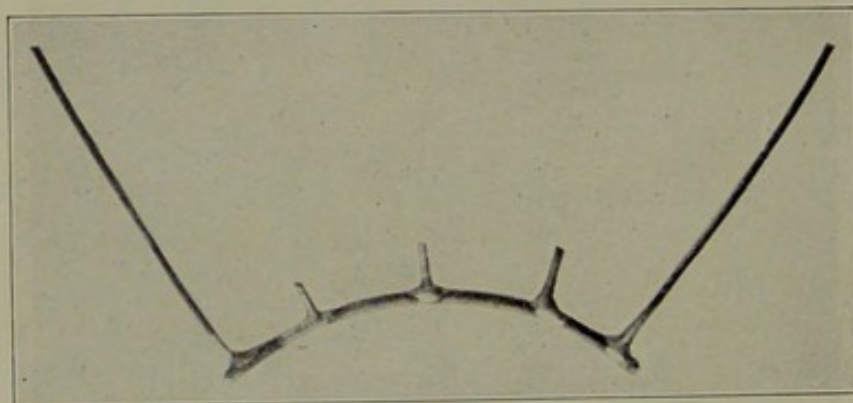


a base in the form of a wire variously anchored and made to lie in contact with either the labial or lingual surfaces of the teeth, these delicate spurs grasping the flattened sides of the necks of the crowns, preventing their rotation and their movement mesially or distally, labially or lin-



gually, yet in no way monopolizing the valuable space between the teeth at their points of contact, as is necessary in the use of bands, clasps, etc. As for example, the lingual movement of all of the incisors and the labial movement of the canines, A, Fig. 241, are resisted and all effectually retained by means of this principle, as shown in B, Fig. 241. The base wire and spurs, in readiness for application, are shown in Fig. 242. A section of base wire of very soft material was carefully bent to lie in close contact with the lingual surfaces of the incisors of the plaster model made

FIG. 242.



after the teeth had been moved labially into correct positions. Points were then marked upon the wire opposite the interdental spaces, and delicate spurs were soldered at the points marked, those intended to lie between the laterals and canines being of considerable length, all as shown in the last engraving.

The teeth having been thoroughly cleansed, the device was slipped into place, the spurs passing through the interdental spaces, and projecting more or less beyond the labial surfaces of the teeth. The lateral spurs were drawn tight, bent backward against the labial surfaces of the canines, and the ends secured by wire ligatures made to engage them and the first premolars. The spur between the central incisors was clipped short so as not to interfere



with the lip, while those between centrals and laterals were bent around the mesio-labial angles of the laterals to resist their tendency to rotate after the manner shown in Fig. 249.

By studying this device carefully it will be seen how extremely simple and compact, yet efficient it is for resisting the movements of the teeth, and as the amount of metal in its construction is reduced to the minimum it is very cleanly, inconspicuous, and the normal contact of the teeth is in no way interfered with, a point that all will appreciate. The firmness with which it is kept in position and the impossibility of its slipping off the teeth can only be understood by a close study of the principle of the device and the forms of the teeth. Let it be remembered that the teeth are suspended, as it were, at their necks between the tines of a fork, and not only do the greater diameters of the teeth toward their cutting edges prevent the device from sliding off, but the contact of the teeth with each other doubly locks the device in place. All can recall how readily a waxed silk ligature may be drawn between the contact points of the teeth, yet how difficult or impossible this is with the unyielding wire ligature, though very delicate, while the spurs of larger size add proportionately to the firmness of attachment of the device.

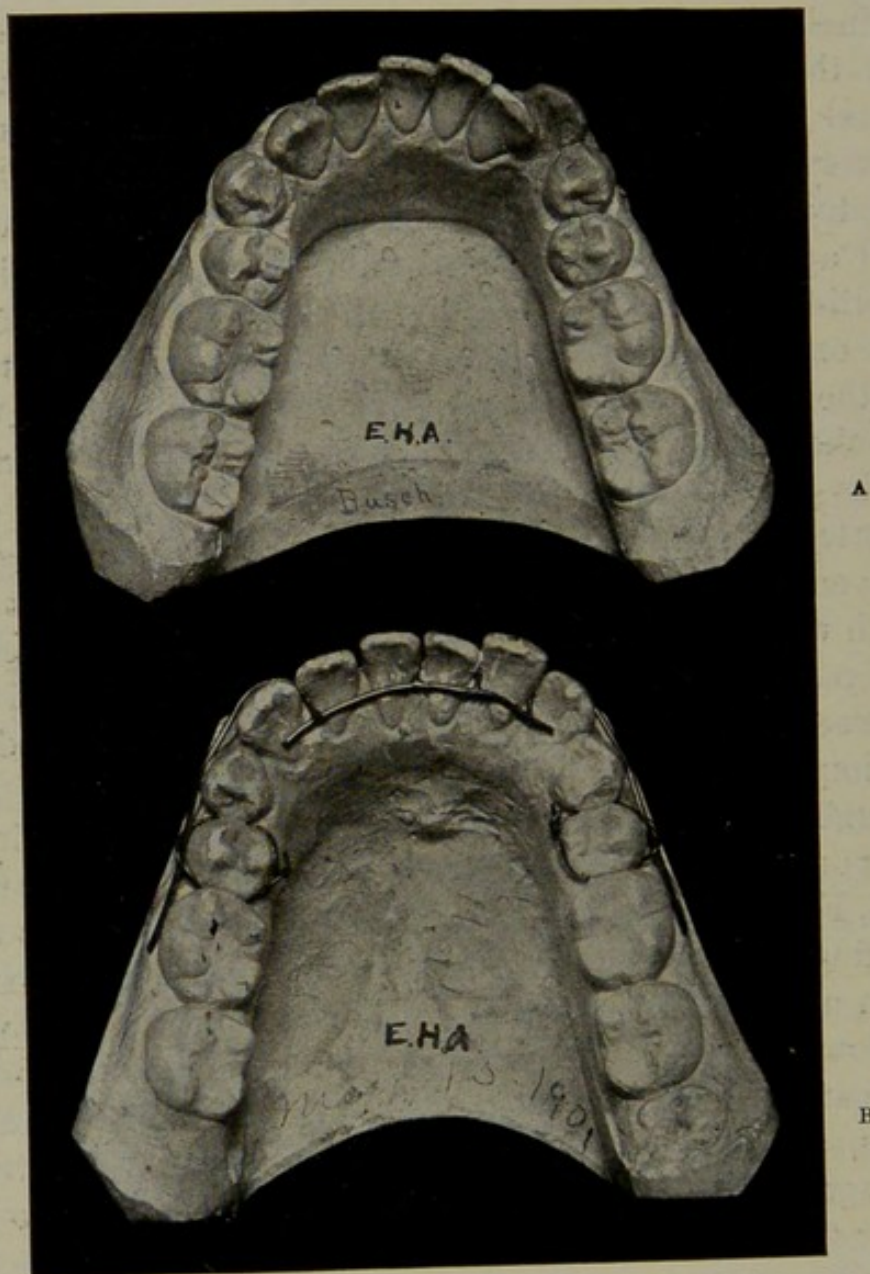
B, Fig. 243 shows the application of the device in antagonizing the tendency of teeth of a lower arch which have been moved from the malpositions shown in A, Fig. 243. In connection with the long spurs which pass out between the canines and laterals, other spurs pass between the centrals, and the right central and lateral, and are bent to engage the mesial angles of these teeth in order to resist their torsal tendencies.

B, Fig. 244 shows the device in position in another case in resisting teeth that have been moved from their malpositions as shown in A, Fig. 244. In this case the spurs are seen projecting beyond the labial surfaces of the teeth



as they pass outward from their attachment to the base wire, through the interdental spaces. These projections are to be considered later. Near the ends of the base wire

FIG. 243.

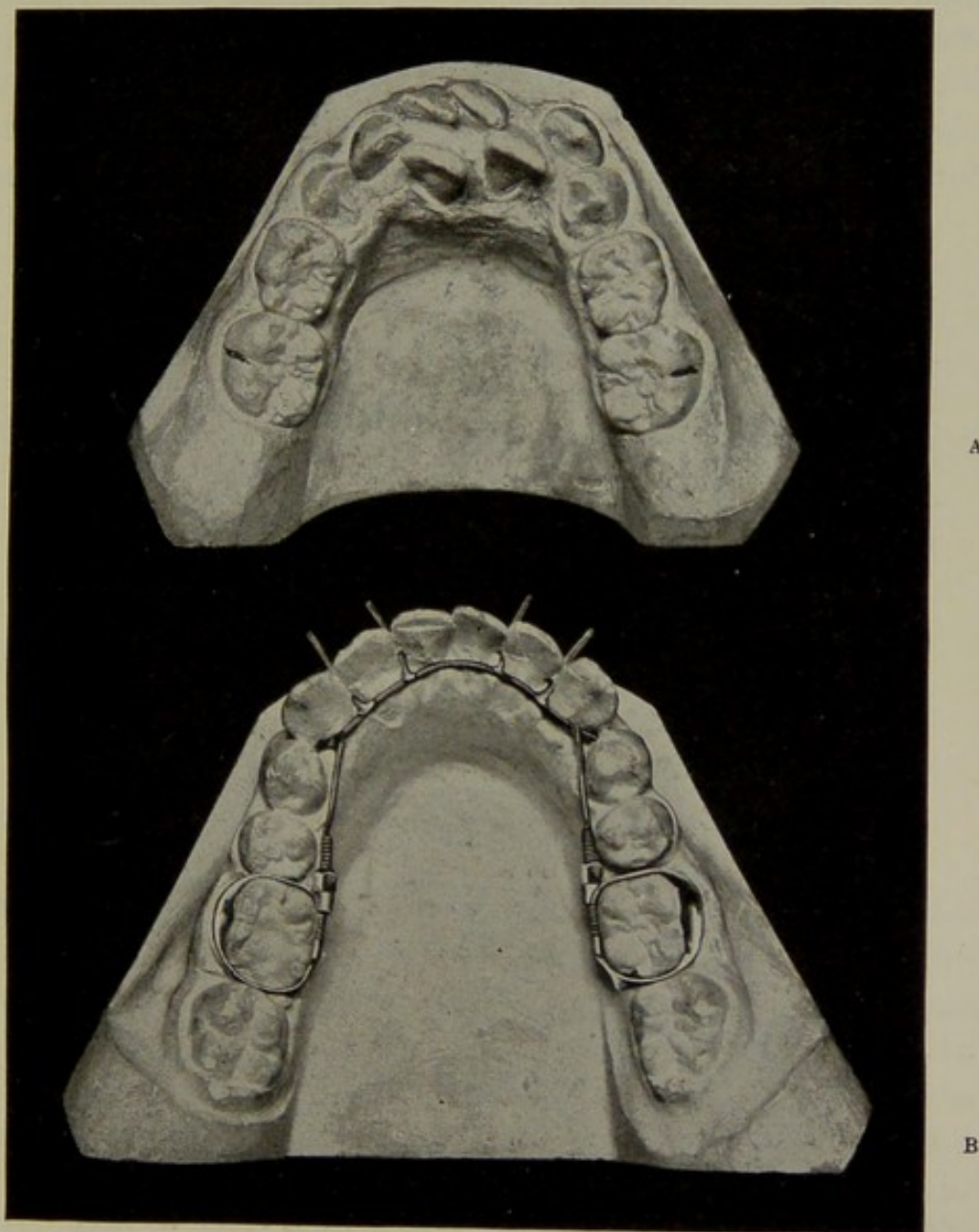


are soldered short sections of wire which pass distally in contact with the premolars and are soldered to the ends of the screws of the clamp bands No. 2 which have been previously fitted to the first molars.



There are various ways of securing the ends of the side wires, such as resting them in sockets formed by the short tubes R soldered to the ends of the screws. Or a larger

FIG. 244.

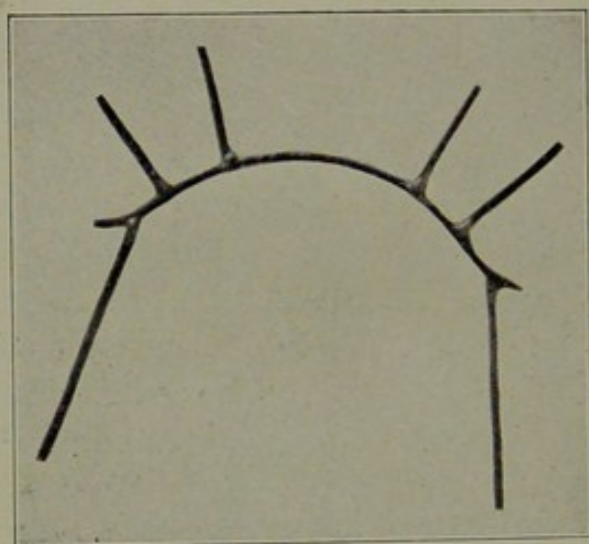


tube may be slipped upon the side wire and after all is adjusted the tube may be slid back to cover the union of the wire and screw ends, but soldering it direct to the screw as here shown is usually best.



Some care is necessary in order to make the side wires of just sufficient length. This is not difficult if the different steps in the making and adjusting of the device be followed in their logical order. First, the base wire is fitted to the proper curve and position upon the teeth of the plaster model; second, the side wires are soldered to the base wire, leaving them longer than will be finally required; next the places are marked upon the base wire at the desired points for the attachment of the incisor spurs, but these are not

FIG. 245.

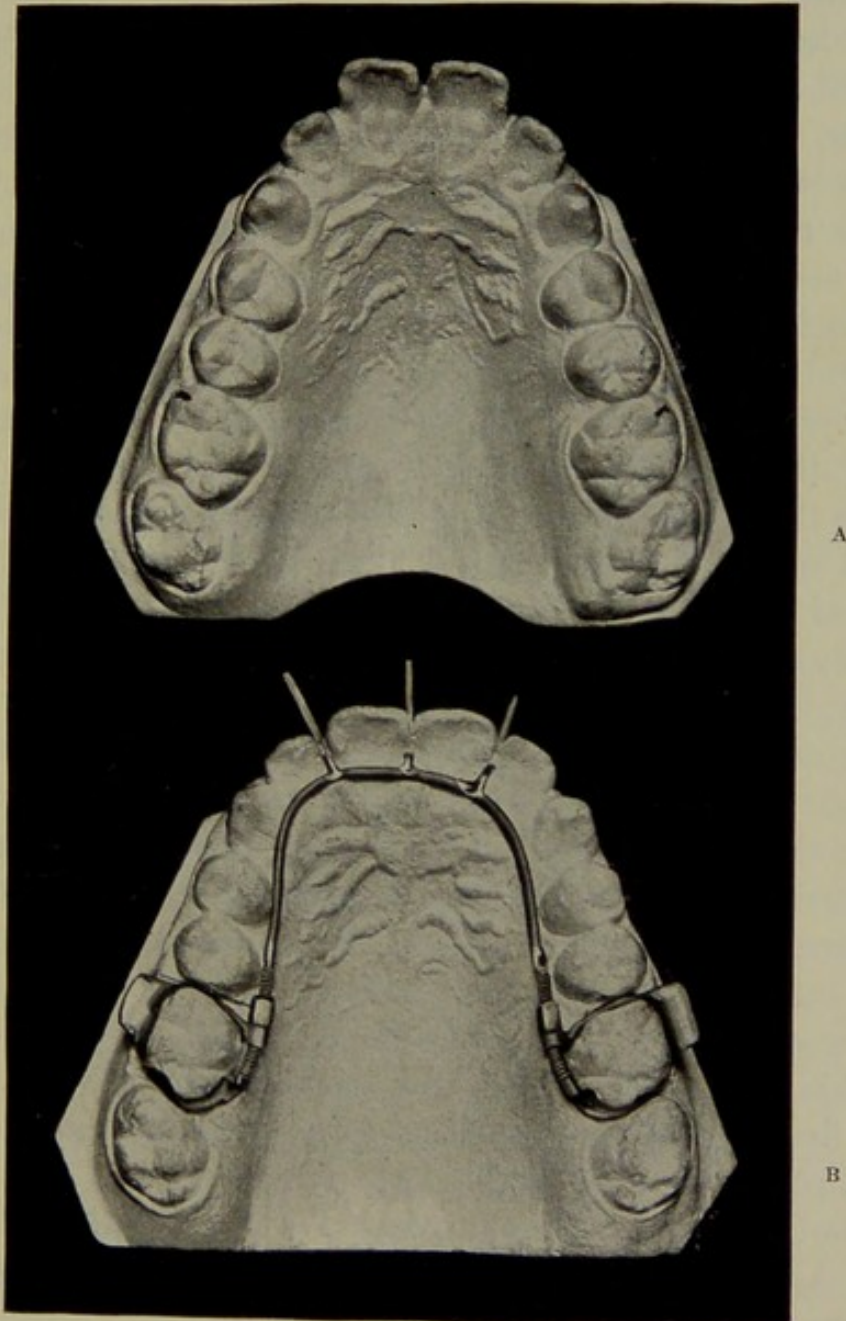


soldered until later; then the anchor bands are most carefully fitted to the first molars (natural teeth). The base and side wires are then tried in position upon the natural teeth and the side wires cut to the precise length required; next the spurs are soldered, as in Fig. 245; and finally the side wires are soldered to the ends of the screws and all adjusted to correct position upon the natural teeth, and after most carefully burnishing the base wire to its correct fit, the projecting ends of the spurs are either cut off close, as they emerge between the teeth, or bent to engage the angles of the incisors to prevent their rotation, if necessary. In all such cases the hooks so made should only be



of sufficient length to give a firm bearing against the angle of the tooth to prevent its turning, Fig. 249. A greater amount would be an unnecessary encumbrance. As the

FIG. 246.



anchor bands are to be worn a long time in such cases it is well to cement them in position.

B, Fig. 246 shows another application of the principle



used in retaining the teeth of the upper arch shown at A, Fig. 246, of a typical case belonging to the first division of the second class, which have been moved from their malpositions, the dental arch having been shortened and widened.

As here used the base wire is continuous, the ends being united by solder to the ends of the screws of the anchor bands, as in the last case. The spurs are shown projecting from the labial surfaces of the incisors. The two outside spurs are to be bent to engage the mesio-labial angles of the laterals and cut off the proper length, as already described. Occupying the interdental space between the central incisors there are two spurs, one above the other. Only one can be shown in the engraving. One is bent to engage the mesio-labial angle of the right central incisor, while the other is bent to the left to antagonize a like movement of the left central. Planes of metal are shown attached to the buccal surfaces of the anchor bands which are to engage the spurs attached to bands on the opposing teeth, in the usual way, as in Fig. 512.

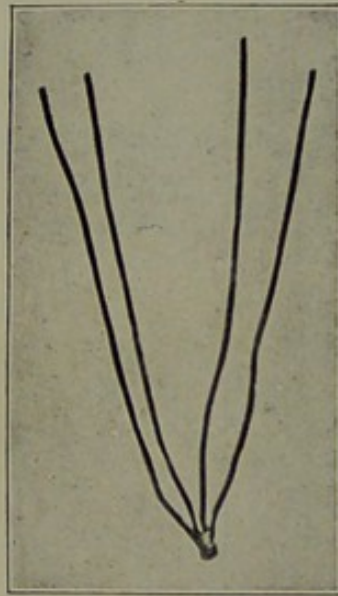
By using a base wire of proper rigidity in this case ample support is given to the lateral halves of the dental arch, while the spurs effectually prevent any labial movement of the incisors. In such cases it may sometimes be desirable to have double instead of single spurs between the centrals and laterals, as well as between the centrals, the extra spurs embracing the disto-labial angles of the centrals. In this way both mesial and distal angles of the centrals are firmly grasped, yet the spurs are so delicate there is ample room for them.

Another plan is to make use of a modification of the T-bar, A, Fig. 251, in connection with the base wire. The author prefers the device shown in Fig. 247, which consists of two loops of ligature wire (largest size), one within the other, to which is soldered at right angles a short section of heavier wire, the latter to rest in contact with the mesio-



labial angles of the central incisors. The four ends of the ligatures are passed between the centrals—two above the base wire and two below, firmly twisted about the base wire in the usual way, and the ends cut off, the object of two ligatures being that in case of one breaking the other will still give the teeth firm support. Another advantage is, there being four strands instead of two passing between the centrals, the T-bar is prevented from twisting and is firmly held in its proper transverse relation to the incisors.

FIG. 247.

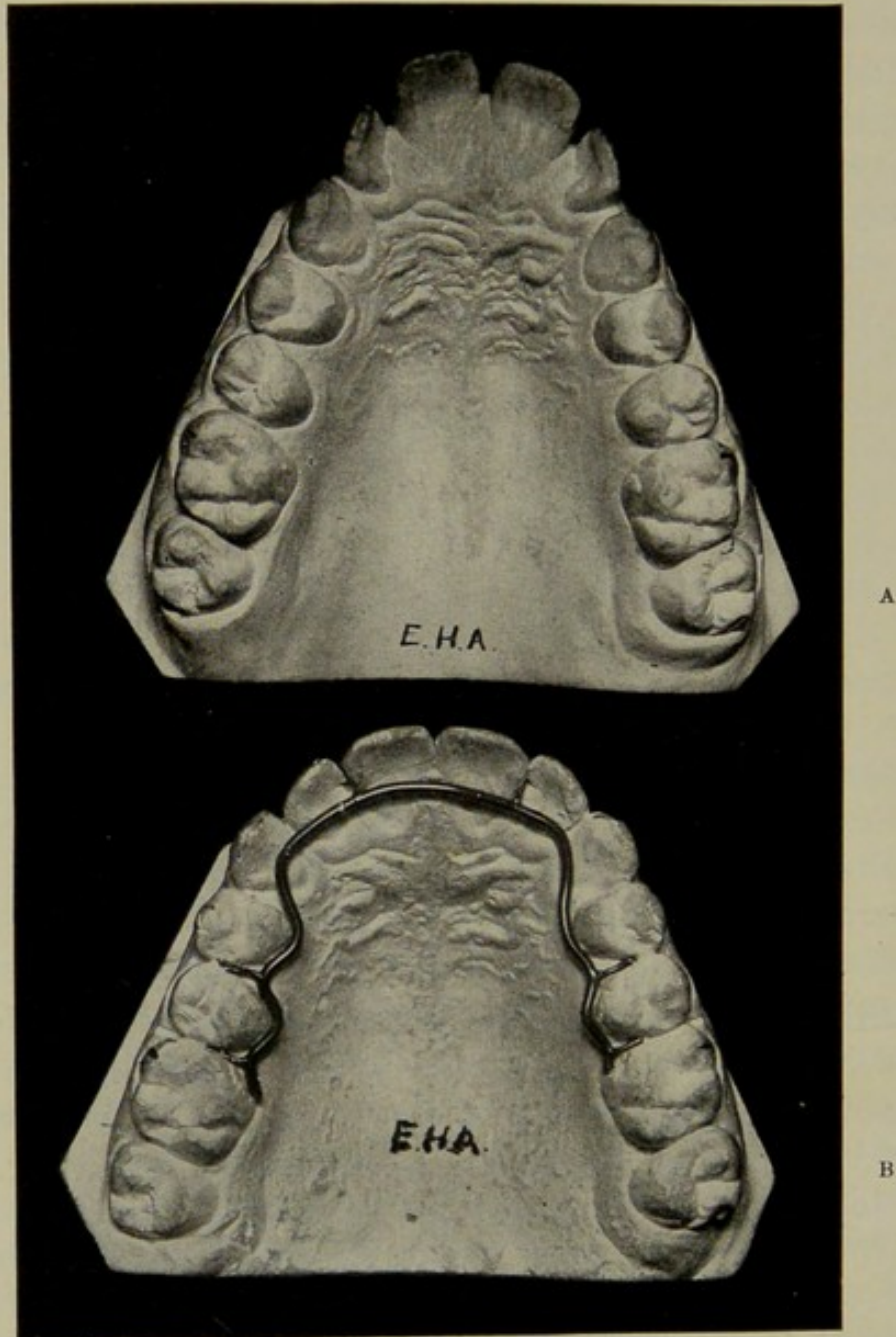


Still another modification in the application of this principle is shown in B, Fig. 248, in the maintenance of the proper length and width of the arch, the teeth of which have been moved from the positions shown in A, Fig. 248. In this case much spring is necessary; the base wire is best made of clasp metal and extends distally on each side and lies in close contact with the lingual surfaces of the premolars and first molars, and also close down against the gum, and, in connection with the usual spurs which occupy the interdental spaces between the incisors additional spurs are soldered to the base wire to en-



gage the interproximal spaces between the premolars, and the premolars and first molars, they being sprung into po-

FIG. 248.

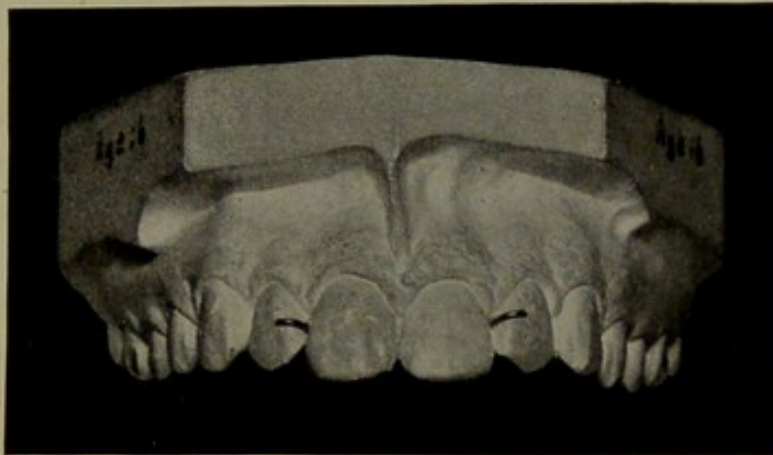


sition and the ends of the spurs being of sufficient length to pass entirely through between the teeth, when they may be cut short, or, if need be, bent in hook-like form as



already described in connection with the incisor spurs, and as shown in Fig. 249 which represents the labial aspect of B, Fig. 248. Of course the apparatus might be extended backward to include one or more of the molars, if desirable.

FIG. 249.



It is hardly to be expected that this principle of retention will supplant that other most excellent form of the band and spur which we have already considered quite thoroughly. Indeed in the hands of those of little experience or the careless it will probably never prove successful, but with the real experts in orthodontia—those possessing the proper technical skill and minds cultivated for weighing the finer problems of retention, it will, we think, meet with great favor. Yet even the skilful orthodontist must not expect to be successful in its use without gradually acquiring skill in its employment, applying it at first only in its simpler forms in simple cases, and as his skill increases he may extend it even to the most complex problems of retention. We would also recommend, as a means of discipline, that he construct and apply these retainers to plaster models of corrected cases. He will thus learn many things that will be of much benefit to him in applying the principles to the natural teeth.

In its use the size, quality, and temper of both the base



wire and that used for spurs is of the greatest importance. As the base wire must be freely bent in order to permit the spurs to take their places in the interdental spaces, it must be very soft so that it may readily be made to re-assume its original ideal form by gently bending and burnishing, and in accomplishing this much patience and skill must be exercised. In cases where the segment of the circle is large and but few spurs are required, as in B, Fig. 241, the base wire may be made of the wire G, but in most cases where the segment of the circle is smaller, as in B, Fig. 244, with a greater number of spurs to be attached, the wire G is too heavy—too difficult of restoring to its correct form—therefore the wire used should be much smaller in diameter. The author now makes use of wire of the same quality as the wire G, but a little over one-half the diameter, or .028". The spurs, in most instances, will probably be best made from hard wire. Iridio-platinum, or platinized gold answers well. If either of these metals are used they may be of even smaller diameter than the base wire, or .020" or .025", yet sometimes it is desirable to have the spurs made of very soft wire. In this case nickel silver wire is best. Experience and judgment only will enable the operator to decide these points.

Where the interdental spaces are reduced to the minimum size on account of the type of teeth with broad necks this form of retention is not so favorable, yet even in these cases, if the spurs be made of hard wire and the diameter diminished by flattening, it may be successfully employed.

The author would take opportunity early in the history of this plan of retention to caution care in the use of these interproximal spurs not to injure the delicate and important gingivæ. There is no reason whatever why these spurs should injure the gum if properly used.

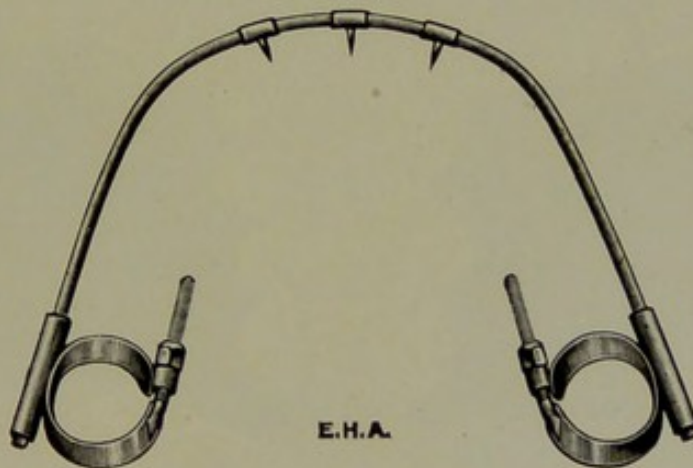
The base wire should always be so shaped and located and the spurs inclined so as to avoid pressure on the soft tissues. To guard against undue pressure of the base wire



when used as in B, Fig. 248, additional fingers or spurs should be soldered to the wire, extended upward and hooked over the occlusal edges of teeth at points that will not interfere with occlusion.

The author also wishes to impress the fact that the principles here involved are radically different from those of the ordinary, time-honored clasps made to slide over the crowns of teeth, which have so long been used as a means of securing both partial artificial dentures and retaining devices. It is a principle entirely unique as applied to retention so far as the author is able to learn from the literature of the past.

FIG. 250.

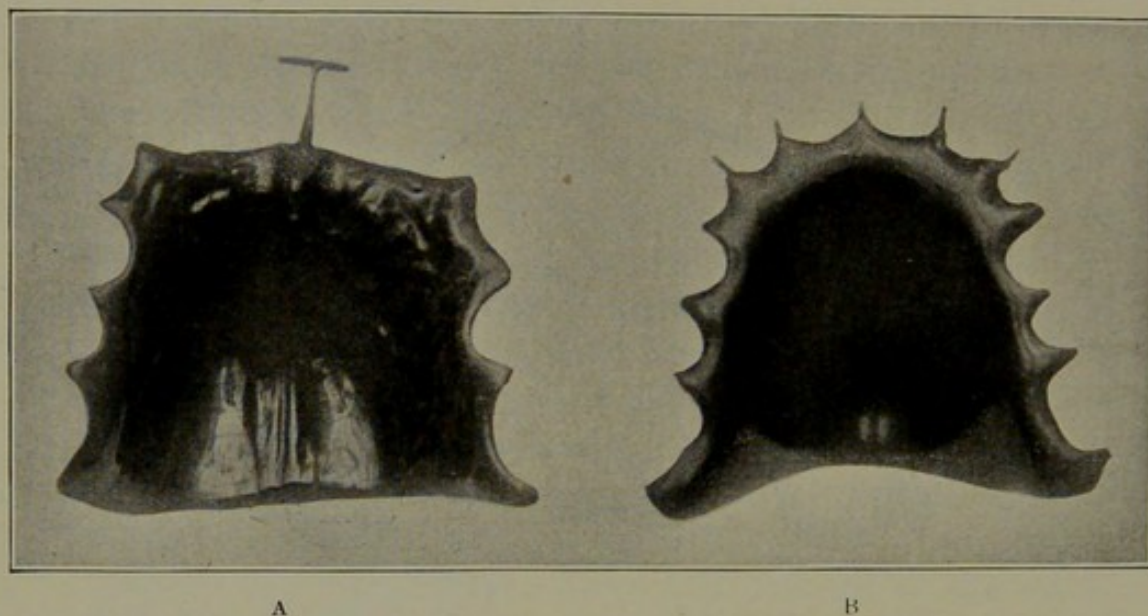


Where a number of teeth have been elevated, as for example the incisors and canines, in those cases known as "open bite," the problem of retention has always been a difficult one, yet even in these cases, with the proper care and skill efficient retention is rendered comparatively easy. Our chief reliance is the spring derived from the expansion arch, with its bearing in the tubes of the D bands which are firmly clamped upon the molars, or anchor teeth. The attachment to the teeth to be retained is best effected by again making use of the principle of the claws or spurs projecting from the arch into the interproximal spaces and grasping the teeth on their mesial and distal surfaces, as



shown in Fig. 250. These spurs are sheath hooks attached at proper points, the angle of the hook being cut off and the remaining rounded projections being made thinner by means of a file. If the spurs are carefully located and the proper form given to the arch so that gentle spring is exerted downward (or upward if in the lower arch), a very perfect support in all directions is given to the loosened teeth. The device will be found to give but little trouble, although slight modification of its form may occasionally be necessary.

FIG. 251.



If some of the teeth in such cases have been rotated their recurrent movement should be combated by bands and spurs in the usual way, and as already described. Or, they may be retained by the band and spur, with wire ligatures made to engage the spur and expansion arch, the same as in effecting their movement originally.

The principle of grasping the teeth by means of interproximal spurs was first employed by the author in connection with a plate and was exhibited before the first meeting of the American Society of Orthodontists held in St. Louis, June 11-13, 1901. This plate is shown in B, Fig. 251.



Gradually the base wire has superseded the plate for the retention of anterior teeth, thereby obviating the necessity of a removable device as was necessary for purposes of cleansing in the use of the plate.

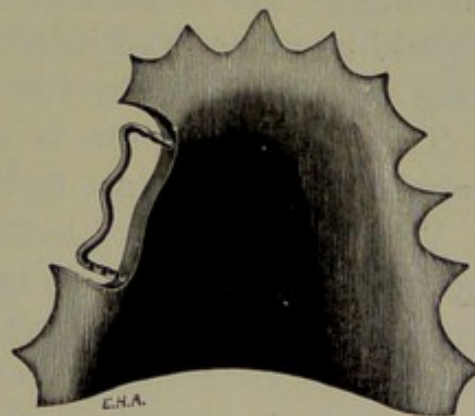
The lingual tendency of molars and premolars, however, may be resisted by a neatly fitting vulcanite plate, as in Fig. 252, partially covering the palatal arch and bearing against the teeth that have been moved.

During the early stage of retention the plate should not extend far enough forward to rest in contact with the incisors or canines, for, owing to their sloping surfaces, the plate is wholly unreliable for their support and would only interfere with other devices, besides being superfluous

FIG. 252.

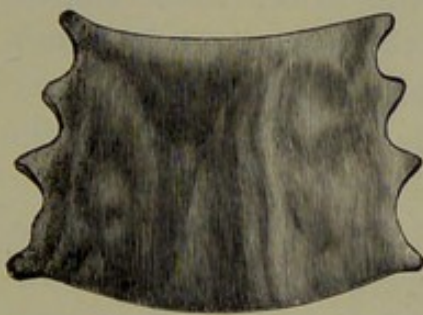

FIG. 253.



material. It may be necessary to secure the plate in position in some instances, which may be done by springing each lateral edge under a lug soldered to a band encircling a molar or premolar, or by means of interproximal spurs which engage the molars, or the molars and premolars. Such bands or spurs may usually be dispensed with after a short time, when the plate has become better settled in position and the force exerted by the teeth less marked.

During the last stage of retention, or when the tendency to resumption of malpositions shall have nearly subsided the bands and spurs upon the incisors may be removed and a plate extending forward and accurately fitting their



lingual surfaces may be used, as in Fig. 253. In this engraving is shown how a portion of the side of a retaining plate has been removed and a piece of the wire G bent in such a way as to bear upon the teeth, the ends of the wire engaging cavities in the plate. By this means pressure, if desirable, may be brought to bear upon the teeth by occasionally removing the staple and pinching it with the regulating pliers.

Some also prefer a vulcanite plate for antagonizing the lingual tendency of the lower molars and premolars. It should be delicate but carefully made, and should cover the lingual surfaces of the teeth, and extend but a short distance beyond the gingivæ laterally, but rather more in the region of the incisor gum. Hooks of platinized gold, made to engage the lingual grooves of the lower first molars, should be vulcanized into the plate to prevent undue pressure upon the gum by the settling of the plate.

This form of plate is also valuable for retaining the regained space of lost teeth, as in Fig. 423.

Where the teeth of both arches have been retained, especially where there has been much crowding and narrowing of the arches, the retaining devices in the lower arch should be worn the longer on account of the well-known fact that the lower teeth through occlusion exercise a greater influence in controlling the positions of the upper teeth than do the uppers in controlling the positions of the lowers.

Other forms of skeleton apparatus, or cemented bands attached to a lingual arch wire, as in Figs. 254 and 255, may also be employed for effecting retention of the lateral halves of both upper and lower dental arches in similar cases.

**Intermaxillary Retention.**—Where the molars have been moved distally in the upper arch and mesially in the lower, as in the treatment of cases belonging to Class II, their tendency to return to their former positions is antagonized



by means of that simple, yet very efficient, plan of reciprocating force between opposite arches, first brought out by the author in the fourth edition of this work, and

FIG. 254.

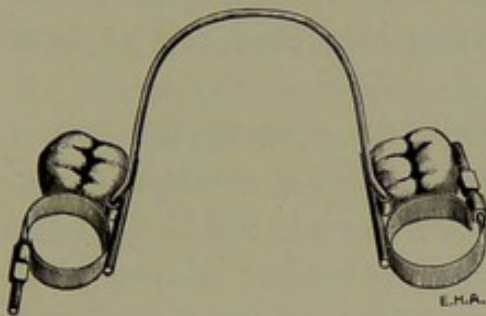
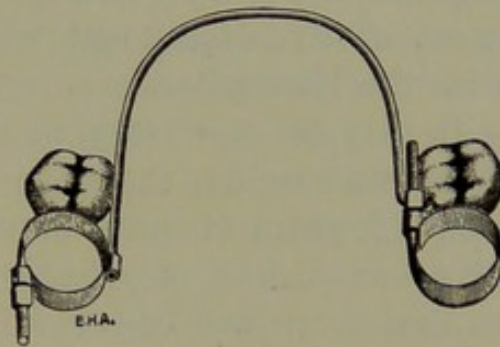
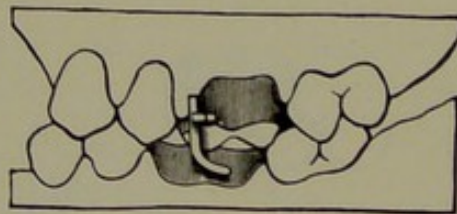


FIG. 255.



again, modified and improved, in the sixth edition, as shown in Fig. 256. It consists of a strong spur made to close in front of a plane of metal, both spur and plane soldered to No. 2 bands which are clamped in cement on opposing

FIG. 256.



molars. It is effective only when the jaws are closed. If the device is properly made and adjusted, only occasional inspection is necessary to keep it in order, and it will be seen how effectually the direction of the tendencies of not only the first molars but of all the molars and premolars of both dental arches on the same side is resisted.

The spur may be made of brass or of nickel silver, about three thirty-seconds of an inch in diameter. The plane of metal soldered to the band upon the upper molar should be about one-fourth to three-eighths of an inch long and about one-eighth of an inch wide and the thickness of a silver ten-cent piece. Great care should be exercised in

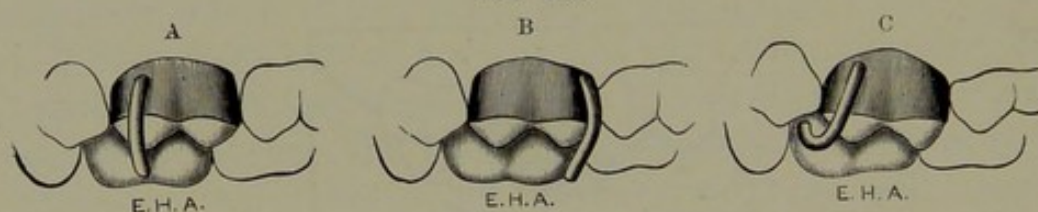


locating and attaching both the plane and spur upon the accurately fitted bands. Finer adjustment may, if necessary, be effected by bending the spur after the cement has become thoroughly hardened, the spur being supported between the strong beaks of the regulating pliers at the point of its attachment while its projecting end is bent with the How pliers.

It may be necessary to occasionally remove the upper band and resolder the plane according to the needs of occlusion. A point of importance to be remembered is that the plane should be attached to the lower edge of the band so that there will be less leverage upon the spur, and consequently less danger of loosening the lower band. This device is also shown in Fig. 512, the first one used in its improved form.

In rare instances spurs set in fillings for accomplishing the same purpose will be found an advantage.

FIG. 257.



A very simple and efficient retaining device for upper molars that have been moved from lingual occlusion, is a band and spur placed upon the upper molar, as in A, Fig. 257, the spur or finger being made to bear against the incline of the buccal surface of the lower molar. These spurs may also be placed mesially or distally somewhat and bear on the mesial or distal angle of a lower molar or premolar, as in B and C, if desirable.

As the strain upon this device is very great and must be long continued, it is of the utmost importance that it be most thoroughly and skilfully adjusted, using only the best cement. With proper care the device will prove very



efficient, and will remain in position almost indefinitely, yet where the strain is very great the band may in time give away at the point where the spur is soldered, especially if it has been overheated in soldering. If it is desired to strengthen the band, this may be readily accomplished by a piece of the heavy band material H made to intervene between spur and band and thoroughly soldered.

The staple form of spur, shown in B, Fig. 258, has some advantages over the single spur, as in its use the strain upon the band is more equally distributed, and it may be bent to bear either buccally, mesially, or distally upon the opposing tooth. At present it is a favorite with the author.

A, Fig. 258 represents the staple form of spur attached to the band transversely, which may be used with advantage to bring resistance on the mesio-proximal or disto-proximal surface of the opposing tooth. The small spurs attached to the staple, as seen in the engraving, were used in a special case for the finer distribution of force upon the opposing tooth.

FIG. 258.

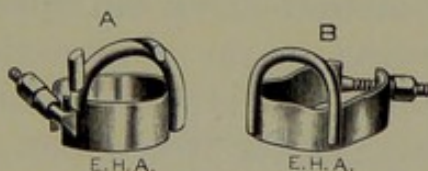
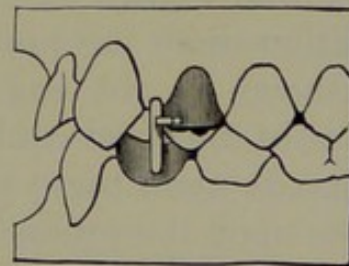


FIG. 259.



In like manner the plane and spur may be employed, and are often preferable, upon the premolars, as in Fig. 259 making use of the No. 1 clamp bands. In this case the spur may be made shorter, and also straight instead of curved.

Sometimes this principle may be employed in making attachments to canines. In such case the band and plane upon the upper canine is dispensed with by taking advantage of its form, and its mesial inclined plane engaging



a flat spur which has been soldered to a No. 1, or a brazed band cemented to the lower canine, as shown in Fig. 260. This spur should be about one-eighth of an inch wide where it engages the upper canine, and rounded at its lower end to avoid irritation of the lip. To be most effective it should incline somewhat forward, and may be adjusted occasionally by bending. In this way not only retention, but the actual movement of the upper canine distally, and of the lower mesially, may be accomplished to some extent, and in many cases this is desirable. It is a favorite device with the author.

FIG. 260.

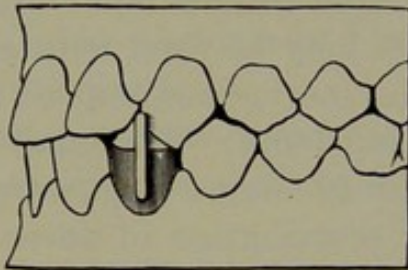


FIG. 261.



It may sometimes be necessary to combine this device with that shown in Fig. 233, the latter being placed in position upon the lower canines instead of on the upper, as shown in the engraving. Owing to the unfavorable shape of the lower canine for banding there is more liability of bands upon these teeth loosening under strain than of those upon the premolars, hence they should be made with the greatest care, always using H band material, and securing the most perfect fit. This band and spur are illustrated in Fig. 261.

Dr. Lourie makes use of a modification of this plan. His method consists in banding the lower first premolar, with the nut of the clamp band No. 1 on the buccal surface of the tooth. The band is pinched and burnished on its lingual surface and made to cover the rudimentary lingual cusp of the tooth. An upright spur is soldered to the bent and burnished portion of the band so that when the jaws



are closed this spur engages the mesial surface of the lingual cusp of the upper first premolar. The full advantage of this principle of retention is not only thus gained, but in a very compact manner, yet this device does not admit of subsequent modification as readily as do those previously described.

Where the reverse order of force has been employed, as in cases belonging to Class III, or where the molars and premolars of the lower jaw have been moved distally and those of the upper jaw mesially, their movements in the direction of their tendencies are effectually antagonized by the same methods as just described, only so attaching the planes and spurs that the spur shall antagonize the distal end of the plane of metal instead of the mesial end.

This same principle of reciprocal retention, may be extended to combat the labial movement of upper incisors that have been moved lingually, which is accomplished by placing upon the lower central incisors plain bands, there being soldered to their labial surfaces strong spurs which project forward and are bent upward sharply at right angles to engage the labio-occlusal edges of the upper incisors, as shown on one incisor in Fig. 262. The stability

FIG. 262.

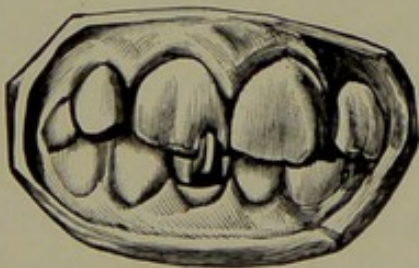
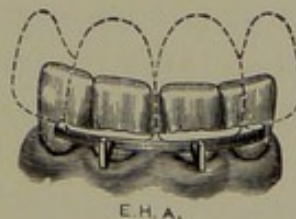


FIG. 263.



of the teeth used as anchorage should be reinforced by a section of the wire G soldered across the lingual surface of their bands and made to bear against the adjoining lateral incisors.

Sometimes it may be desired to place the bands upon the



canines instead of upon the incisors, and connect them by a bar of metal containing the spurs similar to the device shown in Fig. 263.

This device has the further advantage of preventing the lower lip from being drawn against the lingual surfaces of the upper incisors—a habit which seems to be almost universal in these cases, and very difficult but most necessary to overcome.

So far we have but outlined the principles of the various devices which the author has found to be most valuable in retention and daily employed by him in his practice. Under the chapters on Treatment these principles will all be subject to test, and in the numerous cases treated their slight modifications, demanded by the requirements of individual cases, will be noted.



## CHAPTER XV.

### TREATMENT—PRELIMINARY CONSIDERATIONS.

"EVERY art has its own methods of training, its distinctive discipline, its secrets of experience and skill; and mastery depends upon practice of these methods, submission to this discipline, possession of the fruits of this experience, and command of this skill. Between the untrained man and the artist, in every department of creative work, there must be an educational process *severe and prolonged*. This necessity is imposed on men of genius no less rigorously than on men of talent."—HAMILTON WRIGHT MABIE.

BEFORE beginning the treatment of malocclusion of the teeth there should be certain well-defined principles fixed in our minds in regard to the dental apparatus as a whole, for we must constantly bear in mind the intimate relations existing between the teeth and all other tissues and parts of the dental apparatus, and the powerful influences they exert upon one another. We have seen that Nature builds the human denture in accordance with her long-tried and well-established laws, the result being a constant and well-defined pattern; that this pattern, though varied in form, is in principle always the same; and that its variations are slight and always in harmony with the demands of the type of the individual.

We have already noted that when Nature, through certain adverse causes, is unable to fully carry out her normal processes in the building of the dental apparatus, there are in the result defects or variations from the fixed normal plan, shown in malocclusion of the teeth, with consequent impairment of their functions—the extent of the malocclusion being in direct proportion to the extent of the disturbing cause. Also, in the same proportion as malocclusion



exists, will there be disturbance in the harmony and balance of the mouth with the rest of the face.

The longer teeth remain in malocclusion the more fixed becomes the variation from the normal in all co-related muscles and tissues. The tongue never having been permitted the normal freedom of a normal arch, doubtless also fails to develop normally in form and function, and its muscles, together with the muscles of mastication and those about the mouth all become correspondingly modified in order to best adapt themselves to the established conditions of the teeth. In like manner the nose, in size and function, is often modified from the normal.

Logically, then, in the treatment of malocclusion our attention should be directed toward interpreting Nature's wishes and assisting her to carry out her original plan in the building of the denture, working hand in hand with her, for only as we comprehend her wishes in each individual case and assist her, will our efforts be successful in establishing the normal in occlusion and the normal in the balance of the mouth with the rest of the face. It should be obvious, then, to all thoughtful minds, that the demand in treatment should be the removal of pernicious causes, the retention of the full complement of teeth, and the compelling of their normal locking during or subsequent to their normal period of eruption, thus permitting Nature to complete the denture according to her fixed plan and the demands of the individual type.

The method so long followed by all of the "old school" writers of determining an arbitrary course of treatment for each individual case "according to the judgment of the operator," in which extraction is freely resorted to, and the sizes of arches greatly reduced and their forms modified from Nature's intended plan and the demands of the type, has ever resulted, and can only result, in establishing the abnormal—deformity. By such treatment, instead of greater freedom being given to the tongue and normal



function to the teeth, the former is often more restricted and the function of the latter upon the whole rarely improved; and instead of establishing balance, harmony, and beauty of the facial lines, the deformity is ultimately more often found to have been only modified, with a result even far less pleasing than the original condition. Dr. Davenport has well said, "In the treatment of our patients, it is hoped that if we cannot all see our way clearly upon this matter we may at least see far enough not to make the articulations worse by our operations than they were when brought to us."

While in most instances we may rapidly establish the normal sizes of the arches and relations of the teeth, much time will often be required by Nature to effect the normal development of the other tissues of the dental apparatus, the development of which has been arrested. Yet even in this we may often greatly assist Nature by directing our patients as to the proper and necessary closure of their lips and teeth, and proper breathing, and by insisting upon their overcoming pernicious habits of the lips and tongue, and also insisting upon possibly needed treatment of nose and throat. These conditions often call for much tact and persistent patience on the part of the orthodontist.

What we have said presupposes the treatment of cases with the full complement of teeth, which we have had the opportunity to treat during their most active period of growth, development and eruption or during the period in which lie our greatest opportunities for assisting Nature in approximating the nearest to the ideal in the results. Yet many cases are presented for treatment in which there is a lack of the full complement of teeth, through failure to develop, extraction, or caries. The demands for the great object to be accomplished, however, are the same in these cases as when the full complement of teeth is present, and necessitates the establishing of normal occlusion, or as nearly so as the exigencies of the case will permit, by



enlarging the dental arches to their normal size and replacing the missing teeth by artificial substitutes. While the ideal treatment may not always be deemed advisable, it is impossible to lay down any rules for such exceptions.

The carrying out of the ideal in the treatment of such cases presents such apparently great difficulties that it would probably be almost the last one to which the amateur in orthodontia would naturally resort. He would be inclined to compensate for the already diminished size of one arch by reducing the size of the opposing arch still further by extraction. Yet the great difficulty of permanently maintaining the teeth in correct alignment when so treated must not be lost sight of, for it must be remembered that inclined occlusal planes, inharmonious as to size and form are thus brought in contact, with teeth, also, at incorrect angles of inclination, thus tending toward their displacement from wrongly distributed force in occlusion, instead of occlusal planes harmonious as to size and relation with normal angle of inclination of teeth, as intended by Nature, which favors permanency of normal positions and relations. Moreover, by the reduction of the sizes of the dental arches, the tongue and lips must exercise less control in keeping the teeth in correct positions than when exerting their full normal influence, as when the full number of teeth are correctly placed. Furthermore, the invariably detrimental effect on the facial lines, the shortening of the bite, and the impairment of speech, make this plan of treatment so objectionable that it is rarely indeed that the skilful, modern orthodontist would resort to it, for the great perfection to which the regulating appliances have been brought makes easily possible the enlarging of the dental arches and the regaining of the spaces for the full mesio-distal diameter of missing teeth. This fact, together with the ease and permanency with which the missing teeth are replaced, owing to the great advancement in modern prosthetic art, makes this the one plan of practice that will be



most often preferred by the true orthodontist and more and more appreciated by him as his knowledge and experience increase; yet in the cases of very young patients where there has been mutilation, it is often difficult to decide which of the two plans to follow, the serious problem being upon the result of mutilating sound teeth in order to restore the missing teeth by artificial substitutes. Still, if it were always possible to have these restorations made with a very high degree of skill, with mutilation reduced to the minimum, the conservative, ideal plan of treatment would be almost universally desirable.

**Time for Beginning Treatment.**—Recognizing the importance of the principle of normal occlusion as a basis in the treatment of malocclusion, it becomes an axiom that the proper time to begin treatment is as near the beginning of the variation from the normal in the process of the development of the dental apparatus as possible. This may date from the eruption and locking of the first permanent molars into distal occlusion, usually as a result of adenoids, or into mesial occlusion, probably as a result of enlarged tonsils, or it may in rare instances have an even earlier beginning—in the mal-locking of the deciduous teeth.

The age at which the correction of malocclusion may be accomplished extends over quite a wide range of years. All agree that the positions of the teeth may be more readily changed in early childhood than at any other period, yet it has always been argued by the writers of the "old school" that this is a most unpromising age for treatment, as, they say, a young child will not endure suffering or inconvenience, and is unable to appreciate our efforts in its behalf. Much is recorded in orthodontic literature favoring the period of life between the ages of twelve and seventeen years, it being argued that as the operation is such a long and painful one it is useless to begin treatment before the child has arrived at the age when pride begins to assert itself. Then, it is argued, the regulating



appliance would be worn, the inconvenience tolerated, and the pain endured, consequently the hope of success would be greater than with younger children. Again, it is urged that as the operation is such a painful one this age has its disadvantages, especially with girls, it being a critical period in their history, the physical economy being already severely taxed.

Doubtless in the past there has been much reason for the above arguments, for the empirical methods employed, and the awkward, bulky, and inconvenient appliances generally used always caused much annoyance and often real suffering to the patient, and owing to their faulty principles of construction they were necessarily very slow in bringing about desired results, often prolonging continuously for many months or even years operations that were in reality very simple. It is, therefore, but little wonder that young children refused to endure them, that only those pushed on by pride could be induced to persist in their use, and that patients of delicate constitution were deterred from wearing them altogether, for fear of permanent constitutional injury. There is no longer, however, any excuse for such arguments or methods, though unfortunately both are still too often employed. Any child may now undergo an operation for the correction of malocclusion, even though extensive, without fear of impairing its health; for with a properly constructed appliance, skilfully adjusted and operated, little more than inconvenience should be occasioned and the desired tooth movements should be brought about, usually in a very few weeks. The inflicting of real pain and suffering is not only unnecessary, but reprehensible, for it reflects carelessness on the part of the orthodontist, or ignorance, or both. The author has constantly in his practice a large number of young children, some of them quite delicate, and he has yet to observe that they have in any way sustained physical injury or that they have been made more nervous or irritable by wearing the regulating appliances.



Instead of the treatment endangering the normal growth and development of the child, it should be accompanied by the usual growth and development. In fact in many cases pronounced improvement in health has been noticed during treatment, probably largely due to the establishment of normal respiration. And instead of finding young children lacking in appreciation, if they are not caused pain and can see satisfactory changes taking place they become our most tractable, willing, and appreciative patients, the author preferring them to all others. The ease and rapidity with which their teeth can be moved at this tender age should make it the most desirable time of life for the correction of malocclusion. At this writing the author has under treatment a little girl but five years old whose malocclusion is of the third class—typical and well-defined. A more ideal patient it has never been his pleasure to treat, and the progress being made is most gratifying. Dr. Guilhermena P. Mendell has recently completed the treatment of a most pronounced case of malocclusion belonging to the first Division of Class II, which we will discuss later, for a child less than four years of age, making a record as to the early age of the patient.

The author is more and more impressed with the advantages of beginning the treatment early, just as soon as malocclusion is manifest. Then Nature is putting forth her best efforts; then growth and repair are most rapid and the surrounding tissues most yielding; then slight force is sufficient to gently direct each erupting tooth into its correct relation with the line of occlusion. Unless some unusual physical condition of the patient exist it is unquestionably a serious mistake, without the least argument in its favor, to defer the operation until all the teeth shall have erupted, a time-honored custom still often advocated and followed by dentists. To such mistaken practice is directly traceable thousands of cases of pronounced malocclusion, with inevitably distorted facial lines, impaired



speech, etc. By this time the whole dental apparatus will have become involved, the teeth firmly fixed in their malpositions, the facial lines badly marred, and the lips and muscles modified to work in harmony with the complicated malocclusion, all of which might have been easily prevented had the operation been begun at the proper age.

There is another reason in favor of early treatment. We have already seen, in the study of the alveolar process and periodontal membrane, that in young children the sockets of the teeth are large and the septa of bone often lacking to a considerable degree,—Nature seemingly waiting until the positions of the teeth shall be determined before completing this precious structure. Now if the teeth be moved at this time into correct positions *the normal deposition of bone and development of the socket about the root of the tooth will follow*, while, if delayed until the completion of Nature's period of active growth and development of the alveolar process, extensive absorption must take place, and the re-deposited bone may possibly be *less stable in quality*, or, we believe, even lacking entirely in portions in some instances. From experience in a few cases of attempting to correct malocclusion which had been years before unsuccessfully treated, the author has been strongly impressed with the apparently abnormal instability of the teeth which had been used for anchorage. This fact, together with the great difficulty in some cases of maintaining in their new positions teeth that have been moved after maturity, even after a long period of retention, strongly suggests the possibility that the secondary deposit of bone may never be as stable as that deposited during the normal period of development. Indeed the histological investigations of Dr. Noyes seem to confirm this.

There is still another very important reason why the treatment of malocclusion should be begun early. It arrests not only increasing complexities of malocclusion of the teeth but also inharmony in the growth of the bones



of the jaws, and consequent inharmony of growth and improper functioning of the muscles—always more or less an accompaniment of malocclusion, especially in Classes II and III, and in gravity and extent necessarily proportionate to the age of the patient.

While, as we have noted, the period for the treatment of malocclusion may extend to maturity, or, in favorable cases much later, we think it may be regarded as a law that in proportion to the age of patients is their sensitiveness to pain, the time required for treatment, the obstacles to be overcome, the inconvenience, the period of retention, and the uncertainty as to prognosis increased. The absurdity of delaying treatment with the hope that Nature will correct the deformity we have elsewhere pointed out.

**Time Required for Treatment.**—One of the questions always asked by patients is how long a time will be necessary to complete the treatment of their cases. No one can or should attempt to fix any time, other than in a general way, for any prognosis as to individual cases can be made only from the basis of our knowledge of Nature's normal processes in building the human denture, and we must remember that the efforts of the orthodontist are at best only to assist Nature in placing the teeth in normal occlusion during this process, and that she may require many years to complete it. A knowledge of the causes that have been instrumental in deflecting the normal building, the extent of the malocclusion, and the age of the patient must all be carefully considered. So, also, the disposition of the patient and the degree to which we may have his and his parents' co-operation have an important bearing on the time that will be required, for it is well known that without such co-operation our best efforts can count for but little. And we may as well say here that the orthodontist is justified in promptly dismissing any patient who is persistently delinquent in keeping his appointments or in obeying instructions, as failure in the treatment of cases of such



patients is only a question of time, and the orthodontist should take prompt measures to place the responsibility where it belongs. Fortunately such cases are rare, and if the orthodontist be skilful and himself very systematic, so that prompt and gratifying results of his efforts may be apparent, he will usually receive the hearty co-operation of both patient and parents. No orthodontist, however, can or should expect his patients to be prompt unless he himself sets the example. Carelessness and lack of system have no place in the practice of orthodontia. The work is so exacting that only the best in skill and system makes the naming of the approximate time at which a case may be completed even possible. For this reason all attempts to practice orthodontia under the handicapping annoyances incident to combining the work with the general practice of dentistry has ever resulted, and must ever result, in a large percentage of failures.

Carefulness, thoroughness, and prompt and intelligent decision and action at each visit of the patient are imperative, doing only what is clearly indicated, and that without deferring until another time. If an arch is to be changed in form, anchorage shifted, an over-twisted ligature to be renewed, a different attachment added to a band, a band replaced, removed, or a new one added, etc., it should be done promptly, dismissing the patient only after knowing with certainty that each and every part of the regulating appliance is fully performing its work.

Recognizing the time necessary for the development of the denture it must be obvious that the period of treatment, if begun early, must extend through a number of years, especially in cases of marked malocclusal tendency. The plan of treatment to be adopted is to take each case at as near the divergence from the normal process in the building as possible, then assist Nature, as promptly as is consistent with the physiology of tooth movement, with delicate and efficient appliances, in the locking of the maloc-



cluded teeth, say one or more of the first permanent molars, when the regulating appliances should be removed, the teeth thoroughly cleansed, effectively retained, and occasionally inspected. No further treatment may be necessary, especially if the causes have been removed, but if on the eruption of other teeth it becomes certain that they shall require mechanical assistance in order to effect their normal locking, the regulating appliances may again be brought into requisition, and after effecting the necessary movements, again be discontinued.

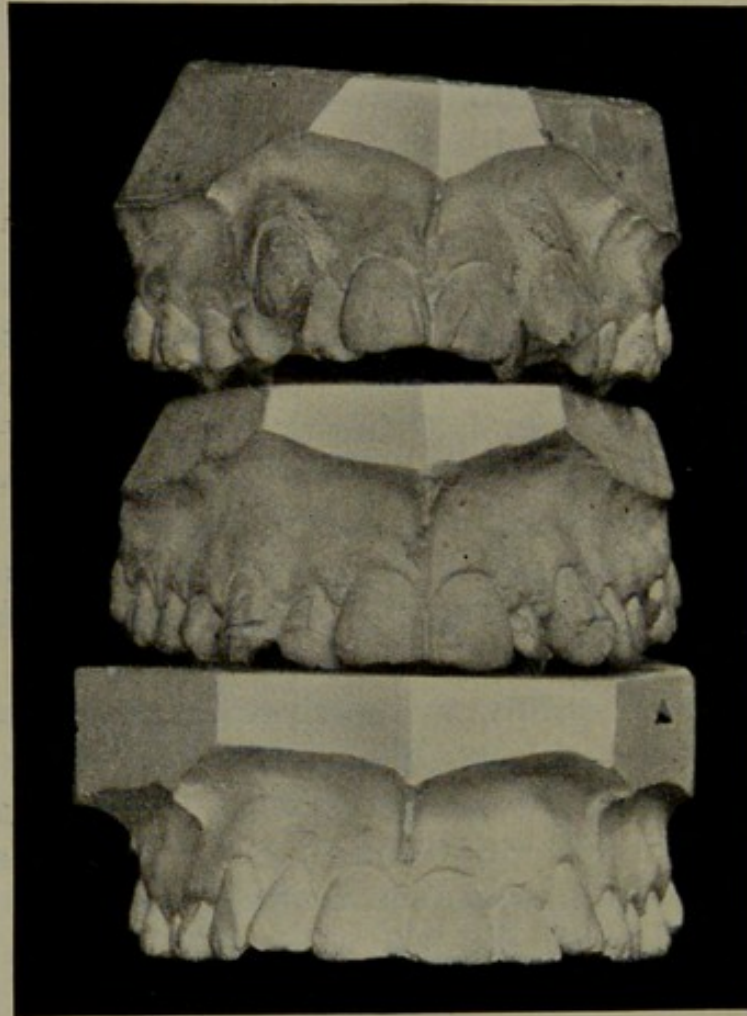
So treatment may extend over a number of periods, especially if complex causes be present, even to the time when the canines shall become fully erupted and firm in their correct positions, but each time the regulating appliances should be removed as soon as the necessary movements are accomplished, giving as much freedom and rest from their use as possible. To compel patients to wear regulating appliances for long periods at a time is needless and reprehensible. As we have said, a few weeks with the proper appliance is all that is needed to effect the necessary movements of any given period.

The time required for treatment as so far outlined refers more especially to cases taken early in their variations from the normal, yet in those cases in which treatment is begun at a much later date, or after all or nearly all of the teeth have erupted more or less completely into malocclusion, as in Figs. 307 and 367, there should also be periods of rest and retention, and the reason is obvious. The alveolar process has been arrested in development and requires much time for the growth necessary to accommodate the teeth in normal occlusion. In such cases all the teeth requiring movement should be moved simultaneously and as far each time as is consistent with the arrest in the alveolar process. The appliances should then be removed and the teeth retained for six months, or in complex cases, for a whole year, when there may be another period of activity



followed by another period of rest and retention, and in some cases even a third period may be desirable. In this way, the alveolar process having been stimulated and given time for growth, better ultimate results will be gained with

FIG. 264.



less probability of injury to the tissues. In the case shown in Fig. 264 three years were found not too long a time for the development of sufficient alveolar process for the needs of the teeth in their new positions. Fig. 265 shows the occlusal view of the upper arch in this case, made at a still later date.

Fig. 202 shows the appliances in position upon the model



at the beginning of treatment. Appliances were worn for short periods on three different occasions, followed by several months of retention in each instance. In the reported treatments of cases throughout our literature we often hear mention of the rapidity with which they have been accomplished, as if that were the principal thing to be desired. In reality, for the reasons we have given, this is, generally speaking, something to be especially avoided

FIG. 265.



and can only reflect a lack of comprehension of the requirements of the physiological laws that should govern the great changes and necessarily great disturbance of the tissues involved.

**Frequency of Seeing Patients.**—During the treatment of malocclusion it is far better to see the patient at regular intervals, and to this end the appointments should be definitely pre-arranged, for it is obvious that if system be observed much greater progress will be made in a given time.



The necessary frequency of the visits depends much on the skill of the orthodontist. The author is convinced that much unnecessary time of both patient and orthodontist is often consumed, not only during visits, but in their frequency. With a truly efficient appliance properly adjusted so that the requisite amount of force may be directed and constantly applied to the moving teeth, a full week may usually be allowed to elapse with perfect propriety without further attention. It is probably better, however, for operators of but limited experience to see their patients regularly twice a week in order to guard against unnecessary delays on account of possible derangement of the appliance.



## CHAPTER XVI.

### TREATMENT OF CASES.—CLASS I.

As already noted in the classification of malocclusion, the number of cases belonging to this class is the greatest and comprises by far the largest variety, the distinguishing characteristics of the class being relative normal relations of the jaws, usually with the teeth crowded and the arches diminished in size, but with the keys to occlusion—the first molars—in correct occlusion mesio-distally, although one or more may be in buccal or lingual occlusion. The malposed teeth are usually, however, confined to those anterior to the molars, and more commonly to the incisors and canines. Both arches are usually involved and often quite similarly.

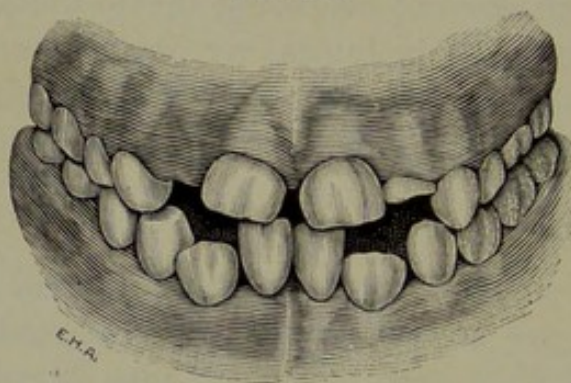
As the mesio-distal relations of the lateral halves of the dental arches are normal in this class, it must follow that if the teeth of each arch be moved into harmony with the line of occlusion both arches must then be in perfect harmony as to size and the teeth be in normal occlusion, with proper facial balance established. The latter, however, may not at once be apparent, as we shall see later, but it must follow ultimately when Nature shall have effected the full development of the alveolar process and the muscles shall have become modified in form and function so as to act normally in their relations with the teeth in occlusion.

That we may clearly establish in the mind of the reader these principles, as well as familiarize him with some of the many forms of malocclusion of the teeth belonging to this class and with the best methods for their correction and retention, a number of cases from the author's practice will be here reported.



Most cases belonging to this class have very simple beginnings. Fig. 266 illustrates a very common beginning of a type of cases, early and proper treatment of which may prevent malocclusion of other teeth upon their eruption. For some cause not always easy to determine there has not been the normal growth in the alveolar process in the region of the lower incisors, which is manifest in a lack of the normal widening of this arch between the deciduous canines. In this case while the lower centrals have erupted in practically normal positions, the laterals have been forced into labial positions. As elsewhere noted,

FIG. 266.

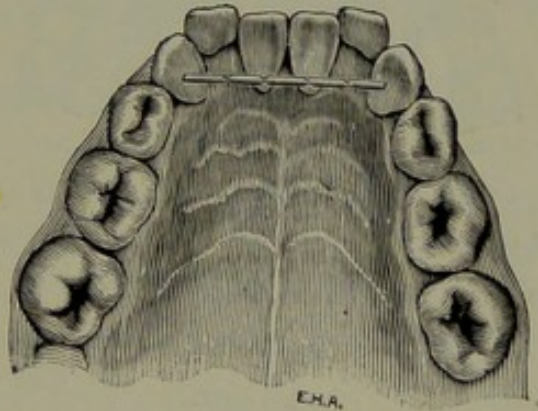


the pressure normally exerted by the lips upon the canines tends to augment this crowded condition, the lower dental arch being thus prevented from exerting its normal widening influence through occlusion upon the upper. As a result the way is rapidly being paved for the permanent narrowing of both arches, and consequent further complications as more of the permanent teeth shall erupt. A very simple, yet efficient method of assisting Nature in antagonizing this narrowing tendency of the arches is to slowly widen the space between the lower canines by lengthening a section of soft wire pointed at each end and made to rest in pits in the enamel of the deciduous canines, as in Fig. 267, the lengthening of the wire being effected by pinches with the regulating pliers. In this way space will be provided not only for the lower lateral incisors, but also



for those of the upper arch by the outward pressure exerted upon the upper canines through the inclined planes of the lower canines. This method is useless unless intelligently managed. The tendency with a beginner is always to renew the pressure too often. By a too rapid movement the influence upon the teeth of the upper arch will soon be lost by the carrying of the lower canines outside of their zone of normal occlusal influence. Once a month is quite often enough to see the patient and extend the movement of the teeth by one or two pinches of the wire. By studying

FIG. 267.



this method its efficiency will be readily seen. Gentle pressure and stimulus long continued are needed to accord with the natural growth of the jaw and as the device is of almost no inconvenience to the patient it may be worn without complaint an indefinite time. The method has long been a favorite with the author and is very useful if employed early.\*

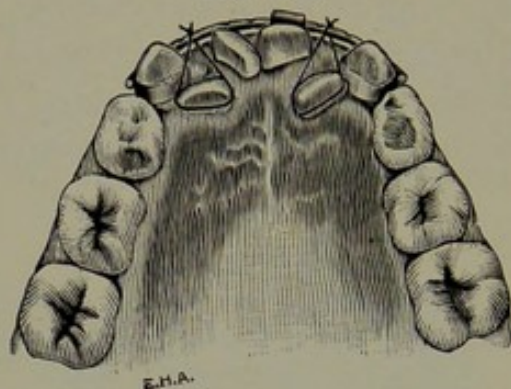
If it be employed before the case has progressed to pronounced displacement of the laterals, Nature's inherent force, together with pressure from the lips, will gradually move the laterals into correct occlusion as space for them is made. Or, force may be exerted upon them by means of wire ligatures embracing the laterals and the pinched wire. Or if the laterals be misplaced lingually instead of labially

\* "A New Force in Orthodontia," *Dental Digest*, vol. 1, No. 1, Angle.



as they more commonly are, force may be exerted upon them by means of rubber wedges placed between each lateral and the pinched wire. In more advanced cases the pinched wire may be employed on the labial surfaces of the teeth and soldered to bands cemented upon the canines,

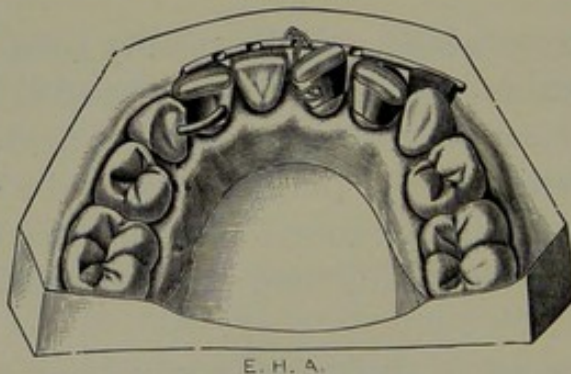
FIG. 268.



with force exerted upon the laterals by means of wire ligatures, as shown in Fig. 268.\*

Fig. 269 shows a modification of this plan of applying force which was used with much satisfaction in the case

FIG. 269.



here illustrated. At the beginning of treatment the deciduous canines were much closer together than here represented, with the right permanent lateral lingually displaced and much closer to the left lateral. The right central was also turned farther upon its axis. A section of an expansion arch was soldered to the labial surfaces of bands ce-

---

\* Angle. Fourth edition.



mented upon the lateral incisors, and a spur which had been soldered to the lingual surface of the one on the left was made to bear in a notch ground in the lingual surface of the canine. An occasional pinch from the regulating pliers widened the distance between the lateral incisors and with them the canines were carried laterally. At the same time the labial movement of the right lateral was effected by a piece of rubber stretched between the right canine and the end of the section of pinched wire. The movement of these teeth provided space for the right central, rotation of which was accomplished in the usual way, as shown, by spurred band and ligature engaging the lengthening section of wire.

The movements of these teeth successfully accomplished through occlusion the few necessary movements of the teeth in the upper arch. The device was so simple and efficient, yet compact, that it gave the patient almost no inconvenience. He was rarely seen oftener than once in six weeks.

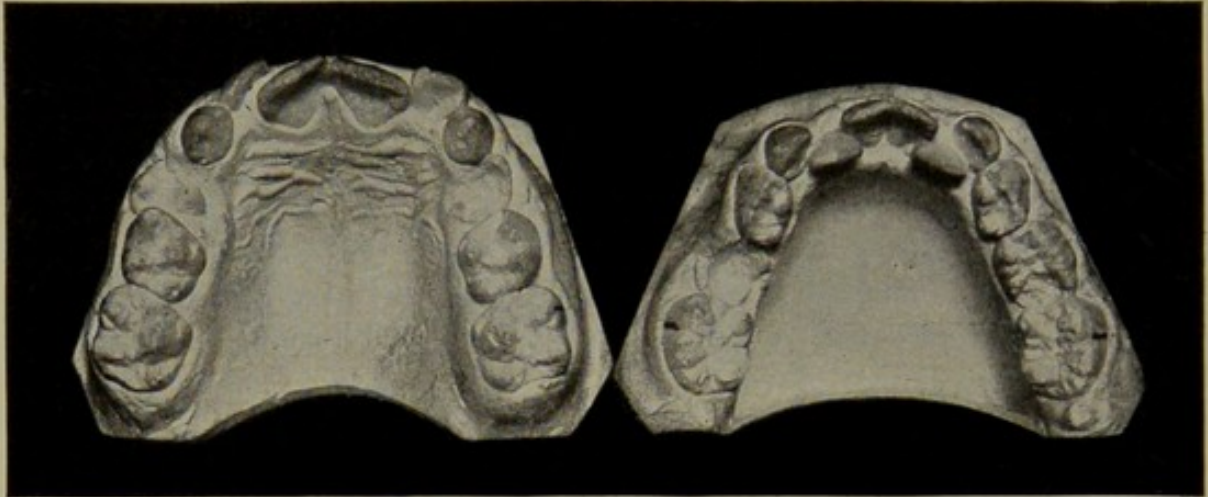
When the teeth had all been moved into harmony with the line of occlusion the device was allowed to remain in place and served the purpose of retention. The rubber wedge, however, was removed and the end of the wire bent to bear firmly against the canine.

This form of device has many uses, especially in the beginnings of similar cases. But in cases further progressed, as in Figs. 270 and 271, the upper arch has become so much involved that it is folly to attempt its treatment indirectly through occlusion. Each dental arch should then be operated upon, and for this purpose there is nothing else so efficient or that gives so complete control of the movements of the teeth as the expansion arch, already described. For its operation in this and similar cases the D bands should be placed upon the permanent first molars, or, they (in smaller size) may be employed upon one or all of the second deciduous molars. Rarely, how-



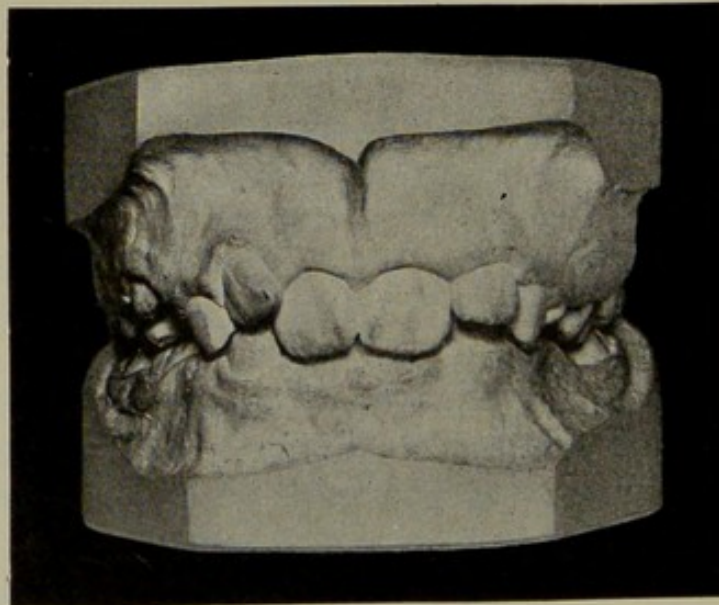
ever, is it advisable to employ all four of the deciduous molars, or even two in the same arch, as anchorage. The

FIG. 270.



expansion arches are then carefully bent to exert force in exactly the direction desired when the wire ligatures

FIG. 271.



are employed, yet at the same time to lie as closely as possible in contact with the teeth without binding or in any way interfering indirectly with the necessary movements of the



malposed teeth, so that the patient may experience as little inconvenience as possible from the presence of the appliances.

In Fig. 272 is shown a more or less common type of malocclusion belonging to this class, as will be readily recognized by the position of the molars. The patient was a boy sixteen years of age. All of the upper anterior teeth are in lingual occlusion, while the lower, through occlusion, have been forced slightly labially. The upper incisors were laced to the expansion arch with wire ligatures,

FIG. 272.

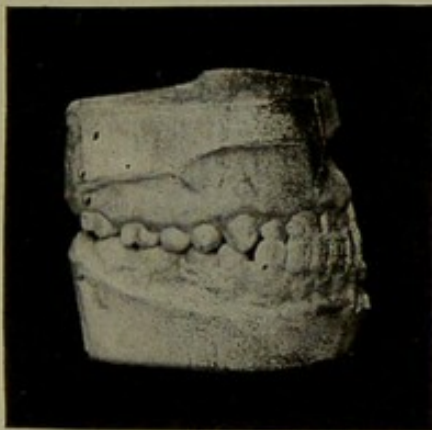
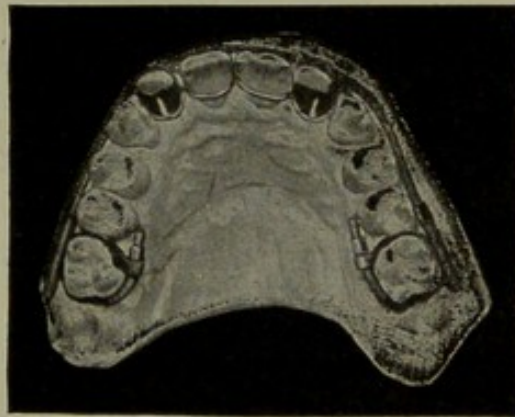


FIG. 273.



and all carried labially by tightening the nuts in front of the tubes on the anchor teeth—the first molars. It will be seen in the next engraving, Fig. 273, that plain bands encircle the lateral incisors to prevent slipping of the ligatures, while plain ligatures are used on the centrals. The engraving illustrates a study model made after completion of the tooth movements and just before the appliances were removed.

The upper teeth were moved outward to correct positions, as shown in the case completed, Fig. 274, in just seven days. The appliance was allowed to remain upon the teeth passively for ten days before its removal, when occlusion alone was depended upon for retention.

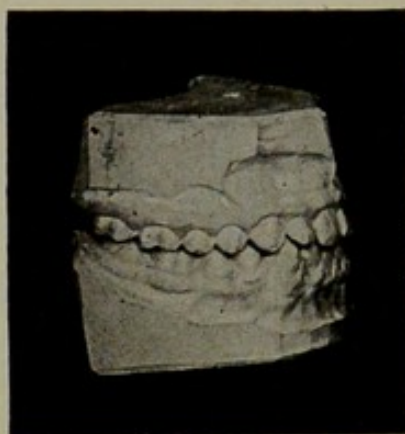No effort was made to change the positions of the lower



incisors, as it was known that the necessary change would be effected by occlusion.

In the treatment of all similar cases there is a strong tendency on the part of many to perpetuate the antiquated

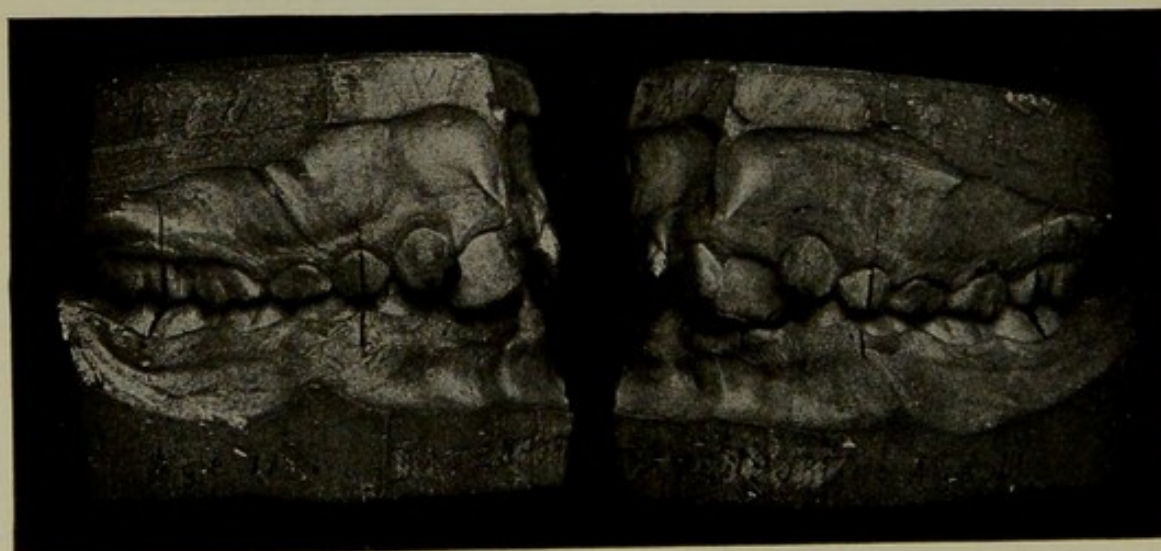FIG. 274.



practice of applying some form of gag to keep the jaws apart and prevent the occlusion from interfering with the

FIG. 275.

FIG. 276.



movement of the teeth. Such useless encumbrances should be abandoned. A good appliance will effect the movement, regardless of the slight hindrance offered by occlusion,



FIG. 278.

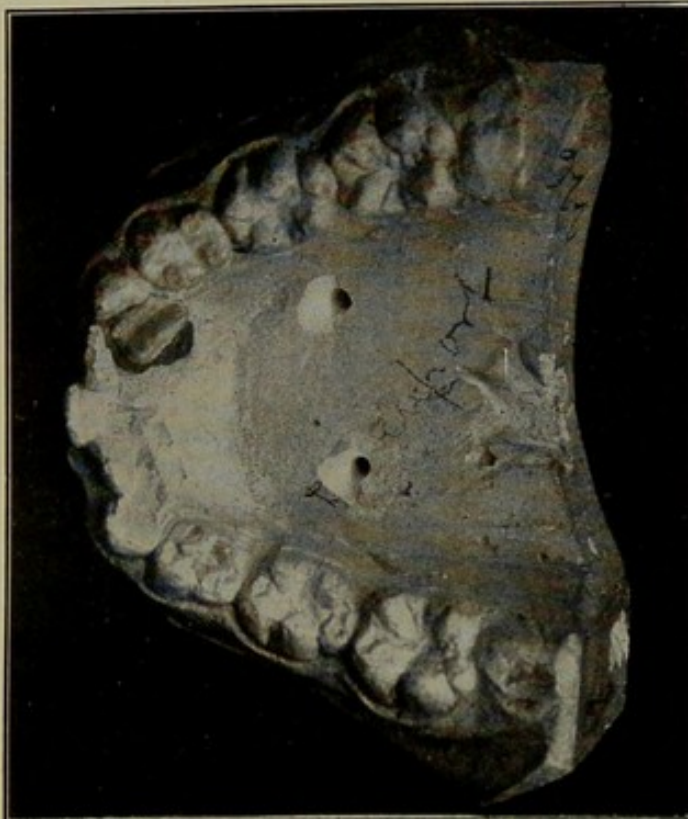
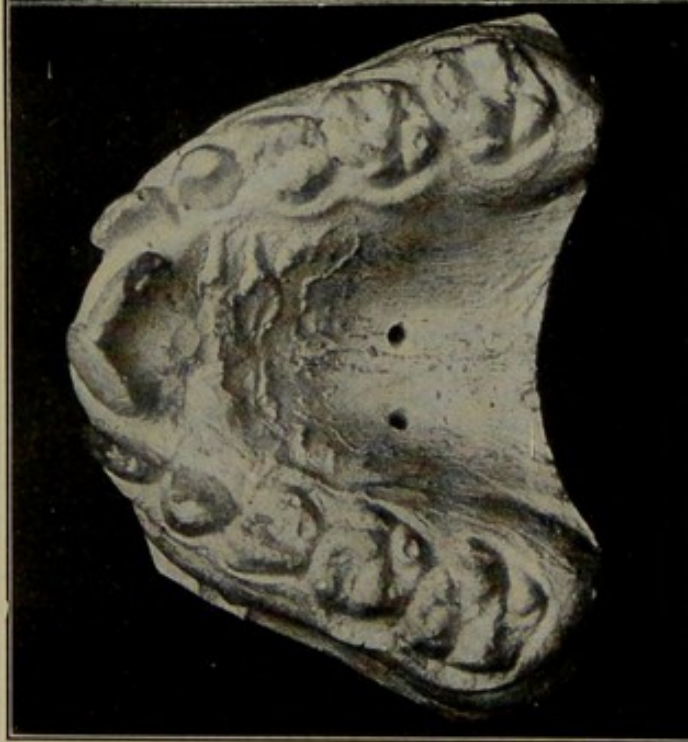

FIG. 277.





which is reduced to the minimum by the patient's natural avoidance of irritating the sensitive moving teeth.

Figs. 275 and 276 represent the malocclusion of another case, that of a boy aged eleven years, and Figs. 277 and 278 show the teeth from the occlusal aspect. The permanent incisors and first molars have erupted. The lower right lateral incisor early took a lingual position and the pressure of the lips acting externally to the arch soon closed the space between the central incisor and the deciduous canine, thereby diminishing the size of the arch to that extent. The pressure of the muscles of the lips and cheeks gradually molded the upper arch to conform to the diminished size of the lower,—only an accentuated condition of that shown in Fig. 9 and of all similar cases allowed to progress.

It will be seen that the molars have locked normally. There is, therefore, the normal mesio-distal relation of the jaws and dental arches, and if in obedience to the law of occlusion the arches be enlarged anteriorly and each of the malposed teeth be placed in harmony with the line of occlusion, there will then be normal occlusion. Although it would at first appear that there is not sufficient room to accommodate all the teeth (and, indeed, extraction was freely advised by several dentists), yet in fact the room was ample, as we shall see.


Again, by studying the profile of the young man's face, Fig. 279, it would seem that to enlarge the arches and place all of the incisors in their correct relation would be to exaggerate to unsightliness the protrusion of the lips, already too prominent, yet in reality this prominence was not exaggerated, but on the contrary reduced and beautiful harmony of balance given to the face for reasons given in the discussion of the art relations of this case in the chapter on Art.

The treatment was simple and is easily understood. The four upper incisors were carefully banded, the thin band



material C being used for the laterals, and the thicker, or F, upon the centrals. Spurs of wire G that inclined forward and downward were attached at the disto-lingual angles of these bands close to the gingival edge. The right lower lateral was also encircled by a plain band having a spur attached near the disto-linguo-gingival margin.

FIG. 279.



D bands were carefully fitted to both upper and lower first molars, and the expansion arches slipped into position, all this occupying but a few moments at each of three different sittings, so that the patient might become gradually accustomed to the wearing of the appliances. He was then dismissed for a week, until all soreness had subsided, after which light pressure through plain ligatures made to encircle expansion arch and spurs was applied, as shown in B, Fig. 195.

Now, by studying the positions of the teeth from the occlusal aspect in Figs. 277 and 278, it will be seen that



both canines in both upper and lower arches must be moved laterally in order to provide space for the lateral incisors as they are moved into their correct positions, or in harmony with their proper lines of occlusion; therefore hook-like notches were made in the ribs of the expansion arches opposite the canines for engaging the ligatures used in forcing these teeth in the direction indicated. At the same time the permanent centrals and laterals were being rotated into their correct positions.

In shaping the upper expansion arch, in order to best exert force upon the teeth to be moved, and at the same time to occupy as little room in the mouth as possible, it was bent to rest in contact with the mesial angle of the right central, but made somewhat wider in the region of the canines in order to permit the widening of the dental arch. In like manner the lower expansion arch was adjusted. As the molar teeth were already in their correct positions bucco-lingually as well as mesio-distally, no lateral spring was given to the expansion arches.

The widening of the dental arches in the region of the deciduous molars in such cases is often good practice, yet the movement of these teeth is not so necessary as that of the deciduous canines, for the reason that the permanent canines and first molars must govern the width and length of the arches. They being correctly placed and their positions maintained, the premolars upon eruption are molded into harmony with them through the buccal and lingual action of the muscles.

It may be well to again impress upon the operator of little experience the great importance of so placing the bands, spurs, ligatures and arch that all will act with the greatest efficiency. A loose band or ligature is, of course, useless, and its wearing but a waste of time. A loose arch, or one operating too near the cutting edges of the teeth is worse than useless.

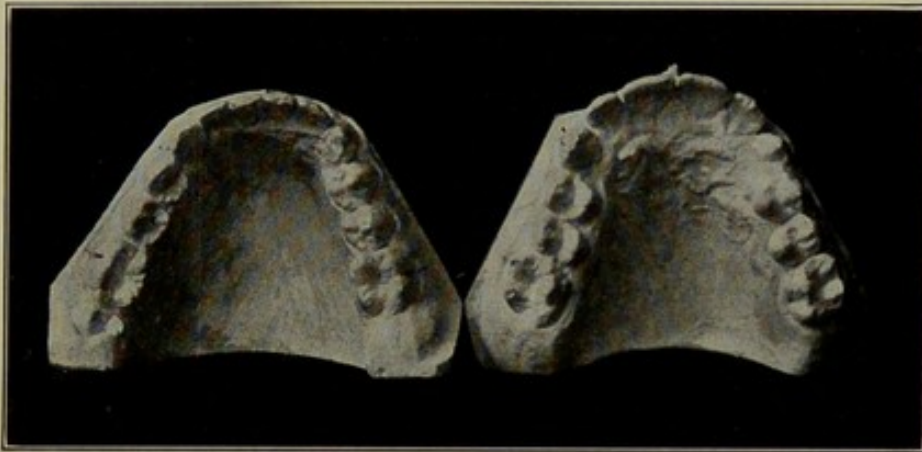
Figs. 280 and 281 show the positions of the teeth from



the occlusal aspect after the necessary movements had been completed. Figs. 282 and 283 show the teeth in occlusion, and Fig. 284 shows the facial lines.

FIG. 280.

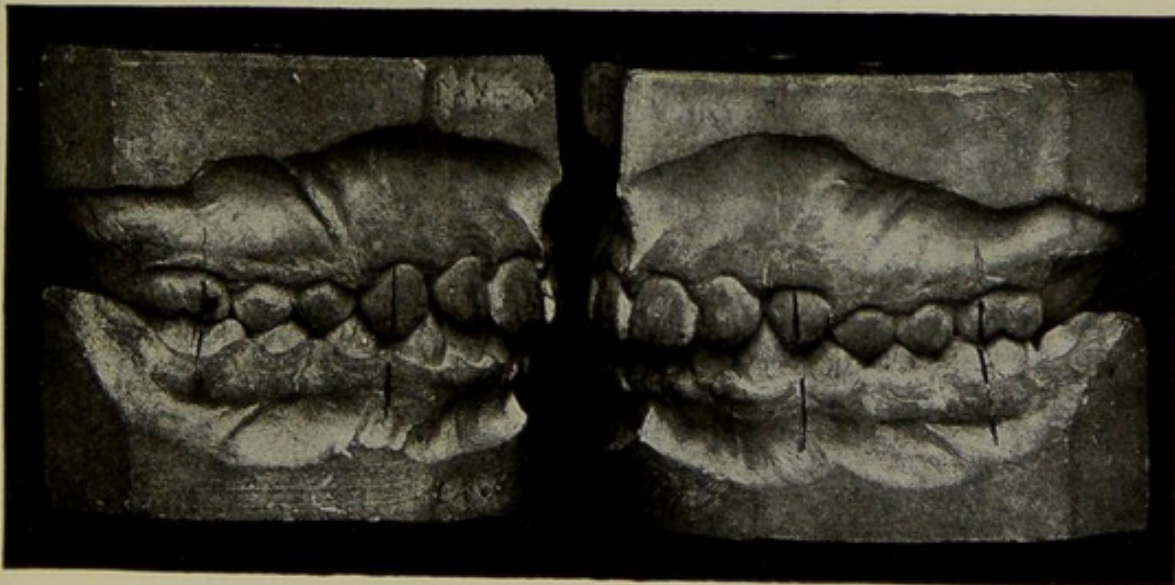FIG. 281.



The expansion arches were allowed to remain in position for a couple of weeks that all soreness might subside before the adjustment of the retaining devices, and a novel method

FIG. 282.

FIG. 283.



of temporary retention was employed by making use of the bands and spurs already in position upon the teeth, in connection with wire ligatures which were wound in and out between the teeth and made to engage the spurs



in such a way as to antagonize the movement of the teeth in the direction of their tendencies, as fully described on pages 268 and 269, and shown in Figs. 216 and 217.

FIG. 284.



After several weeks of temporary retention the upper teeth were permanently retained as illustrated in Fig. 218. The lower incisors were retained by bands placed upon the laterals and connected by a section of wire G soldered at their mesio-lingual angles and made to bear against the intervening centrals. Spurs were also soldered to the disto-labial angles of these bands and made to bear against the deciduous canines, thus preventing the lingual movements of all the lower incisors in the manner indicated in Fig. 235.

A case similar to the one just reported, although less complicated, owing to the normal arrangement of the teeth of the lower arch, is shown in Fig. 285. The effect upon the facial lines was marked and also similar to that in the last case, and for like reasons.



FIG. 285.

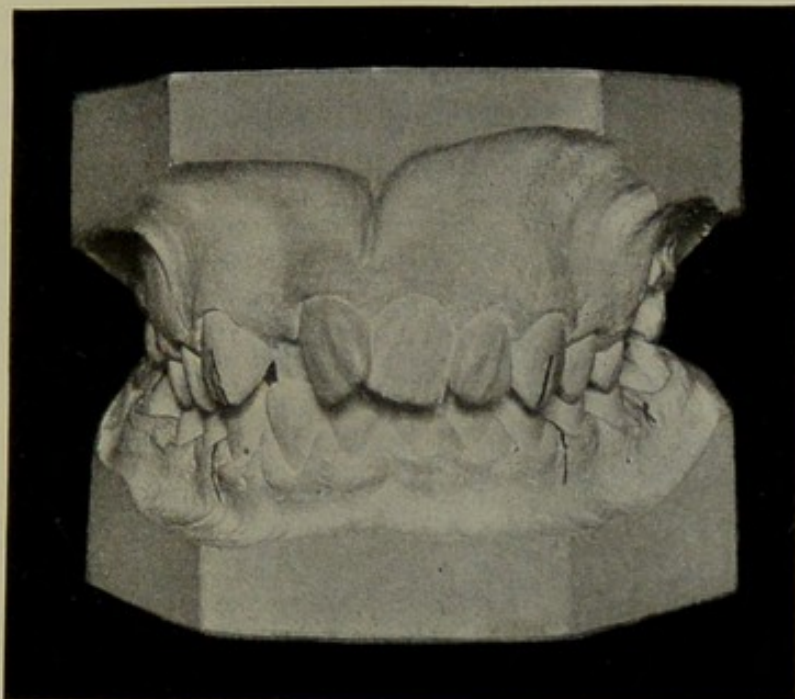
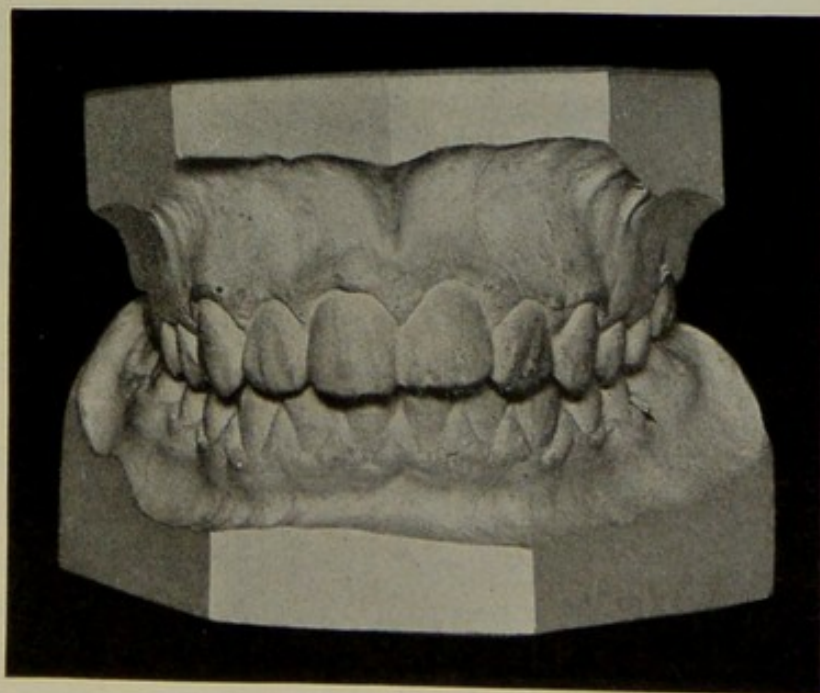


FIG. 286.





In treatment the upper arch was enlarged and each tooth moved into harmony with the line of occlusion by force exerted from the spring of the expansion arch. Neatly fitting bands made from the band material C were cemented upon the central and left lateral incisors, and

FIG. 287.

FIG. 288.



rotary force applied by means of ligatures engaging the arch and spurs soldered to the disto-lingual angles of the bands close to their gingival margins. No spurred band on the inlocked lateral was necessary, a plain ligature only being used and all the ligatures being occasionally tightened by twisting or renewal. The corrected occlusion is shown in Fig. 286.

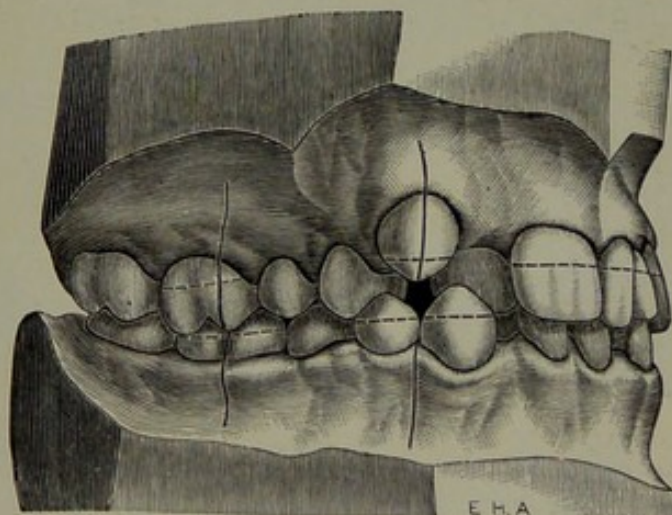
The teeth were retained as in Fig. 230.



The fine harmony established in the balance of the facial lines, as the result of treatment, is shown in Figs. 287 and 288.

Fig. 289 shows a case which has been allowed to progress until the malocclusion has become somewhat complicated. The jaws being in their normal relations and the first molars normally locked, it is easily diagnosed as belonging to this class. Both arches are much reduced from their normal size, with the alveolar process developed in accord with the malpositions of the teeth.

FIG. 289.

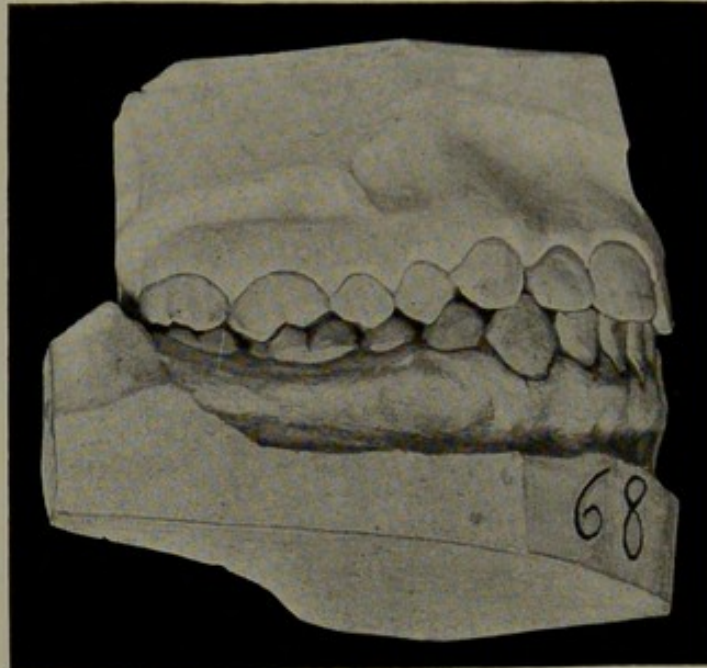


The treatment clearly indicated, is to enlarge the arches and place each tooth in harmony with its line of occlusion. This was accomplished by means of the expansion arches, ligatures and spurred bands, as described in the chapter on Adjustment and Operation of Appliances. The dotted lines seen on the buccal and labial surfaces of the teeth indicate the positions which the expansion arches were made to occupy during treatment, and Fig. 290 shows the case corrected. Each tooth having been placed in harmony with the line of occlusion the two dental arches must and do harmonize as to size, offering to each other mutual support through the harmonious relations of their



inclined occlusal planes. Time only is necessary to effect the full development of the alveolar process and the normal functions and relations of the tongue and lips with the teeth in their new positions.

FIG. 290.



A similar case is shown in Fig. 291. The first molars have locked normally. The deciduous molars are present, but the deciduous canines have been lost, followed by retraction of the incisors of both upper and lower arches largely through lip pressure. The lower permanent canine on the right side is just beginning to erupt which will necessarily cause a still greater bunching of the incisors as well as their movement lingually. The upper right canine has not yet erupted, but its location is apparent, it being almost directly over the root of the lateral. Its eruption must be followed by great disturbance of the upper incisors. Fig. 293 shows the facial lines of the patient.

The treatment of the case consisted in moving labially all of the incisors, providing ample space for the canines,



with firm retention until the complete eruption of the canines and premolars. The movement of these teeth was comparatively easy, but the recurrent tendencies of the

FIG. 292.

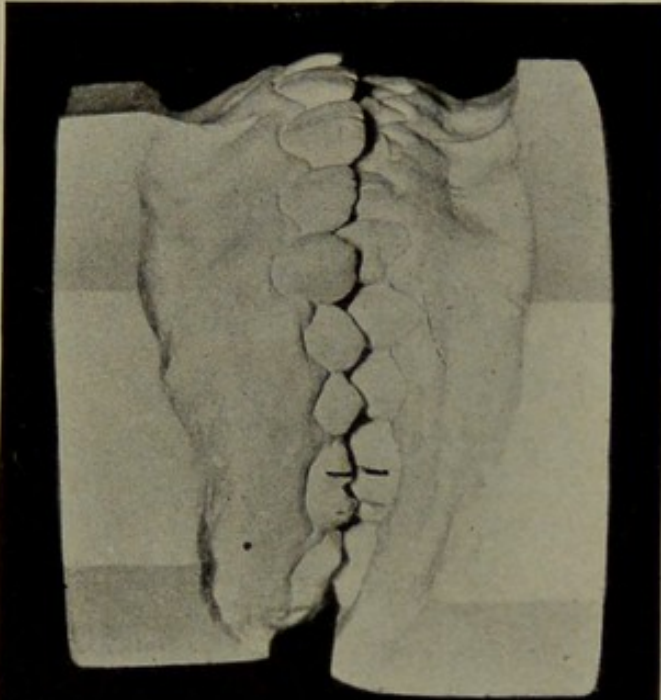
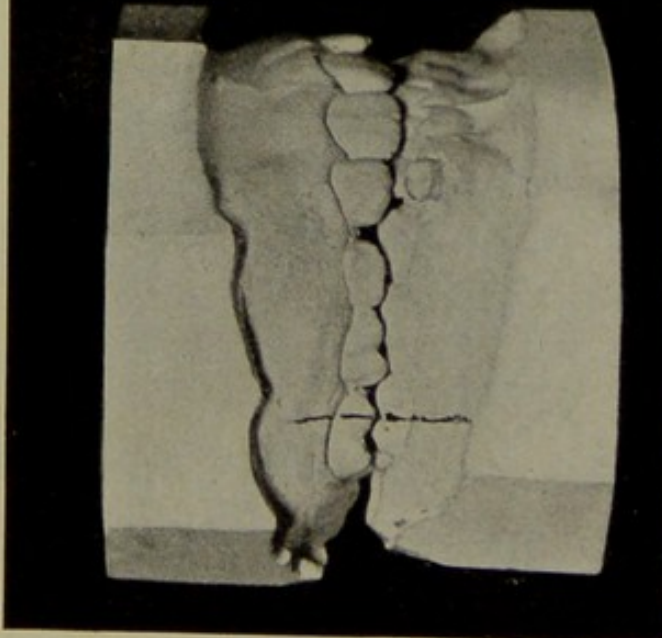


FIG. 291.



incisors, owing to the habit of contracting the lower lip abnormally, were very strong, requiring their retention for quite a protracted period.



Fig. 292 shows the beautiful occlusion that has been established, and here we would again impress an important fact to be observed in all such cases, namely, that the retention of the lower incisors and canines in their full mesio-

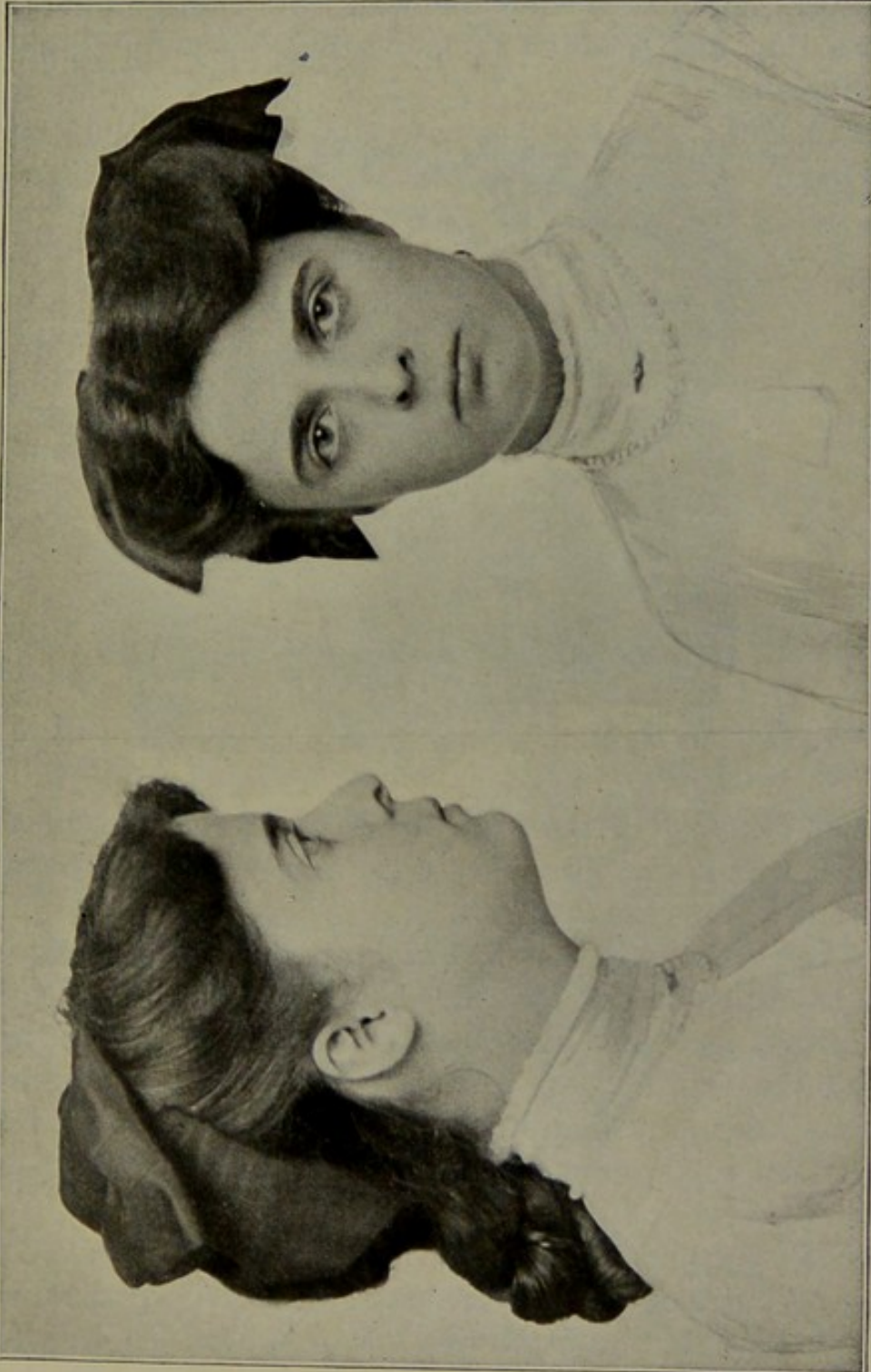FIG. 293.



distal relations—even long after the retention of the upper incisors has been discontinued—is of prime importance, for, as we have seen in the chapter on Occlusion, the lower dental arch is the mold over which the upper is formed and maintained, and without the full normal size of the lower arch, especially in its anterior part, the normal



FIG. 295.



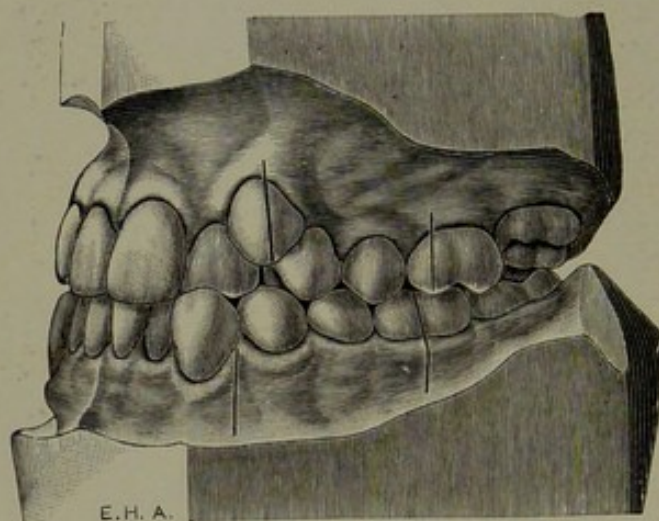


positions of the upper incisors in any such case can never be maintained.

Figs. 294 and 295 show the beautiful balance in the facial lines that has resulted from placing the teeth in normal occlusion.

Fig. 296 shows another case similar to the one just described, but more complicated, there being decidedly

FIG. 296.



greater arrest in the growth of the alveolar process and jaws, which was probably due largely to the premature sacrifice of deciduous teeth.

The relations of the first molars being normal, the plan of treatment clearly required that both dental arches be enlarged and each malposed tooth moved into harmony with the line of occlusion, when there must necessarily follow harmony in the sizes of the arches and Nature's intended relations of the teeth of each arch with those of the opposite arch.

Figs. 297 and 298 show the model of the upper arch from the occlusal and labial aspects, with the expansion arch in position at the beginning of treatment. The incisors were gradually moved labially to conform to the ideal form given to the expansion arch, and at the same time the



dental arch was gradually widened in the region of the premolars by the lateral spring of the expansion arch and wire ligatures, all as carefully described in Chapter XIII. In like manner, also, the lower arch was treated.

FIG. 297.

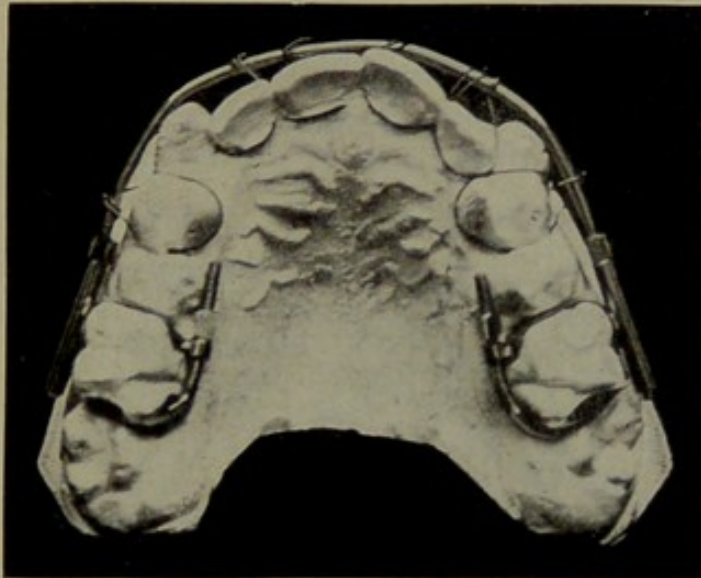


Fig. 299 shows the occlusion of the case after correction, with retaining bands upon the canines, those of each arch being connected by sections of wire G, as in Fig. 401, the

Fig. 298.



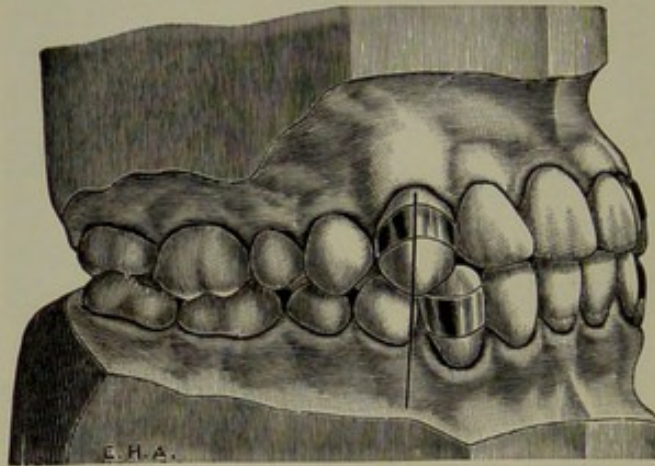
result being to antagonize the lingual tendency of the formerly malposed anterior teeth.

The positions of the teeth in the lateral halves of the arches were maintained in this case by vulcanite plates, as shown in Fig. 252.



There is a bit of history connected with this case that should give much additional interest to it. By studying the case in its original condition it will be seen how defective is the growth of the alveolar process, and how narrowed and reduced in size are the arches. It is a very common and typical case of the first class, demanding, according to the plan of treatment hitherto universally followed by the old school, the sacrifice of teeth, for it was reasoned that in such cases the jaws were too small to accommodate the teeth, usually supposed to be on account of the inheri-

FIG. 299.



tance of the small jaws of one parent and the large teeth of the other; therefore the supposed logical treatment was to help Nature in overcoming her blunder of fashioning a small jaw for the reception of the full complement of well-developed teeth, by reducing the number of teeth—two or four of the premolars being sacrificed, or, in accordance with the plan of some dentists hitherto held to be good practice, all four of the first molars. The arguments for the defence of such practice now seem strange indeed. They were that extraction would not only provide space for the remaining teeth, but that as the first molars were supposed to be more perishable than other teeth and as their eruption so soon followed the completion of the child denture, they should be regarded largely in the na-



ture of deciduous teeth, and their sacrifice of no great consequence. Indeed such sacrifice was often deemed desirable, since, it was argued, their removal would not only furnish room for all the remaining permanent teeth erupted or to erupt, but, stranger still, would assist Nature in her evolutionary process of shortening the jaws so as to be in better keeping with the lessened needs of the teeth due to the change from the coarser foods of primitive man to the soft and finely prepared foods of the highly civilized man.

It had long been a growing conviction with the author, however, that the latter plan was not only absurd, but that the sacrifice of any teeth was unscientific and positively wrong in most cases, and that it should be employed only as a last resort and then only after great deliberation, and failure of the conservative method, for he had already found that in simpler cases the supposed needs for extraction vanished as intelligent treatment for the enlargement of the arches and placing of the teeth in normal occlusion progressed. But in such a pronounced case as this, where there was such marked arrest in the development of the alveolar process, and especially as the patient was a quite delicate girl, treatment without extraction seemed almost hopeless. After much thought, however, it was decided to give the conservative method a thorough trial. As the arches were gradually enlarged much anxiety was occasioned by the very abnormal outward inclinations of all the teeth, and especially of the upper incisors, and much doubt was experienced as to whether the teeth could ever be permanently maintained at such abnormal angles. It seemed to the author that the weight and pressure of the lips and force of occlusion upon the teeth at such angles might ever tend to their displacement. He of course at that time had no realization of the fact that these forces would prove blessings in disguise in stimulating the growth of the tissues, and that we would ultimately have the full growth of jaws and alveolar process, and that the very



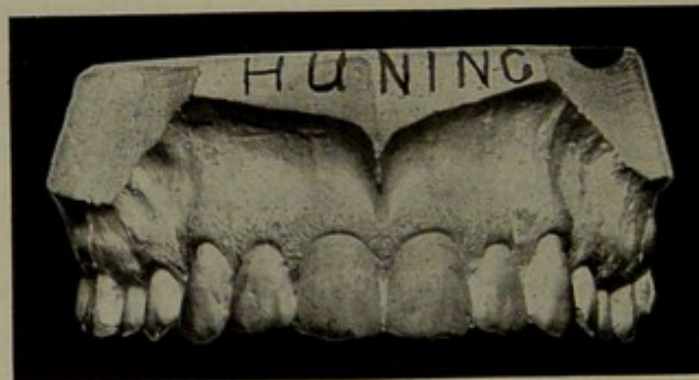apices of the roots, then so convergent, would ultimately be moved outward by Nature to their full normal upright positions. After a number of months of retention it was still a question as to whether a mistake had not been made in retaining the full complement of teeth and whether it

FIG. 300.



would not still be better to extract and reduce the sizes of the arches, but as the teeth were not so prominent as to interfere with the proper balance of the face, retention was continued and one day resulted in the gratifying discovery that very noticeable changes for the better had taken place; that the jaws and alveolar process were rapidly and nor-

FIG. 301.

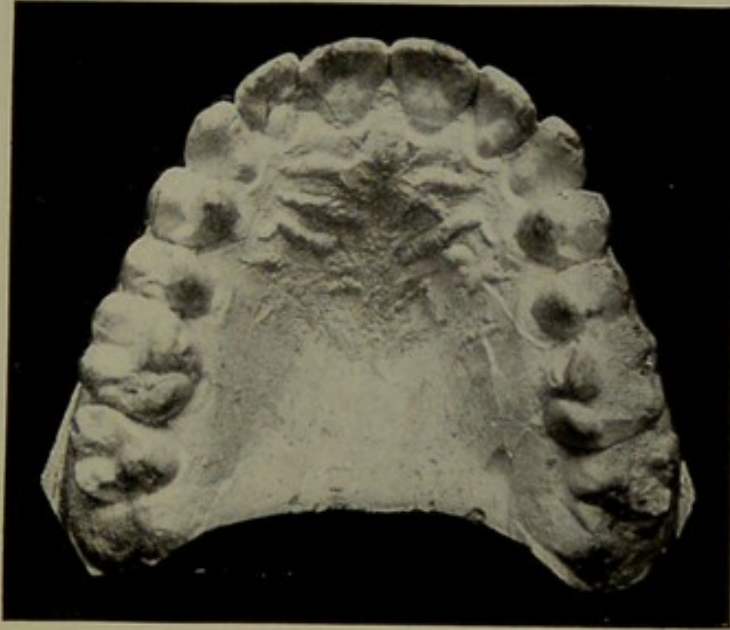

mally developing; and that the teeth were assuming normal angles of inclination, as was shown by comparing the accurate and truthful models made at the time the retaining devices were adjusted, Fig. 300, with the jaws and teeth of the patient. Two years later the growth of these tissues was nearly complete, as shown in Figs. 301 and 302.



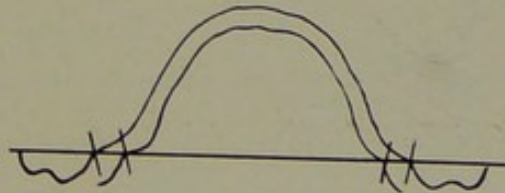
By a comparison through accurate measurements of the models at the beginning of the period of retention and of those made two years later some very noticeable and ex-

FIG. 302.



tremely gratifying results, hitherto unnoticed or recorded, were discovered. For example, the increase in the size of the vault of the arch, shown transversely just anterior to the first molars in Fig. 303.

FIG. 203.



Measurements were also made of the changes that had taken place in the positions and angles of inclination of the teeth and show, Figs. 304 and 305, how pronouncedly the positions of their apices have been shifted as the result of growth. The positions of the teeth at retention are in-



FIG. 304.

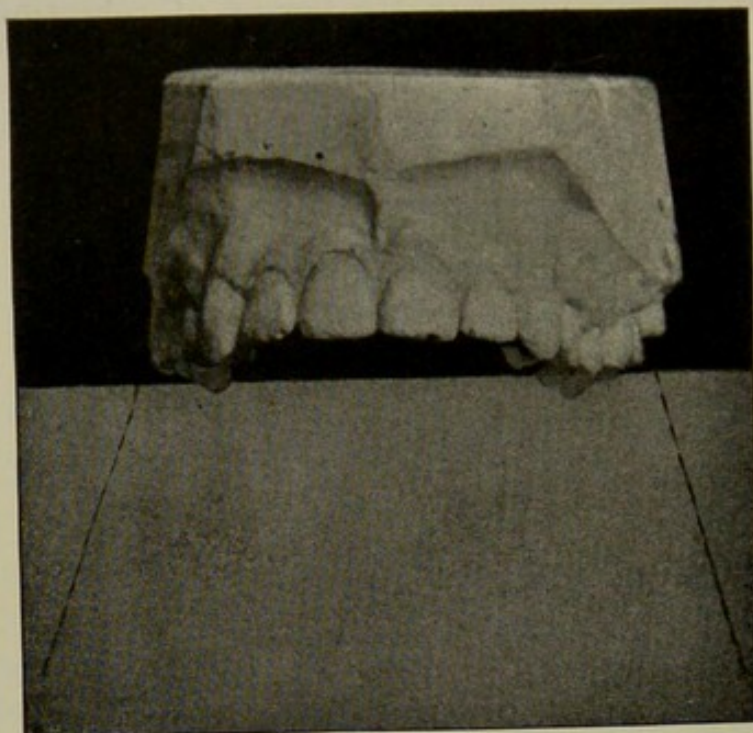
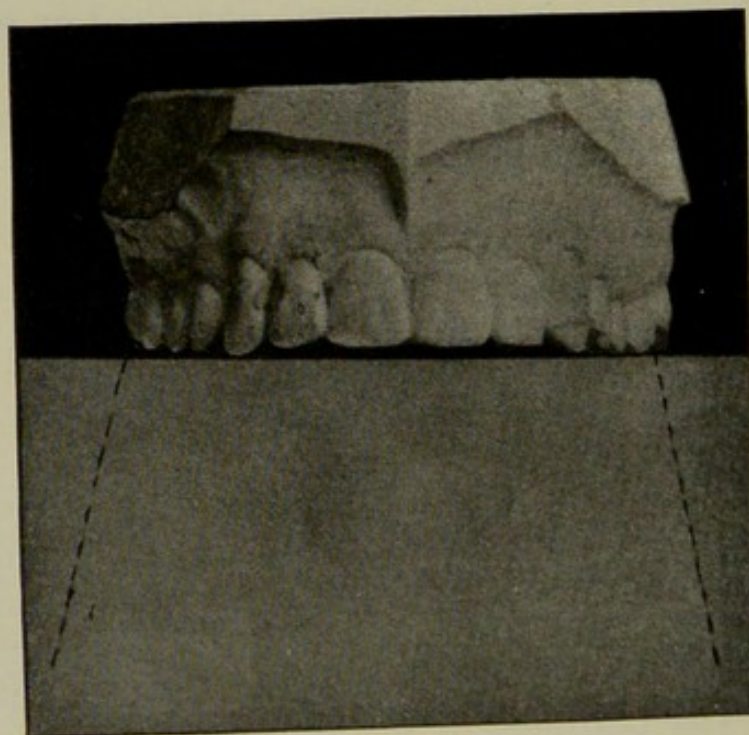

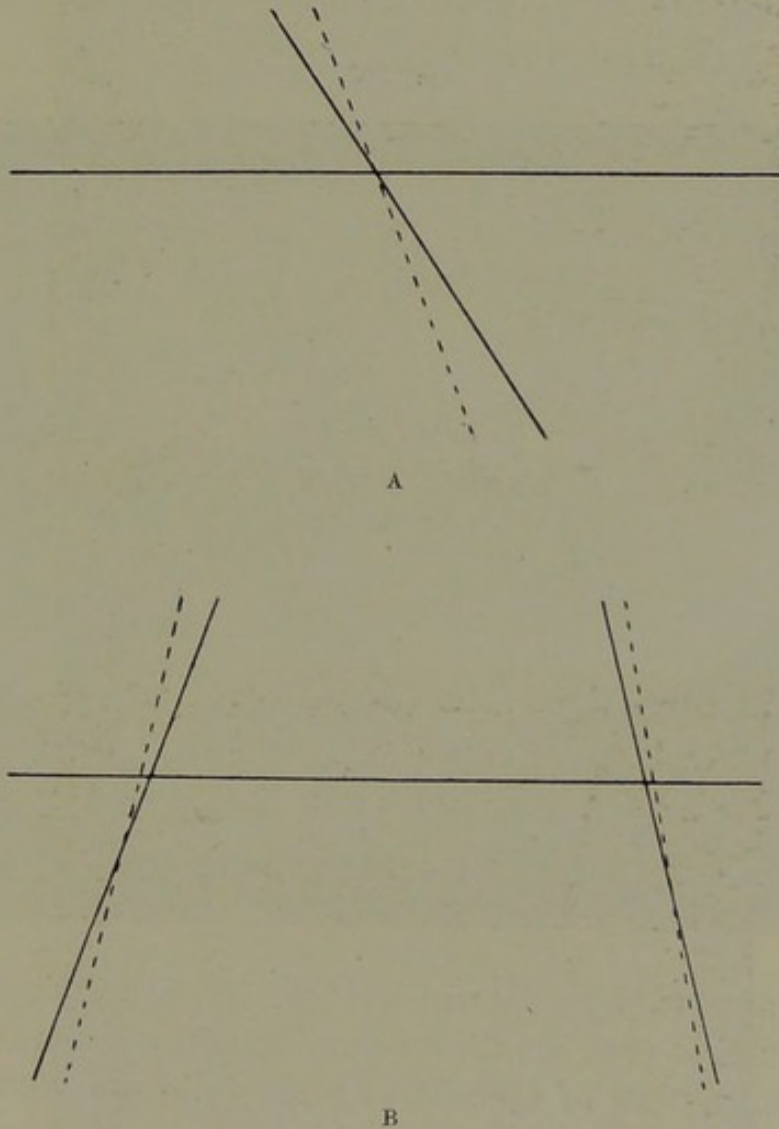
FIG. 305.





dictated by the solid lines in the engraving; Fig. 306, and their positions at the time of making the last model, by the dotted lines. The incisors are represented at A and the molars at B, the horizontal lines corresponding to the line of the gum.

FIG. 306.



Who can estimate the advantages thus given, in freedom to the tongue, in the possibilities for better breathing that have been established in the nasal region consequent on the added growth of the jaws and vault of the arch, and also

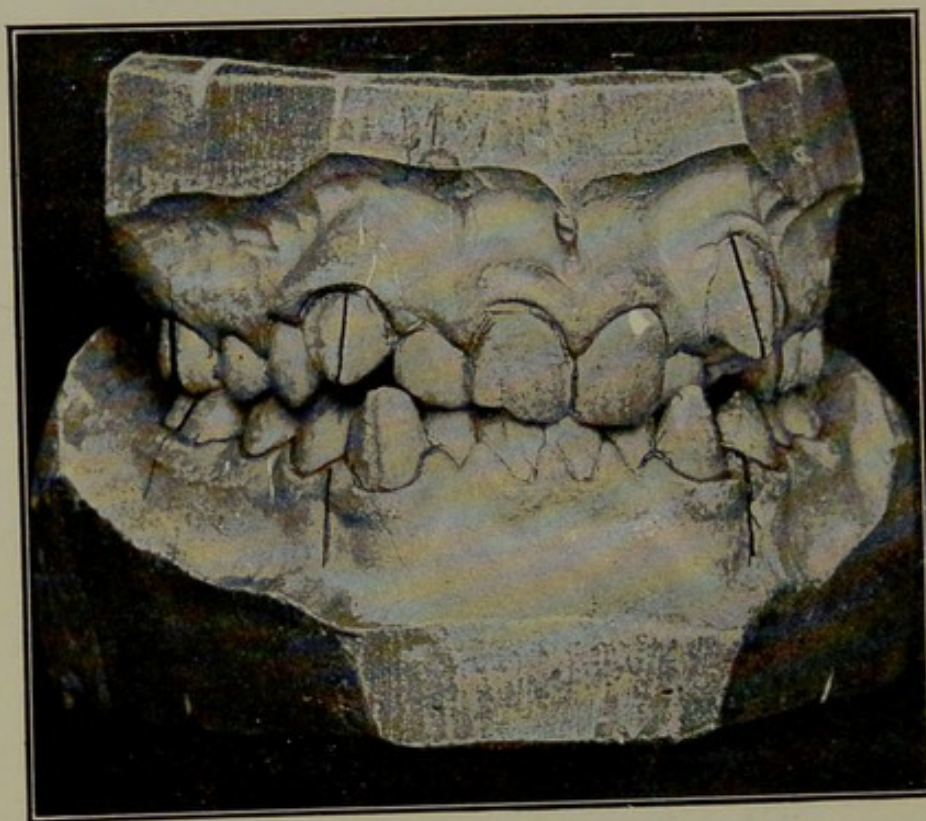

in character and beauty given to the face, as a result of such treatment.

The author greatly regrets that the photographs of the young lady cannot be shown.

Let the reader in fancy compare these changes with what would have been the condition of all of these tissues had four premolars or four first molars been sacrificed. It

FIG. 307.



seemed apparent to the author that the gratifying results shown in this case would be manifest in all similar cases if the same plan of treatment were followed, and should be proof that extraction was no longer necessary. The truth of this has since been confirmed by the results in the large number of other cases treated by him, even where there has been far greater arrest in the development of the alveolar process than that shown in this case, as we shall see later.



The treatment of this case was begun early in 1896 and

FIG. 309.

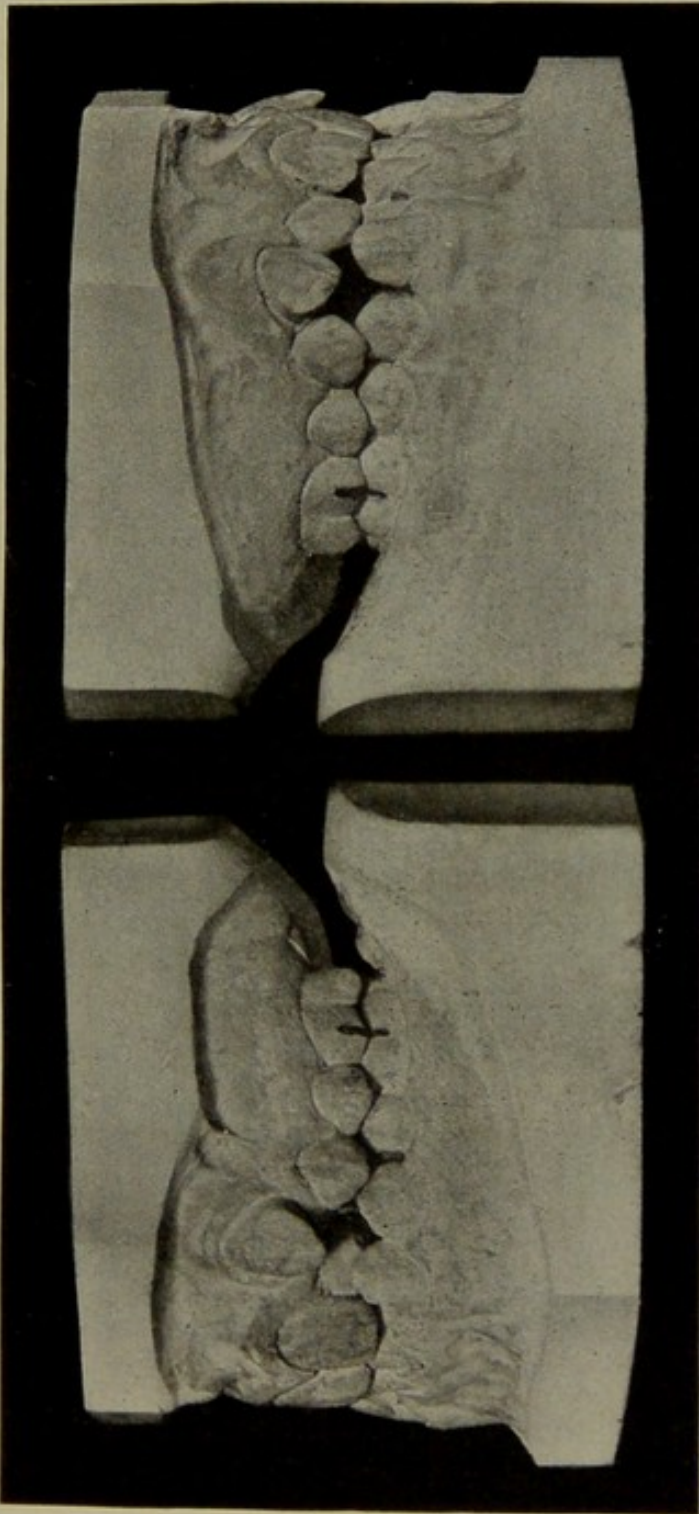


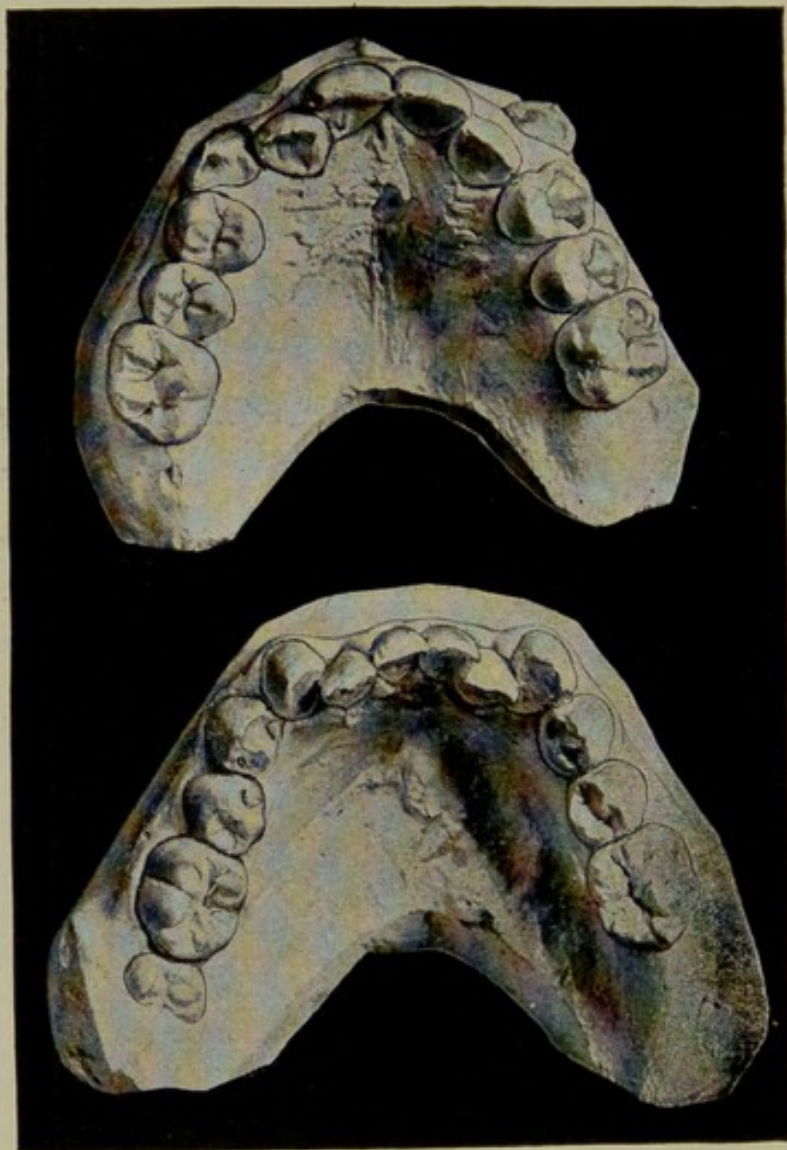
FIG. 308.

was partially reported in the sixth edition of this work, and this, so far as the author is aware, was the first time



this important subject received any definite consideration in dental literature. The possibilities of growth revealed in this case have been an important factor in revolution-

FIG. 310.



izing the practice of orthodontia and should be taken into consideration in the treatment of all cases.

The development of the alveolar process as a result of tooth movement in this case is further discussed in Chapter VII.



By a glance at the first molars it will be seen that the case shown in Figs. 307, 308, 309, and 310, also belongs to this first great class. It is similar to the one last described except that the arches show greater diminution in size and the malocclusion is correspondingly more extensive. It will be seen how pronounced is the arrest in the development of the alveolar process, probably being no more developed in the region of the intermaxillary bones than at the time of shedding of the deciduous teeth.

The effect, as might be supposed, was very noticeable in the facial lines of the patient, as shown in Figs. 311 and

FIG. 311.

FIG. 312.



312, producing a pinched and flattened appearance about the mouth.

As so much space would be required for admission of the upper canines into the line of occlusion, extraction would at first suggest itself, but recognizing the possibilities in growth of tissues following tooth movement it is apparent that such a course would be wrong and that the conservative method should be followed. What was clearly indicated was the restoration of all the teeth to normal occlusion by slightly widening both arches, moving all the incisors labially into line, and elevating, rotating, and moving slightly lingually the upper canines.

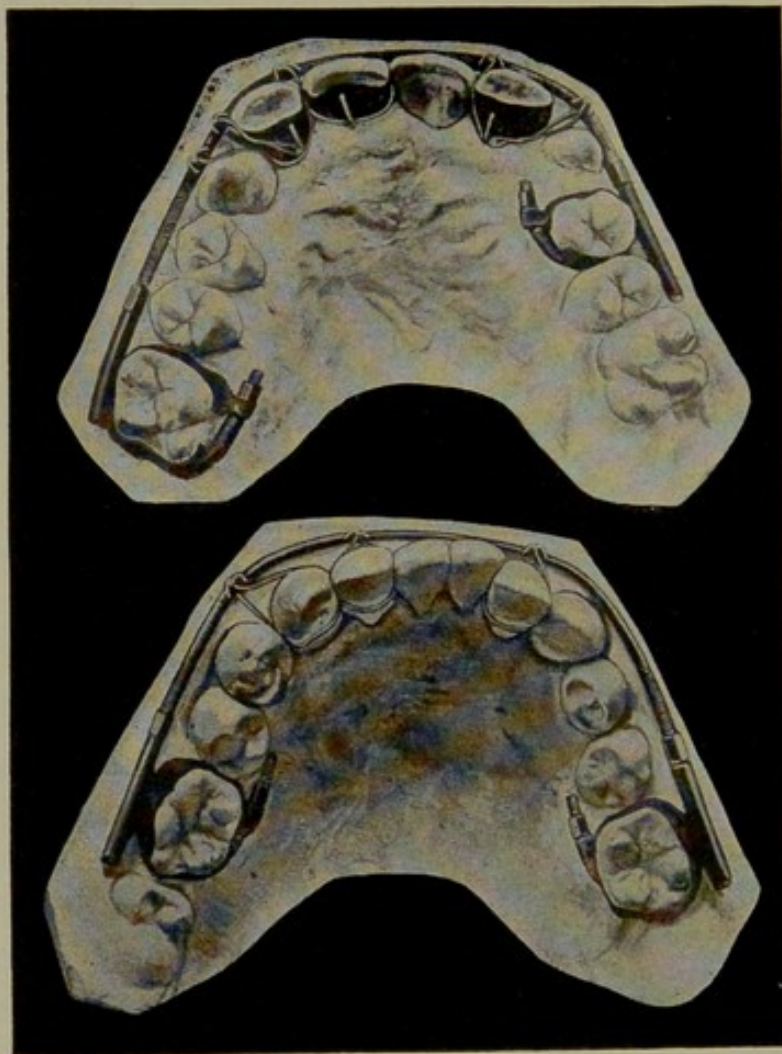
Fig. 313 shows these various movements being accomplished simultaneously in both arches by means of ribbed



expansion arches,\* D bands, spurred bands, wire ligatures, etc.

The anchorage was effected by means of D bands placed upon the first molars in the lower arch, while in the upper

FIG. 313.



arch a D band upon the first molar was used on the right side and an X band on the first premolar on the left side, it

\* Several of the cuts showing the expansion arch were made before the invention of the ribbed arch, therefore soldered spurs on the plain arch to prevent the slipping of the ligatures are shown instead of notches in the ribbed arch as now used, but referred to in the text as though the notched ribbed arch had been used.



being found necessary after a few days of treatment to transfer the anchorage from the left first molar to this tooth, as the molar showed displacement distally in resisting the strain incident to the labial movement of the incisors. It is not surprising that the anchorage of the first molar was insufficient and that the tooth did move distally in this case, as it may in all cases at this age, for the reason that the second molar gives it no support, it being still unerupted and lying in a large open crypt into which the first molar may quite easily be moved. It is usually well in such cases to reinforce the molar, which can easily be done by enlisting the support of one or both of the premolars by means of a wire ligature made to encircle the three teeth, the wire ligature resting on some portion of the D band to prevent its sliding beneath the gum.

It will be noticed that there are two ligatures upon the upper left lateral incisor. One is a plain ligature, as in A, Fig. 195, for effecting the labial movement; the other, as in B, encircles the arch and a spur soldered low down upon the lingual surface of the band upon the lateral. The office of this ligature was partly to assist in carrying the incisor forward, but principally to effect its rotation. A notch in the rib of the expansion arch prevented this ligature from sliding forward and directed the movement of the tooth laterally, the arch being so bent that in shape and spring it bore toward the left and favored this movement, assisted reciprocally by the band, spur and ligatures upon the right lateral. The reason for placing the spurs well toward the gum, important in all such cases, is to resist the tendency of the arch to slide toward the cutting edges of the teeth. This tendency is further opposed by crossing the strands of the ligature near the spur.

The right upper central was also encircled by a ligature which is prevented from sliding off the tooth by the band.

The form of the expansion arch was occasionally modi-



fied by bending to meet the requirements of the moving teeth and prevent bunching.

Not until the incisors had been moved labially sufficiently for the full admission of the canines into the line of occlusion was any effort made toward elevating them in their sockets. This was also effected by enlisting the spring of the expansion arch. Wire ligatures were carefully worked beneath the gum and above the gingival ridges of the canines and given one full twist on the labial surface, followed by a final one-half twist with the pliers. One of the strands was then made to encircle the arch and united with the other strand by twisting, and the ends clipped down to the usual length. This period in the treatment is shown in Fig. 313, made from a study model taken in wax with the appliances in position.

Tension on the canines by the spring of the expansion arch was sustained by an occasional twist of the ligatures, first always pressing upward upon the arch with the finger in order to relieve the strain upon the ligature while twisting. The author no longer believes in forcing the eruption of the canines by mechanical means at this age of the patient. A wider experience has led him to adopt the conservative method, namely, to provide space and allow Nature to effect the erupting in her own way, simultaneously with the development of the previously arrested intermaxillary bones. Better results are thus gained.

The movement of rotation being the most difficult, it was delayed until the teeth were fully erupted to the line of occlusion, when the spurred band, wire ligature, and wedges of rubber were applied after the usual manner for accomplishing the movement, and soon brought about the desired results.

Owing to the lingual inclination of the crowns of the lower incisors no bands were necessary, the ligatures simply encircling the expansion arch and crowns of the teeth. The lateral pressure from the teeth prevented the



ligatures from sliding off. It will be noted that a notch in the ribbed arch directed the movement of the canine laterally as well as labially.

The slight necessary rotation of the second left premolar was accomplished by bands, spurs, ligatures, and rubber wedges, as already described, as soon as the anterior teeth had been moved into correct position to reduce the crowding and permit it to turn.

The teeth of the upper arch were retained in their new positions by a section of wire G soldered to the mesiolingual angles of bands on the canines and made to bear against the lingual surfaces of the intervening incisors, as in Figs. 233 and 322.

The tendency to rotate of the lower canine and the lingual tendency of the incisors were antagonized by a similar device, and the canine was retained by a band and spur, the end of the spur bearing upon the labial surface of the first premolar, as in Fig. 235.

Fig. 314 shows the upper model of the case at the beginning of the period of retention, and Fig. 315 shows the occlusion nearly two years later, and it is interesting to note, by comparing the two engravings, what a marked change has occurred in the alveolar process in the region of the incisors. Nature unaided has shifted the roots of these teeth to closely approximate their ideal positions.

Figs. 316 and 317 represent the face of the patient at this time, and the improvement in the facial contour is very noticeable and gratifying.

In the treatment of similar cases belonging to this class great care should be observed to avoid the displacement of the molars when used as anchorage, and always to carefully maintain their normal mesio-distal relations. Fig. 318 shows the result in a case where this precaution was not observed. The force necessary in moving the incisors and premolars of the lower arch into harmony with the line of occlusion has been so great as to cause a noticeable



movement of the right first lower molar, and the establishment of mal-relations of all of the teeth in this lateral half of the arch. Before the advent of the Baker anchorage

FIG. 314.

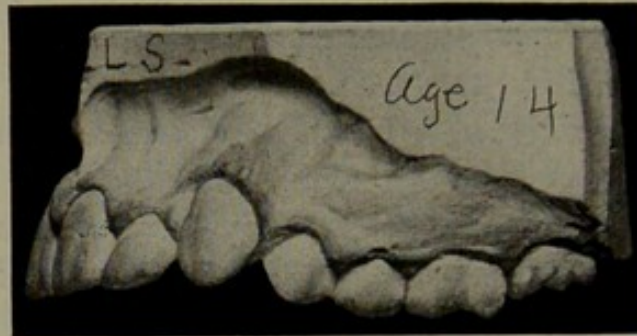
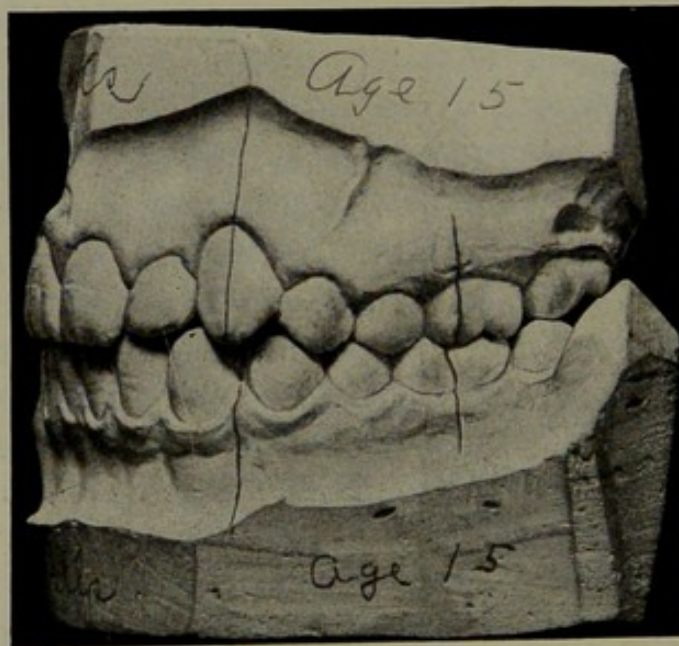

FIG. 315.



this was a common accident in treatment of cases of this kind, and one difficult to avoid, but it is now inexcusable, for by prompt detection and the timely application of intermaxillary force (see page 255) such unfavorable movements may be easily prevented.



FIG. 317.



FIG. 316.

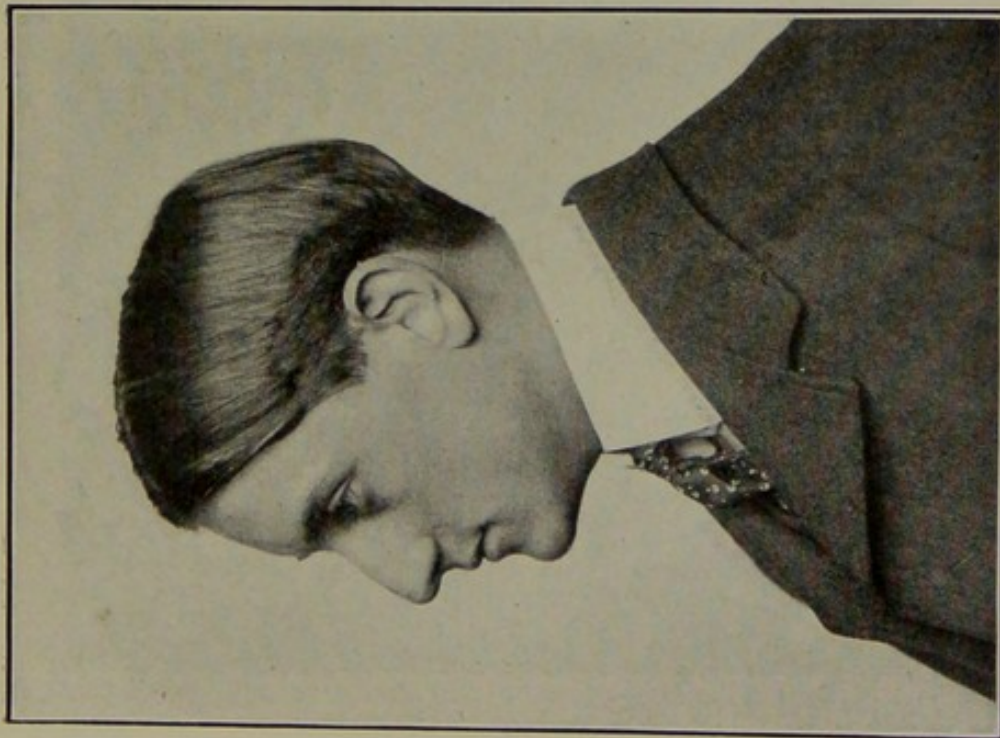




FIG. 318.

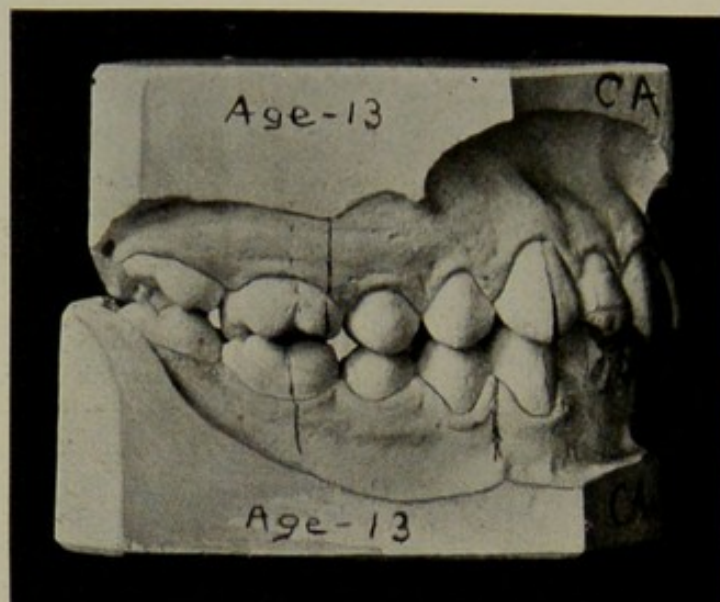
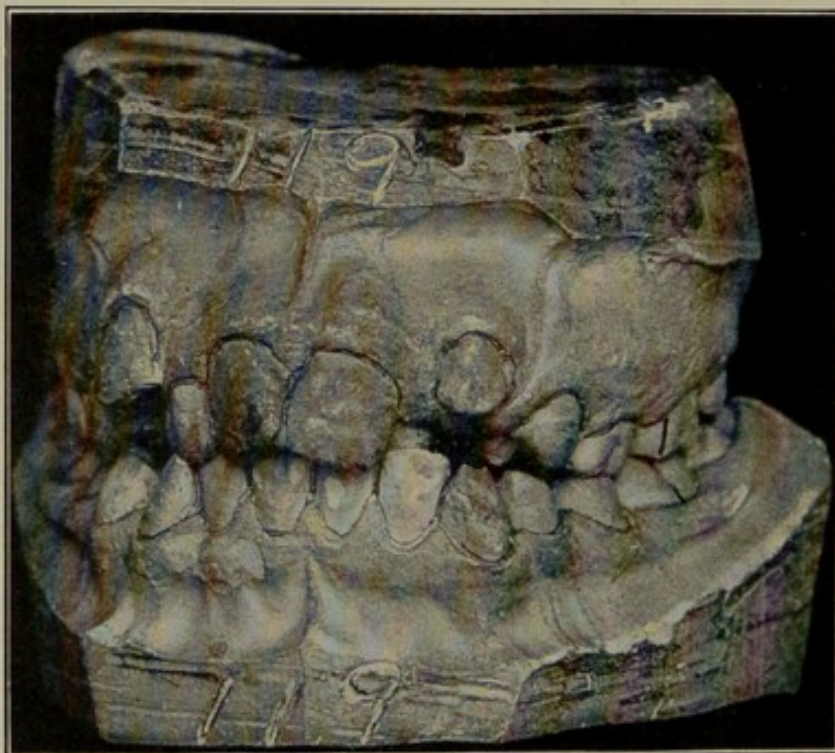

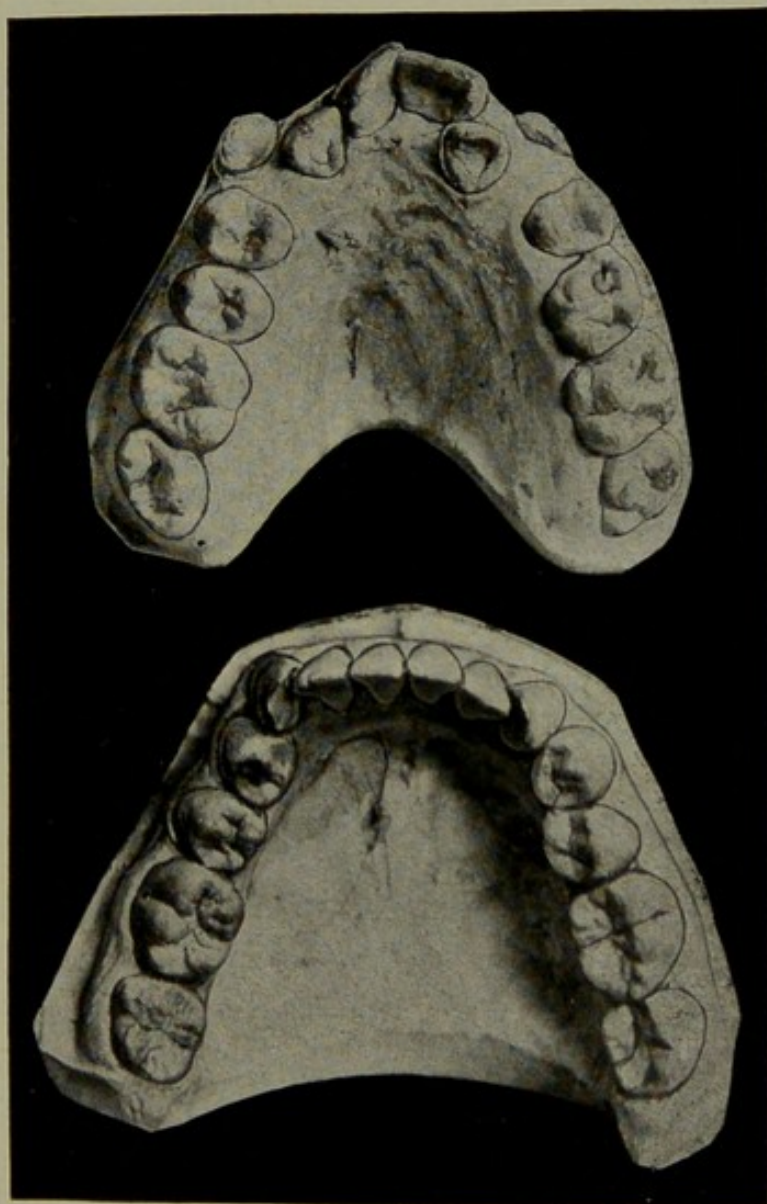
FIG. 319.





In Fig. 319 is shown another case belonging to this class which is represented from the labial aspect, while Fig. 320 shows the occlusal surfaces of the teeth of both arches.

FIG. 320.

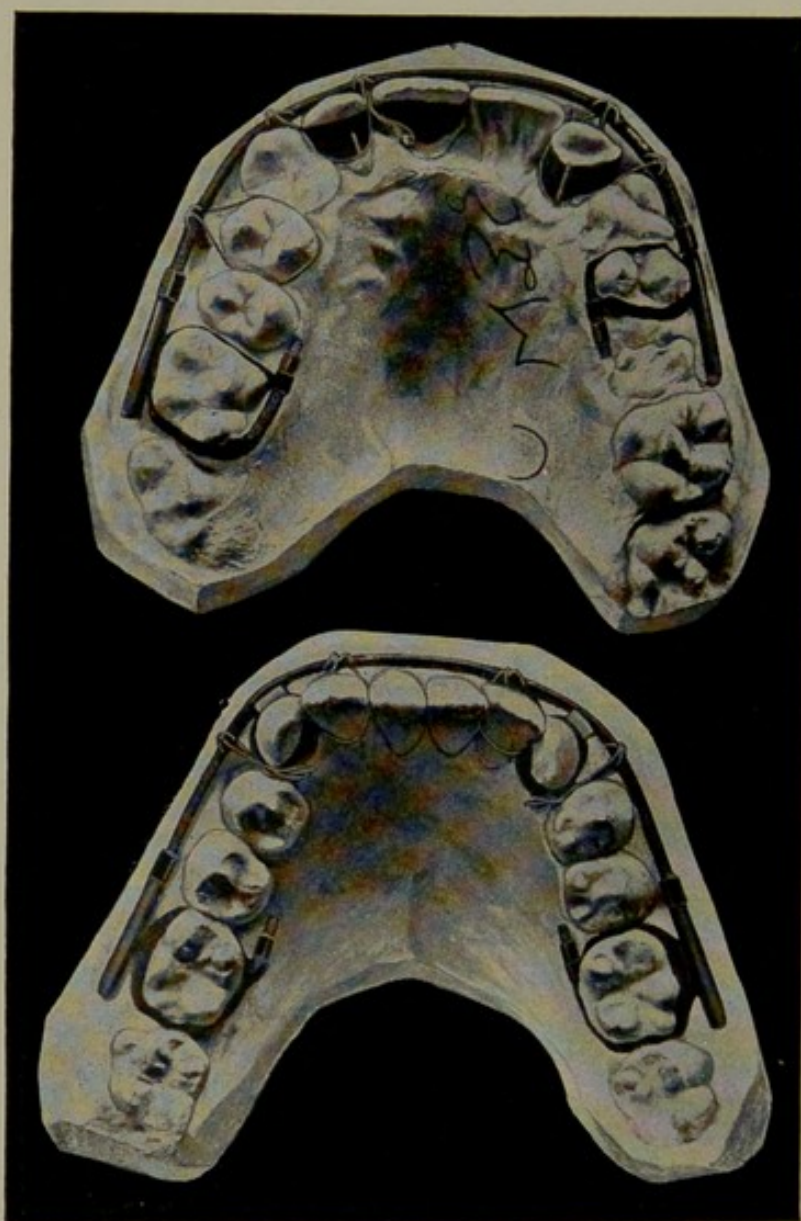


From the positions of the mesio-buccal cusps of the upper first molars relative to the lower first molars, the case is readily diagnosed as belonging to the class under discussion.



The patient was a lad aged thirteen. The strongly developed canines are erupting and have forced the lateral incisors lingually and the centrals into torso-occlusion,

FIG. 321.



while all the lower incisors, though quite even, occupy positions lingual to normal, and the canines are in torso-distal occlusion.

Fig. 321 illustrates a study model of the case made with



the appliances in position. It shows the upper incisors being moved labially *en masse*, by means of the expansion arch, ligatures, and spurred bands, the spur and ligatures acting upon the right central to effect rotation at the same time. It will be noted that the deciduous second molar has been removed and the anchor band X placed upon the first premolar, not in order to secure greater anchorage than that which would be derived from the first permanent molar, but because it was desired to shift the premolar distally somewhat to assist in gaining much needed space for the canine. The loosened temporary molar was not removed, nor change in the anchorage made until sufficient anchorage from the firm permanent molar with a D band had been utilized to move the incisors forward to nearly their correct positions.

The arch was bent to accentuate the labio-buccal movement of the left lateral incisor, the force being reciprocated from the first premolar on the right through its attachment by the ligature, as shown.

The disto-torso-occlusal position of the lower canines here shown is the malposition most often assumed by them, and as their movement is unquestionably one of the most difficult to perform they are too often left undisturbed. But as we now know that there must be complete harmony in the sizes of the arches in order to insure permanency of corrected occlusion, and also that the lower arch is the pattern for controlling the size and form of the upper arch, how important does it appear that these teeth be moved forward and turned in their sockets in all cases, that they may do their part in establishing the full size of the arch. The canines then, as they should, become as keystones not only in the lateral halves of their own arch but in a degree in those of the upper arch, through occlusal influence. Otherwise we must expect a corresponding diminution in the size of the upper arch, with a bunching of the teeth through the influence of the lips.



It must be remembered that space for their accommodation must always be provided before rotation will be possible. They must, therefore, be carried forward until their distal angles shall be free from interference with the mesial angles of the first premolars. To insure this in this case notches were made well forward in the ribbed arch to prevent the ligatures from slipping as the nuts were tightened, as in Fig. 199. In these cases the author has often used with advantage two wire ligatures, one exercising force mesially and the other laterally, directed by notches in the rib of the arch. In this way the most stable attachment is gained and a power exerted equal to the direct application of a jack-screw. With no other form of ligature would it be possible to exert pressure upon the tooth in so effective a manner.

After the canines were moved forward sufficiently to be free from the premolars their rotation was expeditiously effected by occasional tightening of ligatures in the usual manner, the spring of the arch being kept constant by wedges of rubber stretched between it and the tooth bands, as properly shown in the engraving.

The author believes this to be the most powerful and practicable means known for performing these oft-needed movements. If analyzed, it will be seen that the appliance is only a series of levers, made to act in the most effective manner on pure mechanical principles, combining reciprocal and simple anchorage, while permitting the most perfect control over the direction of movement.

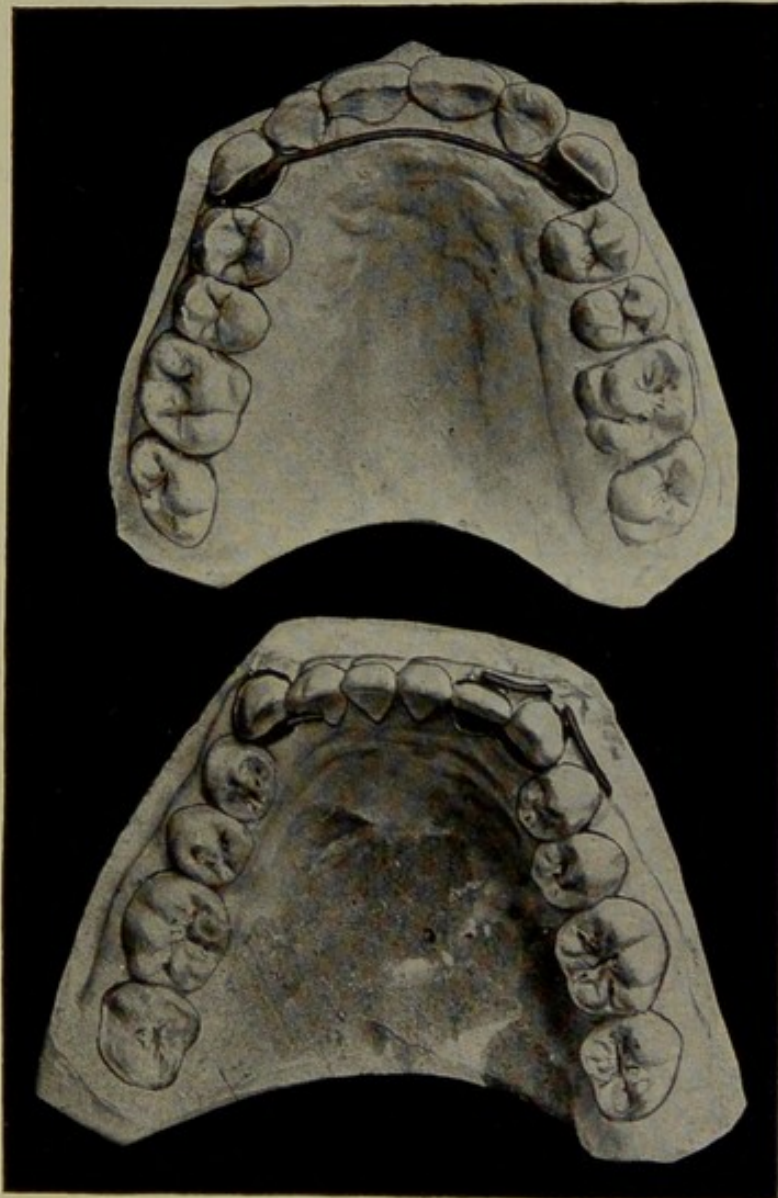
Fig. 322 shows the teeth after they have been moved into harmony with the line of occlusion, with the retaining devices in position.

By studying the original positions of the teeth, together with their corrected positions in this engraving, it will be seen that the connection of the upper canines by bands and a section of wire G, as in Fig. 233, not only resists their torso-labial tendency, but that their infra-occlusal tendency



is also resisted by the resting of the wire upon the linguo-  
gingival ridges of the laterals, whose lingual tendencies  
are in turn resisted by the wire, while their mesial ten-  
dencies are resisted by the centrals. At the same time the

FIG. 322.



laterals prevent the rotation of the centrals by contact with  
their disto-lingual angles, while the mesial angles of the  
centrals are prevented from moving labially by the ten-  
sion of the fibers of the peridental membrane, care having



been exercised to preserve this tension by exerting force for their proper rotation only on their disto-lingual angles. Had they been moved labially before rotation, there would also have been mesial disturbance of the fibers instead of distal disturbance only, necessitating their retention by two bands united by spurs. Much advantage is often to be gained by the intelligent manipulation of the fibers of the periodontal membrane during tooth movement.

The lower right lateral and canine were retained each by a single band and spur, preventing their torso-distal displacement. Of course the same effect would have resulted from soldering the bands together, with one spur only from the band on the canine bearing against the buccal surface of the first premolar; but as the bands were to be worn in this case for nearly two years the difficulty of adjusting both so that one of them would not become loosened and cause injury to the enamel made the plan objectionable.

There is another decided advantage in the use of spurs in all such cases, in that the finer adjustment of the teeth may be easily effected after the application of the retaining devices by stretching a piece of rubber between the anchor tooth and spur to create a leverage, and on the subsequent removal of the rubber wedge, bending back the spur to hold the tooth in position. This simple and very efficient method of effecting such slight movements of teeth as are often necessary on account of slight relapses during retention, must be taken advantage of almost daily by the orthodontist, thus often obviating the necessity for the reapplication of the regulating appliances.

Figs. 323 and 324 represent the occlusion and facial lines of this patient three years after treatment.

Attention is again called to the development to normal contour of the alveolar process in the region of the apices of the roots of the upper incisors consequent upon the establishment of normal occlusion and function of the teeth. It will also be noted that the retention of all of the



FIG. 323.

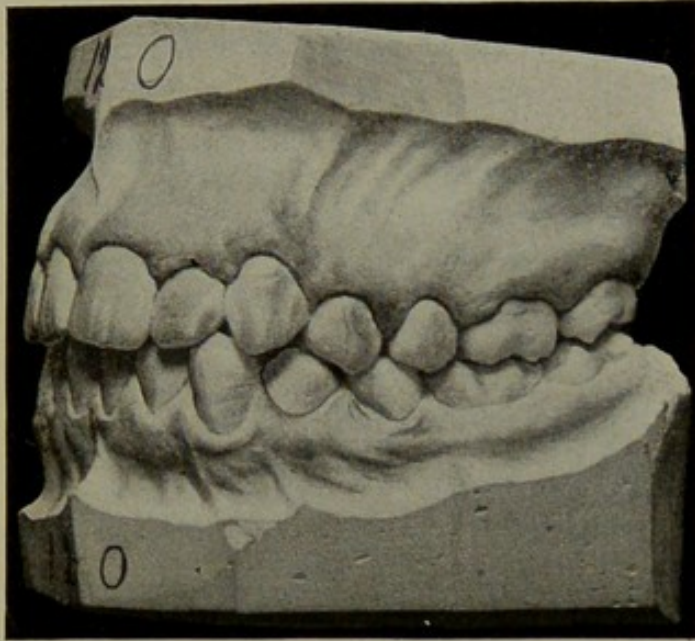



FIG. 324.





teeth has not caused undue prominence of the lips, which are seen to be in harmony with the other lines of the face,

FIG. 326.

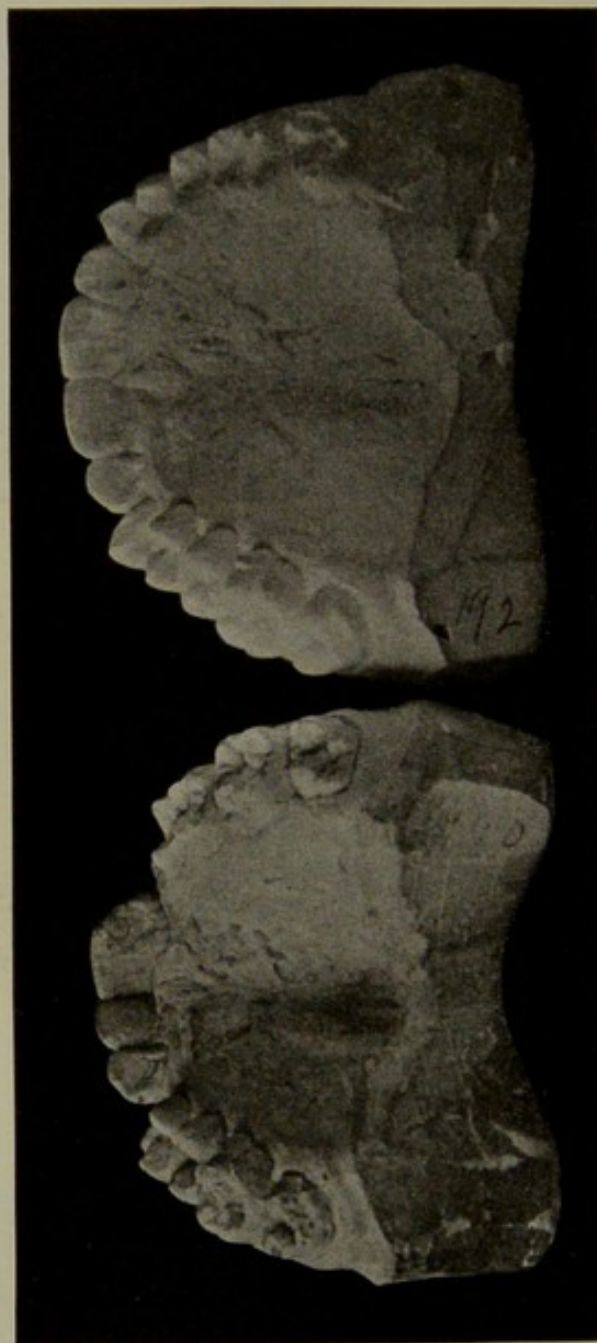

FIG. 325.

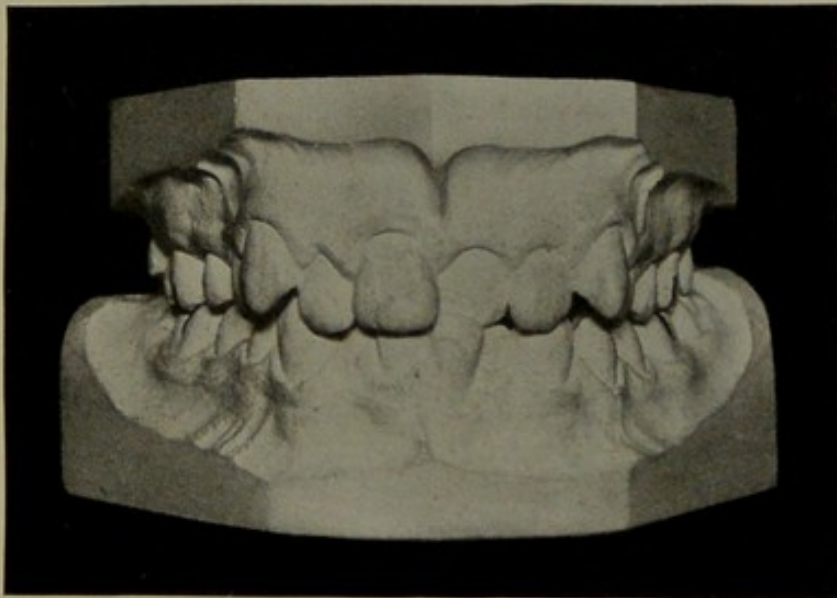
but that it is a far finer result than could possibly have followed that most unwarranted practice of sacrificing one or two teeth from each arch to gain space.



By comparing the two upper arches shown in Figs. 325 and 326 the great change that has taken place in the form of the vault of the arch is seen. This marked enlargement offers many added possibilities to the tongue in speech and song, and in assisting mastication. It also greatly benefits the nose, and might, we think, lend much interest to the rhinologist and offer him food for reflection.

Figs. 327, 328, and 329 show another of the ever varying forms of malocclusion which the incisors may be forced

FIG. 327.



to assume incident to the difficulties of eruption and locking. The relations of the jaws and first molars at once determine the class to which the case belongs and clearly indicate the required treatment which consists of the proper enlargement of the arches so as to afford to each tooth its full normal mesio-distal relation in the arch.

This was easily accomplished by means of expansion arches (plain arches being used as no lateral deflection of force was needed), both upper and lower being applied in the usual way and operated simultaneously.

While the upper incisors were being carried forward and



FIG. 329.

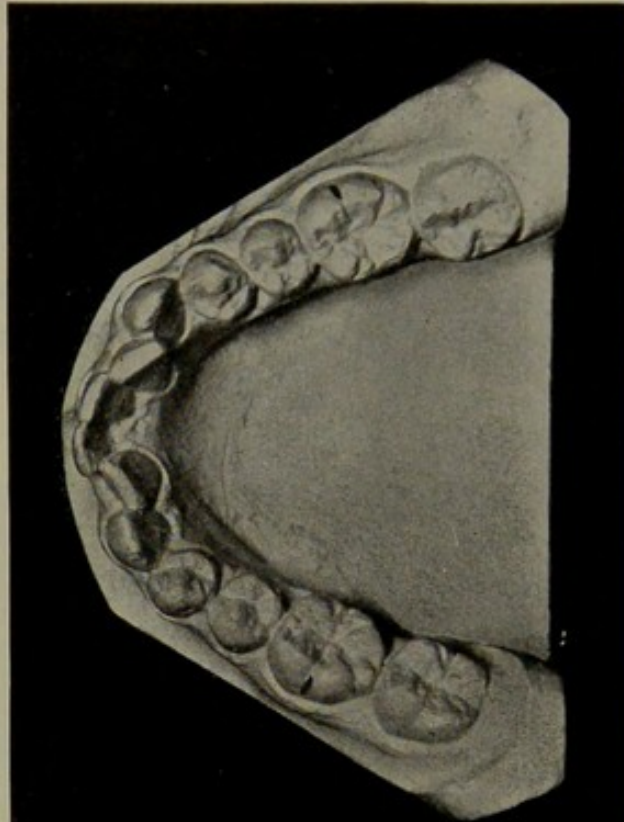


FIG. 328.

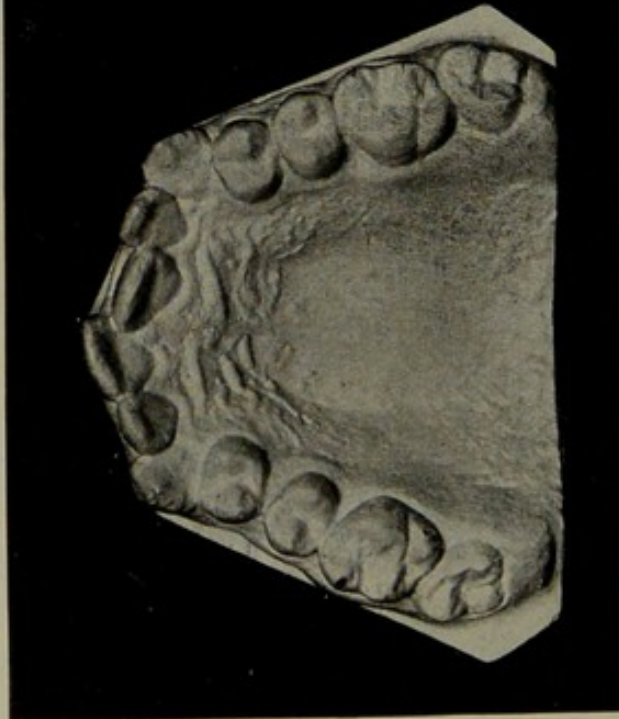




FIG. 331.

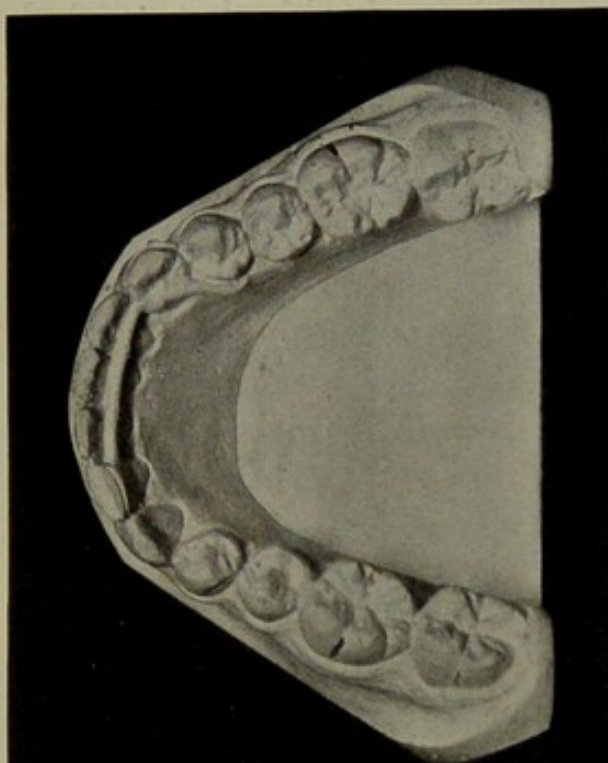
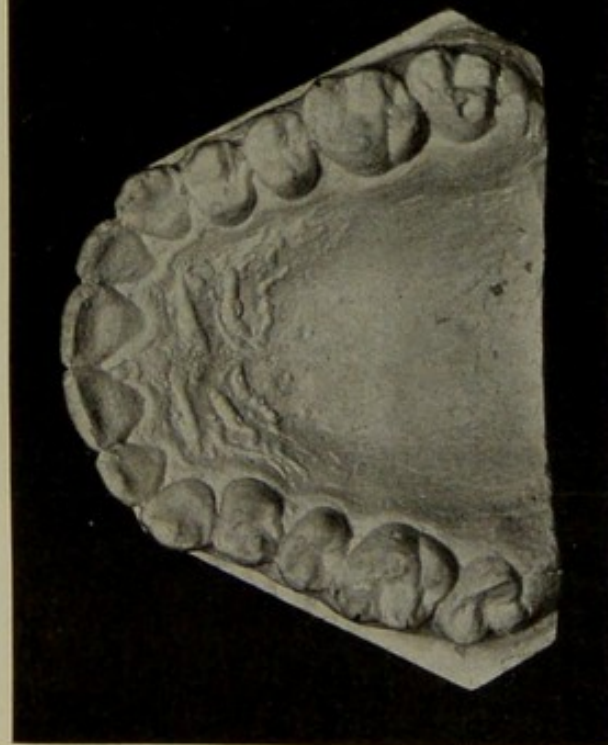

FIG. 330.

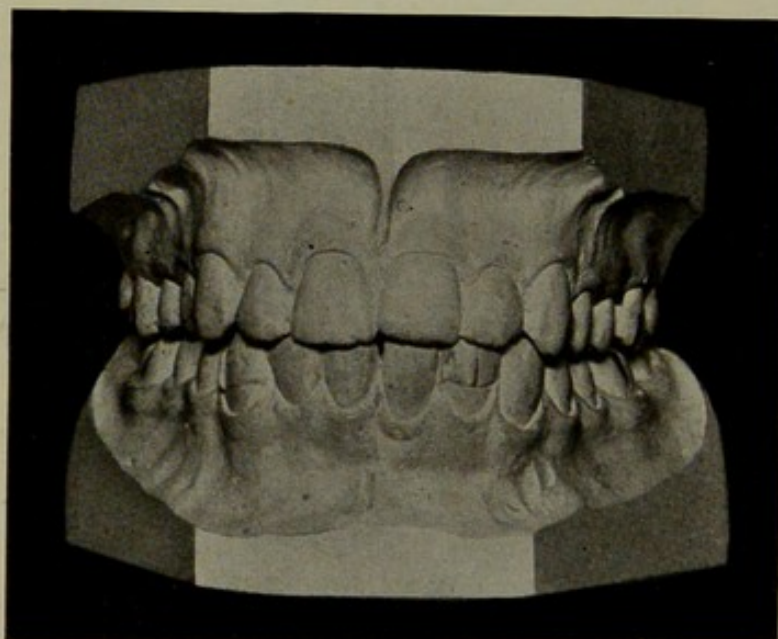




the first premolars moved buccally, the canines were given slight lingual movement through the force exerted by the expansion arch made to bear against their labial surfaces. The lower incisors were moved forward and laterally, as well as rotated, by means of bands, spurs and ligatures adjusted and operated as elsewhere described. Likewise the canines were rotated. The patient was seen once a week and increased tension given, first, by renewal or tightening of the ligatures, giving each as much tension as it would bear, immediately followed by slightly tightening the nuts anterior to the sheaths of the anchor bands.

The correctly adjusted teeth are shown from their occlusal aspects in Figs. 330 and 331, and in occlusion in Fig. 332.

FIG. 332.



The device employed for retaining the lower incisors is shown in Fig. 331. It consisted of a section of the wire G soldered to bands on the left lateral and right canine, with an additional spur soldered to the lingual surface of the band on the canine made to bear against the lingual surface of the first premolar. It will be seen how the teeth are



FIG. 334.



FIG. 333.





FIG. 336.

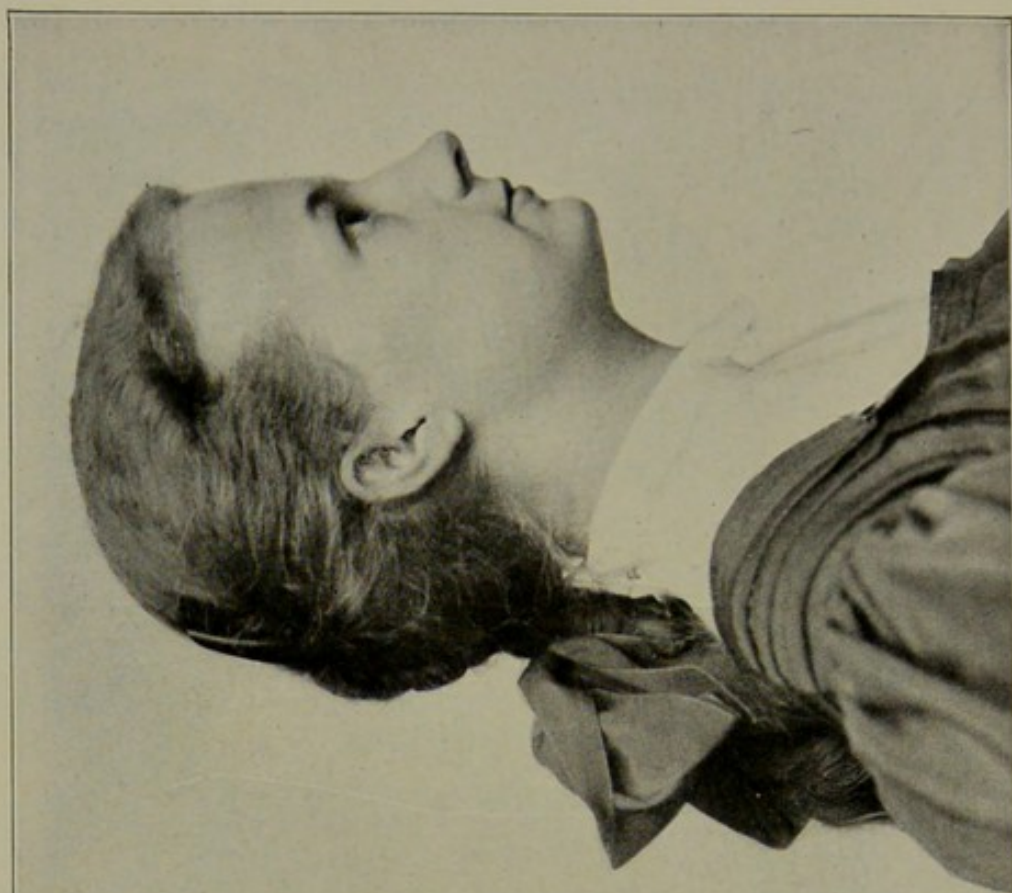
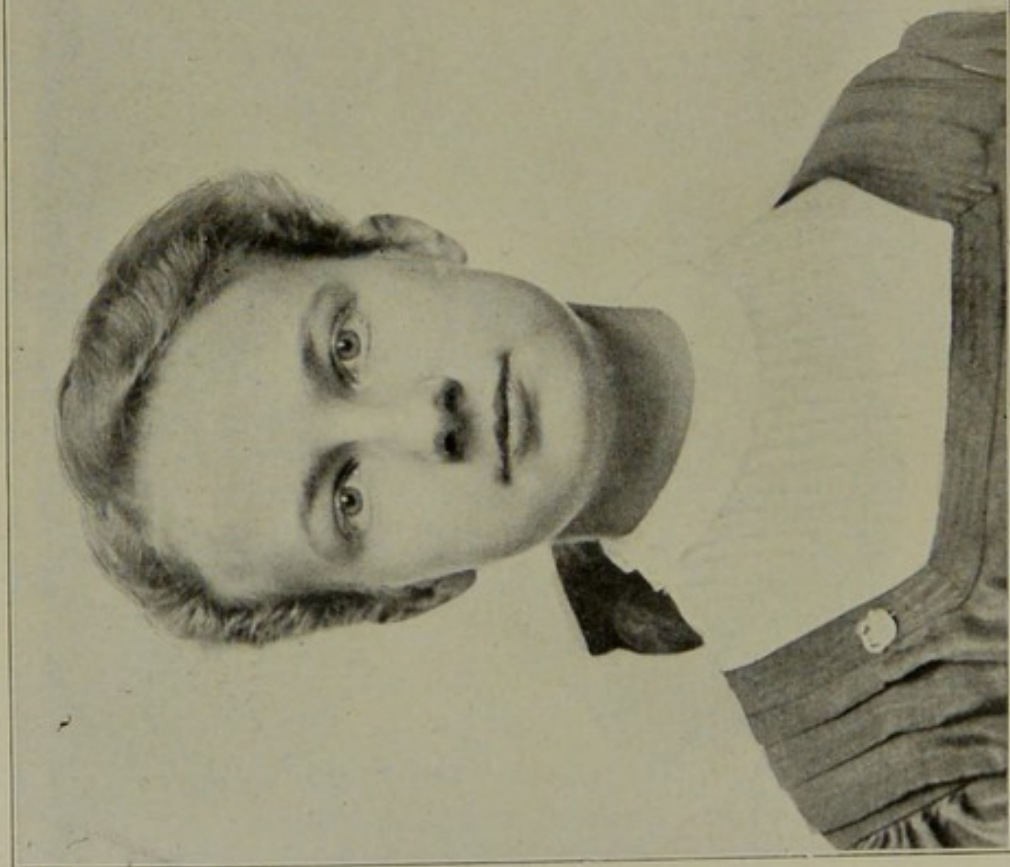
FIG. 335.

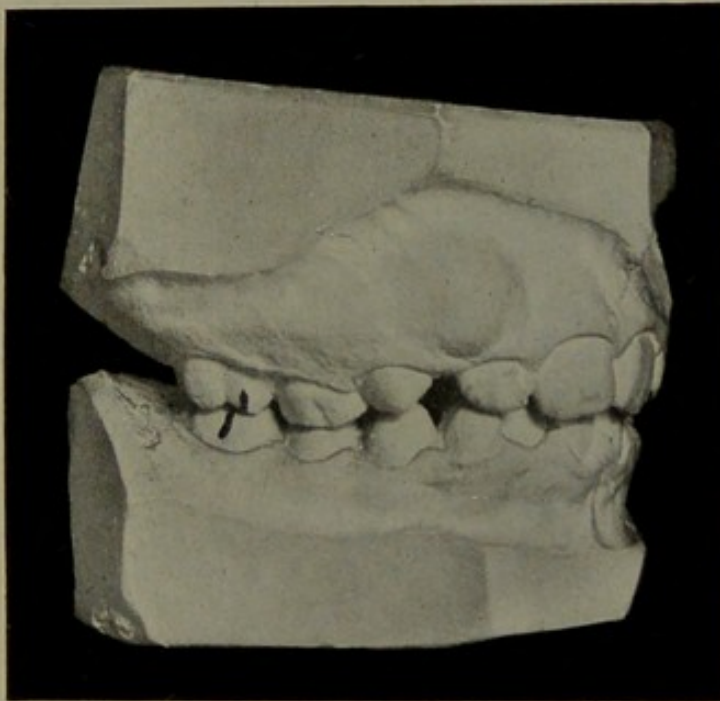




securely and harmoniously held in their new positions by this device. After it had been adjusted for a few days it was found that the wire connecting the bands was not quite long enough to prevent lateral pressure upon the central and right lateral and that they had consequently been forced to slightly overlap. This was easily remedied by two or three pinches of the wire with the regulating pliers.

The retention of the upper anterior teeth was effected

FIG. 337.



with the device shown in Fig. 233, with spurs soldered to the disto-lingual angles of the bands and made to bear against the lingual surfaces of the first premolars. This was found sufficient for the retention of the upper teeth on account of their favorable relations with the lowers. The lower retainer was worn for fully a year and a half.

The changes in the facial lines due to treatment are well shown by comparing Figs. 333 and 334, from photographs which were taken at the beginning of treatment, with Figs. 335 and 336, taken a few months after retention.

Fig. 337 illustrates the mal-relations of the teeth in



another case belonging to this class (the patient aged

FIG. 339.

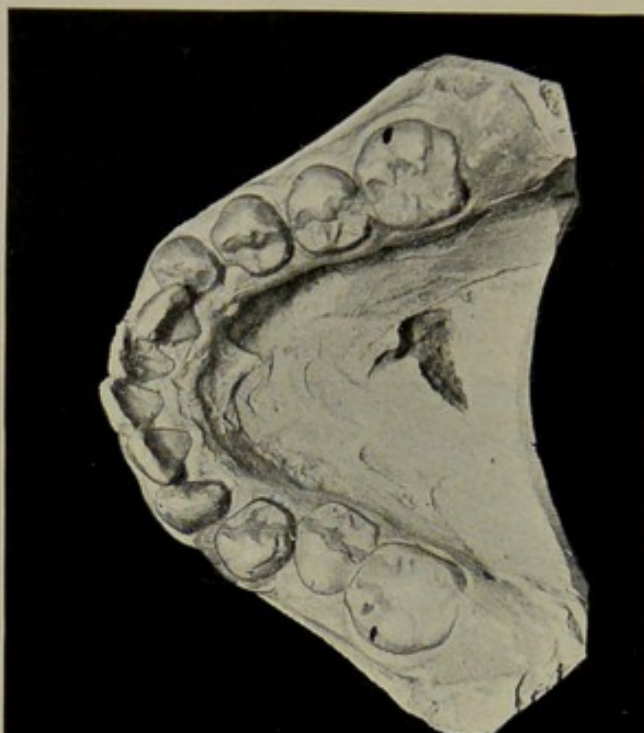
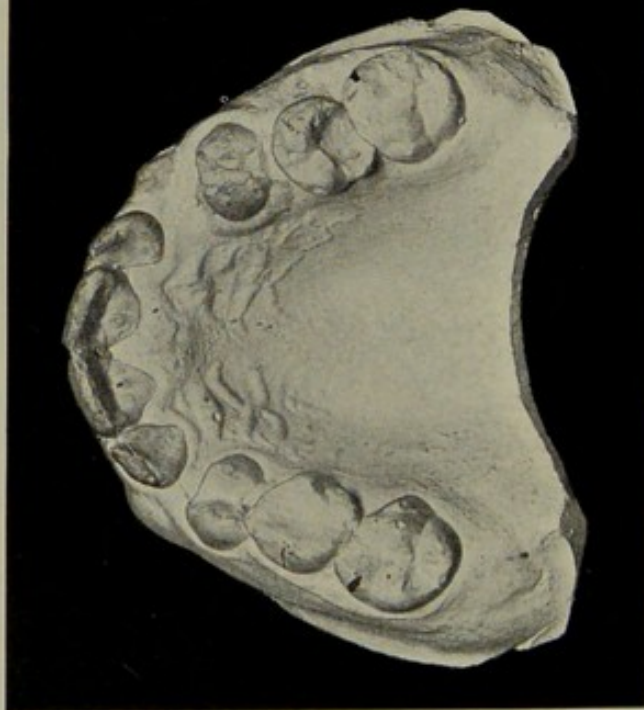


FIG. 338.



twelve), and Figs. 338 and 339 show the teeth from the occlusal aspect.



The premature loss of the upper deciduous canines permitted the rapid shortening of this arch until Nature's intended space for the permanent canines was greatly diminished. The principal resistance to the lingual movement of the incisors being gone, they were rapidly tipped downward and inward through the powerful force exerted by the lip, and made to exert an unnatural force upon the lower incisors which caused a bunching of the teeth of the lower arch and forced the mandible distally somewhat. That this has resulted is shown by the relations of the first molars on the right side. The unnatural distribution of force is rapidly intensifying these conditions which are augmented by the efforts of the upper canines to erupt. Had the full space of the deciduous canines, at the time of their loss, been preserved, the malocclusion would have been prevented to a large extent. It is easy to see how effectually Nature has been thwarted in her normal work of building the alveolar process.

The treatment clearly indicated was to enlarge both dental arches, carrying the incisors well forward and placing each malposed tooth in harmony with the line of occlusion, thus providing ample space for the eruption of the upper canines, and, by proper retention of the teeth, wait for Nature to continue the normal development of the alveolar process and effect the normal eruption of the canines.

The movements of the teeth were accomplished in the usual way, as already described in preceding cases, by the expansion arch, bands, ligatures, etc., the anchor bands being placed upon all four first molars.

Retention of the upper arch was effected by means of bands cemented upon the lateral incisors, connected by a section of the wire G soldered to their mesio-lingual angles and made to bear against the lingual surfaces of the centrals. The wire was also extended distally in the form of a goose-neck to engage the sulcus of the first premolars,



as in Fig. 225, in this way preserving the space required by the canines. The lower incisors and canines were retained as shown in Fig. 233. The lower second premolar was retained by a band and section of wire G soldered to its buccal surface, the end resting against the buccal surfaces of the first molar and premolar. The first molars on the right side were retained in their normal mesio-distal relations, as in Fig. 256.

FIG. 340.



There are certain questions of art as related to the face in this case which are of unusual interest. As the lips of the patient were somewhat thicker than is usual, the degree of the original deformity was partially disguised in the facial lines, which are shown at the beginning of treatment at Fig. 340; and at the time of retention the teeth inclined outward at their cutting edges so much, as a result



of tooth movement, and their apices were so much farther lingual than normal on account of arrest in the development of the intermaxillary bones, that over-prominence of the lips was manifest, as shown in Fig. 341, taken at this time, and indeed criticised by that eminent teacher of art, Mr. E. H. Wuerpel, who suggested that it probably would have been better to have resorted to extraction and thus avoided the necessity for such undue prominence.

FIG. 341.



But the author felt quite certain that conservative treatment, even in this quite exceptional case, was correct; that the unnatural prominence of the lips would prove to be but temporary, and that ultimately, as a result of the lips becoming modified to the new conditions and assuming their normal functions, together with the complete development of the alveolar process and bones of the head, there would finally be harmony of balance of the mouth and lips with the rest of the face.

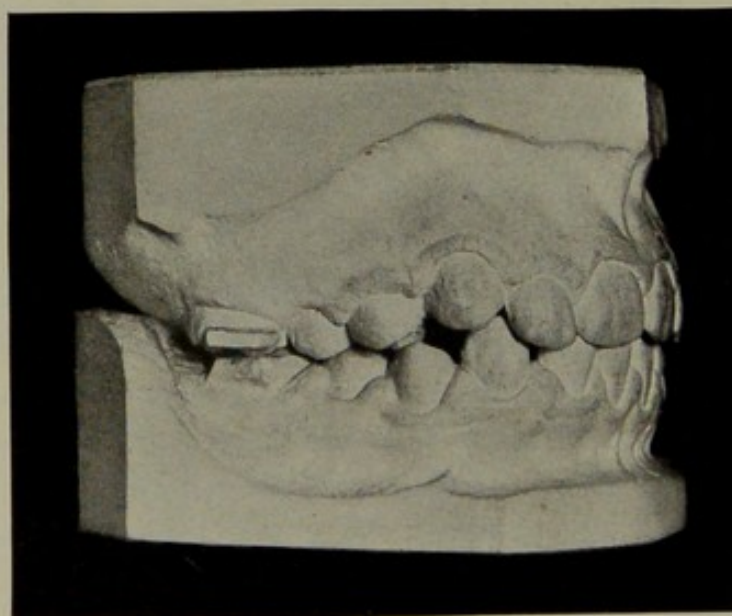


How well this belief has been verified is shown by Fig. 342, which represents the facial lines of the young lady

FIG. 342.



FIG. 343.



five years later than the picture last shown. We may also add that Mr. Wuerpel, upon seeing this picture, expressed



FIG. 345.

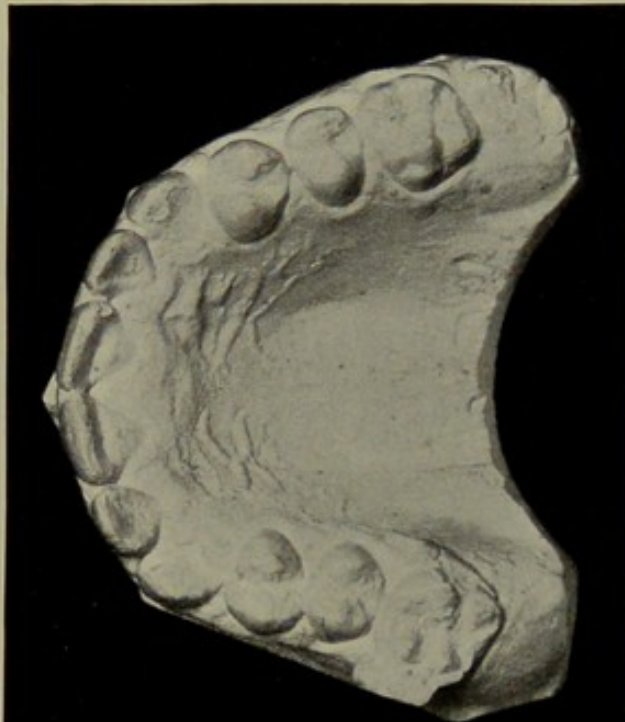
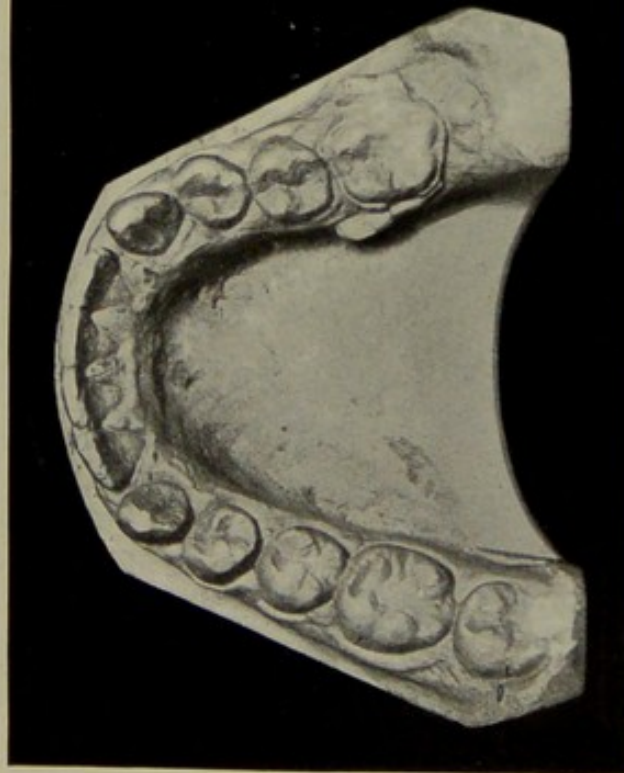


FIG. 344.





much surprise and pleasure at the pronounced improvement.

FIG. 347.

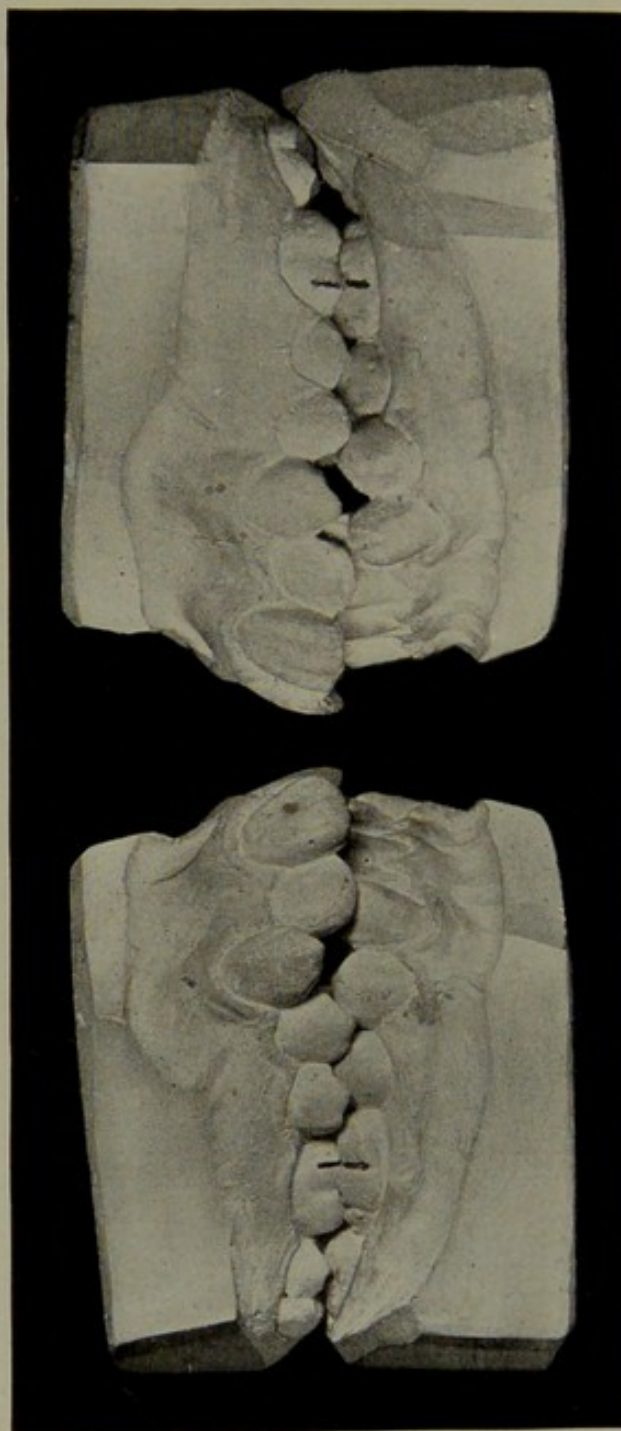


FIG. 346.

The growth of the alveolar process and occlusion of the teeth are shown as they appeared two years after the be-



ginning of treatment in Fig. 343, and the occlusal aspect of the teeth at the same time is shown in Figs. 344 and 345.

FIG. 349.

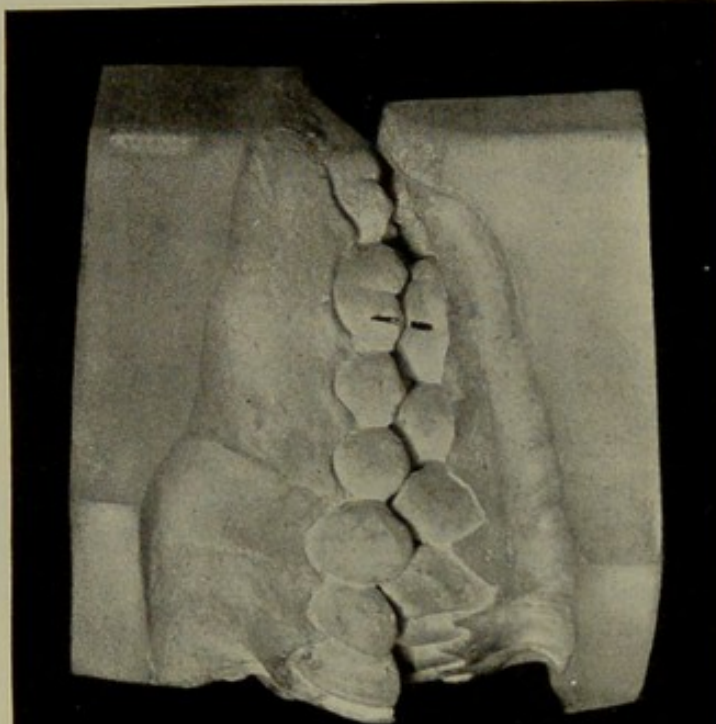
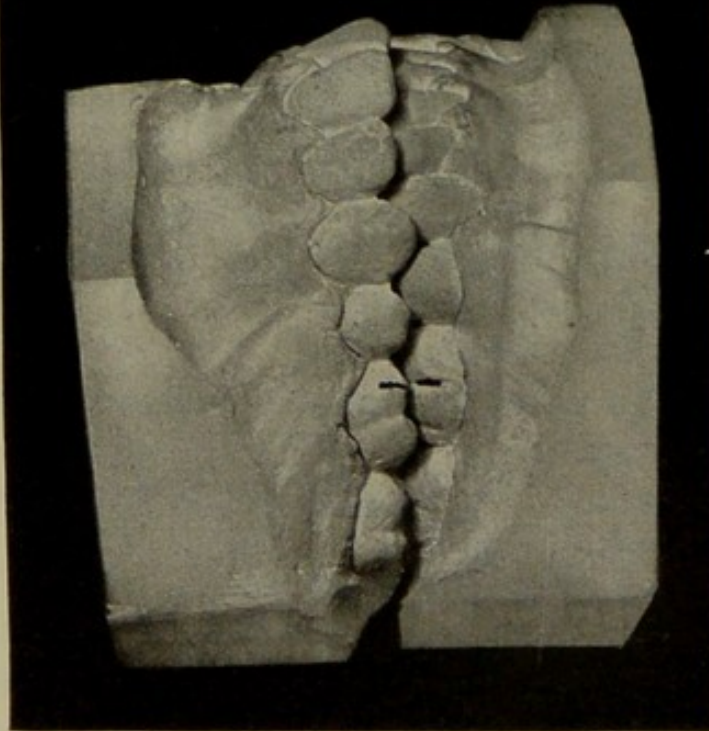


FIG. 348.



Bands are shown upon both upper and lower first molars in the last three pictures. They were to support the plane



and spur in the retention (Fig. 256) of these two teeth in their correct relations, as the tendency to return to their original positions of end to end bite was quite persistent.

The utter absurdity of the doctrine that demands the reduction of the typical number of teeth in order to prevent too great prominence of the lips is illustrated in the results shown in the next case, which was treated by the author

FIG. 350.



some years ago when he was still dominated by that pernicious teaching.

Figs. 346 and 347 show the occlusion from the right and left sides before treatment, and Figs. 348 and 349, after treatment.

By carefully studying the facial lines of the patient before and after treatment, shown in Figs. 350 and 351, it will readily be seen what a blunder was committed in the sacrifice of the first upper and lower premolars on the right side, as is plainly shown in the lack of the proper



fulness of the upper lip and the consequent most unpleasing angle between the nose and lip. The left side of the mouth in the region of the canine is far more pleasing than the right side, and this is easily understood by reference to the occlusion, for on the left side the occlusion is normal,

FIG. 351.



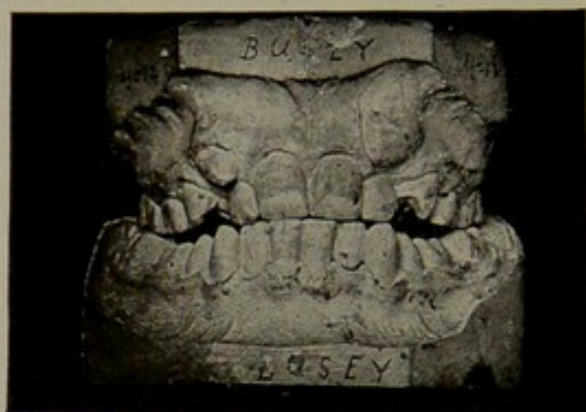while on the right side it is abnormal. The upper and lower right canines have been moved distally into the spaces made vacant by the loss of the first premolars, thereby shortening the right lateral half of both arches and placing the canines at an abnormal angle and relation with the lips, thus robbing the face of its typical contour and proper balance.

Fig. 352 shows the models of the teeth in occlusion, and



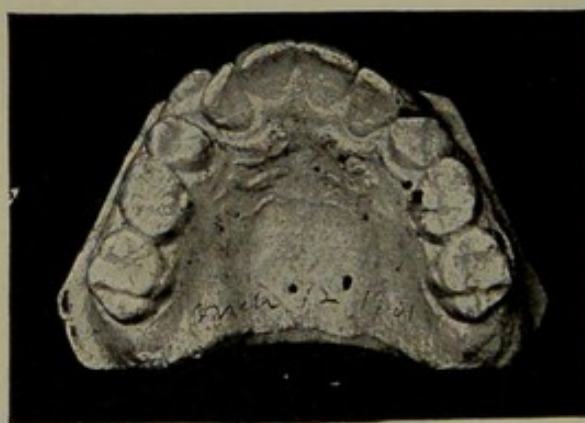Fig. 353 shows the occlusal view of the upper model, in the case of another girl, aged twelve, which is similar to that shown in Fig. 337 except that the constriction of the

FIG. 352.



upper arch is considerably greater. This case is especially interesting by reason of the complete arrest in the development of the alveolar process in the region of the intermaxillary bones, and is another glaring example of the unfor-

FIG. 353.



tunate result following the premature extraction of the upper deciduous canines.

As the type of this patient is entirely different from that of the one illustrated in Fig. 340, the lips being thin and the profile line almost straight, the effect of the malocclu-



sion is more noticeable, and the deficiency in the con-

FIG. 354.



FIG. 355.



tour of the mouth very apparent, especially manifest by the obtuse angle formed between the nose and the upper



lip, as shown in Fig. 354. A front view is shown in Fig. 355.

Who cannot see that this remarkable diminution of the dental arches from their normal size has produced a corresponding diminution from the normal in the contour of the face, and that the logical treatment demands that the arch shall be enlarged to its full normal size and the teeth retained until Nature shall have caught up, as it were, in her work of developing the alveolar process which has been so long arrested? Although this plan of treatment is so clearly demanded in the interests of occlusion and facial balance, its performance occasioned many misgivings, for never before had the author seen a case with the intermaxillary bones and alveolar process so deficient in development, and on account of the extreme lingual positions of the apices of the roots of the teeth, it became apparent that if their crowns were moved labially into harmony with the line of occlusion the angles of protrusion would be so great as to leave the teeth almost procumbent in the process,—this, as well as causing marked “open bite.” It also seemed doubtful whether Nature could or would supply the large amount of bone required for the normal positions of the teeth. Yet in fancy the author could see the most unfortunate result that must follow the extraction of four premolars, which would have been necessary in order to harmonize the sizes of the two arches. He could see the already reduced arches further reduced and the unnatural angles at which the canines would have to stand as they were moved distally to take the place of the first premolars; and the consequent restriction of the tongue and nasal passages coincident with the lack of development of the intermaxillary bones and vault of the arch, and more. As the rest of the bones of the face and head progressed in development, the author could realize how marked would be the ultimate deformity as the lack of proper contour of the mouth thus became gradually intensified. So he deter-



mined to pursue the conservative plan, having faith that if Nature were properly assisted the result, though pos-

FIG. 356.



sibly not ideal, would be far more desirable than if the invariable, time-honored custom of mutilation in such cases were resorted to.

FIG. 357.



It was decided to move the incisors forward only a part of the distance necessary to make space for the canines during the first period of treatment. There they were re-



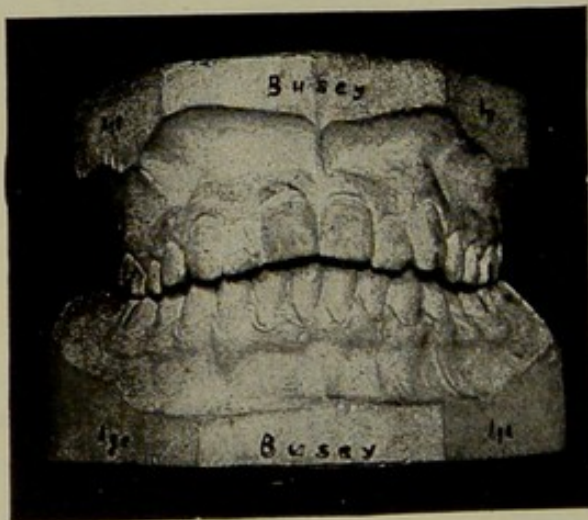
tained in the positions shown in Fig. 356 and the young lady dismissed for one year in order to allow the process to develop. The facial lines of the patient at this time are

FIG. 358.



shown in Fig. 357. Upon her return gratifying changes in the growth of the process and in the positions of the apices of the roots of the teeth were noted, yet it was still doubt-

FIG. 359.



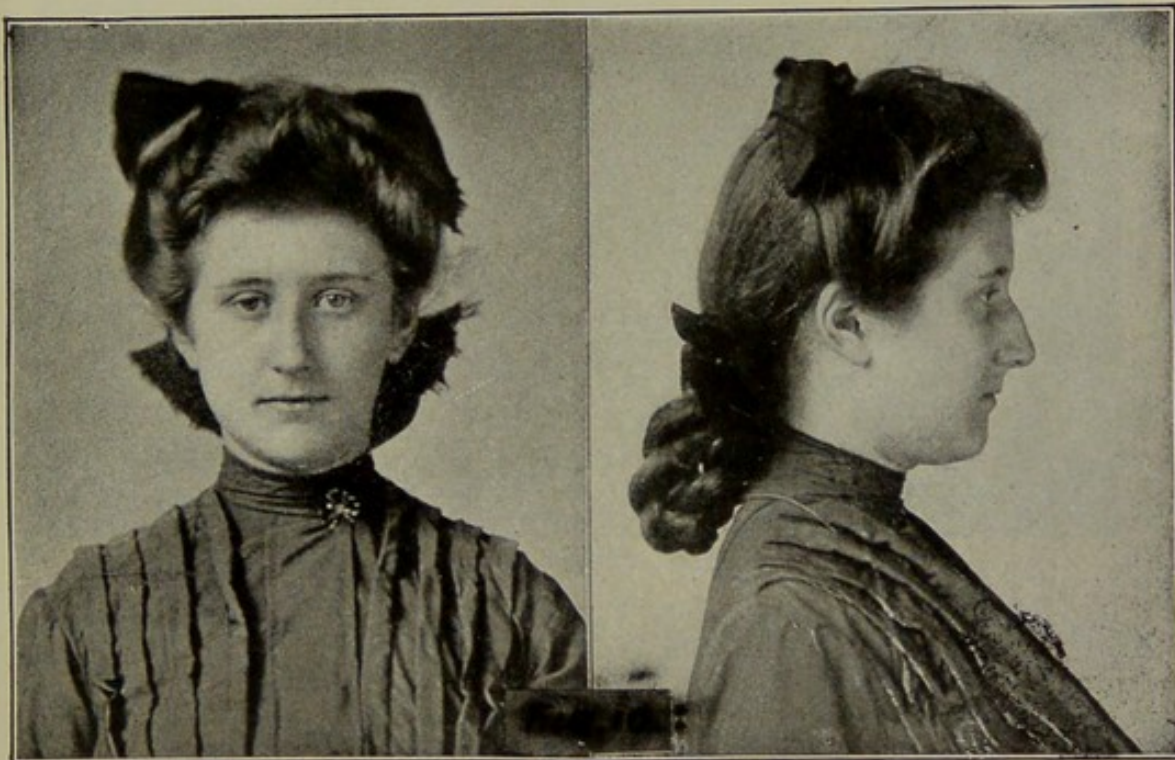ful as to whether the full normal amount of bone would ever be deposited. However, the incisors were then carried forward to correspond with their correct relations with the line of occlusion and the arch slightly widened, the



teeth retained, and the patient dismissed for another year. Upon her next return the results shown were indeed gratifying. The growth of the bone and process had been extensive, the teeth had moved downward so that the "open bite" had disappeared, and the apices of the roots of the incisors had been carried forward until the teeth had attained their approximately normal angle of inclination.

FIG. 360.

FIG. 361.



The occlusal positions of the teeth at this time are shown in Fig. 358 and the occlusion in Fig. 359, and the result upon the facial lines in Figs. 360 and 361. Although the face is still somewhat lacking in normal contour, it will doubtless continue to improve, as the author does not doubt that the growth of the intermaxillary bones and alveolar process will continue for some considerable time.

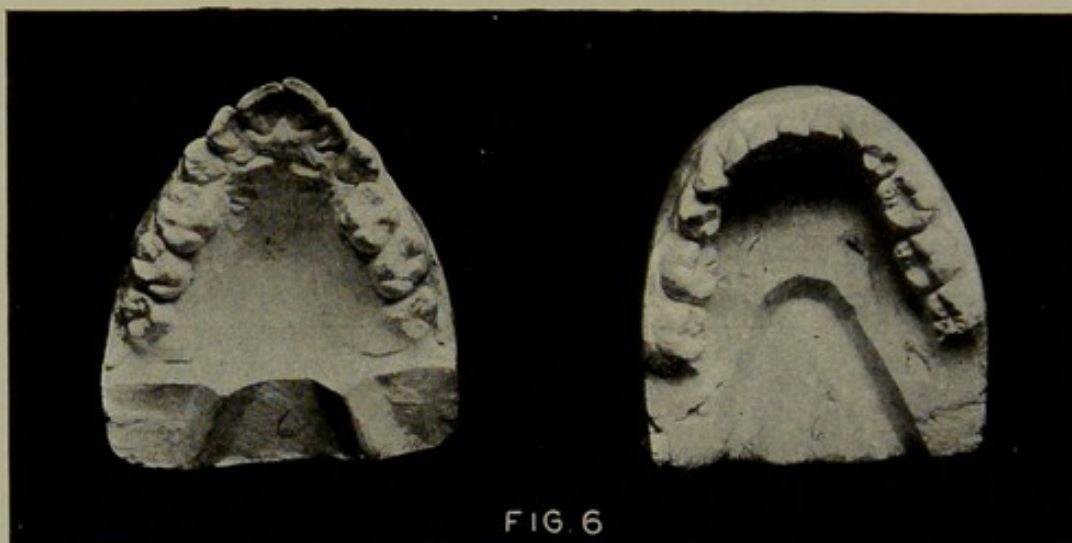
When we consider how promptly Nature has responded, and how generously the missing bone has been supplied in this quite remarkable case, and when we further consider



the results attained in occlusion and in art, and what would have been the results had mutilation been resorted to, it would seem that its practice in any such case should hereafter be regarded as but little less than criminal.

Let us contrast the results in the treatment of this case with those shown in Fig. 362.\* The case originally must

FIG. 362.



have been very similar to that shown in Fig. 352, but in order to harmonize the "large teeth with the small jaws" six beautiful premolars and one first molar were sacrificed resulting in complete chaos in the occlusion, or a far worse condition than could possibly have been present before treatment was begun, and with both speech and facial lines greatly and permanently impaired. The case, as here shown, is one of many similar cases in like condition, the models of which have been sent to the author for consultation.

Fig. 363 shows the occlusion of another case similar to that shown in Fig. 352, with nearly as pronounced arrest

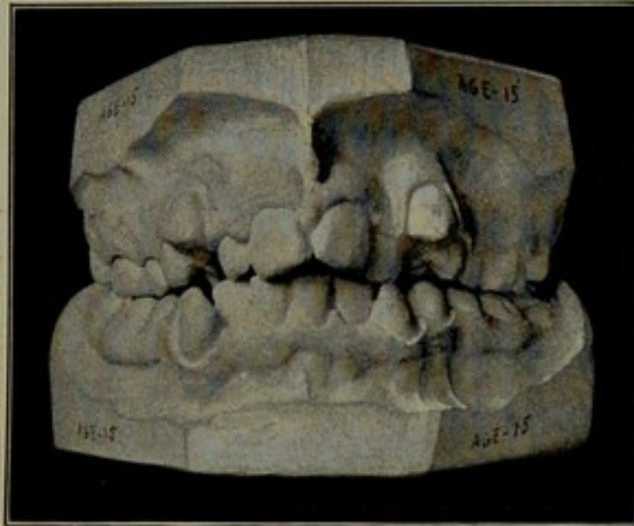
---

\* "The Orthodontia of the Old School," Hopkins. Transactions American Society of Orthodontists, 1904.



in the development of the intermaxillary bones, and Fig. 364 shows the face of the patient at the time of beginning

FIG. 363.



the treatment, and how greatly its natural beauty is marred by the malarrangement of the teeth.

FIG. 364.



Fig. 365 shows the occlusion after one and one-half years of retention, during which time marked growth in



the development of the alveolar process had taken place, although by no means yet complete.

FIG. 365.

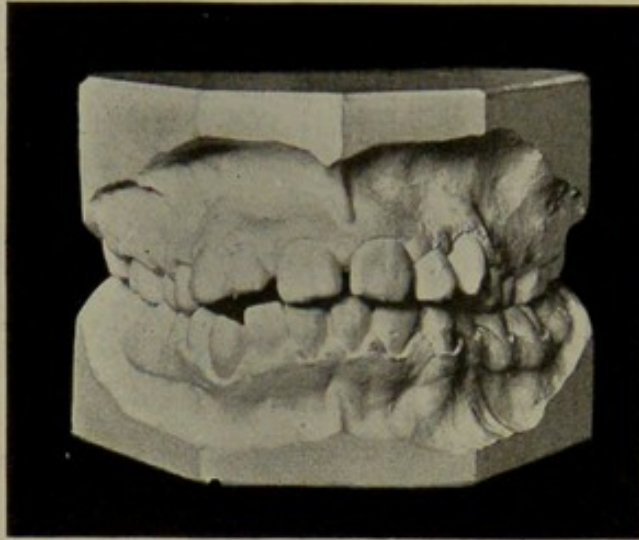


FIG. 366.



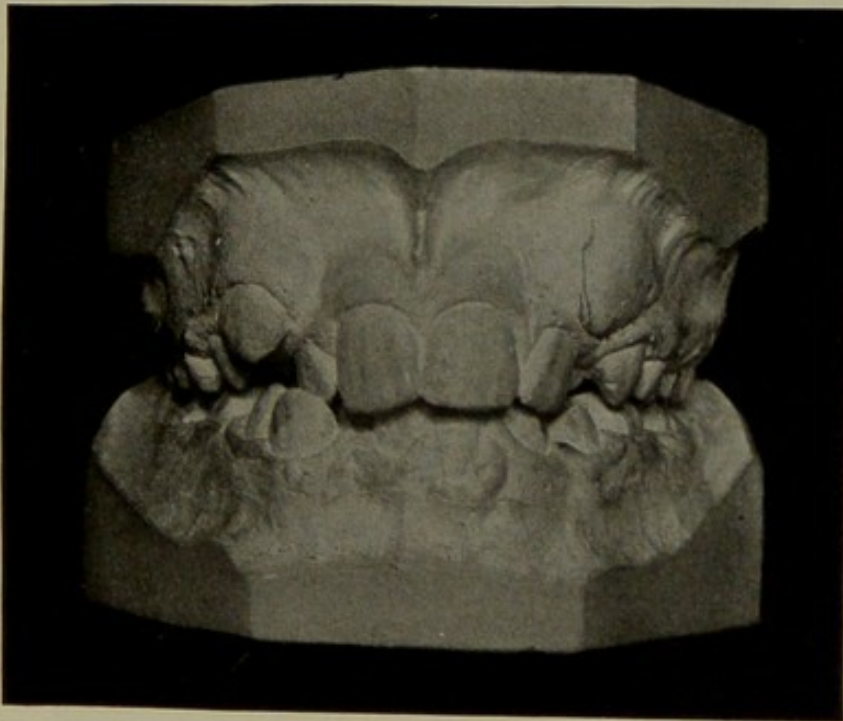
Fig. 366 shows the improvement in the facial lines after the lapse of another year and a half, or three years after



the beginning of retention. The teeth at this time were in fine occlusion, with normal development of the alveolar process. It would be hard to describe the pronounced improvement in the appearance of the patient following the correction of the malocclusion and the changes in the tissues incident thereto.

Figs. 367, 368, and 369, represent the occlusal relations of the teeth of a boy thirteen years of age, and Figs. 370

FIG. 367.



and 371 show the teeth from the occlusal aspect, and from the relations of the first molars the case is readily diagnosed as belonging to this class. The arrest in the development of the alveolar process is greater than in the case last described, almost the limit of possibility in the malocclusion seeming to have been reached.

The effect of this malocclusion on the facial lines of the patient, though very great, most unfortunately cannot be here shown, as through oversight his photograph was not taken at the time of beginning the treatment, and the



mistake was not discovered until treatment had progressed so far as not to permit of showing the original condition of

FIG. 369.

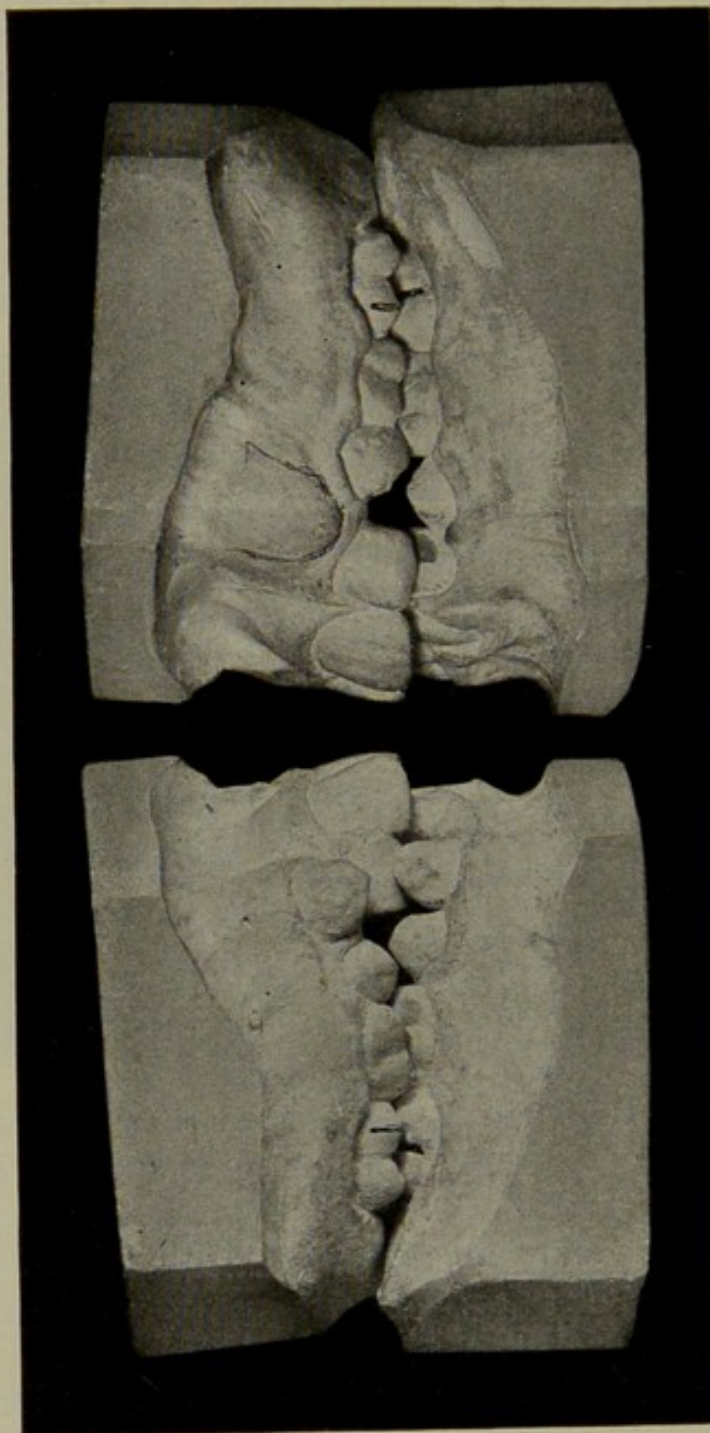


FIG. 368.

the facial lines. The author would here emphasize the importance of vigilance on the part of the orthodontist on this point in order to avoid like serious losses.



Fig. 371.

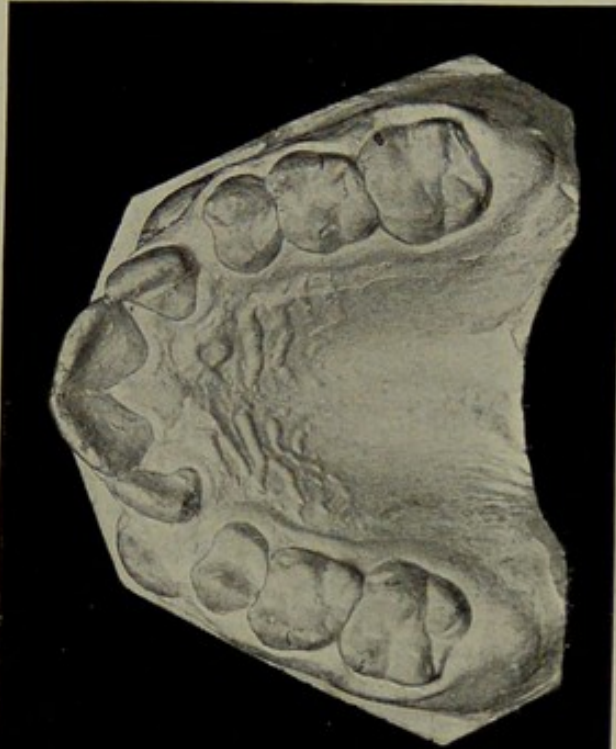


Fig. 370.

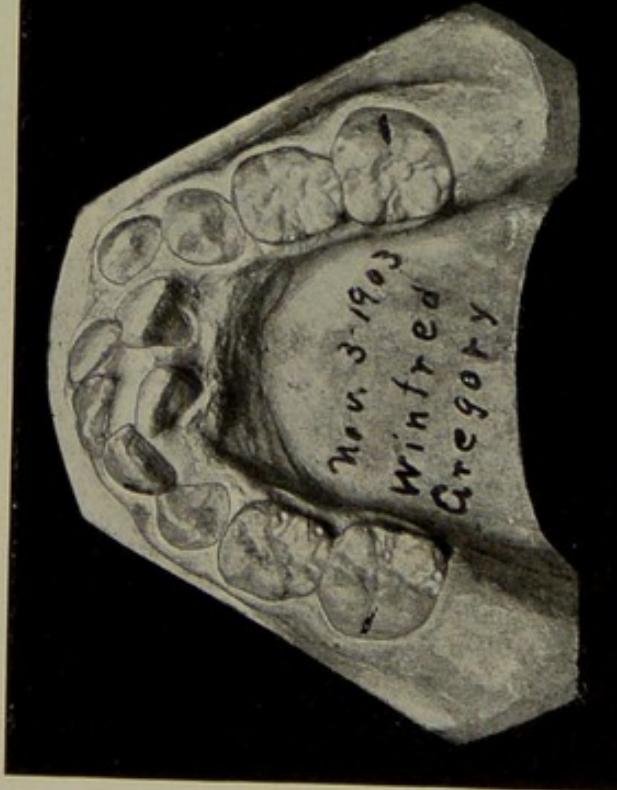



FIG. 373.

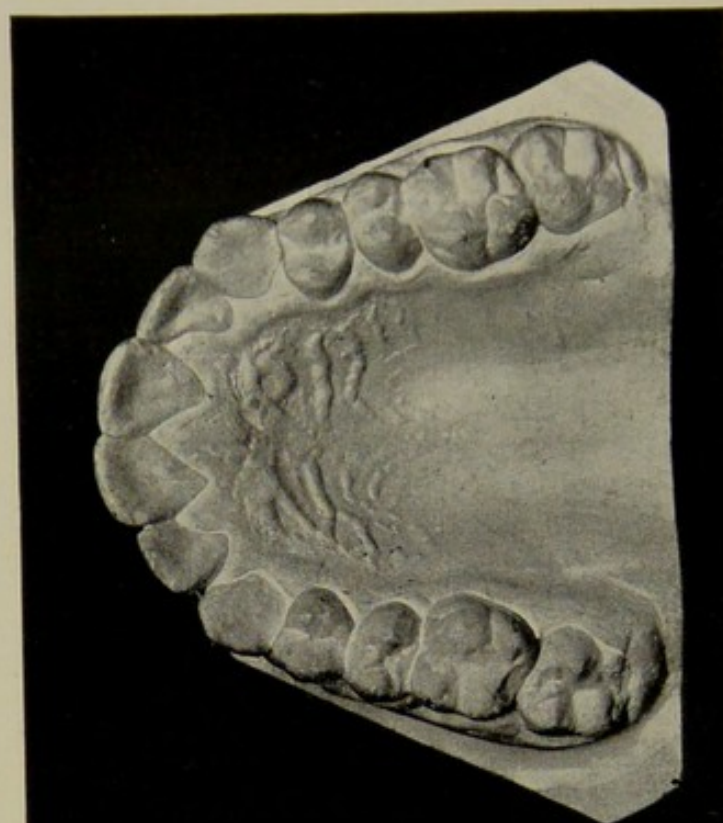


FIG. 372.

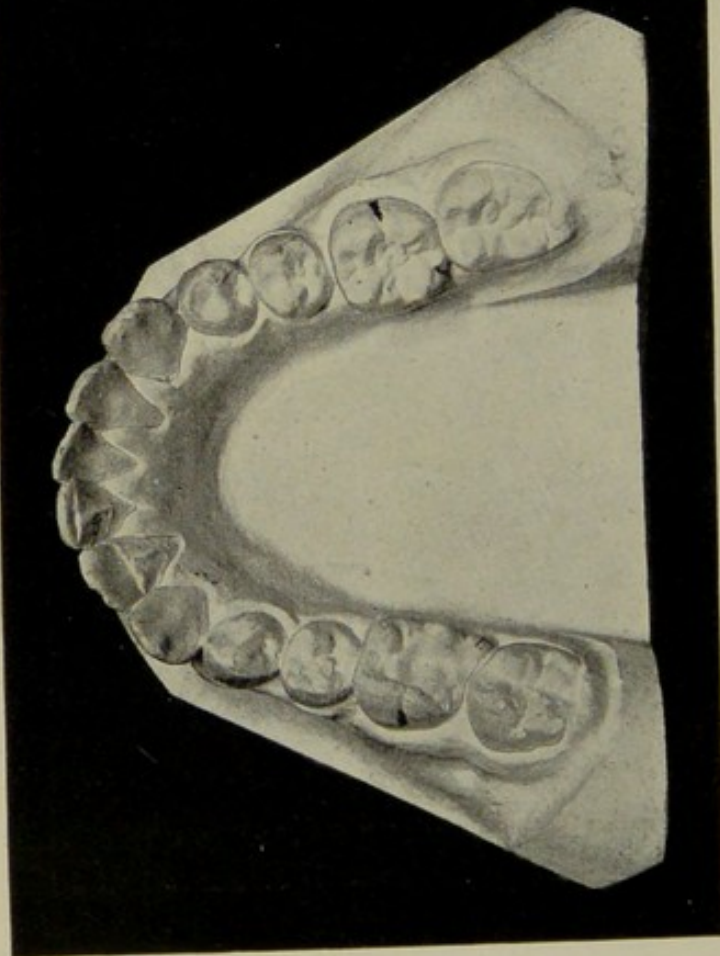




FIG. 375.

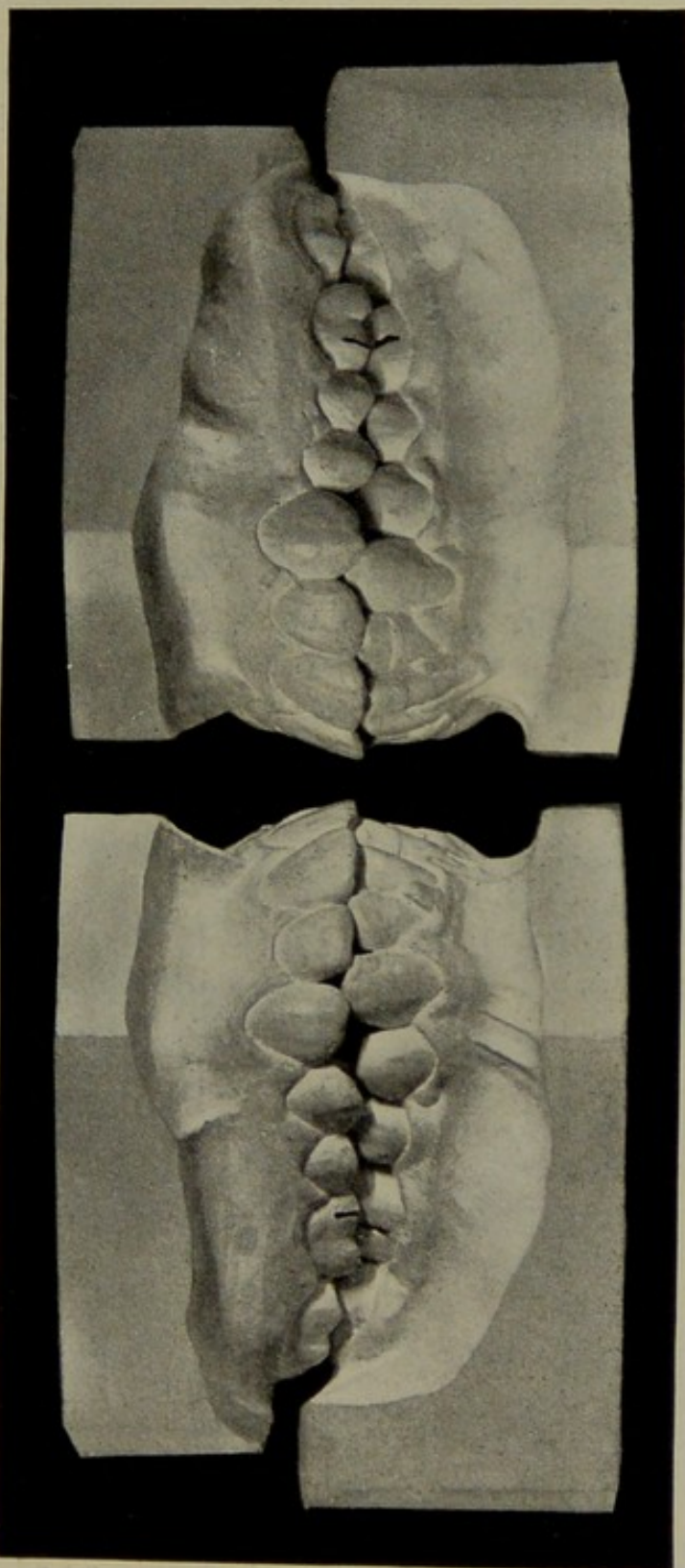


FIG. 374.



The case had a simple beginning, like those early described in this chapter, and shows how rapid and progressive has been the development of the malocclusion.

Again the demands of facial art and occlusion clearly indicate that in treatment all of the teeth must be retained, the arches enlarged to their normal sizes, and at the same time each tooth moved into its correct relation with the line of occlusion. Several periods of rest and activity were necessary in this case to allow for growth in the alveolar process and intermaxillary bones.

The changes in the positions of the teeth, as well as the greatly enlarged dental arches are shown in Figs. 372 and 373 and the occluded relations of the teeth of the two arches are shown in Figs. 374 and 375.

We would again call attention, by a comparison of the original with the present conditions, to the great increase in growth of the alveolar process and intermaxillary bones, and the greater freedom given to the tongue.

Another point of interest is worthy of note. It will be seen how large is the pattern of the incisors and, indeed, of all the teeth, and how apparently out of proportion they originally were with the sizes of the jaws—a most typical case in which to point out the absurdity of the theory, so long maintained, of attributing this apparent inharmony of size to inheritance of large teeth and small jaws.

Although at the time of beginning treatment this boy was rather delicate and undersized, the size and pattern of his teeth clearly indicated that he would ultimately be large in stature, which is indeed, now being abundantly verified.

Figs. 376 and 377 show the boy's face at the time of making the last models.

The movements of the teeth were brought about by means of the ribbed expansion arches, bands and ligatures, in the main as heretofore described. To attempt to describe in finer detail the treatment of this or of any com-



plex case of malocclusion would be tedious and probably

FIG. 377.

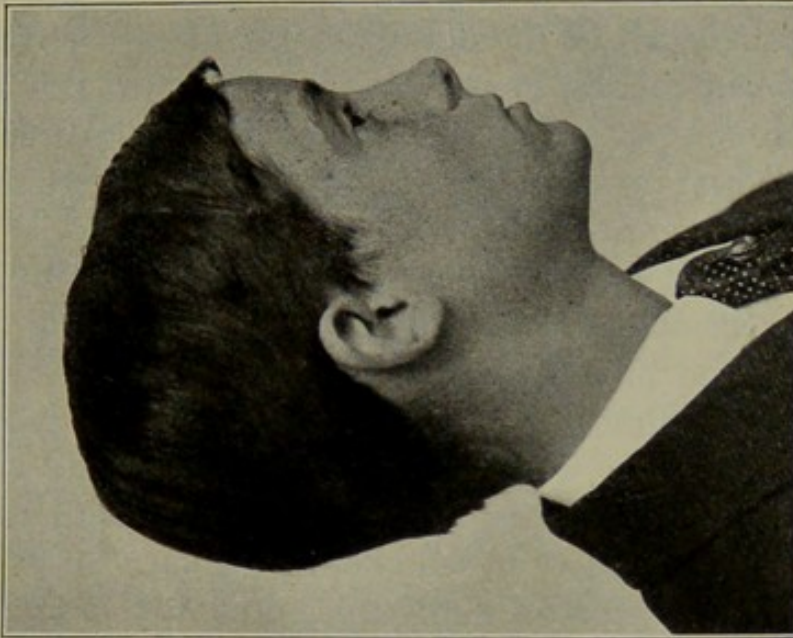



FIG. 376.



unfruitful. It seems to the author that the only possible way for any student to become familiar with the details



is through experience, following the main principles already laid down. Unfortunate as it may be, the artist cannot describe all of the details of his pictures. He can only lay down certain general principles as to the use of brush and colors, which should inspire and direct the student of art in reaching similar or better results by patient, intelligent effort.

It will be seen by referring to Fig. 370 that there is unusual displacement of all of the lower incisors and of the left canine, and that the displacement of the lateral incisors is complete, that is, that the very apices of the roots are far lingual to their normal positions, and as the crowns were moved both labially and laterally the teeth rapidly assumed a dangerously procumbent position. In order to effect the movement of their apices, as well as of their crowns, a device was used which was as efficient as it was simple, and the method so far as the author knows is described here for the first time.

The retaining device, as shown at Fig. 233, was adjusted. It consisted of bands cemented to the canines, connected by a section of wire G made to bear against the lingual surfaces of all the lower incisors, the crowns of which were not yet in perfect alignment, though approximately so. Before cementing the bands in position two of the longer of the delicate tubes R were soldered to their mesiolabial angles on a line parallel with the long axes of the teeth. Similar tubes were attached in like manner to the labial surfaces of bands cemented upon the lateral incisors. Two delicate staples were now bent from the medium-sized lever L, and one of them placed in position, one of the legs of the staple being inserted into the tube attached to the canine band and the other into the tube on the lateral incisor. Having demonstrated its correct dimensions and adaptation it was removed and given a twist so that the leg intended for the lateral incisor would incline forward much farther than the line of axis of the procumbent tooth. It



was now sprung into position, and thus a constant, but gentle force was given to this lateral incisor, the result being to support the crown of the tooth and move its apex slowly labially, this force being resisted by the stronger and more firmly attached anchor tooth—the canine—with the tendency of forcing the apex of its root in the direction opposite to that of the lateral incisor.

In like manner the other staple was made to operate, and although the anchor teeth were slightly disturbed, the apices of the roots of the two laterals were slowly moved into their normal positions. The time occupied in moving the left lateral was about three months. It was of course necessary to occasionally remove and modify the form of the staple in order to maintain the necessary force.

The section of wire G connecting the anchor bands upon the lower canines, before mentioned, not only served as temporary retention for the incisors, but rendered the canines, as anchor teeth, more secure.

The same method as employed in their moving was used in effecting the retention of these teeth, the staple, though without spring, being allowed to rest in position.

In studying the forms of the dental arches in this case at this stage of the treatment, Figs. 372 and 373, it will be observed that they are narrower and longer than normal and might suggest to those who follow the Bonwill law in its application to orthodontia, the advisability of widening and shortening them. This is not necessary. We must remember that the jaws and alveolar process are yet far from their full development, but since we have placed the teeth in their normal relations we have given Nature an opportunity to complete the development, which she must do, normally, and in accordance with the typical demands of the individual, through the now normal workings of the forces which govern occlusion—forces which must ultimately establish and control the normal form of all dental arches where the teeth are in normal relations.



The device for the final mechanical retention of the lower teeth in this case is shown in Fig. 245, and in position on the teeth in B, Fig. 244; and for the upper teeth in B, Fig. 241.

FIG. 378.

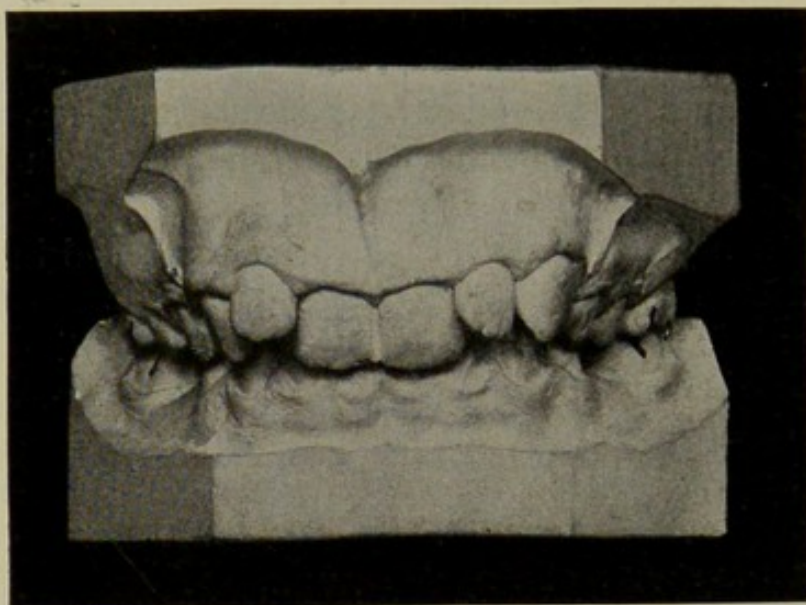
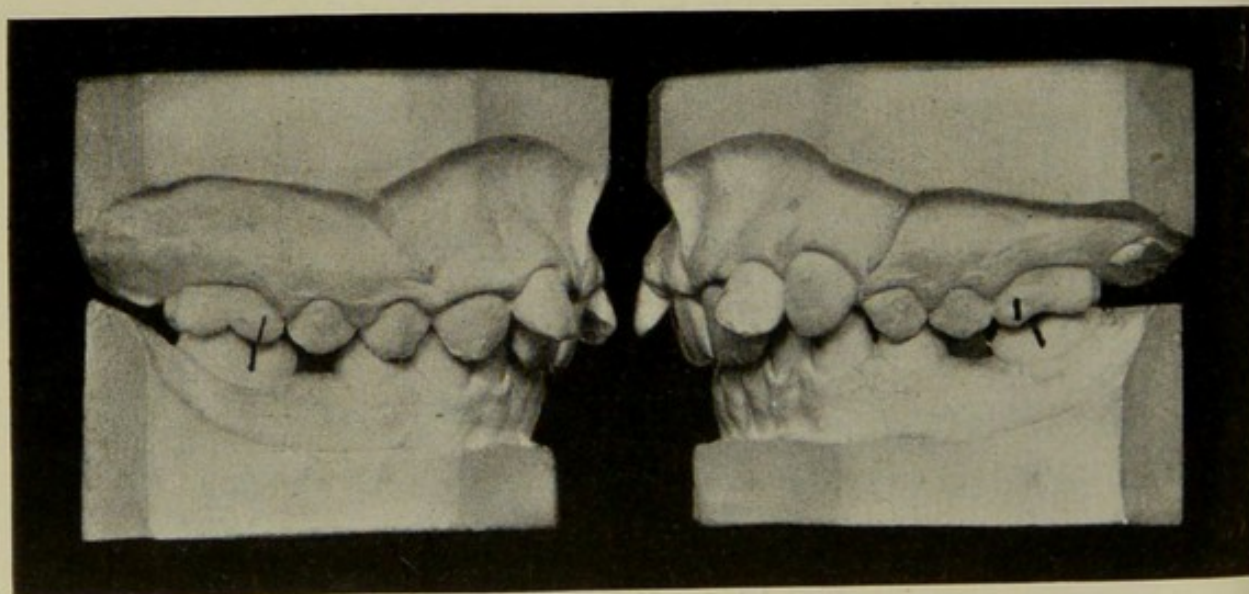


FIG. 379.

FIG. 380.



Figs. 378, 379, and 380 show a case where there is very pronounced mal-relations of the incisors and canines, and if diagnosed superficially it would appear to belong to the second division of the second class of malocclusion, for the



retrusion of the upper centrals and protrusion of the laterals give it the typical appearance of these cases. Yet

FIG. 382.

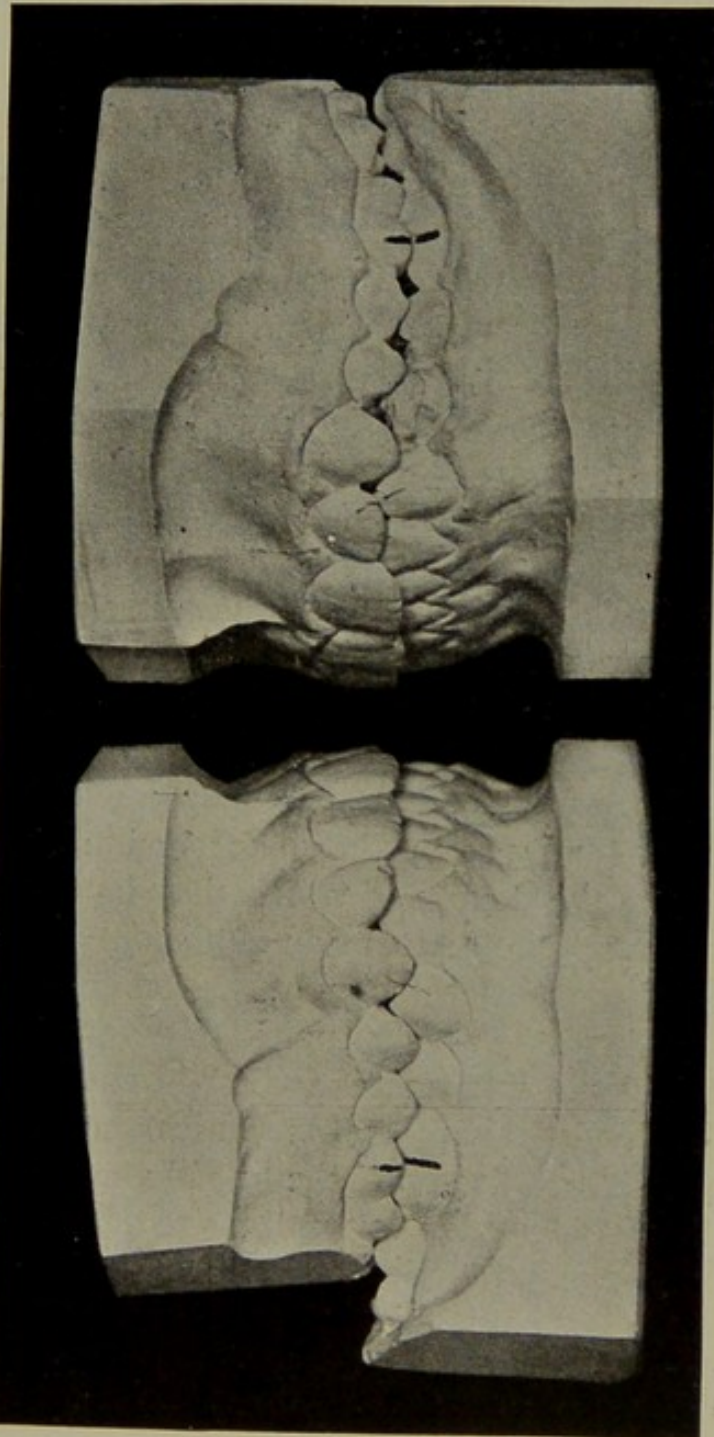


FIG. 381.

by an examination of the relations of the first molars it will be seen that it clearly belongs to the first great class and that when the incisors are brought in harmony with



the line of occlusion there will be ample space for the second lower premolars to erupt, when they will assist individually in supporting not only the weight of the jaws in occlusion, but, of still more importance, the first molars, and directly and indirectly the teeth anterior to the premolars.

Figs. 381 and 382 show the result of carrying out this plan of treatment, or the establishing of the normal in occlusion, by lengthening the lateral halves of the lower arch after the manner described in connection with the cases shown in Figs. 207, 419, 421 and 422, and correcting the positions of the teeth of the upper arch by means of the expansion arch, spurred bands, ligatures, etc., as already frequently indicated. Although there is not yet perfect harmony between the occlusal planes of the premolars on the left side, their full normal relations must follow as time progresses.

By examination of the facial lines at the time treatment was begun, Figs. 383 and 384, it will be noted how much the normal lines demanded by this type of face have been thrown out of balance by the malocclusion, and Figs. 385 and 386 show the degree to which they have already been restored through the restoration of normal occlusion.

Fig. 387 shows the occlusion of the teeth of a girl eleven years of age, and the case is typical of a very common form of malocclusion. The malocclusion is chiefly confined to one side of the dental apparatus and is commonly the result of the premature loss of the deciduous canine, which permits the rapid diminution in the size of the arch, forcing the permanent canine in its effort to erupt into over-prominence, which in turn is reacted upon the lateral, causing its partial or complete lingual displacement, with usually some disturbance of the positions of the centrals.

The disturbance in the balance of the facial lines, as in all cases, is in direct proportion to the degree of the malocclusion. Obviously no greater blunder could be com-



FIG. 384.




FIG. 383.



mitted than the resort to extraction, for as the first molars are in normal relations the full complement of teeth in both

FIG. 386.



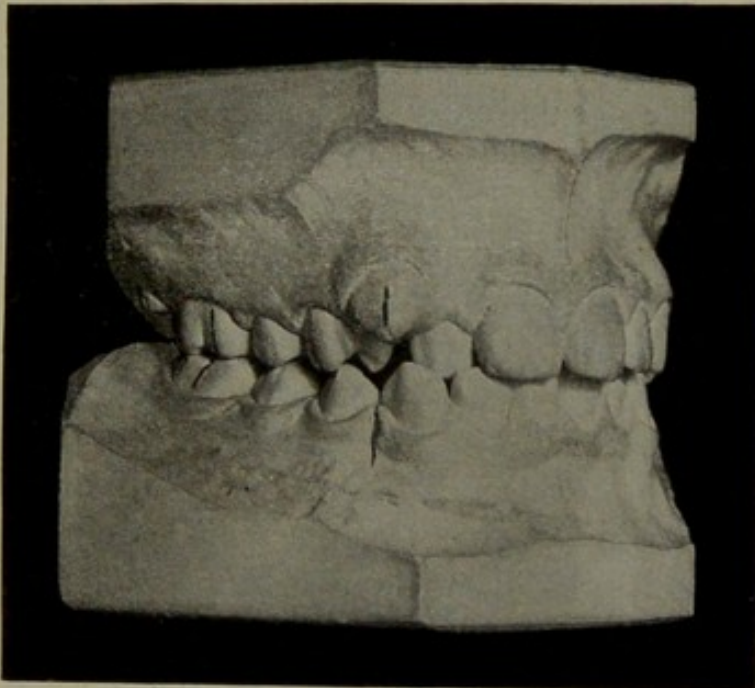
FIG. 385.

upper and lower dental arches is essential to the establishment of harmony in the sizes of the arches,—an invariable requirement in all cases. What is clearly indicated is the



enlarging of the dental arch (one or both as needed, though the teeth of the lower arch in cases of this type are often in excellent alignment), and compelling each tooth to occupy its correct relation with the line of occlusion. And yet this often requires considerable time, skill, and patience, as very often both central incisors, as well

FIG. 387.



as the lateral nearest to the prominent canine, have not only been carried lingually but shifted laterally, changing their relations with the median line and necessitating not only their labial and often torsal movement, but their lateral movement, in order to restore their harmonious relations with the median line. The movement of the lateral and canine of the opposite side of the arch may also be necessary in order to provide room.

All of these movements can best be effected by means of the ribbed expansion arch made to bear against the prominent canine, with force reciprocated from the premolars, laterals and centrals, at the same time giving it a form which will exert spring laterally upon the anterior



teeth. In order to exert this spring the arch should bow out from the teeth on the comparatively normal side, the result of which, if notches be made in the arch at suitable places and wire ligatures be used, is to deflect the centrals and laterals in the desired direction. This is intensified by the occasional renewal of the ligatures and tightening of the nut in front of the sheath of the anchor band on the side of the greatest malocclusion. In rare instances it may also be necessary to enlist the assistance of intermaxillary anchorage, as in Fig. 211. The form of the expansion arch must of course occasionally be modified as the teeth are moved in order to best conserve the energy of the appliance.

The movement of the prominent canine may often be hastened by a piece of rubber stretched between it and the expansion arch.

We have mentioned elsewhere that the canine, from its location and time of taking its position in the arch, may be regarded as the keystone in its lateral half of the dental arch. Now, as in the case last described, the arch having been enlarged for the reception of the keystone, as it were, the chief problem in retention will be to maintain this important part of the structure in position, when it must follow, as in masonry, that all the other portions of the arch will be harmonious as to relation and support. The retention of the canine in such position will resist the movement of all the other teeth in the direction of their tendencies. This is effectually accomplished by the device shown in Fig. 232, consisting of a band cemented to the lateral incisor, to which has been soldered at its disto-labial angle a section of the wire G that is passed transversely across the labial surface of the canine and first and second premolars, its end being securely held by means of a wire ligature surrounding it and the latter tooth. In many instances the device shown in Fig. 233 will be found very efficient. Of course if the laterals have been moved from



FIG. 388.

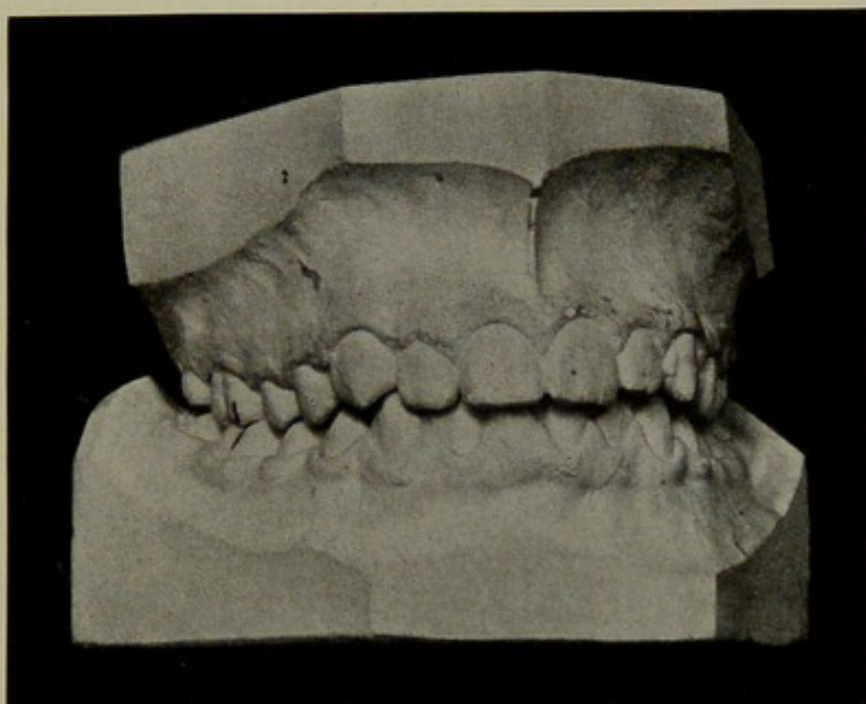


FIG. 389.



FIG. 390.





FIG. 391.

FIG. 392.


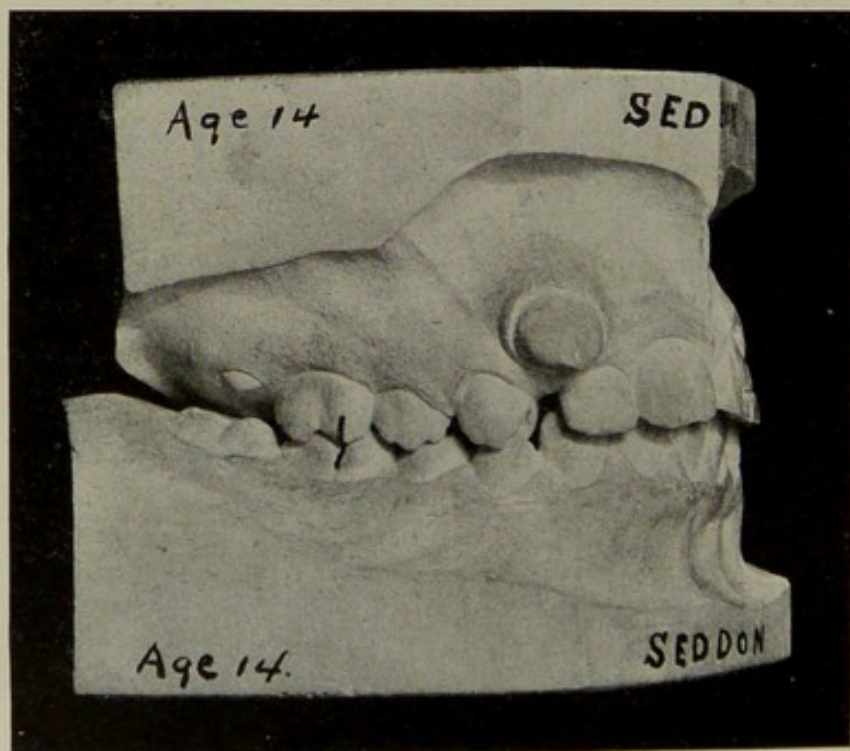


FIG. 393.





torso-occlusion they must be retained in the usual way by bands, spurs, etc.

FIG. 394.

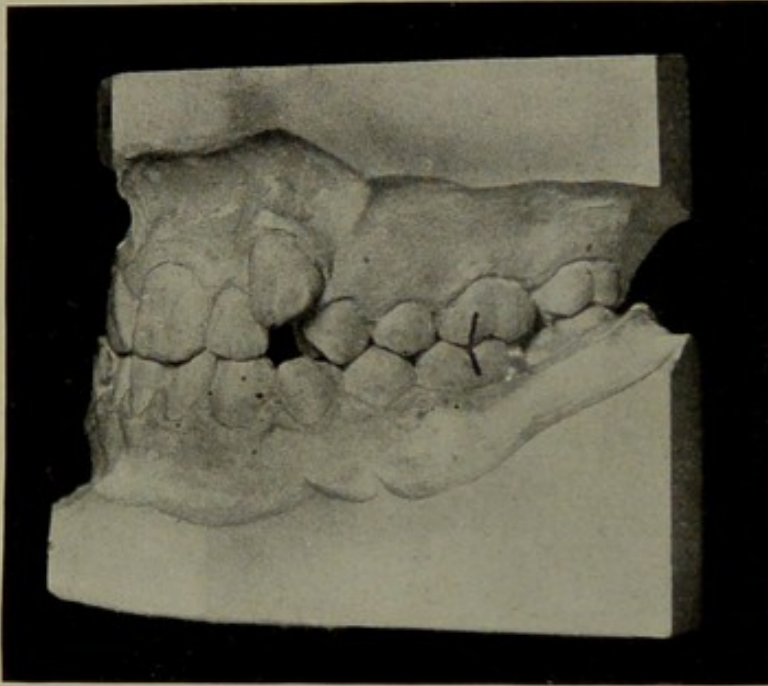


FIG. 395.

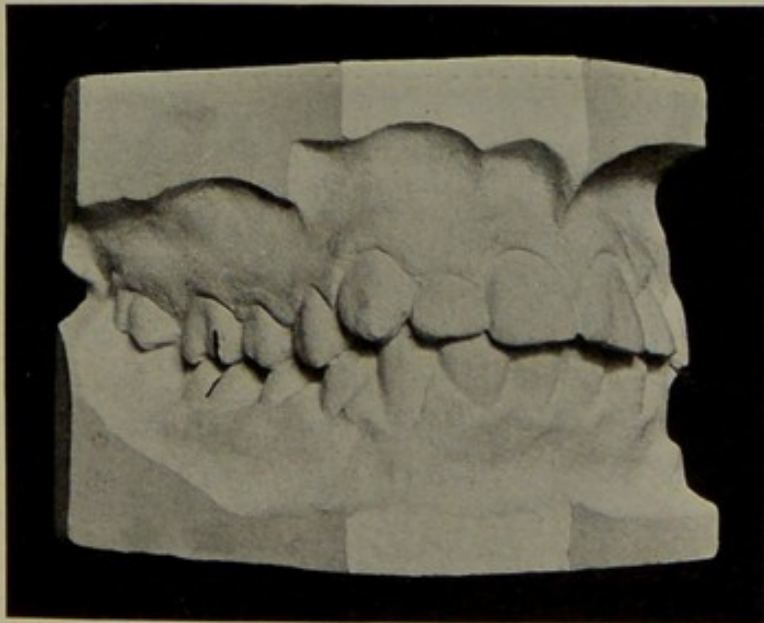


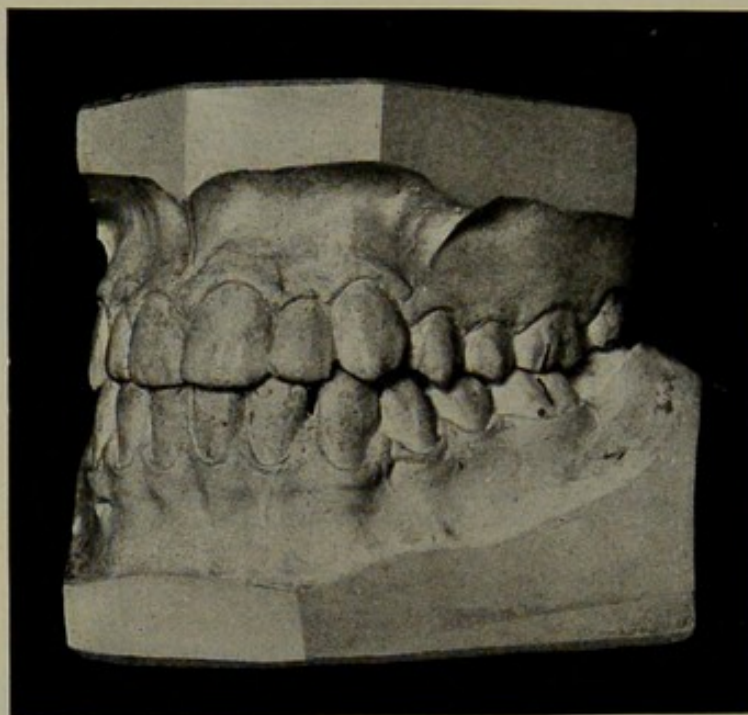
Fig. 388 shows the result of such treatment in this case. Figs. 389 and 390 show the face of the patient at the be-



ginning of treatment, and Figs. 391 and 392 show it at the time the last model was made.

Figs. 393 and 394 show similar cases treated in like manner to the one just described, with the results in occlusion shown in Figs. 395 and 396.

FIG. 396.



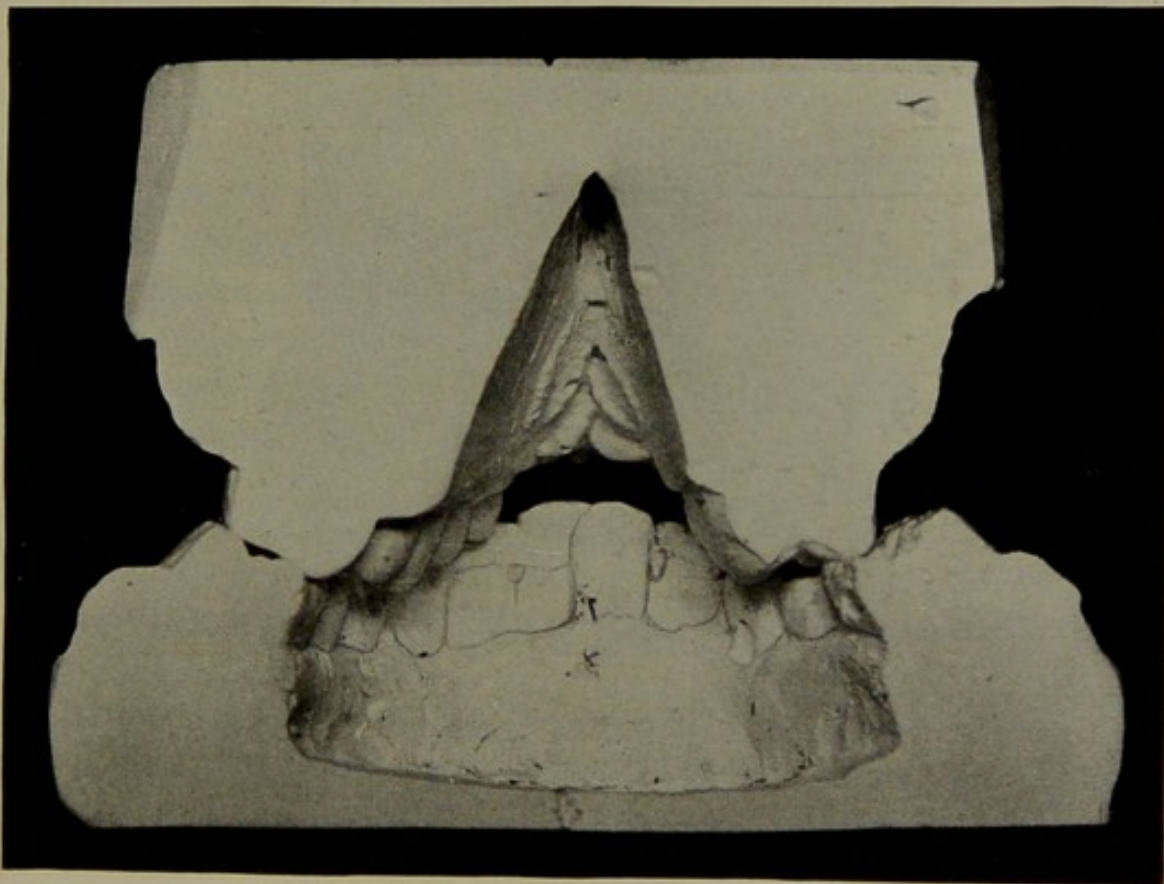
So far we have considered cases belonging to this class in which the malocclusion has been principally confined to the incisors and canines. We will now consider a type not infrequently met with in which the malocclusion is made more complex by reason of the molars and premolars being also more or less involved. The malocclusion may include one or all of the buccal teeth on one or both sides of both arches, the involved upper teeth being in lingual occlusion.

The author would here call special attention to the very pronounced and unfortunate results which *must follow the force thus wrongly distributed*. Normally, as in Fig. 3, the great force upon the teeth incident to mastication is per-



fectly distributed in the direction of the long axes of the teeth, the force tending to maintain the normal width of both arches and the teeth at their proper angles of inclination, while in the form of malocclusion now to be considered, the forces being wrongly distributed tend to diminish the width of the upper arch, especially in the region of the apices of the roots of the teeth, and to abnor-

FIG. 397.



mally widen the lower arch in this region. The effect of this abnormal distribution of force is graphically shown in Fig. 397, which represents the posterior view of the malocclusion in a very pronounced case.

It is easy to understand how the vault of the arch and bones of the nose gradually became involved until normal breathing became impossible, and as the space for the tongue was so greatly restricted, it was with much difficulty

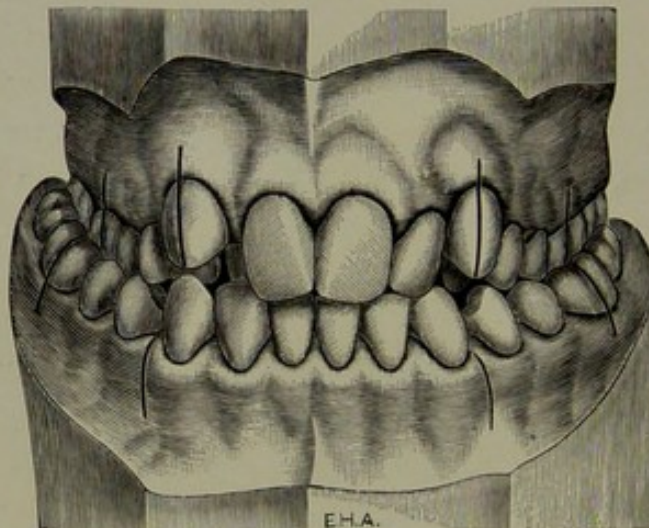


that the man could enunciate his words sufficiently to be understood.

Fig. 398 shows the malocclusion in a case where all of the teeth are involved, and it will be seen that the upper molars are in lingual occlusion and the lower molars in buccal occlusion, although all are in normal mesio-distal relations, thus clearly placing the case in the first great class of malocclusion.

It is interesting to study the beginnings, progress and disastrous effects of such malocclusion upon the develop-

FIG. 398.



ment of the jaws and dental apparatus as a whole, and it should give emphasis to the importance of early treatment, for even this very complicated case had a very simple beginning, dating from the eruption of the first permanent molars. Doubtless at this time the positions of the molars were very nearly normal, but as they came into near relation they failed to lock normally. Probably the points of the cusps upon first coming into contact hesitated, as it were, for a time, but through slight adverse causes were unable to assume their normal relations, hence their inclined planes being once started in wrong directions so continued as their eruption progressed.



The result of such mal-locking is the perversion or wrong distribution of the great force incident to mastication, the effect in the upper arch being, as we have said, to exert a marked mal-influence by preventing the normal widening through growth of the alveolar process and jaw in the region of the first molars. As a result of receiving the force upon the lingual instead of the buccal cusps of the lower first molars these teeth were gradually carried bodily (apices of the roots as well as crowns) buccally to their normal relations with the line of occlusion, the effect being a gradual narrowing, or prevention of growth, of the entire upper arch, with a proportionate abnormal widening of the lower arch, and probably, to some extent, of the entire mandible. The similar mal-locking of each tooth anterior and posterior upon its subsequent eruption and locking was thus made easy, each in taking its position in the arches exercising a corresponding harmful effect on the development of the alveolar process and jaws.

By such perversion of force great inharmony was established, not only as to the forms of the dental arches and the jaws, but, to a very noticeable degree, in the facial lines, giving an unnaturally wide, baggy appearance to the lower part of the face, with abnormal narrowness in the region of the maxilla.

The requirements in treatment of this case ought, it would seem, to be clearly indicated to any thoughtful mind. As the forces through malocclusion have caused the perversion of growth and development, so the correction of the malocclusion must cause these forces to act as stimulants toward the normal in growth and development.

The plan of treatment, then, was to widen the upper arch by moving buccally the molars, premolars and canines, the moving of the lateral incisors labially and out of torsal occlusion, and the rotation of the centrals.

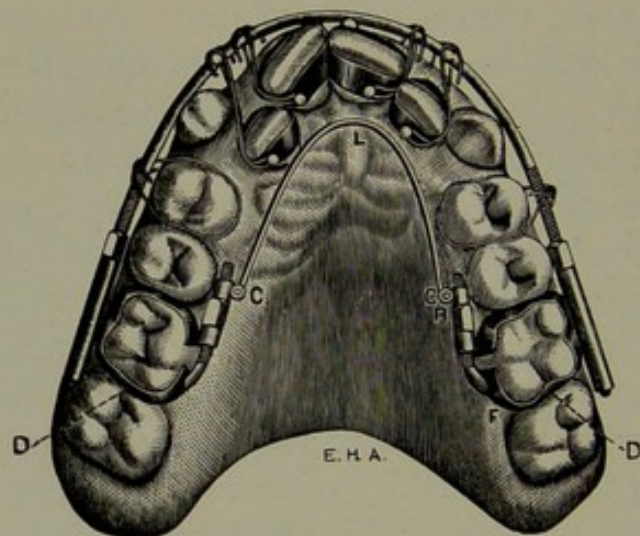
These movements are being effected, as shown from the occlusal aspect of the teeth of the upper arch with the



appliances in position in Fig. 399, the description of which is given in the chapter on Adjustment and Operation of Appliances.

The narrowing of the lower arch was accomplished by means of a device manufactured for the occasion, and is the only instance where an appliance differing from the author's standard forms has been required in the treatment of cases described throughout this book, and even this has been discarded since the addition of the ribbed ex-

FIG. 399.



pansion arch which has been found quite as efficient, and is always ready at hand.

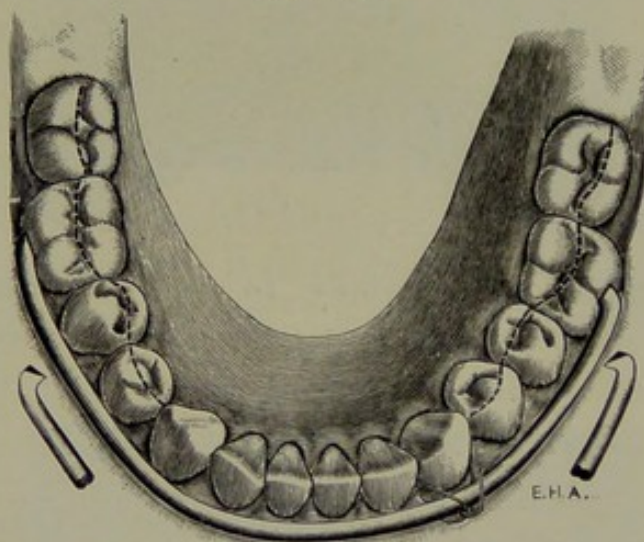
The device used, however, consisted of a piece of Stubb's steel wire slightly less than one-eighth of an inch in diameter, bent to closely conform to the shape of the arch, the temper being so soft as to make this easy of accomplishment. The extreme ends were bent sharply at right angles and filed to sharp, delicate hook-like points, which were made to engage the buccal pits on the first molars, as in Fig. 400. If the points are bent at the proper angle and made extremely sharp, drilling of even delicate pits in the enamel is rarely necessary, as they will readily remain in



position when grasping these teeth at any point, especially just beneath the gingival ridge.

After the device had been tested and found to be of exactly the size necessary, its ends were sprung closer together, in order to conform it to the pattern to which the dental arch was to be molded. It was then tempered to extreme hardness, after which it was polished and given a spring temper by being held in contact with a sheet of thin metal over a flame until its color had changed to a light blue. It was then sprung into position and exerted

FIG. 400.



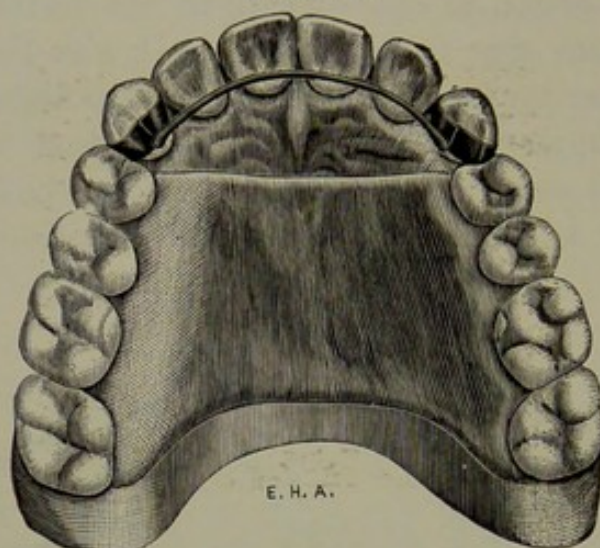
considerable force in a lingual direction upon all the molars and premolars, but the force being so evenly distributed, little inconvenience was experienced by the patient and the dental arch was soon molded into correct shape by the bending of the alveolar process. After its spring had been expended it was allowed to remain as a retaining device for several weeks, held in position by one or two wire ligatures.

Fig. 401 shows the upper arch completed and the retaining devices in position, while Fig. 402 shows both arches completed and the teeth in occlusion. The lingual tendency of the upper incisors and the torso- and infra-occlusal tendencies of the upper canines, as well as the lingual tendency



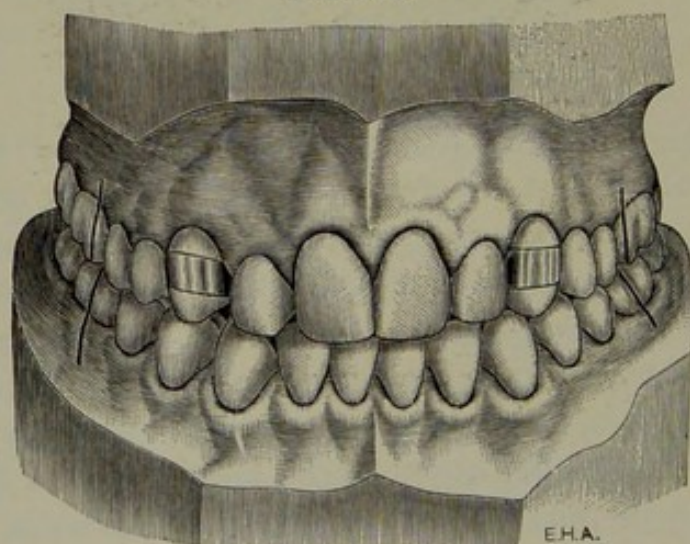
of the molars and premolars, were resisted by double bands connected by a section of the wire G, and a vulcanite plate, as illustrated. The bands upon the canines are also shown in this engraving.

FIG. 401.



It should be unnecessary to mention that different periods of activity and rest were also necessary for the movement of the teeth of the upper arch in this case.

FIG. 402.



Often in less complicated cases we will find a similar locking of one of the upper molars, and through the ab-



normal distribution of the force the perversion of the normal growth of the alveolar process is always rapid and pronounced, hence the malocclusion should be promptly corrected.

FIG. 403.

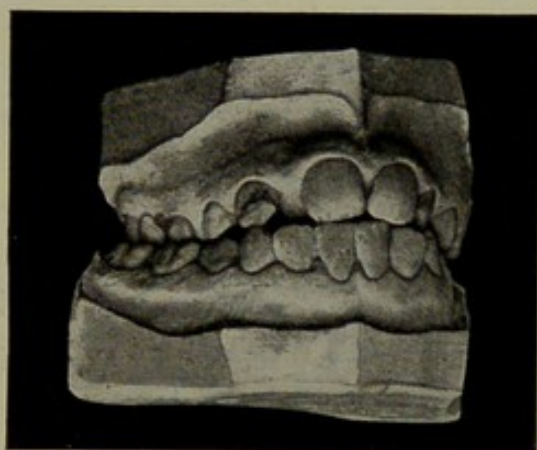
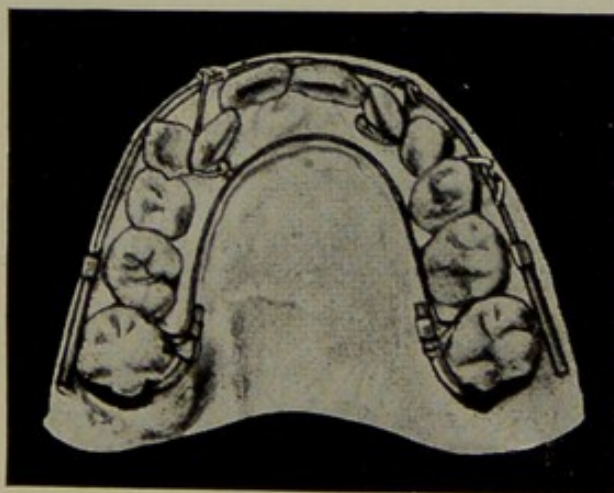


Fig. 403 shows a case where but one of the lateral halves of the upper arch was thrown into lingual occlusion by the lingual locking of the right upper first permanent molar.

FIG. 404.



The patient was a child eight years of age. The deciduous molars and canines are still in position.

The plan of treatment clearly indicated was the widening of the upper arch by moving buccally the teeth of the affected side only, with labial movement of the centrals and



torso-labial movement of the laterals. Fig. 404 shows a view of this arch from the occlusal aspect, with the appliances for accomplishing these movements in position.

It will be seen that all of the teeth on the left side are used as anchorage and their combined resistance concentrated upon the right first permanent molar through the force distributed by the external and internal arches. But a few days were necessary to move this tooth into correct position. A wire ligature was then made to encircle the second deciduous molar and the expansion arch on the right side, thus practically transferring the force to this tooth. Later the right deciduous first molar was moved out in the same way. The object of moving the teeth one at a time on the right side was to avoid overtaxing the anchorage derived from the opposite side of the arch. Had the effort been made to move them all at the same time it is probable that on account of the increased resistance offered by the inlocking of the inclined planes of the cusps of the molars on the abnormal side the displacement of the teeth on the normal side would have been more rapid than the correction of the positions of the teeth on the abnormal side.

While the appliance was acting upon the lateral half of the dental arch, the lateral incisors were carried forward and rotated by bands, spurs, and ligatures, with notches in the expansion arch to prevent the slipping of the latter, and these movements were further assisted by the occasional tightening of the nuts on the expansion arch.

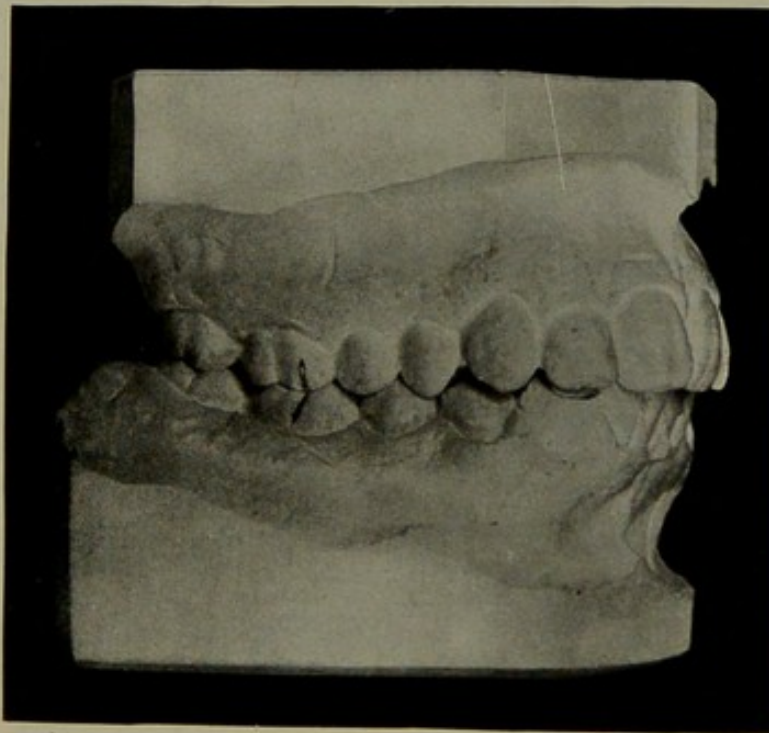
The teeth were retained by a vault plate which maintained the proper width of the arch, and by bands upon the laterals connected lingually by a section of the wire G which effectually prevented the disto-torso-lingual movements of the incisors.

It has been found that the reinforcement of the expansion arch by means of the reinforcement wire, shown on the inside of the dental arch in Fig. 404, is unnecessary



in the case of young patients, especially since the introduction of the ribbed expansion arch, the rib greatly increasing its power. Further experience has also shown that it is usually unnecessary to move out of lingual occlusion similarly inlocked deciduous teeth. Their cusps, however, should be shortened by grinding so that they may not interfere with the normal widening of the arch through growth which is greatly accelerated by the placing in nor-

FIG. 405.



mal occlusion of the first permanent molars. These teeth and the incisors being normally placed and supported, the premolars should erupt and lock normally.

No movements of the lower teeth having been necessary in this case, they of course required no retention.

Fig. 405 shows the occlusion of the teeth eight years after treatment. The facial lines were practically faultless. We regret not being permitted to reproduce them here. They are especially gratifying when we consider the probable result of allowing the malocclusion to develop, which usu-



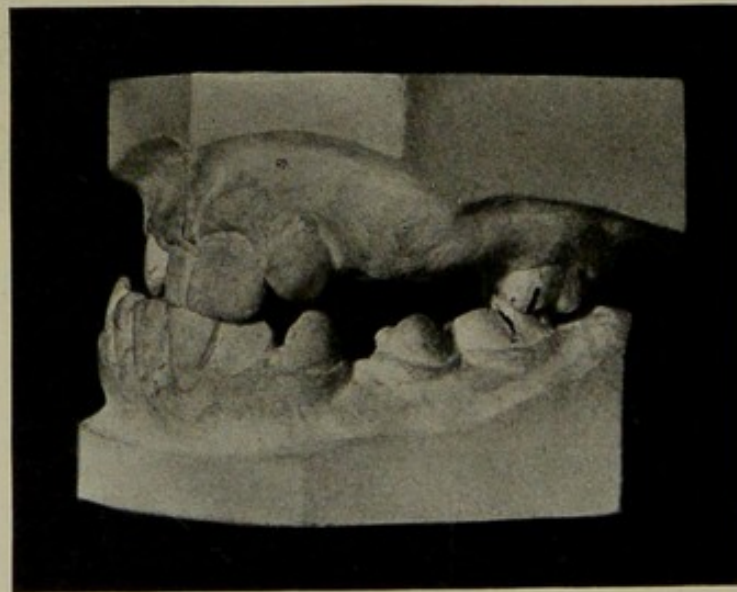
ally produces that unsightly deformity characterized by a twisted appearance so noticeable in the face of the pa-

FIG. 406.

FIG. 407.

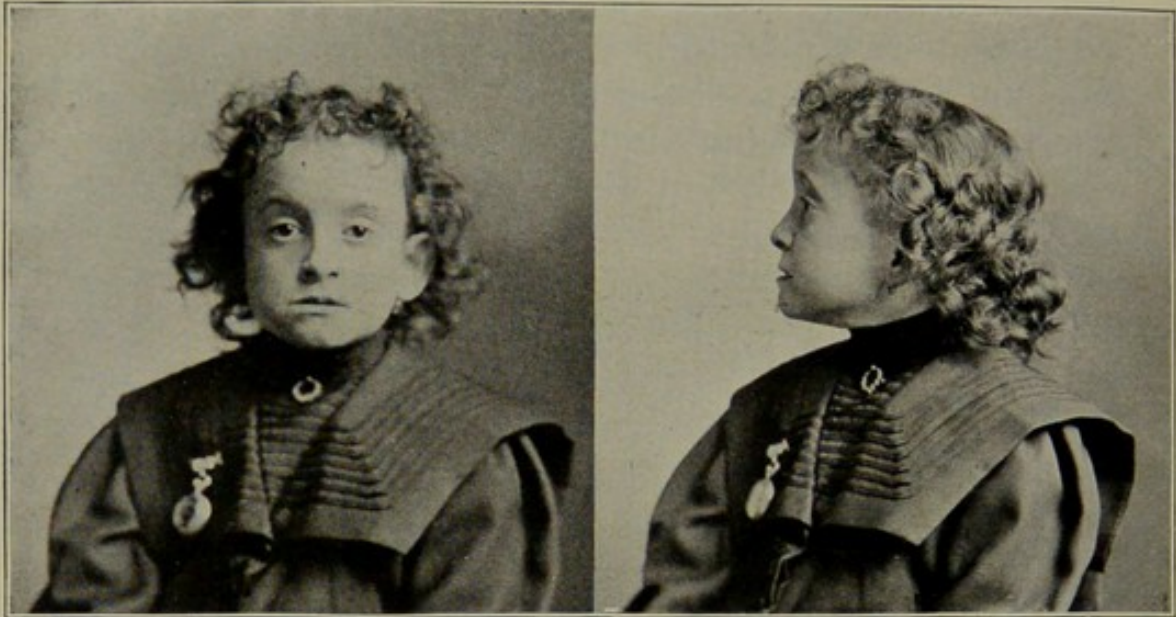

FIG. 408.



tient shown in Figs. 406 and 407, caused by the lingual locking of the right upper molar, which in turn caused the

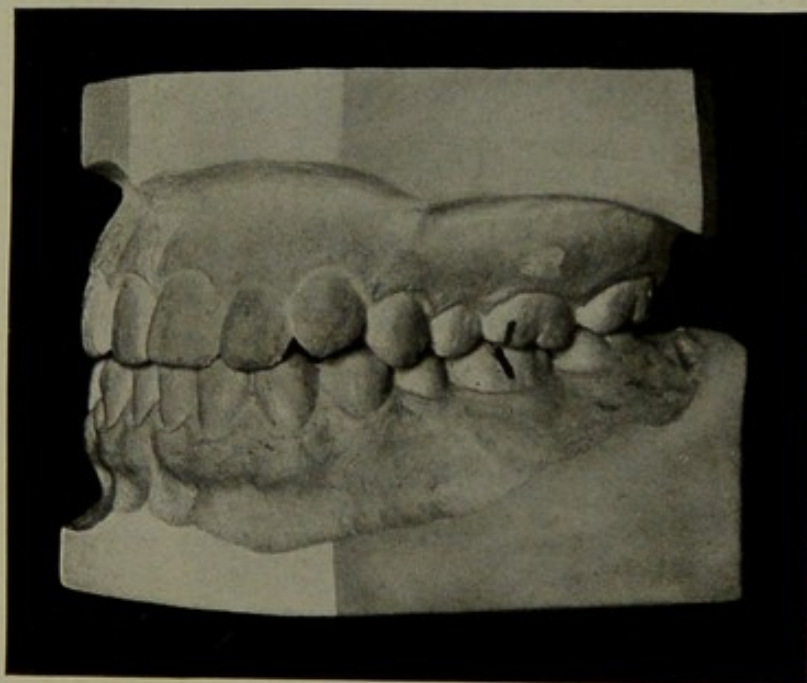


shifting of the mandible from left to right, as shown in the malocclusion of the teeth, Fig. 408.

Fig. 409 shows the occlusion of the teeth six years later, and Figs. 410 and 411 show the comparatively good balance in facial lines which has resulted from the restoration of the teeth to normal relations.

As the lingual locking of the upper molars is a characteristic which we have said may accompany any of the

FIG. 409.



classes, divisions or subdivisions of malocclusion it will be further discussed in considering the treatment of the various cases of other classes in which it occurs.

There is also another form of malocclusion, which, although it may appear in any of the classes, is more often found in the first great class. It is commonly termed "open bite," characterized by more or less space between the upper and lower teeth anterior to the first or second molars, although usually involving only the upper and lower incisors and canines.

The causes of some of the forms of open bite are very



FIG. 411.



FIG. 410.

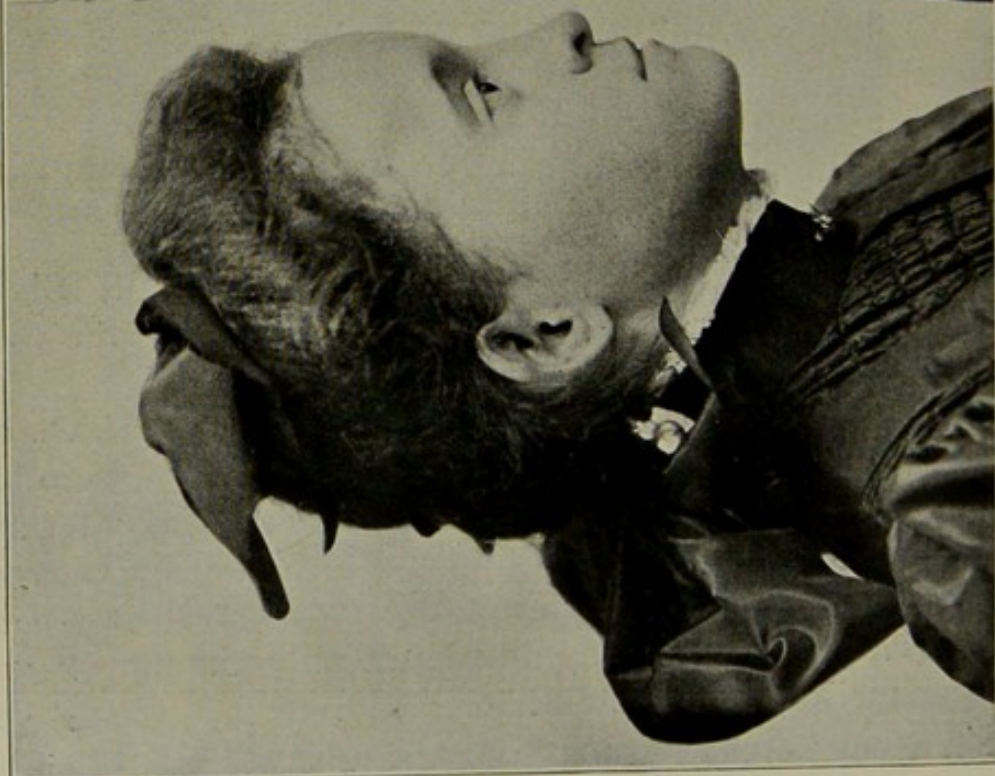



FIG. 412.

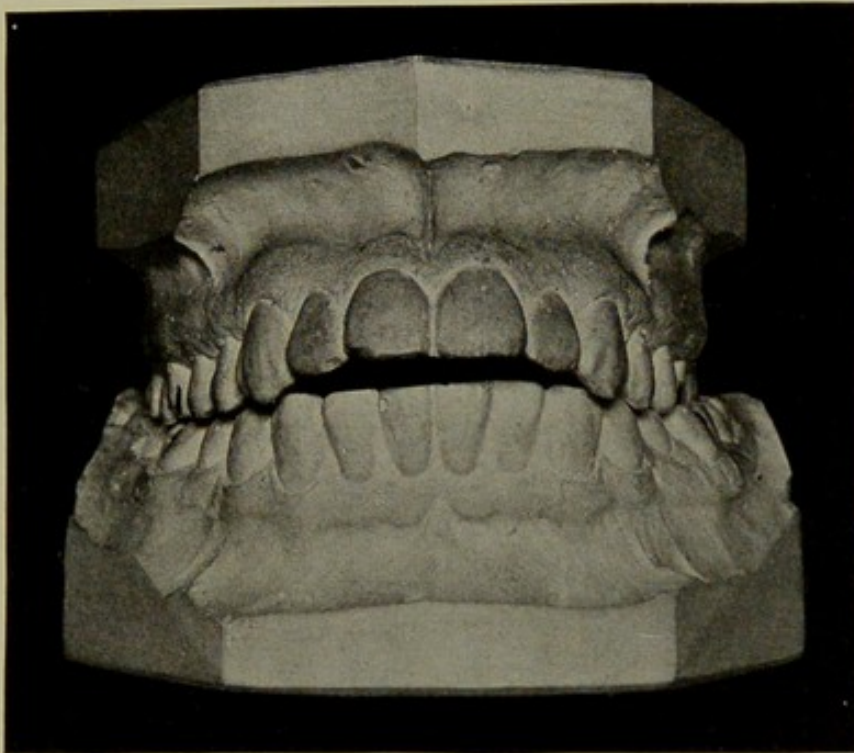
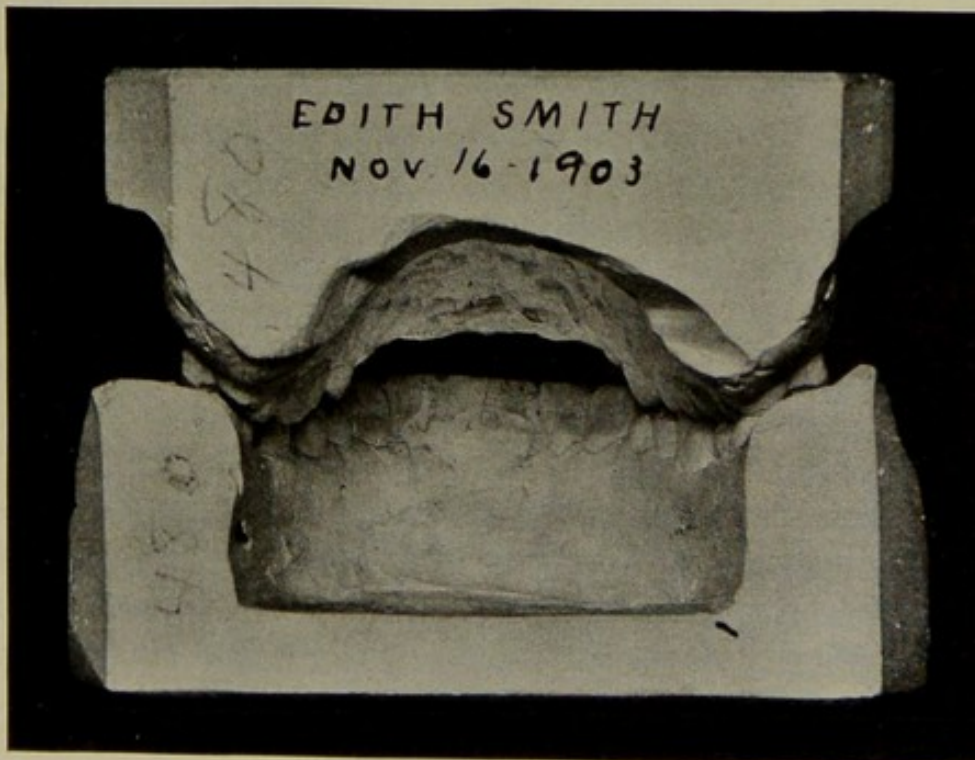


FIG. 413.





obscure. The condition is generally, however, due to the habit of holding the tongue between the cutting edges of the incisors, or frequently protruding it, the form and extent of the space according with the greatly varying habits of the tongue. Fig. 412 shows a quite typical case. The extent of the separation of the incisors is also shown from a posterior view in Fig. 413.

The restoration of the teeth to normal occlusion by movement of the upper centrals and laterals downward and inward is usually not difficult, these being, as before noted, the easiest tooth movements to perform, especially if the eruptive movement be the first accomplished. But this, in most of these cases, is only a minor part of the difficulties encountered by the orthodontist before success in the operation is assured. The real difficulty is in breaking the vicious habits of the tongue which must rest largely with the patient, and the author is convinced that few patients have the strength of will to ever master this habit. His experience in a large percentage of these cases has been most discouraging, and has often occasioned doubt as to the advisability of undertaking cases where the habit and its results are well-established. Very often after the complete restoration of the teeth to normal occlusion and many months of efficient retention he will find, upon the removal of the retaining device, that the habit is still in force and will result in rapidly forcing the teeth into their original mal-relations.

Fig. 414\* shows the method of correcting infra-occlusion of the incisors by means of the expansion arch. The middle of each side of the arch was made to bear against a spur soldered to a band on the canine, which acted as a fulcrum, the center of the arch being sprung over hook-like spurs projecting from the labial surfaces of bands on the central incisors, its spring thus exerting a downward force

---

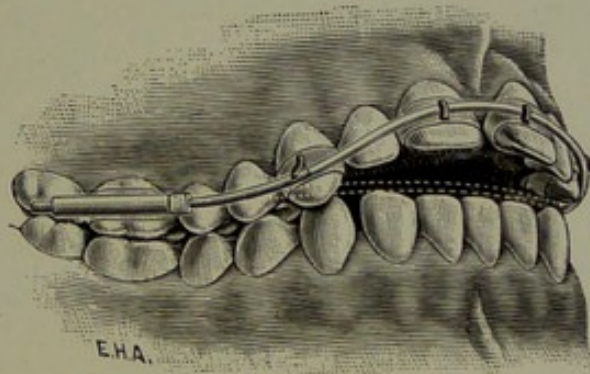
\*Angle. Fourth edition, 1894.



upon them. The use of ligatures instead of spurred bands for the incisors is now preferred. Either of the arches E or the arch B may be used.

This is an excellent method of correcting infra-occlusion of teeth, and yet it must not be forgotten that the force also tends to elevate the anchor teeth and that they must not be overtaxed by the attempt to move too many teeth at once. Not more than one or two should be moved at a time. If pronounced vertical movement of the anchor teeth should occur the bands should be shifted to other molars.

FIG. 414.



In correcting infra-occlusion of the teeth by this method, first shown in the fourth edition of this work, it has since been found that the spurs acting as fulcra are rarely necessary, the spring of the arch gained through the pry of the sheaths of the anchor bands usually being ample. It is well, however, to reinforce this anchorage with intermaxillary force; that is, stretching a delicate rubber ligature from the hook attached to the upper expansion arch to one upon the lower expansion arch, or to attachments on the lower canines, as in Fig. 185.

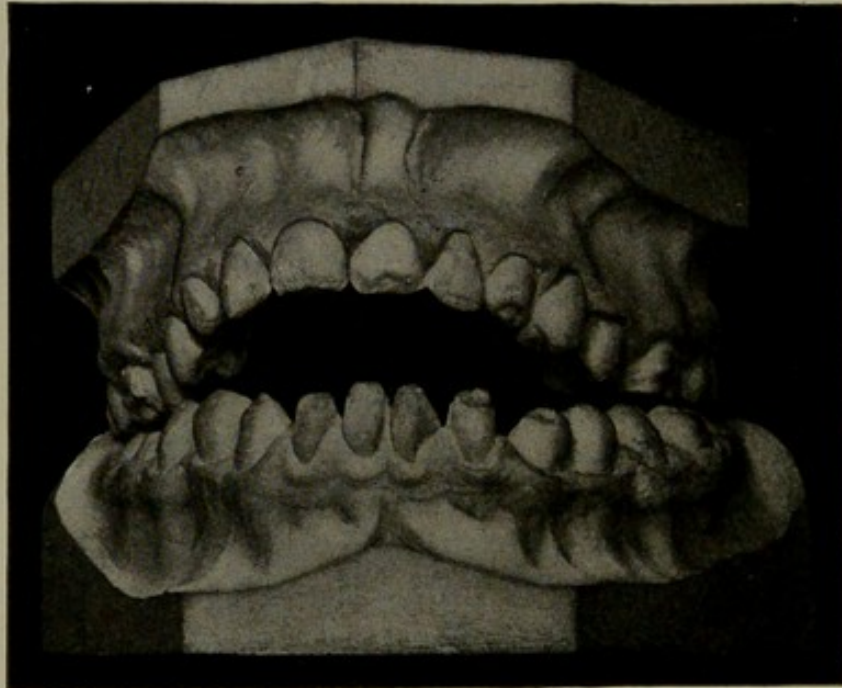
The best means of retaining teeth so elevated is to allow the device employed for their movement to remain in position the requisite time, or to employ methods described in the chapter on Retention.



Fig. 415\* shows another case of pronounced infra-occlusion principally of the incisors, canines, and premolars, of the upper arch. This condition was augmented by slight supra-occlusion of the second molars, which were the only teeth coming in contact when the jaws were closed.

The plan of treatment that seemed most advisable was the shortening of the second molars and the lengthening of all the incisors, canines and premolars. This was accomplished by means of the spring of the expansion arches, reinforced by intermaxillary anchorage, exactly as described in the last case.

FIG. 415.



All of the lower incisors and the canines were banded with delicate, neatly fitting bands made from the thinnest band material (C). These bands were to prevent the ligatures from slipping off the teeth. The upper lateral incisors and canines were banded in like manner for the same purpose. Bands were unnecessary on the upper cen-

---

\* Angle, Chapter on Orthodontia, "The American Text-book of Operative Dentistry," January, 1905.



trals, as the ligatures were twisted above the gingiva on these teeth, thereby preventing their slipping off. The finest of the three sizes of wire ligatures were used in ligating the teeth to the expansion arches, after the latter had been bent to give the greatest downward spring to the upper and upward spring to the lower. The force from this spring was intensified by two of the delicate rubber ligatures which were stretched from one arch to the other and made to engage hooks which had been soft-soldered to the expansion arches opposite the canine teeth. The effect of these ligatures was not only that of assisting in elevating the incisors and canines in their sockets, but also in depressing the second molars, which was probably effected to slight extent. Later these teeth were further slightly shortened by grinding.

It will be noted that the left lower first molar is in buccal occlusion, and that its antagonist is in lingual occlusion. The expansion arches, before insertion, were bent to give spring for the correction of these positions.

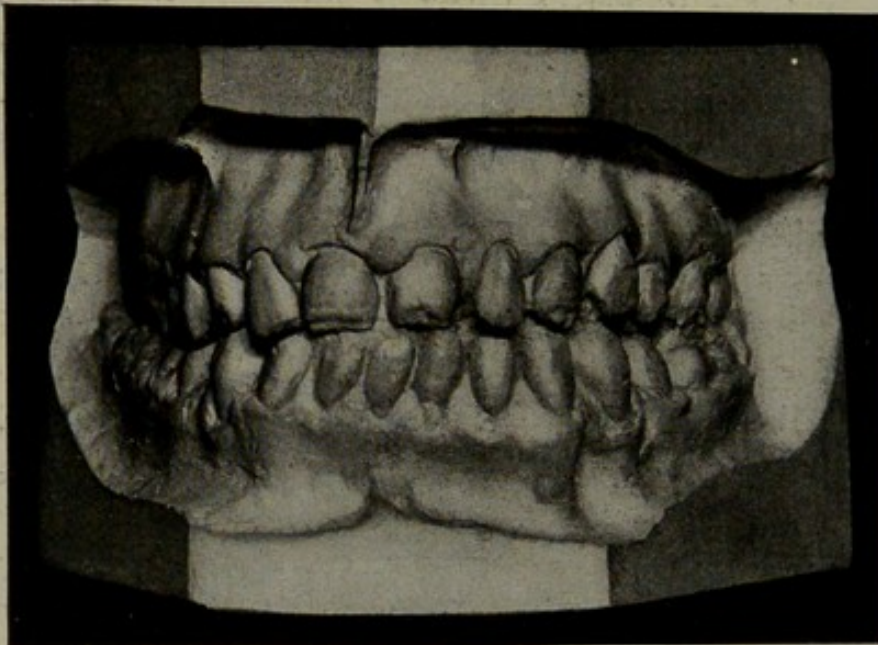
After the movement of the teeth had been continued for about six months a period of rest was given the patient to await the growth of the alveolar process, during which time retention of the teeth was effected simply by allowing the arches and ligatures to remain passively in position. The case was of course occasionally inspected to make sure that all bands and ligatures were in order, and at the end of the period of rest the development of the tissues was noticeable and gratifying. The arches were removed and after bending them to give the necessary spring, they were reinserted and tension again given to the teeth through the adjustment of ligatures, as previously. After continuing the movement very slowly for three months more an impression was taken of the labial and buccal surfaces of the teeth while in occlusion, as illustrated in Fig. 416, which truthfully indicates the relations of the teeth at this time.



Further movement of the teeth seemed to the author unnecessary. The patient was again dismissed with instructions to return for occasional inspection of her teeth, which were retained as formerly by means of the arch and ligatures. These were worn for about a year and then removed. No unfavorable movements of the teeth recurred.

Great caution should be observed in all such extensive operations for elevating the teeth not to excite inflamma-

FIG. 416.



tion or to move the teeth too rapidly. The movement should be very slow, but continuous, otherwise there will be great danger of destroying the pulps. This should be apparent when we remember how extensive must be the changes in the periodontal membrane and alveolar process, and what a severe strain is put upon these tissues incident to effecting such great changes in the positions of the teeth.

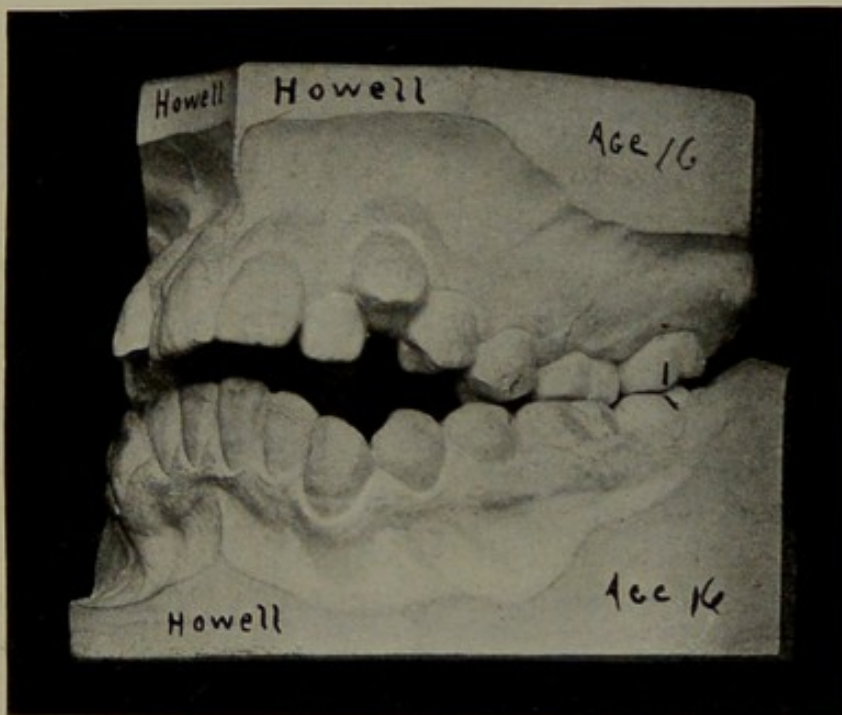
Such cases present many points of interest. One that impresses the author is the readiness and completeness with which the gum tissues, and probably to some extent the alveolar tissues, follow the teeth in these extensive



movements. It is doubtful whether the treatment of these cases should ever be undertaken after maturity, although we have as yet nothing but theory to suggest fear of alveolar disintegration as a result later in life.

Fig. 417 shows another very marked example of this type of cases which is further complicated by diminution in the sizes of the arches and crowding of the anterior teeth, especially the upper, together with lingual relations

FIG. 417.



of the upper first molars with the lowers, with the usual result of modifying the growth of the alveolar process, as already pointed out in connection with the cases described on pages 414 and 419.

In the treatment of this case, begun in April, 1903, it will be observed how extensive must be the elevation in order to bring all the teeth into harmony with the line of occlusion, and how great must be the force necessary to accomplish these movements, and yet by analyzing the true conditions and pursuing a course of treatment in accordance with the



requirements the entire operation may be greatly simplified, with the saving of considerable force.

The first step in treatment to suggest itself would probably be the downward movement of the upper incisors, canines, and premolars, with the elevation of the lower canines and premolars. In the logical plan of treatment, however, this would not be the correct procedure. For the time being the problem of the "open bite" should be ignored, and the case treated as if not complicated therewith. The arches should be enlarged and the teeth moved into alignment. By this time the open bite would be increased instead of diminished, which, of course, should occasion no anxiety, for it would be but the natural result.

What we may consider the second stage of the operation—the movements of elevation—may then be begun, and accomplished as already described in the two cases immediately preceding. As all of the teeth were loosened in the first operation their elevation will require far less force than if this operation had been the first performed, besides taxing the fibers of the peridental membrane and the nervous and vascular systems much less. In fact very little force was needed in this case, but great caution was necessarily exercised in order to avoid inflammation, long periods of rest being allowed for the building of normal bone, etc., the necessity for which has already been pointed out.

The result of following this plan of treatment is shown in Fig. 418, the impressions being taken with the teeth in occlusion two years after the beginning of treatment.

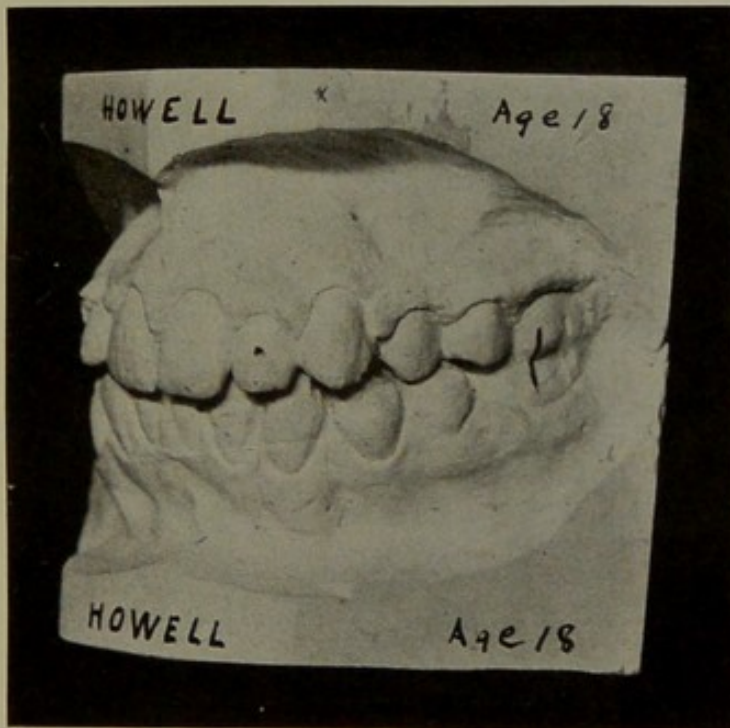
The incisors and canines of the upper arch were retained in the same manner as in the case last described, the upper expansion arch also being allowed to remain in position with the incisors attached thereto by ligatures, and with a button attached to the buccal surface of a band on the lower canine which a very delicate rubber ligature engaged, it also engaging a button on the expansion arch in the



region of the upper canine. Another delicate rubber ligature was also made to operate in like manner on the opposite side of the dental arches. After a time these rubber ligatures were worn only during the sleeping hours, and later only on each alternate night, their wearing being thus gradually discontinued as the teeth became established in their corrected positions.

The holding in correct relations of all four of the first molars was made far more difficult by a very needless

FIG. 418.



blunder committed by a dentist who had attempted the correction of the malocclusion some two years previously. In his effort to reduce the "open bite" he had removed all of the cusps of all of these molars by grinding, thus depriving the teeth of their power for maintaining their normal relations. This necessitated further grinding of these teeth in the effort to establish other cusps for their mutual support, which at best can never be anything but a travesty on Nature's beautiful normal patterns. No



practitioner should ever change the occlusal surface of a tooth until he fully realizes what this change will ultimately mean, not only to the tooth itself but to all the other teeth, and if he be intelligent, even though but beginning to comprehend the great principles of occlusion, he will long hesitate before resorting to mutilation be it ever so slight.

We now come to the consideration of mutilated cases, or cases that have been caused or aggravated by the extraction of one or more teeth.

FIG. 419.

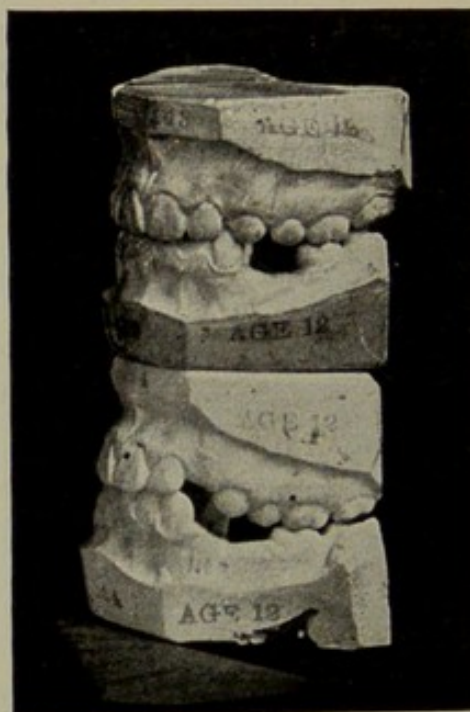

Fig. 419 shows the left sides of two models of a case, before and after treatment. The occlusion on the right side was normal. On the left (upper model) the lateral halves of both arches were shortened, the upper permanent lateral incisor being in contact with the first premolar. The mouth had a shrunk appearance and the incisors were shifted from the median line. This condition was the result of the unfortunate and unnecessary premature loss of the deciduous upper canine and the first and second deciduous lower molars.



It needs but slight reflection to realize what must further follow this unfortunate loss. The permanent upper canine on erupting must be forced into pronounced labial occlusion, with marked disturbance of the left lateral and central, while in the lower jaw marked malocclusion must follow the eruption of the premolars.

The treatment clearly indicated was the lengthening of the left lateral halves of both arches and moving the centrals forward and shifting their positions into harmony with the median line.

This was accomplished in both arches simultaneously by means of expansion arches, bands, and ligatures. No bands on the teeth to be moved were necessary. The incisors were laced to the arch with plain ligatures, as in A, Fig. 195. The notches in the ribbed arches for preventing the ligatures on the upper lateral incisor and lower canine from slipping were placed about opposite the middle of the centrals, so that force produced by tightening the nuts in front of the sheaths of the anchor bands on the first molars exerted a direct mesio-labial movement of these teeth, and as the nuts were tightened only on the affected side the lateral shifting of the incisors, as the arches were lengthened, was natural and easy. See Figs. 207, 321, and 399.

The result of treatment is shown in the lower model, the sides of the arches having been sufficiently lengthened to admit of the eruption of the upper canine and lower premolars.

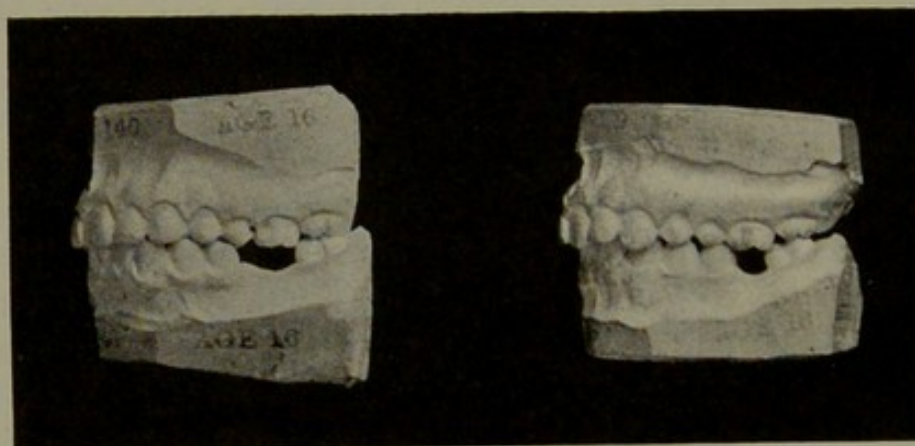
Retention was effected by means of a section of wire G which engaged tubes R, one of which was soldered at its end to the mesial surface of a No. 2 band on the molar, and the other similarly attached to the distal surface of a band on the canine. A few pinches from the regulating pliers slightly lengthened the wire, giving a firm resistance to the distal tendency of the canine, as in Fig. 224. A similar device, Fig. 225, was placed upon the upper lateral



and first premolar. These were worn until the eruption of other teeth made their use no longer necessary.

In the model on the right of the engraving, Fig. 420, is shown a case from which several valuable lessons may be learned. The case was that of a young lady sixteen years old. Two years previous to the making of this model the occlusion of her teeth was practically faultless, and with the exception of the left lower first molar the teeth were of excellent structure and color. At this time this molar was lost through neglect of caries; then followed the tip-

FIG. 420.



ping forward of the second molar—the inevitable result. Its inclined planes being locked in occlusion, as the tipping progressed the mandible was forced to recede, at the same time causing slight forward movement of the left molars, premolars, and canine of the upper arch, resulting in the gradual shifting to nearly complete distal occlusion of the teeth in this lateral half of the lower arch anterior to the space. Pressure from the upper lip gradually molded the upper arch to the diminishing size of the lower, as shown by the bunching of the incisors, while pressure from the lower lip assisted in moving distally the teeth anterior to the space, all of which might have been avoided by the timely insertion of an artificial substitute.



The treatment clearly indicated\* was the lengthening of the lateral half of the lower arch, the tipping to an upright position of the second molar, and the correction of the positions of the teeth in the upper arch, or the restoration of all the occlusal planes of the teeth to their original positions.

The truing of the positions of the upper teeth was accomplished by means of the expansion arch, bands, and ligatures, while the lengthening of the lateral half of the lower arch was effected in the same manner as in the case last described.

The molar was tipped to an upright position by force exerted upon the nut in front of the sheath of the anchor band, and also by bending the expansion arch at the point where it entered the sheath so as to give a spring or pry upward on the mesial end of the sheath and a downward pry on the distal end. The result is shown in the model on the left in the engraving.

The patient was then referred to her dentist for an artificial substitute for the lost molar, which being provided in the form of a bridge served the double purpose of retention and mastication. The requirements of orthodontia and bridging are such as should induce a closer study of their relations, and if, before making bridges for their patients, dentists would refer them to competent orthodontists better results would very often follow. The placing of bridges on leaning piers is unmechanical, and, as applied to the mouth, both unmechanical and unphysiological.

A point we would emphasize in relation to this case is that the changes taking place in this previously faultless arch, as a result of the loss of this first molar, are such as must and do always follow the loss of this tooth. Examine a thousand similar cases and as many similar results will be found.

---

\* Angle. Sixth edition, 1900.



It will be noticed in the model on the right that none of the teeth on this side occlude, but that they merely touch

FIG. 422.

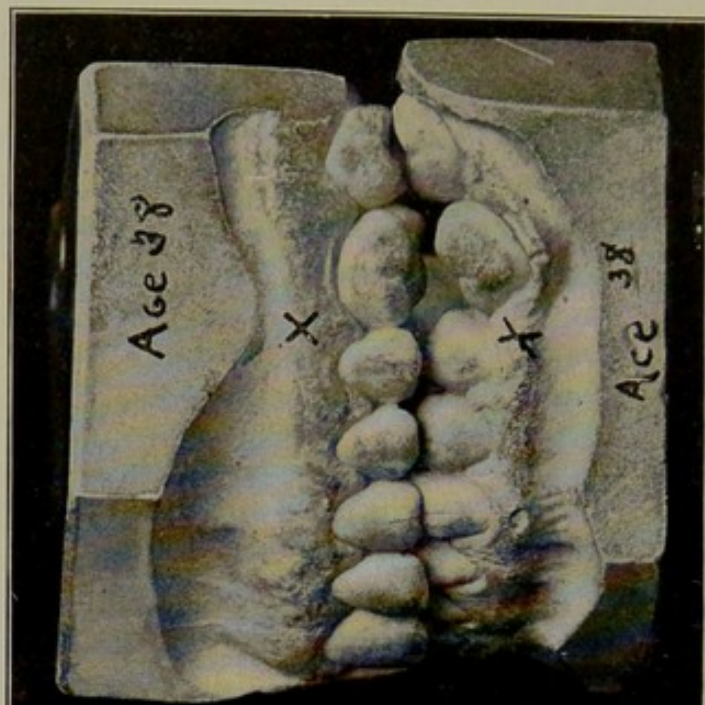
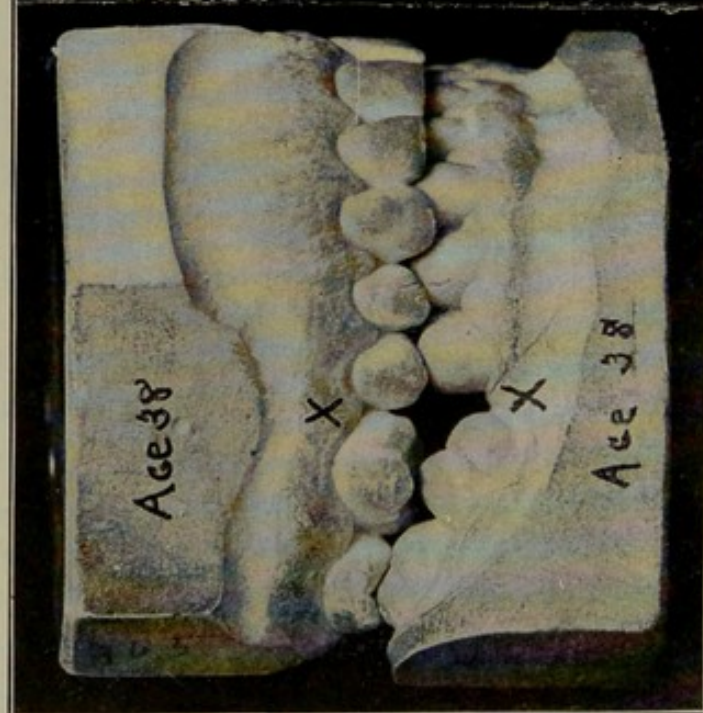
FIG. 421.



at irregular intervals, and are practically worthless for mastication. What we would especially emphasize in this



connection is that the odontocide is not relieved of his responsibilities by the extraction. He must immediately replace the lost tooth by some form of artificial substitute or be certain that he has established conditions that will lead to the serious impairment of the occlusion on the side of the arch from which he has extracted the tooth.

Figs. 421 and 422 show a most unfortunate result from both right and left sides, following the extraction of the four first permanent molars, which, though perfectly sound, were removed at the age of nine years with the idea of making space to prevent malocclusion of the other teeth, and how successful was the effort is readily seen. The result is but natural. Not only have the remaining teeth been rendered almost useless for mastication, but in recent years there has been chronic pericementitis, resulting from the wrongly directed force upon the molars in their tipped and abnormal positions. The facial lines were also greatly marred by the arrest in the development of the alveolar process, as shown in Fig. 424, for without the wedging influence of those most important teeth—the first molars—the teeth anterior could not be pushed forward by the eruption of the second and third molars, which is necessary for the proper contouring of the face.

Gold-capping of the leaning molars, resorted to by the patient's dentist in this case to improve the occlusion, only aggravated the condition, for the gold crowns only gave a longer leverage thereby increasing the force through occlusion for tipping the teeth.

There was but one logical and rational plan of treatment, namely, to regain the lost spaces of the four molars and replace the teeth by artificial substitutes.

To accomplish the movements of the teeth the same general plan of treatment was followed as in gaining the space for the missing first molar in the case last described. All four second molars were encircled by D bands, but before placing the lower bands in position the sheaths were



resoldered to align properly. The ribbed expansion arches were inserted, in which hook-like notches were made just anterior to the four canines. The heavy wire ligatures were looped over the second premolars, brought forward to engage these notches, and firmly twisted, thereby at once exerting a strong tension in a mesial direction on all the second premolars, which in turn was transmitted to the first premolars, canines, and laterals, as in Figs. 207 and 419. This force was of course reciprocated to the second molars to move them distally and in turn transmitted to the third molars.

This appliance having been most carefully and firmly adjusted, it will be seen that the occasional tightening of the nuts in front of the sheaths must result in gradually carrying forward all the teeth anterior to the spaces, and at the same time in moving all the molars distally. The most difficult problem apprehended was to gradually effect at the same time the tipping to an upright position of the greatly leaning lower second molars. Yet by taking advantage of the possibilities of the upward pry of the expansion arch, this was readily effected.

As the movements of the teeth progressed, the spring of the arch from the upward pry gradually became insufficient, necessitating the removal of the lower D bands and the re-soldering of their sheaths in order to again intensify it.

As it was desired to carry all of the teeth anterior to the spaces well forward, the force necessary was so great that before its completion the molars had been moved distally and to upright positions. Their further movement was then arrested by changing the anchorage from simple to stationary, easily effected by bending the arches so as to prevent further upward spring.

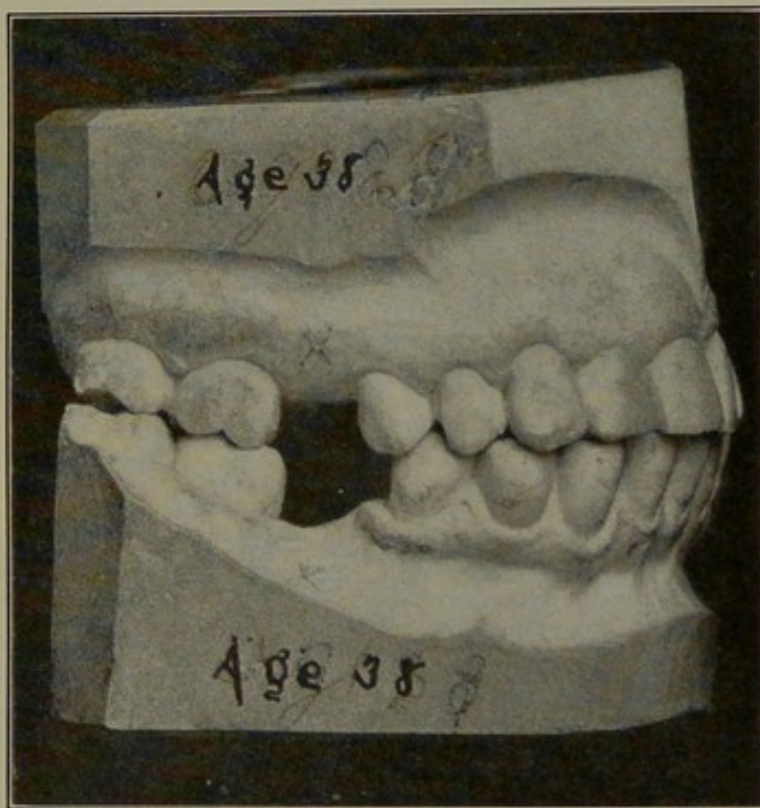
Notwithstanding the advanced age of the patient (thirty-eight years) supposedly unfavorable for the treatment of malocclusion, it being the most advanced age recorded for



such an extensive operation, the author was agreeably surprised to find that the teeth were moved quite as easily and fully as rapidly as is usual in the case of a miss of eighteen, and with no unfavorable symptoms following the movement of any of the teeth.

The result in occlusion is shown in Fig. 423. It will be seen that all the teeth anterior to the space have been

FIG. 423.



carried well forward, and that the molars have been moved distally and into correct relations.

Retention was effected by a vulcanite plate both above and below which bore against the lingual surfaces of the anterior teeth and filled the spaces of the missing molars, and the case was finally referred back to the patient's dentist, who, after some months, skilfully inserted some very perfect bridges.

The remarkable changes in the sizes of the arches and



the relations and inclinations of the teeth are naturally reflected in the lines of the mouth as related to the other

FIG. 425.


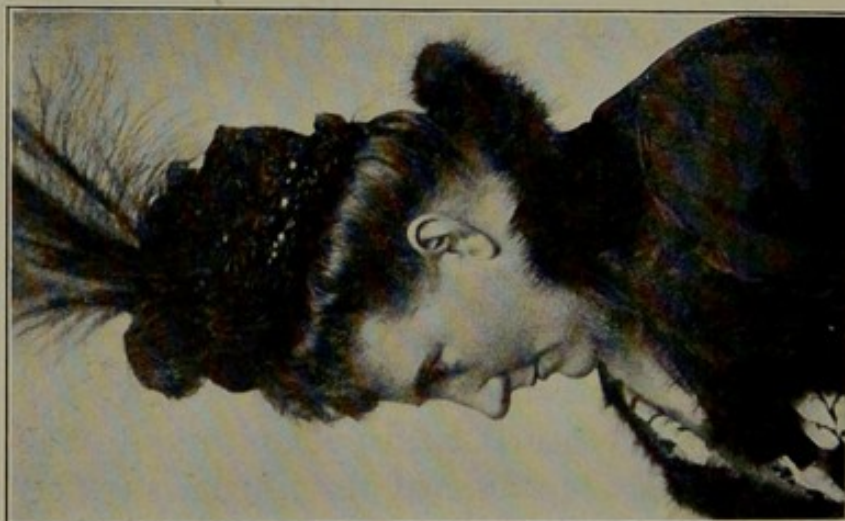


FIG. 424.



features, as will be noted by comparing the face before and after treatment, as shown in Figs. 424 and 425.

Great as are the changes in the facial lines, the close



FIG. 426.

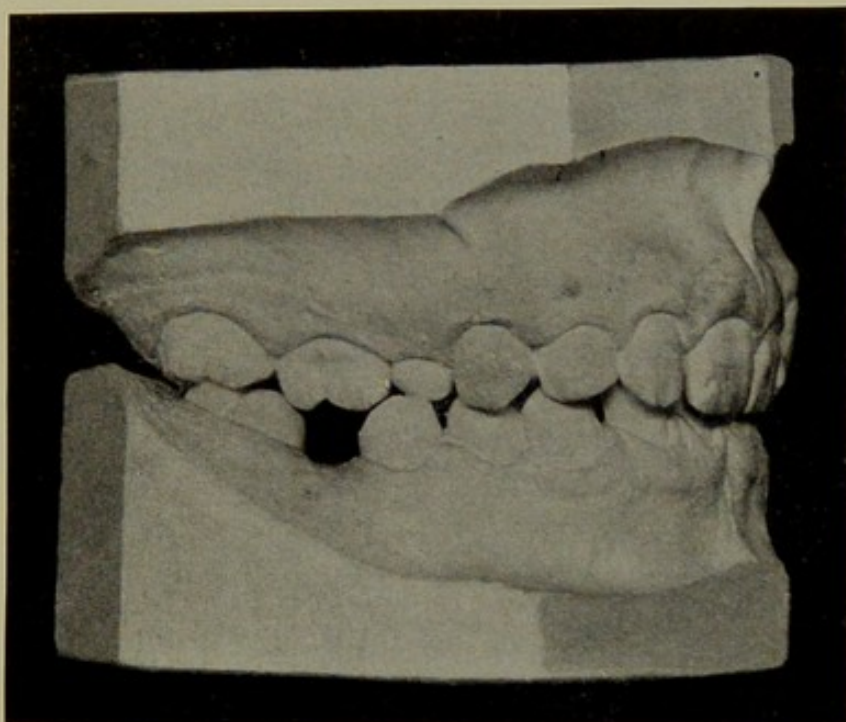


FIG. 427.

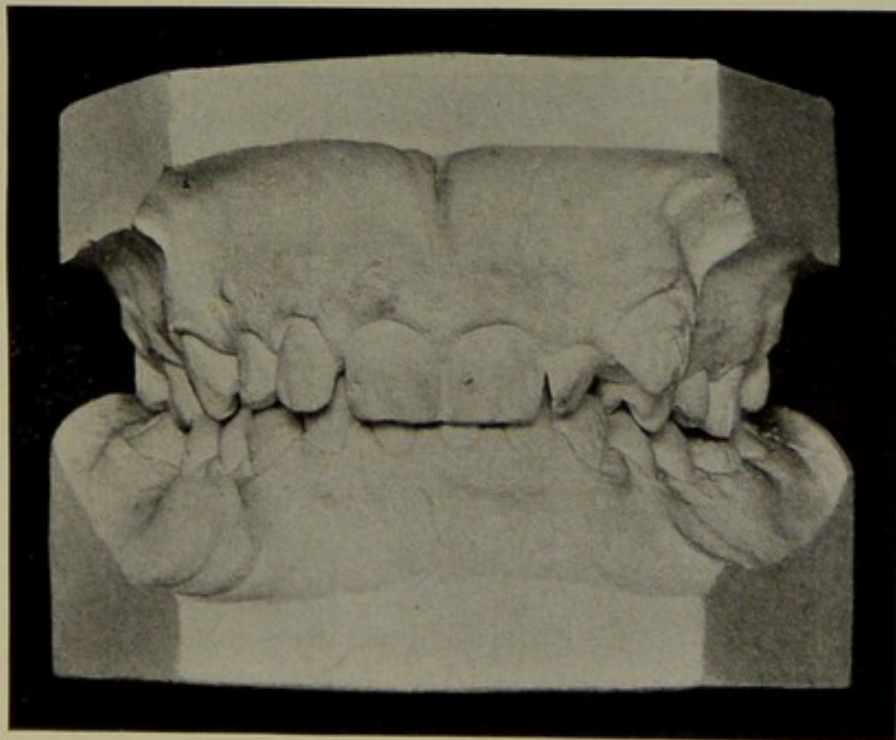




FIG. 428.

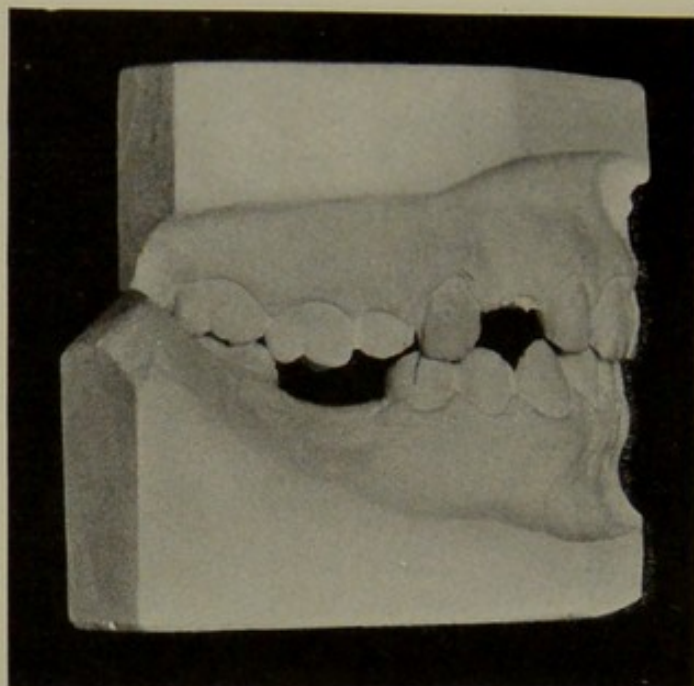
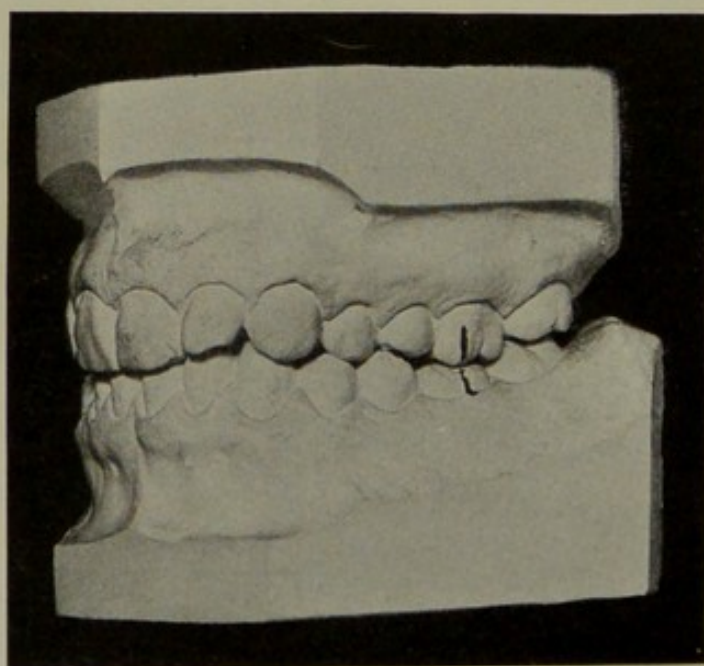


FIG. 429.





student will observe that there is still not complete normal contour of the mouth, which, as we perceive, is but natural when we remember how the arches were robbed in youth of that normal wedging influence of the first molars, so necessary to effect the normal development of the bones of the face and its consequent normal contour.

Figs. 426 and 427 show unfortunate mal-relations of teeth which are directly traceable to the extraction of the first lower molar on the right side, and a filling in the first lower molar on the left which in size and form, though similar to those commonly seen, is in direct violation of Nature's tooth pattern and requirements, not only in the function of mastication but in the maintenance of the normal relations of all the other teeth. The result, from the loss of the molar, and from such a filling, is what must always follow—diminution in the size of the arch; and as the loss of the molar occurred some time before the eruption of the canines, the lingual movement of the upper incisors naturally resulted from the pressure of the lips and the lack of resistance through occlusion of the lower teeth, with the usual added complications of the shifting of the upper incisors to the left and out of harmony with the median line, while the opposite was the result with the lower incisors. The bite, also, has naturally been greatly shortened through lack of normal support from the first molars and the downward and inward movement of the upper incisors.

It must be apparent that without interference the mal-occlusion will be progressive. It is clear in the treatment of this case, that further extraction would only augment the existing conditions, and that the only logical plan was to enlarge the lower arch, regain the full mesio-distal diameter of the space made vacant by the loss of the molar, enlarge the upper arch, and place all of the teeth in their normal positions, which was accomplished by means of the expansion arch operated after the manner already



described for performing the various movements here required. The result of such treatment is shown in Figs. 428

FIG. 431.

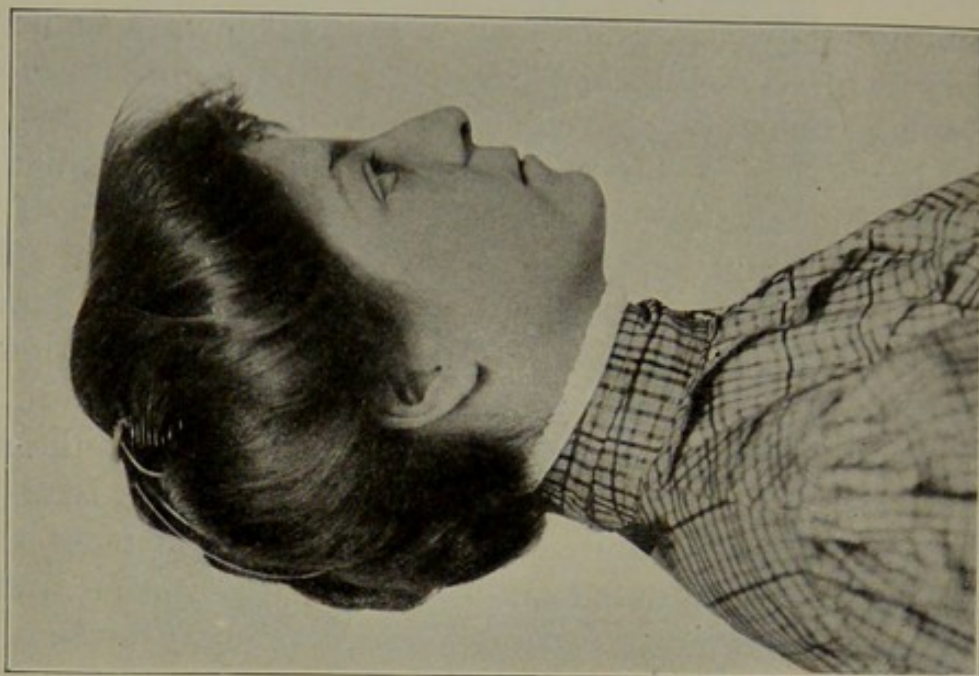
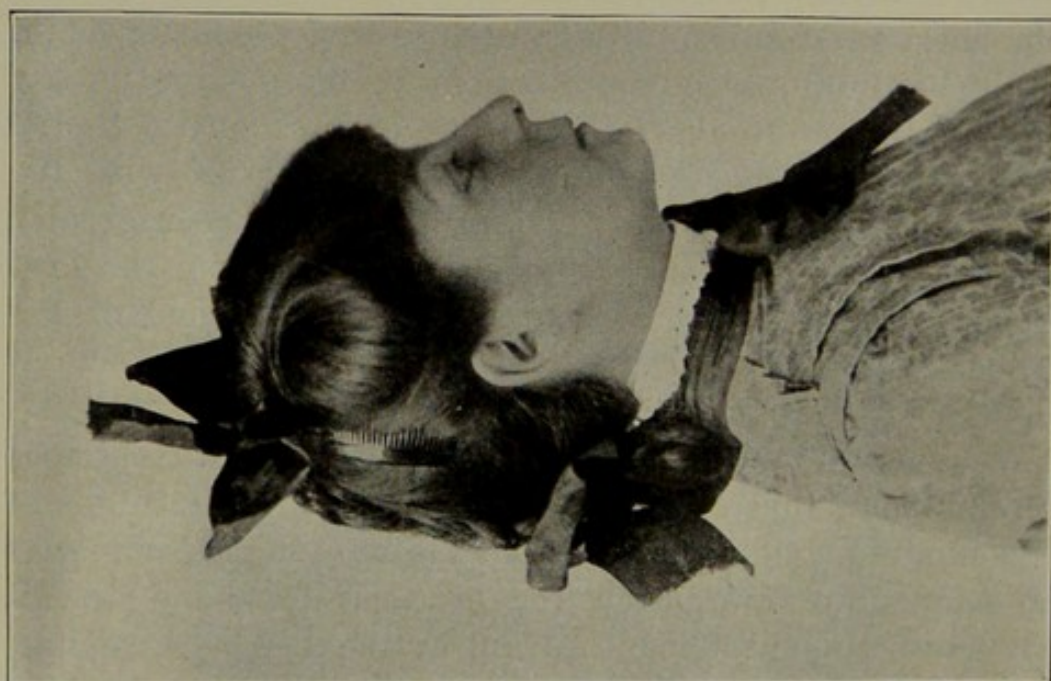


FIG. 430.



and 429. The upper deciduous canine having been lost, its successor is about to erupt, as also shown.



The retention of the lower arch was effected by the proper form of bridge for the missing molar. On the left side it will be seen that there is inharmony between the relations of the canines and premolars which can never be corrected until the diminished crown of the lower molar has been restored to its full mesio-distal diameter and contour.

The profile of the patient before and after treatment is shown in Figs. 430 and 431.

It has been deemed necessary to show but very few simple cases belonging to this class for the reason that all their peculiarities are embraced in the more complex, a thorough understanding of which renders easy the management of the former.



## CHAPTER XVII.

### TREATMENT OF CASES.—CLASS II, DIVISION 1.

It will be remembered that the distinguishing characteristics of cases belonging to this division of this Class are distal occlusion of both lateral halves of the lower arch, more or less undeveloped mandible, narrowed upper arch, lengthened and protruding upper incisors, and lengthened lower incisors. It will also be remembered that those afflicted with this type of malocclusion are in almost every instance affected with some form of nasal obstruction necessitating mouth-breathing which usually begins at an early age, causing the mouth to be held open almost constantly and the lips and buccal muscles to act abnormally. In the effort to breathe, the upper lip is drawn upward and fails to develop in size and function, exercising little restraint upon the labial movement of the incisors. Their protrusion, therefore, becomes more and more pronounced, partially as a result of pressure from the tongue and narrowing of the arch through malocclusion and the action of the buccal muscles, but principally because the lower lip is so frequently forced against their lingual surfaces in swallowing and in the effort to moisten the mucous membrane of the mouth. Both upper and lower incisors become lengthened, probably from lack of function, so that the occlusal edges of the lower are in many cases in contact with the mucous membrane of the hard palate.

It is a common mistake to suppose that this form of malocclusion is the result of over-development of the upper jaw. The author has never seen a case where this condition existed, neither are the teeth of the upper jaw "inherited too far forward," as we have pointed out in the chapter on Occlusion.



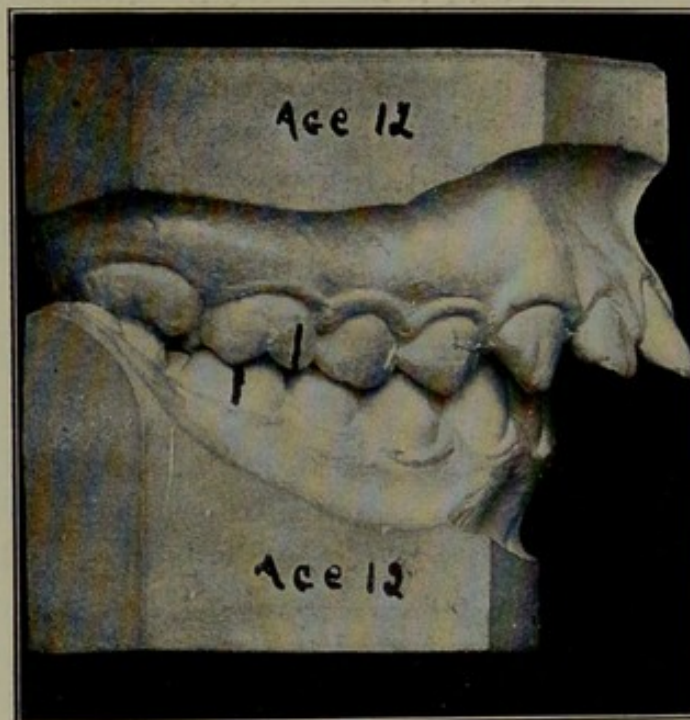
The narrowed upper arch and lengthened upper teeth, the lower jaw diminished in size and distal in relation, the arrest in the development of the nasal apparatus, the modification in form and function of the nose and muscles, and the marred facial lines are but the natural results of the failure of the first permanent molars to lock normally at the time of their eruption, accompanied and probably preceded by pathological conditions of the nose or throat that established the habit of mouth-breathing. It is interesting to note the gradual and progressive development of cases belonging to this class, after once started, through the perverted functions of respiration and occlusion. It seems reasonable to believe that the mandible is arrested in development by being held distally through malocclusion and the abnormal action of the muscles. And there is yet another reason which seems hitherto to have been unnoticed, namely, the abnormal distribution of force on the lower teeth through the malocclusion. Normally the force is distributed on the line of the long axes of the teeth, but when the lower molars lock in distal occlusion the force is received principally upon the anterior half of their crowns, as shown in Fig. 432, the tendency being to drive their apices distally, or at least to prevent their normal movement forward, which would also prevent the normal growth and lengthening of the jaw. This seems most probable when we consider how pronounced is the interference with the normal growth of the mandible, maxilla, and alveolar process, by the abnormal distribution of force in those cases where the upper teeth on erupting lock in lingual occlusion, as has already been pointed out in the consideration of the cases illustrated in Figs. 397 and 398.

Cases belonging to this division usually begin with the mal-locking of the first permanent molars at the time of their eruption, although we now know that they may be established much earlier, or during the development of the deciduous denture, and this is not remarkable since nasal



obstructions from adenoid growths are often well-defined at two and three years of age. They may be so slight at first as to occasion mouth-breathing only at intervals and later disappear entirely, but if sufficient at the time of the eruption of the first permanent molars to deflect the normal relations of these teeth into abnormal (distal) relations—and but a few days would be necessary to accomplish this—the nucleus of conditions would be established

FIG. 432.

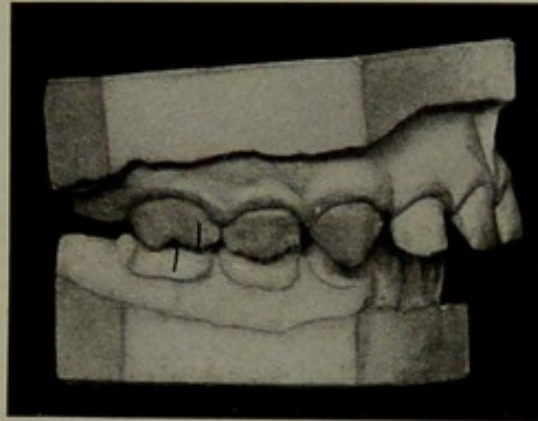


which must progress until all of the conditions of a typical case of either the first or second divisions of this class have developed. Once established it is remarkable what similarity exists between the cases of each division especially those of the first, the differences being chiefly in degree which is usually in proportion to the age of the patient. And as we have already noted in the chapter on Facial Art, the disturbance in the balance of the facial lines is very noticeable and in direct proportion to the degree of the malocclusion.



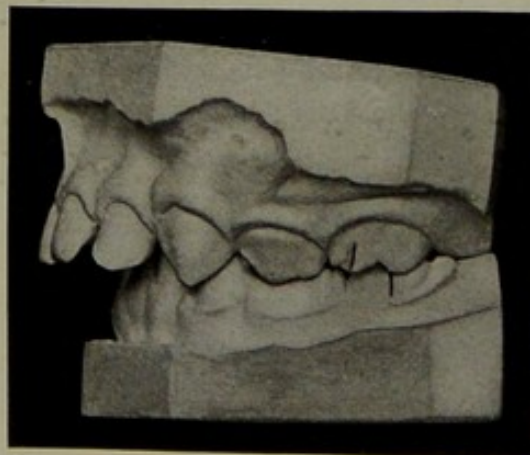
The logical plan of treatment of cases belonging to this division is to divert from abnormal to normal action the forces which are operative in producing the deformity, or, first remove the cause by proper treatment of the nose,

FIG. 433.



making normal breathing not only possible, but actual, and then establish the normal occlusion of the teeth and the retention of the same until all of the tissues and muscles involved shall have become normal in growth and harmon-

FIG. 434.



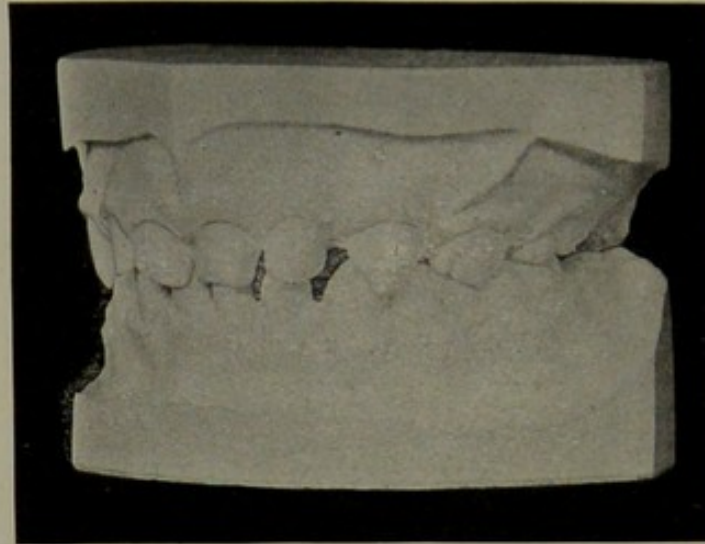
ious in function through their mutual co-operation. Naturally, the earlier the treatment, the more perfect must be the ultimate result.

Figs. 433 and 434 show the occlusion of the teeth in a well-defined case belonging to this division of a child less



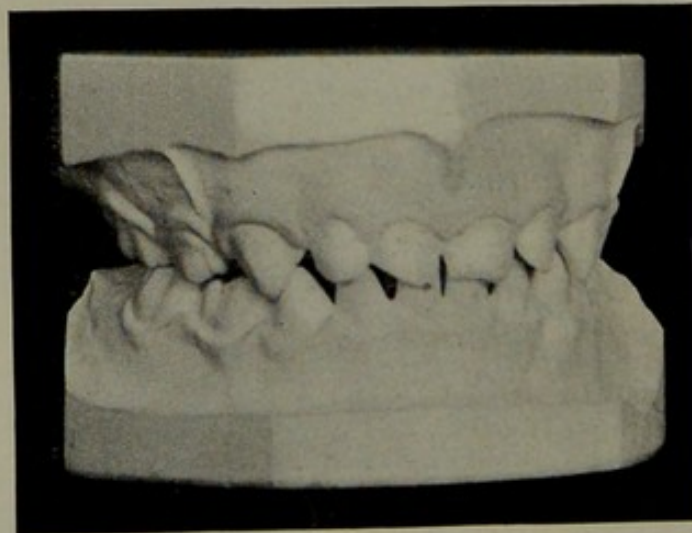
than four years of age. It will be seen that all the lower teeth are in distal occlusion and all of the forces wrongly

FIG. 435.



directed, and that the development must be continuously retrogressive so long as these conditions are permitted to exist.

FIG. 436.



Notwithstanding the complexity of the malocclusion and the extreme youth of the patient the treatment was easily and successfully performed, and Figs. 435 and 436 show the splendid results in the establishment of normal occlusion.



FIG. 438.

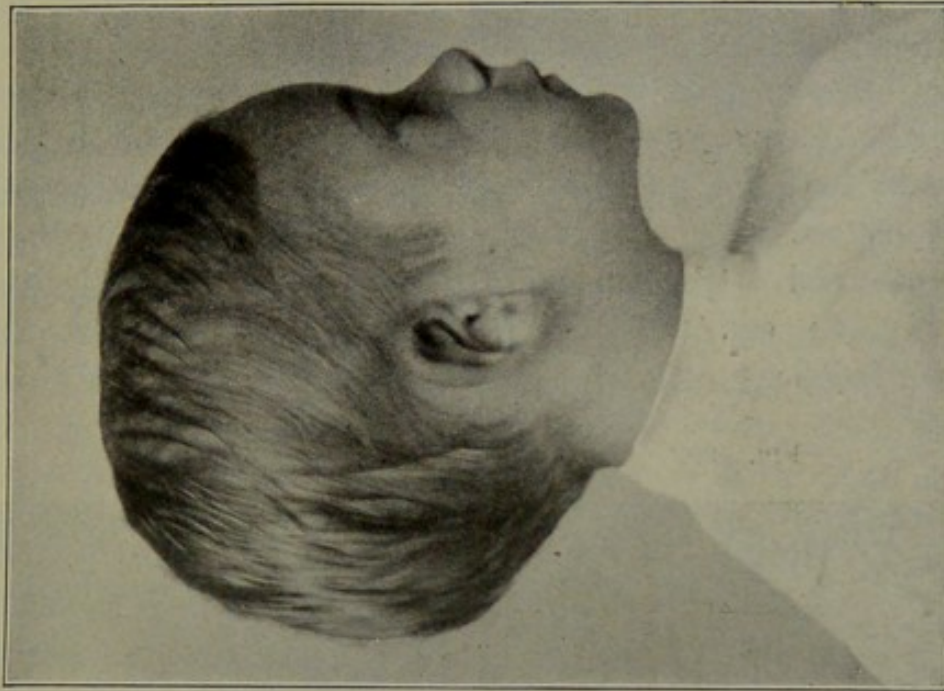
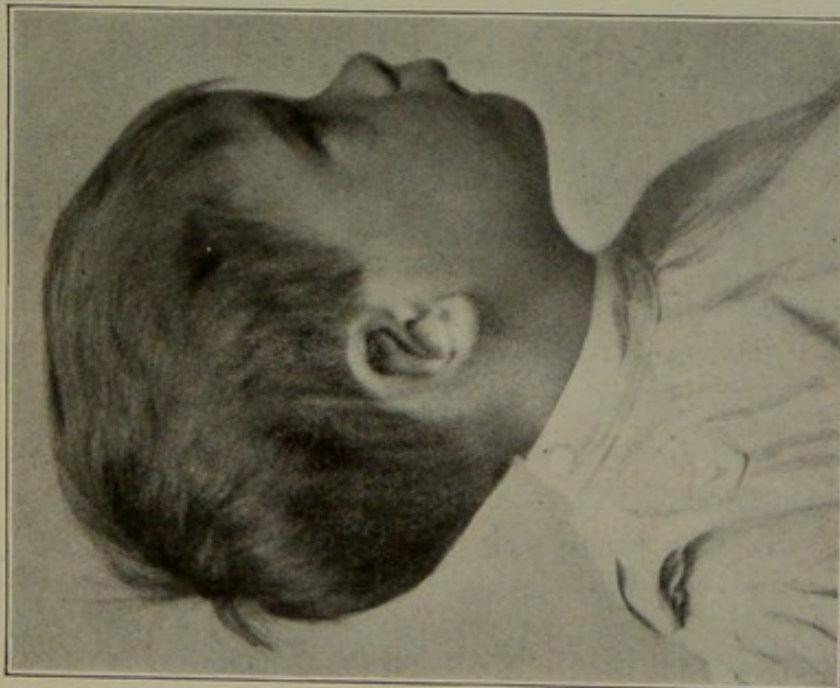


FIG. 437.



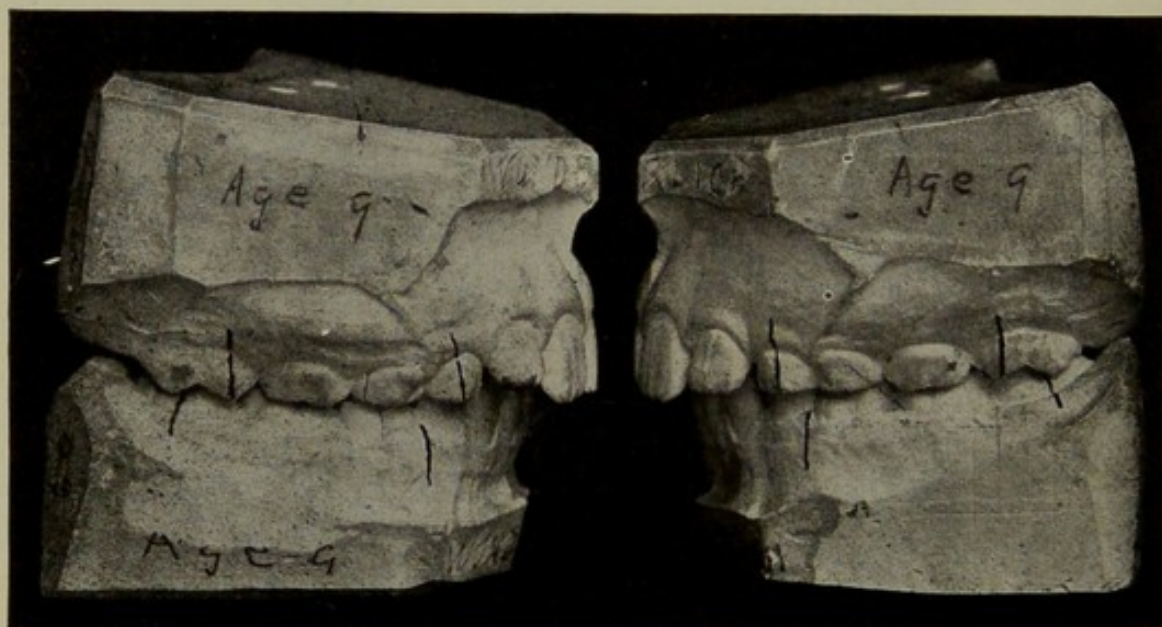


By comparing Fig. 437 with Fig. 438 it will also be noted how marvelous are the changes in the facial lines of this child as a result of this treatment.\*

As the result of intelligent treatment Nature is now permitted to progress normally in her work of building the denture, and the prospects of the ideally normal result, as compared with the possible result in cases that have been allowed to progress until "all of the teeth (permanent) have erupted," ought strongly to impress all thoughtful persons with the gravity of the error of delay.

FIG. 439.

FIG. 440.



Figs. 439 and 440 show the occlusion of the teeth of a boy aged nine years. The cusps of the deciduous teeth being worn nearly smooth it was very easy for the first permanent molars to begin abnormal relations in locking as their eruption proceeded, thus effectually preventing the normal locking of the teeth subsequently to erupt.

---

\* This patient was treated by Dr. Guilhermena P. Mendell, of Minneapolis. It is the youngest case on record where anything like such extensive malocclusion of the deciduous teeth has been corrected. The case was reported at the meeting of the American Society of Orthodontists, September, 1905.



The plan of treatment followed in this case is the most natural, logical, and practicable. It consisted in establishing normal occlusion between the first permanent molars and maintaining them in these relations, and at the same time insisting on the proper treatment of the nose and throat and on the patient's forming the habit of breathing normally.

All four of the first permanent molars were fitted with D bands and the expansion arches slipped into position after first bending them so as to make them lie in close proximity to the dental arches they were to encircle. As there was the proper width of the dental arches between the first molars, no lateral spring was given to the expansion arches, and as no lateral movement of the incisors was necessary the ribbed arches were not needed, the plain arches only being used.

The sheaths of the anchor bands were aligned so that the upper expansion arch rested just below the gingival margins of the incisors, while the lower rested at a point about one-half the distance between the cutting edges of the incisors and the gingival line. No ligatures or plain bands were necessary. Sheath-hooks were soldered to the upper expansion arch at points opposite the lateral incisors and the arch adjusted. The patient was then dismissed for several days until he should become thoroughly accustomed to wearing the appliances and all soreness had subsided. One of the most delicate of the intermaxillary elastics was then adjusted by first hooking it over the sheath of the lower D band, bringing it forward, and slipping it over the sheath-hook on that side, as shown in Fig. 190. The patient was impressed with the necessity of keeping the lips and jaws closed in order that the force of the intermaxillary elastic might be expended in the desired direction and the normal function of the lips established. But only after many weeks of patient persistence was he enabled to overcome the habit of holding the mouth



in the half-open manner characteristic of those suffering from this deformity, even after the successful treatment of the nasal passages.

After wearing the single elastic for a few days another was added in like manner on the other side and the nuts of the upper expansion arch adjusted until all the force of the elastics was expended upon them, and transmitted to the upper molars, the arch not being permitted to bear on the prominent incisors. In this way the force from the intermaxillary elastics was directly reciprocated from one opposing molar to the other, and the mesial movement of the lowers and the distal movement of the uppers thus begun. After about two weeks the patient had become so thoroughly accustomed to the appliances and the force from the ligatures as to be hardly conscious of their presence. Another elastic was then added on each side which was inspected once each week.

As the upper molars were moved distally the nuts were occasionally tightened in order to prevent any force being exerted upon the central incisors, and as the lower molars were moved forward, carrying with them the teeth anterior to them, the anterior part of the lower expansion arch naturally was deflected downward below the gingival margin of the incisors. To remedy this it was removed and carefully bent upward just anterior to the nuts. After a short time the molars had been moved into their normal mesio-distal relations, but the movement was carried somewhat beyond the normal to allow for the adjustment and settling of the retaining devices.

The appliance was then allowed to remain passive for two or three weeks, only the weakest of elastics being used, after which it was removed and the teeth carefully cleansed. The sheaths on the anchor bands were removed by unsoldering, and after the attachment of planes and spurs to the bands by solder at the proper angles they were replaced and firmly cemented, as shown in Fig. 256. The

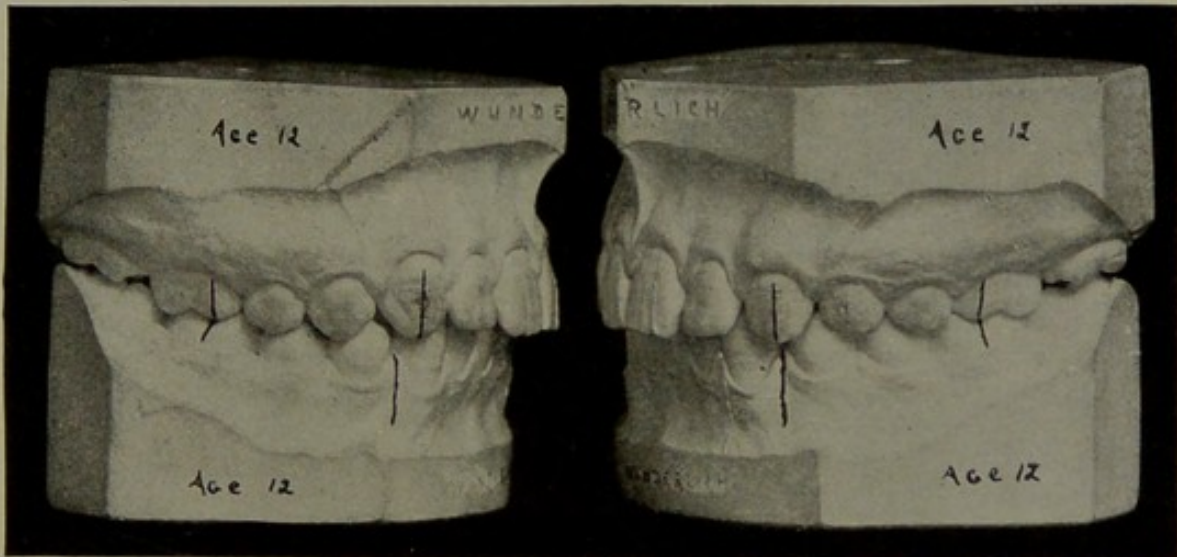


treatment thenceforth consisted in the occasional inspection of the intermaxillary retainers, and insisting on the patient's breathing normally and exercising the normal function of his lips.

Normal conditions now being established, the growth of the denture progressed normally, and as each deciduous tooth was lost its successor erupted and locked in normal occlusion, thus assisting in maintaining the proper relations of the jaws and dental arches.

FIG. 441.

FIG. 442.



Figs. 441 and 442 show the occlusion of the teeth of the boy three years later.

Fig. 443 shows his profile at the time of beginning treatment, and Fig. 444 at the time of making the last model of his teeth.

It will be seen how the unpleasing facial lines have been changed to those of proper balance, and continuous change for the better (or toward the normal) must follow as growth and development progress.

The use of intermaxillary force, as in the treatment of this case, might raise the question as to whether the anchor bands alone would not be sufficient without the



lower expansion arch. Without it the molars would be partially rotated and deflected buccally incident to the

FIG. 443.



great strain upon them necessary to carry all of the lower teeth forward.

FIG. 444.



Figs. 445 and 446 show the mal-relations of the jaws and teeth from both right and left sides of a miss twelve years

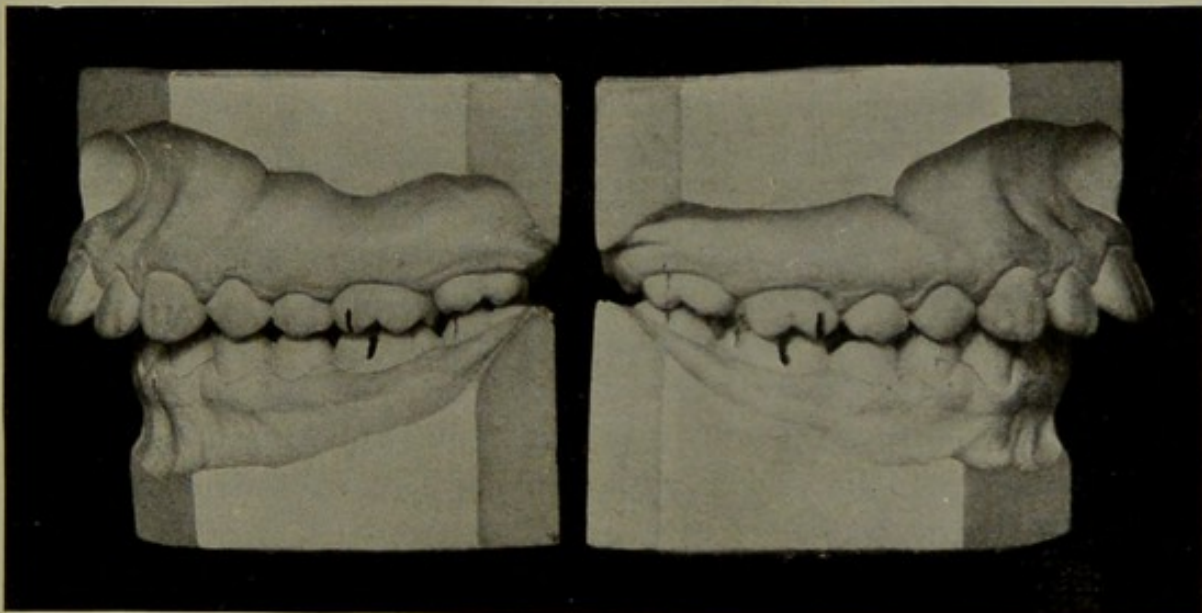


of age. On the right side there is complete distal occlusion, but on the left the teeth are not yet in full distal occlusion, yet as probably all of the inclined planes favor this relation it is only a question of a short time when, if allowed to continue, it must be fully established.

The upper arch is gradually becoming narrowed through the influence of the muscles, and the upper incisors forced labially through the action of the lower lip.

FIG. 445.

FIG. 446.



The same general plan of treatment was followed as in the last case, but as the malocclusion had become more complicated through the eruption of more of the permanent teeth, with greater labial prominence of the upper incisors, the difficulties in treatment became greater, necessitating that the upper arch be shortened in front, and widened in the region of the premolars and canines, and that the crowns of all the upper teeth be tipped distally and those of the lower tipped mesially sufficiently to establish normal occlusion.

As the malocclusion began with the distal locking of the first permanent molars, and the protrusion of the in-



cisors (only a symptom) is the result of the same, the logical plan of treatment is again to begin with the first molars and not with the symptoms, or prominent incisors, as in the older plans of treatment so long followed, leaving the movement of the incisors until the last.\*

Plain expansion arches were adjusted in precisely the same manner as in the case last described, D bands having been placed on all four first molars, and sheath-hooks attached to the upper expansion arch between the lateral incisors and canines. After the patient had become accustomed to wearing the appliances the movement of the teeth was begun through the application of the intermaxillary elastics.

In the treatment of the last case simple-intermaxillary anchorage was employed, that is, the upper and lower molars were pitted against each other, the force being reciprocal, the crowns of the opposing teeth being tipped in opposite directions. In cases similar to the one under consideration, however, it is usually necessary to employ stationary-intermaxillary anchorage, that is, securing such attachments to the lower molars as will prevent their tipping forward, and necessitating that if moved at all they be moved at the apices of their roots as well as at their crowns (see stationary anchorage). In this way the resistance of the lower teeth to the great strain necessary in compelling the distal movements of all of the upper teeth is enormously increased. This was accomplished by exercising unusual care in clamping and burnishing the bands upon the lower molars to fine adaptation and bending the lower expansion arch just anterior to the nuts so that when inserted it would, at its anterior part, rest about one-eighth of an inch below the gingival line and thus exert a spring upward and backward on the crowns

---

\* See paper read by the author before the New York Institute of Stomatology, October 7, 1902. Published in the *International Dental Journal*, October, 1903.



of the molars and prevent their tipping forward. It was then raised upward to about midway of the crowns of the incisors and securely held in this position by means of wire ligatures made to encircle it and each incisor, thus preventing its downward movement, as permitted in the last case. As no anterior attachments were made to the upper expansion arch, it being left free, the force exerted by the intermaxillary elastics upon the upper molars permitted their tipping, which was assisted by the leverage of the expansion arch and sheath-hooks, especially when the mouth was open. Delicate intermaxillary elastics were first employed and after a couple of weeks their number was doubled. The first and second upper molars were moved distally quite rapidly. This was continued rather beyond the required distance. Indirectly, through the attachment of the dental ligament the second premolars had also been drawn distally to a noticeable extent. The movement mesially of all of the lower teeth was also noticeable, though slight.

The bands were now removed from the upper first molars and X bands were placed upon the right upper first and left upper second premolars, the nuts on the arch moved forward, the arch replaced in position, and the elastics again applied, the nuts being turned to points on the arch that would allow the delivery of all of the force to the premolars and none to the incisors. In order to effect the distal movement of the left upper first premolar both upper premolars on the left side were encircled by a wire ligature which was made to rest gingivally to the sheath and occlusally to the screw on the lingual surface. The premolars were soon carried distally the requisite distance, and the canines, also, somewhat, through their fibrous attachments.

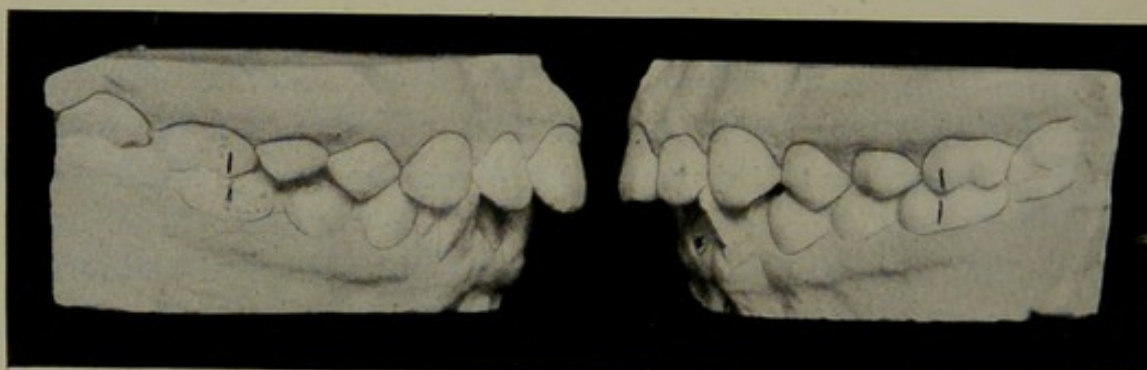
The force was now transferred to the incisors by releasing the nuts of the expansion arches from the sheaths of the X bands; and the wire ligatures were removed from the lower incisors, thus allowing all the lower teeth to tip forward. The upper incisors and canines were soon moved



the desired distance linguo-distally, thus establishing normal mesio-distal contact between all of the teeth of the upper arch, and normal occlusion of the denture.

These movements were effected in about two months. The normal mesio-distal relations of the teeth were maintained by bands upon the lower canines. These bands were made from the band material H and very carefully fitted and cemented. Upon their labial surfaces were soldered flattened spurs of metal which engaged the mesial inclines of the upper canines, as in Fig. 260. The case at this stage is shown in Fig. 447. The spurs were frequently inspected and occasionally modified by bending, in order to increase

FIG. 447.



or diminish the bearing as needed. Later it was found that the molars on the right side were not maintaining their full normal mesio-distal relations. They were promptly encircled by plain clamp bands No. 2 which had been fitted with spur and plane, Fig. 256, and carefully cemented in position. By occasionally bending the spur to give heavier bearing, their full normal relations were soon re-established.

The labial movement of the upper incisors was antagonized by a section of wire G made to bear against their labial surfaces, the ends being soldered to carefully fitted bands upon the canines. The patient was frequently admonished of the importance of establishing the habit of



FIG. 449.

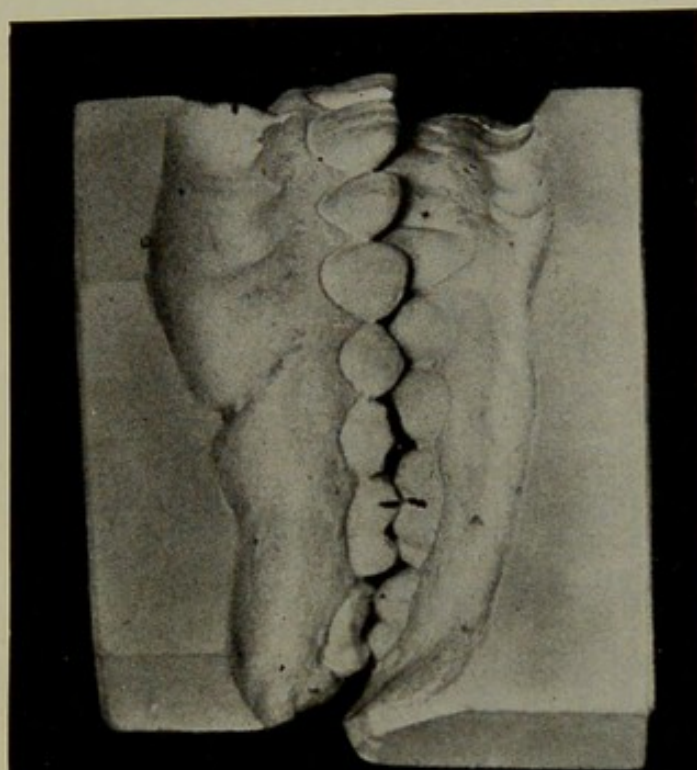
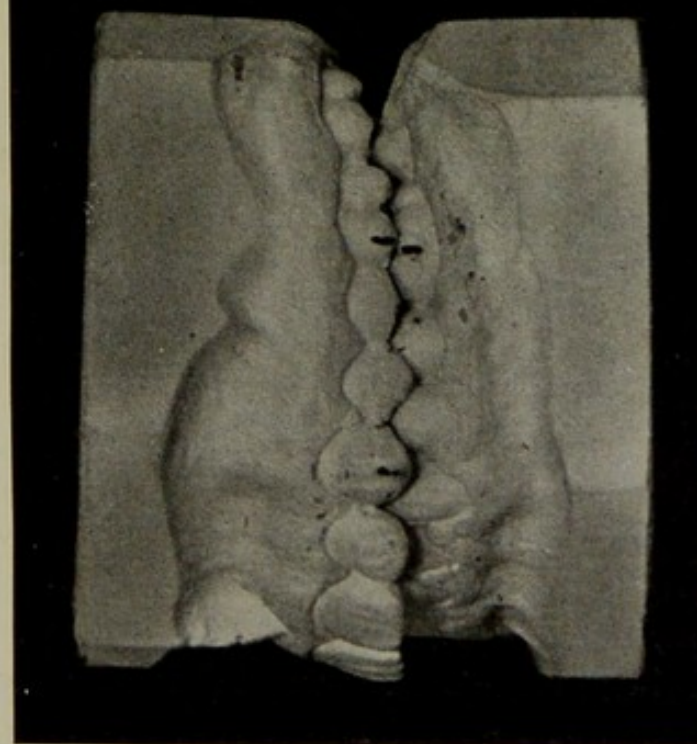


FIG. 448.





normally closing the lips and holding the teeth in correct position. As the nose had been successfully treated during the early stages of the orthodontic operation, normal breathing and normal lip function were gradually established and the patient dismissed after two years. The occlusion at this time is shown in Figs. 448 and 449.

FIG. 450.

FIG. 451.



Figs. 450 and 451 show the front and profile views of the patient's face before treatment, Fig. 452 shows the profile at the time of retention of the teeth, and Figs. 453 and 454 show front and profile views at the time the models shown in Figs. 448 and 449 were made.

It is gratifying to note how progressive has been the growth towards the normal in balance resulting from Nature's being permitted to continue it in a normal manner.

In the treatment of all such cases the degree to which the upper teeth should be moved distally and the lower teeth



FIG. 452.



FIG. 453.





forward must be determined by the operator, and accomplished by the careful and intelligent manipulation of the anchorage and application of force, both of which should be under his complete control.

FIG. 454.



As we have seen elsewhere, Nature exercises the greatest care in correctly placing the upper molars mesio-distally; hence the question may here be appropriately asked, why, if this be true, it is necessary to move the upper molars distally in these cases, as follows in this plan of treatment. This is easy of explanation. The mandible, being undersized through the perversion of forces, the movement of the teeth, if limited to the lower, would compel them to



FIG. 455.

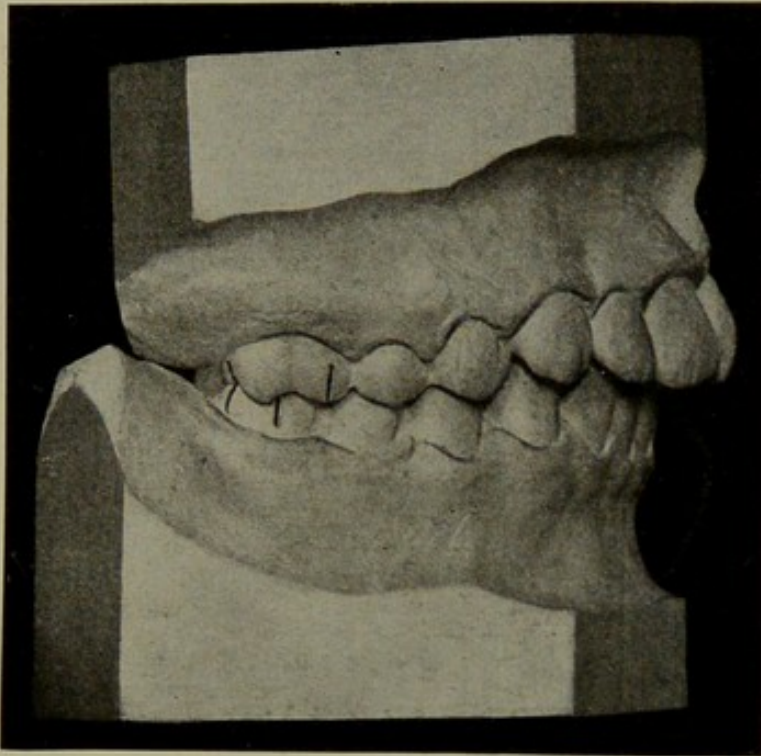


FIG. 456.

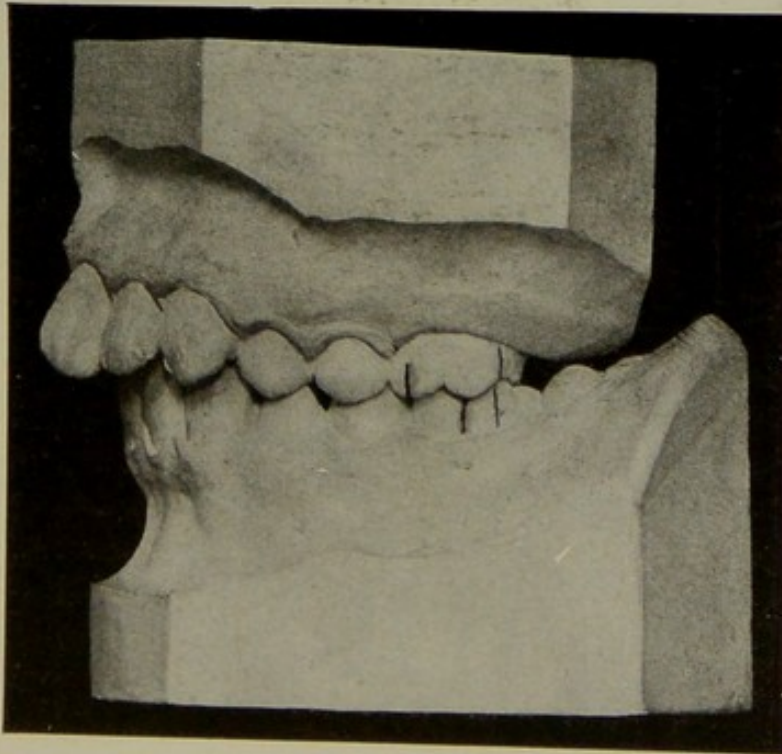




FIG. 457.

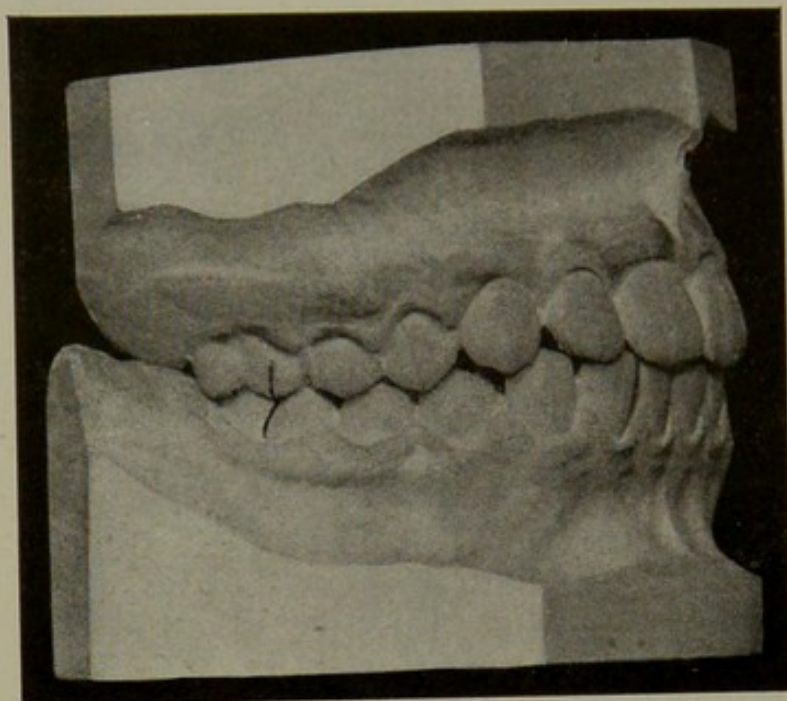
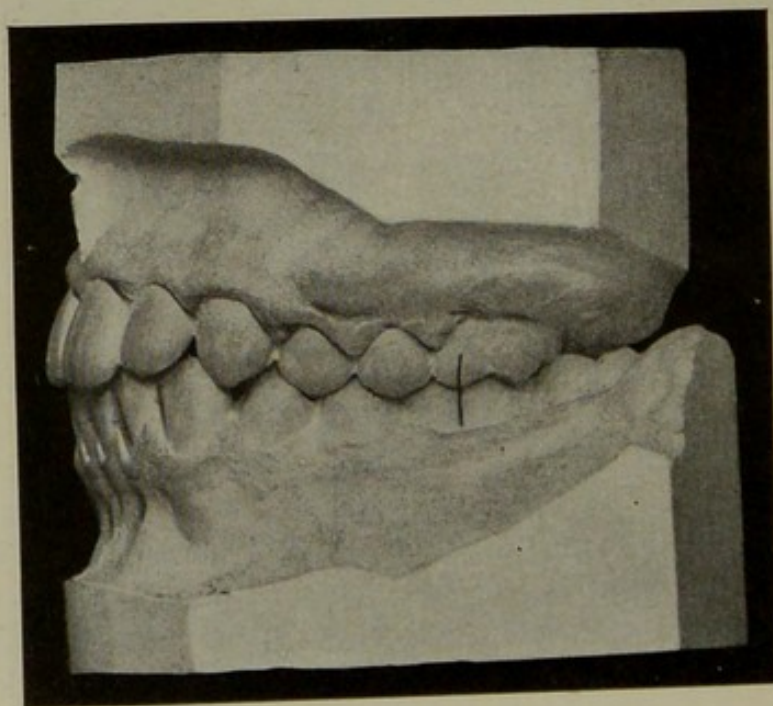


FIG. 458.





lean forward at too great an angle, while by dividing the movements between the teeth of the opposite arches this is prevented, and Nature, being assisted and stimulated through the correct distribution of force upon the teeth and normal functions of the muscles, is enabled to normally develop the mandible and all other tissues involved. Through the stimulus thus given it is quite probable that

FIG. 459.



FIG. 460.



in time the teeth of the upper arch will regain their normal relations with the skull.

Figs. 455 and 456 show the occlusion from the right and left sides of another typical case, with the usual characteristics, and Figs. 457 and 458 show the occlusion after the case has been treated exactly as described in the last case. The resultant changes in occlusion are clearly manifest in the better balance of the facial lines, as will be seen by a comparison of Fig. 459, which shows the face before treatment, with Fig. 460, which shows it after treatment, or at the time of making the models shown in Figs. 457

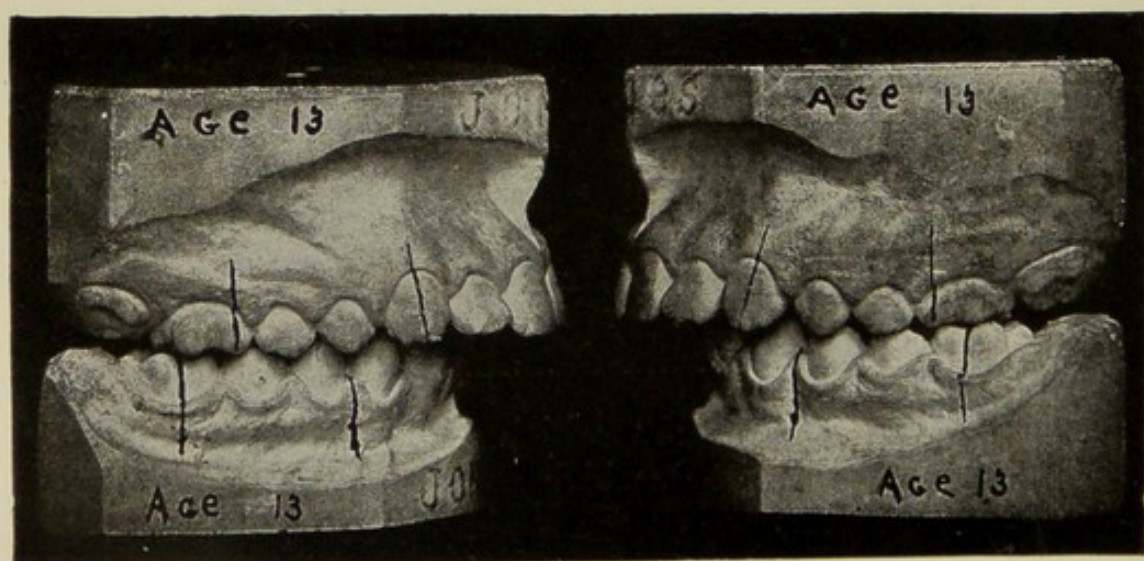


FIG. 461.



FIG. 462.

FIG. 463.





and 458. Fig. 461 shows the still greater improvement in the face incident to the growth of the mandible two years later than in the last picture.

Figs. 462 and 463 show the occlusion from the right and left sides of another most pronounced case belonging to this division.

The treatment was identical with that employed in the last two cases, that is, beginning with the first permanent molars and moving them into their proper mesio-distal re-

FIG. 464.



lations, continuing with the premolars, and finally adjusting the canines and incisors.

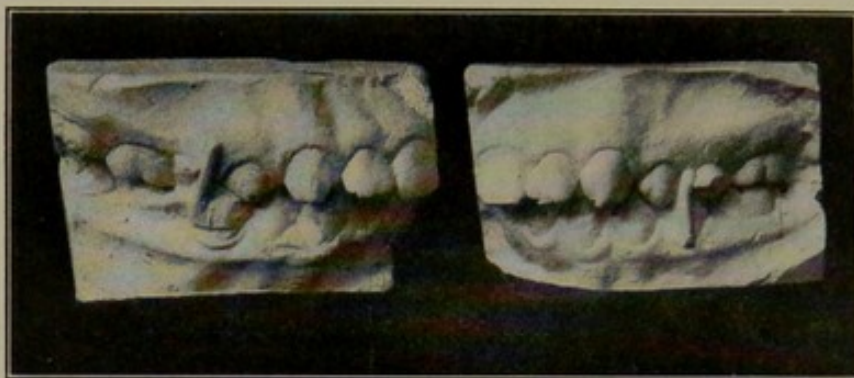Fig. 464 shows the period in treatment immediately after the premolars had been tipped distally into contact with the previously moved first molars. The X bands which in this case had been employed on the first premolars are dimly shown in this study model.

After the canines and incisors had been retracted the molars and premolars were secured by the usual intermaxillary retention. Fig. 465 shows the case at this stage of the operation, and Figs. 466 and 467 illustrate it by better models made six months later, or at the time of removal of



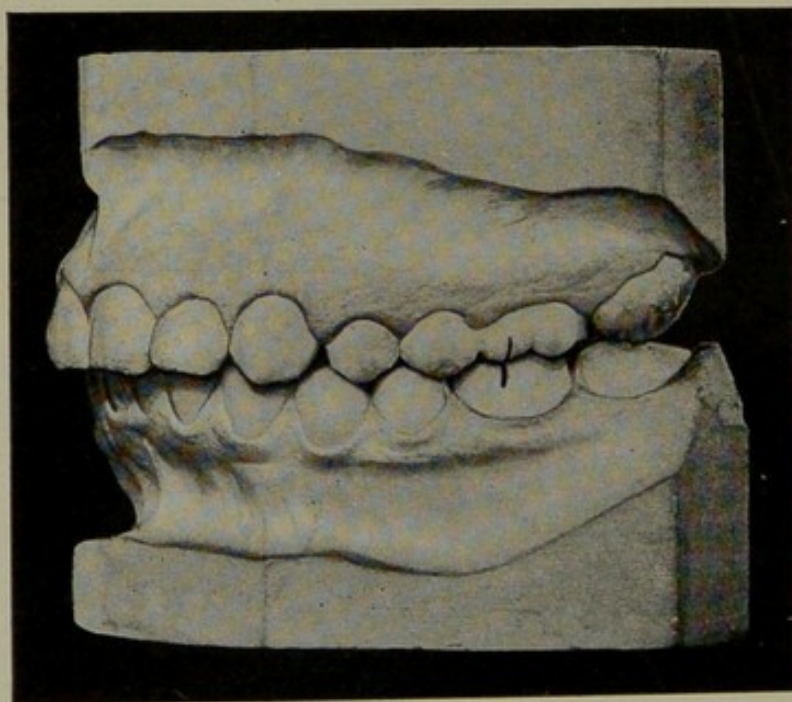
all retaining devices. The change in the facial lines due to treatment are shown in the chapter on Facial Art, Figs. 61, 62, 63, 64, and 65.

FIG. 465.



Figs. 468 and 469 show the face of a boy aged thirteen, and from the receding chin and disturbance of bal-

FIG. 466.



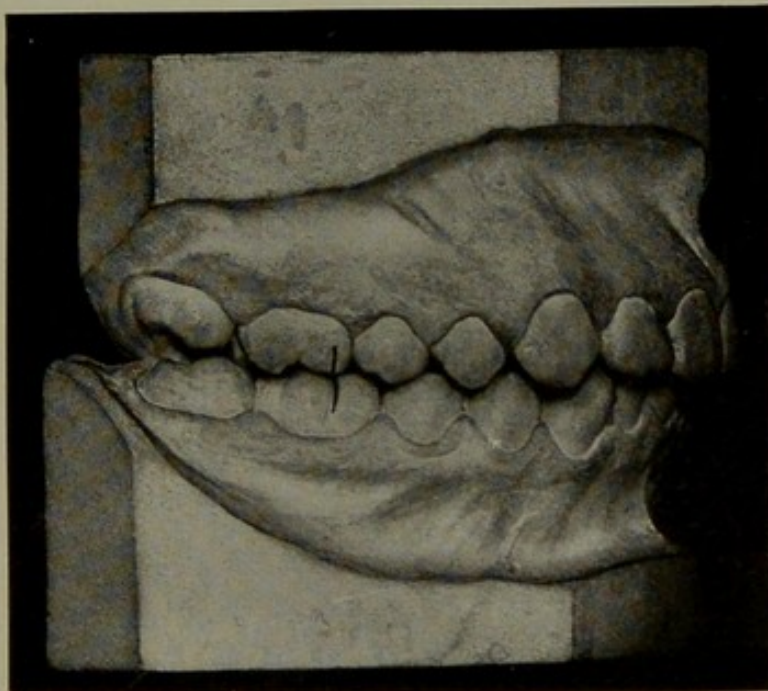
ance in the lines about the mouth it is not difficult to diagnose the cause as malocclusion of the type belonging to this division. By referring to the malocclusion, Figs.



470 and 471, it will be observed that all of the typical characteristics are present.

It will also be noted that the first premolar on the left side is in torsal occlusion. The treatment of the case was proceeded with exactly as in the case shown in Figs. 445 and 446, no effort being made to correct the torsal position of the premolar until after the teeth of both arches had been moved into their normal mesio-distal relations. It having

FIG. 467.



then been loosened, its rotation was more easily accomplished. This was done by means of the traction screw, as in Fig. 635, its angle engaging a staple on the mesio-lingual angle of a band that had been cemented on the premolar, the long sheath of the traction screw being soldered to the lingual surface of a No. 2 band upon the first molar, the screw of which was placed on the buccal surface and in this case pointed distally. This band was also utilized for the usual intermaxillary retention, the plane of metal being soldered to the flat portion of the screw, bearing against which was the spur soldered to a carefully fitted and ce-



FIG. 469.






FIG. 471.

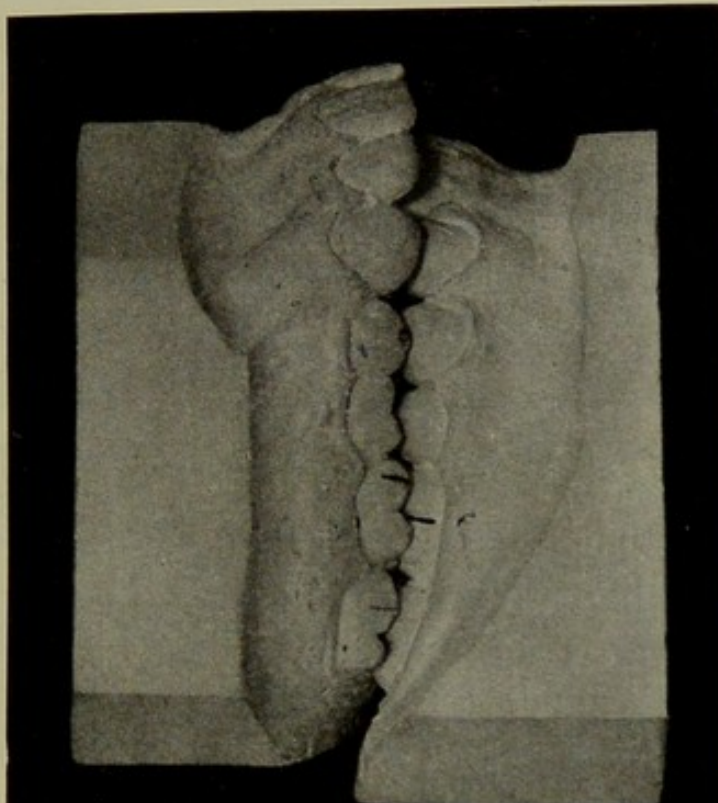
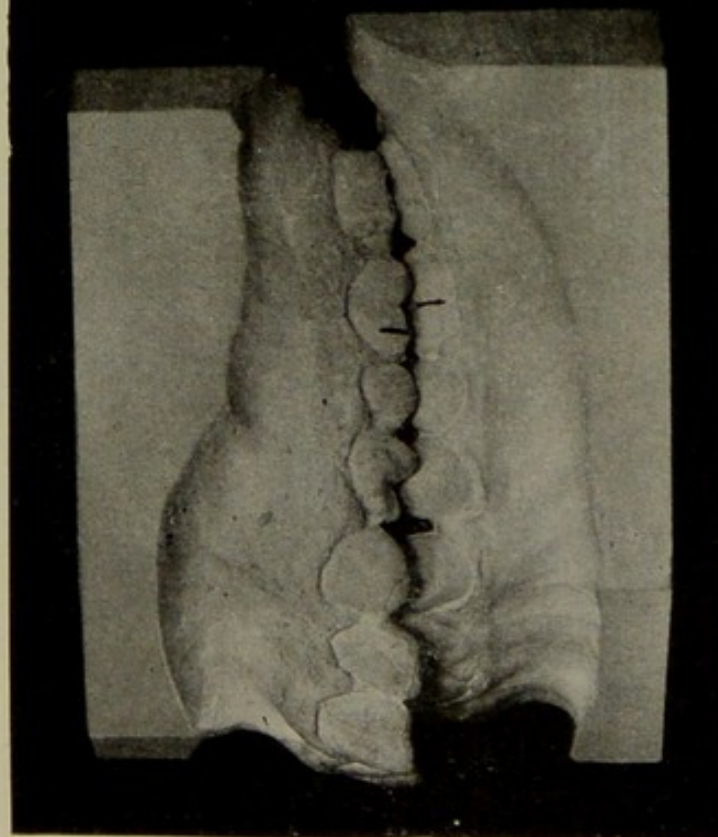


FIG. 470.

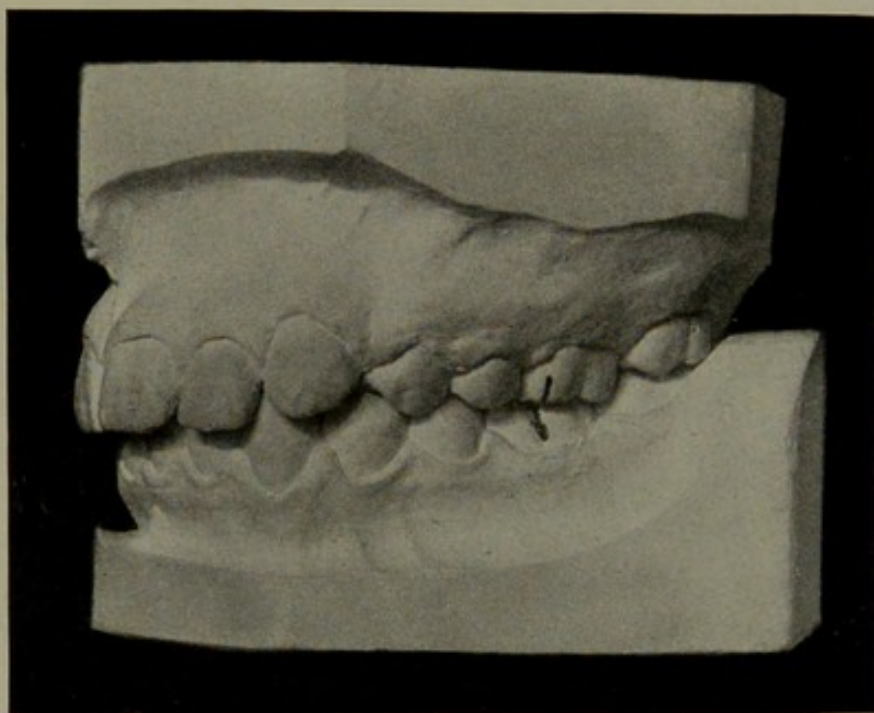




mented band upon the lower first molar. Force was exerted upon the tooth to be rotated by occasional tightening of the nut, and as its lingual cusp was drawn distally the force was reciprocated to its buccal cusp and in the opposite direction by the intervening second premolar.

In a short time the tooth had been rotated a little more than the requisite amount, and, the traction screw occasioning no annoyance, it was allowed to remain as a retainer

FIG. 472.



as long as intermaxillary retention was employed, or about one year.

Both molar and canine intermaxillary retention was employed on the opposite side through bands, planes and spurs, as in Figs. 256 and 260.

The corrected occlusion is shown in Fig. 472, and the improvement in the facial lines in Figs. 473 and 474.

In many of the pronounced, well-established cases belonging to this class the narrowing of the arch in the region of the canines and premolars is often very noticeable,

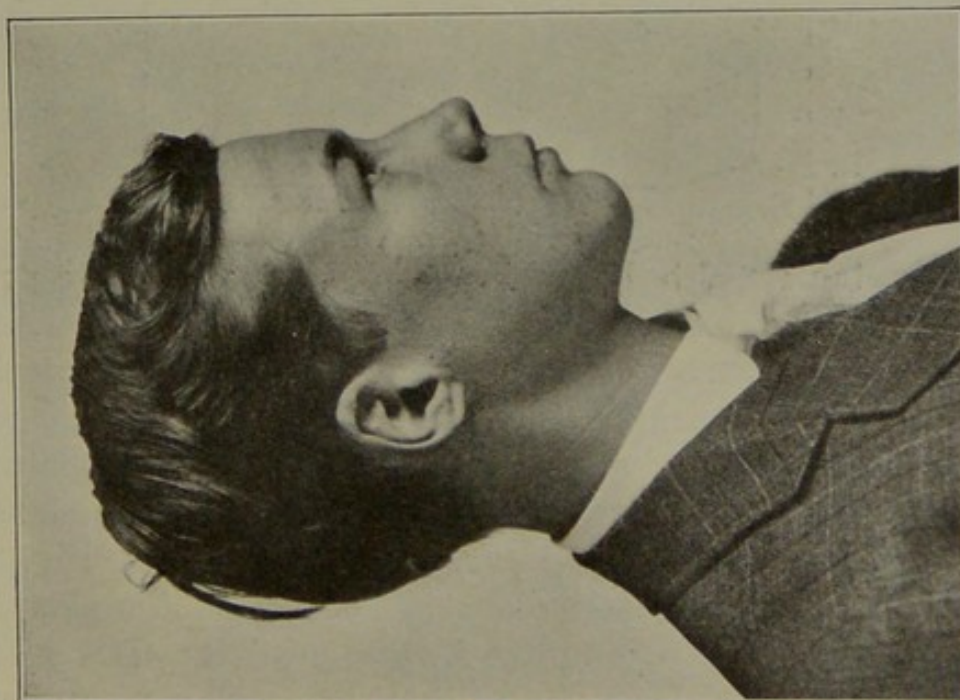

necessitating its widening by the buccal movements of these teeth. This is easily accomplished by giving much lateral

FIG. 474.




FIG. 473.



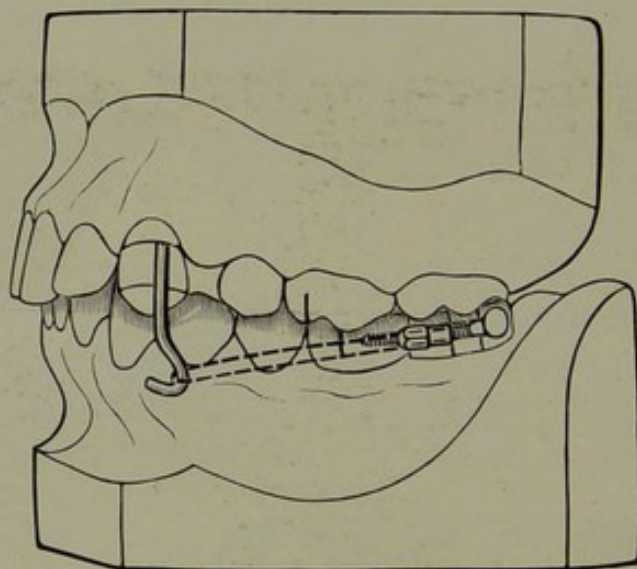
spring to the expansion arch which exerts force laterally upon these teeth through ligatures and which is further



assisted by the wedging force of the incisors as they are made to move distally by the pressure of the arch on their labial surfaces.

Another favorite plan of the author for widening the arch in these cases is to delay this operation until the premolars are carried distally, then remove the expansion arch and substitute for it one of the threadless arches B with much lateral spring. This arch readily glides through the sheaths of the anchor bands and in its efforts to

FIG. 475.



E.H.A.

straighten itself bears with much force against the prominent incisors independently of the intermaxillary elastics, which force is reciprocated to the premolars and canines through their wire ligatures, favoring their buccal movement. Very often in simple cases this force is ample without the additional force from the intermaxillary elastics, yet more often their use also is advisable. See Fig. 206.

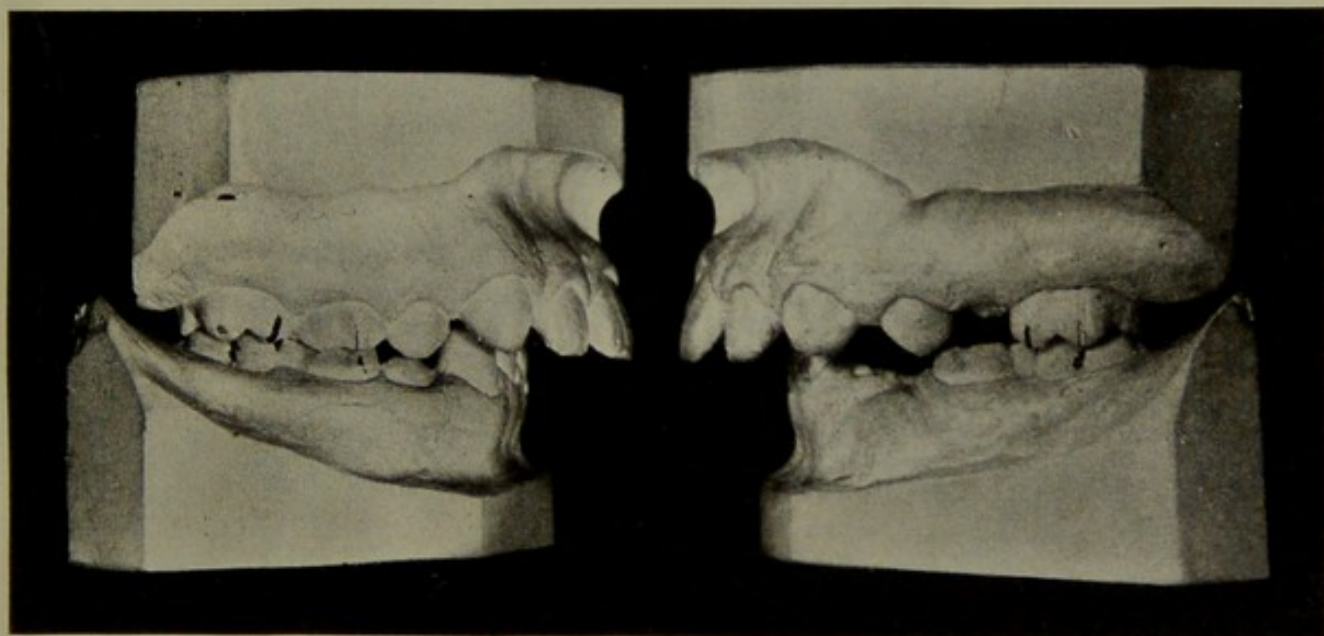
In some well-defined cases belonging to this class the upper canines are found to incline mesially after all the other teeth have been moved into their full normal mesio-distal relations. In cases where it is seen that this will occur, as the movements of the other teeth progress it is



the author's favorite plan to encircle the canines with strong, carefully fitted bands, soldering a piece of wire G to each band parallel with the long axis of the tooth and bending the lower end of the wire forward in the form of a hook about one-fourth of an inch below the point of the cusp. These hooks engage extra intermaxillary elastics which are stretched back to also engage the sheaths of the D bands on the lower first molars, as in Fig. 475. This is an efficient method for accomplishing the movement of these very firmly rooted teeth, and may be employed

FIG. 476.

FIG. 477.



simultaneously with the expansion arches. It may also be used to re-establish the correct positions of these teeth in case of their relapse, thus avoiding the replacing of both expansion arches and the upper D bands.

Figs. 476 and 477 show the occlusion of the teeth in another case belonging to this class—that of a girl ten years of age. The deciduous molars have not yet all been lost. The incisors are unusually protruded for a child of this age, but this is easily accounted for by examining the pictures of the face, Figs. 478 and 479, and noticing how thick



and firm the lips are and with what firmness the lower is

FIG. 479.

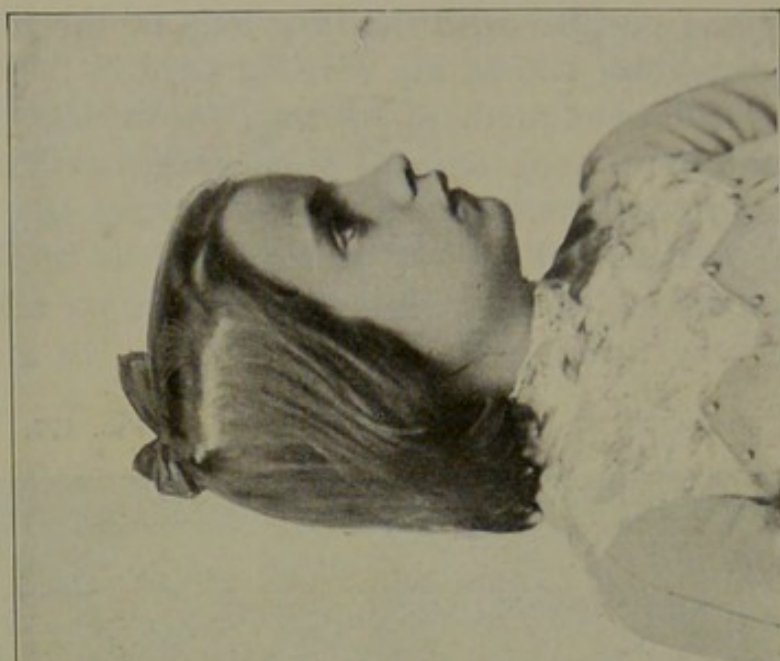

FIG. 478.

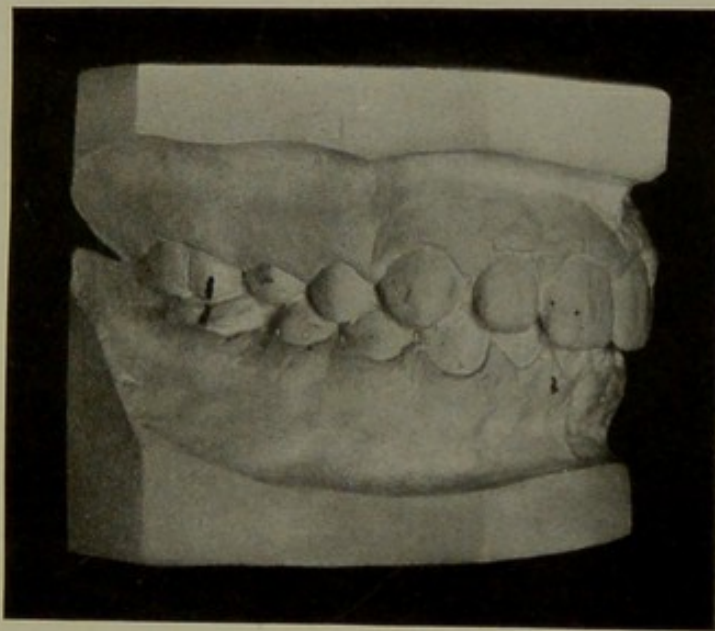


drawn upward and bears against their lingual surfaces. It will also be noticed that there is a space between the

premolar and canine on the right side, necessitating more than the usual distal movement.

The case was treated after the plan already carefully described, the distal movement of the canine being effected simultaneously by the method just outlined, and in connection with the usual other appliances. The result in occlusion is shown in Fig. 480.

FIG. 480.



The improvement in the facial lines at the time of retention is shown in Figs. 481 and 482, and two years after the completion of retention in Figs. 483 and 484.

By far the greatest difficulty in the treatment of this case was to induce the child to discontinue the habit of forcing the lower lip against the lingual surfaces of the incisors, and for this purpose the device shown in Fig. 262 was adjusted at various times for various periods.

In all cases belonging to this division where there has been extraction, with the usual shortening of one or both of the lateral halves of one or both of the dental arches, the malocclusion is necessarily more complex, with increased protrusion of the upper incisors, etc., especially



if the teeth have been extracted from the lower dental arch. The difficulties of treatment in such cases are of course increased, yet we should very rarely depart from the ideal conservative plan, even in these cases. The leaning teeth should be tipped to their normal upright positions, the lost space regained, and the missing teeth, if permanent, sub-

FIG. 481.

FIG. 482.



stituted by the best possible bridge-work in which the *full normal contour of crown and cusps* of the missing teeth is restored. If the lost tooth be deciduous the space must be maintained, allowing its successor full opportunity for eruption.

Figs. 485 and 486 illustrate a case of this description where the first permanent molars had erupted and locked

FIG. 483.



FIG. 484.

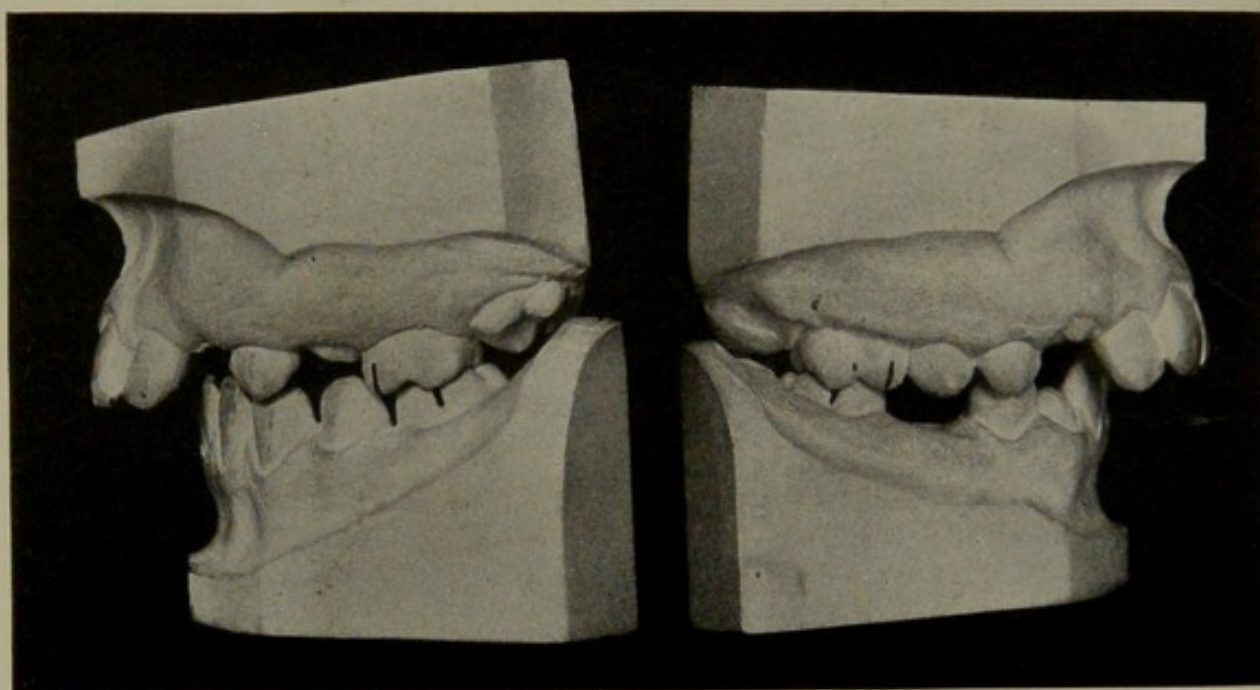




in distal occlusion. Both right upper premolars have erupted, with the canine just emerging from the gum, while the lower first premolar on this side has fully erupted and the canine partially. The second lower deciduous molar has just been lost, with its successor about to erupt. On the left side the upper deciduous canine has recently been lost, with nearly full eruption of the first premolar and partial eruption of the second. In the lower jaw on this

FIG. 485.

FIG. 486.



side the canine and first premolar have fully erupted, the latter being nearly in contact with the first molar. This was occasioned by the unnecessary sacrifice of the second deciduous molar three years previously which had allowed the usual forward tipping of the first permanent molar, and the shifting distally of the mandible and the teeth anterior to the space—the inevitable result.

The X ray revealed a second premolar of normal form and position prevented from erupting by the crowding of its approximal associates. As a result of this extreme

shortening the mesial inclined plane of the lower canine occludes with the distal inclined plane of the upper first

FIG. 487.

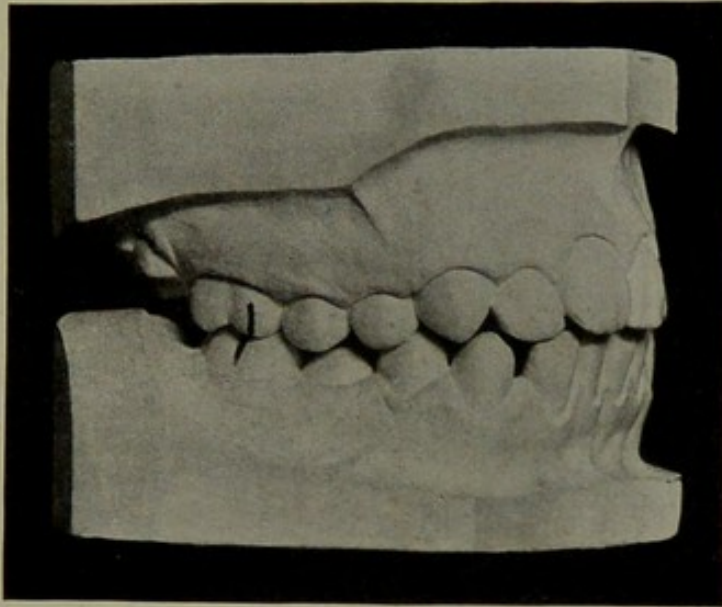
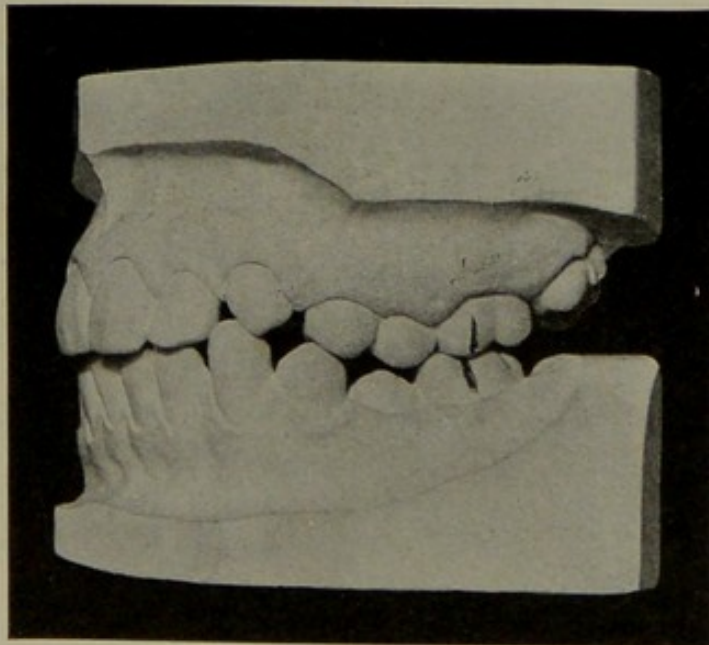


FIG. 488.



premolar, or nearly the width of two premolars distal to its normal position.



FIG. 490.

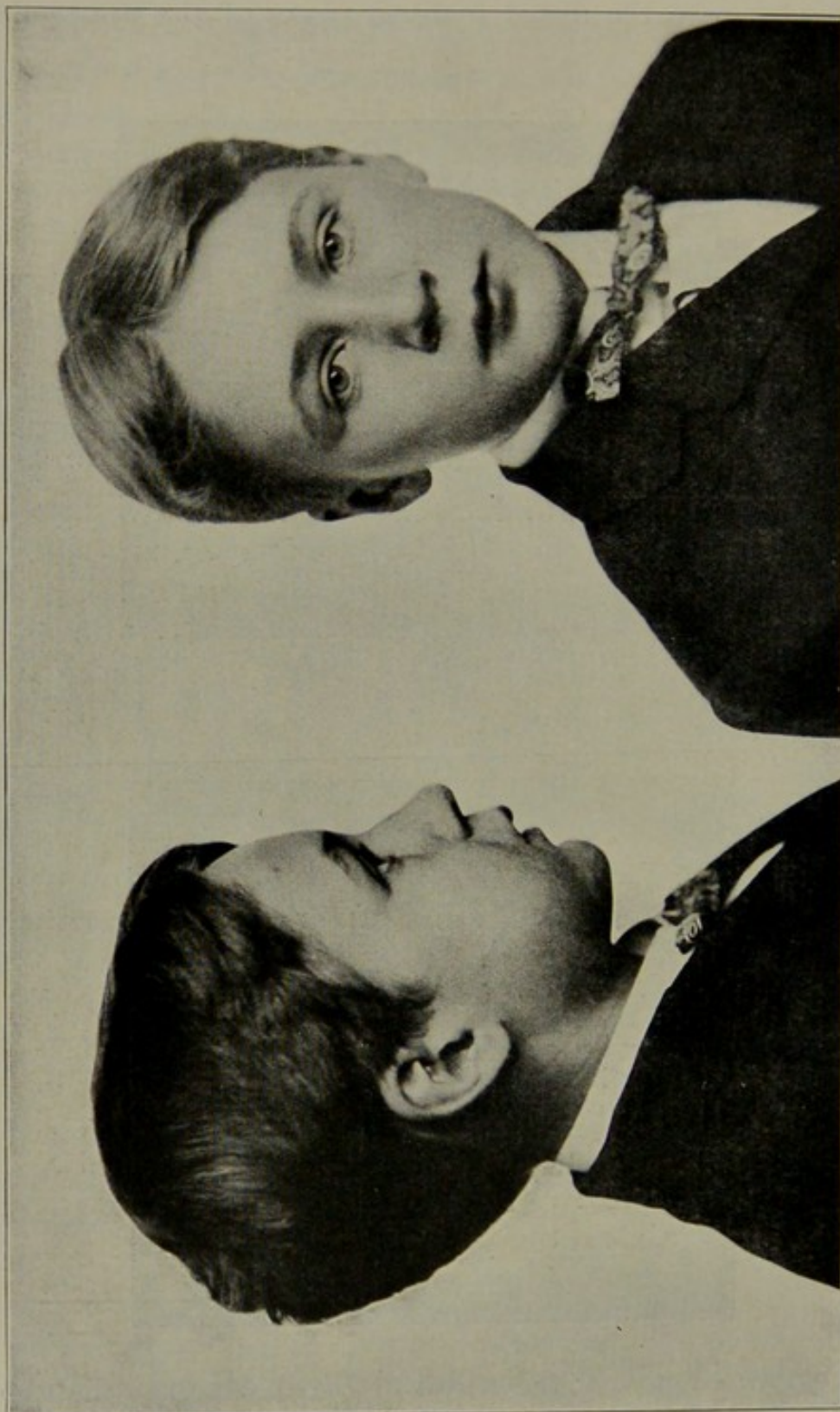



FIG. 492.





In treatment practically two operations are necessary, first, the lengthening of this lateral half of the lower arch, with regaining of the lost space of the missing tooth and tipping of the first molar to its upright position, etc.; and second, the movement mesially of all the lower teeth and distally all the upper teeth into normal mesio-distal relations. These two operations were performed simultaneously. The ribbed expansion arch was employed on the lower arch, and while the intermaxillary elastics were effecting the reciprocal movement of the upper and lower molars, the lower left molar was being tipped to upright position, and the first premolar, canine, and incisors on this side were being carried forward by means of a ligature thrown around both canine and premolar and made to engage a notch in the rib of the expansion arch at a point between the lateral incisor and canine, the arch also being bent to exert a pry upward and backward upon the molar, precisely as described for lengthening one or both of the lateral halves of the arches in Class I, and shown in Fig. 207.

Figs. 487 and 488 show the corrected occlusion, and by comparing Figs. 489 and 490, which show the face before treatment, with Figs. 491 and 492, which show it after treatment, it will be seen what fine balance has been established in the facial lines.

Figs. 493 and 494 show the occlusion of another case belonging to this division in which all of the various peculiarities of these cases are well illustrated. These are rapidly being intensified by reason of the premature loss of deciduous teeth. Granting for the moment that their removal may have been necessary, we insist that it became necessary immediately thereafter to maintain the full mesio-distal diameters of the sacrificed teeth by suitable retaining devices in order to prevent the inevitable diminution in the size of the arch and the grave consequences incident thereto. We again insist that no dentist is re-

lieved of responsibilities following his extraction of permanent teeth unless he takes prompt measures to prevent the malocclusion which otherwise will surely follow.

FIG. 494.

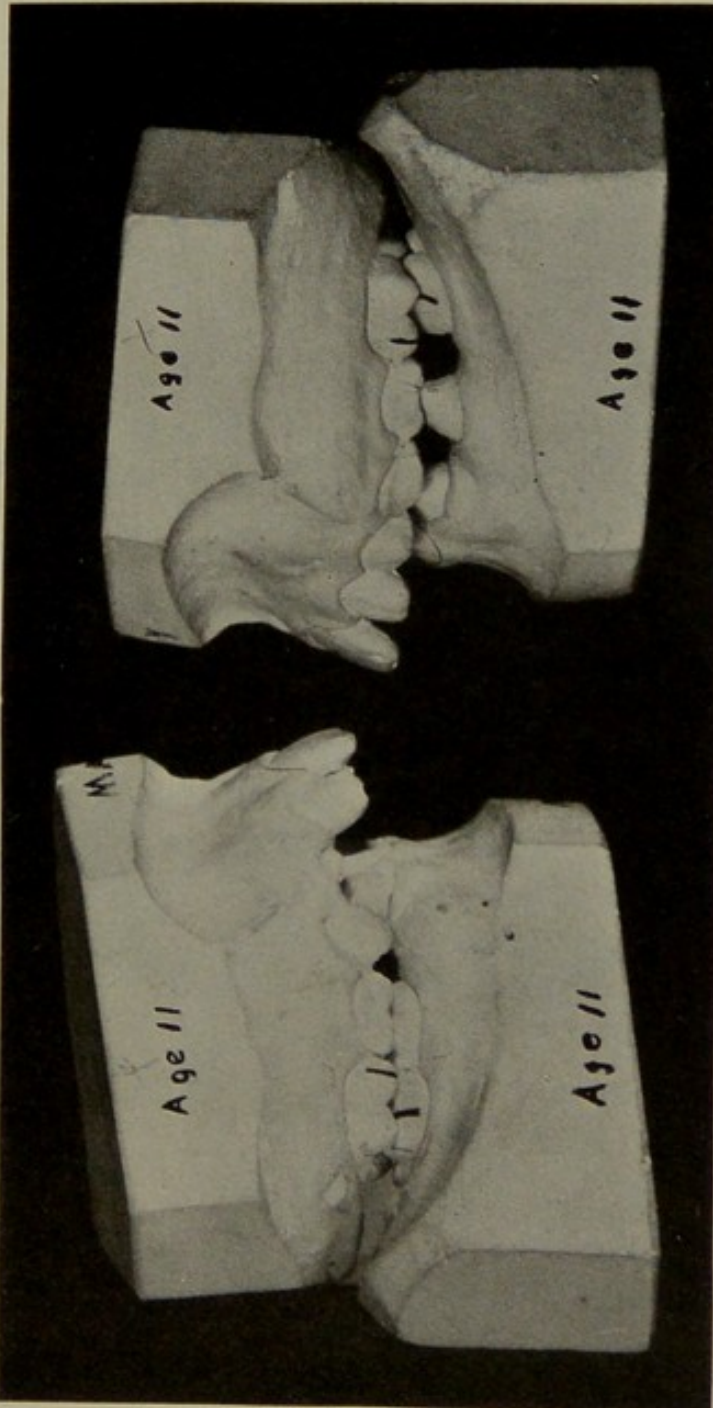


FIG. 493.

By reference to Figs. 495 and 496 it will be observed how greatly the facial lines of this bright, intelligent boy



have been thrown out of balance. We know that the teeth when in correct occlusion are a striking mark of beauty,

FIG. 496.




FIG. 495.

but how unsightly they become when so unfortunately placed as in this case!



There is a shortening of the bite, due to the abnormal distribution of force upon the first molars and the loss of so many deciduous teeth. After requisite enlargement of the lower arch and the establishment of the normal mesio-distal relations of the teeth, the reduction of the prominent incisors, etc., and all had been maintained by proper retaining devices, after methods already described, it was found, as is occasionally the result in these as well as in cases belonging to other classes, that the bite was still too short, and its proper lengthening becomes very necessary in order that the incisors may have their proper relations. Various methods have been resorted to for accomplishing this, but the only one that has proven satisfactory to the author is one that has long been in use, namely, to separate the bite by a vulcanite plate thickened in front and covering the vault of the arch, with depressions in the plate for the reception of the lower incisors so that the full thrust of the jaw may be received upon these teeth instead of upon the molars. The plate is prevented from becoming forced upward in front, and from being loosened in the rear by hooks firmly imbedded in the plate and made to engage the cutting edges of the upper incisors. When properly adjusted this plate should relieve all strain from the first molars which are separated at least three thirty-seconds of an inch. If constantly worn for from two to six months the molars will have become lengthened and the proper length of bite established. The result of this method of treatment is shown in the fine balance that has been given to the facial lines, Figs. 497 and 498, and in the improvement in the occlusion, shown in Figs. 499 and 500.

Figs. 501 and 502 show the occlusion in another most pronounced case of this class. All of the various constant peculiarities following the distal locking of the first molars, due to mouth-breathing, are here present, and these conditions have been intensified by bad dental operations.



FIG. 497.



FIG. 498.

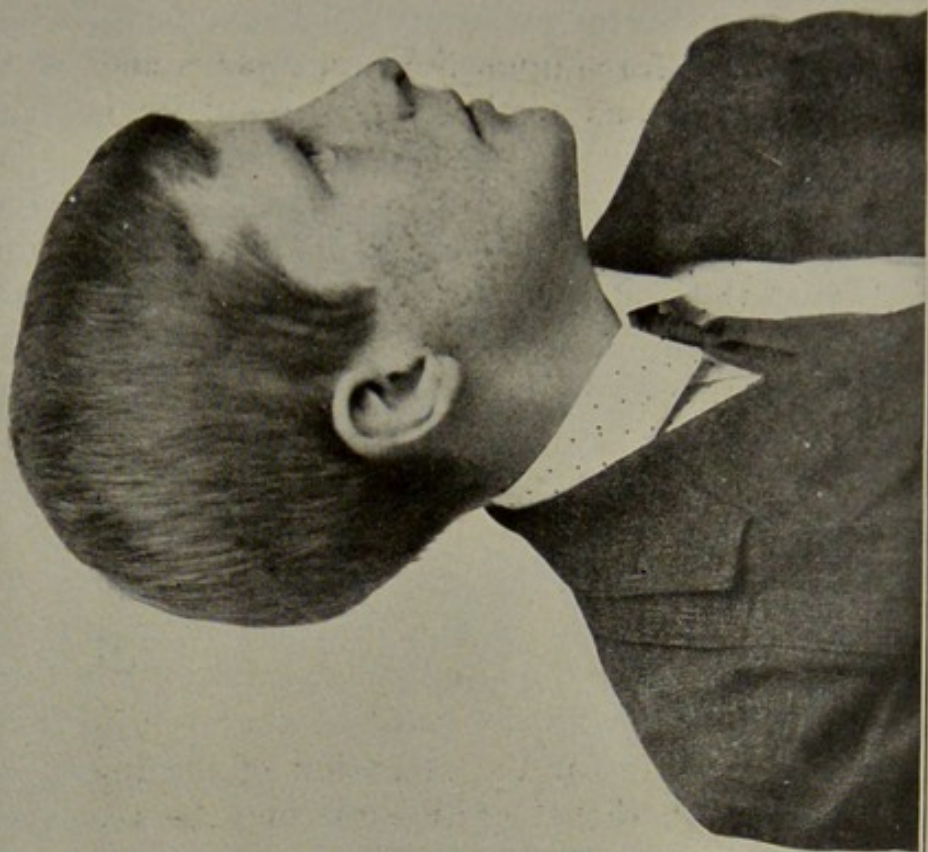

FIG. 500.

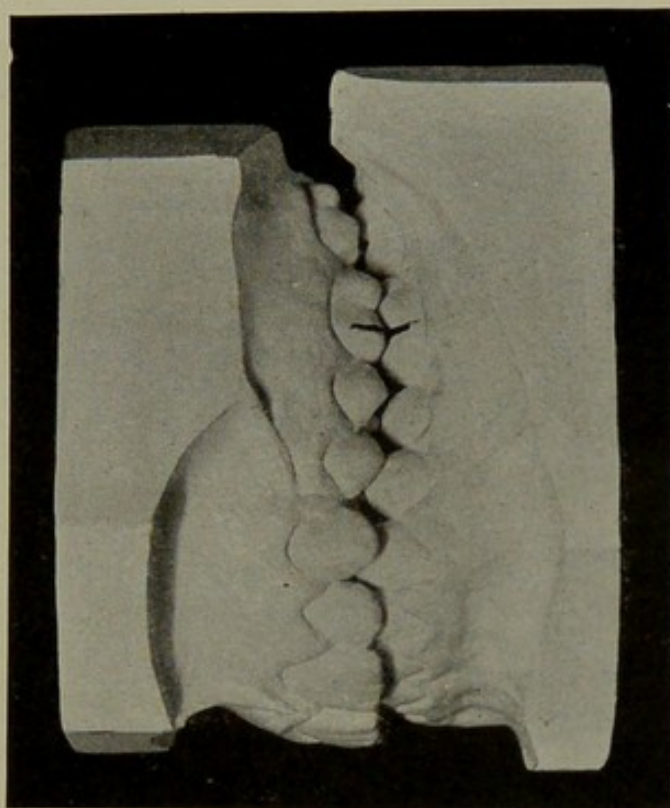


FIG. 499.

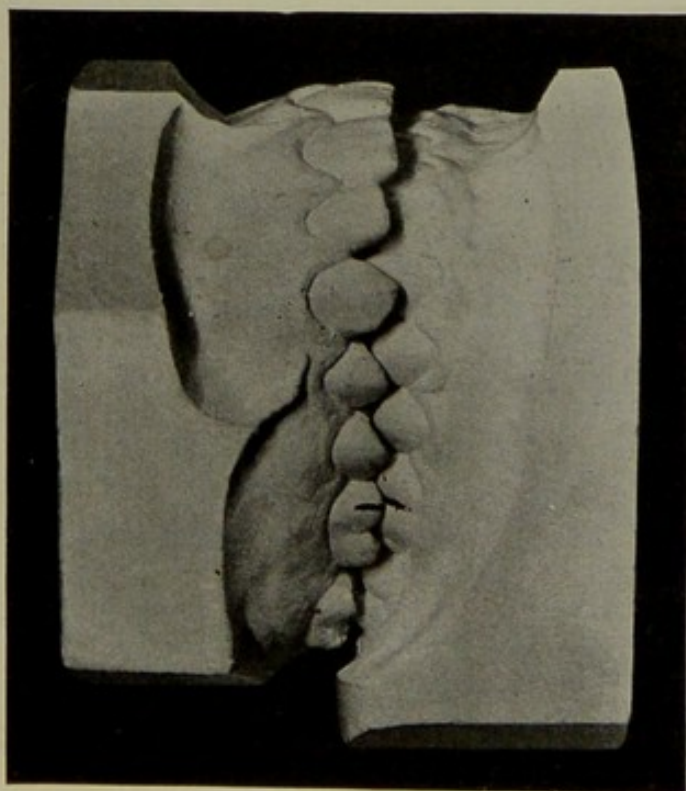




FIG. 502.

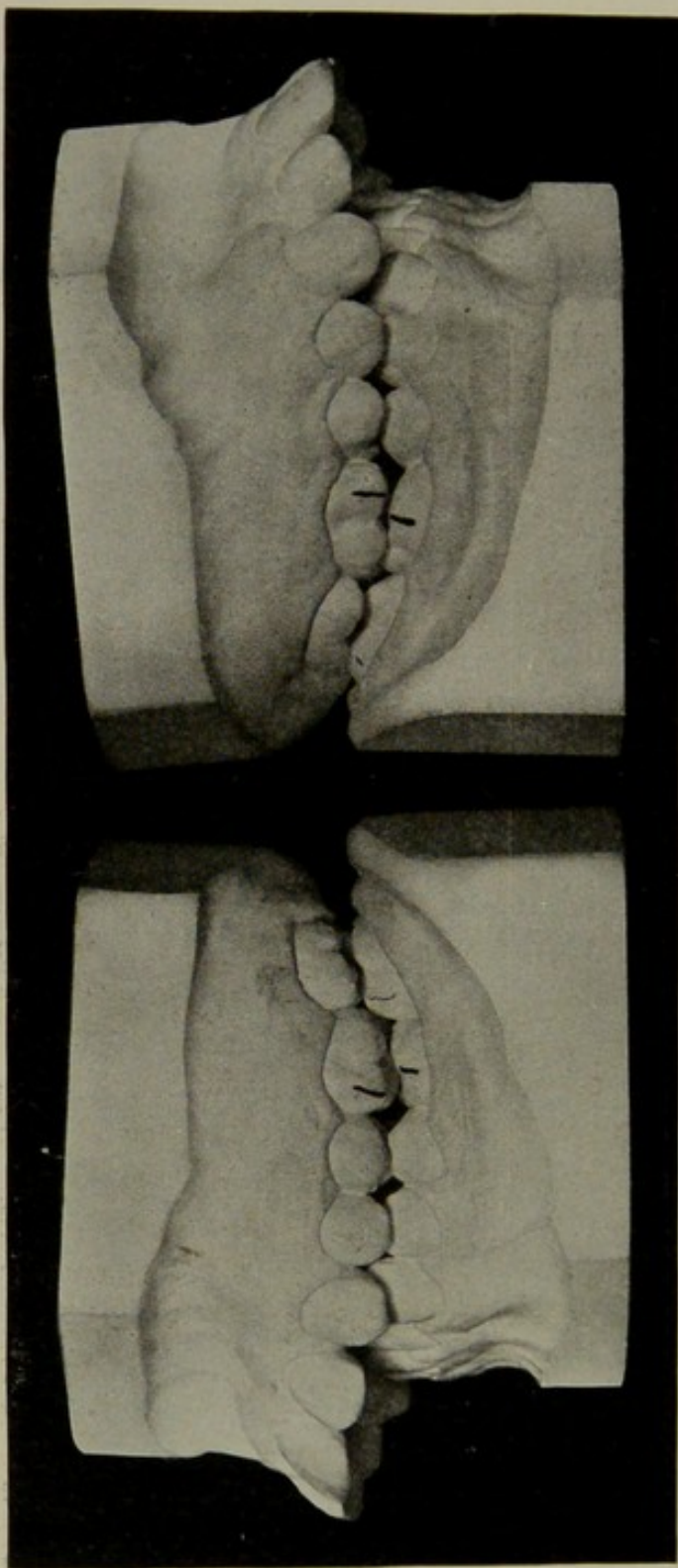



FIG. 501.

FIG. 504.





Very unscientific but familiar forms of fillings have been placed in the lower first molars, causing shortening of both lateral halves of this dental arch and the lengthening of the upper first permanent molar on the left. The effect of such marked malocclusion is strikingly reflected in the facial lines, shown in Figs. 503 and 504.

The treatment consisted in lengthening both lateral halves of the lower dental arch sufficiently to allow the placing of crowns of normal size and contour of cusps upon the lower first molar roots; the shifting distally of all the upper teeth; the reduction of the prominence of the upper incisors to their proper angle of inclination, and the shifting mesially of all the lower teeth into harmony of occlusion with them, and the retention of the same for nearly two years, after plans already described in connection with the treatment of other cases belonging to this class. The corrected occlusion is shown in Figs. 505 and 506.

The improvement in the balance of the facial lines is shown in Figs. 507 and 508, and although still imperfect, it is confidently expected that as time goes on still finer balance will be worked out by Nature in her efforts to establish the normal.

As might be expected the abnormal functioning of the lips in the effort to disguise the deformity has increased their thickness and muscular strength. The difficulty of overcoming this habit was great. It was only mastered by a strong will and determination persistently exercised by day, and the lips held in their proper relations during sleep by strips of surgeon's adhesive plaster extending from the base of the nose to the chin. These were regularly applied and gave no special inconvenience to the patient, with such results as leads the author to believe it a plan often to be followed with advantage in similar cases.

Another point of much interest in connection with this case was the very noticeable increase in self-respect and dignity which gradually developed in this sensitive boy

FIG. 506.

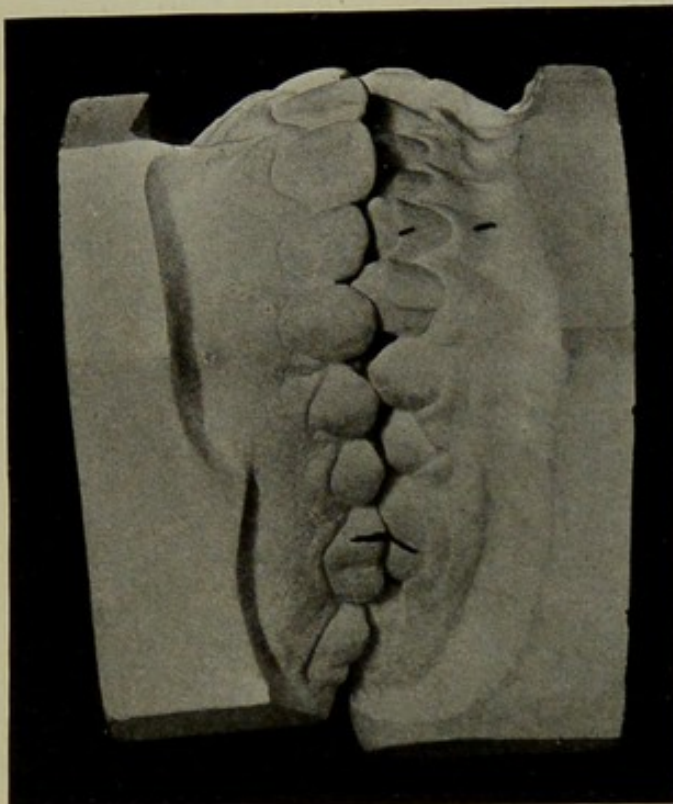
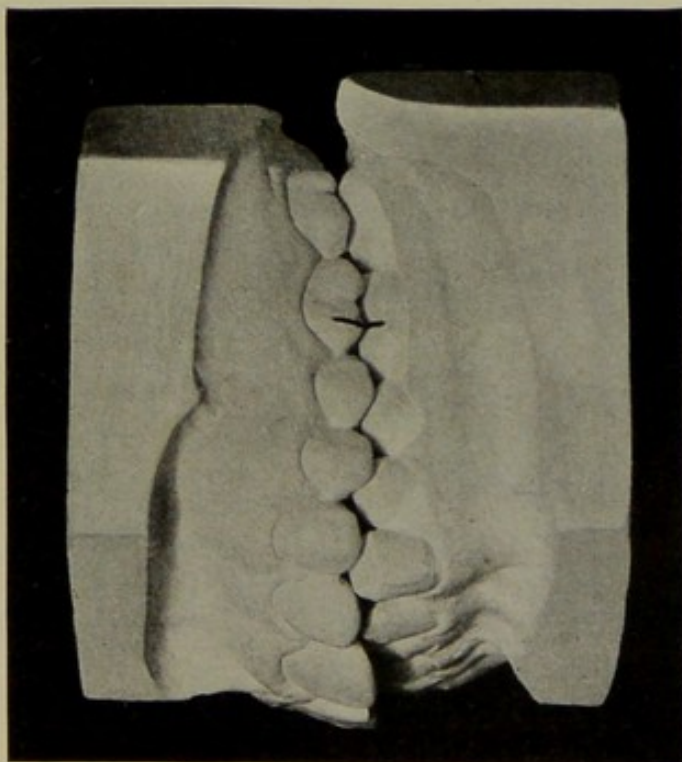


FIG. 505.





as the deformity formerly causing him such real anguish diminished. The author has repeatedly noticed this with

Fig. 508.

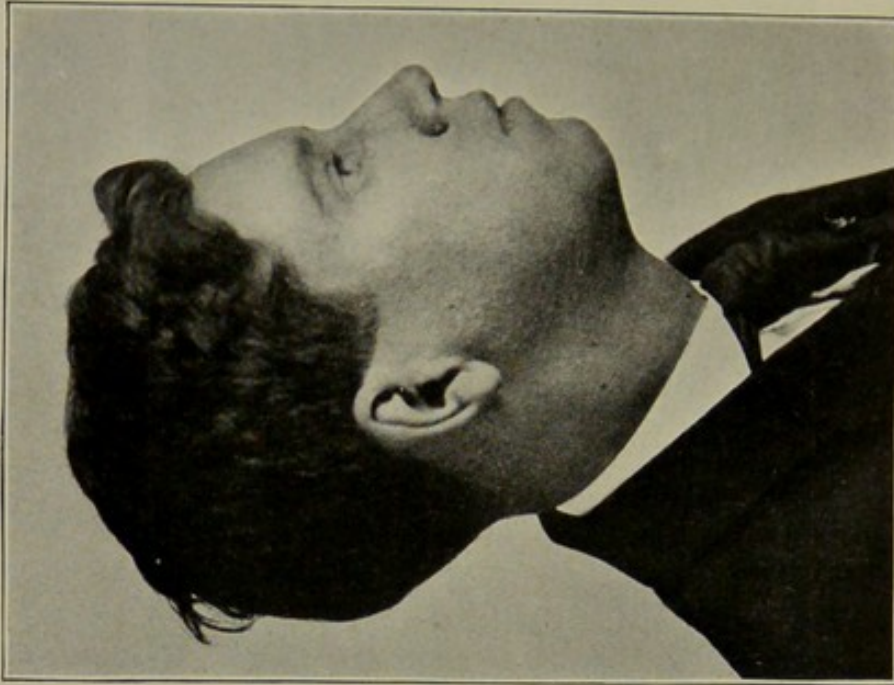

Fig. 507.



other patients, and it adds much interest and pleasure to the work of the orthodontist.



The former plan of treating cases belonging to this division, and still followed by many, was to restore harmony in the sizes of the dental arches by sacrificing two teeth from the upper dental arch, usually the first premolars, and retracting the canines and incisors. The method for retracting the canines and effecting these changes is shown in the Appendix, but the plan is so obviously defective that it is now regarded as obsolete by all orthodontists of the new school. Therefore nothing further need be here added other than to say that by such treatment Nature's intended balance of the facial lines according to the type of the individual was always greatly and permanently disturbed. The upper arch being greatly diminished from its normal size gave a corresponding abnormal restriction to the tongue, with consequent impairment of speech; and the mal-relations of the inclined occlusal planes, thus permanently established, greatly impaired the efficiency of the teeth in the mastication of food, etc., etc.

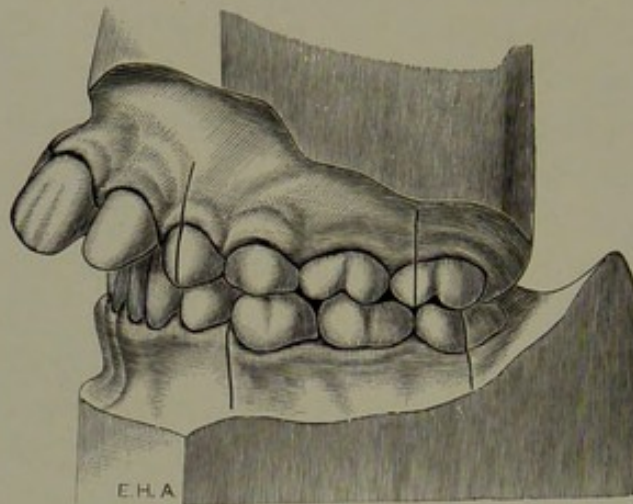
Another plan of treatment to be considered is that introduced by Dr. Norman W. Kingsley, orthodontia's greatest genius. It has many advantages in its favor, and is decidedly preferable to the plan demanding mutilation which we have just mentioned. The Kingsley method consists in having the patient voluntarily move the lower jaw forward the requisite distance to establish normal mesio-distal relations of the teeth of the opposing jaws, or "jumping the bite," as he termed it, and then retaining the teeth in this position. Of course before the teeth of the lower jaw can be made to harmonize with those of the upper the upper arch must be widened in the region of the canines, premolars, and molars, and the prominent upper incisors reduced. For this latter purpose Dr. Kingsley first utilized occipital anchorage.

The greatest difficulty to overcome in following this plan of treatment is to keep the lower jaw forward and the teeth functioning in their normal relations long enough for the



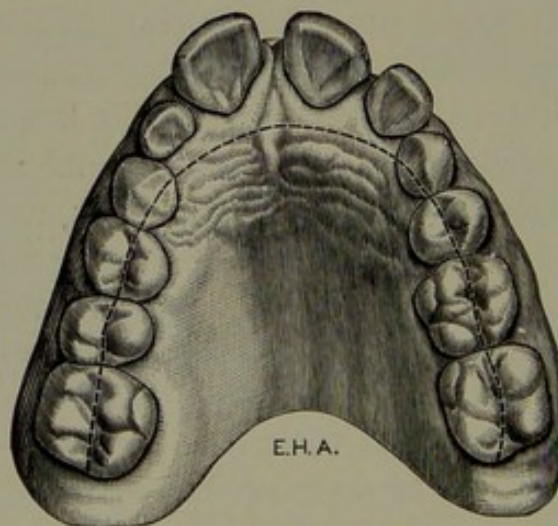
change in all of the tissues involved to become permanent. For this purpose various forms of plates were resorted to, and as most of them were under the control of the patient

FIG. 509.



and annoying to him, he frequently temporarily omitted to wear them, and this often brought discouragement and caused a large percentage of failures. In fact the diffi-


FIG. 510.



culties to be overcome in retention were so great that even the possibilities of success by this method were doubted by many, as strenuous controversies in the literature bear

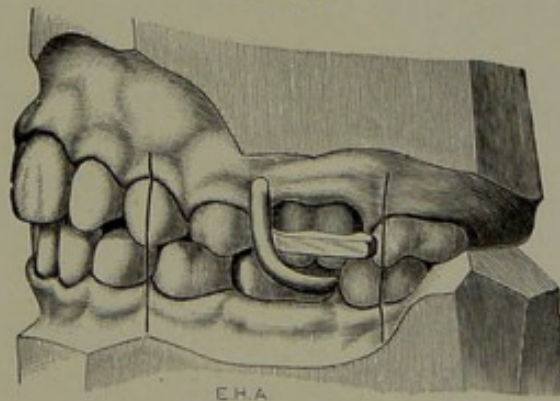
witness. Yet that it could be and was accomplished there is no longer any doubt. The author succeeded in the treatment of several cases, after this method, but only after

FIG. 511.



devising the plan of retention shown in Fig. 512, and then only after the persistent use of the device for usually about two years.

FIG. 512.



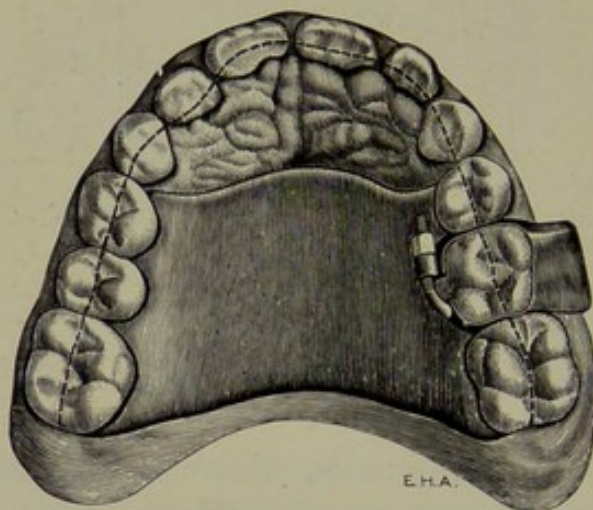
The history of one of these cases, here described, is of unusual interest. The occlusion at the beginning of treatment is shown in Figs. 509 and 510, and additional interest attaches to the case in the fact that the deciduous incisors were protruding, as is shown in Fig. 511, made from a



photograph taken when the child was two years old, though whether or not the deciduous lower molars were in distal occlusion it is now of course impossible to determine.

The corrected occlusion two years after the beginning of treatment is shown in Figs. 512 and 513. The improve-

FIG. 513.



ment in the facial lines of the patient is well shown by a comparison of Fig. 514, taken before treatment was begun, with Fig. 515, taken at this time. The author was greatly gratified with his success in this case and believed it to be a most desirable plan of treatment, as with it the full complement of teeth could be preserved and normal occlusion established, and it seemed the normal facial lines could also be established.

About three years after the discontinuance of retention, on examining the facial lines and the teeth of the patient, an important discovery was made, namely, that although the normal relations had been maintained between the teeth, the mandible had slowly drifted back to probably very nearly its former relations with the skull, but in so doing the crowns of the teeth of the upper arch had been dragged distally to a noticeable degree, while the crowns

FIG. 515.

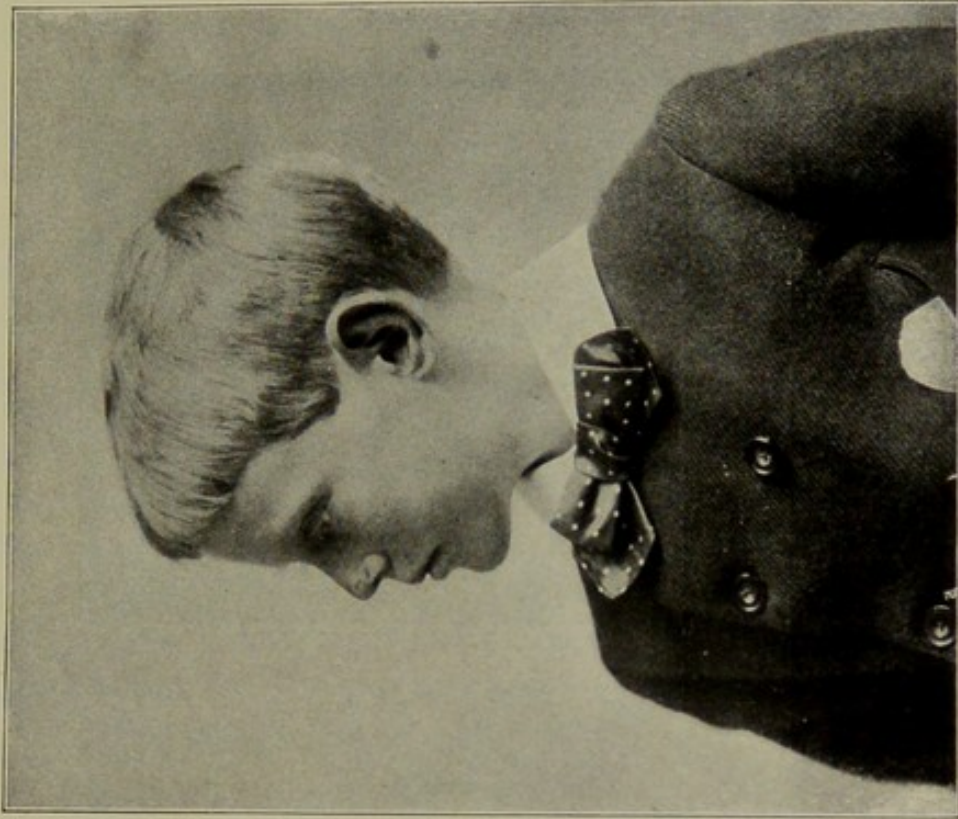


FIG. 514.

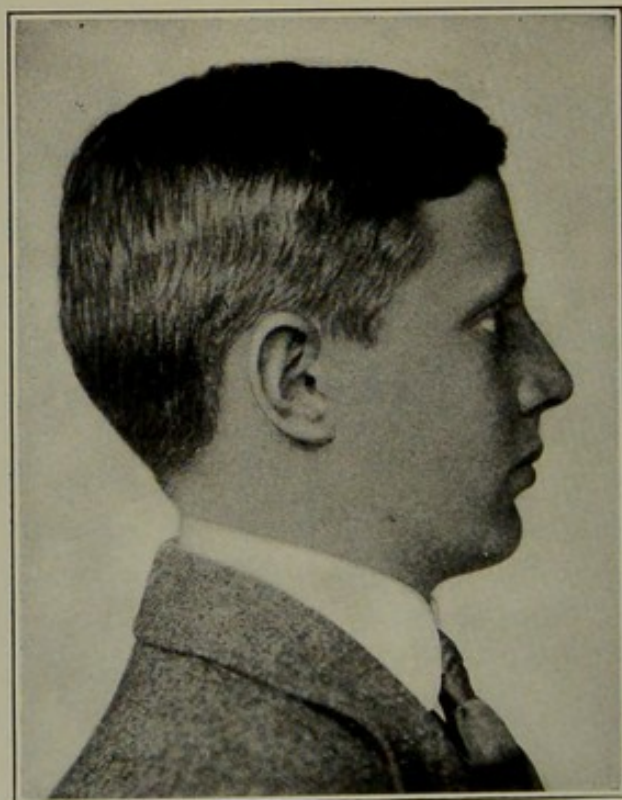




FIG. 516.

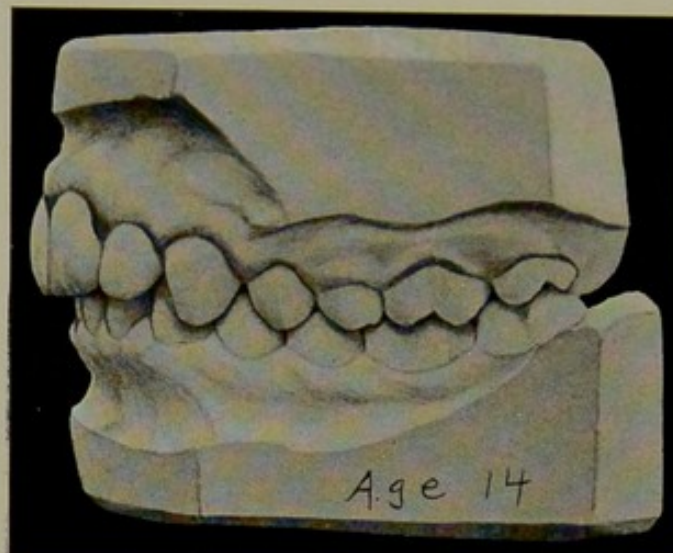

FIG. 517.



of the teeth of the lower arch had been tipped forward. In other words there had been accomplished by the muscles of mastication and persistent, difficult retention, what we now aim to accomplish and do accomplish with the Baker anchorage, often in so short a time as three weeks in patients of this age.

Fig. 516 shows a model of the case taken at the age of fourteen years which clearly shows the changes incident to the recurrent movement of the jaw, and Fig. 517 shows the profile of the face of the young man at this time. The position of the chin in its relation to the rest of the face also confirms the fact that the mandible has slipped back.

This discovery in this case led to the examination of other cases similarly treated, with the same results, so it seems probable that the plan of treatment first described should be regarded as the one most practicable and desirable for this class of cases.

TREATMENT OF CASES.—CLASS II, DIVISION 1, SUBDIVISION.

As already noted in the classification of malocclusion the first Division of the Class just considered, has a Subdivision in which the distal occlusion is unilateral only, the other characteristics being in most cases practically the same as in the full division. It is interesting to note, however, that in many instances the protrusion of the incisors in this subdivision is quite as great as in the division, and this fact has often led to the unfortunate sacrifice of a premolar on both the normal and abnormal sides of the upper dental arch when treatment has been conducted after the older methods regardless of the real requirements of occlusion.

The correct plan of treatment is to establish harmony in the sizes and relations of the arches and normal occlusion, by the movement of the malposed teeth of the lower arch mesially and those of the upper arch distally, at the same time reducing the protrusion of the upper incisors,



and any other malpositions of individual teeth that may exist.

FIG. 519.

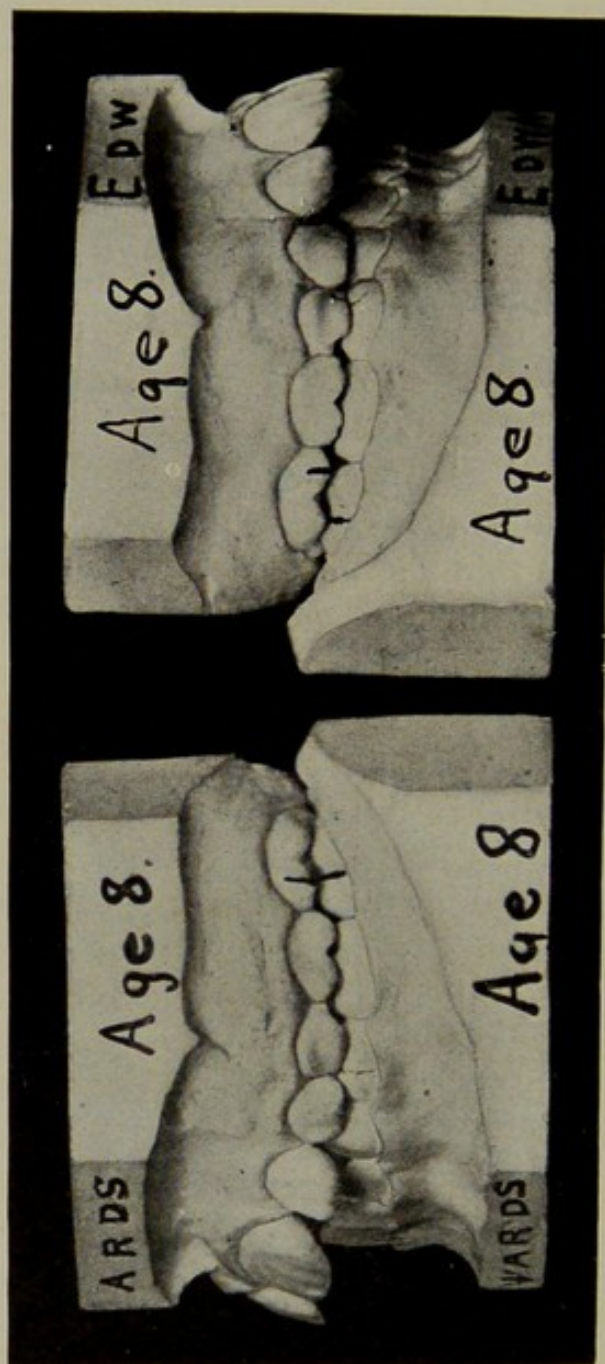


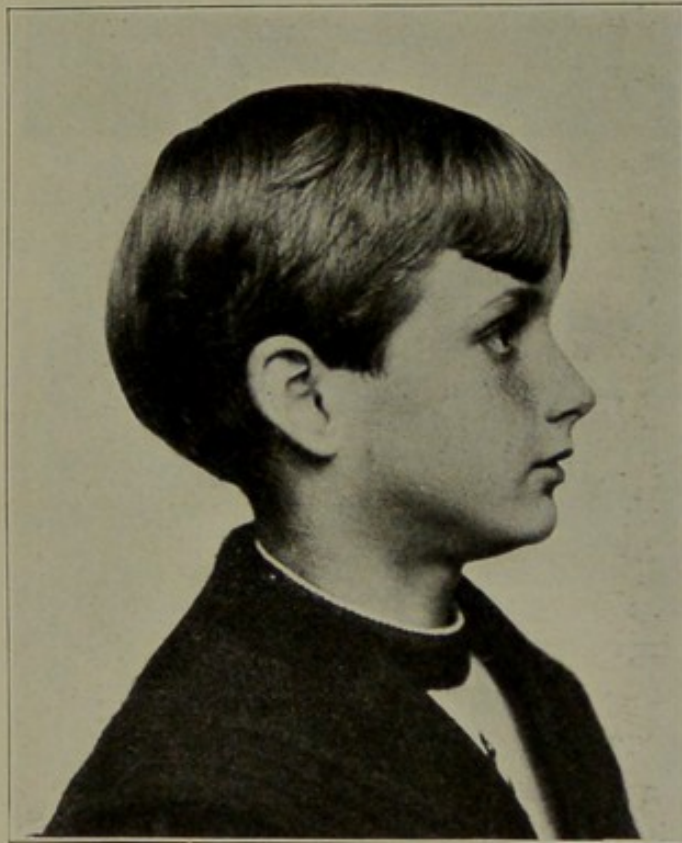
FIG. 518.

The disturbance in the balance of the facial lines is often very pronounced, and is always just in proportion to the extent of the malocclusion.

Figs. 518 and 519 show the occlusion in a typical case belonging to this subdivision—that of a boy eight years of age—and Fig. 520 shows the extent of the disturbance in the balance of the face.

In the treatment the same plan was carried out as that already described in the treatment of cases belonging to the

FIG. 520.



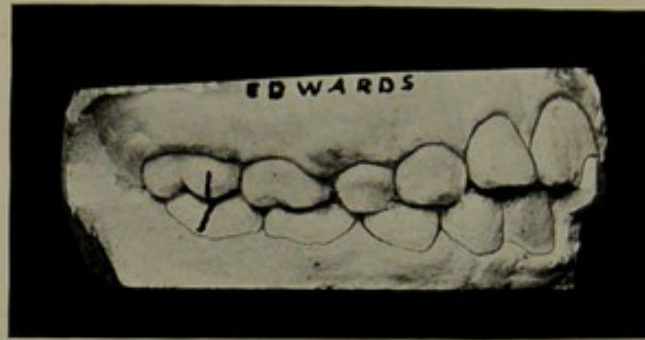
division, the only difference being that the intermaxillary elastics were made to operate only on the affected side.

As the first permanent molars had not yet fully erupted the placing of the anchor bands upon them would have occasioned unnecessary pain, therefore the smaller bands D were placed upon the second deciduous molars. Wire ligatures were not needed in connection with the lower expansion arch, as stationary anchorage was not required. Force upon the upper incisors from the intermaxillary



elastics was prevented by the proper adjustment of the nut of the expansion arch on the sheath of the anchor band

FIG. 521.



on the abnormal side, as already described in connection with other cases. The nut on the opposite side of the arch,

FIG. 522.



as well as those on the lower arch, not being required, were removed. Gradually the upper molar was shifted distally

and the lower teeth mesially the requisite distance, then the force was distributed to the prominent incisors after

FIG. 524.

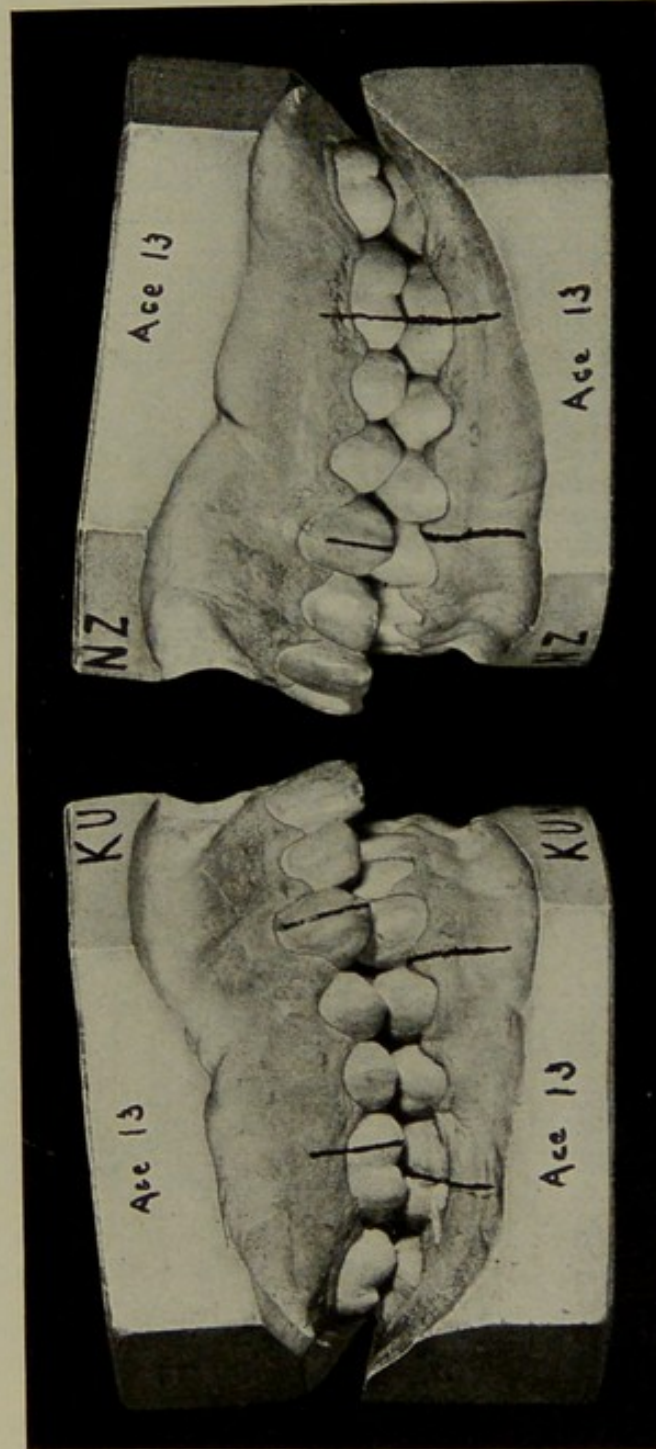


FIG. 523.

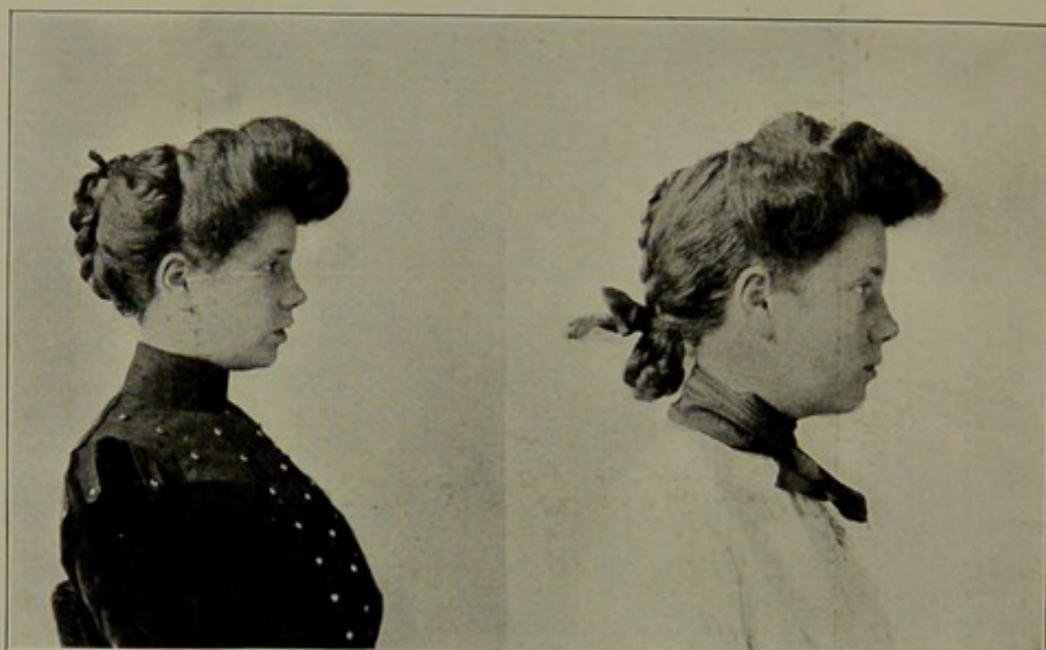loosening the nut so as to give the full bearing of the expansion arch upon them.



At this point, to prevent the shifting of the expansion arch laterally, a single elastic was also made to engage the sheath-hook and the sheath of the lower anchor band on the normal side. All of the teeth were soon brought into normal relations, as shown in Fig. 521.

FIG. 525.

FIG. 526.



Retention was effected by means of the plane and spur made to operate on the second deciduous molars on the right side. The upper incisors were retained by spurs soldered to bands which were cemented upon the lower central incisors, the spurs projecting outward and upward to engage their labial surfaces, as shown on one tooth in the engraving. This device also served the double purpose of assisting in breaking the habit of biting the lower lip.

The facial lines of the patient at the time of retention of the teeth are shown in Fig. 522.

Figs. 523 and 524 show another clearly defined case belonging to this subdivision, of a young lady thirteen years of age. The incisors are less prominent than is usual with such cases, probably due to the pathological conditions of

the nose being less pronounced, permitting more nearly normal breathing and lip function.

FIG. 528.

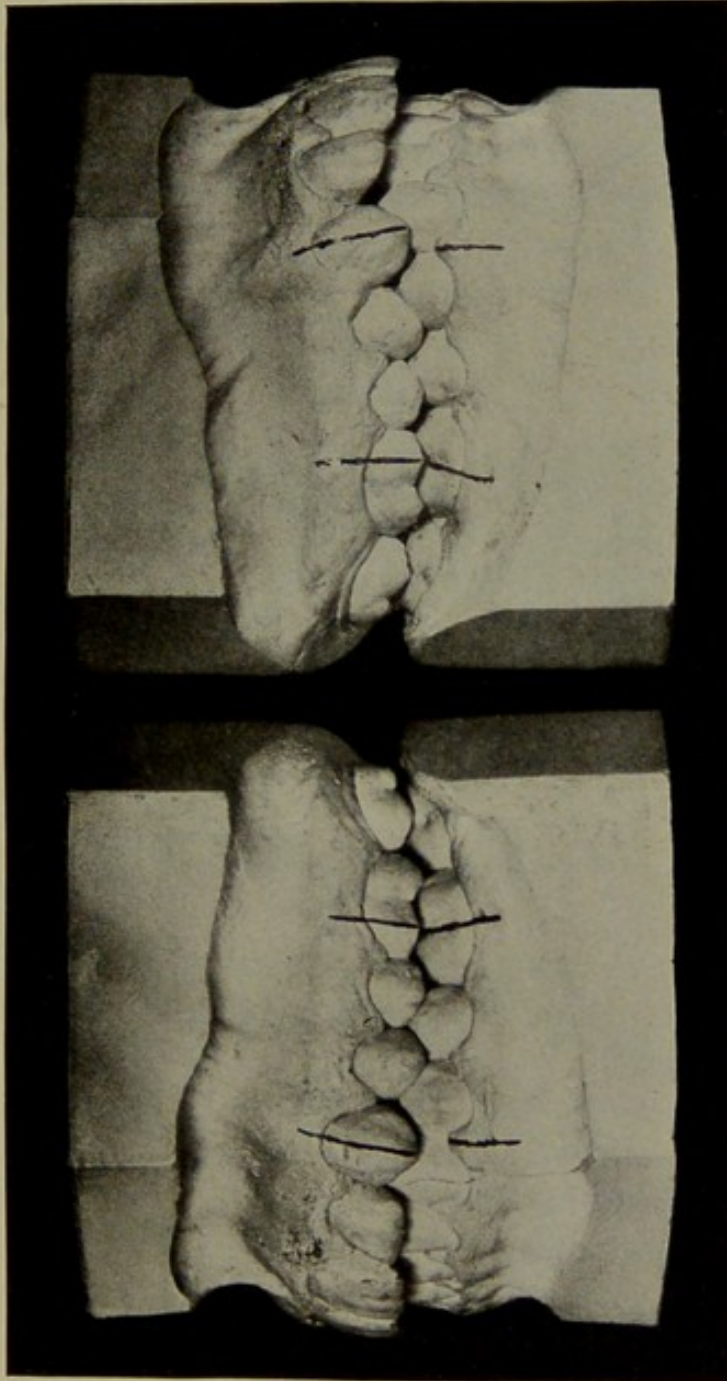


FIG. 527.

Fig. 525 shows the profile of the face, and it will be seen what a coarse expression is given to the mouth as a result of the malocclusion.

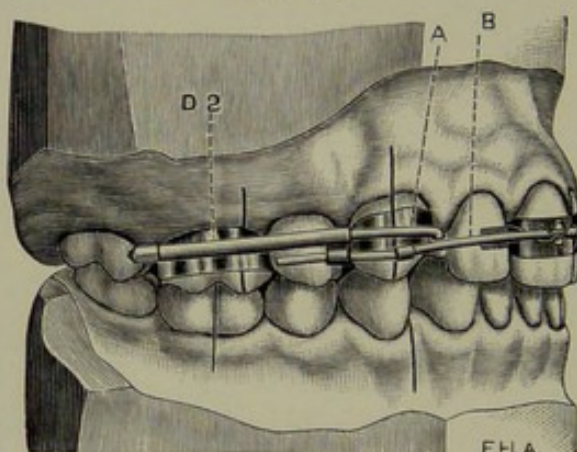


The teeth were restored to normal occlusion in the manner last described, it being necessary, however, to enlist stationary anchorage in the lower arch to effect the requisite distal movement of the upper teeth.

Retention was effected by means of the bands with plane and spur, operated on the right first premolars, as shown in Fig. 529.

Figs. 527 and 528 show the corrected occlusion, and Fig. 526 shows how greatly the balance of the mouth has been improved as a result of this treatment.

FIG. 529.



So similar are these cases in occlusion, habits of patients, and in necessities of treatment that it seems unnecessary to report others.

Cases that are complicated by the loss of teeth should be treated as already described for cases of this sort belonging to the main division.

Before the introduction of the Baker anchorage the only practical plan of treating these cases was the establishment of harmony in the sizes of the arches by sacrificing the first upper premolar on the abnormal side and retracting the incisors and canine to close the space, in the same manner as shown in Fig. 529, in which a combination of the traction screw, arch B, headgear and elastics is employed,

as described in the appendix. The result of such treatment is only improved occlusion instead of normal occlusion.

It is thought by many that treatment by this plan is quicker and easier than by the one just described. This, however, is a mistake, as treatment by the former plan is accomplished more rapidly and easily, besides giving far finer balance to the face, normal freedom to the tongue, and consequently better power of speech, with decidedly more efficient occlusion of the teeth.



## CHAPTER XVIII.

### TREATMENT OF CASES.—CLASS II, DIVISION 2.

It will be remembered that in cases of malocclusion belonging to this Division, as in those of Division 1 of this class, the teeth of the lower arch are in distal occlusion in both its lateral halves. The upper arch, unlike that in cases of Division 1 in which it is abnormally long and narrow, is shortened, with incisors bunched and overlapping, to approximately harmonize in size with the anterior part of the lower arch.

Figs. 530 and 531 show the simple case belonging to this division, of a boy twelve years of age. Unlike the conditions of the other division, the incisors are less elevated in their sockets, owing, probably, to their being better able to functionate, but the result of distal occlusion and recession of the jaw and chin greatly mars the facial lines.

Although these cases are often apparently more complicated than those of the first division, in reality, when we consider all of the various conditions, they are seen to be less so and more easily treated, for being free from pathological conditions of the nose, and with normal functions of the lips, they are under our better control. Although the teeth in many instances are found to be greatly crowded, and all of them in mal-position, yet with the plan of treatment now at our command we can so perfectly control the distribution of force for their movement, both individually and collectively, as to make the operation of establishing normal occlusion not difficult, especially if undertaken in youth. We can also be assured of complete success and with much certainty predict the time in which the operation of tooth movement may be accomplished. And as the patients are normal breathers, naturally hold-

FIG. 530.

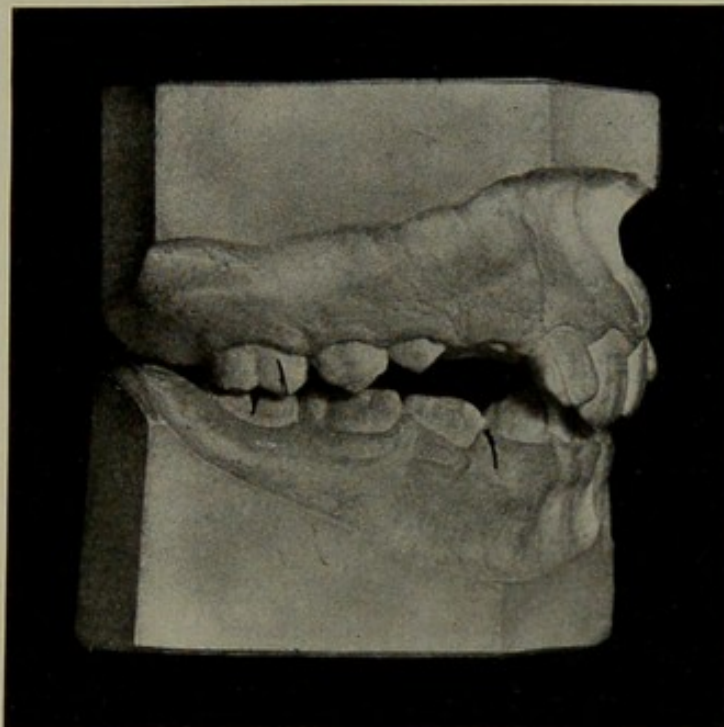
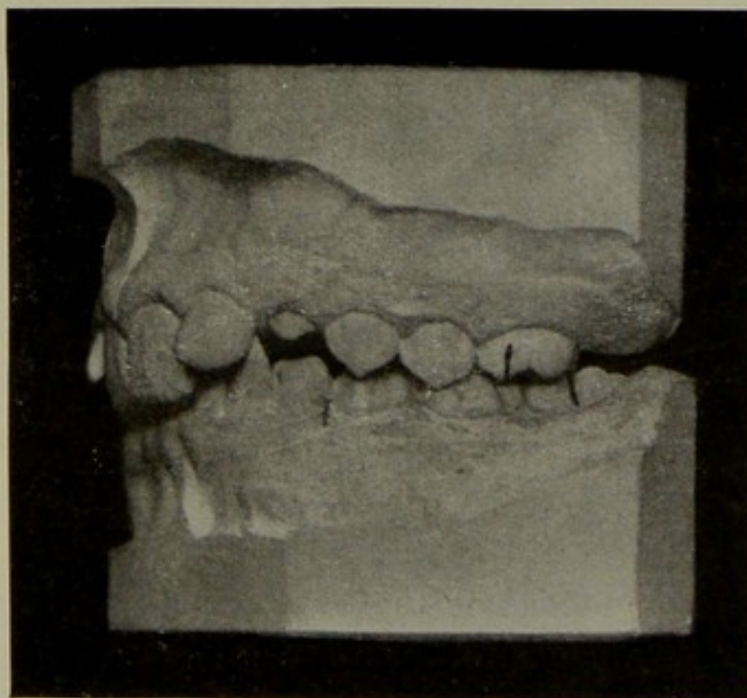


FIG. 531.





ing their jaws closed the requisite amount of time, after proper treatment the cusps of their teeth are locked for their mutual support, thus assisting the retaining devices and obviating the necessity for their being worn so long as is usually required in cases belonging to the first division of this class.

The plan of treatment formerly employed, and still strongly insisted upon by a few writers, necessitated the sacrifice of one or more teeth in the upper arch, usually the first premolars, and the establishment of harmony in the sizes of the arches by the retraction of the teeth anterior to the spaces. The most efficient method of treatment under this plan is shown in Fig. 649. Those still advocating this plan claim that it simplifies the operation and shortens the time of treatment, and that a "sufficiently good occlusion," or "serviceable occlusion" of the remaining teeth, with good balance of the face, are gained.

Although the only practicable plan prior to the acquisition of the intermaxillary anchorage, for reasons already given in considering like treatment in the first division of this class it should be abandoned, for in reality the operation is not made simpler or easier, but on the contrary a longer time is required and more difficulties are encountered than in maintaining the full complement of teeth and placing them all in normal occlusion—the only logical plan. This plan we will now consider.

Briefly, it consists in moving distally all the molars, premolars and canines of the upper arch about one-half the width of a premolar tooth, with a simultaneous and equal mesial movement of all the teeth of the lower arch, thus establishing the normal relations and functions of all their inclined occlusal planes—normal occlusion—and the best possible balance of the facial lines.

As the lower molars in this case had locked in distal occlusion, with normal distribution of force from the lips upon the incisors, it is obvious that the malocclusion thus



begun would be progressive, each succeeding tooth upon its eruption being compelled to lock abnormally, until finally there would be complete malocclusion of all the teeth, with the mandible effectually locked distally to normal, and with consequent inharmony of balance of the mouth and lower part of the face.

For the treatment of this case, as well as for all other cases belonging to this division, no appliance could be more ideal than the expansion arches, either plain or ribbed, the various movements of the incisors being accomplished by means of bands, spurs, and ligatures, as already thoroughly described for accomplishing these movements in cases belonging to Class I, and also in chapter XIII; while at the same time the mesial movement of all the lower, and the distal movement of all the upper teeth is accomplished, also by means of the expansion arches, with intermaxillary elastics made to engage the distal ends of the sheaths of the anchor bands on the lower molars, and the sheath-hooks attached to the upper expansion arch at points opposite the lateral incisors, exactly as described for the treatment of cases belonging to the first division of this class, and in the chapter above referred to.

The force necessary to move outward the central incisors by means of ligatures was reciprocated to the laterals through the ligatures made to engage spurs on their distolingual angles close to the margin of the gum, and the combined force of all assisted somewhat in the distal movement of the upper molars. As the tipping of the molars only was needed in this case, simple-intermaxillary anchorage was employed, the same as used in the case shown in Figs. 439 and 440. Figs. 532 and 533 show the result of such treatment in the case above illustrated.

Figs. 534 and 535 show the right and left sides of the dental arches with the teeth in occlusion of a very complicated case belonging to this division, the patient being a young man twenty-two years of age, with strong, well-



developed teeth and jaws all of the teeth being in malocclusion as a natural result of the mal-locking of the first per-

FIG. 533.

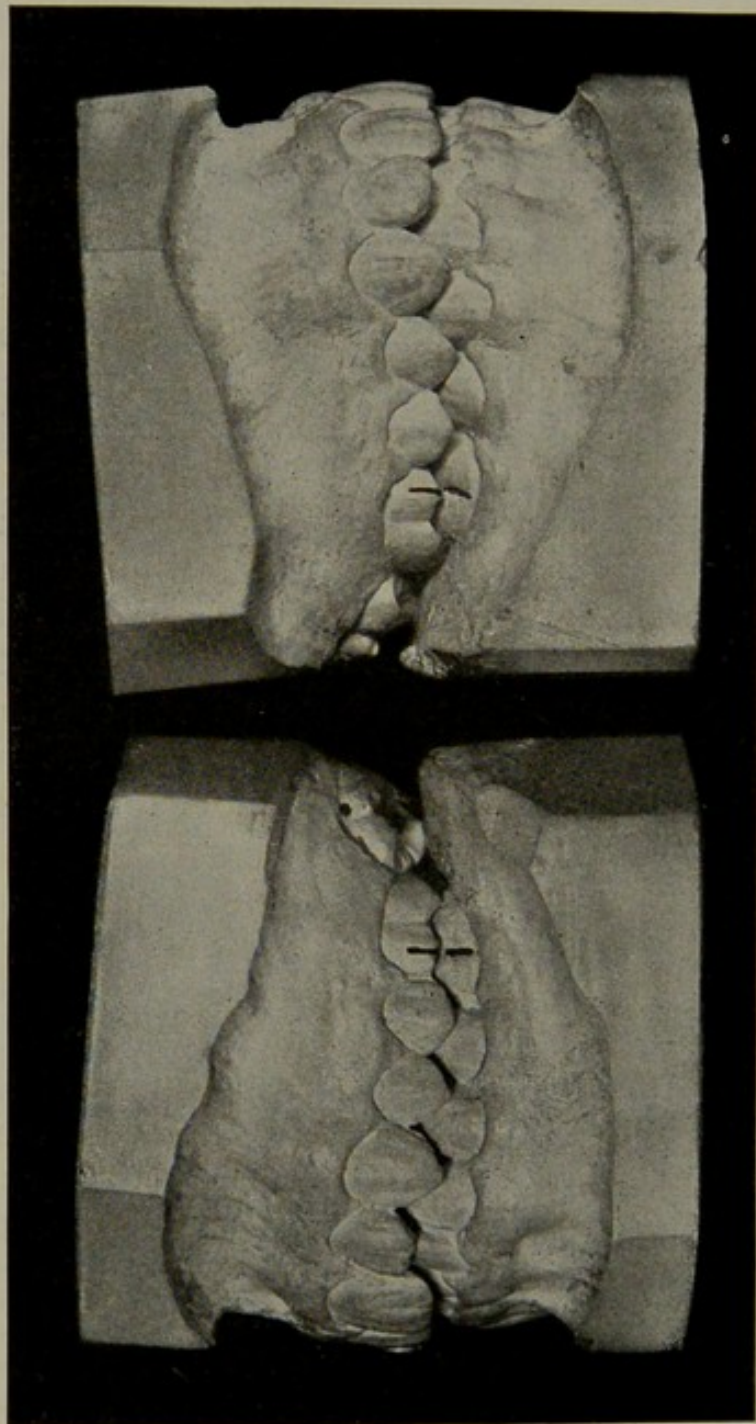


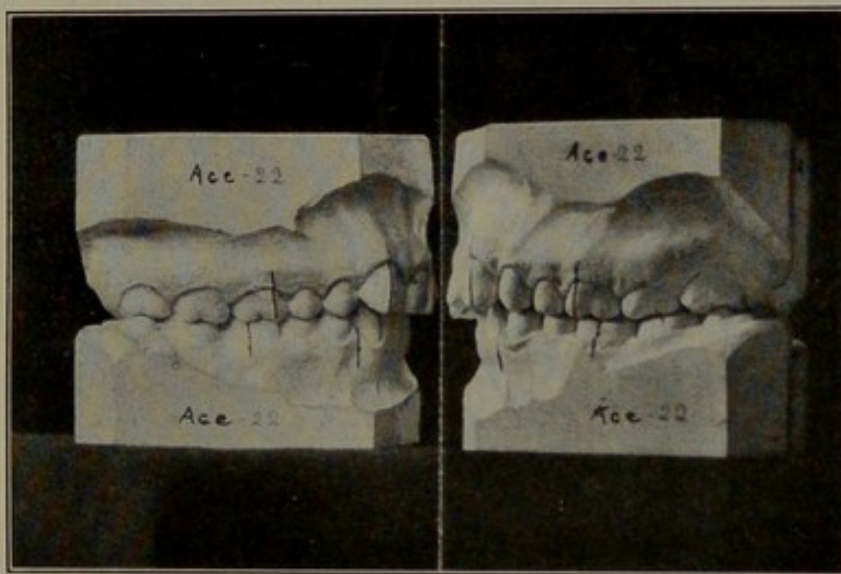
FIG. 532.

manent molars upon their eruption, yet following the above plan of treatment the teeth, even at this age, were all read-

ily moved into normal occlusion. Of course, the golden time for the treatment of this case was at, or soon after, the time of eruption of the first permanent molars, the difficulties having gradually increased with the advance of years. It is quite probable that at that time it would only have been necessary to direct the first molars into normal relations.

FIG. 534.

FIG. 535.



In the treatment of this case anchor bands were placed upon the lower second molars and first upper molars, and, as very little widening of the arches was necessary, the expansion arches were bent to conform approximately to the general forms of the dental arches as they appeared at the time of beginning treatment. As the upper incisors were required to be moved forward and rotated they were fitted with bands carefully cemented into position, with spurs placed at appropriate points on their linguo-gingival margins. After slipping the expansion arches into position, ligatures were made to engage the spurs and arches, and firmly tightened, thus exerting mesial and torsional force. The upper expansion arch, having been provided with sheath-hooks (in this case opposite the canines), the intermaxillary elastics were applied with gentle pressure



at first, which was gradually increased until three were worn on each side.

The appliances were carefully inspected twice each week, the wire ligatures renewed, or tightened by a one-half turn, and the nuts upon the expansion arch anterior to the sheaths tightened until there was an added snug feeling upon the molars. Gradually and far more rapidly than anticipated the firmly imbedded molars of the upper arch were moved distally, while those of the lower arch were carried mesially into full normal mesio-distal relations. The amount of force necessary being about equal in both arches, so far only simple-intermaxillary anchorage was employed.

The molar bands on the upper dental arch were now discontinued and X bands placed upon the second premolars. The nuts on the upper expansion arch were turned forward and after modifying its form to that of an ideal dental arch it was again slipped into position and force again applied to the centrals and laterals by means of fresh wire ligatures. In order to carry the canines distally a wire ligature on each side was made to embrace the three teeth and twisted at a convenient point on the buccal side. To prevent these ligatures from sliding beneath the gum they were made to rest above the sheaths of the anchor bands on the buccal side and beneath the screws on the lingual side.

By renewing the intermaxillary ligatures and continuing to tighten the nuts in front of the sheaths of the anchor bands at intervals, the premolars and canines were gradually made to travel distally into their normal mesio-distal relations with the lower teeth.

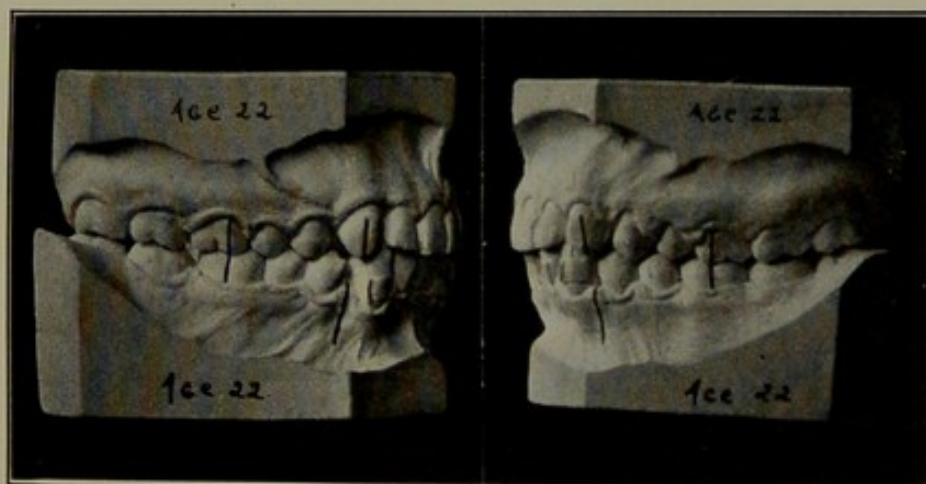
But one elastic on each side, exerting only sufficient force for retention, was now applied. The finer adjustment of the incisors being perfected they were held passively by the ligatures for several weeks, or until all soreness of the teeth had subsided. All appliances were then removed



and the teeth carefully cleansed, and both molar and canine retention, as in Figs. 256 and 260 was applied on both sides while the incisors were retained as in Fig. 233. In about four months the device for the retention of the molars was removed, while the canine and incisor retention was continued for over a year. Recurrent movement of the incisors began to be manifest two or three weeks after the removal of the retaining devices and they were promptly replaced and their correct relations established the second time by means of rubber wedges, followed by bending the spurs, as discussed in the chapter on Retention.

FIG. 536.

FIG. 537.



The improvement in the occlusion of the teeth is shown in Figs. 536 and 537.

Fig. 538 shows the facial lines of the patient before treatment and Fig. 539 shows the result of the establishment of normal occlusion.

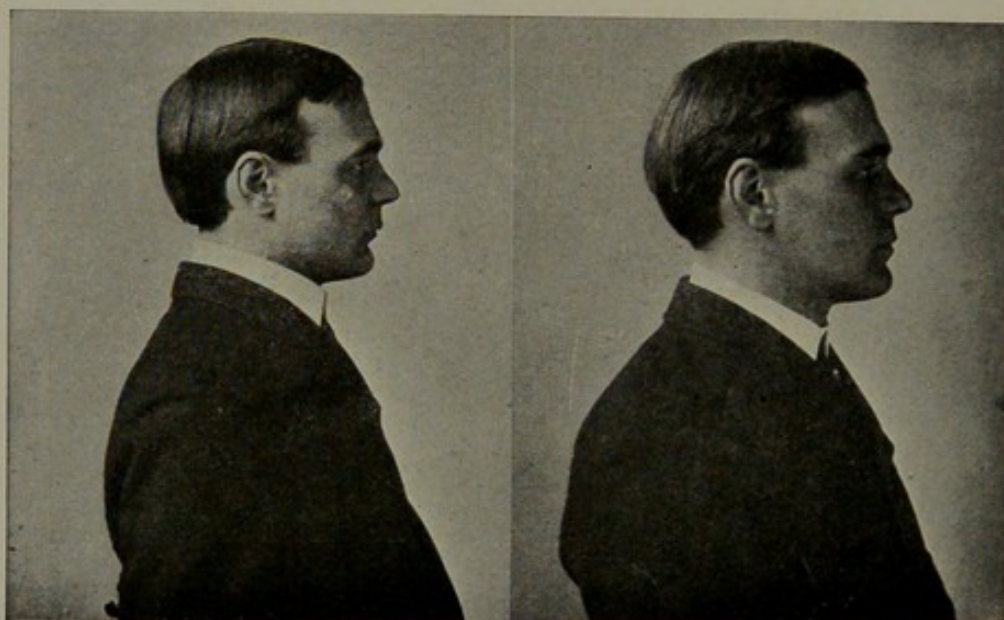
Figs. 540 and 541 show the malocclusion of the teeth of a girl, aged eleven years, clearly belonging to this division, and if we were to rest our examination on the models alone it would seem that the teeth of the lower jaw were in normal mesio-distal relations with the skull while those of the upper, especially the molars of the right side, had, by some force, been moved mesially from their normal rela-



tions with the skull. Yet this is not the fact, as is easily proven by a study of the facial lines in Fig. 542. If we were to resort to the extraction of but a single premolar in the upper arch the possibility of establishing the correct balance of the facial lines would be forever lost. What is clearly indicated in treatment is the shifting mesially of the teeth of the lower arch and distally those of the upper into normal occlusion, and reduction of the prominence of the right upper canine permitting its normal movement downward into the line of occlusion, and the correction of

FIG. 538.

FIG. 539.



the positions of the incisors; and as the upper first molar on the left side in locking assumed lingual relations with the lower, it must be moved buccally while the lower must be moved lingually.

All of these various necessary movements were accomplished by means of the expansion arches and intermaxillary elastics, with wire ligatures made to exert force upon the lateral incisors, all in the usual way, and as already described. The prominent canine was reduced by the expansion arch made to bear against its labial surface, with an intervening wedge of rubber. The buccal movement of

the left upper first molar was effected also by the expansion arch bent so as to exert an outward force upon it, while the

FIG. 541.

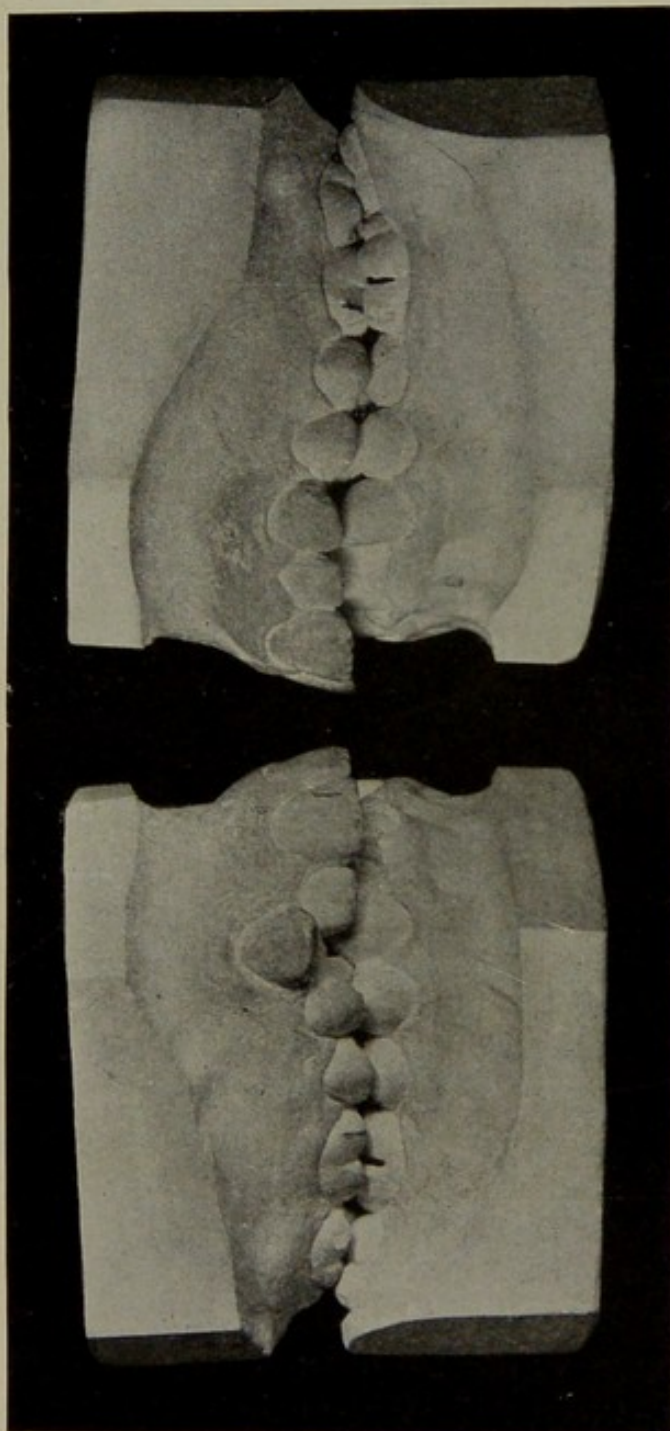


FIG. 540.

opposing molar was moved lingually by bending the ribbed arch so that it would exert an inward force.



The teeth were carefully retained by molar and incisor retention, as in Figs. 256 and 233, the various tooth movements having required about four months' time. An additional spur was soldered to the band which bore the plane of metal upon the first upper molar on the left. This spur

FIG. 542.



projected downward and bore against the buccal surface of the lower first molar between its disto-buccal and fifth cusps, thus compelling the normal buccal relations of these teeth, as in B Fig. 257. It was thought advisable to allow six months for the settling of the molars and growth of the alveolar process before perfecting the adjustment of the incisors.

The occlusion at this stage of the operation is shown in

FIG. 544.

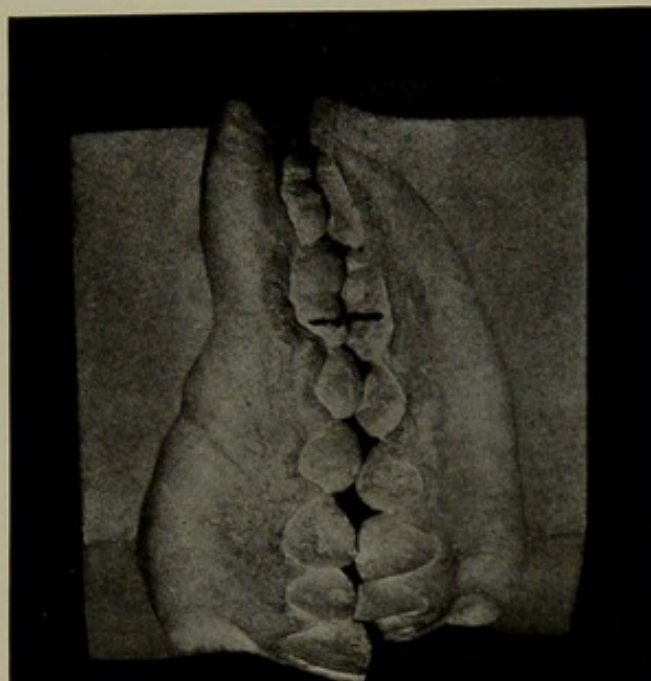
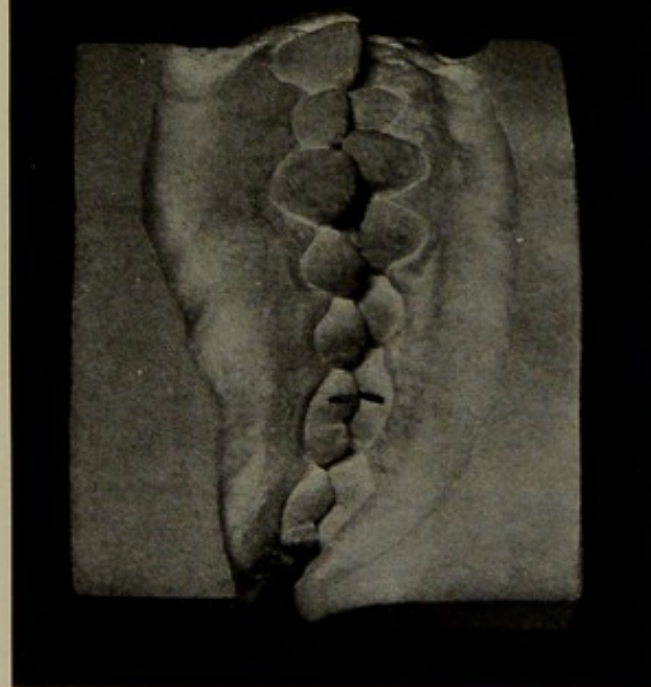


FIG. 543.



Figs. 543 and 544, and the improvement in the facial lines in Fig. 545.



As the molars become settled in their sockets and development of the alveolar process progresses, better occlusion between the incisors will follow.

Occasional inspection of this case will yet be necessary for at least a year.

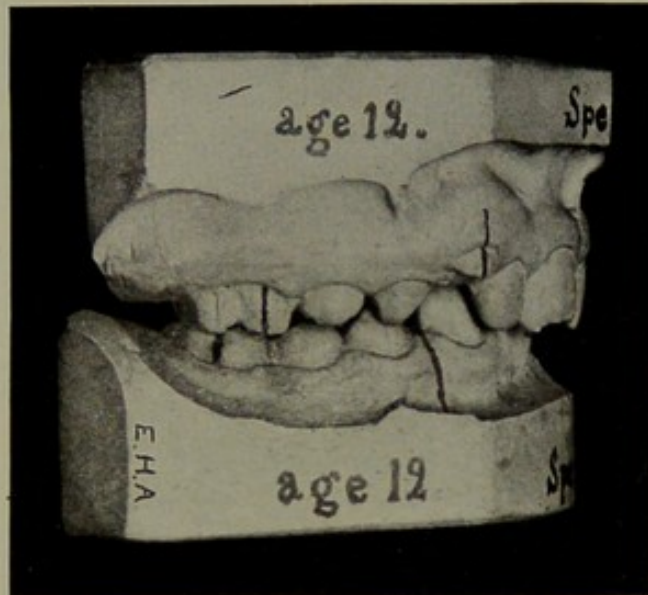
FIG. 545.



Figs. 546 and 547 show another well-defined case belonging to this division, of a girl twelve years of age. All of the usual characteristics are present, namely, complete distal occlusion of the lower molars and premolars, retrusion and bunching of the upper incisors, normal lip function, normal breathing, etc. The deciduous canines have recently been

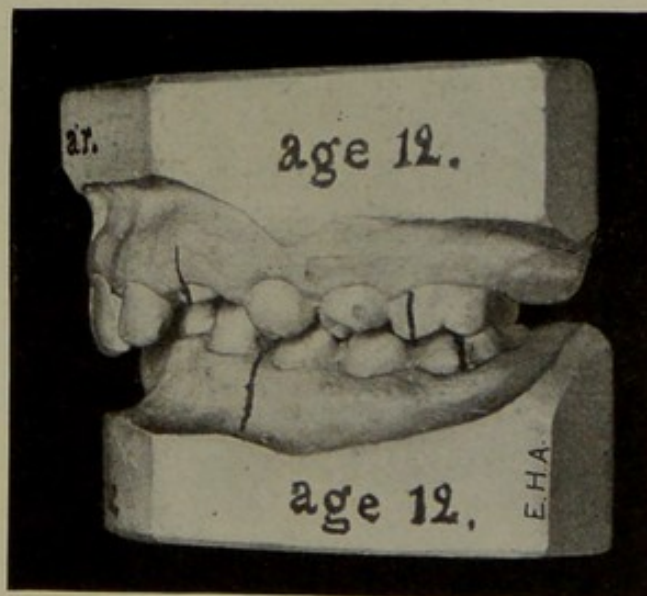
lost and their permanent successors are just beginning to erupt. An added complication—the abnormally short bite

FIG. 546.



—is here present. The molars have failed to erupt their normal length, allowing the lower incisors to come in con-

FIG. 547.

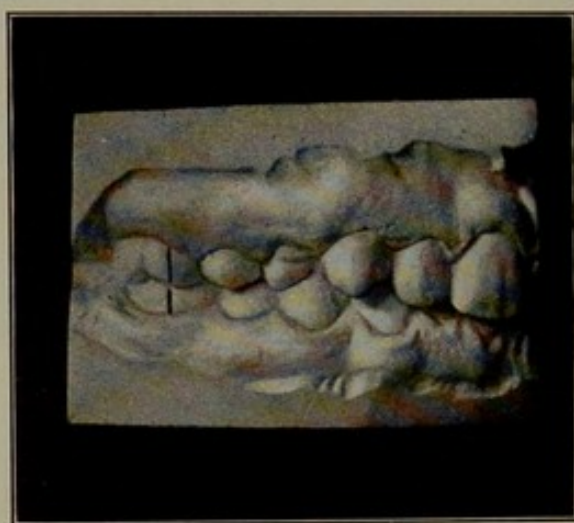


tact with the vault of the arch, while the cutting edges of the upper incisors pass beyond the gingival margins of the



lower. Of course this abnormal telescoping of the incisors is due in no small degree to the tipping downward and inward of the upper incisors from their normal angle, and the tipping lingually of the lower incisors, and although such a condition is more or less present in all cases belonging to this division, yet it is here present to an unusual degree, the principal reason being that the molars have not fully erupted.

FIG. 548.



Placing the teeth in their normal relations will greatly improve the bite, as shown in Fig. 548, where it has been accomplished.

How greatly the face is shortened and thrown out of balance is shown in Figs. 549 and 550, which again emphasizes the truth of the law that the variation from the normal balance of facial lines is in proportion to the degree of malocclusion.

The plan of treatment for restoring the normal mesiodistal relations of the teeth and positions of the incisors was the same as in cases already described. X bands, however, were placed upon the second upper premolars and the second and first premolars were at first ligated together, while the ribbed expansion arch was made to line slightly above the gingival margin of the upper incisors. As with

the centrals and laterals attached by means of the wire

FIG. 549.

FIG. 550.

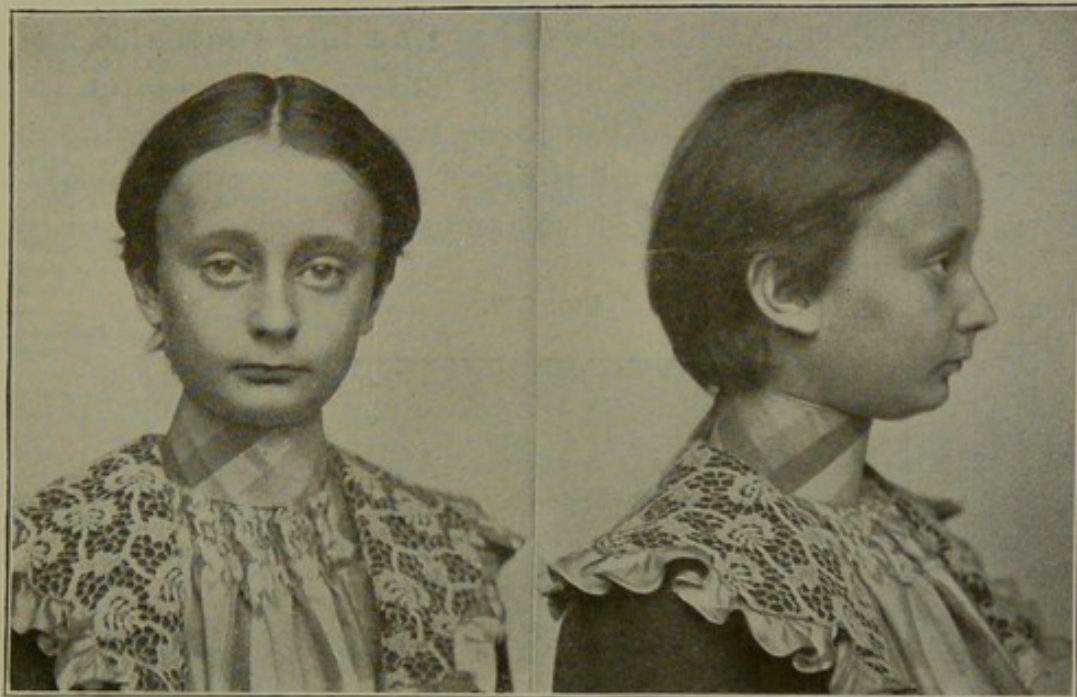


FIG. 551.

FIG. 552.



ligatures in the usual way the expansion arch would naturally spring down. The tendency of the spring thus given



was to lengthen the premolars and shorten the upper incisors while they were moved labially by tightening the nuts in front of the sheaths of the anchor bands, renewal of ligatures, etc. This upward spring also prevented the ligatures from sliding downward on the crowns of the incisors. As the result of the force from the intermaxillary elastics and the spring of the arch, very excellent mesio-distal relations of the teeth were established, as shown in

FIG. 553.

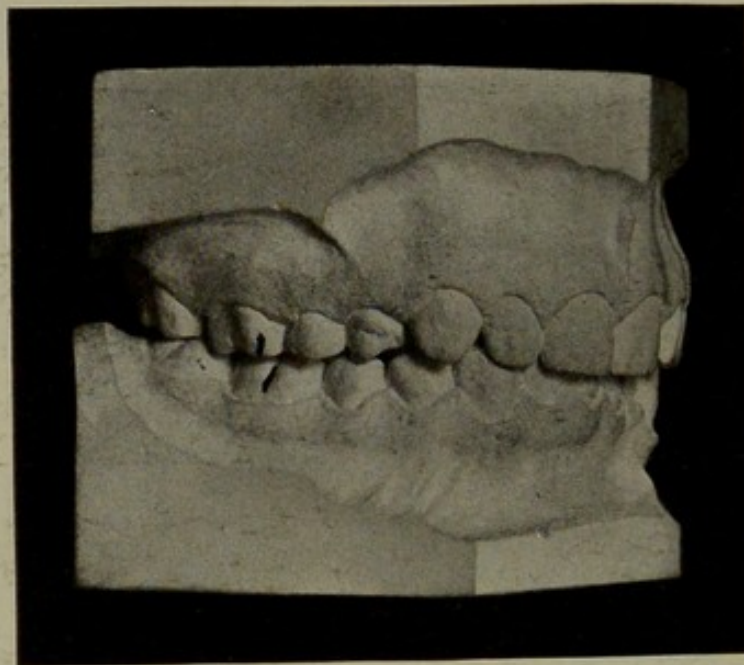


Fig. 548. Figs. 551 and 552 show the facial lines at this time. But the bite is still far too short, and, as Dr. Kirk has well said, "It is of quite as much importance that the proper length of bite be established as it is that any other phase of malocclusion be corrected," and for this purpose the bite plate, as described on page 491, was made use of. It was worn for one year, completely relieving the molars of occlusal contact. As a result they became lengthened to a noticeable degree, and the incisors were possibly shortened to some slight extent.

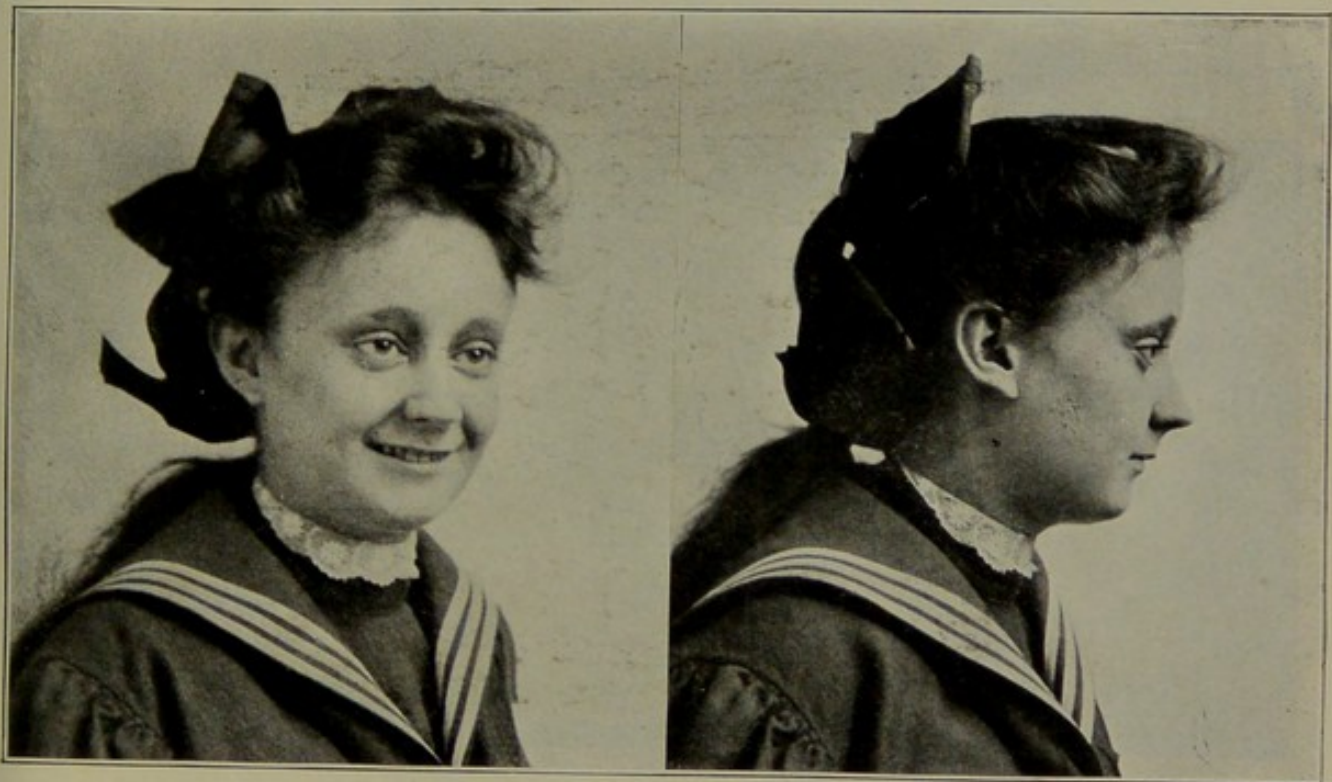Two years after the discontinuance of all treatment a



model of the teeth was made which shows the present condition of the occlusion, Fig. 553; and Figs. 554 and 555 show the facial lines of the patient at the time of making this model. While numerous simpler cases belonging to this division might be reported here, this seems unnecessary as the stories they might tell in occlusion and art and in the methods of accomplishing the various tooth move-

FIG. 554.

FIG. 555.



ments are embraced in the cases already reported, and if these be understood the treatment of simple cases should offer no difficult problems.

TREATMENT OF CASES.—CLASS II, DIVISION 2, SUBDIVISION.

Cases that are easily classified as belonging to this subdivision differ from those of the main division only in degree, the teeth of one of the lateral halves of the arches being normal as to mesio-distal relations, while those of the opposite side are locked in distal occlusion. This is accom-

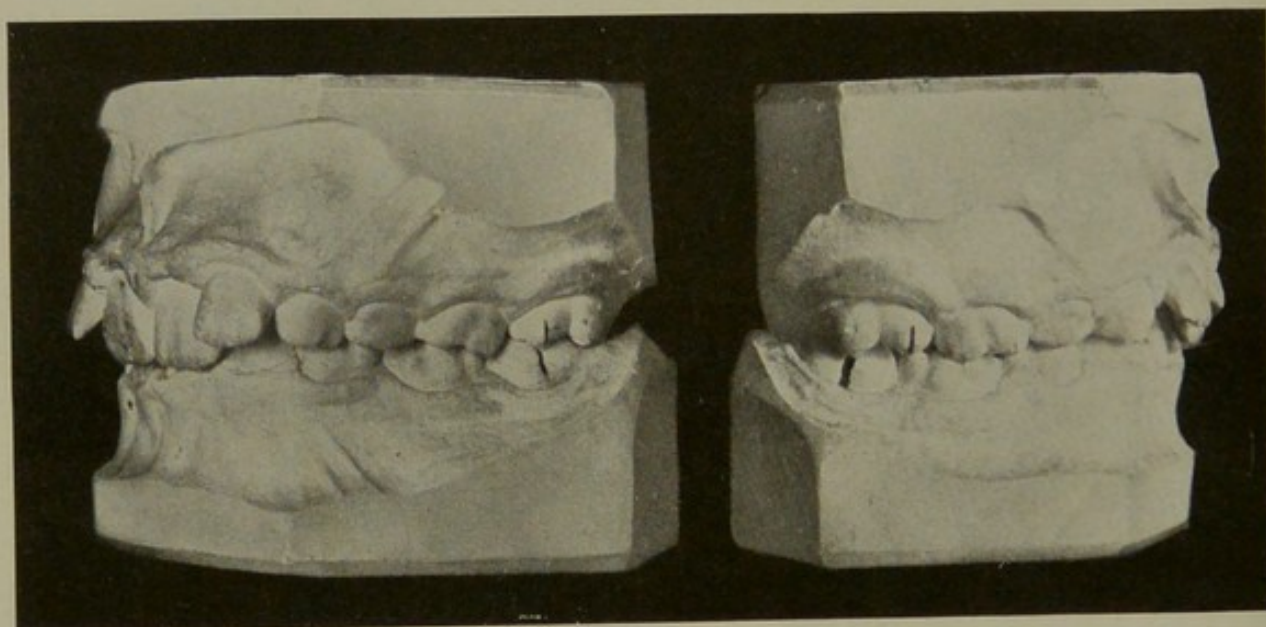


panied by the bunching and overlapping of the incisors which may be limited to those of the upper arch, or, as frequently happens, may also involve those of the lower arch. Of course inharmony in the balance of the facial lines exists in a corresponding degree.

Cases of this type are frequently met with and often present complications in treatment quite as difficult to overcome as are found in cases belonging to the main division, yet as the patients are normal breathers, if no

FIG. 556.

FIG. 557.



vicious habits of the lips exist and the cases are intelligently managed, success may be assured, although the period of retention may often be protracted.\*

Figs. 556 and 557 illustrate a typical case belonging to this subdivision—that of a boy ten years of age.

It will be noted that the first permanent molars, deciduous molars, and canines on the left side are in normal

---

\* Even in these cases vicious habits of the lips, especially the lower, are not infrequent. They should receive close attention.

relations, while those on the right side are locked in com-

FIG. 559.

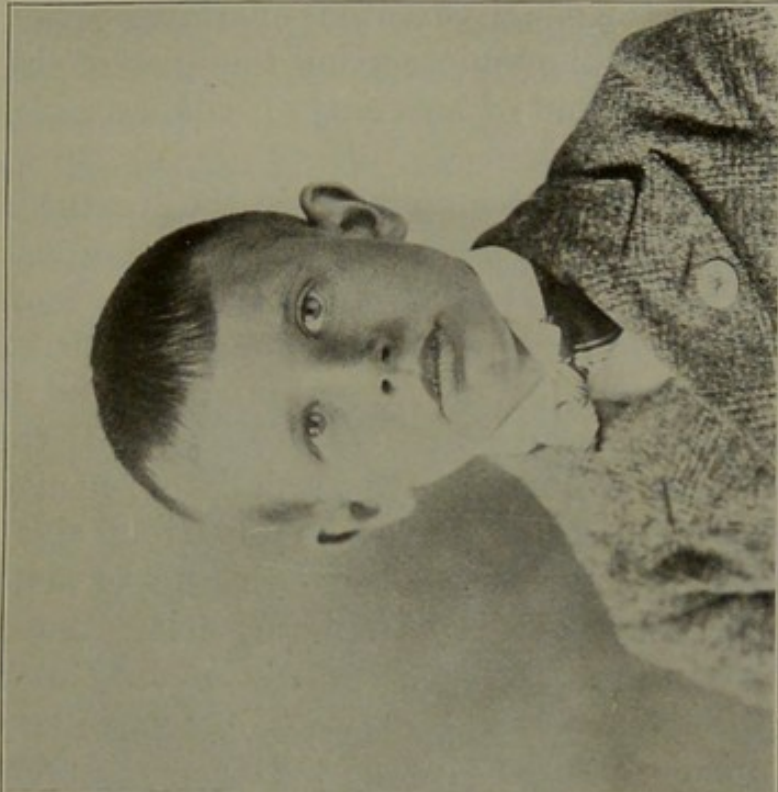
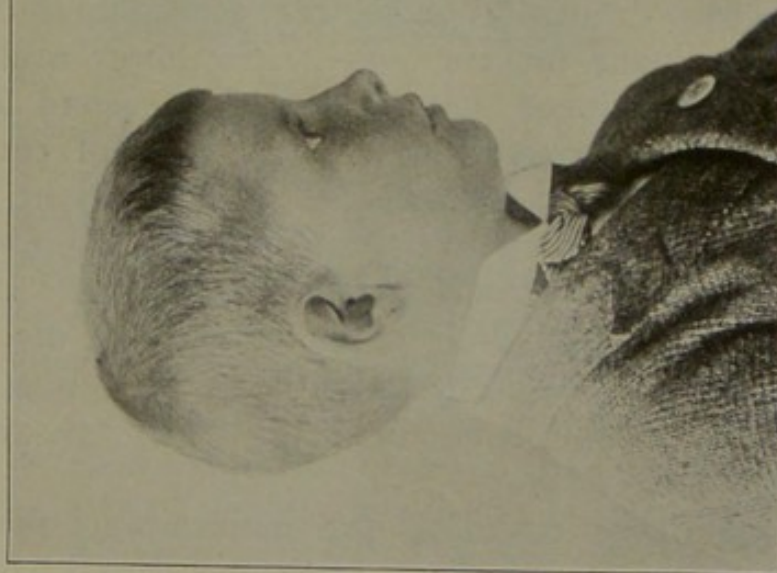


FIG. 558.



plete distal occlusion, with retruding upper central incisors, and that all of the lower incisors, are more or less



lingual to the line of occlusion, with one of them pronouncedly so. The result of this retrusion of the incisors is to produce the usual abnormal overbite.

As a result of the malocclusion the lines of the face are naturally thrown out of harmony of balance, as is shown in Figs. 558 and 559.

The object to be accomplished in the treatment of this, as in all cases, is normal occlusal relations between all of the teeth. This necessitates the labial movement of all the lower incisors and the upper centrals, the torso-lingual movement of the upper laterals, and the slight widening of the upper arch in the region of the canines and first premolars, with the mesial movement of all the lower molars and the canine on the right side, and the slight distal movement of the opposing upper teeth.

For the accomplishment of these various movements in this as well as in all other cases belonging to this subdivision, the expansion arches, with intermaxillary elastics on the abnormal side, give us the most complete control, and in efficiency and simplicity far outrank any other device.

In this case the anchor bands were placed upon the upper second deciduous molars, and in the lower arch on the right first permanent molar and the left second deciduous molar. The intermaxillary elastics were of course employed only on the affected side, very lightly at first and finally increased to two fairly strong elastics, and as the lower molars (permanent and deciduous) were gradually moved forward and their opponents moved distally, the wire ligatures were used efficiently in correcting the various mal-positions of the incisors, all as frequently described.

Intermaxillary retention for maintaining the proper mesio-distal relations of the teeth and dental arches was employed upon the first permanent molars on the right side, as in Fig. 560. The retention of the lower incisors



was secured as in Fig. 233, and of those of the upper arch by bands on the upper lateral incisors, connected by a section of wire G soldered to their mesio-lingual angles, which rested against the lingual surfaces of the centrals.

There remained a strong tendency toward the slight bunching of the upper incisors, which continued until all of the permanent teeth, with the exception of the third molars, had become fully erupted and thoroughly estab-

FIG. 560.



lished. Figs. 561 and 562 show the occlusion of the teeth toward the close of the period of retention.

Figs. 563 and 564 show the excellent balance of the young man's face resulting from the treatment.

Fig. 565 shows another case belonging to this subdivision, of a boy twelve years old. Although the teeth on the right side have not yet locked in full distal occlusion the relations of the inclined planes are such that this must soon result. The teeth of the left side are in nearly ideal occlusion and their forms and relations are nearly faultless, yet if the teeth of the right side were allowed to remain in their present positions derangement of the lower incisors would be almost certain to follow from the disturbance of



the upper lateral which must be carried mesially and lingually as the canine forces its way in eruption.

FIG. 562.

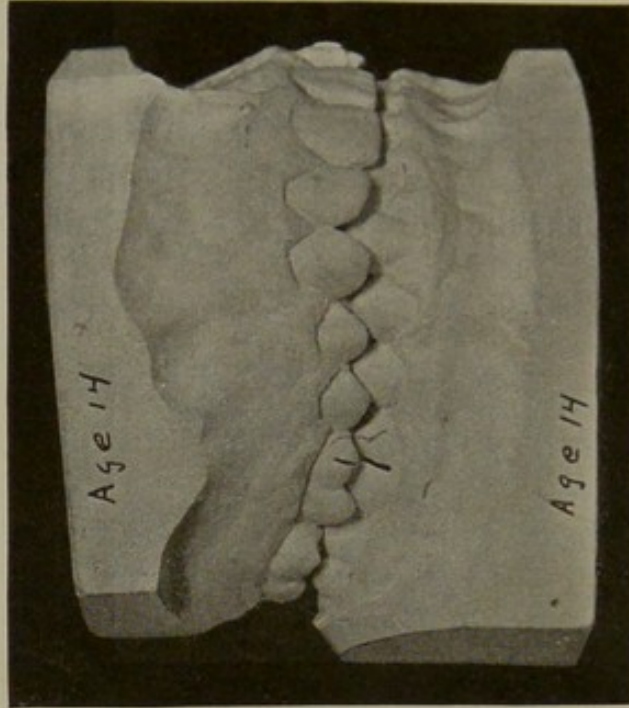
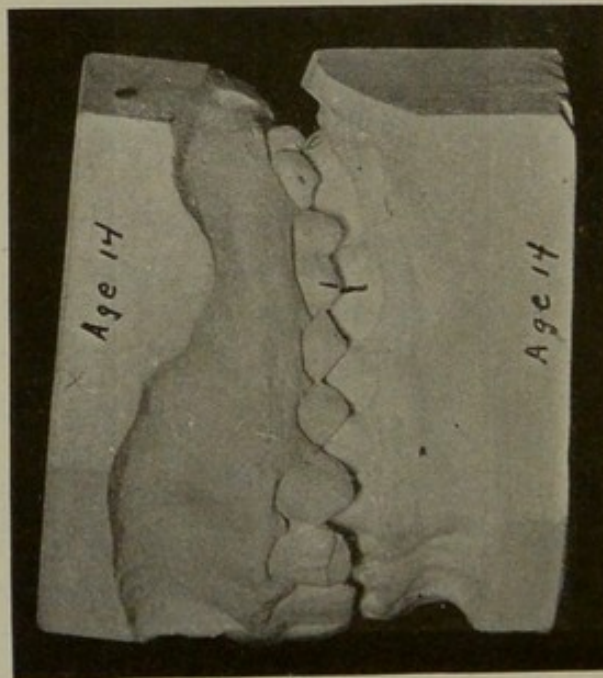


FIG. 561.



For effecting the distal movement of the right upper molars and premolars, as well as the labial movement of

FIG. 564.




FIG. 563.

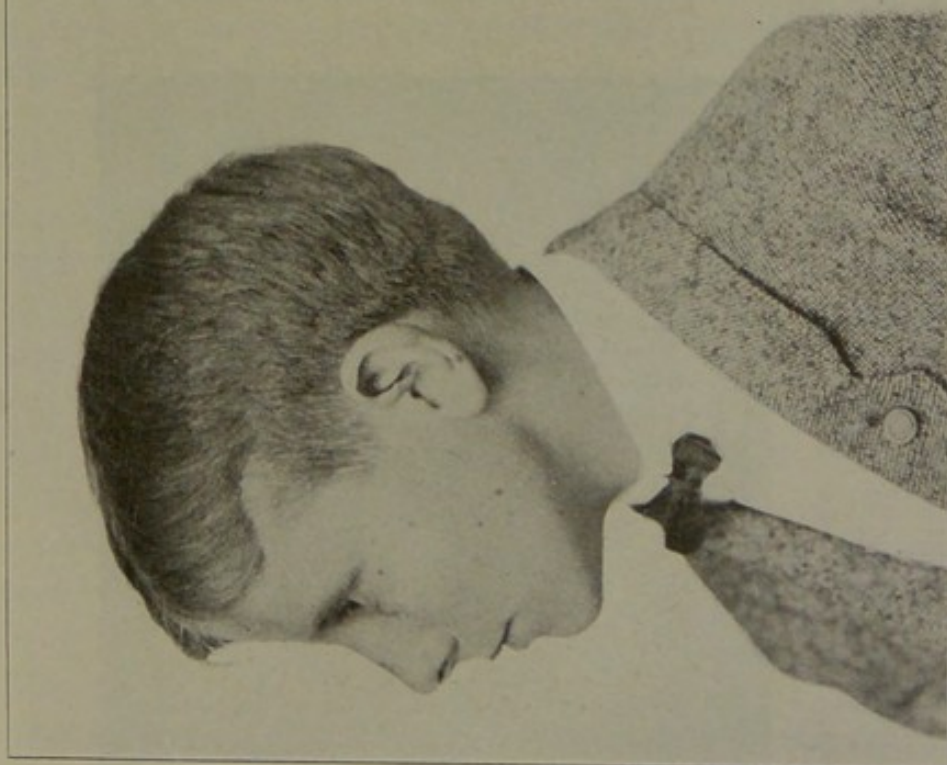




FIG. 566.

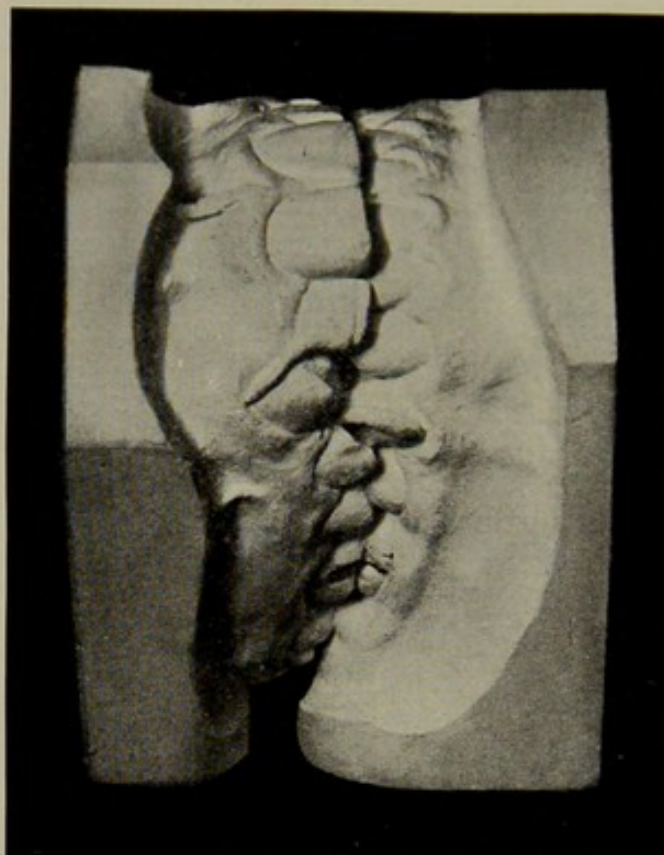
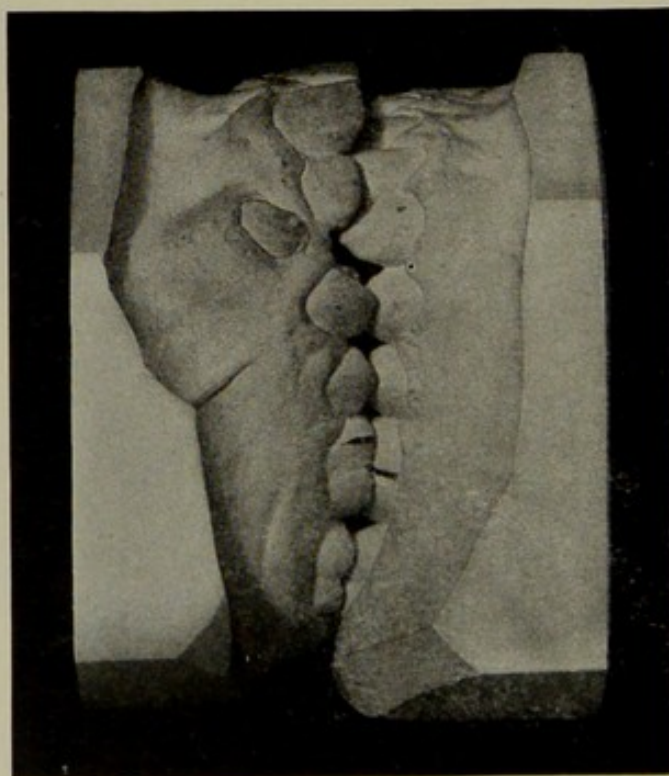


FIG. 565.



the right upper lateral incisor, and the mesial movement of the opposing teeth, the expansion arches, intermaxillary elastics, etc., were adjusted and operated in the usual way.

Fig. 566 shows the corrected occlusion and the manner of retention, which may be used with advantage in similar cases.

The mesial movement of the upper premolars and molars was combatted by a spur made from nickel-silver wire and soldered to a clamp band cemented upon the first lower premolar, which passed upward and lingually to bear against the mesial surface of the crown of its antagonist.

In this way ample space was maintained for the erupting canine. The retention of the lateral was secured by a band cemented upon its crown and carrying a spur which extended upward and bore against the mesio-labial surface of the canine. The force so exerted directed the latter tooth distally as it slowly erupted into the space provided for it. When it had erupted far enough to be interfered with by the spur on the lower premolar the spur was gradually reduced by grinding and finally dispensed with altogether.

In similar cases when the canine shall have taken its full normal position the finer adjustment of the lateral may become necessary, which may be easily accomplished by another spur soldered to its band and made to bear upon the disto-labial surface of the central, with an intervening wedge of rubber that should be removed after the lateral has been correctly adjusted and the spur bent to bear directly against the central for its retention.

Figs. 567 and 568 show another typical case belonging to this subdivision—that of a young man eighteen years of age. It will be seen that all the usual characteristics of cases belonging to this subdivision are present. The left lateral halves of the two arches are abnormal, the lower teeth being in distal occlusion, with bunching of the in-



cisors, and with torso-lingual relations of the upper incisors.

FIG. 567.

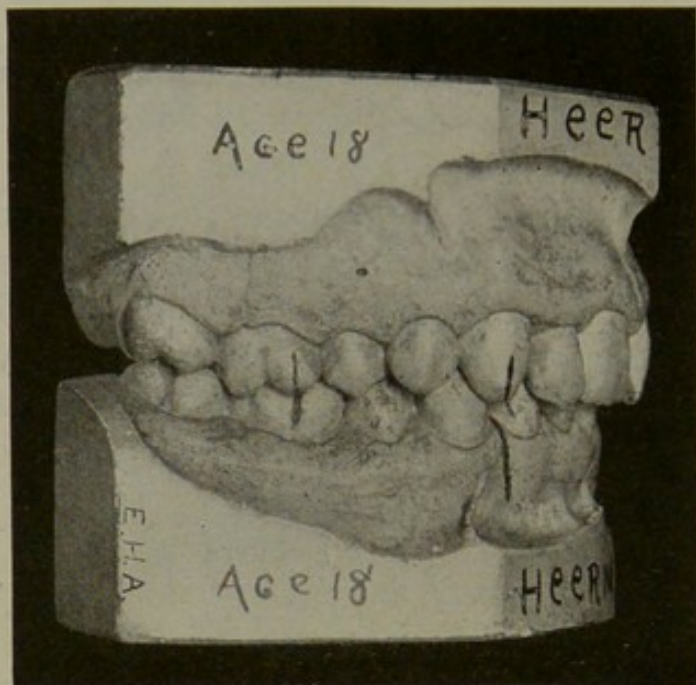
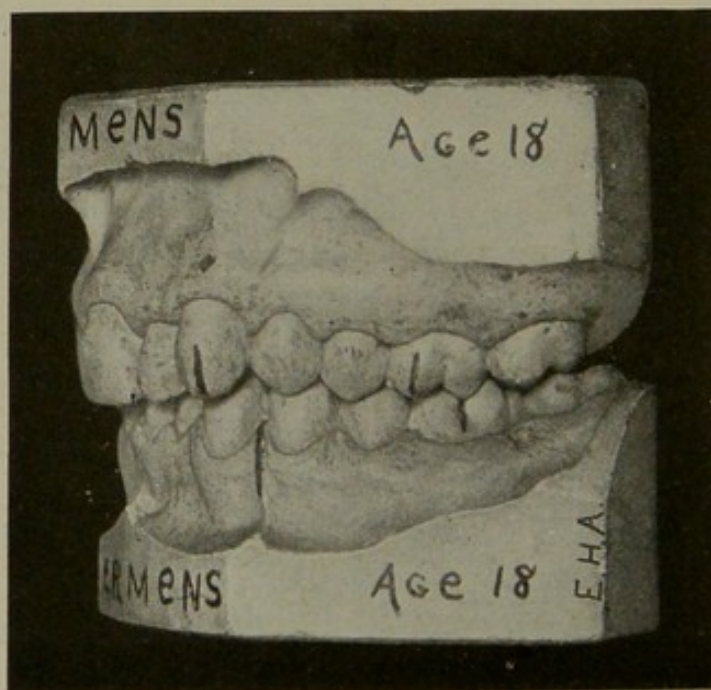


FIG. 568.



The case was treated according to the plan already indicated, and Figs. 569 and 570 show the corrected occlu-

sion which has given normal balance and strength to the

FIG. 569.

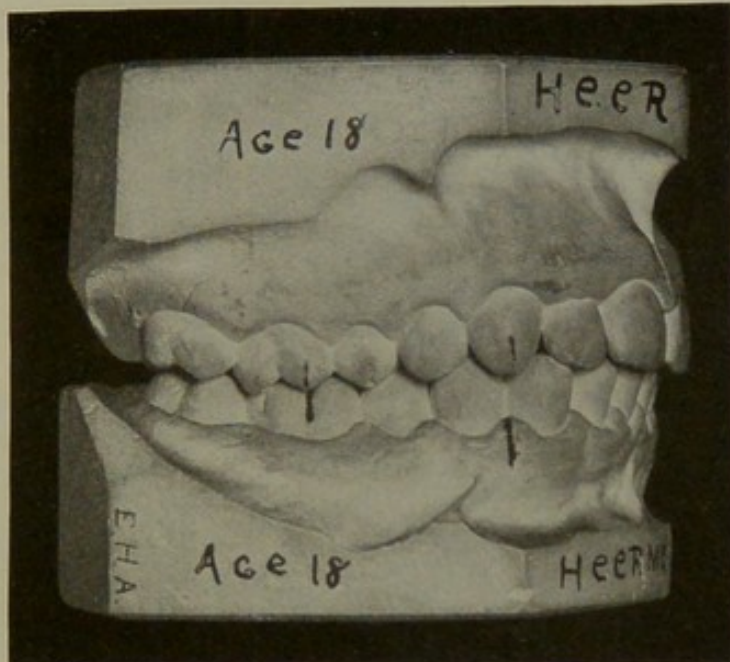
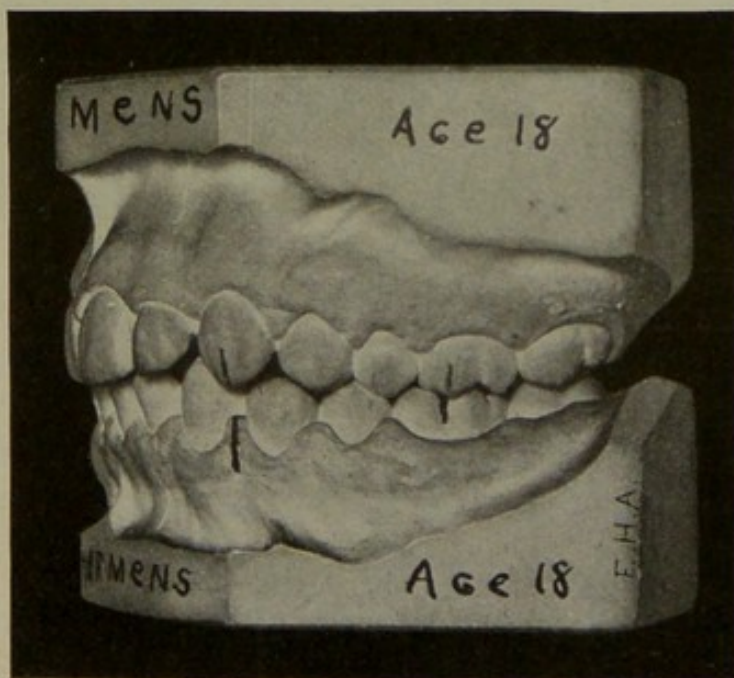


FIG. 570.



face. This is easily verified by comparing the profile of the young man, Fig. 572, taken after treatment, with that



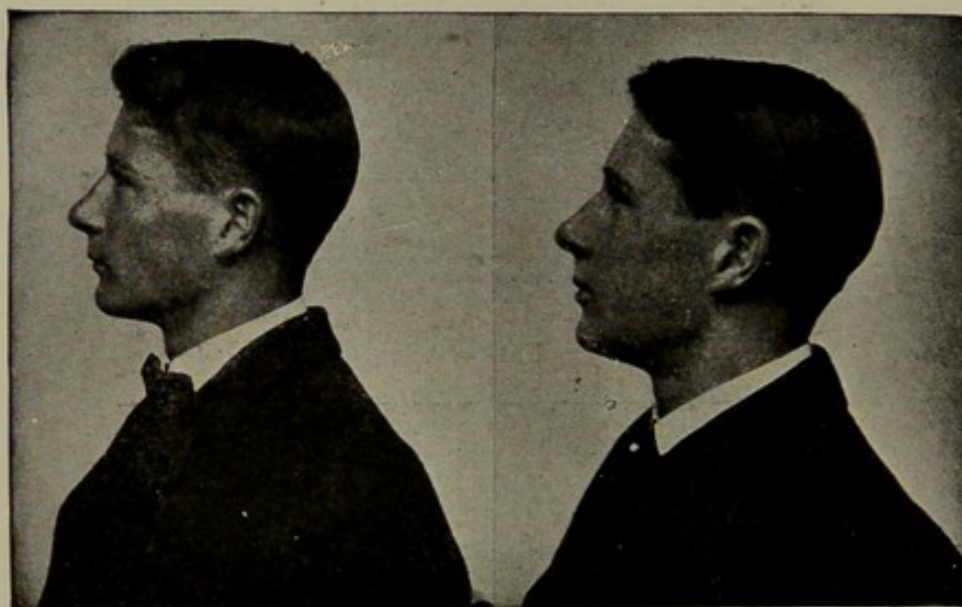
shown in Fig. 571, taken just before the beginning of the operation.

Figs. 573 and 574 show the right and left sides of a case of a boy, aged thirteen, belonging to this subdivision.

The malocclusion is far more complex than is usual in cases belonging to this subdivision, due to the lingual locking of the upper premolars and the first permanent molar on the left, in addition to the distal locking of the lower molars, premolars and canine on this side. This is further

FIG. 571.

FIG. 572.



complicated by the great shortening of the upper arch, due to the pronounced lingual positions of the incisors and arrest in the growth of the alveolar process following the premature loss of the upper deciduous canines through absorption of their roots. The further eruption of the upper canines is rapidly carrying the laterals and first premolars still further into lingual occlusion.

The occlusal aspect of the upper dental arch at this time is shown in Fig. 575 and of the lower in Fig. 577.

The marked diminution from the normal in the sizes of the arches so interfered with the normal functions of the

tongue as to noticeably impair the speech, and also, as might be expected, to greatly impair the balance of the

FIG. 574.

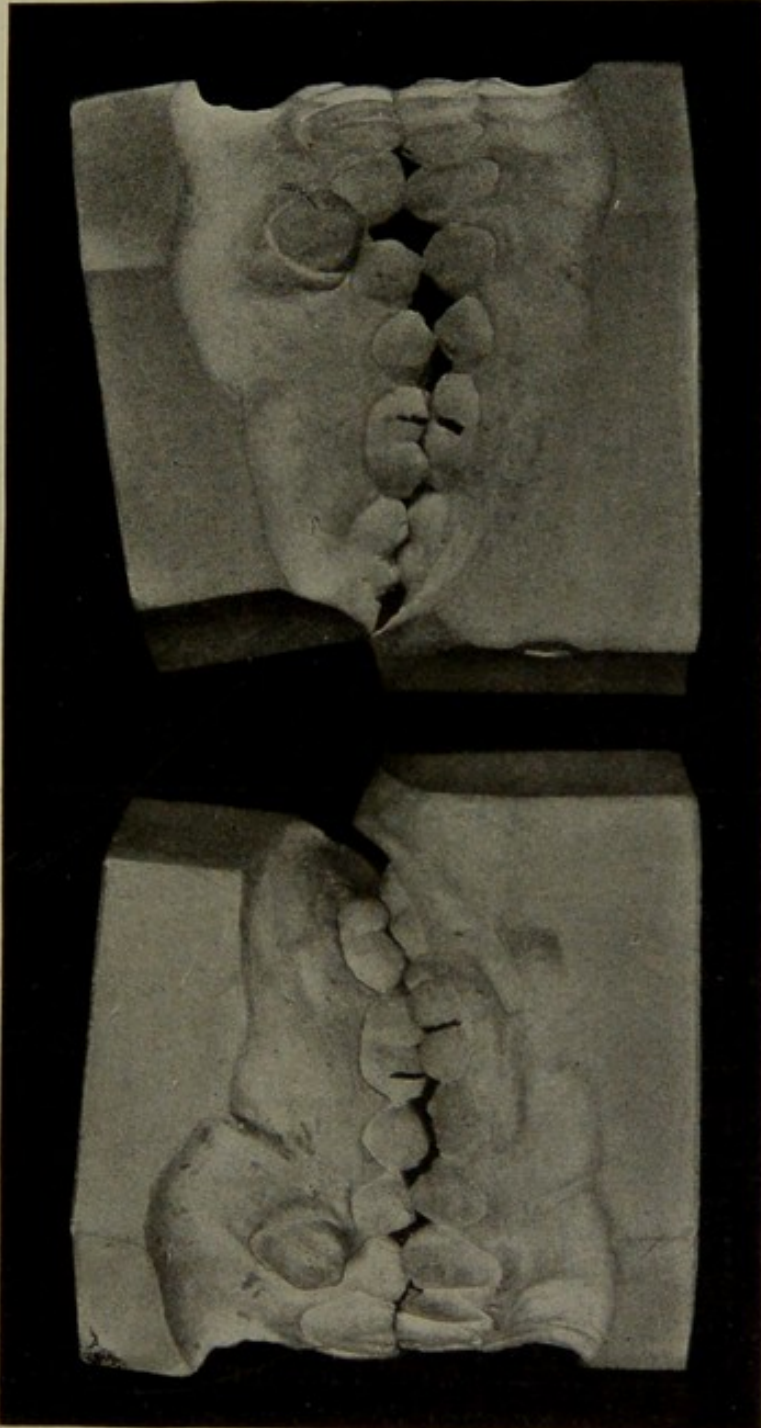


FIG. 573.

facial lines. That such has been the result is clearly shown in the front and profile views of the face, Figs. 579 and 580.



Notwithstanding there is almost complete arrest in the growth and development of the alveolar process, and the apparent impossibility of providing room in so small a jaw for the full number of teeth of such large patterns,

FIG. 575.

FIG. 576.

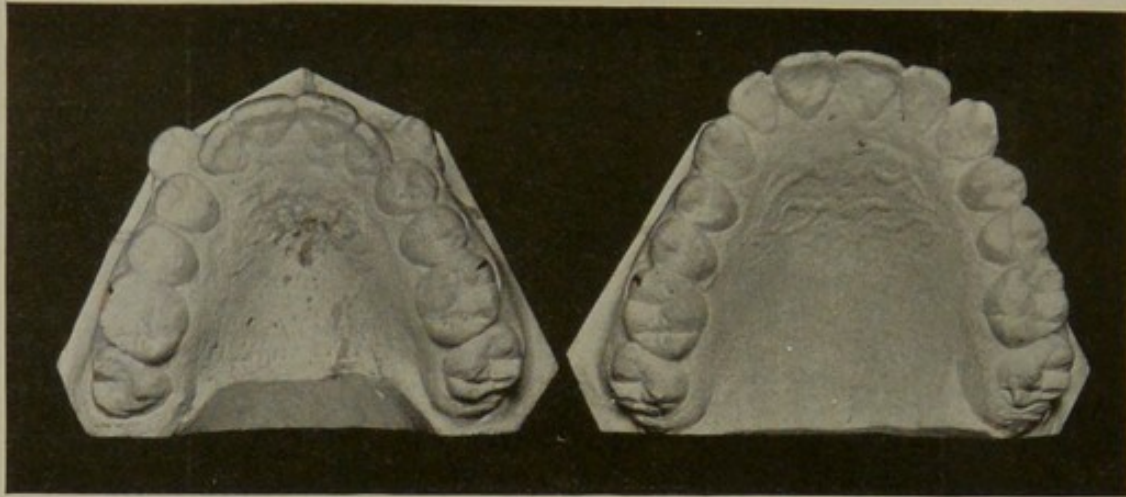
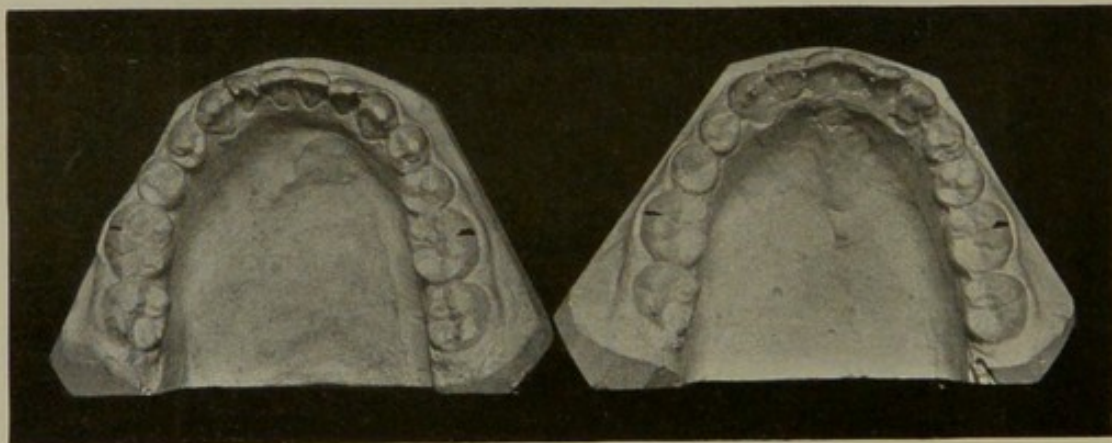


FIG. 577.

FIG. 578.



yet to have extracted a single tooth would have been an irreparable blunder and would have rendered it impossible to ever secure the normal functions of the teeth, tongue, and nose, or to establish Nature's intended contour and balance of the face.

The correct plan of treatment, which ought even in this

remarkable case to be clear and apparent to the reader who has followed us thus far, is to enlarge the upper arch, widening it in the region of the premolars, carrying the

FIG. 580.




FIG. 579.

incisors labially, moving buccally the upper first molar and lingually the lower first molar on the left side, during periods of activity followed by periods of rest, all pre-



cisely as described in the treatment of cases with similar characteristics belonging to the first class, and at the same time carrying the upper molars and premolars on the left side distally and the lowers mesially.

In carrying out this plan of treatment all four first molars were banded, much buccal spring being given to the upper expansion arch and lingual spring to the lower, ribbed arches being used. The distal movement of the upper teeth and the mesial movement of the lower on the left side was begun immediately with two strong intermaxillary elastics. Gradually the upper arch was widened and lengthened until normal mesio-distal, as well as linguobuccal, relations of the molars and premolars were secured. The incisors had been moved forward probably half the requisite distance, affording partial room for the eruption of the canines.

At this period the teeth were retained and the patient dismissed for six months to permit the growth of the bone. As a result of tipping the upper incisors forward and establishing the normal relations between the molars, the upper and lower incisors were greatly separated. This occasioned no anxiety, as the author felt assured that the normal settling of the molars, and the normal growth of the alveolar process in the region of the incisors would in time establish their proper relations as to length of bite. At the end of six months this had occurred to a noticeable degree and the canines had meantime also proceeded most favorably in their movement downward toward their correct positions.

The incisors were then carried forward sufficiently to permit the normal location of the canines, and the arch was widened slightly more than required for occlusion in order to better stimulate the growth of the bone.

The teeth were again retained and the patient dismissed for another six months. Upon his return the positions and relations of the teeth were as shown in Figs. 581 and 582,

which represent models made at this time. Better rela-

FIG. 582.

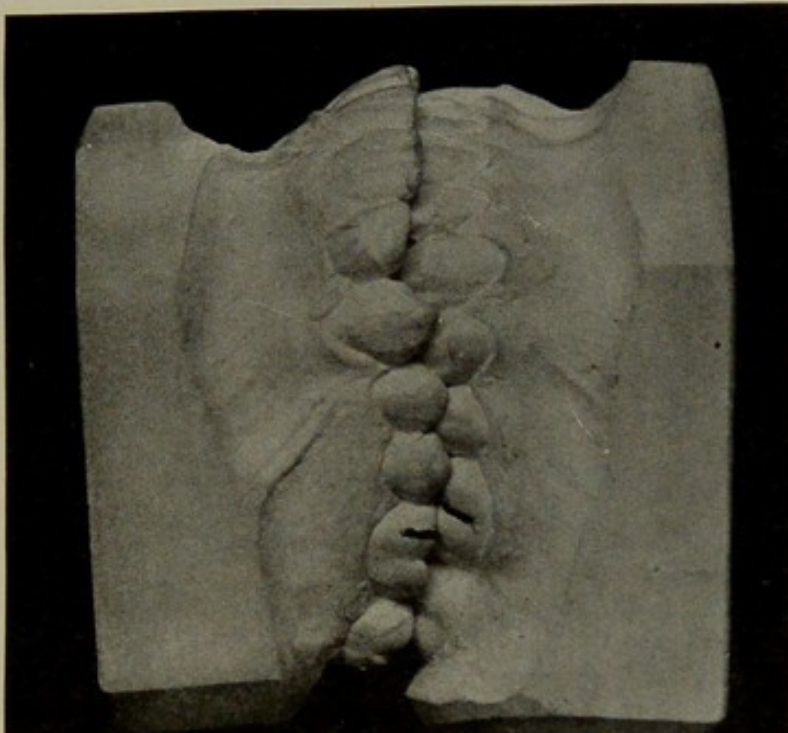
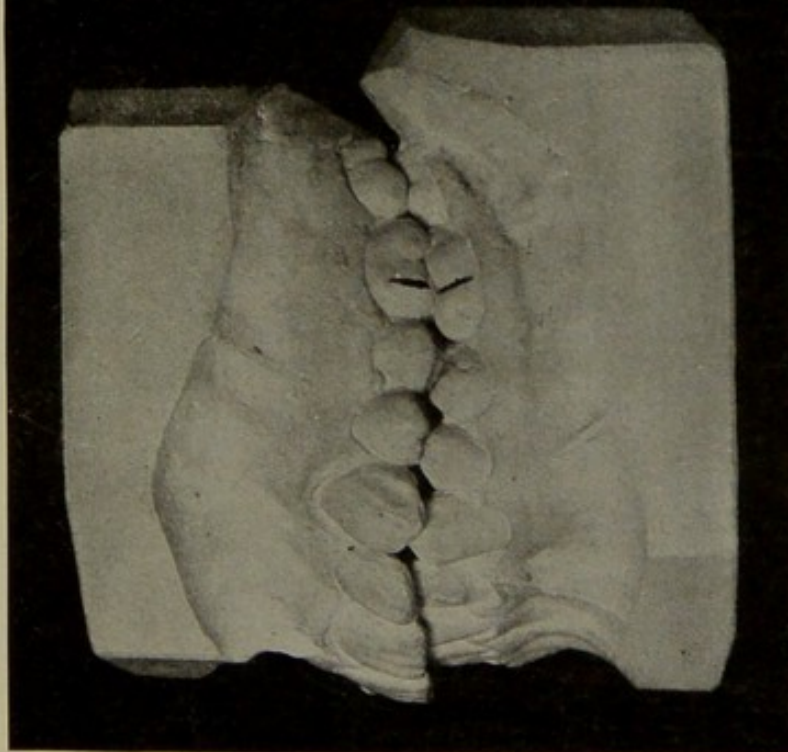


FIG. 581.



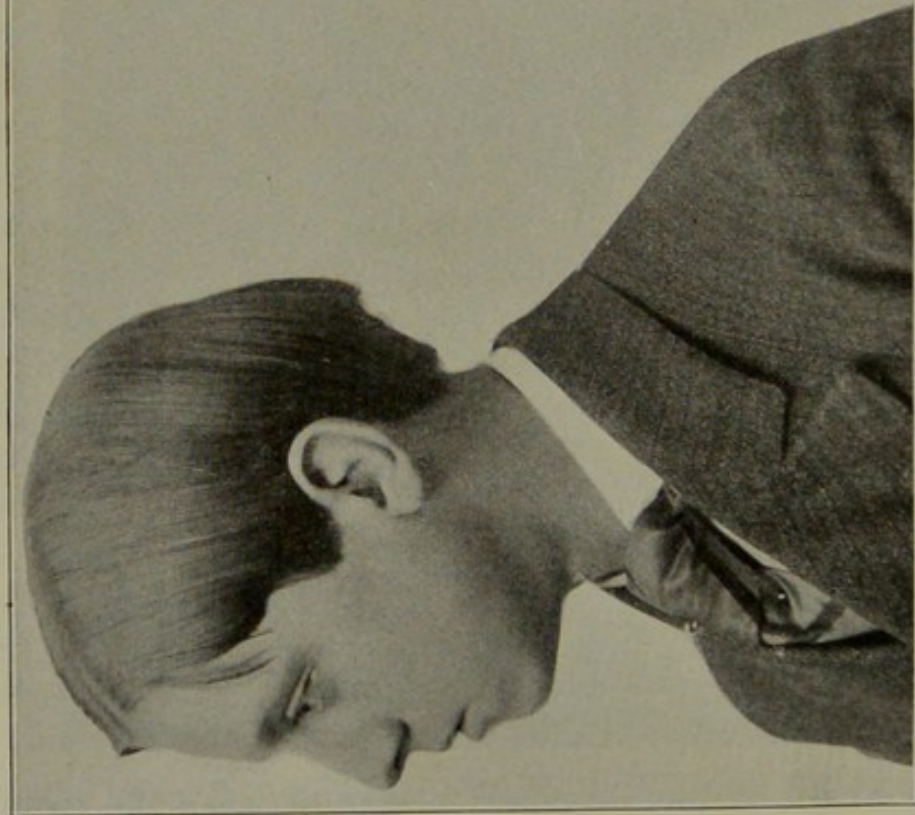
tions of the inclined occlusal planes between the teeth on the left side will undoubtedly follow the still greater de-



FIG. 584.



FIG. 583.



velopment of the alveolar process. The teeth will be inspected occasionally for several months to come.

The occlusal aspect of the teeth after their correction is shown on the right in Figs. 576 and 578, and the gratifying improvement in the contour and balance of the face is shown in Figs. 583 and 584.

It is not difficult to imagine what the facial lines of this young man would have been if, as usual, two or three premolars had been sacrificed pursuant to the unfortunate teachings so long followed in the treatment of similar cases.

The devices for retention used during the last period consisted of plain bands, cemented on the lateral incisors, connected on their lingual surfaces by a section of the wire G made to bear against the gingival ridge of the central incisors. Two sections of wire G were also soldered to the labial surface of the bands on the lateral incisors, which extended distally to the first molars and bore heavily upon the canines, as in Fig. 232. Wire ligatures were made to encircle each of the premolars and the section of wire G which was given lateral spring in order to exercise greater force in their retention. The normal relations of the first molars on the left were maintained by plane and spur, as in Fig. 256, with an additional spur soldered to the band on the upper molar which bore heavily upon the disto-buccal angle of the lower molar, as shown in B Fig. 257.



## CHAPTER XIX.

### TREATMENT OF CASES.—CLASS III, DIVISION 1.

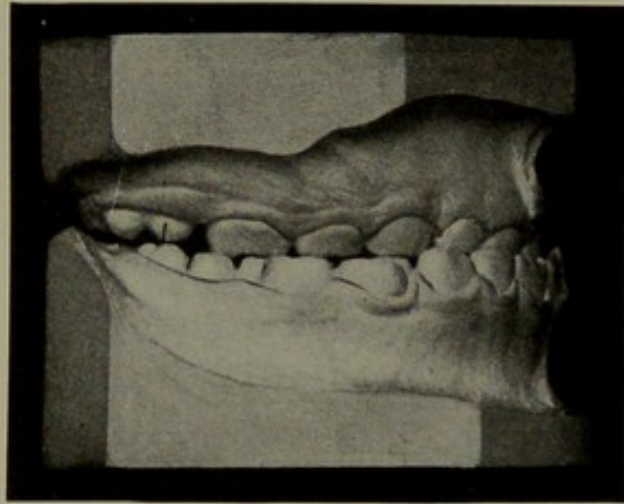
DEFORMITIES under this class begin at about the age of the eruption of the first permanent molars, or even much earlier, and are always associated at this age with enlarged tonsils and the habit of protruding the mandible, the latter probably affording relief in breathing. It is the author's belief that these are potent factors in causing the mesial locking of the permanent teeth as they erupt. When once the mesio-buccal cusp of the upper first molar begins to engage the distal incline of the disto-buccal cusp of the lower first molar, the effect is to mechanically force the mandible forward on each closure of the jaws. This in time forces the deciduous teeth, as well as each succeeding permanent tooth as it erupts, into malocclusion, thereby gradually causing all the other inclined planes to act out of harmony with Nature's intended plan, and accelerating the forward movement of the mandible. Not only this, but the muscles are thus made to exert force on the mandible abnormally and thereby to stimulate it to abnormal growth and malformation. The wrong distribution of the force on the crowns of the teeth through occlusion clearly shows this, also, to be a factor in the development of these deformities. See also page 449.

So, inharmony being once established, it usually progresses rapidly, only a few years being necessary to develop by far the worst type of deformities the orthodontist is called upon to treat, and when they have progressed until the age of sixteen or eighteen, or after the jaws have become developed in accordance with the malpositions of the teeth, the case has usually passed beyond the boundaries of malocclusion only, and into the realm of bone deformities,

for which, with our present knowledge, there is little possibility of affording relief through orthodontic operations.

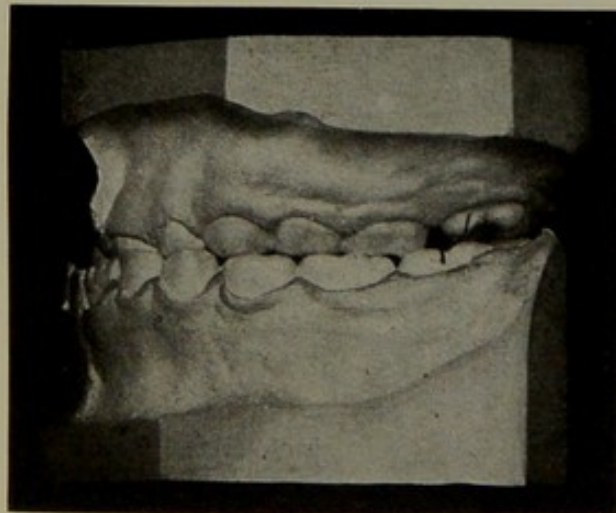
It is the author's belief that if the throat could be properly treated, and the first molars at the time of their erup-

FIG. 585.



tion mechanically assisted into normal occlusion and there compelled to remain by delicate yet efficient retention for a few months, these unsightly deformities would rarely, if ever, develop.

FIG. 586.



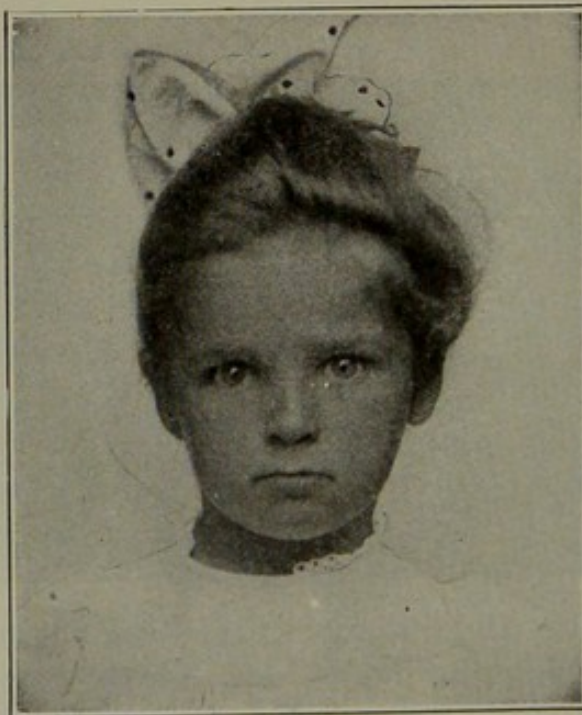There may be, and doubtless are, other factors that enter into their production which are as yet but imperfectly understood, but we are convinced that they are of minor



FIG. 587.



FIG. 588.



importance when compared with those we have mentioned. The time-honored custom of attributing these conditions to heredity and degeneracy, still made prominent in the latest books on orthodontia, has, in the author's opinion, no substantial support.

Figs. 585 and 586 show the malocclusion in the case of a child six years of age, who for some time had been a sufferer from greatly enlarged tonsils. The first molars are erupting and the lowers in taking their positions would soon become locked in mesial occlusion. This is a fair example of these cases at this age.

The deciduous teeth are rapidly conforming to the abnormal occlusion, the lower incisors now closing in front of the upper. The tendency to greater complexity is thus clearly indicated. The effects on the facial lines are shown in Figs. 587 and 588.

The condition has developed rapidly, the contour of the baby face being thus changed in but a few months. The case was promptly referred to a rhinologist who was successful in removing the tonsils, as well as in the subsequent necessary treatment.

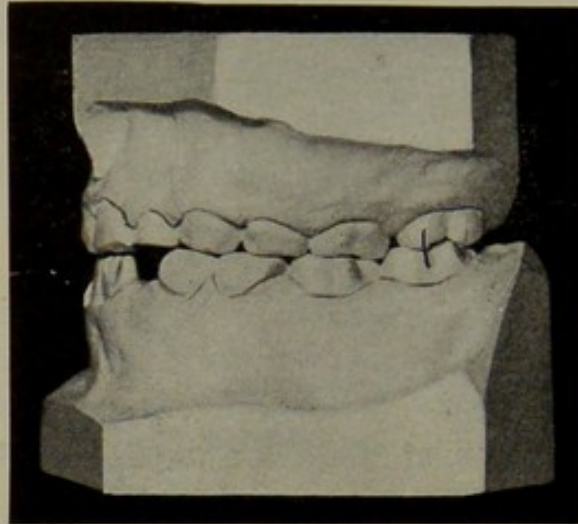
The treatment for the malocclusion was simple and easy. Small D bands were placed upon all four deciduous second molars and the small plain expansion arches were adjusted, as per combination shown in Fig. 210, and force was exerted by means of the intermaxillary elastics made to engage the sheath-hooks on the lower expansion arch, which were placed well forward or opposite the lateral incisors and stretched back over the distal ends of the sheaths of the upper anchor bands. As a result the teeth were shifted into normal relations in a very short time.

They were retained by means of two delicate spurs soldered to the lingual surfaces of accurately fitted bands on the upper deciduous central incisors, the spurs extending downward and somewhat forward in front of the lower centrals and compelling the normal closure of the man-



dible. Figs. 589 and 590 show the occlusion at this stage, the lower deciduous laterals meantime having been lost. The pronounced change in the facial lines resulting from

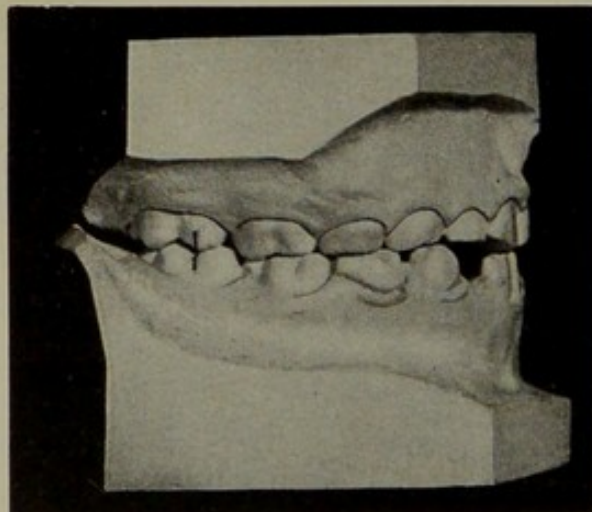
FIG. 589.



the corrected occlusion is shown at this stage in Figs. 591 and 592.

The perversion of the forces of the muscles, inclined planes, etc., having been arrested and the normal functions

FIG. 590.



of the muscles and inclined planes established, it is gratifying to know that although two years have since elapsed the molars still retain their full normal relations, with a con-

tinuation of the normal growth of the denture, and development of the facial lines toward the normal, as shown in Figs. 593 and 594, notwithstanding that retention was discontinued after the loss of the deciduous upper central incisors through absorption of their roots, which occurred only a few weeks after the retaining devices above described had been placed upon them.

FIG. 591.

FIG. 592.



Figs. 595 and 596 show the rapidly developing malocclusion of another case belonging to this class. This case is very similar to the one last described, the patient being but little older. The mandible is being forced forward and the first permanent molars, in their eruption, are assuming mesial relations. The upper central incisors had been but recently lost. The disturbance in the facial balance is well shown in Figs. 597 and 598.

The treatment was identical with that last described and the result in the occlusion of the teeth one year later is shown in Fig. 599, made from an impression in plaster with the jaws closed.

This child had suffered frequent attacks of acute inflammation of the throat and had chronic enlargement of the



FIG. 594.

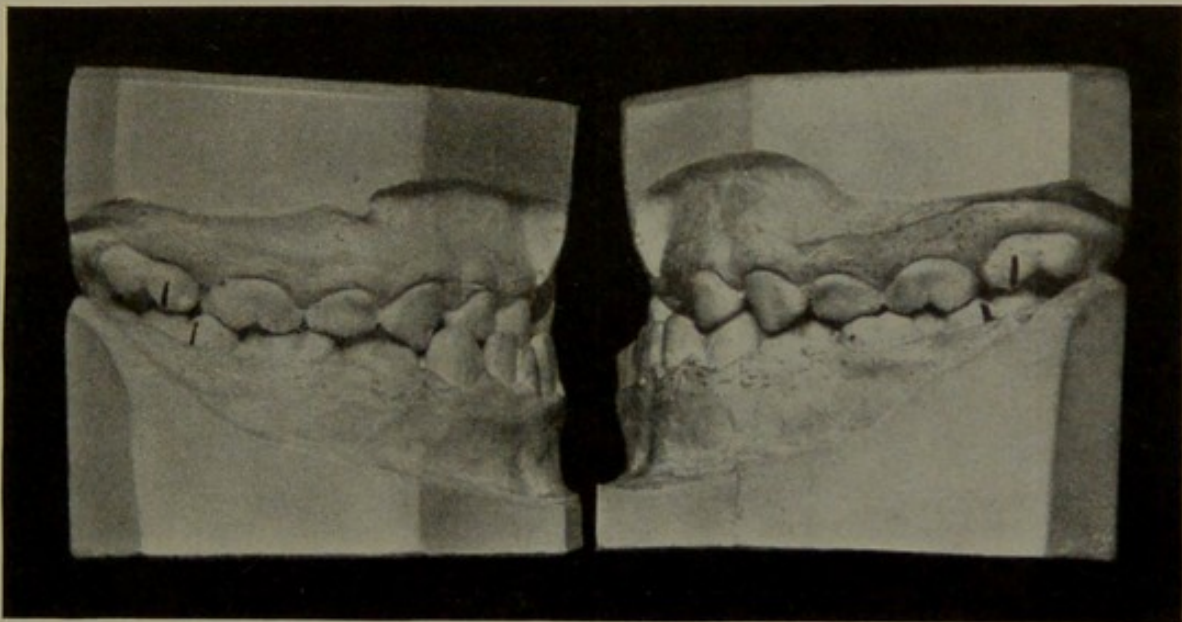


FIG. 593.

tonsils. They were removed by the rhinologist and the throat was greatly benefited by further treatment. Up to the time of the death of the child one year ago the normal relations of the teeth continued, with continued development of the facial lines toward the normal, and every indication of a normal completion of the denture and normal contour of the face.

FIG. 595.

FIG. 596.



Figs. 600 and 601 show the malocclusion in another case of a patient somewhat older, in which the natural progress of the deformity is clearly indicated, for following the abnormal locking of the first permanent molars, all of the teeth anterior thereto have, as they erupted, been forced into mesial occlusion. The resultant inharmony in the facial lines is shown in Fig. 602.

The treatment clearly indicated was to establish harmony in the sizes of the arches and normal relations of the inclined planes of the teeth. Without the intermaxillary anchorage this would have been very difficult or impossible, but by its use the desired changes were effected, and that, too, quite speedily.



The same combination of appliances as that described for the case shown in Figs. 585 and 586 was also used in this case. Anchor bands D were placed upon the upper

FIG. 598.

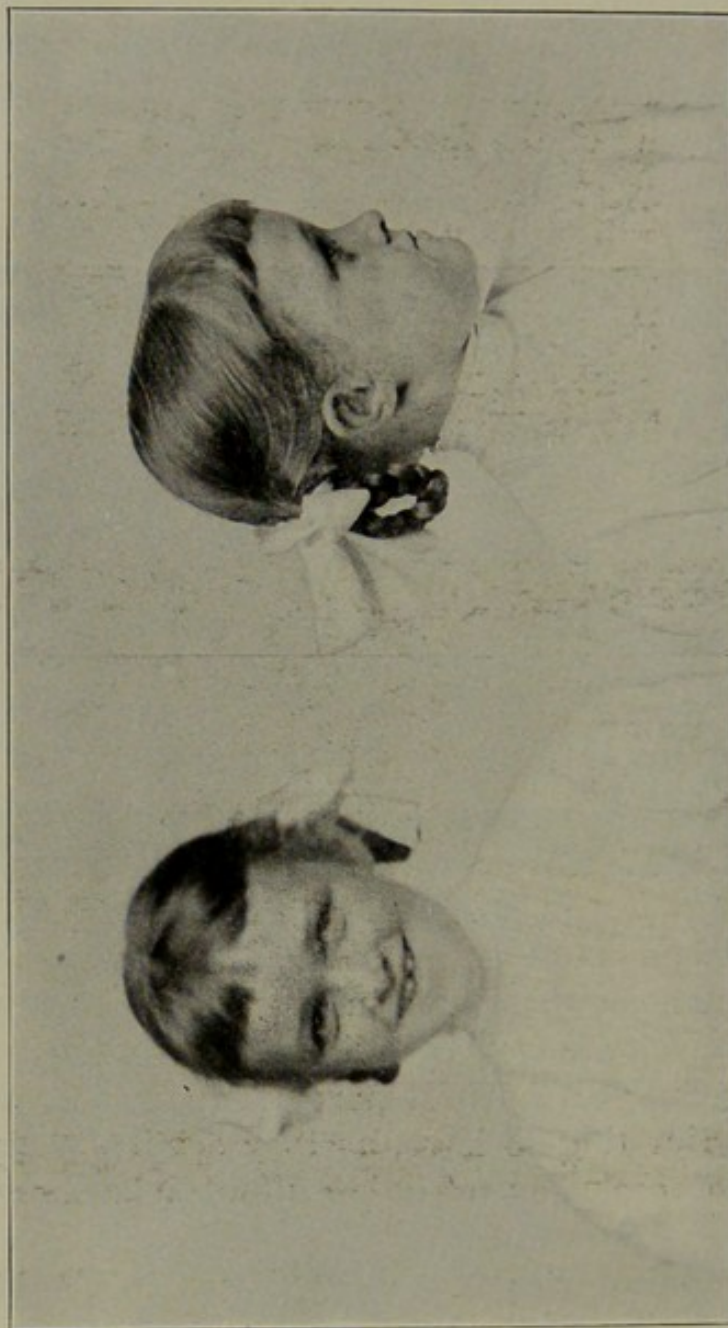


FIG. 597.

first molars, with X bands upon the lower second premolars. The upper incisors were moved forward at the same time by their attachment with ligatures to the expansion

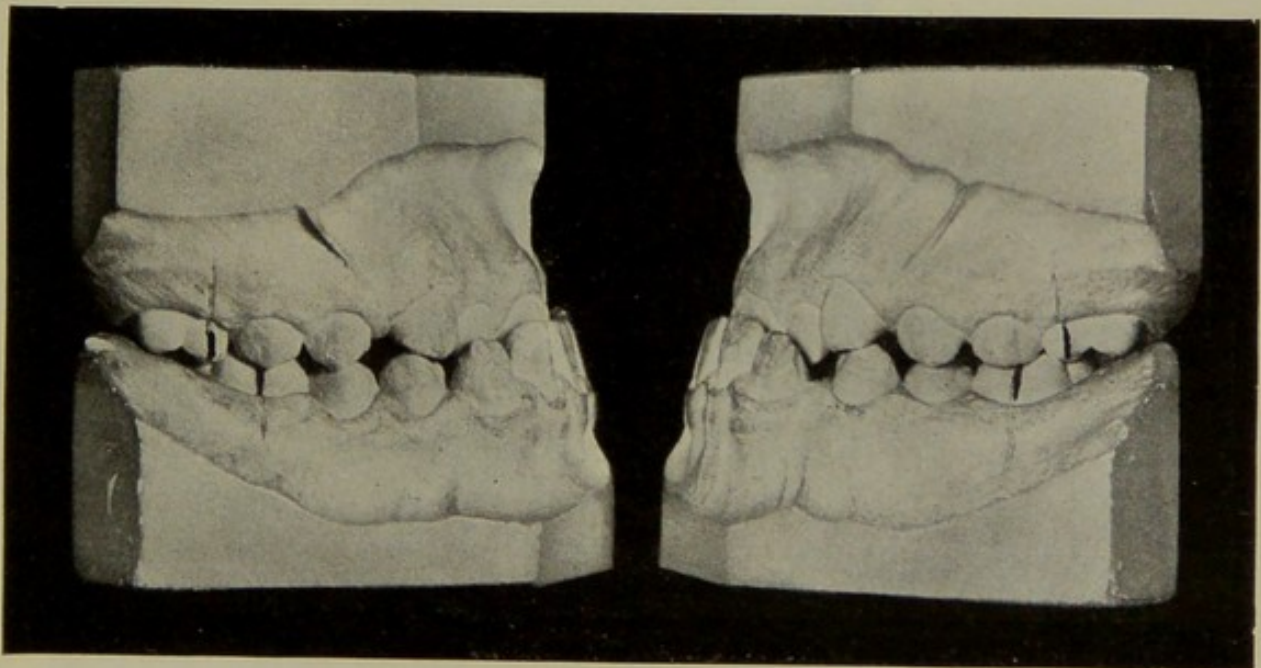
arch, the force being reciprocated from the upper first molars at first directly upon the lower premolars and first permanent molars. Gradually they were moved into their normal mesio-distal relations, when the nuts on the lower

FIG. 599.



FIG. 600.

FIG. 601.



expansion arch were turned forward to allow the force to be received by the incisors and canines.

Somewhat to the author's surprise in the short space of three weeks the teeth were moved into their normal mesio-distal relations, as shown in Figs. 603 and 604. It is quite probable that the mandible was also moved distally



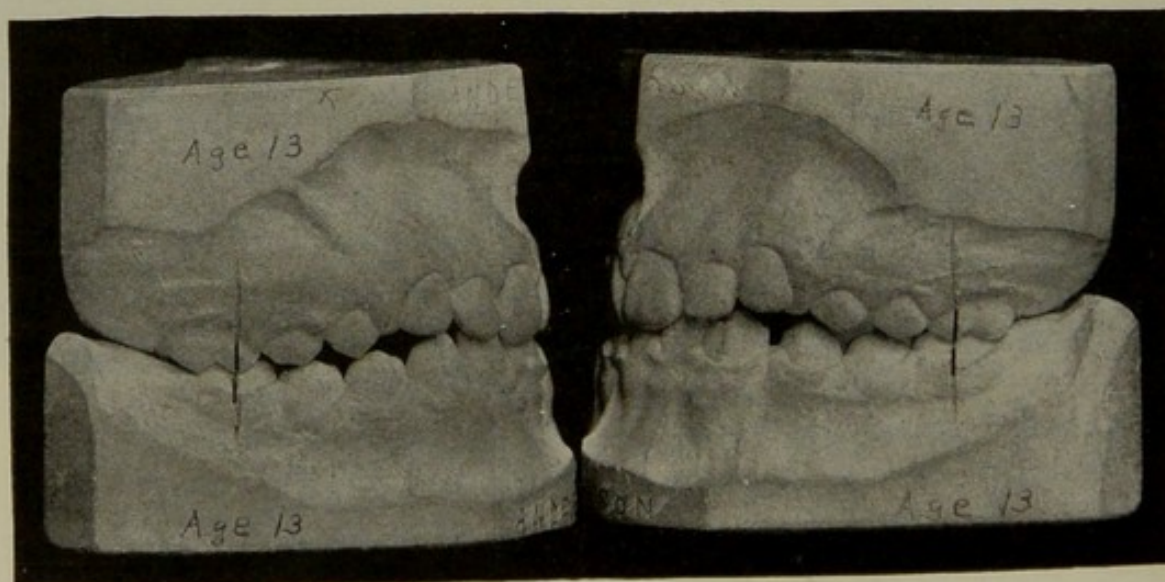
somewhat. In fact this is shown in the facial lines after

FIG. 602.



FIG. 603.

FIG. 604.

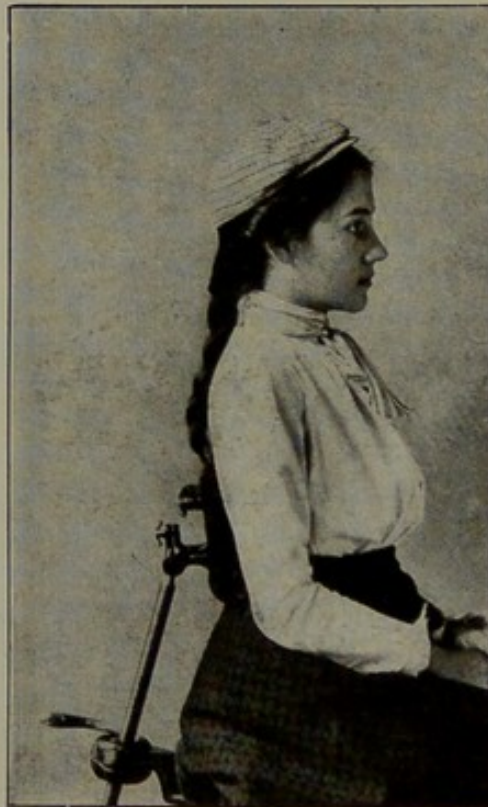

treatment, Fig. 605, but the principal change was in the positions of the crowns of the teeth.

No effort was made to establish better relations between the premolars, the author knowing full well that as these teeth continued their eruption they would necessarily be forced into their correct relations through the influence of their inclined occlusal planes.

The retention was effected by means of the device shown in Fig. 512, and already described in connection with molar

FIG. 605.



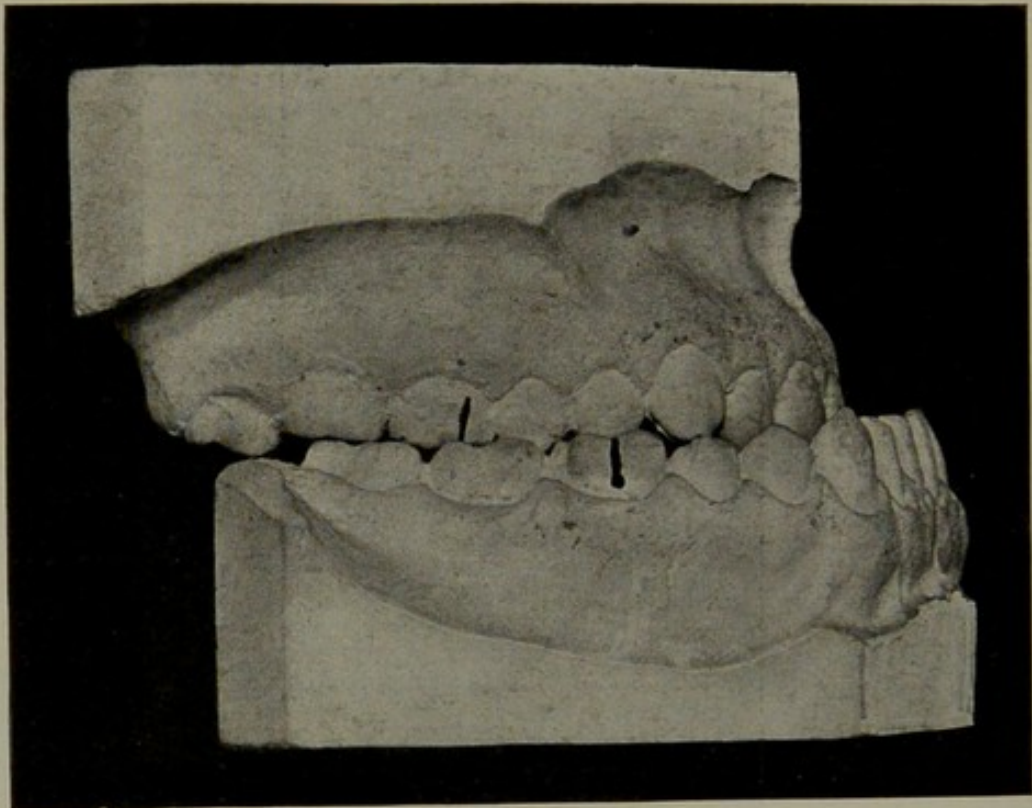
retention in the first Division of Class II, the difference in its use being that the action of the spur was reversed by causing it to close behind the metal plane in this case, instead of in front of it, as in the other Class.

By the introduction of the intermaxillary anchorage the possibilities of success in the treatment of cases belonging to this class have been greatly increased, but after much experience the author is convinced that in well-defined cases where the jaws have become considerably out of



harmony as to size and relations their successful treatment is practically hopeless, for though we may oftentimes improve the occlusion temporarily, if we do not gain the influence and full support of the inclined occlusal planes, failure in most instances must ultimately result. They are good cases for the orthodontist to avoid. There are limits in

FIG. 606.

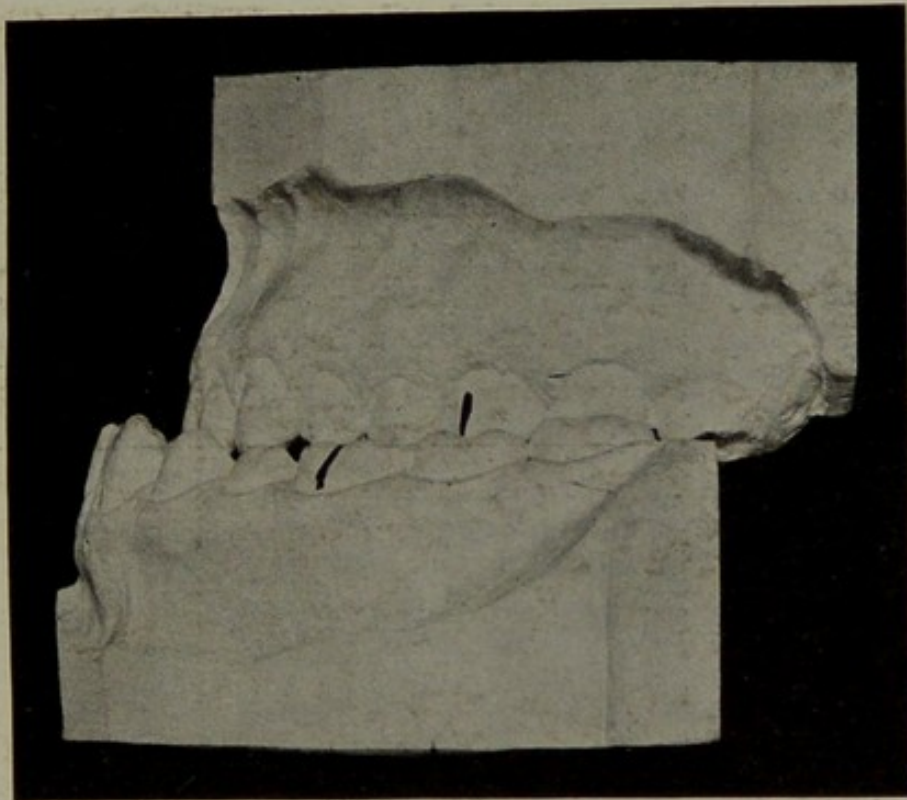


general surgery and we should wisely recognize that there are also limits in orthodontia and intelligently expend our energies upon cases in the treatment of which success is at least probable.

Figs. 606 and 607 show the occlusion of the teeth in one of the most pronounced cases of this type the author has seen uncomplicated by extraction, and how greatly, yet proportionately, the facial lines are marred by the malocclusion is shown in Figs. 608 and 609. It is our belief that the upper jaw and dental arch are normal and in

normal relation to the skull, and that the deformity results wholly from the abnormal form, size, and position of the mandible, which probably might have been successfully corrected if taken at an early age and treated as were the other cases belonging to this class already discussed. The only possible chance for improvement of this and of all

FIG. 607.



similarly advanced cases is the operation suggested by the author some fifteen years ago, which consists in shortening the body of the mandible by the removal of a section of bone from each of its lateral halves, placing the remaining segments in apposition and firmly securing them and gaining union as usual in double or multiple fractures of the jaw as described in the chapter on Operative Surgery. Naturally at first thought the operation would seem very formidable and attended by very great risks, but we know that the recuperative powers of the mandible are great and



that even the severest double comminuted fracture nearly always unites readily, even with the most primitive

FIG. 609.





FIG. 608.



methods of fixation still so commonly employed by physicians, and that, too, frequently in defiance of septic con-

ditions. So it would seem that if the operation be performed skilfully under the most favorable, aseptic conditions, and according to scientific methods of fixation, the risk should not be great and the recovery prompt, with occlusion and facial lines vastly improved. Yet the author would strongly impress the caution that the operation is not one for the reckless experimenter to undertake, but at best it should be performed only as a last resort and then only in rare and favorable cases and under the most favorable environment.

TREATMENT OF CASES.—CLASS III, DIVISION, SUBDIVISION.

As cases belonging to the subdivision of Class III are in unilateral mesial occlusion, the treatment clearly indicated, especially in young patients, is after the same plan we have already described for the full division, exerting force, however, only on the side that is in mesial occlusion. These cases are very rare.



## CHAPTER XX.

### OPERATIVE SURGERY.

WHILE all of tooth movement is essentially surgical, that by the use of appliances may be properly called Conservative Surgery. To distinguish, the operations involving the use of cutting instruments may be designated as Operative Surgery. While such operations should probably be employed only as auxiliary to the conservative method, they are possibly destined to play a more important part in the practice of the future, and will be briefly considered.

**Immediate Movement.**—As the changes in the tissues incident to tooth movement are as a rule necessarily slow, requiring the operation to be more or less protracted, different writers\* from time to time, among whom may be mentioned Tomes, Stellwagen, and Bryan, have advocated the use of forceps to effect the immediate movement of teeth into correct positions.

Dr. Bryan, of Basle, Switzerland, was first to improve on the operation by surgically removing a portion of bone in advance of the moving tooth.†

The immediate movement of teeth has usually been resorted to only where one, or at most two, were to be rotated

---

\*J. Lefoulon, who wrote a work in 1841 (French) which was translated and published in the American Library of Dental Science, says on pages 132 and 133, "Almost all of the writers who have treated on this subject, i. e., regulating, have spoken of artificial luxation. This is a means which we have already condemned, and which we cannot too frequently disapprove. The ancients, and some of the moderns, yet imitate them, employing the 'pelican' for this purpose; a violent maneuver, which exposed them to the risk of breaking the tooth at the neck, and thus to replace a deformity by a mutilation a hundred times worse. Besides it is a cruel operation, which should be rejected the instant mild means can be employed which, at least, are equally efficacious."

† Described in a paper read before the American Dental Society of Europe in August, 1892.



or moved from inlock. The operation has never met with much favor, for it is a practice as inexcusable and impracticable as it is barbarous.

First, it is so formidable that naturally but few care to submit to it.

Second, the risk to the tooth and pulp, as well as to the other tissues involved, is so great that it is wholly unwarrantable.

And last, it is wholly unnecessary, for in cases that would seem most favorable for this operation a suitable appliance will in a very short time effect by the conservative method the desired result, without risk and with but little more than inconvenience to the patient.

**Alveolar Sections.**—The removal of bone in advance of the moving tooth may, we think, be desirable in some cases as auxiliary to the conservative method. While it is probably never necessary in the movement of teeth of young children, in patients of more advanced age, where the bone is dense and of considerable thickness, and absorption slow, it may be resorted to with possible advantage, especially in the reduction of labial protrusion of incisors, as in Fig. 653. Yet in practice it does not seem to lessen the amount of force required, nor hasten the movement of teeth to nearly the extent we might expect. Doubtless if the only obstacle to tooth movement were the resistance of the bone the operation would be greatly hastened by its removal, but when we remember the firm resistance offered by the fibers of the peridental membrane by their attachment to the plate of bone in the rear of the moving teeth, as well as on all sides, this is readily understood.

In the removal of bone it is highly important that only sharp, clean fissure-burs of medium diameter, with end cut, and which have been thoroughly sterilized, be employed, and that the peridental membrane be not injured in the operation. To insure this a thin septum of bone should be allowed to remain between the membrane and the



cavity formed. The cavity should be crescent-shaped, of somewhat greater length than the diameter of the tooth, when practicable, and in depth about two-thirds the length of the root.

**Resection of Peridental Fibers.**—After a careful study of the fibers of the peridental membrane, the direction in which they extend, their distribution and attachment, and knowing the strong resistance offered by them to tooth movement and that they must often be forcibly severed or slowly absorbed at their points of attachment in order to permit of tooth movement, it occurred to the author that it would be but reasonable and wholly in keeping with good practice to surgically sever them.\* He would earnestly caution conservatism, however, advising the severance of only such fibers as would most probably be absorbed.

At first thought it might seem to be a painful operation. In reality it is very simple and nearly painless, provided it is properly performed with suitable instruments. The form of instrument is of much importance, and those most suitable are the iris needle and cataract knife. These seem to be most perfectly adapted also for operations on the peridental membrane. They are illustrated in Fig. 610.

In their use, if we wish to sever the principal obstructing fibers of a tooth, as for example those which resist rotation, Fig. 611, we have but to pass them down along the angle of the root. It has been found better to first adjust the regulating appliances and allow them to exert tension for two or three days, that the fibers may be well tightened by stretching. This facilitates insertion of the delicate blade and makes the severing of the fibers more complete.

In retraction of the canine the severing of the fibers in the rear of the tooth to the depth of one-third the length of the root seems to be sufficient to greatly expedite the movement.

In some cases the duration and difficulty of the movement

---

\* *Dental Cosmos*, November, 1899.



may possibly be lessened by the intelligent combination of methods,—the surgical severing of fibers and removal of

FIG. 610.


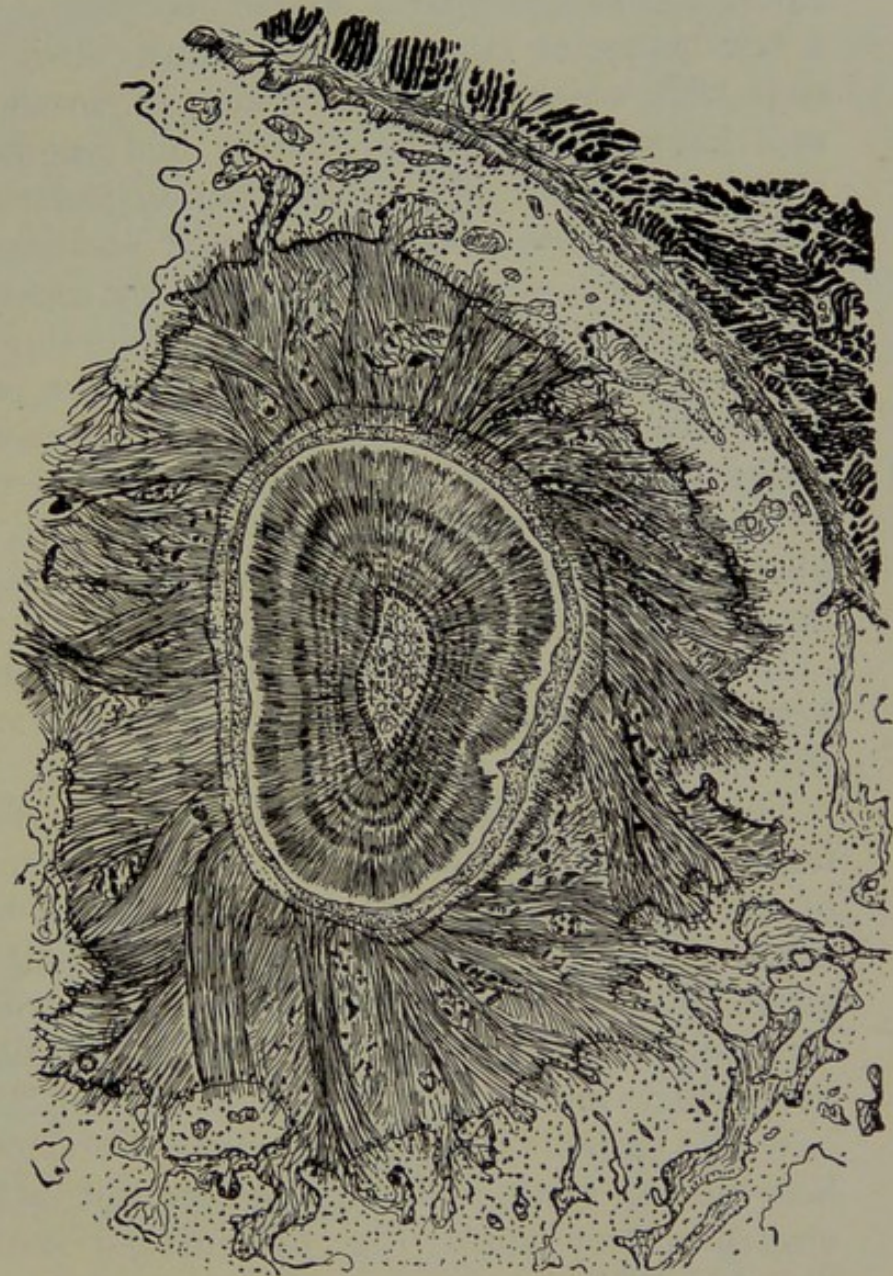


FIG. 611.



bone, in connection with the use of the regulating appliances.

**Section of Frenum Labium.**—A form of malocclusion characterized by a space between the upper central incisors (and



rarely between the lower centrals) is quite frequently encountered.

The closing of this space by drawing together the incisors is a comparatively simple operation, requiring only a few hours, or days at most. But notwithstanding the ease with which these spaces may be closed they are yet well known to be unsatisfactory and annoying cases to treat, on account of the difficulties of permanently establishing the teeth in their corrected positions. For it is usually found, even after months of the most perfect support by the retaining device, that following its removal the teeth will rapidly assume their former positions. By a more careful study of these cases the reason for this becomes obvious,—the cause has not been removed, which, as we have shown in the chapter on Etiology, is usually an abnormal development and attachment of the frenum labium, Fig. 612.

It is evident that the portion of the ligament passing between the teeth must be removed, or so modified that it will no longer act mechanically upon them.

The author has derived partial success by the mere severing of the ligament with a pair of delicate scissors, union of the ends while healing being prevented by occasional manipulation. But the plan now followed by him,\* and which gives the best results, is to take advantage of the contraction of tissue resulting from actual cautery, as rhinologists do in operations on the nose for deflected septum.

With a suitable lancet or bistoury a deep incision is made between the teeth, splitting the ligament, after which an electro-cautery knife, Fig. 613, at red heat, is passed through the incision.

No pain will be occasioned if, preliminary to the operation, the tissue be locally anesthetized. Great care should be exercised in the use of the cautery instrument, which

---

\* *Dental Cosmos*, November, 1899.

FIG. 612.

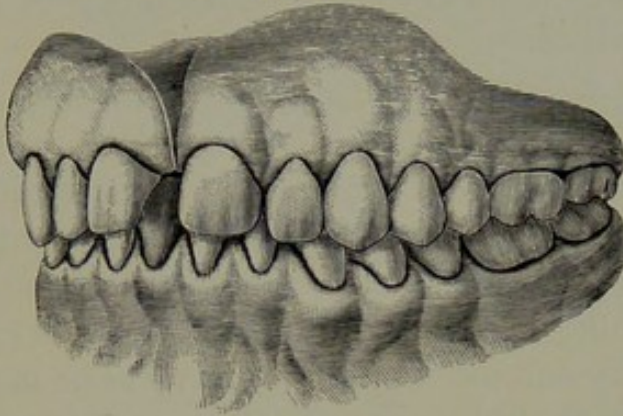
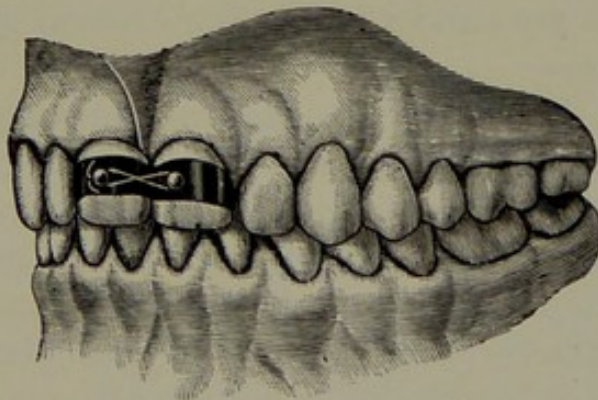


FIG. 613.



FIG. 614.





should come in contact only with the abnormal tissue, the wounding of the peridental membrane being rigidly avoided, and for this reason the clean incision is first made to simplify the operation.

The teeth should be drawn together and mechanically supported for several weeks or months. The author's favorite method of closing the space is by the exertion of pressure by means of a wire ligature occasionally tightened by twisting or renewal, it being made to encircle two short spurs or buttons soldered to the mesio-labial angles of accurately fitting bands cemented upon the teeth to be moved, Fig. 614. The bands should be in position before the operation is performed.

This same device is very satisfactory for retention, or the bands may be removed and replaced by similar bands joined by solder.

Although the contraction due to the cicatricial tissue is considerable, yet when we remember the character and structure of the peridental membrane and the immense number of normal fibers acting to combat this tendency, and that they are practically double in these cases, for two teeth are involved, the necessity for support for a considerable length of time (a year and a half in some cases) should occasion no surprise.

**Double Resection of the Mandible.\***—Several years ago the author became convinced that no operation depending upon tooth movement alone could establish proper relations of the teeth or materially improve the facial lines in certain cases of pronounced over-development of the mandible. It seemed to him, however, that such cases might be successfully treated by the removal of a section of bone from each of its lateral halves, the segments brought into apposition and securely held, the same as in treatment for double

---

\* See *Dental Cosmos*, July and August, 1898, and April, 1903; also *International Dental Journal*, October, 1898, February, May, and August, 1899.

FIG. 615.


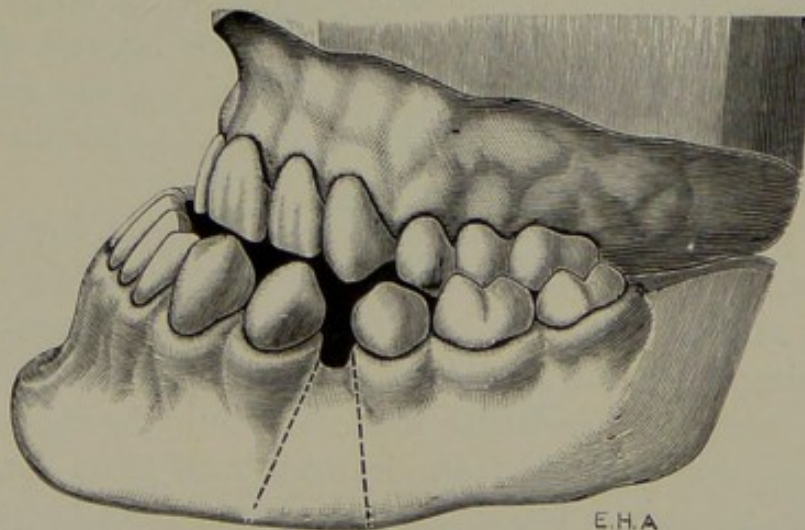


FIG. 616.





fracture of the mandible, and with even greater promise of repair, although the operation was not contemplated except as a remedy for the most aggravated conditions as illustrated in Figs. 615 and 616.

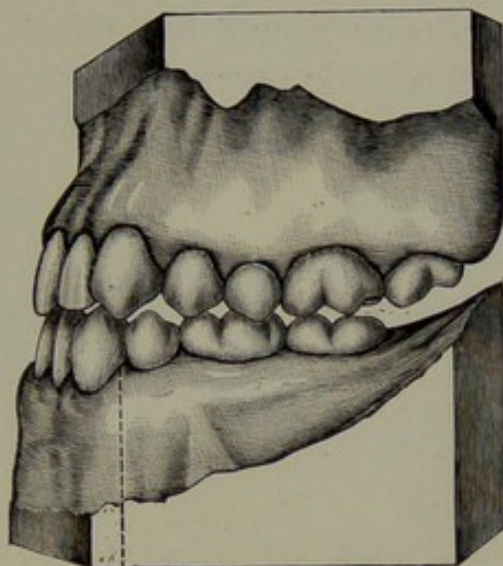
The removal of a single complete section of the mandible had been reported in numerous operations for the relief of ankylosis, tumors, gunshot wounds, etc., but a search of the literature failed to reveal at that time any instance of the removal of complete sections from each of the lateral halves.

The author's proposition was discussed with surgeons and dentists. A few of the former believed it to be practicable; the latter almost invariably predicted certain failure. Since first proposed the operation has been performed twice—once successfully at the Baptist Hospital in St. Louis and although the method of fixation employed was crude, the union was excellent and the result without injury to the pulps of the teeth; and once in New Orleans, when it nearly cost the patient his life, with total loss of the mandible through necrosis. In the latter case, however, failure was not surprising, as the sections were removed at the angles instead of from the body of the jaw, and practically no support was given to the segments of bone, the Barton bandage and wiring the bones being depended upon for fixation, one crude wire ligature being employed on each side. One of these wire ligatures became loosened and dropped out on the third day following the operation, and it was not replaced, the surgeon having become frightened and abandoning the patient.

The plan which the author would suggest for securing fixation, and one which reduces the operation to great simplicity and accuracy, is as follows. As occlusion is the governing principle in determining the extent of reduction of the mandible, accurate models should be made of the teeth of the patient from impressions most accurately taken in plaster. These models should then be placed in

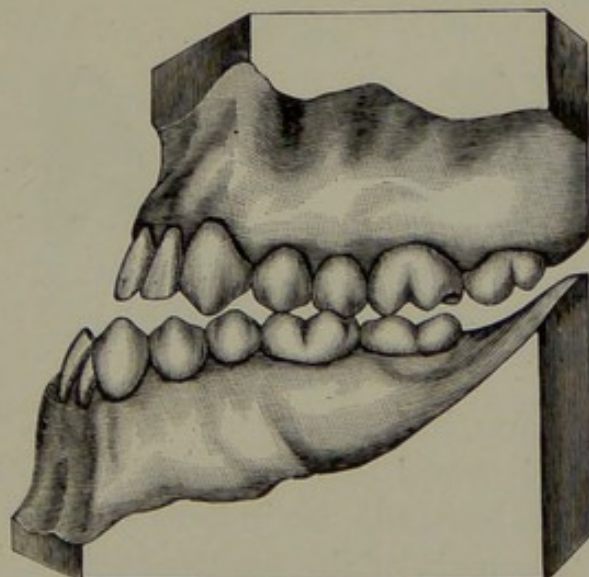
a metal articulator and sections corresponding in extent and location to those it is desired to remove from the man

FIG. 617.



dible should be removed from the plaster model. The plaster mandible should be reduced until the best attainable

FIG. 618.



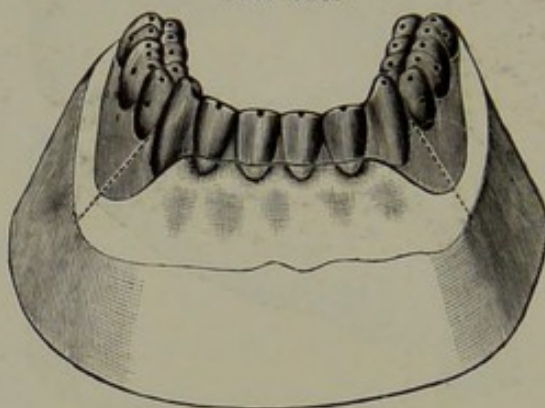
occlusion between the teeth of its segments and those of the upper model have been gained, and the segments united



with thinly mixed plaster of Paris applied into the spaces from the lingual side with a fine camel's-hair brush.

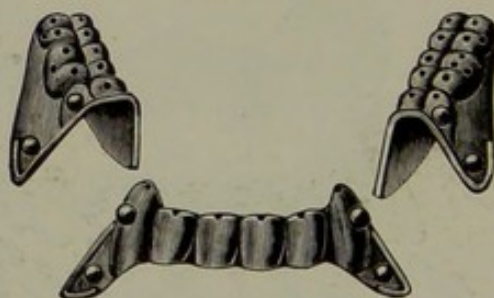
Fig. 617 shows an exact duplicate of the model shown in Fig. 618 which has been so treated. The further perfection of the occlusion should be gained by grinding, or left for future orthodontic operations.

FIG. 619.



The lower model should then be duplicated in suitable metal, and over this, with counter dies a metal plate should be swaged, preferably of silver, as shown in Fig. 619. The plate should be allowed to extend downward a short dis-

FIG. 620.



tance over the gum, but not impinge upon it. It should then be removed and sawed through where the anterior cut of the section is to be made, as indicated by the dotted lines in Fig. 619. The ends of the segments should then be stiffened with half-round wire, and small metal buttons soldered to the plate near the stiffened ends as low down and as high

up as possible both buccally and lingually, as shown in Fig. 620. Numerous holes, suitably located, for the escape of

FIG. 621.

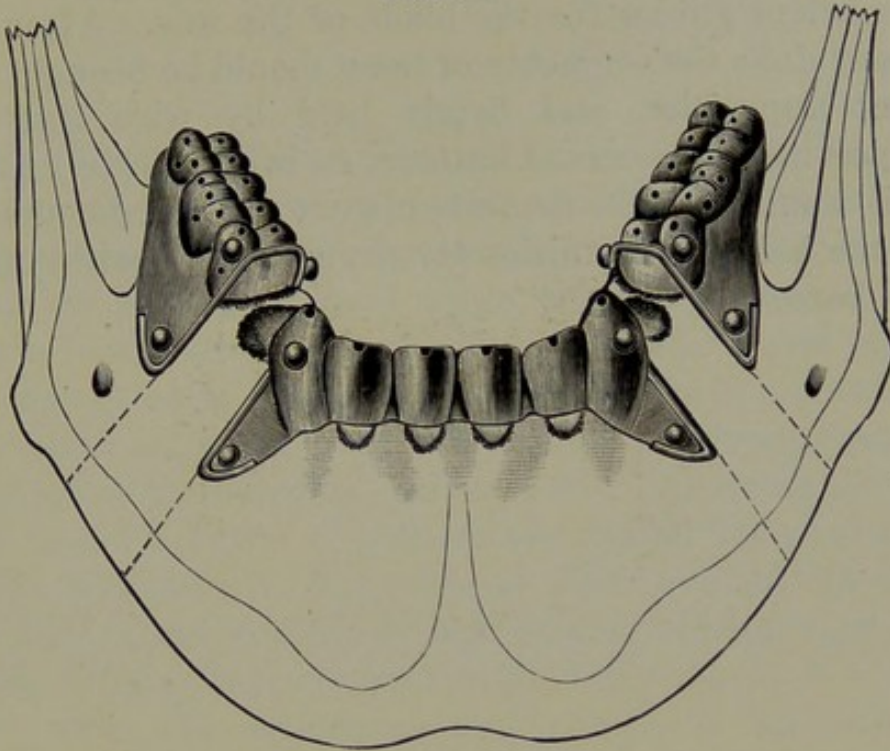
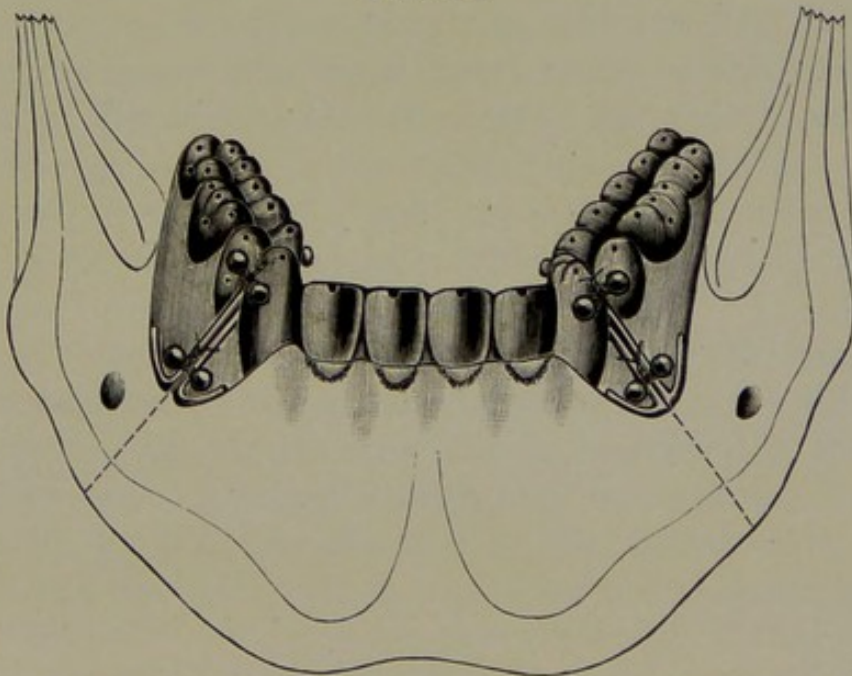


FIG. 622.



the surplus cement should be made in various parts of the plate, the patient's teeth thoroughly cleansed, and all three



segments carefully cemented upon the teeth, as shown in Fig. 621. Then at any convenient time the sections may be removed from the mandible, the ends of the plate offering excellent guides for the blade of the saw. After this has been done the segments of bone should be brought into correct apposition and firmly held by wire ligatures wrapped about the metal buttons, as in Fig. 622.

This would give the firmest support to the segments and offer the best opportunities for prompt and healthy union of the bone.

## APPENDIX.

---

THE following illustrations and their descriptions show a few of the many possible ways in which the jack-screw, traction screw, and levers, the description and history of which has been previously given, may be employed in effecting tooth movement. These combinations are given a separate place in this work in order to avoid confusion to the reader when studying the methods of treatment now regarded as more nearly in accord with the latest advancement in the practice of orthodontia which have been previously considered. Yet some of these are still favorites with the author for minor operations, several new combinations being here shown for the first time.

**Jack-screw.**—In employing the jack-screw for exerting force upon the teeth to be moved the base of the sheath may be secured in various ways, as shown in Fig. 623.\*

First, by means of a small dowel, made by soft-soldering a piece of the wire G into the end of the sheath, which is made to rest in a pit in the anchor tooth, as in A.

Second, by means of a spur made from the wire G soldered to the anchor band, over which the end of the sheath of the jack-screw may be slipped, as in B.

Third, also by means of a dowel made to engage a tube R soldered to the anchor band, as in C. In this way the length of the sheath may also be increased in the rare instances where a longer sheath may be required.

Fourth, by pointing the end of the sheath with a file and letting the point rest in a tube on the anchor band, as in D.

---

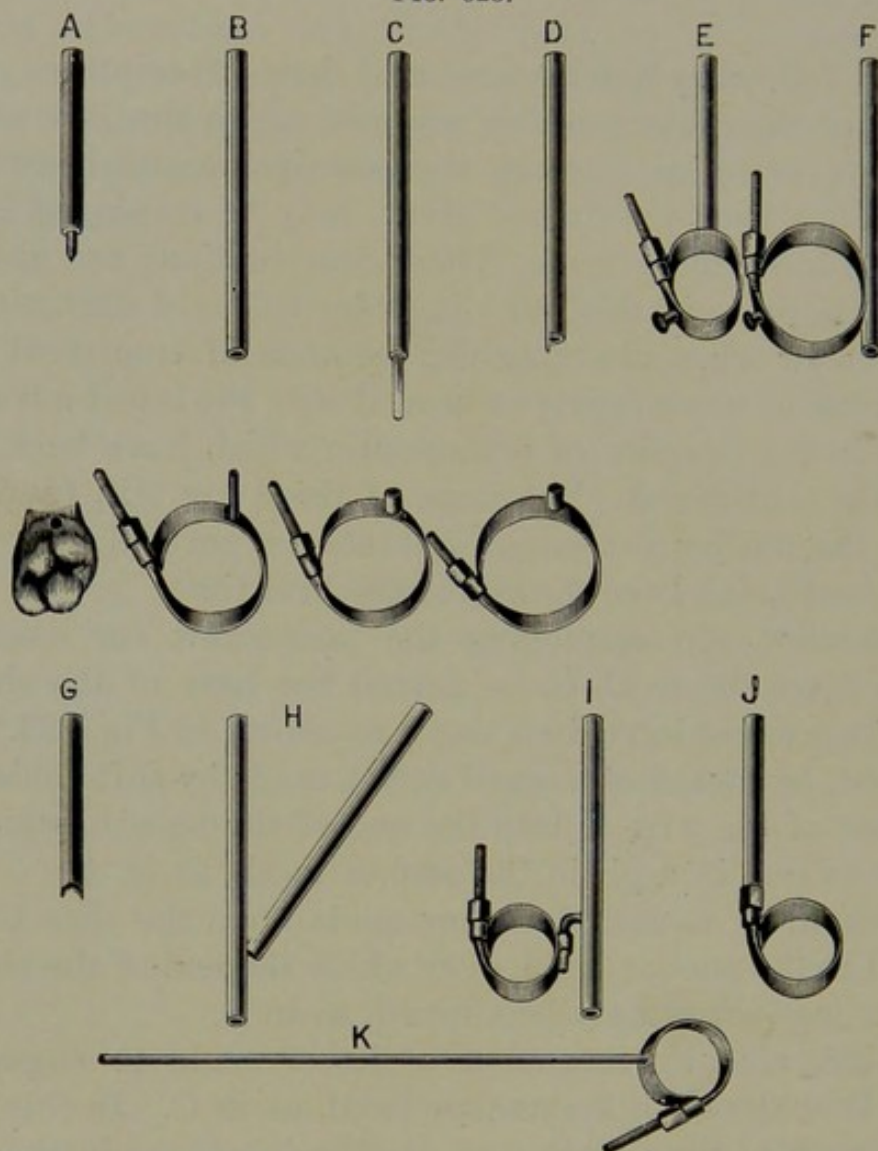
\* Fourth edition, 1894. Angle.



Fifth, by soldering the sheath directly to the anchor band, as in E and F.

Sixth, by notching the end of the sheath, and resting it against a wire, as in G.

FIG. 623.



Seventh, by soldering the end of the sheath directly to another sheath, as in H.

Eighth, by means of a spur made from the wire G soldered to the sheath and engaged with a tube R soldered to the anchor band, as in I.

Ninth, by slipping the end of the sheath over the screw of an anchor band, as in J.

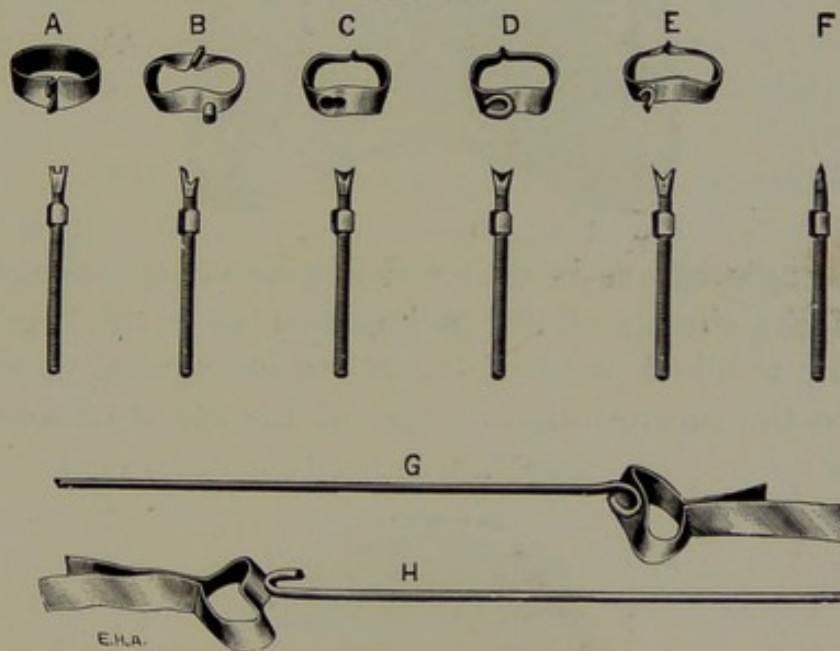
Of these various ways of attaching the sheath, those shown in B, E, F, and J, are preferable.

The point of the jack-screw is held firmly in position in six principal ways, as shown in Fig. 624.\*

First, by engaging a notch in its end with a similar notch in the united ends of the band, as in A, the notches to be made with a separating file.

Second, by pointing the end of the screw and engaging it with small tubes R soldered to the band, as in B.

FIG. 624.



Third, by a mortise in the band to engage the point of the screw, as in C.

Fourth, by an elliptical ring soldered to the band, as in D, and engaging the notched point of the screw.

Fifth, by means of a staple soldered to the band, as in E, and engaging with it the notched point of the screw.

Sixth, by resting the screw, suitably pointed, in a pit formed in the enamel, or in a filling, as in F.

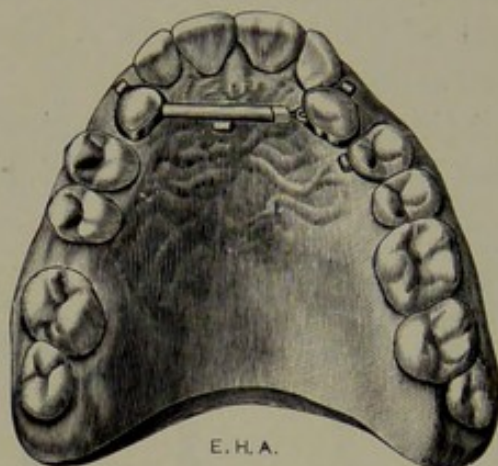
Of these various ways those shown in D and E are preferred.

\* Fourth edition, 1894. Angle.



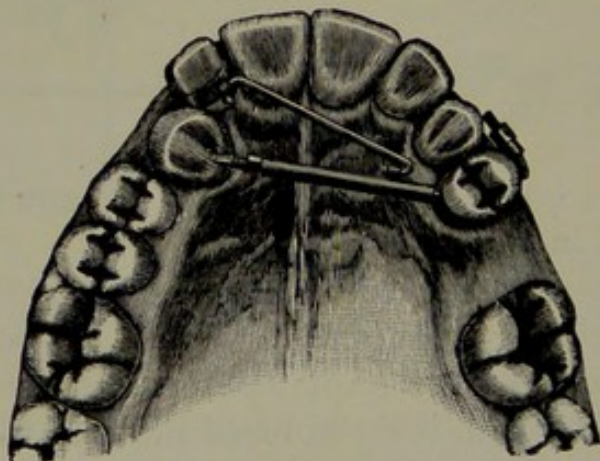
Fig. 625 shows the jack-screw effecting the labial movement of the upper canine teeth, which are provided with plain bands cemented upon their crowns. To the mesio-

FIG. 625.



lingual angle of one is soldered a spur which engages the base of the sheath of the jack-screw (as in B, Fig. 623), while the notched point of the screw engages a staple soldered to the mesio-lingual angle of the other canine. By

FIG. 626.



tightening the nut the teeth are moved in opposite directions. The tubes R, in anticipation of reinforcing anchorage, are also shown,—one upon the side of the sheath of the screw, the other upon the lingual surface of a band encircling the first premolar. As the right canine will



probably be moved into position first, its further progress will be arrested, as well as its anchorage reinforced, by a ligature inclosing the reinforcement tubes, drawn tight and the ends twisted.

Tubes R soldered to the labial surfaces of the bands upon the moving teeth are also shown. These are in anticipation of retention by means of a section of the wire G to be slipped through them, its ends to bear against the labial surfaces of the adjoining teeth.

Fig. 626\* shows a combination in which the jack-screw is made to exert force in moving labially an inlocked canine. The point of the screw engages a pit in the enamel, the base of the sheath having been previously slipped over a spur (B, Fig. 623) soldered to the mesio-lingual surface of the anchor band No. 1 clamped upon the first premolar. Reinforcement of the anchorage was gained by means of a section of the wire G, the ends of which were hooked into tubes, one being soldered near the base of the jack-screw, the other upon the mesio-lingual angle of a band encircling the lateral incisor. Later experience has proved that an easier and better way of attaching the reinforcement wire is to omit the tube from the band, soldering the straight end of the wire directly to the band. The other end of the wire, before bending, is passed straight through the tube in the direction of the base of the screw, then bent, and the surplus wire cut off. The bending of the wire should be the last part of the operation, or after the cementing of the band upon the lateral and the complete adjustment of the screw.

A modification of a similar combination of the jack-screw is shown in Fig. 627,† in the labial movement of an inlocked lateral, the point of the screw engaging a staple on the lingual surface of a band on the malposed tooth. The base

---

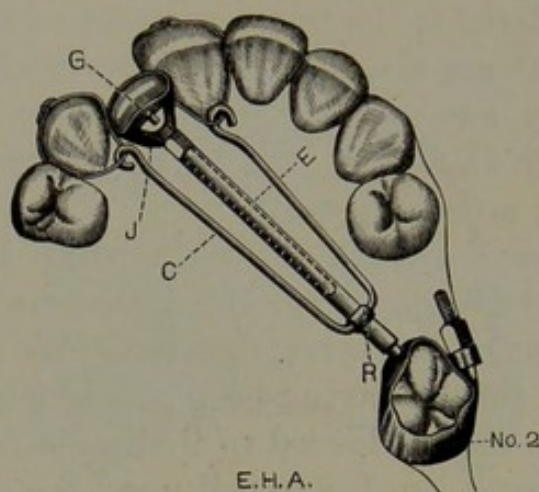
\* Third edition, 1892. Angle.

† Sixth edition, 1900. Angle.



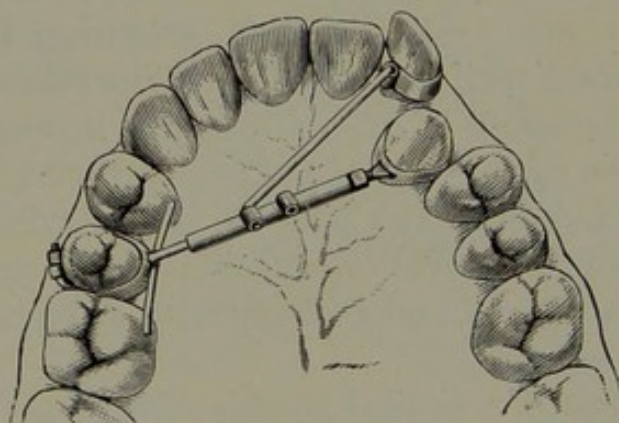
of the screw engages a spur on the anchor band. Reinforcement of the anchorage was gained by a loop made from the wire G which engaged a tube R soldered at right angles to

FIG. 627.



the sheath of the screw on its palatine surface. The ends of the wire, bent in the form of hooks, engage wire ligatures encircling canine and central incisor. This combination is quickly and easily made, and the reinforcement through

FIG. 628.

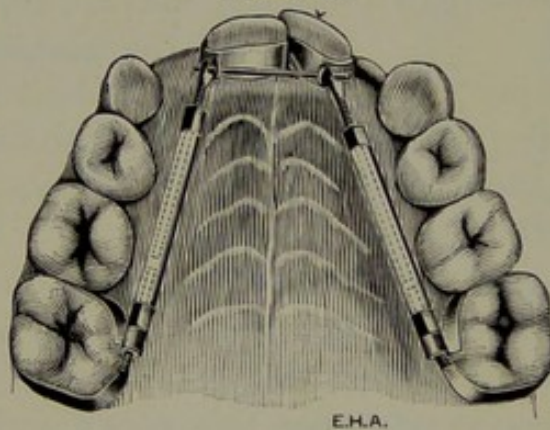


the ligatures is quite as efficient as if bands were used, which, besides requiring more time and trouble in adjusting, would occupy valuable space. Of course such ligature reinforcement would be useless with fibrous ligatures, as slipping and stretching would render them inoperative.

Fig. 628\* shows a combination of the jack-screw where reciprocal anchorage was used to accomplish the lingual movement of the lateral and labial movement of the canine, the sheath of the jack-screw being cut short to allow it to travel forward over the spur as the nut was turned, until its base finally rested against the anchor band, when the lateral was drawn into place and reinforced the anchor tooth in resisting the moving canine.

The extra tube on the sheath of the jack-screw was in anticipation of further reinforcement of anchorage, if it

FIG. 629.



E.H.A.

should be found necessary, by hooking another piece of the wire G into the tube after soldering the other end to a band upon the first premolar. It was not found necessary in this instance, but it is always well to anticipate the possible need of spurs, tubes, etc., in order to avoid the trouble of removal and re-adjustment of appliances, the evil effects of relinquishment of pressure, etc.

Fig. 629\* represents a combination of two jack-screws for moving labially out of inlock two central incisors (one also being in torso-occlusion), the patient being a child eight years of age. The incisors were encircled by plain bands, the union of the bands being made at their disto-

---

\* Fourth edition, 1894. Angle.



lingual angles and notched (as in A, Fig. 624) to hold a straight section of the wire G against which rested the notched points of the jack-screws. The bases of the sheaths were slipped over the ends of the screws of the anchor clamp bands (as in J, Fig. 623) and the force was exerted by tightening the nuts of the jack-screws. Rotation of the central was accomplished at the same time by occasionally tightening the wire ligature (A, Fig. 195) encircling the tooth, its looped ends engaging the wire and union of the band. Retention was effected principally by the occlusion with the lower teeth, the bands, however, having been removed and soldered at points of contact and recemented in position.

In using the jack-screw it is always best to employ as long a sheath as possible, turning the nut close up to the chisel end, in order that there may be ample length of the screw to effect the necessary movement.

Two sheaths are provided for the jack-screw, to afford ample length for all cases. They should, of course, be cut shorter if the case demand. The author has occasionally found it necessary to use this screw and sheath combined only one-fourth of an inch in length, as might be found necessary in restoring to an upright position a molar which had inclined into the space made vacant by the loss of another tooth.

Other combinations in which the jack-screw plays an important part will be described and illustrated under Miscellaneous Combinations.

**Traction Screw.**—Although there are many possible combinations with the traction screw, in reality its uses should be limited to two, or possibly three. Its most important use is that of retraction of that most obstinate tooth, the canine, as shown in Fig. 630.\* This it accomplishes so easily and perfectly, when properly adjusted and managed,

---

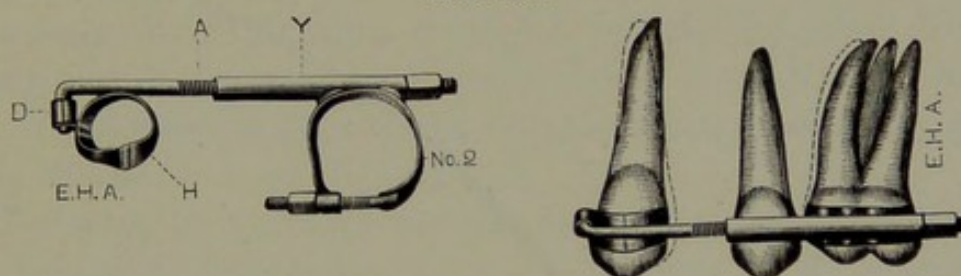
\* First edition, 1887. Angle.



that it easily takes rank, we believe, over all other appliances for this purpose. We shall illustrate the use of this appliance, singly or in combination with other appliances somewhat later, and will here only describe its correct adjustment.

The canine and anchor teeth are carefully banded after the manner previously described for adjustment of the plain and anchor clamp bands. The traction screw is then held in position, and the short and long sheaths made to

FIG. 630.



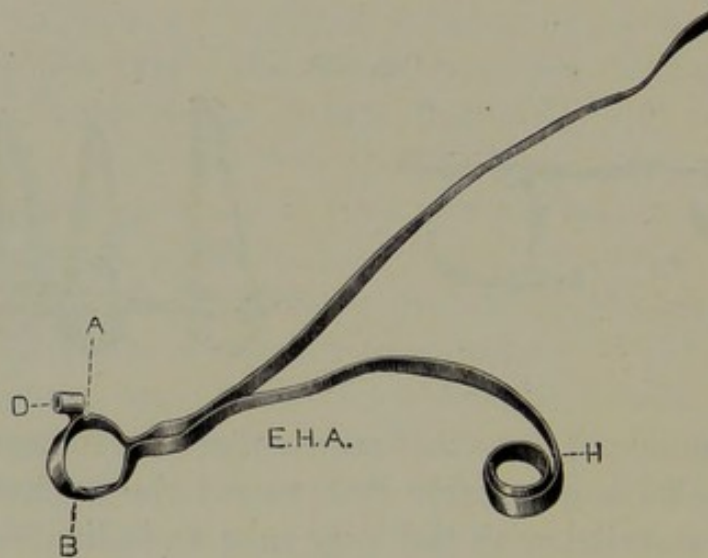
touch the bands at the exact points they are to occupy when soldered. With a suitable instrument the anchor band is scratched parallel with the long tube to indicate its alignment, and the exact point of contact of the edge of the short sheath with the band on the canine is located and indicated by a suitable mark. Lest this be obliterated upon heating the band may be perforated at this point with a small drill. Having noted as accurately as possible the angle at which this tube shall stand to properly line with the right angle of the shaft, minute notches are made in the edge of the band mesially and distally, to line with the end of the tube, Fig. 631. The bands are now removed from the teeth and the right angle of the screw from the short sheath, and a minute piece of solder partially fused upon the edge of the short sheath at the point intended for attachment to the band. The sheath is then held with the solder-placing pliers (Fig. 157) in the left hand, the band being held by its untrimmed ends in the right hand, the end of the tube



lining with the notches A and B, Fig. 631, and the solder fused by contact with the flame at the proper point.

A little experience will enable the operator to make this—the most difficult of all the attachments in this system—easily and quickly, yet it is highly essential that the tubes be attached at the right point and at the proper angle, or the angle of the screw will not fit. Probably the beginner, therefore, may better temporarily wax the tube in position

FIG. 631.



and invest and solder as he would in attachments to be made in bridge- or crown-work.

Be it remembered that the tube attached to the canine band must always stand at right angles to the long axis of the tooth, that a free, hinge-like movement of the tooth in retraction may be gained; not parallel with the long axis, as persisted in by some, with resultant binding and prevention of free movement.

The surplus ends of the bands are now trimmed off and smoothed, and the band deoxidized and cemented in position. While the cement is hardening the long sheath is soldered, according to alignment, to the No. 2 band, using plenty of solder,—a piece one-fourth of an inch square and of the usual sheet thickness. It is then cleansed and



slipped upon the screw and the nut adjusted, the angle is hooked into the tube upon the canine band, and the clamp band slipped over the crown of the molar and gently tightened. It is allowed to remain a day or two before cementing, in order that this operation, so important to perform thoroughly, may be accomplished without interference by pressure from the approximal teeth and so that both the canine and the anchor tooth may move slightly and become more perfectly adjusted to their relations with the two bands.

The proper length of the screw having been determined, the superfluous portion is cut off behind the nut. Never shorten the screw and then attempt to place the nut upon it. Heat must in no instance come in contact with any portion of the shaft of the screw.

Before finally cementing the band in position, it should be removed, cleansed and dried. The crown of the molar should also be thoroughly cleansed and dried, the final cleansing being done with a pledget of cotton moistened with alcohol or ether. The crown being properly protected from moisture, cement is quickly mixed to the proper consistence and the interior of the band nearly filled. The angle of the traction screw is then inserted into the short tube and the anchor band and cement carried down over the crown of the molar with the thumb and finger, forcing the cement well down about the crown. The band is quickly worked into the desired position, and its nut tightened until firmly clamped. The superfluous cement is then wiped off and the patient dismissed until the next sitting before tightening the nut of the traction screw, in order that the cement shall become thoroughly set and the most rigid attachment possible be gained.

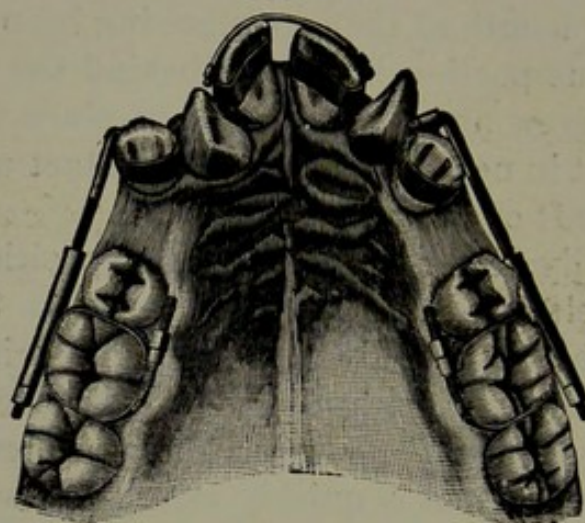
If the operation so far has been carefully performed, the nearest approach to stationary anchorage will have been gained, so that the canine may be moved distally without changing the relation of the occlusal planes of the anchor



tooth with those of the opposite jaw. It is very important, however, not to strain the attachment by overtightening the nut of the traction screw at any time. One-half a revolution of the nut each day, or just enough to exert a slight snug feeling upon the canine is all the force necessary.

Very often patients may be provided with wrenches and trusted to tighten the nut regularly each day themselves. This movement, of all, however, should be conducted with the greatest regularity, and unless the patient can

FIG. 632.



thoroughly comprehend and carry out instructions he should not be depended upon.

It is nearly always best to operate the screw on the outside of the arch, by placing the tube engaging the angle of the screw in the region of the mesio-labial angle of the tooth, or in the same manner as shown on the right in Fig. 632.\*

It is very important that the angle of the screw be passed into the tube its *full length*, otherwise it will be broken when force is exerted.

If it is desired to rotate the canine as it is moved distally, this may be accomplished by using a staple instead of a

---

\* Third edition, 1892. Angle.



tube for engaging the angle of the traction screw, as shown on the left of Fig. 632. In this instance the angle of the screw is parallel with the long axis of the tooth, instead of at right angles to it, as when the tube is used. In this manner force is exerted on one side of the band only, and rotation, as well as retraction, takes place.

In some instances it may be desirable to operate the screw on the lingual side of the arch, as in Fig. 633. The shifting of the canine lingually or labially in its distal movement may be accomplished by bending the screw

FIG. 633.

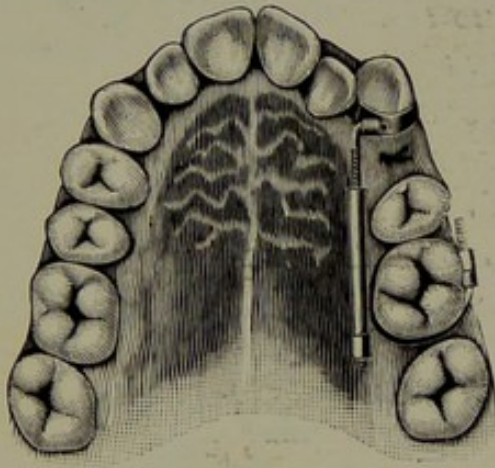
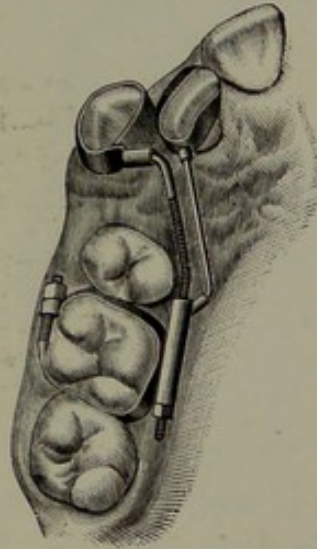


FIG. 634.



where it enters the sheath, as in Fig. 634. As the nut is tightened the screw is gradually straightened as it is drawn into the sheath, thus arranging the teeth in proper alignment.

A method of reinforcing the anchorage is also shown in this engraving, by enlisting the resistance of the lateral incisor. The tooth is banded and provided with one of the tubes R soldered at its disto-lingual angle, which engages a straight section of the wire G, the other end resting in another tube R soldered at an obtuse angle near the end of the sheath. The fine adjustment of this wire may be effected by means of the regulating pliers.



Fig. 635\* shows the use of a traction screw in effecting rotation of a premolar, in combination with the clamp bands Nos. 1 and 2. The angle of the screw engages a staple made of the wire G soldered to the mesio-lingual angle of the band encircling the premolar. By tightening the nut at A traction force is exerted on one side only, while resistance in the opposite direction is offered by the intervening premolar.

FIG. 635.

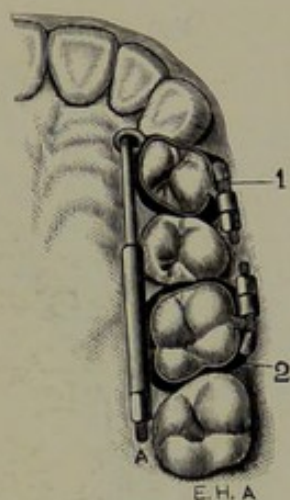
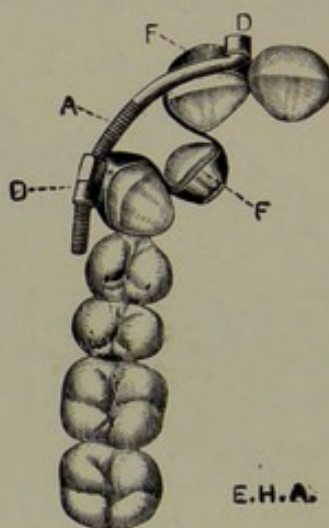


FIG. 636.



E.H.A.

It is well known that rotation of these teeth by ordinary methods is difficult. This method is very efficient and most desirable in many such cases.

In Fig. 636† is shown another use of the traction screw, in effecting the labial movement of a lateral and at the same time providing space for its movement. A strip of band material F is looped around the lateral, the ends resting on the labial surfaces of the adjoining teeth. To one end is soldered vertically one of the short tubes D, while on the other end is a similar tube attached horizontally. Into these tubes the traction screw is placed, being bent to conform to the proper curve of the arch, and as the nut

\* Sixth edition, 1900. Angle.

† First edition, 1887. Angle.

is tightened the ends of the band material are pushed farther apart.

Although efficient it is troublesome on account of its liability to work loose and so requires frequent tightening. It is now rarely used by the author except in the quick readjustment of teeth that have partially relapsed toward their original malpositions through accident during the period of retention.

This device with a straight screw, as in Fig. 637, will be found to be the most simple and efficient for moving into occlusion a single badly lingually leaning premolar—a tooth that would yield reluctantly to the ligatures and expansion arch.

FIG. 637.

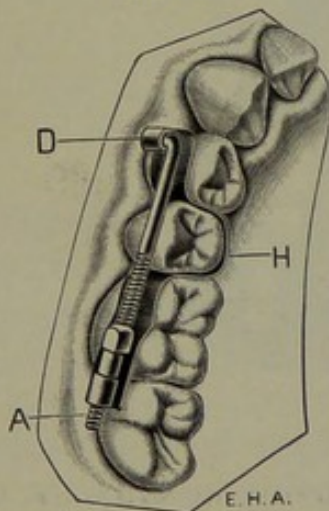
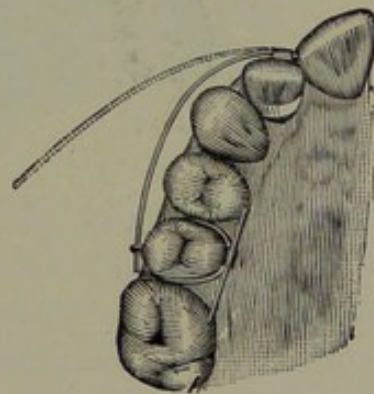


FIG. 638.



**Lever.**—In the movement of rotation of a single lateral incisor by means of the lever L, shown in Fig. 638,\* the plain band, with a tube on its mesio-labial angle, was cemented upon the lateral. One end of the lever engaged the tube; the other end was sprung around and made to engage a hook on the buccal surface of an anchor band on the second premolar, which was reinforced by a section of the wire G passed through the tube R on its lingual

\* Angle. Transactions Ninth International Medical Congress, 1887.



surface, the ends of the reinforcement wire being made to bear against the lingual surfaces of the first molar and first premolar.

Additional reinforcement may often be gained by ligatures made to encircle lever and teeth intervening between the moving tooth and the main anchor tooth. The lever should be occasionally removed and straightened to intensify the force. The various sizes of the levers furnish ample range for the needs of larger teeth, but as the force exerted by the lever is so great the smallest sizes are usually preferable.

FIG. 639.

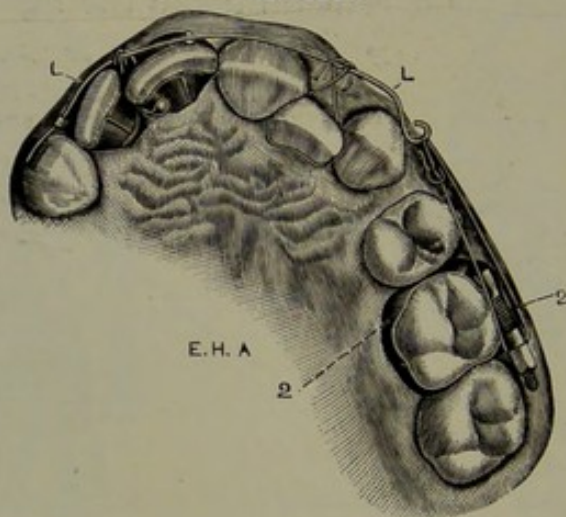


Fig. 639\* shows a combination of the lever for rotating a central and lateral incisor and moving labially the other lateral incisor. The resistance end of the lever is passed through a tube R soldered to the disto-labial angle of a band on the right lateral. The power end, bent in the form of a hook, is secured by a wire ligature engaging the nut on the anchor band on the first molar. This is the author's favorite method of securing this end of the lever, as the strongest anchorage and greatest control are thus secured.

Additional force is applied to the rotating lateral by allowing the end of the lever to bear against the labial

---

\* Sixth edition, 1900. Angle.

surface of the canine, and it is further intensified by an intervening wedge of rubber. At the same time the left lateral is being moved from lingual occlusion and the central rotated by means of wire ligatures, band, and spur, as would be similarly employed if the expansion arch were used instead of the lever.

FIG. 640.

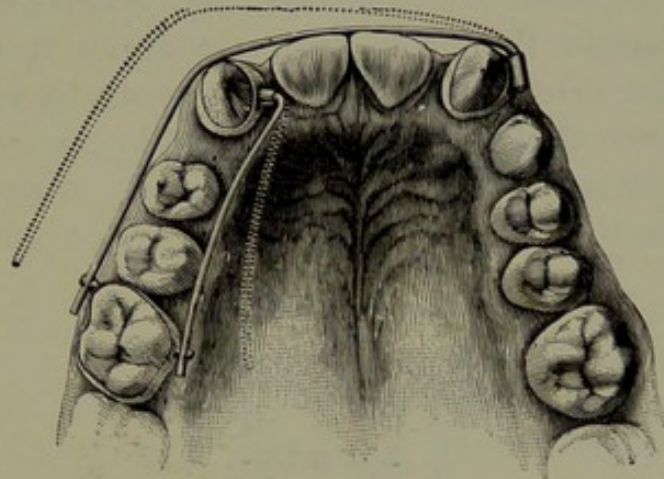


Fig. 640 shows a combination where two levers were used in rotating two upper canines, the ends of the levers engaging tubes R soldered to bands upon the moving teeth. The power ends of the levers engaged hooks soldered to an anchor band upon the first molar, the anchorage being reciprocal.

FIG. 641.

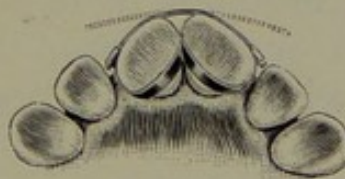

Fig. 641\* shows two central incisors being rotated in opposite directions at the same time by means of the lever. Upon the incisors have been cemented plain bands with tubes R soldered at their disto-labial angles. One end of

---

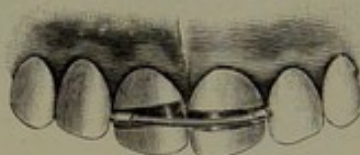
\* Archives of Dentistry, 1888. Angle.



a section of the smallest size of lever wire was inserted into one tube and then into the other by springing and sliding, as a door-bolt is slid into position.

Fig. 642 shows a view from the labial aspect of the appliance in position. The spring of the wire exerts pressure lingually on the mesial angles, while the ends of the lever operate in the opposite direction on the distal angles of the teeth. As the teeth are turned it may be necessary to occasionally remove the lever and straighten it in order to maintain the pressure. Should one tooth be rotated sufficiently before the movement of the other is complete, its further movement should be arrested by a spur soldered to the disto-lingual angle of its band and made to bear

FIG. 642.



against the lateral incisor. If the teeth show a tendency to separate as they rotate this should be prevented by a wire ligature which should inclose the ends of the lever on the labial surface and drawn tight.

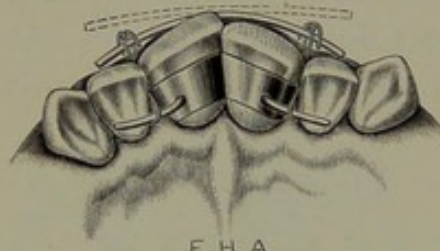
Although this is a simple and efficient method of performing double rotation of the incisors, it must be remembered that in most instances these positions of the teeth are only a symptom, or the result of lateral pressure from narrowing of the arch, which must first be widened to provide room for their occupancy. In such cases the expansion arch is better suited for accomplishing the movement of double rotation of the incisors while widening the arch at the same time, yet where there is sufficient room for the incisors it would be difficult to find a more ideal method than the use of the lever, as above described. This would be peculiarly true in cases where the teeth, after regulating by enlargement of the arch, have, from neglect or en-



forced absence of patients, partially relapsed into their former malpositions during the period of retention.

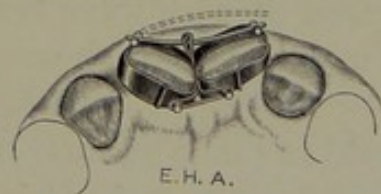
Fig. 643 shows a modification of this principle. The central incisors are banded and spurs of the wire G, previously soldered to their disto-lingual angles, are made to bear against the lateral incisors. Ligatures engage these

FIG. 643.



spurs, passing between the teeth and being firmly twisted to the ends of the lever, binding it down closely in contact with the surfaces of the teeth, the spring of the lever giving labial movement to the lateral incisors and torsal movement to the centrals. The device, being so simple and easily and quickly applied, is a favorite with the author, being often used, either in this form or in some of its many possible modifications for the readjustment of incisors that have partially relapsed from their corrected positions.

FIG. 644.



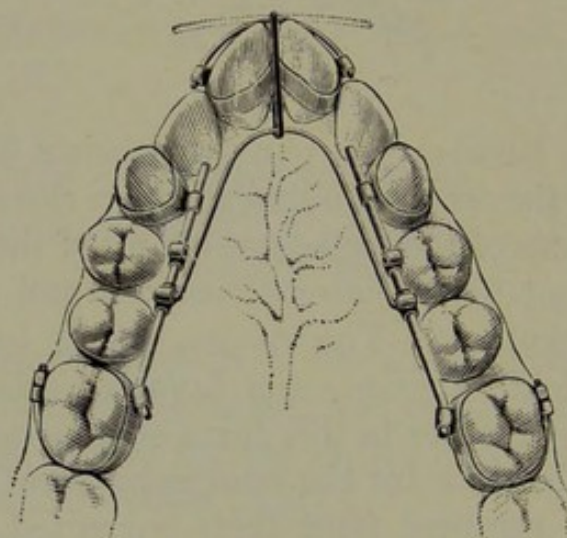
When opposite movements of incisors in double rotation shall be found necessary it may be accomplished by means of the lever L, made to rest in notches in a section of the wire G soldered to the disto-labial angles of the bands, while a wire ligature encircling spurs soldered to the mesio-lingual angles passes between the teeth to inclose the center



of the lever, as in Fig. 644.\* The ligature should occasionally be tightened by twisting. After the teeth have been sufficiently rotated temporary retention may be effected by means of a ligature inclosing the spurs only.

**Miscellaneous Combination.**—Fig. 645† represents one of the author's early combinations of appliances for rotating central incisors and widening the dental arch, the rotation of the incisors to be accomplished through reciprocal force by means of a short section of piano wire, as in Fig. 641, with force exerted against the lateral halves of the arch by

FIG. 645.



means of the spring from another section of piano wire. The ends of this section of wire were bent sharply at right angles and engaged in tubes R which were soldered at right angles to other tubes R slipped onto sections of the wire G, the latter being held in place against the lingual surfaces of the canines and premolars and made secure by resting in tubes R attached to clamp bands on the molars and plain bands on the canines. A ligature engages both sections of the piano wire which serves, through its reciprocal force, to assist the rotation of the centrals and hold in correct position the anterior part of the vault spring.

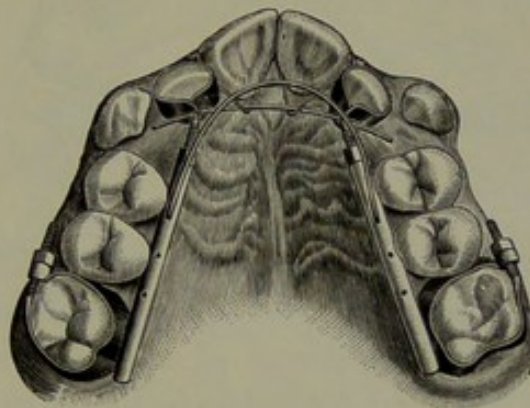
---

\* Sixth edition, 1900. Angle.

† Third edition, 1892. Angle.

This device was formerly in high favor with the author and has many imitations, but since the perfection of the expansion arch and the introduction of wire ligatures it has been entirely superseded in the author's practice. Fig. 646\* shows a combination for widening and lengthening the arch. The notched ends of the jack-screws engage a section of one of the levers L held in position by notches formed in the united ends of bands upon the lateral

FIG. 646.



incisors. The sheaths of the screws were secured to anchor clamp bands No. 2 upon the first molars, as in F, Fig. 623. The incisors were moved forward by turning the nuts of the jack-screws, while the arch was widened by the spring of the lever L, the ends bent sharply at right angles and made to engage delicate holes bored in the sides of the sheaths of the jack-screws, all as clearly shown in the engraving.

A modification of this plan is to exert pressure laterally by means of a third jack-screw in place of the spring, this screw being notched at each end and made to rest in contact with the other screws, anterior to their nuts.

Another combination is shown in Fig. 647,† in which the torso-labial movement of the laterals was effected by means of two jack-screws and two levers. The points of the jack-

---

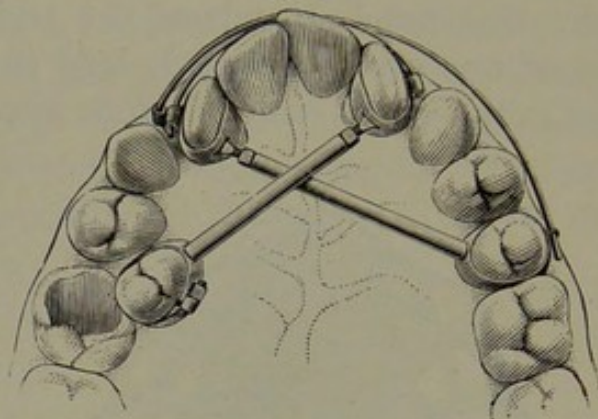
\* Fourth edition, 1894. Angle.

† Third edition, 1892. Angle.



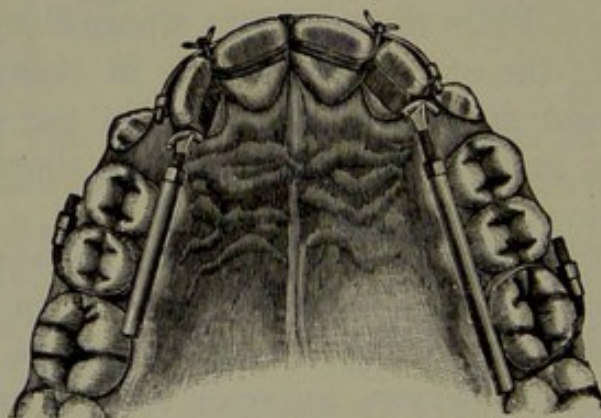
screws engaged mortises in bands on the disto-lingual angles of the laterals, their bases resting over spurred bands on the anchor teeth. As the teeth were moved labially by tightening the nuts of the screws, they were also

FIG. 647.



rotated by the two levers L which were crossed in front. The resistance ends of the levers were inserted in tubes soldered to the labial portions of the bands. One of the power ends was secured by being latched into a hook soldered to the buccal surface of one of the anchor bands, the other being bent sharply at right angles and engaging

FIG. 648.



a tube soldered at right angles to the tube on the band on the opposite lateral, thus exerting a certain amount of reciprocal force.

Another combination for effecting the lengthening of the arch by moving forward all of the incisors by means of two

jack-screws, the points of which engage staples soldered to the disto-lingual angles of bands on the lateral incisors, is shown in Fig. 648.\* The necessary rotation of the incisors was accomplished at the same time by means of a section of one of the levers L, sprung into tubes upon the disto-labial angles of the bands upon the laterals. The central incisors were laced to the lever by means of floss-silk ligatures. As the nuts of the jack-screws were tightened all of the incisors were carried forward. At the same time they were rotated by the elasticity of the lever

FIG. 649.

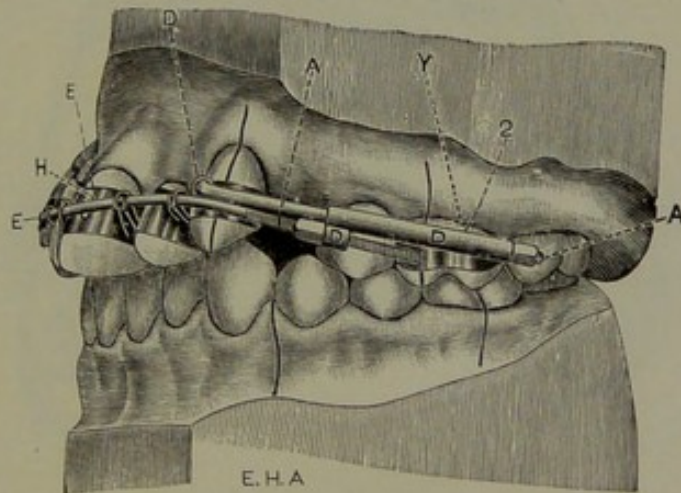


Fig. 649† shows a very important combination of the traction screw and expansion arch for shortening one of the lateral halves of the arch and at the same time correcting malpositions of the teeth.

The traction screw should be first adjusted as already described, and as shown in Fig. 630. In addition it should be provided with one of the tubes D soldered to the side of the sheath Y near its mesial end. This is for the reception and support of one end of the expansion arch in place of the usual D or X band. The nut of the expansion arch is to bear against this tube, and when so used should be reversed, the friction sleeve being turned mesially. The

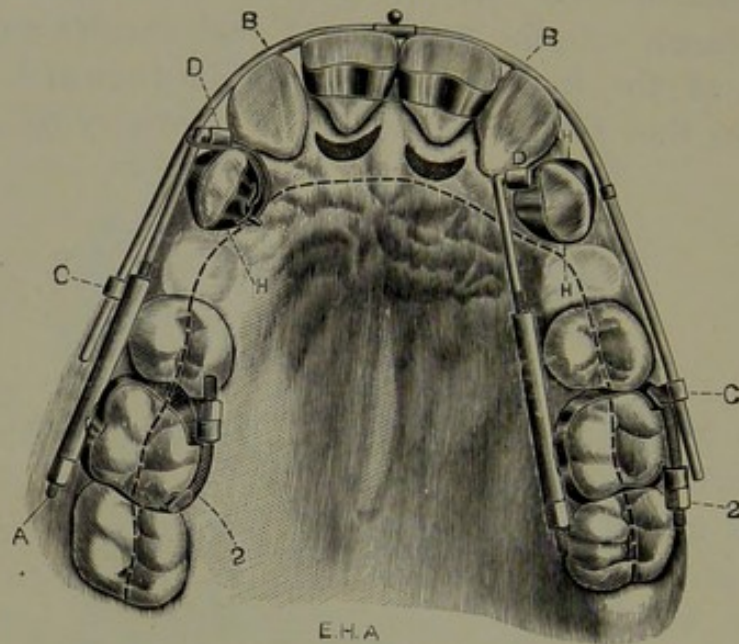
\* Third edition, 1892. Angle.

† Sixth edition, 1900. Angle. Also *Dental Cosmos*, September, 1899.



other end of the expansion arch is supported in the usual way, as in Fig. 199. As the canine is retracted into the space made vacant by the loss of the first premolar the malposed incisors are rotated by means of the ligatures, bands, and spurs, as is well shown in this engraving, and also in Fig. 199.

FIG. 650.



The general position of the incisors is controlled by tightening or loosening the nuts of the expansion arch, as in Fig. 649, in accomplishing the movements of the incisors.

A similar combination may be used on the opposite side of the arch when it is desirable to shorten both of the lateral halves.

Similar combinations of the traction screw with the B arch may be used, as in Fig. 650. For the support of the front of the arch it may be allowed to rest in notches formed in the united ends of the bands on the incisors, as in C, Fig. 651,\* or in notches filed in pieces of the wire G (B, Fig. 651) soldered across the labial surfaces of the bands, as shown in Fig. 652, or against short spurs of the

\* Sixth edition, 1900. Angle.

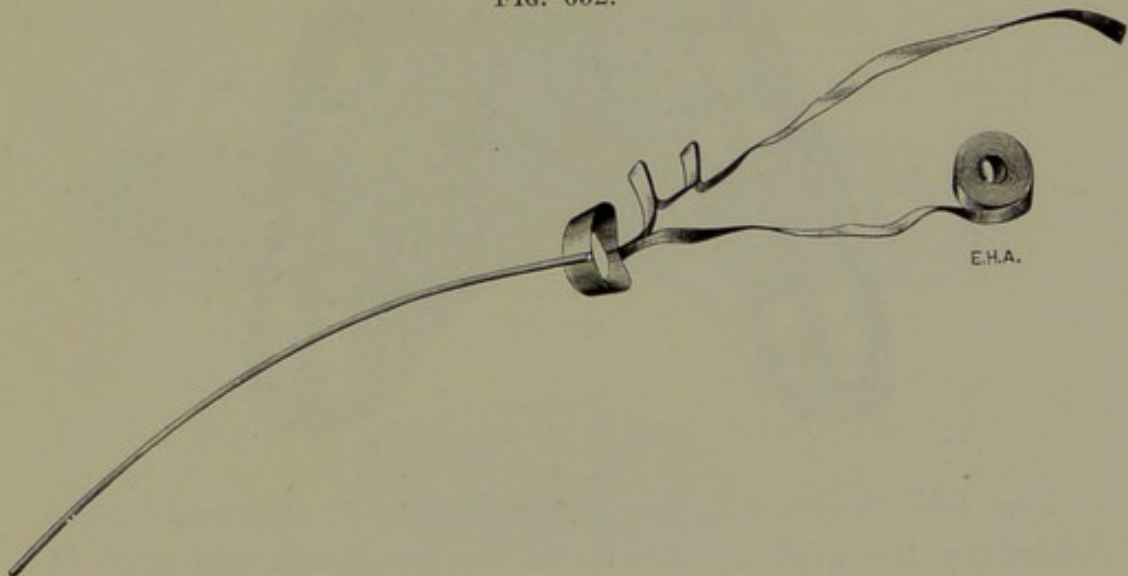
wire G soldered to the labial surface of the band near its upper edge and at right angles to the long axis of the tooth, as in A, Fig. 651. The latter is the author's favorite method, as it presents a neater appearance and effectually

FIG. 651.



prevents the arch from sliding against the gum—the only direction, in reality toward which it tends. The illustration, Fig. 650, shows a combination of the traction screws used as auxiliaries to the headgear, traction bar, and B

FIG. 652.



arch in order to more speedily effect the retraction of the incisors and canines in a typical case belonging to the first division of the second class. The usual extreme care is necessary in applying the traction screws according to directions already given for their proper adjustment.



In the engraving one screw is shown as being operated on the lingual side of the arch. It is more effective when used on the outside, as correctly shown on the left. The spring arch B is adjusted in the usual way, except that the ends of the arch are supported by telescoping short tubes soldered to the sheaths of the traction screws.

Formerly, when extraction in these cases was deemed necessary, this combination was a favorite with the author, especially in cases after maturity of the patient. By its use retraction of the canines could be effected in about one-half the time necessary by any other known method. The surgical removal of bone anterior to the moving teeth, as elsewhere described, still further expedited this movement.

FIG. 653.

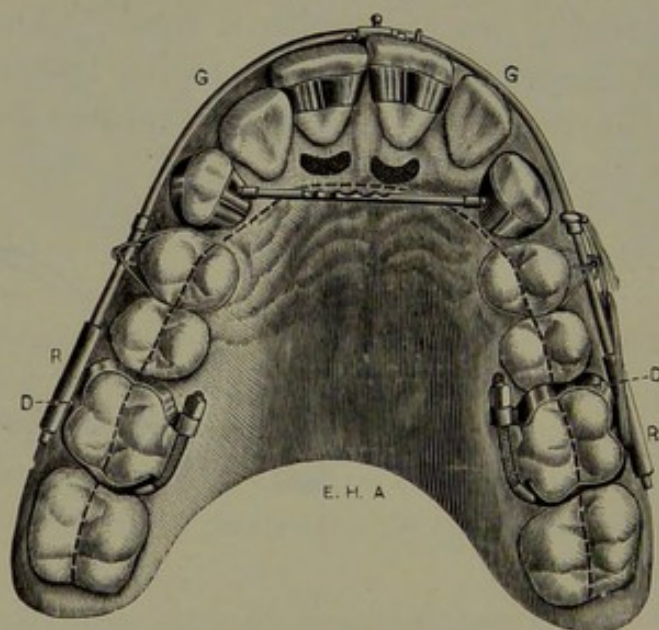
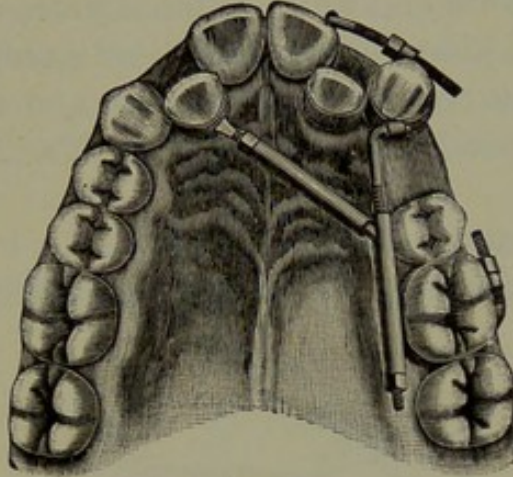


Fig. 653 shows another combination for shortening and widening the arch by means of the headgear and arch B, as already described, the canines being moved laterally by a section of wire G lengthened by pinching with the regulating pliers, as elsewhere described.

Sections of bone lingual to the central incisors have been surgically removed to expedite their lingual movement.

Fig. 654\* shows a combination for retraction of the canine and labial movement of the lateral incisors. While the traction screw was accomplishing the distal movement of the canine it was assisted by the loop and traction screw

FIG. 654.



device, as in Fig. 636, operating upon the incisor, while the other incisor was being moved labially by means of a jack-screw, the base of which rested over a spur soldered to the sheath of the traction screw operating upon the canine.

FIG. 655.

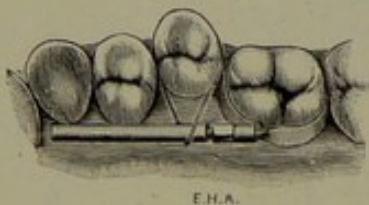


FIG. 656.

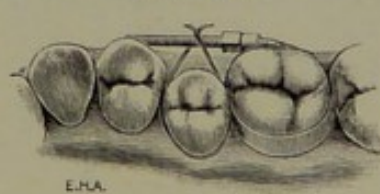
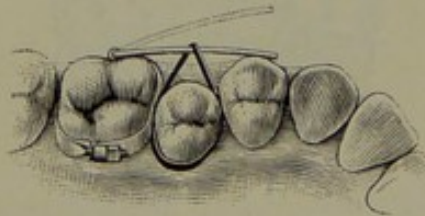


FIG. 657.



Figs. 655,† 656,† and 657,† show simple and convenient methods of moving single teeth that are lingually or la-

\* Third edition, 1892. Angle.

† Fourth edition, 1894. Angle.



bially displaced. In Fig. 655 anchorage is gained for the wire ligature by slipping the short sheath of one of the jack-screws over the end of the screw of the No. 2 band upon the first molar.

In Fig. 656 the screw of the clamp band was lengthened by soldering to its end an additional piece of metal.

In Fig. 657 a piece of the wire G, or a section of the lever L, was bent sharply at right angles and made to engage a tube R soldered to a clamp band No. 2 upon the first molar.

Fig. 658 shows a method of making a long clamp band which is sometimes useful in closing spaces between teeth.

FIG. 658.



To the ends of a section of band material of suitable length are soldered tubes D, one horizontally and one perpendicularly, which engage the angle and screw ends of the traction screw. By tightening the nut the size of the band is diminished and force exerted.

FIG. 659.

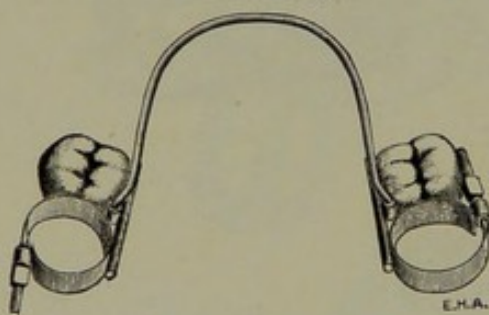
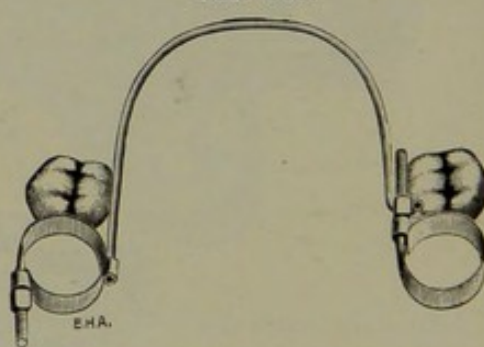


FIG. 660.




Figs. 659\* and 660\* show efficient devices for widening the arch in the region of the premolars. Force is exerted by a lever L of suitable length, its ends being secured by

\* Fourth edition, 1894. Angle.

tubes R which have been soldered at right angles to sections of wire G soldered to the lingual surfaces of the anchor bands, as in Fig. 659, or in a closed-end tube attached directly to the anchor band, as in the left of Fig. 660, or the tube may be soldered to a side of the nut of the clamp band, as on the right. This form of device is often useful in widening the dental arches of children to release lateral pressure upon the centrals, to be followed by a delicate vulcanite plate covering the vault of the arch, for retention, as in Fig. 252.

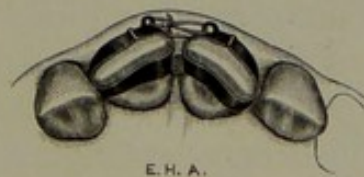Fig. 661 shows a simple and efficient way of making the attachments of the lever directly to the screw ends of the

FIG. 661.



anchor bands by first bending the ends of the lever in the form of a hook, then bending the hook at right angles to the lever. It was suggested by Dr. Edmonds. This ingenious attachment would also be found efficient in adjusting the reinforcement wire, as in Figs. 215 and 404.

FIG. 662.



Another combination of appliances for effecting double rotation of the central incisors is shown in Fig. 662.\* It consists of bands having spurs or tubes soldered at their mesio-labial angles to engage a tightly drawn and twisted

---

\* Sixth edition, 1900. Angle.



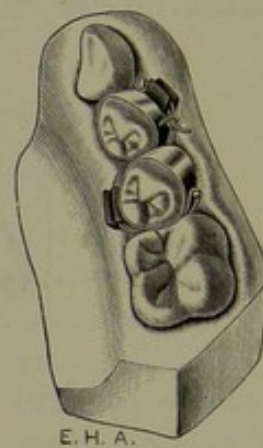
wire ligature. Between the bands is stretched a strip of rubber. By the occasional renewal of the ligature a powerful force is exerted that will turn the teeth readily. Temporary retention is effected by the application of a fresh wire ligature and dispensing with the rubber.

Fig. 663 shows the application of this same principle in the rotation of two lower premolars, which may often be made use of alone, or it may be used as an auxiliary in assisting the ligatures which have been employed in the usual way for rotating these teeth in connection with the

FIG. 663.

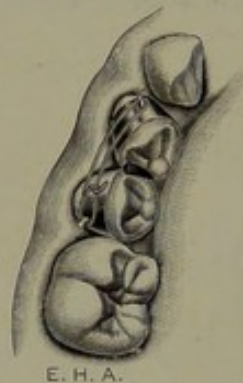

FIG. 664.



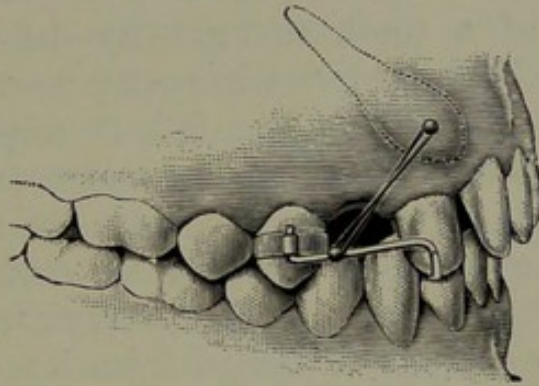
expansion arch; or, it may be employed independently of the expansion arch, though used at the same time.

Still another modification is shown in Fig. 664, where two premolars require rotation in the same direction. The teeth are fitted with plain bands. Short spurs project from the buccal surfaces of these bands and a strand of the wire ligature is looped over the spur on the second premolar, both ends being carried between molar and premolar, then carried back between the premolars to engage a strip of rubber. One strand of the ligature is then made to engage the spur on the first premolar, drawn and twisted firmly with the other strand just posterior to another strip of the rubber which is made to bear against the buccal surface of the first premolar. This produces a constant and powerful

force for the rotation of these teeth. It also is a favorite device with the author and may be used with success without the rubber wedges.

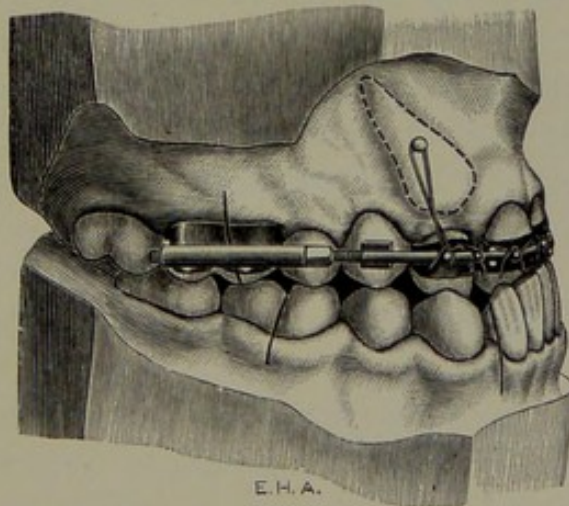
Fig. 665\* represents a very neat and convenient method of forcing the eruption of a canine which had become

FIG. 665.



impacted by the too long retention of the deciduous canine. The first upper premolar was encircled by a No. 1 band; to its labial surface, parallel with the long axis of the tooth,

FIG. 666.



E. H. A.

was soldered a tube R which engaged a section of the wire G bent sharply at right angles, the other end being flattened

---

\* *Dental Cosmos*, 1891. Angle.



and bent to engage the occlusal edge of the lateral. A short section of a common pin was set in the enamel of the impacted tooth. One had also been soldered to the anchor wire. A ligature was then made to connect both pins, which exerted constant pressure.

While this simple and delicate device is perhaps the nearest to the ideal for simple cases, where the forcing of the eruption of a tooth not greatly deflected from its normal incline is desired, yet in such pronounced cases of deflection, as indicated by Fig. 665, in which the tooth is thoroughly imbedded in a strong encasement of bone, the anchorage is not sufficient to overcome the resistance, and the expansion arch, as in Fig. 666, is better, and in some cases even the combining of all the anchorage attainable in this manner, with that gained from intermaxillary anchorage, as in Figs. 186 and 187, is necessary, as we have found in a number of cases.

*FINAL SUGGESTIONS.*

---

I. As normal occlusion of the teeth is the basis not only of all orthodontic operations, but of all other dental operations, it is one of the prime wishes of the author in writing this book to awaken a keener interest in and closer study of occlusion, not only by orthodontists, but by dentists, rhinologists, and all students interested in the artistic proportions of the human face.

Failure to appreciate the requirements of art in the practice of orthodontia is as readily recognizable as its effect is lasting. All who hope to attain true success in practice should cultivate studious observation of normal and abnormal facial lines in their relations to, and dependence upon, occlusion.

II. In studying a case of malocclusion give no thought to methods of treatment or appliances until the case shall have been classified and all peculiarities and variations from the normal in type, occlusion, and facial lines have been thoroughly comprehended. Then the requirements and proper plan of treatment become apparent.

III. In moving a tooth the best result is obtainable by applying only that degree of force necessary to bring about physiological changes in the tissues. The practice of applying great force at irregular intervals serves only to defeat the desired object, for it induces pathological instead of physiological changes in the tissues, exciting inflammation, and causing unnecessary pain. In no instance should the pressure be greater than to cause a snug feeling, which is perhaps the best indication of the proper degree of force.



IV. The wise and skilful orthodontist may and will avoid causing pain, as well as unnecessarily prolonging orthodontic operations, and in so doing will contribute much toward overcoming in the mind of the laity the great prejudice against those operations that has been caused thereby in the past.

V. The normal denture, so beautiful in part and in whole, and contributing so greatly to the beauty, happiness, health, and longevity of the possessor, must, as it is studied and comprehended, impress all thoughtful persons with the great importance of and wonderful future for the specialty of orthodontia. Yet to expect all to succeed in the practice of orthodontia would be as unreasonable as to expect all students of the violin to become artists in its use. Only those who have an aptitude and fondness for the work and who will study the subject broadly, deeply, and thoroughly in all its relations should attempt its specialization. Any incompetent, superficial temporizing in its practice must inevitably react, and oftentimes with telling effect, on the operator.

VI. Success in orthodontic operations does not consist in simply placing the teeth in normal relations, as this is only a stage in treatment, but in the final, the ultimate results, gaged by the functions of mastication, speech, and respiration, as well as by the beauty and balance of the face.


VII. We are just beginning to realize how common and varied are vicious habits of the lips and tongue, how powerful and persistent they are in causing and maintaining malocclusion, how difficult they are to overcome, and how hopeless is success in treatment unless they are overcome.

VIII. The period of the retention of the teeth, after they have been moved into normal occlusion, is one of the most important in treatment, and so complicated and persistent are the delicate forces that tend to derangement of the established occlusion as to necessitate the most thoughtful

consideration of the problems involved, and a degree of skill in overcoming them which much experience alone can develop, even among those with talent for the work.

IX. This book is intended for careful study and analysis, preface and all. Its thoughts are necessarily so interwoven that no man can comprehend it or profit much by reading only parts of it, or the whole superficially. To its readers we commend the advice of Sir Andrew Clark to readers of any book deemed worthy of attention, to "read it at least three times; first, to see what it is all about; secondly, to see what it says; and thirdly, in an attitude of friendly hostility."





# INDEX.

## A

ADENOIDS, 115, 309, 450  
 Adhesive plaster, 496  
 Age, correct for treatment, 30, 309, 310, 313, 440, 452, 519  
 Alveolar process, absorption of, 132, 133  
   arrest in development of, 145, 312, 340, 342, 348, 351, 376, 377, 384, 386, 393, 415, 419, 449, 542, 544  
   bending of, 132, 417  
   changes in, incident to tooth movement, 132, 315, 393, 430, 469  
   changes in, subsequent to tooth movement, 140-143, 319, 336, 343, 344, 350, 355, 364, 546  
   development of, 30, 312, 375, 377, 380, 388, 389, 392, 393, 398, 401, 429, 524, 526, 548  
   disintegration of, 430  
   general consideration of, 118-132  
   modified growth of, 431  
   section of, 567  
 Anchorage, change made in, 361, 440  
   Baker form of, 193, 232, 235, 254, 257, 262, 356, 505, 512, 553  
   defective, 228  
   devices for reinforcing, 582, 583, 584, 585, 591, 593  
   devices for securing, 224, 225  
   for buccal movement of teeth, 420  
   for retention, 266, 432  
   intermaxillary, 194, 202, 224, 233, 256, 260, 356, 408, 428, 432, 455, 456, 479, 488, 507, 516, 530, 557, 561, 610  
   manipulation of, 466  
   occipital, 172, 189, 191, 194, 202, 224, 234, 235, 266, 499  
   reciprocal, 224, 229, 247, 256, 266, 582, 585  
   reinforced, 226, 230, 427, 583, 584, 585, 591  
   simple, 224, 225, 226, 247, 440  
   simple-intermaxillary, 460, 517, 520  
   simple-reciprocal, 362  
   stationary, 224, 227, 229, 247, 256, 258, 440, 507, 589  
   stationary-intermaxillary, 460, 512  
   sources of, 224

Appliances. (See Regulating Appliances)  
 Art. (See Facial Art)  
 Artificial fixation, 566  
 Artificial substitutes for teeth, 96, 168, 265, 307, 308, 437, 439, 482

## B

BAKER anchorage. (See Anchorage)  
 Banding, canines, 217, 302, 428, 479, 587, 588  
   crowded teeth, 238, 240  
   sore teeth, 267  
 Band driver, 208, 240  
 Band material, author's C, 202, 203, 329, 334, 428  
   F, 189, 202, 203, 329  
   H, 189, 202, 203, 462  
 Bands, anchor clamp, adjustment of, 236-240, 245, 252, 587  
   adjustment of for stationary anchorage, 227, 256, 587, 591, 592  
   attachments to, 226, 227  
   author's improvements of, 198  
   cemented, 227, 289  
   description of author's, 202  
   early history of, 169, 170, 171  
   for intermaxillary movements of teeth, 257-259, 455, 457, 460, 461, 471, 479, 519, 520, 528, 534, 546, 558  
   for intermaxillary retention, 299-303, 381-382, 473, 476, 510, 512, 539, 549, 561  
   general uses of, 193, 246, 329, 361, 427, 582, 583, 585, 598, 599, 609  
   long, 228, 606  
   resoldering sheaths of, 239, 439, 456  
   value of, 178  
 Bands, plain, adjustment of, 240, 245, 572, 587  
   and planes for intermaxillary retention, 302-304, 510, 553  
   and spurs for retention. (See Retention)  
   and spurs for rotation, 245, 254, 361, 420, 519, 595-597, 600, 607  
   attachments, 211, 212, 219-221, 230  
   author's method of making, 215-219, 220, 221  
   deoxidizing, 221, 588



- Bands plain, early history of, 169, 170**  
 erroneous methods of making, 213, 216  
 first cemented, 170, 171  
 for canines, 217, 260, 302, 428, 479, 598  
 for intermaxillary movement of teeth, 260  
 for retention, 267, 268  
 for treatment, 329, 335, 361, 370, 398, 426, 572, 583, 585  
 importance of perfect, 240  
 injuries to teeth from wearing, 267, 281, 282  
 inspection of retaining, 280  
 Magill's, 171, 215  
 materials for making, 170, 171, 179, 181, 214, 216  
 notched, 190, 221, 602, 603  
 to prevent slipping of ligatures, 249, 325, 353, 428  
 united for retention, 279, 280, 364, 586  
 value of, 187
- Bite, end-to-end, 32**  
 improved, 528  
 jumping the, 499  
 necessity for lengthening, 491  
 open, 386, 389, 423, 431-433  
 plate for shortening, 491, 530  
 proper length of, 546  
 shortened, 445, 491, 527, 530, 534
- Bridging as related to orthodontia, 437, 441, 445, 482**
- Blowpipe, 208, 210, 217, 222**
- Bone, arrest in development of intermaxillary, 114, 354, 384, 386, 390, 391, 476, 477**  
 bending of, 132, 133, 417  
 changes in incident to tooth movement, 133  
 deformities of, 550  
 growth of, 389, 398, 432, 442, 546  
 redeposited, 132, 312, 388  
 surgical removal of, 566, 567, 604
- Brass wire ligatures. (See Ligatures)**
- C**
- CANINE teeth, abnormal inclination of, 383**  
 as anchor teeth, 401  
 banding, 217, 302, 428, 479, 587, 588  
 buccal movement of, 137, 330, 476-478  
 device for intermaxillary movement of, 260, 479, 481  
 distal locking of lower, 49, 542  
 distal movement of, 132, 383, 534  
 displacement of, 400
- Canine teeth, elevation of, 231, 245, 351, 429, 609, 610**  
 extraction of. (See Loss of Teeth)  
 extreme distal position of lower, 485  
 imbedded, 161  
 impaction of, 36, 98  
 importance of correcting malpositions of, 361  
 infra-occlusion of, 423, 427  
 intermaxillary retention of, 301, 302, 462, 476, 521  
 keystone of the arch, 361, 408  
 labial movement of, 226, 355, 362, 488, 534, 582, 583  
 lateral movement of, 355  
 lingual movement of, 258, 351, 370  
 most common malposition of, 361  
 non-development of, 161  
 occlusion of, 10  
 over-prominence of, 37, 404  
 premature loss of deciduous. (See Deciduous Teeth)  
 providing space for, 336, 354, 362, 375, 376, 387, 408, 435  
 readjustment of, 277, 479  
 reciprocal movement of, 230, 320  
 reduction of prominence of, 522  
 result of mal-eruption of, 360  
 retention of, 275-279, 282, 284, 285, 295, 341, 355, 362, 364, 370, 376, 408, 417, 418, 432, 549  
 retraction of, 227, 229, 260, 383, 471, 512, 587-591, 603, 605  
 rotation of, 351, 354, 362, 370, 590, 591, 595  
 simultaneous movement of first premolar and, 488
- Causes of malocclusion, abnormal frenum labium, 103, 104**  
 cleft palate, 32  
 degeneracy, 552, 553  
 disuse, 102  
 enlarged tongue, 33  
 enlarged tonsils, 550, 555, 557  
 extraction. (See Loss of Teeth)  
 habits, 32, 33, 104-111  
 heredity, 398, 552, 553  
 imperfect fillings, crowns, etc., 97, 445, 496  
 mechanical, 89  
 nasal obstructions. (See also Mouth-breathing), 46, 111-117, 448, 450  
 non-development of teeth. (See Loss of Teeth)  
 prolonged retention of deciduous teeth, 98  
 supernumerary teeth, 99  
 tardy eruption of permanent teeth, 98



- Causes of transposed teeth, 100**
- Cemented bands, (See Bands, clamp and plain)**
- Chin, heavy, 86**  
 lack of development of, 74  
 normally developed, 64, 72, 76, 84  
 receding, 81, 83, 472  
 relation of to the rest of the face, 505  
 type of, 83, 84  
 weak, 85
- Chin retractor, 194**
- Classification of malocclusion, 35, 55, 57**
- Class I, beginnings of, 29, 98, 320, 323, 398**  
 dissimilar cases of, 37, 40, 42, 43  
 distinguishing characteristics of, 36, 319, 325, 340, 351, 359, 403  
 general consideration of, 31, 36, 75-78, 319, 325, 328, 332, 335-336, 340, 342, 343, 351, 360, 367, 373, 384, 390, 393, 402, 414, 423, 431, 434  
 intermaxillary retention in, 382  
 malocclusion chiefly on one side, 404, 419  
 marring of facial lines in. (See Facial Lines)  
 mouth-breathing in, 117  
 protrusion of incisors in, 106  
 result of extraction in treatment of cases in, 383, 390  
 retention of cases in, 331, 334, 337, 341, 344, 355, 364, 370, 373, 375, 382, 391, 400, 402, 411, 417, 420, 427, 432  
 retention of mutilated cases in, 435, 441, 445  
 treatment of cases in, 320, 322, 325, 328, 334, 335, 336, 340, 351, 356, 361, 367, 375, 383, 387, 388, 398, 404, 407, 412, 415, 419, 426, 428, 431, 445  
 treatment of mutilated cases in, 435, 436, 439, 445  
 use of intermaxillary anchorage in, 408
- Class II, advantages of early treatment in, 312, 313**  
 beginnings of, 116  
 developing cases of, 55, 92  
 use of Baker anchorage in, 232, 257  
 use of occipital anchorage in, 234, 235
- Class II, Division 1, beginnings of, 116, 449, 459**  
 cases in, complicated by extraction, 481, 484, 488  
 distinguishing characteristics of, 44, 448, 473, 491
- Class II, Division 1, general consideration of, 32, 44, 81, 448, 451, 454, 458, 476, 479, 483, 488, 491**  
 habits accompanying, 108, 109  
 "jumping the bite" in, 499, 501  
 marring of facial lines in. (See Facial Lines)  
 old plan of treatment of, 499, 603, 604  
 "protrusion cases," 57, 189  
 results following reduction of protruding incisors, 137  
 retention of cases of, 456, 462, 473, 500, 501  
 similarity between cases of, 35, 450  
 treatment of cases of, 451, 452, 455, 459, 469, 471, 473, 481, 488, 491  
 use of stationary-intermaxillary anchorage in, 460  
 use of simple-intermaxillary anchorage in, 460
- Class II, Division 1, Subdivision, distinguishing characteristics of, 49, 505**  
 general consideration of, 49, 50, 505, 507, 510  
 habits accompanying, 108, 109  
 intermaxillary retention in, 298, 303  
 marring of facial lines in. (See Facial Lines)  
 old plan of treatment of, 512  
 retention of cases of, 510, 512  
 treatment of cases of, 505, 507, 512
- Class II, Division 2, beginnings of, 116, 117, 516**  
 distinguishing characteristics of, 50, 514  
 general consideration of, 51, 84, 517, 521, 526  
 marring of facial lines in. (See Facial Lines)  
 old plan of treatment of, 516  
 retention of cases of, 521, 524  
 treatment of cases of, 516, 517, 518, 519, 522, 528
- Class II, Division 2, Subdivision, beginnings of, 117**  
 distinguishing characteristics of, 51, 531, 539  
 general consideration of, 85, 532, 535, 539, 542  
 marring of facial lines in. (See Facial Lines)  
 retention of cases of, 534, 539, 546, 549  
 treatment of cases of, 534, 536, 540, 544, 546
- Class III, Division, advantages of early treatment in, 312, 313**



- Class III, Division, appliances for reduction of cases of, 194, 258  
 association of cases of with enlarged tonsils, 550, 553, 555, 556  
 author's operation for reduction of, 563, 572, 578  
 beginnings of, 550  
 developing cases of, 55, 550  
 distinguishing characteristics of, 52, 550, 555  
 general consideration of, 52, 53, 86, 550, 555, 561, 562  
 marring of facial lines in. (See Facial Lines)  
 retention of cases of, 551, 553, 561  
 treatment of cases of, 553, 555, 557  
 use of Baker anchorage in, 232, 235, 258, 557, 561  
 use of intermaxillary retention in, 303  
 use of occipital anchorage in, 234, 235
- Class III, Subdivision, distinguishing characteristics of, 54  
 general consideration of, 565
- Cribs, 225
- D**
- DECIDUOUS teeth, buccal occlusion of lower, 40  
 distal occlusion of lower, 309, 311, 452, 453  
 disuse of, 103  
 effects of extraction of. (See Loss of Teeth)  
 functions of, 90  
 grinding of, 421  
 importance of, 17, 92, 93  
 importance of maintaining space of, 482, 488  
 intermaxillary retention of, 510, 553  
 malocclusion of, 89, 90, 311, 452, 550, 553  
 mechanical influence of, 92, 93  
 mesial occlusion of lower, 553  
 movement of by lengthening wire, 320-323  
 movement of molars, 91, 420  
 normal development of, 89  
 pitted for spurs, 226, 320  
 premature loss of, 92, 375, 384, 404, 434, 484, 488  
 prolonged retention of, 98  
 protruding incisors, 501  
 retention of, 93  
 shortening cusps of, 421  
 treatment of, 320, 322, 323  
 unnecessary movement of, 421
- Deciduous teeth, used as anchor teeth, 226, 323, 507, 534, 553  
 wearing of, 116, 454
- Dental apparatus, abnormal development of, 88, 311  
 component parts of, 89  
 development of after correction of malocclusion, 140, 307  
 disturbance in development of, 81, 111, 114, 115, 305, 306  
 effect on of lingual locking of molars, 414  
 evil effects of extraction upon, 94, 96  
 malocclusion chiefly on one side in Class I, 404  
 normal development of, 8, 12, 73, 88, 91, 305, 454  
 normal growth of, 457, 555  
 types of, 14, 15
- Dental arches, abnormal development of, 91, 92  
 advantages of enlargement of, 367  
 asymmetrical development of, 91, 93, 320, 435, 539  
 changes in sizes and relations of, 441  
 constriction of upper, 384  
 devices for contraction of, 416  
 diminished in size, 29, 75, 335, 351, 386, 404, 431, 436, 542  
 distal occlusion of both lateral halves of lower, 80, 448  
 distal occlusion of one lateral half of lower, 84  
 effect on of force wrongly distributed, 32, 33, 35, 413  
 effect on of lingual locking of upper first permanent molars, 413, 415, 419  
 enlargement of, 335, 340, 375, 407, 432, 491, 545  
 expanding and shortening lateral halves of upper, 251, 401, 459, 478  
 expansion of upper, 21, 245, 247, 334  
 forces maintaining normal width of, 413  
 harmonious as to size, 335  
 harmonizing sizes of through extraction, 419, 512, 516  
 harmony of sizes of dependent on full complement of teeth, 63, 406  
 influence of lower on upper, 29, 31, 338, 361, 413  
 interdependence of, 26-28, 361  
 lengthening of lateral halves of, 247, 254, 404, 435, 436, 488, 600  
 mutual support of, 25, 27, 335



Dental arches, narrowed and lengthened  
upper, 47, 81, 108, 401, 448, 449,  
459  
narrowed in region of canines and  
premolars, 459, 476  
narrowing, 247, 416  
normal development of, 26, 88, 91  
normal form and relations of, 9, 63  
relations of in Class I, 36, 37, 319,  
328, 335, 336, 367  
relations of in Class II, Division 1,  
46, 448, 459  
relations of in Class II, Division 1,  
Subdivision, 49, 84, 505  
relations of in Class II, Division 2,  
50, 514  
relations of in Class II, Division 2,  
Subdivision, 51, 531  
relations of in Class III, Division,  
52, 86, 550  
relations of in Class III, Subdivision,  
54, 565  
retention of, 290, 341, 417, 420, 445  
shortened by extraction, 92, 434, 481,  
484  
shortened, due to malocclusion, 496,  
542  
shortening of, 247, 250, 459  
shortening of after extraction, 383,  
602  
widening of, 341, 351, 388, 415, 519,  
534, 545, 546, 606  
widening of, in region of deciduous  
teeth, 330  
widening of, in region of premolars  
and canines, 251, 341, 534, 545  
widening one lateral half of, 247, 420  
Dental ligament, 132  
Denture. (See Dental Apparatus)  
Diagnosis, 20, 35, 43, 54, 56, 75, 359,  
402, 472

# E

ETIOLOGY of malocclusion. (See Causes)  
Expansion arch. (See also Regulating  
Appliances)  
adjustment of B, 251  
adjustment of E, 236, 240, 241, 245,  
248, 252, 256  
adjustment of for intermaxillary move-  
ment of teeth, 254, 257-260  
attachments, 222  
author's improvements of, 167, 198,  
256  
B used in combination with traction  
screw, 602-604  
bending for fine adjustment of, 241,  
248, 252, 324, 354, 429, 455

Expansion arch, child's size of, 200, 553  
description of B, 190  
description of E plain, 199  
description of E ribbed, 200, 421  
early forms of, 168, 196, 197  
efficiency of, 246, 247, 252, 254, 534  
E used in combination with traction  
screw, 601  
incorrect use of, 262  
introduction of, 168, 195, 196  
notching E ribbed, 246, 249, 330, 355,  
362, 435  
reinforcement of, 261, 262, 420  
to gain buccal spring from, 251, 252,  
341, 429, 523, 546  
to gain lingual spring from, 523, 546  
uses of B, 251, 478, 512, 603

# F

FACE. (See also Facial Lines), art of,  
61, 376  
beauty of, 348  
correct views of in photographs for  
orthodontists, 159  
deformity of, 95, 422  
harmony of proportion of, 74, 328,  
344, 377  
inharmonious balance of, 517  
lack of proper contour of, 386, 389,  
439, 442, 544  
law of balance of, 62, 63, 65, 73, 76,  
79, 85, 86  
proper contouring of, 93, 142  
relation of chin to, 505  
types of, 61, 66, 72, 74, 81, 83, 84  
Facial lines, harmony of, 60, 61, 62,  
64, 66, 72, 81, 93, 366  
Improved from treatment of malocclu-  
sion, 76, 79, 81, 85, 86, 328, 331,  
335, 340, 356, 364, 373, 376, 378,  
382, 388, 389, 392, 398, 404, 412,  
423, 441, 447, 454, 457, 464, 469,  
471, 472, 476, 481, 488, 491, 496,  
502, 505, 510, 512, 521, 525, 530,  
531, 535, 541, 549, 554, 555, 560  
inharmonious from malocclusion, 44,  
60, 74, 79, 87, 311, 449, 489, 543  
law governing inharmonious of, 44, 47,  
50, 81, 404, 450, 506, 528  
law governing balance of, 62, 63, 65,  
73, 76, 79, 85, 86, 319, 464  
marring of from loss of teeth, 71, 74,  
83, 87, 95, 308, 382, 439, 441,  
447, 522  
marring of from malocclusion, Class  
I, 44, 75, 76, 80, 328, 332, 336,  
351, 373-376, 382, 386, 391, 404,  
411, 422, 441, 447



- Facial lines, marring of from malocclusion. Class II, Division 1, 47, 79, 81, 454, 457, 464, 469, 472, 479, 488, 489, 496, 502  
 marring of from malocclusion, Class II, Division 1, Subdivision, 50, 84, 507, 511  
 marring of from malocclusion, Class II, Division 2, 51, 84, 521, 522, 528  
 marring of from malocclusion, Class II, Division 2, Subdivision, 52, 85, 534, 542, 543  
 marring of from malocclusion, Class III, 53, 86, 553, 555, 557, 562  
 permanently marred, 390  
 relation of to normal occlusion, 63, 65, 66, 71  
 Fillings, imperfect, 97, 445, 496  
 Final suggestions, 610-612  
 Force, application of for tooth movement, 224  
     danger of displacing anchor teeth from too great, 193, 356, 427, 431  
     employed in banding teeth, 215  
     exerted from lengthening wire, 208, 225, 226, 320, 323, 373, 435, 604  
     exerted from lip pressure, 375  
     for movement of apex of root, 401  
     for rotation, 363, 364, 476, 591  
     from arch B, 478  
     from arches E, 324, 370, 420, 435, 437, 523  
     from inclined plane, 270, 271  
     from mastication, 412, 415  
     from occipital anchorage, 191, 192, 234  
     from rubber wedges, 322  
     from wire ligatures, 322, 324, 420  
 Intermaxillary, 257, 262, 356, 427, 457, 460, 461, 488, 553  
 Intermaxillary for movement of incisors, 461, 509  
 Irresistible, 247  
 perversion of, 415, 449, 466, 554  
 proper direction of, 225, 256  
 proper distribution of, 174, 193, 256, 412, 413, 417, 449, 514, 516  
 pulling, 183, 185, 195  
 pushing, 183, 185, 195  
 reciprocal, 230, 231, 246, 247, 251, 269, 299, 407, 440, 456, 460, 476, 478, 488, 559, 598, 599  
 rotary, 183, 186, 187, 195  
 wedging, of incisors, 478  
 wrongly directed, 178, 439  
 Forces governing malocclusion, 25, 28, 29, 30, 550, 554, 557  
 Forces governing malocclusion, establishment of, 457  
     influence of, 328, 449, 451, 459  
 Forces governing normal occlusion, 24, 27, 35, 36, 266, 401, 439, 451, 555  
 Frenum labium, abnormal, 103, 104  
     as related to maxillary suture, 104  
     normal, 104  
     section of, 570
- G**
- GAG, 197, 326  
 German silver. (See Regulating Appliances)
- H**
- HEADGEAR, author's, 191  
     introduction of, 189  
     practical uses of, 191-193, 194, 234, 512, 603, 605  
 Heredity, 398, 552, 553
- I**
- IMPRESSIONS, author's method of taking, 145-148  
     made with teeth in occlusion, 432  
     materials for taking, 144, 145  
     proper trays for, 145  
     uniting, 150  
     varnishing, 151  
 Incisors, abnormal inclination of, 528  
     abnormal overbite of, 51, 78, 528, 534  
     combination of movements of, 245, 249, 323, 370  
     depression of, 530  
     difference in positions of in Divisions 1 and 2, Class II, 44  
     effect on of abnormal lip function, 31, 32  
     elevation of, 47, 429  
     eruption of into malpositions, 29  
     extraction of laterals, 95  
     inclination of, 53, 343, 354  
     infra-occlusion of, 43, 108, 423, 426, 427  
     inharmonious of with median line, 445  
     intermaxillary retention of, 303, 432, 510, 553  
     labial movement of, 225, 325, 336, 340, 351, 353, 354, 361, 367, 388, 407, 420, 488, 505, 517, 534, 545, 558, 585, 592  
     lateral movement of, 370, 407  
     lengthened from lack of function, 448, 449  
     lingual displacement of lower, 106, 322, 400, 404



- Impressions, lingual movement of, 137,  
     258, 471, 496, 505, 534  
     making space for with traction screw,  
         592  
     malformed, 100, 162  
     non-development of lateral, 162  
     non-eruption of, 71  
     occlusion of, 10  
     patterns of, 398  
     pronounced malocclusion of, 40, 402  
     protrusion of, 44-46, 81, 107, 108, 250,  
         403, 448, 459, 479, 505  
     protrusion of increased by extraction,  
         95, 481  
     reciprocal rotation of centrals, 230  
     recurrent movement of, 521  
     recurrent tendencies of, 337  
     retention of, 273-278, 284, 295, 332,  
         341, 355, 362, 364, 370, 376, 388,  
         401, 417, 418, 420, 427, 432, 462,  
         521, 524, 535, 549  
     retraction of, 336, 471, 512  
     retrusion of, 46, 50, 51, 403, 533  
     rotation of, 247, 330, 334, 353, 370,  
         400, 407, 420, 534, 593, 594, 595-  
         597, 600, 601, 607  
     separation of upper and lower, 546  
     temporary retention of, 268  
     to shorten upper, 530  
     wedging force of, 478  
 Instruments, 203, 208, 216, 217, 226,  
     240, 320, 373, 435, 591, 604  
 Intermaxillary anchorage. (See Anchor-  
     age)  
 Intermaxillary elastics, 201, 231, 257,  
     259, 427, 428, 429, 432, 455, 456,  
     461, 479, 488, 507, 510, 517, 530,  
     534, 546, 553  
 Intermaxillary retention. (See Incisors;  
     Canines, Molars, Premolars)  
 Interproximal spurs, 282-295
- J**
- JACK-SCREW, adjustment of, 579-581  
     author's improvements of, 184  
     auxiliaries to, 187, 188  
     combined with traction screw, 605  
     combined with levers, 599, 600  
     description of Dwinelle's, 183  
     invention of, 171  
     power derived from, 362  
     supersedence of, 168  
     uses of, 226, 230, 582, 583, 585, 586  
         599, 600, 605  
 Jaws, author's operation for double re-  
     section of lower, 563, 572-578  
 Jaws, effect on of lingual locking of up-  
     per molars, 414, 415  
     establishment of normal relations of,  
         457  
     growth of, 343  
     inharmonious as to size and relations of,  
         562  
     lack of development of, 44  
     "large teeth and small jaws," 342, 398  
     lower distal to normal, 449  
     normal mesio-distal relations of, 40,  
         42, 43  
     overdevelopment of, 563  
     recurrent movement of lower, 505  
     relations of in malocclusion, 367  
     retrusion of lower, 44  
 Jumping the bite, 499, 501, 502
- L**
- LENGTHENING wire for tooth movement,  
     208, 225, 226, 320, 323, 373, 435,  
     604  
 Lever, author's, 187  
     auxiliaries to, 187, 188  
     combined with jack-screw, 599, 600  
     device for movement of apices of roots,  
         400  
     early use of, 186  
     for buccal movement of premolars, 605  
     for double rotation, 595, 597, 598, 607,  
         608  
     for readjustment of teeth, 597  
     for reinforcement of expansion arch,  
         261, 262, 420, 606, 607  
     for single rotation, 593, 594, 595, 600  
     for widening dental arch, 598, 599,  
         606, 607  
     introduction of piano wire for, 172  
     reinforcement of, 594  
 Ligatures, brass wire, adjustment of,  
     242, 245, 330  
     description of author's, 203  
     for elevation of teeth without bands,  
         354, 426, 427  
     for readjustment of teeth, 269, 597  
     for reinforcing anchorage, 584, 594  
     for temporary retention, 268, 269, 331  
     for separating teeth, 238  
     for simultaneous labial movement of  
         canines and premolars, 253, 488  
     for simultaneous labial movement of  
         first and second premolars, 439,  
         461, 528  
     general uses of in treatment, 246, 248,  
         251, 258, 322, 325, 353, 437, 478,  
         517, 599, 601  
     introduction of, 198, 241



- Ligatures, renewal of, 253, 520**  
 soldered to wire G, 244  
 to prevent sliding beneath gums, 353  
 to prevent slipping of, 249, 260, 353, 435  
 to tighten, 243  
 used to gain stationary anchorage with arch, 461  
 used in double resection of mandible, 578  
 used for rotating, with bands and tubes, 230, 607, 608  
 used for spurs on arch, 223  
 used in retention, 275, 279, 290, 291, 408
- Ligatures, fibrous, 241, 242, 584**  
 rubber. (See Intermaxillary Elastics)
- Line of occlusion, definition of, 22**  
 description of, 21  
 elevation of teeth into, 431  
 teeth placed in harmony with, 330, 334, 335, 340, 375, 388, 406
- Lips, abnormal angle between nose and upper, 383-386**  
 abnormal functions of, 31, 32, 46, 448, 459, 480, 496  
 abnormalities of, 376, 377  
 closed with strips of adhesive plaster, 496  
 influence of pressure of, 321, 328, 343, 361, 375, 436, 445  
 necessity of establishing normal functions of, 455, 462, 464  
 necessity of overcoming pernicious habits of, 111, 481  
 normal functions of, 5, 16, 31, 51, 78, 321, 328  
 pernicious habits of, 107, 108, 481  
 retaining devices to prevent biting of, 303, 304, 510
- Loss of Teeth, complications in treatment due to, 512**  
 effect of extraction on facial lines, 74, 83, 87, 95, 308, 382, 439  
 extraction, 3, 55, 63, 74, 87, 93-96, 481, 482  
 extraction of canines, 95  
 extraction of first permanent molars, 94, 265, 390, 436, 437, 439, 445  
 extraction of lateral incisors, 95  
 extraction of premolars, 229, 382, 390, 499, 505, 512  
 inadvisability of extraction, 93, 342, 344, 348, 351, 386, 390, 406, 544  
 maintaining space after, 271-273, 441, 488  
 non-development, 71, 161, 162  
 non-eruption, 161
- Loss of Teeth, premature, of deciduous canines, 37, 375, 384, 404, 434**  
 premature, of deciduous molars, 90-92, 434, 484, 488  
 regaining space after, 308, 437, 439, 445, 482
- M**
- MALOCCLUSION, advantages of early correction of, 419**  
 beginnings of, 37, 115, 320, 398, 414, 449, 459  
 causes of. (See Causes)  
 classification of, 35  
 chiefly confined to incisors and canines, 412  
 complicated by extraction, 95, 96, 481, 488  
 complicated by pernicious habits, 107, 108, 111, 307, 426, 455  
 definition of, 7  
 development of, 29, 115, 140, 375, 398, 414, 449, 450, 517, 555  
 diagnosis of. (See Diagnosis)  
 forces governing. (See Forces Governing Malocclusion)  
 forms of common to all classes, 41, 43, 423  
 including buccal teeth, 412  
 of deciduous teeth, 89, 90, 311, 452, 550, 553  
 prevention of, 375, 436  
 proper age for correction of, 30, 309, 313, 519  
 relation of to disturbed facial lines. (See Facial Lines)  
 seven positions of, 23  
 tabulated classification of, 58  
 time required for treatment, 313, 317
- Mandible. (See also Jaws), abnormal form of, 563**  
 abnormal position of, 563  
 author's operation for reduction of prominent, 563, 572-578  
 diminished in size, 47  
 distal movement of, 559  
 distal position of, 46, 80, 84  
 lateral displacement of, 40, 555  
 normal development of, 469  
 shifting of, 502
- Maxilla. (See Jaws)**
- Median line, 407, 434, 435, 445**
- Models of cases of malocclusion, cabinet for, 157**  
 from impressions of teeth in occlusion, 432  
 plane for trimming, 156  
 pouring, 152



- Models of cases of malocclusion, repair-  
 ing, 152  
 separating, 152  
 "study," 158, 325, 354, 360  
 trimming, 152, 153  
 uses of, 344  
 value of, 158
- Molars, advantages of early adjustment  
 of, 30  
 artificial substitutes for, 265, 436, 437,  
 439  
 as anchor teeth, 325, 329, 352, 356,  
 361, 375, 427, 439, 455, 460, 519,  
 534, 546, 558  
 asymmetrical locking of, 116  
 buccal movement of upper, 137, 246,  
 415, 522, 523, 545  
 buccal occlusion of lower, 40, 42, 429  
 constancy as to correct location of  
 first, 17, 19, 20, 466  
 displacement of, 228, 353, 356  
 distal locking of lower first, 116, 309,  
 449, 454, 459, 516  
 distal movement of in Class I, 436,  
 440  
 distal movement of upper, 257, 258,  
 303, 456, 461, 488, 508, 517, 520,  
 536, 546  
 distal occlusion of lower, 44, 46, 47,  
 49, 51, 433, 449, 482, 484, 491,  
 516, 533, 542  
 effects of extraction of first. (See  
 Loss of Teeth)  
 effect of imperfect fillings in, 97, 445,  
 446  
 first as basis of diagnosis, 20, 55  
 first as key to occlusion, 19, 20, 55  
 grinding of, 429, 433  
 importance of first, 17, 19, 21, 94  
 intermaxillary movement of, 456, 460  
 intermaxillary retention of, 290, 298-  
 301, 303, 376, 456, 462, 471, 473,  
 476, 501, 521, 524, 534, 539, 549,  
 561  
 lengthened through use of bite plate,  
 491, 530  
 lingual movement of upper, 137, 523,  
 545  
 lingual occlusion of upper, 412, 414,  
 419, 422, 429, 431, 522  
 mal-locking of, 154, 414, 518  
 mesial movement of lower, 257, 303,  
 456, 488, 509, 520, 534, 546  
 mesial occlusion of lower, 52, 553,  
 555, 557  
 necessity for moving uppers distally  
 explained, 466-469  
 normal occlusion of, 10, 36
- Molars, normal mesio-distal relations of,  
 42, 43, 49, 328, 335, 336, 350,  
 359, 367, 403, 471, 473  
 reciprocal movement of upper and  
 lower, 488  
 regaining space for lost, 437, 439, 441,  
 445, 488  
 reinforcement of, 353  
 result of movement of anchor teeth,  
 356, 427  
 retaining regained space of, 272, 277,  
 298, 445  
 retention of, 269, 277, 282, 298  
 rotation of, 244  
 supra-occlusion of, 428  
 tipping to upright position, 436, 437,  
 440, 482, 488  
 wedging influence of, 91, 93, 95, 439,  
 442
- Mouth, effect on of extraction, 94  
 effect on of mouth-breathing, 113, 456  
 harmony of balance of, 377  
 inharmony of with other features, 80,  
 81, 84, 472, 517  
 lack of normal contour of, 75, 351,  
 383, 385, 434  
 weakness of, 85
- Mouth-breathing, causes of, 113, 449  
 effects of, 46, 81, 111, 115, 448, 450,  
 491
- Movements of teeth, after death of pulp,  
 139  
 age limit for, 143  
 antagonizing, 266, 274, 278, 284, 285  
 before full formation of root, 139  
 buccal, 135, 137, 246, 248, 251  
 by lengthening wire. (See Lengthen-  
 ing Wire)  
 collectively, 254, 415, 416  
 combinations of, 245, 253, 323, 337,  
 351, 370, 375, 398, 407, 437,  
 439  
 depression, 134, 228  
 distal, 135, 138, 254, 257, 303  
 elevation, 134, 354, 427, 429, 431  
 immediate, 566, 567  
 intermaxillary, 254, 257, 455, 456, 460,  
 486, 505, 509  
 labial, 133, 135, 245, 252, 253, 325  
 lingual, 135, 137, 251  
 mesial, 135, 138, 254, 303  
 one at a time, 420  
 pain incident to. (See Pain in Tooth  
 Movement)  
 physiological laws governing, 134  
 reciprocal, 230, 456  
 rotation, 134, 245, 354  
 singly, 226, 227



Muscular pressure, influence of ab-  
normal, 29, 31, 32, 46, 51, 328,  
554  
influence of normal, 25, 26, 32, 35,  
330, 451, 505

## N

NASAL obstructions. (See Mouth-breath-  
ing)  
Nomenclature, 24  
Nose, abnormal angle of with upper lip,  
383, 385, 386  
effect on of mouth-breathing, 112-114  
effect on of treatment of malocclusion,  
142, 367, 464  
freedom from pathological conditions  
of, 514  
necessity for treatment of, 451, 455  
normally developed, 76  
pathological conditions of, 265, 449,  
510, 511  
treatment of, 464  
undeveloped, 81, 306

## O

OCCCLUSION, after treatment illustrated,  
364, 370, 380, 382, 389, 391, 398,  
404, 411, 412, 421, 423, 429, 432,  
435, 440, 445, 452, 457, 464, 469,  
476, 481, 488, 491, 496, 502, 510,  
512, 517, 521, 525, 531, 535, 539,  
540, 543, 546, 554, 555, 559  
as related to facial art, 63, 64, 65, 79,  
81  
definition of, 7  
details of, 9-11, 343  
development of, 72, 91  
effect of establishment of, 364  
establishment of normal, 338, 341, 455  
forces governing. (See Forces Govern-  
ing Normal Occlusion)  
general consideration of, 7, 8, 12-16  
improved, 513  
key to, 16, 17, 55, 319  
maintenance of, 27, 93  
of deciduous teeth, 17, 89  
"serviceable," 516  
Open bite, 386, 423, 432, 433  
Orthodontia, as a specialty, 4, 5  
as related to facial art, 60, 62  
breadth of, 2, 8  
co-related sciences, 2, 8  
definition of, 7  
soldering required in, 210  
teaching of, 3, 8  
Overbite, 534

## P

PAIN incident to tooth movement, 177,  
256, 267, 268, 310  
Peridental Membrane, blood supply to,  
130  
cells of, 122  
fibers of, 123-130, 135, 363, 432  
functions of, 122  
intelligent manipulation of, 364  
pathological condition of, 265  
resection of fibers of, 568, 569  
structure of, 122  
Periods of activity and rest in tooth  
movement, 315, 316, 387, 398,  
418, 429, 432, 471, 545, 546  
Photographs, 158, 393  
Piano wire. (See Lever)  
Plaster Plane, 156  
Plates, bite, 491, 530  
for retention, 278, 296, 297, 418, 420,  
441  
for retention after "jumping the bite,"  
500  
for securing anchorage, 225, 278, 296,  
297  
introduction of vulcanite, 173  
Kingsley's modification of, 278  
old forms of, 177, 225  
Pliers, author's band-forming, 208, 216  
author's regulating, 208, 226, 320,  
373, 435, 591, 604  
author's soldering, 217  
How's, 208  
Premolars, as anchor teeth, 352, 361,  
439, 461, 471, 520, 528, 558  
buccal movement of, 137, 246, 248,  
251, 370, 476-478  
deflection of, 92  
displacement of, 228  
distal locking of lower, 49, 51, 542  
distal movement of, 257, 461, 478,  
520, 536, 546  
establishment of full normal relations  
of, 404  
for stationary anchorage, 228  
infra-occlusion of, 423, 427  
intermaxillary retention of, 301-303,  
471, 512, 539  
lengthening, 530  
lingual occlusion of, 412, 542  
mesial movement of, 439, 440, 488,  
546  
non development of, 161  
occlusion of, 10  
providing space for, 404  
retention of, 269, 275-277, 282, 298,  
301, 370, 373, 376, 417, 418, 476,  
549



- Premolars, revealed by the X-ray, 484  
 rotation of, 244, 254, 355, 473, 592, 608  
 sacrifice of, 382, 383, 505, 512, 601  
 simultaneous movement of first and canine, 253, 488  
 simultaneous movement of first and second, 439, 461, 528  
 torsal occlusion of, 473  
 used to reinforce anchor teeth, 353
- Pressure, abnormal, 29, 46, 328  
 deficient muscular, 32  
 from expansion arch, 247  
 from regulating appliances, 163  
 from rubber wedges, 253  
 normal muscular, 25, 26  
 of lips, 31, 51  
 of tongue, 32, 35
- Pulps of teeth, 131, 138
- R**
- REGULATING appliances, accustoming patients to the wearing of, 455  
 combination for movement of anterior teeth only, 320, 322  
 combinations of for treatment, Class I, 323, 325, 329, 330, 334, 335, 340, 351, 355, 361, 362, 367, 370, 375, 398, 407, 408, 416, 420, 426, 428, 435, 437, 439, 445  
 combinations of for treatment, Class II, Division 1, 455, 456, 457, 458, 460, 462, 471, 473, 478, 488, 603-605  
 combinations of for treatment, Class II, Division 1, Subdivision, 507, 510, 512  
 combinations of for treatment, Class II, Division 2, 517, 519, 520, 522, 523, 528, 530  
 combinations of for treatment, Class II, Division 2, Subdivision, 534, 539, 546  
 combinations of for treatment, Class III, 553, 558  
 combination for rotation only, 607, 608  
 combination for forcing eruption, 609, 610  
 combinations of for treatment of mutilated cases, 435, 437, 439, 445, 488, 512  
 complex, 174, 175  
 device for movement of apices of roots, 400, 401  
 device for intermaxillary movement of upper canines, 260, 479, 481
- Regulating appliances, early history of, 168, 182, 183  
 first complete system of, 173  
 for contraction of lower arch, 416, 417  
 for forcible eruption of canines, 609  
 for intermaxillary movement of teeth, Class I, 254, 257, 260, 408  
 for making space for movement of incisors, 592  
 for movement of teeth *en masse*, 415, 416  
 for moving teeth of only one lateral half of arch, 420  
 for reciprocal movement of teeth of opposite arches, 455  
 for retraction of canine. (See Canine Teeth)  
 for rotation of premolars, 473, 476, 592  
 for shortening arches after extraction, 603  
 for shortening bite, 491  
 for tipping molars to upright position, 437, 488  
 for treatment of abnormal frenum labium, 572  
 general consideration of, 163-167, 182  
 inspection of, 456, 520  
 lever combination for double rotation, 596, 597, 607, 608  
 lever combination for single rotation, 593, 594, 595, 600  
 materials for construction of, 173, 179, 184  
 miscellaneous combinations of, 598, 599, 600, 603, 605, 606  
 necessary qualifications of, 174-178  
 obsolete forms of, 175, 176, 326  
 to regain space of lost teeth, 439, 445, 482, 488  
 uses of pinched wire. (See Lengthened Wire)  
 used as retaining devices, 323, 325, 417, 429, 456, 520
- Regulating pliers. (See Pliers)
- Retaining devices, adjustment of, 240, 267, 270, 331, 332  
 bands and spurs, 268, 282, 297, 323, 331, 341, 355, 362, 364, 370, 373, 375, 400, 408, 418, 435, 456, 462, 510, 535, 539, 549, 553  
 bands united, 279, 280, 364, 586  
 base wire and interproximal spurs, 283-295, 296  
 base wire and T-bar, 290, 291  
 bridges, 445, 482  
 for holding lips closed, 496



- Retaining devices, for final mechanical retention, 270, 402  
 for maintaining space of missing teeth, 271, 272, 277, 298, 375, 437, 441, 445  
 for maintaining teeth after elevation, 295, 296, 427, 429, 432  
 for protracted retention, 271  
 "gooseneck" device, 272, 375  
 inspection of, 280, 429, 457  
 lengthened section of wire G, 435  
 materials for construction of, 267  
 materials for construction of interproximal, 294  
 materials for making plane and spur, 299  
 necessary qualifications of, 266, 267  
 planes and spurs for intermaxillary, 290, 299-302, 304, 376, 456, 462, 473, 501, 510, 512, 524, 534, 539, 549, 553, 561  
 plates, 278, 296, 297, 298, 341, 420, 441  
 regulating appliances used as, 323, 417, 429, 432, 456, 520  
 skeleton forms of, 298  
 spurs in pits in enamel, 271  
 to overcome habits, 426, 481, 510  
 use of wire ligatures as, 268, 269, 275, 279, 290
- Respiration, effect of perverted function of, 449  
 necessity of establishing normal, 455  
 normal, 514, 532
- Retention, after elevation, 295, 296, 427, 429, 432  
 after "jumping the bite," 499-501  
 after section of frenum labium, 572  
 author's latest method of, 283, 295  
 chief problem in, 408  
 discontinuance of, 432, 433, 555  
 forms of anchorage in, 266  
 general consideration of, 263-266  
 importance of occlusion in, 264-266, 586  
 intermaxillary, of deciduous teeth, 510  
 of canines. (See Canines)  
 of Class I, II and III. (See Classes)  
 of dental arches, 290, 291, 375, 420  
 of incisors. (See Incisors)  
 of lower teeth, 285, 287, 402, 440, 445  
 of molars. (See Molars)  
 of premolars. (See Premolars)  
 of upper teeth, 290, 402, 417, 440  
 permanent mechanical, 270, 332, 402  
 principles of, 263  
 readjustment of teeth after, 373, 521
- Retention, reciprocal, 303  
 temporary, 267-269, 331  
 time necessary for, 264, 265, 373
- Rhinology, as related to orthodontia, 367, 553
- Roots of teeth, adjustment of, 143, 355  
 changes in position of, 137, 142  
 development of alveolar process over, 364  
 displacement of apex of, 23, 138, 400, 413, 449  
 lingual position of apex of, 386, 400  
 movement of apex of, 136, 137, 142, 143, 344, 345, 376, 377, 385
- Rubber, use of in orthodontia, as intermaxillary ligatures. (See Intermaxillary Elastics)  
 elastics used with headgear, 189, 191, 193, 234, 512  
 for buccal movement of teeth, 249, 251, 253, 362  
 for elevation, 277  
 for labial movement of teeth, 322  
 for lingual movement of teeth, 203, 246, 408, 522  
 for rotation, 203, 230, 269, 354, 355  
 in retention, 282, 364, 521, 539  
 introduction of, 172
- S**
- Scissors, 208
- Skiagraphs,  
 illustrations of, 99, 105, 161, 162  
 use of, 100, 484  
 value of, 160
- Sheath hooks, 198, 202, 257, 455, 460, 510, 517, 519, 553
- Soft-soldering, 222, 429
- Solder, 212
- Soldered attachments, to arches, 202, 222  
 to clamp bands, 226, 227  
 to plain bands, 211, 212, 219, 220, 230
- Soldering, author's pliers for, 207  
 author's method of, 211, 217, 220  
 lamp for, 208, 210, 217, 222  
 spurs, 220, 222  
 tubes, 220
- Speech, impairment of from malocclusion, 1, 308, 390, 414
- Study models. (See Models)
- Supernumerary teeth, 99
- Surgery, alveolar section, 567  
 double resection of mandible, 563, 572, 574-578  
 operative for tooth movement, 566, 567, 604



Surgery, removal of bone, 566, 567, 604  
 resection of peridental fibers, 568  
 section of frenum labium, 569

## T

TABULATED classification of malocclusion, 57, 58

Technique work, 220

Teeth, permanent, abnormal inclination of, 343, 376

all on one side used as anchorage, 420

apparent disproportion of to sizes of jaws, 398, 544

appliances for correcting malposed. (See Regulating Appliances)

artificial substitutes for, 96, 168, 265, 307, 308, 437, 439, 482

buccal occlusion of lower, 40, 42, 414, 429

depression of, 248

development of into malocclusion, 29, 30, 40

displacement of anchor, 225, 227, 228, 248, 427

displacement of retained, 270

distal locking of lowers, 46, 50, 85, 539

disuse of, 102

elevation of, 232, 248

extraction of. (See Loss of Teeth)

function of, 7, 93

grinding of, 14, 323, 421, 429, 433

immediate movement of, 566

impaction of, 36, 98

importance of early correction of, 30

importance of full complement of, 63, 307, 406, 516

injuries to from bands, 280-282

interdependence of, 12, 13, 24, 25, 27, 31, 93, 96

lack of full complement of, 307

lingual occlusion of upper, 42, 412, 431, 542

malocclusion of. (See Malocclusion)

models of. (See Models)

movements of. (See Movements of Teeth)

mutual support of, 11, 12, 13, 265

non-development of, 161, 162

normal angle of inclination of, 389

normal development of, 26, 72

normal occlusion of, 9-11, 60

patterns of individual, 14, 75

providing space between for banding, 238

pulps of, 138, 139

Teeth, reciprocal movement of in opposite arches, 230, 257, 456, 488

regaining space for missing, 308, 439, 445, 482

readjustment of after treatment, 194, 269, 277, 282, 364, 373, 479

reciprocal movement of in same arch, 244

relation of alveolar process to, 118

relation of in normal occlusion to facial lines, 63, 64, 74, 86

relation of to line of occlusion, 23

retention of. (See Retention)

self-adjustment of after movement to correct relations, 141, 561

seven malpositions of, 23, 24, 35

space between upper and lower anterior, 423, 546

supernumerary, 99, 100

"third dentitions," 99

transposed, 100, 101

types of, 14, 75

Throat, inflammation of, 555

pathological conditions of, 265, 465, 550, 551, 557

treatment of, 455

Thumb-sucking, 106

Tissue changes incident to tooth movement, 132, 315, 393, 430, 469

Tissue changes subsequent to tooth movement, 140-143, 319, 336, 343, 344, 350, 355, 364, 546

Tongue, abnormalities of, 33

normal influence of, 32, 33

pernicious habits of, 108, 426

restricted space for, 306, 413, 542

Tonsils, enlarged, effects of, 309, 550, 553, 555

removal of, 553

Tooth movement. (See Movements of Teeth)

Traction Bar A, adjustment of, 191

description of, 191

uses of, 191, 193, 512

Traction screw, adjustment of, 227, 587-590

author's, 172, 185, 186

auxiliaries to, 187, 188

combined with arch B, 602-604

combined with arch E, 601

combined with jack-screw, 605

for movement of lateral incisor, 592

for retraction of canines, 227, 512, 590, 591, 601-605

for retention, 278, 476

for rotation, 473, 590, 591, 592


Trays. (See Impressions)

Treatment, advanced age for, 440




- Treatment, advantages of early, 30, 311, 312  
 conservative, 377  
 demands in, 351, 386, 398, 415  
 different periods of, 282, 315, 316  
 difficulties of, 459  
 difficulties of increased by extraction, 482, 512  
 general consideration of, 305-309, 319  
 general effects of, 347  
 ideals in, 308  
 indication of required, 367, 375, 406, 419, 428, 431, 432, 435, 436, 439, 445, 455, 488, 496, 505, 516, 522  
 logical plan of, 451, 455, 460  
 objects to be accomplished in, 307, 534  
 old plan for Class II, Division 1 cases, 499, 512, 516, 603, 604  
 periods of activity and rest in, 315, 316, 387, 398, 418, 429, 432, 471, 545, 546  
 proper age for, 30, 309, 310, 313, 440, 452, 519  
 gaining space for missing teeth, 308, 439, 445, 482  
 time required for, 178, 310, 313, 315  
 Tubes, author's, 187, 400  
 for rotation, 594, 595  
 for general tooth movements, 598, 600, 607, 609  
 introduction of, 173, 184  
 soldering to screws, 287  
 to reinforce anchorage, 582, 583, 591  
 to solder, 220  
 two united, 212, 261, 606  
 united to bands, 211, 271, 273, 279, 435, 583  
 used in retention, 270, 271, 273, 279, 435, 583  
 Types of faces, 61  
 of teeth, 14, 75
- V**
- VARNISHES for impressions, 151  
 Vault of arch, changes in resulting from treatment, 367  
 lower incisors in contact with, 527  
 measurements of, 345  
 narrowed, 413
- W**
- WIRE, iridio-platinum, 294  
 gold, 294  
 Wire cutters, 208, 220  
 Wire G, description of, 187-189  
 device for intermaxillary anchorage, 479  
 for "gooseneck" device, 271, 375  
 for reinforcing anchorage, 303, 583, 584, 585, 591, 593  
 for securing base of jack-screw, 579, 580, 586  
 lengthened by pinching, 208, 225, 226, 320, 323, 373, 435, 604  
 soft-soldered to ligature wire, 244  
 spurs for retention, 269, 272, 274, 276, 332, 341, 355, 362, 370, 375, 401, 408, 420, 462, 535, 549  
 spurs of for tooth movement, 219, 329, 597, 598, 606, 609  
 spurs of set in fillings, 271, 300  
 staples of, 219, 400, 592  
 to solder, 220  
 to support expansion arch, 603  
 used as base wire, 294  
 used in retention, 272, 273, 435  
 used with retaining plate, 298  
 Wire ligatures. (See Ligatures)  
 Wire, piano. (See Lever)  
 Wrenches, 189, 208
- X**
- X-RAY. (See Skiagraphs)

THE END.







GLASGOW  
UNIVERSITY  
LIBRARY:



