

Irregularities of the teeth and their treatment / by Eugene S. Talbot.

Contributors

Talbot, Eugene S. 1847-1924.
University of Glasgow. Library

Publication/Creation

Philadelphia, Pa. : P. Blakiston, Son & Co., 1888.

Persistent URL

<https://wellcomecollection.org/works/gf2gkuxv>

Provider

University of Glasgow

License and attribution

This material has been provided by This material has been provided by The University of Glasgow Library. The original may be consulted at The University of Glasgow Library. where the originals may be consulted. This work has been identified as being free of known restrictions under copyright law, including all related and neighbouring rights and is being made available under the Creative Commons, Public Domain Mark.

You can copy, modify, distribute and perform the work, even for commercial purposes, without asking permission.



Wellcome Collection
183 Euston Road
London NW1 2BE UK
T +44 (0)20 7611 8722
E library@wellcomecollection.org
<https://wellcomecollection.org>

Dent BL
Archives

107/6
Edinh
hospita



UNIVERSITY
of
GLASGOW

James Ireland
Memorial Library

Dent BL
Archives



30114012582444



100

100

100



IRREGULARITIES OF THE TEETH,
AND
THEIR TREATMENT.





IRREGULARITIES OF THE TEETH,

AND

THEIR TREATMENT.

BY

EUGENE S. TALBOT, M.D., D.D.S.,

PROFESSOR OF DENTAL SURGERY IN THE WOMAN'S MEDICAL COLLEGE; LECTURER ON DENTAL
PATHOLOGY AND SURGERY IN RUSH MEDICAL COLLEGE, CHICAGO.

WITH 152 ILLUSTRATIONS.

PHILADELPHIA:
P. BLAKISTON, SON & CO.,
1012 WALNUT STREET.
1888.

Entered according to Act of Congress, in the year 1887, by
EUGENE S. TALBOT,
In the Office of the Librarian of Congress, at Washington, D. C.

TO MY
TEACHER AND FRIEND,
WALTER S. HAINES, M.D.,
PROFESSOR OF CHEMISTRY, RUSH MEDICAL COLLEGE, CHICAGO.
THIS VOLUME
IS RESPECTFULLY DEDICATED.



ERRATA.

Page 157.—“ Dr. Magill’s Retainer ” should read, “ Dr. Guilford’s Retainer.”

Cuts Nos. 6, 19, 49 and 50 should be credited to Dr. John J. R. Patrick, *Illinois State Dental Society Transactions of 1884.*



PREFACE.

In presenting to the profession a work upon the irregularities of the teeth, the author has endeavored to keep in view the marked progress that has been made in this department of dental science within the past few years. This treatise is intended to embrace all that is necessary to a clear and practical understanding of the etiology and treatment of dental irregularities. Our knowledge of the etiology of the various deformities of the teeth has hardly kept pace with the marked advancement in the methods for their correction, and this fact has induced the author to devote considerable attention to the causes of such conditions, while due consideration has been given to the methods of treatment. No pretense has been made to cyclopædic fulness, inasmuch as it is believed that practicableness and conciseness in a scientific work are preferred by the profession to verbosity and minuteness of detail.

In that portion of the work devoted to descriptive anatomy and to physiology, attention is given to those tissues only that are immediately involved in the study and correction of irregularities. Each subject is considered in the order in which it would naturally present itself to the mind of the operator while the patient is before him, this clinical character being deemed by far the best for a work of this kind. In the treatment of irregularities, mechanical laws are illustrated and applied in the simplest manner possible, each law being applied practically to a case of irregularity; this method

being apparently the best to impress the principal features of the operative treatment of irregularities upon the mind of the student. It would be obviously impossible, as well as useless, to illustrate every position in which a wedge, screw, lever or spring may be applied ; but the author has endeavored to represent, in each illustration, a principle or law so clearly that the student will be able to exemplify each principle in a variety of ways. Although a delicate subject, the matter of fees is necessarily a *terra incognita* to the student, and as such, is believed by the author to be a matter of great importance to both patient and operator.

The author has endeavored to give due credit to those workers in the field of orthodontia that have contributed to its advancement, and if any injustice has been done it has been unintentional. The author desires to acknowledge his indebtedness to Drs. G. Frank Lydston, W. W. Allport, and C. Stoddard Smith for valuable suggestions, and also to the S. S. White Dental Manufacturing Company for the use of many woodcuts.

EUGENE S. TALBOT.

125 STATE ST., CHICAGO,
December, 1887.

CONTENTS.

PART I.—ANATOMY.

CHAPTER I.

	PAGE
THE SUPERIOR MAXILLÆ,	9
THE INFERIOR MAXILLA,	14
THE SUPERIOR ALVEOLAR PROCESS,	17
THE INFERIOR ALVEOLAR PROCESS,	18
ANATOMY AND PHYSIOLOGY OF THE TEETH,	20
DESCRIPTION OF THE TEETH,	21
THE TEMPORARY TEETH,	25

CHAPTER II.

OCCCLUSION OF THE TEETH,	27
THE CROWNS AND ROOTS,	29
TEETH IN POSITION IN THE MAXILLÆ,	29

CHAPTER III.

ETIOLOGY OF IRREGULARITIES,	31
IRREGULARITIES OF THE TEMPORARY TEETH,	31
IRREGULARITIES IN THE SIZE OF THE PERMANENT TEETH,	33
IRREGULARITIES IN THE NUMBER OF THE PERMANENT TEETH,	34
IRREGULARITIES IN THE ARRANGEMENT OF THE PERMANENT TEETH,	36

CHAPTER IV.

ACQUIRED IRREGULARITIES,	40
THE CENTRAL INCISORS,	42
THE LATERAL INCISORS,	43
THE CUSPID TEETH,	43

HEREDITY IN ITS RELATIONS TO IRREGULARITIES,	PAGE 45
ARRESTED MAXILLARY DEVELOPMENT AS A CAUSE OF IRREGU- LARITIES,	50
THE V-SHAPED ARCH,	51
THE SADDLE-SHAPED JAW,	56
IRREGULARITIES CAUSED BY PROLONGED RETENTION OF THE TEMPORARY TEETH,	58

CHAPTER V.

IRREGULARITIES CAUSED BY TOO EARLY EXTRACTION OF THE TEM- PORARY TEETH,	62
FAILURE OF ANTERIOR OCCLUSION,	65
PROTRUSION OF THE UPPER JAW,	65
PROTRUSION OF THE LOWER JAW,	68
IRREGULARITIES OF THE TEETH OF IDIOTS,	68

PART II.—TREATMENT.

CHAPTER I.

THE PROPER PERIOD FOR REGULATING,	72
PHYSIOLOGICAL AND PATHOLOGICAL CHANGES,	75
EXAMINATION OF THE TEETH,	78
DECAY OF THE TEETH,	78
OCCLUSION,	79
FEES,	80

CHAPTER II.

IMPRESSIONS OF THE MOUTH, AND MODELS,	82
STUDY OF THE MODELS,	88
APPLICATION OF FORCE,	93

CHAPTER III.

MECHANICAL FORCES,	97
THE LEVER,	97
PULLEY, WHEEL AND AXLE,	99
THE INCLINED PLANE,	100
THE SCREW,	101

CONTENTS.

xi

	PAGE
THE WEDGE,	104
ELASTIC FORCE,	107
LIGATURES,	111
ELASTICITY OF METALS,	112

CHAPTER IV.

CONSIDERATION OF THE DIFFERENT METHODS,	113
PATRICK'S METHOD,	113
FARRAR'S "	114
BYRNES' "	116
COFFIN'S "	121
AUTHOR'S "	126
PIANO-WIRE,	125
SPREADING THE DENTAL ARCH,	128
REGULATING INDIVIDUAL TEETH,	131

CHAPTER V.

TREATMENT OF SPECIAL FORMS OF IRREGULARITIES,	135
ROTATING TEETH IN THEIR SOCKETS,	135
THE FARRAR METHOD,	135
GUILFORD'S "	138
THE AUTHOR'S "	139
MOVING CROWNS AND ROOTS,	140
FORCED ERUPTION OF THE TEETH,	142
THE MATTESON METHOD,	142
THE AUTHOR'S "	143

CHAPTER VI.

PROTRUDING TEETH, KINGSLEY'S,	145
" " FARRAR'S,	148
PROTRUSION OF THE INFERIOR MAXILLA,	152
ALLAN'S CASE,	152
METHODS OF RETENTION OF THE TEETH AFTER REGULATING,	153
KINGSLEY'S RETAINERS,	154
RICHARDSON'S "	155
RUBBER PLATES WITH GOLD BANDS AND BARS,	156
FARRAR'S RETAINERS,	157
MAGILL'S "	157
THE AUTHOR'S "	159
LENGTH OF TIME REQUIRED TO RETAIN THE TEETH IN PLACE,	159



IRREGULARITIES

OF

THE TEETH.

PART I—ANATOMY.

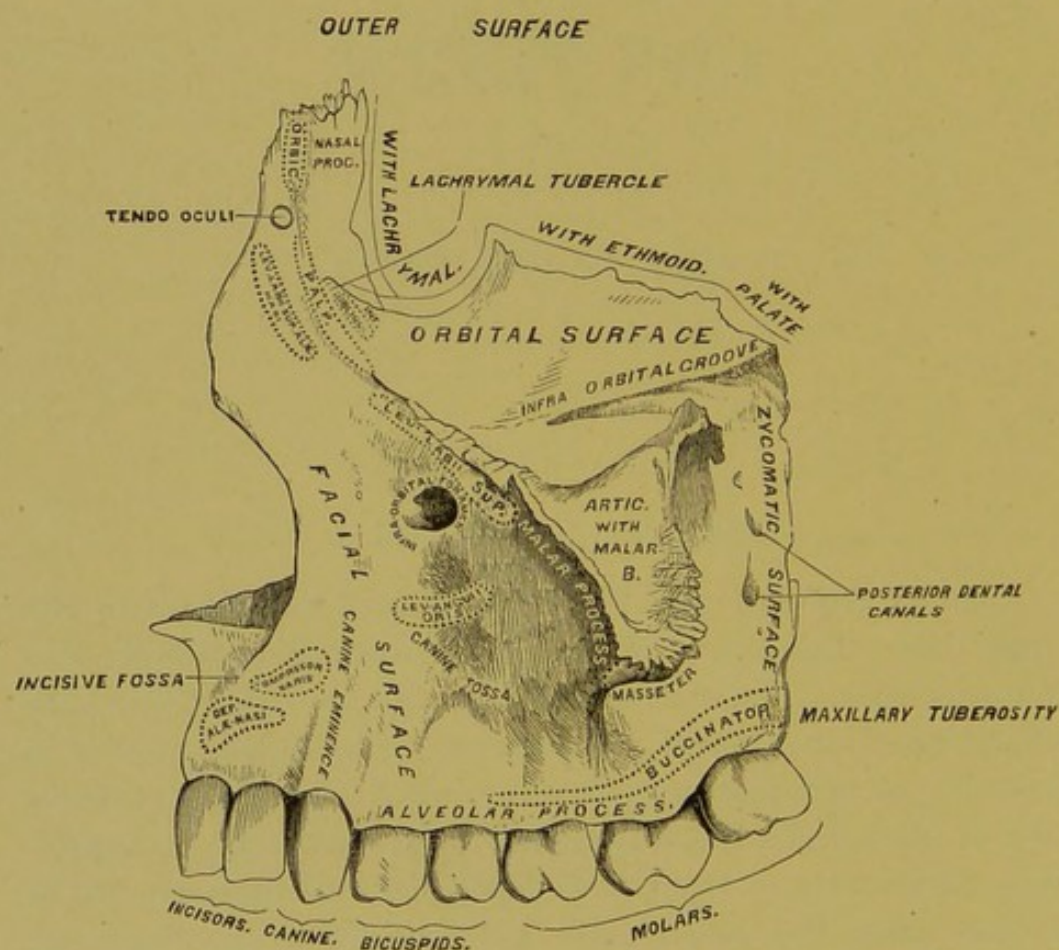
CHAPTER I.

THE SUPERIOR MAXILLÆ.

The two superior maxillary bones form the whole of the upper jaw. Each bone presents for examination a body and four processes. The body, containing the Antrum Highmorianum, has four surfaces: an external or facial, an internal, a posterior or zygomatic, and a superior or orbital. The direction of the facial surface is forward and outward. A depression, the incisive or myrtiform fossa, situated upon the facial surface above the incisor teeth, gives origin to the depressor alæ nasi muscle, the compressor nasi arising external to and a little above it. The canine fossa, situated external to the incisive fossa and separated from it by the canine eminence, is deeper and longer than the latter, and gives origin to the levator anguli oris. Above this fossa is the infra-orbital foramen, transmitting the infra-orbital nerve and artery, and above this the lower margin of the orbit, which gives partial attachment to the levator labii superioris proprius (Fig. 1).

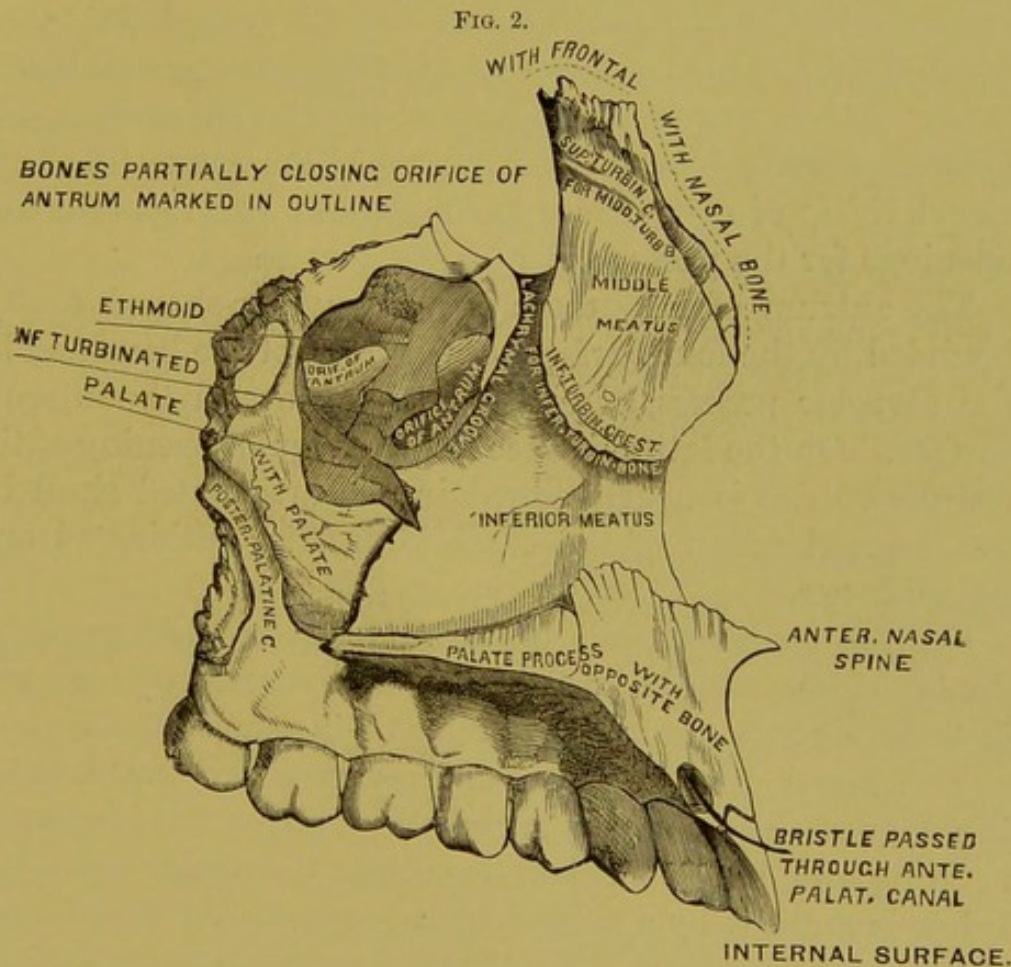
The posterior surface looks backward and outward and forms part of the zygomatic fossa. About its centre are seen the openings of the posterior dental canals, which transmit the posterior dental vessels and nerves. At the lower part of this surface is the maxillary tuberosity, a rounded eminence of bone, especially prominent after the eruption of the wisdom teeth, articulating on the inner side with the tuber-

FIG. 1.



osity of the palate bone. The superior or orbital surface, smooth and triangular, forms part of the floor of the orbit. Internally, it is bounded from in front backward by the lachrymal bone, the os planum of the ethmoid, and the orbital process of the palate bone. Externally, it has a rounded margin, which enters into the formation of the speno-maxillary fissure, and in front it is bounded by a part of the

orbit. Commencing near the middle of the outer border of this surface, and passing forward, is the infra-orbital groove, terminating in a canal, which subdivides into two branches, the infra-orbital, opening just below the margin of the orbit, and the anterior dental canal, which runs into the anterior wall of the antrum and transmits the anterior dental vessels and nerves. The inferior oblique muscle of the eye arises from the anterior and internal part of the surface (Fig. 2).



The internal surface forms a part of the cavity of the mouth and a part of the outer wall of the nose, the two parts being separated by the palatal process. The superior division presents the opening leading into the antrum of Highmore. At the upper border of this opening are several irregular cavities closed in by the ethmoid and lachrymal bones. Commencing near the middle of the posterior border of this sur-

face, and running downward and forward, is a groove, converted into a canal (the posterior palatine) by the articulation of this portion of the bone with the vertical plate of the palate. Below the opening is a concavity forming a part of the inferior meatus of the nose. It is traversed by the maxillary fissure, which receives the maxillary process of the palate bone. A deep groove, converted into a canal by the articulation of the lachrymal and inferior turbinated bones, is situated in front of the opening of the antrum. It is called the lachrymal or nasal duct. Anterior to this is the inferior turbinated crest, which articulates with the inferior turbinated bone. Above this crest is a part of the middle meatus, and below it a part of the inferior meatus of the nose. The inferior division of this surface is rough, and has several small openings for the passage of nutrient vessels.

The antrum of Highmore is a triangular-shaped cavity, bounded by the four surfaces of the body of the bone and by the alveolar process, and with its base toward the internal surface. On the latter surface is the irregular opening of the antrum, which is nearly closed in the articulated skull by the approximation of the ethmoid, inferior turbinated and palate bones.

On the posterior wall of the antrum are the posterior dental canals, and on its floor are seen several conical projections, corresponding to the roots of the molar teeth.

The Malar Process is a rough eminence situated at the junction of the facial and zygomatic surfaces. It is concave in front and behind, articulates above the malar bone, and below is marked by a ridge which separates the facial from the zygomatic surface. The Nasal Process is situated at the side of the nose and extends upward, inward and backward. Its external surface is smooth and concave, and gives attachment to the levator labii superioris alæque nasi, the orbicularis palpebrarum and tendo-oculi muscles, and is perforated by several foramina. The internal surface articulates above with the frontal, and has a rough surface, which closes in the anterior ethmoid cells; below this are seen, from

above downward, the following points of interest: the superior turbinated crest, a part of the middle meatus of the nose, the inferior turbinated crest, and a part of the inferior meatus.

The anterior border is directed obliquely downward and forward, and articulates with the nasal bone; the posterior border presents a groove for the lachrymal duct, and has two margins, the inner articulating with the lachrymal bone, and the outer forming a part of the circumference of the orbit.

The Palatal Process projects inward from the internal surface of the bone.

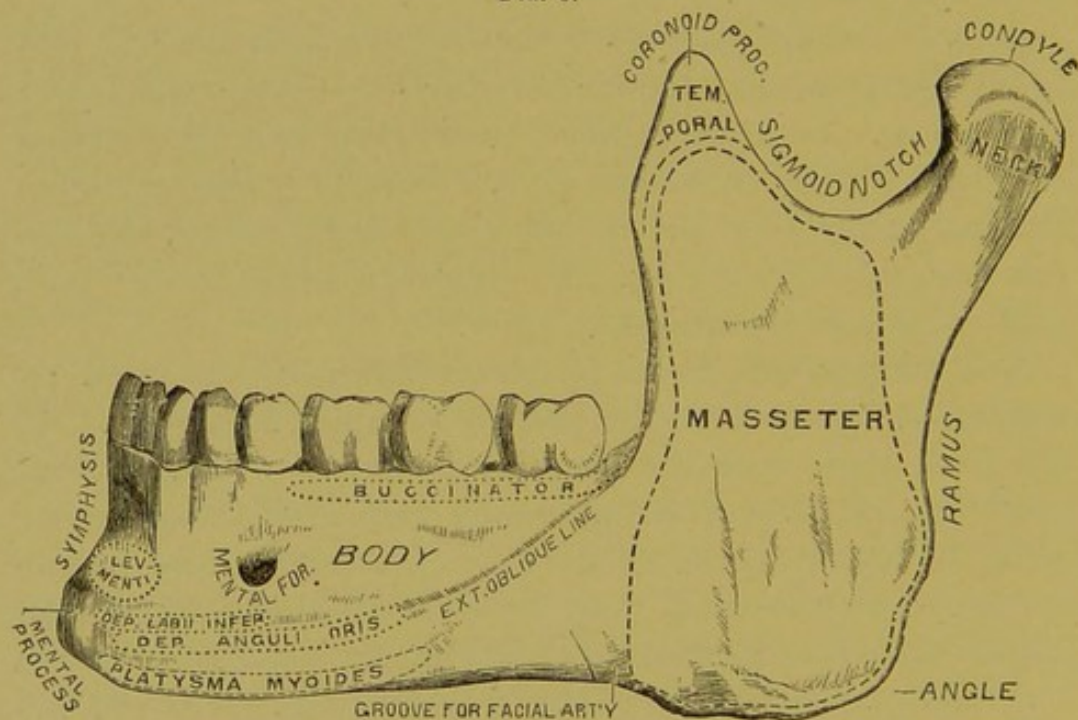
It is a strong process, thicker in front than behind, and forms a large part of the roof of the mouth and of the floor of the nose. Its upper surface, smooth and conical, presents in front the upper orifice of the anterior palatine canal, situated just behind the incisor teeth and transmitting the anterior palatine vessels. The naso-palatine nerves pass through the inter-maxillary suture.

The inferior surface, rough and uneven, is perforated by numerous foramina for the passage of nutrient vessels. At the back part, near the alveolar border, is a longitudinal groove (sometimes a canal), which transmits the posterior palatine vessels and large nerves. The lower orifice of the anterior palatine canal may be seen on this surface. In some bones may be seen a delicate suture, which marks out the inter-maxillary bone; this comprises that portion of the upper jaw which contains the incisor teeth. The outer border of this process unites with the body of the bone. The inner border unites with the bone of the opposite side, and the two form a groove on the upper surface for the reception of the vomer. The anterior border is prolonged forward internally to form the anterior nasal spine. The posterior border articulates with the horizontal plate of the palate bone.

THE INFERIOR MAXILLA.

The inferior maxillary bone (Fig. 3) consists of a body and two rami. The body is horizontal, and curved like a horse-shoe, and presents for examination two surfaces and two borders. The external surface, convex from side to side, presents in its median line a vertical ridge, the symphysis, which indicates the junction of the two pieces of which the bone consists in early life; this ridge terminates below in an eminence—the mental process. Just external to the symphysis, and below the incisor teeth, is the incisive fossa, for

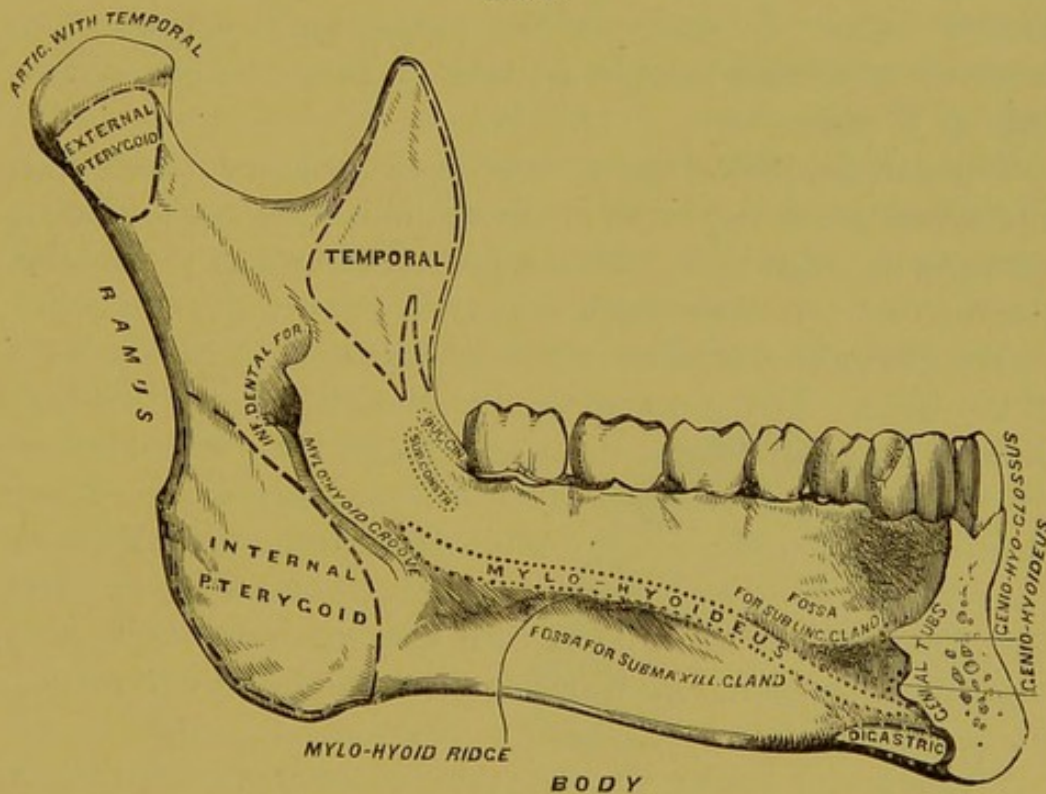
FIG. 3.



the attachment of the levator menti muscle. External to this, and just below the second bicuspid tooth, is the mental foramen, through which pass the mental nerves and artery. Extending outward from the base of the mental process is the external oblique line, at first nearly horizontal, but afterward inclining upward and backward. It is continuous with the anterior border of the ramus, and affords attachment to the depressor labii inferioris and depressor anguli oris, the platysma myoides being inserted below it. The internal

surface (Fig. 4) presents on each side of the median line and just below the centre of the bone, two tubercles called the genial tubercles. The upper pair gives attachment to the genio-hyoglossi muscles, and the lower pair to the genio-hyoidei muscles. External to the genial tubercles is an oval depression for the reception of the sublingual gland. The anterior belly of the digastric muscle is attached to a rough depression below the sublingual fossa. The internal oblique line commences at the back part of the sublingual fossa. It

FIG. 4.



is especially prominent opposite the last two molars, and affords attachment throughout its entire length to the mylohyoid muscle. The superior constrictor of the pharynx is attached to the alveolar margin of this surface near the last molar teeth. Below the ridge is an oblong depression, the submaxillary fossa, for the reception of the submaxillary gland. The inferior border of the body is rounded, and at its junction with the ramus presents a shallow groove, over

which the facial artery turns. Each of the perpendicular portions or rami presents for examination two surfaces, four borders and two processes. The external surface is flat and gives attachment to the masseter muscle. The internal surface presents near its centre the opening of the inferior dental canal.

On the posterior margin of this aperture is a prominent ridge, to which is attached the internal lateral ligament of the lower jaw. At the lower and back part of the opening is a notch leading into a groove (the mylo-hyoidean), which runs downward and forward to the submaxillary fossa. This groove lodges the mylo-hyoidean vessels and nerves. The internal pterygoid muscle is inserted into a rough surface behind this groove.

The inferior dental canal runs downward and forward, in the substance of the bone, as far as the incisor teeth, when it turns to communicate with the mental foramen; it contains the inferior dental vessels and nerves.

The lower border of the ramus is continuous with the body of the bone. The junction of the inferior and posterior borders of the ramus forms the angle of the jaw; it is marked by rough ridges on both sides, the masseter muscle being attached externally, the internal pterygoid internally, and the stylo-maxillary ligament between the two muscles. The anterior border is continuous with the external oblique line. The posterior border is thickened, rounded and covered by the parotid gland.

The superior border presents two processes, an anterior or coronoid and a posterior or condyloid. The coronoid process is a thin, triangular eminence of bone, which gives attachment on either side to the temporal muscle. On the internal surface is the commencement of a ridge which extends to the posterior part of the alveolar process. On the outer side of this ridge is a deep groove, which, with the ridge, gives attachment above to the temporal and below to the buccinator muscle.

The condyloid process consists of two portions, the condyle

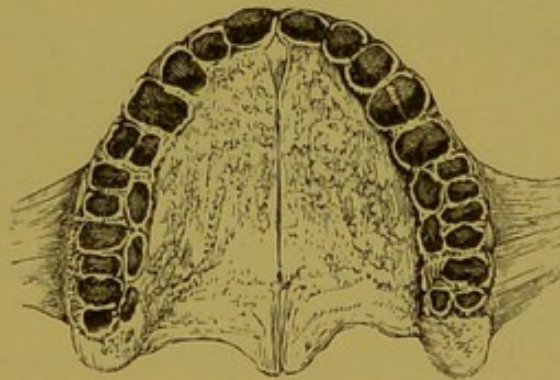
and neck. The long axis of the condyle is transverse, and the outer extremity is a little higher than the inner. It is oblong in form, the articular surface extending farther on the posterior than on the inferior surface. The neck presents externally a tubercle for the attachment of the external lateral ligament. The anterior surface is concave, and has attached to it the external pterygoid muscle. The posterior surface is curved.

THE SUPERIOR ALVEOLAR PROCESS.

The alveolar processes comprise the larger part of the lower borders of the superior maxillæ and the upper border of the inferior maxilla. The alveolar process of each superior maxilla includes the tuberosity, and extends as far forward as the median line of the bone, when it articulates with the process upon the opposite side. It is narrow in front, and gradually enlarges until it reaches the tuberosity, where it becomes rounded upon itself.

If we examine the two articulated superior maxillary bones (Fig. 5), we see that the anterior part is curved, while the posterior part gradually diverges from the central line of ossification of the maxillary bones. The shape varies in different individuals. Some arches are small and others large; the arch is parabolic in some cases and circular in others.

FIG. 5.



The process is composed of two plates of bones, an outer and an inner, which are united at intervals by septa of cancellous tissue. These form the alveoli for the reception of the roots of the teeth. The outer plate is thinner than the inner. In some cases the buccal surfaces of the roots of healthy teeth extend nearly or quite through the outer bony plate.

This plate is continuous with the facial and zygomatic surfaces of the maxillary bone. The inner plate is thicker and stronger than the outer, and is fortified by the palate bones. The external plate is irregular upon the outer surface, prominent over the roots of the teeth, and depressed between the roots or interspaces.

The prominence over the canine teeth, called the canine eminence, is very marked, and decidedly modifies the expression of the face. The sockets of the central incisors are conical and round, those of the lateral incisors conical and slightly flattened upon their mesial and distal surfaces, and not so large as the central sockets.

The pit for the cuspid is conical and much larger than any of the other sockets. The sockets for the bicuspid are flattened upon their anterior and posterior surfaces, and near the apex they are frequently bifurcated. The sockets of the molars are large at the openings, but at about the middle of their length they are divided into three smaller sockets for the reception of the roots. In the case of the third molar the number of sockets ranges from one large cavity to three or four of smaller size.

THE INFERIOR ALVEOLAR PROCESS.

The alveolar process of the inferior maxilla extends from the ramus of one side to the same point on the other. The outline is similar to that of the superior process, the anterior portion being much thinner.

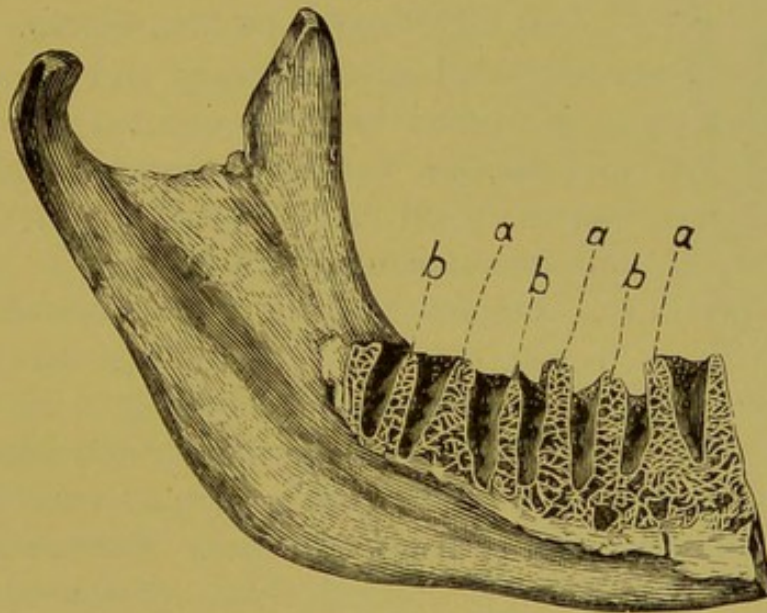
The description given of the structure of the superior process will also apply to the inferior. The outer plate of bone opposite to the molars and bicuspid is thicker than the inner plate, while the inner plate opposite the canines and incisors is thicker than the outer.

The alveoli are arranged along the border of the bone for the reception of the roots of the teeth. They correspond in form to the roots which they accommodate. The alveoli for the central incisors are smaller than those for the lateral. They are conical in shape, and flattened upon their mesial

and distal surfaces. Those for the lateral incisors are larger, and compressed on their mesial and distal surfaces. The sockets for the canines (cuspid, or stomach teeth) are larger, deeper and less compressed than those for the incisors.

The sockets of the bicuspid are considerably flattened upon their lateral surfaces, and are sometimes divided into two cavities. The sockets for the anterior roots of the molars are broad and flattened laterally, while those for the posterior roots are round. The third molar, being naturally of variable form, has sometimes one pit, and again three or four. Each alveolar pit or socket is divided from its

FIG. 6.



neighbor by a small wall or septum, which is made up of cancellated bone, extending about one-eighth of an inch above the inner and outer plate.

The dental septa assist in keeping the teeth firmly in their places.

Fig. 6 illustrates an internal, lateral section of the lower jaw, showing the relation of the alveoli and the septa—*a, a, a*, dental septa—*b, b, b*, dental root septa. It will be observed that the septa are very thin at the margin, and gradually increase in width to the middle of the jaw, where they

become thicker, and are finally lost in the substance of the jaw. Some septa are thicker than others, and where two teeth are widely separated, the width of the septa naturally corresponds to the space between the teeth.

The sockets are lined with a thin plate of compact bony substance, extending from the outer and inner plate of the alveolar process to the apex, where there are small openings for the entrance of nerve and blood vessels for the nourishment of the teeth.

This bony plate has upon its inner surface the elastic periodental membrane, which acts as a cushion for the teeth, while upon the inner surface it is surrounded by spongy bone.

ANATOMY AND PHYSIOLOGY OF THE TEETH.

The Teeth are classified as temporary and permanent. The former term is applied to those erupted in infancy, which are small and delicate, to meet the requirements of the child. The permanent teeth are of a larger and stronger growth, to meet the demands of adult age.

The Temporary, deciduous or milk set consists of twenty teeth, ten in each maxilla, viz.: two central incisors, two lateral incisors, two cuspids and four molars.

The Second or permanent teeth number 32, sixteen in each maxilla, viz.: two central incisors, two lateral incisors, two cuspids, four bicuspids and six molars. For convenience of description a tooth is divided into a crown—that part which is exposed in the mouth—a root or roots, situated in the alveolar process, and a neck, the part connecting the crown with the root. It is also divided, according to the tissues of which it is composed, into the enamel, dentine, cementum, and pulp.

The Enamel (Fig. 7, A) is the hardest structure of the human body. It forms a smooth, dense, external layer on the teeth, and serves as a cap or covering to preserve the dentine of the crown; it is thickest at the cutting and grinding edges of the tooth, and gradually diminishes in thickness until it reaches the neck, where it disappears.

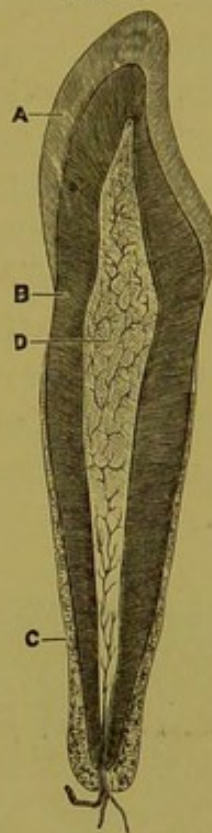
It is nearly inorganic in structure, containing but from one to three per cent. of animal matter.

The Dentine (B), which constitutes the largest part of the tooth and gives it its shape, is an ivory-like substance composed of tubuli surrounding a cavity called the pulp chamber.

The dentine is in many cases very sensitive. Its surface is entirely covered by enamel and cementum. The latter forms the osseous covering of the root portion of the dentine, being thickest at the apex and gradually thinning out toward the neck of the tooth (c). It is a bony substance, receiving its nourishment through the peridental membrane, which latter also nourishes the dentine through the structure of the cementum.

Occupying the chamber in the crown, and the canals in each of the roots of the teeth, is the pulp (D), consisting of a mucoid, gelatinous mass permeated by blood-vessels and nerves, which nourish the dentine. The peridental membrane covers the root of the tooth, and together with the periosteum forms a cushion between the alveolar process and the root of the tooth, thus preventing irritation to the parts during mastication. It is very vascular, and sends numerous blood-vessels into the cementum for the nourishment of the tooth.

FIG. 7.



DESCRIPTION OF THE TEETH.

For convenience of reference the different surfaces of the crowns of the teeth are designated as follows:—

1st. The labial, signifying the surface nearest the lips. (This applies only to the six anterior teeth.)

2d. The buccal, the part nearest the cheek and the buccinator muscle.

3d. The palatine, the surface of the upper teeth next to the hard palate.

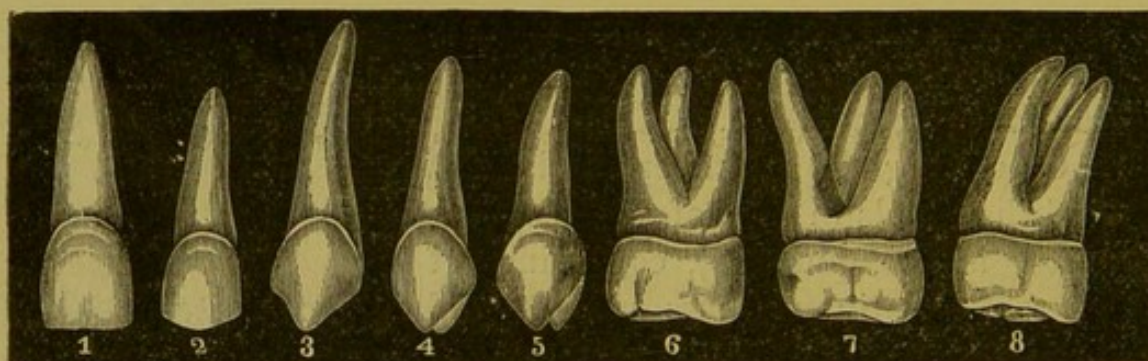
4th. The lingual, or that part of the lower tooth nearest the tongue.

5th. The anterior and posterior in the bicuspid and molars, the mesial and distal surfaces in the case of the six anterior teeth.

6th. The cutting edges of the incisors and cuspids and the grinding surfaces of the bicuspid and molars.

The incisors (Fig. 8, Nos. 1 and 2) are so called from the Latin word *incido* (to cut), their sharp edges fitting them for cutting off such portions of food as may be required for mastication. They act on the same principle as a pair of shears. They

FIG. 8.



are classed as Central and Lateral, the central incisors being the larger. Both are concave on their lingual surfaces and convex on their labial; they are broader at the cutting edge than at the neck.

The Left central is distinguished from the right by the mesial angle being a right angle, while the distal angle is slightly rounded. The root, when normal, is straight, round and conical. Occasionally it is slightly flattened upon its mesial and distal surfaces, and is frequently bent at the end, the apex being directed toward the lateral. The roots of the laterals are shorter, and have about two-thirds the diameter of the centrals.

The Canine teeth (Fig. 8, No. 3), or cuspids, are so called

from the Latin *cuspis* (a spear), because they terminate in a point adapted to the purpose of seizing and tearing flesh. They are convex upon the labial surface and slightly concave upon the lingual. The canines of the opposite sides are distinguished by the mesial angles being shorter than the distal, thus directing the tooth toward the median line.

Each cuspid tooth has a single conical root, sometimes round and sometimes flattened, always larger than the roots of the other teeth and occasionally bent and inclined toward the posterior tooth.

The Bicuspids (Fig. 8, Nos. 4 and 5) are so called from their peculiar shape (*bis*, two, and *cuspis*, a spear). The two-spear or bicuspid teeth are known as the first and second bicuspids. The crowns are rounded, and a groove through the centre divides the grinding surface into two cusps, the outer being the longer. The angles differ in length, the anterior being shorter than the posterior, thus indicating the side of the mesial line to which the tooth belongs. Their roots are flattened upon the anterior and posterior surfaces, and frequently there is but one root, with a groove extending its entire length. Owing to the close resemblance between the crowns of the first and second bicuspids, it is difficult to distinguish them except in the mouth.

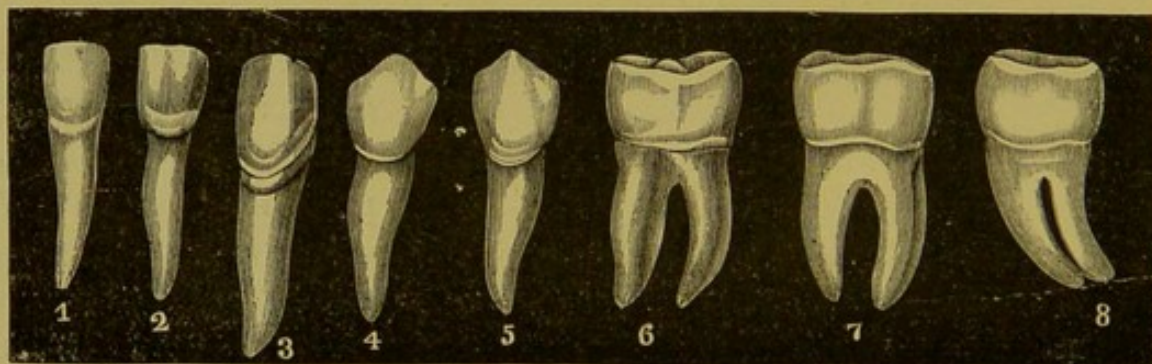
The Molars (Fig. 8, Nos. 6, 7 and 8) (from *moleri*, to grind) are three in number, viz.: first, second and third. The crowns are cuboidal in shape, with from three to five tubercles or cusps, separated by grooves. The crown of the first molar is the largest. The upper molars have three roots, one upon the inner surface, called the palatine root, which is conical in shape, very long and round, and two upon the buccal surface, an anterior and posterior. The anterior buccal root is flattened upon the anterior and posterior surfaces, and is larger than the posterior. The roots diverge, the palatine being the less prominent, which makes it very easy to locate the tooth as belonging upon either the right or left side of the mouth. Frequently the roots of the third

molar unite, forming a single root, slightly curved toward the buccal surface of the jaw.

The lower Incisors (Fig. 9, Nos. 1 and 2) are not so large as the superior incisors. The labial and lingual surfaces are straighter than the corresponding surfaces of the superior incisors, while the mesial and distal angles are both right angles. The laterals are broader than the centrals, which is just the reverse of the superior incisors, and the roots are single, conical, flattened upon their mesial and distal surfaces, and grooved longitudinally.

The Cuspids (No. 3) are slightly convex upon their labial surfaces and somewhat concave upon the lingual surfaces, their crowns terminating in a point. Each of them has a

FIG. 9.



single root, which is longer than any of the roots of the inferior teeth, conical in shape, but slightly flattened upon the mesial and distal sides, and inclined toward the first bicuspid.

The Bicuspids (Nos. 4 and 5), two in number—a first and second—are situated posterior to the cuspids; they have round crowns, which are rather concave upon their grinding surfaces, and a groove running through the centre divides the crown into two parts, a buccal and a lingual cusp. Unlike the superior bicuspids, the outer cusp is the larger and resembles the cuspid tooth, while the lingual cusp is small, being sometimes scarcely developed.

The second bicuspid is larger than the first and more

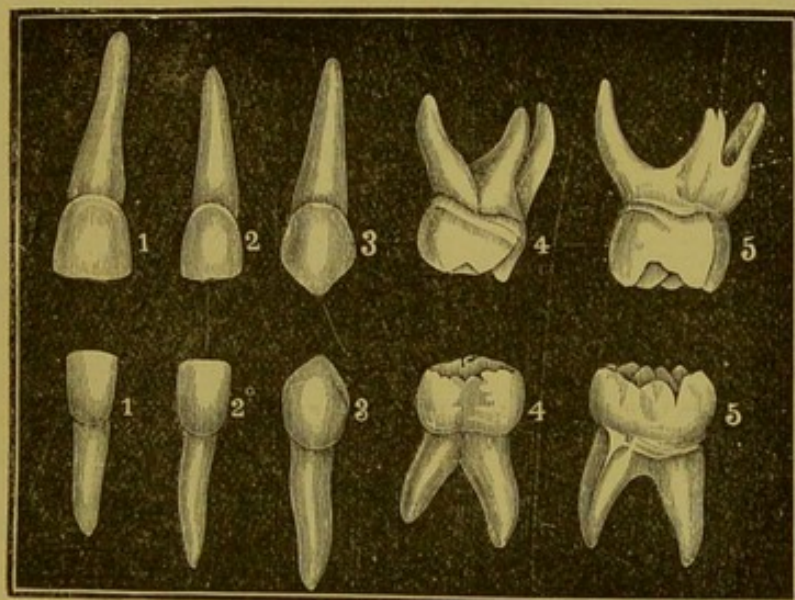
spherical in shape. The roots are single and more or less flattened on their mesial and distal surfaces, and smooth, with a deep groove running through their entire length.

The Molars (Nos. 6, 7 and 8) have large crowns, with two roots and five cusps, three buccal and two lingual, the anterior cusps being the larger.

The second molar has four cusps, which are divided by a crucial depression. The third molar has also four cusps, but they are less distinct than those of the second molar.

The anterior root of these teeth is broad and flattened

FIG. 10.



upon its mesial and distal surfaces, while the posterior root is rather oval. The roots of the third molar are never uniform, being sometimes short, sometimes long, separate or fused together, straight or curved toward the angle of the jaw.

TEMPORARY TEETH.

In general outline, these teeth resemble the permanent teeth. The crowns are much smaller than their namesakes in the permanent set, and the roots are larger in proportion than those of the permanent set. The pulp chambers in the

temporary teeth are also larger in proportion to the size of the tooth. In other respects the crowns of the incisors and cuspids resemble those of the permanent set so closely that further description is unnecessary.

The molars resemble the permanent molars as regards their grinding surfaces and general outline, but are much smaller, being from one-half to two-thirds the size of the permanent molars. Occasionally, it is difficult to distinguish them; but when other resources fail, an unfailing way of determining to which set the tooth belongs is to carry the point of an excavator down along the buccal surface until it reaches the gum. If it be a temporary molar, the instrument will suddenly fall into the neck of the tooth, where the enamel stops abruptly; while, if it be a permanent tooth, the instrument will gradually glide down the enamel until the neck is reached, the enamel of the permanent tooth gradually tapering to a thin edge. The roots of the temporary molars resemble those of the permanent set in form, but diverge considerably to admit the crowns of the permanent teeth between them.

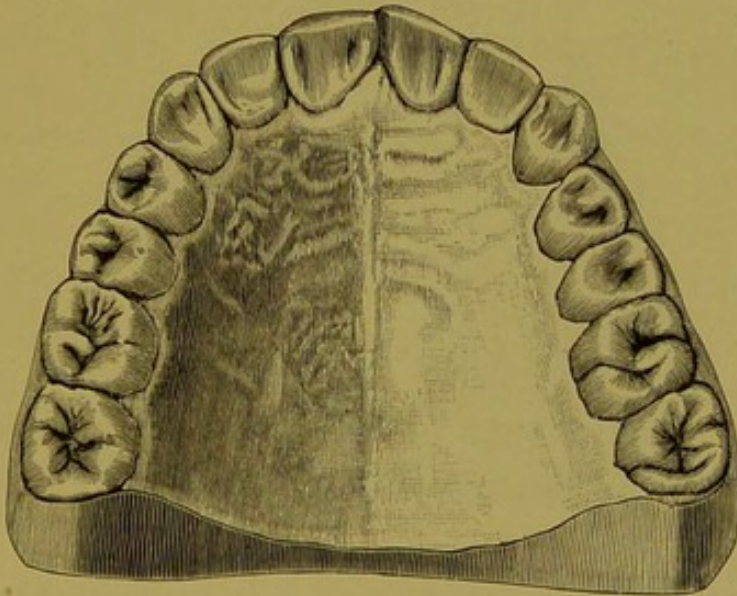
CHAPTER II.

THE OCCLUSION OF THE TEETH.

The teeth of man have a fixed normal relation to one another, and a position in the jaw which best adapts them for the purpose intended, *i. e.*, that of cutting, triturating and grinding food.

It is easy to determine to what class an animal belongs by examining the shape of the teeth and the articulation. When in normal position the teeth are in close contact, and

FIG. 11.

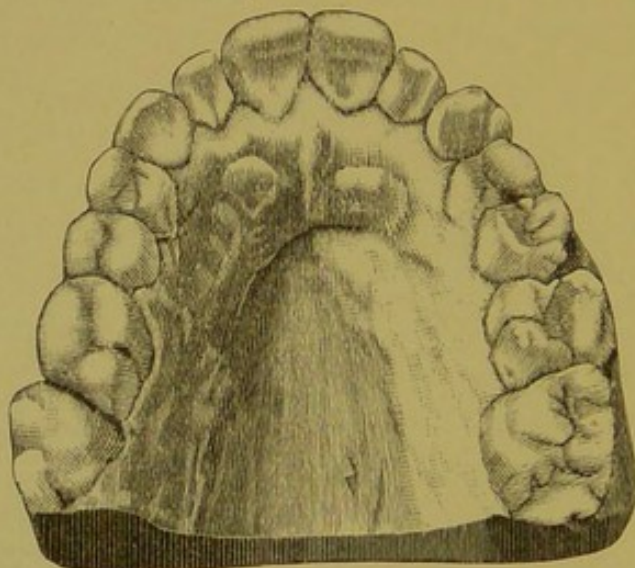


serve as a support to each other, like the stones in an arch. The arch of the teeth varies as much in nations and individuals as do other racial characteristics. The size and shape of the arch affect the appearance as much as, or more, than any of the features. For instance: a small face with a wide-spreading arch would be a great detriment to beauty, or the association of a large face with a narrow arch would result in a face entirely devoid of beauty so far as features are concerned.

The outline of the arch naturally depends upon predominating characteristics; the Englishman, for example, with the round, large head, having a correspondingly large arch (Fig. 11).

Figure 12 illustrates the typical arch of the American woman, narrow and small. Between these typical examples of the two extremes range all of the intermediate grades of characteristic arches. These arches are perfect in contour, and yet neither can be taken as a standard by which to regulate all teeth. Judgment must be used in deciding these points before beginning an effort to change the shape

FIG. 12.



of the arch or the position of the teeth. The teeth are arranged in the alveolar process along the border of the superior and inferior maxillæ in such relation to each other as to form an arched contour. When the jaws come together, the superior set occlude outside of the inferior teeth, demonstrating the fact that the superior arch describes the segment of a larger circle than the inferior. The superior centrals are wider than the inferior centrals, so that they extend over a part of the inferior laterals. The upper laterals cover the remainder of the lower laterals and a part of the lower cuspid. The superior cuspid covers the posterior half of the

inferior cuspid, and the anterior half of the first lower bicuspid, and the relation of the two sets continues in the same proportion to the end of the arch.

By this arrangement of "breaking joints," each tooth is antagonized by two in the opposite jaw. This is an important fact when a tooth is lost, as those remaining are held in position by the occlusion of the teeth opposite, and so retain their usefulness.

THE CROWNS AND ROOTS.

In studying the teeth, it will be observed that the characteristic teeth of the stout, thick-set man are those with crowns broad and short, and roots long and firmly set in the jaw; while the teeth of the tall, slender person are characterized by narrow, long crowns and very short roots.

Teeth with long roots and short crowns require more force in regulating, and less progress is made than with teeth having long crowns and short roots. Care must be exercised in distributing the force with teeth having short roots, to prevent their being pushed out of their sockets. The roots are more liable to be deformed than the crowns; they may be bent or twisted, enlarged at the apex, divergent or adherent, or the root or roots may be in contact with roots of other teeth, and sometimes extra roots are attached. All these abnormal conditions tend to complicate operations.

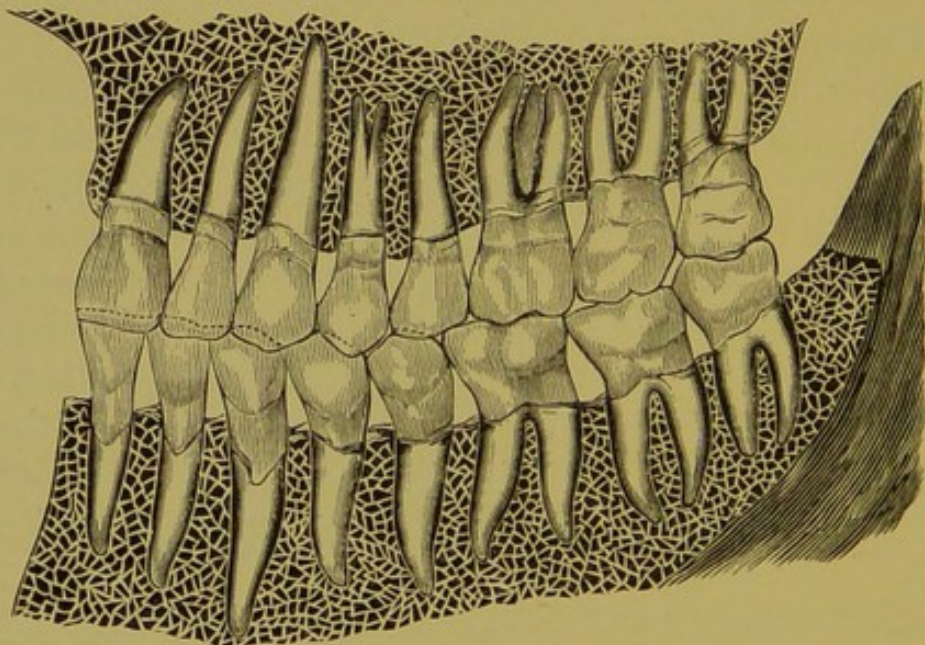
THE TEETH IN POSITION IN THE MAXILLÆ.

The teeth are held firm in their alveolar sockets by a union called gomphosis, which resembles the attachment of a nail in a board. Teeth with one conical root, and those with two or more perpendicular roots, are retained in position by an exact adaptation of the tissues. Teeth having more than one root, and those bent or irregular, receive support from all sides by reason of their irregularity. The teeth are also held in position by the peridental membrane (situated between the alveolar process and the root), by the blood vessels at the apices of the roots, and by the gum, the tissues of

which are continuous with those of the mucous and peridental membranes. Fig. 13 illustrates the position of the teeth in the jaws. The peridental membrane lines the alveolus and covers the roots of the teeth. It is a fibrous tissue, which admits of a slight motion to the teeth, and acts as a cushion to protect the jaws from severe blows and concussions while in the act of tearing and grinding food.

Some teeth are in such close proximity that a rubber dam or floss silk cannot be inserted between them without con-

FIG. 13.



siderable pressure. This tissue is so elastic that teeth that have been forced slightly apart will return to their normal position when they have been relieved from pressure.

This membrane is nourished both by a branch of the artery which passes through an opening in the jaw and the apex of the root and by arteries passing through the alveolar process and mucous membrane at the neck of the tooth.

The nerve supply is derived in a similar manner.

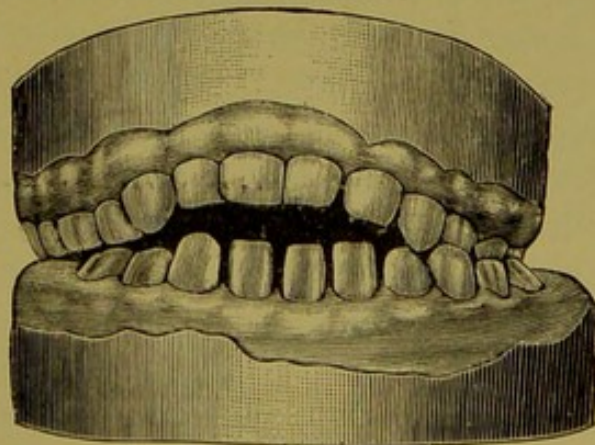
CHAPTER III.

ETIOLOGY OF IRREGULARITIES.

IRREGULARITIES OF THE TEMPORARY TEETH.

Irregularities of the temporary teeth rarely occur, because of the fact that in their development they meet no obstructions in the jaws. They are so small, and the growth of the jaw is so rapid, that the teeth have abundance of room. Absorption and reproduction of bone go on rapidly at this period, and the crypts containing the teeth being located near the surface of the bone, the teeth pass through without difficulty.

The alveolar process is regularly formed, excepting an occasional irregularity from some freak of nature. When irregularities do occur, they are frequently the result of thumb-sucking or some similar cause, or of the inharmonious development of the jaws. The habit of thumb-sucking must manifest itself during the retention of the first set of teeth, as it is acquired from the fifth to the eighteenth month, and the temporary teeth erupt about this time. Irregularities from thumb-sucking are never uniform. They may be located in the centre of the jaw or upon either side, depending upon the hand used, and the thumb or finger inserted. The teeth of either jaw may be prevented from erupting, or the process from developing, by the pressure of the thumb. Fig. 14 will illustrate the case of a child six years old, who contracted the habit at about the tenth month. It will be observed that the teeth of both jaws have erupted to nearly or quite their normal length, notwith-



standing the pressure produced by closing the jaws upon the thumb. The maxillary bones, however, have been retarded in growth. The teeth of the inferior maxilla do not articulate properly with those of the superior maxilla, which is caused by the thumb rotating after the jaws are closed, thus throwing the lower jaw to the left.

The hard palate was flat and normal, showing that the pressure was direct upon the teeth, and that the thumb did not come in contact with the tissues of the mouth. The superior jaw and teeth may be brought forward by absorption and deposition of bone, and the lower teeth and jaw carried backward in the same manner by pressure of the thumb (Fig. 15). The inferior maxilla may, by this cause, be car-

FIG. 15.

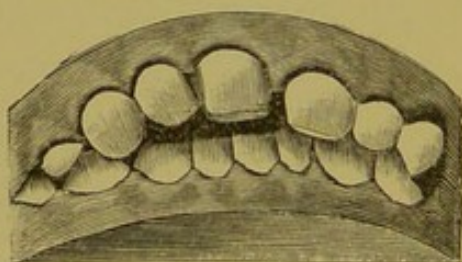
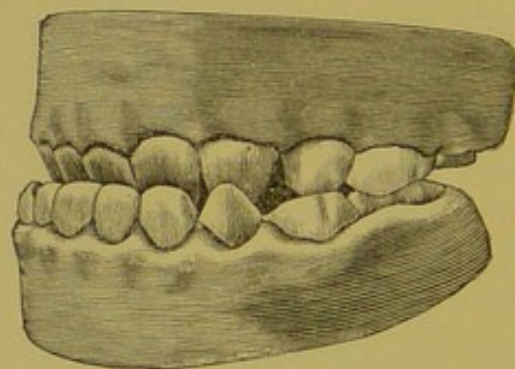


FIG. 16.



ried backward and the angle be a right angle instead of an obtuse one. In thumb-sucking the arch takes the oval shape rather than the sharp angle called the V-shaped arch, unless the teeth project, in which case they have the fan-shaped appearance. In the irregularity known as the prognathous or under-hung jaw, shown in Fig. 16, the anterior teeth of the lower jaw project beyond those of the upper. This is supposed to be an inherited deformity. It seems, rather, to be the result of inharmonious development of the superior and inferior maxillary bones; the rami of the jaw do not assume the proper angle with the body at a proper time in life, or the rami are longer in proportion to the body or to the superior maxilla.

It is not advisable to correct irregularities of the temporary teeth, as the jaws are expanding rapidly and the teeth remain but a few years. The appearance of the first teeth has no effect upon the permanent teeth, and is no indication of the shape or position of the second set. This fact, if impressed upon the minds of parents, would relieve the minds of many.

IRREGULARITIES IN THE SIZE OF THE PERMANENT TEETH.

By comparing the teeth of the present generation with those found in skulls from one to three thousand years old, it will be observed that the size of teeth have altered very slightly. Teeth are generally regular in size; occasionally, however, may be seen excessively large crowns in the central incisors of the upper jaw, and in rare cases we find one incisor larger than the other. Such deformities are necessarily conspicuous. When the crowns are unnaturally large the roots are usually short and stunted, and centrals with large crowns are usually associated with small laterals. The laterals, however, are seldom larger than normal.

When the cuspids exceed the normal size they affect the expression of the face more than any of the other teeth, giving great prominence to the features and a resemblance to the carnivora. The bicuspid and molars are usually normal as to size. The teeth more commonly fall below the average size than exceed it, which fact is particularly applicable to the lateral incisors and wisdom teeth.

When the laterals are abnormally small, they assume a conical shape, the extremely small ones resembling the teeth of the cat. When, as is sometimes seen, the follicles of two teeth unite, the result presents the appearance of a single tooth, the roots of which are divided, and this is the only means of showing the preëxistence of two separate teeth.

IRREGULARITIES IN THE NUMBER OF THE PERMANENT TEETH.

The normal number of permanent teeth is thirty-two, but from various causes the full complement is not always reached, and, on the other hand, it is sometimes exceeded. We cannot agree with Tomes and Salter, who claim that when an irregularity in number exists it is more likely to exceed than fall below this number.

When there are more than the normal number, the superfluous teeth are called supernumerary teeth. They may resemble the natural teeth, or may take a form perfectly round and conical, with short root, or the crown is flattened and the cutting edge serrated. Supernumerary teeth which are similar to any of the natural teeth generally resemble the incisors or molars. We have never seen a second canine or a third bicuspid upon only one side of the jaw. Mr. Salter has observed two canines in one individual, and one example of a supernumerary bicuspid tooth.

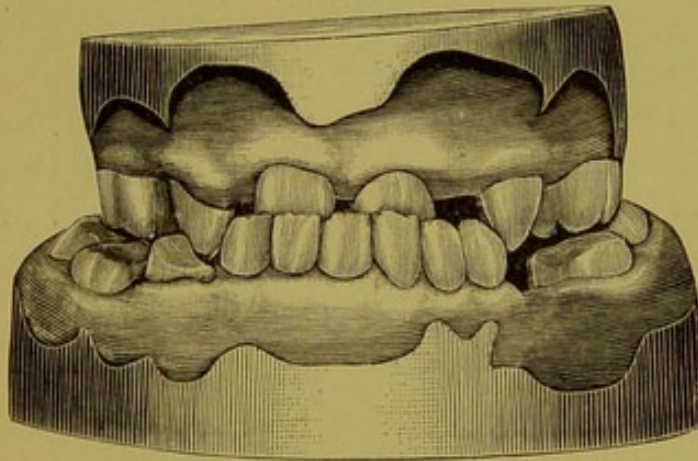
When the central or lateral has a supernumerary of a similar form by its side, it is usually difficult to distinguish the normal from the supernumerary, the latter being nearly perfect in form. The lateral incisor is more commonly duplicated than the central. Wisdom teeth are sometimes accompanied by a supernumerary, in which case there will be four molars upon one side. When the temporary teeth remain in connection with the permanent ones, they are not classed as supernumerary teeth.

The conical and serrated supernumerary teeth are usually found associated with the incisors or wisdom teeth. When found in connection with the incisors, they are either situated between the central incisors or in the palatine surface posterior to the incisors. When joined with the wisdom teeth they are usually upon the buccal surface, but occasionally upon the palatine surface, and sometimes posterior. Such teeth are the result of an extra-epithelial cord and dental follicle. Absence of permanent teeth is common, and cases are recorded in which permanent teeth never erupted. Lin-

derer reports the case of a woman fifty years of age who never had a permanent tooth. Mr. Tomes relates similar cases, but he has never met with a case in which the permanent teeth were all wanting. Cases are on record in which one central incisor was missing, but these are of rare occurrence. Commonly, we find one or both laterals missing, also one or both of the cuspids. They may be imbedded in the jaw, or their follicles may never have existed. If they are in the jaw a tumor will generally locate their position, and may be outlined by the finger.

Fig. 17, taken from the cast of a girl's mouth twenty years of age, illustrates a case with normal teeth missing. She is

FIG. 17.



under my treatment at present. The laterals and bicuspids of the upper jaw and the bicuspids of the lower jaw are missing. When, as is sometimes seen, the temporary teeth are in the place and do the duty of the permanent teeth, they are found most frequently in the following order: 1, the cuspids; 2, molars, and 3, lateral incisors.

The wisdom teeth do not appear at all in many mouths, while in others some of them only are erupted. Prof. Winchell, in his lecture upon "The Degeneracy of Man," states that the early races were invariably supplied with four wisdom teeth, and concludes that, since they do not always appear, and are so prone to disintegration, this

is a strong link in his chain of proof of the degeneracy of man. Other late writers show strong evidence that the wisdom teeth are more perfect and common in existing than in early races.

Dr. J. E. Van Marter, in his study of prehistoric dentistry among the skulls of Umbrian and Etruscan races which existed 500 B. C., says:* "In the photo marked No. 1, the teeth were exceedingly fine in form and preservation. In No. 2, the teeth were equally fine, but only twenty-eight in number, with no trace or sign of there ever having been thirty-two. In the other skulls I noted the same want of the third molars. Evidently, they were never developed. It is worthy of note that in the comparatively few remains of prehistoric skulls in the above collection, there should be such a proportion of those in which the third molar does not appear. About one-fourth of the third molars were wanting. What, then, becomes of the theory that the wisdom teeth are becoming rudimentary and disappearing? Perhaps they disappeared once before, and reappeared again in an age of wisdom, but are now fading away, marking a decadence in that dental evidence of sage understanding."

IRREGULARITIES IN THE ARRANGEMENT OF THE PERMANENT TEETH.

At the age of six years, the temporary teeth and the first permanent molars are in their places in the jaw. By removing the outer plate of bone in the jaw, it will be seen that the germs of the permanent teeth are in their crypts, as is shown in Fig. 18. While the teeth grow independently of the alveolar processes, the processes depend to a great degree upon the teeth for development. With these various conditions existing at the same time, it is not surprising that the teeth are erupted out of a normal position.

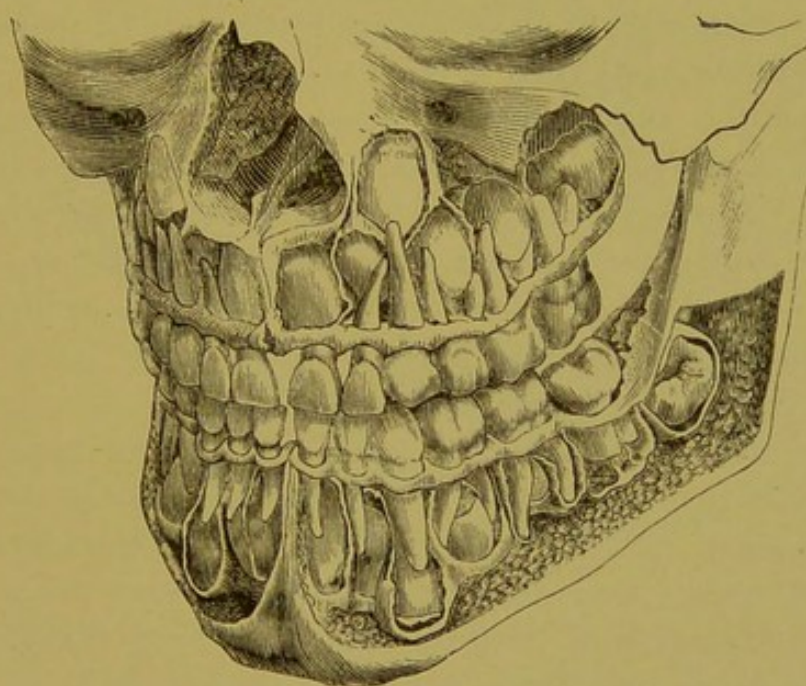
The alveolar processes are, to a certain extent, independent of the jaws. The parts below the mental foramen on

* *Independent Practitioner.*

the lower jaw, and above the palate on the upper jaw, are hard and dense, and are for the attachment of muscles. The alveolar processes, composed of soft and yielding tissue, are expressly for the purpose of the formation of the teeth while in the crypts, and for their retention after they have erupted. When the teeth are removed, the processes are absorbed, and nothing remains in old age but the dense bone.

In intra-uterine life, while the teeth are forming, the alveolar processes cover and protect the crypts in which the germs are located, and as they grow and force their way

FIG. 18.



through the processes, absorption takes place and most of the bone vanishes. After they have passed through, deposition of bone again takes place for the purpose of holding them firmly in place. Again, these teeth are shed and bone is absorbed to admit the second set of teeth, after which new material is deposited for their retention. This is the case under all conditions of their eruption, whether regular or irregular. From the time the first teeth appear until the second set are firmly fixed in position, the alveolar process

has changed three times; consequently, while the teeth grow and develop independently of the alveolar process, the processes are, to a certain extent, dependent upon the teeth for their development, position and shape.

The permanent teeth, taking the place of the temporary teeth, and likely to be deflected in any direction by the slightest obstruction or want of space, are, indeed, "creatures of circumstances."

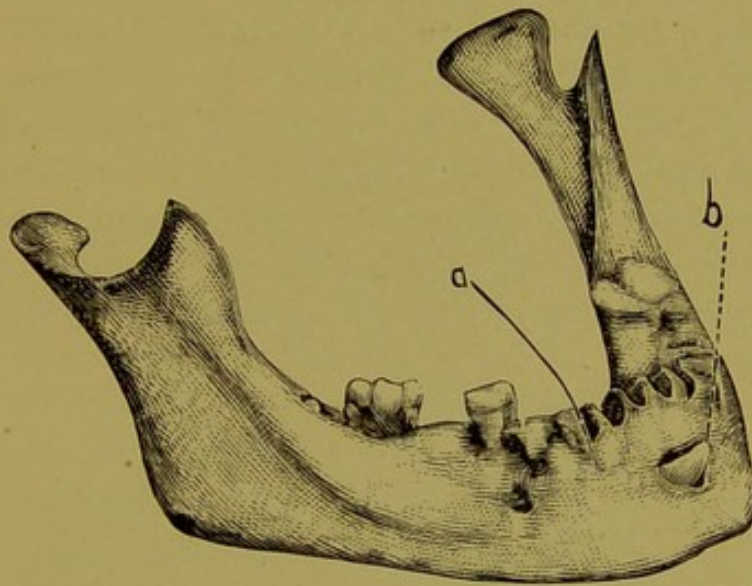
Mr. Tomes says: "The point upon which it is impossible to insist too strongly is this, that the teeth, when they are erupted, do not come down and take their places in a bone already prepared for them; on the contrary, that which is there to start with is absorbed, and the bone in which they are ultimately implanted is built up around them, no matter what position they assume subsequent to their eruption." The size of the jaw does not indicate the size of the alveolar process. The teeth may erupt toward the inner border of the jaw, when the process will naturally build up about them, and will be smaller than the jaw; while, on the other hand, the teeth may be directed outward, and, as a result, the process will be larger than the jaw.

In whatever position the teeth make their appearance in the jaw, the cheeks and lips add materially in directing their position externally, and the tongue internally. The order in which they are erupted may have as much to do with the causation of irregularities as any one thing. This is particularly noticeable when the bicuspid and lateral incisors come down in close proximity, and the cuspids are left outside the arch, or when the centrals, the laterals and cuspids are in place, and some of the bicuspid, which have been retarded in their eruption, are forced abnormally inward. Lateral incisors and wisdom teeth are rather frequently out of position, since their tardy development allows the other teeth to occupy the space.

It will be observed that the crowns of the permanent centrals, on the lower jaw, are situated below and posterior to the roots of the temporary teeth. The permanent crowns,

being larger and requiring more space, naturally crowd outward and conflict with the roots of the temporary teeth, thus producing absorption of the entire root. The roots of the temporary teeth may be all removed by nature in this same way. If the crowns of the permanent teeth do not come in contact with the roots of the temporary teeth, or if from any cause the pulps of the deciduous teeth are destroyed, absorption does not occur to any extent, and the roots are not removed. The permanent teeth are then

FIG. 19.



deflected either into the mouth or out toward the labial or buccal surfaces, or they remain imbedded in the jaws.

When temporary teeth are extracted on account of decay, or to make room for the permanent teeth, the cavity occasioned by such extraction fills up with osseous matter, which deflects the permanent teeth outward or inward, since the tooth cannot penetrate it. Fig. 19 illustrates a case of this kind; *a* represents the site of the extracted deciduous tooth filled with cicatricial tissue; *b*, the permanent canine, which has been deflected outward.

CHAPTER IV.

ACQUIRED IRREGULARITIES.

Under the general head of etiology of acquired irregularities may be mentioned thumb, lip, finger and tongue sucking, and long-continued nipple and sugar-teat sucking. Some common forms of irregularities are ascribed by different writers to thumb-sucking, which, in the author's opinion, cannot be classed under that head of causes. Indeed, we think that irregularities in the permanent teeth are very rarely the result of thumb-sucking. It is a habit acquired in infancy and continued while the first teeth are in the jaw, when the roots are small and short and very impressible. The upper teeth are easily pushed out and the lower pressed in by any constant force. Thumb-sucking tends to enlarge the arch, and, by throwing out the surfaces of the upper teeth, will make spaces between them, at the same time making proper occlusion of the teeth an impossibility. Fig. 20 is taken from the collection of Dr. E. D. Swain, of Chicago.

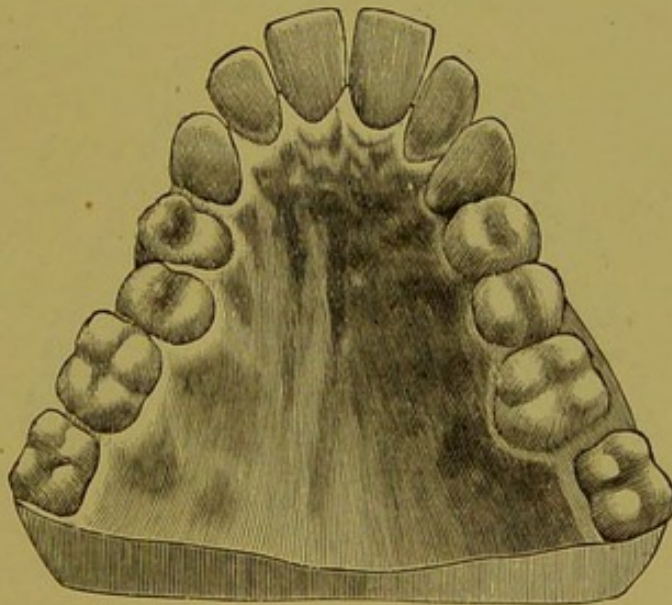
If the habit be not overcome when the second set appears, the superior incisors will be pushed out, making a fan-shaped arch, and the pressure of the object will produce absorption of the processes, or the alveolar process will assume the shape of the object sucked.

In the lower jaw the irregularities are reversed: while the upper teeth are thrown out, elongated and spread apart, the lower incisors are forced inward, shortened and crowded together. Pressure upon the lower jaw in thumb-sucking has a tendency to shorten the angle of the jaw; absorption and deposition of the bone take place, so that the lower teeth articulate one tooth back of the normal position.

Dr. Ballard, of London, observed that the prominence of the central incisors and the vaulted arch was common with idiots, and concluded that thumb-sucking was the cause of this prominence, and, consequently, of the idiocy. While it

is a fact that this peculiar deformity is more frequently found among a given number of idiots than in the same number of healthy persons, it cannot be a result of thumb-sucking, for the following reasons: First, if the irregularity were produced by thumb-sucking, the deformity would exist on one side of the median line, according to the hand which was used, rather than at the median line, where most of these irregularities are located; secondly, the vaulted arch could not be produced by thumb-sucking, as the thumb could not reach the roof of the mouth to produce sufficient pressure to affect the arch. The vaulted arch and the V-shaped

FIG. 20.



jaw are not always associated, the V-shaped jaw being as frequently unaccompanied by the vaulted arch as it is found with it.

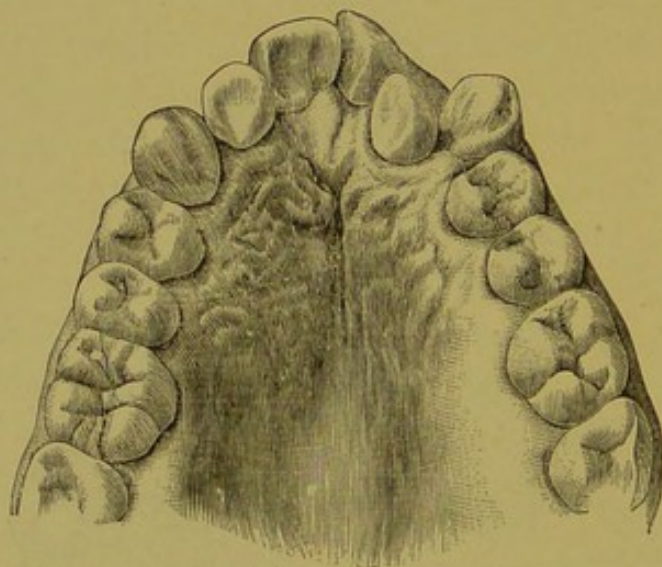
It is agreed that the thumb-sucking during first dentition changes permanently the shape of the jaws; but before the maxillary bones could be affected the teeth would be thrown out of position, and, as has been remarked before, irregularities of the first set of teeth are seldom seen. Sucking of the tongue and sugar-teats is more likely to produce deformities of the bicuspid, molars and hard palate than of the anterior

teeth, owing to the position of the tongue. Deformities occur at the point where the pressure is the greatest.

THE CENTRAL INCISORS.

The central incisors are usually regular in their position, owing to the manner in which they are erupted. They seldom meet with resistance in their transit, as they come down into place outside of the temporary teeth. The lips assist in bringing them into position. Occasionally the centrals have quite a space between them, or are more or

FIG. 21.



less twisted, the mesial surfaces directed outward toward the lip or inward toward the palatine surfaces. These conditions may be due to the retention of the deciduous incisors or their roots; to the resisting properties of a firm suture which unites the two maxillary bones; to the early eruption of the permanent lateral incisors; to arrested development of the maxillary bones; to the presence of supernumerary teeth, which make their appearance sometimes between the centrals and at almost any position on the palatine surfaces; and also to the uncertain progress of the cuspids.

Fig. 21 illustrates the upper jaw of a boy twelve years of

age; it shows the right side of the jaw in a normal condition. The cuspid upon the left side, being large in proportion to the other teeth, has encroached upon the lateral, forcing it into the palatine region, carrying the distal surface of the central around so that the palatine surface is presented to the mesial surface of the right central incisor. The root of the central incisor being round and conical, it is easily rotated in its socket upon coming in contact with another tooth as it emerges from the jaw. The incisors sometimes lap, this being due either to a contracted jaw or to the lateral pressure of the adjoining teeth.

THE LATERAL INCISORS.

The lateral incisors of both jaws frequently erupt in an abnormal position. Owing to the inferior size of their crowns and roots, they are easily influenced out of position by their contact with the centrals or cuspids. The usual deflection of these teeth is directly posterior to the normal position, and slightly or wholly behind the centrals. Their crowns may stand with their labial surfaces parallel with the centrals, or they may rotate to any angle. Their abnormal position may be caused by retention of the temporary teeth of their roots, by inharmonious growth of the alveolar process and teeth, or by contact of the crowns of the cuspids, bicuspid and molars. It is possible for them to project toward the labial surface of the alveolar process from similar causes.

THE CUSPID TEETH.

These teeth very commonly take an abnormal position in the jaw, from several causes. The follicles have a peculiar relation to the other follicles in the jaw; this, together with the extreme length of root and the time of their eruption, makes an irregular appearance almost a certainty. The incisors, with their long roots anteriorly and the bicuspid and molars posteriorly, afford strong barriers to obstruct the regular progress of the cuspids. If the temporary teeth are

allowed to remain until the permanent cuspids are ready to appear, the latter will, in a majority of cases, be pushed into their proper places by the lips and cheeks, which press the cuspids toward the median line, and thus force the process containing the incisor teeth forward. If the bicuspid have worked their way forward, so that there is not space enough for the remaining teeth, the canines will encroach upon the laterals, and either force them out of place or rotate them in their sockets. These teeth are inclined to move toward the median line, and take any position anterior to the bicuspids. Fig. 22 illustrates a model presented to me by Dr. L. D.

FIG. 22.

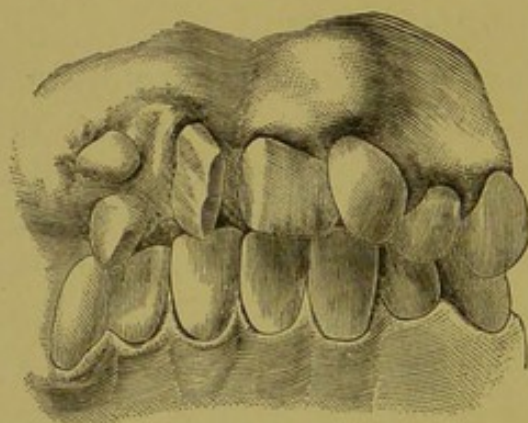
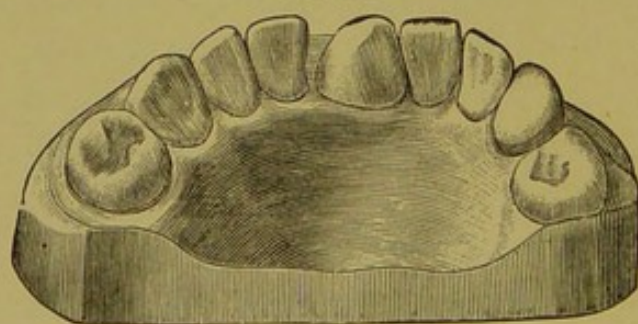


FIG. 23.



Shepard, of Boston. The right cuspid appears through the gum between the central and lateral incisors, while upon the left side a supernumerary tooth stands between the central and lateral, and the left cuspid is erupting between the left central and the supernumerary tooth. The pressure of the cuspids is so great in the jaws as to demoralize all the anterior teeth.

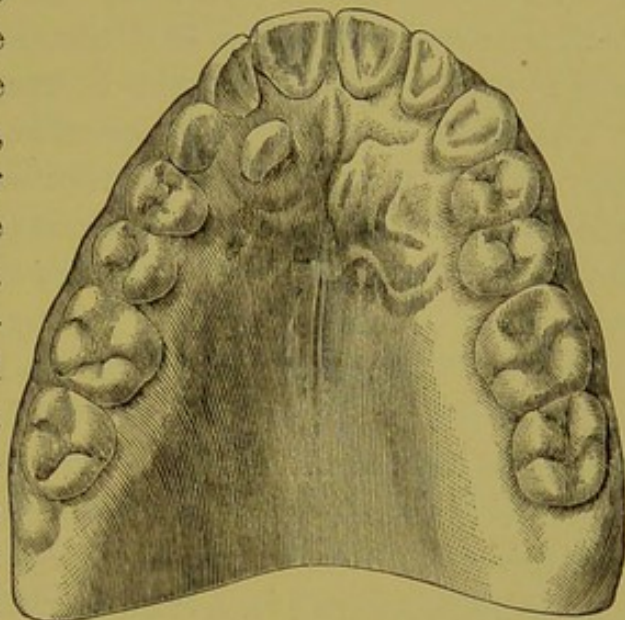
Fig. 23 illustrates the model, presented to me by Dr. John S. Marshall, of Chicago, of the lower

jaw of a woman thirty-seven years of age. It shows the right permanent cuspid situated between the central incisors. This tooth made its appearance when the patient was thirty-two years of age. The right temporary cuspid is still in place.

When the crown of the cuspid is on the palatine surface

of the roots of the laterals and bicuspid (especially if the temporary canine remain in the jaw), it will deflect into the roof of the mouth. Fig. 24 illustrates such a case. When the cuspids begin to erupt they sometimes strike the roots of the lateral incisors, or the first bicuspid, or both, and are rotated in their sockets on the principle of the inclined plane. The molars and bicuspid may work forward and fill all the space, either because the temporary cuspids have been extracted too early or retained too long, and the permanent cuspids remain imbedded in the jaw.

FIG. 24.



Irregularities in the arrangement of the bicuspid and molars are treated under the heads of irregularities caused by protracted retention and too early extraction of the temporary teeth. The causes already enumerated which produce irregularities of the teeth of the upper jaw are also responsible for the irregularities of the teeth of the lower jaw. Added to these causes is the contact of the inferior with the superior teeth. Frequently the cutting edges of the lower teeth, in their development, come in contact with the contracted arch of the upper jaw, and are turned from their regular course. These irregularities are difficult to correct.

HEREDITY IN ITS RELATIONS TO IRREGULARITIES.

It is a fact universally recognized that various morbid conditions and peculiarities of structure are often transmitted from parent to child, through many generations. This law of heredity is almost universal in its application, and its

influence may be either enhanced or depreciated through successive or alternate generations, until we have, upon the one hand, a total disappearance of the hereditary impression, or, upon the other, an increase so great that the condition becomes incompatible with the life of the individual. This variation is a fortunate circumstance, as by it the human race is protected from certain destruction.

This plan of variation is powerful for good or evil, according to the environment of the individual, or of the family to which he belongs. This fundamental evolutionary law of heredity is nowhere more manifest than in the case of perversions of development of both internal and external organs, either embryonal or post-natal, and it is a most powerful factor in the production of deformities of the jaw and irregularities of the teeth. Not only does this hold true in the case of general irregularities due to maxillary deformities, but it also applies to malformations of individual teeth. Thus, the author has observed in a family consisting of mother, daughter and granddaughter, a peculiar fissured condition of the enamel upon the labial surface of a left superior lateral incisor.

It is not uncommon for a child to possess peculiarities of the teeth of one jaw resembling those present in the father, while the other presents irregularities of development precisely identical with those present in the mother; again, one parent may transmit peculiarities of maxillary development, while the other transmits certain characteristic appearances of the teeth. Much has been said of late regarding the influence of ante-natal impressions upon the development of deformities, and if the claims advanced be but half true, it is probable that the teeth and jaws may occasionally suffer their share of the resulting detriment. Evidence of dental deformities from this cause is, of necessity, difficult to obtain. A case is recalled, however, in which a peculiar condition of irregularity of the teeth was attributed by the mother to her constant worry, during gestation, lest the coming child should have teeth as irregular as her own. When dentition was

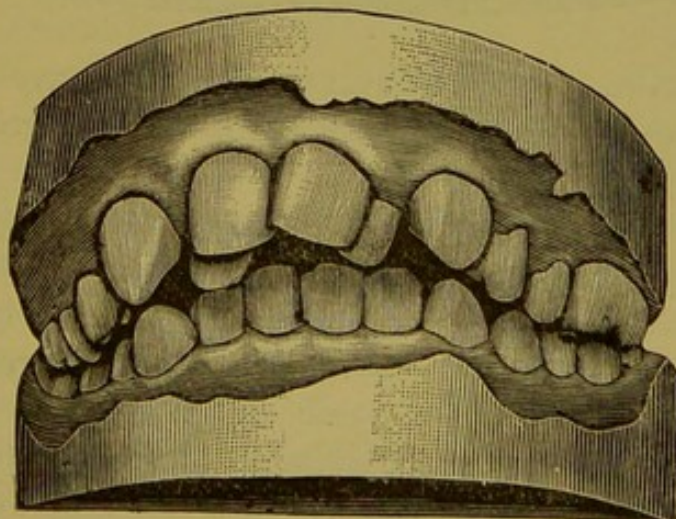
finally completed in the child, the arrangement of the teeth was identical with those of the mother. This case is not by any means advanced as a positive evidence of ante-natal impressions, but because of its suggestiveness.

Notwithstanding what has been said regarding the influence of heredity, it must be confessed that we are often absolutely unable to determine the precise degree of influence exerted by it, even when we are convinced that it is a powerful factor. It is evident to any one, upon reflection, that the causes which will produce deformities independent of hereditary influences will also prevent the latter from acting as they otherwise would.

As has been remarked elsewhere, the teeth are creatures of circumstances, *i. e.*, they are developed independently of the alveolar process, hence their order of development and the resistance imparted by other teeth and roots all combine to produce irregularities; in short, local causes produce a majority of irregularities, and modify formations which might otherwise be the exact counterpart of those presented by the teeth of the parent.

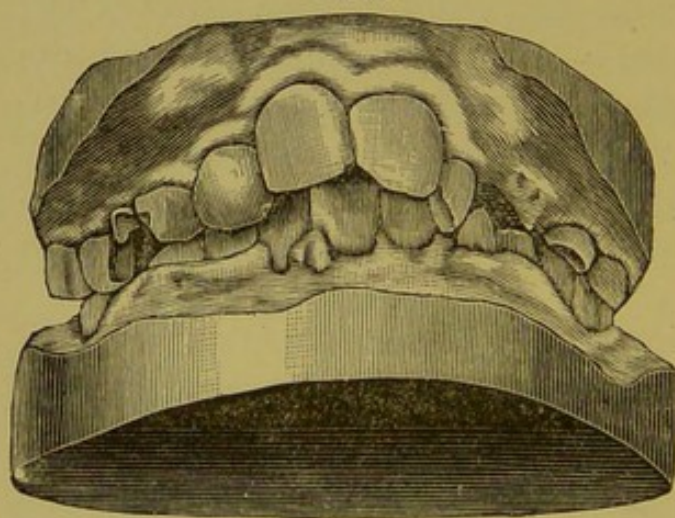
The following cases in practice illustrate this theory. In one family under my observation the father's jaws are well developed, and contain large, strong teeth. The mother's jaws are small, the teeth being regular in the lower maxilla. In the upper maxilla the central incisors are regular and in normal position, but the cuspids, bicuspid and molars have come forward and filled the spaces occupied by the laterals, which were extracted at the

FIG. 25.



age of thirteen. Two sons (their only children) have lower jaws and teeth closely resembling the mother's. The upper jaws and teeth of both resemble the father's in size and strength, but, unlike the father's, they are very irregular in position. These irregularities are not due to limited space in the jaws, which are sufficiently large to admit the teeth with regularity. This tendency to irregularity of position is apparently a marked inheritance from the mother. Fig. 25 is the model of the jaws of the elder son, who is fourteen years of age; as may be observed, the central incisors of the upper jaws are regular, the laterals are forced by the cuspids some distance inside the natural line; the cuspids, bicuspids and molars are

FIG. 26.



anterior to their normal position. Fig. 26 illustrates the jaws of the younger son, aged eleven. The centrals and laterals erupted at the proper time. The cuspids are encroaching upon them to such an extent as will eventually form a V-shaped

arch. Both boys have been under my care from the beginning, the temporary teeth being removed at the proper time.

It will be observed that the tendency toward irregularity in arrangement is decidedly inherited from the mother. The conditions are so modified by local influences that although the hereditarily irregular arrangement comes from the mother, the teeth are not exact counterparts of the mother's irregularity, nor are they alike. It is questionable whether exact counterparts of irregularities are ever inherited from parents. Various local interferences and conditions will, as we have seen, influence this one way or the

other. Transmissions of small jaws and of peculiarities of individual teeth are, however, common.

In 1864, Messrs. Cartwright and Coleman,* of London, examined some 200 skulls in the crypt of Kythe Church, Kent, which had been deposited there for centuries. They found the alveolar processes and teeth perfectly developed and formed.

In 1869, Mr. John R. Mummery, of London, read a paper before the Odontological Society of Great Britain, in which he gave a report of his extended researches, including over 3000 skulls of ancient and modern uncivilized races, and concluded that the early and half-savage people were freer from dental irregularities than moderns. Dr. Nichols, of New York, has examined the mouths of thousands of Indians and Chinese, and says that, with but one exception, he never found an instance of irregularities in either of these races.

I can confirm the statement of Dr. Nichols as regards the Chinese, having examined the teeth of many of them on the Pacific coast. The above reports, together with the testimony of other investigators, show that ancient uncivilized and nomadic barbarians have perfectly-shaped dental arches.

The interesting circumstance that irregularities occur more frequently now than formerly, and among people living in new countries, would suggest the idea that irregularities caused by heredity may result from the intermarriage of different nationalities, the offspring of such unions partaking irregularly and in different degrees of the racial peculiarities of maxillary development of either or both parents. It is probable that the varying character of the food, and the abuse of the teeth incident to the depraved hygiene of modern civilization, have much to do with dental malformations. Again, the higher the evolutionary type of individuals, the more imperfect the teeth and jaws become.

* Kingsley's "Oral Deformities."

The nearer the monkey, and the farther removed from refined and civilized man, the better the teeth. As the animal becomes less and less dependent upon his jaws and teeth for a livelihood, the less perfect these structures become, and after the lapse of many generations marked variations and imperfections of development are logically to be expected.

In conclusion, it may be said that in our studies of dental and maxillary irregularities, we must not only take into consideration the transmission of individual peculiarities, but the all-pervading and general evolutionary law of heredity.

ARRESTED MAXILLARY DEVELOPMENT AS A CAUSE OF IRREGULARITIES.

The superior and inferior maxillæ are developed from separate and distinct ossific centres, those of the inferior being the first of the bones of the skeleton to exhibit signs of ossification; not only do the maxillæ develop independently of each other, but each bone is practically developed in two lateral halves, which subsequently unite by fusion, the line of fusion becoming finally more or less obliterated. The teeth, already laid down at birth, develop and grow independently of the maxillæ and alveolar processes.

Under such circumstances of development and growth it is obvious that perfect harmony must exist, else deformity is sure to ensue, *e. g.*, the separate halves of the maxillæ must have a corresponding degree and mode of development, else irregularity is inevitable. In the same way, a difference in the form of the upper and lower jaws may affect the regularity of the teeth.

A lack of correspondence between alveolus and jaw, or jaw and teeth, is almost certain to cause serious deformity. The greater deformities due to inharmonious development, such as cleft palate, harelip, underhung jaw and protruding upper jaw, are sufficiently familiar, but their relation to irregularities is not generally appreciated. Violate the general

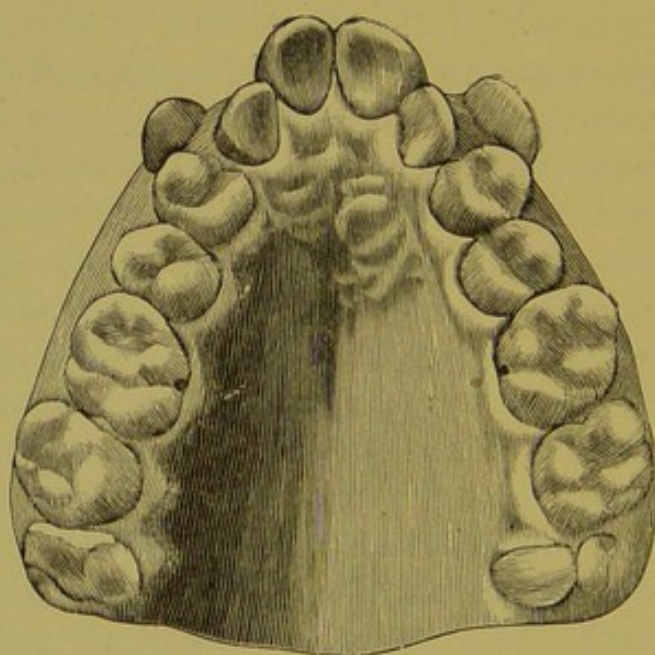
developmental law of harmony, and we may have deformities which, although varying in degree, are precisely identical in kind. When the fact that the foetus is practically developed in two lateral segments is taken into consideration, all deformities which exist, or a predisposition to which exists, at birth become easily understood.

There is a marked difference between the superior and inferior maxillæ in respect to congenital and acquired deformities. The superior maxilla is exposed to pressure and many extraneous influences due to the arrangement of the various bones with which it articulates—there being eight of these articulations. The lower maxilla is developed free and independent of the other bones of the face, and, as a consequence, is in nowise affected by any lack of harmony which may exist between them. Thus, the fact of the relative infrequency of deformity or imperfect development of the inferior maxilla, as compared with the superior, is readily explained. There is another plausible explanation for this difference: The upper jaw, being fixed, is not actively exercised, and, consequently, has no special stimulus to development; the lower jaw, on the other hand, is mobile, and acted upon by powerful muscles in such a manner that an active blood supply becomes necessary. With this increased blood supply comes increased growth and nutrition. There is this to be said, however, in relation to this subject, etc., viz.: that the lower jaw is more likely than the upper to present family characteristics of configuration not within the range of actual deformities.

From what has been said, it is obvious that the consideration of deformities due to arrested development must necessarily be limited to the upper jaw. These deformities merit special attention. There are two principal deformities dependent upon mal-development of the superior maxilla, viz.: The V-shaped arch and the saddle-shaped arch. The most common of the two forms is the V-shaped arch (Fig. 27). The incisors protrude and are rotated in such a manner that their mesial surfaces present anteriorly, forming the point

of the V, the bicuspid region is contracted, and the roof of the mouth may or may not be vaulted; the cuspids are sometimes in the line of the other teeth, and sometimes entirely outside the arch; we occasionally find in these cases the lower incisors crowded, but the bicuspids and molars are nearly always in their proper places. Many theories are advanced in explanation of this deformity. Mr. Charles Tomes says that "this malformation is associated with greatly-enlarged tonsils, which necessitates breathing being carried on with the mouth open. Now, as every one can

FIG. 27.



easily verify for himself, the effect of the mouth being held open is to increase the tension of the soft parts about its angles, and the result of the increased pressure is to bring about a bending inward at the corresponding point, *i. e.*, the bicuspid region; at the same time the median portion of the arch escapes the controlling pressure which would have been exercised by closed lips, and the effect of this is traceable in the excessive prominence of the median pair of incisors, and also in their oblique position, which makes

them correspond with the form assumed by the inner surface of the lips when the mouth is open."

Dr. Norman W. Kingsley says: "The pinched or V-shaped dental arch I believe to be nearly always of congenital origin—that is, an inherited tendency, favored, in all probability, by like circumstances with those which initiated it in the ancestry—while the broad or rounded form is often, if not always, due to mechanical causes."

Mr. Oakley Coles says: "After carefully examining the works of the various writers on the subject of microcephalic idiocy, there seems sufficient evidence to justify the belief that premature ossification of the sutures is the rule in the majority of these cases, and we may therefore assume, if we cannot absolutely conclude, that this influence operates powerfully in the production of the dental deformity known as the lambdoid jaw or V-shaped arch."

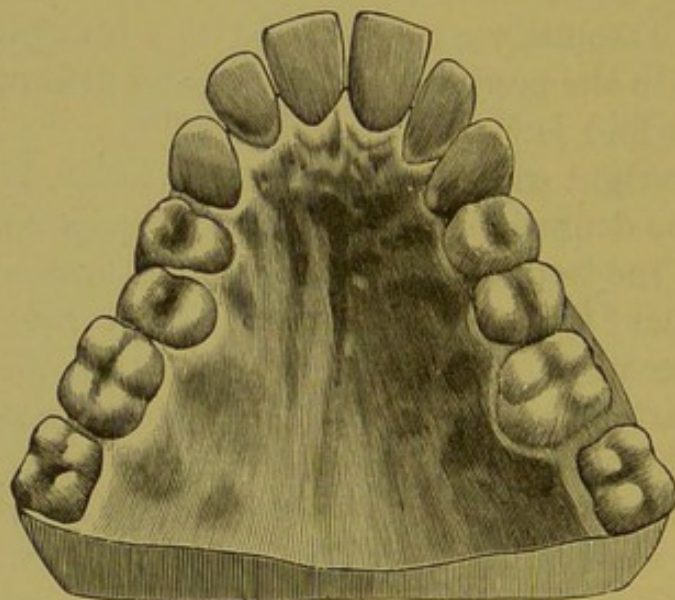
Mr. Cartwright says: "Want of space in the bones of the jaws may be defined as the true cause of irregularity in the position of the teeth in the majority of instances," and then suggests, that "this abnormal condition may be the result of high breeding." It will be observed that the V-shaped arch is nearly always associated with the superior maxilla and with the permanent teeth.

In the opinion of the author, the deformity above described cannot be due to thumb-sucking. In the first place, the teeth chiefly concerned in the deformity—viz.: the central and lateral incisors and the first permanent molars—are all in position, as a rule, from the sixth to the eighth year, and, when erupted, usually present a normal form and position in their alveoli; any changes from the normal, therefore, will be observed, in these cases of V-shaped deformity, to occur after their eruption. Now, the habit of thumb-sucking antedates the eruption of these teeth by a considerable time, and the child is usually broken of its habit long prior to their eruption. It is difficult, upon this ground alone, to appreciate the alleged correlation of the pernicious habit of thumb-sucking with the V-shaped arch. Again, this

deformity always terminates at the median line in an acute angle, while in the thumb-sucker both the temporary and permanent incisors are rounded out. Another important consideration is the fact, that, if due to thumb-sucking, the deformity would be most likely to be upon one or the other side of the median line, according to the position of the force, instead of at the median line. The spaces existing between the teeth of the thumb-sucking child are never seen in the V-shaped arch.

It is noteworthy, also, that the thumb cannot well be carried into the mouth so far as would be necessary to the

FIG. 28.

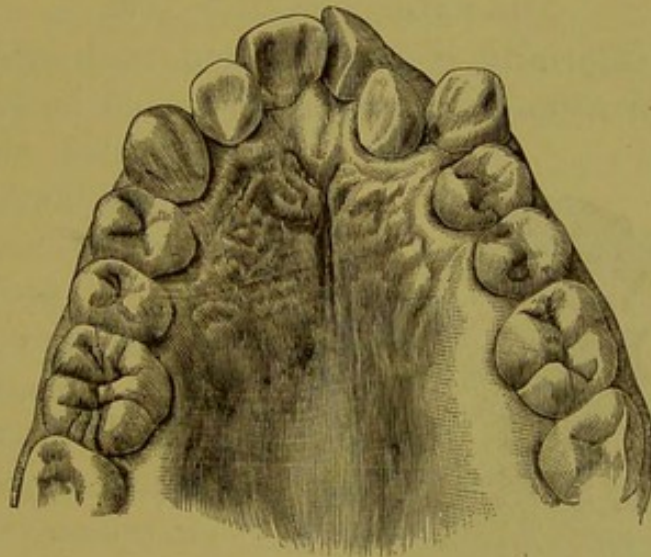


formation of the V-shaped arch; and even were it possible, the resulting deformity would be an arc of a circle rather than an angular V. Fig. 28 shows a perfectly flat arch, the anterior teeth rounded out, with space between them. This is a marked case of thumb-sucking in a child about fourteen years of age. Dr. Kingsley is probably correct in so far as the relation of heredity to the small, undeveloped maxilla is concerned, but that the V-shaped arch is due to heredity *per se* is questionable. When it does occur, it is by acquirement from causes acting locally upon an hereditarily small maxilla. At the beginning of the V-shaped arch we find

the following conditions: The first permanent molars are firmly fixed in the jaw, owing to their size and long roots, the centrals and laterals have erupted, both bicuspid are descending into place against the firm first molars. Owing to the lack of space which obviously exists in the imperfectly-developed maxilla, with which the V-shaped arch is always associated, these teeth cause the alveolar process to be carried forward by absorption and deposition of bone. This forward movement takes place at the point of union of the inter-maxillary and superior maxillary bones.

The roots of the six anterior teeth, being conical in shape,

FIG. 29.



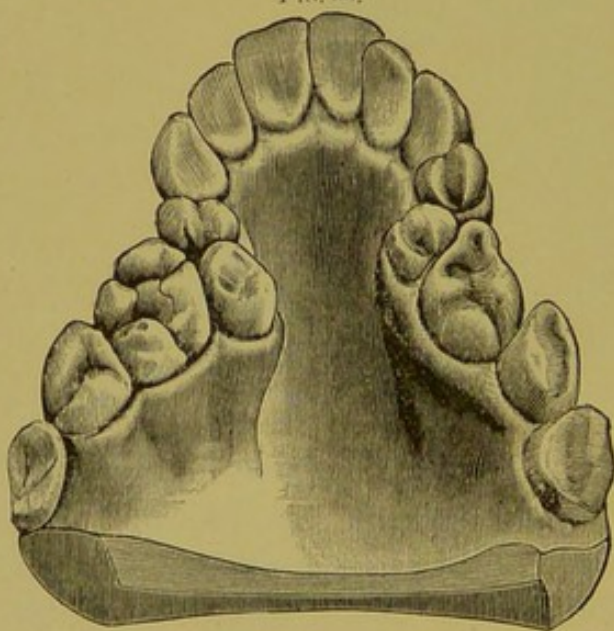
press forward and inward in a rotary manner, the cuspids against the laterals, the laterals against the centrals, and, assisted by the pressure from the muscles of the cheeks and lips, produce an arch, which takes the V shape. Fig. 29 shows the model of the jaw of a boy fourteen years old, demonstrating the cause of the V-shaped arch. The right side is normal, excepting the lateral incisor, which is slightly rotated in its socket. The left side forms half of a perfect V-shaped arch. The abnormal position is owing to the too early extraction of the temporary cuspids, thus giving space

for the first permanent molars and bicuspid to work forward. They filled one-fourth of an inch of the space made vacant by the loss of the temporary cuspids, and forced the permanent cuspid, when erupted, forward. The pressure of the cuspid root, and of the lip and cheek, have carried the lateral incisor into the palate and rotated the centrals around. Had the same conditions existed on the right side, the V-shaped arch would have been complete. The cuspids may be located in a direct line with the other teeth, or, from want of room, may be situated entirely outside the arch. The effect of pressure of the cuspids upon the alveolar process in either case is precisely the same.

THE SADDLE-SHAPED JAW.

Another deformity of the jaw and teeth which is also attributed to thumb-sucking is illustrated in Fig. 30, and

FIG. 30.



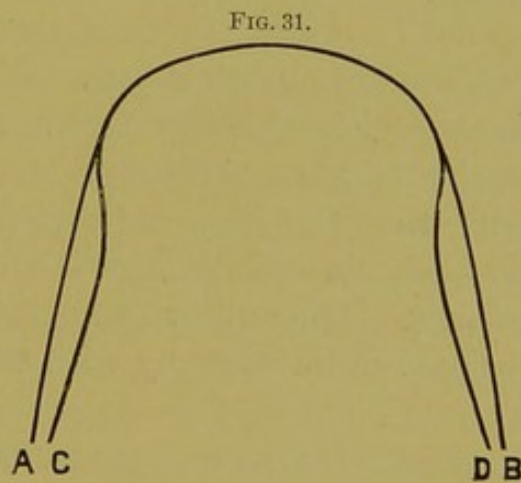
is called the "saddle-shaped jaw." The anterior teeth are usually in a normal position. They either stand straight from the alveolar process or the cutting edges project slightly. They are seldom irregular in position, being protected from the anterior pressure of the posterior teeth by the cuspid teeth. When, as is occasionally the case, the deformity

exists on the lower jaw, we find the incisors and cuspids in a straight line. This straight appearance of the anterior teeth is produced by the anterior pressure of the bicuspids and molars against the cuspids, which are carried forward on a line with the incisors. The bicuspids and first molars are situated considerably inside of the arch—the second

and third molars taking an oblique direction laterally, with the roof of the mouth vaulted. Like the teeth of the V-shaped arch, the first molars, bicuspid, cuspids, and sometimes the incisors, are wedged close together. This fact would naturally suggest as a cause the want of development of the jaw.

A gentleman under my care is possessed of fine physique and well-developed frame, but has peculiarly small jaws and processes compared with the other bones of the body. The teeth of the upper jaw form almost a V-shaped arch, those of the lower jaw the saddle-shaped arch. Like the V-shaped arch, the saddle-shaped arch does not begin to form until after the eruption of the first permanent molars. This deformity has its primary cause in the location of the crowns of the permanent teeth in a dwarfed alveolar process. Instead of the bicuspid and molars being located in the jaws in their normal positions—illustrated in Fig. 31 by A-B—they stand on a line represented by C-D. This abnormal condition in the jaw may be a natural position of the follicles, or the bicuspid may be influenced by the roots of the temporary teeth and the crowns directed toward the roof of the mouth.

On the eruption of the permanent teeth, the order is changed considerably: the centrals and laterals come into position in their natural order, but instead of the bicuspid making their appearance next, the cuspids take their positions. These teeth make a fixed point of resistance in the anterior part of the mouth. The first permanent molar, which is already in position with its long and large roots, is working forward, and has also become a fixed point in the posterior part of the mouth. The space between the first molar and the cuspid is smaller



than the long diameter of the crowns of the bicuspid, and both are crowded in toward the roof of the mouth. It sometimes happens that the first bicuspid erupts and secures its position before the second bicuspid makes its appearance. In this case the crown of the first permanent molar, in working forward, comes in contact with the crown of the second bicuspid in such a manner as to form an inclined plane, and in this way the second bicuspid is carried inside the arch and is often turned in its socket, the cusps facing the anterior and posterior parts of the mouth. Nature provides support for the teeth in whatever position they may assume; the alveolar process is built up about them, giving them strength and firmness.

The extreme lateral position and undeveloped condition of the second and third molars and the alveolar process is caused by the pressure of the tongue. The arch, being contracted to such an extent that the tongue, in the act of swallowing, is forced backward, consequently thickens and spreads out and produces pressure upon the posterior part of the upper and lower jaw. The same condition of the teeth is also noticeable in the jaws when the arch is very shallow, and is also the result of a want of room. It is a mistaken idea that the high arch is always associated with the V-shaped, the saddle-shaped arch, or the arch of the thumb-sucker. The author has observed many such cases, and has noticed quite as many with shallow as with high arches.

IRREGULARITIES CAUSED BY THE PROLONGED RETENTION OF THE TEMPORARY TEETH.

The period of life during which the shedding of the deciduous teeth and the eruption of the permanent set occurs is a most critical one in the formation and arrangement of the permanent teeth. The first small teeth are being supplanted by large ones, and at the same time the jaw is changing. The child should at this time be under the care of a dentist who has the ability to assist nature in perfecting the change. If the process be left entirely to nature, complicated deformities

may arise, which, with judicious treatment, might have been prevented.

As the permanent tooth shows signs of advancing, the temporary tooth upon which it impinges should be examined, and removed if loose or if its room be needed. By attention to this particular, and to the articulation as the teeth take their places, further trouble will often be avoided.

Much depends upon the location of the follicle of the permanent tooth in the alveolar process in its relation to the root of the temporary tooth. These follicles are not always located directly at the apices of single roots or between the roots of the molars, it being common to find them some distance from these points. When this is the case, the vascular papilla (which is situated directly upon the crown of the advancing permanent tooth, and is the organ which nature provides for removing the roots of the temporary teeth) does not perform its function.

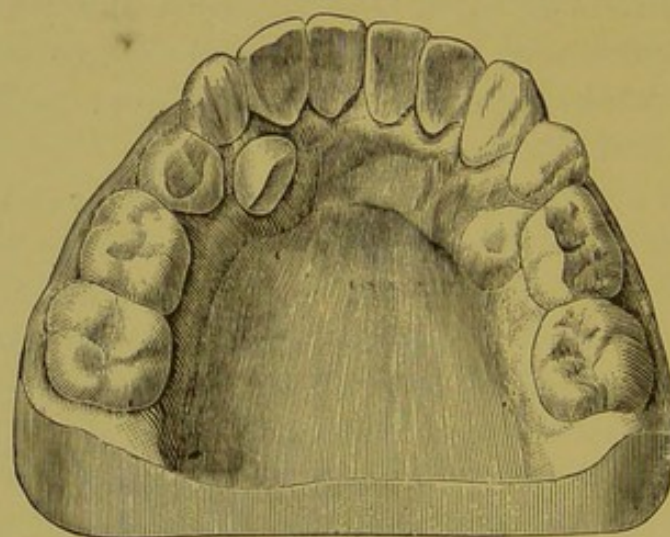
The permanent tooth will remain imbedded in the jaw, or will deflect to one side, and appear either outside or inside of the arch. We sometimes find the permanent tooth forced against a single root or between the roots of a molar and the surrounding healthy tissue. Again, it is more common than otherwise to find the molars decayed and pulps exposed or dead; in such cases the roots of the temporary teeth are never absorbed, and the permanent teeth are either retained until these teeth are removed or are erupted in an abnormal manner. It is a common occurrence to find the crowns of the permanent teeth deflected and making their appearance inside or outside the arch, owing to the long slender conical roots of the temporary incisors and the position of the dental follicle of the permanent incisors. In either case the corresponding tooth of the temporary set should be removed and the permanent tooth pressed into place with the fingers. This same condition of the incisors is liable to occur in the upper jaw, but they are less apt to appear inside of the arch than in the lower jaw. When this occurs, the temporary teeth must be removed and the permanent centrals be pushed

out with the finger until they occlude outside of the inferior incisors.

When they appear outside of the arch, and the temporary incisors are extracted, the pressure of the lips will usually bring them into line. The same conditions occur in regard to the lateral incisors, and the same treatment should be adopted.

It is very important to retain the temporary cuspid until the eruption of the permanent tooth. When this time has arrived, the temporary tooth should be removed to allow the advancing tooth to go into place. Should the temporary tooth remain too long, the permanent cuspid will work its

FIG. 32.

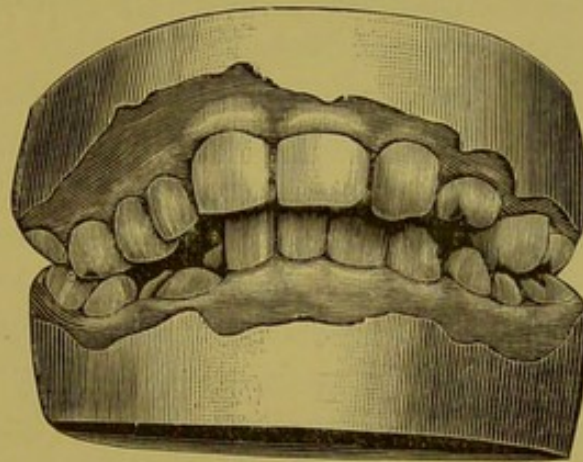


way either inside or outside the arch, as illustrated in Fig. 32. This represents the lower jaw of a man twenty-two years of age. The left temporary cuspid is in position and the permanent cuspid has erupted inside the arch.

The retention of the temporary molars is a fruitful cause of irregularities. Fig. 32 also illustrates the removal of the first temporary molar and its place filled with the first bicuspid; but the second temporary molars are in place, and, as a result, the second bicuspid upon the left side is still in the jaw, while the second bicuspid upon the right side has erupted inside of the arch and below the crown of the tem-

porary molar. Fig. 33 illustrates a case in practice which is one of the most difficult to correct. It is the upper and lower jaw of a girl ten years old. The temporary teeth are all shed from the lower jaw, and the first permanent molars have come forward in such a manner that they prevent the bicuspid and cuspids erupting. The incisors impinge upon the mucous membrane in the roof of the mouth. The tem-

FIG. 33.



porary cuspids and molars are still in position upon the right side of the upper jaw, and the second molar upon the left side. The first bicuspid is just making its appearance through the gum. Had the temporary teeth been extracted at the proper time, a part of this deformity would have been prevented.

CHAPTER V.

IRREGULARITIES CAUSED BY TOO EARLY EXTRACTION OF THE TEETH.

No one cause which can be controlled by the dentist is responsible for so much irregularity of permanent teeth as the premature extraction of temporary teeth. It is an acknowledged fact that temporary teeth require great care in the way of cleansing and filling.

In childhood, the size of the jaw anterior to the first permanent molar is nearly equal to that of the adult; the growth continues posterior to the molars. The ten temporary teeth are supplemented by the same number of permanent teeth. Physiology tells us that the members of the body must be properly exercised to become strong and fully developed. The teeth are no exception to this rule. Decay of deciduous teeth, exposure and death of their pulps, and, finally, extracting, render the act of mastication difficult, resulting in inaction of the jaws and arrested development. If the deciduous teeth had been properly cared for and retained in the jaw, they would have acted as wedges and assisted nature in enlarging the alveolar process.

It is claimed that the jaws are not retarded in their growth by the extraction of the temporary teeth. It is a fact that can be easily demonstrated, that pressure of antagonizing teeth assists in the growth of the jaw. If a thread be drawn between the deciduous teeth regularly each day, and increased gradually in size, it will be observed that the spaces between the teeth will increase, showing that the pressure has expanded the jaw. When a temporary tooth is extracted, the alveolar process which formerly surrounded it has no further function and is absorbed. The jaw loses a certain amount of tissue, which is necessary for the proper support of the permanent tooth, and the diameter of the jaw

is reduced, producing a crowded position of the permanent teeth.

The temporary teeth, when decayed, should be filled and their pulps preserved as long as possible. They should never be removed until they can be pushed out with the finger, or until the permanent tooth makes its appearance. The permanent centrals on the lower jaw commonly appear posterior to the temporary centrals. The former teeth are so much the larger that they lap over the edge of the temporary laterals. When this condition exists, the temporary centrals, and not the laterals, should be extracted. The pressure of the roots of the centrals against the laterals will expand the jaws. A very serious mistake is the extraction of the temporary cuspids to make room for the lateral incisors. The temporary incisors being much smaller than the permanent, when the first teeth are shed the permanent incisors are not only crowded, but often the lateral incisors are obliged to erupt inside of the arch, and frequently the dentist extracts the cuspids to make room for the laterals to go into place. This certainly is bad practice, because, 1st, the anterior part of the jaw will not be properly expanded, as there would be no antagonism of the teeth to produce pressure; 2d, the laterals, as a rule, will not come into the arch; and, 3d, the bicuspids, being the next in order of eruption, make their way forward and take a position next to the laterals, thus preventing the permanent cuspids from coming into place.

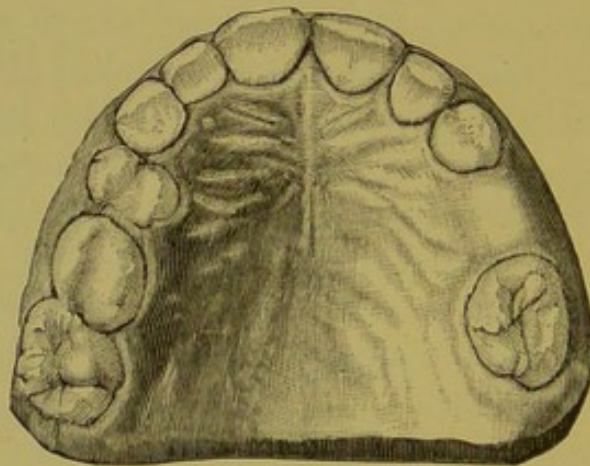
At the time of the eruption of the lateral incisors, absorption of the roots of the temporary cuspids has not commenced. Should the tooth be removed at this period, the alveolar process contracts at that point, which will reduce the size of the jaw, the permanent cuspids being thereby crowded out.

A common cause of irregularities is the too early extraction of the temporary molars. These teeth usually decay early, the pulps become exposed or die, and abscesses result. These conditions produce pain, and the teeth are sacrificed. Then the first permanent molars gradually work forward

and occupy the space of the second bicuspid tooth, the bicuspid, being the next teeth to erupt, work forward, and, when fully erupted, antagonize with the lateral incisors, thus crowding out the cuspids, which are the last to make their appearance.

If a number of casts of the jaws were examined when the temporary molars have been permanently removed, it would be seen that, in the majority of cases, the first permanent molars have come forward from one-sixteenth to one-fourth of an inch, and have crowded the permanent teeth anterior to the first permanent molar. Some writers advance the idea that when the first permanent molars in both jaws have

FIG. 34.



erupted so that they occlude, this will prevent forward progression; but we think this is not the case. These teeth will push forward until they meet resistance. As before mentioned, the temporary teeth should be retained until they loosen from absorption of the roots, or until the permanent teeth appear.

Fig. 34 represents the upper jaw of a girl ten years of age. The temporary cuspids and the first and second molars upon the right side are in place, thus holding the first permanent molars in place, while upon the left side the first and second molars have been removed. The first permanent molar has pushed forward a quarter of an inch, making

it impossible for the bicuspid to come into position. This is usually the case with children whose temporary teeth have been removed. The first permanent molar works its way forward and occupies the space of the second bicuspid, thus crowding the anterior teeth out of place.

FAILURE OF ANTERIOR OCCLUSION.

Want of occlusion is a deformity which does not present itself until the tenth or eleventh year, and is not of common occurrence. Until this period the teeth articulate naturally. The appearance of the teeth then changes; the anterior teeth do not occlude, and when the jaws are closed quite a space is observed. This irregularity occurs at the time of development of the first or second molars, which erupt at greater length than the anterior teeth. This want of occlusion may take place when all of the teeth are in the jaw, or after the first permanent molar has been extracted. If the teeth are all in the jaw, the second molar may pass through the jaw farther than the other teeth, as a result of the patient sleeping with the mouth open, thus removing the pressure from these teeth, or the bicuspid is prevented from erupting their natural length by the impingement of the first permanent molars upon them.

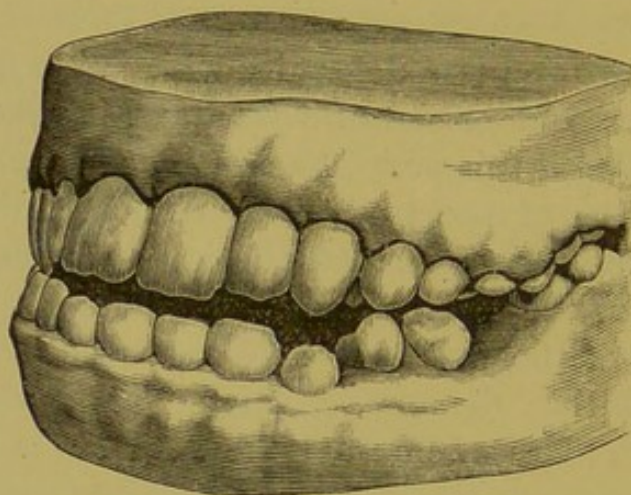
Teeth which are tender upon pressure, caused by inflamed gums or death of pulp and peridental inflammation, or when, from decay, pulps are exposed and thus prevent mastication on account of pain, do not occlude, and the second molar teeth elongate. When the first permanent molars are extracted, the second molars tip forward and the posterior cusps are brought up, causing them to strike the second molars upon the upper jaw, and thus throw the jaws apart. Such a case is illustrated in Fig. 35 (from Dr. A. E. Matteson's collection, Chicago).

PROTRUSION OF THE UPPER JAW.

This deformity (Fig. 36) does not manifest itself to any extent until after the eruption of all the anterior permanent

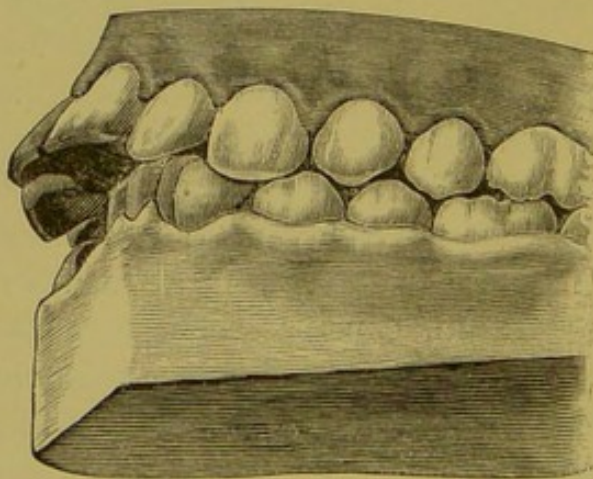
teeth. The question of the teeth having spaces between them, or being crowded together, will depend upon the cause of the deformity. In some cases the teeth project so far that the lips cannot cover them when the mouth is closed. When

FIG. 35.



the alveolar process is involved, there is a fullness of the upper lip at the angle and septum of the nose. The lower lip passes behind the superior incisors instead of covering

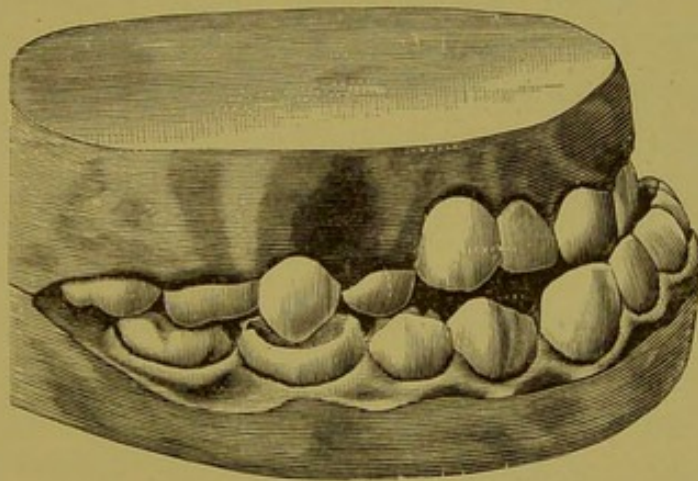
FIG. 36



them. There are many causes for this deformity: heredity, excessive development of the superior maxillary bone, excessive development of the alveolar process, forward pressure of

the incisor teeth by deposition of bone in the formation of sutures, pressure produced by thumb- or lip-sucking, arrested development of the inferior maxilla, deformity in the angle of the lower jaw, causing the teeth to occlude back of the normal bite, forward movement of the teeth produced by lateral pressure of the molars, bicuspid and cuspids, Riggs' disease, produced by tartar and other irritants. Any or all of these elements may be causal. The incisors are sometimes seen at an angle of 45 degrees and protruding from between the lips. This is seen in advanced age. In most cases an irregular development of the alveolar process of the

FIG. 37.



lower jaw is seen. The molar and bicuspid regions being very shallow, the incisor and cuspid regions are correspondingly high, or the molars and bicuspid not being fully developed in the posterior part of the mouth, excessively developed cuspids and incisors are found in the anterior part of the mouth. In either case, when the jaws are closed, the incisors are forced against the palatine surfaces of the superior incisors, acting upon them as an inclined plane and forcing the superior incisors forward. When a tooth or teeth have been forced in a given direction, even after the power is removed, the tendency to move in that direction continues.

PROTRUSION OF THE LOWER JAW.

This deformity (Fig. 37) is not usually very marked, and is associated with the permanent teeth, although we have seen a child with a protruding lower jaw, as seen in Fig. 16, page 32. This deformity may be the result of heredity, of inharmonious development of the jaws, excessive development in the body of the lower jaw, want of harmony in the development of the alveolar process, lack of development in the posterior teeth, and excessive development in the anterior teeth and alveolar process. It may also be due to abnormal position of the follicles of the incisors in the alveolar process, and inattention to the eruption of the permanent incisors. The last two are the most common causes of this deformity. When the incisors make their appearance through the gum, the crowns are directed inward and behind the inferior incisors. When the cutting edges have passed posterior to the inferior incisors, nature cannot correct the deformity; it can be improved only by mechanical interference.

IRREGULARITIES OF THE TEETH OF IDIOTS.

Dr. Langdon Down first called the attention of the profession to this subject in a paper read before the Odontological Society of London, in 1871. He found that, with very few exceptions, the arches of congenital idiots were contracted in width between the bicuspid, and that irregularity in arrangement of the teeth was the rule rather than the exception.

Dr. W. W. Ireland reports that from eighty-one idiots examined thirty-seven had either vaulted or V-shaped arches. When these reports were made public, Drs. Kingsley, of New York, J. W. White and Stellwagen, of Philadelphia, examined the mouths of the inmates of idiotic institutions upon Randall's Island and one in Pennsylvania. Dr. Kingsley observed that in the two hundred idiots of different nationalities he did not see a case of pronounced V-shaped dental arch, and but few cases of narrow palatine arch;

that he found but three or four saddle-shaped palates. Drs. White and Stellwagen found large, well-shaped jaws the rule. In the latter reports no definite statistics of the proportion of regular and irregular jaws and teeth are given; consequently, the accurate condition of the irregularities of the teeth of idiots in the asylums of this country was not known.

The author has endeavored to throw some light upon the subject, and has made extensive and thorough examinations throughout the various institutions in the United States. These unfortunates are classed differently in different institutions, according to the degree of the affliction; for instance, one asylum divided them into feeble-minded, imbecile and idiotic, another into teachable and non-teachable, etc. For convenience we have classed them as high, medium and low grades. This classification was the simplest for the superintendents of all institutions.

Two classes of irregularities were observed—those which developed with the growth of the individual or constitutional irregularities, and those caused by local conditions, and found in the jaws of strong-minded individuals, as, for instance, premature extraction and the retention of temporary teeth. Those only were noted which could be classed as constitutional.

These examinations were conducted by the author where practicable, and, otherwise, by dentists of ability practicing in or near the city where the asylum was located. They filled out blanks prepared for this purpose. The following reports, however, enable us to estimate the condition of the entire class:—*

* For special reports, refer to "Ætiology of Irregularities of the Teeth and Jaws," read before the Dental Section of the Ninth International Medical Congress, held in Washington, Sept. 5th, 1887.

IRREGULARITIES OF THE TEETH.

TABLE NO. I.											
Total Number of DEFORMITIES IN THE JAWS of Both Sexes.											
HIGH GRADE.											
No.	Sex.	Normal.	Large Jaw.	Protrusion Lower Jaw.	Protrusion Upper Jaw.	High Arch.	V-shaped Arch.	Partial V-shaped Arch.	Thumb-sucking.	Saddle-shaped Arch.	Small Teeth.
225	Male.	115	21	5	21	61	11	30	2	38	7
175	Female.	101	11	8	9	40	13	9	5	20	8
400		216	32	13	30	101	24	39	7	58	15
MIDDLE GRADE.											
374	Male.	246	10	15	13	32	21	39	1	26	11
274	Female.	183	10	6	6	19	12	43	5	19	12
648		429	20	21	19	51	33	82	6	45	23
LOW GRADE.											
214	Male.	72	20	15	24	46	27	34	7	29	9
343	Female.	207	15	14	24	40	13	45	11	27	9
557		279	35	29	48	86	40	79	18	56	18
TABLE NO. II.											
Total DEFORMITIES IN THE JAWS.											
No.	Normal.	Large Jaw.	Protrusion Lower Jaw.	Protrusion Upper Jaw.	High Arch.	V-shaped Arch.	Partial V-shaped Arch.	Thumb-sucking.	Saddle-shaped Arch.	Small Teeth.	
1605	924	87	63	97	238	101	200	31	159	56	

Examinations were made in the following institutions: Asylum for Idiots of the State of New York, Syracuse; Massachusetts School for Feeble Minded, South Boston; Illinois Asylum for Feeble-minded Children, Lincoln; Asylum for Idiots, Randall's Island; Minnesota Training School for Idiots and Imbeciles, Faribault; Kansas State Asylum for Idiots and Imbecile Youth, Winfield; Cook County Insane Asylum, Dunning, Ill; Penn Institute for Feeble-minded Children, Elwyn.

It will be acknowledged that in an equal number of strong and feeble-minded persons the larger percentage of irregularities is found in the latter class. These deformities

do not confine themselves to V-, saddle-shaped and high arches, but statistics show a very large percentage of arrested development of maxillary bone, partial V-shaped arch, excessive growth of the superior maxilla, and protruding superior and inferior jaws. These abnormal conditions of jaw are developed in harmony with other abnormal tissues of the individual: as arrested development of external and internal organs, nerve tissue, excessive growth of tissue. Since the above report was tabulated we have visited the Penn institution of feeble-minded children at Elwyn, where, with the assistance of Dr. Wilmarth, a critical examination was made of the mouths of microcephalous and macrocephalous inmates numbering about forty-eight. Out of twenty-eight microcephalous children, all excepting one had small maxillæ, while twenty-three out of the twenty-six macrocephalous had well-developed jaws. These observations agree with those made by Dr. Langdon Down, in 1871. The teeth of the microcephalic children were irregular and crowded, the alveolar process in most cases being larger than the bone proper, and its irregular shape conforming to the position of the teeth. While the alveolar process of the macrocephalic cases was on a line with the maxilla, with sufficient room for the development of the teeth, and in some cases with spaces between them, the majority of the former grade of beings have a marked constriction in the jaws at the bicuspid region.

PART II—TREATMENT.

CHAPTER I.

THE PROPER PERIOD FOR REGULATION.

The proper period at which to begin operative interference in cases of irregularity is of paramount importance, if we desire to obtain the most perfect results; but in deciding the question the following conditions must be considered: 1st. The character of the deformity, the age, health and sex of the patient. 2d. Many irregularities are so slight that, if uninterfered with, nature will, in the majority of instances, accomplish much better results than the ill-advised efforts of the dentist, *e.g.*, the cuspids and incisors quite frequently erupt out of their position, but gradually find their proper places.

3d. There are other cases in which a moderate amount of asymmetry of development has been produced by some imperfect or irregularly erupted tooth, which, being of slight importance in itself, may with propriety be removed. This conservatism is often attended by results as good as could be desired. If, therefore, the teeth are carefully watched by a competent dentist from the time of their eruption until they are fully developed, the necessity of operations for the correction of irregularities in later life is reduced to a minimum.

4th. As illustrative of this fact, it may be stated that if one or more of the anterior superior incisors exhibit a tendency to occlude posteriorly to the cutting edges of the inferior teeth, this may be easily corrected as soon as they appear through the gum. We may thus in a very simple manner correct deformities which, if neglected, would sooner or later require the best of knowledge and mechanical skill and no

end of trouble to remove. Aside from this simple abnormality, however, irregularities of the incisors had best be let alone until after the cuspids have erupted.

In fact, if any of the teeth posterior to the lateral incisors are involved, even in the simple deformity just mentioned, it is wise to defer interference until after both the cuspids and bicuspid have erupted. Their relative positions can thus be studied, and with a single operation their symmetry can be restored. Occasionally, perhaps, an earlier operation would be advisable, but the above rule may be considered the safest in the larger proportion of cases.

From preceding considerations it may be readily observed that no arbitrary rule as to the precise time for interference can be safely given. On the average, however, it may be said approximately that the best time for interference in the majority of cases is from the twelfth to the fourteenth year. At this time, the transitional period between childhood and puberty, all of the teeth are erupted, general nutrition is most active, the osseous system is in the constructive stage, and the formative process is in vigorous operation. At this time, also, the roots of the teeth are not fully developed, but are more or less loosely confined within the alveoli, and the apical foramina are large, thus lessening the liability of impairment of the blood supply and consequent destruction of the pulp.

The conditions mentioned as existing at the twelfth to the fourteenth year being coincident with the completion of the eruption of the teeth, it naturally follows that the reverse holds true; hence, in any case in which the teeth are fully erupted, we may proceed to operate irrespective of the age of the patient.

The probability of a perfectly satisfactory result in regulating decreases yearly after the age of puberty, and after the age of twenty-six the chances of a really satisfactory result are very meagre; for at this time the entire osseous system is fully developed, and there is little probability of extensive deposit of ossific material. It is possible to regulate deformi-

ties even as late as the thirtieth year, but the resulting pain is so severe, and the mechanical force necessary to produce absorption of the obstructive portions of the alveoli is so great, that the end hardly justifies the means. When regulated so late in life, retentive and corrective plates must be worn for years to hold the teeth in place until ossific material shall have formed to retain them in their new position.

In some cases of late correction, absorption of the alveolar process not being followed by compensatory ossific deposit, the mechanical interference produces chronic inflammation of the peridental membrane, *i. e.*, a veritable pyorrhœa alveolaris. I observed this very condition in the mouth of a lady of thirty-five, in whom an extended and, I may add, ill-advised operation had been performed. If the teeth must be regulated at this period of life, the operation should be conducted with great caution and the patient should be duly impressed with a doubtful prognosis. When the patient insists upon an attempt at regulation, and is willing to assume the responsibility of failure, we are perhaps justified in operating in any case of reasonable age.

Having considered in detail the proper period for regulating, we are confronted with another question of perhaps as great importance, *viz.*, the general health and constitutional peculiarities of the patient. Inasmuch as the majority of cases for regulation are youthful, this matter of the general health is no slight consideration. It is an unfortunate fact that the most favorable period for operation is one of the most critical in the life of the patient, so far as the general health is concerned.

From the age of twelve to sixteen, the rapidly-growing boy or girl is subjected to many physical changes, entailing profound disturbances of the general and trophic nervous systems. Prolonged and injudicious hours of study, over-exertion, bad air, improper or insufficient food, sexual irritation, and many other disturbing elements, are apt to become prominent factors in the daily life of the patient.

The matter of sexual disturbance is of especial importance

in females, on account of the new function—menstruation—which asserts itself at this period. When we superadd to these physiological perturbations and circumstances of environment, the perversion of nutrition consequent upon congenital weakness, rachitis, hereditary syphilis or the exanthemata, the important bearing of the condition of the general health upon our operative procedures is very manifest. We should defer operating, therefore, on young persons in delicate health until such time as they have become improved by proper treatment; and it behooves us as scientific dentists to know something of these general conditions, so that we may, in all conscientiousness, place them in proper hands for constitutional treatment. It is in just such cases as these described that the coöperation of a skillful physician is indispensable. A case was recently noted in this city where, from a prolonged operation in regulating, a delicate, puny lady was invalided for two years, solely by the shock produced upon a nervous system primarily unstable.

PHYSIOLOGICAL AND PATHOLOGICAL CHANGES.

It is apparent, to a close observer, that the teeth are constantly changing their positions in the jaw, absorption and deposition of bone going on simultaneously and continuously. This is particularly noticeable at the first eruption of the teeth, and again from the twelfth to the sixteenth year. When the first permanent molar has been removed, the second and third gradually press forward and fill the space.

It will also be noticed that teeth that are erupted out of their position will, in time, often find their way into their proper places; also, when the molars and bicuspid are lost late in life, the anterior teeth are forced forward, thus causing the alveolar arches to project. Again, it is found that when the anterior teeth come in irregularly, they rotate their way into place. These facts indicate that when nature is assisted, whether by mechanical devices or the removal of obstructions, the regulation of malpositions becomes both simple and logical; and, furthermore, that after regulation, the teeth

may be firmly retained in their relatively new positions in the alveolar process.

It stands to reason that the application of light, constant pressure to irregular teeth, in connection with nature's own efforts, will greatly enhance the physiological phenomena of absorption and reproduction of bone. Whether these phenomena will proceed equally or not will depend upon the amount of pressure exerted and the condition of the individual, for it is obvious that in cachexiæ of various kinds disintegration is favored, while tissue-building is correspondingly sluggish. This will serve to impress the immediately vital importance of the degree of pressure and the constitutional condition of the patient in various operations of regulating. When the whole of the alveolar arch is spread laterally, and the force is distributed for a distance upon both sides of the jaw, the bones yield to a certain extent, thus spacing the teeth equally in all directions; and by absorption of the old and deposition of the new bone about them, they become fixed in their new positions. The degree of absorption and change of position is not always equal in all parts of the same tooth, varying chiefly with the direction of the pressure.

When force is applied to the crown, and the tooth has to be moved considerably, there is more absorption at the margin of the alveolus than at its apex. Simple leverage will explain this: the mechanical appliance is the power, and the apex of the tooth is the fulcrum; naturally, the power acts upon the margin of the cavity in which the tooth is imbedded. Or, it might be said that the tooth moves like a spoke in a wheel: the outer part of the crown travels a relatively greater distance than the inner part, or apex. The gradual diminution in diameter from neck to apex is also an important consideration.

When the pressure is too great, then absorption is arrested, on account of the inflammation and pain which result. The operator should avoid causing pain, and this is usually possible. When pain does occur, it should warn him that

the line of demarkation between physiological and pathological changes is being transgressed by mechanical violence. If the pressure be gentle, evenly distributed and constant, no pain will be experienced after the teeth have once begun to yield in the proper direction. But when the force is applied, removed, and reapplied at spasmodic intervals, considerable pain must necessarily result.

The difference between the effects of steady and those of intermittent pressure is illustrated in every-day practice: where teeth have been separated to facilitate the filling of proximate cavities, the vibration of the teeth caused by preparing the cavity and applying the gold produces intense pain, which is relieved by inserting a wedge to distend and steady the teeth by its constant and equable pressure. Individual susceptibility must not be forgotten in this connection; for, as is well known, the impressibility to pain and the power of endurance vary with the temperament and condition of the patient. After the age of twenty-five or six the bones contain more of the earthy and less of the animal matter than during the formative and developmental period, and the constructive stage having passed, it becomes more difficult to move the teeth than in earlier life; and, *pari passu*, with the increased pressure required to effect absorption, a greater degree of pain and inflammation is produced.

In these latter cases of regulating, retentive plates must often be worn, after the malposition of the teeth has been corrected, for two or three years, until a deposition of bone takes place which is sufficiently firm to hold the teeth securely in place. The teeth most difficult to retain are those that have been rotated in the jaw, as they have a tendency to return to their original and faulty positions even after a lapse of three years. By dispensing with the retentive plate for a day or two, and then reinserting it, any deviation in position can be readily noted.

EXAMINATION OF THE TEETH.

When an abnormal condition of the jaw and teeth is presented for examination, the nicest discernment is necessary to decide the best course of regulating. A dentist possessed with ordinary intelligence has no difficulty in correcting an irregularity when a few teeth are out of position, but when the jaws and teeth are both involved, and the features are affected thereby, the question becomes one in which judgment is necessary. That dentists are rarely able to conquer this problem is not to be wondered at when we consider the limited amount of instruction given in most textbooks and colleges. The mouth is one of the most expressive features: more than any of the other features of the face it indicates age and characterizes the race to which it belongs.

The teeth are not developed into type peculiarities until the time of puberty, so that regulating should be delayed as long as is compatible with safety, to allow nature to arrange the teeth as far as possible before interfering with them. Thus, nature frequently corrects extensive irregularities, if left to herself. The facilities for regulating are now so much improved that there is no excuse for allowing deformities to remain, even though they be inherited.

Speech is often interfered with by the contraction of the jaws. The upper or lower jaw, or both, may be so narrow at the bicuspid region that the tongue is forced into the fauces. The roof of the mouth may be high and narrow or flat and shallow; the natural or supernumerary teeth may point in such a direction that the tongue cannot move properly. The incisors may be so separated, or the teeth may be so proportionately small, as to produce spaces sufficient to affect the speech.

DECAY OF THE TEETH.

In frail, anæmic patients, it is often wise to extract a tooth from either side of the jaws, when the teeth are crowded and decay is rapidly going on between them. Which tooth to

remove will depend upon circumstances. Those most decayed or nearest the deformity are the ones to be removed.

If a molar be badly decayed upon one side and a bicuspid upon the other, they should be removed. The condition of the teeth must, to a great extent, govern the operation. The dentist must decide in each particular case.

OCCLUSION.

While the model is the surest and easiest means of studying the occlusion of the teeth, the final conclusions can be drawn from the mouth; hence this part of the subject will be taken up here. It has been shown how the teeth, which are nearly always normal in size, work their way through the jaws and arrange themselves along the alveolar process. These teeth developing individually, it would be natural to expect that in occluding, the cusps of the teeth upon one jaw would not fit into the spaces in the teeth of the opposite jaw. This being the case, owing to the constructive stage of the alveolar process, the teeth will arrange themselves to conform to the articulation of the opposite teeth. The teeth all being in the jaws, and the mesial and distal surfaces of all the teeth touching, if the articulation be not perfect the teeth will rotate in their sockets. If spaces exist between the teeth, they will change their position until the proper occlusion is obtained.

We sometimes find the buccal cusp of one tooth striking the buccal or lingual cusp of the tooth opposite. In such cases one or the other is deflected in or out of the mouth. To correct these cases it may be necessary to extract a tooth, or cut away a cusp or the approximal surfaces of the teeth in order to cause occlusion. Lastly, an examination should be made of the shape and contour of the jaws, the height of the arch, and the inclination of the teeth, to decide upon a suitable impression cup and the best material for taking impressions.

FEES.

In most cases an important consideration in the operation of regulating a set of teeth is the pecuniary reward for it. The specialist in this particular branch should have so prepared himself that he will fully understand and appreciate the requirements of any case which he may undertake to correct. To do this will take much time and anxious thought, for which he should receive a just reward. A thorough understanding as to the proper remuneration for the operation should be established between the dentist and his patient before anything is done.

The models of the jaws should be carefully examined. The temperament and disposition of the patient, as well as the ossific condition of the jaws, should be considered and minutely inquired into. For it will frequently happen that mouths exhibiting very nearly the same deformity will, on account of mental and physiological idiosyncrasies and great difference in density of tissue, require very different treatment in order to accomplish equally favorable results. After these preliminaries have been carefully attended to, as correct an estimate as possible should be made (and at the best it can but approximate) of the expense of regulating the teeth and securing them in their proper position.

At this juncture, and before any operation is begun, a thorough understanding should be established between the operator and the parent or guardian of the approximate cost of the work. It is well not to be too definite in regard to the matter; for it will frequently happen that the operation will require very different appliances and consume more time than was at first anticipated, in which case the operator should be rewarded for his unexpected labor. Or, the operation may be completed in a much shorter time than was anticipated, in which event a proper regard for the patient's rights should prompt a reduction in the fee. A minimum and a maximum price, therefore, should be agreed upon before the operation is undertaken. Conspicuous among the difficulties which come with regulating is, first, to persuade

the patient to submit to the annoyance of wearing the appliance ; and, secondly, to impress upon the patient the necessity of being prompt and faithful in his visits to the dentist. Not appreciating the importance of these operations, patients, and especially children, frequently become discouraged, and are anxious to abandon the treatment before it is completed. The parent too often sympathizes with the child, and without regard for the labor or expense which the dentist has assumed, or the real interest of the patient, the operation is abandoned. The dentist is left without remuneration, although up to this point he has carried out his part of the contract. To secure the continued coöperation of the patient and parent until the completion of the operations, it is but justice to the dentist that he should demand and receive at least one-half of the proposed fee before the work is begun. With this money invested in the operation, the parent will be loth to allow the case to be abandoned before it is finished.

The dentist should, with due regard to the comfort and good of his patient, do all in his power to expedite his operation, so that the suffering and expense may be as light as possible ; but whatever he does should be done with an intelligent understanding of the physiological and pathological conditions with which he is dealing. The patient should, by obedience to the dentist's instructions, do all in his power to facilitate the correction, which will, as a matter of course, greatly reduce the expense of the operation. As a rule, it will be better not to be too minute in detailing the plans intended to be followed and the appliances to be used in the course of the operation, for it will frequently happen that the most carefully-planned procedure will have to be varied during the operation ; in which case disappointment and dissatisfaction might be engendered in the mind of the patient, and lead to a suspicion as to the dentist's ability to accomplish the results at first promised.

CHAPTER II.

IMPRESSIONS OF THE MOUTH, AND MODELS.

Taking the impression of the mouth and jaws is, of necessity, the first step in regulating the teeth. To secure a counterpart of the mouth sufficiently accurate for reference and study, so that when a model is examined it will show the exact contour of the irregularity, requires much care. The position of the teeth, their relations to one another, and the conformation of the jaws can be more easily studied, and accurate conclusions more readily deduced, from the cast than from an examination of the mouth itself. It is not only essential that the teeth should be moved to their proper places, but they must be in harmonious relations to one another; otherwise, they will be inclined to return to their faulty positions: and their normal relations can best be determined by studying the model.

Impressions may be taken in plaster-of-Paris or in modeling compound, but the material employed should depend to a great degree upon the shape of the jaw and the position of the teeth. If the teeth are but slightly irregular, or if the crowns are short and quite irregular, plaster-of-Paris should be used, as it can be removed from the mouth with but little disturbance of the impression.

If, on the other hand, the teeth are irregular and long, and the arch deep, plaster-of-Paris will be apt to adhere to the teeth; in this event only the impression cup will come away, and, as a consequence, the plaster will have to be cut out. In such cases the modeling compound should be used.

Where the plaster is used the patient should occupy an ordinary chair instead of the operating chair, as the head is lower and the operator can have better control of the patient. Protect the clothing by placing two towels under the chin and a newspaper in the lap. Select an impression cup large

enough to enclose the teeth, and build it up with wax so that it will extend beyond the margin of the gums; fill the centre of the cup with soft wax to conform to the palate; and the plaster will be readily carried to all parts of the mouth. Take a quantity of the finest quality of plaster, and mix it in a bowl with sufficient water to make a mixture of the consistency of thick cream; the addition of a little salt will hasten the process of setting. After stirring until the air bubbles have disappeared and the plaster has begun to set, fill the cup and outer edges with it.

The operator should stand to the right of and just behind the patient, with the left arm around the left side of the head, and the forefinger inserted into the mouth. Carry the cup to the mouth, with the thumb and forefinger upon the handle and the middle finger in the centre to steady it, and after it has been inserted into the mouth, with a rotary motion of the right hand press it into place, at the same time raising the lip and pressing out the cheek with the left finger. When the cup is in position, hold it firmly with the middle finger in the centre of the plate against the teeth. Incline the head towards the breast to prevent the plaster passing back to the fauces. Should the stomach become disturbed, and vomiting ensue, it can be evacuated without interfering with the impression.

Test the plaster in the bowl or on the impression cup, and when it will break with a clean fracture, it is time to remove the cup, which can be done by moving the cup backward and forward with the right hand, and pushing out the cheek with the fingers of the left hand to admit the air. Having placed it in the upper towel, held up by the assistant, carefully examine the mouth, and if pieces of plaster are seen, put them in the towel on the proper side of the impression to save time, and set it carefully away, afterwards arranging the pieces in their right places in the impression.

The second towel is for the purpose of removing plaster that may remain about the face.

It is well to explain something of the operation to the patient, as one would naturally anticipate a more serious experience than is actually realized. All of these little details should be strictly attended to, in order to insure a perfect impression at the first sitting, and thus save the patient the annoyance of several applications.

In taking impressions of the lower jaw, the patient should sit higher, so that the mouth will be on a level with the elbow of the operator, who stands in front of the patient; the fingers of the left hand should push out the cheeks and lips while the cup is rotated into place with the right hand. The first and second finger of each hand should rest upon the cup over the bicuspid and molars, the thumbs under the jaw on either side, thus holding the cup firmly in place until the plaster sets, when it should be removed and placed in the towel as before. After a few minutes' hardening, the impression should be placed under running water to remove mucus, saliva, blood or particles of plaster. Should the plaster be broken, the piece can be placed in the positions indicated by the arrangement on the towel, and, when perfectly dry, fastened together by melted black wax. A clean separation of the model is obtained by covering it with a lather of soap and washing off the surplus, or by coating with shellac and oiling to prevent sticking.

The author has used modeling compound with success by heating it in warm water until it is of the consistency of soft dough and placing it in a warmed impression cup in such a manner that it will cover all parts of the teeth and jaws when it is forced into place. The impression cup should be held firmly in place for a moment, and a towel saturated with cold water should be carried to all parts of the mouth to chill the compound. S. S. White's upper and lower impression cups, No. 17 and 18, such as are illustrated in Figs. 38 and 39, should be used in taking impressions in cases of irregularities.

It is a good plan to oil the surface of the impression, thus preventing the compound sticking to the cast.

To obtain the model, place a sufficient quantity of water in a bowl and pour in plaster, allowing it to settle, and thus preventing the formation of air bubbles; add enough plaster to make it of the consistency of cream. Put a drop of water into each depression made by the teeth in the impression, to exclude the air, and add a small additional quantity of plaster. By tapping the cup upon the bench the plaster will fill up the depressions without the formation of air bubbles;

FIG. 38.

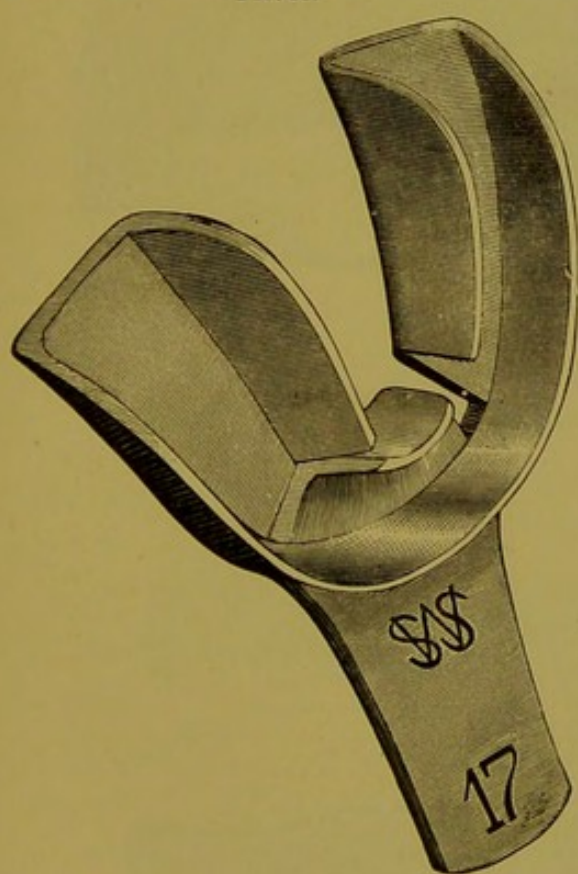
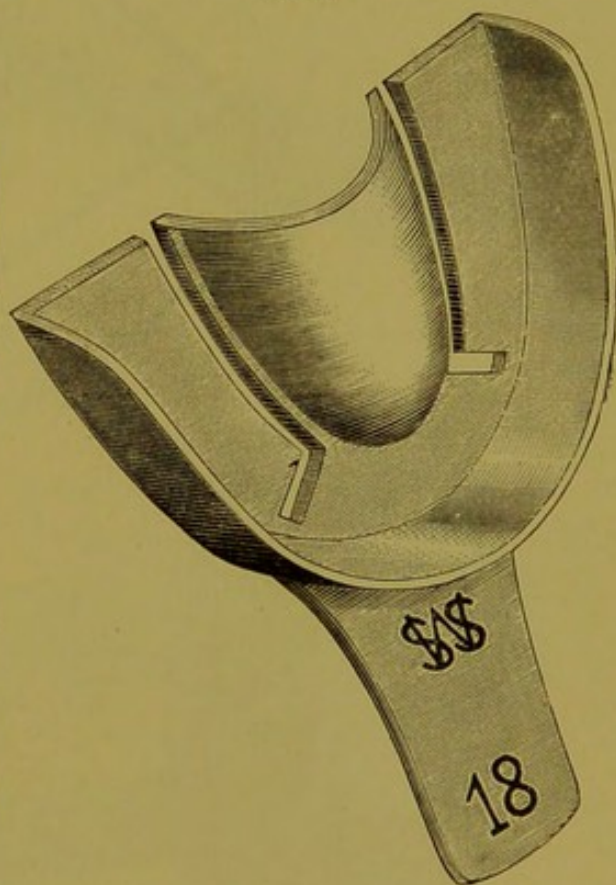


FIG. 39.



the surface should now be covered with plaster, and after mixing in more dry plaster to make it thicken, fill the impression full and place it upside down on a glass slide. Now build out the model until even with the impression cup, and allow it to harden. It is better to let it stand from twelve to twenty-four hours, that it may become thoroughly hardened before being removed.

Having removed the impression, trim the model roughly, and after articulating, trim it so that the body of the model will be parallel with the line of the teeth, and made presentable for inspection. Place the name of the patient and the date of the time the operation was begun on the surface of

FIG. 40.

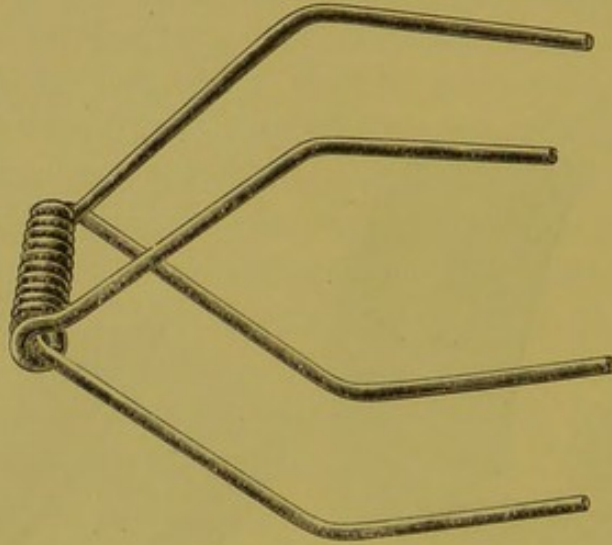
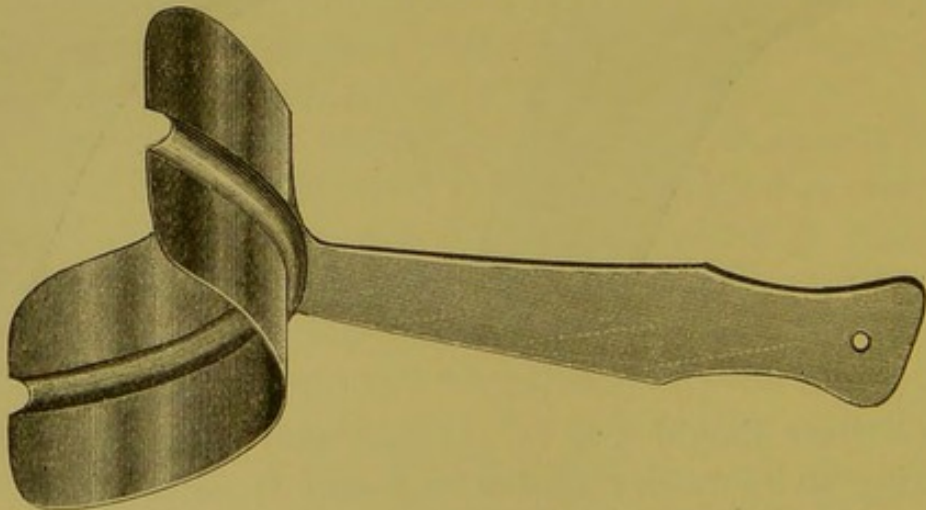


FIG. 41.



the lower model, and the patient's initials upon the upper model, after which the surface should be varnished. A band of elastic rubber will hold them together, or make an articulation of brass wire, as illustrated in Fig. 40, for the purpose

of holding the models in their proper positions, thus preparing them for easy inspection. The upper arms and spiral are made of one piece of wire, No. 18, U. S. gauge. The lower arms are made from another piece of the same wire passed through the spiral and bent to correspond to the upper arms. The models are now articulated, and the wire arms bent to meet the upper and lower surfaces. The surfaces, after being

FIG. 42.

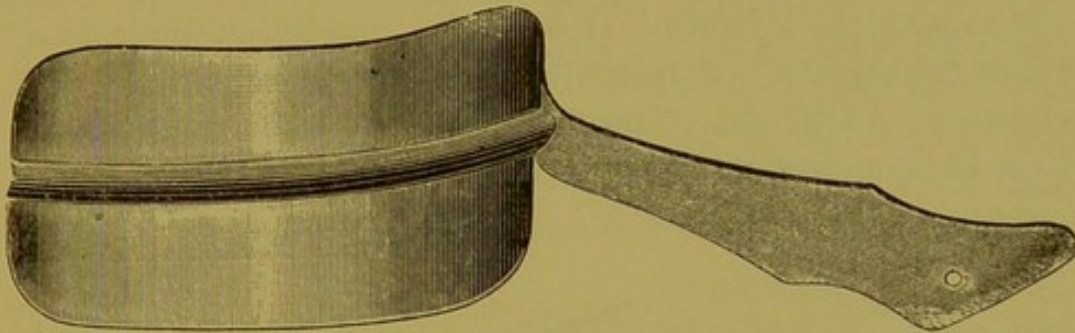
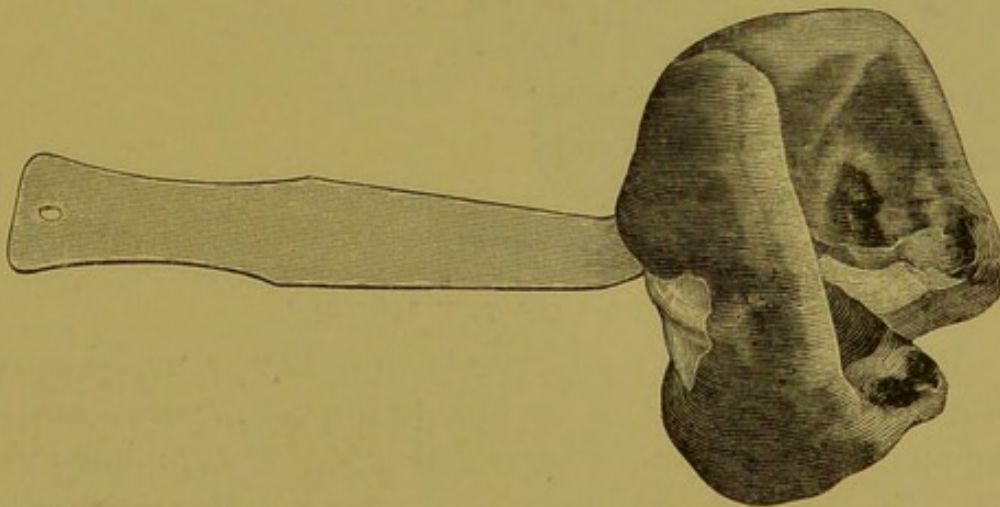


FIG. 43.



saturated with water, should be covered with plaster and the arms united to the model.

The cups for taking impressions of the anterior teeth, illustrated by Fig. 41, and for the molars and bicuspid, Fig. 42, together with suggestions for their use, were devised by Dr. Wm. P. Cooke, of Boston. He prepares a sufficient quantity of wax, and after warming it, places it upon the cup. When

the jaws are in a normal position, and the saliva and mucus removed from the teeth and mucous membrane, the cup with the wax is forced between the lips and against the teeth and cooled with a wet napkin. The patient is requested to open the mouth, when the impression is removed, as shown in Fig. 43. The model, Fig. 44, is obtained by pouring plaster into both upper and lower impressions, thus making a solid model. This is a very desirable way of procuring an accurate and permanent model of the mouth when one is needed for observation and study. It will save time to put them in a place convenient for reference, which receptacle should, of course, be a safe one. The models should be examined from time to time, to note the progress of the operation.

FIG. 44.

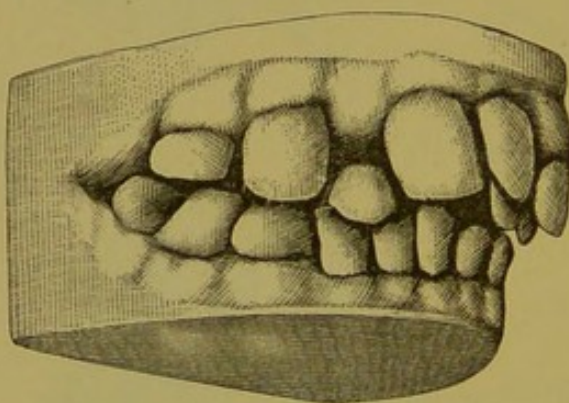
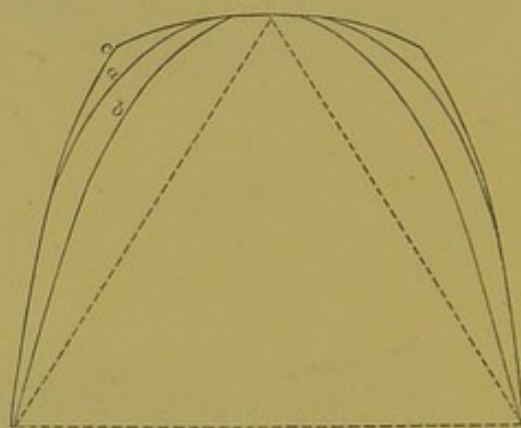


FIG. 45.



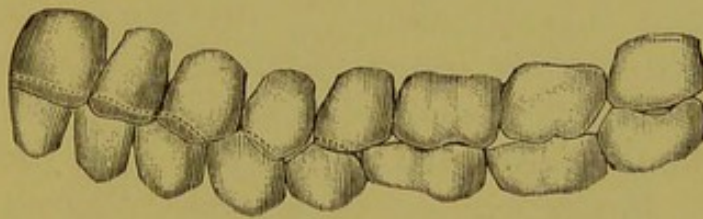
STUDY OF THE MODELS.

It is important in regulating teeth to have a model conveniently near at hand, to be able to improve spare moments by studying it, and thus become thoroughly acquainted with the physiological conditions of the teeth before attempting to come to conclusions regarding the pathology of the case. In determining the character and extent of a deformity some criterion is necessary. In the human skull, taking the two cuspids for our starting-point, we find that the anterior part of the average superior maxilla forms the arc of a circle, and by dropping a line from the cusp of the cuspid to the centre of the wisdom tooth, we see that the posterior part diverges

considerably from the central line. Thus, Fig. 45 shows the three normal lines of the dental arch.

The incisors of the inferior maxilla should close inside of the superior incisors, and the buccal cusps of the bicuspids and molars should occlude at the centre line or sulci of the superior bicuspids and molars. If we hold the articulated skull in our hands, with the buccal surface toward us, we will observe a gentle curve downward from the cuspid to the second bicuspid, then rising until the wisdom teeth are reached; thus, Fig. 46 not only shows the relative positions of the teeth in the jaw, but their relation to one another. As mastication is done principally by the bicuspids and first molars, it is necessary that these teeth articulate perfectly, which is accomplished by the tooth of one jaw interlocking

FIG. 46.



between two teeth of the opposite jaw, thus providing support and surface.

If the arch posterior to the cuspids be uniform, and these teeth are regular and articulate as shown in the cut, they should not be interfered with for a slight deformity existing in any of the six anterior teeth. The cuspids may be spread laterally to make all the room necessary. When this is accomplished and the deformity corrected, all the teeth in the arch will adjust themselves properly. If the irregularity be complicated, and more room required than can be obtained by spreading the cuspids, it is best to enlarge both arches; this will give all the space needed. To change a well-articulated set of teeth so that the cusps of the opposite teeth will strike would be unpardonable.

The arch of the superior and inferior maxilla should have a diameter of sufficient width to prevent an impression of the teeth on the sides of the tongue. Any deviation of the jaws or teeth from this outline is considered a deformity, and should receive the attention of the dentist.

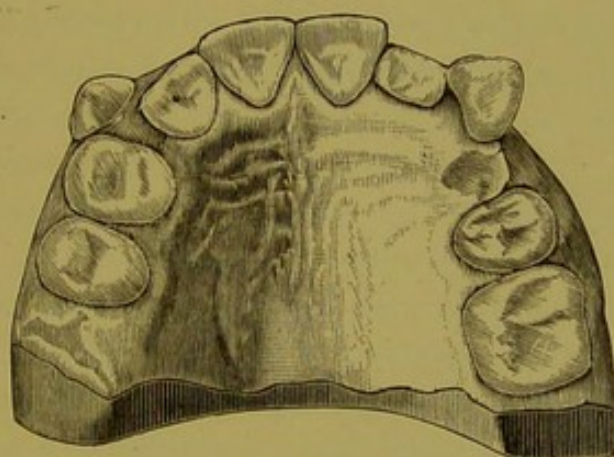
Examining the model with this ideal in mind, we find certain deformities, and the question arises how to treat them. Before proceeding, we will decide, on careful consideration, that one of two conditions exists: either the teeth are in a crowded and irregular condition inside of the proper line, or they are isolated and irregular outside of the line. In the majority of cases the irregularity involves the teeth anterior to the first permanent molars. If space be wanting, the question will arise whether to enlarge the arch by force, or to extract one or more teeth, and thus give the required room. The age of the patient will to a certain extent decide this question. If the temporary teeth are in the mouth, causing irregularities, they must be removed. When the removal of the second teeth becomes a necessity, a tooth should be selected which is the least prominent or which will least affect the expression. A good rule is to retain, if possible, the six anterior teeth. As the cuspids are the most prominent and give expression to the face, they should never be removed; but if one must be sacrificed, the selection lies between the first or second bicuspid and the first molar.

If we find on examination that the teeth are decayed (at the age of twelve or thirteen years it is common to find the first permanent molar decayed), those affected should be extracted if the crowns are wholly or partially destroyed. In the model of the upper teeth of a girl fourteen years of age (Fig. 47), the bicuspid are seen to have advanced so far forward that there is insufficient space for the cuspid to come down into place. Upon examination of this case it was found that the first bicuspid upon the left side and the first permanent molar upon the right side were badly decayed. It was easy to decide which teeth should be sacrificed. The

cuspid upon the left side came into place without assistance. The bicuspid upon the right side were carried back and the right cuspid came into place. It is probable that in the past the first permanent molar has often been extracted without sufficient cause. As this tooth serves an important purpose in mastication on account of its broad surface, I should advise its retention if the crown be in a fair state of preservation. It has served for six years, which fact, in connection with its solidity in the jaws and its central position, is an argument in favor of keeping it as long as possible.

Upon examining the models of the jaws, we occasionally find the articulation posterior to the cuspids perfect, with the

FIG. 47.



cuspids nearly approximating the centrals, and the laterals locked inside of the arch. Whether they are sound or decayed, it may be best in such cases to remove one or both laterals. The general appearance of the teeth will not be injured by this treatment. Dr. Guilford, in the "American System of Dentistry," mentions two cases of this kind, as follows: "The writer had two cases in one year presented to him for the reduction of prominence in the superior front teeth. In each case there was a broken or badly-diseased right central that was past hope of redemption. In these cases it did not happen particularly amiss, for the extraction of the roots afforded room for drawing in the remaining five

teeth, thus easily reducing the deformity, and at the same time closing the space made by their loss. The appearance of the patient in each instance was greatly improved, and the absence of even so large a tooth as the central was scarcely noticeable.

"In another case, a girl eleven years of age had lost a right superior central incisor through a fall from a swing. Two days after the accident, and when the tooth had been mislaid or thrown away, she was brought for treatment. Only two methods of remedying the difficulty suggested themselves. One was the wearing of an artificial tooth, the other drawing the teeth together to close the space. The latter plan was decided upon, and successfully carried into effect, but, unfortunately, as there had been no protrusion formerly, and there was contraction afterward, the superior teeth no longer overlapped the lower ones, but met them edge to edge, thus giving the upper jaw a flattened appearance which was in itself a deformity. The patient was saved the annoyance of wearing an artificial tooth, but her facial expression was injured in consequence."

Irregularities of the inferior incisors are often seen, and if the articulation be normal in the posterior part of the mouth, almost any of the incisors that are out of position may be removed. They resemble one another so closely in size and shape and are so nearly concealed by the lip that their loss will not be observed. The author would suggest that the operator needs to be particularly careful in deciding upon the mode of treatment, as he has seen three cases in which an actual increase of the deformity was produced by a hurried operation. In one of these, a girl ten years of age, a central incisor was removed, and the muscles of the lip, together with lateral pressure of the adjoining teeth pushed against the cuspids, forced the incisors into a crowded condition, thus producing a V-shaped arch. It was ascertained that the articulation of the posterior teeth was not perfect. It has been advised by some authorities to remove a corresponding tooth on the opposite side where want of room compels the

removal of a tooth in the anterior part of the mouth. They claim that there is danger of the incisor moving by the median line when a tooth from one side only is extracted; but we have found that when a tooth is removed back of the canine, it is seldom that the lateral pressure is sufficient to materially move the incisors.

In considering the bicuspid, the one which is the most decayed should be removed. If both are sound and it becomes necessary to extract one, then the first should be chosen. In studying a model, the end to be kept in view is the retention of the teeth in place after they have found their new position. It is very important that the occlusion of the bicuspid and molars should be such that when in position and properly articulated, they will hold one another in place. If this be not accomplished, the incline of the cusps will force the teeth into their original faulty positions.

APPLICATION OF FORCE.

In every appliance for regulating the teeth the object is the same, viz., to exert pressure upon the teeth to be moved. Any appliance for this purpose should be as small as is compatible with effectiveness and strength. When possible, it should be so constructed that it can be applied inside of the arch in such a manner that it will not interfere with speech or mastication, and can be removed by the wearer for cleansing.

It should give as little annoyance and pain as possible, and should not necessitate frequent visits to the dentist for its adjustment. Whether the teeth are to be forced out or drawn in, there are always to be considered a body to be moved (the tooth) and a fixed point of resistance. By studying the model carefully, the operator can determine the amount of force required to move the tooth, and select for the anchorage of the appliance a suitable point opposite, which will more than resist the force required to move the tooth. This point may be one or more of the natural teeth, or a plate may be constructed for the purpose. In applying the appa-

ratus to a tooth, its position in the jaw should be observed, and the inclination of the root or roots must be ascertained to decide whether they stand perpendicularly in the alveolar process or on an incline. All obstructions should be removed by extraction or by lateral pressure.

The force should be applied to the tooth to be moved either at right angles to the long axis of the root (Fig. 48, *a b c*), or at an angle of 45 degrees, *d b c*. By these means the tooth is prevented from rising from the socket. The position of the tooth in the jaw, the density of the alveolar process, the length of the roots, their normal or abnormal condition and length of crowns, will all require consideration in

FIG. 48.

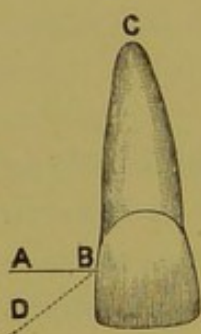
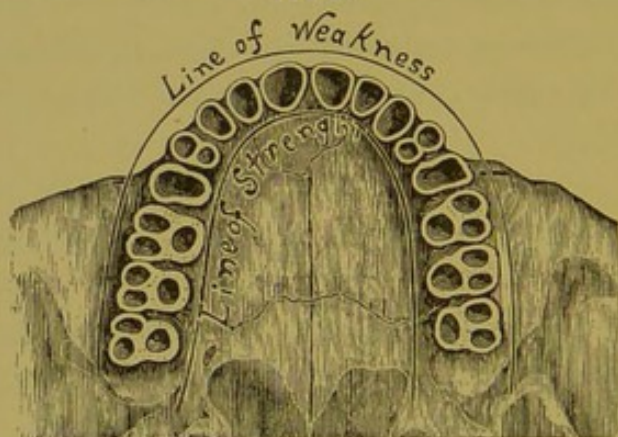


FIG. 49.



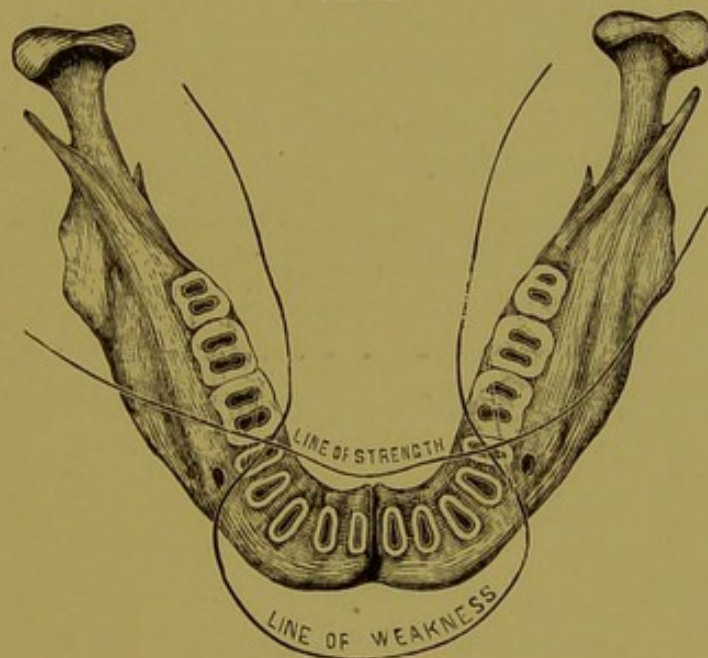
deciding the amount and direction of the force which may be used without elongating the tooth.

If the superior maxillary bone be examined after the teeth are removed, it will be seen that the outer plate of the alveolar process of the superior maxilla is much thinner than the inner plate, which is backed up by the strong, thick bone of the hard palate (Fig. 49), while upon the inferior maxilla the outer plate of bone is thinner as far back as the second bicuspids, and the inner plate is thinner at the part occupied by the molars. The inner plate is thickest between the second bicuspids upon either side, and is reinforced by the symphysis and genial tubercles. The external plate is thickest in spaces occupied by the molars, and is backed by

the external oblique ridge (Fig. 50). When the soft tissues have been removed from the superior maxilla, it is not uncommon to find the roots of sound, healthy teeth extending through the outer plate of bone. After the teeth have been extracted, absorption of the outer plate takes place much more rapidly than of the inner plate. Absorption of the external and internal plates of the inferior maxilla goes on more uniformly than in those of the superior, owing to a more even distribution of bone.

In the application of force, it will be observed that the

FIG. 50.



most pressure is required in the direction of the greatest resistance, and care must be exercised in directing the force toward the weaker parts of the alveolar process. The force should be uniform and steady, and enough to produce absorption of bone without causing inflammation, although in some cases slight inflammation is desired. Here we would discountenance the too rapid movement of teeth, especially when persons are over twenty years of age. I have seen the alveolar process absorbed to such an extent that it was impossible to retain the teeth in their proper places, as new

material was not deposited. I would protest decidedly against the drilling of holes in natural teeth for anchorage, as is practiced by some reputable dentists. There are few cases that cannot be treated by securing a band or cap of thin gold or platinum to the teeth with oxyphosphate of zinc, in which holes may be drilled or hooks or loops soldered at any required point.

CHAPTER III.

MECHANICAL FORCES.

In correcting the irregularities of the teeth, the thoroughly educated dentist will have an opportunity to put in practice his knowledge of the laws of mechanics. These laws are founded upon the action of simple elements which are interposed between the moving power and the resistance, for the purpose of changing the direction of the force. These are called mechanical powers, and are divided into two primary elements—the lever and the inclined plane. The principle of the lever is the basis of the pulley, the wheel and axle. That of the inclined plane is the basis of the wedge and screw. Elasticity, as shown in India-rubber and the spring of metals, although not classified with the primary forces in mechanics, plays an important part in the application of force in regulating teeth. When these laws and their applications are firmly fixed in the mind of the operator, he can readily take advantage of the one which should properly be applied, or, when necessary to apply more than one, can combine them in such a manner as will best accomplish the desired result. The degree and line of force required have much to do with the form of appliances which should properly be used.

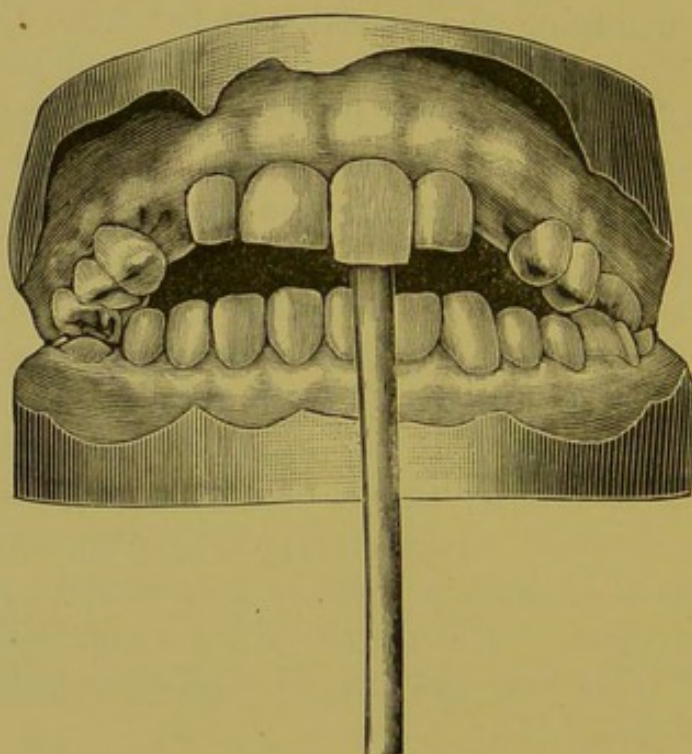
THE LEVER.

The lever consists of a rigid rod, which may be either straight or curved, upheld by a prop or fulcrum, with the resistance and the power to overcome it at opposite ends. There are three kinds of levers: 1st, where the fulcrum is placed between the resistance and power, as in the see-saw; 2d, where the resistance is placed between the power and the fulcrum, as in the wheelbarrow, and, 3d, where the power is between the resistance and the fulcrum, as in a fishing rod. Where the leverage can be multiplied, the

most stubborn cases are obliged to succumb, as is illustrated in rotating teeth set very firmly in the jaw, or those which are crowded closely, or teeth of persons in advanced years, where the alveolar process has become very dense and hard. The increase of power in the lever is obtained by lengthening the rod proportionately or in combining the leverage with another force.

The application of an increased length of rod is limited,

FIG. 51.



for want of space in the mouth; for if above rather limited dimensions it interferes with the tongue or lips. We invariably use the lever in any case in which the anterior superior teeth occlude inside of the inferior teeth, if the case be presented early enough. It is always desirable to regulate these teeth as soon after their eruption as possible, *i. e.*, before the bony tissue becomes dense and hard. Fig. 51 illustrates this simple method.

The young patient should visit the dentist's office early in the forenoon, with the understanding that he is to remain all day. He must remain where the operator can see that the pressure is constant. A round piece of hard wood, wedge-shaped at one end, should be inserted between the teeth, the point resting upon the palatal surface of the superior tooth (which is the body to be removed), the stick resting upon the lower incisor (the fulcrum), and the force applied by the hand upon the lower end of the lever. With constant application of the force the tooth will occlude outside its opponent before the sitting is ended, and this new position will be maintained by the pressure of the lower teeth upon the upper until the new position has become permanent.

THE PULLEY, WHEEL AND AXLE.

The pulley is a wheel with a groove cut into its circumference, and is movable upon its axis. In mechanics the common term for pulley is sheave. The pulley or sheave is placed between the oblong blocks of wood through which the axis passes and supports the pulley in the centre. The cord passing around the pulley is called the tackle. The bucket and weight in the old-fashioned well illustrate the pulley. The wheel and axle is a modification of the pulley. The wheel is fastened securely to the axle, the weight is attached by a rope to the axle, and the power by a rope to the wheel or to handles fixed at right angles to its rim. The steering-gear of a vessel is an illustration of this kind of lever. The forces combined in this appliance can produce but one result in its application to regulating, viz., the rotation of the teeth in their sockets.

The crown and root represent the wheel and axle, the rubber band the power. Fig. 52 illustrates the rotation of a tooth by having a gold band with an arm fitted to the tooth, and a rubber band attached to the arm and stretched to the first bicuspid; as the tooth rotates, the arm is bent at right angles to the band. This application of the wheel and axle will accomplish the rotation of the teeth in the

majority of cases. The difficulty lies in the retention of the teeth after they have been forced into their proper position. The younger the patient the easier this will be accomplished.

To retain them in place, an impression of the teeth is taken in modeling compound, and a model made therefrom. Bands of gold (Fig. 53) are made to fit the plaster teeth with flat- and round-nose pliers, and soldered upon their palatal surfaces. A piece of clasp gold is fitted to these bands and allowed to extend past the lateral incisors; it should then be removed and soldered, and its edges filed perfectly smooth, so as not to interfere with the tongue. The teeth to be

FIG. 52.

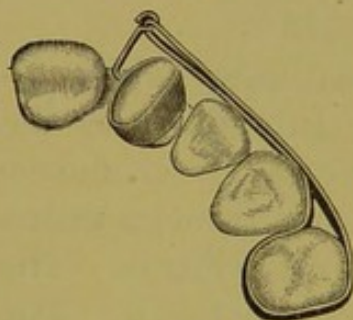
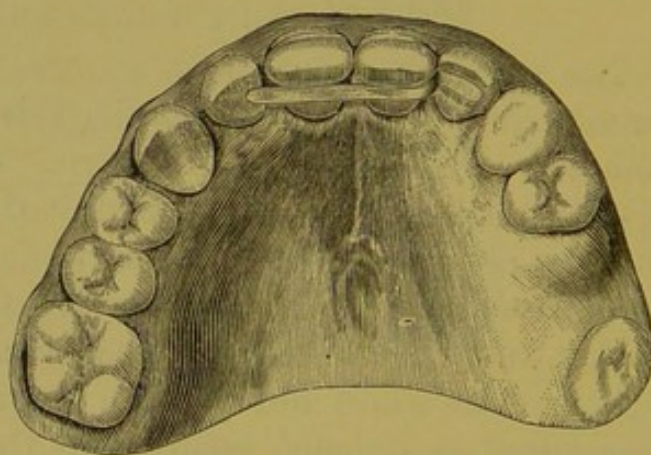


FIG. 53.



FIG. 54.



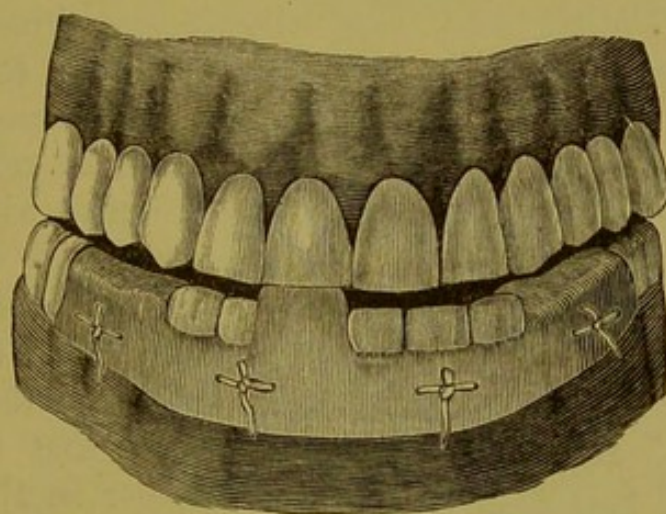
enclosed by the band must be dried, and the band filled with oxyphosphate of zinc and forced into place, as in Fig. 54.

THE INCLINED PLANE.

The inclined plane is a slope or flat surface inclined to the horizon, on which weights may be raised. It is called one of the mechanical powers, because by it a weight can be raised up an incline to a point to which it would be otherwise impossible to lift it. This force is of especial value in cases in which the arch is to be expanded by an appliance; under such circumstances the teeth exert an outward pressure on the opposite jaw, and the articulation of the cusps makes an

inclined plane. If the anterior superior teeth close inside of the inferior teeth, they should be brought out with the lever, and if the inferior teeth are too short to exert a pressure on their opponents, they may be fitted with a platinum cap and cemented securely with the oxyphosphate of zinc. This arrangement will maintain a constant outward pressure upon the superior teeth. Fig. 55 is another illustration of this principle. In this case a metal plate is fastened to the teeth by a ligature instead of an elastic band.

FIG. 55.

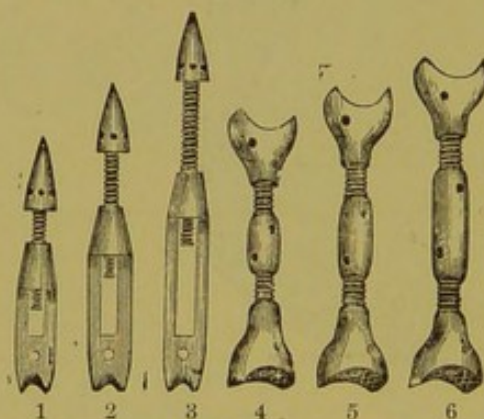


THE SCREW.

The screw, another of the mechanical powers, is also a modification of the inclined plane, and always requires a lever for the purpose of turning it. It may be used for penetrating wood, like a thumb-screw, a gimlet, etc., or it may be used as a moving force, as in raising buildings, or in the familiar letter-press. In these cases it must work in a hollow cylinder with a corresponding thread cut inside, which is called the female screw, or nut. When the screw is turned in the nut it will either advance or recede. This kind of force is of great importance to the dentist. It is a positive force, and when properly applied it can always be depended upon. It is a powerful agent in spreading the dental arch, obstinate cases yielding readily to the pressure.

If the deformity be only on one side of the arch, it will be necessary to obtain either a point opposite, by uniting three or four teeth with bands, and thus giving a strong support, or to insert a rubber plate and vulcanize the nut into place. When the plate is finished, a groove may be cut or a hole drilled to hold the screw in place. The screw may be called a universal force, as it can be made to force teeth in or out. Where the roots are in a diagonal position in the jaw, or are in close proximity to their roots, the screw is very effective. We are indebted to Dr. Wm. H. Dwinell, of New York, for the introduction of the jack-screw as a powerful and direct force in regulating teeth. The following cuts illustrate those now in the market (Fig. 56). Nos. 1, 2, 3 are the original

FIG. 56.

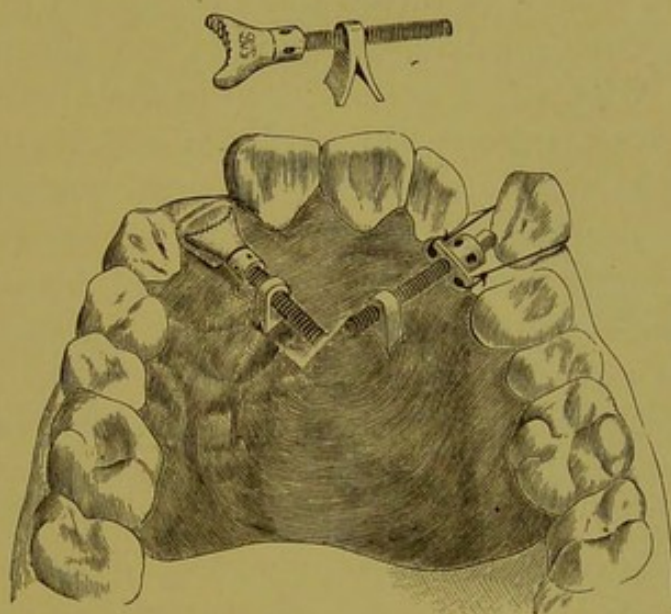


jack-screws introduced by Dr. Dwinell, and are very efficient when combined with rubber plates. The screw is what is termed in mechanics a right-hand thread with a single nut. The distal end of the screw is made conical that it may be directed either in the plate or band around the tooth to be moved. Holes should never be drilled into sound teeth for this purpose. I have invariably been successful in encircling the tooth or teeth with a band of gold or platinum retained in place by the oxyphosphate of zinc, and for the purpose of retaining the band and preventing the accumulation of moisture, have usually drilled a hole through the band to guide the screw.

Nos. 4, 5, 6 show Dr. A. McCullom's invention, and are called compound jack-screws. They are made with a right and left thread, with nuts to correspond, so that when adjusted they will expand or contract if a lever be inserted in the holes drilled through the centre of the bar and moved in either direction. The length of the bars may differ according to the convenience of the operator.

Fig. 57 represents a very effective jack-screw invented by Drs. Lee and Bennett. It consists of a screw and a split-post nut. The plate must be securely fastened in the mouth, but before its insertion the post should be vulcanized into it. The proximal end of one of the screws has a swivel, which is to be fastened to the tooth in order to push it out into line. The other screw has a cross-head upon its proximal end, with holes drilled through it for the purpose of receiving wire ligatures, which have been passed around the tooth to

FIG. 57.



Edinburgh Dental
Hospital and School.

be brought into line. The screw should always be used in combination with a plate or with bands; otherwise, the teeth and gums are liable to be injured. When the bicuspid or molars stand inside of the arch, and a uniform pressure is required on both sides of the arch, we may prevent the nut from working into the gum by placing around the teeth to be moved platinum bands with projectives soldered to the edge nearest their cervical margins (Fig. 58).

FIG. 58.



THE WEDGE.

The wedge is a modification of the inclined plane. The power is applied with a hammer or a sledge to the back of the wedge. It is employed in various ways in ordinary mechanics, as in raising buildings, splitting wood, etc. It is an unsatisfactory force to calculate upon, because the large, flat surfaces produce so much friction. On the other hand, its friction is useful in retaining the wedge in its position. When applied to the teeth, the wedge increases the diameter of the arc of a circle in which the teeth are implanted. It is usually made from a fine-grained wood or of India-rubber. It is a direct and positive force, and is very effective. Teeth with long roots which are set deep in the alveolar process, when the latter is dense and hard, are difficult to start with ordinary regulating appliances. In such cases the wedge is of great service. It will readily move one or two teeth, and not infrequently three will be influenced by its pressure. Wedges made from orange wood are found to be very serviceable, as they can be readily reduced in size as the case may require. When applied to the teeth, they become saturated with saliva, swell, and in so doing force the teeth apart. When a rubber wedge is used, we select one slightly larger than the space between the teeth, and by its elasticity the teeth are spread. The rubber wedge performs its work with greater rapidity, perhaps, but it causes more pain than the wooden wedge. Owing to the elasticity of the rubber, the teeth vibrate with each effort of mastication, whereas they would be held firmly by the wooden wedge.

January 9th, 1879, a woman, twenty-seven years of age, teacher by occupation, came to me for treatment. Upon examination we found the V-shaped arch, dense and hard, and removed the first bicuspid on the right side and the second bicuspid on the left side, securing a silver plate to the first molars. The bands extended around the cuspids, with a nut and screw upon either side. Instead of drawing the cuspids back into the spaces made vacant by the first bicuspids, as we expected to do, the cuspids became the point of

resistance, and the bicuspid and molars upon the right side and the molars on the left side were brought forward into the spaces. As the incisor and cuspid teeth were the only point of resistance, the molars being all loose, we were puzzled how to proceed. We finally decided to use the incisors for the fixed point, and with the compound force of the screw and wedge (Fig. 59) carry the anterior teeth backward. A rubber plate was fitted to the roof of the mouth and about the teeth that were to remain stationary; the edge was beveled where the screw was applied, to prevent this being forced against the gum. I secured a jack-screw of the proper length firmly to the cuspid upon the right side, allowing it

FIG. 59.


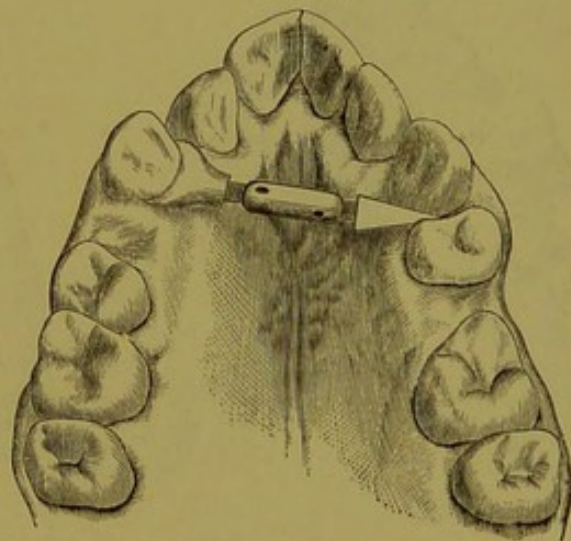


FIG. 60.



to come in contact with the tooth I wished to move, the bicuspid of the opposite side (Fig. 60). When this was forced laterally sufficiently, I removed the nut on the end of the screw, and replaced it with a wedge, which was inserted between the bicuspid and the cuspid. The cuspid being firm, and inflammation having been already produced around the bicuspid, it yielded readily to the powerful pressure of the screw and wedge. When this had proceeded as far as possible, the wedge was removed and a thicker one substituted. As soon as the tooth reached the molar it was secured to it by ligatures, and so held in place. We fastened

our jack-screws firmly to the cuspids and forced them laterally until inflammation set in. Wedges were put upon either end of the screw, being inserted between the cuspids and the lateral incisors (Fig. 61). The laterals, being solid, acted as fulcrums, and the cuspids were easily forced into place. These were then fastened by ligatures.

To move the lateral incisors a short screw was employed, with wedges in which holes had been drilled. To each central a linen thread was tied and then carried around the lateral, over the end of the wedge on the screw, passed

FIG. 61.

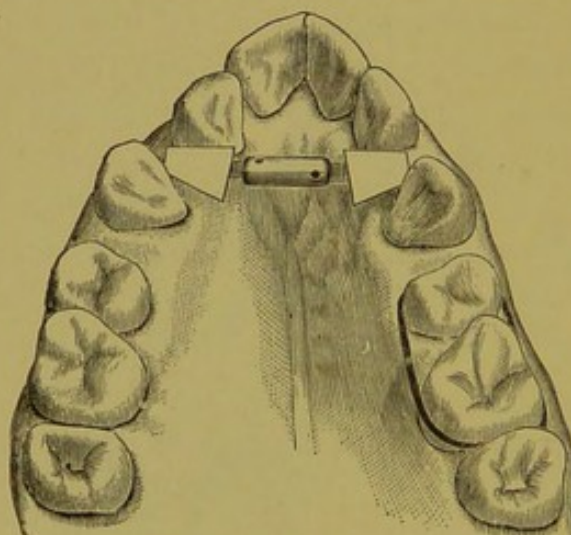
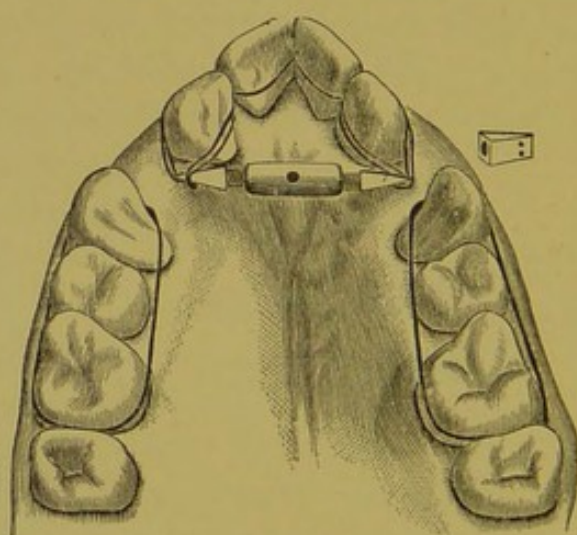


FIG. 62.



through the holes and tied fast (Fig. 62). By turning the screw the laterals were not only forced outward, but were rotated in their sockets. When this was accomplished, a plate was fitted to retain the teeth in place and also to draw the centrals back into the arch. This was done by running a piece of gold wire across the labial surfaces of the centrals, from which a rubber band was carried posteriorly to a loop in the rubber plate. As soon as they reached the proper position, another plate was inserted, with a gold band passing over the outside of the teeth to hold them in place.

ELASTIC FORCE.

Each of the six mechanical forces has its proper place in the art of regulating teeth, and when skillfully applied each is an effective agent. The application of these forces, however, is limited. In looking about for effective powers we find that the force of elasticity as found in India-rubber and the spring of metals combines all that is necessary to render effective either the most rudimentary or the most intricate appliance. The simplicity of the application of this force makes it very desirable in dentistry. Elastic bands cut from French rubber tubing can be universally used, and are applicable to every case of irregularity of the teeth. There is a power in elasticity peculiarly adapted to the correction of irregularities, and which cannot be obtained by any of the forces previously mentioned, viz., a constant, *équable* pressure, which may be either increased or diminished by the application of larger or smaller bands. This constant pressure produces a rapid absorption of the bone which opposes the restoration of the tooth to its normal position.

When the rubber bands are applied to the teeth, the point of resistance becomes a very important feature. The resistance must equal or exceed that of the body to be moved; otherwise, the weaker will be moved by the stronger force. If a tooth upon one side be irregular, a tooth, or, if necessary, several teeth, at the opposite point must be selected to withstand the pressure of the tooth to be moved. This not only requires a thorough knowledge of the anatomy of the teeth and jaws, but ability to judge the comparative resistance of each tooth. We once tried to draw by the gold band and screw power a right superior cuspid into the space made vacant by the loss of a first bicuspid. The point of resistance was the second bicuspid and the first permanent molar. It was found, after turning the nut two or three days, that the bicuspid and molar had been drawn forward half the space instead of moving the cuspid into the expected position.

When the rubber bands are employed in cases requiring much force, it is generally a good plan to fit a rubber plate

to the teeth and jaws, to which arms of rubber or gold are attached in such a manner that the teeth may be drawn in or out, as the case requires. The plate should be fastened by ligatures to fixed teeth, and acts as the point of resistance. Rubber bands cut from tubing (or, better, from rubber dam, as suggested by Dr. G. V. Black) are attached to the arms and carried over the teeth to be moved. Fig. 63 is from the model of the teeth of a boy fourteen years of age. The lower

FIG. 63.

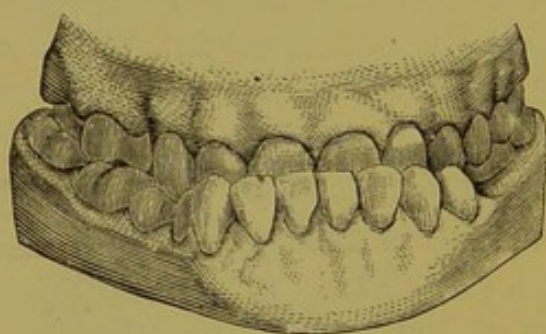


FIG. 65.

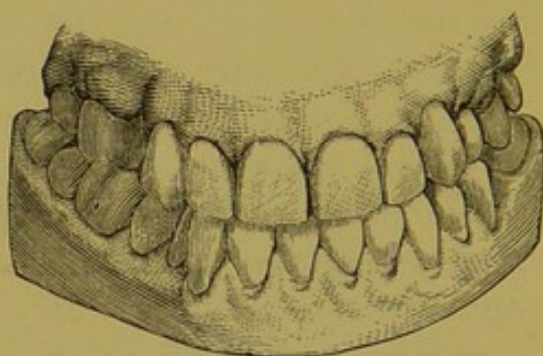


FIG. 64.

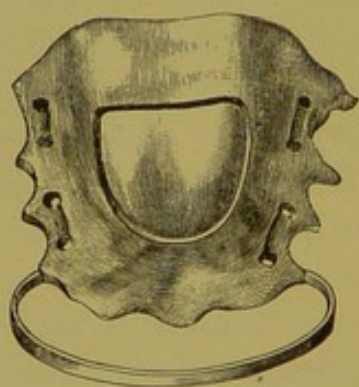
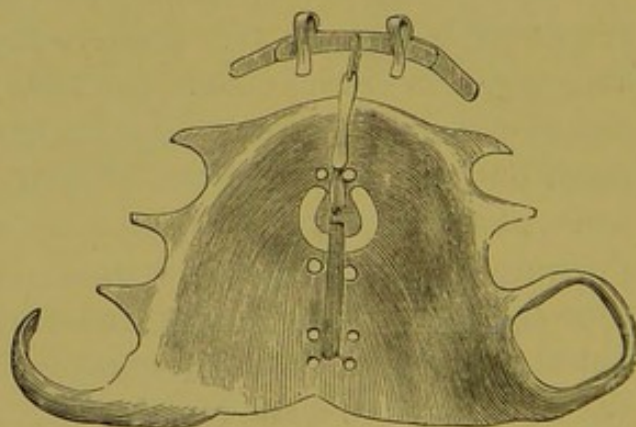


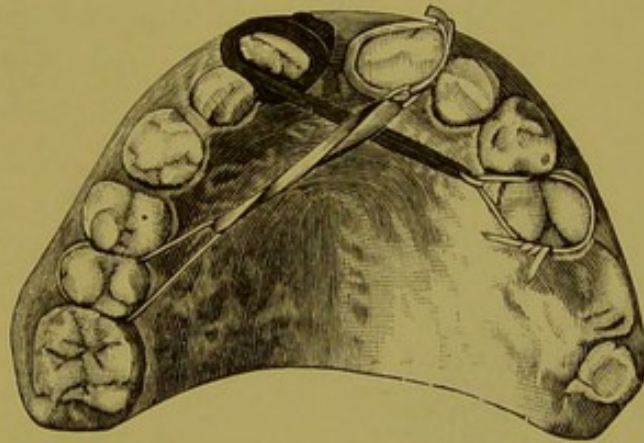
FIG. 66.



jaw occludes outside of the upper jaw. A plate with gold band attachment (Fig. 64) was made to fit the jaw, extending from the first bicuspid around the incisors and cuspids, separated from them by a distance of a quarter of an inch. The plate was secured to the first molars and first bicuspid. Rubber-dam rings were fastened to the band and carried over the incisors and cuspids. The teeth were in a short

time brought out in place, as illustrated in Fig. 65. Fig. 66 illustrates a plate made for the purpose of drawing in the protruding central incisors of the upper jaw. A band of gold is adjusted to the labial surfaces of the teeth, to which hooks are soldered and bent over the cutting edges, to prevent the band slipping up to the gums. An elastic band is fastened to the centre of the plate and attached to the gold between the central incisors. By this means the teeth are readily brought into their proper positions. When moving teeth or twisting them in their sockets by elastic bands, it is desirable to start the teeth with wedges of wood or rubber,

FIG. 67.



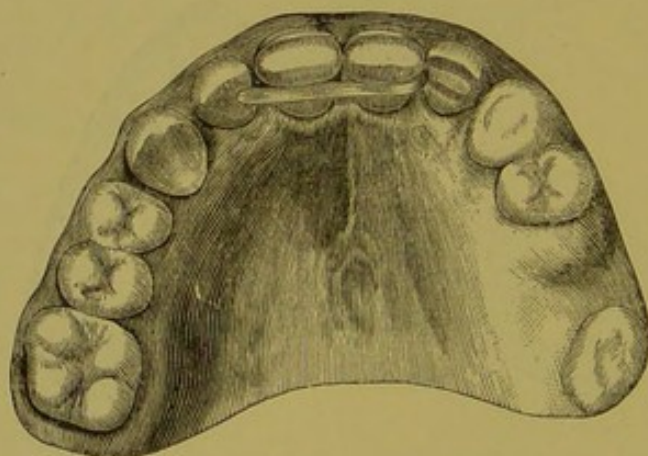
or with the jack-screw, to produce absorption of bone about the roots and make the resisting power less complicated when the bands are finally applied.

Fig. 67 represents the model of the mouth of a woman twenty-six years of age. The central incisors diverge from the median line, and are also twisted in their sockets. Rubber bands were placed about the teeth to draw them together. The pressure required was so great that two bands, each one-fourth of an inch wide, with a linen ligature tied with a surgeon's knot on the outside of the bands, were required. Even with this powerful force it took three weeks to bring the teeth

together. Having produced absorption of the alveolar process, the teeth were easily rotated in their sockets in the following manner:—

A band of platinum was accurately fitted to the crown and soldered. A hook was made by inserting and soldering a pin from an artificial tooth into a hole drilled in the labio-distal angle of the band; this band was fastened upon the tooth with oxyphosphate of zinc; a band of rubber was then attached at one end to the hook, and at the other to a bicuspid, the tooth being thus rotated into place. Another plan is to dry the tooth, coat it with sandarac varnish, and while moist to wind about it a strip, cut from rubber dam, three-

FIG. 68.



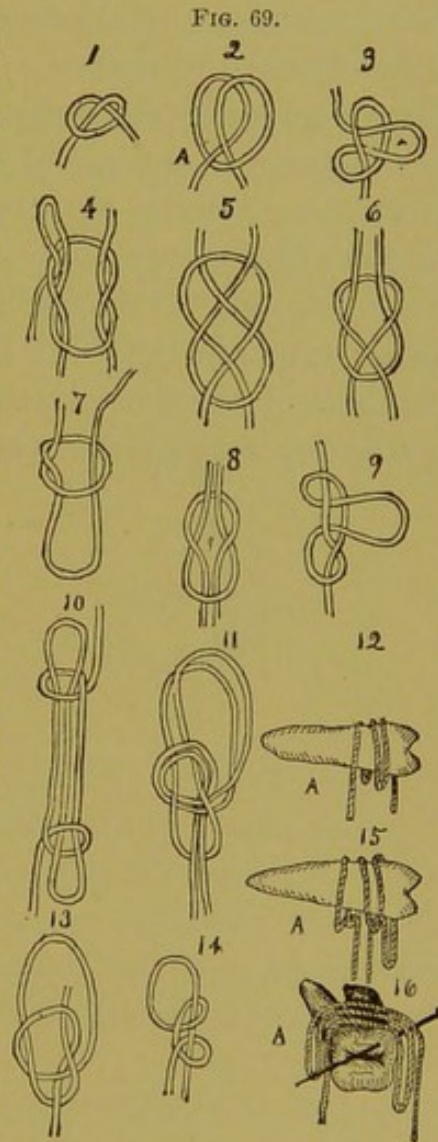
sixteenths of an inch wide and two inches long, with a string tied in its middle, so that the rubber dam doubles upon itself. The band should be wound in the same direction in which the tooth is to be rotated, and the winding should be continued until the end of the rubber reaches the distal edge of the tooth; the string should now be drawn across the mouth and tied to a molar or bicuspid tooth. Either of these arrangements is very effective.

The trying part of these operations is to retain the teeth after they have been brought into place. The following method can be relied upon for this purpose: A band of gold

or platinum, made to fit the teeth, is placed on a model, to which is attached a bar extending beyond the lateral incisors (Fig. 68). This is fastened to the teeth, after they have been dried, with oxyphosphate of zinc. This band must remain on the teeth for from six months to two years, when a deposit of bone will have formed which will in most cases hold the teeth in place.

LIGATURES.

Ligatures are cords, strings, or wires for binding the teeth while regulating, for the attachment of other appliances to the teeth, or for holding them securely after they have found their places. Silk, linen or Chinese grass ligatures serve a good purpose, but the ordinary silk twist found in dry-goods stores does the work better than any other ligature. When ligatures are used to regulate, they act upon the teeth to be moved by attaching them to a fixed point, and also by the shrinkage of the fibre when moistened. Care should be taken in tying the knot of a ligature to avoid its working up under the gum. Various knots can be made for this purpose. Fig. 69 shows some good ones. Since the introduction of Dr. Magill's band for regulating teeth, the ligature has become a very useful adjunct for fastening appliances at any point upon the band where a pin has been previously soldered to it.



THE ELASTICITY OF METALS.

The molecules of metals are held together by a force called cohesion. These particles change in their relative positions when the metal is acted upon by an external force. If this force be removed before these changes exceed a certain limit, the particles return to their previous positions. This power of returning to original form is called elasticity. This elasticity of metals may be utilized, in regulating teeth, with powerful results, which are only limited by the amount of spring which a metal possesses. Metals are classified as perfectly elastic and inelastic, which terms imply that there are many degrees of elasticity between the two extremes. It is now claimed that a metal cannot be perfectly elastic; that is, it cannot go back exactly to its previous form. It is also claimed that every body is elastic in a degree. Pure gold itself belongs to the inelastics; when alloyed with other metals, *e. g.*, platinum, it is a perfectly elastic metal. Some members of the dental profession have utilized this force for regulating with great success.

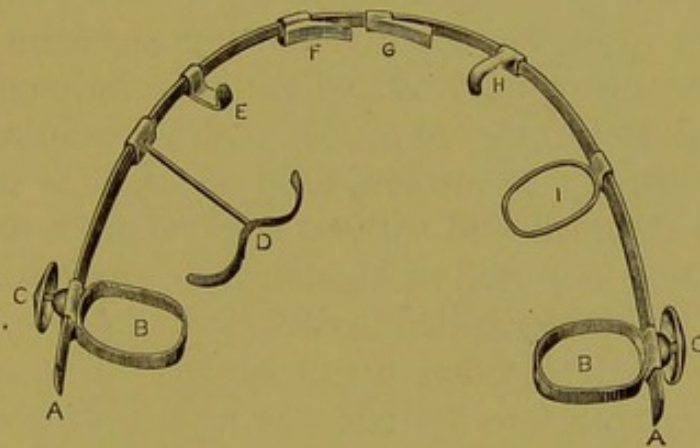
CHAPTER IV.

CONSIDERATION OF DIFFERENT METHODS.

THE PATRICK METHOD.

The system of regulating devised by Dr. J. R. Patrick, of Belleville, Ill., is unlike any of its predecessors. It is based upon the elasticity or spring of a bow-spring wire of platinized gold, which is anchored by suitable bands to teeth selected for this purpose. The wire is half round and of a standard size; the bands for anchorage are attached to suitable slides, fitting the wire accurately, so that they can be at

FIG. 70.



once adjusted to the teeth selected. The force of the bow-spring wire is applied to the teeth which it is desired to move by means of wedges, hooks, T-bars and catches, of shapes and sizes as desired, which are attached to similar slides, all fitting the bow-spring wire, so that any desired number or forms of appliances can be readily adjusted at the same time.

Figure 70 represents the bar or wire, which is bent so as to conform to the buccal surfaces of the teeth; and the different attachments are also shown. In use, the anchor bands are properly adjusted and retained in position by set-screws passing through them, and provided with a head or button

for turning them, as shown. The wire rests upon the buccal surfaces of the molars to which it is attached, and the hooks, wedges or other appliances are brought to the positions desired.

Any tendency of the anchor bands to change their position upon the teeth may be obviated by lining them before adjustment with thin oxyphosphate of zinc. If the bar incline to slip upward toward the gingival margin, this may be obviated by an attachment in the shape of a small hook resting upon one of the teeth.

The apparatus acts as a lever, the power being the elasticity of the bow spring, the fulcrum, the teeth used for anchorage, and the resistance the tooth or teeth to be moved. Rubber bands may also be used as auxiliaries.

This appliance is ingenious and possesses many advantages. It is claimed by the inventor that any form of irregularity can be successfully treated with it. Only one band is needed, and no impression of the mouth is required; being composed entirely of incorruptible metal, it is easily and thoroughly cleansed, and without removal from the mouth. It can also be adjusted or tightened at any time without removal. It can be applied to either jaw with equal facility.

The principal objection urged against this appliance is that the teeth used as fulcrums or attachments are sometimes not sufficiently firm to resist the pressure they are required to sustain, and in that case will move before the tooth which is being operated upon. This could probably be obviated by attaching to more teeth.

The construction must, of necessity, be accurate, and if made by the dentist, requires great nicety of workmanship. But all difficulties of this nature are banished by the fact that it can be obtained at the dental depots.

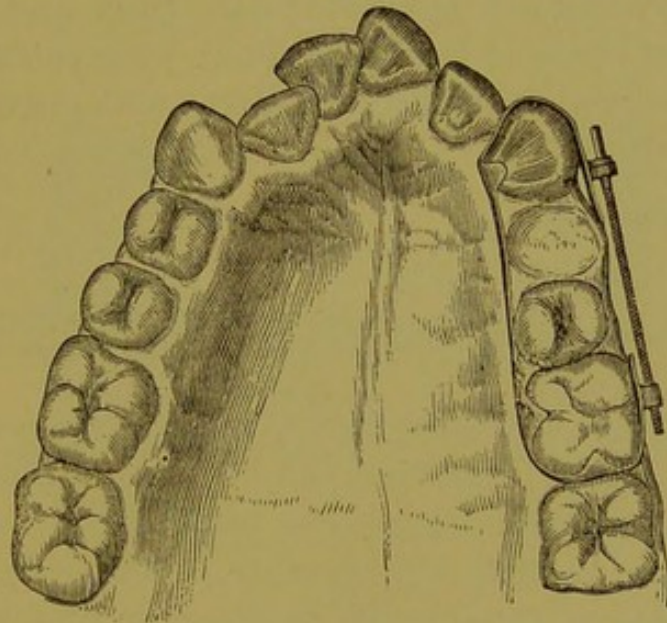
THE FARRAR METHOD.

Of the distinctive systems of apparatus for regulating the teeth, that devised by Dr. J. N. Farrar, of New York, was among the first to be presented to the profession. It was

introduced by him about 1876. The principle upon which it operates is peculiar to the system, which is called by the inventor "The Positive System." In all (or most) methods employed previously, the endeavor was to bring to bear upon the tooth or teeth to be moved a force that should be, so far as possible, *continuous*. Wedges, rubber bands, springs, etc., even the inclined plane, are all examples of this continuous force, which it is the endeavor to continue, in greater or less degree, from the beginning to the end of the operation.

Dr. Farrar's system is peculiar in this, that he uses only

FIG. 71.



the *screw* as a power, which he considers to be the only force capable of being applied with a definite and positive result. His theory is that a tooth should be moved a certain distance, as far as it is safe or proper, at *one* push or thrust, and then retained immovable in that position for a certain length of time. By this means he claims that the tissues in front of the advancing tooth are compressed, and kept compressed, to such a degree that absorption takes place readily and without inflammation, thus making place for the tooth being moved, while at the same time a deposition of tissue

takes place *behind* the tooth, tending to retain it in its new position. This, then, is the principle of the Farrar method: a positive thrust to a known and definite extent, the tooth being retained by the appliance in the new position, and a period of perfect rest allowed to intervene before more force is applied.

The apparatus by which the results are accomplished is constructed of 18-carat gold. An illustration of this appliance is shown in Fig. 71.

In all of his appliances a screw is to be found, upon which the threads are cut—sixty to the inch. The end of the screw is fitted to be turned with a watch key (Fig. 72); one-half a turn twice a day will move the tooth $\frac{1}{120}$ of an inch a day, which rate of progress Dr. Farrar finds, by experiment, to be about the maximum rapidity consistent with safety; and he

FIG. 72.



claims that this will produce only a slight uneasiness or sense of tightness, and no pain. He also claims that patients may be easily instructed to turn the screw themselves, and to regulate the pressure by the sense of tightness, thus saving many visits to the office and the time of the operator.

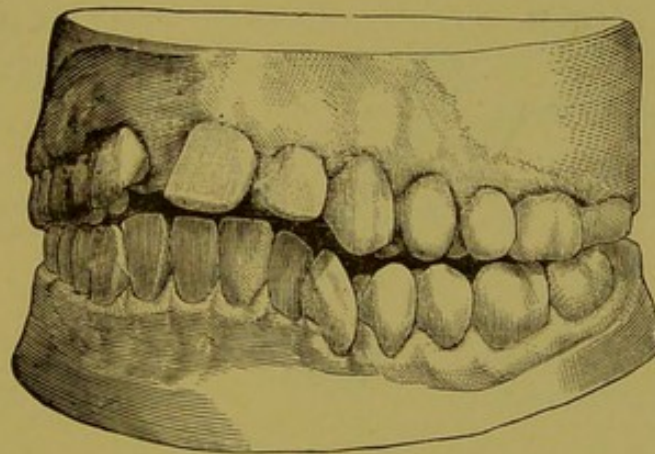
THE BYRNES METHOD.

Dr. B. S. Byrnes, of Memphis, has devised a method of regulating which is worthy of notice.* He uses thin gold bands, 20 or 22 carats fine, the motive power being the spring or elastic force of the bands. No plates are used, the anchorage being obtained upon such of the teeth as are suitable. "The fixed points having been determined, the teeth to be regulated are connected to them by means of a

* *Dental Cosmos*, May, 1886.

thin gold band. This is so manipulated as to form a spring or series of springs, so adjusted as to bear most powerfully on the misplaced tooth or teeth. For instance, in the case of a misplaced incisor, to be drawn inward, a continuous band embracing the first molars on each side is fitted around the outside of the arch. With a dull-pointed instrument like a burnisher, the ribbon is then pressed into the interstices of the teeth over which it passes, thus forming it into a series of small springs. The incisor, being the most prominent point, will naturally be most affected by the pressure exerted by the springs, and in a short time it will be found to have moved away from the band, so that it is no

FIG. 73.



longer affected by the tension of the springs. The apparatus is then removed, the ribbon is annealed, straightened, and a small piece cut out of it; the ends are soldered and it is replaced, and the band formed into a spring, as before."

This method is stated to be equally applicable to both simple and complex conditions. Sometimes the spring of the band may be advantageously supplemented by other aids, as the insertion of a rubber wedge at particular points. The fixture in all cases should be perfectly tight-fitting on the teeth. It may be applied gradually, so that the teeth yield, and the appliance will then more readily go into its place. When the rubber wedge is to be used, it should

be inserted behind the band opposite to one of the interstices; then being stretched, it can be worked to the desired spot, when the ends should be clipped off.

Fig. 73 illustrates a case treated and described by Dr. Byrnes. The patient was a young lady of eighteen years, who had lost the right superior central at the age of eleven. A vulcanite plate had been worn for three and a half years. The remaining upper anterior teeth had been forced outward until they stood at an angle of forty-five degrees when first seen. The lower incisors stood inside the arch, and the chin was consequently wrinkled and upturned. The lips wore a constant pout, the mouth being what is termed peaked, the molars being the only teeth that occluded properly.

FIG. 74.

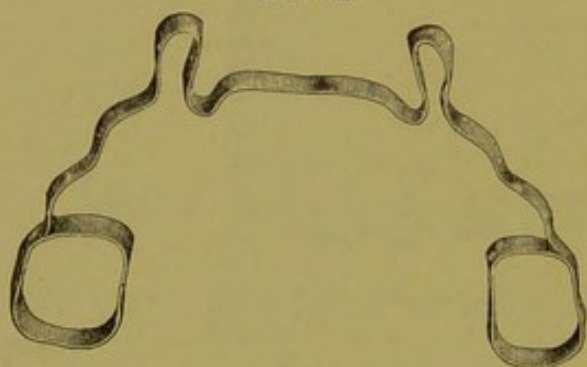



FIG. 75.



In treating this case, it was the object, 1st, to correct the "peakedness" by producing a broader and more oval arch; 2d, the reduction of the projecting teeth; 3d, the improvement of the articulation, and 4th, the closure of the space caused by the loss of the central. The last was undertaken first. A heavy band (Fig. 74) was used to force the cutting edges of the right central and left lateral together. A very thin narrow gold band was then fitted to embrace the necks of these teeth, and a wedge of wood was inserted on the side next the cutting edges, causing the teeth to move vertically toward each other. Another band (Fig. 75) was then constructed to move the incisors backward, and was placed in position without removing the first. It embraced the

cuspid and bicuspid on each side; the connecting band was pressed into the interstices, and rubber wedges inserted. The effect of this was not only to cause backward pressure upon the incisors, but an outward pressure on the cuspid and bicuspid. At the end of three weeks the work was practically accomplished, and the fixture was replaced by that shown in Fig. 76, which completed the movement of the teeth, and acted as a retaining piece. The small hook counteracted the tendency to slip up toward the gum.

The regulation of the lower teeth was begun soon after that of the upper jaw was completed, and was carried through in about three weeks. A band, shown in Fig. 77, was used, clasping the first molars, passing around the bicuspid and

FIG. 76.

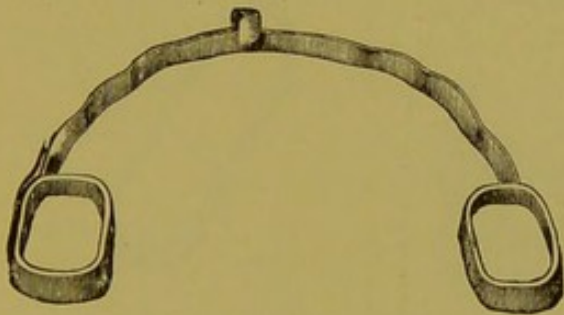



FIG. 77.



FIG. 78.



behind the incisors. A wooden wedge was placed between the incisors and the band, and springs formed by pressing the latter into the interstices between the cuspid and bicuspid. In two weeks this apparatus was replaced by that shown in Fig. 78. A little block of rubber under each of the rings, which rested upon the cuspid, completed the work in a week. The rings being pressed back to preserve the ground already gained, the piece was worn as a retaining plate. The final result is shown in Fig. 79.

Fig. 80 illustrates the teeth of a lady aged twenty-eight. The lower cuspid closed in front of the upper; the dentes sapientes were erupting into a crowded arch, and pushing

FIG. 79.

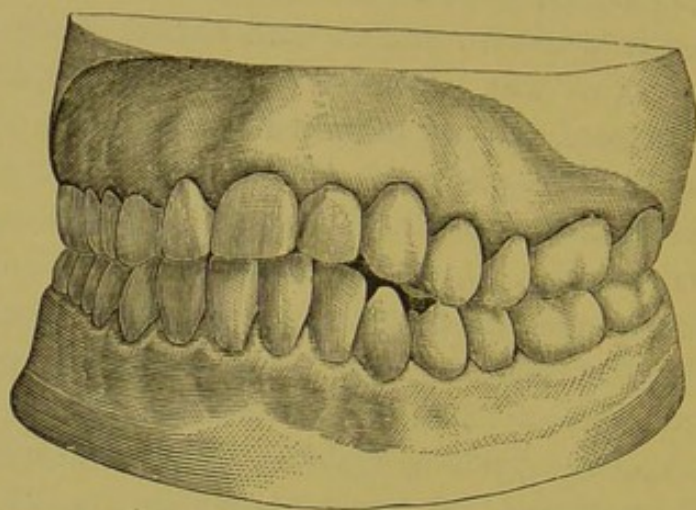


FIG. 80.

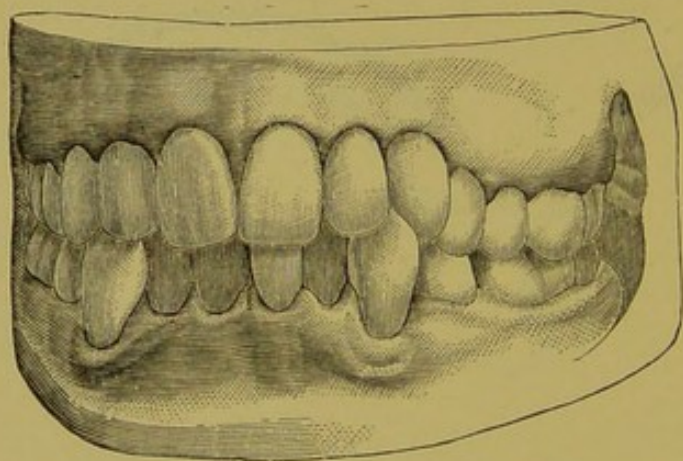
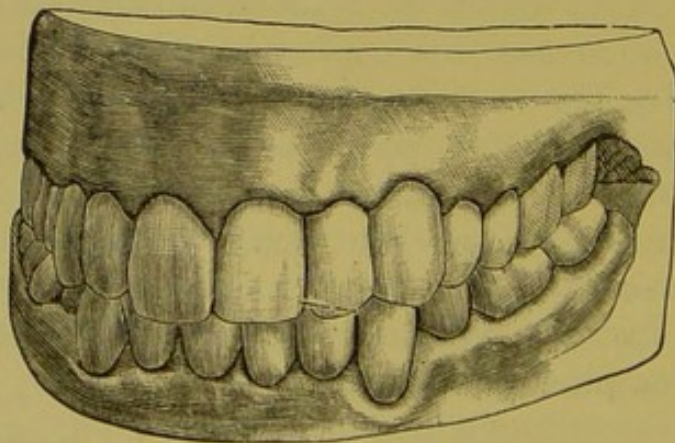


FIG. 81.

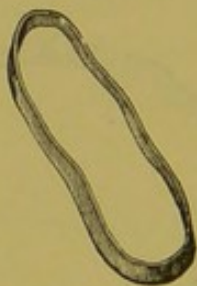

FIG. 82.



the lower cuspids still further forward. The first bicuspids were extracted to make room, and the cuspids were moved backward by means of a band, shown in Fig. 81, which embraced the first molar and cuspid. The molars were capped to prevent occlusion, but the age of the patient preventing rapid movement, the bands were cut and tightened only twice a week. In ten weeks the work was completed—Fig. 82 showing the appearance at the conclusion of the treatment.

Fig. 83 shows the upper jaw of a lady aged twenty-two, who fell at the age of ten years, striking the superior teeth in such a way as to knock out the right lateral and dislocate the other incisors, the left central remaining at an angle of thirty-five degrees after its attachment was again renewed. The incisors were separated from each other, and the deformity much more marked than shown by the cut.

Fig. 84 shows the appliance in position used by Dr. Byrnes in this case, by which the regulation was completed in eight sittings. The connecting band was crimped as shown, thus converting it into a series of springs. Fig. 85 was used in a case in which the right central overlapped the lateral. The springs were adjusted so as to turn the tooth, the work being accomplished in four days, after which it was retained by a simple band, with wings resting on the left central and under the right lateral.

THE COFFIN METHOD.

Dr. Walter H. Coffin, of England, read a paper before Section XII of the International Medical Congress, held at London, in August, 1881, upon "A Generalized Treatment of Irregularities." Upon that occasion he gave the dental profession one of the most valuable appliances for regulating teeth that has ever been devised. It is called by the inventor an "expansion plate." The principle upon which this system of regulating is based is quite different from any other. It was not new when presented as above, having

FIG. 83.

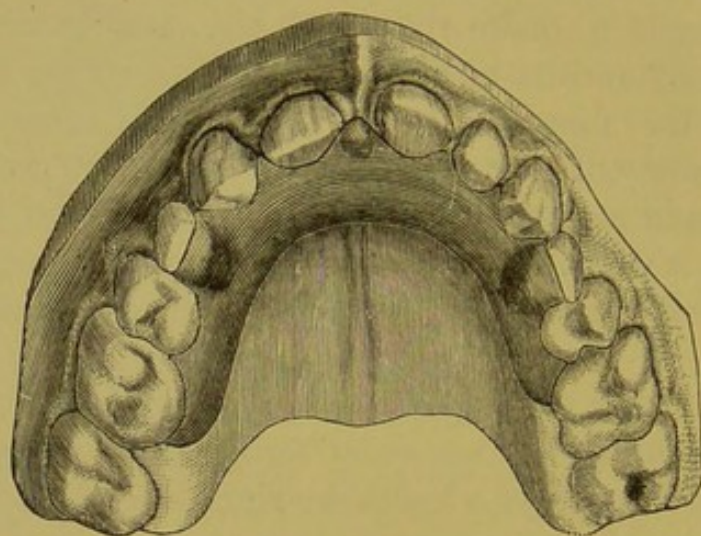


FIG. 84.

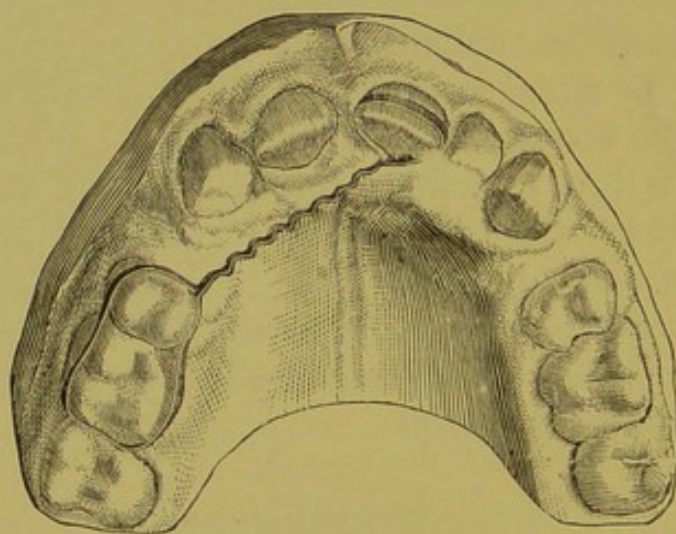
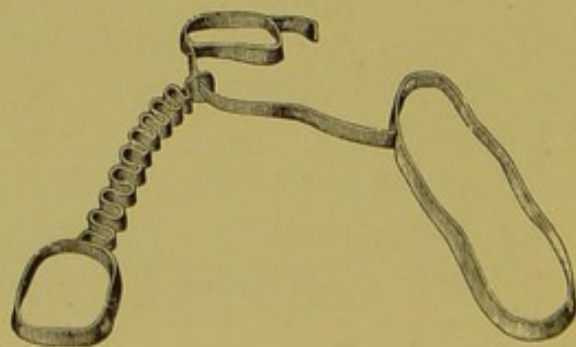


FIG. 85.



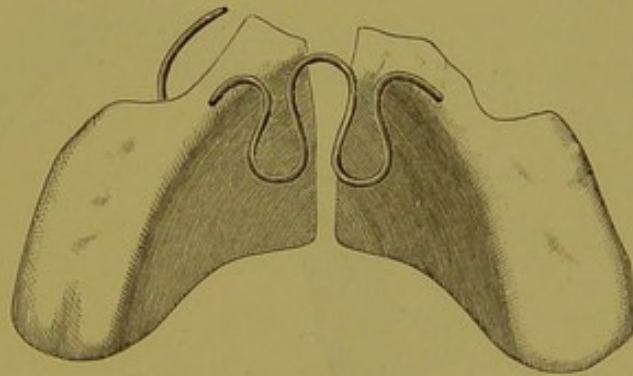
been used by Mr. Coffin and his son for a period of twenty-five years. Since it became known in this country it has come into very general use, and is popularly known as the "Coffin Split Plate" Method.

The principle upon which this method acts is by the construction and adaptation of a vulcanite plate, not only covering the hard palate, but capping the posterior teeth; the plate, after vulcanizing and finishing, is to be split into two halves. These halves are connected by a piece of wire bent into the shape of the letter W (Fig. 86), having the ends flattened and imbedded in the vulcanite plate. This wire, or spring, being suitably adapted to the cast, and bent with the proper shape while cold, is pressed into the wax

FIG. 86.



FIG. 87.



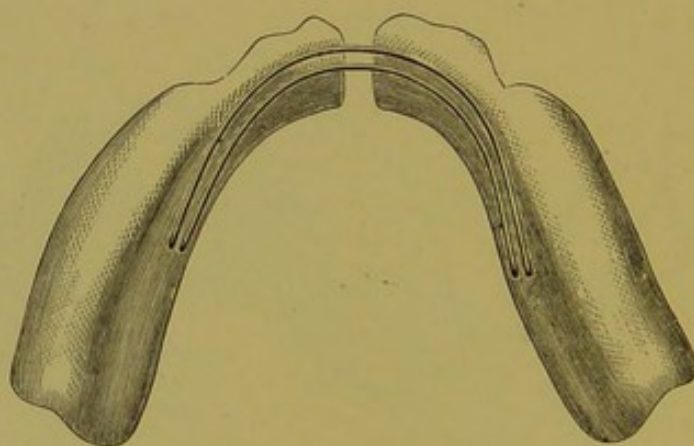
model upon the cast until the proper position is secured. To prevent its displacement while packing, bits of binding-wire may be twisted around it at various points, which will hold firmly in the plaster. A piece of heavy tin-foil covering the wax model on the lingual surface will bring out the rubber with a polished surface under the wire. The piece having been vulcanized, is split lengthwise with a fine saw (Fig. 87). The plate is now introduced and properly fitted. To secure accurate adaptation to the teeth, a perfect impression and a perfect model are necessary. The inventor recommended gutta-percha or ballata gum (modeling compound).

The plate being properly adjusted in the mouth, is worn without any tension for a day or two—until the patient has

become accustomed to its presence. The two halves are then separated by being stretched apart, by which means the piano-wire is converted into a spring of great power and constant tension. Any desired direction may be given to the force, and the pressure thus brought to bear where it is most needed.

The primary effect of this arrangement is, of course, to expand the arch laterally, thus affording room for the rotation or removal of the irregular teeth. In a large majority of cases such an expansion is either absolutely essential or highly desirable, and by no other appliance can it be so readily obtained. The inventor even claims that, paradoxi-

FIG. 88.



cal though it may seem, it is less painful and troublesome to secure in this way ample spaces between all the front teeth at once, than to wedge two of them apart in the ordinary way, with the advantage of easily maintaining their separation.

This appliance, as will be readily seen, is designed for an altered shape or outline of the dental arch; where this is not needed, the power of the spring, or of a suitable spring properly inserted, may be brought to bear upon any tooth which it is desired to operate upon, so as to produce rotation or movement in any direction. In this case the plate is not split, but wire is anchored into it in a suitable position, its

end protruding to bear upon the tooth it is desired to move. Wires can be inserted so as to operate on one or two teeth at the same time (Fig. 87).

The same principle may also be applied to the regulation of teeth in the lower jaw. In this case, the plate (Fig. 88) is made in a horseshoe form, and the wires lie along its lingual aspect in a simple U-shape or semicircle, the plate being divided at the median line.

By stretching the wire more and more as the case progresses, an expansion to a very considerable extent may be effected, and so easily that caution must be observed not to exceed the intended results.

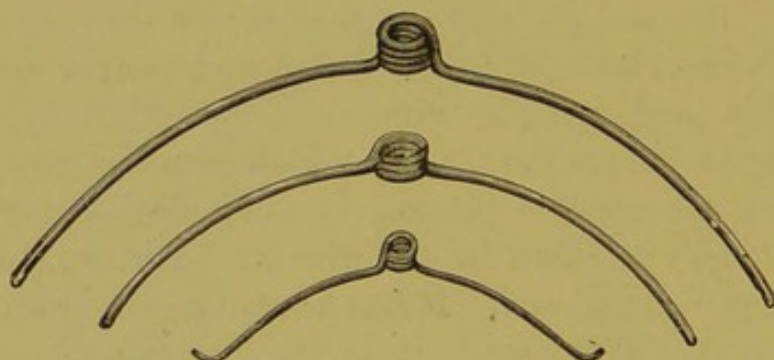
PIANO-WIRE.

Piano-wire is manufactured in Germany, England and America. It is made of the best steel, drawn through a draw-plate to the required size. The polish and temper are given during this process. The wire must be extremely pliable and strong to endure the tension which it undergoes during the tuning process of a piano. It must also be perfect in construction, as any flaw in the wire would cause it to snap when being manipulated. It has advantages over any other wire for dental purposes. It is inexpensive, has greater elasticity than other wires, and can be more easily adapted to a variety of cases. It can be bent in any way necessary to obtain the greatest amount of force, and can be applied to any place in the mouth, on account of its small size and weight. Sizes 18, 19, 20 are better suited to the majority of irregularities, the strength of the wire to perform a given operation depending upon the age and constitution of the individual and the character of the irregularity. In youth or in delicate organizations, No. 20 is the size best adapted to regulate; the sizes should decrease to No. 17 as the years advance, or as the stubbornness of the irregularity demands. The selection of the wire, and adapting it to each special case so as to obtain the best results and avoid producing inflammation, will require the nicest discrimination.

THE AUTHOR'S METHOD—THE COIL SPRING.

In order to obtain the best results, the elasticity of the wire was increased by coiling it from one to three times around a mandril. The author has placed his coil springs at the dental depots for the benefit of those who cannot take the time to make their own springs. The mandril is driven into the bench, and with the right hand the wire is coiled about it as many times as required, the short end being held firmly by the left hand. The coil ends directly at the starting-point, and gives thereby the greatest elasticity and length of arms. When necessary, the long end of the wire can be bent with square-nose pliers to make it on the same plane with the other arm. Fig. 89 shows the coil spring.

FIG. 89.

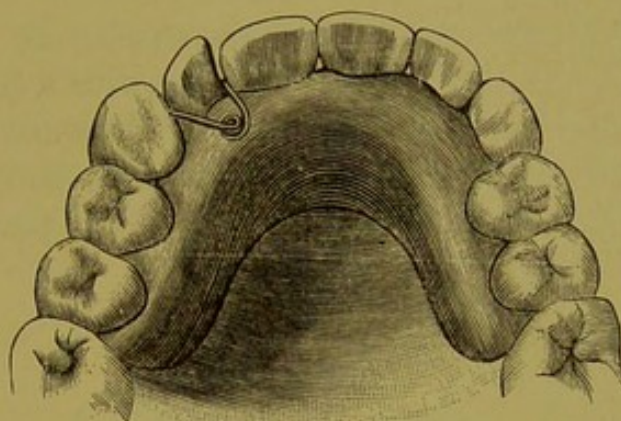


The coil of the spring works on the same principle as the mainspring of an American watch, which between two points measures a uniform period of time. The extremities of the arms of the spring travel over a given space with like uniformity, which gives a mild, uniform pressure to the jaws and teeth. The arms may be bent or cut at any length to suit the case in hand. They may be used in connection with a rubber plate, or with bands of gold or platinum fastened to the teeth with oxyphosphate of zinc. With holes properly drilled in the plate or bands, and the arms fitted into them, the spring will stay in position. When the spring is used without a plate, it may be well to fasten the wire to some of the teeth to prevent its being swallowed.

The following histories will illustrate some of the cases in practice:—

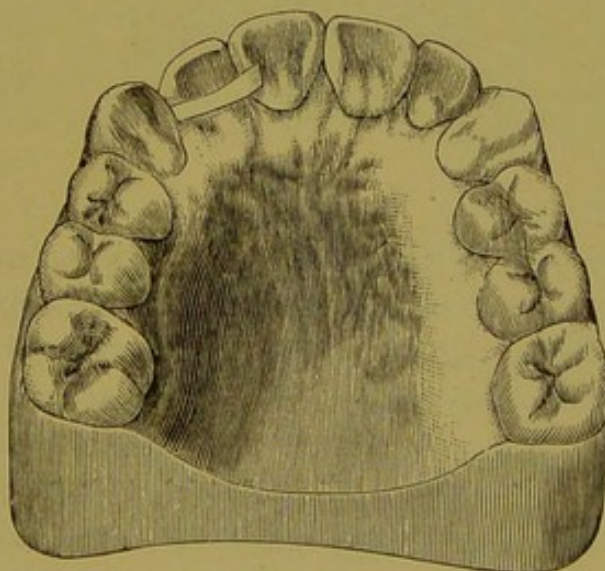
The following models of the mouth of a girl sixteen years of age were presented to the author by Dr. J. F. Austin, of

FIG. 90.



Chicago. The right cuspid had encroached upon the lateral incisor to such an extent as to twist and force it out of position, leaving only about one-half the space necessary to

FIG. 91.



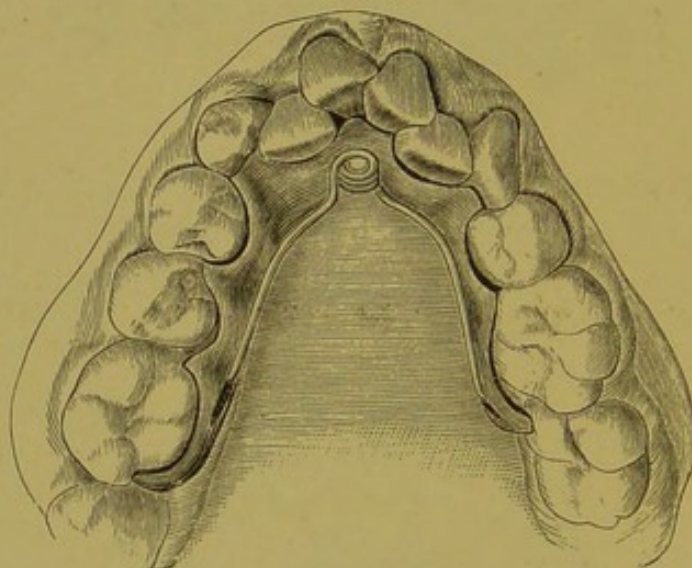
rotate the tooth into place. A plate was made to fit the mouth and teeth, and a coil spring inserted, with arms meeting the cuspid and central incisor. The spring was

secured to the plate by a pin driven into the plate (Fig. 90). By the lateral pressure of the spring the teeth were pushed apart, making space for the teeth to be rotated into place. Fig. 91 shows the tooth secured in position by the Magill retainer.

SPREADING THE DENTAL ARCH.

On an exact plaster model of the case to be regulated a thin, narrow vulcanite plate is formed, with a short vertical post fixed, either before vulcanizing or afterward by drilling, centrally in the plate on the median line. Grooves or slots are, with a wheel bur, cut in the sides of the plate to receive

FIG. 92.



the ends of the spring and prevent its displacement after the coil has been placed on the post. Fig. 92 represents such an appliance in position on a plaster cast of the inferior maxilla of a boy aged twelve years, and it will thus be seen that the movements of the tongue would not be, as in practice they were not, seriously restricted. The tension of the spring is changed by simply bending outward or inward its arms, and in many cases the apparatus may be inserted or removed with great facility, and its action be so continued and controlled that the required expansion may be obtained and maintained by the use of but one plate. This

plate, with spring attached, was removed by the boy twice a day, and teeth and plate cleaned.

In spreading the dental arch the majority of cases require the greatest pressure on the anterior teeth, and an appliance that can be placed inside the arch will exert the greatest influence. The force is equally distributed on both sides of the mouth, and if constant the work will be accomplished rapidly, without inconvenience to the patient. Such an appliance is here illustrated (Fig. 93). It is used in the mouth of a young woman fourteen years of age. A plate is made to fit the teeth and alveolar process, and cut away so that the anterior parts extend far enough forward to inclose

FIG. 93.

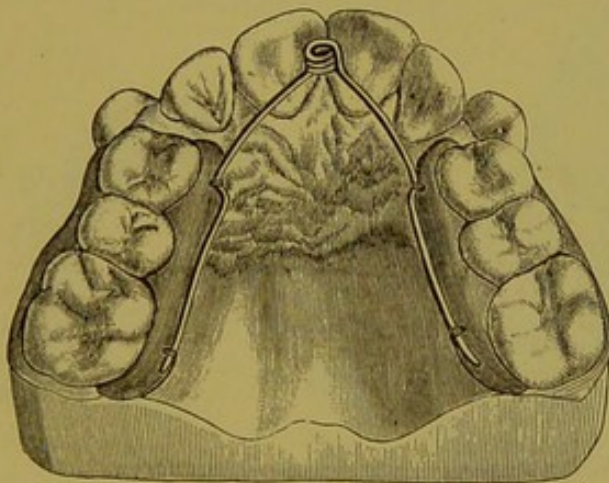
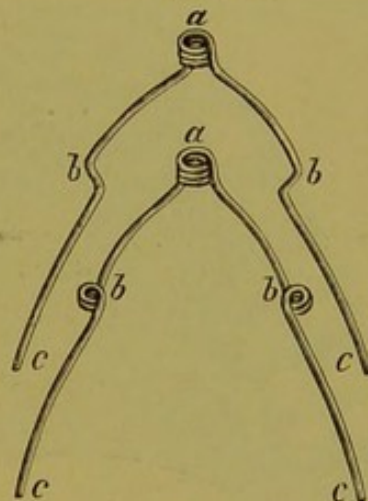


FIG. 94.



the teeth to be moved. A piece of wire is bent into either of the forms shown in Fig. 94, wherein *a* is the coil and fixed point, and *b b* movable arms extending from *a*, and also fixed points; *c c*, movable arms extending from *b b*.

Grooves are cut into the anterior and posterior parts of the plate to correspond with and receive the points *b b* and *c c*. Holes are drilled at these points, and the wires tied to the rubber plates. In order that the anterior teeth may be moved with the greatest force, the arms are so adjusted that the greatest pressure is exerted on the anterior parts of the plates. This appliance is readily removed for cleansing, and returned to place by the patient.

Another appliance for spreading the dental arch that has been successfully used by the author is illustrated in Fig. 95; it consists of a rubber plate made to fit the teeth and jaw. The plate is then sawed lengthwise—commencing at a point anterior to the teeth to be moved; a hole is drilled at the point where the slot stops, to prevent the arms breaking. At the extreme end holes are drilled to receive the spring. To adjust the plate press the arms together and drop the plate into place. Fig. 96 shows the plate out of the mouth. This can be removed and inserted *ad libitum* by the patient.

A form of dental irregularity very difficult to correct is

FIG. 95.

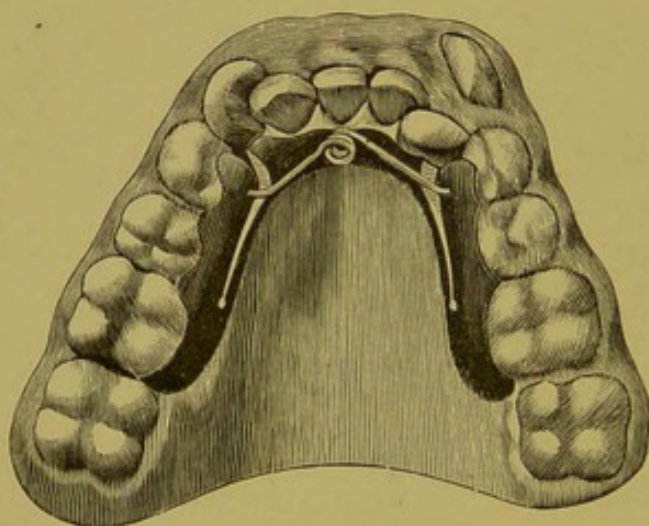
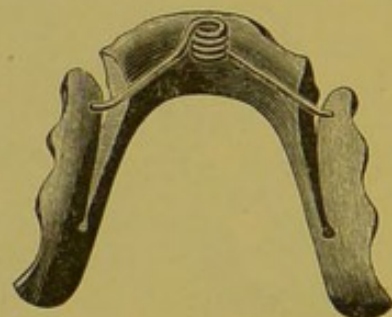


FIG. 96.



found when the cuspids are situated near or in contact with the centrals, while the laterals stand inside of the arch, and when the jaws are closed pass behind the inferior incisors. If these laterals are in near relations to each other, it is by ordinary means well nigh impossible to interact upon them with sufficient pressure to force them apart; the space being quite too short to admit a jack-screw.

Fig. 97 represents such a condition. The cut is made from the cast of a case in practice, the patient being a young woman eighteen years of age, who came under my care in 1883. The superior laterals were then only one-fourth of an

inch apart, and closed behind the inferior incisors. There were but small spaces between the superior centrals and cuspids.

Thin platinum collars were made to fit the laterals, on which, after drilling a hole in the side of each collar, they were firmly fixed with oxyphosphate of zinc. A spring was bent into the form shown by Fig. 98, the ends of the arms being turned at a sharp angle and cut short as seen in the figure.

The spring was then put in place, the arm ends entering the holes in the collars, and the curved arms found to be so closely conformed to the surface of the gums and palatine parts that the fixture was no obstruction to occlusion, and yet could be easily sprung out of position for cleansing pur-

FIG. 97.

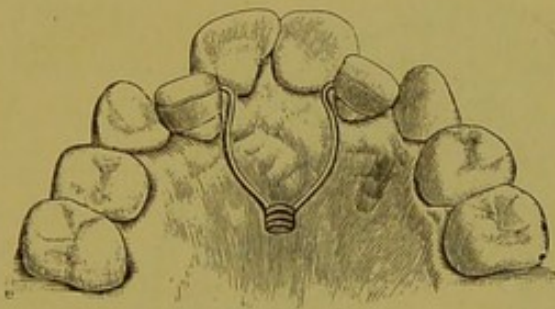
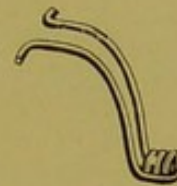

FIG. 98.



poses or for increasing the expansive power of the spring, by simply widening the lateral spread of the arms. Fig. 97 shows the progress made in four weeks' treatment. When the laterals had been moved past the sides of the centrals, they were by other means forced outward into line.

REGULATING INDIVIDUAL TEETH.

To force out central and lateral incisors, I have found the following methods useful: Around the tooth to be moved, and around the molars as nearly opposite the direction the incisor is to travel as possible, fit platinum collars. Solder cups upon the collars directly opposite and in line. Make a spring of piano-wire (Fig. 99), and spring it into

FIG. 99.

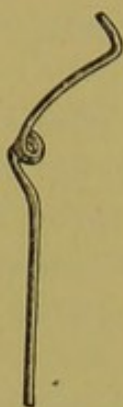

FIG. 100.

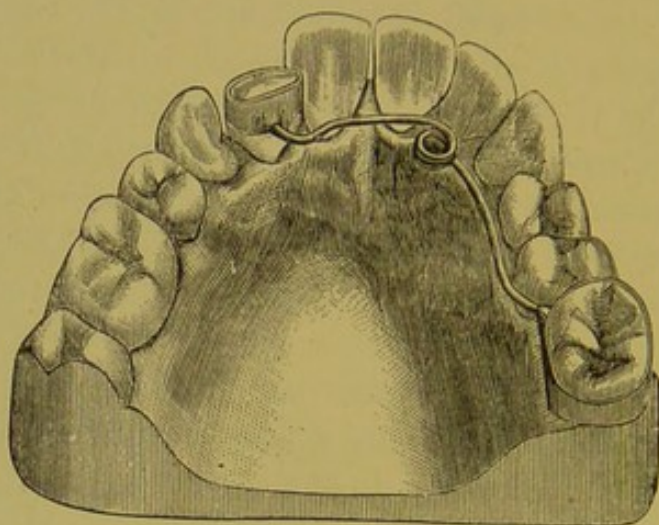


FIG. 101.

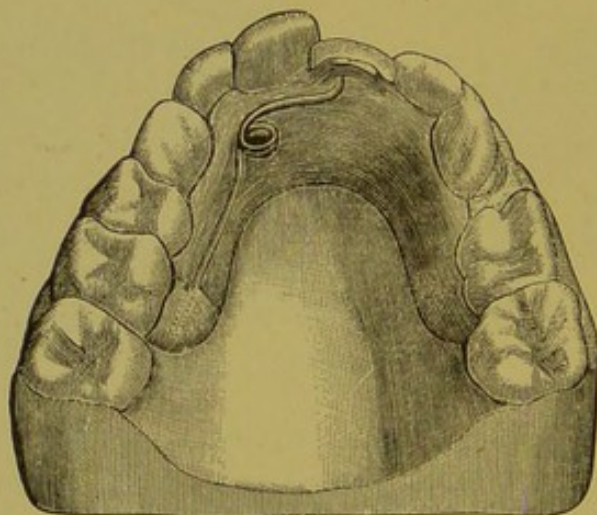
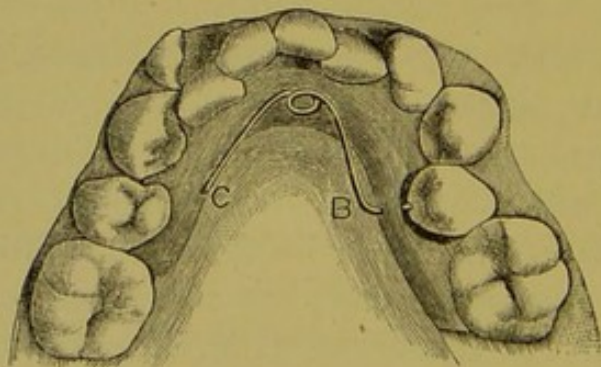


FIG. 102.



the cups soldered upon the collars. In Fig. 100 the appliance is seen in place.

Another method is to make a plate to fit the teeth, thickening it nearly to the cutting edge of the tooth to be moved, and drilling a hole through the thickened part. Directly opposite, at some convenient point on the back part of the plate, drill another hole just deep enough to hold the spring in place (Fig. 101). If the hole in the thickened part be drilled in the proper place, the end of the spring will hit the tooth midway between its cutting edge and the margin of the gum. This spring is very effective. The pressure is constant, and the spring is readily removed for adjustment or for any other purpose.

We frequently find a single tooth situated inside the dental arch, and have trouble in contriving an apparatus suited to the correction of such an irregularity.

The illustrations represent some simple appliances that have been thoroughly tested and found satisfactory, in that they do the work effectively, are easy of adjustment and removal, and may be readily cleansed.

Fig. 102 illustrates a second inferior bicuspid of the right side, having a lingual presentation equal to one-half the thickness of the tooth inside of its normal position. The cut also shows teeth in other malpositions, but for our present purpose these are not considered.

For this case a thin, narrow, close-fitting vulcanite plate was made, and a hole was drilled through the middle of the plate opposite the centre of the tooth to be moved. In the other side another hole was drilled, but not quite through the plate. A suitable spring (Fig. 103) was then made of piano-wire, having a single coil, *A*, and the ends of its arms bent at about a right angle. One of these ends, *C*, was cut short to enter the corresponding hole in the plate, and the other end, *B*, left long enough to go through the plate and impinge on the lingual surface of the bicuspid, leaving a full eighth of an inch between that arm of the spring and the plate, as is clearly shown by Fig. 102. Fig. 104 shows

both arms, *B B*, of the same length, to pass through the plate and impinge on the lingual surfaces of teeth upon opposite sides.

Fig. 105 shows an appliance for pulling out the central

FIG. 103.

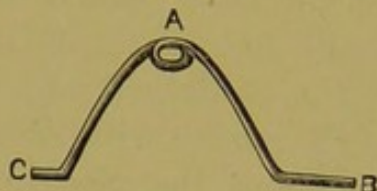
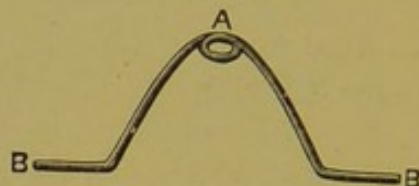
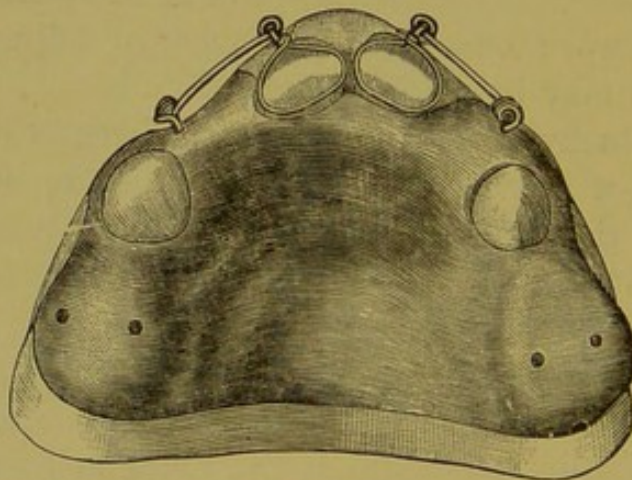


FIG. 104.



incisors. An illustration of the manner of the articulation will be found in Fig. 17, page 35. A plate is made to fit the jaw and teeth, and into it were vulcanized two of the Talbot springs at the lateral incisor region. The wire arms were turned into loops at the extremities to secure a ligature.

FIG. 105.



When the plate was adjusted the arms were bent horizontally, and brought in close proximity to the labial surfaces of the central incisors and securely tied. By this means constant pressure was applied, and the teeth were carried outside of the inferior incisors.

CHAPTER V.

TREATMENT OF SPECIAL FORMS OF IRREGULARITIES.

ROTATING TEETH IN THEIR SOCKETS.

THE FARRAR METHOD.

Dr. Farrar has devised for this purpose a modification of his "positive system," which is illustrated in the following cuts:—

FIG. 106.

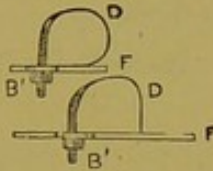


FIG. 107.

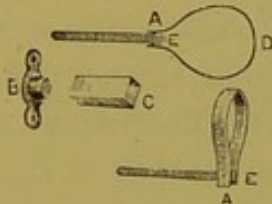
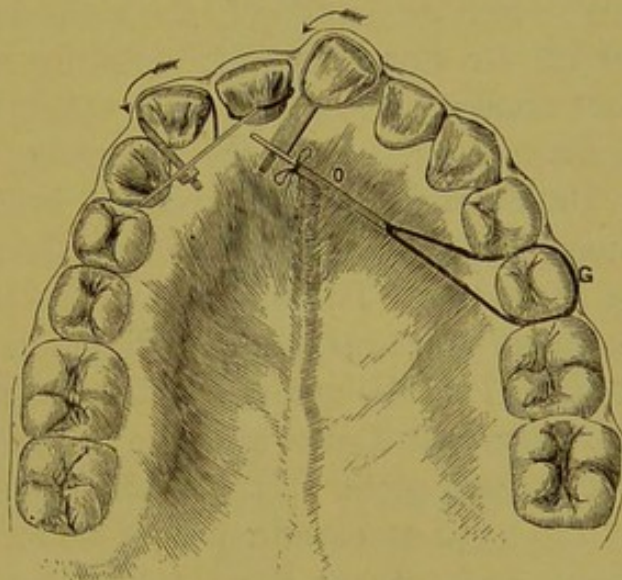


FIG. 108.



Figs. 106 and 107 represent screw-wrenches made of 18-carat gold, with the exception of the screw in Fig. 107, which may be made of brass or steel, as desired. If the form represented in Fig. 106 be used, it is adjusted on the tooth, and the thin gold of which the band is composed is made to hug it by tightening the nut, *B*, and the end of the bar, *F*, resting firmly against the adjacent tooth; tightening the nut once or twice a day causes the tooth to rotate. If the box-wrench (Fig. 107) be used, the arm acts as a lever, to which is attached a band of rubber, and ligature attached to a firm tooth, as shown in Fig. 108. Or, both forms may

be used, as in Fig. 109, the power being obtained by a screw rotating in a swivel, *K*, attached to a distant tooth.

Figs. 110 and 111 show another form of apparatus, so simple and so plainly shown by the cuts as to require little description. The strip of plate resting on the palatal surfaces of the adjoining teeth serves as a fulcrum, and the tooth operated on is rapidly drawn into line and rotated. Fig. 110 represents an actual case treated by Dr. Farrar, and, as he states, the patient, about thirty years of age, manipulated the apparatus himself, reporting only once during the week that the operation was in progress.

Fig. 112 illustrates a right-angle key or wrench, with bevel pinions similar to the right-angle engine attachments which Dr. Farrar uses for turning nuts in localities such as that shown in Fig. 110, or in other localities where it is difficult to use the ordinary wrenches.

Dr. Farrar's "triplex system" is also adapted to the treatment of either of these varieties of irregularity, as illustrated in Fig. 113. "The bearings of the bands upon the different points of the teeth and the directions of their movement are indicated by the arrows, while the details of construction are shown in the figure, and the device is made as follows: A stiff strip of plate, *T*, is bent on a form to loosely fit the necks of the teeth at certain points under the free margin of the gums, and prevent the plate from slipping from the teeth; and the ends of the plate are so shaped as to bear firmly on the distal corners of both teeth. These bearings may be changed by properly bending the ends of the plate as the operation advances. The bridge, *C*, carries two rollers, *W*, between which the thin ribbon loop, *L*, passes, and is caught by its fold on a wire attachment to the middle of bar, *T*, as shown in position on the tooth. The screw, *S*, is swiveled in the *N* end of the metallic ribbon loop, and screws into the threaded end, with the effect of separating the ends of the loop, which thus moves the bridge toward the bar and rotates both incisors.

"Other modifications of this device may be adapted to

different presentations of this class of cases, the main thing to be kept in view being the points of bearing of the bridge, *C*, and the bar, *T*; for while the apparatus will work well

FIG. 109.

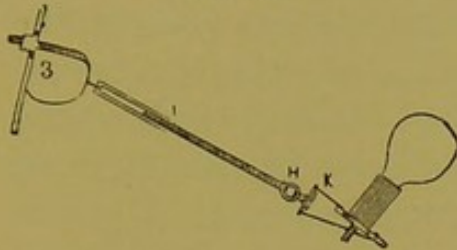


FIG. 112.



FIG. 113.

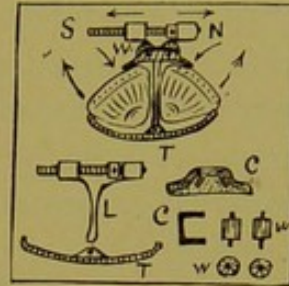


FIG. 110.

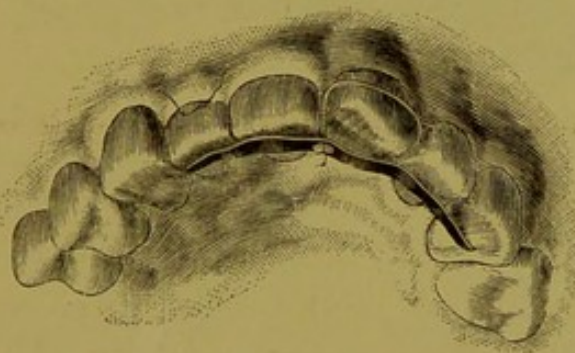


FIG. 114.

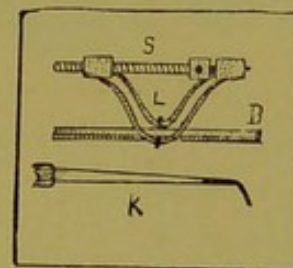
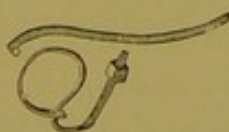


FIG. 111.



when the teeth have small necks, it is difficult of retention upon tapering teeth.

"In some cases a firmer hold on the teeth may be obtained by a pair of narrow loops, the folds of which pass on either side of the bar, around the ends of a pin passing through and projecting from the middle of the bar, as shown in Fig. 114. The bar thus made and connected is easily detached for the purpose of bending its arms to obtain rotative bearings. A key for turning the screw may be readily made from an excavator, shaped as shown at *K*, Fig. 114."

THE GUILFORD METHOD.

Dr. S. H. Guilford has devised a little fixture for correcting malpositions of the central incisors, shown in Figs. 115 and 116. According to his description, it is constructed as

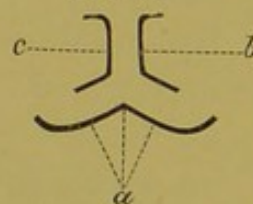
FIG. 115.

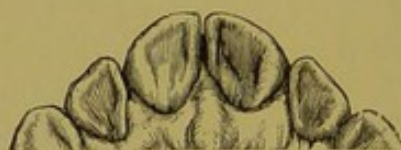

FIG. 116.



FIG. 117.



follows: A piece of gold backing one-eighth of an inch wide and sufficiently long to extend along and a trifle beyond the palatal surfaces of the centrals, is bent to conform as closely as possible to their lingual surfaces, and forward so as to slightly clasp the disto-palatal angles, as shown at Fig. 117. To this are soldered two strips cut from plate-scrap, a little narrower than the first piece, and bent in the form of *b* and *c* (Fig. 117), respectively, which are sufficiently long to extend slightly over the anterior and posterior surfaces of the teeth. After being properly shaped to fit the model, their backs are soldered together and to the part, as shown in Fig. 118. The

FIG. 118.



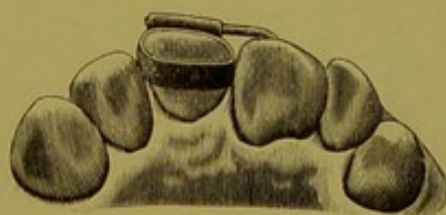part *b c*, which passes between the teeth, is reduced sufficiently with a file, or the teeth may be separated by wedging, to allow the insertion of the fixture. The labial part should rest against

the teeth just at or slightly above the most prominent part of the convexity, while the lingual portion should be near the gum, but not quite touching it. The slightly-curved ends will catch just above the little nodule usually found on the disto-palatal angle near the gum. Thus secured, it cannot be easily displaced. Bend the long palatal arms slightly toward the short labial ones daily, and spring them into position on the teeth. The elasticity of the gold, stiffened by the solder, will do the work. "By this means," says Dr. Guilford," the use of all rubber or silk ligatures, so irritating to the gum and so painful in application, is dispensed with." Fig. 115 illustrates a case treated by Dr. Guilford with this appliance, the cure being complete after a treatment of ten days, the patient having been seen every day. The

FIG. 119.



FIG. 120.



general form of the appliance is also equally useful in correcting teeth in the reverse position, shown in Fig. 116. In this case the construction is reversed, so that the long arm or band may rest on the labial and the short one on the palatal surfaces, and so bent as to throw the distal angles inward.

The same appliance slightly modified, he says, is also useful for rotating a single incisor where its mate is already in position. In this case the end of the appliance is fitted nicely to the tooth in position, while the other half is so shaped as to give the desired pressure on the tooth to be rotated.

THE AUTHOR'S METHOD.

In June, 1884, the following treatment was begun by me for rotating the central incisor of a patient. A platinum band was made to fit the tooth, and a tube of the same

material was soldered lengthwise with the band (Fig. 119). The band was secured to the tooth with the oxyphosphate of zinc, a piece of piano-wire being passed into the tube and allowed to extend to the left central incisor (Fig. 120). The wire was bent every day, and the tooth thus rotated into place. When practicable, we should solder a flat tube to the band for the purpose of holding a flat lever, which would prevent the rotation of the arms.

MOVING CROWNS AND ROOTS.

In most of the operations for regulating teeth, the apices of the roots are in a position either normal or approximat-

FIG. 121.

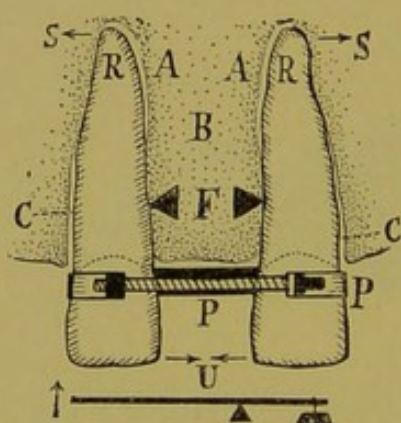
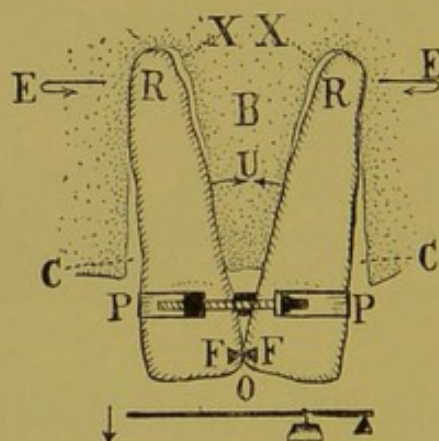


FIG. 122.



ing to it in such a degree as not to require moving. But in some cases it becomes necessary to move the whole root. For this purpose, although the power may be the same, yet it must be made to act in a different manner.

In ordinary moving of teeth, the power is at one end, the resistance at the other, while the fulcrum is in the middle of the tooth to be removed. This is illustrated in Fig. 121, where *P* is the power, *F* the fulcrum, and *S* the resistance. The power being continued, the teeth are drawn in the direction indicated by the arrows, *U*. The first effect of this movement, so far as the roots are concerned, will be to cause them to impinge against the septum *B*, at the point *F*, and

also against the socket wall at the point *S*. They will also separate from the sockets at the points *A* and *C*, as indicated by the arrows. If the force be continued in this direction until the points touch, as in Fig. 122, the lever is changed into one of another variety, in which the power is applied

FIG. 123.

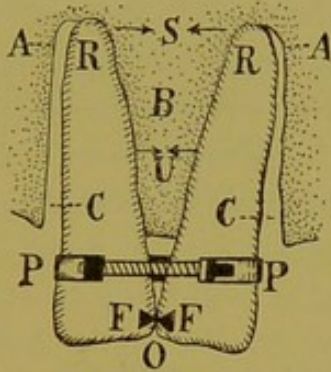
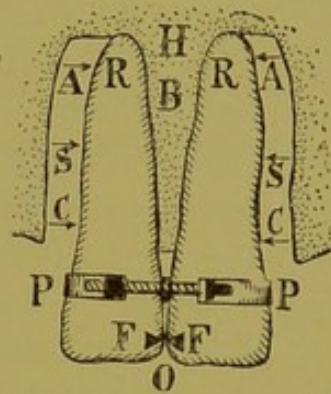


FIG. 124.

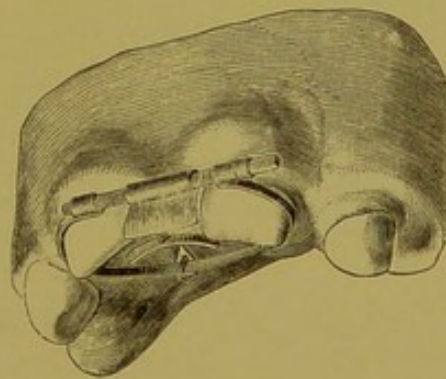


between the fulcrum and the resistance (*X*, Fig. 122). Thus, the same power from the same apparatus acts in exactly the opposite manner, causing the roots to approach each other throughout their length (the fulcrum being at *O*, Fig. 123),

FIG. 125.



FIG. 126.



and leave the socket walls in the same manner. Fig. 124 shows the completion of the operation.

The appliance used by Dr. Farrar in this operation is shown in Figs. 125 and 126. "It is made up of two parts, a clamp band to draw the teeth together, and a lock portion

to hold stationary the cutting edges of the teeth; but while the teeth are being drawn together, only the band portion need be used. On each extremity of a band made of light and strong rolled wire is soldered a nut, one of them being a screw nut. Through these nuts passes a little gold screw, having a head fitted to a watch key. The main point to hold in view in constructing this clamp portion is to insure a close bearing at the gum border, to prevent it from slipping off the teeth. The lock portion, for preventing the overlapping of the crowns when the force is continued after the teeth have been brought in contact, is a simple device, easiest made by bending a small piece of plate about one-quarter of an inch square, or a little larger, trough-like, so as to fit the edges of the teeth; to this is soldered at right angles another piece of plate extending far up between the teeth nearly to the gum; on the upper end of this is soldered, transversely, about one-eighth of an inch of small tubing (smooth bore), through which passes the bolt of the clamp band and from which it is loosely suspended. This part (the trough portion) may be constructed skeleton-like, as shown by Fig. 125, and is more easily kept clean. The clamp is first applied, the force being intermittently applied two or more times a day, or every time the band loosens by the movement of the teeth; but this should never be powerful enough to cause pain. After the teeth are brought in contact or nearly so, the trough portion is added, and the force of the clamp band continued until the roots are brought into the desired position."

FORCED ERUPTION OF THE TEETH.

THE MATTESON METHOD.

Occasionally a single impacted tooth in the jaw does not work its way down sufficiently to occlude with its opposite tooth, or the incisors do not meet when the jaws are closed. Such teeth are to be treated so as to make them as nature intended. Dr. A. E. Matteson, of Chicago, has been successful in using the following methods: A rubber plate was

made to cover the roof of the mouth and to fit the necks of the teeth closely, a French clock spring being adjusted with one end riveted into the central posterior part of the plate (Fig. 127); when the spring was inserted and forced up against the plate, the distal end of the spring touched the necks of the teeth to be drawn out; ligatures were then fastened to the necks of the teeth, and the spring carried up to the plate and fastened to the teeth. If the spring be sufficiently powerful, from two to four teeth may be operated upon at one time.

The spring being movable upon the rivet in the plate, one tooth at a time can be erupted, and then the point of the spring may be turned to the next tooth.

FIG. 127.

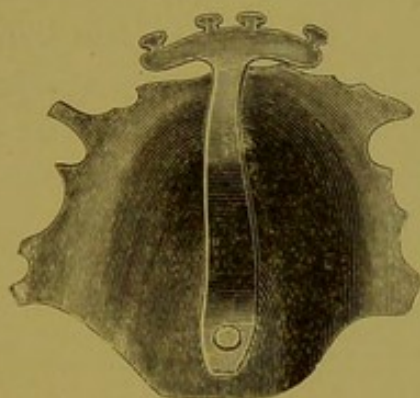


FIG. 128.

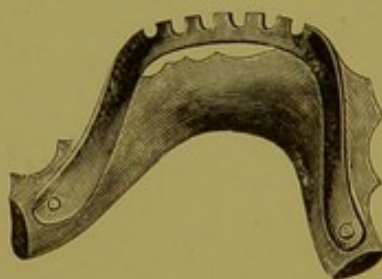


Fig. 128 shows a similar appliance for erupting the teeth on the lower jaw. Erupting teeth is unlike any of the other regulating operations, as no pressure to produce absorption is required.

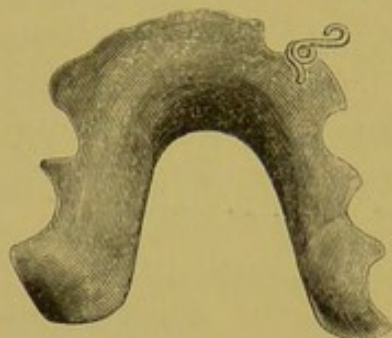
When lateral pressure has been removed, the mildest force is sufficient to draw a tooth out of the process, as the roots are conical and the pressure is directed away from the process instead of against it.

THE AUTHOR'S METHOD.

This appliance consists of a rubber plate, made to fit the jaw and the teeth, with a hole drilled at a point in the

centre of the space made by the missing tooth (Fig. 129). This hole, which is smaller than the coil-wire spring, holds

FIG. 129.



one arm of the spring. The other arm (upon the end of which a loop has been made) meets the neck of the tooth to be moved, and is there secured with a ligature. If the tooth be imbedded in the alveolar process and a ligature cannot be bound to it, a platinum band, with a hook soldered upon it, may be forced up under the gum and secured with

oxyphosphate of zinc. Should this fail, as a last resort a hole may be drilled into the crown, and an eyebolt fastened in with cement, to which a spring may be fastened with a ligature. If more spring to the wire be required, the hole may be drilled in the plate at a longer distance from the tooth to be moved, thus giving a greater sweep to the arm.

CHAPTER VI.

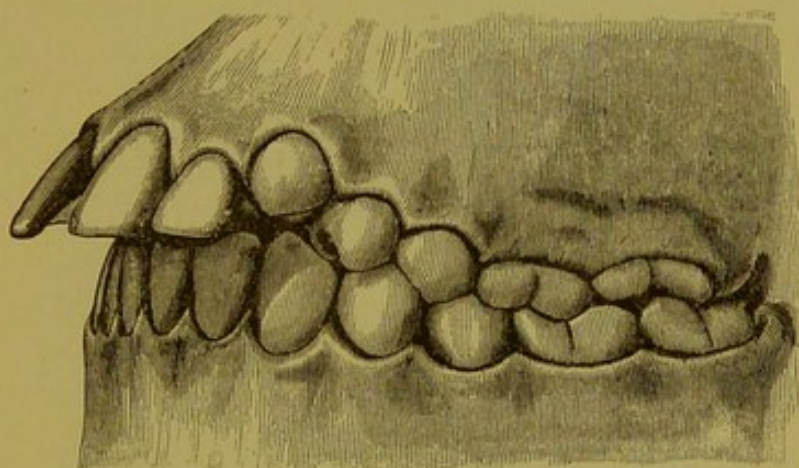
PROTRUDING TEETH.

KINGSLEY'S CASE.

The following case, with the accompanying illustrations, is reported by Dr. Kingsley:—

Fig. 130 shows the condition of the teeth of a child of nine years of age, for which no adequate cause could be given, as it was not hereditary nor the result of thumb-sucking. Treatment was not begun until the patient was

FIG. 130.



thirteen years of age, when the permanent teeth had all made their appearance, and so much did the front teeth protrude that it was with difficulty that the lips could be brought together, the incisors being spread or straggled, and the crowns of extraordinary length.

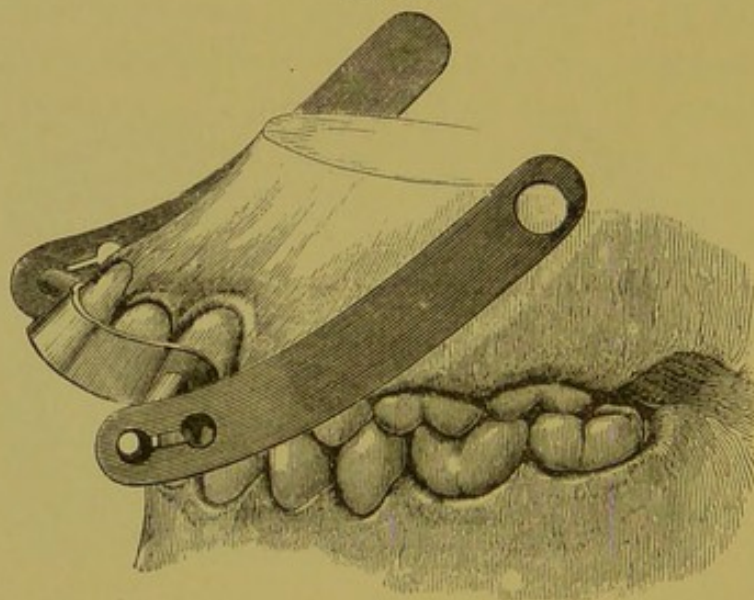
“A frame of gold was made, covering the cutting edges of the incisors and lapping on the cuspids, and a plate of vulcanite adapted to the roof of the mouth, and cut away in front to provide for the retrocession of the teeth.

“Ligatures cut from rubber tubing were attached to the posterior part of the vulcanite plate, one on each side, and

drawn forward and caught on projecting spurs of the gold frame.

"In a short time the arch in front was contracted until the teeth were in contact, but it was not sufficiently reduced. More room being essential, the first bicuspid on each side was removed. The incisors had appeared to lengthen during the process (although, probably, they had not actually done so), and it seemed that they would eventually come down so as to touch the gum of the lower jaw. The attempt was therefore made to shorten the crowns by driving them up into the jaw. The former appliance was continued, and

FIG. 131.



to the gold frame was added a stud or post about one-half an inch long, soldered to it opposite the cuspids, and coming out at each corner of the mouth." This apparatus is shown in Fig. 131. The arms, extending upward, passing outside the cheeks, were made of strips of brass and connected by elastic ligatures, with a leather skull cap, as shown in Fig. 132.

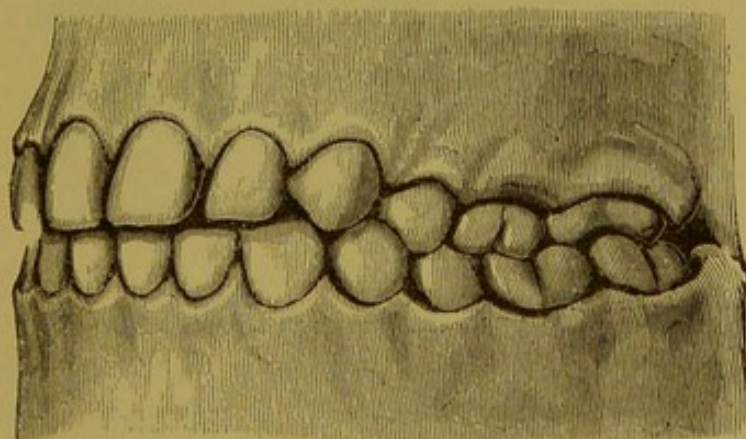
The vulcanite plate was inserted in the mouth, and the rubber ligatures brought forward and caught; the skull cap was then placed on the head, and strong elastic straps were caught over buttons or hooks on the cap, and like buttons or hooks on the cheek-arms, as shown in Fig. 132. The outside

pressure thus forced the teeth up into the jaw, and the inside pressure drew them backward in a direct line. The apparatus did not interfere with the comfort of the patient, and was worn for three months constantly, and part of the time for two months more, at which time the six front teeth were

FIG. 132.

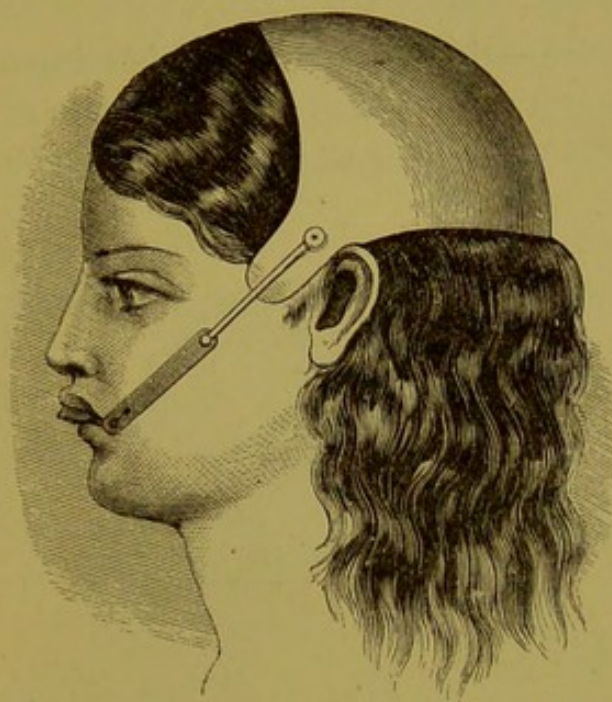

FIG. 133.



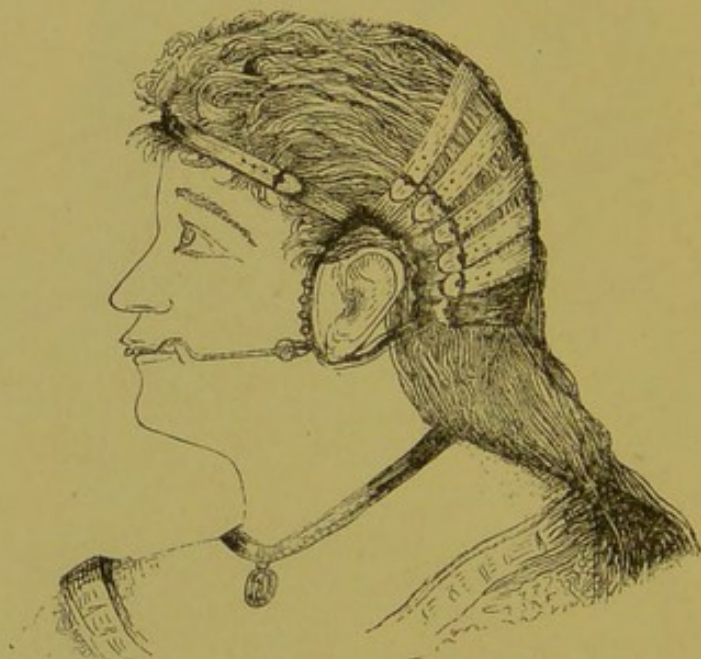carried backward so that the cuspids came in contact with the second bicusps, and the incisors were driven up into their sockets one-quarter the length of their crowns, with the result shown in Fig. 133.

FARRAR'S CASES.

When the abnormal protrusion of the six upper front teeth is very marked, the correction of the irregularity may require a greater degree of anchorage than is afforded by the posterior teeth. Dr. Farrar has devised an apparatus to meet such cases, known as a "bridle apparatus," which is illustrated in Fig. 134.

This is constructed as follows: "A gold strap of rolled wire, having a smooth nut on each end, is bent to conform to the anterior surface of the four or six front teeth, and so fastened

FIG. 134.



by means of screws to clamp bands on the posterior teeth, as shown in Fig. 135.

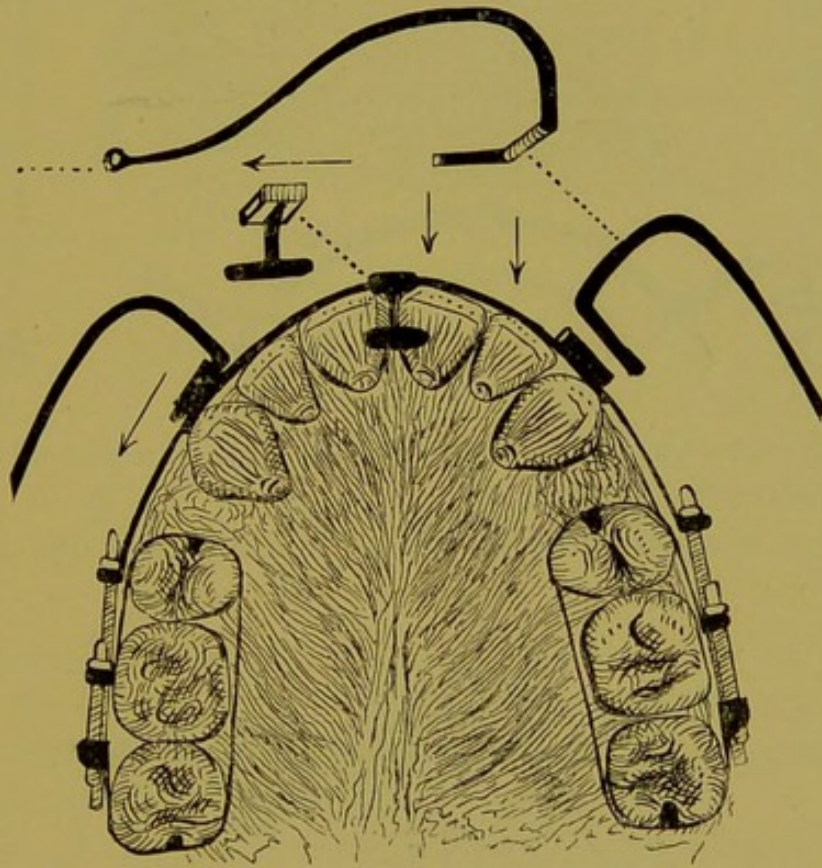
"To prevent this band from slipping up toward the gum troughs have been tried, but they collect food and injure the teeth. I use one or more T pieces made to fit between the teeth, soldered to the band, or to ferrules sliding on the band (Figs. 135 and 138), or to broad plate hooks (Fig. 139).

"Another plan of attaining this end is by the use of a round wire resting upon the lingual surfaces of the teeth, connected in the same way to the front band (Fig. 136).

The nearer these front wires approach the cutting edges of the teeth, the less power it requires to move the teeth.

"The front band is connected with the outside apparatus by means of cylindrical or angular ferrules, or staples soldered to it at points opposite the spaces between the laterals and cuspids. Through these ferrules or staples, which are at a sufficient distance from the corners of the mouth to prevent the dribbling of saliva, are hooked bent cheek-wires.

FIG. 135.

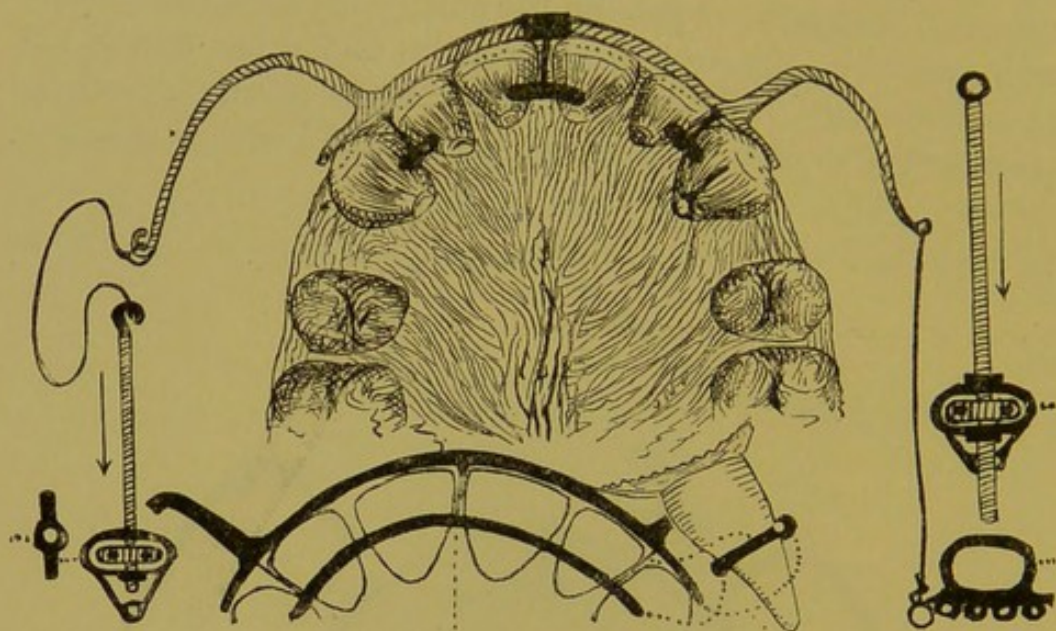


gold (about No. 12 gauge), that project forward and outward, thence pointing toward the ears on a line with the front band (Fig. 134). To prevent the falling over of this curved cheek-wire, one side of the ferrule portion may be filed flat, and the ferrule shaped to correspond by a blow from a hammer; but this is seldom necessary.

"In some cases, in which detachment of the two parts is of no consideration, the cheek-wires may be soldered directly

to the front band piece (the retaining portion of the inside apparatus being dispensed with, Fig. 136), or double band, as shown in Fig. 137. The outer extremities of these cheek-

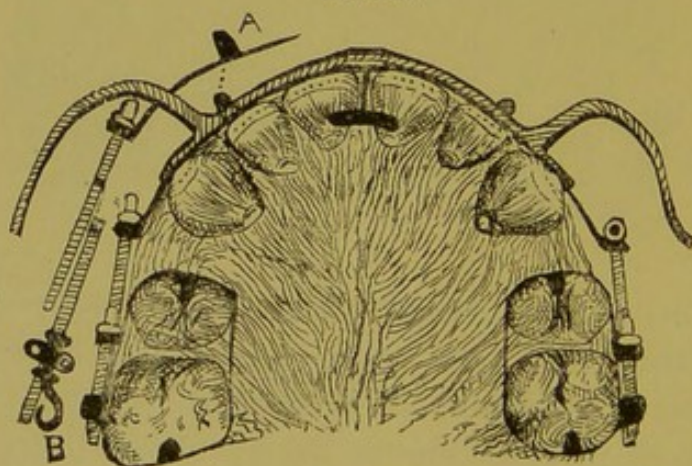
FIG. 136.



wires are screw-cut for drag nuts, one modification of which is illustrated by *B*, 137.

"These wires may be in two or more pieces, but as this

FIG. 137.



causes a pressure upon the cheek, which may crowd upon the anchor apparatus inside of the mouth, it is much better to make the cheek-wire in one piece, which, if bent properly,

will arch from the cheek to the ear-ring without being in contact with the cheek.

"In fact, my experience teaches me that the latter is much the better form. The screw extends through the holes in opposite sides of a small ring, which is caught on one of several hooks soldered to a much larger ring extending around the ear of the patient (Fig. 134). This larger ring (which is necessary to prevent interference with the ear) is fastened to inelastic straps extending around the back of the head and held in place by other straps, as shown. The lower straps and ear-rings constitute the anchorage apparatus. The ear-rings should be about two and a half by three inches in diameter, underlaid by soft leather or felt rings about one-quarter to one-half inch wide, to serve as cushions to protect the skin. In order to have these rings

FIG. 138.

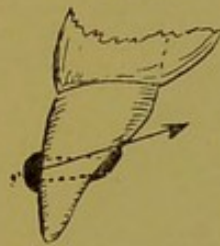
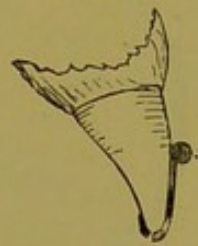

FIG. 139.



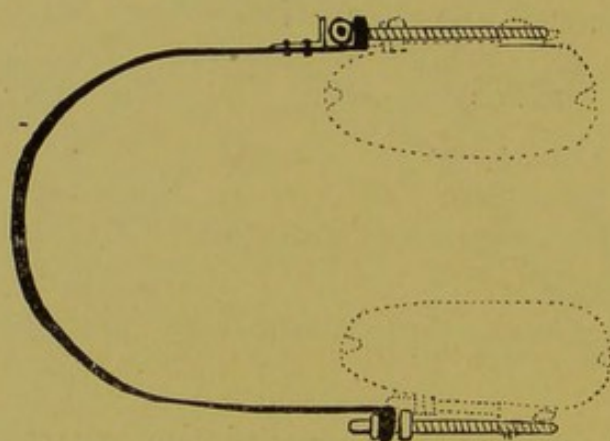
rest in their proper places around the ears, and to permit the harness to bear equally, so as to prevent headache, the several straps should be made capable of being tightened or loosened at will by means of buckles.

"When the apparatus is in position, the friends of the patients are instructed to tighten the posterior bands or to turn the nuts within the smaller rings daily. The patient is advised to call at the office once or twice a week, when, if the position of the teeth has changed sufficiently to render the front bands liable to slip off, the direction of the traction should be changed by raising the nut ring from a lower hook on the ear-ring to one higher."

Fig. 140 illustrates a device for the same purpose, exhibited to the profession by Dr. Farrar in Nov., 1885. This appli-

ance consists of bands of gold or platinum extending around the molars and bicuspid upon either side of the arch. A nut is soldered upon the buccal surfaces for carrying a long screw. A band of gold encircles the arch, and is secured by hooks midway between the cutting edges and necks of the incisor teeth. The ends of the band are bent at right angles, having holes through the ends for the free movement of the screws. The bands and teeth enclosed are the fixed points, and by turning the screws twice a day the anterior teeth are carried to the posterior part of the alveolus. This appliance claims cleanliness and the advantage of being out of sight as its strong points for its recommendation to our use.

FIG. 140.



PROTRUSION OF THE INFERIOR MAXILLA.

ALLAN'S CASE.

Fig. 141 represents a case of protrusion of the inferior maxillary treated by Dr. George S. Allan, of New York.

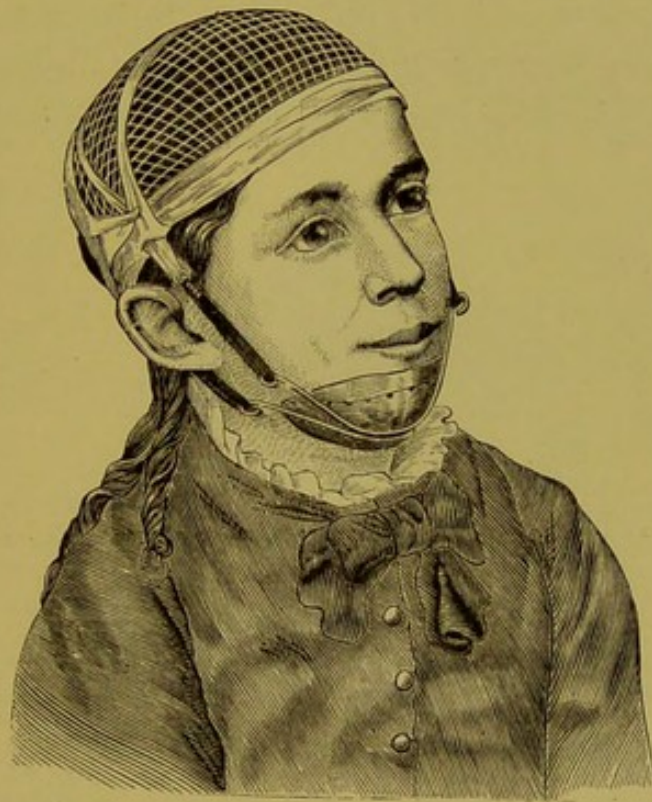The irregularity pertaining solely to the jaw, that alone was operated upon. A brass plate was made to fit the chin, having arms with hooked ends arranged so that the distance between them could be altered by pressing them apart or together. A network was adjusted upon the head, having two hooks on each side, one above and the other below the ear, to which were attached four ligatures of ordinary elastic rubber. The operation proceeded rapidly, and at the end of

two months the irregularity was almost entirely cured. In this operation the result was attained by pushing back the condyles of the jaw into the glenoid cavity, the interarticular cartilage giving way and absorption taking place posterior to the condyles, with a filling in at the anterior side.

METHODS OF RETENTION OF THE TEETH AFTER REGULATING.

No element of regulating the teeth is more difficult than that of securing the teeth firmly after they have been forced

FIG. 141.

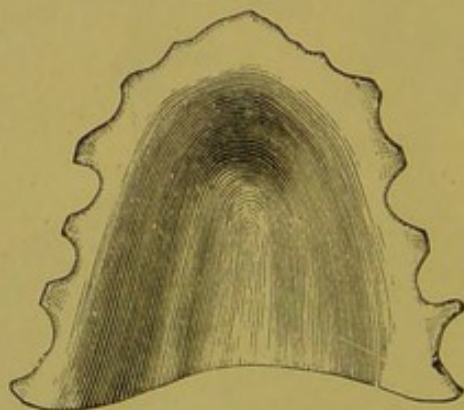


into their new positions. The inclination to return to their original places is increased when the teeth are moved faster than the physiological process of filling in new material is accomplished. Pressure of the lips and tongue exerts influence in producing backward and lateral pressure upon the teeth. The greatest help in this direction is to so plan the operation, either by extraction or by inward or outward pressure (as the case requires), that when completed the posterior teeth will occlude in such a manner that they will

hold one another in proper positions. Dr. Kingsley, in his "Oral Deformities," says: "The articulation of masticating organs is of much more importance than their number, and a limited number of grinding teeth fitting closely on occlusion will be of far greater benefit to the individual than a mouthful of teeth with the articulation disturbed."*

Occlusion, however, will not retain the anterior teeth in position. Nor will it be safe to depend entirely upon occlusion to hold the posterior teeth in position. In most cases other means must be devised for holding the anterior teeth in position. Cases of this kind are apt to be those in which the arch of the superior or inferior maxilla has been spread or the anterior teeth have been moved inward or outward.

FIG. 142.



It is then frequently necessary to spread both arches by simply carrying the teeth of one jaw out to the proper distance and securing them with a retention plate; the teeth of the opposite jaw will in most cases be forced into their positions by their grinding surfaces coming in contact in mastication. Fig. 142 shows one of these retention plates. It fits the roof of the mouth and teeth accurately, and can be readily removed for cleansing. Such a plate is of service upon either jaw for preventing one or all the teeth from rotating back toward the inner part of the mouth.

* *Op. cit.*, p. 43.

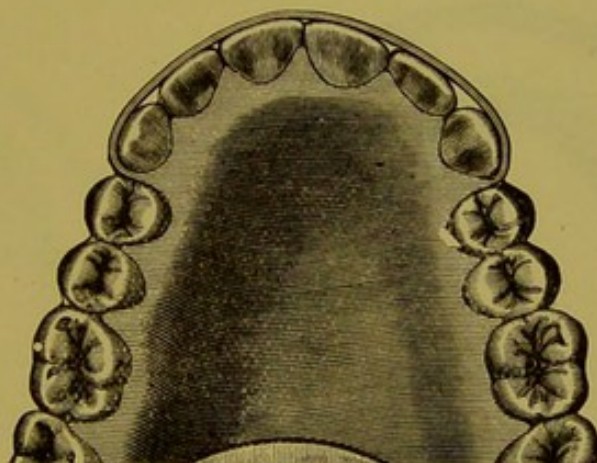
KINGSLEY'S RETAINER.

For holding the anterior teeth in position, the appliance recommended by Dr. Kingsley answers the purpose admirably. It consists of a rubber plate fitting the teeth and the roof of the mouth, and having a band of platinum or gold secured to it. The band passes through a separation in the teeth upon either side, and impinges upon the labial surfaces of the anterior teeth, as represented in Fig. 143. This application will not serve when the teeth are crowded.

RICHARDSON'S RETAINERS.

Where all the teeth in the jaw have been moved, particularly if some have been rotated into position, a retentive plate that comes in contact with all the teeth should be

FIG. 143.



used. A rubber plate will fit each tooth accurately without trouble or expense. Dr. Richardson gave his retentive plate to the profession many years ago, and in many respects it cannot be improved upon. Fig. 144 illustrates this appliance. It is composed of two pieces of rubber, vulcanized upon the labial and lingual surfaces of the teeth of the plaster model. These are trimmed to about a quarter of an inch in width, and fitted to the necks of the teeth and gums. When a tooth is missing upon either side of the jaw, or when spaces exist between the teeth, or there is room behind the molars, the rubber may extend from the outer to the inner

plate, and thus the two pieces be made into one. If, as in the illustration, there be little or no room to carry the rubber from one piece to the other, flattened or round gold wire may be vulcanized or riveted so as to hold the wire in position. The only objection to this appliance is its unsightly appearance. It can, however, be removed by the patient for cleansing.

RUBBER PLATES WITH GOLD BANDS AND BARS.

When single teeth have been rotated in their sockets, or moved in or out for the purpose of perfecting the contour, a simple arrangement for retaining the teeth is to fit a rubber plate to the palatine or lingual surfaces of the teeth, and

FIG. 144.

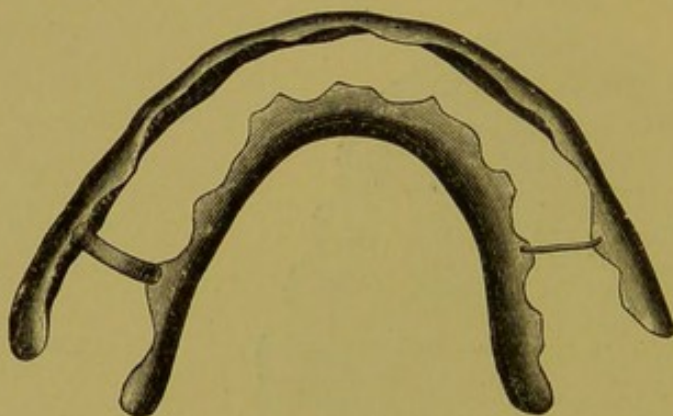
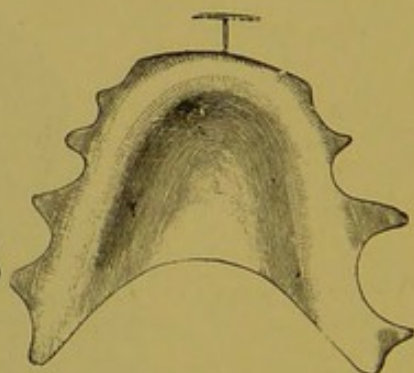


FIG. 145.



attach a bar or clasp of gold to the teeth that have been moved. Fig. 145 illustrates a retaining plate with a bar attached for holding the superior central incisors in their position after regulating. The bicuspid and molars may be treated similarly.

Rubber retainers are apt to be inconvenient for cleansing properly. Patients are inclined to be careless on this account, but should be instructed to attend to this duty after each meal, to prevent the secretions from becoming vitiated, the gums inflamed, and the teeth decayed. Great improvements in these appliances have been made in the past few years, as will be observed on examining some of the methods below.

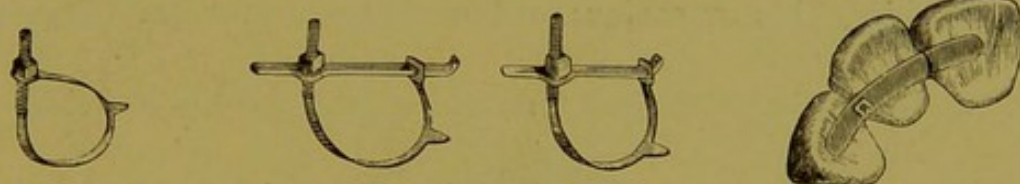
FARRAR'S RETAINERS.

Dr. Farrar, of New York, has invented some ingenious appliances for holding teeth in proper positions, called "Retaining or Anchor Clamps." Some are composed of one piece of gold, others of two pieces. Those having one piece (Fig. 146) are made from square, 18-carat gold wire. This will take a size to correspond with the tooth and the amount of resistance required to hold it in place. A thread is cut from one end to about a third of its length, the remainder of the wire is rolled or hammered into a thin band, about No. 35 or 36 American gauge, and about one twenty-fourth of an inch in breadth. At the distal end a hole is drilled, large enough to allow the screw end to pass through with a thread cut upon it. Small projections should be soldered upon the band and bent so as to catch upon the tooth. When two

FIG. 146.

FIG. 147.

FIG. 148.



pieces of gold are used, the band is made in the manner described in the first case, and bars of the same carat gold rolled to Nos. 22 and 23, American gauge. One end of the bar is bent to an angle of forty-five degrees to prevent the band from slipping. Near the other end of the bar a hole is drilled for the passage of the screw end of Fig. 147.

Both bands may be used for rotating teeth in their sockets, and also for retaining them in place. Fig. 148 shows Dr. Farrar's retaining band in position.

DR. MAGILL'S RETAINER.

Dr. Magill's retainer consists of a band of gold or platinum (Fig. 149) swaged or fitted accurately to the tooth and of sufficient strength to resist the rotary strain and friction in mastication. By trimming the labial surfaces as narrow as

compatible with strength, the band will not appear conspicuous. It should be adjusted midway between the cutting or grinding edges and the gum, and there cemented to the tooth with oxyphosphate of zinc. This can be worn indefinitely without affecting the gums or teeth, and can be cleansed perfectly; hence the bands, bars or levers may be

FIG. 149.

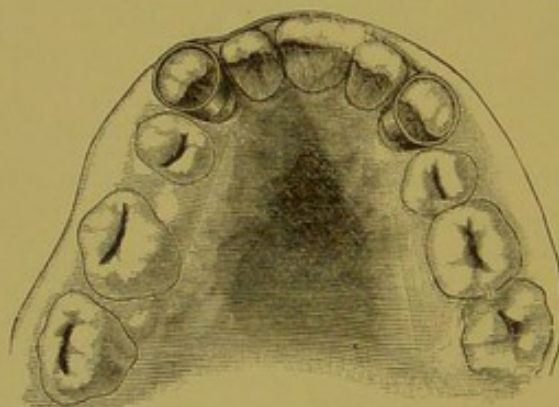


FIG. 150.



firmly soldered for rotating or retaining the teeth after regulating. Fig. 150 shows the application of one of these devices when two teeth are secured in position by a bar extending past fixed teeth on both sides. When two or more teeth are to be held in position, the bands may be secured to the bicuspid or molars on both sides, and a bar of gold

FIG. 151.

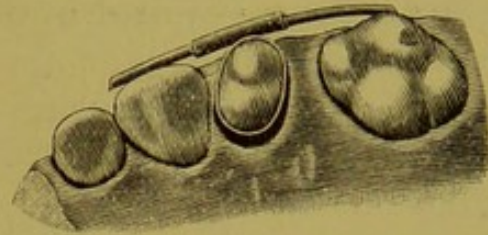


extended from one to the other, upon the lingual or labial surface, as illustrated in Fig. 151, from Dr. Guilford's collection. "Platinum bands were fitted to the two cuspids, and these were connected by a very thin platinum wire passing along and conforming to the outline of the labial surfaces of the incisors."

THE AUTHOR'S RETAINER.

This retainer consists of a band of platinum or gold fitted to the tooth or teeth, with a tube of the same material, the width of the tooth, soldered lengthwise of the band, as illustrated in Fig. 152. The band is fastened to the tooth with oxyphosphate of zinc, and a piece of gold, platinum or piano-wire is passed through the tube and allowed to come in contact with the surface of a firm tooth. Should the tooth that has been regulated move, the wire may be bent so that the tooth may be restored to its proper position. Two or more teeth may be retained in the same manner. The tube may be attached to the labial, buccal, palatine or lingual side of the band, according to the requirements of the case.

FIG. 152.



LENGTH OF TIME REQUIRED TO RETAIN THE TEETH IN THEIR PLACE.

Two reasons governing the time required to retain the plate upon the teeth are, first, the age of the patient; second, the nature of the operation. The time cannot be definitely stated for all persons, even of the same age and condition of case; an approximate period only can be fixed. In young and healthy persons, in whom reconstruction of tissue is rapid, the retainer will be needed but a comparatively short time. If the superior or inferior arches have been enlarged, a retaining plate must be worn until all the teeth have accommodated themselves to their new position, a period that will vary from six months to a year.

Where the teeth have been forced into the arch little or no retention will be required, the pressure of the lips and cheeks often being all that is necessary. Occlusion of the teeth of the opposite jaw aid greatly in retaining the bicuspids and molars.

The most difficult teeth to retain are those that have been rotated in their sockets. The difficulty of correcting the tendency to return to their original positions is so great that the retainers must be kept in place from one to two years, and occasionally even longer than this. The operator will have to use his best judgment as to the proper time to remove them. The number of teeth being moved does not affect the time required, as the bone is as rapidly deposited in one part of the jaw as another. The health of the patient will have considerable influence in the time required. A strong, robust person will recover from the operation more rapidly than one that is anæmic. The retainer should remain as long as circumstances will warrant, when a model should be secured. After the lapse of not longer than a day an examination should be made. If the teeth have not deviated, a week may elapse before making another examination. These examinations should be continued until the operator is satisfied that the teeth are secure. If the teeth should move, the retainer must be replaced, and allowed to remain for from three to six months, when it can be removed and any deviation noted.

INDEX.

- Age, question of, in regulation, 73, 90.
 Allan's case of protruding lower jaw, 152.
 Alveolar plates, 17.
 — process, absorption during regulation, 95.
 — — inferior, 18.
 — — superior, 17.
 — processes, 36.
 Alveoli, 18.
 Alveolus, of temporary teeth, absorption of, 62.
 Antrum, 11, 12.
 Arch, dental, 27.
 — — spreading, 128.
 — high, association with V-shaped and other arches, 58.
 — saddle-shaped, 51, 56.
 — — primary cause of, 57.
 — typical, of American woman, 28.
 — vaulted, 40.
 — V-shaped, 41, 51, 92.
 Arches, of idiots, 68.
 Austin, 127.
 Axle, in regulating, 99.

 Ballard, 40.
 Bennett, 103.
 Bicuspids, 24.
 — importance of occlusion of, 89.
 — irregularities of, 45.
 — removal of, in regulating, 93.
 Black, 109.
 Bridle apparatus for protruding teeth, 148.
 Byrnes' method of regulating, 116.

 Cartwright, 49, 53.
 Chinese, teeth of, 49.
 Coffin's method of regulating, 121.
 — split plate method, 123.
 Coil spring, in regulating, 126.
 Coleman, 49.
 Coles, 53.
 Cooke, impression cups, 87.
 Crowns, 29, 38.
 — moving, 140.
 Crypts, 37.
 Cuspids, 23.
 — abnormal position of, 43.
 — irregular eruption of, 44.

 Cuspids, irregularities of, 43.
 — large, 33.
 — temporary, extraction of, 63.
 — — importance of, 60.

 Decay of teeth, 78.
 Deformities, congenital and acquired, 51.
 — from arrested development, 50, 52.
 Dentine, 21.
 Development, of jaws, arrested in idiots, 71.
 Down, 68, 71.
 Dwinell, 102.

 Elastic force, in regulating, 107.
 Elasticity of metals, 112.
 Enamel, 20.
 Eruption, of teeth, forced, 142.
 — Matteson's method, 142.
 — order of, 38.
 — Talbot's method, 143.
 Expansion plate, Coffin's, 121.
 Extraction, early, irregularities from, 62.

 Farrar's cases of protruding teeth, 148.
 — method of moving crowns and roots, 141.
 — — of regulating, 114.
 — — of rotating teeth, 135.
 — retainers, 157.
 — triplex system, 136.
 Fees, 80.
 Filling, of temporary teeth, 62, 63.
 Force, application of, 93.


 Guilford, 91.
 Guilford's method of rotating teeth, 138.

 Heredity, relation to irregularities, 45.

 Idiots, constitutional irregularities of, 69.
 — irregularities of teeth of, 68.
 — vaulted arch of, 40.
 Impression cups, 84, 85, 87.
 — of lower jaw, 84.
 Impressions of mouth and jaws, 82.
 — how to take, 82, 83.
 Incisors, 22.
 — central, 42.
 — — pulling out, 134.
 — inferior, irregularities of, 92.

- Incisors, irregularities of, 43.
 — lateral, 43.
 Indians, teeth of, 49.
 Ireland, 68.
 Irregularities, acquired, 40.
 — constitutional, of idiots, 69.
 — correction of, relation of age to, 90.
 — etiology, 31.
 — from arrested development, 50.
 — — contact, 45.
 — — early extraction, 62.
 — — retention of temporary molars, 60.
 — — retention of temporary teeth, 58.
 — heredity and, 45.
 — of permanent teeth, 33.
 — of teeth of idiots, 68.
 — of temporary teeth, 31.
 — special forms of, 135.
- Jack-screw, compound, 102.
 — in regulating, 102.
 — of Lee and Bennett, 103.
- Jaw, lower, impression of, 84.
 — — protrusion of, 68.
 — prognathous, 32.
 — saddle-shaped, 56.
 — shape, changed by thumb-sucking, 41.
 — upper, protrusion of, 65.
 — — causes of, 66.
- Jaws, contraction of, interfering with speech, 78.
 — impressions, 82.
 — irregularities of, from arrested development, 50.
 — — of idiots, 69.
- Kingsley, 53, 54, 68.
 Kingsley's case of protruding teeth, 145.
 — retainer for anterior teeth, 155.
- Lee, 103.
 Lever, in regulating and moving, 97.
 Ligatures, in regulating, 111.
- McCullom, 102.
 Macrocephalous children, jaws of, 71.
 Magill's band, 111.
 — retainers, 157.
- Marshall, 44.
 Matteson, 65.
 Matteson's method of forced eruption, 142.
 Maxilla, inferior, 14.
 — — protrusion of, 152.
- Maxilla, inferior, protrusion of, Allan's case, 152.
 — superior, 9.
- Maxillary development, irregularities from, 50.
- Mechanical forces in regulating, 97.
- Membrane, periodontal, 20, 30.
- Metals, elasticity of, 112.
- Microcephalous children, jaws of, 71.
- Modeling compound impressions, 84.
- Models, how to make, 85.
 — mounting, 86.
 — study of, 88.
 — study of teeth by the, 79.
- Molars, 25.
 — importance of occlusion of, 89.
 — irregularities of, 45.
 — temporary, causing irregularities, 60.
 — — extraction, causing irregularities, 63.
- Mouth, impressions of, 82.
- Mummery, 49.
- Nichols, 49.
- Occlusion, 79.
 — anterior, failure of, 65.
 — not retaining anterior teeth, 154.
- Pain, in regulating, 76.
- Patrick method of regulating, 113.
- Piano-wire in regulating, 125.
- Plane, inclined, in regulating, 100.
- Plaster impressions, 82.
- Plates, retentive after regulation, 77.
 — with gold bands, 156.
- Pressure, in regulation, 76.
 — steady and intermittent, 77.
- Process, malar, 12.
 — nasal, 12.
 — palatine, 13.
 — superior alveolar, 17.
- Pulley, in regulating, 99.
- Pulp of teeth, 21.
- Regulation, age for, 73, 90.
 — application of force in, 93.
 — coil spring for, 126.
 — elastic force in, 107.
 — inclined plane in, 100.
 — jack-screw in, 102.
 — late, 74.
 — lever in, 97.
 — ligatures in, 111.
 — mechanical forces in, 97.
 — methods of, 113.
 — — Byrnes', 116.
 — — Coffin's, 121.
 — — Farrar's, 114.
 — — Patrick's, 113.
 — — Talbot's, 126.

- Regulation, of individual teeth, 131.
 — piano-wire in, 125.
 — pressure in, 76.
 — proper time, 72.
 — pulley, wheel and axle in, 99.
 — rapid, 95.
 — removal of teeth for, 90.
 — retention of teeth after, 153.
 — retentive plates after, 77.
 — screw in, 101.
 — wedge in, 104.
- Retainers, Farrar's, 157.
 — Magill's, 157.
 — Richardson's, 155.
 — Talbot's, 159.
- Retention, length of time for, 159.
 — of teeth after regulating, 153.
 — plate, 154.
 — prolonged, irregularities from, 58, 60.
- Richardson's retainers, 155.
- Roots, 29.
 — moving, 140.
- Rotated teeth, difficulty of retaining, 160.
- Rotating teeth in sockets, 135.
- Rotation of teeth, 75.
 — — Farrar's method, 135.
 — — Guilford — 138.
 — — Talbot's — 139.
- Rubber bands, in regulating, 107.
- Saddle-shaped jaw, 56.
- Salter, 34.
- Screw, in regulating, 101.
- Septa, dental, 19.
- Shepard, 44.
- Speech, interfered with by contraction of jaws, 78.
- Stellwagen, 68.
- Talbot's method of forced eruption, 143.
 — — regulating, 126.
 — — rotating teeth, 139.
 — retainer, 159.
- Teeth, absence of, 34.
 — anatomy of, 20.
 — anterior impression cups for, 87.
 — arch of, 27.
 — crowded and irregular, 90.
- Teeth, crowns of, 29, 38.
 — cuspid, 43.
 — decay of, 78.
 — description of, 21.
 — etiology, 31.
 — examination of, 78.
 — forced eruption of, 142.
 — incisors, 42, 43.
 — irregularities of, 33.
 — occlusion of, 27.
 — of idiots, irregularities of, 68.
 — permanent, 20, 33, 34, 36.
 — physiological changes of, 75.
 — physiology of, 20.
 — position of, 29.
 — prehistoric, 36.
 — protruding, 145.
 — — Farrar's cases, 148.
 — — Kingsley's case, 145.
 — regulation of. See *Regulation*.
 — removal of, in regulating, 90.
 — retention of, 58.
 — — after regulating, 153.
 — roots of, 29.
 — rotated, difficult to retain, 160.
 — rotating, in sockets, 135.
 — septa of, 19.
 — sockets of, 18.
 — supernumerary, 34.
 — temporary, 20, 25.
 — — cleansing and filling of, 62, 63.
 — — extraction of, 39.
 — — — irregularities from, 62.
 — — — irregularities of, 33.
 — time for removal of, 63.
 — wisdom, 35.
- Thumb-sucking, 31, 40, 41, 56.
 — — and V-shaped arch, 53.
- Tomes, 34, 35, 38, 52.
- Van Marter, 36.
- Wedge, in regulating, 104.
- Wheel, in regulating, 99.
- White, 68.
- Wilmarth, 71.
- Winchell, 35.
- Wire, piano, 125.











GLASGOW
UNIVERSITY
LIBRARY

